THIRD EDITION

INCLUDES FREE CD

TEXTBOOK OF HEPATOLOGY

From Basic Science to Clinical Practice

Foreword by
Neil McIntyre

Edited by
Juan Rodés
Jean-Pierre Benhamou
Andres Blei
Jürg Reichen
Mario Rizzetto

Associate Editors
Jean-François Dufour
Scott Friedman
Pere Ginès
Dominique-Charles Valla
Fabien Zoulim

Blackwell Publishing

TEXTBOOK OF

Hepatology

From Basic Science to Clinical Practice

Textbook of Hepatology – Third Edition – Companion CD

A companion CD is included at the back of Volume Two. It contains:

- All chapters in PDF format
- A full text search facility, with search words highlighted in the text.

TEXTBOOK OF Hepatology

From Basic Science to Clinical Practice

THIRD EDITION

SECTIONS 1–10 AND INDEX

EDITORS

Juan Rodés MD
Director General, Hospital Clinic; Professor of Medicine, University of Barcelona, Barcelona, Spain

Jean-Pierre Benhamou MD
Professor of Hepatology, Université Denis Diderot Paris 7, Assistance Publique – Hôpitaux de Paris and Inserm U773, Service d'Hépatologie, Hôpital Beaujon, Clichy, France

Andres T. Blei MD
Professor of Medicine and Surgery, Northwestern University Feinberg School of Medicine, Chicago, IL, USA

Jürg Reichen MD
Professor of Medicine, University of Bern; Chief of Hepatology, University Hospital, Bern, Switzerland

Mario Rizzetto MD
Professor of Gastroenterology, University of Turin, Turin, Italy

ASSOCIATE EDITORS

Jean-François Dufour MD
Professor of Hepatology, University of Bern, Bern, Switzerland

Scott L. Friedman MD
Fishberg Professor of Medicine, Chief, Division of Liver Diseases, Mount Sinai School of Medicine, New York, NY, USA

Pere Ginès MD
Professor of Medicine, University of Barcelona, Chief, Liver Unit, Hospital Clinic, Barcelona, Spain

Dominique-Charles Valla MD
Professor of Hepatology, Université Denis Diderot Paris 7, Assistance Publique – Hôpitaux de Paris and Inserm U773, Chief, Service d'Hépatologie, Hôpital Beaujon, Clichy, France

Fabien Zoulim MD PhD
Professor of Medicine, Université Lyon 1, Liver Department, Hospices Civils de Lyon, Head, Inserm U8712, Lyon, France

FOREWORD

Neil McIntyre MD
Emeritus Professor of Medicine, Royal Free and University College School of Medicine, London, UK

Blackwell Publishing

© 2007 by Blackwell Publishing Ltd
Blackwell Publishing, Inc., 350 Main Street, Malden, Massachusetts 02148-5020, USA
Blackwell Publishing Ltd, 9600 Garsington Road, Oxford OX4 2DQ, UK
Blackwell Publishing Asia Pty Ltd, 550 Swanston Street, Carlton, Victoria 3053, Australia

The right of the Author to be identified as the Author of this Work has been asserted in accordance with the Copyright, Designs and Patents Act 1988.

All rights reserved. No part of this publication may be reproduced, stored in a retrieval system, or transmitted, in any form or by any means, electronic, mechanical, photocopying, recording or otherwise, except as permitted by the UK Copyright, Designs and Patents Act 1988, without the prior permission of the publisher.

First published 1991 by Oxford University Press
Second edition 1999 by Oxford University Press

2007 1

Library of Congress Cataloging-in-Publication Data
Textbook of hepatology : from basic science to clinical practice. — 3rd ed. / edited by Juan Rodés . . . [et al.].
p. ; cm.
Rev. ed. of: Oxford textbook of clinical hepatology. 2nd ed. 1999.
Includes bibliographical references and indexes.
ISBN: 978-1-4051-2741-7 (alk. paper)
1. Liver—Diseases. I. Rodés, Juan. II. Oxford textbook of clinical hepatology. III. Title: Hepatology.
[DNLM: 1. Liver Diseases. WI 700 T355 2007]

RC845.O93 2007
616.3′62—dc22

2006101699

ISBN: 978-1-4051-2741-7

A catalogue record for this title is available from the British Library

Set in Minion/Frutiger by Graphicraft Limited, Hong Kong
Printed and bound in Singapore by Markono Print Media Pte Ltd

Commissioning Editor: Alison Brown
Development Editor: Rebecca Huxley, Blackwell Publishing Ltd
Development Editor: Nicki van Berckel, University of Barcelona
Production Controller: Debbie Wyer
Project Manager: Gillian Whytock, Prepress Projects Ltd
CD produced by: Meg Barton, Nathan Harris

For further information on Blackwell Publishing, visit our website:
http://www.blackwellpublishing.com

The publisher's policy is to use permanent paper from mills that operate a sustainable forestry policy, and which has been manufactured from pulp processed using acid-free and elementary chlorine-free practices. Furthermore, the publisher ensures that the text paper and cover board used have met acceptable environmental accreditation standards.

Blackwell Publishing makes no representation, express or implied, that the drug dosages in this book are correct. Readers must therefore always check that any product mentioned in this publication is used in accordance with the prescribing information prepared by the manufacturers. The author and the publishers do not accept responsibility or legal liability for any errors in the text or for the misuse or misapplication of material in this book.

Contents

Volume One

Contributors
Foreword
Preface to the third edition
Preface to the first edition

Section 1 Architecture of the liver, 1

1.1 Macroscopic anatomy of the liver, 3
Jean H.D. Fasel, Holger Bourquain, Heinz-Otto Peitgen and Pietro E. Majno
1.2 Liver and biliary tract histology, 9
Paulette Bioulac-Sage, Brigitte Le Bail and Charles Balabaud
1.3 Ultrastructure of the hepatocyte, 20
Zahida Khan, James M. Crawford and Donna B. Stolz
1.4 Liver sinusoidal endothelial cells, 29
David Semela and Vijay H. Shah
1.5 Kupffer cells, 36
Hartmut Jaeschke
1.6 The hepatic stellate cell, 43
Massimo Pinzani
1.7 Biliary epithelial cells, 52
Jean-François Dufour
1.8 Hepatic stem cells, 58
Tania Roskams
1.9 Embryology of the liver and intrahepatic biliary tract, 65
Frédéric P. Lemaigre

Section 2 Functions of the liver, 73

2.1 Hepatic circulation, 75
2.1.1 Regulation of hepatic blood flow, 75
Christophe Bureau, Jean-Marie Péron and Jean-Pierre Vinel
2.1.2 Hepatic microcirculation, 79
Yoshiya Ito and Robert S. McCuskey
2.1.3 Hepatic lymph and lymphatics, 84
Glen A. Laine and Charles S. Cox Jr
2.2 Functions of the liver, 89
2.2.1 Functional organization of the liver, 89
Paulo Renato A.V. Correa and Michael H. Nathanson
2.2.2 Cell biology of the hepatocyte, 96
Allan W. Wolkoff and Phyllis M. Novikoff
2.2.3 Molecular biology of the liver cell, 101
Sundararajah Thevananther and Saul J. Karpen
2.2.4 Hepatic transport processes, 109
Ronald P.J. Oude Elferink
2.2.5 Modulation of liver function by hepatic nerves, 114
Gerhard P. Püschel
2.2.6 *In vitro* techniques: isolated organ perfusion, slices, cells and subcellular elements, 122
Bruno Stieger
2.3 Metabolism, 129
Intermediate metabolism
2.3.1 Carbohydrates and the liver, 129
Guenther Boden
2.3.2 Lipoprotein metabolism, 133
Erez F. Scapa, Keishi Kanno and David E. Cohen
2.3.3 Protein and amino acid metabolism, 142
Margaret E. Brosnan and John T. Brosnan
2.3.4 Mitochondria and energy formation, 149
Dominique Pessayre
Liver-specific functions
2.3.5 Bilirubin metabolism, 165
Namita Roy-Chowdhury, Yang Lu and Jayanta Roy-Chowdhury
2.3.6 Metabolism of bile acids, 174
Peter L.M. Jansen and Klaas N. Faber
2.3.7 Ammonia, urea production and pH regulation, 181
Dieter Häussinger
2.3.8 Protein synthesis and degradation in the liver, 192
Armin Akhavan and Vishwanath R. Lingappa
2.3.9 Glutathione, 199
José C. Fernández-Checa and Carmen García-Ruiz
2.3.10 Haem biosynthesis and excretion of porphyrins, 207
Hervé Puy and Jean-Charles Deybach
Metabolism of endo/xenobiotics
2.3.11 Vitamins and the liver (A and D), 214
Masataka Okuno, Rie Matsushima-Nishiwaki and Soichi Kojima

2.3.12 Normal iron metabolism, 221
Kyle E. Brown
2.3.13 Normal copper metabolism and reducing copper to subnormal levels for therapeutic purposes, 226
George J. Brewer, Edward D. Harris and Fred K. Askari
2.3.14 Trace elements and the liver, 233
Brent A. Neuschwander-Tetri
2.3.15 Hepatic metabolism of drugs, 241
Chris Liddle and Catherine A.M. Stedman
2.4 Synthetic function, 250
2.4.1 Albumin and other carrier proteins, 250
Richard A. Weisiger
2.4.2 The liver and coagulation, 255
Maria T. DeSancho and Stephen M. Pastores
2.4.3 Function and metabolism of collagen and other extracellular matrix proteins, 264
Rebecca G. Wells
2.5 Regulation of the liver cell mass, 274
2.5.1 Control of liver cell proliferation, 274
Nisar P. Malek and K. Lenhard Rudolph
2.5.2 Regeneration of chronically injured liver, 280
Anna Mae Diehl
2.6 Excretion, 290
2.6.1 Physiology of bile formation, 290
Martin Wagner and Michael Trauner
2.6.2 Motility of the biliary tree, 304
Mayank Bhandari and James Toouli
2.7 Immunology of the liver, 312
2.7.1 Cytokines in liver physiology and liver pathology, 312
Tom Luedde and Christian Trautwein
2.7.2 Intrahepatic lymphocytes, 320
Wajahat Z. Mehal
2.7.3 Antibody production and transport in the liver, 325
Alvin B. Imaeda and Wajahat Z. Mehal

Section 3 Basic concepts in pathobiology, 333

3.1 Hepatocyte apoptosis and necrosis, 335
Henning Schulze-Bergkamen, Marcus Schuchmann and Peter R. Galle
3.2 Ischaemia-reperfusion injury to the liver, 348
Nazia Selzner and Pierre A. Clavien
3.3 Genetics and liver diseases, 356
3.3.1 Genetic polymorphisms in liver disease, 356
Hongjin Huang and Ramsey Cheung
3.3.2 Immunogenetics of liver disease, 364
Peter T. Donaldson
3.3.3 Genetic determinants of complex liver diseases: mouse models and quantitative trait locus analysis, 371
Frank Lammert
3.4 Cellular cholestasis, 384
Stefano Fiorucci
3.5 Oncogenes and tumour suppressor genes, 391
Dipankar Chattopadhyay and Helen Reeves
3.6 Genomics, gene arrays and proteomics in the study of liver disease, 398
Geoffrey W. McCaughan, Nicholas A. Shackel, Rohan Williams, Devanshi Seth, Paul S. Haber and Mark D. Gorrell

Section 4 Pathology, 421

4.1 Histological features, 423
Valeer J. Desmet, Tania Roskams and Miguel Bruguera
4.2 Classifications, scoring systems and morphometry in liver pathology, 433
Pierre Bedossa and Valerie Paradis

Section 5 Investigation of hepatobiliary disease, 441

5.1 Signs and symptoms of liver disease, 443
Jürg Reichen
5.2 Biochemical investigations in the management of liver disease, 451
Igino Rigato, J. Donald Ostrow and Claudio Tiribelli
5.3 Hepatic removal kinetics: importance for quantitative measurements of liver function, 468
Susanne Keiding and Michael Sørensen
5.4 Immunological investigations in liver diseases, 479
Elmar Jaeckel and Michael P. Manns
5.5 Biopsy and laparoscopy, 489
Arthur Zimmermann
5.6 Imaging of the liver, 500
5.6.1 Ultrasonography, 500
Luigi Bolondi, Valeria Camaggi and Fabio Piscaglia
5.6.2 Computerized tomography imaging of the liver, 508
Daniel T. Cohen and Dushyant V. Sahani
5.6.3 Magnetic resonance imaging, 521
Christoforos Stoupis
5.6.4 Angiography, 531
Sanjeeva P. Kalva and Dushyant V. Sahani
5.6.5 Endoscopic retrograde cholangiopancreatography, 540
Alan J. Wigg and James Toouli
5.7 Interventional radiology in hepatobiliary diseases, 549
José Ignacio Bilbao Jaureguízar, Concepció Bru, Joan Falcó Fages and Lluís Donoso
5.8 Positron emission tomography of the liver, 561
Susanne Keiding and Michael Sørensen
5.9 Splanchnic haemodynamic investigations, 567
Didier Lebrec and Richard Moreau
5.10 The Cochrane Hepatobiliary Group, 572
Christian Gluud, on behalf of the Cochrane Hepatobiliary Group

Section 6 Cirrhosis, 581

6.1 The evolution of cirrhosis, 583
John P. Iredale and I. Neil Guha

6.2 Cellular and molecular pathobiology of liver fibrosis and its pharmacological intervention, 590
Scott L. Friedman
6.3 Clinical and diagnostic aspects of cirrhosis, 604
I. Neil Guha and John P. Iredale

Section 7 Portal hypertension and its complications, 621

7.1 Anatomy of the portal venous system in portal hypertension, 623
J. Michael Henderson
7.2 Pathogenesis of portal hypertension, 630
Roberto J. Groszmann and Juan G. Abraldes
7.3 Clinical manifestions and management of bleeding episodes in cirrhotics, 640
Jaime Bosch, Juan G. Abraldes and Juan Carlos García-Pagán
7.4 Haemodynamic assessment of portal hypertension, 658
Juan Carlos García-Pagán, Juan Turnes and Jaime Bosch
7.5 Pathogenesis, diagnosis and treatment of ascites in cirrhosis, 666
Vicente Arroyo, Carlos Terra and Luis Ruiz-del-Arbol
7.6 Hepatorenal syndrome, 711
Pere Ginès and Mónica Guevara
7.7 Pulmonary complications of portal hypertension, 720
Michael J. Krowka
7.8 Hepatic encephalopathy, 728
Dieter Häussinger and Andres T. Blei
7.9 Bacterial infections in portal hypertension, 761
Javier Fernández and Miguel Navasa
7.10 Hypersplenism, 771
P. Aiden McCormick

Section 8 Congenital hepatic fibrosis and non-parasitic cystic lesions of the liver and bile ducts, 779

8.1 Congenital conditions, 781
8.1.1 Congenital hepatic fibrosis, 781
Jean-Pierre Benhamou
8.1.2 Simple cyst of the liver, 783
Valérie Vilgrain
8.1.3 Polycystic kidney disease, 789
Valérie Vilgrain
8.1.4 Polycystic liver disease, 795
Valérie Vilgrain
8.1.5 Biliary hamartomas, 797
Valérie Vilgrain
8.1.6 Peribiliary cysts, 802
Valérie Vilgrain
8.1.7 Caroli syndrome, 805
Jean-Pierre Benhamou
8.1.8 Choledochal cyst, 807
Jean-Pierre Benhamou
8.1.9 Ciliated hepatic foregut cyst, 807
Jean-François Cadranel
8.2 Acquired conditions, 810
8.2.1 Inflammatory cystic diseases, 810
Jean-François Cadranel
8.2.2 Neoplasms including cystadenoma, 813
P. Starkel and André P. Geubel
8.2.3 Post-traumatic cystic diseases, 816
Jean-François Cadranel

Section 9 Viral infections of the liver, 819

9.1 Viral hepatitis, 821
9.1.1 Viral hepatitis, 821
Mario Rizzetto and Fabien Zoulim
9.1.2 The viruses of hepatitis, 823
i) Structure, replication and laboratory diagnosis of hepatitis B virus and hepatitis D virus, 823
Stephan Schaefer and Wolfram H. Gerlich
ii) Structure, replication and laboratory diagnosis of hepatitis C virus, 849
Ralf Bartenschlager
iii) Hepatitis A, 857
Loriana Di Giammarino and Jules L. Dienstag
iv) Hepatitis B, 865
Geoffrey M. Dusheiko
v) Hepatitis D, 875
Antonella Smedile and Mario Rizzetto
vi) Hepatitis C, 881
Alfredo Alberti and Luisa Benvegnù
vii) Hepatitis E, 893
Rakesh Aggarwal and Krzysztof Krawczynski
9.1.3 Prevention and treatment of viral hepatitis, 899
i) Vaccines against hepatitis A, 899
Pierre Van Damme, Koen Van Herck and Philippe Beutels
ii) Hepatitis B vaccines and immunization, 907
Daniel Lavanchy
iii) Therapy of acute viral hepatitis, 917
Markus Cornberg, Heiner Wedemeyer and Michael P. Manns
iv) Antiviral therapy of chronic hepatitis B, 921
Fabien Zoulim and Mario Rizzetto
v) Therapy for chronic hepatitis C, 941
Giorgio Saracco, Fabien Zoulim and Mario Rizzetto
9.2 Systemic virosis producing hepatitis, 957
Alberto Biglino and Mario Rizzetto
9.3 Human immunodeficiency virus and the liver, 974
Vincent Soriano, Pablo Barreiro, Javier García-Samaniego, Luz Martín-Carbonero and Marina Nuñez
9.4 Exotic virus infections of the liver, 988
Pierre E. Rollin, Thomas G. Ksiazek, Alberto Queiroz Farias and Flair José Carrilho

Section 10 Other infections of the liver, 999

10.1 Bacterial, rickettsial and spirochaetal infections, 1001
José M. Sánchez-Tapias
10.2 Fungal infections affecting the liver, 1011
Roderick J. Hay
10.3 Protozoal infections affecting the liver, 1020
10.3.1 Amoebiasis, giardiasis and cryptosporidiosis, 1020
David Kershenobich, Guillermo Robles Diaz and Juan Miguel Abdo
10.3.2 Malaria, 1029
Montse Renom and Pedro L. Alonso
10.3.3 Visceral leishmaniasis, 1034
Manuel Corachan
10.4 Helminthiasis, 1040
10.4.1 Blood flukes (schistosomes) and liver flukes, 1040
Flair José Carrilho, Pedro Paulo Chieffi and Luiz Caetano Da Silva
10.4.2 Echinococcosis of the liver, 1047
S. Bresson-Hadni, G.A. Mantion, J.P. Miguet and D.A. Vuitton
10.4.3 Ascariasis, visceral larva migrans, strongyloidiasis, capillariasis and pentastomiasis, 1058
Marcelo Simão Ferreira and Edna Strauss

Index
Colour plate section follows p. 72

Volume Two

Section 11 Immune disorders of the liver, 1069

11.1 Primary biliary cirrhosis, 1071
E. Jenny Heathcote and Piotr Milkiewicz
11.2 Autoimmune hepatitis, 1089
Diego Vergani and Giorgina Mieli-Vergani
11.3 Sclerosing cholangitis, 1103
Konstantinos N. Lazaridis and Nicholas F. LaRusso
11.4 Vanishing bile duct syndrome, 1111
Frank Grünhage and Tilman Sauerbruch
11.5 Overlap syndromes, 1120
Ulrich Beuers

Section 12 Alcoholic liver disease, 1127

12.1 Epidemiological aspects of alcoholic liver disease, 1129
Juan Caballeria
12.2 Ethanol metabolism and pathogenesis of alcoholic liver injury, 1135
Stephen F. Stewart and Christopher P. Day
12.3 Pathology of alcoholic liver disease, 1148
Elie Serge Zafrani
12.4 Alcoholic liver disease: natural history, diagnosis, clinical features, evaluation, prognosis and management, 1157
Laurent Spahr and Antoine Hadengue
12.5 Management of the alcoholic patient, including alcoholism and extrahepatic manifestations, 1179
Georges-Philippe Pageaux and Pascal Perney

Section 13 Hepatic non-alcoholic steatosis, 1193

13 Non-alcoholic fatty liver and non-alcoholic steatohepatitis, 1195
Geoffrey C. Farrell

Section 14 Toxic liver injury, 1209

14.1 Drug-induced liver injury, 1211
Dominique Pessayre and Dominique Larrey
14.2 Toxic liver injury, 1269
Basuki Gunawan and Neil Kaplowitz
14.3 Hepatic injury due to physical agents, 1277
Bernhard H. Lauterburg and Haithem Chtioui
14.4 Hepatic toxicity induced by herbal medicines, 1281
Felix Stickel and Detlef Schuppan

Section 15 Acute liver failure, 1289

15 Acute liver failure and related syndromes, 1291
François Durand and Jacques Bernuau

Section 16 Genetic and metabolic diseases, 1313

16.1 Wilson's disease, 1315
Michael Schilsky
16.2 Haemochromatosis, 1323
Antonello Pietrangelo
16.3 Alpha 1-antitrypsin deficiency and related disorders, 1330
Jeffrey H. Teckman
16.4 The liver in cystic fibrosis, 1336
Andrew P. Feranchak
16.5 Human hereditary porphyrias, 1343
Elisabeth I. Minder and Xiaoye Schneider-Yin
16.6 Hyperbilirubinaemia, 1352
Peter L.M. Jansen
16.7 The liver in intracellular and extracellular lipidosis, 1360
Dominique P. Germain
16.8 Glycogen storage diseases, 1370
Philippe Labrune
16.9 Mitochondriopathies, 1377
Pierre Rustin
16.10 Genetic cholestatic diseases, 1383
Ronald P.J. Oude Elferink

Section 17 Vascular diseases, 1389

17.1 Hepatic artery diseases, 1391
Peter C. Hayes
17.2 Obstruction of the portal vein, 1395
Juan Carlos García-Pagán, Manuel Hernández-Guerra and Jaime Bosch
17.3 Disorders of the hepatic veins and hepatic sinusoids, 1403
Dominique-Charles Valla
17.4 Congenital vascular malformations, 1418
Guadalupe García-Tsao

Section 18 Tumours of the liver, 1425

18.1 Benign hepatic tumours, 1427
18.1.1 Liver haemangioma, 1427
Jean-Pierre Benhamou
18.1.2 Benign hepatocellular tumours, 1428
Massimo Colombo and Riccardo Lencioni
18.2 Malignant tumours, 1437
18.2.1 Primary liver cell carcinoma, 1437
Jordi Bruix, Alejandro Forner, María Varela, Carmen Ayuso and Josep María Llovet
18.2.2 Malignant mesenchymal tumours of the liver, 1457
Miguel Bruguera and Juan Rodés
18.3 Metastatic tumours, 1464
18.3.1 Metastatic liver disease, 1464
Masamichi Kojiro and Antoni Castells
18.3.2 Carcinoid tumours, 1470
Humphrey J.F. Hodgson

Section 19 Biliary tract diseases, 1479

19.1 Intrahepatic cholestasis, 1481
Olivier Chazouillères and Chantal Housset
19.2 Extrahepatic biliary obstruction: systemic effects, diagnosis and management, 1501
Michelle C. Gallagher and James S. Dooley
19.3 Gallstone disease, 1518
Frank Lammert, Franz-Ludwig Dumoulin and Tilman Sauerbruch
19.4 Cholangitis and biliary tract infections, 1541
Ulrich Beuers
19.5 Haemobilia, 1550
Antonio Lacy and Nader K. Francis
19.6 Biliary dyskinesia, 1561
C. Ritchie Chalmers and Giles J. Toogood
19.7 Benign biliary tumours, 1573
Miguel Bruguera
19.8 Gallbladder carcinoma, 1575
Thomas A. Aloia, Christopher H. Crane and Jean-Nicolas Vauthey
19.9 Cholangiocarcinoma, 1583
Steven S. Strasberg and William G. Hawkins

Section 20 The liver in diseases of other systems, 1607

20.1 The liver in cardiovascular disease, 1609
Susan Tiukinhoy-Laing, Andres T. Blei and Mihai Gheorghiade
20.2 The liver in lung diseases, 1616
Andres T. Blei and Jacob I. Sznajder
20.3 The effect of gastrointestinal diseases on the liver and biliary tract, 1622
Roger W. Chapman and Peter W. Angus
20.4 Total parenteral nutrition-related liver disease, 1634
Sean W.P. Koppe and Alan L. Buchman
20.5 The effect of skin diseases on the liver, 1642
Daniel Glass and Malcolm Rustin
20.6 The liver in urogenital diseases, 1653
Mónica Guevara, Vicente Arroyo and Juan Rodés
20.7 The effect of haematological and lymphatic diseases on the liver, 1662
Miguel Bruguera and Rosa Miquel
20.8 The liver in graft-vs.-host disease, 1671
Enric Carreras, Carmen Martínez and Miguel Bruguera
20.9 The effect of endocrine diseases on liver function, 1680
Anthony J. DeSantis and Andres T. Blei
20.10 Musculoskeletal diseases and the liver, 1694
N. Guañabens, J. van den Bogaerde and H.L.C. Beynon
20.11 Amyloidosis, 1702
Philip N. Hawkins
20.12 Hepatic granulomas, 1709
Laura M. Kulik and Andres T. Blei

Section 21 The impact of liver disease on other systems, 1719

21.1 The effect of liver disease on the cardiovascular system, 1721
Jens H. Henriksen and Søren Møller
21.2 The effect of liver disease on the endocrine system, 1732
Yolanta T. Kruszynska and Pierre M. Bouloux
21.3 Haematological abnormalities in liver disease, 1767
Marco Senzolo and Andrew K. Burroughs
21.4 Haemostasis in liver disease, 1780
Stephen H. Caldwell, Patrick G. Northup and Vinay Sundaram
21.5 The effect of liver disease on the gastrointestinal tract, 1798
Roger W. Chapman and Peter W. Angus
21.6 The effect of liver disease on the skin, 1804
Malcolm Rustin and Daniel Glass
21.7 Effect of liver on the urogenital tract, 1815
Mónica Guevara, Vicente Arroyo and Juan Rodés
21.8 The nervous system in liver disease, 1822
Andres T. Blei
21.9 The effect of liver disease on bone, 1829
Juliet Compston
21.10 The effect of liver disease on nutritional status and energy metabolism, 1836
Michael R. Charlton

Section 22 The liver in specific settings, 1843

22.1 Paediatric liver diseases, 1845
Marianne Samyn and Giorgina Mieli-Vergani
22.2 Liver diseases in the elderly, 1870
Oliver F.W. James
22.3 Liver diseases and pregnancy, 1879
Andrew K. Burroughs and Evangelos Cholongitas

Section 23 The management of liver diseases, 1897

23.1 The general management of liver diseases, 1899
Dominique Guyader
23.2 Nutritional aspects of liver and biliary disease, 1905
Bernard Campillo
23.3 Prescribing drugs in liver disease, 1912
Dominique Larrey and Georges-Phillppe Pageaux
23.4 Management of pretransplant patients, 1922
François Durand

Section 24 Surgery, anaesthesia and the liver, 1931

24.1 General surgical aspects and the risks of liver surgery in patients with hepatic disease, 1933
Jacques Belghiti and Satoshi Ogata
24.2 Anaesthesia and liver disease, 1938
Kalpana Reddy and Susan V. Mallett
24.3 Postoperative jaundice, 1945
Peter Fickert and Michael Trauner
24.4 Hepatobiliary trauma, 1953
K. Raj Prasad, Patrick A. Couglin and Giles J. Toogood

Section 25 Liver transplantation, 1963

25.1 Surgical techniques, 1965
25.1.1 Liver transplantation, 1965
Peter Neuhaus
25.1.2 Split-liver transplantation, 1970
Ramón Charco, Josep Fuster Obregón, Constantino Fondevila and Juan Carlos García-Valdecasas
25.1.3 The surgical technique of living donor liver transplantation using the right hepatic lobe, 1976
Igal Kam, James Trotter and Gregory T. Everson
25.2 Liver transplantation: indications, contraindications and results, 1984
Gregory T. Everson and Fernando E. Membreno
25.3 The perioperative care and complications of liver transplantation, 1996
Mark T. Keegan and David J. Plevak
25.4 Immunosuppression, 2003
James Neuberger
25.5 Recurrent disease and management in liver transplantation, 2010
Xavier Forns and Antoni Rimola
25.6 Post-transplantation management and complications, 2019
Faouzi Saliba and Didier Samuel
25.7 Liver transplantation and quality of life, 2027
Miguel Navasa and Juan Rodés
25.8 Emerging therapies, 2032
25.8.1 Hepatocyte transplantation, 2032
Govardhana Rao Yannam, Jayanta Roy-Chowdhury and Ira J. Fox
25.8.2 Liver support, 2043
Vanessa Stadlbauer and Rajiv Jalan

Section 26 Mathematics in hepatology, 2053

26.1 Models in clinical hepatology, 2055
W. Ray Kim
26.2 Outcomes research in hepatology, 2065
Raymond S. Koff
26.3 Meta-analysis, 2073
Gioacchino Leandro and Andrew K. Burroughs
26.4 Economic considerations in hepatology, 2080
John B. Wong
26.5 Development of the liver interactome: mapping the regulatory networks, 2088
Mario Pagano, Susana Neves, Ravi Iyengar and John Cijiang He

Section 27 Appendices, 2097

27.1 Geographic distribution of infections causing liver disease, 2099
Harriet Hughes and Tom Doherty
27.2 Liver injury in man ascribed to non-drug chemicals and natural toxins, 2105
Regine Kahl and Wim Wätjen
27.3 Rare diseases with hepatic abnormalities, 2122
M. Baraitser and R.M. Winter

Index
Colour plate section follows p. 1268

A companion CD containing all chapters in PDF format with a full text search is included at the back of Volume Two.

Contributors

Juan Miguel Abdo MD
Chief, Clinical Gastroenterology Unit
Mexico General Hospital
Mexico City, Mexico

Juan G. Abraldes MD
Specialist in Hepatology
Liver Unit, Hospital Clinic
Barcelona, Spain

Rakesh Aggarwal MD DM
Professor, Department of Gastroenterology
All India Institute of Medical Sciences
New Delhi, India

Armin Akhavan MD
California Pacific Medical Center
San Francisco, CA, USA

Alfredo Alberti MD
Professor of Clinical and Experimental Medicine
University of Padua
Padua, Italy

Thomas A. Aloia MD
Assistant Professor of Surgery
Baylor College of Medicine
Houston, TX, USA

Pedro L. Alonso MD
Jefe del Servicio
Centro de Salud Internacional
Hospital Clinic
Barcelona, Spain

Peter W. Angus MB BS MD FRACP
Director of Gastroentrology and Hepatology
Austin Hospital
Melbourne, Vic, Australia

Vicente Arroyo MD
Professor of Medicine
Director of the Institute of Digestive and Metobolic Diseases
University of Barcelona
Barcelona, Spain

Fred K. Askari MD PhD
Clinical Assistant Professor, Department of Internal Medicine
University of Michigan Health System
Ann Arbor, MI, USA

Carmen Ayuso MD
Consultant Radiologist
Hospital Clinic
Barcelona, Spain

Charles Balabaud MD
Hepatologist
Hôpital St André
Bordeaux, France

M. Baraitser MD
Consultant in Clinical Genetics
Great Ormond Street Hospital for Children
London, UK

Pablo Barreiro MD
Department of Infectious Diseases
Hospital Carlos III
Madrid, Spain

Ralf Bartenschlager PhD
Head of Department of Molecular Virology
University of Heidelberg
Heidelberg, Germany

Pierre Bédossa MD
Professor of Pathology, Université Denis Diderot Paris 7;
Assistance Publique – Hôpitaux de Paris and Inserm U773;
Department of Pathology, Hôpital Beaujon
Clichy, France

Jacques Belghiti MD
Hôpital Beaujon
Clichy, France

Jean-Pierre Benhamou MD
Professor of Hepatology, Université Denis Diderot Paris 7;
Assistance Publique – Hôpitaux de Paris and Inserm U773;
Service d'Hépatologie, Hôpital Beaujon
Clichy, France

Luisa Benvegnù MD
Department of Clinical and Experimental Medicine
University of Padua
Padua, Italy

Jacques Bernuau MD
Service d'Hépatologie
Hôpital Beaujon
Clichy, France

Ulrich Beuers MD
Professor, Department of Gastroenterology and Hepatology
Academic Medical Center
Amsterdam, The Netherlands

Philippe Beutels BSc MSc PhD
Lecturer in Health Economics
Faculty of Medicine
University of Antwerp
Antwerp, Belgium

H.L.C. Beynon MD
Consultant Physician and Rheumatologist
Royal Free Hospital
London, UK

Mayank Bhandari MB BS MS
Flinders Medical Centre
Bedford Park, SA, Australia

Alberto Biglino MD
Associate Professor of Infectious Diseases
University of Turin;
Head, Infectious Diseases Unit
Cardinal Massaja Hospital
Asti, Italy

José Ignacio Bilbao Jaureguízar MD
Department of Radiology
Clínica Universitaria de Navarra
Pamplona, Spain

Paulette Bioulac-Sage MD
Professor of Pathology
Université Bordeaux
Bordeaux, France

Andres T. Blei MD
Professor of Medicine and Surgery
Northwestern University Feinberg School of Medicine
Chicago, IL, USA

Guenther Boden MD
Laura H. Carnell Professor of Medicine
Chief, Division of Endocrinology, Diabetes and Metabolism
Temple University
Philadelphia, PA, USA

J. van den Bogaerde MD
Royal Free Hospital
London, UK

Luigi Bolondi MD
Department of Internal Medicine and Gastroenterology
University of Bologna
Bologna, Italy

Jaime Bosch MD
Senior Consultant
Liver Unit, Hospital Clinic;
Professor of Medicine
University of Barcelona
Barcelona, Spain

Pierre M. Bouloux MD
Department of Medicine
Royal Free Hospital
London, UK

Holger Bourquain MD
MeVis Research GmbH
Bremen, Germany

S. Bresson-Hadni MD PhD
Professor, Department of Hepatology and Liver Diseases
Hôpital Jean-Minjoz
Besançon, France

George J. Brewer MD
Active Emeritus Professor of Human Genetics and Internal Medicine
University of Michigan Medical School
Ann Arbor, MI, USA

John T. Brosnan DPhil DSc
Professor, Department of Biochemistry
Memorial University of Newfoundland
St. John's, NL, Canada

Margaret E. Brosnan PhD
Professor, Department of Biochemistry
Memorial University of Newfoundland
St. John's, NL, Canada

Kyle E. Brown MD MSc
Assistant Professor, University of Iowa Carver College of Medicine;
Staff Physician, Iowa City Veterans Administration Medical Center
Iowa City, IA, USA

Concepció Bru MD
Senior Consultant Radiologist
Hospital Clinic
Barcelona, Spain

Miguel Bruguera MD
Senior Consultant
Liver Unit, Hospital Clinic
Barcelona, Spain

Jordi Bruix MD
Senior Consultant and BCLC Director
Liver Unit, Hospital Clinic
Barcelona, Spain

Alan L. Buchman MD MSPH FACP FACG FACN AGAF
Associate Professor
Northwestern University Feinberg School of Medicine
Chicago, IL, USA

Christophe Bureau MD
Praticien Hospitalier
CHU Purpan and Inserm U531
Toulouse, France

Andrew K. Burroughs MB ChB FRCP
Professor of Hepatology
University College School of Medicine;
Consultant Physician
Royal Free Hospital
London, UK

Juan Caballeria MD PhD
Senior Consultant
Liver Unit, Hospital Clinic
Barcelona, Spain

Jean-François Cadranel MD
Associate Professor, Collège Médical des Hôpitaux de Paris;
Chief, Liver Unit, Hôpital Laennec
Creil, France

Stephen H. Caldwell MD
Director of Hepatology
University of Virginia
Charlottesville, VA, USA

Valeria Camaggi MD
Department of Internal Medicine and Gastroenterology
University of Bologna
Bologna, Italy

Bernard Campillo MD
Service de Rééducation Digestive
Hôpital Albert Chenevier
Créteil, France

Enric Carreras MD PhD
Senior Consultant
Director of the Stem Cell Transplantation Program
Hospital Clinic
Barcelona, Spain

Flair José Carrilho MD PhD
Full Professor of Gastroenterology
University of São Paulo School of Medicine
São Paulo, Brazil

Antoni Castells MD
Department of Gastroenterology
Hospital Clinic
Barcelona, Spain

C. Ritchie Chalmers MD
MRC Clinical Training Fellow
Hepatobiliary Department
St James's University Hospital
Leeds, UK

Roger W. Chapman BSc MD MB BS FRCP
Consultant Hepatologist
John Radcliffe Hospital
Oxford, UK

Ramón Charco MD PhD
Consultant, Liver Transplant Unit
IMDiM, Hospital Clinic
Barcelona, Spain

Michael R. Charlton MD
Professor of Medicine
Director of Hepatology
Mayo Clinic College of Medicine
Rochester, MN, USA

Dipankar Chattopadhyay MB BS MS MRCS
Clinical Research Associate
Northern Institute of Cancer Research
Newcastle upon Tyne, UK

Oliver Chazouillères MD PhD
Professor of Hepatology
Université Pierre et Marie Curie Paris 6;
Director, Digestive Department, Hôpital Saint-Antoine
Paris, France

Ramsey Cheung MD
Associate Professor
Stanford University School of Medicine
Stanford, CA, USA

Pedro Paulo Chieffi MD PhD
Associate Professor, Department of Gastroenterology
University of São Paulo School of Medicine
São Paulo, Brazil

Evangelos Cholongitas MD
Hepatologist
Royal Free Hospital
London, UK

Haithem Chtioui MD
Department of Clinical Pharmacology
University of Bern
Bern, Switzerland

Pierre A. Clavien MD
Multiorgan Transplant Program
Toronto General Hospital
Toronto, ON, Canada

Daniel T. Cohen MD
Radiology Resident, Department of Radiology
Massachusetts General Hospital
Boston, MA, USA

David E. Cohen MD PhD
Director of Hepatology
Brigham and Women's Hospital;
Associate Professor of Medicine
Harvard Medical School;
Associate Professor of Health Sciences and Technology
Harvard–MIT Division of Health Sciences and Technology
Boston, MA, USA

Massimo Colombo MD
Professor of Gastroenterology
University of Milan
Milan, Italy

Juliet Compston FRCPath FRCP
Professor of Bone Medicine
University of Cambridge;
Honorary Consultant Physician
Addenbrooke's Hospital
Cambridge, UK

Manuel Corachan MD
Senior Consultant in Tropical Medicine
Center for International Health
University Hospital
Barcelona, Spain

Markus Cornberg MD
Department of Gastroenterology
Hanover Medical School
Hanover, Germany

Paulo Renato A.V. Correa MD
Resident, Department of Psychiatry
Yale University School of Medicine
New Haven, CT, USA

Patrick A. Couglin MB ChB MRCS MD
Higher Surgical Trainee,Yorkshire Deanery
Department of Hepatobiliary Surgery
St James's University Hospital
Leeds, UK

Charles S. Cox Jr MD PhD
Director, Pediatric Trauma Program
Distinguished Professor of Surgery and Pediatrics
University of Texas Medical School
Houston, TX, USA

Christopher H. Crane MD
Associate Professor
Program Director and Section Chief, Gastrointestinal Section
University of Texas M.D. Anderson Cancer Center
Houston, TX, USA

James M. Crawford MD PhD
Professor and Chair
Department of Pathology, Immunology and Laboratory Medicine
University of Florida College of Medicine
Gainesville, FL, USA

Luiz Caetano Da Silva MD
Department of Gastroenterology
University of São Paulo School of Medicine
São Paulo, Brazil

Christopher P. Day MD
Centre for Liver Research
University of Newcastle upon Tyne
Newcastle upon Tyne, UK

Maria T. DeSancho MD
Associate Professor of Clinical Medicine
New York Presbyterian Hospital
New York, NY, USA

Anthony J. DeSantis MD
Assistant Professor of Medicine
Northwestern University Feinberg School of Medicine
Chicago, IL, USA

Valeer J. Desmet MD
Emeritus Professor of Pathology
Catholic University of Leuven
Leuven, Belgium

Jean-Charles Deybach MD PhD
President of the French Porphyria Center
Professor of Biochemistry and Molecular Biology
Head of Department of Molecular Genetics and Biochemistry
Hôpital Louis Mourier
Colombes, France

Anna Mae Diehl MD
Florence McAlister Professor
Chief, Division of Gastroenterology
Duke University School of Medicine
Durham, NC, USA

Jules L. Dienstag MD
Carl W. Walter Professor of Medicine
Harvard Medical School;
Physician, Massachusetts General Hospital
Boston, MA, USA

Loriana Di Giammarino MD
Division of Gastroenterology and Hepatology
Center Hospitalier Universitaire Vaudois
University of Lausanne
Lausanne, Switzerland

Tom Doherty MD FRCP DTM&H
Hospital for Tropical Diseases
London, UK

Peter T. Donaldson BSc PhD
Lecturer in Molecular Genetics
University of Newcastle upon Tyne
Newcastle upon Tyne, UK

Lluís Donoso MD
Head, Diagnostic Imaging Centre
Hospital Clinic
Barcelona, Spain

James S. Dooley MD FRCP
Reader and Consultant Hepatologist, Centre for Hepatology
Royal Free and University College School of Medicine
London, UK

Jean-François Dufour MD
Professor of Hepatology
University of Bern
Bern, Switzerland

Franz-Ludwig Dumoulin MD
Professor of Medicine
University of Bonn;
Head, Department of Internal Medicine
St Agnes Hospital
Bocholt, Germany

François Durand MD
Professor of Hepatology, Université Denis Diderot Paris 7;
Assistance Publique – Hôpitaux de Paris and Inserm U773;
Service d'Hépatologie, Hôpital Beaujon
Clichy, France

Geoffrey M. Dusheiko MB BCh FCPSA FRCP FRCP(Ed)
Professor of Medicine, Centre for Hepatology
Royal Free and University College School of Medicine
London, UK

Gregory T. Everson MD
Professor of Medicine and Director of Hepatology
University of Colorado Health Sciences Center
Denver, CO, USA

Klaas N. Faber MD
Academic Medical Center
Amsterdam, The Netherlands

Joan Falcó Fages MD
Senior Consultant Radiologist
UDIAT-CD Hospital Parc Taulí
Sabadell, Spain

Geoffrey C. Farrell MD FRACP
Director, Gastroenterology and Hepatology Unit
The Canberra Hospital;
Professor of Hepatic Medicine
Australian National University
Garran, ACT, Australia

Jean H.D. Fasel MD
Professor and Head of Clinical Anatomy Research Group, Geneva
Centre Médical Universitaire
Geneva, Switzerland

Andrew P. Feranchak MD
Assistant Professor of Pediatrics
University of Texas Southwestern Medical School
Dallas, TX, USA

Javier Fernández MD
Intensive Care Unit, Hepatology
Hospital Clinic
Barcelona, Spain

José C. Fernández-Checa PhD
Professor, Spanish Research Council
Liver Unit, Hospital Clinic
Barcelona, Spain

Peter Fickert MD
Laboratory of Experimental and Molecular Hepatology
Medical University of Graz
Graz, Austria

Stefano Fiorucci MD
Associate Professor of Gastroenterology
Universita Degli Studi di Perugia
Perugia, Italy

Constantino Fondevila MD PhD
Transplant Surgeon
Liver Unit, Hospital Clinic;
Digestive Disease Institute, University of Barcelona
Barcelona, Spain

Alejandro Forner MD
Research Fellow
University of Barcelona
Barcelona, Spain

Xavier Forns MD PhD
Senior Specialist
Liver Unit, Hospital Clinic
Barcelona, Spain

Ira J. Fox MD
Charles W. McLaughlin Professor of Surgery
University of Nebraska Medical Center
Omaha, NB, USA

Nader K. Francis MB ChB FRCS PhD
Consultant Surgeon
Yeovil District Hospital
Somerset, UK

Scott L. Friedman MD
Fishberg Professor of Medicine
Chief, Division of Liver Diseases
Mount Sinai School of Medicine
New York, NY, USA

Josep Fuster Obregón MD
Profesor Titular de Cirugía
Universidad de Barcelona;
Jefe de Sección de Cirugia Hépatica y Trasplante
Hospital Clinic
Barcelona, Spain

Michelle C. Gallagher BSc MB BS MRCP
Consultant Gastroenterologist
The Royal Surrey County Hospital
Guildford, UK

Peter R. Galle MD PhD
Professor of Medicine
Johannes Gutenberg University;
Chief Medical Officer
University Hospital of Mainz
Mainz, Germany

Juan Carlos García-Pagán MD
Consultant in Hepatology
Liver Unit, Hospital Clinic
Barcelona, Spain

Carmen García-Ruiz MD
Del Consejo Superior de Investgaciones Cientificas
Instituto de Investigación Biomedica de Barcelona
Barcelona, Spain

Javier García-Samaniego MD
Department of Infectious Diseases
Hospital Carlos III
Madrid, Spain

Guadalupe García-Tsao MD
Professor of Medicine
Yale University School of Medicine
New Haven, CT, USA

Juan Carlos García-Valdecasas MD
Jefe de Cirugía
Hospital Clinic;
Catedratic de Cirugía
Universidad de Barcelona
Barcelona, Spain

Wolfram H. Gerlich PhD
Professor of Medical Virology
Justus-Liebig University
Giessen, Germany

André P. Geubel MD
Professor, Department of Gastroenterology
Universitaires Saint-Luc
Université Catholique de Louvain
Brussels, Belgium

Dominique P. Germain MD PhD
Professor of Medical Genetics
Centre de Référence de la Maladie de Fabry et des Maladies Héréditaires du Tissu Conjonctif;
Assistance Publique – Hôpitaux de Paris
Paris, France

Mihai Gheorghiade MD
Professor of Medicine and Associate Chief of Cardiology
Northwestern University Feinberg School of Medicine
Chicago, IL, USA

Pere Ginès MD
Professor of Medicine, University of Barcelona;
Chief, Liver Unit, Hospital Clinic
Barcelona, Spain

Daniel Glass MB ChB MRCP
Specialist Registrar in Dermatology
West Hertfordshire Hospitals Trust
Hemel Hempstead, UK

Christian Gluud MD DrMedSci
Head of Copenhagen Trial Unit
Centre for Clinical Intervention Research
Copenhagen University Hospital
Copenhagen, Denmark

Mark D. Gorrell MD PhD
Principal Research Fellow, Faculty of Medicine
University of Sydney;
Principal Scientist, Royal Prince Alfred Hospital
Sydney, NSW, Australia

Roberto J. Groszmann MD
Yale University School of Medicine
New Haven, CT, USA

Frank Grünhage MD
Head, Department of Medicine
University of Bonn
Bonn, Germany

Mónica Guevara MD
Associate Invesitgator
IDIBAPS, Hospital Clinic
Barcelona, Spain

I. Neil Guha MB BS MRCP
Specialist Registrar in Hepatology
Southampton General Hospital
Southampton, UK

Basuki Gunawan MD
Fellow, Gastrointestinal and Liver Division
Keck School of Medicine
University of Southern California
Los Angeles, CA, USA

N. Guañabens MD
Department of Rheumatology, Hospital Clinic
Barcelona, Spain

Dominique Guyader MD PhD
Professor of Hepatology
University of Rennes
Rennes, France

Paul S. Haber MD
Centenary Institute of Cancer Medicine and Cell Biology
Royal Prince Alfred Hospital and The University of Sydney
Sydney, NSW, Australia

Antoine Hadengue MD
Professeur de Médecine et Chef de Service
Service de Gastroentérologie et Hépatologie
Hôpitaux Universitaires de Genève
Geneva, Switzerland

Edward D. Harris PhD
Professor, Department of Nutrition and Food Science
Texas A&M University
College Station, TX, USA

Dieter Häussinger MD
Professor of Internal Medicine
Heinrich Heine University
Dusseldorf, Germany

Philip N. Hawkins MB PhD FRCP FRCPath FMedSci
Professor of Medicine
University College London;
Consultant, National Amyloidosis Centre
Royal Free Hospital
London, UK

William G. Hawkins MD
Assistant Professor
Washington University in St. Louis
Section of Hepatopancreatobiliary Surgery
Barnes-Jewish Hospital
St. Louis, MO, USA

Roderick J. Hay
Head of School, Medicine and Dentistry
Queen's University Belfast
Belfast, UK

Peter C. Hayes BMSc MB ChB MD PhD
Professor of Hepatology
University of Edinburgh;
Consultant, Liver Unit
Royal Infirmary of Edinburgh
Edinburgh, UK

John Cijiang He MD
Department of Pharmacology and Biological Chemistry
Mount Sinai School of Medicine
New York, NY, USA

E. Jenny Heathcote MB BS MD FRCP FRCPC
Professor of Medicine
University of Toronto
Toronto, ON, Canada

J. Michael Henderson MD
Department of General Surgery
The Cleveland Clinic Foundation
Cleveland, OH, USA

Jens H. Henriksen MD
Professor of Clinical Physiology
University of Copenhagen and Hvidovre Hospital
Hvidovre, Denmark

Manuel Hernández-Guerra MD
Liver Unit, Hospital Clinic
Barcelona, Spain

Humphrey J.F. Hodgson FMedSci
Sheila Sherlock Chair of Medicine
Director, The UCL Institute of Hepatology, Hampstead Campus
Vice Dean and Campus Director
Royal Free and University College School of Medicine
London, UK

Chantal Housset MD PhD
Professor of Cell Biology
Université Pierre et Marie Curie Paris 6;
Director, Inserm U680, Hôpital Tenon;
Service de Biochimie–Hormonologie, Hôpital Saint-Antoine
Paris, France

Hongjin Huang PhD
Associate Director, Liver Diseases, Celera
Alameda, CA, USA

Harriet Hughes MD
Hospital for Tropical Diseases
London, UK

Alvin B. Imaeda MD PhD
Yale University School of Medicine
New Haven, CT, USA

John P. Iredale BM DM FRCP FMedSci
Professor of Medicine
University of Edinburgh
Edinburgh, UK

Yoshiya Ito MD PhD
Research Associate
University of Arizona College of Medicine
Tucson, AZ, USA

Ravi Iyengar MD
Department of Pharmacology and Biological Chemistry
Mount Sinai School of Medicine
New York, NY, USA

Elmar Jaeckel MD
Department of Gastroenterology, Hepatology and Endocrinology
Hanover Medical School
Hanover, Germany

Hartmut Jaeschke MD
Department of Pharmacology
University of Arizona
Tucson, AZ, USA

Rajiv Jalan MB BS MD FRCP PhD
Senior Lecturer and Honorary Consultant in Hepatology
The UCL Institute of Hepatology
London, UK

Oliver F.W. James BM FRCP
Professor, Centre for Liver Research
University of Newcastle upon Tyne
Newcastle upon Tyne, UK

Peter L.M. Jansen MD
Professor of Medicine
Academic Medical Center
Amsterdam, The Netherlands

Regine Kahl MD
Professor and Head of Institute of Toxicology
University of Dusseldorf
Dusseldorf, Germany

Sanjeeva P. Kalva MD DNB
Assistant Radiologist
Massachusetts General Hospital;
Clinical Instructor
Harvard Medical School
Boston, MA, USA

Igal Kam MD
Chief of Transplant Surgery
University of Colorado Health Sciences Centre
Denver, CO, USA

Keishi Kanno MD PhD
Research Fellow, Division of Gastroenterology
Brigham and Women's Hospital and Harvard Medical School
Boston, MA, USA

Neil Kaplowitz MD
Professor of Medicine
Keck School of Medicine
University of Southern California
Los Angeles, CA, USA

Saul J. Karpen MD PhD
Associate Professor of Pediatrics
Director, Texas Children's Liver Center
Baylor College of Medicine,
Houston, TX, USA

Mark T. Keegan MB BCh BAO BA MRCPI
Associate Professor of Anesthesia
Consultant in Anesthesia and Critical Care
Mayo Clinic College of Medicine
Rochester, MN, USA

Susanne Keiding MD DSc
Professor, Department of Medicine V
Aarhus University Hospital
Aarhus, Denmark

David Kershenobich MD PhD
Department of Experimental Medicine
National Autonomous University of Mexico
Mexico City, Mexico

Zahida Khan PhD
Department of Pathology
University of Pittsburgh School of Medicine
Pittsburgh, PA, USA

W. Ray Kim MD
Associate Professor of Medicine
Mayo Clinic College of Medicine
Rochester, MN, USA

Raymond S. Koff MD
Clinical Professor of Medicine
University of Connecticut School of Medicine
Farmington, CT, USA

Soichi Kojima PhD
Molecular Cellular Pathology Research Unit
RIKEN
Wako, Japan

Masamichi Kojiro MD
Department of Pathology
Kurume University School of Medicine
Kurume, Japan

Sean W.P. Koppe MD
Fellow in Gastroenterology and Hepatology
Northwestern University Feinberg School of Medicine
Chicago, IL, USA

Krzysztof Krawczynski MD PhD
Distinguished Consultant, Division of Viral Hepatitis
Centers for Disease Control and Prevention
Atlanta, GA, USA

Michael J. Krowka MD
Professor of Medicine
Mayo Clinic College of Medicine
Rochester, MN, USA

Yolanta T. Kruszynska MD
Associate Professor of Medicine
University of California at San Diego
La Jolla, CA, USA

Thomas G. Ksiazek DVM PhD
Branch Chief, Special Pathogens Branch
Centers for Disease Control and Prevention
Atlanta, GA, USA

Laura M. Kulik MD
Transplant Hepatologist
Northwestern Memorial Hospital
Chicago, IL, USA

Philippe Labrune MD PhD
Professor and Head of Department of Paediatric and Medical Genetics
Hôpital Antoine Béclère
Clamart, France

Antonio Lacy MD
Jefe de Sección, Cirugía Gastrointestinal
Institut Clínic de Malaties Digestives i Metaboliques
Hospital Clinic
Barcelona, Spain

Glen A. Laine MD PhD
Wiseman-Lewie-Worth Chair in Cardiology
Director, Michael E. DeBakey Institute
Texas A&M University
College Station, TX, USA

Frank Lammert MD
Professor of Medicine
University of Bonn;
Department of Internal Medicine I
University Hospital Bonn
Bonn, Germany

Dominique Larrey MD PhD
Professor of Hepatology
Montpellier School of Medicine;
Head, Department of Hepatogastroenterology and Transplantation
CHU Saint-Eloi
Montpellier, France

Nicholas F. LaRusso MD
Chair, Department of Internal Medicine
Professor of Medicine and Biochemistry/Molecular Biology
Mayo Clinic College of Medicine
Rochester, MN, USA

Bernhard H. Lauterburg MD
Department of Clinical Pharmacology
University of Bern
Bern, Switzerland

Daniel Lavanchy MD MHEM
Department of Epidemic and Pandemic Alert and Response
World Health Organization
Geneva, Switzerland

Konstantinos N. Lazaridis MD
Assistant Professor of Medicine
Mayo Clinic College of Medicine
Rochester, MN, USA

Brigitte Le Bail MD
Professor of Pathology
Université Bordeaux
Bordeaux, France

Gioacchino Leandro MD
Consultant Gastroenterologist
IRCCS De Bellis
Castellana Grotte, Italy

Didier Lebrec MD
Service d'Hépatologie
Hôpital Beaujon
Clichy, France

Frédéric P. Lemaigre MD PhD
Professor, Christian de Duve Institute of Cellular Pathology
Université Catholique de Louvain
Brussels, Belgium

Riccardo Lencioni MD
Associate Professor of Radiology
University of Pisa
Pisa, Italy

Chris Liddle BSc (Med) MB BS PhD FRACP
Associate Dean, Information Technology
Professor of Clinical Pharmacology and Hepatology
University of Sydney
Sydney, NSW, Australia

Vishwanath R. Lingappa MD
California Pacific Medical Center
San Francisco, CA, USA

Josep María Llovet MD
Professor of Research – ICREA
Liver Unit, Hospital Clinic
Barcelona, Spain

Yang Lu MD
Department of Medicine
Albert Einstein College of Medicine
Bronx, NY, USA

Tom Luedde MD PhD
Institute of Genetics
University of Cologne
Cologne, Germany

Geoffrey W. McCaughan MB BS PhD FRACP
A.W. Morrow Professor of Medicine (Gastroenterology and Hepatology)
The University of Sydney and Royal Prince Alfred Hospital Centenary Research Institute
Sydney, NSW, Australia

P. Aiden McCormick MD
Newman Clinical Research Professor
University College Dublin;
Consultant Hepatologist, Liver Unit
St Vincent's Hospital
Dublin, Ireland

Robert S. McCuskey PhD
Professor of Cell Biology, Pediatrics and Physiology
University of Arizona
Tucson, AZ, USA

Pietro E. Majno MD FRCS
Transplantation Unit
Hôpitaux Universitaires de Genève
Geneva, Switzerland

Nisar P. Malek MD
Consultant in Internal Medicine and Gastroenterology
Hanover Medical School
Hanover, Germany

Susan V. Mallett MB BS FRCA
Consultant Anaesthetist
The Royal Free Hospital
London, UK

Michael P. Manns MD
Department of Gastroenterology
Hanover Medical School
Hanover, Germany

G.A. Mantion MD
Department of Hepatology and Liver Diseases
Hôpital Jean-Minjoz
Besançon, France

Luz Martín-Carbonero MD
Department of Infectious Diseases
Hospital Carlos III
Madrid, Spain

Carmen Martínez MD
Hematology Department
Hospital Clinic
Barcelona, Spain

Rie Matsushima-Nishiwaki MD
First Department of Internal Medicine
Gifu University School of Medicine
Gifu, Japan

Wajahat Z. Mehal MD DPhil
Yale University School of Medicine
New Haven, CT, USA

Fernando E. Membreno MD MSc
Director of Hepatology and Liver Transplantation
Methodist Specialty and Transplant Hospital
San Antonio, TX, USA

Giorgina Mieli-Vergani MD PhD FRCP FRCPCH
Alex Mowat Professor of Paediatric Hepatology
King's College London School of Medicine
London, UK

J.P. Miguet MD
Department of Hepatology and Liver Diseases
Hôpital Jean-Minjoz
Besançon, France

Piotr Milkiewicz MD PhD MRCP
Associate Professor and Reader in Hepatology
Pomeranian Medical School
Szczecin, Poland

Elisabeth Irene Minder ProfDrMed
Chefärztin, Zentrallabor
Stadtspital Triemli
Zurich, Switzerland

Rosa Miquel MD
Servicio de Anatomia Patologica
Hospital Clinic
Barcelona, Spain

Søren Møller MD DMSc
Chief Physician and Associate Professor
Department Clinical Physiology
Hvidovre Hospital
Hvidovre, Denmark

Richard Moreau MD
Service d'Hépatologie
Hôpital Beaujon
Clichy, France

Michael H. Nathanson MD PhD
Professor of Medicine and Cell Biology
Chief, Section of Digestive Diseases
Yale University School of Medicine
New Haven, CT, USA

Miguel Navasa MD
Liver Unit, Hospital Clinic
Barcelona, Spain

James Neuberger DM FRCP
Consultant Physician
Queen Elizabeth Hospital
Birmingham, UK

Peter Neuhaus MD
Professor of Surgery
Charite Campus Virchow Clinic
Berlin, Germany

Brent A. Neuschwander-Tetri MD FACP
Professor of Internal Medicine
Saint Louis University School of Medicine
St. Louis, MO, USA

Susana Neves MD
Department of Pharmacology and Biological Chemistry
Mount Sinai School of Medicine
New York, NY, USA

Patrick G. Northup MD MHES
Assistant Professor, Gastroenterology and Hepatology
University of Virginia
Charlottesville, VA, USA

Phyllis M. Novikoff PhD
Associate Professor
Albert Einstein College of Medicine
Bronx, NY, USA

Marina Nuñez MD
Department of Infectious Diseases
Hospital Carlos III
Madrid, Spain

Satoshi Ogata MD
Hôpital Beaujon
Clichy, France

Masataka Okuno MD
First Department of Internal Medicine
Gifu University School of Medicine
Gifu, Japan

J. Donald Ostrow MD
Affiliated Professor of Medicine
Gastrointestinal and Hepatology Division
University of Washington School of Medicine
Seattle, WA, USA

Ronald P.J. Oude Elferink
Professor of Experimental Hepatology
AMC Liver Center
Amsterdam, The Netherlands

Mario Pagano MD
Department of Pharmacology and Biological Chemistry
Mount Sinai School of Medicine
New York, NY, USA

Georges-Philippe Pageaux MD PhD
Professor of Hepatology
CHU Saint-Eloi
Montpellier, France

Valérie Paradis MD PhD
Professor of Pathology, Université Denis Diderot Paris 7;
Assistance Publique – Hôpitaux de Paris and Inserm U773;
Department of Pathology, Hôpital Beaujon
Clichy, France

Stephen M. Pastores MD
Associate Attending Physician
Memorial Sloan-Kettering Cancer Center
New York, NY, USA

Heinz-Otto Peitgen PhD
Professor and President of MeVis Research
MeVis Research GmbH
Bremen, Germany

Pascal Perney MD
Professor of Internal Medicine
CHU Saint-Eloi
Montpellier, France

Jean-Marie Péron MD PhD
Professor of Hepatogastroenterology
Service d'Hépatogastroenterologie
Toulouse, France

Dominique Pessayre MD
Director of Research
Université Paris 7
Paris, France

Antonello Pietrangelo MD PhD
Professor of Medicine
Center for Hemochromatosis
University of Modena and Reggio Emilia
Modena, Italy

Massimo Pinzani MD PhD
Professor of Medicine
Dipartmento di Medicina Interna
Università delgi Studi di Firenze
Florence, Italy

Fabio Piscaglia MD
Department of Internal Medicine and Gastroenterology
University of Bologna
Bologna, Italy

David J. Plevak MD
Professor of Anesthesiology
Mayo Clinic College of Medicine
Rochester, MN, USA

K. Raj Prasad MS MCh FRCS
Consultant Surgeon
St James's University Hospital
Leeds, UK

Gerhard P. Püschel MD
Full Professor and Head, Department of Biochemistry of Nutrition
Institute of Nutrition Science
University of Potsdam
Potsdam, Germany

Hervé Puy MD PhD
Professor of Biochemistry and Molecular Biology
Vice President of the French Porphyria Center
Hôpital Louis Mourier
Colombes, France

Alberto Queiroz Farias MD PhD
Department of Gastroenterology
University of São Paulo School of Medicine
São Paulo, Brazil

Montse Renom MD
Centro de Salud Internacional
Hospital Clinic
Barcelona, Spain

Kalpana Reddy MB BS FRCA
Specialist Registrar in Anaesthesia and Intensive Care Medicine
Royal London Hospital
London, UK

Helen L. Reeves BM BS BMedSci MRCP FRCP(Ed) PhD
Senior Lecturer and Honorary Consultant Gastroenterologist
University of Newcastle upon Tyne
Newcastle upon Tyne, UK

Jürg Reichen MD
Professor of Medicine
University of Bern;
Chief of Hepatology
University Hospital
Bern, Switzerland

Igino Rigato MD
Liver Research Center
University of Trieste
Trieste, Italy

Antoni Rimola MD PhD
Senior Consultant
Liver Unit, Hospital Clinic
Barcelona, Spain

Mario Rizzetto MD
Professor of Gastroenterology
University of Turin
Turin, Italy

Guillermo Robles-Diaz MD
Department of Experimental Medicine
National Autonomous University of Mexico
Mexico City, Mexico

Juan Rodés MD
Director General
Hospital Clinic;
Professor of Medicine
University of Barcelona
Barcelona, Spain

Pierre E. Rollin MD
Team Leader, Disease Assessment Section
Centers for Disease Control and Prevention
Atlanta, GA, USA

Tania Roskams MD
Professor of Pathology
University of Leuven
Leuven, Belgium

Jayanta Roy-Chowdhury MD MRCP
Professor, Departments of Medicine and Molecular Genetics
Albert Einstein College of Medicine
Bronx, NY, USA

Namita Roy-Chowdhury MD PhD
Professor, Departments of Medicine and Molecular Genetics
Albert Einstein College of Medicine
Bronx, NY, USA

Antoni Rimola MD PhD
Senior Consultant
Liver Unit, Hospital Clinic
Barcelona, Spain

K. Lenhard Rudolph MD
Heisenberg Professor for Regenerative Medicine and Ageing
Hanover Medical School
Hanover, Germany

Luis Ruiz-del-Arbol MD
Associate Professor
Universidad de Alcala and Hospital Ramón y Cajal
Madrid, Spain

Malcolm Rustin BSc MD FRCP
Consultant Dermatologist
The Royal Free Hospital
London, UK

Pierre Rustin PhD
CNRS Research Director
Hôpital Robert Debré
Paris, France

Dushyant V. Sahani MD
Department of Radiology
Massachusetts General Hospital
Boston, MA, USA

Faouzi Saliba MD
Associate Professor
Hôpital Paul Brousse
Villejuif, France

Didier Samuel MD PhD
Professor
Hôpital Paul Brousse
Villejuif, France

Marianne Samyn MD FRCPCH
Consultant Paediatric Hepatologist
King's College London School of Medicine
London, UK

José M. Sánchez-Tapias MD PhD
Senior Consultant
Liver Unit, Hospital Clinic
Barcelona, Spain

Giorgio Saracco MD
Associate Professor of Gastroenterology
University of Turin
Turin, Italy

Tilman Sauerbruch MD
Professor of Medicine
University of Bonn;
Head, Department of Medicine
University Hospital Bonn
Bonn, Germany

Erez F. Scapa MD
Research Fellow, Division of Gastroenterology
Harvard Medical School
Boston, MA, USA

Stephan Schaefer PD DrMed
Provisional Head, Institut für Medizinische Mikrobiologie, Virologie und Hygiene
Universität Rostock
Rostock, Germany

Michael Schilsky MD
Associate Professor of Clinical Medicine
Weill Medical College of Cornell University;
Medical Director, Center for Liver Disease and Transplantation
Weill Cornell Medical Center
New York, NY, USA

Xiaoye Schneider-Yin PhD
Biochemikerin, Zentrallabor
Stadtspital Triemli
Zurich, Switzerland

Henning Schulze-Bergkamen MD
1st Medical Department
University of Mainz
Mainz, Germany

Marcus Schuchmann MD
1st Medical Department
University of Mainz
Mainz, Germany

Detlef Schuppan MD PhD
Professor of Medicine
Harvard Medical School;
Consultant Hepatologist
Beth Israel Deaconess Medical Center
Boston, MA, USA

Nazia Selzner MD PhD
Transplant Hepatology Fellow
Multiorgan Transplant Program
Toronto General Hospital
Toronto, ON, Canada

David Semela MD
Instructor in Medicine
Mayo Clinic College of Medicine
Rochester, MN, USA

Marco Senzolo MD PhD
Consultant Physician in Gastroenterology
University Hospital of Padua
Padua, Italy

Devanshi Seth BSc MSc PhD
Senior Scientist, Royal Prince Alfred Hospital
Sydney, NSW, Australia

Nicholas A. Shackel MD
Centenary Institute of Cancer Medicine and Cell Biology
Royal Prince Alfred Hospital and The University of Sydney
Sydney, NSW, Australia

Vijay H. Shah MD
Associate Professor of Medicine, Physiology and Cancer Cell Biology
Mayo Clinic College of Medicine
Rochester, MN, USA

Marcelo Simão Ferreira MD
University of São Paulo School of Medicine
São Paulo, Brazil

Antonella Smedile MD
Department of Gastroenterology
Molinette Hospital
Turin, Italy

Michael Sørensen MD
Department of Medicine V
Aarhus University Hospital
Aarhus, Denmark

Vincent Soriano MD PhD
Section Chief, Department of Infectious Diseases
Hospital Carlos III
Madrid, Spain

Laurent Spahr MD
Médecin Adjoint Agrégé et Chargé de Cours
Service de Gastroentérologie et Hépatologie
Hôpitaux Universitaires de Genève
Geneva, Switzerland

Vanessa Stadlbauer MD
Clinical Research Fellow
The UCL Institute of Hepatology
London, UK

Peter Starkel MD PhD
Professor, Department of Gastroenterology
Universitaires Saint-Luc
Université Catholique de Louvain
Brussels, Belgium

Catherine A.M. Stedman MB ChB FRACP PhD
Consultant Gastroenterologist and Clinical Pharmacologist
Christchurch Hospital
Christchurch, New Zealand

Stephen F. Stewart MB ChB PhD
Consultant Hepatologist
Freeman Hospital
Newcastle upon Tyne, UK

Felix Stickel MD
Assistant Professor and Consultant Hepatologist
Institute of Clinical Pharmacology
University of Bern
Bern, Switzerland

Bruno Stieger PhD
Department of Medicine
University Hospital
Zurich, Switzerland

Donna B. Stolz PhD
Assistant Director, Center for Biologic Imaging
University of Pittsburgh
Pittsburgh, MA, USA

Christoforos Stoupis MD
Radiologist, Kreisspital
Maennedorf, Switzerland

Steven M. Strasberg MD FRCSC FACS FRCS(Ed)
Pruett Professor of Surgery
Washington University in St. Louis;
Head of Hepatopancreatobiliary Surgery
Barnes-Jewish Hospital
St. Louis, MO, USA

Edna Strauss MD PhD
Professor, School of Medicine
University of São Paulo School of Medicine
São Paulo, Brazil

Vinay Sundaram MD
Senior Resident, Department of Internal Medicine
University of Virginia
Charlottesville, VA, USA

Jacob I. Sznajder MD PhD
Professor of Medicine
Chief, Division of Pulmonary and Critical Medicine
Northwestern University Feinberg School of Medicine
Chicago, IL, USA

Jeffrey H. Teckman MD
Associate Professor of Pediatrics and Biochemistry
Saint Louis University School of Medicine
St. Louis, MO, USA

Carlos Terra MD
Department of Medicine, Hospital Clinic
Barcelona, Spain

Sundararajah Thevananther PhD
Assistant Professor
Texas Children's Liver Center
Baylor College of Medicine
Houston, TX, USA

Claudio Tiribelli MD PhD
Professor of Medicine
Director, Liver Research Center
University of Trieste
Trieste, Italy

Susan Tiukinhoy-Laing MD
Division of Cardiology
Northwestern University Feinberg School of Medicine
Chicago, IL, USA

Giles J. Toogood MD
Consultant in Hepatobiliary Transplantation
St. James's University Hospital
Leeds, UK

James Toouli MB BS FRACS PhD
Professor of Surgery
Flinders University
Adelaide, SA, Australia

Michael Trauner MD
Professor of Medicine
Medical University Graz
Graz, Austria

Christian Trautwein MD
Professor, Medizinische Klinik III
University Hospital
Aachen, Germany

James Trotter MD
Associate Professor, Division of Gastroenterology and Hepatology
University of Colorado Health Sciences Center
Denver, CO, USA

Juan Turnes MD
Research Associate
Liver Unit, Hospital Clinic
Barcelona, Spain

Dominique-Charles Valla MD
Professor of Hepatology, Université Denis Diderot Paris 7;
Assistance Publique – Hôpitaux de Paris and Inserm U773;
Chief, Service d'Hépatologie, Hôpital Beaujon
Clichy, France

Pierre Van Damme MD PhD
Professor, Faculty of Medicine
University of Antwerp;
Director, WHO Collaborating Centre for the Control and Prevention of Viral Hepatitis
Antwerp, Belgium

Koen Van Herck MD
Research Assistant, Department of Epidemiology and Social Medicine
University of Antwerp
Wilrijk, Belgium

María Varela MD
Research Fellow
Liver Unit, Hospital Clinic
Barcelona, Spain

Jean-Nicolas Vauthey MD FACS
Professor of Surgery and Chief of Liver Service
University of Texas M.D. Anderson Cancer Center
Houston, TX, USA

Diego Vergani MD PhD FRCP FRCPath
Professor and Director of the Alex Mowat Immunopathology Laboratory
King's College London School of Medicine
London, UK

Valérie Vilgrain MD
Professor of Radiology, Université Denis Diderot Paris 7;
Assistance Publique – Hôpitaux de Paris;
Chief, Department of Radiology, Hôpital Beaujon
Clichy, France

Jean-Pierre Vinel MD
Professor of Hepatogastroenterology
Service d'Hépatogastroenterologie
Toulouse, France

D.A. Vuitton MD PhD
Emeritus Professor of Clinical Immunology
Université de Franch-Comté
Besançon, France

Martin Wagner MD
Fellow, Medical University Graz
Graz, Austria

Wim Wätjen PhD
Institute of Toxicology
University of Dusseldorf
Dusseldorf, Germany

Heiner Wedemeyer MD
Department of Gastroenterology
Hanover Medical School
Hanover, Germany

Richard A. Weisiger MD PhD
Professor of Medicine
University of California
San Francisco, CA, USA

Rebecca G. Wells MD
Assistant Professor of Medicine and of Pathology and Laboratory Medicine
The University of Pennsylvania School of Medicine
Philadelphia, PA, USA

Alan J. Wigg MB BS FRACP PhD
Consultant Gastroenterology and Hepatologist
Flinders Medical Centre
Adelaide, SA, Australia

Rohan B.H. Williams PhD
School of Biotechnology and Biomolecular Sciences
University of New South Wales
Sydney, NSW, Australia

R.M. Winter MD
Professor of Dysmorphlogy and Clinical Genetics
Institute of Child Health
London, UK

Allan W. Wolkoff MD
Professor, Department of Medicine
Albert Einstein College of Medicine
Bronx, NY, USA

John B. Wong MD
Chief, Division of Clinical Decision Making
Tufts-New England Medical Center;
Professor of Medicine
Tufts University School of Medicine
Boston, MA, USA

Govardhana Rao Yannam MD MRCS
Postdoctoral Research Associate
University of Nebraska Medical Center
Omaha, NE, USA

Elie Serge Zafrani MD
Professor of Pathology
Hôpital Henri Mondor
Creteil, France

Arthur Zimmermann MD
Professor of Pathology
University of Bern
Bern, Switzerland

Fabien Zoulim MD PhD
Professor of Medicine, Université Lyon 1;
Liver Department, Hospices Civils de Lyon;
Head, Inserm U8712
Lyon, France

Foreword

Juan Rodés and I conceived the idea of this book at his summer house in Montferri in the late 1980s, envisaging it as a predominantly European text. We had both been active in the organization of the European Association for the Study of the Liver (EASL) so, not surprisingly, we chose as fellow editors our friends Jean-Pierre Benhamou (France), Johannes Bircher (Switzerland) and Mario Rizzetto (Italy), all past secretaries of EASL. The five of us met several times in different cities to plan the book.

In the preface to the first edition, which appeared in 1991, we noted our wish to produce a comprehensive account of clinical hepatology, covering not only common liver problems but also the rare conditions seen from time to time by gastroenterologists, and general physicians and surgeons, as well as by hepatologists. We felt it important to cover the effects of liver disease on other parts of the body, and to describe how diseases of other systems affected the liver, interactions which often cause confusing clinical pictures. We added some appendices: one listed non-drug chemicals and toxins causing liver damage, another gave the geographical distribution of infectious diseases, and a third listed some rare diseases in which the liver may be involved, particularly in children. These appendices have been retained.

As we noted in the preface to the second edition, the first enjoyed considerable success and achieved much critical acclaim. I certainly found it useful in my own practice. In the second edition the focus on clinical medicine was strengthened, as it has been in this edition, and the emphasis in the basic science sections was placed on new concepts and techniques. As a result of these changes some material has had to be left out so, as is the case with some other reference books, the hungry reader of this edition may well find pearls by returning to some of the chapters in the second edition.

The present edition, which I am delighted to see is accompanied by a CD, has retained the general format of the two earlier editions, but several topics have been greatly expanded. Clinicians will welcome the increased number of subsections on liver transplantation, imaging and the complex area of congenital and acquired non-infectious conditions which cause fibrosis or cystic change in the liver or biliary tract. In the basic science sections there are more contributions dealing with molecular and cell biology, genetic aspects of liver disease and immunology. One interesting innovation is the introduction of a section on mathematics in hepatology, which I suspect will lead to some interesting developments in future editions.

The number of individual contributions has risen from 146 in the first edition to 209 in this one; the number in the basic science sections has doubled – from 25 to 51. The first edition involved 193 authors; 333 have contributed to this one. Based on past experience, the editors' problems in getting manuscripts in on time must have been formidable. Although the book still has a distinctly European flavour there are contributions from many other countries. The proportion coming from the USA has risen from 9% in the first edition to 24% in this one; the American influence is particularly evident in the coverage of molecular and cell biology.

Johannes Bircher and I stepped down as editors for this edition. That our former editorial colleagues enrolled seven others to join them, two of them based in the USA, reflects the increasing complexity of our knowledge of the liver and its diseases. This book is an attempt to clarify the field for others. I wish Juan, Jean-Pierre and Mario and their new colleagues, and their new publisher, Blackwell Publishing Ltd, every success with this splendid third edition.

Neil McIntyre

Preface to the third edition

This is now the third edition of a textbook the first edition of which was conceived and published back in 1992. In this edition, important changes have been introduced to bring the style of the book more up to date under the guidance of Blackwell Publishing Ltd. Their professionalism, management skills and hard work has helped us to produce this new and exciting edition. The editors, Juan Rodés, Jean-Pierre Benhamou, Andres Blei, Jürg Reichen, Mario Rizzetto, and associate editors, Jean-François Dufour, Scott Friedman, Pere Ginès, Dominique-Charles Valla and Fabien Zoulim, would like to express their deepest gratitude, especially to Alison Brown (Publisher) and Rebecca Huxley (Senior Development Editor).

When this book was first published, there were five editors: Neil McIntyre, Johannes Bircher, Jean-Pierre Benhamou, Mario Rizzetto and Juan Rodés. In this edition, two of the former editors have retired but we are honoured that one has continued his involvement by writing the foreword to the book. Their collaboration on the first two editions deserves our grateful recognition as it set the *Textbook of Hepatology* in process. This third edition has brought about significant changes to the editorial team, which now includes friends and colleagues from the other side of the Atlantic, Andres Blei and Scott Friedman. This has achieved our objective of making the *Textbook* more international.

At the first meeting of the editors and associate editors, it was quickly agreed that the *Textbook* should present the substantial scientific progress that has taken place over the last few years: concepts such as genomics, proteomics, gene arrays, metabolomics, bioinformatics, stem cells, molecular and cell biology, and genetics are now extensively covered throughout the book.

The most significant changes can probably be seen in the sections on functions of the liver, basic concepts of pathobiology, assessment of hepatobiliary disease, portal hypertension and its complications, congenital hepatic fibrosis and non-parasitic cystic diseases of the liver, hepatic non-alcoholic steatosis, tumours of the liver, liver transplantation, and mathematics in hepatology. We have encouraged the use of tables and figures to aid interpretation and understanding. The scientific information is current and exhaustive and is essential for clinical decision making whether diagnostic or therapeutic. We also believe that this book fulfils the requisites necessary for it to be highly useful for translational research.

On this occasion the book has over 200 chapters, contributed by authors from five continents. Our objective of delivering an excellent book has been achieved with the help of everyone who has participated in the book. We fully understand the pressures of time on everyone and for this reason we are very grateful to all of them. Our thanks in particular go to Nicki van Berckel, who also found time to have her second baby, Dylan, and the Senior Development Editor at Blackwell Publishing Ltd, Rebecca Huxley, whose experience has been invaluable. Sincerest thanks to all involved in taking this project to completion.

Juan Rodés
Jean-Pierre Benhamou
Andres T. Blei
Jürg Reichen
Mario Rizzetto
Jean-François Dufour
Scott L. Friedman
Pere Ginès
Dominique-Charles Valla
Fabien Zoulim

Preface to the first edition

We all met several times, in different cities, to plan this book. We wanted to produce a comprehensive account of clinical hepatology, covering not only the common hepatological problems but also the rare conditions which are seen from time to time by hepatologists, gastroenterologists, and general physicians. We thought it important to consider how the liver may be affected in diseases of other systems, and to describe the effects of diseases of the liver on other parts of the body, as these interactions often create a confusing clinical picture; these topics occupy two large sections of the book which should be of particular value to general physicians and specialists in other diseases. We felt a need for a fuller than usual account of the effect of infections on the liver; patients with bacterial, fungal and parasitic infections, and those with viral infections other than the classical viral hepatitides, often have abnormal liver function tests, or symptoms or signs suggesting liver disease.

There are chapters on other topics which have received little attention in other texts, such as symptoms and signs, diagnostic strategy, general management, and prescribing and anaesthesia in liver disease. There are chapters on liver disease in children, in the elderly, and in drug addicts and homosexual men, and one on the history of liver disease.

We also thought it would be helpful to have some appendices: listing non-drug chemicals and toxins causing liver damage, the geographical distribution of infectious diseases, and the rare diseases in which the liver may be involved (particularly in children). Another appendix contains the excellent handouts produced for patients by the American Liver Foundation.

Colleagues often remark that it is irritating, when reading chapters with many references, to have to search at the end of the chapter to find the original sources. We therefore decided to use mainly short 'text references' to enable readers to decide quickly if they are already familiar with the source and, if not, to allow them to jot the reference down with the minimum of effort. We consider this experiment to have been worthwhile, but we hope that readers will tell us if they prefer the conventional approach.

More than 200 authors have contributed to this book; nearly all are acknowledged internationally as experts in their field(s) of interest. We are grateful to all of them. We believe that their expertise is reflected in their contributions, many of which we consider to be quite outstanding.

Our major purpose was to provide a book for practising clinicians. We hope this text will prove useful not only to hepatologists, gastroenterologists, and general physicians, but also to specialists in other fields. It was for this reason that we chose the title 'clinical hepatology'. We believe that this book will provide solutions to many of the hepatological problems which arise in clinical practice, but only our readers can tell whether our belief is justified. If, when using this book, you fail to find the information you are seeking, we would be grateful if you could draw these omissions to our attention (using the cards enclosed), so that they can be corrected in the next edition.

Our book is being brought out in English, French, and Spanish. We would like to thank the staff of the Oxford University Press, Flammarion, and Salvat, not only for their willingness to publish it but for their help and enthusiasm during the long gestation period. We are particularly grateful to the executive editor for the book, Irene Butcher, who dealt initially with all the manuscripts, and later with the galleys and page proofs of this English edition.

Neil McIntyre
Jean-Pierre Benhamou
Johannes Bircher
Mario Rizetto
Juan Rodés

1 Architecture of the liver

1.1 Macroscopic anatomy of the liver

Jean H.D. Fasel, Holger Bourquain, Heinz-Otto Peitgen and Pietro E. Majno

External anatomy

Naturally enough, the human liver was first described according to its external appearance. Under this heading, four traditional anatomical lobes can regularly be distinguished that are demarcated by peritoneal folds, hepatic fissures, extrahepatic blood vessels and extrahepatic bile ducts (Fig. 1).

In an anterior view, the liver appears to be unequally divided into a large right and a small left anatomical lobe by the attachment of the falciform ligament, which reaches the liver by extending obliquely to the right from the midline of the anterior body wall and the caudal surface of the anterior portion of the diaphragm. Lying in the free edge of the falciform ligament, from the umbilicus to the notch between the two lobes, is the round ligament (ligamentum teres hepatis), the remains of the left umbilical vein. The round ligament, normally avascular, is accompanied by paraumbilical veins, which connect the portal vein to veins of the anterior abdominal wall and form part of the potential portocaval collateral circulation. On the visceral surface of the liver, the round ligament runs in the fissure for that ligament and joins the lower end of the umbilical part of the left branch of the portal vein. The left lobe regularly ends in a fibrous appendix.

Although the apparent division of the liver on its anterior surface is into the right and left anatomical lobes, the inferoposterior surface shows the liver hilus (also called porta hepatis or transverse fissure) and four longitudinal markings that delimit additional lobes. These landmarks together are customarily considered to form the letter H, and the parts of the liver between the uprights of the letter are the quadrate and caudate (spigelian) lobe. The fossa of the gallbladder separates the quadrate lobe from the remainder of the right lobe; the left boundary of the quadrate lobe is the fissure that lodges the round ligament (also called the umbilical sulcus). The posterior boundary of the quadrate lobe is the porta hepatis, where the hepatoduodenal ligament attaches to the liver, and through which the portal vein, hepatic arteries and bile ducts enter or leave the liver. The porta hepatis is also the anterior margin of the caudate lobe, which cannot easily be seen in the normally attached liver, as it lies above and behind the lesser omentum, its posteroinferior surface forming the anterior wall of the superior recess of the omental bursa. The caudate lobe is largely separated from the remainder of the right anatomical lobe by the fossa of the vena cava. However, a bridge of liver tissue – the caudate process – connects the caudate and the right lobes between the inferior vena cava and the porta hepatis. The inferior end of the caudate lobe sometimes forms a papillary process. The fissures of the round and venous ligaments are usually continuous with each other and are therefore sometimes referred to as the left sagittal fissure.

The ligamentum venosum is a fibrous cord passing from the left branch of the portal vein to the left hepatic vein just before this enters the inferior vena cava. It represents the remains of a venous shunt, the ductus venosus, established in prenatal life to allow blood returning from the placenta to reach the heart

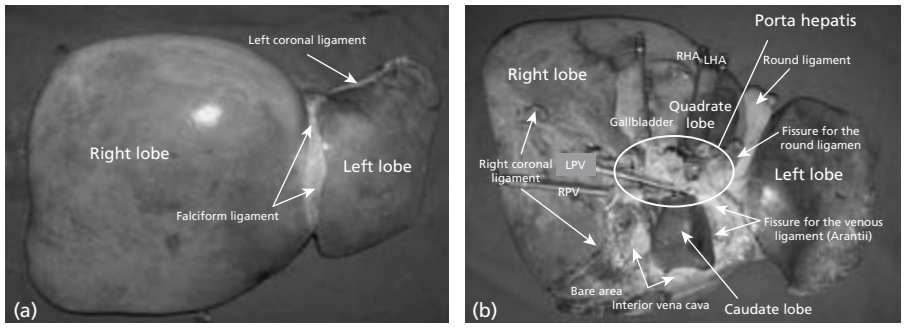

Fig. 1 External aspect of the liver in an anterior (a) and an inferior view (b). Cannulas have been inserted into the right and left branches of the portal vein (RPV, LPV), the right and left branches of the proper hepatic artery (RHA, LHA) and the common bile duct.



Fig. 2 Internal architecture of the same liver as in Fig. 1, seen as a corrosion cast, reproduced in an anterior (a) and an inferior view (b).

without the necessity of passing through the liver. The portal end of the ductus venosus closes within the first 2 days of postnatal life; the hepatic end, however, may remain patent throughout life, and may then receive tributaries from the liver and the hepatogastric ligament, so that it may function as a hepatic vein in the adult [1].

As it passes behind the liver, the inferior vena cava is embedded in a sulcus on the posterior surface of the liver. It is typically attached in the sulcus not only by loose connective tissue and a variable number of smaller hepatic veins that enter it, but also by more dense tissue which forms a transverse band posterior to the vena cava. Sometimes, also, hepatic parenchyma extends posterior to the vena cava, so that the vessel is partly embedded in the liver.

As far as the peritoneal attachments of the liver are concerned, its chief attachment to the diaphragm is by the right and left coronary ligament. These peritoneal bridges consist of an anterior and a posterior layer that bound the bare area (area nuda). In this area, the liver connects to the diaphragm mostly by fibrous attachments and by the hepatic veins. The right and left coronary ligaments extend laterally and form the triangular ligaments. The posterior layer of the right coronary ligament is sometimes called the hepatorenal ligament, because it is in continuity with the posterior parietal peritoneum lying in front of the right kidney. The liver is connected to the stomach and duodenal bulb by the lesser omentum. This extends to the porta hepatis and the fissure for the ligamentum venosum; it is continuous with the posterior coronary ligaments. The portion attaching to the stomach is also called the hepatogastric ligament, and that attaching to the duodenum, the hepatoduodenal ligament. In addition, peritoneal folds can extend from the liver to the right colic flexure.

This basic description of external features of the liver should not be mistaken for a comprehensive presentation. It has particularly to be remembered that the anatomical appearance of the liver, as for every organ, is subject to wide variability.

Internal anatomy

Although the external aspect of the human liver has been known for centuries, comprehensive and systematic investigations regarding the internal architecture of the organ began around 1880. Naturally enough, these studies were undertaken by anatomists [2–4]. Fifty years later, the question was raised again, particularly by surgeons willing to develop hepatic resectional techniques [5–10]. In the past 20 years, we have witnessed a third wave of interest, spurred by the dramatic developments in imaging techniques. These investigations were brought about principally by radiologists and the need for accurate preoperative localization of focal hepatic lesions [11–14].

Summarizing these investigations, the internal architecture of the human liver can be described with reference to several structures, such as the intrahepatic branches of the portal vein, hepatic arteries, bile ducts and hepatic veins (Fig. 2). The branches of the first three entities are densely interwoven within connective tissue sheaths and form the triad credited to Glisson [15]. The dual supply of the liver is taken over by the hepatic artery and the portal vein.

Arterial supply

The most frequently observed pattern of arterial blood supply to the liver consists of a purely coeliac origin, and is by a common hepatic artery. After it has branched off the gastroduodenal artery, it becomes the proper hepatic artery, which further divides into a right and a left hepatic artery. This pattern is considered to occur in between 44% and 88% of cases. The very different frequencies reported in the literature must be considered with caution, particularly because the terminologies and classifications used are of the utmost variability and have led to confusion, as demonstrated by Feigl and colleagues [16].

Variations from the standard pattern above are common. The two most frequent variants are the right hepatic artery originating from the superior mesenteric artery (11–21%) and the left hepatic artery arising from the left gastric artery (10–30%). It has to be remembered that such variant arteries, even when labelled as accessory in the literature, represent the sole supply of a specific territory of the liver [17,18]. Their ligation could produce hepatic ischaemia of the area they supply. Arterial distribution to different hepatic territories is generally assumed to be identical to the distribution of the portal vein [19].

Portal venous supply

In its prevailing pattern, the portal vein is formed from the convergence of the superior mesenteric and splenic veins. It is about 8 cm long and lies anterior to the inferior vena cava and posterior to the neck of the pancreas. It runs obliquely to the right and ascends behind the first part of the duodenum, the common bile duct and the gastroduodenal artery. At this point, it is directly anterior to the inferior vena cava. It enters the right border of the lesser omentum and ascends anterior to the epiploic foramen to reach the right end of the porta hepatis. In the hepatoduodenal ligament, it lies, in general, posterior to both the common bile duct and the hepatic artery. It is surrounded by the hepatic nerve plexus and accompanied by many lymph vessels. It regularly bifurcates into a right and a left portal branch. The right branch is located anterior to the caudate process and enters the right lobe. It gives rise to one to eight branches before dividing, in general, into two major trunks of almost the same diameter [20–22]. The left branch has a longer extrahepatic course and lies more horizontal than the right branch, and is often of smaller calibre. Two portions can regularly be distinguished, the transverse and the umbilical part of the left portal vein. Two to six branches arise from the transverse portion, the transition from the transverse to the umbilical portion regularly gives off one major branch, and the umbilical portion is the origin of 3–26 branches [20–23].

Venous drainage

Many studies have confirmed large variability in hepatic vein anatomy [e.g. 24–26]. In the predominant pattern, most of the hepatic venous effluent drains into the inferior vena cava by means of three major hepatic veins, right, middle and left. These veins have an extrahepatic length of about 1 cm. Within the liver, the main trunks are considered to run between the Glissonian territories (i.e. within the planes that lie between the areas supplied by a given portovenous, arterial and biliary branch) as the intertwining fingers of two hands. They drain adjacent Glissonian territories. In about 70% of individuals, the middle and left hepatic veins join each other to form a common trunk before entering the inferior vena cava. In addition, 10–20 small inferior hepatic veins (not only from the caudate lobe) drain directly into the inferior vena cava at its retrohepatic portion [19,25]. In about 20% of cases, a significant inferior right hepatic vein has been observed. However, these inferior hepatic veins also vary in the extent of their distribution. According to van Leeuwen [27], the area drained by right accessory veins is inversely proportional to the area drained by the conventional right hepatic vein. Sometimes (8% in the study by Masselot and Leborgne [24]), the right hepatic vein is reduced to an accessory vein, with a larger part of the right dorsal area of the liver being drained by right inferior veins and branches of the middle hepatic vein. In the era of increasing surgical demand for anatomical details, Mehran *et al.* [28] emphasized the value of the minor hepatic veins.

Biliary drainage

Hjortsö [5] introduced the concept that the intrahepatic branching of the biliary ducts follows a segmental pattern, in the sense that each region of the liver has its specific type of bile drainage. This view was supported by investigations focusing on the biliary system within the human liver [7,29]. Because it is generally agreed that the intrahepatic bile ducts follow an essentially similar type of branching to the corresponding branches of the portal vein and hepatic artery, the biliary territories are considered to be identical to the portalvenous and arterial territories [30]. In contrast to the portal vein branches, which may communicate, no communications have been observed in biliary branches [31].

Lymphatics

The hepatic lymphatic network – not seen at a macroscopic level – is traditionally subdivided into a superficial and a deep system. The superficial vessels are mainly situated in the liver capsule. The deep ones follow the Glissonian triads or the efferent hepatic veins and are said to drain adjacent Glissonian territories [19,32,33]. Lymphatic vessels may thus leave the liver at the inferior and superior liver hilus (porta hepatis or together with the hepatic veins respectively), or run within the peritoneal attachments of the liver mentioned above [34]. The existence of afferent lymph vessels is controversial [33]. Examples of regional lymph nodes are thus situated at the porta hepatis, at the junction between the hepatic veins and the inferior vena cava or in the anterior mediastinum. Further lymphatic drainage reaches nodes both below and above the diaphragm, the greatest outflow being attributed to the thoracic duct.

Innervation

The liver has a dual innervation. The area nuda and adjacent capsule are supplied by somatoafferent branches of the right phrenic nerve, which also supply the parietal peritoneum of the region. The parenchyma is supplied by vegetative plexus originating from the coeliac plexus and the vagal nerves. They surround the branches of the portal vein, hepatic arteries and biliary ducts or run within the cranial part of the lesser omentum [35]. They are considered to carry sympathetic, parasympathetic and visceroafferent fibres.

Divisions of the liver

The liver has been subdivided on the basis of both its external aspect and its internal architecture. As mentioned, the classical anatomical subdivision is based on external landmarks and discerns four lobes (Fig. 1). This partition has been largely extended, particularly since the 1950s, by surgical classifications based on internal hepatic architecture. Among these, the one most commonly used originates from the work of the French

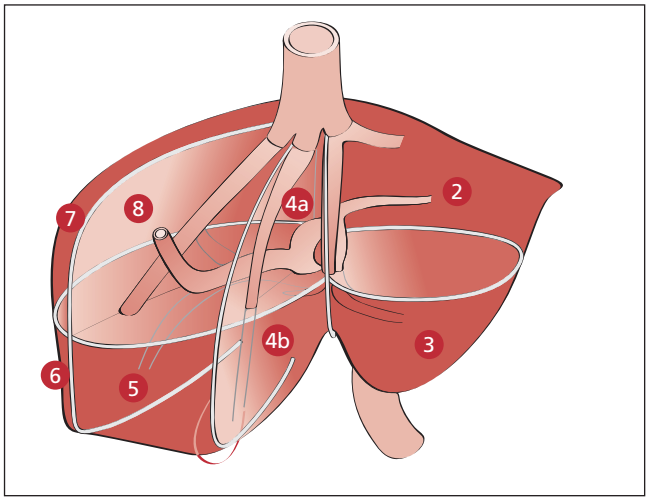

Fig. 3 Schematic subdivision of the liver into eight segments according to Couinaud [9]. From ref. 13, with kind permission of the American Roentgen Ray Society.

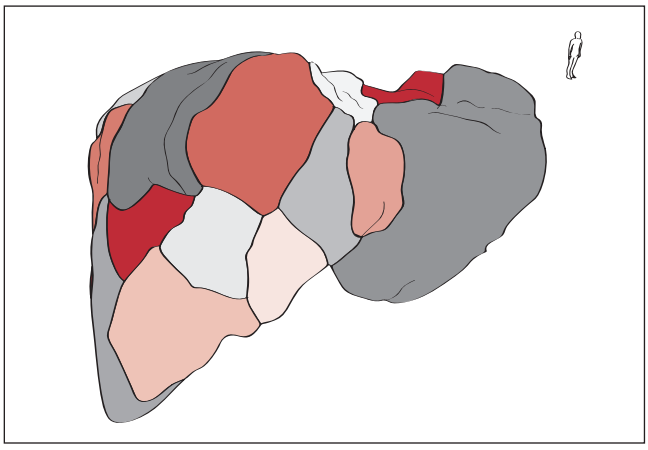

Fig. 4 Anatomical territories at the level of second-order portal venous branches. In the liver under consideration, there are 19 territories, of which 14 are visible in the anterior view illustrated. It becomes apparent that there are many more territories than generally assumed and than suggested by Couinaud's 'eight-segment scheme' [9]. It is this large number of individual vascular territories that has not been considered yet, but which corresponds to anatomical reality. Taking into account this fact explains the seemingly inconsistent observations reported in the literature of different associations of the second-order territories.

surgeon Couinaud [9], which recognized a constant, idealized subdivision of the liver into eight portal segments (Fig. 3). This concept has been adopted worldwide by radiologists and surgeons [36–38]. It has the advantage of offering a scheme that can be easily applied as a very useful referential framework for communication between radiologists, hepatologists and liver surgeons to describe the localization of focal hepatic lesions and the most common types of liver resections. Couinaud's concept can be summarized as follows. The liver is divided into eight territories by means of three vertical and one transverse scissures. The vertical planes contain the inferior vena cava and the right, middle and left hepatic veins. The transverse plane passes through the right and left branches of the portal vein. The liver tissue behind the portal bifurcation is considered as a separate segment, from which the numbering starts in a clockwise pattern, reproduced in Figure 3.

Despite the general acceptance of this eight-segment scheme, an increasing number of anatomical and clinical observations call the concept into question. The *anatomical* literature shows that Couinaud's subdivision is largely contested [5,6,10,22], even by Couinaud himself [39–41]. Publications from the field of *radiology* also challenge Couinaud's concept [42–45]. *Surgeons* have reported discrepancies between Couinaud's concept and intraoperative reality [46–50].

Against this background, our group has reinvestigated the question of vascular territories within the human liver [23]. A systematic analysis of the different levels of the portal venous branching pattern in anatomical corrosion casts allows the following statements to be made. The portal vein irrigates the entire liver. At this level, the liver thus corresponds to *one* territory. The portal vein then bifurcates, in general, into two branches. At the level of these first-order vessels, the liver can thus mostly be subdivided into *two* territories (the right and left hemilivers). There are three territories in cases of portal trifurcation. As far as the next level of branches is concerned (i.e. vessels of the second order), the human liver in fact consists of many more than the eight segments generally assumed. In accordance with the observations mentioned above with regard to the detailed portal venous branching pattern [20–23], 9–43 territories per liver can be observed, with an average of 20 (Fig. 4). It is this large number of territories at second-order level that has not been considered yet. The reader may find this statement surprising, given the attention that anatomists, surgeons and radiologists have given to the organ for centuries and even in the recent past. But we should quote the observation made by Skandalakis and colleagues: 'Despite its multiple vital functions and its regenerative abilities, the liver has been misunderstood at nearly all levels of organization and in almost every period of time since Galen. The most paradoxical aspect of the understanding of hepatic anatomy has not been lack of knowledge but questions of interpretation; there is a tendency to ignore details that do not fit preconceived ideas. Furthermore, mistaken ideas about the liver seem to have taken longer to correct than misconceptions about most of the other organs of the body, with the exception of the brain' [19].

Taking into account the systematic hierarchical organization of intrahepatic branching patterns explains the seemingly inconsistent observations reported in the literature of different associations of the numerous second-order territories [23]. We have therefore submitted a '1–2–20 principle' for discussion (by analogy with Couinaud's 'eight-segment scheme'). This new working concept is intended to contribute to a better understanding of liver anatomy, increased exactness in radiological

localization of hepatic lesions and improved transectional techniques in liver surgery.

Conclusion

Surprisingly enough, the macroscopic anatomy of the liver is far from being definitely described and understood. This statement applies in particular to the concepts evoked for vascular and biliary territories within the organ. The authors suggest using the commonly accepted eight-segment scheme of Couinaud to describe the radiological localization of liver lesions and common hepatectomies, while considering a more loose 1–2–20 concept that allows a more precise description of the anatomy of each individual liver to be given.

References

1 Hollinshead H (1971) *Anatomy for Surgeons*, vol. 2, 2nd edn. New York: Harper & Row, pp. 314–318.
2 Rex H (1888) Beiträge zur Morphologie der Säugerleber. *Morph Jahrb* 14, 517–616.
3 Cantlie J (1898) On a new arrangement of the right and left lobes of the liver. *J Anat Physiol* 32, 4–9.
4 Melnikoff A (1924) Architektur der intrahepatischen Gefässe und Gallengänge des Menschen. *Z Anat Entw Gesch* 70, 411–465.
5 Hjortsö CH (1951) The topography of the intrahepatic duct systems. *Acta Anat* 11, 599–615.
6 Elias H, Petty D (1952) Gross anatomy of the blood vessels and ducts within the human liver. *Am J Anat* 90, 59–111.
7 Healey JE, Schroy PC (1953) Anatomy of the biliary ducts within the human liver. *Arch Surg* 66, 599–616.
8 Gans HG (1955) *Introduction to Hepatic Surgery*. Amsterdam: Elsevier, pp. 1–265.
9 Couinaud C (1957) *Le Foie: Etudes Anatomiques et Chirurgicales*. Paris: Masson.
10 Goldsmith NA, Woodburne RT (1957) The surgical anatomy pertaining to liver resection. *Surg Gynecol Obstet* 105, 310–318.
11 Mukai JK, Stack CM, Turner DA (1987) Imaging of surgically relevant hepatic vascular and segmental anatomy. 1. Normal anatomy. *Am J Roentgenol AJR* 149, 287–292.
12 Soyer P, Roche A, Gad M *et al.* (1991) Preoperative segmental localization of hepatic metastases: utility of three-dimensional CT during arterial portography. *Radiology* 180, 653–658.
13 Soyer P, Bluemke DA, Bliss DF *et al.* (1994) Surgical segmental anatomy of the liver: demonstration with spiral CT during arterial portography and multiplanar reconstruction. *Am J Roentgenol AJR* 163, 99–103.
14 Nelson RC, Chezmar JL, Sugarbaker PH *et al.* (1990) Preoperative localisation of focal liver lesions to specific liver segments: utility of CT during arterial portography. *Radiology* 176, 89–94.
15 Glisson F (1654) *Anatomia Hepatis*. Pullein, London. Cited in: Gans H (1955) *Hepatic Surgery*. Amsterdam: Elsevier, p. 244.
16 Feigl W, Firbas W, Sinzinger H (1973) Ueber das Vorkommen akzessorischer Leberarterien und ihre Genese sowie eine Diskussion ihrer Nomenklatur. *Anat Anz* 134, 139–171.
17 Gupta SC, Gupta SC, Gupta SB (1979) Intrahepatic supply patterns in cases of double hepatic arteries: a study by corrosion casts. *Anat Anz* 146, 166–170.
18 Miyaki TS, Sakagami S, Ito H (1989) Intrahepatic territory of the accessory hepatic artery in the human. *Acta Anat* 136, 34–37.
19 Skandalakis JE, Skandalakis LJ, Skandalakis PN *et al.* (2004) Hepatic surgical anatomy. *Surg Clin North Am* 84, 413–435.
20 Couinaud C (1953) Etude de la veine porte intra-hépatique. *Presse Med* 61, 1434–1438.
21 Laux G, Rapp PE (1953) Le dispositif veineux du lobe de Spigel. *Bull Assoc Anat* 40, 264–271.
22 Platzer W, Maurer H (1966) Zur Segmenteinteilung der Leber. *Acta Anat* 63, 8–31.
23 Fasel JHD, Majno PE, Peitgen HO (2006) Vascular territories in the human liver: a conceptual reappraisal. *Am Surg* (in press).
24 Masselot R, Leborgne J (1978) Etude anatomique des veines sus-hépatiques. *Anat Clin* 1, 109–125.
25 Nakamura S, Tsuzuki T (1981) Surgical anatomy of the hepatic veins and the inferior vena cava. *Surg Gynecol Obstet* 152, 43–50.
26 Van Leeuwen MS, Fernandez A, van Es HW *et al.* (1994) Variations in venous and segmental anatomy of the liver: two- and three-dimensional MR imaging in healthy volunteers. *Am J Roentgenol AJR* 162, 1337–1345.
27 Van Leeuwen MS (1994) Triphasic spiral CT of the liver and 3D liver imaging. Medical thesis, University of Utrecht, Netherlands.
28 Mehran R, Schneider R, Franchebois P (2000) The minor hepatic veins: anatomy and classification. *Clin Anat* 13, 416–421.
29 Faisinger M (1950) The radiology of the intrahepatic biliary tract. *South Afr J Med Sci* 15, 51.
30 Champetier J (1994) Les voies biliaires. In: Chevrel JP (ed.) *Anatomie Clinique*, vol. 2. Paris: Springer, pp. 407–420.
31 Anderhuber F, Lechner P (1986) Occurrence of anastomoses of the intrahepatic bile ducts. *Acta Anat* 125, 42–49.
32 Wolodjko WP (1967) Das Lymphsystem der menschlichen Leber in Beziehung zu ihrer Segmentgliederung. *Z Anat Entw Gesch* 126, 154–171.
33 Trutmann M, Sasse D (1994) The lymphatics of the liver. *Anat Embryol* 190, 201–209.
34 Golab B (1972) Lymphatic vessels of the hepatic ligaments in man. *Folia Morphol (Warsz)* 31, 260–263.
35 Loeweneck H, Feifel G (2004) Bauch. In: Lanz Tv, Wachsmuth W (Begründer) *Praktische Anatomie*, 2 Bd, 6 Teil. Berlin: Springer, p. 262.
36 Bismuth H (1982) Surgical anatomy and anatomical surgery of the liver. *World J Surg* 6, 3–9.
37 Dodd GD III (1993) An American guide to Couinaud's numbering system. *Am J Roentgenol AJR* 161, 574–575.
38 Blumgart LH, Hann LE (2000) Surgical and radiologic anatomy of the liver and biliary tract. In: Blumgart LH, Fong Y (eds) *Surgery of the Liver and the Biliary Tract*, 3rd edn. London: Saunders, pp. 5–10.
39 Couinaud C (1998) Secteur dorsal du foie. *Chirurgie* 123, 8–15.
40 Filipponi F, Romagnoli P, Mosca F *et al.* (2000) The dorsal sector of human liver: embryological, anatomical and clinical relevance. *Hepatogastroenterology* 47, 1726–1731.
41 Abdalla EK, Vauthey JN, Couinaud C (2002) The caudate lobe of the liver: implications of embryology and anatomy for surgery. *Surg Oncol Clin North Am* 11, 835–848.
42 Ohashi I, Ina H, Okada Y *et al.* (1996) Segmental anatomy of the liver under the right diaphragmatic dome: evaluation with axial CT. *Radiology* 200, 779–783.
43 Fasel JHD, Selle D, Evertsz CJ *et al.* (1998) Segmental anatomy of the liver: poor correlation with CT. *Radiology* 206, 151–156.

44 Rieker O, Mildenberger P, Hintze C *et al.* (2000) Segmental anatomy of the liver in computed tomography: do we localize the lesion accurately? *Rofo Fortschr Geb Rontgenstr Neuen Bildgeb Verfahr* 172, 147–152.

45 Fischer L, Cardenas C, Thorn M *et al.* (2002) Limits of Couinaud's liver segment classification: a quantitative computer-based three-dimensional analysis. *J Comput Assist Tomogr* 26, 962–967.

46 Makuuchi M, Hasegawa H, Yamazaki S (1985) Ultrasonically guided subsegmentectomy. *Surg Gynecol Obstet* 161, 346–350.

47 Blumgart LH, Fong Y (2000) *Surgery of the Liver and Biliary Tract*, 3rd edn. London: Saunders, CD-ROM.

48 Cervone A, Sardi A, Conaway GL (2000) Intraoperative ultrasound (IOUS) is essential in the management of metastatic colorectal liver lesions. *Am Surg* 66, 611–615.

49 Scheele J (2001) Anatomiegerechte und atypische Leberresektionen. *Chirurgie* 72, 113–124.

50 Ko S, Murakami G, Kanamura T *et al.* (2004) Cantlie's plane in major variations of the primary portal vein ramification at the porta hepatis: cutting experiment using cadaveric livers. *World J Surg* 28, 13–18.

1.2 Liver and biliary tract histology

Paulette Bioulac-Sage, Brigitte Le Bail and Charles Balabaud

General features

Liver and biliary tract histology, the study of hepatic function, the relation between the structure and function of cells and their organelles and of the extracellular matrix have recently been reviewed in specialized textbooks on pathology [1], biology and pathobiology [2,3] and liver disease [4].

The liver is a voluminous organ (1200–1500 g) that is highly vascularized. It is surrounded by a thin capsule (Glisson's capsule) composed of collagen fibres, scattered fibroblasts, myofibroblasts, small blood vessels and lymphatics. The capsule is thickest around the hilus (or porta hepatis) where blood vessels enter and bile ducts leave the liver. In the parenchyma, the capsule merges with the connective tissue surrounding the portal tracts.

Between the incoming vessels of the portal tracts and the central veins lie the hepatic sinusoids, which allow exchange between blood and unicellular sheets of hepatocytes. In histological sections, portal tracts (which contain branches of the hepatic artery and portal vein, one or two bile ducts, lymphatics, nerves, a few lymphocytes and fibroblasts in loose connective tissue), centrolobular veins (also called the terminal hepatic venule) and the lobular parenchyma are identified (Figs 1 and 2). The apparent structural unit of the liver is the lobule, a polyhedral prism (0.7 × 2 mm), the boundaries of which are limited by four to five portal triads prolonged by connective tissue septa. The centre of the lobule contains the centrolobular vein (Figs 1 and 3). The lobular parenchyma represents approximately 93% of the hepatic parenchyma, portal triads 3% and hepatic veins 4% [5]. At least 15 different cell types can be found in normal liver [6].

Human liver biopsy material (needle or surgical) is usually fixed by immersion for a few hours in 10% neutral formalin. For detailed study of the hepatic parenchyma and sinusoidal cells by electron microscopy (transmission and scanning), it is better to use *in situ* perfusion–fixation of the liver through the portal vein or the hepatic artery. For the localization of antigens (immunocytochemistry) fixed material can be used in many instances. For the performance of *in situ* hybridization and some immunostaining, it can be necessary to use frozen material.

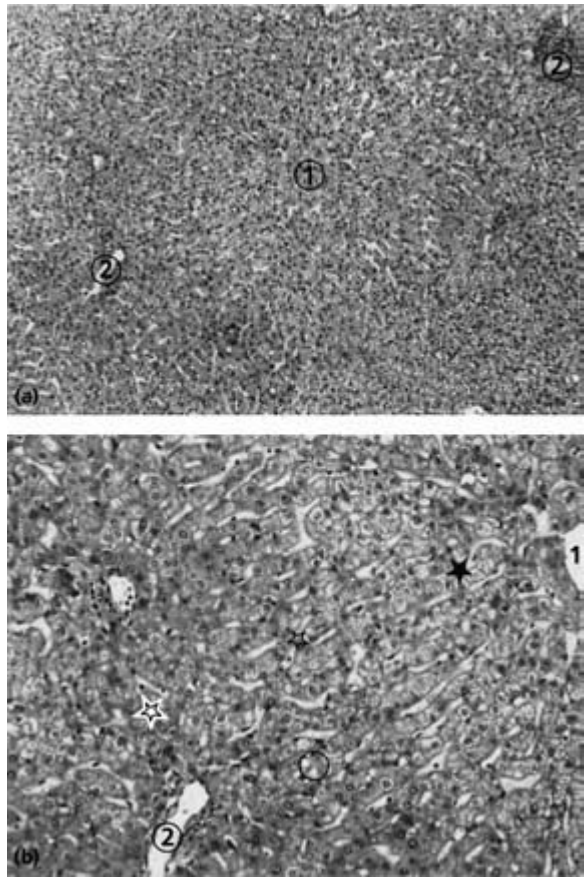

Fig. 1 Hepatic parenchyma: paraffin embedding (5-μm-thick section); haematein eosin saffron; (a) low (× 50) and (b) high (× 230) magnification. The classic lobule cannot easily be seen. Sinusoids lie, from portal tracts (2) to centrolobular veins (1), in between the unicellular sheets of hepatocytes. In medio- and centrolobular zones (black star), sinusoids are larger and radial; in the periportal zone (white star), they are narrower.

The functional unit of the liver

An adequate description of the liver unit should provide not only structural but also secretory and microcirculatory unity [7]. Based on the lobular organization proposed by Matsumoto

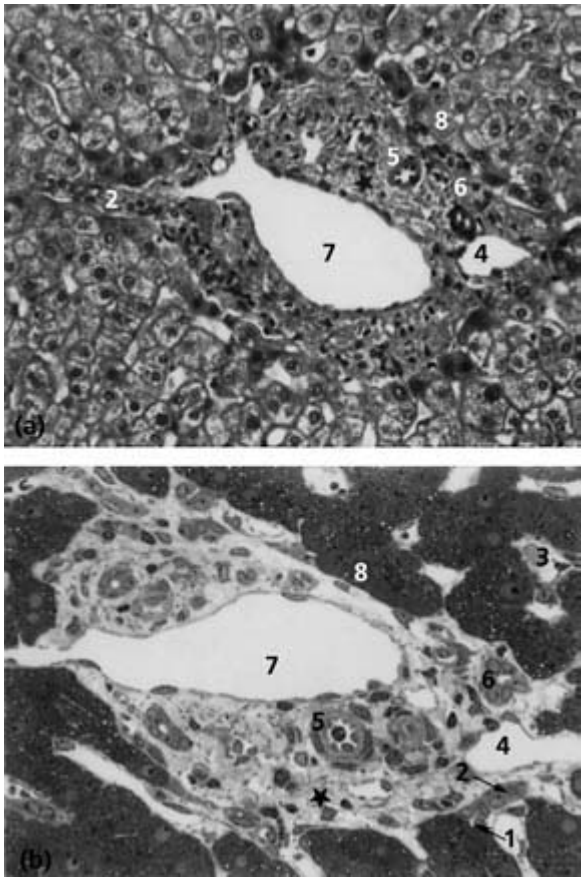

Fig. 2 Small portal tract: (a) paraffin embedding (5-μm-thick section); haematein eosin saffron, × 300; (b) Epon embedding (1-μm-thick section); toluidine blue, × 340. At the periphery of the portal tract, several canals of Hering (1), cholangioles (2) and sinusoids (3), with or without Kupffer cells, can be seen close to venules (4). In the portal tract, arterioles (5) are close to interlobular bile ducts (6), which are lined by a single layer of cuboidal epithelial cells; some inflammatory cells are present in the stroma (*). (7) Portal vein; (8) hepatocytes forming the periportal limiting plate.

Fig. 3 Hepatic lobule: scanning electron microscopy, × 170. A centrolobular vein (1) is visible at the centre of the lobule limited by two portal tracts (2).

[8] the liver microarchitecture is composed of primary lobules (or modules, a term coined to ascribe considerable degrees of variability in the shape and size of primary units as well as in the number of primary units) [9]. Primary modules are structural elements that are responsible for directing and the timing of blood flow: (i) portal veins and their septal branches (and hepatic arteries); (ii) vascular septa, which connect portal veins and septal branches to a continuous supplying surface and act as a 'watershed' between adjacent primary modules; (iii) long portal sinusoids, which originate directly from and in the vicinity of the portal vessels, with an initial tortuous segment and a subsequent straight radially oriented segment; (iv) short septal sinusoids, which are straight radial and lacking the initial tortuous segment that originates from the vascular septum, where inflow-fronts from neighboring portal vessels meet; and (v) a central venular branch located in the centre of the primary module, draining the sinusoids. Reconstruction reveals a group of primary modules integrated into a secondary module. Integration results from a common drainage by the branches of a central venular tree and from the arrangement of portal venular branches and vascular septa, which form a continuous vascular surface over the entire module and separate it from adjacent modules. Reconstructed primary modules are polyhedral, with seven to nine facets, which are either plane, convex or concave. In addition to variable shapes, the primary modules also vary in size (i.e., height, surface area, volume, number and area of vascular septa). Such morphogenetic plasticity is considered an important part of the modular microarchitecture of the liver. Figure 4 illustrates the classic but oversimplified representation of a primary lobule and Figure 5 a more realistic representation of primary modules integrated into a secondary module. This interpretation should permit a better interpretation of histological sections of normal and pathological liver and provide a basis for understanding the metabolic heterogeneity of liver cells and their functional integration into parenchymal units.

Hepatocytes

Hepatocytes are arranged in unicellular plates or laminae (Remak's plates). These hepatic laminae branch and anastomose with one another to form a complicated walling system, the hepatic muralium, a maze-like arrangement of partitions between which the sinusoids interweave and interconnect in a continuous labyrinth [1,2] (Figs 3 and 6). Hepatocytes surrounding the portal tract, which constitute an interface between the connective tissue of the tract and the hepatic parenchyma, form the limiting plate (Fig. 2).

The plates are composed of about 20 large, polyhedral epithelial cells, approximately 30 μm long and 20 μm wide. The mean volume density is 5000 μm^3. These cells (100 billion) make up approximately 80% of the cell population. The hepatocyte is limited by a membrane in which three domains can be distinguished.

The sinusoidal membrane (70% of the total cell surface area)

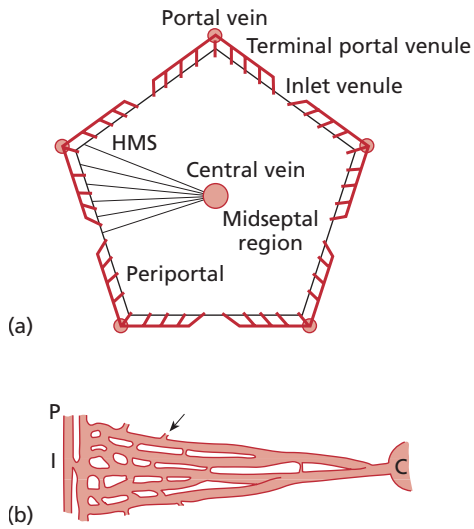

Fig. 4 (a) Two-dimensional view of a pentagonal hepatic lobule. In each corner, there is a portal tract. On each side of the lobule, in the septum, there are two opposite-running terminal portal venules (accompanied by an arterial branch and a ductule). The hepatic lobule is divisible into elementary sectors: the hepatic microcirculatory subunits fed by the inlet venules derived from the portal vein (in the portal tract) and the terminal portal venules. Compared with the periportal region, the mid-septal region is remote from the portal supply. (b) A typical hepatic microcirculatory subunit shaped like a cone with a portal inlet venule (I) at the base, where one afferent vessel spreads into many sinusoids. The cross-connecting sinusoids (arrows) reduce, or drop out, while approaching the centrolobular vein (C). From ref. 10, with permission.

is covered with microvilli (0.5 μm long), which increase the surface area sixfold. This membrane burrows in between hepatocytes, delimiting the interhepatocytic space (Figs 7 and 8). Exchange of materials between the blood and hepatocytes (exo- and endocytosis) through the Disse space is a function solely of the sinusoidal plasma membrane.

The canalicular membrane is the biliary pole of the hepatocyte. It is an intercellular space, formed by the opposition of the edges of gutter-like hemicanals (15% of the total cell surface area; 0.4% of the lobular parenchyma) on the surfaces of neighbouring hepatocytes (average diameter, 0.5–1 μm internal diameter in portal area and 1–1.25 μm in centrolobular area (Figs 6, 7 and 8). The surface is covered by microvilli. The canalicular surface is isolated from the Disse space by tight junctions. Using light microscopy, bile canaliculi are not visible in normal liver; but they can be immunostained with anti-CEA polyclonal and anti-CD10 antibodies. They become visible when distended in cholestatic liver. Tone is provided by an encircling mesh of contractile microfilaments fixed on the zonula adherens, which follow the outline of the microvilli.

The lateral membrane (15% of the cell surface area) is more or less straight, separated from the adjacent lateral membranes by an intercellular space of 15 nm. The junctional complexes – desmosomes, gap junctions, intermediate junctions (zonula adherens) and tight junctions – are special membrane differentiations that fix the liver cells together.

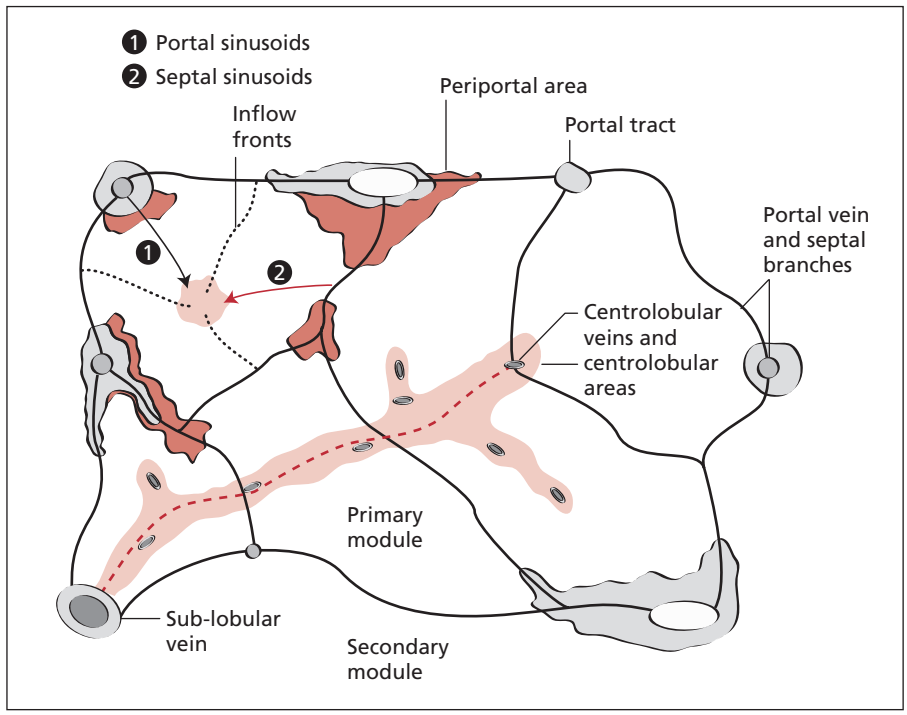

Fig. 5 Schematic distribution of alkaline phosphatase activity in the portal and centrolobular area delineating primary and secondary modules. Portal venular branches and vascular septa form a continuum in which blood is distributed over the surface of the modules and from which the sinusoids originate. From portal vessels, blood flows toward the centre and along the vascular septa. Enzyme activity is highest in endothelial cells at the beginning of the 'portal' sinusoids. From there, activity decreases towards the central venule and is higher at the end of the sinusoids. Staining also decreases from both sides along the vascular septum and is faintest where the 'septal' sinusoids originate. Along the septal sinusoids, alkaline phosphatase activity first decreases and then increases towards the end of the sinusoids. Alkaline phosphatase activity in portal areas (dark red), and in central areas (light red). Adapted from ref. 9, with permission.



Fig. 6 Hepatic parenchyma: scanning electron microscopy, × 1300. Unicellular sheets of hepatocytes are separated by sinusoids from different planes of sectioning. The block often breaks in between the lateral surface of hepatocytes, allowing visualization of the biliary hemicanaliculi (arrow). In sinusoids, some Kupffer cells (black star) and red blood cells (white star) can be seen. The Disse space can also be identified (arrowhead).

The nucleus is spherical and voluminous, occupying 5–10% of the cell volume, with one or more prominent nucleoli and scattered chromatin. About 25% of the cells are binucleate. There appears to be a clear correlation between nuclear size and ploidy. As many as 15% can be tetraploid nuclei. The adult liver has a very low mitotic index, with estimates ranging from 2 mitoses per 1000 cells to 1 per 10 000 cells.

Light microscopy of the liver shows a pale-staining, eosinophilic cytoplasm containing granular clumps of basophilic material. This material corresponds to rough endoplasmic reticulum. Near the bile canaliculi, there are fine brown granules of lipofuchsin pigment. These are more abundant with age, particularly in the centrolobular zone. A few hepatocytes may contain fat vacuoles. Histochemical procedures are essential to identify components such as glycogen, haemosiderin and lipids. Electron microscopy is necessary to visualize organelles: there is an abundant rough and smooth endoplasmic reticulum, a Golgi apparatus close to the biliary pole, numerous mitochondria (1000–1500 per cell) and peroxisomes. The hepatocyte is rich in glycogen, with the quantity depending on the time of the last meal. The cytoskeleton of the cell comprises microfilaments, intermediate filaments and microtubules, which correspond by immunocytochemistry to actin, cytokeratin and tubulin.

The main morphometric data concerning organelles are presented in Figure 9 [11,12]. The whole cellular machinery performs many functions: uptake, transport, synthesis, biotransformation and degradation (proteins, lipids, carbohydrates, hormones, xenobiotics and bile).

With age the number of hepatocytes decreases and hypertrophy, polyploidy, lysosomes, and smooth endoplasmic reticulum increases. The mitochondria and microbodies remain unchanged with age and the microsomal drug-metabolizing capabilities decrease.

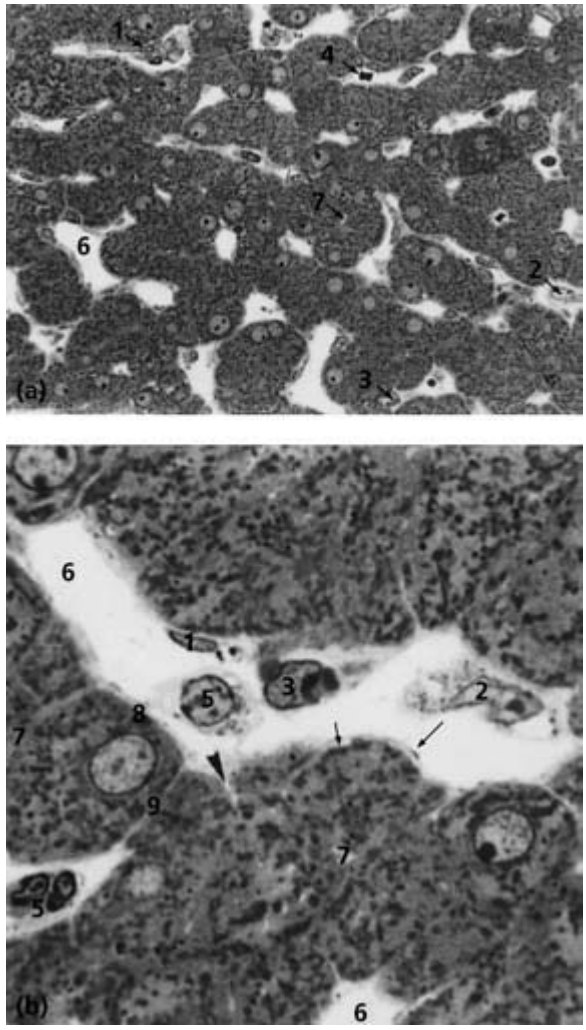

Fig. 7 Sinusoids and sheets of hepatocytes: Epon embedding (1-μm-thick section); toluidine blue (a) × 340; (b) × 1250 magnification. It is possible to identify the sinusoidal cells: endothelial cells with the cell body (1) and the barrier (large arrow), Kupffer cells (2) and stellate cells (3); blood cells, red (4) and white (5), in the sinusoidal lumen (6); the Disse space (small arrow) with the interhepatocytic recess (arrowhead); bile canaliculi (7); the sinusoidal surface (8) and lateral (9) surface of hepatocytes.

Sinusoids

Sinusoids are special capillaries with: (i) a fenestrated endothelial barrier; (ii) resident macrophages (Kupffer cells) 'guarding' the entrance of sinusoids; (iii) liver-associated lymphocytes, some of which are large, granular lymphocytes; and (iv) stellate cells (considered as pericytes) that store vitamin A [13,14] (Fig. 10). Sinusoids have no genuine basement membrane: this facilitates exchange between incoming blood and hepatocytes through the Disse space, as well as immunological defence mechanisms.

In zone 1, sinusoids are tortuous, narrow and anastomotic, but tend to become more parallel and larger in zone 3. The mean diameter (between 7 and 15 μm) is occasionally less than the mean diameter of the red blood cells, which adapt their shape to

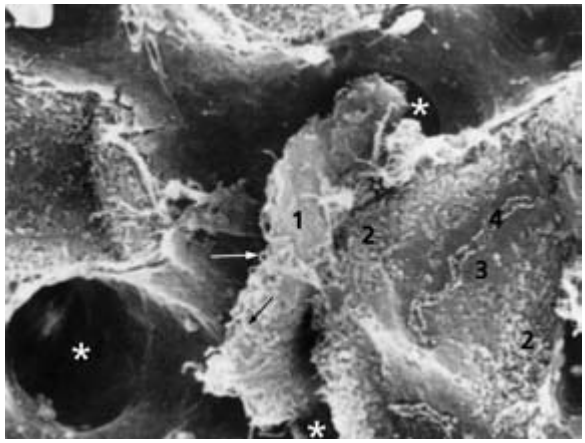

Fig. 8 Kupffer cells: scanning electron microscopy, × 4260. The Kupffer cell (1) with its filipodia (arrow) is located at the branching of several sinusoids (*). The different plasma membranes of the hepatocytes are easily recognizable: the sinusoidal with their microvilli (2), the fairly smooth lateral (3) and canalicular (4) membranes. It is not easy to differentiate collagen bundles from the perisinusoidal cell processes in the Disse space (star).

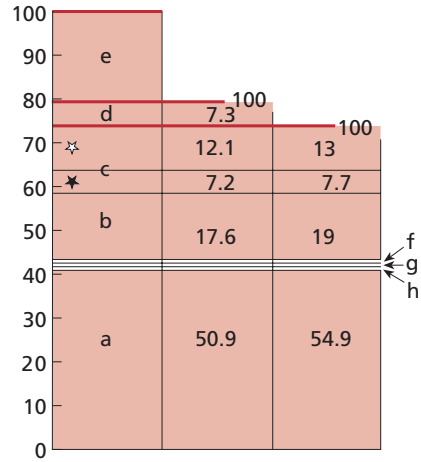

Fig. 9 Morphometric data of hepatocyte organelles. Volumetric composition of the liver expressed as a percentage of the lobular parenchyma (left column), an average hepatocyte (middle column) and hepatocytic cytoplasm (right column). (a) Hyaloplasm; (b) mitochondria; (c) endoplasmic reticulum, rough (white star), smooth (black star); (d) nucleus; (e) extrahepatocytic space (sinusoids and bile canaliculi); (f) lysosomes; (g) lipids; (h) peroxisomes. Lysosomes, lipids and peroxisome volume densities, expressed as a percentage of the cytoplasm, are 2%, 2.1% and 1.3% respectively.

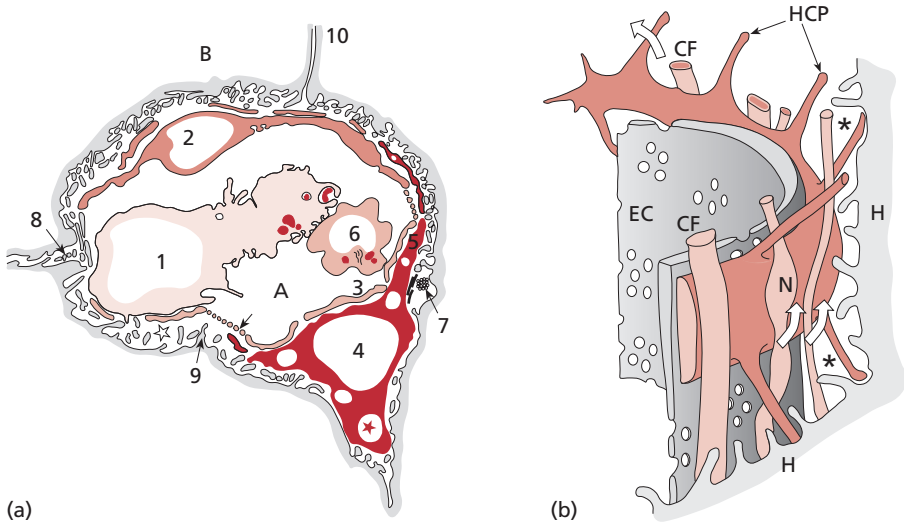

Fig. 10 Diagrammatic representation of sinusoids, sinusoidal cells and Disse space. (a) All four sinusoidal cells are represented in this sinusoid (A) (it is exceptional to see all four, with their nuclei, in the same plane of section) – the Kupffer cell (1), the endothelial cell: cell body (2), processes (3) and fenestrations (arrow); the stellate cell (4) with its lipids (black star) and processes (5); the liver-associated lymphocytes (6). In the Disse space (white star) containing some collagen fibres (7), interhepatocytic recesses (8), sinusoidal membrane microvilli (9) and the lateral membrane (10) of the hepatocyte (B) can be seen. (b) Schema of the sinusoidal wall. Arrows indicate tunnels formed by the processes of the stellate cells and hepatocyte. CF, collagen fibres; H, hepatocyte; HCP, hepatocyte-contacting process of the stellate cell; SP, subendothelial process of the stellate cell; N, nerve fibre; * space of Disse. From ref. 14, with permission.

size differences [15]. The diameter can increase if necessary (up to 180 µm). The mean length is 220–480 µm. The sinusoidal lumina occupy approximately 9–10% of the lobular parenchyma [16].

Sinusoidal cells

These represent about 6% of the lobular parenchyma (2.5%, 2% and 1.4% for endothelial, Kupffer and stellate cells respectively) and 26.5% of all the plasma membranes of the liver. Observation by light microscopy is difficult. Only transmission and scanning electron microscopy and immunocytochemical methods allow correct identification [17].

Endothelial cells

These form the barrier of the sinusoid [18,19]. Their main characteristics are: (i) very thin processes covering a large area (15% of all the plasma membranes of the liver); (ii) fenestrations with a mean diameter of 100 nm, grouped in clusters (sieve plates), which allow the passage of molecules of smaller diameters (Fig. 11) [20]; (iii) numerous pinocytotic vesicles, indicating a high endocytic capacity. They show immunoreactivity with monoclonal antibody MS-1 and express the scavenger receptor, Fc IgG receptor, and also the CD4 molecule. In capillarized sinusoids, where sinusoidal endothelial cells have lost their

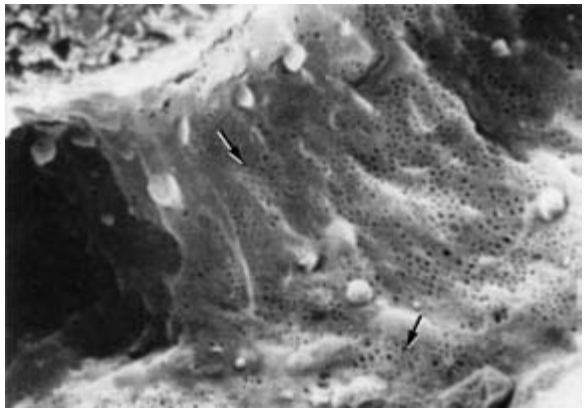

Fig. 11 Endothelial cell: scanning electron microscopy, × 13 440. The endothelial cell processes form the wall of the sinusoid. Fenestrations (arrow) are grouped in clusters, forming so-called sieve plates.

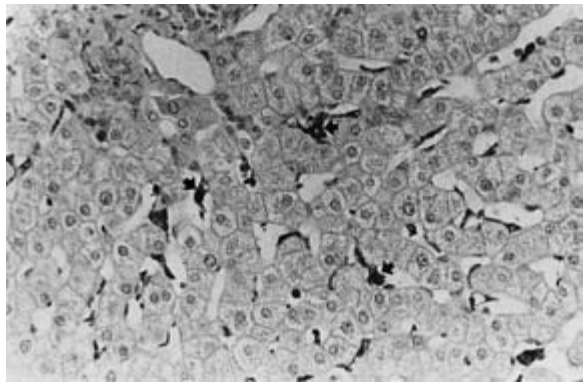

Fig. 13 Kupffer cell identification: paraffin embedding (5-μm-thick section); immunocytochemistry (KP1), × 330. Large Kupffer cells (arrow) are seen in this periportal area.

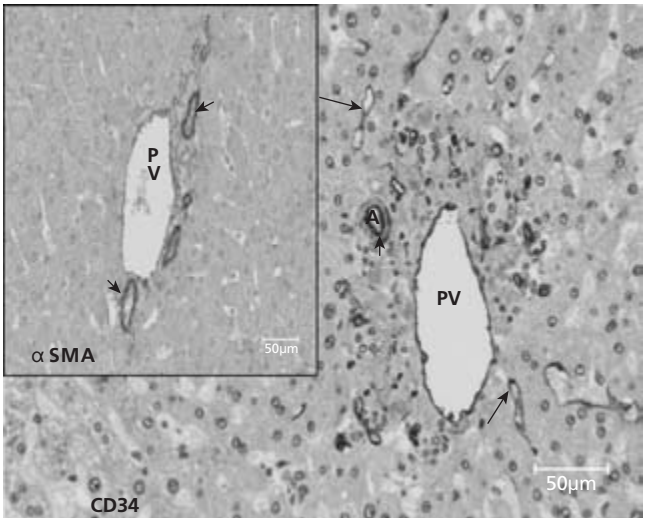

Fig. 12 CD34 immunostaining: all vascular endothelial cells are stained in the portal tract (short black arrow), but not in the sinusoidal endothelial cells, except in a few periportal sinusoids (long black arrow). α-SMA immunostaining (upper left corner): smooth muscle cells of vascular walls are stained but not the hepatic stellate cells in sinusoids.

fenestrations, there is a phenotypic shift towards that of vascular-type endothelium: expression of factor VIII-related antigen, *Ulex europaeus* lectin, CD34 and CD31 molecules. In the normal liver, antibodies such as anti-CD34 stains endothelial cells of vessels but not sinusoidal endothelial cells, except at the immediate periphery of portal tracts (Fig. 12).

Kupffer cells

Attached over a (more or less) large area of the endothelial wall, these cells are located within the sinusoidal lumen [21] (Figs 7 and 8). They are more numerous in zone 1 than in zone 3. They contain numerous lysosomes (almost a quarter of all the lysosomes of the liver). Kupffer cells can be identified with monoclonal antibodies such as KP1 (anti-CD68) (Fig. 13). They phagocytose many substances, such as latex particles, denatured albumin, bacteria and immune complexes. The extent to which Kupffer cells fail to take up colloids in patients with chronic hepatocellular diseases correlates best with indices of the magnitude of portal–systemic blood shunting. Upon stimulation by immunomodulators, Kupffer cells release mediators and cytotoxic agents.

Liver-associated lymphocytes

Far fewer in number (1:10 Kupffer cells), they comprise different types of lymphocytes, among which are large, granular lymphocytes (also named pit cells) [22]. They are resident luminal cells in contact with Kupffer and/or endothelial cells. Liver-associated lymphocytes differ from peripheral blood lymphocytes (phenotype, cytotoxic activity) [19]. They play a role in defence against tumours and viruses.

Hepatic stellate cells

Previously called perisinusoidal or Ito cells, they can be identified by [23]: (i) their cell body, which is often located in an interhepatocytic recess and contains lipids (Fig. 10) including vitamin A in most (but 20% of the cells do not contain lipids); (ii) their long, thin, cytoplasmic processes, surrounding endothelial cell processes; and (iii) their spines, which establish contact with hepatocyte microvilli [14]. No basement membrane surrounds the hepatic stellate cell. This cell, which belongs to the myofibroblast family, can be identified immunocytochemically in human liver by the presence of cellular retinol binding protein (Fig. 14) which stains this cell in its quiescent or activated phenotype [24]. There are approximately 5 to 20 of these cells per 100 hepatocytes. They store vitamin A and

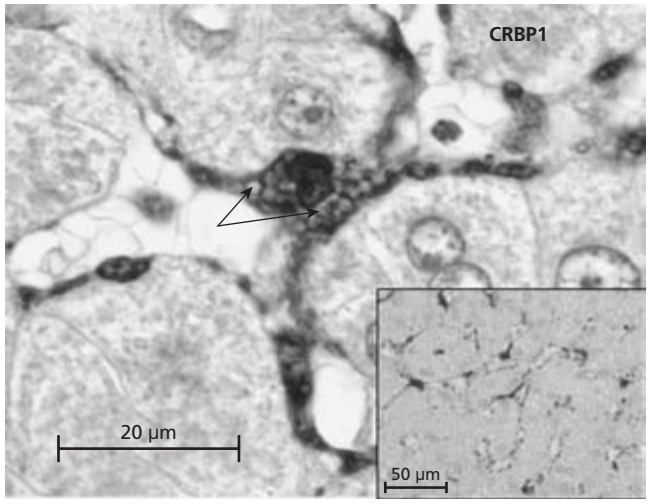

Fig. 14 CRBP 1 immunostaining: at low magnification (right lower corner). Many sinusoids are surrounded by cell bodies and/or processes of hepatic stellate cells. At high magnification lipids are underlined (arrow).

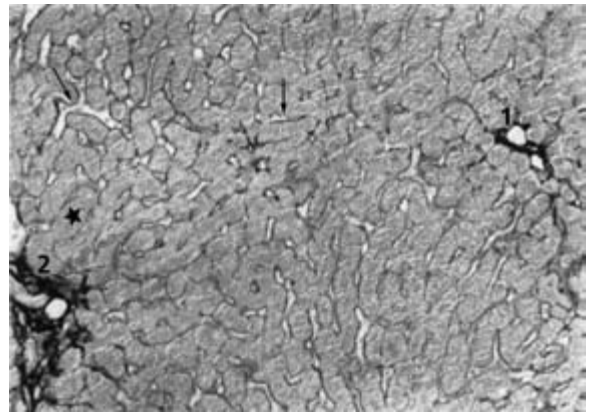

Fig. 15 Identification of the extracellular matrix: paraffin embedding (5-µm-thick section); Sirius red, × 130. This stain allows identification of the thin, perisinusoidal, matricial network (arrow) in between the unicellular, unstained sheets of hepatocytes (star), and of the fibrous tissue around the centrolobular vein (1) and the portal tract (2).

participate in the regulation of microvascular tonus and in the synthesis of the extracellular matrix. This latter function increases when they are activated and transformed into α-smooth muscle actin-positive cells. α smooth muscle actin antibodies (α-SMA) stain smooth muscle cells of the vessel walls, whereas hepatic stellate cells are usually negative in normal liver (Fig. 12).

The Disse space

This lies primarily between the stellate cell sheet and the sinusoidal membrane of the hepatocyte, and represents 2–4% of the hepatic parenchyma [25]. The relatively low porosity of the endothelial barrier (9% of the surface) is compensated for by the presence of a great number of hepatocytic microvilli in the Disse space, and particularly since the endothelial cell lacks a genuine basement membrane. In this space, which is not normally discernible in biopsy material by standard light microscopy, one can observe the different components of the extracellular matrix, which can be identified by immunocytochemistry [26]: these are different types of collagens (mainly type 3 but also types 1 and 4), proteoglycans and fibronectin. The presence of laminin is much debated. This whole network can be visualized by silver or Sirius red staining (Fig. 15).The role of the extracellular matrix is complex: it serves to cement the cells, allows intercellular communication and affects cellular differentiation.

Microcirculation

Blood flows unidirectionally in sinusoids from zone 1 to zone 3. Microcirculation through individual sinusoids is variable [27, 28]. This irregularity is linked to: (i) the presence of inlet, sinusoidal and outlet sphincters composed of sinusoidal lining cells bulging into the lumen; (ii) transient leukocyte plugging; (iii) variations in the morphology of sinusoids in the different zones;

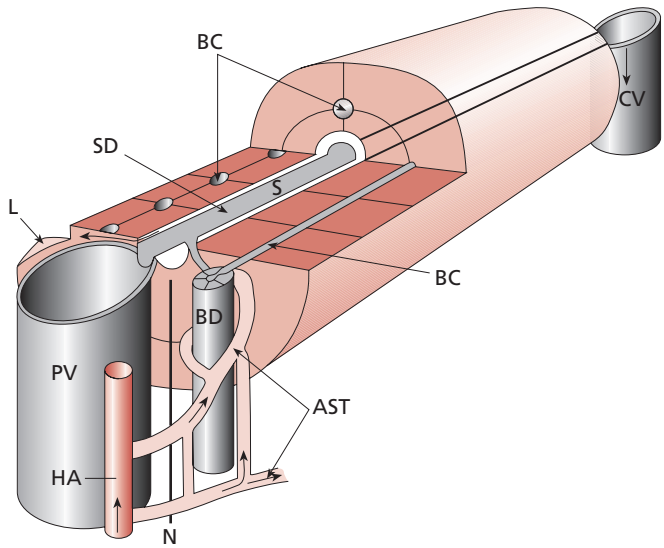

Fig. 16 Diagrammatic representation of the microcirculation and of biliary drainage in the lobule. PV, portal venule; HA, hepatic arteriole; BD, bile ductule; L, lymphatic; N, nerve; AST, arteriosinous twig; S, sinusoid; SD, space of Disse; BC, bile canaliculus; CV, central venule. Arrows indicate direction of flow. Note that the capillaries surrounding the bile duct constitute the peribiliary plexus. From ref. 27, with permission.

(iv) the contribution of arterial flow at the beginning of the sinusoid's pathway (Fig. 16) [27].

The average velocity of erythrocyte flow in sinusoids ranges between 270 and 410 µm/s. There are considerable interactions between blood cells and the sinusoidal wall. Soft, fast-moving red blood cells could help fluid- or solid-phase droplets or particles to penetrate into the Disse space (forced sieving). Compression of the Disse space by less plastic and larger cells such as white blood cells could displace fluids within this space in a downstream direction, promoting the transport of particles

and fluids into and out of the space through the fenestrations (endothelial massage) [15]. Average blood pressure is about 4.8 mmHg in terminal portal branches, 30–35 mmHg in arterial blood and 1.7 mmHg in collecting veins.

The hepatic artery

In the portal tract , the artery feeds the bile duct as the peribiliary vascular plexus, the portal tract interstitium including nerve, and the wall of portal vein. Drainage of these vascular beds is collected as an artery-derived portal system which joins the portal vein in the tract or at the inlet venule on entering the lobule. The hepatic artery therefore can resume the portal flow via the artery-derived portal system. Outside the portal tract, the artery dissociates itself to supply the Glisson's capsule which drains into subcapsular lobules, and the walls of central sublobular and hepatic veins. The latter is the pathway by which arterial blood can bypass the hepatic parenchyma into the hepatic vein [29].

Lymphatics (see also Chapter 2.1.3)

Lymph is collected in lymphatics present in portal triads. Liver lymph is first formed in the perisinusoidal Disse space. The fluid then enters the periportal tissue of the Mall space, which lies between the portal connective tissue and the limiting plate, and then the lymphatic capillaries. Lymph is then conveyed by increasingly large lymphatic vessels to the collecting vessels, which leave the liver at the hilus to reach the thoracic duct. The liver's capsule and portal stroma contain numerous lymphatic vessels, which form loose plexuses that connect at intervals with underlying lymphatic vessels. The antibody D2-40 stains specifically endothelial cells of lymphatics (Fig. 17) [30].

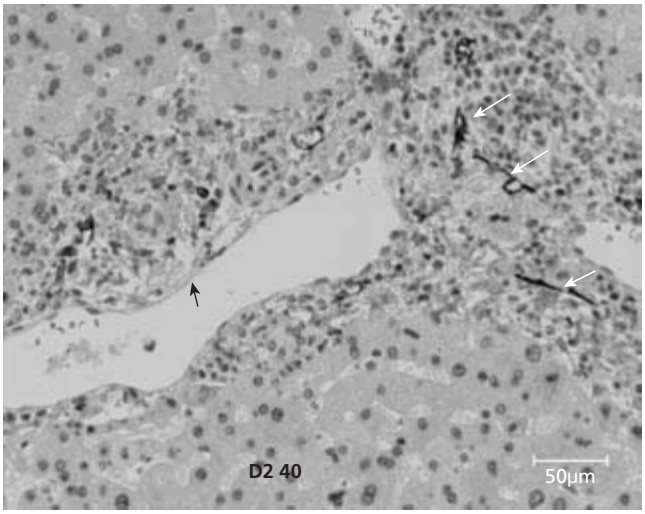

Fig. 17 D2-40 immunostaining: only endothelial cells of lymphatics (black arrow) are stained in this portal tract; vascular endothelial cells (white arrows) are negative.

Nerves (see also Chapter 2.2.5)

Extrinsic innervation of the liver is constituted by McCuskey [31]:

1 efferent sympathetic nerve fibres (preganglionic splanchnic fibres and postganglionic fibres after synapse in the coeliac ganglion) and parasympathetic nerve fibres (preganglionic fibres from the vagus); these play a part in the metabolism of hepatocytes (carbohydrate and perhaps lipid metabolism), haemodynamic regulation and biliary motility;

2 afferent fibres, which are thought to be involved in osmo- and chemoreception; at the hilus, amyelinic fibres form the anterior and posterior plexuses, which communicate with each other, and these enter the liver mainly around the hepatic artery.

Intrinsic innervation is composed of fibres mainly associated with vascular and biliary structures in the portal spaces (Fig. 18). Certain fibres enter the liver lobule, where they form a network around hepatocytes and extend into the sinusoidal wall, sometimes reaching the centrolobular vein. Fluorescence histochemistry and immunohistochemistry have revealed different types of nerve fibres: adrenergic (the most numerous in man), cholinergic and peptidergic. Some neuropeptides have been identified: vasoactive intestinal peptide (in the pathway of cholinergic fibres), neuropeptide Y (in that of adrenergic fibres), substance P, glucagon and calcitonin gene-related peptide [32].

Functional aspects of liver morphology

Consideration of gradient differences in cell and matrix composition (i.e., enzyme activities) of the liver are important when evaluating gene and protein changes as measured by genomic and proteomic methods. Furthermore, these different functional properties between periportal and centrilobular cells and matrix can also help to explain the regional distribution of lesions and susceptibility of cells to certain hepatotoxicants. Not only do hepatocytes have gradients of gene and protein activity that varies from the periportal region to the centrilobular region,

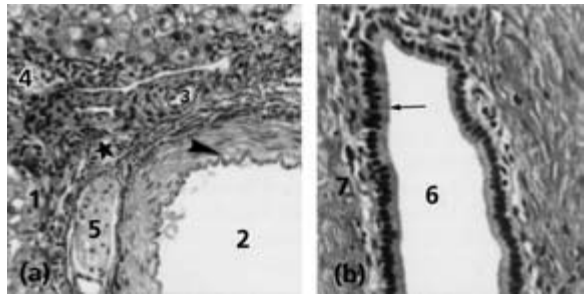

Fig. 18 Large portal tract (partial view): paraffin embedding (5-µm-thick section); haematein eosin saffron; (a) × 115; (b) × 170. (a) A nerve (5) can be seen inside the connective tissue, not far from the limiting plate of hepatocytes (1), a large artery (2), which is easily identifiable by its internal elastic lamina (arrowhead), an arteriole (3) and biliary ducts (4). (b) This large bile duct (6), which is surrounded by a thick fibrous envelope (7), is limited by a cylindrical epithelium (arrow).

but gradients also exist for sinusoidal endothelial, Kupffer and hepatic stellate cells, and for the matrix in the space of Disse [36].

The biliary tract

Intrahepatic biliary tract

The biliary tree contributes to the formation of bile and assures its delivery into the duodenum. It consists of the intrahepatic and extrahepatic biliary tract. In its first and short intrahepatic part, the biliary tree is lined by hepatocytes; it is followed by a series of biliary canals of growing diameter lined by biliary epithelial cells or cholangiocytes. These cells present two distinct poles: an apical pole facing the bile duct lumen, equipped with a variable number of short microvilli, and a basolateral pole in relation to adjacent epithelial cells and the basement membrane.They express high-molecular-weight cytokeratins, and specifically contain CK7 and CK19, in addition to CK8 and CK18 expressed by hepatocytes. Normally, they express class I MHC antigens but not class II, more numerous cell-matrix adhesion molecules than hepatocytes ($\alpha2\beta1$, $\alpha3\beta1$, $\alpha5\beta1$, $\alpha6\beta4$), as well as glutamyl transpeptidase, epithelial membran antigen, carcinoembryonic antigen (cross-reaction at the apex with polyclonal antibody), and various membrane receptors/transporters involved in bile secretion [33]. Recent research has focused on the expression of different types of mucins in normal and neoplastic biliary epithelium. In the intrahepatic and extrahepatic bile ducts MUC1 (detected by Mb DF3) is not expressed, nor are MUC2 or MUC4. MUC5AC and MUC6 are expressed in a minority of cases (13% and 30% respectively), the latter being expressed in peribiliary glands in most cases [34].

Bile flows in the opposite direction to that of plasma flow in the canaliculi along the hepatocyte plates, and next enters small ductules or cholangioles in the periportal area. The junction between the last hepatocyte and the first spindle-shaped biliary cells is called the canal of Hering.

The canals of Hering begin in the lobules, are lined partially by cholangiocytes and partly by hepatocytes, and conduct bile from bile canaliculi to terminal bile ducts in portal tracts. They are not readily apparent on routine histological staining but are highlighted by the biliary cytokeratins CK19 and CK7. There is on average one canal of Hering per 10 μm of bile duct length. The canals represent the true hepatocytic–biliary interface that thus lies within the lobule and not at the limiting plate. The canals of Hering consist of, or harbour, facultative hepatic stem cells in humans (Fig. 19) [35].

In cross-section, cholangioles (or ductules) are lined by three or four cells that become cuboidal and stay on a basement membrane; they usually have an internal diameter of less than 15 μm. Like the canals of Hering they are not usually apparent by light microscopy in normal livers. On occasion, and in cholestatic livers, they become visible at the periphery of the portal triad, lying in the vascular axis of the septal zone (Fig. 2). They drain the bile into the interlobular bile ducts located in portal triads.

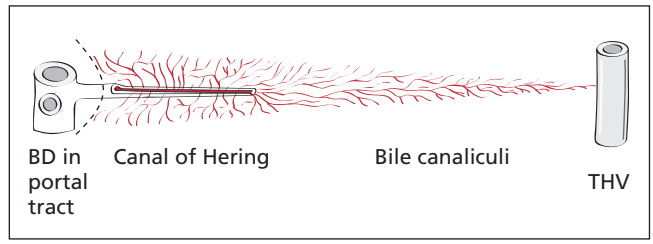

Fig. 19 Proposed relationships of the canal of Hering to the hepatic parenchyma. The terminal bile duct in the portal tract may give rise to a bile ductule (BD), and then a canal of Hering that penetrates directly into the parenchyma and extends on average one-third of the way to the THV. Because the canal of Hering is by definition made up partially by bile duct epithelial cells and hepatocytes (not shown), it can act as a 'trough' for the collection of bile from hepatocellular bile canaliculi. THV, terminal hepatic vein.

Interlobular bile ducts (< 100 μm diameter), lined by a cuboidal epithelium, are accompanied by arteries in the portal tract; their external diameter is quite similar to that of the adjacent artery (ratio 0.7–0.8).

The confluence of two or more interlobular bile ducts forms the septal ducts (> 100 μm diameter), which are lined by a cylindrical epithelium.

Segmental ducts (between 400 and 800 μm diameter), as well as left and right bile ducts, are histologically similar. Like septal ducts, they are lined by columnar cholangiocytes, and situated on a PAS-diastase-positive basement membrane; they are surrounded by dense, irregular and circumferential, but not concentric, fibrous tissue containing many elastic fibres. A peribiliary plexus of capillaries (branches of the hepatic artery) supplies all the intrahepatic bile ducts. This plexus drains principally into hepatic sinusoids. In addition to the enterohepatic cycle, a cholehepatic cycle for mono- and dihydroxyl bile acids has been proposed.

Extrahepatic biliary tract

At the exit from the liver, the biliary tract is composed of three portions with many anatomical variations (in size, position and orientation), particularly at the different confluences [36]:

1 the left and right hepatic ducts (diameter 3–4 mm) emerge from the corresponding lobes and after about 1 cm in the hilus, their confluence gives rise to the common hepatic duct;

2 the accessory biliary apparatus comprises the gallbladder and the cystic duct which joins the common hepatic duct to form the common bile duct;

3 the terminal part of the common bile duct enters the duodenum at the papilla of Vater after traversing the sphincter of Oddi.

Hepatic, cystic and common ducts

The diameter of these ducts is less than 15 mm and their walls are very thin (0.5–1.0 mm). The mucosa is relatively flat or pleated with some short folds; it is composed of a single layer of tall,

columnar cholangiocytes resting on a dense collagenous connective tissue, rich in elastic fibres and containing some small mucous glands. The surface epithelium forms some pits (sacculi of Beale) which are conspicuous in the extraduodenal portion of the common bile duct and the hepatic duct. Entrerochromaffin, serotonin-containing cells have been described in the cystic duct epithelium. Smooth muscle fibres, circular or oblique, are scant and variable in quantity around the common bile duct; this muscularis is reinforced near the duodenum by circular fibres forming the sphincter of Oddi and is most prominent near the cystic duct, in the axis of mucosa folds, where they form the Heister valve (which controls bile flow). The subserosa is a connective tissue, less dense in periphery than in the inner portion, containing collagen and elastic fibres, blood vessels, nerve fibres and occasionnal ganglion cells. Around the common hepatic ducts, the hilar ducts (and a portion of the larger septal ducts) it also contains some tubular and branched mucous glands [37] which share similarities with the Brunner glands of the duodenum.

The gallbladder

Located within a fossa (on the undersurface) of the right lobe of the liver, the gallbladder is a pear-shapped pocket firmly attached to the liver, which stores and evacuates bile. Occasionally, the gallbladder is freely suspended from the liver by a mesentery. This spindle-shaped bag, measuring 6–12 cm in length and 2.5–5 cm in width, may contain 30–50 mL of bile and consists of a fundus, a body, an infundibulum and a neck; the neck forms an 'S' shape that represents its transition with the cystic duct.

The wall is composed of a mucosa (made of a surface epithelium and underlying lamina propria which forms primary and secondary folds when the gallbladder is empty) lying on a plexiform muscularis and an adventitia (or subserosa; Fig. 20) and a serosa. It lacks a muscularis mucosae and a submucosae. The villosities of the mucosa are separated by herniations of the epithelium sometimes extending through the entire width of the muscular layer (Rokitansky–Aschoff sinuses); in normal tissues, they are few and superficial. The mucosa is lined by a single layer of tall (15–25 μm) 'clear' columnar cells supported by a basement membrane. These cells (Fig. 20) have an ovoid basal nucleus and a pale cytoplasm with microvilli at the apex, filamentous glycocalix and core rootlest, only visible by electron microscopy. Mucosecretion can be found in small amounts, without goblet cells. Some basal cells, quite inconspicuous, rounder and smaller (10–15 μm) than columnar cells, are located immediately above the basement membrane, with their nuclei parallel to it; they should not be confused with intraepithelial lymphocytes, which are more common. Rare pencil-like (dark) columnar cells can be seen, consisting of retracted clear columnar cells. No endocrine cells are present within the fundus and body. Within villosities there is little connective tissue with capillaries. A few tubulo-alveolar mucous glands can be found in the lamina propria but only near the neck. Ganglion cells are rare in the lamina propria. The muscularis is not a well-developed layer of variable thickness

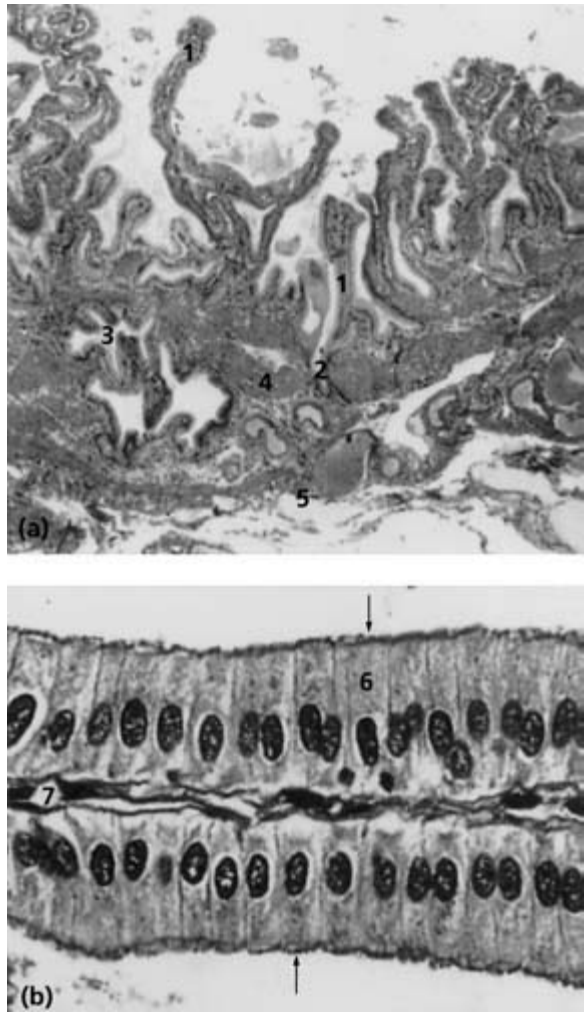

Fig. 20 Gallbladder: paraffin embedding (5-μm-thick section); haematein eosin saffron; (a) low magnification (× 36) and (b) high magnification (× 560). (a) The whole gallbladder wall can be seen: the mucosa with its numerous villosities (1) separated by crypts (2) extending into the connective tissue forming Rokitansky sinuses (3), the muscularis (4) and the adventitia (5). (b) The villosities are limited by a single columnar epithelium (6) with an ovoid nucleus near the basal pole of the cell and a striated apical pole (arrow); their axes are of delicate connective tissue (7).

composed of circular, longitudinal, and oblique smooth-muscle bundles in an elastic loose connective tissue. The adventitia is a connective tissue containing lipocytes, vessels, nerve fibres, ganglion cells, lymphocytes, and Luschka's ducts, which are minor bile ducts that lie in the subserosa connective tissue on the hepatic side; they could be embryonic remnants. On rare occasions, ectopic hepatic, pancreatic, adrenal, gastric and even thyroid tissues have been found in the gallbladder wall. The gallbladder is richly vascularized by blood and lymphatic plexuses located in the lamina propria and in the adventitia; it is innervated by sympathetic motor fibres and numerous sensory nerve endings [38].

The transport properties of biliary epithelial cells and their regulation vary between the various anatomical compartments

of the biliary tract. It is usually assumed that intrahepatic ducts are mainly committed to fluid and electrolyte secretion, whereas extrahepatic bile ducts and gallbladder are considered to be specialized in absorption and mucin synthesis. The plasticity of the biliary epithelium is important.

References

1 MacSween RNM, Scothorne RJ (1994) Developmental anatomy and normal structure. In: MacSween RNM, Anthony PP, Scheuer PJ *et al.* (eds) *Pathology of the Liver*. Edinburgh: Churchill Livingstone, pp. 1–49.

2 Desmet V (2001) Organizational principles in the liver. In: Arias IM, Boyer JL, Chisari FV *et al.* (eds) *The Liver. Biology and Pathobiology*, 4th edn. New York: Raven Press, pp. 3–15.

3 Arias IM, Jakoby WB, Boyer JL *et al.* (eds) (1994) *The Liver. Biology and Pathobiology*. New York: Raven Press.

4 Saxena R, Zucker SD, Crawford JM (2003) Anatomy and physiology of the liver. In: Zakim D and Boyer TD (eds) *Hepatology: A Textbook of Liver Disease*, 4th edn. Philadelphia: Saunders, pp. 3–30.

5 Schroder R, Muller O, Bircher J (1985) The portacaval and splenocaval shunt in the normal rat. A morphometric and functional reevaluation. *J Hepatol* 1, 107–123.

6 Malarkey DE, Johnson K, Ryan L *et al.* (2005) New insights into functional aspects of liver morphology. *Toxicol Pathol* 33, 27–34.

7 Saxena R, Theise ND, Crawford JM (1999) Microanatomy of the human liver – exploring the hidden interfaces. *Hepatology* 30, 1339–1346.

8 Matsumoto T, Kawakami M (1982) The unit-concept of hepatic parenchym: a re-examination based on angioarchitectural studies. *Acta Pathol Jpn* 32, 285–314.

9 Teutsch HF (2005) The modular microarchitecture of human liver. *Hepatology* 42, 317–325.

10 Ekataksin W, Wake K (1997) New concepts in biliary and vascular anatomy of the liver. *Prog Liv Dis* 15, 1–30.

11 Roessner A, Kolde G, Stahl K *et al.* (1978) Ultrastructural morphometric investigations on normal human liver biopies. *Acta Hepato Gastroenterol* 25, 119–123.

12 Rohr HP, Luthy J, Gudat F *et al.* (1976) Stereology of liver biopsies from healthy volunteers. *Virch Arch* 371, 261–263.

13 Bioulac-Sage P, Balabaud C (eds) (1988) *Sinusoids in Human Liver: Health and Disease*. Rijswijk: Kupffer Cell Foundation.

14 Wake K (1995) Structure of the sinusoidal wall in the liver. In Wisse E, Knook DL, Wake K (eds) *Cells of the Hepatic Sinusoid*. Leiden: Kupffer Cell Foundation, pp. 241–246.

15 Wisse E, de Zanger RB, Charels K *et al.* (1985) The liver sieve: considerations concerning the structure and function of endothelial fenestrae, the sinusoidal wall and the space of Disse. *Hepatology* 5, 683–692.

16 Blouin A, Bolender RP, Weibel ER (1977) Distribution of organelles and membranes between hepatocytes and nonhepatocytes in the rat liver parenchyma. A stereological study. *J Cell Biol* 72, 441–455.

17 Burt AD, Le Bail B, Balabaud C *et al.* (1993) Morphologic investigation of sinusoidal cells. *Semin Liver Disease* 13, 21–38.

18 Enomoto K, Nishikawa Y, Omori Y *et al.* (2004) Cell biology and pathology of liver sinusoidal endothelial cells. *Med Electron Microsc* 37, 208–215.

19 Braet F, Luo D, Spector I *et al.* (2001) Endothelial and pit cells in the liver. In: Arias IM, Boyer JL, Chisari FV *et al.* (eds) *The Liver. Biology and Pathobiology*, 4th edn. New York: Raven Press, pp. 437–453.

20 Braet F, Wisse E (2002) Structural and functional aspects of liver sinusoidal endothelial cell fenestrae: a review. *Comp Hepatol* 1, 1.

21 Naito M, Hasegawa G, Ebe Y *et al.* (2004) Differentiation and function of Kupffer cells. *Med Electron Microsc* 37, 16–28.

22 Nakatani K, Kaneda K, Seki S *et al.* (2004) Pit cells as liver-associated natural killer cells: morphology and function. *Med Electron Microsc* 37, 29–36.

23 Li D, Friedman S (2001) Hepatic stellate cells: morphology, function, and regulation in the liver. In: Arias IM, Boyer JL, Chisari FV *et al.* (eds) *The Liver. Biology and Pathobiology*, 4th edn. New York: Raven. Press, pp. 455–473.

24 Lepreux S, Bioulac-Sage P, Gabbiani G *et al.* (2004) Cellular retinol-binding protein-1 expression in normal and fibrotic/cirrhotic human liver: different patterns of expression in hepatic stellate cells and (myo)fibroblast populations. *J Hepatol* 40, 774–780.

25 Greenwel P, Rojkind M (2001) The extracellular matrix of the liver. In: Arias IM, Boyer JL, Chisari FV *et al.* (eds) *The Liver. Biology and Pathobiology*, 4th edn. New York: Raven Press, pp. 469–473.

26 Dubuisson L, Lepreux S, Bioulac-Sage P *et al.* (2001) Expression and cellular localization of fibrillin-1 in normal and pathological human liver. *J Hepatol* 34, 514–522.

27 McCuskey RS (1994) The hepatic microvascular system. In: Arias IM, Boyer JL, Chisari FV *et al.* (eds) *The Liver. Biology and Pathobiology*, 4th edn. New York: Raven Press, pp. 1089–1106.

28 Oda M, Yokomori H, Han JY (2003) Regulatory mechanisms of hepatic microcirculation. *Clin Hemorheal Microcirc* 29, 167–182.

29 Ekataksin W (2000) The isolated artery: an intrahepatic arterial pathway that can bypass the lobular parenchyma in mammalian livers. *Hepatology* 31, 269–279.

30 Evangelou E, Kyzas PE, Trikalinos TA (2005) Comparison of the diagnostic accuracy of lymphatic endothelium markers: Bayesian approach. *Mod Pathol* 18, 1490–1497.

31 McCuskey RS (2004) Anatomy of efferent hepatic nerves. *Anat Rec A Discov Mol Cell Evol Biol* 280, 821–826.

32 Ueno T, Bioulac-Sage P, Balabaud C *et al.* (2004) Innervation of the sinusoidal wall: regulation of the sinusoidal diameter. *Anat Rec Discov Mol Cell Evol Biol* 280, 868–873.

33 Alpini G, McGill JM, Larusso NF (2002) The pathobiology of biliary epithelia. *Hepatology* 35, 1256–1268.

34 Shibahara H, Tamada S, Goto M *et al.* (2004) Pathologic features of mucin-producing bile duct tumors: two histopathologic categories as counterparts of pancreatic intraductal papillary-mucinous neoplasms. *Am J Surg Pathol* 28, 327–328.

35 Theise ND, Saxena R, Portmann BC *et al.* (1999) The canals of Hering and hepatic stem cells in humans. *Hepatology* 30, 1425–1433.

36 Rosai J (2004) Gallbladder and extrahepatic bile ducts. Normal anatomy. In: Rosai J (ed.) *Rosai and Akerman's Surgical Pathology*, 9th edn. Edinburgh: Mosby, Edinburgh, pp. 1035–1036.

37 Terada T, Takanuma Y, Ohta G (1987) Glandular elements around the intrahepatic bile ducts in man; their morphology and distribution in normal livers. *Liver* 7, 1–8.

38 Balemba OB, Salter MJ, Mawe GM (2004) Innervation of the extrahepatic biliary tract. *Anat Rec A Discov Mol Cell Evol Biol* 280, 836–847.

1.3 Ultrastructure of the hepatocyte

Zahida Khan, James M. Crawford and Donna B. Stolz

Introduction to the hepatocyte

The hepatocyte is the chief parenchymal cell of the liver, and is responsible for maintaining a wide range of specialized functions. In mature male rat liver, hepatocytes comprise approximately 87% of the volume of intralobular liver tissue, with the remainder consisting of vascular space and non-parenchymal cells (Fig. 1, Table 1) [1]. Hepatocytes are large, multifaceted, polyhedral cells, with an approximate volume of 6800 μm^3 and a diameter between 10 and 30 μm. They are arranged in anastomosing plate-like cords separated by adjacent vascular sinusoids. Within the hepatic cords, between adjacent hepatocytes, lies a network of bile canaliculi, allowing passage of bile through intercellular channels, which drain into the nearest branch of the bile duct system.

This specialized architecture optimizes the liver's parallel functions as an exocrine gland, an endocrine gland as well as a blood filter. Owing to the liver's unique vascular organization, whereby blood percolates through the sinusoids from the place of inflow (the portal tract) to outflow (the terminal hepatic vein system), hepatocytes are exposed to a lobular gradient of oxygen, nutrients, toxins and other biologically active molecules. As a result, hepatocytes are not a metabolically homogeneous population of cells, and considerable zonal heterogeneity exists in both structure and function. Nevertheless, the hepatocyte cytoplasm throughout the lobule is packed with the requisite variety of organelles, and what follows is a brief description of each organelle or inclusion.

Hepatocytes maintain a particular organization with respect to other non-parenchymal cells residing in the sinusoid (Fig. 2). While fenestrated sinusoidal endothelial cells (SECs) abut most of the basal hepatocyte surface, stellate cells (SCs, also called cells of Ito or fat-storing cells) integrate between the SECs and the hepatocyte and can serve as contractile cells (Chapter 1.6).

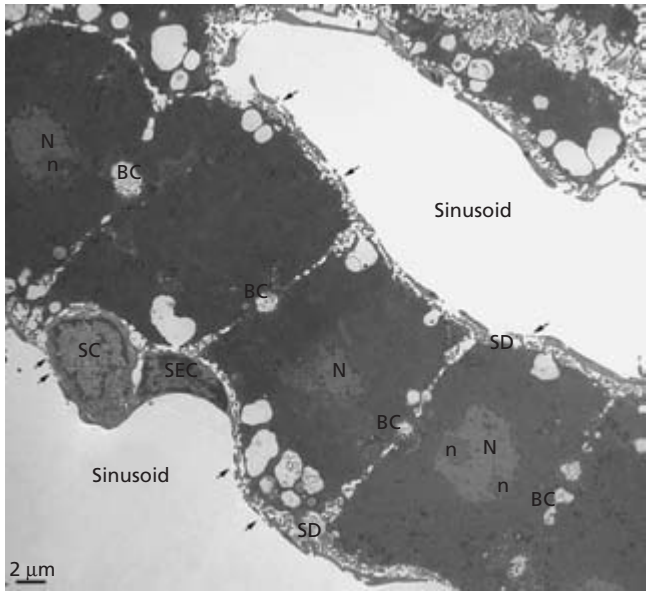

Fig. 1 Low-magnification transmission electron micrograph of a rat hepatic plate. Hepatocytes are aligned as a single layer of cells between the vascular capillaries called sinusoids. Hepatocyte apical membrane domains encircle the bile canaliculus (BC), basal membranes line the space of Disse (SD), while the lateral membranes occupy the remaining plasma membrane, between the BC and the SD. Sinusoidal endothelial cells (SECs) are highly fenestrated (arrows) and abut the hepatocytes along the SD. A stellate cell (SC) is visible within the SD, situated between the SEC and the hepatocyte. The hepatocyte nucleus (N) is centrally located and contains one or two nucleoli (n).

Table 1 Volumes of mononuclear rat hepatocyte organelles and inclusions (from ref. [1]).

Compartment	Volume (μm^3/cell)	Percentage of hepatocyte
Hepatocyte	6791	100
Nucleus	556	8
Cytoplasm	6215	92
Ground substance	4720	69
Lipid droplets	8	1
Mitochondria	1363	20
Peroxisomes	101	1–2
Dense bodies	32	0.5–1

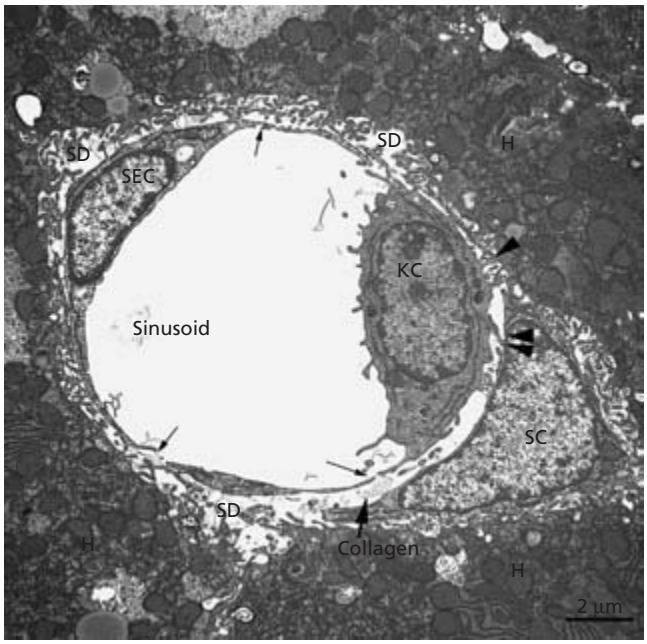

Fig. 2 Non-parenchymal cell organization within the sinusoid with respect to hepatic parenchyma. The sinusoidal endothelial cell (SEC) is fenestrated (arrows) and interacts with the hepatocyte (H) along the space of Disse (SD). Stellate cells (SC) occupy the area within the space of Disse between the SEC and the hepatocytes, often under collagen bundles. The resident macrophage, the Kupffer cell (KC), is adherent to the SEC luminal surface, but cell extensions can protrude through the SEC fenestrations and gaps to interact directly with hepatocytes (arrowhead) or stellate cells (double arrowhead).

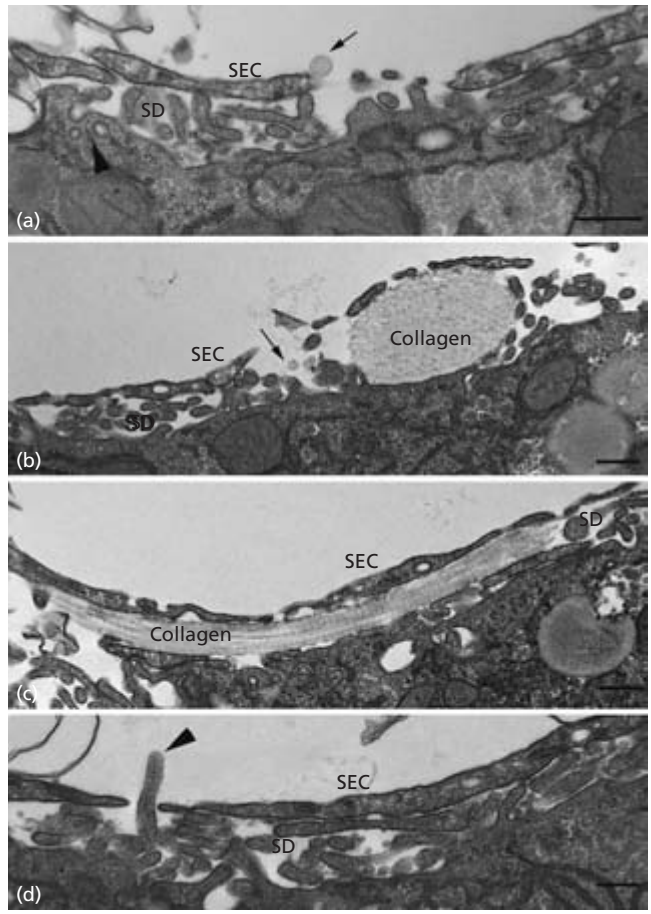

Fig. 3 Ultrastructure of the space of Disse. The space of Disse (SD) occupies the area between the sinusoidal endothelial cell (SEC) and the hepatocyte. The SD is filled with numerous microvilli originating from the hepatocyte (a–d). The basal surface of the hepatocyte has many vesicular structures (a, arrowhead), indicating its capacity for trafficking proteins and other molecules in and out of the cell (see also Fig. 13). Chylomicron remnants (a and b, arrows) are often found in SEC fenestrations and within the SD. Collagen bundles are scattered within the SD (b and c). Microvilli have been observed to protrude through the fenestrations of the SEC (d, arrowhead). Bars: 100 nm.

Kupffer cells, the resident tissue macrophages, attach to the luminal aspect of the SEC surface, but can also span through the SEC gaps and fenestrations to contact hepatocytes and/or stellate cells (Chapter 1.5).

Plasma membrane

Hepatocytes are polarized epithelial cells, yet they do not exhibit the typical basolateral-to-apical axis observed in simple bipolar epithelial cells [2]. On account of their polygonal shape, the hepatocyte's plasma membrane contains domains of subspecialization, which are localized to sinusoidal (basal), lateral, junctional and canalicular (apical) regions (see also Chapter 1.2). Approximately 40% of the hepatocyte surface is exposed to the vascular sinusoids [3]. The fenestrated endothelium lining the sinusoids is intimately associated with at least two faces of a hepatocyte, with no basement membrane in between them, such that each hepatocyte is bathed in plasma on both sides (Figs 1 and 5a). The basal sinusoidal membrane surface of hepatocytes, which delineates the perisinusoidal space (space of Disse), is populated by numerous finger-like projections (microvilli) that greatly enhance the surface area and the hepatocyte's capacity for receptor and transport functions (Fig. 3). Consequently, both coated and uncoated pits can be found at the base of microvilli, along with caveolae and clathrin-coated endocytic vesicles in the adjoining cytoplasm. On rare occasions, a microvillus may protrude through the fenestrae of a SEC and into the sinusoidal lumen (Fig. 3d); however, the functional significance of this finding is unknown. Other components of the space of Disse include chylomicron remnants, scattered collagen bundles and nerve processes.

In contrast, the hepatocyte's lateral membrane surface does not contain microvilli; it does contain Na^+/K^+-dependent ATPase transport activity, and is therefore capable of generating ion gradients that influence the transport function of the entire 'basolateral' domain of the hepatocyte plasma membrane [4]. In general, the lateral membranes of adjacent hepatocytes are relatively straight and separated by an intercellular space of 10 nm [5]. A number of membrane specializations are also present

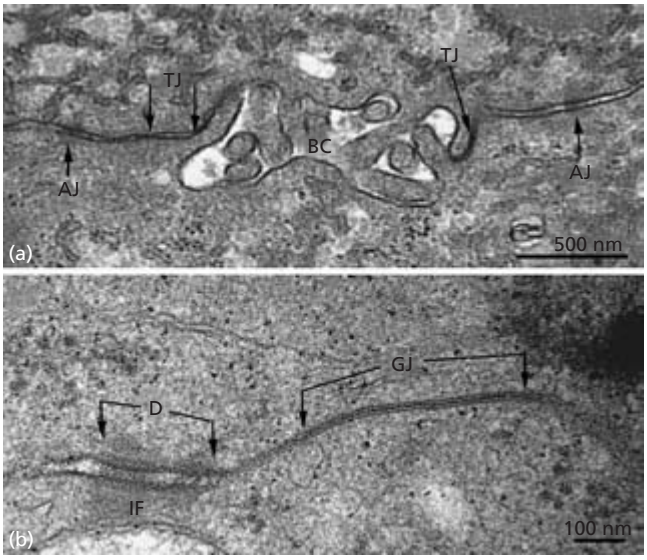

Fig. 4 Junctional components of the hepatocyte lateral membrane. (a) The tight junctions (TJ) surround the bile canaliculus (BC) and physically delineate the BC components from the lateral membrane space. Adherent junctions (AJ) are distal to the TJ and provide cytoskeletal support via microfilament connections. Together, the TJ and AJ are called the apical junctional complex. (b) Within the lateral membrane, desmosomes (D) serve as spot welds between adjacent hepatocytes and stabilize the connection by attachments with intermediate filaments. Gap junctions (GJ) allow for direct communication between cells. Located at areas of closely apposed membrane, gap junctions are composed of plasma membrane-spanning channels. These channels allow for the passage of small molecules such as ions, sugars, amino acids, etc. between cells.

along this region, mainly in the form of intercellular junctions. Saccular unions are simply interdigitating cytoplasmic protrusions of neighbouring plasma membranes. Junctional complexes are also present, consisting of tight junctions, adherent junctions, desmosomes and gap junctions (Fig. 4). Tight junctions, also called zonula occludens, are crucial for limiting the lateral movement of membrane proteins between apical and basolateral domains and maintaining the blood–bile barrier, but do demonstrate a degree of 'leakiness', as observed in the paracellular pathway of bile secretion [6]. Adherent junctions serve in an anchoring capacity and convey physical stability to the junction via actin cytoskeletal attachments. Together with the tight junction, these two components comprise the apical junction complex. Desmosomes, far less numerous in hepatocytes than the other components of the apical junction complexes, are analogous to strong 'spot welds' between neighbouring hepatocytes and are anchored by intermediate filaments. Gap junctions are composed predominantly of connexins and are involved in intercellular communication between hepatocytes in each cord, via exchange of small molecules < 1000 Da, including ions and metabolites.

Unlike the surrounding lateral membrane intercellular junctional region, the bile canalicular region is surrounded by a pericanalicular actin microfilament web integrated within and around the luminal microvilli [5]. The bile canaliculus is a highly specialized intercellular junction formed by plasma membranes of contiguous hepatocytes (Fig. 5). Bile canalicular membranes account for 15% of the hepatocyte's total plasma membrane surface [7]. They measure approximately 1 μm in

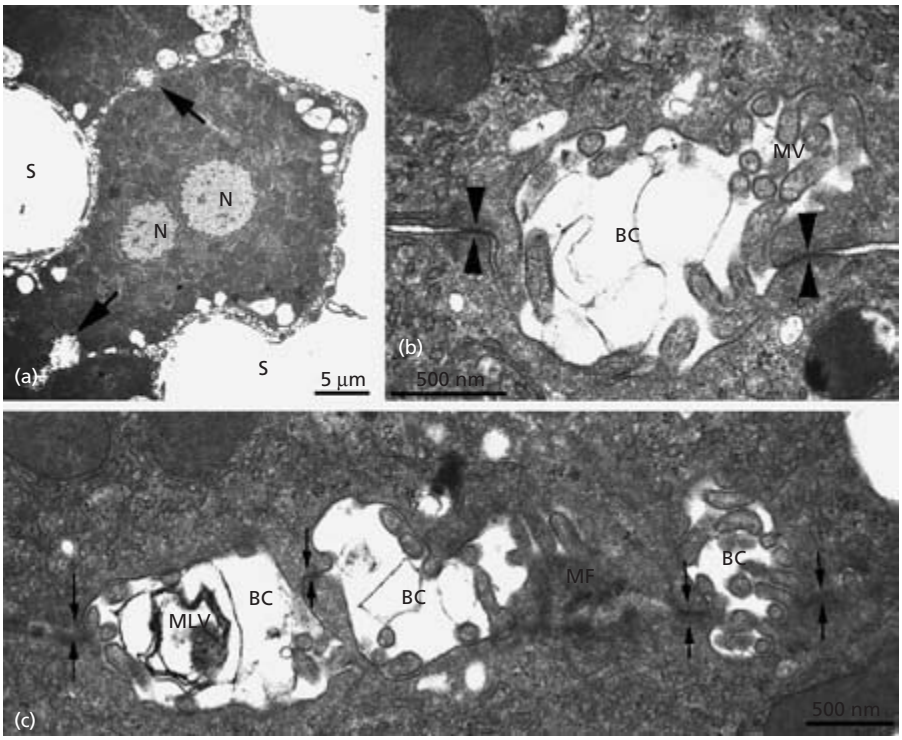

Fig. 5 Ultrastructure of bile canaliculus. (a) Localization of the bile canaliculus within the hepatic plate (arrows); S, sinusoid; N, nucleus (in binucleate hepatocyte). (b) Typical simple bile canaliculus (BC) bounded on either side by tight junctions (between arrowheads). Apical membrane contains many microvilli (MV). Individual lipid vesicles are present within the lumen. (c) Compound bile canaliculi (BC) between adjacent hepatocytes. Each BC is bounded by separate apical junctional complexes (arrows). Areas around the BC are concentrated with microfilaments (MF). A multilamellar vesicle (MLV) is present within one of the BC, the result of secondary transformations of intraluminal biliary lipid.

diameter and constitute the smallest passages of the proximal biliary system, collecting bile that is apically secreted from hepatocytes and channelling it towards the distal biliary tree [5]. The canalicular diameter of periportal hepatocytes is greater than that observed in centrolobular regions; however, structural alterations in canalicular size and morphology are also dependent on hepatocyte exposure to and secretion of bile acids, such as taurocholate [8]. Unilamellar lipid vesicles (~ 60–70 nm in diameter) can be found within the canalicular lumen and adherent to the luminal hemileaflet of the canalicular plasma membrane; their role in the release of phospholipids into the bile canalicular lumen is debated (Fig. 5) [9]. In addition, each bile canaliculus is surrounded by the pericanalicular cytoplasm. This zone (1 μm in radius) is dense in microfilaments, and it may function in canalicular contractility, a normal and spontaneous process that promotes the movement of bile through the canalicular network. Eventually, the bile canaliculus leads to the canals of Hering, which link the intralobular canalicular system to the biliary tree [10,11] (Fig. 6). Canals of Hering contain the purported resident hepatic stem cell, called the oval cell (see Chapter 1.9), which has the ability to differentiate into either a hepatocyte or a biliary epithelial cell (cholangiocyte). The oval cell is specifically associated with the bile canaliculus continuum and forms heterogeneous cell interactions with hepatocytes [12].

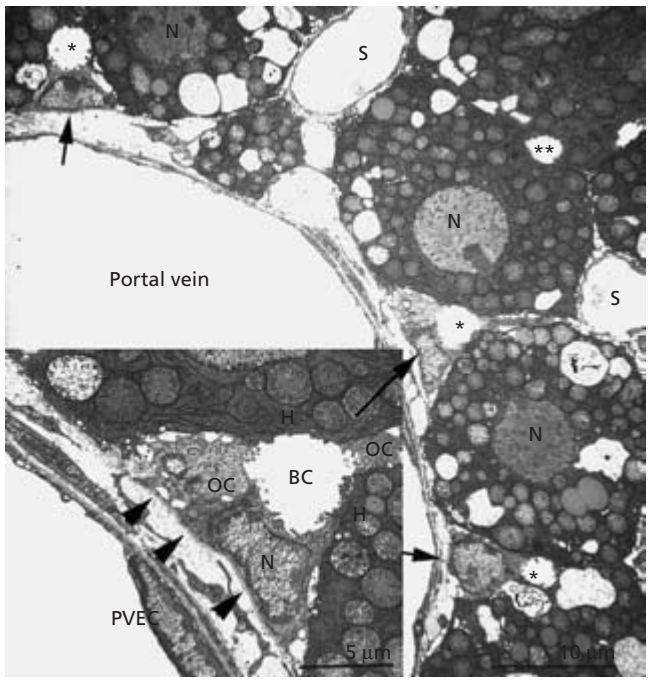

Fig. 6 Localization of canals of Hering (with bile duct epithelial cells and bipotential oval cells) in the periportal region of the mouse liver. The lumina of canals of Hering (*) constitute the terminal channels of the formal biliary tree, and have heterotypical cellular interactions between canal of Hering epithelial cells (arrows) and hepatocytes. These lumina are clearly distinct from homotypical hepatic cellular interactions of upstream bile canaliculi (BC, **). S, sinusoid; N, hepatocyte nucleus. Inset: high magnification of a canal of Hering. Oval cells (OC) are ultrastructurally distinct from mature bile duct epithelial cells or hepatocytes (H), with greatly reduced cytoplasm and a much smaller, oval nucleus. Unlike hepatocytes, oval cells have a basement membrane lining the basal membrane domain (arrowheads). PVEC, portal vein endothelial cell.

Table 2 Surface areas of the major intracytoplasmic organelles in mononuclear rat hepatocytes (from [1]).

Compartment	Surface (μm^2/cell)	Percentage of total membrane
Total intracytoplasmic membrane	120 298	100
Rough ER	23 228	19
Smooth ER	51 682	43
Golgi	3138	3
Mitochondria		
Outer envelope	7450	6
Inner membrane and cristae	34 800	29

Other organelles found in the pericanalicular cytoplasm include Golgi, lysosomes and clear vesicles thought to be involved in the transport of apoproteins and ligands for biliary secretion (see Chapter 2.6) [13,14].

Endoplasmic reticulum

In general, hepatocytes contain a substantial amount of both rough and smooth endoplasmic reticulum (ER) (Table 2). Individual distribution patterns can vary based on lobular differences. The most rough ER is found in zone 1 hepatocytes. Rough ER tends to form a perinuclear network of convoluted, parallel, flattened sacs (cisternae) that are actually continuous with each other, the smooth ER and the nuclear envelope (Fig. 7) [5]. A close association of rough ER with mitochondria has been observed, but there is no evidence of a direct communication between them [1].

Rough ER is the site of synthesis of secreted proteins. Protein synthesis involves translation of mRNA on ribosomes. Ultrastructurally, ribosomes are electron-dense granules measuring 15–30 nm in diameter [15]. It is estimated that a single hepatocyte contains over 10 million membrane-bound ribosomes, which cover the outer surface of rough ER (Fig. 7). In addition, a dynamic pool of free ribosomes and polyribosomes also exists in the cytoplasm, and these are responsible for synthesizing cytoplasmic and organellar proteins for the cell.

In continuity with the rough ER, the smooth ER forms an elaborate meshwork of small, smooth-surfaced tubules that are devoid of ribosomes and can communicate directly with the Golgi complex. Zone 3 hepatocytes contain the most smooth ER, which is often distributed in cytoplasmic regions rich in particulate glycogen (Fig. 7). In hepatocytes, smooth ER is specialized for several important metabolic functions, including the synthesis of lipids and bile acids, the storage of calcium and the glucuronidation of bilirubin. The enzyme glucose-6-phosphatase is localized primarily in the smooth ER, thereby permitting

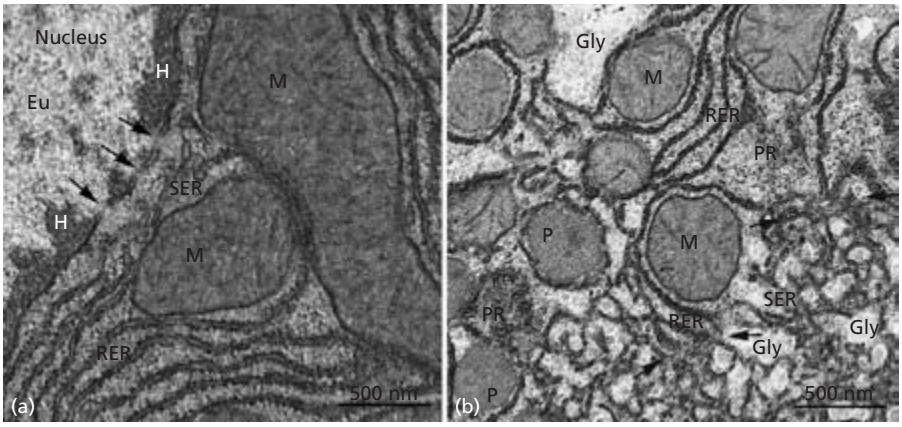

Fig. 7 (a) Hepatocyte nucleus showing euchromatin (Eu), heterochromatin (H) and nuclear pores (arrows) within the nuclear membrane. Smooth endoplasmic reticulum (SER) and rough endoplasmic reticulum (RER) are in close proximity with both the nuclear membrane and mitochondria (M). (b) SER is contiguous with RER as this transition can be seen (between arrows). Peroxisomes (P) and mitochondria (M) are found in close association with both SER and RER. Polyribosomes (PR) can be observed within the cytoplasm as well as particulate glycogen (Gly).

compartmentalization of glucose dephosphorylation from the major glucose-metabolizing systems in the cytoplasm (glycolysis, gluconeogenesis, glycogen synthesis and degradation).

The most crucial function of this organelle in the liver is drug detoxification. Smooth ER houses a number of microsomal mono-oxygenases, including cytochrome P450 enzymes, which are involved in hepatic phase I drug metabolism [16]. In fact, a variety of drugs and xenobiotics, such as phenobarbital, can lead to a massive proliferation of smooth ER, and this is reversed after drug withdrawal via autophagic vacuoles [17]. Of growing concern is the increased susceptibility of zone 3 hepatocytes to toxic injury, as their abundant smooth ER can convert harmless compounds, such as paracetamol and carbon tetrachloride, into damaging free radicals, resulting in liver damage.

Golgi complex

The Golgi apparatus is a highly compartmentalized complex of three to five flattened, parallel cisternae with smooth surfaces, and each layer is separated by a narrow space (20 nm) [5]. These closely packed saccules have dilated peripheral rims and are associated with secretory vesicles. The primary function of the Golgi is to accurately process and sort newly synthesized proteins. This involves posttranslational modifications (e.g. glycosylation, sulphation, phosphorylation), followed by packaging into vesicles that are targeted to the appropriate organelle or plasma membrane. Consequently, the Golgi complex is highly polarized, containing both *cis* and *trans* cisternae (Fig. 8). The convex *cis* surface (forming face) is fenestrated and receives macromolecules delivered by vesicular transport from the ER. Secretory vesicles arise from the concave *trans* surface, which has thicker membranes and forms a *trans*-Golgi network (TGN). In this respect, the Golgi is composed of a dynamic steady-state system of ER-derived membranes [18]. The secretory vesicles vary in size, number and content. In hepatocytes, a large number of Golgi secretory vesicles contain very-low-density lipoproteins (VLDLs), which appear ultrastructurally as spheres 50–70 nm in diameter (Fig. 8) [1]. VLDLs are rich in triglycerides and

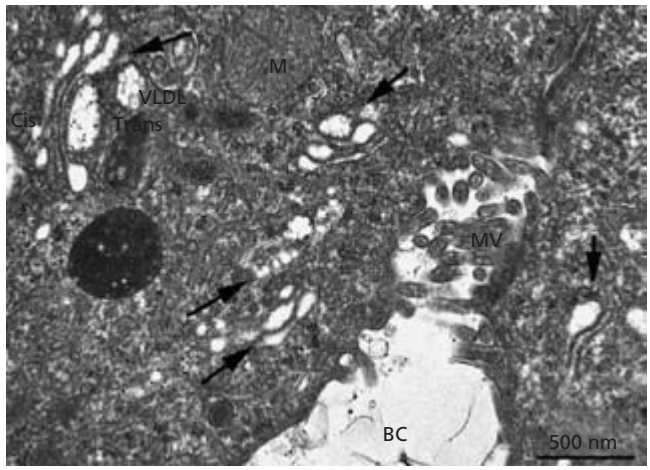

Fig. 8 Golgi apparatuses (arrows) are observed in close proximity to the bile canaliculus (BC). *Cis* and *trans* sides are labelled for one Golgi. Newly synthesized very-low-density lipoproteins (VLDL) are observed within the *trans* Golgi secretory vesicles. A multivesicular body (MVB) is observed in this field.

function in systemic lipid transport. Other vesicles can target acid hydrolases to lysosomes (described below).

Lysosomes, multivesicular bodies and autophagosomes

In general, lysosomes are electron-dense organelles surrounded by a single membrane. They exhibit a high degree of pleomorphism on account of their heterogeneous cargo and variable levels of maturation (Fig. 9). Lysosomes contain an impressive complement of luminal acid hydrolases, including proteases, nucleases, glucosidases, lipases, phospholipases, phosphatases and sulphatases. These hydrolytic enzymes enable the lysosome to degrade the vast majority of biological materials. Consequently, lysosomes can be difficult to identify, as their size and shape, as well as the contents of the individual vesicles, may be either homogenous or heterogeneous, electron dense or

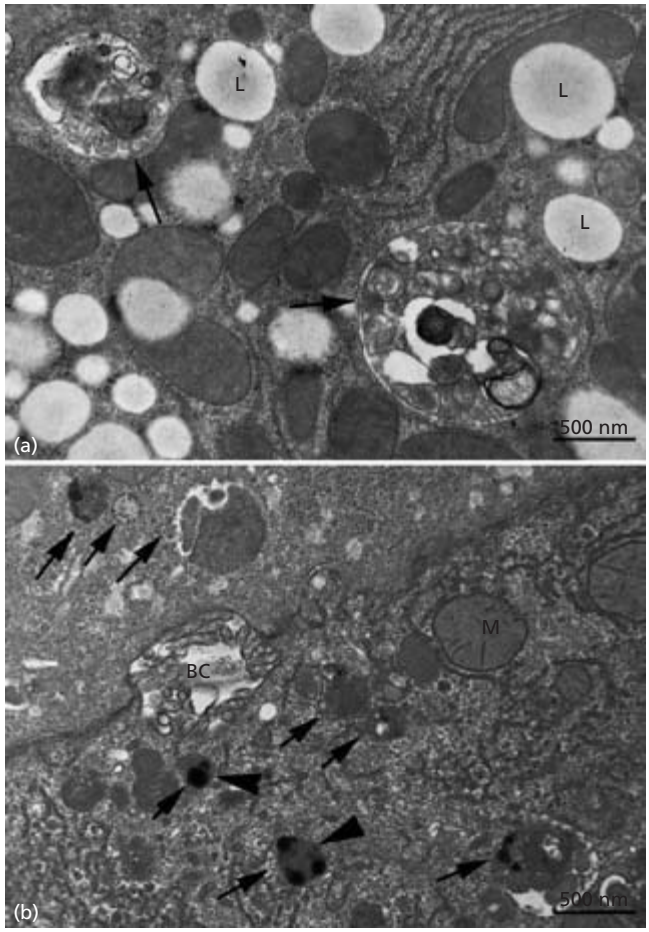

Fig. 9 (a) Lysosomes (arrows) are bounded by a single membrane and are extremely heterogeneous with respect to size, shape and contents. (b) Secondary lysosomes are common within the bile canalicular region of the hepatocyte. These more mature lysosomes are more electron dense (arrows) and often contain lipofuscin granules (arrowheads). BC, bile canaliculus; M, mitochondria; L, lipid.

finely granular, and may contain any number of inclusions [1]. Zone 1 hepatocytes contain the greatest amount of both lysosomes and their associated phosphatase activity.

Primary lysosomes that bud off the TGN are acid phosphatase positive and 25–50 nm in diameter [5]. Primary lysosomes fuse with late endosomes, whose contents are bound for degradation. The acid hydrolases donated by the primary lysosomes are activated by the acidic pH of late endosomes, thus forming a secondary (mature) lysosome. These can form residual bodies that often localize in the cytoplasm surrounding the canalicular region of hepatocytes [1,5]. A variety of secondary lysosomes have been described. Multivesicular bodies (MVB) contain multiple small endocytic vesicles that have turned 'inside-out' and have fused with larger vesicles (Figs 8 and 10) [19]. Eventually, MVB become increasingly electron dense as their contents are degraded. Alternatively, in many epithelial cells, MVB are known to fuse with the plasma membrane and expel the vesicular

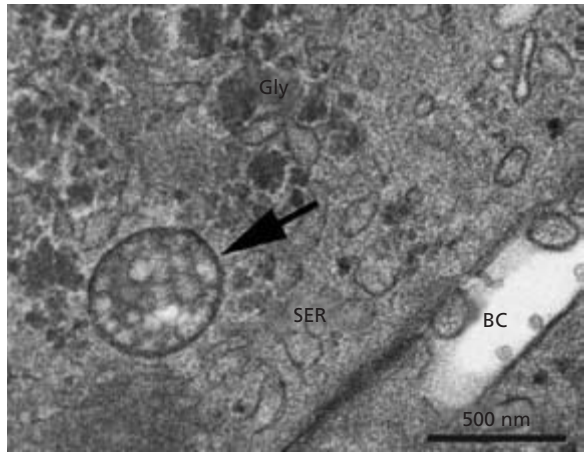

Fig. 10 Multivesicular body (arrowed) close to the bile canaliculus (BC). Glycogen (Gly) and smooth endoplasmic reticulum (SER) are also visible in the field) (see also Fig. 8).

contents into the extracellular space. In keeping with the pericanalicular localization of a portion of hepatocellular lysosomes, lysosomal contents can be discharged across the canalicular membrane of hepatocytes into bile [20]. Autophagosomes are involved in turnover and contain intact or partially digested organelles (Fig. 11). Lipofuscin granules, which are associated with ageing, are actually electron-dense lysosomes containing lipids and a heterogeneous matrix. Interestingly, hepatic lysosomes also appear to function as iron-storage vacuoles (siderosomes) that contain ferritin-like substances [21].

Mitochondria

Mitochondria are the most abundant organelles in hepatocytes (approximately 800 per cell), and they function in generating energy in the form of adenosine triphosphate (ATP) via oxidative phosphorylation. Mitochondria are large organelles, with an average diameter of up to 0.6 μm and an average length of up to 1.0 μm [22] (Fig. 7). They are actually highly mobile organelles, which closely associate with microtubules and constantly change their shape and position in the cell [5]. Mitochondria undergo turnover, with a half-life of 10.5 days, and their remnants are often identifiable in autophagosomes (Fig. 11). Furthermore, although the number of mitochondria decreases with age, mitochondrial volume remains constant because of increases in the size of the remaining organelles.

Ultrastructurally, mitochondria consist of a double membrane surrounding the mitochondrial matrix (Figs 7 and 12). An intermembrane space exists within the double membrane, where apoptosis-related proteins are confined (and subject to release into the cytoplasm if the 'mitochondrial phase transition' is activated). The outer membrane (OM) is smooth and helps to maintain shape. A number of enzymes are localized to the OM [5]. The inner membrane (IM) has numerous shelf-like

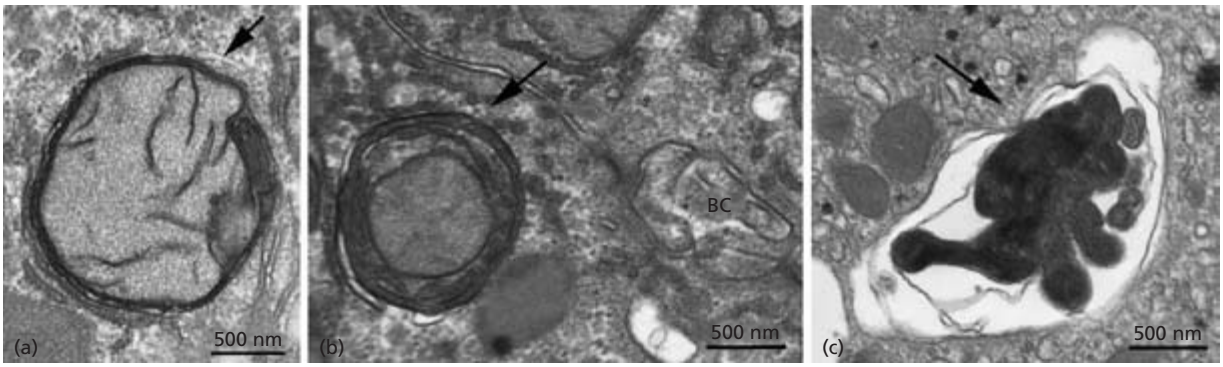

Fig. 11 Mitochondria at various stages of autophagy (arrows) in hepatocytes. (a) Early autophagosome, in which the mitochondrial ultrastructure (cristae) is still visible inside the double-membrane vesicle. (b) More mature mitochondrial autophagosome, in which the cristae structure is less apparent, but more layers of membrane within the autophagosome are visible. (c) More mature autophagosome with mitochondrial components highly condensed within the autophagosome.

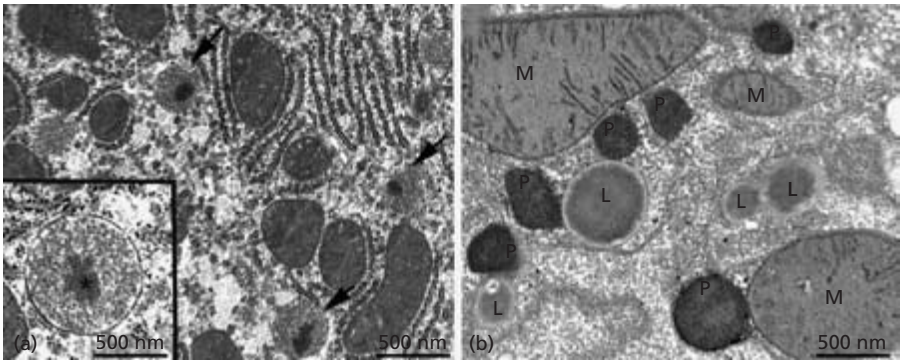

Fig. 12 (a) Peroxisomes (arrows), also called microbodies, are approximately 500 nm in diameter in hepatocytes. They are single membrane-bound organelles and, in rodents when viewed by transmission electron micrography (TEM), a dense core of crystalline urate oxidase is visible (inset, *). (b) Peroxisome (P) morphology can be enzymatically enhanced for light micrography and TEM by staining lightly fixed cells or tissues with 3,3′-diaminobenzidine hydrochloride using the method described by Fahimi [29]. M, mitochondria; L, lipids.

invaginations (cristae), which project into the matrix and greatly increase the IM's surface area for housing the electron transport chain and ATP synthases. The electron-dense mitochondrial matrix contains numerous metabolic enzymes involved in the urea cycle, fatty acid oxidation and the tricarboxylic acid (TCA) or Krebs cycle. Mitochondria are self-replicating, deriving proteins both from nuclear somatic genes and about 30 genes of mitochondrial DNA (mtDNA). In the latter instance, the mitochondrial matrix contains circular mtDNA, RNA and ribosomes, all of which are necessary for synthesizing mitochondria-encoded proteins. Mitochondria also contain electron-dense inclusions, representing calcium stores, which disappear rapidly during hypoxia [1]. Occasionally, other crystalloid structures may be apparent in both normal and diseased liver [23].

Peroxisomes (microbodies)

Unlike mitochondria, peroxisomes contain a fine granular, homogeneous matrix surrounded by a single membrane and are approximately 0.2–1.0 μm in diameter [1] (Figs 7 and 12). There are approximately 200 peroxisomes per hepatocyte, making the liver the organ with the most peroxisomes. These organelles are most abundant in zone 3 hepatocytes [5]. In contrast to the large peroxisomes found in liver and kidney, the peroxisomes of most other mammalian cells are much smaller (only 0.15–0.25 μm in diameter).

The peroxisomal matrix in rats contains a laminated crystalloid core, which is thought to represent the enzyme urate oxidase (Fig. 12). In contrast, peroxisomes from human livers very rarely exhibit this nucleoid core [1]. A vast repertoire of peroxisomal enzymes (e.g. oxidases, hydroxylases) has been identified, and these are involved in the synthesis of bile acids, cholesterol, carbohydrates and plasmalogen (an ether lipid), as well as in the metabolism of amino acids and purines. The initial steps in β-oxidation of very-long-chain fatty acids (VLCFAs) also occur in the peroxisome. Most importantly, the enzyme catalase, which detoxifies cellular H_2O_2, accounts for as much as 40% of total peroxisomal protein [5]. In hepatocytes, non-conventional peroxisomal enzymes have also been described, such as inducible nitric oxide synthase (iNOS, NOS2) [24,25].

The biogenesis of peroxisomes has been studied extensively in yeast [26]. Peroxisomes are continuously turned over and, in hepatocytes, their lifespan is only about 1 day. Of particular interest in liver is the phenomenon of peroxisome proliferation, in which certain stimuli can increase peroxisomal volume and density. This is observed in embryonic and postnatal liver

development, in recovery following partial hepatectomy and in response to various diseases. Specifically, the fibrate class of anti-hyperlipidaemic drugs (ethyl-α-*p*-chlorophenoxyisobutyrate, Clofibrate) and salicylates, as well as endogenous fatty acids, can induce peroxisome proliferation by activating the peroxisome proliferator-activated receptor (PPAR) family of transcription factors in rodents, but not in humans (discussed in later sections).

Intracellular vesicles

Casual inspection of almost any ultrastructural image of the hepatocyte cytoplasm will reveal countless intracellular vesicles approximately 100–200 nm in diameter (Fig. 13). These vesicles enable the endocytosis of extracellular proteins as well as trafficking of membrane proteins and sequestered luminal contents between the many organelles of the hepatocyte. In the first instance, a key mechanism for endocytic internalization of receptor-bound macromolecular ligands from the basolateral plasma membrane is via a highly coordinated coalescence of membrane protein receptors and recruitment of intracellular cytoskeletal and chaperone proteins (including especially the 'cage' molecule, clathrin), engendering first 'clathrin-coated pits' (invaginations of the plasma membrane) and then 'clathrin-coated vesicles' (in the cellular space directly beneath the plasma membrane). In the second instance, the magnitude of the trafficking between organelles such as the ER, Golgi apparatus and plasma membrane is staggering. Overall, the estimated internalization of basolateral plasma membrane area by endocytosis is about 2%/min [14]. The estimated delivery of plasma membrane lipid to the apical (canalicular) membrane of the hepatocyte is 9% of apical membrane area per minute. In order for the hepatocyte to remain at structural steady state, it is therefore necessary for the delivery of membrane lipid to the basolateral plasma membrane at a similar rate of 2%/min. In the case of the canalicular membrane, 8% of the canalicular membrane phospholipid is extruded into bile per minute, as part of normal bile secretion [14]. The remainder of the lipid mass of the canalicular membrane is retrieved back into the hepatocyte via apical endocytosis [27]. Hence, although attention is largely given to defined organelles in discussing the ultrastructure of the hepatocyte, one must acknowledge the profound dynamic contributions of intracellular vesicular traffic.

Additionally, caveolae are small invaginations found on the surface of most cells, including hepatocytes [28]. Latin for 'little caves', caveolae are small (50–100 nm), vessel-shaped invaginations that mediate various aspects of endocytosis including potocytosis, transcytosis and general membrane trafficking.

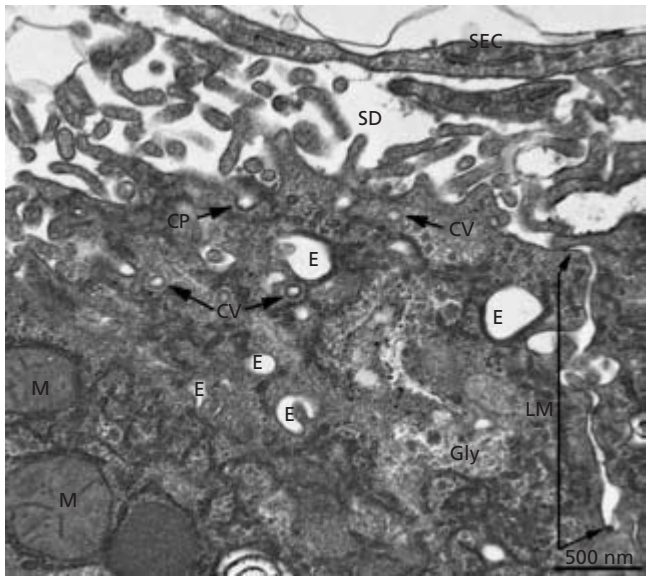

Fig. 13 Intracellular vesicle populations in close proximity to the hepatocyte basolateral membrane. Clathrin-coated pits (CP) regulate receptor-mediated endocytosis of ligands from the basal membrane abutting the space of Disse (SD) and are internalized to form coated vesicles (CV) within the cytoplasm. Coated vesicles can then fuse with endosomes (E), which tightly regulate intracellular trafficking of their contents to other destinations, as well as route contents for recycling or destruction. LM, lateral membrane; SEC, sinusoidal endothelial cell; M, mitochondria; Gly, glycogen.

Nucleus

The nucleus in hepatocytes is round or oval and approximately 6–7 μm in diameter (Figs 1, 5 and 7) [1]. Interestingly, hepatocytes can exhibit one or more centrally localized nuclei, each containing at least one nucleolus (Fig. 5). Within the nucleoplasm, clumps of electron-dense heterochromatin, often closely apposed to the nuclear membrane, can be observed, indicating tightly coiled, inactive chromosomes. Mitotic figures are rare in resting hepatocytes. The double membrane nuclear envelope fuses periodically to form nuclear pores, which are similar to those of other cell types (Fig. 7). The hepatocyte nucleus can also contain a number of inclusions. The most common inclusion is monoparticulate glycogen (30-nm particles), which can accumulate in large or small amounts [5]. Nuclear bodies are also frequent, consisting of 5- to 7-nm filamentous inclusions surrounded by a clear halo [5]. Lipid droplets are rare inclusions in normal hepatocyte nuclei.

References

1 Weibel ER, Staubli W, Gnagi HR *et al.* (1969) Correlated morphometric and biochemical studies on the liver cell. I. Morphometric model, stereologic methods, and normal morphometric data for rat liver. *J Cell Biol* 42, 68–91.

2 Tuma PE, Hubbard AL (2001) The hepatocyte surface: dynamic polarity. In: Arias IM, Boyer JL, Chisari FV *et al.* (eds) *The Liver: Biology and Pathobiology*, 4th edn. Philadelphia: Lippincott Williams & Wilkins, pp. 97–117.

3 Schaffner F, Popper H (1985) Structure of the liver. In: Berk JE (ed.) *Bockus Gastroenterology*. Philadelphia: W.B. Saunders, pp. 2625–2658.

4 Boyer JL, Allen RM, Ng OC (1983) Biochemical separation of Na+,K+-ATPase from a 'purified' light density, 'canalicular'-enriched plasma membrane fraction from rat liver. *Hepatology* 3, 18–28.
5 Phillips MJ, Poucell S, Patterson J *et al.* (1987) *The Liver: an Atlas and Text of Ultrastructural Pathology*. New York: Raven Press.
6 Boyer JL (1983) Tight junctions in normal and cholestatic liver: does the paracellular pathway have functional significance? *Hepatology* 3, 614–617.
7 Rohr HP, Luthy J, Gudat F *et al.* (1976) Stereology of liver biopsies from healthy volunteers. *Virchows Arch A Pathol Anat Histol* 371, 251–263.
8 Layden TJ, Boyer JL (1978) Influence of bile acids on bile canalicular membrane morphology and the lobular gradient in canalicular size. *Lab Invest* 39, 110–119.
9 Oude Elferink RP, Paulusma CC, Groen AK (2006) Hepatocanalicular transport defects: pathophysiologic mechanisms of rare diseases. *Gastroenterology* 130, 908–925.
10 Oshio C, Phillips MJ (1981) Contractility of bile canaliculi: implications for liver function. *Science* 212, 1041–1042.
11 Ujhazy P, Kipp H, Misra S *et al.* (2001) The biology of the bile canaliculus. In: Arias IM, Boyer JL, Chisari FV *et al.* (eds) *The Liver: Biology and Pathobiology*. Philadelphia: Lippincott Williams & Wilkins, pp. 362–372.
12 Saxena R, Theise ND, Crawford JM (1999) Microanatomy of the human liver: exploring the hidden interfaces. *Hepatology* 30, 1339–1346.
13 Jones AL, Schmucker DL, Mooney JS *et al.* (1979) Alterations in hepatic pericanalicular cytoplasm during enhanced bile secretory activity. *Lab Invest* 40, 512–517.
14 Crawford JM (1996) The role of vesicle-mediated transport pathways in hepatocellular bile secretion. *Semin Liver Dis* 16, 169–189.
15 Tanikawa K (1979) *Ultrastructural Aspects of the Liver and its Disorders.* Tokyo: Igaku-Shoin.
16 Fouts JR, Rogers LA, Gram TE (1966) The metabolism of drugs by hepatic microsomal enzymes. Studies on intramicrosomal distribution of enzymes and relationships between enzyme activity and structure of the hepatic endoplasmic reticulum. *Exp Mol Pathol* 5, 475–490.
17 Feldman D, Swarm RL, Becker J (1980) Elimination of excess smooth endoplasmic reticulum after phenobarbital administration. *J Histochem Cytochem* 28, 997–1006.
18 Lippincott-Schwartz J (2001) The endoplasmic reticulum and golgi complex in secretory membrane transport. In: Arias IM, Boyer JL, Chisari FV *et al.* (eds) *The Liver: Biology and Pathobiology*. Philadelphia: Lippincott Williams & Wilkins, pp. 119–131.
19 Cohen JH, Bouic P, Schmitt D *et al.* (1983) Endocytosis of class II histocompatibility antigens and formation of intracytoplasmic granules at the final differentiation stage of human B lymphocytes. *Immunol Lett* 7, 123–127.
20 Nakano A, Marks DL, Tietz PS *et al.* (1995) Quantitative importance of biliary excretion to the turnover of hepatic lysosomal enzymes. *Hepatology* 22, 262–266.
21 Selden C, Owen M, Hopkins JM *et al.* (1980) Studies on the concentration and intracellular localization of iron proteins in liver biopsy specimens from patients with iron overload with special reference to their role in lysosomal disruption. *Br J Haematol* 44, 593–603.
22 Ma MH, Biempica L (1971) The normal human liver cell. Cytochemical and ultrastructural studies. *Am J Pathol* 62, 353–390.
23 Ma MH, Goldfisher S, Biempica L (1972) Morphology of the normal liver cell. *Prog Liver Dis* 4, 1–17.
24 Stolz DB, Zamora R, Vodovotz Y *et al.* (2002) Peroxisomal localization of inducible nitric oxide synthase in hepatocytes. *Hepatology* 36, 81–93.
25 Loughran PA, Stolz DB, Vodovotz Y *et al.* (2005) Monomeric inducible nitric oxide synthase localizes to peroxisomes in hepatocytes. *Proc Natl Acad Sci USA* 102, 13837–13842.
26 Heiland I, Erdmann R (2005) Biogenesis of peroxisomes. Topogenesis of the peroxisomal membrane and matrix proteins. *FEBS J* 272, 2362–2372.
27 Rahner C, Stieger B, Landmann L (2000) Apical endocytosis in hepatocytes in situ involves clathrin, traverses a subapical compartment, and leads to lysosomes. *Gastroenterology* 199, 1692–1707.
28 Calvo M, Tebar F, Opez-Iglesias C *et al.* (2001) Morphologic and functional characterization of caveolae in rat liver hepatocytes. *Hepatology* 33, 1259–1269.
29 Fahimi HD (1969) Cytochemical localization of peroxidatic activity of catalase in rat hepatic microbodies (peroxisomes). *J Cell Biol* 43, 275–288.

1.4 Liver sinusoidal endothelial cells

David Semela and Vijay H. Shah

Introduction

Liver sinusoidal endothelial cells (LSEC) form a highly specialized layer of cells lining the plates of hepatocytes. LSEC constitute a mechanical filter and a metabolic organ that is critically involved in multiple physiological and pathological processes such as liver organogenesis, liver regeneration, chronic inflammatory liver disease and hepatocarcinogenesis. This chapter will review the current knowledge of LSEC and their role in specific liver conditions.

Role of LSEC in liver homeostasis

It is estimated that 1×10^8 (20%) of all cells in the liver are LSEC, which is the most frequent cell type in the liver after hepatocytes. LSEC form the hepatic microvasculature called liver sinusoids, which consist of LSEC plates between plates of hepatocytes. In comparison to the microvasculature of most other organs and large liver blood vessels, liver sinusoids lack an underlying basement membrane [1]. The vascular bed in the liver is characterized by a discontinuous endothelial cell lining and sieve-like endothelial cells with fenestrae (pores) (Fig. 1). These plates filter the fluids that are exchanged between the sinusoidal lumen and the space of Disse, defined as the perisinusoidal space separating the sinusoids from the adjacent hepatocytes (see Chapter 2.1.2) [2]. Endothelial fenestrae measure 150–175 nm, occur at a frequency of 9–13/μm^2 and occupy 6–8% of the total endothelial surface in scanning electron microscopy preparations [3]. Endothelial fenestrae have a lobular gradient in diameter and frequency along a portal to central axis [3], resulting in a higher porosity in centrolobular regions. The diameter of fenestrae can be influenced by different agents, such as serotonin, CCl_4, alcohol, nicotine, pantetheine and pressure [2,4–6]. Because of the limited porosity (< 10%) of the endothelial cells, they constitute a barrier that protects the parenchymal cells from direct contact with the blood. The fenestrated lining blocks the passage of particles larger than about 200 nm, such as chylomicrons [7,8]. Chylomicron remnants, which, after being metabolized by lipoprotein lipase, are smaller (30–80 nm) than chylomicrons, can enter the space of Disse and can be metabolized further by hepatocytes [9]. Fenestrae are surrounded by an intracellular filamentous, fenestrae-associated cytoskeleton ring composed of microfilaments, intermediate filaments and microtubules [10]. The diameter of this ring can increase or decrease, and reorganization of the cytoskeleton can form additional fenestrae within minutes upon stimulation [10–12]. The contraction of fenestrae after serotonin administration is associated with an increase in calcium [10]. Vascular endothelial growth factor (VEGF) induces fenestration in LSEC, possibly through caveolin-1 protein [12].

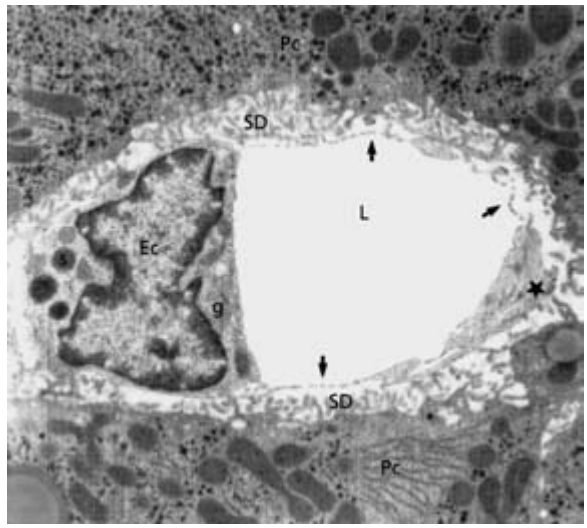

Fig. 1 Endothelial cell surrounding the sinusoidal lumen. The endothelial cell lining is fenestrated and separates the space of Disse from the lumen. It is thought that all transport between the lumen and the parenchymal cells has to pass through this filter. The endothelial lining seems to be supported by processes of fat-storing cells (asterisk). Endothelial cells of the sinusoids have a high endocytotic and digestive capacity, reflected here by the presence of lysosomes, which are quite abundant in these cells. Ec, endothelial cell; g, Golgi apparatus; L, sinusoidal lumen; SD, space of Disse; Pc, parenchymal cell.

LSEC represent an important blood clearance system and possess specialized endocytotic mechanisms for uptake of

various substances (i.e. transferrin, ceruloplasmin, transcobalamine II, heparin, albumin, lipoproteins and hyaluronate) and antigens. Hyaluronate is a high-molecular-mass polysaccharide that is cleared from the circulation by LSEC through receptor-mediated endocytosis. The ability of LSEC to take up hyaluronate is used as a functional marker of sinusoidal endothelial cells [13,14]. Rising serum hyaluronate levels correlate with decreased endocytotic capabilities of LSEC and have been used as an adjunctive test in the assessment of patients with alcoholic liver disease [15]. The mannose receptor has been well studied for its role in binding and internalizing compounds or antigens that contain specific terminal glycoproteins [16, 17]. Ligands are delivered to endosomes and lysosomes after internalization for degradation, and receptors are recycled by returning to the cell surface [17].

LSEC play an important role in immunity and inflammation [18,19]. LSEC facilitate adhesion of leukocytes and lymphocytes by secreting chemokines and expressing molecules such as vascular cell adhesion molecule 1 (VCAM-1), vascular adhesion protein (VAP-1) and intercellular adhesion molecule 1 (ICAM-1) [20–22]. LSEC are in direct contact with bloodborne antigens that traverse the bowel mucosa and enter the portal circulation intact. They are very efficient at antigen uptake through their scavenging receptors [18]. Besides major histocompatibility complex (MHC) class I molecules, they also express MHC class II molecules and can act as antigen-presenting cells to T cells [23,24]. They have been shown to prime naive CD4+ T cells [25]. LSEC can cross-present exogenous antigens and render CD8+ T cells tolerant, possibly explaining the phenomenon of immunological tolerance in liver transplant patients and of avoidance of unwanted autoimmune reactions against food antigens [24,26].

LSEC are key players in angiogenesis and vasculogenesis of the liver, which are defined as the formation of new blood vessels from pre-existing vascular beds and *de novo* organization of endothelial cells into vascular structures respectively. Formation of new blood vessels starts with activation of LSEC, which will then proliferate, migrate and, finally, assemble into vascular structures. As described below, this process requires a complex interplay of cells and angiogenic factors and is found in virtually all physiological and pathological hepatic processes.

Molecular biology and signalling in LSEC

In the past decade, tremendous insight has been gained into the molecular biology and signalling pathways of endothelial cells. Numerous receptors and ligands [i.e. VEGF/VEGF receptors (VEGFR), hepatocyte growth factor (HGF)/c-MET, angiopoietins/Tie, fibroblast growth factor (FGF)/FGF receptor, nitric oxide (NO)/integrins] and their role in proliferation, migration, survival and apoptosis of endothelial cells have been identified. VEGF (VEGF-A), a 45-kDa homodimeric glycoprotein that can be produced and secreted by most mammalian cells is the most important growth and survival factor for LSEC and endothelial cells in general [27]. VEGF expression is upregulated through different cytokines, growth factors and hypoxia-inducible factor (HIF)-1α (Fig. 2) [27]. Its effects are mediated mainly through the cell surface tyrosine kinase receptors VEGFR-1 [also known as fms-like tyrosine kinase (Flt)-1 or FLT-1 in humans] and VEGFR-2 [also known as mouse fetal liver kinase (Flk)-1 or kinase domain region (KDR) in humans] [27]. VEGFR-1 is highly expressed in LSEC and in endothelial cells of hepatic arterioles [28,29]. VEGFR-2 expression in resting liver is limited to endothelial cells of the larger hepatic vessels, whereas LSEC upregulate VEGFR-2 during liver regeneration [28]. VEGFR-3 [fms-like tyrosine kinase (Flt)-4] has not been detected on LSEC in resting or regenerating liver [28]. Most of the endothelial cell signalling studies have used human umbilical vein endothelial cells, so-called HUVECs, rather than LSEC. However, liver-specific data are emerging, especially from studies using partial hepatectomy in rodents as a model for studying LSEC and their cross-talk with hepatocytes during hepatic regeneration [28–32]. The differential effects of VEGFR-1 and -2 in LSEC are summarized in Table 1. It is now well established that VEGF

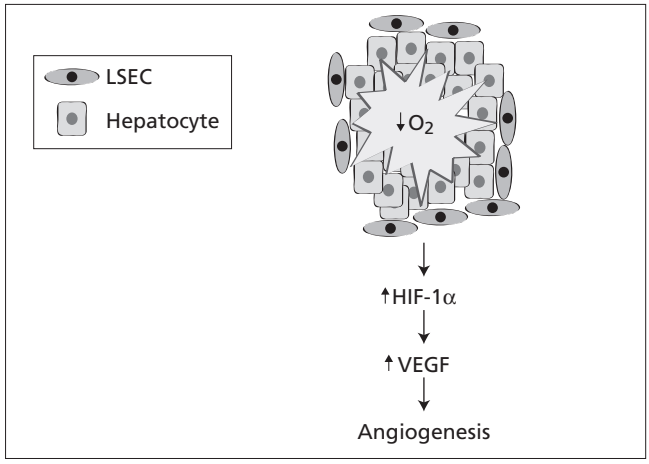

Fig. 2 Hypoxia is a potent stimulator of VEGF expression and angiogenesis. Hypoxia-inducible factor (HIF)-1α is the key transcription factor in hypoxic states in the liver, and it induces the expression of several hypoxia response genes such as *VEGF* and *VEGFR1*. LSEC, liver sinusoidal endothelial cells; HIF-1α, hypoxia-inducible factor 1α; VEGF, vascular endothelial growth factor.

Table 1 Differential effects of VEGF receptors 1 and 2 in liver sinusoidal endothelial cells [27].

VEGF receptor 1	VEGF receptor 2
Release of HGF and IL-6	Migration
Cross-talk with VEGF receptor 2	Proliferation
Induction of MMP-9	Survival
Decoy for VEGF	Angiogenesis

VEGF, vascular endothelial growth factor; HGF, hepatocyte growth factor; IL-6, interleukin-6; MMP-9, matrix metalloproteinase 9.

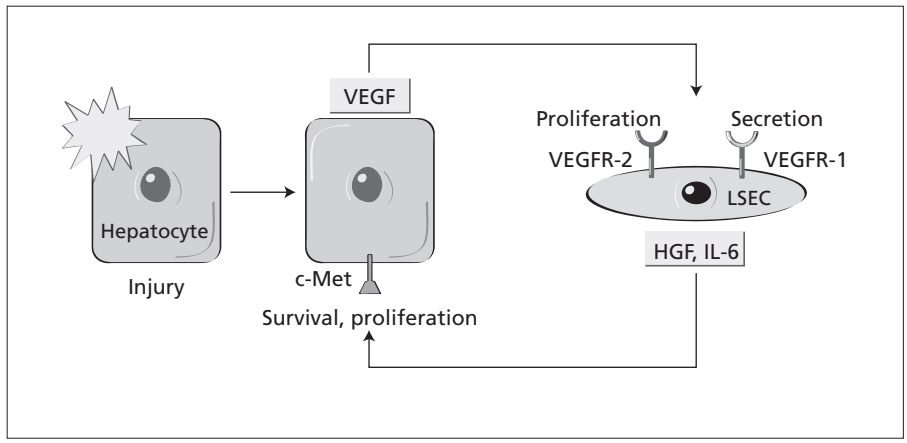

Fig. 3 Paracrine signalling between LSEC and hepatocytes. During liver regeneration, VEGF is produced by hepatocytes and induces the secretion of growth factors such as hepatocyte growth factor (HGF) and interleukin-6 (IL-6) from LSEC, which in turn stimulate hepatocyte proliferation. Activation of VEGFR-2 on LSEC stimulates proliferation, whereas growth and survival are mediated through VEGFR-1. LSEC, liver sinusoidal endothelial cells; VEGF, vascular endothelial growth factor; VEGFR-1, vascular endothelial growth factor receptor 1; VEGFR-2, vascular endothelial growth factor receptor 2; c-Met, hepatocyte growth factor receptor.

secreted by hepatocytes stimulates LSEC proliferation and liver angiogenesis by signalling through VEGFR-2, whereas activation of VEGFR-1 on LSEC induces the secretion of liver-specific growth factors such as HGF and interleukin (IL)-6, which will promote survival and proliferation of hepatocytes during liver regeneration (Fig. 3). Many of the over 70 activated genes during liver regeneration encode angiogenic growth factors and receptors other than the VEGF and HGF/c-Met signalling pathways [i.e. angiopoietins, platelet-derived growth factor (PDGF), fibroblast growth factor (FGF)] (reviewed in [32]). Similar interactions between endothelial cells and hepatocytes are at play during liver organogenesis (see below).

NO is another key signalling pathway in LSEC. Production of NO via endothelial NO synthase (eNOS) is limited to endothelial cells among all liver cell types [21]. LSEC-derived NO regulates blood flow through sinusoids via paracrine effects on hepatic stellate cells [33]. Shear stress is a key regulator of LSEC NO production, a characteristic that may autoregulate hepatic blood flow [34]. For example, if sinusoidal blood flow is high, eNOS-mediated production of NO dilates the vascular bed, thereby decreasing resistance [34]. In cirrhosis, eNOS-derived production in liver is decreased [35]. Other important agonists that activate eNOS include endothelin (via the ET-B receptor), VEGF, estrogen and others [33,36–38]. Inducible NO synthase (iNOS) is induced upon stimulation by liver injury or cytokine induction [39,40]. LSEC produce NO via iNOS in response to interferon (IFN)-γ and lipopolysaccharide (LPS) [41]. In contrast, tumour necrosis factor (TNF)-α and IL-1β, which stimulates the induction of iNOS in hepatocytes, does not induce iNOS in LSEC [41]. Thus, both eNOS and iNOS are important regulators of NO generation in LSEC depending on the haemodynamic/pathophysiological circumstance.

VEGF and NO have recently been shown to be necessary to maintain the phenotype of LSEC [42]. Inhibition of VEGF or NO signalling causes dedifferentiation of LSEC with loss of fenestrae and the appearance of CD31 on the cell surface. Dedifferentiation is also called capillarization and occurs in various liver pathologies.

Recent advances in large-scale screening technologies for genes and proteins and in the isolation of LSEC allow the investigation of different expression patterns between normal LSEC and activated LSEC in diseased liver tissue. These techniques can identify functional genes using cDNA expression libraries from human LSEC isolated, for example, from hepatocellular carcinoma (HCC) or endothelial surface markers using subtractive proteomic mapping [43–45].

LSEC in specific liver conditions

Liver organogenesis

Liver sinusoids form during liver organogenesis by vasculogenesis, which is defined as *de novo* organization of endothelial cells and/or angioblasts into blood vessels in the absence of any pre-existing vascular system. Liver sinusoids develop between gestational weeks 4 and 12 and are accompanied by recruitment of haematopoietic cells to fulfil the intrahepatic haematopoietic function, which begins by week 7 of gestation and reaches a maximum by week 12 of gestation [46,47]. The differentiation of LSEC during liver organogenesis has been studied in human fetuses, and two phases of differentiation have been identified [47]. In an early phase of structural differentiation (gestational weeks 5–12), LSEC lose markers of continuous endothelium (i.e. CD31, CD34, 1F10). The composition of the subendothelial matrix shifts during this phase from a typical vascular basement membrane (rich in laminin, devoid of tenascin) to that of an adult perisinusoidal matrix (low in laminin and rich in tenascin) [47]. A later structural differentiation (gestational weeks 10–20) is characterized by the acquisition of the markers of adult sinusoidal endothelial cells (CD4, ICAM-1, FcR IgG II, CD14) [47].

Endothelial cells are also critical for normal development of the liver parenchyma and induce the outgrowth of the liver bud into the mesenchyme [46]. Cross-talk between LSEC and hepatocytes through VEGF and HGF signalling has been shown to be crucial during liver organogenesis. Knockout mice for *VEGF* [48,49], *VEGFR1* [50,51] or *VEGFR2* [46] result in embryonic

lethality at embryonic (E) days E11–E12, E8.5 and E9.5–E10.5 respectively. *VEGFR2*-deficient mice lack mature endothelial cells and blood vessels and fail to develop a liver bud [46]. Knockout mice for *HGF* [52,53] or the HGF receptor c-Met [54] fail to complete development and also die *in utero* between days E13.5 and E16.5. The livers of these mice are small and show extensive loss of parenchymal cells.

Liver regeneration

LSEC are key players in the process of liver regeneration and have been studied extensively in animal models after partial hepatectomy. Regrowth of liver after resection or liver injury is angiogenesis dependent and can be accelerated by proangiogenic growth factors such as VEGF [29,55–57] or inhibited by LSEC-inhibiting factors such as angiostatin or TNP-470 [58,59]. Detailed studies have shown that, following hepatectomy, LSEC are activated and start to proliferate after hepatocytes, which initially form avascular clusters of 10–14 cells [28,60]. Attracted by chemotactic stimuli, LSEC will migrate and finally revascularize these islands [28,60]. In a final step, the normal architecture of liver sinusoids with fenestrated LSEC is reconstituted [28,60]. Endothelial progenitor cells, mobilized from bone marrow by systemically circulating growth factors and chemokines produced in the regenerating liver, contribute by homing to these sites of neovascularization in the liver and by committing to sinusoidal endothelial cells [61].

On a molecular level, it has been shown that hepatocyte production of VEGF reaches a peak 2–3 days after hepatectomy and is detected mainly in periportal hepatocytes [56,60]. At the same time, LSEC increase the expression of VEGFR-1 and VEGFR-2 and release HGF, which is the most potent stimulator of hepatocyte proliferation (see above and Fig. 3) [28,29]. Neutralizing antibodies against VEGF inhibit LSEC and hepatocyte proliferation, whereas administration of additional VEGF in hepatectomized rodents increases their proliferation [55,56], accelerates gain in liver mass [29] and improves functional hepatic recovery [57].

Hepatocellular carcinoma

Growth of solid tumours such as HCC is dependent on angiogenesis for vascular supply of the malignant tissue [62]. Proliferation of local LSEC and possibly incorporation of circulating endothelial progenitor cells contribute to the formation of new blood vessels in HCC, which is a hypervascular tumour characterized by blood supply derived exclusively from the hepatic artery [62]. This process is regulated by a well-coordinated interplay of various growth factors secreted by hepatocytes, neoplastic cells, hepatic stellate cells and tumour-infiltrating inflammatory cells [63–66]: tumour hypoxia leads to stabilization of HIF-1α with subsequent upregulation of proangiogenic growth factors such as VEGF, which stimulate LSEC proliferation, migration and survival. In addition, genetic mutations in neoplastic hepatocytes lead to secretion of proangiogenic growth factors and LSEC stimulation. Multiple studies have shown the overexpression of VEGF and other endothelial cell growth factors in HCC [67–76]. Various growth factors [i.e. basic FGF, transforming growth factor (TGF)-α, epidermal growth factor (EGF), PDGF] and cytokines (i.e. IL-1β, TNF-α, IFN-α and -γ) increase the secretion of VEGF in HCC cell lines [68]. Expression of VEGF increases gradually during hepatocarcinogenesis from low-grade dysplastic nodules to high-grade dysplastic nodules to early HCC, and correlates with LSEC microvessel density and sinusoidal capillarization, characterized by loss of fenestrae and development of a basement membrane [66,77]. Serum VEGF levels in patients with HCC correlate with tumour expression of VEGF, stage of HCC, absence of tumour capsule, presence of intrahepatic metastasis, presence of microscopic venous invasion and postoperative recurrence [78–81]. The pretreatment serum VEGF level is a significant inverse predictor of survival in HCC patients undergoing resection and in patients with unresectable HCC undergoing transcatheter arterial chemoembolization [75,82].

Antiangiogenic therapies targeting VEGF and other signalling pathways in LSEC are currently being evaluated in patients with HCC [62]. Genomic and proteomic analysis of isolated LSEC from HCC are promising new strategies for the identification of novel markers and LSEC targets for antiangiogenic therapy in HCC [43–45].

Chronic liver disease

Chronic liver disease with fibrosis and cirrhosis leads to the formation of an abundant vascular network and abnormal hepatic microcirculation [83–86]. The deposited matrix proteins of fibrosis contain and sequester different angiogenic factors such as VEGF, which are liberated during remodelling of the connective tissue framework by proteolytic enzymes such as matrix metalloproteinases [87,88]. Additionally, hypoxia-driven hepatocyte production of VEGF is upregulated during fibrogenesis leading to LSEC proliferation and angiogenesis [89,90]. Hypoxia and VEGF induce the expression of type 1 collagen in activated hepatic stellate cells [90,91]. Neutralizing antibodies against VEGFR-1 and VEGFR-2 in murine CCl_4-induced liver fibrosis both suppressed neovascularization in the liver and significantly attenuated the development of fibrosis and the increase in fibrosis markers [92]. Other studies have demonstrated that LSEC are also able to produce extracellular matrix components such as fibronectin, laminin and type 4 collagen when stimulated with TGF-β [93,94].

Development of portal–systemic collateral vessels in portal hypertension is a mechanical consequence of high vascular resistance and increased portal pressure with subsequent opening of collateral vessels [95]. However, recent evidence suggests that active, VEGF-dependent angiogenesis also contributes to this process as the expression of VEGF and VEGFR-2 increases in splanchnic organs after partial portal vein ligation in mice in a

time-dependent fashion during the evolution of portal hypertension [96]. Antibodies against VEGFR-2 and VEGFR-2-specific tyrosine kinase inhibitor, given to these animals after ligation, inhibit the formation of portal–systemic collateral vessels [96]. In liver cirrhosis, NO production from LSEC is diminished, whereas production of the constrictor ET-1 is increased, which contributes to the high vascular resistance in portal hypertension [33,35]. This most likely occurs through defects in posttranslational processing of eNOS [38,39].

LSEC in the ageing liver

With ageing, a decrease in the number of fenestrae in LSEC has been described (pseudocapillarization) [97]. It has been hypothesized that this process may lead to disordered lipid metabolism and enhance atherosclerosis as chylomicron remnants are less and less able to traverse the liver sieve [97,98]. The cause of these age-related changes is unclear, although chronic exposure to oxidants and alcohol have been shown to induce changes in LSEC [9,99].

It is beyond the scope of this chapter to cover all diseases affecting LSEC. Veno-occlusive disease (VOD), drug toxicity, ischaemic–reperfusion injury and rejection after liver transplantation will be discussed in other chapters.

References

1 Braet F, Wisse E (2002) Structural and functional aspects of liver sinusoidal endothelial cell fenestrae: a review. *Comp Hepatol* 1 (1), 1.

2 Horn T, Christoffersen P, Henriksen JH (1987) Alcoholic liver injury: defenestration in noncirrhotic livers – a scanning electron microscopic study. *Hepatology* 7 (1), 77–82.

3 Wisse E, De Zanger RB, Charels K *et al.* (1985) The liver sieve: considerations concerning the structure and function of endothelial fenestrae, the sinusoidal wall and the space of Disse. *Hepatology* 5 (4), 683–692.

4 Fraser R, Clark SA, Day WA *et al.* (1988) Nicotine decreases the porosity of the rat liver sieve: a possible mechanism for hypercholesterolaemia. *Br J Exp Pathol* 69 (3), 345–350.

5 Braet F, De Zanger R, Sasaoki T *et al.* (1994) Assessment of a method of isolation, purification, and cultivation of rat liver sinusoidal endothelial cells. *Lab Invest* 70 (6), 944–952.

6 Braet F, Kalle WH, De Zanger RB *et al.* (1996) Comparative atomic force and scanning electron microscopy: an investigation on fenestrated endothelial cells in vitro. *J Microsc* 181 (1), 10–17.

7 Naito M, Wisse E (1978) Filtration effect of endothelial fenestrations on chylomicron transport in neonatal rat liver sinusoids. *Cell Tissue Res* 190 (3), 371–382.

8 Fraser R, Bosanquet AG, Day WA (1978) Filtration of chylomicrons by the liver may influence cholesterol metabolism and atherosclerosis. *Atherosclerosis* 29 (2), 113–123.

9 Fraser R, Dobbs BR, Rogers GW (1995) Lipoproteins and the liver sieve: the role of the fenestrated sinusoidal endothelium in lipoprotein metabolism, atherosclerosis, and cirrhosis. *Hepatology* 21(3), 863–874.

10 Braet F, De Zanger R, Baekeland M *et al.* (1995) Structure and dynamics of the fenestrae-associated cytoskeleton of rat liver sinusoidal endothelial cells. *Hepatology* 21(1), 180–189.

11 Braet F, Spector I, De Zanger R *et al.* (1998) A novel structure involved in the formation of liver endothelial cell fenestrae revealed by using the actin inhibitor misakinolide. *Proc Natl Acad Sci USA* 95 (23), 13635–13640.

12 Yokomori H, Oda M, Yoshimura K *et al.* (2003) Vascular endothelial growth factor increases fenestral permeability in hepatic sinusoidal endothelial cells. *Liver Int* 23 (6), 467–475.

13 Smedsrod B, Pertoft H, Eriksson S *et al.* (1984) Studies in vitro on the uptake and degradation of sodium hyaluronate in rat liver endothelial cells. *Biochem J* 223 (3), 617–626.

14 Deaciuc IV, Bagby GJ, Lang CH *et al.* (1993) Hyaluronic acid uptake by the isolated, perfused rat liver: an index of hepatic sinusoidal endothelial cell function. *Hepatology* 17 (2), 266–272.

15 Phillips MG, Preedy VR, Hughes RD (2003) Assessment of prognosis in alcoholic liver disease: can serum hyaluronate replace liver biopsy? *Eur J Gastroenterol Hepatol* 15 (9), 941–944.

16 Smedsrod B, Pertoft H, Gustafson S *et al.* (1990) Scavenger functions of the liver endothelial cell. *Biochem J* 266 (2), 313–327.

17 Magnusson S, Berg T (1989) Extremely rapid endocytosis mediated by the mannose receptor of sinusoidal endothelial rat liver cells. *Biochem J* 257 (3), 651–656.

18 Knolle PA, Limmer A (2003) Control of immune responses by scavenger liver endothelial cells. *Swiss Med Wkly* 133 (37–38), 501–506.

19 Jaeschke H (1996) Chemokines, neutrophils, and inflammatory liver injury. *Shock* 6 (6), 403–404.

20 Steinhoff G, Behrend M, Schrader B *et al.* (1993) Expression patterns of leukocyte adhesion ligand molecules on human liver endothelia. Lack of ELAM-1 and CD62 inducibility on sinusoidal endothelia and distinct distribution of VCAM-1, ICAM-1, ICAM-2, and LFA-3. *Am J Pathol* 142 (2), 481–488.

21 Lalor PF, Adams DH (1999) Adhesion of lymphocytes to hepatic endothelium. *Mol Pathol* 52 (4), 214–219.

22 Bird IN, Spragg JH, Ager A *et al.* (1993) Studies of lymphocyte transendothelial migration: analysis of migrated cell phenotypes with regard to CD31 (PECAM-1), CD45RA and CD45RO. *Immunology* 80 (4), 553–560.

23 Lohse AW, Knolle PA, Bilo K *et al.* (1996) Antigen-presenting function and B7 expression of murine sinusoidal endothelial cells and Kupffer cells. *Gastroenterology* 110 (4), 1175–1181.

24 Limmer A, Ohl J, Kurts C *et al.* (2000) Efficient presentation of exogenous antigen by liver endothelial cells to CD8+ T cells results in antigen-specific T-cell tolerance. *Nature Med* 6 (12), 1348–1354.

25 Knolle PA, Schmitt E, Jin S *et al.* (1999) Induction of cytokine production in naive CD4(+) T cells by antigen-presenting murine liver sinusoidal endothelial cells but failure to induce differentiation toward Th1 cells. *Gastroenterology* 116 (6), 1428–1440.

26 Onoe T, Ohdan H, Tokita D *et al.* (2005) Liver sinusoidal endothelial cells have a capacity for inducing nonresponsiveness of T cells across major histocompatibility complex barriers. *Transpl Int* 18 (2), 206–214.

27 Ferrara N, Gerber HP, LeCouter J (2003) The biology of VEGF and its receptors. *Nature Med* 9 (6), 669–676.

28 Ross MA, Sander CM, Kleeb TB *et al.* (2001) Spatiotemporal expression of angiogenesis growth factor receptors during the revascularization of regenerating rat liver. *Hepatology* 34 (6), 1135–1148.

29 LeCouter J, Moritz DR, Li B *et al.* (2003) Angiogenesis-independent endothelial protection of liver: role of VEGFR-1. *Science* 299 (5608), 890–893.

30 Yamane A, Seetharam L, Yamaguchi S *et al.* (1994) A new communication system between hepatocytes and sinusoidal endothelial cells in liver through vascular endothelial growth factor and Flt tyrosine kinase receptor family (Flt-1 and KDR/Flk-1). *Oncogene* 9 (9), 2683–2690.
31 Mochida S, Ishikawa K, Inao M *et al.* (1996) Increased expressions of vascular endothelial growth factor and its receptors, flt-1 and KDR/flk-1, in regenerating rat liver. *Biochem Biophys Res Commun* 226 (1), 176–179.
32 Medina J, Arroyo AG, Sanchez-Madrid F *et al.* (2004) Angiogenesis in chronic inflammatory liver disease. *Hepatology* 39 (5), 1185–1195.
33 Shah V (2001) Cellular and molecular basis of portal hypertension. *Clin Liver Dis* 5 (3), 629–644.
34 Shah V, Haddad FG, Garcia-Cardena G *et al.* (1997) Liver sinusoidal endothelial cells are responsible for nitric oxide modulation of resistance in the hepatic sinusoids. *J Clin Invest* 100 (11), 2923–2930.
35 Rockey DC, Chung JJ (1998) Reduced nitric oxide production by endothelial cells in cirrhotic rat liver: endothelial dysfunction in portal hypertension. *Gastroenterology* 114 (2), 344–351.
36 Sakamoto S, Okanoue T, Itoh Y *et al.* (1997) Intercellular adhesion molecule-1 and CD18 are involved in neutrophil adhesion and its cytotoxicity to cultured sinusoidal endothelial cells in rats. *Hepatology* 26 (3), 658–663.
37 Bauer M, Bauer I, Sonin NV *et al.* (2000) Functional significance of endothelin B receptors in mediating sinusoidal and extrasinusoidal effects of endothelins in the intact rat liver. *Hepatology* 31 (4), 937–947.
38 Fulton D, Gratton JP, Sessa WC (2001) Post-translational control of endothelial nitric oxide synthase: why isn't calcium/calmodulin enough? *J Pharmacol Exp Ther* 299 (3), 818–824.
39 Shah V, Kamath PS (2003) Nitric oxide in liver transplantation: pathobiology and clinical implications. *Liver Transpl* 9 (1), 1–11.
40 Rockey DC, Chung JJ (1997) Regulation of inducible nitric oxide synthase and nitric oxide during hepatic injury and fibrogenesis. *Am J Physiol* 273 (1 Pt 1), G124–G130.
41 Rockey DC, Chung JJ (1996) Regulation of inducible nitric oxide synthase in hepatic sinusoidal endothelial cells. *Am J Physiol* 271 (2 Pt 1), G260–G267.
42 DeLeve LD, Wang X, Hu L *et al.* (2004) Rat liver sinusoidal endothelial cell phenotype is maintained by paracrine and autocrine regulation. *Am J Physiol Gastrointest Liver Physiol* 287 (4), G757–G763.
43 Chen X, Higgins J, Cheung ST *et al.* (2004) Novel endothelial cell markers in hepatocellular carcinoma. *Mod Pathol* 17 (10), 1198–1210.
44 Zhong X, Ran YL, Lou JN *et al.* (2004) Construction of human liver cancer vascular endothelium cDNA expression library and screening of the endothelium-associated antigen genes. *World J Gastroenterol* 10 (10), 1402–1408.
45 Oh P, Li Y, Yu J *et al.* (2004) Subtractive proteomic mapping of the endothelial surface in lung and solid tumours for tissue-specific therapy. *Nature* 429 (6992), 629–635.
46 Matsumoto K, Yoshitomi H, Rossant J *et al.* (2001) Liver organogenesis promoted by endothelial cells prior to vascular function. *Science* 294 (5542), 559–563.
47 Couvelard A, Scoazec JY, Dauge MC *et al.* (1996) Structural and functional differentiation of sinusoidal endothelial cells during liver organogenesis in humans. *Blood* 87 (11), 4568–4580.
48 Carmeliet P, Ferreira V, Breier G *et al.* (1996) Abnormal blood vessel development and lethality in embryos lacking a single VEGF allele. *Nature* 380 (6573), 435–439.
49 Ferrara N, Carver-Moore K, Chen H *et al.* (1996) Heterozygous embryonic lethality induced by targeted inactivation of the VEGF gene. *Nature* 380 (6573), 439–442.
50 Fong GH, Rossant J, Gertsenstein M *et al.* (1995) Role of the Flt-1 receptor tyrosine kinase in regulating the assembly of vascular endothelium. *Nature* 376 (6535), 66–70.
51 Fong GH, Zhang L, Bryce DM *et al.* (1999) Increased haemangioblast commitment, not vascular disorganization, is the primary defect in flt-1 knock-out mice. *Development* 126 (13), 3015–3025.
52 Schmidt C, Bladt F, Goedecke S *et al.* (1995) Scatter factor/hepatocyte growth factor is essential for liver development. *Nature* 373 (6516), 699–702.
53 Uehara Y, Minowa O, Mori C *et al.* (1995) Placental defect and embryonic lethality in mice lacking hepatocyte growth factor/scatter factor. *Nature* 373 (6516), 702–705.
54 Bladt F, Riethmacher D, Isenmann S *et al.* (1995) Essential role for the c-met receptor in the migration of myogenic precursor cells into the limb bud. *Nature* 376 (6543), 768–771.
55 Assy N, Spira G, Paizi M *et al.* (1999) Effect of vascular endothelial growth factor on hepatic regenerative activity following partial hepatectomy in rats. *J Hepatol* 30 (5), 911–915.
56 Taniguchi E, Sakisaka S, Matsuo K *et al.* (2001) Expression and role of vascular endothelial growth factor in liver regeneration after partial hepatectomy in rats. *J Histochem Cytochem* 49 (1), 121–130.
57 Redaelli CA, Semela D, Carrick FE *et al.* (2004) Effect of vascular endothelial growth factor on functional recovery after hepatectomy in lean and obese mice. *J Hepatol* 40 (2), 305–312.
58 Drixler TA, Vogten MJ, Ritchie ED *et al.* (2002) Liver regeneration is an angiogenesis- associated phenomenon. *Ann Surg* 236 (6), 703–712.
59 Greene AK, Wiener S, Puder M *et al.* (2003) Endothelial-directed hepatic regeneration after partial hepatectomy. *Ann Surg* 237 (4), 530–535.
60 Martinez-Hernandez A, Amenta PS (1995) The extracellular matrix in hepatic regeneration. *FASEB J* 9 (14), 1401–1410.
61 Fujii H, Hirose T, Oe S *et al.* (2002) Contribution of bone marrow cells to liver regeneration after partial hepatectomy in mice. *J Hepatol* 36 (5), 653–659.
62 Semela D, Dufour JF (2004) Angiogenesis and hepatocellular carcinoma. *J Hepatol* 41 (5), 864–880.
63 Hanahan D, Folkman J (1996) Patterns and emerging mechanisms of the angiogenic switch during tumorigenesis. *Cell* 86 (3), 353–364.
64 Fukumura D, Xavier R, Sugiura T *et al.* (1998) Tumor induction of VEGF promoter activity in stromal cells. *Cell* 94 (6), 715–725.
65 Jung JO, Gwak GY, Lim YS *et al.* (2003) [Role of hepatic stellate cells in the angiogenesis of hepatoma]. *Kor J Gastroenterol* 42 (2), 142–148.
66 Park YN, Kim YB, Yang KM *et al.* (2000) Increased expression of vascular endothelial growth factor and angiogenesis in the early stage of multistep hepatocarcinogenesis. *Arch Pathol Lab Med* 124 (7), 1061–1065.
67 Yoshiji H, Kuriyama S, Yoshii J *et al.* (2002) Synergistic effect of basic fibroblast growth factor and vascular endothelial growth factor in murine hepatocellular carcinoma. *Hepatology* 35 (4), 834–842.
68 Yamaguchi R, Yano H, Iemura A *et al.* (1998) Expression of vascular endothelial growth factor in human hepatocellular carcinoma. *Hepatology* 28 (1), 68–77.
69 Yamaguchi R, Yano H, Nakashima Y *et al.* (2000) Expression and localization of vascular endothelial growth factor receptors in human hepatocellular carcinoma and non-HCC tissues. *Oncol Rep* 7 (4), 725–729.

70 Mise M, Arii S, Higashituji H *et al.* (1996) Clinical significance of vascular endothelial growth factor and basic fibroblast growth factor gene expression in liver tumor. *Hepatology* 23 (3), 455–464.
71 Nakashima Y, Nakashima O, Hsia CC *et al.* (1999) Vascularization of small hepatocellular carcinomas: correlation with differentiation. *Liver* 19 (1), 12–18.
72 Moon E-J, Jeong C-H, Jeong J-W *et al.* (2003) Hepatitis B virus X protein induces angiogenesis by stabilizing hypoxia-inducible factor-1alpha. *FASEB J* 18(2), 382–384.
73 Miura H, Miyazaki T, Kuroda M *et al.* (1997) Increased expression of vascular endothelial growth factor in human hepatocellular carcinoma. *J Hepatol* 27 (5), 854–861.
74 Chow NH, Hsu PI, Lin XZ *et al.* (1997) Expression of vascular endothelial growth factor in normal liver and hepatocellular carcinoma: an immunohistochemical study. *Hum Pathol* 28 (6), 698–703.
75 Chao Y, Li CP, Chau GY *et al.* (2003) Prognostic significance of vascular endothelial growth factor, basic fibroblast growth factor, and angiogenin in patients with resectable hepatocellular carcinoma after surgery. *Ann Surg Oncol* 10 (4), 355–362.
76 Zhou XD (2002) Recurrence and metastasis of hepatocellular carcinoma: progress and prospects. *Hepatobiliary Pancreat Dis Int* 1 (1), 35–41.
77 Kin M, Torimura T, Ueno T *et al.* (1994) Sinusoidal capillarization in small hepatocellular carcinoma. *Pathol Int* 44 (10–11), 771–778.
78 Poon RT-P, Lau CP-Y, Cheung S-T *et al.* (2003) Quantitative correlation of serum levels and tumor expression of vascular endothelial growth factor in patients with hepatocellular carcinoma. *Cancer Res* 63 (12), 3121–3126.
79 Jinno K, Tanimizu M, Hyodo I *et al.* (1998) Circulating vascular endothelial growth factor (VEGF) is a possible tumor marker for metastasis in human hepatocellular carcinoma. *J Gastroenterol* 33 (3), 376–382.
80 Poon RT, Ng IO, Lau C *et al.* (2001) Serum vascular endothelial growth factor predicts venous invasion in hepatocellular carcinoma: a prospective study. *Ann Surg* 233 (2), 227–235.
81 Kim SJ, Choi IK, Park KH *et al.* (2004) Serum vascular endothelial growth factor per platelet count in hepatocellular carcinoma: correlations with clinical parameters and survival. *Jpn J Clin Oncol* 34 (4), 184–190.
82 Poon R, Lau C, Yu W *et al.* (2004) High serum levels of vascular endothelial growth factor predict poor response to transarterial chemoembolization in hepatocellular carcinoma: a prospective study. *Oncol Rep* 11 (5), 1077–1084.
83 Yamamoto T, Kobayashi T, Phillips MJ (1984) Perinodular arteriolar plexus in liver cirrhosis. Scanning electron microscopy of microvascular casts. *Liver* 4 (1), 50–54.
84 Haratake J, Hisaoka M, Yamamoto O *et al.* (1991) Morphological changes of hepatic microcirculation in experimental rat cirrhosis: a scanning electron microscopic study. *Hepatology* 13 (5), 952–956.
85 Huet PM, Goresky CA, Villeneuve JP *et al.* (1982) Assessment of liver microcirculation in human cirrhosis. *J Clin Invest* 70 (6), 1234–1244.
86 Villeneuve JP, Dagenais M, Huet PM *et al.* (1996) The hepatic microcirculation in the isolated perfused human liver. *Hepatology* 23 (1), 24–31.
87 Kalluri R, Sukhatme VP (2000) Fibrosis and angiogenesis. *Curr Opin Nephrol Hypertens* 9 (4), 413–418.
88 Kalluri R (2003) Basement membranes: structure, assembly and role in tumour angiogenesis. *Nature Rev Cancer* 3 (6), 422–433.
89 Rosmorduc O, Wendum D, Corpechot C *et al.* (1999) Hepatocellular hypoxia-induced vascular endothelial growth factor expression and angiogenesis in experimental biliary cirrhosis. *Am J Pathol* 155 (4), 1065–1073.
90 Corpechot C, Barbu V, Wendum D *et al.* (2002) Hypoxia-induced VEGF and collagen I expressions are associated with angiogenesis and fibrogenesis in experimental cirrhosis. *Hepatology* 35 (5), 1010–1021.
91 Wang Y, Luk J, Ikeda K *et al.* (2004) Regulatory role of vHL/HIF-1alpha in hypoxia-induced VEGF production in hepatic stellate cells. *Biochem Biophys Res Commun* 317 (2), 358–362.
92 Yoshiji H, Kuriyama S, Yoshii J *et al.* (2003) Vascular endothelial growth factor and receptor interaction is a prerequisite for murine hepatic fibrogenesis. *Gut* 52 (9), 1347–1354.
93 Xu B, Broome U, Uzunel M *et al.* (2003) Capillarization of hepatic sinusoid by liver endothelial cell-reactive autoantibodies in patients with cirrhosis and chronic hepatitis. *Am J Pathol* 163 (4), 1275–1289.
94 Rieder H, Armbrust T, Meyer zum Buschenfelde KH *et al.* (1993) Contribution of sinusoidal endothelial liver cells to liver fibrosis: expression of transforming growth factor-beta 1 receptors and modulation of plasmin-generating enzymes by transforming growth factor-beta 1. *Hepatology* 18 (4), 937–944.
95 Bosch J, Pizcueta P, Feu F *et al.* (1992) Pathophysiology of portal hypertension. *Gastroenterol Clin North Am* 21 (1), 1–14.
96 Fernandez M, Vizzutti F, Garcia-Pagan JC *et al.* (2004) Anti-VEGF receptor-2 monoclonal antibody prevents portal-systemic collateral vessel formation in portal hypertensive mice. *Gastroenterology* 126 (3), 886–894.
97 Le Couteur DG, Fraser R, Cogger VC *et al.* (2002) Hepatic pseudocapillarisation and atherosclerosis in ageing. *Lancet* 359 (9317), 1612–1615.
98 Clark SA, Angus HB, Cook HB *et al.* (1988) Defenestration of hepatic sinusoids as a cause of hyperlipoproteinaemia in alcoholics. *Lancet* 2 (8622), 1225–1227.
99 Cogger VC, Mross PE, Hosie MJ *et al.* (2001) The effect of acute oxidative stress on the ultrastructure of the perfused rat liver. *Pharmacol Toxicol* 89 (6), 306–311.

1.5 Kupffer cells

Hartmut Jaeschke

Morphological characteristics and localization of Kupffer cells

Kupffer cells (KC), the largest fixed tissue macrophage population in the body, are located in hepatic sinusoids. They are anchored to the luminal surface of sinusoidal endothelial cells through cytoplasmic processes, some of which can also reach through the fenestrae of the endothelial cells and contact stellate cells and parenchymal cells [1,2]. Other processes can reach across the lumen of the sinusoids to anchor the cell to other endothelial cells [1]. Thus, in contrast to other tissue macrophages, KC are continuously in contact with blood. KC have the typical morphology of macrophages with microvilli, lamellopodia and filopodia on the surface and large numbers of lysosomes and pinocytotic vesicles in the body of the cell (Fig. 1) [1]. In addition, KC show characteristic 'worm-like structures', which represent invaginations of plasma membranes (Fig. 1). The location and the morphological characteristics reflect the main function of KC, which is effectively to remove all foreign material from the blood by phagocytosis or pinocytosis and to eliminate it by lysosomal degradation.

Based on cell number, KC represent approximately 30% of the non-parenchymal cell fraction and about 15% of all liver cells. However, KC account for only 2.5% of the total protein content of the liver [2,3]. The distribution of KC within the sinusoid is variable. The periportal area contains 43% of the cells, the midzonal region about 32%, and the remaining 25% of KC are located in the centrolobular area [4]. The periportal KC are the largest cells, have the highest content of lysosomal enzymes and show the most active phagocytosis [4]. Furthermore, they also generate more superoxide in response to most stimuli [5]. Destruction of predominantly periportal KC reduced hepatic tumour necrosis factor (TNF)α formation during endotoxaemia *in vivo* by 90%, suggesting that the large, periportal KC are also the most active cytokine-producing cells [6].

The origin of KC in the liver is controversial [7–9]. In normal livers, KC have a half-life of several months, which correlates with the small mitotic index [8]. Even when the liver was stressed with partial hepatectomy or zymosan, mitosis accounted for almost all cell recovery during the initial phase [9]. Mononuclear cell recruitment from blood and bone marrow became more important at later time points [9]. On the other hand, it was suggested that KC do not proliferate and are always replaced by blood-derived monocytes with a half-life of 21 days [7]. Furthermore, KC have the sex karyotype of the donor after bone marrow transplantation, supporting the hypothesis that KC are derived from bone marrow cells [10].

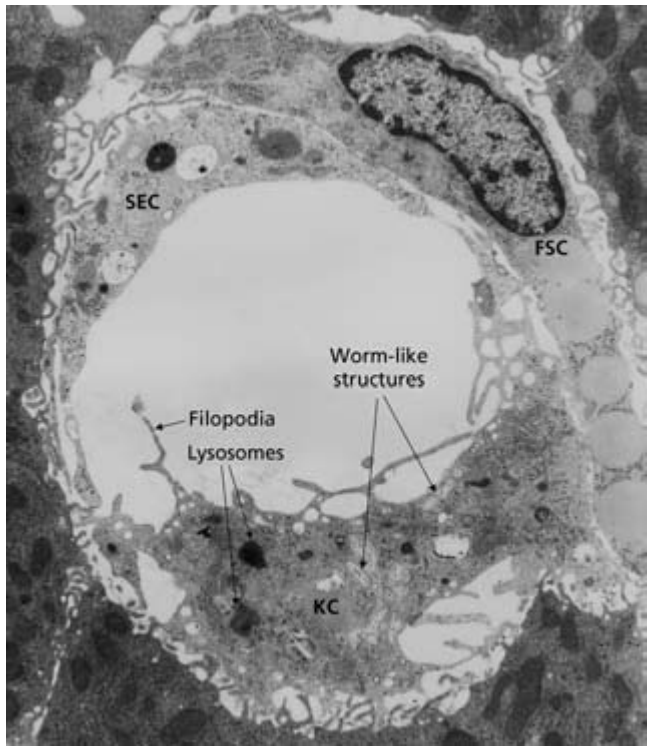

Fig. 1 Kupffer cell (KC), sinusoidal endothelial cell (SEC) and fat-storing cell (FSC) in a sinusoid of rat liver. The Kupffer cell shows characteristic features of macrophages including filopodia, 'worm-like structures' (invaginations of cell membranes) and a high content of lysosomes. Magnification × 5000 (picture courtesy of Dr Robert McCuskey, University of Arizona).

Together, the data indicate that KC can proliferate and can be recruited from the bone marrow. The relative contribution of each pathway depends on the experimental conditions.

Functions of Kupffer cells in the liver

KC, as the resident macrophages, have many functions that are essential for homeostasis in the liver and the innate immune response including phagocytosis, pinocytosis (receptor-mediated endocytosis) and mediator formation [2,11,12]. KC and sinusoidal endothelial cells (SEC) express several receptors, e.g. scavenger receptors and mannose receptors, which can bind endogenous soluble waste molecules (e.g. fibronectin, chondroitin sulphate, collagen) and even viruses, lipopolysaccharide (LPS) and other pathogenic substances. However, internalization and degradation of these soluble molecules by receptor-mediated endocytosis occurs mainly in SEC [11,13]. The main function of KC is to bind and remove particles (> 1 μm in diameter) from blood by phagocytosis, which does not occur in SEC [11].

Phagocytosis

KC *in vivo* phagocytose mainly opsonized particles, which bind to specific receptors [2]. Similar to SEC, KC express Fc-γ receptors [14]. These receptors interact with the Fc domain of immunoglobulin G (IgG) and bind IgG-coated particles and soluble bloodborne IgG–immune complexes. KC phagocytose IgG-coated particles and potentially larger aggregates of immune complexes. Although KC can take up soluble IgG–immune complexes [14], SEC remove them more effectively through endocytosis [11]. KC express scavenger receptors, which are a group of receptors that recognize negatively charged ligands [15]. Oxidized lipoproteins from blood, apoptotic bodies and a variety of pathogens are taken up into KC through scavenger receptors [15,16]. Similarly, scavenger receptors can bind LPS and internalize it without inflammatory mediator formation [17]. Complement is a major host defence system in plasma, and its activation leads to opsonization of pathogens, immunoglobulins and DNA, with larger fragments derived from complement factors C3 and C4, i.e. C3b and C4b. KC express a number of complement receptors, including CR1, CR3 (CD11b/CD18) and CR4 (CD11c/CD18) [18–20]. KC bind, internalize and degrade complement-coated pathogens through receptor-mediated endocytosis or phagocytosis [20]. Fibronectin in plasma is also able to opsonize various endogenous and exogenous substances, which are then bound to fibronectin-specific receptors on KC and internalized through phagocytosis [21]. Although it was generally assumed that KC with their receptors are mainly responsible for the clearance of pathogens from the blood [18], more recent evidence suggests that some bacteria are bound to the surface of KC, where they are internalized and destroyed by infiltrating neutrophils [22]. KC ingest the neutrophils, thus preventing the release of toxic mediators from dying neutrophils [22].

Formation of inflammatory mediators

Upon activation, KC can generate a large amount of inflammatory mediators including cytokines [e.g. TNFα, interleukin (IL)-1, IL-6, IL-10], chemokines (e.g. IL-8), nitric oxide, superoxide and prostanoids [12]. In turn, some of the mediators can bind to KC in an autocrine fashion and either further activate these macrophages (e.g. TNFα) or downregulate proinflammatory mediator formation (e.g. IL-10, IL-13 or prostaglandin E2) [12,23]. Two pathophysiologically important activating pathways in KC will be discussed.

One of the most relevant activators of KC is LPS, a wall component of gut-derived Gram-negative bacteria. LPS activation involves LPS-binding protein (LBP), CD14 and the Toll-like receptor 4 (TLR4) [24]. LBP binds the lipid A portion of LPS with high affinity and can mediate the transfer of LPS to the cell surface receptor CD14 on KC. This activity decreases the amount of LPS necessary to activate KC *in vitro* [25]. On the other hand, LBP can also facilitate the transfer of LPS to lipoproteins [24]. Functional studies in LBP gene knockout mice *in vivo* showed that TNFα formation in response to LPS is unaffected [26]. In addition, administration of recombinant LBP to mice attenuated LPS-induced cytokine formation and protected against LPS-induced liver injury [27]. Thus, the main function of LBP *in vivo* appears to be more to protect against the deleterious effect of LPS and other pathogens rather than being an obligatory mediator for LPS signalling in KC [24,28].

Although rodent or human KC show a low baseline expression of CD14, LPS-induced TNFα formation is still dependent on CD14 [29]. In support of this finding, CD14-deficient mice are insensitive to LPS *in vivo* [30]. CD14 can be upregulated in KC by LPS; increased expression of CD14 was observed in human and rodent livers with inflammatory diseases [24]. The functional significance of CD14 induction could be demonstrated by the reduced inflammatory response and attenuated liver injury in CD14-deficient mice after chronic alcohol treatment [31]. As CD14 is a protein without a transmembrane component, it requires interaction with other proteins, i.e. Toll-like receptors (TLRs), to induce KC activation. Among the 10 currently identified TLRs, TLR2 and TLR4 are highly expressed on macrophages [32]. However, natural mutants of TLR4 and TLR4 gene knockout mice but not animals deficient in TLR2 are completely resistant to LPS [24,32]. TLR4 is specific for LPS [24]. Signalling through TLR4 requires the presence of MD-2 on the cell surface (Fig. 2) [33]. In addition, the cytoplasmic tail of TLR4, which has similarities to the IL-1 receptor family, recruits adapter molecules including MyD88, which binds the serine/threonine kinase IL-1 receptor-associated kinase (IRAK)-1 and -4 [32]. IRAK-4 phosphorylates IRAK-1, which then recruits TNFα receptor-associated factor-6 (TRAF6) to the complex. The IRAK-1/TRAF6 complex dissociates from the receptor and binds transforming growth factor-beta-activated kinase 1 (TAK1) and TAK1-binding proteins (TAB1 and TAB2) (Fig. 2). Whereas IRAK-1 remains at the membrane, the complex of

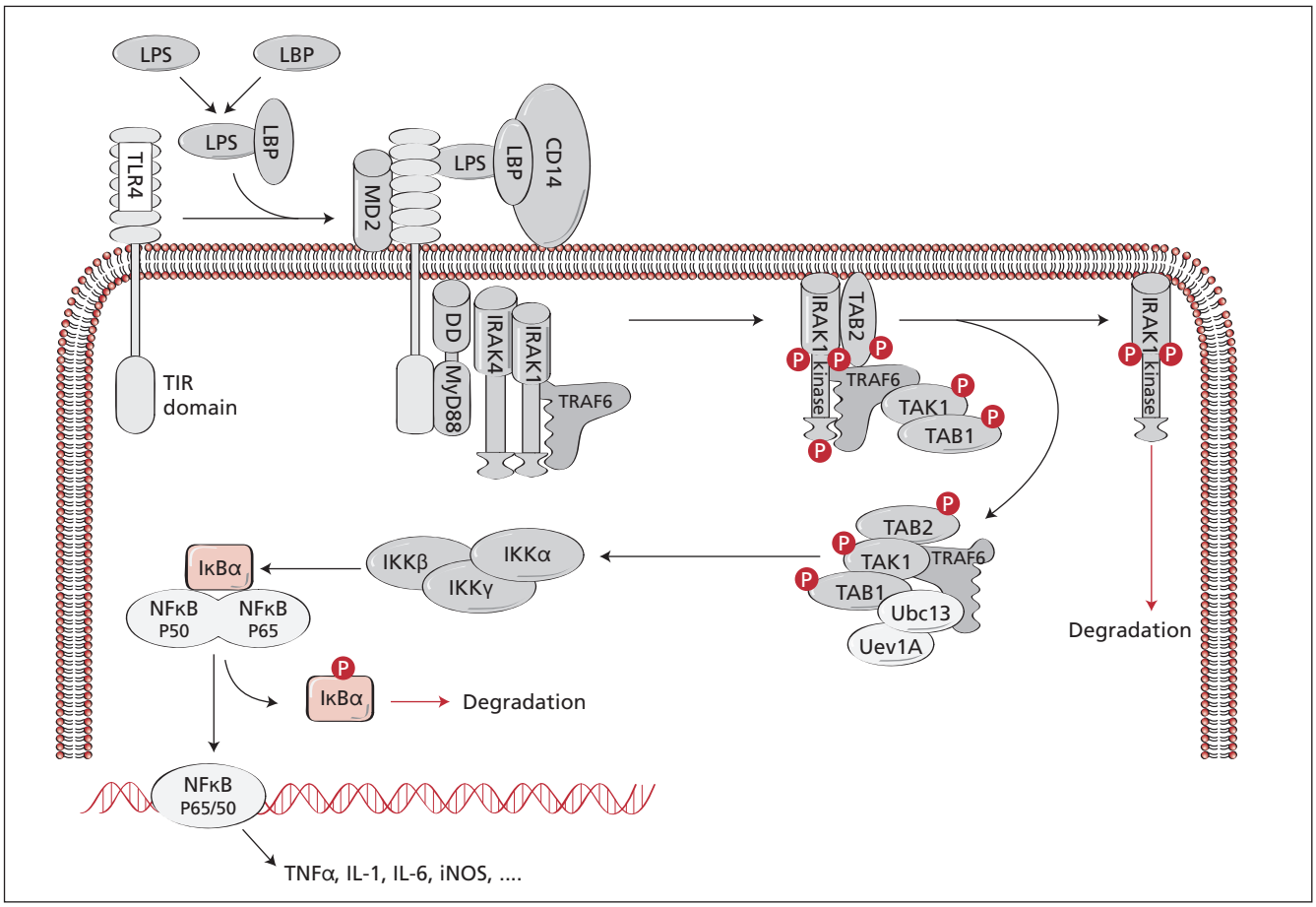

Fig. 2 Toll-like receptor 4 (TLR4) signalling in Kupffer cells (see text for details). Figure adapted from [32]. iNOS, inducible nitric oxide synthase; IRAK, interleukin (IL)-1 receptor-associated kinase; LBP, LPS-binding protein; LPS, lipopolysaccharide, TIR, Toll/IL-1 receptor; TAB, TAK-binding protein; TAK1, transforming growth factor-beta-activated kinase 1; TRAF6, TNF receptor-associated factor 6.

TRAF6/TAK1/TAB1/TAB2 moves into the cytosol and binds additional proteins such as Ubc13 and Uev1A [32], which induces the activation of TAK1 and eventually causes NF-κB activation, its translocation to the nucleus and subsequent formation of various proinflammatory cytokines (Fig. 2) [32]. The critical role of these adapter molecules for LPS signalling in KC is supported by reduced TNFα formation in mice deficient in MD-2 [35], MyD88 [36], IRAK [37] or TAK1 [38]. Despite the importance of the MyD88-dependent signalling pathway for cytokine formation in response to TLR4 activation, MyD88-independent signalling also occurs in macrophages [32,34]. Animals with mutations or a deficiency in the TLR4 receptor are protected against various liver pathogenesis including LPS hepatotoxicity, alcohol-induced liver damage and ischaemia–reperfusion injury [24,34].

Other important stimulators for KC are components of the complement cascade, which can be activated by immune complexes through the classical pathway or by LPS and other microbial surfaces through the alternative pathway [20]. The larger complement fragments C3b and C4b are involved in the opsonization of pathogens, which leads to binding to the complement receptors CR1, CR3 and CR4 on KC and subsequent phagocytosis [20]. On the other hand, the smaller fragments (anaphylatoxins), e.g. C5a, bind to specific high-affinity receptors, e.g. C5aR/CD88, which are members of the rhodopsin subfamily of G protein-coupled receptors [39]. C5aR is constitutively expressed on human and rodent KC [39]. Activation of KC with C5a leads to activation of phospholipases with release of intracellular messengers [40]. Although the detailed intracellular signalling mechanisms for activation of nicotinamide adenine dinucleotide phosphate dehydrogenase (NADPH) oxidase, especially in KC, are not well established, it involves a number of kinases, including protein kinase C, which phosphorylate components such as $p40^{phox}$ and $p47^{phox}$ [40]. These phosphorylation steps trigger translocation of individual components to the cell membrane and induce the assembly of the active enzyme [40].

Pathophysiological role of Kupffer cells

KC activation has been implicated in a growing number of liver diseases with both detrimental and beneficial impacts. The

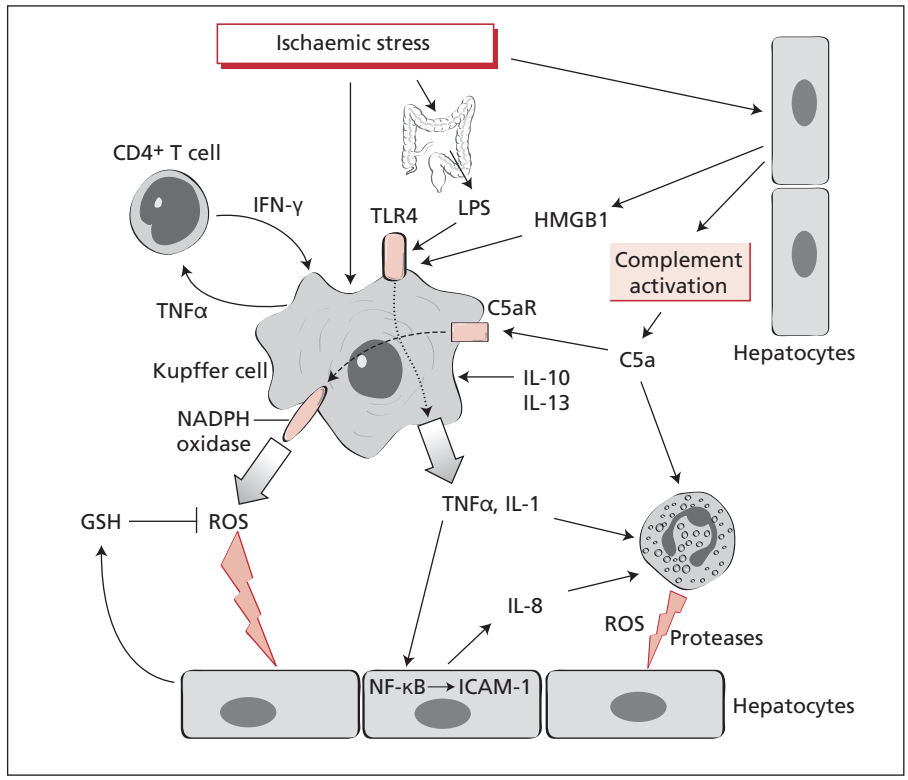

Fig. 3 Central role of Kupffer cells in the pathogenesis of hepatic ischaemia–reperfusion injury (see text for details). Figure adapted from ref. 41. C5aR, C5a receptor; GSH, reduced glutathione; HMGB1, high-mobility group Box 1; ICAM-1, intercellular adhesion molecule-1; IL, interleukin; IFN-γ, interferon-γ; LPS, lipopolysaccharide; ROS, reactive oxygen species; TLR4, toll-like receptor 4.

specific involvement of KC in three relevant injury mechanisms will be highlighted.

Hepatic ischaemia–reperfusion injury

Periods of warm and cold ischaemia can activate KC [41]. Whereas the larger KC of the periportal region are fully activated and generate reactive oxygen, the smaller KC are mainly primed [41,42]. Functional inactivation of KC with gadolinium chloride and other intervention strategies attenuated this oxidant stress and reduced the early reperfusion injury phase [41,42]. Further support for the critical role of a KC-derived vascular oxidant stress in the pathophysiology comes from the observation that reduced glutathione (GSH) released into the sinusoid can detoxify these reactive oxygen species and attenuate reperfusion injury (Fig. 3) [42]. In fact, the enhanced release of GSH from hepatocytes under inflammatory conditions appears to be a general endogenous mechanism to limit a potential detrimental effect of KC-mediated vascular oxidant stress [41]. Consequently, intravenous infusion of GSH attenuated hepatic reperfusion injury by scavenging reactive oxygen in sinusoids [41–43]. Although KC generate mainly superoxide through NADPH oxidase, the major oxidant for GSH in plasma is hydrogen peroxide (H_2O_2) [42]. In addition, H_2O_2 can diffuse into nearby hepatocytes and trigger an intracellular oxidant stress, which is responsible for parenchymal cell damage [44]. Thus, in addition to the interception of vascular reactive oxygen species, strengthening of intracellular defence mechanisms against oxidant stress is a second important intervention strategy to limit tissue injury due to KC activation [45].

Activated KC also generate cytokines and chemokines, which enhance the inflammatory response and promote the infiltration of neutrophils [23,41]. Although more cell death occurs during the later, neutrophil-mediated injury phase, cytotoxic and proinflammatory mediators derived from activated KC determine the severity of the overall inflammatory response and tissue damage. Thus, limiting early KC activation could be an effective intervention strategy. However, KC are activated through multiple mechanisms during ischaemia–reperfusion (Fig. 3). Exposure of isolated KC to hypoxia leads to reactive oxygen formation during reoxygenation [42]. Although this effect is short-lived *in vitro*, the prolonged oxidant stress *in vivo* suggests additional stimuli. The early cell content release during reperfusion induces activation of complement in plasma [46]. Complement factors such as C5a bind to C5aR on KC and induce superoxide formation [42,46]. More recently, it was shown that high-mobility group Box 1 (HMGB1), a nuclear protein, is released from necrotic cells during hepatic ischaemia–reperfusion and triggers cytokine formation [47]. This effect is mediated through binding of HMGB1 to the TLR4 receptor [48]. Thus, KC can be activated through cellular stress during ischaemia and through mediators generated during reperfusion triggering a non-microbial inflammatory response, which is a critical determinant of the overall tissue injury and potential organ failure (Fig. 3).

Although the overall effect of KC activation is in part direct tissue injury and in part the promotion of the inflammatory

response, endogenous IL-13 derived from KC can limit the formation of TNFα during reperfusion [49]. In addition, pharmacological doses of IL-10 or IL-13 suppress the inflammatory response during ischaemia–reperfusion by inhibiting cytokine and chemokine formation [23]. On the other hand, cytokines such as IL-6 were shown to be critical for a regenerative response after reperfusion and, therefore, also have beneficial effects [50]. Thus, KC activation is a critical event in the pathophysiology of hepatic ischaemia–reperfusion injury with both pro- as well as anti-inflammatory mediators being generated by these macrophages (Fig. 3). However, the majority of the literature supports the view that inactivation of KC has an overall beneficial effect in the pathogenesis of this condition.

Alcohol-induced liver disease

Acute and chronic exposure to alcohol (ethanol) causes activation of KC, as indicated by enhanced cytokine and chemokine formation and increased generation of reactive oxygen species [51–53]. However, under certain circumstances, chronic ethanol consumption can also induce tolerance in KC [53]. As alcohol increases the permeability of the mucosal barrier to intestinal microbes and toxins, it is generally accepted that, in animal models of chronic ethanol exposure, e.g. the intragastric feeding model, LPS is one of the key activators of KC and tissue macrophages in alcoholic liver disease (ALD) [54]. The importance of LPS in ALD was demonstrated by reduced liver injury in animals treated with antibiotics [55].

The molecular mechanism of KC activation during alcohol exposure starts with the binding of endotoxin to LBP in plasma. The LPS/LBP complex binds to the CD14 receptor and TLR4, which then transmits the signal intracellularly (Fig. 2). Increasing the expression of CD14 can enhance the sensitivity of ethanol-exposed KC to LPS [52]. Activation of the TLR4 receptor by LPS through CD14 induces the activation of the transcription factors NF-κB and AP-1, which leads to the formation of pro- and anti-inflammatory cytokines, including TNFα, IL-1 and IL-10, CC and CXC chemokines, and priming for reactive oxygen formation [56]. Reduced cytokine formation together with reduced tissue injury in mouse strains deficient in CD14, TLR4 or LBP supports the importance of these signalling events in the development of ALD [51,52]. NF-κB activation together with cytokine and chemokine formation was shown during ALD [56], and inhibition of NF-κB activation with an I-κB superrepressor reduced pathological changes [52]. In addition, enhanced NF-κB activation and cytokine formation in hepatic macrophages isolated from alcohol-fed rats was attenuated after treatment with an iron chelator, suggesting that a labile iron pool within the cell is critical for NF-κB activation and cytokine formation in macrophages [57]. However, LPS may not be the only factor involved in KC activation during ALD [58]. In KC isolated from chronically ethanol-fed rats, LPS-induced TNFα mRNA and protein formation is increased compared with cells from control animals [58]. However, a similar priming effect was also observed when macrophages were exposed to ethanol in culture, indicating that the changes in TNFα formation *in vivo* may not be entirely due to LPS but could at least in part result from a direct effect of ethanol on KC [59]. Interestingly, exposure of KC to ethanol *in vitro* had no effect on TNFα transcription, but prolonged the half-life of the mRNA through a p38 MAP kinase-dependent mechanism [59]. In addition, treatment of hepatic macrophages with retinoic acid inhibited LPS-induced mRNA formation of TNFα and other cytokines [60]. Thus, retinoic acid deficiency during chronic alcohol consumption can contribute to TNFα mRNA stability and promote increased cytokine formation [60].

Acute and chronic ethanol exposure leads to the increased formation of reactive oxygen by KC [51]. Priming and activation of KC for superoxide formation by NADPH oxidase can be triggered *in vivo* by endotoxin, cytokines such as TNFα or complement factors [5,46]. Despite the importance of KC as a source of the oxidant stress during the development of ALD, KC are only one of several critical sources of reactive oxygen formation [51]. Nevertheless, rats treated with inhibitors of NADPH oxidase or mice deficient in $p47^{phox}$, a component of the NADPH oxidase complex, showed less oxidant stress and reduced injury after chronic alcohol exposure [51]. These data suggest that superoxide derived from NADPH oxidase (KC and neutrophils) is critically involved in the injury process. This may be caused by tissue damage by oxidants, e.g. peroxynitrite and hypochlorous acid, or indirectly by promoting cytokine and chemokine formation with recruitment of mononuclear cells and neutrophils [51,58,61]. Taken together, there is clear evidence that hyperactivation of KC after ethanol exposure contributes to the development of inflammatory tissue injury during ALD. On the other hand, KC-derived anti-inflammatory cytokines such as IL-10 exert a beneficial effect in the pathophysiology [62]. Nevertheless, the majority of evidence mainly suggests a detrimental effect of KC activation during ALD.

Drug-induced liver failure

A variety of drugs and chemicals can induce liver injury involving an inflammatory component in the pathogenesis [63,64]. The clinically most relevant drug hepatotoxicity is caused by paracetamol overdose. Within 24–48 h after a toxic dose of paracetamol in rats, liver macrophages are activated [63]. These liver macrophages consist of the resident KC population and newly recruited monocyte-derived cells [63]. The activated macrophages can generate reactive oxygen, cytokines and chemokines [63–66]. As treatment with gadolinium chloride attenuated paracetamol-induced liver injury, it was concluded that liver macrophages contributed to the injury by generating peroxynitrite, as indicated by the formation of nitrotyrosine protein adducts in necrotic hepatocytes [63]. However, more recent experimental evidence suggests that peroxynitrite is actually formed in the mitochondria of centrolobular hepatocytes [67]. Because at least some of the nitric oxide (NO) generated in

hepatocytes is formed by the inducible NO synthase (iNOS), which can be transcriptionally induced by KC-derived cytokines, KC activation may be a critical factor in the pathogenesis. However, formation of IL-10 by KC limits TNFα formation after paracetamol overdose and therefore reduces iNOS induction and peroxynitrite-mediated injury [68]. Complete elimination of KC with liposomally encaspulated chlodronate or the deficiency of the IL-10 gene enhances iNOS induction and aggravates paracetamol-induced liver injury [68,69]. These data suggest that activation of KC during the early phase of paracetamol hepatotoxicity is more beneficial than detrimental [69].

Cytokine formation by activated KC occurs early during paracetamol administration [63,64]. Initially, it was thought that these cytokines contributed to the injury, but the mechanisms remained unclear [64]. As paracetamol toxicity does not involve relevant apoptotic cell death [70], indirect mechanisms such as neutrophil activation may be an explanation. However, although recruited into the liver after paracetamol-induced liver injury, no significant contribution of neutrophils was found [64]. On the other hand, more recent data suggest that TNFα may be important in the regenerative response after paracetamol-induced cell death [71]. In addition, cytokines promote the formation of chemokines responsible for mononuclear cell recruitment in the liver [72]. These macrophages do not appear to cause additional damage, but are involved in removing cell debris and in cell cycle activation and regeneration [72].

References

1 McCuskey RS, McCuskey PA (1990) Fine structure and function of Kupffer cells. *J Electron Microsc Tech* 14, 237–246.

2 Kuiper J, Brouwer A, Knook DL *et al.* (1994) Kupffer and sinusoidal endothelial cells. In: Arias IM, Boyer JL, Fausto N *et al.* (eds) *The Liver: Biology and Pathobiology*, 3rd edn. New York: Raven Press, pp. 791–818.

3 Blouin A, Bolender RP, Weibel ER (1977) Distribution of organelles and membranes between hepatocytes and nonhepatocytes in the rat liver parenchyma. A stereological study. *J Cell Biol* 72, 441–455.

4 Sleyster EC, Knook DL (1982) Relation between localization and function of rat liver Kupffer cells. *Lab Invest* 47, 484–490.

5 Bautista AP, Meszaros K, Bojta J *et al.* (1990) Superoxide anion generation in the liver during the early stage of endotoxemia in rats. *J Leukoc Biol* 48, 123–128.

6 Bautista AP, Skrepnik N, Niesman MR *et al.* (1994) Elimination of macrophages by liposome-encapsulated dichloromethylene diphosphonate suppresses the endotoxin-induced priming of Kupffer cells. *J Leukoc Biol* 55, 321–327.

7 Crofton RW, Diesselhoff-Den Dulk MM, van Furth R (1978) The origin, kinetics, and characteristics of the Kupffer cells in the normal steady state. *J Exp Med* 148, 1–17.

8 Bouwens L, Baekeland M, De Zanger R *et al.* (1986) Quantitation, tissue distribution and proliferation kinetics of Kupffer cells in normal rat liver. *Hepatology* 6, 718–722.

9 Bouwens L, Baekeland M, Wisse E (1984) Importance of local proliferation in the expanding Kupffer cell population of rat liver after zymosan stimulation and partial hepatectomy. *Hepatology* 4, 213–219.

10 Gale RP, Sparkes RS, Golde DW (1978) Bone marrow origin of hepatic macrophages (Kupffer cells) in humans. *Science* 201, 937–938.

11 Smedsrod B (2004) Clearance function of scavenger endothelial cells. *Comp Hepatol* 3 (Suppl. 1), S22.

12 Decker K (1990) Biologically active products of stimulated liver macrophages (Kupffer cells). *Eur J Biochem* 192, 245–261.

13 Seternes T, Sorensen K, Smedsrod B (2002) Scavenger endothelial cells of vertebrates: a nonperipheral leukocyte system for high-capacity elimination of waste macromolecules. *Proc Natl Acad Sci USA* 99, 7594–7597.

14 Lovdal T, Brech A, Kjeken R *et al.* (2001) Receptor-mediated and fluid phase endocytosis in hepatic sinusoidal cells. In: Wisse E, Knook DL, de Zanger R *et al.* (eds) *Cells of the Hepatic Sinusoid*, Vol. 8. Leiden: Kupffer Cell Foundation, pp. 125–131.

15 Pearson AM (1996) Scavenger receptors in innate immunity. *Curr Opin Immunol* 8, 20–28.

16 Van Berkel TJ, De Rijke YB, Kruijt JK (1991) Different fate *in vivo* of oxidatively modified low density lipoprotein and acetylated low density lipoprotein in rats. Recognition by various scavenger receptors on Kupffer and endothelial liver cells. *J Biol Chem* 266, 2282–2289.

17 Haworth R, Platt N, Keshav S *et al.* (1997) The macrophage scavenger receptor type A is expressed by activated macrophages and protects the host against lethal endotoxic shock. *J Exp Med* 186, 1431–1439.

18 Loegering DJ (1986) Kupffer cell complement receptor clearance function and host defense. *Circ Shock* 20, 321–333.

19 Hinglais N, Kazatchkine MD, Mandet C *et al.* (1989) Human liver Kupffer cells express CR1, CR3, and CR4 complement receptor antigens. An immunohistochemical study. *Lab Invest* 61, 509–514.

20 Ember JA, Hugli TE (1997) Complement factors and their receptors. *Immunopharmacology* 38, 3–15.

21 Cardarelli PM, Blumenstock FA, McKeown-Longo PJ *et al.* (1990) High-affinity binding of fibronectin to cultured Kupffer cells. *J Leukoc Biol* 48, 426–437.

22 Gregory SH, Wing EJ (2002) Neutrophil-Kupffer cell interaction: a critical component of host defenses to systemic bacterial infections. *J Leukoc Biol* 72, 239–248.

23 Okaya T, Lentsch AB (2003) Cytokine cascades and the hepatic inflammatory response to ischemia and reperfusion. *J Invest Surg* 16, 141–147.

24 Su GL (2002) Lipopolysaccharides in liver injury: molecular mechanisms of Kupffer cell activation. *Am J Physiol Gastrointest Liver Physiol* 283, G256–G265.

25 Su GL, Klein RD, Aminlari A *et al.* (2000) Kupffer cell activation by lipopolysaccharide in rats: role for lipopolysaccharide binding protein and toll-like receptor 4. *Hepatology* 31, 932–936.

26 Wurfel MM, Monks BG, Ingalls RR *et al.* (1997) Targeted deletion of the lipopolysaccharide (LPS)-binding protein gene leads to profound suppression of LPS responses ex vivo, whereas *in vivo* responses remain intact. *J Exp Med* 186, 2051–2056.

27 Lamping N, Dettmer R, Schroder NW *et al.* (1998) LPS-binding protein protects mice from septic shock caused by LPS or gram-negative bacteria. *J Clin Invest* 101, 2065–2071.

28 Schroder NW, Schumann RR (2005) Non-LPS targets and actions of LPS binding protein (LBP). *J Endotoxin Res* 11, 237–242.

29 Su GL, Goyert SM, Fan MH *et al.* (2002) Activation of human and mouse Kupffer cells by lipopolysaccharide is mediated by CD14. *Am J Physiol Gastrointest Liver Physiol* 283, G640–G645.

30 Haziot A, Ferrero E, Lin XY *et al.* (1995) CD14-deficient mice are

exquisitely insensitive to the effects of LPS. *Prog Clin Biol Res* 392, 349–351.
31 Yin M, Bradford BU, Wheeler MD *et al.* (2001) Reduced early alcohol-induced liver injury in CD14-deficient mice. *J Immunol* 166, 4737–4742.
32 Takeda K, Akira S (2004) TLR signaling pathways. *Semin Immunol* 16, 3–9.
33 Shimazu R, Akashi S, Ogata H *et al.* (1999) MD-2, a molecule that confers lipopolysaccharide responsiveness on Toll-like receptor 4. *J Exp Med* 189, 1777–1782.
34 Schwabe RF, Seki E, Brenner DA (2006) Toll-like receptor signaling in the liver. *Gastroenterology* 130, 1886–1890.
35 Nagai Y, Akashi S, Nagafuku M *et al.* (2002) Essential role of MD-2 in LPS responsiveness and TLR4 distribution. *Nature Immunol* 3, 667–672.
36 Kawai T, Adachi O, Ogawa T *et al.* (1999) Unresponsiveness of MyD88-deficient mice to endotoxin. *Immunity* 11, 115–122.
37 Swantek JL, Tsen MF, Cobb MH *et al.* (2000) IL-1 receptor-associated kinase modulates host responsiveness to endotoxin. *J Immunol* 164, 4301–4306.
38 Sato S, Sanjo H, Takeda K *et al.* (2005) Essential function for the kinase TAK1 in innate and adaptive immune responses. *Nature Immunol* 6, 1087–1095.
39 Zwirner J, Fayyazi A, Gotze O (1999) Expression of the anaphylatoxin C5a receptor in non-myeloid cells. *Mol Immunol* 36, 877–884.
40 El-Benna J, Dang PM, Gougerot-Pocidalo MA *et al.* (2005) Phagocyte NADPH oxidase: a multicomponent enzyme essential for host defenses. *Arch Immunol Ther Exp (Warsz)* 53, 199–206.
41 Jaeschke H (2003) Molecular mechanisms of hepatic ischemia-reperfusion injury and preconditioning. *Am J Physiol Gastrointest Liver Physiol* 284, G15–G26.
42 Jaeschke H (2003) Role of reactive oxygen species in hepatic ischemia-reperfusion injury and preconditioning. *J Invest Surg* 16, 127–140.
43 Bilzer M, Gerbes AL (2000) Preservation injury of the liver: mechanisms and novel therapeutic strategies. *J Hepatol* 32, 508–515.
44 Bilzer M, Jaeschke H, Vollmar AM *et al.* (1999) Prevention of Kupffer cell-induced oxidant injury in rat liver by atrial natriuretic peptide. *Am J Physiol* 276, G1137–G1144.
45 Schauer RJ, Gerbes AL, Vonier D *et al.* (2003) Induction of cellular resistance against Kupffer cell-derived oxidant stress: a novel concept of hepatoprotection by ischemic preconditioning. *Hepatology* 37, 286–295.
46 Jaeschke H, Farhood A, Bautista AP *et al.* (1993) Complement activates Kupffer cells and neutrophils during reperfusion after hepatic ischemia. *Am J Physiol* 264, G801–G809.
47 Tsung A, Sahai R, Tanaka H *et al.* (2005) The nuclear factor HMGB1 mediates hepatic injury after murine liver ischemia–reperfusion. *J Exp Med* 201, 1135–1143.
48 Tsung A, Hoffman RA, Izuishi K *et al.* (2005) Hepatic ischemia/reperfusion injury involves functional TLR4 signaling in non-parenchymal cells. *J Immunol* 175, 7661–7668.
49 Kato A, Okaya T, Lentsch AB (2003) Endogenous IL-13 protects hepatocytes and vascular endothelial cells during ischemia/reperfusion injury. *Hepatology* 37, 304–312.
50 Selzner N, Rudiger H, Graf R *et al.* (2003) Protective strategies against ischemic injury of the liver. *Gastroenterology* 125, 917–936.
51 Arteel GE (2003) Oxidants and antioxidants in alcohol-induced liver disease. *Gastroenterology* 124, 778–790.
52 Hines IN, Wheeler MD (2004) Recent advances in alcoholic liver disease III. Role of the innate immune response in alcoholic hepatitis. *Am J Physiol Gastrointest Liver Physiol* 287, G310–G314.
53 Spitzer JJ, Bautista AP (1998) Tolerance and sensitivity: ethanol and Kupffer cells. *Gastroenterology* 115, 494–496.
54 Bode C, Bode JC (2005) Activation of the innate immune system and alcoholic liver disease: effects of ethanol per se or enhanced intestinal translocation of bacterial toxins induced by ethanol? *Alcohol Clin Exp Res* 29 (11 Suppl.), 166S–171S.
55 Adachi Y, Moore LE, Bradford BU *et al.* (1995) Antibiotics prevent liver injury in rats following long-term exposure to ethanol. *Gastroenterology* 108, 218–224.
56 Nanji AA, Jokelainen K, Rahemtulla A *et al.* (1999) Activation of nuclear factor kappa B and cytokine imbalance in experimental alcoholic liver disease in the rat. *Hepatology* 30, 934–943.
57 Tsukamoto H, Lin M, Ohata M *et al.* (1999) Iron primes hepatic macrophages for NF-kappaB activation in alcoholic liver injury. *Am J Physiol* 277, G1240–G1250.
58 Nagy LE (2003) Recent insights into the role of the innate immune system in the development of alcoholic liver disease. *Exp Biol Med* 228, 882–890.
59 Kishore R, McMullen MR, Cocuzzi E *et al.* (2004) Lipopolysaccharide-mediated signal transduction: stabilization of TNF-alpha mRNA contributes to increased lipopolysaccharide-stimulated TNF-alpha production by Kupffer cells after chronic ethanol feeding. *Comp Hepatol* 3 (Suppl. 1), S31.
60 Motomura K, Ohata M, Satre M *et al.* (2001) Destabilization of TNF-alpha mRNA by retinoic acid in hepatic macrophages: implications for alcoholic liver disease. *Am J Physiol Endocrinol Metab* 281, E420–E429.
61 Jaeschke H (2002) Neutrophil-mediated tissue injury in alcoholic-hepatitis. *Alcohol* 27, 23–27.
62 Grove J, Daly AK, Bassendine MF *et al.* (2000) Interleukin 10 promoter region polymorphisms and susceptibility to advanced alcoholic liver disease. *Gut* 46, 540–545.
63 Laskin DL (1997) Xenobiotic-induced inflammation and injury in the liver. In: McCuskey RS, Earnest DL (eds) *Comprehensive Toxicology,* Vol. 9. New York: Elsevier Science, pp. 151–164.
64 Jaeschke H (2005) Role of inflammation in the mechanism of acetaminophen hepatotoxicity. *Exp Opin Drug Metab Toxicol* 1, 389–397.
65 Jaeschke H, Gores GJ, Cederbaum AI *et al.* (2002) Mechanisms of hepatotoxicity. *Toxicol Sci* 65, 166–176.
66 Jaeschke H, Knight TR, Bajt ML (2003) The role of oxidant stress and reactive nitrogen species in acetaminophen hepatotoxicity. *Toxicol Lett* 144, 279–288.
67 Jaeschke H, Bajt ML (2006) Intracellular signaling mechanisms of acetaminophen-induced liver cell death. *Toxicol Sci* 89, 31–41.
68 Bourdi M, Masubuchi Y, Reilly TP *et al.* (2002) Protection against acetaminophen-induced liver injury and lethality by interleukin 10: role of inducible nitric oxide synthase. *Hepatology* 35, 289–298.
69 Ju C, Reilly TP, Bourdi M *et al.* (2002) Protective role of Kupffer cells in acetaminophen-induced hepatic injury in mice. *Chem Res Toxicol* 15, 1504–1513.
70 Gujral JS, Knight TR, Farhood A *et al.* (2002) Mode of cell death after acetaminophen overdose in mice: apoptosis or oncotic necrosis? *Toxicol Sci* 67, 322–328.
71 Chiu H, Gardner CR, Dambach DM *et al.* (2003) Role of tumor necrosis factor receptor 1 (p55) in hepatocyte proliferation during acetaminophen-induced toxicity in mice. *Toxicol Appl Pharmacol* 193, 218–227.
72 Dambach DM, Watson LM, Gray KR *et al.* (2002) Role of CCR2 in macrophage migration into the liver during acetaminophen-induced hepatotoxicity in the mouse. *Hepatology* 35, 1093–1103.

1.6 The hepatic stellate cell

Massimo Pinzani

Historical notes and nomenclature

The history of hepatic stellate cells (HSC) has not been an easy one. The first trace of their recognition is in a letter that Carl Von Kupffer wrote to the anatomist Waldeyer in 1876 [1]. Von Kupffer, who was studying the hepatic nervous system, observed perisinusoidal star-shaped cells that stained dark with a gold chloride technique used to reveal nerves (Fig. 1). Accordingly, Von Kupffer's first interpretation was that these cells were part of the perivascular nervous network of Waldeyer. In later studies, Von Kupffer changed his view and concluded that HSC were rather a type of phagocyte (as they shared the same distribution of gold particles with true phagocytic cells, today correctly defined as 'Kupffer cells') or, more generally, a 'special endothelial cell of the sinusoids'. Following this brief and confused moment of glory, the concept of HSC fell into limbo for several decades. Between 1928 and the late 1950s, additional key features of HSC (still defined as 'Kupffer cells') were reported: the morphology of a pericyte [2], the presence of intracytoplasmic lipid droplets (i.e. 'fat-storing cells') [3] and the close relationship with branches of the autonomic nervous system [4]. In the early 1970s, work by Kenjiro Wake led to the conclusion that the star-shaped phagocytes described by Kupffer were identical to the fat-storing cells described by Ito, and that the lipid droplets were largely composed of retinoid esters. During the same period, several morphological studies suggested that this cell type could play a role in the pathogenesis of hepatic fibrosis [5–7]. Regardless, liver researchers and clinicians were rather refractory to this concept, in an era in which very little was known about the aetiology and pathogenesis of liver diseases, and the hepatocyte was considered the only relevant liver cell type. The real physiological and pathophysiological relevance of HSC has emerged only in the last 20 years, and there are still many potential issues concerning their role to be resolved. In these years, the knowledge about HSC and, particularly, their profibrogenic role has grown exponentially, and their glory is finally established to the point at which any area of liver disease can now be revisited with respect to the role of HSC. It is quite remarkable that, as for many things, history does not follow a straight line. Although the first intuition of Von Kupffer proved to be misleading, the possible relationship between HSC and the autonomic nervous system has now in fact been validated: nerve endings in the intralobular spaces are localized mainly in the Disse spaces and are oriented towards HSC [3,8]; they express neural cell markers [9], secrete norepinephrine and express a variety of neuroadrenergic receptors [10].

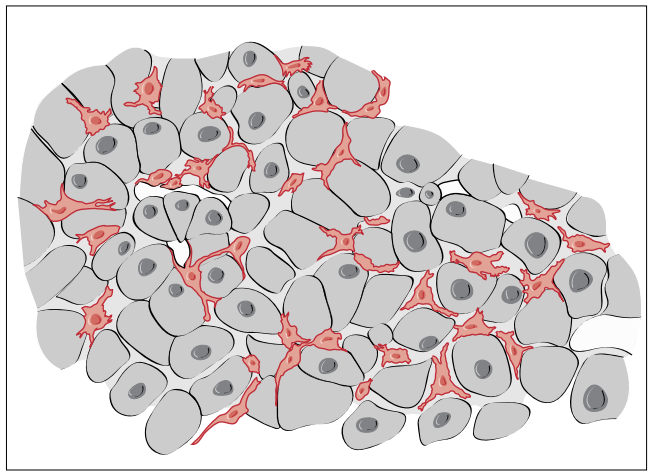

Fig. 1 Reproduction of Kupffer's drawing of the hepatic stellate cells (Sterzellen) in dog liver. Adapted from ref. 4.

Because of this rather controversial and tortuous history, HSC have been referred to by many different names (the most famous being Ito cells, lipocytes, fat-storing cells, perisinusoidal stellate cells). Each of these names bore sources of potential misunderstanding and, finally, in 1996, an international group of investigators actively working on this topic made the recommendation to refer to this cell type as 'hepatic stellate cell' [11].

Anatomy and ultrastructure

Hepatic stellate cells are located in the space of Disse in close contact with hepatocytes and sinusoidal endothelial cells. In human liver, HSC are disposed along the sinusoids with a

Fig. 2 Stellate cells in the porcine liver. The long cytoplasmic processes encompass sinusoids at regular intervals. Golgi's silver method (× 840). From ref. 72.

nucleus-to-nucleus distance of 40 μm, indicating that the sinusoids are equipped with HSC at certain fixed distances [12] (Fig. 2). Therefore, although the total number of HSC constitutes a small percentage of the total number of liver cells (approximately 5–8%), their spatial disposition and spatial extension may be sufficient to cover the entire hepatic sinusoidal microcirculatory network.

The three-dimensional structure of HSC consists of the cell body and several long and branching cytoplasmic processes (Fig. 3). Two main types of cytoplasmic processes are recognized according to their spatial disposition: the *intersinusoidal* or *interhepatocellular* processes and the *perisinusoidal* or *subendothelial* processes. The interhepatocellular processes penetrate the hepatic cell plates and extend to nearby sinusoids [12]. A single HSC may provide interhepatocellular processes to two or more neighbouring sinusoids. The perisinusoidal processes encircle the sinusoid located on the same cell plate by means of a series of adjacent periodic side-branches extending subendothelially. In general, the subendothelial processes appear to adhere to the sinusoidal wall by narrow strands of material resembling a basement membrane. These latter structures, although not continuously distributed, seem to ensure a strong connection between HSC and the sinusoidal endothelium [13]. The minute thorn-like microprojections or spines, termed *hepatocyte-contacting* processes [14], are an important and distinctive element of this cell type. These spines face the microvillous facet of hepatocytes and establish close intercellular contacts between HSC and parenchymal cells [15]. Although the functions of these microprojections are presently unknown, several lines of evidence suggest that they may play a role in epithelial–mesenchymal interactions that promote cell differentiation [15,16]. Another possible function of these processes is to serve as part of a mechanism of contact inhibition of HSC [17].

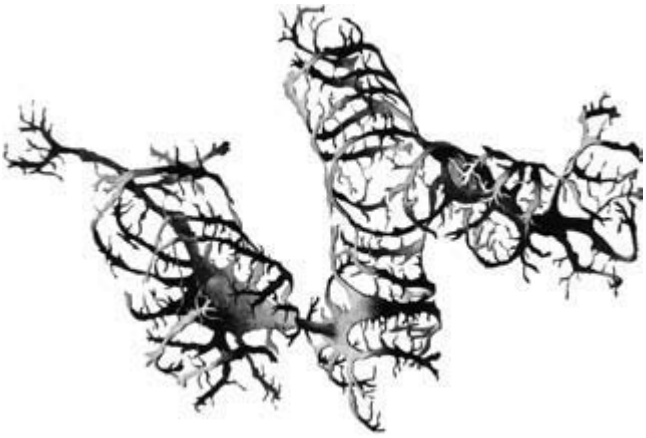

Fig. 3 Drawing of the three-dimensional structure of two hepatic stellate cells of porcine liver. The drawing was made according to the findings obtained by Golgi's silver method. From [73].

The most relevant ultrastructural feature of HSC in adult normal liver is the presence of cytoplasmic lipid droplets ranging in diameter from 1 to 2 μm (Fig. 4). This feature is related to one of the main known physiological functions of HSC, i.e. the hepatic storage of retinyl esters. However, in both rat and human liver, the number of HSC-containing evident lipid droplets varies up to 75% [4,18]; these are mainly located in lobular zone 2. Two types of lipid droplets have been identified: membrane-bound (type 1) and non-membrane-bound (type 2). Membrane-bound lipid droplets appear to derive from multivesicular bodies [4]. The nucleus of HSC in normal liver is oval and frequently indented by lipid droplets in the cytoplasm. One or more nucleoli and, in general, a tendency to a clumped heterochromatin pattern are often observed. Another important ultrastructural feature of these cells is a well-developed rough endoplasmic reticulum, suggesting active protein synthesis. Numerous microtubular structures are present in the cytoplasm together

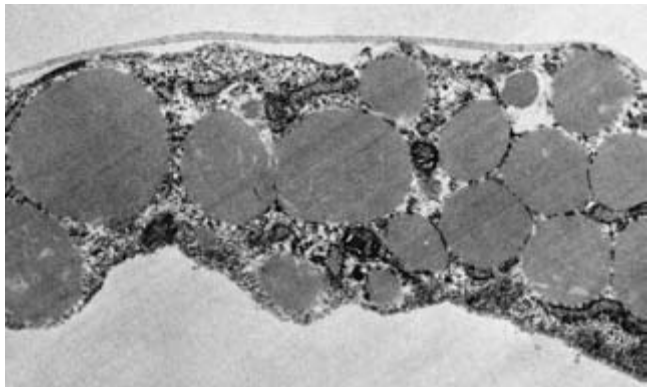

Fig. 4 Transmission electron microphotographs of hepatic stellate cells. Rat hepatic stellate cell in primary culture 3 days after plating. The cell contains numerous large lipid droplets (× 9600). From ref. 74.

with bundles of microfilaments (5 nm thick), particularly along the subsurface cytoplasmic matrix apposed to the neighbouring sinusoidal endothelial cell. Other 10-nm-thick filaments are widely distributed in the cytoplasm, especially around the nucleus and among the rough endoplasmic reticulum area. These microtubules and microfilaments may function as the cytoskeleton of dendritic processes and play a role in lipid synthesis and/or transport. Finally, ultrastructural analysis of the subendothelial processes revealed that these peculiar structures are equipped with massive 5-nm actin-like filaments, thus raising the hypothesis that they may contribute to reinforcing the endothelial lining and/or enhancing the efficiency of contraction of sinusoidal capillaries [4].

Retinoid storage and metabolism

(see also Chapter 2.3.11, Vitamins and the liver)

HSC play a key role in the metabolism and storage of retinoids [19]. In mammals, some 50–80% of total retinol is stored in the liver under normal circumstances. Retinyl esters, derived from esterification of retinol in the intestine, are transported to the liver via the lymphatic route in chylomicrons. Several studies have shown that chylomicron remnant retinyl esters are taken up by hepatocytes. After binding of the newly endocytosed retinoids with specific retinoid-binding proteins (RBP), these compounds are transferred to the neighbouring HSC [20]. In these cells, the uptake as well as the storage and the mobilization of retinoids are mainly regulated by intracellular retinol-binding proteins (CRBP), whose concentration in HSC is 20 times higher than that found in parenchymal cells [21,22]. In addition, *in vitro* experiments have shown that retinol and retinyl acetate can be taken up by HSC through a concentration-dependent gradient [23,24]. In adults, about 80% of total liver retinoids are stored as retinyl esters in HSC [21]. Retinyl esters are a major component of the total lipid mass present in the lipid droplets of HSC. However, the relative percentage of this compound is also dependent on the vitamin A status of the animal. Triacylglycerol is another main component, and its concentration in the droplets does not seem to reflect the nutritional and/or the vitamin A status of the animal. Minor components of the lipid droplets are unesterified retinol, cholesteryl esters, cholesterol, free fatty acids and various phospholipids [25]. Any physiological condition that requires an increased utilization of retinoids at the periphery will result in the mobilization of these compounds from HSC through unknown mechanisms. Several retinoid-related proteins have been identified in stellate cells, including CRBP, retinol palmitate hydrolase, cellular retinoic acid-binding protein (CRABP), bile salt-dependent and -independent retinol ester hydrolase and acyl coenzyme A:retinal acyltransferase [26,27]. Whether stellate cells produce RBP is still in question, because of contradictory reports on the presence of RBP mRNA in stellate cells from different studies [27,28]. Stellate cells also express nuclear retinoid receptors [30], including retinoic acid receptors (RAR)α, β and γ [27,29] and retinoid X receptors (RXR)α and β, but not γ [31].

Intralobular heterogeneity of HSC

Several characteristics of HSC vary according to their location within the liver lobule [32–34]. Considering the classic division of the liver lobule into three zones (zone 1: periportal; zone 2: intermediate; zone 3: pericentral), HSC located in zone 1 appear to be small and contain minute vitamin A–lipid droplets. Perisinusoidal branching processes are short and smoothly contoured with few hepatocyte-contacting processes (Fig. 5), whereas desmin immunoreactivity is present but not particularly intense. HSC located in lobular zone 2 store abundant vitamin A–lipid droplets and extend encompassing processes that show intense desmin immunoreactivity (in the rat). These processes display conspicuous branching and abundant hepatocyte-contacting spines. Proceeding towards the centrilobular vein, HSC become more elongated, assuming a dendritic appearance, whereas their desmin immunoreactivity and vitamin A storage are progressively reduced becoming virtually absent around the centre of the lobule (Fig. 5). It has been reported that the administration of excess vitamin A to rats induces a progressive increase in the number and size of vitamin A–lipid droplets in HSC located in the central zone. Therefore, the intralobular heterogeneity of HSC may reflect, at least, differences in the metabolic handling of vitamin A and in the regulation of sinusoidal blood pressure in different areas of the liver lobule.

Isolation and culture of HSC

HSC isolated from normal liver and activated in culture represent an excellent model for investigating their profibrogenic properties. Nearly all isolation procedures include a first step aimed at obtaining a suspension of non-parenchymal liver cells. For this purpose, adult rat liver is perfused, through the portal vein, with a combination of collagenase (type 4) and pronase. Different technical approaches have been proposed for further purification of a homogeneous population of HSC [35–37].

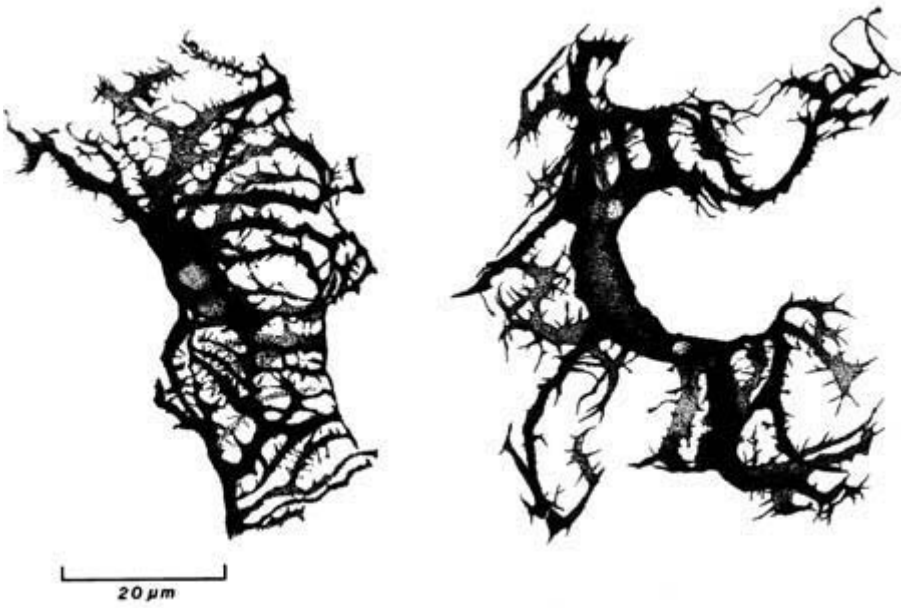

Fig. 5 Camera lucida drawings of Golgi-stained hepatic stellate cells in zone 3 (left) and in the terminal region of the sinusoids (right). Note the spine-like microprojections from the lateral edges of subendothelial processes. Porcine liver (× 1200). From ref. 72.

However, all these purification procedures are based on the low buoyant density of these cells as a result of their large fat content. Accordingly, the final yield of HSC obtained from a single rat liver will vary according to the age, body weight and nutritional status of the animal. The highest yield is usually obtained by employing older rats maintained on a normal diet or younger rats fed on a vitamin A-supplemented diet. Modifications of the methods used to isolate HSC from rat liver have been introduced for the isolation of HSC from mice [38] or from wedge sections of normal human liver [39,40]. In particular, concerning the isolation of HSC from human liver, the use of wedge sections obtained at surgery does not offer the possibility of performing an adequate perfusion of the tissue. Therefore, the total yield/g of tissue and the purity of the cell preparation are generally lower than those obtainable from rat liver. However, a virtually 100% pure HSC culture is obtained from the first subculture (passage 1) by plating the cells on plastic substrata and supplementing the culture medium with rather high concentrations of fetal bovine serum (10–20%). These culture conditions appear to be quite selective for HSC and tend to eliminate contaminating endothelial and Kupffer cells [40]. In case higher cell purity is required (i.e. to obtain a pure population of 'freshly isolated' HSC), it is possible to perform further purification by centrifugal elutriation [41] or cell sorting [42].

Identification of HSC and related hepatic fibrogenic cells

The original method for the identification of HSC isolated from liver tissue was based on the detection of their distinctive morphological features and, particularly, the presence of intracytoplasmic lipid droplets [35]. In addition, the effective presence of vitamin A in the lipid droplets could be verified with additional techniques such as the demonstration of quick-fading green autofluorescence at 330 nm and the demonstration of intense cathodoluminescence on frozen section by electron microscopy [43]. However, as described above, the presence of lipid droplets depends on the nutritional status and, more importantly, is a key feature of only a portion of the total HSC population present in the liver lobule. It has become increasingly apparent that HSC are one subtype within a continuum of related mesenchymal cells that collectively comprise the population of fibrogenic cells in normal and diseased liver. Therefore, the identification of cytoskeletal or surface markers able to differentiate HSC from other liver non-parenchymal cells represents an important issue. The first step should be directed towards the identification of vimentin-positive and cytokeratin/factor VIII/monocyte–macrophage cell marker-negative cells. This approach can enable investigators to restrict their analysis to a subclass of mesenchymal cells including HSC, smooth muscle cells, myofibroblasts and fibroblasts [44]. Further steps are then aimed at differentiating HSC from the other subtypes. Among other cytoskeletal constituents, the intermediate filament desmin, characteristic of cells of muscle origin, is considered as a selective marker for the identification of HSC [45]. Desmin is definitively a reliable marker for the identification of HSC in rat or mouse liver tissue, although, as noted above, some intralobular heterogeneity in the intensity of the immunostaining is present. Unfortunately, none of the commercially available antibodies against desmin permits the reliable staining of desmin in human HSC cultures as well as in human liver tissue. The results range from no staining when using monoclonal antibodies to diffuse cytoplasmic staining (not adequate for intermediate filaments) when employing polyclonal antibodies [39,40]. As the majority of these antibodies produce positive immunostaining in human vascular smooth muscle cells, it is possible that human HSC are either desmin negative or their desmin possesses specific epitopes not recognized by the available antibodies.

Consolidated evidence indicates that the smooth muscle isoform of α-actin (α-SMA) represents an additional cytoskeletal marker for the identification of HSC [46,47]. However, α-SMA is not expressed in HSC early after isolation but only after some time in culture. Consequently, α-SMA is commonly employed as a marker of HSC activation.

While these and other markers are still largely employed [45], the problem of HSC identification in both liver tissue and cell isolates has grown remarkably complex in recent years. As noted above, this is related to increasing evidence for the profibrogenic role of other extracellular matrix (ECM)-producing cells, each with a distinct localization and a characteristic immunohistochemical and/or electron microscopic phenotype [9]. These include fibroblasts and myofibroblasts (MF) of the portal tract, smooth muscle cells localized in vessel walls and MF localized around the centrilobular vein. It is also increasingly evident that the relative participation of these different cell types is dependent on the development of distinct patterns of fibrosis [48]. An important advancement in the identification of HSC and other ECM-producing cells (particularly portal MF) in normal and fibrotic liver (rat and human) was provided by Cassiman and Roskams [9]. In an extensive study of the immunohistochemical expression profiles of mesenchymal (myo)fibroblast-like subpopulations in fibrotic/cirrhotic human and rat liver, these authors confirmed the existence of distinct lineages, with the addition of a new entity defined as 'interface' MF [49]; whether these lineages actually derive from different developmental sources is uncertain. The main cell population present in the perisinusoidal space of liver lobules, defined as 'HSC', stained with all tested markers (Table 1) and showed most intense and most widespread staining with α-SMA and neural cell adhesion molecule (N-CAM) antibodies in human liver, while in rat liver, the largest proportion of HSC was stained by glial fibrillary acidic protein (GFAP) and desmin antibodies. The second subpopulation identified was the 'interface MF', (myo)fibroblast-like cells located at the interface between the portal tract and the parenchyma, or at the interface between the fibrotic septa and the parenchyma. When compared with HSC, interface MF showed no expression of synaptophysin (SYN), neurotrophin receptor tyrosine kinases Trk-B or Trk-C, low-affinity nerve growth factor receptor p75 or neurotrophin (NT) 3, but they did express GFAP, N-CAM, α-SMA, nerve growth factor (NGF), brain-derived nerve growth factor (BDNF), NT-4 and alpha B-crystallin (ABCRYS) in a varying proportion of cells [50,51]. The third subpopulation was the 'septal MF', the (myo)fibroblast-like cells populating the fibrotic septa. They only stained with α-SMA, GFAP, BDNF, ABCRYS, N-CAM and desmin (the last two only in rat) in a varying proportion of cells. This expression profile was identical to that seen in (myo)fibroblast-like cells populating the portal tracts of cirrhotic livers. It is therefore likely that septal MF derive from the expansion of the MF population of the portal tract. On the other hand, interface MF, present in areas of piecemeal necrosis and active fibrogenesis, are likely to derive from the recruitment and activation of HSC. The information derived from this detailed analysis performed in liver tissue can be employed for the identification of HSC and other ECM-producing cells in isolates from human and rat liver [9].

Table 1 Immunohistochemical expression profile of subpopulations of mesenchymal myofibroblast-like cells in fibrotic human and rat liver (from [42]).

	HSC	Interface MF	Septal MF	Portal MF
Desmin (human/rat)	–/+	–/+	–/±	–/±
α-SMA	+	+	+	+
GFAP	+	+	±	±
BDNF	+	±	±	±
ABCRYS	+	+	±	±
N-CAM (human/rat)	+/+	±/+	±/+	±/+
NGF	+	±	–	–
NT-4	+	±	–	–
NT-3	+	–	–	–
Trk-B	+	–	–	–
Trk-C	+	–	–	–
p75	+	–	–	–
Synaptophysin	+	–	–	–

The embryonic origin of HSC

The embryonic origin of HSC still constitutes a rather mysterious issue, which is closely related to the discovery of cell markers able to identify HSC and to differentiate them from other liver ECM-producing cells. In addition, identification of the embryonic origin of stellate cells will improve our understanding of their relationship to other fibrogenic liver cells and will also raise the possibility of using cell lineage-specific promoters to drive transgene expression selectively in stellate cells *in vivo* with a view to applying gene therapy. Based on morphological similarities and positivity for desmin, vimentin and α-SMA, HSC have been considered for many years to be of mesenchymal origin, derived embryologically from septum transversum (in turn arising from cardiac mesenchyme) as it invades the endoderm-derived hepatic bud. However, when HSC were found to contain a host of neural marker proteins, it was speculated that HSC could be of neuroectodermal origin [52]. Other studies have suggested the possibility that hepatocytes and stellate cells may derive from a common endodermal precursor [53]. Finally, recent studies in humans and animal models suggest that HSC may also derive from bone marrow precursors [54–56].

Rodent, human and HSC lines: differences and similarities

Most of the established experience with HSC cultures derives from cells isolated from normal rat or human liver and activated by culture on plastic substrata. It is not possible to make a clearcut distinction in the behaviour of rat, mouse and human

HSC preparations, although it is likely that there are several differences. As a general rule, observations based on rodent HSC cultures are not necessarily true for human HSC and vice versa, and findings must be validated directly between species. There is still quite a lot of uncertainty about the fate of rat HSC after the first culture on plastic, with some authors supporting the possibility of their extinction by apoptosis [57] and others supporting their final differentiation into MF-like cells. On the other hand, human HSC seem to progress to their activated phenotype without showing signs of apparent apoptosis (actually being very resistant to proapoptotic stimuli) and showing cell markers of the so-called 'interface' MF [9]. It is also relevant that human HSC preparations derived from the liver of different individuals show quantitative differences in gene/protein expression and in response to profibrogenic cytokines. It is therefore very much recommended to perform experiments on more than one human HSC preparation to account for these interindividual differences when describing features of this cell type or its response to specific stimuli.

Several groups have proposed the use of HSC lines as an alternative to working with primary cells (for a review see [45]). The use of HSC lines allow easier manipulation, sharing of cells to validate results and transfectability. However, HSC lines always derive from spontaneously or artificially immortalized HSC, and any specific observation needs to be carefully interpreted and not transferred to the biology of primary cells without validation of key findings. Four human HSC lines have been introduced and characterized recently. The LX-1 and LX-2 lines were generated by either SV40 T-antigen immortalization (LX-1) or spontaneous immortalization in low serum conditions (LX-2) [58]. Both lines express α-SMA, vimentin and GFAP. Similar to primary HSCs, both lines express key receptors regulating hepatic fibrosis and also proteins involved in matrix remodelling. Transforming growth factor β1 stimulation increased their α1(I) procollagen mRNA expression. LX-2, but not LX-1, cells are highly transfectable. The human HSC line TWNT-4 was immortalized by retrovirally introducing human telomerase reverse transcriptase (hTERT) into LI 90 cells established from a human liver mesenchymal tumour [59]. TWNT-4 express platelet-derived growth factor receptor β (PDGF-Rβ), α-SMA and type 1 collagen (α1). Another human HSC line was obtained by infecting human HSC with a retrovirus expressing hTERT [60]. When compared with control human HSC, telomerase-positive HSC did not show signs of senescence and could be cultured for at least 69 passages. Telomerase-positive HSC did not undergo oncogenic transformation and exhibited morphological and functional characteristics of activated HSC.

Extrahepatic HSC and the 'stellate cell system'

Stellate cells also exist in extrahepatic organs such as pancreas, lung, kidney, intestine, spleen, adrenal gland, ductus deferens and vocal cords. Hepatic and extrahepatic stellate cells form what has been defined as the 'stellate cell system'. In recent years, particular attention has been given to pancreatic stellate cells and their potential pathogenic role in chronic pancreatitis and pancreatic cancer [61]. Considering the current uncertainty on the origin of HSC, it is even more difficult to know whether or not all these stellate cells derive from a common precursor.

HSC and extracellular matrix homeostasis

In normal liver, the ECM constitutes about 0.5% of liver wet weight. This specialized tissue component can be subdivided into the pericellular matrix interacting with cell membrane components, the classic interstitial matrix structuring the interstitial spaces and basement membranes supporting epithelial, endothelial and mesenchymal cells. In addition to collagens, ECM is made up of minor amounts of several non-collagenous components. These include large glycoproteins such as fibronectin, laminin, nidogen (entactin), tenascin and undulin, several types of sulphated proteoglycans and, as a pure carbohydrate polymer, hyaluronic acid. The space of Disse, where HSC are located, is a virtual space constituted by an ECM network composed of type 4 collagen, associated with non-collagenous components such as laminin and nidogen. In this context, the presence of collagen I and III, although quantitatively relevant, is limited to large-diameter bundles of fibres reinforcing the architecture of the perisinusoidal space. The resulting complex, defined as 'non-fibrillar', ensures an optimal diffusion between hepatocytes and the bloodstream. In normal liver, all the cellular components delimiting the space of Disse, including hepatocytes, appear to be involved in the synthesis of the main ECM components [62,63]. However, the large majority of collagen III, IV and laminin is synthesized by HSC (III > IV > laminin > I) and sinusoidal endothelial cells (IV > III > laminin > I), whereas all cell types synthesize small amounts of collagen I, supporting the concept that, in normal liver, synthesis of this type of collagen is minimally active. In addition, sinusoidal endothelial cells appear to synthesize collagen IV and laminin in much higher amounts than HSC [64]. These observations are fundamental when considering that, during active liver fibrogenesis, HSC become the major ECM-producing cell type, with a predominant production of collagen I [62–64]. Normal ECM turnover implies that the synthesis of new individual components is associated with their continuous slow degradation. In normal liver, HSC and possibly other sinusoidal cells may contribute to the continuous remodelling of the ECM of the space of Disse by producing matrix metalloproteinase 2 (gelatinase or type 4 collagenase) [65] (see also Chapter 6, Cirrhosis).

HSC as liver-specific pericytes

The possible role of HSC as liver-specific pericytes is suggested by their anatomical location, ultrastructural features and close relationship with the autonomous nervous system (Fig. 6).

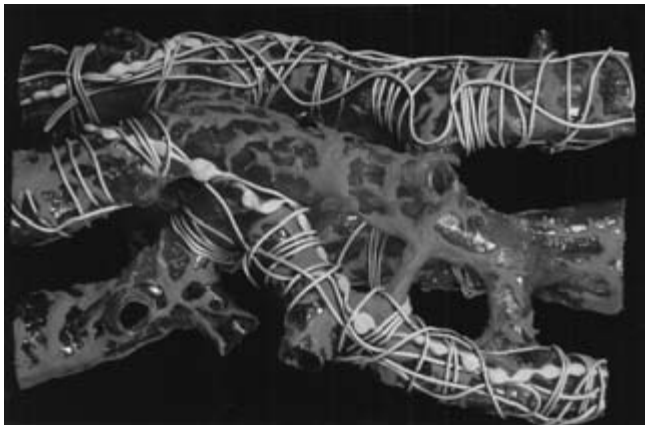

Fig. 6 A three-dimensional model of hepatic sinusoids. Hepatic stellate cells (red) adhere directly to the fenestrated endothelium to make stellate cell–endothelial cell complexes. Nerve fibres (yellow) and collagen fibres (grey) are distributed outside the cell complex, i.e. in the space of Disse. Figure courtesy of Professor K. Wake.

Studies performed over the past decade have shown that HSC isolated from rat or human liver and maintained in culture contract in response to several vasoconstricting stimuli [66]. Contraction of HSC in response to these stimuli has been demonstrated independently from the cell attachment substrata (glass, plastic, silicone membranes or collagen lattices). Importantly, at least after stimulation with thrombin, endothelin-1 and angiotensin II, cell contraction is coupled with an increase in intracellular calcium concentration [67]. These observations contribute greatly to the central issue of considering HSC as pericytes. It should be noted, however, that cultured HSC are characterized by an activated phenotype resembling transitional or MF-like cells rather than quiescent HSC. Therefore, the contractile properties demonstrated in these experiments are likely to be more representative of HSC contractile status in fibrotic liver. Whether or not HSC contract in normal liver tissue still represents a matter for discussion. From the morphological standpoint, some observations argue against the role of HSC in the regulation of sinusoidal blood flow [68]. First, in their *in vivo* tridimensional orientation, HSC do not have a stellate form (typical of their aspect in bidimensional culture on plastic) but rather a 'spider-like' appearance ('arachnocytes') with a small cell body and a series of radiating and parallel slender processes. According to the authors of these observations, cells with this tridimensional appearance are not likely to be 'contraction ready'. Additional limitations to effective cell contraction are offered by the spatial constraints of the space of Disse, by the intracytoplasmic presence of lipid droplets that prevent microfilaments from assembling in a long span and by the ultrastructural evidence of a limited development of contractile filaments in quiescent HSC. Regardless, studies evaluating the hepatic microcirculation by intravital microscopy techniques have suggested that HSC could be involved in the regulation of sinusoidal tone in normal liver [69,70]. An additional matter of debate is provided by studies aimed at quantifying HSC contraction with techniques able to detect the development of contractile forces in response to vasoconstrictors [71]. The results of these studies indicate that the magnitude and kinetics of contraction and relaxation are consistent with the hypothesis that HSC may affect sinusoidal resistance. However, for understandable technical reasons, these data were obtained in rat HSC in primary culture 7 days after isolation, when a certain degree of activation in culture has already occurred. In conclusion, although HSC could be proposed as liver-specific pericytes based on their location, spatial distribution, relationship with the peripheral nervous system and ultrastructural features, no conclusive evidence establishes a role in regulating normal sinusoidal blood flow.

References

1 Kupffer K (1876) Uber Sternzellen der Leber. Briefliche Mitteilung an Professor Waldeyer. *Arch Mikr Anat* 12, 353–358.

2 Zimmerman K (1928) Uber das Verhaltniss der 'Kupfferschen Sternzellen' zum Endothel der Leberkapillaren beim Menschen. *Ztsch Mikr Anat Forsch* 14, 528–548.

3 Ito T, Nemoto M (1952) Uber die Kupfferschen Sternzellen und die 'Fettspeicherungzellen' (fat storing cells) in der Blutkapillarenwand der menschlichen Leber. *Okajima Folia Anat Jpn* 24, 243–258.

4 Wake K (1980) Perisinusoidal stellate cells (fat-storing cells, interstitial cells, lipocytes), their related structure in and around the liver sinusoids, and vitamin A-storing cells in extrahepatic organs. *Int Rev Cytol* 66, 303–353.

5 McGee JO, Patrick RS (1972) The role of perisinusoidal cells in hepatic fibrogenesis. An electron microscopic study of acute carbon tetrachloride liver injury. *Lab Invest* 26, 429–440.

6 McGee JO, Patrick RS (1972) The role of perisinusoidal cells in experimental hepatic fibrogenesis. *J Pathol* 106 (1), vi.

7 Kent G, Gay S, Inouye T *et al.* (1976) Vitamin A-containing lipocytes and formation of type III collagen in liver injury. *Proc Natl Acad Sci USA* 73, 3719–3722.

8 Ueno T, Bioulac-Sage P, Balabaud C *et al.* (2004) Innervation of the sinusoidal wall: regulation of the sinusoidal diameter. *Anat Rec A Discov Mol Cell Evol Biol* 280, 868–873.

9 Cassiman D, Roskams T (2002) Beauty is in the eye of the beholder: emerging concepts and pitfalls in hepatic stellate cell research. *J Hepatol* 37, 527–535.

10 Oben JA, Diehl AM (2004) Sympathetic nervous system regulation of liver repair. *Anat Rec A Discov Mol Cell Evol Biol* 280, 874–883.

11 Letter to the editor (1996) Hepatic stellate cell nomenclature (letter). *Hepatology* 23, 193.

12 Wake K (1988) Liver perivascular cells revealed by gold and silver impregnation methods and electron microscopy. In: Motta P (ed.) *Biopathology of the Liver, an Ultrastructural Approach*. Dordrecht: Kluwer, pp. 23–26.

13 Wake K (1999) Hepatic stellate cells. In: Tanikawa K, Ueno T (eds) *Liver Diseases and Hepatic Sinusoidal Cells*. Tokyo: Springer-Verlag, pp. 56–65.

14 Wake K (1995) Structure of the sinusoidal wall in the liver. In: Wisse E, Knook DL, Wake K (eds) *Cells of the Hepatic Sinusoid*. Leiden: The Kupffer Cell Foundation, pp. 241–246.

15 Wake K, Motomatsu K, Ekataksin W (1991) Postnatal development of the perisinusoidal stellate cells in the rat liver. In: Wisse E, Knook DL, McCuskey RS (eds) *Cells of the Hepatic Sinusoid*. Leiden: The Kupffer Cell Foundation, pp. 269–275.
16 Gressner AM, Lofti S, Gressner G *et al.* (1992) Identification and partial characterization of a hepatocyte-derived factor promoting proliferation of cultured fat-storing cells (parasinusoidal lipocytes). *Hepatology* 16, 1250–1266.
17 Wanson JC, Mosselmans R (1980) Coculture of adult rat hepatocytes and sinusoidal cells: a new experimental model for the study of ultrastructural and functional properties of liver cells. In: Popper H, Bianchi L, Gudat F *et al.* (eds) *Communications of Liver Cells*. Lancaster: MTP Press, pp. 239–251.
18 Sztark F, Dubroca J, Latry P *et al.* (1986) Perisinusoidal cells in patients with normal liver histology. A morphometric study. *J Hepatol* 2, 358–369.
19 Blomhoff R, Wake K (1991) Perisinusoidal stellate cells of the liver: important roles in retinol metabolism and fibrosis. *FASEB J* 5, 271–277.
20 Blomhoff R, Berg T, Norum KR (1988) Transfer of retinol from parenchymal to stellate cells in liver is mediated by retinol-binding protein. *Proc Natl Acad Sci USA* 85, 3455–3458.
21 Blomhoff R, Rasmussen M, Nilsson A *et al.* (1985) Hepatic retinol metabolism. Distribution of retinoids, enzymes, and binding proteins in isolated rat liver cells. *J Biol Chem* 260, 13560–13565.
22 Uchio K, Tuchweber B, Manabe N *et al.* (2002) Cellular retinol-binding protein-1 expression and modulation during in vivo and in vitro myofibroblastic differentiation of rat hepatic stellate cells and portal fibroblasts. *Lab Invest* 82, 619–628.
23 Matsuura T, Nagamori S, Fujise K *et al.* (1989) Retinol transport in cultured fat-storing cells of rat liver. Quantitative analysis by anchored cell analysis and sorting system. *Lab Invest* 61, 107–115.
24 Pinzani M, Gentilini P, Abboud HE (1992) Phenotypical modulation of liver fat-storing cells by retinoids. Influence on unstimulated and growth factor-induced cell proliferation. *J Hepatol* 14, 211–220.
25 Moriwaki K, Blaner WS, Piantedosi R *et al.* (1988) Effects of dietary retinoids and triglyceride on the lipid composition of rat liver stellate cells and stellate cell lipid droplets. *J Lipid Res* 29, 1523–1534.
26 Blaner WS, Hendriks HF, Brouwer A *et al.* (1985) Retinoids, retinoid binding proteins and retinyl palmitate hydrolase distributions in different types of rat liver cells. *J Lipid Res* 26, 1241–1251.
27 Friedman SL, Wei S, Blaner WS (1993) Retinol release by activated rat hepatic lipocytes: regulation by Kupffer cell-conditioned medium and PDGF. *Am J Physiol* 264, G947–952.
28 Blomhoff R, Norum KR, Berg T (1985) Hepatic uptake of [3H]retinol bound to the serum retinol binding protein involves both parenchymal and perisinusoidal stellate cells. *J Biol Chem* 260, 13571–13575.
29 Weiner FR, Blaner WS, Czaja MJ *et al.* (1992) Ito cell expression of a nuclear retinoic acid receptor. *Hepatology* 15, 336–342.
30 Mangelsdorf DJ, Thummel C, Beato M *et al.* (1995) The nuclear receptor superfamily: the second decade. *Cell* 83, 835–839.
31 Ulven SM, Natarajan V, Holven KB *et al.* (1998) Expression of retinoic acid receptor and retinoid X receptor subtypes in rat liver cells: implications for retinoid signalling in parenchymal, endothelial, Kupffer and stellate cells. *Eur J Cell Biol* 77, 111–116.
32 Ballardini G, Groff P, Badiali de Giorgi L *et al.* (1994) Ito cell heterogeneity: desmin-negative Ito cells in normal rat liver. *Hepatology* 19, 440–446.
33 Zou Z, Ekataksin W, Wake K (1998) Zonal and regional differences identified from precision mapping of vitamin A-storing lipid droplets of the hepatic stellate cells in pig liver: a novel concept of addressing the intralobular area of heterogeneity. *Hepatology* 27, 1098–1108.
34 Higashi N, Senoo H (2003) Distribution of vitamin A-storing lipid droplets in hepatic stellate cells in liver lobules – a comparative study. *Anat Rec A Discov Mol Cell Evol Biol* 271, 240–248.
35 Knook DL, Seffelaar AM, De Leuw AM (1982) Fat-storing cells of rat liver. Their isolation and purification. *Exp Cell Res* 139, 468–471.
36 Friedman SL, Roll FJ (1987) Isolation and culture of hepatic lipocytes, Kupffer cells and sinusoidal endothelial cells by density gradient centrifugation with stractan. *Anal Biochem* 161, 207–218.
37 Mantovaara T, Norlinder H, Pertof H (1990) Isolation of the perisinusoidal vitamin A storing cells from rat liver on Ca^{2+} immobilized glass surfaces. *Exp Cell Res* 187, 170–173.
38 Pinzani M, Abboud HE, Gesualdo L *et al.* (1992) Regulation of macrophage-colony stimulating factor in liver fat-storing cells by peptide growth factors. *Am J Physiol Cell Physiol* 262, C876–C881.
39 Friedman SL, Rockey DC, McGuire RF *et al.* (1992) Isolated hepatic lipocytes and Kupffer cells from normal human liver: morphological and functional characteristics in primary culture. *Hepatology* 15, 234–243.
40 Casini A, Pinzani M, Milani S *et al.* (1993) Regulation of transforming growth factor-β1 in human fat-storing cells. *Gastroenterology* 105, 245–253.
41 Maher JJ, Bissell DM, Friedman SL *et al.* (1988) Collagen measured in primary cultures of normal rat hepatocytes derives from lipocytes within the monolayer. *J Clin Invest* 82, 450–459.
42 Geerts A, Niki T, Hellemans K *et al.* (1998) Purification of rat hepatic stellate cells by side scatter-activated cell sorting. *Hepatology* 27, 590–598.
43 Bioulac-Sage P, Balabaud C (1992) Proliferation and phenotypic expression of perisinusoidal cells. *J Hepatol* 15, 284–287.
44 Pinzani M, Gesualdo L, Sabbah GM *et al.* (1989) Effects of platelet-derived growth factor and other polypeptide mitogens on DNA synthesis and growth of cultured rat liver fat-storing cells. *J Clin Invest* 84, 1786–1793.
45 Geerts A (2001) History, heterogeneity, developmental biology, and functions of quiescent hepatic stellate cells. *Semin Liver Dis* 21, 311–335.
46 Ramadori G, Veit T, Schwogler S *et al.* (1990) Expression of the gene of the alpha-smooth muscle-actin isoform in rat liver and in rat fat-storing (Ito) cells. *Virchows Arch B Cell Pathol Incl Mol Pathol* 59, 349–357.
47 Rockey DC, Boyles JK, Gabbiani G *et al.* (1992) Rat hepatic lipocytes express smooth muscle actin upon activation in vivo and in culture. *J Submicrosc Cytol Pathol* 24, 193–203.
48 Pinzani M, Rombouts K (2004) Liver fibrosis: from the bench to clinical targets. *Dig Liver Dis* 36, 231–242.
49 Cassiman D, Libbrecht L, Desmet V *et al.* (2002) Hepatic stellate cell/myofibroblast subpopulations in fibrotic human and rat livers. *J Hepatol* 36, 200–209.
50 Cassiman D, van Pelt J, De Vos R *et al.* (1999) Synaptophysin: a novel marker for human and rat hepatic stellate cells. *Am J Pathol* 155, 1831–1839.
51 Cassiman D, Denef C, Desmet V *et al.* (2001) Human and rat hepatic stellate cells express neurotrophins and neurotrophin receptors. *Hepatology* 33, 148–158.
52 Geerts A (2004) On the origin of stellate cells: mesodermal, endodermal or neuro-ectodermal? *J Hepatol* 40, 331–334.
53 Kiassov AP, Van Eyken P, van Pelt JF *et al.* (1995) Desmin expressing nonhematopoietic liver cells during rat liver development: an

immunohistochemical and morphometric study. *Differentiation* 59, 253–258.

54 Forbes SJ, Russo FP, Rey V *et al.* (2004) A significant proportion of myofibroblasts are of bone marrow origin in human liver fibrosis. *Gastroenterology* 126, 955–963.

55 Baba S, Fujii H, Hirose T *et al.* (2004) Commitment of bone marrow cells to hepatic stellate cells in mouse. *J Hepatol* 40, 255–260.

56 Suskind DL, Muench MO (2004) Searching for common stem cells of the hepatic and hematopoietic systems in the human fetal liver: $CD34^+$ cytokeratin $7/8^+$ cells express markers for stellate cells. *J Hepatol* 40, 261–268.

57 Saile B, Matthes N, Neubauer K *et al.* (2002) Rat liver myofibroblasts and hepatic stellate cells differ in CD95-mediated apoptosis and response to TNF-alpha. *Am J Physiol Gastrointest Liver Physiol* 283, G435–G444.

58 Xu L, Hui AY, Albanis E *et al.* (2005) Human hepatic stellate cell lines, LX-1 and LX-2: new tools for analysis of hepatic fibrosis. *Gut* 54, 142–151.

59 Shibata N, Watanabe T, Okitsu T *et al.* (2003) Establishment of an immortalized human hepatic stellate cell line to develop antifibrotic therapies. *Cell Transplant* 12, 499–507.

60 Schnabl B, Choi YH, Olsen JC *et al.* (2002) Immortal activated human hepatic stellate cells generated by ectopic telomerase expression. *Lab Invest* 82, 323–333.

61 Apte MV, Wilson JS (2004) Mechanisms of pancreatic fibrosis. *Dig Dis* 22, 273–279.

62 Milani S, Herbst H, Schuppan D *et al.* (1989) In situ hybridization for procollagen types I, III and IV mRNA in normal and fibrotic rat liver: evidence for predominant expression in nonparenchymal liver cells. *Hepatology* 10, 84–92.

63 Milani S, Herbst H, Schuppan D *et al.* (1989) Cellular localization of laminin gene transcripts in normal and fibrotic human liver. *Am J Pathol* 134, 1175–1182.

64 Maher JJ, McGuire RF (1990) Extracellular matrix gene expression increases preferentially in rat lipocytes and sinusoidal endothelial cells during hepatic fibrosis in vivo. *J Clin Invest* 86, 1641–1648.

65 Milani S, Herbst H, Schuppan D *et al.* (1994) Differential expression of matrix-metalloproteinase-1 and -2 genes in normal and fibrotic human liver. *Am J Pathol* 144, 528–537.

66 Pinzani M, Gentilini P (1999) Biology of hepatic stellate cells and their possible relevance in the pathogenesis of portal hypertension in cirrhosis. *Semin Liver Dis* 19, 397–410.

67 Pinzani M, Failli P, Ruocco C *et al.* (1992) Fat-storing cells as liver-specific pericytes. Spatial dynamics of agonist-stimulated intracellular calcium transients. *J Clin Invest* 90, 642–646.

68 Ekataksin W, Kaneda K (1999) Liver microvascular architecture: an insight into the pathophysiology of portal hypertension. *Semin Liver Dis* 19, 359–382.

69 Zhang JX, Pegoli W, Jr, Clemens MG (1994) Endothelin-1 induces direct constriction of hepatic sinusoids. *Am J Physiol* 266, G624–632.

70 Zhang JX, Bauer M, Clemens MG (1995) Vessel- and target cell-specific actions of endothelin-1 and endothelin-3 in rat liver. *Am J Physiol* 269, G269–277.

71 Thimgan MS, Yee HF, Jr (1999) Quantitation of rat hepatic stellate cell contraction: stellate cells' contribution to sinusoidal tone. *Am J Physiol* 277, G137–G143.

72 Wake K, Sato T (1993) Intralobalar heterogeneity of perisinusoidal stellate cells in porcine liver. *Cell Tissue Res* 273, 227–237.

73 Wake K (1977) Chapter in: Vidal-Vanaclocha F (ed.) *Functional Heterogeneity of Liver Tissue*. Austin, TX: RG Landes Co.

74 Pinzani M (1995) Novel insights into the biology and physiology of the Ito cell. *Pharmac Ther* 66, 387–412.

1.7 Biliary epithelial cells

Jean-François Dufour

An important minority

The bile duct epithelial cells, also called cholangiocytes, are the cells that cover the biliary tree. At the level of the canal of Hering, they appose to hepatocytes and/or oval cells to collect the bile from the bile canaliculi, which are themselves a space between hepatocytes where the primitive bile is formed. The bile circulates through a maze of conduits that progressively merge into larger ductules and bile ducts lined by cholangiocytes to finally reach the extrahepatic duct, the gallbladder and the choledochus, which are also covered by cholangiocytes. Morphometric studies revealed that biliary epithelial cells represent only 3–5% of the cells present in the liver.

Cholangiocytes are polarized cells with a side facing the bile, which comes from the hepatocytes, and a side facing the portal space and its nourishing peribiliary plexus, whose blood arises from the hepatic artery and flows thereafter in hepatic sinusoids. Not surprisingly, cholangiocytes have important vectorial transport functions secreting and resorbing solutes. Cholangiocytes also possess immunological properties by participating in the immune response and being the target of this response in several important liver diseases such as primary biliary cirrhosis, primary sclerosing cholangitis and chronic rejection after liver transplantation. In this sense, cholangiocytes can be seen as the Achilles' heel of the liver.

Transporters and polarity

The biliary epithelium modifies the primitive bile, which has been secreted by hepatocytes at their bile canalicular membrane. In humans, the contribution of the biliary epithelium to the bile flow is estimated to represent 40% of the bile flow. In contrast to hepatocellular secretion, which accumulates in bile complex molecules such as bile acids, phospholipids, cholesterol and glutathione, cholangiocellular secretion transports essentially water and electrolytes. This secretion relies on the correct arrangement of numerous transporters at the apical and at the basolateral sides of the cholangiocytes. Transepithelial transport of Cl^- ions forms the primary driving force for this secretion. Cl^- ions accumulate in cholangiocytes at the basolateral side through $Na^+/K^+/2Cl^-$ transporters. At the apical pole, opening of the cystic fibrosis transmembrane regulator (CFTR) channel lets Cl^- out of the cell into the lumen [1]. This activity is coupled with the activity of an anion exchanger, which exchanges Cl^- for HCO_3^-. This net release of HCO_3^- carries along water. Bile consisting of more than 98% water and aquaporins (AQP), which form water channels, plays an important role in cholangiocellular bile formation. AQP4 is constitutively expressed on the basolateral membrane, whereas AQP1 is targeted to the apical side of the cholangiocytes. Other proteins support these movements of Cl^- and HCO_3^-: on the basal side, a symporter takes up Na^+ and HCO_3^- and an exchanger takes up Na^+ against H^+ (NHE-1); on the apical side, another exchanger takes up Na^+ against H^+ (NHE-2). Apical Cl^- channels form the principal method of regulation of cholangiocellular secretion. Phosphorylation of CFTR by cyclic adenosine monophosphate (cAMP)-dependent protein kinase (PKA) increases the open permeability of this Cl^- channel. Moreover, cAMP translocates subapical vesicles sequestering CFTR, Cl^-/HCO_3^- anion exchanger and AQP1 to the apical plasma membrane [2,3]. In contrast, ATP depletion, as is the case during ischaemia, results in internalization of these apical membrane proteins [4]. Cl^- channels other than CFTR have been discovered. Among these additional Cl^- channels, CIC2 is regulated by cell volume and protein kinase C (PKC) [5], and another is calcium activated [6]. The importance of these Cl^- channels in liver pathobiology is demonstrated by cystic fibrosis, a disease characterized by mutations in the CFTR gene and with clinical liver disease occurring in only about 30% of the patients (see Chapter 16.4).

Cholangiocytes not only secrete solutes into the biliary lumen, but also reabsorb bile components. The same transporters that reuptake bile acids in the terminal ileum (ASBT) retrieve conjugated bile acids from the bile [7]. It has been found that an alternatively spliced form of ASBT (t-ASBT) is targeted to the basolateral membrane and functions as a bile acid efflux protein [8]. The heteromeric organic solute transporter OSTalpha–OSTbeta, which is also localized in the basolateral membrane of cholangiocytes, may play a similar role in the vectorial transport

of conjugated bile acids and sterols [9]. Translocation of ASBT to the apical membrane increases bile acid absorption by bile ducts, which amplifies bile acid-induced choleresis via cholehepatic shunting [10]. Bile ductular epithelium reabsorbs glucose by the coordinated expression of SGLT1 on the apical domain and GLUT1 on the basolateral domain [11]. SGLT1 has been implicated in invasion of cholangiocytes by *Cryptosporidium parvum*. *C. parvum* recruits SGLT1 and AQP1 to generate a localized water influx near its attachment site [12]. Cholangiocytes can also retrieve glutamate, which is produced by the luminal degradation of glutathione [13].

The cytoskeleton plays an important role in establishing and maintaining polarity by directing integral proteins to specific locations. Scaffolding proteins tether transporters to the underlying cytoskeleton. The ezrin–EBP50 complex accumulates at the apical pole of cholangiocytes. Ezrin concurrently binds actin, EBP50 and PKA. EBP50 is a PSD95-Dlg-ZO1 (PDZ) domain-containing protein that interacts with the carboxy tail of CFTR. This scaffold not only anchors CFTR to the cytoskeleton, but also fixes PKA near CFTR. Disruption of this association ablates cAMP-activated Cl^- channel activity [14]. On the lateral sides of the cholangiocytes, tight junctions restrict the movement of solutes between adjacent cells, maintaining the blood–bile barrier and preventing the apicobasal diffusion of integral membrane proteins. Permeability of the tight junctions in bile ducts is increased by tumour necrosis factor (TNF)α [15]. On their lateral side, cholangiocytes establish contacts through gap junctions. In contrast to hepatocytes, which form gap junctions with connexin 32 and connexin 26, cholangiocellular gap junctions are made of connexin 43 [16]. Finally, biliary epithelial cells are equipped with non-motile cilia. This important structural feature protrudes into the lumen and functions as a mechanoreceptor bent by bile flow. It is now established that polycystic liver and kidney diseases are ciliary diseases (see Chapter 8.1). Polycystin-1 and polycystin-2, which are defective in autosomal dominant polycystic kidney disease, localize to cilia. Loss of fibrocystin, as occurs in autosomal recessive polycystic kidney disease, results in distorted biliary cilia [17].

Regulation of cholangiocyte secretion

Several hormones regulate cholangiocellular secretion. Receptors for secretin, somatostatin, bombesin, vasoactive intestinal polypeptide (VIP), acetylcholine, dopamine and nucleotides are localized on the basolateral membrane of cholangiocytes. Secretin receptors are coupled with G proteins, which activate adenylyl cyclase to produce cAMP, resulting in increased activity of PKA [18]. By favouring the opening of CFTR and by mobilizing subapical vesicles containing CFTR, Cl^-/HCO_3^- exchanger and AQP1, secretin is the principal choleretic hormone; in humans, it more than doubles bile flow. The stimulation of biliary secretion by secretin is inhibited by other hormones linked to G protein-coupled receptors, such as somatostatin [19], gastrin [20] and endothelin-1 [21], which interfere with the production of cAMP. Insulin activates PKC in a calcium-dependent manner, and this inhibits the secretin-induced ductal secretion [22]. The neuropeptides bombesin and VIP stimulate fluid and HCO_3^- secretion from rat cholangiocytes by activating the luminal Cl^-/HCO_3^- exchanger [23,24]. Cholangiocytes express cholinergic M3 receptors, and administration of acetylcholine to rats through the hepatic artery increased HCO_3^- biliary secretion [25]. Using bile duct-ligated rats, it was found that an agonist of the D2 receptor inhibited PKA activity and secretin-induced choleresis via calcium-dependent PKC [26]. Exposure of human cholangiocytes to natriuretic peptide elicits the formation of cGMP, which in turn stimulated Cl^- efflux [27], suggesting a role for this second messenger in biliary physiology.

Nucleotides can be secreted into bile by either hepatocytes or cholangiocytes [28]. Bile contains ATP in micromolar concentrations. Exposure of cholangiocytes to ATP elicits cytosolic calcium oscillations [16]. These signals may be mediated through purinergic P2X receptors [29], which are ATP-gated cation channels, and P2Y receptors [30], which are G protein-coupled receptors linked to phospholipase C and the production of inositol trisphosphate. Stimulation of purinergic receptors enhances ductular secretion via the stimulation of calcium-dependent Cl^- efflux channels and basolateral NHE-1 [31,32]. Importantly, the P2Y receptors are localized in the apical membrane of biliary epithelial cells [31]. Then, nucleotides secreted into the bile canaliculus by hepatocytes modulate, in a paracrine manner downstream, the secretion of biliary epithelial cells.

Inositol trisphosphate elicits complex calcium signals such as calcium oscillations and calcium waves. These signals rely on inositol trisphosphate receptors, which are intracellular channels releasing calcium from the endoplasmic reticulum. Similarly to gap junctions, it appears that biliary epithelial cells use different isoforms from hepatocytes. In contrast to hepatocytes, which express mostly the inositol trisphosphate receptor isoform 2, biliary epithelial cells abundantly express inositol trisphosphate receptor isoform 3 [33]. Cholestasis has been associated with loss of inositol trisphosphate receptors in cholangiocytes and, consequently, impaired calcium signalling [34].

Portal inflammation may participate directly in cholestasis by impairing ductal secretion. A combination of cytokines [interleukin (IL)-6, interferon (IFN)-gamma, IL-1 and TNFα] inhibits cAMP formation and cyclic AMP-dependent Cl^- efflux in isolated bile duct units, but does not affect purinergic/calcium-dependent Cl^- efflux [35].

Cholangiocyte proliferation

Cholangiocyte proliferation is not proportionate to cell death in chronic cholestatic liver leading to the progressive disappearance of intrahepatic bile ducts, which is the hallmark of late-stage

cholangiopathies. Most of the *in vivo* studies investigating cholangiocyte proliferation have been performed in rodents with the bile duct ligation model. Humoral factors are at play, and pressure is not the only trigger in this model as, after selective ligation of lobar ducts, proliferation also occurs in non-ligated lobes [36]. The same second messenger cAMP that plays a central role in stimulating ductular secretion stimulates cholangiocyte proliferation [37]. The density of secretin receptor is increased fivefold on cholangiocytes after bile duct ligation [38], but this seems to have more of a choleretic effect than a proliferative one. The parasympathetic and sympathetic nervous systems both promote cholangiocyte proliferation. Vagotomy markedly impaired expression of cholinergic M3 receptors and cholangiocyte proliferation after bile duct ligation [39]. Chemical adrenergic denervation also decreased cholangiocyte growth, and this effect could be rescued by stimulating adenylyl cyclase with forskolin [40]. This trophic effect of the nervous system on the biliary epithelium is lacking after liver transplantation. Factors counter-regulating adenylyl cyclase, such as gastrin via the CCK-B/gastrin receptor and somatostatin via the SSTR2 receptor, inhibit cholangiocyte hyperplasic reaction in bile duct-ligated rats [19,41]. Biliary epithelium is a target for growth hormone. Activation of growth hormone receptor stimulates the production of insulin-like growth factor (IGF)1, which has an autocrine proliferative effect on cholangiocytes [42]. Hepatocyte growth factor has also been reported to stimulate the proliferation of human cholangiocytes [43].

Bile acids are trophic substances for the biliary epithelium. Taurocholic acid and taurolithocholic acid, which increase cAMP in cholangiocytes, support their proliferative capacity [44,45]. Deoxycholic acid can transactivate epidermal growth factor via a transforming growth factor (TGF)-α-dependent mechanism and induces cell growth [46]. A diet enriched in ursodeoxycholic acid enhanced cholangiocyte proliferation after partial bile duct ligation [47]; the opposite effect has also been reported [48].

In addition, cholangiocytes possess intracellular steroid hormone receptors. Estrogen receptor alpha and beta are expressed in cholangiocytes, whereas only the alpha subtype is expressed in hepatocytes. Estrogens stimulate *in vitro* cholangiocyte proliferation, and *in vivo* administration of the estrogen antagonist, tamoxifen, inhibited cholangiocyte proliferation after bile duct ligation [49]. Nerve growth factor was found to have an additive proliferative effect to estrogens. Nerve growth factor is secreted by cholangiocytes and acts in an autocrine manner to stimulate the ERK pathway [50].

Besides the typical cholangiocyte proliferation, which is a hyperplasic reaction increasing the number and length of the intrahepatic bile ducts, cholangiocytes from the terminal cholangioles show impressive proliferation ability in cases of severe hepatic necrosis. This ductular reaction occurs at the periphery of the portal tracts. It recruits precursor cells and may even leads to hepatocyte metaplasia. It is better visualized on liver biopsies by specific immunohistochemistry (cytokeratin 7 for example) and correlates with the severity of liver damage. These reactive cholangiocytes display specific phenotypical features. They express neuroendocrine markers (chromogranin A, glycolipid A2-B4, S-100 protein, neural cell adhesion molecule [51]), acquire a multidrug-resistant phenotype by upregulating efflux proteins such as MDR1, MRP1 and MRP3 [52] and have been claimed to produce numerous proinflammatory and chemotactic factors (TNFα, IL-6, IL-8 and monocyte chemotactic protein-1) as well as growth factors [hepatocyte growth factor, platelet-derived growth factor-BB, vascular endothelial growth factor (VEGF) and endothelin-1] but, for some of these factors, definitive evidence has not yet been published. Among these factors, some, such as IL-6, may act in an autocrine manner to stimulate further cholangiocytes [53]. Other mediators enable reactive cholangiocytes to influence neighbouring cells, especially portal fibroblasts and endothelial cells [21], and to attract inflammatory cells, in particular polymorphonuclear cells [54]. Human cholangiocytes in cases of polycystic liver disease produce VEGF and angiopoietin-1; these factors have an autocrine proliferative effect on cholangiocytes that express cognate receptors (VEGF receptors 1, 2 and Tie-2), as well as a paracrine effect on the portal vasculature, thus promoting growth of the cysts [55].

Cholangiocyte apoptosis

Cholangiocyte apoptosis is an important physiological and pathophysiological process in the maintenance of tissue homeostasis. In fetal liver, cholangiocyte apoptosis occurs normally during ductal plate remodelling (see Chapter 1.9). After relief of a biliary obstruction, the hyperplasic biliary tree is subjected to remodelling by apoptosis to eliminate superfluous cholangiocytes [56]. In the bile duct ligation model, vagotomy or administration of tamoxifen deprives cholangiocytes of growth stimuli and leads to apoptosis. Pathophysiologically, excessive cholangiocyte apoptosis is an important feature of immune and ischaemic cholangiopathies resulting in ductopenia (a decrease in the number of bile ducts per portal tract). Human cholangiocytes express the Fas receptor, and IFN-gamma and TNFα upregulate its expression, making cholangiocytes a target of T-cytotoxic lymphocytes bearing Fas ligand [57]. In primary biliary cirrhosis, antimitochondrial antibodies of the IgA type translocate through cholangiocytes, and it has been suggested that these antibodies could intracellularly trigger apoptosis by activating caspases [58]. Conjugated bile acids, which are secreted by hepatocytes, may also affect the sensitivity of cholangiocytes to apoptosis. The taurine conjugate of the widely prescribed ursodeoxycholic acid, tauroursodeoxycholic acid, was found to activate the transcription factor CREB in cholangiocytes, protecting these cells from apoptotic stress [59]. Resistance to apoptosis is equally important as it is a central feature of cholangiocyte transformation in cholangiocarcinogenesis (see below).

Cholangiocyte transformation

Cholangiocarcinoma complicates the course of cholangiopathies characterized by inflammation of the bile ducts. Chronic inflammation induces inducible nitric oxide synthase (iNOS) expression in cholangiocytes. This has several consequences: it causes ductular cholestasis by inhibiting cAMP-dependent HCO_3^- and Cl^- secretory mechanisms [60]; it potentiates DNA damage by inhibiting 8-oxodeo-oxyguanine repair [61]; it nitrosylates caspase-9, blocking apoptosis [62]; and, finally, it contributes to cyclo-oxygenase type 2 (COX-2) overexpression [63]. Cholangiocellular expression of COX-2 is also upregulated by deoxycholic acid via transactivation of the epidermal growth factor receptor [64]. This is relevant because COX-2 has been implicated in cholangiocarcinogenesis and is a potential target for oncological therapy. Prostaglandin E2 prevents Fas-mediated apoptosis of cholangiocytes by increasing the expression of the antiapoptotic factor myeloid cell leukaemia-1 (Mcl-1) [65]. This factor can also be upregulated by the inflammatory mediator IL-6, which has been implicated in cholangiocarcinogenesis [66]. Several other antiapoptotic proteins, such as FLIP, Bcl-2 and Bcl-X_L, are overexpressed in malignant biliary epithelium, providing these cells with a survival advantage by evading apoptosis [67].

Immunological aspects

The biliary epithelium is a frontier separating the hepatic parenchyma from a lumen which is in continuity with the intestinal content. Even if this continuity is with the relatively sterile small intestine and even if the bile is an inhospitable milieu for microorganisms with its low glucose concentration, biliary epithelial cells participate in the defence of the organism against invaders. The principal protein in bile is IgA, which binds to pathogens in the biliary and intestinal lumen. In humans, IgAs transit through biliary epithelial cells. Cholangiocytes endocytose IgAs via a specific receptor expressed in their basal membrane. These complexes are transported through the cell to be dispersed into the bile. Peribiliary glands secrete additional mucosal defence factors such as lactoferrin and lysozyme [68].

Toll-like receptors are central to the innate immune response by recognizing pathogen-associated molecular patterns. Normal human cholangiocytes express Toll-like receptors, which mediate the upregulation of beta-defensin-2 via activation of nuclear factor kappaB [69]. Cholangiocytes maintain close cooperation with cells of the immune system. They express adhesion molecules to engage interactions with lymphocytes (ICAM-1, LFA-3). Cytokines such as IFN-gamma and TNFα upregulate the expression of major histocompatibility complex (MHC) class II in biliary epithelial cells [70], but it is unclear to what extent cholangiocytes act as antigen-presenting cells, as they are lacking the co-stimulatory molecules B7-1 (CD80) and B7-2 (CD86). Biliary epithelial cells do not normally express CD40, a member of the TNF receptor superfamily, but do express it in cases of primary biliary cirrhosis [57]. Portal mononuclear cell infiltrate in this disease contains T cells and macrophages positive for CD40 ligand [57]. Immunohistochemistry on biopsies from patients with primary biliary cirrhosis revealed an induction of the expression of MHC II as well as of ICAM-1, the ligand for LFA-1, on biliary epithelial cells, whereas portal lymphocytes stained positive for LFA-1 [71,72].

Cholangiocyte heterogeneity

Not all cholangiocytes are the same. Cells lining small ductules are different from cells lining large ducts. By isolating cholangiocytes according to size, Alpini and co-workers were able to characterize two populations of cholangiocytes with specific functional properties. Small cholangiocytes, which are found in small ducts (15–300 μm), have a diameter around 8 μm, whereas large cholangiocytes, which populate larger ducts (300–800 μm), have a diameter of 15 μm. Both cell types express markers defining biliary epithelial cells: cytokeratins 7 and 19 and γ-glutamyl-transpeptidase. However, in many aspects, these cells appear to be different. The small cholangiocytes are devoid of secretin receptors (SR) and somatostatin receptors ($SSTR_2$), in contrast to the large cholangiocytes whose bile secretion is regulated by these hormones. Consequently, large cholangiocytes express CFTR and Cl^-/HCO_3^- exchanger. The cytochrome P4502E1, an enzyme that participates in redox stress, is expressed only in large cholangiocytes [73]. It is likely that the distribution of the phase I and phase II drug-metabolizing enzymes, which is heterogeneous among cholangiocytes, segregates preferentially between the two populations, explaining why small and large ducts are differently affected by injury and toxins. The proliferative response of small and large cholangiocytes is different. Clinical extrahepatic obstruction such as the experimental model of bile duct ligation results in preferential multiplication of large cholangiocytes. In humans, most of the cholangiocarcinomas arise in large ducts and are probably derived from large cholangiocytes. In contrast, small cholangiocytes display considerable phenotypical plasticity and form a compartment with an important proliferative reserve. Immunological diseases of the biliary epithelium such as primary biliary cirrhosis and autoimmune cholangiopathy primarily affect small cholangiocytes.

References

1 Cohn JA, Strong TV, Picciotto MR *et al.* (1993) Localization of the cystic fibrosis transmembrane conductance regulator in human bile duct epithelial cells. *Gastroenterology* 105, 1857–1864.

2 Doctor RB, Dahl R, Fouassier L *et al.* (2002) Cholangiocytes exhibit dynamic, actin-dependent apical membrane turnover. *Am J Physiol Cell Physiol* 282, C1042–1052.

3 Tietz PS, Marinelli RA, Chen XM *et al.* (2003) Agonist-induced coordinated trafficking of functionally-related transport proteins for water and ions in cholangiocytes. *J Biol Chem* 278, 20413–20419.

4 Doctor RB, Dahl RH, Salter KD *et al.* (2000) ATP depletion in rat cholangiocytes leads to marked internalization of membrane proteins. *Hepatology* 31, 1045–1054.

5 Roman RM, Smith RL, Feranchak AP *et al.* (2001) ClC-2 chloride channels contribute to HTC cell volume homeostasis. *Am J Physiol* 280, G344–353.

6 Schlenker T, Fitz JG (1996) Ca(2+)-activated C1– channels in a human biliary cell line: regulation by Ca2+/calmodulin-dependent protein kinase. *Am J Physiol* 271, G304–310.

7 Lazaridis KN, Pham L, Tietz P *et al.* (1997) At cholangiocytes absorb bile acids at their apical domain via the ileal sodium-dependent bile acid transporter. *J Clin Invest* 100, 2714–2721.

8 Lazaridis KN, Tietz P, Wu T *et al.* (2000) Alternative splicing of the rat sodium/bile acid transporter changes its cellular localization and transport properties. *Proc Natl Acad Sci USA* 97, 11092–11097.

9 Ballatori N, Christian WV, Lee JY *et al.* (2005) OSTalpha-OSTbeta: a major basolateral bile acid and steroid transporter in human intestinal, renal, and biliary epithelia. *Hepatology* 42, 1270–1279.

10 Alpini G, Glaser S, Baiocchi L *et al.* (2005) Secretin activation of the apical Na+-dependent bile acid transporter is associated with cholehepatic shunting in rats. *Hepatology* 41, 1037–1045.

11 Lazaridis KN, Pham L, Vroman B *et al.* (1997) Kinetic and molecular identification of sodium-dependent glucose transporter in normal rat cholangiocytes. *Am J Physiol* 272, G1168–1174.

12 Chen XM, O'Hara SP, Huang BQ *et al.* (2005) Localized glucose and water influx facilitates *Cryptosporidium parvum* cellular invasion by means of modulation of host-cell membrane protrusion. *Proc Natl Acad Sci USA* 102, 6338–6343.

13 Eisenmann-Tappe I, Wizigmann S, Gebhardt R (1991) Glutamate uptake in primary cultures of biliary epithelial cells from normal rat liver. *Cell Biol Toxicol* 7, 315–325.

14 Fouassier L, Duan CY, Feranchak AP *et al.* (2001) Ezrin-radixin-moesin-binding phosphoprotein 50 is expressed at the apical membrane of rat liver epithelia. *Hepatology* 33, 166–176.

15 Mano Y, Ishii M, Okamoto H *et al.* (1996) Effect of tumor necrosis factor alpha on intrahepatic bile duct epithelial cell of rat liver. *Hepatology* 23, 1602–1607.

16 Bode HP, Wang L, Cassio D *et al.* (2002) Expression and regulation of gap junctions in rat cholangiocytes. *Hepatology* 36, 631–640.

17 Masyuk TV, Huang BQ, Ward CJ *et al.* (2003) Defects in cholangiocyte fibrocystin expression and ciliary structure in the PCK rat. *Gastroenterology* 125, 1303–1310.

18 Lenzen R, Alpini G, Tavoloni N (1992) Secretin stimulates bile ductular secretory activity through the cAMP system. *Am J Physiol* 263, G527–532.

19 Tietz PS, Alpini G, Pham LD *et al.* (1995) Somatostatin inhibits secretin-induced ductal hypercholeresis and exocytosis by cholangiocytes. *Am J Physiol* 269, G110–118.

20 Glaser SS, Rodgers RE, Phinizy JL *et al.* (1997) Gastrin inhibits secretin-induced ductal secretion by interaction with specific receptors on rat cholangiocytes. *Am J Physiol* 273, G1061–1070.

21 Fouassier L, Chinet T, Robert B *et al.* (1998) Endothelin-1 is synthesized and inhibits cyclic adenosine monophosphate-dependent anion secretion by an autocrine/paracrine mechanism in gallbladder epithelial cells. *J Clin Invest* 101, 2881–2888.

22 Lesage GD, Marucci L, Alvaro D *et al.* (2002) Insulin inhibits secretin-induced ductal secretion by activation of PKC alpha and inhibition of PKA activity. *Hepatology* 36, 641–651.

23 Cho WK, Mennone A, Boyer JL (1998) Intracellular pH regulation in bombesin-stimulated secretion in isolated bile duct units from rat liver. *Am J Physiol* 275, G1028–1036.

24 Cho WK, Boyer JL (1999) Vasoactive intestinal polypeptide is a potent regulator of bile secretion from rat cholangiocytes. *Gastroenterology* 117, 420–428.

25 Hirata K, Nathanson MH (2001) Bile duct epithelia regulate biliary bicarbonate excretion in normal rat liver. *Gastroenterology* 121, 396–406.

26 Glaser S, Alvaro D, Roskams T *et al.* (2003) Dopaminergic inhibition of secretin-stimulated choleresis by increased PKC-gamma expression and decrease of PKA activity. *Am J Physiol Gastrointest Liver Physiol* 284, G683–694.

27 St Pierre MV, Schlenker T, Dufour JF *et al.* (1998) Stimulation of cyclic guanosine monophosphate production by natriuretic peptide in human biliary cells. *Gastroenterology* 114, 782–790.

28 Chari RS, Schutz SM, Haebig JE *et al.* (1996) Adenosine nucleotides in bile. *Am J Physiol* 270, G246–252.

29 Doctor RB, Matzakos T, McWilliams R *et al.* (2005) Purinergic regulation of cholangiocyte secretion: identification of a novel role for P2X receptors. *Am J Physiol Gastrointest Liver Physiol* 288, G779–786.

30 Roman RM, Feranchak AP, Salter KD *et al.* (1999) Endogenous ATP release regulates Cl– secretion in cultured human and rat biliary epithelial cells. *Am J Physiol* 276, G1391–1400.

31 Dranoff JA, Masyuk AI, Kruglov EA *et al.* (2001) Polarized expression and function of P2Y ATP receptors in rat bile duct epithelia. *Am J Physiol* 281, G1059–1067.

32 Zsembery A, Spirli C, Granato A *et al.* (1998) Purinergic regulation of acid/base transport in human and rat biliary epithelial cell lines. *Hepatology* 28, 914–920.

33 Dufour JF, Luthi M, Forestier M *et al.* (1999) Expression of inositol 1,4,5-trisphosphate receptor isoforms in rat cirrhosis. *Hepatology* 30, 1018–1026.

34 Shibao K, Hirata K, Robert ME *et al.* (2003) Loss of inositol 1,4,5-trisphosphate receptors from bile duct epithelia is a common event in cholestasis. *Gastroenterology* 125, 1175–1187.

35 Spirli C, Nathanson MH, Fiorotto R *et al.* (2001) Proinflammatory cytokines inhibit secretion in rat bile duct epithelium. *Gastroenterology* 121, 156–169.

36 Polimeno L, Azzarone A, Zeng QH *et al.* (1995) Cell proliferation and oncogene expression after bile duct ligation in the rat: evidence of a specific growth effect on bile duct cells. *Hepatology* 21, 1070–1078.

37 Leite MF, Nathanson MH (2005) Signaling pathways in biliary epithelial cells. In: Dufour J-F, Clavien PA (eds) *Signaling Pathways in Liver Diseases*. Berlin: Springer, pp. 17–26.

38 Tietz PS, Hadac EM, Miller LJ *et al.* (2001) Upregulation of secretin receptors on cholangiocytes after bile duct ligation. *Regul Pept* 97, 1–6.

39 LeSage EG, Alvaro D, Benedetti A *et al.* (1999) Cholinergic system modulates growth, apoptosis, and secretion of cholangiocytes from bile duct-ligated rats. *Gastroenterology* 117, 191–199.

40 Glaser S, Alvaro D, Francis H *et al.* (2006) Adrenergic receptor agonists prevent bile duct injury induced by adrenergic denervation by increased cAMP levels and activation of Akt. *Am J Physiol Gastrointest Liver Physiol* 290, G813–826.

41 Glaser S, Benedetti A, Marucci L *et al.* (2000) Gastrin inhibits cholangiocyte growth in bile duct-ligated rats by interaction with cholecystokinin-B/gastrin receptors via D-myo-inositol 1,4,5-triphosphate-, Ca(2+)-, and protein kinase C alpha-dependent mechanisms. *Hepatology* 32, 17–25.

42 Alvaro D, Metalli VD, Alpini G *et al.* (2005) The intrahepatic biliary epithelium is a target of the growth hormone/insulin-like growth factor 1 axis. *J Hepatol* 43, 875–883.

43 Joplin R, Hishida T, Tsubouchi H *et al.* (1992) Human intrahepatic biliary epithelial cells proliferate *in vitro* in response to human hepatocyte growth factor. *J Clin Invest* 90, 1284–1289.

44 Alpini G, Glaser S, Alvaro D *et al.* (2002) Bile acid depletion and repletion regulate cholangiocyte growth and secretion by a phosphatidylinositol 3-kinase-dependent pathway in rats. *Gastroenterology* 123, 1226–1237.

45 Alpini G, Glaser SS, Ueno Y *et al.* (1999) Bile acid feeding induces cholangiocyte proliferation and secretion: evidence for bile acid-regulated ductal secretion. *Gastroenterology* 116, 179–186.

46 Werneburg NW, Yoon JH, Higuchi H *et al.* (2003) Bile acids activate EGF receptor via a TGF-alpha-dependent mechanism in human cholangiocyte cell lines. *Am J Physiol Gastrointest Liver Physiol* 285, G31–36.

47 Barone M, Maiorano E, Ladisa R *et al.* (2004) Ursodeoxycholate further increases bile-duct cell proliferative response induced by partial bile-duct ligation in rats. *Virchows Arch* 444, 554–560.

48 Alpini G, Baiocchi L, Glaser S *et al.* (2002) Ursodeoxycholate and tauroursodeoxycholate inhibit cholangiocyte growth and secretion of BDL rats through activation of PKC alpha. *Hepatology* 35, 1041–1052.

49 Alvaro D, Alpini G, Onori P *et al.* (2000) Estrogens stimulate proliferation of intrahepatic biliary epithelium in rats. *Gastroenterology* 119, 1681–1691.

50 Gigliozzi A, Alpini G, Baroni GS *et al.* (2004) Nerve growth factor modulates the proliferative capacity of the intrahepatic biliary epithelium in experimental cholestasis. *Gastroenterology* 127, 1198–1209.

51 Roskams T, van den Oord JJ, De Vos R *et al.* (1990) Neuroendocrine features of reactive bile ductules in cholestatic liver disease. *Am J Pathol* 137, 1019–1025.

52 Ros JE, Libbrecht L, Geuken M *et al.* (2003) High expression of MDR1, MRP1, and MRP3 in the hepatic progenitor cell compartment and hepatocytes in severe human liver disease. *J Pathol* 200, 553–560.

53 Park J, Gores GJ, Patel T (1999) Lipopolysaccharide induces cholangiocyte proliferation via an interleukin-6-mediated activation of p44/p42 mitogen-activated protein kinase. *Hepatology* 29, 1037–1043.

54 Morland CM, Fear J, Joplin R *et al.* (1997) Inflammatory cytokines stimulate human biliary epithelial cells to express interleukin-8 and monocyte chemotactic protein-1. *Biochem Soc Trans* 25, 232S.

55 Fabris L, Cadamuro M, Fiorotto R *et al.* (2006) Effects of angiogenic factor overexpression by human and rodent cholangiocytes in polycystic liver diseases. *Hepatology* 43, 1001–1012.

56 Bhathal PS, Gall JA (1985) Deletion of hyperplastic biliary epithelial cells by apoptosis following removal of the proliferative stimulus. *Liver* 5, 311–325.

57 Afford SC, Ahmed-Choudhury J, Randhawa S *et al.* (2001) CD40 activation-induced, Fas-dependent apoptosis and NF-kappaB/AP-1 signaling in human intrahepatic biliary epithelial cells. *FASEB J* 15, 2345–2354.

58 Matsumura S, Van De Water J, Leung P *et al.* (2004) Caspase induction by IgA antimitochondrial antibody: IgA-mediated biliary injury in primary biliary cirrhosis. *Hepatology* 39, 1415–1422.

59 Wang L, Piguet AC, Schmidt K *et al.* (2005) Activation of CREB by tauroursodeoxycholic acid protects cholangiocytes from apoptosis induced by mTOR inhibition. *Hepatology* 41, 1241–1251.

60 Spirli C, Fabris L, Duner E *et al.* (2003) Cytokine-stimulated nitric oxide production inhibits adenylyl cyclase and cAMP-dependent secretion in cholangiocytes. *Gastroenterology* 124, 737–753.

61 Jaiswal M, LaRusso NF, Shapiro RA *et al.* (2001) Nitric oxide-mediated inhibition of DNA repair potentiates oxidative DNA damage in cholangiocytes. *Gastroenterology* 120, 190–199.

62 Torok NJ, Higuchi H, Bronk S *et al.* (2002) Nitric oxide inhibits apoptosis downstream of cytochrome C release by nitrosylating caspase 9. *Cancer Res* 62, 1648–1653.

63 Ishimura N, Bronk SF, Gores GJ (2004) Inducible nitric oxide synthase upregulates cyclooxygenase-2 in mouse cholangiocytes promoting cell growth. *Am J Physiol Gastrointest Liver Physiol* 287, G88–G95.

64 Yoon JH, Higuchi H, Werneburg NW *et al.* (2002) Bile acids induce cyclooxygenase-2 expression via the epidermal growth factor receptor in a human cholangiocarcinoma cell line. *Gastroenterology* 122, 985–993.

65 Nzeako UC, Guicciardi ME, Yoon JH *et al.* (2002) COX-2 inhibits Fas-mediated apoptosis in cholangiocarcinoma cells. *Hepatology* 35, 552–559.

66 Isomoto H, Kobayashi S, Werneburg NW *et al.* (2005) Interleukin 6 upregulates myeloid cell leukemia-1 expression through a STAT3 pathway in cholangiocarcinoma cells. *Hepatology* 42, 1329–1338.

67 Okaro AC, Deery AR, Hutchins RR *et al.* (2001) The expression of antiapoptotic proteins Bcl-2, Bcl-X(L), and Mcl-1 in benign, dysplastic, and malignant biliary epithelium. *J Clin Pathol* 54, 927–932.

68 Saito K, Nakanuma Y (1992) Lactoferrin and lysozyme in the intrahepatic bile duct of normal livers and hepatolithiasis. An immunohistochemical study. *J Hepatol* 15, 147–153.

69 Chen XM, O'Hara SP, Nelson JB *et al.* (2005) Multiple TLRs are expressed in human cholangiocytes and mediate host epithelial defense responses to *Cryptosporidium parvum* via activation of NF-kappaB. *J Immunol* 175, 7447–7456.

70 Cruickshank SM, Southgate J, Selby PJ *et al.* (1998) Expression and cytokine regulation of immune recognition elements by normal human biliary epithelial and established liver cell lines *in vitro*. *J Hepatol* 29, 550–558.

71 Bloom S, Fleming K, Chapman R (1995) Adhesion molecule expression in primary sclerosing cholangitis and primary biliary cirrhosis. *Gut* 36, 604–609.

72 Yasoshima M, Nakanuma Y, Tsuneyama K *et al.* (1995) Immunohistochemical analysis of adhesion molecules in the microenvironment of portal tracts in relation to aberrant expression of PDC-E2 and HLA-DR on the bile ducts in primary biliary cirrhosis. *J Pathol* 175, 319–325.

73 LeSage GD, Benedetti A, Glaser S *et al.* (1999) Acute carbon tetrachloride feeding selectively damages large, but not small, cholangiocytes from normal rat liver. *Hepatology* 29, 307–319.

1.8 Hepatic stem cells

Tania Roskams

Introduction

Professor Bizzozero, a pupil of Professor Golgi, linked the presence of mitotic figures in a given cell type to the cell's capacity to regenerate. He classified cells into three types. *Labile* cells divide so as to continually renew the tissue. Typical examples are epidermis and the epithelium of the gastrointestinal tract. *Stable* cells normally do not divide, but under certain stimuli they still have the capacity to do so. A typical example is the liver, which normally is a silent organ, but which harbours an enormous regenerative capacity after injuries like partial hepatectomy or toxic injury. *Permanent* cells like neurones or muscle cells 'never' divide. In biology, however, 'never' does not exist and in the 1990s, *in vitro* experiments showed that almost all tissues and organs, even the brain and muscle, contain cells with a huge growth potential: tissue-specific stem cells.

Different types of stem cells and their niches

What is a stem cell? A stem cell is an undifferentiated cell capable throughout life of renewing itself as well as of generating one or more types of differentiated cells [1–3]. Every adult cell has a 'mother' (who may have parted from her years ago), and a line of ancestors – stem cells – of increasing differentiation potential. The ultimate stem cells are those of the early embryo, which are totipotential. Further down the line, in the fetus and also in the adult, we find multipotential (pluripotential) stem cells. Those closer to final differentiation are called progenitor, committed or transit cells. This nomenclature is still changing.

In continuously renewing lining epithelia, such as the epidermis, stem cells are easy to find because they squat against the basement membrane. In other tissues, such as the liver, the search is frustrating because, by definition, stem cells look bland and undifferentiated. However, they can be visualized by immunohistochemistry, which reveals distinctive proteins (antigens) on their surface or in their cytoplasm (see Plate 1.8.1, facing p. 72).

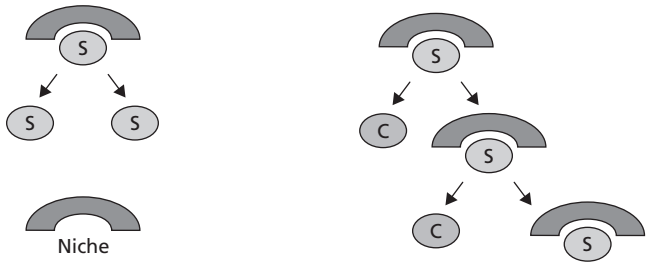

Fig. 1 Schematic representation of symmetrical versus asymmetrical division of stem cells. In symmetrical stem cell division (left), a stem cell (S) generates two stem cells. This happens early in embryonic life. Later on (right), a stem cell generates a stem cell and a committed, somewhat differentiated cell (C). The stem cell niche keeps the stem cell in an undifferentiated state.

When a stem cell replicates, its mitosis can be *symmetrical* (producing two stem cells) or *asymmetrical* (producing one stem cell and one progenitor cell or differentiated cell) (Fig. 1).

A good model to study stem cells is provided by the cells of the blood-forming line; knowledge in this field is so far advanced that therapeutic applications of stem cells are already standard medical practice in haematology [4]. This has happened because the blood's stem cells are relatively easy to find: they have a specific marker, the surface protein CD34, and can be harvested from adult blood, where they represent about 0.01% of the mononuclear cells, and from blood in the umbilical cord and placenta (neonatal blood), where they are more abundant and more prolific [5]. After they have been expanded *ex vivo*, they can be reinjected intravenously, because they know how to home into the bone marrow where they are needed, for example to repopulate a bone marrow destroyed by chemotherapy [6].

This 'sympathy' between blood stem cells and bone marrow runs deeply, and it has taught us something about stem cell biology in general. *In vitro*, blood stem cells totally deprived of a bone marrow-like environment will not survive very long: they need the company of endothelial cells, fat cells, fibroblasts, macrophages, osteoblasts and even some matrix. Normally, in the bone marrow, each haematopoietic stem cell lives in a

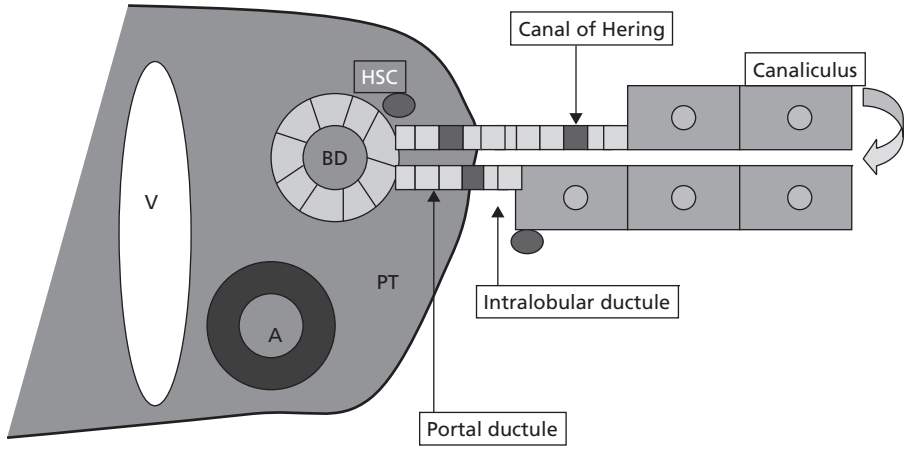

Fig. 2 Anatomy and terminology in human liver. The left side of the figure illustrates the portal tract (PT), containing a branch of the portal vein (V), the hepatic artery (A) and accompanying bile duct (BD). The smallest, most peripheral branches of the biliary tree, the ductules, consist of a portal part (portal ductule) and an intralobular part (intralobular ductule). The canal of Hering is lined partially by hepatocytes and partially by cholangiocytes and forms the connecting piece between the ductules and the canaliculi in between hepatocytes. The progenitor cells are located in the most peripheral branches of the biliary tree, the ductules and the canal of Hering.

microscopic 'niche' of stromal cells that nurse it and provide it with the proper instructions [4,7,8]. Stem cell niches probably also exist in other tissues, but have not been characterized yet.

In the following paragraphs, stem cell properties of hepatocytes and the local progenitor cell compartment in the liver, called 'oval cells' in rodents and the canal of Hering/ductules in human liver, will be discussed (Fig. 2).

Hepatocytes have 'stem cell' properties

In normal circumstances, the liver hardly proliferates and was therefore classified as a 'stable' organ. Hepatocytes in normal adult liver have a lifespan of over a year. After partial hepatectomy, however, proliferation of the main epithelial compartments (hepatocytes and cholangiocytes), followed by proliferation of the mesenchymal cells (hepatic stellate cells and endothelial cells), quickly restores the liver. In rodents, the liver can restore its original volume after two-thirds hepatectomy in approximately 10 days [9,10]. Serial transplantation experiments have shown that hepatocytes have a near infinite capacity to proliferate [11,12]. Since at least 69 doublings can occur, the clonogenic potential of hepatocytes, one of the crucial properties of a stem cell, is confirmed.

Hepatic progenitor cells: localization and activation

When the mature epithelial cell compartments of the liver, hepatocytes and/or cholangiocytes, are damaged or inhibited in their replication, a reserve cell compartment is activated [13]. This compartment, in humans called the progenitor cell compartment and in rodents the oval cell compartment, resides in the smallest and most peripheral branches of the biliary tree, the ductules and canals of Hering [14] (Fig. 2). The *canal of Hering* is a channel lined partly by hepatocytes and partly by cholangiocytes. It represents the anatomical and physiological link between the intralobular canalicular system and the biliary tree. Cells of morphology and immunophenotype intermediate between hepatocytes and cholangiocytes ('intermediate cells', see below) are not recognized in normal tissue. A corollary is that the true interface of hepatocytes and the biliary tree does not reside, as has been assumed, at the 'limiting plate', but rather along an array of sites that project starlike from the portal tracts, along the canals of Hering.

Wilson and Leduc were the first to describe this activation of a 'reserve cell compartment' in mouse after severe dietary injury [15]. Subsequently, several models of so-called oval cell reaction in rodents have been described. Mostly, these models employed potential carcinogenic agents to inhibit the proliferation of mature hepatocytes after a regenerative stimulus: for example, acetaminofluorene intoxication of rats after partial hepatectomy or after administration of a necrogenic dose of carbon tetrachloride [16] or ethionine intoxication in mice. Also, models of fatty liver disease like Ob/Ob mice or PARP-1(–/–) mice are characterized by inhibition of the replication of mature hepatocytes, caused by oxidative stress, and show a striking oval cell response [17,18].

The activation of oval cells, or in human liver the 'ductular reaction', comprises expansion of a transit-amplifying cell compartment of small biliary cells that can differentiate into at least biliary epithelial cells and hepatocytes. The progenitor cells are labelled by biliary type cytokeratins (CK) CK7 and 19, oval cell markers OV6 and OV1, neuroendocrine markers chromogranin A, neural cell adhesion molecule and parathyroid hormone-related peptide, and connexin 43. A subpopulation of ductular/progenitor cells express markers of haematopoietic cells (CD34, c-kit, flt-3, Thy-1), which raised the question of whether progenitor cells could be directly derived from bone marrow stem cells. Most studies, however, are concordant with a progenitor cell niche in the ductules/canals of Hering, at the interface between the parenchyma and the portal tract

mesenchyme. This is also the location where, during embryonic development, bipotential hepatoblasts form the primitive ductal plate, which has the same phenotype as progenitor cells in adult life: ductal plate cells express biliary markers and (immature) hepatocytic markers like alpha-fetoprotein and also haematopoietic markers like CD34.

Progenitor cell activation or ductular reaction is seen in the majority of chronic human liver diseases. Reactive ductules form strands of small cholangiocytes with an oval nucleus and a small rim of cytoplasm [19]. The degree of progenitor cell activation increases with the severity of the disease [20]. In chronic hepatitis, progenitor cell activation correlates with the degree of inflammation [21]. In a variety of chronic liver diseases like chronic hepatitis C, haemochromatosis and (non)alcoholic steatohepatitis, the degree of progenitor cell activation also correlates with the degree of fibrosis and the stage of the disease [17,20]. In moderate and severe degrees of inflammation, intermediate hepatocytes occur, having a phenotype intermediate between progenitor cells/ductular cells and mature hepatocytes (see Plate 1.8.1, facing p. 72). The number of these intermediate hepatocytes gradually increases with greater degrees of inflammation, and also with increasing necrosis in necrotizing hepatitis and with more advanced stages of (non)alcoholic steatohepatitis [17,20,21] (see Plate 1.8.1, facing p. 72). This strongly suggests a greater degree of differentiation of progenitor cells into hepatocytes when there is more hepatocyte damage. In cirrhotic livers, especially in (non)alcoholic steatohepatitis, whole cirrhotic nodules can be composed of intermediate hepatocytes, which ultrastructurally look strikingly 'normal', without Mallory body formation and without fatty change. This suggests that these intermediate hepatocyte-nodules originate from progenitor cells [17]. In parallel, Falkowski *et al.* showed, in a three-dimensional reconstruction study, that sequestered hepatocyte 'buds' in cirrhosis are always in continuity with reactive ductules, strongly suggesting a progenitor cell origin [22].

A trigger for progenitor cell activation is certainly a lack of ability of the mature cell compartments to proliferate. Alongside what we know from rodent models, human liver diseases also exhibit inhibition of replication of mature hepatocytes. Recently, it has been shown that hepatocytes are senescent in the cirrhotic stage of a wide variety of chronic human liver diseases because of telomere shortening. Intriguingly, mesenchymal cells, like endothelial cells and hepatic stellate cells, do not show this replicative senescence [23,24]. Probably, this hepatocyte replicative senescence is in part the result of ongoing proliferation during 20–30 years of chronic liver disease. Chronic inflammation, the presence of growth factors and DNA-damaging agents like reactive oxygen species and nitrogen species also play a role. So, similar to rodent models, replicative senescence of hepatocytes triggers progenitor cell activation in humans as well [13,25].

There have been a number of papers illustrating the role of bone marrow stem cells in producing hepatocytes, both in animal models and in humans. The precise role of these stem cells is not clear, because in several models it has been shown that cell fusion of bone marrow stem cells with damaged hepatocytes took place [26].

The society of liver cells and the surrounding stroma; the liver stem cell niche

The liver consists of epithelial cell types (hepatocytes, cholangiocytes and progenitor cells), mesenchymal cell types (Kupffer cells, endothelial cells, hepatic stellate cells) and stroma. Stroma is present in the portal tracts and in the Disse space (Fig. 3).

The importance of this 'society' of cells and the stroma is illustrated by the fact that hepatocytes, which have a huge growth potential *in vivo*, are very hard to keep alive and differentiated when isolated and placed in culture. When hepatocytes are injured, Kupffer cells secrete interleukin (IL)-6 and transforming growth factor α (TGF-α), which activate hepatic stellate cells. Hepatic stellate cells produce growth factors for hepatocytes and progenitor cells (e.g. hepatocyte growth factor). They also produce matrix components and transforming growth factor β (TGF-β), which inhibits the growth of hepatocytes. Growth factors like hepatocyte growth factor and epidermal growth factor also come from the circulation. The matrix harbours growth factors for hepatocytes and progenitor cells bound to, for example, proteoglycans, which can be quickly released when needed. Release of hepatocyte growth factor by the matrix is in turn inhibited by tissue inhibitor of metalloproteinase (TIMP). Hepatocytes and progenitor cells produce growth factors for endothelial cells, like vascular endothelial growth factor, in order to maintain their vascularization. Recently, a specific growth factor for 'oval cells', TWEAK (transforming growth factor-like weak inhibitor of apoptosis), was described, which does *not* act on hepatocytes [27]. This is an important step in our understanding of the regulation of oval cell reaction versus hepatocyte proliferation. This growth factor is produced by sinusoidal lining cells. Sinusoidal lining cells, like hepatic stellate cells, proliferate in close anatomical relationship with progenitor cells; in addition, stellate cells produce growth factors for which progenitor cells have the receptors, suggesting a true interaction between these cell compartments [13]. We also know that there are different subtypes of hepatic stellate cells/myofibroblasts [28] (see also Chapter 1.6). Studies identifying the stellate cell subtypes that surround the progenitor cells are underway. In general, defining the so-called 'stem cell niche' for adult human liver progenitor cells will be an important goal for the near future.

Progenitor cells seem to be able to survive when hepatocytes are lost as a result of toxic damage or viral infections. Adenosine triphosphate binding cassette (ABC) transporters play both a secretory and a protective role, and a strong upregulation of apical MDR1 and basolateral multidrug resistance protein (MRP)1 and MRP3 in human hepatocytes and in progenitor cell-related bile ductules was observed [29,30]. We hypothesized

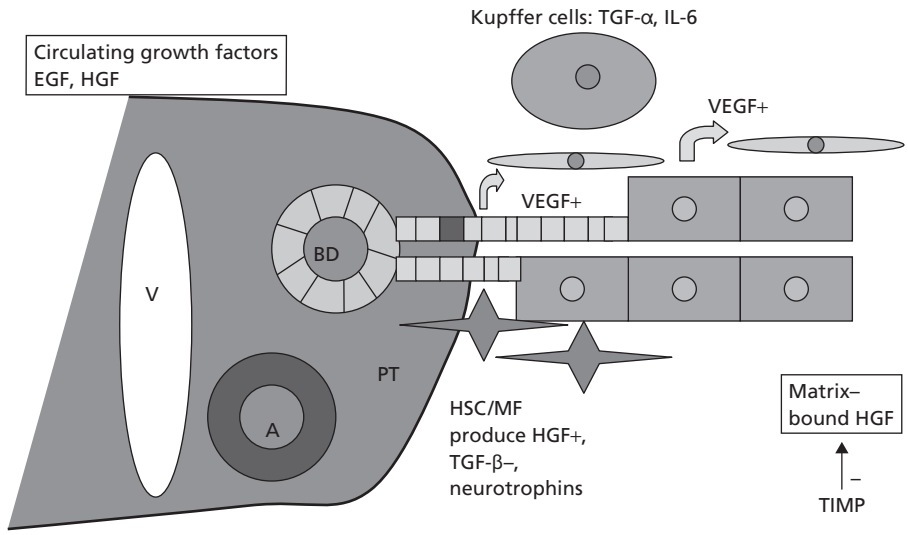

Fig. 3 Society of liver cells. When hepatocytes are injured, Kupffer cells secrete interleukin 6 (IL-6) and transforming growth factor α (TGF-α), which activate hepatic stellate cells. Hepatic stellate cells produce growth factors for hepatocytes and progenitor cells (e.g. hepatocyte growth factor, HGF), matrix components and transforming growth factor β (TGF-β), which inhibits the growth of hepatocytes. Growth factors, such as hepatocyte growth factor and epidermal growth factor (EGF), also come from the circulation. The matrix harbours growth factors for hepatocytes and progenitor cells bound to, e.g. proteoglycans, which can be quickly released when needed. Release of hepatocyte growth factor by the matrix is in turn inhibited by tissue inhibitor of metalloproteinase (TIMP). Hepatocytes and progenitor cells produce growth factors for endothelial cells, such as vascular endothelial growth factor (VEGF), in order to maintain their vascularization. A, hepatic artery; BD, bile duct; PT, portal tract; PV, portal vein.

that this change in expression offers protection against the accumulation of toxic bile constituents and may render these cells resistant to oxidative stress.

The possible role of progenitor cells in liver cancer

In the 19th century, pathologists like Virchow observed that some tumours exhibit features of a range of different organs (teratocarcinoma) and hypothesized that these tumours originated from embryonal rests [31]. Today's stem cells are the modern equivalent of embryonal rests: tumours can originate from malignant transformation of a stem cell on its way to a differentiated mature cell type in a given organ (maturation arrest). In continuously renewing systems like the epidermis, gut and haematopoietic tissue, it is widely accepted that cancer arises from stem cells, because stem cells are the only cells that have a lifespan long enough to acquire the requisite number of genetic changes for neoplastic development. The liver, however, is a silent organ in which several cell types have longevity: hepatocytes and cholangiocytes, but also bipotential progenitor cells residing in the most terminal branches of the biliary tree, the ductules and/or canals of Hering [14]. This implies that, in the liver, several cell types can be carcinogen targets. We know from animal experiments that cell proliferation during carcinogen exposure is a prerequisite to 'fix' any genotypic injury into a heritable form.

Animal models show that hepatocytes are implicated in some models of hepatocellular carcinoma (HCC), while other models, using direct injury to the essentially unipotent cholangiocytes, induce cholangiocarcinoma (CC). Progenitor cells (oval cells in rodents) are activated in many animal models, just like in many instances of human liver damage, irrespective of aetiology, making such cells very likely carcinogen targets. If progenitor cells do give rise to cancer during their maturation/differentiation process (maturation arrest theory), one would expect a range of neoplastic phenotypes, recapitulating stages in normal development, a prediction supported experimentally [32], as well as in human liver tumours (see below). Direct evidence for the involvement of oval cells (progenitor cells) in the histogenesis of HCC was obtained by Dumble *et al.* [33], who isolated oval cells from p53-null mice. When these cells were transplanted into athymic nude mice they produced HCCs.

In *humans*, chronic viral hepatitis B and C, alcoholic and nonalcoholic steatohepatitis, metabolic diseases and mutagens like aflatoxins (toxic metabolites of the food mould *Aspergillus*) are the most important risk factors for the development of HCC (Fig. 4). Chronic inflammatory biliary diseases like primary sclerosing cholangitis, hepatolithiasis (gallstones) and infestation by the liver flukes *Opisthorchis viverrini* and *Clonorchis sinensis* are known risk factors for the development of CC. This underscores the point that oxidative stress and chronic inflammation are common carcinogenic risk factors in all primary liver cancers.

As in rodents, HCC and CC in humans evolve from focal precursor lesions that reflect the stages of multistep carcinogenesis [34] (Fig. 4). Because progenitor cells are activated in most chronic liver diseases that are known risk factors for the development of HCC as well as CC, progenitor cells are potential target cells for carcinogenesis.

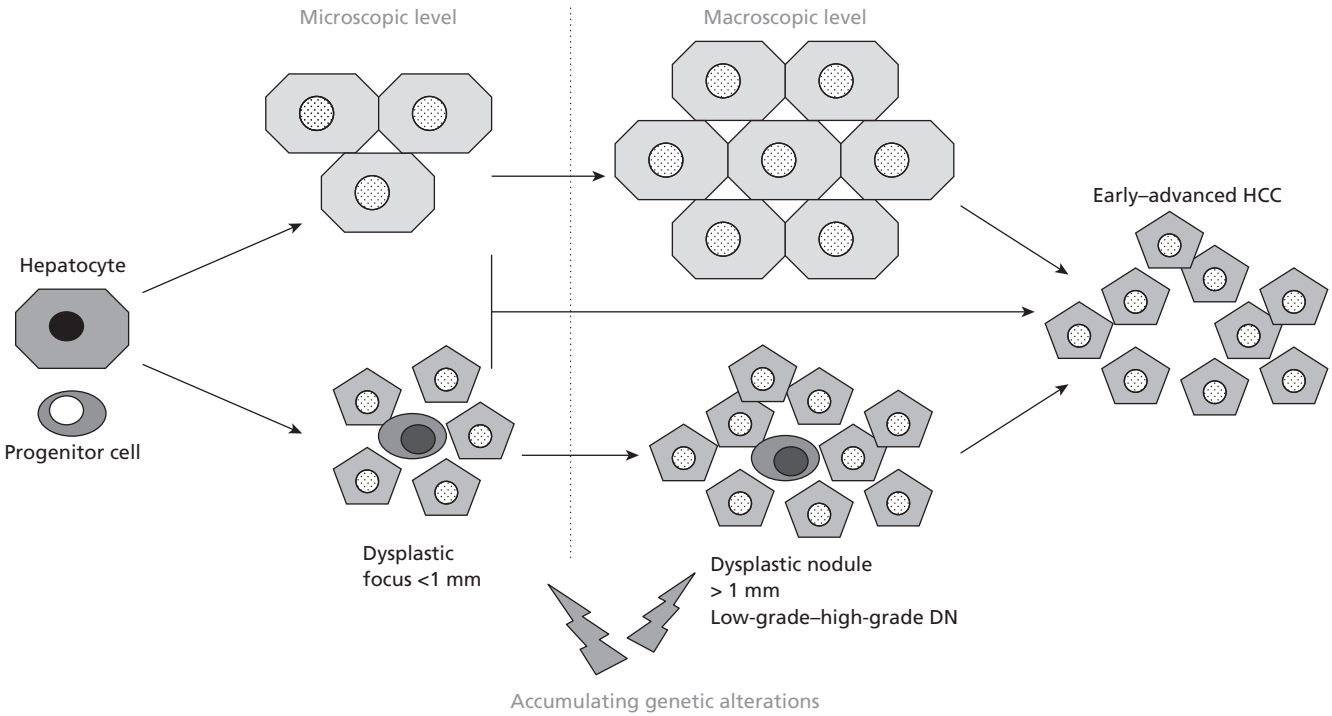

Fig. 4 Hepatocarcinogenesis is a multistep process. The different steps towards malignancy include the microscopically small large-cell and small-cell dysplastic foci (<1 mm). At the macroscopic level, these lesions can evolve into dysplastic nodules (low-grade and high-grade dysplastic nodules). Most of the high-grade dysplastic nodules evolve into cancer (early-advanced stage). The cells of origin can be either hepatocytes or progenitor cells. If progenitor cells give rise to cancer, the earliest premalignant lesions should consist of progenitor cells and their progeny. Indeed about half of the small-cell dysplastic foci, the smallest premalignant lesions known to date, consist of progenitor cells and intermediate cells. DN, dysplastic nodule.

Most tumours still show phenotypical features of their cell of origin and the histopathological classification of tumours is largely based on this. Several studies using detailed immunophenotyping of HCCs showed that a substantial number (28–50%) of human HCCs express markers of progenitor/biliary cells like cytokeratins (CK) 7 and 19, and OV6 [35–38].

Morphologically, these tumours consist of cells with a very immature phenotype and a range of cells with phenotypes intermediate between progenitor cells and hepatocytes. CK19 expression in HCC especially has been associated with a worse prognosis and faster and more recurrence after surgical treatment. Wu *et al.* [39] observed a significantly shorter survival in patients with HCCs expressing cytokeratin antibody AE1–AE3 and CK19 without any treatment. Uenishi *et al.* recently reported that HCCs expressing CK19 and CK7 have a lower tumour-free survival rate after curative resection and demonstrated that CK19 expression was an independent predictor of postoperative recurrence [40]. A recent study by Ding *et al.* [41] correlated overexpression of CK19 with HCC metastasis. In our own consecutive series of 109 HCCs, CK19-positive tumours (in more than 5% of tumour cells) had a higher rate of tumour recurrence after liver transplantation, compared with CK-negative HCCs.

CK19 expression was significantly associated with elevated serum alpha-fetoprotein (>400 ng/mL) and expression of alpha-fetoprotein by the tumour. The association with alpha-fetoprotein, which is also a marker of progenitor cells, is compatible with a progenitor cell origin of these tumours.

Of course, the presence of progenitor cell features in a tumour can be explained in two ways: either the cell of origin is a progenitor cell (maturation arrest theory) or alternatively, tumours dedifferentiate and acquire progenitor cell features during carcinogenesis (dedifferentiation theory). When progenitor cells are the cell of origin of a subtype of primary liver tumours, one would expect that the earliest premalignant precursor lesions would also consist of progenitor cells and their progeny. This is indeed the case: 55% of small-cell dysplastic foci (smaller than 1 mm), the earliest premalignant lesions known to date in humans, consist of progenitor cells and intermediate hepatocytes. This is a very strong argument in favour of the progenitor cell origin of at least part of the HCCs. Large-cell 'dysplastic' foci, on the other hand, consist of mature senescent hepatocytes, being a result of continuous proliferation in chronic liver diseases and not the true precursor lesions of HCC [42].

Moreover, in hepatoblastomas, the most common liver tumour in childhood, cells resembling progenitor cells have been noted [43–45]. This tumour is widely believed to be of stem cell origin, because it can comprise both epithelial and mesenchymal tissue components.

Aberrant expression of p63, a marker for basal/stem cells in several organs including prostate and skin, and of c-kit, a stem cell marker, has been described in CCs, also suggesting a progenitor cell origin of part of these tumours [46].

In many human tumours, it has become apparent that only tumour stem cells are capable of transferring the disease to NOD/SCID mice, so it would not be surprising if hepatic progenitor cells in HCCs are the only cells capable of propagating the tumour in immunodeficient mice [47].

Conclusions

In a wide variety of acute and chronic human liver diseases, progenitor cells proliferate, whereas hepatocytes become senescent in the cirrhotic stage of chronic liver diseases. Because of their bipotential differentiation capacity, progenitor cells are ideal candidates for cell therapy. Alternatively, this cell compartment can be stimulated *in vivo* to stimulate liver regeneration. Better knowledge of the mechanisms of progenitor cell activation and differentiation is needed before these cells can be exploited for regeneration therapy.

References

1 Watt FM, Hogan BL (2000) Out of Eden: stem cells and their niches. *Science* 287, 1427–1430.
2 Alison M, Sarraf C (1998) Hepatic stem cells. *J Hepatol* 29, 676–682.
3 Hall PA (1989) What are stem cells and how are they controlled? *J Pathol* 158, 275–277.
4 Orlic D, Bock TA, Kanz L (eds) (1999) *Hematopoietic Stem Cells. Biology and Transplantation*. New York: New York Academy of Science.
5 Rubinstein P, Carrier C, Caradavou A *et al.* (1998) Outcomes among 562 recipients of placental-blood transplants from unrelated donors. *N Engl J Med* 339, 1565–1577.
6 Levitt DMR (ed.) (1995) *Hematopoietic Stem Cells*. New York: Marcel Dekker.
7 He XC, Zhang J, Li L (2005) Cellular and molecular regulation of hematopoietic and intestinal stem cell behavior. *Ann NY Acad Sci* 1049, 28–38.
8 Zhang J, Niu C, Ye L *et al.* (2003) Identification of the haematopoietic stem cell niche and control of the niche size. *Nature* 425, 836–841.
9 Michalopoulos GK, DeFrances MC (1997) Liver regeneration. *Science* 276, 60–66.
10 Fausto N (2004) Liver regeneration and repair: hepatocytes, progenitor cells, and stem cells. *Hepatology* 39, 1477–1487.
11 Overturf K, Al-Dhalimy M, Finegold M *et al.* (1999) The repopulation potential of hepatocyte populations differing in size and prior mitotic expansion. *Am J Pathol* 155, 2135–2143.
12 Overturf K, Al-Dhalimy M, Manning K *et al.* (1998) Ex vivo hepatic gene therapy of a mouse model of hereditary tyrosinemia type I. *Hum Gene Ther* 9, 295–304.
13 Roskams T, Libbrecht L, Desmet V (2003) Progenitor cells in diseased human liver. *Semin Liver Dis* 23, 385–396.
14 Roskams TA, Thiese ND, Balabaud C *et al.* (2004) Nomenclature of the finer branches of the biliary tree: canals, ductules, and ductular reactions in human livers. *Hepatology* 39, 1739–1745.
15 Wilson JW, Leduc EH (1958) Role of cholangioles in restoration of the liver of the mouse after dietary injury. *J Pathol Bacteriol* 76, 441–449.
16 Alison MR, Golding M, Scarraf CE *et al.* (1996) Liver damage in the rat induces hepatocyte stem cells from biliary epithelial cells. *Gastroenterology* 110, 1182–1190.
17 Roskams T, Yang SQ, Koteish A *et al.* (2003) Oxidative stress and oval cell accumulation in mice and humans with alcoholic and nonalcoholic fatty liver disease. *Am J Pathol* 163, 1301–1311.
18 Yang S, Koteish A, Lin H *et al.* (2004) Oval cells compensate for damage and replicative senescence of mature hepatocytes in mice with fatty liver disease. *Hepatology* 39, 403–411.
19 Roskams T, Desmet V (1998) Ductular reaction and its diagnostic significance. *Semin Diagn Pathol* 15, 259–269.
20 Lowes KN, Brennan BA, Yeoh GC *et al.* (1999) Oval cell numbers in human chronic liver diseases are directly related to disease severity. *Am J Pathol* 154, 537–541.
21 Libbrecht L *et al.* (2000) Deep intralobular extension of human hepatic 'progenitor cells' correlates with parenchymal inflammation in chronic viral hepatitis: can 'progenitor cells' migrate? *J Pathol* 192, 373–378.
22 Falkowski O, Desmet V, Roskams T *et al.* (2003) Regeneration of hepatocyte 'buds' in cirrhosis from intrabiliary stem cells. *J Hepatol* 39, 357–364.
23 Wiemann SU, Desmet V, Roskams T *et al.* (2002) Hepatocyte telomere shortening and senescence are general markers of human liver cirrhosis. *FASEB J* 16, 935–942.
24 Marshall A *et al.* (2005) Relation between hepatocyte G1 arrest, impaired hepatic regeneration, and fibrosis in chronic hepatitis C virus infection. *Gastroenterology* 128, 33–42.
25 Roskams T (2003) Progenitor cell involvement in cirrhotic human liver diseases: from controversy to consensus. *J Hepatol* 39, 431–434.
26 Thorgeirsson SS, Grisham JW (2006) Hematopoietic cells as hepatocyte stem cells: a critical review of the evidence. *Hepatology* 43, 2–8.
27 Jakubowski A, Ambrose C, Parr M *et al.* (2005) TWEAK induces liver progenitor cell proliferation. *J Clin Invest* 115, 2330–2340.
28 Cassiman D, Libbrecht L, Desmet V *et al.* (2002) Hepatic stellate cell/myofibroblast subpopulations in fibrotic human and rat livers. *J Hepatol* 36, 200–209.
29 Ros JE, Roskams T, Geuken M *et al.* (2003) High expression of MDR1, MRP1, and MRP3 in the hepatic progenitor cell compartment and hepatocytes in severe human liver disease. *J Pathol* 200, 553–560.
30 Ros JE, Libbrecht L, Geuken M *et al.* (2003) ATP binding cassette transporter gene expression in rat liver progenitor cells. *Gut* 52, 1060–1067.
31 Sell S (2004) Stem cell origin of cancer and differentiation therapy. *Crit Rev Oncol Hematol* 51, 1–28.
32 Hixson DC, Brown J, McBride AC *et al.* (2000) Differentiation status of rat ductal cells and ethionine-induced hepatic carcinomas defined with surface-reactive monoclonal antibodies. *Exp Mol Pathol* 68, 152–169.
33 Dumble ML, Croager EJ, Yeoh GC *et al.* (2002) Generation and characterization of p53 null transformed hepatic progenitor cells: oval cells give rise to hepatocellular carcinoma. *Carcinogenesis* 23, 435–445.
34 Libbrecht L, Desmet V, Roskams T (2005) Preneoplastic changes in human hepatocarcinogenesis. *Liver Int* 25, 1–12.
35 Yoon DS, Jeong J, Park YN *et al.* (1999) Expression of biliary antigen and its clinical significance in hepatocellular carcinoma. *Yonsei Med J* 40, 472–477.

36 Van Eyken P *et al.* (1988) Cytokeratin expression in hepatocellular carcinoma: an immunohistochemical study. *Hum Pathol* 12, 562–568.
37 Hsia CC, Evarts RP, Natatsukasa H *et al.* (1992) Occurrence of oval-type cells in hepatitis B virus-associated human hepatocarcinogenesis. *Hepatology* 16, 1327–1633.
38 Durnez A (2006) The clinicopathological and prognostic relevance of cytokeratin 7 and 19 expression in hepatocellular carcinoma. A possible progenitor cell organ. *Histopathology* 49, 138–151.
39 Wu PC, Lai VC, Fang JW *et a*l. (1999) Hepatocellular carcinoma expressing both hepatocellular and biliary markers also expresses cytokeratin 14, a marker of bipotential progenitor cells. *J Hepatol* 31, 965–966.
40 Uenishi T, Kubo S, Yamamoto T *et al.* (2003) Cytokeratin 19 expression in hepatocellular carcinoma predicts early postoperative recurrence. *Cancer Sci* 94, 851–857.
41 Ding SJ, Li Y, Tan YX *et al.* (2004) From proteomic analysis to clinical significance: overexpression of cytokeratin 19 correlates with hepatocellular carcinoma metastasis. *Mol Cell Proteomics* 3, 73–81.
42 Libbrecht L, Desmet V, Van Damme B *et al.* (2000) The immunohistochemical phenotype of dysplastic foci in human liver: correlation with putative progenitor cells. *J Hepatol* 33, 76–84.
43 Fiegel HC, Gluer S, Roth B *et al.* (2004) Stem-like cells in human hepatoblastoma. *J Histochem Cytochem* 52, 1495–1501.
44 Xiao JC, Ruck P, Adam A *et al.* (2003) Small epithelial cells in human liver cirrhosis exhibit features of hepatic stem-like cells: immunohistochemical, electron microscopic and immunoelectron microscopic findings. *Histopathology* 42, 141–149.
45 Ruck P, Xiao J-C, Kaiserling E (1996) Small epithelial cells and the histogenesis of hepatoblastoma. Electron microscopic, immunoelectron microscopic, and immunohistochemical findings. *Am J Pathol* 148, 321–329.
46 Nomoto K, Tsuneyama K, Abdel Aziz HO *et al.* (2006) Intrahepatic cholangiocarcinoma arising in cirrhotic liver frequently expressed p63-positive basal/stem-cell phenotype. *Pathol Res Pract* 202, 71–76.
47 Alison MR, Lovell MJ (2005) Liver cancer: the role of stem cells. *Cell Prolif* 38, 407–421.

1.9 Embryology of the liver and intrahepatic biliary tract

Frédéric P. Lemaigre

In the embryo, the liver develops from the endoderm, one of the three germ layers formed during gastrulation [1]. The endoderm is constituted of a single cell-layered epithelium that delineates the primitive gut, and shows a regionalized, anteroposterior (cephalocaudal) gene expression profile [2]. Indeed, the endoderm gives rise to a number of organs, such as the lungs, the thyroid gland, the liver, the intestine and the pancreas, and genes that are specifically active in these organs become expressed in the endoderm before organ morphogenesis is initiated. Thus, endodermal domains are specified, that is they are committed to a differentiation fate, before organ morphogenesis proceeds.

The outgrowth of the liver from the ventral wall of the endoderm gives rise to a bud consisting mainly of liver precursor cells called hepatoblasts [3]. Proliferation of these cells is dependent on interactions with blood vessels, mesenchymal cells and extracellular matrix, and is followed by invasion of the hepatoblasts into the nearby septum transversum mesenchyme.

Further growth of the liver is associated with differentiation of the hepatoblasts into either hepatocytes or biliary cells [4,5]. The hepatocytes progressively acquire their mature morphology and line up to adopt the typical cord-like architecture that is established in concert with the development of the hepatic sinusoids (see Chapter 1.2). The biliary cells differentiate around the branches of the portal vein and, after a multistep morphogenic process, give rise to the intrahepatic bile ducts, which are located in the portal tracts and drain the bile from the bile canaliculi to the extrahepatic biliary tract [6,7]. Development of the hepatocytes and biliary cells is tightly controlled by a network of transcription factors [5,8–10] and by interactions with the extracellular matrix and with non-parenchymal cells such as the haematopoietic cells, which infiltrate the liver during development.

In this chapter, the various steps leading from endoderm specification to the acquisition of a mature liver architecture will be described, and the focus will be on mammalian liver development with specific reference to the mouse as a mammalian model organism.

From endoderm to hepatoblast

Hepatic specification of the endoderm is evidenced by the expression of albumin and α-fetoprotein, which starts in the ventral endoderm region that is adjacent to the developing heart and to the septum transversum mesenchyme. Transcription factors of the FoxA (forkhead-box factors, formerly HNF-3) and GATA families bind to regulatory regions of the albumin gene in the endoderm, at a stage preceding the onset of albumin mRNA synthesis [11,12]. As FoxA and GATA factors are able to bind to condensed chromatin and to induce its decompaction [13], it is likely that FoxA and GATA factors decondense endoderm chromatin to give access to another set of transcription factors, which subsequently allow transcription of the albumin gene to be initiated, and so contribute to hepatic specification of the endoderm [3].

Pioneering tissue transplantation experiments performed by LeDouarin [14], and more recent experiments addressing the molecular mechanisms of early hepatogenesis, revealed that fibroblast growth factors (FGF)-1 and -2, which are expressed by the cardiogenic mesoderm, can induce hepatic gene expression in cultured endoderm, provided that threshold concentrations of FGFs are reached [15,16]. The septum transversum mesenchyme, which is located caudally to the cardiogenic mesoderm and in the vicinity of the prehepatic endoderm at the time of hepatic induction, is a source of bone morphogenic proteins (BMP)-2 and -4. BMPs act cooperatively with FGFs in hepatic induction [17]. Interestingly, BMPs induce expression of the transcription factor GATA4 in cultured endoderm [17], thereby establishing a link between BMP signalling from the septum transversum and GATA-mediated chromatin remodelling in the endoderm.

Expansion of the liver bud

The liver bud, which becomes detectable around the 20th day of gestation in humans or at embryonic (E) day 9 in the mouse, mainly consists of a population of hepatoblasts that is delineated by a continuous basement membrane, and is separated from the

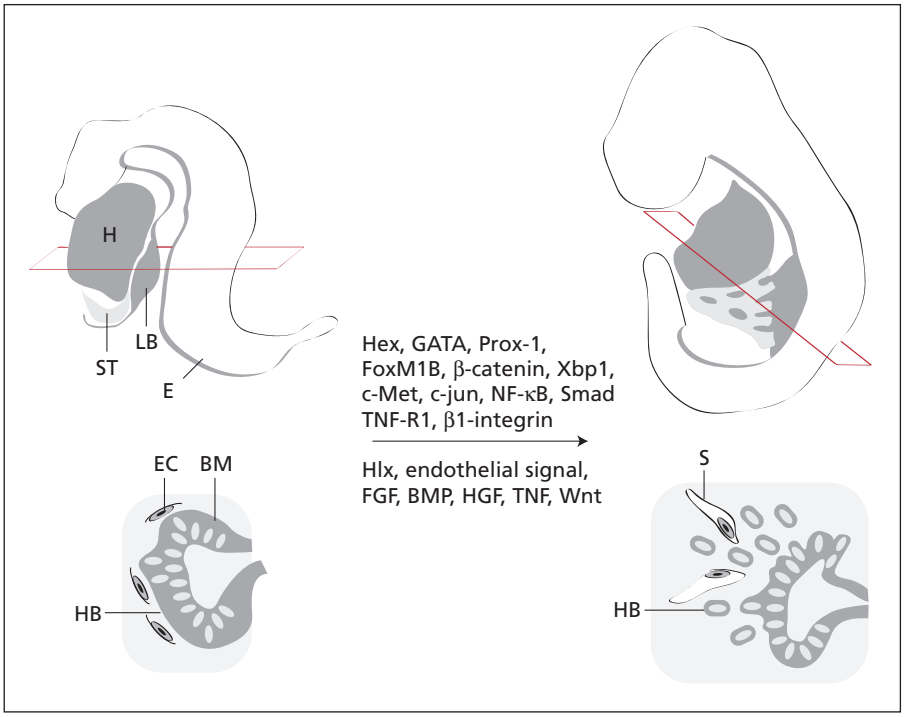

Fig. 1 Expansion of the liver bud is controlled by cell-autonomous and cell-extrinsic mechanisms. When the liver bud (LB) emerges from the endoderm (E) in the vicinity of the developing heart (H), the hepatoblasts (HB) invade the septum transversum (ST). The liver bud is initially delineated by a continuous basement membrane (BM) and is surrounded by an irregular layer of endothelial cells (EC). Cell-autonomous (above the arrow) and cell-extrinsic (below the arrow) regulators modulate differentiation, proliferation and apoptosis of the hepatoblasts. Sinusoids (S) start to develop within the septum transversum.

septum transversum mesenchyme by an irregular layer of endothelial cells (Fig. 1). The hepatoblasts proliferate, the basement membrane is disrupted, and the cells invade the septum transversum. Expansion of the liver bud requires the activity of the proteins Hex, GATA6 and Prox-1, which are transcription factors expressed in the hepatoblasts [18–21]. Hex and GATA6 control cell proliferation and differentiation, respectively, and Prox-1 regulates cell adhesion. The role of Prox-1 was revealed by the analysis of *Prox1–/–* knockout embryos, which display a phenotype characterized by a lack of delamination of the hepatoblasts from the liver bud. The *Prox1–/–* cells fail to migrate through the basement membrane and remain clustered together, most probably as a result of the overexpression of the cell adhesion protein E-cadherin.

Interactions between hepatoblasts and mesoderm-derived cells also regulate liver bud expansion. As yet unidentified signals from the endothelial cells are required to stimulate hepatoblast proliferation, as evidenced by the lack of expansion of the liver bud in *Flk1–/–* embryos, which lack endothelial cells [22]. Septum transversum cells continue to play a role in liver development beyond the endoderm specification stage, as shown by the stimulation of hepatoblast proliferation by BMPs and FGFs [15,17]. How these factors control proliferation is not well understood, but the identification of BMP-responsive *cis*-acting sequences within regulatory sequences of the *Hex* gene suggests that signalling factors control hepatoblast proliferation by regulating the expression of liver-specific transcription factors.

At later stages of liver development, beyond the stage of bud formation, proliferation and survival of the hepatic cells persistently require the activity of a number of transcription factors in hepatoblasts as well as tight control mechanisms orchestrated by interactions involving the mesenchymal cells, the extracellular matrix and the hepatoblasts. FoxM1B , Xbp1 and β-catenin are transcriptional regulators that stimulate hepatoblast proliferation [23–25]. Another transcription factor, Hlx, which is expressed in mesenchymal cells, indirectly stimulates hepatoblast proliferation [26], most probably by controlling the activity or production of growth factors.

Growth factors secreted by the mesenchymal cells include scatter factor/hepatocyte growth factor (HGF). HGF binds to its receptor c-Met at the hepatoblast cell surface and activates a cascade involving the transcription factor c-jun. Mutations in the genes coding for HGF, c-Met or c-jun induce severe liver hypoplasia leading to embryonic lethality [27–30]. Moreover, HGF can stimulate hepatoblast proliferation cooperatively with Wnt-3a, a growth factor involved in a host of developmental processes, which controls gene expression by activating β-catenin [31]. Another growth factor, namely transforming growth factor (TGF)-β, also controls hepatoblast proliferation, as evidenced by the reduced proliferation rate observed in livers of mouse embryos doubly heterozygous for the TGF-β mediators Smad2 and Smad3 [32]. Moreover, deficiency in Smad2 and Smad3 activity is associated with strongly decreased expression of β1-integrin, a receptor for extracellular matrix components. β1-integrin is needed to allow normal hepatogenesis, as β1-integrin-deficient cells fail to colonize the liver [33].

Liver growth also depends on a balance between proliferation and apoptosis. Cell survival relies on the integrity of NF-κB-mediated signalling pathways, as shown by the fact that disruption of the *RelA* or *IκB* kinase genes is associated with intense apoptosis and liver failure [34–37]. When the *NfκB* gene is disrupted in the absence of tumour necrosis factor (TNF) or

of TNF receptor-1, apoptosis is no longer observed, indicating that NF-κB is protective against TNF-induced apoptosis [38,39]. β-catenin, besides its role as a mediator of Wnt in stimulating proliferation of hepatoblasts, is also protective against apoptosis, as evidenced by the high number of apoptotic cells in embryonic liver explants in which β-catenin expression is inhibited [25].

Taken together, the above data indicate that a complex integration of cell-autonomous and cell-extrinsic cues allow the liver to emerge from the endoderm and to grow until it reaches the stage at which the bipotent hepatoblasts enter the hepatocytic or biliary differentiation programme.

Differentiation of hepatoblasts into hepatocytes or biliary cells

Around the eighth week of gestation in humans or around E14 in mouse embryos, the hepatoblasts start to differentiate into either hepatocytes or biliary cells (Fig. 2). The biliary cells are first detected around the branches of the portal vein (see below), while the hepatocytes differentiate in the rest of the parenchyma. Despite intense investigations, this process of cell fate decision remains poorly understood. Hepatocyte differentiation largely depends on the transcription factor HNF-4α [40]. The absence of HNF-4α at the stage when hepatocytes should enter the differentiation programme is associated with a failure to express numerous hepatocytic functions. Another transcription factor, FoxM1B, is critical for biliary differentiation because, in its absence, no biliary cells become detectable [23]. A different role is played by the transcription factor HNF-6, which prevents the premature appearance of biliary markers in the liver and so determines the timing of biliary differentiation [41]. Genes that are controlled by HNF-6 include those coding for HNF-1β, a transcription factor involved in bile duct morphogenesis [42], as well as mediators and regulators of TGF-β signalling [43,44].

Hepatoblast differentiation into either hepatocytes or biliary cells does not exclusively rely on cell-autonomous mechanisms. The Jagged/Notch signalling pathway, which implicates cell–cell regulatory events, is a candidate regulator of hepatoblast fate decisions in the developing liver. This hypothesis stems from the observations that, in patients affected by mutations in the *JAGGED1* gene and suffering from Alagille syndrome (see Chapters 16.10 and 22.1), the liver presents with bile duct paucity (OMIM #118450). Also, mice doubly heterozygous for a *Jagged1* null allele and a hypomorphic *Notch2* allele show lack of bile ducts at birth [45], but it is not yet known what stage of biliary differentiation is affected in these mutant mice. Work with cultured cells revealed that activation of the Notch pathway in isolated mouse hepatoblasts results in repression of hepatocytic differentiation and stimulation of biliary differentiation [46]. There is good evidence that Jagged-1, a Notch ligand, is expressed in the portal mesenchyme when biliary cells start to differentiate. Therefore, a plausible model proposes that hepatoblasts expressing Notch2 interact with the portal mesenchyme cells expressing Jagged-1, and that this triggers biliary

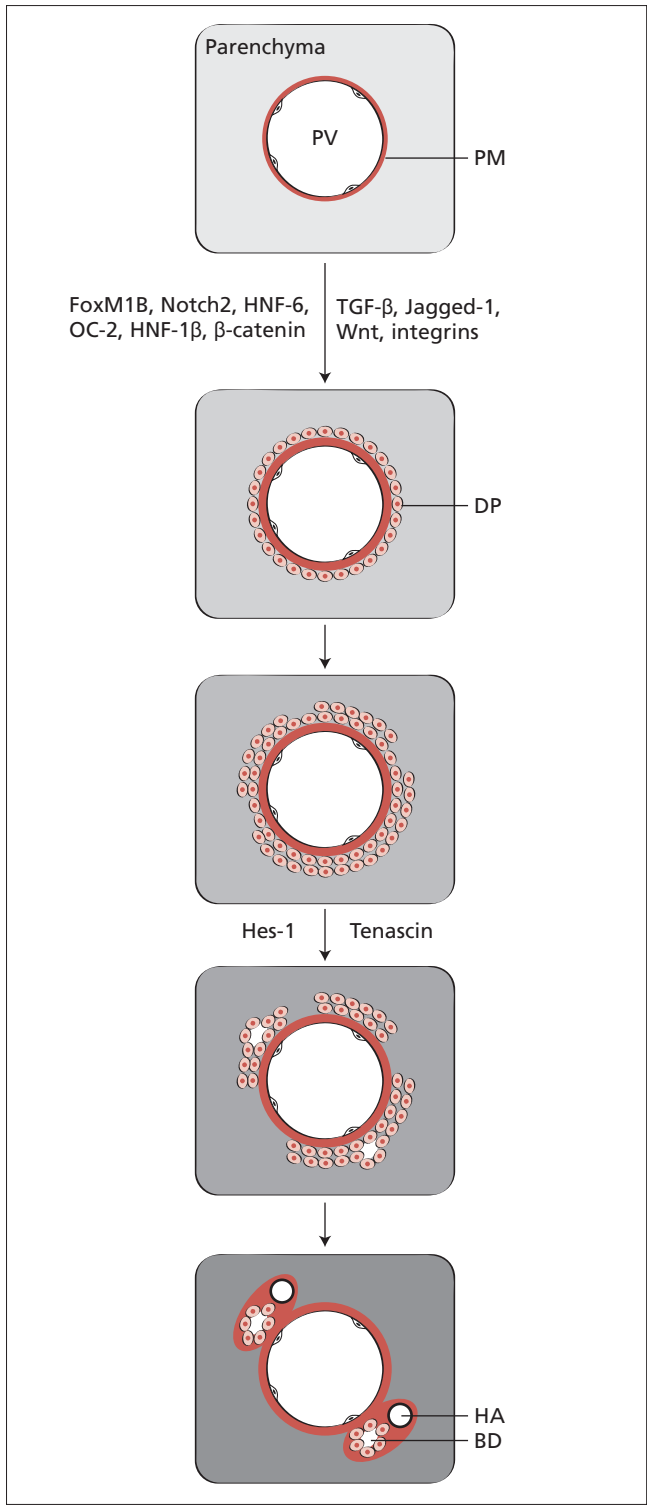

Fig. 2 Development of the bile ducts is controlled by cell-autonomous and cell-extrinsic mechanisms. The hepatoblasts differentiate into biliary cells around the portal mesenchyme (PM) surrounding the branches of the portal vein (PV). The biliary cells form the ductal plate (DP), which becomes bilayered and gives rise to the bile ducts (BD). The branches of the hepatic artery (HA) are associated with the bile ducts. Cell-autonomous (above the arrows) and cell-extrinsic (below the arrows) regulators modulate differentiation and morphogenesis of the bile ducts. The progressive darkening of the parenchyma illustrates the maturation of the hepatocytes.

differentiation of the hepatoblasts while repressing hepatocytic differentiation. However, whether Jagged/Notch signalling is involved in modulating hepatoblast fate decisions *in vivo* awaits further confirmation.

The hepatoblasts express high levels of the Wnt signalling mediator β-catenin [25], which, as mentioned above, promotes proliferation and protects against apoptosis. Experiments with embryonic liver explants revealed that Wnt-3a and β-catenin stimulate expression of the biliary marker cytokeratin 19 (CK19), implicating Wnt/β-catenin signalling in hepatoblast fate decisions [31]. This hypothesis is supported by the observation that liver explants treated with Wnt-3a show a reduced expression of the stem cell marker c-kit, suggesting that Wnt signalling induces the hepatoblasts to exit their bipotential status to enter the biliary differentiation programme. However, this model still needs to be validated by *in vivo* data.

Around the time of hepatoblast cell fate decision, TGF-β signalling occurs as a gradient of activity, which peaks in the hepatoblasts adjacent to the branches of the portal vein. Lower signalling activity is detected at a distance from the portal vein [44]. Increasing TGF-β signalling throughout the parenchyma, as is the case in knockout mice for the Onecut transcription factors HNF-6 or OC-2, induces the expression of biliary markers in all the hepatic cells. The cells then coexpress hepatocyte and biliary markers and are hybrid 'hepatobiliary' cells. In addition, blocking TGF-β signalling inhibits biliary differentiation of the hepatoblasts [44]. Therefore, the intensity, the timing and the location of TGF-β signalling activity are key determinants of hepatoblast fate decision. It is not yet clear how the gradient of TGF-β activity is established and how this gradient interacts with other cell signalling pathways involved in hepatoblast differentiation.

As biliary differentiation occurs around the branches of the portal vein (see below), the portal mesenchyme may promote biliary differentiation, not only by Wnt, Jagged/Notch or TGF-β-mediated signalling, but also via interactions with the extracellular matrix. When the hepatoblasts differentiate into biliary cells, a switch in the expression of integrins is observed. Indeed, hepatoblasts express integrin dimers α1β1, α5β1, α6β1 and α9β1, while the biliary cells show a progressive increase in α6β1 and a decrease in α1β1. In addition, the ductal plate cells start to express the α2β1, α3β1, αVβ1 and α6β4 integrins, which are absent from the hepatoblasts. The increase in α6β1 expression and the biliary-specific expression of α2β1, α3β1 and α6β4, which are laminin receptors, correlate well with the presence of laminin in the portal mesenchyme, suggesting that laminin may be involved in biliary cell development [47].

Maturation of hepatocytes

When the hepatocyte lineage becomes separated from the biliary lineage, the hepatocytes enter a maturation phase that extends beyond birth and consists of the acquisition of a proper morphology and of hepatocyte functions such as urea synthesis, production of apolipoproteins or gluconeogenesis. A set of liver-enriched transcription factors, organized in a dynamic network of auto- and cross-regulatory loops [48], is instrumental in hepatocyte maturation. These factors include those from the HNF-1, FoxA, HNF-4, C/EBP and Onecut families [8–10]. Much is known about the function of these factors as a result of the analysis of mutant mice and from the identification of the factor binding sites in target genes. In some cases, human patients with mutations in genes coding for liver-enriched transcription factors were found. For instance, mutations in the *HNF1a*, *HNF1b* and *HNF4a* genes are associated with maturity-onset diabetes of the young. HNF-1α and HNF-4α control the expression of glucose metabolism-regulating proteins, but they also control a host of liver functions that include amino acid and lipid metabolism. HNF-4α also determines the epithelial morphology of hepatocytes, as a lack of HNF-4α in mice is associated with major alterations in liver architecture [49]. HNF-1β is a regulator of bile duct development (see below), but is also essential for bile acid sensing and fatty acid oxidation [42]. The three FoxA factors (FoxA-1, -2 and -3) have overlapping DNA-binding properties and functions and, like the other liver-enriched transcription factors, they regulate numerous hepatic functions. C/EBP factors also constitute a family of proteins with overlapping functions (reviewed in [50]). C/EBPα is a regulator of glucose and glycogen metabolism, of lipid homeostasis and hepatocyte proliferation. In addition, lack of C/EBPα perturbs the epithelial organization of the liver, but much less so than the absence of HNF-4α. C/EBPβ is a regulator of gluconeogenesis and a critical stimulator of phosphoenolpyruvate carboxykinase gene expression. Finally, with regard to Onecut factors, the function of HNF-6 has been determined mainly by the analysis of *Hnf6* knockout mice, which show abnormal glucose metabolism and major alterations in biliary development [41,51,52]. The Onecut factor OC-2 regulates biliary development [44].

Liver-enriched transcription factors form a regulatory network that is modulated by signalling from the environment. Starting around E12 in the mouse, hepatocytes are in close contact with haematopoietic cells. These cells persist in the liver until birth and exert a paracrine control on hepatocyte maturation (reviewed in ref. 53). Oncostatin M, an interleukin (IL)-6-related cytokine secreted by the haematopoietic cells, synergizes with glucocorticoid hormones to induce liver-specific functions and to control the morphology and cell adhesion properties of hepatocytes [54,55]. The response induced by oncostatin M requires the integrity of the *Jumonji* gene, which codes for a transcription factor expressed in hepatocytes [56]. Conversely, the integrity of hepatocytic functions is required to allow haematopoietic cell differentiation to proceed, as evidenced by the fact that hepatic B lymphopoiesis is impaired when hepatocytes are devoid of HNF-6 [57]. Also, when hepatocytes have matured, they no longer support differentiation of haematopoietic cells [55], indicating that haematopoietic cells and hepatocytes cross-regulate each other dynamically.

Development of the intrahepatic bile ducts

The biliary cells differentiate all around the branches of the portal vein, closely apposed to the portal mesenchyme (Fig. 2). Around the eighth week of gestation in humans, or E15 in mice, biliary cells form a monolayered and nearly continuous ring of cells, called the ductal plate. The ductal plate then becomes bilayered, and it enters a phase of remodelling around the 12th week of gestation in humans (E16 in mice). Lumina start to form between the two cell layers, giving rise to tubular structures that will develop into the intrahepatic bile ducts. Those portions of the ductal plate that are not involved in duct formation progressively disappear, and the ducts become surrounded by portal mesenchyme.

As stated above, transcription factors, cell signalling and cell–matrix interactions promote differentiation of hepatoblasts into biliary cells. Further steps in bile duct morphogenesis are regulated by the transcription factors HNF-6, OC-2, HNF-1β and Hes-1. Indeed, in *Hnf6–/–* and *Hnf1b–/–* mice, biliary cells are present, but the ductal plates fail to develop properly; transient biliary cysts are formed and, at birth, biliary cells surround the portal tracts without giving rise to ducts [41,42]. The biliary histology in these mice is similar to that described in human ductal plate malformations (see Chapter 8.1). In *Oc2–/–* mice, the ductal plate presents with premature dilations [44]. Hes-1, a transcription factor and target of Notch signalling, is dispensable for ductal plate formation, but is critically required for the development of tubular structures from the ductal plate [58].

The identification of transcription factors regulating bile duct morphogenesis has not yet allowed the characterization of several key aspects of duct formation. For instance, the mechanism promoting the formation of the second layer of cells forming the ductal plate is unknown. This most probably occurs by differentiation rather than proliferation, as very few proliferating cells are found in the ductal plate [41,59]. Another unresolved issue is what triggers the regression of those ductal plate portions that are not implicated in duct formation. Apoptosis is involved [60], but the rather low amount of apoptosing cells may not suffice to explain the regression of the ductal plate. Tube formation from the ductal plate requires the activity of the transcription factor Hes-1, but may also be controlled by extracellular matrix components. Indeed, tenascin is specifically found at the interface between the portal mesenchyme and the biliary cells of the developing ducts, but is absent near the ductal plate cells not involved in duct formation [61]. In addition, tubulogenesis is controlled by soluble factors, and there is *in vitro* evidence that HGF, insulin and EGF may participate in this process in the liver, but these results need to be confirmed *in vivo*.

Finally, novel insights into the mechanisms of bile duct morphogenesis may derive from the understanding of diseases that present with biliary cysts in the liver. Biliary cells have a primary cilium at their apical surface, and deficiencies in cilium formation or function are associated with bile duct anomalies [62]. Such diseases include the autosomal recessive form of polycystic kidney disease (ARPKD). ARPKD patients have mutations in the *PKHD1* gene, which codes for polyductin/fibrocystin, a protein associated with the primary cilium. The function of the cilium is not well understood, but some data favour the hypothesis that they sense fluid flow and induce a cellular response that controls tubulogenesis. Animal models such as the PCK rat [62] or transgenic mice with a targeted mutation of the *Pkhd1* gene [63] show biliary cysts and ductal plate malformations. The study of these animals should provide more insight into the role of the cilium in bile duct morphogenesis.

Vascular development in the liver

The right vitelline vein gives rise to the portal vein, which ramifies into several branches that connect with the hepatic sinusoids [64]. The precursors of the hepatic sinusoids become detectable around the fourth week of gestation in humans, i.e. during liver bud expansion [65,66]. They form sinusoid-like vessels that separate the hepatoblasts. At this stage, the endothelial cells express markers of continuous endothelia. Later, when the hepatocytes become organized in cords, the sinusoidal endothelium expresses markers of adult sinusoids, indicating that sinusoids undergo a process of maturation [66]. Interestingly, morphogenesis of the hepatic sinusoids depends on interactions with hepatocytes. This was concluded from the analysis of *Hnf4a–/–* mouse livers, in which abnormal differentiation of hepatocytes is associated with profound malformations of the hepatic sinusoids [49].

Sinusoids are separated from hepatocytes by the space of Disse, within which the hepatic stellate cells are found. These cells become detectable in the prenatal period, namely around the 12th week of gestation in humans or E13.5 in mice [67]. Their embryological origin is not well established but, on the basis of their gene expression profile, it has been suggested that they originate from the mesenchyme or from the neuroectoderm [68].

The hepatic artery usually arises from the coeliac trunk and ramifies in the portal tracts of the liver. There are differences between rodents and humans as to the timing of hepatic artery branch formation. In mice, the hepatic artery branches develop within a few days of birth in the vicinity of well-formed bile ducts [69], while in humans they become detectable around the 20th week of gestation, adjacent to the ductal plate [70]. Interestingly, hepatic artery branch development is dependent on the integrity of the biliary structures. Indeed, treatment of rats with a drug that promotes cholangiocyte proliferation induces a parallel remodelling of the hepatic artery branches [71]. In *Hnf6–/–* or *Hnf1b–/–* mouse livers, the bile ducts fail to form, and hepatic artery branches are either hyperplastic or absent [69]. Moreover, in humans, the ductal plate malformations found in Meckel syndrome or in Jeune syndrome are associated with anomalies of the hepatic artery branches [69].

It can be concluded that, throughout liver development, differentiation and morphogenesis of the hepatocytes, bile ducts and blood vessels depends on cross-regulations involving dynamic cell-intrinsic and cell-extrinsic mechanisms. The characterization of these mechanisms is ongoing and is a prerequisite for the full understanding of the pathophysiology of liver diseases.

References

1 Wells JM, Melton DA (1999) Vertebrate endoderm development. *Annu Rev Cell Dev Biol* 15, 393–410.

2 Grapin-Botton A, Melton DA (2000) Endoderm development: from patterning to organogenesis. *Trends Genet* 16, 124–130.

3 Zaret KS (2002) Regulatory phases of early liver development: paradigms of organogenesis. *Nature Rev Genet* 3, 499–512.

4 Lemaigre F, Zaret KS (2004) Liver development update: new embryo models, cell lineage control, and morphogenesis. *Curr Opin Genet Dev* 14, 582–590.

5 Zhao R, Duncan SA (2005) Embryonic development of the liver. *Hepatology* 41, 956–967.

6 Shiojiri N (1997) Development and differentiation of bile ducts in the mammalian liver. *Microsc Res Tech* 39, 328–335.

7 Lemaigre FP (2003) Development of the biliary tract. *Mech Dev* 20, 81–87.

8 Costa RH, Kalinichenko VV, Holterman AX *et al.* (2003) Transcription factors in liver development, differentiation, and regeneration. *Hepatology* 38, 1331–1347.

9 Schrem H, Klempnauer J, Borlak J (2002) Liver-enriched transcription factors in liver function and development. Part I: the hepatocyte nuclear factor network and liver-specific gene expression. *Pharmacol Rev* 54, 129–158.

10 Schrem H, Klempnauer J, Borlak J (2004) Liver-enriched transcription factors in liver function and development. Part II: the C/EBPs and D site-binding protein in cell cycle control, carcinogenesis, circadian gene regulation, liver regeneration, apoptosis, and liver-specific gene regulation. *Pharmacol Rev* 56, 291–330.

11 Gualdi R, Bossard P, Zheng M *et al.* (1996) Hepatic specification of the gut endoderm in vitro: cell signaling and transcriptional control. *Genes Dev* 10, 1670–1682.

12 Bossard P, Zaret KS (1998) GATA transcription factors as potentiators of gut endoderm differentiation. *Development* 125, 4909–4917.

13 Cirillo LA, Lin FR, Cuesta I *et al.* (2002) Opening of compacted chromatin by early developmental transcription factors HNF3 (FoxA) and GATA-4. *Mol Cell* 9, 279–289.

14 LeDouarin NM (1975) An experimental analysis of liver development. *Med Biol* 53, 427–455.

15 Jung J, Zheng M, Goldfarb M *et al.* (1999) Initiation of mammalian liver development from endoderm by fibroblast growth factors. *Science* 284, 1998–2003.

16 Serls AE, Doherty S, Parvatiyar P *et al.* (2005) Different thresholds of fibroblast growth factors pattern the ventral foregut into liver and lung. *Development* 132, 35–47.

17 Rossi JM, Dunn NR, Hogan BL *et al.* (2001) Distinct mesodermal signals, including BMPs from the septum transversum mesenchyme, are required in combination for hepatogenesis from the endoderm. *Genes Dev* 15, 1998–2009.

18 Keng VW, Yagi H, Ikawa M *et al.* (2000) Homeobox gene Hex is essential for onset of mouse embryonic liver development and differentiation of the monocyte lineage. *Biochem Biophys Res Commun* 276, 1155–1161.

19 Martinez Barbera JP, Clements M, Thomas P *et al.* (2000) The homeobox gene Hex is required in definitive endodermal tissues for normal forebrain, liver and thyroid formation. *Development* 127, 2433–2445.

20 Sosa-Pineda B, Wigle JT, Oliver G (2000) Hepatocyte migration during liver development requires Prox1. *Nature Genet* 25, 254–255.

21 Zhao R, Watt AJ, Li J *et al.* (2005) GATA6 is essential for embryonic development of the liver but dispensable for early heart formation. *Mol Cell Biol* 25, 2622–2631.

22 Matsumoto K, Yoshitomi H, Rossant J *et al.* (2001) Liver organogenesis promoted by endothelial cells prior to vascular function. *Science* 294, 559–563.

23 Krupczak-Hollis K, Wang X, Kalinichenko VV *et al.* (2004) The mouse Forkhead Box m1 transcription factor is essential for hepatoblast mitosis and development of intrahepatic bile ducts and vessels during liver morphogenesis. *Dev Biol* 276, 74–88.

24 Reimold AM, Etkin A, Clauss I *et al.* (2000) An essential role in liver development for transcription factor XBP-1. *Genes Dev* 14, 152–157.

25 Monga SP, Monga HK, Tan X *et al.* (2003) Beta-catenin antisense studies in embryonic liver cultures: role in proliferation, apoptosis, and lineage specification. *Gastroenterology* 124, 202–216.

26 Hentsch B, Lyons I, Li R *et al.* (1996) Hlx homeo box gene is essential for an inductive tissue interaction that drives expansion of embryonic liver and gut. *Genes Dev* 10, 70–79.

27 Schmidt C, Bladt F, Goedecke S *et al.* (1995) Scatter factor/hepatocyte growth factor is essential for liver development. *Nature* 373, 699–702.

28 Uehara Y, Minowa O, Mori C *et al.* (1995) Placental defect and embryonic lethality in mice lacking hepatocyte growth factor/scatter factor. *Nature* 373, 702–705.

29 Bladt F, Riethmacher D, Isenmann S *et al.* (1995) Essential role for the c-met receptor in the migration of myogenic precursor cells into the limb bud. *Nature* 376, 768–771.

30 Hilberg F, Aguzzi A, Howells N *et al.* (1993) c-jun is essential for normal mouse development and hepatogenesis. *Nature* 365, 179–181.

31 Hussain SZ, Sneddon T, Tan X *et al.* (2004) Wnt impacts growth and differentiation in ex vivo liver development. *Exp Cell Res* 292, 157–169.

32 Weinstein M, Monga SP, Liu Y *et al.* (2001) Smad proteins and hepatocyte growth factor control parallel regulatory pathways that converge on beta1-integrin to promote normal liver development. *Mol Cell Biol* 21, 5122–5131

33 Fassler R, Meyer M (1995) Consequences of lack of beta 1 integrin gene expression in mice. *Genes Dev* 9, 1896–1908.

34 Beg AA, Sha WC, Bronson RT *et al.* (1995) Embryonic lethality and liver degeneration in mice lacking the RelA component of NF-κB. *Nature* 376, 167–170.

35 Li Q, Van Antwerp D, Mercurio F *et al.* (1999) Severe liver degeneration in mice lacking the IkappaB kinase 2 gene. *Science* 284, 321–325.

36 Li ZW, Chu W, Hu Y *et al.* (1999) The IKKbeta subunit of IkappaB kinase (IKK) is essential for nuclear factor kappaB activation and prevention of apoptosis. *J Exp Med* 189, 1839–1845.

37 Rudolph D, Yeh WC, Wakeham A *et al.* (2000) Severe liver degeneration and lack of NF-kappaB activation in NEMO/IKKgamma-deficient mice. *Genes Dev* 14, 854–862.

38 Doi TS, Marino MW, Takahashi T *et al.* (1999) Absence of tumor necrosis factor rescues RelA-deficient mice from embryonic lethality. *Proc Natl Acad Sci USA* 96, 2994–2999.

39 Rosenfeld ME, Prichard L, Shiojiri N *et al.* (2000) Prevention of hepatic apoptosis and embryonic lethality in RelA/TNFR-1 double knockout mice. *Am J Pathol* 156, 997–1007.

40 Li J, Ning G, Duncan SA (2000) Mammalian hepatocyte differentiation requires the transcription factor HNF-4alpha. *Genes Dev* 14, 464–474.

41 Clotman F, Lannoy VJ, Reber M *et al.* (2002) The onecut transcription factor HNF6 is required for normal development of the biliary tract. *Development* 129, 1819–1828.

42 Coffinier C, Gresh L, Fiette L *et al.* (2002) Bile system morphogenesis defects and liver dysfunction upon targeted deletion of HNF1beta. *Development* 129, 1829–1838.

43 Plumb-Rudewiez N, Clotman F, Strick-Marchand H *et al.* (2004) The transcription factor HNF-6/OC-1 inhibits the stimulation of the HNF-3α/Foxa1 gene by TGFβ in mouse liver. *Hepatology* 40, 1266–1274.

44 Clotman F, Jacquemin P, Plumb-Rudewiez N *et al.* (2005) Control of liver cell fate decision by a gradient of TGFβ signaling modulated by Onecut transcription factors. *Genes Dev* 19, 1849–1854.

45 McCright B, Lozier J, Gridley T (2002) A mouse model of Alagille syndromeP: Notch2 as a genetic modifier of Jag1 haploinsufficiency. *Development* 129, 1075–1082.

46 Tanimizu N, Miyajima A (2004) Notch signaling controls hepatoblast differentiation by altering the expression of liver-enriched transcription factors. *J Cell Sci* 117, 3165–3174.

47 Couvelard A, Bringuier AF, Dauge MC *et al.* (1998) Expression of integrins during liver organogenesis in humans. *Hepatology* 27, 839–847.

48 Odom DT, Zizlsperger N, Gordon DB *et al.* (2004) Control of pancreas and liver gene expression by HNF transcription factors. *Science* 303, 1378–1381.

49 Parviz F, Matullo C, Garrison WD *et al.* (2003) Hepatocyte nuclear factor 4alpha controls the development of a hepatic epithelium and liver morphogenesis. *Nature Genet* 34, 292–296.

50 Lekstrom-Himes J, Xanthopoulos KG (1998) Biological role of the CCAAT/enhancer-binding protein family of transcription factors. *J Biol Chem* 273, 28545–28548.

51 Jacquemin P, Durviaux SM, Jensen J *et al.* (2000) Transcription factor hepatocyte nuclear factor 6 regulates pancreatic endocrine cell differentiation and controls expression of the proendocrine gene ngn3. *Mol Cell Biol* 20, 4445–4454.

52 Lannoy VJ, Decaux JF, Pierreux CE *et al.* (2002) Liver glucokinase gene expression is controlled by the onecut transcription factor hepatocyte nuclear factor-6. *Diabetologia* 45, 1136–1141.

53 Kinoshita T, Miyajima A (2002) Cytokine regulation of liver development. *Biochim Biophys Acta* 1592, 303–312.

54 Kamiya A, Kinoshita T, Ito Y *et al.* (1999) Fetal liver development requires a paracrine action of oncostatin M through the gp130 signal transducer. *EMBO J* 18, 2127–2136.

55 Kinoshita T, Sekiguchi T, Xu MJ *et al.* (1999) Hepatic differentiation induced by oncostatin M attenuates fetal liver haematopoiesis. *Proc Natl Acad Sci USA* 96, 7265–7270.

56 Anzai H, Kamiya A, Shirato H *et al.* (2003) Impaired differentiation of fetal hepatocytes in homozygous jumonji mice. *Mech Dev* 120, 791–800.

57 Bouzin C, Clotman F, Renauld JC *et al.* (2003) The onecut transcription factor hepatocyte nuclear factor-6 controls B lymphopoiesis in fetal liver. *J Immunol* 171, 1297–1303.

58 Kodama Y, Hijikata M, Kageyama R *et al.* (2004) The role of notch signaling in the development of intrahepatic bile ducts. *Gastroenterology* 127, 1775–1786.

59 Fabris L, Strazzabosco M, Crosby HA *et al.* (2000) Characterization and isolation of ductular cells coexpressing neural cell adhesion molecule and Bcl-2 from primary cholangiopathies and ductal plate malformations. *Am J Pathol* 156, 1599–1612.

60 Terada T, Nakanuma Y (1995) Detection of apoptosis and expression of apoptosis-related proteins during human intrahepatic bile duct development. *Am J Pathol* 146, 67–74.

61 Terada T, Nakanuma Y (1994) Expression of tenascin, type IV collagen and laminin during human intrahepatic bile duct development and in intrahepatic cholangiocarcinoma. *Histopathology* 25, 143–150.

62 Masyuk TV, Huang BQ, Ward CJ *et al.* (2003) Defects in cholangiocyte fibrocystin expression and ciliary structure in the PCK rat. *Gastroenterology* 125, 1303–1310.

63 Moser M, Matthiesen S, Kirfel J *et al.* (2005) A mouse model for cystic biliary dysgenesis in autosomal recessive polycystic kidney disease (ARPKD). *Hepatology* 41, 1113–1121.

64 Lassau JP, Bastian D (1983) Organogenesis of the venous structures of the human liver: a hemodynamic theory. *Anat Clin* 5, 97–102.

65 Gouysse G, Couvelard A, Frachon S *et al.* (2002) Relationship between vascular development and vascular differentiation during liver organogenesis in humans. *J Hepatol* 37, 730–740.

66 Couvelard A, Scoazec JY, Dauge MC *et al.* (1996) Structural and functional differentiation of sinusoidal endothelial cells during liver organogenesis in humans. *Blood* 87, 4568–4580.

67 Wandzioch E, Kolterud A, Jacobsson M *et al.* (2004) Lhx2–/– mice develop liver fibrosis. *Proc Natl Acad Sci USA* 101, 16549–16554.

68 Geerts A (2001) History, heterogeneity, developmental biology, and functions of quiescent hepatic stellate cells. *Semin Liver Dis* 21, 311–335

69 Clotman F, Libbrecht L, Gresh L *et al.* (2003) Hepatic artery malformations associated with a primary defect in intrahepatic bile duct development. *J Hepatol* 39, 686–692.

70 Libbrecht L, Cassiman D, Desmet V *et al.* (2002) The correlation between portal myofibroblasts and development of intrahepatic bile ducts and arterial branches in human liver. *Liver* 22, 252–258.

71 Masyuk TV, Ritman EL, LaRusso NF (2003) Hepatic artery and portal vein remodeling in rat liver: vascular response to selective cholangiocyte proliferation. *Am J Pathol* 162, 1175–1182.

2 Functions of the liver

2.1 Hepatic circulation

2.1.1 Regulation of hepatic blood flow

Christophe Bureau, Jean-Marie Péron and Jean-Pierre Vinel

Approximately 100 mL of blood passes through 100 g of liver every minute, which represents 25–30% of the cardiac output (CO). This very large flow is brought from two different sources:

- the hepatic artery provides roughly one-third of the blood and 50% of the oxygen delivered to the liver;
- the portal vein accounts for two-thirds of total hepatic blood flow (HBF) and 50% of hepatic oxygen supply. It drains blood from the spleen, the omentum and splanchnic organs, carrying to the liver most substances absorbed through the gut.

Significant changes in HBF are observed under physiological conditions. Thus, HBF decreases during sleeping and during exercise [1]; it increases after a meal [1]; it is enhanced during expiration and reduced by inspiration [2,3]. Finally, it diminishes as age increases [4].

In the normal liver, resistance to blood flow is low, with a pressure gradient below 5 mmHg between the portal vein and the hepatic veins. HBF is regulated through three different sites of resistance:

- terminal hepatic arterioles, richly supplied in smooth muscle cells, for arterial flow;
- arterioles of splanchnic organs for portal venous flow;
- sinusoids and terminal hepatic venules [5,6] for intrahepatic resistance, which influences both total HBF and flow distribution within the liver.

Changes in resistances, hence in HBF, are under the command of so-called 'intrinsic mechanisms', neural and humoral factors, and can be caused by drugs.

Intrinsic mechanisms

Pressure flow autoregulation

Within the physiological range of pressures, resistance is adapted so that blood flow through a vascular bed remains constant. This autoregulatory mechanism has been demonstrated in the hepatic artery, but not in the portal venous vascular bed. It has been suggested that perivascular smooth muscle cell tone changes as a response to stretching. This response could be mediated by adenosine [7].

Hepatic arterial buffer response

It has been shown almost a century ago [8] that occlusion of the portal vein induces an immediate increase in the blood flow to the hepatic artery. The hepatic artery is almost fully dilated at low portal flows, as evidenced by the inability of adenosine infusion to induce further dilatation; it is almost fully constricted at high portal flows, as shown by lack of further constriction to norepinephrine [9]. Such a compensatory mechanism cannot maintain total liver blood flow, but oxygenation of the liver parenchyma is generally considered to be improved by an increased efficiency of oxygen extraction [10,11]. Using different models of blood flow reduction in pigs, Bracht *et al.* [12] observed a 52% reduction in portal venous flow, which was associated with a 100% increase in hepatic arterial flow. However, hepatic oxygen extraction changed with the cause of decreased blood flow: it increased in a model of tamponade, but did not when abdominal flow was reduced [12]. In such conditions, hepatic oxygenation could therefore be compromised.

Several mechanisms could account for this autoregulation:

- changes in resistance in the terminal vessels in response to changes in sinusoidal pressure;
- changes in $p\mathrm{O}_2$, which might in turn change vascular resistance through a direct action on perivascular smooth muscle cells;
- changes in the concentration of vasoactive molecules secondary to changes in blood flow.

Accordingly, a fall in portal blood flow would induce an increase in the local concentration of vasodilators, which would in turn increase arterial blood flow. Conversely, an increase in portal flow would remove vasodilators, causing arterial vasoconstriction.

Experimental data support the role of adenosine in mediating this autoregulation. Intraportal injections of adenosine elicit

hepatic arterial vasodilatation. Adenosine is released at a constant rate in the space of Mall, which contains the hepatic arterioles and portal venules, and its concentration is regulated by washout into these vessels, principally the portal vein. If flow in the portal vein is reduced, the concentration of adenosine rises, causing dilatation of the hepatic arteriole [13–15]. It has been shown in the rabbit [16] that 8-phenyltheophylline, an adenosine receptor antagonist, inhibited this response which, on the contrary, was potentiated by dipyridamole, an adenosine uptake inhibitor. Adenosine triphosphate (ATP) is also able to dilate the hepatic arterial vascular bed [16], at least in part through nitric oxide (NO) production [17]. A non-selective P_1-purinoreceptor antagonist [8-(*p*-sulphophenyl)-theophylline] has been found to inhibit the ATP-mediated arterial buffer response. These results suggest that hepatic artery dilatation induced by ATP is partly mediated through activation of P_1-purinoreceptors after catabolism of ATP to adenosine [16].

In patients with cirrhosis, hepatic artery vascular responsiveness to altered portal blood flow seems to be blunted [18]. However, this impairment in acute hepatic arterial buffer response (HABR) could be accounted for by the continuous activation of HABR, which has been observed in cirrhotic patients [19]. Accordingly, HABR seems to be preserved in cirrhosis and could play a protective role in hepatic circulation [20].

Such a buffer response has not been found in the portal vein. Actually, changes in hepatic arterial flow do not cause significant changes in the portal venous flow [14].

Veno-arterial response

Elevation of hepatic vein pressure induces an increase in hepatic arterial resistance and a decrease in arterial blood flow [21]. The precise mechanism of this response remains unknown.

It has also been shown that an increase in portal pressure increases resistance in the splanchnic vascular bed [22] which, in turn, tends to decrease portal venous inflow.

After a meal, total HBF increases, owing to enhanced mesenteric (hence portal) blood flow, but also hepatic arterial blood flow [23]. This suggests that autoregulation can be overcome by mechanisms as yet unknown. It could be due to the presence in the portal blood of substances with vasodilating properties on the hepatic artery, for example bile salts [24] and hormones such as glucagon or vasoactive inhibitory polypeptide (VIP) [25]. Furthermore, after a meal, pO_2 tends to decrease, and pCO_2, pH and osmolarity to increase in portal blood. All these changes have been shown to augment hepatic arterial blood flow [26].

Neural regulation

Hepatic denervation after liver transplantation has no major deleterious effects on HBF [27], which suggests that, in normal subjects, neural regulation probably plays little role in the regulation of HBF.

Parasympathetic nerves

Parasympathetic nerves play no major role in the regulation of HBF as neither denervation nor electrical stimulation of parasympathetic nerves nor drugs with anticholinesterase activity affect HBF [28]. However, hepatic vagal nerves could play a role in the distribution of blood flow within the liver by dilating sinusoids [29], thereby increasing the ratio of perfused to non-perfused sinusoids.

Sympathetic nerves

Denervation of the hepatic sympathetic nerves in urethane-anaesthetized rats has no influence on HBF, indicating that the sympathetic nerves have no tonic influence on HBF [28]. Their stimulation induces constriction of both arteries and, to a lesser extent, portal vessels [30]. This results in a decrease in HBF through activation of α-adrenergic receptors, as it can be prevented by treatment with phentolamine, an α-adrenoceptor antagonist [28].

Carneiro and Donald [31] showed an inverse relationship between carotid sinus pressure, on the one hand, and resistance in liver vessels, on the other hand, so that hypotension induces vasoconstriction of the hepatic arterial and portal systems. The maximum increase in resistance was 45% and 22% for the arterial and portal beds respectively. Because of vasoconstriction mediated through activation of both α_2-adrenergic receptors and the renin–angiotensin system, up to 40% of blood volume can be expelled from the liver into the systemic circulation without compromising liver function [32]. This phenomenon may play an important role in the control of haemodynamics because about 30% of the liver volume is blood, making this organ the major blood reservoir of the body.

The importance of liver innervation in the regulation of systemic haemodynamics is further exemplified by the interactions between portal blood flow and renal function. Actually, it has been shown in rats that a 50% decrease in intrahepatic portal flow decreased urine flow by 38% and sodium excretion by 44%, although systemic arterial blood pressure was not significantly changed [33]. This so-called 'hepatorenal reflex' (HRR) is mediated through activation of hepatic afferent nerves by adenosine, which results in a sympathetic reflex to the kidneys causing fluid retention. HRR is abolished by hepatic denervation. In cirrhotic rats exhibiting water and sodium retention, renal dysfunction was partially corrected by intrahepatic administration of 8-phenyltheophylline, an adenosine receptor antagonist [34]. HRR could therefore play a role in water and sodium retention observed in cirrhosis.

Humoral regulation

Secretin, cholecystokinin-pancreozymin (CCK-PZ) and glucagon [35] have a vasodilator effect on the hepatic artery and increase arterial blood flow. Furthermore, glucagon, at a dose too low to

induce vasodilatation, antagonizes the vasoconstrictor response to several stimuli (such as sympathetic nerve stimulation or vasopressin infusion) [36]. It could therefore play a protective role in hepatic blood flow, when systemic conditions induce reduction of blood flow in most other territories [37]. Prostacyclin [38] and epinephrine at low doses [39] also have a vasodilator effect. In contrast, epinephrine at high doses [39], dopamine [40], norepinephrine [38], angiotensin [36] and vasopressin [41] reduce liver blood flow through vasoconstriction of splanchnic and hepatic arteries. The role of these humoral factors under physiological conditions remains to be determined. Animal studies suggest that histamine, angiotensin II as well as hepatic nerve stimulation induce constriction of hepatic venous sphincters, which could contribute to flow regulation and protect the liver from changes in central venous pressure.

NO plays a key role in the regulation of HBF. It increases splanchnic blood flow by its vasodilating action at the level of the mesenteric arterioles [42]. Furthermore, it increases flow within the sinusoids, and regulation of intrahepatic resistance is ascribed to a precise equilibrium between the production of NO, a potent vasodilator [43], and endothelin, a powerful vasoconstrictor [44]. This is achieved by contraction or relaxation of perisinusoidal stellate cells [43,45]. Carbon monoxide (CO), a byproduct of the breakdown of haem by haem oxygenase, could also play a role in smooth muscle relaxation [46]. In the normal rat, NO has been shown to be a potent vasodilatory mediator in the hepatic arterial circulation, although it had little effect in the portal venous vascular bed [47]. In the same set of experiments, CO was shown to have no effect on the hepatic artery, whereas it maintained portal venous vascular tone in a relaxed state [47].

An imbalance between increased endothelin production and a decrease in NO production, added to an exaggerated contractility of stellate cells, is considered to play a major role in the increased hepatic resistance that characterizes portal hypertension [48].

Effects of drugs

Several factors determine the effects of drugs on HBF:

- their action on blood pressure elicits baroreflex constriction or dilatation in the hepatic arterial bed, which tends to mask any direct effect on hepatic vasculature;
- interactions between arterial and portal flow regulation may hinder the specific effect of a drug on one of these flows;
- in human subjects, only total hepatic blood flow is measured, which may further obscure different changes in the hepatic arterial and the portal venous vascular beds.

Volatile anaesthetics can significantly alter hepatic perfusion. Halothane causes a dose-dependent decrease in portal venous blood flow, and hepatic arterial flow may decrease simultaneously [49].

β-Adrenergic stimulants such as isoproterenol, salbutamol and terbutaline cause intrahepatic arterial vasodilatation [50,51]. Dopamine has been found to induce hepatic arterial vasodilatation and to increase HBF [52]. Angiotensin-converting enzyme (ACE) inhibitors, such as captopril, reduce HBF [53]. Calcium antagonists, such as nifedipine [54] or verapamil [55], have a direct vasodilating effect on the hepatic arterial bed, so that, in spite of a reduction in systemic arterial pressure, HBF is increased. Glyceryl trinitrate reduces HBF [54], probably through a reflex vasoconstrictor response to a decrease in blood pressure.

Finally, it is to be noted that ethanol has been shown to increase portal blood flow without changing hepatic arterial blood flow [56].

References

1 Hopkinson BR, Schenk WG Jr (1968) The electromagnetic measurement of liver blood flow and cardiac output in conscious dogs during feeding and exercise. *Surgery* 63, 970–975.

2 Horvath SM, Kelly T, Folk GE Jr *et al.* (1957) Measurement of blood volumes in the splanchnic bed of the dog. *Am J Physiol* 189, 573–575.

3 Moreno AH, Burchell AR, Van der Woude R *et al.* (1967) Respiratory regulation of splanchnic and systemic venous return. *Am J Physiol* 213, 455–465.

4 Wynne HA, Cope LH, Mutch E *et al.* (1989) The effect of age upon liver volume and apparent liver blood flow in healthy man. *Hepatology* 9, 297–301.

5 Lautt WW, Greenway CV, Legare DJ *et al.* (1986) Localization of intrahepatic portal vascular resistance. *Am J Physiol* 251, G375–G381.

6 Shah V, Haddad FG, Garcia-Cardena G *et al.* (1997) Liver sinusoidal endothelial cells are responsible for nitric oxide modulation of resistance in the hepatic sinusoids. *J Clin Invest* 100, 2923–2930.

7 Ezzat WR, Lautt WW (1987) Hepatic arterial pressure-flow autoregulation is adenosine mediated. *Am J Physiol* 252, H836–H845.

8 Burton-Opitz R (1911) The vascularity of the liver: the influence of the portal blood flow upon the flow in the hepatic artery. *Q J Exp Physiol* 4, 93–102.

9 Lautt MM, Dallas JL, Waleed RE (1990) Quantitation of the hepatic arterial buffer response to graded changes in portal blood flow. *Gastroenterology* 98, 1024–1028.

10 Llautt WW (1977) Hepatic vasculature: a conceptual review. *Gastroenterology* 73, 1163–1169.

11 Mathie RT, Blumgart LH (1983) The hepatic haemodynamic response to acute portal venous blood flow reductions in the dog. *Pflugers Arch* 399, 223–227.

12 Bracht H, Takala J, Tenhunen JJ *et al.* (2005) Hepatosplanchnic blood flow control and oxygen extraction are modified by the underlying mechanism of impaired perfusion. *Crit Care Med* 33, 645–653.

13 Lautt WW (1983) Relationship between hepatic blood flow and overall metabolism: the hepatic arterial buffer response. *Fed Proc* 42, 1662–1666.

14 Lautt WW, Legare DJ, d'Almeida MS (1985) Adenosine as putative regulator of hepatic arterial flow (the buffer response). *Am J Physiol* 248, H331–H338.

15 Lautt WW (1985) Mechanism and role of intrinsic regulation of hepatic arterial blood flow: hepatic arterial buffer response. *Am J Physiol* 249, G549–G556.

16 Browse DJ, Mathie RT, Benjamin IS *et al.* (2003) The role of ATP and adenosine in the control of hepatic blood flow in the rabbit liver in vivo. *Comp Hepatol* 2, 9.

17 Mathie RT, Ralevic V, Alexander B *et al.* (1991) Nitric oxide is the mediator of ATP-induced dilatation of the rabbit hepatic arterial vascular bed. *Br J Pharmacol* 103, 1602–1606.

18 Iwao T, Toyonaga A, Shigemori H *et al.* (1996) Hepatic artery hemodynamic responsiveness to altered portal blood flow in normal and cirrhotic livers. *Radiology* 200, 793–798.

19 Aoki T, Imamura H, Kaneko J *et al.* (2005) Intraoperative direct measurement of hepatic arterial buffer response in patients with or without cirrhosis. *Liver Transpl* 11, 684–691.

20 Richter S, Mucke I, Menger MD *et al.* (2000) Impact of intrinsic blood flow regulation in cirrhosis: maintenance of hepatic arterial buffer response. *Am J Physiol Gastrointest Liver Physiol* 279, G454–G462.

21 Hanson KM, Johnson PC (1966) Local control of hepatic arterial and portal venous flow in the dog. *Am J Physiol* 211, 712–720.

22 Mitzner W (1974) Effect of portal venous pressure on portal venous inflow and splanchnic resistance. *J Appl Physiol* 37, 706–711.

23 Katz ML, Bergman EN (1969) Simultaneous measurements of hepatic and portal venous blood flow in the sheep and dog. *Am J Physiol* 216, 946–952.

24 Mitchell GG, Torrance HB (1966) The effects of a bile-salt sodium dehydrocholate upon liver blood-flow in man. *Br J Surg* 53, 807–808.

25 Eriksson LS, Hagenfeldt L, Mutt V *et al.* (1989) Influence of vasoactive intestinal polypeptide (VIP) on splanchnic and central hemodynamics in healthy subjects. *Peptides* 10, 481–484.

26 Gelman S, Ernst EA (1977) Role of pH, PCO2 and O2 content of portal blood in hepatic circulatory autoregulation. *Am J Physiol* 233, E255–E262.

27 Colle I, Van Lierberghe H, Troisi R *et al.* (2004) Transplanted liver: consequence of denervation for liver functions. *Anat Rec A Discov Mol Cell Evol Biol* 280, 924–931.

28 Kurosawa M, Unno T, Aikawa Y *et al.* (2002) Neural regulation of hepatic blood flow in rats: an in vivo study. *Neurosci Lett* 321, 145–148.

29 Koo A, Liang IY (1979) Parasympathetic cholinergic vasodilator mechanism in the terminal liver microcirculation in rats. *Q J Exp Physiol Cogn Med Sci* 64, 149–159.

30 Greenway CV, Lawson AE, Mellander S (1967) The effects of stimulation of the hepatic nerves, infusions of noradrenaline and occlusion of the carotid arteries on liver blood flow in the anaesthetized cat. *J Physiol* 192, 21–41.

31 Carneiro JJ, Donald DE (1977) Change in liver blood flow and blood content in dogs during direct and reflex alteration of hepatic sympathetic nerve activity. *Circ Res* 40, 150–158.

32 Carneiro JJ, Donald DE (1977) Blood reservoir function of dog spleen, liver, and intestine. *Am J Physiol* 232, H67–H72.

33 Ming Z, Smyth DD, Lautt WW (2002) Decreases in portal flow trigger a hepatorenal reflex to inhibit renal sodium and water excretion in rats: role of adenosine. *Hepatology* 35, 167–175.

34 Ming Z, Lautt WW (2004) Reflex regulation by portal blood flow on renal function in healthy and cirrhotic rats: role of adenosine-A conceptual review. *Proc West Pharmacol Soc* 47, 33–34.

35 Richardson PD, Withrington PG (1977) The effects of glucagon, secretin, pancreozymin and pentagastrin on the hepatic arterial vascular bed of the dog. *Br J Pharmacol* 59, 147–156.

36 Richardson PD, Withrington PG (1976) The inhibition by glucagon of the vasoconstrictor actions of noradrenaline, angiotensin and vasopressin on the hepatic arterial vascular bed of the dog. *Br J Pharmacol* 57, 93–102.

37 Richardson PD, Withrington PG (1982) Physiological regulation of the hepatic circulation. *Annu Rev Physiol* 44, 57–69.

38 Hassan S, Pickles H (1983) Epoprostenol (prostacyclin,PGI2) increases apparent liver blood flow in man. *Prostaglandins Leukotr Med* 10, 449–454.

39 Richardson PD, Withrington PG (1979) Responses of the hepatic arterial and portal venous vascular beds of the dog to intra-arterial infusions of noradrenaline and adrenaline: inhibition of the hepatic arterial vasoconstrictor responses by intraportal infusions of glucagon. *Br J Pharmacol* 66, 82P.

40 Richardson PD, Withrington PG (1978) Responses of the canine hepatic arterial and portal venous vascular beds to dopamine. *Eur J Pharmacol* 48, 337–349.

41 Hanson KM (1970) Vascular response of intestine and liver to intravenous infusion of vasopressin. *Am J Physiol* 219, 779–784.

42 Kusayama T, Yamazaki J, Nagao T (1996) Flow dependence of nitric oxide-mediated pressure change in rat mesenteric beds with different tonus. *Eur J Pharmacol* 312, 301–307.

43 Mittal MK, Gupta TK, Lee FY *et al.* (1994) Nitric oxide modulates hepatic vascular tone in normal rat liver. *Am J Physiol* 26, G416–G422.

44 Zhang JX, Pegoli W Jr, Clemens MG (1994) Endothelin-1 induces direct constriction of hepatic sinusoids. *Am J Physiol* 266, G624–G632.

45 Kawada N, Tran-Thi TA, Klein H *et al.* (1993) The contraction of hepatic stellate (Ito) cells stimulated with vasoactive substances. Possible involvement of endothelin 1 and nitric oxide in the regulation of the sinusoidal tonus. *Eur J Biochem* 213, 815–823.

46 Suematsu M, Goda N, Sano T *et al.* (1995) Carbon monoxide: an endogenous modulator of sinusoidal tone in the perfused rat liver. *J Clin Invest* 96, 2431–2437.

47 Pannen BHJ, Bauer M (1998) Differential regulation of hepatic arterial and portal venous vascular resistance by nitric oxide and carbon monoxide in rats. *Life Sci* 62, 2025–2033.

48 Rockey DC (2003) Vascular mediators in the injured liver. *Hepatology* 37, 4–12.

49 Gatecel C, Losser MR, Payen D (2003) The postoperative effects of halothane versus isoflurane on hepatic artery and portal vein blood flow in humans. *Anesth Analg* 96, 740–745.

50 Hirsch LJ, Ayabe T, Glisk G (1976) Direct effects of various catecholamines on liver circulation in dogs. *Am J Physiol* 230, 1394–1399.

51 Richardson PDI, Withrington PG (1978) Pressure-flow relationships and effects of noradrenaline and isoprenaline on the hepatic arterial and portal venous vascular beds of the dog. *J Physiol* 282, 451–470.

52 Richardson PDI, Withrington PG (1978) Responses of the canine hepatic arterial and portal venous vascular beds to dopamine. *Eur J Pharmacol* 48, 337–349.

53 Crossley IR, Bihari D, Gimson AE *et al.* (1984) Effects of converting enzyme inhibitor on hepatic blood flow in man. *Am J Med* 76, 62–65.

54 Feely J (1984) Nifedipine increases and glyceryl trinitrate decreases apparent liver blood flow in normal subjects. *Br J Pharmacol* 17, 83–85.

55 Meredith PA, Elliot HL, Pasanisi F *et al.* (1985) Verapamil pharmacokinetics and apparent hepatic and renal blood flow. *Br J Pharmacol* 20, 101–106.

56 Kawasaki T, Carmichael FJ, Salvidia V *et al.* (1990) Relationship between portal venous and hepatic arterial blood flows: spectrum of response. *Am J Physiol* 259, G1010–G1018.

2.1.2 Hepatic microcirculation

Yoshiya Ito and Robert S. McCuskey

Hepatic circulation (see also Chapter 2.1.1)

The mammalian liver has a dual blood supply. Approximately 80% of the blood entering the liver is poorly oxygenated venous blood supplied by the portal vein, whereas the remainder is well oxygenated and supplied by the hepatic artery. These blood vessels enter at the hilus (porta hepatic), where efferent bile ducts as well as lymphatics also exit the organ. The venous drainage of the liver courses independently of the above structures to drain into the inferior vena cava near the diaphragm.

Within the liver, distributing branches of the portal vein and hepatic artery course in parallel and, after repeated branching, terminal branches of these vessels (portal venules and hepatic arterioles) supply blood to the hepatic sinusoids (Fig. 1). The sinusoids are the principal vessels involved in transvascular exchange between the blood and the parenchymal cells. Branches of hepatic arterioles also supply the capsule of the liver as well as the bile ducts, where they feed a peribiliary plexus of capillaries which, in turn, drains into the sinusoids. Portal and arterial blood flowing through the sinusoids is collected in small branches of the hepatic veins (central or terminal hepatic venules) through which the blood is returned through larger hepatic veins to the inferior vena cava (Fig. 1). Lymphatic vessels originate as blind-ending capillaries in the connective tissue spaces (portal tracts) associated with the portal veins and hepatic arteries (Fig. 1). The fluid contained in these lymphatics flows toward the hepatic hilus and eventually into the cisternae chyli.

Hepatic microvascular system

The hepatic microvascular system comprises all the intrahepatic vessels with internal diameters < 300 μm. It thus includes all blood and lymphatic vessels immediately involved in the delivery and removal of fluids to and from the hepatic parenchyma, namely portal venules, hepatic arterioles, sinusoids, central venules and lymphatics. The principal sites for regulating blood flow and solute exchange are in the sinusoidal network, which exhibits structural and functional heterogeneity. Although the factors that regulate blood flow through the hepatic microvascular system and their relation to hepatic structure and function are incompletely understood, perturbations of the hepatic microcirculation in many disease states results in alterations in the perfusion of the sinusoids, hepatic oxygenation and the exchange processes between the blood contained in the sinusoids and surrounding parenchymal cells [1–3].

Figure 1 illustrates the hepatic microvascular system: afferent and efferent microvascular connections to the sinusoids within a single hepatic lobule as determined principally by *in vivo* microscopic studies. Most blood enters the sinusoids from portal venules. These inlets are reported to be guarded by sphincters composed of sinusoidal lining cells termed the afferent or inlet sphincters (Fig. 1) [4–6]. Arterial blood enters some of the sinusoids, principally through branches of hepatic arterioles, arteriosinus twigs that terminate in sinusoids near their origins from portal venules (Fig. 1) [6–8]. In addition, occasional

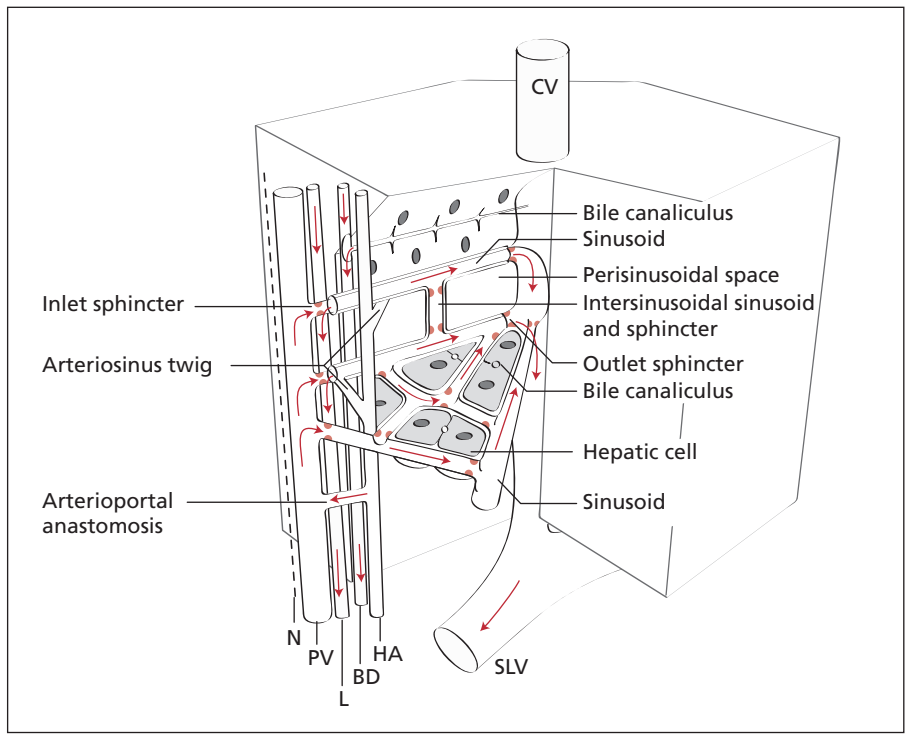

Fig. 1 Hepatic microvasculature as determined by *in vivo* microscopic studies over a period of more than 50 years [4–7]. PV, portal venule; HA, hepatic arteriole; L, lymphatic; BD, bile ductile; N, nerve; CV; central venule; SLV, sublobular hepatic venule. Arrows indicate direction of flow.

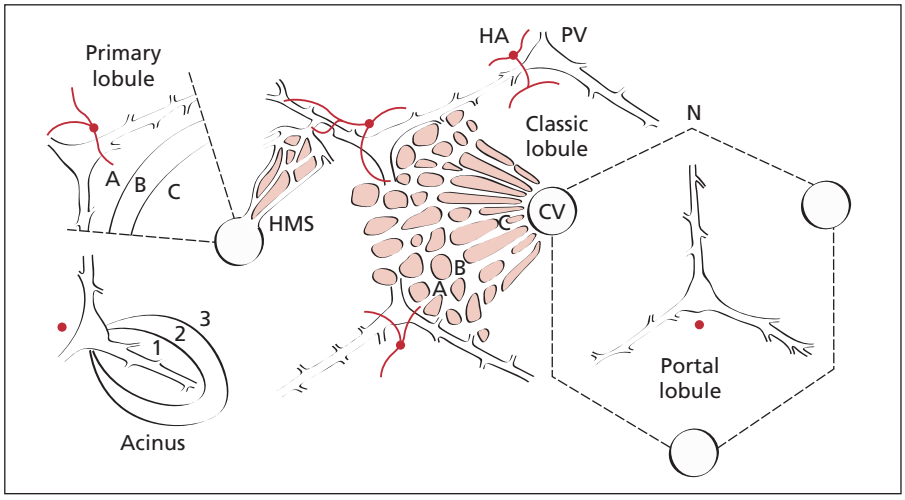

Fig. 2 Contiguous hepatic lobules illustrating the interconnecting network of sinusoids derived from two portal venules (PV). Note that the sinusoids become more parallel as they course towards the central venule (CV), which forms the axis of the classic lobule (centre). Hepatic arterioles (HA) supply blood to sinusoids near the periphery of the lobule, usually by terminating in inlet venules or terminal portal venules. As a result, three zones (1,2,3) of differing oxygenation and metabolism have been postulated by Rappaport [20] to comprise a hepatic acinus, with its axis being the portal tract (lower left). Several acini would comprise the portal lobule (lower right) described by Mall [61]. Matsumoto and Kawakami [14] proposed that each classic lobule contains several cone-shaped subunits with convex surfaces fed by portal and arterial blood at the periphery and with their apices at the central venule (upper left). A, B and C represent haemodynamically equipotential lines in a 'primary lobule'. Recently, a modification by Ekataksin *et al*. [15] further subdivided lobules into conical hepatic microcirculatory subunits (HMS), each being supplied by a single inlet venule.

direct connections (arterioportal anastomoses, APA) have been observed within the terminal portal venules [6,8]. The frequency of these APAs appears to be species dependent [8]. As all these structures are independently contractile, the sinusoids receive a varying mixture of portal venous and hepatic arterial blood [6,8]. Some evidence suggests that, between the hilus and periphery of hepatic lobes, the fraction of blood delivered to the sinusoids by the hepatic artery differs [9]. Finally, occasional branches of hepatic arterioles cross the lobule to supply capillaries in the walls of large hepatic veins [10].

The organization of the sinusoid network exhibits heterogeneity. Near portal venules and hepatic arterioles, sinusoids are arranged in interconnecting polygonal networks; further away from the portal venules, the sinusoids become organized as parallel vessels that terminate in central venules (terminal hepatic venules) (Fig. 2) [11–13]. Short intersinusoidal sinusoids connect adjacent parallel sinusoids (Figs 1 and 2) [6].

Blood leaving the sinusoids and flowing into the central venules passes through outlet or efferent sphincters composed of sinusoidal lining cells (Fig. 1) [6]. Sinusoidal lining cells are also reported to serve as sphincters within the sinusoid network and to regulate the distribution of blood flow in short segments of sinusoids [6].

Hepatic microvascular functional units

The organization of the hepatic microvasculature into structural or functional units related to liver function and disease has been the subject of some debate during the past century (Fig. 2) [2]. It should be noted, however, that none of the proposed concepts is mutually exclusive. Studies using three-dimensional reconstruction of sectioned livers, scanning electron microscopic examination of corrosion casts and *in vivo* microscopy of several species support the concept of the functional unit being a conical microvascular subunit of the classic lobule [14] (Fig. 2). Recently, these 'primary lobules' were renamed 'hepatic microvascular subunits (HMS)' and were demonstrated to consist of a group of sinusoids supplied by a single inlet venule and its associated termination of a branch of the hepatic arteriole from the adjacent portal space (Fig. 2) [15].

Morphological sites for regulating the hepatic microcirculation

There are several potential morphological sites for regulating blood flow through the sinusoids. These include the various segments of the afferent portal venules and hepatic arterioles, the sinusoids themselves, as well as central venules. These vessels contain several types of contractile cells.

Portal venules and central venules contain in their walls limited amounts of smooth muscle relative to their luminal size but, nevertheless, they are contractile and responsive to pharmacological agents. Hepatic arterioles are more responsive because of a complete investment of smooth muscle and relatively small lumina. The principal site of regulation of blood flow through the sinusoids, however, is thought to reside in the sinusoid itself, where the major blood pressure fall occurs in the liver [6,16]. *In vitro* primary culture studies and *in vivo* microscopic studies

of the hepatic microcirculation have also identified the sinusoid as a principal site of regulation within normal and injured livers [3,17,18].

The structure of the hepatic sinusoids is mainly composed of endothelial cells, Kupffer cells and hepatic stellate cells. The sinusoidal endothelial and Kupffer cells are responsive to a wide variety of pharmacodynamic substances. By contracting (or swelling), they may selectively reduce the patency of the sinusoid lumen, thereby altering the rate and distribution of blood flow [6,19]. Evidence for sphincters at the inlet of sinusoids from portal venules and at the outlets of sinusoids into central venules was initially reported by a number of investigators using *in vivo* microscopy [4,5,7], but others failed to find any evidence for such sphincters [20]. Most methods, including electron microscopy, have failed to demonstrate either smooth muscle fibres or other contractile cells at these locations in healthy animals. Sinusoidal endothelial cells were subsequently identified by high-resolution *in vivo* microscopy to act as sphincters by swelling or contracting in response to vasoactive substances, thereby narrowing the sinusoidal lumen and limiting blood flow [6]. The relative role of Kupffer vs. endothelial cells in this process is not resolved, but both appear to be involved.

Recently, attention has focused on the hepatic stellate cell as the cell responsible for controlling sinusoidal diameter, being located in the space of Disse. Hepatic stellate cells possess extensively long, branching cytoplasmic processes, surrounding the sinusoidal wall [21]. These structural features of hepatic stellate cells are similar to pericytes in other organs, indicating that hepatic stellate cells are specialized pericytes in the liver. Hepatic stellate cells exhibit contractile properties, which have been demonstrated in *in vitro* primary culture systems [22–24] and in the perfused liver [17,18]. Both their anatomical location and contractility or relaxation in response to various vasoactive substances have led to the proposal that hepatic stellate cells serve to regulate the diameters and blood flow at the sinusoidal level.

As a result of these structures, blood flow through individual sinusoids is variable. At sites where the lumen is narrowed by the bulging, nuclear regions of sinusoidal lining cells, flow may be impeded by leukocytes that transiently plug the vessel and obstruct flow [25]. Transient leukocyte plugging is more frequent in the periportal sinusoids, which are narrower and more tortuous than those in the centrolobular region. The more plastic erythrocytes usually flow easily through such sites unless the lumen is reduced or near zero. Some sinusoids, however, may act as thoroughfare channels and have relatively constant rates of blood flow, while others have more intermittent flow [26]. This may depend not only on the distribution of intrasinusoidal sphincter cells but also on the distribution of arteriosinus twigs (AST) and the contribution of arterial blood flowing to individual sinusoids. For example, arterial blood flowing into an individual sinusoid through a dilated AST may increase the rate of sinusoidal blood flow [27]. Because of the delivery of arterial blood at higher pressure, some arterial blood may even reverse the entry of portal blood into the sinusoids. As a result, the AST, in concert with the initial segment of the sinusoid in which it terminates, may form a 'functional' arterioportal anastomosis so that arterial blood is delivered into the portal venules [6,28]. In the anaesthetized healthy animal, however, terminal branches of the hepatic arteriole containing flow are seen infrequently so that most blood delivered to the sinusoids is derived from the portal venules [28]. Consistent with this is the *in vivo* microscopic observation that the velocity of flow in sinusoids as well as in portal and central venules located near the capsule of the liver is not significantly altered by hepatic arterial occlusion in healthy anaesthetized rats [29]. However, arterial inflow to the sinusoids may be more significant in regions near the hepatic hilum [9].

The frequency distribution of the wide variations in blood flow in the sinusoids exhibits a polymodal pattern composed of several Gaussian distributions [26]. These wide variations in flow are due to the structural features previously described for the sinusoids and also to intermittent arterial inflow into the sinusoids [6,27]. Blood pressure in portal and central venules has been measured to be about 6–7 cm H_2O and 1.5–3.0 cm H_2O respectively [16,17]. Arterial blood enters the sinusoid at pressures ranging from 12 to 25 cm H_2O [27].

Regulation of sinusoidal perfusion by vasoactive mediators

As mentioned previously, various sinusoidal lining cells including sinusoidal endothelial cells, Kupffer cells and hepatic stellate cells play a role in regulating the diameters of sinusoids and influencing the distribution and velocity of blood flow in these vessels [2,3,30]. Recently, hepatic stellate cells have received the most attention in the liver as the cell responsible for controlling the diameters of sinusoids [31,32]. A number of vasoactive substances have been reported to change intrahepatic vascular resistance by affecting the hepatic stellate cells. Among them are three vasoactive mediators, endothelin, nitric oxide and carbon monoxide, which contribute to the regulation of sinusoidal blood flow and will be discussed in this section. With respect to other mediators, including eicosanoids, cytokines and neural and humoral elements, see Chapter 2.2.5 and other reviews [2,32,33].

Endothelins (ETs)

Endothelin is a potent and longlasting vasoconstrictor. Hepatic stellate cell contractility in response to ET has been established in primary culture system [20–22]. *In vivo* microscopic studies have demonstrated that ET-1 narrows the lumens of sinusoids in isolated perfused livers [17], as well as in livers with intact afferent and efferent vessels [34]. The constricted sites of the sinusoids elicited by ET-1 are colocalized with the sites of hepatic stellate cells [17]. The active constriction of the sinusoids in response to ET-1 contributes to the reduction in sinusoidal perfusion and results in insufficient hepatic tissue oxygenation [34].

Two classes of ET receptors have been identified, namely the ET_A receptor subtype and ET_B receptor subtype. ET_A receptor, which is expressed on the vascular smooth muscle cells, mediates vasoconstriction. On the other hand, ET_B receptor, which is expressed on the endothelial cells, mediates vasodilatation through nitric oxide (NO) production. In the sinusoids of the liver, both ET_A and ET_B receptors are expressed. The ET_A receptor is expressed only on hepatic stellate cells and hepatocytes, whereas the ET_B receptor is expressed on all hepatic cell types including Kupffer cells, endothelial cells, hepatic stellate cells and hepatocytes. Of particular interest is that both ET_A and ET_B receptors are predominantly identified in the hepatic stellate cells [35]. In the intact liver, ET-1-induced vasoconstriction of the sinusoids is mediated by ET_A receptors, but not by ET_B receptors [36]. However, sinusoidal constriction in response to ET_B receptor agonist is revealed when endothelial nitric oxide synthase (eNOS) is inhibited simultaneously [37]. A critical balance between ETs and NO may be a determinant that regulates sinusoidal perfusion.

Some controversy exists regarding the principal site of ET-1-induced vasoconstriction within the normal liver, because ETs act not only on hepatic stellate cells but also on upstream preterminal portal venular smooth muscles and portal venular actin filaments [38]. In fact, the preterminal portal venules [39] or portal venules [40–42] constrict in response to ETs. This raises the question of whether or not the diameters of sinusoids may decrease as a result of passive recoil when inflow is reduced or eliminated and intrasinusoidal pressure falls. An *in vivo* microscopic study reported that clamping of the portal vein dramatically reduced sinusoidal blood flow in most sinusoids to near zero [30]. Then, the lumina of these vessels rapidly returned to their initial diameters upon restoration of portal blood flow. Thus, it appears that sinusoidal blood pressure normally distends the sinusoidal wall, which can recoil when the pressure drops. In the absence of elastic fibres in the space of Disse, it is likely that hepatic stellate cells are responsible for this reaction given the nature of their attachment to parenchymal cells by obliquely oriented microprojections from the lateral edges of their subendothelial processes [43].

In chronic liver diseases including fibrosis and cirrhosis, hepatic stellate cells are activated to transform into myofibroblasts, which are characterized by the expression of smooth muscle-type contractile proteins such as α-actin. The phenotypical changes in hepatic stellate cells as well as upregulation of a contractile intracellular signalling pathway enhance the contractile response of hepatic stellate cells to ETs [31,44]. In addition, upregulated expression of ET receptors [45] as well as decreased activity of eNOS [46] also contribute to the exacerbated response of hepatic stellate cells to ETs. Therefore, during chronic liver injury, hepatic stellate cells are thought to be responsible for the pathogenesis of increased intrahepatic vascular resistance.

In acute liver injury elicited by endotoxaemia and hepatic ischaemia/reperfusion [47,48], sinusoidal constriction in response to ET-1 is increased despite no evidence of phenotypical transformation of hepatic stellate cells. The mechanisms of increased response to ET during acute liver injury appear to be dependent on an increased expression of ET_B receptor together with disassociation of the ET_B receptor from activation of eNOS [3,37]. This disassociation is, at least in part, the result of overexpression and binding of caveolin-1 to eNOS. Increased response to ET occurring in the hepatic microcirculation reduces sinusoidal blood flow, leading to the development of ischaemia and the progression of injury.

Nitric oxide (NO)

The main biological effect of NO is relaxation of vascular smooth muscle cells, thereby reducing the vascular tone, through activation of soluble guanylate cyclase (sGC). In the liver, sinusoidal endothelial cells constitutively produce NO, which is synthesized by eNOS [46]. NO causes relaxation of isolated hepatic stellate cells *in vitro* [23]. Endogenous NO production in sinusoidal endothelial cells modulates the intrahepatic vascular resistance in the perfused liver [49,50] and regulates the sinusoidal diameters in the intact liver [51]. In addition to the vasodilative effect of NO, it also exerts a protective role in liver microcirculation by preventing leukocyte and platelet adhesion to the sinusoidal endothelium. However, several studies have shown that NO exhibits a minor vasodilatory effect on the sinusoids in the perfused liver [18] as well as in the intact liver [52]. The low level of biologically active NO in and around the sinusoids might not serve as a major endogenous modulator of sinusoidal vascular resistance in the normal liver [53]. Haemoglobulin in erythrocytes flowing through the sinusoids would rapidly trap NO released from the sinusoidal endothelial cells [54]. Rather, NO is thought to play an important role in regulating the sinusoidal vascular tone within the normal liver by counterbalancing the local vasoconstrictors such as ETs [37] and norepinephrine [49]. Thus, sinusoidal vascular tone appears to be maintained under the fine balance between vasoconstrictors and vasodilators. Conversely, an imbalance of NO and ETs contributes to changes in vascular tone characteristic of the disease process. In the cirrhotic liver, decreased activity of eNOS results in reduced generation of NO [46,50], and the vasodilative response to NO is impaired [55]. As a result, reduced bioavailability of hepatic NO in liver cirrhosis contributes to sinusoidal constriction and increased intrahepatic vascular tone [50]. The reduced production of hepatic NO in cirrhotic livers is attributed not only to upregulated expression of caveolin-1, an NOS inhibitory protein [56], but also to a decrease in eNOS activator, Akt, and phosphorylation of eNOS [57].

Carbon monoxide (CO)

CO has been considered a gaseous mediator analogous to NO. Like NO, CO serves as an endogenous factor that keeps

sinusoids in a relaxed state [58]. In the perfused liver, endogenously generated CO from the haem oxygenase (HO) reaction serves as a vasorelaxant to the hepatic sinusoids. The principal sites of action of CO in the hepatic sinusoids colocalize with the hepatic stellate cells [18]. Isolated hepatic stellate cells are relaxed by CO *in vitro* [18]. The mechanism by which CO maintains the low vascular tone of the sinusoids appears to involve sGC-mediated relaxation of hepatic stellate cells.

CO is produced by HO, which is an enzyme responsible for the degradation of protohaem IX to form biliverdin, free divalent ion (Fe^{2+}) and CO. HO mainly exists as two isoforms, HO-1 and HO-2. In the liver, HO-1 is induced ubiquitously among all types of hepatic cells by stressors, but prominently in Kupffer cells, whereas HO-2 is constitutively expressed on hepatocytes [54]. It is likely that CO constitutively generated by HO-2 in hepatocytes maintains sinusoidal blood flow under ordinary conditions. Considering the anatomical orientation of the hepatic parenchymal cells in and around the sinusoids, HO-2 in parenchymal cells is positioned where CO released by HO-2 can directly access the hepatic stellate cells to modulate their contractility without being captured by haemoglobulin in the circulation [54]. However, in the innervated liver *in vivo*, CO appears to exhibit a minimal vasodilatory effect on the sinusoids [59]. The sinusoidal blood flow *in vivo* is finely regulated and is affected by various factors including neural and humoral regulation, the hepatic arteriolar inflowing and the haemodynamics from the splanchnic circulation. Instead, in the stressed liver, CO overproduced by HO-1 appears to be necessary to protect the liver microcirculation [48,59,60]. Under stressed conditions in the liver, the HO/CO system counterbalances the vasoconstrictive effect of ET-1 to regulate sinusoidal vascular tone [59,60].

References

1 McCuskey RS (1993) Functional morphology of the liver with emphasis on microvasculature. In: Tavoloni N, Berk PD (eds) *Hepatic Transport and Bile Secretion*. New York: Raven Press, pp. 1–10.

2 McCuskey RS (1994) The hepatic microvascular system. In: Arias IM, Boyer JL, Fausto N *et al.* (eds) *The Liver: Biology and Pathobiology*, 3rd edn. New York: Raven Press, pp. 1089–1106.

3 Clemens MG, Zhang JX (1999) Regulation of sinusoidal perfusion: in vivo methodology and control by endothelins. *Semin Liver Dis* 19, 383–396.

4 Bloch EH (1955) The *in vivo* microscopic vascular anatomy and physiology of the liver as determined by the quartz-rod method of transillumination. *Angiology* 6, 340–349.

5 Knisely MH, Harding F, Debacker H (1957) Hepatic sphincters. *Science* 125, 1023–1026.

6 McCuskey RS (1966) A dynamic and static study of hepatic arterioles and hepatic sphincters. *Am J Anat* 119, 455–487.

7 Irwin JW, MacDonald J (1953) Microscopic observation of the intrahepatic circulation in the guinea pigs. *Anat Rec* 117, 1–15.

8 Bloch EH (1970) The termination of hepatic arterioles and the functional unit of the liver as determined by microscopy of the living organ. *Ann NY Acad Sci* 170, 78–87.

9 Conway JG, Popp JA, Thurman RG (1985) Microcirculation in periportal and pericentral regions of lobule in perfused rat liver. *Am J Physiol* 249, G449–G456.

10 Ekataksin W (2000) The isolated artery: an intrahepatic arterial pathway that can bypass the lobular parenchyma in mammalian livers. *Hepatology* 31, 269–279.

11 Hase T, Brim J (1966) Observation of the microcirculatory architecture of the rat liver. *Anat Rec* 156, 157–174.

12 Kardon RH, Kessel RG (1980) Three-dimensional organization of the hepatic microcirculation in the rodent as observed by scanning electron microscopy of corrosion casts. *Gastroenterology* 79, 72–81.

13 Wisse E, DeZanger RB, Jacobs R *et al.* (1983) Scanning electron microscopic observations on the structure of portal veins, sinusoids, and central veins. *Scanning Electron Microsc* 3, 1441–1452.

14 Matsumoto T, Kawakami M (1982) The unit-concept of hepatic parenchyma – a re-examination based on angio architectural studies. *Acta Pathol Jap* 32, 285–314.

15 Ekataksin W, Zou Z, Wake K *et al.* (1995) HMS, hepatic microcirculatory subunits in mammalian species: intralobular 'grouping' of liver tissue with definition enhanced by the 'drop-out' sinusoids. In: Wisse E, Knook DL, Wake K (eds) *Cells of the Hepatic Sinusoids*, Vol. 5. Leiden: Kupffer Cell Foundation, pp. 247–251.

16 Nakata K, Leong GF, Brauer RW (1960) Direct measurement of blood pressures in minute vessels of the liver. *Am J Physiol* 199, 1181–1188.

17 Zhang JX, Pegoli W, Clemens MG (1994) Endothelin-1 induced direct constriction of hepatic sinusoids. *Am J Physiol* 266, G624–G632.

18 Suematsu M, Goda N, Sano T *et al.* (1995) Carbon monoxide: an endogenous modulator of sinusoidal tone in the perfused rat liver. *J Clin Invest* 96, 2431–2437.

19 Nakata K (1967) Microcirculation and hemodynamical analysis of the blood circulation in the liver. *Acta Pathol Jap* 17, 361–376.

20 Rappaport AM (1973) The microcirculatory hepatic unit. *Microvasc Res* 6, 212–228.

21 Wake K (1980) Peri-sinusoidal stellate cells (fat-storing cells, interstitial cells, lipocytes), their related structure in and around the liver sinusoids, and vitamin A-storing cells in extrahepatic organs. *Int Rev Cytol* 66, 303–353.

22 Pinzani M, Failli P, Ruocco C *et al.* (1992) Fat-storing cells as liver-specific pericytes: special dynamics of agonist-stimulated intracellular calcium transients. *J Clin Invest* 90, 642–646.

23 Kawada N, Tran-Thi TA, Klein H *et al.* (1993) The contraction of hepatic stellate (Ito) cells stimulated with vasoactive substances. Possible involvement of endothelin 1 and nitric oxide in the regulation of the sinusoidal tonus. *Eur J Biochem* 213, 815–822.

24 Rockey DC, Housset CN, Friedman SL (1993) Activation-dependant contractility of rat hepatic lipocytes in culture and *in vivo*. *J Clin Invest* 92, 1795–1804.

25 Wisse E, DeZanger RB, Jacobs R *et al.* (1985) The liver sieve: consideration concerning the structure and function of endothelial fenestrae, the sinusoid wall and the space of Disse. *Hepatology* 5, 683–692.

26 Koo A (1987) Nervous control of the hepatic microcirculation. In: Tsuchiya M, Asano M, Mishima Y (eds) *Microcirculation – an Update*, Vol. 2. Amsterdam: Excerpta Medica, pp. 335–338.

27 Rappaport AM (1977) Microcirculatory units in the mammalian liver. *Bibl Anat* 16, 116–120.

28 McCuskey RS, Vonnahme FJ, Grun M (1983) In vivo microscopic and electron microscopic observations of the hepatic microvascular system following portacaval anastomosis. *Hepatology* 3, 96–104.

29 Koo A, Liang IYS, Cheng K (1976) Effect of the ligation of the hepatic artery on the microcirculation in the cirrhotic liver in the rat. *Aust J Exp Biol Med Sci* 54, 287–295.
30 McCuskey RS (2000) Morphological mechanisms for regulating blood flow through hepatic sinusoids. *Liver* 20, 3–7.
31 Reynaert H, Thompson MG, Thomas T *et al.* (2002) Hepatic stellate cells: role in microcirculation and pathophysiology of portal hypertension. *Gut* 50, 571–581.
32 Rockey DC (2003) Vascular mediators in the injured liver. *Hepatology* 37, 4–12.
33 Ueno T, Bioulac-Sage P, Balabaud C *et al.* (2004) Innervation of the sinusoidal wall: regulation of the sinusoidal diameter. *Anat Rec* 280A, 868–873.
34 Okumura S, Takei Y, Kawano S *et al.* (1994) Vasoactive effect of endtothelin-1 on rat liver *in vivo*. *Hepatology* 19, 155–161.
35 Housset C, Rockey DC, Bissell DM (1993) Endothelin receptors in rat liver: lipocytes as a contractile target for endothelin 1. *Proc Natl Acad Sci USA* 90, 9266–9270.
36 Zhang JX, Bauer M, Clemens MG (1995) Vessel and target cell specific actions of endothelin-1 and endothelin-3 in rat liver. *Am J Physiol* 269, G269–G277.
37 Bauer M, Bauer I, Sonin NV *et al.* (2000) Functional significance of endothelin B receptors in mediating sinusoidal and extrasinusoidal effects of endothelins in the intact rat liver. *Hepatology* 31, 937–947.
38 Oda M, Tsukada N, Honda K *et al.* (1987) Hepatic sinusoidal endothelium – its functional implications in the regulation of sinusoidal blood flow. In: Tsuchiya M, Asano M, Mishima Y *et al.* (eds) *Microcirculation – an Update*, Vol. 2. Amsterdam: Excerpta Medica, pp. 317–320.
39 Kaneda K, Ekataksin W, Sogawa M *et al.* (1998) Endothelin-1-induced vasoconstriction causes a significant increase in portal pressure of rat liver: localized constrictive effect on the distal segment of preterminal portal venules as revealed by light and electron microscopy and serial reconstruction. *Hepatology* 27, 735–747.
40 Bauer M, Zhang JX, Bauer I *et al.* (1994) ET-1 induced changes in the hepatic microcirculation: sinusoidal and extrasinusoidal sites of action. *Am J Physiol* 267, G143–G149.
41 Ito Y, Katori M, Majima M *et al.* (1996) Constriction of mouse hepatic venules and sinusoids by endothelins through ETB receptor subtype. *Int J Microcirc Clin Exp* 16, 250–258.
42 Oda M, Yokomori H, Han JY (2003) Regulatory mechanisms of hepatic microcirculation. *Clin Hemorheol Microcirc* 29, 167–182.
43 Wake K (1996) Sinusoidal structure and dynamics. In: Vidal-Vanaclocha F (ed.) *Functional Heterogeneity of Liver Tissue: from Cell Lineage Diversity to Sublobular Compartment-specific Pathogenesis.* Austin, TX: R.G. Landes Co., pp. 57–67.
44 Rockey DC, Weisiger RA (1996) Endothelin induced contractility of stellate cells from normal and cirrhotic rat liver: implication for regulation of portal pressure and resistance. *Hepatology* 24, 233–240.
45 Leivas A, Jimenez W, Bruix J *et al.* (1998) Gene expression of endothelin-1 and ET(A) and ET(B) receptors in human cirrhosis: relationship with hepatic hemodynamics. *J Vasc Res* 35, 186–193.
46 Rockey DC, Chung JJ (1998) Reduced nitric oxide production by endothelial cells in cirrhotic rat liver: endothelial dysfunction in portal hypertension. *Gastroenterology* 114, 344–351.
47 Pannen BH, Bauer M, Zhang JX *et al.* (1996) A time-dependent balance between endothelins and nitric oxide regulating portal resistance after endotoxin. *Am J Physiol* 271, H1953–H1961.
48 Pannen BH, Al-Adili F, Bauer M *et al.* (1998) Role of endothelins and nitric oxide in hepatic reperfusion injury in the rat. *Hepatology* 27, 755–764.
49 Mittal MK, Gupta TK, Lee FY *et al.* (1994) Nitric oxide modulates hepatic vascular tone in normal rat liver. *Am J Physiol* 267, G416–G422.
50 Shah V, Haddad FG, Garcia-Caidena G *et al.* (1997) Liver sinusoidal endothelial cells are responsible for nitric oxide modulation of resistance in the hepatic sinusoids. *J Clin Invest* 100, 2923–2930.
51 Bauer C, Walcher F, Kalweit U *et al.* (1997) Role of nitric oxide in the regulation of the hepatic microcirculation *in vivo*. *J Hepatol* 27, 1089–1095.
52 Nishida J, McCuskey RS, McDonnell D *et al.* (1994) Protective role of NO in hepatic microcirculatory dysfunction during endotoxemia. *Am J Physiol* 267, G1135–G1141.
53 Suematsu M, Wakabayashi Y, Ishimura Y (1996) Gaseous monoxides: a new class of microvascular regulator in the liver. *Cardiovasc Res* 32, 679–686.
54 Goda N, Suzuki K, Naito M *et al.* (1998) Distribution of heme oxygenase isoforms in rat liver. Topographic basis for carbon monoxide-mediated microvascular relaxation. *J Clin Invest* 101, 604–612.
55 Dudenhoefer AA, Loureiro-Silva MR, Cadelina GW *et al.* (2002) Bioactivation of nitroglycerin and vasomotor response to nitric oxide are impaired in cirrhotic rat livers. *Hepatology* 36, 381–385.
56 Shah V, Toruner M, Haddad F *et al.* (1999) Impaired endothelial nitric oxide synthase activity associated with enhanced caveolin binding in experimental cirrhosis in the rat. *Gastroenterology* 117, 1222–1228.
57 Morales-Ruiz M, Cejudo-Martn P, Fernandez-Varo G *et al.* (2003) Transduction of the liver with activated Akt normalizes portal pressure in cirrhotic rats. *Gastroenterology* 125, 522–531.
58 Suematsu M, Kashiwagi S, Sano T *et al.* (1994) Carbon monoxide as an endogenous modulator of hepatic vascular perfusion. *Biochem Biophys Res Commun* 205, 1333–1337.
59 Rensing H, Bauer I, Zhang JX *et al.* (2002) Endothelin-1 and heme oxygenase-1 as modulators of sinusoidal tone in the stress-exposed rat liver. *Hepatology* 36, 1453–1465.
60 Wakabayashi Y, Takamiya R, Mizuki A *et al.* (1998) Carbon monoxide overproduced by heme oxygenase-1 causes a reduction of vascular resistance in perfused rat liver. *Am J Physiol* 277, G1088–G1096.
61 Mall FP (1906) A study of the structural unit of the liver. *Am J Anat* 5, 227–308.

2.1.3 Hepatic lymph and lymphatics

Glen A. Laine and Charles S. Cox Jr

Basic lymphatic biophysics

Lymphatic vessels are found throughout the body, developing embryologically from the venous system. Lymphatics are thin-walled vessels lined by endothelium and, with the exception of initial or collecting lymphatics, they are surrounded by lymphatic smooth muscle. A series of valves divides segments of lymphatic vessels into 'lymphangions', the operational unit of the lymphatic system. Lymphatic valves ensure unidirectional flow of lymph from the periphery of the body and organ systems

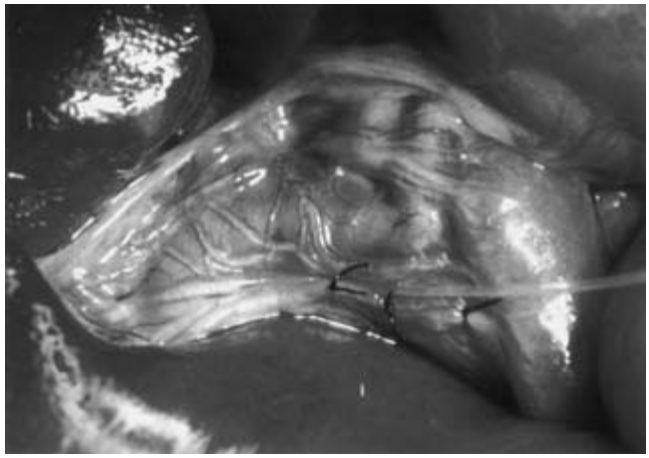

Fig. 1 Photograph of the liver (on the left) covered with ascites fluid. The portal vein runs across the field flowing from right to left into the liver. A large number of translucent lymphatics are seen exiting the liver at the hilus, coursing over the portal vein and flowing from left to right in the photograph. Lymphatic valves can be seen as points of constriction in some of lymphatic vessels. One of the large lymphatics in the photograph has been cannulated for the purposes of lymph collection. The lymphatic catheter is tied in place with lengths of black suture. A large lymph node can be seen at the right of the photograph. See also Plate 2.1.3.1, facing p. 72.

to the central venous circulation. Lymph nodes are located at various points along lymphatic vessels. Lymphatics serve three major functions: (i) removal of oedema fluid from all body systems; (ii) transport of lipids from the gastrointestinal lacteals to the central venous circulation; and (iii) transportation of antigens to lymph nodes for processing and formation of sensitized lymphocytes, which are also returned to the central venous circulation. Lymphatics serve to maintain normal interstitial fluid volume, normal fat metabolism and a normal immune system.

Figure 1 (see also Plate 2.1.3.1, facing p. 72) shows a photograph of the liver (on the left) covered by ascites fluid. The portal vein runs across the field flowing from right to left into the liver. A large number of translucent lymphatics are seen exiting the liver at the hilus, coursing over the portal vein and flowing from left to right in the photograph. Lymphatic valves can be seen as points of constriction in some of the lymphatic vessels. One of the large lymphatics in this photograph has been cannulated for the purposes of lymph collection. The lymphatic catheter is tied in place with lengths of black suture. A large lymph node can be seen at the right of the photograph.

The hepatic lymphatic system is quite unique, generating approximately 75% of total body lymph. Approximately 80% of hepatic lymph exits the liver via the hilar lymphatics, then enters the cisterna chyli. The remaining 20% of lymph flows through lymphatics along the hepatic veins. The hepatic sinusoids (also referred to as hepatic capillaries) are very permeable to plasma proteins with pores of approximately 100–200 μm or larger opening from the sinusoids into the hepatic interstitium or 'space of Disse' [1]. The 'reflection coefficient' is a term used to describe the permeability of capillaries to plasma proteins. The reflection coefficient ranges from 0 to 1, with 0 describing a system totally permeable to plasma proteins (e.g. the liver) and a reflection coefficient of 1 being a capillary bed totally impermeable to protein (e.g. the brain). As the hepatic sinusoids or capillaries have a reflection coefficient of near 0, plasma, along with a full complement of plasma proteins and clotting factors, moves freely from the hepatic vasculature into the space of Disse and is collected by the hepatic lymphatics [2]. This also explains the well-documented ability of hepatic lymph to clot.

Should the liver develop excess interstitial fluid volume, it is one of the few organs that can move this excess fluid across the Glisson's capsule as a transudate, resulting in ascites. As plasma proteins cross the sinusoids without restriction, there is some controversy as to why hepatic lymph and hepatic ascites fluid is not identical to circulating plasma. Sieving of proteins at another barrier such as the hepatic interstitium or Glisson's capsule could explain this phenomenon.

In pathological conditions causing increased sinusoidal pressures and overproduction of interstitial fluid, the liver can alter sinusoidal permeability, increasing the sinusoidal reflection coefficient by decreasing the size of sinusoidal openings into the space of Disse. This change in hepatic sinusoidal permeability is secondary to collagen deposition or fibrosis, i.e. sinusoidal capillarization [3,4]. Unfortunately, decreasing the size of pores from the sinusoids into the hepatic interstitium limits the movement of antigenic material into the hepatic interstitium and, ultimately, into the lymphatic system, thus minimizing exposure of the lymph nodes to antigens and compromising the immune response. This is of particular importance in the liver because the portal blood from the intestine may carry pathogens or other antigenic material from the intestine, which can be caught by Kupffer cells and broken down for potential delivery to lymph nodes, thus stimulating lymphocyte production. It should be pointed out that pathogens or toxic substances may also reach the circulation via the lymphatic system. New techniques for cannulating the lymphatics from various organs, particularly the intestine, and shunting the lymph to the outside of the body removes these toxic substances, particularly in trauma patients, thus minimizing secondary organ damage [5]. These cannulation techniques should be applied with caution as shunting lymph to the exterior of the body can have several negative consequences. In particular, excessive fluid volume may be lost, plasma proteins can be depleted, thus reducing plasma colloid osmotic pressure, and patients may become immunologically compromised secondary to removal of lymphocytes. Mechanically separating and reinfusing lymphocytes can overcome immune issues, while intravenous volume infusion, including concentrated albumin, will address fluid volume and colloid osmotic pressure issues.

Lymphatic contractions

Lymphatics throughout the body and in the liver have additional unique characteristics not found in other vessels. Lymphatics are

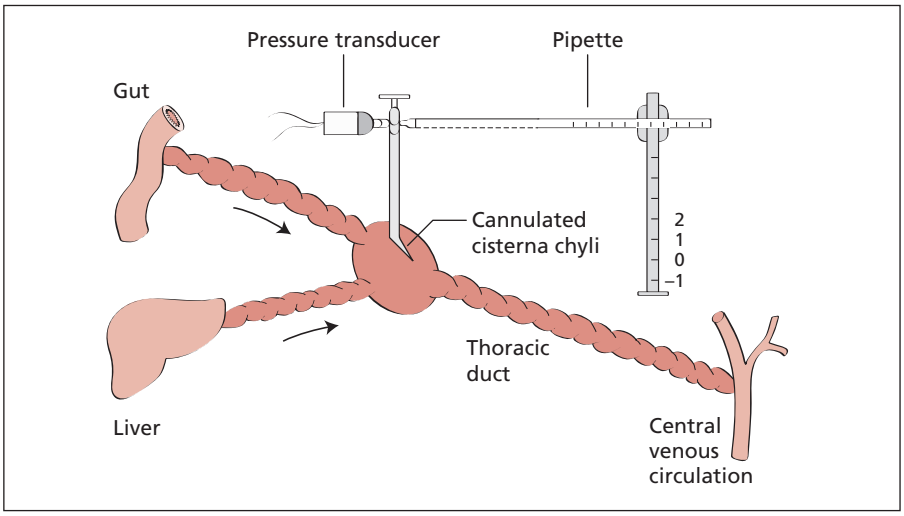

Fig. 2 Schematic representation of the liver and gut lymphatic system. Liver and gut lymph both flow into the cisterna chyli, through the thoracic duct and into the central venous circulation. Lymphatic valves prevent retrograde lymph flow.

capable of rhythmic contractions similar to the heart, yet respond to preload or stretch like smooth muscle. Lymph can thus be propelled forwards by either external compression or rhythmic contractions of the lymphatics, with valves ensuring unidirectional flow. The lymphatic pump has finite capabilities: much as the heart cannot overcome very high afterloads, the lymphatic system cannot overcome central venous pressures at their physiological extremes. The importance of lymph being able to respond to elevated outflow pressures including lymphatic obstructions or elevated central venous pressure cannot be overemphasized. Lymphatics can employ the standard mechanisms or techniques used by muscles to generate greater force of contraction and more flow, including hypertrophy and increasing contraction frequency. Bypassing lymphatic obstructions by growing new lymphatic vessels is often observed. When central venous pressure is elevated throughout the body, growing new lymphatics or 'lymphangiogenesis' is of no significant value as all new lymphatic vessels will be presented with elevated outflow pressures no matter where they enter the venous circulation.

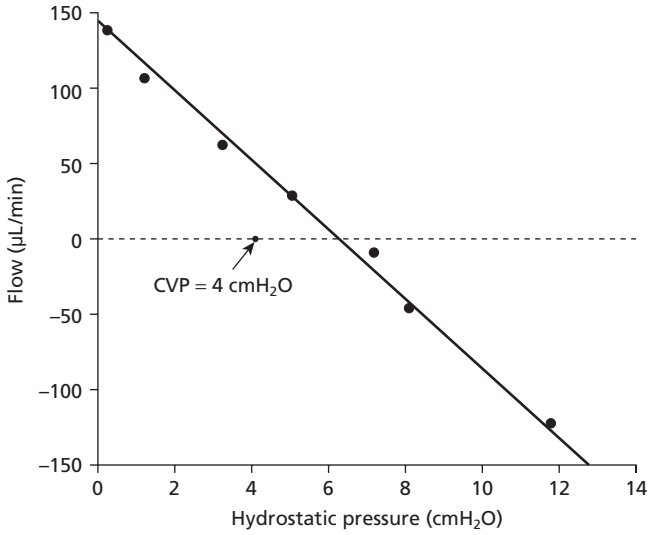

Fig. 3 Flow through the calibrated pipette (μL/min) plotted as a function of the hydrostatic pressure head (cmH_2O) developed by elevating the pipette connected to the cisterna chyli. Low central venous pressure (CVP) model, 4 cmH_2O.

Importance of central venous pressure

To demonstrate the importance of maintaining a low central venous pressure to ensure normal lymph flow and decrease the chances of oedema formation and organ dysfunction, a simple experiment was performed. As seen in the schematic Figure 2, lymph from both the liver and the gut flows into the cisterna chyli. Lymph then enters the thoracic duct and returns to the subclavian vein or central venous circulation. Introducing a fluid-filled catheter into a lymphatic – taking care not to cause obstruction – we can measure fluid flow into or out of the cisterna chyli. The fluid-filled and calibrated pipette may be raised or lowered to adjust the outflow pressure experienced by the lymphatic system. The hydrostatic zero is set at the point of cisterna chyli cannulation. In Figure 3, flow from the cisterna chyli through the pipette (μL/min) was recorded as hydrostatic pressure was increased (cmH_2O). As pipette height – and thereby outflow pressure – is increased, flow from the lymphatic system decreases. When the hydrostatic pressure head in the elevated pipette overcomes cisterna chyli pressure, flow in the pipette reverses direction and begins flowing into the lymphatic system. The contents of the pipette along with lymph from the liver and intestine then flow together into the thoracic duct and central veins. This is a scenario for a normal or low central venous pressure of approximately 4 cmH_2O. Figure 4 presents data from the same system in which central venous pressure has been elevated to 14 cmH_2O. Again, as pipette height is elevated, flow into the pipette from the cisterna chyli decreases until flow stops. At this

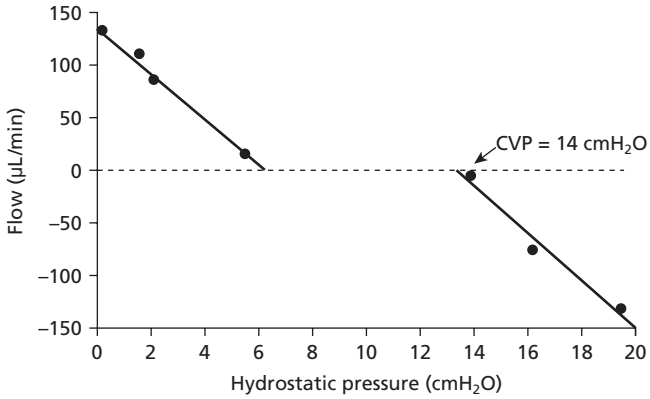

Fig. 4 Flow through the calibrated pipette (μL/min) plotted as a function of hydrostatic pressure head (cmH_2O) generated secondary to pipette elevation with an elevated central venous pressure (CVP) of 14 cmH_2O. Note the decrease and then cessation of flow prior to elevated driving pressure becoming greater than CVP. Decreased or arrested lymph flow must accumulate as oedema or ascites fluid.

point, the force driving lymph from the liver and gut cannot overcome the hydrostatic pressurehead of the catheter and pipette and cannot overcome central venous pressure. Further elevation of the pipette results in a state of no lymph flow until the hydrostatic pressure within the catheter and pipette reaches the same level as the central venous pressure, in this case 14 cmH_2O. At this time, flow from the pipette into the cisterna chyli, thoracic duct and central venous circulation begins. Retrograde flow into the liver and the gut is prevented by unidirectional valves. This experiment was performed to demonstrate the critical role that central venous pressure plays in maintaining lymph flow and minimizing oedema and ascites formation. This is particularly important in patients receiving large-volume fluid resuscitations or vasoactive drugs, which can increase central venous pressure. It should be pointed out that the hepatic vasculature is also highly sensitive to central venous pressure elevation as there is no restriction for fluid movement from the sinusoids into the hepatic interstitium. Any change in venous outflow pressure results in large fluid fluxes from the hepatic circulation into the hepatic interstitium and lymphatic vessels.

We should also point out the concept of 'lymphatic interaction'. When lymphatics from two or more organs converge, lymphatic interaction takes place. Some organs are capable of producing larger lymph flows at higher driving pressures, while others produce small volumes of lymph at low driving pressures. For example, the lymph from the liver and gut converges in the cisterna chyli. As the liver can generate a greater lymph driving pressure and volume lymph flow, lymph flow from the intestine can be compromised because of its lower driving pressure. A study by Stewart and Laine [6] clearly demonstrated that an increase in liver lymph flow can reduce gut lymph flow, through hepatic lymphatic interaction, thus potentiating gut oedema. This mechanism could potentially potentiate oedema in the spleen, pancreas and gallbladder or any other organ system with lymph entering the cisterna chyli when the liver is producing large volumes of lymph.

Clinical conditions impacting on hepatic fluid balance and lymphatic function

Factors that affect fluid balance within the hepatoportal circulation include intra- and extrahepatic venous outflow obstruction. Intrahepatic diseases/conditions such as cirrhosis and schistosomiasis cause portal venous hypertension and an alteration in intestinal microvascular fluid balance. Extrahepatic processes include the Budd–Chiari syndrome, constrictive pericarditis/right heart failure and the abdominal compartment syndrome (which is both a cause and an effect of altered hepatoportal fluid flux). To discuss these specific entities, it is useful to consider how intra-abdominal physical forces affect hepatoportal lymph flow.

Extrahepatic causes of increased hepatoportal microvascular fluid flux

Budd–Chiari syndrome

The Budd–Chiari syndrome can be the cause of hepatoportal venous hypertension resulting from hepatic vein obstruction. Hepatic venous obstruction leaves no route for egress of hepatic arterial and portal venous inflow. Hepatic congestion, ascites and portal hypertension result. The extent and rapidity of occlusion determine the clinical presentation.

Abdominal compartment syndrome

The abdominal compartment syndrome (ACS) is defined as the combination of (i) intra-abdominal pressure greater than 25 mmHg, (ii) progressive organ dysfunction and (iii) improved organ dysfunction after decompression. Primary ACS is a complication of damage control laparotomy for trauma. The space-occupying nature of abdominal packs together with ongoing bleeding and progressive bowel oedema all contribute to increased intra-abdominal pressure (IAP). Primary ACS can occur in patients who fail non-operative management of abdominal solid organ injuries because of ongoing bleeding either within the abdominal cavity or into the retroperitoneum. Secondary ACS is the development of increased IAP due to resuscitation-induced bowel oedema and ascites. We have shown that alterations in hepatoportal lymph flow are critical in the pathophysiology of both syndromes. In a series of experiments, we demonstrated that abrupt elevation in IAP, as with primary ACS, stopped lymph flow through the cisterna chyli. In contrast, with secondary ACS, lymph flow via the cisterna chyli is increased as the result of an increased lymph driving pressure that exceeds the lymphatic outflow (intra-abdominal) pressure. However, the increase in lymph flow is not sufficient to prevent the development of gut oedema and ascites.

Pathophysiology of extrahepatic causes of increased hepatoportal fluid flux

Internal occlusion of the hepatic veins/suprahepatic inferior vena cava or external compression of the abdominal venous outflow due to ACS serve to increase microvascular filtration across the liver and intestinal microcirculation. Elk *et al.* [7] studied lymphatic function in the liver after hepatic venous pressure elevation. Using a model that measured lymph flow and lymphatic driving pressure, the effects of venous pressure elevation could be studied. Their studies showed that small increases in hepatic venous pressure substantially increased liver lymph flow. The increased liver lymph flow was associated with both increased effective lymphatic driving pressure and decreased effective resistance to lymph flow. One reason why the liver is exceptionally sensitive to any increase in venous pressure is that the hepatic sinusoids are almost freely permeable to protein. Therefore, the plasma protein osmotic pressure opposing fluid filtration from the microvessels is ineffective in opposing fluid filtration from the sinusoids. Two other considerations affect hepatoportal lymph flow/fluid flux: ascites formation and hepatic–intestinal lymphatic interactions. Microvascular fluid flux that overwhelms the ability to maintain fluid balance in the liver results not only in organ congestion/oedema but also in transudation of fluid into the abdominal cavity as ascites. When this occurs in large volumes, further extrahepatic compression of the venous outflow may occur. The lymphatic vessels that drain the intestine and liver empty into the cisterna chyli and, from there, into the thoracic duct. Therefore, pressure within the cisterna chyli is outflow pressure for both hepatic and intestinal lymphatics. The finding that elevating lymphatic outflow pressure to an organ undergoing increased microvascular filtration has a marked oedemagenic effect is important. Increasing hepatic lymph flow serves to increase pressure within the cisterna chyli to 6 mmHg. With moderately increased portal vein pressures, intestinal lymph flow increased, but the elevated cisterna chyli pressure results in a marked increase in intestinal oedema and intestinal ascites formation. The interaction between intestinal and hepatic lymphatics becomes significant because extrahepatic causes of increased hepatoportal lymph flow often increase intestinal microvascular fluid flux and lymph flow as well.

Intrahepatic causes of increased hepatoportal fluid flux

The main clinical problem associated with portal hypertension – most commonly due to alcoholic or postviral cirrhosis – is variceal haemorrhage. However, the focus of this section is on the effects of disease processes on microvascular and lymphatic function. The increased resistance to portal flow is caused by deposition of collagen in the space of Disse (sinusoidal) and by regenerating nodules that distort the small hepatic veins (postsinusoidal). Thus, in cirrhosis, there is both sinusoidal hypertension and splanchnic portal venous hypertension. As noted above, small increases in hepatic microvascular pressures drastically increase hepatic lymph flow on account of the unique nature of the sinusoidal microvasculature. If hepatic microvascular pressures rise high enough, the amount of trans-sinusoidal fluid flux overwhelms the lymphatic flow capacity, and ascitic fluid (hepatic lymph) passes through the hepatic capsule into the peritoneal cavity. Over time, as collagen is laid down in the space of Disse, the microvasculature undergoes a process termed capillarization. This results in a reduction in the hydraulic conductivity and permeability to proteins across the sinusoidal microvascular barrier. Ultimately, the protein concentration of hepatic lymph (and ascitic fluid) decreases. Both the liver and the intestine are important sites of ascites formation. Clinically significant ascites is uncommon in patients with prehepatic portal hypertension. Reasons for this clinical phenomenon include the lack of increased hepatic lymph flow and maintained hepatic protein synthesis.

References

1 Granger HJ, Barrowman JA (1984) Gastrointestinal and liver edema. In: Staub NC, Taylor AE (eds) *Edema*. New York: Raven Press, pp. 615–656.

2 Laine GA, Hall GT, Laine SH *et al.* (1979) Transinusoidal fluid dynamics in canine liver during venous hypertension. *Circ Res* 45, 317–323.

3 Schaffner F, Popper H (1963) Capillarization of hepatic sinusoids. *Gastroenterology* 44, 239–242.

4 Reichen J, Le M (1986) Verapamil favorably influences hepatic microvascular exchange and function in rats with cirrhosis of the liver. *J Clin Invest* 78(2), 448–455.

5 Cox CS Jr, Fisher U, Allen S *et al.* (2004) Lymphatic diversion prevents myocardial edema following mesenteric ischemia/reperfusion. *Microcirculation* 11, 1–8.

6 Stewart R, Laine G (2001) Flow and lymphatic networks: Interaction between hepatic and intestinal lymph vessels. *Microcirculation* 8, 221–227.

7 Elk JR, Drake RE, Williams JP *et al.* (1988) Lymphatic function in the liver after hepatic venous pressure elevation. *Am J Physiol* 254(17), G748–G752.

2.2 Functions of the liver

2.2.1 Functional organization of the liver

Paulo Renato A. V. Correa and Michael H. Nathanson

Introduction

Liver architecture is characterized by a few key anatomical features: the portal triad, the central vein and the sinusoids. This apparent simplicity is in contrast to the vast number of functions performed by the liver. Considered one of the central organs of metabolism, the liver is able to synthesize or degrade a wide variety of molecules in a regulated way. This includes substances as different as carbohydrates, lipids, amino acids, bile acids and exogenous compounds. In addition, the liver produces most of the circulating plasma proteins, including its most abundant component, albumin. It may seem paradoxical that this basic structure is associated with such complex functions. However, with the development of more sophisticated experimental methods, the molecular heterogeneity of hepatocytes is now appreciated, and a much more subtle organization of the liver has been revealed, which in fact shows an intricate pattern of distribution for the different liver functions. In this chapter, the ideas regarding the relationship between structure and function in the liver will be reviewed.

Liver structure, circulation and microcirculation

Liver cells

The liver contains a number of cell types including hepatocytes, cholangiocytes, stellate cells, portal fibroblasts, endothelial cells, macrophages, pit cells and oval cells. Nevertheless, a single cell type, the hepatocyte, accounts for two-thirds of the liver mass [1]. The importance of hepatocytes results not only from the fact that they are the principal constituent of liver, but also from the number, variety and complexity of biological processes that they perform. They synthesize and secrete plasma proteins, including albumin, coagulation factors, lipoproteins and acute phase reactants. It is in the hepatocytes that the metabolism of carbohydrates, lipids, amino acids, bilirubin and xenobiotics takes place. Finally, bile, the main exocrine secretory product of liver, is produced by hepatocytes.

Liver cell plates

The portal triad is composed of terminal branches of the two blood vessels that perfuse the liver, the portal vein and the hepatic artery, plus a bile duct, which drains the bile produced by hepatocytes. The central veins drain the blood from the sinusoids towards the hepatic vein and inferior vena cava [2]. The sinusoids are special vessels lined by fenestrated and discontinuous endothelial cells [3]. In cross-sectional view, the hepatocytes form cords of cells oriented as if radiating from the central vein. Each of these cords of hepatocytes forms a plate of cells in three dimensions (Fig. 1). The cell plate is formed in such a way that each hepatocyte has its apical or canalicular border facing other hepatocytes, where they form a bile canaliculus. The basolateral region of each hepatocyte is separated from the sinusoidal endothelium by the space of Disse. The cell plates anastomose extensively, although each cell plate is typically one hepatocyte in thickness. The plates are limited on both sides by sinusoids [4].

Functional unit of hepatic parenchyma

A functional unit should represent the simplest element into which the organ can be divided that still reflects the organ function as a whole. In the case of the liver, several structures have been proposed as the functional unit, including the hepatic lobule and the hepatic acinus. However, on a cell and molecular level, the cell plate can be seen as the functional unit of the liver [5].

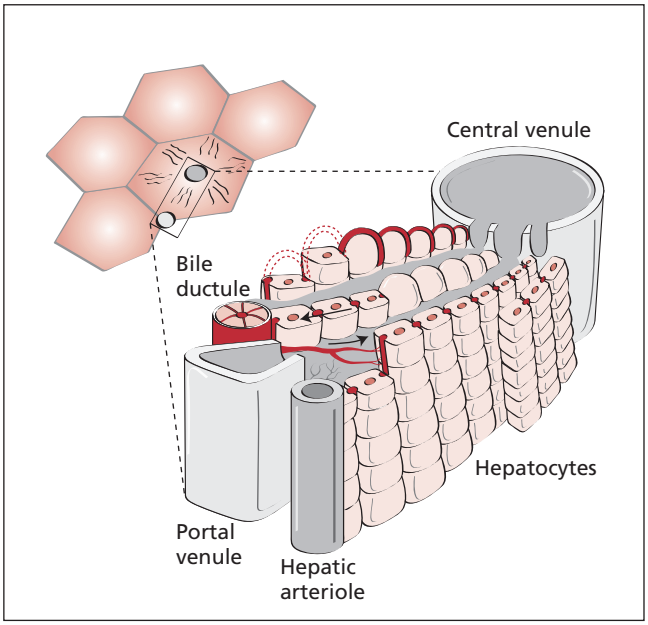

Fig. 1 The liver cell plate. The basic structural and functional unit of the liver is the liver cell plate, which is the sheet or plate of hepatocytes extending from the portal triad (portal venule, hepatic arteriole and bile ductule) to the central venule. Note that blood flows through the sinusoids, from the portal triad to the central venule, while bile (dark red) flows through bile canaliculi, in the opposite direction to the bile ductule. Gradients in protein expression along the liver cell plate result in zonal differences in biochemical, metabolic and signalling pathways.

Protein synthesis and gene expression

Gene expression in the cell plate

The liver secretes 1.2 g of albumin per kg of body weight per day [6]. In addition, the enzymatic machinery necessary to maintain metabolic processes has to be modified constantly, as the hormonal stimuli change to reflect the metabolic demands of the body. This ongoing, adaptive process of protein synthesis means that the expression of numerous genes has to be tightly regulated in hepatocytes. This matching of functional demand and protein synthesis is controlled by both hormonal and metabolic signals. It also creates the opportunity for the differential expression of genes across the liver cell plate and, therefore, the compartmentalization of the various metabolic and synthetic pathways to specific regions along the cell plate. This concept has been called the 'metabolic zonation' of the liver [7]. The main idea for this model was derived from studies on carbohydrate metabolism, in which it was demonstrated that two physiologically opposite metabolic processes, gluconeogenesis and glycolysis, could be performed simultaneously by hepatocytes in the periportal and pericentral regions respectively [8]. Further research, including of other metabolic pathways, confirmed that the concept of metabolic zonation is applicable to many liver functions and reflects an important level of metabolic control [7]. This compartmentalized expression of proteins has been demonstrated for a number of enzymes and receptors, including hydroxymethylglutaryl (HMG)-CoA reductase [9], cholesterol 7α-hydroxylase [10], glutamine synthetase [11], the glucose transporter GLUT-1 [12], carbamoylphosphate synthetase [13], the epidermal growth factor (EGF) receptor [14] and the V_{1a} vasopressin receptor [15].

Regulation of compartmentalized gene expression in the cell plate

Identification of the stimuli responsible for the differential transcription of genes across the liver cell plate has been an area of interest, in order to understand how metabolic zonation is generated. This differential gene expression that results in zonation can be understood in part by analysing the microcirculation of the liver. The liver structure creates a specific pattern of blood circulation. Blood arrives through the hepatic artery and portal vein, spreads through the sinusoids and is drained by the central vein. In this trajectory from the portal pole of the cell plate to the central vein, the composition of blood changes as it bathes the hepatocytes. This change in composition results in a biochemical and gaseous gradient along the cell plate. Consequently, the hepatocytes located near the portal pole of the liver cell plate will be exposed to blood with different concentrations of oxygen, carbon dioxide and many other factors from those near the central vein pole. According to the current model, this difference in the microenvironment to which hepatocytes are exposed is responsible for functional differences noted across the cell plate. One example that has been well characterized is blood oxygen level-dependent gene expression [16]. This is illustrated by erythropoietin (EPO) gene transcription in the livers of anaemic mice [17]. EPO is a hormone normally secreted by the kidneys that stimulates the production of red blood cells by the bone marrow [18]. EPO expression is dependent on oxygen tension in blood, and its mRNA levels increase when the oxygen tension is decreased [19]. In the case of anaemic animals, *in situ* hybridization identified copies of EPO mRNA in hepatocytes close to the central vein, but not in those near the portal region. This experiment demonstrates that the level of oxygen tension is not the same along the liver cell plate, and that gene expression differs in hepatocytes located near the central vein because they are subjected to lower oxygen tensions. The result described for EPO can be extrapolated to other genes with the identification of the DNA sequence called hypoxia-responsive element (HRE) [20–22]. HRE is in the promoter region of certain genes and works as an anchoring site for the hypoxia-inducible factor (HIF), a transcription factor of the helix–loop–helix family. In situations where the oxygen level is decreased, the levels of HIF increase. HIF then binds HRE and directs the synthesis of mRNA for the corresponding gene [23]. HIF mRNA is most concentrated among hepatocytes near the central vein, although there is not a zonal distribution of HIF at the protein level [24]. Other mechanisms by which differential gene expression can be

attained are by changes not only in the microenvironment, but also in the intrinsic sensitivity of hepatocytes to hormones. The effects of hormones, growth factors and cytokines on cells are generally mediated by the corresponding receptors on the plasma membrane. One of the known effects of receptor stimulation is to modify the expression of other genes, allowing the cell to adapt to the demands of that specific moment. By expressing different levels of receptors, cells can respond in different ways to the microenvironment and therefore express distinct sets of genes [25,26]. Glucagon, V_{1a} vasopressin, insulin and α1 and β1 adrenergic receptors predominate in the areas surrounding the central vein, while EGF and adenosine triphosphate (ATP) receptors are more concentrated near the portal vein [14,15].

Metabolism

Metabolic considerations deal with the differential metabolism of the main categories of small molecules across the liver cell plate. These include metabolism of oxidative energy, carbohydrates, lipids, amino acids and nitrogen, bile formation and metabolism of xenobiotics.

Oxidative energy metabolism

The liver has a high metabolic activity and, therefore, its energy demands are significant. Oxygen is the final substrate oxidized in the respiratory chain, and its gradient decreases from the periportal to pericentral region, so hepatocytes located near the portal region have higher levels of oxidative metabolism. As a result, hepatocytes near the portal region not only have higher activities of succinate dehydrogenase and cytochrome oxidase, but they also contain mitochondria that are larger, rounded and have more cristae to sustain higher levels of oxidative reactions [27,28].

Carbohydrate metabolism

The most important aspect of zonation of carbohydrate metabolism in the liver is the spatial segregation of gluconeogenesis in periportal hepatocytes and glycolysis in the pericentral region. This zonation is essential for the liver to regulate the blood glucose concentration properly [29]. There is considerable evidence that enzymes involved in gluconeogenic reactions, such as glucose-6-phosphatase, fructose-1,6-biphosphatase and phosphoenolpyruvate carboxykinase (PEPCK), predominate in the periportal area. The activity of glucose-6-phosphatase is twofold higher in periportal areas, in both rats and humans [30]. Studies using perfused rat livers confirm the periportal zonation of gluconeogenesis, although the directional flow of blood has been shown to be important for the location of gluconeogenesis induced by glucagon. The zonal heterogeneity of glucose-6-phosphatase and PEPCK starts at postnatal days 5 and 1, respectively, and is fully developed by the second week of age. This is believed to be a consequence of a change to a diet rich in fat and protein after birth, as opposed to the constant source of glucose during pregnancy. By the time of weaning, the adult pattern has been established [13].

Glycolysis is localized to the pericentral region, with enzymes such as glucokinase and pyruvate kinase showing levels of around twice that observed in the periportal areas [31,32]. In terms of glucose uptake, the glucose transporter GLUT-2 is expressed in all hepatocytes, while the GLUT-1 isoform is expressed only in the subset of the most pericentral hepatocytes [12]. Another important aspect is the zonation of glycogen synthetase and glycogen phosphorylase in periportal areas, although this distribution may play a minor role in determining glycogen deposition secondary to the availability of glucose-6-phosphate.

Lipid metabolism

Lipid metabolism can be subclassified into lipogenesis, β-oxidation, ketogenesis, cholesterol biosynthesis and lipoprotein metabolism. In contrast to carbohydrate metabolism, the zonation of lipid metabolism is much less pronounced [33].

Lipogenesis, the synthesis of lipids, requires enzymes such as ATP-dependent citrate lyase and acetyl-CoA carboxylase. These two key enzymes are expressed to a slightly greater extent in pericentral regions [34,35]. This difference is more pronounced in female animals than in males. Similarly, fatty acid synthase activity is twice as high in pericentral hepatocytes than in periportal hepatocytes in females, but not in males.

β-Oxidation of fatty acids is active throughout the cell plate, because the enzymatic activity of 3-hydroxyacyl-CoA dehydrogenase does not show a portal to central gradient [34]. However, the higher volume of mitochondria in the periportal zone suggests a slightly higher level of β-oxidation in this region [36]. Studies with the enzyme carnitine palmitoyltransferase I are inconsistent, with some showing higher periportal activity, while others do not [37,38]. There is also variability in the results depending on the experimental design. Results using bezafibrate and clofibrate, showing increased carnitine acetyltransferase in periportal compared with pericentral hepatocytes, could not be reproduced with the drug clofibrate [39]. In addition, the results showing higher periportal activity first observed in rats have not been reproduced in humans [40]. Finally, although there is a gradient in the expression levels of fatty acid binding protein (FABP), with higher levels in the periportal region, this finding may not represent increased utilization of fatty acids in the periportal area but, rather, a gradient in the concentration of fatty acids due to directional blood flow [41].

Ketogenesis is another example of a process with a poorly defined gradient. β-Hydroxybutyrate dehydrogenase, a key enzyme of ketogenesis, is preferentially expressed in the pericentral region. However, the rate of ketogenesis is almost equal in hepatocytes isolated from the pericentral and periportal regions, in the absence of glucagon [34]. In the presence of that hormone, ketogenesis is significantly higher in periportal hepatocytes [42].

Ketogenesis is important during periods of starvation or diabetes, and the study of its distribution in those conditions might provide a clearer picture, but such studies are lacking.

Cholesterol biosynthesis is a metabolic pathway controlled primarily by the activity of the enzyme HMG-CoA reductase [43]. This enzyme is distributed predominantly in periportal hepatocytes, coinciding with the periportal expression of another enzyme involved in cholesterol synthesis, HMG-CoA synthase [9,44]. Drugs such as cholestyramine and mevinolin initially induce the expression of these two enzymes in periportal hepatocytes, although regions more pericentral are eventually affected as well, until a homogeneous distribution is achieved. This probably means that, under normal circumstances, cholesterol synthesis is a periportal event, although other hepatocytes might be recruited in periods of increased demand.

Lipoprotein metabolism involves the synthesis of apoenzymes that combine with lipids to form lipoprotein particles. Lipoprotein metabolism also involves the synthesis and degradation of cholesterol esters [45]. No zonation is observed for very-low-density lipoprotein (VLDL) secretion in normal rats, while there is a twofold ratio for the lipase implicated in cholesterol transport from high-density lipoproteins to tissues when comparing periportal with pericentral hepatocytes [46]. In normally fed rats, there is no zonation in the activity of lysosomal cholesteryl ester hydrolase (CEH) and acyl-CoA:cholesterol acyltransferase (ACAT), while the activity of both cytosolic and microsomal CEH is increased in the pericentral region. However, concentrations of free and esterified cholesterol in homogenates, cytosol and microsomes of periportal and pericentral cells are similar. Treatment with cholestyramine raises the pericentral/periportal ratio of ACAT and abolishes the heterogeneity in microsomal CEH, whereas the pericentral dominance of cytosolic CEH and the homogeneous distribution of lysosomal CEH are not affected [47].

Amino acid and nitrogen metabolism

The distribution of two enzymes related to nitrogen metabolism, carbamoylphosphate synthetase, involved in the synthesis of urea, and glutamine synthetase, involved in the synthesis of glutamine, is one of the best examples of liver function zonation. Glutamine synthase is expressed in very few hepatocytes surrounding the central vein, while carbamoylphosphate synthetase is present in the remainder of the parenchyma. Treatment of liver with CCl_4 destroys the pericentral hepatocytes and abolishes glutamine synthetase activity, without evidence of compensatory expression in the remaining cells. Glutamate dehydrogenase activity forms a gradient with increased levels of expression towards the pericentral region. Glutaminase activity predominates in periportal hepatocytes [11]. Periportal predominance of urea synthesis has also been demonstrated in the perfused rat liver. Therefore, there is practically no overlap between the hepatocytes involved in the synthesis of urea and glutamine. This clear separation is accompanied by zonation of the membrane transporters and enzymes associated with the uptake and processing of substrates in those pathways. The uptake of glutamine and glutamate displays a pronounced heterogeneity and shows a strong correlation with the metabolism of ammonia [48]. Sodium-independent transport of glutamine is two- to threefold higher in pericentral hepatocytes. There is also considerable evidence that the sodium-dependent uptake of glutamate is exclusively pericentral, showing a direct correlation with glutamine synthetase distribution. In addition, α-ketoglutarate is almost exclusively taken up by pericentral, glutamine synthetase-containing hepatocytes. Up to 60% of α-ketoglutarate taken up by pericentral hepatocytes can be converted to glutamine [49].

Bile formation and secretion

Metabolism of key components of bile, including bile acids, bilirubin and glutathione, is compartmentalized along the liver cell plate. The expression of cholesterol 7α-hydroxylase, an enzyme involved in the synthesis of bile acids, is highly zonated. The ratio of expression in the pericentral to periportal region is approximately 8:1. Treatment with cholestipol leads to induction of expression in the periportal region, with the pericentral/periportal ratio dropping to 2. The production of bile acid is more than fourfold higher in pericentral compared with periportal hepatocytes. The enzyme cholesterol 26-hydroxylase shows a pericentral/periportal ratio of around 3 before and 4 after stimulation with cholestipol. These results indicate that bile acid synthesis is predominantly pericentral [10]. Conjugation of bilirubin is a central aspect of its metabolism in terms of bile secretion. Total activity of UDP-glucuronyl transferase, the enzyme responsible for the conjugation of bilirubin to glucuronic acid, is more intense in the pericentral region [50]. Glutathione is an important factor that protects hepatocytes from oxidative injuries. It is also the main component of bile acid-independent bile flow. The intracellular glutathione concentration is significantly higher in periportal hepatocytes, although there is no difference in the activity of glutathione synthetase or glutamylcystein synthetase. Glutathione-mediated antioxidant reactions are catalysed by the enzymes glutathione-*S*-transferases (GST) and glutathione peroxidases. The pericentral predominance of GST has been demonstrated for several isoforms [51]. Contrasting with the GST distribution, glutathione peroxidase activity is around twofold higher in periportal hepatocytes, and a selenium-dependent isoform has been localized by immunohistochemistry to that region as well [52].

Metabolism of xenobiotics

Phase I in the biotransformation of xenobiotics is catalysed by microsomal cytochrome P-450 mono-oxygenases. Total cytochrome P-450 content shows a slight increase from the periportal to the pericentral region. Pericentral hepatocytes also have a larger area of smooth endoplasmic reticulum and a higher

surface density of cytochrome P-450 [53]. In addition, phenobarbital increases cytochrome P-450 in pericentral areas and induces the proliferation of endoplasmic reticulum. Several cytochrome P-450-dependent reactions have been localized to the pericentral region. Pericentral localization has also been shown for 7-ethoxycoumarin-*O*-demethylase, 7-ethoxyresofurin-*O*-deethylase, aniline *p*-hydrolase, benzphetamine *N*-demethylase and microsomal ethanol oxidation [54]. These and other enzymes are more prominently induced in periportal cells after phenobarbital. These findings, along with immunohistochemistry and *in situ* hybridization, indicate that most enzymes of the cytochrome P-450 family are predominantly expressed in pericentral hepatocytes, although each specific enzyme has its characteristic pattern of distribution that can be modified during induction with drugs. NADPH-cytochrome *c* reductase activity is also higher in pericentral hepatocytes of both rats and humans.

Signalling

Signalling is central to the understanding of the liver as a functional unit and involves both the response of hepatocytes to external hormonal stimuli and the internal coordination of those responses coded in the form of second messengers [55]. Hepatocytes express a wide range of plasma membrane receptors, many of which share common second messengers [56]. Agonists or ligands for these receptors include glucagon, vasopressin, ATP, insulin and growth factors such as EGF, hepatocyte growth factor (HGF) and insulin-like growth factor (IGF). The chemical messages generated by these agonists often consist of one or more of a few main types: phosphorylation or dephosphorylation of kinases, phosphatases and other proteins [57]; generation of inositol 1,4,5-trisphosphate and an associated increase in free cytosolic calcium [58]; stimulation or inhibition of cAMP production [59]; stimulation or inhibition of nitric oxide and cGMP production [59]; phosphorylation of phospholipids [60]; and changes in membrane polarity [61]. Every aspect of hepatocyte function is regulated by these messengers, including secretion, gluconeogenesis, glycogenolysis, protein synthesis, gene transcription, cell cycle progression and apoptosis [62–65]. There is evidence in both isolated hepatocyte couplets and triplets [66] and the intact liver [67,68] that second messenger signals are coordinated among hepatocytes. Calcium oscillations are synchronized in isolated hepatocyte couplets, and calcium waves travel from cell to cell without delay [66]. In the intact liver, there is a similarly coordinated progression of calcium oscillations [68] and calcium waves [67] along cords of hepatocytes. Intercellular coupling via gap junctions is important for coordination of second messenger signals [66] but it is not the sole determinant. The direction of calcium waves along the hepatic acinus depends upon the agonist. For example, vasopressin induces calcium waves that travel from the pericentral to the periportal region [67,69], whereas ATP-induced calcium signals begin at random locations within the hepatic acinus [69]. The V_{1a} vasopressin receptor is expressed most heavily among pericentral hepatocytes [67], so agonist-specific patterns of calcium signalling *in vivo* have been attributed to such differences in receptor distribution. The molecular mechanism by which calcium signals are coordinated and oriented along the liver cell plate has been examined in detail in isolated triplets of primary hepatocytes [70,71] and in liver cell lines [72]. Collectively, these studies suggest that three factors are necessary. First, adjacent cells must communicate directly via gap junctions. This is consistent with the observations that second messengers such as calcium and inositol 1,4,5-trisphosphate can cross gap junctions in hepatocytes [73]. Second, in order for signals to propagate over distances greater than one or two cells, each cell must be stimulated, so that all the cells are in an excitable state. Third, one cell or group of cells must have increased expression of hormone receptor relative to the other cells. This feature allows that particular cell to have increased sensitivity to agonist, so that it will serve as a pacemaker for the other hepatocytes [72]. As the lobular distribution of different hormone receptors varies, this final feature allows the respective agonists to generate distinct signalling patterns across the hepatic lobule, which can in turn allow agonist-specific tissue responses even though different agonists activate the same second messengers. There are several examples illustrating how liver function depends on the coordinated response to second messengers. In the isolated perfused rat liver, hormone-induced changes in both bile flow and glucose release are altered by agents that block gap junctions [74]. However, gap junction blockers do not alter bile secretion or glucose release in livers treated with agents that increase second messengers independent of hormone receptors [74]. These results suggest that the lobular pattern of second messenger activation is an important component of the liver's response to hormonal stimulation. Only subtle changes in glucose release and bile flow occur in mice lacking connexin 32, the predominant gap junction in hepatocytes [75,76], but connexin 32 knockout mice treated with endotoxin have slightly worse hypoglycaemia and much worse cholestasis than wild-type mice treated with endotoxin [77]. Intercellular signalling may also be important for liver regeneration. It has been shown that the lobular gradient of V_{1a} vasopressin receptors is accentuated after partial hepatectomy and that the organized calcium wave generated is important in promoting choleresis during the initial phase of the postoperative period [78]. Thus, intra- and intercellular signalling that is properly coordinated across the hepatic lobule shapes liver function in health as well as in disease.

Conclusion

Characterizing the effects of agonists and intracellular messengers on gene expression will probably help to answer the fundamental question of how gradients of enzymes, receptors and even cell structure are generated across the liver cell plate. Comparison of regulatory sequences of genes expressed in the pericentral and periportal region and identification of

transcription factors acting on those elements will probably provide additional insights. Progress has been made in characterizing the transcription factors involved in the differentiation of epithelial cells into hepatocytes [79], but those factors responsible for the phenotype variation along the liver cell plate still remain unidentified.

Acknowledgement

This work was supported by NIH grants DK57751 and DK45710.

References

1 Kmiec Z (2001) Cooperation of liver cells in health and disease. *Adv Anat Embryol Cell Biol* 161 (III–XIII), 1–151.
2 Oda M, Yokomori H, Han JY *et al.* (2003) Regulatory mechanisms of hepatic microcirculation. *Clin Hemorheol Microcirc* 29 (30–4), 167–182.
3 McCuskey RS, Reilly FD (1993) Hepatic microvasculature: dynamic structure and its regulation. *Semin Liver Dis* 13 (1), 1–12.
4 Motta PM (1977) The three-dimensional fine structure of the liver as revealed by scanning electron microscopy. *Int Rev Cytol Suppl* 6, 347–399.
5 Barbera-Guillem E, Vidal-Vanaclocha F (1988) Sinusoidal structure of the liver. *Revis Biol Celular* 16, 1–34, 54–68.
6 Papageorgopoulos C, Caldwell K, *et al.* (1999) Measuring protein synthesis by mass isotopomer distribution analysis (MIDA). *Anal Biochem* 267 (1), 1–16.
7 Gebhardt R (1992) Metabolic zonation of the liver: regulation and implications for liver function. *Pharmacol Ther* 53 (3), 275–354.
8 Brinkmann A, Katz N, Sasse D *et al.* (1978) Increase of the gluconeogenic and decrease of the glycolytic capacity of rat liver with a change of the metabolic zonation after partial hepatectomy. *Hoppe Seylers Z Physiol Chem* 359 (11), 1561–1571.
9 Singer D II, Kawka W, Kazazis DM *et al.* (1984) Hydroxymethylglutaryl-coenzyme A reductase-containing hepatocytes are distributed periportally in normal and mevinolin-treated rat livers. *Proc Natl Acad Sci USA* 81 (17), 5556–5560.
10 Ugele B, Kempen HJ, Kempen JM *et al.* (1991) Heterogeneity of rat liver parenchyma in cholesterol 7 alpha-hydroxylase and bile acid synthesis. *Biochem J* 276 (Pt 1), 73–77.
11 Moorman AF, Vermeulen JL, Charles R *et al.* (1989) Localization of ammonia-metabolizing enzymes in human liver: ontogenesis of heterogeneity. *Hepatology* 9 (3), 367–372.
12 Tal M, Kahn BB, Lodish HF *et al.* (1991) Expression of the low Km GLUT-1 glucose transporter is turned on in perivenous hepatocytes of insulin-deficient diabetic rats. *Endocrinology* 129 (4), 1933–1941.
13 Jungermann K (1986) Dynamics of zonal hepatocyte heterogeneity. Perinatal development and adaptive alterations during regeneration after partial hepatectomy, starvation and diabetes. *Acta Histochem Suppl* 32, 89–98.
14 Chabot JG, Walker P, Pelletier G (1986) Distribution of epidermal growth factor binding sites in the adult rat liver. *Am J Physiol* 250 (6 Pt 1), G760–G764.
15 Tordjmann T, Berthon B, Combettes L *et al.* (1996) The location of hepatocytes in the rat liver acinus determines their sensitivity to calcium-mobilizing hormones. *Gastroenterology* 111 (5), 1343–1352.
16 Kietzmann T, Jungermann K (1997) Modulation by oxygen of zonal gene expression in liver studied in primary rat hepatocyte cultures. *Cell Biol Toxicol* 13 (4–5), 243–255.
17 Koury ST, Bondurant MC, Koury MJ *et al.* (1991) Localization of cells producing erythropoietin in murine liver by in situ hybridization. *Blood* 77 (11), 2497–2503.
18 Koury MJ, Bondurant MC (1991) The mechanism of erythropoietin action. *Am J Kidney Dis* 18 (4 Suppl 1), 20–23.
19 Gopfert T, Gess B, Eckard KU *et al.* (1996) Hypoxia signalling in the control of erythropoietin gene expression in rat hepatocytes. *J Cell Physiol* 168 (2), 354–361.
20 Hirsch-Ernst KI, Kietzmann T, Ziemann T *et al.* (2000) Physiological oxygen tensions modulate expression of the mdr1b multidrug-resistance gene in primary rat hepatocyte cultures. *Biochem J* 350 Pt 2, 443–451.
21 Jungermann K, Kietzmann T (2000) Oxygen: modulator of metabolic zonation and disease of the liver. *Hepatology* 31 (2), 255–260.
22 Vargiu C, Belliardo S, Cravanzola C *et al.* (2000) Oxygen regulation of rat hepatocyte iNOS gene expression. *J Hepatol* 32 (4), 567–573.
23 Wang GL, Semenza GL (1996) Molecular basis of hypoxia-induced erythropoietin expression. *Curr Opin Haematol* 3 (2), 156–162.
24 Keitzmann T, Cornesse Y, Brechtel K *et al.* (2001) Perivenous expression of the mRNA of the three hypoxia-inducible factor a-subunits, HIF1a, HIF2a and HIF3a, in rat liver. *Biochem J* 354, 531–537.
25 Kietzmann T, Krones-Herzig A, Jungermann K *et al.* (2002) Signaling cross-talk between hypoxia and glucose via hypoxia-inducible factor 1 and glucose response elements. *Biochem Pharmacol* 64 (5–6), 903–911.
26 Oinonen T, Nikkola E, Lindros KO *et al.* (1993) Growth hormone mediates zone-specific gene expression in liver. *FEBS Lett* 327 (2), 237–240.
27 Sokal EM, Trivedi P, Protmann B *et al.* (1989) Developmental changes in the intra-acinar distribution of succinate dehydrogenase, glutamate dehydrogenase, glucose-6-phosphatase, and NADPH dehydrogenase in the rat liver. *J Pediatr Gastroenterol Nutr* 8 (4), 522–527.
28 Wimmer M, Pette D (1979) Microphotometric studies on intraacinar enzyme distribution in rat liver. *Histochemistry* 64 (1), 23–33.
29 Jungermann K (1985) Metabolic zonation of liver parenchyma: regulation of the glucostat of the liver. *Naturwissenschaften* 72 (2), 76–84.
30 Jungermann K (1983) Functional significance of hepatocyte heterogeneity for glycolysis and gluconeogenesis. *Pharmacol Biochem Behav* 18 (Suppl 1), 409–414.
31 Fischer W, Ick M, Katz NR (1982) Reciprocal distribution of hexokinase and glucokinase in the periportal and perivenous zone of the rat liver acinus. *Hoppe Seylers Z Physiol Chem* 363 (4), 375–380.
32 Zierz S, Katz N, Jungermann K *et al.* (1983) Distribution of pyruvate kinase type L and M2 in microdissected periportal and perivenous rat liver tissue with different dietary states. *Hoppe Seylers Z Physiol Chem* 364 (10), 1447–1453.
33 Jungermann K, Katz N (1989) Functional specialization of different hepatocyte populations. *Physiol Rev* 69 (3), 708–764.
34 Katz NR, Fischer W, Giffhorn S *et al.* (1983) Distribution of enzymes of fatty acid and ketone body metabolism in periportal and perivenous rat-liver tissue. *Eur J Biochem* 135 (1), 103–107.
35 Katz NR, Fischer W, Ick M *et al.* (1983) Heterogeneous distribution of ATP citrate lyase in rat-liver parenchyma. Microradiochemical determination in microdissected periportal and perivenous liver tissue. *Eur J Biochem* 130 (2), 297–301.
36 Loud AV (1968) A quantitative stereological description of the ultrastructure of normal rat liver parenchymal cells. *J Cell Biol* 37 (1), 27–46.
37 Guzman M, Castro J (1989) Zonation of fatty acid metabolism in rat liver. *Biochem J* 264 (1), 107–113.

38 Tosh D, Alberti KG, Aquis L *et al.* (1989) Clofibrate induces carnitine acyltransferases in periportal and perivenous zones of rat liver and does not disturb the acinar zonation of gluconeogenesis. *Biochim Biophys Acta* 992 (3), 245–50.
39 Gerondaes P, Alberti KG, Aquis L *et al.* (1988) Interactions of inhibitors of carnitine palmitoyltransferase I and fibrates in cultured hepatocytes. *Biochem J* 253 (1), 169–173.
40 Gerondaes P, Alberti KG, Aquis L *et al.* (1988) Fatty acid metabolism in hepatocytes cultured with hypolipidaemic drugs. Role of carnitine. *Biochem J* 253 (1), 161–167.
41 Iseki S, Kondo H, Hitomi M *et al.* (1990) Localization of liver fatty acid-binding protein and its mRNA in the liver and jejunum of rats: an immunohistochemical and in situ hybridization study. *Mol Cell Biochem* 98 (1–2), 27–33.
42 Tosh D, Alberti GM, Aquis L *et al.* (1988) Glucagon regulation of gluconeo-genesis and ketogenesis in periportal and perivenous rat hepatocytes. Heterogeneity of hormone action and of the mitochondrial redox state. *Biochem J* 256 (1), 197–204.
43 Singh RP, Kumar R, Kapur N *et al.* (2003) Molecular regulation of cholesterol biosynthesis: implications in carcinogenesis. *J Environ Pathol Toxicol Oncol* 22 (2), 75–92.
44 Li AC, Tanaka RD, Callaway K *et al.* (1988) Localization of 3-hydroxy-3-methylglutaryl CoA reductase and 3-hydroxy-3-methylglutaryl CoA synthase in the rat liver and intestine is affected by cholestyramine and mevinolin. *J Lipid Res* 29 (6), 781–796.
45 Kang S, Davis RA (2000) Cholesterol and hepatic lipoprotein assembly and secretion. *Biochim Biophys Acta* 1529 (1–3), 223–230.
46 Verhoeven AJ, Jansen H (1989) Secretion of liver lipase activity by periportal and perivenous hepatocytes. *Biochim Biophys Acta* 1001 (2), 239–242.
47 Romero JR, Fresnedo O, Isusi E *et al.* (1999) Hepatic zonation of the formation and hydrolysis of cholesteryl esters in periportal and perivenous parenchymal cells. *Lipids* 34 (9), 907–913.
48 Haussinger D, Lamers WH, Moorman AF *et al.* (1992) Hepatocyte heterogeneity in the metabolism of amino acids and ammonia. *Enzyme* 46 (1–3), 72–93.
49 Burger HJ, Gebhardt R, Mayer C *et al.* (1989) Different capacities for amino acid transport in periportal and perivenous hepatocytes isolated by digitonin/collagenase perfusion. *Hepatology* 9 (1), 22–28.
50 Ullrich D, Fischer G, Katz N *et al.* (1984) Intralobular distribution of UDP-glucuronosyltransferase in livers from untreated, 3-methylcholanthrene- and phenobarbital-treated rats. *Chem Biol Interact* 48 (2), 181–190.
51 Wolf CR, Moll E, Frieberg T *et al.* (1984) Characterization, localization and regulation of a novel phenobarbital-inducible form of cytochrome P450, compared with three further P450-isoenzymes, NADPH P450-reductase, glutathione transferases and microsomal epoxide hydrolase. *Carcinogenesis* 5 (8), 993–1001.
52 Kera Y, Sippel HW, Pentilla KE *et al.* (1987) Acinar distribution of glutathione-dependent detoxifying enzymes. Low glutathione peroxidase activity in perivenous hepatocytes. *Biochem Pharmacol* 36 (12), 2003–2006.
53 Kanai K, Kanamura S, Watanabe J *et al.* (1986) Peri- and postnatal development of heterogeneity in the amounts of endoplasmic reticulum in mouse hepatocytes. *Am J Anat* 175 (4), 471–480.
54 Gascon-Barre M, Benbrahim N, Tremblay C *et al.* (1989) Hepatic zonation of drug metabolizing enzymes. Studies on hepatocytes isolated from the periportal or perivenous region of the liver acinus. *Can J Physiol Pharmacol* 67 (9), 1015–1022.
55 Nathanson MH (1994) Cellular and subcellular calcium signaling in gastrointestinal epithelium. *Gastroenterology* 106 (5), 1349–1364.
56 Pierce KL, Premont RT, Lefkowitz RJ *et al.* (2002) Seven-transmembrane receptors. *Nature Rev Mol Cell Biol* 3 (9), 639–650.
57 Wong W, Scott JD (2004) AKAP signalling complexes: focal points in space and time. *Nature Rev Mol Cell Biol* 5 (12), 959–970.
58 Berridge MJ, Bootman MD, Roderick HL *et al.* (2003) Calcium signalling: dynamics, homeostasis and remodelling. *Nature Rev Mol Cell Biol* 4 (7), 517–529.
59 Beavo JA, Brunton LL (2002) Cyclic nucleotide research – still expanding after half a century. *Nature Rev Mol Cell Biol* 3 (9), 710–718.
60 Bondeva, T, Pirola L, Bugarelli-Leva G *et al.* (1998) Bifurcation of lipid and protein kinase signals of PI3Kgamma to the protein kinases PKB and MAPK. *Science* 282 (5387), 293–296.
61 Rosenmund C, Stern-Bach Y, Stevens CF *et al.* (1998) The tetrameric structure of a glutamate receptor channel. *Science* 280 (5369), 1596–1599.
62 Pusl T, Nathanson MH (2004) The role of inositol 1,4,5-trisphosphate receptors in the regulation of bile secretion in health and disease. *Biochem Biophys Res Commun* 322 (4), 1318–1325.
63 Zhou XY, Shibusawa N, Naik K *et al.* (2004) Insulin regulation of hepatic gluconeogenesis through phosphorylation of CREB-binding protein. *Nature Med* 10 (6), 633–637.
64 Fruman DA, Mauvais-Jarvis F, Pollard D *et al.* (2000) Hypoglycaemia, liver necrosis and perinatal death in mice lacking all isoforms of phosphoinositide 3-kinase p85 alpha. *Nature Genet* 26 (3), 379–382.
65 Reinehr R, Becker S, Hongen A *et al.* (2004) Involvement of the Src family kinase yes in bile salt-induced apoptosis. *Gastroenterology* 127 (5), 1540–1557.
66 Nathanson MH, Burgstahler AD (1992) Coordination of hormone-induced calcium signals in isolated rat hepatocyte couplets: demonstration with confocal microscopy. *Mol Biol Cell* 3 (1), 113–121.
67 Nathanson MH, Burgstahler AD, Mewnone A *et al.* (1995) Ca2+ waves are organized among hepatocytes in the intact organ. *Am J Physiol* 269 (1 Pt 1), G167–171.
68 Robb-Gaspers LD, Thomas AP (1995) Coordination of Ca2+ signaling by intercellular propagation of Ca2+ waves in the intact liver. *J Biol Chem* 270 (14), 8102–8107.
69 Motoyama K, Karl IE, Flye MW *et al.* (1999) Effect of Ca2+ agonists in the perfused liver: determination via laser scanning confocal microscopy. *Am J Physiol* 276 (2 Pt 2), R575–585.
70 Tordjmann T, Berthon B, Claret M *et al.* (1997) Coordinated intercellular calcium waves induced by noradrenaline in rat hepatocytes: dual control by gap junction permeability and agonist. *EMBO J* 16 (17), 5398–5407.
71 Tordjmann T, Berthon B, Jacquemin E *et al.* (1998) Receptor-oriented intercellular calcium waves evoked by vasopressin in rat hepatocytes. *EMBO J* 17 (16), 4695–4703.
72 Leite MF, Hirata K, Pusl T *et al.* (2002) Molecular basis for pacemaker cells in epithelia. *J Biol Chem* 277 (18), 16313–16323.
73 Saez JC, Connor JA, Spray DC *et al.* (1989). Hepatocyte gap junctions are permeable to the second messenger, inositol 1,4,5-trisphosphate, and to calcium ions. *Proc Natl Acad Sci USA* 86 (8), 2708–2712.
74 Nathanson MH, Rios-Velez L, Burgstahler AD *et al.* (1999) Communication via gap junctions modulates bile secretion in the isolated perfused rat liver. *Gastroenterology* 116 (5), 1176–1183.
75 Nelles E, Butzler C, Jung D *et al.* (1996) Defective propagation of signals generated by sympathetic nerve stimulation in the liver of connexin 32-deficient mice. *Proc Natl Acad Sci USA* 93 (18), 9565–9570.

76 Temme A, Stumpel F, Sohl G *et al.* (2001) Dilated bile canaliculi and attenuated decrease of nerve-dependent bile secretion in connexin 32-deficient mouse liver. *Pflugers Arch* 442 (6), 961–966.
77 Correa PR, Guerra MT, Leite MF *et al.* (2004) Endotoxin unmasks the role of gap junctions in the liver. *Biochem Biophys Res Commun* 322 (3), 718–726.
78 Nicou A, Serriere V, Prigent S *et al.* (2003) Hypothalamic vasopressin release and hepatocyte Ca2+ signaling during liver regeneration: an interplay stimulating liver growth and bile flow. *FASEB J* 17 (13), 1901–1903.
79 Parviz F, Matullo C, Garrison WD *et al.* (2003) Hepatocyte nuclear factor 4alpha controls the development of a hepatic epithelium and liver morphogenesis. *Nature Genet* 34 (3), 292–296.

2.2.2 Cell biology of the hepatocyte

Allan W. Wolkoff and Phyllis M. Novikoff

The hepatocyte has been a classical subject for cell biological study [1]. In great part, this is a result of its abundance, availability for experimental examination and diversity of function. The cell biology of the hepatocyte is a large area that could not be covered in its entirety in a single brief overview. Consequently, this chapter will focus on the biology of the hepatocyte as it relates to cell polarity, cell–cell junctions and communication, the cytoskeleton and plasma membrane function as related to receptor-mediated endocytosis.

Cell polarity

Although the hepatocyte functions as a typical polarized epithelial cell, its organization is unique (Fig. 1). Unlike most polarized epithelial cells (e.g. intestinal epithelial cell), with distinct basal and apical plasma membrane domains on opposite sides of the cell, the apical domain of the hepatocyte represents a small portion of the plasma membrane (approximately 10%) and lies between cells, set off from the basolateral plasma membrane by tight junctions (see below) and forming the bile canaliculus. The basolateral (sinusoidal) and apical (canalicular) plasma membranes have distinct lipid and protein compositions, and these help to define their differential functions (Fig. 2). In general, the basolateral plasma membrane has transporters that remove substances (e.g. bile acids, drugs) from the portal venous blood by facilitated diffusion along a concentration gradient, whereas the apical plasma membrane has transporters that pump substances against a steep concentration gradient from the cell interior into the bile canaliculus using adenosine triphosphate (ATP) hydrolysis as the source of energy. Once in the bile canaliculus, there is little return of these substances to the portal blood, because of the seal that is produced by the tight junction between cells (see below).

The factors that lead to the differential sorting of proteins to specific plasma membrane domains in the hepatocyte are not entirely understood. Although most polarized epithelial cells sort proteins directly to their final destination from the site of synthesis [2], initial evidence suggested that plasma membrane proteins trafficked to the basolateral plasma membrane after synthesis, and that those destined for the apical plasma membrane were subsequently internalized into a vesicle and delivered to the apical plasma membrane by a transcytotic process [2]. Subsequent studies revealed that a number of the apical transport pumps were delivered directly to the apical plasma membrane after synthesis [3]. Further studies suggested that apical plasma membrane proteins that had only a single transmembrane-spanning region, such as dipeptidyl peptidase IV (DPPIV), rather than the multimembrane-spanning excretory pumps, took the indirect route [4]. Interestingly, DPPIV targets directly to the apical plasma membrane in most epithelial cells other than hepatocytes [5]. The lipid compositions of basolateral and apical plasma membranes from hepatocytes are also distinct [6,7]. Cholesterol content of the apical membrane is substantially higher than that of the basolateral membrane [6], and this is reflected in reduced membrane fluidity of apical compared with basolateral membranes [7]. The mechanisms for differential sorting of lipids to these plasma membrane domains are not known.

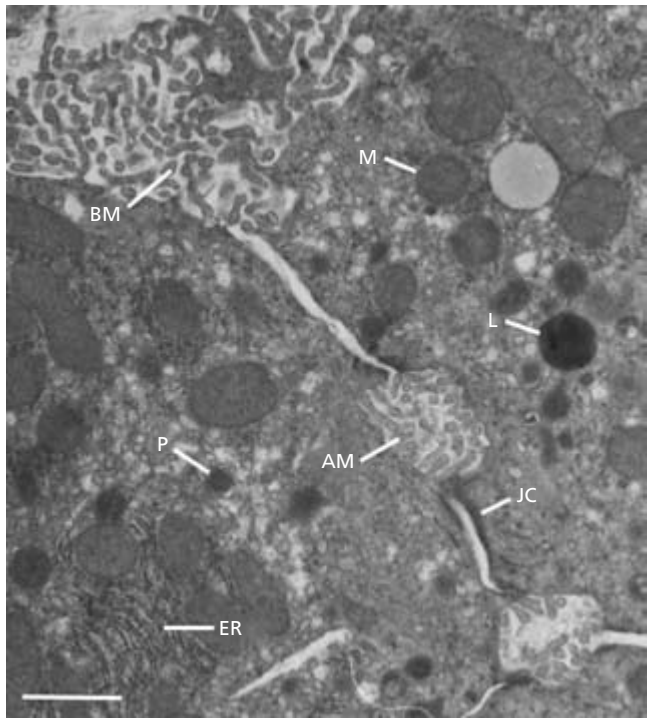

Fig. 1 Electron micrograph of a hepatocyte. The apical–basal polarity of hepatocytes is delineated by two different domains of plasma membrane, a basolateral (sinusoidal) membrane (BM) and an apical (bile canalicular) membrane (AM). Both plasma membrane domains have microvilli. Those at the BM are more numerous, longer and more slender than those at the AM. The BM microvilli project into the space of Disse where they come into direct contact with sinusoidal blood flow. The AM microvilli from adjacent hepatocytes project into a lumen to form the bile canaliculus and are exposed to bile. Junctional complexes (JC) are found adjacent to the apical membrane at the periphery of the bile canaliculus. Also labelled are endoplasmic reticulum (ER), lysosomes (L), mitochondria (M) and peroxisomes (P). Bar = 1 μm.

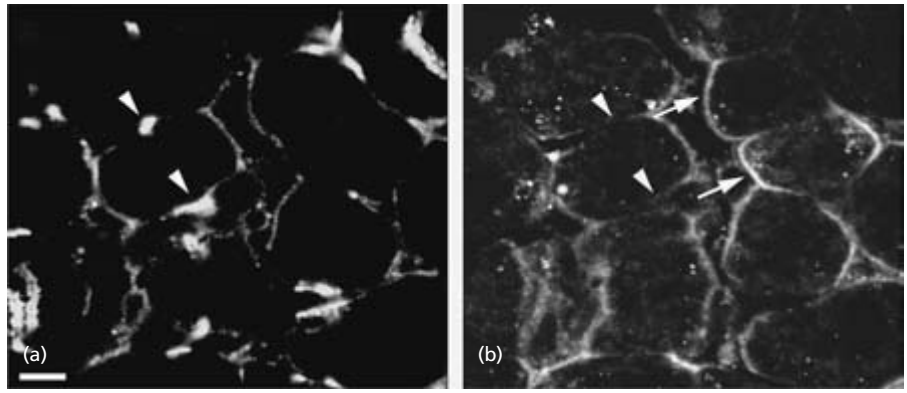

Fig. 2 Colocalization of (a) actin and (b) the organic anion transporter OATP1A1 [55] in a section of rat liver by fluorescence confocal microscopy. A section of rat liver was aldehyde fixed, and OATP1A1 was visualized by exposure to primary antibody followed by Cy3-coupled secondary antibody. Actin filaments were subsequently visualized using fluorescein isothiocyanate (FITC) phalloidin. As seen from the arrowheads in (a), actin is especially abundant around the bile canaliculi (apical plasma membrane). As seen from the arrows in (b), OATP1A1 is present on the sinusoidal (basolateral) plasma membrane and is not present in areas identified as bile canaliculi (arrowheads). Bar = 10 μm.

Cell–cell junctions and communication

Hepatocytes interact with each other by specific intercellular junctional complexes that serve to establish cellular polarity as well as structure the organ into well-defined plates of cells [8]. These complexes surround the bile canaliculi (apical plasma membrane) and include desmosomes as well as gap, tight and adherens junctions. Tight junctions are the most apical of these junctional complexes, establishing cell polarity and providing a barrier function that prevents solute and water flow through the paracellular space [9]. They form a continuous band around each cell and are composed of a complex of several integral membrane proteins that include occludin and claudins [9,10]. A number of peripheral membrane proteins, including ZO-1, ZO-2 and ZO-3, are found in this complex [9,10]. Interestingly, gap junctional proteins have been found to interact with occludin and ZO-1, and coordinate regulation of these complexes has been suggested [8–11]. Desmosomes are found in areas that resemble dense plaques and are localized towards the basolateral side of tight junctions. They are attached to the cytoplasmic intermediate filament network and are composed of proteins from at least three distinct gene families, namely cadherins, armadillo proteins and plakins [12]. The adherens junction is another contact structure localized towards the basolateral side of tight junctions where it serves to anchor bundles of actin filaments. These junctions also represent large complexes of proteins that include cadherins and catenins [13,14].

Gap junctions are the major subcellular structures that permit the transfer of low-molecular-weight molecules between adjacent cells [9,15,16]. These molecules include various signal transduction agents such as inositol 1,4,5-triphosphate (IP_3) and cyclic adenosine monophosphate (cAMP), as well as Ca^{2+} and electrical signals [16–18]. The gap junctions are constituted by binding of hexamers of a connexin protein that form hemichannels at the surface of each of two adjacent cells. Although over 20 connexins have been described, the major connexin in hepatocytes is connexin 32, although there is a small amount of connexin 26 as well [16]. Recent studies have indicated that mutations in the connexin 32 gene are responsible for the X-linked form of Charcot–Marie–Tooth syndrome, a neurological disorder presenting as a peripheral neuropathy [19]. Interestingly, there is no evidence for liver dysfunction in these individuals. However, when liver from connexin 32 knockout mice was stressed following endotoxin administration, a more prolonged hypoglycaemia and cholestasis were observed, when compared with wild-type animals [16]. These alterations in hepatic stress response probably result from uncoupling of intercellular signalling mechanisms and suggest that similar abnormalities may be seen in connexin 32-deficient patients under conditions of stress.

Cytoskeleton

The hepatocyte cytoskeleton is an important determinant of polarized cell function. The major components of the cytoskeleton are intermediate filaments, microtubules and microfilaments. In contrast to microfilaments and microtubules that are polymers of actin and tubulin, respectively, over 50 different intermediate filament proteins have been described, and they are expressed in a cell type-specific manner. On the basis of structural characteristics, the intermediate filament proteins have been divided into five types [20,21]. Types 1 and 2 consist of two groups of keratins, representing the largest subgroups of intermediate filament proteins. Epithelial cells express at least one type 1 (acidic) and one type 2 (neutral/basic) keratin which, in the case of hepatocytes, are keratin 8 (type 2) and keratin 18 (type 1). These proteins form a complex network residing just below the actin-based microfilaments that surround the plasma membrane and are anchored to the plasma membrane at desmosomes, which are specialized junctions between adjacent cells. Although the function of intermediate filaments in hepatocytes is not known, several transgenic mouse models have indicated that altered expression of the hepatocyte keratins is associated with increased hepatocyte mechanical fragility and susceptibility to injury [20,22–24].

Microfilaments, polymers of actin, form a thin belt around the periphery of hepatocytes [25]. Interestingly, these actin filaments are especially concentrated around the bile canalicular (apical) plasma membrane (Fig. 2) [26]. Although it has been suggested that this abundant bile canalicular distribution might

be important for contraction of the canaliculus and the consequent force that initiates bile flow [27,28], there has been little recent work in this potentially important area. Within the hepatocyte, actin filaments are organized into networks and bundles, under the regulation of a number of proteins that bind to actin. Although actin structures are important determinants of cell shape and motility in many cell types, their function in the hepatocyte remains to be clarified. As these bundles of actin lie immediately below the hepatocyte plasma membrane [25], they form a barrier to entry into the cell of structures such as endocytic vesicles (see below). Myosins are molecules that can bind to actin and move on microfilaments in the presence of ATP [29]. They have the ability to bind specific vesicular cargo and facilitate its movement thorough the microfilamentous barrier [29]. Directly below and arranged perpendicular to the actin layer is a network of microtubules [25].

Microtubules are polymers of tubulin that emanate from an organizing centre. In hepatocytes, this microtubule organizing centre is near the nucleus. Owing to the biochemical characteristics of tubulin, its polymers (microtubules) have a directional polarity in which what has been termed the minus end is at the microtubule organizing centre near the cell nucleus, while the plus end is towards the cell surface [25,30]. Functionally, these polarized regions of the microtubule can be differentiated by the rate at which extension in the presence of unpolymerized tubulin occurs: the minus end grows slowly, while the plus end grows rapidly, on account of its preferential binding of tubulin. Recent studies have indicated an important role for microtubules in serving as 'railway tracks' along which intracellular vesicles and organelles can ride, powered by kinesins and dyneins, microtubule-based motors [31].

Receptor-mediated endocytosis

Receptor-mediated endocytosis is a process in which the binding of a ligand to a specific cell surface receptor initiates an intricate series of events resulting in internalization of the ligand–receptor complex into a vesicle that is processed to discrete destinations within the cell (Fig. 3). A hepatocyte-specific ligand that has been the subject of much investigation is asialoorosomucoid (ASOR). ASOR is prepared by removal of the terminal sialic acid residues on the carbohydrate chains of orosomucoid (α1-acid glycoprotein). This desialylated glycoprotein binds virtually irreversibly to a receptor on the hepatocyte surface plasma membrane that has been termed the asialoglycoprotein receptor [32]. Although the physiological function of this receptor is not known, it mediates internalization and processing of its bound ligand by a process that serves as a prototype for receptor-mediated endocytosis of other ligands, including low-density lipoproteins [33,34]. Following binding of ASOR to its cell surface receptor, the ligand–receptor complex is internalized into a vesicle that is coated with the protein clathrin [35–37]. Following uncoating, this vesicle acidifies [38], and this results in the unbinding of ligand from receptor [39]. This endocytic vesicle then undergoes a series of fissions, the consequence of which is the eventual segregation of ligand from receptor, resulting in their localization into separate daughter vesicles [33,35,36]. Following segregation, one group of daughter vesicles that contain the majority of receptor and a reduced content of ligand recycles to the cell surface. The other group of daughter vesicles that contain little receptor but most of the ligand [40] traffics through the cell to the lysosome, where ligand is degraded [33,36,39]. Lysosomes are spherical membrane-delimited organelles, first discovered in hepatocytes by biochemical procedures and then demonstrated in intact hepatocytes by microscopy [41,42]. Subsequently, these organelles were shown to be ubiquitous in virtually all cell types, where they play a major role in degradation of endocytosed and endogenous macromolecules [42,43]. This degradative function is mediated by enzymes within lysosomes that include a variety

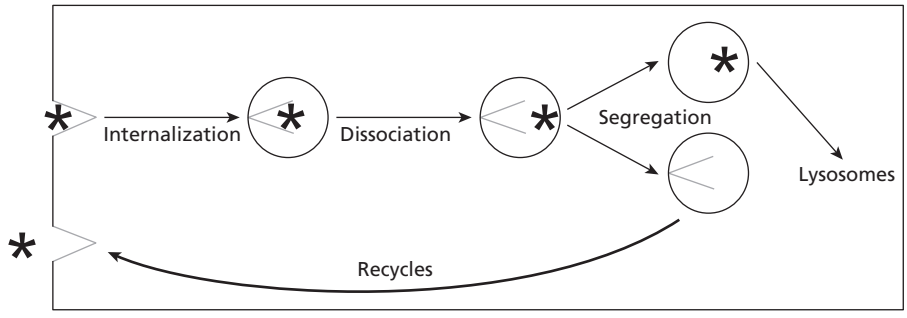

Fig. 3 Pathway of receptor-mediated endocytosis. Asialoorosomucoid (ASOR) is a hepatocyte-specific ligand that has been the subject of much investigation. ASOR (indicated by *) binds virtually irreversibly to a receptor on the hepatocyte surface plasma membrane that has been termed the asialoglycoprotein receptor. Binding to its receptor initiates internalization of the complex into an endocytic vesicle. Following acidification of this vesicle, ligand dissociates from receptor. This endocytic vesicle then undergoes a series of fissions that result in the eventual segregation of ligand from receptor and their localization into separate daughter vesicles. Following segregation, one group of daughter vesicles that contain the majority of receptor and a reduced content of ligand recycles to the cell surface. The other group of daughter vesicles that contain little receptor but most of the ligand traffics through the cell to the lysosome, where ligand is degraded [33,36,39]. Although the physiological function of the asialoglycoprotein receptor is not known, it mediates internalization and processing of its bound ligand by a process that serves as a prototype for receptor-mediated endocytosis of many other ligands.

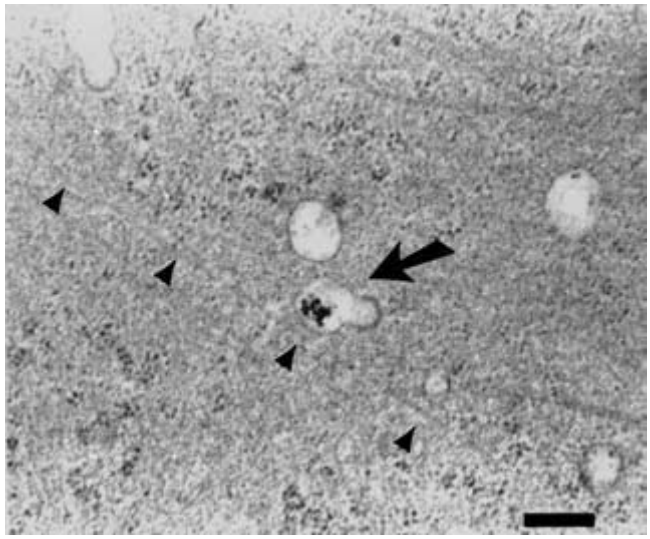

Fig. 4 Association of an endocytic vesicle with a microtubule in a hepatocyte. This is a transmission electron micrograph obtained 60 min after single-wave endocytosis of gold-conjugated ASOR by overnight cultured rat hepatocytes. An endocytic vesicle containing the gold label (arrow) is found in close proximity to a microtubule (arrowheads). In the endocytic vesicle shown in this micrograph, label is localized to one pole. Bar = 200 nm. Reprinted from ref. 30, with permission.

of acid hydrolases capable of breaking down the major classes of biological macromolecules (e.g. carbohydrates, lipids, proteins, nucleic acids) into smaller components. In hepatocytes, lysosomes are distributed throughout the cytoplasm with a greater concentration near the bile canaliculus. Lysosomes exhibit a heterogeneous morphological appearance, and the different types are referred to in the literature as dense bodies, autophagic vacuoles, phagocytic vacuoles, pinocytic vacuoles, multivesicular bodies, residual bodies and tubular lysosomes. All types of lysosomes contain at least one acid hydrolase. Defects in their membrane or deficiencies in their enzyme content have resulted in the development of a number of human pathologies including a variety of lysosomal storage diseases [44].

Although little was known about the mechanism by which endocytic vesicles undergo fission and sort ligand from receptor, a number of studies suggested a role for microtubules and molecular motors in this process [25,30,33,45–52]. After internalization of ligand–receptor complexes, endocytic vesicles attach to and move along microtubules (Fig. 4). In recent studies, the process of segregation of ligand and receptor in early endocytic vesicles was reconstituted *in vitro* on microtubules using a novel fluorescence microscopy procedure in which microtubules have been attached to the surface of glass microscopy chambers (Fig. 5) [53,54]. In these studies, rat liver



Fig. 5 Fission of a microtubule-bound endocytic vesicle *in vitro*. Texas red asialoorosomucoid (ASOR)-containing vesicles and rhodamine-labelled microtubules are in the top row. The bottom row shows the asialoglycoprotein receptor as visualized following incubation with a primary antibody and a Cy2-labelled secondary antibody. Time in seconds after addition of 50 μM ATP is shown at the upper left of each panel. Initially, the arrowhead points to a single vesicle that contains both ligand and receptor. Following the addition of ATP, this vesicle is seen to elongate and eventually to split into two daughter vesicles. Although both these daughter vesicles contain fluorescent ASOR, the one on the right contains almost all the receptor. Bar = 10 μm.

endocytic vesicles were fluorescently labelled by injection of rats with fluorescent ASOR for 5 or 15 min prior to liver harvest and vesicle purification. It was found that 5-min vesicles contained both ASOR and its receptor, indicating that they were early (presegregation) endocytic vesicles. In contrast, 15-min vesicles contained ligand but little receptor, indicating that they were late (postsegregation) endocytic vesicles. These two groups of vesicles bound to microtubules in the microscopy assay, and a substantial fraction of each group moved along the microtubules following ATP addition. However, only the early endocytic vesicles underwent fission into daughter vesicles [53,54]. Evidence suggested that this fission event was mediated by a classical kinesin motor molecule that moves towards the plus end of microtubules and a novel minus-end directed kinesin known as KifC2 [54]. The activity of KifC2 was regulated by Rab4, a small guanosine 5′-triphosphate (GTP) binding protein that is present on these early endocytic vesicles [31,54]. The late endocytic vesicles had a different complement of motor molecules and Rab proteins [31], being highly associated with dynein, a motor molecule that mediates minus end-directed movement on microtubules, Rab7, and Kif3A, a plus end-directed kinesin that was not present on the early endocytic vesicles [31,54]. These studies indicate that, over this relatively short time (10 min), acquisition and exchange of specific motor and regulatory proteins regulates the transition of early to late endocytic vesicles. The mechanism by which these important processes occur is currently under investigation.

Summary

Although simple in appearance, the hepatocyte is a complex and unique epithelial cell with subcellular structures that support important and life-sustaining biological processes. There has been much recent progress in the elucidation of these cellular components at the molecular level, and it has become apparent that there is a great deal of interaction and cross-talk between these structures within the cell. Despite this progress and novel insight into structure–function relationships within the hepatocyte, much remains to be learned regarding areas that include mechanisms to define and maintain cell polarity, cytoskeletal and motor function and interaction, and trafficking mechanisms for subcellular components. The importance of such investigation is not just theoretical, but may have major implications regarding the pathobiology and treatment of the many disorders characterized by disruption of normal hepatocyte function and homeostasis.

Acknowledgement

Supported by NIH grants CA006576, DK41918 and DK23026.

References

1 Novikoff AB, Essner E (1960) The liver cell. Some new approaches to its study. *Am J Med* 29, 102–131.
2 Ihrke G, Martin GV, Shanks MR *et al.* (1998) Apical plasma membrane proteins and endolyn-78 travel through a subapical compartment in polarized WIF-B hepatocytes. *J Cell Biol* 141, 115–133.
3 Kipp H, Arias IM (2002) Trafficking of canalicular ABC transporters in hepatocytes. *Annu Rev Physiol* 64, 595–608.
4 Bastaki M, Braiterman LT, Johns DC *et al.* (2002) Absence of direct delivery for single transmembrane apical proteins or their 'secretory' forms in polarized hepatic cells. *Mol Biol Cell* 13, 225–237.
5 Casanova JE, Mishumi Y, Ikehara Y *et al.* (1991) Direct apical sorting of rat liver dipeptidylpeptidase IV expressed in Madin–Darby canine kidney cells. *J Biol Chem* 266, 24428–24432.
6 Kremmer T, Wisher MH, Evans WH (1976) The lipid composition of plasma membrane subfractions originating from the three major functional domains of the rat hepatocyte cell surface. *Biochim Biophys Acta* 455, 655–664.
7 Storch J, Schachter D, Inoue M *et al.* (1983) Lipid fluidity of hepatocyte plasma membrane subfractions and their differential regulation by calcium. *Biochim Biophys Acta* 727, 209–212.
8 Kojima T, Yamamoto T, Murata M *et al.* (2003) Regulation of the blood–biliary barrier: interaction between gap and tight junctions in hepatocytes. *Med Electron Microsc* 36, 157–164.
9 Kojima T, Spray DC, Kokai Y *et al.* (2002) Cx32 formation and/or Cx32-mediated intercellular communication induces expression and function of tight junctions in hepatocytic cell line. *Exp Cell Res* 276, 40–51.
10 Yamamoto T, Kojima T, Murata M *et al.* (2004) IL-1beta regulates expression of Cx32, occludin, and claudin-2 of rat hepatocytes via distinct signal transduction pathways. *Exp Cell Res* 299, 427–441.
11 Kojima T, Sawada N, Chiba H *et al.* (1999) Induction of tight junctions in human connexin 32 (hCx32)-transfected mouse hepatocytes: connexin 32 interacts with occludin. *Biochem Biophys Res Commun* 266, 222–229.
12 Yin T, Green KJ (2004) Regulation of desmosome assembly and adhesion. *Semin Cell Dev Biol* 15, 665–677.
13 Tepass U (2002) Adherens junctions: new insight into assembly, modulation and function. *BioEssays* 24, 690–695.
14 Nagafuchi A (2001) Molecular architecture of adherens junctions. *Curr Opin Cell Biol* 13, 600–603.
15 Kojima T, Sawada N, Duffy HS *et al.* (2001) Gap and tight junctions in liver: composition, regulation, and function. In: Arias IM, Boyer JL, Chisari FV *et al.* (eds) *The Liver, Biology and Pathobiology*, 4th edn. Philadelphia: Lippincott Williams & Wilkins, pp. 29–46.
16 Correa PR, Guerra MT, Leite MF *et al.* (2004) Endotoxin unmasks the role of gap junctions in the liver. *Biochem Biophys Res Commun* 322, 718–726.
17 Revel JP, Karnovsky MJ (1967) Hexagonal array of subunits in intercellular junctions of the mouse heart and liver. *J Cell Biol* 33, C7–C12.
18 Spray DC (1996) Molecular physiology of gap junction channels. *Clin Exp Pharmacol Physiol* 23, 1038–1040.
19 Bergoffen J, Scherer SS, Wang S *et al.* (1993) Connexin mutations in X-linked Charcot–Marie–Tooth disease. *Science* 262, 2039–2042.
20 Omary MB, Ku NO, Toivola DM (2002) Keratins: guardians of the liver. *Hepatology* 35, 251–257.
21 Kumemura H, Harada M, Omary MB *et al.* (2004) Aggregation and loss of cytokeratin filament networks inhibit golgi organization in liver-derived epithelial cell lines. *Cell Motil Cytoskeleton* 57, 37–52.
22 Ku NO, Michie SA, Soetikno RM *et al.* (1996) Susceptibility to hepatotoxicity in transgenic mice that express a dominant-negative human keratin 18 mutant. *J Clin Invest* 98, 1034–1046.

23 Ku NO, Michie S, Oshima RG *et al.* (1995) Chronic hepatitis, hepatocyte fragility, and increased soluble phosphoglycokeratins in transgenic mice expressing a keratin 18 conserved arginine mutant. *J Cell Biol* 131, 1303–1314.
24 Zatloukal K, Stumptner C, Fuchsbichler A *et al.* (2004) The keratin cytoskeleton in liver diseases. *J Pathol* 204, 367–376.
25 Novikoff PM, Cammer M, Tao L *et al.* (1996) Three-dimensional organization of rat hepatocyte cytoskeleton: relation to the asialoglycoprotein endocytosis pathway. *J Cell Sci* 109, 21–32.
26 Bergwerk AJ, Shi X, Ford AC *et al.* (1996) Immunologic distribution of an organic anion transport protein in rat liver and kidney. *Am J Physiol* 271, G231–G238.
27 Tsukada N, Phillips MJ (1993) Bile canalicular contraction is coincident with reorganization of pericanalicular filaments and co-localization of actin and myosin-II. *J Histochem Cytochem* 41, 353–363.
28 Tsukada N, Ackerley CA, Phillips MJ (1995) The structure and organization of the bile canalicular cytoskeleton with special reference to actin and actin-binding proteins. *Hepatology* 21, 1106–1113.
29 Chan W, Calderon G, Swift AL *et al.* (2005) Myosin II regulatory light chain is required for trafficking of bile salt export protein to the apical membrane in Madin–Darby canine kidney cells. *J Biol Chem* 280, 23741–23747.
30 Goltz JS, Wolkoff AW, Novikoff PM *et al.* (1992) A role for microtubules in sorting endocytic vesicles in rat hepatocytes. *Proc Natl Acad Sci USA* 89, 7026–7030.
31 Bananis E, Nath S, Gordon K *et al.* (2004) Microtubule-dependent movement of late endocytic vesicles *in vitro*: requirements for dynein and kinesin. *Mol Biol Cell* 15, 3688–3697.
32 Stockert RJ (1995) The asialoglycoprotein receptor: relationships between structure, function, and expression. *Physiol Rev* 75, 591–609.
33 Wolkoff AW, Klausner RD, Ashwell G *et al.* (1984) Intracellular segregation of asialoglycoproteins and their receptor: a prelysosomal event subsequent to dissociation of the ligand–receptor complex. *J Cell Biol* 98, 375–381.
34 Stockert RJ, Potvin B, Tao L *et al.* (1995) Human hepatoma cell mutant defective in cell surface protein trafficking. *J Biol Chem* 270, 16107–16113.
35 Mellman I (1996) Endocytosis and molecular sorting. *Annu Rev Cell Dev Biol* 12, 575–625.
36 Mukherjee S, Ghosh RN, Maxfield FR (1997) Endocytosis. *Physiol Rev* 77, 759–803.
37 Marsh M, McMahon RT (1999) The structural era of endocytosis. *Science* 285, 215–220.
38 Forgac M (1998) Structure, function and regulation of the vacuolar (H^+)-ATPases. *FEBS Lett* 440, 258–263.
39 Harford J, Wolkoff AW, Ashwell G *et al.* (1983) Monensin inhibits intracellular dissociation of asialoglycoproteins from their receptor. *J Cell Biol* 96, 1824–1828.
40 Geuze HJ, Slot JW, Strous GJAM *et al.* (1984) Intracellular receptor sorting during endocytosis: comparative immunoelectron microscopy of multiple receptors in rat liver. *Cell* 37, 195–204.
41 De Duve C, Wattiaux R (1966) Functions of lysosomes. *Annu Rev Physiol* 28, 435–492.
42 Novikoff AB, Novikoff PM (1988) Lysosomes. In: Arias IM, Jakoby WB, Popper H *et al.* (eds) *The Liver: Biology and Pathobiology*, 2nd edn. New York: Raven Press, pp. 227–239.
43 Cuervo AM (2004) Autophagy: in sickness and in health. *Trends Cell Biol* 14, 70–77.
44 Vellodi A (2005) Lysosomal storage disorders. *Br J Haematol* 128, 413–431.
45 Jin M, Snider MD (1993) Role of microtubules in transferrin receptor transport from the cell surface to endosomes and the Golgi complex. *J Biol Chem* 268, 18390–18397.
46 Satir P (1994) Motor molecules of the cytoskeleton. Possible functions in the hepatocyte. In: Arias IM, Boyer JL, Fausto N *et al.* (eds) *The Liver: Biology and Pathobiology*, 3rd edn. New York: Raven Press, pp. 45–52.
47 Thatte HS, Bridges KR, Golan DE (1994) Microtubule inhibitors differentially affect translational movement, cell surface expression, and endocytosis of transferrin receptors in K562 cells. *J Cell Physiol* 160, 345–357.
48 Lafont F, Burkhardt JK, Simons K (1994) Involvement of microtubule motors in basolateral and apical transport in kidney cells. *Nature* 372, 801–803.
49 Oda H, Stockert RJ, Collins C *et al.* (1995) Interaction of the microtubule cytoskeleton with endocytic vesicles and cytoplasmic dynein in cultured rat hepatocytes. *J Biol Chem* 270, 15242–15249.
50 Hamm-Alvarez SF, Wei X, Berndt N *et al.* (1996) Protein phosphatases independently regulate vesicle movement and microtubule subpopulations in hepatocytes. *Am J Physiol* 271, C929–C943.
51 Hamm-Alvarez SF, Sheetz MP (1998) Microtubule-dependent vesicle transport: modulation of channel and transporter activity in liver and kidney. *Physiol Rev* 78, 1109–1129.
52 Murray JW, Bananis E, Wolkoff AW (2000) Reconstitution of ATP-dependent movement of endocytic vesicles along microtubules *in vitro*: an oscillatory bidirectional process. *Mol Biol Cell* 11, 419–433.
53 Bananis E, Murray JW, Stockert RJ *et al.* (2000) Microtubule and motor-dependent endocytic vesicle sorting *in vitro*. *J Cell Biol* 151, 179–186.
54 Bananis E, Murray JW, Stockert RJ *et al.* (2003) Regulation of early endocytic vesicle motility and fission in a reconstituted system. *J Cell Sci* 116, 2749–2761.
55 Wang P, Wang JJ, Xiao Y *et al.* (2005) Interaction with PDZK1 is required for expression of organic anion transporting protein 1A1 (OATP1A1) on the hepatocyte surface. *J Biol Chem* 280, 30143–30149.

2.2.3 Molecular biology of the liver cell

Sundararajah Thevananther and Saul J. Karpen

Introduction

The diversified and specialized liver functions are primarily supported by hepatocytes, which exhibit enormous capacity to respond to stressors and environmental cues effectively by activating discrete cell signalling cascades initiated at the cell surface receptors. Eventually, short-term and long-term changes occur within the cell, by modification of the activity of a broad variety of resident proteins (such as kinases, phosphatases and P-450 enzymes), modulation of the transcription of mRNA molecules

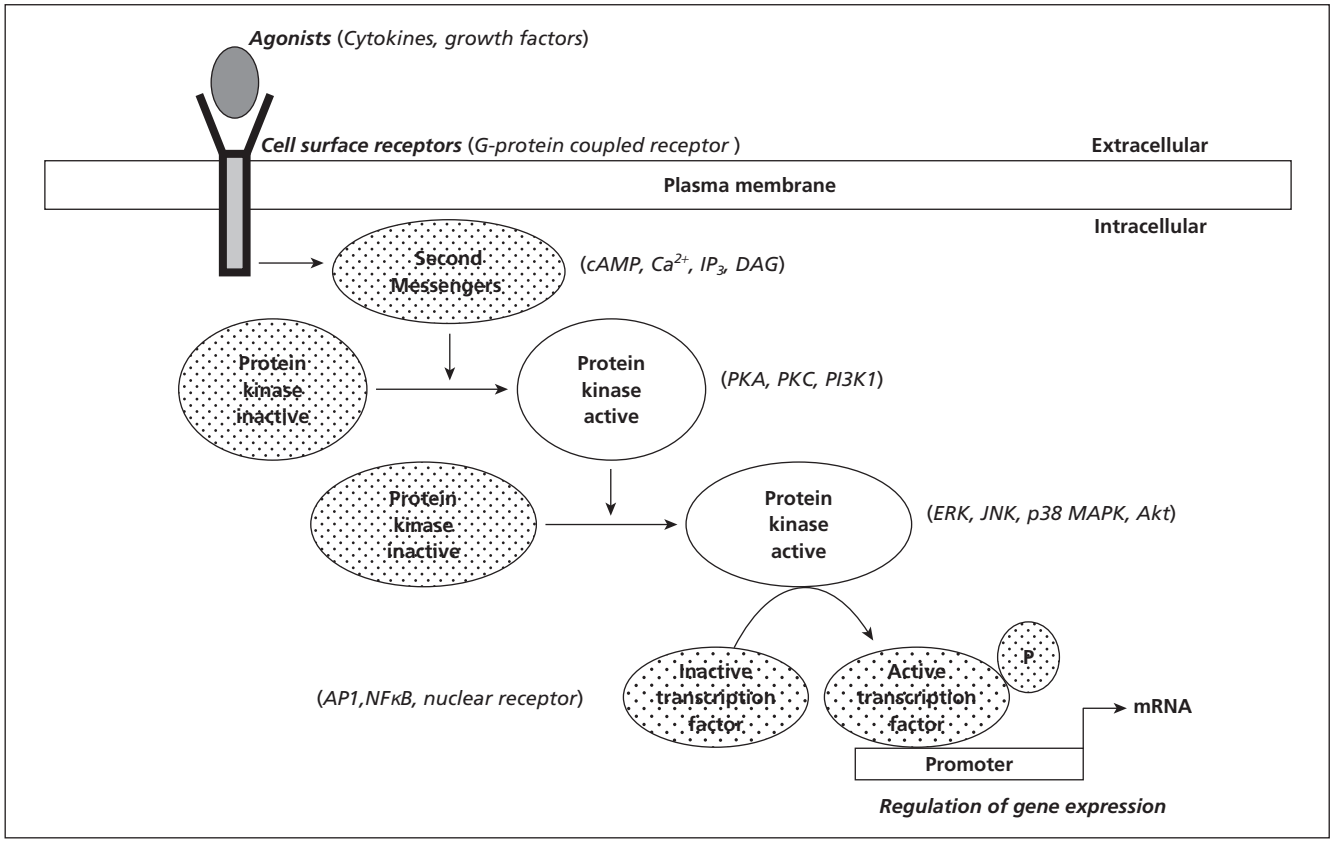

Fig. 1 General outline of liver cell signalling. See main text for definitions of abbreviations.

and synthesis of new proteins and by changes in the function or expression of nuclear transcription factors. Altogether, these processes are known as molecular adaptation, and the molecular arsenal within hepatocytes applied to cell signalling is interrelated, balanced and poised for the ultimate goal of reducing toxicity and restoring homeostasis in the most effective and expedient fashion possible. Without such an integrated, complex and balanced set of signalling responses, hepatocytes may be underdeveloped or over-reaching in their responses to stressors.

In essence, the general plan of cell signalling is to spread out the signal to as many proteins and effector molecules as possible in order to provide the maximum effective response. In some ways, it is tempting to think that the processes of cell signalling are deeply ingrained in the hepatocyte's central position at the crossroads of metabolism, which involves the production, handling and detoxification of dietary products and potential toxins from within (endobiotics) as well as from the environment (xenobiotics). The scope of this chapter will be limited to highlighting the role of signal transduction in the regulation of gene expression by its influence on the activity of transcription factors. This will include a description of key components of prototype signal transduction pathways in the liver cell with specific details regarding receptor activation, generation of second messengers, activation of kinases and phosphatases, posttranslational modification of critical hepatic transcription factors and their role in the regulation of gene expression in the liver (Fig. 1). A detailed description of all the interrelated and competing mechanisms at play in the hepatocyte that constitute cell signalling is beyond the scope of this chapter, and the reader is referred to several recent excellent reviews [1–10].

Signal transduction

Activation of cell surface receptors and ion channels

Receptors and ion channels expressed at the cell surface 'sense' changes in the extracellular milieu of hepatocytes and modify the biological response to a multitude of physiological and pathological factors. Initiating changes in cell function and gene expression in response to environmental cues is one of the central and evolutionarily conserved ways in which the hepatocyte enacts its responses.

G protein-coupled receptors

G protein-coupled receptors are heptahelical transmembrane proteins whose activity is modulated via changes in agonist concentrations at the cell surface. Receptor–agonist interactions

initiate a cascade of downstream events that is critically dependent on the subset of trimeric G proteins (α, β, γ) that interact with receptors. Receptor–G_α protein interaction leads to the activation and dissociation of G_α from $G_{\beta\gamma}$ and generation of second messengers such as cyclic adenosine monophosphate (cAMP), inositol 1,4,5-triphosphate (IP_3) and diacylglycerol (DAG). Cellular responses to fluctuations in hormones and growth factors are dependent on the types and abundance of G protein-coupled receptors expressed at the sinusoidal and canalicular surface of hepatocytes [11].

Receptor tyrosine kinases

Peptide growth factor signalling is transduced mostly via the activation of receptor tyrosine kinases (RTKs). RTKs are a class of cell surface receptors with a single transmembrane domain separating the extracellular domains, with affinity for peptide growth factors such as insulin and epidermal growth factor, from the intracellular cytoplasmic domains with tyrosine kinase activity. Autophosphorylation of RTKs activates a cascade of small GTPases such as Ras, Rac, RhoA and Cdc42 [9].

Ion channels

Ion channels play integral roles in modulating a variety of synthetic and secretary functions of hepatocytes. Hepatocytes express ligand-gated and voltage-sensitive anion and cation channels that regulate ion exchange with the extracellular milieu. Cell volume regulation is one of the most fundamental homeostatic mechanisms and essential for normal hepatocyte function [12]. Cell swelling evokes a series of signalling events resulting in the activation of K^+ and Cl^- efflux via ion channels, which plays a key role in the regulatory volume decrease and restoration of homeostasis [13]. Ion fluxes induced by the activity of ion channels influence several key events in the life cycle of hepatocytes, such as cell cycle control, proliferation, survival and apoptosis [14]. Several ion channels are linked to the cytoskeleton, and ion channel function is greatly affected by the changes in the submembranous cytoskeleton.

Generation of second messengers

Activation of cell surface receptors and ion channels results in the generation of second messengers such as cyclic nucleotides (cAMP, cGMP), lipids (IP_3, DAG), Ca^{2+}, prostaglandins and nitric oxide (NO).

cAMP

A large number of hormones, peptides and neurotransmitters interact with several G protein-coupled receptors. The αs subunit of G proteins ($G_{\alpha s}$) activates adenylate cyclase, which catalyses the generation of cAMP from adenosine triphosphate (ATP). Increase in intracellular cAMP levels leads to the activation of a cAMP-dependent kinase, protein kinase A (PKA). The effects of cAMP are primarily mediated via the activation of PKA and influence a wide range of metabolic, synthetic and secretory functions of hepatocytes. For example, PKA phosphorylates hormone-sensitive lipase and perilipin, and results in increased lipolysis. Conversely, activation of the αi subunit of G proteins ($G_{\alpha i}$) inhibits lipolysis via the inhibition of adenylate cyclase and reductions in the intracellular cAMP levels. Phosphodiesterases participate in the termination of cAMP/PKA signalling by hydrolysing and reducing intracellular cAMP levels [4].

Lipids

IP_3 and DAG play important roles in the activation of Ca^{2+} signalling and protein kinase C (PKC). Agonists such as ATP and vasopressin binding at the $G_{\alpha q}$ protein-coupled cell surface receptors lead to the generation of IP_3 and DAG. The αq subunit of G protein interacts with the enzyme phospholipase C (PLCβ) and activates the translocation of the enzyme to the plasma membrane. In addition, the dimeric βγ subunits enhance the membrane tethering of PLCβ, promote the hydrolysis of phosphatidylinositol 4,5-bisphosphate and stimulate the production of Ca^{2+}-mobilizing second messengers IP_3 and DAG. IP_3, in turn, activates the release of Ca^{2+} via the activation of IP_3 receptors (IP_3Rs) located in the endoplasmic reticulum, whereas DAGs play a role in the activation of conventional and novel PKCs.

In addition to G protein-coupled receptors, the phosphoinositide signalling pathway can be activated by the agonist-induced dimerization and tyrosine autophosphorylation of RTKs, creating high-affinity docking sites for SH2-containing PLCγ, which in turn catalyses the generation of IP_3 and DAG [15].

Ca^{2+}

Intracellular Ca^{2+} is a versatile second messenger in hepatocytes that plays a central role in regulating multiple hepatic functions and influencing varied processes such as secretion, contraction, metabolism, gene transcription and cell proliferation and apoptosis [16]. Intracellular cytosolic Ca^{2+} levels are influenced by upstream signalling events that activate the release of Ca^{2+} from intracellular stores (endoplasmic reticulum, Golgi, nucleoplasmic reticulum) as well as the Ca^{2+} influx from the extracellular milieu. The spatial and temporal patterns of calcium signals are believed to be responsible for determining the specificity and functional outcome of Ca^{2+} signalling. The subcellular distribution of the three isoforms of IP_3 receptors (types 1, 2 and 3), which differ in their affinity for IP_3 and regulation by Ca^{2+}, shape the amplitude, duration and wave patterns of Ca^{2+} transients in the cytosol. Nucleoplasmic reticulum enriched in type 2 IP_3Rs serves as a distinct reservoir of Ca^{2+} within the nuclei and is responsible for the localized generation of Ca^{2+} signals within the nucleus. The versatility of Ca^{2+} signalling within hepatocytes is underlined by their distinct ability to independently modulate Ca^{2+} signalling in the cytosolic vs. nuclear compartments [6,17,18].

Prostanoids

Prostaglandins are believed to play a role in mitogenic signal transduction in the regenerating liver and hepatocellular

carcinoma. Phospholipase A_2 (PLA_2) activity leads to arachidonic acid release from the plasma membrane. Metabolism of arachidonic acids by the cyclo-oxygenases (COXs) leads to the generation of prostanoids, including prostaglandins and thromboxanes, in the liver. Hepatocyte growth factor receptor-mediated activation of mitogen-activated protein kinases (MAPKs) and elevations in intracellular Ca^{2+} are believed to play a role in the activation of PLA_2 [19,20].

Nitric oxide (NO)

The free radical NO has emerged in recent years as a small signalling molecule playing protective roles against hepatocyte apoptosis induced by tumour necrosis factor α (TNFα) and Fas ligand [21]. NO is synthesized in the cytosol and mitochondria by constitutive and inducible nitric oxide synthases (cNOS and iNOS). Under normal conditions, lower levels of NO generated act as a messenger and cytoprotective (antioxidant) factor, via direct interactions with transition metals and other free radicals. However, proinflammatory signalling leads to elevations in NO, which in turn binds and activates soluble guanylyl cyclase, leading to the conversion of guanosine triphosphate (GTP) into cyclic GMP (cGMP). Increased cGMP levels via the activation of protein kinase G (PKG) protect hepatocytes against ischaemia–reperfusion injury [22].

Activation of signalling cascades

Protein kinases influence cellular functions by catalysing the addition of a phosphate group to proteins at serine, threonine or tyrosine residues, thus serving as molecular switches discretely turning 'on' and 'off' protein function in a specific manner [23]. Hepatocellular signalling cascades often consist of multiple protein kinases acting in tandem, facilitating signal amplification and target protein modification in order to adapt and respond to the changes in the environment. Among the multiple protein kinases expressed in hepatocytes, the following are discussed below based on their functional significance for hepatocytes.

Protein kinase A

PKA is a tetrameric holoenzyme consisting of two regulatory and two catalytic subunits. cAMP binding at the regulatory subunits results in the dissociation of the PKA–protein complex. The activated catalytic subunits are released from cytoplasmic anchoring sites and phosphorylate a variety of cytoplasmic and nuclear substrates on serine sites within the canonical sequence X-Arg-Arg-X-Ser-X. Binding of MgATP at the regulatory subunit I (RI) stabilizes the holoenzyme by raising the threshold for cAMP concentrations required for activation. Autophosphorylation of the regulatory subunit II (RII) leads to the destabilization of the holoenzyme and activation of catalytic subunits. The specificity of PKA action is determined in part by anchoring PKA to subcellular sites through the association of the regulatory subunits with A-kinase anchoring proteins. PKA activity plays a key role in the polarized localization of proteins and lipids into distinct apical and canalicular membrane domains in hepatocytes [24,25].

Protein kinase C (PKC)

PKCs are a family of serine/threonine kinases and consist of a family of at least 12 isoforms, classified into classical, novel and atypical PKCs based on their distinct mode of activation. The conventional PKC isoforms (cPKCα, βI, βII and γ) are activated by Ca^{2+} and phospholipids such as DAGs. The novel PKC isoforms (nPKCδ, ε, η and θ) are Ca^{2+} independent, and the atypical PKC isoforms (aPKCζ and λ) are independent of both Ca^{2+} and DAG [26].

Mitogen-activated protein kinases

MAPKs are important signal transducing enzymes connecting cell surface receptors to critical regulatory targets within hepatocytes. MAPK activity is controlled by a three-tiered cascade of MAPKs, MAPK kinases (MAPKK, MKK or MEK) and MAPKK kinase or MEK kinase (MAPKKK or MEKK). Several effector kinases such as MAPK-activated protein kinases (MAPKAPs) are activated by MAPKs, and MAPK signalling is attenuated by the action of MAPK phosphatases [5].

Hepatocytes express at least four distinct groups of MAPKs, i.e. extracellular signal-regulated kinases (ERK1/2 or p44/42 MAPK), c-jun N-terminal kinases (JNK1 and 2), p38 MAPK (p38α/α/γδ) and ERK5 [27–29]. Several growth factor and cytokine actions are mediated via the activation of multiple MAPK signalling pathways, influencing hepatocyte survival and proliferation. ERK1/2 activation in response to the activation of receptor tyrosine kinases by growth factors stimulates hepatocyte proliferation and survival [30]. Whereas JNK1/2 and p38 MAPK, collectively known as the stress-activated protein kinases (SAPKs), are activated by ultraviolet radiation, inflammatory cytokines and DNA damaging agents are linked to divergent liver functions such as the downregulation of gene expression during acute phase response, hepatocyte proliferation during liver regeneration and hepatocyte apoptosis [3,31–33].

Several distinct mechanisms ensure the specificity of MAPK activation. First, scaffolding proteins such as JIP1 organize JNK1/2 (MAPK), MKK7 (MAPKK) and MLK1 (MAPKKK) into a specific signalling cassette. Second, sequential physical interaction between members of a given cascade ensures the effective activation of a signalling pathway, as in the case of JNK1/2, which is bound by the N-terminal extension of MKK4 (MAPKK), which also interacts with the catalytic domain of MEKK1 (MAPKKK). Typically, the phosphoacceptor sites of MAPKs are composed of serine or threonine followed by a proline, and the neighbouring amino acids further increase the specificity of binding by the catalytic pocket of the kinase. Finally, full specificity is ensured through a docking interaction mediated by an additional site in the kinase that recognizes a distinct site other than the phosphoacceptor site in the substrate. For example, JNK recognizes and interacts with a short sequence that precedes the two principal

phosphoacceptor sites, Ser63 and Ser73, outside its catalytic pocket,[2,8].

Phosphatidylinositol-3-kinases (PI3Ks)

PI3Ks are heterodimers consisting of a catalytic subunit (p110) and a regulatory subunit (p85), and they phosphorylate at the 3′-OH group of the inositol ring in inositol lipids. Upon activation of receptor tyrosine kinases, PI3Ks associate with the receptor through its SH2 domains in the regulatory subunit, leading to the activation of the catalytic subunit of the enzyme. PI3K activity is responsible for the generation of the second messenger phosphatidylinositol 3,4,5-trisphosphate (PIP_3) from phosphatidylinositol 4,5-biphosphate at the inner leaflet of the plasma membrane. PIP_3 binding at the PH domain of proteins such as Akt/protein kinase B (PKB) and activation of downstream signalling play important roles in tumorigenesis and tumour progression in hepatocellular carcinoma. The PTEN phosphatase is a natural antagonist of the PI3K/Akt signalling pathway, and hepatitis B virus X protein (HBx)-mediated activation of Akt signalling is associated with a decrease in PTEN levels [34]. In addition to their effects on hepatocyte proliferation and metastasis, PI3K/Akt pathways influence vesicular trafficking, bile formation and bile acid secretion [35,36].

Rho GTPases

Apart from the heterotrimeric G proteins, which transduce signals from the serpentine G protein-coupled receptors (GPCRs), another superfamily of small G proteins, consisting of the Rho family of GTPases (Rho, Rac, Cdc42), plays key roles in the regulation of a variety of cellular processes in hepatocytes. Activation of receptor tyrosine kinases and GPCRs leads to the activation of Rho guanine nucleotide exchange factors (GEFs) and their Rho GTPase substrates. GEFs destabilize the inactive GDP–G protein complex, inducing the release of GDP and the binding of cytosolic GTP, activating the G proteins. GTPase-activating proteins (GAPs) induce the hydrolysis of GTP bound to G proteins and inactivate them [9].

The Rho family of GTPase-mediated signalling molecules plays key roles in the organization of the cell cytoskeleton and the cell–cell and cell–matrix interactions, which influence hepatocyte polarity, gene transcription and growth regulation. Additionally, small GTPases play integral roles in the activation of JNK signalling and stimulation of DNA synthesis in primary hepatocytes in response to known agonists such as TNFα and hepatocyte growth factor [37].

Transcription factors and regulation of gene expression

In addition to alterations in the activity of cell surface receptors, second messengers and intracellular kinases, one of the major ways in which hepatocytes respond to external stimuli in a sustained fashion is to reprogramme mRNA transcription. In general, the primary mediators of gene regulation are nuclear proteins, typically referred to as transcription factors. In many ways, transcription factors can be thought of as proteins that bridge the gap between DNA regulatory sequences in genes (promoter regions) and the freely mobile proteins in the cell that execute changes initiated by cell signalling cascades [38,39]. Although, in a general sense, transcription factors can be thought of as DNA-binding proteins, they cannot effect transcription alone [40]. It is best to consider these DNA-binding proteins as anchors for the transcription factor complex, which includes co-regulators, cofactors, chromatin-modifying proteins and RNA polymerases, which together constitute a transcription initiation complex. Recent evidence even indicates that small RNA molecules are components of the transcription initiation complex [41,42]. A detailed review of the role of all members of the transcription initiation complex in regulating gene expression in hepatocytes is beyond the scope of this chapter, but highlighting a few select transcription factors, families and their interactions and responses to cell signalling processes will serve as informative examples of hepatocyte response [7,43,44]. Given their central roles as the ultimate effector molecules of cell signalling cascades, we will focus on the following target transcription factors and families: AP1, NFκB, the forkhead family and multiple members of the nuclear receptor superfamily.

AP1 and NFκB

These two transcription factor complexes have become recognized as the centrepieces of the hepatocyte's response to inflammation and infection, but they also play pivotal roles in cell survival, growth response to injury and apoptosis [3,31,45–51]. Nearly all cells in the body engage AP1 and NFκB complexes in response to stressors and injury, and their central role in hepatocyte functions ranges from acute phase response and intermediary metabolism to toxin disposal. In addition, it is important to recognize that AP1 and NFκB are both critically involved in the development of the liver, as single gene deletions in critical components of these two proteins are lethal *in utero*, and the mice do not form livers [32,52–54].

AP1 is a complex of two proteins that contains either homodimers of c-jun or heterodimers of c-jun with c-fos. These are potent regulators of gene transcription for those genes that have AP1 response elements, but they also interact with multiple different proteins in order to spread out the signal [55]. It is important to note that there are many different pathways that lead to the activation of AP1, and they generally involve phosphorylation of pre-existing components of the AP1 complex that then activates it. The one that appears to be most relevant is one of the MAPKs, in particular c-jun N-terminal kinase or JNK [33]. Once JNK is activated, it phosphorylates c-jun. AP1 target genes are numerous in the liver and are present not only in hepatocytes, but also in Kupffer cells, stellate cells, cholangiocytes and all associated inflammatory cells. In Kupffer cells and inflammatory cells, activated AP1 induces the expression of a broad variety of cytokines and other secreted inflammatory

proteins. In hepatocytes, activation of both c-jun and AP1 alters the expression of several genes essential for cell survival, whereas sustained activation of JNK and AP1 can be deleterious to the cell [50].

The other primary component of the two-pronged induction of intracellular signalling associated with inflammation is NFκB. Similar in concept to AP1, activation of select kinases activates NFκB by releasing it from an inactive complex. Like AP1, NFκB is a two-part transcription factor assembly (p50 and p65) that is retained in the cytoplasm in an inactive form in complex with other proteins including an inhibitor, IκB [47,56). In response to the activation of certain cell surface receptors (e.g. cytokine receptors), upstream kinases activate IκB kinase (IKK), which leads to the phosphorylation and degradation of inhibitory IκB and releases NFκB, which then targets to the nucleus. Once in the nucleus, NFκB can change gene expression by binding to target sequences within appropriate promoter contexts. As is the case for AP1, the NFκB protein complex has activities that extend far beyond those of binding to DNA elements in promoter regions, and also has broad interactions with a variety of proteins involved in transcription as well as basic cellular functions and cell survival. Finally, NFκB plays a critical role in cell cycle regulation and hepatocellular carcinogenesis, perhaps best understood in its role as an antiapoptotic agent [51,57]. Although we now understand a lot more about NFκB and AP1, it is quite apparent that the competing, overlapping and contradictory target gene regulations of these two potent transcription factors are still being determined. One example of NFκB activation leading to export of toxins is the rapid and profound activation of the *MDR1b* gene by NFκB [58]. This multispecific substrate transporter is responsible for the export of a broad variety of toxins and drugs from the hepatocyte.

Among the more interesting and exciting findings over the past few years is an ongoing relationship between adaptive immunity and innate immunity, which extends beyond T and B cells to incorporate hepatocytes as the central components of the immune system. This is an ancient arrangement, conserved through evolution, with homologies between the fat body in *Drosophila* and mammalian livers [59,60]. With respect to innate immunity, hepatocytes have receptors for pathogens and pathogen-specific molecules on their cell surface, generally grouped as members of the Toll-like receptor (TLR) family [10,61,62]. This makes intuitive sense, recognizing where the liver is anatomically, the constant delivery of foods, toxins, bacteria and bacterial products to the portal circulation and its role as an excretory organ. Among the more recent findings is that activation of TLR4, the cell surface receptor for lipopolysaccharide, activates a broad variety of changes in cell signalling within hepatocytes. This central player in innate immunity activates many components of the acute phase response, including activation of AP1 and NFκB. The other overlapping means of responding to inflammatory signals is generally referred to as adaptive immunity, via activation of receptors for the central proinflammatory cytokines TNFα, interleukin (IL)-1β and IL-6, the three main cytokines involved in the liver's response to inflammation. In liver disease, complex and overlapping activations of multiple intracellular signalling pathways from the TLRs and cytokine receptors may be 'firing' simultaneously.

Forkhead (HNF3) family

The HNF3 α, β and γ isoforms identified as key regulators of the expression of serum proteins (e.g. transferrin, albumin, transthyretin) are more accurately referred to as members of the forkhead (FOXa) family of transcription factors [63,64]. These transcription factors are involved in growth, development, neoplasia, inflammation, regeneration and response to injury, and are themselves regulated by posttranslational modifications such as phosphorylation and interaction with other cellular proteins.

Nuclear receptors

Members of the nuclear receptor (NR) superfamily are intimately involved in orchestrating the transcriptional programme of a broad range of processes and functions within hepatocytes [65]. These ligand-regulated transcription factors can directly modulate the response to either excess or insufficient endobiotics, nutritional substances and inflammation, as well as engaging the protective response to exogenous substances such as drugs and toxins (xenobiotics) [7,66]. Nuclear receptors are present in all metazoans, and there are 48 members of the human nuclear receptor superfamily. The structural organization of nuclear receptors has been relatively preserved among its members, and includes activation domains, DNA-binding domains and, of particular interest, the ligand-binding domains. The nuclear receptor activity is regulatable by small molecule ligands. Many of these ligands are substances involved in liver metabolism such as fatty acids, sterols and bile acids. There is overwhelming evidence in recent years suggesting that several genes involved in diverse cellular processes in the liver, such as regulation of glucose metabolism, fatty acid synthesis and oxidation, cholesterol metabolism and bile acid homeostasis, are all regulated by NR superfamily members [38,67–71]. For example, intracellular bile acid homeostasis is primarily regulated by three nuclear receptors, CAR, PXR and FXR, of which the last two can be activated directly by primary bile acids acting as ligands. Over the past few years, it has been clear that the nuclear receptors CAR, PXR and FXR are central to the adaptive response to cholestasis, orchestrating changes in membrane transport, metabolism, conjugation and export of bile acids in states where bile acids are inappropriately retained intracellularly [66].

These three nuclear receptors cannot function alone, or as homodimers, but function as heterodimers partnering with the central nuclear receptor, RXR. It is likely that the ligand for RXR is 9 cis-retinoic acid, whereas PXR is activated by a broad variety

of xenobiotics, including drugs such as rifampicin, whereas CAR activation is complex and may not involve any ligand binding [72]. These nuclear receptors are not immune to interactions with cell signalling cascades. Most nuclear receptors are phosphoproteins and, in particular, the nuclear receptor partner, RXR, is highly regulatable by a cell signalling cascade such as JNK [1,73]. Moreover, activation of cell signalling molecules such as JNK, AP1 and NFκB, can directly regulate several of these nuclear receptors either by direct interactions or by competition for binding to sites in promoter regions. Animal models of activation of inflammation with either lipopolysaccharide or cytokines generally reduce the functional activity and occasionally the mRNA expression of CAR, FXR and PXR. In the context of inflammation, activation of certain cell signalling pathways negatively affects the capacity of hepatocytes to handle bile acids, exacerbating the ongoing liver disease. Thus, there seems to be synergy, in a negative fashion, between chronic inflammatory signalling and ongoing liver disease from any initiating cause. Recent evidence suggests that there may be ways of interfering with this impaired response using a variety of nuclear receptor ligands.

In addition to direct modification of nuclear receptors by cell signalling pathways, there are known direct interactions of key signalling intermediates and nuclear receptors. Among the more relevant interactions is the NFκB binding to the DNA-binding domain of RXR, which interferes with its function [74]. Moreover, there are components of the transcription factor assembly, which not only include nuclear receptors and core regulators but also AP1 and other small molecules, that can shuttle between the cytoplasm and the nucleus and participate in transcription.

Conclusions of integration of cell signalling and transcription

In addition to rapid activation of signal transduction cascades that facilitate the hepatocyte to elicit a quick response to stressors, long-term changes and cellular adaptation appear to be best effected by changes in the transcriptional programme, by ultimately altering the function and efficacy of regulatory transcription factors. These, in turn, can alter the expression and function of cellular proteins involved in signal transduction, thereby providing an effective feedback mechanism. Some of the cellular responses are components of the acute phase response, and are generally thought to be beneficial in the short term but, if prolonged and persistent, could be detrimental. It is a delicate balancing act that the hepatocytes perform in order to safely and effectively perform their duties as the central responders to xenobiotics and stressors. Of therapeutic interest is that cell signalling cascades (kinases), as well as NR family members, are potential therapeutic targets, which may be able to augment the beneficial aspects of the integration of cell signalling and transcriptional reprogramming and minimize the negative consequences.

References

1 Rochette-Egly C (2003) Nuclear receptors: integration of multiple signalling pathways through phosphorylation. *Cell Signal* 15, 355–366.
2 Bogoyevitch MA, Boehm I, Oakley A *et al.* (2004) Targeting the JNK MAPK cascade for inhibition: basic science and therapeutic potential. *Biochim Biophys Acta* 1697, 89–101.
3 Brenner DA (1998) Signal transduction during liver regeneration. *J Gastroenterol Hepatol* 13(Suppl.), S93–95.
4 Carmen GY, Victor SM (2006) Signalling mechanisms regulating lipolysis. *Cell Signal* 18, 401–408.
5 Chang L, Karin M (2001) Mammalian MAP kinase signalling cascades. *Nature* 410, 37–40.
6 Gasper LD, Pierodon N, Thomas AP (2005) Calcium signaling. In: Dufour JF, Clavien PA (eds) *Signaling Pathways in Liver Diseases*. Berlin: Springer-Verlag.
7 Karpen SJ (2002) Nuclear receptor regulation of hepatic function. *J Hepatol* 36, 832–850.
8 Nishina H, Wada T, Katada T (2004) Physiological roles of SAPK/JNK signaling pathway. *J Biochem (Tokyo)* 136, 123–126.
9 Schiller MR (2006) Coupling receptor tyrosine kinases to Rho GTPases-GEFs what's the link. *Cell Signal* 18, 1834–1843.
10 Schwabe RF, Seki E, Brenner DA (2006) Toll-like receptor signaling in the liver. *Gastroenterology* 130, 1886–1900.
11 Hepler JR, Gilman AG (1992) G proteins. *Trends Biochem Sci* 17, 383–387.
12 Haussinger D, Reinehr R, Schliess F (2006) The hepatocyte integrin system and cell volume sensing. *Acta Physiol (Oxford)* 187, 249–255.
13 Lang F, Ritter M, Volkl H *et al.* (1993) The biological significance of cell volume. *Ren Physiol Biochem* 16, 48–65.
14 Stutzin A, Hoffmann EK (2006) Swelling-activated ion channels: functional regulation in cell-swelling, proliferation and apoptosis. *Acta Physiol (Oxford)* 187, 27–42.
15 Balla T (2006) Phosphoinositide-derived messengers in endocrine signaling. *J Endocrinol* 188, 135–153.
16 Nathanson MH, Schlosser SF (1996) Calcium signaling mechanisms in liver in health and disease. *Prog Liver Dis* 14, 1–27.
17 Echevarria W, Leite MF, Guerra MT *et al.* (2003) Regulation of calcium signals in the nucleus by a nucleoplasmic reticulum. *Nature Cell Biol* 5, 440–446.
18 Leite MF, Thrower EC, Echevarria W *et al.* (2003) Nuclear and cytosolic calcium are regulated independently. *Proc Natl Acad Sci USA* 100, 2975–2980.
19 Adachi T, Nakashima S, Saji S *et al.* (1995) Roles of prostaglandin production and mitogen-activated protein kinase activation in hepatocyte growth factor-mediated rat hepatocyte proliferation. *Hepatology* 21, 1668–1674.
20 Wu T (2006) Cyclooxygenase-2 in hepatocellular carcinoma. *Cancer Treat Rev* 32, 28–44.
21 Hatano E, Bennett BL, Manning AM *et al.* (2001) NF-kappaB stimulates inducible nitric oxide synthase to protect mouse hepatocytes from TNF-alpha-and Fas-mediated apoptosis. *Gastroenterology* 120, 1251–1262.
22 Kim JS, Ohshima S, Pediaditakis P *et al.* (2004) Nitric oxide: a signaling molecule against mitochondrial permeability transition- and pH-dependent cell death after reperfusion. *Free Radic Biol Med* 37, 1943–1950.
23 Hunter T (1995) Protein kinases and phosphatases: the yin and yang of protein phosphorylation and signaling. *Cell* 80, 225–236.

24 Mukhopadhayay S, Ananthanarayanan M, Stieger B *et al.* (1997) cAMP increases liver Na^+-taurocholate cotransport by translocating transporter to plasma membranes. *Am J Physiol* 273, G842–848.

25 Gatmaitan ZC, Nies AT, Arias IM (1997) Regulation and translocation of ATP-dependent apical membrane proteins in rat liver. *Am J Physiol* 272, G1041–1049.

26 Newton AC (2001) Protein kinase C: structural and spatial regulation by phosphorylation, cofactors, and macromolecular interactions. *Chem Rev* 101, 2353–2364.

27 Liang T, Xu S, Yu J *et al.* (2005) Activation pattern of mitogen-activated protein kinases in early phase of different size liver isografts in rats. *Liver Transpl* 11, 1527–1532.

28 Nishioka H, Kishioka T, Iida C *et al.* (2006) Activation of mitogen activated protein kinase (MAPK) during D-galactosamine intoxication in the rat liver. *Bioorg Med Chem Lett* 16, 3019–3022.

29 Bradham CA, Stachlewitz RF, Gao W *et al.* (1997) Reperfusion after liver transplantation in rats differentially activates the mitogen-activated protein kinases. *Hepatology* 25, 1128–1135.

30 Desbois-Mouthon C, Wendum D, Cadoret A *et al.* (2006) Hepatocyte proliferation during liver regeneration is impaired in mice with liver-specific IGF-1R knockout. *FASEB J* 20, 773–775.

31 Gunawan BK, Liu ZX, Han D *et al.* (2006) c-Jun N-terminal kinase plays a major role in murine acetaminophen hepatotoxicity. *Gastroenterology* 131, 165–178.

32 Eferl R, Sibilia M, Hilberg F *et al.* (1999) Functions of c-Jun in liver and heart development. *J Cell Biol* 145, 1049–1061.

33 Czaja MJ (2003) The future of GI and liver research: editorial perspectives. III. JNK/AP-1 regulation of hepatocyte death. *Am J Physiol Gastrointest Liver Physiol* 284, G875–879.

34 Michl P, Downward J (2005) Mechanisms of disease: PI3K/AKT signaling in gastrointestinal cancers. *Z Gastroenterol* 43, 1133–1139.

35 Webster CR, Blanch CJ, Phillips J *et al.* (2000) Cell swelling-induced translocation of rat liver Na(+)/taurocholate cotransport polypeptide is mediated via the phosphoinositide 3-kinase signaling pathway. *J Biol Chem* 275, 29754–29760.

36 Webster CR, Anwer MS (1999) Role of the PI3K/PKB signaling pathway in cAMP-mediated translocation of rat liver Ntcp. *Am J Physiol* 277, G1165–1172.

37 Auer KL, Contessa J, Brenz-Verca S *et al.* (1998) The Ras/Rac1/Cdc42/SEK/JNK/c-Jun cascade is a key pathway by which agonists stimulate DNA synthesis in primary cultures of rat hepatocytes. *Mol Biol Cell* 9, 561–573.

38 Glass CK (2006) Going nuclear in metabolic and cardiovascular disease. *J Clin Invest* 116, 556–560.

39 Smith JM, Koopman PA (2004) The ins and outs of transcriptional control: nucleocytoplasmic shuttling in development and disease. *Trends Genet* 20, 4–8.

40 Smith CL, O'Malley BW (2004) Coregulator function: a key to understanding tissue specificity of selective receptor modulators. *Endocr Rev* 25, 45–71.

41 Jeong JW, Kwak I, Lee KY *et al.* (2006) The genomic analysis of the impact of steroid receptor coactivators ablation on hepatic metabolism. *Mol Endocrinol* 20, 1138–1152.

42 Togashi M, Borngraeber S, Sandler B *et al.* (2005) Conformational adaptation of nuclear receptor ligand binding domains to agonists: potential for novel approaches to ligand design. *J Steroid Biochem Mol Biol* 93, 127–137.

43 Wagner M, Trauner M (2005) Transcriptional regulation of hepatobiliary transport systems in health and disease: implications for a rationale approach to the treatment of intrahepatic cholestasis. *Ann Hepatol* 4, 77–99.

44 Kaplowitz N (2002) Biochemical and cellular mechanisms of toxic liver injury. *Semin Liver Dis* 22, 137–144.

45 Kountouras J, Boura P, Lygidakis NJ (2001) Liver regeneration after hepatectomy. *Hepatogastroenterology* 48, 556–562.

46 Herrlich P (2001) Cross-talk between glucocorticoid receptor and AP-1. *Oncogene* 20, 2465–2475.

47 Heyninck K, Wullaert A, Beyaert R (2003) Nuclear factor-kappa B plays a central role in tumour necrosis factor-mediated liver disease. *Biochem Pharmacol* 66, 1409–1415.

48 Vanden Berghe W, De Bosscher K, Vermeulen L *et al.* (2002) Induction and repression of NF-kappa B-driven inflammatory genes. *Ernst Schering Res Found Workshop*, 233–278.

49 Morgan ET, Li-Masters T, Cheng PY (2002) Mechanisms of cytochrome P450 regulation by inflammatory mediators. *Toxicology* 181–182:207–210.

50 Sakurai T, Maeda S, Chang L *et al.* (2006) Loss of hepatic NF-kappaB activity enhances chemical hepatocarcinogenesis through sustained c-Jun N-terminal kinase 1 activation. *Proc Natl Acad Sci USA* 103, 10544–10551.

51 Liu H, Lo CR, Czaja MJ (2002) NF-kappaB inhibition sensitizes hepatocytes to TNF-induced apoptosis through a sustained activation of JNK and c-Jun. *Hepatology* 35, 772–778.

52 Karin M (2006) Nuclear factor-kappaB in cancer development and progression. *Nature* 441, 431–436.

53 Tanaka M, Fuentes ME, Yamaguchi K *et al.* (1999) Embryonic lethality, liver degeneration, and impaired NF-kappa B activation in IKK-beta-deficient mice. *Immunity* 10, 421–429.

54 Beg AA, Sha WC, Bronson RT *et al.* (1995) Embryonic lethality and liver degeneration in mice lacking the RelA component of NF-kappa B. *Nature* 376, 167–170.

55 Hess J, Angel P, Schorpp-Kistner M (2004) AP-1 subunits: quarrel and harmony among siblings. *J Cell Sci* 117, 5965–5973.

56 Baldwin AS Jr (1996) The NF-kappa B and I kappa B proteins: new discoveries and insights. *Annu Rev Immunol* 14, 649–683.

57 Dobrovolskaia MA, Kozlov SV (2005) Inflammation and cancer: when NF-kappaB amalgamates the perilous partnership. *Curr Cancer Drug Targets* 5, 325–344.

58 Cherrington NJ, Slitt AL, Li N *et al.* (2004) Lipopolysaccharide-mediated regulation of hepatic transporter mRNA levels in rats. *Drug Metab Dispos* 32, 734–741.

59 Meister M, Lemaitre B, Hoffmann JA (1997) Antimicrobial peptide defense in *Drosophila*. *Bioessays* 19, 1019–1026.

60 Sondergaard L (1993) Homology between the mammalian liver and the *Drosophila* fat body. *Trends Genet* 9, 193.

61 Liu S, Gallo DJ, Green AM *et al.* (2002) Role of toll-like receptors in changes in gene expression and NF-kappa B activation in mouse hepatocytes stimulated with lipopolysaccharide. *Infect Immun* 70, 3433–3442.

62 Vodovotz Y, Liu S, McCloskey C *et al.* (2001) The hepatocyte as a microbial product-responsive cell. *J Endotoxin Res* 7, 365–373.

63 Costa RH, Kalinichenko VV, Holterman AX *et al.* (2003) Transcription factors in liver development, differentiation, and regeneration. *Hepatology* 38, 1331–1347.

64 Clevidence DE, Overdier DG, Tao W *et al.* (1993) Identification of nine tissue-specific transcription factors of the hepatocyte nuclear factor 3/forkhead DNA-binding-domain family. *Proc Natl Acad Sci USA* 90, 3948–3952.

65 Folkertsma S, van Noort PI, Brandt RF *et al.* (2005) The nuclear receptor ligand-binding domain: a family-based structure analysis. *Curr Med Chem* 12, 1001–1016.
66 Boyer JL (2005) Nuclear receptor ligands: rational and effective therapy for chronic cholestatic liver disease? *Gastroenterology* 129, 735–740.
67 Houten SM, Watanabe M, Auwerx J (2006) Endocrine functions of bile acids. *EMBO J* 25, 1419–1425.
68 Tirona RG, Kim RB (2005) Nuclear receptors and drug disposition gene regulation. *J Pharm Sci* 94, 1169–1186.
69 Eloranta JJ, Meier PJ, Kullak-Ublick GA (2005) Coordinate transcriptional regulation of transport and metabolism. *Methods Enzymol* 400, 511–530.
70 Ory DS (2004) Nuclear receptor signaling in the control of cholesterol homeostasis: have the orphans found a home? *Circ Res* 95, 660–670.
71 Dussault I, Forman BM (2002) The nuclear receptor PXR: a master regulator of 'homeland' defense. *Crit Rev Eukaryot Gene Expr* 12, 53–64.
72 Karpen SJ (2005) Exercising the nuclear option to treat cholestasis: CAR and PXR ligands. *Hepatology* 42, 266–269.
73 Rochette-Egly C (2005) Dynamic combinatorial networks in nuclear receptor-mediated transcription. *J Biol Chem* 280, 32565–32568.
74 Fernandez-Martin JL, Kurian S, Farmer P *et al.* (1998) Tumor necrosis factor activates a nuclear inhibitor of vitamin D and retinoid-X receptors. *Mol Cell Endocrinol* 141, 65–72.

2.2.4 Hepatic transport processes

Ronald P.J. Oude Elferink

The liver takes up amino acids, sugars and nucleic acids that are absorbed in the small intestine. For each of these classes of nutrients, specific transporters are present in the sinusoidal membrane of the hepatocytes. Similarly, transporters are present that mediate the secretion of metabolites from the hepatocyte to the blood for delivery to peripheral tissues. The apical membrane of two adjacent hepatocytes forms the bile canaliculus in which primary bile is secreted. Evidently, this also involves a large set of transporters for the highly diverse spectrum of compounds that are excreted into bile.

In general, four types of transport processes across membranes can be discerned [1]:

- simple diffusion;
- facilitated diffusion;
- secondary active transport;
- primary active transport.

Simple diffusion

The plasma membrane bilayer, mainly made up of phospholipids and cholesterol, forms a tight barrier for hydrophilic compounds. Hence, all hydrophilic and amphipathic compounds need transporter proteins in order to enter cells. In principle, hydrophobic compounds are able to diffuse through plasma membrane. However, it is becoming more and more evident that most, if not all, bioactive compounds in the body are transported in and out of cells through transporter proteins. This does not exclude the possibility that hydrophobic compounds (including certain drugs) can enter cells partly or entirely through simple diffusion. An important difference between simple diffusion and protein-mediated transport is that the rate of entry into cells is linearly related to the concentration outside the cell. In contrast, protein-mediated transport of organic compounds can be saturated at sufficiently high concentrations of the transported compound.

Facilitated diffusion

This is the simplest form of transport mediated by transporter proteins and always follows the concentration gradient. Two types of transporters can be discerned in this context: channels and exchangers (Fig. 1).

Channels

Channels simply represent pores in the membrane that are made up of one or more protein subunits. Certain regions of these

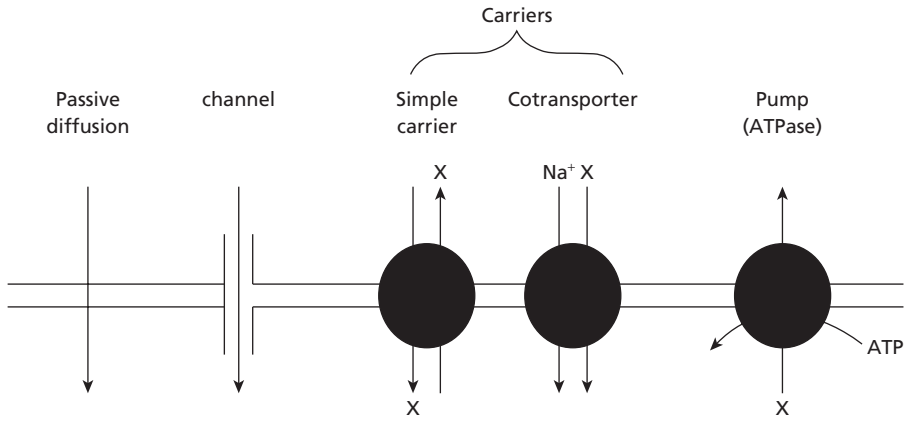

Fig. 1 Different classes of transporter proteins.

proteins form cylindrical α-helices that pass through the membrane. The simplest channels consist of six such transmembrane regions, which are arranged in such a way that they form a pore in the membrane bilayer. The pores can be in an open and a closed state. The transition between these two states is highly regulated by intracellular messengers, voltage, pH or ion concentration. In the opened state, the pore only allows passage of ions for which the channel has affinity. Typically, channels only transport electrolytes such as Na^+, K^+ and Cl^- and not organic compounds such as glucose or amino acids, which are too big to pass through a channel. Most channels are highly specific for certain ions. Thus, a chloride channel only transports Cl^- and not Na^+ or K^+. Channels do not undergo a change in conformation during the transport of a single molecule across the membrane. They simply represent a pore that is in the open or closed state. As a consequence, transport through channels is virtually insaturable. In addition, transport rates through channels are orders of magnitude faster than through carrier proteins.

An important example of a channel is the cystic fibrosis transmembrane regulator (CFTR); this is a channel specific for Cl^- ions that is regulated by intracellular cyclic adenosine monophosphate (cAMP) and by intracellular adenosine triphosphate (ATP) levels. This channel is defective in cystic fibrosis. The functioning of many cell types depends on proper channel function of CFTR and, therefore, many tissues are affected in patients with cystic fibrosis. CFTR is also expressed in cholangiocytes and contributes to bile flow generated by these cells [2].

Carrier proteins

A second form of facilitated diffusion is through carrier proteins. In contrast to channels, these proteins bind a substrate and subsequently undergo a conformational change to release the substrate at the other side of the membrane. Substrates can be either electrolytes or organic compounds. Usually, carriers can transport in either direction, although the affinity of binding on each side of the membrane may be different. Simple carriers transport substrates only down their concentration gradient. Usually, carriers are much less tightly regulated than channels. An example of a carrier is the glucose transporter GLUT2 that is present in the basolateral membrane of hepatocytes [3]. This carrier can mediate either the uptake of glucose into the hepatocyte or the release from cells depending on the prevailing concentration in the cytosol and the sinusoidal blood.

Secondary active transport

Cotransport (symporters) and countertransport (antiporters)

More complicated forms of carriers are the symporters and antiporters (Fig. 1). These transporters bind two different substrates either on the same side of the membrane (symporter) or on the opposite side of the membrane (antiporter). In this way, the transport of one substrate is coupled to that of the other. This mechanism can be used to derive energy from a concentration gradient of the first substrate and use this to drive the transport of the second substrate. Many symporters have the Na^+ ion as the driving force for transport of a second substrate. As the sodium concentration outside the cell is high whereas it is low within the cell, transport of the sodium ion down its concentration gradient (into the cell) can be used to transport a second substrate up its concentration gradient. An example of this coupled transport is the system A transporter for neutral amino acids [4]. By coupling transport of amino acids to that of sodium, the cell is capable of concentration of the amino acid in the cytosol (uphill transport).

An example of an antiporter or countertransport system is the anion exchanger AE2, which is present in the apical membrane of hepatocytes and cholangiocytes [5]. This transporter exchanges Cl^- ions for HCO_3^- ions and is important for intracellular pH homeostasis. Because the intracellular Cl^- concentration is much lower than that outside the cell, this transporter can mediate the extrusion of bicarbonate. In this way, inward chloride transport down the concentration gradient is coupled to outward and uphill bicarbonate transport.

Primary active transport

ATPases

The most complex type of transport is primary active transport, which is always mediated by transport ATPases (Fig. 1). These transporters use the energy liberated by the hydrolysis of ATP to drive transport against the concentration gradient. In this way, enormous concentration gradients (100- to 1000-fold) can be generated. Examples of such transporters are the Ca^{2+} ATPases that pump calcium ions outside the cell and inside the endoplasmic reticulum. This transport can involve more than one type of substrate. For example, the Na^+-K^+ ATPase, which is the motor of many transport processes in the cell, extrudes Na^+ ions from the cell and allows entry of K^+ ions. This causes the large concentration difference of these two ions between the cytosol and the extracellular milieu, which is used by many different secondary active transporters. Transport ATPases not only exist for electrolytes but also for organic compounds. Notably, the superfamily of ATP binding cassette (ABC) transporters mediates a host of different transport processes involving drugs, lipids, peptides and many other compounds [6].

Relevant transport systems in the hepatocyte

As described above, the main motor of transport across the plasma membrane of all cells including the hepatocyte is the Na^+-K^+ ATPase (Fig. 2). Potassium concentrated in the cell is partly lost via the potassium channel in the basolateral membrane. This creates an inside negative membrane potential,

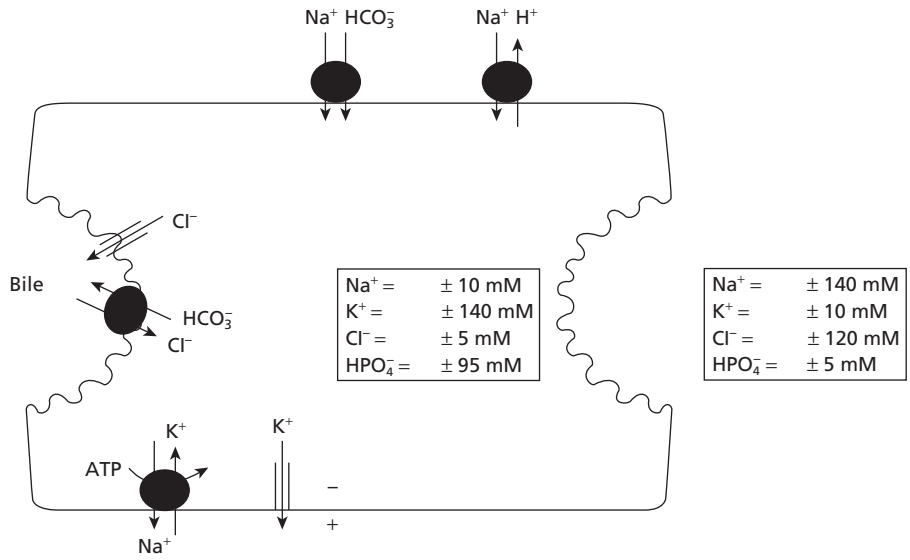

Fig. 2 The main transporters for electrolytes in hepatocytes.

which is also used by many transport processes. Maintenance of a proper intracellular pH (slightly lower than the external pH) is of crucial importance to many enzymatic reactions in the cytosol. As hepatocytes take up and extrude many acidic compounds, pH homeostasis must be quite active in hepatocytes. Intracellular acidification can be counteracted by sodium-dependent bicarbonate uptake across the basolateral membrane as well as by sodium-proton exchange (NHE1 exchanger) across this membrane, although the latter seems to be less active in hepatocytes. The canalicular membrane harbours a chloride–bicarbonate exchanger (AE2) that is capable of acidifying the intracellular milieu. The latter transporter is activated by alkaline pH and cAMP [7].

There are two kinds of glucose carriers: one type (SGLT family) mediates active uptake by cotransport with sodium. This is important, for example, in the apical membrane of enterocytes that need to concentrate glucose from the lumen. The second type of glucose carriers are bidirectional transporters (the GLUT family), which merely transport glucose down the concentration gradient The liver is a professional glucose-producing organ and, therefore, the latter class (more specifically GLUT2) is active in this cell type (Fig. 3). There is a large family of amino

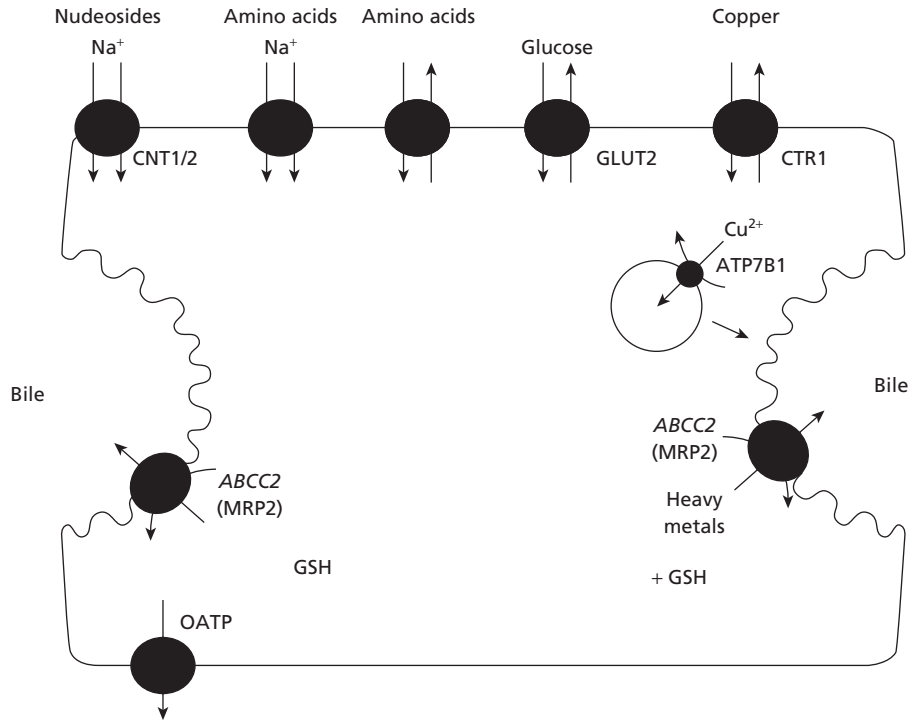

Fig. 3 Transporters for various solutes in hepatocytes. GSH, glutathione.

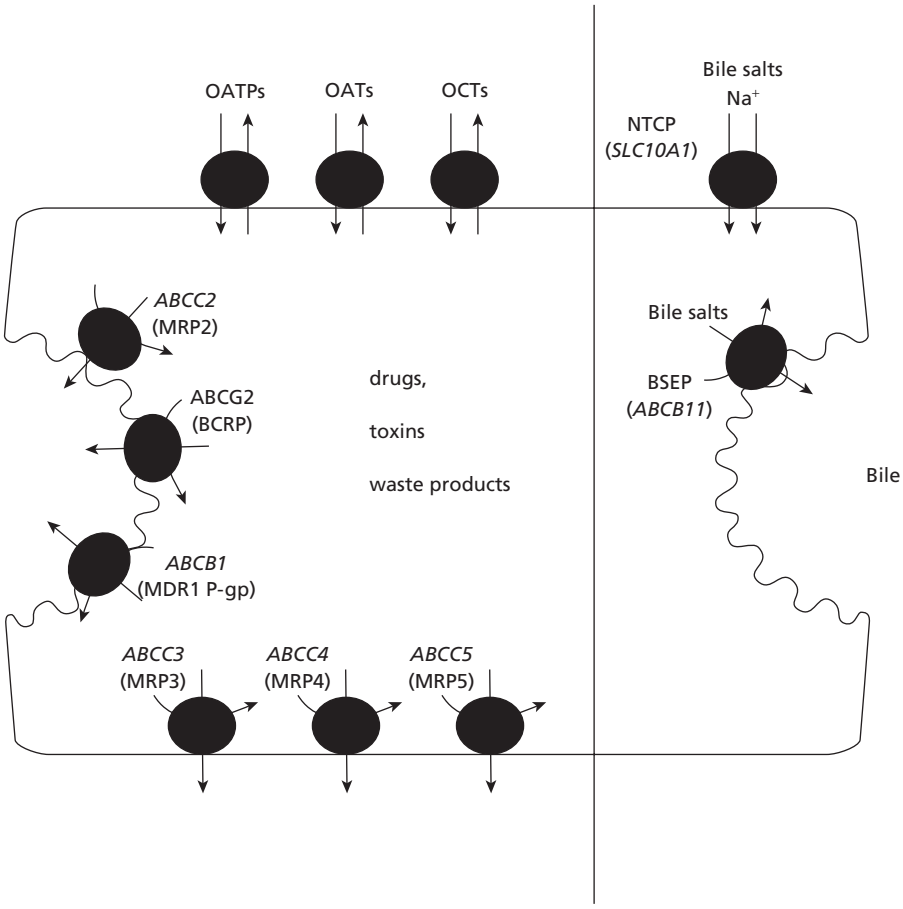

Fig. 4 Transporters in hepatocytes for drugs (left) and bile salts (right).

acid transporters (members of the solute carrier family; SLCs), some of which are mere exchangers and others which are sodium driven and therefore concentrative. The difference between these transporters mainly involves different substrate specificity [8].

The liver expresses concentrative (sodium-dependent) transporters for nucleosides from the CNT family. Concentrative uptake of nucleosides is particularly important during cell division, as illustrated by the fact that these transporters are upregulated during hepatic regeneration [9].

The liver plays an important role in homeostasis and disposition of metal ions. Copper is taken up into hepatocytes by the carrier CTR1 [10]. Heavy metals are also taken up by hepatocytes and disposed into bile. For some heavy metals, the latter process is mediated by ABCC2 (MRP2, the canalicular pump for organic compounds), which transports cadmium, zinc and copper in a glutathione-dependent mechanism [11]. Under normal conditions, however, most copper secretion into bile is mediated by a vesicular pathway in which copper is first sequestered into vesicles by the ATP-dependent copper transporter ATP7B, which is deficient in Wilson's disease (see Chapter 16.1).

The hepatocyte is also a major supplier of glutathione (GSH) to peripheral tissues. GSH is very important in all cells for detoxification of peroxides via GSH-dependent peroxidases. GSH is also important for detoxification of drugs and toxins via conjugation with this tripeptide. To this end, the hepatocyte secretes relatively large amounts of this valuable tripeptide into the circulation. The mechanism has not been fully elucidated, but may involve the members of the OATP family, which are involved in the uptake of a major spectrum of drugs [12].

The hepatocyte fulfils a very important role in the detoxification of drugs, toxins and waste products. To this end, it is harnessed with a spectrum of transporters, both in the basolateral and in the apical membrane (Fig. 4). The transporters in the basolateral membrane involve members of the OATP, the OAT and the OCT families, which are all members of the superfamily of solute carriers (SLCs) [13]. These transporters are largely thought to be simple carriers, although they can also be secondarily active. An example of the latter case is the OATPs, which may take up drugs by simultaneous countertransport of GSH. As the intracellular GSH concentration is more than 100-fold higher than the plasma concentration, this represents a very powerful concentrative mechanism for drug uptake into the liver. These noxious compounds can be conjugated with charged moieties such as glucuronide, glutathione and sulphate, and subsequently pumped into bile across the canalicular membrane by different ABC transporters. These involve ABCC2 (MRP2), which largely transports organic anions (stimulated or not by

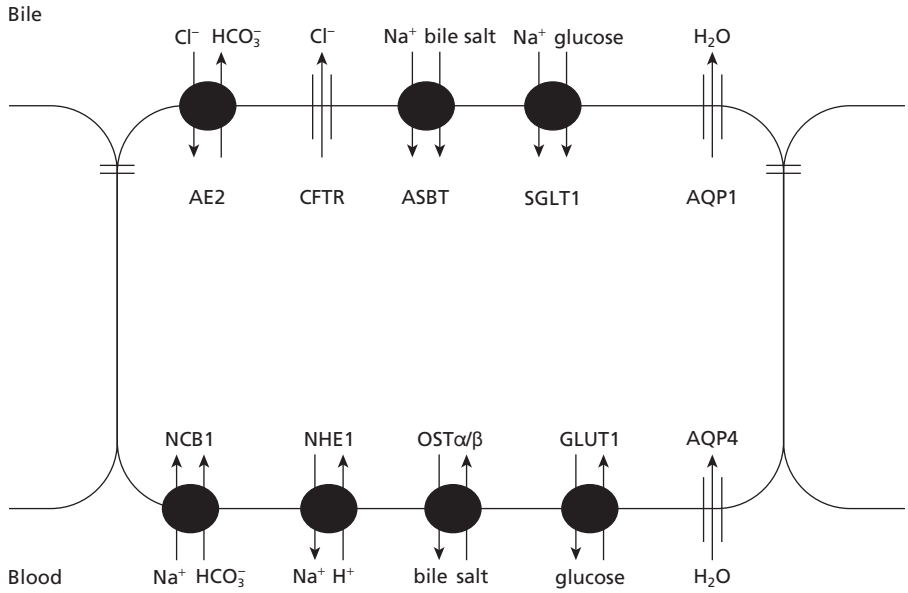

Fig. 5 Some important transport systems in cholangiocytes.

GSH), ABCG2 (breast cancer-related protein, BCRP), which transports many charged and uncharged compounds, and ABCB1 (MDR1 P-glycoprotein), which mainly transports uncharged or cationic amphilic compounds [6]. Conjugated compounds can also be transported back into the blood by pumps such as ABCC3, ABCC4 and ABCC5, resulting in urinary excretion after filtration or active excretion in the kidney.

Finally, bile salts are taken up into the hepatocyte via a sodium-dependent mechanism involving NTCP (SLC10A1). This secondary active transport ensures concentration within the hepatocyte. At the canalicular pole of the cell, the ABCB11 (or bile salt export pump, BSEP) pumps the bile salts into the canaliculus. ATP hydrolysis provides sufficient energy to reach concentration gradients of more than 100-fold. This combined secondary active transport across the basolateral membrane and primary active transport across the canalicular membrane leads to concentration gradients across the hepatocyte of more than 1000-fold (from low micromolar to high millimolar concentrations). More detailed information on the transporters involved in bile formation can be found in Chapter 2.6.

Transport in cholangiocytes

Cholangiocytes modify bile mainly by excretion of bicarbonate. Net bicarbonate excretion is thought to occur by simultaneous action of the chloride bicarbonate exchanger AE2 and the chloride channel CFTR (Fig. 5), although there are also data to suggest that CFTR is capable of excreting bicarbonate by itself. The localization of AE2 in the apical membrane of hepatocytes and cholangiocytes [5] is striking, as this transporter is localized in the basolateral membrane of various other epithelia, such as parietal cells and enterocytes [14]. Similar to the situation in hepatocytes, bicarbonate can be taken up across the basolateral membrane via sodium-dependent bicarbonate transport (NCB1). It is postulated that water channels (aquaporins) contribute to the net water flow into bile ducts. Indeed, aquaporin 1 (AQP1, in the apical membrane) and aquaporin 4 (AQP4, in the basolateral membrane) are expressed in the cholangiocyte, but it is not clear how much these channels contribute to water flow [15].

Bile flow is stimulated by the hormone secretin, which induces intracellular production of cAMP upon binding to its receptor. It has become clear recently that cAMP induces the mobilization of various transporter proteins from intracellular stores to the plasma membrane. Insertion of CFTR, AE2 and aquaporin provides a mechanism to stimulate bicarbonate excretion by cholangiocytes and subsequent water flow [16].

Cholangiocytes are able to absorb bile salts via the sodium-dependent bile salt transporter ASBT followed by transport via the bile salt exchanger OSTα/β in the basolateral membrane [17]. It is not clear how bile salt absorption by bile ducts quantitatively compares with excretion by hepatocytes. Probably only minor amounts of bile salt are reabsorbed in the bile ducts.

Cholangiocytes also reabsorb glucose that has entered bile via the sodium-dependent glucose transporter SGLT1 in the apical membrane of these cells. The absorbed glucose is then released into the blood via the glucose carrier GLUT1 in the basolateral membrane [18].

References

1 Stein WD (1986) *Transport and Diffusion across Cell Membranes*. Orlando: Academic Press.
2 Feranchak AP, Sokol RJ (2001) Cholangiocyte biology and cystic fibrosis liver disease. *Semin Liver Dis* 21, 471–488.
3 Mueckler M (1994) Facilitative glucose transporters. *Eur J Biochem* 219, 713–725.
4 Moseley RH (1996) Hepatic amino acid transport. *Semin Liver Dis* 16, 137–145.

5 Martinez-Anso E, Castillo JE, Diez J *et al.* (1994) Immunohistochemical detection of chloride/bicarbonate anion exchangers in human liver. *Hepatology* 19, 1400–1406.
6 Borst P, Oude Elferink RP (2002) Mammalian ABC transporters in health and disease. *Annu Rev Biochem* 71, 537–592.
7 Strazzabosco M, Boyer JL (1996) Regulation of intracellular pH in the hepatocyte. Mechanisms and physiological implications. *J Hepatol* 24, 631–644.
8 Moseley RH (1996) Hepatic amino acid transport. *Semin Liver Dis* 16, 137–145.
9 Pastor-Anglada M, Felipe A, Casado FJ *et al.* (1998) Nucleoside transporters and liver cell growth. *Biochem Cell Biol* 76, 771–777.
10 Wijmenga C, Klomp LW (2004) Molecular regulation of copper excretion in the liver. *Proc Nutr Soc* 63, 31–39.
11 Dijkstra M, Havinga R, Vonk RJ *et al.* (1996) Bile secretion of cadmium, silver, zinc and copper in the rat. Involvement of various transport systems. *Life Sci* 59, 1237–1246.
12 Ballatori N, Hammond CL, Cunningham JB *et al.* (2005) Molecular mechanisms of reduced glutathione transport: role of the MRP/CFTR/ABCC and OATP/SLC21A families of membrane proteins. *Toxicol Appl Pharmacol* 204, 238–255.
13 Hediger MA, Romero MF, Peng JB *et al.* (2004) The ABCs of solute carriers: physiological, pathological and therapeutic implications of human membrane transport proteins. Introduction. *Pflugers Arch* 447, 465–468.
14 Alper SL, Darman RB, Chernova MN *et al.* (2002) The AE gene family of Cl/HCO^{3-} exchangers. *J Nephrol* 15 (Suppl. 5), S41–S53.
15 Marinelli RA, Pham LD, Tietz PS *et al.* (2000) Expression of aquaporin-4 water channels in rat cholangiocytes. *Hepatology* 31, 1313–1317.
16 Tietz PS, Marinelli RA, Chen XM *et al.* (2003) Agonist-induced coordinated trafficking of functionally related transport proteins for water and ions in cholangiocytes. *J Biol Chem* 278, 20413–20419.
17 Ballatori N, Christian WV, Lee JY *et al.* (2005) OSTalpha-OSTbeta: a major basolateral bile acid and steroid transporter in human intestinal, renal, and biliary epithelia. *Hepatology* 42, 1270–1279.
18 Masyuk AI, Masyuk TV, Tietz PS *et al.* (2002) Intrahepatic bile ducts transport water in response to absorbed glucose. *Am J Physiol Cell Physiol* 283, C785–C791.

2.2.5 Modulation of liver function by hepatic nerves

Gerhard P. Püschel

Anatomical background

Hypothalamic centres

The two principal hypothalamic regions where the signals for the neural control of liver functions are generated are the ventromedial hypothalamic nucleus and the lateral hypothalamic area. The former sends signals to the liver via sympathetic autonomic nerves and, in general terms, enhances the release of fuel substrates from the liver. The latter sends parasympathetic signals to the liver which favour the replenishment of hepatic energy stores. The function of the ventromedial and lateral hypothalamic nuclei is modulated and coordinated by the periventricular region which receives nervous and humoral (e.g. leptin, insulin, glucose) signals from the periphery and other brain regions.

Afferent hepatic nerves

There are two types of afferent nerves emerging from the liver: vagal and spinal afferent nerves.

The vagal afferent neurons are located in the nodose ganglia. They project their central processes to the nucleus of the solitary tract. Their axons travel with the common hepatic branch of the vagus nerve, to which, however, they contribute only a minor portion. The vagal afferents terminate in the outer layers of the larger branches of the extrahepatic and intrahepatic bile ducts and in the adventitia of the portal vein. They transmit information about metabolite, hormone or cytokine concentration to the hypothalamus. Terminals of the vagal afferents have not been detected in the intralobular area of the liver parenchyma in rat. Because rat parenchyma is scarcely innervated in general, this might not reflect the intralobular distribution of vagal afferent nerves in other vertebrate species including man [1].

The spinal afferents stem from the dorsal root of the lower half of the thoracic medulla. Calcitonin gene-related peptide (CGRP) appears to be an accepted specific marker that has been used for immunohistochemical studies on their distribution along with retrograde labelling studies. Both techniques indicate that the intrahepatic distribution of spinal afferents is similar to that of vagal afferents. No CGRP-positive fibres were detected in the parenchyma of rodents or guinea pig and, in human liver, few fibres were detected in the portal tract [2].

Efferent hepatic nerves

Sympathetic hepatic nerves originate from the ventromedial hypothalamic nucleus. Fibres descend via the medullary reticular formation to the intermediolateral cell column in the thoracolumbar spinal cord. From here, preganglionic neurons project to a collateral ganglia, i.e. the coeliac ganglion and superior mesenteric ganglion, where the postganglionic sympathetic nerve fibres originate [3,4]. The postganglionic nerves enter the liver via an anterior and a posterior portal plexus accompanying the hepatic artery and portal vein. A few fibres also enter the liver together with the hepatic vein. In most mammals including man, aminergic nerves enter the liver lobules to a varying extent. They are found in close vicinity to stellate cells but also contact hepatocytes, sinusoidal endothelial cells and Kupffer cells. Density is highest close to the portal fields and declines along the sinusoid.

Parasympathetic hepatic efferent nerves originate in the lateral hypothalamic area, whence connections aim at the nucleus

vagus/ambiguous. These vagal nuclei supply efferent parasympathetic nerves to the hepatic branch of the vagal nerve. The parasympathetic fibres form a plexus that is separate from that of the catecholaminergic nerves [4] and enter the liver at the hilus together with the sympathetic fibres. Parasympathetic nerves normally synapse on postsynaptic nerves at intramural ganglia. Few reports exist about hilar or intrahepatic parasympathetic ganglia, and their existence is still a matter of debate [4]. Functional evidence argues in favour of their existence. It has been assumed, however, that part of the parasympathetic fibres of the hepatic branch of the vagus nerve indirectly affect liver function by modulating sympathetic nerve activity in the coeliac ganglion [5]. Cholinergic fibres terminate at the terminal branches of the hepatic artery, portal vein and bile duct or in the portal area. In no vertebrate species have intralobular cholinergic nerves been detected histochemically [3].

Species differences

One has to keep in mind that the intrahepatic distribution and density of liver nerve terminals varies greatly between species. Man and guinea pig, among mammals, have the highest density of intralobular nerves, followed by dog and cat, whereas the most commonly used rodent animal models have a rather scarce intralobular innervation [6]. This holds true for a large array of neurotransmitters, i.e. catecholamines, and various neuropeptides. The density of intralobular innervation is inversely correlated with the density of gap junction between hepatocytes [4,7], indicating that a cell-to-cell signal propagation might compensate for direct innervation in animals with sparse innervation.

Regulation by hepatic nerves of liver haemodynamics

Regulation of macrovascular haemodynamics

In vivo stimulation of sympathetic splanchnic nerves in cats and dogs reduced hepatic blood flow and lowered the blood volume in intrahepatic capacitance vessels, thereby replenishing the systemic circulation [8] (Fig. 1). In isolated liver perfused with constant pressure, stimulation of sympathetic hepatic nerves reduced portal and arterial flow, whereas stimulation of sympathetic hepatic nerves in livers perfused with constant flow increased perfusion pressure. Independent of the perfusion model, a redistribution of flow was observed as a consequence of the regulation of the sinusoidal haemodynamics.

Regulation of sinusoidal haemodynamics

In vivo microscopy revealed that stimulation of the vagus dilated sinusoids and opened previously closed sinusoids in rat liver, reducing the erythrocyte flow velocity in each individual liver sinusoid without affecting the total volumetric flow in the observed microscopic field. In contrast, stimulation of sympathetic hepatic nerves in isolated perfused rat liver resulted in a redistribution of flow, apparently closing some sinusoids and leaving part of the parenchyma hypoxic [8] (Fig. 1). The regulation of the sinusoidal blood flow occurs at the level of presinusoidal sphincters [9] or by contractile cells, most probably stellate cells, along the sinusoid [10]. In addition to the intrasinusoidal haemodynamics, the fluid exchange between the sinusoid and the Disse space may be regulated by variation in the size of the fenestrae and, hence, the porosity of the sinusoidal endothelial cell in response to, for example, serotonin and nitric oxide [9]. Thus, the access of macromolecular complexes to the hepatocyte may be regulated [11]. Via these haemodynamic changes, hepatic nerve action may secondarily affect liver metabolism.

Regulation of liver metabolism by hepatic nerves

Liver metabolism is tightly regulated. It is subject to control by metabolite levels, circulating hormones and efferent hepatic nerves. These different modes of control are tightly interrelated. This makes it difficult to discern the contribution of one particular branch of this control system, i.e. the direct modulation of liver metabolism by hepatic efferent nerves (Fig. 1). In addition, haemodynamic variations in response to circulating mediators or locally released neurotransmitters may affect liver metabolism because they lead to hypo- or hyperperfusion of the parenchyma with subsequent changes in oxygen and substrate supply or metabolite washout. Different experimental approaches have been taken to eliminate these confounding factors in order to assess the direct impact of hepatic nerves on liver metabolism. Studies in whole animals with removed or clamped endocrine organs have been used as well as different models of isolated perfused liver. All these systems have their particular limitations [12]. Nevertheless, all the data taken together provide strong evidence for the possibility of a direct control by efferent nerves of hepatic metabolism.

On the other hand, afferent hepatic nerves in whole animal studies and liver perfusion systems have been shown to convey information about portal or hepatic metabolite levels to the central nervous system (CNS) or to locally integrate information about metabolite levels.

Regulation by efferent sympathetic hepatic nerves

Carbohydrate metabolism

In whole animal studies in cat, dog, pig, sheep, rabbit, rat and man, stimulation of splanchnic nerves or liver nerves increased systemic blood glucose levels or hepatic glucose output determined by microdialysis [12, and references therein]. The majority of experiments were performed under conditions that supposedly precluded indirect humoral modulation of hepatic

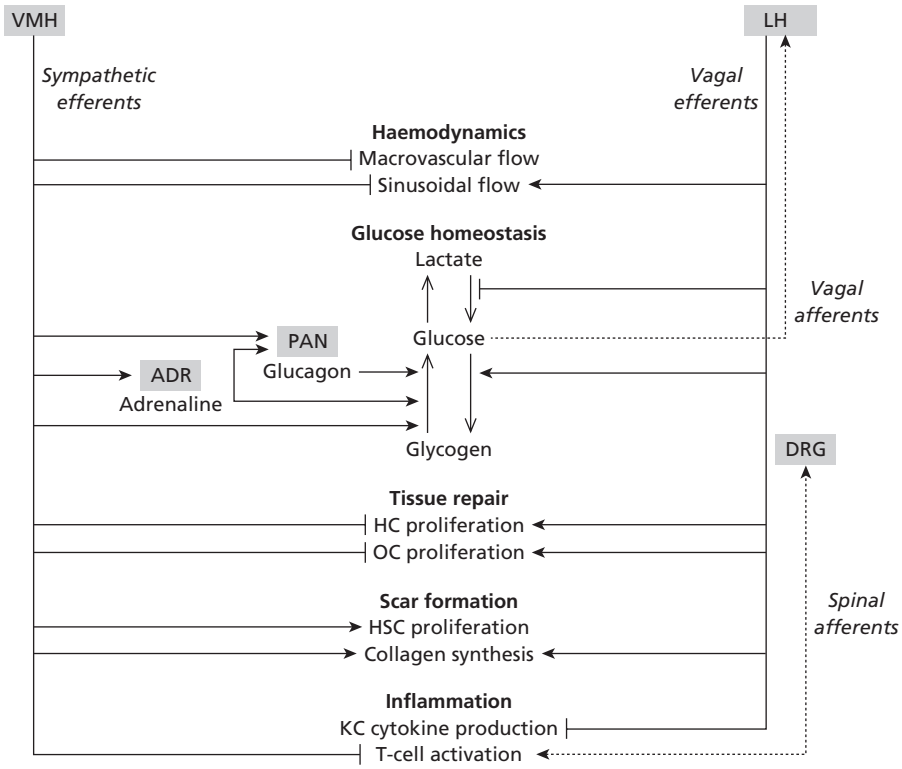

Fig. 1 Modulation by hepatic nerves of liver functions. Various functions of hepatocytes and non-parenchymal liver cells are modulated by a direct and indirect action of sympathetic and parasympathetic efferent hepatic nerves. The CNS can be informed about hepatic metabolite levels by vagal afferents. Spinal afferents can modulate immune cell function by retrograde signalling. ADR, adrenals; DRG, dorsal root ganglia; HC, hepatocyte; HSC, hepatic stellate cell; KC, Kupffer cell; LH, lateral hypothalamus; OC, oval cell; PAN, pancreas; VMH, ventromedial hypothalamus; → stimulation; —| inhibition.

glucose output, i.e. in adrenalectomized and/or pancreatectomized animals or by hormonal clamp of the pancreas. Similarly, in perfused guinea pig, mouse, rat or tree shrew, liver electrical field stimulation of nerve bundles around the liver hilus enhanced hepatic glucose output and, depending on the perfusion medium (erythrocyte-free vs. erythrocyte-containing), increased hepatic lactate output or shifted lactate uptake to output [12]. The increase in glucose output was independent of haemodynamic alterations. It was accompanied by a noradrenalin spillover and was blocked by α adrenergic receptor antagonists. Glycogenolysis was the primary source of nerve stimulation-dependent released glucose, whereas gluconeogenesis, which was inhibited by mercaptopicolinic acid, contributed only a minor fraction to nerve stimulation-dependent glucose output but accounted for almost 100% of the basal hepatic glucose output in rat livers perfused with erythrocyte-containing media.

Conflicting evidence exists concerning the physiological significance of direct neural sympathetic control of hepatic glucose output for systemic glucose supply in response to stress or activity. The activity of sympathetic hepatic nerves is suppressed by high and increased by low blood glucose levels. Direct stimulation of hepatic glucose release by sympathetic hepatic liver nerves appears to be able to blunt insulin- or activity-induced hypoglycaemia in *in vivo* animal models, in which hormonal response is impaired as a result of surgical removal or pharmacological clamping of endocrine pancreas and adrenals. However, if the endocrine axis is intact, an activity- or hypoglycaemia-dependent increase in circulating glucagon rather than hepatic sympathetic nerve action was the main stimulus to augment hepatic glucose production [12]. With functionally intact adrenals and endocrine pancreas, the action of hepatic nerves appeared to be dispensable for stress-induced glucose release in different animal and human models.

Lipid metabolism

Much less information is available about the modulation by sympathetic hepatic nerves of hepatic lipid metabolism. In whole animal studies, liver denervation caused a reduction in hepatic carnitine palmitoyltransferase activity, fatty acid oxidation and very-low-density lipoprotein (VLDL) formation. This was taken as indirect evidence that sympathetic hepatic nerves might increase hepatic fatty acid utilization. In perfused liver, however, ketone body formation and the secretion of the VLDL apolipoprotein B was suppressed rather than increased by stimulation of sympathetic hepatic nerves or infusion of sympathetic neurotransmitters [12]. The different timeframe might account for this apparent discrepancy. Also, cholesterol production from ^{14}C acetate decreased after surgical dissection of the splanchnic nerve, indicating that an elevated sympathetic tone might augment hepatic cholesterol synthesis. No information is available concerning the relative contribution to the control of hepatic lipid metabolism of hepatic nerves compared with humoral control systems; however, as for the control of carbohydrate

metabolism, direct control of lipid metabolism by hepatic nerves is presumably of minor importance.

Other metabolic functions

Independently of the accompanying haemodynamic alterations, stimulation of sympathetic hepatic nerves in perfused liver increased urate formation, reduced bile acid synthesis and bile flow and attenuated xenobiotic extraction [12]. Stimulation of sympathetic hepatic nerves led to a rapid swelling of hepatocytes and stellate cells as a result of a redistribution of electrolytes and a compensatory release of the organic osmolytes taurine and myoinosital from these cells [13]. Amino acid and ammonia metabolism were also affected by sympathetic nerve stimulation; however, the effects were largely dependent on haemodynamic alterations. Thus, urea and glutamine output as well as ammonia uptake were reduced, while glutamate and glutathione output was increased [12].

Mechanism of intrahepatic signal propagation of efferent sympathetic nerves

The apparent lack of intralobular nerve terminals, especially in rodents, was inconsistent with the observation that electrical stimulation of hepatic nerves elicited pronounced metabolic changes that were independent of haemodynamic alterations. Two models were proposed to explain the apparent discrepancy: a hepatocyte-to-hepatocyte signal propagation via gap junctions; and a signal propagation by paracrine stimulation of hepatocytes with mediators released from non-parenchymal liver cells in response to stimulation of hepatic nerves. Evidence for both models was brought forward.

Inositol trisphosphate, which is generated in hepatocytes in response to noradrenalin released from nerve terminals in the periportal region, can diffuse via gap junctions and propagate the signal from hepatocyte to hepatocyte to the perivenous region along the acinus. Pharmacological blockade of gap junctional conductivity as well as downregulation or elimination of the gap junction protein connexin 32 inhibited the nerve stimulation-dependent increase in glucose output [12].

The other model supposes that nerves ending close to non-parenchymal liver cells, specifically hepatic stellate cells, elicit the release of eicosanoids, which can act on hepatocytes further downstream in the sinusoid. In support of this hypothesis, nerve stimulation-dependent increase in glucose output from isolated perfused liver was attenuated by inhibition of phospholipase A_2 or cyclo-oxygenase in rat and in the more densely innervated guinea pig liver. Prostaglandin $F_{2\alpha}$, which was released from hepatic stellate cells in response to synaptic concentrations of noradrenalin and adenosine triphosphate (ATP) and appeared as spillover in perfused rat liver after electrical field stimulation of hepatic nerves, stimulated glucose output from perfused rat livers and glycogen phosphorylase activity in isolated rat hepatocytes via the prostaglandin $F_{2\alpha}$ (FP) receptor. In contrast to hepatic stellate cells, Kupffer cells appeared not to contribute to nerve stimulation-dependent eicosanoid formation [12].

Regulation by efferent parasympathetic hepatic nerves

Much less information is available on the contribution of parasympathetic hepatic nerves in the control of liver metabolism. Most information concerns the hepatic glucose balance (Fig. 1). The insulin-dependent glycogen deposition in isolated perfusion systems or hepatocyte cultures is surprisingly low when compared with the *in vivo* situation. A possible explanation for this enigma may be that *in vivo* parasympathetic efferent nerves act in parallel to insulin to warrant an efficient glucose clearance from the portal blood. In favour of such a model, stimulation of the parasympathetic nuclei in the lateral hypothalamus or the peripheral cut end of the hepatic branch of the vagus nerve activated glycogen synthase in rabbit, and acute hepatic vagotomy diminished the rate of glycogen deposition after a glucose load [14]. In rats that had undergone acute selective hepatic vagotomy, replenishment of glycogen stores after refeeding was severely impaired [15], and incorporation of labelled glucose into glycogen was decreased [16]. In perfused rat liver, the small insulin-dependent glucose uptake was markedly potentiated by stimulation of hepatic nerves after α and β adrenergic receptor blockade. In support of a physiological significance of these experiments, it was also found that the firing rate of the hepatic efferent branch of the vagus nerve was linearly related to blood glucose concentrations between 3 and 25 mM, the physiological range of (portal) glucose concentrations [17]. However, a simple synergism between the parasympathetic neurotransmitter acetylcholine and insulin has been excluded [18].

Parasympathetic control of hepatic glucose balance is not restricted to the increase in glucose uptake. In the postresorptive phase, liver produces glucose from gluconeogenesis by default. Part of this gluconeogenesis depends on the presence of glucagon. After pharmacological blockade of sympathetic signal transmission, electrical field stimulation of hepatic nerves inhibited the glucagon-elicited glucose release from perfused rat liver. Similarly, stimulation of hepatic nerves *in vivo* in cat decreased basal glucose output if sympathetic nerve fibres were destroyed prior to the experiment [12]. Conversely, selective hepatic vagotomy increased basal glucose output [16] or attenuated the suppression by insulin of glucagon-induced glucose output [15] from rat livers *in vivo*. Most recent evidence suggests that an impairment of this parasympathetic control of hepatic glucose production might contribute to the fatty acid-induced hepatic overproduction of glucose in type 2 diabetes [19]. It was suggested that hypothalamic sensing of elevated free fatty acids increases the vagal output to the liver, which results in a decrease in glycogenolysis to compensate for the fatty acid-dependent increase in hepatic gluconeogenesis.

Contribution of afferent nerves to metabolic regulation

Many studies show the existence of portal sensors for metabolites or hormones. These sensors modulate the discharge rate of

afferents in response to portal infusions of glucose [17], amino acids [20], fatty acids and, to a lesser extent, lipids [21] as well as hormones [22,23]. Integration of these signals in the CNS affects feeding behaviour and hepatic metabolism (Fig. 1).

As an example, portal infusion of 2,5-anhydro-D-mannitol increased the discharge rate of vagal afferents, inhibited hepatic glucose release and augmented food intake. The last effects were abolished after hepatic branch vagotomy [24]. Similarly, portal infusion of fatty acid [25] or mercaptoacetate [26] augmented the discharge rate of vagal afferents and inhibited feeding. The afferents might thus be physiologically relevant for fat-induced hypophagia, and an improper function of hepatic afferents has been implicated as one possible cause contributing to aberrant feeding behaviour in diabetic animals [27]. Central registration of the abundance of hepatic glycogen stores via hepatic afferents has also been implicated in fasting-induced mobilization of free fatty acids from adipose tissue.

The existence of two types of osmo- (or sodium-) sensitive afferent fibers has been firmly established with electrophysiological methods in the hepatic branch of the vagus nerve: one increasing the discharge rate in response to hyperosmolarity, the other increasing the discharge rate in response to hypoosmolarity. Although both fibres have been implicated in the regulation of vasopressin release [28], the evidence is, however, somewhat controversial [29], and a physiological relevance might be limited to a very short-term reaction to an oral hypo- or hyperosmolar load.

Metabolite sensing in the portal area also allows the distinction between exogenous gut-derived glucose, which reaches the liver via the portal vein, and endogenous glucose, which enters the hepatic circulation via the hepatic artery. Delivery of exogenous glucose builds up a portal–arterial glucose gradient with higher glucose concentration in the portal vein that generates a portal signal. This portal signal increases the insulin-dependent hepatic glucose extraction in living dogs [30], isolated rat liver simultaneously perfused via portal vein and hepatic artery [31] and in conscious freely moving rats [32]. Conversely, increase in the glucose concentration in the hepatic artery abolishing the gradient between portal vein and hepatic artery attenuated hepatic glucose uptake in comparison with the same glucose load administered solely via the portal vein [33], despite an equally high glucose load to the liver. The size of the gradient seems to be irrelevant as long as the portal glucose concentration is about 1 mM above the arterial concentration [34]. A further increase did not result in a parallel increase in fractional glucose extraction. The increase by the portal signal in insulin-dependent glucose uptake is most probably mediated by parasympathetic fibres [35]. The portal signal is probably generated by glucose-sensitive neurons in the portal vein whose discharge rate is inversely correlated with the portal glucose concentration. Because the isolated perfused liver is disconnected from signal input from the CNS, it was assumed that the portal–arterial glucose gradient might be sensed by an intrahepatic neuronal network [35]. However, the hypothalamus cannot be excluded as an additional arterial reference site. There is evidence that GLP-1 might be involved in the generation of the signal in response to the portal–arterial glucose gradient [36]. The portal signal was absent in mice lacking the GLP-1 receptor [37]. A recent study showed that, in humans, hepatic glucose extraction was not greater after duodenal glucose administration than after peripheral glucose administration [38]. Assuming that duodenal glucose administration, in contrast to peripheral glucose administration, will create a portal–arterial glucose gradient, this might indicate that a portal signal does increase hepatic glucose uptake in humans.

The portal signal might not only be relevant to insulin-dependent hepatic glucose disposal but also to the coordination between hepatic and peripheral glucose deposition. Two opposing observations were made in this regard. In dog, a portal–arterial glucose gradient increased hepatic but decreased peripheral (hind limb) glucose utilization [39], whereas in mice, the portal signal increased peripheral but not hepatic glucose extraction and resulted in hypoglycaemia. Sensing of the portal–arterial gradient was dependent on the Glut2 glucose transporter and GLP-1 receptor (probably in the portal sensing area). For the portal signal to increase peripheral glucose uptake, the Glut4 transporter and AMP kinase but not the insulin receptor were required in skeletal muscle [40].

Interplay between hepatic nerves and humoral control of extrahepatic metabolism

Hepatic afferent and efferent nerves may modulate the hormone-dependent regulation of extrahepatic metabolism either by altering the level of circulating hormones or by adjusting the sensitivity of peripheral tissues to circulating hormones. Evidence was provided for both routes. Thus, adrenaline release from suprarenal glands in response to insulin-induced hypoglycaemia in dogs was attenuated by hepatic denervation [41]. However, this was not observed in exercise-induced hypoglycaemia in vagotomized rats [42]. There is indirect evidence that autonomous nerve activity might influence the hepatic extraction rate of glucoregulatory hormones, however, direct evidence is lacking [12]. Although signalling by hepatic nerves appears not directly to influence insulin degradation by the liver or pancreatic insulin release after portal (prandial) glucose delivery, it might modulate insulin-dependent glucose utilization. A putative hepatic factor called hepatic insulin sensitizing substance (HISS) that was released in response to the stimulation of vagal efferents increased insulin-dependent glucose deposition in skeletal muscle in rat, cat and dog [43,44]. In an insulin sensitivity assay, the amount of glucose needed to achieve euglycaemia after injection of an insulin dose was reduced by about 50% in animals that either underwent mechanical hepatic denervation or vagotomy or received the parasympathetic antagonist atropine or the NO synthase inhibitor L-NAME (N-nitro-L-arginine methyl ester). The effect of pharmacological or mechanical denervation was reversed by

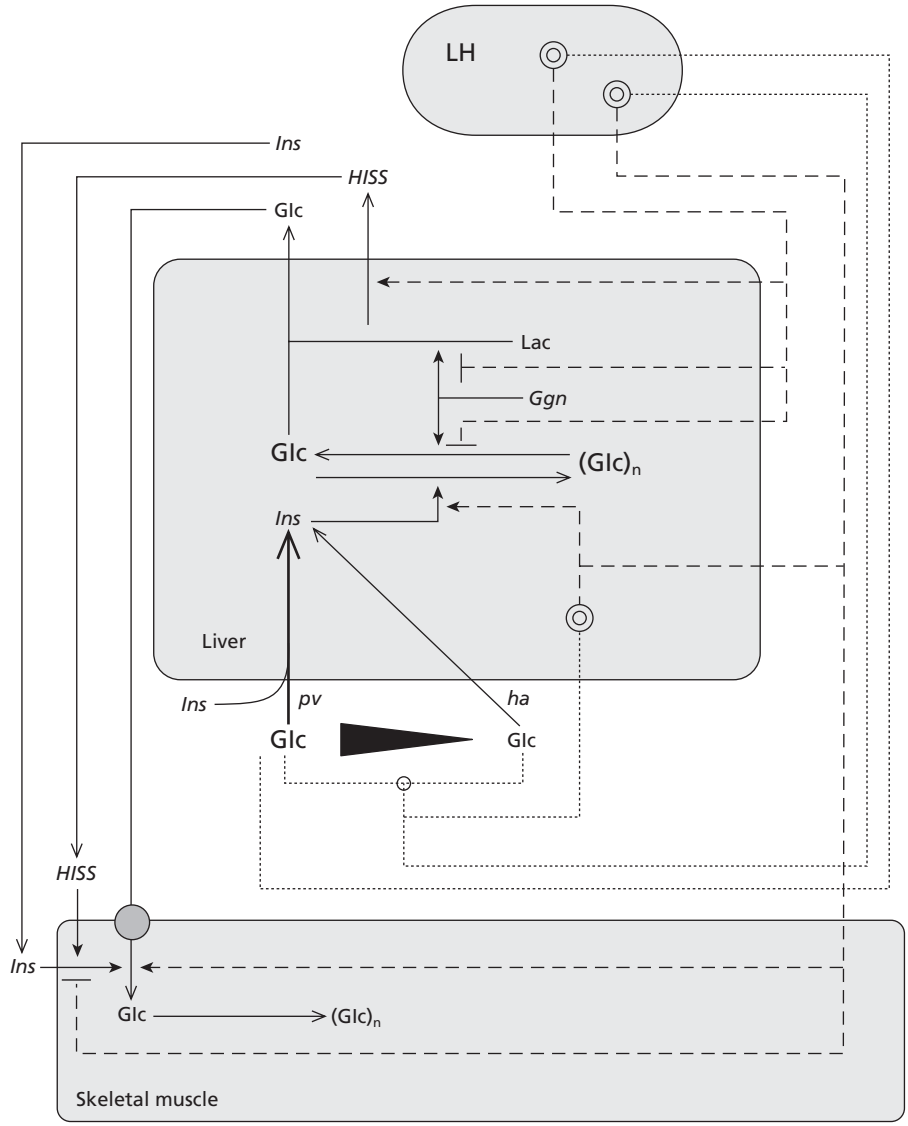

Fig. 2 Parasympathetic control of hepatic and extrahepatic glucose utilization. Glucose delivery from the gut is sensed by portal glucose sensors either as absolute glucose concentration or as a portal–arterial glucose gradient. Thereby, a portal signal is generated which is integrated either locally by a putative intrahepatic neuronal network or by the brain. Via the efferent parasympathetic nerves, this signal suppresses the glucagon-stimulated glycogenolysis and gluconeogenesis, and potentiates the insulin-dependent glycogen synthesis. Parasympathetic efferents also stimulate the release of a putative hepatic insulin sensitizing substance (HISS), which augments skeletal muscle insulin-dependent glucose uptake. The portal signal, by an ill-defined mechanism possibly involving parasympathetic efferents to the skeletal muscle, appears to inhibit insulin-dependent and to increase insulin-independent glucose uptake. Ggn, glucagon; Glc, glucose; $(Glc)_n$, glycogen; ha, hepatic artery; Ins, insulin; Lac, lactate; pv, portal vein; …… vagal afferents; – – – – vagal efferents; → stimulation; —| inhibition.

an intraportal infusion of either acetylcholine or the synthetic NO source SIN-1 (3-morpholinosydnonimine) or nitroglycerin, thus implying the sequential action of muscarinergic and nitrergic parasympathetic nerve fibres in the release of HISS [12,43]. The role of parasympathetic nerves in glucose handling is summarized in Figure 2.

Regulation by hepatic nerves of hepatic immune function and liver repair

From *in vivo* studies, it has long been evident that the hepatic nerves may impact on the severity of toxic liver injury [45]. Elevation of the sympathotonus in spontaneously hypertensive rats [46] or by electrical stimulation of the ventromedial hypothalamic area aggravated CCl_4– or demethylnitrosamine-induced liver damage. *In vitro* studies with perfused rat liver indicate that this effect was not entirely due to elevated circulating catecholamine levels but could be attributed, at least in part, to a direct action of hepatic nerves [47]. In contrast, sympathetic hepatic nerves conferred a protection rather than a sensitization to immune cell-mediated liver injury, while peptidergic afferent nerves sensitized to immune cell-dependent liver injury [48]. Thus, depending on the noxious principle, hepatic nerve activity may be either protective or detrimental in the development of liver damage. Possible explanations for this ambiguous role of hepatic nerves are given below.

Regulation by hepatic nerves of regeneration of parenchyma and scar formation

In response to an acute toxic damage, the liver attempts to compensate for the loss of parenchyma by hepatocyte proliferation. If the hepatocyte compartment loses its capacity to divide, another progenitor cell compartment comes into play, the oval

cell compartment. Recent work has demonstrated that the activation of the oval cell compartment is enhanced by decreasing the sympathetic impact on the liver [49]. Proliferation of a hepatic progenitor cell compartment was enhanced by activation of the parasympathetic input (Fig. 1). Similarly, hepatocyte proliferation, which was dependent on an intact parasympathetic supply to the liver, was observed after lesioning the sympathetic nuclei in the ventromedial hypothalamic area [50]. Liver may also react to loss of parenchyma by scar formation. The principal sources of fibrous material for this scar formation are hepatic stellate cells. Indirect evidence was provided that both parasympathetic and sympathetic hepatic nerves, which terminate in close proximity to hepatic stellate cells, might increase scar formation by stimulating hepatic stellate cell proliferation and collagen synthesis [49] (Fig. 1).

Both inhibition of parenchymal cell proliferation and stimulation of hepatic stellate cell proliferation and collagen formation might contribute to the exacerbation by sympathetic hepatic nerves of toxic liver damage observed *in vivo*.

Regulation by hepatic nerves of immune cell function

Resident macrophages (Kupffer cells) that are a rich source of cytokines during local and systemic inflammation are the major immune cell population of the liver. They are in close contact with hepatic nerve endings. Stimulation of the efferent branch of the parasympathetic nervous system attenuated the endotoxin-elicited cytokine production in non-parenchymal liver cells and thereby prevented the development of an endotoxinaemic shock [51]. Apart from Kupffer cells, T cells contribute significantly to the immune cell compartment of the liver. While their number is low under normal conditions, their number dramatically increases during inflammation due to recruitment from the circulation. Although, in contrast to Kupffer cells, they appear not to be in direct contact with hepatic nerve endings, their function may be modulated by neurotransmitters released into the tissue. Immune cell function may be modulated by sympathetic neurotransmitters and opioids, which might inhibit the cytokine release from hepatic immune cells and prevent their activation [48] (Fig. 1). Thereby, sympathetic neurotransmitters may attenuate the immune cell-dependent liver injury caused in hepatitis models such as endotoxin/galactosamine hepatitis. In contrast to the potentially beneficial effect of sympathetic efferent nerves on immune cell-mediated liver injury, peptidergic afferent nerves appear to be of crucial importance to induce and maintain galactosamine/endotoxin hepatitis in mice. Elimination of spinal afferents by capsaicin treatment of neonatal mice completely abolished the development of inflammation in this model. The deleterious effect of peptidergic afferents seems to be mediated by neurokinins [52]. In addition to stimulating immune cells, peptidergic afferent nerves may act directly on the hepatocyte to increase apoptosis. They also appear to increase hepatic fibrosis [53]. Along with the modulation of immune cell function, these last two mechanisms may contribute to the aggravation of liver injury by peptidergic afferent nerves in hepatitis models.

Impact of hepatic denervation after transplantation

During liver transplantation all hepatic nerves are transected and reinnervation of allografts is scarce. Although this apparently does not lead to a gross dysregulation of hepatic functions, some side-effects of liver transplantation might possibly be attributed to the persisting denervation [54], although unequivocal evidence is still lacking. Thus the hepatic vasoconstrictory response to hypovolemia is lacking, making patients more susceptible to hypovolemic shock. The transplanted liver appears to be insulin-resistant due to the lack of a parasympathetic input and patients who have undergone liver transplantation in comparison with kidney transplant patients are prone to weight gain as a result of an increased fat intake, which may be due to the missing portohypothalamic signalling in response to fatty acid ingestion.

References

1 Berthoud HR (2004) Anatomy and function of sensory hepatic nerves. *Anat Rec A Discov Mol Cell Evol Biol* 280, 827–835.

2 Akiyoshi H, Gonda T, Terada T (1998) A comparative histochemical and immunohistochemical study of aminergic, cholinergic and peptidergic innervation in rat, hamster, guinea pig, dog and human livers. *Liver* 18, 352–359.

3 Uyama N, Geerts A, Reynaert H (2004) Neural connections between the hypothalamus and the liver. *Anat Rec A Discov Mol Cell Evol Biol* 280, 808–820.

4 McCuskey RS (2004) Anatomy of efferent hepatic nerves. *Anat Rec A Discov Mol Cell Evol Biol* 280, 821–826.

5 Berthoud HR, Powley TL (1993) Characterization of vagal innervation to the rat celiac, suprarenal and mesenteric ganglia. *J Auton Nerv Syst* 42, 153–169.

6 Metz W, Forssmann WG (1980) Innervation of the liver in guinea pig and rat. *Anat Embryol (Berl)* 160, 239–252.

7 Reilly FD, McCuskey PA, McCuskey RS (1978) Intrahepatic distribution of nerves in the rat. *Anat Rec* 191, 55–67.

8 Gardemann A, Püschel GP, Jungermann K (1992) Nervous control of liver metabolism and hemodynamics. *Eur J Biochem* 207, 399–411.

9 Oda M, Yokomori H, Han JY (2003) Regulatory mechanisms of hepatic microcirculation. *Clin Hemorheol Microcirc* 29, 167–182.

10 Ueno T, Bioulac-Sage P, Balabaud C *et al.* (2004) Innervation of the sinusoidal wall: regulation of the sinusoidal diameter. *Anat Rec A Discov Mol Cell Evol Biol* 280, 868–873.

11 Gatmaitan Z, Varticovski L, Ling L *et al.* (1996) Studies on fenestral contraction in rat liver endothelial cells in culture. *Am J Pathol* 148, 2027–2041.

12 Püschel GP (2004) Control of hepatocyte metabolism by sympathetic and parasympathetic hepatic nerves. *Anat Rec A Discov Mol Cell Evol Biol* 280, 854–867.

13 Häussinger D (2004) Neural control of hepatic osmolytes and parenchymal cell hydration. *Anat Rec A Discov Mol Cell Evol Biol* 280, 893–900.

14 Shimazu T (1996) Innervation of the liver and glucoregulation: roles of the hypothalamus and autonomic nerves. *Nutrition* 12, 65–66.

15 Xue C, Aspelund G, Sritharan KC *et al.* (2000) Isolated hepatic cholinergic denervation impairs glucose and glycogen metabolism. *J Surg Res* 90, 19–25.

16 Matsuhisa M, Yamasaki Y, Shiba Y *et al.* (2000) Important role of the hepatic vagus nerve in glucose uptake and production by the liver. *Metabolism* 49, 11–16.

17 Niijima A (1989) Neural mechanisms in the control of blood glucose concentration. *J Nutr* 119, 833–840.

18 Akpan JO, Gardner R, Wagle SR (1974) Studies on the effects of insulin and acetylcholine on activation of glycogen synthase and on glycogenesis in hepatocytes. *Biochem Biophys Res Commun* 61, 222–229.

19 Lam TK, Pocai A, Gutierrez-Juarez R *et al.* (2005) Hypothalamic sensing of circulating fatty acids is required for glucose homeostasis. *Nature Med* 11, 320–327. Epub Feb 27 2005.

20 Torii K, Niijima A (2001) Effect of lysine on afferent activity of the hepatic branch of the vagus nerve in normal and L-lysine-deficient rats. *Physiol Behav* 72, 685–690.

21 Randich A, Spraggins DS, Cox JE *et al.* (2001) Jejunal or portal vein infusions of lipids increase hepatic vagal afferent activity. *Neuroreport* 12, 3101–3105.

22 Nishizawa M, Nakabayashi H, Kawai K *et al.* (2000) The hepatic vagal reception of intraportal GLP-1 is via receptor different from the pancreatic GLP-1 receptor. *J Auton Nerv Syst* 80, 14–21.

23 Uneyama H, Niijima A, Tanaka T *et al.* (2002) Receptor subtype specific activation of the rat gastric vagal afferent fibers to serotonin. *Life Sci* 72, 415–423.

24 Lutz TA, Niijima A, Scharrer E (1996) Intraportal infusion of 2,5-anhydro-D-mannitol increases afferent activity in the common hepatic vagus branch. *J Auton Nerv Syst* 61, 204–208.

25 Cox JE, Tyler WJ, Randich A *et al.* (2001) Celiac vagotomy reduces suppression of feeding by jejunal fatty acid infusions. *Neuroreport* 12, 1093–1096.

26 Lutz TA, Diener M, Scharrer E (1997) Intraportal mercaptoacetate infusion increases afferent activity in the common hepatic vagus branch of the rat. *Am J Physiol* 273, R442–445.

27 la Fleur SE, Ji H, Manalo SL *et al.* (2003) The hepatic vagus mediates fat-induced inhibition of diabetic hyperphagia. *Diabetes* 52, 2321–2330.

28 Adachi A, Kobashi M (1998) Role of hepatic afferent nerves in the controle of saline and water intake. In: Häussinger D, Jungermann K (eds) *Liver and the Nervous System*. Norwell, MA: Kluwer Academic Publisher.

29 Carlson SH, Wyss JM (1999) Hepatic denervation does not affect plasma vasopressin response to intragastric hypertonic saline in conscious rats. *Am J Physiol* 277, E161–E167.

30 Adkins BA, Myers SR, Hendrick GK *et al.* (1987) Importance of the route of intravenous glucose delivery to hepatic glucose balance in the conscious dog. *J Clin Invest* 79, 557–565.

31 Gardemann A, Strulik H, Jungermann K (1986) A portal-arterial glucose concentration gradient as a signal for an insulin-dependent net glucose uptake in perfused rat liver. *FEBS Lett* 202, 255–259.

32 Cardin S, Emshwiller M, Jackson PA *et al.* (1999) Portal glucose infusion increases hepatic glycogen deposition in conscious unrestrained rats. *J Appl Physiol* 87, 1470–1475.

33 Hsieh PS, Moore MC, Neal DW *et al.* (2000) Importance of the hepatic arterial glucose level in generation of the portal signal in conscious dogs. *Am J Physiol Endocrinol Metab* 279, E284–292.

34 Ogihara N, Kawamura W, Kasuga K *et al.* (2004) Characterization of the portal signal during 24-hour glucose delivery in unrestrained, conscious rats. *Am J Physiol Endocrinol Metab* 6, 6.

35 Stümpel F, Jungermann K (1997) Sensing by intrahepatic muscarinic nerves of a portal-arterial glucose concentration gradient as a signal for insulin-dependent glucose uptake in the perfused rat liver. *FEBS Lett* 406, 119–122.

36 Nishizawa M, Moore MC, Shiota M *et al.* (2003) Effect of intraportal glucagon-like peptide-1 on glucose metabolism in conscious dogs. *Am J Physiol Endocrinol Metab* 284, E1027–1036. Epub 2003 Feb 4.

37 Burcelin R, Da Costa A, Drucker D *et al.* (2001) Glucose competence of the hepatoportal vein sensor requires the presence of an activated glucagon-like peptide-1 receptor. *Diabetes* 50, 1720–1728.

38 Fery F, Tappy L, Deviere J *et al.*(2004) Comparison of intraduodenal and intravenous glucose metabolism under clamp conditions in humans. *Am J Physiol Endocrinol Metab* 286, E176–183. Epub 2003 Oct 7.

39 Moore MC, Cardin S, Edgerton DS *et al.* (2004) Unlike mice, dogs exhibit effective glucoregulation during low-dose portal and peripheral glucose infusion. *Am J Physiol Endocrinol Metab* 286, E226–233. Epub 2003 Sep 30.

40 Burcelin R, Crivelli V, Perrin C *et al.* (2003) GLUT4, AMP kinase, but not the insulin receptor, are required for hepatoportal glucose sensor-stimulated muscle glucose utilization. *J Clin Invest* 111, 1555–1562.

41 Lamarche L, Yamaguchi N, Peronnet F (1995) Hepatic denervation reduces adrenal catecholamine secretion during insulin-induced hypoglycemia. *Am J Physiol* 268, R50–57.

42 Latour MG, Cardin S, Helie R *et al.* (1995) Effect of hepatic vagotomy on plasma catecholamines during exercise-induced hypoglycemia. *J Appl Physiol* 78, 1629–1634.

43 Lautt WW (2004) A new paradigm for diabetes and obesity: the hepatic insulin sensitizing substance (HISS) hypothesis. *J Pharmacol Sci* 95, 9–17.

44 Moore MC, Satake S, Baranowski B *et al.* (2002) Effect of hepatic denervation on peripheral insulin sensitivity in conscious dogs. *Am J Physiol Endocrinol Metab* 282, E286–296.

45 Foster JH (1963) Nervous factors in toxic liver injury. *Surg Forum* 14, 74–76.

46 Hsu CT, Schichijo K, Ito M *et al.* (1993) The effect of chemical sympathectomy on acute liver injury induced by carbon tetrachloride in spontaneously hypertensive rats. *J Auton Nerv Syst* 43, 91–96.

47 Iwai M, Shimazu T (1996) Exaggeration of acute liver damage by hepatic sympathetic nerves and circulating catecholamines in perfused liver of rats treated with D-galactosamine. *Hepatology* 23, 524–529.

48 Neuhuber WL, Tiegs G (2004) Innervation of immune cells: evidence for neuroimmunomodulation in the liver. *Anat Rec A Discov Mol Cell Evol Biol* 280, 884–892.

49 Oben JA, Diehl AM (2004) Sympathetic nervous system regulation of liver repair. *Anat Rec A Discov Mol Cell Evol Biol* 280, 874–883.

50 Kiba T (2002) The role of the autonomic nervous system in liver regeneration and apoptosis – recent developments. *Digestion* 66, 79–88.

51 Borovikova LV, Ivanova S, Zhang M *et al.* (2000) Vagus nerve stimulation attenuates the systemic inflammatory response to endotoxin. *Nature* 405, 458–462.

52 Bang R, Biburger M, Neuhuber WL *et al.* (2004) Neurokinin-1 receptor antagonists protect mice from CD95- and tumor necrosis factor-alpha-mediated apoptotic liver damage. *J Pharmacol Exp Ther* 308, 1174–1180. Epub 2003 Nov 14.

53 Casini A, Lippe IT, Evangelista S *et al.* (1991) Sensory denervation with capsaicin reduces the liver collagen deposition induced by common bile duct obstruction in rats. *Adv Exp Med Biol* 298, 285–293.
54 Colle I, Van Vlierberghe H, Troisi R *et al.* (2004) Transplanted liver: consequences of denervation for liver functions. *Anat Rec A Discov Mol Cell Evol Biol* 280, 924–931.

2.2.6 *In vitro* techniques: isolated organ perfusion, slices, cells and subcellular elements

Bruno Stieger

The liver simultaneously fulfils a variety of functions. It is an important mediator of energy homeostasis, is central in the biosynthesis of plasma proteins, plays a key role in the metabolism of endogenous metabolic endproducts and xenobiotics and produces bile [1]. The liver consists of a variety of different cell types, the vast majority being hepatocytes complemented with endothelial cells, stellate cells and Kupffer cells. The elucidation of the mechanisms involved in the interplay of these various cell types, as well as understanding the physiological processes running in parallel, requires a variety of different *in vivo* and *in vitro* methods. An early successful example of the application of *in vitro* techniques was the demonstration with an isolated perfused liver setup that the liver is the predominant site of albumin synthesis in the body [2]. *In vitro* methods use systems ranging from those with great complexity such as perfused liver or primary hepatocytes to sometimes seemingly simple approaches such as membrane vesicles isolated from plasma membrane domains or intracellular organelles, as well as cloned proteins studied in heterologous expression systems.

This chapter intends to give an overview of commonly used *in vitro* methods in the delineation of the various functions of the liver. All topics covered in this chapter have been reviewed extensively. Therefore, the reader is referred to the references to retrieve in-depth information. In some cases, references will be made to individual findings. They will often relate to problems of transport research, as our laboratory has gained most of its methodological experience in this area. Owing to space limitations, a selection of references had to be made.

Perfused liver

The perfused liver permits the investigation of liver function under conditions that resemble normal physiology. There are examples in which liver function can be studied in an almost *in vivo* situation, e.g. by the *in vivo* determination of the clearance of asialorosomucoid from the circulation by the asialoglyoprotein receptor [3], in the bile fistula rat with collection of bile and testing for the clearance of cholephilic substances [4] or assessing the integrity of tight junctions using markers such as dextrans [5]. There are, however, critical limitations to these models: there is only a limited amount of blood that can be sampled and the number of data points that can be obtained in a single experiment is limited. Also, the composition of the blood cannot be controlled or altered without possibly harming the animal. Diversion of bile leads to a depletion of the bile salt pool and, consequently, to alterations in bile formation.

Perfusion of the liver is possible *in situ* or in an isolated setup [6–10]. The first setup allows the study of the liver in a condition with intact innervation in a living animal. In all setups, the essential components are a pump, an oxygenator, a system to control the temperature of the perfusate and a flow regulator. Two directions of perfusate flow are possible. In the antegrade mode, the inflow of the perfusate is via the portal vein with efflux via the hepatic vein, whereas in the retrograde mode, the direction of flow is reversed to influx via the hepatic vein and efflux via the portal vein. The perfusate may be delivered to the organ in an open (non-recirculating or single-pass perfusion) or in a recirculating manner. The recirculating setup is useful for the study of compounds which are slowly taken up by the liver or are slowly secreted. Accumulation of such compounds in the perfusate will facilitate their detection. The drawback of this setup is the accumulation of toxic metabolites in the perfusate, which will consequently impair the vitality of the perfused organ. The perfused organ is unique in that the relative contribution of various compartments of the liver to the clearance of substances from the perfusate can be studied. Such experiments are performed and analysed by the multiple indicator dilution method [11]. Furthermore, using specific inhibitors or activators, the contribution of various different cell types to whole organ physiology can be studied.

Methods have been developed to perfuse lobes or parts of human liver [12]. The human liver samples have to be of high quality and high viability for successful perfusions and good results.

Liver slices

The investigation of liver functions using the perfused liver setup is a powerful methodology, in particular with respect to the elucidation of whole organ homeostasis. However, it is limited to organ availability, which is particularly difficult for studies with human liver. Samples of high-quality human livers are limited for *in vitro* studies by ethical considerations and by the severe shortage of donor organs. An alternative approach is to use liver slices [13–15]. Liver slices are used to study hepatic drug metabolism as well as hepatotoxicity of xenobiotics [15], but they are also applied to transport research [14,16]. A particular advantage of liver slices is that they can be used to isolate intermediate metabolites of drugs or endogenous substances, as such metabolites accumulate in the culture medium during the culture period. However, this also occurs with toxic metabolites, which can become a limiting factor of the culture time.

The slices have a diameter of about 6–10 mm and a thickness of a few 100 μm. For best results, they are prepared by specialized

equipment employing mechanical high-precision tissue slicers. Using a mechanical device allows the preparation of multiple slices with very similar thickness from small tissue cylinders and is important to increase the reproducibility of results. The mechanical preparation of the liver slices has the advantage that it allows the investigation of liver tissue with its different cell types in a physiological architecture. Hence, cell types different from hepatocytes can be investigated [17]. Furthermore, tissue slicing can be applied to livers of various species without modifications. This is different from enzymatic methods for cell isolation, which require adaptations to different species. Hence, liver slices are ideally suited to investigate species differences. Additionally, liver slices can also be used to assess interorgan as well as intraorgan differences in hepatic functions. The optimal thickness of the slices is determined by the following consideration, which is crucial for the viability and survival time. Slices exceeding a certain thickness will lead to damaged cells in their core as a result of limited supply of nutrients and/or oxygen with consequent ischaemia and will lead, ultimately, to necrosis. In contrast, slices below a certain thickness will have a large proportion of damaged cells in comparison with the total number of cells in one slice. The thickness of the slices also influences the access of macromolecules (e.g. proteins) to the cells in the interior of the slice.

Isolated hepatocytes and liver cell lines

The perfused liver and liver slices allow us to study liver function in a context close to an *in vivo* situation. The availability of human liver samples for *in vitro* studies is limited. However, if such material is available, the amount may exceed what is necessary for *in vitro* experiments. Owing to the large number of hepatocytes available from one perfusion, many more experimental data points can be obtained from one single liver (or experiment). Therefore, studies with isolated hepatocytes are an important tool in *in vitro* liver research.

Primary hepatocytes can be isolated from many species with collagenase perfusion. This is usually done with the two-step procedure or a modification thereof developed by Berry and Friend [18–22]. Primary hepatocytes can be used immediately after isolation to perform the investigations in suspension. This system allows experiments to be performed for only a few hours. However, primary hepatocytes can also be stored in suspension at 4°C in University of Wisconsin solution (up to 48 h for primary rat hepatocytes) [23,24]. Alternatively, primary hepatocytes can be cultured in a monolayer configuration for a few days. It is important to realize that primary cultured hepatocytes gradually lose many liver-specific functions [19,25] leading, among other problems, to downregulation of the expression of hepatocellular transport systems [26].

To improve the degree of differentiation over extended culture times, various culture methods have been used. Hepatocytes can be cultivated in a so-called sandwich configuration [20,27]. In this setup, hepatocytes are cultivated on collagen for a short time period and thereafter covered with a layer of collagen. This leads to a marked improvement in cell polarity and expression of liver-specific functions. An alternative approach is to cultivate hepatocyte couplets rather than monolayers of single hepatocytes [28]. This system has the advantage of being polar and competent for canalicular secretion. It also offers the unique potential to study intracellular processes at the light microscopic level [29]. Coculturing of hepatocytes with other cells can be used to improve the state of differentiation of primary cultured hepatocytes [30]. However, this setup has an important limitation. Investigations of hepatocyte-specific functions in such mixed culture systems require careful control experiments to demonstrate hepatocyte specificity of findings.

As in the intact liver, the lack of direct accessibility of the canalicular lumen in primary cultured hepatocytes and in cultured liver slices is basically problematic. This lack of access becomes important in experiments in which transport of metabolites or cholephilic substances across the canalicular membrane is to be investigated. In order to circumvent this problem, primary cultured hepatocytes have been cultured on gas-permeable, porous supports, and canaliculi were subsequently punctured with microneedles to collect primary bile [31]. Alternatively, the dependence of the functional integrity of tight junctions on the presence of millimolar calcium has been explored [32]. Transport experiments in the presence and absence of calcium chelators were used to determine canalicular transport in sandwich-cultured primary hepatocytes [33].

Isolation of cells from the liver is not restricted to hepatocytes. It is also possible to isolate cholangiocytes and functional bile duct units for *in vitro* experiments [34]. A combination of several methods is necessary to obtain highly purified Kupffer cells [35]. For the study of the structure and function of hepatic endothelial fenestrae, isolation and culture of endothelial cells was instrumental [36].

Experiments with primary cultured hepatocytes require a sufficient supply of fresh liver tissue of high quality for cell isolation. In the case of human hepatocytes, this is often difficult. Therefore, many different hepatoma cell lines were established. All these cell lines can be cultured and propagated easily. However, all of them show different and variable degrees of differentiation [37,38]. This variable differentiation requires selection of hepatomas expressing the functions to be studied. Bile acids in the culture medium may induce, to some degree, differentiation of hepatoma cell lines [39]. As an alternative source of hepatocyte cell lines, primary hepatocytes have been transformed by transfection with simian virus 40 large T antigen [40].

Primary cultured hepatocytes are hard to expand. Using culture conditions in the presence and absence of serum, it was possible to expand first dedifferentiated hepatocytes and to obtain, after expansion, some degree of hepatocytic differentiation by changing to a chemically defined culture medium containing growth factors [41]. Alternatively, generation of cell hybrids has been used to establish cell lines stably expressing hepatocyte-

specific functions [42,43]. Among them, WIF-B cells and clones thereof have proved to be a most valuable tool in the study of hepatocytic functions and the generation of hepatocyte polarity *in vitro*.

Recently, a new avenue for obtaining a large number of hepatoctyes has opened. Adult stem cells, in particular bone marrow-derived stem cells, have demonstrated an unexpected plasticity. Evidence has been presented that subpopulations of bone marrow-derived stem cells can be differentiated *in vivo* and *in vitro* into hepatocytes [44–47]. Similar results were reported for stem cells derived from umbilical cord blood [48,49] or for monocytes [50]. However, these findings are controversially debated [51,52]. If *in vitro* differentiation of stem cells into hepatocytes can be established as a routine method, this would provide a seemingly unlimited source of hepatocytes. Hepatocytes derived from adult stem cells could potentially also be used for autologous transplantation and, hence, avoid the necessity of lifelong immunosuppression after heterologous cell (or organ) transplantation. The adult liver contains progenitor cells at different stages of differentiation [53]. Mitaka and coworkers were able to isolate so-called small hepatocytes from rat liver. In contrast to hepatocytes, small hepatocytes can be expanded into differentiated hepatocytes in culture [54]. These hepatocytes also become competent for bile secretion [55]. It seems unlikely, however, that small hepatocytes will constitute a major source of differentiated hepatocytes, as their rate of expansion is very slow and does not exceed a limited number of cell divisions. Michalopoulos and coworkers developed a method to obtain organoids in culture in a two-step procedure [56]. This procedure led to aggregates of different cell types, some of which resembled liver cell plates. This approach could be useful for studying the interaction of different cell types *in vitro*.

Isolated subcellular fractions

In order to study single cellular processes under well-defined and controlled conditions, working with subcellular fractions offers an ideal complementation to experiments with isolated cells. This is particularly important if experimental conditions are to be controlled on either side of biological membranes. There are many different methods for isolating subcellular fractions [57]. It should be kept in mind that subcellular fractions are usually heterogeneous and not free from contaminating membranes of different subcellular origin [58–60]. By combining different isolation procedures, the purity of the isolated fractions can be significantly improved, but at the expense of the yield of the subcellular fraction of interest.

Using isolated subcellular fractions allows us to perform experiments in conditions such as, for example, broad pH ranges, which are not compatible with cell vitality. Such conditions are required, for example, to investigate the energetics of transport processes or to investigate leak permeabilities of membranes. However, the latter may be introduced by the isolation method [61]. Additionally, experiments can be performed in the absence of cytosolic binding proteins [62]. This is important for the liver, which handles a large variety of poorly water-soluble, but tightly protein bound, substances. Subcellular fractions also allow us to study the sidedness of membrane-associated processes, in particular transport processes [63]. Transport experiments using subcellular fractions are performed with the rapid filtration technique [64,65]. This methodology allows us to work with very short incubation times, which are often shorter than what can be achieved in isolated organs or cells.

A prominent example of the power of isolated subcellular fractions is the dissection of hepatocellular processes involved in vectorial bile acid transport [62,66]. While work with the isolated perfused rat liver and isolated hepatocytes clearly established the uptake mechanisms for bile acids into hepatocytes, the elucidation of the secretory step across the canalicular membrane was only possible with isolated canalicular membrane vesicles. It was only possible to demonstrate with isolated vesicles that canalicular bile salt secretion is a primary active, adenosine triphosphate (ATP)-dependent process [67].

Additionally, it is also possible to identify the subcellular localization of proteins (such as, for example, the bile salt export pump) or cellular processes in the absence of antibodies [68,69]. Also, experiments with isolated plasma membrane fractions from the basolateral (sinusoidal and lateral) membrane and from the canalicular plasma membrane vesicles allow the study of domain-specific transport processes without the complication of simultaneous efflux of transported substrates, as occurs in other setups. Experiments with subcellular fractions are not restricted to experiments with plasma membrane-derived vesicles, but can also be performed with isolated organelles.

Cloned proteins

In order to characterize an individual protein functionally, it is necessary to obtain the pure protein in a sufficient amount for biochemical experiments. This requires the purification of the protein of interest. This is not feasible in many cases for membrane proteins. An attractive alternative approach is to clone membrane proteins and subsequently to study them in heterologous expression systems. A very powerful method for isolating proteins is to use functional expression cloning of the transport protein of interest in *Xenopus laevis* oocytes [70,71]. This technique is particularly well adapted to clone uptake transport systems, for example from hepatocytes [72]. This method of cloning starts by expressing total mRNA in oocytes in order to test whether the desired transport function is expressed. After enrichment of the mRNA of interest, a cDNA library is constructed and subsequently screened by *in vitro* translation of cRNA, which is expressed in oocytes. Once a single clone is obtained, the cDNA can be sequenced and cRNA used for transient expression of the cloned transport protein in oocytes for full characterization. In the case of proteins belonging to gene families or where limited sequence information is available, cloning of desired proteins is possible by homology screening of

Table 1 Comparison of K_m values of Na^+-dependent taurocholate transport in different experimental systems in rat liver.

Experimental system		K_m (μM)	Reference
Perfused liver		25	[86]
		61	[87]
Hepatocyte monolayers		33	[88]
		30	[89]
Hepatocyte suspensions		19	[90]
		26	[91]
		21	[92]
		12	[93]
		30	[94]
Membrane vesicles		56	[95]
		52	[96]
		46	[97]
Xenopus laevis oocytes		25	[98]
COS-7	Transient	29	[99]
HPTC	Stable	25	[100]
McArdle RH-7777	Stable	13	[101]
CHO 9–6	Stable	34	[102]
HeLa	Stable	8	[103]

libraries. Such an approach was used, for example, to clone rat organic anion transport protein 1a4 (Oatp1a4, formerly Oatp2 [73,74], or the bile salt export pump (Bsep) [75]).

For full characterization of transport proteins mediating uptake of, for example, bile acids or amino acids, transporters are heterologously expressed transiently or permanently in mammalian cells (for examples, see Table 1). It is important that the expression system does not contain an endogenous transport activity. In cases where endogenous transport systems are present, e.g. in oocytes, it may be difficult to characterize the exogenous transporter clearly. This is, for example, the case for amino acids [76]. Interestingly, oocytes show barely any uptake activity for bile acids but express an export system [77].

Many export systems in the canalicular membrane belong to the superfamily of ATP-binding cassette (ABC) transport proteins. To demonstrate the ability of Bsep to transport bile acids in an ATP-dependent manner and to characterize this transporter functionally, it was transiently expressed with the baculovirus system in the Sf9 cell line from insects [75]. As conjugated bile acids are poorly membrane permeable, isolated membrane vesicles are used to perform transport studies. Thus, there is no need to isolate specifically inside-out vesicles.

In order to demonstrate that the transport protein of interest was cloned, a full characterization with respect to kinetic parameters and driving forces is required. This necessitates complete information on the properties of the transport protein of interest in its 'natural' environment in organs, cells or membrane vesicles. As an example, the rat sodium bile acid cotransporter Ntcp, heterologously expressed in various expression systems, is compared with respect to its kinetic parameters as determined *in situ* in Table 1. Comparison of Ntcp expressed in amphibian *X. laevis* oocytes and mammalian cell lines revealed similar transport properties for all the different expression systems. These data indicate that membrane composition may not necessarily be a critical parameter for the characterization of transport proteins in heterologous expression systems.

Heterologous expression of membrane proteins also works well for intracellular proteins such as, for example, cytochrome P-450s (e.g. a recent example in [78]). Cells transfected with individual human CYPs are the starting material for the preparation of microsomal fractions expressing individual CYPs. Such microsomes are widely used to study *in vitro* drug metabolism.

Epithelial transport is unidirectional or vectorial for many substrates. Polar expression of transport systems in polarized cell lines such as the renal Madin Darby canine kidney (MDCK) cell line or the pig kidney cell line LLCP-K_1 allows the reconstitution of 'secretory' units. For example, Ntcp and organic anion-transporting polypeptides are expressed in the basolateral plasma membrane of hepatocytes and are sorted to the basolateral plasma membrane domain in transfected MDCK cells [79,80]. The organic anion transporter multidrug resistance protein 2 (Mrp2) and Bsep are expressed in the canalicular membrane of hepatocytes and are sorted to the apical domains of transfected MDCK cells [80,81]. Coexpression of basolateral uptake systems with these apical transporters allows the study of vectorial transport of Mrp2 and Bsep substrates [80,81]. Such systems can be viewed as 'columnar hepatocytes' and have the advantage of direct experimental access to the apical membrane domain. Additionally, in epithelial cell lines transfected with uptake and export transport systems, transcellular flux of substrates is reconstructed. In principle, multiple transport systems can be stably transfected into heterologous expression systems, as has been demonstrated for coexpression of Oatps and Mrps [82].

Outlook

With the development of powerful methods for large-scale sequencing, for the analysis of the entire transcriptome or protein pattern of cells or for the simultaneous detection of intermediates of different metabolic pathways, additional important tools have been made available for the study of hepatic functions in health and disease [83–85]. Utilizing these new methods together with the established methods of *in vitro* techniques will undoubtedly lead to important synergies and, consequently, to a much better understanding of physiological and pathophysiological hepatocellular processes. Ultimately, these new approaches should improve both diagnostics and treatment of patients.

References

1 Arias IM, Boyer JL, Fausto N *et al.* (eds) (2001) *The Liver: Biology and Pathobiology*, 4th edn. Philadelphia, PA: Lippincott Williams & Wilkins, p. 1088.

2 Miller LL, Bly CG, Watson ML *et al.* (1951) The dominant role of the liver in plasma protein synthesis. *J Exp Med* 94, 431–453.
3 Ashwell G, Morell AG (1974) The role of surface carbohydrates in the hepatic recognition and transport of circulating glycoproteins. *Adv Enzymol Relat Areas Mol Biol* 41, 99–128.
4 Kuipers F, Havinga R, Bosschieter H *et al.* (1985) Enterohepatic circulation in the rat. *Gastroenterology* 88, 403–411.
5 Rahner C, Stieger B, Landmann L (1996) Structure–function correlation of tight junctional impairment after intrahepatic and extrahepatic cholestasis in rat liver. *Gastroenterology* 110, 1564–1578.
6 Meijer DK, Keulemans K, Mulder GJ (1981) Isolated perfused rat liver technique. *Methods Enzymol* 77, 81–94.
7 Gores GJ, Kost LJ, LaRusso NF (1986) The isolated perfused rat liver: conceptual and practical considerations. *Hepatology* 6, 511–517.
8 Wolkoff AW, Johansen KL, Goeser T (1987) The isolated perfused rat liver: preparation and application. *Anal Biochem* 167, 1–14.
9 Brouwer KL, Thurman RG (1996) Isolated perfused liver. *Pharm Biotechnol* 8, 161–192.
10 vom Dahl S, Haussinger D (1997) Experimental methods in hepatology. Guidelines of the German Association for the Study of the Liver (GASL). Liver perfusion – technique and applications. *Z Gastroenterol* 35, 221–226.
11 Tirona RG, Schwab AJ, Geng W *et al.* (1998) Hepatic clearance models: comparison of the dispersion and Goresky models in outflow profiles from multiple indicator dilution rat liver studies. *Drug Metab Dispos* 26, 465–475.
12 Melgert BN, Olinga P, Weert B *et al.* (2001) Cellular distribution and handling of liver-targeting preparations in human livers studied by a liver lobe perfusion. *Drug Metab Dispos* 29, 361–367.
13 Lerche-Langrand C, Toutain HJ (2000) Precision-cut liver slices: characteristics and use for in vitro pharmaco-toxicology. *Toxicology* 153, 221–253.
14 Olinga P, Hof IH, Merema MT *et al.* (2001) The applicability of rat and human liver slices to the study of mechanisms of hepatic drug uptake. *J Pharmacol Toxicol Methods* 45, 55–63.
15 Vickers AE, Fisher RL (2004) Organ slices for the evaluation of human drug toxicity. *Chem Biol Interact* 150, 87–96.
16 Elferink MG, Olinga P, Draaisma AL *et al.* (2004) LPS-induced downregulation of MRP2 and BSEP in human liver is due to a posttranscriptional process. *Am J Physiol Gastrointest Liver Physiol* 287, G1008–1016.
17 van de Bovenkamp M, Groothuis GM, Draaisma AL *et al.* (2005) Precision-cut liver slices as a new model to study toxicity-induced hepatic stellate cell activation in a physiologic milieu. *Toxicol Sci* 85, 632–638.
18 Berry MN, Friend DS (1969) High-yield preparation of isolated rat liver parenchymal cells: a biochemical and fine structural study. *J Cell Biol* 43, 506–520.
19 Strain AJ (1994) Isolated hepatocytes: use in experimental and clinical hepatology. *Gut* 35, 433–436.
20 LeCluyse EL, Bullock PL, Parkinson A *et al.* (1996) Cultured rat hepatocytes. *Pharm Biotechnol* 8, 121–159.
21 Berry MN, Grivell AR, Grivell MB *et al.* (1997) Isolated hepatocytes – past, present and future. *Cell Biol Toxicol* 13, 223–233.
22 Gebhardt R, Hengstler JG, Muller D *et al.* (2003) New hepatocyte in vitro systems for drug metabolism: metabolic capacity and recommendations for application in basic research and drug development, standard operation procedures. *Drug Metab Rev* 35, 145–213.
23 Sandker GW, Weert B, Merema MT *et al.* (1993) Maintenance of viability and transport function after preservation of isolated rat hepatocytes in various simplified University of Wisconsin solutions. *Biochem Pharmacol* 46, 2093–2096.
24 Mitry RR, Hughes RD, Dhawan A (2002) Progress in human hepatocytes: isolation, culture and cryopreservation. *Semin Cell Dev Biol* 13, 463–467.
25 Maher JJ (1988) Primary hepatocyte culture: is it home away from home? *Hepatology* 8, 1162–1166.
26 Rippin SJ, Hagenbuch B, Meier PJ *et al.* (2001) Cholestatic expression pattern of sinusoidal and canalicular organic anion transport systems in primary cultured rat hepatocytes. *Hepatology* 33, 776–782.
27 Berthiaume F, Moghe PV, Toner M *et al.* (1996) Effect of extracellular matrix topology on cell structure, function, and physiological responsiveness: hepatocytes cultured in a sandwich configuration. *FASEB J* 10, 1471–1484.
28 Graf J, Boyer JL (1990) The use of isolated rat hepatocyte couplets in hepatobiliary physiology. *J Hepatol* 10, 387–394.
29 Milkiewicz P, Roma MG, Elias E *et al.* (2002) Pathobiology and experimental therapeutics in hepatocellular cholestasis: lessons from the hepatocyte couplet model. *Clin Sci (Lond)* 102, 603–614.
30 Guillouzo A, Morel F, Langouet S *et al.* (1997) Use of hepatocyte cultures for the study of hepatotoxic compounds. *J Hepatol* 26 (Suppl 2), 73–80.
31 Petzinger E, Follmann W, Acker H *et al.* (1988) Primary liver cell cultures grown on gas permeable membrane as source for the collection of primary bile. *In Vitro Cell Dev Biol* 24, 491–499.
32 Harhaj NS, Antonetti DA (2004) Regulation of tight junctions and loss of barrier function in pathophysiology. *Int J Biochem Cell Biol* 36, 1206–1237.
33 Liu X, LeCluyse EL, Brouwer KR *et al.* (1999) Biliary excretion in primary rat hepatocytes cultured in a collagen-sandwich configuration. *Am J Physiol* 277, G12–21.
34 Boyer JL (1996) Bile duct epithelium: frontiers in transport physiology. *Am J Physiol* 270, G1–5.
35 Valatas V, Xidakis C, Roumpaki H *et al.* (2003) Isolation of rat Kupffer cells: a combined methodology for highly purified primary cultures. *Cell Biol Int* 27, 67–73.
36 Gatmaitan Z, Varticovski L, Ling L *et al.* (1996) Studies on fenestral contraction in rat liver endothelial cells in culture. *Am J Pathol* 148, 2027–2041.
37 Miyazaki M, Namba M (1994) Hepatocellular carcinomas. In: Hay RJ, Park J-G, Gazdar A (eds) *Atlas of Human Tumor Cell Lines*. San Diego, CA: Academic Press, pp. 185–212.
38 Ferro M, Bassi AM, Penco S *et al.* (1993) Use of established hepatoma cell lines in biotoxicology. *Cytotechnology* 11 (Suppl 1), S126–129.
39 Ng KH, Le Goascogne C, Amborade E *et al.* (2000) Reversible induction of rat hepatoma cell polarity with bile acids. *J Cell Sci* 113, 4241–4251.
40 Kobayashi N, Noguchi H, Fujiwara T *et al.* (2000) Establishment of a highly differentiated immortalized adult human hepatocyte cell line by retroviral gene transfer. *Transplant Proc* 32, 2368–2369.
41 Block GD, Locker J, Bowen WC *et al.* (1996) Population expansion, clonal growth, and specific differentiation patterns in primary cultures of hepatocytes induced by HGF/SF, EGF and TGF alpha in a chemically defined (HGM) medium. *J Cell Biol* 132, 1133–1149.
42 Blumrich M, Zeyen-Blumrich U, Pagels P *et al.* (1994) Immortalization of rat hepatocytes by fusion with hepatoma cells. II. Studies on

the transport and synthesis of bile acids in hepatocytoma (HPCT) cells. *Eur J Cell Biol* 64, 339–347.

43 Cassio D, Hamon-Benais C, Guerin M *et al.* (1991) Hybrid cell lines constitute a potential reservoir of polarized cells: isolation and study of highly differentiated hepatoma-derived hybrid cells able to form functional bile canaliculi in vitro. *J Cell Biol* 115, 1397–1408.

44 Theise ND, Nimmakayalu M, Gardner R *et al.* (2000) Liver from bone marrow in humans. *Hepatology* 32, 11–16.

45 Alison MR, Poulsom R, Jeffery R *et al.* (2000) Hepatocytes from non-hepatic adult stem cells. *Nature* 406, 257.

46 Schwartz RE, Reyes M, Koodie L *et al.* (2002) Multipotent adult progenitor cells from bone marrow differentiate into functional hepatocyte-like cells. *J Clin Invest* 109, 1291–1302.

47 Avital I, Inderbitzin D, Aoki T *et al.* (2001) Isolation, characterization, and transplantation of bone marrow-derived hepatocyte stem cells. *Biochem Biophys Res Commun* 288, 156–164.

48 Hong SH, Gang EJ, Jeong JA *et al.* (2005) In vitro differentiation of human umbilical cord blood-derived mesenchymal stem cells into hepatocyte-like cells. *Biochem Biophys Res Commun* 330, 1153–1161.

49 Wang Y, Nan X, Li Y *et al.* (2005) Induction of umbilical cord blood-derived β_2m-c-Met$^+$ cells into hepatocyte-like cells by coculture with CFSC/HGF cells. *Liver Transpl* 11, 635–643.

50 Ruhnke M, Ungefroren H, Nussler A *et al.* (2005) Differentiation of in vitro-modified human peripheral blood monocytes into hepatocyte-like and pancreatic islet-like cells. *Gastroenterology* 128, 1774–1786.

51 Menthena A, Deb N, Oertel M *et al.* (2004) Bone marrow progenitors are not the source of expanding oval cells in injured liver. *Stem Cells* 22, 1049–1061.

52 Cantz T, Sharma AD, Jochheim-Richter A *et al.* (2004) Reevaluation of bone marrow-derived cells as a source for hepatocyte regeneration. *Cell Transplant* 13, 659–666.

53 Sell S (2001) Heterogeneity and plasticity of hepatocyte lineage cells. *Hepatology* 33, 738–750.

54 Mitaka T, Sato F, Mizuguchi T *et al.* (1999) Reconstruction of hepatic organoid by rat small hepatocytes and hepatic nonparenchymal cells. *Hepatology* 29, 111–125.

55 Sidler Pfandler MA, Hochli M, Inderbitzin D *et al.* (2004) Small hepatocytes in culture develop polarized transporter expression and differentiation. *J Cell Sci* 117, 4077–4087.

56 Michalopoulos GK, Bowen WC, Zajac VF *et al.* (1999) Morphogenetic events in mixed cultures of rat hepatocytes and nonparenchymal cells maintained in biological matrices in the presence of hepatocyte growth factor and epidermal growth factor. *Hepatology* 29, 90–100.

57 Packer L, Fleischer S (eds) (1997) *Biomembranes*. San Diego, CA: Academic Press.

58 Stieger B, Murer H (1983) Heterogeneity of brush-border-membrane vesicles from rat small intestine prepared by a precipitation method using Mg/EGTA. *Eur J Biochem* 135, 95–101.

59 Murer H, Gmaj P, Stieger B *et al.* (1989) Transport studies with renal proximal tubular and small intestinal brush border and basolateral membrane vesicles: vesicle heterogeneity, coexistence of transport system. *Methods Enzymol* 172, 346–364.

60 Kast C, Stieger B, Winterhalter KH *et al.* (1994) Hepatocellular transport of bile acids. Evidence for distinct subcellular localizations of electrogenic and ATP-dependent taurocholate transport in rat hepatocytes. *J Biol Chem* 269, 5179–5186.

61 Murer H, Biber J, Gmaj P *et al.* (1984) Cellular mechanisms in epithelial transport: advantages and disadvantages of studies with vesicles. *Mol Physiol* 6, 55–82.

62 Meier PJ (1996) Hepatocellular transport systems: from carrier identification in membrane vesicles to cloned proteins. *J Hepatol* 24 (Suppl 1), 29–35.

63 Walter H (1975) Tightness and orientation of vesicles from guinea-pig kidney estimated from reactions of adenosine triphosphatase dependent on sodium and potassium ions. *Eur J Biochem* 58, 595–601.

64 Murer H, Kinne R (1980) The use of isolated membrane vesicles to study epithelial transport processes. *J Membr Biol* 55, 81–95.

65 Boyer JL, Meier PJ (1990) Characterizing mechanisms of hepatic bile acid transport utilizing isolated membrane vesicles. *Methods Enzymol* 192, 517–533.

66 Meier PJ, Boyer JL (1990) Preparation of basolateral (sinusoidal) and canalicular plasma membrane vesicles for the study of hepatic transport processes. *Methods Enzymol* 192, 534–545.

67 Keppler D, Arias IM (1997) Hepatic canalicular membrane. Introduction: transport across the hepatocyte canalicular membrane. *FASEB J* 11, 15–18.

68 Stieger B, O'Neill B, Meier PJ (1992) ATP-dependent bile-salt transport in canalicular rat liver plasma-membrane vesicles. *Biochem J* 284, 67–74.

69 Kaufmann M, Muff R, Stieger B *et al.* (1994) Apical and basolateral parathyroid hormone receptors in rat renal cortical membranes. *Endocrinology* 134, 1173–1178.

70 Sigel E (1990) Use of *Xenopus* oocytes for the functional expression of plasma membrane proteins. *J Membr Biol* 117, 201–221.

71 Romero MF, Kanai Y, Gunshin H *et al.* (1998) Expression cloning using *Xenopus laevis* oocytes. *Methods Enzymol* 296, 17–52.

72 Hagenbuch B, Jacquemin E, Meier PJ (1994) Na^+-dependent and Na^+-independent bile acid uptake systems in the liver. *Cell Physiol Biochem* 4, 198–205.

73 Hagenbuch B, Meier PJ. (2004) Organic anion transporting polypeptides of the OATP/*SLC*21 family: phylogenetic classification as OATP/*SLCO* superfamily, new nomenclature and molecular/functional properties. *Pflugers Arch* 447, 653–665.

74 Noe B, Hagenbuch B, Stieger B *et al.* (1997) Isolation of a multispecific organic anion and cardiac glycoside transporter from rat brain. *Proc Natl Acad Sci USA* 94, 10346–10350.

75 Gerloff T, Stieger B, Hagenbuch B *et al.* (1998) The sister of P-glycoprotein represents the canalicular bile salt export pump of mammalian liver. *J Biol Chem* 273, 10046–10050.

76 Van Winkle LJ (1993) Endogenous amino acid transport systems and expression of mammalian amino acid transport proteins in *Xenopus* oocytes. *Biochim Biophys Acta* 1154, 157–172.

77 Shneider BL, Moyer MS (1993) Characterization of endogenous carrier-mediated taurocholate efflux from *Xenopus laevis* oocytes. *J Biol Chem* 268, 6985–6988.

78 Omasa T, Kim K, Hiramatsu S *et al.* (2005) Construction and evaluation of drug-metabolizing cell line for bioartificial liver support system. *Biotechnol Prog* 21, 161–167.

79 Sun AQ, Ananthanarayanan M, Soroka CJ *et al.* (1998) Sorting of rat liver and ileal sodium-dependent bile acid transporters in polarized epithelial cells. *Am J Physiol Gastrointest Liver Physiol* 275, G1045–1055.

80 Cui Y, Konig J, Keppler D (2001) Vectorial transport by double-transfected cells expressing the human uptake transporter SLC21A8 and the apical export pump ABCC2. *Mol Pharmacol* 60, 934–943.

81 Mita S, Suzuki H, Akita H *et al.* (2005) Vectorial transport of bile salts across MDCK cells expressing both rat Na^+-taurocholate

cotransporting polypeptide and rat bile salt export pump. *Am J Physiol Gastrointest Liver Physiol* 288, G159–167.
82 Kopplow K, Letschert K, Konig J *et al.* (2005) Human hepatobiliary transport of organic anions analyzed by quadruple-transfected cells. *Mol Pharmacol* 68, 1031–1038.
83 Shackel NA, Gorrell MD, McCaughan GW (2002) Gene array analysis and the liver. *Hepatology* 36, 1313–1325.
84 Chignard N, Beretta L (2004) Proteomics for hepatocellular carcinoma marker discovery. *Gastroenterology* 127, S120–125.
85 Griffin JL, Bollard ME (2004) Metabonomics: its potential as a tool in toxicology for safety assessment and data integration. *Curr Drug Metab* 5, 389–398.
86 Reichen J, Paumgartner G (1976) Uptake of bile acids by perfused rat liver. *Am J Physiol* 231, 734–742.
87 Dietmaier A, Gasser R, Graf J *et al.* (1976) Investigations on the sodium dependence of bile acid fluxes in the isolated perfused rat liver. *Biochim Biophys Acta* 443, 81–91.
88 Van Dyke RW, Stephens JE, Scharschmidt BF (1982) Bile acid transport in cultured rat hepatocytes. *Am J Physiol Gastrointest Liver Physiol* 243, G484–492.
89 Liang D, Hagenbuch B, Stieger B *et al.* (1993) Parallel decrease of Na(+)-taurocholate cotransport and its encoding mRNA in primary cultures of rat hepatocytes. *Hepatology* 18, 1162–1166.
90 Schwarz LR, Burr R, Schwenk M *et al.* (1975) Uptake of taurocholic acid into isolated rat-liver cells. *Eur J Biochem* 55, 617–623.
91 Anwer MS, Kroker R, Hegner D (1976) Effect of albumin on bile acid uptake by isolated rat hepatocytes. Is there a common bile acid carrier? *Biochem Biophys Res Commun* 73, 63–71.
92 Blitzer BL, Ratoosh SL, Donovan CB *et al.* (1982) Effects of inhibitors of Na^+-coupled ion transport on bile acid uptake by isolated rat hepatocytes. *Am J Physiol Gastrointest Liver Physiol* 243, G48–53.
93 Kuhn WF, Gewirtz DA (1988) Stimulation of taurocholate and glycocholate efflux from the rat hepatocyte by arginine vasopressin. *Am J Cell Physiol* 254, G732–740.
94 Follmann W, Petzinger E, Kinne RK (1990) Alterations of bile acid and bumetanide uptake during culturing of rat hepatocytes. *Am J Cell Physiol* 258, C700–712.
95 Inoue M, Kinne R, Tran T *et al.* (1982) Taurocholate transport by rat liver sinusoidal membrane vesicles: evidence of sodium cotransport. *Hepatology* 2, 572–579.
96 Duffy MC, Blitzer BL, Boyer JL (1983) Direct determination of the driving forces for taurocholate uptake into rat liver plasma membrane vesicles. *J Clin Invest* 72, 1470–1481.
97 Zimmerli B, Valantinas J, Meier PJ (1989) Multispecificity of Na^+-dependent taurocholate uptake in basolateral (sinusoidal) rat liver plasma membrane vesicles. *J Pharmacol Exp Ther* 250, 301–308.
98 Hagenbuch B, Stieger B, Foguet M *et al.* (1991) Functional expression cloning and characterization of the hepatocyte Na+/bile acid cotransport system. *Proc Natl Acad Sci USA* 88, 10629–10633.
99 Boyer JL, Ng OC, Ananthanarayanan M *et al.* (1994) Expression and characterization of a functional rat liver Na+ bile acid cotransport system in COS-7 cells. *Am J Physiol Gastrointest Liver Physiol* 266, G382–387.
100 Platte HD, Honscha W, Schuh K *et al.* (1996) Functional characterization of the hepatic sodium-dependent taurocholate transporter stably transfected into an immortalized liver-derived cell line and V79 fibroblasts. *Eur J Cell Biol* 70, 54–60.
101 Torchia EC, Shapiro RJ, Agellon LB (1996) Reconstitution of bile acid transport in the rat hepatoma McArdle RH-7777 cell line. *Hepatology* 24, 206–211.
102 Schroeder A, Eckhardt U, Stieger B *et al.* (1998) Substrate specificity of the rat liver Na(+)-bile salt cotransporter in *Xenopus laevis* oocytes and in CHO cells. *Am J Physiol Gastrointest Liver Physiol* 274, G370–375.
103 Hata S, Wang P, Eftychiou N *et al.* (2003) Substrate specificities of rat oatp1 and ntcp: implications for hepatic organic anion uptake. *Am J Physiol Gastrointest Liver Physiol* 285, G829–839.

2.3 Metabolism

2.3.1 Carbohydrates and the liver

Guenther Boden

Introduction

After a carbohydrate-containing meal, the liver maintains plasma glucose concentration within a narrow range by taking up one-quarter to one-third of the absorbed glucose, oxidizing some of it and storing the rest as glycogen or converting it into fat. In the postabsorptive state, the liver provides much needed glucose to the central nervous system and other glucose-utilizing tissues by breaking down glycogen (a process called glycogenolysis, GL) and/or by new formation of glucose from non-glucose precursors (a process called gluconeogenesis, GNG). Disturbances of any one of these processes can result in either hyperglycaemia or hypoglycaemia. This chapter focuses on glucose, the physiologically most important carbohydrate, and gives a brief overview of the pivotal role of the liver in glucose metabolism under normal and abnormal conditions.

Hepatic glucose metabolism in the postprandial state

After a meal, the liver plays a pivotal role in maintaining blood glucose homeostasis by regulating, minute by minute, hepatic glucose production and uptake.

Glucose production

After a mixed meal (~ 60% carbohydrate, ~ 20% fat and ~ 15% protein), endogenous glucose production (EGP; over 90% of which comes from the liver, with the remainder derived from the kidneys) falls to very low rates (0–20% of basal) (reviewed in [1]). During this period, blood sugar concentrations are predominantly maintained by absorption of meal-derived glucose, while EGP decreases to 20% or less of basal (postabsorptive rates). As intestinal absorption of carbohydrate decreases several hours after the meal, EGP rises slowly towards basal levels.

These changes in EGP are controlled primarily by two pancreatic hormones, insulin and glucagon.

Insulin is secreted by the pancreatic β cells directly into the portal circulation. The liver extracts and degrades between 50% and 80% of the insulin entering it on first pass [2,3] and, thus, even basal insulin concentrations are approximately three times higher in the portal than in the peripheral circulation [1]. Insulin secretion is stimulated by changes in blood levels of glucose, fatty acids and amino acids (with glucose being the strongest secretagogue). Insulin secretion can be modified by an as yet unidentified portal signal (presumably mediated by the parasympathetic nervous system) [4], by several gastrointestinal hormones including glucose-dependent intestinal peptide (GIP) and glucagon-like peptide 1 (GLP1) [2,5], and by the central nervous system (cephalic phase).

Hepatic glucose production is exquisitely sensitive to changes in insulin levels. The four- to 10-fold rise in hepatic sinusoidal insulin typically seen after a carbohydrate-rich meal almost completely inhibits hepatic glucose production. There is little information on the effect of insulin on renal glucose production, but insulin presumably suppresses renal glucose production as well. Insulin suppresses EGP through direct and indirect actions. In the direct pathway, insulin lowers glucose production primarily by stimulating glycogen synthesis [6]. In the indirect pathway, by inhibiting proteolysis and lipolysis, insulin decreases the supply of gluconeogenic precursors such as amino acids and free fatty acids (FFAs) to the liver. This results in a decrease in glucose production, presumably by reducing GNG [7,8]. In addition, insulin can lower hepatic GNG and blood glucose levels by direct action on adenosine triphosphate (ATP)-sensitive K channels in the mediobasal hypothalamus [9].

Glucagon is secreted by the pancreatic α cells. Like insulin, glucagon is secreted directly into the portal circulation but, unlike insulin, the liver degrades only ~ 15–25% of the glucagon entering it [10]. Glucagon secretion is stimulated by

hypoglycaemia, amino acids, and sympathetic and parasympathetic nervous stimulation. Glucagon secretion is decreased by hyperglycaemia, and high FFA and somatostatin levels. Glucagon rapidly increases EGP by promoting glycogenolysis via an increase in the phosphorylase reaction [6]. After a mixed meal containing carbohydrates, protein and fat, both insulin and glucagon concentrations rise in the portal circulation, but the rise in insulin exceeds that of glucagon. The net effect is an increase in the insulin/glucagon ratio and a sharp decrease in EGP. After a protein/fat-rich meal containing little or no carbohydrates, glucagon rises much more than insulin. The low insulin/glucagon ratio results in a rise in EGP, which prevents the hypoglycaemia that would occur if the amino acid-stimulated insulin secretion was unopposed by a larger amino acid-stimulated glucagon secretion.

Glucose uptake

The liver takes up one-quarter to one-third of an ingested glucose load during the initial 4–5 h after ingestion of a mixed meal. Most of this glucose is stored as glycogen; the remainder is oxidized or converted into fat.

Postprandial glycogen synthesis is driven by portal venous hyperglycaemia and by high insulin/glucagon ratios. Hyperinsulinaemia stimulates glycogen synthase flux, while hyperglycaemia inhibits glycogen phosphorylase flux [6]. Thus, postprandial hyperglycaemia and hyperinsulinaemia together stimulate glycogen synthesis and inhibit GL, resulting in a rapid and profound decrease in EGP.

Glycogen is synthesized via two different pathways. The direct pathway (glucose to glucose-6-phosphate to glucose-1-phosphate to UDP glucose to glycogen) accounts for ~ 50% of glycogen synthesis during the postabsorptive phase and increases postprandially to 60–70% of glycogen synthesis, while the indirect pathway (three carbon glucose precursors to glucose-6-phosphate to glucose-1-phosphate to UDP glucose to glycogen) accounts for the remainder [1].

Hepatic glucose metabolism in the postabsorptive state

During the postabsorptive state, all macronutrients have ceased to enter the circulation from the digestive tract and all meal-associated changes in hormone secretion have returned to basal. For practical purposes, it is the time after an overnight fast and before breakfast. Under these conditions, the liver of a healthy person weighing ~ 70 kg produces glucose at a rate of ~ 10 g/h, of which ~ 6 g/h is taken up by the central nervous system, with the rest going to all other tissues including skeletal muscle, adipose tissue, red blood cells, renal medulla, etc. [11]. The postabsorptive blood glucose concentration of a person weighing 70 kg is ~ 90 mg/dL, and ~ 19 g of glucose, i.e. less than a 2-h supply, is present in the extracellular space (assumed to be ~ 30% of body weight).

The vital role of the liver in supplying glucose for use mainly in the central nervous system during an overnight fast is regulated by insulin and glucagon. The low postabsorptive insulin levels reduce glycogen synthesis to very low rates and allow glucagon to stimulate GL, resulting in an increase in EGP to ~ 10 g/h. Hence, it has been estimated that, after an overnight fast, basal plasma glucagon levels are responsible for 75% or more of EGP [12].

Gluconeogenesis (GNG) and glycogenolysis (GL)

EGP has two components. GNG, which is the formation of glucose from non-glucose precursors (lactate, pyruvate, glucogenic amino acids and glycerol), and GL, which is glucose derived from the breakdown of glycogen stored in the liver. Despite its physiological importance, accurate and quantitative information from human subjects on rates of GNG and GL is limited, primarily because of methodological problems. Specifically, the labelled precursors used to measure GNG are diluted to an unpredictable degree in the oxalocetic acid pool, which is shared by GNG and the tricarboxylic acid cycle [13]. Recently, however, several methods have become available that allow non-invasive measurement of *in vivo* rates of GNG and GL in humans [14–17]. Of those, the ^2H_2O method, which was developed and validated by Landau *et al.* [17] to measure GNG, is currently most widely used. This method depends on the incorporation of ^2H from ^2H_2O into carbon 5 of glucose (Fig. 1). It measures GNG from all sources, including lactate, pyruvate, glucogenic amino acids and glycerol, and avoids the problems related to precursor dilution. On the other hand, the ^2H_2O method determines only GNG-derived glucose that enters the glucose space, that is the glucose-6-phosphate to glucose flux. It does not detect GNG-derived glucose that is deposited in glycogen or cycles from glucose-6-phosphate to glycogen and back to glucose-6-phosphate and thus does not enter the blood. When GNG is determined by this method, GL can be calculated by subtracting

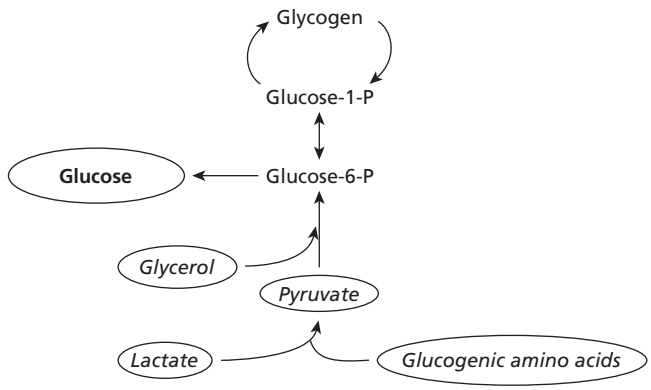

Fig. 1 Schematic representation of GNG as measured with ^2H_2O. This method determines glucose derived from pyruvate and glycerol, which enters the glucose space.

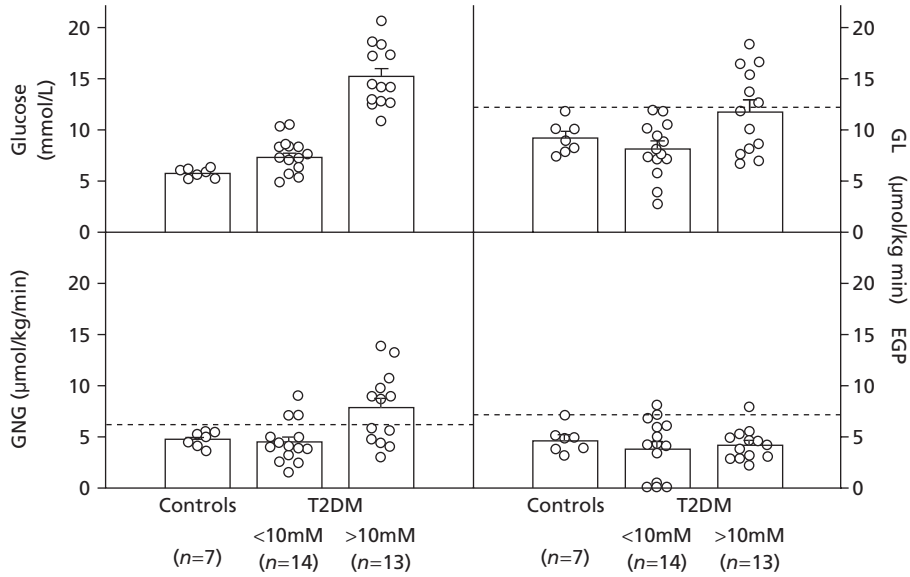

Fig. 2 Plasma glucose, GNG, GL and EGP in 14 patients with type 2 diabetes mellitus (T2DM) who had fasting plasma glucose levels of < 10 mM, in 13 patients with T2DM with fasting plasma glucose levels of > 10 mM and in seven non-diabetic control subjects. Shown are means ± SE. Broken horizontal lines represent mean ± 2 SD of control subjects. The data show that higher rates of GNG and EGP are seen mostly in patients with fasting plasma glucose levels > 10 mmol/L who have more than modest degrees of insulin deficiency [26].

GNG from EGP (GL = EGP–GNG). GL can also be obtained by directly measuring liver glycogen concentration with ^{13}C-nuclear magnetic resonance spectroscopy in combination with magnetic resonance imaging of the liver volume and isotopic measurement of EGP [14]. Use of these newer methods have shown the following:

1 In healthy people after an overnight fast, GNG and GL contribute about equally to EGP. As fasting progresses, the absolute contribution of GNG (in µmol/h) remains essentially unchanged, whereas GL decreases as glycogen stores become depleted. As a result, after more than 40 h of fasting, GNG accounts for over 90% of EGP.

2 Acutely rising serum insulin levels reduce EGP primarily by suppressing GL and, to a much lesser extent, GNG [18,19].

3 Acute elevations of plasma FFA levels raise GNG and lower GL, whereas acute lowering of FFA levels lower GNG and raise GL [20]. Because of the reciprocal changes in GNG and GL, EGP remains essentially unchanged [21]. This so-called hepatic autoregulation of EGP seems to be regulated by insulin in the following way. Rising FFA levels stimulate GNG and insulin secretion. The rise in insulin levels suppresses GL.

4 Abnormally elevated plasma FFA levels cause hepatic insulin resistance, i.e. they inhibit insulin-mediated suppression of EGP, which is due to inhibition by FFA of the normal insulin suppression of GL [19].

5 After a mixed meal, net hepatic glycogen synthesis increases by ~ 50% resulting in about 20% of the ingested glucose being deposited as glycogen in the liver [22].

Diabetes

Patients with type 2 diabetes frequently have higher rates of GNG and EGP than non-diabetic control subjects [23–26]. There is, however, a great deal of overlap in GNG and EGP between diabetic patients and non-diabetic control subjects, and absolutely higher than normal rates of GNG and EGP are usually seen only in patients with fasting plasma glucose concentrations of > 10 mmol/L [26] (Fig. 2). It needs to be recognized, however, that the 'normal' rates of GNG and EGP in patients with type 2 diabetes are abnormal in view of the fact that insulin and glucose levels are commonly elevated in these patients and that both hyperglycaemia and hyperinsulinaemia inhibit EGP in healthy subjects. In addition, patients with type 2 diabetes also seem to have dysfunctional hepatic autoregulation. For instance, when plasma FFA levels were lowered in patients with type 2 diabetes, these patients were unable to compensate for the decrease in GNG with an increase in GL; when FFA levels were raised, GNG rose but GL did not decrease appropriately [27].

In patients with type 1 diabetes mellitus, injection of insulin resulted in an acute decrease in EGP, which was due to a decrease in GL with little change in GNG (glucose concentrations were clamped at 6.5 mmol/L) [28]. In patients with type 1 diabetes during a phase of acute insulin deficiency, which developed 4–8 h after the last insulin injection, EGP rose from 9.5 to 14.3 mmol/L, which was again due to an increase in GL with little change in GNG, and glucose rose from 6.2 to 10.5 mmol/L. Thus, acute regulation of EGP in patients with type 1 diabetes is brought about primarily by changes in GL with little or no participation of GNG [28].

The reason for the increased EGP in patients with type 2 diabetes is incompletely compensated hepatic insulin resistance. Although the causes of the hepatic insulin resistance are not completely understood, there are known defects in postreceptor insulin signalling. The normally functioning direct and indirect insulin pathways (see above), which result in insulin-induced suppression of EGP, involve tyrosine phosphorylation of several intracellular proteins including insulin receptor substrates (IRS-1/2), phosphoinositide-3 kinase (PI3K),

phosphoinositide-dependent kinase (PDK-1), protein kinase B (Akt) and glycogen synthase kinase-3 (GSK-3) [29]. In obesity-associated insulin resistance, the most common type of hepatic insulin resistance, instead of tyrosine phosphorylation, there is serine phosphorylation of IRS-1/2 by several serine kinases including pyruvate kinase C (PKC) and IκB kinase (IKK). Serine phosphorylation results in degradation of IRS-1/2 and thereby interrupts insulin signalling [30].

Non-alcoholic fatty liver disease (NAFLD) (see also Chapter 13)

NAFLD refers to a series of liver disorders ranging from simple steatosis to steatohepatitis, advanced fibrosis and cirrhosis in patients who do not abuse ethanol. In the United States, steatosis has been estimated to occur in more than two-thirds of the obese population and in more than 90% of morbidly obese subjects. Steatohepatitis affects ~ 20% of obese and ~ 50% of morbidly obese people. All obese diabetic patients have at least some degree of steatosis, while ~ 50% have steatohepatitis and ~ 90% have cirrhosis (reviewed in [31]).

Hepatic insulin resistance and increased generation of inflammatory cytokines are currently believed to be important for the development of steatohepatitis. In that respect, high fat feeding in rodents results in hepatic and systemic insulin resistance, as well as hepatic steatosis associated with subacute hepatic inflammation, activation of the proinflammatory NF-κB pathway and the production of several cytokines [32].

Cirrhosis

Cirrhosis of the liver is the result of many different causes, including hepatitis induced by toxins (most frequently by ethanol), NAFLD (see above), by viral infections (hepatitis A, B and C) [33] and by autoimmune inflammatory disorders (see Section 6, Cirrhosis). Thus, it is a heterogeneous disorder, which makes discussion of carbohydrate metabolism in cirrhosis difficult. In general, however, many patients with moderate liver disease, who are in a reasonably normal nutritional state, have normal or near-normal EGP rates (1.8–2.2 mg/kg/min after an overnight fast) and blood glucose levels. As most of these patients are insulin resistant [34], their normal rate of EGP and blood glucose levels are the result of compensated hepatic, as well as peripheral, insulin resistance. A significant proportion of cirrhotic patients, however, are glucose intolerant, indicating that they are unable to meet the increased insulin requirements of a carbohydrate load [35].

Several studies have reported that the contribution of GL to EGP is decreased and the contribution of GNG is increased in patients with cirrhosis. For instance, Petersen *et al.* [35] have determined changes in hepatic glycogen content with ^{13}C-nuclear magnetic resonance spectroscopy [14] before and after an overnight fast and found that net hepatic GL was 3.5 times lower (13% vs. 40% of EGP) in cirrhotic patients than in healthy control subjects whereas GNG was increased (87% vs. 60% of EGP). Comparable results were obtained in the same patients when GNG was measured with the $^{2}H_2O$ method [35]. Earlier, Owen *et al.* [36] had determined EGP and GNG by measuring arterial venous differences of glucose and GNG precursors across the liver. They found that, after an overnight fast, GNG accounted for 67% and GL for 33% of hepatic glucose production in cirrhotic patients. This was an increase in GNG and a decrease in GL compared with healthy subjects studied with the same technique by Wahren *et al.* [37]. The reason for the relative decrease in GL is not clear, but may be related to a decrease in glycogen content in patients with cirrhosis of the liver. Thus, it appears that many patients with cirrhosis of the liver maintain a relatively normal hepatic glucose production by increasing GNG to compensate for a decrease in GL. This may be one reason why these patients have a tendency to become protein depleted.

References

1 Cherrington AD (2001) Control of glucose production in vivo by insulin and glucagon. In: Jefferson LS, Cherrington AD (eds) *The Endocrine Pancreas and Regulation of Metabolism.* New York: Oxford University Press, pp. 759–785.

2 Ishida T, Chap Z, Chou J *et al.* (1983) Differential effects of oral, peripheral intravenous, and intraportal glucose on hepatic glucose uptake and insulin and glucagon extraction in conscious dogs. *J Clin Invest* 72, 590–601.

3 Duckworth WC, Bennett RG, Hamel FG (1998) Insulin degradation: progress and potential. *Endocr Rev* 19, 608–624.

4 Stumpel F, Jungermann K (1997) Sensing by intrahepatic muscarinic nerves of a portal-arterial glucose concentration gradient as a signal for insulin-dependent uptake in the perfused rat liver. *FEBS* 406, 119–122.

5 Radziuk J, Inculet R (1983) The effects of ingested and intravenous glucose and glucogenic substrate in normal man. *Diabetes* 32, 977–981.

6 Petersen KF, Laurent D, Rochman DL *et al.* (1998) Mechanism by which glucose and insulin net hepatic glycogenolysis in humans. *J Clin Invest* 101, 1203–1209.

7 Prager R, Wallace O, Olefskey JM (1987) Direct and indirect effects of insulin to inhibit hepatic glucose output in obese subjects. *Diabetes* 36, 607–611.

8 Ader M, Bergman RN (1990) Peripheral effects of insulin dominate suppression of fasting hyperglycemia. *Am J Physiol* 258, E1029–E1032.

9 Pocal A, Lam TKT, Gutierrez-Juarez R *et al.* (2005) Hypothalamic K_{ATP} channels control hepatic glucose production. *Nature* 434, 1026–1031.

10 Dobbins RL, Davis SN, Neal DW *et al.* (1995) Compartmental modeling of glucagon kinetics in the conscious dog. *Metabolism* 44, 452–459.

11 Cahill GF, Jr (1970) Starvation in man. *N Engl J Med* 282, 668–675.

12 Liljenquist JE, Mueller GL, Cherrington AD *et al.* (1977) Evidence for an important role of glucagon in the regulation of hepatic glucose production in normal man. *J Clin Invest* 59, 369–374.

13 Katz J (1985) Determination of gluconeogenesis in vivo with ^{14}C-labeled substrates. *Am J Physiol Regul Integr Comp Physiol* 248, R391–R399.

14 Rothman DL, Magnusson I, Katz LD *et al.* (1991) Quantitation of hepatic glycogenesis and gluconeogenesis in fasting humans with ^{13}C NMR. *Science* 254, 573–576.
15 Hellerstein MK, Neese RA, Linfoot P *et al.* (1997) Hepatic gluconeogenic fluxes and glycogen turnover during fasting in humans. A stable isotope study. *J Clin Invest* 100, 1305–1319.
16 Katz J, Tayek JA (1998) Gluconeogenesis and the Cori cycle in 12-, 20-, and 40-h-fasted humans. *Am J Physiol* 275, E537–E542.
17 Landau BR, Wahren J, Chandramouli V *et al.* (1996) Contributions of gluconeogenesis to glucose production in the fasted state. *J Clin Invest* 98, 378–385.
18 Gastaldelli A, Toschi E, Pettiti M *et al.* (2001) Effect of physiological hyperinsulinemia on gluconeogenesis in nondiabetic subjects and in type 2 diabetic patients. *Diabetes* 50, 1807–1812.
19 Boden G, Cheung P, Stein TP *et al.* (2002) FFA cause hepatic insulin resistance by inhibiting insulin suppression of glycogenolysis. *Am J Physiol* 283, E12–E19.
20 Chen X, Iqbal N, Boden G (1999) The effects of free fatty acids on gluconeogenesis and glycogenolysis in normal subjects. *J Clin Invest* 103, 365–372.
21 Boden G (2003) Effects of free fatty acids on gluconeogenesis and glycogenolysis. *Life Sci* 72, 977–988.
22 Taylor R, Magnussen I, Rothman DL *et al.* (1996) Direct assessment of liver glycogen storage by 13C-nuclear magnetic resonance spectroscopy and regulation of glucose homeostasis after a mixed meal in normal subjects. *J Clin Invest* 97, 126–132.
23 Ferrannini E, Barrett E, Bevilacqua S *et al.* (1983) Effect of fatty acids on glucose production and utilization in man. *J Clin Invest* 72, 1737–1747.
24 Magnusson I, Rothman DL, Katz LD *et al.* (1992) Increased rate of gluconeogenesis in type II diabetes mellitus. *J Clin Invest* 90, 1323–1327.
25 Wajngot A, Chandramouli V, Schumann WC *et al.* (2001) Quantitative contributions of gluconeogenesis to glucose production during fasting in type 2 diabetes mellitus. *Metabolism* 50, 47–52.
26 Boden G, Chen X, Stein TP (2001) Gluconeogenesis in moderately and severely hyperglycemic patients with type 2 diabetes mellitus. *Am J Physiol* 280, E23–E30.
27 Boden G, Chen X, Capulong E *et al.* (2001) Effects of free fatty acids on gluconeogenesis and autoregulation of glucose production in type 2 diabetes. *Diabetes* 50, 810–816.
28 Boden G, Cheung P, Homko C (2003) Effects of acute insulin excess and deficiency on gluconeogenesis and glycogenolysis in type 1 diabetes. *Diabetes* 52, 133–137.
29 Zick Y (2001) Insulin resistance: a phosphorylation-based uncoupling of insulin signaling. *Trends Cell Biol* 11, 437–441.
30 Samuel VT, Liu ZX, Qu X *et al.* (2004) Mechanism of hepatic insulin resistance in non-alcoholic fatty liver disease. *J Biol Chem* 279, 32345–32353.
31 Angulo P (2002) Nonalcoholic fatty liver disease. *N Engl J Med* 346, 1221–1231.
32 Cai D, Yuan M, Frantz DF *et al.* (2005) Local and system insulin resistance resulting from hepatic activation of IKK-β and NF-κB. *Nature Med* 11, 183–190.
33 Fartoux L, Poujol-Robert A, Guechot J *et al.* (2005) Insulin resistance is a cause of steatosis and fibrosis progression in chronic hepatitis C. *Gut* 54 (7), 1003–1008.
34 Stewart A, Johnston DG, Alberti KGMM (1983) Hormone and metabolic profiles in alcoholic liver disease. *Eur J Clin Invest* 13, 397–403.
35 Petersen KF, Krssak M, Navarro V *et al.* (1999) Contributions of net hepatic glycogenolysis and gluconeogenesis to glucose production in cirrhosis. *Am J Physiol* 276, E529–E535.
36 Owen OE, Reichle FA, Mozzoli MA *et al.* (1981) Hepatic, gut and renal substrate flux rates in patients with hepatic cirrhosis. *J Clin Invest* 68, 240–252.
37 Wahren J, Felig P, Cerasi E *et al.* (1972) Splanchnic and peripheral glucose and amino acid metabolism in diabetes mellitus. *J Clin Invest* 51, 1870–1878.

2.3.2 Lipoprotein metabolism

Erez F. Scapa, Keishi Kanno and David E. Cohen

Introduction

Lipoproteins are macromolecular aggregates of lipids and proteins that function to transport otherwise insoluble lipid molecules through the plasma. This chapter will discuss the structure and function of lipoproteins. Emphasis will be placed on the transport of triglycerides and cholesterol, which constitute the principal lipids carried by lipoprotein particles.

Triglycerides, which consist of three fatty acids esterified to a glycerol molecule, are insoluble in water [1]. Triglycerides are either absorbed from the diet following a meal or assembled by the liver. Lipoproteins transport triglycerides to muscles, which utilize the fatty acids as a key source of energy. Triglycerides are also transported to adipose tissue, where the fatty acids are taken up by adipocytes, reassembled and stored for later use by the body.

Cholesterol is a critical regulator of membrane structure and function. Its concentration in membranes preserves bilayer fluidity and governs the formation of microdomains. Microdomains facilitate the association of plasma membrane proteins that participate in critical cell functions, including signal transduction and receptor–ligand binding. In addition to its role in membrane biology, cholesterol is the substrate for bile salt and steroid hormone biosynthesis (see also Chapter 2.3.6) [2]. Oxidized cholesterol molecules (i.e. oxysterols) serve as ligands for nuclear hormone receptors, which regulate cellular lipid metabolism [3]. Although cholesterol is absorbed in substantial amounts by the intestine, there does not appear to be a dietary cholesterol requirement. This is because virtually all cells in the body synthesize cholesterol molecules.

An important determinant of the physical state of cholesterol is whether the hydroxyl group is esterified to a long-chain fatty acid. For cholesterol to reside in membranes, this hydroxyl group must be unesterified. Molecules of esterified cholesterol (i.e. cholesteryl esters) are too insoluble even to be accommodated within membrane bilayers in more than trace quantities.

The liver is the only organ capable of degrading cholesterol and eliminating it from the body. As a result, excess cholesterol

must be transported by lipoproteins through the plasma to the liver. This process is commonly referred to as reverse cholesterol transport.

Lipoprotein structure

Overview

Although different types of lipoprotein particles circulate in the plasma, their structures are similar (Fig. 1), reflecting common physicochemical mechanisms for transporting water-insoluble lipids. Lipoproteins are assembled from polar and neutral lipids, as well as specific proteins, which are referred to as apoproteins or apolipoproteins. Apolipoproteins are amphiphilic proteins capable of interacting with both lipids and the surrounding aqueous environment of the plasma. The principal lipid components of lipoproteins include the non-polar lipids, triglycerides and cholesteryl esters, and the polar lipids, phospholipids and unesterified cholesterol [1]. The hydrophobic core of a lipoprotein particle contains non-polar lipids. The amphiphilic coat comprises polar lipids and apolipoproteins, which create a stable emulsion of the core. The phospholipids orient themselves as a monolayer surrounding the hydrophobic core, and the apoproteins align themselves at the lipid–plasma interface [4]. Because it is a polar lipid, unesterified cholesterol resides within the phospholipid monolayer of the surface coat of the lipoprotein.

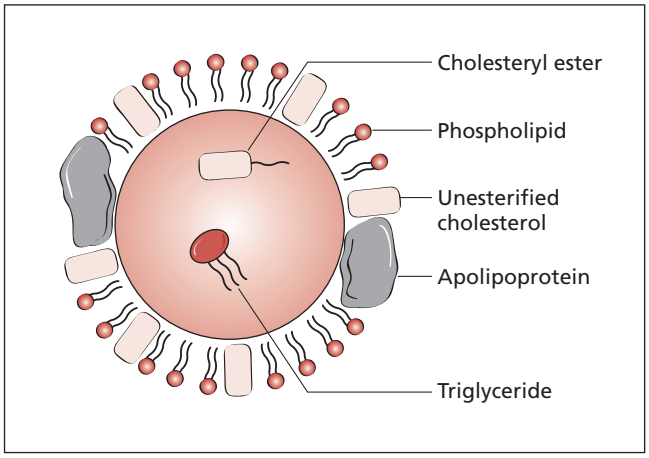

Fig. 1 Lipoprotein structure. The surface coat of lipoprotein particles comprises the polar lipids, unesterified cholesterol and phospholipids, as well as apolipoproteins. The non-polar lipids, cholesteryl esters and triglycerides, are contained in the core. Unless otherwise indicated in subsequent figures, phospholipid and whesterified cholesterol molecules are not shown for clarity.

The lipoproteins present in plasma are: chylomicrons (CM), very-low-density lipoproteins (VLDL), low-density lipoproteins (LDL), intermediate-density lipoproteins (IDL) and high-density lipoproteins (HDL). The characteristics of lipoproteins [4], which are categorized by density using ultracentrifugation or by electrophoretic mobility using agarose gels, are listed in Table 1. Lipoprotein size increases in proportion to the triglyceride and cholesteryl ester contents of the core, whereas the percentage of phospholipids comprising the coat decreases as a result of the corresponding decrease in surface-to-volume ratio. The density of lipoproteins is proportional to their protein contents, and inversely proportional to their lipid contents, whereas mobility on agarose gels depends upon both size and charge [4].

Apolipoproteins

Apolipoproteins are commonly identified using the abbreviation 'apo' followed by a capital letter identifying the particular protein (e.g. apoA-I). From a structural standpoint, an important common feature of these proteins is their amphiphilicity (i.e. their capacity to interact with both lipids and water). This property is primarily attributable to α-helical secondary structural elements with distinct hydrophobic and hydrophilic surfaces. These allow apolipoproteins to orient themselves at the lipid–water interface of lipoproteins and stabilize the particles. In general, apolipoproteins associate reversibly with lipids and,

Table 1 Characteristics of plasma lipoproteins.[a]

	CM	VLDL	IDL	LDL	HDL
Density (g/mL)	< 0.95	0.95–1.006	1.006–1.019	1.019–1.063	1.063–1.210
Diameter (nm)	75–1200	30–80	25–35	18–25	5–12
Total lipid (% wt)	98	90	82	75	67
Composition (% dry weight)					
Protein	2	10	18	25	33
Triglyerides	83	50	31	9	8
Unesterified cholesterol plus cholesteryl esters	8	22	29	45	30
Phospholipids (% wt lipid)	7	18	22	21	29
Electrophoretic mobility[b]	None	Pre-β	β	β	α or pre-β

[a]Adapted from ref. 4 with permission.
[b]Electrophoretic mobility of lipoprotein particles is designated relative to migration of plasma α- and β-globulins.

thereby, may exchange among lipoprotein particles in plasma. The exceptions are apoB-48 and apoB-100. Hydrophobic β-sheet elements contained in apoB-48 and apoB-100 embed within the lipid aggregate of lipoprotein particles, so that these apolipoproteins remain tightly associated with their respective lipoprotein particles and do not exchange [5].

Triglyceride delivery to muscle and adipose tissue: metabolism of apoB-containing lipoproteins

Overview

The apoB-containing lipoproteins include CM, VLDL, IDL and LDL. Their primary function is the delivery of dietary and endogenous triglycerides to muscle and fat tissue. As will be discussed later, a secondary function of apoB-containing lipoproteins is to assist with reverse cholesterol transport.

ApoB

A single apoB gene is transcribed principally in the intestine and liver. Other than its tissue-specific expression, regulation of apoB expression is largely posttranscriptional. As depicted in Figure 2, a key point in the posttranscriptional regulation of apoB metabolism occurs when mRNA transcripts from the apoB gene undergo an editing process [6]. A cytosine within the mRNA coding sequence is converted to a uracil. As a result, a codon that is normally translated into a glutamine is instead converted to a stop codon, resulting in a truncated apoB protein. The editing process is the result of tissue-specific expression of proteins collectively known as the apoB editing complex. The catalytic protein apobec-1 is responsible for deaminating cytosine [6]. In humans, apoB editing occurs in the intestine and not the liver. As a result, the edited apoB transcript in the intestine is translated into a 2152-amino-acid (aa) protein. Owing to the absence of apobec-1 expression in liver, the full-length 4536-aa protein is translated. Because intestinal apoB is 48% of the length in aa of the apoB expressed in liver, the proteins are referred to as apoB-48 and apoB-100 respectively.

Assembly and secretion of apoB-containing lipoproteins

ApoB-48 and apoB-100 undergo posttranslational modification in the endoplasmic reticulum. Disulphide bond formation appears to occur cotranslationally and requires the presence of protein disulphide isomerase (PDI), which is a luminal protein in the endoplasmic reticulum that mediates protein folding [7].

The secretion of apoB-containing lipoproteins depends critically upon the availability of triglycerides and the presence of microsomal transfer protein (MTP). MTP is a heterodimeric protein consisting of M and P subunits. The P subunit of MTP is PDI. The M subunit of MTP catalyses intermembrane transfer of triglycerides and other lipids *in vitro*. Whereas the precise role of MTP in lipoprotein assembly and secretion is incompletely understood, it appears that MTP–apoB binding and MTP lipid transfer activity are required for particle formation. Figure 3 illustrates a schematic model of how MTP participates in the assembly of apoB-containing lipoproteins, a process commonly referred to as lipidation. Consistent with its critical role in the assembly of CM and VLDL, mutations in MTP result in abetalipoproteinaemia, which is characterized by hypolipidaemia and absence in plasma of apoB-containing lipoproteins [8]. During lipoprotein assembly within the hepatocyte or enterocyte, a single apoB-100 or apoB-48 becomes embedded in a VLDL or CM particle respectively [9].

Once assembled, secretion of CM and VLDL occurs by exocytosis. CM particles first enter the lymph and subsequently the blood via the thoracic duct. In contrast, VLDL particles are secreted from the liver directly into the bloodstream. CM particles are generally larger and more variable in size than VLDL [10]. Whereas particle assembly occurs by a similar mechanism, the cellular pathways for secretion of CM and VLDL differ. Anderson's disease (also known as CM retention disease) represents a failure of exocytosis of CM from enterocytes in the setting of normal VLDL secretion [10]. Moreover, CM secretion can be inhibited pharmacologically without affecting VLDL secretion [10].

When the intracellular supply of triglyceride molecules is reduced, degradation of apoB-48 and apoB-100 occurs by both

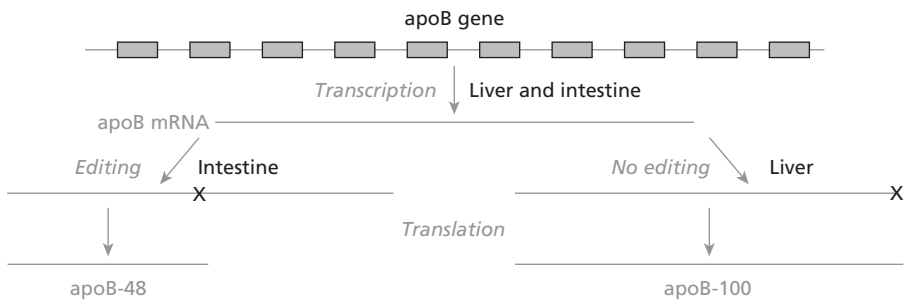

Fig. 2 Editing of apoB mRNA. The apoB gene, with exons represented by squares and introns by lines, is transcribed in both the intestine and the liver. In the intestine, but not the liver, a protein complex containing apobec-1 modifies a single nucleotide in the apoB mRNA. As a result, the codon containing this nucleotide is converted to a premature stop codon, as indicated by the position of the 'X'. The protein that is translated in the intestine (apoB-48) is only 48% as long as the full-length protein that is translated in the liver (apoB-100).

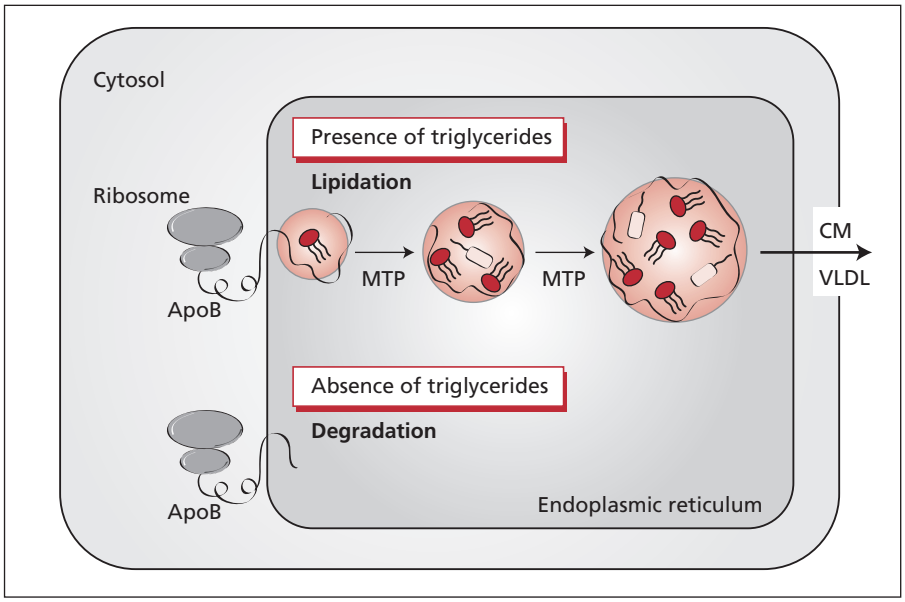

Fig. 3 Assembly and secretion of CM and VLDL particles. CM and VLDL particles are assembled and secreted by similar mechanisms in the enterocyte and hepatocyte respectively. The apoB protein (i.e. apoB-48 or apoB-100) is translated by ribosomes and enters the lumen of the endoplasmic reticulum. If triglycerides are available, the apoB protein is lipidated by the action of microsomal triglyceride transfer protein (MTP) in two distinct steps, accumulating triglyceride as well as cholesteryl ester molecules. The resulting CM or VLDL particle is secreted by exocytosis into the lymphatics by enterocytes or into the plasma by hepatocytes. In the absence of triglycerides, the apoB protein is degraded.

proteasomal and non-proteasomal pathways [11]. Similarly, the genetic absence of MTP results in rapid intracellular degradation of apoB-48 and apoB-100 [12]. In either case, lipoprotein secretion is reduced. Constitutive translation of apoB-48 allows for the prompt and highly efficient absorption of large quantities of triglycerides from the diet following a meal [10]. During fasting, apoB-48 is degraded in the intestine, whereas, in liver, continued lipidation of apoB-100 with endogenous triglycerides ensures that the metabolic demands of muscle tissue are met. When insulin levels are low, fatty acids are released from adipose tissue through the action of hormone-sensitive lipase and delivered to the liver via plasma. Among the metabolic fates of these fatty acids is incorporation into VLDL particles for delivery to muscle tissue. In the setting of insulin resistance, an inappropriately high flux of fatty acids from adipose tissue to the liver serves to increase VLDL secretion [13].

Intravascular metabolism of apoB-containing lipoproteins

As depicted in Figure 4, the delivery of triglycerides by apoB-containing lipoproteins to muscle and adipose tissue is determined to a large extent by tissue-specific expression and activity of lipoprotein lipase (LPL). LPL is abundantly expressed only on the vascular surface endothelia that line the capillary beds of cardiac, skeletal muscle and adipose tissues [14]. This enzyme hydrolyses triglycerides in the cores of CM and VLDL to form monoglycerides and fatty acids. Fatty acids that are taken up by muscle cells are consumed by oxidative metabolism as a direct source of energy. Within adipose tissue, fatty acids are re-esterified and stored as triglyceride droplets.

LPL is synthesized in parenchymal cells of muscle and adipose tissues. Within each tissue, the LPL expression level depends on metabolic demand for fatty acids and can vary severalfold. Once translated, the protein is exocytosed and translocated across both the intercellular space and the endothelial cell. LPL is then anchored to the vascular surface of the endothelial cell by electrostatic interactions with charged sulphated proteoglycans on the plasma membrane. When infused intravascularly, heparin displaces LPL by competing for binding to these proteoglycans.

The relative expression of LPL in muscle vs. adipose tissue plays a key role in the preferential trafficking of triglycerides to muscle tissue during fasting and to adipose tissue in the postprandial state [14]. This is achieved principally by posttranscriptional mechanisms. In the fed state, insulin increases LPL mRNA levels in adipocytes, apparently by increasing mRNA stability. In the fasted state, altered glycosylation patterns of LPL in adipocytes lead to cellular retention of the enzyme and decreased expression on the endothelial surface.

Before encountering LPL, triglyceride-rich CM and VLDL particles must first acquire apoC-II (Fig. 4a), which is required for LPL activity (Fig. 4b). In contrast to apoB molecules, which remain embedded in CM and VLDL, apoC-II is an exchangeable apolipoprotein. ApoC-II molecules are acquired by CM and VLDL by exchange from HDL particles, which serve as a reservoir for exchangeable apoproteins in addition to their functions in cholesterol transport which are described below [15,16]. Within approximately 5 min following lipoprotein secretion, CM and VLDL acquire the content of apoC-II that is required for optimal LPL activity [16]. This lag period appears to be important for allowing widespread vascular distribution of apoB-containing lipoproteins to occur prior to hydrolysis [16]. Consistent with a central role in promoting lipoprotein–LPL interactions, patients with genetic defects in apoC-II manifest high plasma triglyceride concentrations [17].

Owing to the large sizes of triglyceride-rich lipoproteins, a single particle interacts with multiple LPL molecules [16]. Each LPL is bound and activated by one molecule of apoC-II (Fig. 4b). VLDL and CM also undergo a series of binding and detachment events during catabolism. Because several molecules of LPL simultaneously catabolize triglycerides from VLDL or CM, hydrolysis occurs at a rapid rate so that half the core triglycerides are consumed in approximately 10–15 min.

Whereas apoC-II promotes LPL-mediated hydrolysis of triglycerides in the cores of CM and VLDL, apoC-III functions to inhibit LPL activity [16]. ApoC-III appears to be secreted in association with CM and VLDL particles, and concentrations of apoC-III in plasma correlate directly with plasma triglyceride concentrations [15]. The function of apoC-III may be to help promote the widespread distribution of these triglyceride-rich particles throughout the body.

The activity of LPL reduces the triglyceride contents of CM and VLDL particles, which become relatively enriched in cholesteryl esters. Lipolysis of apoB-containing particles continues until about 80% of the initial triglyceride content has been removed from CM and about 50% from VLDL [16]. At this point, apoC-II is transferred to HDL, and HDL-associated apoE is acquired (Fig. 4c) [18]. The resulting CM and VLDL particles that contain apoE but lack apoC-II are referred to as 'remnants' [19].

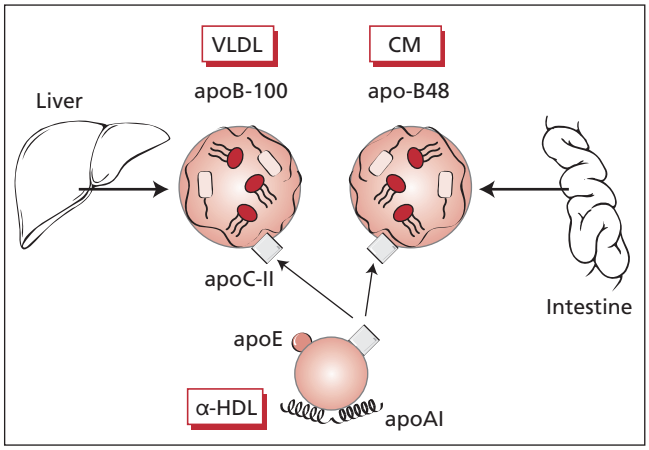

(a)

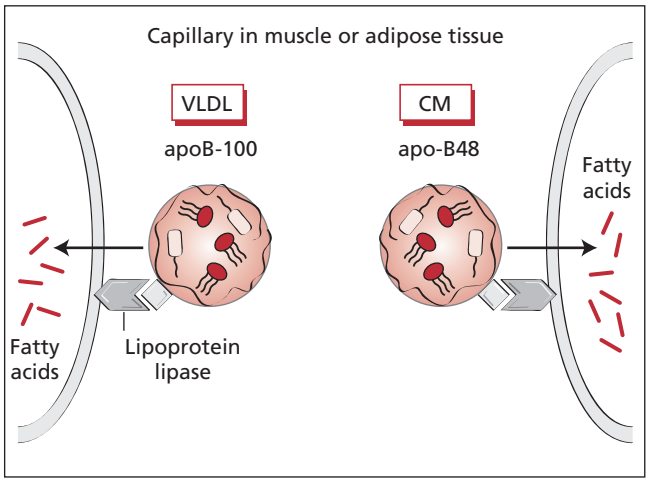

(b)

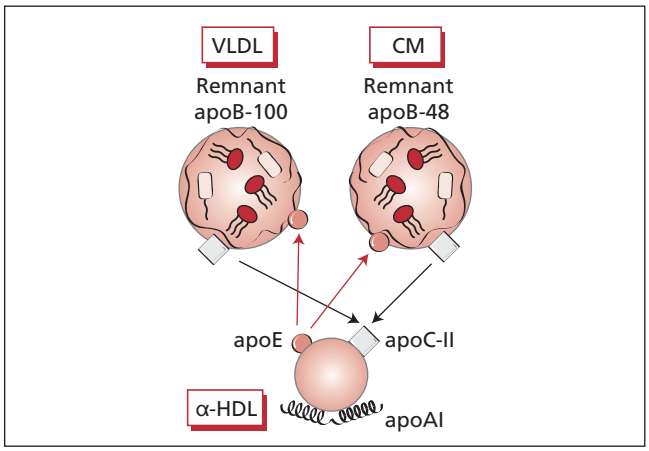

(c)

Removal of apoB-containing lipoproteins from the circulation

ApoE plays a central role in CM and VLDL remnant uptake by receptor-mediated pathways. It is expressed in most tissues, but most prominently in liver and brain. In humans, apoE exists as three isoforms, apoE-2, apoE-3 and apoE-4 [20]. These isoforms differ in primary structure as a result of amino acid substitutions that influence the physical–chemical properties of the molecule by altering intramolecular disulphide bond formation [20]. Epidemiologically, inheritance of apoE-4 has been correlated with increased risk of developing Alzheimer's disease [21].

As illustrated in Figure 5, the liver efficiently removes CM remnants through receptor-mediated clearance [22]. Once the activity of LPL has sufficiently reduced particle size, CM remnants enter the space of Disse via endothelial fenestrations [19]. Within the space of Disse, CM remnants interact with heparan sulphate proteoglycan (HSPG) molecules. This represents the first of three steps in the process of CM uptake and is referred to as sequestration. Sequestration accounts for the rapid disappearance

Fig. 4 (*opposite*) Metabolism of apoB-containing lipoproteins. (a) Following secretion, CM and VLDL particles are activated for lipolysis when they encounter HDL particles in the plasma and acquire the exchangeable apolipoprotein apoC-II. (b) When CM and VLDL circulate into capillaries of muscle or fat tissue, apoC-II promotes binding of the particle to lipoprotein lipase, which is bound to the surface of endothelial cells. Lipoprotein lipase mediates hydrolysis of triglycerides, but not cholesteryl esters, from the core of the lipoprotein particle. The resulting fatty acids are taken up into muscle or fat tissue. (c) Upon completion of hydrolysis, CM and VLDL lose affinity for lipoprotein lipase. When an HDL particle is encountered, apoC-II is transferred back to HDL particles in exchange for apoE. The resulting particles are CM and VLDL remnants.

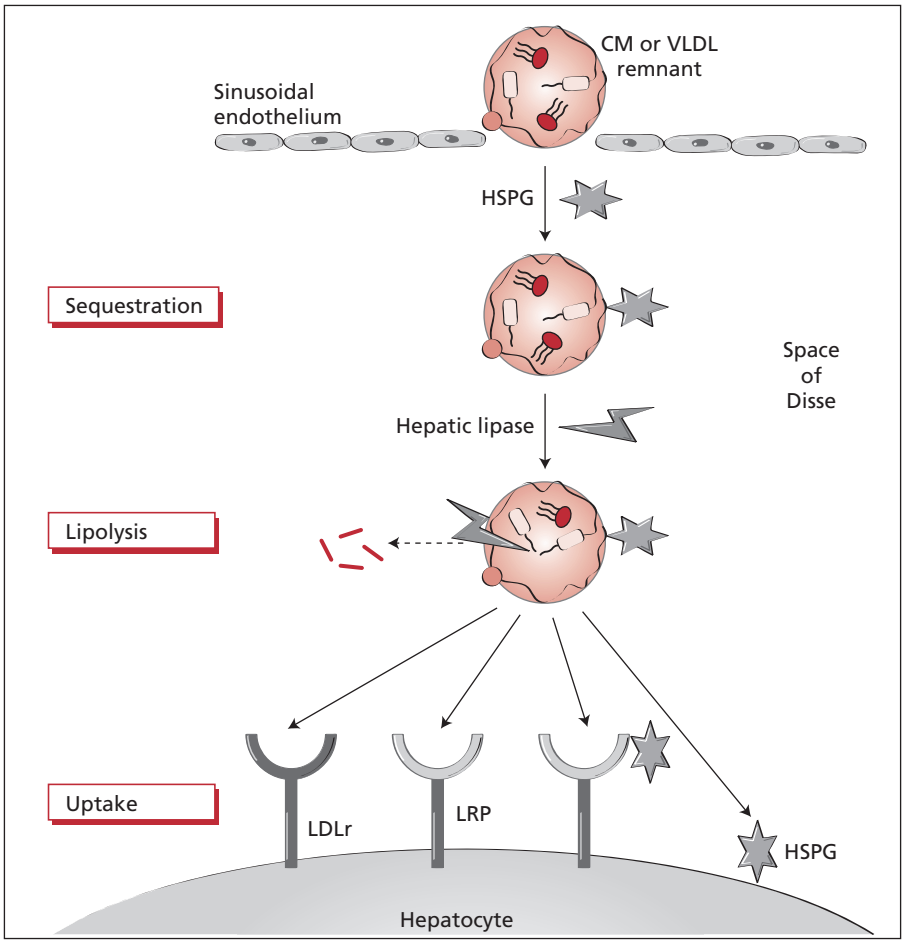

Fig. 5 Hepatic uptake of remnant particles. The activity of lipoprotein lipase results in remnant lipoprotein particles that are small enough in size to enter the space of Disse. Remnant lipoproteins are sequestered in the space of Disse by binding to high-molecular-weight heparan sulphate proteoglycan (HSPG) molecules. This is followed by binding of hepatic lipase, which promotes lipolysis of some residual triglycerides in the core of the remnant lipoproteins and the release of fatty acids (as indicated by the dashed arrow). Uptake of remnant lipoprotein particles into hepatocytes is mediated by the LDL receptor (LDLr), the LDL-related protein (LRP), a complex formed between LRP and HSPG or HSPG alone. Figure adapted from ref. 19, with permission.

of CM remnants from plasma. The second phase of CM clearance is a lipolytic processing step that occurs within the space of Disse. CM remnants bind to hepatic lipase, which is expressed by hepatocytes. It promotes CM remnant uptake by further modifying the lipid content of the particle. Finally, remnant particles are taken up into hepatocytes. The LDL receptor is a high-affinity receptor for apoE [23] that is expressed mainly in the liver, but also on a variety of cell types [22]. The LDL receptor-related protein (LRP) also plays a central role in the uptake of remnant particles through apoE-mediated interactions [19,20,24]. In addition, CM remnant uptake occurs through interactions with HSPG alone or in combination with LRP [19]. On account of these redundant mechanisms for CM remnant uptake, CM remnant particles do not tend to accumulate, even if one of the receptor pathways is disrupted [19].

About half of VLDL remnants are cleared directly by the liver, essentially as described for CM remnant particles. However, the remaining VLDL remnants are subjected to additional LPL-mediated triglyceride hydrolysis to form IDL particles, which are smaller remnant particles that may be cleared from the plasma by the same mechanisms [25]. A fraction of IDL is subject to further triglyceride hydrolysis by hepatic lipase. Presumably because of the decrease in size that ensues, apoE dissociates from the particles, forming LDL. LDL are cholesteryl ester-rich particles that contain apoB-100, but no other apolipoproteins [16].

Plasma clearance of LDL particles occurs as the result of interactions with the LDL receptor [23]. Because the LDL receptor is the only receptor that effectively clears LDL particles from the plasma, mutations in the LDL receptor or proteins that support its function constitute the genetic basis for familial hypercholesterolaemia [23,26]. The LDL receptor is regulated in response to cellular cholesterol levels. When intracellular cholesterol levels are reduced, such as occurs during therapy with statin drugs, the LDL receptor is upregulated as a result of the proteolytic processing and activity of sterol response element binding protein 2 (SREBP-2) [27].

Reverse cholesterol transport: HDL metabolism

Overview

Whereas apoB-containing lipoproteins function primarily in

the delivery of triglycerides to muscle and adipose tissue, HDL particles are largely responsible for reverse cholesterol transport [28], whereby excess cholesterol molecules from tissues are removed and delivered to the liver for elimination via bile.

Apolipoproteins associated with HDL

ApoA-I is the major structural protein of HDL particles. It is the principal determinant of particle structure and receptor binding. ApoA-II is also a major apolipoprotein of HDL, but its precise role in the structure and metabolism of HDL is not well understood [29]. ApoA-I and apoA-II are both exchangeable apolipoproteins, and HDL particles may contain apoA-I alone or both apoA-I and apoA-II. As described above, other exchangeable apolipoproteins that are critical for apoB-containing particle metabolism variably associate with HDL particles.

Formation of HDL particles

The process of HDL formation begins when lipid-poor apoA-I secreted by the liver interacts with adenosine triphosphate (ATP) binding cassette protein A1 (ABCA1) on the plasma membrane of hepatocytes (Fig. 6) [30]. Although ABCA1 is expressed on the plasma membrane of a variety of cell types, its presence in hepatocytes regulates HDL formation [31]. In patients with Tangier disease, genetic inactivation of ABCA1 leads to a marked reduction in plasma HDL concentrations [32]. ABCA1 is required for cellular efflux of phospholipids and unesterified cholesterol in response to interactions between apoA-I in plasma and the hepatocyte plasma membrane [30,32]. The interaction of apoA-I and ABCA1 results in the formation of small pre-β-migrating HDL (pre-β-HDL) particles that are discoidal in shape [33].

Formation of pre-β-HDL is an essential step in reverse cholesterol transport, but these particles are not optimized for the removal of cholesterol from plasma membranes of extrahepatic tissues. Therefore, it is critical that pre-β-HDL undergo a maturation process to form spherical α-migrating HDL. α-HDL particles are referred to as HDL for simplicity and are highly efficient acceptors of excess cholesterol from cells. The maturation process is accomplished by the activity of lecithin–cholesterol acyltransferase (LCAT) [16]. LCAT is a circulating enzyme that is synthesized in liver. As shown in Figure 6b, it binds to HDL particles and catalyses the transfer of a fatty acid from phosphatidylcholine (also known as lecithin) to the hydroxyl group of unesterified cholesterol. The result is the formation of a cholesteryl ester and a lysophosphatidylcholine molecule [34]. The lysophosphatidylcholine is transferred to albumin in the plasma [16]. The newly formed cholesteryl ester spontaneously relocates from the surface of HDL to the core of the particle. As a result, LCAT transforms discoidal pre-β-HDL to spherical HDL particles.

HDL-mediated removal of cholesterol from cells

Efflux of unesterified cholesterol from plasma membranes to α-migrating HDL particles is the principal mechanism for cholesterol removal from cells in extrahepatic tissues (Fig. 6a and b) [35]. When the particle is in close proximity to a cell, unesterified cholesterol molecules within the plasma membrane desorb and traverse the aqueous plasma until they are incorporated into the phospholipid-rich surface coat of HDL. This is a process of passive diffusion that is controlled principally by the cholesterol concentration gradient between plasma membranes and HDL. Scavenger receptor class B type 1 (SR-BI) is expressed on a variety of cell types. *In vitro*, this receptor mediates the bidirectional flux of unesterified cholesterol between cells and HDL particles [30]. It has been proposed that HDL particles in the plasma may become tethered by SR-BI to cells [30] and, when the concentration gradient favours cellular efflux, this could promote the net movement of unesterified cholesterol to HDL [30]. Recent studies *in vitro* also suggest that ATP binding cassette proteins G1 and G4 may play significant roles in promoting cholesterol movement from cells to HDL particles [36].

Optimization of HDL-mediated cholesterol removal from cells

Ongoing cholesterol removal from cells to the surface coat of HDL requires a sustained concentration gradient [37]. This is achieved by the collective activities of three circulating plasma proteins (Fig. 6a and b). In addition to allowing HDL to mature from a discoidal to a spherical particle, LCAT activity allows unesterified cholesterol that is transferred to the surface of spherical HDL particles to be relocated to the core.

Whereas LCAT removes unesterified cholesterol from the surface of the particle, its enzymatic activity also consumes surface phosphatidylcholines, which are essential for HDL to increase in size and to accept additional cholesterol molecules from cells [16]. Phospholipid transfer protein (PLTP) is a plasma protein that replenishes the surface coat of HDL using phospholipids from remnant apoB-containing lipoprotein particles. The gradient for this transfer of phospholipids is established by the activity of LPL. As triglycerides contained within the cores of VLDL and CM are hydrolysed by LPL, their surface-to-volume ratio increases. PLTP removes excess surface phospholipids and transfers them to HDL particles [38]. This replaces phosphatidylcholine molecules that are hydrolysed by LCAT, allowing for particle growth. Based on studies in genetically engineered mice, PLTP activity constitutes the source of as much as 80% of HDL phospholipids [38].

Cholesterol ester transfer protein (CETP) promotes the transfer of cholesteryl esters from the cores of HDL particles to remnants of apoB-containing lipoproteins in exchange for triglyceride molecules from the cores of the remnant particles.

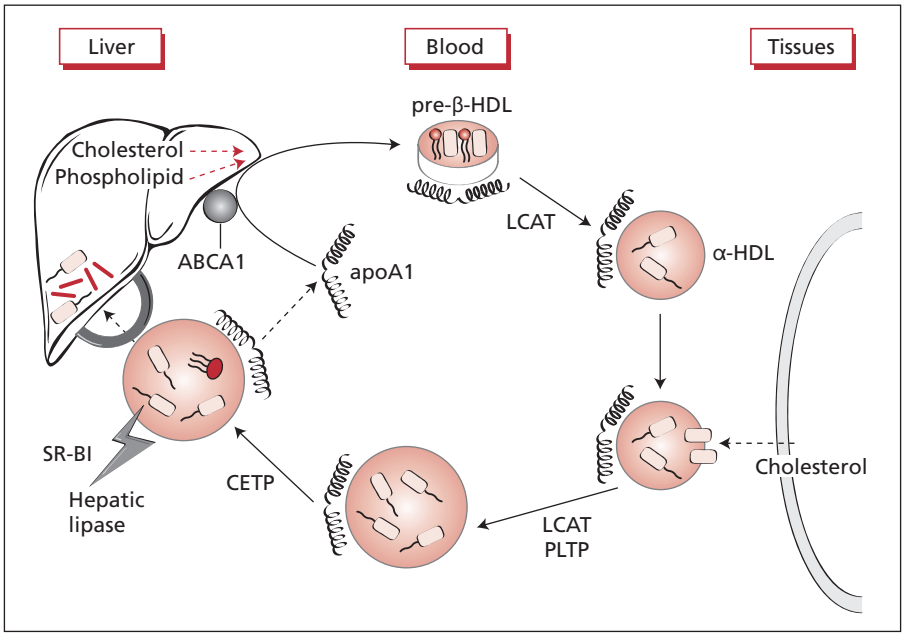

(a)

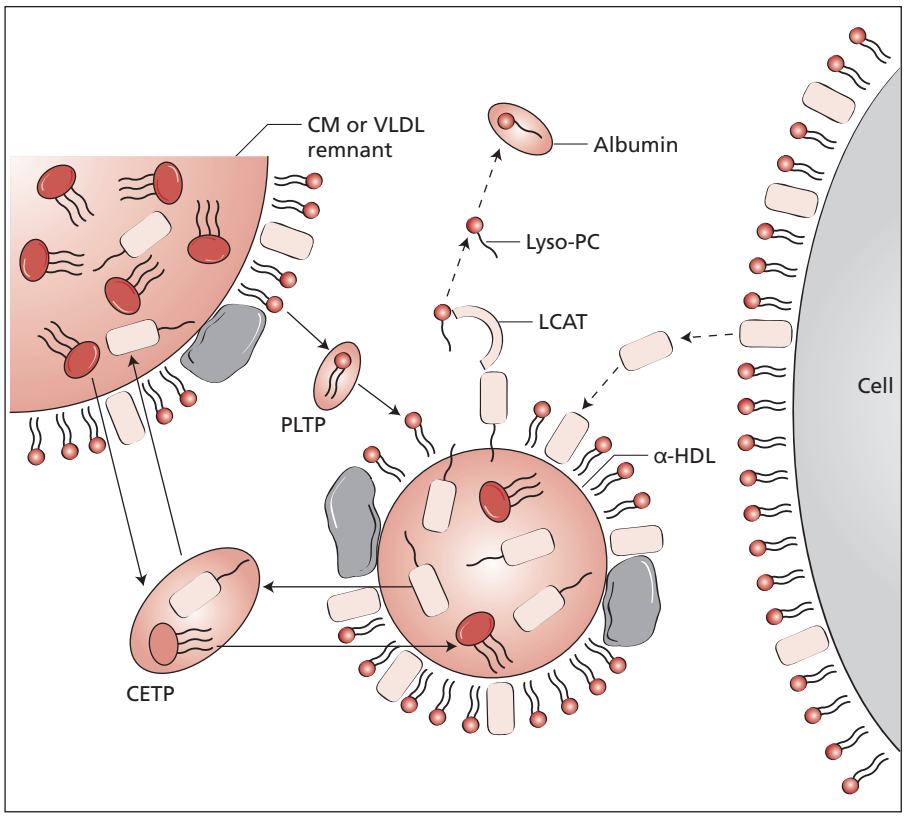

(b)

Fig. 6 Reverse cholesterol transport. (a) The process of reverse cholesterol transport begins when apoA-I is secreted from the liver. ApoA-I in plasma interacts with ATP binding cassette protein AI (ABCA1), which incorporates a small amount of phospholipid and unesterified cholesterol from hepatocyte plasma membranes to form a discoidal-shaped pre-β-HDL particle. On account of the activity of lecithin–cholesterol acyltransferase (LCAT) in plasma, pre-β-HDL particles mature to form spherical α-HDL. Spherical α-migrating HDL particles function to accept excess unesterified cholesterol from the plasma membranes of cells in a wide variety of tissues. The unesterified cholesterol is transferred from the cell to nearby HDL particles by diffusion through the plasma. As explained in (b), LCAT and phospholipid transfer protein (PLTP) increase the capacity of HDL to accept unesterified cholesterol molecules from cells by allowing for expansion of the core and the surface coat of the particle. Cholesteryl ester transfer protein (CETP) exchanges some of the cholesteryl ester molecules from the core of HDL for triglycerides from the core of remnant particles. Whereas remnant particles are taken up by a variety of receptors on the liver (Fig. 5), HDL particles interact with scavenger receptor class B type I (SR-BI), which mediates selective hepatic uptake of cholesteryl esters, but not apoA-I. This process is facilitated when hepatic lipase hydrolyses triglycerides from the core of the particle. The remaining apoA-I molecules may begin the cycle of reverse cholesterol transport again. In (a), solid arrows indicate metabolic events in HDL metabolism, whereas dashed arrows denote transfer of molecules. (b) LCAT, PLTP and CETP promote the removal of excess cholesterol from the plasma membranes of cells. LCAT removes a fatty acid from a phosphatidylcholine molecule in the surface coat of α- (or pre-β-)HDL and esterifies an unesterified cholesterol molecule on the surface of the particle. The resulting lysophosphatidylcholine (lyso-PC) becomes bound to albumin in the plasma, whereas the cholesteryl ester migrates spontaneously into the core of the lipoprotein particle. The unesterified cholesterol molecules that are consumed by LCAT are replaced by unesterified cholesterol from cells. HDL phospholipids that are consumed by LCAT action are replaced with excess phospholipids from remnant particles by the activity of PLTP. As described in (a), CETP increases the efficiency of cholesterol movement to the liver by exchanging cholesteryl ester molecules from the core of α-HDL for triglycerides from the core of remnant particles. In (b), solid arrows denote protein-mediated lipid transfer, whereas dashed arrows indicate that lipids move by diffusion through the plasma.

This transfer of cholesteryl esters allows HDL to continue to accept cholesterol from tissues. Moreover, it utilizes remnant particles, which have completed their function in triglyceride delivery and are destined for hepatic clearance, for the ancillary purpose of assisting with reverse cholesterol transport. The activity of CETP also enriches HDL with triglycerides, forming the more buoyant HDL particles. As described below, this helps to increase the efficiency with which HDL delivers cholesterol to the liver [39,40]. Considering that a fraction of VLDL remnants are ultimately transformed into LDL particles, the activity of CETP also increases plasma LDL cholesterol concentrations, while decreasing the plasma concentrations of HDL cholesterol.

Hepatic uptake of HDL cholesterol from plasma

In addition to the cholesterol that is delivered to the liver by remnant particles via CETP, HDL transports cholesterol directly to the liver. As illustrated in Figure 6a, SR-BI, which is highly expressed in liver, promotes the selective uptake of lipids, but not protein, from HDL particles [41].

The process of SR-BI-mediated selective lipid uptake into hepatocytes is facilitated by the activity of hepatic lipase. Hepatic lipase promotes hydrolysis of HDL triglycerides and phospholipids, and this optimizes the SR-BI-mediated hepatic uptake of cholesteryl esters [42]. When the HDL particle decreases in size, apoA-1 molecules dissociate and interact with ABCA1 to promote the formation of new pre-β-HDL particles [33].

Summary and conclusions

This chapter has described how the structures of lipoproteins are optimally suited for their functions in the transport of insoluble triglyceride and cholesterol molecules through the plasma. The primary role of apoB-containing lipoproteins is to deliver dietary triglycerides from the intestine and endogenous triglycerides from the liver to muscle or adipose tissue depending upon metabolic needs. HDL metabolism facilitates the transport of excess cellular cholesterol from extrahepatic tissues to the liver. Owing to the activity of CETP in plasma, remnants of apoB-containing lipoproteins also assist with reverse cholesterol transport. An appreciation of these principles should provide the foundation for understanding genetic and acquired disorders of lipoprotein metabolism, as well as the molecular and cellular mechanisms of lipid-lowering therapies.

Acknowledgements

This work was supported by National Institutes of Health (grants DK56626 and DK48873), an Established Investigator Award from the American Heart Association and an International HDL research Awards Program grant to DEC. ES is the recipient of an American Liver Foundation Irwin M. Arias Postdoctoral Research Fellowship Award.

References

1 Small DM (1986) *The Physical Chemistry of Lipids: From Alkanes to Phospholipids. Handbook of Lipid Research*. New York: Plenum Press.
2 Agellon LB (2002) Metabolism and function of bile acids. In: Vance DE, Vance JE (eds) *Biochemistry of Lipids, Lipoproteins and Membranes*, 4th edn. Amsterdam: Elsevier, pp. 433–448.
3 Chawla A, Repa JJ, Evans RM *et al.* (2001) Nuclear receptors and lipid physiology: opening the X-files. *Science* 294 (5548), 1866–1870.
4 Jonas A (2002) Lipoprotein structure. In: Vance DE, Vance JE (eds) *Biochemistry of Lipids, Lipoproteins and Membranes*, 4th edn. Amsterdam: Elsevier, pp. 483–504.
5 Vance JE (2002) Assembly and secretion of lipoproteins. In: Vance DE, Vance JE (eds) *Biochemistry of Lipids, Lipoproteins and Membranes*, 4th edn. Amsterdam: Elsevier, pp. 505–526.
6 Anant S, Davidson NO (2001) Molecular mechanisms of apolipoprotein B mRNA editing. *Curr Opin Lipidol* 12 (2), 159–165.
7 Wang L, Fast DG, Attie AD (1997) The enzymatic and non-enzymatic roles of protein-disulfide isomerase in apolipoprotein B secretion. *J Biol Chem* 272 (44), 27644–27651.
8 Wetterau JR, Aggerbeck LP, Bouma ME *et al.* (1992) Absence of microsomal triglyceride transfer protein in individuals with abetalipoproteinemia. *Science* 258 (5084), 999–1001.
9 Hussain MM, Shi J, Dreizen P (2003) Microsomal triglyceride transfer protein and its role in apoB-lipoprotein assembly. *J Lipid Res* 44 (1), 22–32.
10 Hussain MM (2000) A proposed model for the assembly of chylomicrons. *Atherosclerosis* 148 (1), 1–15.
11 Pan M, Cederbaum AI, Zhang YL *et al.* (2004) Lipid peroxidation and oxidant stress regulate hepatic apolipoprotein B degradation and VLDL production. *J Clin Invest* 113 (9), 1277–1287.
12 Wang S, McLeod RS, Gordon DA *et al.* (1996) The microsomal triglyceride transfer protein facilitates assembly and secretion of apolipoprotein B-containing lipoproteins and decreases cotranslational degradation of apolipoprotein B in transfected COS-7 cells. *J Biol Chem* 271 (24), 14124–14133.
13 Ginsberg HN (2000) Insulin resistance and cardiovascular disease. *J Clin Invest* 106 (4), 453–458.
14 Mead JR, Irvine SA, Ramji, DP (2002) Lipoprotein lipase: structure, function, regulation, and role in disease. *J Mol Med* 80 (12), 753–769.
15 Shachter NS (2001) Apolipoproteins C-I and C-III as important modulators of lipoprotein metabolism. *Curr Opin Lipidol* 12 (3), 297–304.
16 Fielding PE, Fielding CJ (2002) Dynamics of lipoprotein transport in the human circulatory system. In: Vance DE, Vance JE (eds) *Biochemistry of Lipids, Lipoproteins and Membranes*, 4th edn. Amsterdam: Elsevier, pp. 527–552.
17 Jong MC, Hofker MH, Havekes LM (1999) Role of ApoCs in lipoprotein metabolism: functional differences between ApoC1, ApoC2, and ApoC3. *Arterioscler Thromb Vasc Biol* 19 (3), 472–484.
18 Cooper AD (1997) Hepatic uptake of chylomicron remnants. *J Lipid Res* 38 (11), 2173–2192.
19 Mahley RW, Ji ZS (1999) Remnant lipoprotein metabolism: key pathways involving cell-surface heparan sulfate proteoglycans and apolipoprotein E. *J Lipid Res* 40 (1), 1–16.
20 Mahley RW, Rall SC, Jr (2000) Apolipoprotein E: far more than a lipid transport protein. *Annu Rev Genomics Hum Genet* 1, 507–537.
21 Corder EH, Saunders AM, Strittmatter WJ *et al.* (1993) Gene dose of apolipoprotein E type 4 allele and the risk of Alzheimer's disease in late onset families. *Science* 261 (5123), 921–923.

22 Schneider WJ (2002) Lipoprotein receptors. In: Vance DE, Vance JE (eds) *Biochemistry of Lipids, Lipoproteins and Membranes*, 4th edn. Amsterdam: Elsevier, pp. 553–572.
23 Brown MS, Goldstein JL (1986) A receptor-mediated pathway for cholesterol homeostasis. *Science* 232 (4746), 34–47.
24 Herz J, Hamann U, Rogne S *et al.* (1988) Surface location and high affinity for calcium of a 500-kd liver membrane protein closely related to the LDL-receptor suggest a physiological role as lipoprotein receptor. *EMBO J* 7 (13), 4119–4127.
25 Packard CJ, Shepherd J (1997) Lipoprotein heterogeneity and apolipoprotein B metabolism. *Arterioscler Thromb Vasc Biol* 17 (12), 3542–3556.
26 Garcia CK, Wilund K, Arca M *et al.* (2001) Autosomal recessive hypercholesterolemia caused by mutations in a putative LDL receptor adaptor protein. *Science* 292 (5520), 1394–1398.
27 Horton JD, Goldstein JL, Brown MS (2002) SREBPs: activators of the complete program of cholesterol and fatty acid synthesis in the liver. *J Clin Invest* 109 (9), 1125–1131.
28 Silver DL, Jiang XC, Arai T *et al.* (2000) Receptors and lipid transfer proteins in HDL metabolism. *Ann NY Acad Sci* 902, 103–111; discussion 111–102.
29 Blanco-Vaca F, Escola-Gil JC, Martin-Campos JM *et al.* (2001) Role of apoA-II in lipid metabolism and atherosclerosis: advances in the study of an enigmatic protein. *J Lipid Res* 42 (11), 1727–1739.
30 Yancey PG, Bortnick AE, Kellner-Weibel G *et al.* (2003) Importance of different pathways of cellular cholesterol efflux. *Arterioscler Thromb Vasc Biol* 23 (5), 712–719.
31 Timmins JM, Lee JY, Boudyguina E *et al.* (2005) Targeted inactivation of hepatic Abca1 causes profound hypoalphalipoproteinemia and kidney hypercatabolism of apoA-I. *J Clin Invest* 115 (5), 1333–1342.
32 Lawn RM, Wade DP, Garvin MR *et al.* (1999) The Tangier disease gene product ABC1 controls the cellular apolipoprotein-mediated lipid removal pathway. *J Clin Invest* 104 (8), R25–31.
33 Rye KA, Barter PJ (2004) Formation and metabolism of prebeta-migrating, lipid-poor apolipoprotein A-I. *Arterioscler Thromb Vasc Biol* 24 (3), 421–428.
34 Jonas A (2000) Lecithin cholesterol acyltransferase. *Biochim Biophys Acta* 1529 (1–3), 245–256.
35 Rothblat GH, de la Llera-Moya M, Atger V *et al.* (1999) Cell cholesterol efflux: integration of old and new observations provides new insights. *J Lipid Res* 40 (5), 781–796.
36 Wang N, Lan D, Chen W *et al.* (2004) ATP-binding cassette transporters G1 and G4 mediate cellular cholesterol efflux to high-density lipoproteins. *Proc Natl Acad Sci USA* 101 (26), 9774–9779.
37 Ng DS (2004) Insight into the role of LCAT from mouse models. *Rev Endocr Metab Disord* 5 (4), 311–318.
38 Jiang XC, Bruce C, Mar J *et al.* (1999) Targeted mutation of plasma phospholipid transfer protein gene markedly reduces high-density lipoprotein levels. *J Clin Invest* 103 (6), 907–914.
39 Rye KA, Clay MA, Barter PJ (1999) Remodelling of high density lipoproteins by plasma factors. *Atherosclerosis* 145 (2), 227–238.
40 Barter PJ, Brewer HB, Jr, Chapman MJ *et al.* (2003) Cholesteryl ester transfer protein: a novel target for raising HDL and inhibiting atherosclerosis. *Arterioscler Thromb Vasc Biol* 23 (2), 160–167.
41 Acton S, Rigotti A, Landschulz KT *et al.* (1996) Identification of scavenger receptor SR-BI as a high density lipoprotein receptor. *Science* 271 (5248), 518–520.
42 Martinez LO, Jacquet S, Terce F *et al.* (2004) New insight on the molecular mechanisms of high-density lipoprotein cellular interactions. *Cell Mol Life Sci* 61 (18), 2343–2360.

2.3.3 Protein and amino acid metabolism

Margaret E. Brosnan and John T. Brosnan

Introduction

The liver is a major organ of amino acid metabolism. It is responsible for the disposal of much of the dietary amino acid load; it is the only organ with a complete urea cycle; it is capable of synthesizing some amino acids; and it produces glucose from muscle-derived amino acids during starvation and in diabetes. Hepatic amino acid metabolism is finely regulated. There is evidence that the liver is largely responsible for maintaining circulating amino acid homeostasis. The liver also plays a critical role in the biosynthesis of key molecules from amino acids, e.g. creatine and glutathione. It also uses amino acids and glutathione in the conjugation of xenobiotics and toxic molecules to ensure their elimination from the body. In addition, there is good evidence that amino acids play a crucial regulatory role in controlling the turnover of hepatic proteins.

Amino acid pools and amino acid transport

Rapidly frozen rat liver contains a total of 20 μmol/g, which translates into an intracellular concentration of about 40 mM [1]. This figure ignores compartmentation between and within cells, however. Nevertheless, it gives an accurate picture of the magnitude of the hepatic intracellular amino acid pool. Given that the liver cell, like plasma, experiences an osmotic pressure of about 305 mOsM, it is apparent that free amino acids account for about 13% of all intracellular osmolytes. The amino acids with the highest hepatic concentrations include taurine (7.5 mM), aspartate (6.3 mM), glutamate (2.8 mM), glutamine (10.6 mM), glycine (4.0 mM) and alanine (4.7 mM). By also measuring plasma amino acids, intracellular/extracellular concentration ratios can be calculated (Table 1). Very high ratios (> 10) were identified for taurine, aspartate, glutamate, glutamine, glycine, alanine and histidine. No amino acid displayed a ratio significantly less than 1. These ratios are largely a result of the operation of hepatic amino acid transporters.

Hepatocytes communicate with their environment via their plasma membranes, either by signal transduction or via transport. Enormous progress has been made in the field of amino acid transport as our knowledge has advanced from kinetic to molecular characterization. Different amino acid transporters are responsible for the transport of groups of structurally similar amino acids. Transport of the three classes of amino acids (zwitterionic, cationic and anionic) is effected by a number of different transporters with different (though overlapping) specificities. Energetically, we can divide these transport systems into two classes: sodium-linked transporters (an example of secondary active transport) that employ the Na^+ electrochemical

Table 1 Hepatic intracellular amino acid concentrations and intracellular/extracellular concentration ratios.

Amino acid	Hepatic concentration (mM)	Intracellular/extracellular ratio
Taurine	7.53	57
Aspartate	6.27	412
Threonine	0.46	1.8
Serine	0.53	3.0
Asparagine	0.13	3.2
Glutamate	2.83	29
Glutamine	10.63	18
Proline	1.21	6.5
Glycine	3.97	17
Alanine	4.65	11
Citrulline	0.09	1.4
Valine	0.27	1.7
Methionine	0.18	3.3
Isoleucine	0.19	2.4
Leucine	0.30	2.2
Tyrosine	0.09	0.8
Phenylalanine	0.12	2.1
Ornithine	0.31	5.2
Lysine	0.98	2.9
Histidine	1.01	20
Arginine	0.10	0.8

From ref. 1.

gradient to drive inward amino acid translocation against a concentration gradient; and sodium-independent transporters that facilitate amino acid transport in either direction, depending on the concentration gradient (an example of facilitated diffusion).

Among the most important hepatic amino acid transporters are systems A, ASC, L and N for neutral (zwitterion) amino acids, system y^+ for cationic amino acids and X^-_{AG} and X^-_C for anionic amino acids [2]. System A is a sodium-dependent transporter with preference for neutral amino acids with small side-chains (e.g. alanine and serine). System ASC is also sodium dependent and exhibits a preference for alanine, serine, cysteine and threonine, although it can also transport bulky amino acids such as leucine, valine and methionine at a lower rate. This transporter exhibits a marked trans-stimulation and is thought to exchange the extracellular and intracellular pools of a number of amino acids. System L favours amino acids with bulky side-chains (branched-chain and aromatic amino acids). It is not sodium dependent, and its active exchange properties suggest that it may mediate efflux from cells rather than influx. System N is a sodium-dependent transporter with rather narrow substrate specificity. It transports glutamine, asparagine and histidine – amino acids that contain nitrogen in their side-chains. The most active cationic transporter is system y^+, a high-affinity sodium-independent transporter that acts on lysine, histidine and arginine. Two anionic transporters are of note. System X^-_{AG} transports glutamate and aspartate, and this is accompanied by sodium cotransport and potassium countertransport. System X^-_C transports cystine into hepatocytes in exchange for glutamate and is thought to provide the limiting substrate (cysteine) for hepatic glutathione synthesis. Much progress has recently been made in the molecular and kinetic characterization of these transporters. Nevertheless, it is apparent that the combination of a multitude of transporters with overlapping specificity and differing energetics, as well as facilitation of both uptake and exchange, makes the physiological interpretation of the roles of these transporters challenging.

These amino acid transporters are regulated with regard to both their expression and the cell types in which they are expressed. For example, system A activity is rapidly stimulated by glucagon via a mechanism that does not require protein synthesis. System A activity is also upregulated by insulin via a mechanism that requires gene transcription. Uptake of the anionic amino acids, glutamate and aspartate, is much more rapid in hepatocytes at the perivenous terminus of the hepatic acinus than in the periportal hepatocytes [3].

Metabolic disposal of dietary amino acids

Adults ingesting a typical western diet consume ~ 80–100 g of protein per day. The common textbook statement that these amino acids are oxidized in the liver cannot be true because, even if no other fuel were oxidized there, it would oblige the consumption of more oxygen than the liver actually consumes [4]. The solution to this conundrum is threefold. First, there is appreciable oxidation of a number of amino acids in the gastrointestinal tract [5]. Secondly, the branched-chain amino

acids (which comprise about 20% of total dietary amino acids) largely escape splanchnic metabolism and are mostly metabolized in skeletal muscle. Thirdly, even in the fed state, the hepatic disposal of amino acids involves the conversion of their carbon skeletons to glucose and to ketone bodies, which are released, as universal fuels, for other tissues. This enables the liver to accommodate dietary amino acid disposal within the bounds of its oxygen consumption. In an adult in nitrogen balance, the daily dietary amino acid intake must be oxidized in a 24-h period. If the liver were too efficient in the clearance of absorbed amino acids, none would be available for peripheral tissues. Rather, after meals, the liver must consume only excess amino acids. An equal priority, however, is to have sufficient amino acids available for protein synthesis both in peripheral tissues and in the liver itself. In the postprandial period, the liver will metabolize amino acids released by peripheral tissues, principally muscle.

The catabolism of individual amino acids is tightly controlled, particularly the essential amino acids. This control is accomplished in a number of ways. An important role may be ascribed to glucagon, which is secreted at a higher rate upon ingestion of a high-protein meal. Glucagon activates phenylalanine hydroxylase by means of phosphorylation; it stimulates glycine and glutamine catabolism; and, together with glucorticoids, it induces the synthesis of a number of amino acid-catabolizing enzymes. Glucagon can also regulate the catabolism of a variety of amino acids, as evidenced by the generalized hypoaminoacidaemia in patients suffering from glucagonoma. A variety of mechanisms prevent the depletion of amino acids, in particular the essential amino acids. Many enzymes that initiate amino acid catabolism exhibit rather high K_ms for their amino acid substrates. However, simple Michaelis–Menten kinetics do not provide sufficient sensitivity to substrate concentrations. A number of additional mechanisms have evolved to conserve these amino acids. The hepatic isoform of *S*-adenosylmethionine synthase, the first enzyme of methionine catabolism, is activated by its product, *S*-adenosylmethionine. This regulatory feature provides the necessary sigmoidal dependence on amino acid concentrations [6]. Another regulatory stratagem is provided by the inducibility of some of the enzymes of essential amino acid catabolism. Enzymes such as tyrosine aminotransferase, ornithine aminotransferase, tryptophan dioxygenase, threonine dehydratase and histidase exhibit large-amplitude (as much as 10-fold) changes in activity. They also have short half-lives, so that they promptly return to very low activities when the stimulus is removed. The importance of these effects is clear – the induction of these enzymes permits increased catabolism of these amino acids when the supply is high, whereas the return to very low activities when the supply is low conserves these essential amino acids [7].

Covalent modification of key enzymes is also employed as a regulatory strategem. The branched-chain α-keto acid dehydrogenase (BCKDH), the controlling enzyme complex of branched-chain amino acid catabolism, is inhibited by phosphorylation; removal of the phosphate by a protein phosphatase reverses the inhibition. The BCKDH phosphatase is activated by α-ketoisocaproate. This mechanism produces a system that is particularly sensitive to α-keto acid concentration as it serves both as a substrate and as an agent that facilitates the conversion of the BCKDH to the active form. Phenylalanine hydroxylase, the flux-generating step in phenylalanine catabolism, affords another example of regulation by substrate concentration and by covalent modification. The enzyme can exist in both dimeric and tetrameric forms. Glucagon activates the enzyme by means of protein kinase A phosphorylation. In addition to its role as a substrate, phenylalanine promotes its conversion to the more active, tetrameric form. Both types of activation appear to act synergistically. Again, as in the control of BCKDH, this mechanism produces a regulatory system that is particularly sensitive to substrate (phenylalanine) concentration, much more so than could be accomplished via Michaelis–Menten kinetics alone.

Hepatic zonation of amino acid metabolism

Metabolic heterogeneity of hepatocytes along the hepatic acinus is also an important feature of hepatic amino acid metabolism. This phenomenon is well established for both glutamine and ornithine metabolism. The liver contains both glutaminase and glutamine synthetase. However, they are not expressed in the same hepatocytes. Glutaminase is found in the periportal region, for about the first third of the hepatic acinus, and can efficiently provide ammonia to carbamoylphosphate synthetase for urea synthesis. Glutamine synthetase is found in the perivenous hepatocytes where it is restricted to a layer of no more than one or two cells, which surround the terminal hepatic venule. Glutamine synthetase plays an important role in determining the low ammonia concentration of blood that leaves the liver, as it removes ammonia which has escaped the urea cycle [8]. Ornithine aminotransferase is also restricted to the same perivenous hepatocytes as glutamine synthetase; indeed, the entire pathway of arginine catabolism occurs in these hepatocytes [9]. Thus, the localization of the arginine catabolic pathway in hepatocytes that do not contain the urea cycle ensures that urea synthesis is not compromised by catabolic depletion of the cycle intermediates.

Hepatic amino acid metabolism during starvation

Gluconeogenesis from amino acids plays a crucial role during starvation in providing glucose for obligatory glucose-utilizing tissues, particularly the brain. These amino acids are primarily derived from skeletal muscle although, in the very short term, amino acids derived from hepatic proteolysis are also employed. The pattern of amino acids released by muscle is not a reflection of the amino acid composition of muscle protein. Rather, there is a considerable intramuscular amino acid metabolism that reconfigures the pattern of released amino acids. More than 50%

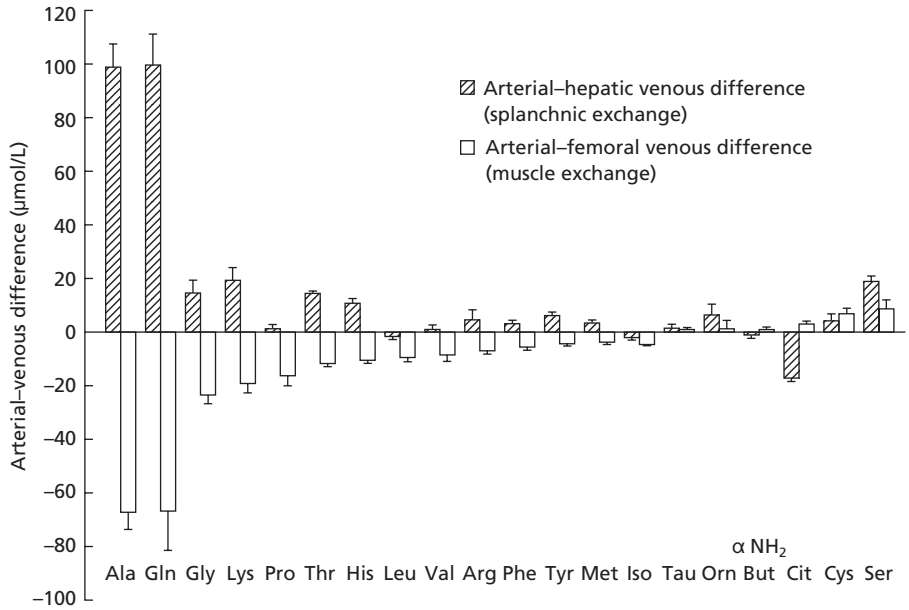

Fig. 1 Net splanchnic and peripheral exchange of amino acids in normal, postabsorptive man. Reproduced, with permission, from ref. 10.

of the released amino acids consist of alanine and glutamine. The carbon skeleton of alanine primarily arises from pyruvate of glycolytic origin. Its amino group arises, via transamination, from other amino acids, principally the branched-chain amino acids. This alanine is converted to glucose by the liver. This 'glucose–alanine cycle' plays a major role in ferrying these amino groups to the liver for detoxification, without the risk of hyperammonaemia. However, it does not really produce 'new' glucose; rather, it recycles glucose carbon, and some investigators have referred to it as 'glucopalaeogenesis' to emphasize the point that it produces 'old' glucose. The glutamine released by muscle has a variety of fates, including renal metabolism for acid–base regulation and use as a fuel by the small intestine. Alanine is an important product of intestinal glutamine metabolism and also becomes available to the liver for gluconeogenesis. Alanine is, therefore, generally acknowledged as the principal glucogenic amino acid. Yet, the role played by other amino acids should not be overlooked. Such amino acids as glycine, lysine, proline, threonine, histidine, arginine, phenylalanine and tyrosine are released by muscle and converted to glucose by the liver (Fig. 1). Although individually of less importance than alanine and glutamine, together they make a substantial contribution to hepatic gluconeogenesis [10].

Specialized functions of amino acids

Amino acids display considerable metabolic plasticity and, therefore, play a variety of roles. These include roles in one-carbon metabolism, biosyntheses, glutathione function and cell signalling. A number of these roles are highlighted below, rather than providing an exhaustive account.

Amino acids, methylation reactions and one-carbon metabolism

The folic acid, one-carbon pool provides cells with considerable flexibility in providing one-carbon groups of different oxidation states for biosynthetic and other purposes. Amino acids are the key providers of these one-carbon groups, which are generated during the catabolism of glycine, serine, histidine and tryptophan. The catabolism of serine and glycine probably supplies the bulk of the one-carbon pool by the reactions catalysed by serine hydroxymethyltransferase (reaction 1) and the glycine cleavage enzyme (reaction 2):

$$\text{Serine} + \text{THF} \leftrightarrow \text{glycine} + \text{N}^5,\text{N}^{10}\text{-methylene THF} \quad (1)$$

$$\text{Glycine} + \text{NAD}^+ + \text{THF} \rightarrow \text{CO}_2 + \text{NADH} + \text{N}^5,\text{N}^{10}\text{-methylene THF} + \text{NH}_4^+ \quad (2)$$

(Tetrahydrofolate is abbreviated as THF). In addition, labile methyl groups are provided directly in the diet as methionine and choline. The one-carbon pool provides one-carbon groups for functions such as the synthesis of purine nucleotides and thymine. However, it is the abundance and variety of methylation reactions that best illustrate the importance of one-carbon metabolism.

Figure 2 provides an outline of methionine metabolism (also see Chapter 2.3.9). The key first step is the conversion of methionine to *S*-adenosylmethionine (SAM). SAM is the universal methyl donor for a remarkably large number of methylation reactions. Indeed, a recent bioinformatic analysis of a number of genomes, including human, suggests that between 0.6% and 1.6% of all genes may code for methyltransferases.

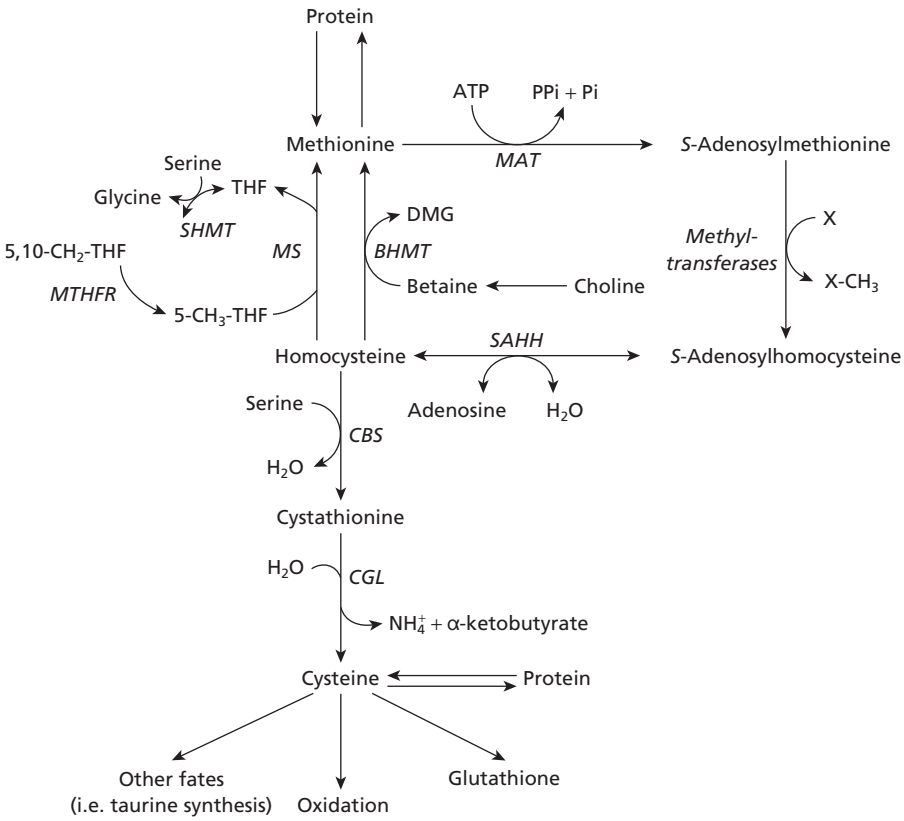

Fig. 2 Methionine metabolism in liver. MAT, methionine adenosyltransferase; SAHH, *S*-adenosylhomocysteine hydrolase; BHMT, betaine:homocysteine methyltransferase; SHMT, serine hydroxymethyltransferase; MTHFR, methylenetetrahydrofolate reductase; CBS, cystathionine β-synthase; CGL, cystathionine γ-lyase; MS, methionine synthase.

Methyltransferases catalyse the transfer of methyl groups from SAM to an acceptor to produce the methylated acceptor and *S*-adenosylhomocysteine (SAH) [11]. These methyltransferases include enzymes involved in the synthesis of small molecules (e.g. creatine, carnitine, phosphatidylcholine, epinephrine), methylation of nucleic acids (DNA methylation is a major mechanism for the regulation of gene expression, chromosome inactivation and genomic imprinting), RNA methylation (e.g. RNA capping), methylation of specific amino acid residues of proteins (e.g. protein repair, intracellular localization) and detoxification (e.g. methylation of arsenite and xenobiotic compounds).

Although methylation reactions occur in all cells of the body, they are of the greatest quantitative significance in the liver. Creatine synthesis (reaction 3) and phosphatidylcholine synthesis (reaction 4) account for about 70% of SAM utilization in the body:

$$\text{Guanidinoacetate} + \text{SAM} \rightarrow \text{creatine} + \text{SAH} \quad (3)$$

$$\text{Phosphatidylethanolamine} + 3\ \text{SAM} \rightarrow \text{phosphatidylcholine} + 3\ \text{SAH} \quad (4)$$

Reaction (3) is catalysed by guanidinoacetate methyltransferase (GAMT) and reaction (4) by phosphatidylethanolamine methyltransferase (PEMT). The liver is the dominant site of both GAMT and PEMT expression.

SAH, once produced by methylation reactions, is hydrolysed to adenosine and homocysteine [11]. Some of this homocysteine is released into the plasma. We now appreciate that the liver is the principal source of plasma homocysteine because of the quantitatively dominant role played by the liver in methylation reactions. This is significant because elevated plasma homocysteine has been implicated as a risk factor for cardiovascular disease, Alzheimer's disease and fractures. Metabolism of homocysteine, rather than its release into the circulation, is the fate of most of the homocysteine that arises within the liver. Homocysteine may be metabolized in two different ways – by trans-sulphuration and by remethylation. The trans-sulphuration pathway consists of two enzymes, cystathionine β-synthase and cystathionine γ-lyase. This sequence of reactions is irreversible, which means that methionine can be converted to cysteine but cysteine cannot be converted to methionine. This, in turn, provides the biochemical basis for the well-known nutritional observation that methionine is an essential amino acid but that cysteine is not essential, provided that an adequate supply of methionine is available.

Homocysteine metabolism also occurs via remethylation to methionine [11]. In the liver, this can occur via two quite separate enzymes. Methionine synthase, one of only two vitamin B12-requiring enzymes in mammals, employs N^5-methylTHF as a methyl donor. This N^5-methylTHF arises as a result of the reduction of N^5,N^{10}-methyleneTHF by reduced nicotinamide

adenine dinucleotide phosphate (NADPH), a reaction catalysed by methylenetetrahydrofolate reductase (MTHFR). Methionine synthase occurs ubiquitously throughout the body. However, a second enzyme, betaine:homocysteine methyltransferase (BHMT), which is found in the liver and kidneys of humans, can also remethylate homocysteine to methionine. In this case, the methyl group is provided by betaine, which arises during choline catabolism and is also a minor dietary constituent.

Methionine metabolism provides a fascinating example of the interplay between amino acid metabolism and vitamin status. Deficiencies of a number of B vitamins are known to cause elevated plasma homocysteine. As the two enzymes of the trans-sulphuration pathway contain pyridoxal phosphate as prosthetic groups, pyridoxal deficiency impairs this pathway and increases homocysteine levels. As methionine synthase contains methylcobalamin as its prosthetic group and employs N^5-methylTHF as a substrate, it is hardly surprising that deficiency of either vitamin B12 or folic acid results in elevated plasma homocysteine [12].

Deeper analysis reveals more sophisticated interactions. Methionine synthase can be viewed as playing two critical roles. On the one hand, homocysteine retains the carbon skeleton of methionine, and its methylation conserves this essential amino acid. Support for this function of methionine synthase is afforded by findings that a higher proportion of homocysteine is remethylated to methionine on feeding a diet low in methionine. However, methionine synthase also plays a crucial role in folate metabolism. This is best exemplified by the methyl trap hypothesis, which accounts for the fact that cobalamin deficiency often results in a functional folate deficiency [13]. This hypothesis postulates that cobalamin deficiency, which leads to decreased methionine synthase activity, will result in an accumulation of much of a cell's folate as N^5-methylTHF, with consequent depletion of the other THF coenzymes. The methyl trap is exacerbated by the fact that N^5-methylTHF is the principal folate form that is provided to cells from the circulation and must be metabolized by methionine synthase to provide the other THF coenzymes that are required by the cell. Clearly, there is a very close interrelationship between the metabolism of methionine, homocysteine and folate.

Creatine synthesis

Although the liver does not employ the creatine kinase system for its energy metabolism, it is very much involved in creatine synthesis. Creatine and creatine:phosphate break down spontaneously to creatinine, which is excreted in the urine. In young adults, some 1.5–2 g of creatinine are excreted each day, which means that a comparable quantity of creatine must be replaced. Replacement occurs by a combination of diet and synthesis in omnivores, but strict vegetarians need to synthesize all their creatine. Creatine synthesis involves a very simple metabolic pathway, but it requires no fewer than three amino acids. The first step, catalysed by the glycine:L-arginine amidinotransferase (AGAT), involves the transfer of an amidino group from arginine to glycine to produce guanidinoacetate and ornithine (reaction 5):

$$\text{Glycine} + \text{arginine} \rightarrow \text{guanidinoacetate} + \text{ornithine} \quad (5)$$

The second reaction involves the methylation of guanidinoacetate to produce creatine (reaction 3). This reaction is predominantly found in the liver, which is the principal site of creatine synthesis. However, in humans, both liver and kidney can produce guanidinoacetate. A consideration of the quantitative aspects of creatine synthesis is revealing. After accounting for the 0.5 g of creatine that may be obtained in the diet, it is calculated that an 18- to 29-year-old man will synthesize about 1.5 g of creatine per day. This requires 2 g of arginine, which is about 40–50% of all the arginine ingested by an individual with a typical North American protein intake. In addition, as noted above, creatine synthesis consumes approximately 35% of SAM-derived methyl groups. Creatine synthesis is clearly a major pathway in amino acid metabolism.

Glutathione synthesis and function

(see also Chapter 2.3.9)

Glutathione (γ-glutamyl-cysteinyl glycine) plays important roles in many tissues but is particularly important in the liver. It exists in both reduced (GSH) and oxidized glutathione disulphide (GSSG) forms, which are interconverted by the enzyme glutathione reductase (reaction 6):

$$\text{GSSG} + \text{NADPH} + \text{H}^+ \Leftrightarrow 2\,\text{GSH} + \text{NADP}^+ \quad (6)$$

In cells, the great bulk of glutathione (~ 95%) occurs in the reduced form.

A detailed review of glutathione metabolism is found in Chapter 2.3.9.

Regulatory functions of amino acids in liver

In addition to their roles as substrates for key biosyntheses (e.g. protein, glutathione and creatine synthesis) and in intracellular metabolism (urea cycle, malate–aspartate shuttle), amino acids are important regulatory molecules that act through signalling pathways. In the liver, this is particularly apparent in the control of protein synthesis and proteolysis, as both are very active processes. Although the liver only accounts for about 2% of body weight, it is responsible for about 18% of total body protein synthesis (53 g/day in a 70-kg man) [14]. This rate of hepatic protein synthesis can increase substantially during inflammation and infections when the synthesis of acute-phase proteins is greatly increased. In healthy individuals, the liver produces about 15–20 g of albumin per day; this is very sensitive to nutritional status, in particular to protein intake. Hepatic proteolysis, which is a highly active process, is also sensitive to nutritional status, being markedly increased early in starvation. Amino

acids, together with insulin, are major controllers of both hepatic protein synthesis and proteolysis.

The synthesis of individual proteins is generally regulated by rates of gene expression, which affect the abundance of individual mRNAs. In addition to this primarily transcriptional control of the synthesis of specific proteins, regulation also occurs at the translational level and can affect the synthesis of classes of proteins or even of all proteins. Amino acids and insulin increase hepatic protein synthesis through partly shared signalling networks. Leucine is the principal amino acid that promotes protein synthesis in a variety of tissues, including the liver. Its effects in liver are not as global as in muscle, although it does increase the synthesis of a number of strategically important proteins. An outline of the mechanism of this effect has become apparent through the work of Kimball and Jefferson [15], although much remains to be learned.

Provision of leucine to hepatocytes results in enhanced phosphorylation of 4E-BP1 (the binding protein for the eukaryotic initiation factor, eIF4E) and S6K1, the ribosomal protein S6 kinase. Enhanced phosphorylation of 4E-BP1 releases eIF4E, which is required for the binding of mRNA to the 43S preinitiation complex. Phosphorylation of S6K1 results in its activation and, subsequently, in the phosphorylation of ribosomal protein (rp) S6. In turn, the phosphorylation of rpS6 results in the enhanced translation of mRNAs that contain an uninterrupted stretch of pyrimidine bases adjacent to the 5′ cap. Proteins encoded by these mRNAs include ribosomal proteins, elongation factors and polyA-binding proteins. Both 4E-BP1 and S6K1 are downstream targets of the serine/threonine protein kinase, mTOR, which is viewed as a key target of leucine's action. Amino acids that increase cell volume (*vide infra*) can also stimulate hepatic protein synthesis.

Hepatic protein turnover is mediated both by proteosome-catalysed proteolysis and by macroautophagy; the latter process is dominant in the liver and is regulated by both insulin and amino acids [16]. Macroautophagy is a complex process in which cytoplasmic material is sequestered in autophagosomes, followed by acidification of these organelles and their fusion with lysosomes. It is a non-specific process in that most constituents of the cytosol are engulfed and degraded. However, proteins constitute the great bulk of cytoplasmic material, so that macroautophagy is rightly characterized as a means of effecting protein turnover. There seem to be two parallel means whereby amino acids suppress macroautophagy. Amino acids that are transported into cells via sodium-linked, concentrative transporters tend to increase cell hydration and inhibit

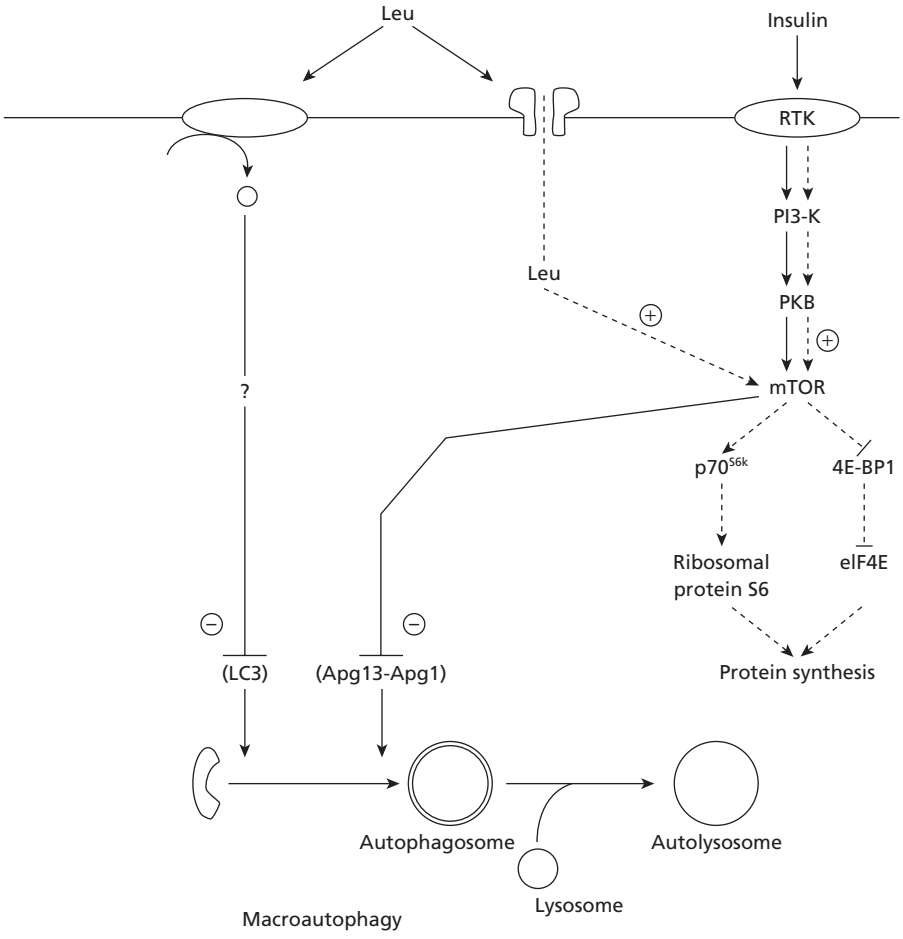

Fig. 3 Proposed signalling pathways for leucine (Leu) and regulatory amino acids in the control of macroautophagy and protein synthesis. One pathway for macroautophagy is independent of mTOR, does not affect protein synthesis and may involve leucine's interaction with a plasma membrane sensor. The other signalling pathway involves an intracellular leucine sensor, requires mTOR and both stimulates protein synthesis and suppresses macroautophagy; it shares common elements with insulin's signalling pathway. Reproduced, with permission, from ref. 18.

macroautophagy via a mitogen-activated protein (MAP) kinase-mediated mechanism. The other mechanism involves amino acids (e.g. leucine, phenylalanine and tyrosine) that are not concentrated within the liver but appear to exert their actions via an mTOR-mediated pathway.

Recent studies have clarified the mechanism by which glutamine and system A substrates affect macroautophagy. The accumulation of these amino acids within cells, together with the cotransported Na+ (which is partly exchanged for K+), is followed by a flux of water into the cell to equilibrate the osmotic pressure on both sides of the cell membrane. The resulting increase in cell volume (cell hydration) results in an immediate activation of MAP kinases, in particular ERK and $p38^{MAPK}$. This latter kinase brings about the inhibition of macroautophagy at the level of the formation of the autophagosome [17]. More work is needed to elucidate the complete mechanism, but the key role of cell swelling is confirmed by experiments that demonstrated a comparable degree of inhibition of proteolysis when cells were swollen in hypo-osmotic media.

Amino acids such as leucine, phenylalanine and tyrosine are agonists for another mechanism whereby amino acids inhibit macroautophagy [16,18]. The mechanism appears to involve mTOR, as rpS6, which is downstream from mTOR, becomes rapidly phosphorylated with the same kinetics as the inhibition of proteolysis. Rapamycin, an inhibitor of mTOR, could partly overcome the inhibition of autophagic proteolysis by amino acids. Again, much work remains before we will have a complete picture of the mechanism. The phosphorylation of rpS6 does not implicate this protein in the inhibition of macroautophagy; rather, it should be taken as indicating an efficient regulatory system in which mTOR activation plays a role in both the stimulation of protein synthesis and the suppression of proteolysis. There is also evidence for an mTOR-independent mechanism whereby these amino acids can suppress macroautophagy. This appears to be another example of redundant cell signalling systems. Figure 3 summarizes these mechanisms.

These new insights into amino acid-mediated cell signalling have considerable physiological significance. Amino acids signal their availability for anabolic processes, not only by being available as substrates, but also by more sophisticated mechanisms. Simultaneously, they signal the need to suppress catabolic processes. mTOR and cell hydration emerge as important 'interpreters' of amino acid availability. Recent studies also suggest that leucine may act via mTOR-independent mechanisms. It is clear that mTOR is not only an amino acid-responsive kinase but also a more general nutrient sensor; it can be antagonized by the adenosine monophosphate (AMP)-stimulated kinase which responds to the AMP/ATP ratio. The interaction and synergy of amino acid signalling with that of insulin remains to be fully elucidated. Finally, a crucial unsolved issue is the identification of the precise molecule(s) that interact(s) with regulatory amino acids such as leucine. However, it can be confidently asserted that recent work on amino acid signalling has revealed a new vista in amino acid metabolism that is likely to become even more important in the future.

References

1 Wijekoon EP, Skinner C, Brosnan ME *et al.* (2005) Amino acid metabolism in the Zucker diabetic fatty rat: effects of insulin resistance and of type 2 diabetes. *Can J Physiol Pharmacol* 82, 506–514.

2 Malandro MS, Kilberg MS (1996) Molecular biology of amino acid transporters. *Annu Rev Biochem* 65, 305–336.

3 Stoll B, McNelly S, Buscher HP *et al.* (1991) Functional hepatocyte heterogeneity in glutamate, aspartate and alpha-ketoglutarate uptake; a histoautoradiographical study. *Hepatology* 13, 247–253.

4 Jungas RL, Halperin ML, Brosnan JT (1992) Quantitative analysis of amino acid oxidation and related gluconeogenesis in humans. *Physiol Rev* 72, 419–448.

5 Stoll B, Henry J, Reeds PJ *et al.* (1998) Catabolism dominates the first-pass intestinal metabolism of dietary essential amino acids in milk protein-fed piglets. *J Nutr* 128, 606–614.

6 Martinov MV, Vitvitsky VM, Moshasov EV *et al.* (2000) A substrate switch: a new mode of regulation in the methionine metabolic pathway. *J Theor Biol* 204, 521–532.

7 Krebs HA (1972) Some aspects of the regulation of fuel supply in omnivorous animals. *Adv Eng Regul* 10, 397–420.

8 Haussinger D (1996) Hepatic glutamine transport and metabolism. *Adv Enzymol Relat Areas Mol Biol* 72, 43–86.

9 O'Sullivan D, Brosnan JT, Brosnan ME (1998) Hepatic zonation of the catabolism of arginine and ornithine in the perfused rat liver. *Biochem J* 330, 627–632.

10 Felig P (1975) Amino acid metabolism in man. *Annu Rev Biochem* 44, 933–955.

11 Finkelstein JD (1990) Methionine metabolism in mammals. *J Nutr Biochem* 1, 228–237.

12 Selhub J (1999) Homocysteine metabolism. *Annu Rev Nutr* 19, 217–246.

13 Shane B, Stokstad EL (1985) Vitamin B_{12}–folate interrelationships. *Annu Rev Nutr* 5, 115–141.

14 Brosnan JT, Young VR (2003) Integration of metabolism 2: protein and amino acids. In: Gibney MJ, Macdonald IA, Roche HM (eds) *Nutrition and Metabolism.* Oxford: Blackwell Science, pp. 43–73.

15 Kimball SR, Jefferson LS (2004) Molecular mechanisms through which amino acids mediate signaling through the mammalian target of rapamycin. *Curr Opin Nutr Metab Care* 7, 39–44.

16 Meijer AJ, Dubbelhuis PF (2003) Amino acid signaling and the integration of metabolism. *Biochem Biophys Res Commun* 313, 397–404.

17 Haussinger D, Graf D, Weiergraber OH (2001) Glutamine and cell signaling in liver. *J Nutr* 131, 25095–25145.

18 Kadowaki M, Kanazawa T (2003) Amino acids as regulators of proteolysis. *J Nutr* 133, 20525–20565.

2.3.4 Mitochondria and energy formation

Dominique Pessayre

Mitochondria are double-membrane organelles derived evolutionarily from bacteria. They have their own DNA and reproduce asexually, but only women transmit mitochondrial DNA. Mitochondria represent remarkable biochemical machines that are able to harness the energy produced by the oxidation of fat and other energetic substrates in a form usable by the cell.

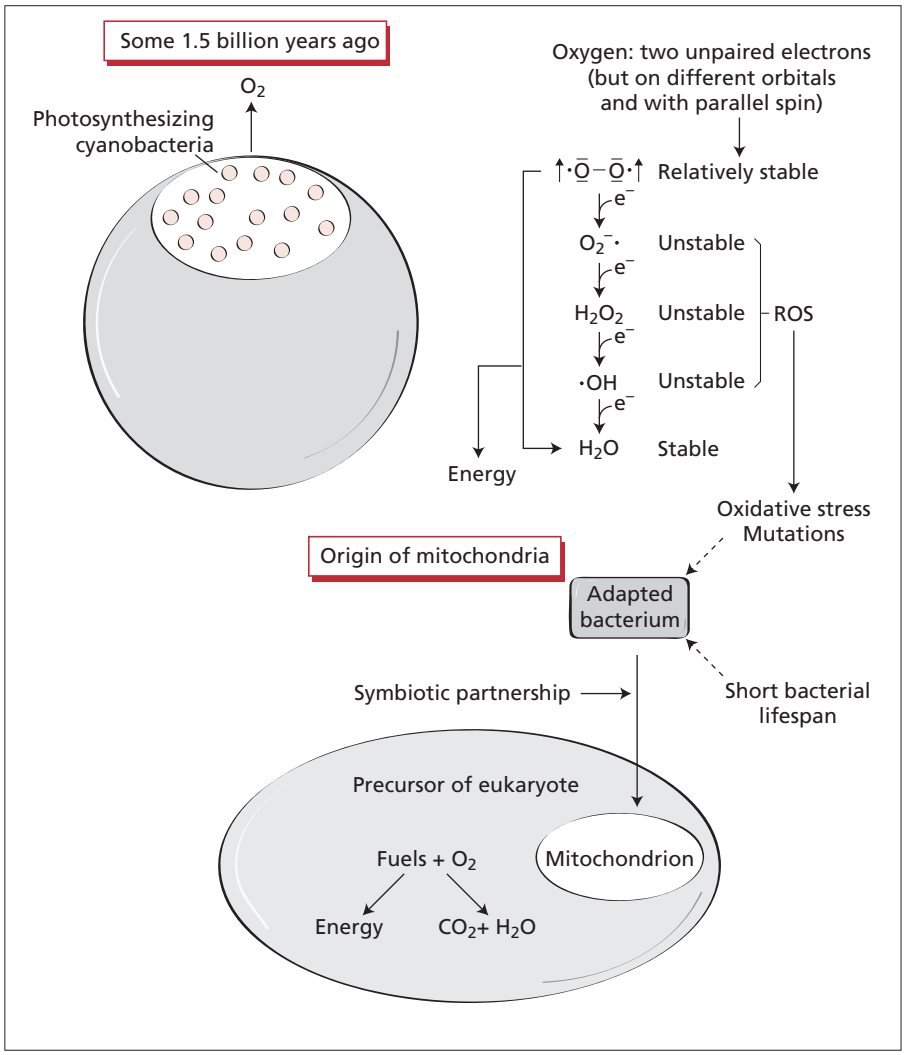

Fig. 1 Oxygen and the origin of mitochondria. Some 1.5 billion years ago, photosynthesizing cyanobacteria began releasing oxygen in the atmosphere. Although oxygen is a diradical, it is relatively stable because its two unpaired electrons are located on different orbitals and have a parallel spin. Yet, oxygen is avid for electrons. Its full reduction into water (by four successive electrons) releases considerable energy. However, its incomplete reduction by one, two or three electrons produces reactive oxygen species (ROS), which cause oxidative stress and gene mutations. The resulting high mutation rate, combined with the short lifespan and rapid turnover of bacteria, has enabled them to adapt quickly to the oxidizing environment. Thanks to a symbiotic partnership, these adapted bacteria have become our present-day mitochondria. They indirectly burn fuels with oxygen to provide considerable energy, with limited ROS formation and no immediate toxicity.

Origin and structure of mitochondria

Some 1.5 billion years ago, photosynthesizing cyanobacteria began releasing oxygen in the earth's atmosphere (Fig. 1) [1]. Oxygen is an atypical molecule (Fig. 1). Although it is a diradical, its two unpaired electrons are located on different orbitals and have a parallel spin, making oxygen a relatively stable molecule [2]. Yet, oxygen is avid for electrons. Its incomplete reduction by one, two or three successive electrons produces reactive oxygen species (ROS), which react with biological molecules to cause oxidative stress and gene mutations (Fig. 1) [1]. However, the full reduction of oxygen by four successive electrons forms a stable product (water) and releases considerable energy (Fig. 1). Therefore, the advent of oxygen evolutionarily was both a severe threat to life (due to the toxicity of ROS) and also a great opportunity (due to the energetic potential of fuel oxidation).

Thanks to their short lifespan and rapid turnover, bacteria took advantage of the high mutation rate triggered by ROS to adapt quickly to the new oxygen environment (Fig. 1). They developed biochemical machines enabling them indirectly to burn fuels with oxygen and produce usable energy, while minimizing ROS formation and toxicity. Rather than trying to emulate the biochemical perfection of bacteria, other forms of life have associated with them. Through a symbiotic partnership, these adapted bacteria have become our present-day mitochondria (Fig. 1) [3].

Like their bacterial ancestors, mitochondria have two membranes. The circular outer membrane surrounds the intermembrane space, while the folded inner membrane invaginates into cristae, which protrude into the mitochondrial matrix.

Like bacteria, mitochondria also have their own circular DNA located in the mitochondrial matrix [4].

Mitochondrial DNA (mtDNA)

Sperm cell mitochondria are ubiquitinated and are degraded in the fertilized ovum, so that mtDNA is only transmitted by women [5]. Most somatic cells, including hepatocytes, contain

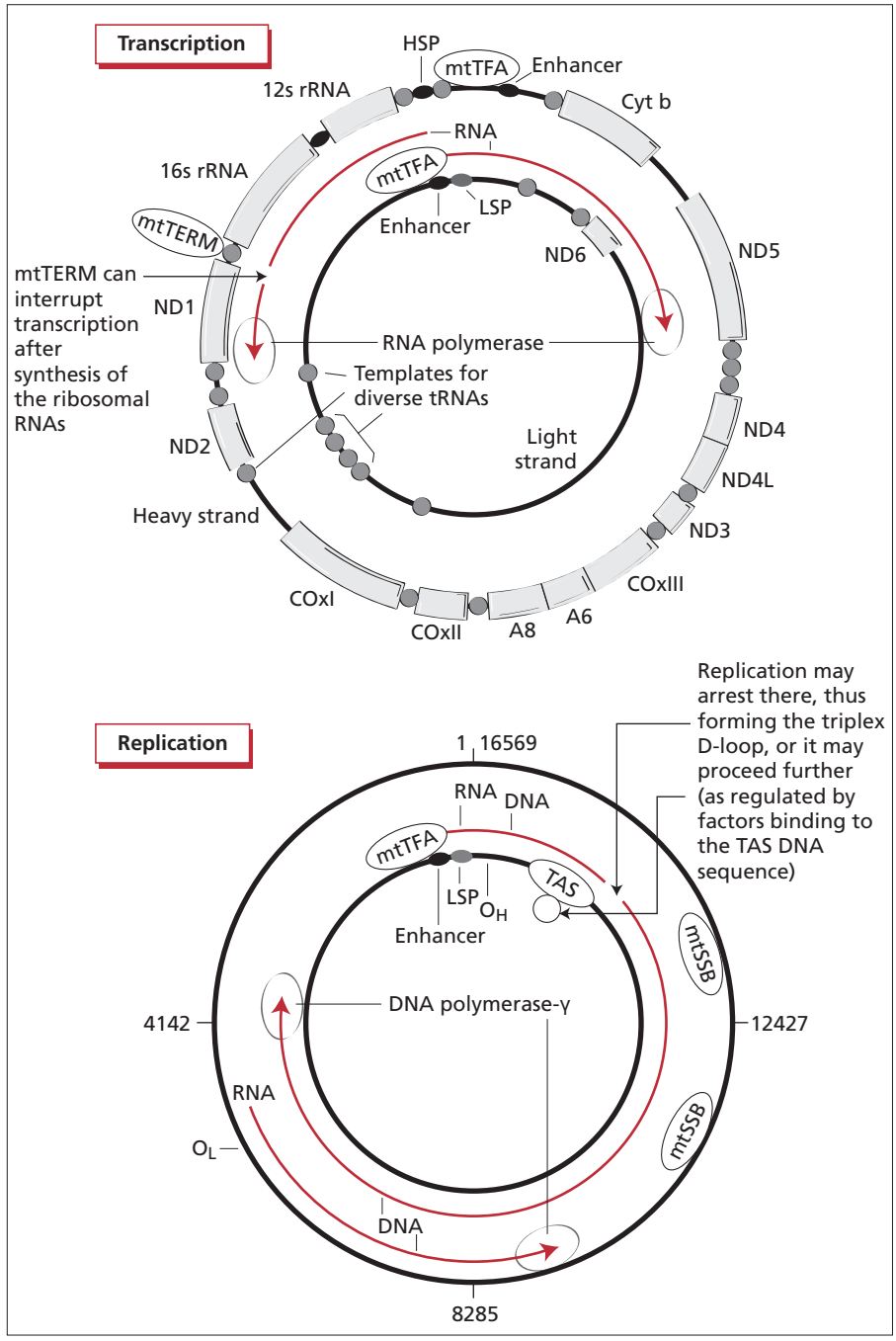

Fig. 2 Transcription and replication of the mitochondrial genome. The human mitochondrial DNA (mtDNA) is a double-stranded circular DNA of 16 569 bp. Its transcription is mediated by a mitochondrial RNA polymerase and is enhanced by the binding of mitochondrial transcription factor A (mtTFA) to enhancer elements located upstream of the heavy strand promoter (HSP) and the light strand promoter (LSP). Transcription of the heavy strand starts at nucleotide 561 (within the HSP) and proceeds counterclockwise. After synthesis of the two ribosomal RNAs, transcription may be arrested by the binding of mitochondrial termination factor (mtTERM), or it may proceed to form a large polycistronic precursor RNA encoding for 12 polypeptides and 14 tRNAs. Transcription of the light strand starts at nucleotide 407 (within the LSP) and proceeds clockwise to form a single polycistronic precursor RNA, encoding one polypeptide and eight tRNAs. The replication of mtDNA is mediated by DNA polymerase γ and is asymmetrical. Only the heavy strand is replicated initially. Replication starts at the origin of replication of the heavy strand (O_H), after a short RNA primer formed by the transcriptional machinery. The need for this RNA primer explains why mtTFA also modulates the replication of mtDNA. Mitochondrial single-stranded binding protein (mtSSB) binds to the single-stranded heavy chain and also activates replication. Replication of the heavy strand proceeds clockwise. It may arrest after a few hundred basepairs (thus forming the basal 'D-loop'), probably due to the binding of regulatory factors to the termination-associated sequence (TAS). Alternatively, replication may continue to form the whole daughter heavy strand. When the displacement front has gone beyond the origin of replication of the light strand (O_L), the replication of the light strand then starts counterclockwise after a short RNA primer introduced by a DNA primase. A6 and A8, subunit 6 or 8 of ATP synthase; cyt b, cytochrome *b*; COx, subunit of cytochrome *c* oxidase; ND, subunit of NADH dehydrogenase; rRNA, ribosomal RNA. Grey dots represent the 22 different mitochondrial tRNAs, which also serve as punctuations.

hundreds of mitochondria, and each mitochondrion usually contains a few copies of mtDNA. All mtDNA copies are identical in healthy young persons. However, in persons with inborn mitochondrial cytopathies and in elderly subjects, intact mtDNA copies coexist with mtDNA genomes with point mutations or DNA rearrangements, such as deletions or duplications.

The human mtDNA is a small (16 569 bp), circular, double-stranded DNA (Fig. 2), which is normally twisted into a supercoiled form [4]. The proportion of heavy vs. light DNA bases differs slightly between the two mtDNA strands. Their different buoyancies on denaturing caesium chloride gradients have led to their appellation as the 'heavy strand' and the 'light strand' respectively. At the so-called 'displacement loop' (D-loop), mtDNA contains a third DNA strand. This localized triplex structure is due to the interrupted replication of the heavy strand, as discussed below.

Although most of the ancient bacterial genes have been lost, or have migrated to nuclear DNA [6], the human mtDNA still

encodes for the two ribosomal mitochondrial RNAs, all 22 mitochondrial tRNAs and 13 of the polypeptides of the respiratory chain, including adenosine triphosphate (ATP) synthase [4]. Information is tightly packed on mtDNA (Fig. 2). With the exception of a few regulatory sequences, mtDNA consists mainly of coding sequences with no introns. Furthermore, the short DNA sequences encoding for mitochondrial tRNAs also serve as punctuation dots [4].

The transcription of mtDNA is mediated by a mitochondrial RNA polymerase and is enhanced by the binding of mitochondrial transcription factor A (mtTFA) to enhancer sequences located upstream of the heavy strand promoter and the light strand promoter [4]. Mitochondrial transcription factor B (mtTFB) may favour the interaction with RNA polymerase [4]. As shown in Fig. 2, the transcription of the heavy strand proceeds counterclockwise, while the transcription of the light strand runs clockwise.

DNA polymerase γ replicates mtDNA. It has proofreading activity, enabling it to remove the last added nucleotide, if mispaired [4]. The replication of mtDNA is asymmetrical (Fig. 2). Only the heavy strand is initially replicated. Replication starts at the origin of replication of the heavy strand (O_H), after a short RNA primer. This primer is formed by the transcriptional machinery and begins at the site for the initiation of transcription of the heavy strand. The need for this RNA primer explains why mtTFA enhances not only the transcription, but also the replication of mtDNA (Fig. 2). Other factors enhancing mtDNA replication are mitochondrial single-stranded binding protein (mtSSB) and the DNA helicase, twinkle. Replication of the heavy strand proceeds clockwise. It can arrest after a few hundred basepairs, thus forming the basal D-loop, or can proceed further on. The arrest or continuation of replication may be modulated by the binding of regulatory factors to the termination-associated sequence (TAS) (Fig. 2). When about two-thirds of the heavy strand has been replicated, and the displacement front has gone past the origin of replication of the light strand (O_L), the light strand begins to be replicated counterclockwise, after a short RNA primer introduced by a mitochondrial DNA primase [4].

Whereas mitochondria contain all the enzymes necessary for base excision repair, they cannot remove some bulky DNA lesions, such as pyrimidine dimers and interstrand cross-links [7,8]. However, heavily damaged mtDNA molecules can be degraded by mitochondrial nucleases, and then replaced by the synthesis of new mtDNA molecules replicated from unaltered mtDNA templates [8].

Mitochondrial protein import

With the exception of the 13 polypeptides encoded by mtDNA, the thousand or so other proteins present in mitochondria are encoded by nuclear DNA, synthesized within the cytoplasm and imported into the mitochondria, either cotranslationally or posttranslationally (Fig. 3) [9,10]. Although all imported polypeptides enter the mitochondria through the Tom40 (translocase of outer membrane 40) complex, import routes then differ with the destination of the protein (Fig. 3) [9].

- Polypeptides that are destined to form β-barrel proteins inside the outer membrane are carried by small Tim (translocase of the inner membrane) proteins of the intermembrane space to the SAM (sorting and assembly machinery) complex, which inserts these proteins into the outer membrane (Fig. 3).
- Polypeptides that are destined to form multispanning proteins in the inner membrane are carried by the same small Tim proteins to the Tim22 (translocase of inner membrane 22) complex (also called the 'twin-pore translocase' because of its two pores), which inserts these proteins inside the inner membrane (Fig. 3) [9].
- Finally, polypeptides that are destined for the mitochondrial matrix are usually synthesized with an N-terminal, positively charged presequence achieving an α-helical configuration. These polypeptides cross the inner mitochondrial membrane through the Tim23 complex (also called the 'presequence translocase'). Their import is driven by the membrane potential and also by an ATP-driven pulling mechanism mediated by mitochondrial Hsp70, which is bound to Tim44. Mitochondrial processing peptidase (MPP) then removes the presequence inside the matrix (Fig. 3).

Most enzymes responsible for the tricarboxylic acid cycle, and all the proteins or enzymes involved in the replication, stability, translation and repair of mtDNA, are targeted to the mitochondrial matrix. Respiratory chain polypeptides are targeted to the inner mitochondrial membrane, except for cytochrome *c*, which is targeted to the intermembrane space but mostly associates with cardiolipin on the cytosolic face of the mitochondrial inner membrane. Finally, some β-oxidation enzymes are targeted to the mitochondrial inner membrane, while others are directed to the mitochondrial matrix.

Mitochondrial β-oxidation of fatty acids

Although peroxisomes contribute to the oxidation of fatty acids (particularly that of very-long-chain fatty acids), fatty acid oxidation mainly occurs within mitochondria.

Unlike medium-chain or short-chain fatty acids, long-chain fatty acids cannot directly enter the mitochondria. They must first be activated into a CoA thioester and then transported into the mitochondria by a carnitine-dependent shuttle (Fig. 4) [11]. On the cytosolic face of the outer mitochondrial membrane, acyl-CoA synthetase initially synthesizes an acyl-adenylate intermediate and then forms the acyl-CoA thioester, with the concomitant degradation of one ATP into AMP and pyrophosphate. Carnitine palmitoyl transferase I (CPT I), which is located on the cytosolic face of the outer mitochondrial membrane, next transfers the acyl group from CoA to carnitine (Fig. 4). The acyl-carnitine formed is then translocated across the inner mitochondrial membrane by carnitine acyl-carnitine translocase, in exchange for free carnitine. Finally, carnitine palmitoyl transferase II, which is located on the matrix side of the inner membrane, reforms the long-chain fatty acyl-CoA derivative inside the mitochondrial matrix (Fig. 4).

Fig. 3 Mitochondrial import of proteins. The mitochondrial proteins, which are encoded by nuclear DNA, are synthesized by cytosolic ribosomes and are imported cotranslationally or posttranslationally into the mitochondria. In the latter case, cytosolic chaperones (hsp) maintain the polypeptide in an import-competent form. All imported polypeptides cross the mitochondrial outer membrane (OM) through the translocase of outer membrane 40 (Tom40) complex. Import routes then differ with the destination of the polypeptide. (1) Polypeptides that are destined to form β-barrel proteins in the OM are brought by small Tim (translocase of the inner membrane) proteins (Tim9 and Tim10) to the sorting and assembly machinery (SAM) complex, which inserts these proteins into the OM. (2) Polypeptides that are destined to form multispanning proteins in the inner membrane (IM) are brought by the same small Tim proteins (Tim9 and Tim10) to the translocase of inner membrane 22 (Tim22) complex. Tim22, which is also called the 'twin translocase' on account of its two pores, inserts these proteins into the IM. (3) Finally, polypeptides that are destined for the mitochondrial matrix usually contain an N-terminal, positively charged presequence. They cross the inner membrane through the Tim23 complex (also called the 'presequence translocase of the inner membrane'). Their mitochondrial import is driven both by the membrane potential (Aψ) and by an ATP-driven pulling mechanism mediated by mitochondrial hsp70 (mtHsp70), which is anchored to Tim44. Mitochondrial processing peptidase (MPP) then removes the presequence in the matrix.

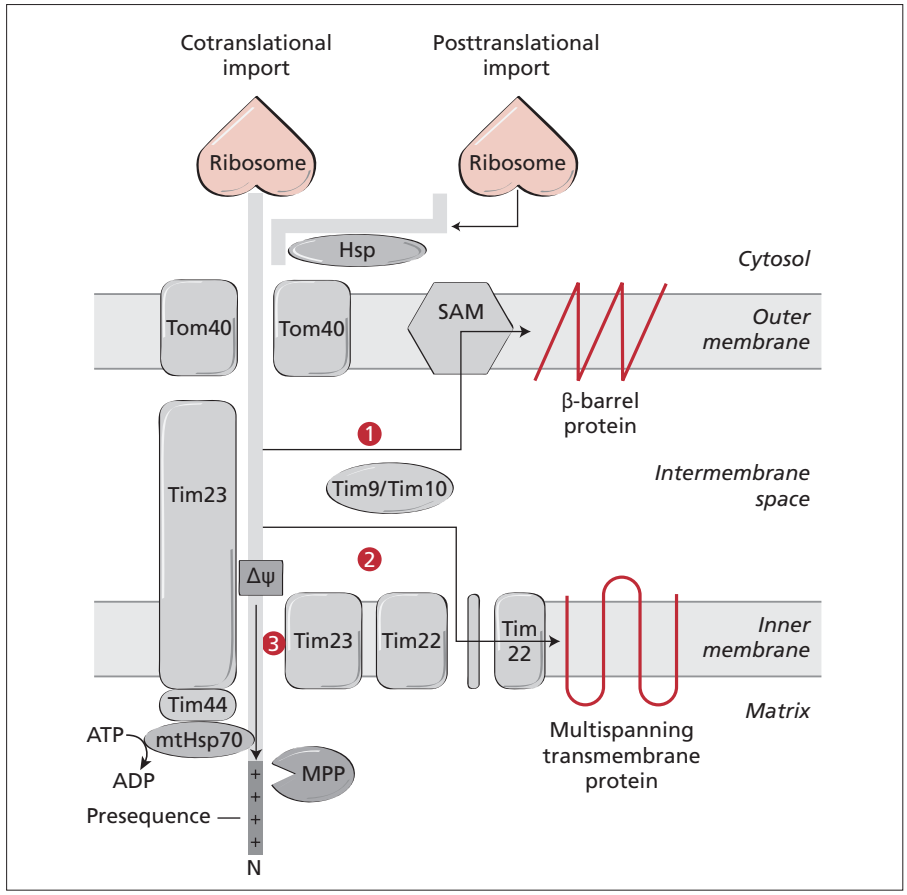

Fig. 4 Activation and mitochondrial uptake of long-chain fatty acids. (1) On the cytosolic face of the mitochondrial outer membrane (OM), the long-chain fatty acid (LCFA) is transformed by acyl-CoA synthetase into acyl-CoA. (2) Carnitine palmitoyl transferase I (CPT I), which is located on the cytosolic face of the outer membrane, transfers the acyl group from CoA to carnitine. It is unclear whether the acyl-carnitine formed is released directly into the intermembrane space by CPT I or whether it is first released outside and then crosses the outer membrane. (3) The acyl-carnitine derivative is translocated across the mitochondrial inner membrane (IM) by carnitine acyl-carnitine translocase (CACT) in exchange for free carnitine. (4) Carnitine palmitoyl transferase II (CPT II), which is located on the matrix side of the inner membrane, then reforms acyl-CoA inside the mitochondrial matrix.

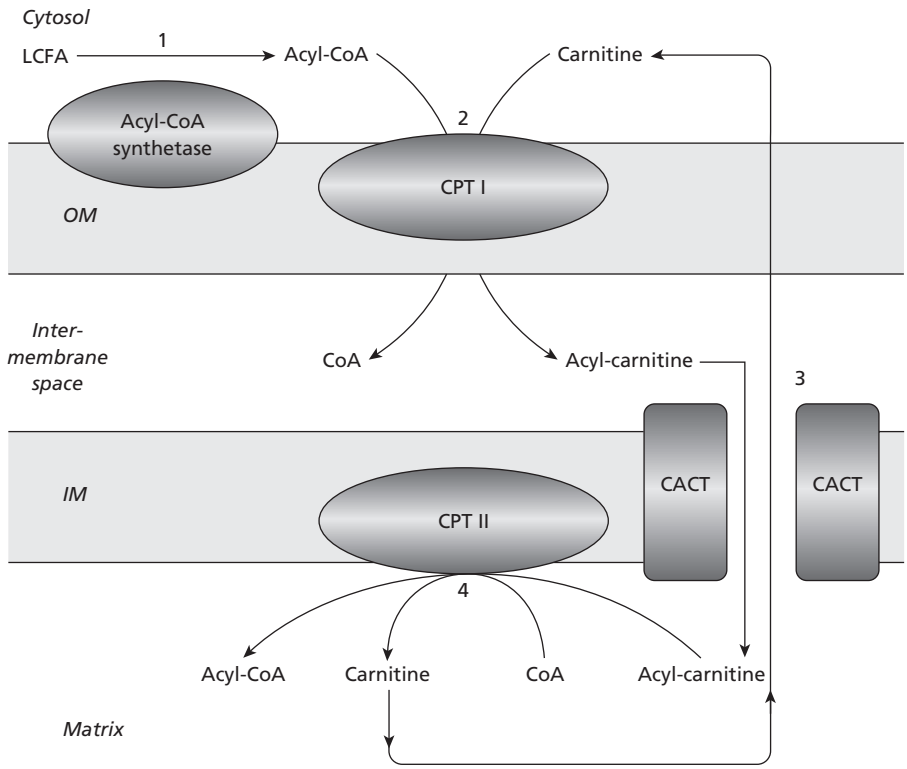

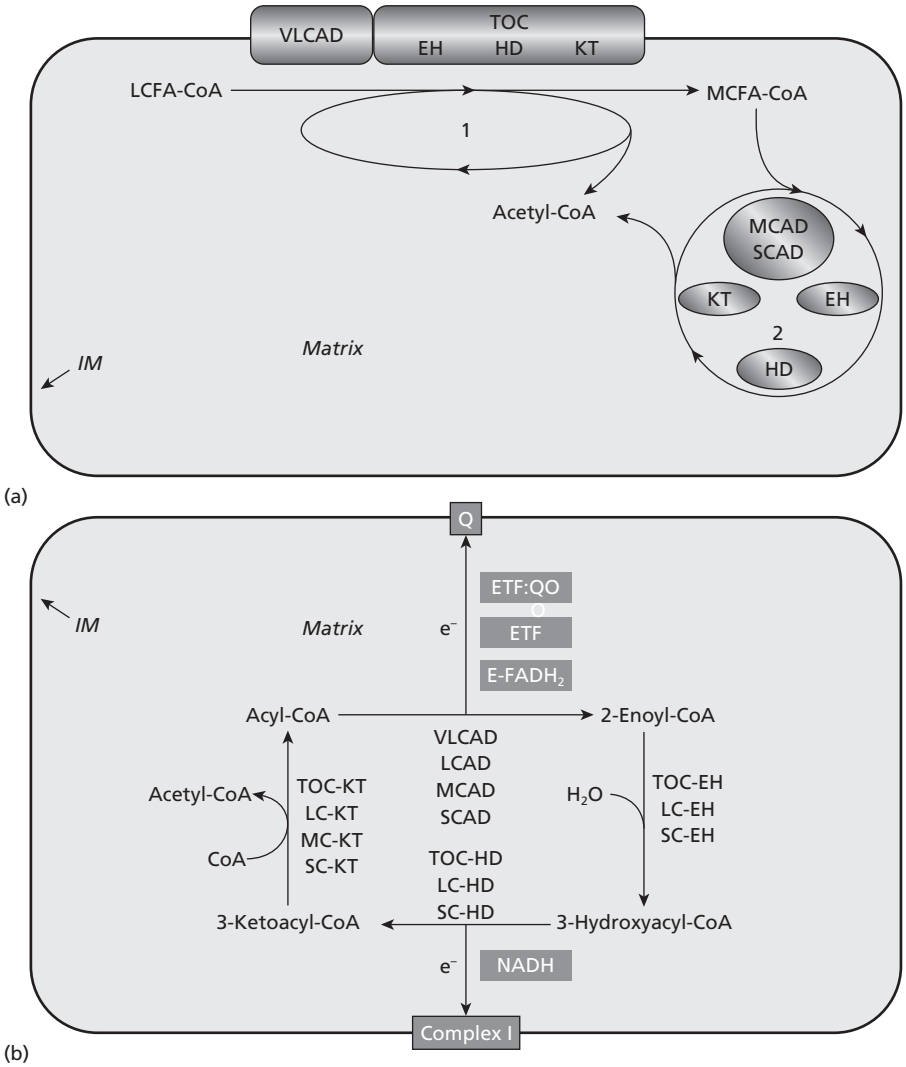

Fig. 5 Mitochondrial β-oxidation of long-chain fatty acids. (a) Successive action of membrane-bound and then soluble β-oxidation enzymes. (1) The saturated, long-chain fatty acyl-CoA (LCFA-CoA) is shortened to a medium-chain fatty acyl-CoA (MCFA-CoA) by the membrane-bound, very-long-chain acyl-CoA dehydrogenase (VLCAD) and the membrane-bound, trifunctional β-oxidation complex (TOC), which has enoyl-CoA hydratase (EH), 3-hydroxyacyl-CoA dehydrogenase (HD) and 3-ketoacyl-CoA thiolase (KT) activities. (2) The MCFA-CoA is then further split into its acetyl-CoA subunits by soluble matricial enzymes, including medium-chain and short-chain acyl-CoA dehydrogenases (MCAD and SCAD) and soluble EH, HD and KT enzymes specific for long-chain (LC), medium-chain (MC) and short-chain (SC) fatty acids. (b). β-Oxidation intermediates and fate of electrons. The β-oxidation cycle successively involves a first dehydrogenation, a hydration step, a second dehydrogenation and, finally, thiolysis, which releases acetyl-CoA. Electrons coming from acyl-CoA dehydrogenases are transferred to an enzyme-bound FAD, thus forming E-$FADH_2$, and are then shuttled by electron transfer flavoprotein (ETF) and ETF-ubiquinone oxidoreductase (ETF:QO), to the ubiquinone (Q) of the respiratory chain, thus forming ubiquinol. Electrons coming from 3-hydroxyacyl-CoA dehydrogenases are transferred to NAD^+, thus forming NADH, which feeds electrons into complex 1 of the respiratory chain.

Mitochondrial β-oxidation progressively shortens the acyl-CoA by two carbon units at each cycle (Fig. 5) [11]. Each β-oxidation cycle involves a first dehydrogenation leading to *trans*-2-enoyl-CoA, a hydration step forming L-3-hydroxyacyl-CoA, a second dehydrogenation leading to 3-ketoacyl-CoA and, finally, thiolytic cleavage by CoA, releasing acetyl-CoA and an acyl-CoA shortened by two carbon atoms.

First membrane-bound and then soluble enzymes successively shorten a saturated long-chain fatty acyl-CoA (Fig. 5) [12]. The membrane-bound, very-long-chain acyl-CoA dehydrogenase (VLCAD) is also very active with long-chain fatty acids and mediates the first dehydrogenation step of the β-oxidation cycle. The membrane-bound, trifunctional β-oxidation complex (TOC) then completes the β-oxidation cycle through its enoyl-CoA hydratase, 3-hydroxyacyl-CoA dehydrogenase and 3-ketoacyl-CoA thiolase activities. This membrane-bound system (VLCAD and TOC) may shorten the saturated long-chain fatty acid into a medium-chain fatty acid (Fig. 5). Further shortening is then mediated by matrix enzymes, including medium-chain and short-chain acyl-CoA dehydrogenases (MCAD and SCAD) and soluble enoyl hydratases, 3-hydroxyacyl-CoA dehydrogenases and 3-ketoacyl-CoA thiolases specific for long-, medium- or short-chain fatty acids (Fig. 5) [11,12].

Owing to the high activity of the membrane-bound system, the soluble, long-chain acyl-CoA dehydrogenase (LCAD) is redundant for the β-oxidation of saturated long-chain fatty acids. However, LCAD is involved in the β-oxidation of unsaturated long-chain fatty acids, thus compensating for the poor activity of VLCAD for unsaturated substrates [12].

The two main steps regulating the β-oxidation flux are carnitine palmitoyl transferase I, which modulates the entry of long-chain fatty acids into the mitochondria, and acyl-CoA dehydrogenases, whose activities are relatively sluggish compared with the high activities of other β-oxidation enzymes [13].

Each β-oxidation cycle removes four electrons. The two electrons removed by acyl-CoA dehydrogenases transiently form an enzyme-bound E-$FADH_2$. These electrons are then shuttled by electron transfer flavoprotein (ETF) and ETF-ubiquinone

oxidoreductase (ETF:QO) to the ubiquinone (Q) of the respiratory chain close to complex III, thus forming ubiquinol (Fig. 5). In contrast, the electrons removed by 3-hydroxyacyl-CoA dehydrogenases are transferred to NAD^+ to form nicotinamide adenine dinucleotide (NADH), which feeds electrons into complex I of the respiratory chain (Fig. 5). As discussed below, electrons coming from E-$FADH_2$ will produce about two ATP molecules, while those coming from NADH will form about three ATP molecules [14]. Therefore, each round of mitochondrial β-oxidation eventually leads to about five ATP molecules and one molecule of acetyl-CoA. The latter can either condense into ketone bodies, as discussed below, or may eventually undergo the tricarboxylic acid cycle to generate much more energy.

Tricarboxylic acid cycle

The final oxidation of acetyl-CoA by the tricarboxylic acid cycle (also termed the 'citric acid cycle', starts with the condensation of acetyl-CoA with oxaloacetate to form citrate (Fig. 6) [14]. This reaction is carried out by citrate synthase and involves the formation a citryl-CoA intermediate, which is then hydrolysed into CoA and citrate.

The tricarboxylic acid cycle then proceeds with the isomerization of citrate into isocitrate (mediated by aconitase), the oxidative decarboxylation of isocitrate into CO_2 and α-ketoglutarate (mediated by isocitrate dehydrogenase), and the CoA-supported oxidative decarboxylation of α-ketoglutarate into CO_2 and succinyl CoA (mediated by the α-ketoglutarate dehydrogenase complex). The cycle further proceeds with the cleavage of the thioester bond of succinyl-CoA to form succinate and one high-energy guanosine 5′-triphosphate (GTP) (mediated by the reversibly acting, succinyl-CoA synthetase). Finally, the cycle ends up with three steps resembling those involved in the β-oxidation process, with the dehydrogenation of succinate into fumarate (mediated by succinate dehydrogenase), the hydration of fumarate into malate (mediated by fumarase) and the dehydrogenation of malate into oxaloacetate (mediated by malate dehydrogenase). The overall stoichiometry of the tricarboxylic acid cycle is: acetyl-CoA + 2 H_2O + 3 NAD^+ + FAD + GDP + Pi → 2 CO_2 + 3 NADH + $FADH_2$ + GTP + 2 H^+ + CoA. As each of the three NADH molecules will eventually give about three ATP molecules and the single $FADH_2$ will form about two ATP molecules, the global energy yield of one citric acid cycle is about 11 ATP molecules, as well as one energy-rich GTP molecule, which can be used as such or can generate one more ATP molecule [14].

It is noteworthy that molecular oxygen is not immediately used in this cycle nor in the β-oxidation cycle. The oxygen

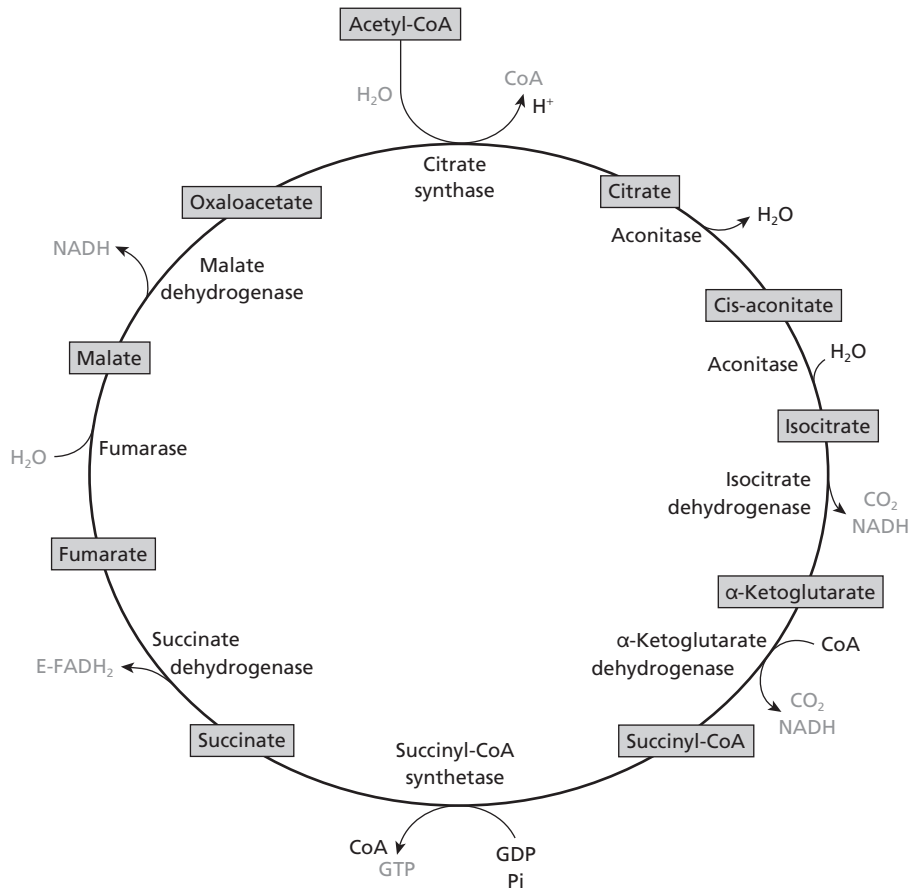

Fig. 6 Tricarboxylic acid cycle. The final oxidation of the acetate moiety of acetyl-CoA by the tricarboxylic acid cycle produces one molecule of energy-rich GTP, three molecules of NADH and one molecule of enzyme-bound $FADH_2$ within succinate dehydrogenase (E-$FADH_2$). NADH and E-$FADH_2$ then transfer their electrons to the respiratory chain to produce ATP.

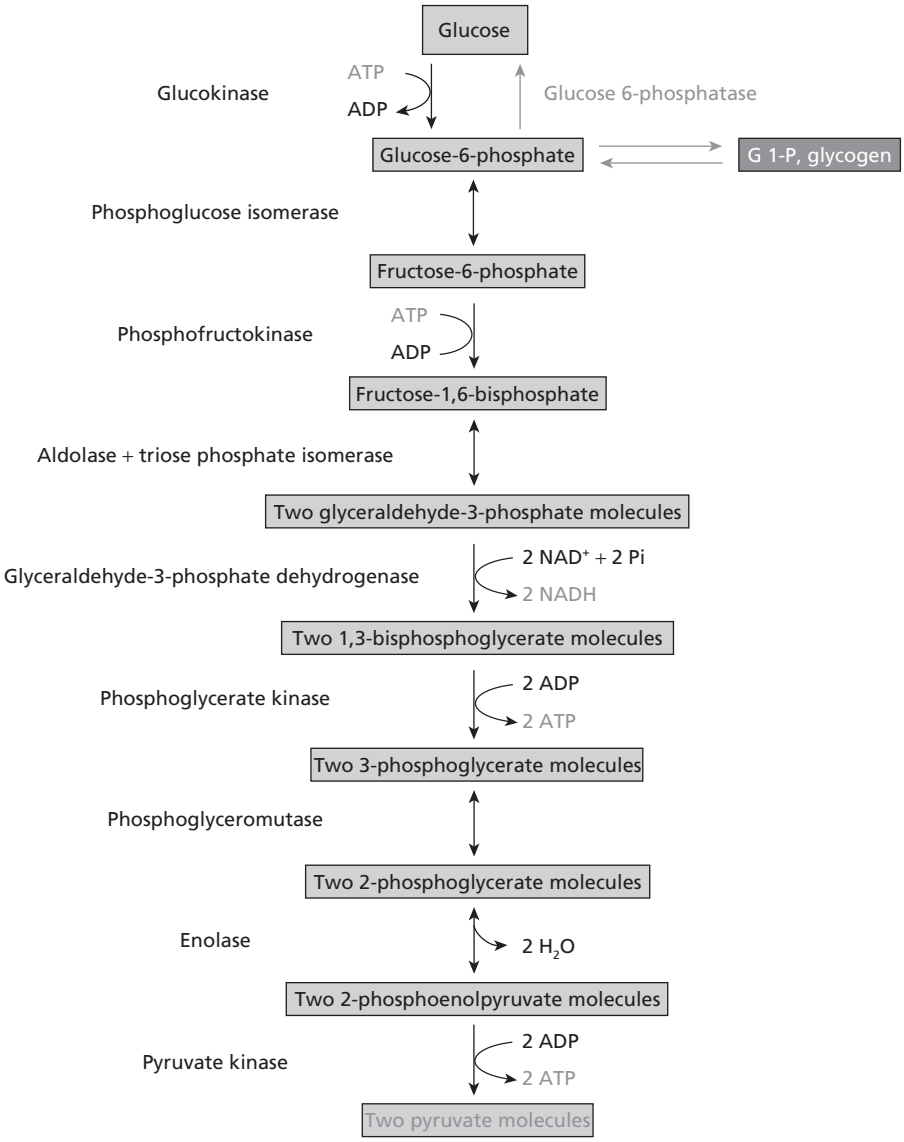

Fig. 7 Glycolysis. The glycolysis of glucose in the cytoplasm forms two molecules of pyruvate. Unless the generated NADH and pyruvate are further oxidized in mitochondria, glycolysis itself only generates two net molecules of ATP.

atoms, which end up in CO_2, come from water. However, as discussed below, the electrons, which are passed by NADH and $FADH_2$ to the respiratory chain, end up in molecular oxygen to form water. This transfer of electrons regenerates the oxidized cofactors (NAD^+ and FAD), which are necessary to sustain β-oxidation and the tricarboxylic acid cycle. Thus, even though molecular oxygen is not involved in the tricarboxylic acid cycle, oxygen is mandatory at the next step, explaining why the tricarboxylic acid cycle can only function in the presence of oxygen. In the absence of oxygen, the only metabolic pathway that can transiently provide some feeble energy is glycolysis.

Cytosolic glycolysis and the mitochondrial oxidation of pyruvate

Glycolysis is defined as the process that converts glucose into pyruvate [14]. This process, which occurs in the cytoplasm, starts with the phosphorylation of glucose into glucose-6-phosphate. This reaction is catalysed by glucokinase in the liver and hexokinase in other organs (Fig. 7). Glucose-6-phosphate is a branching point in glucose metabolism. Its reversible isomerization to glucose-1-phosphate can lead to UDP-glucose formation and glycogen synthesis, whereas its reversible isomerization into fructose-6-phosphate can lead to glycolysis. The first committed step in glycolysis is the irreversible phosphorylation of fructose-6-phosphate into fructose-1,6-bisphosphate by phosphofructokinase. After a series of enzymatic reactions detailed in Figure 7, including the reduction of NAD^+ into NADH by glyceraldehyde-3-phosphate dehydrogenase, glycolysis ends up with the irreversible transformation of phosphoenol pyruvate into pyruvate, a reaction catalysed by pyruvate kinase (Fig. 7). Both phosphofructokinase and the liver-type pyruvate kinase are tightly regulated (through allosteric and phosphorylation events) to prevent the liver from consuming glucose when glucose is more

urgently needed by brain or muscle [14]. The net stoichiometry of glycolysis is: glucose + 2 NAD^+ + 2 ADP + 2 Pi → 2 pyruvate + 2 NADH + 2 H^+ + 2 ATP + 2 H_2O [14].

Glycolysis cannot proceed unless the formed NADH is reoxidized into the NAD^+ required by glyceraldehyde-3-phosphate dehydrogenase. When there is a transient incapacity of mitochondria to reoxidize the formed NADH (for example, during strenuous muscular exercise or during tissue ischaemia), some transient relief can be obtained from the reversible reaction catalysed by lactate dehydrogenase: NADH + H^+ + pyruvate → NAD^+ + lactate. The regeneration of NAD^+ allows glycolysis to continue, while the formed lactate can be oxidized at later times in the same organ (e.g. in the resting muscle) or in other organs, such as the liver. In the meantime, however, the energy yield is only two molecules of ATP for one molecule of glucose consumed, so that anaerobic glycolysis is a most wasteful way of generating energy.

However, under normal aerobic conditions, mitochondria reoxidize the NADH formed by glycolysis. Because the inner mitochondrial membrane is impermeable to NADH, its electrons rather than NADH are transferred to mitochondria. This can be achieved by two mitochondrial shuttles: the malate–aspartate or the glycerol phosphate shuttles [14]. In the cytosol, NADH regenerates NAD^+ by transferring its electrons to either oxaloacetate or dihydroxyacetone phosphate, which then diffuse into the mitochondria, where they release their electrons to regenerate either NADH (in the malate–aspartate shuttle) or an enzyme-bound $FADH_2$ molecule (in the glycerol phosphate shuttle) [14]. These reduced cofactors then form ATP through oxidative phosphorylation, as discussed below.

Under normal aerobic conditions, mitochondria also oxidize the pyruvate (or lactate) formed by glycolysis (Fig. 8). Mitochondrial carriers transport pyruvate or lactate into the mitochondria, where the pyruvate dehydrogenase complex catalyses the reaction: pyruvate + NAD^+ + CoA → acetyl-CoA + NADH. The oxidation of this acetyl-CoA in the tricarboxylic acid cycle will then generate considerable energy. Whereas the anaerobic glycolysis of glucose into pyruvate and lactate only

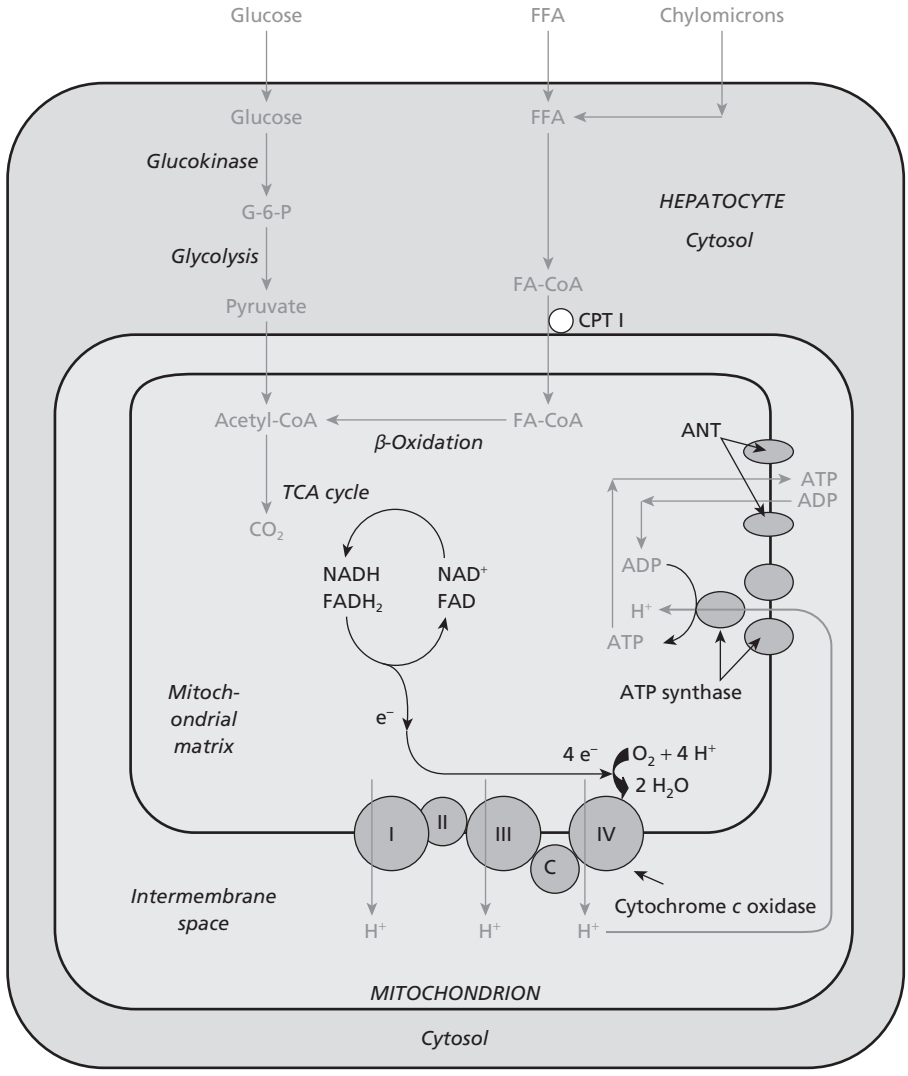

Fig. 8 Oxidative metabolism and energy production by mitochondria. The oxidation of pyruvate and free fatty acids (FFA) inside mitochondria produces NADH and $FADH_2$, which transfer their electrons to the mitochondrial respiratory chain. The flow of electrons in complexes 1, 3 and 4 is coupled with the extrusion of protons from the mitochondrial matrix into the intermembrane space. When energy is needed, these protons re-enter the matrix through ATP synthase to generate ATP from ADP. The adenine nucleotide translocator (ANT) then exchanges the formed ATP for cytosolic ADP. G-6-P, glucose 6-phosphate; LCFA-CoA, long-chain fatty acyl-CoA; CPT I, carnitine palmitoyl transferase I; TCA cycle, tricarboxylic acid cycle; *c*, cytochrome *c*.

forms two ATP molecules, the complete aerobic oxidation of glucose can provide up to 38 ATP molecules, thanks to the oxidative phosphorylation system [14].

Oxidative phosphorylation system

Oxidative phosphorylation is the process whereby the electrons stored in NADH or enzyme-bound $FADH_2$ are reacted with oxygen to form water, while part of the energy released by this exergonic reaction is harnessed to form ATP. To achieve this aim, electrons are first transferred through different respiratory chain complexes, where the electron transfer potential is converted, step by step, into an electrochemical proton gradient, which is finally converted into a phosphate transfer potential by forming energy-rich ATP molecules [14]. An analogy may be the pumping up of water behind a dam by a thermal engine, and then the opening of water valves allowing the hydrostatic flow of water into a hydroelectric turbine that generates electricity used to charge small batteries.

A total of five complexes constitute the oxidative phosphorylation system [15]. Complexes 1–4 constitute the respiratory chain, while complex 5 is ATP synthase. Depending on their original sources (NADH or enzyme-bound $FADH_2$), electrons enter the respiratory chain at different sites.

- The two electrons coming from NADH are transferred to complex 1 (also termed 'NADH-ubiquinone oxidoreductase' or 'NADH dehydrogenase'). Within this large, L-shaped complex, electrons are successively transferred to one flavin mononucleotide (FMN) and several iron–sulphur clusters to be finally donated to ubiquinone (Q), thus forming ubiquinol (QH_2). Concomitantly, four protons are pumped from the mitochondrial matrix into the intermembrane space. Therefore, the stoichiometry of the reaction catalysed by complex I is: NADH $+ 5\,H^+_{in} + Q \rightarrow NAD^+ + 4\,H^+_{out} + QH_2$ [16].
- The two electrons coming from the enzyme-bound $FADH_2$ of succinate dehydrogenase are given to complex 2. Unlike complexes 1, 3 or 4, complex 2 does not translocate protons from the mitochondrial matrix into the intermembrane space. It only transfers two electrons to ubiquinone, thus forming ubiquinol.
- Finally, the electrons coming from the enzyme-bound $FADH_2$ of acyl-CoA dehydrogenases are directly transferred by ETF and ETF:QO to ubiquinone, thus forming ubiquinol. Thus, whatever their initial site of entry (complex 1, complex 2 or ubiquinone), electrons end up in ubiquinol.

Q and QH_2 are highly mobile molecules within the inner mitochondrial membrane, allowing QH_2 to transfer its two electrons to complex 3 (also termed 'ubiquinol:cytochrome *c* oxidoreductase' or 'cytochrome bc_1'). The redox active sites of complex 3 include a cytochrome *b* with two haems (b-562 and b-566), an iron–sulphur protein (ISP) and a membrane-anchored cytochrome c_1. The 'Q cycle' theory postulates that complex 3 contains two sites for $Q/Q^-/QH_2$: an outside Q_o site located in close proximity to the intermembrane space and an inner Q_i site located in close proximity to the matrix (Fig. 9) [15]. At the outside Q_o site, ubiquinol would produce ubiquinone by releasing its two protons into the intermembrane space and by giving one electron to the ISP (to be given next to cytochrome c_1 and then cytochrome *c*) and the second electron to cytochrome *b* [17]. Cytochrome *b* would then recycle this electron in the Q_i site, as explained in the legend to Figure 9. Another theory holds that ubiquinol donates its two electrons to cytochrome *b*, which then gives them to the ISP, en route for cytochrome c_1 and cytochrome *c* (Fig. 9) [18]. Whatever the path(s) of electrons, the net stoichiometry of the reaction catalysed by complex 3 is: QH_2 + 2 oxidized cytochrome *c* (Fe^{3+}) + 2 $H^+_{in} \rightarrow$ Q + 2 reduced cytochrome *c* (Fe^{2+}) + 4 H^+_{out} [15].

Four reduced cytochrome *c* molecules finally transfer four electrons to complex 4 (cytochrome *c* oxidase), where the four electrons are successively, but quickly, reacted with an oxygen molecule, which is held in a tight cage so that partially reduced oxygen species are not released, but only water is safely formed [15]. The generation of water also consumes four protons, which are taken from the matrix side. Concomitantly, complex 4 transports four protons from the mitochondrial matrix into the intermembrane space. Therefore, the stoichiometry of the reaction catalysed by complex 4 is: 4 reduced cytochrome *c* (Fe^{2+}) + O_2 + 8 $H^+_{in} \rightarrow$ 4 oxidized cytochrome *c* (Fe^{3+}) + 2 H_2O + 4 H^+_{out} [15].

Thus, the transfer of electrons through complexes 1, 3 and 4 of the respiratory chain is coupled with the extrusion of protons from the mitochondrial matrix into the mitochondrial intermembrane space. This creates a large electrochemical potential across the inner membrane, thus creating a reservoir of latent, potential energy (Fig. 8).

When energy is needed, the increase in ADP stimulates the re-entry of protons through ATP synthase (also called 'F_1F_0-ATPase', 'H^+-ATPase' or 'complex 5'), and the energy that is liberated by this re-entry is harnessed in the synthesis of ATP from ADP. The ATP formed is then extruded from mitochondria by the adenine nucleotide translocator in exchange for cytosolic ADP (Fig. 8). ATP is then used by all the cellular processes that require energy (e.g. maintenance of transmembrane ion gradients, anabolic syntheses, cell motility, muscular contraction).

ATP synthase is a wonderful biological engine (Fig. 10) [19,20]. Its transmembrane F_0 portion contains a non-rotating moiety consisting of the a subunits and a rotor made of a dozen or so c subunits (c-ring rotor). The re-entry of protons through a channel located at the junction of the a subunits and the c-ring triggers the rotation of the c-ring and the attached γ stalk. The γ stalk rotates within a cap made of three pairs of alternating α and β subunits ($\alpha_3\beta_3$ cap), which is kept immobile by the $a/b_2/\delta$ stator [20]. The rotating stalk is asymmetrical. When the stalk rotates within the $\alpha_3\beta_3$ cap, it causes rhythmic deformations of the catalytic β subunits, which may alternatively tighten around ADP and P_i, close to form ATP and fully open to release ATP. As there are three catalytic sites, one 360° rotation of the γ stalk gives rise to three ATP molecules [19].

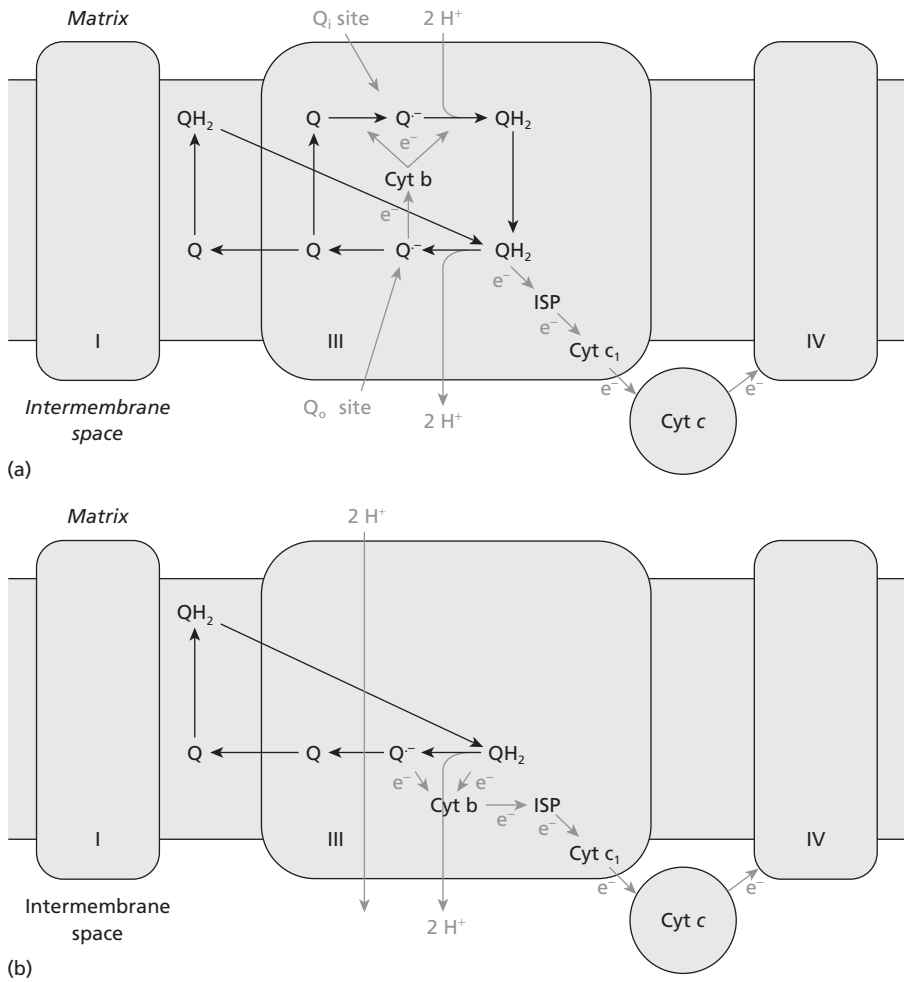

Fig. 9 Current hypotheses for the flow of electrons within complex 3. (a) The classical 'Q cycle' theory postulates that complex 3 contains two sites for ubiquinone (Q) and its redox partners, the ubisemiquinone anion radical ($Q^{\cdot -}$) and ubiquinol (QH_2). The outside Q_o site would be close to the intermembrane space, and the inner Q_i site close to the matrix. Two successive ubiquinol molecules coming from other complexes may enter the outside Q_o site of complex 3, where each ubiquinol molecule would produce ubiquinone by releasing its two protons into the intermembrane space. In the process, ubiquinol would give one electron to the iron–sulphur protein (ISP), which then transfers this electron to cytochrome c_1, which in turn gives it to cytochrome *c*. The semiubiquinone anion radical formed from ubiquinol would then give its electron to cytochrome *b* (cyt b), thus forming ubiquinone, which would be returned to the region between complex 1 and complex 3. Concomitantly, cytochrome *b* would recycle the electrons that it receives at the Q_o site by sending them to the Q_i site. At this Q_i site, cytochrome *b* would first give one electron to Q, thus forming $Q^{\cdot -}$, and the next electron to $Q^{\cdot -}$, thus forming QH_2. The formed ubiquinol would then move to the Q_o site to be oxidized in exchange for ubiquinone coming from the Q_i site to be reduced. Thus, according to this scheme, for two ubiquinol molecules releasing their protons through their oxidation at the Q_o site, one molecule of ubiquinol would be regenerated at the Q_i site. (b) Another theory holds that ubiquinol instead donates its two electrons to cytochrome *b*, which then gives them to the iron sulphur protein (ISP), en route for cytochrome c_1, and cytochrome *c*.

Because the driving force for ATP synthesis is the re-entry of protons, and because the flow of electrons along the respiratory chain extrudes protons at three different sites, the number of ATP molecules that can be synthesized differs with the site of electron entry into the chain. The electrons that are transferred from NADH cause the extrusion of protons at complex 1, complex 3 and complex 4 and can lead to the synthesis of about three ATP molecules for one molecule of NADH reoxidized [14]. In contrast, the electrons that are transferred by enzyme-bound $FADH_2$ bypass complex 1 and only permit the synthesis of about two ATP molecules for one $FADH_2$ reoxidized [14].

Interestingly, ATP synthase is a reversible machine. When the mitochondrial membrane potential is low, for example during ischaemia, ATP synthase functions in the reverse mode. Its ATPase activity consumes the meagre amounts of ATP formed by glycolysis to pump protons into the intermembrane space and partially to restore the mitochondrial membrane potential, which is needed to maintain mitochondrial protein import and mitochondrial viability. This ATP-depleting effect can be prevented by the binding of a matricial protein termed the inhibitor of F_1F_0-ATPase (IF_1) [21]. When the membrane potential is low (e.g. during ischaemia) and when anaerobic glycolysis causes extensive lactate formation and matrix acidification, IF_1 then binds to the F_1 moiety of ATP synthase to inhibit its ATPase activity. This attenuates the selfish use of cell ATP by deenergized mitochondria.

Except for these extreme circumstances, when mitochondria consume cell ATP for their own needs, mitochondria instead provide the cell with energy.

Regulation of fuel oxidation by energy demands

Mitochondria are thrifty organelles. They only burn fuels inasmuch as fuel oxidation is needed to satisfy the energy demands of the cell. This balance is achieved through several mechanisms, including built-in, autoregulatory mechanisms adapting fuel oxidation (and thus ATP generation) to ATP consumption.

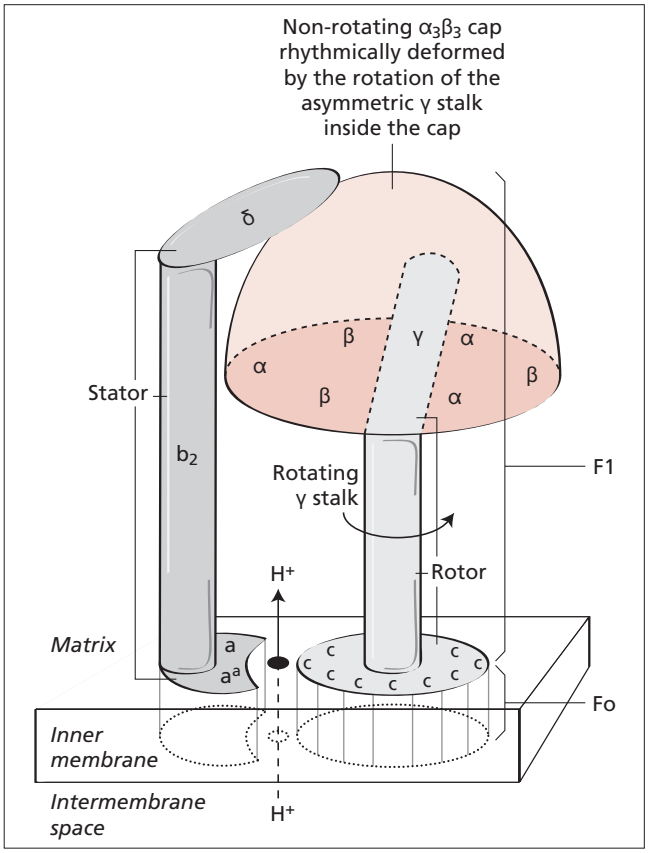

Fig. 10 ATP synthase. The transmembrane F_0 portion of ATP synthase contains a non-rotating moiety (the a subunits) and a membrane-embedded rotor made of a dozen c subunits (the c-ring rotor). The re-entry of protons at the junction of the a subunits and the c-ring rotor triggers the rotation of the c-ring rotor and the attached γ rod, which rotates within an immobile cap made of three pairs of alternating α and β subunits ($\alpha_3\beta_3$ cap). The cap is prevented from rotating by the a/b_2/δ stator. The rotating γ stalk is asymmetrical (depicted illustratively as a bend on the figure). Its rotation within the $\alpha_3\beta_3$ cap causes rhythmic deformations of the catalytic β subunits, which may successively tighten around ADP and Pi, close to form ATP and fully open to release ATP. As there are three catalytic sites, one 360° rotation of the γ stalk produces three ATP molecules.

When energy demands are high, and ADP is high, a massive re-entry of protons into the matrix through ATP synthase decreases the mitochondrial membrane potential. This unleashes the flow of electrons in the respiratory chain, with three consequences. First, the increased flow of electrons increases the rate of proton extrusion by the respiratory chain, thus allowing the continued re-entry of protons through ATP synthase to sustain high rates of ATP generation. Second, the increased flow of electrons ends up in cytochrome *c* oxidase, thus increasing oxygen consumption. Finally, the increased rate of respiration is associated with an increased reoxidation of NADH and $FADH_2$ into NAD^+ and FAD, which are required to drive the oxidation of glucose, pyruvate, acyl-CoA and acetyl-CoA.

In contrast, when little energy is needed by the cell, ATP synthase is barely active and only translocates a few protons back into the matrix. The high mitochondrial membrane potential blocks the extrusion of protons into the matrix. Electrons are stuck in the respiratory chain. Oxygen consumption is low. The limited reoxidation of NADH into the NAD^+ required for mitochondrial β-oxidation and the tricarboxylic acid cycle may limit the capacity of mitochondria to oxidize fat and pyruvate. Thus, the tricarboxylic acid cycle and oxidative phosphorylation system have built-in mechanisms that automatically adapt fuel oxidation to energy consumption.

This automatic adaptation is further tuned by the regulatory effects of ATP on several critical enzymatic steps [14]. Indeed, the activities of pyruvate dehydrogenase, citrate synthase, isocitrate dehydrogenase and α-ketoglutarate dehydrogenase are modulated by ATP levels, in order to increase fuel oxidation when ATP is low and, instead, to prevent fuel oxidation when ATP is high [14].

A last level of regulation involves the effects of nuclear genes on mitochondrial function and biogenesis.

Nuclear control of mitochondrial function and biogenesis

Both mitochondrial function and mitochondrial biogenesis are controlled by nuclear genes [22]. When mitochondrial function is insufficient to sustain the cellular drain of ATP, cell ADP increases. Adenylate kinase then converts two ADP molecules into one ATP molecule and one AMP molecule [23]. The increase in AMP is sensed by AMP-activated protein kinase (AMPK), which turns off ATP-consuming pathways and switches on ATP-producing catabolic pathways [23]. In particular, AMPK phosphorylates and inactivates acetyl-CoA carboxylase, thus decreasing the synthesis of malonyl-CoA. This prevents the inhibition of CPT I by malonyl-CoA, thus allowing the translocation of long-chain fatty acyl-CoA into the mitochondria and extensive β-oxidation [23]. Finally, AMPK increases several mitochondrial oxidative enzymes, such as succinate dehydrogenase, citrate synthase and cytochrome *c* [24,25].

Several other factors may also modulate mitochondrial function and biogenesis in the liver, although their roles have mostly been studied in skeletal muscles, whose energy requirements vary widely with the degree of physical activity. These other factors include the Ca^{2+}/calmodulin-dependent protein kinase (CaMK), the peroxisome proliferator-activated receptor γ coactivator 1 (PGC-1) and nuclear respiratory factors 1 and 2 (NRF-1 and NRF-2). In muscles, it has been shown that CaMK induces the expression of PGC-1, which itself induces the expression of NRF-1 and NRF-2. NRF-1 and NRF-2 increase the synthesis of nuclear DNA-encoded polypeptides of the respiratory chain and also induce mtTFA [22,26]. PGC-1 binds to, and coactivates, the transcriptional function of NRF-1 on the promoter for mtTFA, which increases the transcription and replication of mtDNA [26]. Finally, PGC-1 binds to, and cooperates with, peroxisome

proliferator-activated receptor-α (PPAR-α) in the transcriptional activation of nuclear genes encoding peroxisomal and mitochondrial β-oxidation enzymes, including CPT I and medium-chain acyl-CoA dehydrogenase [27]. As a consequence of these concerted actions on both nuclear genes and mtDNA genes, PGC-1 increases both the number of cardiac mitochondria and also their individual capacity to oxidize fat and to generate energy through oxidative phosphorylation [28]. Interestingly, both the AMPK- and the CaMK-mediated signals seem to act coordinately, as AMPK was required for energy deprivation-induced increases in the expression of CaMK and PGC-1 [29]. Together with the immediate regulations described in the preceding section, these nuclear changes may allow cells to increase or decrease fuel consumption depending on the energy demands of the cell.

Yet a last type of regulation concerns the different use of energetic fuels under fasted, fed or overfed conditions.

Different use of fuels by hepatic mitochondria in fasted, fed or overfed conditions (see also Chapter 13)

The handling of fuels by hepatic mitochondria is regulated in order to deliver ketone bodies and glucose to other organs when food is not available, but to store energy as glycogen and fat after meals.

In the fasting state, low insulin levels allow the massive release of free fatty acids from adipose tissue [30]. During fasting conditions, hepatic malonyl-CoA levels are low, allowing extensive mitochondrial import of long-chain free fatty acids, and thus active fatty acid β-oxidation. However, the acetyl-CoA moieties generated by hepatic mitochondrial β-oxidation are not fully oxidized in the liver, which would not be able to use this enormous amount of energy. Instead, acetyl-CoA moieties condense into ketone bodies (acetoacetate and β-hydroxybutyrate), which are secreted by the liver to be oxidized later in muscles and other peripheral tissues by the tricarboxylic acid cycle, thus sparing glucose [30]. The liver concomitantly provides other organs, such as the brain, with glucose formed from glycogen and gluconeogenesis.

In contrast, after meals, a slight increase in blood glucose increases the release of insulin by pancreatic β cells. In adipocytes, insulin inhibits hormone-sensitive lipase, thus blocking adipose tissue lipolysis. In the liver, glucose inactivates glycogen phosphorylase and activates glycogen synthetase, thus increasing glycogen stores [14]. Furthermore, both insulin and glucose trigger free fatty acid synthesis from glucose [31]. This is due to the posttranslational activation of several enzymes [14] and also to translational regulation [31]. Indeed, glucose activates carbohydrate response element binding protein (ChREBP), with two consequences. First, ChREBP stimulates liver-type pyruvate kinase, thus increasing the glycolysis of glucose into pyruvate [32]. In mitochondria, pyruvate forms acetyl-CoA, which condenses with oxaloacetate to form citrate that translocates to the cytoplasm. Citrate lyase then catalyses the reaction: citrate + ATP + CoA + H_2O → acetyl-CoA + oxaloacetate + ADP + P_i. The acetyl-CoA, which is thus regenerated in the cytosol, is then used by acetyl-CoA carboxylase to form malonyl-CoA, which is required for the elongation of free fatty acids by fatty acid synthase. Second, ChREBP stimulates the transcription of all lipogenic genes, including acetyl-CoA carboxylase, fatty acid synthase and stearoyl-CoA desaturase, thus further increasing hepatic fatty acid and triacylglycerol synthesis [33]. Insulin cooperates with glucose in increasing fatty acid synthesis. Indeed, insulin increases the transcription of sterol regulatory element-binding protein-1c (SREBP-1c), which increases the transcriptional activation of all the enzymes required for the hepatic synthesis of fatty acids [31]. Thus, both glucose via ChREBP and insulin via SREBP-1c can increase the hepatic synthesis of free fatty acids. Furthermore, the malonyl-CoA generated by acetyl-CoA carboxylase also prevents mitochondrial β-oxidation. Malonyl-CoA inhibits CPT I, which controls the entry of long-chain fatty acids into mitochondria [30]. After a carbohydrate meal, high malonyl-CoA levels inhibit CPT I and prevent fatty acid β-oxidation [30]. Free fatty acids are not degraded, but are instead directed towards the formation of triglycerides, which are partly stored in the liver and partly secreted as very-low-density lipoproteins.

Teleologically, these various changes can be viewed as maintaining/increasing fat and glycogen stores when food is plentiful and, in contrast, using up fat and sparing glucose when food is not available. In the past, these changes have provided a satisfactory balance between energy storage and energy use, when high physical activity ensured high rates of fuel oxidation by skeletal muscle mitochondria. Nowadays, however, food intake often exceeds the limited capacity of mitochondria to burn fuels in inactive persons, causing a progressive increase in body fat stores [34].

In relatively overfed subjects, the increased hepatic synthesis of free fatty acids causes the accumulation of triglyceride droplets in the cytoplasm of hepatocytes [34]. However, the liver does not enlarge indefinitely. A new equilibrium is reached when the increased synthesis of fat is compensated by increased output pathways, including an increased mitochondrial β-oxidation of fatty acids [34]. Several adaptive changes may allow hepatic mitochondria to oxidize more fat in overfed subjects [34]. A first mechanism could be the increased hepatic concentrations of free fatty acids (FFAs) in these subjects, which may force the entry of FFAs into the mitochondria [34]. A second mechanism may involve changes in CPT I expression and its sensitivity to malonyl-CoA inhibition. CPT I is upregulated in rodent models of diabetes, and its affinity for its physiological inhibitor, malonyl-CoA, is decreased [35,36]. Loss of CPT I inhibition by malonyl-CoA could explain why β-oxidation can increase in plethoric subjects, despite high insulin and malonyl-CoA levels, which would normally block the entry of long-chain fatty acids into mitochondria [34]. An important upstream mediator of these diverse changes may be PPAR-α.

PPAR-α is activated by long-chain free fatty acids and increases the expression of enzymes involved in peroxisomal and mitochondrial β-oxidation, including CPT I [35]. PPAR-α activation also increases uncoupling protein 2 mRNA [37]. This uncoupling protein might allow the re-entry of protons from the intermembrane space into the mitochondrial matrix. This could decrease the mitochondrial membrane potential, unleash the flow of electrons in the respiratory chain, increase mitochondrial respiration and allow better reoxidation of NADH into the NAD^+ required for fatty acid oxidation.

Although these adaptive changes prevent further expansion of hepatic fat stores in overfed subjects, they do not prevent some steatosis. The unsaturated lipids of fat deposits can then be oxidized by the ROS formed by mitochondria, thus triggering lipid peroxidation and oxidative stress [34].

Formation of reactive oxygen species

The incomplete reduction of oxygen by one, two or three electrons produces ROS. The strategy devised by bacteria and mitochondria to limit ROS formation is initially to store electrons in a form (NADH or E-$FADH_2$) that is unreactive with oxygen, then to transport these electrons through a respiratory chain, which is mostly insulated from oxygen, and, finally, quickly to react four electrons with oxygen within cytochrome *c* oxidase to safely produce water. However, the insulation of upstream respiratory complexes from oxygen is not perfect (Fig. 11). A small fraction of the electrons that pass through complex 1 and complex 3 react with oxygen to form the superoxide anion [38]. Complex 1 releases the superoxide anion into the mitochondrial matrix, while complex 3 releases superoxide

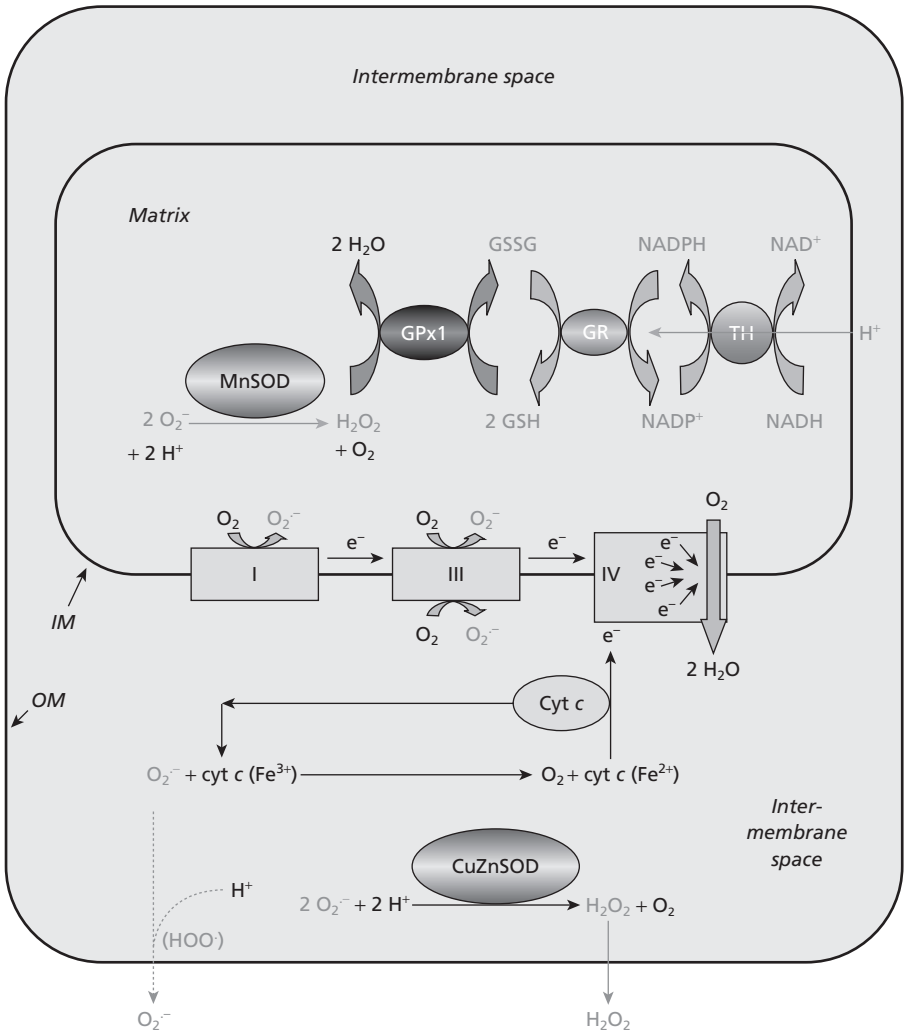

Fig. 11 Formation and inactivation of reactive oxygen species (ROS) in mitochondria. Most of the electrons that enter the respiratory chain finish in cytochrome *c* oxidase (complex 4), where four electrons are added quickly and in a tight cage to oxygen, so that ROS are not released, but only water is safely formed. However, upstream to complex 4, a few of the electrons donated to the respiratory chain react with oxygen to form the superoxide anion radical ($O_2^{\cdot-}$). Complex 1 generates $O_2^{\cdot-}$ on the matrix side. Complex 3 forms $O_2^{\cdot-}$ both in the matrix and in the intermembrane space. In the matrix, manganese superoxide dismutase (MnSOD) dismutates two molecules of the superoxide anion into one oxygen molecule and one molecule of hydrogen peroxide (H_2O_2). Glutathione peroxidase 1 (GPx1) then reduces H_2O_2 into water while oxidizing two reduced glutathione (GSH) molecules into glutathione disulphide (GSSG). Glutathione reductase (GR) then regenerates GSH at the expense of NADPH. Finally, an energy-linked $NAD(P)^+$ transhydrogenase (TH) uses NADH and the mitochondrial membrane potential to regenerate NADPH from $NADP^+$. In the intermembrane space, the superoxide anion is detoxified by its reaction with oxidized (ferric) cytochrome *c* to form reduced (ferrous) cytochrome *c*, which donates its electron to complex 4 of the respiratory chain, thus regenerating oxidized cytochrome *c*. Although copper zinc superoxide dismutase (CuZnSOD) is mostly cytosolic, it is also imported into the intermembrane space of mitochondria, where it dismutates $O_2^{\cdot-}$ into H_2O_2. Although most of the ROS formed by mitochondria are detoxified within mitochondria, some molecules of H_2O_2 can cross the outer membrane. In the acidic intermembrane space, $O_2^{\cdot-}$ may be protonated to the uncharged, hydroperoxyl radical ($HO_2\cdot$), which may also cross the outer membrane to regenerate $O_2^{\cdot-}$ in the cytosol. IM, inner membrane; OM, outer membrane.

into both the mitochondrial matrix and the intermembrane space (Fig. 11) [38]. Other possible site(s) for superoxide formation may be ETF (electron transfer protein) and/or ETF:QO (ETF:quinone oxidoreductase) [38]. Superoxide generation by ETF and/or ETF:QO has been proposed as one possible explanation for the higher formation of superoxide when muscle mitochondria are energized with palmitoyl carnitine than with complex 1 substrates [38]. Overall, it is estimated that 1–2% of the oxygen consumed by mitochondria may be transformed into the superoxide anion, and that mitochondria represent the most important source of ROS in cells [39].

Being unable to completely prevent ROS formation, mitochondria have devised several systems to eliminate these ROS (Fig. 11). In particular, the superoxide radical anion is dismutated by mitochondrial manganese superoxide dismutase into hydrogen peroxide, which is detoxified into water by mitochondrial glutathione peroxidase 1 (Fig. 11) [39].

Nevertheless, residual levels of ROS can impair mitochondrial structure and function. The superoxide anion can remove one iron molecule from the cubane (4Fe–4S) cluster of mitochondrial aconitase, thus inactivating aconitase and hampering fuel oxidation in the tricarboxylic acid cycle [40]. ROS can also damage mitochondrial proteins, cardiolipin and mtDNA, thus progressively impairing mitochondrial function [41]. In some pathological conditions, a very large formation of mitochondrial ROS can trigger, or can help to trigger, mitochondrial permeability transition, which irreversibly disables mitochondria and leads to their autophagic degradation [42].

Finally, some molecules of hydrogen peroxide and possibly also of the superoxide anion (the latter probably crossing the membrane as the hydroperoxyl radical) may leak out of mitochondria [43,44] and may eventually damage extramitochondrial cell constituents, such as nuclear DNA. However, mitochondrial constituents, including mtDNA, are the main targets of mitochondrial ROS.

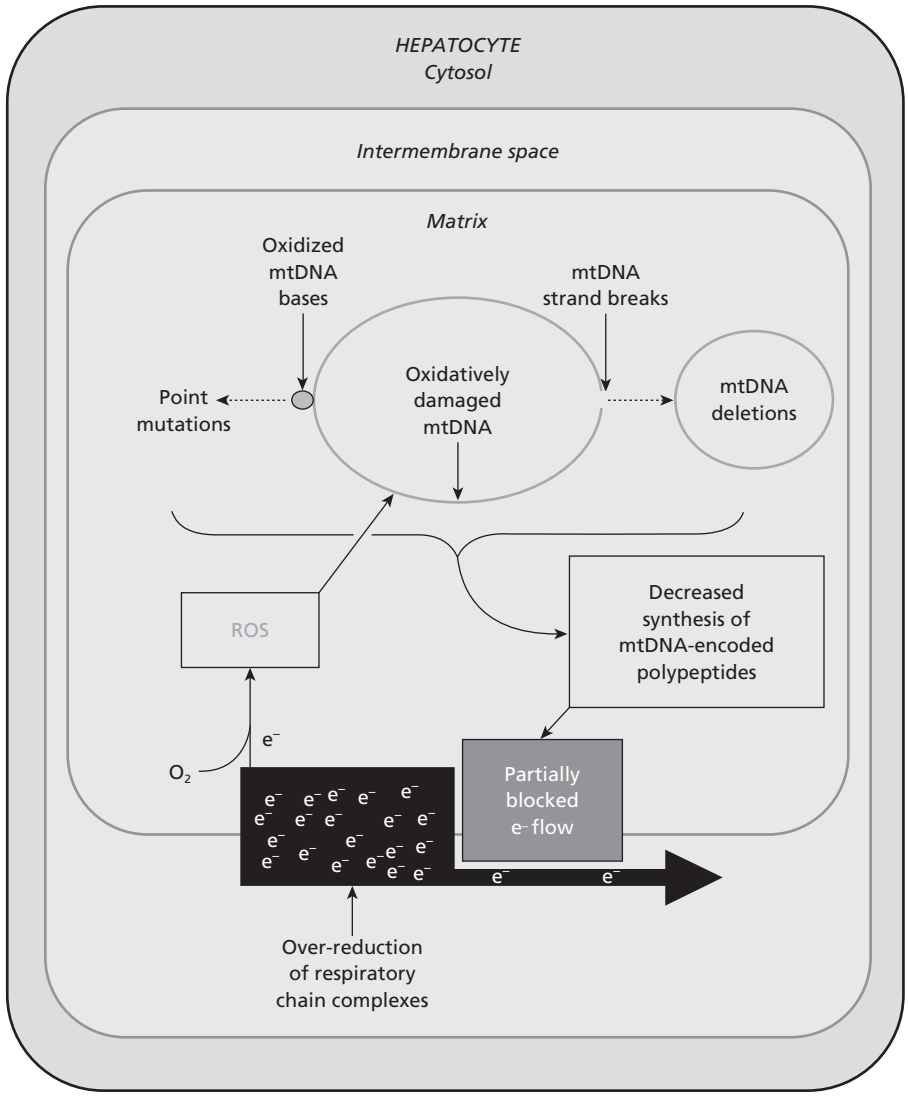

Fig. 12 Ageing of mtDNA. Reactive oxygen species (ROS) formed by the mitochondrial respiratory chain damage mtDNA. They form oxidized mtDNA bases, which may occasionally cause point mutations, and they also form mtDNA strand breaks, which may occasionally cause mtDNA deletions. Eventually, these mtDNA lesions and mutations may decrease the synthesis of mtDNA-encoded polypeptides, thus partially hampering the flow of electrons in the respiratory chain. In the overly reduced complex 1 and complex 3, the accumulated electrons may increasingly react with oxygen to form the superoxide anion radical. The increased ROS formation may further damage mtDNA. This vicious cycle, together with a decreased import of DNA repair enzymes as a consequence of the decreased membrane potential, could explain why mtDNA deletions and point mutations, which are exceptional before 40 years of age, then start to accumulate exponentially during old age.

Ageing of mitochondrial DNA

Mitochondrial ROS play an important role in the ageing process (Fig. 12). ROS oxidize mtDNA bases to form, in particular, 8-oxo-deoxyguanosine. During mtDNA replication, this modified guanine can mispair with an adenine (instead of a cytosine), and this mispairing can cause mtDNA point mutations. ROS also cause mtDNA strand breaks, which can occasionally lead to mtDNA deletions.

As these mutations accumulate over the years, they may eventually decrease the synthesis of mtDNA-encoded polypeptides, thus partially blocking the flow of electrons in the respiratory chain (Fig. 12). The over-reduction of upstream respiratory complexes may then increase mitochondrial ROS formation. Furthermore, as the mitochondrial membrane potential decreases, the membrane potential-driven import of DNA repair enzymes from the cytosol into the mitochondrial matrix may become impaired [45]. Thus, both increased mtDNA damage (due to the increased mitochondrial ROS formation) and decreased mtDNA repair (due to decreased import of repair enzymes) could explain why mtDNA deletions and point mutations increase exponentially during old age [46,47].

Overview

When photosynthesizing cyanobacteria began releasing oxygen in the atmosphere, bacteria took advantage of their quick turnover, and the high mutation rate caused by oxygen-derived ROS, to mutate and adapt to the oxygen environment. They developed truly wonderful biochemical machines, enabling them first to survive and then to thrive with energy in the new oxygen environment. Instead of trying to emulate the biochemical perfection of bacteria, other forms of life have associated with them. Assisted and controlled by nuclear genes, our mitochondrial partners oxidize or save fuels as needed, just to provide cells with the exact amount of energy they need.

However, as in all partnerships, there is some hardship. We are totally dependent on mitochondria, so that their failure is also a significant threat to health. Inborn defects, drugs or cytokines that impair mitochondrial function can cause steatosis, cell dysfunction or cell death. Furthermore, although mitochondria provide energy, they also form reactive oxygen species that contribute to ageing and death.

Death and reproduction have permitted the slow selection and adaptation of the host, providing mitochondria with an ever-adapting environment. While new species of the host have arisen and then become extinct, the mitochondrial clones have endured.

References

1 Floyd RA (1990) Role of oxygen free radicals in carcinogenesis and brain ischemia. *FASEB J* 4, 2587–2597.

2 McCord JM (2000) The evolution of free radicals and oxidative stress. *Am J Med* 108, 652–659.

3 Yang D, Oyaizu Y, Oyaizu H *et al.* (1985) Mitochondrial origins. *Proc Natl Acad Sci USA* 82, 4443–4447.

4 Taanman JW (1999) The mitochondrial genome: structure, transcription, translation and replication. *Biochim Biophys Acta* 1410, 103–123.

5 Sutovsky P, Moreno RD, Ramalho-Santos J *et al.* (1999) Ubiquitin tag for sperm mitochondria. *Nature* 402, 371–372.

6 Mourier T, Hansen AJ, Willerslev E *et al.* (2001) The human genome projects reveals a continuous transfer of large mitochondrial fragments to the nucleus. *Mol Biol Evol* 18, 1833–1837.

7 Croteau DL, Stierum RB, Bohr VA (1999) Mitochondrial DNA repair pathways. *Mutat Res* 434, 137–148.

8 LeDoux SP, Driggers WJ, Hollensworth S *et al.* (1999) Repair of alkylation and oxidative damage in mitochondrial DNA. *Mutat Res* 434, 149–159.

9 Rehling P, Brandner K, Pfanner N (2004) Mitochondrial import and the twin-pore translocase. *Nature Rev* 5, 519–530.

10 Mukhopadhyay A, Ni L, Weiner H (2004) A co-translational model to explain the in vivo import of proteins into Hela cell mitochondria. *Biochem J* 382, 385–392.

11 Bartlett K, Eaton S (2004) Mitochondrial β-oxidation. *Eur J Biochem* 271, 462–469.

12 Liang X, Le W, Zhang D *et al.* (2001) Impact of the mitochondrial enzyme organization on fatty acid oxidation. *Biochem Soc Trans* 29, 279–282.

13 Eaton S (2002) Control of mitochondrial β-oxidation flux. *Prog Lipid Res* 41, 197–239.

14 Stryer L (1988) *Biochemistry*, 3rd edn. New York: W.H. Freeman and Co.

15 Saraste M (1999) Oxidative phosphorylation at the *fin de siècle*. *Science* 283, 1488–1493.

16 Friedrich T, Bottcher B (2004) The gross structure of the respiratory complex I: a Lego System. *Biochim Biophys Acta* 1608, 1–9.

17 Trumpower BL (1990) The protonmotive Q cycle. Energy transduction by coupling of proton translocation to electron transfer by the cytochrome bc1 complex. *J Biol Chem* 265, 11409–11412.

18 Matsumo-Yagi A, Hatefi Y (2001) Ubiquinol:cytochrome *c* oxidoreductase (Complex III). Effects of inhibitors on cytochrome b reduction in submitochondrial particles and the role of ubiquinone in complex III. *J Biol Chem* 276, 19006–19011.

19 Boyer PD (1999) What makes ATP synthase spin? *Nature* 402, 247–249.

20 Capaldi RA, Aggeler R (2002) Mechanism of the F_1F_0-type ATP synthase, a biological rotary motor. *Trends Biochem Sci* 27, 154–160.

21 Cabezón E, Montgomery MG, Leslie AG *et al.* (2003) The structure of bovine F1-ATPase in complex with its regulatory protein IF1. *Nat Struct Biol* 10, 744–750.

22 Scarpulla RC (1997) Nuclear control of respiratory chain expression in mammalian cells. *J Bioenerget Biomembr* 29, 109–119.

23 Frøsig C, Jørgensen SB, Hardie DG *et al.* (2004) 5´-AMP-activated protein kinase activity and protein expression are regulated by endurance training in human skeletal muscle. *Am J Physiol Endocrinol Metab* 286, E411–417.

24 Winder WW, Holmes BF, Rubink DS *et al.* (2000) Activation of AMP-activated protein kinase increases mitochondrial enzymes in skeletal muscle. *J Appl Physiol* 88, 2219–2226.

25 Ojuka EO (2004) Role of calcium and AMP kinase in the regulation of mitochondrial biogenesis and GLUT4 levels in muscle. *Proc Nutr Soc* 63, 275–278.

26 Wu H, Kanatous SB, Thurmond FA *et al.* (2002) Regulation of mitochondrial biogenesis in skeletal muscle by CaMK. *Science* 296, 349–352.

27 Vega RB, Huss JM, Kelly DP (2000) The coactivator PGC-1 cooperates with peroxisome proliferator-activated receptor α in the transcriptional control of nuclear genes encoding mitochondrial fatty acid oxidation enzymes. *Mol Cell Biol* 20, 1868–1876.
28 Lehman JJ, Barger PM, Kovacs A *et al.* (2000) Peroxisome proliferator-activated receptor γ coactivator-1 promotes cardiac mitochondrial biogenesis. *J Clin Invest* 106, 847–856.
29 Zong H, Ren JM, Young LH *et al.* (2002) AMP kinase is required for mitochondrial biogenesis in response to chronic energy deprivation. *Proc Natl Acad Sci USA* 25, 15983–15987.
30 McGarry JD, Foster DW (1980) Regulation of hepatic fatty acid oxidation and ketone body production. *Annu Rev Biochem* 49, 395–420.
31 Browning JD, Horton JD (2004) Molecular mediators of hepatic steatosis and liver injury. *J Clin Invest* 114, 147–152.
32 Yamashita H, Takenoshita M, Sakurai M *et al.* (2001) A glucose-responsive transcription factor that regulates carbohydrate metabolism in the liver. *Proc Natl Acad Sci USA* 98, 9116–9121.
33 Lizuka K, Bruick RK, Liang G *et al.* (2004) Deficiency of carbohydrate response element binding protein (ChREBP) reduces lipogenesis as well as glycolysis. *Proc Natl Acad Sci USA* 101, 7281–7286.
34 Pessayre D, Fromenty B (2005) NASH: a mitochondrial disease. *J Hepatol* 42, 928–940.
35 Brady LJ, Brady PS, Rosmos DR (1985) Elevated hepatic mitochondrial and peroxisomal oxidative capacities in fed and starved adult obese (ob/ob) mice. *Biochem J* 231, 439–444.
36 Cook J, Gamble MSV (1987) Regulation of carnitine palmitoyl transferase by insulin results in decreased activity and decreased apparent Ki values for malonyl CoA. *J Biol Chem* 262, 2050–2055.
37 Chavin KD, Yang SQ, Lin HZ *et al.* (1999) Obesity induces expression of uncoupling protein-2 in hepatocytes and promotes liver ATP depletion. *J Biol Chem* 274, 5692–5700.
38 St-Pierre J, Buckingham JA, Roebuck SJ *et al.* (2002) Topology of superoxide production from different sites in the mitochondrial electron transport chain. *J Biol Chem* 277, 44784–44790.
39 Kowaltowski AJ, Vercesi AE (2001) Reactive oxygen generation by mitochondria. In: Lemasters JJ, Nieminen AL (eds) *Mitochondria in Pathogenesis*. New York: Kluwer Academic/Plenum Publishers, pp. 281–300.
40 Walden WE (2002) From bacteria to mitochondria: aconitase yields surprises. *Proc Natl Acad Sci USA* 99, 4138–4140.
41 Demeilliers C, Maisonneuve C, Grodet A *et al.* (2002) Impaired adaptive resynthesis and prolonged depletion of hepatic mitochondrial DNA after repeated alcohol binges in mice. *Gastroenterology* 123, 1278–1290.
42 Elmore SP, Qian T, Grissom SF *et al.* (2001) The mitochondrial permeability transition initiates autophagy in rat hepatocytes. *FASEB J* 15, 2286–2287.
43 De Grey ADNJ (2002) $HO_2^{\cdot}$: the forgotten radical. *DNA Cell Biol* 21, 251–257.
44 Wallace MA, Liou LL, Martins J *et al.* (2004) Superoxide inhibits 4Fe-4S cluster enzymes involved in amino acid biosynthesis. Cross-compartment protection by CuZn-superoxide dismutase. *J Biol Chem* 279, 32055–32062.
45 Szczesny B, Hazra TK, Papaconstantinou J *et al.* (2003) Age-dependent deficiency in import of mitochondrial DNA glycosylases required for repair of oxidatively damaged bases. *Proc Natl Acad Sci USA* 100, 10670–10675.
46 Cortopassi GA, Shibata D, Soong NW *et al.* (1992) A pattern of accumulation of a somatic deletion of mitochondrial DNA in aging human tissues. *Proc Natl Acad Sci USA* 89, 7370–7374.
47 Wang Y, Michikawa Y, Mallidis C *et al.* (2001) Muscle-specific mutations accumulate with aging in critical human mtDNA control sites for replication. *Proc Natl Acad Sci USA* 98, 4022–4027.

2.3.5 Bilirubin metabolism

Namita Roy-Chowdhury, Yang Lu and Jayanta Roy-Chowdhury

Bilirubin in medical history

Bilirubin has attracted the attention of physicians since antiquity. Its chemistry, metabolism and disposal have been studied systematically during the last two centuries as a model for hepatic disposal of biologically important organic anions of limited aqueous solubility [1]. The discovery of several inherited disorders of bilirubin metabolism and excretion during the twentieth century has led to renewed interest in inherited diseases associated with jaundice, some of which continue to pose a therapeutic challenge, providing impetus for further research. While physicians are mainly concerned with the toxic effect of bilirubin and its importance as a liver function test, the antioxidant property of bilirubin may provide a physiological defence against oxidative injury.

Formation of bilirubin

Sources of bilirubin

Bilirubin is the breakdown product of the haem moiety of haemoglobin, other haemoproteins, such as cytochromes, catalase, peroxidase and tryptophan pyrrolase, and a small pool of free haem. In humans, 250–400 mg of bilirubin is produced daily, of which approximately 20% is produced from non-haemoglobin sources [2]. Following the injection of radiolabelled porphyrin precursors (glycine or δ-aminolaevulinic acid), an 'early-labelled peak' of bilirubin (ELP) is excreted in bile within 72 h [3]. The initial component of ELP is derived mainly from hepatic haemoproteins. This is followed by a slower component, derived from both erythroid and non-erythroid sources, which becomes prominent in conditions associated with 'ineffective erythropoiesis', e.g. congenital dyserythropoietic anaemias, megaloblastic anaemias, iron-deficiency anaemia, erythropoietic porphyria and lead poisoning [4], and in accelerated erythropoiesis [5]. The 'late-labelled peak' appears at approximately 110 days in humans and coincides with the half-life of erythrocytes.

Enzymatic mechanism of bilirubin formation

The microsomal haem oxygenase (HO) enzymes catalyse the oxidation of haem (Fig. 1). Three molecules of O_2 are consumed

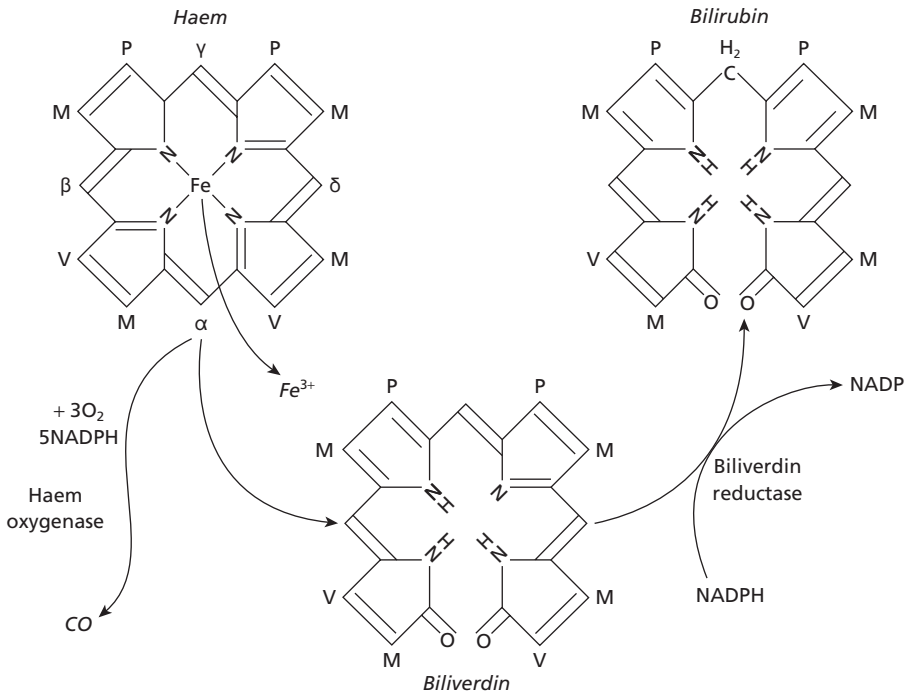

Fig. 1 Enzyme-catalysed degradation of haem. Haem degradation begins by haem oxygenase-catalysed oxidation of the α-bridge carbon of haem, which is converted to CO, leading to opening of the tetrapyrrole ring and release of the iron molecule. The resulting biliverdin molecule is subsequently reduced to bilirubin by cytosolic biliverdin reductase.

in this reaction and a reducing agent, such as nicotinamide adenine dinucleotide phosphate hydrogenase (NADPH), is needed. The α-methene bridge carbon is eliminated as CO and the iron molecule is released [6]. Of the three forms of HO, HO-1 is ubiquitous and inducible by haem [8] and stress [7]; HO-2 is a constitutive protein, expressed mainly in the brain and the testis. The catalytic activity of HO-3 is low, and this protein may function mainly as a haem binding protein. CO produced by HO activity has a vasodilatory effect and regulates the vascular tone in the liver, heart and other organs during stress. Similarly, biliverdin and its product bilirubin are potent antioxidants, which may protect tissues under oxidative stress [7,9] (see below).

Biliverdin is reduced to bilirubin by the action of cytosolic biliverdin reductases, which require NADH or NADPH for activity [10]. As discussed later, bilirubin requires energy-consuming metabolic steps for excretion in bile. Thus, the physiological advantage of its formation is not clear. The strong antioxidant activity of bilirubin may be particularly important during the neonatal period, when other antioxidants are scarce in body fluids.

Measurement of bilirubin production

Bilirubin production can be quantified from the turnover of intravenously administered radioisotopically labelled bilirubin. Plasma bilirubin clearance is proportional to the reciprocal of the area under the radiobilirubin disappearance curve [11]. Bilirubin removal is calculated as the product of plasma bilirubin concentration and clearance. At a steady state of plasma bilirubin concentration, bilirubin removal equals bilirubin production. More conveniently, bilirubin formation can be quantified from CO, which is generated in equimolar amounts with bilirubin. Following rebreathing in a closed system, CO production is calculated from the CO concentration in the rebreathing mask and/or the increment in blood carboxyhaemoglobin saturation [12]. A small fraction of the CO may be formed by intestinal bacteria, which can be a significant source of CO in intestinal bacterial overgrowth syndromes [13].

Inhibition of bilirubin production

Substances, such as tin-protoporphyrin and tin-mesoporphyrin, that bind irreversibly to HO, but are not broken down, serve as 'dead-end' inhibitors of the enzyme and reduce bilirubin production [14]. Injection of tin-mesoporphyrin lowers serum bilirubin levels by 76% in neonates [15].

Chemical characteristics of bilirubin

The tetrapyrrole structure of bilirubin IXα (1,8-dioxo-1,3,6,7-tetramethyl-2,8-divinylbiladiene-a,c-dipropionic acid [17]) was solved by Fischer and Plieninger [18]. X-ray crystallography has revealed that the propionic acid side-chains of bilirubin form hydrogen bonds with the pyrrolic and lactam sites on the opposite half of the molecule, giving rise to a distorted 'ridge tile' structure [19] (Fig. 2). Formation of hydrogen bonds requires the interpyrrolic bridges at the 5 and 15 position of bilirubin to be in *trans* or 'Z' configuration, whereby bilirubin is termed bilirubin IXα-ZZ. Engagement of all polar groups (two propionic acid carboxyls, four NH groups and two lactam oxygens) of bilirubin by the hydrogen bonds makes the molecule insoluble

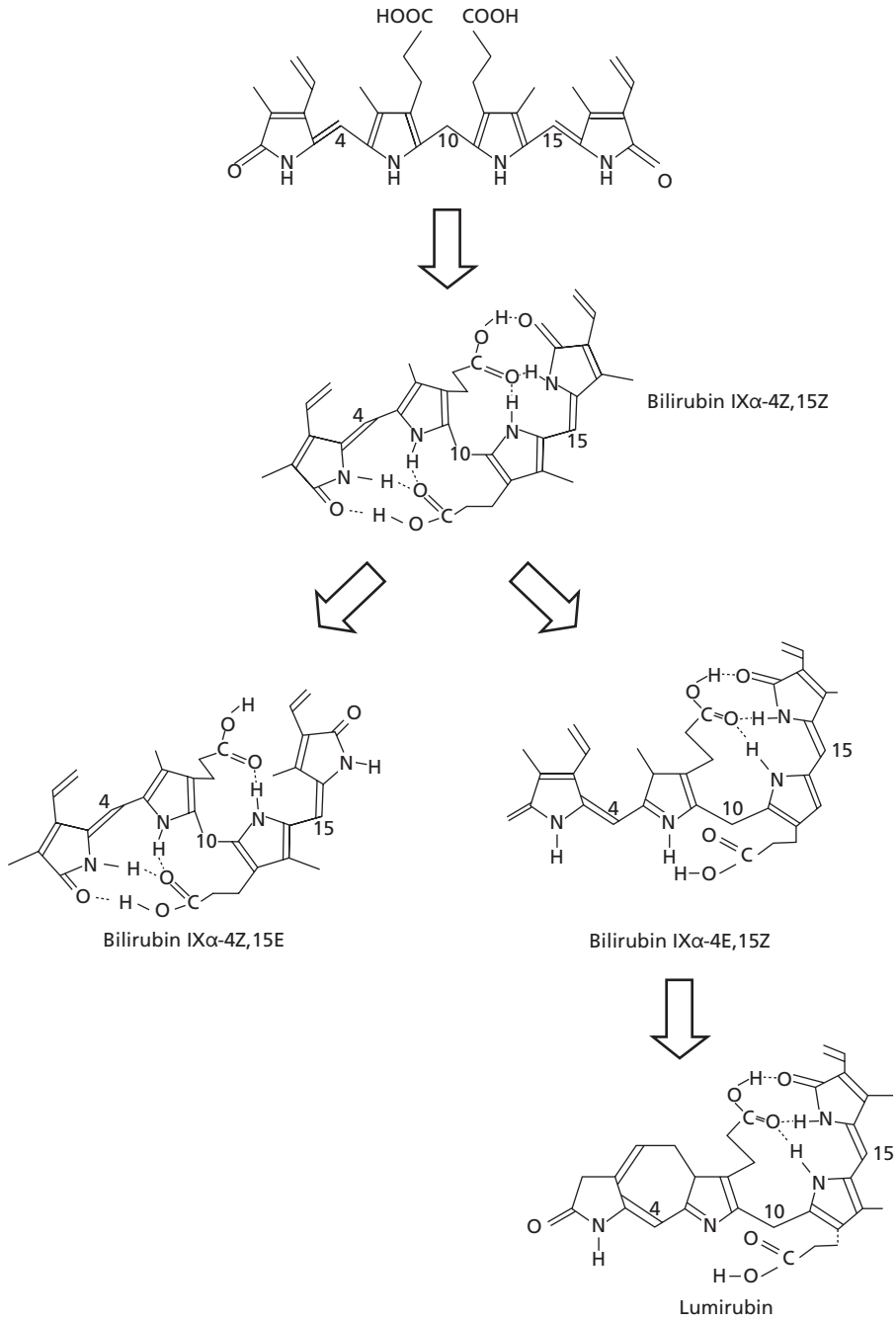

Fig. 2 Internal hydrogen bonding and photoisomerization of bilirubin. The carboxylic acid moiety of the propionic acid side-chains of bilirubin form internal hydrogen bonds with contralateral NH groups and the lactam oxygen, thereby engaging all polar groups of the molecule and making it insoluble in water. Upon exposure to light, configurational changes (Z to E) occur at the C4 and C15 interpyrrolic bridges, disrupting the hydrogen bonds. The bilirubin IXα-4E,15Z configurational isomer can be cyclized forming the so-called lumirubin. These configurational and geometric isomers are more polar than the hydrogen-bonded bilirubin IXα-4Z,15Z and are excreted in bile without requiring glucuronidation.

in water, necessitating chemical modification for excretion in bile. Disruption of the hydrogen bonds is accomplished *in vivo* by enzyme-catalysed esterification of the propionic acid carboxyl groups with a glycosyl moiety, mainly glucuronic acid (*vide infra*).

The hydrogen bonds 'bury' the central methane bridge, so that the unconjugated bilirubin reacts very slowly with diazo reagents, whereas bilirubin glucuronides, which lack hydrogen bonds, react rapidly ('direct' van den Bergh reaction). The addition of 'accelerators' such as methanol, ethanol, 6 M urea or dimethyl sulphoxide to plasma disrupts the hydrogen bonds of bilirubin, so that both conjugated and unconjugated bilirubin react rapidly with diazo reagents ('total' van den Bergh reaction).

Bilirubin glucuronides in normal bile are 1-O-acyl conjugates linked to the propionic acid carboxyl of bilirubin in a β-D-ester linkage, which is hydrolysable by β-glucuronidase. However, during cholestasis, the migration of the 1-O-acyl bond from the C1 position to the C2, C3 or C4 position results in the generation of β-glucuronidase-resistant pigments [20], which are detectable in serum and bile by chromatographic analysis [21].

In cases of prolonged accumulation of conjugated bilirubin in plasma, as in cases of cholestasis or Dubin–Johnson syndrome, the pigment may become covalently bound to albumin [22]. This irreversibly protein-bound form, often termed delta-bilirubin, is included in the 'direct' fraction of bilirubin and is not eliminated in the bile or urine, which results in delayed clearance even after biliary obstruction or cholestasis is resolved.

Effect of light

The main absorption band of unconjugated bilirubin IXα is at 450–474 nm in most organic solvents. Upon exposure to light, the 'Z' (*trans*) configuration of the 5 and/or 15 carbon bridges of bilirubin switches to the 'E' (*cis*) configuration. The resulting configurational isomers, ZE, EZ or EE, lack internal hydrogen bonds, are more polar than bilirubin IXα-ZZ and can be excreted in bile without conjugation [23]. The non-hydrogen-bonded molecule can be stabilized slowly by cyclization of the vinyl substituent in the endovinyl half of bilirubin IXα-EZ with the methyl substituent on the internal pyrrole ring, forming the stable structural isomer, E-cyclobilirubin. Because of its stability, this molecule is quantitatively important during phototherapy for neonatal jaundice [24]. Light and oxygen can also degrade a fraction of the bilirubin molecules into colourless fragments and biliverdin [25].

Quantification of bilirubin

Bile pigments can be quantified as native or derivatized tetrapyrroles, or after conversion to azoderivatives. Conversion to azodipyrroles by reaction with diazo reagents is the most common method of measuring serum bilirubin levels in clinical laboratories. Electrophilic attack on the central bridge splits bilirubin into two diazotized azodipyrrole molecules. As discussed above, conjugated bilirubin reacts rapidly ('direct' fraction), while total bilirubin is determined after adding an accelerator. Unconjugated bilirubin is calculated by subtracting the direct fraction from total bilirubin. As 10–15% of unconjugated bilirubin may give a 'direct' diazo reaction, this method slightly overestimates conjugated bilirubin.

Bilirubin and its conjugates in serum or bile can be quantified more accurately as intact bilirubin tetrapyrroles by high-pressure liquid chromatography [26–28]. Bilirubin mono- and diconjugates can be converted to methyl esters by alkaline methanolysis prior to separation [29] but, because the sugar groups are cleaved off, this method does not permit identification of specific conjugates.

For repeated bilirubin measurements in jaundiced infants, as an extension of clinical evaluation of jaundice, bilirubin levels can be assessed by measurement of the intensity of yellow discoloration of the skin using a special reflectance photometer [30]. Two slide tests (Ektachem) are available for determination of total bilirubin and the unconjugated, conjugated and irreversibly protein-bound fractions.

Bilirubin toxicity

Unconjugated bilirubin is toxic to many cell types, intracellular organelles and physiological processes. Bilirubin inhibits DNA synthesis [31] and ATPase activity of brain mitochondria [32], and uncouples oxidative phosphorylation. It has been reported to inhibit Ca^{2+}-activated, phospholipid-dependent protein kinase C activity and cAMP-dependent protein kinase activity [33]. Which of these toxic effects is the predominant cause of bilirubin encephalopathy remains unclear at this time. Clinically, toxic effects of bilirubin, particularly on the brain, are seen in neonates and patients with severe inherited deficiency of bilirubin conjugation. Yellow discoloration of the hippocampus, basal ganglia and nuclei of the cerebellum and brain stem, found in infants with acute bilirubin encephalopathy, is termed kernicterus. Such discoloration is not found in patients with chronic encephalopathy, in whom focal necrosis of neurons and glia is seen [34].

As all toxic effects of bilirubin are abrogated by tight binding to albumin, cerebral toxicity is usually seen when there is a molar excess of bilirubin over albumin in plasma. At serum-unconjugated bilirubin concentrations over 20 mg/dL, newborn babies are at risk of kernicterus. However, kernicterus can occur at lower concentrations in the presence of substances such as sulphonamides, radiographic contrast dyes and coumarin, which inhibit albumin–bilirubin binding by competitive or allosteric displacement [35,36]. Although immaturity of the blood–brain barrier in neonates has been implicated in the increased susceptibility of neonates to kernicterus, evidence to support this concept is insufficient. Normally, bilirubin entering the brain is cleared rapidly, but the pigment may bind to damaged and oedematous brain inhibiting its clearance, thereby increasing the susceptibility to bilirubin encephalopathy [37].

Potential beneficial effects of products of haem breakdown

Although clinicians are mainly concerned with the importance of bilirubin levels as a marker of liver disease and with the toxic effects of the pigment, biliverdin and bilirubin may exert some beneficial effects by virtue of their strong antioxidant properties. This may be relevant during the newborn period, when the level of other natural antioxidants is low. Bilirubin, which is toxic to neuronal cells at high concentrations, has been reported to have cytoprotective activity at lower concentrations. An inverse relationship between serum bilirubin levels and risk of ischaemic coronary artery disease has been observed [38], although whether such a protective effect extends to subjects with Gilbert syndrome is questionable [39]. Study of a large number of subjects in the United States has shown that the odds ratio for colorectal cancer is reduced to 0.295 in men and 0.186 in women per 1 mg/dL increment in serum bilirubin levels [40]. Similarly, a previous large study showed an inverse relationship between serum bilirubin levels and cancer mortality in a Belgian

population [41]. However, such associations do not conclusively prove a causative role for bilirubin, because possible confounding variables may exist.

Bilirubin in body fluids

About 4% of bilirubin in normal plasma is conjugated, but the clinical diazo-based methods overexpress this fraction (see above). In haemolytic jaundice, there is a proportional increase in plasma-unconjugated and -conjugated bilirubin. In contrast, in inherited disorders of bilirubin conjugation, the conjugated bilirubin is absent or reduced in proportion. In biliary obstruction or hepatocellular diseases, both conjugated and unconjugated bilirubin accumulate in plasma. Bilirubin is present in exudates and other albumin-containing body fluids and binds to the elastic tissue of skin and sclera. Haem in subcutaneous haematomas is sequentially converted to biliverdin and bilirubin, resulting in a transition from green to yellow discoloration. Because of tight binding to albumin, unconjugated bilirubin is not excreted in urine in the absence of albuminuria, but conjugated bilirubin, which is less strongly bound to albumin, appears in urine. Bilirubin is present in normal human bile predominantly as diglucuronide, with bilirubin monoglucuronide and unconjugated bilirubin accounting for less than 10% and 1–4% of the pigments respectively. In the presence of reduced bilirubin glucuronidating capacity of the liver, as in Gilbert syndrome and Crigler–Najjar syndrome type 2 (see Chapter 16.6), the proportion of bilirubin monoglucuronide increases to 30% or above. In addition to the glucuronides, small amounts of glucosyl, xylosyl and mixed conjugates of bilirubin are found in human bile.

Disposition of bilirubin

Disposition of bilirubin by hepatocytes comprises several specific steps, including transport of bilirubin to hepatocytes from sites of production, uptake by and storage within hepatocytes, enzyme-catalysed conjugation with glucuronic acid, active transport into the bile canaliculus and degradation in the intestinal tract. These steps are summarized in Figure 3 and discussed briefly below.

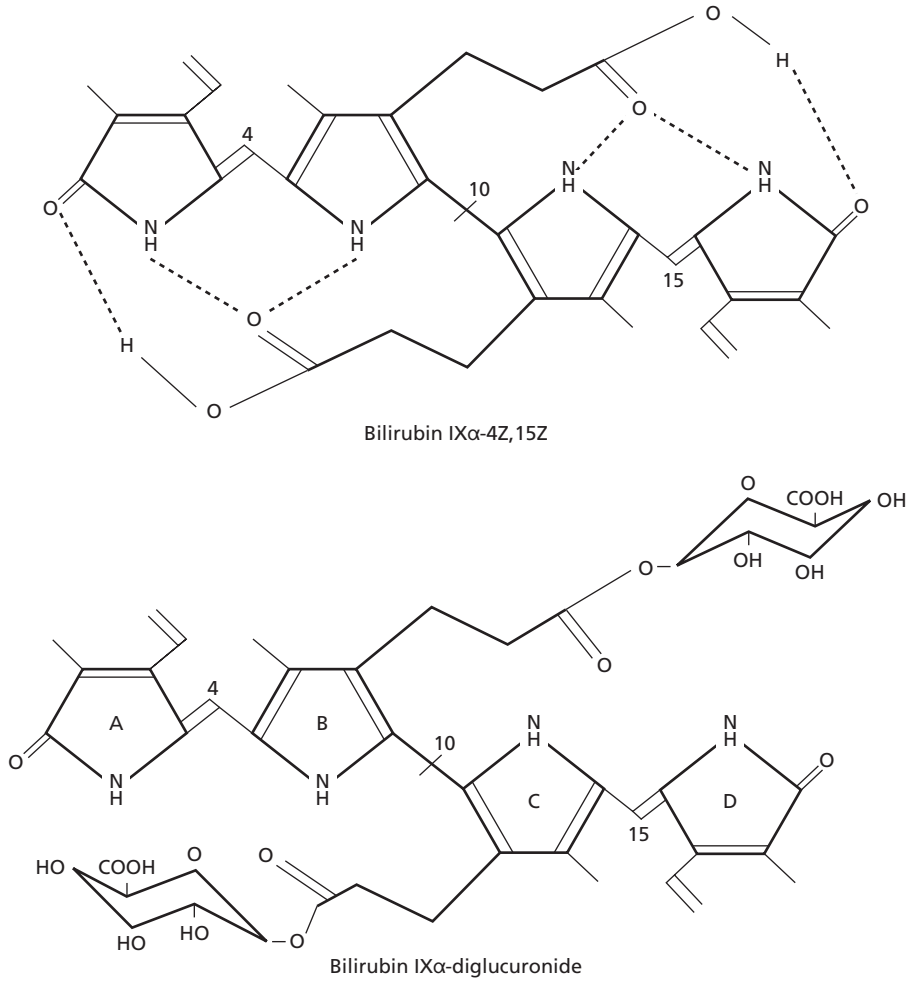

Fig. 3 Glucuronidation disrupts internal hydrogen bonding of bilirubin. Glucuronidation of the propionic acid carboxyl groups results in disruption of the internal hydrogen bonds, making the molecule more polar and secretable in bile. Disruption of hydrogen bonding exposes the central CHH bridge to diazo reagents, whereby bilirubin glucuronides give the direct van den Bergh reaction.

Transport in plasma

Unconjugated bilirubin circulates in plasma bound tightly but reversibly to albumin, which prevents its excretion in urine, except during albuminuria. Albumin binding keeps bilirubin in solution and abrogates its toxic effects. Conjugated bilirubin is bound less tightly to albumin, and the unbound fraction is excreted in the urine. As mentioned above, during prolonged conjugated hyperbilirubinaemia, a fraction of conjugated bilirubin becomes irreversibly bound to albumin. This fraction, termed delta-bilirubin, is not excreted in the bile or urine and disappears slowly, reflecting the long half-life of albumin [22]. A small unbound fraction of unconjugated bilirubin is thought to be responsible for its toxicity [42]. Albumin has one high-affinity primary binding site for bilirubin. Additional sites are occupied when bilirubin is in molar excess. Normal plasma concentration of albumin (500–700 μmol/L) exceeds that of bilirubin (3–17 μmol/L). However, during exaggerated neonatal jaundice and in patients with Crigler–Najjar syndrome, the molar concentration of unconjugated bilirubin may exceed that of albumin. Hypoalbuminaemia resulting from inflammatory states, chronic malnutrition or liver disease may precipitate bilirubin toxicity. Sulphonamides, anti-inflammatory drugs, cholecystographic contrast media, fusidic acid, azapropazone, sodium caprylate and N-acetyl tryptophan displace bilirubin from albumin and increase the risk of kernicterus in jaundiced infants [43]. Binding of short-chain fatty acids to albumin causes conformational changes, decreasing bilirubin binding. Because of its pathophysiological importance, various methods have been devised to measure the unbound fraction of bilirubin and the reserve albumin binding capacity. These include ultrafiltration, ultracentrifugation, gel chromatography, affinity chromatography on albumin agarose polymers, dialysis and electrophoresis. Rapid degradation of unbound bilirubin by H_2O_2 and horseradish peroxidase has been used to distinguish it from the bound fraction.

Uptake by hepatocytes

At the sinusoidal surface of the hepatocyte (Fig. 4), bilirubin dissociates from albumin and is taken up by the hepatocyte by facilitated diffusion that requires inorganic anions, such as Cl^-. The protein(s) involved in sinusoidal bilirubin uptake have not been identified. A member of the organic anion transport protein family, termed OATP2 (also termed SLC21A6), has been proposed as the sinusoidal bilirubin transporter [44], but its importance in bilirubin transport has been questioned [45].

Storage within the liver cell

After entering the hepatocyte, bilirubin binds to the major cytosolic proteins, glutathione-*S*-transferases (GSTs, formerly designated ligandin or Y-protein). The GST proteins, which constitute 5% of the liver cytosol, bind various drugs, hormones, organic anions [46], a cortisol metabolite [47] and azo-dye carcinogens [48]. Bilirubin is a ligand for GSTs, but not a substrate for glutathione transfer. Binding to GSTs reduces the efflux of bilirubin from hepatocytes, thereby increasing its net uptake (Fig. 4). GST binding inhibits non-specific diffusion of bilirubin into various subcellular compartments, thereby preventing specific organellar toxicity, such as inhibition of mitochondrial respiration by bilirubin that is seen *in vitro* [49].

Conjugation of bilirubin

Conversion of unconjugated bilirubin to bilirubin diglucuronide or monoglucuronide by esterification of both or one of the propionic acid carboxyl groups is critical for efficient biliary excretion of bilirubin (Fig. 4).

Bilirubin uridine diphosphoglucuronate glucuronosyltransferase

Bilirubin is one of the many endogenous and exogenous substrates whose conjugation with glucuronic acid is mediated by one or more isoform of uridine diphosphoglucuronate glucuronosyltransferase (UGTs). UGTs are enzymes concentrated in the endoplasmic reticulum (ER) and nuclear envelope of many cell types [50]. They catalyse the transfer of the glucuronic acid moiety of UDP-glucuronic acid to the aglycone substrates, forming polar and usually less bioreactive products. Bilirubin glucuronidation is catalysed predominantly by a single UGT isoform, UGT1A1 [51]. The UGT superfamily of genes comprises two major families, UGT1 and UGT2. Nine isoforms within the UGT1A subfamily are expressed from a series of exons clustered in a unique manner on chromosome 2 at the 2q37 region [61]. Four consecutive exons (exons 2–5) located at the 3′ end of the UGT1A locus are used in nine different mRNAs. These encode the identical carboxy-terminal domains of these UGT isoforms, which contain the UDP-glucuronic acid binding site. Upstream of these four common region exons is a series of unique exons, each preceded by a separate promoter. Only one of these exons is utilized in a specific UGT mRNA. The unique exon encodes the variable N-terminal domain of the nine different UGT isoforms that impart aglycone specificity to the individual isoforms. Depending on which promoter is used, transcripts of various lengths are generated. In all cases, the unique exon, located at the 5′ end of the transcript, is spliced to exon 2, and the intervening sequence is spliced out. The genes are named according to the unique first exon. Thus, UGT1A1 utilizes the unique exon 1A1, UGT1A6 utilizes exon 1A6, etc. [53].

The presence of a separate promoter upstream from each unique region exon permits differential regulation of individual UGT isoforms during development and in response to inducing agents. UGT1A1 is expressed after birth [54] and is induced by phenobarbital and clofibrate [55]. Delayed expression of UGT1A1 is a major cause of neonatal hyperbilirubinaemia in primates. Treatment of rats with triiodothyronine markedly

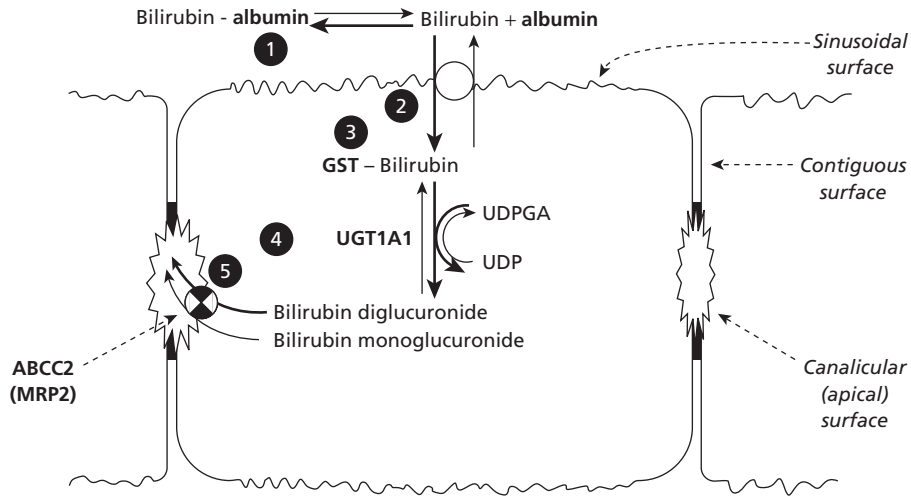

Fig. 4 Bilirubin throughput by hepatocytes. Bilirubin is transported from sites of production to hepatic sinusoids bound to albumin (1). At the sinusoidal surface of hepatocytes, bilirubin dissociates from albumin and enters hepatocytes by facilitated diffusion (2). Binding to cytosolic glutathione-*S*-transferases (GSTs) increases net uptake of bilirubin by inhibiting its efflux (3). Bilirubin is converted to mono- and diglucuronide by the action of UGT1A1, which catalyses the transfer of the glucuronic acid moiety from UDP-glucuronic acid (UDPGA) to bilirubin (4). Bilirubin glucuronides are actively transported into bile against a concentration gradient by the ATP-utilizing pump ABCC2 (also termed MRP2) (5).

reduces UGT activity towards bilirubin, whereas the activity towards 4-nitrophenol is increased [56].

In humans, the expression of UGT1A1 is limited to hepatocytes and, to a lesser extent, the proximal small intestine. UGTs are integral to ER membranes. In addition to the enzyme content, UGT1A1 activity is affected by the lipids of the ER membrane. UGT activity in native microsomal vesicles is latent [57], probably because the ER membranes pose a barrier to the polar sugar donor UDP-glucuronic acid or as a result of the constraint of the enzyme by the membranes. Based on hydrophobicity analysis, the major portion of mature UGT molecules, including the UDP-glucuronic acid and the aglycone binding sites, is thought to be located within the ER cisternae. There is a single 17-amino-acid membrane-spanning segment and a 26-amino-acid cytoplasmic tail at the carboxy-terminal end of the molecule. Full enzyme activity is manifested *in vitro* by treatment of the microsomes with membrane-permeabilizing agents, such as digitonin or alamethacin. UDP-N-acetylglucosamine (UDP-glucNac) stimulates the internalization of UDP-glucoronic acid into intact microsomal vesicles and is thought to be the natural activator of UGTs within hepatocytes. UGT1A1 forms homodimers within the ER membrane, which may be required for its full catalytic activity [58]. In addition, it may interact with other UGT isoforms, as well as other proteins of the ER.

Canalicular excretion of conjugated bilirubin

Conjugated bilirubin undergoes unidirectional transport into the bile against a concentration gradient, so that bilirubin concentration in the bile can be as high as 150-fold that in the hepatocyte. The electrochemical gradient of –35 mV, generated by the sodium pump, may help in the canalicular transport but, by itself, is too small to account for this large concentration gradient. The energy for the uphill transport of bilirubin and many other non-bile salt organic anions is derived from adenosine triphosphate (ATP) hydrolysis by the canalicular ATP-binding cassette protein, ABCC2 [also termed the MDR-related protein 2 (MRP2) or the multispecific organic anion transporter, MOAT]. ABCC2 pumps glutathione-, glucuronic acid- or sulphate-conjugated compounds across the canalicular membrane [59,60]. Canalicular transport of organic anions is unidirectional from the cytoplasm of the hepatocyte into the bile. Canalicular transport may be assisted by the membrane potential, but the contribution of membrane potential in organic anion transport has not been quantified. Mutant animals that lack ATP-dependent canalicular transport of non-bile acid organic anions retain normal activity with respect to potential-driven canalicular transport of non-bile acid organic anions, including bilirubin glucuronides [60]. The ATP-dependent canalicular organic anion transport is mediated by a canalicular membrane protein, termed canalicular multispecific organic anion transporter (cMOAT) or MRP2 [61].

Maximal bilirubin secretory capacity (Tmax) into the bile canaliculus depends on bile flow, which has bile salt-dependent and non-bile salt-dependent components. Bile acids increase the trafficking of vesicles containing MRP2 and the bile salt export pump (BSEP) from the Golgi apparatus to the apical domain of hepatocyte plasma membranes, thereby increasing the concentration of the transporters in the canalicular membrane [61].

Fate of bilirubin in the gastrointestinal tract

Although conjugated bilirubin is not substantially absorbed from the intestines, a fraction of the small amount of unconjugated bilirubin that is excreted in bile is absorbed and undergoes enterohepatic circulation. In situations in which increased amounts of unconjugated bilirubin are excreted in bile, such as e.g. during phototherapy for neonatal jaundice or Crigler–Najjar syndrome, absorption of unconjugated bilirubin from the intestine may be clinically significant [62]. In these cases,

interruption of bilirubin reabsorption by ingestion of various substances, including calcium salts, can enhance the effect of phototherapy [63].

Degradation of bilirubin by intestinal bacteria generates urobilinogen and related products [64]. A major portion of the urobilinogen reabsorbed from the intestine is excreted in bile, but a small fraction is excreted in urine. Urobilinogen is colourless; its oxidation product, urobilin, contributes to the colour of normal urine and stool. During severe intrahepatic cholestasis or complete obstruction of the bile duct, urobilinogen and urobilin are absent in urine and stool, resulting in pale (so-called clay-coloured) stool. In liver disease and states of increased bilirubin production, urinary urobilinogen excretion is increased.

Alternative routes of bilirubin elimination

In the absence of bilirubin glucuronidation, a fraction of bilirubin is excreted as hydroxylated products [65], probably by the action of microsomal P450s [66] and mitochondrial bilirubin oxidase in liver [67] and other tissues.

During intrahepatic or extrahepatic cholestasis, conjugated bilirubin accumulates in plasma. In total biliary obstruction, renal excretion becomes the major pathway of bilirubin excretion [68]. Renal excretion of conjugated bilirubin depends on glomerular filtration of the non-protein-bound fraction of conjugated bilirubin.

References

1 Chen TS, Chen PS (1984) *Understanding the Liver. A History*. Westport, CT: Greenwood Press, p. 99.

2 London IM, West R, Shemin D *et al.* (1950) On the origin of bile pigment in normal man. *J Biol Chem* 184, 351–358.

3 Schwartz S, Johnson JA, Stephenson BD *et al.* (1971) Erythropoietic defects in protoporphyria: a study of factors involved in labelling of porphyrins and bile pigments from ALA-^{3}H and glycine-^{14}C. *J Lab Clin Med* 78, 411–434.

4 Robinson SH (1977) Origins of the early-labeled peak. In: Berk PD, Berlin NI (eds) *Bile Pigments: Chemistry and Physiology*. Washington, DC: US Government Printing Office, pp. 175–188.

5 Come SE, Shohet SB, Robinson SH (1974) Surface remodeling vs. whole-cell hemolysis of reticulocytes produced with erythroid stimulation or iron deficiency anemia. *Blood* 44, 817–830.

6 Tenhunen R, Marver HS, Schmid R (1969) Microsomal heme oxygenase: characterization of the enzyme. *J Biol Chem* 244, 6388–6394.

7 Elbirt KK, Bonkovsky HL (1999) Heme oxygenase: recent advances in understanding its regulation and role. *Proc Assoc Am Phys* 111, 438–447.

8 Ishizawa S, Yoshida T, Kikuchi G (1983) Induction of heme oxygenase in rat liver. *J Biol Chem* 258, 4220–4225.

9 Hayashi S, Takamiya R, Yamaguchi T *et al.* (1999) Induction of heme oxygenase-1 suppresses venular leukocyte adhesion elicited by oxidative stress: role of bilirubin generated by the enzyme. *Circ Res* 85, 663–671.

10 Tenhunen R, Ross ME, Marver HS *et al.* (1970) Reduced nicotinamide-adenine dinucleotide phosphate dependent biliverdin reductase: partial purification and characterization. *Biochemistry* 9, 298–303.

11 Jones EA, Bloomer JR, Berk PD *et al.* (1977) Quantitation of hepatic bilirubin synthesis in man. In: Berk PD, Berlin NI (eds) *Bile Pigments: Chemistry and Physiology*. Washington, DC: US Government Printing Office, pp. 189–205.

12 Berk PD, Rodkey FL, Blaschke TF *et al.* (1974) Comparison of plasma bilirubin turnover and carbon monoxide production in man. *J Lab Clin Med* 83, 29–37.

13 Westlake DW, Roxburgh JM, Talbot G (1961) Microbial production of carbon monoxide from flavinoids. *Nature* 189, 510–511.

14 Kappas A, Drummond GS, Henschke C *et al.* (1995) Direct comparison of tin-mesoporphyrin, an inhibitor of bilirubin production, and phototherapy in controlling hyperbilirubinemia in term and near-term newborns. *Pediatrics* 95 (4), 468–474.

15 Valaes T, Petmezaki S, Henschke C *et al.* (1994) Control of jaundice in preterm newborns by an inhibitor of bilirubin production: studies with tin-mesoporphyrin. *Pediatrics* 93 (1), 1–11.

16 Berk PD, Jones EA, Howe RB *et al.* (1980) Disorders of bilirubin metabolism. In: Bondy PK, Rosenberg LE (eds) *Metabolic Control and Disease*, 8th edn. Philadelphia: Saunders, p. 1009.

17 Grandchamp B, Bissel DM, Licko V *et al.* (1981) Formation and disposition of newly synthesized heme in adult rat hepatocytes in primary cultures. *J Biol Chem* 256, 11677–11683.

18 Fischer H, Plieninger H (1942) Synthese des biliverdins (uteroverdins) und bilirubins der biliverdine XIII, und III, sowie der Vinulneoxanthosaure. *Hoppe Seyler Z Physiol Chem* 274, 231.

19 Bonnett R, Davis E, Hursthouse MB (1976) Structure of bilirubin. *Nature* 262 (5566), 327–328.

20 Compernolle F, Van Hees GP, Blanckaert N *et al.* (1978) Glucuronic acid conjugates of bilirubin-IXalpha in normal bile compared with post-obstructive bile. Transformation of the 1-O-acylglucuronide into 2-, 3-, and 4-O-acylglucuronides. *Biochem J* 171, 185–201.

21 Jansen PL (1981) β-Glucuronidase-resistant bilirubin glucuronides in cholestatic liver disease – determination of bilirubin metabolites in serum by means of high-pressure liquid chromatography. *Clin Chim Acta* 110, 309–317.

22 Lauff JJ, Kasper ME, Ambros RT (1983) Quantitative liquid chromatographic estimation of bilirubin species in pathological serum. *Clin Chem* 29, 800–805

23 McDonagh AF, Palma LA, Lightner DA (1982) Phototherapy for neonatal jaundice. Stereospecific and regiospecific photoisomerization of bilirubin bound to human serum albumin and NMR characterization of intramolecularly cyclized photoproducts. *J Am Chem Soc* 104, 6867.

24 Itho S, Onishi S (1985) Kinetic study of the photochemical changes of (ZZ)-bilirubin IX bound to human serum albumin. Demonstration of (EZ)-bilirubin IX as an intermediate in photochemical changes from (ZZ)-bilirubin IX to (EZ)-cyclobilirubin IX. *Biochem J* 226, 251–258.

25 McDonagh AF (1975) Thermal and photochemical reactions of bilirubin IX. *Ann NY Acad Sci* 244, 553–569.

26 Onishi S, Itho S, Kawade N *et al.* (1980) An accurate and sensitive analysis by high pressure liquid chromatography of conjugated and unconjugated bilirubin IXa and in various biological fluids. *Biochem J* 185, 281–284.

27 Spivak W, Carey MC (1985) Reverse-phase h.p.l.c. separation, quantification and preparation of bilirubin and its conjugates from native bile. *Biochem J* 225, 787–805.

28 Roy Chowdhury J, Roy Chowdhury N (1982) Quantitation of bilirubin and its conjugates by high pressure liquid chromatography. *Falk Hepatol* 11, 1649–1650.

29 Blanckaert N, Kabra PM, Farina FA *et al.* (1980) Measurement of bilirubin and its mono- and diconjugates in human serum by alkaline methanolysis and high performance liquid chromatography. *J Lab Clin Med* 96, 198–212.

30 Schumacher RE, Thornbery JM, Gutcher GR (1985) Transcutaneous bilirubinometry: a comparison of old and new methods. *Pediatrics* 76 (1), 10–14.

31 Schiff D, Chan G, Poznasky MJ (1985) Bilirubin toxicity in neural cell lines N115 and NBR10A. *Pediatr Res* 19 (9), 908–911.

32 Mustafa MG, Cowger ML, King TE (1969) Effects of bilirubin on mitochondrial reactions. *J Biol Chem* 244 (23), 6403–6414.

33 Sano K, Nakamura H, Tamotsu M (1985) Mode of inhibitory action of bilirubin on protein kinase C. *Pediatr Res* 19 (6), 587–590.

34 Vaughan VC, Allen FC, Diamond LK (1950) Erythroblastosis fetalis. IV. Further observations on kernicterus. *Pediatrics* 6, 706.

35 Gourley GR (1997) Bilirubin metabolism and kernicterus. *Adv Pediatr* 44, 173–229.

36 Odell GB (1973) Influence of binding on the toxicity of bilirubin. *Ann NY Acad Sci* 226, 225–237.

37 Lee K-S, Gartner LM (1983) Management of unconjugated hyperbilirubinemia in the newborn. *Semin Liver Dis* 3 (1), 52–64.

38 Breimer LH, Wannamethee G, Ebrahim S *et al.* (1995) Serum bilirubin and risk of ischemic heart disease in middle-aged British men. *Clin Chem* 41, 1504–1508.

39 Bosma PJ, van der Meer, IM, Bakker CT *et al.* (2003) UGT1A1*28 allele and coronary heart disease: the Rotterdam Study. *Clin Chem* 49, 1180–1181.

40 Zucker SD, Horn PS, Serman KE (2004) Serum bilirubin levels in the U.S. population: gender effect and inverse correlation with colorectal cancer. *Hepatology* 40, 827–835.

41 Temme EHM, Zhang J, Schouten EG *et al.* (2001) Serum bilirubin and 10-year mortality risk in a Belgian population. *Cancer Causes Control* 12, 887–894.

42 Bowen WR, Porter E, Waters WF (1959) The protective action of albumin in bilirubin toxicity in new born puppies. *Am J Dis Child* 98, 568–573.

43 Brodersen R (1986) Aqueous solubility, albumin binding and tissue distribution of bilirubin. In: Ostrow JD (ed.) *Bile Pigments and Jaundice*. New York: Marcel Dekker, pp. 157–181.

44 Cui Y, Konig J, Leier I *et al.* (2000) Hepatic uptake of bilirubin and its conjugates by the human organic anion-transporting polypeptide 2 (symbol SLC21A6). *J Biol Chem* 276, 9626–9630.

45 Wang P, Kim RB, Roy-Chowdhury J *et al.* (2003) Organic anion transport protein SLC21A6 (OATP2) is not sufficient for bilirubin transport. *J Biol Chem* 278 (23), 20695–20696

46 Levi AJ, Gatmaitan Z, Arias IM (1969) Two hepatic cytoplasmic protein fractions, Y and Z, and their possible role in the hepatic uptake of bilirubin, sulfobromophthalein, and other anions. *J Clin Invest* 48, 2156–2167.

47 Morey KS, Litwack G (1969) Isolation and properties of cortisol metabolite binding proteins of rat liver cytosol. *Biochemistry* 8, 4813–4821.

48 Ketterer B, Ross-Mansell P, Whitehead JK (1967) The isolation of carcinogen-binding protein from livers of rats given 4-dimethylaminoazobenzene. *Biochem J* 103, 316–324.

49 Kamisaka K, Gatmaitan Z, Moore CL *et al.* (1975) Ligandin reverses bilirubin inhibition of liver mitochondrial respiration in vitro. *Pediatr Res* 9 (12), 903–905.

50 Roy Chowdhury J, Novikoff PM, Roy Chowdhury N *et al.* (1985) Distribution of uridinediphosphoglucuronate glucuronosyl transferase in rat tissues. *Proc Natl Acad Sci USA* 82, 2990–2994.

51 Bosma PJ, Seppen J, Goldhoorn B *et al.* (1994) Bilirubin UDP-glucuronosyltransferase 1 is the only relevant bilirubin glucuronidating isoform in man. *J Biol Chem* 269 (27), 17960–17964

52 Ritter JK, Chen F, Sheen YY *et al.* (1992) A novel complex locus UGT1 encodes human bilirubin, phenol and other UDP-glucuronosyltransferase isozymes with identical carboxy termini. *J Biol Chem* 267 (5), 3257–3261.

53 Mackenzie PI, Owens IS, Burchell B *et al.* (1997) The UDP glucosyltransferase gene superfamily: recommended nomenclature update based on evolutionary divergence. *Pharmacogenetics* 7 (4), 255–269.

54 Wishart GJ (1978) Functional heterogeneity of UDP-glucuronosyl transferase as indicated by its differential development and inducibility by glucocorticoids. *Biochem J* 174 (2), 485–489.

55 Roy Chowdhury J, Roy Chowdhury N, Moscioni AD *et al.* (1983) Differential regulation by triiodothyronine of substrate-specific uridinediphosphoglucuronate glucuronyl transferases in rat liver. *Biochim Biophys Acta* 761 (1), 58–65.

56 Lilienblum W, Walli AK, Bock KW (1982) Differential induction of rat liver microsomal UDP-glucuronosyltransferase activities by various inducing agents. *Biochem Pharmacol* 31 (6), 907–913.

57 Bossuyt X, Blanckaert N (1997) Carrier-mediated transport of uridine diphosphoglucuronic acid across the endoplasmic reticulum membrane is a prerequisite for UDP-glucuronosyltransferase activity in rat liver. *Biochem J* 323, 645–648.

58 Ghosh SS, Sappal BS, Ganjam VK *et al.* (2001) Homodimerization of human bilirubin-uridine-diphosphoglucuronate glucuronosyltransferase-1 (UGT1A1) and its functional implications. *J Biol Chem* 276, 42108–42115

59 Ishikaowa T, Muller M, Klunemann C *et al.* (1990) ATP-dependent primary active transport of cysteinyl leukotrienes transport system for glutathione S-conjugates. *J Biol Chem* 265 (31), 19279–19286.

60 Nishida T, Gatmaitan Z, Roy-Chowdhury J *et al.* (1992) Two distinct mechanisms for bilirubin glucuronide transport by rat bile canalicular membrane vesicles. *J Clin Invest* 90 (5), 2130–2135.

61 Gatmaitan ZC, Nies AT, Arias IM (1997) Regulation and translocation of ATP-dependent apical membrane proteins in rat liver. *Am J Physiol* 272, G1041–G1049.

62 Brodersen R, Herman LS (1963) Intestinal reabsorption of unconjugated bilirubin. A possible contributing factor in neonatal jaundice. *Lancet* 1, 1242.

63 Van der Veere CN, Jansen PL, Sinaasappel M *et al.* (1997) Oral calcium phosphate: a new therapy for Crigler–Najjar disease? *Gastroenterology* 112, 455–462.

64 Watson CJ (1977) The urobilinoids: milestones in their history and some recent developments. In: Berk PD, Berlin NI (eds) *Bile Pigments: Chemistry and Physiology*. Washington, DC: US Government Printing Office, pp. 469–482.

65 Berry CS, Zarembo JE, Ostrow JD (1972) Evidence for conversion of bilirubin to dihydroxyl derivatives in the Gunn rat. *Biochem Biophys Res Commun* 49 (5), 1366–1375.

66 Kapitulnik J, Ostrow JD (1978) Stimulation of bilirubin catabolism in jaundiced Gunn rats by an inducer of microsomal mixed function mono oxygenases. *Proc Natl Acad Sci USA* 75 (2), 682–685.

67 Cardenas-Vazquez R, Yokosuka O *et al.* (1986) Enzymic oxidation of unconjugated bilirubin by rat liver. *Biochem J* 236 (3), 625–633.
68 Cameron JL, Filler RM, Iber FL *et al.* (1966) Metabolism and excretion of 1^4C-labeled bilirubin in children with biliary atresia. *N Engl J Med* 274 (5), 231–236.

2.3.6 Metabolism of bile acids

Peter L.M. Jansen and Klaas Nico Faber

Introduction

Bile acids are synthesized in the liver from cholesterol; they are secreted in bile and stored in the gallbladder. After a meal, the gallbladder contracts, and stored bile is transferred to the duodenum and via the jejunum to the ileum. This movement is stimulated by intestinal propulsion. In the ileum, 90–95% of bile salts are reabsorbed and returned to the liver. The remainder is lost to the colon, where primary bile salts are transformed by bacterial metabolism into secondary bile salts. Some of the secondary bile salts are also reabsorbed, and the rest is removed with the faeces. Primary and secondary bile salts return to the liver via the portal circulation. In the liver, bile salts are taken up into hepatocytes, thereby completing the enterohepatic cycle.

Bile acids serve a number of functions: (i) they are the main solutes in bile and, as such, they are important for the generation of the so-called bile salt-dependent bile flow; (ii) bile salts are indispensable for the secretion of cholesterol and phospholipids from the liver; (iii) in bile, bile salts form mixed micelles that keep fat-soluble organic compounds in solution, including fat-soluble vitamins; (iv) in the intestine, bile salts promote the dissolution and hydrolysis of triglycerides by pancreatic enzymes; (v) bile salts act as signalling molecules in the regulation of enzymes and transporters of drug and intermediary metabolism.

The adult human liver produces about 500 mg of bile acids per day [1,2]. About three times this amount represents the total bile acid pool size that cycles through the enterohepatic circulation [2]. Bile acids complete an enterohepatic cycle about eight times per day. Enterohepatic cycling represents an efficient system for reusage of active components. Enterohepatic cycling not only serves to reclaim bile acids, but it also enables bile acids to act as messengers that carry signals from intestine to liver. Thus, they regulate their own synthesis and transport rates. Bile acids are also able to repress hepatic fatty acid and triglyceride synthesis [3,4].

Biosynthesis and metabolic defects

At least 16 different enzymes are involved in the biosynthesis of bile salts [1,5,6]. Most of these enzymes are active in the neutral (or classic) and acidic (or alternative) pathways, the two main routes for the conversion of cholesterol to the primary bile acids cholic acid (CA) and chenodeoxycholic acid (CDCA) (Fig. 1). The neutral pathway starts with the hydroxylation of the sterol nucleus of cholesterol by 7α-hydroxylase (CYP7A1) in the endoplasmic reticulum. CYP7A1 is regarded as the rate-limiting enzyme in bile acid biosynthesis, exemplified by the fact that mice deficient for Cyp7a1 have a 75% reduced bile acid pool size causing vitamin deficiencies, lipid malabsorption and liver failure [7–9]. The acidic pathway starts with the hydroxylation of the cholesterol side-chain by sterol 27-hydroxylase (CYP27). The CYP27 product, 5-cholesten-3β-27-diol, is not a substrate for CYP7A1, but is hydroxylated at the C7 position by an alternative P450 enzyme, CYP7B1. From here on, the neutral and acidic pathways largely overlap. Double hydroxylated CDCA and triple hydroxylated CA are the principal bile acids. Their ratio depends on the activity of sterol 12α-hydroxylase (CYP8B1). Bile acid synthesis is completed in hepatocyte peroxisomes, where bile acid coenzyme A:amino acid N-acyltransferase (BAAT) conjugates either taurine or glycine to CA or CDCA. At least 95% of the bile acid pool is generated through these two pathways. Extensive intracellular transport of bile acid intermediates occurs between various organelles. Transport in and out of these organelles may be mediated by transport proteins, but these have not been characterized in detail yet.

Bile acid synthesis defects (BASD) are rare genetic disorders that are the underlying cause of approximately 2% of persistent cholestasis in infants (see also Chapter 16.10, Genetic cholestatic diseases). BASDs are recognized by the absence or reduction of normal primary bile salts in serum and/or urine. Instead, non-typical bile acids and sterols are often detected in the body fluids of these patients. These can be identified by fast atom bombardment ionization–mass spectrometry (FAB-MS) and gas chromatography–mass spectrometry (GC-MS). Disease-causing mutations have been identified in 9 out of the 16 bile acid biosynthesis enzymes (Table 1). Cholestasis is a common clinical presentation of these diseases. The associated liver diseases may vary from mild to life-threatening but, in many cases, can be managed by replacement of deficient primary bile salts. This not only leads to restoration of normal bile function, but also induces feedback inhibition on the production of toxic bile acid intermediates.

Patients with CYP7A1 deficiency have a markedly reduced bile acid synthesis rate [10]. Symptoms include hyperlipidaemia, premature vascular disease and gallstones. A mutation in the *CYP7A* gene that results in truncation of the enzyme has been detected in these patients. Only one case of CYP7B1 deficiency has been reported to date [11]. This child produced no primary bile acids, and serum concentrations of the toxic 27α-hydroxy cholesterol were increased. A mutation was identified in the *CYP7B1* gene that truncates and inactivates the enzyme. In addition, it was found that expression of CYP7A, at both the mRNA and activity level, was absent. Bile acid treatment was ineffective, suggesting that the biosynthesis of toxic 27α-hydroxy cholesterol cannot be suppressed.

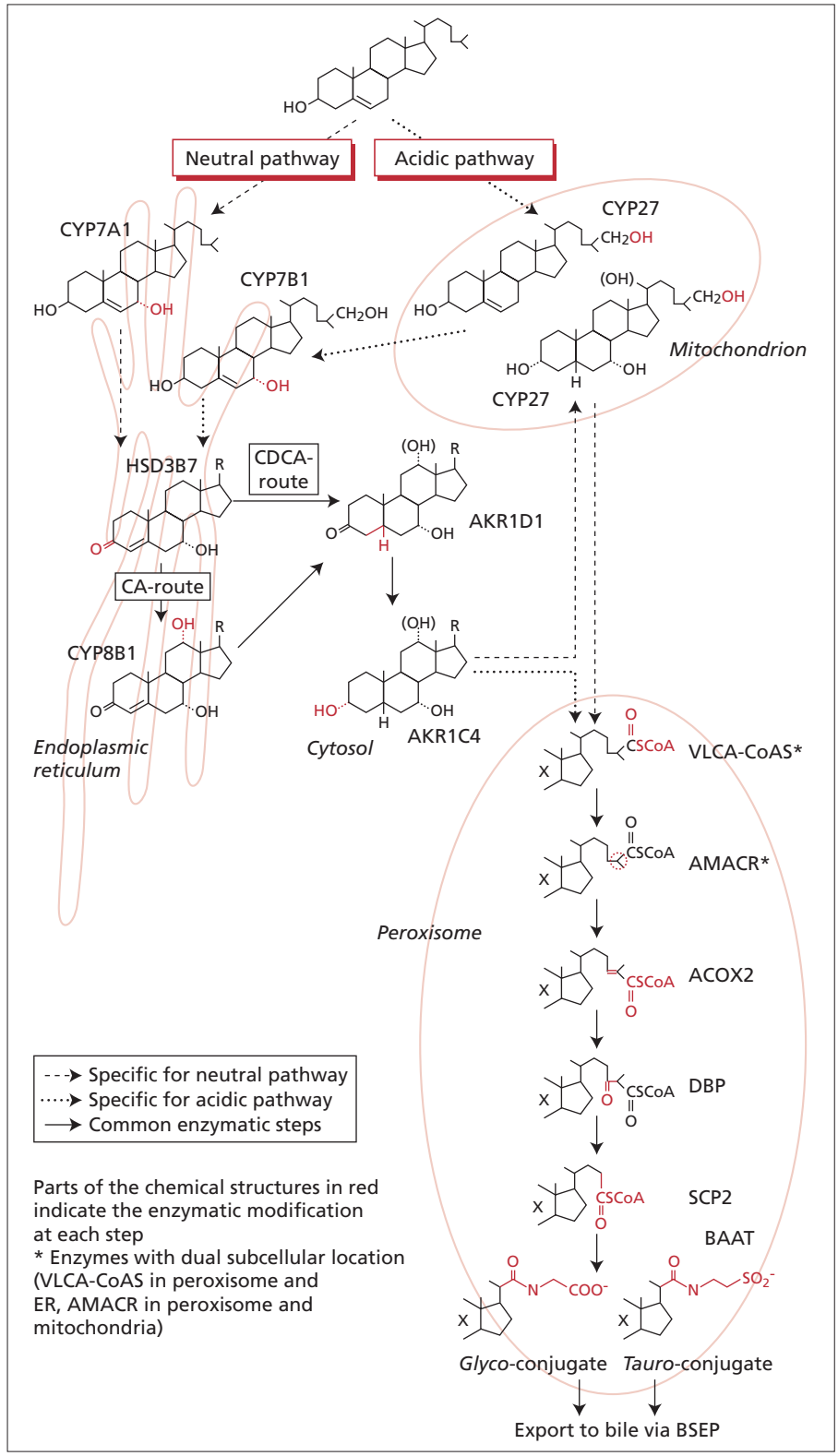

Fig. 1 Biosynthesis of bile acids in the liver. AMACR, α-methylacyl-CoA racemase; BSEP, bile salt export pump; ER, endoplasmic reticulum.

Table 1 Enzymes of the neutral and acidic pathways of bile acid synthesis.

Enzyme	Abbreviation	Mw	Tissue	Organelle	Disease symptoms	Mouse knock-out [ref.]
Cholesterol 7α-hydroxylase	CYP7A1	57 660	Liver	ER	Hypercholesterolemia, premature gallstone disease, NH	[7,8]
Sterol 27-hydroxylase	CYP27A1	56 900	Many	Mito	CTX; progressive CNS neuropathy, cholestanol and bile alcohol accumulation	[65]
Oxysterol 7α-hydroxylase	CYP7B1	58 255	Many, liver enriched	ER	Hyperoxysterolaemia, NLF	[66]
3β-hydroxy-Δ^5-C_{27} steroid oxidoreductase	HSD3B7	40 929	Many	ER	NLF, hepatotoxic bile acid intermediate accumulation	
Sterol 12α-hydroxylase	CYP8B1	58 078	Liver	ER	ND	
Δ^4-3-oxosteroid 5β-reductase	AKR1D1	37 377	Many	Cytosol	NLF, hepatotoxic bile acid intermediate accumulation	
3α-hydroxysteroid dehydrogenase	AKR1C4	37 095	Many	Cytosol	ND	
Bile acid CoA synthetase	BACS	70 312		ER/Perox	ND	
Very long-chain acyl-coenzyme A synthetase	VLCA-CoAS					
Alpha-methylacyl-CoA racemase 2-methylacyl-CoA racemase	AMACR	42 359	Liver Kidney	Perox/Mito	Adult onset sensory motor neuropathy, neonatal liver disease, pristanic acid accumulation	
Branched-chain acyl CoA oxidase	ACOX2	76 826	Many	Perox	Nd	
D-bifunctional enzyme	DBP	79 686	Many	Perox	Hypotonia, liver enlargement, developmental defects, pristanic acid/C_{27} bile acid accumulation	[67]
Thiolase 2 sterol carrier protein-2/sterol carrier protein-x	SCP2 SCPx	58 993	Liver enriched	Perox	ND	[68] [69]
Bile acid CoA: amino acid N-acyltransferase	BAAT	46 296	Liver only	Perox	Familial hypercholanaemia, fat malabsorption, vitamin K deficiency	
Enzymes of alternative routes						
Cholesterol 24-hydroxylase	CYP46A1	56 821	Brain	ER	ND	
Cholesterol 25-hydroxylase	CH25H	31 700	Many	ER	NH with fibrosis	Cited in ref. 1
Oxysterol 7α-hydroxylase	CYP39A1	54 129	Many	ER	ND	Cited in ref. 1

Mito, mitochondrion; ER, endoplasmic reticulum; Perox, peroxisome; CTX, Cerebrotendinous xanthomatosis; ND, no disease; NLF, neonatal liver failure; NH, neonatal hepatitis.

Mutations in the gene encoding 3β-hydroxy C_{27}-steroid dehydrogenase/isomerase (3βHSD) represent the most common disorders of bile acid biosynthesis [12–16]. Clinical manifestations may start at any age and include cholestasis, fat malabsorption, vitamin deficiency, pruritus and poor growth. Urine and plasma bile acid levels are high and consist of abnormal conjugates of the unoxidized precursors di- and tri-hydroxy-Δ-5-cholenic acids. These abnormal bile acids are poorly transported across the canalicular membrane and interfere with the adenosine triphosphate (ATP)-dependent transport of cholic acid. 3βHSD deficiency can be treated successfully by administration of primary bile acids. Patients with Δ^4-3-oxosteroid 5β reductase deficiency (AKR1D1) present with neonatal cholestasis [17,18]. Urine and serum levels of primary bile acids were low but Δ^4-3-oxo bile acid concentrations were elevated. Administration of primary bile acids constitutes successful therapy in these patients. Treatment by ursodeoxycholic acid is not sufficient, probably because this bile acid does not feedback to inhibit bile acid synthesis and thus does not prevent the production of hepatotoxic Δ^4-3-oxo bile acids.

Cerebrotendinous xanthomatosis (CTX) is caused by a deficiency of mitochondrial CYP27 [19,20]. CTX is a slowly progressive chronic disease characterized by early dementia and xanthomata. Bile acid synthesis is reduced, but the clinical manifestations are caused by the accumulation of cholesterol and cholestenol in the brain. This gradually disrupts the myelin sheets surrounding the neurons. If diagnosed early, CTX can be treated effectively with bile acid therapy. Deficiency of the conjugation enzyme BAAT has been reported to cause familial hypercholanaemia (FHCA). Patients present with high serum bile salt concentrations, fat malabsorption and vitamin K deficiency [21].

The final enzymatic steps of bile acid biosynthesis take place in peroxisomes. Zellweger syndrome (ZS) is a genetic disorder that affects the formation of these organelles. Mutations in over a dozen different genes have been shown to be the molecular cause of ZS or the related disorders neonatal adrenoleucodystrophy and Refsum disease [22]. These genes encode proteins that are involved in transporting newly synthesized enzymes to peroxisomes or are essential for the formation of the peroxisomal membrane. Indirectly, these mutations also affect the enzymes in peroxisomes. This may also affect bile acid synthesis. Patients present with cerebral neuronal migration disorder, craniofacial dysmorphism, psychomotor retardation and chronic liver disease. ZS is generally fatal in the first 2 years of life. Biochemically, these patients are characterized by increased levels of very-long-chain fatty acids, atypical mono-, di- and tri-C_{27} hydroxy bile acids (such as cholestanoic acid) and hyperpipecolic acidaemia.

Hepatic secretion and enterohepatic cycling of bile salts

Although bile salts can diffuse through membranes, hepatocytes and ileal mucosal cells express proteins that efficiently pump bile salts in and out of these cells. The sodium-dependent taurocholate cotransporting polypeptide (NTCP, SLC10A1) is located at the sinusoidal plasma membrane domain of hepatocytes (Fig. 2). The apical sodium-dependent bile salt transporter (ASBT, SLC10A2) is similar to NTCP, but is specifically expressed at the luminal surface of mucosa cells in the ileum [23,24]. These are high-affinity bile salt transport systems that allow the absorption of bile salts from the portal blood or the bowel lumen respectively. Both are sodium dependent with an out-to-in sodium gradient that drives this transport. In

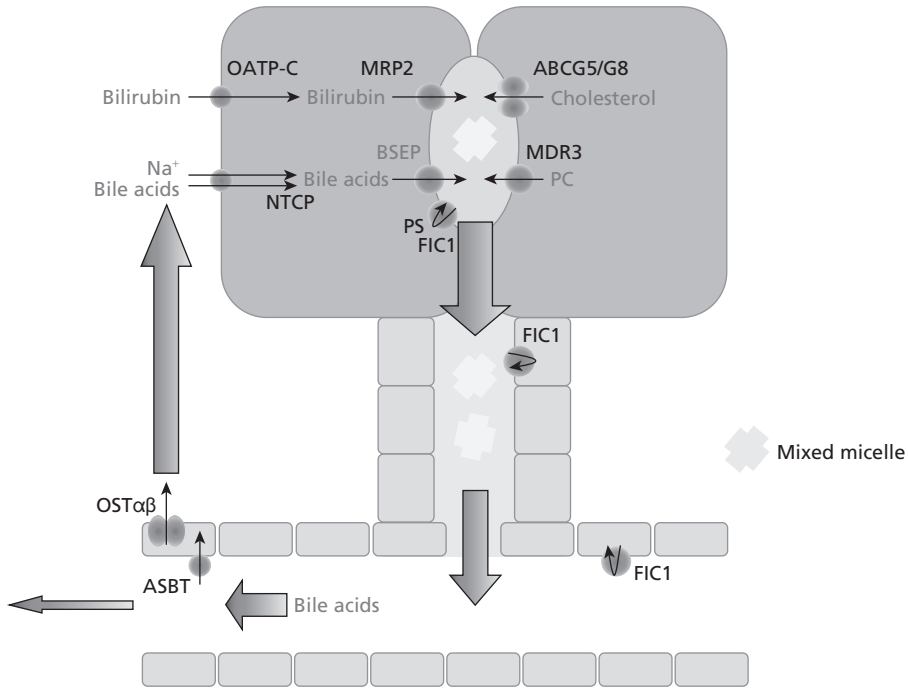

Fig. 2 Transporters involved in bile formation in liver and intestine. PC, phosphatidylcholine; PS, phosphatidylserine; GGT, gamma-glutamyltransferase.

addition, hepatocytes contain other transport proteins that may import bile salts, including the organic anion transporting polypeptide-C (OATP-C, SLC21A6), OATP-A (SLC21A3), OATP-B (SLC21A9) and OATP8 (SLC21A8) [25]. These transporters have a broad substrate specificity, they are bidirectional and do not need sodium for their transport activity. NTCP is believed to be the predominant bile salt transporter responsible for efficient hepatic uptake. Only a small fraction of portal blood bile salts spills over in the general circulation. Even the high bile salt concentrations that enter the portal circulation after a meal are efficiently dealt with by the liver.

No clinically important genetic defects of NTCP have been recognized thus far. In two children with familial hypercholanaemia, NTCP was normal [26]. In acquired forms of cholestasis, such as autoimmune, alcoholic and drug-induced hepatitis, obstructive cholestasis and primary biliary cirrhosis, NTCP levels are reduced [27–29]. This is a meaningful adaptation as it prevents the intracellular accumulation of bile salts.

How bile salts traverse the interior of the hepatocyte is not clear. In the simplest model, bile salts just dissolve in the cytosol. In this model, the cytosolic bile salt concentration is governed by the net balance between passive influx and active efflux. As bile salts are cytotoxic, influx and efflux of bile salts has to be well coordinated in order to avoid accumulation. This calls for a well-organized short-term regulation of influx and efflux transport proteins.

Bile salt secretion from hepatocytes to bile is mediated by the bile salt export pump BSEP (ABCB11). This is a bile salt-specific pump with the highest affinity for tauro- and glycochenodeoxycholic acid [30,31]. However, it also transports taurocholic acid, glycocholic acid and tauroursodeoxycholic acid and even unconjugated bile acids, albeit with lower affinity [31,32]. BSEP is a member of a large family of proteins known as the ATP-binding cassette (ABC) transporters, which have a wide range of transport functions. These proteins use ATP to pump their substrates against steep concentration gradients. This enables BSEP to build up a biliary bile salt concentration into the millimolar range, a concentration well above the critical micellar concentration. Pure bile salt micelles are extremely cytotoxic because of a detergent-like membranolytic activity. This activity has to be neutralized, and this is accomplished by incorporation of phospholipids, cholesterol and other organic molecules.

In the canalicular lumen, bile salt micelles interact with the lumen-facing leaflet of the canalicular membranes that is enriched with phosphatidylcholine and cholesterol [33]. These are extracted into the bile salt micelle and contribute to the formation of the characteristic bile salt–phospholipid–cholesterol mixed micelle. Phospholipid transfer from the inner to the outer leaflet that faces the canalicular lumen is mediated by multidrug-resistant protein 3, MDR3 (ABCB4; in rodents mdr2, abcb4) [34]. Genetic deficiency of MDR3 causes a disease called progressive familial intrahepatic cholestasis (PFIC) type 3 [35,36] (Table 2). In this disease, phospholipid transfer through the canalicular membrane is abrogated, and this results in bile without phospholipids. Bile salt transfer is undisturbed, and the bile that is produced under these conditions is extremely cytotoxic. It damages surrounding hepatocytes and bile duct epithelial cells. Hence, liver histology of these patients shows portal inflammation, bile duct proliferation and periportal fibrosis.

BSEP gene mutations are the cause of PFIC type 2 or benign recurrent intrahepatic cholestasis (BRIC) type 2 (see also Chapter 16.10, Genetic cholestatic diseases). PFIC type 2 is characterized by neonatal hepatitis and persistent cholestasis with malabsorption, stunted growth and haemorrhagic diathesis as a result [37,38]. Patients often present with subdural haematoma in the first months of life. This can be prevented by early vitamin K supplementation. This disease provides proof for the functional importance of BSEP. Less severe defects cause a more benign type of relapsing cholestasis, BRIC type 2 [39].

PFIC type 1 and BRIC type 1 result from mutations of the *FIC1* gene affecting the FIC1 (ATP8B1) protein [40,41]. As an aminophospholipid translocator, malfunction of FIC1 affects the distribution of phosphatidylserine (PS) across the two plasma membrane leaflets. Too much PS in the outer membrane leaflet makes the outer membrane leaflet unstable. *Fic1*–/– mice have excessive outer leaflet-anchored proteins in their bile [42]. How cholestasis develops from FIC1 deficiency is not well understood.

Drug-induced cholestasis is a frequently observed, clinically relevant adverse effect of drugs. A great number of drugs and complementary medication can cause this disease. Many *BSEP*

Table 2 Transport defects.

Transport protein	Abbreviation	Membrane domain	Tissue	Disease symptoms	Mouse knock-out [ref.]
FIC1	ATP8B1	Canalicular	Liver, bile duct, intestine, pancreas	PFIC type 1, cholestasis first episodic later permanent, low GGT; BRIC type 1, episodic cholestasis; intrahepatic cholestasis of pregnancy	[70]
BSEP	ABCB11	Canalicular	Liver	PFIC type 2, permanent cholestasis, low GGT; BRIC type 2, episodic cholestasis	[71]
MDR 3	ABCB4	Canalicular	Liver	PFIC type 3, cholestasis, pruritus, high GGT; intrahepatic cholestasis of pregnancy; intrahepatic cholelithiasis	[34]

gene mutations and polymorphisms have been described [43–46]. However, a relation between these polymorphisms and drug-induced cholestasis or hepatitis remains difficult to prove and, to date, no clear connection between these and drug-induced cholestasis has been established.

The ASBT (SLC10A2) mediates the uptake of bile salts in the terminal ileum and is responsible for the preservation of bile salts in the enterohepatic circulation [24,47]. Mutations that affect the function of this protein cause bile acid-induced diarrhoea [48]. Jejunum also expresses OATP-B. However, OATP-B has a rather narrow substrate specificity and is not a good bile salt carrier [49,50]. Rat jejunum expresses Oatp3 that can serve as alternative transporter for glycine- and taurine-conjugated bile salts.

Organic solute transporter (OST) α and β act as heterodimers and mediate bile salt transport across the serosal membrane, thus allowing bile salt entry into the portal circulation [51]. They are specifically expressed in the ASBT-containing cells of the terminal ileum but also in hepatocytes. ASBT and OSTαβ are responsible for the vectorial transport of bile salts from the intestinal lumen to the portal circulation.

Bile acids as signalling molecules

It has long been known that bile acid synthesis and enterohepatic cycling are highly regulated processes. In recent years, important progress has been made in understanding the molecular mechanism involved in this process, recognizing that bile salts themselves are the crucial signalling molecules.

The nuclear hormone receptors (NHR) belong to a family of proteins that, upon binding an appropriate ligand, can activate or suppress gene expression [52] (see also Chapter 3.4, Cellular cholestasis). Promoter regions of genes contain characteristic nucleotide sequences for binding NHRs. These consist of two hexamers separated by a spacer of 0–8 nucleotides. Class II NHRs function as heterodimers in which the common retinoid X receptor RXRα complexes with a partner that can be farnesoid X receptor (FXR), constitutive androstane receptor (CAR), pregnane X receptor (PXR), the liver X receptor (LXR), the retinoic acid receptor (RAR), the peroxisomal proliferator-activated receptor (PPAR) or the vitamin D receptor (VDR) [53]. These members of the NHR family have received their names from the first ligands identified. Natural and much more potent ligands have been characterized for these NHRs, making their historic names deceptive as they do not reflect their actual function. A typical example is FXR, which is strongly activated by bile acids. NHRs reside either in the nucleus (PXR) or in the cytoplasm and move to the nucleus upon binding a ligand (CAR) [54]. Drugs, bile acids and intermediates of bile acid biosynthesis, the oxysterols, are major ligands for these NHRs. FXR binds bile salts with high affinity and thus serves as a bile acid biosensor. FXR affects a great number of target genes, with an emphasis on genes related to bile acid synthesis and transport, lipid and carbohydrate metabolism.

In the human small intestine, ASBT expression is negatively regulated by bile salts; at high bile salt concentrations, the expression of ASBT is downregulated [55,56]. This is mediated by the FXR-dependent induction of a protein called small heterodimer partner-1 (SHP-1). This protein negatively interferes with the RAR:RXR-dependent transcription of ASBT. Expression of the export proteins OSTαβ is also controlled by FXR [57]. Activation of FXR leads to an increased expression of OSTαβ. Thus, bile acids regulate their own intestinal absorption, and FXR regulation protects ileum cells from high bile salt concentrations.

After intestinal absorption, bile acids are taken up from the portal blood into the liver. Here they also bind and activate FXR, which induces SHP-1 expression. SHP-1 then interferes with LXR-dependent transcription of *CYP7A1* and with RAR:RXR-dependent transcription of *NTCP*, thus reducing bile acid biosynthesis as well as bile acid uptake [52,58]. NTCP is downregulated during cholestasis, and this is caused by SHP-dependent and SHP-independent mechanisms. For the short-term regulation, it is relevant to note that Ntcp is a cAMP-dependent phosphoprotein. This allows the rapid regulation of Ntcp activity by phosphorylation [59].

While hepatic bile acid synthesis and uptake are negatively regulated by FXR, bile acid export is positively regulated. The *BSEP* gene contains a bile acid response element that provides a site for interaction with FXR:RXRα that increases transcription of this gene [60,61]. The combined downstream effects of bile acid-activated FXR results in the protection of hepatocytes against bile acid toxicity. Bile acids and drugs also serve as ligands for PXR, CAR and VDR [62]. The main function of these proteins is to provide protection against bile salt and drug toxicity. They have overlapping ligand specificity and regulate the transcription of an overlapping number of target genes, which includes many members of the cytochrome P450 family and ABC transport proteins. Induction of these proteins allows detoxification by biotransformation and secretion of harmful substances. Proof of these concepts comes from studies with *PXR*–/– and *CAR*–/– knockout mice, which are quite vulnerable to bile salt and drug toxicity [63,64].

Conclusions

Bile acids are important as emulsifiers of fat in the intestine, and an intact enterohepatic cycling of bile salts is indispensable for daily nutrition. Without bile, patients rapidly lose weight and become catabolic. Bile acids are also necessary for the intestinal uptake of fat-soluble vitamins. Therefore, infants with cholestasis often present with haemorrhagic complications due to vitamin K deficiency.

In view of the many proteins associated with bile acid metabolism, it is perhaps not surprising that there are many genetic diseases that affect bile acid biosynthesis or secretion. Cholestasis is a common phenotype in these diseases. A proper admixture of the three main components of bile – bile acids, phospholipids and cholesterol – is needed not only to prevent gallstone formation but also to avoid hepatocyte and bile duct damage. Retention of bile acids due to impaired secretion may

result in hepatocyte injury. However, the liver possesses a number of adaptations that function to prevent the accumulation of bile acids. Liver injury occurs when adaptation fails.

For the treatment of cholestatic liver disease, the repertoire of drugs and interventions is limited. Primary bile salts are used for the treatment of the genetic bile acid synthesis defects. Ursodeoxycholic acid is useful for the treatment of chronic cholestatic liver diseases, in particular primary biliary cirrhosis. Also, patients with intrahepatic cholestasis of pregnancy and patients with MDR3 deficiency benefit from ursodeoxycholic acid treatment. Partial external biliary diversion is a therapeutic option for patients with PFIC types 1 and 2. For severe genetic forms of cholestasis, liver transplantation is a life-saving procedure. Gene therapy and hepatocyte transplantation remain unfulfilled promises. New insights into transcriptional regulation by NHRs offer an opportunity for drug development, and this will be likely to expand the number of drugs available for the treatment of cholestatic liver disease.

References

1 Russell DW (2003) The enzymes, regulation, and genetics of bile acid synthesis. *Annu Rev Biochem* 72, 137–174.

2 Bisschop PH, Bandsma RH, Stellaard F *et al.* (2004) Low-fat, high-carbohydrate and high-fat, low-carbohydrate diets decrease primary bile acid synthesis in humans. *Am J Clin Nutr* 79 (4), 570–576.

3 Chawla A, Repa JJ, Evans RM *et al.* (2001) Nuclear receptors and lipid physiology: opening the X-files. *Science* 294 (5548), 1866–1870.

4 Watanabe M, Houten SM, Wang L *et al.* (2004) Bile acids lower triglyceride levels via a pathway involving FXR, SHP, and SREBP-1c. *J Clin Invest* 113 (10), 1408–1418.

5 Bjorkhem I, Eggertsen G (2001) Genes involved in initial steps of bile acid synthesis. *Curr Opin Lipidol* 12 (2), 97–103.

6 Bove KE, Heubi JE, Balistreri WF *et al.* (2004) Bile acid synthetic defects and liver disease: a comprehensive review. *Pediatr Dev Pathol* 7 (4), 315–334.

7 Ishibashi S, Schwarz M, Frykman PK *et al.* (1996) Disruption of cholesterol 7alpha-hydroxylase gene in mice. I. Postnatal lethality reversed by bile acid and vitamin supplementation. *J Biol Chem* 271 (30), 18017–18023.

8 Schwarz M, Lund EG, Setchell KD *et al.* (1996) Disruption of cholesterol 7alpha-hydroxylase gene in mice. II. Bile acid deficiency is overcome by induction of oxysterol 7alpha-hydroxylase. *J Biol Chem* 271 (30), 18024–18031.

9 Arnon R, Yoshimura T, Reiss A *et al.* (1998) Cholesterol 7-hydroxylase knockout mouse: a model for monohydroxy bile acid-related neonatal cholestasis. *Gastroenterology* 115 (5), 1223–1228.

10 Pullinger CR, Eng C, Salen G *et al.* (2002) Human cholesterol 7alpha-hydroxylase (CYP7A1) deficiency has a hypercholesterolemic phenotype. *J Clin Invest* 110 (1), 109–117.

11 Setchell KD, Schwarz M, O'Connell NC *et al.* (1998) Identification of a new inborn error in bile acid synthesis: mutation of the oxysterol 7alpha-hydroxylase gene causes severe neonatal liver disease. *J Clin Invest* 102 (9), 1690–1703.

12 Clayton PT, Leonard JV, Lawson AM *et al.* (1987) Familial giant cell hepatitis associated with synthesis of 3 beta, 7 alpha-dihydroxy-and 3 beta, 7 alpha, 12 alpha-trihydroxy-5-cholenoic acids. *J Clin Invest* 79 (4), 1031–1038.

13 Ichimiya H, Nazer H, Gunasekaran T *et al.* (1990) Treatment of chronic liver disease caused by 3 beta-hydroxy-delta 5-C27-steroid dehydrogenase deficiency with chenodeoxycholic acid. *Arch Dis Child* 65 (10), 1121–1124.

14 Witzleben CL, Piccoli DA, Setchell K (1992) A new category of causes of intrahepatic cholestasis. *Pediatr Pathol* 12 (2), 269–274.

15 Horslen SP, Lawson AM, Malone M *et al.* (1992) 3 beta-hydroxy-delta 5-C27-steroid dehydrogenase deficiency; effect of chenodeoxycholic acid therapy on liver histology. *J Inherit Metab Dis* 15 (1), 38–46.

16 Jacquemin E, Setchell KD, O'Connell NC *et al.* (1994) A new cause of progressive intrahepatic cholestasis: 3 beta-hydroxy-C27-steroid dehydrogenase/isomerase deficiency. *J Pediatr* 125 (3), 379–384.

17 Setchell KD, Suchy FJ, Welsh MB *et al.* (1988) Delta 4-3-oxosteroid 5 beta-reductase deficiency described in identical twins with neonatal hepatitis. A new inborn error in bile acid synthesis. *J Clin Invest* 82 (6), 2148–2157.

18 Shneider BL, Setchell KD, Whitington PF *et al.* (1994) Delta 4-3-oxosteroid 5 beta-reductase deficiency causing neonatal liver failure and hemochromatosis. *J Pediatr* 124 (2), 234–238.

19 Cali JJ, Hsieh CL, Francke U *et al.* (1991) Mutations in the bile acid biosynthetic enzyme sterol 27-hydroxylase underlie cerebrotendinous xanthomatosis. *J Biol Chem* 266 (12), 7779–7783.

20 Sawada N, Sakaki T, Kitanaka S *et al.* (2001) Structure–function analysis of CYP27B1 and CYP27A1. Studies on mutants from patients with vitamin D-dependent rickets type I (VDDR-I) and cerebrotendinous xanthomatosis (CTX). *Eur J Biochem* 268 (24), 6607–6615.

21 Carlton VE, Harris BZ, Puffenberger EG *et al.* (2003) Complex inheritance of familial hypercholanemia with associated mutations in TJP2 and BAAT. *Nature Genet* 34 (1), 91–96.

22 Depreter M, Espeel M, Roels F (2003) Human peroxisomal disorders. *Microsc Res Tech* 61 (2), 203–223.

23 Meier PJ, Eckhardt U, Schroeder A *et al.* (1997) Substrate specificity of sinusoidal bile acid and organic anion uptake systems in rat and human liver. *Hepatology* 26 (6), 1667–1677.

24 Wong MH, Oelkers P, Craddock AL *et al.* (1994) Expression cloning and characterization of the hamster ileal sodium-dependent bile acid transporter. *J Biol Chem* 269 (2), 1340–1347.

25 Kullak-Ublick GA, Stieger B, Meier PJ (2004) Enterohepatic bile salt transporters in normal physiology and liver disease. *Gastroenterology* 126 (1), 322–342.

26 Shneider BL, Fox VL, Schwarz KB *et al.* (1997) Hepatic basolateral sodium-dependent-bile acid transporter expression in two unusual cases of hypercholanemia and in extrahepatic biliary atresia. *Hepatology* 25 (5), 1176–1183.

27 Kojima H, Nies AT, Konig J *et al.* (2003) Changes in the expression and localization of hepatocellular transporters and radixin in primary biliary cirrhosis. *J Hepatol* 39 (5), 693–702.

28 Zollner G, Fickert P, Silbert D *et al.* (2003) Adaptive changes in hepatobiliary transporter expression in primary biliary cirrhosis. *J Hepatol* 38 (6), 717–727.

29 Zollner G, Fickert P, Zenz R *et al.* (2001) Hepatobiliary transporter expression in percutaneous liver biopsies of patients with cholestatic liver diseases. *Hepatology* 33 (3), 633–646.

30 Gerloff T, Stieger B, Hagenbuch B *et al.* (1998) The sister of P-glycoprotein represents the canalicular bile salt export pump of mammalian liver. *J Biol Chem* 273 (16), 10046–10050.

31 Noe J, Stieger B, Meier PJ (2002) Functional expression of the canalicular bile salt export pump of human liver. *Gastroenterology* 123 (5), 1659–1666.

32 Mita S, Suzuki H, Akita H *et al.* (2005) Vectorial transport of bile salts across MDCK cells expressing both rat Na^+-taurocholate cotransporting polypeptide and rat bile salt export pump. *Am J Physiol Gastrointest Liver Physiol* 288 (1), G159–G167.

33 Crawford AR, Smith AJ, Hatch VC *et al.* (1997) Hepatic secretion of phospholipid vesicles in the mouse critically depends on mdr2 or MDR3 P-glycoprotein expression. Visualization by electron microscopy. *J Clin Invest* 100 (10), 2562–2567.

34 Smit JJ, Schinkel AH, Oude Elferink RP *et al.* (1993) Homozygous disruption of the murine mdr2 P-glycoprotein gene leads to a complete absence of phospholipid from bile and to liver disease. *Cell* 75 (3), 451–462.
35 Deleuze JF, Jacquemin E, Dubuisson C *et al.* (1996) Defect of multidrug-resistance 3 gene expression in a subtype of progressive familial intrahepatic cholestasis. *Hepatology* 23 (4), 904–908.
36 De Vree JM, Jacquemin E, Sturm E *et al.* (1998) Mutations in the MDR3 gene cause progressive familial intrahepatic cholestasis. *Proc Natl Acad Sci USA* 95 (1), 282–287.
37 Strautnieks SS, Bull LN, Knisely AS *et al.* (1998) A gene encoding a liver-specific ABC transporter is mutated in progressive familial intrahepatic cholestasis. *Nature Genet* 20 (3), 233–238.
38 Jansen PL, Strautnieks SS, Jacquemin E *et al.* (1999) Hepatocanalicular bile salt export pump deficiency in patients with progressive familial intrahepatic cholestasis. *Gastroenterology* 117 (6), 1370–1379.
39 van Mil SW, van der Woerd WL, van der Brugge G *et al.* (2004) Benign recurrent intrahepatic cholestasis type 2 is caused by mutations in ABCB11. *Gastroenterology* 127 (2), 379–384.
40 Bull LN, Carlton VE, Stricker NL *et al.* (1997) Genetic and morphological findings in progressive familial intrahepatic cholestasis [Byler disease (PFIC-1) and Byler syndrome]: evidence for heterogeneity. *Hepatology* 26 (1), 155–164.
41 Bull LN, van Eijk MJ, Pawlikowska L *et al.* (1998) A gene encoding a P-type ATPase mutated in two forms of hereditary cholestasis. *Nature Genet* 18 (3), 219–224.
42 Paulusma CC, Groen A, Kunne C *et al.* (2006) Atp8b1 deficiency in mice reduces resistance of the canalicular membrane to hydrophilic bile salts and impairs bile salt transport. *Hepatology* 44 (1), 195–204.
43 Noe J, Kullak-Ublick GA, Jochum W *et al.* (2005) Impaired expression and function of the bile salt export pump due to three novel ABCB11 mutations in intrahepatic cholestasis. *J Hepatol* 43 (3), 536–543.
44 Pauli-Magnus C, Lang T, Meier Y *et al.* (2004) Sequence analysis of bile salt export pump (ABCB11) and multidrug resistance p-glycoprotein 3 (ABCB4, MDR3) in patients with intrahepatic cholestasis of pregnancy. *Pharmacogenetics* 14 (2), 91–102.
45 Hayashi H, Takada T, Suzuki H *et al.* (2005) Two common PFIC2 mutations are associated with the impaired membrane trafficking of BSEP/ABCB11. *Hepatology* 41 (4), 916–924.
46 Wang L, Soroka CJ, Boyer JL (2002) The role of bile salt export pump mutations in progressive familial intrahepatic cholestasis type II. *J Clin Invest* 110 (7), 965–972.
47 Craddock AL, Love MW, Daniel RW *et al.* (1998) Expression and transport properties of the human ileal and renal sodium-dependent bile acid transporter. *Am J Physiol* 274 (1 Pt 1), G157–G169.
48 Wong MH, Oelkers P, Dawson PA (1995) Identification of a mutation in the ileal sodium-dependent bile acid transporter gene that abolishes transport activity. *J Biol Chem* 270 (45), 27228–27234.
49 Kullak-Ublick GA, Ismair MG, Stieger B *et al.* (2001) Organic anion-transporting polypeptide B (OATP-B) and its functional comparison with three other OATPs of human liver. *Gastroenterology* 120 (2), 525–533.
50 Kobayashi D, Nozawa T, Imai K *et al.* (2003) Involvement of human organic anion transporting polypeptide OATP-B (SLC21A9) in pH-dependent transport across intestinal apical membrane. *J Pharmacol Exp Ther* 306 (2), 703–708.
51 Dawson PA, Hubbert M, Haywood J *et al.* (2005) The heteromeric organic solute transporter alpha-beta, Ostalpha–Ostbeta , is an ileal basolateral bile acid transporter. *J Biol Chem* 280 (8), 6960–6968.
52 Chiang JY (2004) Regulation of bile acid synthesis: pathways, nuclear receptors, and mechanisms. *J Hepatol* 40 (3), 539–551.
53 Karpen SJ (2002) Nuclear receptor regulation of hepatic function. *J Hepatol* 36 (6), 832–850.
54 Moore JT, Moore LB, Maglich JM *et al.* (2003) Functional and structural comparison of PXR and CAR. *Biochim Biophys Acta* 1619 (3), 235–238.
55 Neimark E, Chen F, Li X *et al.* (2004) Bile acid-induced negative feedback regulation of the human ileal bile acid transporter. *Hepatology* 40 (1), 149–156.
56 Li H, Chen F, Shang Q *et al.* (2005) FXR-activating ligands inhibit rabbit ASBT expression via FXR-SHP-FTF cascade. *Am J Physiol Gastrointest Liver Physiol* 288 (1), G60–G66.
57 Lee H, Zhang Y, Lee FY *et al.* (2006) FXR regulates organic solute transporter alpha and beta in the adrenal gland, kidney and intestine. *J Lipid Res* 47 (1), 1006–1011.
58 Denson LA, Sturm E, Echevarria W *et al.* (2001) The orphan nuclear receptor, shp, mediates bile acid-induced inhibition of the rat bile acid transporter, ntcp. *Gastroenterology* 121 (1), 140–147.
59 Mukhopadhyay S, Ananthanarayanan M, Stieger B *et al.* (1998) Sodium taurocholate cotransporting polypeptide is a serine, threonine phosphoprotein and is dephosphorylated by cyclic adenosine monophosphate. *Hepatology* 28 (6), 1629–1636.
60 Ananthanarayanan M, Balasubramanian N, Makishima M *et al.* (2001) Human bile salt export pump promoter is transactivated by the farnesoid X receptor/bile acid receptor. *J Biol Chem* 276 (31), 28857–28865.
61 Plass JR, Mol O, Heegsma J *et al.* (2002) Farnesoid X receptor and bile salts are involved in transcriptional regulation of the gene encoding the human bile salt export pump. *Hepatology* 35 (3), 589–596.
62 Handschin C, Meyer UA (2005) Regulatory network of lipid-sensing nuclear receptors: roles for CAR, PXR, LXR, and FXR. *Arch Biochem Biophys* 433 (2), 387–396.
63 Guo GL, Lambert G, Negishi M *et al.* (2003) Complementary roles of farnesoid X receptor, pregnane X receptor, and constitutive androstane receptor in protection against bile acid toxicity. *J Biol Chem* 278 (46), 45062–45071.
64 Stedman CA, Liddle C, Coulter SA *et al.* (2005) Nuclear receptors constitutive androstane receptor and pregnane X receptor ameliorate cholestatic liver injury. *Proc Natl Acad Sci USA* 102 (6), 2063–2068.

2.3.7 Ammonia, urea production and pH regulation

Dieter Häussinger

Ammonia plays a central role in nitrogen metabolism. It is a major byproduct of protein and nucleic acid catabolism, and its nitrogen can be incorporated into urea, amino acids, nucleic acids and many other nitrogenous compounds. Ammonia is present in body fluids as both NH_3 and NH_4^+, and these are in equilibrium according to the equation:

$$NH_3 + H^+ \leftrightarrow NH_4^+$$

The pK_a of this reaction is 9.25, so that at physiological pH there is a great excess of the ionized form. NH_3 can diffuse freely across membranes via aquaporins [1] and NH_4^+ is carried in liver by an active transport system, the RhB glycoprotein [2].

The blood ammonia concentration is normally below 35 μmol/L; this is important as ammonia is neurotoxic at higher concentrations. Excessive cerebral ammonia uptake in hyperammonaemic states leads to astrocytic glutamine accumulation and cerebral oedema, which is important in the pathogenesis of hepatic encephalopathy [3–5].

The liver is the most important site of ammonia metabolism; it removes much of the toxic ammonia presented to it by urea and glutamine synthesis. By doing so, the liver also plays a major role in the metabolic regulation of systemic pH, because hydrogen ions released from NH_4^+ during the synthesis of urea neutralize the excess bicarbonate produced by the breakdown of amino acids (see below).

Urea is electroneutral and is transported across biological membranes by facilitated diffusion. A phloretin-sensitive urea transporter is also present in liver [6], and an aquaglyceroporin, AQP9 [7], and UT-B1 [8] have also been identified as urea transporters in liver. Although urea is not further metabolized by mammalian enzymes, it interferes with the activity of K^+ channels in the plasma membrane [9] and can cause liver cell shrinkage at concentrations found in uraemia. Urea is excreted by the kidney, and is normally present in plasma and body fluids at a concentration of 3.0–6.5 mmol/L.

Sources of ammonia

Whereas urea production takes place largely within the liver, much of the ammonia used in urea synthesis is derived, directly or indirectly, from extrahepatic tissues. Ammonia is released from the intestine and the kidneys, whereas liver, resting muscle, and brain remove ammonia from the blood [10]; 25% of the nitrogen utilized in urea synthesis reaches the liver via the portal vein, from ammonia formed in the small intestine and colon (see below) [10–13]. Most of the nitrogen transported to the liver for incorporation into urea is carried not as ammonia but as amino acids, such as alanine or glutamine (see also Chapter 2.3.3).

Within the liver, glutamate and glutamine are major sources of ammonia. Glutamate is released directly from protein, but more importantly it is formed from other amino acids (except lysine and threonine) released from protein breakdown in aminotransferase reactions. Glutamate is directly formed by deamidation of glutamine, and from proline and histidine. Ammonia is released from glutamate by its oxidative deamination by glutamate dehydrogenase, a mitochondrial enzyme. Glutamate dehydrogenase is present in most tissues, but its activity is highest in the liver.

Amino acids can also be transaminated with glyoxalate to form glycine, which is deaminated by glycine oxidase to yield ammonia; this pathway is thought to be quantitatively important in mammalian ammonia production. Ammonia is generated by the deamidation of glutamine and asparagine and in the histidine lyase reaction. Ammonia is also generated from serine, threonine, cysteine, cystathione and homoserine, in pyridoxal phosphate-dependent deamination reactions, which occur mainly in the liver. Ammonia is also produced by amine oxidases, but the amounts involved are small. In addition, ammonia can be generated from the metabolism of purines and pyrimidines. Most of the ammonia produced from purine nucleotides is derived from adenosine monophosphate (AMP), in a reaction catalysed by adenylate deaminase. This pathway becomes particularly important during exercise when ammonia formation and release from muscle is increased [14].

Ammonia from the intestine

The intestine is a major site of ammonia production. Some 15–30% of the urea synthesized by the liver is degraded by bacterial ureases in the gut, with the liberation of ammonia and carbon dioxide [3,15]. Urea is hydrolysed in the mucosa or the juxtamucosal area of the colon, and to a lesser extent in the small intestine [16]. The ammonia generated in these reactions is completely absorbed and returns to the liver to be converted back to urea. The oral administration of antibiotics, such as neomycin, reduces the bacterial degradation of urea in the intestine [17].

A second source of ammonia from the gut, quantitatively of equal importance, is the intestinal mucosa itself. The small intestine produces a significant quantity of ammonia, which comes primarily from the metabolism of glutamine removed from arterial blood. The fractional glutamine extraction in the human jejunum and ileum is 24% and 9% respectively [18]. The small intestine also produces ammonia from the intraluminal amino acids, alanine, leucine and glutamine, but not from threonine, serine and glycine [19]. Most of the ammonia produced in the colon comes from bacterial degradation of urea and other nitrogenous substances; nonbacterial production accounts for only 10% of the ammonia produced in the colon; in the dog, ammonia produced by the small intestine is approximately equal to that produced in the uncleansed colon [18]. The ammonia from the intestine enters the portal circulation and the ammonia concentration in the portal vein is up to 10-fold greater than elsewhere in the circulation.

Ammonia detoxication by the liver

There are two major pathways for ammonia detoxication by the liver: urea and glutamine synthesis [10–13,20,21]. Both pathways are embedded into a sophisticated structural and functional organization in the liver acinus [10–13,20,21].

Urea production

Approximately 90% of surplus nitrogen in humans enters the urea cycle for irreversible conversion to urea, which is excreted by the kidneys. Approximately 30 g of urea is excreted daily in healthy adults. Using tracer techniques, it has been observed that calculated urea production exceeds urinary urea excretion by about 20–30% [22]. This difference is attributed to extrarenal losses, largely accounted for by the intestinal hydrolysis of urea.

The urea cycle and its enzymes

The urea cycle comprises five enzymes (Fig. 1): carbamoyl-phosphate synthetase I (CPS I), ornithine transcarbamylase (OTC), argininosuccinate synthetase (ASS), argininosuccinate

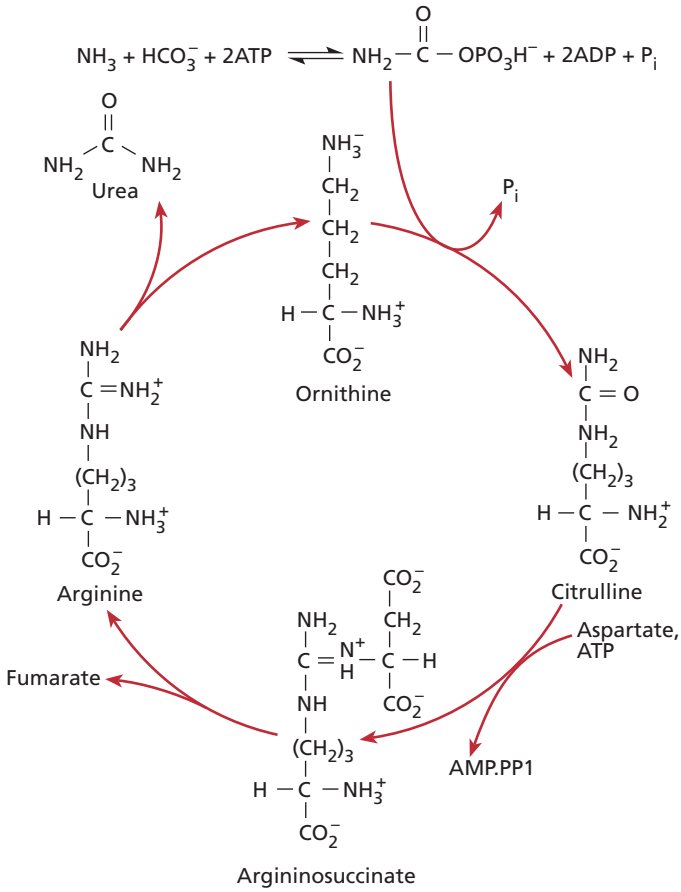

Fig. 1 The urea cycle.

lyase (ASL) and arginase. For efficient functioning of the pathway *in vivo*, however, further proteins are required, such as liver glutaminase [23], mitochondrial carbonic anhydrase V [24], *N*-acetylglutamate synthetase [25], the mitochondrial ornithine/citrulline antiporters ORNT1 and ORNT2 [26,27] and citrin, the mitochondrial aspartate/glutamate antiporter [28].

The liver is quantitatively the major organ involved in urea synthesis and it is doubtful whether other cell types, such as enterocytes, can produce significant amounts of urea [29]. However, at least some urea cycle enzymes are found in extrahepatic tissues, where they are involved in providing arginine for nitric oxide (NO) synthesis (the so-called citrulline–NO cycle) [30].

The initial reaction of the urea cycle is the formation of carbamoyl phosphate from ammonia and bicarbonate (not CO_2), a reaction catalysed by CPS I, which requires *N*-acetylglutamate as an allosteric cofactor. Condensation of carbamoyl phosphate with ornithine yields citrulline (by OTC); this in turn condenses with aspartate to give argininosuccinate (by ASS), a reaction that requires the cleavage of two further high-energy phosphate bonds. Argininosuccinate is hydrolysed to fumarate and arginine (by argininosuccinase). Arginine is cleaved by arginase to give urea and ornithine. OTC, like CPS I, is also a major mitochondrial protein [31]; the remaining enzymes are in the cytoplasm of hepatocytes. This necessitates the entry of ornithine into mitochondria and the exit of citrulline, which is brought about by the ornithine/citrulline transporters ORNT1 and 2.

This series of reactions, returning to ornithine, is known as the 'urea cycle'. It takes part not only in the removal of potentially toxic ammonia, but also in the irreversible removal of bicarbonate [32,33]. Although the arginase reaction is the major fate of arginine in liver, arginine can also be used for NO synthesis or undergo decarboxylation to form agmatine. Agmatinase converts arginine to putrescine and urea; however, the physiological role of this pathway is unclear [34].

Regulation of urea synthesis

Short-term regulation of urea synthesis occurs at the levels of substrate provision and enzyme activities, whereas long-term control is transcriptionally effected by changes in enzyme concentrations. Substrate provision for the urea cycle depends on amino acid delivery, the activity of amino acid transport systems, and amino acid metabolizing enzymes, and these factors are therefore important determinants of urea synthesis *in vivo*. The hepatic ureagenic response in humans is acutely sensitive to the plasma amino-nitrogen concentration, and urea production from an exogenous amino acid load is directly related to the plasma amino-nitrogen concentration, up to at least a concentration of 15 mmol/L [35]. Urea synthesis cannot therefore be saturated at realistic substrate concentrations.

In vitro, ASS seems to be the rate-limiting enzyme of the urea cycle at saturating ammonia concentrations. At physiologically low ammonia concentrations, however, carbamoyl phosphate synthesis is the rate-controlling step in urea synthesis [36].

Short-term regulation of urea synthesis primarily takes place at the level of ammonia and bicarbonate provision for mitochondrial CPS I, which presumably is the rate-controlling enzyme for the cycle at physiological substrate concentrations [11,12,21]. The K_m (NH_4^+) of CPS I is 1–2 mmol/L, that is, far above the portal NH_4^+ concentration of 0.2–0.3 mmol/L. Thus, the urea cycle has a low affinity for ammonia. This low affinity is in part compensated for by mitochondrial glutaminase, which is activated by its own product, ammonia, in the physiological concentration range [37]. This unique feature of liver glutaminase makes this enzyme a mitochondrial amplification system for ammonia, and glutaminase activity becomes an important determinant of urea cycle flux [12,13,21,23]. All factors known to increase urea synthesis, such as glucagon, ammonia, increased amino acid loads or alkalosis, activate glutaminase and accordingly, via amplification, ammonia provision for CPSI. Urea synthesis is also controlled at the level of mitochondrial bicarbonate supply, which is determined by pH, the CO_2 concentration and the activity of mitochondrial carbonic anhydrase V. This enzyme is required for the fast conversion of CO_2 into HCO_3^-, which is the substrate for CPS I. Its inhibition by acetazolamide blocks urea synthesis [24,38].

Short-term increases in ureagenesis are also thought to be mediated via *N*-acetylglutamate, a cofactor that stimulates CPS I activity [39], although its role as a short-term regulator of overall flux through the urea cycle has been disputed [40]. An intraperitoneal injection of a complete amino acid mixture causes rapid activation of ureagenesis. *N*-Acetylglutamate increases fivefold, causing a fivefold increase in the activity of CPS I [41]. Because the half-life of *N*-acetylglutamate in the liver is about 20 min, there is also a rapid response to a reduced protein intake. The concentration of ornithine may also play a role in the regulation of CPS I activity, and of flux through the urea cycle [42].

The activities of CPS I, ASS, and ASL are subject to allosteric regulation by MgATP and free Mg^{2+}. There is no feedback inhibition of the urea cycle by urea within the physiological concentration range. Only at very high urea concentrations is there some inhibition of ASL [43].

In the longer term, there are changes in urea-cycle enzyme expression following alterations in dietary protein [43–46]. Glucagon, insulin and glucocorticoids are major mediators of these responses [47]. When protein intake is increased, there is a proportional increase in the total hepatic content of all five urea-cycle enzymes, resulting in increased urea production. Long-term regulation of urea-cycle enzymes [20] primarily occurs at the level of transcription [48,49], and several proteins associated with the urea cycle such as ORNT1 [26] or glutaminase [50] are regulated in parallel. mRNA levels for CPS I and ASS also increase immediately following partial hepatectomy [51]. Glucagon, which increases during starvation, and glucocorticoids, which increase protein breakdown, are both associated with increased enzyme levels [52] and urea production. Glucagon also regulates urea synthesis by rapid mechanisms, by activation of mitochondrial glutaminase [53], amino acid transport [54], *N*-acetylglutamate synthesis [55], and stimulation of hepatic proteolysis [56]. Insulin probably has no direct effect on urea synthesis, but is a powerful modulator of other known hormonal regulators such as glucagon and a potent inhibitor of liver proteolysis [57], and is therefore still a major regulator of urea synthesis *in vivo*. Hypothyroidism is associated with increased activity of the urea-cycle enzymes in rat liver. There is no change in urea-cycle activity with hyperthyroidism [58], although urea synthesis from infused amino acids increases [59]. Growth hormone lowers urea production, possibly by reducing the supply of nitrogen to the liver [60,61]. Pregnancy and ageing are also associated with reduced urea synthesis [62,63]. Caloric restriction upregulates CPS I and glutaminase [64], whereas reduction in protein intake decreases urea synthesis [65].

Endotoxaemia [66] and interleukin-1 increase urea synthesis from amino acids *in vivo* [67]. In livers from endotoxaemic rats, arginase and nitric oxide synthetase can compete for arginine [68,69]. A short circuit of the urea cycle occurs under these conditions, because arginine is converted directly to citrulline and NO by inducible nitric oxide synthase; however, compared with total urea-cycle flux, this pathway of arginine metabolism is small in the hepatocyte. Flux through this citrulline–NO cycle in nonhepatic tissues is controlled by the expression of arginase and ASS and, like inducible nitric oxide synthase, is primarily regulated by cytokines [30].

Arginine protects against ammonia intoxication by stimulating *N*-acetylglutamate synthetase [70]. Carnitine reduces plasma ammonia and protects against acute ammonia intoxication by increasing urea synthesis [71]. Juvenile visceral steatosis mice with a defect in carnitine transport exhibit decreased expression of urea-cycle enzymes [72]. Here, probably, the accumulation of long-chain fatty acids results in an activated protein (AP)-1-dependent inhibition of the glucocorticoid activation of transcription [73]. In addition, CPS I is irreversibly inhibited by fatty acylation at physiological concentrations of palmitoyl-CoA [74]. Such phenomena provide a link between fatty acid metabolism and urea synthesis.

Drugs may influence urea synthesis. Sodium valproate increases plasma ammonia concentrations and reduces urea synthesis by 30% [75] due to a decrease of CPS I activity, but renal ammoniagenesis is also affected [76]. There is a dose-dependent inhibition of urea synthesis by acetylsalicylic acid.

Studies using isolated perfused liver preparations have shown that the pH of the perfusate influences the rate of urea production [24,77,78]. Such observations are consistent with the hypothesis that the liver plays a central role in the metabolic regulation of systemic pH (see later). Acetazolamide and loop diuretics containing a sulfonamide moiety inhibit the activity of mitochondrial carbonic anhydrase V and act as inhibitors of urea synthesis by impairing bicarbonate supply for carbamoyl phosphate synthesis [79].

Ammonia detoxication by glutamine synthesis

The other major pathway for ammonia fixation in liver is glutamine synthesis. Liver glutamine synthetase is a cytosolic enzyme and its localization in liver is restricted to a small hepatocyte subpopulation at the perivenous end of the liver acinus [23,80]. These cells are free of urea-cycle enzymes [12,21]. Thus, following the direction of sinusoidal blood flow, the two ammonia detoxication systems, urea and glutamine synthesis, are anatomically switched behind each other and present the sequence of a low- and high-affinity system for ammonia detoxication respectively [12,21]. The cells that contain glutamine synthetase have been termed perivenous scavenger cells [81], because they eliminate with high affinity the ammonia that was not used by the upstream urea-synthesizing compartment. They are of crucial importance for the maintenance of nontoxic ammonia levels in the hepatic vein: selective damage of perivenous scavenger cells does not impair upstream urea synthesis, but leads to hyperammonaemia due to a failure of scavenger function [82]. Both *in vivo* and *in vitro*, some 7 to 25% of the ammonia delivered via the portal vein escapes periportal urea synthesis and is used for glutamine synthesis [23,83]. In line

with their specialization to scavenge ammonium by glutamine synthesis, the perivenous scavenger cells strongly express the NH_4^+ transporter RhB glycoprotein [2], ornithine aminotransferase [84] and the glutamate transporter GLT1 [85], and exhibit high-affinity uptake systems for α-ketoglutarate, malate and other dicarboxylates [86,87], which serve as carbon precursors for glutamine synthesis. The mechanisms underlying the strict zonal expression of glutamine synthetase are not settled [88], but may involve an intronic silencer element of the gene [89] and the Wnt/β-catenin pathway [85,90].

Small amounts of glutamine synthetase are also expressed by Kupffer cells [91]. Glutamine synthetase is strongly induced in activated hepatic stellate cells, which may significantly contribute to ammonia detoxication in fibrotic liver injury [92].

Short-term regulation of glutamine synthesis occurs at the level of substrate supply [87] and covalent modifications of the enzyme [93]. Because of the exclusive downstream localization of glutamine synthetase in the liver acinus, flux through the urea cycle in the periportal compartment will determine the amount of ammonia reaching the perivenous scavenger cells. Accordingly, all factors that regulate urea synthesis will indirectly exert control on glutamine synthesis. Also, the availability of carbon skeletons can control the rate of glutamine synthesis.

In vivo, glutamine synthetase activity is downregulated by hypophysectomy [94], endotoxaemia [93] and following portocaval anastomosis [95,96]. Glutamine and cell swelling decrease, whereas insulin and glucocorticoids increase, the levels of glutamine synthetase expression [97–99]. The age-related increase in oxidized protein in the liver and brain is accompanied by a loss of glutamine synthetase activity [100] and acetaminophen inhibits its catalytic activity [101].

The intercellular glutamine cycle and ammonia detoxication [12,13,21]

Whereas glutamine synthetase is localized in perivenous hepatocytes, glutaminase is located in periportal hepatocytes and in the mitochondria together with CPS. Here, glutaminase acts as a pH- and hormone-modulated ammonia amplifier and is an important determinant of urea-cycle flux in view of the physiologically low ammonia concentrations, which are about one order of magnitude lower than the K_m (ammonia) of CPS. Periportal glutaminase and perivenous glutamine synthetase are simultaneously active (the so-called intercellular glutamine cycle) [23]: glutamine utilized for ammonia amplification in periportal hepatocytes is resynthesized in perivenous scavenger cells from the ammonia that escaped upstream urea synthesis (Fig. 2). The regulatory properties of the intercellular glutamine cycle allow the liver to become a net producer or net consumer

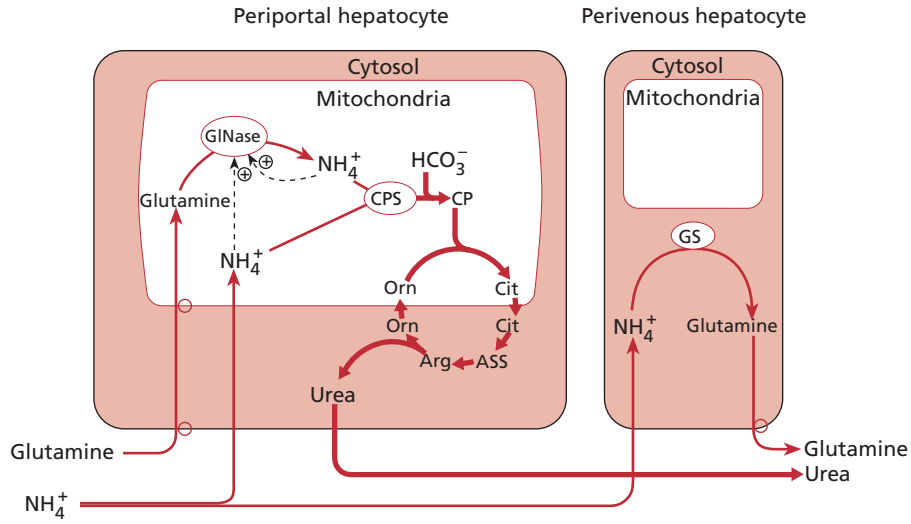

Fig. 2 Structural and functional organization of hepatic ammonia and glutamine metabolism. Periportal hepatocytes contain urea-cycle enzymes and glutaminase, whereas glutamine synthetase is located in perivenous scavenger cells. Urea and glutamine synthesis are anatomically switched behind each other and represent functionally the sequence of a periportal high-capacity, but low-affinity, system and a perivenous high-affinity system for ammonia detoxication. Periportal glutaminase acts as a pH-modulated amplifier of the mitochondrial ammonia concentration and is an important determinant of urea-cycle flux. Ammonia that escapes periportal urea synthesis ('low-affinity system') is disposed of by the perivenous scavenger glutamine synthetase ('high-affinity system'). This guarantees the effective detoxication of ammonia, even when urea-cycle flux is inhibited in acidosis. At normal extracellular pH, glutaminase flux equals glutamine synthetase flux (the so-called 'intercellular glutamine cycle'): portal ammonia is completely converted into urea. In acidosis, glutaminase flux and urea synthesis decrease, whereas glutamine synthetase flux increases due to an increased ammonia delivery to perivenous hepatocytes: the liver switches ammonia detoxication from urea to net glutamine synthesis. From ref. 21.

of glutamine depending on the nutritional and hormonal conditions [53,102]. Intercellular glutamine cycling also provides an effective means to shift hepatic ammonia detoxication from urea to net glutamine synthesis in acidosis.

Urea and ammonia metabolism in liver disease

Urea synthesis is reduced in severe liver disease [103] in parallel with glutamine synthesis [104], and this tends to be correlated with deterioration in other markers of hepatocellular function [105,106]. The metabolic zonation in the human hepatic lobules with respect to urea and glutamine metabolism is preserved in fibrotic lesions, but is lost in cirrhotic nodules [107].

In patients with well-compensated cirrhosis, urea production rates are similar to those of healthy controls under basal conditions, but the maximal urea production capacity in response to a protein or amino acid load is significantly reduced [35,108,109]. Reduction in the maximal capacity for urea production in patients with cirrhosis is due to a decreased activity of all five urea-cycle enzymes [110,111]. Near-normal urea production rates in cirrhosis, despite the reduced capacity of the urea cycle, are in part achieved by increased ammonia amplification due to a 4–5-fold increase in glutaminase activity [104,112,113]. Zinc supplementation speeds up the kinetics of nitrogen conversion from amino acids into urea in those with cirrhosis, but not in healthy individuals [114]. This can be explained by the zinc dependence of several urea-cycle enzymes and carbonic anhydrase V, and zinc deficiency, which is frequently found in cirrhosis.

In patients with liver disease, there is a tendency for blood ammonia levels to rise. The main reason for this is presumably the failure of the liver, because of portosystemic shunting and hepatocellular dysfunction, to remove ammonia from the portal venous blood. Liver cirrhosis is characterized by a severe scavenger cell defect [104], which also occurs after portocaval shunting [95,115]. Intestinal ammonia production is only slightly altered in liver cirrhosis [10], but may increase upon intestinal overgrowth with urease-containing bacteria [116,117]. In the presence of severe liver impairment and portosystemic shunting, skeletal muscle becomes an important organ in ammonia homeostasis [118]. In patients with chronic liver failure, muscle takes up more ammonia and releases much more glutamine than in control subjects [119,120]. The extraction of ammonia from the circulation is significantly less in patients with cirrhosis and muscle wasting [121]. Exercise causes a greater release of ammonia from muscle in patients with cirrhosis than in control subjects [122].

In patients with cirrhosis the blood ammonia, which is already high, may occasionally rise further as a result of gastrointestinal bleeding, renal failure, acid–base disturbances, diuretics and infections. Such infections inhibit perivenous glutamine synthetase, due to an inactivating tyrosine nitration of the enzyme [93].

Urea-cycle disorders [123,124]

Deficiencies in all five urea-cycle enzymes, *N*-acetylglutamate synthetase [125,126] and glutamine synthetase [127] have been described in humans. A genetic defect of ORNT1 leads to the hyperornithinaemia–hyperammonaemia–homocitrullinaemia syndrome [26,27], and citrin mutations can cause adult-onset type 2 citrullinaemia [29] and idiopathic neonatal hepatitis [128]. These disorders are rare and their clinical features are discussed in Chapter 22.1.

pH regulation and the liver [12,21,129,130]

The regulation of the acidity of the extracellular fluid is due primarily to the control of plasma CO_2 and HCO_3^- by the lungs, liver and kidneys. Despite its modest buffer capacity at physiological pH, the bicarbonate buffer is of special interest because the concentrations of its constituents, HCO_3^- and CO_2, can be regulated very effectively. According to the Henderson–Hasselbalch equation:

$$pH = 6.1 + \log[HCO_3^-]/[CO_2]$$

Mechanisms for the maintenance of extracellular pH must keep the $[HCO_3^-]/[CO_2]$ ratio constant. Thus, CO_2 and HCO_3^-, which are continuously generated during the oxidation of energy fuels, need to be eliminated from the body at the same velocity as they are generated metabolically. Whereas the complete oxidation of fat and carbohydrates yields CO_2 and water as the only products and the lungs fulfil the role of regulating P_{CO_2}, the hydrolysis of proteins yields bipolar amino acids, whose complete oxidation generates not only CO_2 and water, but also HCO_3^- and NH_4^+. The latter are derived from the carboxylic and amino/amido moieties of amino acids, respectively, and arise in almost equal amounts. The daily oxidation of 100 g of protein produces about 1 mol of HCO_3^- and 1 mol of NH_4^+. Thus, protein oxidation creates a strong alkali burden for the body, and the major pathway for removal of HCO_3^- is hepatic urea synthesis, which consumes 2 mol of HCO_3^- per mol of urea produced:

$$2NH_4^+ + HCO_3^- \rightleftharpoons NH_2CONH_2 + H^+ + 2H_2O$$

$$HCO_3^- + H+ \rightleftharpoons CO_2 + H_2O$$

$$\text{Summary: } 2NH_4^+ + 2HCO_3^- \rightarrow NH_2CONH_2 + CO_2 + 3H_2O$$

In chemical terms, urea synthesis is an irreversible, energy-driven neutralization of the strong base HCO_3^- by the weak acid NH_4^+, and the average daily excretion of 30 g of urea is equivalent to the disposal of about 1 mol of HCO_3^- per day. Thus, a major function of hepatic urea synthesis is to effect this neutralization, without which the body would otherwise be confronted by a major load of alkali [32]. *In vitro* studies showed a sensitive control of hepatic urea formation by extracellular pH, which establishes a homeostatic feedback control loop between

bicarbonate-consuming urea synthesis and the actual acid–base status. In this respect, it is important that the structural and functional organization of the pathways of ammonia detoxication in the liver acinus uncouples urea synthesis from the vital need to detoxify ammonia [33]. Whenever the pH and/or the HCO_3^- concentration drop in the extracellular space, the liver responds with a decrease of urea synthesis relative to the rate of protein catabolism and oxidation. Consequently, a fraction of the bicarbonate generated during protein breakdown is retained in the body and can be used to correct the underlying acidosis. The efficiency of such a mechanism is high: a 10% inhibition of ureogenesis relative to protein breakdown in acidosis will retain about 100 mmol HCO_3^- per day. In a well-balanced acid–base situation, however, the rate of bicarbonate removal (urea synthesis) from the organism must match the rate of bicarbonate production (protein catabolism) and the regulation of urea-cycle flux appears to be controlled by the rate of protein breakdown only.

pH control of urea synthesis occurs at the level of substrate provision, but not within the urea cycle itself. The mechanisms involved include pH-dependent changes in the NH_3/NH_4^+ ratio, the pH dependence of amino acid transport across the hepatocyte membrane, and the regulatory properties of mitochondrial glutaminase and carbonic anhydrase V. These enzymes adjust in a pH-dependent manner the input of the substrates ammonia and HCO_3^- into the CPS reaction, which is, *in vivo*, the rate-controlling step of urea synthesis. Lowering the extracellular pH from 7.4 to 7.3 already inhibits ammonia formation by liver glutaminase by 70% [33], mainly due to an inhibition of glutamine transport across the plasma and mitochondrial membranes [131]. Uptake across the plasma membrane is accomplished by SN1, which couples glutamine/Na^+ symport to H^+ antiport [132], and these transport characteristics may explain the inhibition of glutamine uptake by periportal cells and simultaneous augmentation of glutamine export from perivenous hepatocytes in acidosis [133]. Also, the uptake of other amino acids into the liver is inhibited in acidosis. This shifts the site of amino acid catabolism from the liver to nonhepatic tissues [134–136]. The other enzyme, mitochondrial carbonic anhydrase V, is also sensitively controlled by pH and plays an important role in providing HCO_3^- inside the mitochondria for CPS [24], because the mitochondrial membrane is impermeable to HCO_3^- but not to CO_2 [137] and the rate of spontaneous (uncatalysed) conversion of CO_2 into HCO_3^- is by far not fast enough to meet the bicarbonate requirements for intramitochondrial biosynthetic pathways [24]. In acidosis, both carbonic anhydrase and glutaminase are inhibited and, consequently, also irreversible bicarbonate consumption and urea synthesis. The regulatory properties of catalysed and uncatalysed intramitochondrial bicarbonate formation also allow discrimination of respiratory from metabolic acidosis, such that urea synthesis is inhibited much more strongly in metabolic than in respiratory acidosis. Even at a normal extracellular pH *in vitro*, the liver can respond to a decrease in buffer capacity of the extracellular HCO_3^-/CO_2 system with an inhibition of urea synthesis and a sparing of bicarbonate.

The structural and functional organization of the pathways of nitrogen metabolism in the liver eliminates the threat of hyperammonaemia, which would otherwise result from an acidosis-induced inhibition of urea synthesis: perivenous scavenger cells maintain ammonia homeostasis by glutamine synthesis when upstream urea synthesis is switched off (Fig. 2). Acidosis shifts hepatic ammonia detoxication from bicarbonate-consuming urea synthesis to net glutamine synthesis, which is the result of both increased perivenous glutamine formation and reduced glutamine consumption at periportal glutaminase. Thus, intercellular glutamine cycling in the liver is an elegant means to adjust ammonia flux into either urea or glutamine depending on the acid–base situation. Glutamine formed by the liver and other organs during acidosis is hydrolysed in the kidney and the NH_4^+ is excreted as such into the urine. This process of so-called renal ammoniagenesis has long been known to be stimulated in acidosis and involves the action of kidney glutaminase, which is regulated by pH in an opposite way to the liver enzyme [138].

Thus, the kidneys function as a spillover for surplus NH_4^+, which cannot be disposed of by urea synthesis [130] (Fig. 3). This renal contribution is critical for the pH-stat function of the liver, because otherwise accumulation of surplus NH_4^+ in the organism, albeit in the form of glutamine, would override the acid–base control of hepatic HCO_3^- elimination by an inadaequate NH_4^+- (or glutamine-)driven stimulation of urea synthesis. With respect to ammonia and HCO_3^- homeostasis, the liver and kidney act as a team and impairment of one organ's function will give rise to acid–base disturbances. It is important to stress that it is the change of urea synthesis relative to protein breakdown that affects the bicarbonate pool in the body, whereas absolute changes of urea synthesis do not allow conclusions on bicarbonate homeostasis unless the rate of protein oxidation is assessed simultaneously. Failure to do so has led in the past to erroneous conclusions.

Clinical consequences [139–141]

Alkalosis is reportedly present in up to 70% of cirrhotic patients, whereas acidosis is found in less than 10%, which is usually a metabolic acidosis [139–141] and follows sepsis, shock and lactate accumulation. In alkalotic cirrhotic patients, the alkalosis was 13–60% metabolic, 20–50% respiratory and 10–30% mixed respiratory/metabolic [139–143]. In fulminant hepatic failure, alkalosis is present in about 75% of patients; in 30% of these cases, the alkalosis is metabolic [140]. Clearly, the acid–base status in patients with liver disease is influenced not only by the severity of liver disease itself, but also by many variables including accompanying morbidities and drugs.

Metabolic alkalosis in cirrhosis is often attributed to potassium deficiency and hyperaldosteronism, particularly as a result of diuretic therapy [144], but it may also be found without these

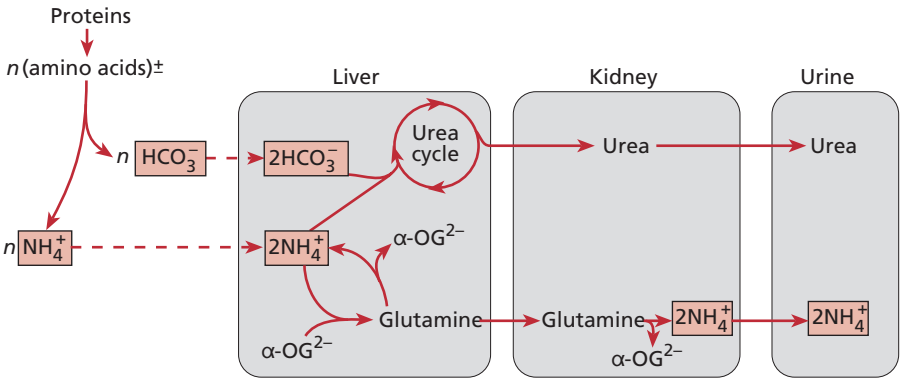

Fig. 3 Coordinated regulation of HCO_3^- and NH_4^+ homeostasis by the liver and kidneys. NH_4^+ and HCO_3^- arise in almost equimolar amounts during protein oxidation. Whereas urea synthesis irreversibly consumes HCO_3^- and NH_4^+ in a 1:1 stoichiometry, HCO_3^- is spared when urea synthesis is switched off in acidosis ('bicarbonate homeostatic response' of the liver). Under these conditions, NH_4^+ homeostasis is maintained by NH_4^+ excretion into urine ('ammonium homeostatic response' of the kidney). A feedback control loop between bicarbonate-consuming urea synthesis and the extracellular pH, $[CO_2]$ and $[HCO_3^-]$ adjusts hepatic HCO_3^- consumption to the needs of acid–base homeostasis. In metabolic acidosis, flux through the urea cycle and hepatic glutaminase is decreased, whereas flux through hepatic glutamine synthetase and renal glutaminase is increased. The coordination of these processes results in NH_4^+ disposal from the organism without concomitant HCO_3^- removal in acidosis. From ref. 79.

factors. Metabolic alkalosis in liver cirrhosis may be the result of an impaired urea synthesis [145], as suggested by an inverse relationship between plasma bicarbonate concentration in humans *in vivo* and the capacity for hepatic urea synthesis *in vitro* [104,112,146]. In view of the relationship between urea synthesis and bicarbonate homeostasis, metabolic alkalosis may not only be seen as a consequence of impaired urea synthesis, but also as representing an important driving force for residual urea synthesis in cirrhosis. This may explain why acidotic episodes can provoke hyperammonaemia in cirrhosis. In view of this, careful attention has to be paid to the acid–base status, and metabolic acidosis requires treatment [147].

The pathogenesis of respiratory alkalosis in cirrhotic patients is less clear, but elevated progesterone and oestradiol levels [148], hypoxaemia and hyperammonaemia may play a role [144,149]. It was hypothesized that hyperventilation and respiratory alkalosis represent a compensatory response of the cirrhotic patient in order to counteract the low-grade cerebral oedema that develops in response to hyperammonaemia and other precipitating factors of hepatic encephalopathy [5].

Although the liver plays a key role in lactate metabolism and lactate levels tend to be moderately elevated, overt lactic acidosis is relatively uncommon in liver disease and is usually found only when there are other factors that would increase lactate production or cause further decreases in hepatic uptake of lactate, such as shock, sepsis and bleeding [144]. In fulminant hepatitis, the development of lactic acidosis is associated with a uniformly high mortality; it has been attributed to tissue hypoxia resulting from arteriovenous shunting, as it occurred in patients with an apparently adequate systemic blood pressure, blood flow and arterial oxygen tension [150].

References

1 Jahn TP, Moller AL, Zeuthen T *et al.* (2004) Aquaporin homologues in plants and mammals transport ammonia. *FEBS Lett* 574, 31–36.
2 Weiner ID, Miller RT, Verlander JW (2003) Localization of the ammonium transporters, Rh B glycoprotein and Rh C glycoprotein, in the mouse liver. *Gastroenterology* 124, 1432–1440.
3 Hawkins RA, Jessy J, Mans AM *et al.* (1993) Effect of reducing brain glutamine synthesis on metabolic symptoms of hepatic encephalopathy. *J Neurochem* 60, 1000–1006.
4 Häussinger D, Laubenberger J, vom Dahl S *et al.* (1994) Proton magnetic resonance spectroscopy studies on human brain myo-inositol in hypo-osmolarity and hepatic encephalopathy. *Gastroenterology* 107, 1475–1480.
5 Häussinger D, Kircheis G, Fischer R *et al.* (2000) Hepatic encephalopathy in chronic liver disease, a clinical manifestation of astrocyte swelling and low-grade cerebral edema? *J Hepatol* 32, 1035–1038.
6 vom Dahl S, Häussinger D (1996) Characterization of phloretin-sensitive urea export from the perfused rat liver. *Biol Chem* 377, 25–37.
7 Carbrey JM, Gorelick-Feldman DA, Kozono D *et al.* (2003) Aquaglyceroporin AQP9, solute permeation and metabolic control of expression in liver. *Proc Natl Acad Sci USA* 100, 2945–2950.
8 Sands JM (2003) Mammalian urea transporters. *Annu Rev Physiol* 65, 543–566.
9 Hallbrucker C, von Dahl S, Ritter M (1994) Effects of urea on K^+ fluxes in perfused rat liver. *Pfluegers Arch Physiol* 428, 552–560.
10 Olde Damink S, Deutz N, Dejong C *et al.* (2002) Interorgan ammonia metabolism in liver failure. *Neurochem Int* 41, 177–188.
11 Meijer AJ, Lamers WH, Chamuleau RAFM (1990) Nitrogen metabolism and ornithine cycle function. *Physiol Rev* 70, 701–748.
12 Häussinger D, Lamers WH, Moorman AFM (1993) Metabolism of amino acids and ammonia. *Enzyme* 46, 72–93.

13 Häussinger D (1998) Hepatic glutamine transport and metabolism. *Adv Enzymol Rec Adv Mol Biol* 72, 43–86.
14 Lowenstein JM (1972) Ammonia production in muscle and other tissues, the purine nucleotide cycle. *Physiol Rev* 52, 382–414.
15 Jones EA, Smallwood RA, Craigie A *et al.* (1969) The enterohepatic circulation of urea nitrogen. *Clin Sci* 37, 825–836.
16 Wolpert E, Phillips SF, Summerskill WH (1971) Transport of urea and ammonia production in the human colon. *Lancet* 2, 1387–1390.
17 Wolpert E, Phillips SF, Summerskill WH (1970) Ammonia production in the human colon. Effects of cleansing, neomycin and acetohydroxamic acid. *N Engl J Med* 283, 159–164.
18 Weber FL, Veach G (1979) The importance of the small intestine in gut ammonium production in the fasting dog. *Gastroenterology* 77, 235–240.
19 Weber FL Jr, Friedman DW, Fresard KM (1988) *Am J Physiol* 254, G264–G268.
20 Morris SM (2002) Regulation of enzymes of the urea cycle and arginine metabolism. *Annu Rev Nutr* 22, 87–105.
21 Häussinger D (1990) Nitrogen metabolism in liver: structural and functional organization and physiological relevance. *Biochem J* 267, 281–290.
22 Walser M, Bodenlos LJ (1959) Urea metabolism in man. *J Clin Invest* 38, 1617–1626.
23 Häussinger D (1983) Hepatocyte heterogeneity in glutamine and ammonia metabolism and the role of an intercellular glutamine cycle during ureogenesis in perfused rat liver. *Eur J Biochem* 133, 269–275.
24 Häussinger D, Gerok W (1985) Hepatic urea synthesis and pH regulation. Role of CO_2, HCO_3^-, pH and the activity of carbonic anhydrase. *Eur J Biochem* 152, 381–386.
25 Beliveau-Carey G, Cheung CW, Cohen NS *et al.* (1993) Regulation of urea and citrulline synthesis under physiological conditions. *Biochem J* 292, 241–247.
26 Camacho JA, Obie C, Biery B *et al.* (1999) Hyperornithinaemia-hyperammonaemia-homocitrullinuria syndrome is caused by mutations in a gene encoding a mitochondrial ornithine transporter. *Nat Genet* 22, 151–158.
27 Camacho JA, Rioseco-Camacho N, Andrade D *et al.* (2003) Cloning and characterization of human ORNT2, a second mitochondrial ornithine transporter that can rescue a defective ORNT1 in patients with the hyperornithinemia-hyperammonemia-homocitrullinuria syndrome, a urea cycle disorder. *Mol Genet Metab* 79, 257–271.
28 Kobayashi K, Sinasac DS, Iijima M *et al.* (1999) The gene mutated in adult-onset type II citrullinaemia encodes a putative mitochondrial carrier protein. *Nat Genet* 22, 159–163.
29 Wu G (1995) Urea synthesis in enterocytes of developing pigs. *Biochem J* 312, 717–723.
30 Husson A, Brasse-Lagnel C, Fairand A *et al.* (2003) Argininosuccinate synthetase from the urea cycle to the citrulline-NO cycle. *Eur J Biochem* 270, 1887–1899.
31 Clarke S (1976) The polypeptides of rat liver mitochondria, identification of a 36, 000 dalton polypeptide as the subunit of ornithine transcarbamylase. *Biochem Biophys Res Comm* 71, 1118–1124.
32 Atkinson DE, Bourke E (1984) The role of ureagenesis in pH homeostasis. *Trends Biochem Sci* 9, 297.
33 Häussinger D, Gerok W, Sies H (1984) Hepatic role in pH regulation, role of the intercellular glutamine cycle. *Trends Biochem Sci* 9, 300–302.
34 Morris SM Jr (2004) Recent advances in arginine metabolism. *Curr Opin Clin Nutr Metab Care* 7, 45–51.
35 Vilstrup H (1980) Synthesis of urea after stimulation with amino acids, relation to liver function. *Gut* 21, 990–995.
36 Meijer AJ, Lof C, Ramos IC *et al.* (1985) Control of ureogenesis. *Eur J Biochem* 148, 189–196.
37 Häussinger D, Sies H (1979) Hepatic glutamine metabolism under the influence of the portal ammonia concentration in the perfused rat liver. *Eur J Biochem* 101, 179–184.
38 Dodgson SJ, Forster RE II (1986) Carbonic anhydrase, inhibition results in decreased urea production by hepatocytes. *J Appl Physiol* 60, 646–652.
39 Shigesada K, Aoyagi K, Tatibana M (1978) Role of acetylglutamate in ureotelism. Variations in acetylglutamate level and its possible significance in control of urea synthesis in mammalian liver. *Eur J Biochem* 85, 385–391.
40 Lund P, Wiggins D (1984) Is N-acetylglutamate a short-term regulator of urea synthesis? *Biochem J* 218, 991–994.
41 Stewart PM, Walser M (1980) Short term regulation of ureagenesis. *J Biol Chem* 255, 5270–5280.
42 Lund P, Wiggins D (1986) The ornithine requirement of urea synthesis. Formation of ornithine from glutamine in hepatocytes. *Biochem J* 239, 773–776.
43 Menyhart J, Grof J (1977) Urea as a selective inhibitor of argininosuccinate lyase. *Eur J Biochem* 75, 405–409.
44 Schimke RT (1962) Differential effects of fasting and protein-free diets on levels of urea cycle enzymes in rat liver. *J Biol Chem* 237, 1921–1924.
45 Schimke RT (1963) Studies on factors affecting the levels of urea cycle enzymes in rat liver. *J Biol Chem* 238, 1012–1018.
46 Snodgrass PJ, Lin RC (1981) Induction of urea cycle enzymes of rat liver by amino acids. *J Nutr* 111, 586–601.
47 Morris SM Jr, Moncman CL, Rand KD *et al.* (1987) Regulation of mRNA levels for five urea cycle enzymes in rat liver by diet, cyclic AMP, and glucocorticoids. *Arch Biochem Biophys* 256, 343–353.
48 Morris SM Jr (1992) Regulation of enzymes of urea and arginine synthesis. *Annu Rev Nutr* 12, 81–101.
49 Takiguchi M, Mori M (1995) Transcriptional regulation of genes for ornithine cycle enzymes. *Biochem J* 312, 649–659.
50 Dhahbi JM, Mote PL, Wingo J *et al.* (1999) Calories and aging alter gene expression for gluconeogenic, glycolytic, and nitrogen-metabolizing enzymes. *Am J Physiol* 277, E352–E360.
51 Tygstrup N, Bak S, Krog B *et al.* (1995) Gene expression of urea cycle enzymes following two-thirds partial hepatectomy in the rat. *J Hepatol* 22, 349–355.
52 Sigsgaard I, Almdal T, Hansen BA *et al.* (1988) Dexamethasone increases the capacity of urea synthesis time dependently and reduces the body weight of rats. *Liver* 8, 193–197.
53 Häussinger D, Gerok W, Sies H (1983) Regulation of flux through glutaminase and glutamine synthetase in isolated perfused rat liver. *Biochim Biophys Acta* 755, 272–278.
54 Fehlmann M, Le Cam A, Freychet P (1979) Insulin and glucagon stimulation of amino acid transport in isolated rat hepatocytes. Synthesis of a high affinity component of transport. *J Biol Chem* 254, 10431–10437.
55 Staddon JM, Bradford NM, McGivan JD (1984) Effects of glucagon *in vivo* on the N-acetylglutamate, glutamate and glutamine contents of rat liver. *Biochem J* 217, 855–857.

56 vom Dahl S, Hallbrucker C, Lang F *et al.* (1991) Regulation of liver cell volume and proteolysis by glucagon and insulin. *Biochem J* 278, 771–777.

57 Hallbrucker C, vom Dahl S, Lang F *et al.* (1991) Inhibition of hepatic proteolysis by insulin. Role of hormone-induced alterations of the cellular K^+ balance. *Eur J Biochem* 199, 467–474.

58 Marti J, Portoles M, Jimenez-Nacher I *et al.* (1988) Effect of thyroid hormones on urea biosynthesis and related processes in rat liver. *Endocrinology* 123, 2167–2174.

59 Marchesini G, Fabbri A, Bianchi GP *et al.* (1989) Hepatic conversion of amino-nitrogen to urea in thyroid diseases. II. A study in hyperthyroid patients. *Metabolism* 43, 1023–1029.

60 Dahms WT, Owens RP, Kalhan SC *et al.* (1989) Urea synthesis, nitrogen balance, and glucose turnover in growth-hormone-deficient children before and after growth hormone administration. *Metabolism* 38, 197–203.

61 Wothers T, Grofte T, Jorgensen JO *et al.* (1994) Effects of growth hormone (GH) administration on functional hepatic nitrogen clearance: studies in normal subjects and GH-deficient patients *J Clin Endocrinol Metab* 78, 1220–1224.

62 Kalhan SC, Tserng KY, Gilfillan C *et al.* (1982) Metabolism of urea and glucose in normal and diabetic pregnancy. *Metabolism* 31, 824–833.

63 Fabbri A, Marchesini G, Bianchi G *et al.* (1994) Kinetics of hepatic amino-nitrogen conversion in ageing man. *Liver* 14, 288–294.

64 Dhahbi JM, Mote PL, Wingo J *et al.* (2001) Caloric restriction alters the feeding response of key metabolic enzyme genes. *Mech Ageing Dev* 122, 1033–1048.

65 Picou D, Phillips M (1972) Urea metabolism in malnourished and recovered children receiving a high or low protein diet. *Am J Clin Nutr* 25, 1261–1266.

66 Nielsen SS, Grofte T, Tygstrup N *et al.* (2005) Effect of lipopolysaccharide on in vivo and genetic regulation of rat urea synthesis. *Liver Int* 25, 177–183.

67 Heindorff H, Almdal T, Vilstrup H (1994) The in vivo effect of interleukin-1 beta on urea synthesis is mediated by glucocorticoids in rats. *Eur J Clin Invest* 24, 388–392.

68 Wettstein M, Gerok W, Häussinger D (1994) Endotoxin-induced nitric oxide synthesis in the perfused rat liver: effects of L-arginine and ammonium chloride. *Hepatology* 19, 641–647.

69 Stadler J, Barton D, Beil-Moeller H *et al.* (1995) Hepatocyte nitric oxide biosynthesis inhibits glucose output and competes with urea synthesis for L-arginine. *Am J Physiol* 268, G183–G188.

70 Kim S, Paik WK, Cohen PP (1972) Ammonia intoxication in rats: protection by N-carbamoyl-L-glutamate plus L-arginine. *Proc Natl Acad Sci USA* 69, 3530–3533.

71 Costell M, O'Connor JE, Miguez MP *et al.* (1984) Effects of L-carnitine on urea synthesis following acute ammonia intoxication in mice. *Biochem Biophys Res Commun* 120, 726–733.

72 Tomomura M, Imamura Y, Horiuchi M (1992) Abnormal expression of urea cycle enzyme genes in juvenile visceral steatosis (jvs) mice. *Biochim Biophys Acta* 1138, 167–171.

73 Tomomura M, Tomomura A, Dewan MA *et al.* (1996) Long-chain fatty acids suppress the induction of urea cycle enzyme genes by glucocorticoid action. *FEBS Lett* 399, 310–312.

74 Corvi MM, Soltys CL, Berthiaume LG (2001) Regulation of mitochondrial carbamoyl-phosphate synthetase 1 activity by active site fatty acylation. *J Biol Chem* 276, 45704–45712.

75 Hjelm M, Oberholzer V, Seakins J *et al.* (1986) Valproate-induced inhibition of urea synthesis and hyperammonaemia in healthy subjects. *Lancet* ii(8511), 859.

76 Marini AM, Zaret BS, Beckner RR (1988) Hepatic and renal contributions to valproic acid-induced hyperammonemia. *Neurology* 38, 365–371.

77 Lueck JD, Miller LL (1970) The effect of perfusate pH on glutamine metabolism in the isolated perfused rat liver. *J Biol Chem* 245, 5491–5497.

78 Häussinger D, Gerok W, Sies H (1986) The effect of urea synthesis on extracellular pH in isolated perfused rat liver. *Biochem J* 236, 261–265.

79 Häussinger D, Kaiser S, Stehle T *et al.* (1986) Liver carbonic anhydrase and urea synthesis. The effect of diuretics. *Biochem Pharmacol* 35, 3317–3322.

80 Gebhardt R, Mecke D (1983) Heterogeneous distribution of glutamine synthetase among rat liver parenchymal cells in situ and in primary culture. *EMBO J* 2, 567–570.

81 Häussinger D, Stehle T (1988) Hepatocyte heterogeneity in response to icosanoids. The perivenous scavenger cell hypothesis. *Eur J Biochem* 175, 395–403.

82 Häussinger D, Gerok W (1984) Hepatocyte heterogeneity in ammonia metabolism: impairment of glutamine synthesis in CCl_4 induced liver cell necrosis with no effect on urea synthesis. *Chem Biol Interact* 48, 191–194.

83 Cooper AJ, Nieves E, Coleman AE *et al.* (1987) Short-term metabolic fate of [^{13}N]ammonia in rat liver in vivo. *J Biol Chem* 262, 1073–1080.

84 Kuo FC, Hwu WL, Valle D *et al.* (1991) Colocalization in pericentral hepatocytes in adult mice and similarity in developmental expression pattern of ornithine aminotransferase and glutamine synthetase mRNA. *Proc Natl Acad Sci USA* 88, 9468–9472.

85 Cadoret A, Ovejero C, Terris B *et al.* (2002) New targets of beta-catenin signaling in the liver are involved in the glutamine metabolism. *Oncogene* 21, 8293–8301.

86 Stoll B, Hussinger D (1989) Functional hepatocyte heterogeneity. Vascular 2-oxoglutarate is almost exclusively taken up by perivenous, glutamine-synthetase-containing hepatocytes. *Eur J Biochem* 181, 709–716.

87 Stoll B, McNelly S, Buscher HP *et al.* (1991) Functional hepatocyte heterogeneity in glutamate, aspartate and alpha-ketoglutarate uptake: a histautoradiographical study. *Hepatology* 13, 247–253.

88 Lie-Venema H, Hakvoort TBM, van Hemert FJ *et al.* (1998) Regulation of the spatiotemporal pattern of expression of the glutamine synthetase gene. *Prog Nucleic Acid Res Mol Biol* 61, 243–308.

89 Gaunitz F, Deichsel D, Heise K *et al.* (2005) An intronic silencer element is responsible for specific zonal expression of glutamine synthetase in the rat liver. *Hepatology* 41, 1225–1232.

90 Ueberham E, Arendt E, Starke M *et al.* (2004) Reduction and expansion of the glutamine synthetase expressing zone in livers from tetracycline controlled TGF-beta1 transgenic mice and multiple starved mice. *J Hepatol* 41, 75–81.

91 Bode JG, Peters-Regehr T, Kubitz R *et al.* (2000) Expression of glutamine synthetase in macrophages. *J Histochem Cytochem* 48, 415–422.

92 Bode JG, Peters-Regehr T, Gressner AM *et al.* (1998) De novo expression of glutamine synthetase during transformation of hepatic stellate cells into myofibroblast-like cells. *Biochem J* 335, 697–700.

93 Görg B, Wettstein M, Metzger S *et al.* (2005) Lipopolysaccharide-induced tyrosine nitration and inactivation of hepatic glutamine synthetase in the rat. *Hepatology* 41, 1065–1073.

94 Wong BS, Chenoweth ME, Dunn A (1980) Possible growth hormone control of liver glutamine synthetase activity in rats. *Endocrinology* 106, 268–274.

95 Girard G, Butterworth RF (1992) Effect of portacaval anastomosis on glutamine synthetase activities in liver, brain, and skeletal muscle. *Dig Dis Sci* 37, 1121–1126.

96 Häussinger D, Lamers WH, Moorman AF (1993) Hepatocyte heterogeneity in the metabolism of amino acids and ammonia. *Enzyme* 46, 72–93.

97 Abcouwer SF, Bode BP, Souba WW (1995) Glucocorticoids regulate rat glutamine synthetase expression in a tissue-specific manner. *J Surg Res* 59, 59–65.

98 Warskulat U, Newsome W, Noe B *et al.* (1996) Anisoosmotic regulation of hepatic gene expression. *Biol Chem* 377, 57–65.

99 Labow BI, Souba WW, Abcouwer SF (2001) Mechanisms governing the expression of the enzymes of glutamine metabolism – glutaminase and glutamine synthetase. *J Nutr* 131, 2467S–2474S.

100 Stadtman ER, Starke-Reed PE, Oliver C *et al.* (1992) Protein modification in aging. *EXS* 62, 64–72.

101 Bulera SJ, Birge RB, Cohen SD *et al.* (1995) Identification of the mouse liver 44-kDa acetaminophen-binding protein as a subunit of glutamine synthetase. *Toxicol Appl Pharmacol* 134, 313–320.

102 Cooper AJ, Nieves E, Rosenspire KC *et al.* (1988) Short-term metabolic fate of 13N-labeled glutamate, alanine, and glutamine(amide) in rat liver. *J Biol Chem* 263, 12268–12273.

103 Rudman D, DiFulco TJ, Galambos JT *et al.* (1973) Maximal rates of excretion and synthesis of urea in normal and cirrhotic subjects. *J Clin Invest* 52, 2241–2249.

104 Kaiser S, Gerok W, Haussinger D (1988) Ammonia and glutamine metabolism in human liver slices: new aspects on the pathogenesis of hyperammonaemia in chronic liver disease. *Eur J Clin Invest* 18, 535–542.

105 Vilstrup H, Bucher D, Krog B *et al.* (1982) Elimination of infused amino acids from plasma of control subjects and of patients with cirrhosis of the liver. *Eur J Clin Invest* 12, 197–202.

106 Vilstrup H, Iversen J, Tygstrup N (1986) Glucoregulation in acute liver failure. *Eur J Clin Invest* 16, 193–197.

107 Racine-Samson L, Scoazec JY, D'Errico A *et al.* (1996) The metabolic organization of the adult human liver: a comparative study of normal, fibrotic, and cirrhotic liver tissue. *Hepatology* 24, 104–113.

108 Rypins EB, Henderson JM, Fulenwider JT *et al.* (1980) A tracer method for measuring rate of urea synthesis in normal and cirrhotic subjects. *Gastroenterology* 78, 1419–1424.

109 Rafoth RJ, Onstad GR (1975) Urea synthesis after oral protein ingestion in man. *J Clin Invest* 56, 1170–1174.

110 Khatra BS, Smith RB III, Millikan WJ (1974) Activities of Krebs-Henseleit enzymes in normal and cirrhotic human liver. *J Lab Clin Med* 84, 708–715.

111 Maier KP, Talke H, Gerok W (1979) Activities of urea-cycle enzymes in chronic liver disease. *Klin Wschr* 57, 661–665.

112 Häussinger D, Steeb R, Gerok W (1990) Ammonium and bicarbonate homeostasis in chronic liver disease. *Klin Wschr* 68, 175–182.

113 Matsuno T, Goto I (1992) Glutaminase and glutamine synthetase activities in human cirrhotic liver and hepatocellular carcinoma. *Cancer Res* 52, 1192–1194.

114 Marchesini G, Fabbri A, Bianchi G *et al.* (1996) Zinc supplementation and amino acid-nitrogen metabolism in patients with advanced cirrhosis. *Hepatology* 23, 1084–1092.

115 Häussinger D, Lamers WH, Moorman AF (1992) Hepatocyte heterogeneity in the metabolism of amino acids and ammonia. *Enzyme* 46, 72–93.

116 Hansen BA, Vilstrup H (1985) Increased intestinal hydrolysis of urea in patients with alcoholic cirrhosis. *Scand J Gastroenterol* 20, 346–350.

117 Lai D, Gorbach SL, Levitan R (1972) Intestinal microflora in patients with alcoholic cirrhosis: urea-splitting bacteria and neomycin resistance. *Gastroenterology* 62, 275–279.

118 Lockwood AH, McDonald JM, Reiman RE *et al.* (1979) The dynamics of ammonia metabolism in man. Effects of liver disease and hyperammonemia. *J Clin Invest* 63, 449–460.

119 Bessman SP, Bessman AN (1955) The cerebral and peripheral uptake of ammonia in liver disease with an hypothesis for the mechanism of hepatic coma. *J Clin Invest* 34, 622–628.

120 Fazekas JF, Ticktin HE, Shea JG (1957) Effect of 1-glutamic acid on metabolism of patients with hepatic encephalopathy. *Am J Med Sci* 234, 145–149.

121 Ganda OP, Ruderman NB (1976) Muscle nitrogen metabolism in chronic hepatic insufficiency. *Metabolism* 25, 427–430.

122 Allen SI, Conn HO (1960) Observations on the effect of exercise on blood ammonia concentration in man. *Yale J Biol Med* 33, 133–144.

123 Bachmann C (2002) Mechanisms of hyperammonemia. *Clin Chem Lab Med* 40, 653–662.

124 Brusilow SW, Horwich AL (2001) Urea cycle enzymes. In: Scriver CR, Beaudet AL, Sly WS *et al.* (eds) *The Metabolic Basis of Inherited Disease*. 8th edn. New York: McGraw Hill, pp. 1909–1963.

125 Caldovic L, Morizono H, Panglao MG *et al.* (2003) Null mutations in the N-acetylglutamate synthase gene associated with acute neonatal disease and hyperammonemia. *Hum Genet* 112, 364–368.

126 Schmidt E, Nuoffer JM, Haberle J *et al.* (2005) Identification of novel mutations of the human N-acetylglutamate synthase gene and their functional investigation by expression studies. *Biochim Biophys Acta* 1740, 54–59.

127 Häberle J, Gorg B, Rutsch F *et al.* (2005) Congenital glutamine deficiency with glutamine synthetase mutations. *N Engl J Med*, 353, 1956–33.

128 Saheki T, Kobayashi K, Iijima M *et al.* (2004) Adult-onset type II citrullinemia and idiopathic neonatal hepatitis caused by citrin deficiency: involvement of the aspartate glutamate carrier for urea synthesis and maintenance of the urea cycle. *Mol Genet Metab* 81, S20–S26.

129 Häussinger D (1988) *pH Homeostasis*. London: Academic Press.

130 Bourke E, Häussinger D (1992) pH homeostasis: the conceptual change. *Contrib Nephrol* 100, 58–88.

131 Lenzen C, Soboll S, Sies H *et al.* (1987) pH control of hepatic glutamine degradation. Role of transport. *Eur J Biochem* 16, 483–488.

132 Fei YJ, Sugawara M, Nakanishi T *et al.* (2000) Primary structure, genomic organization, and functional and electrogenic characteristics of human system N 1, a Na^+- and H^+-coupled glutamine transporter. *J Biol Chem* 275, 23707–23717.

133 Bode BP (2001) Recent molecular advances in mammalian glutamine transport. *J Nutr* 131, 2475S–2485S.

134 Fafournoux P, Demigne C, Remesy C *et al.* (1983) Bidirectional transport of glutamine across the cell membrane in rat liver. *Biochem J* 216, 401–408.

135 Boon L, Blommaart PJ, Meijer AJ *et al.* (1994) Acute acidosis inhibits liver amino acid transport: no primary role for the urea cycle in acid-base balance. *Am J Physiol* 267, F1015–F1020.

136 Christensen HN, Kilberg M (1995) Hepatic amino acid transport primary to the urea cycle in regulation of biologic neutrality. *Nutr Rev* 53, 74–76.
137 Balboni E, Lehninger AL (1986) Entry and exit pathways of CO_2 in rat liver mitochondria respiring in a bicarbonate buffer system. *J Biol Chem* 261, 3563–3570.
138 Curthoys NP, Watford M (1995) Regulation of glutaminase activity and glutamine metabolism. *Annu Rev Nutr* 15, 133–159.
139 Oster JR, Perez GO (1988) Acid–base homeostasis and pathophysiology in liver disease. In: Epstein M (ed.) *The Kidney in Liver Disease*, 3rd edn. Baltimore: Williams & Wilkins, pp. 119–131.
140 Record CO, Iles RA, Cohen RD *et al.* (1975) Acid–base and metabolic disturbances in fulminant hepatic failure. *Gut* 16, 144–149.
141 Dölle W (1965) *Der Säure-Basenstoffwechsel bei Leberzirrhose*. Hüthig Verlag, Heidelberg.
142 Moreau R, Hadengue A, Soupison T *et al.* (1993) Arterial and mixed venous acid-base status in patients with cirrhosis. Influence of liver failure. *Liver* 13, 20–24.
143 Bernardi M, Predieri S (2005) Disturbances of acid-base balance in cirrhosis: a neglected issue warranting further insights. *Liver Int* 25, 463–466.
144 Oster JR, Perez GO (1986) Acid-base disturbances in liver disease. *J Hepatol* 2, 299–306.
145 Guder W, Häussinger D (1987) Renal and hepatic nitrogen metabolism in systemic acid–base regulation. *J Clin Chem Clin Biochem* 25, 457–466.
146 Häussinger D (1990) Organization of hepatic nitrogen metabolism and its relation to acid-base homeostasis. *Klin Wschr* 68, 1096–1101.
147 Häussinger D, Steeb R, Gerok W (1992) Metabolic alkalosis as driving force for urea synthesis in liver disease: pathogenetic model and therapeutic implications. *Clin Investig* 70, 411–415.
148 Lustik SJ, Chhibber AK, Kolano JW *et al.* (1997) The hyperventilation of cirrhosis: progesterone and estradiol effects. *Hepatology* 25, 55–58.
149 Wichser J, Kazemi H (1974) Ammonia and ventilation: site and mechanism of action. *Respir Physiol* 20, 393–406.
150 Bihari D, Gimson AE, Lindridge J *et al.* (1985) Lactic acidosis in fulminant hepatic failure. Some aspects of pathogenesis and prognosis. *J Hepatol* 1, 405–416.

2.3.8 Protein synthesis and degradation in the liver

Armin Akhavan and Vishwanath R. Lingappa

Introduction

The proper physiological function of various organs relies on the expression of biologically active molecules such as antibodies, hormones and neurotransmitters as well as various ligands and receptors, and the signalling and other molecules by which they act. Many of these molecules are proteins, encoded in genes. Some are non-protein molecules (e.g. lipids, sugars and other small molecules such as nitric oxide gas) whose existence requires the action of proteins (e.g. enzymes that are involved in their synthesis). The DNA of the genes encoding these proteins must be transcribed and processed into mRNAs and exported out of the nucleus into the cytoplasm, as a prerequisite for gene expression. This occurs by complex mechanisms that are outside the scope of this review. Once in the cytoplasm, mRNAs can be either quiescent, as a result of binding proteins that prevent their translation into proteins, or actively engaged in making their encoded polypeptides.

One important function of the liver is the synthesis and secretion of a wide range of proteins into the bloodstream, including blood clotting factors and transporter proteins such as lipoproteins and albumin. Another important function is the synthesis and correct localization of integral membrane proteins of the plasma membrane and other compartments. A common feature of these classes of proteins is that their fates are determined very early during translation of the mRNAs in which they are encoded. The nascent chains of these proteins are targeted to the membrane of the endoplasmic reticulum (ER), a specialized intracellular compartment that initiates their journey by subsequent vesicle fission and fusion through the secretory pathway (Fig. 1). Regulatory steps along the way ultimately determine the amount, function and/or localization of these proteins. Some of these steps, such as the initial event of translocation across (for a secretory protein) or integration into (for a membrane protein) the membrane of the ER, are, in their simplest manifestation, irreversible events. However, under certain conditions, these irreversible steps are overcome by cellular machineries that degrade undesired proteins, and thereby end their action. In this chapter, we describe first the fundamentals of early events in mRNA translation and degradation of newly synthesized secretory and membrane proteins. Subsequently, we discuss regulatory mechanisms of protein synthesis and degradation with emphasis on examples relevant to liver function and pathophysiology.

Principles of posttranscriptional gene expression

Translation of mRNA to protein

Translation of mRNA into protein starts by (i) binding of methionyl-tRNA ($tRNA_{Met}$) to the small ribosomal subunit (40S), (ii) recruitment of the complex to mRNA at the first AUG codon and (iii) joining of the large ribosomal subunit (60S) to the mRNA–40S complex. The eukaryotic initiation factors (eIF) are involved in all three steps of translation initiation [1]. Shortly before the start of translation, the eIF2 (composed of α, β and γ subunits) forms a complex with GTP and $tRNA_{Met}$ to facilitate binding to the small ribosomal subunit. The binding of this preinitiation complex, known as the 43S complex, to mRNA is assisted both in *cis* and in *trans*. The *cis* element referred to is the 'cap', a modified guanine nucleotide at the 5′ end of mRNA, which in many cases is critical for the recruitment of 43S by the eIF4 complex [2]. The eIF4 complex is composed of several proteins including: eIF4E, which physically binds the

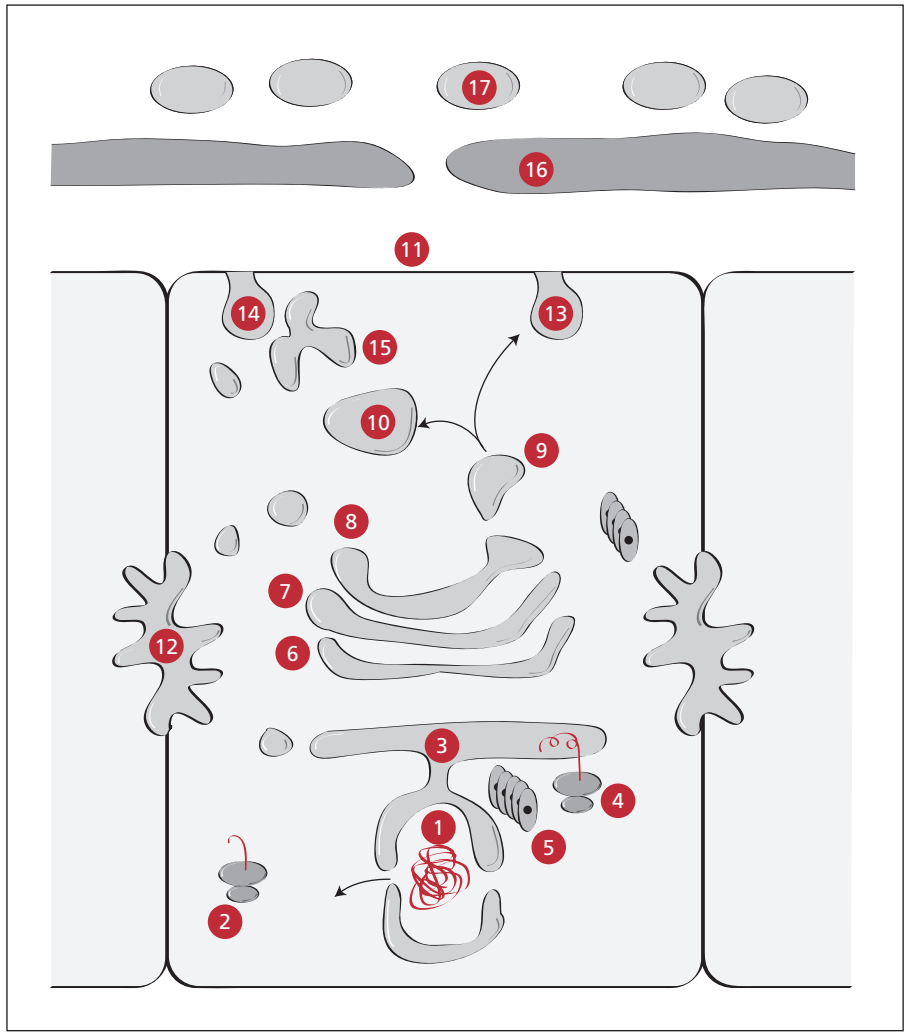

Fig. 1 Synthesis, maturation and degradation of a membrane glycoprotein. A schematic diagram of a hepatocyte is shown indicating numbered key compartments relevant to protein synthesis and degradation. Let us consider the pathway involved in integral membrane protein biogenesis and illustrate the roles of each compartment. First, the mRNA is transcribed, processed and exported from the nucleus (1) via the nuclear pores (see arrow). Translation is initiated in the cytoplasm on free ribosomes (2) in the cytosol. Secretory and integral membrane protein nascent chains are targeted to the ER (3) via the signal recognition particle (SRP), which binds the signal sequence and is released upon interaction with the SRP receptor at the cytoplasmic face of the ER membrane (4). This results in opening of the translocon in the ER membrane and translocation/integration of the nascent polypeptide into the ER membrane. Concurrently, the nascent chain interacts with luminal proteins (such as molecular chaperones) and undergoes posttranslational modifications (such as glycosylation and signal sequence cleavage). The maturation of polypeptides continues as they exit the ER and transit the Golgi complex, composed of *cis* (6), medial (7) and *trans* (8) stacks, by vesicle fission and fusion. Vesicles (9) leaving the trans-Golgi network can take a number of different paths depending on various determinants of trafficking pathways. Thus, the mature protein is transported to its final destination at the lysosome (10) or apical (11) or basolateral (12) plasma membrane. All these events involve vesicle fusion (13). Vesicles also form by internalization from the plasma membrane (14), leading to various endosome-related compartments (15) including the lysosome (10). Before exit from the ER, membrane proteins are scrutinized by proteins termed molecular chaperones for abnormal structural features and/or covalent modifications. If recognized as misfolded or unassembled, the protein is bound by the molecular chaperone, transported out of the ER through the translocon 'in reverse' and sent for degradation by the 26S proteasome (5). There are multiple forms of the proteasome in multiple locations within the cytoplasm. Also shown are the endothelial cells (16) and red blood cells (17) on the basolateral side of the hepatocyte. Note that the apical plasma membrane comprises the bile canaliculus in the hepatocyte and represents a very small surface area compared with the much larger basolateral surface on the bloodstream side.

cap structure; eIF4A, which unwinds the secondary structures in the 5′ untranslated region (UTR); and eIF4G, which plays a scaffolding role by interacting with other eIFs. Subsequent to the formation of the ribosome–mRNA complex, the ribosome starts translation at the AUG codon corresponding to the first methionine. According to one proposal, the ribosome scans the mRNA molecule at the 5′ UTR until it reaches the first AUG codon in a favourable context (known as the Kozak sequence) [3]. An alternative mechanism for translation initiation has also been proposed (described below).

Targeting to the secretory pathway

While the basic aspects of translation initiation and elongation of secretory and membrane proteins are identical to those of the cytoplasmic proteins, the biogenesis of these different classes of proteins diverges shortly after the start of translation. Sorting and targeting of membrane and secretory proteins to the ER starts when the signal sequence emerges from the ribosome. Despite very little sequence homology between them, signal sequences can be best characterized as an extension of 20–50 amino acids containing a stretch of hydrophobic residues (the H-domain) sandwiched between a charged (N-domain) and a polar (C-domain) region, typically predicted to have a beta bend in secondary structure [4]. Extensive biochemical analyses in cell-free systems have established that the H-domain of the signal sequence is recognized by a cytoplasmic *trans*-acting factor termed the signal recognition particle (SRP). Mammalian SRP is a ribonucleoprotein consisting of six polypeptides (SRP9, SRP14, SRP19, SRP54, SRP68 and SRP72, where the numbers correspond to their molecular weight) and an RNA (SRP-RNA) [5]. Signal sequence recognition and SRP-RNA binding is attained through SRP54, a GTPase that mediates ER targeting of the ribosome–nascent chain complex when bound to GTP. During targeting, GTP hydrolysis is inhibited by both the ribosome and the signal sequence. Thus, translation is transiently arrested until targeting is completed. Following targeting, the interaction between the SRP and SRP receptor (SR) stimulates GTP hydrolysis, SRP release and the resumption of protein synthesis. SR is also composed of two GTPase subunits. The α subunit (SRα) is closely related to the GTPase domain of SRP54. SRα interacts with SRβ, which is an integral membrane protein with a GTPase domain related to Sar1 and the ARF family.

Translocation across the ER

Following ER targeting, translation resumes, with the chain entering the aqueous environment of the translocation channel, also termed the translocon. During translocation of the polypeptide chain, the ribosome is classically viewed as forming a tight seal with the translocon. This seal shields the nascent chain from the cytosolic environment [6]. At this point, many irreversible decisions are taken, and the nascent chain is folded, covalently modified and assembled into a functional unit through a dynamic network of protein–protein interactions [7]. Signal peptidase and oligosaccharyl transferase (OST) are responsible for cleavage of the signal sequence at the C-domain and addition of sugar residues to the consensus N-linked glycosylation sites respectively. The folding and assembly of the nascent chain is assisted by ER resident proteins such as calnexin, immunoglobulin heavy chain binding protein (BiP), protein disulphide isomerase (PDI) and others. In addition, in the course of translocation, whereas secretory proteins completely cross the ER membrane to enter the lumen, individual segments of topologically distinct membrane proteins are partitioned between the cytosol, the lumen and the ER membrane. In order to accommodate these modifications and cope with the complexity of the topology of membrane proteins, the translocon must provide a dynamic environment for the growing polypeptide [8]. In eukaryotes, the translocon is formed from heteromeric membrane proteins referred to as the Sec61 complex (with α, β and γ subunits) [9]. This complex is necessary and, in some cases, sufficient for translocation. The translocation of the majority of proteins is facilitated by the translocating chain-associating membrane (TRAM), a multispanning glycoprotein that aids the formation of a tight ribosome–membrane junction through a signal sequence-dependent process [10]. In addition, the translocon complex interacts with the ribosome, the signal peptidase complex and the OST, as well as the translocon-associated protein (TRAP), in a manner that accommodates the enormous diversity of proteins that transit the secretory pathway. Therefore, the profile of secretory and membrane protein synthesis is dependent not only on signals encoded by the primary amino acid sequence (such as the signal sequence) but also on a dynamic interplay between cellular factors whose interactions with the nascent chain during translocation ultimately determine protein topology and folding. Mutations in the genes that encode components of the ER translocation and processing machinery have been identified in patients with autosomal-dominant polycystic liver disease [11]. The precise mechanism of integration into the ER membrane remains unclear. The simple-minded notion that hydrophobic domains are stabilized in the bilayer as they emerge from the ribosome seems untenable in the light of evidence that the translocation channel is aqueous [12,13], that multiple transmembrane loops are positioned in some cases before integration occurs [14,15] and the occurrence of discrete charged, extracytoplasmic sequences (termed stop transfer effector sequences) that are necessary for integration at subsequent hydrophobic domains, at least in some cases [16,17]. However, a specific integration receptor has yet to be identified for transmembrane protein biogenesis. Of particular interest is evidence of *trans*-acting factors that can alter the fate of a nascent chain, taking a polypeptide that would be destined to be an integral membrane protein and, instead, directing it to a different translocation/folding pathway by which it is secreted [18,19].

Beyond the ER

During and subsequent to translation and translocation, the newly synthesized proteins are either degraded (described in the next section) or further processed and matured in order to contribute to the protein's physiological function. Maturation involves non-covalent folding and covalent, post- and cotranslational modifications, as well as trafficking through the secretory pathway to the correct final destination. These events may be interconnected, for example some posttranslational modifications occur in specialized compartments (e.g. sialylation of proteins in the *trans*-Golgi network). In other cases, a posttranslational

modification is a requisite for a particular compartmental trafficking event (e.g. the role of mannose residue phosphorylation in directing lysosomal enzymes out of the secretory pathway and to those organelles; see [20]).

Proteins destined for posttranslational maturation leave the ER either by a signal-mediated event (i.e. receptor–ligand interaction) or by bulk flow through budding and fusion of vesicles with consecutive organelles [21]. Budding of ER vesicles is driven by polymerization of a protein called coat protein II (COPII) from specialized ER exit sites. These vesicles lose their coat and fuse to the so-called vesicular tubular clusters (VTCs), also known as the ER–Golgi intermediate compartment. The cargo is then taken from VTCs in vesicles to the Golgi complex. ER resident proteins, however, recycle back to the ER in vesicles coated with a different protein, termed COPI.

The processing and sorting of proteins continues at the Golgi complex by sequential progress through the *cis*-, medial- and *trans*-Golgi cisternae. Transport of the cargo from *trans*-Golgi to the plasma membrane, lysosome or to other endomembranes takes place by clathrin-coated vesicles. In addition to COP coatomers and clathrin, various adapter proteins are involved in the transport of cargo between secretory compartments. The lectin ERGIC-53, for example, is involved in the transport of various glycoprotein cargo including clotting factors V and VIII [22]. Mutations in ERGIC-53 or an associated protein (MCFD2) cause a bleeding disorder, probably by disrupting the secretion of blood clotting factors by the liver [23].

An important dimension of postsynthetic sorting that is particularly prominent in the liver, but will not be discussed in detail here, involves directing proteins to the apical vs. the basolateral aspects of the plasma membrane [24] (see Chapter 2.2.2). In the liver, the apical plasma membrane is limited to the bile canalicular membrane, while the much larger basolateral aspect is in contact with the bloodstream via the sinusoidal space (discussed in Chapter 2.2.2). The exocyst is a cytoplasmic particle comprising multiple proteins that is involved in the trafficking of vesicles during apical vs. basolateral sorting [24]. Recent evidence suggests a regulatory connection between protein synthesis and trafficking, by which, perhaps, cells are able to 'keep count' of proteins synthesized and targeted to one membrane face vs. another [25–27]. Thus, Sec61β, a component of the translocon complex, has been associated with binding components of the exocyst, although the molecular mechanism of this interaction and the regulatory feedback loops involved remain unclear.

Degradation

Among a large number of proteases involved in protein degradation, the best understood are the lysosomal and the 26S proteasomal degradation pathways. The former takes place in lysosomes, a membrane-enclosed acidic environment filled with hydrolytic enzymes. The lysosomal degradation pathway is critical for bulk proteolysis by visceral tissues such as the liver and for clearance of unwanted proteins recycled from the plasma membrane [28]. The proteasomal degradation pathway, on the other hand, is largely involved in processes that require fine control of protein degradation. The 26S proteasome consists of a central hollow cylinder (the 20S proteasome) and two caps on each end (the 19S caps). The 20S proteasome is composed of distinct proteases arranged with their active sites facing the inner chamber. The 19S cap includes protein subunits with ATPase activity, which unfold proteins and move them to the interior chamber. Perhaps the best understood function of proteasomes is in ER-associated degradation (ERAD) [29]. It is generally believed that the ER is equipped with machinery for the selection of misfolded or unassembled proteins that are recognized through exposure of structural tags (such as disulphide bonds) or posttranslational modifications (such as signal sequence cleavage and glycosylation) [7]. These proteins are generally believed to be misfolded forms recognized by the ER molecular chaperones that exercise a 'quality control' function over protein products before they enter the later stages of the secretory pathway. The journey of such misfolded molecules through the secretory pathway is blocked at the level of ER where they are, instead, targeted for return to the cytoplasm and destruction by the 26S proteasome complex. For example, the majority of mutations in the low-density lipoprotein receptor, which cause familial hypercholesterolaemia, result in its intracellular retention and, hence, the inability of the liver to maintain lipoprotein metabolism [30]. Other liver disorders that are caused by defective trafficking of secretory and membrane proteins include α-1-antitrypsin deficiency [31] and Laron syndrome (as a consequence of mutations in growth hormone receptor) [32].

The details of the ERAD machinery are best understood in the case of glycoproteins (Fig. 1) [33]. The lectin chaperones calnexin and calreticulin identify aberrant sugar residues on glycoproteins and retain these proteins in the ER through successive cycles of removal and readdition of glucose residues to the core sugars initially added during translocation across the ER membrane. These cycles offer the misfolded protein an opportunity to refold in a productive manner. If successful, the correctly refolded molecule is deglycosylated, released and exported to the vesicles destined for the Golgi apparatus. If refolding is unsuccessful, the consequence can be degradation by the 26S proteasome. Before degradation by the proteasome, however, these polypeptides must recross the ER membrane through a process referred to as retrotranslocation or dislocation [34]. Numerous genetic and biochemical studies have suggested that Sec61, in addition to its well-established role in translocation, is also critical for the disposal of unwanted proteins from the ER into the cytosol. Recently, two parallel reports identified Derline-1 as an ER membrane protein responsible for retrotranslocation of certain substrates [35,36]. In all cases, the driving force for extracting the polypeptide from the ER membrane is likely to be provided by the p97 ATPase complex [34]. During extraction from the ER membrane, unwanted proteins are covalently modified by the addition of a chain of small molecules referred to as ubiquitin (Ub). The polyubiquitylated proteins are targeted

to the 26S proteasome, which ultimately cleaves them into small peptides but spares the Ub moiety. In order to facilitate proteasomal degradation, N-glycans are removed prior to proteolysis by a ubiquitous cytosolic N-glycanase [37].

In some cases, unwanted proteins are selected for degradation at sites other than the ER, such as in the nucleus. A recent study has identified that the characteristics of nuclear degradation machinery resemble those of ERAD [38].

Translational control of gene expression

In order to cope with the environmental and physiological challenges constantly encountered by organs and cells, the production of proteins is subject to regulation at all levels of synthesis. Since protein synthesis requires both amino acids and metabolic energy, in some instances, such as in starvation, regulation of translation initiation is an important survival factor. Regulation of protein synthesis is also important in cases where variations of protein levels are essential for the progress of cells through specific stages, such as the steps of the cell cycle and development.

Regulation of translation initiation in *cis* and in *trans*

Control of translation initiation is widespread, relying on both the structural features of individual mRNAs (*cis*-regulatory factors) and the molecules involved in the translation initiation process (*trans*-regulatory factors). Alternative models for the recruitment of ribosomes to mRNA have been proposed that are independent of the cap, such as use of an internal RNA structure known as the internal ribosomal entry site (IRES) [39]. These structures were first found in picornavirus mRNA [40] and later in hepatitis C virus and related pestiviruses [41]. These viruses manipulate cellular eIFs, either by phosphorylation or through degradation, in a manner that blocks the cap-dependent translation without compromising IRES-mediated translation [42]. By doing so, the essential eIFs, which are normally engaged by the cap-dependent translation of host mRNA, are now hijacked for the translation of viral mRNA through IRES-dependent initiation. IRES-dependent translation initiation has also been described for a number of cellular mRNAs including BiP, fibroblast growth factor 2, vascular endothelial growth factor and so on [2]. Some cellular mRNAs contain a 5′ cap-dependent initiation site in addition to an IRES element located in their coding region [43]. This enables proteins of distinct functions to be generated by alternative translation initiation of a single mRNA molecule. In an extreme case, the translation of the fibroblast growth factor 2 can generate five different products through four IRES sites in addition to cap-dependent translation.

In eukaryotes, IRES-dependent translation initiation is mainly involved in the expression of a selective number of genes under conditions in which cap-dependent protein synthesis is blocked, such as during stress, some stages of the cell cycle and apoptosis [42]. At least four kinases have been identified that are activated in response to viral infection, low levels of haem in red blood cells, amino acid starvation and during the ER stress response. These kinases typically inhibit translation initiation through phosphorylation of eIF2α. In addition, degradation of eIF4G, which prevents cap-dependent translation, has been reported in cells undergoing apoptosis or infected with certain viruses [43]. Thus, the rate and the level of translation, as well as the site of translation initiation, are governed by structural elements of mRNA and modification of eIFs.

Regulation of protein degradation

Examples of cellular processes regulated by degradation include apoptosis, development, cell cycle, antigen processing and lipid metabolism by the liver [44]. In addition, the half-life of normally short-lived proteins is thought to be determined by degradation through recognition of signals inherent in their amino acid sequence. Among these signals, the best characterized is the N-degron of the N-end rule pathway, in which the half-life of a protein is determined by the identity of its N-terminal amino acid [45].

Lipid metabolism by the liver is a prime example of regulated degradation [46]. The liver enzyme 3-hydroxy-3-methylglutaryl coenzyme A reductase (HMGR) is an integral membrane protein of the ER, and it functions as a rate-limiting enzyme for the synthesis of cholesterol. HMGR degradation is accelerated in the presence of sterol precursors of cholesterol when production is unnecessary. This process, which is similar to ERAD, is inhibited when the flux through the sterol pathway is low and HMGR activity is essential for cholesterol production. In addition to HMGR, sterol regulation by the liver is subject to regulated degradation at other levels. For example, apolipoprotein 100 (ApoB) is also degraded by the ERAD if not assembled into very-low-density lipoprotein particles in the liver secretory pathway [47,48]. Therefore, proteolysis directs many cellular processes, primarily by controlling the levels of intracellular proteins, a function that was originally solely assigned to transcription and translational control.

Future prospects: regulation of translocation and targeting

Relative to translation initiation and degradation, regulatory events at the level of targeting and translocation have primarily been limited to examples involving proofreading (accuracy) functions. However, because many important and irreversible events govern targeting and translocation steps, regulation at this stage may influence key features of proteins including localization, structure and function. In the following section, we will discuss the stages of translocation and targeting that could be points of regulation. We will also present a new view, in which these regulatory stages could control protein conformation, a concept that may provide a rationale for many phenomenological

observations of protein function that cannot be explained by conventional views [49].

The opportunity to regulate targeting begins as soon as the signal sequence emerges from the ribosome. Recognition of the signal sequence by the SRP results in a transient arrest in translation [50]. At this point, the time window of translation arrest and, hence, the rate of synthesis could be regulated by signalling events. The strength of interaction between SRP and the signal sequence could also be modified in a manner preferable for some signal sequences over the others. In extreme cases, dissociation of SRP from the signal sequence may prevent targeting and generate a cytoplasmic protein that serves a different function, the same function at a distinct cellular location or that may be rapidly degraded. The last possibility has been described recently for PrP as a result of the inefficiency of signal sequence function, which generates proteasomally degraded cytosolic protein [51]. Alternatively, in the absence of bound SRP, polypeptide chains may be synthesized in the cytoplasm and, hence, available for signalling molecules and posttranslational modifications that would otherwise be inaccessible during cotranslational translocation. These modified molecules may than be translocated across the ER through posttranslational translocation [52]. Posttranslational modifications will not necessarily provide steric hindrance for translocation across the Sec61 channel, as N-linked glycosylation moieties are well tolerated for retrotranslocation through the same channel.

The next opportunity for regulation comes after targeting when the nascent chain–ribosome complex is docked at the translocon. According to the dogma, the growing chain is protected from cytosolic factors by virtue of a tight seal formed between the ribosome and the ER membrane. However, it has been shown recently that the length of the polypeptide chain accessible to cytosolic proteases varies depending on the heterogenous signal sequence [53]. Although a physiological significance for this phenomenon remains to be demonstrated, it can promote the exposure of an otherwise shielded mature domain to cytosolic factors. Indeed, pause transfer sequences have been identified in ApoB that mediate sufficient temporal and spatial opening of the ribosome membrane junction to allow for interaction with cytoplasmically applied macromolecules [54].

Each step in protein biogenesis represents a unique opportunity for regulation. Translation initiation, for example, is the last step at which a cell can decide whether to express a particular gene or not. Degradation, on the other hand, is the only way to diminish the amounts of an already existing protein. What could the regulatory process at the level of translocation accomplish that is unique and inaccessible during translation initiation or degradation? During translocation, a nascent polypeptide must acquire its proper structure through an array of interactions and modifications by ER resident proteins and cytosolically accessible molecules, as well as the ribosome. At this stage, a nascent chain is directed to multiple folded states, some of which are thermodynamically unfavourable. With reference to most developing processes, plasticity is conceivable for early translocational events that shape the structure of a protein. For instance, *trans*-acting factors (such as TRAM) could influence the energetics of protein folding by changing the environment of the translocon in favour of one structure over the others [55,18]. By doing so, for any unique amino acid sequence, multiple structures and, hence, functions could be assigned. Functionally and conformationally distinct proteins could be selected either by signalling molecules that impinge on *trans*-acting factors during translocation or by selective degradation during or after synthesis. There is precedence for both these mechanisms. First, in the case of PrP, at least three conformationally distinct forms have been identified arising from a single amino acid sequence. Two of these forms span the membrane once in the opposite direction, and the third form is fully translocated across the membrane [56]. An ER membrane protein (TRAP alpha) has been identified that favours the expression of secretory PrP over the membrane forms [18,19]. Consistent with the existence of different structures, multiple functions have been identified for PrP as both a proapoptotic and an antiapoptotic factor [57]. Second, degradation is another way in which functionally desired proteins can be selected. Cotranslational degradation is commonly observed for a large fraction of newly synthesized proteins [58,59]. In the case of the cystic fibrosis transmembrane conductance regulatory (CFTR) gene, less than 30% of newly synthesized molecules transit to post-ER compartments, with the majority of the wild-type molecules retained in the ER [60]. Whereas the ER-retained fraction degrades rapidly (half-life = 20–40 min), the post-ER fraction is remarkably stable with a half-life of hours. This quantitative heterogeneity persists even after inhibiting ER-to-Golgi traffic, indicating that differential stability is not a mere consequence of distinct localization. Instead, differential stability reflects different structural states, each with a unique folding thermodynamic. Although in the case of CFTR, the energetically unfavourable structural variant is retained in the ER, energetically unfavourable mutant proteins have been identified that exit the ER with an efficiency similar to wild type in a tissue-specific manner [61]. Together, these findings imply that the commonly observed cotranslational degradation is not merely a way to rid the cell of non-functional molecules that are structurally unstable. ERAD and other degradative machinery may serve to prune gene expression and eliminate *functional* protein conformations that are not desired at that precise time or by certain cell types. More studies are needed to see whether this and other alternative notions of regulated gene expression are generally valid or represent unusual variations observed for a small number of specialized proteins.

References

1 Gbauer F, Hentze MW (2004) Molecular mechanisms of translational control. *Nature Rev Mol Cell Biol* 5, 827–835.

2 Gingras AC, Raught B, Sonenberg N (1999) eIF4 initiation factors: effectors of mRNA recruitment to ribosomes and regulators of translation. *Annu Rev Biochem* 68, 913–963.

3 Kozak M (1986) Point mutations define a sequence flanking the AUG initiator codon that modulates translation by eukaryotic ribosomes. *Cell* 44, 283–292.
4 Martoglio B, Doberstein B (1998) Signal sequences: more than just greasy peptides. *Trends Cell Biol* 10, 410–415.
5 Keenan RJ, Fremann DM, Stroud RM *et al.* (2001) The signal recognition particle. *Annu Rev Biochem* 70, 755–775.
6 Jungnickel B, Rapoport TA (1995) A posttargeting signal sequence recognition event in the endoplasmic reticulum membrane. *Cell* 82, 261–270.
7 Ellgaard L, Molinari M, Helenius A (1999) Setting the standards: quality control in the secretory pathway. *Science* 286, 1882–1888.
8 Hegde RS, Lingappa VR (1997) Membrane protein biogenesis: regulated complexity at the endoplasmic reticulum. *Cell* 91, 575–582.
9 Johnson AE, Waes MA (1999) The translocon: a dynamic gateway at the ER membrane. *Annu Rev Cell Dev Biol* 15, 799–842.
10 Voigt S, Jungnickel B, Hartmann E *et al.* (1996) Signal sequence-dependent function of the TRAM protein during early phases of protein transport across the endoplasmic reticulum. *J Cell Biol* 134, 25–35.
11 Drenth JPH, Martina JA, van de Kerkhof R *et al.* (2004) Polycystic liver disease is a disorder of cotranslational protein processing. *Trends Mol Med* 11, 37–42.
12 Gilmore R, Blobel G (1985) Translocation of secretory proteins across the microsomal membrane occurs through an environment accessible to aqueous perturbants. *Cell* 42, 497–505.
13 Simon SM, Blobel G (1991) A protein-conducting channel in the endoplasmic reticulum. *Cell* 65, 371–380.
14 Borel AC, Simon SM (1996) Biogenesis of polytopic membrane proteins: membrane segments assemble within translocation channels prior to membrane integration. *Cell* 85, 379–389.
15 Skach WR, Lingappa VR (1993) Amino-terminal assembly of human P-glycoprotein at the endoplasmic reticulum is directed by cooperative actions of two internal sequences. *J Biol Chem* 268, 23552–23561.
16 Yost CS, Lopez CD, Prusiner SB *et al.* (1990) Non-hydrophobic extracytoplasmic determinant of stop transfer in the prion protein. *Nature* 343, 669–672.
17 Falcone D, Do H, Johnson AE *et al.* (1999) Negatively charged residues in the IgM stop-transfer effector sequence regulate transmembrane polypeptide integration. *J Biol Chem* 274, 33661–33670.
18 Hegde RS, Voigt S, Lingappa VR (1998) Regulation of protein topology by trans-acting factors at the endoplasmic reticulum. *Mol Cell* 2, 85–91.
19 Fons RD, Bogert BA, Hegde RS (2003) Substrate-specific function of the translocon-associated protein complex during translocation across the ER membrane. *J Cell Biol* 160, 529–539.
20 Dell'Angelica EC, Payne GS (2001) Intracellular cycling of lysosomal enzyme receptors: cytoplasmic tails' tales. *Cell* 106, 395–398.
21 Lee MCS, Miller EA, Goldberg J *et al.* (2004) Bi-directional protein transport between the ER and Golgi. *Annu Rev Cell Dev Biol* 20, 87–123.
22 Appenzeller C, Anderson H, Kappeler F *et al.* (1999) The lectin ERGIC-53 is a cargo transport receptor for glycoproteins. *Nature Cell Biol* 6, 330–334.
23 Zhang B, Cunningham MA, Nichols WC *et al.* (2003) Bleeding due to disruption of a cargo-specific ER-to-Golgi transport complex. *Nature Genet* 34, 220–225.
24 Zegers MM, Hoekstra D (1998) Mechanisms and functional features of polarized membrane traffic in epithelial and hepatic cells. *Biochem J* 336, 257–269.
25 Guo W, Novick P (2004) The exocyst meets the translocon: a regulatory circuit for secretion and protein synthesis? *Trends Cell Biol* 14, 61–63.
26 Lipschutz JH, Lingappa VR, Mostov KE (2003) The exocyst affects protein synthesis by acting on the translocation machinery of the endoplasmic reticulum. *J Biol Chem* 278, 20954–20960.
27 Toikkanen JH, Miller KJ, Soderlund H *et al.* (2003) Beta subunit of the Sec61p endoplasmic reticulum translocon interacts with the exocyst complex in *Saccharomyces cerevisiae*. *J Biol Chem* 278, 20946–20953.
28 Dunn WA (1994) Autophagy and related mechanisms of lysosome-mediated protein degradation. *Trends Cell Biol* 4, 139–143.
29 Trombetta ES, Parodi AJ (2003) Quality control and protein folding in the secretory pathway. *Annu Rev Cell Dev Biol* 19, 649–676.
30 Hobbs HH, Russell DW, Brown MS *et al.* (1990) The LDL receptor locus in familial hypercholesterolemia: mutational analysis of a membrane protein. *Annu Rev Genet* 24, 133–170.
31 Stoller JK, Aboussouan LS (2005) Alpha1-antitrypsin deficiency. *Lancet* 365, 2225–2236.
32 Laron Z (1993) Disorders of growth hormone resistance in childhood. *Curr Opin Pediatr* 5, 474–480.
33 Helenius A, Abi M (2004) Roles of N-linked glycans in the endoplasmic reticulum. *Annu Rev Biochem* 73, 1019–1049.
34 Tsai B, Ye Y, Rapoport TA (2002) Retro-translocation of proteins from the endoplasmic reticulum into the cytosol. *Nature Rev Mol Cell Biol* 3, 246–255.
35 Lilley BN, Ploegh H (2004) A membrane protein required for dislocation of misfolded proteins from the ER. *Nature* 429, 834–840.
36 Ye Y, Shibata Y, Ron D *et al.* (2004) A membrane protein complex mediates retro-translocation from the ER lumen into the cytosol. *Nature* 429, 841–847.
37 Suzuki T, Park H, Lennarz WJ (2002) Cytoplasmic peptide: N-glycanase (PNGase) in eukaryotic cells: occurrence, primary structure, and potential functions. *FASEB J* 16, 635–641.
38 Gardner RG, Nelson ZW, Gottschling DE (2005) Degradation-mediated protein quality control in the nucleus. *Cell* 120, 803–815.
39 Vagner S, Galy B, Pyronnet S *et al.* (2001) Attracting the translation machinery to internal ribosome entry sites. *EMBO Rep* 2, 893–898.
40 Pelletier J, Sonenberg N (1988) Internal initiation of translation of eukaryotic mRNA directed by a sequence derived from poliovirus RNA. *Nature* 334, 320–325.
41 Tsukiyama-Kohara K, Iizuka N, Kohara M *et al.* (1992) Internal ribosomal entry site within hepatitis C viruses. *J Virol* 66, 1476–1483.
42 Komar AA, Hatzoglous M (2005) Internal ribosome entry sites in cellular mRNAs: mystery of their existence. *J Biol Chem* 280, 23425–23428.
43 Dever TE (2002) Gene-specific regulation by general translation factors. *Cell* 108, 545–556.
44 Varshavsky A (2005) Regulated protein degradation. *Trends Biochem Sci* 30, 283–286.
45 Varshavsky A (1996) The N-end rule: functions, mysteries, uses. *Proc Natl Acad Sci USA* 93, 12142–12149.
46 Hampton RY (2002) Proteolysis and sterol regulation. *Annu Rev Cell Dev Biol* 18, 345–378.
47 Fisher EA, Zhou M, Mitchell DM *et al.* (1997) The degradation of apolipoprotein B100 is mediated by the ubiquitin-proteasome pathway and involves heat shock protein 70. *J Biol Chem* 272, 20427–20434.
48 Ginsberg HN (1997) Role of lipid synthesis, chaperone proteins and proteasomes in the assembly and secretion of apoprotein B-containing

lipoproteins from cultured liver cells. *Clin Exp Pharmacol Physiol* 24, A29–A32.
49 Lingappa VR, Rutkowski DT, Hegde RS *et al.* (2002) Conformational control through translocational regulation: a new view of secretory and membrane protein folding. *BioEssays* 24, 741–748.
50 Wolin SL, Walter P (1989) Signal recognition particle mediates a transient elongation arrest of preprolactin in reticulocyte lysate. *J Cell Biol* 109, 2617–2622.
51 Rane NS, Yokovich JL, Hegde RS (2004) Protection from cytosolic prion protein toxicity by modulation of protein translocation. *EMBO J* 23, 4550–4559.
52 Hansen W, Garcia PD, Walter P (1986) In vitro protein translocation across the yeast endoplasmic reticulum: ATP-dependent posttranslational translocation of the prepro-alpha-factor. *Cell* 45, 397–406.
53 Rutkowski DT, Lingappa VR, Hegde RS (2001) Substrate-specific regulation of the ribosome-translocon junction by N-terminal signal sequences. *Proc Natl Acad Sci USA* 98, 7823–7828.
54 Hegde RS, Lingappa VR (1996) Sequence-specific alteration of the ribosome-membrane junction exposes secretory proteins to the cytosol. *Cell* 85, 217–228.
55 Hegde RS, Voigt S, Rapoport TA *et al.* (1998) TRAM regulates the exposure of the nascent secretory proteins to the cytosol during translocation into the endoplasmic reticulum. *Cell* 92, 621–631.
56 Hegde RS, Mastrianni JA, Scott MR *et al.* (1998) A transmembrane form of the prion protein in neurodegenerative disease. *Science* 279, 827–834.
57 Saghafi S, Spilman P, Tan Z *et al.* (2006) Cellular prion protein topology determines pro- and anti-apoptotic functions (submitted).
58 Schubert U, Anton LC, Gibbs J *et al.* (2000) Rapid degradation of a large fraction of newly synthesized proteins by proteasomes. *Nature* 404, 770–774.
59 Turner GC, Varshavsky A (2000) Detecting and measuring cotranslational protein degradation in vivo. *Science* 289, 2117–2120.
60 Kopito RR (1999) Biosynthesis and degradation of CFTR. *Physiol Rev* 79, S167–S173.
61 Sekijima Y, Wiseman RL, Matteson J *et al.* (2005) The biological and chemical basis for tissue-selective amyloid disease. *Cell* 121, 73–85.

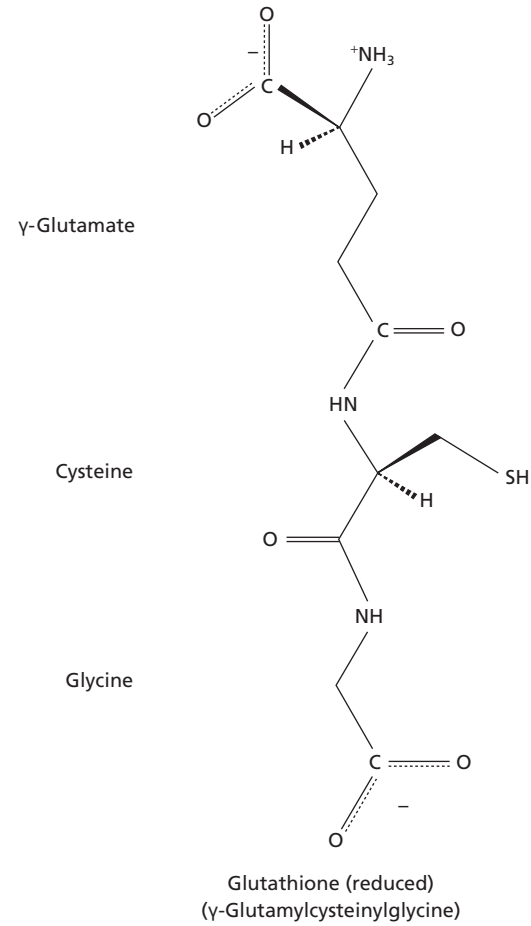

Fig. 1 Structure of GSH and its constituent amino acids. The bond between glutamate and cysteine determines the stability and resistance of GSH to hydrolysis, while its functions are mainly determined by the SH group of cysteine in its reduced form.

2.3.9 Glutathione

José C. Fernández-Checa and Carmen García-Ruiz

Introduction

The tripeptide glutathione (GSH) is one of the most intensively studied intracellular non-protein thiols on account of the critical role that it plays in cell biochemistry and physiology. GSH is a tripeptide found in high concentrations in all cells. It is synthesized from glutamate, cysteine and glycine in the cytosol in two steps, each requiring adenosine triphosphate (ATP) hydrolysis. GSH has certain structural features responsible for its stability and biological functions. For instance, the peptide bond linking the amino-terminal glutamate and the cysteine residue of GSH is through the γ-carboxyl group of glutamate rather than the conventional α-carboxyl group (Fig. 1). This unusual arrangement resists degradation by intracellular peptidases and is subject to hydrolysis by only one known enzyme, γ-glutamyltranspeptidase (GGT). Furthermore, the carboxyl-terminal glycine moiety of GSH protects the molecule against cleavage by intracellular γ-glutamylcyclotransferase. As a consequence, GSH is only metabolized extracellularly by GGT, which acts on the external face of certain cell types. Moreover, the sulphydryl group of cysteine is required for GSH's functions, in particular the regulation of disulphide bonds of proteins and the disposal of electrophiles and oxidants.

Despite its exclusive synthesis in the cytosol, GSH is distributed in intracellular organelles, including endoplasmic reticulum (ER) and mitochondria. GSH is found predominantly in its reduced form except in the ER, where it exists mainly as oxidized glutathione (GSSG) to provide the adequate environment necessary for protein metabolism. A tight connection between ER and cytosol is necessary to ensure an appropriate secretory function of the ER, as GSH in the cytosol reduces protein

disulphide isomerase and restores normal disulphide formation and secretory rates. In mitochondria, however, GSH is mainly found in reduced form and represents a minor fraction of the total GSH pool (10–15%). Considering the volume of the mitochondrial matrix, the concentration of mitochondrial GSH (mGSH) may be similar to that of cytosol (10–14 mM). Owing to the widespread roles of GSH in cell physiology, changes in GSH homeostasis have been implicated in the aetiology and progression of a number of human diseases. In this chapter, we review its regulation and functions and its role in oxidative stress, hepatocyte death and liver diseases.

GSH homeostasis

GSH biosynthesis

GSH exists in high concentrations in all types of cells and is synthesized from precursor amino acids in the cytosol in two steps. The regulation of GSH biosynthesis is dependent mainly on cysteine availability and enzymatic activity [1,2]. The liver has unique features regarding GSH regulation, as hepatocytes are able to convert methionine to cysteine through the trans-sulphuration pathway. In addition, the rate of GSH biosynthesis in the hepatocyte is balanced by its rate of export, mainly into plasma and bile. The synthesis of GSH from its constituent amino acids, L-glutamate, L-cysteine and L-glycine, involves two ATP-requiring enzymatic steps (Fig. 2). The first step in GSH biosynthesis is rate limiting and catalysed by γ-glutamylcysteine synthetase (GCS), which exhibits an absolute requirement for either Mg^{2+} or Mn^{2+}. GCS is composed of a heavy (GCS-HS) and a light (GCS-LS) subunit, and each is encoded by different genes in both rat and human. The heavy subunit exhibits all the catalytic activity of the isolated enzyme and feedback inhibition by GSH. The light subunit, on the other hand, plays an important regulatory role in the overall function of the enzyme and allows the holoenzyme to be catalytically more efficient and less subject to inhibition by GSH than the heavy subunit alone.

GCS is regulated physiologically by two important factors: GSH inhibition and cysteine availability. Thus, inhibition by GSH is non-allosteric and involves binding of GSH to the glutamate site of the enzyme. A second binding site for GSH has been described and involves interaction with the thiol moiety of GSH. On the other hand, the availability of its precursor, L-cysteine, also regulates GCS. The apparent K_m values of GCS for glutamate and cysteine are 1.8 and 0.1–0.3 mM respectively. The intracellular glutamate concentration is severalfold higher than the K_m value of GCS for glutamate, but the intracellular cysteine concentration approximates the apparent K_m value of GCS for cysteine. Hence, both the availability of intracellular cysteine and the activity of GCS greatly influence the rate of GSH synthesis.

The second step in the synthesis of GSH is catalysed by GSH synthetase (GS) (Fig. 2). This enzyme has not been studied as extensively as GCS. However, GS is not subject to feedback inhibition by GSH. Overexpression of GS fails to increase GSH levels as opposed to overexpression of GCS, which increases GSH. However, GS deficiency in humans can result in dramatic metabolic consequences because the accumulated γ-glutamylcysteine is converted to 5-oxoproline, which can cause severe metabolic acidosis [3].

Because the availability of cysteine is a critical determinant of GSH synthesis, factors that regulate intracellular cysteine levels ultimately contribute to GSH biosynthesis and, hence, cellular GSH levels. Among these, the transport of cysteine or cystine (and its subsequent reduction to cysteine intracellularly) or methionine transport modulate the intracellular levels of GSH. The transport of methionine is effective in regulating GSH biosynthesis through the subsequent conversion of methionine into cysteine by the trans-sulphuration pathway (Fig. 3), which operates only in hepatocytes. In addition to the intracellular cysteine availability, the regulation of GCS is a critical step in GSH homeostasis. The activity of GCS is regulated at both the transcriptional and the posttranscriptional levels, and hormones may modulate hepatic GSH biosynthesis through GCS regulation [4].

GSH degradation

In contrast to GSH synthesis, GSH degradation occurs exclusively in the extracellular space and only in cells that express the enzyme GGT. GGT, which is abundant on the apical surface of most transporting epithelia, including liver canalicular and bile ductular membranes, is the only enzyme that can initiate catabolism of GSH, glutathione-*S*-conjugates and glutathione complexes under physiological conditions. Because GGT is a plasma membrane-bound enzyme with its active site on the extracellular surface of the membrane, export of GSH and its adducts into the extracellular space is the initial, and presumably regulated, step in their turnover in all mammalian cells. GGT removes the glutamyl moiety from GSH and GSH-containing compounds to yield cysteinylglycine or cysteinylglycine-*S*-

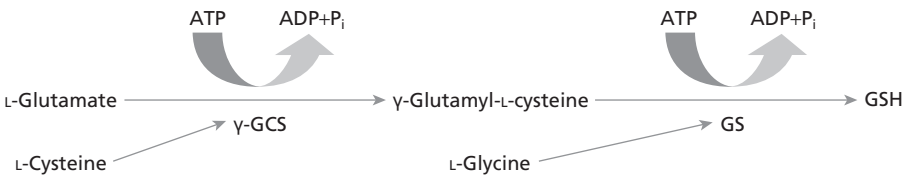

Fig. 2 GSH synthesis. The biosynthesis of GSH needs glutamate, cysteine and glycine, which are bound in two steps catalysed by γ-GCS and GS, which adds glycine to γ-glutamylcysteine. Both enzymes require ATP hydrolysis and, hence, the synthesis of GSH is energy consuming. In addition to γ-GCS, which is the rate-limiting enzyme, the availability of cysteine regulates GSH synthesis.

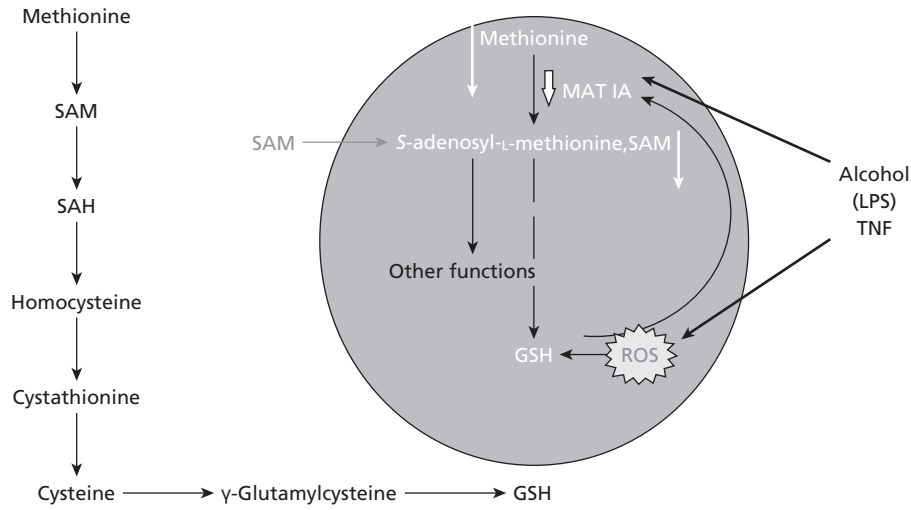

Fig. 3 The trans-sulphuration pathway and role of *S*-adenosyl-L-methionine (SAM) in alcohol-induced GSH regulation. In addition to the limited availability of cysteine in the biosynthesis of GSH, methionine meets the need for cysteine. It is channelled for GSH biosynthesis through the trans-sulphuration pathway, in which the sulphur of methionine is converted into cysteine. A key component of this process is SAM, which acts as a GSH precursor in hepatocytes and, hence, prevents GSH depletion induced by agents such as alcohol. LPS, lipopolysaccharide; ROS, reactive oxygen species; TNF, tumour necrosis factor.

conjugates. These compounds are substrates for dipeptidases, which hydrolyse the peptide bond between cysteine and glycine. Dipeptidases are also ectoproteins; thus, these reactions also occur in the extracellular space. The hepatic transport of GSH into plasma and bile thus contributes to its extrahepatic metabolism, which has been reviewed elsewhere [5].

Biological functions

Detoxification of Michael electrophiles and metals

Detoxification of xenobiotics or their metabolites is one of the major functions of GSH. GSH, being a nucleophile, targets electrophiles with αβ unsaturated carbonyl moieties or Michael electrophiles. These compounds form conjugates with GSH either spontaneously or enzymatically in reactions catalysed by GSH *S*-transferases [1]. This reaction results not only in the removal of the electrophile via its subsequent metabolism or transport out of the cell, but also in the potential depletion of GSH, particularly if GSH biosynthesis does not match the rate of electrophile elimination. The metabolism of GSH conjugates begins with cleavage of the γ-glutamyl moiety by GGT, leaving a cysteinyl–glycine conjugate. The cysteinyl–glycine bond is cleaved by dipeptidase, resulting in a cysteinyl conjugate. This is followed by N-acetylation of the cysteine conjugate, forming a mercapturic acid. The metabolism of GSH conjugates to mercapturic acid begins in the biliary tree, intestine or kidney, but the formation of the N-acetylcysteine conjugate usually occurs in the kidney.

In addition to exogenous compounds, many endogenously formed compounds also follow similar metabolic pathways. Some examples include estradiol-17-β, leukotrienes and prostaglandins [4,6]. GSH also forms metal complexes via non-enzymatic reactions. GSH is one of the most versatile and pervasive metal-binding ligands and plays an important role in metal transport, storage and metabolism. GSH functions in the mobilization and delivery of metals between ligands, in the transport of metals across cell membranes, as a source of cysteine for metal binding and as a reductant or cofactor in redox reactions involving metals. The sulphydryl group of the cysteine moiety of GSH has a high affinity for metals, forming thermodynamically stable but kinetically labile mercaptides with a number of metals, including mercury, silver, cadmium, arsenic, lead, gold, zinc and copper.

Maintenance of thiol status

As the dominant non-protein thiol in mammalian cells, GSH is essential in maintaining the intracellular redox balance and the essential thiol status of proteins [1,4,6]. To achieve this, GSH undergoes thiol–disulphide exchange in a reaction catalysed by thiol-transferase, as follows:

$$\text{Protein–SSG} + \text{GSH} \rightarrow \text{protein–SH} + \text{GSSG}$$

As this reaction is reversible, the equilibrium is determined by the redox state of the cell, which depends on the concentrations of GSH and GSSG [proportional to the log of $(\text{GSH})^2/(\text{GSSG})$]. Normally, cellular GSSG is kept very low (< 1% of the total GSH pool) so that protein mixed disulphide formation is limited. The thiol–disulphide equilibrium within the cell is known to regulate a diverse number of metabolic processes, including enzyme activity, transport activity and gene expression, via alteration of redox-sensitive *trans*-activating factors.

Antioxidant function

As a consequence of aerobic metabolism, all aerobic organisms are subject to a certain level of physiological oxidative stress. Mitochondrial respiration of xenobiotic transformation through cytochrome P450s yields reactive oxygen species (ROS) such as superoxide ($O_2^{-}\cdot$) and hydrogen peroxide, and can lead to the further production of toxic oxygen radicals that can cause lipid peroxidation and cell injury. The endogenously produced

hydrogen peroxide is reduced by GSH in the presence of selenium-dependent GSH peroxidase. As a result, GSH is oxidized to GSSG, which in turn is reduced back to GSH by GSSG reductase at the expense of nictoinamide adenine dinucleotide phosphate hydrogenase (NADPH), forming a redox cycle. Either GSH peroxidase or GSH *S*-transferase can reduce organic peroxides. Hydrogen peroxide can also be reduced by catalase, which is present only in the peroxisome. In the mitochondria, GSH is particularly important because there is no catalase and, therefore, GSH is responsible for maintaining a functionally competent organelle [7,8]. Because mitochondria are essential for cell function, mitochondrial GSH is a vital antioxidant that regulates cell death pathways and, hence, is of significance in disease progression. In addition, GSH also works as a coenzyme for several other antioxidant enzymes such as glutaredoxins and thioredoxins.

Cysteine storage and the γ-glutamyl cycle

One of the most important functions of GSH is to store cysteine. Cysteine is extremely unstable in the extracellular space and rapidly auto-oxidizes to cystine, in a process producing potentially toxic ROS. The γ-glutamyl cycle, first described by Meister in the early 1970s, allows GSH to serve as a continuous source of cysteine [6]. In this cycle, GSH is released from the cell by carrier-mediated transporter(s), and the ectoenzyme GGT then transfers the γ-glutamyl moiety of GSH to an amino acid (the best acceptor being cystine), forming γ-glutamyl amino acid and cysteinylglycine. The γ-glutamyl amino acid can then be transported back into the cell to complete the cycle. Once inside the cell, the γ-glutamyl amino acid can be metabolized further to release the amino acid and 5-oxoproline, which can be converted to glutamate and used for resynthesis of GSH. Cysteinylglycine is broken down by dipeptidase to generate cysteine and glycine, and cysteine is then taken up and converted back to GSH, a process that occurs in most types of cells. Once inside the cell, the majority of cysteine is incorporated into GSH; some is incorporated into protein, depending on the need of the cell, and some is degraded into sulphate and taurine. For most cells, this mechanism provides a continuous source of cysteine. Thus, the γ-glutamyl cycle allows the efficient utilization of GSH as cysteine storage.

GSH compartmentation: mitochondrial GSH

GSH is synthesized exclusively in the cytosol of cells; however, it is distributed intracellularly, including in the ER and mitochondria. While GSH in the ER is important for the assembly and secretory pathway for proteins, GSH in mitochondria (mGSH) plays an essential role in the maintenance of a functionally competent organelle and has been recognized more recently to regulate cell death/survival pathways [8]. Mitochondria are the main consumers of molecular oxygen in the cell, and this process functions as a transducing device to provide the energy required for ATP synthesis in oxidative phosphorylation. Most of the oxygen consumed during oxidative phosphorylation is fully reduced to water; however, a minor percentage of oxygen is partially reduced by a single electron, generating superoxide anion that acts on the matrix side of mitochondria and from which other ROS and oxidants (e.g. hydrogen peroxide) arise as byproducts of aerobic respiration. Although mitochondria are exposed to the constant generation of oxidant species, the organelle remains functional because of the existence of an antioxidant defence system, starting with transformation of superoxide anion into hydrogen peroxide by manganese superoxide dismutase (MnSOD). If the accumulation of hydrogen peroxide is not limited, it may either oxidize mitochondrial components (proteins, lipids, DNA) or participate in a chain of reactions (Haber–Weiss–Fenton) that generate more reactive free radicals, e.g. hydroxyl radical.

The task of controlling endogenous ROS in mitochondria is mainly accomplished by GSH, because mitochondria lack catalase, and because GSH is an integral component of the redox cycle with the participation of the GSH peroxidase and NADPH-dependent GSSG reductase. Moreover, a balance between the activity of MnSOD and the GSH redox cycle must exist to ensure the efficient disposal of hydrogen peroxide [7]. As mGSH concentration is high, moderate depletion of mGSH would not be expected to have a negative impact on the disposal of hydrogen peroxide by GSH peroxidase or on mitochondrial function. However, the depletion of mGSH below a critical level would compromise the adequate reduction of hydrogen peroxide, particularly in conditions of stimulated ROS generation from the mitochondrial electron transport chain. Thus, under complex 3 inhibition by antimycin A, stimulated hydrogen peroxide generation is only observed when GSH is depleted to 2–3 nmol/mg protein [9], which corresponds to the range of the K_m of GSH peroxidase for GSH (3 mM). Furthermore, because of the existence of GSH *S*-transferases (GST) in mitochondria, GSH also ensures the reduction of organic hydroperoxides, including products of lipid peroxidation [7].

Thus, as inferred from its versatility in reducing oxidants and in conjugating electrophiles, mGSH plays an essential role in maintaining mitochondria in a healthy state, and its depletion may be a key event in disease pathogenesis and sensitization of cells to oxidant and drug-induced cell injury. In addition, by regulating the redox environment, mGSH influences the mitochondrial cell death pathway through mitochondrial membrane permeabilization (MMP), which is recognized to play a role in pathophysiology.

mGSH transport

The concentration of mGSH is in the range of cytosolic GSH. However, unlike cytosol, mitochondria do not contain the enzymatic machinery to synthesize GSH from its constituent amino acids. Therefore, mGSH arises from the cytosol by

carrier-mediated transport located in the inner membrane that overcomes the unfavourable entry against an electrochemical gradient [10]. The earlier characterization of the transport of GSH into rat liver mitochondria indicated an active, energy-dependent process stimulated by ATP and inhibited by glutamate and upon collapse of the protonmotive force with protonophores [7,10].

Although hepatic mGSH transport has been functionally expressed in *Xenopus laevis* oocytes, the identification of the carrier(s) responsible had remained elusive until recently [11]. Indeed, the functional expression of the hepatic 2-oxoglutarate carrier in mitochondria from *Xenopus laevis*, demonstrating the transport of reduced GSH in a phenylsuccinatesensitive manner, further confirmed the suggestion that the 2-oxoglutarate carrier contributes to the transport of GSH in liver mitochondria [11]. The initial rate of 2-oxoglutarate transport in rat liver mitochondria was reduced following depletion of mGSH, suggesting a 2-oxoglutarate/GSH exchange. In contrast to the transport of GSH in kidney mitochondria, which occurs with a single kinetic component, the kinetics of GSH in rat liver mitochondria display a high-affinity and a low-affinity component. Moreover, the kinetics of 2-oxoglutarate transport in rat liver mitochondria exhibited a single Michaelis–Menten component with sensitivity to phenylsuccinate and GSH. Interestingly, the transport of 2-oxoglutarate was dependent on mitochondrial membrane fluidity, a characteristic feature of the hepatic mitochondrial transport of GSH (see below).

Thus, these studies suggest that the 2-oxoglutarate carrier may be responsible for the low-affinity transport of GSH in rat liver mitochondria in exchange for matrix 2-oxoglutarate. However, the identification of alternative carriers that account for the high-affinity transport of GSH in liver mitochondria remains to be established. In this regard, uncoupling protein 2 (UCP2) has been suggested to favour the mitochondrial transport of GSH. Although it may be conceivable that the transport of protons back into the matrix by UCP2 may favour the movement of GSH, the role of UCP2 in the transport of GSH into mitochondria remains speculative.

Regulation of mGSH transport

Recent cumulative evidence in hepatocytes and isolated mitochondria indicates that the transport of mGSH is highly dependent on appropriate membrane physical properties [8]. The function of membrane proteins including carriers can be modulated by the microenvironment of the membrane in which they are inserted, and lipid composition determines the dynamic properties of biological membranes. Both the cholesterol/phospholipid molar ratio and the (un)saturation of fatty acyl groups in phospholipids contribute to the membrane fluidity changes that correspond to the transition of membranes from gel to a liquid crystalline state. Cholesterol enrichment of cellular membranes or large multilamellar liposomes have been shown to decrease membrane fluidity monitored by fluorescence polarization of specific probes without an effect on the lifetime of the excited state of the probe. On the other hand, highly unsaturated fatty acyl chains (e.g. 20:4 and 22:6) in phospholipids are unlikely to associate with cholesterol and may thus create fluid membrane domains.

As the function of the electron transport chain can be affected by the lipid composition of the mitochondrial inner membrane, the regulation of mitochondrial GSH transport by membrane fluidity has been examined in isolated rat liver mitochondria enriched in cholesterol (reviewed in [8]). Cholesterol incorporated into mitochondria by incubation with a cholesterol–bovine serum albumin (BSA) mixture results in increased cholesterol content (two- to threefold). Although the bulk of cholesterol (70–80%) is found in the outer membrane after exposure to the cholesterol–BSA complex, the cholesterol incorporated in the inner membrane is twice as great as that present in control mitoplasts. The measurement of fluorescence polarization of fluorescent probes indicates decreased membrane fluidity in the cholesterol-enriched mitochondria. Cholesterol-enriched mitochondria display impaired initial rates of GSH uptake at different GSH concentrations, whereas the uptake of adenosine diphosphate (ADP) through the adenine nucleotide translocator remains unaffected. Moreover, the fluidization of cholesterol-enriched mitochondria by A_2C restored the mitochondrial transport of GSH despite increased cholesterol content. Thus, in addition to its regulation by the protonmotive force, ATP hydrolysis and glutamate, the mitochondrial transport of GSH is dependent on appropriate membrane fluidity.

GSH and cell death regulation

Through the maintenance of protein sulphydryls in the appropriate redox state, GSH can regulate important death/survival pathways, which modulate the fate of cells in response to apoptotic stimuli. A number of studies have shown that intracellular GSH loss, such as that induced by stimulated efflux out of the cell or its consumption, sensitizes different cell types to a variety of apoptotic stimuli (reviewed in [12]). For instance, epithelial HeLa cells expressing mutated cystic fibrosis transmembrane conductance regulator (CFTR) display resistance to hydrogen peroxide-mediated apoptosis accompanied by higher intracellular GSH stores and lower mitochondrial Bax levels. Recent studies in mouse hepatocytes in which the GSH levels were depleted by diethylmaleate or paracetamol indicated a sensitization to tumour necrosis factor (TNF)-induced apoptosis. In examining the activation of stress kinases and NF-κB-dependent survival genes, GSH depletion in the cytosol/nuclei resulted in sustained activation of Jun N-terminal kinase (JNK) by TNF. Intriguingly, while GSH depletion did not impair the nuclear DNA binding of NF-κB induced by TNF, it did prevent the induction of NF-κB-dependent survival genes such as inducible nitric oxide synthase (iNOS). These data show a differential dependence on GSH levels between the NF-κB DNA-binding activity and its transactivation, with the latter showing a requirement for critical GSH

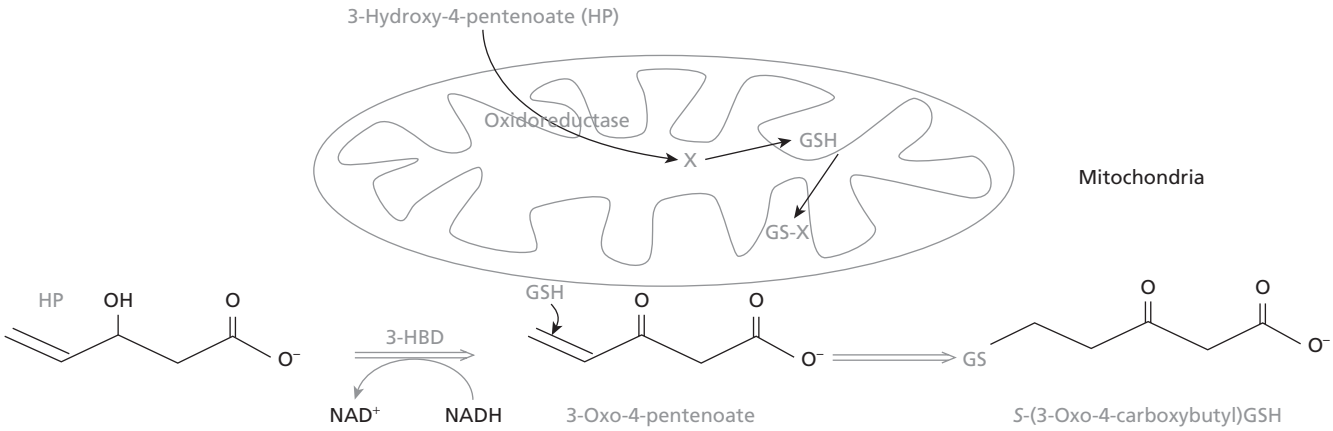

Fig. 4 Depletion of mitochondrial GSH. The biotransformation of HP into a Michael electrophile, 3-oxo-4-pentenoate, occurs selectively in the mitochondrial matrix thanks to the 3-HBD. This αβ unsaturated carbonyl is then conjugated with GSH yielding *S*-(3-oxo-4-carboxybutyl)GSH, resulting in the depletion of mitochondrial GSH. This pharmacological approach has been useful to learn specifically about the relevance of mitochondrial GSH in cell death regulation.

levels. Although the DNA binding of NF-κB can be modulated by the redox environment, recent findings indicate a novel pathway for the redox regulation of NF-κB based on mass spectrometry and molecular modelling of the *S*-glutathionylation of cysteine 62 of the p50 subunit of NF-κB. Thus, depending on the extent and mechanism of GSH depletion (efflux from cytosol of cells vs. decreased GSH/GSSG ratio), a limited storage of cell GSH can promote cell death through sustained JNK activation and/or suppression of NF-κB-dependent survival pathways.

In addition to the redox regulation of these death-promoting components, the engagement of the death-inducing signalling complex (DISC) and caspase-8 activated by ligation of death receptors relies on the appropriate redox environment for proper function. Through this mechanism, adequate GSH levels are required to ensure active DISC and caspase-8 activity after Fas stimulation in CEM and H9 cells. However, this dependence has not been observed in HepG2 or Hepa1–6 cells, indicating that the requirement of GSH for active DISC is cell-type specific. In hepatocytes, for instance, the role of GSH in sensitization to Fas or TNF is controversial. The length (prolonged vs. acute) and extent of GSH depletion (cytosolic vs. mitochondrial) may determine the fate of hepatocytes after Fas or TNF challenge. Thus, the existence of additional factors, e.g. the presence of redox-active thioredoxin in different cell types, may determine the outcome of the delicate balance between physiological antioxidants (GSH) and endogenously produced oxidants (ROS and nitric oxide) in the progression of apoptosis signalling.

Role of mGSH and susceptibility to cell death

Recently, pharmacological approaches have been used selectively to deplete mGSH in order to examine its role in the susceptibility of primary hepatocytes to death stimuli. By exploiting the selective biotransformation of (R,S)-3-hydroxy-4-pentenoate (HP) into a Michael acceptor within mitochondria by the (R)-3-hydroxybutanoate NAD^+ oxidoreductase (3-HBD) (Fig. 4), it has been possible selectively to deplete the mGSH pool in intact hepatocytes while sparing cytosolic GSH, underscoring the specific role of mGSH in apoptosis induced by TNF [13]. Preincubation of primary cultured rat hepatocytes with HP results in sensitization to TNF-mediated cell death in the absence of any other sensitization approach such as blocking protein or total RNA synthesis or NF-κB activation. mGSH-depleted hepatocytes exposed to TNF exhibit a significant and early generation of peroxides that precedes the loss of mitochondrial membrane potential, release of cytochrome *c* and apoptotic and necrotic demise. Similar findings have been observed when the depletion of mGSH is induced by chronic ethanol intake, which are reversed upon repletion of mGSH. On the other hand, overexpression of a mitochondrial GSH transporter, the dicarboxylate carrier, which results in substantially higher mGSH levels, protects NKK-52E cells from oxidant-induced apoptosis. In addition, mGSH depletion by triterpenoid derivatives in pancreatic cancer cells enhances apoptosis by a redox-dependent mechanism, thus further validating the crucial role of mGSH in controlling cell survival [14]. Moreover, mGSH depletion by HP has been shown to sensitize cultured hepatocytes to hypoxia-induced cell death [15]. Thus, mitochondria are both a source and a target of ROS. Through the maintenance of superoxide anion-induced hydrogen peroxide generated on the matrix side of the mitochondrial inner membrane, the pool of mGSH serves as a critical line of defence that controls the fate of cells in response to apoptosis stimuli.

In addition to ensuring the appropriate redox state of critical mitochondrial proteins (e.g. components of the mitochondrial permeability transition pore complex), GSH in mitochondria may also be vital in guarding the integrity of lipids. A recent study demonstrated the critical role of cardiolipin, in collaboration with proapoptotic Bcl-2 family members, in the formation of supramolecular openings in the outer mitochondrial membrane [16]. In addition to its fundamental role as a housekeeping lipid in the organization of individual complexes into functional

units of the respiratory chain, cardiolipin has a defined distribution pattern within mitochondria and may serve as a functional link in the action of BH1–3 multidomain proteins, e.g. Bax, or BH3-only Bid, to elicit the release of cytochrome *c*. Cytochrome *c* is bound to the inner membrane by cardiolipin. Recent studies in rat liver mitochondria have characterized a two-step process in the release of cytochrome *c*, consisting of the detachment of this protein from its membrane-anchoring lipid, cardiolipin, followed by permeabilization of the outer membrane allowing the release of cytochrome *c* into the extramitochondrial environment. As the peroxidation of cardiolipin contributes to the transition from tight to loose conformation of cytochrome *c*, an additional aspect of the protective role of mGSH might involve protection of cardiolipin from ROS attack. In this regard, hepatocellular mGSH depletion by HP leads to intact cardiolipin loss and subsequent accumulation of peroxidized cardiolipin in mitochondrial membranes. Whether this step is essential for mitochondrial membrane permeabilization (MMP) and, hence, apoptosome assembly by TNF is currently being investigated in liposomes reconstituted with intact vs. peroxidized cardiolipin. Thus, either through the maintenance of vital mitochondrial proteins and/or cardiolipin, mGSH depletion associated with disease states (such as hypoxia–reperfusion injury, toxic bile acid-induced damage and chronic alcohol intake) will favour conditions for cell damage.

GSH depletion in liver diseases

Because GSH is a critical antioxidant, and ROS are recognized in the pathophysiology of liver diseases, GSH depletion is associated with, and contributes to, the progression of liver diseases. In this capacity, GSH depletion may contribute to bile acid-induced liver damage, ischaemia–reperfusion liver injury and hepatitis B and C-induced liver damage [17,18].

Alcohol-induced liver damage is among the best characterized of diseases associated with GSH depletion (see also Section 12, Alcoholic liver disease). Hepatic mitochondria are recognized targets of ethanol metabolism in the liver. Studies in animal models of chronic ethanol feeding demonstrate functional alterations in oxidative phosphorylation, while patients with alcoholic hepatitis display mitochondria with morphological aberrations. Therefore, we examined the regulation of mGSH status and transport in experimental models of chronic alcohol feeding (reviewed in [19]). Our earlier observations more than a decade ago indicated that chronic ethanol intake selectively reduced the levels of mGSH in hepatocytes. Furthermore, similar findings have been observed in rats fed ethanol intragastrically, reproducing some of the pathological findings seen in patients ranging from steatosis to inflammation and fibrosis. These studies demonstrate a progressive depletion of mGSH with ethanol intake that precedes signs of liver injury in the ethanol-fed mice. Moreover, intragastric alcohol-fed mice also exhibit mGSH depletion that is prevented by MnSOD overexpression, indicating that mGSH levels are regulated by oxidative stress. The depletion of mGSH caused by chronic alcohol feeding is seen preferentially in perivenous hepatocytes and results from a defective transport of GSH from cytosol into mitochondria, as demonstrated in *in vitro* and *in vivo* tracer kinetic studies. Consistent with the observations that mGSH depletion caused by alcohol intake is secondary to impaired transport of GSH, we have documented decreased membrane fluidity in alcohol-fed livers [19]. Furthermore, acetaldehyde stimulates *de novo* synthesis of cholesterol in HepG2 cells, which then traffics to the mitochondrial inner membrane resulting in increased order parameter and impaired transport of GSH into mitochondria [20]. The fluidization of mitochondria from alcohol-fed livers or from acetaldehyde-treated HepG2 cells with A_2C restores the ability of mitochondria to transport GSH. In agreement with the impairment of mitochondrial GSH transport by alcohol intake, raising cytosolic GSH levels with N-acetylcysteine, a GSH precursor, does not increase the mGSH level in hepatocytes from alcohol-fed livers. However, *S*-adenosyl-L-methionine (SAM), which, in addition to its role in promoting GSH synthesis, can prevent alterations of membrane lipid composition including cholesterol/phospholipid increase, prevents alcohol-induced membrane fluidity loss in alcohol-fed rats and normalizes the mGSH levels. Exogenous SAM prevents TNF-induced MAT1A downregulation [21], which can also contribute to the depletion of SAM and subsequent GSH levels (Fig. 3). Interestingly, treatment of alcohol-fed rats with tauroursodeoxycholic acid replenishes mGSH levels through restoration of mitochondrial membrane fluidity.

Thus, alcohol-stimulated cholesterol increase and subsequent deposition in mitochondrial membranes accounts for the impairment of GSH transport in mitochondria, leading to depleted mGSH levels. In addition to the observations in hepatocytes, the depletion of mGSH has also been observed in alveolar type 2 cells from alcohol-fed rats resulting from impaired transport of GSH into mitochondria.

In cirrhosis, which is also associated with mitochondrial dysfunction, similar findings of mGSH dysregulation may occur. For instance, secondary biliary cirrhosis in rats induced by bile duct ligation will deplete mGSH, which occurs earlier than the observed decrease in GSH levels in liver homogenates. Although the mechanism is not entirely clear, mitochondria from bile duct-ligated rats exhibit altered lipid composition, with a two- to threefold increase in the cholesterol/phospholipid ratio in the mitochondrial inner membrane, thus raising the possibility of impaired transport of GSH into mitochondria.

Thus, as cholesterol influences the mitochondrial transport of GSH via the modulation of membrane physical properties, the transport of cholesterol to mitochondria may be significant in pathological states such as alcohol-induced liver disease (ALD). Most of the cholesterol in membranes is located in the plasma membrane, representing 65–80% of the total cellular cholesterol. Mitochondria, however, are cholesterol-poor organelles, with the outer mitochondrial membrane containing more cholesterol than the inner membrane.

Although the transport to and function of cholesterol in mitochondria is best understood in steroidogenic cells, the transport of cholesterol to hepatic mitochondria may be important in the bile acid synthesis pathway through its conversion into 27-hydroxycholesterol by the sterol 27-hydroxylase (Cyp27). In addition to its function as a precursor for bile acid synthesis, 27-hydroxycholesterol regulates liver steatosis by acting as a ligand of the liver X receptor (LXR) transcription factor via induction of sterol regulatory element-binding protein (SREBP)-1c. While steroidogenic acute regulatory protein (StAR) is key for the transport of cholesterol in steroidogenic cells, a recently purified protein from rat liver mitochondria has been shown to transport cholesterol to the mitochondrial inner membrane [22]. An intermembrane protein of 57.5 kDa, which transports cholesterol between mitochondrial membranes, has been purified by cholesterol affinity chromatography. In addition, a recent study has reported the detection of StAR in human liver cells, correlating its presence with the 27-hydroxylation of cholesterol, a process that occurs in the mitochondria and is considered the rate-limiting step in bile acid synthesis via the CYP27A1-initiated 'acidic' pathway [23]. A better understanding of this process and its regulation may identify novel therapeutic targets to maintain mitochondrial function and improve mGSH transport in liver diseases.

There is also a novel mechanism for cholesterol enrichment of mitochondrial inner membrane. Acetaldehyde can stimulate *de novo* cholesterol synthesis in HepG2 cells through ER stress [20], a process characterized by the accumulation of unfolded or misfolded proteins in the ER, which signals the induction of responsive genes [24]. Acetaldehyde increases the levels of GADD153 and the ER-associated transcription factor SREBP, which regulates cholesterol synthesis by activation of the rate-limiting enzyme hydroxymethylglutaryl-CoA reductase (HMGCoAR). The acetaldehyde-stimulated mitochondrial cholesterol content in HepG2 is preceded by increased levels of GADD153 and SREBP1, mimicked by the ER stress-inducing agents tunicamycin and homocysteine and prevented by the HMGCoAR inhibitor lovastatin. In addition, homocysteine, a toxic non-protein sulphur-containing amino acid formed exclusively upon demethylation of the essential amino acid methionine, contributes to alcohol-induced liver injury through ER stress [25]. Indeed, feeding mice betaine to promote methylation of homocysteine into methionine ameliorates alcohol-induced ER stress in mouse livers, indicating that homocysteine-induced ER stress contributes to alcohol-induced liver injury. Hence, alcohol intake leads to hyperhomocysteinaemia, which in turn may elicit ER stress, thereby promoting alcohol-induced liver injury.

GSH and hepatotoxicity (see also Section 14, Toxic liver injury)

mGSH is of critical relevance in hepatotoxicity because of its role in downregulating ROS and oxidants generated in the mitochondrial electron transport chain and maintaining overall mitochondrial function. For instance, patients taking LipoKinetix, a dietary supplement marketed as a weight loss agent, developed acute hepatotoxicity, which improved spontaneously after its use was discontinued. Usnic acid, a metabolite found in lichen, is a key constituent of LipoKinetix; usnic acid induces hepatocyte necrosis associated with disruption of mitochondrial respiration and energy metabolism, leading to ATP depletion and GSH depletion [26]. Furthermore, usnic acid increases hydrogen peroxide production in mitochondria, indicating that the depletion of mGSH is necessary for the sensitization of hepatocytes to usnic acid cytotoxicity. These findings suggest that usnic acid may be responsible, at least in part, for hepatotoxicity and liver failure seen in patients taking LipoKinetix.

Paracetamol (*N*-acetyl-*p*-aminophenol, APAP) is a widely used analgesic that is considered safe when taken at therapeutic doses. However, hepatocellular necrosis occurs at higher doses or under conditions that enhance the susceptibility to APAP. APAP hepatotoxicity is mediated by its metabolite *N*-acetyl-*p*-benzoquinone imine (NAPQI), which is generated by liver cytochrome P450, particularly cytochrome P450 2E1 (CYP2E1), and is detoxified by conjugation with GSH. NAPQI initiates its toxicity by first attacking mitochondria, followed by mGSH depletion. Although APAP can decrease GSH in both cytosol and mitochondria, the kinetics of GSH depletion in hepatocytes exposed to APAP indicate that the depletion of mGSH precedes that of cytosolic GSH, establishing the relevance of this GSH pool in the hepatotoxicity of APAP [27]. Interestingly, *N*-acetyl-*m*-aminophenol (AMAP), a non-hepatotoxic regioisomer of APAP, depletes cytosolic GSH but not mGSH. Like many other drugs, APAP cytotoxicity in hepatocytes is mediated through MMP, and agents that block it, such as ciclosporin A, protect hepatocytes against APAP-induced cell death. The synergism between alcohol intake and susceptibility to APAP further illustrates the sensitization to APAP hepatocellular toxicity by mGSH depletion. Selective depletion of mGSH caused by chronic ethanol feeding contributes to the enhanced susceptibility to APAP toxicity. Furthermore, ethanol induces CYP2E1, and the enhanced APAP toxicity induced by chronic ethanol is closely associated with the magnitude of both CYP2E1 induction and mGSH depletion, as the APAP toxicity disappears when CYP2E1 and the mGSH pool return to control levels after alcohol withdrawal [28]. Thus, these observations not only explain the likely mechanisms by which ethanol potentiates the toxicity of APAP, but also help to explain the low frequency with which the interaction is observed given the high incidence of concomitant use of alcohol and APAP.

References

1 DeLeve L, Kaplowitz N (1991) Glutathione metabolism and its role in hepatotoxicity. *Pharmacol Ther* 52, 287–305.

2 Hammond CL, Lee TK, Ballatori N (2001) Novel roles for glutathione

in gene expression, cell death, and membrane transport of organic solutes. *J Hepatol* 34, 946–954.
3 Huang CS, He W, Meister A *et al.* (1995) Amino acid sequence of rat kidney glutathione synthetase. *Proc Natl Acad Sci USA* 92, 1232–1236.
4 Fernández-Checa J, Lu SC, Ookhtens *et al.* (1992) The regulation of hepatic glutathione. In: Tavoloni N, Berk PD (eds) *Hepatic Anion Transport and Bile Secretion: Physiology and Pathophysiology*. New York: Marcel Dekker, pp. 363–395.
5 Ballatori N, Hammond CL, Cunningham JB *et al.* (2005) Molecular mechanisms of reduced glutathione transport: role of the MRP/CFTR/ABCC and OATP/SLC21A families of membrane proteins. *Toxicol Appl Pharmacol* 204, 238–255.
6 Meister A (1988) Glutathione. In: Aria IM, Jakoby WB, Popper H *et al.* (eds) *The Liver: Biology and Pathobiology*, 2nd edn. New York: Raven Press, pp. 401–417.
7 Fernández-Checa JC, Kaplowitz N, Garcia-Ruiz C *et al.* (1997) GSH transport in mitochondria: defense against TNF-induced oxidative stress and alcohol-induced defect. *Am J Physiol* 273, G7–17.
8 Fernandez-Checa JC, Kaplowitz N (2005) Hepatic mitochondrial glutathione: transport and role in disease and toxicity. *Toxicol Appl Pharmacol* 204, 263–273.
9 Garcia-Ruiz C, Colell A, Morales A *et al.* (1995) Role of oxidative stress generated from the mitochondrial electron transport chain and mitochondrial glutathione status in loss of mitochondrial function and activation of transcription factor nuclear factor-kappa B: studies with isolated mitochondria and rat hepatocytes. *Mol Pharmacol* 825–834.
10 Martensson J, Lai JC, Meister A (1990) High-affinity transport of glutathione is part of a multicomponent system essential for mitochondrial function. *Proc Natl Acad Sci USA* 87, 7185–7189.
11 Coll O, Colell A, Garcia-Ruiz C *et al.* (2003) Sensitivity of the 2-oxoglutarate carrier to alcohol intake contributes to mitochondrial glutathione depletion. *Hepatology* 38, 692–702.
12 Fernandez-Checa JC (2003) Redox regulation and signaling lipids in mitochondrial apoptosis. *Biochem Biophys Res Commun* 304, 471–479.
13 Garcia-Ruiz C, Colell A, Mari M *et al.* (2003) Defective TNF-α-mediated hepatocellular apoptosis and liver damage in acidic sphingomyelinase knockout mice. *J Clin Invest* 111, 197–208.
14 Samudio I, Konopleva M, Hail N *et al.* (2005) 2-cyano, 3, 12-dioxooleana, 1, 9, diene, 28-imidazolide (CDDO-IM) directly targets mitochondrial glutathione to induce apoptosis in pancreatic cancer. *J Biol Chem* 280, 36273–36282.
15 Lluis JM, Morales A, Blasco C *et al.* (2005) Critical role of mitochondrial glutathione in the survival of hepatocytes during hypoxia. *J Biol Chem* 280, 3224–3232.
16 Kuwana T, Mackey MR, Perkins G *et al.* (2002) Bid, Bax and lipids cooperate to form supramolecular openings in the outer mitochondrial membrane. *Cell* 111, 331–342.
17 Gumpricht E, Dahl R, Yerushalmi B *et al.* (2002) Nitric oxide ameliorates hydrophobic bile acid-induced apoptosis in isolated rat hepatocytes by non-mitochondrial pathways. *J Biol Chem* 277, 25823–25830.
18 Otani K, Korenaga M, Beard MR *et al.* (2005) Hepatitis C virus core protein, cytochrome P450 2E1, and alcohol produce combined mitochondrial injury and cytotoxicity in hepatoma cells. *Gastroenterology* 128, 96–107.
19 Fernandez-Checa JC, Colell A, Garcia-Ruiz C (2002) S-Adenosyl-L-methionine and mitochondrial reduced glutathione depletion in alcoholic liver disease. *Alcohol* 27, 179–183.
20 Lluis JM, Colell A, Garcia-Ruiz C *et al.* (2003) Acetaldehyde impairs mitochondrial glutathione transport in HepG2 cells through endoplasmic reticulum stress. *Gastroenterology* 124, 708–724
21 Mari M, Colell A, Morales A *et al.* (2004) Acidic sphingomyelinase downregulates the liver-specific methionine adenosyltransferase 1A, contributing to tumor necrosis factor-induced lethal hepatitis. *J Clin Invest* 113, 895–904.
22 Soccio RE, Breslow JL (2004) Intracellular cholesterol transport. *Arterioscler Thromb Vasc Biol* 24, 1150–1160.
23 Hall EA, Ren S, Hylemon PB *et al.* (2005) Detection of the steroidogenic acute regulatory protein, StAR, in human liver cells. *Biochim Biophys Acta* 1733, 111–119.
24 Kaufman RJ (1999) Stress signaling from the lumen of the endoplasmic reticulum: coordination of gene transcriptional and translational controls. *Genes Dev* 13, 1211–1233.
25 Ji C, Kaplowitz N (2003) Betaine decreases hyperhomocysteinemia, endoplasmic reticulum stress, and liver injury in alcohol-fed mice. *Gastroenterology* 124, 1488–1499.
26 Han D, Canali R, Rettori D *et al.* (2003) Effect of glutathione depletion on sites and topology of superoxide and hydrogen peroxide production in mitochondria. *Mol Pharmacol* 64, 1136–1144.
27 Vendemiale G, Grattagliano I, Altomare E *et al.* (1996) Effect of acetaminophen administration on hepatic glutathione compartmentation and mitochondrial energy metabolism in the rat. *Biochem Pharmacol* 52, 1147–1154.
28 Zhao P, Slattery JT (2002) Effects of ethanol dose and ethanol withdrawal on rat liver mitochondrial glutathione: implication of potentiated acetaminophen toxicity in alcoholics. *Drug Metab Dispos* 30, 1413–1417.

2.3.10 Haem biosynthesis and excretion of porphyrins

Hervé Puy and Jean-Charles Deybach

Introduction

Synthesis of porphyrins occurs in nearly all living cells: in animals for haem production and in plants for chlorophyll production. Porphobilinogen (PBG) and δ-aminolaevulinic acid (ALA) are linear porphyrin precursors, whereas porphyrins are molecules that are cyclic precursors of haem. In mammalian cells, haem synthesis occurs mostly in liver and erythropoietic tissues. Eight enzymes are involved in haem synthesis from succinyl CoA and glycine; the biosynthetic pathway starts in the mitochondrion and, after passing through three cytoplasmic stages, re-enters the mitochondrion for the final steps of haem formation. Therefore, the first and last three enzymes are found in mitochondria and the others in the cytosol (Fig. 1). All these enzymes are encoded by nuclear genes, and their full-length human cDNA and genomic sequences have been isolated and characterized [1]. Haemoproteins, including haemoglobin or myoglobin, mitochondrial or microsomal cytochromes, catalase, peroxidase, nitric oxide synthase, prostaglandin endoperoxide

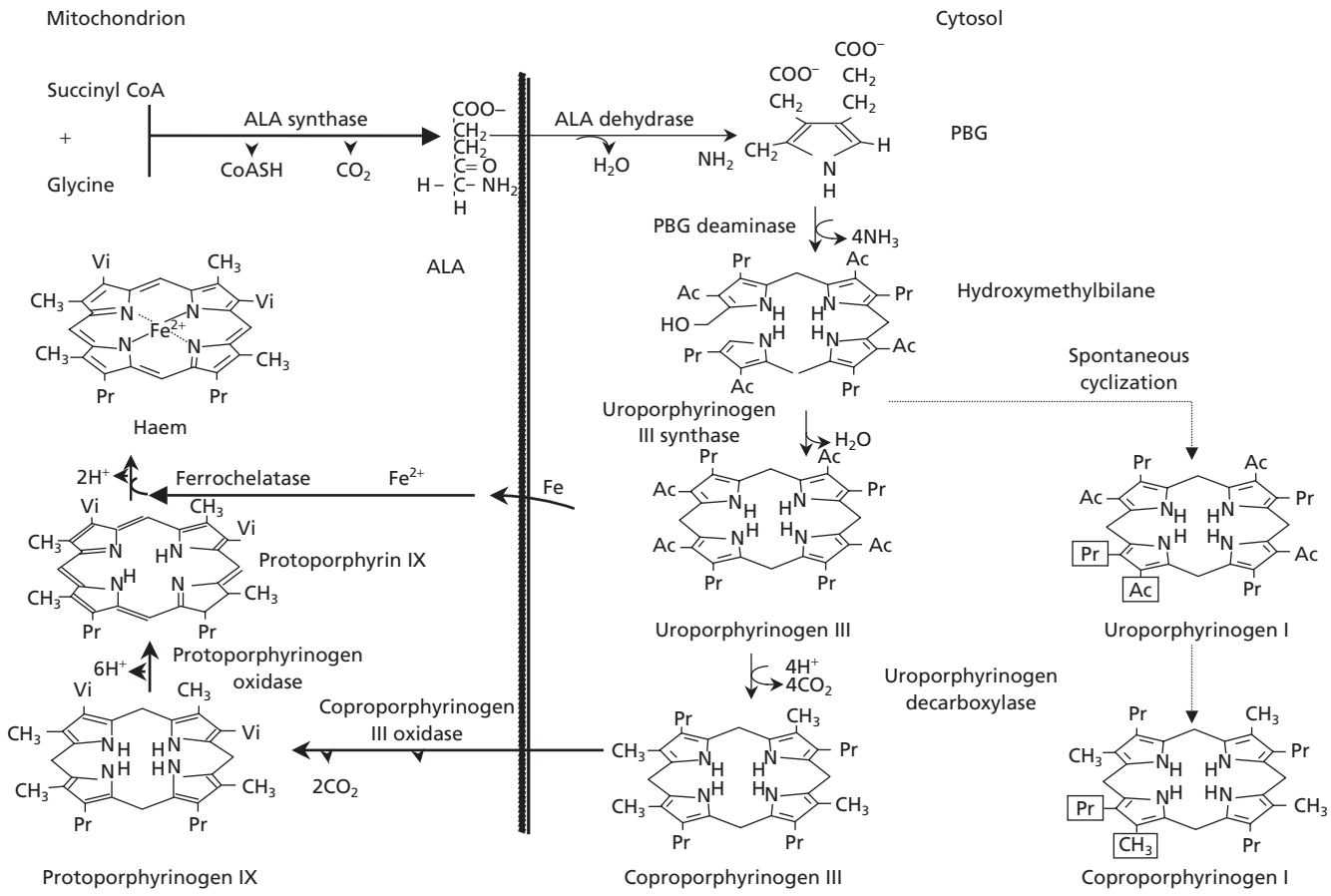

Fig. 1 The haem biosynthetic pathway. Subcellular distribution of enzymes and intermediates in the synthesis of haem is shown. ALA, δ-aminolaevulinic acid; PBG, porphobilinogen; Ac, acetyl (CH_2-COOH); CoASH, coenzyme A; Pr, propionyl (CH_2-CH_2-COOH); Vi, vinyl (CH=CH_2).

synthase, guanylate cyclase or tryptophan pyrrolase, play very important roles in electron and oxygen transport, in the activation of oxygen or hydrogen peroxide and, finally, in hydrogen peroxide decomposition.

Haem biosynthesis

Structure of porphyrins

Porphyrins are cyclic tetrapyrroles in which the pyrrole rings, conventionally designated as A, B, C and D, are linked through their carbon atoms by methene (–CH=) bridges (Fig. 1). All the cyclic tetrapyrrole intermediates of the biosynthetic pathway, with the exception of protoporphyrin IX, the last intermediate, are porphyrinogens, which are reduced forms that are rapidly oxidized to porphyrins when exposed to air with the loss of six protons. Porphyrins emit intense red fluorescence when exposed to light at around 400 nm. Thus, spectrofluorometric methods provide very sensitive detection and quantification of porphyrins (Soret band).

The naturally occurring porphyrins all have side-chains on the carbon atoms of the pyrrole rings. The porphyrin isomers differ in the arrangement of the side-chain substituents (e.g. acetyl and propionyl in uroporphyrins; methyl and propionyl in coproporphyrins). Water solubility of porphyrins is favoured by the presence of carboxylic acid side-chains. Uroporphyrin, the most water-soluble of the porphyrins, is excreted predominantly in urine, coproporphyrin mostly in urine and partly in bile, whereas protoporphyrin, the least soluble, is excreted only in the bile. There are four isomers of each of these porphyrins; only the I and III isomers occur in nature. In isomer I, the side-chains are arranged symmetrically around the ring; in isomer III, the substituents on ring D are reversed [2]. In animals, the complex between ferrous iron and protoporphyrins is usually called haem.

Biosynthesis

The two types of cells in the body that are responsible for synthesizing most of the haem are the erythropoietic cells (80%)

and the liver parenchymal cells (20%). The steps in the pathway are outlined in Figure 1.

Synthesis of porphyrin precursors: δ-aminolaevulinic acid and porphobilinogen

ALA synthase (EC 2.3.1.37), the first enzyme in the pathway, is a mitochondrial protein that requires pyridoxal phosphate as a cofactor. Two different isoenzymes, erythroid-specific or housekeeping, are encoded by two separate genes on different chromosomes (see below). It catalyses the condensation of glycine and succinyl-CoA, which is produced by the tricarboxylic acid cycle, to form ALA, which is exclusively committed to the synthesis of haem. ALA dehydrase (EC 4.2.1.24) then catalyses the condensation of two molecules of ALA to form monopyrrole PBG. The ALA dehydrase gene, situated on chromosome 9, has two codominant alleles, 1 and 2 [3]. The isoenzymes produced in the liver and erythroid tissue through tissue-specific alternative splicing are identical, with the form of splicing determined by activation of an untranslated region. The ALA dehydrase-2 isoenzyme is more electronegatively charged than ALA dehydrase-1, and its affinity for lead, which inhibits its activity by competing with the zinc atoms needed for catalytic action, is therefore higher. As a consequence, individuals with the ALA dehydrase-2 genotype are more vulnerable to lead exposure.

Synthesis of coproporphyrinogen III

Two cytoplasmic enzymes, PBG deaminase (EC 4.3.1.8) and uroporphyrinogen III cosynthetase (cosynthetase; EC 4.2.1.75), convert four molecules of PBG to uroporphyrinogen III (with liberation of four molecules of ammonia). PBG deaminase catalyses the polymerization of four molecules of PBG, yielding a linear tetrapyrrole intermediate, hydroxymethylbilane (Fig. 1). In this reaction, four units of PBG are assembled head-to-tail by the deaminase, starting with ring A and building round to ring D, to form the unrearranged bilane. The deaminase furnishes a straight-chain tetrapyrrole, hydroxymethylbilane, but it is not an enzyme for ring closure. The PBG deaminase contains, at its catalytic site, a dipyrrolomethane cofactor. The function of the dipyrrolomethane cofactor appears to be that of anchoring the substrate molecules at the catalytic site and directing the condensation of PBG to form the tetrapyrrole. Uroporphyrinogen III cosynthase then rapidly converts the intermediate into uroporphyrinogen III, a cyclic tetrapyrrole with eight carboxyl side-chains. In the absence of this ring-closing and side-chain-rearranging enzyme, an abortive I isomeric uroporphyrin is formed spontaneously, and, after partial decarboxylation to I isomeric coproporphyrinogen, is excreted via the hepatobiliary route as well as in urine. Uroporphyrinogen decarboxylase (EC 4.1.1.37), encoded on the short arm of chromosome 1, catalyses the stepwise decarboxylation of uroporphyrinogen III and converts the four acetic acid side-chains to methyl groups to form coproporphyrinogen III. The reactions, passing through 7-, 6- and 5-carboxylic states of the porphyrin molecule, take place at a single catalytic site. Only isomer III can be used in the remaining steps [3].

Synthesis of haem

Coproporphyrinogen oxidase (EC 1.3.3.3), encoded by a gene on chromosome 9, selectively converts two propionic acid chains to vinyl groups on the III isomeric form of coproporphyrinogen and then catalyses the stepwise decarboxylation to produce protoporphyrinogen IX. This mitochondrial enzyme, which requires copper for its action, is not membrane bound and was shown to be present in the intermembrane space. This localization implies that protoporphyrinogen oxidase (EC 1.3.3.4) must cross the inner membrane because haem is formed within the inner membrane (Fig. 2). Protoporphyrinogen

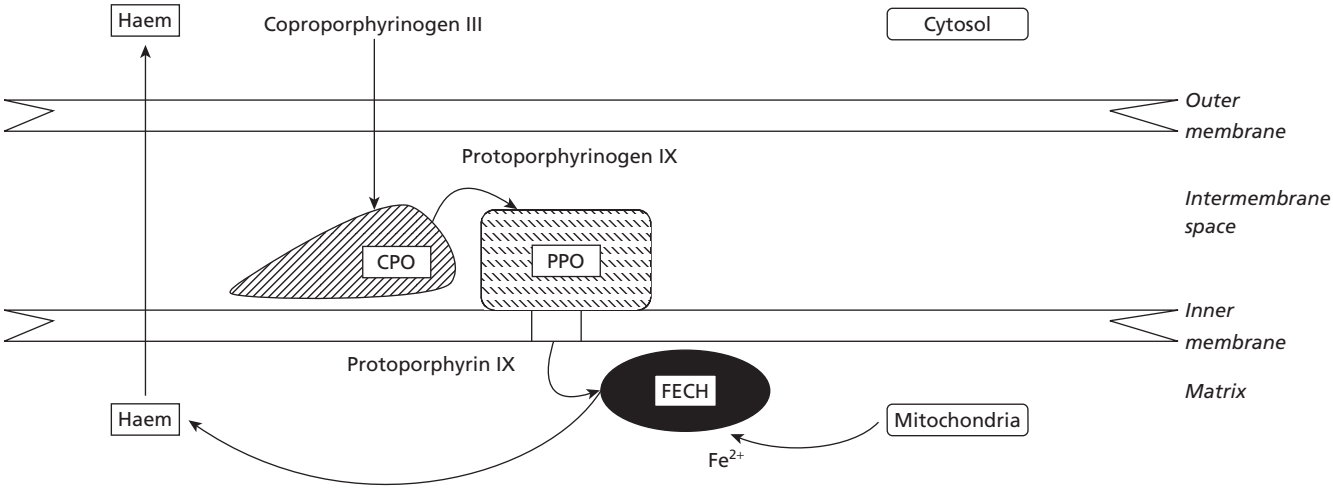

Fig. 2 Haem biosynthetic pathway. Association of the three terminal enzymes (coproporphyrinogen oxidase CPO, protoporphyrinogen oxidase PPOX, ferrochelatase FECH) with the inner mitochondrial membrane.

oxidase, encoded by a gene on chromosome 1, catalyses the oxidation of protoporphyrinogen IX to protoporphyrin IX: six hydrogen atoms are removed (four from methylene bridges and two from pyrrole rings). Only oxidized molecules (porphyrins) are brightly coloured, whereas reduced porphyrins (porphyrinogens) are colourless. The final enzymatic step in haem synthesis is the insertion of iron by the enzyme ferrochelatase (EC 4.99.1.1), which is encoded by a gene on chromosome 18 and is localized to the inner membrane of mitochondria. Unlike the three preceding enzymes in the haem biosynthetic pathway, which use porphyrinogens as substrates, ferrochelatase uses protoporphyrin IX; other dicarboxyl porphyrins, such as deutero- and mesoporphyrin IX, serve as good substrates for this enzyme *in vitro*. Only the reduced form of iron (Fe^{2+}), and not Fe^{3+}, is incorporated into protoporphyrin IX by the enzyme. Co^{2+} and Zn^{2+} are more efficient substrates for the enzyme than Fe^{2+}. Therefore, various rates of ferrochelatase activity can be obtained *in vitro*, depending upon which metal and porphyrin substrates are used. Moreover, in humans, ferrochelatase deficiency leads to free protoporphyrin accumulation, whereas iron deficiency leads to zinc protoporphyrin accumulation. The biosynthesis of haem requires 8 mol of glycine and 8 mol of succinic acid [3]. Each of the enzymes and their respective deficiency diseases are described in Chapter 16.5, Human hereditary porphyrias.

Haem catabolism

All cells are able to handle haem left over from the breakdown of haem proteins, thus preventing toxic accumulation of the compound. Haem oxygenase 1 (HO-1, EC 1.14.99.3), situated in the endoplasmic reticulum, is considered as a heat shock protein that is ubiquitously expressed, but is present in especially large amounts in liver and spleen, where the main degradation of haemoglobin takes place. Combined with nicotinamide adenine dinucleotide phosphate hydrogenase (NADPH) cytochrome 450 reductase, it cleaves one of the methene bridges of the porphyrin ring and generates carbon monoxide. The linear tetrapyrrol, biliverdin, is oxidized to bilirubin and excreted via the liver–bile route, whereas the liberated iron is reutilized. HO-1 activity is induced by a variety of stimuli, including haem itself, heavy metals, organic chemicals, endotoxins, hyperthermia, hypoglycaemia, burns and oxidative stress. Stimuli that increase HO-1 gene expression could accelerate the flux of metabolites through the haem biosynthetic pathway, and may thereby trigger clinical symptoms in some forms of hepatic porphyria by overload of the deficient enzyme [4]. The isoenzyme haem oxygenase 2 (HO-2), encoded by another gene, is not induced by the same agents that increase the transcription of the ubiquitous gene. This HO-2 gene is strongly expressed in brain, where it may serve to supply the tissue with carbon monoxide, a neuronal messenger that binds to the haem prosthetic group of guanylate cyclase generating cyclic GMP.

Regulation of haem synthesis

The mechanisms applied in the control of haem biosynthesis differ between liver and bone marrow, the two tissues that make haem in the largest amounts. Both erythroid-specific and non-erythroid or 'housekeeping' transcripts have been identified for each of the first four enzymes in the pathway. ALA is the first intermediate in the haem biosynthetic pathway exclusively committed to haem synthesis, and the rate of ALA synthesis is an important controlling step for haem formation. Erythroid-specific and housekeeping transcripts for the first step enzyme ALA synthase are encoded by two separate genes on different chromosomes: the erythroid-specific gene, expressed only in fetal liver and adult bone marrow (ALA synthase-2 on chromosome X), and the housekeeping gene, expressed in all cells (ALA synthase-1 on chromosome 3). For ALA dehydrase, porphobilinogen deaminase and uroporphyrinogen synthase, each transcript is activated from the same gene [5].

In the liver

In the liver, the haemoprotein enzymes formed, including cytochrome P450s, are rapidly turned over in response to current metabolic needs. ALA synthase-1 has many features of a rate-limiting enzyme in the production of haem. The rate of this enzyme turnover is very rapid; the half-life of mitochondrial ALA synthase-1 is among the shortest of all mitochondrial proteins. The ALA synthase-1 activity in normal liver is the lowest among all enzymes in the haem biosynthetic pathway. The free intracellular haem pool inhibits ALA synthase-1 activity via a negative feedback regulation (Fig. 3). Four potential targets for regulating the formation of the enzyme by haem have been identified: regulation of the production of ALA synthase at either (i) the transcriptional level or (ii) the translational level with a destabilization of ALA synthase mRNA by haem; (iii) modulation of the rate of entry of the enzyme into the mitochondria; or (iv) direct inhibition (Fig. 4). Basal or uninduced hepatic ALA synthase-1 provides sufficient ALA and haem to maintain normal levels of liver haemoproteins but, when the synthesis of the cytochrome P450 enzymes is induced and more haem synthesis is required, ALA synthase-1 is induced. The activity of PBG deaminase, the third enzyme in the pathway, is close to that of ALA synthase-1. Increased hepatic ALA synthase activity has been described during acute attacks in patients with acute porphyrias. ALA synthase induction is a secondary phenomenon; it is the result of exposure to several factors (such as drugs, hormones) that act on an enzyme more or less derepressed by haem deficiency. Under these conditions of ALA synthase-1 induction and increased ALA production, such as in an acute attack of an acute hepatic porphyria, PBG deaminase can become a rate-limiting metabolic step. This would account for the especially marked increases in ALA and PBG that are produced and excreted in acute intermittent porphyria (see Chapter 16.5). The activity of HO, the rate-limiting enzyme for

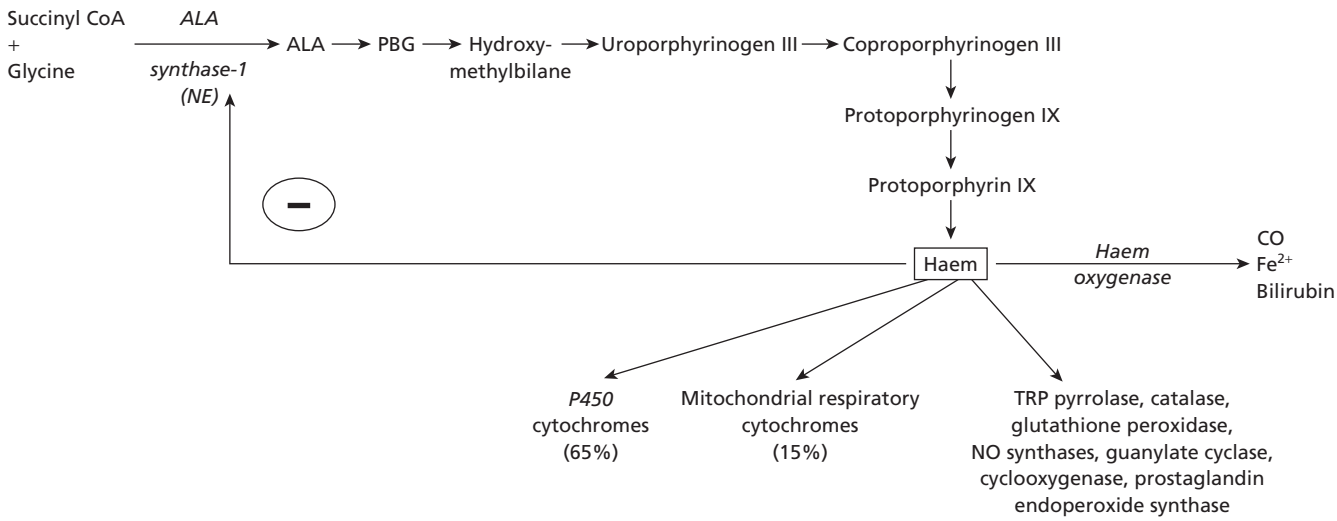

Fig. 3 Regulation of haem biosynthesis in the liver. ALA synthase-1 is rate limiting and feedback regulated by the intracellular concentration of haem. NE, non-erythroid form; TRP, tryptophan; NO, nitric oxide.

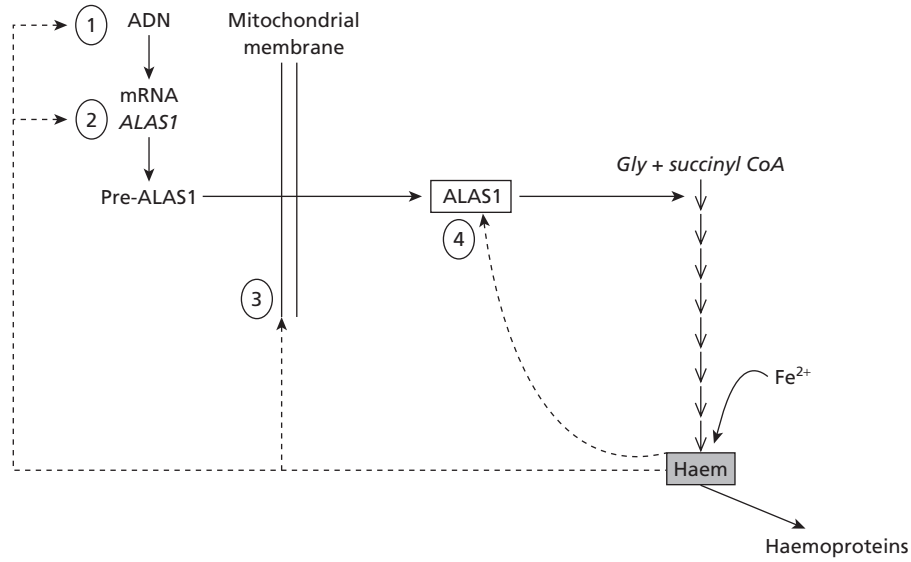

Fig. 4 Retroinhibition of hepatic ALA synthase-1 (ALAS1) activity via a negative feedback regulation mediated by the free intracellular haem pool. Four potential targets for regulating the formation of the enzyme by haem are identified: (1) the transcriptional level (*trans*-regulating factor haem responsive element: HRE), (2) the translational level with a destabilization of ALA synthase mRNA by haem, (3) modulation of the rate of entry of the enzyme into the mitochondria (mediated by a haem regulatory motif: HRM), (4) direct inhibition of the enzyme activity.

haem degradation to CO, iron and bile pigment, can also influence the level of regulatory free haem in hepatocytes. Starvation leads to increased HO activity, which may contribute to precipitating a crisis in acute hepatic porphyrias by depleting haem [6]. Conversely, attacks of these disorders can be prevented by a high carbohydrate diet. Thus, mechanisms for both haem synthesis and degradation can regulate haem formation.

In erythroid cells

In the erythroid cell, the synthesis of the enzymes participating in the formation of haem is under the control of iron and erythropoietin, formed under hypoxic conditions. Indeed, regulatory influences in the erythrocyte act during cell differentiation and, in contrast to the liver, the erythrocyte also responds to stimuli for haem synthesis by increasing its cell numbers to meet changing requirements for haemoglobin. The haemoglobinization of the erythroid cell is controlled by the ALA synthase-2 isoenzyme, which exhibits a 75% identity in the C-terminal part with ALA synthase-1. This enzyme, produced by a gene on the X chromosome, is not inducible by the drugs that induce ALA synthase-1 in the liver and is not repressed by exogenous haem treatment. ALA synthase-2 activity is induced only during the period of active haem synthesis of the red cell, and its rate of formation, and thus its activity in the cell, is in the end regulated by the amount of free iron present. The erythroid ALA synthase-

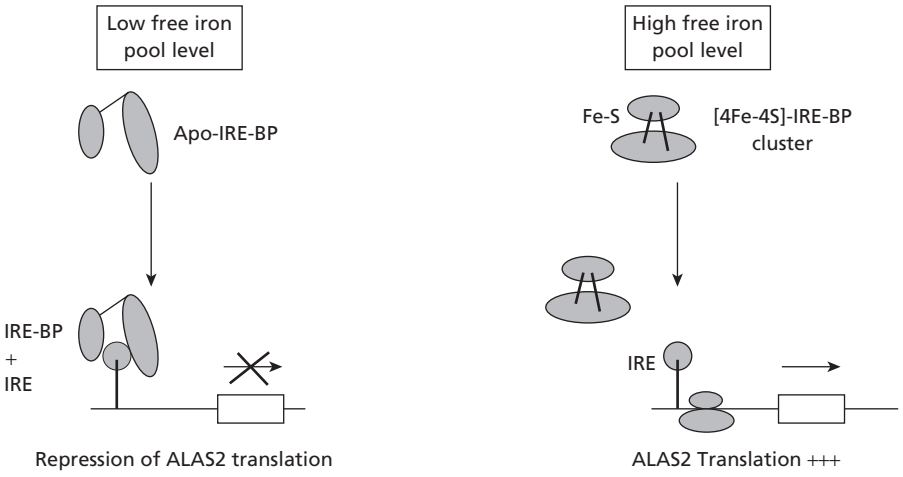

Fig. 5 Regulation of ALA synthase-2 translation by free iron/IRE/IRE-BP. In iron deficiency, the mRNA of erythroid ALA synthase-2 is blocked by attachment to an iron responsive element (IRE) of an IRE-binding protein (IRE-BP), and translation of this key enzyme is inhibited. In the presence of an excess of iron, the lack of attachment leads to an increase in the translation of the enzyme.

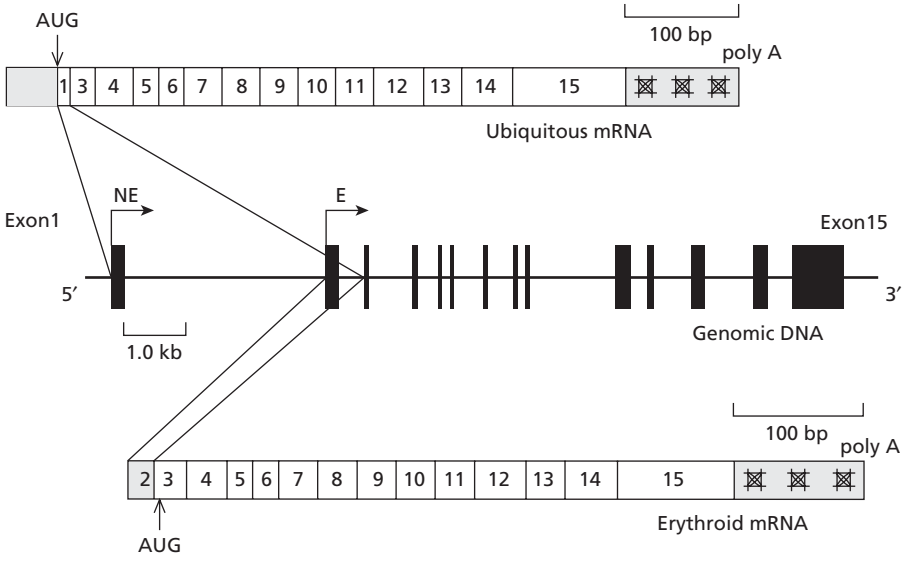

Fig. 6 Gene structure of the human porphobilinogen deaminase gene and its two transcripts produced by alternative splicing. NE, non-erythroid promoter; E, erythroid promoter.

2 gene encodes an iron-responsive element (IRE), which is a stable stem–loop structure on the mRNA with affinity for a specific cytosolic protein, the IRE-binding protein (IRE-BP). If there is enough free iron present in the erythroid cell, the IRE-BP is modified by the formation of sulphur/iron clusters; it then loses its ability to bind the IRE sequence. ALA synthase-2 translation is increased as a result, and the rate of formation of haem, and thus of globin chains as well, is activated. In iron deficiency, the unmodified IRE-BP blocks ALA synthase-2 translation by associating with its mRNA, and haem synthesis is consequently inhibited by lack of ALA synthase activity (Fig. 5). ALA dehydrase and PBG deaminase are other sites of regulation mediated by alternative splicing. The single PBG deaminase gene is located at chromosome 11q24.1–24.2 and contains 15 exons. It encodes erythroid-specific and ubiquitous isoforms of PBG deaminase that are generated by the use of separate promoters and alternative splicing of the two primary transcripts. The isoforms differ only at their NH_2 ends where the ubiquitous isoform extends for an additional 17 residues, making a polypeptide of 361 amino acids (Fig. 6).

The upstream promoter is active in all tissues, and thus the enzyme encoded by the larger transcript was termed the 'housekeeping PBG deaminase'. The other promoter, located 3 kb downstream, is active only in erythroid cells. It displays some structural homology with the β-globin gene promoter, suggesting that some common *trans*-acting factors may coregulate the transcription of these genes during erythroid development. The expression of ALA synthase-2, ALA dehydrase and PBG deaminase erythroid isogenes is determined by *trans*-activation of nuclear factor GATA-1, CACC box and NF-E2 binding sites in the promoter areas [7]. Ferrochelatase, the final enzyme in haem biosynthesis, may also play a significant role in controlling the rate of haem formation in erythroid cells. Ferrochelatase deficiency in human protoporphyria results in the accumulation of protoporphyrin almost exclusively in erythroid tissue, even though ferrochelatase is deficient in all other tissues in these

patients. This finding suggests that ferrochelatase activity can become rate limiting in erythroid cells, but not in other tissues, when the enzyme itself or its substrate, iron, is partially deficient. Although protoporphyrin is excreted only in the bile and accumulates in the liver in some patients, it presumably originates in the bone marrow.

Excretion of porphyrins and of porphyrin precursors

Porphyrins and porphyrin precursors are excreted in urine and/or bile (Table 1). In relation to the total rate of haem synthesis, excretion of porphyrins is very small; in other words, few porphyrins (and porphyrin precursors, ALA, PBG) 'escape' during haem formation and therefore are not transformed into bilirubin. Each day, bone marrow and liver synthesize about 375 mg of haem. In humans, the mean level of ALA excreted in urine is ~ 3 mg/day; this means that less than 0.5% of ALA synthesized each day has not been used for haem synthesis [8].

Urine

Porphyrin precursors

ALA and PBG are excreted only in the urine. After injection of labelled precursors, a large fraction of labelled ALA is excreted unaltered in urine; a small fraction is much more efficiently incorporated into hepatic haem than into haemoglobin in erythropoietic cells, probably because of the relative impermeability of the erythropoietic cell membrane to ALA. Injection-labelled PBG cannot be demonstrated in the liver, probably because it also does not pass the liver cell membrane; the impermeability of the cell membrane is only relative as, in instances where the amount of endogenous PBG is considerably increased (for instance acute porphyrias), huge amounts of PBG are found in urine. Moderately increased excretion of precursors is also observed in patients with hepatic diseases [8].

Porphyrins

Coproporphyrin is the predominant porphyrin in normal human urine (Table 1). However, urine contains only 30–35% of the total coproporphyrin; the remainder is found in bile. This urinary and faecal distribution is combined with a differential excretion of coproporphyrin isomers. The type 3 isomer predominates (70%) over the type 1 in urine, whereas the reverse is found in bile. It is now widely accepted that the unequal excretion rates of the isomers can be attributed to a hepatic carrier that favours the excretion of the I isomer [9]. In several human liver diseases with impaired hepatic excretory mechanisms, there is an increase in the total isomer ratio towards a predominance of the type 1 compound [2]. Other porphyrins present in normal human urine include uroporphyrin and traces of porphyrins with seven, six and five carboxyl groups. The intermediates (porphyrinogens) are unstable and rapidly oxidize to their corresponding porphyrins, and a large fraction of the porphyrins present in urine are excreted in this form of reduced colourless precursors. Freshly voided urine from patients with acute porphyria may have little if any increase in concentrations of preformed porphyrin; this probably explains why urine is frequently normal in colour when freshly passed, but darkens gradually on exposure to light and air. PBG can also be converted non-enzymatically to porphyrins (mostly uroporphyrin type 1): it is therefore very important to protect urine from light and to store it between 4 and 10°C if measurement of precursors has to be carried out.

Table 1 Normal values of haem pathway metabolites in humans: data from the Centre Français des Porphyries.

	Urine (per mmol creatinine)		Faeces (per g dry weight)		Red blood cell (per L)		Plasma (per L)	
	Normal value	Method	Normal value	Method	Normal value	Method	Normal value	Method
δ-Aminolaevulinic acid (μmol)	0–3	Ion-exchange chromatography	–	–	–	–	–	
Porphobilinogen (μmol)	0–1		–	–	–	–	–	
Total porphyrin (nmol)	–	–	10–200	Quantitative spectrophotometry	500–1900	Quantitative fluorimetric scanning	10–20	Quantitative fluorimetric scanning
Uroporphyrin (nmol)	0–10	Quantitative spectrophotometry	0–2	HPLC	0–6	HPLC	Lack of fluorescence emission spectroscopy (620–630 nm)	
Coproporphyrin (nmol)	0–20		0–60	HPLC	50–180	HPLC		
Protoporphyrin (nmol)	–	–	0–150	HPLC	300–1800	HPLC		

HPLC, high-pressure liquid chromatography.

Faeces

Significant amounts of porphyrins are excreted in faeces (mostly all of the protoporphyrin and 70% of coproporphyrin; Table 1). They may represent pigments that have reached the intestinal tract with the bile, except dicarboxylic porphyrins, which are mainly of dietary origin and may be derived from haem proteins of ingested food or intestinal haemorrhages; they may also be formed by intestinal microorganisms. Because of this, faecal porphyrins should be measured only if the patient's food has been devoid of bleeding or ingestion of meat in the past 3 days.

The mechanism by which protoporphyrin is excreted into bile has been studied mostly after description(s) of fatal liver disease in erythropoietic protoporphyria (see Chapter 16.5). Among haem-forming tissues, the bone marrow is the major source of protoporphyrin, a very poorly water-soluble compound: in the plasma, over 90% of protoporphyrin is bound to albumin with some bound to haemopexin. Hepatic uptake may occur through a process similar to that for other organic anions (such as bilirubin) that are bound to albumin. In the isolated, *in situ*-perfused rat liver, the overall disappearance of protoporphyrin follows first-order kinetics. Within the hepatocyte, protoporphyrin is associated with several proteins, among them one of the Z class of liver cytosolic proteins [10]. The rate-limiting step for the overall transport of protoporphyrin from plasma to bile appeared to be canalicular secretion, as less than 5% of the protoporphyrin extracted by liver was secreted into bile. This secretion should be mediated by the ABCG2/BCRP transporter, a member of the ATP-binding cassette (ABC) family [11]. The basal rate of bile secretion of porphyrins has been studied in healthy humans [12]: the flow of protoporphyrin is slightly higher than the flow of coproporphyrin; the flow of uroporphyrin is the lowest. Hepatic conjugation with glucuronic acid does not occur for protoporphyrin and coproporphyrin. Approximately 85% of hepatic protoporhyrin remains metabolically unaltered before being eliminated by bile secretion; 15% of protoporphyrin extracted by the liver may be converted to bilirubin, with non-haemoglobin haem species as intermediaries, and is also excreted in bile.

Hepatic infusion of micelle-forming bile acids facilitates canalicular protoporphyrin secretion [13]: the micelle-forming taurocholate increased biliary protoporphyrin concentration (by more than six times) and secretion (by more than 12 times) considerably more than dehydrocholate (a non-micelle-forming bile acid). Some bile acids (taurocholate and glycocholate) increase protoporphyrin metabolism 1.7- to 2.7-fold over control values. There are a number of direct and indirect ways in which bile acids might alter the metabolism of protoporphyrin, including either the stimulation of the activity of enzymes such as ferrochelatase and HO or the solubilization of protoporphyrin [14]. Before its final faecal excretion, a significant proportion of protoporphyrin is reabsorbed in the intestine and may circulate through the enterohepatic system [13]. However, it is not yet known how much intestinal microorganisms or food contribute to the total fecal porphyrin excretion.

References

1 Anderson KE, Sassa S, Bishop DF *et al.* (2001) The porphyrias. In: Scriver CR, Beaudet AL, Sly WS *et al.* (eds) *The Metabolic Basis of Inherited Disease*, 8th edn, Vol. 1. New York: McGraw-Hill Publications, pp. 2991–3062.

2 Mauzerall DC (1998) Evolution of porphyrins. *Clin Dermatol* 16, 195–201.

3 Dailey HA (1997) Enzymes of heme biosynthesis. *J Biol Inorg Chem* 2, 411–417.

4 Ponka P (1999) Cell biology of heme. *Am J Med Sci* 318, 241–256.

5 May BK, Dogra SC, Sadlon TJ *et al.* (1995) Molecular regulation of heme biosynthesis in higher vertebrates. *Prog Nucleic Acid Res Mol Biol* 51, 1–51.

6 Deybach JC, Puy H (2003) Acute intermittent porphyria from clinical to molecular aspects. In: Kadish KM, Smith KM, Guilard R (eds) *Porphyrin Handbook*. San Diego, CA: Academic Press Publications, pp. 319–338.

7 Thunell S, Harper P, Brock A *et al.* (2000) Porphyrins, porphyrin metabolism and porphyrias. *Scand J Clin Lab Invest* 60, 541–560.

8 Doss MO, Sassa S (1994) The porphyrias. In: Noe DA, Rock RC (eds) *Laboratory Medicine. The Selection and Interpretation of Clinical Laboratory Studies*. Baltimore, MD: Williams & Wilkins Publications, pp. 535–553.

9 Kaplowitz N, Javitt N, Kappas A (1972) Coproporphyrin I and 3 excretion in bile and urine. *J Clin Invest* 51, 2895–2891.

10 Vincent SH, Muller-Eberhard U (1985) A protein of the Z class of liver cytosolic proteins in the rat that preferentially blins heme. *J Biol Chem* 260, 14521–14528.

11 Zhou S, Zong Y, Ney PA *et al.* (2005) Increased expression of the Abcg2 transporter during erythroid maturation plays a role in decreasing cellular protoporphyrin IX levels. *Blood* 105, 2571–2576.

12 McCormack LR, Liem HH, Strum WB *et al.* (1982) Effects of haem infusion on biliary secretion of porphyrins, haem and bilirubin in man. *Eur J Clin Invest* 12, 257–262.

13 Ibrahim GW, Watson CJ (1968) Enterohepatic circulation and conversion of protoporphyrin to bile pigment in man. *Proc Soc Exp Biol Med* 127, 890–895.

14 Berenson MM, Marin JJ, Larsen R *et al.* (1987) Effect of bile acids on hepatic protoporphyrin metabolism in perfused rat liver. *Gastroenterology* 93, 1086–1093.

2.3.11 Vitamins and the liver (A and D)

Masataka Okuno, Rie Matsushima-Nishiwaki and Soichi Kojima

Summary

The metabolism, pathological relevance and therapeutic applications of retinoids (vitamin A and its derivatives) and vitamin D are reviewed in human hepatic disorders. Both vitamins have profound effects on cell activities, including cell growth, differentiation and apoptosis. Retinoids consist of several molecular species, including retinoic acid (RA), retinol and retinylesters. Dietary retinoids are packed in nascent chylomicrons that are taken up by the liver, in which hepatic stellate cells (HSC) store

the majority of body retinoids as retinylesters. The liver supplies retinoids as retinol to meet the requirements of peripheral tissues through binding to its specific binding protein, retinol-binding protein. RA is biosynthesized from retinol in target cells and exerts its biological functions through two distinct nuclear receptors, RA receptor (RAR) and retinoid X receptor (RXR). An isomer of RA, 9,13-di-*cis*-RA, is involved in the development of liver fibrosis. Retinoids are prime candidates for cancer chemoprevention by reversing the carcinogenic processes through regulating cell proliferation and differentiation. Acyclic retinoid, a synthetic retinoid, successfully suppresses the development of hepatocellular carcinoma (HCC) in cirrhotic patients. Eradication of malignant clones by inducing apoptosis ('clonal deletion') is suggested as a mechanism of the chemopreventive effect. Photolysis of provitamin D3 to previtamin D3 and its thermal isomerization to vitamin D3 take place in the skin. Vitamin D3 is metabolized in the liver to 25-hydroxyvitamin D3, and then in the kidney to its biologically active form, 1,25-dihydroxyvitamin D3 [1,25$(OH)_2$D3]. As the liver plays a major role in the formation of 1,25$(OH)_2$D3, osteodystrophy often occurs in patients with chronic liver diseases. 1,25$(OH)_2$D3 binds to its nuclear receptor, vitamin D receptor (VDR), which forms a heterodimer with RXR and regulates downstream genes mainly related to calcium metabolism. VDR is expressed in non-parenchymal liver cells but not in hepatocytes. Vitamin D also has immunomodulatory effects, and polymorphisms of VDR are implicated in some autoimmune diseases, including autoimmune hepatitis and primary biliary cirrhosis. Use of vitamin D for the treatment of HCC is also suggested.

Metabolism and function of retinoids

Vitamin A and its analogues, collectively termed retinoids, have profound effects on cell activities, including cell growth, differentiation, apoptosis, reproduction and morphogenesis [1]. Natural retinoids consist of retinoic acid (RA, an active metabolite that binds to its nuclear receptors), retinol (a transport form in the plasma) and retinylesters (storage forms in the tissues) (Fig. 1) [2]. All natural retinoids originate in the diet as either retinylesters or provitamin A carotenoids. Dietary retinylesters and carotenoids are subjected to a series of metabolic conversions to form retinol in the intestinal mucosa. Retinol is absorbed with other dietary lipids, esterified to retinylesters and packed in nascent chylomicrons. The chylomicrons are secreted into the lymphatic system and then enter into the circulation. Most chylomicron retinylesters are taken up by the liver, the major storage site of body retinoids. The liver stores retinoids in the form of retinylesters and supplies retinoids as retinol after hydrolysis of the esters to meet the requirements of peripheral tissues.

There are specific binding proteins for retinol in the plasma and cells, retinol-binding protein (RBP) and cellular retinol-binding protein (CRBP) respectively [3]. RBP is synthesized in hepatic parenchymal cells (hepatocytes) and secreted into the plasma after binding to retinol. Although RBP has a small molecular weight of 21 kDa, as RBP usually binds to transthyretin (TTR) and forms a RBP–retinol–TTR complex, it can avoid renal glomerular filtration. After delivery of retinol to target tissues, apo-RBP loses the binding to TTR, is rapidly secreted through the glomerulus and is reabsorbed by the renal proximal tubules where RBP is degraded to its constituent amino acids. Because RBP has a short half-life of approximately 12 h, it can be used as a sensitive diagnostic tool, particularly in diseases of the liver and kidney and in malnutrition. Plasma levels of RBP as well as retinol and TTR decrease in patients with acute and chronic liver diseases. RBP and TTR levels are found to correlate highly with the reduction of traditional markers such as prothrombin and albumin, which indicate the severity of liver damage. Two types of hepatic cells are known to participate in retinoid storage and metabolism, hepatocytes and HSCs [4]. HSCs play central roles in the storage of retinoids in the liver (more than 75% of hepatic retinoid), although HSCs account for only around 5% of the total liver population. Hepatocytes take up retinoids from chylomicrons and secrete them as retinol after binding to RBP, which is also synthesized by hepatocytes. The mechanism by which retinoids are transferred between hepatocytes and HSCs remains unsolved, although some pathways are postulated. It is believed that HSCs take up retinol from a retinol–RBP complex in the intercellular space that is secreted by hepatocytes. However, some suggest that intracellular retinol bound to CRBP is transferred directly between hepatocytes and HSCs by means of membrane contacts, including desmosomes and other direct intercellular channels. HSCs esterify retinol into retinylesters (mostly retinyl palmitate) and store the esters in the cytoplasm.

A small portion of dietary retinoids is converted to RA, a bioactive hormone, absorbed through the portal vein and present in the plasma bound to albumin. The majority of RA is biosynthesized in the cells of peripheral tissues and modulates the expression of various target genes [2]. Biosynthesis of RA is mediated by alcohol dehydrogenase and aldehyde dehydrogenase, which convert retinol to retinal and retinal to RA respectively. CRBP transfers retinol to these enzymes and helps in the formation of RA. Excess RA binds to cellular RA-binding protein (CRABP) in the cytoplasm and is further oxidized to an inactive metabolite by cytochrome P450 (CYP). For example, CYPRA1 is a novel P450 that inactivates RA by hydroxylation. CRABP acts as a buffering system to control the intracellular concentration of RA, thereby provoking or inhibiting RA actions. Some enzymes and proteins that modulate biosynthesis or degradation of RA are under the control of RA itself. For example, the expression of alcohol dehydrogenase, CRBP and CRABP is upregulated by RA. Thus, the intracellular concentration of RA is under the positive and negative feedback control of RA itself. These regulatory systems can impose a type of check-and-balance mechanism on RA biosynthesis and thus its function.

Retinoid receptors

RAs exert their biological functions through two distinct nuclear receptors, RAR and RXR [5] (Fig. 2a). Both RAR and RXR

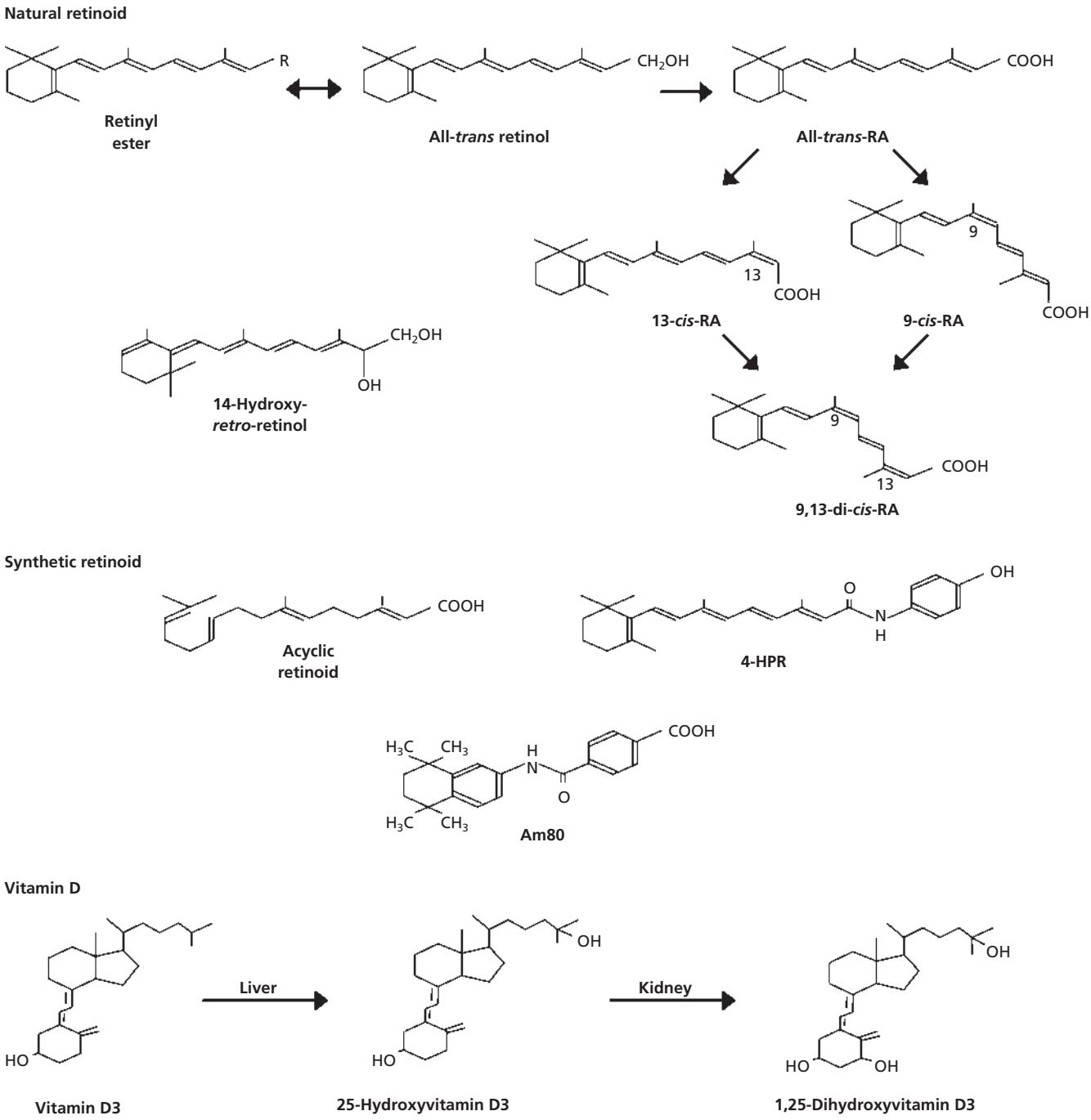

Fig. 1 Chemical structures of retinoids and vitamin D. Retinylesters (R: fatty acid) stored in the liver are hydrolysed to all-*trans*-retinol that is then transported to target cells after binding to RBP in the circulation. RA, a bioactive hormone, is biosynthesized from retinol by alcohol dehydrogenase and aldehyde dehydrogenase in the target cells. This RA-generating process is irreversible (one-way reaction). Two isomers of RA, all-*trans*-RA and 9-*cis*-RA, activate retinoid nuclear receptor, RAR, whereas only 9-*cis* RA activates the other retinoid receptor, RXR. Another isomer of RA, 13-*cis*-RA, is used clinically for the prevention of head and neck cancers, and 9,13-di-*cis*-RA has pathological significance in liver fibrosis. 14-Hydroxy-*retro*-retinol enhances lymphocyte proliferation independently of known retinoid receptors. A number of synthetic retinoids have been developed for pharmacological applications including cancer chemotherapy and chemoprevention. Acyclic retinoid and 4-HPR successfully prevent the development of HCC and breast cancer, respectively, in clinical trials. Am80 is a promising retinoid aiming to induce second remission in relapsed acute promyelocytic leukaemia (APL) patients who have become resistant to RA therapy. Exposure to solar ultraviolet light converts a derivative of cholesterol (7-dehydrocholesterol) to previtamin D3 in the skin, which is rapidly subjected to thermal isomerization to vitamin D3. Vitamin D3 is metabolized in the liver to 25-hydroxyvitamin D3, and then in the kidney to its biologically active form, 1,25-dihydroxyvitamin D3 [1,25$(OH)_2$D3].

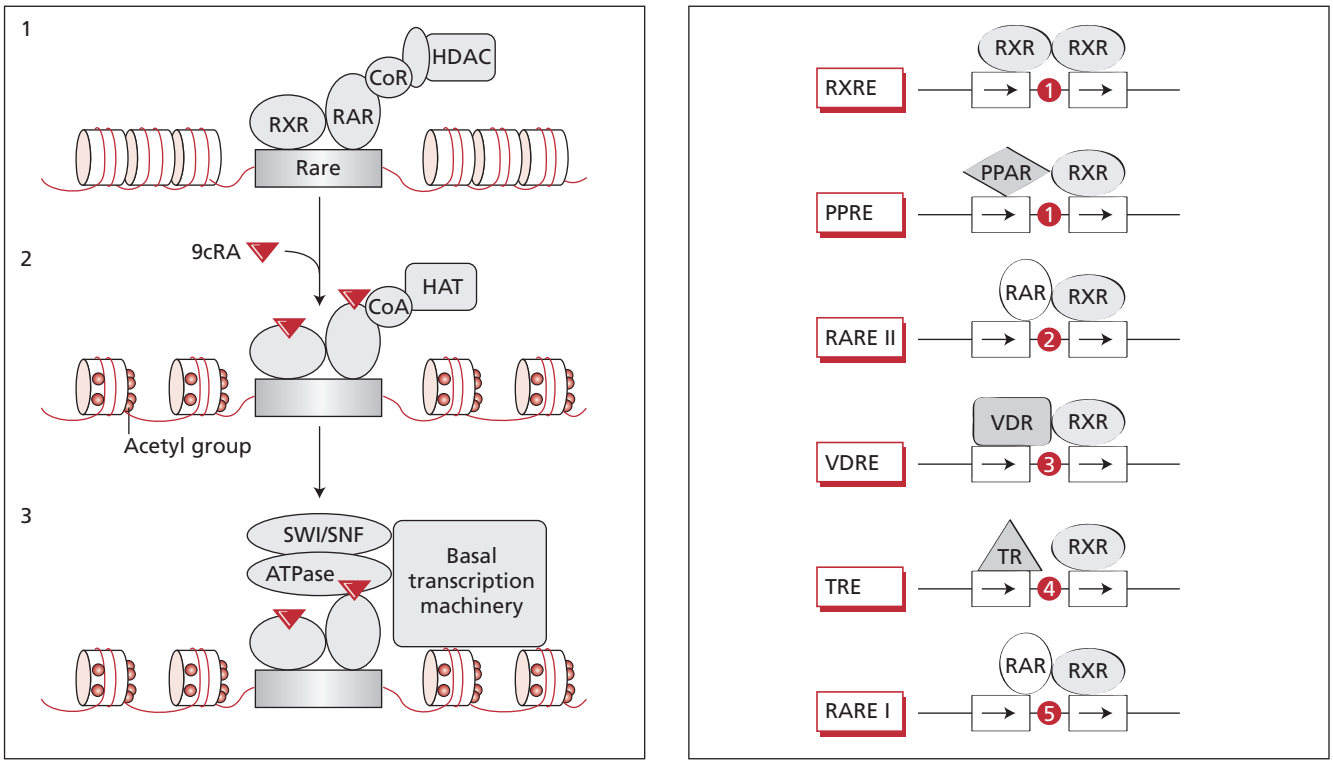

(a) (b)

Fig. 2 (a) Transcriptional repression and activation of RAR–RXR heterodimer. In the absence of ligands (RA), RAR–RXR heterodimer is linked to corepressor complexes (CoR) and associated with histone deacetylases (HDACs). HDACs remove acetyl groups from histones, induce chromatin compaction and silence the promoter region of the target genes (repression). Binding of RA to the receptor induces its conformational alteration, which destabilizes the interaction with CoR and, instead, allows a connection to coactivators (CoAs) (derepression). CoAs mediate the association between the heterodimer and histone acetyltransferase (HAT) complexes, which induces acetylation of histones and thus leads to chromatin decondensation. Subsequently, activation of transcription takes place by contact with the basal transcription machinery, ATPase and other related factors (transactivation). (b) Direct repeats serve as hormone-response elements for RAR, RXR, VDR, thyroid receptor (TR) and peroxisome proliferator activator receptor (PPAR). The elements consist of direct repeats of core sequence AGGTCA (arrows in boxes) separated by defined numbers of nucleotides (the nucleotide number is shown between the two boxes). RXR functions as a master regulator, forming homo- and heterodimers with RXR, PPAR, RAR, VDR and TR.

consist of three subtypes, α, β and γ, characterized by a modular domain structure. The RA molecule contains four coupled double bonds and thus has several stereoisomers, including all-*trans*-RA (atRA) and 9-*cis*-RA (9cRA), 13-*cis*-RA (13cRA) and 9,13-di-*cis*-RA (dcRA) (Fig. 1). RAR interacts with both atRA and 9cRA, whereas RXR binds only to 9cRA. 13cRA and dcRA are relatively weak ligands for RAR and do not bind to RXR. AtRA and 13cRA are used for the treatment and prevention of cancer, as discussed later. DcRA is involved in the development of liver fibrosis by inducing tissue plasminogen activator in HSCs and subsequently activating transforming growth factor-β, the most potent fibrogenic cytokine [6]. Both RAR and RXR have a DNA-binding domain called C-domain and a ligand-binding domain (E-domain). RXR forms a homodimer as well as heterodimers with RAR and several other nuclear receptors. These dimers bind to their respective response elements and subsequently activate or inhibit the expression of target genes. RAR and RXR bind to an RA response element (RARE) and an RXR response element (RXRE) respectively. These elements consist of direct repeats of the core sequence AGGTCA separated by a defined number of nucleotides. RARE has direct repeat spacers of two or five nucleotides (DR-2 and DR-5 respectively), and RXRE has a spacer of one nucleotide (DR-1) (Fig. 2b). The tissue-specific expression patterns of the receptors suggest that distinct functions of each subtype and functional redundancy make the retinoid signalling highly complex. The detailed mechanism of transactivation via RAR–RXR heterodimers has been revealed recently [7] (Fig. 2a). In the absence of RA, the RAR–RXR heterodimer binds to corepressor complexes that link between the heterodimer and histone deacetylases (HDACs). HDACs induce chromatin condensation and gene silencing by removing acetyl groups from nucleosomal histones. The binding of RA to ligand-binding domains of RAR and RXR induces the conformational changes in the domain, which allows the interaction between RAR/RXR and coactivators. Coactivators recruit histone acetyltransferases (HATs) such as

CREB-binding proteins or p300 that induce the acetylation of histone amino-terminal tails, resulting in nucleosomal repulsion and chromatin decondensation. On the other hand, a novel retinol (but not RA) metabolite, 14-hydroxy-*retro*-retinol (Fig. 1), induces lymphocyte proliferation, the activity of which cannot be substituted by any isomers of RA, implying the presence of other orphan receptors and/or other retinoid signalling pathways independent of nuclear receptors.

In HCC, both local deficiency of retinoids in the tumour tissues and unresponsiveness of the cancer cells to retinoids lead to loss of retinoid signalling and normal cell function, which seems to be linked to the development of cancer (see also Chapter 18.2, Malignant tumours) [8,9]. Alcohol consumption accelerates retinoid depletion in the cirrhotic liver associated with hepatitis virus infection, which may be related to its enhanced carcinogenic state [10]. RXRα is phosphorylated in HCC cells by extracellular signal-regulated kinase (Erk) 1/2 (also called mitogen-activated protein kinase), loses its function and is accumulated in the cancer cells [11,12], leading to their enhanced proliferation. In addition, RARβ is suggested to be a tumour suppressor gene in some tumours such as head and neck cancer [7,13]. As the RARβ–RXR heterodimer is more activated by retinoids than the RARα–RXR heterodimer, expression of RARβ as well as RXRα may be advantageous in suppressing tumour cell growth. Cells with normal retinoid signalling would be deleted and, as a result, only the remaining cells with impaired response might survive during the carcinogenic process.

Chemoprevention of HCC (see also Chapter 18.2)

Retinoids inhibit carcinogenesis at several steps (i.e. initiation, promotion and progression) and are thus prime candidates for cancer chemoprevention [14]. Recent advances in understanding the molecular mechanisms of carcinogenesis and the parallel progress in molecular targeting have stimulated the development of novel synthetic retinoids for cancer chemotherapy and chemoprevention. Some retinoids work as agonists that enhance the transactivation via RARE or RXRE, whereas others function as antagonists that inhibit the transcription induced by natural RA. In addition, novel mechanisms of retinoid receptor-independent induction of apoptosis have been reported recently with some synthetic retinoids such as 4-hydroxyphenyl retinamide (4-HPR, fenretinide) [7] (Fig. 1). In clinical studies, striking successes have been achieved in the therapy of acute promyelocytic leukaemia (APL) as well as the prevention of several malignancies, including cancers of the oral cavity, head and neck, breast, skin and liver [7,13,15]. Now, differentiation induction therapy with RA and a synthetic RAR ligand, Am80 (Fig. 1), has become standard in the treatment of APL. 13cRA is used clinically for the prevention of cancers in the oral cavity, head and neck region and the skin [7,13].

HCC, one of the most frequent cancers in the world, is an important target of cancer prevention by retinoid. HCC is closely linked to hepatitis viral infection and commonly arises in livers with chronic inflammation. The annual incidence of HCC reaches approximately as high as 3–7% in hepatitis virus-infected cirrhotic patients [16]. Moreover, the annual incidence rises to approximately 20–25% after the curative removal of the primary HCC [17,18]. Such a high carcinogenic state of the cirrhotic liver is a major cause of the limited 5-year survival rate (approximately 40%) even after the curative treatment [19]. Therefore, a new strategy to prevent post-therapeutic recurrence of HCC is required to improve further the therapeutic outcome of HCC. A number of clinical studies have attempted different strategies to suppress the development of HCC. For example, interferon (IFN) suppresses hepatic necroinflammation and thus serves to reduce the incidence of HCC [20,21]. IFN may belong to a category of biopreventive (or immunopreventive) agents, functioning as a biological response modifier. On the other hand, retinoids are chemopreventive agents, as the retinoid seems to act directly on (pre)malignant cells without modulating hepatic necroinflammation. We have developed a synthetic acyclic retinoid (all-*trans*-3,7,11,15-tetramethyl-2,4,6,10,14-hexadecapentanoic acid or polyprenoic acid), aiming for the chemoprevention of HCC (Fig. 1). A double-blind and placebo-controlled clinical study [22,23] has shown that oral administration of acyclic retinoid for 12 months significantly reduced the incidence of post-therapeutic recurrence and subsequently improved survival. In that clinical trial, serum lectin-reactive α-fetoprotein (AFP-L3), which indicates the presence of unrecognizable cancer cells in the remnant liver, disappeared in the acyclic retinoid group after administration [24]. These findings await validation in independent studies. This observation suggests a new concept in cancer chemoprevention, 'clonal deletion', the removal of latent malignant (or premalignant) cells that are invisible by diagnostic images from the organ with a hypercarcinogenic state such as cirrhosis–HCC sequence [25,26]. This concept may explain the reason why only a short-term administration (12 months) of acyclic retinoid has brought about a long-term suppressive effect on the development of HCC for several years. Once (pre)malignant clones are deleted, it would take at least several years for the development of *de novo* cancer in the cirrhotic liver. Acyclic retinoid not only functions as a RXRα ligand but also suppresses phosphorylation of RXRα by inactivating the Ras/Erk system, and thereby restores the function of RXRα [27]. Restoration of the function of RXRα leads to apoptosis induction of the cancer cells, which is a mechanism of clonal deletion. The detailed underlying molecular mechanisms of retinoid-induced apoptosis are discussed elsewhere [26]. Acyclic retinoid is now being tested in a clinical trial in Japan, aimed at chemoprevention of HCC.

Metabolism and function of vitamin D

Vitamin D is known as a 'sunshine vitamin' [28] because of its dependency on sunlight for conversion to an active metabolite. There are six vitamin D compounds, vitamin D2–D7, sharing a common basal structure with different side-chains. Among these,

vitamin D2 (ergocalciferol) and vitamin D3 (cholecalciferol) exert high biological activities. In particular, vitamin D3 is the major vitamin D species in man. The first step in vitamin D3 production normally takes place in the skin. Exposure to solar ultraviolet light converts a derivative of cholesterol, 7-dehydrocholesterol (provitamin D3), to previtamin D3 in the skin via a photolysis reaction. Previtamin D3 is then rapidly subjected to thermal isomerization to vitamin D3 in the skin. Vitamin D3 originating from either the skin or the diet is transported to the liver microsome via the circulation, where it is converted by vitamin D 25-hydroxylase to 25-hydroxyvitamin D3 [25(OH)D3], the major circulating form of vitamin D3 (Fig. 1). The 25-hydroxylation reaction is the prerequisite step for the subsequent 1α-hydroxylation and 24-hydroxylation reactions in the kidney. Namely, 25(OH)D3 enters the circulation again and, in the renal mitochondria, it is converted to 1α,25-dihydroxyvitamin D3 [1,25(OH_2)D3], the active form of vitamin D3, by 25(OH)D3 1α-hydroxylase, whereas the 24-hydroxylation reaction leads to inactivation and disposal of vitamin D3. Both reactions are strictly controlled by serum phosphorus as well as by parathyroid hormone, calcium and 1,25(OH_2)D3.

Presently, six cytochrome P450s (CYP2C11, 27A1, 2D25, 2R1, 3A4 and 2J3) are found to exhibit vitamin D 25-hydroxylation activities, and CYP27B1 and CYP24 have been established as 1α-hydroxylase and 24-hydroxylase respectively [29]. CYP24 metabolizes vitamin D and 1,25(OH_2)D3 to their excretion products [30]. As 24-hydroxylase is induced by 1,25(OH_2)D3 itself, the vitamin has a negative feedback system. Thus, vitamin D, like retinoids, is really more of a hormone than a vitamin.

Vitamin D plays a central role in calcium and phosphate homeostasis and is essential for the proper development and maintenance of bone, thus acting on the major target organs, bone and intestine, through a vitamin D receptor (VDR), which belongs to the class II steroid hormone superfamily and is closely related to RAR and RXR [30] (Fig. 2b). VDR forms a heterodimer with RXR and regulates the downstream genes via vitamin D-responsive element (VDRE), consisting of a direct repeat of consensus AGGTCA separated by three nucleotides (DR-3) (Fig. 2b). Among such genes, as described above, CYP24 (24-hydroxylase) is the most inducible gene, and participates in the degradation of vitamin D. When VDR interacts with 1,25(OH_2)D3, VDR moves away from the corepressor and acquires the ability to recruit coactivators after forming a heterodimer with RXR at VDRE, which is similar to the regulation of RAR/RXR (Fig. 1a). VDR is expressed not only in the well-known target cells such as osteoblasts and renal tubule cells, but also in a variety of cells including colon cells, lymphocytes and promyelocytes, suggesting novel functions for the hormone beyond osseous tissues [30]. Indeed, 1,25(OH_2)D3 is a potent regulator of cell growth and differentiation, with recent evidence showing inhibition of tumour invasion, angiogenesis and tumour cell death [31]. For example, 1,25(OH_2)D3 has been shown to induce terminal differentiation of promyelocytes to monocytes [32].

The liver is generally considered to be negative for VDR, although it is obviously a direct target organ of 1,25(OH_2)D3 [33]. This may be explained by the low expression of VDR in hepatic parenchymal cells but significant expression in non-parenchymal cells including sinusoidal endothelial, Kupffer, stellate and biliary epithelial cells [34]. VDR expression is also positive in HCC, and thus experimental and clinical trials to use 1,25(OH_2)D3 for the treatment of HCC have been suggested [31,35].

Osteodystrophy (osteomalacia and osteoporosis) is often seen in patients with advanced chronic liver diseases [36]. Serum 25(OH)D3 concentrations of < 80 nmol/L are associated with reduced calcium absorption, osteoporosis and increased fracture risk [37]. However, although serum levels of 1,25(OH_2)D3 are low in cirrhotic patients, this does not correlate with the bone formation rates [38]. Thus, the pathogenesis of the bone disease is multifactorial, including not only altered vitamin D metabolism, but also other factors such as impaired vitamin K activity, malnutrition and hypogonadism.

A potential link between vitamin D and the immune system has emerged as an interesting area of investigation [39]. Vitamin D interacts with helper T lymphocytes and thereby suppresses the inflammatory responses. For example, inflammatory bowel diseases (IBDs), including ulcerative colitis and Crohn's disease, are closely related to vitamin D deficiency [40]. In addition, VDR deficiency has been shown to exacerbate IBD in experimental animals. Vitamin D-deficient mice on low-calcium diets developed severe IBD, and 1,25(OH_2)D3 treatment of mice improved IBD symptoms [39]. Thus, the idea of using vitamin D for the suppression of IBD has been proposed. The link between VDR polymorphisms and two autoimmune-related liver diseases, autoimmune hepatitis and primary biliary cirrhosis, has also been suggested, although the underlying mechanism has not yet been clarified [41,42].

Because both retinoids and vitamin D are fat-soluble vitamins and can thus accumulate when intake is excessive, less toxic synthetic analogues have been developed for use as clinical therapeutics (for detailed descriptions of their toxic effects, see Chapter 14.2, Toxic liver injury, and Chapter 14.4, Hepatic toxicity induced by herbal medicines).

Acknowledgements

This study was supported partly by Grants-in-Aid from the Ministry of Education, Culture, Sports, Science and Technology of Japan (16290215 to SK). We are grateful to Drs T. Sano, S. Adachi, Y. Takano, A. Obora, I. Yasuda, Y. Shiratori, H. Moriwaki and Y. Muto (Gifu University, Japan).

References

1 Hansen LA, Sigman CC, Andreola F *et al.* (2000) Retinoids in chemoprevention and differentiation therapy. *Carcinogenesis* 21, 1271–1279.

2 Blaner WS, Olson JA (1994) Retinol and retinoic acid metabolism. In: Sporn MB, Roberts AB, Goodman DS (eds) *The Retinoids: Biology, Chemistry, and Medicine*, 2nd edn. New York: Raven Press, pp. 229–255.

3 Soprano DR, Blaner WS (1994) Plasma retinol-binding protein. In: Sporn MB, Roberts AB, Goodman DS (eds) *The Retinoids: Biology, Chemistry, and Medicine*, 2nd edn. New York: Raven Press, pp. 257–281.

4 Blomhoff R, Wake K (1991) Perisinusoidal stellate cells of the liver: important roles in retinol metabolism and fibrosis. *FASEB J* 5, 271–277.

5 Mangelsdorf DJ, Umesono K, Evans RM (1994) The retinoid receptors. In: Sporn MB, Roberts AB, Goodman DS (eds) *The Retinoids: Biology, Chemistry, and Medicine*, 2nd edn. New York: Raven Press, pp. 319–349.

6 Okuno M, Sato T, Kitamoto T *et al.* (1999) Increased 9,13-di-*cis* retinoic acid in rat hepatic fibrosis: implication for a potential link between retinoid loss and TGF-β mediated fibrogenesis *in vivo*. *J Hepatol* 30, 1073–1080.

7 Altucci L, Gronemeyer H (2001) The promise of retinoids to fight against cancer. *Nature Rev Cancer* 1, 181–193.

8 Kojima S, Okuno M, Matsushima-Nishiwaki R *et al.* (2004) Acyclic retinoid in the chemoprevention of hepatocellular carcinoma. *Int J Oncol* 24, 797–805.

9 Okuno M, Kojima S, Matsushima-Nishiwaki R *et al.* (2004) Retinoids in cancer chemoprevention. *Curr Cancer Drug Targ* 4, 285–298.

10 Adachi S, Moriwaki H, Muto Y *et al.* (1991) Reduced retinoid content in hepatocellular carcinoma with special reference to alcohol consumption. *Hepatology* 14, 776–780.

11 Matsushima-Nishiwaki R, Okuno M, Adachi S *et al.* (2001) Phosphorylation of retinoid X receptor a at serine 260 impairs its metabolism and function in human hepatocellular carcinoma. *Cancer Res* 61, 7675–7682.

12 Adachi S, Okuno M, Matsushima-Nishiwaki R *et al.* (2002) Phosphorylation of retinoid X receptor suppresses its ubiquitination in human hepatocellular carcinoma. *Hepatology* 35, 332–340.

13 Hong WK, Itri LM (1994) Retinoids and human cancer. In: Sporn MB, Roberts AB, Goodman DS (eds) *The Retinoids: Biology, Chemistry, and Medicine*, 2nd edn. New York: Raven Press, pp. 597–630.

14 Moon RC, Metha RG, Rao KVN (1994) Retinoids and cancer in experimental animals. In: Sporn MB, Roberts AB, Goodman DS (eds) *The Retinoids: Biology, Chemistry, and Medicine,* 2nd edn. New York: Raven Press, pp. 573–595.

15 Chen ZX, Xue YQ, Zhang R *et al.* (1991) A clinical and experimental study on all-trans retinoic acid-treated acute promyelocytic leukemia patients. *Blood* 78, 1413–1419.

16 Shiratori Y, Yoshida H, Omata M (2001) Different clinicopathological features of hepatocellular carcinoma in relation to causative agents. *J Gastroenterol* 36, 73–78.

17 Kumada T, Nakano S, Takeda I *et al.* (1997) Patterns of recurrence after initial treatment in patients with small hepatocellular carcinoma. *Hepatology* 25, 87–92.

18 Koda M, Murawaki Y, Mitsuda A *et al.* (2000) Predictive factors for intrahepatic recurrence after percutaneous ethanol injection therapy for small hepatocellular carcinoma. *Cancer* 88, 529–537.

19 Kakumu S (2002) Trends in liver cancer researched by the liver cancer study group of Japan. *Hepatol Res* 24, S21–S27.

20 Nishiguchi S, Kuroki T, Nakatani S *et al.* (1995) Randomized trial of effects of interferon-alpha on the incidence of hepatocellular carcinoma in chronic active hepatitis C with cirrhosis. *Lancet* 346, 1051–1055.

21 Yoshida H, Shiratori Y, Moriyama M *et al.* (1999) Interferon therapy reduces the risk for hepatocellular carcinoma: National surveillance program of cirrhotic and noncirrhotic patients with chronic hepatitis C in Japan. *Ann Intern Med* 131, 174–181.

22 Muto Y, Moriwaki H, Ninomiya M *et al.*(1996) Prevention of second primary tumors by an acyclic retinoid, polyprenoic acid, in patients with hepatocellular carcinoma. *N Engl J Med* 334, 1561–1567.

23 Muto Y, Moriwaki H, Saito A (1999) Prevention of second primary tumors by an acyclic retinoid in patients with hepatocellular carcinoma. *N Engl J Med* 340, 1046–1047.

24 Moriwaki H, Yasuda I, Shiratori Y *et al.* (1997) Deletion of serum lectin-reactive a-fetoprotein by acyclic retinoid: a potent biomarker in the chemoprevention of second primary hepatoma. *Clin Cancer Res* 3, 727–731.

25 Moriwaki H, Okuno M, Shiratori Y *et al.* (2000) Clonal deletion, a novel strategy of cancer control that falls between cancer chemoprevention and cancer chemotherapy: a clinical experience in liver cancer. In: Okita K (ed.) *Frontiers in Hepatology: Progress in Hepatocellular Carcinoma Treatment.* Tokyo: Springer-Verlag, pp. 97–103.

26 Okuno M, Sano T, Matsushima-Nishiwaki R *et al.* (2001) Apoptosis induction by acyclic retinoid: a molecular basis of 'clonal deletion' therapy for hepatocellular carcinoma. *Jpn J Clin Oncol* 31, 359–362.

27 Matsushima-Nishiwaki R, Okuno M, Takano Y *et al.* (2003) Molecular mechanism for growth suppression of human hepatocellular carcinoma cells by acyclic retinoid. *Carcinogenesis* 24, 1353–1359.

28 DeLuca HF (2004) Overview of general physiologic features and functions of vitamin D. *Am J Clin Nutr* 80, 1689S–1696S.

29 Ohyama Y, Yamasaki T (2004) Eight cytochrome P450s catalyze vitamin D metabolism. *Front Biosci* 9, 3007–3018.

30 Jones G, Strugnell SA, DeLuca HF (1998) Current understanding of the molecular actions of vitamin D. *Physiol Rev* 78, 1193–1231.

31 Pourgholami MH, Morris DL (2004) 1,25-Dihydroxyvitamin D3 in lipiodol for the treatment of hepatocellular carcinoma: cellular, animal and clinical studies. *J Steroid Biochem Mol Biol* 89–90, 513–518.

32 Suda T, Ueno Y, Fujii K *et al.* (2002) Vitamin D and bone. *J Cell Biochem* 88, 259–266.

33 Sandgren ME, Bronnegard M, DeLuca HF (1991) Tissue distribution of the 1,25-dihydroxyvitamin D3 receptor in the male rat. *Biochem Biophys Res Commun* 181, 611–616.

34 Gascon-Barre M, Demers C, Mirshahi A *et al.* (2003) The normal liver harbors the vitamin D nuclear receptor in nonparenchymal and biliary epithelial cells. *Hepatology* 37, 1034–1042.

35 Dalhoff K, Dancey J, Astrup L *et al.* (2003) A phase II study of the vitamin D analogue Seocalcitol in patients with inoperable hepatocellular carcinoma. *Br J Cancer* 89, 252–257.

36 Crosbie OM, Freaney R, McKenna MJ *et al.* (1999) Bone density, vitamin D status, and disordered bone remodeling in end-stage chronic liver disease. *Calcif Tissue Int* 64, 295–300.

37 Heaney RP (2004) Functional indices of vitamin D status and ramifications of vitamin D deficiency. *Am J Clin Nutr* 80, 1706S–1709S.

38 Diamond T, Stiel D, Mason R *et al.* (1989) Serum vitamin D metabolites are not responsible for low turnover osteoporosis in chronic liver disease. *J Clin Endocrinol Metab* 69, 1234–1239.

39 Cantorna MT, Zhu Y, Froicu M *et al.* (2004) Vitamin D status, 1,25-dihydroxyvitamin D3, and the immune system. *Am J Clin Nutr* 80, 1717S–1720S.

40 Andreassen H, Rungby J, Dahlerup JF *et al.* (1997) Inflammatory bowel disease and osteoporosis. *Scand J Gastroenterol* 32, 1247–1255.
41 Vogel A, Strassburg CP, Manns MP (2002) Genetic association of vitamin D receptor polymorphisms with primary biliary cirrhosis and autoimmune hepatitis. *Hepatology* 35, 126–131.
42 Fan L, Tu X, Zhu Y *et al.* (2005) Genetic association of vitamin D receptor polymorphisms with autoimmune hepatitis and primary biliary cirrhosis in the Chinese. *J Gastroenterol Hepatol* 20, 249–255.

2.3.12 Normal iron metabolism

Kyle E. Brown

Introduction

Iron is an essential nutrient, but one with considerable potential for toxicity. It is therefore understandable that the uptake and disposition of iron are controlled by elaborate physiological mechanisms. Although the highly regulated nature of iron metabolism has been recognized for decades, the mechanisms governing its regulation have only recently been elucidated. This has been made possible by the discovery of a variety of proteins involved in iron transport, as well as the iron-regulatory hormone, hepcidin. The aim of this chapter is to provide an overview of iron metabolism with an emphasis on these new discoveries, particularly as they relate to the liver.

Overview of iron metabolism

Before describing these discoveries, a brief review of iron metabolism is necessary. Iron metabolism is a highly conservative process characterized by recycling. The body of the average adult male contains approximately 5 g of iron, of which the single largest component is the haemoglobin contained in the erythrocytes. At the end of their relatively short lifespan, these cells are destroyed, their haemoglobin catabolized and the resulting iron made available for reuse in the synthesis of haemoglobin, myoglobin or any of a number of iron-requiring enzymes, including the cytochrome P450 system, ribonucleotide reductase and the prolyl hydroxylases. In an iron-replete individual, some iron is stored, primarily in the liver, spleen and bone marrow. Hence, once absorbed, iron is conserved. This observation is underscored by the fact that there is no regulated pathway for the excretion of iron, and daily iron loss is negligible, resulting mostly from desquamation of cells.

Given the lack of a regulated means of excreting iron, the control of iron uptake is clearly of paramount importance. The duodenum and proximal jejunum are the main sites of absorption of dietary iron. Haem iron is absorbed more efficiently than non-haem iron, apparently by endocytosis of the intact iron–protoporphyrin complex at the enterocyte brush border. Iron is then liberated from the haem moiety by the action of haem oxygenase and enters the intracellular iron pool from which it can be transferred across the basolateral membrane, bind to transferrin and enter the circulation. In contrast, the absorption of non-haem iron is more limited, in part as a result of its more complex uptake. As detailed below, absorption of non-haem iron requires reduction of ferric iron at the brush border membrane, followed by internalization by a proton-coupled transporter. Presumably, once iron derived from non-haem sources enters the intracellular iron pool within the enterocyte, its fate is similar to that of haem-derived iron. It is worth noting that, although a great deal has been learned about the mechanisms controlling iron absorption, iron stores exert a major influence on this process under physiological conditions but the means by which iron stores are sensed remains unclear.

Iron transport and uptake mechanisms

Because of the ability of iron to catalyse the production of reactive intermediates, its uptake and transit through the body require mechanisms to diminish its reactivity and thus prevent free radical generation. One of the means by which this is accomplished is by the binding of iron to proteins for transportation and storage. Thus, iron is transported in the blood bound to transferrin. Each molecule of transferrin can bind two atoms of ferric iron. Transferrin-bound iron is taken up at the cell membrane by the interaction of transferrin with the extracellular ligand-binding domain of the transferrin receptor 1 (TfR1). Upon binding of transferrin to TfR1, the entire complex is internalized by receptor-mediated endocytosis. Iron dissociates from transferrin in the acidic milieu of the endosome and then enters the intracellular iron pool, from which it is incorporated into iron-containing proteins, while apotransferrin and TfR1 are recycled to the cell membrane.

The abundance of TfR1 is regulated by cellular iron status, while the identical mechanism controls expression of the iron-storage protein ferritin in an inverse manner. Cellular iron content determines the composition of a cytosolic protein termed the iron regulatory protein 1 (IRP1). Under iron-replete conditions, IRP1 contains a 4Fe–4S cluster that is unable to bind to iron-responsive elements (IRE) in the mRNAs of TfR1 and ferritin. When cellular iron content is low, the iron–sulphur cluster is disassembled, liberating an apo-IRP that binds to specific stem–loop structures in the 3′ or 5′ untranslated regions (UTRs) of the mRNAs encoding these proteins. In the case of TfR1, the IREs are located in the 3′ UTR, and binding of IRP1 increases the stability of the message and enhances the synthesis of TfR1. Conversely, binding of IRP1 to the IREs in the 5′ UTR of ferritin mRNA mediates translation repression. Thus, under iron-replete conditions, there is more rapid turnover of TfR1 mRNA, leading to diminished translation and cell-surface expression of TfR1, reduced uptake of transferrin-bound iron and an expanded capacity for iron storage through increased synthesis

of ferritin. Cellular iron deficiency, on the other hand, reverses these phenomena by promoting TfR1 expression and uptake of transferrin-bound iron while diminishing synthesis of ferritin.

In contrast to TfR1, the recently described transferrin receptor 2 (TfR2) has a rather restricted tissue distribution, with the liver the predominant site of expression, and lower levels reported in erythroid precursors and enterocytes [1]. Interestingly, both the 3′ and the 5′ UTRs of TfR2 mRNA lack IREs, indicating that its regulation differs from that of TfR1. Consistent with this observation, hepatic TfR2 expression is not downregulated by iron overload [2]. Given that the liver is a major site for iron storage, the high level of expression of TfR2 and its lack of responsiveness to iron status might be viewed as a protective mechanism, selectively diverting iron to hepatocytes under conditions in which circulating levels of transferrin-bound iron are high and peripheral iron stores are replete. However, the notion that TfR2 merely serves as a reserve is contradicted by the finding that subjects with mutations affecting TfR2 develop a form of non-*HFE* haemochromatosis (type 3) [3]. These observations indicate that TfR2 must serve additional functions, perhaps playing a role in modulating intestinal iron uptake and/or sensing of body iron stores.

In normal individuals, nearly all cellular acquisition of iron from blood occurs via transferrin receptor-mediated uptake, as virtually all the iron in the circulation is bound to transferrin. In circumstances in which the binding capacity of transferrin becomes saturated, as for example in iron loading disorders, iron forms low-molecular-weight complexes, the most abundant of which is iron citrate. It has been known for years that hepatic clearance of this non-transferrin-bound iron (NTBI) is rapid and highly efficient. Furthermore, studies in isolated perfused rat livers and cultured hepatocytes indicated that hepatic uptake of NTBI involves a membrane carrier protein whose iron transport function is subject to competition by other divalent metal ions. Based on these characteristics, it appears that the recently discovered divalent metal transporter 1 (DMT1; also known as DCT1 and Nramp-2) is the major transporter accounting for hepatic uptake of NTBI.

Using a cDNA library prepared from iron-deficient rat intestine, the DMT1 transcript was identified by its ability to increase iron uptake in *Xenopus* oocytes [4]. DMT1 has subsequently been shown to transport various divalent metal ions in a manner that is coupled to the transport of protons. Although DMT1 mRNA is broadly expressed in mammalian tissues including liver, its highest level of expression is found in the proximal intestine, consistent with its role in the absorption of dietary non-haem iron. Two isoforms of DMT1 have been described. The form of DMT1 that predominates in the intestine has an IRE in its 3′ UTR, indicating that the stability of this transcript is regulated by cellular iron status in a manner similar to that of TfR1. Reciprocal changes in duodenal DMT1 expression *vis-à-vis* iron status have been demonstrated in iron-deficient rats and in humans with iron deficiency and iron overload [5]. Collectively, these data provide evidence for a negative feedback loop in which iron status regulates intestinal DMT1 expression, which in turn controls iron uptake.

Less is known about the regulation and function of DMT1 in the liver. Data concerning the regulation of DMT1 expression by iron status in the liver are inconsistent, with some studies reporting that iron deficiency increases DMT1 mRNA in a manner similar to that of the intestine, while others find no change with altered iron status. Rather surprisingly, livers of rats fed an iron-deficient diet are reported to lack DMT1 immunoreactivity, while those from animals fed an iron-enriched diet demonstrate a pattern of DMT1 reactivity similar to that in the livers of animals fed a control diet, only much more intense [6]. This finding may reflect induction of the non-IRE-regulated form of DMT1, which contains metal responsive elements in its 5′ regulatory region. Nonetheless, it is unclear why the IRE-regulated form of DMT1 (which is also present in liver) is repressed in liver under conditions of iron deficiency. It is evident that the regulation of DMT1 expression in the liver requires further study.

Questions also remain regarding the cellular localization of DMT1 in the liver. While *in situ* hybridization of DMT1 mRNA demonstrated diffuse, low-level expression confined to hepatocytes, results of quantitative polymerase chain reaction (PCR) studies on carefully isolated liver cell populations indicate that DMT1 transcripts are present in hepatocytes, sinusoidal endothelial cells, Kupffer cells and hepatic stellate cells, with the highest levels of expression observed in the last two cell types [7]. These results are particularly interesting in view of the finding that DMT1 immunoreactivity in normal rat liver is observed along the sinusoids, consistent with expression of the transporter on the microvilli of hepatocytes, where it can take up NTBI (or other divalent metals) from the subendothelial space. However, based on the PCR results and the immunostaining, one or more types of sinusoidal lining cells may also acquire iron from sinusoidal blood via DMT1. Further studies are needed to determine the sources and significance of non-parenchymal cell DMT1 expression.

Another issue relevant to DMT1 in liver is the mechanism by which iron is reduced prior to uptake by the transporter. Under physiological conditions, iron exists predominantly in the ferric (+3) state. Uptake by cellular transport systems requires that iron undergoes reduction to the ferrous (+2) state. Recent studies have identified a ferric reductase that is highly expressed in the proximal intestine, termed duodenal cytochrome *b* (Dcytb) [8]. A haem protein, Dcytb, is upregulated by conditions that stimulate iron absorption, including iron deficiency, chronic anaemia and hypoxia. The mechanism by which its expression is upregulated in these conditions is unclear, as there are no obvious IREs in the mRNA of Dcytb. Nevertheless, the localization of Dcytb on the brush border of duodenal enterocytes closely mirrors that of DMT1, supporting the concept that Dcytb supplies ferrous iron to DMT1. Presumably, hepatocellular uptake of NTBI via DMT1 has a similar requirement for ferrous iron. However, whether the reductase that serves this

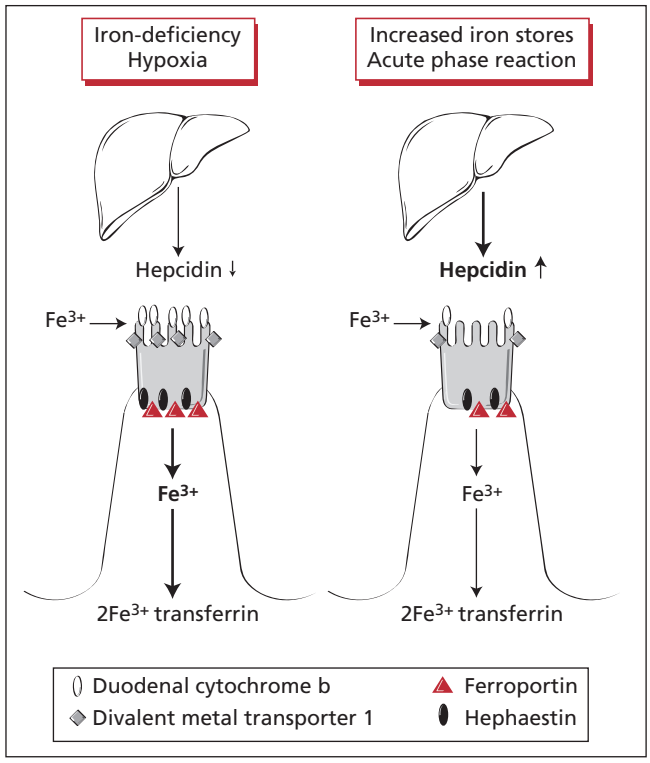

Fig. 1 Schematic representation of effects of various stimuli on hepcidin and its effects on iron transporters in the enterocyte. Dcytb, duodenal cytochrome *b*; DMT1, divalent metal transporter 1; Fpn, ferroportin; Heph, hephaestin.

function on hepatocytes (and other liver cells that express DMT1) is identical to Dcytb is currently unknown.

Iron mobilization and export (see Fig. 1)

Given that the liver is a site of iron storage under physiological conditions, it is apparent that there must be mechanisms by which iron stored in the liver can be mobilized and exported to extrahepatic tissues. Under normal physiological circumstances, Kupffer cells play a prominent role in interorgan iron trafficking. One of the primary sites of erythrocyte turnover, Kupffer cells, along with the reticuloendothelial cells of the spleen and bone marrow, ingest senescent or damaged red blood cells, catabolize the haemoglobin and release the iron. Collectively, the quantity of iron that is recycled from erythrocytes through the macrophage compartment on a daily basis is severalfold greater than that taken up through the intestine. Hence, the contribution of Kupffer cells to total body iron economy is both qualitatively and quantitatively important. It is therefore not surprising that Kupffer cells are the major type of liver cell that express a recently described iron exporter, ferroportin (Fpn; also known as Ireg1 and MTP1) [9–11].

In the intestine, Fpn expression is upregulated by iron deficiency and anaemia. Although this makes sense from a physiological perspective, it is somewhat surprising in view of the presence of IREs in the 5′ UTR of Fpn mRNA, rather than in the 3′ UTR as would be expected, given the similarity of its regulation to that of DMT1 and TfR1. As illustrated by the example of ferritin, binding of IRPs to IREs in the 5′ region generally results in translational repression. It has been proposed that the IRE in the 5′ UTR may be non-functional in the intestine. If so, this suggests that Fpn expression may be regulated by different mechanisms in different tissues and/or cell types, as the intensity of Fpn staining of Kupffer cells in murine livers is reported to increase with iron loading [11].

Consistent with its role in iron absorption, Fpn is expressed at high levels along the basolateral membrane in mature enterocytes of the duodenal villi. In addition, Fpn transcripts are also detected in liver, spleen, kidney and placenta. In murine liver, hepatocytes as well as Kupffer cells show immunoreactivity for Fpn, albeit less intense. The quantitative PCR study on isolated cells from rat livers discussed above reported similar levels of Fpn transcripts in hepatocytes, Kupffer cells and stellate cells, and lower levels in sinusoidal endothelial cells [7]; however, Fpn protein has not been demonstrated in the last two cell types. Interestingly, the subcellular localization of Fpn appears to differ between hepatocytes and Kupffer cells, being localized to the plasma membrane along the sinusoidal border in the former and cytoplasmic in the latter [11]. It has been proposed that the intracellular localization of Fpn in Kupffer cells (which is also observed in RAW267.4 cells, a murine macrophage cell line) indicates that Fpn does not directly export iron across the plasma membrane in these cells but, rather, that it may participate in intracellular trafficking of iron, perhaps through the secretory pathway. Further studies are needed to determine whether Fpn is involved in multiple pathways of iron export.

Like cellular uptake of iron, efflux of iron from cells requires ferroxidase activity. It has been known for some time that ceruloplasmin, a copper-containing plasma ferroxidase synthesized by hepatocytes, plays an important role in iron homeostasis. Aceruloplasminaemia results in a form of iron overload that is recapitulated in mice with a targeted disruption of the ceruloplasmin gene [12]. Interestingly, although the ceruloplasmin knockout mice accumulate iron in both hepatocytes and Kupffer cells, intestinal iron absorption is unaffected by ceruloplasmin deficiency.

The recent discovery of a homologue of ceruloplasmin that is expressed at high levels in intestinal villi, termed hephaestin, probably accounts for this observation [13]. Despite their similarities, the function of hephaestin is distinct from that of ceruloplasmin, as mutations in hephaestin lead to iron deficiency rather than iron overload. This is illustrated by the sex-linked anaemia (*sla*) mouse, in which a mutation in hephaestin impairs the transfer of iron out of the enterocyte, resulting in microcytic, hypochromic anaemia. The divergent phenotypes of the ceruloplasmin knockout and the *sla* mouse appear to indicate that one ferroxidase has little if any ability to substitute functionally for the other. As hephaestin is membrane bound, this may indicate a

requirement for close physical proximity of the ferroxidase to Fpn for efficient iron export, at least in the enterocyte. In this context, it is interesting to contrast hepatocytes, which have low levels of Fpn protein and lack detectable hephaestin transcripts, with Kupffer cells, which have more robust levels of Fpn and express hephaestin transcripts, albeit at levels that are considerably lower than the intestine [7]. Taken together, these observations suggest either that the ferroxidase activity of ceruloplasmin can indeed substitute for hephaestin in Fpn-expressing cells in the liver (but not in the intestine), or that hepatocytes and possibly Kupffer cells as well may employ additional means to promote iron export, such as upregulation of hephaestin in response to iron loading and/or the expression of alternative exporters or ferroxidases.

Another gene involved in iron metabolism that is highly expressed in the liver as well as the intestine is HFE (see also Chapter 16.2, Haemochromatosis). Originally identified on the basis of a high frequency of HFE mutations in patients with genetic haemochromatosis, wild-type HFE protein forms a complex at the plasma membrane with TfR1 and β2-microglobulin. Studies in transfected cells indicate that the stoichiometry of these components influences the rate of recycling of TfR1, thus modulating iron uptake [14]. Nonetheless, the precise mechanism whereby HFE mutations lead to iron loading remains speculative. While immunohistochemistry for HFE demonstrates a distinctive pattern of intracellular perinuclear staining in the epithelial cells of the small intestine [15], immunoreactivity for HFE in liver has been variously ascribed to bile ducts, sinusoidal lining cells, Kupffer cells and endothelial cells. Furthermore, these studies are at variance with results of PCR and Western blot analysis of isolated liver cells demonstrating that hepatocytes are the major source of HFE in rat liver, with a minor contribution from Kupffer cells [7]. Additional studies are needed to resolve this discrepancy and provide further insight into the function of HFE.

In contrast to the genes encoding HFE and proteins involved in iron transport, haemojuvelin mRNA is not abundantly expressed in the intestine. Rather, the highest levels of expression are seen in skeletal muscle, with lower levels in cardiac muscle and liver, where haemojuvelin transcripts are localized to periportal hepatocytes. Haemojuvelin was discovered by positional cloning of the locus associated with juvenile haemochromatosis [16]. Subsequently, two groups have reported that targeted deletion of haemojuvelin in mice results in iron overload [17,18]. While the function of haemojuvelin is unknown, it has been proposed that haemojuvelin is 'upstream' of hepcidin in the pathways controlling iron metabolism, as both patients with iron overload resulting from haemojuvelin mutations and haemojuvelin knockout mice fail to respond to their iron burden with an appropriate increase in hepcidin. A direct interaction between these two proteins seems unlikely, however, given that hepatic expression of haemojuvelin is not altered in mice treated with parenteral iron, while the same livers show a robust increase in hepcidin mRNA. Thus, the available data demonstrate lack of responsiveness of haemojuvelin to iron as well as divergent regulation of haemojuvelin and hepcidin in normal animals treated with iron.

A major advance in the understanding of iron metabolism was the discovery of the iron regulatory hormone hepcidin. Hepcidin was originally identified as an antimicrobial peptide isolated from human urine [19]. The liver is the predominant source of hepcidin, where the 84-amino-acid prepropeptide is synthesized and cleaved to yield 20- and 25-amino-acid peptides that are released into the circulation and filtered by the kidney. Consistent with release into the blood from hepatocytes, hepcidin immunoreactivity is observed along the sinusoidal borders of hepatocyte membranes, with accentuated staining of periportal (zone 1) hepatocytes [20].

The initial finding linking hepcidin to iron metabolism came about through the use of subtractive hybridization to identify genes upregulated by iron overload in murine livers [21]. Later studies demonstrated that hepcidin knockout mice develop a form of iron overload reminiscent of hereditary haemochromatosis [22], while mice with overexpression of hepcidin have severe iron-deficiency anaemia [23]. These data led to the conclusion that hepcidin is a negative regulator of intestinal iron absorption, an inference that has since been confirmed by administration of synthetic hepcidin to rodents.

In addition to iron status, hepcidin expression is modulated by hypoxia and inflammation [24]. In the latter case, hepcidin is an acute-phase reactant, and its induction in response to inflammatory mediators accounts for several phenomena associated with anaemia of chronic disease [25,26]. Although the responsiveness of hepcidin to interleukin-1, interleukin-6 and tumour necrosis factor-α is established, the mechanism by which these mediators influence hepcidin expression is not known. Evidence to date indicates that hepcidin expression is regulated primarily at the transcriptional level. CCAAT enhancer binding protein α, a transcription factor involved in the control of many hepatocyte-specific genes, is a major positive regulator of hepcidin gene expression in the basal state [27]. However, the mechanisms involved in the induction or suppression of hepcidin expression in response to various stimuli have not been delineated, including the means by which iron status modulates hepcidin. There are no apparent IREs in the hepcidin transcript. Furthermore, isolated hepatocytes do not respond to exogenous iron in cell culture [21], suggesting that, *in vivo*, some other cell type senses iron levels and communicates that information to hepatocytes. Although Kupffer cells are likely candidates for this function, recent studies in rodents have shown an appropriate hepcidin response to iron following elimination of Kupffer cells [28,29]. Hence, this aspect of hepcidin biology remains poorly understood.

Subsequent studies have provided insight into the mechanisms by which hepcidin modulates iron absorption. Within a week of being placed on a low-iron diet, rats show a twofold increase in intestinal iron absorption that is temporally associated with a significant drop in hepatic hepcidin expression, and

increases in duodenal mRNAs for Dcytb, DMT1 and Fpn [30] (see Fig. 1). Although the increase in Fpn mRNA under these circumstances is of relatively small magnitude, the increase in Fpn protein is more substantial. A similar pattern is seen in the intestine of hepcidin knockout mice, providing additional evidence that hepcidin suppresses the expression of these iron transporters. While the role of hepcidin in the regulation of Dcytb and DMT1 has not been characterized, several reports have established that Fpn is a major target of hepcidin's action. As suggested by the observations discussed above, hepcidin appears to regulate Fpn expression by two distinct mechanisms. The first is at the level of Fpn transcripts, which are decreased following stimulation of endogenous hepcidin production or administration of recombinant hepcidin [31]. The second involves binding of hepcidin to Fpn at the cell membrane, causing internalization and degradation of Fpn, thus diminishing iron transfer [32]. These mechanisms are clearly not mutually exclusive and, while either or both probably contribute to the decrease in intestinal iron absorption in response to hepcidin, it is unclear at present whether Fpn expression in liver cells is regulated in the same manner. In mice treated with iron, intestinal Fpn expression is low, consistent with the known effects of hepcidin. In the liver, however, Fpn is increased, particularly in Kupffer cells [11]. This may result from enhanced translation due to the presence of the IRE in the 5′ UTR of Fpn mRNA. If so, this effect must predominate over the hepcidin-induced increase in Fpn turnover. Alternatively, the distinctive intracellular pattern of Fpn in Kupffer cells implies that Fpn may not physically interact with hepcidin in macrophages, again raising the possibility of differential regulation of Fpn in liver vs. intestine. Further characterization of the effect of hepcidin on the regulation of iron transporters in the liver and its physiological consequences will help to clarify these issues.

The development of iron overload in hepcidin knockout mice [22] and humans with mutations in the hepcidin gene [33] is clearly explicable by the effects of hepcidin on intestinal iron absorption. Since the discovery of hepcidin, several authors have reported that hepcidin expression fails to increase in response to increased iron stores in other disease states characterized by iron loading. For example, hepcidin expression is inappropriately low in iron-loaded subjects with hereditary haemochromatosis [34] and haemojuvelin mutations [16]. Similar findings are reported in a variety of iron-loading anaemias [35]. These observations have led to the concept that 'upstream' iron-related proteins such as HFE and haemojuvelin must in some way control hepcidin expression such that, when these proteins are mutated, dysregulation of hepcidin results. It is clear that the response of hepcidin is defective in all these disorders, as 'appropriate' levels of hepcidin would prevent the progressive accumulation of iron. Nonetheless, it is unclear whether there are direct interactions between hepcidin and other 'upstream' iron regulatory proteins, or whether endogenous iron loading (secondary to HFE or haemojuvelin mutations, for example, as opposed to administration of dietary or parenteral iron) leads to aberrant sensing of iron stores, thus accounting for the dysregulation of hepcidin expression, which then becomes the final common pathway of iron overload. Efforts to elucidate this question are limited by the current lack of knowledge regarding the mechanism by which iron status regulates hepcidin expression.

References

1 Kawabata H, Yang R, Hirama T *et al.* (1999) Molecular cloning of transferrin receptor 2. *J Biol Chem* 274, 20826–20832.

2 Fleming RE, Migas MC, Holden CC *et al.* (2000) Transferrin receptor 2: continued expression in mouse liver in the face of iron overload and in hereditary hemochromatosis. *Proc Natl Acad Sci USA* 97, 2214–2219.

3 Roetto A, Totaro A, Piperno A *et al.* (2001) New mutations inactivating transferrin receptor 2 in hemochromatosis type 3. *Blood* 97, 2555–2560.

4 Gunshin H, Mackenzie B, Berger UV *et al.* (1997) Cloning and characterization of a mammalian proton-coupled metal-ion transporter. *Nature* 388, 482–488.

5 Zoller H, Koch RO, Theurl I *et al.* (2001) Expression of duodenal iron transporters divalent-metal iron transporter 1 and ferroportin 1 in iron deficiency and iron overload. *Gastroenterology* 120, 1412–1419.

6 Trinder D, Oates PS, Thomas C *et al.* (2000) Localisation of divalent metal transporter 1 (DMT1) to the microvillus membrane of rat duodenal enterocytes in iron deficiency, but to hepatocytes in iron overload. *Gut* 46, 270–276.

7 Zhang A-S, Xiong S, Tsukamoto H *et al.* (2004) Localization of iron metabolism-related mRNAs in rat liver indicate that HFE is expressed predominantly in hepatocytes. *Blood* 103, 1509–1514.

8 McKie AT, Barrow D, Latunde-Dada GO *et al.* (2001) An iron-regulated ferric reductase associated with the absorption of dietary iron. *Science* 291, 1755–1758.

9 Donovan A, Brownlie A, Zhou Y *et al.* (2000) Positional cloning of zebrafish *ferroportin*1 identifies a conserved vertebrate iron exporter. *Nature* 403, 776–781.

10 McKie AT, Marciani P, Rolfs A *et al.* (2000) A novel duodenal iron-regulated transporter, IREG1, implicated in the basolateral transfer of iron to the circulation. *Mol Cell* 5, 299–309.

11 Abboud S, Haile DJ (2000) A novel mammalian iron-regulated protein involved in intracellular iron metabolism. *J Biol Chem* 275, 19906–19912.

12 Harris ZL, Durley AP, Man TK *et al.* (1999) Targeted gene disruption reveals an essential role for ceruloplasmin in cellular iron efflux. *Proc Natl Acad Sci USA* 96, 10812–10817.

13 Vulpe CD, Kuo Y-M, Murphy TL *et al.* (1999) Hephaestin, a ceruloplasmin homologue implicated in intestinal iron transport, is defective in the *sla* mouse. *Nature Genet* 21, 195–199.

14 Waheed A, Grubb JH, Zhou XY *et al.* (2002) Regulation of transferrin-mediated iron uptake by HFE, the protein defective in hereditary hemochromatosis. *Proc Natl Acad Sci USA* 99, 3117–3122.

15 Parkkila S, Waheed A, Britton RS *et al.* (1997) Immunohistochemistry of HLA-H, the protein defective in patients with hereditary hemochromatosis, reveals unique pattern of expression in gastrointestinal tract. *Proc Natl Acad Sci USA* 94, 2534–2539.

16 Papanikolaou G, Samuels ME, Ludwig EH *et al.* (2004) Mutations in *HFE*2 cause iron overload in chromosome 1q-linked juvenile hemochromatosis. *Nature Genet* 36, 77–82.

17 Huang FW, Pinkus JL, Pinkus GS *et al.* (2005) A mouse model of juvenile hemochromatosis. *J Clin Invest* 115, 2187–2191.
18 Niederkofler V, Salie R, Arber S (2005) Hemojuvelin is essential for dietary iron sensing, and its mutation leads to severe iron overload. *J Clin Invest* 115, 2180–2186.
19 Park CH, Valore EV, Waring AJ *et al.* (2001) Hepcidin, a urinary antimicrobial peptide synthesized in the liver. *J Biol Chem* 276, 7806–7810.
20 Kulaksiz H, Gehrke SG, Janetzko A *et al.* (2004) Pro-hepcidin: expression and cell specific localisation in the liver and its regulation in hereditary haemochromatosis, chronic renal insufficiency, and renal anaemia. *Gut* 53, 735–743.
21 Pigeon C, Ilyin G, Courselaud B *et al.* (2001) A new mouse liver-specific gene, encoding a protein homologous to human antimicrobial peptide hepcidin, is overexpressed during iron overload. *J Biol Chem* 276, 7811–7819.
22 Nicolas G, Bennoun M, Devaux I *et al.* (2001) Lack of hepcidin gene expression and severe tissue iron overload in upstream stimulatory factor 2 (USF2) knockout mice. *Proc Natl Acad Sci USA* 98, 8780–8785.
23 Nicolas G, Bennoun M, Porteu A *et al.* (2002) Severe iron deficiency anemia in transgenic mice expressing liver hepcidin. *Proc Natl Acad Sci USA* 99, 4596–4601.
24 Nicolas G, Chauvet C, Viatte L *et al.* (2002) The gene encoding the iron regulatory peptide hepcidin is regulated by anemia, hypoxia, and inflammation. *J Clin Invest* 110, 1037–1044.
25 Nemeth E, Rivera S, Gabayan V *et al.* (2004) IL-6 mediates hypoferremia of inflammation by inducing the synthesis of the iron regulatory hormone hepcidin. *J Clin Invest* 113, 1271–1276.
26 Lee P, Peng H, Gelbart T *et al.* (2005) Regulation of hepcidin transcription by interleukin-1 and interleukin-6. *Proc Natl Acad Sci USA* 102, 1906–1910.
27 Courselaud B, Pigeon C, Inoue Y *et al.* (2002) C/EBPα regulates hepatic transcription of hepcidin, an antimicrobial peptide and regulator of iron metabolism. *J Biol Chem* 277, 41163–41170.
28 Montosi G, Corradini E, Garuti C *et al.* (2005) Kupffer cells and macrophages are not required for hepatic hepcidin activation during iron overload. *Hepatology* 41, 545–552.
29 Lou D-Q, Lesbordes J-C, Nicolas G *et al.* (2005) Iron- and inflammation-induced hepcidin gene expression in mice is not mediated by Kupffer cells *in vivo*. *Hepatology* 41, 1056–1064.
30 Frazer DM, Wilkins SJ, Becker EM *et al.* (2002) Hepcidin expression inversely correlates with the expression of duodenal iron transporters and iron absorption in rats. *Gastroenterology* 123, 835–844.
31 Yeh K-Y, Yeh M, Glass J (2004) Hepcidin regulation of ferroportin 1 expression in the liver and intestine of the rat. *Am J Physiol* 286, G385–G394.
32 Nemeth E, Tuttle MS, Powelson J *et al.* (2004) Hepcidin regulates cellular iron efflux by binding to ferroportin and inducing its internalization. *Science* 306, 2090–2093.
33 Roetto A, Papanikolaou G, Politou M *et al.* (2003) Mutant antimicrobial peptide hepcidin is associated with severe juvenile hemochromatosis. *Nature Genet* 33, 21–22.
34 Bridle KR, Frazer DM, Wilkins SJ *et al.* (2003) Disrupted hepcidin regulation in *HFE*-associated haemochromatosis and the liver as a regulator of body iron homeostasis. *Lancet* 361, 669–673.
35 Papanikolaou G, Tzilianos M, Christakis JI *et al.* (2005) Hepcidin in iron overload disorders. *Blood* 105, 4103–4105.

2.3.13 Normal copper metabolism and lowering copper to subnormal levels for therapeutic purposes

George J. Brewer, Edward D. Harris and Fred K. Askari

Introduction

In this chapter, we will first provide a review of current knowledge about copper metabolism. Copper is an essential trace element, and the normal diet contains an average of about 1.0 mg. This is about 25% more than is required, and most of the excess is normally excreted by the liver into the bile for loss in the stool. Hence, the liver is important in regulating copper balance and other aspects of metabolism. Excellent progress has been made in understanding copper metabolism in the body, thanks in part to discoveries of the genes that cause two copper-related diseases, ATP7A for Menkes' disease and ATP7B for Wilson's disease (see Chapter 16.1). Progress has also been helped by the elucidation of the roles of copper chaperones, evolutionarily conserved genes whose protein products facilitate transfer of copper to target proteins or vesicles. In the second part of the chapter, a new area involving copper will be reviewed, that of the therapeutic use of lowering copper to subnormal levels to treat cancer and diseases of inflammation and fibrosis.

Copper metabolism and its role in health and disease

Introduction

The essentiality of copper in human health has been recognized for more than 70 years. Severe copper deficiency, whether genetic or acquired, can produce devastating disease and death. The toxic properties of copper were brought to the forefront of scientific attention when a disease described by Wilson in the early 1900s called 'hepatolenticular degeneration' was later discovered to be due to copper accumulation and toxicity [1]. The liver plays a prominent role in copper distribution to organs and regulates overall system homeostasis. Bile, not urine, for eventual loss in the stool, is the major excretory route for copper. Normal urine copper loss is 20–50 μg/day, whereas stool copper loss is in the order of 1.0 mg/day. Transport through the blood to the absorption surfaces of cells has yet to be clarified with certainty. Transport through the membrane and into cytosolic proteins, however, is becoming better understood [2]. The discovery of two structurally related membrane-bound Cu-ATPases, ATP7A and ATP7B, defective in Menkes' and Wilson's diseases, respectively, has provided insight into intracellular copper movement and control of its excretion from the cell. These discoveries have also provided unprecedented biochemical insights into diseases of copper metabolism and have formed the basis upon which much of the current theories of cellular copper movement and homeostasis rest.

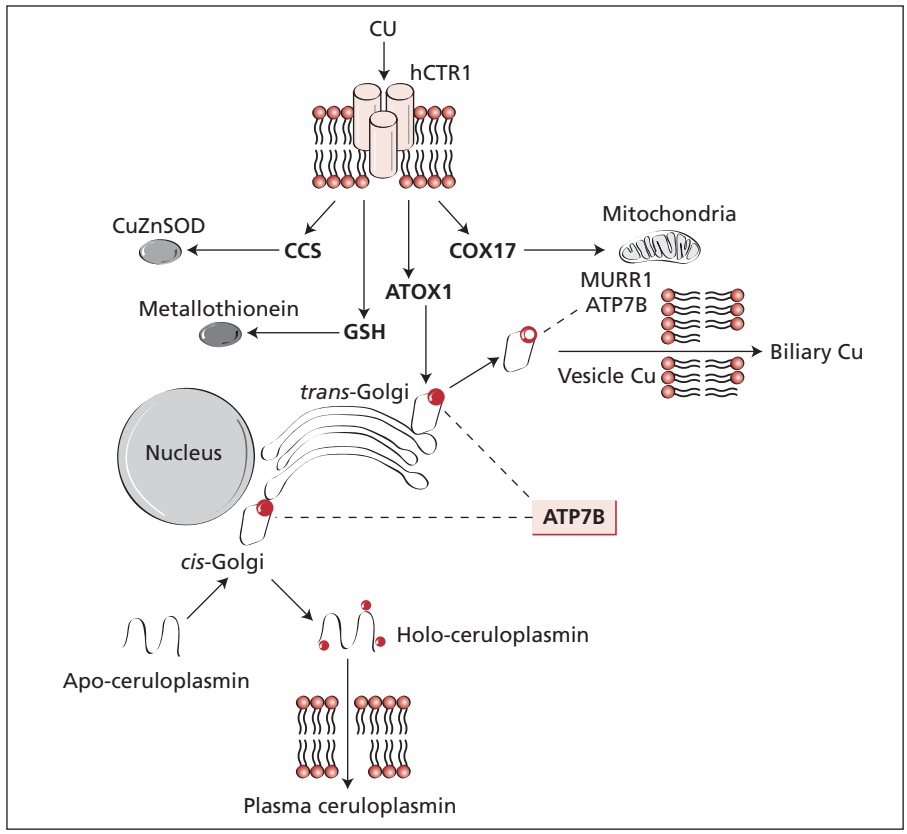

Fig. 1 Overview of liver copper metabolism. Shown are protein chaperones (ATOX1, CCS, COX17) that move intracellular Cu to target proteins. Major excretory routes are the bile and via incorporation into ceruloplasmin. ATP7B, the only Cu-ATPase expressed in liver, performs dual functions in secreting copper from the liver. CuZnSOD, copper/zinc superoxide dismutase; GSH, glutathione; hCTR1, copper transporter.

Chemical properties and copper toxicity

Because copper is a redox metal, unfettered copper is a potential oxidant (or reductant) of cellular proteins, lipids and nucleic acids. This property mandates copper to be in a bound form and not a free ion in blood, extracellular fluids or cytosol. Of its two major valencies, Cu(I) and Cu(II), Cu(I) behaves as a progenitor of free radicals. As a $3d^{10}$ metal ion, Cu(I) also has the potential to antagonize Zn(II). Protein-bound forms of copper are generally responsible for targeted transport to functional biomolecules. The metallothioneins, a family of sulphydryl-rich metal-binding proteins, limit the buildup of mobile copper in cells and work with excretory systems to maintain a steady-state level in the cytosol. Metallothionein synthesis *de novo* is prompted by sudden influxes of copper and other metals into the cell, which clearly demonstrates a genetic-level response system to prevent buildup of copper and other toxic metals in cells and tissues [3]. The protective effects of metallothionein are overwhelmed over time, however, when systems designed to transport copper into bile or release copper from the cell fail to function because of genetic mutations.

The role of the liver in copper homeostasis

The prevailing understanding is that copper absorption occurs mostly at the intestinal mucosa, and copper utilization culminates with the incorporation of Cu(I) and Cu(II) ions into cellular enzymes or storage proteins. The liver intervenes as a major hub for copper distribution to peripheral organs or excretion in the bile (Fig. 1). Dietary copper entering the liver from the portal circulation passes into the liver parenchymal cells after being handed off from binding sites primarily on serum albumin. Transport through the membranes will be discussed below. Upon entering the hepatocytes, copper is met by glutathione (GSH) and sequestered. Another series of proteins, the copper chaperones (Table 1), direct copper to intracellular enzymes or organelles. When bound to chaperones, copper is then positioned to be incorporated directly into either enzymes such as copper/zinc superoxide dismutase [4] or vesicles that represent intracellular compartments along the secretory pathway [5]. The intracellular compartments represent staging areas for incorporating copper into ceruloplasmin or into biliary canaliculi. For example, ATP7B, a Cu-ATPase that is defective in Wilson's disease, is positioned strategically to receive copper from ATOX1 (formerly HAH1), a copper chaperone, and excrete copper from liver via the biliary canaliculi [6]. Precisely how ATP7B governs the movement of copper into the bile is unknown but, clearly, an impairment in that step shifts copper homeostasis towards a failure of biliary excretion and the amassing over time of large amounts of copper in the liver and the rest of the body. Thus, a fault in both copies of the ATP7B gene prevents biliary copper excretion and holo-ceruloplasmin biosynthesis, which are the hallmarks of Wilson's disease.

Table 1 Copper chaperones and transporters.

	Organism	Target or function	Reference
Chaperone			
ATX1	Yeast	CCC_2 protein	[30]
ATOX1	Human orthologue of ATX1 (formerly HAH1)	ATP7A, ATP7B	[6]
CCS	Yeast, human (formerly Lys7 in yeast)	Apo-superoxide dismutase	[12]
COX17	Yeast, mouse, human	Mitochondria	[13]
Transporters			
Ctr1p	Yeast	Membrane copper transport	[7]
hCTR1	Human orthologue of Ctr1p	Membrane copper transport	[7]

Transmembrane movement and the copper chaperones

Gaining access to a cell requires movement across the membrane. hCTR1, a membrane copper transporter in humans (Table 1), has a counterpart in the yeast, Ctr1p, and it is through studies of the yeast protein that many of the properties of copper transporters in humans have become known [7]. Based on these studies, one can surmise that hCtr1 is selective only for Cu(I). This observation necessitates a copper reductase enzyme that changes Cu(II) to Cu(I) to coordinate with transmembrane movement. Precisely how the Cu(I) ions move through the hCTR1 portal is unknown, but recent data suggest that a mechanism involving endocytosis of the carrier is an option [8,9].

Once inside the cell, the metabolic fate of copper relies on copper chaperones, as introduced in the previous section. Chaperones are copper-binding proteins that perform two important functions: (i) sequestering copper to prevent free metal-catalysed oxidations; and (ii) recognizing and conducting copper transfer to intracellular proteins or vesicles. Ions generally rely on the mass action principle to drive the movement of freely diffusible forms. Because free copper concentration is negligible in a cell, it cannot drive reactions and, because of the demand of the many different proteins that require copper for function, intracellular movement relies on copper-binding transport proteins to target specific proteins [10]. A chaperone-bound copper in transit is able to exchange with a target protein, such as enzymes or other proteins, or a membrane-bound Cu-ATPase. Copper chaperones emulate the copper sites on the target protein, thus facilitating the transprotein transfer of copper from chaperone to target [11]. At the present time, several such chaperones are known (Table 1). CCS (copper chaperone for superoxide dismutase) delivers copper to a major antioxidant enzyme in the cell [12]. COX17 is required to move copper into the mitochondria for the binding and assembly of cytochrome *c* oxidase [13] and is essential in embryonic development [14]. ATOX1 mediates the entrance of copper into the secretory pathway through ATP7A and ATP7B, which drive an energy-dependent relocation of copper into vesicles [15].

Cu-ATPases in absorption and cellular homeostasis

There are two phases to intracellular copper transport and movement; these are soluble and vesicle associated. The soluble phase includes components that provide copper to cytosolic enzymes; the vesicle phase is believed to be part of the *trans*-Golgi network for excreting copper from cells. As noted above, two different but functionally similar Cu-ATPases, ATP7A and ATP7B (Table 2), provide the entrance. Wilson's and Menkes' diseases have roots in genetic impairments in ATP7B and ATP7A respectively. ATP7A is found in practically every cell tested, with the exception of adult hepatocytes [16]. ATP7B is prominent in liver, kidney and brain and plays less of a role in other organs [17]. Vesicles laden with ATP7A or ATP7B are mobile and transverse the space between the Golgi and cell surfaces to release copper as part of intestinal absorption or into the biliary canaliculi at the apical surface of hepatocytes. Vesicles that contain ATP7A provide copper to enzymes such as tyrosinase (pigmentation) [18], lysyl oxidase (connective tissue integrity) [19], dopamine-β-monooxygenase (neurotransmitter biosynthesis) [20] or peptidylglycine α-amidating monooxygenase (PAM, neuropeptide hormone biosynthesis; Table 3) [21]. Enhancing the concentration of extracellular copper instigates movement of vesicles towards the plasma membrane [22]. Movement and direction are a function of residues in the N-terminal, copper-binding domain of ATP7A. An exposed dileucine signal at the C-terminal is believe to control

Table 2 Copper regulatory proteins.

Regulatory proteins	Defect	Reference
ATP7A	Causes Menkes' disease	[16]
ATP7B	Causes Wilson's disease	[17]
Murr1	Causes canine copper toxicosis in Bedlington terriers	[25]
XIAP	None known – interacts with Murr1	[29]

Table 3 Neuropeptide hormones that depend on peptidylglycine α-amidating monooxygenase for activity.

Hormone	Biological function	Adverse effects with ageing
Gastrin	Gastric acid secretion	Gastric cancer
Adrenomedullin	Prostate cell growth	Prostrate hypertrophy, cancer
Oleamide	Sleep, lipid synthesis	Sleep disorders, depression
Pancreastatin	Insulin control	Type 2 diabetes
Oxytocin	Water homeostasis	General hydration, skin laxity
Vasopressin	Water homeostasis	General hydration, skin laxity
Substance P	Emotions	Depression
Substance K	Neural transmission	Brain function
Galanin	Neuron modulator	Perception of pain, food intake, memory
Neuropeptide Y	Appetite	Obesity
Cholecystokinin	Satiation	Hyperphagia
Calcitonin	Bone metabolism	Osteoporosis
Releasing hormones		
Corticotrophin	Corticosteroid levels	Immunocompetence, infection
Thyrotrophin	Thyroid hormone levels	Metabolic pace
Melanocyte	Pigmentation, energy	Skin colour, obesity
Gonadotrophin	Sexual hormones	Sexual development, drive

localization of vesicles to the *trans*-Golgi network [23]. Connecting ATP7A and ATP7B, two functionally similar proteins, with two dissimilar diseases has given invaluable insight into pathways of copper movement and homeostasis. Identifying ATP7B with Wilson's disease is a clear indication that ATP7B (i) incorporates copper into ceruloplasmin for excretion into the plasma and (ii) delivers copper to the apical environment of the liver cell. Identifying ATP7A with Menkes' disease tags this Cu-ATPase as an indispensable factor in the absorption of copper across the intestine as well as movement across the blood–brain barrier [24] and into other cells such as the kidney. Moreover, connecting ATP7A-laden vesicles with copper incorporation into apo-tyrosinase, apo-lysyl oxidase and apo-PAM gives a molecular understanding of the phenotypes that are seen in experimental copper deficiencies and inborn genetic diseases, such as Menkes' disease, and age-related impairments in copper metabolism.

Future directions

Several recent discoveries could have an important impact on our understanding of copper metabolism and disease. Murr1 (Table 2) is the name given to a factor that is defective in canines that amass liver copper [25]. The discovery of Murr1 has resolved a mystery as to why Bedlington terriers and some other canine breeds have a Wilson-like copper toxicosis yet, unlike Wilson's disease, have a perfectly functional ATP7B. In humans, the *MURR1* gene maps to chromosome 2. Stuehler *et al.* [26] reported that 19 (30%) of 63 patients with Wilson's disease had mutations in the *MURR1* gene. As to its mechanism, recent studies have shown that Murr1 binds to ATP7B, possibly to direct the movement of that protein to the apical surface of hepatocytes, which is essential to release copper into the bile [27]. Murr1, however, is detected in all tissues and cell types, which suggests that its role in copper homeostasis extends beyond ATP7B binding and movement [28]. A unique interaction between Murr1 and an apoptosis-suppressing protein, XIAP (Table 2), leads to a reduced level of copper in the cell [29]. XIAP, which is known to inhibit certain caspases, interacts with Murr1 to hasten its destruction through a ubiquitin-dependent proteolysis. Cells from *XIAP* knockout mice have reduced copper levels, whereas cells in which Murr1 is suppressed have the expected elevation in cellular copper. The data, therefore, suggest that XIAP indirectly controls cellular copper homeostasis by regulating the turnover of Murr1.

A second discovery relates ATOX1 to the immunophillin protein FKBP52 [30]. The latter is required to render immunosuppressive factors functional. Precisely why ATOX1 binds strongly to the protein is unclear at this time, but the data suggest other factors, regulatory or structural, are involved in the pathway of copper movement in cells. Finally, recognizing that ATP7A is required to incorporate copper into PAM in the brain [21] has linked copper with the biosynthesis of at least 15 neuropeptide hormones, all requiring this structural modification to become functional (Table 3). By being a critical factor in the activation of neuropeptide hormones, copper is elevated to the point of being one of the most important biominerals in cognitive development in early life and, in the later stages, in senescence, diabetes, osteoporosis, cancer and other disorders that occur with ageing.

Lowering copper to subnormal levels for therapeutic purposes

Introduction

In the past, lowering copper levels for therapeutic purposes was used primarily for the treatment of Wilson's disease, a disease of

copper accumulation and copper toxicity. Wilson's disease is covered in Chapter 16.1, and here therefore, we are not referring to Wilson's disease, but to a series of disease conditions that now appear to be potentially treatable by lowering copper levels. Copper levels are essentially normal in these diseases to begin with, but are lowered by therapy to a midrange, not so low as to cause clinical copper deficiency, but low enough to inhibit certain processes involved in specific diseases (for reviews see [31–33]). These processes are angiogenesis, fibrosis and inflammation, and the diseases are cancer, diseases of excessive fibrosis and diseases of excessive inflammation.

Copper and angiogenesis

It is now well established that angiogenesis is required for cancer growth and progression [34,35], and that antiangiogenic therapies are a valid approach to cancer treatment [36]. The essential role of copper in angiogenesis is not so well known, but nonetheless the research in this area dates back two decades [37,38]. It was shown that mild copper deficiency in rabbits, produced by penicillamine and a low copper diet, reduced the angiogenic response in the cornea to known angiogenic stimulants [38]. Tumours explanted to brains of rats and rabbits made copper deficient by this same approach grew more slowly and failed to show vascular invasion of normal tissue, compared with tumours explanted into control rabbits [39,40].

Most of the antiangiogenic, anticancer work that has been done using the lowered copper level approach, subsequent to the work mentioned above, has been done using the anticopper drug, tetrathiomolybdate (TM), originally introduced for the treatment of Wilson's disease [41]. This drug has also been used for the antifibrotic and anti-inflammatory studies discussed later in the chapter. The only significant toxicity of copper-lowering therapy with TM in these diseases is overtreatment. The mild copper deficiency produced from overtreatment causes mild bone marrow suppression with anaemia and/or leucopenia, easily corrected by decreasing the dose of TM.

Lowering copper levels with TM for cancer therapy

Preclinical studies

Numerous preclinical studies have established the efficacy of TM in preventing the growth of various cancers in mice. One study used transgenic mice (Her-2/*neu*) genetically programmed to develop mammary cancer during the first year of life [42]. TM given daily by oral gavage beginning on day 100 completely prevented the development of visible mammary tumours, while most of the controls had developed gross tumours by day 270 ($P < 0.01$). The study was stopped, and a few TM-treated mice were autopsied. Histological sections of the breasts in these mice revealed small, avascular clusters of tumour cells. A few TM-treated mice were followed after stopping TM, and they all developed gross mammary tumours.

Another study used xenografts of SUM149 inflammatory breast cancer cells in mice, and TM markedly inhibited tumour growth and caused reduced microvessel density compared with controls [42]. In another study, Dunning prostate cancer cells were injected into nude mice [43]. TM treatment retarded tumour growth. Combination therapy with TM and the PHSCN peptide sequence, a competitive inhibitor of a fibronectin sequence, improved survival and the number of metastatic lesions.

In a lung cancer model study in mice, Lewis lung high metastatic cancer cells were injected into the upper leg [44]. Radiation therapy significantly slowed tumour growth, TM therapy also significantly slowed tumour growth, and the combination was additive in slowing tumour growth. The effect of TM in squamous cell carcinoma cells was evaluated in another mouse study and showed dramatic inhibition of tumour growth [45]. A combination study with doxorubicin against the SUM149 inflammatory breast cancer cells injected into nude mice was reported [46]. TM or doxorubicin alone significantly inhibited tumour growth, while the combination completely prevented tumour growth. Apoptosis of tumour cells was enhanced in all treatment groups, but especially in the combination therapy group.

A study of TM therapy was carried out in dogs affected with a variety of advanced and metastatic cancers [47]. Nine dogs in this 13-dog study were evaluable. Three of the nine had relatively prolonged periods of disease stabilization, and a fourth dog, with metastatic osteosarcoma, had a relatively prolonged partial remission.

Clinical studies

A phase I/II study of 42 patients with advanced and metastatic cancer was carried out [48]. Eighteen patients were evaluable. Freedom from progression averaged 11 months, much longer than the 1–2 months expected in this type of patient if they were on no treatment. Quality of life was stabilized after steady deterioration in the period prior to treatment. Particularly positive results were seen in a few patients. One patient, with metastatic chondrosarcoma, has survived 5 years with what appears to be a complete remission. Using a blood flow-sensitive ultrasound technique, it was possible to show drastic blood flow reduction in a metastasis as a result of TM therapy in a patient with metastatic renal cancer.

Nine phase II trials of TM therapy in specific advanced cancers have been initiated. One, on renal cancer, has been completed and published [49]. Four out of nine evaluable patients had at least 6 months of disease stabilization, but results overall were not strongly positive. Preliminary results in other trials, such as mesothelioma and hepatocellular cancer, are more encouraging.

Mechanism of action

The anticancer mechanism of action almost certainly involves reducing copper availability. This conclusion is based in part on *in vitro* studies in which TM inhibition of endothelial cell tube

formation, under the influence of fibroblastic growth factor, was abrogated by copper supplementation [42]. Second, anticancer effects have been obtained with two different anticopper drugs, TM as reviewed above and penicillamine as studied by Brem *et al.* [39,40]. These two drugs both lower copper availability, but through completely different mechanisms of action.

A further conclusion is that the anticancer mechanism of action of lowering copper levels is almost certainly due to anti-angiogenic effects. *In vitro* studies of TM action have shown inhibition of numerous angiogenic cytokines [vascular endothelial growth factor, fibroblastic growth factor, interleukin-6, nuclear factor kappa B (NF-κB), and interleukin-8] [42]. *In vivo* studies during TM therapy have also shown inhibition of angiogenic cytokines, including NF-κB [50]. Both clinical and preclinical studies have shown inhibition of blood flow or decreased microvessel density as a result of TM therapy [48]. Numerous angiogenic cytokines have been shown to bind copper or to be copper dependent [33].

Lowering copper levels with TM for antifibrotic therapy

The pathway for fibrosis involves activation of transforming growth factor beta (TGF-β), a cytokine that activates connective tissue growth factor (CTGF), which in turn activates numerous genes involved in fibrosis (see Section 6, Cirrhosis). Excessive activation of this pathway is believed to cause fibrotic disease, such as pulmonary fibrosis, cirrhosis of various types, interstitial renal fibrosis (the endstage of many types of kidney disease) and scleroderma, to name but a few [51]. It has been hypothesized that this pathway is copper dependent, based upon one of the activators of TGF-β being SPARC (secreted protein acidic and rich in cysteine), known to be copper dependent, and the high cysteine content of CTGF, often an indicator of copper binding [33].

The copper dependence of fibrosis was tested in the bleomycin mouse model of pulmonary fibrosis. TM therapy almost completely prevented the pulmonary fibrosis from bleomycin [52]. TGF-β protein levels were elevated in the lungs of bleomycin-treated animals, and this elevation was almost completely prevented by TM [53]. Protection by TM against fibrotic disease was also tested in the carbon tetrachloride mouse model of cirrhosis [54]. After 12 weeks of carbon tetrachloride injections, untreated mice developed severe fibrosis. Fibrosis from carbon tetrachloride injections was prevented by TM therapy. Serum TGF-β levels were elevated by carbon tetrachloride, and this elevation was almost completely prevented by TM. The protection of TM against excessive fibrosis seems to be independent of any effect of TM on preventing inflammation [52–54].

Lowering copper levels with TM for anti-inflammatory therapy

It was noted in the bleomycin studies that TM therapy inhibited tumour necrosis factor (TNF)α messenger levels in the lungs of bleomycin-treated animals at 7 days compared with bleomycin-treated controls [53]. This led to a series of four studies evaluating TM therapy in inflammation models. In all four cases, TM therapy strongly inhibited the inflammatory responses [54,55]. These models are concanavalin A-induced hepatitis, paracetamol (acetaminophen)-induced hepatitis, adriamycin-induced cardiac inflammation and injury, and lupus adenopathy in the *lpr* mouse model. In most of these models, concomitant with suppression by TM of markers of inflammation and injury, inhibition of serum TNFα and/or another inflammatory cytokine, interleukin-1-beta (IL-1β), was shown when toxin- or disease-challenged animals were compared with the same animals receiving TM therapy. Inhibition of these cytokines seems to reduce inflammation, as shown by the efficacy of TNFα antibodies in various inflammatory diseases [56–59]. The mechanism by which TM inhibits these cytokines is not known. One possibility is that suppression of IL-2 release by activated T lymphocytes, which has been shown to result from TM therapy, results in less activation of inflammatory cells and therefore less release of TNFα and IL-1β by these cells.

Comment on prospects for antifibrotic and anti-inflammatory therapy with TM

Only clinical trials will determine whether copper-lowering therapy with TM will have clinical efficacy in fibrotic and inflammatory diseases is clinical trials. This approach is further advanced with fibrotic than with inflammatory diseases. Clinical trials are either under way, or under active planning, for idiopathic pulmonary fibrosis, primary biliary cirrhosis and scleroderma. There is essentially no effective treatment for fibrotic diseases such as these. Regarding inflammatory diseases, much of modern medicine deals with the discomfort and additional injury produced by inflammation in a large variety of diseases, many of them autoimmune. Therapeutic agents, such as steroids, non-steroidal anti-inflammatory drugs (NSAIDs), chemotherapeutic drugs and antibodies against specific inflammatory proteins (such as TNFα), have some efficacy. However, efficacy is only partial, and myriads of patients have continuing discomfort and tissue injury in spite of the best treatment. Time will tell whether copper-lowering therapy with TM can be of value against these diseases.

Summary

In this chapter we have first reviewed and summarized the exciting progress in understanding normal copper metabolism. The discovery that genetic defects in ATP7A and ATP7B cause Menkes' and Wilson's diseases, respectively, has not only provided a molecular basis for these diseases, but has also allowed an increasingly detailed understanding of copper transport and utilization in the body. The discoveries of numerous chaperones for moving copper between specific molecules has not only provided insight into mechanisms of copper movement, but also

Table 4 Published therapeutic uses of lowering copper to subnormal levels.

Mechanism	Diseases	Reference to work so far
Angiogenesis	Cancer	[39,40,42–50]
	Retinopathy	[60]
Antifibrosis	Pulmonary fibrosis	[52,53]
	Cirrhosis	[54]
Anti-inflammatory	Concanavalin A	[54]
	Paracetamol liver injury	[55]

underscores two principles about copper. One is that free copper is very toxic and simple diffusion and molecular uptake is not permissible. The second is the extreme evolutionary conservatism of copper-handling molecules, which go back in evolution at least as far as yeast.

Second, we have reviewed a new area for the use of anticopper drugs (summarized in Table 4). For a very long time, anticopper drugs have had one primary clinical use, the treatment of copper toxicity from excessive accumulation of copper such as in Wilson disease, canine copper toxicosis or copper-poisoned sheep. Here, we introduce the concept that lowering copper availability to a midrange can have therapeutic efficacy in a wide array of diseases.

References

1 Wilson SA (1912) Progressive lenticular degeneration: a familial nervous disease associated with cirrhosis of the liver. *Brain* 34, 295–507.

2 Harris ED (2003) Basic and clinical aspects of copper. *Crit Rev Clin Lab Sci* 40 (5), 547–586.

3 Sone T, Yamaoka K, Minami Y *et al.* (1987) Induction of metallothionein synthesis in Menkes' and normal lymphoblastoid cells is controlled by the level of intracellular copper. *J Biol Chem* 262 (12), 5878–5885.

4 Bartnikas TB, Gitlin JD (2003) Mechanisms of biosynthesis of mammalian copper/zinc superoxide dismutase. *J Biol Chem* 278 (35), 33602–33608.

5 Harrison MD, Jones CE, Dameron CT (1999) Copper chaperones: function, structure and copper-binding properties. *J Biol Inorg Chem* 4 (2), 145–153.

6 Hamza I, Schaefer M, Klomp LW *et al.* (1999) Interaction of the copper chaperone HAH1 with the Wilson disease protein is essential for copper homeostasis. *Proc Natl Acad Sci USA* 96 (23), 13363–13368.

7 Sharp PA (2003) Ctr1 and its role in body copper homeostasis. *Int J Biochem Cell Biol* 35 (3), 288–291.

8 Klomp AE, Tops BB, Van Denberg IE *et al.* (2002) Biochemical characterization and subcellular localization of human copper transporter 1 (hCTR1). *Biochem J* 364 (Pt 2), 497–505.

9 Petris MJ, Smith K, Lee J *et al.* (2003) Copper-stimulated endocytosis and degradation of the human copper transporter, hCtr1. *J Biol Chem* 278 (11), 9639–9646.

10 Markossian KA, Kurganov BI (2003) Copper chaperones, intracellular copper trafficking proteins. Function, structure, and mechanism of action. *Biochemistry (Mosc)* 68 (8), 827–837.

11 Huffman DL, O'Halloran TV (2001) Function, structure, and mechanism of intracellular copper trafficking proteins. *Annu Rev Biochem* 70, 677–701.

12 Culotta VC, Klomp LW, Strain J *et al.* (1997) The copper chaperone for superoxide dismutase. *J Biol Chem* 272 (38), 23469–23472.

13 Beers J, Glerum DM, Tzagoloff A (1997) Purification, characterization, and localization of yeast Cox17p, a mitochondrial copper shuttle. *J Biol Chem* 272 (52), 33191–33196.

14 Takahashi Y, Kako K, Kashiwabara S *et al.* (2002) Mammalian copper chaperone Cox17p has an essential role in activation of cytochrome C oxidase and embryonic development. *Mol Cell Biol* 22 (21), 7614–7621.

15 Prohaska JR, Gybina AA (2004) Intracellular copper transport in mammals. *J Nutr* 134 (5), 1003–1006.

16 Mercer JF, Livingston J, Hall B *et al.* (1993) Isolation of a partial candidate gene for Menkes disease by positional cloning. *Nature Genet* 3 (1), 20–25.

17 Lutsenko S, Efremov RG, Tsivkovskii R *et al.* (2002) Human copper-transporting ATPase ATP7B (the Wilson's disease protein): biochemical properties and regulation. *J Bioenerg Biomembr* 34 (5), 351–362.

18 Petris MJ, Strausak D, Mercer JF (2000) The Menkes copper transporter is required for the activation of tyrosinase. *Hum Mol Genet* 9 (19), 2845–2851.

19 Tchaparian EH, Uriu-Adams JY, Keen CL *et al.*(2000) Lysyl oxidase and P-ATPase-7A expression during embryonic development in the rat. *Arch Biochem Biophys* 379 (1), 71–77.

20 Barnes N, Tsivkovskii R, Tsivkovskaia N *et al.* (2005) The copper-transporting ATPases, Menkes and Wilson disease proteins, have distinct roles in adult and developing cerebellum. *J Biol Chem* 280 (10), 9640–9645.

21 Steveson TC, Ciccotosto GD, Ma XM *et al.* (2003) Menkes protein contributes to the function of peptidylglycine alpha-amidating monooxygenase. *Endocrinology* 144 (1), 188–200.

22 Petris MJ, Mercer JF, Culvenor JG *et al.* (1996) Ligand-regulated transport of the Menkes copper P-type ATPase efflux pump from the Golgi apparatus to the plasma membrane: a novel mechanism of regulated trafficking. *EMBO J* 15 (22), 6084–6095.

23 Petris MJ, Camakaris J, Greenough M *et al.* (1998) A C-terminal di-leucine is required for localization of the Menkes protein in the trans-Golgi network. *Hum Mol Genet* 7 (13), 2063–2071.

24 Qian Y, Tiffany-Castiglioni E, Welsh J *et al.* (1998) Copper efflux from murine microvascular cells requires expression of the Menkes disease Cu-ATPase. *J Nutr* 128 (8), 1276–1282.

25 van De SB, Rothuizen J, Pearson PL *et al.* (2002) Identification of a new copper metabolism gene by positional cloning in a purebred dog population. *Hum Mol Genet* 11 (2), 165–173.

26 Stuehler B, Reichert J, Stremmel W *et al.* (2004) Analysis of the human homologue of the canine copper toxicosis gene MURR1 in Wilson disease patients. *J Mol Med* 82 (9), 629–634.

27 Tao TY, Liu F, Klomp L *et al.* (2003) The copper toxicosis gene product Murr1 directly interacts with the Wilson disease protein. *J Biol Chem* 278 (43), 41593–41596.

28 Wijmenga C, Klomp LW (2004) Molecular regulation of copper excretion in the liver. *Proc Nutr Soc* 63 (1), 31–39.

29 Burstein E, Ganesh L, Dick RD *et al.* (2004) A novel role for XIAP in copper homeostasis through regulation of MURR1. *EMBO J* 23 (1), 244–254.

30 Portnoy ME, Rosenzweig AC, Rae T *et al.* (1999) Structure-function analyses of the ATX1 metallochaperone. *J Biol Chem* 274 (21), 15041–15045.
31 Brewer GJ (2001) Copper control as an antiangiogenic anticancer therapy: lessons from treating Wilson's disease. *Exp Biol Med* 226 (7), 665–673.
32 Brewer GJ, Merajver SD (2002) Cancer therapy with tetrathiomolybdate: antiangiogenesis by lowering body copper – a review. *Integr Cancer Ther* 1 (4), 327–337.
33 Brewer GJ (2003) Tetrathiomolybdate anticopper therapy for Wilson's disease inhibits angiogenesis, fibrosis and inflammation. *J Cell Mol Med* 7 (1), 11–20.
34 Folkman J (1971) Tumor angiogenesis: therapeutic implications. *N Engl J Med* 285 (21), 1182–1186.
35 Folkman J (1995) Angiogenesis in cancer, vascular, rheumatoid and other disease. *Nature Med* 1 (1), 27–31.
36 Brem S (1999) Angiogenesis and cancer control: from concept to therapeutic trial. *Cancer Control* 6 (5), 436–458.
37 Raju KS, Alessandri G, Ziche M *et al.* (1982) Ceruloplasmin, copper ions, and angiogenesis. *J Natl Cancer Inst* 69 (5), 1183–1188.
38 Ziche M, Jones J, Gullino PM (1982) Role of prostaglandin E1 and copper in angiogenesis. *J Natl Cancer Inst* 69 (2), 475–482.
39 Brem SS, Tsanaclis AM, Zagzag D (1990) Anticopper treatment inhibits pseudopodial protrusion and the invasive spread of 9L gliosarcoma cells in the rat brain. *Neurosurgery* 26 (3), 391–396.
40 Brem SS, Zagzag D, Tsanaclis AM *et al.* (1990) Inhibition of angiogenesis and tumor growth in the brain. Suppression of endothelial cell turnover by penicillamine and the depletion of copper, an angiogenic cofactor. *Am J Pathol* 137 (5), 1121–1142.
41 Brewer GJ, Hedera P, Kluin KJ *et al.* (2003) Treatment of Wilson disease with ammonium tetrathiomolybdate: III. Initial therapy in a total of 55 neurologically affected patients and follow-up with zinc therapy. *Arch Neurol* 60 (3), 379–385.
42 Pan Q, Kleer CG, van Golen KL *et al.* (2002) Copper deficiency induced by tetrathiomolybdate suppresses tumor growth and angiogenesis. *Cancer Res* 62 (17), 4854–4859.
43 van Golen KL, Bao L, Brewer GJ *et al.* (2002) Suppression of tumor recurrence and metastasis by a combination of the PHSCN sequence and the antiangiogenic compound tetrathiomolybdate in prostate carcinoma. *Neoplasia* 4 (5), 373–379.
44 Khan MK, Miller MW, Taylor J *et al.* (2002) Radiotherapy and antiangiogenic TM in lung cancer. *Neoplasia* 4 (2), 164–170.
45 Cox C, Merajver SD, Yoo S *et al.* (2003) Inhibition of the growth of squamous cell carcinoma by tetrathiomolybdate-induced copper suppression in a murine model. *Arch Otolaryngol Head Neck Surg* 129 (7), 781–785.
46 Pan Q, Bao LW, Kleer CG *et al.* (2003) Antiangiogenic tetrathiomolybdate enhances the efficacy of doxorubicin against breast carcinoma. *Mol Cancer Ther* 2 (7), 617–622.
47 Kent MS, Madewell BR, Dank G *et al.* (2004) An anticopper antiangiogenic approach for advanced cancer in spontaneously occurring tumors, using tetrathiomolybdate: a pilot study in a canine animal mode. *J Trace Elem Exp Med* 17 (1), 9–20.
48 Brewer GJ, Dick RD, Grover DK *et al.* (2000) Treatment of metastatic cancer with tetrathiomolybdate, an anticopper, antiangiogenic agent: Phase I study. *Clin Cancer Res* 6 (1), 1–10.
49 Redman BG, Esper P, Pan Q *et al.* (2003) Phase II trial of tetrathiomolybdate in patients with advanced kidney cancer. *Clin Cancer Res* 9 (5), 1666–1672.
50 Pan Q, Bao LW, Merajver SD (2003) Tetrathiomolybdate inhibits angiogenesis and metastasis through suppression of the NFkappaB signaling cascade. *Mol Cancer Res* 1 (10), 701–706.
51 Border WA, Noble NA (1994) Transforming growth factor beta in tissue fibrosis. *N Engl J Med* 331 (19), 1286–1292.
52 Brewer GJ, Ullenbruch MR, Dick RB *et al.* (2003) Tetrathiomolybdate therapy protects against bleomycin-induced pulmonary fibrosis in mice. *J Lab Clin Med* 141 (3), 210–216.
53 Brewer GJ, Dick R, Ullenbruch MR *et al.* (2004) Inhibition of key cytokines by tetrathiomolybdate in the bleomycin model of pulmonary fibrosis. *J Inorg Biochem* 98 (12), 2160–2167.
54 Askari FK, Dick RB, Mao M *et al.* (2004) Tetrathiomolybdate therapy protects against concanavalin A and carbon tetrachloride hepatic damage in mice. *Exp Biol Med* 229 (8), 857–863.
55 Ma S, Hou G, Dick RD *et al.* (2004) Tetrathiomolybdate protects against liver injury from acetaminophen in mice. *J Appl Res Clin Exp Ther* 4 (3), 419–426.
56 Elliott MJ, Maini RN, Feldmann M *et al.* (1993) Treatment of rheumatoid arthritis with chimeric monoclonal antibodies to tumor necrosis factor alpha. *Arthritis Rheum* 36 (12), 1681–1690.
57 Shanahan JC, St Clair W (2002) Tumor necrosis factor-alpha blockade: a novel therapy for rheumatic disease. *Clin Immunol* 103 (3 Pt 1), 231–242.
58 D'Haens G, Van Deventer S, Van Hogezand R *et al.* (1999) Endoscopic and histological healing with infliximab anti-tumor necrosis factor antibodies in Crohn's disease: a European multicenter trial. *Gastroenterology* 116 (5), 1029–1034.
59 Mease PJ, Goffe BS, Metz J *et al.* (2000) Etanercept in the treatment of psoriatic arthritis and psoriasis: a randomised trial. *Lancet* 356 (9227), 385–390.
60 Elner SG, Elner VM, Yoshida A *et al.* (2005) Effects of tetrathiomolybdate in a mouse model of retinal neovascularization. *Invest Ophthalmol Vis Sci* 46 (1), 299–303.

2.3.14 Trace elements and the liver

Brent A. Neuschwander-Tetri

Life would not be possible without a large number of 'trace' elements, each serving critical roles in metabolism and function (Table 1). This chapter reviews the function and relevant biology of trace elements with respect to the liver. Because copper has a special role as a trace element with respect to normal liver function and liver disease, it is covered in more detail in Chapter 2.3.13 and is not discussed further here.

Trace elements are necessary for normal function and are therefore associated with morbid deficiency states. They are also commonly toxic when present in excess, and this chapter will touch briefly on toxicity as it relates to the essential trace elements. Actual values for liver, plasma and total body content of the trace elements that are used to assess deficiency states and toxicity are catalogued in other resources and are not reviewed here [1–4]. Although such values are important in forensic medicine and epidemiological studies, they are rarely relevant to the routine practice of clinical medicine [5]. Accurate

Table 1 Physiological trace elements in the body.[a]

Element	Function(s)	Causes of deficiency	Deficiency: hepatic consequences	Deficiency: non-hepatic consequences	Changes in liver disease
Arsenic	Uncertain[b]				
Cobalt	Cobalamin (vitamin B12)	Multiple	Fatty liver disease	Multiple	Impaired elimination of vitamin B12 degradation products
Chromium	Improves insulin signalling	Defined diet without supplementation	Impaired glucose tolerance	Impaired glucose tolerance	Hepatic accumulation in chronic liver disease
Fluorine	Uncertain[b]				
Iodine	Thyroid hormone				
Lead	Uncertain[b]				
Manganese	Cofactor for multiple enzymes (e.g. MnSOD, pyruvate carboxylase, phosphoenolpyruvate carboxykinase, arginase, prolidase)	Defined diet without supplementation	Impaired glucose tolerance, elevated ammonia levels, impaired cholesterol synthesis, impaired clotting factor synthesis	Impaired glucose tolerance, dermatitis	Decreased urinary excretion and increased liver concentration in alcoholic cirrhotics [58] Increased levels in globus pallidus in cirrhotics, may cause extrapyramidal symptoms [53]
Molybdenum	Xanthine oxidase Aldehyde oxidase Sulphite oxidase	Defined diet without supplementation	Altered sulphur amino acid metabolism	Not established	
Nickel	Nickel[b] known to have a catalytic role in six bacterial enzymes (including urease), but no eukaryotic enzymes				
Selenium	See Table 2	Dietary protein deficiency Dietary protein solely from Se-deficient areas	Oxidant stress	See text	Low serum levels in chronic liver disease [26]
Silicon	Uncertain[b]				
Tin	Uncertain[b]				
Vanadium	Uncertain[b]				
Zinc	Cofactor for multiple enzymes and transcription factors	Increased urinary loss in cirrhosis Alcoholism Malabsorption (e.g. coeliac disease, inflammatory bowel disease)	Altered ammonia metabolism	Encephalopathy in cirrhotics	Low serum levels in chronic liver disease [26] Low liver levels in alcoholic cirrhosis [58]

[a]Copper is discussed in Chapter 2.3.13.
[b]Certain elements may have physiological roles based on animal studies of specific dietary deficiencies, but requirements and specific functions in humans are not known [5,7].

assessment of trace element levels in organs such as the liver continues to be refined as technologies such as scanning transmission electron microscopic analysis are developed. Nonetheless, the necessity and function of certain elements such as boron, nickel, tin and vanadium continues to be debated (Table 1) because dietary deficiency models in animals sometimes suggest that they are essential, yet their specific functions at the molecular level have not been established [5,6]. Described below are the functions of major trace elements relevant to the liver with special emphasis on selenium, an element now recognized to play a unique role in human biology. The importance of many trace elements in nutrition and disease was reviewed extensively by an expert panel [7], and the summary below includes many of their key findings.

Selenium

Selenium has a special role in the normal function of the liver and tissues throughout the body. Found directly below sulphur on the periodic table, selenium thus shares many of the chemical properties of sulphur [8]. In fact, most selenium in the body is found in selenoproteins, which contain the amino acid selenocysteine (Sec), a modification in which selenium is found in place of the sulphur atom of cysteine. Failure to produce selenoproteins in the liver causes liver necrosis in mice, attesting to the importance of selenium in normal liver function [9]. Selenium is also incorporated into proteins as selenomethionine from ingested selenomethionine. In contrast to the specific incorporation of Sec in proteins, selenomethionine (Se-met) replaces methionine arbitrarily during translation depending on the relative abundance of Se-met [10]. Although Se-met may exert different local steric effects from methionine, it has not been found to have specific biological functions [11].

The story of how Sec becomes incorporated into selenoproteins is one that has challenged the accepted dogma of protein synthesis pathways as it has unfolded over the past three decades. While one possible mechanism of selenium incorporation could be replacement of the sulphur atom in cysteine by selenium through posttranslational peptide modification, the surprising reality is that Sec is preformed as a unique amino acid and incorporated during translation. The conceptual difficulty this raised is that it contradicted the decades-old paradigm that the 64 possible ribonucleotide triplets of mRNA encode either insertion of 20 specific amino acids or translational termination. Understanding how Sec, now considered to be the 21st amino acid, could be synthesized and incorporated during translation required a revision of this paradigm.

Through a number of elegant experiments conducted over the past two decades, Sec is now recognized to be translationally inserted into nascent peptide chains by a unique transfer RNA, t-RNA$^{[Ser]Sec}$, which recognizes the UGA codon, a codon canonically identified as a termination signal (Fig. 1). In the context of several proteins acting *in trans* and a specific *cis*-acting hairpin sequence in the 3′ untranslated regions of selenoprotein mRNA transcripts, the UGA codon is recognized as the signal for Sec insertion into nascent peptides [12–15]. Genetic deletion of t-RNA$^{[Ser]Sec}$ in mice is embryonically lethal, attesting to the importance of this pathway [9]. Adding to this complexity was the finding that t-RNA$^{[Ser]Sec}$ directly participates in the enzymatic formation of Sec. The t-RNA is first charged with serine, but the bound serine is subsequently converted to Sec while still

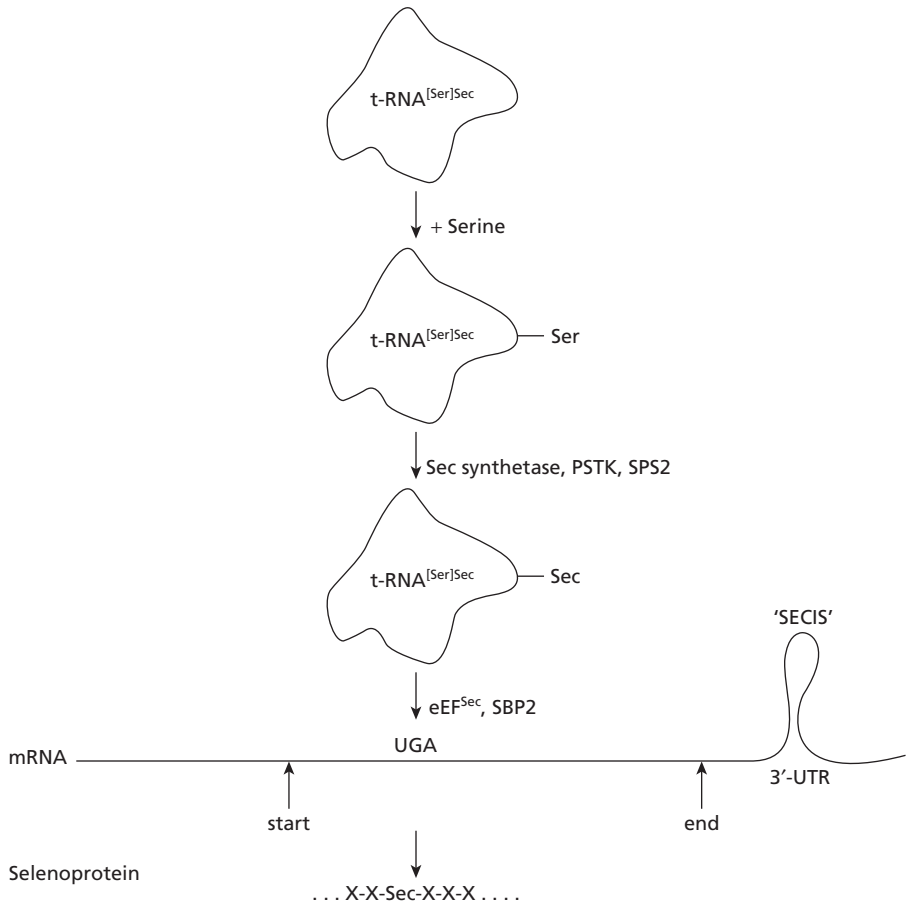

Fig. 1 Synthesis of selenoproteins. Selenocysteine (Sec) is synthesized from the serine (Ser) carbon backbone on t-RNA$^{[Ser]Sec}$. t-RNA$^{[Ser]Sec}$ is a unique transfer RNA that is required for both Sec synthesis and translational incorporation of Sec into nascent selenoproteins. Sec synthesis is facilitated by an uncharacterized Sec synthetase and selenophosphate synthetase 2 (SPS2). Selenoprotein mRNAs contain an essential stem–loop *cis* element, the Sec insertion sequence (SECIS), in the 3′ untranslated region (3′ UTR) that is required for the recognition of the UGA codon as a Sec codon rather than a termination signal. Binding of t-RNA$^{[Ser]Sec}$ to the mRNA–ribosomal complex is also facilitated by other unusual factors including a Sec-specific elongation factor (eEF^{Sec}) and SECIS binding protein 2 (SBP2).

attached to t-RNA$^{[Ser]Sec}$ [16]. In no other case is a t-RNA known to participate catalytically in the modification of a bound amino acid. The unique enzymes needed for these steps were first elucidated in bacteria and then defined in eukaryotes, although many details remain to be clarified [12,17]. An interesting recent observation with respect to liver disease is that the antigenic epitope for antisoluble liver antigen (anti-SLA), an antibody associated with autoimmune hepatitis, appears to be t-RNA$^{[Ser]Sec}$ [18].

Biological functions of selenium

The biological functions of selenium are mediated primarily by Sec in selenoproteins. Early tracer studies with ^{75}Se identified several major selenoproteins that included glutathione peroxidase (GPx) and selenoprotein P (SelP). Until recently, computer algorithms used to identify open reading frames in genes could not accurately identify UGA codons that encode Sec instead of translational termination. However, the recognition of an obligate and unique 3′ *cis* element in selenoprotein transcripts led to new computational approaches that subsequently identified a total of 25 putative selenoproteins, now identified as the 'selenoproteome' of the mammalian genome (Table 2) [19]. Reconciling the selenoproteome with previously identified selenoproteins has been complicated by the existence of multiple alternative splice forms of many of the transcripts.

The enzymatic function of selenoproteins typically depends on the presence of a negatively charged deprotonated selenium and, for this reason, the Sec is usually located within the active site. The pK_a of the selenol group of Sec is substantially higher than the analogous sulphydryl of cysteine and, as such, is mostly deprotonated ($R\text{-}Se^-$) at physiological pH. By comparison, the pK_a of cysteine is lower, and it is mostly protonated (R-SH) at physiological pH. Thus, Sec is a much more facile nucleophile than cysteine at reactive sites of selenoprotein enzymes. Three examples of selenoproteins are described below.

The first selenoprotein to be characterized was glutathione peroxidase 1 (GPx1), an enzyme that catalytically eliminates hydrogen peroxide and lipid hydroperoxides in the cytosol and mitochondria using glutathione as an electron donor. The highest cellular concentrations of GPx1 are found in the liver. Catalase, a non-selenium-dependent enzyme, also eliminates hydrogen peroxide but is confined to peroxisomes and does not participate in the general intracellular defence against oxidant stress. Moreover, catalase does not eliminate lipid hydroperoxides. Although oxidant stress impairs normal cellular functions, overexpression of GPxs may adversely influence normal redox-mediated cellular signalling [20]. For example, mice that overexpress GPx1 in the liver develop features of insulin resistance, suggesting that too much antioxidant defence could have a negative impact on normal insulin signalling [21].

Another selenoprotein, thioredoxin reductase (TrxR), plays an important role in most organs in maintaining normal redox status. TrxR-1 is localized to the cytoplasm where, in addition to its role in thiol redox regulation, it is essential for deoxynucleotide synthesis. Another form, TrxR-2, is located within mitochondria and prevents oxidant injury caused by the constitutive release of superoxide from the mitochondrial electron transport chain. Deletion of TrxR (but not GPx1 or SelP) induces a cellular stress response [22], and human tumour cells treated with tumour necrosis factor (TNF)α undergo increased apoptosis when they lack Sec in TrxR. In addition, non-physiological trace elements such as gold and platinum actively inhibit TrxR [23].

All Sec-containing selenoproteins except SelP contain only one Sec, whereas SelP, thought to serve as a transport protein for selenium, has 10 Sec. Although many tissues express SelP, impaired liver synthesis of SelP reduces serum levels by 75% in mice, indicating that the liver serves a primary role in the synthesis and secretion of this selenium transport protein [9,24]. Evidence that liver-synthesized and secreted SelP is required by other organs is provided by a liver-specific knockout of SelP in mice that demonstrates impaired renal synthesis of selenoproteins [25].

Deficiency states

Profound liver-specific deficiency of selenoproteins causes liver necrosis and death in genetically modified mice that cannot synthesize selenoproteins in the liver [9]. Dietary selenium deficiency in humans is unlikely to mimic this extreme phenotype, and such overt liver manifestations of selenium deficiency have not been described clinically. However, low selenium levels have been found in patients with chronic liver disease [26–28], and selenium-deficient rodents have higher serum liver enzymes and markers of oxidant stress [29,30]. Studies in cultured cells have shown that selenium deficiency in hepatocytes leads to cell death by oxidative stress, but many malignant hepatocellular carcinoma cell lines survive in culture despite selenium deficiency, possibly indicating the resistance of liver cancer to normal oxidant-mediated mechanisms of cell death.

A diverse diet usually contains sufficient selenium to meet the recommended daily allowance of 55–70 μg per day and prevent a deficiency state. However, with the new recognition of multiple Sec-containing proteins, this assertion is being revisited to determine whether some of the previously unknown proteins may be impaired by inadequate selenium status despite a diet containing the currently recommended amount [31,32]. Dietary protein is an important source of selenium. Rats fed a protein-deficient diet had low GPx levels and exhibited increased sensitivity to liver injury induced by carbon tetrachloride [33], abnormalities that could be ameliorated by selenium supplements [34]. Acute alcohol feeding has also been shown to decrease hepatic selenium levels in animal studies, whereas deficiency states in people are usually associated with consuming food produced in a limited geographical region (e.g. certain regions in New Zealand and China) and are associated with growth retardation, defective spermatogenesis, cataracts and cardiomyopathy.

Table 2 Selenoprotein functions.

Selenoprotein	Function	Comments
GPx1[a]	Eliminates cytosolic hydrogen peroxide and lipid hydroperoxides; most abundant in the liver	First selenoprotein characterized; also called cystosolic GPx
GPx2	Gastrointestinal mucosal antioxidant, inhibits absorption of lipid hydroperoxides [36]	Originally described in gut mucosa but also found in liver
GPx3	Plasma antioxidant	Secreted glycoprotein, kidneys may be the major source; 'plasma GPx'
GPx4	Eliminates diverse hydroperoxides [59]	May regulate intracellular signalling [60]; 'phospholipid hydroperoxide GPx'
GPx6	Unknown function	Identified by genomic analysis [19]
H	Hypothetical protein	
I	Selenocysteine synthesis	
J	Hypothetical protein	
K	Putative membrane protein	
M	Unknown function [61]	Abundant in brain
N, SEPN1	Possible antioxidant in muscle	Possible role in muscular dystrophy; requires prenylation for function, HMG-CoA reductase inhibitors may interfere and cause myopathy [62]
O	Hypothetical protein	
P, SelP	Selenium storage and transport [24]	10 selenocysteines per molecule, widely expressed in different organs; liver may be the major source of circulating SelP
R, MsrB1	Methionine sulfoxide reductase [63]	
S	Putative membrane protein	
SPS2	Essential for $tRNA^{[Ser]Sec}$ synthesis	Possible selenium donor
T	Hypothetical protein	
Trx1	Catalyses flavin-mediated reduction of oxidized thioredoxin	Localized to cytosol
Trx2	Thioredoxin reduction	Localized to mitochondria
Trx3	Thioredoxin reduction	Localized to testis
V	Hypothetical protein	
W	Probable antioxidant function	Most abundant in cardiac and skeletal muscle
X	Hypothetical protein	mRNA abundant in liver, leukocytes
Z	Hypothetical protein	mRNA abundant in liver, kidney
DI-1[b]	Catalyses the monodeiodination of thyroxine (T4) to the active thyroid hormone (T3) or inactive form (rT3)	Found in liver, may play a role in liver-specific effects of thyroid hormone
DI-2	Conversion of T4 to T3 and rT3	Not localized to liver
DI-3	Conversion of T4 to rT3	Primarily localized to the CNS
Sep15, 15 kDa protein	Possible role in endoplasmic reticulum protein folding	High expression in liver; localized to the endoplasmic reticulum [35,64]

[a]GPx, glutathione peroxidase (note, GPx5 is not a selenoprotein).
[b]DI, iodothyronine diodinase [65].
CNS, central nervous system; HMG-CoA, hydroxymethylglutaryl-CoA.
Adapted from refs 19, 12 and 10.

As is true of many other trace elements and vitamins, suboptimal health attributed to mild and clinically undetected deficiency states has been proposed and is the basis for selenium supplementation as an antioxidant in many multivitamins and other supplements. Disease states that have been attributed to moderately low selenium levels include cancer, susceptibility to viral infections, progression of AIDS, defective spermatogenesis, arthritis, vascular disease, asthma and immune system dysregulation [12,35]. Mice lacking both GPx1 and GPx2 have been found to develop ulcerative colitis and colon cancers, attesting to the potential importance of selenium enzymes in preventing inflammation and neoplasia [36,37]. On the other hand, the selenium-dependent thioredoxin pathway is antiapoptotic and may favour the survival of malignant cells.

Selenium provided in dietary supplements is typically in forms such as sodium selenite or selenate, although the primary dietary source may be selenomethionine in plant proteins [11,38]. Other organic forms of selenium have been found to be a potentially useful source as well [39] and, despite major differences between selenite supplements and selenate supplements

[40], the best approach to dietary selenium supplementation has not been established.

Toxicity of selenium

In general, excess selenium intake is rare in humans but is a significant environmental issue for animals. Liver selenium levels are increased in elderly people from the Faeroe Islands where whales are a dietary mainstay, and also in Inuits of the Arctic North American continent [41]. Environmentally, selenium accumulates in the groundwater in specific geographical regions having poor drainage, and wetland birds that dwell in such regions develop selenium toxicity. Cattle and sheep grazing in such regions also develop colourfully named syndromes such as 'blind staggers' and 'alkali disease' attributed to selenium toxicity, although hepatic manifestations of selenium toxicity have not been described.

Routes of selenium excretion have not been fully identified. The liver converts Se-met to Sec, and Sec is converted to serine and selenide, possibly involving an enzyme that specifically removes selenium from Sec [42]. Selenide is di- or trimethylated and then exhaled or excreted [11]. Additionally, a water-soluble carbohydrate conjugate, Se-methyl-N-acetylselenohexosamine, has been identified as a major urinary selenium metabolite in one study [43]. Whether secretory mechanisms can compensate for excessive intake is unknown, although selenium levels do reach a steady-state level during nutritional supplementation with Se-met [11]. The specific role of the liver in these metabolic pathways has not been established.

Zinc

The liver plays a central role in zinc homeostasis, removing it from albumin in the blood and distributing it to the body as needed. Hormonal stimuli such as glucocorticoids and epinephrine upregulate hepatic zinc uptake by upregulating hepatic metallothionein levels [44]. Zinc serves as an essential cofactor for over 100 enzymes and zinc finger transcription factors that are necessary for intermediary metabolism in the liver and other organs. It serves a major antioxidant function as a cofactor for copper–zinc superoxide dismutase, the first line of defence against cytosolic reactive oxygen intermediates generated in the liver. The specific effects of zinc deficiency on these metabolic steps have not been fully elucidated.

Excretion of zinc is mostly in the stool; biliary secretion is minimal, and most zinc lost in the stool originates from gut mucosa and pancreatic secretions. Cirrhotics have increased urinary zinc loss and can become zinc deficient. Zinc supplements, typically zinc sulphate, 220 mg three times daily in cirrhotics, may be effective in treating portosystemic encephalopathy and muscle cramps [26,45–47], although these data have been disputed [48]. Zinc supplements increase metallothionein expression, which can impair normal copper uptake. This is the desired effect when zinc is used to treat Wilson's disease, but the importance of impaired copper uptake in cirrhotics taking zinc supplements requires further investigation.

Chromium

Chromium in its various forms is both an industrial toxin and a commonly used dietary supplement. The toxicity of chromium depends on its redox state. Whereas Cr VI (i.e. chromate) is a known industrial toxin and carcinogen, Cr III is hypothesized to improve insulin sensitivity by enhancing postreceptor insulin signalling [49]. Cr VI is a strong oxidizing agent but is rapidly reduced to Cr III when ingested. The effect of Cr III on insulin signalling is the rationale for its promotion in forms such as chromium picolinate as a dietary supplement to prevent or improve diabetes. It has also been promoted as an aid in weight reduction and as a stimulant for increasing muscle mass, although controlled clinical trials have not confirmed these claims. The uptake of chromium by hepatocytes is facilitated by an anion channel, probably the same channel that mediates the uptake of other anions such as phosphate.

Chromium has the potential to accumulate in the liver of patients with chronic liver disease, and excess dietary supplements should be avoided in this group [7]. One case of severe hepatotoxicity attributed to chromium picolinate use has been reported [50]. It is not secreted into the bile and, thus, cholestasis is not a cause of chromium accumulation. Accumulation in the liver may develop in long-term peritoneal dialysis patients, although the significance of this is uncertain [51].

Manganese

Manganese is a cofactor for a number of enzymes important for intermediary metabolism, including the hepatic urea cycle enzyme arginase. However, deficiency syndromes and how they affect normal metabolism in the liver are not well described [52]. A provocative finding with respect to fatty liver disease was that manganese-deficient animals developed insulin resistance and glucose intolerance, but clinical studies of supplements have not been found to improve insulin sensitivity or diabetes. As a cofactor for prolinase, an enzyme needed for proline synthesis, and glucosyltransferases, enzymes needed for glycosaminoglycan synthesis, manganese also plays a role in extracellular matrix production and maturation.

Manganese absorbed from food is avidly taken up by the liver and distributed to tissues bound to transferrin and albumin. The mechanisms of absorption appear to be regulated in parallel with iron absorption such that iron deficiency increases manganese absorption from the gastrointestinal tract and iron excess reduces manganese absorption. Excess manganese is secreted into the bile, and some authorities recommend that supplements should be avoided in patients with chronic liver disease to avoid hepatic accumulation [7]. Manganese has been shown to accumulate in the globus pallidus of the brain in patients with cirrhosis [53].

Cobalt

Cobalt is best known as the catalytic centre of the corrin ring in cobalamin, the active core of vitamin B12. Vitamin B12 is synthesized by gut bacteria and is thus not directly affected by altered hepatic metabolism. However, the liver plays a central role in enterohepatic circulation of vitamin B12 and the disposal of corrinoid metabolites of vitamin B12 through biliary secretion of degradation products. Alterations in vitamin B12 function leading to manifestations of a deficiency state have thus been attributed to altered hepatic metabolism of B12 [54].

Molybdenum

Molybdenum is an essential cofactor for three enzymes: sulphite oxidase, xanthine oxidase and aldehyde oxidase. Sulphite oxidase is essential for the hepatic metabolism of sulphur-containing molecules such as cysteine and the formation of taurine. Whether molybdenum deficiency impairs the production of the bile acid taurocholic acid or alters the function of bile is not known. The second molybdenum enzyme, xanthine oxidase, metabolizes purines and is required for the elimination of degraded nucleotides. It has also been proposed to be a significant source of superoxide generation during ischaemia–reperfusion injury. Lastly, aldehyde oxidase requires molybdenum as a cofactor. It is known for its role in the hepatic metabolism of ingested ethanol from toxic acetaldehyde to acetate, but it also plays a key role in eliminating other more toxic aldehydes such as the lipid peroxidation product 4-hydroxynonenal.

Despite these known metabolic roles of molybdenum, there are no recognized hepatic effects of molybdenum deficiency or excess. This metal does undergo enterohepatic circulation and crosses cell membranes through an anion channel. It interacts with copper to form thiomolybdate complexes that increase copper elimination and cause copper deficiency. This interaction is the rationale for its use to promote copper excretion in patients with Wilson's disease.

Toxicity and elimination of trace elements

The liver has a central role in the uptake and disposition of many trace elements, especially the heavy metals [55]. Metallothionein, a cytosolic metal-binding protein composed of 25–30% cysteines, binds heavy metals, prevents their toxic interaction with other cellular components and facilitates their elimination. Metallothionein is especially important in the uptake and detoxification of cadmium [56]. Stress markedly upregulates hepatic metallothionein expression, but the reason for this is uncertain [57]. The liver also has the highest glutathione levels of any organ, and glutathione plays an important role in the biliary secretion of heavy metals, especially copper, cadmium, mercury, lead and zinc [55]. Although cholestasis is commonly associated with hepatic copper accumulation, the impact of impaired biliary secretion on the disposal of other heavy metals is less certain.

Summary

Trace elements serve essential metabolic functions in the liver, and the liver plays a central role in the disposition of most trace elements. Much work is needed to identify optimal measures of trace element adequacy and the functional consequences of deficiency states.

References

1 Versieck J (1985) Trace elements in human body fluids and tissues. *Crit Rev Clin Lab Sci* 22, 97–184.

2 Aalbers TG, Houtman JP, Makkink B (1987) Trace-element concentrations in human autopsy tissue. *Clin Chem* 33, 2057–2064.

3 Iyengar V, Woittiez J (1988) Trace elements in human clinical specimens: evaluation of literature data to identify reference values. *Clin Chem* 34, 474–481.

4 Rahil-Khazen R, Bolann BJ, Myking A *et al.* (2002) Multi-element analysis of trace element levels in human autopsy tissues by using inductively coupled atomic emission spectrometry technique (ICP-AES). *J Trace Elem Med Biol* 16, 15–25.

5 Linder MC (1984) Other trace elements and the liver. *Semin Liver Dis* 4, 264–276.

6 Nielsen FH (1985) The importance of diet composition in ultratrace element research. *J Nutr* 115, 1239–1247.

7 Institute of Medicine Food and Nutrition Board (2001) *Dietary Reference Intakes for Vitamin A, Vitamin K, Boron, Chromium, Copper, Iodine, Iron, Manganese, Molybdenum, Nickel, Silicon, Vanadium, and Zinc. A Report of the Panel on Micronutrients, Subcommittees on Upper Reference Levels of Nutrients and of Interpretation and Uses of Dietary Reference Intakes, and the Standing Committee on the Scientific Evaluation of Dietary Reference Intakes*. Washington, DC: National Academy Press.

8 Jacob C, Giles GI, Giles NM *et al.* (2003) Sulfur and selenium: the role of oxidation state in protein structure and function. *Angewandte Chem Int Edn in English* 42, 4742–4758.

9 Carlson BA, Novoselov SV, Kumaraswamy E *et al.* (2004) Specific excision of the selenocysteine $tRNA^{[Ser]Sec}$ (*Trsp*) gene in mouse liver demonstrates an essential role of selenoproteins in liver function. *J Biol Chem* 279, 8011–8017.

10 Behne D, Kyriakopoulos A (2001) Mammalian selenium-containing proteins. *Annu Rev Nutr* 21, 453–473.

11 Schrauzer GN (2000) Selenomethionine: a review of its nutritional significance, metabolism and toxicity. *J Nutr* 130, 1653–1656.

12 Driscoll DM, Copeland PR (2003) Mechanism and regulation of selenoprotein synthesis. *Annu Rev Nutr* 23, 17–40.

13 Ramos A, Lane AN, Hollingworth D *et al.* (2004) Secondary structure and stability of the selenocysteine insertion sequences (SECIS) for human thioredoxin reductase and glutathione peroxidase. *Nucleic Acids Res* 32, 1746–1755.

14 Diamond AM (2004) On the road to selenocysteine. *Proc Natl Acad Sci USA* 101, 13395–13396.

15 Howard MT, Aggarwal G, Anderson CB *et al.* (2005) Recoding

elements located adjacent to a subset of eukaryal selenocysteine-specifying UGA codons. *EMBO J* 24, 1596–1607.
16 Carlson BA, Xu X-M, Kryukov GV *et al.* (2004) Identification and characterization of phosphoseryl-tRNA[Ser]Sec kinase. *Proc Natl Acad Sci USA* 101, 12848–12853.
17 Mehta A, Rebsch CM, Kinzy SA *et al.* (2004) Efficiency of mammalian selenocysteine incorporation. *J Biol Chem* 279, 37852–37859.
18 Torres-Collado AX, Czaja AJ, Gelpi C (2005) Anti-tRNP[(ser)sec]/SLA/LP autoantibodies. Comparative study using in-house ELISA with a recombinant 48.8 kDa protein, immunoblot, and analysis of immunoprecipitated RNAs. *Liver Int* 25, 410–419.
19 Kryukov GV, Castellano S, Novoselov SV *et al.* (2003) Characterization of mammalian selenoproteomes. *Science* 300, 1439–1443.
20 Arthur JR (2000) The glutathione peroxidases. *Cell Mol Life Sci* 57, 1825–1835.
21 McClung JP, Roneker CA, Mu W *et al.* (2004) Development of insulin resistance and obesity in mice overexpressing cellular glutathione peroxidase. *Proc Natl Acad Sci USA* 101, 8852–8857.
22 Mostert V, Hill KE, Burk RF (2003) Loss of activity of the selenoenzyme thioredoxin reductase causes induction of hepatic heme oxygenase-1. *FEBS Lett* 541, 85–88.
23 Nordberg J, Arnér ESJ (2001) Reactive oxygen species, antioxidants, and the mammalian thioredoxin system. *Free Radic Biol Med* 31, 1287–1312.
24 Hill KE, Zhou J, McMahan WJ *et al.* (2003) Deletion of selenoprotein P alters distribution of selenium in the mouse. *J Biol Chem* 278, 13640–13646.
25 Schweizer U, Streckfuss F, Pelt P *et al.* (2005) Hepatically derived selenoprotein P is a key factor for kidney but not for brain selenium supply. *Biochem J* 386, 221–226.
26 Loguercio C, De Girolamo V, Federico A *et al.* (2001) Relationship of blood trace elements to liver damage, nutritional status, and oxidative stress in chronic nonalcoholic liver disease. *Biol Trace Elem Res* 81, 245–254.
27 Jain SK, Pemberton PW, Smith A *et al.* (2002) Oxidative stress in chronic hepatitis C: not just a feature of late stage disease. *J Hepatol* 36, 805–811.
28 Aboutwerat A, Pemberton PW, Smith A *et al.* (2003) Oxidant stress is a significant feature of primary biliary cirrhosis. *Biochim Biophys Acta* 1637, 142–150.
29 Matsumoto K-I, Ui I, Satoh K *et al.* (2002) Evaluation of oxidative damage in the liver of selenium-deficient rats. *Redox Rep* 7, 351–354.
30 Moskovitz J, Stadtman ER (2003) Selenium-deficient diet enhances protein oxidation and affects methionine sulfoxide reductase (MsrB) protein level in certain mouse tissues. *Proc Natl Acad Sci USA* 100, 7486–7490.
31 Brown KM, Arthur JR (2001) Selenium, selenoproteins and human health: a review. *Public Health Nutr* 4, 593–599.
32 Pagmantidis V, Bermano G, Villette S *et al.* (2005) Effects of Se-depletion on glutathione peroxidase and selenoprotein W gene expression in the colon. *FEBS Lett* 579, 792–796.
33 Gonzalez-Reimers E, Lopez-Lirola A, Olivera RM *et al.* (2003) Effects of protein deficiency on liver trace elements and antioxidant activity in carbon tetrachloride-induced liver cirrhosis. *Biol Trace Elem Res* 93, 127–140.
34 He Y-T, Liu D-W, Ding L-Y *et al.* (2004) Therapeutic effects and molecular mechanisms of anti-fibrosis herbs and selenium on rats with hepatic fibrosis. *World J Gastroenterol* 10, 703–706.
35 Diwadkar-Navsariwala V, Diamond AM (2004) The link between selenium and chemoprevention: a case for selenoproteins. *J Nutr* 134, 2899–2902.
36 Esworthy RS, Aranda R, Martín MG *et al.* (2001) Mice with combined disruption of *Gpx*1 and *Gpx*2 genes have colitis. *Am J Physiol Gastroint Liver Physiol* 281, G848–G855.
37 Chu FF, Esworthy RS, Chu PG *et al.* (2004) Bacteria-induced intestinal cancer in mice with disrupted *Gpx*1 and *Gpx*2 genes. *Cancer Res* 64, 962–968.
38 Schrauzer GN (2001) Nutritional selenium supplements: product types, quality, and safety. *J Am Coll Nutr* 20, 1–4.
39 Li L, Xie Y, El-Sayed WM *et al.* (2004) Characteristics of selenazolidine prodrugs of selenocysteine: toxicity, selenium levels, and glutathione peroxidase induction in A/J mice. *Life Sci* 75, 447–459.
40 Mueller AS, Pallauf J, Rafael J (2003) The chemical form of selenium affects insulinomimetic properties of the trace element: investigations in type II diabetic dbdb mice. *J Nutr Biochem* 14, 637–647.
41 Milman N, Laursen J, Byg K-E *et al.* (2004) Elements in autopsy liver tissue samples from Greenlandic Inuit and Danes. V. Selenium measured by X-ray fluorescence spectrometry. *J Trace Elem Med Biol* 17, 301–306.
42 Mihara H, Kurihara T, Watanabe T *et al.* (2000) cDNA cloning, purification, and characterization of mouse liver selenocysteine lyase. Candidate for selenium delivery protein in selenoprotein synthesis. *J Biol Chem* 275, 6195–6200.
43 Kobayashi Y, Ogra Y, Ishiwata K *et al.* (2002) Selenosugars are key and urinary metabolites for selenium excretion within the required to low-toxic range. *Proc Natl Acad Sci USA* 99, 15932–15936.
44 Cousins RJ (1986) Toward a molecular understanding of zinc metabolism. *Clin Physiol Biochem* 4, 20–30.
45 Reding P, Duchateau J, Bataille C (1984) Oral zinc supplementation improves hepatic encephalopathy. Results of a randomised controlled trial. *Lancet* 2, 493–495.
46 Marchesini G, Fabbri A, Bianchi G *et al.* (1996) Zinc supplementation and amino acid-nitrogen metabolism in patients with advanced cirrhosis. *Hepatology* 23, 1084–1092.
47 Kugelmas M (2000) Preliminary observation: oral zinc sulfate replacement is effective in treating muscle cramps in cirrhotic patients. *J Am Coll Nutr* 19, 13–15.
48 Baskol M, Ozbakir O, Coskun R *et al.* (2004) The role of serum zinc and other factors on the prevalence of muscle cramps in non-alcoholic cirrhotic patients. *J Clin Gastroenterol* 38, 524–529.
49 Vincent JB (2000) Quest for the molecular mechanism of chromium action and its relationship to diabetes. *Nutr Rev* 58, 67–72.
50 Cerulli J, Grabe D, Gauthier I *et al.* (1998) Chromium picolinate toxicity. *Ann Pharmacother* 32, 428–431.
51 Borguet F, Wallaeys B, Cornelis R *et al.* (1996) Transperitoneal absorption and kinetics of chromium in the continuous ambulatory peritoneal dialysis patient – an experimental and mathematical analysis. *Nephron* 72, 163–170.
52 Keen CL, Ensunsa JL, Watson MH *et al.* (1999) Nutritional aspects of manganese from experimental studies. *Neurotoxicology* 20, 213–223.
53 Spahr L, Butterworth RF, Fontaine S *et al.* (1996) Increased blood manganese in cirrhotic patients: relationship to pallidal magnetic resonance signal hyperintensity and neurological symptoms. *Hepatology* 24, 1116–1120.
54 Lambert D, Benhayoun S, Adjalla C *et al.* (1997) Alcoholic cirrhosis and cobalamin metabolism. *Digestion* 58, 64–71.

55 Ballatori N (1991) Mechanisms of metal transport across liver cell plasma membranes. *Drug Metab Rev* 23, 83–132.
56 Klaassen CD, Liu J (1998) Metallothionein transgenic and knock-out mouse models in the study of cadmium toxicity. *J Toxicol Sci* 23 (Suppl 2), 97–102.
57 Jacob ST, Ghoshal K, Sheridan JF (1999) Induction of metallothionein by stress and its molecular mechanisms. *Gene Expr* 7, 301–310.
58 Rodriguez-Moreno F, Gonzalez-Reimers E, Santolaria-Fernandez F *et al.* (1997) Zinc, copper, manganese, and iron in chronic alcoholic liver disease. *Alcohol* 14, 39–44.
59 Ran Q, Liang H, Gu M *et al.* (2004) Transgenic mice overexpressing glutathione peroxidase 4 are protected against oxidative stress-induced apoptosis. *J Biol Chem* 279, 55137–55146.
60 Imai H, Nakagawa Y (2003) Biological significance of phospholipid hydroperoxide glutathione peroxidase (PHGPx, GPx4) in mammalian cells. *Free Radic Biol Med* 34, 145–169.
61 Korotkov KV, Novoselov SV, Hatfield DL *et al.* (2002) Mammalian selenoprotein in which selenocysteine (Sec) incorporation is supported by a new form of Sec insertion sequence element. *Mol Cell Biol* 22, 1402–1411.
62 Baker SK (2005) Molecular clues into the pathogenesis of statin-mediated muscle toxicity. *Muscle Nerve* 31, 572–580.
63 Kim H-Y, Gladyshev VN (2004) Methionine sulfoxide reduction in mammals: characterization of methionine-R-sulfoxide reductases. *Mol Biol Cell* 15, 1055–1064.
64 Korotkov KV, Kumaraswamy E, Zhou Y *et al.* (2001) Association between the 15-kDa selenoprotein and UDP-glucose:glycoprotein glucosyltransferase in the endoplasmic reticulum of mammalian cells. *J Biol Chem* 276, 15330–15336.
65 Beckett GJ, Arthur JR (2005) Selenium and endocrine systems. *J Endocrinol* 184, 455–465.

2.3.15 Hepatic metabolism of drugs

Chris Liddle and Catherine A.M. Stedman

General concepts

Drug metabolism is the process by which drug molecules are chemically altered, usually to more polar metabolites that exhibit increased water solubility to allow elimination in urine or bile and/or increased access to excretory transporters. The liver is quantitatively and qualitatively the most important site of drug metabolism, although extrahepatic metabolism of drugs is also well recognised, both in the gastrointestinal mucosa and by circulating enzymes such as esterases. Drug metabolism is likely to be a byproduct of metabolic pathways that metabolize endogenously synthesized compounds (endobiotics) such as steroids, sterols, bile acids and eicosanoids. This is supported by the observation that hepatic enzymes involved in drug metabolism often have these endobiotic compounds as substrates, and that some hepatocellular transporters that handle bile acids also transport drugs [1,2].

One of the most surprising features of hepatic drug-metabolizing pathways is their ability to cope with a seemingly endless array of drug substrates. Thus, many of the newer fully synthetic drugs that have no close structural counterparts in nature are successfully metabolized by the liver and irreversibly removed or 'cleared' from the body. This broad substrate recognition is achieved by the presence of multiple drug-metabolizing enzymes in the hepatocyte, and many can metabolize multiple substrates. For example, the calcium channel blocker nifedipine is almost entirely metabolized by the cytochrome P450 (P450) CYP3A4, an enzyme with very broad substrate recognition that is responsible for the metabolism of some 50% of all therapeutic drugs. In contrast, the benzodiazepine diazepam is metabolized by P450s belonging to the CYP2C, 2D and 3A subfamilies to several primary metabolites, some retaining pharmacological activity. Thus, individual drugs may be metabolized in very different ways, and variation in the expression of individual enzymes and transporters for genetic or other reasons may have complex effects, which may sometimes be difficult to model and predict in advance.

Central role of the liver in drug metabolism

In terms of both gross anatomy and microstructure, the liver is ideally designed as a drug clearance organ (Fig. 1). Most foreign chemical compounds (xenobiotics), including therapeutic drugs, enter the body by absorption from the gastrointestinal tract. As covered in Chapter 2.1.1 of this book, venous drainage from most of the gastrointestinal tract is via the portal vein to the liver. Along with drug-metabolizing enzymes and drug transporters expressed in the intestinal mucosa, the liver provides an effective barrier that prevents xenobiotics from entering the systemic circulation. The fraction of an absorbed drug metabolized on this initial postabsorptive pass through the liver is termed 'first-pass clearance' and, factored together with the fraction of the drug absorbed from the gastrointestinal tract, determines the 'bioavailability' or the fraction of an orally administered drug that reaches the systemic circulation as intact drug [3]. For some drugs, the extent of first-pass clearance can be so great that oral administration is largely ineffective; for example, glyceryl trinitrate and lidocaine (lignocaine).

Within the hepatic lobular architecture, drug metabolism is not evenly distributed. Some important drug-metabolizing P450s such as CYP3A4 are predominantly expressed in pericentral (zone 3) hepatocytes [4]. One reason for this functional specialization may be that metabolism can give rise to highly toxic electrophilic intermediates, which may lead to cell death. With metabolic segregation, only pericentral necrosis occurs, rather than massive necrosis if highly reactive molecules cannot be successfully detoxified.

Drug-metabolizing enzymes

Phase I metabolism refers to a basic structural alteration of a drug molecule, whereas in phase II metabolism, a water-soluble

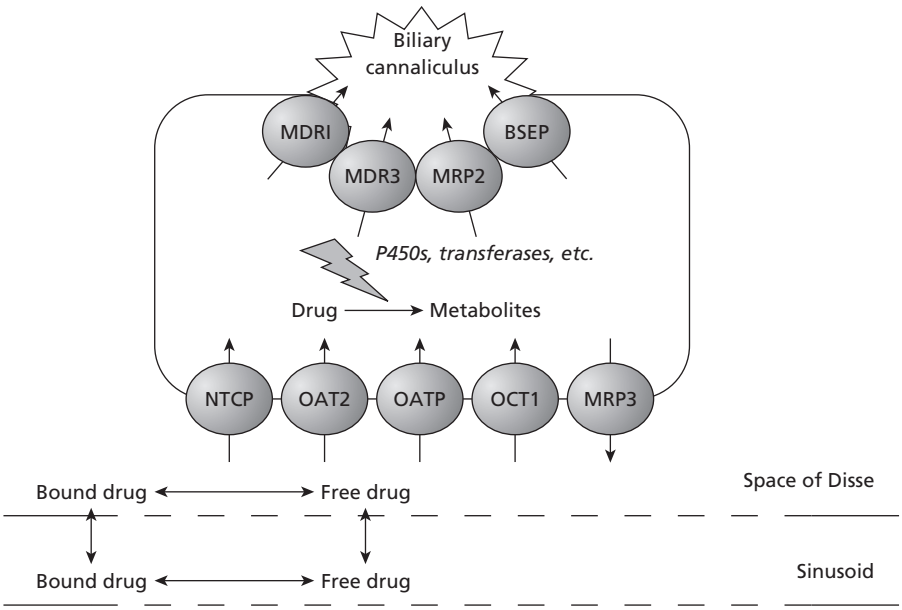

Fig. 1 Organization of drug metabolism at the level of the hepatocyte. Portal blood enters hepatic sinusoids where free drug molecules are transported into hepatocytes. Within hepatocytes, enzyme-mediated metabolism occurs prior to excretion of drug and drug metabolites by transport into bile or back into the circulation. BSEP, bile salt export pump; MDR, multidrug resistance protein; MRP, multidrug resistance-associated protein; OAT, organic anion transporter; OCT, organic cation transporter; NTCP, Na^+-taurocholate cotransporting polypeptide.

Table 1 Major human drug-metabolizing cytochrome P450s and receptors responsible for inductive regulation.

Cytochrome P450 family	Member	Regulating receptor
CYP1	CYP1A1	AhR
	CYP1A2	AhR
CYP2	CYP2A6	CAR
	CYP2A13	
	CYP2B6	CAR, PXR
	CYP2C8	PXR
	CYP2C9	CAR, PXR
	CYP2C18	
	CYP2C19	PXR, CAR
	CYP2D6	
	CYP2E1	
	CYP2F1	
	CYP2J2	
CYP3	CYP3A4	PXR, CAR
	CYP3A5	PXR, CAR
	CYP3A7[a]	PXR

AhR, aryl hydrocarbon receptor; CAR, constitutive androstane receptor; PXR, pregnane X receptor.
[a]Expressed in fetal liver and uterine endometrium.

moiety is attached or 'conjugated' to the drug. P450 enzymes are the predominant catalysts of phase I metabolism in the liver. P450s comprise a gene superfamily with 57 members in the human genome. A subset of approximately 15 P450 enzymes belonging to the CYP1, 2 and 3 gene families mediates 70–80% of all phase I-dependent metabolism of therapeutic drugs (Table 1) and participates in the metabolism of countless other xenobiotic chemicals. P450s from other families subserve a variety of specialized functions, particularly cholesterol and steroid synthesis and fatty acid metabolism [1,5].

P450 enzymes function as mono-oxygenases that insert one atom of oxygen into the substrate molecule. They have been alternatively referred to as 'mixed function oxidases' on account of their wide substrate specificities. Within hepatocytes, drug-metabolizing P450s are located in the smooth endoplasmic reticulum, in contrast to some synthetic P450s that are localized to the mitochondrial inner membrane. Drug-metabolizing P450 enzymes accomplish a wide variety of metabolic reactions including aliphatic and aromatic hydroxylation, *O*-, *S*- and *N*-dealkylation, oxidative and reductive dehalogenation, *N*-oxidation and *N*-hydroxylation, demethylation and deamination [6]. For example, CYP2D6 catalyses the *O*-demethylation of codeine to form morphine (Fig. 2), where the metabolite possesses greater pharmacological activity than the parent drug. Phase I-generated metabolites may be sufficiently water soluble for immediate elimination or may form substrates for phase II enzymes.

Phase II metabolism involves the conjugation of a hydrophilic chemical moiety to a drug molecule. Enzymes that accomplish this task are collectively known as 'transferases', as they catalyse the transfer of a moiety from a donor molecule to the drug recipient. For example, the UDP-glucuronosyltransferases (UGT) catalyse the transfer of the sugar α-glucuronic acid from the donor molecule uridine-α-glucuronide to a substrate molecule, as exemplified by morphine (Fig. 2). Most transferases also belong to gene families with individual members catalysing the conjugation of a distinct but often overlapping range of substrates. A list of enzymes commonly involved in phase II human drug metabolism is presented in Table 2. An important function of phase II enzymes is the detoxification of reactive molecules that may be generated by phase I drug metabolism [7].

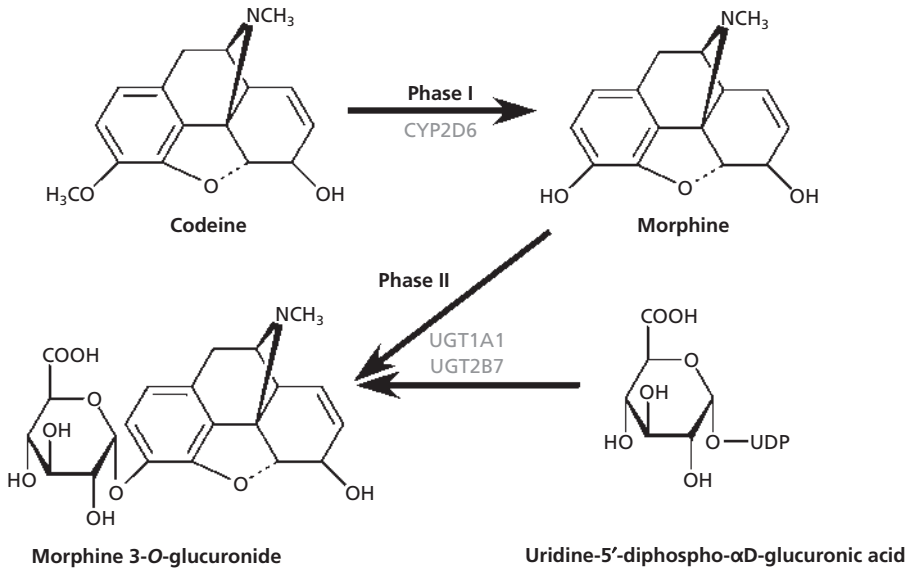

Fig. 2 Phases of hepatic drug metabolism as exemplified by codeine. Codeine is converted to morphine by CYP2D6-mediated *O*-demethylation, a phase I reaction. Morphine is subsequently conjugated by phase II enzymes UDP-glucuronosyltransferases (UGT) to form both 3-*O*- and 6-*O*-glucuronide metabolites, the pharmacologically inactive 3-*O* metabolite being shown in this figure.

Table 2 Some major human phase II drug-metabolizing enzymes and receptors implicated in regulation.

Superfamily	Function	Substrate examples	Gene families[a]	Receptors implicated in regulation[b]	
Glutathione *S*-transferases (GST)	Catalyse nucleophilic attack by GSH on non-polar compounds	Adriamycin, BCNU, busulfan, carmustine, chlorambucil, cyclophosphamide, DDT, inorganic arsenic, pesticides	GSTA[c] GSTM GSTP GSTS GSTT1 GSTZ GSTO	GSTA2	CAR, PXR AhR
Sulphotransferases (SULT)	Sulphation	Steroid hormones, bile acids, isoflavones, paracetamol, minoxidil	SULT1[d] SULT2 SULT4	SULT1A1 SULT2A1	CAR VDR
N-acetyltransferases (NAT)	*N*-acetylation, *O*-acetylation	Arylamines *N*-hydroxylated heterocyclic amines	NAT1 NAT2		
UDP-glucuronosyltransferases (UGT)	Glucuronidation	Bilirubin, paracetamol, morphine, zidovudine, NSAIDs	UGT1A UGT2B	UGT1A1 UGT1A6 UGT2B4 UGT2B7	PXR, CAR, HNF1α AhR, SHP FXR, ?PPAR HNF1α

BCNU, carmustine; GSH, reduced glutathione; NSAID, non-steroidal anti-inflammatory drug.
[a]Only significant human families are listed.
[b]Only nuclear receptors implicated in the regulation of human enzymes are listed.
[c]Cytosolic GSTs are shown; mitochondrial and microsomal GSTs are not shown.
[d]Only cytosolic SULTs are included in the nomenclature.

Drug transporters

Cloning and characterization of plasma membrane-bound hepatocyte transporters has revealed that many drugs enter and exit hepatocytes by energy-dependent transporters rather than by simple diffusion (Fig. 1, Table 3) [8]. The predominant transporters involved in drug uptake are members of the solute carrier (SLC) transporter superfamily, which are located on the sinusoidal (basolateral) plasma membrane. In contrast, transporters responsible for the excretion of drugs and drug metabolites from hepatocytes belong to the ATP-binding cassette (ABC) transporter superfamily and are located on

Table 3 Major hepatic drug transporters: nomenclature, function and nuclear receptor regulation.

Trivial symbol (gene symbol)	Name	Nuclear receptor	Function and substrates
Basolateral membrane of hepatocyte			
OATP1B1 (SLCO1B1)[a] OATP1B3 (SLCO1B3)[b]	Organic anion-transporting proteins	FXR, HNF1α, ?PXR	Hepatic uptake of organic anions and cations e.g. enalapril, digoxin, HMG-CoA reductase inhibitors, BA, bilirubin
OCT1 (SLC22A1)	Organic cation transporter		Hepatic uptake of hydrophilic organic cations e.g. cimetidine, choline, dopamine, acyclovir, zidovudine
OAT2 (SLC22A7)	Organic anion transporter		Hepatic uptake of organic anions and drugs e.g. salicylate, methotrexate, non-steroidal anti-inflammatory drugs
NTCP (SLC10A1)	Na^+-taurocholate cotransporting polypeptide	SHP/FXR	Na^+-dependent uptake of conjugated BA from portal blood
MRP1 (ABCC1)	Multidrug resistance-associated proteins	PXR	Drug export from hepatocytes, e.g. VP16, colchicine, etoposide
MRP3 (ABCC3)		PXR, FTF ?CAR	Organic solute transporter: extrudes BA conjugates, methotrexate, etoposide
MRP4 (ABCC4)			Mediates glutathione efflux from hepatocytes into blood by cotransport with BA; also exports purine and nucleoside analogues
Canalicular membrane of hepatocyte			
MDR1 (ABCB1)	Multidrug resistance-1	PXR	Excretion of organic cations, xenobiotics and cytotoxins to bile e.g. colchicine, doxirubicin, adriamycin, vinblastine, paclitaxel, vincristine
MDR3 (ABCB4)	Multidrug resistance-3	FXR, PPARα	Phospholipid export pump: translocates phosphatidylcholine from inner to outer leaflet of membrane bilayer
MRP2 (ABCC2)	Multidrug resistance-associated protein-2	PXR,CAR ?FXR	Mediates multispecific organic anion transport into bile, e.g. bilirubin diglucuronide, sulphates, glutathione conjugates, vinblastine, sulphinpyrazone
BSEP (ABCB11)	Canalicular bile salt export pump	FXR	ATP-dependent transport of monovalent bile salts and ?paclitaxel into bile
FIC1 (ATP8B1)	Familial intrahepatic cholestasis-1		Potential aminophospholipid-translocating ATPase
AE2 (SLC4A2)	Chloride–bicarbonate anion exchanger isoform-2		Facilitates bicarbonate secretion into bile, stimulates BA-independent bile flow
ABCG5/ABCG8	'Half ABC transporters'	FXR, PXR LXR	Transport sterols into bile. May partially mediate biliary cholesterol secretion
BCRP (ABCG2)	'Half ABC transporters'		Mediates cellular extrusion of sulphated conjugates, ?estramustine

BA, bile acids; CAR, constitutive androstane receptor; FTF, fetal transcription factor (also called liver receptor homologue 1, LRH1); FXR, farnesoid X receptor; LXR, liver X receptor; MDR1 protein is also known as P-glycoprotein; PPAR, peroxisome proliferator-activated receptor; PXR, pregnane X receptor; SHP, short heterodimer partner; HNF, hepatocyte nuclear factor.
[a]OATP1B1 is also known as OATP-C, OATP2, LST-1.
[b]OATP1B3 is also known as OATP8, LST-2.

the biliary canalicular (apical) plasma membrane, where they mediate the excretion of drugs into bile, or on the sinusoidal membrane, where they mediate efflux back into the circulation. Hepatocyte transporters and their functions are covered in more detail in Chapter 2.2.4.

Interindividual differences in drug metabolism

Clinicians are well aware that individual dose requirements of drugs for patients can very widely, even in the absence of obvious confounding factors such as drug–drug interactions [9]. For many drugs, a significant component of this interindividual difference can be attributed to variability in drug metabolism [10]. Importantly, metabolism cannot be reliably predicted by simple anthropomorphic characteristics such as body mass, body surface area, gender, age or race. While some variability can now be attributed to allelic variation within drug-metabolizing genes (Table 4), hepatic and intestinal expression of the most important and abundant human P450 enzyme CYP3A4 exhibits a unimodal distribution that cannot be explained by genetic polymorphism [5]. As CYP3A4 is intimately involved in the metabolism of many endogenously synthesized compounds, such as bile acids and ecosinoids in addition to therapeutic drugs, it now seems likely that variation in CYP3A4 may be the result of homeostatic regulatory mechanisms. In this respect, nuclear receptors that have endogenous ligands, such as the farnesoid X receptor (FXR) and the

Table 4 Genetic polymorphisms of some major human drug-metabolizing enzymes and transporters.

Gene	Major allelic variants	Prevalence of PM phenotype (%)		Examples of drugs affected by PM status
		Caucasian	Asian	
CYP1A2	CYP1A2*1K	–	–	Phenytoin, caffeine
CYP2A6	CYP2A6*4, CYP2A6*9	~ 0	2–4	Nicotine
CYP2B6	CYP2B6*6	–	–	Cyclophosphamide
CYP2C9	CYP2C9*2, CYP2C9*3	1–2	0.04	Phenytoin, glipizide, tolbutamide, warfarin, irbesartan
CYP2C19	CYP2C19*2, CYP2C19*3	2–5	10–25[a]	Diazepam, omeprazole, lansoprazole, imipramine, fluoxetine, sertraline, nelfinavir
CYP2D6	CYP2D6*4, CYP2D6*5, CYP2D6*10, CYP2D6*17, CYP2D6*41, CYP2D6*2xn[b]	5–10	1–2	Codeine, metoprolol, tricyclic antidepressants, venlafaxine, ondansetron, tropisetron, perhexiline
DPD	DPYD*2A	3	?	5-Fluorouracil
NAT	NAT2*5B, NAT2*6A[c]	50	< 40	Isoniazid, procainamide, hydralazine, sulphonamides
TPMT	TPMT*2, TPMT*3A, TPMT*3C	0.3	< 0.3	Azathioprine, 6-mercaptopurine
UGT1A1	UGT1A1*28, UGT1A1*6, UGT1A1*27	0.5–10	~ 3	Irinotecan, lamotrigine
MDR1	C3435T, G2677T	–	–	Digoxin, ciclosporin, tacrolimus, protease inhibitors
OATP1B1	OATP-C*5, OATP-C*1b	< 2%	–	Pravastatin

DPD, dihydropyrimidine dehydrogenase; PM, poor metabolizer; TPMT, thiopurine *S*-methyltransferase.
[a]The CYP2C19 PM phenotype is more common throughout Polynesia and Micronesia, with an incidence between 38% and 79%.
[b]CYP2D6 gene duplication results in increased CYP2D6 activity, the ultrarapid metabolizer (UM) phenotype. At least 75 CYP2D6 alleles have been identified.
[c]Phenotypes include slow, intermediate or fast acetylators. NAT1*, wide heterogeneity; NAT2*, at least 13 point mutations described [36].

pregnane X receptor (PXR), as well as other transcription factors important in the expression of liver-predominant genes such as hepatocyte nuclear factor 4α (HNF4α) and CCAAT/enhancer-binding protein β (C/EBPβ), have all been shown to be important regulators of CYP3A4 gene transcription [11–14].

Regulation of drug-metabolizing pathways

In an evolutionary sense, the ability to respond to a potentially toxic chemical challenge through the upregulation of endobiotic and xenobiotic metabolizing and transporting genes would be expected to confer a survival advantage. It is therefore not surprising that many drug disposition pathways are inherently variable and are capable of responding to a wide range of chemical stimuli. Recent work has shown that several drug-metabolizing and -transporting genes are subject to adaptive regulation, predominantly by nuclear receptors [15]. Members of the nuclear receptor superfamily function as ligand-activated transcription factors and have critical roles in diverse cellular processes. A subset of nuclear receptors that heterodimerize with the receptor for 9-*cis* retinoic acid-α (RXR) recognises a range of small lipophilic molecules that includes xenobiotic compounds, including a range of therapeutic drugs. The two receptors identified to date that have this role are PXR and the constitutive androstane receptor (CAR) [16]. PXR and CAR are capable of transcriptional induction of an array of drug-metabolizing and -transporting genes that cover all phases of hepatic drug disposition (Tables 1–3). In addition, nuclear receptors that appear to have exclusively endobiotic ligands such as the farnesoid X receptor (FXR) and the vitamin D receptor (VDR) have also been implicated in the regulation of drug-metabolizing pathways. Interestingly, PXR, FXR and VDR are all capable of binding and responding to bile acids, reinforcing the concept that drug metabolism is interrelated with cholesterol and bile acid homeostasis [17]. CAR appears to subserve additional roles in bilirubin and energy homeostasis [18], although its precise roles as an endogenous regulator remain enigmatic.

Role of genetic variation (pharmacogenetics)

The term 'pharmacogenetics' can be defined as the study of genetically determined variation in drug response. Pharmacogenomics is the use of genetic information to individualize drug therapy, a science that is still in its infancy. We now recognize that many genes involved in drug metabolism and transport are subject to genetic polymorphism, which may result in changes in drug disposition and, hence, both drug efficacy and drug toxicity [9,10]. All phases of drug disposition are now recognized to be affected by genetic variability, and some clinically relevant examples are listed in Table 4.

To date, genetic variation in cytochrome P450-mediated metabolism has been most intensively studied, and polymorphic forms of P450s are responsible for the development of a significant number of adverse drug reactions (ADRs) [19].

High-throughput analysis of P450 polymorphisms is already commercially available, but its impact on drug prescribing is not yet clear. All genes encoding P450 enzymes in families 1–3 are polymorphic to some degree. However, the functional importance of the variant alleles differs, and the frequencies of their distribution in different ethnic groups also vary. In general, four phenotypes can be identified: poor metabolizers (PMs), who lack the functional enzyme; intermediary metabolizers (IMs), who are heterozygous for one deficient allele or carry two alleles that cause reduced activity; extensive metabolizers (EMs), who have two normal alleles; and ultrarapid metabolizers (UMs), who have multiple gene copies, a trait that is dominantly inherited. The consequences of PM status have been well characterized for some genotypes (e.g. CYP2D6), and this results in slow drug metabolism, high drug concentrations at ordinary dosage, a higher risk of ADRs and, in some cases, no response to some prodrugs (e.g. codeine). In contrast, UM status results in non-response to drugs that are substrates for the enzyme, particularly well demonstrated with tricyclic antidepressants. For nortriptyline, the optimum dose varies from as low as 20 mg/day in PMs to 500 mg/day in UMs [19]. While genotyping CYP2D6 mutations could prove clinically useful, over 70 allelic variants of this gene have been described, which makes this approach technically difficult and expensive.

An alternative approach to assessing variation in hepatic metabolism is to phenotype through the use of pharmacokinetic studies in which the patient is given a marker drug for a particular metabolic pathway and serum or urinary drug levels are used to estimate the rate of clearance. While technically feasible, this approach has not been widely adopted largely because of the inconvenience and cost involved, with clinicians usually opting for a pragmatic approach, adjusting drug dose based on signs of efficacy or toxicity. At present, the only pharmacogenetic test in routine clinical use is the genotyping or phenotyping of thiopurine *S*-methyltransferase (TPMT), an enzyme that is crucial for the detoxification of the immunosuppressant 6-mercaptopurine, particularly in bone marrow where alternative metabolism through xanthine oxidase is not present [20].

More recently, it has been appreciated that genetic polymorphism has important effects on phase II enzymes as well as drug transporters such as MDR1 and OATP2. There is still controversy as to whether, and to what extent, the pharmacokinetics and pharmacodynamics of drugs are modified by the various genotypes of *MDR1*. In contrast to the P450 polymorphisms, no loss-of-function mutations have been described for *MDR1* in humans, and the differences between genotypes with respect to protein expression are moderate when compared, for example, with CYP2D6 [21].

Factors determining the rate of hepatic drug clearance

Several factors determine the rate at which the liver clears a drug from the body [22]. The most important of these are: (i) hepatic blood flow, which determines the rate at which drugs are delivered to the liver; (ii) binding to plasma proteins, as only unbound drug can be taken up by hepatocytes; (iii) affinity for hepatocyte uptake transporters; and (iv) the intrinsic affinity of hepatic enzymes for the drug as a substrate. The relative importance of these factors varies greatly for individual drugs, with hepatic blood flow being the main determinant of the rate of metabolism for very high metabolic clearance drugs and the other factors assuming more importance for drugs with low metabolic clearance. This has significant implications for patients with liver disease (see below).

Metabolic drug–drug interactions

At the level of hepatic drug metabolism, the two mechanisms of drug–drug interactions are induction and inhibition of drug-metabolizing enzymes. Examples of both are listed in Table 5. Inductive drug–drug interactions occur when an inducing drug causes an increase in the metabolism of coadministered drugs with a resultant diminution in their therapeutic effect. The most important enzyme affected by this form of interaction is CYP3A4 because of the potential magnitude of its induction and the vast array of drugs metabolized by this P450 enzyme [23]. Only relatively recently have the mechanisms of CYP3A4 induction by inducing drugs such as rifampicin, phenytoin, carbamazepine and the herbal remedy St John's Wort been elucidated. Most, if not all, CYP3A4-inducing drugs are now recognized to be ligands for PXR, a nuclear receptor that is highly expressed in hepatocytes and intestinal epithelial cells. PXR/RXR heterodimers bind to response elements in the regulatory upstream region of the CYP3A4 gene, resulting in transcriptional activation [12]. Several other drug-metabolizing genes and drug transporters are also induced by ligand-activated PXR, while a lesser number are activated by other receptors, including CAR and the aryl hydrocarbon receptor (AhR) [24,25].

Inhibition of metabolism by coadministered drugs is also a common cause of drug–drug interactions and occurs by two basic mechanisms. The most common mechanism of inhibition is simple competition between drugs for access to the catalytic pocket of the relevant drug-metabolizing enzyme. Some drugs are highly effective competitors for P450 enzymes, including cimetidine, ketoconazole and indinavir. The second way in which drugs inhibit P450s, often referred to as 'mechanism-based P450 inhibition', involves the formation of a catalytically inactive, covalently bound complex between a metabolite of the substrate drug and the P450 enzyme [26]. Macrolide antibiotics such as erythromycin and clarithromycin as well as tamoxifen, fluoxitine and the anti-HIV agents ritonavir and delavirdine are examples of drugs that interact in this way.

Role of metabolism in drug activation and drug toxicity

Drug metabolism usually results in metabolites with less pharmacological activity and less toxicity, but this is not always the

Table 5 Drug substrates, inhibitors and inducers of some cytochrome P450 enzymes.

P450 enzyme	Common drug substrates	Inhibitors	Inducers
CYP1A2	Clozapine, clomipramine, estrogen, fluvoxamine, haloperidol, tacrine, theophylline	Amiodarone, cimetidine, fluoroquinolones, ticlopidine	Polycyclic aromatic hydrocarbons omeprazole, ritonavir, phenobarbital
CYP2C9	Phenytoin, warfarin, tolbutamide, glipizide	Amiodarone, fluconazole, miconazole, phenylbutazone, sulphinpyrazone	Carbamazepine, phenobarbital, rifampin, St John's Wort
CYP2D6	Alprenolol, bufuralol, carvedilol, metoprolol, propranolol, timolol, amitriptyline, clomipramine, desipramine, imipramine, nortriptyline, flecainide, mexiletine, propafenone, fluoxetine, haloperidol, paroxetine, perphenazine, venlafaxine, codeine, dextromethorphan	Clomipramine, quinidine, fluoxetine, haloperidol, paroxetine	Not inducible
CYP2E1	Paracetamol, benzene, ethanol, isoflurane, theophylline	Disulfiram, diethyl-dithiocarbamate	Ethanol, isoniazid
CYP3A	Diltiazem, felodipine, nifedipine, verapamil, ciclosporin, tacrolimus, alprazolam, midazolam, triazolam, atorvastatin, lovastatin, clarithromycin, erythromycin, indinavir, nelfinavir, ritonavir, saquinavir, losartan, sildenafil	Diltiazem, verapamil, itraconazole, ketoconazole, clarithromycin, erythromycin, troleandomycin, delavirdine, indinavir, ritonavir, saquinavir, grapefruit juice, mifepristone, nefazodone	Rifabutin, rifampin, rifapentine, carbamazepine, phenobarbital, phenytoin, topiramate, efavirenz, nevirapine, St John's Wort

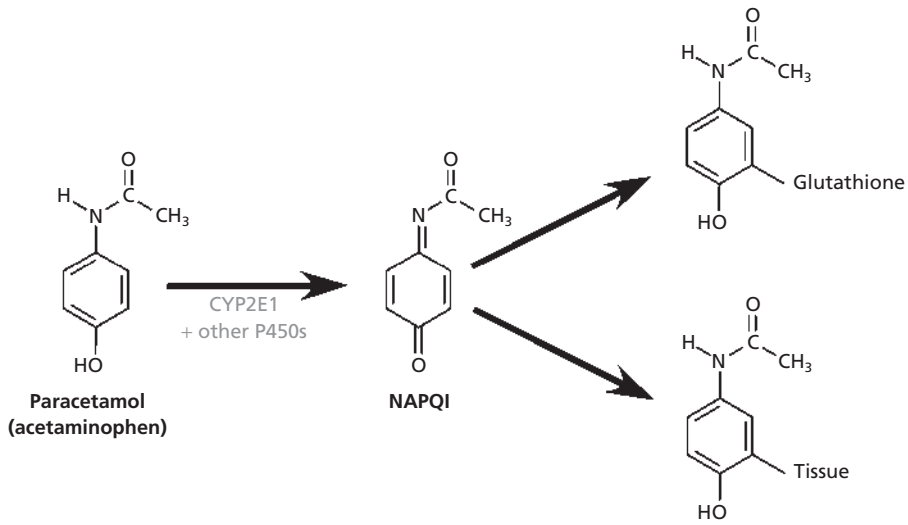

Fig. 3 Metabolic activation of paracetamol (acetaminophen) to a hepatotoxic metabolite. Phase I metabolism, predominantly mediated by CYP2E1, involves *N*-hydroxylation of paracetamol to form the electrophilic intermediate *N*-acetyl-*p*-benzoquinone imine (NAPQI). NAPQI is in turn detoxified by a spontaneous reaction with hepatic glutathione. Non-detoxified NAPQI can bind covalently to macromolecules within hepatocytes causing hepatic necrosis, as occurs in paracetamol overdose.

case. For example, irinotecan, a drug used for the chemotherapy of colorectal cancer, is a prodrug that requires metabolic activation by CYP3A4 to a compound named SN-38, which is the active pharmacological agent. SN-38 is subsequently detoxified by conjugation with α-glucuronic acid catalysed by UGT1A1. Individuals with the common genetic hyperbilirubinaemia Gilbert's syndrome are partially deficient in UGT1A1 and experience excessive toxicity when administered standard doses of irinotecan [27]. Metabolic activation applies not only to therapeutic drugs. Of concern is that some procarcinogens, such as heterocyclic amines, can be activated by P450 enzymes to carcinogenic metabolites [28].

Drug metabolism also contributes to both dose-related and idiosyncratic drug-induced hepatotoxicity. Paracetamol is a classic example of dose-related toxicity. The P450-mediated phase I metabolism of paracetamol (acetaminophen) gives rise to the reactive intermediate *N*-acetyl-*p*-benzoquinone imine (NAPQI), which is detoxified by a spontaneous reaction with hepatic glutathione (Fig. 3), a cysteine-containing triamino acid peptide. In the setting of paracetamol overdose, the rate of formation of NAPQI exhausts hepatic-reduced glutathione stores, and hepatocellular toxicity ensues [7]. While reactive metabolites have been identified for many drugs exhibiting idiosyncratic toxicity, the mechanisms by which tissue damage

occurs and propagates remain poorly understood. It is thought that some idiosyncratic hepatic reactions to drugs are the result of drug metabolites being covalently bound to cellular proteins, either causing altered protein function or engendering an immunological response with subsequent recruitment of inflammatory cells, production of proinflammatory cytokines and Fas- or porin-mediated induction of apoptosis [7] (see also Chapters 3.1 and 14.1). In the past, it has been difficult to estimate the likelihood of a drug causing idiosyncratic hepatotoxicity, but recent advances in proteomics and metabolomics may begin to allow prediction of the proclivity of a drug to cause this form of toxicity, before human studies are undertaken [29].

Drug metabolism in liver disease, portal hypertension and systemic disease states

Liver disease and portal hypertension

In advanced liver disease, drug metabolism mediated by some P450 enzymes or enzyme subfamilies, particularly CYP1A, 2C19 and 3A, appears to be impaired to an extent that cannot be explained by simple hepatocellular loss, and suggests specific downregulation of these genes [30]. This loss of metabolism varies with the cause of liver disease; for example, in patients with a predominant cholestatic aetiology, CYP3A activity is relatively preserved [31], possibly because of positive regulation by retained bile acids acting though PXR and FXR. There is a strong relationship between quantitative measures of hepatic drug metabolism such as the aminopyrine breath test and the Child–Pugh score [30], although such metabolic measurements may not be better predictors of the severity of liver disease than clinical assessment in combination with more readily available and less expensive biochemical tests.

In the presence of portal hypertension, hepatic blood flow may be reduced in combination with increased portal–systemic shunting through collateral blood vessels. This can dramatically increase the bioavailability of high clearance drugs, for example propranolol, a drug that is commonly used in cirrhotic patients to lower portal vascular pressure. Such patients often require a relatively low dose of this drug to achieve a therapeutic effect and avoid side-effects such as excessive bradycardia. At the other end of the spectrum, the rate of metabolism of low clearance drugs is particularly sensitive to any factor that affects the availability of drug-metabolizing enzymes, as occurs with loss of hepatocellular mass in liver disease. A good example is diazepam, which exhibits a 50% reduction in clearance in advanced liver disease [32]. An additional factor that alters drug disposition in advanced liver disease is decreased plasma protein binding due to decreased hepatic protein synthesis. This results in increased action of drugs that usually circulate in a highly bound state. Issues relating to prescribing drugs in patients with liver diseases are covered in Chapter 23.3.

Drug metabolism in inflammatory states

In the early 1980s, it was recognized that theophylline toxicity occurred in children with influenza, despite being on a non-toxic dose of the drug prior to falling ill [33]. It was subsequently shown that several inflammatory states were associated with decreased expression of some hepatic P450 enzymes and that interleukin-1, interleukin-6, interferons and bacterial lipopolysaccharide were capable of mediating this phenomenon, predominantly operating through transcriptional repression [34]. More recently, it has been proposed that some patients with advanced cancer may experience excessive toxicity from chemotherapy because of diminished hepatic metabolism of anticancer drugs, even when the malignant process does not directly involve the liver. In this situation, it appears that the cancer is modulating drug-metabolizing enzymes through either the direct or the indirect release of proinflammatory cytokines [35].

References

1 Nebert DW, Russell DW (2002) Clinical importance of the cytochromes P450. *Lancet* 360 (9340), 1155–1162.

2 Handschin C, Meyer UA (2005) Regulatory network of lipid-sensing nuclear receptors: roles for CAR, PXR, LXR, and FXR. *Arch Biochem Biophys* 433 (2), 387–396.

3 Shen DD, Kunze KL, Thummel KE (1997) Enzyme-catalyzed processes of first-pass hepatic and intestinal drug extraction. *Adv Drug Deliv Rev* 27 (2–3), 99–127.

4 Yokose T, Doy M, Taniguchi T *et al.* (1999) Immunohistochemical study of cytochrome P450 2C and 3A in human non-neoplastic and neoplastic tissues. *Virchows Arch* 434 (5), 401–411.

5 Wilkinson GR (2005) Drug metabolism and variability among patients in drug response. *N Engl J Med* 352 (21), 2211–2221.

6 Ortiz de Montellano PR (ed.) (1995) *Cytochrome P-450: Structure, Mechanism and Biochemistry*, 2nd edn. New York: Plenum Press.

7 Park BK, Kitteringham NR, Maggs JL *et al.* (2005) The role of metabolic activation in drug-induced hepatotoxicity. *Annu Rev Pharmacol Toxicol* 45, 177–202.

8 Mizuno N, Niwa T, Yotsumoto Y *et al.* (2003) Impact of drug transporter studies on drug discovery and development. *Pharmacol Rev* 55 (3), 425–461.

9 Weinshilboum R (2003) Inheritance and drug response. *N Engl J Med* 348 (6), 529–537.

10 Meyer UA (2004) Pharmacogenetics – five decades of therapeutic lessons from genetic diversity. *Nature Rev Genet* 5 (9), 669–676.

11 Gnerre C, Blattler S, Kaufmann MR *et al.* (2004) Regulation of CYP3A4 by the bile acid receptor FXR: evidence for functional binding sites in the CYP3A4 gene. *Pharmacogenetics* 14 (10), 635–645.

12 Goodwin B, Hodgson E, Liddle C (1999) The orphan human pregnane X receptor mediates the transcriptional activation of CYP3A4 by rifampicin through a distal enhancer module. *Mol Pharmacol* 56 (6), 1329–1339.

13 Tirona RG, Lee W, Leake BF *et al.* (2003) The orphan nuclear receptor HNF4α determines PXR- and CAR-mediated xenobiotic induction of CYP3A4. *Nature Med* 9 (2), 220–224.

14 Martinez-Jimenez CP, Gomez-Lechon MJ, Castell JV *et al.* (2005) Transcriptional regulation of the human hepatic CYP3A4:

identification of a new distal enhancer region responsive to CCAAT/enhancer-binding protein β isoforms (liver activating protein and liver inhibitory protein). *Mol Pharmacol* 67 (6), 2088–2101.
15 Tirona RG, Kim RB (2005) Nuclear receptors and drug disposition gene regulation. *J Pharm Sci* 94 (6), 1169–1186.
16 Liddle C, Goodwin B (2002) Regulation of hepatic drug metabolism: role of the nuclear receptors PXR and CAR. *Semin Liver Dis* 22 (2), 115–122.
17 Eloranta JJ, Kullak-Ublick GA (2005) Coordinate transcriptional regulation of bile acid homeostasis and drug metabolism. *Arch Biochem Biophys* 433 (2), 397–412.
18 Goodwin B, Moore JT (2004) CAR: detailing new models. *Trends Pharmacol Sci* 25 (8), 437–441.
19 Ingelman-Sundberg M (2004) Pharmacogenetics of cytochrome P450 and its applications in drug therapy: the past, present and future. *Trends Pharmacol Sci* 25 (4), 193–200.
20 Givens RC, Watkins PB (2003) Pharmacogenetics and clinical gastroenterology. *Gastroenterology* 125 (1), 240–248.
21 Eichelbaum M, Fromm MF, Schwab M (2004) Clinical aspects of the MDR1 (ABCB1) gene polymorphism. *Ther Drug Monit* 26 (2), 180–185.
22 Birkett DJ (2002) *Pharmacokinetics Made Easy*, 2nd edn. Roseville, NSW: McGraw-Hill.
23 Liddle C, Robertson GR (2003) Predicting inductive drug-drug interactions. *Pharmacogenomics* 4 (2), 141–152.
24 Maglich JM, Stoltz CM, Goodwin B *et al.* (2002) Nuclear pregnane x receptor and constitutive androstane receptor regulate overlapping but distinct sets of genes involved in xenobiotic detoxification. *Mol Pharmacol* 62 (3), 638–646.
25 Whitlock JP, Jr (1999) Induction of cytochrome P4501A1. *Annu Rev Pharmacol Toxicol* 39, 103–125.
26 Zhou S, Yung Chan S, Cher Goh B *et al.* (2005) Mechanism-based inhibition of cytochrome P450 3A4 by therapeutic drugs. *Clin Pharmacokinet* 44 (3), 279–304.
27 Innocenti F, Iyer L, Ratain MJ (2001) Pharmacogenetics of anticancer agents: lessons from amonafide and irinotecan. *Drug Metab Dispos* 29 (4 Pt 2), 596–600.
28 Wogan GN, Hecht SS, Felton JS *et al.* (2004) Environmental and chemical carcinogenesis. *Semin Cancer Biol* 14 (6), 473–486.
29 Liebler DC, Guengerich FP (2005) Elucidating mechanisms of drug-induced toxicity. *Nature Rev Drug Discov* 4 (5), 410–420.
30 Villeneuve JP, Pichette V (2004) Cytochrome P450 and liver diseases. *Curr Drug Metab* 5 (3), 273–282.
31 George J, Murray M, Byth K *et al.* (1995) Differential alterations of cytochrome P450 proteins in livers from patients with severe chronic liver disease. *Hepatology* 21 (1), 120–128.
32 Hebert MF. Guide to drug doses in hepatic disease. In: Speight TM, Holford NHG (eds) *Avery's Drug Treatment,* 4th edn. Auckland: Adis International Ltd.
33 Kraemer MJ, Furukawa CT, Koup JR *et al.* (1982) Altered theophylline clearance during an influenza B outbreak. *Pediatrics* 69 (4), 476–480.
34 Morgan ET (2001) Regulation of cytochrome P450 by inflammatory mediators: why and how? *Drug Metab Dispos* 29 (3), 207–212.
35 Slaviero KA, Clarke SJ, Rivory LP (2003) Inflammatory response: an unrecognised source of variability in the pharmacokinetics and pharmacodynamics of cancer chemotherapy. *Lancet Oncol* 4 (4), 224–232.

2.4 Synthetic function

2.4.1 Albumin and other carrier proteins

Richard A. Weisiger

Soluble proteins make up 6.4–8.3% of plasma by weight [1], a value comparable to their concentration in cell water [2]. Many plasma proteins are synthesized by the liver. Their concentrations may decrease in the setting of liver disease, malnutrition or protein-losing states such as nephrotic syndrome, severe burns, bowel inflammation, intestinal lymphangiectasia or major bleeding episodes. The most abundant plasma proteins have little or no enzymatic activity. Instead, their function is typically binding to other molecules, generically referred to as *ligands*. Some plasma binding proteins that have been characterized are listed in Table 1. Most of these proteins bind to only one (or a few related) molecules with high affinity. For example, haemopexin binds haem, retinol-binding protein binds retinol, and transferrin binds iron. In contrast, other binding proteins such as albumin and alpha-fetoprotein are far less selective.

Albumin is the most important serum binding protein in terms of concentration (about 4.2%) [1,3] and number of different ligands bound. The latter include fatty acids [4], unconjugated bilirubin [5], many divalent cations such as copper [6,7], hydrophobic bile acids [6] and a variety of drugs and toxins [6,8–11] (Table 2). Albumin's broad specificity reflects not only

Table 1 Soluble binding proteins found in plasma.

Binding protein	Ligand	References
Afamin	Vitamin E, probably others	[18,65,36]
Albumin	See Table 2	
Alpha-fetoprotein	Long-chain fatty acids, bilirubin, many others	[66]
Avidins	Biotin	[67]
Ceruloplasmin	Copper	[68]
Cholesterol ester transfer protein	Cholesterol	[33]
Corticosteroid-binding globulin	Steroid hormones	[69]
Folate-binding protein	Folic acid	[6]
Haptoglobin	Haemoglobin	[6]
Haemopexin	Haem	[6]
Lipocalins	Retinoids, arachidonic acid, steroids, pheromones	[70]
Lipoproteins	Triglycerides, cholesterol, bile acids, vitamin E	[6]
Phospholipid transfer protein	Phospholipids	[71,72]
Retinol-binding protein	Retinols	[73,74]
Sex hormone-binding globulin	Testosterone, dihydrotestosterone, estradiol	[75]
Thyroxine-binding globulin	Thyroxine	[76]
Transcobalamins	Vitamin B12	[77,78]
Transcortin	Corticoids	[79]
Transferrin	Iron	[6]
Transthyretin	Thyroxine	[73]
Vitamin D-binding protein	Vitamin D	[6]

Table 2 Some molecules bound by plasma albumin.

Amino acids (tryptophan, cysteine)	[17,80]
Bilirubin	[5,6,29]
Cationic metal ions (Ag, Ca, Cd, Co, Cu, Hg, Mg, Mn, Ni, Zn)	[3,6,7,81–83]
Chloride	[6]
Many drugs (e.g. coumadin, digitalis, ibuprofen, diazepam, lidocaine, furosemide, valproic acid, phenytoin)	[6,8]
Medium- and long-chain fatty acids	[6,84]
Certain bile acids (e.g. lithocholate, chenodeoxycholate)	[6,85]
Certain steroid hormones (cortisone, estradiol, progesterone, aldosterone)	[6]
Thyroxine	[6, 86]
Certain toxins (e.g. aflatoxin, digitoxin, 'organic anions')	[9–11]

the presence of several discrete binding sites [6], but also its ability to adapt its three-dimensional conformation in response to binding [12,13], thus creating a better fit between the binding site and the ligand. This ability is termed *conformational adaptability* [14]. Even when no ligands are bound, albumin is constantly sampling from a large library of conformations in a process known as *conformational breathing* [14]. This variability helps to explain why it took so long to crystallize albumin in a form suitable for determining its detailed three-dimensional structure [6,15,16].

Human serum albumin consists of a single polypeptide chain of 585 amino acids with a molecular weight of 66 700 Da [9,17]. It contains six homologous subdomains that individually retain binding capacity when separated by proteolysis [15]. It is part of a multigene family that also includes alpha-fetoprotein, afamin and vitamin D-binding protein [15,18]. Synthesis of albumin is restricted to the liver, and albumin levels typically decline as the severity of liver disease worsens. The serum albumin concentration is an important part of the Child–Pugh score for assessing the severity of liver disease [19], but is not used in the MELD score for determining liver transplantation priority, in part because such critically ill patients often have other conditions (such as gastrointestinal bleeding) that may lower the albumin level [20,21]. Hyperalbuminaemia, when seen, is nearly always due to dehydration rather than increased synthesis.

Functions of albumin and other plasma binding proteins

Convection

The primary function of blood is to transport molecules to and from tissues by convection (flow). Without this function, important metabolites such as glucose and oxygen would become depleted, and products of metabolism such as carbon dioxide and lactate would accumulate to toxic levels. The most dramatic example of failure of convective transport is cardiac arrest, which causes rapid and severe damage to most tissues. However, selective failure of convective transport can occur even with normal cardiac output if binding protein concentrations are low. For example, a very low haemoglobin level selectively blocks convective transport of oxygen, causing ischaemia. Congenital absence of transcobolamin blocks vitamin B12 transport, causing brain damage [22,23]. Congenital retinol-binding deficiency blocks the transport of retinol, causing atrophy of the retina [24]. Congenital haptoglobin deficiency is associated with seizures caused by the accumulation of haemoglobin and its degradation products in the brain [25]. Interestingly, congenital lack of serum albumin causes few manifestations in otherwise healthy persons, probably because other plasma proteins with overlapping binding specificities compensate for its absence [26]. Nevertheless, critically ill patients with hypoalbuminaemia have greatly decreased survival rates even with normal nutrition, and replacing albumin seems to improve their survival [27].

The rate at which a molecule is transported by the bloodstream is proportional to its concentration. For lipophilic and amphipathic molecules, this concentration is very low unless binding proteins are present, reflecting their limited solubility in water and their strong tendency to bind to tissues. Plasma binding proteins may increase the rate of convective transport of their ligands by many orders of magnitude. They are often called *carrier proteins* in recognition of this important role.

It may seem counterintuitive that protein binding can make a ligand more available to tissues. Indeed, bilirubin is cleared by liver much more efficiently in the absence of albumin than in its presence [28], suggesting that the opposite should be true. However, the maximum possible concentration of unbound bilirubin in plasma is so tiny, about 7 nM [29], that normal blood flow cannot deliver nearly enough bilirubin to the liver to keep up with the rate of production, even if the efficiency of removal is 100%. On the other hand, the concentration of albumin-bound bilirubin in plasma is large enough that only a small fraction needs to be removed to keep up with bilirubin production. In summary, protein binding makes ligands more available to sites of metabolism and excretion within the body by increasing their rates of convection from one tissue to another.

By a similar mechanism, binding proteins are also important in hormone signalling. Thyroid and steroid hormones are relatively hydrophobic and tend to bind strongly to tissues [30,31]. In the absence of binding proteins, these hormones bind to the first cells they encounter [30,31], thus preventing rapid signalling to other cells. By competing with cellular binding sites for these hormones, plasma binding proteins for thyroid [32], steroid [6,33] and other lipophilic hormones maintain a uniform circulating pool that bathes all cells with similar hormone concentrations, allowing changes in hormone levels to propagate rapidly and uniformly throughout the body [30]. In general, the activity of a hormone is proportional to the unbound ('free') hormone concentration [34]. Plasma hormone binding proteins buffer this concentration against rapid changes while promoting a uniform distribution throughout the body.

Diffusion

Convection alone cannot deliver dissolved molecules to the cell surface. No matter how vigorously the extracellular fluid is 'stirred' (e.g. by flow or turbulence), a very thin layer of unstirred plasma always remains just above the plasma membrane [35]. The only way for soluble molecules to cross this layer is by diffusion. The thickness of this layer varies among tissues. It is relatively small in the liver, where fenestrations in the endothelial cells allow plasma proteins direct access to the subendothelial (Disse) space [36]. Erythrocytes passing through the liver sinusoids may 'massage' the endothelium, thus both increasing the rate of exchange of plasma with the subendothelial space [36] and reducing the thickness of the unstirred layer. In contrast, cells in less metabolically active tissues may be located one or more cell diameters from the nearest capillary, requiring metabolites to diffuse much greater distances to reach them.

Diffusion is the random motion of dissolved molecules across a concentration gradient. Although the unstirred plasma layer is typically very small, it can greatly limit the rate at which small molecules move into and out of cells [35,37]. According to Fick's law, the steady diffusional flux (J) is proportional to the concentration difference of the diffusing molecule (ΔC) and its diffusion constant (D) (a measure of its rate of random motion) and inversely related to the square of the thickness of the layer (x) (Eq. 1).

$$J = \Delta C\, \mathrm{D}/x^2 \qquad (1)$$

Because of their low solubility in water [29,38], many hydrophobic molecules such as fatty acids and bilirubin cannot even approach a sufficient concentration in plasma to drive observed rates of uptake across this layer in the liver and other metabolically active tissues [37]. In much the same way that they increase convection, binding proteins also increase the diffusional flux of their ligands by increasing the amount of dissolved ligand available for diffusion [37]. While it is true that binding to the protein lowers the ligand's diffusion constant by a factor of about 10, this is more than compensated for by the increase in the soluble concentration (often by many orders of magnitude). These higher concentrations allow for larger values of ΔC, resulting in a net increase in the diffusion rate [37].

Interactions with cell membranes

Cellular uptake of protein-bound ligands may occur by several possible mechanisms. Some binding proteins randomly release their ligands in the general vicinity of the target cell membrane, while others deliver them carefully to specific sites on the cell surface or even within the cell. Many cells have receptors for binding proteins on their surface (e.g. transferrin [6]). Binding to these receptors is typically followed by receptor-mediated endocytosis of the entire protein–ligand complex, dissociation of the ligand from the binding protein in the acid lysosomal compartment and return of the binding protein to the plasma [6]. In other cases, however, the complex may serve a signalling function. Sex steroid-binding protein allows certain sex hormones to activate adenyl cyclase without ever entering the cell by reversibly binding to a specific G protein-linked receptor on the cell surface [39]. Only certain sex hormones are able to activate the receptor when bound to the binding protein [39].

Cellular uptake may also draw on a pool of unbound ligand at the cell surface that is rapidly replenished by dissociation from the binding protein. Dissociation may either be spontaneous or catalysed by an interaction of the binding protein with the cell surface. If sufficiently slow, the rate of dissociation may limit the rate of cellular uptake by allowing the unbound ligand concentration to become depleted at the cell surface. Dissociation-limited uptake has been demonstrated for avidly bound molecules such as bilirubin and fatty acids [37,40]. Indeed, the affinity of albumin for bilirubin and long-chain fatty acids may represent a compromise between the need to limit the toxicity of these molecules (which favours more avid binding) and the need for rapid dissociation of the ligand from albumin prior to uptake (which favours less avid binding). Under physiological conditions, the hepatic uptake rate of fatty acids and bilirubin is influenced by many processes (including the rates of plasma flow into the liver, diffusion across the unstirred plasma layer, transport across the plasma membrane, diffusion through the cell cytoplasm and metabolism or excretion), each of which has a roughly comparable rate [41]. The detailed process by which binding proteins facilitate diffusion of their ligands across extracellular water layers was first defined by Bass and Pond [42] and has since been validated in a variety of physiological settings [43–45].

Limiting toxicity

Many molecules that bind to plasma proteins are potentially toxic. This includes endogenous molecules such as bilirubin and long-chain fatty acids, heavy metal ions such as iron and copper, and exogenous drugs and toxins such as digitalis, aminoglycosides and warfarin. These molecules cause little or no toxicity while bound to plasma proteins, but interfere with critical cell functions when present at sufficient concentrations within tissues. Binding to plasma proteins provides a relatively safe place to store these molecules while they await cellular metabolism or elimination.

For example, children with congenital absence of hepatic bilirubin uridine diphosphate (UDP)-glucuronal transferase may develop brain damage (kernicterus) from the accumulation of high levels of unconjugated bilirubin in neural tissues [46]. Bilirubin inhibits important cellular functions such as the Na^+/K^+-ATPase and peptide phosphorylation in the brain [47,48]. However, brain damage does not occur until the storage capacity of plasma albumin is exceeded [6,46]. Likewise, long-chain fatty acids can cause damage to cell membranes and inhibit some enzymes when present at high concentrations [49–51]. However, high plasma concentrations are needed to

support maximum cardiac and skeletal muscle output. Binding of more than 99.99% of the plasma fatty acids to albumin greatly reduces this potential toxicity while keeping the fatty acids in a form that is rapidly available for metabolism. Finally, in patients with haemochromatosis, liver and other tissues do not become loaded with iron until after transferrin is saturated [52], allowing the formation of small iron complexes that are rapidly cleared by the liver [53,54]. Without binding proteins such as transferrin, iron ions release toxic free radicals as they repeatedly cycle between the ferrous and ferric states [55].

Plasma binding proteins also influence drug effectiveness and toxicity. Warfarin causes toxicity by blocking the formation of clotting factors in the liver, an effect that is used therapeutically by the drug coumadin. However, the full effect of a daily dose of coumadin does not become manifest until after the plasma binding sites on albumin have been loaded. Persons with hypoalbuminaemia are more susceptible to warfarin toxicity [56,57]. Hypoalbuminaemia is also a risk factor for aminoglycoside toxicity [58]. In a similar way, plasma binding increases the amount of a dietary toxin that must be ingested to produce toxicity. The important role of plasma binding in modulating tissue concentrations of drugs is underscored by the fact that measurement of unbound drug concentrations is increasingly used to monitor therapy [59]. Monitoring unbound concentrations is particularly important in patients with disturbed plasma binding due to hypoalbuminaemia or the presence of competitive inhibitors of binding such as uraemic toxins or certain drugs [59].

Targeting ligands to specific tissues

Binding proteins may help to direct their ligands to specific tissues that express receptors for the protein. This mechanism makes optimum use of ligands that are in limited supply or may cause toxicity if delivered to the wrong tissues. For example, transcobalamins target vitamin B12 to cells expressing the transcobalamin receptor [60], and transferrin targets iron to cells expressing the transferrin receptor [6]. When expressed, the receptor for sex steroid-binding globulin renders cells sensitive to the hormonal effects of certain steroid hormones [39].

Oncotic functions

Albumin provides approximately 80% of the colloid osmotic pressure in normal blood, reflecting its high concentration and relatively low molecular weight. Significant decreases in serum albumin levels due to liver failure, bleeding, nephrotic syndrome or protein-losing enteropathy are associated with the accumulation of fluid in extracellular compartments (e.g. oedema, ascites) [61]. Cerebral oedema may be life threatening and reflects not only low albumin levels, but also increased permeability of the cerebral vessels [62]. Administration of albumin reduces the reaccumulation of ascites after paracentesis [63] and has been used to treat cerebral oedema as well [64].

References

1 Bennet JC, Plum F (eds) (1996) *Cecil Textbook of Medicine*, 20th edn. Philadelphia, PA: W.B. Saunders Co.

2 Luby-Phelps K, Lanni F, Taylor DL (1988) The submicroscopic properties of cytoplasm as a determinant of cellular function. *Annu Rev Biophys Biophys Chem* 17, 369–396.

3 Peters T, Reed RG (1978) Serum albumin as a transport protein. In: Sund H (ed.) *Transport by Proteins*. Berlin: Walter de Gruyter, pp. 57–73.

4 Ashbrook JD, Spector AA, Santos EC *et al.* (1975) Long chain fatty acid binding to human plasma albumin. *J Biol Chem* 250, 2333–2338.

5 Brodersen R (1979) Binding of bilirubin to albumin. *CRC Crit Rev Clin Lab Sci* 11, 305–399.

6 Carter DC, Ho JX (1994) Structure of serum albumin. *Adv Protein Chem* 45, 153–203.

7 Masuoka J, Saltman P (1994) Zinc(II) and copper(II) binding to serum albumin. A comparative study of dog, bovine, and human albumin. *J Biol Chem* 269, 25557–25561.

8 Meijer DK, van der Sluijs P (1989) Covalent and noncovalent protein binding of drugs: implications for hepatic clearance, storage, and cell-specific drug delivery. *Pharm Res* 6, 105–118.

9 Kragh-Hansen U (1990) Structure and ligand binding properties of human serum albumin. *Dan Med Bull* 37, 57–84.

10 Dirr HW, Schabort JC (1987) Characterization of the aflatoxin B1-binding site of rat albumin. *Biochim Biophys Acta* 913, 300–307.

11 Doucet J, Fresel J, Hue G *et al.* (1993) Protein binding of digitoxin, valproate and phenytoin in sera from diabetics. *Eur J Clin Pharmacol* 45, 577–579.

12 Hvidt AA, Wallevik K (1972) Conformational changes in human serum albumin as revealed by hydrogen-deuterium exchange studies. *J Biol Chem* 247, 1530–1535.

13 Wilting J, Kremer JM, Ijzerman AP *et al.* (1982) The kinetics of the binding of warfarin to human serum albumin as studied by stopped-flow spectrophotometry. *Biochim Biophys Acta* 706, 96–104.

14 Scheider W (1977) Real-time measurement of dielectric relaxation of biomolecules: kinetics of a protein-ligand binding reaction. *Ann NY Acad Sci* 303, 47–58.

15 Geisow MJ (1992) Human serum albumin structure – solved. *Trends Biotechnol* 10, 335–337.

16 Petitpas I, Grune T, Bhattacharya AA *et al.* (2001) Crystal structures of human serum albumin complexed with monounsaturated and polyunsaturated fatty acids. *J Mol Biol* 314, 955–960.

17 Peters T, Jr (1985) Serum albumin. *Adv Protein Chem* 37, 161–245.

18 Lichenstein HS, Lyons DE, Wurfe, MM *et al.* (1994) Afamin is a new member of the albumin, alpha-fetoprotein, and vitamin D-binding protein gene family. *J Biol Chem* 269, 18149–18154.

19 Schneider PD (2004) Preoperative assessment of liver function. *Surg Clin North Am* 84, 355–373.

20 Srikureja W, Kyulo NL, Runyon BA *et al.* (2005) MELD score is a better prognostic model than Child–Turcotte–Pugh score or discriminant function score in patients with alcoholic hepatitis. *J Hepatol* 42, 700–706.

21 Freeman RB, Jr, Wiesner RH, Roberts JP *et al.* (2004) Improving liver allocation: MELD and PELD. *Am J Transplant* 4 (Suppl 9), 114–131.

22 Qian L, Quadros EV, Regec A *et al.* (2002) Congenital transcobalamin II deficiency due to errors in RNA editing. *Blood Cells Mol Dis* 28, 134–142; discussion 143–135.

23 Kaikov Y, Wadsworth LD, Hall CA *et al.* (1991) Transcobalamin II deficiency: case report and review of the literature. *Eur J Pediatr* 150, 841–843.

24 Seeliger MW, Biesalski HK, Wissinger B *et al.* (1999) Phenotype in retinol deficiency due to a hereditary defect in retinol binding protein synthesis. *Invest Ophthalmol Vis Sci* 40, 3–11.

25 Manoharan A (1997) Congenital haptoglobin deficiency. *Blood* 90, 1709a.

26 Russi E, Weigand K (1983) Analbuminemia. *Klin Wochenschr* 61, 541–545.

27 Vincent JL, Dubois MJ, Navickis RJ *et al.* (2003) Hypoalbuminemia in acute illness: is there a rationale for intervention? A meta-analysis of cohort studies and controlled trials. *Ann Surg* 237, 319–334.

28 Stollman YR, Gartner U, Theilmann L *et al.* (1983) Hepatic bilirubin uptake in the isolated perfused rat liver is not facilitated by albumin binding. *J Clin Invest* 72, 718–723.

29 Brodersen R (1979) Bilirubin. Solubility and interaction with albumin and phospholipid. *J Biol Chem* 254, 2364–2369.

30 Mendel CM, Weisiger RA, Jones AL *et al.* (1987) Thyroid hormone-binding proteins in plasma facilitate uniform distribution of thyroxine within tissues: a perfused rat liver study. *Endocrinology* 120, 1742–1749.

31 Mendel CM, Kuhn RW, Weisiger RA (1991) Uptake of corticosterone by the perfused rat liver. *Endocrinology* 129, 27–32.

32 Ekins R, Edwards P, Newman B (1982) The role of binding-proteins in hormone delivery. In: Ekins RP (ed.) *Free Hormones in Blood*. New York: Elsevier Press, pp. 3–43.

33 Ruggeri RB (2005) Cholesteryl ester transfer protein: pharmacological inhibition for the modulation of plasma cholesterol levels and promising target for the prevention of atherosclerosis. *Curr Topics Med Chem* 5, 257–264.

34 Mendel CM, Cavalieri RR, Köhrle J (1992) Thyroxine (T_4) transport and distribution in rats treated with EMD 21388, a synthetic flavonoid that displaces T_4 from transthyretin. *Endocrinology* 130, 1525–1532.

35 Barry PH, Diamond JM (1984) Effects of unstirred layers on membrane phenomena. *Physiol Rev* 64, 763–872.

36 Wisse E, De Zanger RB, Charrels K *et al.* (1985) The liver sieve: considerations concerning the structure and function of endothelial fenestrae, the sinusoidal wall and the space of Disse. *Hepatology* 5, 683–692.

37 Weisiger RA (1998) Impact of extracellular and intracellular diffusion barriers on hepatic uptake kinetics. In: Linehan JH (ed.) *Whole Organ Approaches to Cellular Metabolism*. New York: Springer-Verlag, pp. 389–423.

38 Vorum H, Brodersen R, Kragh-Hansen U *et al.* (1992) Solubility of long-chain fatty acids in phosphate buffer at pH 7.4. *Biochim Biophys Acta Lipids Lipid Metab* 1126, 135–142.

39 Rosner W, Hryb DJ, Khan MS *et al.* (1999) Sex hormone-binding globulin mediates steroid hormone signal transduction at the plasma membrane. *J Steroid Biochem Mol Biol* 69, 481–485.

40 Weisiger RA (1985) Dissociation from albumin: a potentially rate-limiting step in the clearance of substances by the liver. *Proc Natl Acad Sci USA* 82, 1563–1567.

41 Luxon BA, Holly DC, Milliano MC, Weisiger RA (1998) Sex differences in multiple steps in the hepatic transport of palmitate support a balanced uptake mechanism. *Am J Physiol* 274, G52–G61.

42 Bass L, Pond SM (1988) The puzzle of rates of cellular uptake of protein-bound ligands. In: Rescigno A (ed.) *Pharmacokinetics: Mathematical and Statistical Approaches to Metabolism and Distribution of Chemicals and Drugs*. London: Plenum Press, pp. 241–265.

43 Weisiger RA, Pond SM, Bass L (1989) Albumin enhances unidirectional fluxes of fatty acid across a lipid-water interface: theory and experiments. *Am J Physiol* 257, G904–G916.

44 Weisiger RA, Pond SM, Bass L (1991) Hepatic uptake of protein-bound ligands: extended sinusoidal perfusion model. *Am J Physiol* 261, G872–G884.

45 Pond SM, Davis CKC, Bogoyevitch MA *et al.* (1992) Uptake of palmitate by hepatocyte suspensions: facilitation by albumin? *Am J Physiol* 262, G883–G894.

46 Ahlfors CE, Wennberg RP (2004) Bilirubin–albumin binding and neonatal jaundice. *Semin Perinatol* 28, 334–339.

47 Hansen TW (2001) Bilirubin brain toxicity. *J Perinatol* 21 (Suppl 1), S48–51; discussion S59–62.

48 Kawai K, Cowger ML (1981) Effect of bilirubin on ATPase activity of human erythrocyte membranes. *Res Commun Chem Pathol Pharmacol* 32, 123–135.

49 Rhoads DE, Ockner RK, Peterson NA *et al.* (1983) Modulation of membrane transport by free fatty acids: inhibition of synaptosomal sodium-dependent amino acid uptake. *Biochemistry* 22, 1965–1970.

50 Khan WA, Blobe GC, Hannun YA (1992) Activation of protein kinase C by oleic acid. *J Biol Chem* 267, 3605–3612.

51 Gordon GB (1977) Saturated free fatty acid toxicity. II. Lipid accumulation, ultrastructural alterations, and toxicity in mammalian cells in culture. *Exp Mol Pathol* 27, 262–276.

52 Franchini M, Veneri D (2005) Recent advances in hereditary hemochromatosis. *Ann Haematol* 84, 347–352.

53 Brissot P, Wright TL, Ma WL *et al.* (1985) Efficient clearance of non-transferrin-bound iron by rat liver Implications for hepatic iron loading in iron overload states. *J Clin Invest* 76, 1463–1470.

54 Wright TL, Brissot P, Ma WL *et al.* (1986) Characterization of non-transferrin-bound iron clearance by rat liver. *J Biol Chem* 261, 10909–10914.

55 Herbert V, Shaw S, Jayatilleke E *et al.* (1994) Most free-radical injury is iron-related: it is promoted by iron, hemin, holoferritin and vitamin C, and inhibited by desferoxamine and apoferritin. *Stem Cells* 12, 289–303.

56 Tincani E, Mazzali F, Morini L (2002) Hypoalbuminemia as a risk factor for over-anticoagulation. *Am J Med* 112, 247–248.

57 Piroli RJ, Passananti GT, Shively CA *et al.* (1981) Antipyrine and warfarin disposition in a patient with idiopathic hypoalbuminemia. *Clin Pharmacol Ther* 30, 810–816.

58 Gamba G, Contreras AM, Cortes J *et al.* (1990) Hypoalbuminemia as a risk factor for amikacin nephrotoxicity. *Rev Invest Clin* 42, 204–209.

59 Dasgupta A (2002) Clinical utility of free drug monitoring. *Clin Chem Lab Med* 40, 986–993.

60 Sennett C, Rosenberg LE, Mellman IS (1981) Transmembrane transport of cobalamin in prokaryotic and eukaryotic cells. *Annu Rev Biochem* 50, 1053–1086.

61 Halvorsen L, Holcroft JW (1988) Albumin: mechanisms of edema formation. *Nutr Clin Pract* 3, 222–225.

62 Blei AT, Larsen FS (1999) Pathophysiology of cerebral edema in fulminant hepatic failure. *J Hepatol* 31, 771–776.

63 Arroyo V (2002) Pathophysiology, diagnosis and treatment of ascites in cirrhosis. *Ann Hepatol* 1, 72–79.

64 Gurkan F, Haspolat K, Yaramis A *et al.* (2001) Beneficial effect of human albumin on neonatal cerebral edema. *Am J Ther* 8, 253–254.

65 Voegele AF, Jerkovic L, Wellenzohn B *et al.* (2002) Characterization of the vitamin E-binding properties of human plasma afamin. *Biochemistry* 41, 14532–14538.

66 Aoyagi Y, Ikenaka T, Ichida F (1979) Alpha-fetoprotein as a carrier protein in plasma and its bilirubin-binding ability. *Cancer Res* 39, 3571–3574.
67 Korpela J (1984) Avidin, a high affinity biotin-binding protein, as a tool and subject of biological research. *Med Biol* 62, 5–26.
68 Giurgea N, Constantinescu MI, Stanciu R *et al.* (2005) Ceruloplasmin – acute-phase reactant or endogenous antioxidant? The case of cardiovascular disease. *Med Sci Monit* 11, RA48–51.
69 Breuner CW, Orchinik M (2002) Plasma binding proteins as mediators of corticosteroid action in vertebrates. *J Endocrinol* 175, 99–112.
70 Flower DR (1996) The lipocalin protein family: structure and function. *Biochem J* 318 (Pt 1), 1–14.
71 Stein O, Stein Y (2005) Lipid transfer proteins (LTP) and atherosclerosis. *Atherosclerosis* 178, 217–230.
72 van Tol A (2002) Phospholipid transfer protein. *Curr Opin Lipidol* 13, 135–139.
73 Raghu P, Sivakumar B (2004) Interactions amongst plasma retinol-binding protein, transthyretin and their ligands: implications in vitamin A homeostasis and transthyretin amyloidosis. *Biochim Biophys Acta* 1703, 1–9.
74 Zanotti G, Berni R (2004) Plasma retinol-binding protein: structure and interactions with retinol, retinoids, and transthyretin. *Vitam Horm* 69, 271–295.
75 Rosner W, Hryb DJ, Khan MS *et al.* (1991) Sex hormone-binding globulin: anatomy and physiology of a new regulatory system. *J Steroid Biochem Mol Biol* 40, 813–820.
76 Palha JA (2002) Transthyretin as a thyroid hormone carrier: function revisited. *Clin Chem Lab Med* 40, 1292–1300.
77 Fernandes-Costa F, Metz J (1982) Vitamin B12 binders (transcobalamins) in serum. *Crit Rev Clin Lab Sci* 18, 1–30.
78 von Castel-Dunwoody KM, Kauwell GP, Shelnutt KP *et al.* (2005) Transcobalamin 776C→G polymorphism negatively affects vitamin B-12 metabolism. *Am J Clin Nutr* 81, 1436–1441.
79 Yamamoto M, Ariyoshi Y, Matsui N (1982) The serum concentrations of unbound, transcortin bound and albumin bound cortisol in patients with dysproteinemia. *Endocrinol Jpn* 29, 639–646.
80 Bowmer CJ, Lindup WE (1978) Binding of phenytoin, L-tryptophan and O-methyl red to albumin. Unexpected effect of albumin concentration on the binding of phenytoin and L-tryptophan. *Biochem Pharmacol* 27, 937–942.
81 Zucker SD, Goessling W, Zeidel ML *et al.* (1994) Membrane lipid composition and vesicle size modulate bilirubin intermembrane transfer. Evidence for membrane-directed trafficking of bilirubin in the hepatocyte. *J Biol Chem* 269, 19262–19270.
82 Kragh-Hansen U, Vorum H (1993) Quantitative analyses of the interaction between calcium ions and human serum albumin. *Clin Chem* 39, 202–208.
83 Lovstad RA (2004) A kinetic study on the distribution of Cu(II)-ions between albumin and transferrin. *Biometals* 17, 111–113.
84 Spector AA (1975) Fatty acid binding to plasma albumin. *J Lipid Res* 16, 165–179.
85 Takikawa H, Sugiyama Y, Hanano M *et al.* (1987) A novel binding site for bile acids on human serum albumin. *Biochim Biophys Acta* 926, 145–153.
86 Hoshikawa S, Mori K, Kaise N *et al.* (2004) Artifactually elevated serum-free thyroxine levels measured by equilibrium dialysis in a pregnant woman with familial dysalbuminemic hyperthyroxinemia. *Thyroid* 14, 155–160.

2.4.2 The liver and coagulation

Maria T. DeSancho and Stephen M. Pastores

Introduction

The liver plays a major role in haemostasis, as most of the coagulation factors, anticoagulant proteins and components of the fibrinolytic system are synthesized by hepatic parenchymal cells. Additionally, the reticuloendothelial system of the liver helps to regulate coagulation and fibrinolysis by clearing these coagulation factors from the circulation. Finally, because the liver is a highly vascularized organ with vital venous systems draining through the parenchyma, liver diseases can affect abdominal blood flow and predispose patients to significant bleeding problems.

The aetiology of impaired haemostasis resulting from abnormal liver function is often multifactorial and may include impaired coagulation factor synthesis, synthesis of dysfunctional coagulation factors, increased consumption of coagulation factors, altered clearance of activated coagulation factors and quantitative and qualitative platelet disorders. In this chapter, we will review the normal physiology of haemostasis, describe the role of the liver in the haemostatic system and discuss the coagulation abnormalities that may occur in patients with liver disease and during liver transplantation.

Physiology of haemostasis

Normal haemostatic balance is dependent on a complex interplay between procoagulant, anticoagulant and fibrinolytic proteins. Initiation of coagulation begins when tissue factor (TF) is exposed after an injury to the vessel wall (Fig. 1). TF forms a

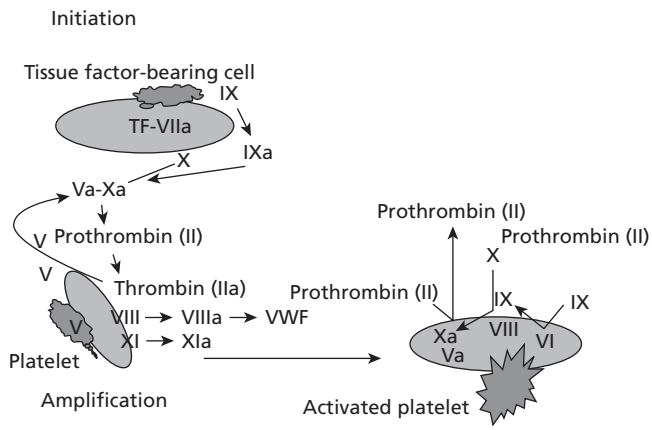

Fig. 1 Tissue factor (TF) is the major initiator of coagulation. Tissue factor-bearing cells include stimulated monocytes, endothelial cells and vascular smooth muscle cells. Exposure of TF to blood is rapidly followed by the formation of a complex between TF and factor VIIa that activates both factor IX and X, leading to generation of thrombin. Thrombin also activates factor V, VIII, XI and platelets.

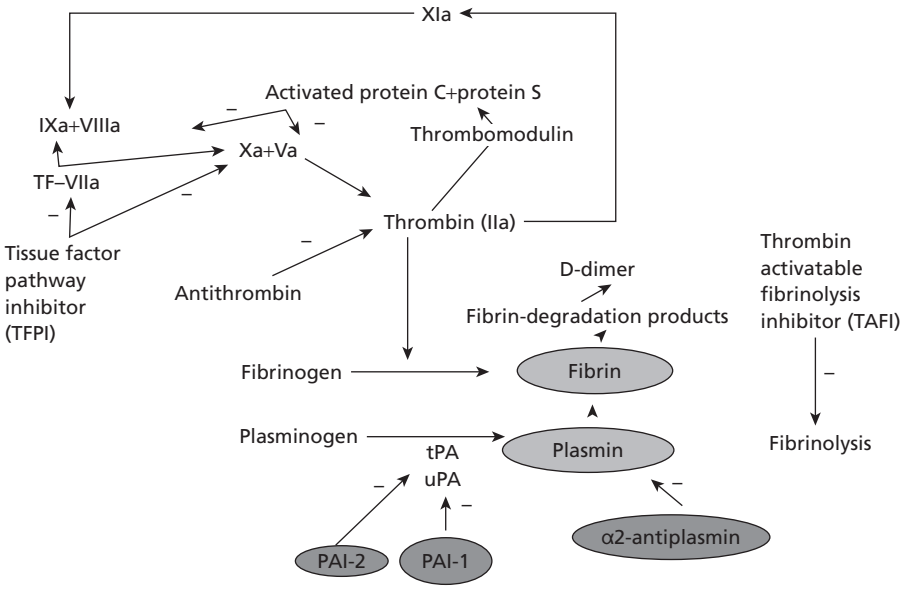

Fig. 2 The fibrinolytic and natural anticoagulant pathways.

complex with activated factor VII (factor VIIa) present in the plasma. The TF/factor VIIa complex converts factor X to factor Xa, which, in turn, along with a cofactor, factor Va, converts prothrombin (factor II) to thrombin (factor IIa) [1]. Although this process generates a small amount of thrombin, this thrombin serves to prime the coagulation cascade by increasing the enzymatic activity of factor VIIa, making it 100-fold more active. In addition, thrombin activates factor V, VIII, XI and platelets, which form the infrastructure to amplify the enzymatic reactions of the coagulation cascade. Ultimately, thrombin is formed directly by the TF/VIIa complex activating factor X to Xa or indirectly by converting factor IX to factor IXa, which in turn complexes with its cofactor, factor VIIIa, to convert factor X to factor Xa. The large amount of thrombin that is generated cleaves fibrinogen to fibrin monomers, which in turn spontaneously polymerize and are cross-linked by factor XIIIa (which itself is activated by thrombin) to produce a stable clot. At this time, thrombin-activatable fibrinolysis inhibitor (TAFI) becomes fully active and serves to diminish the incorporation and activation of plasminogen, leading to delayed clot lysis (Fig. 2).

TF-dependent generation of thrombin is rapidly inhibited by TF pathway inhibitor (TFPI), which binds TF/VIIa/Xa forming the quaternary complex TFPI/Xa/TF/VIIa, which is internalized by the TF-bearing cell. The main endogenous anticoagulant system is the protein C-dependent system. Protein C and its cofactor protein S are both vitamin K-dependent factors synthesized by the liver. Protein C binds to an endothelial cell protein C receptor (ECPR) and is activated by thrombin bound to thrombomodulin, another endothelial cell membrane-based protein [2]. The activated protein C complex inactivates factors VIIIa and Va (Fig. 2). Another important endogenous anticoagulant system involves antithrombin (AT), also primarily produced in the liver, which inactivates thrombin (IIa), factors Xa, IXa, XIa and XIIa. The anticoagulant activity of AT can be increased by up to 1000-fold in the presence of heparin. Another vitamin K-dependent anticoagulant is protein Z, whose structure is similar to coagulation factors VII, IX, X, protein C and protein S. However, in contrast to these other vitamin K-dependent factors, protein Z is not a serine protease and plays an important role in inhibiting coagulation by serving as a cofactor for the inactivation of factor Xa by forming a complex with the plasma protein Z-dependent protease inhibitor. The role of alterations in the protein Z levels has been evaluated in different disease states, with conflicting findings [3]. Finally, to prevent excess clotting, fibrin is digested by the fibrinolytic system, the major components of which are plasminogen and tissue-type plasminogen activator (tPA) (Fig. 2). Both these proteins are incorporated into polymerizing fibrin, where they interact to generate plasmin, which in turn acts on fibrin to dissolve the preformed clot. Plasminogen binds to fibrin at specific lysine binding sites and to tPA. The binding of plasminogen to tPA converts the proenzyme plasminogen to active proteolytic plasmin. Plasmin cleaves polymerized fibrin strands at multiple sites and releases fibrin degradation products (FDPs) [3].

The fibrinolytic system is regulated by three serine proteinase inhibitors: alpha2-antiplasmin (α_2-PI), plasminogen activator inhibitor-1 (PAI-1) and plasminogen activator inhibitor-2 (PAI-2) (Fig. 2). α_2-PI is secreted by the liver, is present within platelets and serves to immediately inactivate free plasmin, whereas PAI-1 is the most important and most rapidly acting physiological inhibitor of both tPA and urokinase-type plasminogen activator (uPA). PAI-2, originally purified from human placenta, inhibits both two-chain tPA and two-chain uPA with comparable efficiency, but it is less effective towards single-chain tPA [4].

Role of the liver in the haemostatic system

The liver is the primary site of synthesis of most of the clotting factors and the proteins involved in the fibrinolytic system. These include all the vitamin K-dependent coagulation proteins (factors II, VII, IX, X, protein C, protein S and protein Z), as well as factor V, XIII, fibrinogen, antithrombin, α_2-PI and plasminogen. The notable exceptions are von Willebrand factor (VWF), tPA, thrombomodulin, TPFI and uPA. The VWF, tPA, thrombomodulin and TFPI are synthesized in endothelial cells, while uPA is expressed by endothelial cells, macrophages, renal epithelial cells and some tumour cells [4].

Vitamin K, a fat-soluble vitamin, is required to achieve proper levels of procoagulant factors (II, VII, IX and X) and anticoagulant factors (proteins C, S and Z). These factors require vitamin K as a cofactor for post-ribosomal modification to render them physiologically active. All the vitamin K-dependent factors have in their amino-terminal several glutamic acid residues that must be converted to gamma-carboxyglutamic acid residues. This process is crucial to allow these proteins to bind calcium ions to form bridges to phospholipid surfaces, which are essential for the formation of activation complexes [5]. Finally, the liver plays a vital role in the regulation of anticoagulation. Removal of activated clotting and fibrinolytic factors, especially tPA, is mediated through the hepatic reticuloendothelial system [6].

Haemostatic abnormalities in liver disease

Various haemostatic abnormalities can occur in patients with liver disease and, in general, the severity of these abnormalities is dependent on the degree of hepatic dysfunction (Table 1).

Table 1 Hemostatic changes in patients with liver disease.

Haemostatic abnormality	Mechanism
Hypocoagulability	Decreased synthesis of coagulation factors (except VIII and VWF) Hypofibrinogenaemia (endstage liver failure) Vitamin K deficiency (II, VII, IX, X) Decreased clearance of degraded coagulation factors
Hypercoagulability	Decreased synthesis of natural anticoagulant proteins antithrombin (AT), proteins C, S and Z Decreased clearance of activated coagulation factors
Dysfibrinogenaemia	Synthesis of abnormal fibrinogen
Hyperfibrinolysis	Increased levels of circulating tPA activity due to impaired hepatic clearance Decreased synthesis of fibrinolytic inhibitors (PAI-1 and α2-antiplasmin) Decreased thrombin-activatable fibrinolytic inhibitor (TAFI)
Quantitative and qualitative platelet defects:	Decreased bone marrow production (due to decreased thrombopoietin) Splenic sequestration
Thrombocytopenia	Immune-mediated platelet destruction Folate and vitamin B12 deficiencies
Thrombocytopathies	Direct effect of ethanol Non-specific platelet aggregation abnormalities

Coagulation defects in acute liver disease

Liver disease can cause both quantitative and qualitative abnormalities in coagulation factors. Commonly, the vitamin K-dependent factors decrease first, starting with factor VII and protein C owing to their short half-life (6 h), followed by reductions in factor II and X levels. Factor V levels are decreased in both acute and chronic liver disease [7]. Factor IX levels are usually only modestly reduced until advanced stages of liver disease. In contrast, VWF (synthesized by the endothelial cells) and factor VIII levels may be normal even in the presence of advanced liver disease because there is an increased production of factor VIII by the sinusoidal endothelial cells when the liver is damaged, combined with decreased clearance of the VWF/factor VIII complex.

Fibrinogen levels are rarely decreased and may even be elevated because of abnormal non-functional fibrinogen (dysfibrinogenaemia) related to defective polymerization. A decrease in fibrinogen levels may indicate the presence of disseminated intravascular coagulation (DIC) or progression to fulminant hepatitis with hepatic failure.

In a study of patients with significant liver injury and associated coagulopathy, factors II, V, VII and X were reduced to a similar degree and were significantly lower than factors IX and XI [8]. Factor VIII, however, was increased as well as interleukin 6 (IL-6), tumour necrosis factor-alpha (TNFα), thrombin–antithrombin (TAT) and soluble TF levels [9]. Of note, all the decreased factor levels were directly activated by TF. In patients with acute fulminant hepatic failure, the haemostatic alterations are attributed to quantitative and qualitative platelet defects, impaired synthesis and clearance of the coagulation factors and related inhibitory proteins and enhanced fibrinolysis. DIC may also play a role; however, DIC is difficult to distinguish from changes resulting from impaired hepatic synthesis and clearance alone [10]. In a study of 42 patients with acute fulminant hepatic failure, the activities of plasminogen and its inhibitor α_2-PI were reduced while tPA activity was normal. PAI-1, however, was greatly increased, indicating a shift towards inhibition of fibrinolysis in these patients. TAT complex levels and D-dimer, a fragment of cross-linked

fibrin in plasma, were also significantly increased, indicating activation of coagulation and fibrinolysis respectively. Thus, gross abnormalities of the fibrinolytic system occur in fulminant liver failure but, because inhibitory activity appears to be present in adequate quantities, this limits the incidence of bleeding due to fibrinolysis [11].

Coagulation defects in chronic liver disease

In patients with liver cirrhosis, most coagulation factors and inhibitors of the coagulation and fibrinolytic systems are markedly reduced because of impaired protein synthesis, except for factor VIII and fibrinogen levels, which may be normal or increased. Possible explanations for the increased factor VIII levels are the increased hepatic biosynthesis of VWF and decreased expression of low-density lipoprotein receptor-related protein, both of which modulate the level of factor VIII in plasma, rather than increase factor VIII synthesis [12]. Because fibrinogen is an acute-phase reactant, its synthesis tends to be preserved in patients with stable cirrhosis.

The deficiencies in vitamin K-dependent factors in cirrhosis may occur by several mechanisms, including reduced hepatic synthesis and reduced absorption of bile salts required for absorption of vitamin K-dependent factors, which may occur in the setting of cholestatic liver disease. Other contributing factors include poor oral intake and treatment with antibiotics that destroy the intestinal bacteria that synthesize vitamin K. As with acute liver disease, the reductions in coagulation factors parallel the degree of progression of liver disease.

In addition to impaired synthesis of clotting factors, excessive fibrinolysis, DIC, thrombocytopenia and platelet dysfunction account for the diverse spectrum of haemostatic defects in chronic or endstage liver disease [13] (Table 1).

The abnormalities of the fibrinolytic system are complex and result from impaired synthesis and altered clearance of the fibrinolytic factors. One of the most striking mechanisms is an imbalance between tPA and its specific inhibitor (PAI-1), which results in an increase in free tPA in the plasma and a reduction in α_2-PI. TAFI plays an important regulatory role in fibrinolysis. TAFI is a procarboxypeptidase synthesized by the liver and, upon activation by thrombin or plasmin, TAFI is converted into TAFIa. TAFIa inhibits fibrinolysis by removing C-terminal lysines from partially degraded fibrin, causing a decrease in the cofactor function of fibrin in the plasminogen activation catalysed by tPA, resulting in decreased plasmin generation [14,15]. Thrombin is the most likely activator of TAFI and, when thrombin is complexed to thrombomodulin, TAFI activation is increased by more than 1000-fold [16]. The levels of TAFI are markedly reduced in cirrhotic patients and correlate with the severity of disease [16,17].

In addition to the reduced hepatic synthesis of clotting factors, cirrhotic patients also have a significant deficit of natural anticoagulants, particularly protein C and antithrombin [18]. Activated protein C (APC), is the main anticoagulant that, in combination with its cofactor protein S, downregulates thrombin generation *in vivo* by inhibiting the action of the cofactors factors Va and VIIIa. AT complexed to endothelial heparin-like substances inhibits thrombin (factor IIa) directly through the formation of an equimolar complex and indirectly through the inhibition of the serine proteases (factors IX, X, XI and XII). Thrombin formation is also downregulated by the TFPI, which specifically inhibits the complex of TF and VIIa [1].

Recent studies have indicated that standard coagulation tests such as prothrombin time (PT) and activated partial thromboplastin time (aPTT) may not reflect the true coagulation status of patients with liver cirrhosis. This is because these tests do not take into account the activation of the primary endogenous anticoagulant protein C, levels of which are considerably reduced in cirrhosis. Tripodi *et al.* [19] reported impairment of thrombin generation measured without thrombomodulin, consistent with the reduced levels of procoagulant factors typically seen in cirrhosis. However, when the test was modified by adding thrombomodulin, patients generated as much thrombin as control subjects. The authors concluded that thrombin generation is normal in cirrhosis and that the reduction in procoagulant factors in these patients is compensated for by the reduction in anticoagulant factors, thus leaving the coagulation balance unaltered. Furthermore, their findings suggest that measurement of thrombin generation in the presence of thrombomodulin may be more suitable for the evaluation of bleeding risk [19].

Thrombocytopenia

Patients with liver disease may develop quantitative (thrombocytopenia) and/or qualitative platelet abnormalities (thrombocytopathies) such as impaired platelet adhesion and aggregation. The aetiology of thrombocytopenia in these patients is often attributed to splenic sequestration (hypersplenism), but may also occur as a result of platelet destruction mediated by platelet-associated immunoglobulins (PAIgG) [20] and impaired hepatic synthesis and/or increased degradation of thrombopoietin (TPO) by platelets sequestered in the congested spleen [21].

Mild to moderate thrombocytopenia occurs in 16–52% of patients with acute hepatitis with or without cirrhosis. Severe thrombocytopenia can occur as a consequence of aplastic anaemia, a rare complication of acute hepatitis [22]. Idiopathic immune thrombocytopenia (ITP) has also been reported in patients with hepatitis C [23]. Cocaine may cause thrombotic thrombocytopenic purpura associated with toxic acute hepatitis [24]. Ethanol directly suppresses platelet formation and decreases the lifespan of platelets, both of which contribute to thrombocytopenia commonly seen with alcohol-related liver disease [25]. Other aetiologies including medications, folate and vitamin B12 deficiencies, severe infections and DIC should also be considered in evaluating thrombocytopenia in patients with liver disease within the appropriate clinical setting.

Thrombocytopenia is a more common feature of chronic liver disease and has been reported in 49–64% of cirrhotic

patients [26]. The primary mechanism for thrombocytopenia is thought to be due to hypersplenism secondary to portal hypertension, which results in increased platelet sequestration and destruction. There is also increased destruction of platelets by immunological mechanisms that result from increased PAIgG. Increased levels of PAIgG have been reported in 55–88% of patients with chronic liver disease [20,27]. The elevated levels of PAIgG correlate inversely with the platelet count in some [20,28], but not all studies [27]. Recently, diminished protein synthesis in the liver has been reported to cause inadequate synthesis of TPO [29]. TPO is a glycoprotein produced primarily in the liver that acts to increase the basal production rate of megakaryocytes and platelets. TPO levels are significantly lower in cirrhotic patients with thrombocytopenia than in those with normal platelet counts. Serum TPO levels correlate inversely with the severity of liver disease [30,31]. Finally, platelet counts post liver transplantation also correlate with TPO levels, regardless of splenic size [32].

Intravascular activation and increased consumption of platelets in the diseased liver as a result of low-grade DIC is also a possible but controversial mechanism of thrombocytopenia. In patients with alcohol-induced cirrhosis, the thrombocytopenia may result from folate deficiency, direct toxic effects of ethanol on megakaryocytopoiesis [33,34] and increased platelet activation [35].

Platelet function abnormalities

In patients with chronic liver disease, impaired platelet aggregation with different agonists including adenosine diphosphate (ADP), thrombin, epinephrine and ristocetin has been described [36]. The abnormal platelet aggregation is thought to be caused by circulating platelet inhibitors (fibrin degradation products and D-dimers), plasmin degradation of platelet receptors, dysfibrinogenaemia and excess nitric oxide synthesis [13,37]. Conversely, hyper-responsiveness rather than a defective platelet/VWF interaction is observed in cirrhosis, which may compensate for other haemostatic problems; this appears to be mediated primarily by increased VWF levels [38]. The platelet function defects may account for the prolongation of the bleeding time in 40% of patients with cirrhosis and correlates with disease severity [39,40]. Erythropoietin is the primary stimulus to erythrocyte production and also induces megakaryocyte formation. Treatment with erythropoietin significantly increases platelet counts and platelet function in patients with alcoholic liver cirrhosis [41].

Disseminated intravascular coagulation

Low-grade DIC is commonly found in patients with endstage liver disease (ESLD). This syndrome is typically characterized by thrombocytopenia, prolongation of the PT and aPTT, decreased fibrinogen and elevated levels of fibrin degradation products (FDPs). Additionally, elevated levels of prothrombin activation fragment F1 + 2, fibrinopeptide A, D-dimer and TAT complexes are also observed in varying degrees [42–44]. The frequency and severity of DIC tends to correlate with the stage of liver disease [13,42,44,45].

The aetiology of DIC in chronic liver disease is multifactorial and includes release of procoagulants from injured hepatocytes, impaired clearance of activated clotting factors, decreased synthesis of coagulation inhibitors and endotoxin entry into the portal circulation [13].

The diagnosis of DIC in patients with chronic or endstage liver disease is often difficult and challenging, as the coagulation defects in both disorders are quite similar. Typically, an elevated D-dimer is more specific for DIC as it indicates activation of both coagulation and fibrinolysis, whereas high levels of fibrinogen degradation products (FDP) or dysfunctional fibrinogen are more common in ESLD [46]. Importantly, decreasing levels of factor VIII and fibrinogen with an increased D-dimer level on serial testing is more characteristic of DIC.

Clinically significant DIC is uncommon in patients with liver disease, usually complicates severe bacterial infections or severe sepsis and can also develop in patients with peritoneovenous shunts [47].

Haemostatic changes in liver transplant

Complex coagulation disorders may occur during liver transplantation including preoperative coagulation abnormalities due to the underlying liver disease and haemostatic changes related to the transplantation, all of which may contribute to severe bleeding. Prior to the anhepatic phase, there are usually no serious haemostatic alterations. Bleeding during transplantation is greatly influenced by the activation of the fibrinolytic system, which occurs during the anhepatic and reperfusion phases. The hyperfibrinolysis is mediated by an intense release of tPA and a lack of hepatic clearance during the neohepatic period. A second fibrinolytic burst results from release of tPA by the endothelial cells of the revascularized graft [48]. Conversely, PAI-1 decreases during the anhepatic period and increases during the neohepatic period [49]. A preserved capacity to generate thrombin and less fibrinolytic activation during the anhepatic phase occurs in primary biliary cirrhosis compared with other types of cirrhosis [50].

Factors that influence the risk of bleeding during liver surgery also include the presence of cirrhosis, portal hypertension, high levels of central venous pressure, renal dysfunction and the length of graft preservation [49]. A hypercoagulable state has occasionally been reported in some patients with neoplasm or Budd–Chiari syndrome [45,51]. Platelet count decreases during liver transplantation with a nadir at the time of reperfusion, and may worsen in the case of a damaged organ graft. It has been suggested that the transplanted liver has a major role in the thrombocytopenia with intrahepatic platelet sequestration, local thrombin generation on the damaged graft endothelium,

Table 2 Laboratory features of coagulopathy of liver disease.

Laboratory abnormality	Haemostatic defect
Prolonged PT and normal aPTT	PT corrects with mixing studies → factor VII deficiency
Prolonged PT and aPTT	PT and aPTT correct with mixing studies → factors I, II, V, X deficiencies
Prolonged thrombin time (TT) and reptilase time (RT)	Dysfibrinogenaemia
Shortened euglobulin lysis time	Decreased PAI-1, decreased α_2-PI, increased tPA (during liver transplant)
Thrombocytopenia (verified by manual interpretation of the peripheral blood smear)	Platelet sequestration Immune-mediated thrombocytopenia Decreased synthesis of thrombopoietin
Prolonged bleeding time/abnormal platelet aggregation studies	Thrombocytopathies
Marked increase in D-dimer, low fibrinogen and normal factor VIII	Possible DIC (in the proper clinical setting)

platelet extravasation and increased phagocytosis by the Kupffer cells as potential mechanisms. Platelet function abnormalities have also been described after revascularization, whereby hypothermia enhances splanchnic platelet dysfunction and prolongs coagulation reaction time by reducing enzymatic activity [52]. Release of exogenous heparin from the harvested graft after donor heparinization or endogenous heparin-like substances from the damaged ischaemic graft endothelium may also play a role in the coagulopathy at reperfusion [53]. Haemodilution secondary to fluid replacement and the preservation solution from the donor liver can additionally reduce plasma levels of coagulation factors at reperfusion [54].

Laboratory testing for coagulation defects in liver disease

Initial standard screening tests in patients with liver disease should include a PT, aPTT, complete blood count with examination of the peripheral blood smear and a fibrinogen level. In selected patients, additional testing should include a D-dimer test, thrombin time (TT), reptilase time (RT), euglobulin clot lysis time and a bleeding time (Table 2).

Often, the clotting tests remain normal until clotting factor levels fall to less than 30–40% of normal. In mild liver disease, the PT is prolonged, but the aPTT is usually normal. As the liver disease progresses, both PT and aPTT levels are prolonged, although in compensated cirrhosis, the high factor VIII level may blunt the prolongation of the aPTT. It is important to note, however, that international normalized ratio (INR) values may not be accurately reflective of the coagulopathy in patients with ESLD [55].

Fibrinogen levels are either normal or increased in patients with stable chronic liver disease.

In decompensated cirrhosis or DIC, severe hypofibrinogenaemia (< 100 mg/dL) is present, resulting in marked prolongation of the PT, aPTT and TT. Functional abnormalities of fibrinogen or dysfibrinogenaemias are diagnosed by a prolongation of the TT and RT.

Therapy for haemostatic abnormalities in liver disease

The management of haemostatic abnormalities in patients with liver disease is often difficult and challenging. Therapy is directed at correction of haemostatic defects in patients who are actively bleeding or who require surgery or other invasive procedures. Additionally, therapy should be targeted to the type of procedure and site and severity of bleeding. The bleeding risk appears to be higher in patients with multiple haemostatic defects, renal failure or a previous history of bleeding.

Vitamin K

Vitamin K deficiency in patients with severe acute liver disease may be treated with one dose of 10 mg of vitamin K administered intravenously (i.v.) [56]. In patients whose prolonged PT does not completely correct with vitamin K therapy, impaired hepatic synthesis of coagulation factors from parenchymal liver disease must be suspected as the cause of the coagulopathy. Other patient subgroups in whom vitamin K may be useful include patients with primary biliary cirrhosis and those with chronic liver disease who are receiving broad-spectrum antibiotics and have poor nutritional intake [57].

Plasma

Fresh frozen plasma (FFP) is prepared from units of whole blood and from plasmapheresis. Plasma contains all the coagulation

factors. Transfusion of FFP is the main therapy for patients with liver disease and coagulopathy who are actively bleeding [58]. However, the response to FFP is unpredictable. The use of FFP for the correction of moderate to severe coagulopathy prior to invasive procedures, e.g. percutaneous liver biopsy, is controversial and more studies are needed [59]. In general, it is recommended that, if the PT is prolonged by < 4 seconds, percutaneous biopsy can be undertaken safely. If the PT is prolonged by 4–6 seconds, FFP transfusion may allow the PT to decrease to the desired range. However, if the PT is prolonged by > 6 seconds, other biopsy techniques may need to be considered [60]. The recommended dose of FFP is 10–15 mL/kg. In the majority of patients with chronic liver disease, repeated transfusions of FFP every 12 h may be required for complete correction of the PT. There is currently no consensus on the volume of FFP or type of infusion regimens required to prevent or treat bleeding [13,59]. If FFP is given, repeat coagulation tests should be performed as soon as the infusion is completed to guide further management [59]. Potential adverse effects of FFP include volume overload, transmission of bloodborne infections, transfusion-related acute lung injury (TRALI) and allergic, febrile or haemolytic reactions.

Cryoprecipitate

Cryoprecipitate is prepared from FFP and is rich in fibrinogen, factor VIII, VWF, factor XIII and fibronectin. Each bag of cryoprecipitate contains 80–100 IU/mL factor VIII and at least 140 mg of fibrinogen [59]. Cryoprecipitate is indicated in patients with severe coagulopathy and hypofibrinogenaemia (< 100 mg/dL) or dysfibrinogenaemia.

DDAVP

Deamino-8-D-arginine vasopressin (desmopressin acetate or DDAVP) is a synthetic analogue of antidiuretic hormone, which raises the plasma levels of factor VIII and VWF and enhances platelet adhesion to the vessel wall. The agent is usually administered at a dose of 0.3 μg/kg by i.v. infusion over 20–30 min. In patients with liver cirrhosis, DDAVP may be used to shorten or normalize the prolonged bleeding time in those who need invasive procedures [61]. However, in two randomized trials, DDAVP did not reduce intraoperative blood loss and transfusion requirements in patients undergoing hepatectomy or control bleeding in cirrhotic patients with acute variceal bleeding [62,63].

Platelets

Platelet transfusions are indicated in patients with liver disease who are actively bleeding and have a platelet count below 50 000/μL or known history of platelet dysfunction. Prophylactic platelet transfusions may be necessary before invasive procedures (e.g. percutaneous liver biopsy) in patients with platelet counts < 50 000/μL [64]. A 1-h post-transfusion platelet count is commonly used to determine the efficacy of platelet transfusion and to guide subsequent therapy. Patients with marked splenomegaly, however, may not respond with an increase in platelet count after transfusion because of increased sequestration of the transfused platelets. Failure to increase the platelet count after transfusion may also be observed in patients with DIC, severe infection and alloimmunization due to platelet-specific and/or human leukocyte antigen (HLA) antibodies [13].

Antifibrinolytic agents

Epsilon aminocaproic acid, tranexamic acid and aprotinin are antifibrinolytic agents that inhibit plasmin generation and have been demonstrated to decrease bleeding associated with fibrinolysis in chronic liver disease [65] and intraoperative blood loss and transfusion requirements during liver transplantation [66–68]. These agents are contraindicated in patients with DIC and must only be used in selected patients with bleeding caused by excessive fibrinolysis.

Recombinant factor VIIa (rFVIIa)

Recombinant activated factor VII (rFVIIa) is a genetically engineered concentrate of human coagulation factor VIIa, which is structurally similar to native human plasma-derived factor VIIa. By enhancing thrombin generation on activated platelets, rFVIIa promotes the formation of a stable fibrin clot that is resistant to premature lysis [69]. This agent is Food and Drug Administration (FDA) approved for the treatment of haemophilia A and B patients with inhibitors against factors VIII and IX. Limited studies have shown correction of coagulopathy and decreased bleeding with the use of rFVIIa in patients with acute and chronic hepatic failure [70]. In these studies, rFVIIa was administered at doses ranging from 5 to 80 mg/kg i.v. for at least two doses [71–73]. Further studies are needed to identify the optimal dosing and confirm the safety, efficacy and cost–benefit of rFVIIa in patients with liver disease. Similarly, rFVIIa has been used to control bleeding associated with coagulopathy in patients undergoing orthotopic liver transplantation, including Jehovah's Witness patients [74]. Caution should be undertaken in administering rFVIIa to patients with DIC, coronary artery disease and severe sepsis because of their higher risk of thrombosis [75,76].

Thrombopoietin

TPO is a relatively lineage-specific cytokine that stimulates megakaryocyte growth and maturation *in vitro* and is a potent *in vivo* thrombopoietic growth factor. This cytokine may be potentially useful for reducing bleeding in patients with thrombocytopenia due to liver disease or preparing these patients for liver transplantation [77], although it is not FDA approved to date.

Conclusions

The liver plays a crucial role in haemostasis as it is responsible for the synthesis of most of the clotting and fibrinolytic proteins and the clearance of these coagulation factors from the circulation. Acute and chronic liver diseases are associated with a spectrum of haemostatic defects, and their severity tends to parallel the degree of hepatic injury. The aetiology of impaired haemostasis due to liver disease is multifactorial and includes impaired synthesis of coagulation factors, vitamin K deficiency, altered clearance of activated coagulation factors, excessive fibrinolysis, DIC and quantitative and qualitative platelet disorders. Standard laboratory testing should be supplemented with more specific tests of activation of the coagulation and fibrinolytic systems. The management of symptomatic haemostatic changes in patients with liver disease requires a multidisciplinary approach directed at correction of the haemostatic defects in patients who are actively bleeding or who require surgery or other invasive procedures.

References

1 Rosenberg RD, Aird WC (1999) Vascular-bed-specific hemostasis and hypercoagulable states. *N Engl J Med* 340(20), 1555–1564.

2 Esmon CT (2003) The protein C pathway. *Chest* 124(3 Suppl), 26S–32S.

3 Sofi F, Cesari F, Fedi S *et al.* (2004) Protein Z: 'light and shade' of a new thrombotic factor. *Clin Lab* 50(11–12), 647–652.

4 Cesarman-Maus G, Hajjar KA (2005) Molecular mechanisms of fibrinolysis. *Br J Haematol* 129(3), 307–321.

5 Borowski M, Furie BC, Bauminger S *et al.* (1986) Prothrombin requires two sequential metal-dependent conformational transitions to bind phospholipid. conformation-specific antibodies directed against the phospholipid-binding site on prothrombin. *J Biol Chem* 261(32), 14969–14975.

6 Greenberg DL, Davie EW (2001) Blood coagulation factors: their complimentary DNA, genes and expression. In: Coluan RW, Hirsh J, Marder VJ, Clower AW, George JN (eds) *Hemostasis and Thrombosis: Basic Principles and Clinical Practice*. Philadelphia, PA: Lippincott Williams and Wilkins, pp. 21–57.

7 Mammen EF (1994) Coagulation defects in liver disease. *Med Clin North Am* 78(3), 545–554.

8 Kerr R (2003) New insights into haemostasis in liver failure. *Blood Coagul Fibrinolysis* 14(Suppl 1), S43–45.

9 Kerr R, Newsome P, Germain L *et al.* (2003) Effects of acute liver injury on blood coagulation. *J Thromb Haemost* 1(4), 754–759.

10 Pereira SP, Langley PG, Williams R (1996) The management of abnormalities of hemostasis in acute liver failure. *Semin Liver Dis* 16(4), 403–414.

11 Pernambuco JR, Langley PG, Hughes RD *et al.* (1993) Activation of the fibrinolytic system in patients with fulminant liver failure. *Hepatology* 18(6), 1350–1356.

12 Hollestelle MJ, Geertzen HG, Straatsburg IH *et al.* (2004) Factor VIII expression in liver disease. *Thromb Haemost* 91(2), 267–275.

13 Kujovich JL (2005) Hemostatic defects in end stage liver disease. *Crit Care Clin* 21(3), 563–587.

14 Wang W, Boffa MB, Bajzar L *et al.* (1998) A study of the mechanism of inhibition of fibrinolysis by activated thrombin-activatable fibrinolysis inhibitor. *J Biol Chem* 273(42), 27176–27181.

15 Nesheim M, Bajzar L (2005) The discovery of TAFI. *J Thromb Haemost* 3(10), 2139–2146.

16 Colucci M, Binetti BM, Branca MG *et al.* (2003) Deficiency of thrombin activatable fibrinolysis inhibitor in cirrhosis is associated with increased plasma fibrinolysis. *Hepatology* 38(1), 230–237.

17 Van Thiel DH, George M, Fareed J (2001) Low levels of thrombin activatable fibrinolysis inhibitor (TAFI) in patients with chronic liver disease. *Thromb Haemost* 85(4), 667–670.

18 Castelino DJ, Salem HH (1997) Natural anticoagulants and the liver. *J Gastroenterol Hepatol* 12(1), 77–83.

19 Tripodi A, Salerno F, Chantarangkul V *et al.* (2005) Evidence of normal thrombin generation in cirrhosis despite abnormal conventional coagulation tests. *Hepatology* 41(3), 553–558.

20 Sanjo A, Satoi J, Ohnishi A *et al.* (2003) Role of elevated platelet-associated immunoglobulin G and hypersplenism in thrombocytopenia of chronic liver diseases. *J Gastroenterol Hepatol* 18(6), 638–644.

21 Rios R, Sangro B, Herrero I *et al.* (2005) The role of thrombopoietin in the thrombocytopenia of patients with liver cirrhosis. *Am J Gastroenterol* 100(6), 1311–1316.

22 Zeldis JB, Dienstag JL, Gale RP (1983) Aplastic anemia and non-A, non-B hepatitis. *Am J Med* 74(1), 64–68.

23 Narita R, Asaumi H, Abe S *et al.* (2003) Idiopathic thrombocytopenic purpura with acute hepatitis C viral infection. *J Gastroenterol Hepatol* 18(4), 462–463.

24 Balaguer F, Fernandez J, Lozano M *et al.* (2005) Cocaine-induced acute hepatitis and thrombotic microangiopathy. *JAMA* 293(7), 797–798.

25 Scharf RE, Aul C (1988) Alcohol-induced disorders of the hematopoietic system. *Z Gastroenterol* 26 (Suppl 3), 75–83.

26 Bashour FN, Teran JC, Mullen KD (2000) Prevalence of peripheral blood cytopenias (hypersplenism) in patients with nonalcoholic chronic liver disease. *Am J Gastroenterol* 95(10), 2936–2939.

27 Pereira J, Accatino L, Alfaro J *et al.* (1995) Platelet autoantibodies in patients with chronic liver disease. *Am J Hematol* 50(3), 173–178.

28 Nagamine T, Ohtuka T, Takehara K *et al.* (1996) Thrombocytopenia associated with hepatitis C viral infection. *J Hepatol* 24(2), 135–140.

29 Panasiuk A, Prokopowicz D, Zak J *et al.* (2004) Reticulated platelets as a marker of megakaryopoiesis in liver cirrhosis; relation to thrombopoietin and hepatocyte growth factor serum concentration. *Hepatogastroenterology* 51(58), 1124–1128.

30 Ishikawa T, Ichida T, Sugahara S *et al.* (2002) Thrombopoietin receptor (c-mpl) is constitutively expressed on platelets of patients with liver cirrhosis, and correlates with its disease progression. *Hepatol Res* 23(2), 115–121.

31 Giannini E, Botta F, Borro P *et al.* (2003) Relationship between thrombopoietin serum levels and liver function in patients with chronic liver disease related to hepatitis C virus infection. *Am J Gastroenterol* 98(11), 2516–2520.

32 Goulis J, Chau TN, Jordan S *et al.* (1999) Thrombopoietin concentrations are low in patients with cirrhosis and thrombocytopenia and are restored after orthotopic liver transplantation. *Gut* 44(5), 754–758.

33 Peltz S (1991) Severe thrombocytopenia secondary to alcohol use. *Postgrad Med* 89(6), 75–76, 85.

34 Levine RF, Spivak JL, Meagher RC *et al.* (1986) Effect of ethanol on thrombopoiesis. *Br J Haematol* 62(2), 345–354.

35 Ogasawara F, Fusegawa H, Haruki Y *et al.* (2005) Platelet activation in patients with alcoholic liver disease. *Tokai J Exp Clin Med* 30(1), 41–48.

36 Thomas DP, Ream VJ, Stuart RK (1967) Platelet aggregation in

patients with Laennec's cirrhosis of the liver. *N Engl J Med* 276(24), 1344–1348.
37 Albornoz L, Bandi JC, Otaso JC *et al.* (1999) Prolonged bleeding time in experimental cirrhosis: role of nitric oxide. *J Hepatol* 30(3), 456–460.
38 Beer JH, Clerici N, Baillod P *et al.* (1995) Quantitative and qualitative analysis of platelet GPIb and von Willebrand factor in liver cirrhosis. *Thromb Haemost* 73(4), 601–609.
39 Blake JC, Sprengers D, Grech P *et al.* (1990) Bleeding time in patients with hepatic cirrhosis. *Br Med J* 301(6742), 12–15.
40 Hsu WC, Lee FY, Lee SD *et al.* (1994) Prolonged bleeding time in cirrhotic patients: relationship to peripheral vasodilation and severity of cirrhosis. *J Gastroenterol Hepatol* 9(5), 437–441.
41 Homoncik M, Jilma-Stohlawetz P, Schmid M *et al.* (2004) Erythropoietin increases platelet reactivity and platelet counts in patients with alcoholic liver cirrhosis: a randomized, double-blind, placebo-controlled study. *Aliment Pharmacol Ther* 20(4), 437–443.
42 Vukovich T, Teufelsbauer H, Fritzer M *et al.* (1995) Hemostasis activation in patients with liver cirrhosis. *Thromb Res* 77(3), 271–278.
43 Bakker CM, Knot EA, Stibbe J *et al.* (1992) Disseminated intravascular coagulation in liver cirrhosis. *J Hepatol* 15(3), 330–335.
44 Violi F, Ferro D, Basili S *et al.* (1995) Prognostic value of clotting and fibrinolytic systems in a follow-up of 165 liver cirrhotic patients. CALC group. *Hepatology* 22(1), 96–100.
45 Kemkes-Matthes B, Bleyl H, Matthes KJ (1991) Coagulation activation in liver diseases. *Thromb Res* 64(2), 253–261.
46 Carr JM (1989) Disseminated intravascular coagulation in cirrhosis. *Hepatology* 10(1), 103–110.
47 Harmon DC, Demirjian Z, Ellman L *et al.* (1979) Disseminated intravascular coagulation with the peritoneovenous shunt. *Ann Intern Med* 90(5), 774–776.
48 Porte RJ, Knot EA, Bontempo FA (1989) Hemostasis in liver transplantation. *Gastroenterology* 97(2), 488–501.
49 Ozier Y, Steib A, Ickx B *et al.* (2001) Haemostatic disorders during liver transplantation. *Eur J Anaesthesiol* 18(4), 208–218.
50 Segal H, Cottam S, Potter D *et al.* (1997) Coagulation and fibrinolysis in primary biliary cirrhosis compared with other liver disease and during orthotopic liver transplantation. *Hepatology* 25(3), 683–688.
51 Lewis JH, Bontempo FA, Awad SA *et al.* (1989) Liver transplantation: intraoperative changes in coagulation factors in 100 first transplants. *Hepatology* 9(5), 710–714.
52 Himmelreich G, Hundt K, Neuhaus P *et al.* (1992) Decreased platelet aggregation after reperfusion in orthotopic liver transplantation. *Transplantation* 53(3), 582–586.
53 Bayly PJ, Thick M (1994) Reversal of post-reperfusion coagulopathy by protamine sulphate in orthotopic liver transplantation. *Br J Anaesth* 73(6), 840–842.
54 Rohrer MJ, Natale AM (1992) Effect of hypothermia on the coagulation cascade. *Crit Care Med* 20(10), 1402–1405.
55 Robert A, Chazouilleres O (1996) Prothrombin time in liver failure: time, ratio, activity percentage, or international normalized ratio? *Hepatology* 24(6), 1392–1394.
56 Pereira SP, Rowbotham D, Fitt S *et al.* (2005) Pharmacokinetics and efficacy of oral versus intravenous mixed-micellar phylloquinone (vitamin K1) in severe acute liver disease. *J Hepatol* 42(3), 365–370.
57 Sallah S, Bobzien W (1999) Bleeding problems in patients with liver disease. Ways to manage the many hepatic effects on coagulation. *Postgrad Med* 106(4), 187–190, 193–195.
58 Kaul VV, Munoz SJ (2000) Coagulopathy of liver disease. *Curr Treat Options Gastroenterol* 3(6), 433–438.
59 O'Shaughnessy DF, Atterbury C, Bolton Maggs P *et al.* (2004) Guidelines for the use of fresh-frozen plasma, cryoprecipitate and cryosupernatant. *Br J Haematol* 126(1), 11–28.
60 Grant A, Neuberger J (1999) Guidelines on the use of liver biopsy in clinical practice. British Society of Gastroenterology. *Gut* 45(Suppl 4), IV1–IV11.
61 Mannucci PM (2000) Desmopressin (DDAVP) in the treatment of bleeding disorders: the first twenty years. *Haemophilia* 6(Suppl 1), 60–67.
62 de Franchis R, Arcidiacono PG, Carpinelli L *et al.* (1993) Randomized controlled trial of desmopressin plus terlipressin vs. terlipressin alone for the treatment of acute variceal hemorrhage in cirrhotic patients: a multicenter, double-blind study, new Italian endoscopic club. *Hepatology* 18(5), 1102–1107.
63 Wong AY, Irwin MG, Hui TW *et al.* (2003) Desmopressin does not decrease blood loss and transfusion requirements in patients undergoing hepatectomy. *Can J Anaesth* 50(1), 14–20.
64 Sue M, Caldwell SH, Dickson RC *et al.* (1996) Variation between centers in technique and guidelines for liver biopsy. *Liver* 16(4), 267–270.
65 Hu KQ, Yu AS, Tiyyagura L *et al.* (2001) Hyperfibrinolytic activity in hospitalized cirrhotic patients in a referral liver unit. *Am J Gastroenterol* 96(5), 1581–1586.
66 Kahl BS, Schwartz BS, Mosher DF (2003) Profound imbalance of pro-fibrinolytic and anti-fibrinolytic factors (tissue plasminogen activator and plasminogen activator inhibitor type 1) and severe bleeding diathesis in a patient with cirrhosis: correction by liver transplantation. *Blood Coagul Fibrinolysis* 14(8), 741–744.
67 Boylan JF, Klinck JR, Sandler AN *et al.* (1996) Tranexamic acid reduces blood loss, transfusion requirements, and coagulation factor use in primary orthotopic liver transplantation. *Anesthesiology* 85(5), 1043–1048; discussion 30A–31A.
68 Neuhaus P, Bechstein WO, Lefebre B *et al.* (1989) Effect of aprotinin on intraoperative bleeding and fibrinolysis in liver transplantation. *Lancet* 2(8668), 924–925.
69 Hedner U (2004) Dosing with recombinant factor VIIa based on current evidence. *Semin Hematol* 41(1 Suppl 1), 35–39.
70 Ejlersen E, Melsen T, Ingerslev J *et al.* (2001) Recombinant activated factor VII (rFVIIa) acutely normalizes prothrombin time in patients with cirrhosis during bleeding from oesophageal varices. *Scand J Gastroenterol* 36(10), 1081–1085.
71 Shami VM, Caldwell SH, Hespenheide EE *et al.* (2003) Recombinant activated factor VII for coagulopathy in fulminant hepatic failure compared with conventional therapy. *Liver Transpl* 9(2), 138–143.
72 Pavese P, Bonadona A, Beaubien J *et al.* (2005) FVIIa corrects the coagulopathy of fulminant hepatic failure but may be associated with thrombosis: a report of four cases. *Can J Anaesth* 52(1), 26–29.
73 Bosch J, Thabut D, Bendtsen F *et al.* (2004) Recombinant factor VIIa for upper gastrointestinal bleeding in patients with cirrhosis: a randomized, double-blind trial. *Gastroenterology* 127(4), 1123–1130.
74 Jabbour N, Gagandeep S, Peilin AC *et al.* (2005) Recombinant human coagulation factor VIIa in Jehovah's Witness patients undergoing liver transplantation. *Am Surg* 71(2), 175–179.
75 O'Connell KA, Wood JJ, Wise RP *et al.* (2006) Thromboembolic adverse events after use of recombinant human coagulation factor VIIa. *JAMA* 295(3), 293–298.
76 Ramsey G (2006) Treating coagulopathy in liver disease with plasma transfusions or recombinant factor VIIa: an evidence-based review. *Best Pract Res Clin Haematol* 19(1), 113–126.

77 Kuter DJ, Begley CG (2002) Recombinant human thrombopoietin: basic biology and evaluation of clinical studies. *Blood* 100(10), 3457–3469.

2.4.3 Function and metabolism of collagen and other extracellular matrix proteins

Rebecca G. Wells

Introduction

The extracellular matrix (ECM) occupies a small percentage of the volume of the normal liver, yet plays a disproportionately important role in liver function in health and disease. ECM proteins are both signalling molecules and architectural elements of the liver and are responsible for maintaining the differentiated state of normal hepatocytes and non-parenchymal cells. In liver fibrosis and cirrhosis, there are changes in the distribution, quantity and relative proportions of collagens and other ECM proteins (Fig. 1); these result in altered cell phenotypes, architectural distortion with abnormal blood flow, impaired diffusion and altered cell signalling.

ECM proteins in the normal liver

The normal liver encompasses physically separate regions with different matrix and cellular compositions. The matrix in the capsule and surrounding the bile ducts and central venous region is similar to that in other epithelial organs, with an organized basement membrane of collagen IV, laminin, entactin and perlecan. The interstitium of the portal space contains the fibrillar collagens I, III and V as well as collagen VI and fibronectin [1].

The space of Disse, which lies in between sinusoidal endothelial cells (SEC) and hepatocytes, has a matrix unique in the liver and the body. This narrow space, less than 1 μM wide, lacks the continuous laminin, perlecan and entactin that are found in most basement membranes [2]. Although collagen IV is present, it is in discrete discontinuous deposits not associated with laminin or perlecan. Fibronectin is abundant, applied closely to the microvilli of hepatocytes. Collagens III and VI are also found in the space of Disse, collagen III in discontinuous deposits and collagen VI arranged relatively homogeneously, increasing from the portal to the central region [3]. Structure is provided by a continuous network of thick collagen I cables, which extend into the lobular areas from the adjacent portal tracts [1]. This unusual matrix is essential for maintaining the differentiation of hepatocytes and SEC as well as other non-parenchymal cells [4]. Gradients of matrix material are found in the sinusoids and may have functional relevance, resulting in phenotypical differences between cells in the periportal vs. central regions [1,5].

ECM proteins in the fibrotic liver

Fibrosis results in a nearly 10-fold increase in the expression of matrix proteins in the liver. The most impressive change is the capillarization of the sinusoids, in which the sparse, atypical matrix of the space of Disse is replaced by a complete and continuous basement membrane, with accompanying loss of fenestration of the sinusoidal endothelium. This process begins with an increase in cellular isoforms of fibronectin in the space of Disse, followed by increases in collagens I, III and IV and the appearance of laminin. As fibrosis progresses, portal to central gradients are lost, and the new matrix becomes continuous [6] (see also Chapters 4.1 and 6.1). This results in loss of the differentiated phenotype of the resident cells of the space of Disse, in particular SEC, hepatocytes and hepatic stellate cells (HSC). Additionally, the increased ECM impairs the normal exchange of soluble proteins and fluids between sinusoidal blood and adjacent liver cells.

When fibrosis advances to cirrhosis, the normal architecture of the liver is lost with the formation of increasingly dense fibrous septae of fibronectin and collagens I, III, V and VI. These bands of matrix may become progressively stabilized (for example through collagen cross-linking) and protease resistant, impeding remodelling and the resolution of cirrhosis.

Structure and key features of specific ECM proteins

The ECM and its individual components are multifunctional. They have architectural and barrier functions, regulate growth factors and are themselves signalling molecules (Table 1). There are multiple complex interactions between different matrix components, making it difficult to understand the function of individual proteins. A variety of related mesenchymal cells in the liver synthesize normal and pathological matrix, suggesting that fibrosis is best understood as a generalized process rather than one limited to specific ECM molecules or specific fibrogenic cells such as HSC (see also Chapters 6.1 and 6.2).

Fig. 1 (*opposite*) Distribution of major matrix components in normal and fibrotic liver**.** A liver acinus is shown graphically to demonstrate changes in extracellular matrix (ECM) distribution in normal and diseased liver. Note that continuity between portal, parenchymal and central structures is not shown due to controversy regarding their relative anatomy. The size of the space of Disse compared with the sinusoidal space is greatly exaggerated, particularly in the normal liver. The interrelationship between different ECM components is not well understood and is shown only schematically. The organized basement membrane shown contains collagens VIII, XIX, XV, XIV and XVIII in addition to collagen IV, laminin, perlecan, and entactin. Proteoglycans other than perlecan are not shown. PV, portal vein; CV, central vein; HA, hepatic artery; SC, hepatic stellate cell; EC, sinusoidal endothelial cell; PF, portal fibroblast; SD, space of Disse; BD, bile duct; H, hepatocyte; TS, thick, organized septa; S, sinusoid; P, portal tract.

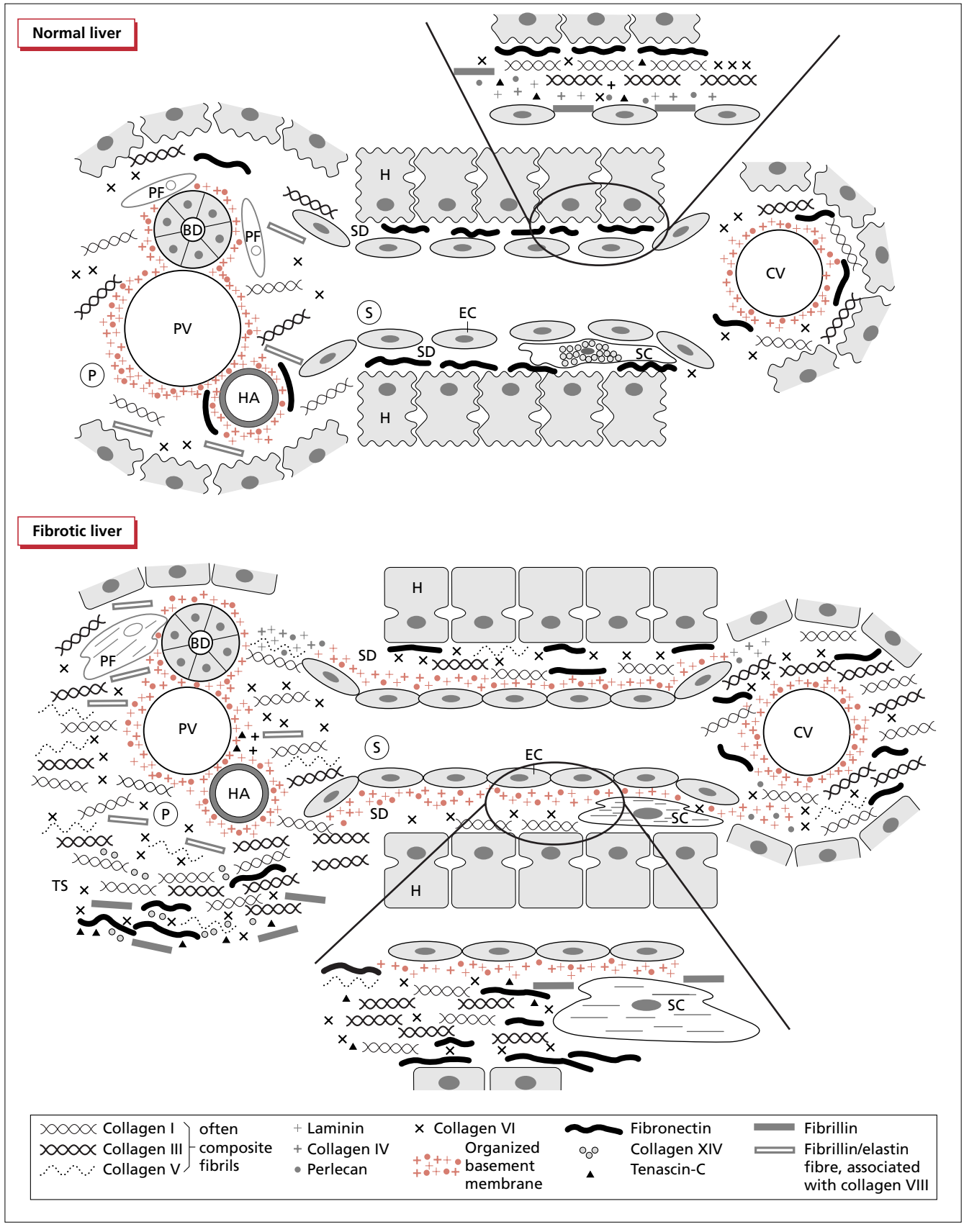
Normal liver
PF
BD
PF
PV
P
HA
H
SD
S
EC
SD
SC
H
CV
Fibrotic liver
H
BD
PF
SD
PV
HA
P
S
EC
SD
SC
CV
TS
H
SC
Collagen I
Collagen III
Collagen V
often composite fibrils
Laminin
Collagen IV
Perlecan
Collagen VI
Organized basement membrane
Fibronectin
Collagen XIV
Tenascin-C
Fibrillin
Fibrillin/elastin fibre, associated with collagen VIII

Table 1 Functions of ECM proteins in the liver.

Mechanical and architectural
Tensile strength
Resilience
Scaffolds for supramolecular assemblies
Anchors and connectors for blood vessels, nerves, other cells and other matrix components
Filtration barrier
Migration substrates and barriers
Signalling
Ligands for integrins and other signalling receptors
Signalling receptors and coreceptors
Sources of biologically active fragments (regulation of growth and apoptosis)
Sequestration and targeting of growth factors
Damage sensors

Collagens

Collagen structure and synthesis

The major structural proteins in both normal and fibrotic liver are collagens, ECM proteins with sizeable domains of Gly-Xaa-Yaa repeats, where X and Y are often proline and hydroxyproline respectively. This basic structure, with a central glycine and a rotation-limiting proline, allows the formation of a rigid triple helix (Fig. 2). Variations in chain composition among collagen family members are important for function, allowing differences in structural characteristics and network formation as well as different interactions with proteoglycans, receptors, growth factors and other ECM proteins in supramolecular assemblies (Table 2).

The fibrillar collagens (see below) are the most abundant collagens in the liver, and their synthesis is potentially regulated at multiple steps. Although the topic is beyond the scope of this chapter, the fibrillar collagens are subject to significant transcriptional and posttranscriptional regulation; transcription of the collagen α1(I) chain in particular is regulated by complex interactions involving both 5′ stem–loop and 3′ untranslated region (UTR) binding proteins [7]. The fibrillar collagens are synthesized with N- and C-terminal propeptide sequences, the latter playing an important role in protein folding. Nascent chains undergo several kinds of posttranslational modification: vitamin C-dependent proline hydroxylation by prolyl-4-hydroxylase on the polypeptides, which is essential for the stability of the triple helix, hydroxylation on lysine residues by lysyl hydroxlase, which is important for fibril packing, and N- and O-linked glycosylation. After secretion into the extracellular space, collagen chains are cleaved by N- and C-propeptidases and form fibrils. Fibril formation is also modulated at multiple levels including retention of the N-terminal propeptides of collagens III and V, which can regulate lateral fibril growth, and association with the FACIT collagens or decorin (see below), which can regulate fibril thickness [4].

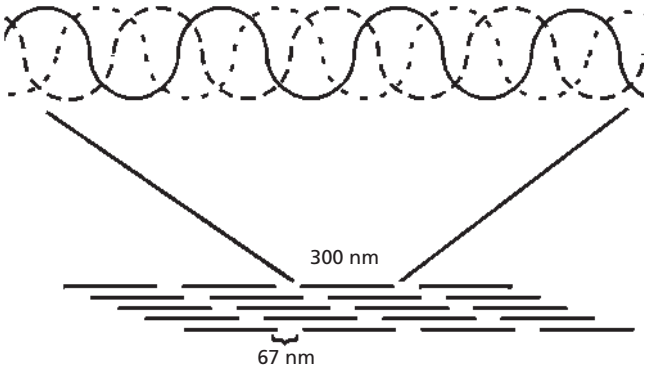

Fig. 2 Fibril arrangement of the fibrillar collagens. Collagen chains made up of repeating Gly-Xaa-Yaa motifs form right-handed triple helices 300 nm long (top). The hydrogen atom side-chains of the glycine residues pack into the centre of the triple helix; the rigid helical geometry is maintained by the proline and hydroxyproline residues, which usually occupy the second and third positions of the repeat. Fibrils of collagens I, III and V are formed by the staggered, parallel packing of many triple helices with a periodicity of 67 nm (bottom).

Collagen cross-linking enzymes

Mature collagen fibrils undergo interchain cross-linking, which is essential for mechanical stability. There are three major families of enzymes important in collagen cross-linking; these enzymes also participate in cross-linking of other matrix molecules including elastin and fibronectin. Tissue transglutaminase is a multifunctional protein which mediates the formation of ε-(γ-glutamyl lysine) cross-links in collagens and other ECM molecules, rendering them resistant to proteolysis [8]. It is increased in transdifferentiating HSC in culture and is found in myofibroblasts in the fibrotic liver [9–11]. Cross-links typical of tissue transglutaminase action have been demonstrated in the residual fibrous septae of rats with partially resolved fibrosis, suggesting that cross-linking modulates matrix degradation and fibrosis resolution [12] (see also Chapter 6.1).

The lysyl oxidases (LOX) catalyse the oxidative deamination of lysine and hydroxylysine in collagen and of lysine in elastin, leading to the formation of aldehydes, which then condense with neighbouring groups to form covalent cross-links. Although present in the normal liver, LOX family members increase dramatically in fibrosis, including very early after injury and before fibrogenic myofibroblasts appear [13,14]. LOX-mediated cross-links render collagens resistant to degradation and may also play a causal role in the initiation of fibrosis [13,15].

Lysyl hydroxylases catalyse the conversion of lysine into hydroxylysine and thereby determine the route of collagen cross-linking by LOX. The hydroxylysine route appears to be particularly important in diminishing the susceptibility of collagen to proteolysis and is the major pathway for cross-link formation in human cirrhosis [7,16,17].

Collagens in the liver

Ten collagens have been identified in the adult liver. These are divided into two groups based on structure, the fibrillar and the

Table 2 Collagens of the liver.

Type	Composition	Structure
Fibrillar		
I	$[\alpha1(I)]_2[\alpha2(I)]$	300-nm rigid fibrils, 67-nm periodicity Uninterrupted triple helices Forms composite structures with collagens III and V Non-collagenous N- and C-terminal propeptides cleaved before fibril assembly
III	$[\alpha1(III)]_3$	Same as for collagen I
V	$[\alpha1(V)]_2[\alpha2(V)])$	Same as for collagen I
Non-fibrillar		
Network forming		
IV	$[\alpha1(IV)]_2[\alpha2(IV)]$	400-nm-long chains Triple helix with multiple interruptions Forms filamentous network via N- and C-terminal and lateral associations
VI	$[\alpha1(VI)][\alpha2(VI)][\alpha3(VI)]$	105-nm triple helix Large N- and C-terminal globular domains with von Willebrand factor (VWF) A and fibronectin (Fn) type 3 repeats Forms antiparallel dimers, then tetramers and networks
VIII	$[\alpha1(VIII)]_2[\alpha2(VIII)]$	130-nm-long chains Interrupted triple helices Large C-terminal and small N-terminal globular domains Forms hexagonal lattices in some tissues
FACITS (fibril associated with interrupted triple helices)		
XIV	$[\alpha1(XIV)]_3$	Two short collagenous domains with three non-collagenous domains Glycosaminoglycan (GAG) modified N-terminal domain with Fn type 3 repeats and VWF A domains Associates with surface of collagen fibrils
XIX	$[\alpha1(XIX)]_3$	Five short collagenous and six non-collagenous domains Associates with surface of collagen fibrils
Multiplexins (multiple triple-helical domains and interruptions)		
XV	$[\alpha1(XV)]_3$	Interrupted triple helix Large N- and C-terminal globular domains Chondroitin sulphate GAGs Highly homologous to collagen XVIII
XVIII	$[\alpha1(XVIII)]_3$	Interrupted triple helix Large N- and C-terminal globular domains Heparan sulphate GAGs Cleavage of C-terminal domain NC1 generates endostatin

non-fibrillar collagens (see Table 1). Although the fibrillar collagens, particularly collagens I and III, are generally regarded as the most important in fibrosis on the basis of their quantity as well as mechanical characteristics, it is now understood that other collagens also contribute to fibrosis in important ways.

Fibrillar collagens (I, III and V)

The fibrillar collagens I, III and V all increase significantly in fibrosis; together with collagen IV, they are the most abundant ECM proteins in the liver. They are mechanically important, contributing tensile strength. The fibrillar collagens do not form separate structures but, rather, may be incorporated into composite fibrils, with the relative contribution of each collagen determining the diameter and mechanical properties of the fibril as well as the sensitivity of the fibril to different proteases [4,18,19].

Collagen I has few interruptions in the Gly-Xaa-Yaa structure, enabling it to form rigid triple-helical fibrils, with three amino acids per turn. Many other matrix molecules (including collagens III, V, VI, fibronectin and proteoglycans) are found on the surface of collagen I. Collagen III is structurally similar. It is the first collagen to increase in chronic liver disease; although later replaced in part by collagen I, it remains highly expressed [20]. Collagen V is an abundant collagen that acts as a connector to

other collagen types and may be important in initiating the growth of other collagen fibrils [21,22].

Non-fibrillar collagens

The collagens in this group do not form fibrils but, instead, contain combinations of collagenous and non-collagenous domains that enable them to form a variety of different three-dimensional structures. The non-fibrillar collagens in the liver can be divided into three groups based on structure: the network-forming collagens, the FACITS (fibril-associated with interrupted triple helices) and the multiplexins (multiple triple-helical domains and interruptions).

Network-forming collagens (IV, VI, and VIII) The network-forming collagens have many interruptions in their triple-helical chains, which give them flexibility. This flexibility enables them to make linear, axial and lateral associations and so form networks, not fibres [23]; it also allows them to interact with multiple other proteins and macromolecules.

Collagen IV, the main component of most basement membranes, has many variants, although in liver it occurs almost exclusively in the form $[\alpha1(IV)]_2[\alpha2(IV)]$. The ends of this collagen cross-link to enable the formation of a three-dimensional network, which anchors and stabilizes other basement membrane components, including perlecan and laminin. Collagen IV is synthesized primarily by endothelial cells, suggesting an active role for these cells in the capillarization of the sinusoids [24].

Collagen VI is a heterotrimeric collagen that forms branching filamentous networks and binds to many additional matrix proteins [4,23,25]. It surrounds the fibres of loosely packed collagens I and III and may anchor structures such as nerves, blood vessels and other cells into place, in part by interconnections with collagen IV in endothelial cell basement membranes [25,26]. Collagen VI is increased up to 10-fold in liver fibrosis. Soluble collagen VI is increased in the circulation of patients with chronic liver disease, which can promote mesenchymal cell (and potentially HSC) proliferation, and is also a potent inhibitor of apoptosis. For these reasons, collagen VI has been proposed as a sensor for tissue damage, with the release of the soluble form stimulating proliferation of surrounding cells and wound healing [4,27,28].

Collagen VIII forms tetrahedral assemblies and, in some cases, hexagonal lattices [23]. It appears to be associated with the basement membrane as well as the elastic fibres of the portal triad, and may serve as a bridge between other matrix molecules. It is especially important in the vasculature, playing a role in angiogenesis [29–31]. Although collagen VIII has been minimally studied in the liver, in other injury models it stimulates smooth muscle cell migration and matrix metalloproteinase (MMP) synthesis and thus may be involved in differentiation and remodelling in wound healing [29,32].

FACIT collagens (XIV, XIX) The FACITs consist of alternating short triple-helical domains and non-triple-helical domains and, as a result, are highly flexible. Rather than forming fibrils themselves, they associate with pre-existing fibrils of other collagens.

Collagen XIV (also known as undulin) is widely expressed in liver, particularly on the surface of mature, dense fibrils of collagens I and III; it is not seen in the disorganized tissue of actively fibrogenic regions [33,34]. Interestingly, the procollagen I N-proteinase (which cleaves the N-propeptide of collagen I) is bound to collagen XIV, raising the possibility that collagen XIV provides spatial control in regulating the growth of the fibrillar collagens [35]. In the liver, collagen XIV is absent from the sinusoidal space, but is abundant in the portal tract. It increases in fibrosis and can suppress proliferation of HSC and fibroblasts; these effects, as well as its association with dense collagen fibres, suggest a role in established rather than ongoing fibrosis [4]. The other FACIT collagen in the liver, collagen XIX, is primarily found in basement membranes and, to a small extent, in the sinusoids [36]. It has a significant vascular association and may be involved in angiogenesis.

Multiplexin collagens (XV, XVIII) The multiplexin collagens XVIII and XV are structurally homologous proteoglycans with central triple-helical domains and multiple non-collagenous regions which give them flexibility. Collagen XVIII derived from tissues is heparan sulphate linked, whereas collagen XV has chondroitin sulphate modifications [37–39]. Both are found in basement membranes, where they may organize the basement membrane and link it to the underlying matrix.

Collagen XVIII is unusual in that it is increased only twofold in diseased liver compared with normal liver. It is synthesized primarily by hepatocytes and biliary epithelial cells in both states, and is localized in a continuous distribution in both basement membranes and the perisinusoidal space [36,40,41]. Most of the increase in collagen XVIII in disease is along sinusoids that have undergone capillarization, suggesting that it may contribute to this process. Collagen XVIII is also found in the diseased liver in the basement membrane surrounding ductular hepatocytes, proliferating bile ductules and cirrhotic nodules; this distribution implies a potential role in ECM breakdown and remodelling, as well as the ductular reaction and angiogenesis [40,41]. Intact collagen XVIII supports endothelial cell survival, migration and proliferation, and also has the potential to sequester heparan sulphate and heparan sulphate-binding growth factors [31]. The C-terminal globular domain of collagen XVIII can be cleaved by a variety of proteases including MMPs and elastases to generate endostatin, a heparin-binding protein that inhibits angiogenesis and mediates apoptosis [39].

Non-collagenous proteins of the ECM

Fibronectin

Fibronectin is an abundant and widely distributed ECM glycoprotein with multiple domains, including a heparin-binding N-terminus, a collagen-binding domain and an Arg-Gly-Asp

(RGD) motif-containing cell-binding domain with multiple repeated sequences termed type 3 repeats. Unlike many other matrix components, assembly of fibronectin is driven by interaction with its integrins (via the cell-binding domain), suggesting that it plays a particularly important role in the interaction between cells and the surrounding ECM. In the normal liver, fibronectin is found in the portal region around basement membranes and also in a perisinusoidal, speckled pattern; it is the most abundant ECM protein in the normal space of Disse, coating hepatocytes as well as normal collagen fibrils [2]. With its multiple domains, fibronectin probably functions to connect the surfaces of both endothelial cells and hepatocytes to collagen bundles. Fibronectin is one of the first matrix proteins to increase in fibrosis, with significantly increased deposition in the space of Disse, the portal region and fibrotic bands; as a result, it has been called a fibrotic 'pacemaker' [2,42,43].

There are multiple splice variants of fibronectin. Variant EIIIA is expressed primarily during repair of liver injury. It stimulates the activation of fibroblasts and HSC to myofibroblasts in culture [44]. Transforming growth factor (TGF)-β induces production of EIIIA by endothelial cells, suggesting one mechanism among many whereby TGF-β induces fibrosis [45].

Tenascin-C

The tenascins are oligomeric glycoproteins with complex, multidomain structures including fibronectin type 3 repeats. Although the tenascins are highly conserved across vertebrate species and are tightly regulated, their functions are not well understood. Tenascin-C is the best characterized member of the family and the only one known to be expressed in the liver. It antagonizes cell attachment to fibronectin and appears to block fibronectin-mediated signalling at the level of focal adhesion kinase and Rho-mediated pathways; it stimulates growth pathways, including Wnt pathways [46–48]. Tenascin-C also binds multiple additional proteins including integrins, a variety of proteoglycans, adhesion molecules and collagens [49].

Tenascin-C is upregulated in liver fibrosis. In the normal liver, it is found as discontinuous deposits in the sinusoids, but is absent from portal tracts [50–52]. In rat models of fibrosis, tenascin-C is expressed transiently and is found in early septae (at the interface between the parenchyma and the scar) but not in organized areas of fibrosis, suggesting that it has a role in early deposition of ECM. Tenascin-C in the fibrotic liver is synthesized and secreted by HSC [13,50–53].

Laminins

The laminins are a family of large heterotrimeric (α, β, γ chains) glycoproteins typically found in basement membranes associated with collagen IV, perlecan and a variety of other molecules including the glycoprotein nidogen (entactin). They self-assemble into a mesh-like structure and play an important role in the architecture of the basement membrane. Laminins interact with cell surface receptors to regulate additional functions including development and differentiation [54].

Several laminin chains are found in the liver, although their distributions vary [55,56]. In the normal liver, laminins are found in the basement membrane structures of the portal region, with small, focal deposits in the sinusoidal space [1,2]. In the cirrhotic liver, there is a marked increase in laminin deposition, which is found surrounding single or small groups of hepatocytes. Laminin is heavily deposited in the space of Disse in the fibrotic liver along with collagen IV and perlecan, eventually forming a continuous basement membrane [2]. HSC are important laminin-producing cells [56].

Elastin and fibrillin

Elastin and the fibrillins are the major components of elastic fibres in the body and are responsible for many of the mechanical properties of tissues, in particular resilience. Elastic fibres are formed from fibrillin microfibrils with or without a core of elastin. Assembly begins with fibrillin arrays forming transglutaminase cross-linked beaded microfibrils. Elastin binds to these microfibrils, undergoes ordered self-assembly and is then stabilized by LOX-mediated cross-links, which render it highly protease resistant [57]. The function of the different elastic fibres in the liver is not well understood. Both fibrillin and elastin bind to multiple other ECM components including collagens and proteoglycans. Fibrillin can mediate signalling by binding to integrin $\alpha_V\beta_3$; it also binds to TGF-β and may regulate TGF-β targeting [57]. Fibrillin may be cleaved into antiadhesive fragments by proteases, potentially modulating cell/matrix interactions and enhancing cell migration [58].

Fibrillin-1, the only family member studied in the liver, is found associated with elastin in vessel walls and portal tract connective tissue. Unlike elastin, fibrillin-1 is also found adjacent to the limiting plate and lining the sinusoids, forming a continuous network in the space of Disse, where it may have a mechanical role in sinusoidal wall adaptation to variations in blood flow [59]. Fibrillin-1 expression increases in fibrosis where it is found in areas of newly developing matrix (surrounding myofibroblasts invading the parenchyma), around the ductular basement membrane and in the dense septae of organized matrix [58, 59]. Elastin, unlike fibrillin, is not found around invading myofibroblasts or in the space of Disse [58,60,61]. Fibrillin is thought to be produced by both quiescent and activated HSC and portal fibroblasts; elastin, in contrast, appears be produced only by portal fibroblasts and myofibroblasts [58,59].

Proteoglycans and hyaluronic acid

Proteoglycans are proteins with glycosaminoglycan (GAG) modifications. They have multiple functions including maintaining the structural integrity of the ECM, forming a highly charged barrier to the passage of other molecules and regulating growth factor signalling by binding to and sequestering many growth factors including fibroblast growth factor (FGF)-2. Some proteoglycans, in particular the syndecans, heparan sulphate proteoglycans that increase dramatically in fibrosis, are now recognized as signalling receptors [62–65]. Additionally,

certain proteases copurify with proteoglycans; this is increased in cirrhosis. There is a fivefold increase in proteoglycan expression in fibrosis. Given the many functions of proteoglycans, they are likely to play a significant role in regulating liver function [66].

Heparan, dermatan and chondroitin sulphate proteoglycans are found in the normal liver, with heparan sulphate proteoglycans comprising approximately 60% of the total [66]. In the cirrhotic liver, chondroitin and dermatan sulphate proteoglycans are disproportionally increased; there are also subtle changes in the side-chain composition of individual proteoglycans, which may affect their function [62,66]. Heparan sulphate proteoglycans are primarily synthesized by hepatocytes in the normal and diseased liver while, in contrast, increases in chondroitin and dermatan sulphate proteoglycans in disease are mediated largely by HSC [66].

The basement membrane proteoglycans include perlecan and collagens XVIII and XV (see above). Perlecan is a large, modular heparan sulphate proteoglycan that interacts with a variety of other proteins including other basement membrane proteins (laminin, collagen IV), heparan sulphate-binding growth factors and fibrillin-1. Perlecan serves as an architectural component of the basement membrane as well as a reservoir for growth factors and a filter for soluble proteins [67]. In the normal liver, perlecan is present in the portal and central venous basement membranes as well as the sinusoids. In fibrosis, it is increased up to eightfold and is modified with the addition of chondroitin sulphate as well as heparan sulphate. Perlecan is increased around reactive bile ductules and markedly increased in sinusoids and the space of Disse, where it is incorporated into the basement membrane, reflecting the capillarization of the sinusoids [62–64,68]. SEC are a major source of perlecan *in vivo* [43].

Decorin, a small chondroitin sulphate proteoglycan, is also increased in cirrhosis. Decorin binds to collagen VI, fibronectin and thrombospondin and appears to be required for the assembly of collagen XIV to the surface of collagen I [4]. Normally located in the space of Disse and portal region, decorin is found prominently in the fibrotic septae of the diseased liver [68,69].

Hyaluronic acid (HA) is a pure carbohydrate polymer composed of repeating disaccharide units present in the extracellular matrix. HA has a high rate of turnover for an ECM molecule, and liver SEC are responsible for a significant amount of its catabolism [70]. It is a minor component of the liver ECM, although significantly increased in fibrotic livers [71,72]; HA and one of its receptors, CD44, increase in parallel in liver fibrosis [73]. An ECM rich in HA is highly hydrated, promotes migration and is specifically important in the migration of HSC in liver disease [74].

Other matrix proteins

A variety of other matrix proteins are present in the liver and upregulated during fibrogenesis including, although not limited to, entactin, thrombospondin, vitronectin, secreted protein acidic and rich in cysteine (SPARC; osteonectin), the *GPI*-linked protein glypican and the proteoglycans aggrecan and betaglycan.

Receptors for ECM proteins

Many of the functions of ECM molecules are mediated by their signalling receptors, heterodimeric (α, β) membrane proteins termed integrins. Matrix-bound integrins initiate cell signalling through a variety of pathways and thereby regulate cell growth, differentiation and migration; in the liver, they are important regulators of fibrosis and tissue remodelling. Integrin expression by the different cells of the liver reflects the specific composition of the underlying matrix, such that hepatocytes and SEC express a unique panel of integrins while biliary epithelial cells express integrins typical of most epithelial cells. In fibrosis, hepatocyte and SEC integrin expression changes to a more epithelial-like pattern and may contribute to the development of fibrosis [75,76]. Integrins may play a role in initiating and maintaining the activation of HSC; they also potentially regulate contractility, proliferation and apoptosis in activated cells [77].

A newly identified class of membrane proteins, the discoidin domain receptors (DDRs), are non-integrin tyrosine kinase receptors for fibrillar collagens. In HSC, these receptors may mediate collagen-induced MMP upregulation and proliferation, although their role in liver fibrosis is not known [78].

Matrix homeostasis and degradation in the liver

Matrix deposition in the normal liver is a dynamic process reflecting ongoing synthesis and degradation. Because the collagens and other matrix proteins of the fibrotic liver are highly cross-linked (see above) and relatively resistant to proteolysis, their degradation requires a specialized group of more than 25 proteases, the MMPs. The MMPs are divided into five families, although they show significant functional overlap [79] (see also Chapter 6.1).

Several MMPs deserve note. The interstitial collagenases (MMPs -1, -8, -13 and possibly -2 and -14) are the only MMPs able to cleave native collagens I and III in their triple-helical domains, and they play a key role in fibrosis and its resolution. The gelatinases (MMPs -2 and -9), however, are also important as they degrade collagen IV, elastin, fibronectin and laminin in addition to denatured fibrillar collagens that have been partially unfolded by interstitial collagenases. MMP-2 (gelatinase A) demonstrates increased activity in parallel with the development of fibrosis, particularly at intermediate stages; it degrades the normal perisinusoidal matrix as part of the parenchymal remodelling involved in progression of disease, enabling HSC migration [80–83].

Regulation of matrix degradation is important in both normal and diseased tissue. In the normal liver, avoiding excess degradation is critical for avoiding tissue injury. In fibrosis, there are changes in both deposition and degradation of matrix

components. Resolution of fibrosis requires remodelling of the abnormal matrix; mice expressing a collagenase-resistant collagen I have decreased resolution of fibrosis even after removal of the original profibrogenic insult [84]. The expression and proteolytic activation of the MMPs are subject to complex regulation by growth factors, other proteases including other MMPs, and the matrix itself via integrin-mediated signalling. An important level of regulation is derived from a family of inhibitors, the tissue inhibitors of metalloproteinases (TIMPs), which bind in a non-covalent and reversible manner to the active sites of the MMPs. TIMP-1 and -2 have both been shown to be highly upregulated in fibrosis [81,85,86]. Their importance is illustrated by the demonstration that matrix deposition is enhanced in a CCl_4 model of fibrosis in mice overexpressing TIMP-1 in the liver [87]. HSCs are a key cellular source of the MMPs, their activators and the TIMPs [83].

Conclusion

The ECM is now recognized to be a complex and dynamic rather than a static component of the liver. Although the fibrillar collagens and fibronectin are justifiably the subject of much attention, there is increasing appreciation for the role of other collagens, proteoglycans and additional minor components of the ECM in regulating liver function. Liver cells and the ECM have a bidirectional relationship: almost all liver cells produce some matrix, and most are in turn phenotypically regulated by the ECM. Recent research has focused on the role of fibrogenic cells in addition to HSC and will probably yield important insights in the future. A further area of intense research will be on new functions of the matrix including mechanisms of ECM-mediated regulation of cell phenotype.

References

1 Martinez-Hernandez A, Amenta PS (1993) The hepatic extracellular matrix. I. Components and distribution in normal liver. *Virchows Arch A Pathol Anat Histopathol* 423 (1), 1–11.

2 Hahn E, Wick G, Pencev D *et al.* (1980) Distribution of basement membrane proteins in normal and fibrotic human liver: collagen type IV, laminin, and fibronectin. *Gut* 21 (1), 63–71.

3 Loreal O, Clement B, Schuppan D *et al.* (1992) Distribution and cellular origin of collagen VI during development and in cirrhosis. *Gastroenterology* 102 (3), 980–987.

4 Schuppan D, Ruehl M, Somasundaram R *et al.* (2001) Matrix as a modulator of hepatic fibrogenesis. *Semin Liver Dis* 21 (3), 351–372.

5 Reid LM, Fiorino AS, Sigal SH *et al.* (1992) Extracellular matrix gradients in the space of Disse: relevance to liver biology. *Hepatology* 15 (6), 1198–1203.

6 Martinez-Hernandez A, Amenta PS (1993) The hepatic extracellular matrix. II. Ontogenesis, regeneration and cirrhosis. *Virchows Arch A Pathol Anat Histopathol* 423 (2), 77–84.

7 Brenner DA, Waterboer T, Choi SK *et al.* (2000) New aspects of hepatic fibrosis. *J Hepatol* 32(1 Suppl), 32–38.

8 Mehta K, Fok JY, Mangala LS (2006) Tissue transglutaminase: from biological glue to cell survival cues. *Front Biosci* 11, 173–185.

9 Grenard P, Bresson-Hadni S, El Alaoui S *et al.* (2001) Transglutaminase-mediated cross-linking is involved in the stabilization of extracellular matrix in human liver fibrosis. *J Hepatol* 35 (3), 367–375.

10 Mirza A, Liu SL, Frizell E *et al.* (1997) A role for tissue transglutaminase in hepatic injury and fibrogenesis, and its regulation by NF-kappaB. *Am J Physiol* 272 (2 Pt 1), G281–288.

11 Schnabel C, Sawitza I, Tag CG *et al.* (2004) Expression of cytosolic and membrane associated tissue transglutaminase in rat hepatic stellate cells and its upregulation during transdifferentiation to myofibroblasts in culture. *Hepatol Res* 28 (3), 140–145.

12 Issa R, Zhou X, Constandinou CM *et al.* (2004) Spontaneous recovery from micronodular cirrhosis: evidence for incomplete resolution associated with matrix cross-linking. *Gastroenterology* 126 (7), 1795–1808.

13 Desmouliere A, Darby I, Costa AM *et al.* (1997) Extracellular matrix deposition, lysyl oxidase expression, and myofibroblastic differentiation during the initial stages of cholestatic fibrosis in the rat. *Lab Invest* 76 (6), 765–778.

14 Kim Y, Peyrol S, So CK *et al.* (1999) Coexpression of the lysyl oxidase-like gene (LOXL) and the gene encoding type III procollagen in induced liver fibrosis. *J Cell Biochem* 72 (2), 181–188.

15 Vater CA, Harris ED, Jr, Siegel RC (1979) Native cross-links in collagen fibrils induce resistance to human synovial collagenase. *Biochem J* 181 (3), 639–645.

16 Ricard-Blum S, Bresson-Hadni S, Vuitton DA *et al.* (1992) Hydroxypyridinium collagen cross-links in human liver fibrosis: study of alveolar echinococcosis. *Hepatology* 15 (4), 599–602.

17 van der Slot AJ, Zuurmond AM, van den Bogaerdt AJ *et al.* (2004) Increased formation of pyridinoline cross-links due to higher telopeptide lysyl hydroxylase levels is a general fibrotic phenomenon. *Matrix Biol* 23 (4), 251–257.

18 Geerts A, Schuppan D, Lazeroms S *et al.* (1990) Collagen type I and III occur together in hybrid fibrils in the space of Disse of normal rat liver. *Hepatology* 12 (2), 233–241.

19 Romanic AM, Adachi E, Kadler KE *et al.* (1991) Copolymerization of pNcollagen III and collagen I. pNcollagen III decreases the rate of incorporation of collagen I into fibrils, the amount of collagen I incorporated, and the diameter of the fibrils formed. *J Biol Chem* 266 (19), 12703–12709.

20 Ramadori G, Knittel T, Saile B (1998) Fibrosis and altered matrix synthesis. *Digestion* 59 (4), 372–375.

21 Birk DE, Fitch JM, Babiarz JP *et al.* (1988) Collagen type I and type V are present in the same fibril in the avian corneal stroma. *J Cell Biol* 106 (3), 999–1008.

22 Becker J, Schuppan D, Rabanus JP *et al.* (1991) Immunoelectron microscopic localization of collagens type I, V, VI and of procollagen type III in human periodontal ligament and cementum. *J Histochem Cytochem* 39 (1), 103–110.

23 Knupp C, Squire JM (2005) Molecular packing in network-forming collagens. *Adv Protein Chem* 70, 375–403.

24 Herbst H, Frey A, Heinrichs O *et al.* (1997) Heterogeneity of liver cells expressing procollagen types I and IV in vivo. *Histochem Cell Biol* 107 (5), 399–409.

25 Griffiths MR, Shepherd M, Ferrier R *et al.* (1992) Light microscopic and ultrastructural distribution of type VI collagen in human liver: alterations in chronic biliary disease. *Histopathology* 21 (4), 335–344.

26 Keene DR, Engvall E, Glanville RW (1988) Ultrastructure of type VI collagen in human skin and cartilage suggests an anchoring function for this filamentous network. *J Cell Biol* 107 (5), 1995–2006.

27 Ruhl M, Sahin E, Johannsen M *et al.* (1999) Soluble collagen VI drives serum-starved fibroblasts through S phase and prevents apoptosis via down-regulation of Bax. *J Biol Chem* 274 (48), 34361–34368.

28 Atkinson JC, Ruhl M, Becker J *et al.* (1996) Collagen VI regulates normal and transformed mesenchymal cell proliferation in vitro. *Exp Cell Res* 228 (2), 283–291.

29 Shuttleworth CA (1997) Type VIII collagen. *Int J Biochem Cell Biol* 29 (10), 1145–1148.

30 Sawada H, Konomi H (1991) The alpha 1 chain of type VIII collagen is associated with many but not all microfibrils of elastic fiber system. *Cell Struct Funct* 16 (6), 455–466.

31 Ricard-Blum S, Dublet B, van der Rest M (2000) *Unconventional Collagens. Type VI, VII, VIII, IX, X, XII, XIV, XVI, and XIX*. Oxford: Oxford University Press.

32 Hou G, Mulholland D, Gronska MA *et al.* (2000) Type VIII collagen stimulates smooth muscle cell migration and matrix metalloproteinase synthesis after arterial injury. *Am J Pathol* 156 (2), 467–476.

33 Schuppan D, Cantaluppi MC, Becker J *et al.* (1990) Undulin, an extracellular matrix glycoprotein associated with collagen fibrils. *J Biol Chem* 265 (15), 8823–8832.

34 Milani S, Grappone C, Pellegrini G *et al.* (1994) Undulin RNA and protein expression in normal and fibrotic human liver. *Hepatology* 20 (4 Pt 1), 908–916.

35 Colige A, Beschin A, Samyn B *et al.* (1995) Characterization and partial amino acid sequencing of a 107-kDa procollagen I N-proteinase purified by affinity chromatography on immobilized type XIV collagen. *J Biol Chem* 270 (28), 16724–16730.

36 Myers JC, Li D, Bageris A *et al.* (1997) Biochemical and immunohistochemical characterization of human type XIX defines a novel class of basement membrane zone collagens. *Am J Pathol* 151 (6), 1729–1740.

37 Halfter W, Dong S, Schurer B *et al.* (1998) Collagen XVIII is a basement membrane heparan sulfate proteoglycan. *J Biol Chem* 273 (39), 25404–25412.

38 Li D, Clark CC, Myers JC (2000) Basement membrane zone type XV collagen is a disulfide-bonded chondroitin sulfate proteoglycan in human tissues and cultured cells. *J Biol Chem* 275 (29), 22339–22347.

39 Iozzo RV (2005) Basement membrane proteoglycans: from cellar to ceiling. *Nature Rev Mol Cell Biol* 6 (8), 646–656.

40 Jia JD, Bauer M, Sedlaczek N *et al.* (2001) Modulation of collagen XVIII/endostatin expression in lobular and biliary rat liver fibrogenesis. *J Hepatol* 35 (3), 386–391.

41 Musso O, Rehn M, Saarela J *et al.* (1998) Collagen XVIII is localized in sinusoids and basement membrane zones and expressed by hepatocytes and activated stellate cells in fibrotic human liver. *Hepatology* 28 (1), 98–107.

42 Odenthal M, Neubauer K, Meyer zum Buschenfelde KH *et al.* (1993) Localization and mRNA steady-state level of cellular fibronectin in rat liver undergoing a CCl4-induced acute damage or fibrosis. *Biochim Biophys Acta* 1181 (3), 266–272.

43 Rescan PY, Loreal O, Hassell JR *et al.* (1993) Distribution and origin of the basement membrane component perlecan in rat liver and primary hepatocyte culture. *Am J Pathol* 142 (1), 199–208.

44 Tomasek JJ, Gabbiani G, Hinz B *et al.* (2002) Myofibroblasts and mechano-regulation of connective tissue remodelling. *Nature Rev Mol Cell Biol* 3 (5), 349–363.

45 George J, Wang SS, Sevcsik AM *et al.* (2000) Transforming growth factor-beta initiates wound repair in rat liver through induction of the EIIIA-fibronectin splice isoform. *Am J Pathol* 156 (1), 115–124.

46 Wenk MB, Midwood KS, Schwarzbauer JE (2000) Tenascin-C suppresses Rho activation. *J Cell Biol* 150 (4), 913–920.

47 Midwood KS, Schwarzbauer JE (2002) Tenascin-C modulates matrix contraction via focal adhesion kinase- and Rho-mediated signaling pathways. *Mol Biol Cell* 13 (10), 3601–3613.

48 Ruiz C, Huang W, Hegi ME *et al.* (2004) Growth promoting signaling by tenascin-C (corrected). *Cancer Res* 64 (20), 7377–7385.

49 Hsia HC, Schwarzbauer JE (2005) Meet the tenascins: multifunctional and mysterious. *J Biol Chem* 280 (29), 26641–26644.

50 Van Eyken P, Geerts A, De Bleser P *et al.* (1992) Localization and cellular source of the extracellular matrix protein tenascin in normal and fibrotic rat liver. *Hepatology* 15 (5), 909–916.

51 Yamada S, Ichida T, Matsuda Y *et al.* (1992) Tenascin expression in human chronic liver disease and in hepatocellular carcinoma. *Liver* 12 (1), 10–16.

52 Van Eyken P, Sciot R, Desmet VJ (1990) Expression of the novel extracellular matrix component tenascin in normal and diseased human liver. An immunohistochemical study. *J Hepatol* 11 (1), 43–52.

53 Miyazaki H, Van Eyken P, Roskams T *et al.* (1993) Transient expression of tenascin in experimentally induced cholestatic fibrosis in rat liver: an immunohistochemical study. *J Hepatol* 19 (3), 353–366.

54 Colognato H, Yurchenco PD (2000) Form and function: the laminin family of heterotrimers. *Dev Dyn* 218 (2), 213–234.

55 Sasaki T, Giltay R, Talts U *et al.* (2002) Expression and distribution of laminin alpha1 and alpha2 chains in embryonic and adult mouse tissues: an immunochemical approach. *Exp Cell Res* 275 (2), 185–199.

56 Kikkawa Y, Mochizuki Y, Miner JH *et al.* (2005) Transient expression of laminin alpha1 chain in regenerating murine liver: restricted localization of laminin chains and nidogen-1. *Exp Cell Res* 305 (1), 99–109.

57 Kielty CM, Sherratt MJ, Shuttleworth CA (2002) Elastic fibres. *J Cell Sci* 115 (Pt 14), 2817–2828.

58 Lorena D, Darby IA, Reinhardt DP *et al.* (2004) Fibrillin-1 expression in normal and fibrotic rat liver and in cultured hepatic fibroblastic cells: modulation by mechanical stress and role in cell adhesion. *Lab Invest* 84 (2), 203–212.

59 Dubuisson L, Lepreux S, Bioulac-Sage P *et al.* (2001) Expression and cellular localization of fibrillin-1 in normal and pathological human liver. *J Hepatol* 34 (4), 514–522.

60 Porto LC, Chevallier M, Peyrol S *et al.* (1990) Elastin in human, baboon, and mouse liver: an immunohistochemical and immunoelectron microscopic study. *Anat Rec* 228 (4), 392–404.

61 Velebny V, Kasafirek E, Kanta J (1983) Desmosine and isodesmosine contents and elastase activity in normal and cirrhotic rat liver. *Biochem J* 214 (3), 1023–1025.

62 Kovalszky II, Nagy JO, Gallai M *et al.* (1997) Altered proteoglycan gene expression in human biliary cirrhosis. *Pathol Oncol Res* 3 (1), 51–58.

63 Roskams T, Moshage H, De Vos R *et al.* (1995) Heparan sulfate proteoglycan expression in normal human liver. *Hepatology* 21 (4), 950–958.

64 Roskams T, Rosenbaum J, De Vos R *et al.* (1996) Heparan sulfate proteoglycan expression in chronic cholestatic human liver diseases. *Hepatology* 24 (3), 524–532.

65 Tkachenko E, Rhodes JM, Simons M (2005) Syndecans: new kids on the signaling block. *Circ Res* 96 (5), 488–500.

66 Gressner AM (1994) Activation of proteoglycan synthesis in injured liver – a brief review of molecular and cellular aspects. *Eur J Clin Chem Clin Biochem* 32 (4), 225–237.

67 Levavasseur F, Loreal O, Lietard J *et al.* (1995) Basement membrane gene expression in the liver. *J Hepatol* 22 (2 Suppl), 10–19.
68 Gallai M, Kovalszky I, Knittel T *et al.* (1996) Expression of extracellular matrix proteoglycans perlecan and decorin in carbon-tetrachloride-injured rat liver and in isolated liver cells. *Am J Pathol* 148 (5), 1463–1471.
69 Hogemann B, Edel G, Schwarz K *et al.* (1997) Expression of biglycan, decorin and proteoglycan-100/CSF-1 in normal and fibrotic human liver. *Pathol Res Pract* 193 (11–12), 747–751.
70 McCourt PA (1999) How does the hyaluronan scrap-yard operate? *Matrix Biol* 18 (5), 427–432.
71 Scott JE, Bosworth TR, Cribb AM *et al.* (1994) The chemical morphology of extracellular matrix in experimental rat liver fibrosis resembles that of normal developing connective tissue. *Virchows Arch* 424 (1), 89–98.
72 Murata K, Ochiai Y, Akashio K (1985) Polydispersity of acidic glycosaminoglycan components in human liver and the changes at different stages in liver cirrhosis. *Gastroenterology* 89 (6), 1248–1257.
73 Satoh T, Ichida T, Matsuda Y *et al.* (2000) Interaction between hyaluronan and CD44 in the development of dimethylnitrosamine-induced liver cirrhosis. *J Gastroenterol Hepatol* 15 (4), 402–411.
74 Kikuchi S, Griffin CT, Wang SS *et al.* (2005) Role of CD44 in epithelial wound repair: migration of rat hepatic stellate cells utilizes hyaluronic acid and CD44v6. *J Biol Chem* 280 (15), 15398–15404.
75 Scoazec JY (1995) Expression of cell–matrix adhesion molecules in the liver and their modulation during fibrosis. *J Hepatol* 22 (2 Suppl), 20–27.
76 Languino LR, Wells RG (2001) Integrins. In: Arias IM (ed.) *The Liver: Biology and Pathobiology*, 4th edn. Philadelphia: Lippincott Williams & Wilkins, pp. 475–482.
77 Zhou X, Murphy FR, Gehdu N *et al.* (2004) Engagement of alphavbeta3 integrin regulates proliferation and apoptosis of hepatic stellate cells. *J Biol Chem* 279 (23), 23996–24006.
78 Olaso E, Ikeda K, Eng FJ *et al.* (2001) DDR2 receptor promotes MMP-2-mediated proliferation and invasion by hepatic stellate cells. *J Clin Invest* 108 (9), 1369–1378.
79 Benyon RC, Arthur MJ (2001) Extracellular matrix degradation and the role of hepatic stellate cells. *Semin Liver Dis* 21 (3), 373–384.
80 Takahara T, Furui K, Funaki J *et al.* (1995) Increased expression of matrix metalloproteinase-II in experimental liver fibrosis in rats. *Hepatology* 21 (3), 787–795.
81 Benyon RC, Iredale JP, Goddard S *et al.* (1996) Expression of tissue inhibitor of metalloproteinases 1 and 2 is increased in fibrotic human liver. *Gastroenterology* 110 (3), 821–831.
82 Takahara T, Furui K, Yata Y *et al.* (1997) Dual expression of matrix metalloproteinase-2 and membrane-type 1-matrix metalloproteinase in fibrotic human livers. *Hepatology* 26 (6), 1521–1529.
83 Bedossa P, Paradis V (2003) Liver extracellular matrix in health and disease. *J Pathol* 200 (4), 504–515.
84 Issa R, Zhou X, Trim N *et al.* (2003) Mutation in collagen-1 that confers resistance to the action of collagenase results in failure of recovery from CCl4-induced liver fibrosis, persistence of activated hepatic stellate cells, and diminished hepatocyte regeneration. *FASEB J* 17 (1), 47–49.
85 Iredale JP, Benyon RC, Arthur MJ *et al.* (1996) Tissue inhibitor of metalloproteinase-1 messenger RNA expression is enhanced relative to interstitial collagenase messenger RNA in experimental liver injury and fibrosis. *Hepatology* 24 (1), 176–184.
86 Herbst H, Wege T, Milani S *et al.* (1997) Tissue inhibitor of metalloproteinase-1 and -2 RNA expression in rat and human liver fibrosis. *Am J Pathol* 150 (5), 1647–1659.
87 Yoshiji H, Kuriyama S, Miyamoto Y *et al.* (2000) Tissue inhibitor of metalloproteinases-1 promotes liver fibrosis development in a transgenic mouse model. *Hepatology* 32 (6), 1248–1254.

2.5 Regulation of the liver cell mass

2.5.1 Control of liver cell proliferation

Nisar P. Malek and K. Lenhard Rudolph

Control of liver cell cycle entry and progression

The liver is a quiescent organ that has enormous capacity to regenerate in response to injury [1]. This capacity is regulated through the ordered activation and inactivation of regulatory proteins which govern the entry and exit of liver cells from the cell cycle [2]. Our understanding of the molecular basis of these processes is mainly derived from studies in cultured primary hepatocytes, established liver cancer cell lines and also from the analysis of mouse strains with defined defects in genes that are involved in cell cycle regulation. Given the enormous amount of data that have been published on the regulation of hepatocyte proliferation, we will focus only on the role of key cell cycle regulatory proteins in liver cell cycle control in this chapter. Special emphasis will be given to studies that have used mouse model systems to explore liver cell regeneration *in vivo*.

The two-third hepatectomy model in mice and rats has been used extensively to explore the basic molecular mechanism of liver cell proliferation [3]. During the process of liver regeneration, hepatocytes proceed through different stages, which have previously been organized into a so-called initiation or priming phase during which the quiescent hepatocytes are rendered replication competent, the division phase in which the hepatocytes proceed through different phases of the cell cycle and finally divide into two cells, and a termination phase which leads to the termination of liver cell proliferation when organ mass is restored [4].

Under physiological conditions, i.e. in the absence of organ damage or loss, quiescent liver cells are arrested in the G0 state of the cell cycle. A central mediator of cellular quiescence is the retinoblastoma (Rb) protein [5]. Depending on its phosphorylation status, Rb can either repress or activate the expression of a multitude of critical target genes, which control the entry into the division phase of the hepatocyte cell cycle. Hypophosphorylated Rb binds to proteins of the E2F family of transcription factors and blocks their transactivation capacity [6]. Upon phosphorylation, Rb releases E2F, which leads to the expression of E2F target genes and progression into the cell cycle. Using inducible Rb knockout mice, it was shown that acute loss of Rb function in hepatocytes results in unscheduled induction of cell proliferation even in the absence of sufficient mitogenic stimulation [7].

In addition to Rb, a proteolytic system maintains quiescence of hepatocytes by limiting the expression of cyclins to restricted phases of the cell cycle. This system consists of the anaphase-promoting complex (APC) and the skp/cullin/F-box (SCF) multiprotein complex [8]. These degradation systems regulate the ubiquitylation and subsequent proteasomal turnover of cyclins and other important cell cycle regulators. Ablation of the APC2 subunit of APC in mouse liver leads to the accumulation of cyclin A, which induces an unscheduled entry of mouse hepatocytes into the cell cycle [9]. Together, these studies show that the proliferative quiescence of hepatocytes is an actively maintained state, which requires the activity of several proteins and multiprotein complexes.

Upon liver cell damage or loss of organ mass, liver cells exit G0 and enter the G1 phase. An important mediator of this process is the cyclin D protein which, after binding to cdk4 (cyclin-dependent kinase 4 or 6), can phosphorylate the Rb protein, thus allowing the activation of the E2F-dependent transcriptional programme. Cyclin D1 is a highly unstable protein with a half-life of ~ 15 min [10]. Therefore, induction and maintenance of cyclin D1 expression is primarily dependent on continuous transcription of the cyclin D1 gene. Several signalling cascades activate the cyclin D1 promoter in response to mitogenic stimulation, thereby connecting extracellular mitogenic signalling cascades with the core cell cycle machinery, namely phosphorylation of the Rb protein [2]. Conversely, overexpression of cyclin D1 in mouse hepatocytes leads to cell cycle entry without further mitogenic stimulation. Nevertheless, even short-term expression of cyclin D1 in liver cells leads to severe

genetic alterations, including centrosome abnormalities and chromosomal aberrations, reinforcing the notion that central regulators of cell proliferation are frequently involved in cellular transformation processes [11,12]. The expression of cyclin D/cdk4 kinase complexes during the G1 phase leads to the induction of cyclin E/cdk2 activity through E2F-dependent transcription of the cyclin E gene. Importantly, the loss of the cyclin D1 gene in the mouse can be fully rescued through the expression of the cyclin E cDNA in the cyclin D genomic locus. Therefore, the only essential downstream function of cyclin D is to allow cyclin E expression during the G1 phase of the cell cycle [13]. Cyclin E expression also promotes proliferation of mouse hepatocytes *in vivo*; however, this function requires the coexpression of the skp2 protein, a member of the F-box protein family, which plays a crucial role in the destruction of the cyclin kinase inhibitor p27kip1 [14,15]. Cyclin kinase inhibitors (cki) fall into two classes: the ink4 group (p15, p16, p18, p19) and the cip/kip group (p21, p27, p57). The main function of ckis is to regulate the activity of cyclin/cdk complexes throughout the cell division cycle by directly binding and inhibiting the active kinase complex [16]. However, this dogma has recently been challenged through the generation of mouse models with deletions in the cyclin E1/E2 and cdk2 genes [17,18]. Surprisingly, the phenotype of cdk2 knockout mice is restricted to a defect in meiotic cell division, while cell proliferation in cyclin E1/E2 double knockout mice was only impaired when cells were released from quiescence. Moreover, p27 and p21 still inhibited the cell division after overexpression in cdk2 knockout cells, indicating that cdk2 cannot stand as the essential target of these ckis [19]. Nevertheless, loss or overexpression of these proteins in hepatocytes leads to severe phenotypes in the corresponding mouse models. For instance, liver-specific overexpression of p21 in transgenic mice leads to a dramatic impairment in liver cell proliferation, runted liver and body growth and a significant increase in polyploid cells [20]. Stabilization of the p27 protein through loss of skp2 also blocks hepatocyte proliferation in G1 but, at the same time, leads to cellular growth and an increase in cell size of the affected hepatocytes [21]. In these experiments, cellular growth was accompanied by multiple rounds of endoreduplication [21]. Conversely, serial transplantation experiments using p27 knockout hepatocytes showed that loss of this protein greatly increases the proliferative abilities of liver cells [22]. Together, these findings demonstrate that p27 turnover is critical for the control of hepatocyte proliferation by regulating a molecular switch, which controls proliferation or cellular growth of hepatocytes.

Polyploidization might also serve a physiological role as it is frequently accompanied by cellular growth. In fact, an increase in DNA content without a concurrent mitotic division but followed by an enlargement in cell mass might offer an alternative to mitosis in certain cell types including liver cells. Recently, an elegant study using isolated rat hepatocytes and live cell videomicroscopy characterized the mechanism of liver cell polyploidization at the cellular level. It was shown that the generation of 4n hepatocytes is a result of impaired cytokinesis in a fraction of 2n mononuclear liver cells, which results in the generation of binucleated 2n hepatocytes. These cells then underwent normal mitosis which, however, required the clustering of two centrosomes at each pole of the cells and ultimately resulted in the formation of a bipolar spindle and 4n hepatocytes [23]. The molecular mechanisms that control these processes are unknown at this point.

Another important regulator of liver cell proliferation is the Foxm1b protein, a member of the Forkhead Box (Fox) family of transcription factors. Foxm1b expression controls the expression of several cell cycle regulatory proteins including the cdc25B phosphate, cyclin D1 and cyclin B1. Overexpression of Foxm1b accelerates the onset of hepatocyte DNA replication, while loss of the protein leads to a failure to enter mitosis and polyploidization, demonstrating the protein's central role in the process of liver regeneration [24]. Importantly, loss of Foxm1b also leads to an almost complete inhibition of liver cancer formation after treatment of Foxm1b knockout (Foxm1b–/–) mice with the DNA-damaging agent diethylnitrosamine (DEN). While Foxm1b–/– mice still developed altered enzyme foci, which represent the earliest detectable lesions in this model system, they did not show hepatocellular adenomas or carcinomas. Interestingly, all tumours in Foxm1b–/– mice showed strong nuclear p27kip1 expression, suggesting that this cki prevented cellular division in response to DEN treatment [25].

An important role in the development of liver cancer (see Chapter 18.2.1) was also demonstrated for the transcription factor c-jun. C-jun mediates several cellular processes, including proliferation and survival. Using inducible c-jun knockout mice to study its role in liver cancer development, it was demonstrated that inactivation of this transcription factor significantly reduced the number and size of hepatic tumours. The impaired tumour development coincided with the induction of the tumour suppressor protein p53, which led to the induction of noxa, a proapoptotic gene, and subsequent death of the transformed cells. These studies pointed to an antiapoptotic role of c-jun through the suppression of the p53 gene, thus promoting the early stages of hepatocellular carcinoma (HCC) development [26,27].

Telomere shortening, senescence and telomerase

Despite the ability of liver cells to re-enter the cell cycle during organ regeneration, it has long been observed that liver regeneration is impaired at the endstage of chronic liver diseases and during cirrhosis formation (see Chapters 6.1–6.3 and 2.5.2), indicating that the regenerative capacity of human liver cells is limited. A potential explanation for this phenomenon might come from telomere biology. Telomeres consist of simple tandem nucleotide repeats [(TTAGGG)n in humans] that are located at each end of chromosomes [27]. Telomeres are heterochromatic and do not encode any gene product, but have an essential function for cell viability, which is to cap and protect

the chromosomal ends. As the chromosomal end is in principle similar to a double-strand break, chromosomal capping is necessary to avoid activation of DNA damage responses, chromosomal fusions and chromosomal instability (CIN). Beside the length of telomere repeats, the higher order structure [28,29] of the telomeres formed by the binding of specific proteins to the telomere [30] is important for the telomere capping function. Owing to the end-replication problem of DNA polymerase and processing of the telomere termini during the cell cycle, telomeres shorten during each round of cell division by 50–100 bp in human cells [31]. The ongoing telomere shortening is compensated for by the enzyme 'telomerase', which can synthesize telomeres *de novo* [32,33]. Telomerase consists of two essential components: telomerase reverse transcriptase (TERT), which is the catalytic subunit of the enzyme; and telomerase RNA component (TERC), which is the functional RNA and serves as a template for telomere sequence synthesis. In humans, telomerase is active during embryogenesis but is repressed postnatally in most somatic tissues and remains active only in immature germ cells and certain stem and progenitor cells [34].

On account of the repression of telomerase, telomeres of human cells shorten during each cell division (see above), and the replicative lifespan of human cells is limited by this mechanism to 50–70 cell divisions [35]. However, overexpression of telomerase can elongate the lifespan of primary human cells including hepatocytes [36,37]. Telomere shortening limits the lifespan of primary human cells by inducing senescence, which is characterized by a permanent cell cycle arrest. Senescence is induced when telomeres reach a critical short length and lose their capping function. It has been shown that the dysfunctional telomeres provoke a DNA damage response including the activation of ATM/ATR/p53/Chk2/p21/p16 pathways [38,39]. When cells lose p53 or Chk2 function, they can bypass the senescence checkpoint and continue to proliferate despite the presence of telomere dysfunction [40,41]. As a consequence, chromosomal fusions and breakage of fused chromosomes induce CIN (see below and [42]), and cells will eventually reach a second checkpoint called crisis, which is characterized by massive CIN and apoptosis [43].

In humans, telomeres shorten during ageing in a variety of tissues and organs [44]. There is some correlation between age-related telomere shortening and cell turnover of different organs, and the rate of telomere shortening is increased during chronic diseases that increase the rate of cell turnover [44]. There is growing evidence that telomere shortening and senescence impair the regenerative capacity of organs and tissues during human ageing and chronic disease [44].

Telomere shortening, senescence and telomerase in ageing liver and chronic liver diseases

Normal healthy liver does not show significant levels of telomerase activity [45]. The liver is a quiescent organ with a very low rate of cell division, yet the liver shows significant telomere shortening during ageing [46]. During chronic liver disease, low levels of telomerase reactivation have been detected by some investigators. However, it remains a subject of debate to what extent this really reflects telomerase activation of regenerating hepatocytes or whether it is induced by infiltration of telomerase-positive lymphocytes. It has been shown in a variety of studies that there is accelerated telomere shortening during chronic liver disease and at the cirrhosis stage [46], clearly indicating that the level of telomerase is not sufficient to compensate for telomere shortening during chronic liver disease. Telomere shortening in chronic liver disease and cirrhosis predominantly affects hepatocytes, and there is an accumulation of SA-βGal (senescence marker)-positive hepatocytes during cirrhosis development [46]. In agreement with these data, an activation of senescence checkpoint signalling has been detected at the cirrhosis stage.

Direct experimental evidence for a role of telomere shortening in cirrhosis formation came from studies in telomerase knockout mice. Telomere shortening in mTERC–/– mice led to impaired liver regeneration and premature development of fibrosis and steatosis in response to chronic liver damage [47]. Impaired liver regeneration correlated with the induction of senescence in hepatocytes with critically short telomeres. Thus, telomere shortening led to a reduction in the pool of proliferative cells that have the capacity to re-enter the cell cycle and to regenerate the organ in response to damage [48]. In addition, the studies in mTERC–/– mice support the concept that telomerase gene therapy can improve the regenerative capacity of organs with critically short telomeres *in vivo* [47].

These concepts derived from mouse models and the telomere length analysis from human diseased liver (see above) indicate that telomere shortening and senescence contribute to a decrease in hepatocyte proliferation that is recognized during cirrhosis development in humans [49,50]. Together, these studies have led to a new model of cirrhosis formation [51]; according to this model, telomere shortening and senescence limit the regenerative capacity of hepatocytes during chronic liver disease. When the regenerative reserve of the liver falls beneath a critical threshold, stellate cells become activated and form fibrotic scar tissue (Fig. 1). The data from mouse models indicate that telomerase activation could be used for the treatment of liver cirrhosis. However, a detailed understanding of telomere shortening and telomerase reactivation during cancer formation is necessary to predict the potential cancer risk of such therapies.

Telomere shortening, senescence and telomerase in liver cancer

Telomere shortening and senescence are regarded as potent tumour suppressor mechanisms inhibiting immortal growth of transformed cells in the human body. In line with this hypothesis, over 90% of human tumours show a reactivation of telomerase, indicating that telomere stabilization is essential

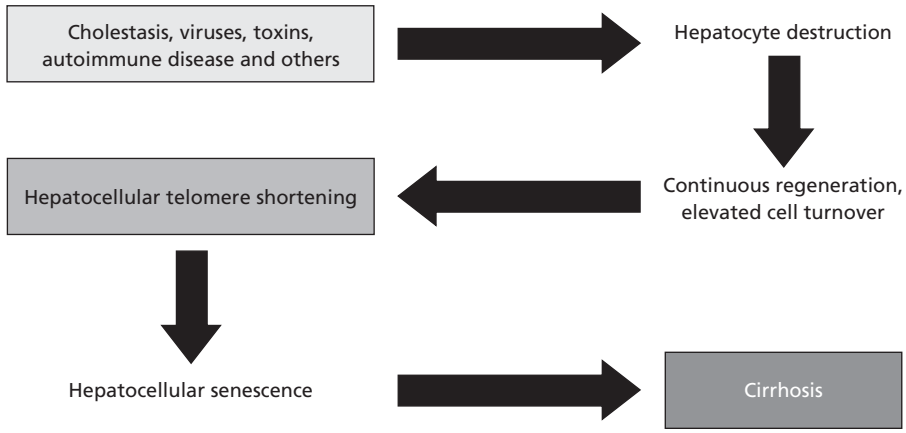

Fig. 1 The telomere hypothesis of cirrhosis formation (reprinted with permission from [46]). Chronic liver diseases lead to an elevated rate of hepatocyte cell turnover, which accelerates telomere shortening, finally culminating in hepatocyte senescence and cessation of regeneration. Continuous liver damage at this point provokes an activation of stellate cells and fibrotic scarring (see Chapters 1.6, 6.1 and 6.2).

for tumour survival and progression [52]. However, in the vast majority of human cancers including HCC, telomeres are very short, much shorter than in the non-transformed surrounding tissue. These data point to an apparent paradox: on the one hand, telomere shortening and senescence are supposed to function as a tumour suppressor mechanism but, on the other hand, telomere shortening is associated with tumour development, indicating that it might represent a tumour risk factor. Indeed, the risk of HCC development increases sharply at the cirrhosis stage (see Chapters 6.3 and 18.2.1), which is characterized by telomere shortening (see above), and the majority of HCC show significant telomere shortening compared with non-transformed surrounding tissue or regenerative nodules [52]. In addition, a strong increase in cancer incidence has been observed in other tissues during ageing and at the endstage of chronic diseases, indicating that senescence as a tumour suppressor mechanism functions well in young age and in tissues with long telomeres but loses effectiveness in tissues with shortened telomeres.

A possible explanation came from studies in mTERC–/– mice revealing a dual role for telomere shortening during cancer initiation and progression. In line with the classical view that telomere shortening acts as a tumour suppressor mechanism, tumour progression was impaired in mTERC–/– mice [53,54]. Impaired tumour progression correlated with activation of senescence signalling pathways (upregulation of p53) in tumour cells of mTERC–/– compared with mTERC+/+ mice. Upregulation of p53 in tumour cells of mTERC–/– mice correlated with increased rates of apoptosis and impaired proliferation of tumour cells *in vivo* [55]. In contrast to the suppression of macroscopic tumours, telomere shortening in mTERC–/– mice was associated with an increase in tumour initiation [55,56]. Increased tumour initiation induced by telomere shortening was linked to chromosomal instability, which is a major mechanism driving tumorigenesis in aged humans and at the endstage of chronic disease. When telomeres lose the capping function, CIN evolves because chromosomes will fuse, and breakage of the chromosomes occurs during anaphase of the cell cycle. As a morphological correlate, chromatin bridges of stretched and

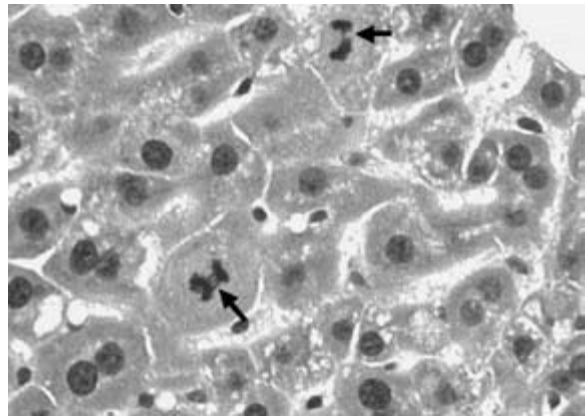

Fig. 2 Telomere shortening induces chromosomal instability (CIN). Loss of telomere capping function results in chromosomal fusions. When cells containing fused chromosomes enter the cell cycle, the chromosomal fusions will break during anaphase. As a morphological correlate, chromatin bridges are seen in anaphase (anaphase bridges, black arrows). The breakage of fused chromosomes results in chromosomal gains and losses in the daughter cells and newly generates telomere free ends at the breakpoints, which will again fuse and break during the next round of cell division. These repeated 'fusion–bridge–breakage cycles' generate CIN of cells with dysfunctional telomeres.

breaking chromosomes appear during anaphase (Fig. 2). A sharp increase in anaphase bridges was observed during liver regeneration and in early tumours of mTERC–/– mice, pointing to a mechanism of tumour initiation in response to telomere shortening [44,52]. Together, these data suggest that telomere shortening has a dual role in cancer formation. On the one hand, telomere shortening induces CIN and tumour initiation. On the other hand, telomere shortening suppresses progression of tumours, which instead need to stabilize telomere ends to avoid an overload of instability and cancer cell death (Fig. 3). This suggests that telomere shortening during ageing and chronic (liver) disease could contribute to the increased rate of tumour initiation observed in this clinical setting (see

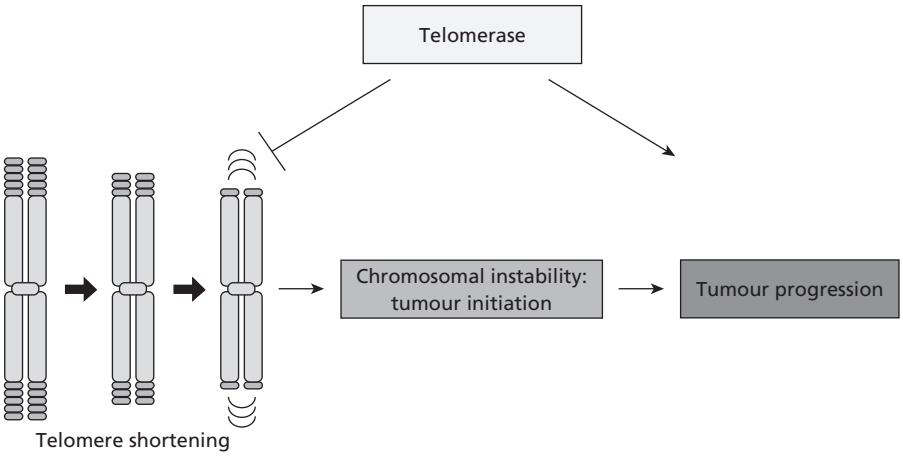

Fig. 3 Telomere shortening has a dual role in cancer. Telomere shortening causes chromosomal fusions and fusion–bridge–breakage cycles (Fig. 2) resulting in CIN and tumour initiation. However, tumour progression requires stabilization of telomere ends to limit ongoing CIN. The telomere hypothesis of HCC development indicates that telomeres shorten during chronic liver diseases and cirrhosis formation. This results in telomere dysfunction, CIN and HCC initiation. At this stage, massive CIN selects for reactivation of telomerase necessary for the stabilization of chromosomes.

Chapters 6.3 and 18.2.1). However, the tumours that evolve in response to telomere shortening apparently need to reactivate telomerase to stabilize telomeres and to prevent ongoing CIN to allow tumour progression. This model could explain the coexistence of critically short telomeres, CIN and high levels of telomerase activity prevalent in most human epithelial cancer cells including HCC [52]. In support of the hypothesis that telomere shortening leads to CIN and cancer initiation in human HCC, a strong correlation between telomere shortening and increase in copy number of chromosome 8 – a hallmark cytogenetic alteration in human HCC – was observed [57]. As tumour suppression in response to telomere shortening was linked to an activation of senescence signalling involving p53 (see above), it appeared a logical consequence that loss of p53 amplified the development of CIN and epithelial cancer initiation induced by telomere shortening in mTERC–/– mice [58]. Heterozygous deletion of p53 alleviated suppression of hepatocarcinogenesis in mice with short telomeres [59]. In humans, the p53 signalling pathway is defective in over 70% of HCC [60], indicating that there could be a cooperation between telomere shortening and loss of p53 function. The role of telomerase reactivation in tumours arising from cells with dysfunctional telomeres and mutant p53 has now to be investigated. Recent data in mouse models have revealed experimental evidence that massive telomere dysfunction induced apoptosis independent of p53 gene status [61], indicating that telomerase activation and telomere stabilization might be essential for tumour progression even in the absence of p53. In agreement with this assumption, it was found that oligonucleotide telomerase inhibitors impaired the growth of p53 mutant human hepatoma in a xenotransplant model [62].

Regarding the use of telomerase activators for improvement of hepatocyte regeneration at the cirrhosis stage (see above), it will be important to elucidate which of the mechanisms induced by telomere dysfunction – impaired regeneration, increased tumour initiation, impaired tumour progression – is dominantly affecting organismal survival. One mouse study has revealed that, in the setting of chronic liver damage, the negative impact of telomere shortening on liver regeneration outweighs the tumour suppressor effects of telomere shortening on hepatocarcinogenesis in terms of overall survival [63].

Outlook

Research work over the last decades has improved our understanding of the control of liver cell proliferation during regeneration, cirrhosis formation and hepatocarcinogenesis. In cancer, promising molecular therapies are now emerging. Similarly, it appears possible that the mechanisms of cell cycle control, telomere length control and senescence will translate into the development of new therapies to improve endogenous regeneration and cell transplantation therapies. Additional areas of interest are: (i) the development of biological ageing markers to improve individual therapies and the assessment of individual risk of disease progression; and (ii) the identification of markers indicating the risk of tumour development, thus allowing the optimization of tumour prevention and screening.

References

1 Fausto N (2004) Liver regeneration and repair: hepatocytes, progenitor cells, and stem cells. *Hepatology* 39 (6), 1477–1487.
2 Sherr CJ, Roberts JM (2004) Living with or without cyclins and cyclin-dependent kinases. *Genes Dev* 18 (22), 2699–2711.
3 Michalopoulos GK, DeFrances M (2005) Liver regeneration. *Adv Biochem Eng Biotechnol* 93, 101–134.
4 Zimmermann A (2004) Regulation of liver regeneration. *Nephrol Dial Transplant* 19 (Suppl 4), 6–10.
5 Liu H, Dibling B, Spike B *et al.* (2004) New roles for the RB tumor suppressor protein. *Curr Opin Genet Dev* 14 (1), 55–64.
6 Attwooll C, Denchi EL, Helin K (2004) The E2F family: specific functions and overlapping interests. *EMBO J* 23 (24), 4709–4716.
7 Mayhew CN, Bosco EE, Fox SR *et al.* (2005) Liver-specific pRB loss results in ectopic cell cycle entry and aberrant ploidy. *Cancer Res* 65 (11), 4568–4577.
8 Vodermaier HC (2004) APC/C and SCF: controlling each other and the cell cycle. *Curr Biol* 14 (18), R787–796.

9 Wirth KG, Ricci R, Gimenez-Abian JF *et al.* (2004) Loss of the anaphase-promoting complex in quiescent cells causes unscheduled hepatocyte proliferation. *Genes Dev* 18 (1), 88–98.

10 Diehl JA, Cheng M, Roussel MF *et al.* (1998) Glycogen synthase kinase-3beta regulates cyclin D1 proteolysis and subcellular localization. *Genes Dev* 12 (22), 3499–3511.

11 Nelsen CJ, Kuriyama R, Hirsch B *et al.* (2005) Short term cyclin D1 overexpression induces centrosome amplification, mitotic spindle abnormalities, and aneuploidy. *J Biol Chem* 280 (1), 768–776.

12 Nelsen CJ, Rickheim DG, Timchenko NA *et al.* (2001) Transient expression of cyclin D1 is sufficient to promote hepatocyte replication and liver growth in vivo. *Cancer Res* 61 (23), 8564–8568.

13 Geng Y, Whoriskey W, Park MY *et al.* (1999) Rescue of cyclin D1 deficiency by knockin cyclin E. *Cell* 97 (6), 767–777.

14 Nelsen CJ, Hansen LK, Rickheim DG *et al.* (2001) Induction of hepatocyte proliferation and liver hyperplasia by the targeted expression of cyclin E and skp2. *Oncogene* 20 (15), 1825–1831.

15 Carrano AC, Eytan E, Hershko A *et al.* (1999) SKP2 is required for ubiquitin-mediated degradation of the CDK inhibitor p27. *Nature Cell Biol* 1 (4), 193–199.

16 Sherr CJ, Roberts JM (1999) CDK inhibitors: positive and negative regulators of G1-phase progression. *Genes Dev* 13 (12), 1501–1512.

17 Geng Y, Yu Q, Sicinska E *et al.* (2003) Cyclin E ablation in the mouse. *Cell* 114 (4), 431–443.

18 Ortega S, Prieto I, Odajima J *et al.* (2003) Cyclin-dependent kinase 2 is essential for meiosis but not for mitotic cell division in mice. *Nature Genet* 35 (1), 25–31.

19 Martin A, Odajima J, Hunt SL *et al.* (2005) Cdk2 is dispensable for cell cycle inhibition and tumor suppression mediated by p27(Kip1) and p21(Cip1). *Cancer Cell* 7 (6), 591–598.

20 Wu H, Wade M, Krall L *et al.* (1996) Targeted in vivo expression of the cyclin-dependent kinase inhibitor p21 halts hepatocyte cell-cycle progression, postnatal liver development and regeneration. *Genes Dev* 10 (3), 245–260.

21 Kossatz U, Dietrich N, Zender L *et al.* (2004) Skp2-dependent degradation of p27kip1 is essential for cell cycle progression. *Genes Dev* 18 (21), 2602–2607.

22 Karnezis AN, Dorokhov M, Grompe M *et al.* (2001) Loss of p27(Kip1) enhances the transplantation efficiency of hepatocytes transferred into diseased livers. *J Clin Invest* 108 (3), 383–390.

23 Guidotti JE, Bregerie O, Robert A *et al.* (2003) Liver cell polyploidization: a pivotal role for binuclear hepatocytes. *J Biol Chem* 278 (21), 19095–19101.

24 Wang X, Kiyokawa H, Dennewitz MB *et al.* (2002) The Forkhead Box m1b transcription factor is essential for hepatocyte DNA replication and mitosis during mouse liver regeneration. *Proc Natl Acad Sci USA* 99 (26), 16881–16886.

25 Kalinichenko VV, Major ML, Wang X *et al.* (2004) Foxm1b transcription factor is essential for development of hepatocellular carcinomas and is negatively regulated by the p19ARF tumor suppressor. *Genes Dev* 18 (7), 830–850.

26 Eferl R, Ricci R, Kenner L *et al.* (2003) Liver tumor development. c-Jun antagonizes the proapoptotic activity of p53. *Cell* 112 (2), 181–192.

27 Behrens A, Sibilia M, David JP *et al.* (2002) Impaired postnatal hepatocyte proliferation and liver regeneration in mice lacking c-jun in the liver. *EMBO J* 21 (7), 1782–1790.

28 Blackburn EH (1991) Structure and function of telomeres. *Nature* 350 (6319), 569–573.

29 Griffith JD, Comeau L, Rosenfield S *et al.* Mammalian telomeres end in a large duplex loop. *Cell* (1999) 97 (4), 503–514.

30 Phan AT, Mergny JL (2002) Human telomeric DNA: G-quadruplex, i-motif and Watson–Crick double helix. *Nucleic Acids Res* 30 (21), 4618–4625.

31 Smogorzewska A, De Lange T (2004) Regulation of telomerase by telomeric proteins. *Annu Rev Biochem* 73, 177–208.

32 Allsopp RC, Chang E, Kashefi-Aazam M *et al.* (1995) Telomere shortening is associated with cell division in vitro and in vivo. *Exp Cell Res* 220 (1), 194–200.

33 Meyerson M, Counter CM, Eaton EN *et al.* (1997) hEST2, the putative human telomerase catalytic subunit gene, is up-regulated in tumor cells and during immortalization. *Cell* 90 (4), 785–795.

34 Nakayama J, Tahara H, Tahara E *et al.* (1998) Telomerase activation by hTRT in human normal fibroblasts and hepatocellular carcinomas. *Nature Genet* 18 (1), 65–68.

35 Allsopp RC, Harley CB (1995) Evidence for a critical telomere length in senescent human fibroblasts. *Exp Cell Res* 219 (1), 130–136.

36 Bodnar AG, Ouellette M, Frolkis M *et al.* (1998) Extension of life-span by introduction of telomerase into normal human cells. *Science* 279 (5349), 349–352.

37 Wege H, Le HT, Chui MS *et al.* (2003) Telomerase reconstitution immortalizes human fetal hepatocytes without disrupting their differentiation potential. *Gastroenterology* 124 (2), 432–444.

38 d'Adda di Fagagna F, Reaper PM, Clay-Farrace L *et al.* (2003) A DNA damage checkpoint response in telomere-initiated senescence. *Nature* 426 (6963), 194–198.

39 Satyanarayana A, Greenberg RA, Schaetzlein S *et al.* (2004) Mitogen stimulation cooperates with telomere shortening to activate DNA damage responses and senescence signaling. *Mol Cell Biol* 24 (12), 5459–5474.

40 Gire V, Roux P, Wynford-Thomas D *et al.* (2004) DNA damage checkpoint kinase Chk2 triggers replicative senescence. *EMBO J* 23 (13), 2554–2563.

41 Chin L, Artandi SE, Shen Q *et al.* (1999) p53 deficiency rescues the adverse effects of telomere loss and cooperates with telomere dysfunction to accelerate carcinogenesis. *Cell* 97 (4), 527–538.

42 Kirk KE, Harmon BP, Reichardt IK *et al.* (1997) Block in anaphase chromosome separation caused by a telomerase template mutation. *Science* 275 (5305), 1478–1481.

43 Wright WE, Shay JW (1992) The two-stage mechanism controlling cellular senescence and immortalization. *Exp Gerontol* 27 (4), 383–389.

44 Djojosubroto MW, Choi YS, Lee HW *et al.* (2003) Telomeres and telomerase in aging, regeneration and cancer. *Mol Cells* 15 (2), 164–175.

45 Lechel A, Manns MP, Rudolph KL (2004) Telomeres and telomerase: new targets for the treatment of liver cirrhosis and hepatocellular carcinoma. *J Hepatol* 41, 491–497.

46 Wiemann SU, Satyanarayana A, Tsahuridu M *et al.* (2002) Hepatocyte telomere shortening and senescence are general markers of human liver cirrhosis. *FASEB J* 16 (9), 935–942.

47 Rudolph KL, Chang S, Millard M *et al.* (2000) Inhibition of experimental liver cirrhosis in mice by telomerase gene delivery. *Science* 287 (5456), 1253–1258.

48 Satyanarayana A, Wiemann SU, Buer J *et al.* (2003) Telomere shortening impairs organ regeneration by inhibiting cell cycle re-entry of a subpopulation of cells. *EMBO J* 22 (15), 4003–4013.

49 Delhaye M, Louis H, Degraef C *et al.* (1999) Hepatocyte proliferative activity in human liver cirrhosis. *J Hepatol* 30 (3), 461–471.

50 Delhaye M, Louis H, Degraef C *et al.* (1996) Relationship between hepatocyte proliferative activity and liver functional reserve in human cirrhosis. *Hepatology* 23 (5), 1003–1011.
51 Tillmann HL, Manns MP, Rudolph KL (2005) Merging models of hepatitis C virus pathogenesis. *Semin Liver Dis* 25 (1), 84–92.
52 Satyanarayana A, Manns M, Rudolph K (2004) Telomeres and telomerase: a dual role in hepatocarcinogenesis. *Hepatology* 40 (2), 276–283.
53 Greenberg RA, Chin L, Femino A *et al.* (1999) Short dysfunctional telomeres impair tumorigenesis in the INK4a(delta2/3) cancer-prone mouse. *Cell* 97 (4), 515–525.
54 Gonzalez-Suarez E, Samper E, Flores JM *et al.* (2000) Telomerase-deficient mice with short telomeres are resistant to skin tumorigenesis. *Nature Genet* 26 (1), 114–117.
55 Rudolph KL, Millard M, Bosenberg MW *et al.* (2001) Telomere dysfunction and evolution of intestinal carcinoma in mice and humans. *Nature Genet* 28 (2), 155–159.
56 Farazi PA, Glickman J, Jiang S *et al.* (2003) Differential impact of telomere dysfunction on initiation and progression of hepatocellular carcinoma. *Cancer Res* 63 (16), 5021–5027.
57 Plentz R, Gebel M, Mann M *et al.* (2005) Telomere shortening correlates with increasing aneuploidy of chromosome 8 on a cellular level in primary human hepatocellularcarcinoma, *Hepatology* 42, 522–526.
58 Artandi SE, Chang S, Lee SL *et al.* (2000) Telomere dysfunction promotes non-reciprocal translocations and epithelial cancers in mice. *Nature* 406 (6796), 641–645.
59 Farazi PA, Glickmann J, Horner J *et al.* (2006) Cooperative interactions of p53 mutation, telomere dysfunction, and chronic liver damage in hepatocellular carcinoma. *Cancer Res* 66 (9), 4766–4773.
60 Tannapfel A, Busse C, Weinans L *et al.* (2001) INK4a-ARF alterations and p53 mutations in hepatocellular carcinomas. *Oncogene* 20 (48), 7104–7109.
61 Lechel A, Satyanarayana A, Ju Z *et al.* (2005) The cellular level of telomere dysfunction determines induction of senescence or apoptosis in vivo. *EMBO Rep* 6 (3), 275–281.
62 Djojosubroto MW, Chin AC, Go N *et al.* (2005) Telomerase antagonists GRN163 and GRN163L inhibit tumor growth and increase chemosensitivity of human hepatoma. *Hepatology* 42 (5), 1127–1136 .
63 Wiemann SU, Satyanarayana A, Buer J *et al.* (2004) Contrasting effects of telomere shortening on organ homeostasis, tumor suppression, and survival during chronic liver damage. *Oncogene* 24 (9), 1501–1509.

2.5.2 Regeneration of chronically injured liver

Anna Mae Diehl

As in other organs, maintenance of tissue integrity in the liver requires a balance between cell death and regeneration so that cells undergoing natural age-related apoptosis are replaced by healthy cells that maintain vital tissue-specific functions. Liver injury amplifies the rate and magnitude of cell death. Consequently, recovery from liver damage necessitates accentuated regenerative responses to restore liver architecture and function to the premorbid state.

The adult liver has tremendous regenerative capacity, as evidenced by complete reconstitution of functional liver mass within weeks of partial hepatectomy (PH) [1]. The regenerative response evoked by acute liver damage has been studied for decades. That work identified several factors that promote the proliferation of mature hepatocytes and delineated pathways that modulate hepatocyte cell cycle progression and viability (reviewed in [2,3]). Because regeneration of bile ducts and hepatic blood vessels following acute liver injury has been less well studied (reviewed in [4,5]), how replacement of those structures is coordinated with recovery of the hepatocyte mass is less certain. Nevertheless, because hepatic regeneration following acute injury has been the subject of numerous recent reviews, it will not be discussed extensively in this chapter. Rather, we will focus on mechanisms that mediate the regeneration of chronically injured livers.

Chronic liver damage results from insufficient regeneration

Chronic liver injury poses a significant health threat. Chronic liver damage is among the leading causes of premature death in adults [6,7]. Given that the liver typically regenerates completely following massive acute injury, it is curious that repetitive, seemingly milder, insults are often not completely repaired, leading to persistent (and sometimes progressive) liver damage. This observation raises the intriguing possibility that chronic liver damage is more attributable to subpar repair than to unusually severe injury.

That insufficient liver regeneration may play a key role in the pathogenesis of chronic liver damage of various aetiologies merits consideration. At first glance, this concept appears to contradict liver biopsy evidence of increased hepatocyte DNA synthesis in chronically damaged livers [8]. Although the latter finding suggests that a regenerative response is attempting to repair the injured tissue, it must not match the substantially increased rate of liver cell death because hepatocyte 'dropout', 'piecemeal necrosis', apoptosis and 'ballooning' (indicative of ongoing necrosis) generally predominate [9]. In addition, chronic liver injury itself sometimes results in replacement of hepatocytes and bile ducts with fibrous tissue. Thus, persistent liver injury appears gradually to deplete regenerative capacity, resulting in sustained loss of normal liver architecture and function.

Why liver regeneration falters during chronic injury is unclear. It is not known whether certain injuries also inhibit regeneration, or if some individuals are simply unable to mount a normal regenerative response to injury that is efficiently repaired by most others. Similarly, it is poorly understood how age, gender, diet, comorbid conditions and their treatments affect any given individual's hepatic regenerative capacity, thus changing the degree of liver damage that ensues during chronic exposure to a constant level of injury. All these questions have obvious clinical relevance. Thus, it is imperative that we learn more about the mechanisms that regulate the regeneration of chronically injured livers.

Unfortunately, research in this area is sparse. In contrast to acute liver regeneration studies that typically focus on proliferative responses of mature hepatocytes, most investigations of repair in chronically injured livers focus on fibrogenesis. Consequently, it is poorly understood how dying hepatocytes or cholangiocytes are replaced during chronic liver injury. Also unknown is how efforts to compensate for increased rates of hepatic epithelial cell death relate to fibrotic responses, including increased proliferation of hepatic stellate cells (HSC) and their activation to a more myofibroblastic phenotype. The remainder of this chapter will summarize information about mechanisms that mediate the replacement of various liver cell populations in chronically injured livers, highlighting differences between acute and chronic repair.

Mechanisms for hepatocyte replacement during liver injury

Proliferation of mature hepatocytes

Healthy livers

Mature hepatocytes rarely replicate in healthy adult livers. The low proliferative index matches the low prevalence of hepatocyte apoptosis. In health, there is a gradient of hepatocyte DNA synthesis across the liver lobule, with most proliferation occurring in periportal hepatocytes and least in hepatocytes near terminal hepatic venules [3]. This gradient may be driven by the progressive decline in proliferative activity in ageing progeny from resident, periportal progenitor cells [10]. Alternatively, the portal-to-central gradient of soluble, gut-derived hepatotrophic factors may be responsible for the fall off in proliferative activity [11,12]. Portal blood might also carry in precursor cells from the marrow-like environment of the spleen, which may provide a reservoir for exogenous liver progenitors [13]. The potential importance of portal venous factors (soluble or cellular) as regulators of basal levels of hepatocyte proliferation is supported by evidence that otherwise healthy livers atrophy when deprived of portal blood [12]. Also, hepatocyte proliferation normally fluctuates over the course of the day and is highest postprandially, when portal venous blood flow to the liver increases [14].

Acutely injured livers

Acute loss of liver mass generally elicits a robust proliferative response in residual healthy hepatocytes, as evidenced by dramatically increased rates of DNA synthesis and mitoses in mature-appearing (i.e. differentiated) adult hepatocytes after 70% PH or acute exposure to hepatotoxins [3]. However, the ultimate proliferative capacity of any given mature hepatocyte has been difficult to assess. In uninjured livers, most mature hepatocytes have exited proliferative phases of the cell cycle and live in a growth-arrested (G0) state. The extent to which some or all of these cells can re-enter the cell cycle and replicate after liver injury remains uncertain, despite decades of research.

When cultured in the presence of growth factors, primary adult hepatocytes proliferate poorly on most matrices, despite robustly upregulating prereplicative genes and DNA synthesis. Sparse proliferation may merely be an artefact of arduous isolation protocols or suboptimal culture conditions [3]. Indeed, hepatocyte transplantation experiments have generated support for the concept that mature hepatocytes generally retain considerable capacity for proliferation *in vivo*. In one study, labelled hepatocytes isolated from adult rat donor livers were transplanted directly into one lobe of a recipient rat's liver after ligating portal vein branches to the other lobes [15]. Deprived of portal blood flow, those segments involuted. Eventually, the entire liver mass was reconstituted by donor hepatocytes. Based on the number of hepatocytes that were transplanted, the authors concluded that a single hepatocyte can divide at least 34 times, giving rise to 1.7×10^{10} daughter cells. This implies that a single rat hepatocyte has the clonogenic potential to generate 50 adult rat livers. However, it is difficult to exclude the possibility that the donor liver cells used in these studies might have included progenitor cells.

Another widely cited argument for the high proliferative capability of mature hepatocytes is the adult liver's ability to regenerate completely after PH [1]. Indeed, the ancient Greek myth about Prometheus revolves around the liver's ability to regenerate after pieces of liver have been removed. To monitor the kinetics of DNA synthesis following PH, rats were partially hepatectomized and killed at various times during the first day and 1, 2, 3, 7 and 14 days after PH. One hour before killing, each rat was injected intraperitoneally with tritiated thymidine or bromodeoxyuridine to label newly synthesized DNA, and autoradiography or immunohistochemistry was done to calculate the hepatocyte labelling index during the previous hour [16,17]. These studies demonstrate that DNA synthesis (S phase) in mature hepatocytes begins at around 24 h, and the labelling index reaches its peak value of 3–4% on day 3 after PH. This represents a 26-fold (2600%) increase in the hepatocyte labelling index over basal, pre-PH values. During the same time, hepatocytes double their ploidy, suggesting that half the observed labelling index increase is due to DNA accumulation and half to cell division. If this interpretation is valid, then the hepatocyte production rate increases 13-fold during the initial 72 h after PH. However, the morphometry of regenerating livers suggests that hepatocyte proliferation may not be this robust because the hepatic acini increase in size by only about 15% during this time period. This is not sufficient to accommodate the number of hepatocytes that would be generated by an acute 1300% increase in proliferative activity [16]. This finding suggests that much of the acute post-PH increase in hepatocyte labelling index occurs because damaged hepatocyte DNA is being repaired. Nevertheless, some mature hepatocytes do proliferate after PH [3].

Traditionally, the PH model is considered to be a 'pure' model of regeneration because the remnant liver lobes are not directly manipulated (i.e. injured) at the time of PH [1]. However, serum aminotransferase levels usually increase after PH. Also,

careful inspection of liver sections typically reveals increased apoptotic bodies, as well as scattered foci of swollen hepatocytes, that are variably associated with haemorrhage and small cell infiltrates [18–20]. Thus, in many ways, PH resembles acute exposure to hepatotoxic drugs because both insults result in liver injury and abrupt loss of functioning hepatocytes. Subpopulations of surviving mature hepatocytes subsequently proliferate and the liver regenerates its mass within 10–14 days [21].

Chronically injured livers

In contrast to hepatocytes in healthy livers, mature hepatocytes in chronically injured livers exhibit markedly reduced and delayed proliferative responses to PH [22,23]. The replication defect appears to be intrinsic to the hepatocytes themselves, as primary hepatocytes isolated from chronically injured livers respond poorly to mitogens in cell culture [24]. The mechanisms for inhibited proliferative capacity are being elucidated, and seem to be related to chronic injury-related stress. Even very mild forms of chronic liver injury, such as steatosis, elicit such stress. Hepatocytes in fatty livers are chronically exposed to increased levels of inflammatory mediators, including tumour necrosis factor (TNF)α and interleukin (IL)-6, cytokines that promote hepatocyte replication in healthy livers. Chronic exposure to TNFα increases reactive oxygen species production and can also induce cellular apoptosis. Hepatocytes typically survive these threats by upregulating various antiapoptotic and antioxidant defences [25,26]. However, these survival mechanisms are apparently insufficient for complete protection because rates of hepatocyte apoptosis are increased in both experimental animals and patients with fatty livers [27,28], and surviving hepatocytes exhibit evidence of oxidative damage to nuclear and mitochondrial DNA [27].

Viable but damaged cells in chronically injured livers elicit various adaptive mechanisms, including the induction of stress-related kinases that activate cyclin-dependent kinase inhibitors to restrict cell cycle progression [23]. The resultant replicative senescence prevents the duplication of sublethally damaged hepatocytes, while preserving liver-specific functions. Although this is generally beneficial, it compromises the efficiency of liver regeneration by removing mature hepatocytes from the regenerative response. Hence, recovery from a superimposed injury (such as PH) is prolonged in fatty livers, and the liver remains damaged for longer.

Stress-related replicative senescence in mature hepatocytes is not a phenomenon that is restricted to chronic fatty liver diseases. Mature hepatocytes of mice that are genetically deficient in PARP, an important DNA repair enzyme, also exhibit replicative senescence [24]. Although the livers of young PARP-deficient mice appear grossly normal, closer inspection demonstrates accumulation of hepatocytes with damaged DNA. Following PH, induction of DNA synthesis in mature, PARP-deficient hepatocytes is significantly inhibited. Moreover, the rate of entry into S phase is markedly reduced when primary hepatocytes from PARP-deficient mice are cultured with mitogens. Given that cellular DNA damage triggers growth arrest, the findings in PARP-deficient mice are not surprising. Together with the results from mice with fatty livers [23], and patients with chronic viral hepatitis [9], these data demonstrate that most viable hepatocytes in chronically injured livers have sustained damage and become senescent. Consequently, mechanisms other than mature hepatocyte replication must be evoked to replace dying hepatocytes.

Hepatocyte hypertrophy and polyploidy

Hepatocytes enlarge (i.e. hypertrophy) in many chronic liver diseases. A report from Thorgeirsson's group [29] suggests that hepatic hypertrophy is a compensatory mechanism to restore normal liver mass when hepatocyte proliferation is inhibited. Rats that underwent PH after being treated with 5-fluorouracil to inhibit hepatocyte proliferation were able to recover liver mass without inducing hepatic DNA synthesis. The initial, acute restoration of liver mass was accomplished by enlargement (hypertrophy) of the periportal hepatocytes. However, the hypertrophied state was not stable because, once the DNA synthesis inhibitor was withdrawn, the enlarged hepatocytes entered the cell cycle, and normal liver structure and DNA content were re-established [29]. Therefore, hypertrophy of residual surviving hepatocytes appears to be a temporizing response that transiently boosts liver mass following a bout of hepatocyte death.

DNA replication without cell division (i.e. polyploidy) contributes to cellular hypertrophy. Polyploidy occurs whenever DNA damage outstrips base excision repair mechanisms [30]. This occurs following exposure to 5-fluorouracil and other DNA-damaging agents. Hepatocytes with non-lethal damage become arrested in G2 so that they can be repaired, while those that acquired irreparable DNA damage after exiting the G1 checkpoint are deleted. Even in healthy animals, acute liver injury evoked by PH increases the number of polyploid hepatocytes [31]. Sustained exposure to oxidative stress amplifies this response. Thus, hepatocyte polyploidy is increased in chronically injured livers, indicating that the proportion of mature hepatocytes that are capable of replication is reduced.

Differentiation of hepatic progenitors

Although replication of mature hepatocytes is severely crippled during chronic liver injury, atrophy is a relatively rare, late response to chronic injury. Hence, there must be other mechanisms to replace dead hepatocytes. Studies of liver biopsies from patients and animals with various aetiologies of chronic liver injury indicate that expansion and differentiation of hepatic progenitors are the predominant forces that maintain hepatocyte mass in chronically injured livers.

Even healthy adult livers contain progenitors [32]. These progenitor populations are heterogeneous [33]. Some are bipotential (i.e. capable of generating either cholangiocytes or hepatocytes), but whether any are more pluripotent is debated [34–37]. Thus, it is uncertain whether resident hepatic progenitors can generate other types of liver cells (e.g. endothelial cells, stellate cells, resident hepatic immune cells) or non-hepatic epithelia (e.g. pancreas, intestine, kidney, lung). Liver progenitor subpopulations might be replenished from extrahepatic sources, such as bone marrow, but the extent to which this occurs is also debated, as is the process involved (i.e. fusion or transdifferentiation) [38–42]. Whether or not any of these progenitors are true stem cells, capable of infinite self-renewal while generating progeny that differentiate into adult liver cells, is obscure.

Resident hepatic progenitors (oval cells)

Phenotype

To date, the best characterized hepatic progenitors are small cells with scant cytoplasm and an oval-shaped nucleus that reside along the canals of Hering. These cells have been dubbed 'oval cells', 'ductular cells' or 'neocholangiolar cells' based on their morphology and localization along structures that comprise the proximal portion of the intrahepatic biliary system [32,34,43,44]. Expansion of oval cells commonly occurs in various types of chronic liver injury, and is typically described by hepatic pathologists as 'ductular reaction' or 'neocholangiolar proliferation' [9,45–48]. Oval cells variably express poorly characterized cytokeratin antigens, such as OV-1 and OV-6, isoforms of pyruvate kinase (muscle pyruvate kinase; mpk) and γ-glutamyltransferase (γ-GT) that distinguish them from mature hepatocytes and cholangiocytes [49–51]. Some also express surface markers, including c-kit, Sca-1 and CD34, and chemokine receptors (CXCR-4) that are expressed by other types of progenitors [35,52–54]. That oval cells are capable of differentiating into cholangiocytes or hepatocytes is demonstrated by their ability to generate progeny that express biliary cytokeratins, such as CK19, or hepatocyte proteins, such as HNF-4α, α-fetoprotein and albumin [55,56].

Regulatory factors

Immunohistochemistry demonstrates that oval cells accumulate in the livers of patients with chronic viral hepatitis, autoimmune and congenital liver diseases and alcoholic and non-alcoholic fatty liver disease [9,45–48]. Similar cells accumulate in rodents with chronic liver disease [23]. Oval cell accumulation parallels fibrosis stage. Hence, the greatest expansion of oval cells occurs in cirrhotic livers, where oval cells typically localize near activated HSC [23,48]. This association may be driven by paracrine signalling, because HSC produce stem cell-derived factor (SDF)-1, the ligand for CXCR-4 that is expressed by oval cells [54]. Both cell types produce hedgehog (Hh) family ligands (unpublished data). Hh proteins are potent morphogens that promote the viability of various types of progenitor cells [37], including the endodermal progenitors that generate the embryonic liver bud [57]. Similar to other epithelial progenitors [37], some mouse oval cells and stellate cells from mice, rats and humans also express Patched, the cell surface receptor for Hh (unpublished data). Thus, oval cells and HSC may provide each other with important viability signals that permit each cell population to expand during chronic liver injury.

Origin and fate

Other than fairly circumstantial evidence that biliary damage induces oval cells to differentiate into cholangiocytes, and hepatocyte death provokes differentiation along the hepatocyte lineage [32], little is known about factors that determine oval cell fate. It is not known whether some oval cells are true stem cells, capable of infinite self-renewal, or if oval cells are merely progeny of a more stem cell-like progenitor that resides in the liver or some other tissue(s). Experiments with mice that have been rendered genetically deficient in telomerase suggest that stem-like cells do play a role in maintaining adult liver mass.

Because infinite self-renewal is a unique characteristic of stem cells, they require telomerase to repair chromosomal deletions that occur during DNA replication [58]. Consequently, telomerase activity is generally high in fetal tissues and falls with age [59]. However, there are significant tissue-related differences in this ageing response [60]. Adult rat, mice and human livers retain considerable telomerase activity [61]. In healthy adult livers, telomerase mRNA is detected in occasional sinusoidal cells and rare hepatocytes (but not in most mature hepatocytes and cholangiocytes). Injured livers have many more telomerase-positive cells, with frequent expression noted in sinusoidal cells and infiltrating mononuclear cells, and occasional expression in proliferative, ductular cells and hepatocytes [62,63].

Given these findings (and contrary to some studies cited earlier), it is unlikely that most mature hepatocytes can replicate indefinitely, and not surprising that widespread telomere shortening occurs in regenerating livers following the acute injury of PH [64]. Cells with critically shortened telomeres are senescent and never re-enter the cell cycle. Thus, following an acute injury, regeneration is accomplished by subpopulations of non-senescent cells with sufficient telomere reserves to support replication.

These non-senescent cells may encompass a spectrum of the more differentiated progeny of rare liver stem-like cells that persist into adulthood. If true, the latter are the 'seeds' that generate replacement hepatocytes to continuously replenish liver cells that are consumed during day-to-day hepatocyte turnover. The requirement for stem-like cells in adult livers was unmasked by provoking sudden massive hepatocyte loss in telomerase-deficient mice that cannot maintain their stem cell populations. Unlike normal mice, such mice become cirrhotic after experiencing a single insult that abruptly deletes a large number of hepatocytes (e.g. PH) [65]. In retrospect, similarly dismal

outcomes were reported in older studies that subjected adult rats to hepatic irradiation (another type of stem cell-depleting insult) prior to PH [66]. Inherited stem cell depletion that results from dysfunctional telomere maintenance also promotes cirrhosis in humans [67].

Together, these findings demonstrate that adult liver mass is maintained by progenitors that continuously differentiate to replace dying mature hepatocytes. This process is taxed when liver injury increases the death rate of more mature liver cells. Whether oval cells are the telomerase-expressing progenitors that fuel regeneration is unknown. It is also conceivable that liver progenitors may simply require factors produced by some other type of telomerase-positive stem cell.

Potential extrahepatic sources of hepatic progenitors

Bone marrow and umbilical cord blood harbour multipotent stem-like cells. Several laboratories have shown that transplantation of bone marrow- or cord blood-derived progenitors can rescue mice from various types of fatal, acute liver damage. Repopulation of recipient liver parenchyma with donor-derived hepatocytes has been demonstrated repeatedly [39,40,42,68–74]. However, the extent and duration of repopulation has varied widely among different reports. Few studies have examined whether reconstitution of the hepatocyte compartment is preceded by the appearance of donor-derived oval cells, and those that have looked report discrepant results.

Grompe and collaborators have presented compelling evidence that donor cells simply fuse with recipient hepatocytes to regenerate livers in their FAH-deficient mouse model of tyrosinaemia and liver failure [75,76]. However, the general relevance of these findings is uncertain because FAH deficiency damages progenitor cells [77]. Further confounding data interpretation in these experiments, donor bone marrow cells were obtained from animals with Fanconi's anaemia, another progenitor cell defect [78]. Thus, it is difficult to know whether fusion of progenitors and residual mature hepatocytes occurs predominantly when progenitors are defective or is a more typical response.

Studies of mice with other types of acute and chronic liver injury suggest that fusion is probably not a common phenomenon during liver regeneration [40,72,79,80]. These studies also demonstrate that differentiation of donor-derived cells into hepatocytes can definitely occur in living animals. These findings complement abundant data from cell culture experiments showing that bone marrow- and cord blood-derived progenitors can differentiate into functional hepatocytes [41,74]. Less certain is whether this generation of hepatocytes from extrahepatic progenitors evolves through oval cell-like intermediaries, and how often this mechanism is evoked during repair of acute or chronic liver injury. Thus, it remains conceivable that circulating stem-like cells mainly provide factors that optimize the differentiation and proliferation of resident liver progenitors, including oval cells.

Mechanisms that regulate cholangiocyte replacement

Proliferation of mature cholangiocytes

Evidence for DNA synthesis in bile duct cells (i.e. large cholangiocytes) after PH or carbon tetrachloride-induced liver injury demonstrates that, like mature hepatocytes, mature cholangiocytes can also proliferate under certain circumstances [81,82]. During post-PH liver regeneration, bile duct DNA synthesis is coincident with that of liver sinusoidal cells, following peak hepatocyte DNA synthesis by about a day. Studies in cultured cholangiocytes, as well as in experimental animals demonstrate that cholangiocyte proliferation is induced by some of the same factors that promote hepatocyte proliferation, including insulin, insulin-like growth factor, hepatocyte growth factor (HGF), IL-6 and epidermal growth factor (EGF). Also, like hepatocyte proliferation, cholangiocyte proliferation is inhibited by transforming growth factor (TGF)-β [83,84]. In addition to these factors, various neurohumoral factors regulate cholangiocyte proliferation. Vagotomy has potent antiproliferative effects on cholangiocytes, despite exacerbating cholangiocyte apoptosis induced by bile duct ligation [83]. Serotonin also inhibits cholangiocyte proliferation. In contrast, cholangiocytes proliferate in response to nerve growth factor (NGF), which increases spontaneously following bile duct ligation [84]. Estrogens also promote cholangiocyte proliferation, while estrogen antagonists, such as tamoxifen, inhibit it [85].

Cholangiocytes produce several growth-regulatory peptides, including HGF, IL-6 and NGF, and use these to autoregulate their proliferation [4,84]. Net proliferative activity appears to be governed by modulation of protein kinase A (PKA) and protein kinase C (PKC) signalling, with the former stimulating p42/p44 and p38 mitogen-activated protein kinases (MAPK) and cellular proliferation, while the latter inhibits these events. In addition to directly promoting proliferation, some trophic factors, such as taurocholate, also activate AKT and phosphatidyl-inositol-3 (PI3) kinase. The upregulation of these survival pathways enhances the actions of cholangiocyte mitogens.

HSC produce some of the neurohumoral factors and cytokines that regulate cholangiocyte growth. This is intriguing, particularly as the phenotype of stellate cells themselves is also modulated by these factors. Thus, it is likely that cross-talk between stellate cells and adjacent cholangiocytes regulates the response to bile duct injury.

Expansion and differentiation of cholangiocyte progenitors

Many types of acute and chronic liver injury (not merely injury that is restricted to bile ducts) are followed by proliferation of immature bile ductular cells. Some of these cells are bipotential hepatic progenitors (oval cells), and others are their immediate progeny (small cholangiocytes). It has even been suggested that

hepatocytes might transdifferentiate into hepatocytes during some types of bile duct injury [86]. Proliferation of immature ductular cells is most evident along the edges of portal triads, at the portal–parenchymal interface, where small ductular-like structures (i.e. neocholangioles) accumulate. As recovery proceeds, these structures disappear, presumably because the ductular cells that are differentiating along the cholangiocyte lineage migrate into bile ducts to replace dying mature cholangiocytes.

Chronic bile duct damage: cell death exceeds replacement

Given that mature cholangiocytes can proliferate, and adult livers normally contain progenitors for cholangiocytes, it is uncertain why ductopenia and bile duct strictures are consequences of certain types of chronic liver injury. Bile ducts are particularly vulnerable to damage from chronic immune attack, ischaemia and obstruction [4]. The relative contributions of increased cholangiocyte death rates and inhibited cholangiocyte replacement to eventual bile duct destruction remain largely unexamined. However, studies of liver biopsies from patients with primary biliary cirrhosis suggest that loss of cholangiocyte progenitors (i.e. defective repair) is important [87]. Such livers exhibit reduced numbers of canals of Hering, the most proximal portion of the bile drainage pathway with a cholangiocyte lining. Oval cells localize to canals of Hering. Thus, reduced numbers of these structures may signify a depletion of progenitor pools that are available to replace dying bile duct cells, leading to eventual ductopenia.

Mechanisms that regulate hepatic endothelial replacement

The hepatic endothelium is targeted for destruction during acute and chronic liver injury induced by ischaemia–reperfusion and hepatotoxins, including chemotherapeutic agents and ethanol. Endothelial damage also occurs in more obscure hepatic vasculopathies, such as Budd–Chiari syndrome, and during hepatic allograft rejection. Thus, endothelial cells must be replaced during repair of various types of liver injury. The mechanisms for this are poorly understood.

The endothelia of large blood vessels and many capillary beds are replenished by circulating endothelial progenitors, some of which are derived from bone marrow progenitors [88,89]. There has been relatively little research about the role of bone marrow-derived endothelial progenitors in maintaining (or restoring) hepatic vascular integrity. *In situ* analysis of donor and recipient cells following liver and bone marrow transplantation suggests that this may occur. However, whether or not circulating endothelial progenitors contribute significantly to endothelial repair in other settings has been debated [90,91].

Certain resident liver cells produce matrix molecules and soluble factors that regulate angiogenesis [5]. For example, HSC are rich local sources of leptin and vascular endothelial growth factor. Thus, it is conceivable that increased release of these factors by activated stellate cells in the subendothelial spaces of injured livers may stimulate the proliferation of residual mature endothelial cells and/or differentiation of nearby endothelial progenitors. Conversely, endothelial cells themselves express adhesion molecules and chemotactic molecules that recruit other types of cells, including bone marrow-derived endothelial progenitors, into the liver [92]. The hepatic sinusoidal endothelia might also elaborate signals that influence the phenotype of resident stellate cells. Pertinent to these points, Wanless and colleagues have suggested that endothelial dysfunction may contribute to the genesis of cirrhosis during chronic liver injury [93,94].

Mechanisms that regulate hepatic stellate cell replacement

Healthy livers

Virtually nothing is known about the mechanisms that maintain HSC populations in healthy livers. Even in uninjured livers, mesenchymal populations are composed of heterogeneous cell types [95–98]. The prototypical 'quiescent' HSC is retinoid rich and expresses several neural markers, such as glial fibrillary acidic protein and nestin, as well as desmin, a mesenchymal marker [99,100]. In uninjured livers, histological assessment of retinoid-rich sinusoidal cells suggests that the ratio of HSC to hepatocytes is relatively constant [100,101]. Long-term coculture studies of mature hepatocytes and HSC demonstrate that HSC processes can form tight junctions with hepatocytes, suggesting that cell-to-cell communication between hepatocytes and HSC may regulate the phenotypes of both cell types [102]. However, because standard isolation protocols do not yield perfectly pure populations of quiescent HSC [99], and standard culture conditions quickly activate HSC to a myofibroblastic phenotype that expresses α-smooth muscle actin (Asma) and type 1 collagen [95], characterization of the gene expression profile of truly quiescent HSC has proved difficult. Recently, Tsukamoto and colleagues reported culture conditions that appear to revert activated HSC to a more quiescent phenotype. Under such conditions, HSC resemble mature adipocytes, expressing transcription factors, such as PPARγ and C/EBP family members, that induce genes that promote lipid accumulation and inhibit the production of inflammatory mediators, type 1 collagen and smooth muscle cell markers, such as Asma [103].

Acute liver injury

During both acute and chronic liver injury, the liver accumulates HSC [98,104]. Following acute liver injury evoked by PH, HSC in the residual liver become activated to a myofibroblastic phenotype and proliferate [105–107]. In the rat, the onset of HSC proliferation lags behind that of the hepatocyte

compartment by ~ 24 h. Attempts to isolate HSC during the first few days following PH have demonstrated that acute liver injury dramatically accentuates the physical association that exists between hepatocytes and HSC. Thus, most HSC (and hepatocyte) preparations from post-PH livers are significantly contaminated with the other cell type [108]. This has confounded efforts to analyse the effect of acute liver injury on HSC gene expression.

Brenner and colleagues have used another strategy to address this question. Recently, they generated double transgenic mice that express genes that encode two different fluorescent markers (EGFP and RGFP) under the respective control of two promoters that transduce distinct genes that are induced during HSC activation (Asma and type 1 collagen) [98]. Consequently, EGFP and RGFP mark cells that have turned on gene expression of Asma and/or collagen in these double transgenic mice. Initial studies of the double transgenic mice have yielded somewhat unanticipated results. Namely, unlike cultures of primary HSC that coordinately upregulate Asma and collagen gene expression during spontaneous *in vitro* activation, transgenic mice respond to liver injury by accumulating cells that express Asma alone (without collagen induction), collagen alone (without Asma) and cells that co-induce both Asma and collagen. Only the last subpopulation matches the culture-activated HSC that have formed the basis of our current understanding of activated HSC. Much remains to be learned about the two other subpopulations and, at this point, it remains uncertain which subpopulation contains the prototypical 'quiescent' HSC that have acquired an activated phenotype. This is a critical issue because cells that are (+) for Asma or collagen I alone might also contribute to the repair of injured livers.

Chronic liver injury

A major difference between the HSC response to acute and chronic liver injury appears to be the duration of HSC activation [98]. Following circumscribed (acute) liver injury, proliferation of activated, myofibroblastic HSC occurs transiently because activated HSC ultimately undergo apoptosis [109]. Hence, apoptosis of injury-activated myofibroblastic HSC plays a major role in reducing the liver burden of these cells back to basal levels [110].

The fact that activated HSC survive at all, let alone proliferate transiently, is intriguing because the microenvironment of injured livers contains numerous noxious factors, including proapoptotic cytokines such as TGF-β. Activated HSC are not impervious to TGF-β because they express receptors for this cytokine and activate TGF-β-regulated signalling cascades to induce collagen gene expression [111]. However, unlike neighbouring hepatocytes, myofibroblastic HSC do not undergo growth arrest or apoptosis when confronted with TGF-β.

In endodermally derived tissues, such as the kidney and liver, cells that are resistant to TGF-β-mediated apoptosis are known to be involved in mesenchymal–epithelial transitions [112]. In fact, in the kidney, it is TGF-β-resistant cells with an epithelial lineage that are driven to acquire a fibroblastic phenotype when exposed to TGF-β (so-called 'epithelial-to-mesenchymal transition' or EMT). Removal of TGF-β or exposure to HGF promotes reversion of the fibroblastic-appearing cells to their more typical, epithelial phenotype ('mesenchymal-to-epithelial transition' or MET) [113]. At present, it is unproven whether similar events occur in the liver. However, the kidney data are certainly provocative given evidence that TGF-β promotes cirrhosis (i.e. accumulation of myofibroblastic cells at the expense of mature hepatocytes) [95,98], while HGF limits the accumulation of activated HSC [110] and promotes the reconstitution of the hepatic parenchyma after liver injury [114]. In this regard, it is important to recall the close physical association between activated, myofibroblastic HSC and oval cells (putative liver epithelial progenitors) in chronically injured livers. Might cirrhosis result from events that drive oval cells (or their progenitors) along a fibroblastic, as opposed to an epithelial, lineage (i.e. EMT)? Conversely, do treatments that promote 'reversal' of cirrhosis simply induce the opposite response (i.e. MET)? Research is needed to delineate the mechanisms that direct repair towards one, as opposed to the other, response.

Summary

This review has summarized evidence that liver remodelling (repair) is a daily event in healthy adults. 'Healthy' remodelling/repair involves both proliferation of mature liver cells and differentiation of their progenitors. Chronic liver injury stresses these responses, unmasking inefficiencies and deficiencies in mechanisms that are designed to balance the reconstitution of different liver cell populations, thereby preserving normal liver architecture and function. Chronic liver damage manifests when healthy remodelling/repair responses are broken. Chronic hepatitis, cirrhosis and hepatocellular carcinoma are extreme manifestations of dysfunctional repair.

References

1 Higgins GM, Andersen RM (1931) Experimental pathology of liver: restoration of liver of the white rat following partial surgical removal. *Arch Pathol* 12, 186–202.
2 Fausto N, Riehle KJ (2005) Mechanisms of liver regeneration and their clinical implications. *J Hepatobiliary Pancreat Surg* 12, 181–189.
3 Michalopoulos GK, DeFrances M (2005) Liver regeneration. *Adv Biochem Eng Biotechnol* 93, 101–134.
4 Strazzabosco M, Fabris L, Spirli C (2005) Pathophysiology of cholangiopathies. *J Clin Gastroenterol* 39, S90–S102.
5 Medina J, Arroyo AG, Sanchez-Madrid F *et al.* (2004) Angiogenesis in chronic inflammatory liver disease. *Hepatology* 39, 1185–1195.
6 Vong S, Bell BP (2004) Chronic liver disease mortality in the United States, 1990–1998. *Hepatology* 39, 476–483.
7 Adams LA, Lymp JF, St Sauver J *et al.* (2005) The natural history of nonalcoholic fatty liver disease: a population-based cohort study. *Gastroenterology* 129, 113–121.

8 Vemuru RP, Aragona E, Gupta S (1992) Analysis of hepatocellular proliferation: study of archival liver tissue is facilitated by an endogenous marker of DNA replication. *Hepatology* 16, 968–973.
9 Clouston AD, Powell EE, Walsh MJ *et al.* (2005) Fibrosis correlates with a ductular reaction in hepatitis C: roles of impaired replication, progenitor cells and steatosis. *Hepatology* 41, 809–818.
10 Zajicek G, Oren R, Weinreb MJ (1985) The streaming liver. *Liver* 5, 293–300.
11 Kennedy S, Rettinger S, Flye MW *et al.* (1995) Experiments in transgenic mice show that hepatocytes are the source for postnatal liver growth and do not stream. *Hepatology* 22, 160–168.
12 Schweizer W, Duda P, Tanner S *et al.* (1995) Experimental atrophy/hypertrophy complex (AHC) of the liver portal vein, but not bile duct obstruction, is the main driving forces for the development of AHC in the rat. *J Hepatol* 23, 71–78.
13 Fernandez-Salguero P, Pineau T, Hilbert DM *et al.* (1995) Immune system impairment and hepatic fibrosis in mice lacking the dioxin-binding Ah receptor. *Science* 268, 638–639.
14 Souto M, Llanos JM (1985) The circadian optimal time for hepatectomy in the study of liver regeneration. *Chronobiol Int* 2, 169–175.
15 Ilan Y, Roy-Chowdhury N, Prakash R *et al.* (1997) Massive repopulation of rat liver by transplantation of hepatocytes into specific lobes of the liver and ligation of portal vein branches to other lobes. *Transplantation* 64, 8–13.
16 Zajicek G, Arber N, Schwartz-Arad D (1991) Streaming liver. VIII: Cell production rates following partial hepatectomy. *Liver* 11, 347–351.
17 Werlich T, Stiller KJ, Machnik G (1998) Experimental studies on the stem cell concept of liver regeneration. *Exp Toxicol Pathol* 50, 73–77.
18 Kanashima R, Nagasue N, Kobayashi M *et al.* (1980) A comparative study of lysomal enzyme contents in blood and liver of rats following partial hepatectomy. *Hepatogastroenterology* 27, 448–456.
19 Colletti LM, Kunkel SL, Green M *et al.* (1996) Hepatic inflammation following 70% hepatectomy may be related to up-regulation of epithelial neutrophil activating protein-78. *Shock* 6, 397–402.
20 Greco M, Moro L, Pellecchia G *et al.* (1998) Release of matrix proteins from mitochondria to cytosol during prereplicative phase of liver regeneration. *FEBS Lett* 427, 179–182.
21 Chung H, Hong DP, Jung JY *et al.* (2005) Comprehensive analysis of differential gene expression profiles on carbon tetrachloride-induced rat liver injury and regeneration. *Toxicol Appl Pharmacol* 206, 27–42.
22 Yang SQ, Lin HZ, Mandal AK *et al.* (2001) Disrupted signaling and inhibition of liver regeneration in obese mice with fatty livers: implications for nonalcoholic fatty liver disease pathogenesis. *Hepatology* 34, 694–706.
23 Roskams T, Yang SQ, Koteish A *et al.* (2003) Oxidative stress and oval cell accumulation in mice and humans with alcoholic and non-alcoholic fatty liver disease. *Am J Pathol* 163, 1301–1311.
24 Yang S, Koteish A, Lin H *et al.* (2004) Oval cells compensate for damage and replicative senescence of mature hepatocytes in mice with fatty liver disease. *Hepatology* 39, 403–411.
25 Rashid A, Wu T-C, Huang CC *et al.* (1999) Mitochondrial proteins that regulate apoptosis and necrosis are induced in mouse fatty liver. *Hepatology* 29, 1131–1138.
26 Yang SQ, Zhu H, Li Y *et al.* (2000) Mitochondrial adaptations to obesity-related oxidant stress. *Arch Biochem Biophys* 378, 259–268.
27 Gao D, Wei C, Chen L *et al.* (2004) Oxidative DNA damage and DNA repair enzyme expression are inversely related in murine models of fatty liver disease. *Am J Physiol Gastrointest Liver Physiol* 287, G1070–1077.
28 Feldstein AE, Gores GJ (2005) Apoptosis in alcoholic and non-alcoholic steatohepatitis. *Front Biosci* 10, 3093–3099.
29 Nagy P, Teramoto T, Factor VM *et al.* (2001) Reconstitution of liver mass via cellular hypertrophy in the rat. *Hepatology* 33, 339–345.
30 Strathdee G, Sansom OJ, Sim A *et al.* (2001) A role for mismatch repair in control of DNA ploidy following damage. *Oncogene* 20, 1923–1927.
31 Zajicik G, Schwartz-Arad D, Bartfeld E (1989) The streaming liver. V: Time and age-dependent changes of hepatocyte DNA content, following partial hepatectomy. *Liver* 9, 164–171.
32 Fausto N (2004) Liver regeneration and repair: hepatocytes, progenitor cells, and stem cells. *Hepatology* 39, 1477–1487.
33 Thorgeirsson SS, Grisham JW (2003) Overview of recent experimental studies on liver stem cells. *Semin Liver Dis* 23, 303–312.
34 Novikoff PM, Yam A (1998) Stem cells and rat liver carcinogenesis: contributions of confocal and electron microscopy. *J Histochem Cytochem* 46, 613–626.
35 Jensen CH, Jauho EI, Santoni-Rugiu E *et al.* (2004) Transit-amplifying ductular (oval) cells and their hepatocytic progeny are characterized by a novel and distinctive expression of delta-like protein/preadipocyte factor 1/fetal antigen 1. *Am J Pathol* 164, 1347–1359.
36 Liu C, Schreiter T, Dirsch O *et al.* (2004) Presence of markers for liver progenitor cells in human-derived intrahepatic biliary epithelial cells. *Liver Int* 24, 669–678.
37 Jones PH (1997) Epithelial stem cells. *Bioessays* 19, 683–690.
38 Austin TW, Lagasse E (2003) Hepatic regeneration from hematopoietic stem cells. *Mech Dev* 120, 131–135.
39 Grompe M (2003) The role of bone marrow stem cells in liver regeneration. *Semin Liver Dis* 23, 363–372.
40 Grove JE, Bruscia E, Krause DS (2004) Plasticity of bone marrow-derived stem cells. *Stem Cells* 22, 487–500.
41 Jang YY, Collector MI, Baylin SB *et al.* (2004) Hematopoietic stem cells convert into liver cells within days without fusion. *Nature Cell Biol* 6, 532–539.
42 Dalakas E, Newsome PN, Harrison DJ *et al.* (2005) Hematopoietic stem cell trafficking in liver injury. *FASEB J* 19, 1225–1231.
43 Oh SH, Hatch HM, Petersen BE (2002) Hepatic oval 'stem' cell in liver regeneration. *Semin Cell Dev Biol* 13, 405–409.
44 Saxena R, Theise N (2004) Canals of Hering: recent insights and current knowledge. *Semin Liver Dis* 24, 43–48.
45 Roskams T, Desmet V (1998) Ductular reaction and its diagnostic significance. *Semin Diagn Pathol* 15, 259–269.
46 Mandache E, Vidulescu C, Gherghiceanu M *et al.* (2002) Neoductular progenitor cells regenerate hepatocytes in severely damaged liver: a comparative ultrastructural study. *J Cell Mol Med* 6, 59–73.
47 Falkowski O, An HJ, Ianus IA *et al.* (2003) Regeneration of hepatocyte 'buds' in cirrhosis from intrabiliary stem cells. *J Hepatol* 39, 357–364.
48 Eleazar JA, Memeo L, Jhang JS *et al.* (2004) Progenitor cell expansion: an important source of hepatocyte regeneration in chronic hepatitis. *J Hepatol* 41, 983–991.
49 Tian YW, Smith PG, Yeoh GC (1997) The oval-shaped cell as a candidate for a liver stem cell in embryonic, neonatal and precancerous liver: identification based on morphology and immunohistochemical staining for albumin and pyruvate kinase isoenzyme expression. *Histochem Cell Biol* 107, 243–250.

50 Roskams T, De Vos R, Van Eyken P *et al.* (1998) Hepatic OV-6 expression in human liver disease and rat experiments: evidence for hepatic progenitor cells in man. *J Hepatol* 29, 455–463.

51 Libbrecht L, Desmet V, Van Damme B *et al.* (2000) The immunohistochemical phenotype of dysplastic foci in human liver: correlation with putative progenitor cells. *J Hepatol* 33, 76–84.

52 Crosby HA, Nijjar SS, de Goyet J de V *et al.* (2002) Progenitor cells of the biliary epithelial cell lineage. *Semin Cell Dev Biol* 13, 397–403.

53 Hatch HM, Zheng D, Jorgensen ML *et al.* (2002) SDF-1alpha/CXCR4: a mechanism for hepatic oval cell activation and bone marrow stem cell recruitment to the injured liver of rats. *Cloning Stem Cells* 4, 339–351.

54 Kollet O, Shivtiel S, Chen YQ *et al.* (2003) HGF, SDF-1, and MMP-9 are involved in stress-induced human CD34+ stemcell recruitment to the liver. *J Clin Invest* 112, 160–169.

55 Malhi H, Irani AN, Gagandeep S *et al.* (2002) Isolation of human progenitor liver epithelial cells with extensive replication capacity and differentiation into mature hepatocytes. *J Cell Sci* 115, 2679–2688.

56 Wang X, Foster M, Al-Dhalimy M *et al.* (2003) The origin and liver repopulating capacity of murine oval cells. *Proc Natl Acad Sci USA* 100(Suppl. 1), 11881–11888.

57 Deutsch G, Jung J, Zheng M *et al.* (2001) A bipotential precursor population for pancreas and liver with embryonic endoderm. *Development* 128, 871–881.

58 Henson NL, Heaton ML, Holland BH *et al.* (2005) Karyotypic analysis of adult pluripotent stem cells. *Histol Histopathol* 20, 769–784.

59 von Zglinicki T, Martin-Ruiz CM (2005) Telomeres as biomarkers for ageing and age-related diseases. *Curr Mol Med* 5, 197–203.

60 Prowse KR, Creider CW (1995) Developmental and tissue-specific regulation of mouse telomerase and telomere length. *Proc Natl Acad Sci USA* 92, 4818–4822.

61 Yamaguchi Y, Nozawa K, Savoysky EH *et al.* (1998) Change in telomerase activity of rat organs during growth and aging. *Exp Cell Res* 242, 120–127.

62 Ogami M, Ikura Y, Nishiguchi S *et al.* (1999) Quantitative analysis and in situ localization of human telomerase RNA in chronic liver disease and hepatocellular carcinoma. *Lab Invest* 79, 15–26.

63 Kotoula V, Hytiroglou P, Pyrpasopouloou A *et al.* (2002) Expression of human telomerase reverse transcriptases in regenerative and precancerous lesions of cirrhotic livers. *Liver* 22, 57–69.

64 Satyanarayana A, Wiemann SU, Buer J *et al.* (2003) Telomere shortening impairs organ regeneration by inhibiting cell cycle re-entry of a subpopulation of cells. *EMBO J* 22, 4003–4013.

65 Rudolph KL, Chang S, Millard M *et al.* (2000) Inhibition of experimental liver cirrhosis in mice by telomerase gene delivery. *Science* 287, 1185–1187.

66 Geraci JP, Jackson KL, Mariano MS *et al.* (1985) Hepatic injury after whole-liver irradiation in the rat. *Radiat Res* 101, 508–518.

67 Mason PJ, Wilson DB, Bessler M (2005) Dyskeratosis congenita – a disease of dysfunctional telomere maintenance. *Curr Mol Med* 5, 159–170.

68 Petersen BE, Bowen WC, Patrene KD *et al.* (1999) Bone marrow as a potential source of hepatic oval cells. *Science* 284, 1168–1170.

69 Theise ND, Badve S, Saxena R *et al.* (2000) Derivation of hepatocytes from bone marrow cells in mice after radiation-induced myeloablation. *Hepatology* 31, 235–240.

70 Avital I, Inderbitzin D, Aoki T *et al.* (2001) Isolation, characterization, and transplantation of bone marrow-derived hepatocyte stem cells. *Biochem Biophys Res Commun* 288, 156–164.

71 Gao J, Denni JE, Muzic RF *et al.* (2001) The dynamic *in vivo* distribution of bone marrow-derived mesenchymal stem cells after infusion. *Cells Tissues Organs* 169, 12–20.

72 Herzog EL, Chai L, Krause DS (2003) Plasticity of marrow-derived stem cells. *Blood* 102, 3483–3493.

73 Kucia M, Ratajczak J, Ratajczak MZ (2005) Bone marrow as a source of circulating CXCR4+ tissue-committed stem cells. *Biol Cell* 97, 133–146.

74 Laurson J, Selden C, Hodgson HJ (2005) Hepatocyte progenitors in man and in rodents – multiple pathways, multiple candidates. *Int J Exp Pathol* 86, 1–18.

75 Wang X, Willenbring H, Akkari Y *et al.* (2003) Cell fusion is the principal source of bone-marrow-derived hepatocytes. *Nature* 422, 897–901.

76 Vassilopoulos G, Wang PR, Russell DW (2003) Transplanted bone marrow regenerates liver by cell fusion. *Nature* 422, 901–904.

77 Zebrini C, Weinberg DS, Hollister KA (1992) DNA ploidy abnormalities in the liver of children with hereditary tyrosinemia type I. Correlation with histopathologic features. *Am J Pathol* 140, 1111–1115.

78 Li X, Leteurtre F, Rocha V *et al.* (2003) Abnormal telomere metabolism in Fanconi's anaemia correlates with genomic instability and the probability of developing severe aplastic anaemia. *Br J Haematol* 120, 836–845.

79 Theise ND, Krause DS (2002) Bone marrow to liver: the blood of Prometheus. *Semin Cell Dev Biol* 13, 411–417.

80 Jang YY, Sharkis SJ (2004) Metamorphosis from bone marrow derived primitive stem cells to functional liver cells. *Cell Cycle* 3, 980–982.

81 Tracy TF, Jr, Bailey PV, Goerke ME *et al.* (1991) Cholestasis without cirrhosis alters regulatory liver gene expression and inhibits hepatic regeneration. *Surgery* 110, 176–182; discussion 182–173.

82 LeSage GD, Glaser SS, Marucci L *et al.* (1999) Acute carbon tetrachloride feeding induces damage of large but not small cholangiocytes from BDL rat liver. *Am J Physiol* 276, G1289–1301.

83 de Groen PC, Vroman B, Laakso K *et al.* (1998) Characterization and growth regulation of rat intrahepatic bile duct epithelial cell line under hormonally derived serum-free conditions. *In Vitro Cell Dev Biol Anim* 34, 704–710.

84 LeSage GD, Glaser SS, Alpini G (2001) Regulation of cholangiocyte proliferation. *Liver* 21, 73–80.

85 Alvaro D, Alpini G, Onori P *et al.* (2002) Alfa and beta estrogen receptors and the biliary tree. *Mol Cell Endocrinol* 193, 105–108.

86 Michalopoulos GK, Barua L, Bowen WC (2005) Transdifferentiation of rat hepatocytes into biliary cells after bile duct ligation and toxic biliary injury. *Hepatology* 41, 535–544.

87 Saxena R, Hytiroglou P, Thung SN *et al.* (2002) Destruction of canals of Hering in primary biliary cirrhosis. *Hum Pathol* 33, 983–988.

88 Asahara T, Kawamoto A (2004) Endothelial progenitor cells for postnatal vasculogenesis. *Am J Physiol Cell Physiol* 287, C572–579.

89 Tavian M, Zheng B, Oberlin E *et al.* (2005) The vascular wall as a source of stem cells. *Ann NY Acad Sci* 1044, 41–50.

90 Fujii H, Hirose T, Oe S *et al.* (2002) Contribution of bone marrow cells to liver regeneration after partial hepatectomy in mice. *J Hepatol* 36, 653–659.

91 Stadtfeld M, Graf T (2005) Assessing the role of hematopoietic plasticity for endothelial and hepatocyte development by non-invasive lineage tracing. *Development* 132, 203–213.

92 Theuerkauf I, Zhou H, Fischer HP (2001) Immunohistochemical patterns of human liver sinusoids under different conditions of pathologic perfusion. *Virchows Arch* 438, 498–504.

93 Wanless IR, Shiota K (2004) The pathogenesis of nonalcoholic steatohepatitis and other fatty liver diseases: a four-step model including the role of lipid release and hepatic venular obstruction in the progression to cirrhosis. *Semin Liver Dis* 24, 99–106.
94 Ward NL, Haninec AL, Van Slyke P *et al.* (2004) Angiopoietin-1 causes reversible degradation of the portal microcirculation in mice: implications for treatment of liver disease. *Am J Pathol* 165, 889–899.
95 Friedman SL (2004) Stellate cells: a moving target in hepatic fibrogenesis. *Hepatology* 40, 1041–1043.
96 Pinzani M, Rombouts K (2004) Liver fibrosis: from the bench to clinical targets. *Dig Liver Dis* 36, 231–242.
97 Ramadori G, Saile B (2004) Portal tract fibrogenesis in the liver. *Lab Invest* 84, 153–159.
98 Bataller R, Brenner DA (2005) Liver fibrosis. *J Clin Invest* 115, 209–218.
99 Geerts A, Niki T, Hellemans K *et al.* (1998) Purification of rat hepatic stellate cells by side scatter-activated cell sorting. *Hepatology* 27, 590–598.
100 Senoo H (2004) Structure and function of hepatic stellate cells. *Med Electron Microsc* 37, 3–15.
101 Enzan H, Himeno H, Hiroi M *et al.* (1997) Development of hepatic sinusoidal structure with special reference to Ito cells. *Microsc Res Tech* 39, 336–349.
102 Riccalton-Banks L, Liew C, Bhandari R *et al.* (2003) Long-term culture of functional liver tissue: three-dimensional coculture of primary hepatocytes and stellate cells. *Tissue Eng* 9, 401–410.
103 She H, Xiong S, Hazra S *et al.* (2005) Adipogenic transcriptional regulation of hepatic stellate cells. *J Biol Chem* 280, 4959–4967.
104 Jin YL, Enzan H, Kuroda N *et al.* (2003) Tissue remodeling following submassive hemorrhagic necrosis in rat livers induced by an intraperitoneal injection of dimethylnitrosamine. *Virchows Arch* 442, 39–47.
105 Ramalho LN, Zucoloto S, Ramalho FS *et al.* (2003) Effect of antihypertensive agents on stellate cells during liver regeneration in rats. *Arq Gastroenterol* 40, 40–44.
106 Balabaud C, Bioulac-Sage P, Desmouliere A (2004) The role of hepatic stellate cells in liver regeneration. *J Hepatol* 40, 1023–1026.
107 Higashi N, Sato M, Kojima N *et al.* (2005) Vitamin A storage in hepatic stellate cells in the regenerating rat liver: with special reference to zonal heterogeneity. *Anat Rec A Discov Mol Cell Evol Biol* 286, 899–907.
108 Mabuchi A, Mullaney I, Sheard P *et al.* (2004) Role of hepatic stellate cells in the early phase of liver regeneration in rat: formation of tight adhesion to parenchymal cells. *Comp Hepatol* 3 (Suppl. 1), S29.
109 Rippe RA (1998) Life or death: the fate of the hepatic stellate cell following hepatic injury. *Hepatology* 27, 1447–1448.
110 Kim WH, Matsumoto K, Bessho K *et al.* (2005) Growth inhibition and apoptosis in liver myofibroblasts promoted by hepatocyte growth factor leads to resolution from liver cirrhosis. *Am J Pathol* 166, 1017–1028.
111 Date M, Matsuzaki K, Matsushita M *et al.* (2000) Modulation of transforming growth factor beta function in hepatocytes and hepatic stellate cells in rat liver injury. *Gut* 46, 719–724.
112 Valdes F, Alvarez AM, Locascio A *et al.* (2002) The epithelial mesenchymal transition confers resistance to the apoptotic effects of transforming growth factor Beta in fetal rat hepatocytes. *Mol Cancer Res* 1, 68–78.
113 Li Y, Yang J, Dai C *et al.* (2003) Role for integrin-linked kinase in mediating tubular epithelial to mesenchymal transition and renal interstitial fibrogenesis. *J Clin Invest* 112, 503–516.
114 Shiota G, Kunisada T, Oyama K *et al.* (2000) In vivo transfer of hepatocyte growth factor gene accelerates proliferation of hepatic oval cells in a 2-acetylaminofluorene/partial hepatectomy model in rats. *FEBS Lett* 470, 325–330.

2.6 Excretion

2.6.1 Physiology of bile formation

Martin Wagner and Michael Trauner

Physiological functions of bile

Bile secretion represents the exocrine function of the liver, which is accomplished by both hepatocytes and bile duct epithelial cells (cholangiocytes). Bile has several important physiological functions: it is critical for lipid digestion and absorption; it represents an important route of elimination for various endo- and xenobiotics; and it also has important trophic and immunological properties (Table 1).

Table 1 Physiological functions of bile.

Lipid digestion and absorption	Bile acids promote dietary lipid absorption in the small intestine by solubilizing lipids and their digestion products as micelles
Excretion of endobiotics	Elimination of excess cholesterol, conjugated bilirubin, aged proteins and metals
Excretion of xenobiotics	Elimination of lipophilic, highly protein-bound drugs, toxins and carcinogens after hepatic conversion into amphipathic metabolites
Mucosal defence	Achieved by antibacterial properties of bile acids and secretion of secretory IgA
Signalling properties	Bile acids regulate their own synthesis, biliary excretion and intestinal uptake, cholangiocyte proliferation and gallbladder secretory activity

Bile composition

Bile is a complex aqueous solution consisting of organic and inorganic solutes, the latter comprising mainly electrolytes found in similar concentrations as in plasma. Organic constituents include bile acids, bile pigments such as bilirubin, cholesterol, phospholipids and proteins such as albumin and immunoglobins (Ig) (Fig. 1, Table 2). Bile acids are synthesized from cholesterol in pericentral hepatocytes and – together with bile acids returning to the liver via the enterohepatic circulation – are actively secreted into bile [1]. In bile, they form mixed micelles with phospholipids and cholesterol, thereby promoting their biliary elimination. Formation of mixed micelles also lowers the detergent activity of monomeric bile acids in the bile

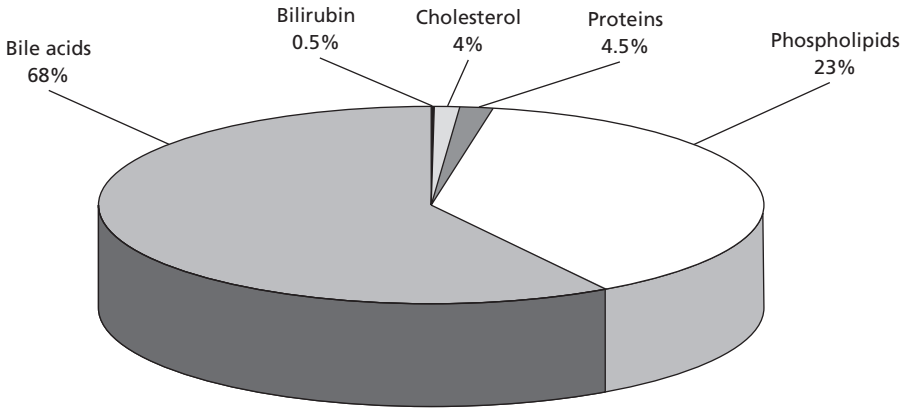

Fig. 1 Bile composition. Typical bile composition in healthy humans. Values are derived from Moseley RH (1996) Bile secretion and cholestasis. In: Kaplowitz N (ed.) *Liver and Biliary Disease*, 2nd edn. Baltimore: William & Wilkins, pp. 185–204.

Table 2 Bile composition.

Water
Organic anions
Bile acids, bilirubin, glutathione
Lipids
Cholesterol, phosphatidylcholine
Proteins, peptides, amino acids
Plasma proteins (e.g. albumin, IgA), hepatocellular enzymes (e.g. alkaline phosphatase)
Electrolytes
Na^+, K^+, Cl^-, HCO_3^-, Ca^{2+}, Mg^{2+}, SO_4^{2-}, PO_4^{2-}
Nucleotides
Adenosine triphosphate (ATP), diphosphate (ADP), monophosphate (AMP)
Heavy metals
Cu^{2+}, Mn^{2+}, Fe^{2+}, Zn^{2+}

duct lumen and prevents toxicity of high biliary bile acid concentrations (mM) to cholangiocytes [2]. The major bile pigment is bilirubin, the endproduct of haem metabolism. Unconjugated bilirubin is rapidly taken up by hepatocytes and converted into more hydrophilic glucuronides, which are then excreted and give bile its typical colour [3].

Lipid digestion and absorption

Bile acids promote dietary lipid absorption by solubilizing lipids as micelles in the small intestine. These absorptive micelles contain solubilized fatty acids and monoglycerides formed by the action of pancreatic enzymes on dietary triglycerides. Fat-soluble vitamins are also poorly absorbed without bile acids [1,4]. There are two reasons for the high intestinal concentrations of bile acids above their critical micellar concentrations required for solubilization of biliary lipids: bile acids are concentrated in the gallbladder; and cell membranes and paracellular junctions within the biliary systems are impermeable to ionized bile acids [1,4].

Excretory function

Bile is not only an important route of elimination for xenobiotics including drugs and their metabolites, environmental toxins and carcinogens, but also for endogenous compounds (termed endobiotics) such as cholesterol, bilirubin, sex steroids and metals including copper and iron. As the liver is equipped with phase I (hydroxylation) and phase II (conjugation) enzymes (e.g. P-450 cytochromes, sulphatases, glucuronidases), these compounds can be either detoxified (e.g. unconjugated bilirubin converted into bilirubin diglucuronide) or otherwise metabolized (e.g. cholesterol converted into bile acids) before being excreted into bile. As such, cholesterol excretion into bile is one of the most important routes for cholesterol elimination from the body. Per day, roughly 1.1 g of cholesterol is eliminated via faeces, of which one-third is converted to bile acids and two-thirds are excreted as neutral steroids [5].

Signalling

Bile components such as bile acids not only serve as detergents for the digestion and absorption of dietary lipids and vitamins, but also have a broad spectrum of signalling properties within the liver and following their excretion into the biliary tract and the intestine. As such, bile acids modulate the expression of genes involved in bile formation (e.g. induction of the bile salt export pump, BSEP) and bile acid metabolism (e.g. suppression of the rate-limiting enzyme of bile acid synthesis, cholesterol 7α-hydroxylase, CYP7A1) by binding and activating nuclear receptors such as the classical bile acid receptor farnesoid X receptor, FXR [5,6]. Moreover, bile acids can activate second messenger systems such as cyclic adenosine monophosphate (cAMP) and kinases such as protein kinase A (PKA), protein kinase C (PKC), phosphatidylinositol 3-kinase (PI3K) and mitogen-activated protein kinases (MAPK) (see below) [6,7]. This enables bile acids to regulate their own synthesis and excretion in hepatocytes, and to modulate cholangiocyte and intestinal functions such as cellular proliferation and enterohepatic circulation [5,8,9]. Bile acids can induce the production of intestinal factors that send signals to the liver: an important example is the fibroblast growth factor 15 (FGF15). It is produced in the intestine, reaches the liver via the portal circulation and binds to a hepatic FGF receptor (FGFR4). This cascade ultimately contributes to the negative feedback inhibition of bile acid synthesis [10].

Mucosal defence

Bile also plays a critical role in mucosal immunity of the intestine through biliary excretion of Ig and the antibacterial properties of bile acids. Secretory IgA aggregates bacteria, inhibits their motility and prevents their adherence to the epithelial cells [11]. Growth of anaerobes is readily suppressed by the unconjugated (but not conjugated) cholic acid (CA), chenodeoxycholic acid (CDCA) and ursodeoxycholic acid (UDCA) in the intestinal flora, while growth of aerobes is less affected. *In vitro* studies suggest that unconjugated dihydroxy bile acids [e.g. deoxycholic acid (DCA)] also have antibacterial activity against *Helicobacter pylori* [12]. Moreover, in addition to their detergent bacteriostatic activities, bile acids may limit intestinal bacterial overgrowth and translocation by transcriptional modulation of an inflammatory response via stimulation of the bile acid receptor FXR in the intestine [13]. Bile also contains significant amounts of the antioxidant tocopherol, which may prevent oxidative injury to the bile duct epithelium and intestine.

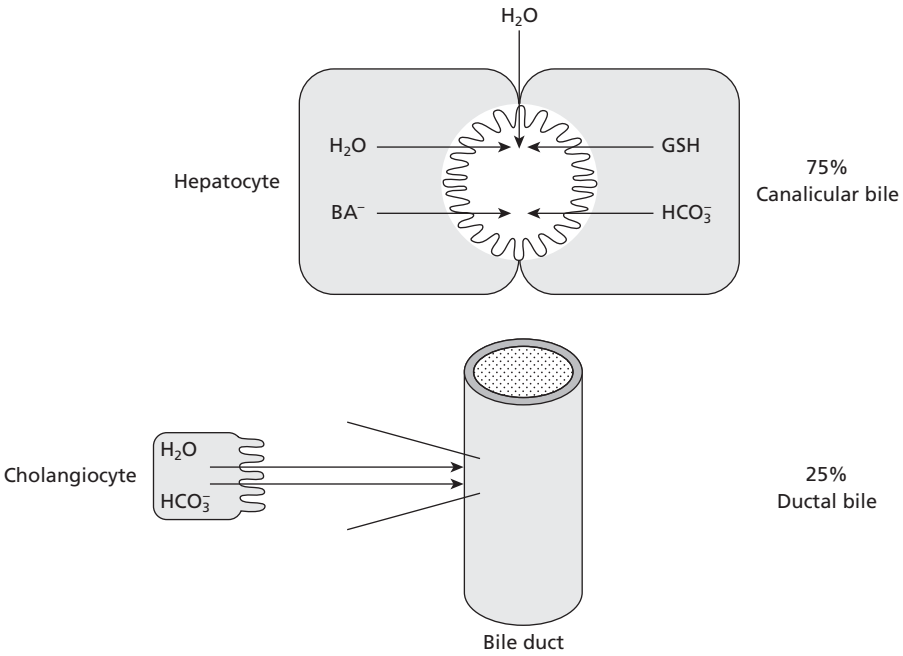

Fig. 2 Origin of bile. Seventy per cent of total bile production originates from hepatocytes. The majority of canalicular bile is formed by active excretion of bile acids (BA; bile acid-dependent fraction). Hepatocellular bicarbonate (HCO_3^-) and glutathione (GSH) secretion are the major constituents of the bile acid-independent fraction. Depending on species, up to 30% of bile comes from bile ducts, with HCO_3^- accounting for the most relevant proportion. Water (H_2O) passively follows the osmotic gradients generated by the actively excreted biliary compounds at the level of hepatocytes and cholangiocytes.

General principles of bile secretion

Anatomical considerations

Bile is secreted into bile canaliculi, which are minute channels arranged as a network of tubuli between adjacent hepatocytes. The hepatocyte is a polygonal polarized cell with three functionally distinct membrane domains: the basal (sinusoidal) membrane comprising approximately 35% of the cell surface; the lateral (intercellular) membrane comprising 50%; and the apical (canalicular) membrane constituting about 15% of the cell surface. As the endothelial cells of hepatic sinusoids are fenestrated, the sinusoidal membrane is in direct contact with plasma via the space of Disse. The sinusoidal membrane contains uptake systems for membrane-impermeable organic solutes that utilize sodium and pH gradients across the membrane. The canalicular membrane contains adenosine triphosphate (ATP)-dependent transporters that excrete organic solutes such as bile acids and glutathione into the canalicular lumen. Tight junctions seal off the bile canaliculi and separate the canalicular from the basolateral domain. The lipid composition of the canalicular membrane differs from that of the basolateral membrane, which explains its relative resistance to the detergent action of high concentrations of bile acids (mM) in bile. The canaliculi empty bile into small terminal bile ductules, termed canals of Hering and lined in part by cholangiocytes and hepatocytes; these are followed by intralobular ducts that are fully lined with cholangiocytes. After entering the portal tract, the interlobular ducts finally acquire a basal membrane and are supplied by a peribiliary vascular plexus. The interlobular ducts are followed by septal ducts, area ducts, segmental ducts and the hepatic right and left duct. Finally, bile is stored in the gallbladder (if present) and reaches the intestine via the common bile duct. Functionally, bile ducts can be divided into small (< 15-μm diameter) and large (> 15-μm diameter) ducts [8].

Osmotic principle of bile formation

Bile secretion is an osmotic process driven by active excretion of organic solutes (i.e. mainly bile acids, bicarbonate, glutathione), which is coupled to passive para- and transcellular inflow of water and filterable solutes (e.g. electrolytes, glucose, amino acids) until an osmotic equilibrium is achieved (Fig. 2). As tight junctions between the hepatocytes are negatively charged, cations can passively follow the actively excreted anions into bile canaliculi, while the negative charges of the tight junctions prevent backdiffusion of the excreted anions. In contrast to renal excretion, hydrostatic filtration (as occurs in glomeruli) does not play a role in bile formation [14]. Up to 95% of bile consists of water, which can cross the plasma membrane through the lipid portion of the bilayer by diffusion or through aquaporin water channels (AQPs) in response to the osmotic gradients generated by the active transport of solutes. In contrast to previous assumptions, the transcellular route for water accounts for most of the water flux with only a minimal paracellular contribution via the tight junctions. Transcellular water movement across cholangiocytes can be 10 times higher than in hepatocytes [15].

Canalicular and ductal bile formation

Normal bile production in man accounts for approximately 600 mL/day. Bile is primarily secreted at the level of bile canaliculi of hepatocytes (canalicular bile), followed by modifications

through the bile duct epithelium (ductal bile) (Fig. 2). This canalicular fraction accounts for ~ 75% of daily bile production in man and is further modified by secretory and absorptive processes as it passes along the bile ductules and ducts. The quantity of ductal bile varies significantly by species and in response to hormonal stimuli, ranging from as little as 5% in rats to as much as 25–40% of bile secretion in man [16]. Canalicular bile acid excretion is a saturable ATP-dependent process mediated by ATP-binding cassette (ABC) transporters for bile acids and non-bile acid organic anions, and represents the rate-limiting step in bile formation. Ductal modifications in bile composition only take place in ductules > 15 μm in diameter that express transport systems such as the cystic fibrosis transmembrane conductance regulator (CFTR) and hormone (e.g. secretin, vasoactive intestinal peptide) receptors [8,17,18]. Secretin is released after vagal stimulation and contact of acidic gastric content with the duodenal mucosa, resulting in induction of a bicarbonate-rich bile secretion from bile ducts and alkalinization of the biliary pH. The effects of secretin on ductal bile secretion are counteracted by other hormones such as gastrin and somatostatin [8,18].

Bile acid-dependent and -independent bile flow

Canalicular excretion of conjugated bile acids – the most abundant biliary organic solutes – represents the major driving force for the 'bile acid-dependent' fraction of bile flow (Fig. 3). Bile acids are highly concentrated up to 1000-fold in bile via active transport mechanisms from sinusoidal blood into bile, the major concentration step being from the cytoplasm into the bile canaliculus (~ 100-fold). In addition to their osmotic activity, bile acids promote canalicular phospholipid and cholesterol secretion and form mixed biliary micelles with them. Bile acids that do not form micelles and/or have a high critical micellar concentration (e.g. C23- or C22-nor-bile acids) have greater choleretic effects as they are osmotically more active. Hypercholeresis induced by nor-bile acids is mainly accompanied by ductal bicarbonate (HCO_3^-) secretion resulting from exchange to non-ionic diffusion of unconjugated bile acids across the bile duct epithelium (so-called 'cholehepatic shunting') [1,4].

Canalicular excretion of reduced glutathione (GSH) and HCO_3^- accounts for the major components of the 'bile acid-independent' fraction of bile flow [16] (Fig. 3). However, HCO_3^- secretion occurs mainly at the level of bile duct epithelial cells (cholangiocytes), in response to stimulation by hormones and neuropeptides such as secretin, vasoactive intestinal peptide and bombesin.

Enterohepatic circulation of bile acids and other biliary constituents

Many biliary compounds such as bile acids, bilirubin, estrogens or drugs undergo an intensive enterohepatic circulation, i.e. are reabsorbed in the intestine, taken up again by the liver and resecreted into bile (Fig. 4); some compounds repeat this cycle several times before being eliminated in the faeces. As a result of the high degree of intestinal bile acid conservation, only 0.5 g of bile acids are lost through faecal excretion and must be replaced by *de novo* bile acid synthesis, accounting for only 3–5% of the bile acids excreted into bile [1,4,5,19]. Unconjugated bile acids, which are reabsorbed after bacterial deconjugation in the intestine, are almost completely reamidated with glycine and taurine. The human bile acid pool circulates from 6 to 10 times a day, resulting in a daily bile salt excretion of 20–40 g. The human pool size accounts for approximately 50–60 μmol/kg body weight, averaging 3–4 g of bile acids in total. Bile acid concentrations in the bile canaliculus and ductules/ducts are in the range of 20–50 mmol/L and reach concentrations as high as 300 mmol/L in the gallbladder, whereas they are diluted to 1–10 mmol/L in

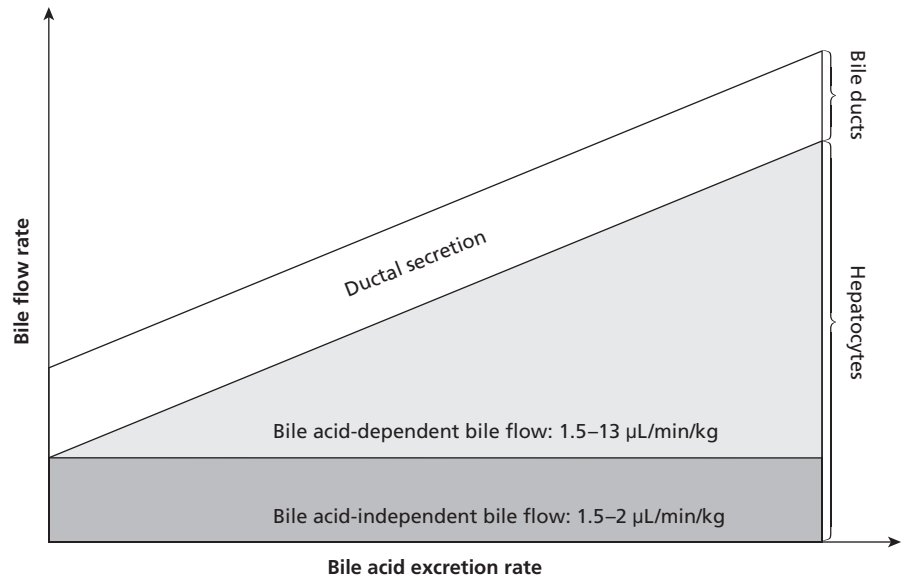

Fig. 3 Determinants of bile flow. Hepatocellular/canalicular bile flow and ductal bile flow contribute to total bile flow. Canalicular bile flow consists of a bile acid-independent fraction and a bile acid-dependent fraction, the latter increasing as a function of bile acid excretion. Modified from Moseley RH (1996) Bile secretion and cholestasis. In: Kaplowitz N (ed.) *Liver and Biliary Disease*, 2nd edn. Baltimore: William & Wilkins, pp. 185–204, and Boyer JL (1986) Mechanisms of bile secretion and hepatic transport. In: Andreoli TE, Hoffman JF, Fanestil DD *et al*. (eds) *Physiology of Membrane Disorders*, 2nd edn. New York: Plenum Publishing, pp. 609–636.

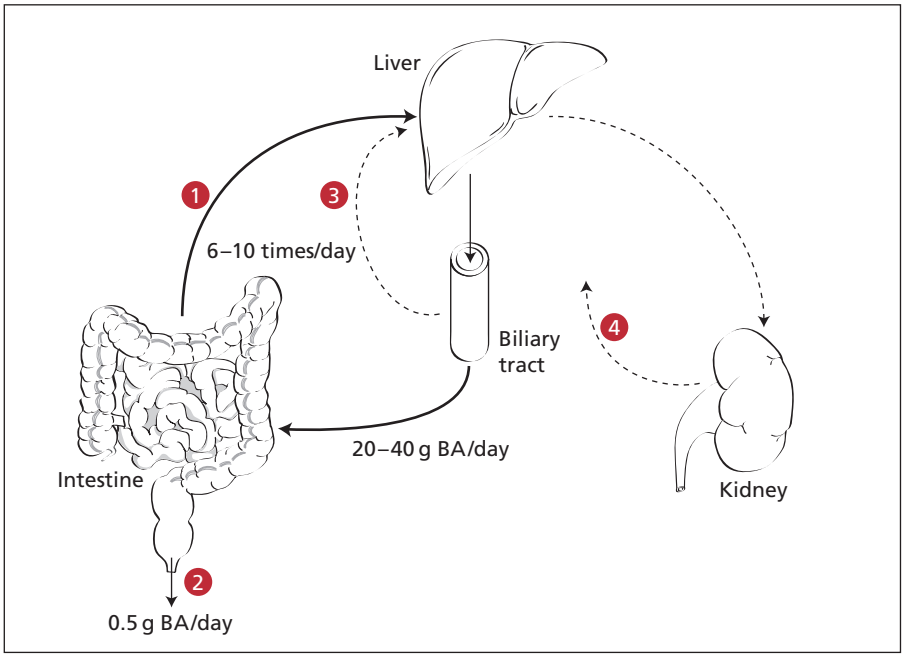

Fig. 4 Enterohepatic circulation of bile acids (BA). Bile acids circulate from 6 to 10 times a day between liver and intestine. The liver excretes 20–40 g of bile acids per day into the biliary tract, which are reabsorbed in the terminal ileum and taken up again by the liver (1). Only 0.5 g are lost via faeces (2) and must be replaced by *de novo* synthesis in the liver. (3) Cholehepatic shunting from cholangiocytes via the peribiliary plexus is quantitatively negligible under physiological conditions, but may become an important escape route for bile acids under cholestatic conditions. (4) Nephrohepatic shunting minimizes renal loss of glomerularly filterable bile acids that have escaped the first-pass clearance of the liver.

the gastrointestinal tract and – following their intestinal reabsorption – are as low as 20–50 μmol/L in the portal vein and only 5 μmol/L after efficient first-pass extraction in the systemic venous plasma [4].

Bile acids that escape the first-pass clearance by the liver are filtered at the glomerulus and excreted into urine, where they are reabsorbed by transporters in the brush border of the proximal convoluted tubule ('nephrohepatic' cycle between kidney and liver [4,20] (Fig. 4). Under normal conditions, urinary bile acid losses are minimal as a result of this renal bile acid conservation. However, some metabolic liver products are preferentially excreted into plasma and, subsequently, urine rather than bile, even under normal conditions. Under pathological, cholestatic conditions with disruption of the enterohepatic circulation, these pathways may be 'alternatively' used by biliary compounds not normally excreted into urine [21]. Bile acids may also undergo 'cholehepatic shunting' from the bile duct lumen, via cholangiocytes and the periductular capillary plexus, back to hepatocytes [20] (Fig. 4). Although this pathway plays a minor role for conjugated bile acids under normal physiological conditions, it may also become an important escape route under cholestatic conditions with bile stasis in obstructed ducts [20].

Hepatocellular mechanisms of bile secretion

Formation of canalicular bile includes: (i) uptake of biliary constituents at the basolateral/sinusoidal membrane; (ii) transcellular/intracellular transport; followed by (iii) canalicular excretion (Fig. 5). Bile formation normally depends not only on the proper function of hepatobiliary transport systems, but also on an intact cytoskeleton, as required for the movement of vesicles and bile canalicular contractions, cell junctions that seal off the bile canaliculi and maintain cell polarity, and signal transduction cascades that regulate and coordinate these processes [22] (Fig. 6).

Hepatocellular uptake of biliary compounds

Bile acids encounter the basolateral (sinusoidal) membrane of hepatocytes mostly in their albumin-bound form. While dihydroxy bile acids are almost completely albumin bound, protein binding decreases with the degree of bile acid hydroxylation [4]. Bile acid–albumin complexes pass the fenestrae of the sinusoidal epithelium into the space of Disse, where bile acids dissociate from albumin [23,24]. Bile acids are then efficiently removed from portal plasma by high-affinity, low K_m-transporting polypeptides in the basolateral sinusoidal membrane. Hepatic first-pass clearance of conjugated bile acids ranges from 75% to 90% depending on their biochemical structure [23]. Unconjugated bile acids enter the hepatocyte mainly by passive diffusion or via Na^+-independent mechanisms, while conjugated bile acids are taken up largely by Na^+-dependent mechanisms. Under normal conditions, bile acid uptake occurs mainly in periportal hepatocytes of zone 1. Under cholestatic or postprandial conditions with higher bile acid concentrations, hepatocytes are also recruited in zone 3. Hepatocytes in zone 1 are also more efficiently involved in the canalicular excretion of bile acids than those in zone 3. This indicates that, under physiological conditions, bile acid-dependent bile flow appears to be predominantly a function of zone 1 [23,25].

High-affinity Na^+-dependent bile salt uptake into hepatocytes is mediated by a Na^+/taurocholate cotransporter (NTCP/*SLC10A1*) whereas a family of multispecific organic anion transporters (OATPs/*SLC21A*) facilitate Na^+-independent bile

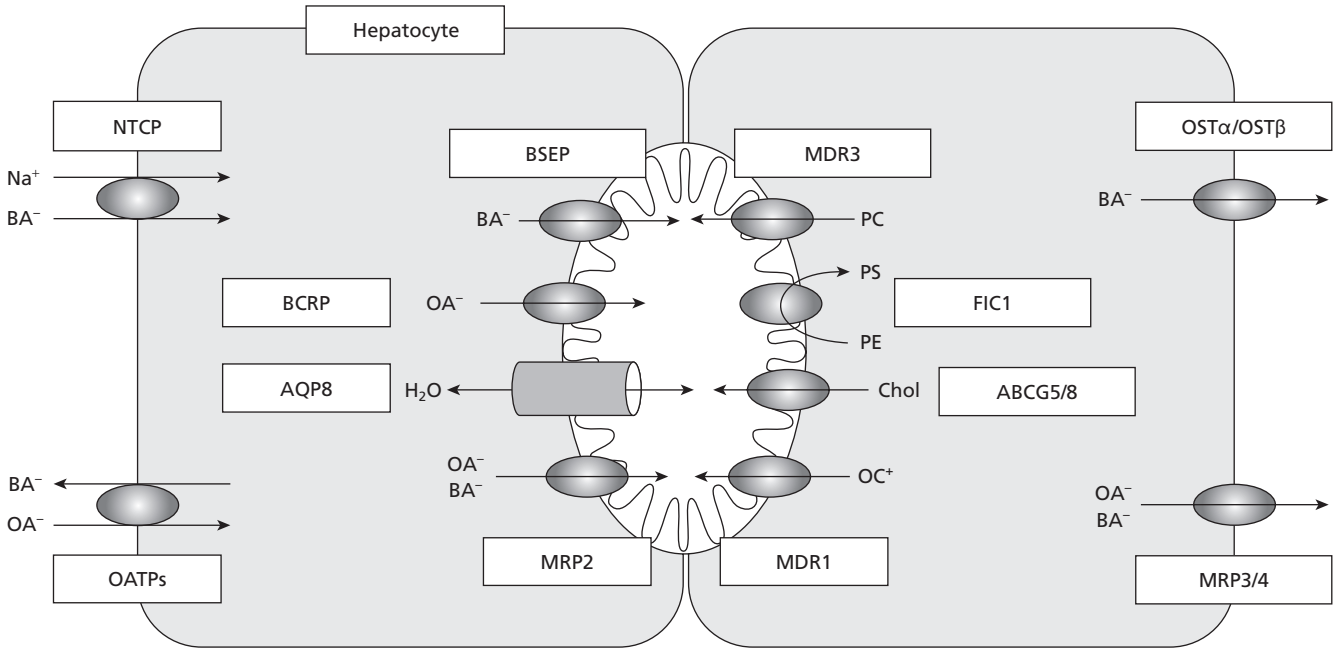

Fig. 5 Hepatocellular transport proteins. Bile acids (BA^-) and non-bile acid organic anions (OA^-) are taken up by the liver via the Na+/taurocholate cotransporter (NTCP) and organic anion transport proteins (OATPs) located at the basolateral membrane. On the canalicular pole, the bile salt export pump (BSEP) actively transports bile acids into the lumen and is the main determinant of the bile acid-dependent bile flow. The multidrug resistance-associated protein (MRP)2 actively excretes bilirubin, glutathione (GSH) and also certain divalent (e.g. glucuronidated and sulphated) bile acids. Water passively follows along an osmotic gradient mainly via water channels, termed aquaporins (AQP). Excretion of lipids is mediated by the multidrug resistance (MDR) protein MDR3, which flips phosphatidylcholine (PC) from the inner to the outer leaflet of the canalicular membrane, and by the two-half transporter ABCG5/8, which transports cholesterol (Chol). The definitive function of FIC1 is still unclear, but it may represent a flippase for aminophospholipids [phosphatidylserine (PS), phosphatidylethanolamine (PE)] from the outer to the inner lipid layer. Organic cations (OC+) and many drugs are effluxed via another member of the MDR family, MDR1. BCRP, breast cancer-related protein. Basolateral excretion of bile acids is mediated via the ABC transporters MRP3 and MRP4 and via the organic solute transporter OSTα/OSTβ.

acid uptake and mostly amphipathic organic compounds including conjugated and unconjugated bile acids [26] (Fig. 5). Na^+-independent bile acid uptake is quantitatively less important than Na^+-dependent uptake and is mediated by exchange with intracellular anions (e.g. GSH, HCO_3^-). In contrast to NTCP, OATPs are not restricted exclusively to hepatocytes, but are also expressed in multiple tissues including kidney, neuronal structures and intestine. Apart from conjugated and unconjugated bile acids, OATPs also have broader substrate preferences, including bilirubin, neutral steroids, eicosanoids, numerous xenobiotics and many more [27]. Additional basolateral uptake systems include organic anion transporters (OATs) and organic cation transporters (OCTs) [28].

In addition to these uptake systems, the basolateral membrane also contains efflux pumps. Members of the multidrug resistance-related proteins (MRPs) MRP3/*ABCC3* and MRP4/*ABCC4* are normally expressed at very low levels in hepatocytes (Fig. 5), but can be upregulated in cholestasis, which may explain the shift towards renal excretion of bile acids in patients with chronic, longstanding cholestasis [5]. Members of the OATP family also remain candidates for bile acid efflux at the basolateral membrane, as they may be able to operate as bidirectional exchangers. The heteromeric organic solute transporter alpha-beta, OSTα/OSTβ, represents another basolateral bile acid export system [29].

Intracellular transport of biliary compounds

The mechanisms of intracellular bile acid transport from the basolateral to the canalicular hepatocyte membrane are poorly understood. Two possible transfer mechanisms have been proposed: carrier-mediated diffusion and vesicular transport. For a given bile acid, the intracellular transport mechanism largely depends on its intracellular concentration, hydrophobicity and the affinity for intracellular binding proteins. Significant amounts of bile acids cannot exist in free (unbound) form in the cytoplasm, as their detergent properties would be toxic [23]. Under physiological conditions, the majority of amidated bile acids bind to intracellular bile acid-binding proteins and diffuse to the canalicular membrane along the prevailing basolateral → canalicular bile acid concentration gradient [26]. Bile acid-binding proteins also frequently have other (predominant) physiological functions. As such, 3α-hydroxysteroid dehydrogenase (3α-HSD), glutathione *S*-transferases (GST) and the liver fatty acid-binding proteins (L-FABP) have been implicated

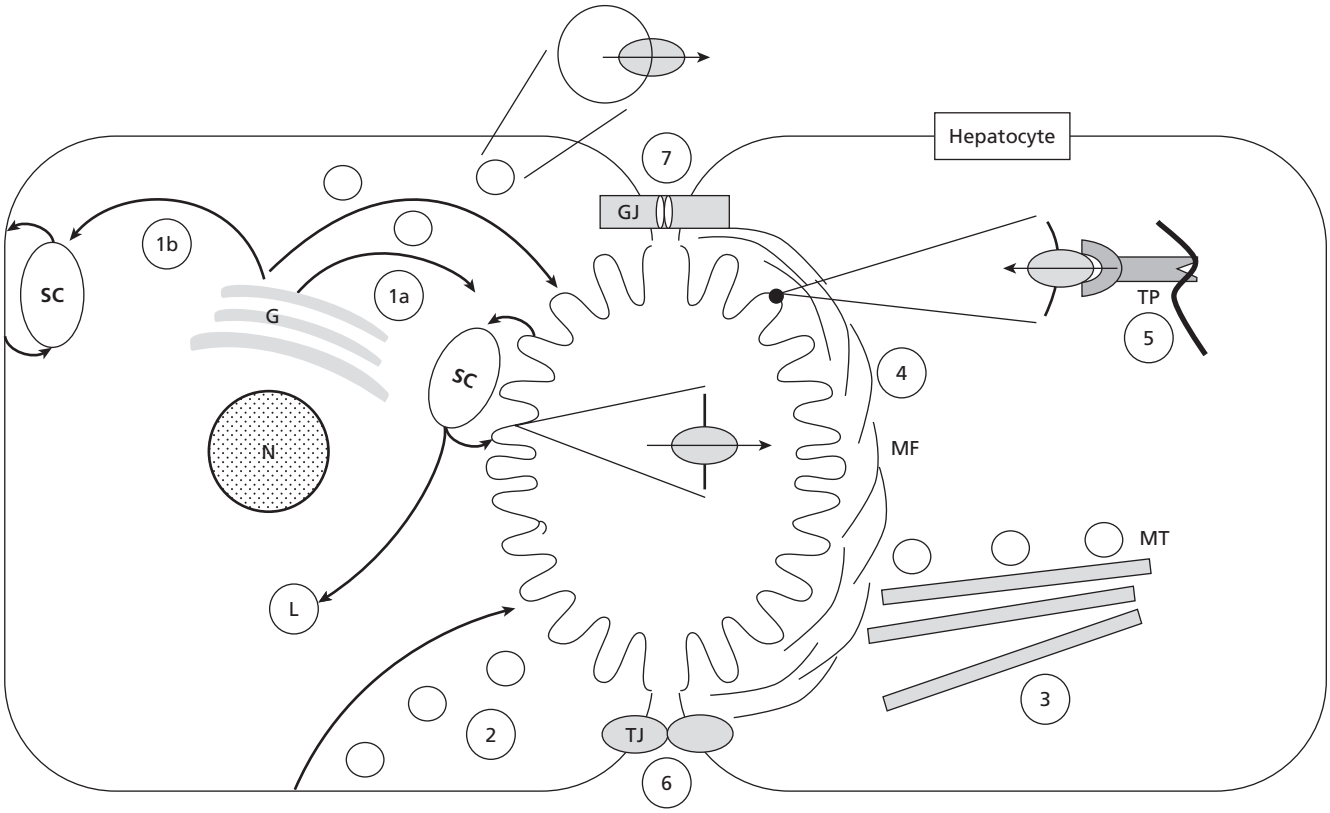

Fig. 6 Role of vesicular targeting, cytoskeleton and cell junctions for bile secretion. (1a) Vesicles containing canalicular transport proteins are either directly targeted from the Golgi apparatus (G) to the canalicular membrane or intermediately stored in a subapical compartment (SC) from which a rapid insertion into the canalicular membrane is possible. The other way around, there is retrieval from the canalicular membrane into the subapical compartment, possibly followed by lysosomal (L) and proteosomal degradation of the transport protein. (1b) Vesicular trafficking also occurs at the basolateral membrane. Similarly, transporter cycling between a submembranous compartment and the basolateral membrane can occur. (2) A microtubule-dependent transcytotic vesicular pathway mediates the transfer of solutes and proteins into bile. (3) Microtubules (MT) are also responsible for the transport of transporter-containing vesicles from the Golgi apparatus to the plasma membrane or a submembranous compartment. (4) The pericanalicular microfilament sheath (MF) consisting of an actin–myosin network mediates canalicular contractions, which in turn facilitate bile flow from pericentral to periportal regions. (5) Tethering proteins (TP) cross-link transport proteins with actin filaments. (6) Tight junctions (TJ) seal off the canalicular space and prevent regurgitation of biliary constituents while (7) gap junctions (GJ) facilitate intercellular communication. N, nucleus.

as hepatocellular bile acid-binding proteins for their intracellular transfer [30].

The more hydrophobic bile acids are, the more they tend to depend on vesicular trafficking for their transcellular transport. [31]. Thus, under high bile acid loads, hydrophobic bile acids (e.g. lithocholic acid) may accumulate within membrane-bound compartments and may be transported by vesicle-mediated mechanisms. As the evidence for vesicular transport has mostly been obtained indirectly from (microtubule) inhibition studies, the results could also reflect impaired targeting of transporters rather than 'true' direct vesicular transport of biliary constituents [7,32].

Canalicular mechanisms of bile secretion

Canalicular bile secretion represents the rate-limiting step in bile formation. Most canalicular transporters belong to the class of ATP-binding cassette (ABC) transporters (see Chapter 2.2.4) such as the multidrug resistance (MDR) P-glycoproteins (ABCB subfamily) or the MRP (ABCC subfamily) [5] (Fig. 5). As such, the canalicular membrane contains a bile salt export pump (BSEP/*ABCB11*) for monovalent bile acids, a conjugate export pump (MRP2/*ABCC2*) for divalent bile acids and various other amphipathic conjugates, including bilirubin diglucuronide and GSH (a major determinant of bile acid-independent canalicular bile flow), and a multidrug export pump (MDR1/*ABCB1*) for bulky amphipathic organic cations (e.g. various drugs) (Fig. 5) [5,9]. Another transport system is the breast cancer-related protein (BCRP/*ABCG2*) for sulphated conjugates, including dehydroepiandrosteronesulphate and estrone-3 sulphate. After secretion, biliary bile acids drive the secretion of phosphatidylcholine and cholesterol from the outer leaflet of the canalicular membrane. The continuous transport of phospholipids from the inner to the outer leaflet is mediated by the murine

phospholipid flippase Mdr2/*Abcb4* or its human orthologue MDR3/*ABCB4* [2,33]. Biliary cholesterol transport was long thought to be passive, but recent studies suggest a role for the sterol half-transporters ABCG5/8, which also mediate efflux of plant sterols such as sitosterol [34]. The relevance of these transporters is exemplified by the development of severe cholestasis as a result of hereditary defects in the various transport systems [35].

Under physiological conditions, bile acid and lipid excretion are tightly coupled. Bile acids solubilize phospholipids and cholesterol from the canalicular membrane. With increasing bile acid output and as a function of bile acid hydrophobicity, biliary phospholipid excretion increases [2]. Biliary phospholipids consist almost exclusively of phosphatidylcholine, while the canalicular membrane also contains sphingomyelin, phosphatidylserine and -etholamine, which are critical determinants of membrane polarity and fluidity [2]. Mdr2/MDR3 is a specific flippase for phosphatidylcholine but not sphingomyelin and phosphatidylserine and -etholamine. A common hypothesis for coupled bile acid–phospholipid excretion suggests that the translocation of phospholipids to the outer canalicular leaflet results in phospholipid-rich, less rigid microdomains. Simultaneously, ongoing bile acid excretion via BSEP leads to high supramicellar concentrations of bile acids that further destabilize these microdomains. Phospholipid translocation then leads to the formation of vesicles that pinch off as vesicular structures [2,36]. The high biliary concentrations of phospholipids and cholesterol also protect cholangiocytes from the detergent effects of bile acids via the formation of mixed micelles. This is supported by findings in Mdr2 gene knockout mice (Mdr2–/–) [33], which develop sclerosing cholangitis attributed to the misbalance in the biliary bile acid/phospholipid ratio, resulting in a toxic bile that damages the bile duct epithelium [37].

Additional canalicular transporters include the putative aminophospholipid flippase FIC1/*ATP8B1*, mutations in which are responsible for familial intrahepatic cholestasis type 1 [5] and aquaporins (i.e. AQP8 on the canalicular membrane), water channels that mediate transcellular water transport (see above). The most relevant ATP-independent transporter at the canalicular membrane is a Cl^-/HCO_3^- exchanger (AE2/*SLC4A2*), which, together with MRP2, accounts for the largest part of the bile acid-independent canalicular bile fraction [5,9]. Taken together, AE2 and MRP2 are the major driving forces for bile acid-independent bile flow, while BSEP drives bile acid-dependent flow (Fig. 5).

Vesicular trafficking and bile formation

Movement of vesicles within hepatocytes (vesicular trafficking) serves: (i) to regulate the number of transporters within the cell membrane by targeting of transport and other membrane proteins to and from the cell surface; and (ii) to transport compounds contained within the vesicular lumen (transcytosis), for example, immunoglobulins, hydrophobic bile acids or hormones (Fig. 6). Rapid insertion and retrieval of canalicular transporters such as MRP2, Mdr2 (MDR3 in humans) and BSEP to and from the canalicular membrane are necessary to rapidly meet the varying demands of normal bile secretion. Canalicular ABC transporters reside within submembranous endosomal pools that can be mobilized in response to several stimuli such as bile acids themselves, hypo-osmolarity (resulting in cell swelling), pH changes (alkalinization), cAMP, activation of PKC, PI3K and MAPK [32]. Additive effects of bile acids and cAMP further suggest the existence of different intrahepatic pools for the recruitment of ABC transporters to the canalicular membrane, one mobilized by taurocholate, the other by cAMP. While Mdr1 and Mdr2 are directly targeted from the Golgi apparatus to the canalicular membrane, Bsep follows an indirect route via subapical intracellular pools before entering the canalicular membrane [32] (Fig. 6). Pulse–chase experiments have revealed that Bsep undergoes rapid cycling between the canalicular membrane and a subapical endocytotic compartment [38,39].

In addition to targeting and insertion, retrieval of transporters from the canalicular membrane is also a tightly regulated process [7]. Hyperosmolarity and other pathological stimuli such as endotoxin (lipopolysaccharide, LPS), cytokines, biliary obstruction, phalloidin and oxidative stress result in retrieval of membrane transporters with a reduction in the number of functional transporters in the canalicular membrane. The retrieved membrane transporters may initially undergo reinsertion from a subapical vesicular compartment, but are later degraded by the lysosomal or ubiquitin–proteasome pathway [5,7] (Fig. 6).

Recent evidence suggests that not only canalicular but also basolateral membrane transporters (e.g. Ntcp) are regulated by insertion and retrieval in a similar fashion. As such, Ntcp may recycle between the basolateral membrane and a submembranous pool [6,40]. Phosphorylation of specific tyrosine residues on the cytoplasmic tail of rat Ntcp appears to be involved in targeting of this basolateral transporter to this specific plasma membrane domain [5,40].

Role of cytoskeleton in bile formation

The importance of an intact cytoskeleton for bile formation (Fig. 6) is emphasized by findings in cholestasis, where cytoskeletal changes result in the loss of apical microvilli, diminished contractility of the canalicular membrane and impaired vesicle movement, and may contribute to the leakiness of tight junctions [22].

Microtubules (MTs)

Targeting of membrane components, transcytosis and canalicular exocytosis/endocytosis of vesicles ('vesicular trafficking') depend on intact MTs. Canalicular ABC transporters (e.g. Bsep, Mrp2, Mdr2) are targeted in tubulovesicular compartments that move along MTs [6,7,39,41]. Vesicle transport along MTs is driven by the motor proteins dynein and kinesin [41]. Bile acids

can interfere with the function of these motor proteins [42]. Stimulation of bile acid and other organic anion excretion can be abrogated by MT inhibitors such as colchicine and vinblastin [43], consistent with the notion that mobilization of additional transporters via vesicular trafficking depends on MTs.

Intermediate filaments (IFs)

These are expressed in hepatocytes as cytokeratin (CK) 8 and 18, which mechanically support the bile canaliculus as pericanalicular sheaths. The CK–IF network has long been considered a rather static structure for mechanical stability of hepatocytes; however, studies in gene knockout mice have revealed their importance for non-mechanical functions as well, such as modulation of toxic stress and apoptosis [44]. IF networks also provide a flexible intracellular scaffolding for actin and microtubules [45–47] and thus may be critical for normal bile formation.

Microfilaments

These are enriched in the pericanalicular area and form a contractile web around the canaliculus. Actin microfilaments provide contractile activity of the bile canaliculi and, therefore, play an important role in intrahepatic propulsion of bile. Disruption of microfilaments (e.g. by actin inhibitors such as cytochalasins B and D) results in dilatation of the bile canaliculi and cholestasis [45]. Under normal conditions, actin filaments are also intimately associated with tight junctions. Cholestasis interferes with this association, resulting in disturbed tight junction morphology and function [22]. Moreover, microfilaments are also involved in the regulation of hepatic bile acid uptake via translocation of the bile acid importer Ntcp from a submembranous endosomal compartment into the basolateral membrane [48]. Thus, targeting of Ntcp to the plasma membrane consists of two steps: (i) delivery of Ntcp to the region of the plasma membrane via MTs; and (ii) insertion of Ntcp into the plasma membrane, in a microfilament- and cAMP-sensitive fashion [48]. Impaired actin polymerization also inhibits cycling of Bsep from the canaliculus to its intracellular compartments [39].

Tethering proteins

These cross-link actin microfilaments and integral membrane proteins. The dominant protein of the ezrin–radixin–moesin family, radixin, interacts with the cytoplasmatic domain of the canalicular bilirubin export pump MRP2. Mice lacking radixin have lower canalicular Mrp2 and develop conjugated hyperbilirubinaemia, as radixin may be required for proper canalicular localization of Mrp2 [49]. However, radixin may also be essential for maintenance of the canalicular localization of other ABC transporters including Bsep, and plays a critical role in the general ultrastructure of the canalicular membrane. In addition, recent studies using yeast two-hybrid screens have identified HAX-1 – a cytoskeleton-associated, cortactin-interacting protein – as a binding partner of Bsep, Mdr1 and Mdr2; these studies suggest a role for HAX-1 in the internalization of BSEP, and possibly other ABC transporters, from the canalicular membrane [50]. With a similar approach, myosin II regulatory light chain was identified as playing a role in Bsep trafficking to the apical membrane [51]. This suggests that (at least for Bsep) different tethering proteins may be involved in insertion and retrieval. At the cholangiocyte level, binding of CFTR and Na^+/H^+ exchanger (NHE)3 to the actin cytoskeleton via the ezrin/EBP50 complex is essential for the reciprocal regulation of CFTR and NHE3 activities by PKA [52].

Cell junctions and bile formation

Cell junctions play a critical role in bile formation by maintaining cell polarization and osmotic gradients, as well as by participating in cell communication required for coordination of bile secretion (Fig. 6).

Tight junctions

Throughout the gastrointestinal tract, tight junctions create the paracellular barrier required to separate tissue spaces and maintain electrochemical gradients used for transport. In the liver, tight junctions form a 'blood–bile barrier', separating sinusoidal blood from the canalicular content. Tight junctions between the hepatocytes have a negative charge and are thus cation selective, preventing backdiffusion of the actively secreted anions. Localization and expression of major tight junction proteins [i.e. zonula occludens-1 (ZO-1) and occludin] are altered in cholestasis, resulting in increased paracellular permeability, regurgitation of biliary constituents into plasma and collapse of the osmotic gradient in the bile canaliculi [22,53].

Gap junctions

These are hexameric hemichannels that consist of connexin 26 and 32 in hepatocytes and allow cell-to-cell movement of solutes, ions, water and second messengers, providing an intercellular communication pathway. Cell-to-cell signalling via gap junctions thus provides a mechanism for coordinating the response of hepatocytes to external stimuli (e.g. hormones). This can be achieved via synchronized spread of hormone-induced Ca^{2+} waves [54]. Thus, gap junctions enable coordinated contractions of bile canaliculi from centrizonal to periportal hepatocytes through intercellular communication. Impaired gap junction communication and disturbed Ca^{2+} signalling may contribute to cholestasis [22].

Mechanisms of ductal bile formation

Bile ductules and ducts not only represent the collecting system for bile, but are also capable of modifying canalicular bile by secretory and reabsorbtive processes during passage through the intrahepatic biliary tree. Experiments in rats suggest that only larger bile ducts (> 15 μm diameter) contribute to ductal bile secretion, while small bile ducts remain 'passive' [8,55]. Bile duct epithelial cells (cholangiocytes) are equipped with

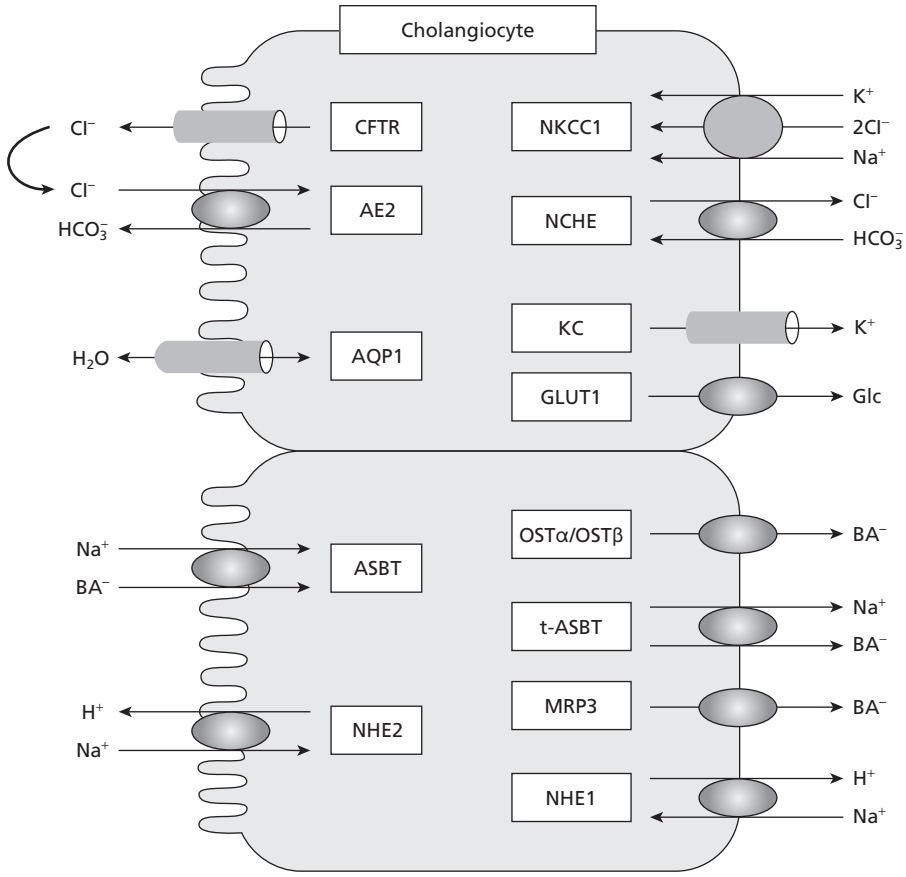

Fig. 7 Cholangiocellular transport proteins. The chloride/bicarbonate (Cl^-/HCO_3^-) anion exchanger (AE2) mediates ductular HCO_3^- excretion in exchange for Cl^-, which is extruded by the cystic fibrosis transmembrane conductance regulator (CFTR). Efflux of Cl^- generates a lumen-negative potential, which favours movement of Na^+ into the bile duct lumen through a paracellular pathway followed by water along the osmotic gradients via aquaporins (AQP). Ductal bile acid (BA^-) reabsorption is mediated via the apical sodium-dependent bile acid cotransporter ASBT; basolateral bile acid export is mediated by a truncated form of ASBT (t-ASBT), the multidrug resistance-associated protein (MRP)3 or organic solute transporter OSTα/OSTβ. HCO_3^- uptake is mediated via the basolateral Cl^-/HCO_3^- exchanger (NCHE). A Na^+-K^+-ATPase and K^+ channel (KC) maintain the Na^+ gradient and membrane potential difference. A $Na^+/K^+/2Cl^-$ cotransporter (NKCC1) actively imports Cl^- ions and is a major determinant of the consecutive apical fluid secretion. Reabsorption of glucose (Glc) is mediated via a basolateral glucose transporter (GLUT1). NHE, Na^+/H^+ exchanger.

transporters and hormone receptors required for their secretory and absorptive functions (Fig. 7). The majority of biliary bile acids is conjugated and absorbed in a Na^+-dependent manner via the apical bile acid transporter Asbt [56] (Fig. 7). Monomeric unconjugated bile acids and dihydroxy bile acids and C23 nor-dihydroxy bile acids can passively enter cholangiocytes in exchange for HCO_3^-, thus inducing a bicarbonate-rich hypercholeresis, a mechanism termed 'cholehepatic shunting' [21,23]. Conjugated bile acids can efflux to the plasma of the periductal capillary plexus [4] (Fig. 7). However, bile acid uptake into cholangiocytes may serve trophic and signalling functions of bile acids in cholangiocytes, rather than contributing to a cholehepatic shunting of conjugated bile acids under physiological conditions [57]. Still, cholehepatic shunting may play a role under cholestatic conditions to limit bile acid stasis in obstructed bile ducts [20].

The CFTR/*ABCC7* Cl^- channel and the Cl^-/HCO_3^- anion exchanger (AE2/*SLC4A2*) provide the molecular basis for ductal bile (bicarbonate) secretion and are expressed only in large bile ducts (Fig. 7). Apical Cl^- efflux is mediated by CFTR, a cAMP-dependent Cl^- channel that is encoded by *ABCC7* and activated by secretin via the second messenger cAMP [8,18]. In addition to cAMP-dependent CFTR, there are Ca^{2+}-dependent Cl^- channels that may represent important therapeutic targets in cystic fibrosis. Opening of Cl^- channels in the apical membrane leads to efflux of Cl^- and the generation of a lumen-negative potential, which favours movement of Na^+ into the bile duct lumen through a paracellular pathway and water via aquaporins. Moreover, the change in the apical Cl^- gradient facilitates HCO_3^- extrusion via AE2. Thus, bile undergoes increasing dilution and alkalinization as it traverses the bile duct system. In addition, the cholangiocyte contains several exchange systems mediating the movement of ions required for ductal bile secretions (Fig. 7). Cholangiocytes also reabsorb glucose and amino acids [8]. As in hepatocytes, vesicular trafficking and regulated insertion of transporters into the apical membrane play a critical role in bile formation [58]. For example, secretin induces exocytosis of preformed vesicles containing AQP1 and CFTR in cholangiocytes [18].

Modification of bile by gallbladder epithelium

In species that possess a gallbladder, most of the bile acid pool during the fasting state is stored in that organ, where bile acids are present in concentrations up to 300 mM [4]. Such high concentrations are achieved by removal of water and electrolytes

by the gallbladder epithelium via a Na^+/H^+ exchanger, which also results in acidification of bile. As the gallbladder epithelium is exposed to a much more aggressive biliary milieu for longer periods of time than the bile duct epithelium, mucins are required as an additional protective factor. Unconjugated bile acids can traverse the gallbladder epithelium by simple diffusion, while conjugated bile acids require active transport systems. As such, the human gallbladder epithelium contains bile acid and organic anion uptake systems such as ASBT and OATP-A, and exporters such as MRP2 and MRP3 [59,60]. Cholesterol secretion into the gallbladder lumen is mediated via ABCG5/8 [61].

Regulation of bile secretion

To meet physiological demands and daily variations, transcriptional and posttranscriptional mechanisms regulate hepatobiliary transport processes and bile formation. Rapid changes in bile secretory function are usually mediated by posttranscriptional events [e.g. insertion/retrieval of transporters, direct transporter modifications by phosphorylation (P) and phosphoinositide (PI)-3-kinase products (PI-P_{1-3})], while transcriptional changes have more delayed but long-term effects [7].

Transcriptional regulation

Ligand-activated nuclear (orphan) receptors (NRs) and liver-enriched transcription factors play a key role in the transcriptional regulation of hepatobiliary transport (Table 3) (also see Chapter 2.2.3). NRs are activated by biliary constituents (e.g. bile acids, bilirubin), lipid products (e.g. oxysterols) and xenobiotics and facilitate the positive feedforward and negative feedback regulation of hepatic transport and phase I/II metabolism of these compounds [62]. So far, three nuclear receptors have been shown to be activated by bile acids: the farnesoid X receptor FXR (*NR1H4*) by classic bile acids such as chenodeoxycholic acid, deoxycholic acid, lithocholic acid and cholic acid; the pregnane X receptor PXR (*NR1I2*) by lithocholic acid and potentially ursodeoxycholic acid; and the vitamin D receptor VDR (*NR1I1*) by hydrophobic bile acids such as lithocholic acid [62–64]. The constitutive androstane receptor CAR (*NR1I3*) is activated by bilirubin [20,63], but a role for bile acid sensing has been postulated. These are class II nuclear receptors, which heterodimerize with the retinoid X receptor alpha RXRα (*NR2B1*) before binding to distinct DNA response elements of target gene promoters. In addition to these ligand-activated nuclear receptors, other factors such as the hepatocyte nuclear factor (HNF) family of transcription factors, CCAAT/enhancer binding protein (C/EBP), sterol-responsive element binding protein (SREBP), signal transducers and activators of transcription (STAT) and nuclear factor kappa B (NFκB) also play an important role in the regulation of hepatobiliary transporter expression (Table 3). These transcription factors are activated by hormones, cytokines and their signalling cascades [5].

Posttranscriptional mechanisms

In addition to transcriptional regulation of transport systems, posttranscriptional and posttranslational changes such as targeting and sorting, transporter redistribution, transporter protein degradation (e.g. via lysosomal or the ubiquitin–proteasome pathway), direct protein modifications [e.g. (de-) phosphorylation, (de-) glycosylation], changes in membrane fluidity or *cis*-/*trans*-inhibition of transport systems by cholestatic agents (e.g. drugs) can also play an important role in the regulation of hepatobiliary transport [5–7,32].

Second messenger systems and bile secretion

Bile secretion by hepatocytes and cholangiocytes is rapidly regulated by the integration of signals from prosecretory/choleretic and antisecretory/cholestatic hormones (Table 4). Signals from these hormones are translated into activation of second messenger systems such as cAMP, cGMP and changes in cytosolic Ca^{2+} (for details see Chapter 2.2.3) [6,16]. Downstream kinases (e.g. PKA, PKC, MAPK, PI3K) in turn then further transduce these signals and alter target protein (i.e. transporter) function via phosphorylation/dephosphorylation. Some hormones (e.g. secretin, bombesin) act exclusively at the level of cholangiocytes because their receptors are only present on those cells and not on hepatocytes. In contrast, the glucagon and vasopressin receptors are selectively expressed on hepatocytes. In addition to hormones, gases (NO, CO) and bile acids themselves are capable of activating some of these signalling cascades (Table 4). NO stimulates bile flow by activation of guanylyl cyclase, resulting in the formation of cGMP, which in turn stimulates GSH and HCO_3^- excretion [65,66]. Higher concentrations may be cholestatic by impairing bile canalicular contraction [67], increasing tight junction permeability [68] and impairing ductular bile secretion [69]. Inhibition of CO, which accumulates during haem metabolism, increases bile acid-dependent bile flow and bile acid secretion [70].

cAMP–protein kinase A (PKA)

cAMP stimulates sinusoidal bile acid uptake, transcytotic vesicle trafficking and canalicular excretion of bile acids, other organic anions and HCO_3^- in hepatocytes [6]. In contrast to cAMP, cGMP does not stimulate bile acid excretion but only bile acid-independent bile flow by promoting biliary HCO_3^- and GSH excretion [65]. cAMP increases Ntcp content in sinusoidal membranes and Mrp2, Mdr2 and Bsep in canalicular membranes in a microtubule-dependent fashion [6]. The cAMP effects are thought to be mediated via PKA, a cAMP-dependent kinase, which in turn results in activation of the PI3K pathway and increases in cytosolic Ca^{2+} (see below), ultimately leading to vesicle movement and transporter translocation. Moreover, Ntcp is a serine/threonine phosphatide which, on addition of cAMP, is dephosphorylated, leading to increased retention of Ntcp in the plasma membrane [6]. In addition to Ntcp, Oatp1

Table 3 Transcriptional regulation of bile secretion: role of nuclear receptors, ligands/activators, target genes and physiological effects.

Nuclear receptor	Ligands/activators	Target genes (examples)	Effects
FXR (*NR1H4*)	Bile acids: chenodeoxycholic acid > deoxycholic acid = lithocholic acid > cholic acid	Basolateral uptake systems in liver (e.g. NTCP, OATP2, OATP8), canalicular export pumps (BSEP, MRP2, MDR3), bile acid synthesis enzymes (e.g. CYP7A1, CYP8B1)	Stimulation of bile acid-dependent and -independent bile flow (glutathione excretion). Reduction in hepatocellular bile acid uptake and bile acid synthesis (indirectly via induction of transcriptional repressor SHP)
PXR (*NR1I2*)	Rifampicin, dexamethasone, bile acids (lithocholic acid, potentially ursodeoxycholic acid), phenobarbital, statins, St John's Wort, xenobiotics	Hepatobiliary transporters (MRP2, MRP3, MDR1, rodent Oatp2), phase I and II detoxifying enzymes, bile acid synthesis (CYP7A1)	Stimulation of alternative basolateral bile acid efflux, stimulation of bilirubin glucuronidation and excretion, stimulation of phase I and II detoxification reactions in liver
CAR (*NR1I3*)	Bilirubin, phenobarbital, several xenobiotics	Hepatobiliary transporters (MRP2, MRP3, MRP4, MDR1), phase I and II detoxifying enzymes	Stimulation of alternative basolateral bile acid efflux, stimulation of bilirubin glucuronidation and excretion, stimulation of phase I and II detoxification reactions
PPARα (*NR1C1*)	Fatty acids, fibrates, statins, eicasanoids, leukotrienes, NSAIDs	Hepatobiliary transporters (ASBT, rodent Mdr2)	Stimulation of biliary phospholipid excretion (via Mdr2), stimulation of bile acid uptake in terminal ileum (via ASBT)
VDR (*NR1I1*)	Lithocholic acid, vitamin D	Bile acid detoxifying cytochromes and enzymes (CYP3A4, SULT2A1) in intestine and liver, hepatobiliary transporters (MRP3, ASBT)	Stimulation of intestinal bile acid detoxification, physiological effect on bile formation still unclear
GR (*NR3C1*)	Glucocorticoids, potentially ursodeoxycholic acid	Bile acid uptake systems (ASBT, NTCP)	Stimulation of bile acid uptake and canalicular excretion, beneficial effects in cholestatic jaundice ('steroid whitewash') may be mediated by direct transporter effects (induction of bilirubin export pump MRP2) in addition to anti-inflammatory effects
STAT5	Prolactin, placental lactogen, growth hormone	Hepatobiliary transporters (NTCP)	Stimulation of hepatic bile acid uptake
HNF1α (*TCF1*)	–	Hepatobiliary transporters (OATP2, OATP8, rodent Ntcp, Oatp1, Oatp2, Oatp4, OATP1B1, OATP1A3, Asbt)	Master transcription factor for the regulation of uptake transport systems on the basolateral membrane
HNF4α (*NR2A1*)	–	Hepatobiliary transporters (OATP2, rodent Ntcp, Oatp1), bile acid synthesis enzymes (CYP7A1, CYP8B1)	Mainly indirect effects via HNF1α in the regulation of uptake transport systems on the basolateral membrane

NSAIDs, non-steroidal anti-inflammatory drugs.

transport activity has also been shown to be regulated by serine phosphorylation [71,72].

Ca^{2+}–protein kinase C (PKC)

The effects of intracellular Ca^{2+} on bile secretion are complex, given the multiple levels of actions and the multitude of possible effects, including increases in tight junction permeability, reduction in basolateral bile acid uptake, stimulation of bile canalicular contractions and canalicular excretion of bile acids and non-bile acid organic anions [6]. Some of these Ca^{2+} effects are mediated by PKC. Tauroursodeoxycholic acid (TUDCA) stimulates hepatocyte exocytosis by increasing cytosolic Ca^{2+} and translocation of the Ca^{2+}-sensitive PKCα to the hepatocellular membrane [73,74]. This may stimulate the insertion of canalicular transporters into the canalicular membrane. In contrast, the cholestatic taurolithocholic acid (TLCA) translocates Ca^{2+}-independent PKCε to the canalicular membrane, reduces binding of PKCα and impairs hepatobiliary exocytosis [73,74].

Phosphatidylinositol 3-kinase (PI3K)

Several different bile acids have been shown to activate PI3K [6]. PI3K is required for vesicular trafficking of ABC transporters

Table 4 Hormones and other mediators, their second messengers and effects on bile formation.

Hormone/mediator	Second messenger	Target cells/effect
Secretin	cAMP ↑, PKA	Cholangiocytes: stimulation of a bicarbonate-rich flow
Somatostatin	cAMP ↓	Cholangiocytes: inhibition of basal and secretin-induced bile flow
Gastrin	IP_3, Ca^{2+}, PKC ↑	Cholangiocytes: no effect on basal bile flow and bicarbonate excretion, but inhibition of secretin-induced choleresis
Bombesin	Unknown (independent of cAMP, cGMP and Ca^{2+})	Cholangiocytes: induction of a bicarbonate-rich bile flow
VIP	Unknown (cAMP independent, yet unidentified pathways)	Cholangiocytes: induction of a bicarbonate-rich bile flow Hepatocytes: mild stimulation of bile acid-dependent bile flow in rodents
Glucagon	cAMP ↑, Ca^{2+}	Hepatocytes: stimulation of bile acid-independent bile flow
Vasopressin	IP_3, Ca^{2+}, PKC	Hepatocytes: reduction in bile acid-independent bile flow
Insulin	↓ Secretin-induced cAMP in cholangiocytes	Cholangiocytes: inhibition of secretin-induced ductal bile secretion Hepatocytes: stimulation of bile acid-independent canalicular bile fraction
Acetylcholine	IP_3, Ca^{2+}	Cholangiocytes: induction of a bicarbonate-rich bile flow
Endothelin	IP_3, Ca^{2+}, ↓ secretin-induced cAMP	Hepatocytes: inhibition of bile flow, endothelin antagonists increase bile acid-independent bile flow (glutathione and bicarbonate excretion) Cholangiocytes: inhibition of secretin-induced choleresis
NO	cGMP ↑	Hepatocytes: stimulation of bile acid-independent bile flow (bicarbonate and glutathione excretion)
Bile acids		
Ursodeoxycholic acid	Ca^{2+}, PKCα ↑, MAPK	Hepatocytes: stimulation of vesicular exocytosis, canalicular insertion of canalicular transporters (Mrp2 and Bsep); stimulation of bile acid-dependent and -independent bile flow Cholangiocytes: stimulation of Cl^- excretion and Cl^-/HCO_3^- exchange
Lithocholic acid	PKCε ↑, PKCα ↓	Hepatocytes: inhibits PKCα-dependent Bsep phosphorylation and activation, reduction in bile acid-dependent bile flow

VIP, vasoactive intestinal polypeptide.

from intracellular pools to the bile canaliculus in response to bile acids and cell swelling. Inhibition of PI3K with wortmannin inhibits taurocholate-induced bile flow by about 50%, underlining the importance of the PI3K pathway. In addition, PI3K is also required for maximal transport activity of Mrp2, Mdr2 and Bsep [32,75,76]. Moreover, PI3K is involved in cell swelling- and cAMP-induced Ntcp translocation at the basolateral membrane [6].

Mitogen-activated protein kinases (MAPK)

MAPK signalling pathways (ERK1/2 and p38) mediate, at least in part, stimulation of bile flow and Bsep translocation to the canalicular membrane induced by changes in cell volume (swelling) and TUDCA [6,7].

Biliary compounds regulating bile secretion

In addition to classic hormonal signals, secretory functions of the biliary epithelium are also paracrinally regulated by molecules secreted into bile (e.g. bile acids, GSH, purinergic mediators). As such, ATP is released into bile in mM concentrations and binds to purinergic receptors on cholangiocytes where this process stimulates ductal bicarbonate secretion [77].

Acknowledgements

This work was supported by grants P15502 and P18613-B05 from the Austrian Science Fund, grant 10266 from the Jubilee Funds of the Austrian National Bank and a GEN-AU grant from the Austrian Ministry for Science (to MT).

References

1 Hofmann AF (1999) Bile acids: the good, the bad, and the ugly. *News Physiol Sci* 14, 24–29.
2 Oude Elferink RP, Groen AK (2000) Mechanisms of biliary lipid secretion and their role in lipid homeostasis. *Semin Liver Dis* 20(3), 293–305.
3 Jansen PL, Bosma PJ, Chowdhury JR (1995) Molecular biology of bilirubin metabolism. *Prog Liver Dis* 13, 125–150.
4 Hofmann AF (1999) The continuing importance of bile acids in liver and intestinal disease. *Arch Intern Med* 159(22), 2647–2658.

5 Trauner M, Boyer JL (2003) Bile salt transporters: molecular characterization, function, and regulation. *Physiol Rev* 83(2), 633–671.
6 Anwer MS (2004) Cellular regulation of hepatic bile acid transport in health and cholestasis. *Hepatology* 39(3), 581–590.
7 Haussinger D, Schmitt M, Weiergraber O *et al.* (2000) Short-term regulation of canalicular transport. *Semin Liver Dis* 20(3), 307–321.
8 Marzioni M, Glaser SS, Francis H *et al.* (2002) Functional heterogeneity of cholangiocytes. *Semin Liver Dis* 22(3), 227–240.
9 Kullak-Ublick GA, Stieger B, Meier PJ (2004) Enterohepatic bile salt transporters in normal physiology and liver disease. *Gastroenterology* 126(1), 322–342.
10 Inagaki T, Choi M, Moschetta A *et al.* (2005) Fibroblast growth factor 15 functions as an enterohepatic signal to regulate bile acid homeostasis. *Cell Metab* 2(4), 217–225.
11 Reynoso-Paz S, Coppel RL, Mackay IR *et al.* (1999) The immunobiology of bile and biliary epithelium. *Hepatology* 30(2), 351–357.
12 Itoh M, Wada K, Tan S *et al.* (1999) Antibacterial action of bile acids against *Helicobacter pylori* and changes in its ultrastructural morphology: effect of unconjugated dihydroxy bile acid. *J Gastroenterol* 34(5), 571–576.
13 Inagaki T, Moschetta A, Lee YK *et al.* (2006) Regulation of antibacterial defense in the small intestine by the nuclear bile acid receptor. *Proc Natl Acad Sci USA* 103(10), 3920–3925.
14 Sperber I (1959) Secretion of organic anions in the formation of urine and bile. *Pharmacol Rev* 11, 109–134.
15 Marinelli RA, Gradilone SA, Carreras FI *et al.* (2004) Liver aquaporins: significance in canalicular and ductal bile formation. *Ann Hepatol* 3(4), 130–136.
16 Nathanson MH, Boyer JL (1991) Mechanisms and regulation of bile secretion. *Hepatology* 14, 551–566.
17 Alpini G, Roberts S, Kuntz SM *et al.* (1996) Morphological, molecular, and functional heterogeneity of cholangiocytes from normal rat liver. *Gastroenterology* 110(5), 1636–1643.
18 Baiocchi L, LeSage G, Glaser S *et al.* (1999) Regulation of cholangiocyte bile secretion. *J Hepatol* 31(1), 179–191.
19 Kullak-Ublick GA (2000) Hepatic transport of bile salts. *Semin Liver Dis* 20, 273–292.
20 Trauner M, Wagner M, Fickert P *et al.* (2005) Molecular regulation of hepatobiliary transport systems: clinical implications for understanding and treating cholestasis. *J Clin Gastroenterol* 39(4), S111–S124.
21 Hofmann AF (1993) The cholehepatic circulation of unconjugated bile acids: an update. In: Paumgartner G, Stiehl A, Gerok W (eds) *Bile Acids and the Hepatobiliary System*. Boston: Kluwer, pp. 143–160.
22 Trauner M, Meier PJ, Boyer JL (1998) Molecular pathogenesis of cholestasis. *N Engl J Med* 339(17), 1217–1227.
23 Meier PJ (1995) Molecular mechanisms of hepatic bile salt transport from sinusoidal blood into bile. *Am J Physiol* 269(6 Pt 1), G801–G812.
24 Arias IM (1990) The biology of hepatic endothelial cell fenestrae. *Prog Liver Dis* 9, 11–26.
25 Kullak-Ublick G-A, Stieger B, Hagenbuch B *et al.* (2000) Hepatic transport of bile salts. *Semin Liver Dis* 20, 273–292.
26 Meier PJ, Stieger B (2002) Bile salt transporters. *Annu Rev Physiol* 64, 635–661.
27 Hagenbuch B, Meier PJ (2003) The superfamily of organic anion transporting polypeptides. *Biochim Biophys Acta* 1609(1), 1–18.
28 Faber KN, Muller M, Jansen PL (2003) Drug transport proteins in the liver. *Adv Drug Deliv Rev* 55(1), 107–124.
29 Dawson PA, Hubbert M, Haywood J *et al.* (2005) The heteromeric organic solute transporter {alpha}–{beta}, Ost{alpha}–Ost{beta}, is an ileal basolateral bile acid transporter. *J Biol Chem* 280(8), 6960–6968.
30 Agellon LB, Torchia EC (2000) Intracellular transport of bile acids. *Biochim Biophys Acta* 1486(1), 198–209.
31 Crawford JM, Strahs DC, Crawford AR *et al.* (1994) Role of bile salt hydrophobicity in hepatic microtubule-dependent bile salt secretion. *J Lipid Res* 35(10), 1738–1748.
32 Kipp H, Arias IM (2000) Intracellular trafficking and regulation of canalicular ATP-binding cassette transporters. *Semin Liver Dis* 20(3), 339–351.
33 Smit JJ, Schinkel AH, Oude Elferink RP *et al.* (1993) Homozygous disruption of the murine mdr2 P-glycoprotein gene leads to a complete absence of phospholipid from bile and to liver disease. *Cell* 75(3), 451–462.
34 Yu L, Hammer RE, Li-Hawkins J *et al.* (2002) Disruption of Abcg5 and Abcg8 in mice reveals their crucial role in biliary cholesterol secretion. *Proc Natl Acad Sci USA* 99(25), 16237–16242.
35 Jansen PL, Sturm E (2003) Genetic cholestasis, causes and consequences for hepatobiliary transport. *Liver Int* 23(5), 315–322.
36 Crawford AR, Smith AJ, Hatch VC *et al.* (1997) Hepatic secretion of phospholipid vesicles in the mouse critically depends on mdr2 or MDR3 P-glycoprotein expression. Visualization by electron microscopy. *J Clin Invest* 100(10), 2562–2567.
37 Fickert P, Fuchsbichler A, Wagner M *et al.* (2004) Regurgitation of bile acids from leaky bile ducts causes sclerosing cholangitis in Mdr2 (Abcb4) knockout mice. *Gastroenterology* 127(1), 261–274.
38 Kipp H, Pichetshote N, Arias IM (2001) Transporters on demand: intrahepatic pools of canalicular ATP binding cassette transporters in rat liver. *J Biol Chem* 276(10), 7218–7224.
39 Wakabayashi Y, Lippincott-Schwartz J, Arias IM (2004) Intracellular trafficking of bile salt export pump (ABCB11) in polarized hepatic cells: constitutive cycling between the canalicular membrane and rab11-positive endosomes. *Mol Biol Cell* 15(7), 3485–3496.
40 Anwer MS, Gillin H, Mukhopadhyay S *et al.* (2005) Dephosphorylation of Ser-226 facilitates plasma membrane retention of Ntcp. *J Biol Chem* 280(39), 33687–33692.
41 Hamm-Alvarez SF, Sheetz MP (1998) Microtubule-dependent vesicle transport: modulation of channel and transporter activity in liver and kidney. *Physiol Rev* 78(4), 1109–1129.
42 Marks DL, LaRusso NF, McNiven MA (1995) Isolation of the microtubule-vesicle motor kinesin from rat liver: selective inhibition by cholestatic bile acids. *Gastroenterology* 108(3), 824–833.
43 Crawford JM, Berken CA, Gollan JL (1988) Role of the hepatocyte microtubular system in the excretion of bile salts and biliary lipid: implications for intracellular vesicular transport. *J Lipid Res* 29(2), 144–156.
44 Zatloukal K, Stumptner C, Fuchsbichler A *et al.* (2004) The keratin cytoskeleton in liver diseases. *J Pathol* 204(4), 367–376.
45 Tsukada N, Ackerley CA, Phillips MJ (1995) The structure and organization of the bile canalicular cytoskeleton with special reference to actin and actin-binding proteins. *Hepatology* 21(4), 1106–1113.
46 Omary MB, Coulombe PA, McLean WH (2004) Intermediate filament proteins and their associated diseases. *N Engl J Med* 351(20), 2087–2100.
47 Omary MB, Ku NO, Toivola DM (2002) Keratins: guardians of the liver. *Hepatology* 35(2), 251–257.
48 Dranoff JA, McClure M, Burgstahler AD *et al.* (1999) Short-term regulation of bile acid uptake by microfilament-dependent translocation of rat ntcp to the plasma membrane. *Hepatology* 30(1), 223–229.

49 Kikuchi S, Hata M, Fukumoto K *et al.* (2002) Radixin deficiency causes conjugated hyperbilirubinemia with loss of Mrp2 from bile canalicular membranes. *Nature Genet* 31(3), 320–325.
50 Ortiz DF, Moseley J, Calderon G *et al.* (2004) Identification of HAX-1 as a protein that binds bile salt export protein and regulates its abundance in the apical membrane of Madin–Darby canine kidney cells. *J Biol Chem* 279(31), 32761–32770.
51 Chan W, Calderon G, Swift AL *et al.* (2005) Myosin II regulatory light chain is required for trafficking of bile salt export protein to the apical membrane in Madin-Darby canine kidney cells. *J Biol Chem* 280(25), 23741–23747.
52 Fouassier L, Duan CY, Feranchak AP *et al.* (2001) Ezrin–radixin–moesin-binding phosphoprotein 50 is expressed at the apical membrane of rat liver epithelia. *Hepatology* 33(1), 166–176.
53 Mitic LL, Van Itallie CM, Anderson JM (2000) Molecular physiology and pathophysiology of tight junctions I. Tight junction structure and function: lessons from mutant animals and proteins. *Am J Physiol Gastrointest Liver Physiol* 279(2), G250–G254.
54 Echevarria W, Arias IM (2004) Gap junctions in the liver. In: Trauner M, Jansen PLM (eds) *Molecular Pathogenesis of Cholestasis*. New York, NY: Landes Bioscience, Kluwer Academic/Plenum Publishers, pp. 36–47.
55 Kanno N, Lesage G, Glaser S *et al.* (2000) Functional heterogeneity of the intrahepatic biliary epithelium. *Hepatology* 31(3), 555–561.
56 Lazaridis KN, Pham L, Tietz P *et al.* (1997) Rat cholangiocytes absorb bile acids at their apical domain via the ileal sodium-dependent bile acid transporter. *J Clin Invest* 100(11), 2714–2721.
57 Lesage G, Glaser S, Alpini G (2001) Regulation of cholangiocyte proliferation. *Liver* 21(2), 73–80.
58 Tietz PS, Marinelli RA, Chen XM *et al.* (2003) Agonist-induced coordinated trafficking of functionally related transport proteins for water and ions in cholangiocytes. *J Biol Chem* 278(22), 20413–20419.
59 Rost D, Konig J, Weiss G *et al.* (2001) Expression and localization of the multidrug resistance proteins MRP2 and MRP3 in human gallbladder epithelia. *Gastroenterology* 121(5), 1203–1208.
60 Chignard N, Mergey M, Veissiere D *et al.* (2001) Bile acid transport and regulating functions in the human biliary epithelium. *Hepatology* 33(3), 496–503.
61 Plosch T, Bloks VW, Terasawa Y *et al.* (2004) Sitosterolemia in ABC-transporter G5-deficient mice is aggravated on activation of the liver-X receptor. *Gastroenterology* 126(1), 290–300.
62 Karpen SJ (2002) Nuclear receptor regulation of hepatic function. *J Hepatol* 36(6), 832–850.
63 Eloranta JJ, Kullak-Ublick GA (2005) Coordinate transcriptional regulation of bile acid homeostasis and drug metabolism. *Arch Biochem Biophys* 433(2), 397–412.
64 Chiang JY (2004) Regulation of bile acid synthesis: pathways, nuclear receptors, and mechanisms. *J Hepatol* 40(3), 539–551.
65 Trauner M, Nathanson MH, Rydberg StA *et al.* (1997) Endotoxin impairs biliary glutathione and HCO_3^- excretion and blocks the choleretic effect of nitric oxide in rat liver. *Hepatology* 25, 1184–1191.
66 Myers NC, Grune S, Jameson HL *et al.* (1996) cGMP stimulates bile acid-independent bile formation and biliary bicarbonate excretion. *Am J Physiol* 270(3 Pt 1), G418–G424.
67 Dufour JF, Turner TJ, Arias IM (1995) Nitric oxide blocks bile canalicular contraction by inhibiting inositol trisphosphate-dependent calcium mobilization. *Gastroenterology* 108(3), 841–849.
68 Burgstahler AD, Nathanson MH (1995) NO modulates the apicolateral cytoskeleton of isolated hepatocytes by a PKC-dependent, cGMP-independent mechanism. *Am J Physiol* 269(5 Pt 1), G789–G799.
69 Spirli C, Fabris L, Duner E *et al.* (2003) Cytokine-stimulated nitric oxide production inhibits adenylyl cyclase and cAMP-dependent secretion in cholangiocytes. *Gastroenterology* 124(3), 737–753.
70 Sano T, Shiomi M, Wakabayashi Y *et al.* (1997) Endogenous carbon monoxide suppression stimulates bile acid-dependent biliary transport in perfused rat liver. *Am J Physiol* 272(5 Pt 1), G1268–G1275.
71 Glavy JS, Wu SM, Wang PJ *et al.* (2000) Down-regulation by extracellular ATP of rat hepatocyte organic anion transport is mediated by serine phosphorylation of oatp1. *J Biol Chem* 275(2), 1479–1484.
72 Guo GL, Klaassen CD (2001) Protein kinase C suppresses rat organic anion transporting polypeptide 1- and 2-mediated uptake. *J Pharmacol Exp Ther* 299(2), 551–557.
73 Paumgartner G, Beuers U (2002) Ursodeoxycholic acid in cholestatic liver disease: mechanisms of action and therapeutic use revisited. *Hepatology* 36(3), 525–531.
74 Paumgartner G, Beuers U (2004) Mechanisms of action and therapeutic efficacy of ursodeoxycholic acid in cholestatic liver disease. *Clin Liver Dis* 8(1), 67–81, vi.
75 Misra S, Ujhazy P, Varticovski L *et al.* (1999) Phosphoinositide 3-kinase lipid products regulate ATP-dependent transport by sister of P-glycoprotein and multidrug resistance associated protein 2 in bile canalicular membrane vesicles. *Proc Natl Acad Sci USA* 96(10), 5814–5819.
76 Misra S, Varticovski L, Arias IM (2003) Mechanisms by which cAMP increases bile acid secretion in rat liver and canalicular membrane vesicles. *Am J Physiol Gastrointest Liver Physiol* 285(2), G316–G324.
77 Strazzabosco M, Fabris L, Spirli C (2005) Pathophysiology of cholangiopathies. *J Clin Gastroenterol* 39(4 Suppl. 2), S90–S102.

2.6.2 Motility of the biliary tree

Mayank Bhandari and James Toouli

Introduction

The presence of the gallbladder and biliary tract was described in some of the earliest recorded observations of man [1], but their role in digestion was not appreciated. In the sixteenth century, a membrane near the distal end of the common bile duct, thought to impede reflux of duodenal contents into the bile duct, was described but it was not until 1887 that this structure was described as a sphincter and named after Rugero Oddi, who published a detailed description of its anatomy [2]. Following the discovery of the hormone cholecystokinin (CCK), it was shown to contract the gallbladder and reduce sphincter of Oddi resistance. These and subsequent studies firmly established that an intimate relationship existed between gallbladder contraction, sphincter of Oddi function and the flow of bile into the duodenum.

Anatomy

Embryology

The gallbladder and bile ducts arise from the caudal portion of a diverticular anlage that originates from the ventral floor of the

foregut. The pancreas develops from two foregut buds in the region of the future duodenum. Anatomical studies showed that the distal muscularis propria of the bile duct and pancreatic duct are independent from duodenal musculature. In studies of the human fetus, Boyden showed that the sphincter of Oddi, appearing approximately 5 weeks after the intestinal musculature, arises *de novo* from mesenchyme.

Morphology

The biliary tract comprises the bile ducts, gallbladder, cystic duct and the sphincter of Oddi. Bile flows from the hepatocytes into canaliculi, which communicate with numerous interlobular ducts. These in turn drain into two main hepatic ducts. The main right and left hepatic ducts fuse at the porta hepatis to form the common hepatic duct. The cystic duct joins the common hepatic duct at a variable distance caudal to the porta hepatis to form the common bile duct.

The human gallbladder is a pear-shaped muscular sac with a resting volume of 35–50 mL. It lies in the fossa on the right inferior surface of the liver. The gallbladder is divided anatomically into the blunt-ended fundus, the body and the neck, which leads to the cystic duct. A sacculation at the neck of the gallbladder is known as Hartman's pouch. The cystic duct is of variable length, usually joining the common hepatic duct at an acute angle to form the common bile duct.

The common bile duct passes dorsal to the first part of the duodenum lying in a groove either within or posterior to the head of the pancreas and enters the second part of the duodenum through the major duodenal papilla in association with the pancreatic duct of Wirsung. The junction of the terminal common bile duct, pancreatic duct and duodenum at the papilla assumes one of three configurations that may be likened to a Y, V or U. In approximately 70% of subjects, the ducts open into a common channel and thus have a Y configuration. This common channel drains into the duodenum through a single orifice on the duodenal papilla of Vater. In approximately 20% of subjects, the common channel is almost non-existent, and the two ducts have a common V shape opening on the papilla. In 10% of subjects, the common bile duct and pancreatic duct have separate openings on the tip of the papilla; these openings lie adjacent to each other and give a U-shaped configuration. The terminal parts of the common bile duct and pancreatic duct, the common channel and major duodenal papilla of Vater are invested by varying thickness of smooth muscle and together form the sphincter of Oddi segment.

The major part of the human sphincter of Oddi lies within the duodenal wall and is anatomically and functionally independent of the duodenal muscle.

Distinct sphincters lie at the terminal end of the common bile duct (sphincter choledochus), the terminal end of the pancreatic duct (sphincter pancreaticus) and the common channel (sphincter ampullae) [3]. However, more recently, Hand [4], using a combination of radiological, duct cast techniques and histological sectioning methods, did not distinguish separate sphincters and concluded from his human autopsy studies that the common bile duct and pancreatic duct become fused in a common connective tissue sheath outside the duodenal wall and pass together through a slit in the duodenal muscle known as the 'choledochal window'. The lumina, however, do not join at this level but are separated by a thick muscular septum. In most subjects, fusion of the two lumina occurs in the submucosal layer of the duodenum to form a common channel varying in length between 2 and 17 mm. Before entering the duodenum, each duct becomes completely surrounded by circular muscle, some of which forms a figure of eight pattern around the two ducts. The point at which the smooth muscle starts on each duct is readily identified radiologically as a notch. Distal to the notch, each lumen becomes narrow as it traverses the duodenal wall, this narrowing being associated with a thickening of the duct wall due to smooth muscle, connective tissue and mucous glands. As the ducts pass through the duodenal wall, longitudinal muscle fibres interdigitate between the circular ductular muscle fibres and the duodenal muscle. The ducts emerge from the duodenal muscle layers to have a course of variable length through the duodenal submucosa before opening on to the papilla of Vater; throughout this submucosal course, the ducts are ensheathed by circularly orientated smooth muscle. Manometric studies in man support Hand's description of the sphincter of Oddi in that separate sphincteric zones have not been identified [5].

The mucosa of the human sphincter of Oddi segment is lined by columnar epithelium and contains numerous mucus-secreting glands. The mucosa is thrown into longitudinal folds likened to mucosal valvules [6]. These folds are least marked proximally and increase distally, becoming maximal in the common channel. The mucosal folds may occasionally be seen projecting through the orifice of the duodenal papilla.

Innervation

The extrahepatic biliary tract is innervated by dense networks of extrinsic and intrinsic nerves that regulate smooth muscle tone and epithelial cell function of the extrahepatic biliary tree. The coeliac ganglia contribute both motor and sensory nerves made up of sympathetic fibres, which originate in the T7–T10 spinal segments. Hepatic plexus is formed by nerve fibres from both the vagi, which supply parasympathetic motor nerves to the extrahepatic biliary system [7].

The wall of the biliary tract is composed of three layers, namely serosal, muscularis and mucosal layers. Ganglionated nerve plexuses are located in the subserosal and the subepithelial layers. Histochemical studies have shown that the gallbladder is richly supplied with both adrenergic and cholinergic ganglia. In addition, studies [8] have shown the presence of immunoreactive peptidergic nerves that can be labelled to detect vasoactive intestinal polypeptide (VIP). The sphincter of Oddi has a rich ganglionic plexus. It has a predominance of cholinergic ganglia and a smaller number of adrenergic ganglia.

Immunohistochemical studies from our laboratory have demonstrated the presence of a wide range of peptidergic neurones in the sphincter region. These include galanin, substance P and somatostatin-containing nerves. In addition, the inhibitory transmitter nitric oxide has been demonstrated in nerves to the sphincter and is thought to have an important function in modulating sphincter relaxation. It has been shown that the nerves in the sphincter region communicate with the proximal biliary tract, the gallbladder and the duodenum [9,10].

Physiology

Gallbladder

Fluid transport and its regulation

The gallbladder concentrates hepatic bile by selective reabsorption of bile constituents. In addition, studies have shown that, under both physiological and pathological conditions, reversal of fluid transport across the gallbladder mucosa occurs, and net secretion into the gallbladder lumen results. Sodium and chloride ions are absorbed from the gallbladder lumen by both active and passive transport mechanisms. Water absorption is thought to be passive and secondary to active solute movement resulting from osmotic equilibration of transported solute within the epithelium. The secretion of water and electrolytes by the gallbladder mucosa is an active process that can take place against hydrostatic and osmotic gradients [11]. Animal *in vitro* and *in vivo* studies have demonstrated that a number of gastrointestinal peptides affect gallbladder fluid transport. Cyclic adenosine monophosphate (cAMP) acts as a second messenger for the effects of several mediators and has been implicated in sodium and chloride transport in rabbit and necturus gallbladder. Vasoactive intestinal polypeptide (VIP) and secretin have been shown to modify gallbladder fluid transport at concentrations that suggest a physiological role. However, other peptides, such as glucagon, cholecystokinin, neurotensin, bombesin, motilin and somatostatin, which have been shown to enhance absorption *in vitro*, may act to potentiate or inhibit the effects of the major peptides [12].

Application of prostaglandins of the E and F series to *in vitro* animal gallbladder preparations have demonstrated inhibition of fluid absorption by arachidonic acid [13]. In animal studies, bile salts, female sex hormones and autonomic nerve stimulation have also been shown to influence fluid transport.

During fasting, the normal gallbladder absorbs fluid at a rate corresponding to one-third of the fasting gallbladder volume. After feeding, there is reversal of the direction of gallbladder transport from a net absorption to a net secretion into the gallbladder lumen. The net water transport across the gallbladder wall may be influenced by both humoral factors and autonomic nerves. During inflammation of the gallbladder, often associated with cystic duct obstruction, the absorptive capacity of the gallbladder mucosa is lost, and net secretion into the lumen results, producing a hydrops. This pathological effect appears to be mediated by prostaglandin release due to the formation of lysolecithin by hydrolysis of phospholipid in the gallbladder. This process can be reversed by indomethacin, supporting the belief that at least part of the change in fluid transport may result from endogenous prostaglandin formation.

Gallbladder motility

Gallbladder filling depends on the rate of bile secretion from the liver and the resistance to flow through the sphincter of Oddi. Only 50% of secreted hepatic bile enters the gallbladder during fasting; the remaining bile passes into the duodenum without concentration by the gallbladder. Release of CCK after ingestion of food causes the gallbladder to have a slow steady contraction which delivers bile into the duodenum for 20 min or longer while generating an intraluminal gallbladder pressure that is generally only a little elevated above that in the common bile duct. About 75% of gallbladder volume is ejected during CCK stimulation. The slow emptying of the gallbladder is typical of a graded tonic smooth muscle contraction such as that which occurs in the fundus of the stomach during gastric emptying of liquids. The hormones that affect gallbladder motility are shown in Table 1.

Estimations of human fasting gallbladder volume by ultrasound techniques have shown a mean volume of approximately 17 mL in normal subjects. In the past, it was thought that the gallbladder volume gradually increased during fasting until the mean maximal volume was reached and only emptied after a food stimulus. However, studies in dogs [14] and opossums have shown that the gallbladder contracts by up to 40% of maximal contractile capacity during the interdigestive period, and that these gallbladder contractions occur during phase II of the migrating motor complex (MMC). The periodic gallbladder contractions during fasting empty concentrated viscous bile and enable gallbladder refilling with dilute hepatic bile. Studies in man using ultrasound estimation of gallbladder volume confirm that a similar cyclical pattern of gallbladder volume changes occur, in association with phase III of the MMC [15]. The controlling mechanism that produces gallbladder volume changes during fasting is unknown. A potential candidate is motilin, a hormone produced by the mucosa of the proximal small intestine. Serum motilin levels show cyclic changes during MMC cycles with the peak values preceding phase III MMC

Table 1 Hormones affecting gallbladder motility.

Prokinetic agents	Inhibitors
CCK	VIP
Secretin (with CCK)	Somatostatin
Motilin	Neurotensin
Substance P	Pancreatic polypeptide
Gastrin releasing peptide	Peptide YY
Neuropeptide Y	Histamine (H2 receptors)
Histamine (H1 receptors)	

activity. In animal studies, motilin has been shown to produce gallbladder contraction [14].

The ability of a fatty meal to elicit gallbladder contraction has been well documented in man and a number of animal species. Proteins entering the duodenum also produce gallbladder contraction, but carbohydrates have only a minimal effect. Endogenous CCK is released from the mucosa of the proximal small intestine, and studies that measure serum CCK levels by radioimmunoassay have shown that gallbladder contraction induced by intraduodenal infusion of fat correlates directly with the level of circulating CCK [16].

The role of autonomic nerves in regulating gallbladder volume is not clear. The innervation of the gallbladder mainly plays a facilitatory role to that of gastrointestinal hormones and peptides, which are the prime regulators of gallbladder motility. In one study, increased fasting volume of the human gallbladder was demonstrated after vagotomy [17]. A number of studies have investigated the effect of vagal stimulation and vagotomy on gallbladder contractility [18], but the results have generally been inconclusive. Similarly, studies of sympathetic innervation have produced inconstant and variable findings, and the role of the sympathetic autonomic nervous system in gallbladder motility requires further study [19].

Cystic duct

Accumulating evidence suggests that the cystic duct is not merely a passive conduit between the gallbladder and the common bile duct, but may play an active role in the flow of bile into and out of the gallbladder. Histologically, an anatomically prominent sphincter, as described by Lutken, does not appear to be present; however, a thin layer of smooth muscle is evident in the wall of the duct and, along with the prominent mucosal folds that make up the valves of Heister, the cystic duct may act as a variable resistor to flow.

Flow studies in dogs have demonstrated resistance to flow across the cystic duct, the resistance being equal whether perfusion was carried either into or out of the gallbladder [20]. Significant reductions in flow were induced following systemic intravenous or local intra-arterial injection of morphine, adrenalin or CCK, suggesting that the cystic duct performs like a sphincter in modulating flow through its lumen. Studies in the prairie dog gallstone model have shown that cystic duct resistance to flow increases prior to gallstone formation in these animals [21]. These studies suggest that abnormalities in cyst duct formation may be implicated in the pathophysiology of gallstone formation.

Common bile duct

The role of the common bile duct in the control of bile flow has been confused because of anatomical differences in the species studied. As in the cystic duct, histological studies in man have demonstrated only thin longitudinally orientated layers of smooth muscle within the walls of the common bile duct [22]. The major tissue component appears to be elastic fibres. However, in other species such as sheep, the common bile duct is invested with circularly orientated smooth muscle which exhibits peristaltic activity.

The weight of evidence suggests that the human common bile duct does not have a primary propulsile function. However, the elastic fibres and the longitudinally orientated smooth muscle provide a tonic pressure that may help to overcome the tonic resistance of the sphincter of Oddi. The diameter of the human common bile duct before and after cholecystectomy has been the subject of controversy. Part of the controversy has resulted from methodology used in determining duct size. It has become quite obvious that duct size as determined by ultrasonography and magnetic resonance cholangiography (MRC) cannot be equated to duct size determined by endoscopic retrograde cholangiography (ERCP) or intraoperative extraluminal measurements. Ultrasound and MRC measurement records the non-distended lumen, whereas at ERCP, contrast produces distension. Intraoperative measurements include wall thickness. In general, the normal diameter of the common bile duct as determined by ultrasound is less than 6 mm, by retrograde cholangiography less than 10 mm, and by intraoperative extraluminal measurements less than 12 mm. What has become clear is that the common bile duct does not increase in diameter significantly following cholecystectomy [23,24]. The major cause of dilated common bile duct is increased intraluminal pressure, which is generally produced by either primary or secondary obstruction at the sphincter of Oddi.

Motility of the sphincter of Oddi

The primary function of the sphincter of Oddi is to control the delivery of bile and pancreatic juice into the duodenum. This is possible because of low pressure within the bile duct. Approximately 800–1500 mL of bile flows through the human sphincter of Oddi. Various studies in animals and man have tried to evaluate the mechanism by which the sphincter of Oddi controls the flow of bile and pancreatic secretions. These studies have shown that there is anatomical variability between species and also that the sphincter of Oddi motility differs from one species to another. Thus, while many commonalities exist, one has to be circumspect in translating animal data directly into the motility and function of the human sphincter of Oddi.

Sphincter of Oddi motility studies in animals

In vivo studies in dogs, cats, rabbits, monkeys and opossums have demonstrated that the sphincter of Oddi exhibits muscle contractions that are independent of duodenal activity. The results from the dog studies suggested that the sphincter of Oddi has a milking effect on bile, thus propelling small volumes of fluid from the common bile duct into the duodenum [25]. Manometric and electromyographic studies of the opossum sphincter of Oddi demonstrated phasic contractions that

propagate along the entire length from the cephalic to the caudal end [26]. The common bile duct and pancreatic duct proximal to the sphincter do not demonstrate spontaneous motor activity.

Analysis of simultaneous cineradiography, trans-sphincteric flow and electromyographic recordings from the opossum sphincter of Oddi has demonstrated the effect of the phasic contractions on the flow of bile into the duodenum. The predominant mechanism of common bile duct emptying in the opossum is the antegrade sphincter of Oddi phasic contraction. A wave of contraction begins at the junction of the common bile duct and sphincter of Oddi stripping the contents of the sphincter of Oddi segment into the duodenum. During the period of sphincter of Oddi contraction, flow into the common bile duct ceases, and there is no flow from the common bile duct into the sphincter of Oddi segment. Next, the sphincter of Oddi relaxes, and passive flow of bile occurs from the common bile duct into the sphincter of Oddi segment. After filling of the sphincter of Oddi segment, a wave of contraction begins again at the junction of the common bile duct and sphincter segment, and the cycle repeats itself. The overall effect of the phasic contractions is to promote flow from the common bile duct into the duodenum. During sphincter contraction, or systole, flow from the common bile duct into the sphincter of Oddi segment stops, and flow into the sphincter segment occurs only during sphincter relaxation or diastole. Increasing the frequency of sphincter contractions by administering the sphincter agonists phenylephrine (50 μg/kg i.v.) and bethanechol (30 μg/kg i.v.) decreased the diastolic interval between contractions and decreased the time available for passive flow of fluid from the common bile duct into the sphincter segment. Initially, an increase in the frequency of sphincter phasic contractions produced an increase in flow across the sphincter. However, as the frequency of contractions increases further, flow decreases because of the decrease in the diastolic interval. When the frequency of contractions exceeds eight per minute, the diastolic interval is abolished, and there is no flow across the sphincter of Oddi segment in the opossum. Recent studies have shown that the sphincter may act as a pump or a resistor and that the bile duct pressure influences it [27]. This intrinsic activity is controlled by interstitial nerves of Cajal and is modulated by hormones [28], peptides such as adenosine triphosphate (ATP) and adenosine [29] and nitric oxide [30].

In cats, an intravenous bolus of CCK inhibited the phasic contractions and produced a fall in sphincter tone. Following administration of the neurotoxin tetrodotoxin, CCK administration no longer produced inhibition, but instead caused contraction in the sphincter of Oddi. The investigators concluded that CCK produces its effect by stimulation of non-adrenergic non-cholinergic inhibitory neurones, with this effect overriding a lesser, direct smooth muscle stimulatory action of the hormone [28]. Neurohistochemical studies have demonstrated both adrenergic and cholinergic neurons within the sphincter of Oddi, and experiments in animals have determined the pharmacological effects of histamine, cholinergic and adrenergic stimulation on the sphincter muscle [26]. However, the physiological significance of these drug actions on the sphincter of Oddi requires further investigation.

The function of the vagus nerve in sphincter of Oddi physiology remains obscure. Sphincter of Oddi neurons probably receive vagal input, and their activity is modulated by release of neuropeptides from sensory fibres, a significant source of excitatory synaptic input to these cells arising from the duodenum. This duodenum–sphincter of Oddi circuit is likely to play an important role in the coordination of sphincter of Oddi tone with gallbladder motility in the process of gallbladder emptying [31]. Studies in dogs suggested that, following vagal transaction, the resistance to flow across the sphincter of Oddi is decreased [32]. However, in the prairie dog, increased resistance to flow through the sphincter of Oddi occurs after truncal vagotomy. Results from vagal stimulation studies have failed to define clearly the role of the vagus in biliary dynamics.

Studies carried out in opossums with chronically implanted electrodes positioned in the sphincter of Oddi and the small intestine have demonstrated that the phasic activity of the sphincter of Oddi is omnipresent [33]. However, the frequency of the phasic contractions varies periodically during fasting. Four phases that are analogous to the phases of the intestinal interdigestive MMC have been described for the sphincter of Oddi. Food ingestion and the intravenous infusion of CCK and pentagastrin abolish the periodic nature of the interdigestive sphincter of Oddi contractions and, in this species, ingested food produced an increase in contractile frequency, which increased the flow of bile into the duodenum. The physiological function of the periodic sphincter of Oddi contractions during fasting might be similar to that proposed for intestinal MMC, which is to act as a housekeeper to eliminate any debris that may accumulate at the lower end of the bile duct. In addition, this activity of the sphincter may modulate the volume of bile passing into either the duodenum or the gallbladder during fasting.

The Australian opossum sphincter of Oddi demonstrates an activity that is similar to that of the human sphincter. In this species, inhibition of sphincter phasic contractions promotes the flow of bile. It has been shown that this inhibition is mediated by neural release of nitric oxide [28]. There is evidence that nitric oxide mediates the caerulein and CCK octapeptide-mediated relaxation of the canine sphincter of Oddi [34]. Table 2 illustrates the effects of various bioactive agents on the sphincter of Oddi.

Sphincter of Oddi motility in man

Cineradiographic studies of the human sphincter of Oddi exhibit rhythmic contractions that propel contrast into the duodenum [35]. Sphincter of Oddi pressure studies conducted at the time of biliary tract surgery demonstrated variations in pressure thought to be the manometric equivalent of the cineradiographic contractions [36]. Resistance to outflow of fluid from the common bile duct into the duodenum was also demonstrated by the intraoperative studies. This resistance was

Table 2 Effects of various bioactive agents on the sphincter of Oddi.

Stimulator	Inhibitor
Morphine met-encephalin	Tramadol
Galanin	Glucagon
Substance P	CGRP
CCK	CCK
Neuropeptide Y	Peptide YY
Nitric oxide	Somatostatin

CGRP, calcitonin gene-related peptide.

reduced after administration of CCK octapeptide or smooth muscle relaxants such as amylnitrite [37].

Manometric recordings from within the sphincter of Oddi segment [38] have been made via a pressure-sensitive catheter introduced into the sphincter of Oddi via a duodenoscope (Fig. 1). They have demonstrated that the human sphincter of Oddi is characterized by prominent phasic contractions superimposed on a basal sphincter of Oddi pressure 3 mmHg above the pressure in the common bile duct and pancreatic duct (Fig. 2). The amplitude of the phasic contractions is approximately 130 mmHg, and the mean frequency is four per min.

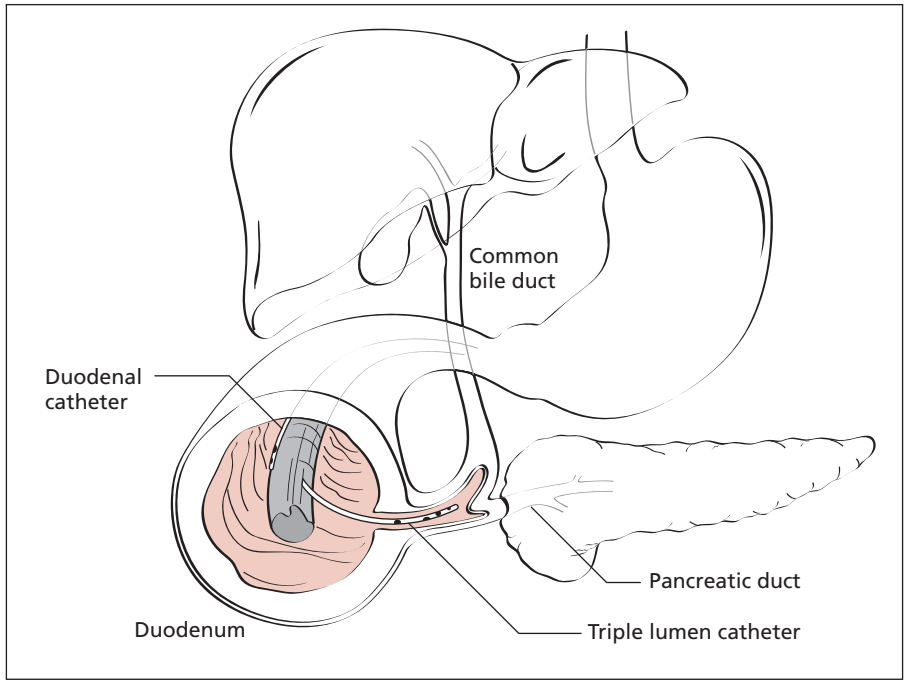

Fig. 1 Sphincer of Oddi manometry using a triple lumen perfused catheter. The catheter is introduced into the bile duct via the biopsy channel of a duodenoscope. The recording ports of the catheter are positioned to register pressure changes from the sphincter. A separate catheter attached to the endoscope records duodenal pressure.

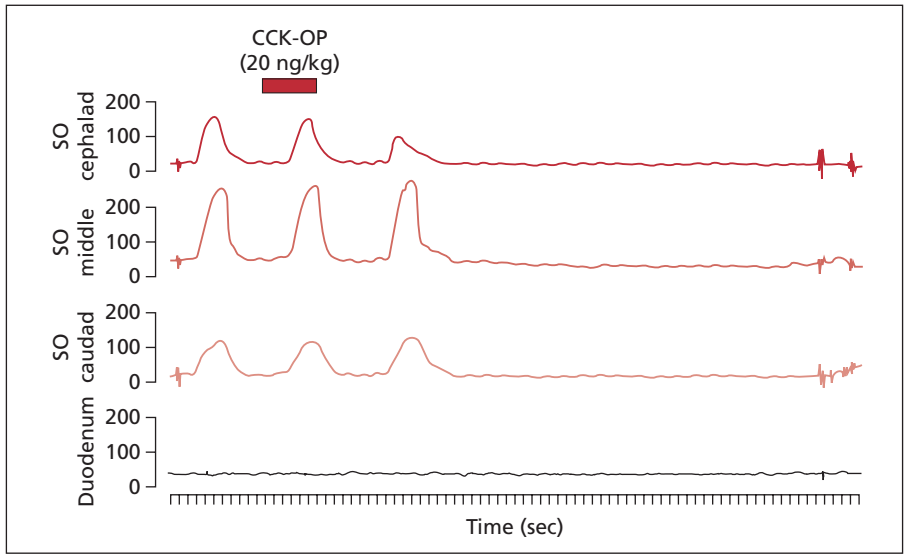

Fig. 2 Recording from the Sphincter of Oddi and a separate duodenal catheter. The sphincter contractions are characterized by phasic contractions which are superimposed on a basal pressure. Administration of the octapeptide of cholecystokinin produces inhibition of the phasic contractions and a fall in basal pressure.

Table 3 Pressures recorded from the sphincters of Oddi of normal subjects.

	Normal		Abnormal
	Median	Range	
Basal pressure (mmHg)	15	3–35	> 40
Amplitude (mmHg)	135	95–195	> 300
Frequency (n/min)	4	2–6	> 7
Sequences (%)			
Antegrade	80	12–100	
Simultaneous	13	0–50	
Retrograde	9	0–50	

Analysis of the direction of propagation of the phasic contractions during a continuous 3-min period demonstrated that the majority of contractions (60%) are orientated in an antegrade direction from the common bile duct towards the duodenum. A smaller number of contractions occurred either simultaneously (24%) or had a retrograde orientation (15%). Intravenous bolus injection of CCK octapeptide (20 ng/kg) normally produces inhibition of the phasic contractions and a fall in the basal sphincter of Oddi pressure. Table 3 shows the pressures recorded from the sphincter of Oddi of normal subjects. Studies from patients with T-tubes inserted in the common bile duct following bile duct exploration [39] have shown that the frequency of sphincter of Oddi phasic contractions during fasting exhibits a periodicity in relation to duodenal MMC, similar to that demonstrated in the opossum.

Following the ingestion of a meal, bile flow across the sphincter of Oddi is promoted by inhibition or reduction in the amplitude of the phasic contractions and a fall in the sphincter of Oddi basal pressure. This effect on the human sphincter of Oddi is similar to that following intravenous injection of the CCK octapeptide. Consequently, in man, unlike the American opossum, bile flow occurs mainly between sphincter of Oddi phasic contractions during the period of diastole. The phasic contractions do propel small volumes of bile into the duodenum, but this is not the major means by which bile flow occurs. The phasic contractions in man may function to prevent reflux of duodenal contents into either the bile or the pancreatic ducts, and to maintain the ducts free from small debris. In order to promote flow across the human sphincter of Oddi, inhibition or reduction in the phasic contractions and a fall in basal pressure is necessary.

References

1 Glenn F, Grafe WR, Jr (1966) Historical events in biliary tract surgery. *Arch Surg* 93, 848–852.

2 Oddi R (1887) D'une disposition a sphincter speciale de l'ouverture du canal cholidoque. *Arch Ital Biol* 8, 371–322.

3 Boyden EA (1937) The sphincter of Oddi in man and certain representative mammals. *Surgery* 1, 24–37.

4 Hand BH (1963) An anatomical study of the choledochoduodenal area. *Br J Surg* 50, 486–494.

5 Toouli J, Geenen JE, Hogan WJ *et al.* (1982) Sphincter of Oddi motor activity: a comparison between patients with common bile duct stones and controls. *Gastroenterology* 82, 111–117.

6 Tansy MF, Salkin L, Innes DL *et al.* (1975) The mucosal lining of the intramural common bile duct as a determinant of ductal opening pressure. *Am J Dig Dis* 20, 613–625.

7 Burnett W, Gairns FW, Bacsich J (1964) Some observations on the innervation of the extrahepatic biliary system in man. *Ann Surg* 159, 8–26.

8 Sundler F, Alumets J, Hakanson R *et al.* (1977) VIP innervation of the gallbladder. *Gastroenterology* 72, 1375–1377.

9 Wen-Qin Cai, Gabella G (1983) Innervation of the gallbladder and biliary pathways in the guinea pig. *J Anat* 136, 97–109.

10 Padbury RTA, Furness JB, Baker RA *et al.* (1993) Projection of nerve cells from the duodenum to the sphincter of Oddi and gallbladder of the Australian possum. *Gastroenterology* 104, 130–136.

11 Saccone GTP, Harvey JR, Baker RA *et al.* (1994) Intramural neural pathways between the duodenum and sphincter of Oddi in the Australian brush-tailed possum *in vivo*. *J Physiol* 481(2), 447–456.

12 Wood JR, Svanvik J (1983) Gallbladder water and electrolyte transport and its regulation. *Gut* 24, 579–593.

13 Wood JR, Brennan LJ, Hombrey JM *et al.* (1982) Effects of regulatory peptides on gallbladder function. *Scand J Gastroenterol* 17(Suppl.), 78.

14 Thornell E, Jansson R, Kral JG *et al.* (1979) Inhibition of prostaglandin synthesis as a treatment of biliary pain. *Lancet* 1, 584.

15 Takahashi I, Suzuki T, Aizawa *et al.* (1982) Comparison of gallbladder contractions induced by motilin and cholecystokinin in dogs. *Gastroenterology* 82, 419–424.

16 Toouli J, Bushell M, Stevenson G *et al.* (1986) Gallbladder emptying in man related to fasting duodenal migrating motor contractions. *Aust NZ J Surg* 56, 147–151.

17 Weiner I, Kazutomo I, Fagan CJ *et al.* (1981) Release of cholecystokinin in man, correlation of blood levels with gallbladder contraction. *Ann Surg* 194, 321–327.

18 Johnson FE, Boyden EA (1952) The effect of double vagotomy on the motor activity of the human gallbladder. *Surgery* 32, 591–601.

19 Benevantano TC, Rosen RG (1969) The physiological effect of acute vagal section of canine biliary dynamics. *J Surg Res* 9, 331–334.

20 Persson CGA (1972) Adrenoreceptors in the gall bladder *Acta Pharmacol* 32, 177–185.

21 Scott GW, Otto WJ (1979) Resistance and sphincter-like properties of the cystic duct. *Surg Gynaecol Obstet* 149, 177–182.

22 Pitt HA, Roslyn JJ, Kuchenbocker SL *et al.* (1981) The role of cystic duct resistance in the pathogenesis of cholesterol gallstones. *J Surg Res* 30, 508–514.

23 Toouli J, Watts J McK (1971) In vitro motility studies on the canine and human extrahepatic biliary tracts. *Aust NZ J Surg* 40, 380–387.

24 Le Quesne LP, Wihtsid CG, Hand BT (1959) The common bile duct after cholecystectomy. *Br Med J* 1, 329–332.

25 Hunt DR, Scott AJ (1989) Changes in bile duct diameter after cholecystectomy: 5 year perioperative study. *Gastroenterology* 97, 1485–1488.

26 Watts J McK, Dunphy JE (1966) The role of the common bile duct in biliary dynamics. *Surg Gynaecol Obstet* 122, 1207–1281.

27 Toouli J, Dods WJ, Honda R *et al* (1983) Motor function of the opossum sphincter of Oddi. *J Clin Invest* 71, 208–220.

28 Grivell MB, Woods CM, Grivell AR *et al.* (2004) The possum sphincter of Oddi pumps or resists flow depending on common bile duct pressure: a multilumen manometry study. *J Physiol* 558(Pt 2), 611–622.
29 Behar J, Biancani P (1980) Effect of cholecystokinin and the octapeptide of cholecystokinin on the feline sphincter of Oddi and gallbladder. Mechanisms of action. *J Clin Invest* 66, 1231–1239.
30 Woods CM, Toouli J, Saccone GT (2003) A2A and A3 receptors mediate the adenosine-induced relaxation in spontaneously active possum duodenum *in vitro*. *Br J Pharmacol* 138(7), 1333–1339.
31 Baker RA, Saccone GTP, Toouli J (1993) Nitric oxide mediates nonadrenergic, noncholinergic neural relaxation of the sphincter of Oddi of the Australian brush tailed possum. *Gastroenterology* 105, 1746–1753.
32 Onesmo B, Balemba MJ, Salter GM (2004) Innervation of the extrahepatic biliary tract. *Anat Rec A Discov Mol Cell Evol Biol* 280(1), 836–847.
33 Pitt HA, Doty JE, Roslyn JJ *et al.* (1981) The role of altered extrahepatic biliary function in the pathogenesis of gallstones after vagotomy. *Surgery* 90, 418–425.
34 Honda R, Toouli J, Dodds WJ *et al.* (1982) Relationship of sphincter of Oddi spike bursts to gastro-intestinal myoelectric activity in conscious opossums. *J Clin Invest* 69, 770–778.
35 Woods CM, Mawe GM, Toouli J *et al.* (2005) Sphincter of Oddi: understanding its control and function. *Neurogastroenterol Motility* 17, 31–40.
36 Hess W (1979) Physiology of the sphincter of Oddi. In: Classen M, Geenen J, Kawai K (eds) *The Papilla Vateri and its Diseases*. Proceedings of the International Workshop of the World Congress of Gastroenterology held in Madrid, 1978. Köln: Verlag Gerhard Witzstock, pp. 14–21.
37 Cushieri A, Hughes JH, Cohen M (1972) Biliary pressure studies during cholecystectomy. *Br J Surg* 59, 267–273.
38 Butsch WL, McGowan JM, Waslters W (1936) Clinical studies on the influence of certain drugs in relation to biliary pain and to the variations in intrabiliary pressure. *Surg Gynaecol Obstet* 63, 451–456.
39 Geenen JE, Hogan WJ, Dodds WJ *et al.* (1980) Intraluminal pressure recording from the human sphincter of Oddi. *Gastroenterology* 78, 371–324.

2.7 Immunology of the liver

2.7.1 Cytokines in liver physiology and pathology

Tom Luedde and Christian Trautwein

Cellular communication by cytokines

It is of fundamental importance that cells are able to communicate with each other. This is achieved by the interaction of cellular receptors, which signal internally to the nucleus, and external factors, which are able to bind these receptors. Cytokines are small-molecular-weight messengers secreted by one cell to alter the behaviour of either itself (autocrine messenger), a closely related cell (paracrine messenger) or cells in different organs (endocrine messenger). Whereas most cytokines are soluble, some may be membrane bound, e.g. Fas ligand (FasL). They are produced by virtually all cell types and have a broad variety of functions. Cytokines produced by leukocytes with effects mainly on other white blood cells are named interleukins (ILs). Cytokines with a chemoattractant activity are called chemokines. Cytokines that interfere with viral replication are called interferons, and those causing differentiation and proliferation of stem cells are called colony-stimulating factors [1].

Basic principles of cytokine action in the liver

The liver is an exceptional organ in terms of its metabolic, synthetic and detoxifying functions. In addition, it has the unique potential to regenerate after tissue loss and, for example, plays an important role in the regulation process that keeps blood glucose stable. All these and many other functions represent the organ's ability to execute the proper reaction towards the body's demands and keep it in homeostasis. Therefore, the liver appears to be a preferred source for and target of cytokine signalling, and the regulation of the network connecting cytokines, receptors and signalling pathways in the liver is tremendously complex.

Initially, knowledge about the function of cytokines in the liver was mainly based on studies in cell culture systems using immortalized hepatoma cell lines. This enabled the elucidation of signalling networks downstream of cytokine receptors, but these experimental systems did not allow analysis of intercellular communication in a physiological milieu. Subsequently, the use of transgenic animals and the gene knockout technology facilitated the analysis of cytokine effects in an intact organism, but again these studies were limited by the embryonic lethality of mice with germline deletion(s) of crucial genes. Currently, conditional gene targeting based on the cre/loxP system has emerged as a powerful new tool for the study of gene functions *in vivo* in the adult mouse. This technique allows a specific gene to be deleted only in a particular tissue, leaving its expression elsewhere in the body intact.

Cytokine pathways evolved very early in evolution. For example, the nuclear factor (NF)κB signalling pathway – a key mediator of the action of tumour necrosis factor (TNF) in higher organisms – is already found in *Drosophila* and molluscs [2], where its function is to combat infection. This physiological function has mainly been preserved in higher organisms, but the same pathway is also integrated into many other organs' functions, e.g. during development, growth control or the control of cell death. NFκB signalling withholds several 'control elements' that keep this pathway and its components in a stable balance to avoid organ damage under normal conditions. In fact, increasingly, studies now underscore the fact that the deregulation of cytokine-related pathways in the liver may amplify or mediate liver damage in response to various pathogenic agents.

Cytokines are key modulators of liver function

Hepatocytes express a variety of receptors for cytokines, which can be divided into different families (Table 1). Among these, death receptor ligands from the TNF family of cytokines are involved in almost all critical processes in liver physiology and pathology. This family comprises several ligands, e.g. TNF, FasL

Table 1 Cytokines in the liver.

TNF family	IL-6 family	IL-1 family	Growth factors	Interferons	Chemokines
TNF	IL-6	IL-1α	HGF	IFNγ	IL-8
FasL	LIF	IL-1β	EGF		ENA-78
TRAIL	OSM		TGFα		IP-10
	Cardiotropin 1		TGFβ		MIP-2
	CNF		IGF-I		
	IL-11		IGF-II		
			PDGF		
			FGF-1 and FGF-2		
			Activin A		

TNF, tumour necrosis factor; FasL, Fas ligand; TRAIL, tumour necrosis factor-related apoptosis-inducing ligand; IL-6, interleukin 6; LIF, leukaemia inhibitory factor; OSM, oncostatin M; CNF, ciliary neurotropic factor; IL-11, interleukin 11; IL-1α/β, interleukin 1α/β; HGF, hepatocyte growth factor; EGF, epidermal growth factor; TGFα/β, transforming growth factor α/β; IGF-I/II, insulin-like growth factor I/II; PDGF, platelet-derived growth factor; FGF-1/2, fibroblast growth factor 1/2; IFNγ, interferon γ; IL-8, interleukin 8; ENA-78, epithelial neutrophil-activating peptide 78; IP-10, interferon-inducible protein 10; MIP-2, macrophage inflammatory protein 2.

and tumour necrosis factor-related apoptosis-inducing ligand (TRAIL), which exist in a soluble or cell bound form and activate structurally related receptor proteins known as the TNF receptor superfamily, including TNF receptor 1 (TNF-R1), TNF-R2, Fas and death receptor 3 (DR3), DR4 and DR5 [3]. The IL-6 family of cytokines has several members which, by interacting with adaptor molecules, complex with a signal transducing molecule named gp130, thereby activating downstream pathways and signal molecules such as the signal transducers and activators of transcription (STAT) (mainly STAT-3) [4]. IL-1 members activate similar downstream targets as TNF, e.g. NFκB. Moreover, receptors for growth factors, such as epidermal growth factor (EGF), transforming growth factors (TGF)α and TGFβ, hepatocyte growth factor (HGF), insulin-like growth factor (IGF)-1 and IGF-2, may control proliferation of hepatocytes during embryogenesis or liver regeneration [5].

Non-parenchymal cells (NPCs) of the liver, function both as recipients of cytokine-driven messages, and also synthesize cytokines. Kupffer cells (KCs), resident tissue macrophages, synthesize pro-inflammatory cytokines such as IL-1, IL-6 and TNF upon activation as a result of phagocytosis or binding of endotoxin [6]. These released cytokines stimulate hepatocytes and other non-parenchymal liver cells in a paracrine manner. Activation of KCs may also be induced by cytokines such as interferon gamma (IFNγ), the receptors of which are expressed on KCs. Chemokines released by KCs and hepatic stellate cells (HSCs) mediate migration of neutrophils and blood monocytes. Moreover, sinusoidal endothelial cells are targets for pro-inflammatory cytokines to express cell adhesion molecules and may also produce cytokines [7]. Cytokines are also critical regulators of hepatic fibrosis and injury (see Chapter 6.2, Cellular and molecular pathobiology, pharmacological intervention and biochemical assessment of liver fibrosis).

Due to the complexity of the cytokine network, it is not the intention of this chapter to describe in detail the action of all these cytokines in the liver. For a brief overview, Table 2 summarizes the functions of some key cytokines in models of liver physiology and pathology. In contrast, we will focus mainly on the action of one cytokine as an example of how cytokines and cytokine-dependent signalling pathways are involved in the physiological function of the liver and how their alteration can lead to the development and progression of liver disease. Recent studies have revealed that alterations of TNF and TNF-dependent signalling pathways have an enormous impact in different liver disease models and thus might be an attractive target for pharmaceutical intervention, as has become the case for inflammatory bowel disease or rheumatoid arthritis [8].

Death receptor ligands modulate cell death in the liver

Excessive hepatocyte apoptosis and necrosis have been implicated in a number of acute and chronic liver diseases, e.g. viral and autoimmune hepatitis, cholestatic disease, alcoholic or drug-/toxin-induced liver injury and transplantation-associated liver damage, including graft rejection [9]. Studies in patients and animal models have strongly implicated death receptor ligands such as TNF in the induction of apoptosis and in triggering destruction of the liver [10].

TNF was originally identified by its capacity to induce haemorrhagic necrosis in mouse tumours [11], but severe side-effects led to a failure of its use as a systemic anticancer chemotherapeutic agent [12,13]. A very prominent effect was the direct cytotoxic role of TNF for human hepatocytes, resulting in increased levels of serum aminotransferases and bilirubin. Since then, many clinical studies have underscored the crucial role of TNF in fulminant hepatic failure (FHF) and other liver diseases. TNF participates in many forms of hepatic pathology, including ischaemia–reperfusion injury, alcoholic and viral hepatitis and injury from hepatotoxins [14–17]. Exogenous TNF induces

Table 2 Cytokine function in different models of liver physiology and pathology.

Biological model and reference	Cytokines involved	Cytokine function
Liver development [6]	FGF-1 and FGF-2	Differentiation of hepatic endoderm
	HGF	Growth of hepatoblasts
	OSM	Differentiation of hepatocytes
	TGFβ	Induction of Vg1
Liver regeneration [5,65]	TNF	Induction of IL-6 production in KCs
	TNF, IL-6	Priming of hepatocytes ($G_0 \rightarrow G_1$)
	HGF, EGF, TGFα	Growth factors, cell cycle progression (G1→S)
	TGF-β, Activin A	Inhibition of liver regeneration
	IFNγ	Inhibition of liver regeneration
	ENA-78, MIP-2 and other CXC chemokines	Stimulation of hepatocyte proliferation
Acute phase response [6,53]	IL-1α/β, TNF	Stimulation of synthesis of type 1 acute-phase proteins (APPs) (C-reactive protein, serum amyloid-A)
	IL-6, CNF, OSM, LIF	Stimulation of synthesis of type 2 APPs (fibrinogen, haptoglobin)
Liver fibrosis [6]	TNF, IL-1, IL-6, IL-8	Damage factors
	TGFβ, PDGF, TNF, IGF-1, IL-1	Activating factors
	TGFβ, PDGF, TNF	Surviving factors
Acute and chronic liver failure [9]	TNF, FasL, TGFβ	Hepatocyte apoptosis, necrosis
	IL-6	Survival signal
Liver cancer [6,66]	HGF, IGF-2, TGFα, TGFβ	Hepatic mitogens
	TNF, IL-1, HGF, EGF	Metastasis
	TNF	Possibly pro- and anti-tumorogenic effects, pro-proliferative vs. pro-apoptotic

FGF-1/2, fibroblast growth factor 1/2; HGF, hepatocyte growth factor; OSM, oncostatin M; TGFβ, transforming growth factor β; TNF, tumour necrosis factor α; IL-6, interleukin 6; EGF, epidermal growth factor; TGFα, transforming growth factor α; IFNγ, interferon γ; ENA-78, epithelial neutrophil-activating peptide 78; MIP-2, macrophage inflammatory protein 2; CXC, IL-1α/β, interleukin 1α/β, CNF, ciliary neurotropic factor; LIF, leukaemia inhibitory factor; IL-8, interleukin 8; PDGF, platelet-derived growth factor; IGF-I, insulin-like growth factor I; FasL, Fas ligand; IGF-2, insulin-like growth factor 2; TGFα, transforming growth factor α.

FHF and hepatocyte apoptosis in combination with other toxins [17]. In patients with FHF, serum levels of TNF, TNF-R1 and TNF-R2 are markedly increased and these changes correlate directly with disease activity. In explanted livers of patients with FHF, infiltrating mononuclear cells expressed high amounts of TNF and hepatocytes overexpressed TNF-R1 [18]. Thus, it is very likely that the TNF system is involved in the pathogenesis of hepatic failure in humans, and its significance has also been shown clearly in several animal models of hepatic failure, e.g. the endotoxin/D-galactosamine (GalN) and the concanavalin A (ConA) models [19,20].

TNF activates pro- and antiapoptotic signalling cascades

(see also Chapter 3.1)

Activation of the caspase cascade

Fas and TNF facilitate programmed cell death in a similar manner by activation of caspases. The most important target of both pathways orchestrating cellular death is the aspartate-specific cysteine protease or caspase cascade, consisting of initiator caspases such as caspases-8 and -9 and executioner caspases, e.g. caspase-3, -6 and -7. As proteolytic cleavage generates the mature caspases, one way in which these enzymes are activated is via the action of proteases, including other caspases [21]. TNF signals through two distinct cell surface receptors, TNF-R1 and TNF-R2, of which TNF-R1 initiates the majority of TNF's biological activities. Binding of TNF to its receptor leads to the release of the inhibitory protein silencer of death domains (SODD) from TNF-R1's intracellular domain. This leads to the recognition of the intracellular TNF-R1 domain by the adapter protein TNF receptor-associated death domain (TRADD), which in turn recruits Fas-associated death domain (FADD). FADD recruits caspase-8 to the TNF-R1 complex, where it becomes activated and initiates the protease cascade, leading to activation of executioner caspases and apoptosis (Fig. 1). In contrast to TNF-dependent signalling, Fas can interact directly with the death domain of FADD without recruiting TRADD [22,23]. In several studies, involvement of mitochondria and the release of

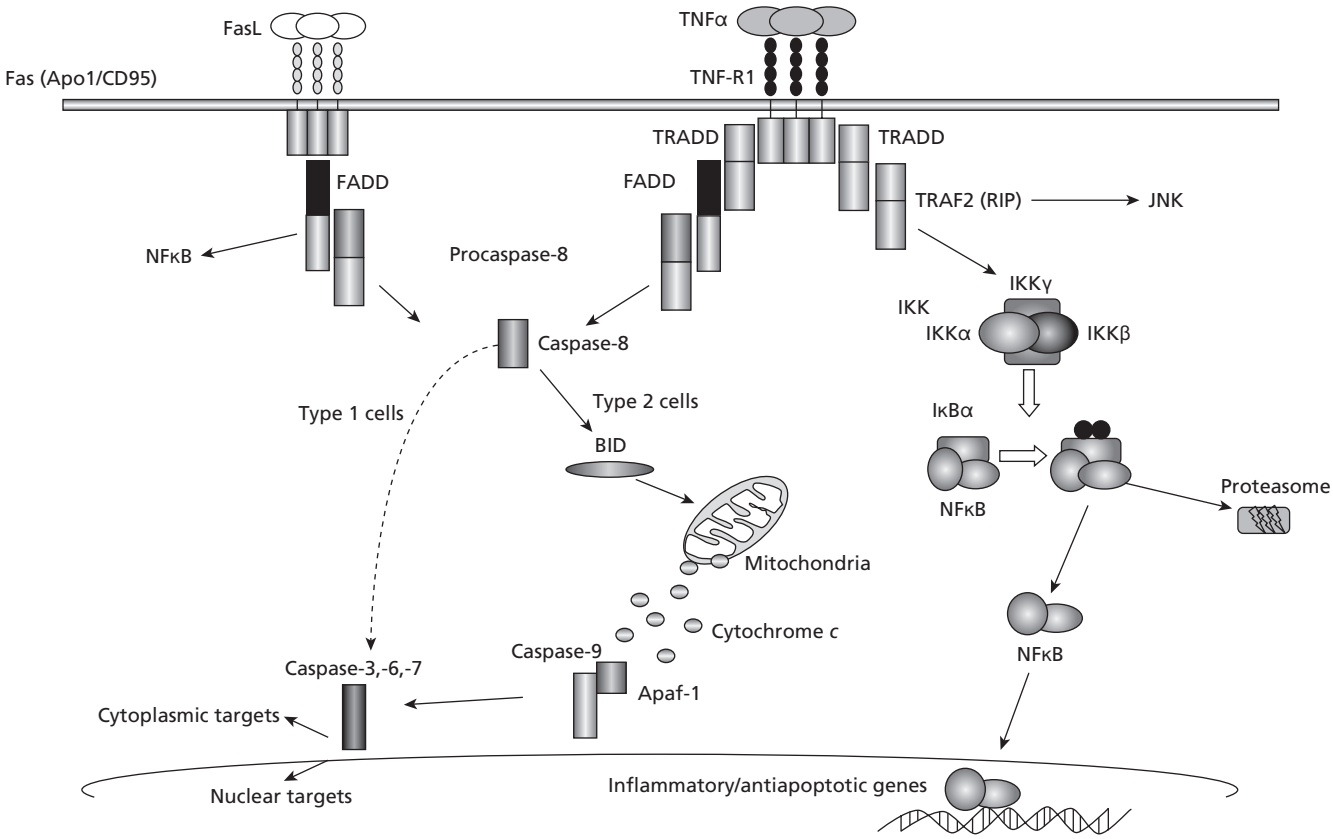

Fig. 1 FasL- and TNFα-dependent signalling in the liver.

cytochrome *c* in the apoptotic process has been demonstrated, and this was also shown for Fas- and TNF-mediated apoptosis in the liver [24,25].

Activation of the NFκB pathway

In addition to activation of caspases, ligand binding of TNF to its receptor also leads to the activation of alternative pathways, e.g. the nuclear factor (NF)κB pathway. Activation of the NFκB pathway is mediated by interaction of both TNF receptors with the receptor-associated factors 1 and 2 (TRAF-1 and TRAF-2). NFκB is a transcription factor consisting of a dimer of different subunits (e.g. p50 and p65), which is normally retained in the cytoplasm through interaction with its inhibitor IκB. TNF-induced activation of NFκB relies on phosphorylation of two conserved serines (Ser32 and Ser36 in human IκBα) in the *N*-terminal regulatory domain of IκBs. After phosphorylation, the IκBs undergo a second posttranslational modification: polyubiquitination followed by the degradation of IκB proteins by the proteasome, thus releasing NFκB from its inhibitory IκB binding partner, so that it can translocate to the nucleus and activate transcription of NFκB-dependent target genes [26]. A high-molecular-weight complex that mediates the phosphorylation of IκB has been purified and characterized. This complex consists of three tightly associated IκB kinase (IKK) polypeptides: IKK1 (also called IKKα) and IKK2 (IKKβ) are the catalytic subunits of the kinase complex [27–29]. Moreover, it contains a regulatory subunit called NEMO (NFκB essential modulator), IKKγ or IKKAP-1 [30–32]. In the context of TNF-mediated apoptosis, NFκB appears to provide a prosurvival signal. Evidence that NFκB governs critical antiapoptotic proteins comes from well-described animal models. Injection of TNF into mice and addition of TNF to hepatic cells resulted in activation of nuclear translocation and of DNA binding of NFκB [33].

In contrast to Fas-mediated apoptosis, hepatocytes are resistant to apoptosis induced by TNF or lipopolysaccharide (LPS), a potent inducer of endogenous TNF in the liver, unless they are treated with inhibitors of transcription (e.g. cycloheximide or actinomycin D), which block the expression of (antiapoptotic) proteins [17,34,35]. Specific blockade of NFκB activation by adenoviral-directed overexpression of the NFκB superrepressor IκB (which retains the dimeric NFκB in the cytoplasm as it contains mutations at the phosphorylation sites) significantly enhanced TNF-mediated apoptosis of hepatocytes [36]. A similar result was obtained by treatment of hepatocytes with the proteasome inhibitor lactacystin, which prevents degradation of IκBs, and an antibody against p65 protein [37].

Further evidence for the central role of the NFκB pathway in preventing apoptosis in hepatocytes comes from genetic

experiments. Knockout mice lacking the p65 subunit of NFκB die between embryonic (E) days 15 and 16 as a result of fetal hepatocyte apoptosis [38]. This is caused by increased sensitivity towards TNF, as TNF/p65 double-deficient mice are rescued from embryonic lethality [39]. It is presumed to involve the transcriptional induction of various apoptotic suppressors. Among these genes are the cellular inhibitors of apoptosis (c-IAPs), e.g. c-IAP1 and c-IAP2, which bind directly and inhibit effector caspases, such as caspase-3 and caspase-7, and prevent activation of procaspase-6 and procaspase-9 [40].

TNF in experimental disease models of the liver

TNF/NF-κB in liver regeneration

(see also Chapter 2.5.2)

In mammals, the liver is distinguished by its capacity to regenerate lost parenchymal mass in response to, for example, surgical resection, viral injury or toxic exposure [5]. Therefore, it has been a major challenge to evaluate the extra- and intracellular events that orchestrate this highly complex process driving quiescent, fully differentiated hepatocytes through distinct stages including priming of hepatocytes, cell cycle progression, proliferation and cessation of regeneration [41]. A well-established model for studying liver regeneration is that of partial (two-thirds) hepatectomy (PH) in rodents.

Several growth factors can interact with receptors on the cell membrane activating intracellular signalling pathways involved in target gene activation in hepatocytes. The growth factors have been characterized according to their mitogenic capacity. Therefore, at present, hepatocyte growth factor (HGF), epidermal growth factor (EGF) and transforming growth factor (TGF)α can be classified as mitogens, while insulin and epinephrine are classified as comitogens. These factors activate intracellular signalling cascades such as the Ras/MAPkinase pathway, which couple the extracellular signals to the major regulating molecules of the cell cycle machinery, such as the cyclin-dependent kinases (CDK) [41].

Besides the direct role of growth factors, cytokines such as TNF and IL-6 are also involved in priming hepatocytes towards cell cycle progression. Initially, it was found that there is cascade of events leading, first, to elevated TNF and, consecutively, to increased IL-6 serum levels. Additionally, experiments indicated that anti-TNF antibodies inhibit proliferation of hepatocytes, again indicating that the molecule might be involved in controlling cell cycle progression of hepatocytes. The importance of TNF and NFκB signalling was further confirmed by the fact that liver regeneration is defective in TNFR-1 knockout mice, which do not show hepatic NFκB activation after PH [42]. However, it remains uncertain whether NFκB is able directly to promote hepatocyte proliferation in this model. NFκB can directly stimulate the transcription of genes that encode G1 cyclins, and a κB site is present within the cyclin D1 promoter [43,44]. However, recent results questioned a direct involvement in hepatocytes and highlighted its role in non-parenchymal cells (NPC) such as KCs. Chaisson *et al.* [45] used transgenic mice that expressed the non-degradable IκBα superrepressor specifically in hepatocytes, and these mice showed normal hepatocyte proliferation after PH. Moreover, mice lacking the IKKβ (IKK2) subunit in hepatocytes showed normal liver regeneration [46]. TNF-induced NFκB activation in NPCs leads to the production of another important cytokine, IL-6. IL-6 is not absolutely necessary for liver regeneration, but has a protective, antiapoptotic function in this process [47], underscoring the fact that, instead of a direct proliferative effect, TNF-dependent NFκB activation in NPC is part of an IL-6 production pathway that protects hepatocytes from apoptosis during liver regeneration.

TNF/NF-κB in liver cancer (see also Chapter 18.2.1)

According to Hanahan and Weinberg [48], tumorigenesis requires six essential alterations to normal cell physiology: self-sufficiency in growth signals; insensitivity to growth inhibition; evasion of apoptosis; immortalization; sustained angiogenesis; and tissue invasion and metastasis. As outlined in this chapter, TNF and NFκB are able to induce several of these cellular alterations. A recent study demonstrated constitutive activation of NFκB in hepatocellular carcinoma (HCC) [49]. Moreover, two important animal studies using transgenic and conditional knockout mice that alter expression of specific members of the TNF/NFκB axis have highlighted the essential function of this pathway in the initiation and promotion of carcinogenesis in the liver:

In one study, the function of TNF/NFκB has been studied in an inflammatory liver carcinogenesis model by using the mdr-2 knockout mouse that develops a chronic cholangitis and subsequently hepatocellular carcinomas (HCC) [50]. The authors demonstrated that early neoplastic events in this model are related to the biliary system and occur independently of cytokine effects on hepatocytes. In contrast, during later steps of tumour promotion, TNF is expressed mainly by endothelial and inflammatory cells, subsequently leading to activation of NFκB in the surrounding hepatocytes. Interestingly, when this activation of NFκB is blocked by transgenic overexpression of a non-degradable IκB form, no effect on early events of carcinogenesis are detected, whereas during later stages of tumorigenesis the number and size of tumours was markedly decreased in these mice compared with mice that could activate NFκB, which was accompanied by stronger apoptosis of hepatocytes. A similar effect could be shown by treatment with anti-TNF-antibodies. Thus, the authors concluded that acquisition of oncogenic mutations renders hepatocytes specifically sensitive towards apoptosis, which has to be blocked by NFκB activated by TNF in order for promotion of HCC.

In another study, the different outcomes of NFκB function in hepatocytes were compared with those in non-parenchymal liver

cells including KCs in a chemical liver carcinogenesis model [51]. After exposure of young mice to the carcinogenic drug diethylnitrosamine (DEN), hepatocytes undergo apoptosis, which is enhanced in mice with a conditional IKK2 knockout that cannot activate NFκB specifically in hepatocytes. This increased apoptosis then leads to the release of cytokines including TNF and IL-6 from hepatic KCs, which in turn stimulates hepatocellular proliferation leading to increased size and number of liver tumours, compared with wildtype mice. The central role of cytokines released by the non-parenchymal liver cells in this model is underscored by the fact that mice also lacking IKK2 in hepatocytes and KCs and which have a defect in NFκB activation in both cell types secrete less of the cytokines such as TNF and IL-6 and therefore develop less rather than more HCCs.

Taken together, these and similar studies have highlighted the new therapeutic options of cytokine targeting in the liver. Instead of treating the primary cause of inflammation, which is often not possible in chronic hepatitis, treatment of the secondary events that lead to tumours, (e.g. anti-TNF-dependent strategies), might be a more realistic aim in cancer treatment.

TNF/NF-κB in local and systemic insulin-resistance (see also Chapter 2.3.1)

Recent studies have revealed that local inflammation and cytokines produced by liver cells also have a strong impact on systemic functions. For example, feeding of mice with a high-fat diet that leads to systemic insulin resistance is accompanied by hepatic NFκB activation and increased secretion of the cytokines TNF, IL-6 and IL-1β [52]. Furthermore, by constitutively activating NFκB in the liver using the hepatocyte-specific overexpression of a dominant active IKK2 form, an increased local and systemic insulin resistance is observed in these mice, even when fed a normal diet. This effect was mediated by an increased release of NFκB-dependent cytokines from the liver and was accompanied by a reduced insulin receptor-dependent signalling. Complementing this finding, the inhibition of hepatic NFκB signalling leads to diminished cytokine release and decreased insulin resistance in mice fed with a high-fat diet [53], thus underscoring the therapeutic potential of cytokine modulation in the development of diabetes mellitus.

IL-6: a protective cytokine in liver failure?

IL-6 belongs to a family of cytokines comprising IL-6, IL-11, leukaemia inhibitory factor (LIF), oncostatin M, ciliary neurotropic factor, novel neurotrophin 1/B cell stimulating factor 3 and cardiotropin 1 [4]. IL-6 binds to hepatocytes by interacting with an 80-kd membrane glycoprotein (gp80) that complexes with a signal transducing molecule, gp130 (Fig. 2a). Binding of gp130 leads to dimerization of the intracellular domains of two gp130 molecules, which promotes association

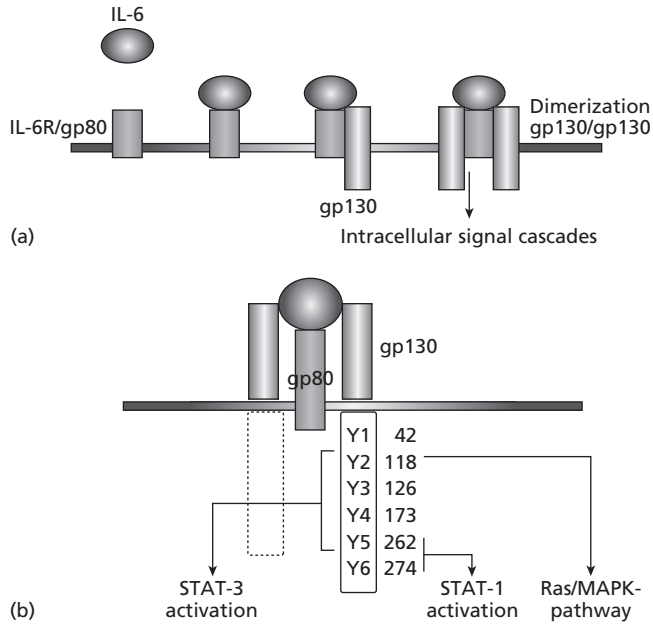

Fig. 2 IL-6 dependent signalling. (a) IL-6 binding and receptor dimerization. (b) Signal transduction through gp130.

with receptor-associated Janus kinases (JAKs: JAK1, JAK2, and TYK). The JAKs become activated and phosphorylate different tyrosine residues on the gp130 molecule. Depending on the location of the phosphorylated tyrosines, signal transducers and activators of transcription (STAT) proteins (mainly STAT-3) and also the Ras/mitogen-activated protein (MAP) kinase pathway become activated and trigger numerous downstream effects mediated by the signalling of IL-6 and related cytokines (Fig. 2b) [4].

As outlined above, IL-6 is one of the key regulators of the initial steps of liver regeneration. An important role of IL-6-dependent signalling in the liver is also attributed to the induction of the acute phase response [54,55]. STAT-3 participates in transcriptional activation. gp130 may also promote anti-apoptotic effects in different cell types. For example, activation of STAT-3 in B cells and human myeloma cells activates anti-apoptotic genes such as *BCL2* and *BCLXL*, protecting them from Fas-dependent apoptosis [56]; similar results occur in T cells: STAT-3-deficient T cells are severely impaired in IL-6-induced proliferation – due to the profound defect in IL-6-mediated prevention of apoptosis. In hepatocytes, IL-6 protects from transforming growth factor (TGF)β-induced apoptosis by blocking TGFβ-induced activation of caspase-3 via rapid tyrosine phosphorylation of phosphatidylinositol 3 kinase (PI 3 kinase), which constitutively activates the protein kinase Akt [57].

In humans, there is strong evidence that IL-6 is directly involved in the pathogenesis of different diseases, including multiple myeloma and congestive heart disease [58,59]. Recently, we analysed the potential role of IL-6 in the development of

acute and chronic liver injury in humans and examined its pathophysiological basis in animal models. We found a direct correlation of IL-6 expression in serum and liver tissue with disease progression in patients with FHF. Additionally, there was an abolished acute-phase response and an increased susceptibility to LPS-induced liver injury in mice deficient for functional gp130 in hepatocytes [60,61], allowing us to define genes that are protective during T cell-mediated liver injury [62].

Cytokines and cytokine-dependent pathways as a therapeutic target

As outlined above, a growing number of studies have implicated cytokines and cytokine-dependent pathways in the development of liver failure, chronic liver disease, hepatic inflammation and liver carcinogenesis. Numerous chemical compounds, monoclonal antibodies and viral vectors that inhibit or modulate cytokines (e.g., TNF or the NFκB pathway) are under development [63]. For example, pharmacological inhibitors of caspases, including the caspase-8 inhibitor IETD-CHO and the caspase-3 inhibitor DEVD-CHO, have shown beneficial effects in experimental *in vivo* models of TNFα- and Fas-induced liver failure [64,65]. However, the examples given in this chapter also emphasize the complexity of functions that these pathways regulate depending on the disease model or cell type. Therefore, the pharmacological inhibition of a specific molecule or pathway in a certain clinical setting might result in unpredictable and fatal consequences in the same or other tissues and organs. Currently, there is no pharmacological method that allows the specific targeting of molecules in a certain tissue. Hence, at present, animal models that allow gene targeting in a specific cell type will prove to be valuable tools to define more clearly the effects of the modulation of cytokines, cytokine receptors or cytokine-dependent pathways. Alternatively, future research efforts might highlight the role of more downstream effectors of cytokine pathways, the function of which can be attributed specifically to a certain role in pathogenesis such as carcinogenesis, which could then be targeted by a systemic drug therapy.

One of the most difficult problems in clinical hepatology is the progression of chronic inflammation, including chronic hepatitis or primary sclerosing cholangitis (PSC) towards hepatocellular or cholangiocellular carcinoma, respectively. Although huge diagnostic efforts are taken in the surveillance of these patients, cancer is still not always diagnosed in time for a curative treatment. With a more thorough understanding of the function of cytokines in the liver, gained from animal disease models, it might be possible to improve diagnostic tools as well as to develop drugs that inhibit or slow down the sequence from inflammation to cancer.

References

1 Parkin J, Cohen B (2001) An overview of the immune system. *Lancet* 357, 1777–1789.

2 Montagnani C, Kappler C, Reichhart JM *et al.* (2004) Cg-Rel, the first Rel/NF-kappaB homolog characterized in a mollusk, the Pacific oyster *Crassostrea gigas*. *FEBS Lett* 561, 75–82.

3 Schulze-Osthoff K, Ferrari D, Los M *et al.* (1998) Apoptosis signaling by death receptors. *Eur J Biochem* 254, 439–459.

4 Streetz KL, Luedde T, Manns MP *et al.* (2000) Interleukin 6 and liver regeneration. *Gut* 47, 309–312.

5 Michalopoulos GK, DeFrances MC (1997) Liver regeneration. *Science* 276, 60–66.

6 Decker K (1990) Biologically active products of stimulated liver macrophages (Kuppfer cells). *Eur J Biochem* 192, 245–261.

7 Ramadori G, Armbrust T (2001) Cytokines in the liver. *Eur J Gastroenterol Hepatol* 13, 777–784.

8 Siddiqui MA, Scott LJ (2005) Infliximab: a review of its use in Crohn's disease and rheumatoid arthritis. *Drugs* 65, 2179–2208.

9 Neuman MG (2001) Apoptosis in diseases of the liver. *Crit Rev Clin Lab Sci* 38, 109–166.

10 Luedde T, Liedtke C, Manns MP *et al.* (2002) Losing balance: cytokine signaling and cell death in the context of hepatocyte injury and hepatic failure. *Eur Cytokine Netw* 13, 377–383.

11 Carswell EA, Old LJ, Kassel RL *et al.* (1975) An endotoxin-induced serum factor that causes necrosis of tumors. *Proc Natl Acad Sci USA* 72, 3666–3670.

12 Feinberg B, Kurzrock R, Talpaz M *et al.* (1988) A phase I trial of intravenously-administered recombinant tumor necrosis factor-alpha in cancer patients. *J Clin Oncol* 6, 1328–1334.

13 Kimura K, Taguchi T, Urushizaki I *et al.* (1987) Phase I study of recombinant human tumor necrosis factor. *Cancer Chemother Pharmacol* 20, 223–229.

14 Colletti LM, Remick DG, Burtch GD *et al.* (1990) Role of tumor necrosis factor-alpha in the pathophysiologic alterations after hepatic ischemia/reperfusion injury in the rat. *J Clin Invest* 85, 1936–1943.

15 Felver ME, Mezey E, McGuire M *et al.* (1990) Plasma tumor necrosis factor alpha predicts decreased long-term survival in severe alcoholic hepatitis. *Alcohol Clin Exp Res* 14, 255–259.

16 Gonzalez-Amaro R, Garcia-Monzon C, Garcia-Buey L *et al.* (1994) Induction of tumor necrosis factor alpha production by human hepatocytes in chronic viral hepatitis. *J Exp Med* 179, 841–848.

17 Leist M, Gantner F, Naumann H *et al.* (1997) Tumor necrosis factor-induced apoptosis during the poisoning of mice with hepatotoxins. *Gastroenterology* 112, 923–934.

18 Streetz K, Leifeld L, Grundmann D *et al.* (2000) Tumor necrosis factor alpha in the pathogenesis of human and murine fulminant hepatic failure. *Gastroenterology* 119, 446–460.

19 Gantner F, Leist M, Lohse AW *et al.* (1995) Concanavalin A-induced T-cell-mediated hepatic injury in mice: the role of tumor necrosis factor. *Hepatology* 21, 190–198.

20 Pfeffer K, Matsuyama T, Kundig TM *et al.* (1993) Mice deficient for the 55 kd tumor necrosis factor receptor are resistant to endotoxic shock, yet succumb to *L. monocytogenes* infection. *Cell* 73, 457–467.

21 Martin SJ, Green DR (1995) Protease activation during apoptosis: death by a thousand cuts? *Cell* 82, 349–352.

22 Ashkenazi A, Dixit VM (1998) Death receptors: signaling and modulation. *Science* 281, 1305–1308.

23 Chen G, Goeddel DV (2002) TNF-R1 signaling: a beautiful pathway. *Science* 296, 1634–1635.

24 Bradham CA, Qian T, Streetz K *et al.* (1998) The mitochondrial permeability transition is required for tumor necrosis factor alpha-

mediated apoptosis and cytochrome c release. *Mol Cell Biol* 18, 6353–6364.
25 Yin XM, Wang K, Gross A *et al.* (1999) Bid-deficient mice are resistant to Fas-induced hepatocellular apoptosis. *Nature* 400, 886–891.
26 Yamamoto Y, Gaynor RB (2004) IkappaB kinases: key regulators of the NF-kappaB pathway. *Trends Biochem Sci* 29, 72–79.
27 DiDonato JA, Hayakawa M, Rothwarf DM *et al.* (1997) A cytokine-responsive IkappaB kinase that activates the transcription factor NF-kappaB. *Nature* 388, 548–554.
28 Mercurio F, Zhu H, Murray BW *et al.* (1997) IKK-1 and IKK-2: cytokine-activated IkappaB kinases essential for NF-kappaB activation. *Science* 278, 860–866.
29 Regnier CH, Song HY, Gao X *et al.* (1997) Identification and characterization of an IkappaB kinase. *Cell* 90, 373–383.
30 Mercurio F, Murray BW, Shevchenko A *et al.* (1999) IkappaB kinase (IKK)-associated protein 1, a common component of the heterogeneous IKK complex. *Mol Cell Biol* 19, 1526–1538.
31 Rothwarf DM, Zandi E, Natoli G *et al.* (1998) IKK-gamma is an essential regulatory subunit of the IkappaB kinase complex. *Nature* 395, 297–300.
32 Yamaoka S, Courtois G, Bessia C *et al.* (1998) Complementation cloning of NEMO, a component of the IkappaB kinase complex essential for NF-kappaB activation. *Cell* 93, 1231–1240.
33 FitzGerald MJ, Webber EM, Donovan JR *et al.* (1995) Rapid DNA binding by nuclear factor kappa B in hepatocytes at the start of liver regeneration. *Cell Growth Differ* 6, 417–427.
34 Lehmann V, Freudenberg MA, Galanos C (1987) Lethal toxicity of lipopolysaccharide and tumor necrosis factor in normal and D-galactosamine-treated mice. *J Exp Med* 165, 657–663.
35 Leist M, Gantner F, Bohlinger I *et al.* (1994) Murine hepatocyte apoptosis induced in vitro and in vivo by TNF-alpha requires transcriptional arrest. *J Immunol* 153, 1778–1788.
36 Nagaki M, Naiki T, Brenner DA *et al.* (2000) Tumor necrosis factor alpha prevents tumor necrosis factor receptor-mediated mouse hepatocyte apoptosis, but not fas-mediated apoptosis: role of nuclear factor-kappaB. *Hepatology* 32, 1272–1279.
37 Bellas RE, FitzGerald MJ, Fausto N *et al.* (1997) Inhibition of NF-kappa B activity induces apoptosis in murine hepatocytes. *Am J Pathol* 151, 891–896.
38 Beg AA, Baltimore D (1996) An essential role for NF-kappaB in preventing TNF-alpha-induced cell death. *Science* 274, 782–784.
39 Doi TS, Marino MW, Takahashi T *et al.* (1999) Absence of tumor necrosis factor rescues RelA-deficient mice from embryonic lethality. *Proc Natl Acad Sci USA* 96, 2994–2999.
40 Deveraux QL, Roy N, Stennicke HR *et al.* (1998) IAPs block apoptotic events induced by caspase-8 and cytochrome *c* by direct inhibition of distinct caspases. *EMBO J* 17, 2215–2223.
41 Fausto N (2000) Liver regeneration. *J Hepatol* 32, 19–31.
42 Yamada Y, Kirillova I, Peschon JJ *et al.* (1997) Initiation of liver growth by tumor necrosis factor: deficient liver regeneration in mice lacking type I tumor necrosis factor receptor. *Proc Natl Acad Sci USA* 94, 1441–1446.
43 Guttridge DC, Albanese C, Reuther JY *et al.* (1999) NF-kappaB controls cell growth and differentiation through transcriptional regulation of cyclin D1. *Mol Cell Biol* 19, 5785–5799.
44 Hinz M, Krappmann D, Eichten A *et al.* (1999) NF-kappaB function in growth control: regulation of cyclin D1 expression and G0/G1-to-S-phase transition. *Mol Cell Biol* 19, 2690–2698.
45 Chaisson ML, Brooling JT, Ladiges W *et al.* (2002) Hepatocyte-specific inhibition of NF-kappaB leads to apoptosis after TNF treatment, but not after partial hepatectomy. *J Clin Invest* 110, 193–202.
46 Maeda S, Chang L, Li ZW *et al.* (2003) IKKbeta is required for prevention of apoptosis mediated by cell-bound but not by circulating TNFalpha. *Immunity* 19, 725–737.
47 Wuestefeld T, Klein C, Streetz KL *et al.* (2003) Interleukin-6/glycoprotein 130-dependent pathways are protective during liver regeneration. *J Biol Chem* 278, 11281–11288.
48 Hanahan D, Weinberg RA (2000) The hallmarks of cancer. *Cell* 100, 57–70.
49 Tai DI, Tsai SL, Chang YH *et al.* (2000) Constitutive activation of nuclear factor kappaB in hepatocellular carcinoma. *Cancer* 89, 2274–2281.
50 Pikarsky E, Porat RM, Stein I *et al.* (2004) NF-kappaB functions as a tumour promoter in inflammation-associated cancer. *Nature* 431(7007): 461–6.
51 Maeda S, Kamata H, Luo JL *et al.* (2005) IKKbeta couples hepatocyte death to cytokine-driven compensatory proliferation that promotes chemical hepatocarcinogenesis. *Cell* 121, 977–990.
52 Cai D, Yuan M, Frantz DF *et al.* (2005) Local and systemic insulin resistance resulting from hepatic activation of IKK-beta and NF-kappaB. *Nature Med* 11, 183–190.
53 Arkan MC, Hevener AL, Greten FR *et al.* (2005) IKK-beta links inflammation to obesity-induced insulin resistance. *Nature Med* 11, 191–198.
54 Trautwein C, Boker K, Manns MP (1994) Hepatocyte and immune system: acute phase reaction as a contribution to early defence mechanisms. *Gut* 35, 1163–1166.
55 Zhang D, Sun M, Samols D *et al.* (1996) STAT3 participates in transcriptional activation of the C-reactive protein gene by interleukin-6. *J Biol Chem* 271, 9503–9509.
56 Catlett-Falcone R, Landowski TH, Oshiro MM *et al.* (1999) Constitutive activation of Stat3 signaling confers resistance to apoptosis in human U266 myeloma cells. *Immunity* 10, 105–115.
57 Chen RH, Chang MC, Su YH *et al.* (1999) Interleukin-6 inhibits transforming growth factor-beta-induced apoptosis through the phosphatidylinositol 3-kinase/Akt and signal transducers and activators of transcription 3 pathways. *J Biol Chem 274*, 23013–23019.
58 Ludwig H, Nachbaur DM, Fritz E *et al.* (1991) Interleukin-6 is a prognostic factor in multiple myeloma. *Blood* 77, 2794–2795.
59 Tsutamoto T, Hisanaga T, Wada A *et al.* (1998) Interleukin-6 spillover in the peripheral circulation increases with the severity of heart failure, and the high plasma level of interleukin-6 is an important prognostic predictor in patients with congestive heart failure. *J Am Coll Cardiol* 31, 391–398.
60 Streetz KL, Tacke F, Leifeld L *et al.* (2003) Interleukin 6/gp130-dependent pathways are protective during chronic liver diseases. *Hepatology* 38, 218–229.
61 Streetz KL, Wustefeld T, Klein C *et al.* (2003) Lack of gp130 expression in hepatocytes promotes liver injury. *Gastroenterology* 125, 532–543.
62 Klein C, Wustefeld T, Assmus U *et al.* (2005) The IL-6-gp130-STAT3 pathway in hepatocytes triggers liver protection in T cell-mediated liver injury. *J Clin Invest* 115, 860–9.
63 Karin M, Cao Y, Greten FR *et al.* (2002) NF-kappaB in cancer: from innocent bystander to major culprit. *Nature Rev Cancer* 2, 301–310.
64 Bajt ML, Lawson JA, Vonderfecht SL *et al.* (2000) Protection against Fas receptor-mediated apoptosis in hepatocytes and nonparenchymal cells by a caspase-8 inhibitor in vivo: evidence for a postmitochondrial processing of caspase-8. *Toxicol Sci* 58, 109–117.

65 Bajt ML, Vonderfecht SL, Jaeschke H (2001) Differential protection with inhibitors of caspase-8 and caspase-3 in murine models of tumor necrosis factor and Fas receptor-mediated hepatocellular apoptosis. *Toxicol Appl Pharmacol* 175, 243–252.

2.7.2 Intrahepatic lymphocytes

Wajahat Z. Mehal

Introduction

The immune system is central to liver injury in a variety of diseases including autoimmunity, viral hepatitides and many drug reactions. Such immune-mediated pathology will be discussed in detail in the sections focusing on individual diseases. This section will discuss the unique lymphocyte populations and immune properties of the healthy liver. The anatomical location of the liver constantly exposes it to large amounts of foreign antigens, and the most common immunological response to these is the development of antigen-specific immunological tolerance. This is much more complex than the immune system simply not responding to the antigen. Foreign antigens in the liver result in a range of dynamic immune responses that ultimately result in physical removal of lymphocytes, decreased ability of lymphocytes to become activated and the development of regulatory lymphocytes.

Understanding the molecular and cellular mechanisms underlying immune responses to hepatic antigens is directly relevant to viral hepatitis because antigens of hepatitis B virus (HBV) and hepatitis C virus (HCV) and alloantigens after transplantation induce varying degrees of immune tolerance. In many pathological situations, there is, however, a robust immune response to foreign and even self-antigens. An understanding of the factors that regulate the balance between induction of tolerance and the mounting of an immune response is necessary to design disease-specific therapies. In addition to conventional immune responses, novel roles in regulating liver fibrosis have also been identified for liver lymphocytes.

Localization and function

The healthy liver contains a very large and diverse population of lymphocytes [1]. Intrahepatic lymphocytes are defined as lymphocytes that are firmly attached to the liver and are not simply in the intrahepatic blood. The size of the intrahepatic population in the healthy liver is easily underestimated on microscopy but, on digestion, 1 g of healthy human and murine liver tissues yields approximately 10 million lymphocytes [2,3]. Taking the size of the liver into account, this is approximately 30% as many lymphocytes as in the spleen. The unexpected abundance of lymphocytes in the healthy liver is matched by their variety.

Table 1 Lymphocyte populations in the liver and spleen.

	Normal liver (%)	Spleen (%)
TCR-αβ	25	60
TCR-γδ	10	2–3
Natural killer T (NK-T) cells	30	1–2
Natural killer (NK) cells	25	5
B cells	5	25
Dendritic cells (DC)	5	2–3
c-kit+ cells	<1	<1
	Most in cell cycle	Most in G0
	Most with activation markers	Few with activation markers

Table 1 displays the types and percentages of intrahepatic lymphocytes and contrasts these features with those of the spleen.

Natural killer (NK) and NK-T cells

The liver contains a large population of NK and NK-T cells. NK cells were initially identified as Pit cells and large granular lymphocytes. They express inhibitory and excitatory receptors that predominantly use the presence of major histocompatibility complex (MHC) class I antigens on other cells to establish self and non-self [4]. The best known function of NK cells is cytotoxicity, and they possess a number of proapoptotic mediators such as CD95 ligand and perforin/granzyme, as well as secretion of interferon (IFN)-γ and tumour necrosis factor (TNF)α [5]. Unlike other lymphocytes, NK cells demonstrate spontaneous cytotoxicity, which can be further enhanced by IFN-α/β, interleukin (IL)-2, IL-12, IL-15 and IL-18 [6]. The cytotoxic activity of NK cells has been demonstrated in a range of *in vivo* model systems to provide protection against tumours, viruses and other intracellular pathogens such as malarial parasites. Activation of NK cells also serves as a bridge to activation of the adaptive immune response. This is predominantly through secretion of IFN-γ, resulting in an upregulation of adhesion and co-stimulatory molecules, activation of dendritic cells and recruitment of more NK cells from the bone marrow [7].

NK-T cells share many of the features of NK cells (expression of NK1.1 and IL-2Rβ) but, in addition, have features of classic T cells [expression of an αβ T-cell receptor (TCR), CD3, CD69 and CD62L] [8,9]. As such, NK-T cells are positioned between the innate and adaptive immune systems. This is further reflected by the limited diversity of their TCRs. In mice, NK-T cells express TCR with an invariant Vα14–Jα281alpha chain paired with a Vβ8 beta chain. The TCRs of NK-T cells undergo selection and activation on the class I-like molecule CD1, which is expressed on hepatocytes, and also on dendritic cells, B cells, T cells and macrophages [10]. As suggested by their phenotype, NK-T cells have functions that overlap with NK cells, particularly a robust

cytotoxic response. Unlike NK cells, NK-T cells require a stimulatory signal for the development of cytotoxicity. This is typically activation by the TCR, but may be as little as the presence of IL-2 or IL-18 [6]. The identity of the natural antigens recognized by the NK-T cell receptor on the CD1 molecule has been an area of great interest. The three-dimensional structure of the CD1 molecule predicts that it accommodates hydrophobic ligands, and this has been confirmed experimentally [11,12]. It is important to note that CD1 (unlike class I MHC molecules) is relatively invariant. There is, however, much more structural promiscuity, with one CD1 molecule able to bind a wide range of lipid antigens [13]. In addition, humans have five isoforms of CD1, providing further flexibility in lipid antigen presentation. This allows NK-T cells to monitor CD1-expressing cells for the presence of a wide variety of microbial lipid molecules, as well as abnormal lipid molecules on neoplastic cells.

In addition to delivering a cytotoxic signal to cells expressing unusual lipid molecules presented on CD1, activation of NK-T cells results in activation of NK cells and other cell types including CD8+ T cells and B cells via cross-talk. Kupffer cells are an important intermediary for the activation of NK cells by NK-T cells [14]. NK-T cells may have additional novel functions, such as limiting fibrosis by inducing apoptosis of hepatic stellate cells, which are currently being explored.

Collectively, NK and NK-T cells provide the liver with a large population of lymphocytes with cytotoxic function. This cytotoxic function is important in the removal of tumour cells with loss of class I molecules or expression of abnormal lipid molecules, and also removal of cells that express non-self lipids from pathogens.

Dendritic cells and presentation of hepatic antigens to the immune system

The best characterized functions of dendritic cells (DC) are the phagocytosis of antigens from peripheral tissues, migration to lymph nodes and maturation into efficient antigen presentation cells resulting in activation of T cells [15]. While these are certainly important, it has become clear that DC can also regulate the immune response and induce tolerance to self- and foreign antigens [16]. Dendritic cells collectively express many cell surface markers, including CD11c, CD8, CD11b, CD40, CD80, CD83, CD86, B220, CD45, MHC class I and II. There has been much controversy on the classification of subsets of DC based on selective expression of these markers. The reciprocal expression of CD8 and CD11b has been used to divide DC into CD8+CD11b– (lymphoid DC) and CD8–CD11b+ (myeloid DC) [17]. Lymphoid DC are present in the thymus and in the liver at a much lower percentage. In the thymus, they are responsible for deleting developing T cells with autoreactive potential, and thus may be specialized for maintaining tolerance [18]. For example, infusion of donor lymphoid DC prior to cardiac transplantation prolongs graft survival. Plasmacytoid DC form another well-defined population, which is identified in mice by the presence of B220 expression and, in humans, by CD123 [19]. In both species, plasmacytoid DC produce large amounts of type 1 interferons upon stimulation by pathogens via pattern recognition receptors, or activated T cells via CD40. In addition, maturation of DC is associated with upregulation of MHC class II, CD80, CD86 and enhanced ability to prime T cells.

Hepatic DC reside mostly around the portal triads and have an immature phenotype based on lack of expression of co-stimulatory molecules, but they do express MHC class I and II. Consistent with this phenotype, they are able to internalize antigen by phagocytosis and have poor ability to activate T cells. It has been shown recently that the liver is a major site for the translocation of immature DC from the blood to the lymphatic compartment [20,21]. Immature DC will phagocytose carbon-laden particles, enter the liver, translocate across the sinusoidal endothelium and drain to the coeliac nodes. This process is relatively fast, with carbon-laden DC appearing in coeliac nodes within 2 h of injection into the venous circulation. During their passage through the liver, there is frequent contact with Kupffer cells and some upregulation of MHC class II, suggesting DC maturation. Antigen presentation by murine hepatic DC results in poor allostimulation of T cells *in vitro* and, *in vivo*, results in secretion of IL-10 in secondary lymphoid tissue. This is in contrast to the production of IFN-γ and IL-12 by mature bone marrow-derived DC [22]. Most features of hepatic DC suggest that they have a weak ability to induce T-cell activation and are biased to tolerization. The unique anatomy of the liver allows naive T cells in the blood to come into contact with hepatic DC, further augmenting liver DC-induced tolerance.

Unlike other organs, there is a significant amount of evidence that non-DC liver cell populations can present hepatic antigens to naive T cells [23–26]. As efficient antigen presentation requires the coordinated presentation of MHC–peptide complexes, co-stimulatory molecules and the presence of appropriate cytokines, it was predicted that antigen presentation by such non-professional antigen-presenting cells will result in weak T-cell priming. This was confirmed by *in vitro* antigen presentation experiments using hepatocytes, sinusoidal endothelium and Kupffer cells [24–26]. The best *in vivo* evidence for antigen presentation is for sinusoidal endothelium [27]. This unique population expresses molecules that promote antigen uptake, including the mannose and scavenger receptors. In addition, they express a number of co-stimulatory molecules including CD40, CD80 and CD86. Antigen presentation by sinusoidal endothelial cells results in passive apoptosis of CD8+ T cells and development of CD4+ T cells towards a regulatory phenotype [23]. From studies in transgenic mice, it is also clear that antigen expression limited to hepatocytes results in T-cell tolerance with low levels of antigen, and deletion of T cells with high levels of antigen. As antigen originally limited to a single cell population can be taken up by other cell populations and subsequently presented (cross-presentation), the conclusions from transgenic expression of antigen on hepatocytes are not definitive.

Table 2 Phenotype and known functions of intrahepatic lymphocytes.

TCRαβ	These make up the majority of T cells. Posses either CD4 or CD8 as coreceptors and have a polyclonal TCR. They are activated by engagement of the TCR by appropriate MHC–peptide complex. CD8+ T cells typically become cytotoxic T cells on activation. CD4+ T cells can differentiate into Th1 (inflammatory; cytokines IFN-γ, LT-α) or Th2 (helper; cytokines IL-4, IL-5, IL-10) cells or have features of both
TCR low CD4–CD8–	An unusual cell type found in the liver with low levels of TCR, lacking CD4 and CD8 coreceptors, but possessing B220. They also possess activation markers, are undergoing cell cycle, and a proportion are also undergoing apoptosis. Most probably mature T cells that have undergone activation and are now undergoing apoptosis. May contain generated extrathymic T cells
TCR-γδ	T cells with a distinctive TCR able to recognize antigen independent of MHC molecules. They recognize antigens that are poorly recognized by conventional T cells and have cytotoxic function as well as cytokine secretion biased towards a Th2 profile
Natural killer NK-T	TCR receptor of limited diversity and additional inhibitory receptors. Low numbers in most organs except for bone marrow and liver. Activated via the TCR and have high cytotoxicity potential with production of IFN-γ, TNFα, IL-2 and IL-4
Natural killer (NK)	Many of the features of NK-T cells but no TCR. Similar to NK-T cells, present in high percentage in bone marrow and liver. Demonstrate spontaneous cytotoxicity, especially if target does not express MHC class I molecules
B	Undergo development in bone marrow and possess a polyclonal immunoglobulin receptor. On activation via cell surface IgM, produce immunoglobulin which can cause complement-mediated lysis and recruit other cells and molecules
Dendritic (DC)	Naive cells phagocytose and acquire specialized antigen-presenting function on activation The liver is a major site for the activation and translocation of DC from blood to the lymphatic compartment

TCR-γδ T cells

T cells with the γδ TCR constitute a small but distinct lymphoid population in the blood and other organs of most mammals [28–30]. The γδ TCR is composed of a relatively small number of germline gene segments, with non-diverse canonical γδ TCRs predominating in different anatomical sites. The crystal structure of the γδ TCR reveals similarities with the immunoglobulin molecule, predicting that the γδ TCR can bind antigens directly rather than as an antigen–MHC complex [31]. This is borne out by functional experiments, and γδ T cells can clearly recognize heat shock proteins directly, but some γδ TCRs can also recognize antigen bound to class II and class Ib molecules [32]. Major classes of γδ TCR ligands are microbe-derived alkyl amines and metabolites of the isoprenoid biosynthesis pathway. Upon activation, γδ T cells possess a range of effector functions, including granule and CD95L-dependent cytotoxicity, production of a range of cytokines including IFN-γ, TNFα, IL-10, transforming growth factor (TGF)-β and IL-4 [33]. γδ T cells also produce cytokines which are relatively unique to them, including fibroblast growth factor-7 and connective tissue growth factor, suggesting a role in maintaining epithelial integrity and wound repair [34]. These properties suggest that γδ T cells fulfil a role in initiating an immune response against pathogenic antigens such as phosphoantigens that are not well recognized by conventional T cells and, as they can recognize antigen directly without the need for antigen processing, they can respond earlier than conventional αβ T cells.

The above features of γδ T cells apply to hepatic γδ T cells. In addition to this, in mice, the liver is an organ shown to be uniquely enriched in a Thy-1-positive γδ T-cell population, which makes up about 50% of hepatic γδ T cells. The Thy-1-positive γδ T-cell population has a limited γ and δ TCR repertoire and is known to secrete greater amounts of IL-4 than other γδ T cells and relatively large amounts of IFN-γ [35]. Some of these properties are analogous to NK-T cells, suggesting a similar differentiation programme in the liver for these two different cell types.

TCR-αβ T cells (see Table 2)

These are the most familiar T cells that make up the majority of T cells in the secondary lymphoid organs (spleen and lymph nodes) [15]. A number of differences between the liver and the secondary lymphoid organs are present. The vast majority of αβ T cells in lymph nodes and spleen are naive and do not express activation markers, whereas in the liver, the majority express activation markers such as CD69 or CD44 high. A significant percentage of liver αβ T cells also express an unusual molecule, B220, which is typically associated with B cells, but is also found on T cells undergoing activation-induced apoptosis [36]. Cell cycle analysis shows that, consistent with the presence of activation markers, the majority of αβ T cells in the liver are undergoing cell cycle, and approximately 15% at any time have evidence of apoptosis. Thus, in contrast to the naive population of T cells in lymph nodes, αβ T cells in the normal liver are activated, undergoing cell cycle and also undergoing cell death.

Two related sets of experimental observations provided important clues to the origin of this large and peculiar liver αβ T-cell population. First, when large numbers of T cells in mice are activated near simultaneously, there is mobilization of αβ T cells from lymph nodes and spleen, followed over 1–2 days by a massive accumulation of αβ T cells in the liver [37]. Secondly, direct infusion of activated T cells into the portal vein results in retention of the vast majority in the liver [38]. These and other data have established that the normal liver has the unusual capacity to retain activated T cells, which contrasts with other organs in which retention occurs in the presence of inflammation. The

healthy liver has a unique set of features responsible for retention of activated T cells. Hepatic sinusoids have an interconnected set of channels with relatively low blood flow and a diameter of approximately 6.5 μM. This approximates the diameter of naive T cells, but is less than that of activated T cells. The sinusoids are also populated with a very mobile population of Kupffer cells, which traverse sinusoids, blocking and frequently reversing blood flow [39]. This low flow, interrupted flow pattern maximizes the contact of activated T cells entering the liver with the sinusoidal endothelium and other cells in the sinusoidal lumen. One prediction from this is that selectins, which are important in initiating rolling of fast-moving lymphocytes, will have a minimal role in hepatic retention of lymphocytes and this is the case from studies on selectin-deficient mice. The integrins that are responsible for firm adhesion of lymphocytes are important in hepatic retention of T cells, with intercellular adhesion molecule (ICAM)-1 and vascular cell adhesion molecule (VCAM)-1 having the major role [38,40]. Normal hepatic vascular and sinusoidal endothelium also express vascular adhesion protein (VAP)-1, which enhances lymphocyte retention by its enzymatic activity as an amine oxidase [41].

After retention in the liver, activated T cells can undergo cell division, effector function with release of IFN-γ, perforin/granzyme-induced cytotoxicity and apoptosis. Certain features promote intrahepatic apoptosis of intrahepatic T cells, including the presence of large quantifies of high-affinity antigen, particularly on Kupffer cells, and a large population of responding T cells. These features are most closely met with soluble food antigens entering the liver in large quantities. This results in apoptosis of activated T cells entering the liver with specificity for food antigens, ensuring that food antigens do not promote significant T-cell responses. An important molecular signal which induces apoptosis in hepatic CD8+ T cells is the alternative co-stimulatory molecule B7-H1 [42]. In its absence, an immune response results in less intrahepatic T cell apoptosis and greater liver injury [43]. Even in the absence of intrahepatic antigen, there is hepatic retention and eventual T-cell apoptosis, but also significant effector function. For example, most of the antiviral T-cell response against hepatitis B antigens is non-cytolytic [44]. This is followed by a more limited cytolytic response against hepatocytes with remaining viral antigen [45]. Such regulation of the two effector responses is presumed to clear viral infections with the induction of minimum hepatocyte apoptosis.

Regulation of the hepatic T-cell response

The hepatic immune response encompasses extremes, with hyporesponsiveness and tolerance on most exposures to foreign antigens, but a florid response with fulminant liver failure in others. A central question in liver immunology is understanding how the immune components reviewed above are regulated. There are a number of candidate processes, many or all of which may be important. T-cell apoptosis in response to high-affinity antigen has already been noted above. Hepatocyte injury is an important stimulus to an effective hepatic immune response in experimental models. This may overcome hepatic hyporesponsiveness by the generation of danger signals that were hypothesized over a decade ago and have recently been identified as metabolites of nucleotide degradation along the uric acid pathway [46]. Production of type 1 interferons (IFN-α/β) triggered by viral infection of hepatocytes is another candidate, resulting in recruitment of T cells and stimulation of IL-15, which promotes CD8+ T-cell survival [47,48]. In addition, type 1 interferons may provide a vital maturation signal to hepatic DC. Type 1 interferons may therefore provide an important switch between tolerance and an adaptive T-cell response. Finally, regulatory T cells in the liver may induce immunosuppression above the baseline in conditions such as hepatocellular cancer (HCC) and chronic viral hepatitis [49,50]. The concept of regulator T cells has been investigated for over 30 years, but better tools in the last 10 years have allowed this field to develop [51]. In principle, these are functionally hyporesponsive cells with very little or no production of IL-12, but production of IL-10, TGF-β and CTLA-4. The best characterized T-cell type with regulator function is the thymic-derived CD4+ T cells also expressing the CD25 marker [52]. However, NK-T and γδ T cells can also have similar functional properties. There is direct evidence for increased CD4+CD25+ T cells within tumour tissue of patients with HCC [49]. In patients with chronic HBV, the frequency of circulating regulatory T cells was significantly higher than in non-infected individuals [50]. These studies are preliminary but suggest a significant role for regulatory T cells in shaping the hepatic immune response.

Lymphocytes and liver fibrosis

The majority of liver pathology resulting in fibrosis has a significant inflammatory component. This is certainly true for chronic viral infections, but also for alcoholic liver diseases and non-alcoholic steatohepatitis. This observation raises questions about the influence of the inflammatory response, distinct from hepatocyte injury, in the progression of fibrosis. It also raises questions about the ability of stellate cells to proliferate and function in the setting of a florid T-cell response such as in chronic HBV infection.

A comparable amount of liver injury has been shown to result in greater fibrosis in the setting of a T helper (Th)2 immune response than a Th1 immune response [53]. The presence of IFN-γ in the Th1 response is central to minimizing liver fibrosis. Hepatic CD8+ T cells from fibrotic livers are able to induce fibrosis when transferred into mice with no liver injury, demonstrating the profibrogenic ability of such CD8+ T cells independent of liver injury [54]. Finally, experiments in mice lacking the co-stimulatory molecule B7-H1 demonstrate that B7-H1 expressed on hepatic stellate cells protects them from T cell-mediated cytotoxicity by inducing apoptosis of activated T cells [55].

References

1 Park S, Murray D, John B *et al.* (2002) Biology and significance of T-cell apoptosis in the liver. *Immunol Cell Biol* 80 (1), 74–83.

2 Crispe IN (2003) Hepatic T cells and liver tolerance. *Nature Rev Immunol* 3 (1), 51–62.

3 Mehal WZ, Azzaroli F, Crispe IN (2001) Immunology of the healthy liver: old questions and new insights. *Gastroenterology* 120 (1), 250–260.

4 Kane KP, Lavender KJ, Ma BJ (2004) Ly-49 receptors and their functions. *Crit Rev Immunol* 24 (5), 321–348.

5 Smyth MJ, Cretney E, Kelly JM *et al.* (2005) Activation of NK cell cytotoxicity. *Mol Immunol* 42 (4), 501–510.

6 Dao T, Mehal WZ, Crispe IN (1998) IL-18 augments perforin-dependent cytotoxicity of liver NK-T cells. *J Immunol* 161 (5), 2217–2222.

7 Wiltrout RH (2000) Regulation and antimetastatic functions of liver-associated natural killer cells. *Immunol Rev* 174, 63–76.

8 Moretta L, Bottino C, Pende D *et al.* (2002) Human natural killer cells: their origin, receptors and function. *Eur J Immunol* 32 (5), 1205–1211.

9 Elewaut D, Kronenberg M (2000) Molecular biology of NK T cell specificity and development. *Semin Immunol* 12 (6), 561–568.

10 Mandal M, Chen XR, Alegre ML *et al.* (1998) Tissue distribution, regulation and intracellular localization of murine CD1 molecules. *Mol Immunol* 35 (9), 525–536.

11 Seki S, Habu Y, Kawamura T *et al.* (2000) The liver as a crucial organ in the first line of host defense: the roles of Kupffer cells, natural killer (NK) cells and NK1.1 Ag+ T cells in T helper 1 immune responses. *Immunol Rev* 174, 35–46.

12 Schmieg J, Gonzalez-Aseguinolaza G, Tsuji M (2003) The role of natural killer T cells and other T cell subsets against infection by the pre-erythrocytic stages of malaria parasites. *Microbes Infect* 5 (6), 499–506.

13 Bendelac A, Rivera MN, Park SH *et al.* (1997) Mouse CD1-specific NK1 T cells: development, specificity, and function. *Annu Rev Immunol* 15, 535–562.

14 Wesley JD, Robbins SH, Sidobre S *et al.* (2005) Cutting edge: IFN-gamma signaling to macrophages is required for optimal Valpha14i NK T/NK cell cross-talk. *J Immunol* 174 (7), 3864–3868.

15 Janeway C, Travers P, Capra D *et al.* (2005) *Immunobiology: the Immune System in Health and Disease*, 6th edn. London: Current Biology; Garland Publications.

16 Mellor AL, Munn DH (2004) IDO expression by dendritic cells: tolerance and tryptophan catabolism. *Nature Rev Immunol* 4 (10), 762–774.

17 Lau AH, Thomson AW (2003) Dendritic cells and immune regulation in the liver. *Gut* 52 (2), 307–314.

18 McLellan AD, Kampgen E (2000) Functions of myeloid and lymphoid dendritic cells. *Immunol Lett* 72 (2), 101–105.

19 Colonna M, Trinchieri G, Liu YJ (2004) Plasmacytoid dendritic cells in immunity. *Nature Immunol* 5 (12), 1219–1226.

20 Kudo S, Matsuno K, Ezaki T *et al.* (1997) A novel migration pathway for rat dendritic cells from the blood: hepatic sinusoids-lymph translocation. *J Exp Med* 185 (4), 777–784.

21 Matsuno K, Ezaki T, Kudo S *et al.* (1996) A life stage of particle-laden rat dendritic cells in vivo: their terminal division, active phagocytosis, and translocation from the liver to the draining lymph. *J Exp Med* 183 (4), 1865–1878.

22 Thomson AW, Drakes ML, Zahorchak AF *et al.* (1999) Hepatic dendritic cells: immunobiology and role in liver transplantation. *J Leuk Biol* 66 (2), 322–330.

23 Crispe IN (2003) Hepatic T cells and liver tolerance. *Nature Rev Immunol* 3 (1), 51–62.

24 Bertolino P, Heath WR, Hardy CL *et al.* (1995) Peripheral deletion of autoreactive CD8+ T cells in transgenic mice expressing H-2Kb in the liver. *Eur J Immunol* 25 (7), 1932–1942.

25 Knolle PA, Uhrig A, Hegenbarth S *et al.* (1998) IL-10 down-regulates T cell activation by antigen-presenting liver sinusoidal endothelial cells through decreased antigen uptake via the mannose receptor and lowered surface expression of accessory molecules. *Clin Exp Immunol* 114 (3), 427–433.

26 Roland CR, Walp L, Stack RM *et al.* (1994) Outcome of Kupffer cell antigen presentation to a cloned murine Th1 lymphocyte depends on the inducibility of nitric oxide synthase by IFN-gamma. *J Immunol* 153 (12), 5453–5464.

27 Limmer A, Ohl J, Kurts C *et al.* (2000) Efficient presentation of exogenous antigen by liver endothelial cells to CD8+ T cells results in antigen-specific T-cell tolerance. *Nature Med* 6 (12), 1348–1354.

28 Pennington DJ, Silva-Santos B, Hayday AC (2005) Gammadelta T cell development – having the strength to get there. *Curr Opin Immunol* 17 (2), 108–115.

29 Kabelitz D, Wesch D (2003) Features and functions of gamma delta T lymphocytes: focus on chemokines and their receptors. *Crit Rev Immunol* 23 (5–6), 339–370.

30 Hayday AC (2000) [gamma][delta] cells: a right time and a right place for a conserved third way of protection. *Annu Rev Immunol* 18, 975–1026.

31 Allison TJ, Winter CC, Fournie JJ *et al.* (2001) Structure of a human gammadelta T-cell antigen receptor. *Nature* 411 (6839), 820–824.

32 Allison TJ, Garboczi DN (2002) Structure of gammadelta T cell receptors and their recognition of non-peptide antigens. *Mol Immunol* 38 (14), 1051–1061.

33 Tsukaguchi K, de Lange B, Boom WH (1999) Differential regulation of IFN-gamma, TNF-alpha, and IL-10 production by CD4(+) alphabetaTCR+ T cells and vdelta2(+) gammadelta T cells in response to monocytes infected with *Mycobacterium tuberculosis*-H37Ra. *Cell Immunol* 194 (1), 12–20.

34 Girardi M, Lewis J, Glusac E *et al.* (2002) Resident skin-specific gammadelta T cells provide local, nonredundant regulation of cutaneous inflammation. *J Exp Med* 195 (7), 855–867.

35 Gerber DJ, Azuara V, Levraud JP *et al.* (1999) IL-4-producing gamma delta T cells that express a very restricted TCR repertoire are preferentially localized in liver and spleen. *J Immunol* 163 (6), 3076–3082.

36 Mehal WZ, Crispe IN (1998) TCR ligation on CD8+ T cells creates double-negative cells in vivo. *J Immunol* 161 (4), 1686–1693.

37 Huang L, Soldevila G, Leeker M *et al.* (1994) The liver eliminates T cells undergoing antigen-triggered apoptosis in vivo. *Immunity* 1 (9), 741–749.

38 Mehal WZ, Juedes AE, Crispe IN (1999) Selective retention of activated CD8+ T cells by the normal liver. *J Immunol* 163 (6), 3202–3210.

39 MacPhee PJ, Schmidt EE, Groom AC (1995) Intermittence of blood flow in liver sinusoids, studied by high resolution in vivo microscopy. *Am J Physiol* 269, G692.

40 Lalor PF, Shields P, Grant A *et al.* (2002) Recruitment of lymphocytes to the human liver. *Immunol Cell Biol* 80 (1), 52–64.

41 Lor PF, Edwards S, McNab G *et al.* (2002) Vascular adhesion protein-1 mediates adhesion and transmigration of lymphocytes on human hepatic endothelial cells. *J Immunol* 169 (2), 983–992.

42 Zha Y, Blank C, Gajewski TF (2004) Negative regulation of T-cell function by PD-1. *Crit Rev Immunol* 24 (4), 229–237.
43 Dong H, Zhu G, Tamada K *et al.* (2004) B7-H1 determines accumulation and deletion of intrahepatic CD8(+) T lymphocytes. *Immunity* 20 (3), 327–336.
44 Guidotti LG, Chisari FV (2001) Noncytolytic control of viral infections by the innate and adaptive immune response. *Annu Rev Immunol* 19, 65–91.
45 Anon (2005) Oscillating CD8$^+$ T cell effector functions after antigen recognition in the liver. *Immunity* 23 (1), 53–63.
46 Shi Y, Evans JE, Rock KL (2003) Molecular identification of a danger signal that alerts the immune system to dying cells. *Nature* 425 (6957), 516–521.
47 Salazar-Mather TP, Orange JS, Biron CA (1998) Early murine cytomegalovirus (MCMV) infection induces liver natural killer (NK) cell inflammation and protection through macrophage inflammatory protein 1alpha (MIP-1alpha)-dependent pathways. *J Exp Med* 187 (1), 1–14.
48 Mattei F, Schiavoni G, Belardelli F *et al.* (2001) IL-15 is expressed by dendritic cells in response to type I IFN, double-stranded RNA, or lipopolysaccharide and promotes dendritic cell activation. *J Immunol* 167 (3), 1179–1187.
49 Unitt E, Rushbrook SM, Marshall A *et al.* (2005) Compromised lymphocytes infiltrate hepatocellular carcinoma: the role of T-regulatory cells. *Hepatology* 41 (4), 722–730.
50 Franzese O, Kennedy PT, Gehring AJ *et al.* (2005) Modulation of the CD8+-T-cell response by CD4+ CD25+ regulatory T cells in patients with hepatitis B virus infection. *J Virol* 79 (6), 3322–3328.
51 Chang KM (2005) Regulatory T cells and the liver: a new piece of the puzzle. *Hepatology* 41 (4), 700–702.
52 Shevach EM (2002) CD4+ CD25+ suppressor T cells: more questions than answers. *Nature Rev Immunol* 2 (6), 389–400.
53 Shi Z, Wakil AE, Rockey DC (1997) Strain-specific differences in mouse hepatic wound healing are mediated by divergent T helper cytokine responses. *Proc Natl Acad Sci USA* 94 (20), 10663–10668.
54 Safadi R, Ohta M, Alvarez CE *et al.* (2004) Immune stimulation of hepatic fibrogenesis by CD8 cells and attenuation by transgenic interleukin-10 from hepatocytes. *Gastroenterology* 127 (3), 870–882.
55 Yu MC, Chen CH, Liang X *et al.* (2004) Inhibition of T-cell responses by hepatic stellate cells via B7-H1-mediated T-cell apoptosis in mice. *Hepatology* 40 (6), 1312–1321.

2.7.3 Antibody production and transport in the liver

Alvin B. Imaeda and Wajahat Z. Mehal

Introduction and description of B-cell differentiation

The liver is uniquely positioned between the external and internal immune environments and needs to function in a dual role of surveillance against dangerous pathogens and tolerance of benign food antigens. The previous two chapters have focused on the roles of cytokines and T cells in the liver and immune function, and Chapter 1.5 has reviewed Kupffer cells. This chapter will focus on immunoglobulin (Ig) and B cells, particularly IgA, as it is the most thoroughly studied immunoglobulin in the liver. IgA plays an important role in the immunity of the gut and liver, and also helps to prevent unnecessary inflammatory responses against benign or easily cleared antigens.

B cells initially develop in the bone marrow where they undergo a series of developmental steps that result in secretion of immunoglobulin with little affinity for self-antigens, but high affinity for a large but finite repertoire of foreign antigens. Within the bone marrow, an irreversible random process of gene segment rearrangement occurs, bringing several gene segments together to form the variable region of an immunoglobulin receptor. If a successful rearrangement occurs, further rearrangement on the other chromosome is halted, allowing expression of a receptor of a single specificity. B cells expressing receptors with high affinity for self-antigens undergo programmed cellular death, minimizing the production of autoantibodies. The developing cells home to different tissues including spleen, peripheral lymph nodes and gut-associated lymphoid tissue (GALT). There, they express cell surface IgM and IgD receptors, and require ligation of these receptors by specific antigen in order to undergo further maturation. Maturation can occur through both T cell-dependent and T cell-independent mechanisms. T cell-independent B-cell activation results primarily in IgM-producing plasma cells, whereas T cell-dependent activation allows gene rearrangement resulting in a γ, α or ε constant region to produce IgG, IgA or IgE respectively. A process called somatic hypermutation introduces many point mutations throughout the variable region of the gene, and B cells with appropriate affinity for antigen are selected to divide and mature [1]. Adhesion molecules and chemokines control homing of the B cells to specific tissues where they mature into plasma cells or memory cells. Immunoglobulin class switching from IgM to IgG, IgA or IgE is controlled, at least in part, by locally produced cytokines. For example, B cells primed with antigen in the lamina propria preferentially become IgA-producing B cells as a result of transforming growth factor (TGF)-β, interleukin (IL)-6 and IL-10 produced by the stromal cells in this tissue [2].

The liver plays an important role in the biology and function of the mucosal humoral immune system. It plays a key role in the transport, function and clearance of IgA. The cell biology of IgA was delineated in animal liver and bile models in the 1980s. Limited confirmatory studies were carried out with human systems with some interesting differences found in the physiology among different species. The normal patterns of IgA metabolism are altered in disease states such as cirrhosis, and especially in all stages of alcoholic liver disease.

IgA synthesis

IgA is produced by the body in larger quantities than any other antibody isotype. Its serum half-life is 5–6 days compared with

Table 1 IgA subtypes and their characteristics.

	Serum	Secretory tissues
IgA form	Monomeric IgA1 80–90% IgA2 10–20%	Dimeric/polymeric IgA1 40–70% IgA2 30–60%
J chain and secretory chain	Nearly absent	Present
Origin	Bone marrow	Local mucosal tissue
Function	Unknown, possibly opsonization and ADCC	Neutralization and clearance, no significant opsonization or ADCC
Catabolism	ASGP-R on hepatocytes?	ASGP-R on hepatocytes? Through secretions after transcytosis
Alcohol effects	Increased IgA2	IgA1 deposits in hepatic sinusoids and renal mesangium

ADCC, antibody-dependent, cell-mediated cytotoxicity; ASGP-R, asialoglycoprotein receptor.

20–23 days for IgG, and most of the IgA is present in external secretions. Consequently, blood levels for IgA are much lower than those of IgG [3,4]. Humans have two different isotypes of IgA, IgA1 and IgA2 (Table 1). Bone marrow, spleen and serum have approximately 80–90% IgA1 and 10–20% IgA2, whereas mucosal tissues have a higher percentage, approximately 30–60%, of IgA2 [5,6]. The majority of IgA is monomeric or dimeric, with very small amounts of tetrameric forms. The predominant form in human serum is monomeric (mIgA), whereas at mucosal surfaces, secretory IgA is dimeric or polymeric (pIgA) [7–9]. Each monomer consists of two alpha heavy chains and two kappa or lambda light chains, linked by disulphide bonds. Two additional chains are covalently bound to human secretory IgA. In the dimeric form, a small glycoprotein called the J chain links the two immunoglobulin molecules together by the Fc portion of the alpha chains [10]. Additionally, a secretory chain component (SC) from the polymeric immunoglobulin receptor is attached to the Fc portion as the immunoglobulin is secreted into the luminal compartment as described below [11] (see Fig. 1a).

IgA is synthesized by antigen-primed plasma cells in the GALT, which includes Peyer's patches, isolated lymphoid follicles and the lamina propria just beneath the basement membrane of gut surface epithelia. Therefore, IgA must be transported back to its primary site of action on the luminal aspect of the epithelium. Secretory component (SC) is an approximately 550-amino-acid polypeptide with five Ig-like domains and is expressed preferentially on the basolateral membrane (submucosal side) of intestine, lung, breast and other secreting organs. Polymeric, but not monomeric, forms of IgA bind to SC on the basolateral surface of cells [12]. The complex is internalized into endocytic vesicles and, through a SC-directed process called transcytosis, it is specifically routed to the apical (luminal) surface of the epithelial cell. There, the complex is cleaved and released into the external environment [12,13] (see Fig. 1b). A component of SC remains attached to the IgA complex and may serve to protect the molecule from environmental proteases [14].

IgA secretion in the hepatobiliary system: rats vs. human

The discovery of IgA as the major protein component of bile in rats led to the study of IgA in the hepatobiliary system and the eventual understanding of the synthesis and secretion of IgA as described above [15]. Hepatobiliary transport of IgA results in IgA secretion into bile. This results in transport of IgA into the gut with localization of its effector function in surveillance of the bile and gut mucosa and eventual excretion.

Significant species differences in the transport of IgA are present. The rat, rabbit and chicken are efficient at hepatic transport of plasma IgA into bile, whereas man, dog and guinea pig are inefficient at this transport [16]. This correlates with expression of SC, as the efficient transporters express SC on hepatocytes, whereas man and the other inefficient transporters express SC on intra- and extrahepatic biliary epithelium but not hepatocytes [12,17,18]. These species differences result in widely different quantities of biliary excretion of pIgA, about 35 mg/kg/day for rats and rabbits and only about 1 mg/kg/day for man, dog and guinea pig [16]. Therefore, widely different amounts of pIgA are available in these different species to survey the biliary compartment. This suggests that different quantities of pIgA are available to protect the luminal gut compartment in different species. However, Jonard *et al.* [7] have shown that, in contrast to rat, the primary source of pIgA to enter the intestinal lumen in humans is from the bowel mucosa, not from bile. Similarly, the primary source of human biliary pIgA, although far less concentrated than in rats, is from the biliary ductal epithelium and perhaps the gallbladder mucosa and not hepatocytes as in rats [17–19]. Although no specific evidence exists to explain this dichotomy, the two systems seem to employ different strategies. In rats, IgA originates from plasma cells primed in the gut, traverses the mesenteric lymph system or portal venous blood and is then secreted by hepatocytes into the bile and drained back into the gut. A system with high pIgA concentration, but probably lower specificity, is present in the rat. In man, a more

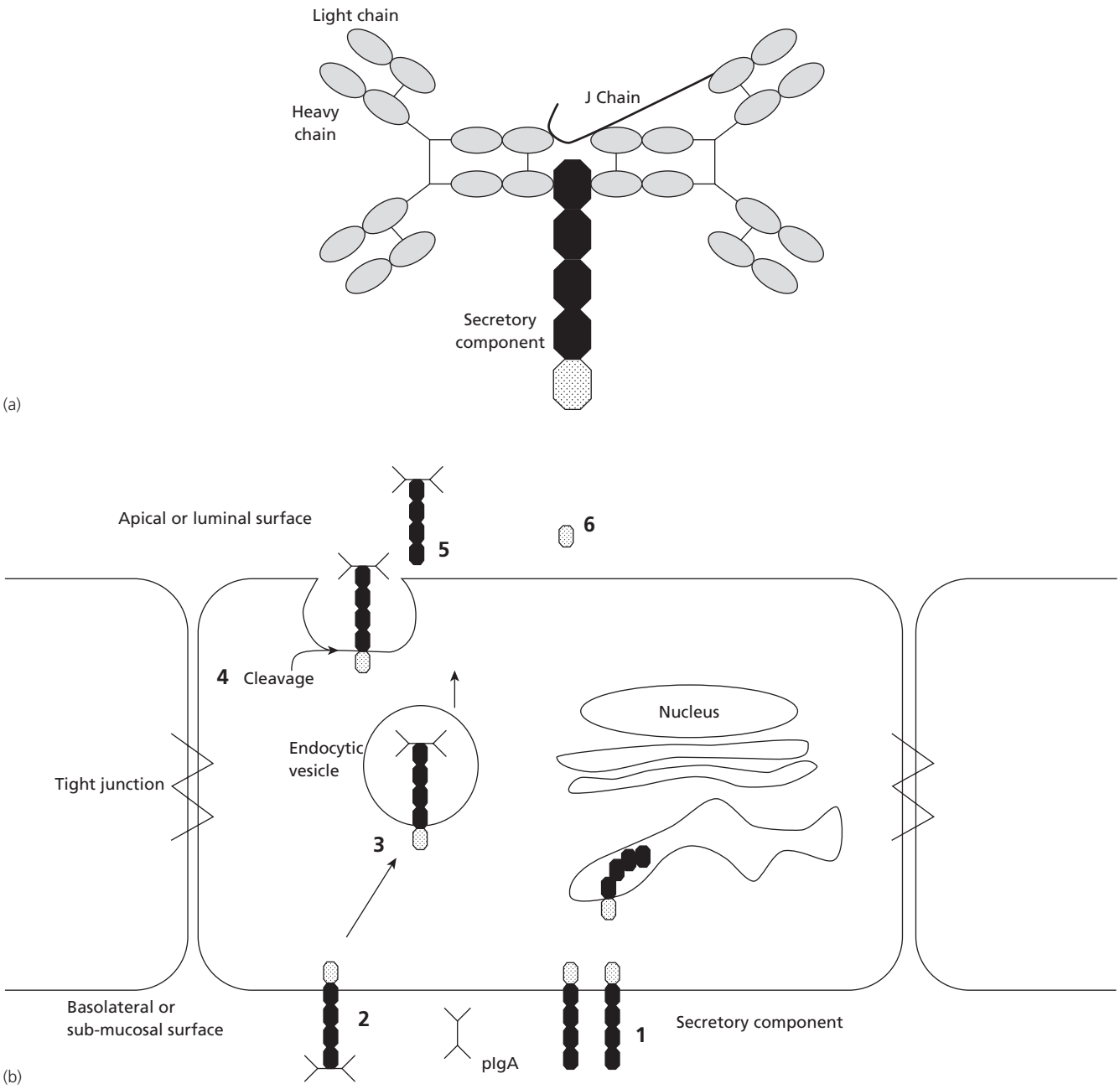

Fig. 1 (a) Topographical representation of interaction between two monomeric IgA molecules, J chain and secretory component. Each ellipse represents an immunoglobulin domain. (b) Diagrammatic representation of transcytosis of IgA. (1) Expression of secretory component on the basolateral membrane. (2) Binding of pIgA to secretory component [note: this includes J chain; see (a)]. (3) Endocytosis of the pIgA–secretory component complex. (4) Cleavage of secretory component and exocytosis. (5) Secretory IgA (sIgA). (6) Cytoplasmic tail of secretory component.

localized priming in the lamina propria to supply gut IgA or in peribiliary lymph nodes to supply biliary IgA provides smaller quantities of probably highly specific antibodies. It is important to note that IgM also binds to SC, and small amounts of IgM as well as IgG are found in human bile [8].

Multiple other factors probably influence secretion of IgA into bile. This has been examined to a limited extent in animal models and cell culture models. As might be expected, bile flow decreases the concentration of IgA secreted into bile [20]. Other factors regulate expression of SC in some model systems, and thus may also influence secretion of pIgA into bile and other compartments. For example, androgen increases free SC in rat tears, and estradiol stimulates secretion of SC into the uterine cavity [21,22]. In cultured rat hepatocytes, dexamethasone and cortisol increase secretion of SC. This is inhibited by an inhibitor of protein synthesis and, interestingly, is also inhibited by

estradiol [23]. Finally, interferon gamma and tumour necrosis factor (TNF)α upregulate expression of SC on a human colonic carcinoma cell line [18,24]. The role of these mediators of IgA secretion in humans is not known.

Immunoglobulin catabolism

Studies in mice and primates aimed at identifying sites of IgA catabolism have shown that the greatest uptake of radiolabelled mIgA and pIgA occurs in the liver. Parenchymal cells are more active than non-parenchymal cells in the uptake. Competitive inhibition studies with asialofeutin suggest that the receptor responsible for this uptake is the asialoglycoprotein receptor (ASGP-R) [25]. The ASGP-R is expressed on hepatocytes of many species, including humans. It binds to terminal galactose residues on desialylated glycoproteins and directs them to vesicles that fuse to lysosomes, leading to degradation of the proteins. Only about 0.5–8% of ligands that bind the ASGP-R escape the degradative pathway and are then secreted into bile [26]. This suggests that the primary function of binding of IgA to ASGP-R is for clearance of IgA. This is more important for serum IgA, the predominant subtype of which is IgA1, as mucosal IgA2 can be excreted through stool and other secretions. Studies looking at ASGP-R binding and catabolism of IgA1 vs. IgA2, using *in vitro* or a somewhat artificial *in vivo* system, have shown contradictory results [18,27,28].

The transferrin receptor can bind IgA1 when expressed on renal mesangial cells and possibly when expressed on dividing lymphocytes. The functional significance of this interaction is unclear, but transferrin receptor has been implicated in IgA nephropathy [29,30]. A possible role for transferrin receptor in the binding and clearance of IgA in the liver has not been determined.

IgG and IgM are also cleared by the liver, but by different mechanisms and cell types than IgA. Studies in rats show that IgG is catabolized in tissues throughout the body including skin, muscle, liver, kidney, bone marrow and spleen. On a weight basis, liver and spleen are the most active, and non-parenchymal cells are much more active in catabolism than hepatocytes [31]. The Fc receptor Brambell (FcRB) is a saturable receptor that binds and protects IgG from lysosomal catabolism and is likely to be responsible for its longer half-life than other immunoglobulins [32]. In studies of IgM catabolism, 60–80% of IgM is degraded in the liver. Again, in contrast to IgA, non-parenchymal cells are more active than parenchymal cells in degradation of IgM [33].

The function of IgA in the hepatobiliary system

IgA is the predominant form of immunoglobulin that affects the mucosal surfaces. This includes the intestinal, respiratory and reproductive tracts, the lactating breast and the salivary and tear glands. Mucosal IgA is not an effective opsonin for phagocytosis, and it does not effectively fix complement. Additionally, it acts primarily in the environment in which complement and phagocytes are not normally present. Its inability to induce inflammation may be important in order to maintain both the physical epithelial barrier and tolerance against benign antigens [29]. IgA thus serves as the first line of defence in preventing agents from penetrating the epithelial barrier. IgA may also allow clearance of pathogens in secretions, bile and stool through transcytosis of bacteria that have penetrated the epithelium or by interception of intracellular virus or bacteria during transcytosis. IgA is involved in neutralization of bacterial toxins, bacteria, viruses, food antigens and other toxins. In fact, IgA antibodies against multiple organisms or toxins have been demonstrated in bile, either occurring naturally or after infection or inoculation with agents including cholera toxin (rat) [34, 35], *Vibrio cholerae* (rat, monkey) [18,36], *Escherichia coli* (man) [37] and *Giardia lamblia* (rat) [38]. Finally, CD89, the FcαRI, is a relatively newly described Fc receptor for IgA. It is expressed on phagocytes, including Kupffer cells. Binding of IgA-opsonized organisms by CD89 is expected to result in phagocytosis and clearance of bloodborne pathogens, as well as antibody-dependent, cell-mediated cytoxicity (ADCC) [29]. Interestingly, mucosal type IgA (sIgA) does not bind this receptor, only serum pIgA and IgA immune complexes. IgA–antigen complexes are not cleared through hepatocytes into bile in man; however, alternative pathways to clear IgA complexes in the liver are present. These include the FcαRI on Kupffer cells and the ASGP-R on hepatocytes that primarily direct their ligands to lysosomes [39]. Secretion of IgA into bile in man may primarily serve to provide an immune surveillance mechanism for the biliary tree, rather than a major source of IgA for the intestinal lumen. However, IgA-deficient individuals are not particularly prone to severe biliary tract infections, and IgM may provide additional protection [40].

Immunoglobulins and liver disease

Liver disease has interesting effects on IgA, particularly alcoholic liver disease. Severe liver damage or cirrhosis of any aetiology can lead to an elevation in serum IgA [41,42]. Interestingly, however, alcohol use even with only mild changes in liver histology leads to elevations in serum IgA [43,44]. This has been called an IgA-associated disorder linking it to such diseases as Berger's disease (primary IgA nephropathy), Henoch–Schonlein purpura and IgA-producing myeloma.

The mechanism of increased serum IgA and deposits in the liver sinusoids is unclear. A simple explanation is that alcohol affects hepatic IgA catabolism, perhaps by decreasing uptake via ASGP-R [28]. This probably accounts for some of these findings; however, evidence suggests that the situation is more complex with an increase in IgA synthesis. There is some evidence that IgA-producing B cells are spontaneously active in alcoholic liver disease, although T-cell function is depressed [45,46]. Multiple studies have shown an increase in IgA antibodies against

bacteria or bacterial products, as well as dietary components in alcoholic liver disease [47–49]. The specific reasons for this increase in response to microbial and food antigens are unclear but may include disease-specific, disease-non-specific and severity-related mechanisms. Alcohol may influence immune function by decreasing Kupffer cell phagocytic activity or by decreasing gut epithelial barrier function leading to increased antigen availability [50,51]. Severe liver damage of any aetiology may additionally lead to decreased clearance of antigens, leading to increased stimulation of the mucosal immune system. Interestingly, hepatic sinusoidal IgA is primarily mIgA, whereas serum shows an increase in the proportion of pIgA2 [41,42,52]. The reasons for the increased proportion of IgA2 in serum, and the IgA1 in hepatic sinusoidal deposits in alcoholic liver disease, remain to be fully investigated. Limited evidence suggests that sinusoidal IgA deposits may be found in non-alcoholic steatohepatitis (NASH) that are indistinguishable from those seen with alcoholic liver disease [53].

Of additional interest is the finding that patients with alcoholic liver disease have increased titres of IgA and IgG antibodies that recognize acetaldehyde-modified protein condensates [54]. This suggests a direct link between alcohol metabolites and antigen stimulation of IgA-producing plasma cells, implying a role for these antibodies in alcohol-related liver disease. However, no liver-related pathogenicity of the increased titres of IgA has been shown, and these antibodies may decrease hepatic inflammation [55].

In addition to alcohol-related liver disease, serum IgA is elevated in primary biliary cirrhosis (PBC) [42,56]. Reports of elevation of IgA in extrahepatic biliary obstruction have not been confirmed, but serum SC is elevated in both extrahepatic biliary obstruction and PBC [42]. Elevations in serum and mucosal IgA in PBC may be mechanistically related to pathogenesis of the disease, rather than being a result of the liver injury. Specifically, IgA antibodies against pyruvate dehydrogenase complex are proposed to bind to this complex during transcytosis in salivary, lachrymal and biliary epithelial cells [57]. This complex is part of the antimitochondrial antibody–antigen complex implicated as self-antigen in PBC. This binding could potentially contribute to the pathogenesis, but this has not been proven (see Chapter 11.1).

In the healthy liver, B cells make up only about 5% of lymphocytes. In disease states such as autoimmune hepatitis, PBC, chronic hepatitis B and chronic hepatitis C, collections of lymphocytes termed intrahepatic lymphoid follicles (ILFs) have been seen. In chronic hepatitis C, these have been shown to include well-formed germinal centres similar to those in spleen that allow differentiation, clonal selection and affinity maturation of B cells [58]. As discussed for antibodies above, the functional significance of B-cell collections in the liver has not been defined in any of these diseases. In hepatitis B and hepatitis C, the T-cell response is the main determinant in clearing infection, and the role of antibodies in clearance, control or even persistence is not known (please see Chapter 9.1 for a full discussion of hepatitis B and hepatitis C).

IgA nephropathy associated with liver disease

Liver disease is a common cause of IgA nephropathy; in fact, it is the most common form of secondary IgA nephropathy [59]. The majority of the data for IgA nephropathy associated with liver disease are from patients with alcoholic liver disease; however, this form of nephropathy is seen in some patients with liver disease of other aetiologies as well [52]. The incidence of glomerular abnormalities seen in patients with liver disease ranges from 50% to 100% of those with cirrhosis. The glomerular deposits are usually mesangial IgA deposits [60]. Small amounts of IgG, IgM and complement may also be present. Like the deposits in the hepatic sinusoids and in primary IgA nephropathy, the mesangial deposits in hepatic IgA nephropathy are primarily IgA1 [59]. This may be a consequence of the increased production and decreased clearance of IgA or, alternatively, antigen(s) or immune complexes may drive this deposition. Recent studies investigating the role of the FcαRI in IgA nephropathy and alcoholic nephropathy have suggested that increases in IgA stimulate shedding of the FcαRI. It is proposed that complexes of the receptor and IgA may contribute to the pathogenesis [29,61]. Additionally, increased renal mesangial expression of the transferrin receptor which binds IgA has been implicated in the pathogenesis of this disease [30]. Regardless, only a small percentage of patients have clinically apparent disease. One series found 9.6% of all cirrhotic patients with nephritis and 1.6% with nephrotic syndrome [62]. Most patients are asymptomatic and may have only microscopic haematuria and mild proteinuria [59]. Treatment options for alcoholic IgA nephropathy have not been defined, and overall prognosis is directly related to the degree of underlying liver disease.

References

1 Janeway C, Travers P, Capra D *et al.* (2005) *Immunobiology: the Immune System in Health and Disease*, 6th edn. London: Garland Publications.

2 Fagarasan S *et al.* (2001) In situ class switching and differentiation to IgA-producing cells in the gut lamina propria. *Nature* 413, 639–643.

3 Conley ME, Delacroix DL (1987) Intravascular and mucosal immunoglobulin A: two separate but related systems of immune defense? *Ann Intern Med* 106, 892.

4 Mestecky J *et al.* (1986) The human IgA system: a reassessment. *Clin Immunol Immunopathol* 40, 105.

5 Crago SS *et al.* (1984) Distribution of IgA1-, IgA2- and J chain-containing cells in human tissues. *J Immunol* 132, 16.

6 Kett K *et al.* (1986) Different subclass distribution of IgA-producing cells in human lymphoid organs and various secretory tissues. *J Immunol* 136, 3631.

7 Jonard PP *et al.* (1984) Secretion of immunoglobulins and plasma proteins from the jejunal mucosa: transport rate and origin of polymeric immunoglobulin A. *J Clin Invest* 74, 525–535.

8 Delacroix DL *et al.* (1982) Selective transport of polymeric immunoglobulin A in bile: quantitative relationships of monomeric and polymeric immunoglobulin A, immunoglobulin M and other proteins in serum, bile and saliva. *J Clin Invest* 70, 230–241.

9 Newkirk MM *et al.* (1983) Estimation of polymeric IgA in human serum: an assay based on binding of radiolabeled human secretory component with applications in the study of IgA nephropathy, IgA monoclonal gammopathy, and liver diseases. *J Immunol* 130, 1176.

10 Mestecky J *et al.* (1974) Site of J chain attachment to human polymeric IgA. *Proc Natl Acad Sci USA* 71, 544.

11 Kuhn LC, Kraehenbuhl JP (1981) The membrane receptor for polymeric immunoglobulin is structurally related to secretory component from rabbit liver and mammary gland. *J Biol Chem* 256, 12490–12495.

12 Takahashi I, Nakane PK, Brown WR (1982) Ultrastructural events in the translocation of polymeric IgA by rat hepatocytes. *J Immunol* 128, 1181–1187.

13 Breitfeld PP *et al.* (1990) Deletions in the cytoplasmic domain of the polymeric immunoglobulin receptor differentially affect endocytotic rate and postendocytotic traffic. *J Biol Chem* 265, 13750–13757.

14 Brown WR, Newcomb RW, Ishiazaka K (1970) Proteolytic degradation of exocrine and serum immunoglobulins. *J Clin Invest* 49, 1374–1380.

15 Lemaitre-Coelho I, Jackson GDF, Vaerman JP (1977) Rat bile as a convenient source of secretory IgA and free secretory component. *Eur J Immunol* 7, 588–590.

16 Brown WR, Kloppel TM (1989) The liver and IgA: immunological, cell biological and clinical implications. *Hepatology* 9 (5), 763–784.

17 Nagura H *et al.* (1981) IgA in human bile and liver. *J Immunol* 126, 587–595.

18 Tomana M, Kulhavy R, Mestecky J (1988) Receptor-mediated binding and uptake of immunoglobulin A by human liver. *Gastroenterology* 94, 762–770.

19 Green FHY, Fox H (1972) An immunofluorescent study of the distribution of immunoglobulin-containing cells in the normal and inflamed human gall bladder. *Gut* 13, 379–384.

20 Kloppel TM *et al.* (1987) Uncoupling of the biliary secretory pathways for IgA and its receptor, secretory component, by brief periods of cholestasis. *Am J Physiol* 253 (2), G232–G240.

21 Sullivan DA, Wira CR (1981) Estradiol regulation of secretory component in the female reproductive tract. *J Steroid Biochem* 15, 439–444.

22 Sullivan DA, Bolch KJ, Allansmith MR (1984) Hormonal influence on the secretory immune system of the eye: androgen regulation of secretory component levels in rat tears. *J Immunol* 132, 1130–1135.

23 Wira CR, Colby E (1985) Regulation of secretory component by glucocorticoids in primary cultures of rat hepatocytes. *J Immunol* 134, 1744–1748.

24 Kvale D *et al.* (1988) Tumor necrosis factor-alpha up-regulates expression of secretory component, the epithelial receptor for polymeric Ig. *J Immunol* 140, 3086–3089.

25 Moldoveanu Z *et al.* (1990) Site of catabolism of autologous and heterologous IgA in non-human primates. *Scand J Immunol* 32, 577–583.

26 Schif JM, Fisher MM, Underdown BJ (1984) Receptor-mediated biliary transport of immunoglobulin A and asialoglycoprotein: sorting and missorting of ligands revealed by two radiolabeling methods. *J Cell Biol* 98, 79–89.

27 Hopf U *et al.* (1978) In vivo and in vitro binding of IgA to plasma membranes of hepatocytes. *Scand J Immunol* 8, 543–549.

28 Rifai A *et al.* (2000) The N-glycans determine the differential blood clearance and hepatic uptake of human immunoglobulin (Ig)A1 and IgA2 isotypes. *J Exp Med* 191 (12), 2171–2181.

29 Monteiro RC, van de Winkel JGJ (2003) IgA Fc receptors. *Annu Rev Immunol* 21, 177–204.

30 Moura IC *et al.* (2001) Identification of the transferrin receptor as a novel immunoglobulin (Ig)A1 receptor and its enhanced expression on mesangial cells in IgA nephropathy. *J Exp Med* 194, 417–425.

31 Henderson LA, Baynes JW, Thorpe SR (1982) Identification of sites of IgG catabolism in the rat. *Arch Biochem Biophys* 215 (1), 1–11.

32 Junghans RP, Anderson CL (1996) The protection receptor for IgG catabolism is the B2-microglobulin-containing neonatal intestinal transport receptor. *Proc Natl Acad Sci USA* 93, 5512–5516.

33 Chroneos ZC, Baynes JW, Thorpe SR (1995) Identification of liver endothelial cells as the primary site of IgM catabolism in the rat. *Arch Biochem Biophys* 319 (1), 63–73.

34 Vaerman JP *et al.* (1985) Neutralization of cholera toxin by rat bile secretory IgA antibodies. *Immunology* 54, 601–603.

35 Tamaru T, Brown WR (1985) IgA antibodies in rat bile inhibit cholera toxin-induced secretion in ileal loops in situ. *Immunology* 55, 579–583.

36 Cooper GN *et al.* (1984) Intestinal antibodies in rats following exposure to live *Vibrio cholerae*. *Aust J Exp Biol Med Sci* 62, 465–477.

37 Dahlgren UIH, Svanvik J, Eden CS (1986) Antibodies to *Escherichia coli* and anti-adhesive activity in paired serum, hepatic and gall bladder bile samples. *Scand J Immunol* 24, 251–260.

38 Loftness TJ *et al.* (1984) Occurrence of specific secretory immunoglobulin A in bile after inoculation of Giardia lamblia trophozoites into rat duodenum. *Gastroenterology* 87, 1022–1029.

39 Schiff JM, Huling SL, Jones AL (1986) Receptor-mediated uptake of asialoglycoprotein by the primate liver initiates both lysosomal and transcellular pathways. *Hepatology* 6, 837–847.

40 Cunningham-Rundles C (2001) Physiology of IgA and IgA deficiency. *J Clin Immunol* 21 (5), 303–309.

41 Van De Wiel A *et al.* (1987) Characteristics of serum IgA and liver IgA deposits in alcoholic liver disease. *Hepatology* 7 (1), 95–99.

42 Delacroix DL *et al.* (1983) Changes in size, subclass, and metabolic properties of serum immunoglobulin A in liver diseases and in other diseases with high serum immunoglobulin A. *J Clin Invest* 71, 358–367.

43 Seilles E *et al.* (1995) Serum secretory IgA and secretory component in patients with non-cirrhotic alcoholic liver diseases. *J Hepatol* 22, 278–285.

44 Goldin RD, Cattle S, Boylston TW (1986) IgA deposition in alcoholic liver disease. *J Clin Pathol* 39, 1181–1185.

45 Van De Wiel A *et al.* (1987) Spontaneous IgA synthesis by blood mononuclear cells in alcoholic liver disease. *Scand J Immunol* 25, 181–187.

46 Nouri-Aria KT *et al.* (1986) T and B cell function in alcoholic liver disease. *J Hepatol* 2, 195–207.

47 Nolan JP *et al.* (1986) IgA antibody to lipid A in alcoholic liver disease. *Lancet* 1, 176–179.

48 Staun-Olsen P *et al.* (1983) *Escherichia coli* antibodies in alcoholic liver disease. *Scand J Gastroenterol* 18, 889–896.

49 Bjorneboe M, Prytz H, Orskov F (1972) Antibodies to intestinal microbes in serum of patients with cirrhosis of the liver. *Lancet* 1, 58–60.

50 Lahnborg G, Friman L, Bergman L (1981) Reticuloendothelial function in patients with alcoholic cirrhosis. *Scand J Gastroenterol* 16, 481–489.

51 Van De Wiel A, Schuurman H, Kater L (1987) Alcoholic liver disease: an IgA-associated disorder. *Scand J Gastroenterol* 22, 1025–1030.

52 Van De Wiel A *et al.* (1986) Characteristics of IgA deposits in liver and skin of patients with liver disease. *Am J Clin Pathol* 86, 724–730.

53 Nagore N, Scheuer PJ (1988) Does a linear pattern of sinusoidal IgA deposition distinguish between alcoholic an diabetic liver disease? *Liver* 8 (5), 281–286.
54 Viitala K *et al.* (1997) Serum IgA, IgG, and IgM antibodies directed against acetaldehyde-derived epitopes: relationship to liver disease severity and alcohol consumption. *Hepatology* 25 (6), 1418–1424.
55 Parlesak A, Schafer C, Bode C (2002) IgA against gut-derived endotoxins: does it contribute to suppression of hepatic inflammation in alcohol-induced liver disease? *Dig Dis Sci* 47 (4), 760–766.
56 Fukuda Y, Imoto M, Hayakawa T (1985) Serum levels of secretory immunoglobulin A in liver disease. *Am J Gastroenterol* 80, 237–241.
57 Palmer JM *et al.* (2000) Secretory autoantibodies in primary biliary cirrhosis (PBC). *Clin Exp Immunol* 122 (3), 423–428.
58 Murakami J *et al.* (1999) Functional B-cell response in intrahepatic lymphoid follicles in chronic hepatitis C. *Hepatology* 30 (1), 143–150.
59 Pouria S, Feehally J (1999) Glomerular IgA deposition in liver disease. *Nephrol Dialysis Transplant* 14, 2279–2282.
60 Newell G (1987) Cirrhotic glomerulonephritis: incidence, morphology, clinical features, and pathogenesis. *Am J Kidney Dis* 9 (3), 183–190.
61 Launay P *et al.* (2000) Fcá receptor (CD89) mediates the development of immunoglobulin A (IgA) nephropathy (Berger's disease). Evidence for pathogenic soluble receptor-IgA complexes in patients and CD89 transgenic mice. *J Exp Med* 191, 1999–2009.
62 Nakamoto Y *et al.* (1981) Characteristics of hepatic IgA glomerulonephritis as the major part. *Virchows Arch A* 392, 45–54.

3 Basic concepts in pathobiology

3.1 Hepatocyte apoptosis and necrosis

Henning Schulze-Bergkamen, Marcus Schuchmann and Peter R. Galle

Introduction

The balance between cell division and cell death is a basic feature of the development and maintenance of liver homeostasis. There is increasing evidence that inappropriately controlled cell death is associated with several liver diseases. Liver failure and liver cancer are prototypical settings with uncontrolled massive cell death, on the one hand, or resistance to apoptosis, which is considered to be a hallmark of cancer cells, on the other hand. From the point of view of a metazoan organism, a single cell has many ways to die or survive at the wrong time: one separates an impairment of the intrinsic active cell death programme, apoptosis, from death due to (oncotic) necrosis, autophagy or mitotic catastrophe.

This chapter will mainly focus on the molecular mechanisms involved in the apoptotic cell death programme. Possible interactions between non-apoptotic and apoptotic cell death pathways are delineated, and new targets for the design of therapeutics that are aimed at modulating the death of liver cells are discussed.

The phenomenon of apoptosis and its morphology

Apoptosis is a common property of multicellular organisms in order to eliminate unwanted and potentially harmful cells. Apoptosis is actively controlled and occurs in a programmed fashion; thus, it is also referred to as programmed cell death (PCD).

Morphological observations, which today are recognized as distinct apoptotic morphological changes, were first described by Carl Vogt in 1842. The phenomenon of PCD was first called apoptosis (Greek, meaning 'falling off') in 1972, occurring in the liver after portal vein ligation [1]. However, it took about two decades before the importance of active cell death became generally accepted as a mechanism of controlling tissue and organ cellularity in concert with its functional counterpart, mitosis. Apoptosis is now known to play a fundamental role in physiological processes such as mammalian development and immune reactions [2]. During embryonic growth, apoptosis is the main mechanism for the removal of unnecessary tissue. In the adult organism, apoptosis regulates the balance between cell proliferation and death. When cells are no longer needed, infected, aged or have become seriously damaged, they are cleared by apoptosis [3]. In the immune system, potentially autoreactive and useless immune cells are mainly eliminated by apoptosis.

Morphological features in the pathobiology of liver diseases, now recognized as part of the apoptotic process, have been described in earlier chapters. Terms such as 'shrinking necrosis', 'acidophil bodies' and 'Councilman bodies' were used to describe apoptotic hepatocytes before the term 'apoptosis' was coined [4]. Along with the distinct morphological alterations, apoptosis is accompanied by various biochemical changes. As these changes are not specific for hepatocyte apoptosis, morphological assessment still presents the 'gold standard' for the identification of apoptotic cell death.

During the process of apoptosis, cells shrink and lose their contact with neighbouring cells [5]. Chromatin condenses at the nuclear membrane and the nucleolus dissociates. At the same time, the cytoplasm shows condensation and the formation of cytoplasmic blebs ('zeiosis'). Fragmentation of the cytoplasm and the nucleus results in membrane-bound, subcellular fragments, referred to as apoptotic bodies, which still contain intact organelles.

An inherent part of the apoptotic programme is the rapid phagocytosis of apoptotic bodies. Apoptotic hepatocytes are mainly phagocytosed by Kupffer cells. This process requires the recognition of membrane markers that are expressed on the outer surface of apoptotic cells [6]. An important signal for removal is the outside exposure of phosphatidylserine, which is normally localized exclusively to the inner leaflet of the plasma membrane. However, in liver cells, the asialoglycoprotein receptor may mainly mediate the clearance of apoptotic cells [7].

Phagocytosis of apoptotic cells is typically not accompanied by profound inflammatory reactions. Apoptotic bodies maintain their membrane integrity, thus avoiding the liberation of potentially toxic intracellular contents. In addition, the clearance

by Kupffer cells is a rapid process, which prevents triggering of the immune response that may follow spontaneous lysis of apoptotic bodies. However, in pathological conditions, hepatocellular apoptosis may cause inflammatory reactions such as infiltration of neutrophils [8]. The same applies for necrosis, in which membrane integrity is lost, and the resulting cytolysis elicits an inflammatory response [9].

Presumably, the most remarkable feature of apoptosis is its highly regulated nature. The molecular pathways leading to apoptosis are tightly controlled by a complex network of proteins and their endogenous inhibitors. Various checkpoints in apoptosis pathways allow the cell to prevent the engagement of the death machinery under physiological conditions or to start or continue the death programme in pathological conditions.

Biochemistry of apoptosis

As a result of the activation of intracellular proteases and endonucleases, profound biochemical changes such as DNA fragmentation and degradation of cellular proteins accompany apoptosis.

Transglutaminases

Transglutaminases are a family of thiol- and Ca^{2+}-dependent acyltransferases, which catalyse cross-links between glutamine and lysine residues. Transglutaminase 2 is known to be induced during the *in vivo* apoptotic programme and appears to be required for the formation of the rigid structure of the tightly scaled apoptotic bodies that contain extensively cross-linked proteins. Recently, it has been shown that the clearance of apoptotic hepatocytes is defective in the absence of transglutaminase 2, resulting in the accumulation of apoptotic cells and inflammatory reactions [10].

Proteases

Apoptosis is accompanied by the proteolytic breakdown of structural proteins and proteins involved in signalling [11]. The activation of cysteinyl aspartate-specific proteases, caspases, is central to most apoptotic pathways and occurs in a programmed fashion. Originally, caspases were identified in the nematode *Caenorhabditis elegans* [12]. The human genome encodes 13 distinct caspases. Caspases are synthesized as inactive precursors. Upon specific cleavage at defined aspartate residues, they are activated. The so-called 'initiator caspases', including caspase-2, -8, -9 and -10, are recruited to large protein complexes such as the death-inducing signalling complex (DISC) or the apoptosome (see below). These caspases cleave and activate 'executioner' caspases, mainly caspase-3, -6, and -7, which subsequently cleave other proteins, e.g. poly-(ADP-ribose) polymerase or histone H1. Caspase activation has been viewed as being synonymous with apoptotic cell death. However, caspases also contribute to processes that do not culminate in cell death [13]. For example, caspases-1, -4 and -5 are involved in inflammatory cytokine production and may not propagate cell death signals.

Apart from caspases, other proteases such as cathepsins have been implicated in hepatocyte apoptosis. Cathepsins are among the most abundant lysosomal enzymes. Activation of death receptors as well as different stress stimuli can trigger permeabilization of lysosomes, resulting in a translocation of cathepsins into the cytoplasm. Cathepsin activity can result in apoptotic features, dependent on and independent of caspase activity [14]. Cathepsin B actively participates in hepatocyte apoptosis, e.g. after exposure of hepatocytes to tumour necrosis factor (TNF) [15]. In cathepsin B knockout mice, hepatocytes are resistant to TNF-mediated apoptosis [16]. Inhibition of cathepsin B attenuates hepatic injury after bile duct ligation [17].

Calpains have also been implicated in apoptotic cell death in the liver after ischaemic injury [18]. Calpains are a group of calcium-dependent, non-lysosomal cysteine proteases contributing to cell injury by proteolysis of a plethora of substrates.

Endonucleases

Endonuclease activity results in a characteristic fragmentation of genomic DNA into oligonucleosomes ('DNA laddering'). First, DNA is cleaved into 300- and 50-kb fragments [19]. Second, DNA is cleaved into 180- to 200-bp fragments, resulting from multiple single-stranded nicks in the internucleosomal linker region.

Methods for the investigation of apoptosis

There is general agreement that the only universal features of apoptosis are the distinct morphological changes, such as chromatin condensation and nuclear fragmentation [20]. Widely used methods include the identification of the characteristic internucleosomal DNA fragmentation by DNA laddering after gel electrophoresis [5] or an *in situ* demonstration using the terminal deoxynucleotidyl transferase-mediated deoxyuridine triphosphate nick end labelling (TUNEL) assay [21]. DNA laddering or positive TUNEL staining, however, are not an unequivocal proof of apoptosis, as they may not distinguish internucleosomal DNA cleavage of apoptosis from the pattern of DNA cleavage in necrosis, e.g. in the model of bile duct ligation-associated liver injury [22]. An evaluation of the cellular morphology by electron microscopy may additionally be performed.

Some routine flow cytometry methods are based on the fact that DNA fragmentation is associated with a decrease in the DNA binding of dyes such as propidium iodide, which can be readily detected by flow cytometry [23].

Detection of proteins involved in the apoptotic process is an additional possibility for assessing apoptosis, although most candidate proteins are not absolutely specific for apoptosis. Another marker for apoptosis is phosphatidylserine, which is

externalized at the cell membrane in the early phase of apoptosis and can be detected by annexin V labelling in flow cytometry [24].

An additional approach to investigate apoptosis pathways is to monitor the activity of caspases. A number of assays have been developed that measure caspase activity through the use of specific fluorogenic substrates [25]. In addition, cleaved caspase substrates such as cytokeratin 18 can be detected by enzyme-linked immunosorbent assay (ELISA) or by immunoblotting, e.g. in the sera of patients undergoing liver injury. It is important to note, however, that caspase activity does not automatically reflect apoptosis cascades (see below).

Activation of mitochondria is a central event in apoptosis, but also occurs in other modes of cell death. It is reflected by a mitochondrial outer membrane permeabilization (MOMP), which can be measured by flow cytometry or by detection of proteins released from the mitochondrial space (e.g. cytochrome *c*).

In conclusion, no specific assay or parameter, except the morphological changes *in vivo*, allows a clear distinction between apoptosis and other cell death patterns.

Mechanisms of apoptosis

Although apoptosis of hepatocytes can be triggered by several different stimuli, apoptotic signalling is mainly transduced by two major molecular pathways, an extrinsic pathway mediated by death receptors on the cell surface and an intrinsic pathway, which is triggered at the mitochondrial level (Fig. 1). Both pathways culminate in the activation of caspases and endonucleases, which ultimately degrade the cellular constituents.

Extrinsic death pathway

The extrinsic death pathway is initiated by binding of death receptor ligands to specific death receptors on the cell surface (Fig. 2). Death receptors belong to the TNF superfamily, which is characterized by a sequence of two to five cysteine-rich extracellular repeats. The death receptors share a homologous intracellular death domain (DD), which is essential for the transduction of the apoptotic signal [26]. The most widely expressed death receptors on hepatocytes are CD95 (Fas/APO-1) and TNF receptor 1 (CD120a).

CD95 (Fas/APO-1)/CD95L

Among the death receptors, CD95 has been characterized most extensively [27]. It is a widely expressed glycosylated transmembrane protein that is expressed in most tissues. Hepatocytes constitutively express CD95 on their surface, rendering the liver highly sensitive towards CD95-mediated apoptosis [28]. Thus, mice injected with agonistic CD95 antibodies rapidly die of liver failure. Correspondingly, human hepatocytes are highly sensitive to CD95 triggering *in vitro* [28,29]. The ligand of CD95, CD95L, is a transmembrane protein mainly expressed on activated T and B cells, as well as in immune-privileged sites such as the testis and eyes. Under pathological conditions, CD95L is also found in the liver, e.g. on activated T cells and on hepatocytes. In addition to a membrane-bound form, a soluble form of CD95L exists, which is generated by extracellular metalloproteinase activity [30].

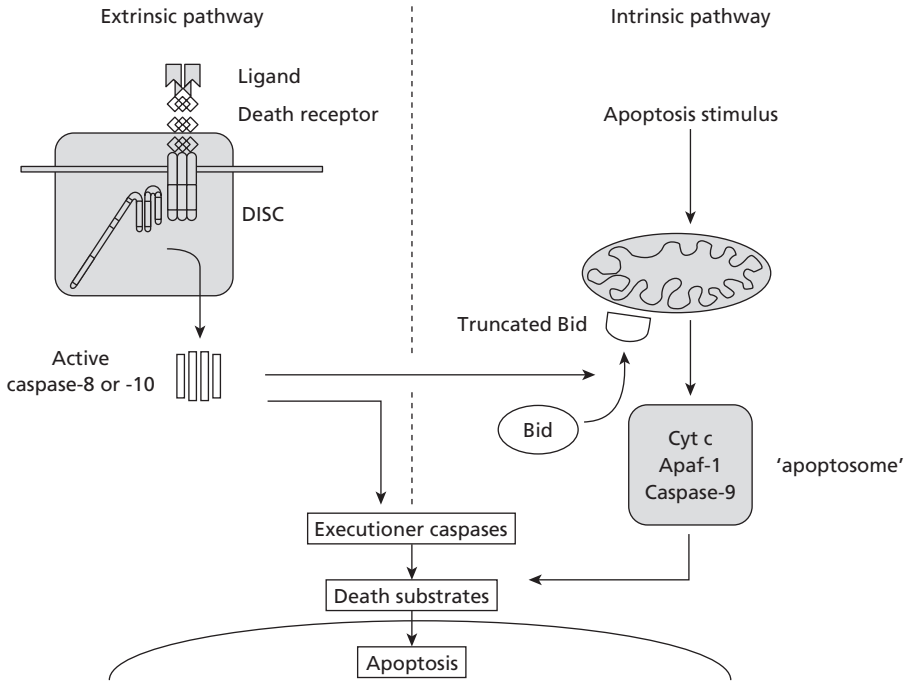

Fig. 1 The two main pathways for the initiation of apoptosis. Apoptosis can be triggered by two alternative pathways. The extrinsic pathway is initiated by binding of ligands to specific death receptors on the cell surface. The intrinsic pathway is initiated at the mitochondria by various stimuli. Initiator caspases such as caspase-8, -9 and -10 activate executioner caspases such as caspase-3, -6 and -7. Executioner caspases cleave death substrates and, finally, apoptosis occurs. Apaf-1, apoptotic protease activating factor-1; cyt c, cytochrome c; DISC, death-inducing signalling complex.

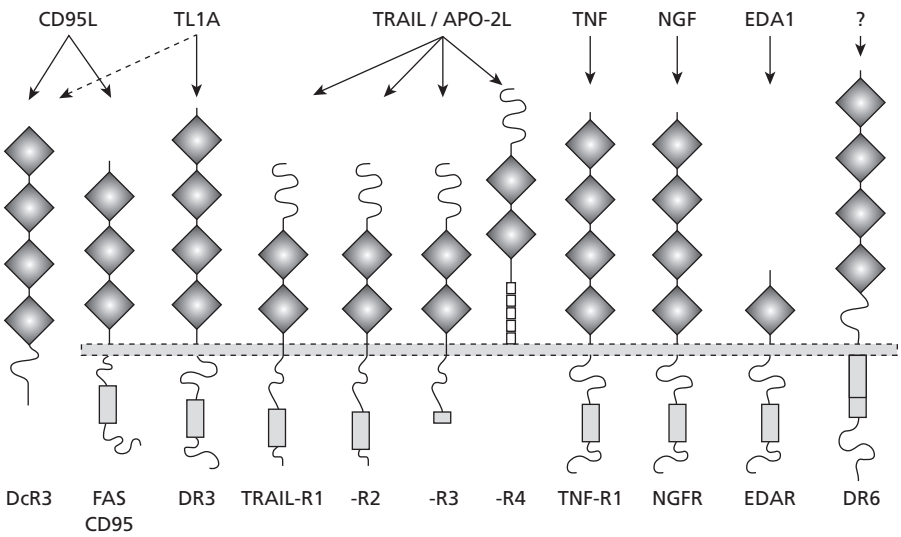

Fig. 2 Death receptors and their ligands. So far, eight members of the death receptor family have been characterized: TNFR1 (tumour necrosis factor receptor 1), CD95 (also known as APO-1 or Fas), DR3, TRAIL-R1 and TRAIL-R2 (TNF-related apoptosis-inducing ligand receptor 1 and 2), DR6, ectodysplasin A receptor (EDAR) and nerve growth factor receptor (NGFR). Death receptors are distinguished by a cytoplasmic region termed the death domain. After triggering by their corresponding ligands, a number of molecules are recruited to the death domains. Death ligands also interact with decoy receptors (DcRs) that do not possess death domains [TRAIL-R3, TRAIL-R4, DcR3 and osteoprotegrin (not shown)]. Receptors are given below the scheme, ligands at the top. The question mark indicates the unknown ligand for DR6. TL1A, endothelial cell-derived TNF-like factor.

The crucial determinant of death receptor signalling is the formation of a multimeric complex of proteins triggered by receptor cross-linking with their natural ligands. The structure formed is called the death-inducing signalling complex (DISC) [31]. The DISC of CD95 consists of trimerized CD95, the adapter Fas-associated death domain protein (FADD/Mort1), caspase-8 and caspase-10 [32]. FADD is recruited to the DISC after trimerization of CD95 and is capable of binding caspase-8 and -10, resulting in activation of the caspase cascade.

Depending on the cell type, either of two different pathways is activated downstream of CD95 after DISC formation. In type I cells, the death signal is propagated by a cascade that is initiated by the activation of large amounts of caspase-8 at the DISC and subsequent activation of downstream caspases. In type II cells, propagation of the apoptotic signal depends on its amplification via mitochondria [33]. *In vivo* studies with Bid-deficient mice indicate that hepatocytes are CD95 type II cells [34].

TNF

TNFR1 can signal a diverse range of activities including apoptosis, proliferation and inflammation. Its ligand, TNF, is produced by many cell types, including lymphoid cells and macrophages, and also activates TNFR2. At least one of these two TNF receptors is present in almost every cell [35]. Although most of the biological activities of TNF appear to be transduced by TNFR1, many can also be mediated by TNFR2. Exposure to TNF results in activation of transcription factors, such as AP-1 and NFκB. Following ligand-induced trimerization, TNFR1 recruits a multivalent adapter molecule, termed TNFR1-associated death domain protein, which binds to a number of signalling molecules such as TRAF2, FADD and RIP. TNF-induced apoptosis is most likely to be mediated via FADD-induced caspase-8 recruitment, while TRAF2 and RIP recruitment results in activation of the protein kinase JNK, AP-1 and NFκB. NFκB and AP-1 mediate important immunoregulatory functions. NFκB activation can also protect cells against apoptosis.

TNF-related apoptosis-inducing ligand (TRAIL)

The death receptor ligand TRAIL is a type II transmembrane protein that interacts with at least five members of the TNF receptor superfamily [36]. TRAIL rapidly induces apoptosis in a wide variety of transformed cell lines. TRAIL-R1 and -R2 contain a cytoplasmic death domain and are capable of transducing an apoptotic signal upon ligation of TRAIL [37]. TRAIL-R1 and -R2 are also present on hepatocytes. However, it is debatable whether the TRAIL receptor is expressed on hepatocytes and whether these cells are sensitive to the specific ligand TRAIL [38].

Transforming growth factor (TGF)-beta

TGF-β1 can induce growth arrest and apoptosis in many cell types including hepatocytes [39]. The specific high-affinity receptors of TGF-β1 are present on essentially all cells, and TGF-β1 is expressed in most tissues. TGF-β1 is released, e.g. from activated hepatic stellate cells (HSC), and acts as a profibrogenic master cytokine by the following mechanisms:

- It stimulates the transdifferentiation of HSC into myofibroblasts.
- It stimulates matrix synthesis in myofibroblasts.
- It inhibits matrix degradation.
- It induces apoptosis of hepatocytes.

Intrinsic death pathway

The intrinsic pathway is initiated at the mitochondrial level. Mitochondria act as integrating sensors of various death stimuli. A range of BH3-only members of the Bcl-2 family

(see below) trigger the mitochondrial signalling cascade by acting as sentinels for cell stress, damage or infection [40]. Upon activation, they are mobilized to initiate mitochondrial outer membrane permeabilizatiion (MOMP) through post-translational modification, resulting in the release of effector molecules such as cytochrome *c*, Smac/DIABLO (second mitochondrial-derived activator of caspase/directed IAP binding protein with low pI) and apoptosis-inducing factor (AIF) from the intermembranous space of mitochondria. Once cytochrome *c* is released into the cytosol, the apoptosome is assembled, which is a multiprotein complex in which Apaf-1 serves as an oligomerization platform for assembly and autoproteolytic activation of caspase-9. Subsequently, caspase-9 activates further downstream caspases. Smac/DIABLO facilitates caspase activation by sequestering caspase inhibitors. AIF is thought to induce apoptotic changes in a caspase-independent manner.

Molecules involved in the regulation of hepatocyte apoptosis

A variety of molecules influence the apoptotic sensitivity of hepatocytes in physiological and pathological conditions. Key molecules that are thought to play a major role in hepatic apoptosis pathways are discussed below.

p53

Mutations in the *TPp53* gene (the gene that encodes human p53) are the most common genetic alteration observed in human cancer [41]. p53, as a guardian of the genome, transduces the diversity of signals arising from stress and damage into tumour-suppressive apoptotic and growth-arresting responses. p53 can be activated by kinases such as the DNA-dependent protein kinase and ATM (ataxia telangiectasia, mutated). ATM phosphorylates p53, which leads to the abrogation of p53 binding to the ubiquitin ligase Mdm-2 and activation of p53. Subsequently, p53 regulates the expression of several pro- and antiapoptotic genes at transcriptional and posttranscriptional levels. For example, in the context of DNA damage, p53 can result in the transcriptional activation of the BH3-only proteins Puma and Noxa, which can promote MOMP. In addition, p53 can transcriptionally activate death receptors as well as death ligands. A transcription-independent proapoptotic effect involves direct interactions of p53 and MOMP inducers at the mitochondrial level.

Bcl-2 family

The Bcl-2 family is a well-established family of proteins playing a pivotal role in preserving mitochondrial integrity. Common to all Bcl-2 family members are the Bcl-2 homology regions (BH1–4). These proteins are predominantly localized to the outer mitochondrial membrane (OMM), but also to other cellular membranes. The family is split into multidomain antiapoptotic proteins (e.g. Bcl-2, Bcl-x_L and Mcl-1), multidomain proapoptotic proteins containing three BH domains (e.g. Bax and Bak) and the proapoptotic BH3-only proteins containing only one BH region (e.g. Bid, Bim, Noxa, Puma). Multidomain proapoptotic Bcl-2 proteins are thought to catalyse MOMP by triggering oligomerization of BH3-only proteins (Fig. 3). BH3-only proteins most probably initiate MOMP by inducing

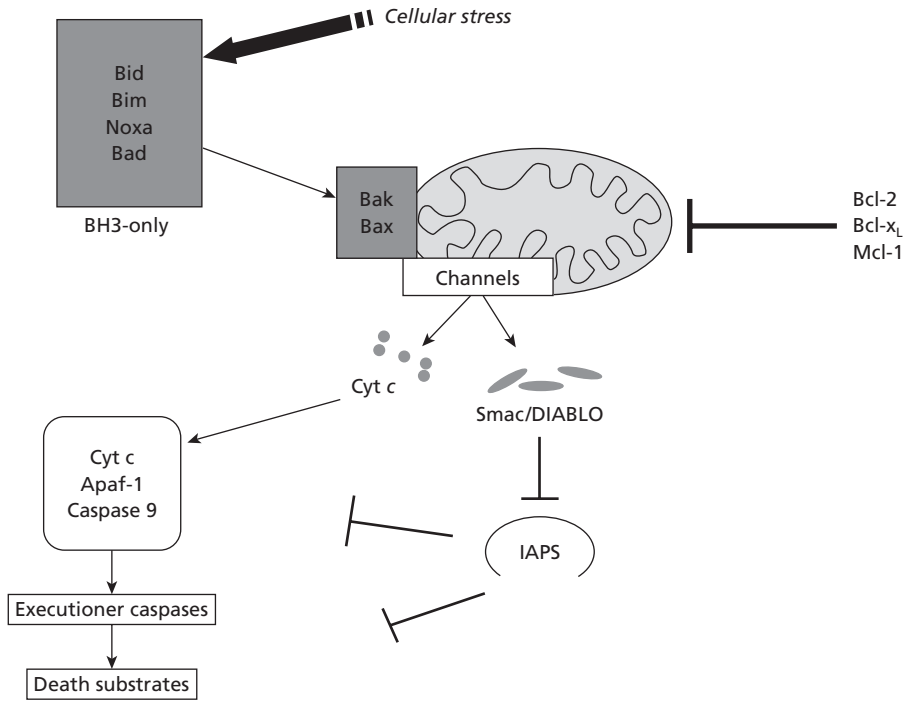

Fig. 3 Regulation of mitochondrial activation. Various stimuli can initiate mitochondrial activation. A subfamily of proapoptotic Bcl-2 proteins, the 'BH3-only proteins', act as sentinels for cell stress and damage and can be mobilized to initiate mitochondrial outer membrane permeabilization (MOMP) by triggering oligomerization of Bax and/or Bak in the outer mitochondrial membrane. Oligomerization results in the formation of channels that permit the escape of several molecules into the cytoplasm.

oligomerization of Bax and Bak in the OMM [42]. Bax and Bak can form channels in the OMM through which many proteins escape from the mitochondrial intermembranous space. BH3-only proteins fall into two subfamilies: those that can directly trigger opening of the Bax–Bak channel to precipitate MOMP (such as Bid and Bim) and those that sensitize the opening of the channel by neutralizing members of the antiapoptotic Bcl-2 family (such as Puma and Noxa). The antiapoptotic members, Bcl-2 representing the paradigm, mainly reside in the OMM and counter the effect of proapoptotic members.

Inhibitor of apoptosis (IAP) family

In humans, eight members of the IAP family have been identified so far, including XIAP, c-IAP1/2 and survivin. IAPs are endogenous inhibitors of caspases and therefore counteract apoptosis. They may also function as ubiquitin ligases, promoting the degradation of caspases. Some of the proteins that are released from mitochondria, e.g. Smac/DIABLO, can bind to IAPs and thereby relieve their caspase inhibition.

NFκB

NFκB was originally discovered as a result of its role in regulating gene expression in immune and inflammatory responses. However, activation of NFκB can protect liver cells from the apoptotic cascade induced by TNF and other stimuli, mainly by its effect on the transcription of antiapoptotic genes, e.g. c-FLIP, cellular IAPs and Bcl-x_L [43].

FLIP

FLIPs [FADD-like interleukin-1β-converting enzyme-like protease (FLICE/caspase-8)-inhibitory proteins] interfere directly at the level of death receptors. In human cells, two splice variants, a long form ($FLIP_L$) and a short form ($FLIP_S$), have been identified, both sharing structural homology with procaspase-8 but lacking catalytic activity. The structural homology allows FLIP molecules to bind to the DISC and thereby prevent the activation of caspase-8 [2].

Regulation of apoptosis under physiological conditions

Apoptosis under physiological conditions allows the removal of damaged or unwanted cells with virtually no proinflammatory response in the surrounding tissue. In rodents, only about one to five apoptotic cells per 10 000 hepatocytes are found [44], preferentially located in zone 3 around the hepatic venules [45]. It has been proposed that hepatocytes originate from the portal area and progress towards the perivenular region, where they are eliminated via apoptosis.

On increased functional demand, e.g. in overfeeding, in pregnancy, during severe protein loss or after treatment with a wide range of drugs (such as phenobarbital), rodent liver enlarges as a result of hypertrophy and hyperplasia. Once the stimulus is removed, the liver returns to its normal size by removing excessive hepatocytes via apoptosis.

Regulation of apoptosis under pathological conditions

Balance between cell division and cell death is a basic feature in the development and maintenance of liver homeostasis. Disturbances in this balance can cause liver diseases: too much cell death can cause liver injury, too little cell death is a prerequisite for the development of hepatocellular carcinoma. Thus, a tight control of the equilibrium between life and death in the liver is necessary.

During liver injury, hepatocytes, endothelial cells and cholangiocytes are driven to die by apoptosis due to the accumulation of cytokines such as TNF, IL-1β and interferon (IFN)-γ, as well as toxic metabolites, reactive oxygen species (ROS), bile acids and other substances.

Deregulation of the apoptosis programme is pathophysiologically involved in acute as well as chronic liver diseases, including cholestasis [46], hepatitis C [47] and alcoholic and non-alcoholic steatohepatitis (NASH) [48,49]. The most dramatic liver disease, fulminant hepatic failure (FHF), is characterized by uncontrolled massive death of hepatocytes [28], e.g. in patients with acute Wilson disease [50].

In both humans and rodents, apoptosis of hepatocytes in acute and chronic liver diseases is generally mediated by death receptors, in particular CD95. Increased CD95 expression has been observed in several liver diseases [28]. High CD95 expression makes hepatocytes quite sensitive to cytotoxic T cells expressing CD95L. In addition, the specific ligand of CD95, CD95L, can be detected in sera of patients with liver diseases. For example, CD95L derived from the placenta can enter the liver via the fetomaternal circulation causing liver damage in patients with haemolysis, elevated liver enzymes and low platelets (HELLP) syndrome [51]. In contrast, enhanced expression of CD95L on hepatocellular carcinoma cells might result in active destruction of lymphocytes, thus contributing to an immune evasion of cancer cells [52].

Caspases play an important role in liver injury. Their activity reflects the extent of liver injury. For example, increased caspase activation can be found not only in liver biopsies, but also in sera from patients with hepatitis C [53]. In addition, serum caspase activity correlates with the extent of steatosis and the progression of fibrosis [54]. Other proteases, such as cathepsin D, can induce cell death independently of caspase activity via triggering of AIF release from mitochondria [55].

Toxic and metabolic liver injury

Several drugs and toxins or their metabolites can cause liver injury by both necrosis and/or apoptosis. For many hepatotoxic

substances, evidence for induction of apoptosis has been obtained, e.g. for ethanol [28], paracetamol [56] and cytostatic drugs [57]. In alcoholic hepatitis, hepatocyte apoptosis is frequently observed and correlates with disease severity. Apoptosis is partly induced by CYP2E1-dependent formation of ROS and lipid peroxides, which can cause mitochondrial activation. In addition, the CD95 as well as the TNF death receptor system contribute to liver injury.

In NASH, apoptosis is also involved in disease progression [49]. As in alcoholic hepatitis, expression of the death receptors CD95 and TNFR1 is significantly enhanced on hepatocytes [48]. In addition, the lysosomal enzyme cathepsin B is thought to play an important role in apoptosis induction in NASH, as its inhibition profoundly inhibits liver injury.

Viral hepatitis and immune-mediated liver diseases

Viral infections of the liver can cause apoptosis. Councilman bodies, a characteristic pathological feature of viral hepatitis, closely resemble apoptotic cells. Apoptosis can be induced either as a direct cytopathic effect of viruses or as a result of the host immune response. In hepatitis B or C, activated cytotoxic T cells expressing CD95L may kill infected hepatocytes expressing CD95 [28]. Other pathways, including the TNF system, have also been implicated in hepatocyte apoptosis during viral infection. Elimination of virus-infected cells by apoptosis may be counteracted by viral-encoded proteins, which abrogate apoptotic pathways, e.g. CrmA. In hepatitis C, multiple virus-derived proteins counteract apoptosis induction as a possible mechanism to maintain persistent infection [8].

In autoimmune hepatitis, lymphocytic infiltration also causes hepatocyte apoptosis. In host-vs.-graft reaction in allograft rejection, upregulation of apoptosis-associated factors, such as TGF-β1, is observed.

Cholestatic liver disease

Bile acids have been shown to trigger hepatocyte apoptosis by activation of death receptors, in particular CD95 [46]. Interestingly, CD95-dependent apoptosis has been described as being activated in the absence of ligand interaction. TRAIL-R2 is also transcriptionally induced in persistent cholestasis and is thought to contribute to liver injury [58].

Hepatic fibrosis

In contrast to physiological conditions, increased hepatocyte apoptosis under pathological conditions is associated with an inflammatory response. Upon persistent inflammation, fibrogenesis can occur, mainly as a consequence of the activation of hepatic stellate cells (HSC) following their transdifferentiation into myofibroblasts [59]. Kupffer cells, the major phagocytes of apoptotic bodies in the liver, can express death ligands and proinflammatory cytokines, thereby accelerating hepatocyte apoptosis and inflammatory reactions. Importantly, HSC also engulf apoptotic bodies in the liver, a process that is associated with activation of quiescent HSC and with production of TGF-β, a potent profibrogenic cytokine.

Hepatocarcinogenesis

The development of hepatocellular carcinoma (HCC) has been associated with defective apoptosis and increased cell proliferation. HCC cells often show alterations in the expression of tumour suppressor genes, DNA repair genes, genes involved in the cell cycle and genes involved in apoptosis. Mutations in the tumour suppressor gene p53 are among the most common alterations observed in HCC [60]. The p53 protein is activated as a result of DNA damage. Dysfunctional p53 allows the tumour cell to escape apoptosis induction (see section on Molecules involved in the regulation of hepatocyte apoptosis). Other alterations leading to apoptosis resistance are downregulation of death receptors, such as CD95, or enhanced expression of anti-apoptotic proteins, such as Bcl-x_L. In addition, expression of CD95L enables HCC cells to actively kill immune cells [52].

Hepatocyte necrosis

Contrary to the controlled cellular death programme in apoptosis, necrosis (or recently renamed oncosis or oncotic necrosis) is a more chaotic mechanism of cell death. It results from metabolic disruption with energy depletion and loss of adenosine triphosphate (ATP), ion dysregulation and enhanced degradative hydrolase activity. In the presence of oxygen, toxic oxygen species may be generated followed by lipid peroxidation. Loss of ATP leads to cellular oedema, rounding and swelling of mitochondria, dilation of the endoplasmic reticulum, lysosomal disruption and the formation of plasma membrane protrusions called blebs [61]. Bleb formation, which is caused by disrupted cellular volume control and cytoskeletal disturbances, is reversible, e.g. after reoxygenation. If injury continues, necrotic cell death occurs by failure of the plasma membrane permeability barrier, leading to bleb rupture and the release of cellular components. The release of cellular contents triggers an inflammatory response in the surrounding tissue [1].

Similar to the intrinsic death pathway in apoptosis, damage to mitochondria appears to be a key event in early progression of necrosis [9]. In addition, proteases are involved in the induction of necrotic cell death. Calpains, for example, have been implicated as an intracellular mediator leading to necrosis. Upon activation, they dissociate from the membrane and exert proteolytic activity on a plethora of substrates, such as cytoskeletal and membrane proteins, resulting in an alteration of the mitochondrial membrane potential [62]. Interestingly, necrosis can also be regulated and may involve caspase activation [63].

Cell death by necrosis can frequently be observed in ischaemic injury in the liver, e.g. during shock, liver surgery or

transplantation. A typical stimulus for necrosis in the liver is cold hepatic ischaemia followed by reperfusion, which leads to necrosis within minutes [64].

Recent studies report a major role of necrotic cell death in chronic liver injury as well. In the model of experimental bile duct ligation in rats, liver injury is almost exclusively caused by necrosis [22]. However, CD95-mediated apoptosis has also been discussed as contributing to liver injury in cholestasis [46].

Other forms of cell death in liver injury

During the last decade, most research activities in hepatology dealing with liver injury focused on the evaluation of apoptosis pathways. In the past, the terms 'programmed cell death (PCD)' and 'apoptosis' have frequently been used as synonyms, and PCD as well as apoptosis has been equated with caspase activation. However, there is accumulating evidence that hepatocytes can die via PCD without typical features of apoptosis or necrosis and independently of caspase activation. Caspase-independent cell death is an important protective mechanism for an organism to eliminate harmful cells in case of a failure of caspase activation [13]. Thus far, various forms of caspase-independent PCD have been described, depicted as autophagy, paraptosis, mitotic catastrophe, anoikis and others (Fig. 4). In autophagy, cells die by chewing themselves up [65]. Unlike apoptosis, cells are degraded with little or no help from phagocytes and use their own lysosomal system for degradation. Autophagy helps to eliminate longlived proteins and plays an important role in cellular remodelling. Hepatocytes of liver grafts show autophagic vacuoles after reperfusion, suggesting that warm reperfusion acts as a stress stimulus triggering autophagic degeneration [66]. The role of autophagy in the pathogenesis of other liver diseases continues to be explored. In carcinogenesis of HCC, breakdown of autophagy might play an important role [67].

The differentiation between autophagy and another form of cell death, called paraptosis, is not clear so far. Paraptosis is characterized by swelling of mitochondria and the endoplasmic reticulum (ER), leading to cytoplasmic vacuolation [68]. Its role in liver injury has not yet been defined. The same applies for another type of cell death depicted as mitotic catastrophe. It results from abnormal mitosis due to defective cell cycle checkpoints and leads to the formation of interphase cells with multiple micronuclei [69]. Anoikis occurs if hepatocytes lose their contact with the extracellular matrix. Indicators of apoptosis do not appear until the cell has become non-adherent, because the loss of adhesion is the cause and not the result of cell death. For hepatocyte survival, β1 integrin-mediated attachment to hepatic extracellular matrix is a prerequisite to avoid anoikis [70].

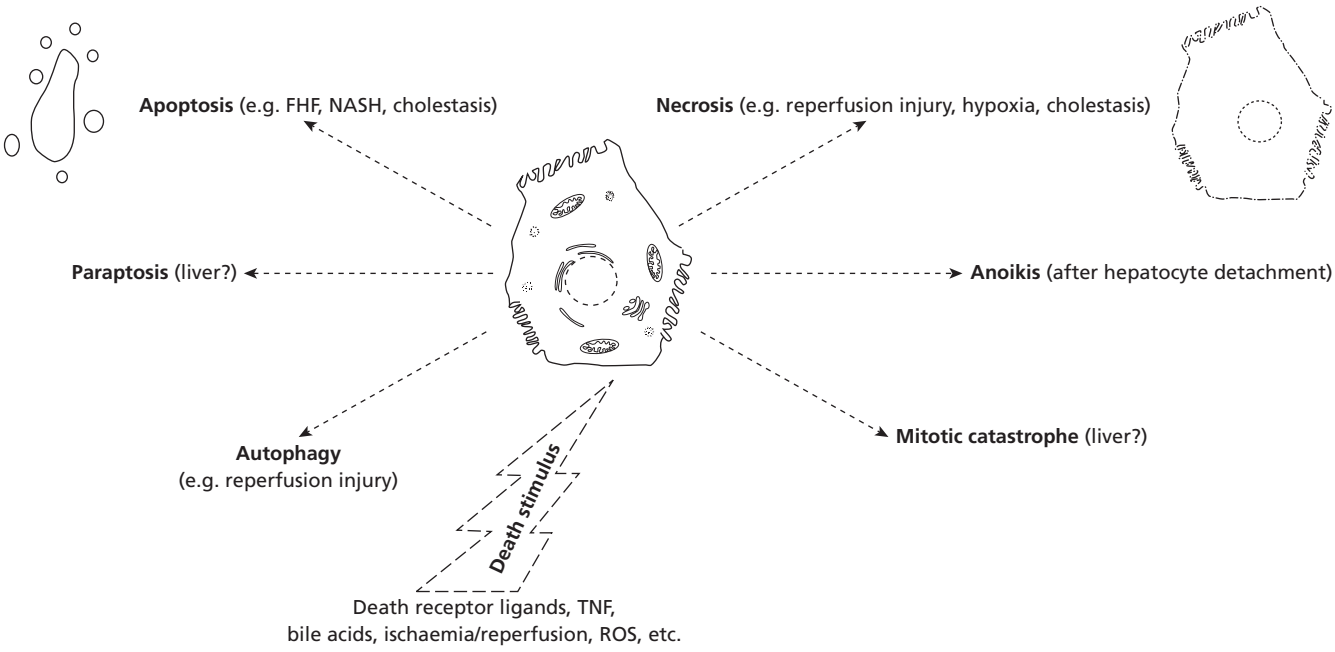

Fig. 4 Modes of cell death in the liver. Hepatocytes can die from different modes of cell death. Apoptosis occurs in physiological as well as pathological conditions and represents a highly organized and genetically controlled type of cell death leading to shrinkage of the cell and disintegration into small apoptotic bodies. Paraptosis involves cytoplasmic vacuolation independent of caspase activity and in the absence of typical nuclear changes. Its role in liver diseases is not yet defined. Necrosis (or oncosis/oncotic necrosis) leads to cellular oedema and disruption of the cell membrane, e.g. in reperfusion liver injury. In autophagy, the cell's own lysosomal system leads to degradation of organelles and cell death. Breakdown of autophagy has been hypothesized to contribute to the development of hepatocellular carcinoma. Anoikis occurs if hepatocytes lose their contact with the extracellular matrix. Mitotic catastrophe occurs after mitotic failure, but has not been described as contributing to liver injury so far. FHF, fulminant hepatic failure; NASH, non-alcoholic steatohepatitis; ROS, reactive oxygen species; TNF, tumour necrosis factor.

Mixed patterns of cell death in liver injury

Hepatocyte apoptosis and necrosis as well as other forms of cell death may occur in parallel in pathological conditions. The contribution of certain specific death modes to liver injury is often elusive for the following reasons:

1 Morphological and molecular overlaps. Although many biochemical and immunological assays have been developed to characterize apoptosis, none of the changes monitored in these assays is unique to apoptosis (see the section on Methods for the investigation of apoptosis).

2 Certain death stimuli may lead to different modes of cell death. In various liver diseases, critical death stimuli have been identified. However, death stimuli such as cytokines, bile acids or ROS can trigger different modes of cell death in parallel. For example, if detoxification of ROS is impaired in the liver, oxidative stress occurs, e.g. in obstructive cholestasis [71]. A decision between necrotic and apoptotic cell death upon oxidative stress may depend on the intracellular ATP level. A marked depletion in ATP facilitates necrotic cell death, whereas high levels of ATP favour the development of apoptosis.

3 Molecular switches between different modes of cell death. Apoptosis induction may be followed by secondary necrosis, when ATP is eventually depleted during apoptosis [72]. Ineffective elimination of apoptotic bodies may also result in a switch from apoptosis to necrosis caused by an inflammatory response. In contrast, if the necrosis pathway is inhibited, death stimuli may eventually force the cell into apoptosis [64]. Several mediators, such as nitric oxide (NO), have been described to function as potent modulators of death programmes by ATP depletion or inactivation of caspases.

4 Activation of proteases may result in different death modes. Lysosomal proteases, such as cathepsins, may trigger different death modes in liver injury. Low release of lysosomal proteases triggers apoptosis, whereas massive release leads to necrosis [73]. Calpains have been implicated as an intracellular mediator leading to apoptosis as well as necrosis [74,75].

5 Cross-talk between different proteolytic systems. Cross-talk between caspases, cathepsins, calpains and other proteases influences the mode of cell death in liver injury and further complicates the differentiation between specific death programmes.

6 Underestimation of apoptotic cell death. The extent of apoptotic cell death is frequently underestimated because: (i) apoptosis is a rapid event with an estimated duration of 2–3 h; and (ii) only scattered single cells may be affected, and apoptotic bodies, which are readily eliminated, are small.

Targeting cell death in liver diseases

Liver injury is caused by a complex picture of cell death patterns. As the apoptosis programme is deranged in a series of liver diseases, many therapeutic approaches target the apoptotic cascade (Fig. 5). A series of publications describe successful rescue of animals from FHF, for example by blocking caspase activity [76], expression of antiapoptotic Bcl-2 family members [77] and expression of dominant negative FADD/MORT1 [78,79]. The discovery of RNA interference opens up new opportunities to specifically target apoptosis pathways, e.g. through down-regulating genes encoding CD95 or caspase-8 [80,81]. Other approaches target death receptor ligands. For example, FLINT (LY498919) has been shown to effectively bind CD95L and LIGHT, another TNF receptor family ligand, and may have therapeutic benefits in liver diseases in which the pathogenesis is believed to be related to inappropriate apoptosis [82].

Caspases are an attractive target not only for antiapoptotic interventions in acute, but also in chronic hepatitis [83]. Caspase inhibitors have already entered clinical trials in patients with liver diseases, e.g. in patients with hepatitis C [84]. However, inhibition of caspases might not be effective in

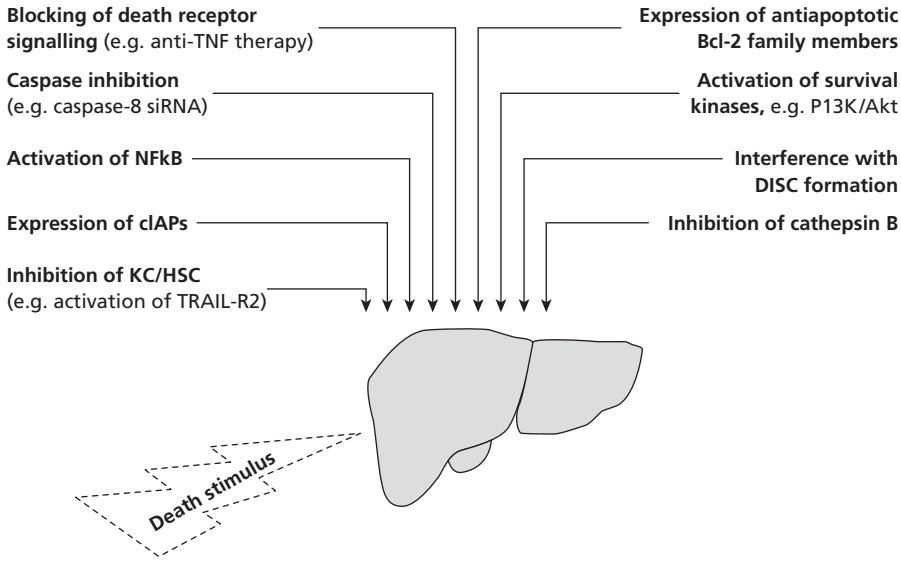

Fig. 5 Prosurvival strategies for the treatment of liver diseases. Much effort has been devoted to the search for strategies to inhibit liver injury. Most of these efforts target apoptosis pathways, such as inhibition of caspases and death receptor signalling. KC, Kupffer cells; HSC, hepatic stellate cells; cIAP, cellular inhibitor of apoptosis; DISC, death-inducing signalling complex; siRNA, small interfering RNA.

certain complex pathophysiological conditions for the following reasons:

- Interference with caspase activity may not alter the extent of death, but rather the shape of the demise [85].
- Caspase inhibitors can prevent the appearance of certain, but not all features of apoptosis [86].
- Deletion of single caspases may have only localized and partial effects on cell death, whereas broad-range caspase inhibitors may inhibit unrelated proteases, whose activity may be necessary for survival.
- Several forms of cell death, including apoptosis-like death, can occur in a caspase-independent manner or are even accelerated by caspase inhibitors.

Other approaches to reducing cell death in liver injury include inhibition of calpains and cathepsins. Calpain inhibition reduces the number of apoptotic sinusoidal endothelial cells (SEC). This may be of special interest for the prevention of reperfusion injuries in clinical transplantation, as apoptosis of SEC is a key feature in this scenario [87]. Inhibition of cathepsin B is of therapeutic interest, e.g. for the attenuation of hepatic injury in cholestasis [88] or reperfusion injury [89].

Targeting of TGF-β may also inhibit hepatocyte apoptosis. Experimental therapeutic strategies are focused on inactivation of TGF-β by overexpression of soluble TGF-β receptors as scavengers, by intracellular overexpression of mediators inhibiting TGF-β signalling or by inhibition of TGF-β synthesis.

Other approaches include inhibition of MOMP by expression of antiapoptotic members of the Bcl-2 family as well as pharmacological inhibition of the permeability transition pore of mitochondrion-specific ion channels.

Growth factors such as hepatocyte growth factor have been shown to inhibit CD95-mediated apoptosis of human hepatocytes and might be applied in liver diseases in which the CD95 system is involved [90].

The design of antiapoptotic therapeutic strategies should consider the overlapping death programmes in hepatocytes. Inhibition of apoptosis may have little effect on the survival of liver cells if a decrease in apoptosis is compensated for by an increase in the fractions of cells that undergo permanent growth arrest with features of cell senescence or die through the process of mitotic catastrophe. Considering the fact that switches between different cell death modes can occur that are dependent on the mediators and tissue conditions, targeting of individual death pathways may not be sufficient to ameliorate liver injury effectively. In addition, blocking of cell death in the liver may not only promote survival of hepatocytes, but also that of potentially harmful cells, including hepatic NKT cells. NKT cells are abundant in the normal liver and are thought to contribute to the pathophysiology of FHF and other forms of liver injury [91]. An antiapoptotic therapy regimen may also trigger liver fibrosis by preventing cell death of HSC [92]. Finally, promotion of cell survival in liver injury may favour carcinogenesis of HCC, as death of abnormal cells in the liver is an important process in preventing clonal expansion and tumour formation (Fig. 6).

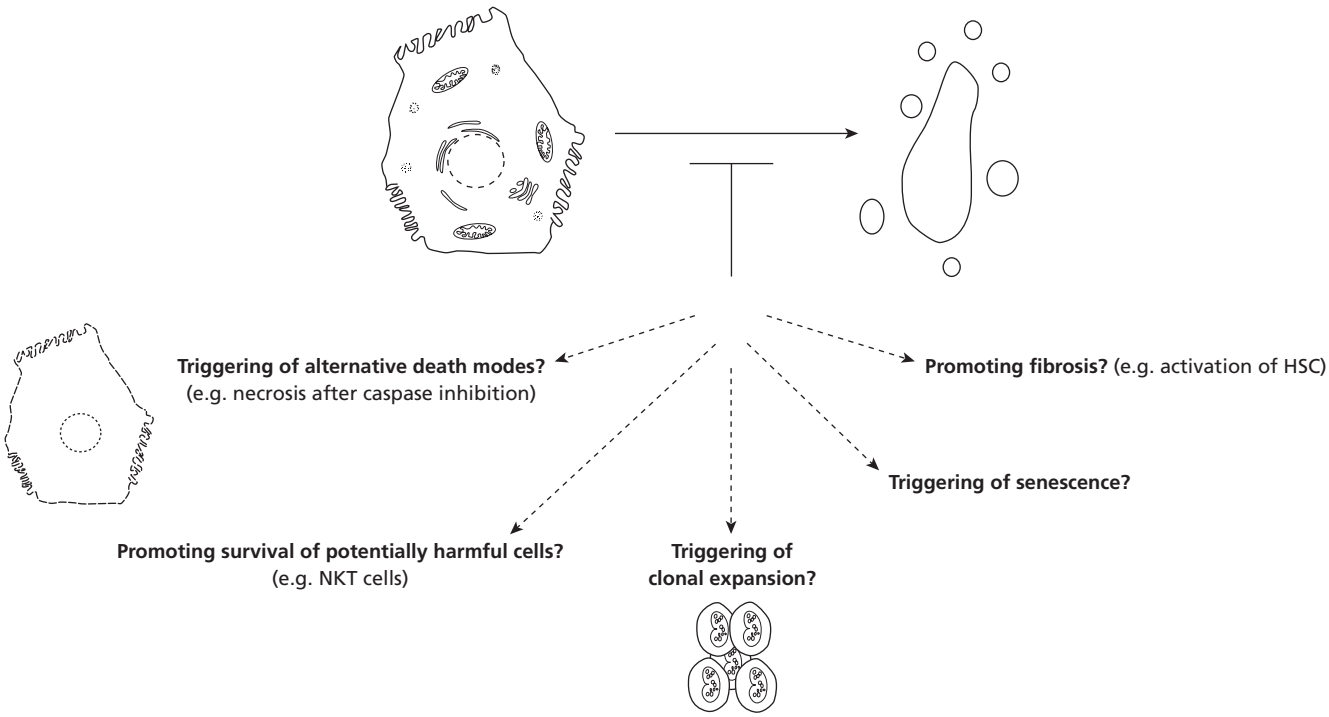

Fig. 6 Pitfalls of antiapoptotic therapy strategies for liver diseases. Targeting death pathways in the liver is a powerful tool for the treatment of liver diseases. However, possible side-effects should be considered. Senescence: a signal transduction programme leading to irreversible cell cycle arrest. HSC, hepatic stellate cells; NKT cells, natural killer T cells.

Despite possible limitations, the investigation of novel approaches for the inhibition of liver cell death will probably lead to new treatment options in clinical hepatology.

Conclusion

Death programmes in the liver enable the elimination of damaged and unwanted cells *in vivo*. In acute and chronic liver injury, the balance between death and survival is disturbed. Enhanced liver cell death through apoptosis and necrosis is a key pathogenic feature of liver diseases. However, under pathological conditions, various cell death patterns in hepatocytes cannot be classified as either necrosis or apoptosis, e.g. various forms of programmed cell death independent of caspase activity. In addition, overlaps between the signalling pathways of different death programmes make exclusive definitions artificial. It still remains elusive which factors determine the type of death. Research currently being conducted in this exciting field is likely to be beneficial for the future treatment of liver diseases.

References

1 Kerr JF, Wyllie AH, Currie AR (1972) Apoptosis: a basic biological phenomenon with wide-ranging implications in tissue kinetics. *Br J Cancer* 26 (4), 239–257.

2 Krammer PH (2000) CD95's deadly mission in the immune system. *Nature* 407 (6805), 789–795.

3 Jacobson MD, Weil M, Raff MC (1997) Programmed cell death in animal development. *Cell* 88 (3), 347–354.

4 Alison MR, Sarraf CE (1994) Liver cell death: patterns and mechanisms. *Gut* 35 (5), 577–581.

5 Wyllie AH, Kerr JF, Currie AR (1980) Cell death: the significance of apoptosis. *Int Rev Cytol* 68:251–306.

6 Savill J, Fadok V, Henson P *et al.* (1993) Phagocyte recognition of cells undergoing apoptosis. *Immunol Today* 14 (3), 131–136.

7 Dini L, Falasca L, Lentini A *et al.* (1993) Galactose-specific receptor modulation related to the onset of apoptosis in rat liver. *Eur J Cell Biol* 61 (2), 329–337.

8 Guicciardi ME, Gores GJ (2005) Apoptosis: a mechanism of acute and chronic liver injury. *Gut* 54 (7), 1024–1033.

9 Rosser BG, Gores GJ (1995) Liver cell necrosis: cellular mechanisms and clinical implications. *Gastroenterology* 108 (1), 252–275.

10 Szondy Z, Sarang Z, Molnar P *et al.* (2003) Transglutaminase 2–/– mice reveal a phagocytosis-associated crosstalk between macrophages and apoptotic cells. *Proc Natl Acad Sci USA* 100 (13), 7812–7817.

11 Patel T, Gores GJ, Kaufmann SH (1996) The role of proteases during apoptosis. *FASEB J* 10 (5), 587–597.

12 Miura M, Zhu H, Rotello R *et al.* (1993) Induction of apoptosis in fibroblasts by IL-1 beta-converting enzyme, a mammalian homolog of the C. elegans cell death gene ced-3. *Cell* 75 (4), 653–660.

13 Kroemer G, Martin SJ (2005) Caspase-independent cell death. *Nature Med* 11 (7), 725–730.

14 Jaattela M (2004) Multiple cell death pathways as regulators of tumour initiation and progression. *Oncogene* 23 (16), 2746–2756.

15 Werneburg NW, Guicciardi ME, Bronk SF *et al.* (2002) Tumor necrosis factor-alpha-associated lysosomal permeabilization is cathepsin B dependent. *Am J Physiol Gastrointest Liver Physiol* 283 (4), G947–956.

16 Guicciardi ME, Miyoshi H, Bronk SF *et al.* (2001) Cathepsin B knockout mice are resistant to tumor necrosis factor-alpha-mediated hepatocyte apoptosis and liver injury: implications for therapeutic applications. *Am J Pathol* 159 (6), 2045–2054.

17 Canbay A, Guicciardi ME, Higuchi H *et al.* (2003) Cathepsin B inactivation attenuates hepatic injury and fibrosis during cholestasis. *J Clin Invest* 112 (2), 152–159.

18 Kohli V, Madden JF, Bentley RC *et al.* (1999) Calpain mediates ischemic injury of the liver through modulation of apoptosis and necrosis. *Gastroenterology* 116 (1), 168–178.

19 Oberhammer F, Wilson JW, Dive C *et al.* (1993) Apoptotic death in epithelial cells: cleavage of DNA to 300 and/or 50 kb fragments prior to or in the absence of internucleosomal fragmentation. *EMBO J* 12 (9), 3679–3684.

20 Cotter TG, al-Rubeai M (1995) Cell death (apoptosis) in cell culture systems. *Trends Biotechnol* 13 (4), 150–155.

21 Gavrieli Y, Sherman Y, Ben-Sasson SA (1992) Identification of programmed cell death in situ via specific labeling of nuclear DNA fragmentation. *J Cell Biol* 119 (3), 493–501.

22 Gujral JS, Liu J, Farhood A *et al.* (2004) Functional importance of ICAM-1 in the mechanism of neutrophil-induced liver injury in bile duct-ligated mice. *Am J Physiol Gastrointest Liver Physiol* 286 (3), G499–507.

23 Nicoletti I, Migliorati G, Pagliacci MC *et al.* (1991) A rapid and simple method for measuring thymocyte apoptosis by propidium iodide staining and flow cytometry. *J Immunol Methods* 139 (2), 271–279.

24 Homburg CH, de Haas M, von dem Borne AE *et al.* (1995) Human neutrophils lose their surface Fc gamma RIII and acquire annexin V binding sites during apoptosis in vitro. *Blood* 85 (2), 532–540.

25 Stennicke HR, Salvesen GS (1997) Biochemical characteristics of caspases-3, -6, -7, and -8. *J Biol Chem* 272 (41), 25719–25723.

26 Tartaglia LA, Ayres TM, Wong GH *et al.* (1993) A novel domain within the 55 kd TNF receptor signals cell death. *Cell* 74 (5), 845–853.

27 Schmitz I, Kirchhoff S, Krammer PH (2000) Regulation of death receptor-mediated apoptosis pathways. *Int J Biochem Cell Biol* 32 (11–12), 1123–1136.

28 Galle PR, Hofmann WJ, Walczak H *et al.* (1995) Involvement of the CD95 (APO-1/Fas) receptor and ligand in liver damage. *J Exp Med* 182 (5), 1223–1230.

29 Schulze-Bergkamen H, Untergasser A, Dax A *et al.* (2003) Primary human hepatocytes – a valuable tool for investigation of apoptosis and hepatitis B virus infection. *J Hepatol* 38 (6), 736–744.

30 Suda T, Hashimoto H, Tanaka M *et al.* (1997) Membrane Fas ligand kills human peripheral blood T lymphocytes, and soluble Fas ligand blocks the killing. *J Exp Med* 186 (12), 2045–2050.

31 Kischkel FC, Hellbardt S, Behrmann I *et al.* (1995) Cytotoxicity-dependent APO-1 (Fas/CD95)-associated proteins form a death-inducing signaling complex (DISC) with the receptor. *EMBO J* 14 (22), 5579–5588.

32 Lavrik I, Golks A, Krammer PH (2005) Death receptor signaling. *J Cell Sci* 118 (Pt 2), 265–267.

33 Scaffidi C, Fulda S, Srinivasan A *et al.* (1998) Two CD95 (APO-1/Fas) signaling pathways. *EMBO J* 17 (6), 1675–1687.

34 Li S, Zhao Y, He X *et al.* (2002) Relief of extrinsic pathway inhibition by the Bid-dependent mitochondrial release of Smac in Fas-mediated hepatocyte apoptosis. *J Biol Chem* 277 (30), 26912–26920.

35 Tartaglia LA, Goeddel DV (1992) Two TNF receptors. *Immunol Today* 13 (5), 151–153.
36 Wiley SR, Schooley K, Smolak PJ *et al.* (1995) Identification and characterization of a new member of the TNF family that induces apoptosis. *Immunity* 3 (6), 673–682.
37 Walczak H, Degli-Esposti MA, Johnson RS *et al.* (1997) TRAIL-R2: a novel apoptosis-mediating receptor for TRAIL. *EMBO J* 16 (17), 5386–5397.
38 Mori E, Thomas M, Motoki K *et al.* (2004) Human normal hepatocytes are susceptible to apoptosis signal mediated by both TRAIL-R1 and TRAIL-R2. *Cell Death Differ* 11 (2), 203–207.
39 Oberhammer FA, Pavelka M, Sharma S *et al.* (1992) Induction of apoptosis in cultured hepatocytes and in regressing liver by transforming growth factor beta 1. *Proc Natl Acad Sci USA* 89 (12), 5408–5412.
40 Huang DC, Strasser A (2000) BH3-only proteins – essential initiators of apoptotic cell death. *Cell* 103 (6), 839–842.
41 Levine AJ (1997) p53, the cellular gatekeeper for growth and division. *Cell* 88 (3), 323–331.
42 Danial NN, Korsmeyer SJ (2004) Cell death: critical control points. *Cell* 116 (2), 205–219.
43 Schuchmann M, Galle PR (2002) Dead or alive – NF-kappaB, the guardian which tips the balance. *J Hepatol* 36 (6), 827–828.
44 Bursch W, Taper HS, Lauer B *et al.* (1985) Quantitative histological and histochemical studies on the occurrence and stages of controlled cell death (apoptosis) during regression of rat liver hyperplasia. *Virchows Arch B Cell Pathol Incl Mol Pathol* 50 (2), 153–266.
45 Benedetti A, Jezequel AM, Orlandi F (1988) Preferential distribution of apoptotic bodies in acinar zone 3 of normal human and rat liver. *J Hepatol* 7 (3), 319–324.
46 Miyoshi H, Rust C, Roberts PJ *et al.* (1999) Hepatocyte apoptosis after bile duct ligation in the mouse involves Fas. *Gastroenterology* 117 (3), 669–677.
47 Patel T, Roberts LR, Jones BA *et al.* (1998) Dysregulation of apoptosis as a mechanism of liver disease: an overview. *Semin Liver Dis* 18 (2), 105–114.
48 Ribeiro PS, Cortez-Pinto H, Sola S *et al.* (2004) Hepatocyte apoptosis, expression of death receptors, and activation of NF-kappaB in the liver of nonalcoholic and alcoholic steatohepatitis patients. *Am J Gastroenterol* 99 (9), 1708–1717.
49 Feldstein AE, Canbay A, Angulo P *et al.* (2003) Hepatocyte apoptosis and fas expression are prominent features of human nonalcoholic steatohepatitis. *Gastroenterology* 125 (2), 437–443.
50 Strand S, Hofmann WJ, Grambihler A *et al.* (1998) Hepatic failure and liver cell damage in acute Wilson's disease involve CD95 (APO-1/Fas) mediated apoptosis. *Nature Med* 4 (5), 588–593.
51 Strand S, Strand D, Seufert R *et al.* (2004) Placenta-derived CD95 ligand causes liver damage in hemolysis, elevated liver enzymes, and low platelet count syndrome. *Gastroenterology* 126 (3), 849–858.
52 Strand S, Hofmann WJ, Hug H *et al.* (1996) Lymphocyte apoptosis induced by CD95 (APO-1/Fas) ligand-expressing tumor cells – a mechanism of immune evasion? *Nature Med* 2 (12), 1361–1366.
53 Bantel H, Lugering A, Poremba C *et al.* (2001) Caspase activation correlates with the degree of inflammatory liver injury in chronic hepatitis C virus infection. *Hepatology* 34 (4 Pt 1), 758–767.
54 Seidel N, Volkmann X, Langer F *et al.* (2005) The extent of liver steatosis in chronic hepatitis C virus infection is mirrored by caspase activity in serum. *Hepatology* 42 (1), 113–120.
55 Bidere N, Lorenzo HK, Carmona S *et al.* (2003) Cathepsin D triggers Bax activation, resulting in selective apoptosis-inducing factor (AIF) relocation in T lymphocytes entering the early commitment phase to apoptosis. *J Biol Chem* 278 (33), 31401–31411.
56 Tsukidate K, Yamamoto K, Snyder JW *et al.* (1993) Microtubule antagonists activate programmed cell death (apoptosis) in cultured rat hepatocytes. *Am J Pathol* 143 (3), 918–925.
57 Muller M, Strand S, Hug H *et al.* (1997) Drug-induced apoptosis in hepatoma cells is mediated by the CD95 (APO-1/Fas) receptor/ligand system and involves activation of wild-type p53. *J Clin Invest* 99 (3), 403–413.
58 Higuchi H, Grambihler A, Canbay A *et al.* (2004) Bile acids up-regulate death receptor 5/TRAIL-receptor 2 expression via a c-Jun N-terminal kinase-dependent pathway involving Sp1. *J Biol Chem* 279 (1), 51–60.
59 Canbay A, Friedman S, Gores GJ (2004) Apoptosis: the nexus of liver injury and fibrosis. *Hepatology* 39 (2), 273–278.
60 Staib F, Hussain SP, Hofseth LJ *et al.* (2003) TP53 and liver carcinogenesis. *Hum Mutat* 21 (3), 201–216.
61 Lemasters JJ, DiGuiseppi J, Nieminen AL *et al.* (1987) Blebbing, free Ca2+ and mitochondrial membrane potential preceding cell death in hepatocytes. *Nature* 325 (6099), 78–81.
62 Aguilar HI, Botla R, Arora AS *et al.* (1996) Induction of the mitochondrial permeability transition by protease activity in rats: a mechanism of hepatocyte necrosis. *Gastroenterology* 110 (2), 558–566.
63 Schwab BL, Guerini D, Didszun C *et al.* (2002) Cleavage of plasma membrane calcium pumps by caspases: a link between apoptosis and necrosis. *Cell Death Differ* 9 (8), 818–831.
64 Jaeschke H, Lemasters JJ (2003) Apoptosis versus oncotic necrosis in hepatic ischemia/reperfusion injury. *Gastroenterology* 125 (4), 1246–1257.
65 Gozuacik D, Kimchi A (2004) Autophagy as a cell death and tumor suppressor mechanism. *Oncogene* 23 (16), 2891–2906.
66 Lu Z, Dono K, Gotoh K *et al.* (2005) Participation of autophagy in the degeneration process of rat hepatocytes after transplantation following prolonged cold preservation. *Arch Histol Cytol* 68 (1), 71–80.
67 Shintani T, Klionsky DJ (2004) Autophagy in health and disease: a double-edged sword. *Science* 306 (5698), 990–995.
68 Sperandio S, de Belle I, Bredesen DE (2000) An alternative, nonapoptotic form of programmed cell death. *Proc Natl Acad Sci USA* 97 (26), 14376–14381.
69 Castedo M, Perfettini JL, Roumier T *et al.* (2004) Cell death by mitotic catastrophe: a molecular definition. *Oncogene* 23 (16), 2825–2837.
70 Pinkse GG, Voorhoeve MP, Noteborn M *et al.* (2004) Hepatocyte survival depends on beta1-integrin-mediated attachment of hepatocytes to hepatic extracellular matrix. *Liver Int* 24 (3), 218–226.
71 Gujral JS, Farhood A, Bajt ML *et al.* (2003) Neutrophils aggravate acute liver injury during obstructive cholestasis in bile duct-ligated mice. *Hepatology* 38 (2), 355–363.
72 Lemasters JJ, Nieminen AL, Qian T *et al.* (1998) The mitochondrial permeability transition in cell death: a common mechanism in necrosis, apoptosis and autophagy. *Biochim Biophys Acta* 1366 (1–2), 177–196.
73 Bursch W (2001) The autophagosomal–lysosomal compartment in programmed cell death. *Cell Death Differ* 8(6), 569–581.
74 Squier MK, Miller AC, Malkinson AM *et al.* (1994) Calpain activation in apoptosis. *J Cell Physiol* 159 (2), 229–237.
75 Arora AS, de Groen P, Emori Y *et al.* (1996) A cascade of degradative hydrolase activity contributes to hepatocyte necrosis during anoxia. *Am J Physiol* 270 (2 Pt 1), G238–245.

76 Rodriguez I, Matsuura K, Ody C *et al.* (1996) Systemic injection of a tripeptide inhibits the intracellular activation of CPP32-like proteases in vivo and fully protects mice against Fas-mediated fulminant liver destruction and death. *J Exp Med* 184 (5), 2067–2072.
77 Lacronique V, Mignon A, Fabre M *et al.* (1996) Bcl-2 protects from lethal hepatic apoptosis induced by an anti-Fas antibody in mice. *Nature Med* 2 (1), 80–86.
78 Streetz K, Leifeld L, Grundmann D *et al.* (2000) Tumor necrosis factor alpha in the pathogenesis of human and murine fulminant hepatic failure. *Gastroenterology* 119 (2), 446–460.
79 Schuchmann M, Varfolomeev EE, Hermann F *et al.* (2003) Dominant negative MORT1/FADD rescues mice from CD95 and TNF-induced liver failure. *Hepatology* 37 (1), 129–135.
80 Zender L, Hutker S, Liedtke C *et al.* (2003) Caspase 8 small interfering RNA prevents acute liver failure in mice. *Proc Natl Acad Sci USA* 100 (13), 7797–7802.
81 Song E, Lee SK, Wang J *et al.* (2003) RNA interference targeting Fas protects mice from fulminant hepatitis. *Nature Med* 9 (3), 347–351.
82 Wroblewski VJ, McCloud C, Davis K *et al.* (2003) Pharmacokinetics, metabolic stability, and subcutaneous bioavailability of a genetically engineered analog of DcR3, FLINT [DcR3(R218Q)], in cynomolgus monkeys and mice. *Drug Metab Dispos* 31 (4), 502–507.
83 Bajt ML, Vonderfecht SL, Jaeschke H (2001) Differential protection with inhibitors of caspase-8 and caspase-3 in murine models of tumor necrosis factor and Fas receptor-mediated hepatocellular apoptosis. *Toxicol Appl Pharmacol* 175 (3), 243–252.
84 Valentino KL, Gutierrez M, Sanchez R *et al.* (2003) First clinical trial of a novel caspase inhibitor: anti-apoptotic caspase inhibitor, IDN-6556, improves liver enzymes. *Int J Clin Pharmacol Ther* 41 (10), 441–449.
85 Leist M, Single B, Castoldi AF *et al.* (1997) Intracellular adenosine triphosphate (ATP) concentration: a switch in the decision between apoptosis and necrosis. *J Exp Med* 185 (8), 1481–1486.
86 McCarthy NJ, Whyte MK, Gilbert CS *et al.* (1997) Inhibition of Ced-3/ICE-related proteases does not prevent cell death induced by oncogenes, DNA damage, or the Bcl-2 homologue Bak. *J Cell Biol* 136 (1), 215–227.
87 Natori S, Selzner M, Valentino KL *et al.* (1999) Apoptosis of sinusoidal endothelial cells occurs during liver preservation injury by a caspase-dependent mechanism. *Transplantation* 68 (1), 89–96.
88 Guicciardi ME, Gores GJ (2004) Cheating death in the liver. *Nature Med* 10 (6), 587–588.
89 Baskin-Bey ES, Canbay A, Bronk SF *et al.* (2005) Cathepsin B inactivation attenuates hepatocyte apoptosis and liver damage in steatotic livers after cold ischemia–warm reperfusion injury. *Am J Physiol Gastrointest Liver Physiol* 288 (2), G396–402.
90 Schulze-Bergkamen H, Brenner D, Krueger A *et al.* (2004) Hepatocyte growth factor induces Mcl-1 in primary human hepatocytes and inhibits CD95-mediated apoptosis via Akt. *Hepatology* 39 (3), 645–654.
91 Ajuebor MN, Aspinall AI, Zhou F *et al.* (2005) Lack of chemokine receptor CCR5 promotes murine fulminant liver failure by preventing the apoptosis of activated CD1d-restricted NKT cells. *J Immunol* 174 (12), 8027–8037.
92 Wright MC, Issa R, Smart DE *et al.* (2001) Gliotoxin stimulates the apoptosis of human and rat hepatic stellate cells and enhances the resolution of liver fibrosis in rats. *Gastroenterology* 121 (3), 685–698.

3.2 Ischaemia–reperfusion injury to the liver

Nazia Selzner and Pierre A. Clavien

Ischaemic injury of the liver can be divided into three types: (i) cold (or hypothermic); (ii) warm (or normothermic); and (iii) rewarming [1,2]. Cold ischaemia occurs almost exclusively in the transplant setting where it is applied intentionally to reduce the metabolic activities of the graft while the organ awaits implantation. Warm ischaemia occurs during liver surgery, trauma, shock and transplantation, when hepatic inflow occlusion (Pringle manoeuvre) or inflow and outflow (total vascular exclusion) are induced to minimize blood loss while dividing liver parenchyma. Rewarming ischaemia occurs during manipulation of the graft (for example, *ex situ* split liver preparation) or during the period of implantation of the graft when the cold liver is subjected to room or body temperature. Of note, injury to the liver cells after any type of ischaemia is apparent mainly after reperfusion when oxygen supply and blood elements are restored to the liver. While the main mechanisms of injury appear to share common pathways, recent evidence suggests important differences between cold and warm ischaemic injury. Therefore, the two forms of ischaemia and the protective strategies for each form will be discussed separately in this chapter.

Warm (normothermic) ischaemia

Warm ischaemic injury is common during liver surgery, various forms of shock, trauma and transplantation. For example, ischaemia is intentionally applied to the liver by occluding hepatic inflow (Pringle manoeuvre) during the time of transection of the liver parenchyma to prevent bleeding. Ischaemia is tolerated only for a period of about 1 h in normal and about 30 min in cirrhotic livers, and the duration of ischaemia correlates with the degree of reperfusion injury [3].

Warm ischaemia leads rapidly to the death of hepatocytes [4,5]. The severe injury of hepatocytes is preceded by massive death of endothelial cells [6]. Kupffer cells, the resident hepatic macrophages, play a major role in the mechanism of warm ischaemic injury. Upon reperfusion, Kupffer cells are activated [7]. This is evidenced by structural changes, formation of oxygen free radicals, increased phagocytosis and release of various cytokines including tumour necrosis factor alpha (TNFα) (Fig. 1) [8–10]. After reperfusion, leukocytes adhere to the denuded sinusoids and contribute significantly to the injury [11,12]. Both TNFα and interleukin 1 (IL-1), released by activated Kupffer cells, can upregulate CD11b expression on leukocytes and recruit these cells into the sinusoids [13]. The mechanism of injury involves the release of reactive oxygen intermediates. Other potential substances released by neutrophils include various proteases and hypochloric acid [14]. There is a growing body of evidence suggesting that host T cells also participate in hepatic ischaemic injury. TNFα and IL-1 can recruit and activate CD4+ T lymphocytes in the liver during the early phase of reperfusion [15], which autoamplify Kupffer cell activation and neutrophil recruitment into the liver [16].

Leukocyte recruitment into sinusoids during the early phase of reperfusion is also mediated through activation of the complement cascade. The complement chains rapidly activated by cellular proteins released during reperfusion engage complement receptors on neutrophils and their recruitment into sinusoids [17].

Further binding of the various components mentioned above (cytokines, oxygen free radicals, etc.) to their respective receptors during the early stages of reperfusion initiates the complex machinery leading to the death of hepatocytes.

Different forms of cell death

Two distinct forms of cell death are recognized: necrosis, a passive mechanism of cell death due to overwhelming injury; and a more tightly regulated process called programmed cell death or apoptosis (see Chapter 3.1). They can be distinguished by morphological and biochemical criteria as well as by their sensitivity to pharmacological or genetic manipulation.

The main features of necrosis are early cell and organelle swelling, ion dysregulation, adenosine triphosphate (ATP) depletion and activation of degradative enzymes. These processes culminate in the rupture of the cell membrane with release of intracellular proteins, metabolites and ions. The cell debris represents a strong stimulus for inflammatory processes, which typically accompany necrosis.

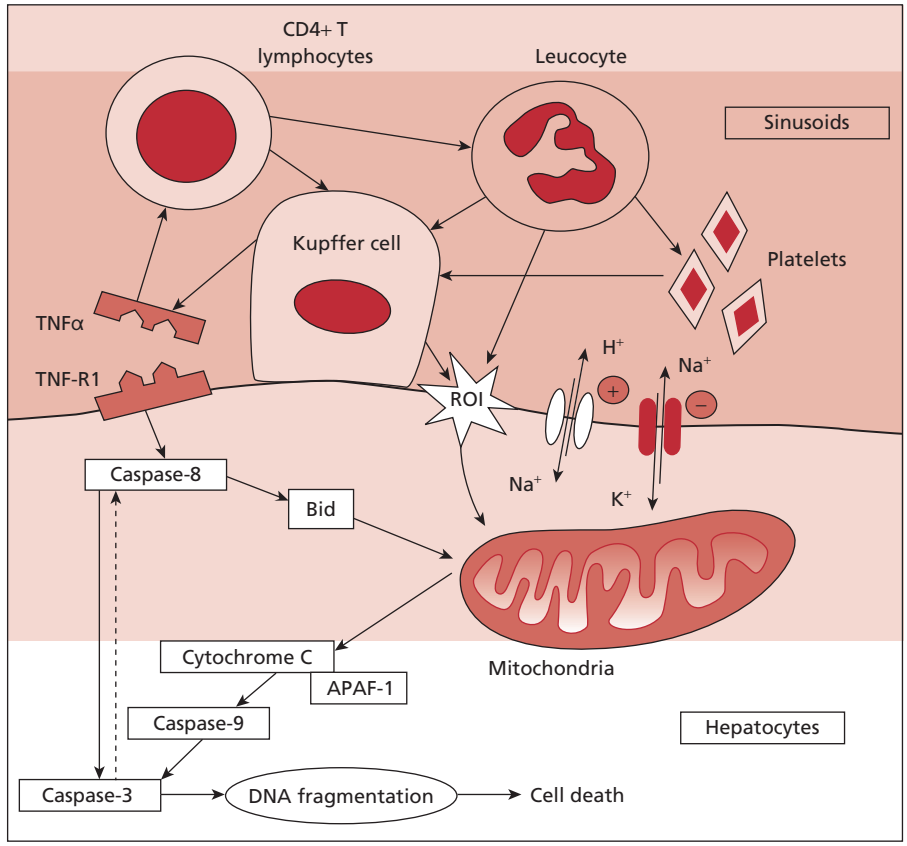

Fig. 1 Mechanisms of warm ischaemic injury. Major pathways including TNFα-mediated cell death and generation of reactive oxygen intermediates (ROI) are indicated.

Apoptosis was originally described in lymphoid cells and appears to be the primary process by which normal cell death occurs during development or by which cell numbers are maintained in tissues with rapid cell turnover such as intestinal epithelium or skin. Under physiological conditions, apoptosis occurs as a continuous and serial event affecting selective cells with rapid and silent removal of the dead cells though macrophages. Studies with cytosolic extracts of cells, which have been induced to undergo apoptosis in a synchronous manner, have shown that apoptosis can be divided into biochemically and morphologically distinct phases. In the first phase, the 'initiation phase', a tightly regulated molecular machinery involving various proteases is activated. In the second 'committed or effector phase', the molecular machinery becomes fully activated, as shown by the ability of the cytosolic extracts of committed cells to induce apoptotic changes in nuclei. Only after this, in the third phase, or 'degradation phase', do the hallmarks of apoptosis become evident. These include morphological changes including DNA fragmentation and the formation of apoptotic bodies.

Necrosis and apoptosis have long been viewed as fundamentally different processes. Although necrosis was thought to be the predominant form of death triggered by severe cellular injury or extreme environmental perturbation, cell death with features of apoptosis can occur after major stress to the cells. Whether necrosis or apoptosis predominates and eventually accounts for a given cell's demise may depend on both intrinsic (e.g. cell type, developmental state of the cell, ATP or fat content) [18] and extrinsic factors (e.g. the nature and severity of the insult, pharmacological interventions). Further complicating the task of distinguishing necrosis from apoptosis, these death cascades may share some common mediators. Lemasters [19] introduced the theory of 'necrapoptosis' for such mixed forms of cell death. It postulates that a process begins with a common death signal or toxic stress that culminates in either cell lysis (necrotic cell death) or programmed cellular resorption (apoptosis), depending on other modifying factors such as the decline in cellular ATP levels or fat content (steatosis) (Fig. 2).

In the context of hepatic ischaemia and reperfusion injury, a controversy has emerged in recent years over whether necrotic or apoptotic cell death accounts for the severe parenchymal injury [4,20]. Some investigators reported that the overwhelming majority of parenchymal injury observed is caused by massive necrotic alterations [4]. In contrast, others showed that specific inhibition of apoptosis significantly prevented parenchymal injury and improved animal survival after prolonged periods of ischaemia [21–24]. For example, we have demonstrated that apoptotic cell death is initiated by binding of TNFα to the specific receptor TNF-R1 on the cell membrane of hepatocytes in a mouse model of normothermic ischaemic injury [9] (Fig. 1). The apoptotic signal is then transferred into the cell where

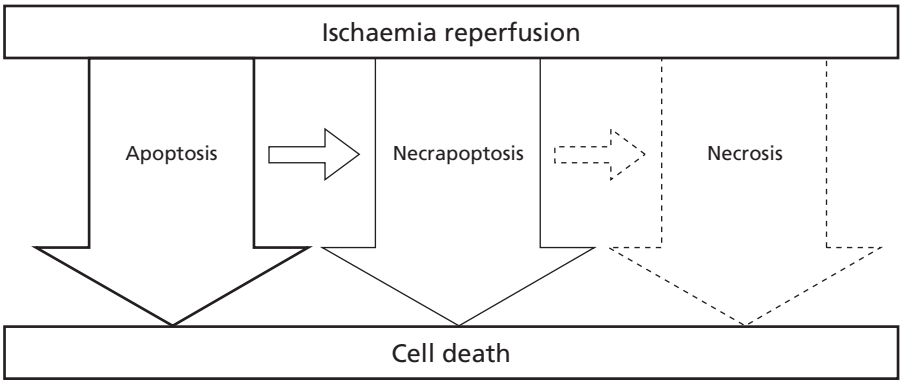

Fig. 2 Mixed forms of cell death with apoptotic and necrotic features have been proposed and have led to the creation of the term 'necrapoptosis'. Death pathways with early features of apoptosis followed by some necrotic changes are possible, depending on the nature and the severity of the insult and on the condition of the affected cell.

different caspases are activated. This process leads to DNA fragmentation and cell death. In this process, the mitochondria act as amplifiers of the signal, allowing even weak signals to have deleterious effects [25]. Blocking early mechanisms of apoptosis (the first and second phases from above) can prevent parenchymal injury. Several protective strategies based on specific blockage of the pathways of injury have been developed over the past decades. These strategies can be divided into surgical interventions and the use of pharmacological agents.

Protective strategies

Surgical strategies

While many strategies to protect against warm ischaemic injury have been proposed in various animal models, only two have finally made the transition into clinical practice, namely intermittent clamping [3] and ischaemic preconditioning [26].

Ischaemic preconditioning consists of a brief period of ischaemia followed by a short interval of reperfusion before the actual surgical procedure, with a prolonged ischaemic stress [27]. During the surgery, hepatic inflow is occluded by placing a vascular clamp or a loop around the portal triad (i.e. portal vein, hepatic artery and bile duct), rendering the whole organ ischaemic. After an ischaemic interval of 10–15 min, the clamp is removed and the liver is reperfused for 10–15 min before the prolonged ischaemic insult (Fig. 3). Our current understanding of the underlying biological principle is that cells primed by various kinds of subinjurious stress trigger defence mechanisms against subsequent lethal injury of the same or a different type [28–30]. The phenomenon was initially discovered in the myocardium by Murry *et al.* [31] in 1986. Subsequently, beneficial effects were shown in various tissues including skeletal muscle [32], kidney [33], lung [34], intestine [35] and liver [26,36–38]. Although the benefit of ischaemic preconditioning in the liver has already been suggested in a clinical pilot study [26] and a large randomized study [38], knowledge of the molecular mechanisms remains vague. Several mediators have been proposed to play a critical role in the protective pathways including adenosine [27], nitric oxide [36], oxidative stress [39], some heat shock proteins (Hsps; e.g. Hsp72 and haem oxygenase 1/Hsp32) [40] and TNFα [9,41,42].

In addition to the extracellular mediators, studies in heart and liver indicate that the ischaemic preconditioning process involves the activation of intracellular messengers such as protein kinase C, adenosine monophosphate-activated protein kinase, p38 mitogen-activated protein kinase, Ik kinase and signal transducers and activators of transcription [43–45]. The downstream consequences of these pathways could be cytoprotective by abrogation of cell death pathways (such as activation of vacuolar ATP, inhibition of intracellular sodium accumulation and cell swelling), stimulation of antioxidant and other cellular protective mechanisms, and by initiation of entry into the cell cycle.

Intermittent clamping consists of multiple cycles of short intervals of ischaemia (10–30 min) and reperfusion (5–15 min) [46] (Fig. 3). Although the protective mechanisms of this concept still remain elusive, intermittent clamping is currently used in practice by many centres. In a prospective randomized study, Belghiti *et al.* [3] showed that cycles of short intervals of ischaemia (15 min) and reperfusion (5 min) provided protection in patients undergoing major liver resection. We have compared this protocol with ischaemic preconditioning [22] in a mouse model and found that both strategies provide comparable protection for ischaemic intervals of up to 75 min. For longer ischaemic intervals, only intermittent clamping conferred significant protection. We therefore concluded that ischaemic preconditioning is preferable for most liver resections because each period of reperfusion in the intermittent clamping strategy may cause significant bleeding.

Pharmacological strategies

Many pharmacological agents have been shown to confer protection against ischaemic injury in the liver. However, none of these strategies has found its way into routine clinical practice.

Caspase inhibition

Caspases belong to the family of cysteine proteinases. Specific isoforms are involved in the initiation and execution phase of

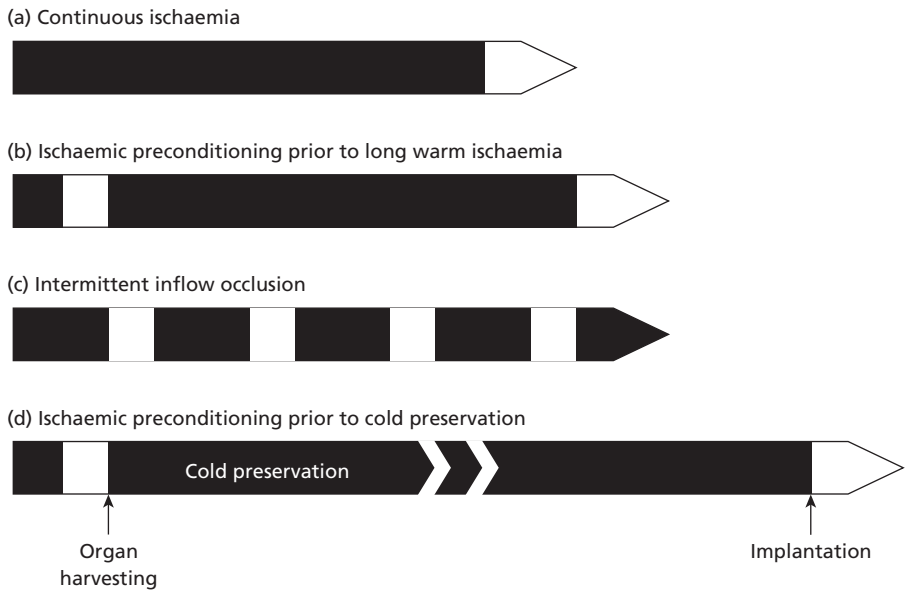

Fig. 3 Several surgical strategies exist to overcome the negative effects of prolonged ischaemia ■ (solid box) and reperfusion □ (open box) (a). To prevent warm ischaemic injuries, the options include ischaemic preconditioning (b) and intermittent inflow occlusion (c). Experimental studies suggest that normothermic ischaemic preconditioning prior to hypothermic preservation also protects against cold ischaemic injuries (d).

apoptosis. Among these isoforms, caspase-8 is activated during the early phases, and caspase-3 is activated during the late phase of apoptosis [25]. Suppression of their activation, or inhibition of their activity, reduces or completely abolishes apoptosis in cell culture models. In a rat model of warm ischaemia, Cursio *et al.* [23,47] demonstrated maximal caspase activation 3 h after reperfusion. Pretreatment of the animals with a specific caspase inhibitor 2 min prior to ischaemia resulted in significant improvement in lethal injury that normally occurred 24–48 h after ischaemia. The protective effect of caspase inhibition has also been confirmed by other groups in different models of cold and warm ischaemia [21,48].

Other proteases, such as calpain, have been reported as mediators of preservation–reperfusion injury [49–51]. Calpains are a group of non-lysosomal, cytoplasmic, calcium-dependent cysteine proteases involved in proteolysis of several cytoskeletal and membrane proteins [52]. Several group have reported the protective effects of calpain inhibition in cold [53,54] and warm ischaemic injury [5].

TNFα as initiator of the apoptotic cascade

In 1990, Colletti *et al.* [10] provided the first evidence suggesting that prolonged ischaemic intervals lead to a burst of various cytokines including TNFα. Other groups subsequently confirmed this finding [9,42,55]. Various approaches to block the TNFα signalling pathway upon reperfusion have been used, including TNFα antibody [10,41,55], pretreatment with the methylxanthine derivate, pentoxifylline (inhibitor of TNFα synthesis and release in Kupffer cells) [9] or the use of TNF-R1 knockout mice [9]. Each of these approaches was found to confer protection against reperfusion injury and animal death after prolonged ischaemic insult to the liver. The finding that TNFα acts at an early stage before any evidence of morphological features suggests that this cytokine represents an appealing target for preventive strategies. However, so far, no clinical studies have been presented that would show a beneficial effect of pentoxifylline on ischaemic liver injury.

The role of Kupffer cells and antioxidants

There is growing evidence that the activation of resident macrophages (Kupffer cells) of the liver contributes to ischaemic injury in the liver [55–57]. Activated Kupffer cells release a variety of potentially harmful mediators, including TNFα [9,10,41] and reactive oxygen species [56,58,59], during the reperfusion period.

The most damaging form of reactive oxygen species generated in mitochondria of the Kupffer cells is the hydroxyl radical ($OH^{\bullet}$). One of the major and most sensitive targets of $OH^{\bullet}$ is the mitochondrial DNA [57–60]. $OH^{\bullet}$ attacks deoxyribose and causes the release of nucleic acids of mitochondrial DNA, resulting in strand breaks. $OH^{\bullet}$ can also directly attack bases, leading to modifications with a loss of DNA integrity and, hence, impaired transcription. Although the role of reactive oxygen species in a number of liver diseases is generally accepted, the detailed mechanisms of reactive oxygen involvement are under debate. The most convincing hypothesis of reactive oxygen-induced cell injury is the destruction of cellular membranes through peroxidation of lipids. In addition, all mitochondrial constituents, proteins, lipids and mitochondrial DNA [61], are potential targets for reactive oxygen species-mediated damage. Through such damage, a gradual impairment of defences in mitochondria will enhance the effect of further oxidative stress. In the liver, the involvement of reactive oxygen has been suggested in apoptotic cell death of hepatocytes and endothelial cells [62]. One possible explanation is that oxidative stress can induce the mitochondrial membrane permeability transition, a central event preceding cell death [63]. Another potential target of reactive oxygen species could be the caspases [64]. Caspases

can be activated by low concentrations of hydrogen peroxide, while higher levels inhibit enzymatic activity, presumably due to oxidation of critical sulphydryl groups.

Owing to the central role of oxidative stress in the setting of ischaemia–reperfusion, a large number of studies have attempted to identify methods to either prevent or neutralize oxidative stress [65–68]. It has also been demonstrated that strategies aiming at overexpressing antioxidant proteins (e.g. superoxide dismutase [69,70]) may confer protection against extended ischaemic injury. However, none of these strategies has found its way into routine clinical practice, with the exception of some antioxidant ingredients that were introduced into preservation solutions.

Cold (hypothermic) ischaemia

Liver transplantation has experienced dramatic success over the past 15 years and has become the treatment of choice for many patients with endstage liver disease. While major progress has been made in several areas of transplantation, such as selection of recipients and immunosuppression, ischaemic injury remains an important limiting factor for the full success of the procedure. During the various phases of transplantation, the liver graft is exposed to different types of ischaemic stress, including normothermic ischaemia before or during harvesting of the organ from the donor, cold ischaemia during the period of preservation and rewarming during graft implantation.

Hypothermia, while necessary to slow metabolism during the period of preservation, causes morphological changes in some sinusoidal endothelial cells [21,71–73]. They become rounded, detached and slough into the sinusoidal lumen; however, most cells remain alive until reperfusion as assessed by Trypan blue [74] and *in situ* terminal deoxynucleotidyl transferase-mediated dUTP nick end labelling (TUNEL) assay studies [73]. Adhesion of the platelets to the sinusoid lining induces sinusoidal endothelial cell (SEC) apoptosis upon reperfusion of the cold ischaemic liver [75]. Finally, leukocytes and platelets synergistically exacerbate SEC injury by the induction of apoptosis [76].

The injuries due to low-temperature preservation are different from warm ischaemic injury in many aspects. The main feature of the warm ischaemia type of injury is massive and early (3–6 h) apoptosis of hepatocytes after reperfusion. In contrast, cold storage is associated with diffuse SEC damage within 30–60 min of reperfusion while hepatocytes remain morphologically normal [77]. The degree of endothelial cell detachment has been shown to correlate with the duration of cold ischaemia [1,78–79]. Several recent reports have pointed out that activation of matrix metalloproteinases is a critical feature of SEC detachment during cold hepatic preservation prior to reperfusion [80]. Matrix metalloproteinases are also important contributors to angiogenesis.

Upon reperfusion of the cold preserved graft, SEC undergo apoptosis with subsequent DNA fragmentation and cell death [73]. The strong correlation between the degree of apoptosis and graft viability suggests that SEC apoptosis is a critical process in cold ischaemic injury. While a number of intracellular mediators of apoptosis are known, the data regarding the initiating extracellular processes are scarce. Disruption of the endothelial wall leads to leukocyte [11,56,76,81] and platelet adhesion [75,82], which induces microcirculatory disturbances.

Protective strategies

Cooling of the organ and preservation solutions

Reduction of metabolic activity by cooling of the organ to 1–4°C was among the first strategies designed to protect against ischaemic injury [83]. This strategy may safely preserve the liver for transplantation for up to 8 h, whereas livers kept at room temperature tolerate only about 1 h of ischaemia. Cooling requires the application of a perfusion/preservation solution. Thus, efforts were directed at designing an effective solution that would extend the period for safe preservation. The development of University of Wisconsin (UW) cold preservation solution in the mid-1980s [83] provided a breakthrough in liver transplantation allowing organ sharing across large distances. The solution was developed empirically and was supposed to act on the known and speculated negative effects of hypothermia. These negative effects include: (i) cell swelling caused by inhibition of the membrane pump Na^+/K^+ ATPase regulating cell volume; (ii) intracellular acidosis caused by anaerobic metabolism and lactate accumulation [84]; (iii) disturbances in the homeostasis of cytosolic Ca [85]; and (iv) free-radical generation [86]. The solution contains a cocktail of substances such as lactobionate, raffinose, phosphate buffer, glutathione, colloids (hydroxyethylstarch) and various ions. Despite the lack of understanding as to how the ingredients confer protection, the UW solution still remains the most widely used preservation solution. Other solutions such as Eurocollins (with high glucose content and very high osmolarity) or Celsior (with mannitol, glutamate and histidine buffer) are less effective and have been abandoned in clinical practice. Finally, Bretschneider's histidine–tryptophan–ketoglutarate (HTK) was designed for cardiac preservation and was formulated to retard acidosis (histidine), to prevent membrane injury (tryptophan) and to provide a substrate for energy metabolism (ketoglutarate). This solution was also tested by several groups in liver transplantation and has been shown to be equally as effective as the UW solution during the usual periods of cold preservation used in human transplantation [87,88].

Ischaemic preconditioning

As in the warm ischaemic liver, ischaemic preconditioning is potentially an effective approach to preventing preservation injury [89] (Fig. 3). Our group has recently demonstrated that ischaemic preconditioning is protective during the period of cold storage of the liver prior to reperfusion, by reducing endothelial cell detachment and matrix metalloproteinase activity [89]. The protective effect is mediated by a short sublethal

burst of oxygen free radicals. Indeed, a mild burst of oxidative stress generated during the process of ischaemic preconditioning induces natural defence mechanisms against subsequent lethal injury, as also demonstrated in a model of warm ischaemia [39]. However, the clinical benefit and applicability of ischaemic preconditioning in liver transplantation remains to be established.

Conclusion

Ischaemia and reperfusion injuries remain important in liver surgery, transplantation and various forms of shock. Hepatic ischaemia can be divided into two types, normothermic (warm) and cold (organ preservation) ischaemia. While some injurious mechanisms are common for these two types, such as initial apoptosis of SEC followed by hepatocyte injury, critical differences exist, such as resistance of hepatocytes to cold ischaemic injury. Apoptosis appears to be involved in both types of injury as various antiapoptotic strategies have been shown by several groups to confer a high degree of protection, including improved survival following long ischaemic insult. The future lies in a better understanding of the underlying mechanisms of injury, and a closer look at protective strategies such as ischaemic preconditioning may lead to the identification of effective molecules enhancing tolerance to ischaemic injury.

References

1 Clavien PA, Harvey PR, Strasberg SM (1992) Preservation and reperfusion injuries in liver allografts. An overview and synthesis of current studies. *Transplantation* 53 (5), 957–978.

2 Selzner N, Rudiger H, Graf R *et al.* (2003) Protective strategies against ischemic injury of the liver. *Gastroenterology* 125 (3), 917–936.

3 Belghiti J, Noun R, Malafosse R *et al.* (1999) Continuous versus intermittent portal triad clamping for liver resection: a controlled study. *Ann Surg* 229 (3), 369–375.

4 Gujral JS, Bucci TJ, Farhood A *et al.* (2001) Mechanism of cell death during warm hepatic ischemia–reperfusion in rats: apoptosis or necrosis? *Hepatology* 33 (2), 397–405.

5 Kohli V, Madden JF, Bentley RC *et al.* (1999) Calpain mediates ischemic injury of the liver through modulation of apoptosis and necrosis. *Gastroenterology* 116 (1), 168–178.

6 Kohli V, Selzner M, Madden JF *et al.* (1999) Endothelial cell and hepatocyte deaths occur by apoptosis after ischemia–reperfusion injury in the rat liver. *Transplantation* 67 (8), 1099–1105.

7 Caldwell-Kenkel JC, Currin RT, Tanaka Y *et al.* (1991) Kupffer cell activation and endothelial cell damage after storage of rat livers: effects of reperfusion. *Hepatology* 13 (1), 83–95.

8 Jaeschke H (1999) Kupffer cell-induced oxidant stress during hepatic ischemia–reperfusion: does the controversy continue? *Hepatology* 30 (6), 1527–1528.

9 Rudiger HA, Clavien PA (2002) Tumor necrosis factor alpha, but not Fas, mediates hepatocellular apoptosis in the murine ischemic liver. *Gastroenterology* 122 (1), 202–210.

10 Colletti LM, Remick DG, Burtch GD *et al.* (1990) Role of tumor necrosis factor-alpha in the pathophysiologic alterations after hepatic ischemia/reperfusion injury in the rat. *J Clin Invest* 85 (6), 1936–1943.

11 Clavien PA, Harvey PR, Sanabria JR *et al.* (1993) Lymphocyte adherence in the reperfused rat liver: mechanisms and effects. *Hepatology* 17 (1), 131–142.

12 Jaeschke H, Smith CW (1997) Mechanisms of neutrophil-induced parenchymal cell injury. *J Leukoc Biol* 61 (6), 647–653.

13 Bajt ML, Farhood A, Jaeschke H (2001) Effects of CXC chemokines on neutrophil activation and sequestration in hepatic vasculature. *Am J Physiol Gastrointest Liver Physiol* 281 (5), G1188–1195.

14 Weiss SJ. (1989) Tissue destruction by neutrophils. *N Engl J Med* 320 (6), 365–376.

15 Zwacka RM, Zhang Y, Halldorson J *et al.* (1997) CD4(+) T-lymphocytes mediate ischemia/reperfusion-induced inflammatory responses in mouse liver. *J Clin Invest* 100 (2), 279–289.

16 Le Moine O, Louis H, Demols A *et al.* (2000) Cold liver ischemia–reperfusion injury critically depends on liver T cells and is improved by donor pretreatment with interleukin 10 in mice. *Hepatology* 31 (6), 1266–1274.

17 Jaeschke H, Farhood A, Bautista AP *et al.* (1993) Complement activates Kupffer cells and neutrophils during reperfusion after hepatic ischemia. *Am J Physiol* 264 (4 Pt 1), G801–809.

18 Selzner M, Rudiger HA, Sindram D *et al.* (2000) Mechanisms of ischemic injury are different in the steatotic and normal rat liver. *Hepatology* 32 (6), 1280–1288.

19 Lemasters JJ. (1999) Necrapoptosis and the mitochondrial permeability transition: shared pathways to necrosis and apoptosis. *Am J Physiol* 276 (1 Pt 1), G1–6.

20 Clavien PA, Rudiger HA, Selzner M (2001) Mechanism of hepatocyte death after ischemia: apoptosis versus necrosis. *Hepatology* 33 (6), 1555–1557.

21 Natori S, Selzner M, Valentino KL *et al.* (1999) Apoptosis of sinusoidal endothelial cells occurs during liver preservation injury by a caspase-dependent mechanism. *Transplantation* 68 (1), 89–96.

22 Rudiger HA, Kang KJ, Sindram D *et al.* (2002) Comparison of ischemic preconditioning and intermittent and continuous inflow occlusion in the murine liver. *Ann Surg* 235 (3), 400–407.

23 Cursio R, Gugenheim J, Ricci JE *et al.* (1999) A caspase inhibitor fully protects rats against lethal normothermic liver ischemia by inhibition of liver apoptosis. *FASEB J* 13 (2), 253–261.

24 Bilbao G, Contreras JL, Eckhoff DE *et al.* (1999) Reduction of ischemia–reperfusion injury of the liver by *in vivo* adenovirus-mediated gene transfer of the antiapoptotic Bcl-2 gene. *Ann Surg* 230 (2), 185–193.

25 Scaffidi C, Fulda S, Srinivasan A *et al.* (1998) Two CD95 (APO-1/Fas) signaling pathways. *EMBO J* 17 (6), 1675–1687.

26 Clavien PA, Yadav S, Sindram D *et al.* (2000) Protective effects of ischemic preconditioning for liver resection performed under inflow occlusion in humans. *Ann Surg* 232 (2), 155–162.

27 Peralta C, Hotter G, Closa D *et al.* (1997) Protective effect of preconditioning on the injury associated to hepatic ischemia-reperfusion in the rat: role of nitric oxide and adenosine. *Hepatology* 25 (4), 934–937.

28 Jaeschke H (2003) Molecular mechanisms of hepatic ischemia-reperfusion injury and preconditioning. *Am J Physiol Gastrointest Liver Physiol* 284 (1), G15–26.

29 Cavalieri B, Perrelli MG, Aragno M *et al.* (2002) Ischemic preconditioning attenuates the oxidant-dependent mechanisms of reperfusion cell damage and death in rat liver. *Liver Transpl* 8 (11), 990–999.

30 Schauer RJ, Gerbes AL, Vonier D *et al.* (2003) Induction of cellular resistance against Kupffer cell-derived oxidant stress: a novel concept

of hepatoprotection by ischemic preconditioning. *Hepatology* 37 (2), 286–295.
31 Murry CE, Jennings RB, Reimer KA (1986) Preconditioning with ischemia: a delay of lethal cell injury in ischemic myocardium. *Circulation* 74 (5), 1124–1136.
32 Pang CY, Forrest CR (1995) Acute pharmacologic preconditioning as a new concept and alternative approach for prevention of skeletal muscle ischemic necrosis. *Biochem Pharmacol* 49 (8), 1023–1034.
33 Turman MA, Bates CM (1997) Susceptibility of human proximal tubular cells to hypoxia: effect of hypoxic preconditioning and comparison to glomerular cells. *Ren Fail* 19 (1), 47–60.
34 Du ZY, Hicks M, Winlaw D *et al.* (1996) Ischemic preconditioning enhances donor lung preservation in the rat. *J Heart Lung Transplant* 15 (12), 1258–1267.
35 Hotter G, Closa D, Prados M *et al.* (1996) Intestinal preconditioning is mediated by a transient increase in nitric oxide. *Biochem Biophys Res Commun* 222 (1), 27–32.
36 Peralta C, Closa D, Hotter G *et al.* (1996) Liver ischemic preconditioning is mediated by the inhibitory action of nitric oxide on endothelin. *Biochem Biophys Res Commun* 229 (1), 264–270.
37 Yadav SS, Sindram D, Perry DK *et al.* (1999) Ischemic preconditioning protects the mouse liver by inhibition of apoptosis through a caspase-dependent pathway. *Hepatology* 30 (5), 1223–1231.
38 Clavien PA, Selzner M, Rudiger HA *et al.* (2003) A prospective randomized study in 100 consecutive patients undergoing major liver resection with versus without ischemic preconditioning. *Ann Surg* 238 (6), 843–850; discussion 851–852.
39 Rudiger HA, Graf R, Clavien PA (2003) Sub-lethal oxidative stress triggers the protective effects of ischemic preconditioning in the mouse liver. *J Hepatol* 39 (6), 972–977.
40 Redaelli CA, Tian YH, Kubulus D *et al.* (2002) Hyperthermia preconditioning induces renal heat shock protein expression, improves cold ischemia tolerance, kidney graft function and survival in rats. *Nephron* 90 (4), 489–497.
41 Colletti LM, Kunkel SL, Walz A *et al.* (1996) The role of cytokine networks in the local liver injury following hepatic ischemia/reperfusion in the rat. *Hepatology* 23 (3), 506–514.
42 Peralta C, Fernandez L, Panes J *et al.* (2001) Preconditioning protects against systemic disorders associated with hepatic ischemia–reperfusion through blockade of tumor necrosis factor-induced P-selectin up-regulation in the rat. *Hepatology* 33 (1), 100–113.
43 Carini R, De Cesaris MG, Splendore R *et al.* (2000) Ischemic preconditioning reduces Na(+) accumulation and cell killing in isolated rat hepatocytes exposed to hypoxia. *Hepatology* 31 (1), 166–172.
44 Carini R, De Cesaris MG, Splendore R *et al.* (2001) Signal pathway involved in the development of hypoxic preconditioning in rat hepatocytes. *Hepatology* 33 (1), 131–139.
45 Teoh N, Dela Pena A, Farrell G (2002) Hepatic ischemic preconditioning in mice is associated with activation of NF-kappaB, p38 kinase, and cell cycle entry. *Hepatology* 36 (1), 94–102.
46 Makuuchi M, Mori T, Gunven P *et al.* (1987) Safety of hemihepatic vascular occlusion during resection of the liver. *Surg Gynecol Obstet* 164 (2), 155–158.
47 Cursio R, Gugenheim J, Panaia-Ferrari P *et al.* (1998) Improvement of normothermic rat liver ischemia/reperfusion by muramyl dipeptide. *J Surg Res* 80 (2), 339–344.
48 Kobayashi A, Imamura H, Isobe M *et al.* (2001) Mac-1 (CD11b/CD18) and intercellular adhesion molecule-1 in ischemia–reperfusion injury of rat liver. *Am J Physiol Gastrointest Liver Physiol* 281 (2), G577–585.
49 Wang M, Sakon M, Umeshita K *et al.* (2001) Prednisolone suppresses ischemia–reperfusion injury of the rat liver by reducing cytokine production and calpain mu activation. *J Hepatol* 34 (2), 278–283.
50 Squier MK, Miller AC, Malkinson AM *et al.* (1994) Calpain activation in apoptosis. *J Cell Physiol* 159 (2), 229–237.
51 Arora AS, de Groen P, Emori Y *et al.* (1996) A cascade of degradative hydrolase activity contributes to hepatocyte necrosis during anoxia. *Am J Physiol* 270 (2 Pt 1), G238–245.
52 Croall DE, DeMartino GN (1991) Calcium-activated neutral protease (calpain) system: structure, function, and regulation. *Physiol Rev* 71 (3), 813–847.
53 Kohli V, Gao W, Camargo CA, Jr *et al.* (1997) Calpain is a mediator of preservation-reperfusion injury in rat liver transplantation. *Proc Natl Acad Sci USA* 94 (17), 9354–9359.
54 Upadhya GA, Topp SA, Hotchkiss RS *et al.* (2003) Effect of cold preservation on intracellular calcium concentration and calpain activity in rat sinusoidal endothelial cells. *Hepatology* 37 (2), 313–323.
55 Wanner GA, Muller PE, Ertel W *et al.* (1999) Differential effect of anti-TNF-alpha antibody on proinflammatory cytokine release by Kupffer cells following liver ischemia and reperfusion. *Shock* 11 (6), 391–395.
56 Jaeschke H, Farhood A (1991) Neutrophil and Kupffer cell-induced oxidant stress and ischemia–reperfusion injury in rat liver. *Am J Physiol* 260 (3 Pt 1), G355–362.
57 Mochida S, Arai M, Ohno A *et al.* (1994) Oxidative stress in hepatocytes and stimulatory state of Kupffer cells after reperfusion differ between warm and cold ischemia in rats. *Liver* 14 (5), 234–240.
58 Rymsa B, Wang JF, de Groot H (1991) $O2^{-}$. release by activated Kupffer cells upon hypoxia–reoxygenation. *Am J Physiol* 261 (4 Pt 1), G602–607.
59 Jaeschke H (1998) Mechanisms of reperfusion injury after warm ischemia of the liver. *J Hepatobiliary Pancreat Surg* 5 (4), 402–408.
60 Coito AJ, Buelow R, Shen XD *et al.* (2002) Heme oxygenase-1 gene transfer inhibits inducible nitric oxide synthase expression and protects genetically fat Zucker rat livers from ischemia-reperfusion injury. *Transplantation* 74 (1), 96–102.
61 Boveris A, Chance B (1973) The mitochondrial generation of hydrogen peroxide. General properties and effect of hyperbaric oxygen. *Biochem J* 134 (3), 707–716.
62 Adachi S, Zeisig M, Moller L (1995) Improvements in the analytical method for 8-hydroxydeoxyguanosine in nuclear DNA. *Carcinogenesis* 16 (2), 253–258.
63 Richter C, Gogvadze V, Laffranchi R *et al.* (1995) Oxidants in mitochondria: from physiology to diseases. *Biochim Biophys Acta* 1271 (1), 67–74.
64 Omar R, Nomikos I, Piccorelli G *et al.* (1989) Prevention of postischaemic lipid peroxidation and liver cell injury by iron chelation. *Gut* 30 (4), 510–514.
65 Karwinski W, Soreide O (1997) Allopurinol improves scavenging ability of the liver after ischemia/reperfusion injury. *Liver* 17 (3), 139–143.
66 Ozaki M, Nakamura M, Teraoka S *et al.* (1997) A novel anti-oxidant compound, protects the rat liver from ischemia–reperfusion injury. *Transpl Int* 10 (2), 96–102.
67 Zhong Z, Froh M, Connor HD *et al.* (2002) Prevention of hepatic ischemia-reperfusion injury by green tea extract. *Am J Physiol Gastrointest Liver Physiol* 283 (4), G957–964.
68 Sewerynek E, Reiter RJ, Melchiorri D *et al.* (1996) Oxidative damage in the liver induced by ischemia–reperfusion: protection by melatonin. *Hepatogastroenterology* 43 (10), 898–905.

69 Rauen U, Polzar B, Stephan H *et al.* (1999) Cold-induced apoptosis in cultured hepatocytes and liver endothelial cells: mediation by reactive oxygen species. *FASEB J* 13 (1), 155–168.
70 Czaja MJ (2002) Induction and regulation of hepatocyte apoptosis by oxidative stress. *Antioxid Redox Signal* 4 (5), 759–767.
71 Otto G, Wolff H, David H (1984) Preservation damage in liver transplantation: electron-microscopic findings. *Transplant Proc* 16 (5), 1247–1248.
72 McKeown CM, Edwards V, Phillips MJ *et al.* (1988) Sinusoidal lining cell damage: the critical injury in cold preservation of liver allografts in the rat. *Transplantation* 46 (2), 178–191.
73 Gao W, Bentley RC, Madden JF *et al.* (1998) Apoptosis of sinusoidal endothelial cells is a critical mechanism of preservation injury in rat liver transplantation. *Hepatology* 27 (6), 1652–1660.
74 Holloway CM, Harvey PR, Strasberg SM (1990) Viability of sinusoidal lining cells in cold-preserved rat liver allografts. *Transplantation* 49 (1), 225–229.
75 Sindram D, Porte RJ, Hoffman MR *et al.* (2000) Platelets induce sinusoidal endothelial cell apoptosis upon reperfusion of the cold ischemic rat liver. *Gastroenterology* 118 (1), 183–191.
76 Sindram D, Porte RJ, Hoffman MR *et al.* (2001) Synergism between platelets and leukocytes in inducing endothelial cell apoptosis in the cold ischemic rat liver: a Kupffer cell-mediated injury. *FASEB J* 15 (7), 1230–1232.
77 Clavien PA (1998) Sinusoidal endothelial cell injury during hepatic preservation and reperfusion. *Hepatology* 28 (2), 281–285.
78 Momii S, Koga A (1990) Time-related morphological changes in cold-stored rat livers. A comparison of Euro-Collins solution with UW solution. *Transplantation* 50 (5), 745–750.
79 Gao W, Washington MK, Bentley RC *et al.* (1997) Antiangiogenic agents protect liver sinusoidal lining cells from cold preservation injury in rat liver transplantation. *Gastroenterology* 113 (5), 1692–1700.
80 Upadhya GA, Strasberg SM (1999) Evidence that actin disassembly is a requirement for matrix metalloproteinase secretion by sinusoidal endothelial cells during cold preservation in the rat. *Hepatology* 30 (1), 169–176.
81 Takei Y, Marzi I, Gao WS *et al.* (1991) Leukocyte adhesion and cell death following orthotopic liver transplantation in the rat. *Transplantation* 51 (5), 959–965.
82 Cywes R, Packham MA, Tietze L *et al.* (1993) Role of platelets in hepatic allograft preservation injury in the rat. *Hepatology* 18 (3), 635–647.
83 Belzer FO, Southard JH (1988) Principles of solid-organ preservation by cold storage. *Transplantation* 45 (4), 673–676.
84 Woods HF, Krebs HA (1971) Lactate production in the perfused rat liver. *Biochem J* 125 (1), 129–139.
85 Marsh DC, Belzer FO, Southard JH (1990) Hypothermic preservation of hepatocytes. II. Importance of Ca2 and amino acids. *Cryobiology* 27 (1), 1–8.
86 Brass CA, Narciso J, Gollan JL (1991) Enhanced activity of the free radical producing enzyme xanthine oxidase in hypoxic rat liver. Regulation and pathophysiologic significance. *J Clin Invest* 87 (2), 424–431.
87 Hatano E, Kiuchi T, Tanaka A *et al.* (1997) Hepatic preservation with histidine-tryptophan-ketoglutarate solution in living-related and cadaveric liver transplantation. *Clin Sci (Lond)* 93 (1), 81–88.
88 Erhard J, Lange R, Scherer R *et al.* (1994) Comparison of histidine-tryptophan-ketoglutarate (HTK) solution versus University of Wisconsin (UW) solution for organ preservation in human liver transplantation. A prospective, randomized study. *Transpl Int* 7 (3), 177–181.
89 Sindram D, Rudiger HA, Upadhya AG *et al.* (2002) Ischemic preconditioning protects against cold ischemic injury through an oxidative stress dependent mechanism. *J Hepatol* 36 (1), 78–84.

3.3 Genetics and liver diseases

3.3.1 Genetic polymorphisms in liver disease

Hongjin Huang and Ramsey Cheung

Polymorphisms associated with liver diseases

Similar to other complex diseases, the clinical manifestations of liver diseases are the outcome of the interactions between host genetic determinants and environmental factors. In recent years, there have been an increasing number of studies to identify genetic variations that are associated with different phenotypes of liver diseases. A single nucleotide polymorphism (SNP), the most common type of genetic variation, is a stable single base substitution distributed throughout the human genome. The frequency of a given SNP in individuals has been estimated to be 1 in 1000 base pairs. In the following discussion, we only include associations between SNPs and disease susceptibilities, and focus our discussion on the 'validated markers', which are defined as SNPs that have a positive association with similar clinical endpoints in two or more independent studies (Table 1).

Non-alcoholic fatty liver diseases (NAFLD): MTP (see also Chapter 13.1)

According to the Third National Health and Nutrition Examination Survey, NAFLD may account for 5.5% of the population with unexplained aminotransferase levels [1], making this the most common cause of liver disease. In fact, 'burned-out' non-alcoholic steatohepatitis (NASH) is likely to be the major cause of 'cryptogenic' cirrhosis [2]. The clinical presentation of NAFLD and NASH are similar, but predictors of progressive liver disease include an aspartate aminotransferase (AST)/alanine aminotransferase (ALT) ratio > 1, older age, presence of type 2 diabetes mellitus or obesity or presence of metabolic syndrome [3–5]. However, despite the fact that a majority of individuals with obesity and insulin resistance will have steatosis, only 9–26% and 25% of those groups, respectively, will ever develop NASH [6,7], suggesting that other environmental and genetic factors also play a determining role. One family study reported the presence of NASH in seven out of eight studied kindreds, while another study found that 18% of 90 patients with NASH had an affected first-degree relative, supporting the role of genetic risk factors [8,9]. So far, the only validated genetic association with NASH is in the microsomal triglyceride transfer protein (*MTP*) gene. The G allele of the promoter SNP −493G/T in *MTP* leads to decreased transcription of *MTP*, resulting in a reduced export of triglyceride from hepatocytes and increased intracellular accumulation of triglyceride [10]. Bernard *et al.* [10] reported the association of −493G/T with biological surrogates of NASH, such as ALT, sex and body mass index (BMI) in 271 type 2 diabetic patients. Namikawa *et al.* [11] reported its direct association with NASH in 63 patients with biopsy-proven NASH in comparison with 150 healthy control subjects. We have confirmed this association in a study of 127 NAFLD patients (50 of whom had biopsy-proven NASH) and 60 normal subjects with matched BMI. In our study, 128T [in complete linkage disequilibrium (LD) with − 493G/T] was associated with a decreased risk of NASH relative to both the 'normal' group (OR = 0.2, $P = 0.0001$) and the 'steatosis only' group [odds ratio (OR) = 0.4, $P = 0.05$] [12]. The various approaches to determine the role of genes in NAFLD have been reviewed recently by Day [13].

Alcoholic liver disease: ADH, ALDH2 and CYP2E1 (see also Section 12)

Although excessive alcohol intake is the major risk factor for alcoholic liver disease, and fatty change of the liver is almost universal in subjects with excessive alcohol use, only a minority of these subjects develop alcoholic hepatitis, and 4–20% develop cirrhosis [14,15]. Factors associated with the development of alcoholic liver disease other than the level of alcohol consumption typically include gender, nutrition and coexisting

Table 1 Genetic markers validated in two or more studies in liver diseases.

Gene	Polymorphism	Country	Patients	Controls	*P*	Endpoint	Year	Authors	Ref.
Nonalcoholic fatty liver disease (NAFLD)									
MTP	*–493G/T*	Japan	63	150	0.001	NASH[a] vs. normal[b]	2004	Namikawa *et al.*	[11]
		US	127	60	0.0001	NASH[a] vs. normal[b]	2005	Huang *et al.*	[12]
Alcoholic liver disease (ALD)									
ADH2	*ADH2*1*	Japan	80	60[b]	0.029	ALC[c] vs. ALNC[d]	1995	Yamauchi *et al.*	[19]
		China	75	235[b]	<0.05	ALC[c] vs. normal[b]	1997	Chao *et al.*	[20]
		Australia	114	200[b]	<0.05	ALC[c] vs. normal[b]	2002	Frenzer *et al.*	[21]
		China	165	65[b]	<0.05	ALD[e] vs. AD[f]	2002	Yu *et al.*	[22]
		Korean	22	100[b]	<0.05	ALC[c] vs. normal[b]	2004	Kim *et al.*	[23]
ALDH2	*ALDH2*1*	China	75	235[b]	<0.05	ALC[c] vs. normal[b]	1997	Chao *et al.*	[20]
		China	165	65[b]	<0.05	ALD[e] vs. AD[f]	2002	Yu *et al.*	[22]
		Korean	22	100[b]	<0.05	ALC[c] vs. normal[b]	2004	Kim *et al.*	[23]
CYP2E1	*CYP2E1*c2*	Japan	80	60[b]	0.013	ALC[c] vs. ALNC[d]	1995	Yamauchi *et al.*	[19]
		Japan	68		0.019	ALD[e] vs. heavy drinkers	1997	Tanaka *et al.*	[24]
		Korean	22	100[b]	<0.05	ALC[c] vs. normal[b]	2004	Kim *et al.*	[23]
Primary biliary cirrhosis (PBC)									
CTLA1	*49A/G*	England	200	200	0.000063	PBC[g] vs. normal[b]	2000	Agarwal *et al.*	[29]
		China	77	160	0.0046	PBC[g] vs. normal[b]	2004	Fan *et al.*	[30]
VDR	*BsmII*	Germany	74	214	0.009	PBC[g] vs. normal[b]	2002	Vogel *et al.*	[31]
		Hungary	33	160	<0.03	PBC[g] vs. normal[b]	2002	Lakatos *et al.*	[32]
		Hungary	31	51	0.01	PBC[g] vs. normal[b]	2000	Halmos *et al.*	[33]
		China	58	160	0.01	PBC[g] vs. normal[b]	2005	Fan *et al.*	[34]
IFN response in chronic hepatitis C									
IL10	*–592A/C, –819C*	Australia	43		<0.05	SVR[h] vs. NR[i]	1999	Edwards-Smith *et al.*	[39]
		UK	303		<0.05	SVR[h] vs. NR[i]	2003	Knapp *et al.*	[40]
MxA	*–88G/T*	Japan	115		0.0018	SVR[h] vs. NR[i]	2000	Hijikata *et al.*	[42]
		Japan	159		<0.05	SVR[h] vs. NR[i]	2001	Hijikata *et al.*	[43]
		Japan	235		<0.05	SVR[h] vs. NR[i]	2004	Suzuki *et al.*	[44]
CCR5	*59029G/A*	US	171		0.05	SVR[h] vs. NR[i]	2003	Promrat *et al.*	[46]
		Japan	105		0.03	SVR[h] vs. NR[i]	2004	Konishi *et al.*	[47]
Fibrosis risk in chronic hepatitis C									
DDX5	*S480A*	US	1051		<0.05	F3-4 vs. F0-2	2004	Huang *et al.*	[53]
CPT1A	*A275T*	US	1133		<0.05	F3-4 vs. F0-2	2005	Huang *et al.*	[54]
HFE	*C282Y*	US	119		0.01	Mean fibrosis stage	2002	Bonkovsky *et al.*	[57]
		Germany	246	200[b]	<0.05	F2-4 vs. F0-1	2003	Gehrke *et al.*	[58]
		Germany	166		0.026	F2-4 vs. F0-1	2004	Geier *et al.*	[59]
TGFB1	*L10P, R25P*	Germany	46		0.024	Mean fibrosis stage	2002	Gewaltig *et al.*	[62]
		Germany	210	50[b]	<0.05	F3-4 vs. F0-2	2005	Wang *et al.*	[63]
TNF	*–308G/A*	US	144		0.03	F4 vs. F0-3	2000	Yee *et al.*	[65]
		India	52		0.04	F3-4 vs. F0-2	2004	Goyal *et al.*	[66]

For each disease or trait, we only included the 'validated markers', defined as SNPs that have a positive association, with the same or similar clinical endpoints, in two or more independent studies.

[a] Non-alcoholic steatohepatitis.
[b] Normal healthy population.
[c] Alcoholic liver cirrhosis.
[d] Alcoholic liver non-cirrhosis.
[e] Alcoholic liver diseases.
[f] Alcohol dependent.
[g] Primary biliary cirrhosis.
[h] Sustained virological responders.
[i] Non-responders.

viral hepatitis [14]. A study of 15 924 male twin pairs found high concordance for alcoholism and related cirrhosis among monozygotic twins, suggesting that genetics may play a major role [16]. Most research has focused on the candidate genes of enzymes involved in alcohol metabolism. Alcohol dehydrogenase (ADH), cytochrome P-4502E1 (*CYP2E1*) and aldehyde dehydrogenase-2 (ALDH2) are the three key enzymes responsible for hepatic metabolism of ethanol and its metabolite, acetaldehyde. ADH consists of three genes, *ADH1*, *ADH2* and *ADH3*, forming a gene cluster on chromosome 4q21–23 [17]. The *ADH2*1* polymorphism results in a less active beta 2 subunit. Similarly, the c2 allele at the 5′ flanking region of *CYP2E1* causes a lower basal *CYP2E1* activity and, in the *ALDH2*2* polymorphism, a G/A mutation at codon 487 produces an inactive ALDH2 [18]. To a certain extent, these genotypes have accounted for the individual differences in alcohol and acetaldehyde blood concentrations after drinking [18]. Multiple studies, with sample sizes varying from 80 to 328, have confirmed the association of these polymorphisms with alcohol-induced liver fibrosis, alcoholic cirrhosis and hepatocellular carcinoma (Table 1) [19–24].

Primary biliary cirrhosis (PBC): CTLA-4 and VDR

(see Chapter 11.1)

PBC is a chronic autoimmune disease with destruction of the intrahepatic bile ducts. Over 90% of patients have detectable antimitochrondrial antibody, directed at the pyruvate dehydrogenase E2 complex. The disease predominantly affects women with a female to male ratio of 9:1, and a peak incidence in the fifth decade of life. It is more common in northern Europe [25]. Genetic factors clearly play an important role, with a concordance rate of PBC in monozygous twins of up to 63%, the second highest rate among autoimmune diseases [26]. In addition, 4–6% of the first-degree relatives of patients with PBC also develop the disease. However, different from most autoimmune conditions, PBC has only weak association with human leucocyte antigen (HLA) alleles (the usual genetic elements for autoimmunity) [27], suggesting that other genetic factors may play an important role, in addition to environmental factors. Cytotoxic T-lymphocyte antigen-4 (CTLA-4) is expressed by activated T cells, and negatively regulates the activation of T cells [28]. The SNP 49A/G leads to the change of Thr to Ala in the protein leader peptide, reducing the inhibitory function of CTLA-4 [28]. The 49A/G polymorphism was first associated with the predisposition to PBC in a large study of 200 Caucasian patients [29], and the results were confirmed recently in 77 Chinese PBC patients [30]. Another gene, vitamin D receptor (*VDR*), codes for the receptor of an immunomodulator, 1,25-dihydroxyvitamin D3. Polymorphisms in *VDR* have been associated with various other autoimmune diseases [27]. The *Bsm*II polymorphism in *VDR* has been significantly associated with PBC in German, Hungarian and Chinese patients [31–34].

Treatment response in patients with chronic hepatitis C: IL-10, MxA, CCR5

Several viral and host factors, such as pretreatment viral load, hepatitis C virus (HCV) genotype, rapid or early virological response, absence of cirrhosis, younger age, sex and race, have been identified as predictors of response to interferon (IFN)-based antiviral therapy [35,36]. Nevertheless, genetic markers could complement and improve the current predictive value in making treatment decisions. SNPs within the promoter region of the gene for the cytokine interleukin 10 (IL-10) have been studied extensively. IL-10, an immune suppressor, inhibits the secretion of proinflammatory and antiviral cytokines, as well as the development and activation of CD4+ T-helper lymphocytes with a Th1 phenotype [37]. Three well-defined promoter SNPs, –1082, –819 and –592, (with the last two in complete LD), influence the level of IL-10 secretion [38]. Edwards-Smith *et al.* [39] found that, in 43 HCV patients, those with genotypes or haplotypes of these three SNPs resulted in higher expression of the IL-10 gene and had a poor response to IFNα therapy. This association was confirmed in a larger study with 303 HCV patients treated with IFN [40]. The second SNP related to IFN response has been identified in gene *MxA*, which is induced by IFN and involved in clearance of HCV in IFN-treated patients [41]. Hijikata *et al.* [42] first reported the significant association of –88G/T with sustained virological response to IFN therapy in a cohort of 115 HCV patients, and confirmed the results when more patients ($n = 159$) were enrolled [43]. The association was validated in another independent cohort of 235 patients [44]. However, all these studies were conducted in a Japanese population, and the association in non-Japanese populations has not been established. The third SNP has been reported in the CC chemokine receptor 5 (CCR5) gene, which codes for a receptor for cell entry of human immunodeficiency virus-1 (HIV-1). Its promoter, SNP 59029, has been associated with HIV disease progression [45]. This marker was marginally associated with a sustained response to IFN therapy in 171 patients with mixed races [46], and the association was confirmed in 105 Japanese patients [47].

Fibrosis progression in patients with chronic hepatitis C: DDX5, CPT1A, HFE, TGF-β1 and TNF

(see also Section 6)

The fibrosis progression rate is highly variable among subjects with chronic hepatitis C infection. Overall, it is estimated that only about 20% of chronically infected subjects progressed to cirrhosis after 20 years [48]. Previously identified clinical risk factors for fibrosis progression included male gender, excessive alcohol use, older age at time of infection and the presence of steatosis on liver biopsy [49–51]. However, many patients with these characteristics have mild disease, while other patients without these factors have cirrhosis [52]. Therefore, host genetic factors are important in determining fibrosis risk in HCV patients.

In a multicentre study of over 1000 chronic hepatitis C patients from four US academic centres, we have identified two novel genetic polymorphisms that were associated with fibrosis risk [53,54]. DDX5, a RNA helicase also known as p68, has previously been shown to interact with the HCV RNA-dependent RNA polymerase in the NS5B region [55]. This suggests that DDX5 is a human cellular factor involved in HCV RNA replication. The second one is CPT1A, a key enzyme in the carnitine-dependent transport across the mitochondrial inner membrane. Deficiency of CPT1A causes a decreased rate of fatty acid beta-oxidation, resulting in fatty liver diseases [56]. Our results indicate that DDX5 and CPT1A SNPs are associated with the risk of developing bridging fibrosis/cirrhosis in multiple cohorts [53,54].

At least three studies have also identified polymorphisms of the *HFE* (haemochromatosis) gene as contributing to fibrosis risk. C282Y and H63D are the two common missense mutations in *HFE*, contributing to hepatic iron overload. Bonkovsky *et al.* [57] first reported in a study of 119 HCV patients that patients with the C282Y mutation had a higher mean fibrosis score (stage 2.6 vs. 1.8) compared with those without the mutation. In a similar study, C282Y was associated with advanced fibrosis (F2–4 vs. F0–1) in 246 HCV patients [58]. A third analysis of 166 patients further confirmed the positive association of C282Y with advanced fibrosis (F2–4) [59]. Another well-studied gene is the gene coding for transforming growth factor β1 (TGF-β1), a profibrogenic cytokine that stimulates the synthesis and inhibits the degradation of a large number of extracellular matrix proteins [60]. Two coding SNPs, L10P and R25P, could potentially change the secretion levels of TGF-β1 [61]. These two SNPs have been correlated with higher stages of fibrosis in a study of 46 patients [62], and were associated with bridging fibrosis/cirrhosis (F3–F4) in 210 Caucasian patients [63]. The other validated SNP for fibrosis risk is the promoter SNP –308A in the gene for tumour necrosis factor (TNF). As a major inflammatory mediator, TNFα could affect liver fibrogenesis by stimulating hepatic stellate cells [64]. The –308A promoter SNP was significantly associated with cirrhosis in 144 patients with chronic hepatitis C [65], and with bridging fibrosis/cirrhosis in 52 patients [66].

Identification of disease-associated polymorphisms: candidate gene vs. genome-wide study

Genetic studies to identify disease associations can be broadly divided into candidate gene studies, which use resequencing or association approaches, and genome-wide studies, which use genome-wide linkage mapping or genome-wide association approaches. So far, most published genetic studies in liver diseases have focused on the candidate gene approach, in which polymorphisms in a few candidate genes with known biological functions have been studied (Tables 1 and 2). While this approach does identify interesting markers, it limits the findings to known biological pathways. However, genome-wide association study is becoming feasible as a result of the completion of the human genome sequence, the deposition of millions of SNPs into public databases, the rapid improvements in SNP genotyping technology and the International HapMap Project.

Genome-wide association studies, in which a dense set of SNPs across the genome are typed to survey the disease association, have at least two advantages. First, in comparison with the candidate gene approach, a genome-wide study offers an unbiased, yet fairly comprehensive, option for all genes and diseases independent of any known pathophysiology. Second, for most complex diseases caused by common variants with modest effects, the association approach is much more powerful than the linkage approach [67–69].

Markers in a genome-wide scan can be selected based on LD or potential functions, or the combination of both. LD is the non-random association of alleles at two or more loci on a chromosome. The rationale for LD-based markers is that most of the common SNPs in the genome can be divided into groups (haplotype blocks), in which the genotype of one SNP accurately predicts those of the correlated neighbouring ones. On the basis of current data, it is estimated that a few hundred thousand well-chosen SNPs should be adequate to cover most of the genome [67–69]. Obviously, this approach is dependent on the clear understanding of the LD pattern, and efficient statistical methods to select the tagging SNPs, both of which are still in progress. On the other hand, based on the fact that most mutations causing Mendelian disorders are missense mutations, Botstein and Risch [70] proposed that genome-wide association should focus on missense mutations. As there are only one or two missense SNPs per gene, this strategy requires only 30 000–60 000 SNPs [67]. In the genome-wide study we performed on patients with chronic hepatitis C, 68.3% of SNPs are coding functional SNPs (missense, nonsense, acceptor and donor splice sites); the remainder are non-coding, putative regulatory SNPs that may affect the level of gene expression, i.e. SNPs located at putative transcription factor binding sites, or 5′/3′ untranslated regions [53,54].

Study design and data analysis

Despite the increasing interest in finding genetic markers associated with different liver diseases, very few markers have been validated in multiple studies (Tables 1 and 2). This is a common problem observed in other disease association studies and precludes these markers from being usefully incorporated into clinical practice [71]. In a comprehensive review by Hirschhorn *et al.* [71] of > 600 positive disease associations that have been reported, 166 (27.7%) have been studied three or more times, but only six (1%) have been consistently replicated. Similarly, we found that, of the > 115 associations in different liver diseases that have been reported, 28 SNPs (24%) have been studied in two or more sample sets, but only 14 SNPs (12%) have been

Table 2 Polymorphisms reported in liver disease.

Diseases	SNPs/genes reported[a]	SNPs/genes reported in more than two studies[b]	SNPs/genes validated in more than two studies[c]
Non-alcoholic fatty liver disease (NAFLD)	*ADRB2, ADRB3, AGT, ALDH2, CD14, HFE, IL10, IL1B, MTP, PEMT, PPARA, PPARG, TGFB1, TNF*	*MTP, PPARA*	*MTP*
Alcohol-induced liver disease (ALD)	*ADH1, ADH2, ADH3, ALDH2, CD14, CTLA4, CYP2E1, IL10, IL1RN, SOD2*	*ADH1, ADH2, ADH3, ALDH2, CYP2E1, IL-1RN*	*ADH2, ALDH2, CYP2E1*
Primary biliary cirrhosis (PBC)	*ABCB1, CD14, CD14* ligand, *CTLA4, CYP2D6, CYP2E1, FAS, HLA, IL10, IL1B, L1RN, IL-2, IL6, MBL2, MDR1, NOS3, NR1I2, NRAMP1, PXR, SPP1, TNF, VDR*	*CTLA4, IL-10, TNF, VDR*	*CTLA4, VDR*
IFN response in chronic hepatitis C	*CCR2, CCR5, CTLA4, NB3, HFE, HLA-B, HLA-DRB1, IFNG, IL10, IL1B, IRF1, LMP2, LMP7, MBL, MxA, OPN, RANTES, TAP1, TAP2, TGFB1, TNFA*	*CCR2, CCR5, IL-10, LMP7, MxA, RANTES, TNFA*	*CCR5, IL-10, MxA*
Fibrosis risk in chronic hepatitis C	*ACE, AGT, AGTR1, ApoE, C5, CR2, CCR3, CCR5, COMT, CPT1A, CX3CR1, CYP17, CYP2C19, DDX5, EPHX1, F2, F5, FAS, HFE, HLA, HO1, IFNG, IL10, IL1A, IL1B, IL1RA, IL4, IL6, LDLR, LTA, MBL, MCP1, MCP2, MMP1, MMP3, MMP9, MPO, MTHFR, P53, RANTES, SRD5A2, TAP2, TFR1, TGFB1, TNF*	*CPT1A, DDX5, HFE, IL1B, TFR1, TGB1, TNF, MPO, HLA*	*CPT1A, DX5, HFE, TGB1, TNF*

For each disease or trait, we included: a, all reported associations; b, associations reported in two or more studies; and c, validated associations. The 'validated markers' are described in detail in the text and Table 1.

validated with positive associations (Table 2). The number of validated makers would be even less (2–3, ~ 1%) if the criteria of Hirschhorn *et al.* [71] were applied.

Here, we discuss the main issues encountered in the association studies and possible solutions. Some of these problems have been reviewed in detail recently [68,72–74].

Sample size

The power to detect an association is determined by the effect size of a disease locus, the frequency of the disease allele(s), the frequency of the tested marker allele(s), the extent of LD between the tested marker and the disease locus and the sample size [75]. While the first four factors are intrinsic properties of the disease and genetic allele, sample size is the only controllable variable that will determine the statistical power of a study. If, in an ideal association study scenario, we assume an OR of 2 as effect size, a 10% frequency of the disease allele and a 100% LD between the tested marker and the disease allele, the required sample size is close to 300 cases and control subjects for detecting such an association, with a statistical power of 80% at a significance level of $P < 0.05$. Obviously, most of the studies listed in Table 2 are undersized even for such an optimal scenario, which is the main source of false positives (type 1 error) and non-replicable results. For the study of complex diseases including liver diseases, sample size should ideally be calculated based on more practical or suboptimal conditions, such as weak effects, rare alleles and partial LD [75]; therefore, the required sample size would be even larger.

Control population

The selection of control subjects is critical as any systematic difference between cases and control subjects can appear as a disease association. One solution is the matched case–control design. Depending on the specific liver disease, the general demographics and related risk factors, such as age, sex, alcohol consumption, viral subtype, etc., should be similar between cases and control subjects. More importantly, the most serious confounder from the genetics perspective is ethnicity, also known as population stratification [76]. This occurs when the cases and control subjects are unintentionally drawn from two or more ethnic groups or subgroups. Stratification will occur if one of these subgroups has higher disease prevalence, or the frequency of some markers varies substantially between ethnic groups. Therefore, cases that contain a predominant ethnic group must be matched to appropriate control subjects of the same ethnicity. If possible, a few sets of control populations can be selected based on various substructures that might exist in the case population. Another solution is to use family-based studies such as the transmission disequilibrium test (TDT). This method is immune to false-positive results from ethnic admixture because ethnicity is controlled internally. The disadvantages are that it requires the affected offspring and their parents to be accessible, and 50% more genotyping than in case–control studies to achieve similar power [73,74,76]. This approach is also not feasible for diseases such as alcoholic cirrhosis or chronic hepatitis C, where it would be hard to find a family with multiple members with alcoholic cirrhosis or infected with HCV.

Clinical endpoints

To identify replicable genetic markers, it is important to have well-defined, commonly acceptable and clinically relevant phenotypes with minimal sampling error. For example, in studying fibrosis risk in patients with chronic hepatitis C, we chose fibrosis stage as the clinical endpoint. We have defined 'cases' as patients with bridging fibrosis or cirrhosis (stage 3–4), while 'control subjects' are those with no or mild fibrosis (stage 0–2). By grouping patients in this manner, we maximized our chances of identifying SNPs associated with fibrosis progression if such SNPs really existed. We intentionally did not group patients according to fibrosis progression rate, which is a value calculated from fibrosis stage on liver biopsy and estimated duration of infection. There were at least three potential sources of error in using fibrosis rate as the clinical endpoint: sampling variation from liver biopsy, uncertainty in determining the duration of HCV infection by recall of risk factor(s), and linearity of fibrosis progression rate. Numerous studies have demonstrated that the accuracy of staging fibrosis in a liver biopsy specimen is affected by the liver biopsy size, quality and experience of the examining pathologist [77–80]. However, such variation is nearly always limited to a single stage [77–80]. Fibrosis staging from liver biopsy is more accurate at the extremes, especially for cirrhosis [80,81], or when fibrosis is stratified into mild (metavir F0–1) vs. advanced (metavir F2–4).

Follow-up genotyping

It is important to realize that, in most cases, the original positive marker may be in LD with the true disease loci or with another marker of better allele frequency or effect size. To explore this possibility, positive associations should be followed up by testing adjacent markers and constructing the haplotype structure in the region.

Interaction with other genetic or environmental factors

If the association is dependent on gene–gene and gene–environment interactions, the association is only replicable in populations with appropriate genetic and environment characteristics [67,71]. In PBC, for example, there is a geographical pattern and the genetic association is often limited to certain geographical areas [26].

Suggested work flow for a genetic epidemiological study

Based on the above discussions, we propose a work flow for future association studies in liver disease as shown in Figure 1.

An ideal case–control association study should comprise a minimum of two large sample sets, namely discovery and

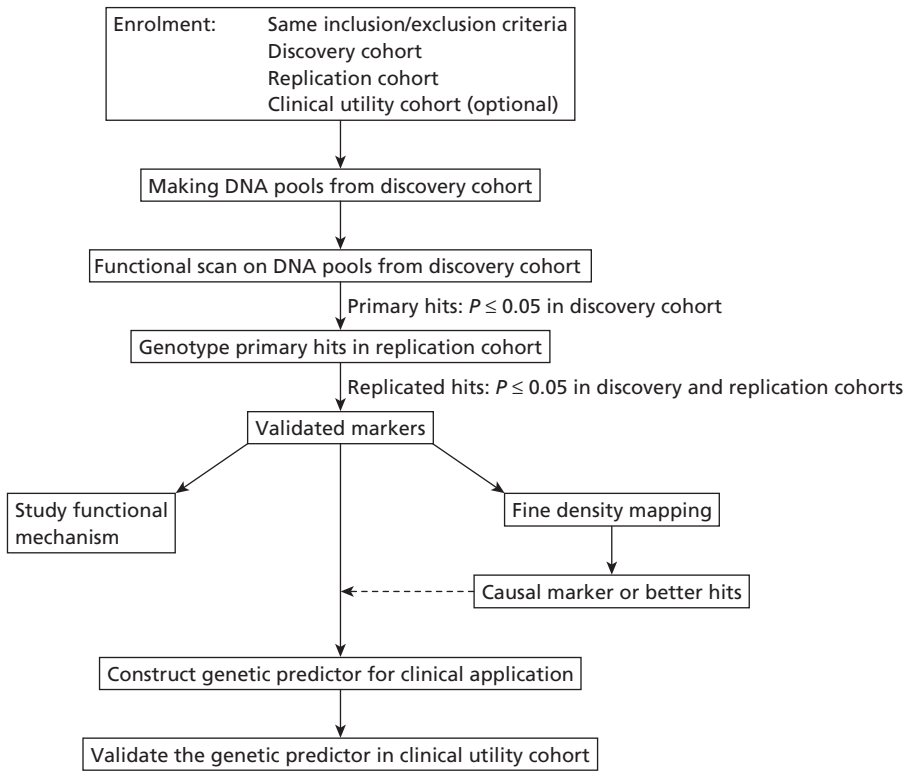

Fig. 1 Proposed study design for association studies between genetic markers and disease phenotypes.

replication cohorts, with a minimum of 250 cases and 250 control subjects in each cohort. All subjects should be enrolled under the same inclusion and exclusion criteria, using well-defined clinical endpoint(s) of interest. DNAs from the discovery cohort are pooled based on the studied clinical endpoints, major risk factors and demographics. Genome-wide scan is performed on pools of the discovery cohort, and significant markers from discovery can be genotyped in the replication cohort. 'Validated markers' are defined as those markers with significant association in both the discovery and the replication cohorts, with the same risk allele and ORs of similar magnitude. Validated markers are individually genotyped in all samples from the discovery and replication cohorts to confirm the association. For all confirmed markers, additional SNPs in the same LD block should be genotyped to identify causal mutations or markers with better ORs and/or allele frequencies. Simultaneously, functional mechanisms of these markers and their genes should be studied in relation to specific liver disease. Furthermore, using combined discovery and replication samples as training sets, statistical methods can be employed to construct the genetic signature selected from all validated hits. The predictive model will then be verified in the clinical utility cohort.

Summary

Association studies have identified interesting genetic polymorphisms influencing disease manifestations and treatment responses in patients with liver diseases. However, most genetic studies in liver diseases have utilized candidate gene approaches, which limit findings to the few genes with known biological function. In addition, small sample size and lack of replication sample sets further hinder the identification of 'true' disease-associated markers. At present, over 10 million SNPs have been identified in over 26 000 genes in the human genome, a small fraction (< 1%) of which, so-called 'functional SNPs' that alter the functions of the gene products, are likely to be potential disease-causing SNPs. A functional genomic scan, performed on a large scale, with well-designed sample sets enables investigators to identify reliable genetic markers that can be integrated into clinical practice.

References

1 Clark JM, Brancati FL, Diehl AM (2003) The prevalence and etiology of elevated aminotransferase levels in the United States. *Am J Gastroenterol* 98(5), 960–967.

2 Ong J, Younossi ZM, Reddy V *et al.* (2001) Cryptogenic cirrhosis and posttransplantation nonalcoholic fatty liver disease. *Liver Transpl* 7(9), 797–801.

3 Angulo P, Keach JC, Batts KP *et al.* (1999) Independent predictors of liver fibrosis in patients with nonalcoholic steatohepatitis. *Hepatology* 30(6), 1356–1362.

4 Neuschwander-Tetri BA, Caldwell SH (2003) Nonalcoholic steatohepatitis: summary of an AASLD Single Topic Conference. *Hepatology* 37(5), 1202–1219.

5 Marchesini G, Bugianesi E, Forlani G *et al.* (2003) Nonalcoholic fatty liver, steatohepatitis, and the metabolic syndrome. *Hepatology* 37(4), 917–923.

6 Wanless IR, Lentz JS (1990) Fatty liver hepatitis (steatohepatitis) and obesity: an autopsy study with analysis of risk factors. *Hepatology* 12(5), 1106–1110.

7 Erbey JR, Silberman C, Lydick E (2000) Prevalence of abnormal serum alanine aminotransferase levels in obese patients and patients with type 2 diabetes. *Am J Med* 109(7), 588–590.

8 Struben VM, Hespenheide EE, Caldwell SH (2000) Nonalcoholic steatohepatitis and cryptogenic cirrhosis within kindreds. *Am J Med* 108(1), 9–13.

9 Willner IR, Waters B, Patil SR *et al.* (2001) Ninety patients with nonalcoholic steatohepatitis: insulin resistance, familial tendency, and severity of disease. *Am J Gastroenterol* 96(10), 2957–2961.

10 Bernard S, Touzet S, Personne I *et al.* (2000) Association between microsomal triglyceride transfer protein gene polymorphism and the biological features of liver steatosis in patients with type II diabetes. *Diabetologia* 43(8), 995–999.

11 Namikawa C, Shu-Ping Z, Vyselaar JR *et al.* (2004) Polymorphisms of microsomal triglyceride transfer protein gene and manganese superoxide dismutase gene in non-alcoholic steatohepatitis. *J Hepatol* 40(5), 781–786.

12 Huang H, Merriman RB, Chokkalingam AP *et al.* (2005) Novel genetic markers associated with risk of non-alcoholic steatohepatitis in patients with non-alcoholic fatty liver diseases. *Gastroenterology* 128(4, Suppl. 2), A694–695.

13 Day CP (2004) The potential role of genes in nonalcoholic fatty liver disease. *Clin Liver Dis* 8(3), 673–691.

14 Diehl AM (2002) Liver disease in alcohol abusers: clinical perspective. *Alcohol* 27(1), 7–11.

15 Maddrey WC (2000) Alcohol-induced liver disease. *Clin Liver Dis* 4(1), 115–131.

16 Hrubec Z, Omenn GS (1981) Evidence of genetic predisposition to alcoholic cirrhosis and psychosis: twin concordances for alcoholism and its biological end points by zygosity among male veterans. *Alcohol Clin Exp Res* 5(2), 207–215.

17 Yoshida A, Hsu LC, Yasunami M (1991) Genetics of human alcohol-metabolizing enzymes. *Prog Nucleic Acid Res Mol Biol* 40, 255–287.

18 Higuchi S, Matsushita S, Masaki T *et al.* (2004) Influence of genetic variations of ethanol-metabolizing enzymes on phenotypes of alcohol-related disorders. *Ann NY Acad Sci* 1025, 472–480.

19 Yamauchi M, Maezawa Y, Mizuhara Y *et al.* (1995) Polymorphisms in alcohol metabolizing enzyme genes and alcoholic cirrhosis in Japanese patients: a multivariate analysis. *Hepatology* 22(4 Pt 1), 1136–1142.

20 Chao YC, Young TH, Tang HS *et al.* (1997) Alcoholism and alcoholic organ damage and genetic polymorphisms of alcohol metabolizing enzymes in Chinese patients. *Hepatology* 25(1), 112–117.

21 Frenzer A, Butler WJ, Norton ID *et al.* (2002) Polymorphism in alcohol-metabolizing enzymes, glutathione S-transferases and apolipoprotein E and susceptibility to alcohol-induced cirrhosis and chronic pancreatitis. *J Gastroenterol Hepatol* 17(2), 177–182.

22 Yu C, Li Y, Chen W *et al.* (2002) Genotype of ethanol metabolizing enzyme genes by oligonucleotide microarray in alcoholic liver disease in Chinese people. *Chin Med J (Engl)* 115(7), 1085–1087.

23 Kim MS, Lee DH, Kang HS *et al.* (2004) [Genetic polymorphisms of alcohol-metabolizing enzymes and cytokines in patients with alcohol induced pancreatitis and alcoholic liver cirrhosis.] *Korean J Gastroenterol* 43(6), 355–363.

24 Tanaka F, Shiratori Y, Yokosuka O *et al.* (1997) Polymorphism of alcohol-metabolizing genes affects drinking behavior and alcoholic liver disease in Japanese men. *Alcohol Clin Exp Res* 21(4), 596–601.
25 Kaplan MM, Gershwin ME (2005) Primary biliary cirrhosis. *N Engl J Med* 353(12), 1261–1273.
26 Selmi C, Invernizzi P, Zuin M *et al.* (2005) Genetics and geoepidemiology of primary biliary cirrhosis: following the footprints to disease etiology. *Semin Liver Dis* 25(3), 265–280.
27 Invernizzi P, Selmi C, Mackay IR *et al.* (2005) From bases to basis: linking genetics to causation in primary biliary cirrhosis. *Clin Gastroenterol Hepatol* 3(5), 401–410.
28 Tivol EA, Schweitzer AN, Sharpe AH (1996) Costimulation and autoimmunity. *Curr Opin Immunol* 8(6), 822–830.
29 Agarwal K, Jones DE, Daly AK *et al.* (2000) CTLA-4 gene polymorphism confers susceptibility to primary biliary cirrhosis. *J Hepatol* 32(4), 538–541.
30 Fan LY, Tu XQ, Cheng QB *et al.* (2004) Cytotoxic T lymphocyte associated antigen-4 gene polymorphisms confer susceptibility to primary biliary cirrhosis and autoimmune hepatitis in Chinese population. *World J Gastroenterol* 10(20), 3056–3059.
31 Vogel A, Strassburg CP, Manns MP (2002) Genetic association of vitamin D receptor polymorphisms with primary biliary cirrhosis and autoimmune hepatitis. *Hepatology* 35(1), 126–131.
32 Lakatos LP, Bajnok E, Hegedus D *et al.* (2002) Vitamin D receptor, oestrogen receptor-alpha gene and interleukin-1 receptor antagonist gene polymorphisms in Hungarian patients with primary biliary cirrhosis. *Eur J Gastroenterol Hepatol* 14(7), 733–740.
33 Halmos B, Szalay F, Cserniczky T *et al.* (2000) Association of primary biliary cirrhosis with vitamin D receptor BsmI genotype polymorphism in a Hungarian population. *Dig Dis Sci* 45(6), 1091–1095.
34 Fan L, Tu X, Zhu Y *et al.* (2005) Genetic association of vitamin D receptor polymorphisms with autoimmune hepatitis and primary biliary cirrhosis in the Chinese. *J Gastroenterol Hepatol* 20(2), 249–255.
35 Lindsay KL (2002) Introduction to therapy of hepatitis C. *Hepatology* 36 (5S1), S114–120.
36 Ferenci P (2004) Predictors of response to therapy for chronic hepatitis C. *Semin Liver Dis* 24(S2), 25–31.
37 Moore KW, O'Garra A, de Waal Malefyt R *et al.* (1993) Interleukin-10. *Annu Rev Immunol* 11, 165–190.
38 Eskdale J, Keijsers V, Huizinga T *et al.* (1999) Microsatellite alleles and single nucleotide polymorphisms (SNP) combine to form four major haplotype families at the human interleukin-10 (IL-10) locus. *Genes Immun* 1(2), 151–155.
39 Edwards-Smith CJ, Jonsson JR, Purdie DM *et al.* (1999) Interleukin-10 promoter polymorphism predicts initial response of chronic hepatitis C to interferon alfa. *Hepatology* 30(2), 526–530.
40 Knapp S, Hennig BJ, Frodsham AJ *et al.* (2003) Interleukin-10 promoter polymorphisms and the outcome of hepatitis C virus infection. *Immunogenetics* 55(6), 362–369.
41 Giannelli G, Guadagnino G, Dentico P *et al.* (2004) MxA and PKR expression in chronic hepatitis C. *J Interferon Cytokine Res* 24(11), 659–663.
42 Hijikata M, Ohta Y, Mishiro S (2000) Identification of a single nucleotide polymorphism in the MxA gene promoter (G/T at nt –88) correlated with the response of hepatitis C patients to interferon. *Intervirology* 43(2), 124–127.
43 Hijikata M, Mishiro S, Miyamoto C *et al.* (2001) Genetic polymorphism of the MxA gene promoter and interferon responsiveness of hepatitis C patients: revisited by analyzing two SNP sites (–123 and –88) *in vivo* and *in vitro*. *Intervirology* 44(6), 379–382.
44 Suzuki F, Arase Y, Suzuki Y *et al.* (2004) Single nucleotide polymorphism of the MxA gene promoter influences the response to interferon monotherapy in patients with hepatitis C viral infection. *J Viral Hepat* 11(3), 271–276.
45 Kostrikis LG, Huang Y, Moore JP *et al.* (1998) A chemokine receptor CCR2 allele delays HIV-1 disease progression and is associated with a CCR5 promoter mutation. *Nature Med* 4(3), 350–353.
46 Promrat K, McDermott DH, Gonzalez CM *et al.* (2003) Associations of chemokine system polymorphisms with clinical outcomes and treatment responses of chronic hepatitis C. *Gastroenterology* 124(2), 352–360. Erratum in: *Gastroenterology* (2003) 124(4), 1168.
47 Konishi I, Horiike N, Hiasa Y *et al.* (2004) CCR5 promoter polymorphism influences the interferon response of patients with chronic hepatitis C in Japan. *Intervirology* 47(2), 114–120.
48 Thomas DL, Seeff LB (2005) Natural history of hepatitis C. *Clin Liver Dis* 9(3), 383–498.
49 Poynard T, Bedossa P, Opolon P (1997) Natural history of liver fibrosis progression in patients with chronic hepatitis C. The OBSVIRC, METAVIR, CLINIVIR, and DOSVIRC groups. *Lancet* 349, 825–832.
50 Wright M, Goldin R, Fabre A *et al.* (2003) Measurement and determinants of the natural history of liver fibrosis in hepatitis C virus infection: a cross sectional and longitudinal study. *Gut* 52, 574–579.
51 Ramesh S, Sanyal AJ (2004) Hepatitis C and nonalcoholic fatty liver disease. *Semin Liver Dis* 24, 399–413.
52 Marcellin P, Asselah T, Boyer N (2002) Fibrosis and disease progression in hepatitis C. *Hepatology* 36, S47–56.
53 Huang H, Shiffman ML, Cheung RC *et al.* (2006) Identification of two gene variants associated with risk of advanced fibrosis in patients with chronic hepatitis C. *Gastroenterology* 130, 1679–1687.
54 Huang H, Wright TL, Tuason O *et al.* (2005) Association of fibrosis risk in HCV patients with a missense single nucleotide polymorphism in a gene encoding carnitine palmitoyltransferase 1A (CPT1A). *J Hepatol* 42(Suppl. 2), 22.
55 Goh PY, Tan YJ, Lim SP *et al.* (2004) Cellular RNA helicase p68 relocalization and interaction with the hepatitis C virus (HCV) NS5B protein and the potential role of p68 in HCV RNA replication. *J Virol* 78(10), 5288–5298.
56 Bonnefont JP, Djouadi F, Prip-Buus C *et al.* (2004) Carnitine palmitoyltransferases 1 and 2: biochemical, molecular and medical aspects. *Mol Aspects Med* 25, 495–520.
57 Bonkovsky HL, Troy N, McNeal K *et al.* (2002) Iron and HFE or TfR1 mutations as comorbid factors for development and progression of chronic hepatitis C. *J Hepatol* 37(6), 848–854.
58 Gehrke SG, Stremmel W, Mathes I *et al.* (2003) Hemochromatosis and transferrin receptor gene polymorphisms in chronic hepatitis C: impact on iron status, liver injury and HCV genotype. *J Mol Med* 81(12), 780–787.
59 Geier A, Reugels M, Weiskirchen R *et al.* (2004) Common heterozygous hemochromatosis gene mutations are risk factors for inflammation and fibrosis in chronic hepatitis C. *Liver Int* 24(4), 285–294.
60 Border WA, Noble NA (1994) Transforming growth factor beta in tissue fibrosis. *N Engl J Med* 331(19), 1286–1292.
61 He B, Xu C, Yang B *et al.* (1998) Linkage and association analysis of genes encoding cytokines and myelin proteins in multiple sclerosis. *J Neuroimmunol* 86(1), 13–19.
62 Gewaltig J, Mangasser-Stephan K, Gartung C *et al.* (2002) Association

of polymorphisms of the transforming growth factor-beta1 gene with the rate of progression of HCV-induced liver fibrosis. *Clin Chim Acta* 316(1–2), 83–94.
63 Wang H, Mengsteab S, Tag CG *et al.* (2005) Transforming growth factor-beta1 gene polymorphisms are associated with progression of liver fibrosis in Caucasians with chronic hepatitis C infection. *World J Gastroenterol* 11(13), 1929–1936.
64 Friedman SL (1997) Molecular mechanisms of hepatic fibrosis and principles of therapy. *J Gastroenterol* 32(3), 424–430.
65 Yee LJ, Tang J, Herrera J *et al.* (2000) Tumor necrosis factor gene polymorphisms in patients with cirrhosis from chronic hepatitis C virus infection. *Genes Immun* 1(6), 386–390.
66 Goyal A, Kazim SN, Sakhuja P *et al.* (2004) Association of TNF-beta polymorphism with disease severity among patients infected with hepatitis C virus. *J Med Virol* 72(1), 60–65.
67 Hirschhorn JN, Daly MJ (2005) Genome-wide association studies for common diseases and complex traits. *Nature Rev Genet* 6(2), 95–108.
68 Wang WY, Barratt BJ, Clayton DG *et al.* (2005) Genome-wide association studies: theoretical and practical concerns. *Nature Rev Genet* 6(2), 109–118.
69 Goldstein DB, Ahmadi KR, Weale ME *et al.* (2003) Genome scans and candidate gene approaches in the study of common diseases and variable drug responses. *Trends Genet* 19(11), 615–622.
70 Botstein D, Risch N (2003) Discovering genotypes underlying human phenotypes: past successes for mendelian disease, future approaches for complex disease. *Nature Genet* 33(Suppl.), 228–237.
71 Hirschhorn JN, Lohmueller K, Byrne E *et al.* (2002) A comprehensive review of genetic association studies. *Genet Med* 4, 45–61.
72 Colhoun HM, McKeigue PM, Davey Smith G (2003) Problems of reporting genetic associations with complex outcomes. *Lancet* 361, 865–972.
73 Cardon LR, Bell JI (2001) Association study designs for complex diseases. *Nature Rev Genet* 2(2), 91–99.
74 Risch NJ (2000) Searching for genetic determinants in the new millennium. *Nature* 405(6788), 847–856.
75 Zondervan KT, Cardon LR (2004) The complex interplay among factors that influence allelic association. *Nature Rev Genet* 5(2), 89–100.
76 Cardon LR, Palmer LJ (2003) Population stratification and spurious allelic association. *Lancet* 361(9357), 598–604.
77 Regev A, Berho M, Jeffers LJ *et al.* (2002) Sampling error and intraobserver variation in liver biopsy in patients with chronic HCV infection. *Am J Gastroenterol* 97, 2614–2618.
78 Bedossa P, Dargere D, Paradis V (2003) Sampling variability of liver fibrosis in chronic hepatitis C. *Hepatology* 38, 1449–1457.
79 Afdal NH, Nunes D (2004) Evaluation of liver fibrosis: a concise review. *Am J Gastroenterol* 99, 1160–1174.
80 Rousselet MC, Michalak S, Dupre F *et al.* (2005) Sources of variability in histological scoring of chronic viral hepatitis. *Hepatology* 41, 257–264.
81 Poynard T, Mathurin P, Lai CL *et al.*; PANFIBROSIS Group (2003) A comparison of fibrosis progression in chronic liver diseases. *J Hepatol* 38(3), 257–265.

3.3.2 Immunogenetics of liver disease

Peter T. Donaldson

Immunogenetics is now recognized as a major subspeciality within the field of complex disease genetics. Understanding the genetic basis of complex disease has been heralded as one of the major challenges of the postgenome era. There are three major goals: (i) to use the new genetics in disease diagnosis; (ii) to use the new genetics in patient management and care (including development of individualized therapies – although this is more suited to pharmacogenetics); and (iii) to use the new genetics to advance our understanding of disease pathology. Of these three promises, the last is perhaps the most realistic for immunogenetics.

Immunogenetics grew out of an early interest in the immune recognition of tumours and blossomed with the advent of transplantation in a clinical setting. Consequently, a major focus for this subspeciality has been (and still is) the human major histocompatibility complex (MHC). More recently, the genome project has revealed a vast array of inherited variation in immune regulatory proteins, and it now seems that almost all 'immune response (IR) genes' are polymorphic. As the immune response is a central process in most, if not all, human diseases, it is of no surprise to find that IR genes play a very significant role in the development and progression of non-Mendelian (complex) liver disease.

The first immunogenetic studies in liver disease were conducted in the early 1970s [1]. These investigations broke most of the rules for genetic association studies that we know today, but nevertheless described key genetic associations upon which much later work has been based. Not all those early studies have withstood the test of time (Table 1). Those that do survive scrutiny have evolved. This evolution reflects a growing knowledge of the human genome, a better understanding of linkage disequilibrium and a better understanding of the role played by haplotypes.

Today, immunogenetics is split into two broad categories concerning either MHC or non-MHC genes. The strongest and most reproducible genetic associations in liver disease are with MHC alleles and haplotypes. However, there is an increasing body of evidence to suggest involvement of non-MHC IR genes. In this section, I will consider the state of knowledge for both MHC and non-MHC IR genes in liver disease, discuss some of the current theories to explain these associations and try to illustrate the way forward for immunogenetic studies.

Human MHC

The human MHC maps to 7.6 Mb of chromosome 6p21.3. The full map of the human MHC was published recently and is more complex than previously envisaged [2]. The extended MHC (xMHC) encodes 421 gene loci, of which 252 are

Table 1 Summary of early studies of HLA in autoimmune and viral liver disease.

Disease	Association	Author and year
PSC	A1 and **B8**	Schrumpf *et al*. (1982)
	B12 (44) (later B44)	Chapman *et al*. (1983)
	DR3	Chapman *et al*. (1983)
	DR13	Farrant *et al*. (1992)
Type 1 AIH	**A1 and B8**	Mackay & Morris (1972)
	Dw3 (later DR3)	Opelz *et al*. (1977)
	DR3	Donaldson *et al*. (1991)
	DRw4 (later DR4)	Williams *et al*. (1978)
	DR4	Donaldson *et al*. (1991)
PBC	A1 and B8	Eddleston *et al*. (1974)
	DR2	Miyamori *et al*. (1983)
	DR3	Ercilla *et al*. (1979)
	DR4	Johnston *et al*. (1987)
	DR8	Gores *et al*. (1987)
	DR11	Gores *et al*. (1987)
HBV	DR2	Almarri and Batchelor (1994)*
	DR6	van Hattum *et al*. (1987)
	DR7	Almarri and Batchelor (1994)*
HCV	**DR5-DQ3**	Peano *et al*. (1994)
	DR5-DQ3	Zavaglia *et al*. (1996)

AIH, autoimmune hepatitis; HBV, hepatitis B virus; HCV, hepatitis C virus; PBC, primary biliary cirrhosis; PSC, primary sclerosing cholangitis. All the above studies are described as 'early' either on grounds of the year of the original publication or on the basis of the technology used for HLA typing. With one exception (*) all were based on serological typing, which is based on restriction fragment length polymorphism (RFLP) analysis. Associations which have been widely replicated are highlighted. Note that nomenclature has changed and technology has evolved permitting higher resolution genotyping and subdivision of some allelic families. For example, the DR6 family can be divided into approximately 63 *DRB1*13* and 48 *DRB1*14* alleles.

expressed genes, 30 are classified as transcripts and 139 are pseudogenes. The xMHC is characterized by extreme linkage disequilibrium and a very high degree of polymorphism (56 of the 252 expressed xMHC genes are known to be polymorphic). This polymorphism includes single nucleotide polymorphism (SNPs), deletion/insertion polymorphism (DIPs) and two large regions of duplication.

Within the xMHC, it is possible to recognize clusters and superclusters that appear to have arisen from both small- and large-scale segmental duplications. Currently, six clusters and six superclusters are recognized. Among these are three that are of immediate interest: the human leucocyte antigen (HLA) class I supercluster, the tumour necrosis factor (TNF) cluster and the HLA class II cluster.

The HLA class I supercluster comprises: the classical HLA *A*, *B* and *Cw* loci; the non-classical HLA *E*, *F* and more distant *HFE* locus; the class I-like genes *MICA* and *MICB*; and 12 pseudogenes. Both classical and non-classical HLA class I gene products are involved in the natural killer (NK) cell-mediated immune responses through presentation of antigens to CD8+ T cells and recognition of the leukocyte receptor complex or natural killer complex. The expression profile of the class I-like *MICA* and *MICB* indicates a possible role in mucosal immunity. HFE, on the other hand, although resembling a classical HLA class I protein (including the interaction with β2-microglobulin), is involved in iron metabolism, rather than in antigen processing and presentation. Although early studies described genetic linkage between the HLA *A* locus and idiopathic haemochromatosis (IH), this was later found to be a result of linkage disequilibrium with the *HFE* locus 4 Mb telomeric of HLA *A*.

The TNF gene cluster comprises the genes encoding TNFα, lymphotoxin-α and lymphotoxin-β. All three are cytokines involved in the inflammatory immune response.

The HLA class II cluster comprises the classical HLA *DP*, *DQ* and *DR* genes and the non-classical HLA *DM* and *DO* genes. The products of these genes form heterodimers involved in antigen presentation to CD4+ T cells (*DP*, *DQ*, *DR*) and peptide exchange and loading into class II molecules (*DM*, *DO*).

Interestingly, although there are many class I-like genes in the genome, there are (as yet) no class II-like genes outside the xMHC.

Genes of the human MHC in clinical liver disease

Despite the apparent complexity of the xMHC, studies in liver disease have concentrated on relatively few of the genes encoded therein. The areas of interest include members of the HLA class I supercluster (HLA *A*, *B* and, to a lesser extent, *Cw* and *MICA*), the class II cluster (HLA *DR*, *DQ* and, to a lesser extent, *DP*) and a single member of the TNF cluster (*TNFA*). In addition, a few studies have looked at the MHC-encoded complement genes *C4A* and *C4B*. A map of the xMHC can be found at www.nature.com/nrg/journal/v5/n12/poster/MHCmap; data on individual genes can found at www.ncbi.nih.gov/MHC; and up-to-date HLA nomenclature can be found at www.anthonynolan.org.uk/research.

Much has been written about how we should study genetically complex diseases. However, very little of this advice has (until recently) had any impact on the strategies applied to the study of genetically complex liver diseases. The basic data that would indicate to a classical geneticist that the diseases listed below have a significant heritable component are simply not available. Most of these diseases are rare in families, and most are diseases of adulthood presenting in later life, ruling out the possibilities of genetic studies based on linkage analysis of families or affected sib pairs. Consequently, studies of these diseases have been almost entirely restricted to case–control association analyses. Yet despite this, there have been some very promising findings in this area of research, in particular in the study of autoimmune and, more recently, viral liver diseases.

Table 2 Summary of HLA haplotypes in autoimmune liver disease.

Disease	Population	Haplotype	Risk ratio
PBC	Japan	***DRB1****0803-DQ3-DPB1*0501*	NA
	NEC-Europe and NEC-USA	***DRB1*0801****-DQA1*0401-DQB1*0402*	8.16
PSC	NEC-Europe	[a]*B8-**MICA*008**-TNFA*2-DRB3*0101-**DRB1*0301**-DQB1*0201*	2.69
		*DRB3*0101-DRB1*1301-DQA1*0103-**DQB1*0603***	3.8
		MICA*008*-DRB5*0101-DRB1*1501-DQA1*0102-**DQB1*0602***	1.52
		*DRB4*0103-DRB4*0401-DQA1*03-**DQB1*0302***	0.26
		*DRB4*0103-DRB1*0701-DQA1*0201-**DQB1*0303***	0.15
		MICA*002	0.15
AIH	NEC-Europe and NEC-USA	[a]*A1-B8-MICA*008-TNFA*2-DRB3*0101-**DRB1*0301**-DQB1*0201*	4.6–5.51
		*DRB4*0103-**DRB1*0401**-DQA1*0301-DQB1*0301*	3.3–3.7
		*DRB5*0101-**DRB1*1501**-DQA1*0102-DQB1*0602*	0.32–0.4
	Japan	*Bw54-DRB4*-**DRB1*0405**-DQA1*0301-DQB1*0401*	
	Argentina and Brazil	Adults: *DRB4*0101-**DRB1*0405***	10.4
		Children: *DRB3*0101-**DRB1*1301**-DQA1*0103-DQB1*0603*	16.3
		Children: *DRB3*0101-**DRB1*0301**-DQA1*0501-DQB1*0201*	3.0

NEC, northern European Caucasoid. All studies are based on adult cases unless otherwise marked. Protective haplotypes are underlined and have risk values < 1. The current allele(s) of interest (i.e. candidate primary susceptibility/resistance allele shown) are in bold on each haplotype.
[a]HLA 8.1 haplotype.

The MHC and autoimmune liver disease

The strongest associations have been reported in the autoimmune liver diseases, primary sclerosing cholangitis (PSC) and type 1 autoimmune hepatitis (AIH) (Table 2) [3]. At first glance, there are striking similarities between the two. Both PSC and AIH are associated with an increased frequency of the HLA 8.1 haplotype. However, closer scrutiny reveals that susceptibility and resistance for these diseases may map to different gene loci within the MHC. Thus, in PSC, MHC-encoded susceptibility appears to involve either a combination of *DRB–DQB* and the *MICA* alleles or perhaps *MICA* alone [3], whereas in type 1 AIH, MHC-encoded susceptibility appears to be related very closely to specific *DRB1* alleles that carry lysine or arginine at position 71 [4].

Primary sclerosing cholangitis

In PSC, studies have consistently reported an increased risk of disease associated with the HLA 8.1 haplotype and with the HLA *DRB3*0101-DRB1*1301-DQA1*0103-DQB1*0603* haplotype [3]. The association with the HLA *DRB5*0101-DRB1*1501-DQA1*0102-DQB1*0602* haplotype is more controversial [5]. Interestingly, other than B8, there have been no reproducible associations with classical HLA class I alleles in PSC [5], indicating that susceptibility and resistance to PSC do not map to these gene loci. However, data on *MICA* allele frequencies in PSC indicate a five- to sixfold increased risk of PSC associated with homozygosity for *MICA*008* and a 14-fold reduced risk associated with one or more copies of the *MICA*002* allele (Table 2) [3,5]. This provides strong evidence to suggest a significant role for *MICA* in MHC-encoded susceptibility/resistance to PSC. Yet, *MICA* alone cannot account for all the observed MHC associations as the HLA *DRB3*0101-DRB1*1301-DQA1*0103-DQB1*0603* haplotype does not carry *MICA*008*, and neither of the other two HLA haplotypes associated with disease resistance carry *MICA*002*.

These observations have important implications for our understanding of the pathogenesis of PSC. In PSC, the potential involvement of the *MICA* genes indicates a more prominent role for the innate immune response. MICα molecules are expressed on gastrointestinal and thymic epithelia and are also seen in non-diseased liver. MICα molecules may be induced by stress including heat shock. These molecules are ligands for T cells expressing the NKG2D activatory receptor, which activates γδ T cells and NK cells. The 'normal' liver has a large resident population of γδ T cells, NK and natural (N)T cells, and increased numbers of γδ T cells and NK cells have also been documented in PSC livers [6].

There is evidence that *MICA*008* homozygosity may be associated with a loss of MICα function. All *MICA* alleles carry a variable number of short tandem repeat (STR) sequences. The STR encoded on all *MICA*008* haplotypes, the 5.1STR, encodes a MICα molecule with a short, perhaps even, unstable cytoplasmic segment. If PSC arises as a result of infection, heat shock induction of MICα on biliary epithelium would be a crucial step in the activation of intrahepatic γδ T cells and NK cells, leading to cytokine secretion and cytolytic effector functions. In individuals homozygous for *MICA*008*, unstable expression of MICα may cause failed immune activation, with the consequence of

persistent infection. Persistent infection carries with it an ever-increasing risk of recognition of self (auto)antigens through collateral damage and/or exposure of cryptic epitopes.

There is particular interest in innate immunity in inflammatory bowel disease (IBD) at present, and it is tempting, given the observation that two-thirds of all PSC patients may develop ulcerative colitis (UC) at some stage in their illness, to consider the potential for genetic overlap, in which case a common link with innate immunity would perhaps be fitting. Indeed, studies of the MHC suggest that PSC patients with concurrent IBD are less likely to have the *DR4* or *DR7* haplotypes than those without [7], and more recent studies indicate that the *CARD*4 polymorphism associated with increased risk of IBD and UC may be a risk factor for PSC/UC overlap [8].

Autoimmune hepatitis type 1

In Europe and North America, there are very clear strong associations between increased risk for type 1 AIH and both the HLA 8.1 and *DRB4*0101-DRB1*0401-DQA1*0301-DQB1*0301* haplotypes (Table 2) [4]. The latter association is secondary to the former and is more pronounced in patients with late-onset disease. There no are significant associations with HLA *A*, *B* or *Cw* on the second haplotype, no significant associations (independent of HLA 8.1) with either *TNFA* or *MICA* and no single shared *DQA*, *DQB* or *DPB* allele or sequence carried on both these haplotypes. These observations led to the development of the 'lysine/arginine DRβ-71 hypothesis' in type 1 AIH [4].

According to this hypothesis, MHC-encoded susceptibility and resistance depends primarily on the amino acid residue encoded at position 71 of the DRβ polypeptide. Both *DRB1*0301* and *DRB1*0401* encode lysine at position 71, and susceptibility alleles in other populations (including *DRB1*0404* and *DRB1*0405*) have arginine 71 (Table 3). These are both basic, highly charged, polar amino acids and are positioned over the P4 and P7 binding pockets of the expressed HLA-DR molecule. The allele *DRB1*1501*, which is associated with a reduced risk of type 1 AIH, encodes alanine 71, a small non-charged residue. Substitution of lysine/arginine for alanine would have a profound effect on the peptide-binding properties of the expressed DR molecule, and it this idea upon which the 'lysine/arginine DRβ-71 hypothesis' is based.

Type 1 AIH is a classical autoimmune disease. The genetic association with HLA *DRB1* points to the MHC class II antigen presenting pathway and events in T-cell activation as the key to understanding disease initiation. This fits well with the characteristics of type 1 AIH as a predominantly T cell-mediated disease. However, the lysine/arginine 71 model does not tell us much about the autoantigen in type 1 AIH and is not universal. A number of alternative models have been proposed, but none of them fits the European/North American data [4]. Different models for each population (if they are valid) may suggest that different genetic associations have arisen in different populations, depending on the prevailing environmental risk factors: for example, in South America, where hepatitis A virus is endemic, persistent infection is associated with carriage of the HLA *DRB1*1301* [9] allele, the same allele carried by the majority of children who develop type 1 AIH in that population. Thus, these HLA associations may provide the 'molecular footprint' of the prevailing environmental trigger(s) that precipitate the disease in different populations.

A further level of complexity exists whereby European and North American patients with *DRB1*0301* have quite different clinical characteristics from those with the *DRB1*0401* haplotype, although both haplotypes carry lysine 71 [4], indicating that, although lysine/arginine 71 may be the primary determinant of disease susceptibility (at least in European and North America) to type 1 AIH, other genes within the MHC (or closely linked genes) may modify the clinical phenotype.

Primary biliary cirrhosis (PBC)

Studies of PBC [3,10], the most common of the three autoimmune liver diseases, consistently report weak but significant associations with alleles of the HLA DR8 family (*DRB1*0801* in Europeans and *DRB1*0803* in Japan). The risk of disease for those with these alleles is approximately two to three times greater than for those without (Table 2). However, in Europeans, this association accounts for only 15–25% of patients. This may indicate that the true association lies elsewhere along the chromosome with *DRB1*0801* acting as a linkage marker.

In the case of PBC, these findings are not in keeping with the picture of a T cell-mediated autoimmune disease, suggesting that some thought should be given to the role of non-classical MHC and other immunogenes in PBC.

The MHC and viral hepatitis

The relationship between the host MHC IR genes and viral hepatitis has been quite widely explored (see Table 4), with particular emphasis being placed on HLA [3,11]. In most cases, the risk of infection is not itself genetically determined, but host HLA genes do play a role in determining the outcome following exposure to the virus. Not all the immunogenetic studies in viral hepatitis have been replicated but, among the more reproducible and interesting findings are the following observations: individuals who have the *DRB1*1301* [12] allele are more prone to persistent hepatitis A virus (HAV) infection; individuals with *DRB1*1302* [13] are more prone to persistent hepatitis B virus (HBV) infection; and individuals with *DQB1*0301* haplotypes [14,15] are more likely to have self-limiting hepatitis C virus (HCV) infection (Table 4).

Most studies on the immunogenetics of viral liver disease are based on the European population where the major concern has been HCV. Although there have been a few studies of HAV and HBV, with the exception of the two studies above [12,13], most of these have been based on small numbers, and the findings from these studies have not been widely replicated. In contrast,

Table 3 *DRB1* alleles and amino acids associated with type 1 AIH.

Allele	Amino acid (single letter code) and position				
	13	26	67–72	74	86
DRB1*0301	**S**	**Y**	**LLEQKR**	**R**	**V**
DRB1*0401	**H**	**F**	**LLEQKR**	**A**	**G**
DR1*0404	**H**	**F**	**LLEQRR**	**A**	**G**
DRB1*0405	**H**	**F**	**LLEQRR**	**A**	**G**
DRB1*1301	**S**	**F**	**ILEDER**	**A**	**V**
*DRB1*1501*	R	F	ILEQAR	A	V

Bold type illustrates the major susceptibility alleles for type 1 AIH. Underlining denotes association in paediatric cases of type 1 AIH from Argentina. Normal type shows protective haplotype. Sequences for second expressed DRB gene on each haplotype are not shown. Analysis of pooled data for the King's and Mayo published series (205 patients) indicates tyrosine (Y) at DRβ-26 has odds ratio (OR) of 3.52 and arginine (R) at DRβ-74 has an OR of 3.74; whereas lysine (K) at DRβ-71 has an OR of 8.78 and all three possibilities are highly significant ($P < 0.00000001$).

there is a considerable volume of work on HCV, much of which has been replicated.

At first glance, the current literature on HLA and HCV appears to be contradictory [3,8,11,12]. There are a number of reasons for this. Many of the early studies focused on the potential relationship between HLA and the risk of infection with HCV. Early studies were based on poor-quality HLA serotyping and were often based on small numbers [16]. More recently, investigators have used DNA-based techniques focusing on the role of HLA in determining outcome following viral infection. Even so, many studies remain small (with low numbers in informative subgroups), and most studies fail to correct for confounding variables such as viral genotype, viral load, route of infection, gender, age and alcohol intake.

Currently, one major finding stands out from the rest. Alric *et al.* [14] found a higher frequency of the *DRB1*11-DQB1*0301* haplotype in French patients with untreated self-limiting (acute) infection compared with those with persistent (chronic) infection. This is particularly pertinent because the majority (estimated at 50–80%) of those infected with HCV become chronic carriers. Cramp *et al.* [15] later suggested that a different haplotype, *DRB*04-DQB1*0301*, was responsible for this effect. In each case, the authors found increased frequencies of the predominant *DQB1*0301* haplotype in their particular population, thus suggesting that the *DQB1*0301* allele is responsible for this effect, rather than a particular *DRB1* allele.

Based on these observations [14,15], we may expect that individuals with *DQB1*0301* would have a more vigorous immune response to HCV peptides, and indeed they do [17]. In addition, studies have shown that these patients have a greater response to a range of HCV peptides and are more likely to have a multispecific IR as opposed to a monospecific response when challenged with different HCV-derived peptides *in vitro* (M. Cramp, unpublished observations). A multispecific IR may be essential to combat mechanisms by which the virus evades immune-mediated destruction.

Although the data on *DQB1*0301* are very exciting, there are dissenting voices. Studies in the Irish population have been particularly informative in describing associations with the HLA 8.1 haplotype rather than with either of the common *DQB1*0301* haplotypes above [3,18]. The Irish study population [18] is unique in being composed of a single cohort of women who contracted HCV following immunization with a single batch of infected rhesus antibody. Thus, in this series, the confounding variables of gender, viral genotype, viral load and route of infection are all neutral. However, the findings reported in this cohort have not been replicated in the population at large.

Overlap between MHC associations in autoimmune and viral liver disease

It is interesting to note that the key HLA haplotypes in viral infection (Table 4) are also implicated in type 1 AIH and PSC (Table 2). Although there is no absolute correlation between haplotypes that promote viral persistence and those which promote autoimmune disease, there are significant areas of overlap. For example, *DRB1*0301* and *DRB1*1301* promote viral persistence and autoimmunity, whereas *DRB1*1501* and *DRB1*0701*, which protect from type 1 AIH and PSC, respectively, may both promote HCV persistence. This may all be coincidence, reflecting the fact that the HLA alleles above are all common alleles. However, there are many other common *DRB1* alleles that do not appear in these lists, and it is interesting to speculate about the potential biological basis of this overlap.

Non-MHC immune response genes in clinical liver disease

In the last decade, there has been a plethora of studies investigating non-MHC IR genes. This has been fuelled by the genome project and the knowledge that nearly all human genes are polymorphic. Thus, any gene that encodes an immune-active protein may be targeted for study. This has created a vast, mostly negative, literature populated with failed genetic association studies. Investigators have simply thrown caution to the wind and selected candidates of convenience rather biologically plausible candidates. Early success with the MHC has also fuelled a false expectation that all studies will reveal relatively strong genetic effects (odds ratios > 3). With hindsight, we now know this is not likely in the majority of cases and, therefore, we need to plan our studies so that we can detect relatively weak effects (odds ratios as low as 1.2).

If we consider the key processes in the immune response, we can break our list of candidates into subsections dealing with:

early antigen presentation (so-called signal 1), involving HLA, the T-cell receptor (TCR) and immunoglobulin genes; late antigen presentation (so-called signal 2), involving, among other genes, those encoding the cytotoxic T-lymphocyte antigen-4 (CTLA-4) molecule and related accessory molecules (CD28, as well as B7.1 and B7.2, also known as CD80 and CD81); inflammation, especially the cytokine networks; termination, restoration and repair, especially cytokines involved with wound healing and apoptosis.

In addition, there are a number of genes involved in the innate immune response that do not fall easily into this simple division, for example the killer cell immunoglobulin-like receptor (KIR) genes.

Genes involved in early antigen presentation in clinical liver disease

Other than HLA, very little is known about the role of the other genes involved in early antigen presentation in either autoimmune or viral liver disease. Although there are some early data on both Ig and TCR genes in type 1 AIH, investigators have avoided studying these gene complexes because most of their variation arises from somatic mutation and recombination.

Genes involved in late antigen presentation in clinical liver disease

One of the critical processes in the immune response is governed by the balance between rival accessory molecules CTLA-4 and CD28. In the immediate aftermath of MHC–peptide–TCR interaction, a second signal is required to determine the course of events. Initially, CD4+ T cells expressing CD28 interact with the antigen-presenting cells (APC) through the CD80/CD81 ligand to provide this signal. However, it appears that switching from immune activation to immune memory occurs through the upregulation of CTLA-4 on CD4+, CD25+ T cells. These cells compete with the CD28+ T cells, effectively downregulating the immune response. There are numerous SNPs in the *CTLA*4 gene on chromosome 2q33; two of these, commonly referred to as A+49G and CT60 [7], have received particular attention [3,19]. Preliminary studies of the A+49G SNP identified associations with both PBC and type 1 AIH, although these have not been replicated in all populations studied [3]. This may reflect both closer linkage with the functional SNP CT60 (which has not yet been investigated in either disease) or the relatively weak effect of this polymorphism, which may demand large-scale studies for reproducible results.

As T-cell immune responses predominate in immunity to both HBV and HCV, we may also expect *CTLA*4 to have a potential role in determining the outcome following viral infection. However, data to support this have not been forthcoming, although there is an isolated (and unconfirmed) report of an association with response to interferon/ribavirin in HCV [20].

Genes involved in inflammation in clinical liver disease

The inflammatory immune response is orchestrated by the cytokine network. Cytokines are also important in wound healing and repair and in the downregulation (termination) of the immune response.

Early studies in liver disease focused on the MHC-encoded proinflammatory cytokine tumour necrosis factor α gene (*TNFA*). Although mostly negative, this stimulated interest in investigating other (non-MHC-encoded) cytokine genes in liver disease, starting with the proinflammatory cytokines, interleukin (IL)-1 and IL-6, interferon-γ, then spreading to the immunoregulatory cytokines IL-4 and IL-10. For the most part, these studies examined preselected single SNPs or, occasionally, multiple SNPs in the target gene. With a few possible exceptions (including preliminary data on *IL*1 genes in PBC [10], and on the *IL*10 promoter polymorphisms in alcoholic liver disease [21] and HCV [22]), these studies have been blank or remain controversial.

Overall, the lack of success in the majority of these studies can be attributed to the complexity of the cytokine network (especially the degree of redundancy in the system), the limited scope of many of these studies and the small numbers available for study. We must also question the non-hypothesis-constrained approach of many investigators, which, although valid under some circumstances, will always have a much larger failure rate than a hypothesis-based approach.

Genes involved in termination of the immune response, restoration of immune homeostasis and tissue repair in clinical liver disease

Termination of the immune response is an important process that is often overlooked by immunologists in their search to understand disease pathology. Key within this process is apoptosis and, recently, there has been some interest in the potential role of polymorphism in the FAS gene (correct gene name TNF receptor superfamily 6 or *TNFRSF*6) in both autoimmune and viral liver disease, although studies so far have failed to identify any significant relationships.

Termination of the immune response is also linked with restoration of immune homeostasis and tissue repair. The latter process is particular important in liver disease where abnormalities in the tissue repair mechanisms may lead to fibrosis and cirrhosis. Key components in tissue repair are the family of matrix metalloproteinases (MMPs) and their tissue inhibitors (tissue inhibitors of matrix metalloproteinases or TIMPs). These genes encode a complex network of interacting proteins that regulate collagen metabolism. These proteins have immune regulatory properties and interact with various cytokines including IL-1 and transforming cell growth factor beta (TCGF-β). Studies of *MMP*1, *MMP*3 and *MMP*9 as well as *TGFB*1 and various *IL*1

Table 4 Summary of key HLA haplotypes associated with acute (self-limiting) vs. protracted (chronic) infection in viral hepatitis.

Virus	Population	Haplotype/allele
HAV	Argentina	Children: *DRB3*0101-**DRB1*1301**-DQA1*0103-DQB1*0603*
HBV	Gambia acute infection	*DRB3*0301-**DRB1*1302**-DQA1*0102-DQB1*0501* *DRB3*0301-**DRB1*1302**-DQA1*0102-DQB1*0604* [a]*DRB3*0301-**DRB1*1301**-DQA1*0103-DQB1*0603*
HCV	NEC-Europe acute infection	*DRB3*0101-DRB1*1101-DQA1*0501-**DQB1*0301*** *DRB3*0101-DRB1*1104-DQA1*0501-**DQB1*0301*** *DRB4*0103-DRB1*0401-DQA1*03-**DQB1*0301*** [b]***DRB1*0101**-DQA1*0101-DQB1*0501*
HCV	NEC-USA Black-USA	***DRB1*0101**-DQA1*0101-DQB1*0501* DRB1*0101-*DQA1*0101-DQB1*0501*
HCV	NEC-Europe chronic infection	[c]*DRB5*0101-DRB1*1501-DQA1*0102-DQB1*0602* *DRB3*0101-**DRB1*0301**-DQA1*0501-DQB1*0201* [c]*DRB4*0103-DRB1*0701-DQA1*0201-DQB1*0201*

NEC, northern European Caucasoid. Summary represents key selected studies only. All studies based on adult cases unless marked otherwise.
[a]This association was neither confirmed nor refuted by Thursz *et al.* [13].
[b]This association applies to the Irish rhesus patient study group only.
[c]These two haplotypes are consistently found at higher frequencies in patients with chronic HCV infection but are rarely statistically significant. However, the effect of the haplotype may be weak and most studies are underpowered to detect such weak effects.

family member genes have been conducted in PSC. Associations have been described with both *MMP*3 [23] and *MMP*1 [24], although there is no consensus on the former observation, and the latter report has yet to be confirmed in an independent series.

Non-MHC genes involved in the innate immune response in clinical liver disease

Innate and adaptive immunity overlap and interact. In clinical liver disease, studies of the MHC have considered the complement genes *C2*, *C4A*, *C4B*, as well as *MICA* and *TNFA*, all of which have roles in innate immunity. Although there are strong reported associations with specific *C4* alleles in AIH [4] and PBC [10], these may be secondary to linkage disequilibrium with genes of the MHC class II cluster.

More recently, investigators have started to look at the KIR genes. The KIR genes map to chromosome 19q13.4 within the leukocyte receptor complex cluster (LRC). KIRs form receptor–ligand pairs with particular groups of HLA class I *B* and *Cw* alleles and are involved in regulation of NK cell activation. Because the KIR and HLA genes are located on different chromosomes, some individuals lack appropriate pairings and may be more susceptible to failure of NK regulation. The KIR region shows variation in gene content, number and type as well as allelic polymorphism and is particularly complex. The *KIR2DL3* haplotype has been associated with resolving HCV infection, suggesting a role for NK cells in HCV clearance [25]. However, this association is dependent upon possession of a particular HLA class I family group, and the full meaning of this association is not yet clear.

Directions for future studies

Much can be learned about potential disease genes by looking at studies of other (similar) diseases. Investigations in IBD provide an excellent example.

IBD is a complex clinical syndrome, made up mostly of Crohn's disease and ulcerative colitis. Genetic studies reveal a polygenic picture with a number of gene loci suspected, and recent studies have identified several of the major players in susceptibility to both Crohn's disease and ulcerative colitis. The identification of *CARD15* as a major gene for Crohn's disease has changed the perception of the disease pathology, highlighting likely mechanisms of disease genesis and informing the debate on which genes to investigate in related disorders. The recent identification of the gene *CARD4*, which encodes the human NOD1 homologue (located on chromosome 7 – a linkage region for IBD), may have implications for PSC, as it has been shown to be particularly common in IBD patients with ulcerative colitis and PSC.

Overall, studies of the MHC in autoimmune and viral liver disease have been more fruitful than those of non-MHC genes. HLA polymorphisms are mostly functional and are biologically relevant; HLA genes are inherited in tightly conserved haplotypes with several other IR genes, each encoding key components in both the innate as well as the acquired immunity. Thus, HLA haplotypes may each carry several disease-promoting alleles,

possibly acting as multihit disease cassettes. This multihit model may explain the relative strength of MHC associations compared with those for non-MHC genes. However, we should not be complacent. So far, studies have considered only 12 of the 56 polymorphic genes of the human MHC, and there is much work still to be done unravelling the role of MHC genes in liver disease.

In contrast, non-MHC genes may have relatively weak effects (although not exclusively, for example *CARD15*), and few of the studies conducted so far in liver disease have been designed to detect such small risk values. To be successful, future studies of liver disease will need to be inclusive and based on large collections of well-characterized patients. They will need to employ high-throughput genotyping and will have to explore whole pathways and networks, rather than single preselected SNPs and genes as most current studies have done.

References

1 Tiwari JL, Terasaki PI (1985) Gastroenterology. In: Tiwari JL, Terasaki PI (eds) *HLA and Disease Associations*, 1st edn. New York: Springer-Verlag, pp. 232–263.

2 Horton R, Wilming L, Rand V *et al.* (2004) Gene map of the extended human MHC. *Nature Rev Genet* 5, 889–899.

3 Donaldson PT (2004) Recent advances in clinical practice: genetics of liver disease: immunogenetics and disease pathogenesis. *Gut* 53, 599–608.

4 Donaldson PT (2002) Genetics in autoimmune hepatitis. *Semin Liver Dis* 22, 353–363.

5 Donaldson PT, Norris S (2001) Immunogenetics in PSC. *Balliere's Best Pract Res Clin Gastroenterol* 15, 611–627.

6 Doherty DG, O'Farrelly C (2003) Lymphoid repertoires in healthy liver. In: Gershwin ME, Vierling JM, Manns MP (eds) *Liver Immunology*, 1st edn. Philadelphia: Hanley Belfus, pp. 31–46.

7 Donaldson PT, Norris S (2002) Evaluation of the role of MHC class II alleles, haplotypes and selected amino acid sequences in primary sclerosing cholangitis. *Autoimmunity* 35, 555–564.

8 McGovern DPB, Hysi P, Ahmed T *et al.* (2005) Association between a complex insertion/deletion polymorphism in NOD1 (CARD4) and susceptibility to inflammatory bowel disease. *Hum Mol Genet* 14, 1245–1250.

9 Pando M, Larriba J, Fernandez GC *et al.* (1999) Paediatric and adult forms of type 1 autoimmune hepatitis in Argentina: evidence for differential genetic predisposition. *Hepatology* 30, 1374–1380.

10 Jones DEJ, Donaldson PT (2003) Genetic factors in the pathogenesis of primary biliary cirrhosis. *Clin Liver Dis* 7, 841–864.

11 Thio CL, Thomas DL, Carrington M *et al.* (2000) Chronic viral hepatitis and the human genome. *Hepatology* 31, 819–827.

12 Fainboim L, Velasco MCC, Marcos CY *et al.* (2001) Protracted, but not acute, hepatitis A virus infection is strongly associated with HLA-DRB1*1301, a marker for paediatric autoimmune hepatitis. *Hepatology* 33, 1512–1517.

13 Thursz MR, Kwiatkowski D, Allsopp COM *et al.* (1995) Association between an MHV class II allele and clearance of hepatitis B virus in the Gambia. *N Engl J Med* 332, 1065–1069.

14 Alric L, Fort M, Izopet J *et al.* (2000) Study of host- and virus-related factors associated with spontaneous hepatitis C virus clearance. *Tissue Antigens* 56, 154–158.

15 Cramp M, Carucci P, Underhill J *et al.* (1998) Association between HLA class II genotype and spontaneous clearance of hepatitis C viremia. *J Hepatol* 29, 207–213.

16 Donaldson PT (1999) HLA and susceptibility to hepatitis C virus – commentary. *Eur J Clin Invest* 29, 280–283.

17 Harcourt G, Hellier S, Bunce M *et al.* (2001) Effect of HLA class II genotype on T helper lymphocyte responses and viral control in hepatitis C virus infection. *J Viral Hepatol* 8, 174–179.

18 McKiernan SM, Hagan R, Curry M *et al.* (2000) The MHC is a major determinant of viral status, but not fibrotic stage, in individuals infected with hepatitis C. *Gastroenterology* 118, 1124–1130.

19 Ueda H, Howson JM, Esposito L *et al.* (2003) Association of the T-cell regulatory gene CTLA4 with susceptibility to autoimmune disease. *Nature* 423, 506–511.

20 Yee LJ, Perez KA, Tang J *et al.* (2003) Association of CTLA4 polymorphisms with sustained response to interferon and ribavirin therapy for chronic hepatitis C virus infection. *J Infect Dis* 187, 1264–1271.

21 Grove J, Daly AK, Bassendine MF *et al.* (2000) Interleukin-10 promoter region polymorphism and susceptibility to advanced alcoholic liver disease. *Gut* 46, 540–545.

22 Yee LJ, Tang J, Gibson AW *et al.* (2001) Interleukin-10 polymorphisms as predictors of sustained response in antiviral therapy for chronic hepatitis C infection. *Hepatology* 33, 708–712.

23 Satsangi J, Chapman RWG, Haldar N *et al.* (2001) A functional polymorphism of the stromelysin gene (MMP-3) influences susceptibility to primary sclerosing cholangitis. *Gastroenterology* 121, 124–130.

24 Wienke K, Louka AS, Spurkland A *et al.* (2004) Association of matrix metalloproteinase-1 and -3 promoter polymorphisms with clinical subsets of Norwegian primary sclerosing cholangitis patients. *J Hepatol* 41, 209–214.

25 Khakoo SI, Thio CL, Martin MP *et al.* (2004) HLA and NK cell inhibitory receptor genes in resolving hepatitis C virus infection. *Science* 305, 872–874.

3.3.3 Genetic determinants of complex liver diseases: mouse models and quantitative trait locus analysis

Frank Lammert

Introduction

Many common liver diseases are the result of complex interactions between environmental factors and multiple genes. It is assumed that a large number of liver-specific disease genes determine the clinical outcomes of patients following exposure to acute or chronic liver injury, and that individuals who carry certain combinations of these genes are most susceptible. In the past decade, techniques and resources for genome analysis, in particular quantitative trait locus (QTL) analysis, have been established to identify and localize the genes that contribute to polygenic (complex) diseases in rodent models under defined environmental conditions. QTL analysis is based on experimental crosses of genetically distinct inbred mouse strains. This chapter describes the impact of these genomic approaches in mouse models on our understanding of the complex genetics of chronic

liver diseases. Complex liver diseases such as liver fibrosis and hepatocellular carcinoma demonstrate how mouse models represent an invaluable tool to identify unknown pathomechanisms, to investigate how systems of genes work together in health and disease processes and to define new therapeutic targets.

Monogenic and polygenic (complex) liver diseases

Even in the early 1900s, the wide variability in the severity of liver diseases led clinicians to suggest that there are hereditary factors affecting the traits. However, simple (monogenic) diseases (also known as Mendelian traits) represent only a small portion of the total number of human liver disorders, with Wilson's disease [1] and classic haemochromatosis [2] as prominent examples. In contrast, many common liver diseases are determined by the interaction of multiple genes (epistasis) and the interactions of these genes with different environmental factors (polygenic or multifactorial diseases). The risk alleles are not sufficient to cause the disease, but they confer susceptibility to manifestation and/or progression of the disease. Examples of such complex liver diseases include liver cirrhosis and hepatocellular carcinoma.

The approaches to identifying the genetic determinants of complex liver diseases can be separated into different categories: candidate gene methods that test genetic variants of a potential susceptibility gene for association with a liver disease; and positional cloning approaches (forward genetics), which use genetic markers to perform an unbiased scan of the whole genome. Candidate gene association studies are often based on unrelated cases and control subjects and offer the advantages of speed, relatively low cost and the possibility of identifying genes with small allele effects [3]. However, prior knowledge of the pathophysiology is a requirement for the candidate gene approach, and therefore limits its utility.

In addition to human genetics, mouse models can be used for gene discovery in complex diseases (Fig. 1), as recently highlighted by the Complex Trait Consortium [4]. Whereas genetic studies in humans are often hindered by difficulty in ascertaining sufficient numbers of affected individuals and the fact that environmental factors are difficult to control, mouse genetics offers more accessible and lower cost tools for gene identification. Compared with humans, genetic analysis in mice is facilitated by: (i) inbreeding of mouse strains, i.e. mating of siblings through at least 20 generations, to reduce allelic diversity; (ii) rapid and systematic generation of progeny; (iii) the ability to control environmental influences; and (iv) powerful experimental systems unique to mice [5].

To date, case–control (association-based) studies for the detection of QTLs have dominated studies of complex diseases in humans, whereas in mouse genetics, linkage (segregation-based) studies prevail. Linkage studies observe the co-inheritance of genetic markers and target loci in a segregating population. In contrast, large samples of unrelated human individuals are traditionally analysed using association-based approaches, which compare the frequency of specific genotypes between cases and control subjects.

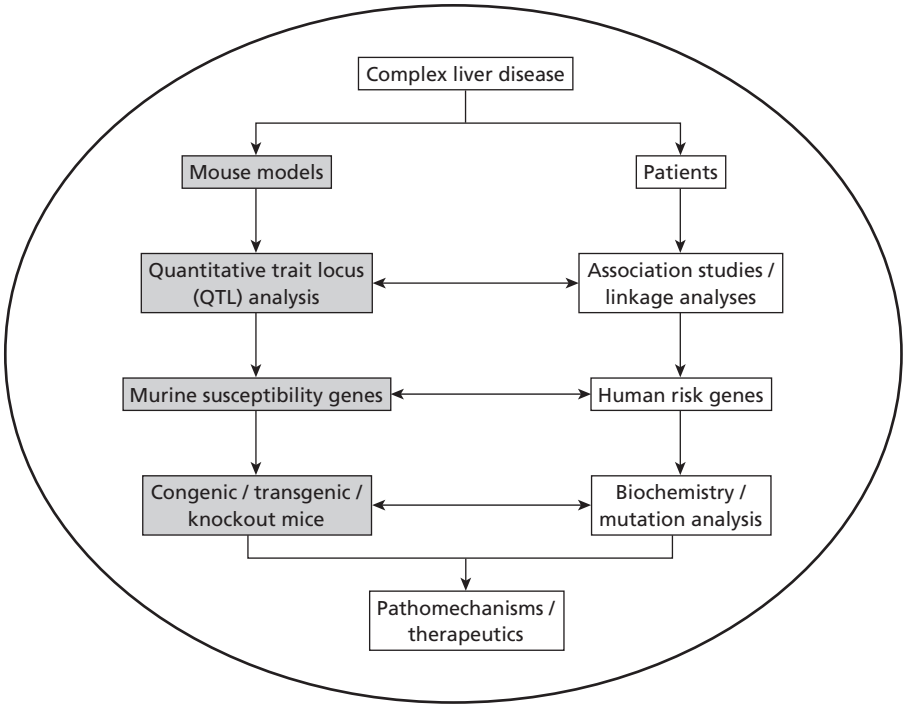

Fig. 1 Complementary genetic analysis of complex liver diseases in mice and humans. Human risk genes can be identified in association (case–control) studies or linkage analyses in families. Mouse models allow the identification of susceptibility genes using quantitative trait locus (QTL) analysis and congenic mice. The pathophysiological consequences of biochemical alterations and mutations in humans can be studied in transgenic and knockout mice. It should be noted that the experimental findings can be transferred between mice and humans at each step in the analysis.

Table 1 Experimental design of a QTL analysis in inbred mice.

Experimental step	Items
1 Inbred strain survey	Selection of strains, finding a phenotypical difference among inbred strains
2 Characterization of parental strains and F1 progeny	Inheritance pattern, differences in expression for gender and age, subphenotypes
3 Experimental cross	F2 or backcross, size of cross
4 Genome analysis	Selection of genetic markers, selective genotyping, phenotypical pooling
5 Data analysis	QTL mapping software, thresholds for statistical significance
6 Functional testing of candidate genes	Congenics, transgenics and knockout mice

Quantitative trait locus (QTL) analysis in inbred mice

A QTL is a genetic locus whose alleles affect the phenotypical variation of a disease [4]. For locus identification, a segregating experimental cross of inbred mouse strains is phenotyped and then genotyped for markers that differ between the parental strains and are distributed evenly throughout the entire genome. In general, QTLs are mapped by statistically locating the genomic regions in which the degree of genotypical similarity correlates maximally with the degree of phenotypical similarity among the progeny [6–8]. Table 1 lists the experimental stages of QTL analysis.

The first step in QTL analysis is an inbred strain survey. By definition, inbred mice are the result of at least 20 brother × sister matings, resulting in mice that are homozygous for all alleles and thus genetically identical. For a strain survey, a quantitative phenotype is determined in multiple inbred strains in response to an environmental challenge such as a high-fat diet or exposure to hepatotoxins. To increase the likelihood of resolving the genetic complexity, the phenotype of interest should be very narrowly defined, or a subset of the overall disease phenotype should be chosen for the genetic analysis. The strains are then ordered along the phenotypical spectrum to identify genetically susceptible and resistant strains. Figure 2 illustrates an example, the strain survey for CCl_4-induced liver fibrosis [9], showing hepatic hydroxyproline concentrations, which reflect collagen contents in liver, as a quantitative trait in seven inbred mouse strains [10].

Once the strain spectrum is determined, the genetic variability that gives rise to the phenotypical differences can be explored by *in silico* and/or experimental QTL analysis. Experimental crossing of inbred mouse strains can be regarded as the central procedure in QTL analysis (Table 1). Two inbred strains that differ phenotypically are bred to obtain intercross or backcross progeny (Fig. 3). An intercross (F2) tests genotype–phenotype associations in a cross of F1 progeny. Whereas F1 mice are heterozygous at every locus and genetically identical to each other, a recombination of the parental genetic material is possible during meiosis of the F1 mice and becomes genotypically and phenotypically visible in the F2 generation. A continuously distributed quantitative trait in an F2 design suggests that multiple genes contribute to the phenotype, as expected for a polygenic trait (Fig. 4). Similarly, a backcross tests marker–trait association in progeny obtained by backcrossing F1 mice to one of the parental lines (Fig. 3).

Microsatellites (simple sequence length polymorphisms, SSLPs) have been widely used as genetic markers in QTL analysis. These markers are short repetitive DNA sequences [e.g. $(CA)_n$] with known chromosomal locations throughout the mouse genome. Because microsatellites are abundant, vary in size across inbred mouse strains and are easily determined by polymerase chain reaction (PCR)-based assays, they are convenient for use as genetic markers in QTL studies. More recently, single nucleotide polymorphisms (SNPs) have been identified and genotyped in large panels of inbred mice [11,12]. A SNP can be considered to be a form of point mutation that has been evolutionarily successful enough to recur in a significant proportion of a species'

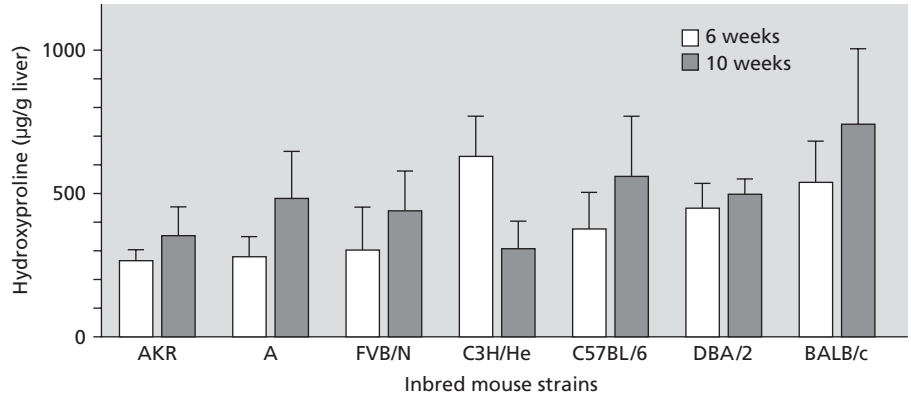

Fig. 2 Inbred strain survey for liver fibrosis. Hepatic hydroxyproline levels (representing hepatic collagen contents) in inbred mouse strains before and after treatment with CCl_4. Hydroxyproline levels (µg/g liver) at 6 and 10 weeks are represented by white and grey bars respectively. Strains AKR, A and FVB/N were significantly more resistant towards hepatic fibrosis, whereas C57BL/6, DBA/2 and BALB/c mice were more susceptible. From ref. 10, with permission.

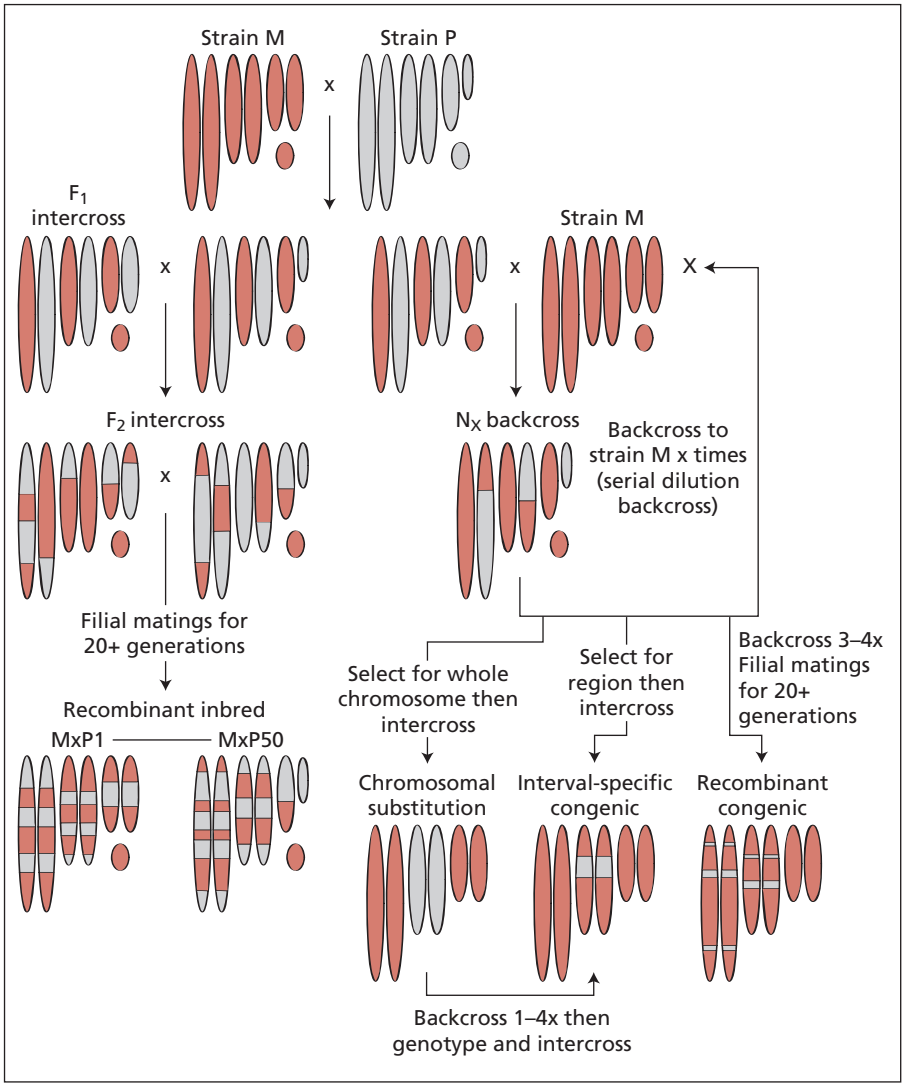

Fig. 3 Experimental mouse crosses for QTL analysis (see text for details). M, maternal; P, paternal.

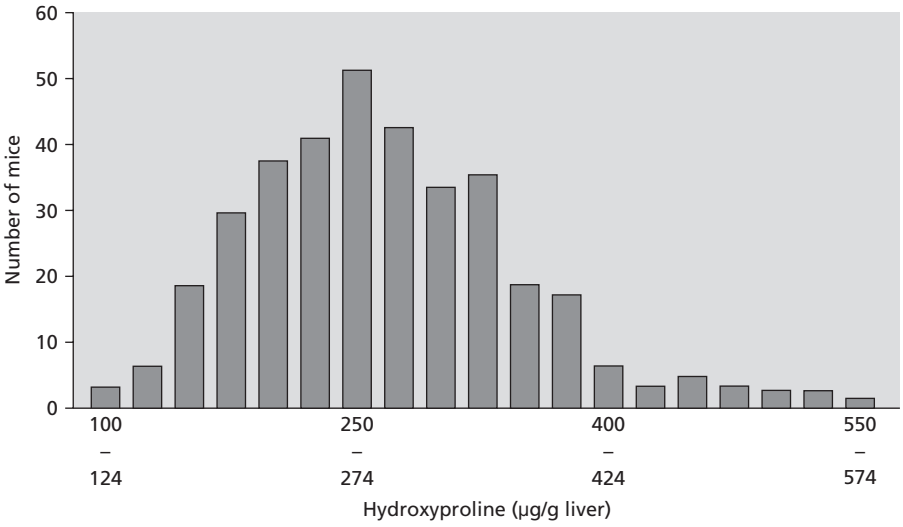

Fig. 4 Polygenic inheritance of liver fibrosis. Distribution of hepatic hydroxyproline levels in intercross (F2) progeny of fibrosis-susceptible BALB/c and resistant A/J mice [(A/J × BALB/c)F1 × (A/J × BALB/c)F1] after treatment with CCl_4 for 6 weeks. According to hydroxyproline levels (μg/g liver), mice were divided into phenotypical classes, as indicated on the abscissa. The intercross shows a normal (Gaussian) distribution of hydroxyproline levels, consistent with polygenic (non-Mendelian) inheritance of fibrosis susceptibility. From ref. 10, with permission.

Table 2 QTL analysis of complex liver diseases in inbred mice.

Liver disease	QTLs	References
Cholesterol cholelithiasis	Lith1 (lithogenic gene 1) – Lith23	[32,34–40,75,76]
Haemochromatosis	Hfe-modifier 1 – Hfe-modifier 4	[26]
Liver fibrosis	Hfib1 (hepatic fibrogenic gene 1) – Hfib2	[10,53]
Non-alcoholic fatty liver disease	Lcho1 (liver cholesterol accumulation 1) – Lcho4	[77,78]
Porphyria cutanea tarda	Hcbip1 (hexachlorobenzene-induced porphyria 1) – Hcbip2	[79,80]
Schistosomiasis	Rsm1 (resistance to *Schistosoma mansoni* 1)	[81]

population. The two SNP alleles can be reliably determined (e.g. using TaqMan assays), but genetic diversity and thus information content across different strains is lower compared with microsatellites (see Chapter 3.6 for more information about molecular techniques).

For the final QTL analysis, all intercross or backcross progeny are phenotyped and genotyped for microsatellites or SNPs that differ between the parental strains and densely cover the whole genome (Table 1). The rationale behind QTL identification is the fact that parental alleles are distributed randomly to offspring. Therefore, for any loci not contributing to a disease phenotype, parental alleles are randomly represented between sufficiently large pools of susceptible and resistant mice. However, strain-specific alleles for loci that determine susceptibility are over-represented in the affected progeny. Linkage analysis of phenotypes and genotypes is performed using genetic mapping software such as MapManager QTX [13] or R/qtl [14], which allow user-friendly identification (e.g. by regression analysis or interval mapping) [15] and statistical validation of linkage. The logarithm of the odds ratio (LOD) score, the traditional statistics for genetic linkage, is a measure of the strength of evidence for the presence of a QTL. The LOD score is the odds ratio comparing the hypothesis of a QTL at a particular location vs. that of no QTL. LOD scores ≥ 3 are generally considered to indicate significant results, albeit theoretical thresholds have been calculated for specific cross designs [16] and, alternatively, empirical thresholds, which correct for multiple testing, can be calculated by permutation tests [17].

Table 2 lists complex liver diseases that have been studied in QTL analyses and are discussed in the following sections.

Liver fibrosis

Fibrosis or scarring of the liver is a common consequence of all chronic liver diseases irrespective of aetiology (see also Section 6). It represents the generalized response of the liver to chronic injury and is characterized by excessive deposition of extracellular matrix by activated hepatic stellate cells [18–20]. The molecular basis of this process is complex and involves the interplay of many factors, of which growth factors, cytokines and chemoattractants are prominent. The marked variability in progression of fibrosis has been attributed to age, gender and environmental factors [21], but host genetic factors are also likely to contribute to the variable course of fibrosis in response to chronic injury [22]. Shi *et al.* [9] were first to show that the fibrotic response differs among inbred mouse strains. Liver injury induced with CCl_4 resulted in severe fibrosis in BALB/c mice, whereas C57BL/6 mice developed comparatively less fibrosis. Of note, fibrogenic BALB/c mice exhibited a T-helper 2 (Th2) response, whereas C57BL/6 mice displayed a Th1 response, consistent with the common paradigm that Th1/Th2 cytokine subsets modulate the fibrotic response of the liver [23].

Subsequently, Hillebrandt *et al.* [10] performed a systematic inbred strain survey (Fig. 2) to identify unknown susceptibility loci for liver fibrosis. For QTL analysis, F1 hybrids of susceptible BALB/c and resistant A/J inbred strains were intercrossed to obtain 358 F2 progeny. Linkage analysis of phenotypes and genotypes identified QTLs on chromosomes 2 and 15 that significantly affect the histological stage of fibrosis and hepatic collagen content [10].

Haemochromatosis

QTL analysis can also be used to identify gene loci that determine the severity and progression of a monogenic disease, and not manifestation of the disease *per se*. Hereditary haemochromatosis is a common disorder of iron homeostasis characterized by increased dietary iron absorption and progressive iron accumulation, mainly in the liver (see also Chapter 16.2). Most patients are homozygous for the C282Y mutation in the *HFE* gene encoding an atypical human leucocyte antigen (HLA) class I protein that interacts with the transferrin receptor 1 and regulates the iron regulator hepcidin [24]. However, not all individuals carrying the haemochromatosis-predisposing genotype in the general population become iron loaded [25]. Genetic modifiers have been shown to influence disease penetrance, but their number and chromosomal locations remain unknown, and their identification is hampered by complex interactions with environmental factors. To circumvent these difficulties, Bensaid *et al.* [26] bred congenic inbred mouse strains for the *Hfe* gene that differ strongly in their propensity to develop hepatic iron loading. Strains are denoted as congenic (Fig. 3) if a chromosomal region has been transferred from one strain to another by recurrent backcrossing (≥ 10) of a founder individual to a recipient strain [27]. Marker-assisted breeding of congenic mouse strains (speed congenics) is possible over five generations

[28]. To localize the loci controlling hepatic iron loading, 1028 progeny from an F2 intercross between the C57BL/6 and DBA/2 Hfe-deficient strains were selectively genotyped and phenotyped for iron overload. The QTL analysis, which is denoted 'modifier scan' in this setting, identified four loci on chromosomes 7, 8, 11 and 12 that modify the haemochromatosis phenotype. The LOD scores of all three loci were > 6, indicating significant linkage, and the QTL regions contained several genes recently shown to exert important roles in the regulation of iron metabolism [26].

A similar QTL analysis employed mice deficient in the product of the β_2-microglobulin class I light chain gene, which fail to express HFE and other major histocompatibility complex (MHC) class I family proteins and manifest many characteristics of the haemochromatosis phenotype [29]. Analysis of the iron-loading phenotype in β_2-microglobulin congenic strains showed that the genetic background is a major determinant in iron loading. Resistance and susceptibility to iron overload segregated as complex traits in backcross progeny. Both studies [26,29] demonstrate the polygenic pattern of hepatic iron loading in Hfe-deficient mice and indicate that multiple modifier genes influence the severity of iron overloading and haemochromatosis, which was originally considered to represent a classic monogenic liver disease [2]. Examination of candidate genes residing at the modifier loci and genetic analysis of the syntenic chromosomal regions in humans will provide important insights into the heterogeneous disease presentation observed among *HFE* C282Y homozygotes [25].

Cholelithiasis (see also Chapter 19.3)

Familial clustering and an increased concordance of the trait in monozygotic twins compared with dizygotic twins [30] indicate that gallstone disease has a strong genetic component. However, the identification of human lithogenic genes is hampered by the multifactorial pathogenesis of gallstones. Gallstones are likely to result from the complex interaction of susceptibility genes, female gender, advanced age and environmental factors such as high-carbohydrate, high-fat and low-fibre diets and low physical activity [31]. The mouse is a suitable model to study the pathogenesis of cholesterol gallstone formation, as inbred mouse strains challenged with a lithogenic diet (containing 15% fat, 1% cholesterol and 0.5% cholic acid) show different prevalence rates of cholesterol gallstones [5,32]. As a tool for genetic mapping, Khanuja *et al.* [32] used recombinant inbred (RI) strains derived from strains representing the extremes of a strain survey. RI strains [33] are derived by successive (≥ 20) crosses between siblings from an initial cross between two parental strains (Fig. 3). These RI strains are homozygous for one of the parental alleles at every locus, but differ in the representation of these strains across the genome. RI strains can accelerate mapping by circumventing the costly and time-consuming experimental crosses. Recently, the genotypes of RI lines have been determined for very dense sets of SNPs [12]. Thus, a method for rapid identification of QTLs is to perform a phenotype survey across an RI panel whose parental strains represent phenotypical extremes of the inbred strain survey, and to identify the QTLs underlying the RI strain phenotype data.

With respect to cholecystolithiasis, QTL mapping in experimental crosses of several inbred mouse strains was successfully employed to localize the whole ensemble of lithogenic (Lith) loci that determine the gallstone phenotypes in inbred mouse lines. The results of several QTL analyses have been summarized in a 'gallstone map' [5] (Fig. 5). As illustrated, the formation of gallstones and mucin, which is considered to be a precursor to stone formation, is a polygenic trait determined by several loci on different chromosomes [5]. The Lith1 locus on chromosome 2 was identified in a genomewide scan of backcross progeny from the gallstone-susceptible strain C57L/J and the resistant strain AKR/J [32]. Since then, more than 20 murine Lith loci and several candidate genes (ABC transporters for biliary lipids, nuclear receptors, mucins) have been identified (Table 2) [34–40]. Lith1 and other loci have been confirmed and fine-mapped in congenic strains generated by introgressing the susceptible Lith alleles into resistant background strains, which induces hypersecretion of biliary cholesterol and other gallstone-related phenotypes [41].

Genomic toolbox for narrowing susceptibility loci: from QTL to gene

A QTL can be large and usually contains hundreds of genes, but identifying the causal gene remains difficult. Because the resolution of QTL mapping is low, any linked region(s) identified probably span(s) many megabases (Mb). The identification of recombinant progeny within the critical region can narrow the candidate region, or SNP association studies can be performed across the region. If strain sequence data are available, one can proceed to direct sequence comparison to identify polymorphisms. The literature is revisited once linkage has been established to query the locus as a region for any known risk factors, and also to determine whether candidate genes from any relevant microarray studies reside within the region [42]. It is important to generate a gene list for the linked region, and to examine the genes that could have a pathobiological function related to the liver disease. Afterwards, selective breeding strategies can be pursued in mice to harness *in vivo* genetic recombination to narrow the candidate region and therefore reduce the number of candidate genes. Examples of selective breeding include interval-specific congenic strains and recombinant congenic strains (Fig. 3). The comparison between different congenic strains possessing overlapping chromosomal interval regions helps to define the region that harbours the QTL gene more precisely [7]. Recombinant congenic strains are formed by crossing two inbred strains, followed by a few backcrosses to one of the parental strains and subsequent inbreeding without selection [43]. Such inbred strains consist of randomly fixed chromosomal segments of the donor strain on the background of the recipient strain to which it was backcrossed. Alternatively,

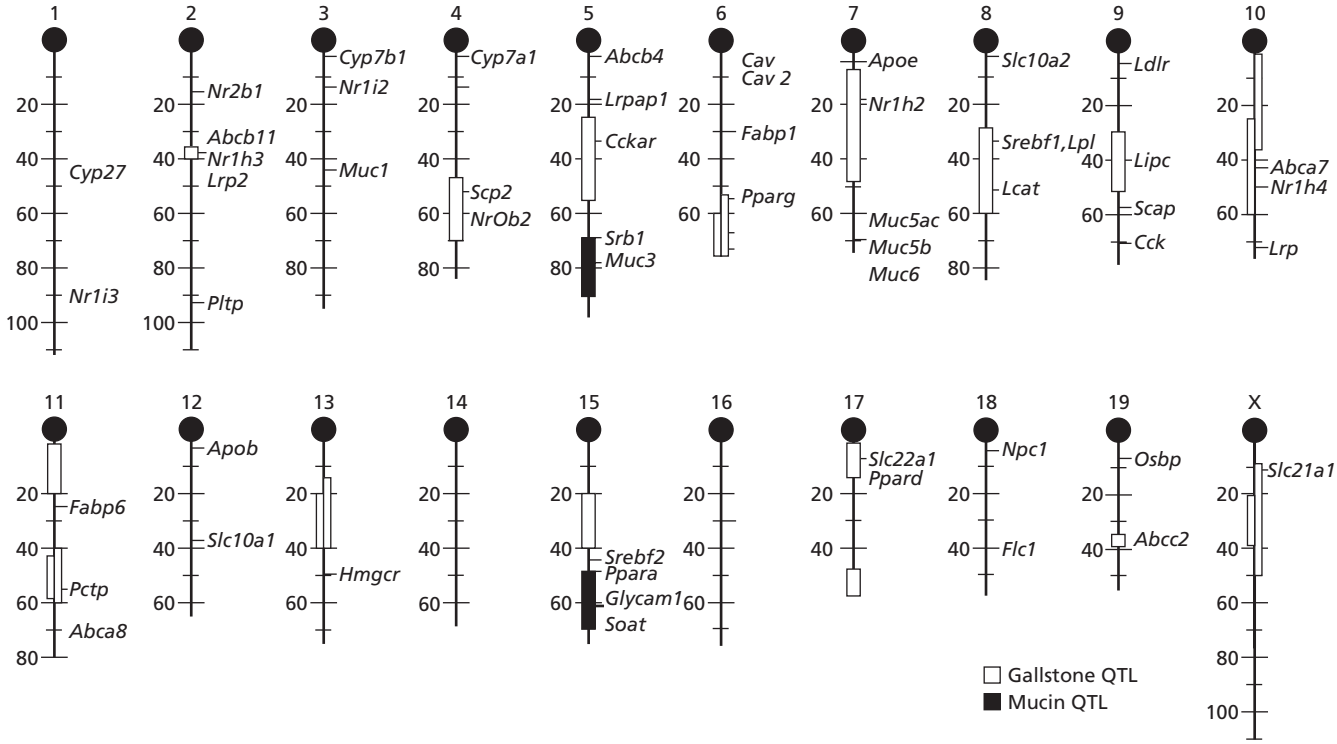

Fig. 5 Murine 'gallstone map'. Composite map of candidate genes and quantitative trait loci (QTLs) for cholesterol gallstone formation. A vertical line represents each mouse chromosome, with the centromere at the top; genetic distances from the centromere (horizontal black lines) are indicated to the left of the chromosomes in centiMorgans (cM). Gallstone QTLs (Lith genes) are represented by white rectangles, and QTLs for mucin formation, a common precursor of stones, by black rectangles. Candidate genes are indicated by horizontal lines with the gene symbols to the right. Updated from ref. 5, new version available from http://pga.jax.org/qtl/index.

Table 3 Summary of bioinformatics tools for dissection of mouse QTLs [45].

Bioinformatics tool	Methodology	Resolution
Comparative genomics	Identifies regions of chromosomal synteny in QTLs that are concordant across species	10–20 Mb
Combined cross analysis	Recodes genotype information from multiple crosses detecting a shared QTL into one susceptible and one resistant genotype to combine the crosses in a single QTL analysis	10–20 Mb
Genomewide haplotype analysis	Associates conserved haplotype patterns across the genome with a phenotype in inbred strains	< 5 Mb
Interval-specific haplotype analysis	Detects regions identical by descent within QTLs shared in multiple crosses	< 5 Mb
Sequence comparison	Searches strain-specific sequence databases for regulatory or coding polymorphisms within the QTL interval	10–20 genes
Expression comparison	Searches microarray databases to identify genes expressed in an organ of interest or genes exhibiting differential expression between the strains of interest	10–20 genes

consomic mice (also known as chromosome substitution strains) may be used (Fig. 3), which are panels of inbred strains bred to differ by a single chromosome [44]. By comparing the phenotypes of these mice, one can determine which chromosome confers a specific phenotype [42].

Recently developed bioinformatics methods, including comparative genomics, combined cross analysis, genomewide and interval-specific haplotype analysis, followed by sequence and expression analysis, each facilitated by public databases, provide new tools for narrowing mouse QTLs (Table 3; see Plate 3.3.3.1, facing p. 72) [45,46] (see Chapter 3.6). Comparative genomics is based on the structural conservation among all mammalian genomes. The gene content and linear organization of genes along chromosomal segments in mice correspond to that found in humans, with ~ 340 syntenic segments conserved between the two species [47]. Experimental evidence suggests that causal genes underlying rodent QTLs are often conserved as disease genes in humans. Therefore, cross-species conservation (synteny) can be used to compare linked regions across human and animal models and to determine whether candidate loci

across a number of model organisms are likely to harbour orthologous genes. However, as chromosomal segments conserved between rodents and humans are often large, comparative genomic analysis only modestly narrows a QTL interval in most cases (Table 3).

Combined cross analysis and haplotype analysis are based on the unusual nature of the inbred mouse genome, which is a mixture of DNA from different subspecies [48]. Combined cross analysis is a statistical method of integrating data from existing QTL crosses to narrow the QTL interval provided that the same causal gene underlies the QTL in each cross [49]. QTLs are often found at the same chromosomal location in multiple crosses, and all strains carrying the susceptibility allele at a QTL share the same ancestral allele of the causal gene. Thus, combined cross analysis provides increased power to detect QTLs with small effects [49].

An alternative way to narrow QTL intervals based on the structure of the genome is haplotype analysis [50]. Genomewide and interval-specific haplotype analysis can be used to narrow experimentally derived QTLs (Table 3). The innovative idea of a computer algorithm to link phenotypes to genotypes in inbred mouse strains [51] stimulated the development of genomewide haplotype analysis, which predicts the location of QTLs affecting a trait without a priori knowledge of the loci. It should be noted that these methods have also been called 'association mapping', as they are based on genetic association, whereas experimental QTL analysis (Table 1) employs genetic linkage. There are now several newly developed computational methods that input phenotype values across inbred strains of mice to rapidly predict genetic susceptibility loci without the need to derive experimental crosses of inbred strains. Each of these methods uses a database of strain-specific genetic markers. The methods also use strain data on characteristic combinations of SNP alleles on single chromosomes that are inherited together (haplotypes). Inbred mice share haplotypes across 30–60% of the mouse genome [11]. Pletcher *et al.* [52] grouped inbred strains based on inferred haplotypes (determined by three consecutive SNPs) and tested for phenotypical differences between the groups. They sequentially applied sliding three-SNP windows across the genome to identify QTLs in which the different haplotype groups showed distinct phenotypes. This type of analysis was applied for a phenotype that scored the formation of gallstones in 25 strains of male mice [52]. Eleven regions were produced that exceeded the threshold for statistical significance at a genomewide level ($P = 0.0004$), and seven of these regions fell within the range of experimentally identified QTLs for gallstone formation or mucin accumulation (Table 4, Fig. 5).

In interval-specific haplotype analysis, genetic markers covering a critical QTL interval are grouped into the strains that carry the high allele and those that possess the low allele. Any region with genotypes that are shared between the high-allele strains but differ from the low-allele strains is considered a haplotype region likely to contain the QTL gene [45]. To refine a QTL for liver fibrosis on mouse chromosome 2, which was detected previously in an experimental intercross between fibrosis-susceptible BALB/c and the resistant A/J inbred strains, we [53] used interval-specific haplotype analysis with a dense SNP map and hepatic collagen concentrations from seven inbred mouse strains (Fig. 2) as input quantitative data. We inferred haplotypes from three-SNP windows with an average size of 900 kb and calculated the strength of the genetic association at each haplotype on the basis of the genotype–phenotype pairings. The refined QTL separated into two long-range haplotypes, which carry the complement factor 5 (C5) as QTL gene at the distal end [53]. Haplotype association mapping is still a developing method, and issues that need to be addressed include the required number of

Table 4 Comparison of *in silico* and experimental QTLs for cholecystolithiasis (modified from [52]).

In silico QTL			Experimental QTL		Reference
Chromosome	QTL position (Mb)	*P* value	Cross	QTL position (Mb, 95% CI)[a]	
2	173–175	0.000078	(129S1 × CAST)F2	176 (159–182)	[38]
3	84–87	0.000418	–	–	
4	28–29	0.000388	(A × AKR) × AKR	4 (0–29)	[34]
5	99–102	0.000135	(SM × NZB)F2	106 (60–115)	[52]
6	10–13	0.000127	(DBA/2 × CAST)F2	2 (0–15)	[37]
10	79–82	0.000225	–	–	
11	95–97	0.000349	(SWR × AKR) × AKR[b]	122 (95–129)	[35]
12	40–46	0.000279	–	–	
14	59–63	0.000190	–	–	
15	82–95	0.000088	(A × AKR) × AKR	102 (89–telomere)	[34]
16	69–71	0.000173	(129S1 × CAST)F2	70 (49–95)	[38]

[a]QTL regions were defined as experimentally determined 95% confidence intervals (CI) or as ± 10-cM intervals around the peak position with the highest logarithm of the odds ratio score.

[b]QTL for gallbladder mucin, an early step in gallstone formation.

inbred strains and the minimum SNP density to detect small haplotypes [45].

The molecular bases for QTLs are DNA polymorphisms affecting the expression or the function of a gene product. Genome sequence databases enable *in silico* sequence comparisons of whole QTL intervals to detect sequence variants. Sequence comparison of susceptible and resistant strains can reveal strain-specific polymorphisms underlying QTLs. If genomic sequence data for strains of interest are not available, individual candidate genes within the QTL are resequenced in those strains to find genetic changes that could be responsible for a phenotype. These include alterations in the coding sequence that change an amino acid sequence or the stop codon, sequence alterations in a splice junction that may affect processing of the mRNA transcript, and sequence alterations in other non-coding regulatory regions. DNA regions can also be compared across species to highlight regions of conservation. Specific software tools [54,55] assess the degree of conservation and are useful in detecting which non-coding regions are likely to be functionally important. A complementary strategy to searching sequence databases is investigating gene expression databases to identify genes that are differentially expressed between strains for many tissues. Such expression differences can be mapped to chromosomal intervals with QTL mapping methods such as WebQTL [56,57]. WebQTL is a website (http://www.genenetwork.org/) that contains genotype and expression data from many RI strain sets. The WebQTL databases comprise several biological traits and microarray-based gene expression data (including liver) from the RI lines. A search function detects correlations between RNA expression and biological traits, and mapping functions identify QTLs for a selected trait.

Functional genomics

Gene arrays (transcriptomics) and proteomics are increasingly used to phenotypically characterize the expression profiles of liver tissue or serum from patients with liver diseases (see Chapter 3.6). Expression data provide much insight into the pathobiology of a process, but do not necessarily reveal underlying disease genes, as the causal gene residing in a QTL may not be differentially expressed in the disease state. However, gene arrays can also be incorporated into functional genomics of complex liver diseases, as illustrated by the examples below.

Liver metabolism

Fine mapping of QTLs and validation of positional candidates are time-consuming and not always successful. Therefore Schadt and his group [58] developed a hybrid procedure to map loci involved in complex traits that leverages the strengths of forward and reverse genetic approaches (see Plate 3.3.3.2, facing p. 72). By integrating genotypes and hepatic microarray data in RI strains and experimental crosses, they showed that clinical QTLs controlling cholesterol and leptin levels and other metabolic traits are enriched for clusters of QTLs that determine the hepatic expression levels of genes associated with these metabolic traits (eQTLs). By matching patterns of gene expression in segregating mouse populations (forward genetics) with expression responses induced in knockout mice (reverse genetics), genes controlling clusters of eQTLs and clinical QTLs could be mapped (see Plate 3.3.3.2, facing p. 72). The utility of this approach was demonstrated by identifying 5-lipoxygenase as the gene underlying a QTL with pleiotropic effects on lipid metabolism in an F2 cross between strains C57BL/6 and DBA/2 [58].

Hepatocellular carcinoma

The majority of cDNA microarray-based gene expression profiling studies on human hepatocellular carcinoma (HCC) have focused on identifying genes associated with clinical features of HCC patients (see Chapters 3.5 and 18.2.1). Although notable success has been achieved, this approach still faces significant challenges on account of the heterogeneous nature of HCC (and other cancers) as well as the many confounding factors embedded in gene expression profile data. The underlying molecular basis for HCC heterogeneity, which hampers both treatment and prognostic predictions, is still largely unknown. Genetically modified mice have been used extensively for analysing the molecular mechanisms that occur during tumour development. However, in many cases, it is uncertain to what extent the mouse models reproduce features observed in the corresponding human conditions [59]. This is due largely to lack of precise methods for direct and comprehensive comparison at the molecular level of the mouse and human tumours. These limitations can be overcome by cross-species comparison of multiple gene expression data sets from human tumours and mouse models, which allow the identification of critical regulatory modules in the expression profiles. The success of this new experimental approach, comparative functional genomics, suggests that gene expression signatures reflecting similar HCC phenotypes are conserved across species and that integration of independent data sets enhances the ability to identify key regulatory elements in tumour development [60].

For most microarray studies, the challenge resides in deriving biological meaning from an overwhelming amount of data. Although the ability to measure large numbers of genes affords new insight by identifying genes that would not have been imagined to participate in a process, it is difficult to derive meaning from even a small experiment without analysis tools that identify biological themes present in expression data [GenMAPP, MAPPFinder (http://www.genmapp.org/), EASE (http://david.abcc.hcifcrf.gov/)]. These tools visualize gene expression data on maps representing biological pathways and groupings of genes, and identify over-represented functional gene categories with respect to all assayed genes using a number of categorization systems, including gene ontology, biological pathways, chromosomal localizations and protein domains.

Recently, microarray analysis was used to determine global gene expression patterns of HCCs from seven different mouse models and human HCCs from predefined subclasses to obtain direct comparison of the molecular features of mouse and human HCCs [59]. Gene expression patterns in HCCs from Myc, E2f1 and Myc/E2f1 transgenic mice were most similar to those of the better survival group of human HCCs, whereas the expression patterns in HCCs from Myc/TGFα transgenic mice and in diethylnitrosamine-induced mouse HCCs were most similar to those of the poorer survival group of human HCCs (see Plate 3.3.3.3, facing p. 72). These results suggest that these two classes of mouse models recapitulate the molecular characteristics of subclasses of human HCCs. In contrast, gene expression patterns of HCCs from Acox1 knockout and ciprofibrate-treated mice were least similar to those observed in either subclass of human HCCs [59]. As hepatocarcinogenesis is driven by peroxisome proliferation in these two models, the findings are in line with previous studies suggesting that humans are insensitive to the hepatotoxic effects of peroxisome proliferation [61]. The similarity of gene expression profiles between human and mouse models is in good agreement with the phenotypical HCC characteristics. Human HCCs with increased proliferation, decreased apoptosis and higher genomic instability can be paired with mouse models with the same characteristics. Thus, this approach can effectively identify appropriate mouse models to study human HCCs. Furthermore, cross-species similarity of gene expression patterns allows prioritization of genes obtained from human gene expression profiling studies and focus on genes whose expression is altered during hepatocarcinogenesis in both species (see Plate 3.3.3.3, facing p. 72).

Functional testing of QTL genes in genetically engineered mice

Although the unequivocal identification of the gene underlying a QTL is technically demanding [7,62], recently, genes for several QTLs including liver fibrosis, cholelithiasis, diabetes, obesity, atherosclerosis and modifiers of colorectal cancer have been identified successfully [63]. The tracking of a particular genetic variant with disease in susceptible strains of mice, and the nature of the sequence alteration, with attention towards the predicted impact on protein function, are important considerations in making the case for the involvement of a particular gene. However, in order to verify that a particular allele is pathogenic, additional functional testing has to be performed. Formal proof of gene discovery requires demonstration that replacement with a gene variant produces the phenotypical variant of interest [4].

Gene targeting followed by transgenic complementation, e.g. with recombined bacterial artificial chromosomes [64,65] or knockin technology [66] in mice, are *in vivo* approaches that are appropriate for functional validation. For liver fibrosis, interval-specific congenic mice (Fig. 3) and transgenesis with recombined bacterial artificial chromosomes demonstrated that the gene encoding complement factor C5 [67] underlies a QTL on mouse chromosome 5 [53]. Genetically engineered mice for candidate genes may also be available from several sources, which should be queried before generating a mouse model *de novo* [42]. For example, Bay Genomics PGA (http://baygenomics.ucsf.edu/) and the German Gene Trap Consortium (http://tikus.gsf.de/) have generated libraries from insertional mutations in mouse embryonic stem (ES) cells available to the scientific community for the purpose of generating knockout mice. 'Gene trap' vectors carrying reporter genes for localizing expression and other multipurpose alleles amenable to a wide range of postinsertional modifications were used in ES cells to randomly inactivate genes, and thousands of genes have been trapped [68,69]. Short interfering (si) RNA technology for posttranscriptional gene silencing is an emerging technology for both *in vitro* and *in vivo* functional testing that may also be applied to functional validation of candidate genes in liver diseases [42]. Alternatively, pharmacological interventions using antibodies or small molecules can be used. For example, small molecule inhibitors of the C5 receptor displayed antifibrotic effects *in vivo*, further supporting the identity of C5 and the fibrogenic QTL on chromosome 12 [53].

Suggested workflow for gene discovery in mouse models of complex liver diseases and future perspectives for clinical practice

Based on the above discussions, Figure 6 proposes a workflow for studies to discover genes for complex liver diseases in mouse models. Once a susceptibility locus has been identified in the mouse and the QTL has been narrowed by the above approaches and proven to be pathophysiologcially relevant in mice, these results should be investigated in humans. The final proof of a causal QTL gene can be produced by demonstrating the phenotype in genetically engineered mice and confirming the association of the gene with the disease in human populations, as recently reported for *Tnfsf4* in atherosclerosis [70] and *C5* in liver fibrosis [53]. Previous studies have focused on nucleotide polymorphisms as genetic variants, but variation in gene copy number might be yet another source of interindividual differences. Recently, copy number variation of the *Fcgr3* gene encoding a receptor for Fc fragments of immunoglobulins was identified as a determinant of susceptibility to immunologically mediated glomerulonephritis in rats and humans [71]. The finding that gene copy number polymorphism predisposes to an immunologically mediated disease in two mammalian species provides evidence for the importance of genome plasticity in the evolution of complex diseases. It is to be expected that these mechanisms also apply to liver diseases, albeit experimental proof has yet to be provided.

The mouse studies demonstrate how QTL analysis leads to the identification of new gene loci affecting complex liver diseases.

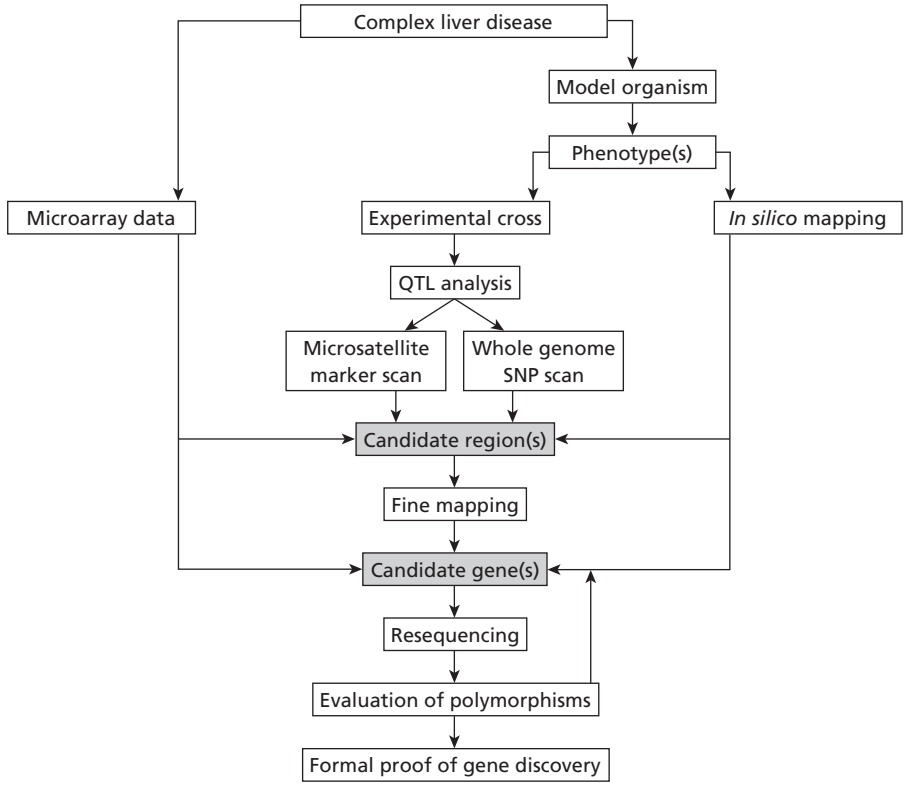

Fig. 6 Flow diagram of the gene discovery process in complex liver diseases. Modified from [42].

Moreover, the findings indicate that similar sets of genes regulate complex liver diseases in mouse models and humans and that variations in evolutionarily conserved genes alter the same pathobiological pathways across species [72]. In the future, the whole ensemble of susceptibility genes in mouse models of liver diseases will be studied in association and family studies in humans. As pointed out, multiple genes contribute to complex liver diseases, but most genetic studies in humans have focused on single genes. Recently, a study from Australia [73] detected associations between polymorphisms in six genes (*APOE*, *CCR5*, *CTLA4*, *HFE*, *MTP*, *SOD2*) and progressive liver fibrosis in chronic hepatitis C, with individual odds ratios ranging from 2.1 to 4.5. The odds ratios between rapidly progressing fibrosis and the possession of at least three, four or five at-risk alleles increased to 9.1, 15.5 and 24.1 respectively [73]. Using logistic regression analysis, a predictive equation could be developed and tested using a second cohort of patients with advanced fibrosis. Future combined analyses of human genes will be facilitated by the recent completion of the International HapMap Project [74], which catalogues the common patterns of DNA sequence variation of all human genes in different populations worldwide. It is anticipated that haplotype-based studies in large, well-characterized cohorts with chronic liver diseases will allow the determination of genetic risk profiles that promote rapid disease progression and help to select the most beneficial and personalized therapies (see Plate 3.3.3.4, facing p. 72).

References

1 Roberts EA, Schilsky ML (2003) A practice guideline on Wilson disease. *Hepatology* 37, 1475–1492.
2 Bacon BR (1989) Joseph H. Sheldon and hereditary hemochromatosis: historical highlights. *J Lab Clin Med* 113, 761–762.
3 Risch N, Merikangas K (1996) The future of genetic studies of complex human diseases. *Science* 273, 1516–1517.
4 The Complex Trait Consortium (2003) The nature and identification of quantitative trait loci: a community's view. *Nature Rev Genet* 4, 911–916.
5 Lammert F, Carey MC, Paigen B (2001) Chromosomal organization of candidate genes involved in cholesterol gallstone formation: a murine gallstone map. *Gastroenterology* 120, 221–238.
6 Lander ES, Schork NJ (1994) Genetic dissection of complex traits. *Science* 265, 2037–2048.
7 Darvasi A (1998) Experimental strategies for the genetic dissection of complex traits in animal models. *Nature Genet* 18, 19–24.
8 Doerge RW (2002) Mapping and analysis of quantitative trait loci in experimental populations. *Nature Rev Genet* 3, 43–52.
9 Shi Z, Wakil AE, Rockey DC (1997) Strain-specific differences in mouse hepatic wound healing are mediated by divergent T helper cytokine responses. *Proc Natl Acad Sci USA* 94, 10663–10668.
10 Hillebrandt S, Goos C, Matern S *et al.* (2002) Genome-wide analysis of hepatic fibrosis in inbred mice identifies the susceptibility locus Hfib1 on chromosome 15. *Gastroenterology* 123, 2041–2051.
11 Wiltshire T, Pletcher MT, Batalov S *et al.* (2003) Genome-wide single-nucleotide polymorphism analysis defines haplotype patterns in mouse. *Proc Natl Acad Sci USA* 100, 3380–3385.

12 Yalcin B, Fullerton J, Miller S *et al.* (2004) Unexpected complexity in the haplotypes of commonly used inbred strains of laboratory mice. *Proc Natl Acad Sci USA* 101, 9734–9739.

13 Manly KF, Cudmore RH, Meer JM (2001) Map Manager QTX, cross-platform software for genetic mapping. *Mamm Genome* 12, 930–932.

14 Broman KW, Wu H, Sen S *et al.* (2003) R/qtl: QTL mapping in experimental crosses. *Bioinformatics* 19, 889–890.

15 Lander ES, Botstein D (1989) Mapping mendelian factors underlying quantitative traits using RFLP linkage maps. *Genetics* 121, 185–199.

16 Lander E, Kruglyak L (1995) Genetic dissection of complex traits: guidelines for interpreting and reporting linkage results. *Nature Genet* 11, 241–247.

17 Churchill GA, Doerge RW (1994) Empirical threshold values for quantitative trait mapping. *Genetics* 138, 963–971.

18 Gressner AM (1998) The cell biology of liver fibrogenesis – an imbalance of proliferation, growth arrest and apoptosis of myofibroblasts. *Cell Tissue Res* 292, 447–452.

19 Friedman SL (2004) Mechanisms of disease: mechanisms of hepatic fibrosis and therapeutic implications. *Nature Clin Pract Gastroenterol Hepatol* 1, 98–105.

20 Bataller R, Brenner DA (2005) Liver fibrosis. *J Clin Invest* 115, 209–218.

21 Poynard T, Bedossa P, Opolon P (1997) Natural history of liver fibrosis progression in patients with chronic hepatitis C. *Lancet* 349, 825–832.

22 Bataller R, North KE, Brenner DA (2003) Genetic polymorphisms and the progression of liver fibrosis: a critical appraisal. *Hepatology* 37, 493–503.

23 Wynn TA (2004) Fibrotic disease and the T_H1/T_H2 paradigm. *Nature Rev Immunol* 4, 583–594.

24 Feder JN, Gnirke A, Thomas W *et al.* (1996) A novel MHC class I-like gene is mutated in patients with hereditary haemochromatosis. *Nature Genet* 13, 399–408.

25 Adams PC, Reboussin DM, Barton JC *et al.* (2005) Hemochromatosis and iron-overload screening in a racially diverse population. *N Engl J Med* 352, 1769–1778.

26 Bensaid M, Fruchon S, Mazeres C *et al.* (2004) Multigenic control of hepatic iron loading in a murine model of hemochromatosis. *Gastroenterology* 126, 1400–1408.

27 Snell GD (1978) Congenic resistant strains of mice. In: Morse HC (ed.) *Origins of Inbred Mice*. New York, NY: Academic Press, pp. 119–155.

28 Markel P, Shu P, Ebeling C *et al.* (1997) Theoretical and empirical issues for marker-assisted breeding of congenic mouse strains. *Nature Genet* 17, 280–284.

29 Sproule TJ, Jazwinska EC, Britton RS *et al.* (2001) Naturally variant autosomal and sex-linked loci determine the severity of iron overload in beta 2-microglobulin-deficient mice. *Proc Natl Acad Sci USA* 98, 5170–5174.

30 Katsika D, Grjibovski A, Einarsson C *et al.* (2005) Genetic and environmental influences on symptomatic gallstone disease: a Swedish study of 43 141 twin pairs. *Hepatology* 41, 1138–1143.

31 Lammert F, Sauerbruch T (2005) Mechanisms of disease: the genetic epidemiology of gallbladder stones. *Nature Clin Pract Gastroenterol Hepatol* 2, 423–433.

32 Khanuja B, Cheah YC, Hunt M *et al.* (1995) Lith1, a major gene affecting cholesterol gallstone formation among inbred strains of mice. *Proc Natl Acad Sci USA* 92, 7729–7733.

33 Bailey DW (1971) Recombinant-inbred strains. An aid to finding identity, linkage, and function of histocompatibility and other genes. *Transplantation* 11, 325–327.

34 Lammert F, Wang DQ, Wittenburg H *et al.* (2002) Lith genes control mucin accumulation, cholesterol crystallization, and gallstone formation in A/J and AKR/J inbred mice. *Hepatology* 36, 1145–1154.

35 Wittenburg H, Lammert F, Wang DQ *et al.* (2002) Interacting QTLs for cholesterol gallstones and gallbladder mucin in AKR and SWR strains of mice. *Physiol Genomics* 8, 67–77.

36 Wittenburg H, Lyons MA, Li R *et al.* (2003) FXR and ABCG5/ABCG8 as determinants of cholesterol gallstone formation from quantitative trait locus mapping in mice. *Gastroenterology* 125, 868–881.

37 Lyons MA, Wittenburg H, Li R *et al.* (2003) Lith6: a new QTL for cholesterol gallstones from an intercross of CAST/Ei and DBA/2J inbred mouse strains. *J Lipid Res* 44, 1763–1771.

38 Lyons MA, Wittenburg H, Li R *et al.* (2003) New quantitative trait loci that contribute to cholesterol gallstone formation detected in an intercross of CAST/Ei and 129S1/SvImJ inbred mice. *Physiol Genomics* 14, 225–239.

39 Lyons MA, Korstanje R, Li R *et al.* (2005) Single and interacting QTLs for cholesterol gallstones revealed in an intercross between mouse strains NZB and SM. *Mamm Genome* 16, 152–163.

40 Wittenburg H, Lyons MA, Li R *et al.* (2005) Association of a lithogenic Abcg5/Abcg8 allele on chromosome 17 (Lith9) with cholesterol gallstone formation in PERA/EiJ mice. *Mamm Genome* 16, 495–504.

41 Paigen B, Schork NJ, Svenson KL *et al.* (2000) Quantitative trait loci mapping for cholesterol gallstones in AKR/J and C57L/J strains of mice. *Physiol Genomics* 4, 59–65.

42 Burch LH, Schwartz DA (2005) Finding fibrosis genes: the lung. In: Varga J, Brenner DA, Phan SH (eds) *Fibrosis Research: Methods and Protocols*. Totowa, NJ: Humana Press, pp. 293–313.

43 Demant P, Hart AA (1986) Recombinant congenic strains – a new tool for analyzing genetic traits determined by more than one gene. *Immunogenetics* 24, 416–422.

44 Nadeau JH, Singer JB, Matin A *et al.* (2000) Analysing complex genetic traits with chromosome substitution strains. *Nature Genet* 24, 221–225.

45 DiPetrillo K, Wang X, Stylianou IM *et al.* (2005) Bioinformatics toolbox for narrowing rodent quantitative trait loci. *Trends Genet* 21, 683–692.

46 Flint J, Valdar W, Shifman S *et al.* (2005) Strategies for mapping and cloning quantitative trait genes in rodents. *Nature Rev Genet* 6, 271–286.

47 Pennacchio LA, Baroukh N, Rubin EM (2003) Human–mouse comparative genomics: successes and failures to reveal functional regions of the human genome. *Cold Spring Harb Symp Quant Biol* 68, 303–309.

48 Wade CM, Kulbokas EJ, Kirby AW *et al.* (2002) The mosaic structure of variation in the laboratory mouse genome. *Nature* 420, 574–578.

49 Li R, Lyons MA, Wittenburg H *et al.* (2005) Combining data from multiple inbred line crosses improves the power and resolution of quantitative trait loci mapping. *Genetics* 169, 1699–1709.

50 Cuppen E (2005) Haplotype-based genetics in mice and rats. *Trends Genet* 21, 318–322.

51 Grupe A, Germer S, Usuka J *et al.* (2001) In silico mapping of complex disease-related traits in mice. *Science* 292, 1915–1918.

52 Pletcher MT, McClurg P, Batalov S *et al.* (2004) Use of a dense single nucleotide polymorphism map for in silico mapping in the mouse. *PLoS Biol* 2, e393.

53 Hillebrandt S, Wasmuth HE, Weiskirchen R *et al.* (2005) Complement factor 5 is a quantitative trait gene that modifies liver fibrogenesis in mice and humans. *Nature Genet* 37, 835–843.

54 Dubchak I, Brudno M, Loots GG *et al.* (2000) Active conservation of noncoding sequences revealed by three-way species comparisons. *Genome Res* 10, 1304–1306.

55 Mayor C, Brudno M, Schwartz JR *et al.* (2000) VISTA: visualizing global DNA sequence alignments of arbitrary length. *Bioinformatics* 16, 1046–1047.
56 Chesler EJ, Lu L, Wang J *et al.* (2004) WebQTL: rapid exploratory analysis of gene expression and genetic networks for brain and behavior. *Nature Neurosci* 7, 485–486.
57 Chesler EJ, Lu L, Shou S *et al.* (2005) Complex trait analysis of gene expression uncovers polygenic and pleiotropic networks that modulate nervous system function. *Nature Genet* 37, 233–242.
58 Mehrabian M, Allayee H, Stockton J *et al.* (2005) Integrating genotypic and expression data in a segregating mouse population to identify 5-lipoxygenase as a susceptibility gene for obesity and bone traits. *Nature Genet* 37, 1224–1233.
59 Lee JS, Chu IS, Mikaelyan A *et al.* (2004) Application of comparative functional genomics to identify best-fit mouse models to study human cancer. *Nature Genet* 36, 1306–1311.
60 Thorgeirsson SS, Lee JS, Grisham JW (2006) Functional genomics of hepatocellular carcinoma. *Hepatology* 43, S145–S150.
61 Lee JS, Thorgeirsson SS (2005) Genetic profiling of human hepatocellular carcinoma. *Semin Liver Dis* 25, 125–132.
62 Moore KJ, Nagle DL (2000) Complex trait analysis in the mouse: the strengths, the limitations and the promise yet to come. *Annu Rev Genet* 34, 653–686.
63 Korstanje R, Paigen B (2002) From QTL to gene: the harvest begins. *Nature Genet* 31, 235–236.
64 Zhang Y, Buchholz F, Muyrers JP *et al.* (1998) A new logic for DNA engineering using recombination in *Escherichia coli*. *Nature Genet* 20, 123–128.
65 Glaser S, Anastassiadis K, Stewart AF (2005) Current issues in mouse genome engineering. *Nature Genet* 37, 1187–1193.
66 Nebert DW, Dalton TP, Stuart GW *et al.* (2000) 'Gene-swap knock-in' cassette in mice to study allelic differences in human genes. *Ann NY Acad Sci* 919, 148–170.
67 Guo RF, Ward PA (2005) Role of C5a in inflammatory responses. *Annu Rev Immunol* 23, 821–852.
68 Stryke D, Kawamoto M, Huang CC *et al.* (2003) BayGenomics: a resource of insertional mutations in mouse embryonic stem cells. *Nucleic Acids Res* 31, 278–281.
69 Schnutgen F, De-Zolt S, van Sloun P *et al.* (2005) Genomewide production of multipurpose alleles for the functional analysis of the mouse genome. *Proc Natl Acad Sci USA* 102, 7221–7226.
70 Wang X, Ria M, Kelmenson PM *et al.* (2005) Positional identification of TNFSF4, encoding OX40 ligand, as a gene that influences atherosclerosis susceptibility. *Nature Genet* 37, 365–372.
71 Aitman TJ, Dong R, Vyse TJ *et al.* (2006) Copy number polymorphism in Fcgr3 predisposes to glomerulonephritis in rats and humans. *Nature* 439, 851–855.
72 Paigen K (1995) A miracle enough: the power of mice. *Nature Med* 1, 215–220.
73 Richardson MM, Powell EE, Barrie HD *et al.* (2005) A combination of genetic polymorphisms increases the risk of progressive disease in chronic hepatitis C. *J Med Genet* 42, e45.
74 Altshuler D, Brooks LD, Chakravarti A *et al.* (2005) A haplotype map of the human genome. *Nature* 437, 1299–1320.
75 Machleder D, Ivandic B, Welch C *et al.* (1997) Complex genetic control of HDL levels in mice in response to an atherogenic diet. Coordinate regulation of HDL levels and bile acid metabolism. *J Clin Invest* 99, 1406–1419.
76 Paigen B, Schork NJ, Svenson KL *et al.* (2000) Quantitative trait loci mapping for cholesterol gallstones in AKR/J and C57L/J strains of mice. *Physiol Genomics* 4, 59–65.
77 Schwarz M, Davis DL, Vick BR *et al.* (2001) Genetic analysis of cholesterol accumulation in inbred mice. *J Lipid Res* 42, 1812–1819.
78 Rangnekar AS, Lammert F, Igolnikov A *et al.* (2006) Quantitative trait loci analysis of mice administered the methionine-choline deficient dietary model of experimental steatohepatitis. *Liver Int* 26, 1000–1005.
79 Akhtar RA, Smith AG (1998) Chromosomal linkage analysis of porphyria in mice induced by hexachlorobenzene-iron synergism: a model of sporadic porphyria cutanea tarda. *Pharmacogenetics* 8, 485–494.
80 Robinson SW, Clothier B, Akhtar RA *et al.* (2002) Non-ahr gene susceptibility loci for porphyria and liver injury induced by the interaction of 'dioxin' with iron overload in mice. *Mol Pharmacol* 61, 674–681.
81 Correa-Oliveira R, James SL, McCall D *et al.* (1986) Identification of a genetic locus, Rsm-1, controlling protective immunity against *Schistosoma mansoni*. *J Immunol* 137, 2014–2019.

3.4 Cellular cholestasis

Stefano Fiorucci

Cholestasis is defined as the impairment of normal bile flow resulting either from a functional defect at the level of the hepatocyte or from obstruction at the bile duct level [1]. Non-obstructive cholestasis can result from infections, the use of certain drugs and autoimmune, metabolic or genetic disorders. In recent years, a number of transport proteins involved in bile formation have been identified (see Chapter 16.10, Genetic cholestatic diseases). The recognition that specific gene mutations lead to progressive familial intrahepatic cholestasis has provided compelling evidence of the importance of these hepatic transporters in bile formation. Full details on inherited cholestatic disorders are described elsewhere (see Chapter 16.10). This chapter is focused on changes in hepatocellular transporter expression observed in experimental and human cholestatic conditions.

Accumulation of bile acid and bilirubin is the hallmark of cholestasis. The hepatic clearance of bile acids and bilirubin can be divided into four phases that include the following: phase 0, hepatic uptake; phase I, metabolism (e.g. hydroxylation); phase II, detoxification (e.g. conjugation); and phase III, excretion. These processes are regulated by a number of nuclear receptors (NRs) and their ligands that are the major determinants of the functional expression of genes that determine these pathways, together with enzymes that control bile acid synthesis (Tables 1 and 2).

Molecular basis of hepatobiliary transport

The main membrane transporters that primarily determine hepatic bile production are now largely characterized at the molecular level. Most of them have been cloned from both human and rodent tissues [2]. Information on the localization, nomenclature and function of hepatobiliary transporters is listed elsewhere in this book (see Chapter 2.3.6).

Table 1 The nuclear receptor superfamily.

Class I: Homodimers; steroid receptors	Class II: RXR heterodimers	Class III: Orphan homodimers	Class IV: Orphan monomers	Class V: Ligand-binding domain less
GR Glucocorticoid receptor AR Androgen receptor ER Estrogen receptor MR Mineralocorticoid receptor PR Progesterone receptor	CAR Constitutive androstane receptor FXR Farnesoid X receptor LXR Liver X receptor PPAR Peroxisomal proliferator receptor PXR Pregnane X receptor RAR Retinoic acid receptor TR Thyroid receptor VDR Vitamin D receptor	RXR Retinoid X receptor COUP-TF Chicken ovalbumin upstream promoter transcription factor HNF4 Hepatocyte nuclear factor 4	LRH-1 Liver receptor homologue 1	SHP Small heterodimer partner

Table 2 Nuclear receptors involved in the regulation of bile acid synthesis and secretion.

Nuclear receptor	Ligands	Target genes
RXRα	9-*cis* retinoic acid	Heterodimeric partner of other class II receptors[a]
RAR	All-*trans* retinoic acid	*NTCP*, *MRP2*
FXR	Bile acids	*BSEP*, *SHP*, *UGTs*, *SULTs*, *MRP2*, *MDR3*
PXR	Xenobiotics, ursodeoxycholic acid, rifampicin C	*CYP3A*, *OATP*, *MRP2*, *MRP4*, *GST*
CAR	Xenobiotics, phenobarbital	*CYP3A*, *OATP-C*, *MRP2*, *MRP4*, *UGT*, *SULTs*, *GSTs*
LXR	Oxysterols	*CYP7A*, *CYP8B*, *ABCG5/8*
SHP	None	Inhibits *CYP7A*, *CYP8B*, *NTCP*
FTF	Bile acids	*CYP7A*, *CYP7A*, *8B1*, *MRP3*
VDR	Vitamin D	*CYP3A*, *SULTs*
HNF1	None	*NTCP*, *CYP7A*

[a]See Table 1.

Sinusoidal uptake of biliary solutes

The sinusoidal membrane of hepatocytes contains several carrier proteins that facilitate entry into the liver of bile acids and other lipid-soluble organic substances, including physiological substrates (i.e. bilirubin), as well as drugs and xenobiotics. Bile salt uptake (phase 0) is mediated by Na^+-dependent and -independent mechanisms. The Na^+ taurocholate co-transporting polypeptide (NTCP) and a growing family of multispecific organic anion transporters are the major proteins involved in this step of bile formation. NTCP is exclusively expressed in the liver, strictly localized on the basolateral membrane of hepatocytes and is the predominant Na^+-dependent bile acid transporter of the hepatocyte. The NTCP transports mainly conjugated bile salts, taking advantage of the membrane-inward direction of the Na^+ gradient, which is maintained by the Na^+/K^+-ATPase of the hepatocytes [1,2].

The sinusoidal Na^+-independent transport of bile acids and organic anions is mediated by the growing family of organic anion-transporting polypeptides (OATPs). The OATPs are a family of polyspecific transporters with overlapping substrate affinity that are involved in the uptake of unconjugated bile acids. In addition, OATPs mediate the uptake of bilirubin conjugates, thyroid hormones, neutral steroids, reduced glutathione, bicarbonate and xenobiotics [2–4]. In contrast to NTCP, OATPs are expressed in extrahepatic tissues, particularly the small intestine, kidney and brain, underscoring their role in the overall disposition of amphipathic compounds. In addition, some OATPs work as bidirectional transporters at high intracellular substrate concentrations, allowing the extrusion of potentially dangerous compounds. Other transport proteins, such as the liver homologues of the kidney organic anion transporters (OATs) and polyspecific organic cation transporters (OCTs), have also been identified recently at the sinusoidal domain of hepatocytes [3].

Canalicular transport of biliary solutes

After intracellular transport, which might involve binding, sequestration, biotransformation or conjugation, endo- and xenobiotics are secreted across the canalicular membrane of the hepatocyte. This process (which provides the primary driving force for the generation of bile flow, phase III) is mediated by transporters of the ATP-binding cassette (ABC) superfamily [5]. ABC transporters present in the canalicular membrane are: (i) the bile export pump (BSEP), which mediates secretion of bile acids into the canaliculus; (ii) the multidrug-resistant associated protein 2 (MRP2), which transports anionic conjugates of many lipophilic substances and reduced glutathione; (iii) the multidrug-resistant 1 (*MDR1*) gene product, which acts as a transporter of bulky cationic compounds and steroids; and (iv) the *MDR3* gene product, which acts as a phospholipid flippase. Three additional 'half ABC transporters', which contain only six of the 12 transmembrane domains typical of ABC transporters, have been identified recently in the canalicular membrane: ABCG5 and ABCG8, which regulate cholesterol secretion, and ABCG2, which preferentially transports sulphate conjugates. The canalicular membrane also contains an anion exchanger that excretes bicarbonate into bile, and a P-type ATPase (familial intrahepatic cholestasis 1; FIC1) thought to participate in the transport of aminophospholipids from the outer to the inner leaflet of liver or biliary cell membranes.

Basolateral transport

Sinusoidal bile acids efflux (phase III) is mediated by OATPs or ABC transporters located at the basolateral membrane of hepatocytes. MRP3 and MRP4 transport, among other physiological substrates, non-sulphated and sulphated bile salts [6,7]. Although MRP3 is minimally expressed in normal livers, it is inducible. MRP4 is expressed in the liver to a greater degree and

functions as an ATP-dependent co-transporter of reduced glutathione, together with monoanionic bile acids. Given the vectorial nature of hepatobiliary transport, the export to the portal blood of compounds normally excreted into bile might serve as an alternative pathway for elimination of biliary constituents, limiting the accumulation of toxic endo- and xenobiotics when the canalicular secretory pathway is disrupted.

Hepatocellular changes in cholestatic diseases

With the exception of paediatric cholestasis or familial progressive cholestasis, where specific mutations have been identified, in cholestatic diseases, alterations in transporter expression are thought to represent a compensatory (anticholestatic) response that aims to limit hepatocellular accumulation of potentially toxic biliary constituents and provide alternative excretory routes for bile access in cholestasis [8]. Thus, cholestatic injury in rodents results in a marked reduction in mRNA and protein levels of Ntcp and other organic anion-transporting proteins (i.e. Oatp1 and Mrp2) and, to a lesser extent, of Bsep. Thus, Bsep is more stably expressed than the other transporters (Ntcp, Oatp1 and Mrp2) and might continue to excrete bile salts even under cholestatic conditions [9–14]. In contrast, expression of Mdr1 at the canalicular membrane and isoforms of Mrp (Mrp1, Mrp3 and Mrp4) at the basolateral membrane increases following cholestatic injury. In addition, Oatp isoforms, Oatp2 and Oatp4, are relatively well preserved under cholestatic conditions. The maintained expression of Oatp2 and Oatp4 might facilitate efflux of bile salts by virtue of their function as anion exchangers. Similarly, the observed upregulation of Mrp3 and Mrp4 might contribute to the secretion of sulphated bile salts, which are increased in cholestasis. Upregulation of basolateral Mrp3 might also explain the appearance of conjugated bilirubin in plasma and urine during cholestasis. Finally, under cholestatic conditions, adaptive changes in organic anion transporters also occur in the kidney, favouring the renal excretion of bile acids and other biliary constituents [14]. Expression of NTCP and OATP2, as well as BSEP and MRP2, is reduced in patients with acute inflammation-induced cholestasis, highlighting a role for proinflammatory mediators in regulating transporter expression [15]. In primary biliary cirrhosis (PBC), changes in transporter expression evolve in a stage-dependent manner. In early PBC stages, no change in bile acid or organic anion transporters is seen. With disease progression, OATP2 and NTCP are partially downregulated, whereas MRP3 and MDR1 expression is upregulated. The expression of canalicular BSEP and MRP2 is essentially unchanged [16–19].

Molecular mechanisms of regulation of hepatic transporters in cholestasis

One of the more intriguing, and increasingly appreciated, means of hepatic self-regulation in bile acid synthesis and endo-/xenobiotic transport is provided by members of the NR superfamily [20–22]. NRs are ligand-inducible transcription factors that specifically regulate the expression of target genes involved in metabolism, development and reproduction. NRs can be divided into at least five classes [23–26] (Table 1).

1 Class I ('classical' or 'steroid') receptors include those for progesterone, estrogens, androgens, glucocorticoids and mineral corticoids. Type 1 receptors are sequestered in non-productive associations with heat shock proteins and, in this state, do not influence the rate of transcription of their cognate promoters. These receptors bind to palindromic repeats in a homodimeric head-to-head arrangement only in the presence of ligand.

2 Class II includes receptors for thyroid hormone, all-*trans* retinoic acid (RAR) and vitamin D3. Unlike type 1 receptors, these receptors bind constitutively to response elements that contain direct or inverted repeats and exhibit promiscuous dimerization patterns, many involving heterodimerization with retinoid X receptor (RXR). This class could be further divided into permissive heterodimers, in which RXR ligand is able to activate transcription (e.g. peroxisome proliferator-activating receptor), and non-permissive heterodimers that require the ligand of the RXR partner receptor to activate the transcription (Table 1).

3 A third subclass contains 9-*cis* retinoic acid, orphan receptors and other receptors that form a functional unit as homodimers.

4 This class contains a nuclear orphan receptor LRH-1 (liver receptor homologue 1).

5 This class includes receptors such as SHP (small heterodimer partner), the product of a FXR–RXR responsive gene that retains the typical receptor structure but lacks the DNA-binding domain.

Several ligand-activated transcription factors and members of the NR superfamily are involved in the regulation of expression/activity of key steps in bile acid synthesis and transmembrane transport (Table 2); among these, the farnesoid X receptor (FXR), the constitutive androstane receptor (CAR) and pregnane X receptor (PXR) are the best characterized (Table 1; Fig. 1). FXR is a cellular sensor of bile acids [20,21,23,27–31]. The hydrophobic bile acid chenodeoxycholic acid (CDCA) is the most potent physiological agonist of FXR. FXR is expressed in the liver, intestine, adrenal glands and kidney, and regulates various critical steps in the enterohepatic circulation of bile acids. Upon ligation by CDCA and/or other synthetic and non-synthetic ligands, FXR complexes with RXR to increase the expression of BSEP, MDR3 and MRP2 in the liver and IBAPB (the ileal bile acid-binding protein) in the small intestine [32]. FXR also activates the transcription of the short or small heterodimeric partner (*SHP*), which in turn inhibits transcription of *CYP7A* and *CYP8B* [22,29,30,33] (Fig. 1), thereby providing feedback inhibition of bile acid synthesis. These adaptive changes mediated by FXR protect the liver from the injurious effects of the hepatic accumulation of bile acids during cholestasis. Thus, there has been considerable interest in the development of synthetic FXR agonists for the treatment of cholestatic liver disease, and several compounds have been shown to be

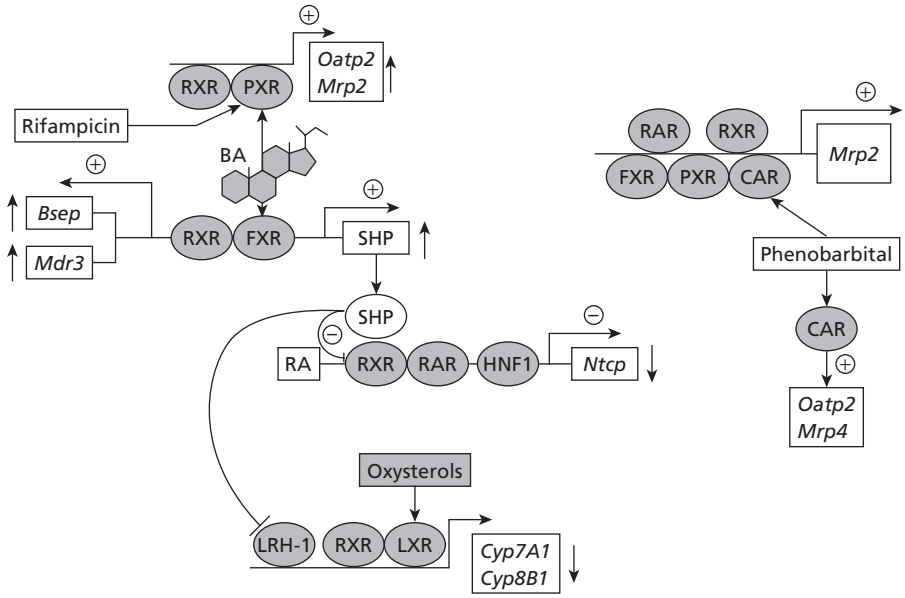

Fig. 1 Molecular mechanisms mediating the regulation of hepatocellular transporters by nuclear receptors (NRs). Left. FXR is a bile acid sensor. In the presence of increased concentrations of bile acids in hepatocytes, FXR complexes with RXR and, in its heterodimeric form, induces the expression of the SHP. In its turn, SHP inhibits the expression of Ntcp. In addition, SHP displaces LRH-1 from its binding site in the promoter of Cyp7A1 and Cyp8B1, causing a suppression of the conversion of cholesterol into bile acids. In addition, FXR activation causes a direct induction of Bsep and Mdr3. These changes lead to reduced bile acid uptake and synthesis and increased excretion through Bsep and Mdr3. Bile acids are also PXR ligands. Activation of PXR upregulates the expression of Oatp2 and Mrp2. Rifampicin is a PXR ligand. Right. Activation of Car by phenobarbital leads to upregulation of Mrp2 expression and induction of Oatp2 and Mrp4.

hepatoprotective in rat and mouse models of cholestasis [34,35]. Synthetic FXR ligands protect rats from ethinylestradiol-induced cholestasis by increasing the expression of Shp, Bsep and Mrp2 and reducing the synthesis of Cyp7a1 and Cyp8b1 as well as the expression of Ntcp [36,37]. Further emphasizing the essential role of *Fxr* in cholestasis, mice harbouring a mutated *Fxr* gene appear to be unable to upregulate Bsep and other *Fxr*-regulated events in response to feeding with cholic acid. *Fxr* null mice also develop cholesterol gallstones because of deficiency in the excretion of bile acids and phospholipids [33].

CAR, the constitutive androstane receptor, is another important nuclear receptor involved in adaptive responses to cholestasis and hyperbilirubinaemia [38]. CAR plays an important role in the detoxification of bile acids by stimulating bile acid sulphation through the activation of steroid sulphotransferases (SULT2A9). CAR also mediates the response of the liver to phenobarbital and has been shown to be an important determinant of the expression of pathways involved in bilirubin clearance including hepatic uptake by Oatp2, binding to the intracellular proteins gluthathione-*S*-transferases (A1 and 2), conjugation with glucuronide by the microsomal bilirubin uridine 5′ diphosphate-glucuronosyltransferase (UGT1A1), and excretion of bilirubin diglucuronide into bile by Mrp2. Activation of CAR in mice is necessary and sufficient to mediate resistance to the hepatotoxicity of lithocholic acid. CAR also coordinately upregulates both Sult2a1, which sulphates hydroxy-bile acids, and Mrp4. In humans, the CAR agonist phenobarbital reduces jaundice in neonates and both serum bilirubin and bile acid levels in patients with PBC [38–43].

PXR (NR112) is closely related to CAR, and both nuclear receptors coordinately regulate a similar group of genes that determine hepatic oxidative metabolism, conjugation reactions and transmembrane transport [44–46]. Examples of these genes include many of the cytochrome P-450s, the glutathione-*S*-transferases, the uridine 5′ diphosphate-glucuronosyltransferases, the sulphotransferases (*SULT*s), the *MRP*s and the *OATP*s, all of which are important in the elimination of xenobiotics and the hepatic clearance of endogenous compounds such as bile acids and bilirubin. Pxr stimulates expression of Oatp2, which is involved in bile acid and organic anion or cation transport, and Cyp3a, which is involved in bile acid hydroxylation and detoxification. Finally, another transcription factor, hepatocyte nuclear factor 1α (HNF1α), appears to play a role in mediating bile acid-induced suppression of *OATP2* [47]. Thus, changes in transporter expression during cholestasis appear to be mediated by biliary constituents, mainly bile acids acting on a set of NRs including FXR, PXR and CAR, as well as HNF1α.

Therapeutic perspectives

Ursodeoxycholic acid (UDCA) is a weak, if any, ligand for FXR but a better ligand for PXR [48]. The anticholestatic effect of UDCA is, at least in part, mediated by stimulation of transporter expression or function. UDCA stimulates vesicular exocytosis and insertion of transporters in the canalicular membrane, and increases Bsep, Mrp2, Mrp3 and Mrp4 protein levels in experimental animals and BSEP, MDR3 and MRP4 on the canalicular membrane in humans [49,50]. More recently, UDCA has also been shown to increase Cyp3a4 expression, a relevant detoxification pathway for bile acids. Other studies have found no effects of UDCA on CYP3A metabolic activity in patients with PBC [51,52]. UDCA therapy also increases the hydrophobicity of the bile acid pool and has antiapoptotic and anti-inflammatory effects that could be affecting the clinical outcome. Thus, it is not clear to what extent UDCA's beneficial effect in cholestasis relates to its properties as a NR ligand.

Rifampicin is an effective treatment for severe pruritus in the cholestatic patient and has been associated with increased

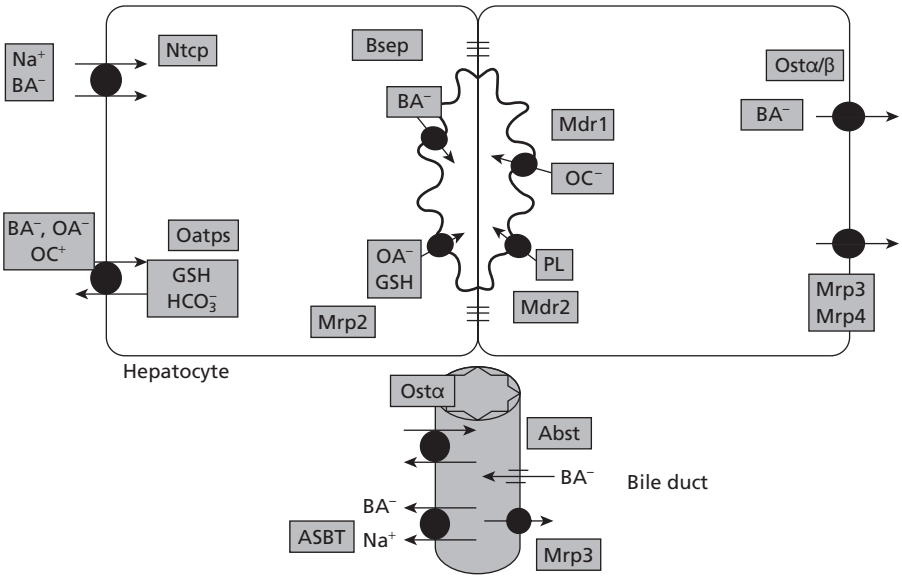

Fig. 2 Adaptive changes in hepatic transporters in rodent models of cholestasis. Animal models of obstructive cholestasis associate with changes in the expression/activity of several hepatocellular transporters. These changes represent an adaptation rather than a causative factor, but might contribute to maintain the functional disturbance observed in cholestatic disorders. Adaptive changes include reduction in expression of Ntcp and Oatp and increased expression/activity of Mrp1, Mrp3 and Mdr1. Bsep remains largely unchanged as well as Mdr2. Administration of an FXR ligand increases Bsep, Mrp2, Mrp3 and Mrp4 expression [36].

urinary excretion of bile acid glucuronides [53,54]. Rifampicin is a potent PXR ligand and increases the expression of CYP3A4, UGT1A1, MRP2, MRP3 and CYP3A metabolism in patients with PBC [44,45]. Long-term treatment of patients with PBC with rifampicin tends to decrease serum bilirubin levels and induces remission in some patients with benign recurrent intrahepatic cholestasis. The beneficial effects on pruritus have been postulated to be mediated by phase I hydroxylation reactions of the hydrophobic bile acids lithocholic and deoxycholic acid via CYP3A4 followed by glucuronidation or sulphation. Owing to complementary action, an interesting therapeutic approach would be the combination of rifampicin plus UDCA in the treatment of cholestatic disorders [50]. The ability of these two drugs to increase the expression of CYP3A4, UGT1A1 and MRP2 (rifampicin) and BSEP, MDR3 and MRP4 (UDCA) suggests that the two drugs might have additive effects [55].

In addition to FXR, CAR and PXR, other receptors such as the retinoic acid receptor, the vitamin D receptor and the glucocorticoid receptor are involved in regulating some of these pathways. Corticosteroids have been shown to stimulate expression of Bsep and Mrp2 [56] in hepatocytes and cholangiocellular transporters in cholangiocytes [57]. These effects account for the beneficial effects of corticosteroids in the treatment of cholestatic jaundice ('steroid whitewash') [57].

Gene transcriptional regulation is enormously complex, and multiple or redundant nuclear factors are almost always involved. This suggests that combinations of specific nuclear receptor ligands may be useful in maximizing the induction of gene expression. In addition, other cofactors, activators, repressors, histone acetylators and methylation reactions also influence gene transcription and may become appropriate targets in the future for therapeutic intervention with small molecules as their specific actions are defined [58].

Note

By convention, the names of human hepatobiliary transporter genes are capitalized, whereas rodent genes and their products are written in lower case with capitalization of the first letter. In addition, transporter genes are set in italics, whereas gene products are set in roman.

Another FXR-regulated bile acid transporter the organic solute transporter (OST)α/β has been identified in hepatocytes, cholangiocytes and intestinal and renal cells. Activation of this transporter increases excretion of bile acids for hepatocytes [59].

References

1 Trauner M, Boyer JL (2003) Bile salt transporters: molecular characterization, function, and regulation. *Physiol Rev* 83, 633–671.
2 Meier PJ, Stieger B (2002) Bile salt transporters. *Annu Rev Physiol* 64, 635–661.
3 Pellicciari R, Constantino C, Fiorucci S (2005) Farnesoid X receptor: from structure to potential clinical applications. *J Med Chem* 48, 5383–5403.
4 Li L, Meier PJ, Ballatori N (2000) Oatp2 mediates bidirectional organic solute transport: a role for intracellular glutathione. *Mol Pharmacol* 58, 335–340.
5 Borst P, Elferink RO (2002) Mammalian ABC transporters in health and disease. *Annu Rev Biochem* 71, 537–592.
6 König J, Rost D, Cui Y *et al.* (1999) Characterization of the human multidrug resistance protein isoform MRP3 localized to the basolateral hepatocyte membrane. *Hepatology* 29, 1156–1163.
7 Rius M, Nies AT, Hummel-Eisenbeiss *et al.* (2003) Cotransport of reduced glutathione with bile salts by MRP4 (ABCC4) localized to the basolateral hepatocyte membrane. *Hepatology* 38, 374–384.
8 Trauner M, Meier PJ, Boyer JL (1998) Molecular pathogenesis of cholestasis. *N Engl J Med* 339, 1217–1227.

9 Lee JM, Trauner M, Soroka CJ *et al.* (2000) Expression of the bile salt export pump is maintained after chronic cholestasis in the rat. *Gastroenterology* 118, 163–172.

10 Schrenk D, Gant TW, Preisegger KH *et al.* (1993) Induction of multidrug resistance gene expression during cholestasis in rats and nonhuman primates. *Hepatology* 17, 854–860.

11 Soroka CJ, Lee JM, Azzaroli F *et al.* (2001) Cellular localization and up-regulation of multidrug resistance-associated protein 3 in hepatocytes and cholangiocytes during obstructive cholestasis in rat liver. *Hepatology* 33, 783–791.

12 Pei QL, Kobayashi Y, Tanaka Y *et al.* (2002) Increased expression of multidrug resistance-associated protein 1 (mrp1) in hepatocyte basolateral membrane and renal tubular epithelia after bile duct ligation in rats. *Hepatol Res* 22, 58–64.

13 Wagner M, Fichert P, Zollner G *et al.* (2003) Role of farnesoid X receptor in determining hepatic ABC transporter expression and liver injury in bile duct-ligated mice. *Gastroenterology* 125, 825–838.

14 Lee J, Azzaroli F, Wang L *et al.* (2001) Adaptive regulation of bile salt transporters in kidney and liver in obstructive cholestasis in the rat. *Gastroenterology* 121, 1473–1484.

15 Zollner G, Fickert P, Zeng R *et al.* (2001) Hepatobiliary transporter expression in percutaneous liver biopsies of patients with cholestatic liver diseases. *Hepatology* 33, 633–646.

16 Zollner G, Fickert P, Silbert D *et al.* (2003) Adaptive changes in hepatobiliary transporter expression in primary biliary cirrhosis. *J Hepatol* 38, 717–727.

17 Wagnar M, Fickert P, Zollner G (2003) Role of farnesoid X receptor in determining hepatic ABC transporter expression and liver injury in bile duct-ligated mice. *Gastroenterology* 125, 825–838.

18 Oswald M, Kullak-Ublick GA, Paumgartner G *et al.* (2001) Expression of hepatic transporters OATP-C and MRP2 in primary sclerosing cholangitis. *Liver* 21, 247–253.

19 Kullak-Ublick GA, Beuers U, Fahney C *et al.* (1997) Identification and functional characterization of the promoter region of the human organic anion transporting polypeptide gene. *Hepatology* 26, 991–997.

20 Pellicciari R, Costantino G, Fiorucci S (2005) Farnesoid x receptor: from structure to potential clinical applications. *J Med Chem* 48, 5383–5403.

21 Parks DJ, Blanchard SG, Bledsoe RK *et al.* (1999) Bile acids: natural ligands for an orphan nuclear receptor. *Science (Wash DC)* 284, 1365–1368.

22 Seol W, Choi HS, Moore DD (1996) An orphan nuclear hormone receptor that lacks a DNA binding domain and heterodimerizes with other receptors. *Science (Wash DC)* 272, 1336–1339.

23 Kliewer SA, Lehmann JM, Willson TM (1999) Orphan nuclear receptors: shifting endocrinology into reverse. *Science* 284, 757–760.

24 Maglich JM, Sluder A, Guan X *et al.* (2001) Comparison of complete nuclear receptor sets from the human, *Caenorhabditis elegans* and *Drosophila* genomes. *Genome Biol* 2, 0029.1–0029.7.

25 Aranda A, Pascual A (2001) Nuclear hormone receptors and gene expression. *Pharm Rev* 83(1), 1269–1299.

26 Kliewer SA, Umesono K, Mangelsdorf DJ *et al.* (1992) Retinoid X receptor interacts with nuclear receptors in retinoic acid, thyroid hormone and vitamin D3 signalling. *Nature* 355, 446–449.

27 Chawla A, Repa JJ, Evans RM *et al.* (2001) Nuclear receptors and lipid physiology: opening the X-files. *Science* 294, 1866–1870.

28 Wang H, Chen J, Hollister K *et al.* (1999) Endogenous bile acids are ligands for the nuclear receptor FXR/BAR. *Mol Cell* 3, 543–553.

29 Goodwin B, Jones SA, Price RR *et al.* (2000) A regulatory cascade of the nuclear receptors FXR, SHP-1 and LRH-1 represses bile acid biosynthesis. *Mol Cell* 6, 517–526.

30 Lu TT, Makishima M, Repa JJ *et al.* (2000) Molecular basis for feedback regulation of bile acid synthesis by nuclear receptors. *Mol Cell* 6, 507–515.

31 Forman BM, Goode E, Chen J *et al.* (1995) Identification of a nuclear receptor that is activated by farnesol metabolites. *Cell* 81, 687–693.

32 Sinal CJ, Tohkin M, Miyata M *et al.* (2000) Targeted disruption of the nuclear receptor FXR/BAR impairs bile acid and lipid homeostasis. *Cell* 102, 731–744.

33 Denson LA, Sturm E, Echevarria W *et al.* (2001) The orphan nuclear receptor, shp, mediates bile acid-induced inhibition of the rat bile acid transporter, NTCP. *Gastroenterology* 121, 140–147.

34 Maloney PR, Parks DJ, Haffner CD *et al.* (2000) Identification of a chemical tool for the orphan nuclear receptor FXR. *J Med Chem* 43, 2971–2974.

35 Pellicciari R, Fiorucci S, Camaioni E *et al.* (2002) 6alpha-ethyl-chenodeoxycholic acid (6-ECDCA), a potent and selective FXR agonist endowed with anticholestatic activity. *J Med Chem* 45, 3569–3572.

36 Fiorucci S, Clerici C, Antonelli E *et al.* (2005) Protective effects of 6-ethyl chenodeoxycholic acid, a farnesoid X receptor (FXR) ligand, in estrogen induced cholestasis. *J Pharmacol Exp Ther* 313, 604–612.

37 Lu Y, Binz J, Numerick MJ *et al.* (2003) Hepatoprotection by the farnesoid X receptor agonist GW4064 in rat models of intra- and extrahepatic cholestasis. *J Clin Invest* 112, 1678–1687.

38 Kast HR, Goodwin B, Tarr PT *et al.* (2002) Regulation of multidrug resistance-associated protein 2 (ABCC2) by the nuclear receptors pregnane X receptor, farnesoid X-activated receptor, and constitutive androstane receptor. *J Biol Chem* 277, 2908–2915.

39 Saini SP, Sonoda J, Xu L *et al.* (2004) A novel constitutive androstane receptor-mediated and CYP3A-independent pathway of bile acid detoxification. *Mol Pharmacol* 65, 292–300.

40 Assem M, Schuetz EG, Leggas M *et al.* (2004) Interactions between hepatic Mrp4 and Sult2a as revealed by the constitutive androstane receptor and Mrp4 knockout mice. *J Biol Chem* 279, 22250–22257.

41 Huang W, Zhang J, Moore DD (2004) A traditional herbal medicine enhances bilirubin clearance by activating the nuclear receptor CAR. *J Clin Invest* 113, 137–143.

42 Bloomer JR, Boyer JL (1975) Phenobarbital effects in cholestatic liver disease. *Ann Intern Med* 82, 310–317.

43 Zhang J, Huang W, Qatanani M *et al.* (2004) The constitutive androstane receptor and pregnane X receptor function coordinately to prevent bile acid-induced hepatotoxicity. *J Biol Chem* 279, 49517–49522.

44 Xie W, Radominska-Pandya A, Shi Y *et al.* (2001) An essential role for nuclear receptors SXR/PXR in detoxification of cholestatic bile acids. *Proc Natl Acad Sci USA* 98, 3375–3380.

45 Staudinger L, Goodwin B, Jones SA *et al.* (2001) The nuclear receptor PXR is a lithocholic acid sensor that protects against liver toxicity. *Proc Natl Acad Sci USA* 98, 3369–3374.

46 Beigneux AP, Moser AH, Shigenaga JK *et al.* (2002) Reduction in cytochrome P-450 enzyme expression is associated with repression of CAR (constitutive androstane receptor) and PXR (pregnane X receptor) in mouse liver during the acute phase response. *Biochem Biophys Res Commun* 293, 145–149.

47 Jung D, Kullak-Ublick GA (2003) Hepatocyte nuclear factor 1 α: a key mediator of the effect of bile acids on gene expression. *Hepatology* 37, 622–631.

48 Paumgartner G, Beuers U (2002) Ursodeoxycholic acid in cholestatic liver disease: mechanisms of action and therapeutic use revisited. *Hepatology* 36, 525–531.
49 Fickert P, Zollner G, Fuchsbichler A *et al.* (2001) Effects of ursodeoxycholic and cholic acid feeding on hepatocellular transporter expression in mouse liver. *Gastroenterology* 121, 170–183.
50 Marshall HU, Wagner M, Zollner G *et al.* (2005) Complementary stimulation of hepatobiliary transport and detoxification systems by rifampicin and ursodeoxycholic acid in humans. *Gastroenterology* 129, 476–485.
51 Zollner G, Fickert P, Fuchsbichler A *et al.* (2003) Role of nuclear bile acid receptor, FXR, in adaptive ABC transporter regulation by cholic and ursodeoxycholic acid in mouse liver and kidney. *J Hepatol* 39, 628–630.
52 Dilger K, Denk A, Heeg MH *et al.* (2005) No relevant effect of ursodeoxycholic acid on cytochrome P450 3A metabolism in primary biliary cirrhosis. *Hepatology* 41, 595–602.
53 Ghent CN, Carruthers SG (1988) Treatment of pruritus in primary biliary cirrhosis with rifampin. Results of a double-blind, crossover, randomized trial. *Gastroenterology* 94, 488–493.
54 Wietholtz H, Marschall HU, Sjovall J *et al.* (1996) Stimulation of bile acid 6 alpha-hydroxylation by rifampicin. *J Hepatol* 24, 713–718.
55 Boyer JL (2005) Nuclear receptor ligands: rational and effective therapy for chronic cholestatic liver disease? *Gastroenterology* 129, 735–740.
56 Kubitz R *et al.* (1999) Regulation of the multidrug resistance protein 2 in the rat liver by lipopolysaccharide and dexamethasone. *Gastroenterology* 116, 401–410.
57 Alvaro D *et al.* (2002) Corticosteroids modulate the secretory processes of the rat intrahepatic biliary epithelium. *Gastroenterology* 122, 1058–1069.
58 Rizzo G, Renga B, Antonelli E *et al.* (2005) The methyl transferase PRMT1 functions as co-activator of farnesoid X receptor (FXR)/9-cis retinoid X receptor and regulates transcription of FXR responsive genes. *Mol Pharmacol* 68, 551–558.
59 Boyer JL, Trauner M, Mennone A *et al.* (2006) Upregulation of a basolateral FXR-dependent bile acid efflux transporter OSTalpha-OSTbeta in cholestasis in humans and rodents. *Am J Physiol Gastrointest Liver Physiol* 290: G1124–G1130.

3.5 Oncogenes and tumour suppressor genes

Dipankar Chattopadhyay and Helen Reeves

Introduction

Hepatocytes are highly differentiated cells with multiple metabolic and synthetic functions. In a normal adult, the life expectancy of a hepatocyte is more than 1 year, with little basal proliferation and only 0.01% of hepatocytes in the 'S phase' of the cell cycle at any one time [1,2]. The liver, however, is the major detoxifying organ of the body and is the first in line to be injured by ingested toxins. Accordingly, the liver has unusual properties of regeneration. Partial (70%) hepatectomy studies in rodents, in which the original liver mass can be restored within 7 days, highlight the dramatic nature of this regenerative capacity (see also Chapter 2.5). This response is complex and involves many growth factors and cytokines as well as the hormones insulin and glucagon. Neither the precise triggers of the early events nor the signals turning off the growth response are clearly understood. What is appreciated, however, is that persistent abuse of this tightly regulated proliferative response can result in failures in the control of these processes, which in turn can contribute to the development and progression of hepatocellular cancer (HCC). HCC most often occurs on a background of chronic liver injury associated with an ongoing healing response, of which perpetual hepatocyte proliferation is a key part. This, in association with the disorganized architecture that characterizes cirrhosis, provides an environment in which DNA damage is (i) most likely to occur and (ii) remain unrepaired (see also Chapter 18.2).

The architecture of the cirrhotic liver is disrupted by bands of fibrous scarring and regenerating nodules of hepatocytes. These nodules of hepatocytes lose the network of communicating venules, arterioles and bile ducts that are in close contact with the hepatic sinusoids in normal liver. As injury continues, the replication potential of hepatocytes gradually diminishes. The relative contribution of other cell types, such as hepatic progenitor cells or even bone marrow stem cells, to the restoration of liver mass increases [3]. Furthermore, cells with a growth advantage, whatever their origin, may flourish rather than be destroyed. The process of hepatocarcinogenesis is a progressive multistep one, perhaps originating from one aberrant monoclonal population of hepatocytes within a regenerative nodule, but in which a series of successive events brings about hyperplasia, followed by dysplasia, eventually followed by malignant transformation into an early and then advanced HCC [4]. Significant 'events' are the molecular changes that occur in the DNA of key growth regulatory genes that are responsible for the liver's appropriate response to injury (see Fig. 1). These genes are often called oncogenes (growth-promoting genes) or tumour suppressor genes (growth-suppressive genes). Damage to these genes can disrupt proliferative control at a number of levels, including at the cell surface receptor level (IGFR, TGFBRII), the level of cytosolic signalling cascades (Ras, Raf, β-catenin) and also within the nucleus of the cell (TP53, p16). Each of these examples is an established oncogene or a tumour suppressor gene, the dysfunction of which can contribute to the development of HCC.

Genetic instability

Cancers are characterized by disorganized and accelerated growth of immortalized abnormal cells. The key features of malignant cells, as defined by Hanahan and Weinburg in 2000 [5], include the loss of normal contact inhibition, independence towards growth and antigrowth signals, resistance to apoptosis and the development of angiogenic and metastatic capabilities. These features are acquired as a result of the progressive accumulation of genetic and epigenetic events disrupting key regulatory pathways. A 'genetic' event implies that the genomic DNA is damaged in some way – perhaps by mutation, deletion or amplification of a key gene sequence. An 'epigenetic' event is one that indirectly affects the level of expression of a gene without changing its genetic sequence, an example of this being promoter hypermethylation masking transcription factor binding sites and resulting in reduced expression. Why tumours are 'genetically unstable' is unclear. In the case of HCC, it may be that numerous genetic abnormalities occur as a result of chronic liver injury associated with oxidative stress and depleted antioxidant defences. Damage to the DNA of a single cell may escape notice as a result of overstretched repair mechanisms. If the DNA damage inactivates a proapoptotic gene or activates a

Table 1 Oncogenes involved in the development and progression of HCC.

Oncogene	Method(s) of deregulation	Consequences
Ras isoforms	Activating mutation Hypomethylation and overexpression	Sustained activation of the Ras/Raf/MAP kinase pathway resulting in inappropriate mitogenic stimulation
Cyclin D1	Activating mutation ↑ wild-type levels	Cell cycle deregulation, accelerated G1/S transition
β-catenin	Mutation resistant to degradation	Sustained activation of LEF/TCF4 mitogenic signalling
c-myc	Allelic gain Hypomethylation resulting in ↑ expression	Inappropriate mitogenic stimulation
Gankyrin	Increased expression	Blocking the activity of p53 and Rb

proliferative gene, the cell may survive inappropriately or grow more rapidly, particularly in an environment encouraging hepatocyte regeneration. This growing clone of hyperproliferative or apoptosis-resistant cells may be more prone to further DNA damage.

There is some evidence, however, that tumours may be 'genetically unstable' and prone to DNA damage at the outset [6]. The commonest type of genetic instability in HCC is chromosomal instability, or CIN. DNA mutation is generally common in genetic instability, but CIN is particularly characterized by aneuploidy/variation in chromosome number and multiple areas of allelic imbalance as a result of deletions or gains of parts of chromosomes. Regions gained in cancers may contain additional copies of oncogenes, while those deleted may contain tumour suppressor genes. Extensive demethylation in centromeric sequences is common in human cancers and may have a role in the development of aneuploidy [7], while the progressive shortening of chromosome telomeres during cell division may also contribute [8,9].

Oncogenes

Oncogenes are DNA sequences that were first discovered in transforming retroviruses. Subsequent works revealed that not only were these DNA sequences capable of inducing neoplastic transformation in mammalian cells but, moreover, they were present in human neoplastic tissues. Thus, these viral oncogenes, or 'genes that cause cancer', were initially thought to be disseminated by retroviruses. Instead, they are now known to be present in all eukaryotes. Oncogenes and their gene products show close species homology and have remained almost unchanged through evolution. Genes homologous to these retroviral genes are present in normal cells and are often termed proto-oncogenes. Proto-oncogenes play pivotal roles in regulating normal cellular growth, differentiation and development. Mechanisms for activation of proto-oncogenes to oncogenes include point mutations, gross DNA rearrangements, gene amplification and promoter insertion. A number of proto-oncogenes have been found to be inappropriately active or overexpressed in both preneoplastic and neoplastic hepatocellular lesions, as summarized in Table 1. They include genes enhancing the activity of key proliferative signalling cascades, such as the Ras/Raf/MAP kinase cascade and the Wnt pathway, as well as some downstream cell cycle regulators.

When in its active guanosine 5′-triphosphate (GTP)-bound state, the Ras protein is responsible for recruiting Raf kinase to the cell membrane and initiating the MAP kinase cascade, a key regulator of cellular proliferation. Increased activity occurs at each of level of the Ras/Raf/MAP kinase cascade in HCC. Activating mutations rendering Ras permanently in its GTP-bound state occasionally occur in HCC, while overexpression of wild-type Ras is very common [10]. Furthermore, the Ras partner, c-Raf kinase, is reportedly elevated in up to 100% of HCC and 91.2% of cirrhotic livers. The level of c-Raf overexpression is usually higher in HCC relative to cirrhotic tissues in the same individual [11]. In human HCC, increased expression of MAP kinase is also common [12]. Activated MAP kinases translocate to the nucleus and phosphorylate transcription factors, promoting the expression of proliferative genes. Overexpression of MAP kinase correlates with the increased expression of c-fos and cyclin D1, the latter promoting acceleration through the G1 checkpoint of the mammalian cell cycle. RhoB is another member of the *Ras* gene family that is overexpressed in HCC [13]. It is more associated with transformation and motility than proliferation and possibly plays a role in intrahepatic metastases of human HCC [13].

The hallmark of Wnt signalling is the stabilization of cytoplasmic β-catenin, followed by its nuclear translocation and association with LEF/TCF transcription factors. In the absence of a Wnt signal, β-catenin is phosphorylated by functional interactions with glycogen synthase kinase 3β (GSK3β), axin and the adenomatous polyposis coli (APC) protein. It is subsequently ubiquitinated and degraded via the proteosome. Inappropriate stabilization of cellular β-catenin may result in transcriptional activation of the target genes of Wnt signalling, e.g. c-*myc*, *cyclin D1* and *PPARα*, thereby mediating cellular proliferation and tumour progression. Activating mutations of β-catenin are reportedly present in 18–41% of HCC [14,15]. Mutations in

AXIN1, also necessary for efficient β-catenin degradation, are present in some HCCs and lead to β-catenin accumulation without any mutation in the β-catenin gene itself [16].

The c-myc protein is a multifunctional nuclear phosphoprotein that plays a role in cell cycle progression, apoptosis and cellular transformation. It functions as a transcription factor and is a downstream product of proliferative signalling cascades such as Wnt. The c-*myc* gene may be hypomethylated, amplified or rearranged in human HCC. It is commonly overexpressed in this cancer and has been shown to produce increased hepatocyte proliferation in an animal transgenic mouse model when coexpressed with transforming growth factor (TGF)-α [17]. Additional animal model data confirming increased expression of c-myc in diethylnitrosamine-induced murine preneoplastic foci of altered hepatocytes (FAH) suggests that its overexpression may be an early event in chemical hepatocarcinogenesis [18].

Gankyrin is a novel protein that has oncogenic properties and is overexpressed in HCC [19]. Its effects are predominantly related to its inactivation of key tumour suppressor proteins such as Rb, P16 and TP53, and it is described in more detail later in this chapter.

The mechanisms described above relate to specific genes altered by rearrangement, amplification, mutation or promoter hypomethylation. However, viral proteins disrupting proto-oncogene function also have a major role to play in HCCs arising in association with hepatitis B virus (HBV) and, to some extent, hepatitis C virus (HCV) infection. In HCC related to HBV, random integration of viral DNA into human chromosomal DNA occurs. Occasionally, this integration can interrupt the expression or function of growth-suppressive genes. Often, however, this integration enables the production of a viral protein termed HBx. The HBx protein serves the virus by promoting hepatocellular proliferation, but similarly contributes to the process of hepatocarcinogenesis. HBx activates cell signalling cascades including the MAP kinase and Janus family tyrosine kinases (JAK)/signal transducer and activators of transcription (STAT) pathways [20]. It acts as a cotranscription factor for oncogenic proteins such as c-myc, c-jun and c-fos or Ras [21]. The HBx protein may also promote cell survival by interaction with the Wnt pathway. It suppresses GSK3β activity, thereby inhibiting both β-catenin phosphorylation and its subsequent degradation. Furthermore, HBx influences the activity of Src kinase [22], a tyrosine kinase that also contributes to β-catenin localization and activity [23]. In cancers relating to HCV infection, the HCV core protein may contribute to cancer development. It promotes apoptosis resistance by interacting with several intracellular pathways, including indirect enhancement of NFκB activity [24] and inhibition of tumour necrosis factor (TNF)-induced and *Fas*-mediated apoptosis [25].

Tumour suppressor genes

The normal function of a tumour suppressor gene (TSG) is to inhibit cellular proliferation. Unlike oncogenes, they are 'recessive', as loss of function of both alleles is considered necessary to generate a mutant phenotype. The most extensively studied TSG is *TP53*, one allele of which is already mutated in the germline in the inherited Li–Fraumeni syndrome associated with the development of multiple cancers. HCC, like the majority of cancers, is most often sporadic in nature, therefore requiring both alleles to 'acquire' rather than inherit a means of inactivation. Methods of TSG inactivation/silencing include allelic loss, mutation, promoter hypermethylation and aberrant alternative splicing. While much is known about *TP53* in HCC, other TSGs include the retinoblastoma gene (*Rb*) and the cell cycle inhibitors *p16*, *p21* and *p27*. These and others have been reviewed recently [10] and are summarized in Table 2.

TP53 is located on chromosome 17p13 and encodes a nuclear protein that is involved in several cellular functions including the regulation of G1 to S transition in the cell cycle, DNA repair and apoptotic cell death. In a normal cell, the half-life of TP53 is short. However, in the presence of DNA damage caused by a carcinogen or UV light, for example, it is produced in increased amounts, becomes more stable as a result of inhibition of degradation and induces either a growth arrest or apoptosis depending on the extent of DNA damage. TP53 is therefore regarded as a gatekeeper for cellular proofreading in response to many stress signals, including DNA damage. As the DNA repair network plays a key role in faithful maintenance of the genome, abrogation of TP53 function is detrimental and potentiates increased genome instability, cancer development and progression. A reduction in wild-type TP53 function in HCC can occur as a result of an inactivating point mutation, reduced expression as a result of promoter hypermethylation or loss of an allele of *TP53*, and also as a result of interference from other cellular or viral proteins.

Although mutation of *TP53* is common in HCC, both the incidence and the specific nucleotide base changes vary with different geographical regions. The presence of a unique mutational spectrum of *TP53* has provided a strong molecular link between carcinogen exposure and HCC development. In South Africa and the Qidong area of China, a significant number of HCCs have a *TP53* R249S mutation [26,27]. This 'hotspot' mutation is associated with the high intake of aflatoxin 1 in food and may have contributed to the high incidence of HCC in theses areas [28]. In other regions where aflatoxin levels in food are low or undetectable, no such mutational specificity of the *TP53* gene has been detected.

Both host and non-host proteins can contribute to TP53 inactivation in HCC. MDM2 is a cellular protein transcriptionally activated by TP53, which in turn inhibits TP53 activity as part of a negative autoregulatory feedback loop. MDM2 inhibits the nuclear localization of TP53, inhibits the transactivation function of TP53, but also promotes its degradation. MDM2 is a ligase that promotes the ubiquitination and subsequent proteosomal destruction of TP53. Although numbers of studies on MDM2 in HCC are small, there is accumulating evidence indicating overexpression of MDM2 in this cancer, providing yet

Table 2 Tumour suppressor genes (TSG) involved in the development and progression of HCC.

TSG	Method(s) of deregulation	Consequences
P53 growth-suppressive transcription factor	Mutation and accumulation of inactive protein (28–67%) Allelic loss of 17p13 and loss of expression (17–70%)	Loss of induction of key growth-suppressive genes (*p21*, *GADD45*), apoptosis resistance secondary to disrupted targets (Bax, PIDD, NOXA, PERP, reactive oxygen species), loss of prevention of new blood vessel formation (TSP1, BAI1, Maspin, GD-AIF)
IGFR2 growth-inhibitory tyrosine kinase receptor	Inactivating mutation (25%) Allelic loss of 6q26 (23–36%)	Associated with ↑ IGF2 (hepatocyte mitogen) and ↓ TGF-β (growth inhibitor) signalling (early event)
Rb retinoblastoma protein	Inactivating mutation (15%) Allelic loss of 13q14 (18–70%)	E2F release and stimulation of G1/S cell cycle progression (early event)
PTEN	Inactivating mutation (4%) Allelic loss of 10q23 (17–27%)	Disrupts PI3 kinase/MTOR pathway. Associated with ↓ IGF secretion and ↓ VEGF expression (possibly a late event)
AXIN	Inactivating mutation (6%) Allelic loss of 16p13 (22–40%)	β-catenin accumulation, therefore loss of suppression of β-catenin-stimulated LEF/TCF4 mitogenic signalling
p16 CKI inhibitor	Allelic loss of 9p21 (20–30%) Promoter of hypermethylation	Loss of cyclin-dependent kinase inhibitor function, accelerated cell cycle progression; defective response to DNA damage
E-cadherin	Allelic loss of 16q22 (26–54%) Promoter of hypermethylation	Decreased degradation of β-catenin
RASSF1 ras association domain family protein	Allelic loss of 3p21 (62%) Promoter of hypermethylation	Loss of Ras-regulated proapoptosis, loss of inhibition of cyclin D1 accumulation
BRCA2	Allelic loss of 13q12 (18–19%) Promoter of hypermethylation Occasional germline mutation	Defect in DNA repair of double-strand breaks leading to impaired genomic integrity and cell cycle control
RIZ1 Rb interacting zinc finger protein transcription factor	Allelic loss of 1p36 (26–46%)	Loss results in inhibition of G2/M and accelerated cell cycle progression; loss of induction of apoptosis
KLF6	Allelic loss of 10p15 (40%) Inactivating mutation (0–10%)	Loss promotes proliferation, possibly as a result of lack of upregulation of cell cycle inhibitor p21

IGF, insulin-like growth factor; MTOR, mammalian target of rapamycin; VEGF, vascular endothelial growth factor.

more means of inactivating TP53 in circumstances when it is both wild type and its expression retained [29,30].

In HCC secondary to HBV infection, the presence of the HBx protein can interfere with tumour suppressor functions. The HBx protein can inhibit *TP53* sequence-specific transcriptional activation [31], TP53-mediated apoptosis [32], as well as TP53 binding to transcription-nucleotide excision repair (NER) factors, such as XPB [33]. HCV proteins may also contribute. HCV is an RNA virus, and its genome contains an open reading frame encoding a large polyprotein precursor that is then processed by a combination of cellular and viral proteases into three or four structural and at least six non-structural proteins. HCV NS5A is a non-structural protein that possibly plays a role in the development of chronic liver disease and HCC [34]. It reportedly forms complexes with TP53, repressing TP53 transactivation function by disrupting its normal DNA binding. The HCV core protein may also repress the transcriptional activity of the *TP53* promoter and is a further possible mechanism of abrogating the activity of TP53 in HCV-induced HCC [35].

The retinoblastoma susceptibility (*Rb*) gene is another TSG whose dysfunction is known to contribute to hepatocarcinogenesis. The Rb protein is a core element governing cell cycle progression. Essentially, Rb controls the cell cycle at the G1/S boundary, restricting release of the E2F transcription factor [36] by virtue of its own cyclical phosphorylation. The activity or phosphostatus of Rb depends on the activity of the cyclin-dependent kinase, CDK4, which in turn depends on interactions with agonists such as cyclin D1 and inhibitors such as P16INK4. Overall, the Rb pathway is inactivated in a number of human HCC cell lines [37] and in the majority of HCCs [38]. Cyclin D1/CDK4 phosphorylates and inactivates Rb, and mechanisms contributing to Rb inactivation in HCC include cyclin D1 overexpression [39] as well as overactivity of CDK4 as a result of reduced expression of the Cdk4 inhibitor p16INK4 [40]. Viral proteins may also alter Rb activity. HCV core protein reportedly decreases the expression of Rb, thus allowing E2F to be constitutively active, possibly promoting rapid cell proliferation [41].

Gankyrin, as mentioned previously, has been cloned by cDNA subtractive hybridization in HCC [19] and can be identified by

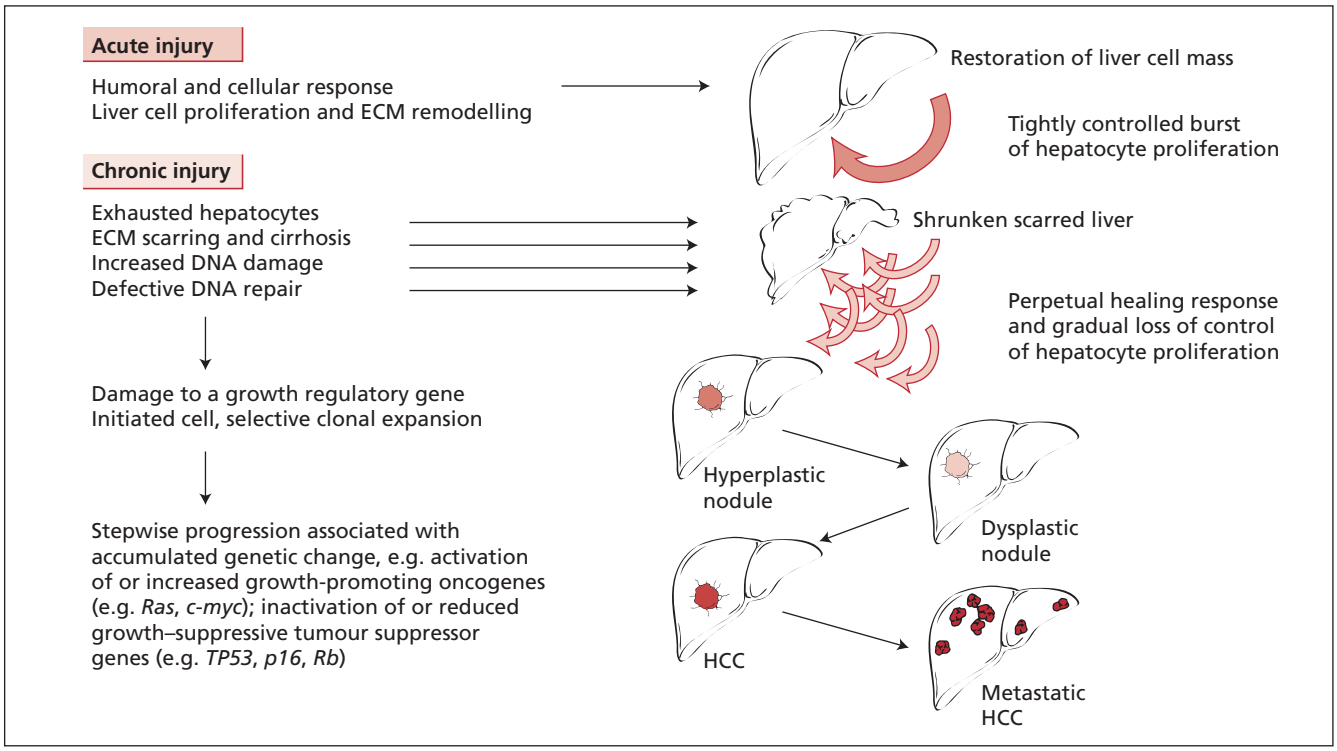

Fig. 1 The development and progression of HCC is associated with accumulated genetic change. The closely regulated burst of hepatocyte proliferation that occurs in response to acute liver injury is represented, as are the events that occur in response to persistent injury. The wound healing myofibroblast response creates a scarred distorted liver within which hepatocytes continue to regenerate, creating nodules of cells that lack the structural organization of normal liver plates and sinusoids. Within this abnormal environment, a combination of depleted defences against DNA damage, failing DNA repair mechanisms and exhausted hepatocyte replication potential permits cells that gain a proliferative advantage to survive and expand. The stepwise progression of phenotypically abnormal hepatocytes, from hyperplastic to dysplastic to early and, finally, advanced HCCs, is associated with accumulated genetic or molecular events. In particular, these events include DNA damage enhancing the activities of growth-promoting oncogenes and inactivating the growth-suppressive effects of tumour suppressor genes. The result of accumulated damage is accelerated growth of increasingly abnormal cells and the progression of HCC.
ECM, extracellular matrix.

in situ examination as a highly expressed oncoprotein in HCC [42]. During hepatic carcinogenesis, gankyrin promotes the release of E2F activity as a result of binding Rb directly and bringing about its phosphorylation and inactivation [42]. Gankyrin also promotes CDK4 phosphorylation of Rb by competing with the tumour suppressor P16INK4 in its binding and inhibition of CDK4 [43]. In addition, gankyrin suppresses the activity of TP53. It interacts with MDM2, the key TP53 ubiquitin ligase, promoting the proteosomal degradation of TP53 [44]. Thus, gankyrin overexpression is common and highly disruptive in HCC. Devising a means of destroying it may prove valuable therapeutically in the years to come.

DLC1 (deleted in liver cancer 1) is a putative TSG first reported by Yuan *et al.* in 1998 [45]. A recent *in vitro* study has confirmed DLC1 as a Rho GTPase activating protein (Rho GAP) [46]. In mammalian cells, Rho GAPs are important regulators in the switching between active GTP-bound and inactive guanosine 5′-diphosphate (GDP)-bound Rho proteins. They stimulate the intrinsic GTPase activity of Rho proteins and catalyse their conversion into the inactive GDP state. This attenuates the signal-transducing activities of Rho proteins, and Rho GAPs therefore act as negative regulators. The loss of activity of such a negative modulator may therefore confer a proliferative advantage to a cell. Deletion of the *DLC1* gene is present in a subset of hepatoma cell lines and primary HCCs [47], and it is likely that epigenetic alterations also contribute to its inactivation in primary HCC [46]. Restoration of DLC1 expression can inhibit the proliferation of hepatoma cells [47], promote caspase-3-mediated apoptosis and inhibit invasiveness *in vitro*, as well as contribute to a reduction in the ability of the cells to form tumours in athymic nude mice [48].

A number of other candidate tumour suppressor genes have been proposed in HCC, one of the most recent of which is Kruppel-like factor 6 (*KLF6*). KLF6, a ubiquitously expressed transcription factor, has been identified as a TSG inactivated by allelic loss and mutation in a number of cancers, including HCC [49]. While work to characterize the biology of this and other candidate TSGs and oncogenes continues, we recognize that there are likely to be many more unknown genetic or biological events taking place. However, there is hope that, with continued effort, we will eventually understand enough about these processes to start to make a difference to the way in which we

manage this common, dismal malignancy. Presently, although we know that HCC most often occurs in individuals with cirrhotic liver disease, we have neither the accurate safe methods nor the means to identify individuals with cirrhosis within our population, let alone identify those with HCC. Understanding the molecular pathogenesis of these conditions will help us to identify both the biomarkers of the future, for use as more sensitive and less invasive diagnostic and prognostic tests, as well as, hopefully, the means to restore the control of regulated hepatocyte growth. In this way, we would hope not only to detect early malignant disease in at-risk individuals and treat it more effectively, but possibly even to prevent its development and/or progression.

References

1 Diehl AM, Rai R (1996) Review: regulation of liver regeneration by pro-inflammatory cytokines. *J Gastroenterol Hepatol* 11 (5), 466–470.

2 Michalopoulos GK, DeFrances MC (1997) Liver regeneration. *Science* 276 (5309), 60–66.

3 Forbes F, Alison M (2005) Liver stem cells in persistent viral infection, liver regeneration and cancer. In: Thomas H, Lemon S, Zuckerman A (eds) *Viral Hepatitis*, 3rd edn. Oxford: Blackwell Publishing.

4 Coleman WB (2003) Mechanisms of human hepatocarcinogenesis. *Curr Mol Med* 3 (6), 573–588.

5 Hanahan D, Weinberg RA (2000) The hallmarks of cancer. *Cell* 100 (1), 57–70.

6 Cahill DP, Kinzler KW, Vogelstein B *et al.* (1999) Genetic instability and Darwinian selection in tumours. *Trends Cell Biol* 9 (12), M57–60.

7 Esteller M (2003) Cancer epigenetics: DNA methylation and chromatin alterations in human cancer. *Adv Exp Med Biol* 532, 39–49.

8 Plentz RR, Schlegelberger B, Flemming P *et al.* (2005) Telomere shortening correlates with increasing aneuploidy of chromosome 8 in human hepatocellular carcinoma. *Hepatology* 42 (3), 522–526.

9 Satyanarayana A, Manns MP, Rudolph KL (2004) Telomeres and telomerase: a dual role in hepatocarcinogenesis. *Hepatology* 40 (2), 276–283.

10 Kremer-Tal S, Day CP, Reeves HL (2005) The genetic basis of hepatocellular cancer. In: Ali S, Mann DM, Friedman SL (eds) *Liver Diseases: Biochemical Mechanisms and New Therapeutic Insights*. Enfield, NH: Science Publishers.

11 Hwang YH, Choi JY, Kim S *et al.* (2004) Over-expression of c-raf-1 proto-oncogene in liver cirrhosis and hepatocellular carcinoma. *Hepatol Res* 29 (2), 113–121.

12 Huynh H, Nguyen TT, Chow KH *et al.* (2003) Over-expression of the mitogen-activated protein kinase (MAPK) kinase (MEK)-MAPK in hepatocellular carcinoma: its role in tumor progression and apoptosis. *BMC Gastroenterol* 3 (1), 19.

13 Genda T, Sakamoto M, Ichida T *et al.* (1999) Cell motility mediated by rho and Rho-associated protein kinase plays a critical role in intrahepatic metastasis of human hepatocellular carcinoma. *Hepatology* 30 (4), 1027–1036.

14 de La Coste A, Romagnolo B, Billuart P *et al.* (1998) Somatic mutations of the beta-catenin gene are frequent in mouse and human hepatocellular carcinomas. *Proc Natl Acad Sci USA* 95 (15), 8847–8851.

15 Miyoshi Y, Iwao K, Nagasawa Y *et al.* (1998) Activation of the beta-catenin gene in primary hepatocellular carcinomas by somatic alterations involving exon 3. *Cancer Res* 58 (12), 2524–2527.

16 Satoh S, Daigo Y, Furukawa Y *et al.* (2000) AXIN1 mutations in hepatocellular carcinomas, and growth suppression in cancer cells by virus-mediated transfer of AXIN1. *Nature Genet* 24 (3), 245–250.

17 Murakami H, Sanderson ND, Nagy P *et al.* (1993) Transgenic mouse model for synergistic effects of nuclear oncogenes and growth factors in tumorigenesis: interaction of c-myc and transforming growth factor alpha in hepatic oncogenesis. *Cancer Res* 53 (8), 1719–1723.

18 Alexandre K, Jacobovitz D, Galand P (1990) Immunohistochemical detection of c-myc and c-erbA products in diethylnitrosamine-induced preneoplastic and neoplastic liver lesions in rats. *Carcinogenesis* 11 (7), 1189–1194.

19 Higashitsuji H, Itoh K, Nagao T *et al.* (2000) Reduced stability of retinoblastoma protein by gankyrin, an oncogenic ankyrin-repeat protein overexpressed in hepatomas. *Nature Med* 6 (1), 96–99.

20 Arbuthnot P, Capovilla A, Kew M (2000) Putative role of hepatitis B virus X protein in hepatocarcinogenesis: effects on apoptosis, DNA repair, mitogen-activated protein kinase and JAK/STAT pathways. *J Gastroenterol Hepatol* 15 (4), 357–368.

21 Natoli G, Avantaggiati ML, Chirillo P *et al.* (1994) Induction of the DNA-binding activity of c-jun/c-fos heterodimers by the hepatitis B virus transactivator pX. *Mol Cell Biol* 14 (2), 989–998.

22 Bouchard MJ, Wang LH, Schneider RJ (2001) Calcium signaling by HBx protein in hepatitis B virus DNA replication. *Science* 294 (5550), 2376–2378.

23 Muller T, Choidas A, Reichmann E *et al.* (1999) Phosphorylation and free pool of beta-catenin are regulated by tyrosine kinases and tyrosine phosphatases during epithelial cell migration. *J Biol Chem* 274 (15), 10173–10183.

24 You LR, Chen CM, Lee YH (1999) Hepatitis C virus core protein enhances NF-kappaB signal pathway triggering by lymphotoxin-beta receptor ligand and tumor necrosis factor alpha. *J Virol* 73 (2), 1672–1681.

25 Marusawa H, Hijikata M, Chiba T *et al.* (1999) Hepatitis C virus core protein inhibits Fas- and tumor necrosis factor alpha-mediated apoptosis via NF-kappaB activation. *J Virol* 73 (6), 4713–4720.

26 Bressac B, Kew M, Wands J *et al.* (1991) Selective G to T mutations of p53 gene in hepatocellular carcinoma from southern Africa. *Nature* 350 (6317), 429–431.

27 Aguilar F, Hussain SP, Cerutti P (1993) Aflatoxin B1 induces the transversion of G→T in codon 249 of the p53 tumor suppressor gene in human hepatocytes. *Proc Natl Acad Sci USA* 90 (18), 8586–8590.

28 Hsu IC, Metcalf RA, Sun T *et al.* (1991) Mutational hotspot in the p53 gene in human hepatocellular carcinomas. *Nature* 350 (6317), 427–428.

29 Jablkowski M, Bocian A, Bialkowska J *et al.* (2005) A comparative study of P53/MDM2 genes alterations and P53/MDM2 proteins immunoreactivity in liver cirrhosis and hepatocellular carcinoma. *J Exp Clin Cancer Res* 24 (1), 117–125.

30 Luo YL, Cheng RX, Feng DY (2001) [Role of functional inactivation of p53 from MDM2 overexpression in hepatocarcinogenesis]. *Hunan Yi Ke Da Xue Xue Bao* 26 (1), 13–16.

31 Wang XW, Forrester K, Yeh H *et al.* (1994) Hepatitis B virus X protein inhibits p53 sequence-specific DNA binding, transcriptional activity, and association with transcription factor ERCC3. *Proc Natl Acad Sci USA* 91 (6), 2230–2234.

32 Wang XW, Gibson MK, Vermeulen W *et al.* (1995) Abrogation of p53-induced apoptosis by the hepatitis B virus X gene. *Cancer Res* 55 (24), 6012–6016.

33 Jia L, Wang XW, Harris CC (1999) Hepatitis B virus X protein inhibits nucleotide excision repair. *Int J Cancer* 80 (6), 875–879.

34 Gong GZ, Jiang YF, He Y *et al.* (2004) HCV NS5A abrogates p53 protein function by interfering with p53-DNA binding. *World J Gastroenterol* 10 (15), 2223–2227.
35 Ray RB, Steele R, Meyer K *et al.* (1997) Transcriptional repression of p53 promoter by hepatitis C virus core protein. *J Biol Chem* 272 (17), 10983–10986.
36 Muller H, Helin K (2000) The E2F transcription factors: key regulators of cell proliferation. *Biochim Biophys Acta* 1470 (1), M1–12.
37 Suh SI, Pyun HY, Cho JW *et al.* (2000) 5-Aza-2′-deoxycytidine leads to down-regulation of aberrant p16INK4A RNA transcripts and restores the functional retinoblastoma protein pathway in hepatocellular carcinoma cell lines. *Cancer Lett* 160 (1), 81–88.
38 Azechi H, Nishida N, Fukuda Y *et al.* (2001) Disruption of the p16/cyclin D1/retinoblastoma protein pathway in the majority of human hepatocellular carcinomas. *Oncology* 60 (4), 346–354.
39 Joo M, Kang YK, Kim MR *et al.* (2001) Cyclin D1 overexpression in hepatocellular carcinoma. *Liver* 21 (2), 89–95.
40 Hui AM, Sakamoto M, Kanai Y *et al.* (1996) Inactivation of p16INK4 in hepatocellular carcinoma. *Hepatology* 24 (3), 575–579.
41 Cho JW, Baek WK, Suh SI *et al.* (2001) Hepatitis C virus core protein promotes cell proliferation through the upregulation of cyclin E expression levels. *Liver* 21 (2), 137–142.
42 Tan L, Fu XY, Liu SQ *et al.* (2005) Expression of p28GANK and its correlation with RB in human hepatocellular carcinoma. *Liver Int* 25 (3), 667–676.
43 Lozano G, Zambetti GP (2005) Gankyrin: an intriguing name for a novel regulator of p53 and RB. *Cancer Cell* 8 (1), 3–4.
44 Higashitsuji H, Itoh K, Sakurai T *et al.* (2005) The oncoprotein gankyrin binds to MDM2/HDM2, enhancing ubiquitylation and degradation of p53. *Cancer Cell* 8 (1), 75–87.
45 Yuan BZ, Miller MJ, Keck CL *et al.* (1998) Cloning, characterization, and chromosomal localization of a gene frequently deleted in human liver cancer (DLC-1) homologous to rat RhoGAP. *Cancer Res* 58 (10), 2196–2199.
46 Wong CM, Lee JM, Ching YP *et al.* (2003) Genetic and epigenetic alterations of DLC-1 gene in hepatocellular carcinoma. *Cancer Res* 63 (22), 7646–7651.
47 Ng IO, Liang ZD, Cao L *et al.* (2000) DLC-1 is deleted in primary hepatocellular carcinoma and exerts inhibitory effects on the proliferation of hepatoma cell lines with deleted DLC-1. *Cancer Res* 60 (23), 6581–6584.
48 Zhou X, Thorgeirsson SS, Popescu NC (2004) Restoration of DLC-1 gene expression induces apoptosis and inhibits both cell growth and tumorigenicity in human hepatocellular carcinoma cells. *Oncogene* 23 (6), 1308–1313.
49 Kremer-Tal S, Reeves HL, Narla G *et al.* (2004) Frequent inactivation of the tumor suppressor Kruppel-like factor 6 (KLF6) in hepatocellular carcinoma. *Hepatology* 40 (5), 1047–1052.

3.6 Genomics, gene arrays and proteomics in the study of liver disease

Geoffrey W. McCaughan, Nicholas A. Shackel, Rohan Williams, Devanshi Seth, Paul S. Haber and Mark D. Gorrell

The completed sequencing of the human genome in the year 2000 revealed that it encoded approximately 30 000 genes [1]. The functions of approximately 50% of these genes have been defined or proposed, leaving at least half the human genome with unrecognized functions. It has been estimated that these 30 000 genes encode approximately 100 000 proteins (produced predominantly by alternative splicing) [2]. Consequently, the human proteome consists of approximately 100 000 proteins/polypeptides. This enormous wealth of information has led to an explosion of studies that have characterized disease or pathophysiological states based on sampling of the human genome or proteome. This chapter reviews the emerging data from such studies related to the examination of liver diseases and liver pathobiology.

Terminology

Functional genomics

Functional genomics is the study of gene function through the utilization of high-throughput technologies, in addition to the information obtained by gene sequencing and mutation analysis (Fig. 1). Since these technologies have become available in the last 10 years, an insurmountable volume of data has been generated. It is a challenge to sift through these data and to extract meaningful information. It has been aptly put by Duyk that 'we must guard against committing the mortal sin of genomics by confusing throughput with output, which too often blurs the distinction between data and knowledge. Instead, we must

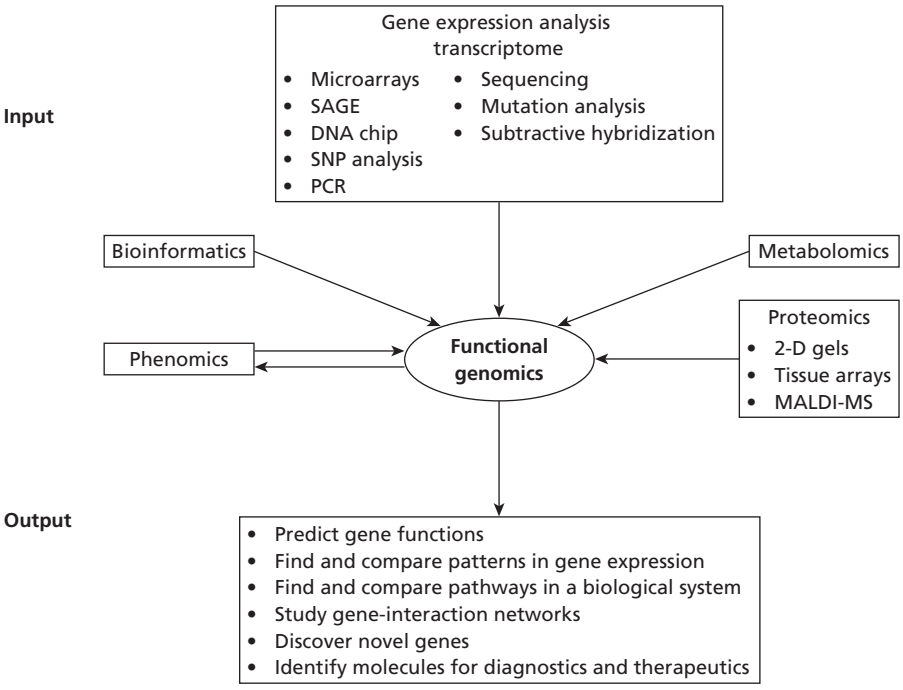

Fig. 1 Overview of functional genomics methodologies. This figure depicts a number of approaches and techniques that generate a plethora of information within a cell or organism with which to study functional genomics. A comprehensive understanding of this information with respect to functioning of genes, transcripts and proteins is essential to build functional maps of their interactions and discover novel diagnostic and therapeutic targets. The rapid development of such high-throughput technologies is no doubt building an unprecedented understanding of functional genomics in all organisms.

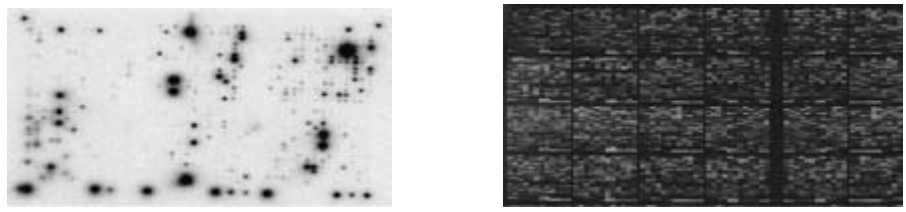

(a) (b)

Fig. 2 Gene array examples showing two examples of the common types of gene array. (a) One-probe gene array, in this case using a radionucleotide probe hybridized to a nylon membrane spotted with cDNAs. Affymetrix GeneChip™ is another example of a single-probe experiment but uses a completely different high-density array and a fluorophore labelled probe. (b) Comparative hybridization (multiplexing) using two probes labelled with Cy3 and Cy5 fluorophores on a glass slide microarray.

maintain the necessary focus to achieve an ever-more operational understanding of all the molecular components and the interactions that define a cell or an organism' [3].

Gene arrays

Gene arrays are tools used to simultaneously display expression profiles of thousands of genes with the aim of comparing the patterns of gene expression (profiles) of whole organisms, disease states or other aspects of pathophysiology. The technology involves high-density spotting of gene-specific DNA sequences arrayed in predetermined coordinates on a solid matrix, followed by probing with labelled RNA/DNA samples to interrogate the expression of the arrayed genes in these samples (Fig. 2). Currently, there are in excess of 235 companies that are actively involved in developing microarray technology. A recent report in *Nature* presents a list of companies and technologies that encompasses a wide range of gene array platforms including single nucleotide polymorphisms (SNP), whole genome genotyping, microRNA chips and specialized bioinformatics software in addition to platforms for expression profiling (http://www.nature.com.opac.library.usyd.edu.au/nature/journal/v435/n7044/pdf/435995a.pdf).

The gene expression profile defined by gene arrays has been called a 'transcriptome'. The liver transcriptome from adult humans has been studied using cDNA arrays in recent years [4]. A comprehensive summary of the liver transcriptome defined by different gene array technologies was reviewed recently [5]. Gene arrays are discussed in detail in later sections.

Proteomics

Proteomics is the global analysis of protein expression in a cell, tissue or body fluid to determine the function, interaction and importance in different environments and conditions, such as health and disease. Various techniques, for example two-dimensional electrophoresis, mass spectrophotometry (MS), matrix assisted laser desorption/ionization (MALDI), electrospray ionization (ESI), tissue arrays and antibody arrays, have progressed rapidly in proteomics in recent years. Proteomics is discussed in detail in later sections.

Bioinformatics

Bioinformatics refers to the use of mathematical, statistical and computational techniques to collect, analyse and store large quantities of data from biological systems. Bioinformatics includes programmes that allow normalization of data, calculate statistical significance of gene/protein expression levels and allocate gene function through data mining. Bioinformatics can handle large data sets by means of specially derived algorithms for various functions, including identification of differential gene expression, molecular pathways and gene/protein networks. Several open source and commercial bioinformatics software packages are available for high-throughput data analysis. For more information on bioinformatics tools, see later sections.

Methodologies

Gene arrays

There are a variety of gene arrays available as 'off-the-shelf' products. These include arrays covering the whole genome and specialized arrays that sample select gene expression. The basic principle involved in each is to immobilize small fragments of DNA for hundreds to thousands of genes in a grid format. Regardless of the chemistry involved in preparing the microarrays, the multiple steps involved remain similar (Fig. 3).

Microarray reproducibility within and between laboratories and across platforms has been a major issue in dealing with generated data [6]. As with other molecular biology techniques, variability is introduced at each step. This includes the variability introduced at the time of printing and the lack of standardized approaches in handling array platforms across laboratories. Variability introduced at each step is compounded, and successive sources of experimental errors are amplified, as the experiment proceeds (Figs 3 and 4).

New methodologies can minimize experimental variability at the time of performing microarray experiments. Variability can be dealt with at the time of normalization and analysis using statistical packages designed specifically to address such issues. To reduce disparities and to reproduce microarray data across laboratories, 'minimal information about a microarray

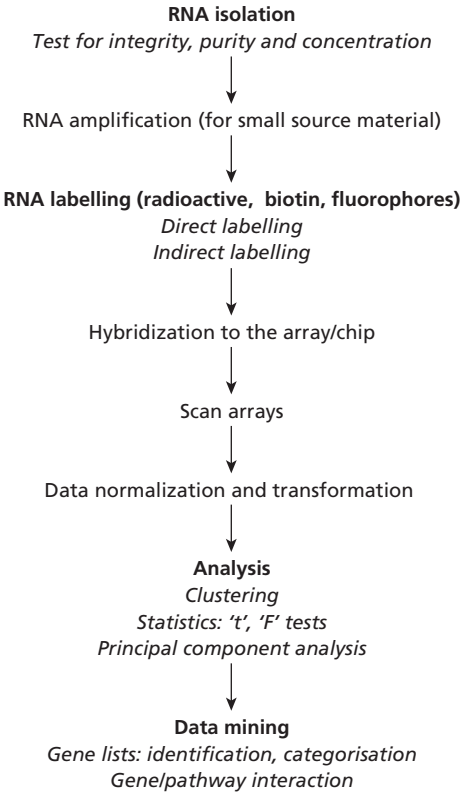

Fig. 3 Microarray experimental outline. A flowchart of the steps involved in a microarray experiment. The importance of proper RNA isolation and ensuring good quality RNA is used is critical.

experiment' (MIAME) guidelines set standards to facilitate the publication of microarray data. Conforming to MIAME-compliant protocols (http://www.mged.org/Workgroups/MIAME/miame.html) should ensure the quality and reproducibility of the data. Recent articles [7,8] suggest that robust and reproducible microarray results can be obtained across platforms as well as laboratories, provided the experimental and analytical methods are standardized.

Experimental design

Experimental design is clearly an important step in microarray analysis (Fig. 5). Underlying every successful microarray experi-

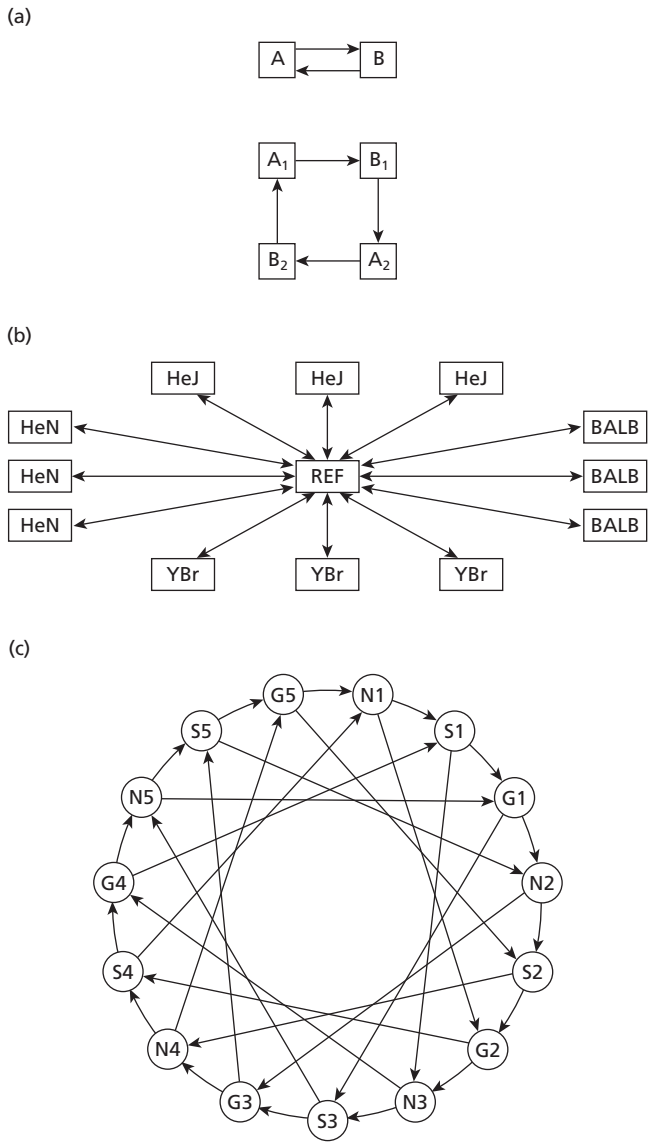

Fig. 5 Microarray experimental design. Experimental design in microarray experiments is a fundamental and often overlooked aspect. The experimental design can take many forms: (a) simple pairwise comparisons on two samples or sequential pairwise comparisons of multiple samples; (b) comparison of multiple samples to a common reference; or (c) cross comparison of all samples to each other in an experiment.

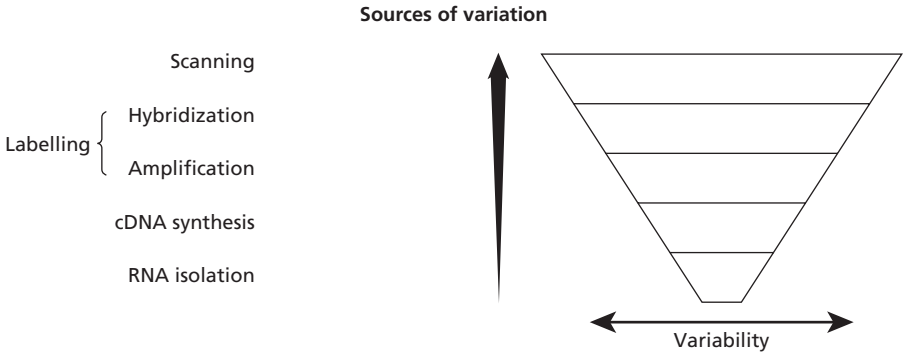

Fig. 4 Gene array experimental variation. A graphical depiction of the increasing variation in gene array experiments. Variability can be biological or technical. Importantly, technical error can be amplified at each step leading to uninterpretable or widely varying results. Minimizing methodological variation is a principal goal of gene array analysis to enable discrimination between individual and disease phenotype differences.

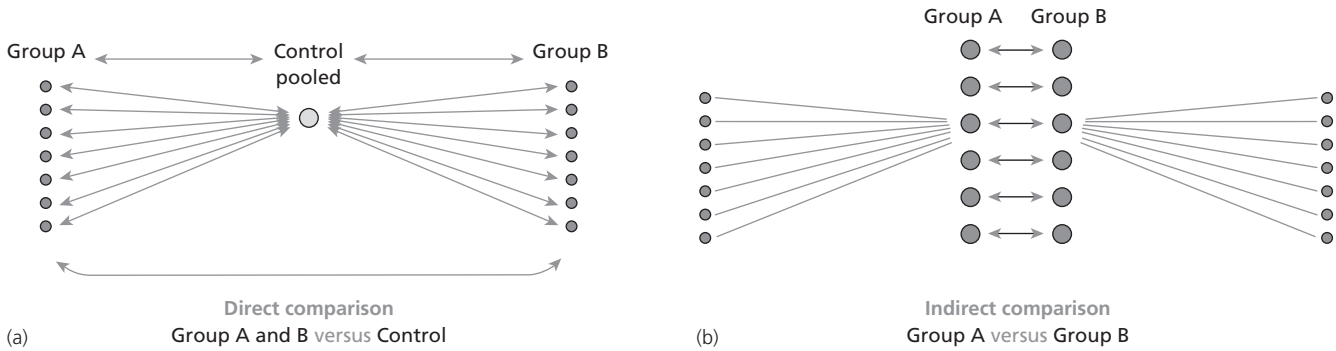

Fig. 6 Replicates in microarray experiments. The use of replicates is a critical aspect of microarray experiments. Replicates can be of two forms including (a) biological replicates in which multiple different individual samples are compared to a common control (direct comparison) or (b) technical replicates in which multiple replicates of the same samples are compared (indirect comparison). The preferred method is now the use of multiple biological replicates as this often overcomes many of the problems addressed by technical replicates when a large number of samples are analysed.

ment, the first and foremost task is to ensure that the design of the experiment is chosen to answer the specific biological question being asked. The experimental design is particularly important if the researcher chooses to use comparative two-fluorophore cohybridization. In this case, one is limited to comparing only those two samples that have been cohybridized. Choice of experimental design can vary from a simple experiment with only a simple two-group comparison to extremely complex experiments in which several groups/individual samples are compared with each other within and between groups [9] (Fig. 5).

Currently, microarray data have a resolution limit. Actual real small-fold differences in gene expression can be impossible to resolve from background variability or 'noise'. Gene array experimental 'noise' can be defined in multiple ways, including biological noise (individual phenotype variation, sex, age, diurnal changes, etc.) and technical noise (sample preparation, labelling, hybridisation efficiency, etc.). There are typically two complementary approaches used to address the problem of 'noise' in microarray experiments, downstream validation and the use of replicates. Validation of microarray results commonly uses more sensitive, independent and quantitative analysis tools such as quantitative polymerase chain reaction (qPCR) and downstream protein studies [10]. The frequent use of a small number of samples in microarray experiments has meant that statistical analysis is often unable to provide meaningful results. Therefore, the use of replicates is an important consideration in experimental design (Fig. 6). There are two kinds of replicates.

Biological replicates

Hybridizations of multiple independent samples belonging to one group are compared with samples from another group or with a reference, for example tissue from multiple test samples independently treated with drug 1 (group A) and drug 2 (group B) hybridized individually to a common reference pool and analysed statistically for direct and indirect comparisons.

Technical replicates

Repeat hybridization of the same two samples to multiple slides, for example samples from groups A and B treated with drugs 1 and 2, respectively, pooled (or individual) within the respective treatments and hybridized with each other on multiple arrays. To be able to compare samples and identify differential expression with confidence, it is necessary to include as many replicates as possible in the study. Replication facilitates estimation of experimental variability such that appropriate statistical measures (ANOVA, t-statistics, B-statistics) provide increased precision in the identification of differential expression.

Pooling of samples

Pooling samples before hybridization has been a subject of considerable debate in gene array experiments [11,12]. It is generally accepted that pooling affects the data quality and inference of results, but the exact nature of the effects is unknown. Therefore, the loss of specific information about individual samples on pooling means that this approach is generally discouraged. However, in a situation in which individual biological variability is to be reduced (e.g. for finding biomarkers or expression patterns of a group), there is an advantage in pooling together samples of a certain type. Pooling minimizes the individual differences within a group while highlighting the differences between groups. The high cost of performing microarrays is also a major factor encouraging researchers to pool samples. To overcome the shortcomings of pooling vs. non-pooling, samples with enough RNA should be hybridized individually during experimentation and, if required, data can be pooled at the time of analysis. If the amount of RNA is limited, samples can be pooled for microarrays and used singly for downstream qPCR to confirm gene array expression [10]. Conditions under which pooling is advisable and the number of arrays and samples needed for pooling have been defined [11,12].

Source of RNA

Isolation of RNA from samples is the initial and one of the most important aspects of a gene array experiment. RNA can be obtained from whole organisms, different organs or specific cell types within an organ. Techniques for isolating RNA from archival preserved tissues, either frozen or in formalin, are now available. Cell lines and primary cell cultures are yet another source of RNA. Laser capture microdissection and flow cytometry enable the isolation of specific cell populations from tissues (tumours, epithelial, stellate and inflammatory cells). Reagents and commercial kits are also available for isolating RNA from as few as 10 cells.

Commercially available standardized kits are readily available from various sources (Ambion, Invitrogen, Clontech and Qiagen). These kits help the researcher to isolate RNA with their specific requirements from a diverse range of biomaterials including prokaryotic cells and all types of animal tissues. Regardless of the source of RNA, integrity (purity and quality) is the single most important factor for successful microarray hybridization. Contaminating genomic DNA and organic solvents and salts from the RNA extraction process can severely interfere with the downstream processing of microarray experiments and produce undesirable results. There are several ways of assessing the quality and integrity of RNA. A visual analysis of total RNA is performed using electrophoresis with sharp bands for 28S and 18S rRNA and a > 1.7:1 ratio for 28S:18S rRNA being considered the benchmark for intact RNA (Fig. 7). For determining quantity and integrity, spectrophotometric measurement of absorbance at A230 nm, A260 nm and A280 nm wavelengths is recommended. A ratio of 1.7–2.0 for A260:A280 and ≥ 1.5 for A260:A230 is generally considered to be a measure of quality RNA, but impurities such as phenol, surfactants and DNA that absorb strongly in the 220- to 280-nm region can lead to misleading spectrophotometer readings. RNA can be purified by repeat extractions or using column-based methods to remove contaminating phenol. The RNA isolation method is a major consideration in experimental design, especially as some methods are incompatible with downstream labelling or hybridization. Further, the use of two different RNA isolation methods in the same microarray experiment is often not valid, given the variability and unique characteristics of the many available methods.

A comprehensive standardized system that has become a popular method of choice and is included as a standard protocol in MIAME is the use of the Agilent bioanalyser (Palo Alto, CA, USA) (Fig. 7) [13]. The bioanalyser can assess RNA degradation, DNA contamination and estimate amounts of RNA from picogram amounts of starting material. Importantly, the RNA quality within and across laboratories can be standardized using Agilent's software to calculate the RNA integrity number (RIN). The RIN ranges from 1 (totally degraded RNA) to 10 (completely intact RNA), and this is useful in comparing array data from various sources and across laboratories.

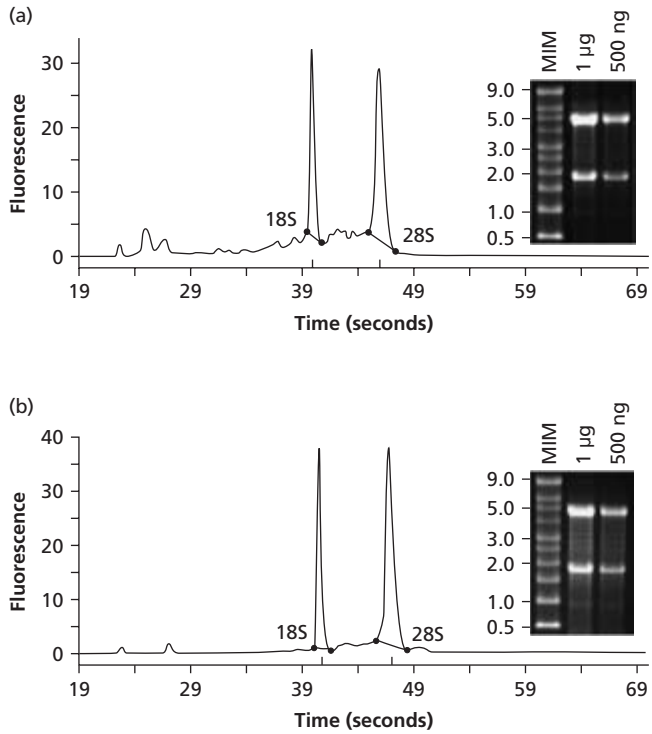

Fig. 7 Agilent Bioanalyzer assessment of RNA quality. RNA quality is one of the most important aspects of gene array analysis. RNA quality can be assessed in a number of ways including the use of an Agilent Bioanaylzer as shown here. Good-quality RNA does not have genomic DNA contamination and has a 28S to 18S ratio of intensity of > 1.7:1. (a) Human heart total RNA; (b) HeLa S3 total RNA. Reproduced with kind permission of Agilent Technologies.

RNA amplification

Microarray experiments require RNA in microgram quantities (5–100 µg) for hybridization. It becomes necessary to use amplification of RNA in cases in which obtaining the starting material is a limitation, for example microdissected biopsies, fine-needle aspirates, sorted cells and embryonic tissue. In the process of generating amplified RNA, the sensitivity of detection for low-abundance transcripts improves. However, amplification is generally avoided if possible because of uncertainty regarding the relative representation of genes within the gene pool following amplification. This is because the amplification efficiency between transcripts and batches of enzymes may not be equal. With optimized protocols, routine RNA amplification actually improves the quality of microarray results by providing more array-to-array consistency [14]. There are two major methods of RNA amplification: linear and exponential.

- Linear amplification was first described by Eberwine [15] and uses a T7 promoter and T7 RNA polymerase-dependent system that amplifies transcripts in proportion to their original abundance relative to each other. Using this method, mRNA amplifications of > 1000-fold can be achieved while still retaining the original relative transcript profile. Many of the commercially available amplification systems use this principle. Over the

last decade, the T7 polymerase-based system has been refined to the extent that RNA can be amplified from as little as 1 ng of starting material and purified and labelled with fluorophores using a single kit.

- Exponential amplification utilizes PCR-based techniques with a mix of DNA polymerases and patented technology for modified oligonucleotides that amplify full-length transcripts with fidelity. The PCR is terminated in the exponential phase to avoid saturation during the reaction plateau, therefore maintaining the original relative transcript representation profile. SMART kits from Clontech Laboratories, Palo Alto, CA, USA, have been used to amplify cDNAs from RNA and used for microarrays [16–18].

Sample labelling

Radioactive, fluorescent and biotin labels are incorporated into the sample material used to interrogate the DNA targets on the arrays. Radioactive labels (^{32}P and ^{33}P) were commonly used before fluorophores were made available. Biotin is a popular label for single-colour assays, such as the Affymetrix system. Fluorophores [generally cyanine (Cy) dyes] are available to detect more than a single colour simultaneously and assist in the screening of more than one sample on the same array. Multiplexing two (or more) colour fluorophores saves samples, time and costs and, as a result, is widely used in a research-based setting. The principal advantage of using more than one fluorophore is the incorporation of a common standard across all experiments. Statistical methods for the analysis of two-colour arrays are well defined but, as yet, there is no consensus for a single probe method. However, there are other issues, such as the unequal efficiencies of incorporation of fluorophores during transcription, that confound interpretation of multiplexed experiments.

Array platforms

There are three types of platforms on which DNA is immobilized using combinatorial chemistries:

- filter or membrane arrays: nylon and plastic;
- glass slides;
- glass beads with microfibres.

The source of gene probes fixed on the above platforms can consist of genome-wide or specific information using:

- cDNA libraries;
- short oligonucleotide clone sets and expressed sequence tags (ESTs);
- long oligonucleotide clone sets and ESTs;
- focused DNA sets for specialized research/diagnostic areas.

Since the inception of DNA microarrays almost a decade ago, a number of array designs and platforms have been developed. The initial design used hundreds to thousands of cDNA or oligonucleotide probes immobilized in a grid format on nylon or plastic platforms. The next generation of array platforms were on glass slides with combinatorial chemistries to covalently bind DNA to the treated slide surface. cDNAs and oligonucleotides are printed on these slides using robotic arrayers. With recent advances in this technology, more than 30 000 DNA spots can be accommodated on a single glass array. The extent of coverage of the genome depends on the source of cDNA and oligonucleotide libraries. Affymetrix uses a different technology to synthesize the DNA target on the surface of the array. The feature density of this approach is now 5 μm and falling, enabling millions of DNA targets to be arrayed on a single GeneChip™. This enables each gene to be represented by multiple probes along the length of the transcript, and each sequence is also arrayed as a single base mismatch control of specificity. An alternative approach uses sequentially arranged glass beads in a capillary fibre, which can be rapidly probed in minutes while being highly sensitive [19–21]. In addition to complete transcriptome expression profiling, custom-made specialized arrays can also be manufactured. Such specialized arrays are generally low-density arrays and consist of specific sets of genes, for example cytokines, cancer genes and toxicology-related genes, for specialized research and/or diagnostic purposes.

Proteomics

Introduction

An organism's proteome is the complex effector of gene expression and the ultimate molecular mediator of biology and disease. However, the relationship between protein and mRNA transcript expression is not always obvious, and many proteins are regulated by posttranslational modifications (PTM) such as phosphorylation [22]. Therefore, while proteomic methods are complementary to transcriptome studies, they offer unique insights into normal physiology and pathobiology [23–25]. In contrast to transcriptome analysis, in which the expression of tens of thousands of mRNAs can be examined in a single experiment, the high-throughput analysis of the proteome is limited to hundreds or a few thousand proteins at best [24,26]. Further, the complexity of the proteome, relative abundance, sample preparation and methods of analysis all greatly influence the protein expression data obtained in these experiments. Current proteomic methods are limited by sample preparation, with prefractionation being the norm to obtain meaningful protein expression data.

Proteomic methodologies: general

Proteomic methods can be divided into those in which known peptides are assayed (closed systems) and those in which novel peptides can be analysed and/or identified (open systems). Antibody and peptide arrays are examples of closed systems, whereas MS analysis can identify potentially novel peptides [27,28]. MS methods can be further divided into those techniques that can identify proteins (based on sequence data or weight-matching protein digests) or methods that identify unique MS profiles without identifying individual proteins [for example surface-enhanced laser desorption/ionization (SELDI) profiling] [26,29,30]. Most proteomic methods involve the same basic sequential sample processing: (i) sample preparation;

(ii) sample prefractionation; (iii) sample separation; and (iv) protein identification [26,29–33]. The array variation in this approach differs by attaching protein or antibody to a substrate instead of sample separation.

An alternative classification of proteomic methods is 'top-down' or 'bottom-up' [34]. 'Top-down' proteomics studies whole proteins using methods such as two-dimensional gel electrophoresis. In contrast, 'bottom-up' proteomics uses an approach in which complex protein solutions are subject to proteolysis prior to separation (typically by chromatographic methods).

Sample preparation

Proteins, in contrast to nucleic acids, have a highly variable chemistry that frequently impedes the analysis of complete proteomes [25,35,36]. Protein interactions with lipids and nucleotides as well as other proteins need to be disrupted. Typically, a combination of detergents, reducing agents and chaotropic denaturing salts are used. To avoid non-experimental protein modification, protease, kinase and phosphatase inhibitors are included in sample buffers. Sample preparation is often biased towards the downstream methods of analysis and frequently represents the first stage in fractionating a sample for efficient analysis [37,38]. The complexity of a protein sample and the charge are primary determinants of the efficiency of MS ionization, a critical determinant of MS analysis accuracy [25,35,36]. Therefore, sample preparation and prefractionation are frequently combined before sample separation.

Sample prefractionation

Proteome complexity in virtually all organs or cells is so great that no current separation method is capable of resolving even a significant minor fraction of the proteins contained in a sample. Therefore, most biological samples are pre/subfractionated before protein separation [31,39]. Sample prefractionation can take many forms, including charge separation, affinity capture and chemical modification. Alternatively, prefractionation can be combined with cellular subfractionation to obtain membrane, nuclei and other intracellular organelles [40–42]. Laser capture microdissection can be used selectively to isolate cell subpopulations for analysis, although this approach is at the limit of sensitivity in current proteomic research [43,44]. One of the major limitations of current proteomics techniques is the inability to resolve low-abundance proteins from the few highly expressed proteins such as intracellular actin and serum albumin that account for more than 90% of the protein mass [25,35] (haemoglobin, transferrin, immunoglobulin, haptoglobin, complement and antitrypsin are other highly abundant serum proteins). This is critically important, as many proteins mediating signalling or useful as biomarkers are expressed in nanomolar or lower concentrations [25,45–47]. Therefore, an additional aim of prefractionation is to concentrate the samples following removal of these interfering high-abundance proteins. However, these approaches are not without flaws as more than 97% of the low-molecular-weight proteins are bound to larger carrier proteins [48]. Therefore, prefractionation may remove proteins of interest from the subsequent analysis. Most investigators now use panels of prefractionation methods prior to protein separation. One of the most intriguing and promising prefractionation methods uses chemical modification, such as the use of enzyme suicide substrates followed by biotin avidin affinity [49,50]. This approach has the advantage of selectively targeting a known protein subfraction. An alternative approach to selectively identifying protein subfractions uses activity-based protein profiling (ABPP), a strategy in which fluorophore-labelled (typically rhodamine), active site-directed probes are used to tag a protein [51].

Sample separation

The ability to separate and resolve individual proteins within a sample has typically been performed by two-dimensional gel electrophoresis [35,36] (Fig. 8). The first dimension, referred to as isoelectric focusing, resolves proteins based on charge using immobilized pH gradients. The second dimension resolves



Fig. 8 Two-dimensional gel electrophoresis of F344 rat liver. Protein map of F344 rat liver analysed using 2-D gel electrophoresis. Comparison of such protein maps from two different conditions reveals differentially expressed proteins as a result of the treatment. Courtesy of Large Scale Biology Corp.

proteins based on size using sodium dodecyl sulphate-polyacrylamide gel electrophoresis (SDS-PAGE) gels. Individual proteins are visualized by Coomassie, silver or fluorophore staining (such as SYPRO ruby) [35,36,52]. A typical two-dimensional gel will resolve 1500–3000 protein spots. If the pH gradient is spread across several gels (zoom gels), 5000–10 000 proteins can be resolved. An interesting variation of the classical two-dimensional gel is DiGE (differential gel electrophoresis), in which protein samples to be compared are labelled with fluorescent dyes, mixed and then resolved on a two-dimensional gel [52,53]. In a manner similar to microarray analysis, the relative abundance is determined by resultant fluorescence. This approach has the advantage of avoiding ambiguities in spot match across gels and uses multiple common internal standards.

There are multiple limitations to two-dimensional gels including under-representation of basic and hydrophobic membrane proteins and the propensity of certain proteins to precipitate at their isoelectric point in the first dimension [54]. Additionally, two-dimensional gels are difficult to automate as well as being labour and time intensive [54]. Therefore, chromatographic techniques are now being widely adopted and frequently preferred to two-dimensional gel analysis in proteomic research [54]. There are a number of chromatographic techniques including affinity, ion-exchange, size-exclusion and reverse-phase liquid chromatography [54]. Additionally, chromatographic methods can be used to perform isoelectric focusing, chromatofocusing, free flow electrophoresis and capillary electrophoresis [54]. Combining a chromatographic first dimension followed by a second dimension separation by capillary electrophoresis or reverse-phase liquid chromatography can achieve greater resolution and sensitivity than a classical two-dimensional gel approach [54]. Over 12 000 unique proteins can be identified in a single sample using a two-dimensional chromatography approach [54]. Further, chromatography methods are readily automated, can be multiplexed and allow online MS characterization as well as protein recovery.

Protein identification

Protein identification relies on a number of MS techniques with two basic components: an ionization module and a mass analyser. The ionization module adds charge to the protein (typically by addition of a proton), and the mass analyser typically records time of flight (TOF) of a protein across an electric field (proportional to the mass) [36,54,55]. The most common proteomics technique to date is MALDI-TOF, in which an isolated sample is applied to a surface with an analyte (i.e. 2,5-dihydroxybenzoic acid), ionized and subjected to TOF. Although MS is capable of extremely accurate mass determination, the accuracy rapidly declines with proteins greater than 5 kDa [36,54,55]. Therefore, protein fragments, typically following trypsin digest, are best analysed by MS. This method is known as peptide mass fingerprinting (PMF). However, as the ionization efficiency of protein fragments is variable, MS analysis is not quantitative. Sequence information can be deduced by controlled fragmentation of peptides with MS to give peptide fragments that differ by the mass of a particular amino acid. This method is known as 'MS/MS' or 'tandem MS analysis'. Correct identification of a protein is dependent on the MS accuracy in determining molecular weight. Therefore, as many forms of posttranslational modification (PTM) change the mass of the protein, MS analysis is an ideal method of determining whether a protein has been modified in this manner [36,54,55]. However, many PTMs may be missed as MS sequence coverage of a protein is rarely complete.

The above discussion of MS analysis shows how proteins can be identified. However, MS analysis can be used to give characteristic MS profiles without identifying constituent proteins. This is done with SELDI using a ProteinChip Array (Cipehergen Biosystems) [56,57]. In this approach, prefractionation is performed using chemical (i.e. anion exchange) or biochemical (i.e. antibody) techniques. The immobilized protein subfraction on the chip is then treated with laser desorption/ionization (LDI) and subject to TOF (SELDI-TOF). This is essentially a modification of the MALDI technique in which all proteins are captured. MALDI-TOF requires sample separation before MS as each spot on the MALDI plate corresponds to a single protein; in contrast, SELDI-TOF relies on subfractionation of the chip and identification of individual proteins based on mass (not a protein fragment). However, although MALDI-TOF and SELDI-TOF can predict peptide mass up to ~ 300 kDa, the accuracy for large peptides (> 30 kDa) is poor [35,36,56,57]. Therefore, SELDI-TOF does not always accurately identify proteins, but is capable of generating MS profiles that may or may not be unique in a comparative analysis of closely related samples.

Proteomic array platforms

Array platforms in proteomic research fall into two groups. First, individual antibodies are arrayed on a surface and probed with protein samples [55,58]. Detection relies on prior protein sample labelling with a fluorophore or using a fluorescent second antibody. This is also known as forward-phase arrays (FPA). The second method arrays a protein sample, which is then probed with labelled antibody. This second technique is known as reverse-phase arrays (RPA). FPAs are plagued by low sensitivity and high variability. Current FPA platforms of many hundreds of antibodies are being used with limited success. RPAs, in contrast, have the necessary reproducibility and sensitivity for the analysis of clinical specimens. However, RPAs have to be custom made for each sample and are expensive.

Conclusions: proteomic methods

It is clear that proteomic analysis has the potential to offer unique and critically important insights into normal human biology and disease. In contrast to transcriptome analysis, proteomics is hampered by multiple technical difficulties that make it more demanding than gene array analysis. Presently, proteomic methods sample rather than profile the proteome. Additionally, sample preparation and prefractionation are critical aspects of successful proteome analysis. However, the promise of proteomic techniques in biodiscovery, biomarker

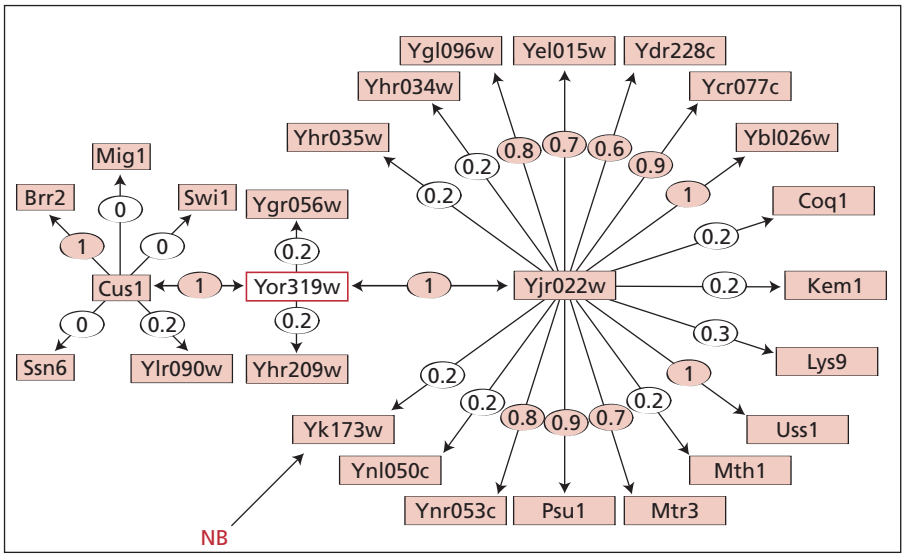

Fig. 9 Protein interaction map. Protein interaction map of *Saccharomyces cerevisiae*, including predicted biological scores. Courtesy of Hybrigenics SA.

identification and prediction of toxic responses will ensure that this is an area of functional genomics research that will continue to attract intense attention.

Bioinformatics

The explosion of high-throughput techniques since the advent of the genome sequencing projects has led to the need for innovative statistical analysis of data. Although strong quantitative traditions exist in other domains of biology and biomedical research, the adoption of quantitative approaches (as opposed to semi-quantitative or qualitative approaches) is relatively new in cell and molecular biology. There is now an established and fruitful interface between the disciplines of biology, statistics and computer science to aid these problems. In this section, we will discuss a selection of issues relevant to the interpretation of data from high-throughput experimental platforms. While the emphasis is on expression microarrays, much of the discussion is, or will be, relevant to other postgenomic measurement systems.

It is now well understood that microarray data are subject to a bewildering variety of systematic biases related to experimental and data acquisition processes [59,60]. The data processing and statistical procedures required to correct these effects collectively fall under the term 'normalization'. These include intensity-dependent biases [61–63], spatial-dependent biases and, in the case of printed glass arrays, biases related to the printing order of spotted clones or oligonucleotides [59,60].

The requirements of data analysis following these basic preprocessing and normalization steps are dependent on the overall aim of the investigation. For laboratory-scale studies, where the aim of the experiment is typically to obtain new information regarding the action of genes and pathways in the biological system under study, the emphasis should be placed on exploratory analysis. The notion of 'exploratory analysis' should not be confused with lack of statistical rigour. Methods developed in multivariate statistics over the last century may also be applied in the exploratory analysis of microarray data, for example unsupervised learning methods ('clustering' or 'pattern discovery') such as hierarchical clustering or the self-organizing map (SOM) can be used to identify groups of genes (Fig. 9) whose expression levels are related across a set of experimental conditions [4,64].

For larger scale studies, the same techniques can of course be applied but, if the aim of the study relates to the identification of genes that are predictive for a given disease or condition, then the well-established methodology of supervised learning is required [65]. Supervised learning techniques are readily available in many microarray data analysis packages and in all the generic statistical computing packages (SPSS, SAS, R/S-Plus).

The identification of differentially expressed genes is the first step, albeit a challenging one, in the overall data interpretation process. Taking a set of dozens or hundreds of genes and constructing a biologically plausible hypothesis remains an immensely difficult and time-consuming task. A vast conglomeration of data relating to gene product function exist in a variety of forms, including as free text in abstracts and papers, in 'comments fields' of biological databases (such as NCBI or Ensemble) and in more specialized, curated databases (e.g. Mouse Genome Informatics). While much of this information is readily available via web servers, such devices are optimal when used for obtaining information about a single transcript or gene product. The integration of this information from large sets of genes still results in a problem of manual data collation; thus, there is a great need for the development of methods for large-scale analysis of functional data.

Several recent developments have significant implications in relation to this goal. First, the work of the Gene Ontology Consortium has a standardized format that has largely become a default for the presentation of information about the function of gene products covering the entire spectrum of cell and molecular biology. Gene Ontology is not a database *per se* but a controlled vocabulary of terms (an 'ontology'). It should not be confused with metabolic or signalling pathway databases, such as KEGG or Reactome [66]. Several interesting analyses have been made using comparative functional genomics by analysing microarray data across many distantly related species to identify conserved 'modules' of genes whose gene products have consistent functions [67]. Such modules could be used as a basis for comparing cellular function across different conditions. In terms of annotation *per se*, there is an increasing amount of work being undertaken on literature extraction and analysis techniques, based on natural language processing, to automatically define annotational data of interest (for example to extract protein–protein interactions from publications). Although most of this work is currently in the area of methodological development, several interesting applications of text mining concepts have been published that point to the potential that these techniques might have in the future for the interpretation of high-throughput experiments [68].

Gene array data in liver disease

The liver transcriptome

As noted above, there are estimated to be in excess of 32 000 protein-encoding genes in the human genome. Furthermore, there are an unknown number of functionally significant alternatively spliced transcripts arising from these genes that may exceed 100 000. How many of these transcripts are expressed in the liver is unknown. Resources for identifying and comparing organ transcriptomes are rare. One method of inferring complexity is to examine GenBank human UniGene clusters of non-redundant gene sets [69]. These UniGene clusters are compiled from mRNA and ESTs and, as a group, represent a species' transcriptome [69]. Currently, the human UniGene assembly of clusters (Build 180) has over 5 million sequences representing 52 888 non-redundant transcripts. Parsing keyword searches [parsing string used ('liver' or 'hepatic') and 'human' for UniGene Build 180] identified approximately 26% of transcripts (representing 13 627 clusters) in liver tissue; this compares with brain (46%), lung (40%), kidney (35%), colon (32%) and heart (23%). Coulouarn *et al.* [70] used a similar approach and identified 12 638 non-redundant clusters from liver tissue (UniGene Build 129). Further, serial analysis of gene expression (SAGE) libraries can also provide some insight into the complexity of the liver transcriptome [71,72]. Two SAGE libraries from normal human liver identified 15 496 and 18 081 unique transcripts from a total number of 66 308 and 125 700 tags respectively [71,72]. In a SAGE comparison of multiple organs, 32 131 unique tags were identified (from a total of 455 325 tags); of these, 56% were expressed in the liver compared with brain (75%), breast (81%) and colon (91%) [73]. Therefore, it is clear that the normal liver has a complex transcriptome expressing many thousands of transcripts. Interestingly, the SAGE comparison of gene transcripts from various tissues has identified organ-related chromosomal domains such as 6p12.1 associated with hepatic xenobiotic metabolism [73].

Microarray analysis of normal human liver by Yano *et al.* [4] highlights many of the problems in examining the non-diseased liver transcriptome. A total of 2418 genes were examined in five normal patients with only 50% of these transcripts being detected in four out of five patients. Furthermore, only 27% of genes had coordinate expression in these normal patients. Therefore, in addition to the liver having a complex transcriptome, there appears to be significant individual variability in transcript expression. This is further highlighted by the observation of Enard *et al.* [74], who found that duplicate liver samples from the same individual differed by 12% (technical variation) but that intraspecies variation was as pronounced as interspecies variation in hepatic mRNA transcript expression comparing chimpanzees and humans. Focused specialized arrays such as the Liverpool nylon array targeting the liver transcriptome have now been synthesized and include in excess of 10 000 target genes [70]. However, such approaches fail to detect differential gene expression for transcripts not expressed in normal liver that are expressed in disease.

Gene arrays in human liver disease

Presently there are in excess of 200 published gene array studies of human liver disease or studies that utilize human liver tissue (Table 1). This represents roughly 40% of the greater than 500 published papers utilizing gene arrays to study human pathobiology. Most of these studies attempt to understand pathobiology by examining mRNA transcript expression. There are few publications in human liver disease where gene expression is correlated with clinical outcome.

Hepatitis C virus (HCV) infection (see also Section 9)
Acute HCV infection has been examined in experimental infection in the chimpanzee. Bigger *et al.* [75] used DNA array technology to study acute HCV infection in a single animal that cleared the virus. They described the strong early induction of interferon (IFN)γ-induced genes such as *ISG15* and *ISG16* with the later induction of Th1-associated transcripts such as *MIG* (CXCL9) and *IP10* (CXCL10). These genes were upregulated > 40-fold at the time of viral clearance. Also, induction of apoptosis genes (*FAS* and *TNFR*), cellular proliferation genes (*PCNA* and cyclin) and transcripts related to lipid metabolism (apidophilin) were detected.

Su *et al.* [76] used similar methods to compare chimpanzees that cleared acute HCV infection with an animal that had virus persistence. They observed upregulation of many transcripts.

Table 1 Summary of processes observed in genomics and proteomics studies of human liver disease.

Pathology	Processes observed	Reference
Normal liver	Variability of non-diseased liver transcript expression	[4,70,71]
	Acute phase response transcript expression	[70]
Hepatitis C (HCV)	Chronic infection induction of Th1 immune response, fibrosis, apoptosis and proliferation-associated genes	[75,76, 79,88,192,193]
	Acute infection induction of IFN and T cell-associated genes with viral clearance	[75,76]
	In vitro hepatocyte disruption of RIG-1 signalling in response to NS3/4A	[77]
	In vitro hepatocyte induction of NFκB response to NS5A	[194]
	IFN-associated gene induction in response to IFN and ribavirin treatment in chronic infection	[78]
	Tumour-associated gene expression including biomarker identification in HCV-associated HCC	[83,158,159[a],195–197]
	IFN- and TRAIL-associated gene expression in HCV recurrence post liver transplantation	[84,85]
Hepatitis B (HBV)	Chronic HBV infection induction of IFN, fibrosis and proliferation-associated genes	[79,88]
	HBV fibrosis (marker study)	[154[a]]
	HBV inflammation (marker study)	[161[a]]
Autoimmune hepatitis (AIH)	Chronic AIH cirrhosis induction of apoptosis inhibitors and Th1/Th2 gene expression	[80,82]
Alcohol-associated liver disease (ALD)	Annexin- and stellate cell-associated gene induction in chronic alcoholic liver disease	[89,163[a]]
Non-alcoholic fatty liver disease (NAFLD)	Steatotic liver disease	[92,93[b],94]
	Decreased expression of mitochondrial-associated gene expression in non-alcoholic steatohepatitis (NASH)	[92]
Biliary liver disease	Chronic primary biliary cirrhosis (PBC)s, Wnt pathway gene expression	[82,91]
	Chronic primary sclerosing cholangitis (PSC) cirrhosis, epithelial- and endothelial-associated gene expression	[91] [162[a]]
	Mac-2Bp expression in PSC-associated cholangiocarcinoma (marker study)	[95]
	Imprinting gene expression in embryonic compared with perinatal biliary atresia	
Hepatocellular carcinoma (HCC)	HCC differentiation- and progression-associated gene expression (marker studies)	[81,99,154[a],165,166,197[a]]
	Molecular signature in viral hepatitis-associated HCC	[100,102,103, 154[a],199]
	Metastatic HCC development-associated gene expression including osteopontin expression	[106,200]
	Prognosis/recurrence of HCC including association with RhoC expression	[107,108]
Cholangiocarcinoma	PSF2 upregulation in intrahepatic cholangiocarcinoma	[109,201]
	Mac-2Bp expression in cholangiocarcinoma (marker study)	[162[a]]

[a]Proteomic analysis.
[b]Combination of transcriptome and proteome analysis.

Those genes associated with the early response (which correlated with viral load) included many IFNα-induced genes including *STAT1*, 2′-5′ oligoadenylate synthetase, *Mx1*, *ISP15* and *p27*. Furthermore, there was induction of lipid pathway genes such as fatty acid synthetase and sterol response element binding protein (SREBP). These lipid pathway genes were associated with viral replication, and blockade of these two pathways using *in vitro* replicon experiments led to a decrease in viral replication. Additionally, there was downregulation of peroxisome proliferator-activated receptor (PPAR)α as well as hepatic lipase C and flotillin 2. The reduction in PPARα would be expected to be associated with insulin resistance, a feature of chronic HCV but, prior to this, it was not an expected aspect of acute HCV infection. Whether HCV replication *per se* results in insulin resistance clearly warrants further study. Clearance of HCV was associated with the late induction of T helper 1 (Th1) transcripts such as *CXCL9* and *CXCL10*, MHC expression and T-cell molecules such as CD8 and granzyme A. Of interest was the induction of IFNα-induced genes early in infection, as observed by Bigger *et al.* [75], but the timing did not correlate with clearance as high levels of these transcripts continued in the animal with viral persistence. This has also been seen in human studies.

Functional studies in HCV replicon systems has shown that NS3/4A was able to inhibit IFNα antiviral effector function by blocking the phosphorylation of IRF-3, a key protein in the antiviral response [77]. Thus, chronic HCV infection induces a persistent intrahepatic IFNα antiviral response, but the virus itself escapes the response via an inhibition of the effector arm. However, the intrahepatic IFNα-induced gene response is variable among individual patients. This response has been identified, by microarrays, to be higher in patients not responding to pegylated IFN and ribavirin therapy, suggesting an increased resistance to the effector arm that cannot be amplified by exogenous therapy [78]. In contrast, patients who had a sustained viral response (SVR) to pegylated IFN therapy had a lower expression of IFN genes that, by inference, can be amplified by exogenous therapy resulting in viral clearance.

Chronic HCV infection has been studied in a number of ways using array analysis. The study by Honda *et al.* [79] profiled gene expression using microarrays in individuals with chronic hepatitis B (HBV) and chronic HCV, comparing them with a single non-diseased control subject. The study examined liver biopsy material. Honda *et al.* [79] concluded that chronic HCV infection was associated with a predominant anti-inflammatory, proproliferative, antiapoptotic intrahepatic gene profile. However, an analysis of the data in these experiments indicated widespread upregulation of proinflammatory genes such as interleukin (IL)-2 receptor, *CD69*, *CD44*, IFNγ-inducible protein, major histocompatibility complex (MHC) class 1 genes and monokine induced by IFNγ. Similar findings were made in HCV cirrhosis in which proinflammatory Th1-associated transcript expression predominated [80]. HCV-associated cirrhosis has also been shown to display upregulation of a wide variety of fibrotic genes such as platelet-derived growth factor (PDGF) and transforming growth factor (TGF)-β3. These studies have also identified potential novel mediators of HCV-associated injury such as frizzled-related proteins, discoidin domain-related protein 1 (DDR1), EMMPRIN and SARP-3 [80]. These results have been expanded and analysed more rigorously by a comparison of gene profiles in patients with HCV cirrhosis, HCV and hepatocellular carcinoma (HCC) and normal liver [81]. Importantly, this analysis aimed to exclude genes expressed in normal liver, other forms of cirrhosis or HCC. This study identified 87 upregulated and 45 downregulated genes that appear to be markers of HCV liver injury [81]. Genes such as *ILxR* (IL-13 receptor a2), *CCR4* and cartilage glycoprotein 39 (GP-39) were identified [81]. The last transcript was also identified in chronic HCV infection by a totally different genomics approach, namely suppressive subtractive hybridization [82].

The premalignant behaviour of intrahepatic HCV infection has been studied by our group by comparing HCV cirrhosis with and without HCC [83]. This approach identified upregulation of many oncogenes (i.e. *TEL* oncogene), immune genes (IFNγ associated) and fibrosis genes (integrins) as well as cell signalling (G-coupled receptor kinase) and proliferation-associated genes (cyclin K) in cirrhosis complicated by HCC. This indicates that there might be a premalignant cirrhotic response in HCV infection. The data suggest that there is more cellular proliferation, immune activation and fibrosis in the liver of patients with HCC than in those with cirrhosis alone. A key area of future research will be to ascertain whether such a profile can be recognized before HCC actually develops. If so, it may be used to identify and screen high-risk patients.

Gene array analysis of HCV recurrence in transplant allografts has shed new light on the molecular mechanisms of viral recurrence [84,85]. HCV recurrence in the graft is associated with expression of IFNγ-associated genes such as *CXCL10* (IP-10), *CXCL9* (HuMIG) and *RANTES* [85,86]. Further, antiviral IFNγ-associated gene expression is seen in chronic HCV recurrence and during acute rejection associated with HCV recurrence [85]. Additionally, upregulation of the NF-kappa beta (NFκB) pathway during acute rejection in association with HCV recurrence appears to alter cellular apoptosis via changes in the expression of TRIAL-associated genes [85]. Importantly, chronic HCV recurrence in grafts is associated with Th1-associated gene expression similar to that seen in chronically HCV-infected individuals who have not been transplanted [85]. In contrast, cholestatic HCV recurrence, which follows an aggressive course, is associated with a Th2 cytokine profile [85]. This suggests that the Th1 immune response suppresses viral replication while being profibrogenic [85,86]. In cholestatic HCV recurrence, the unchecked viral replication is directly fibrogenic [85,86].

HBV infection (see also Section 9)

Acute HBV infection has been analysed in the chimpanzee [87]. This study revealed several findings. First, that there was no differential gene expression during the initial phase of HBV infection and the first phase of HBV replication. This is in direct contrast to HCV infection and suggests that HBV infection acts in the initial phase as a 'stealth virus', failing to induce a significant innate immune response [87,88]. Intrahepatic gene induction is first seen during the phase of viral clearance. Gene expression during the early phase of infection was associated with T-cell receptor and antigen presentation. Following this, T-cell effector function (granzymes), T-cell recruitment (chemokines) and monocyte activation-associated gene expression was observed. A later phase of clearance was associated with the expression of B cell-related genes. At the time of writing, there are no published studies of acute or chronic HBV infection in the human. We have studied HBV cirrhotic explants and have found less differential gene expression compared with normal liver than in HCV-associated cirrhosis. This state of chronic HBV infection is characterized by upregulation of stress point, cell cycle and immune system genes. Similar findings have been reported by others (personal communications).

Alcoholic liver disease (ALD) (see also Chapter 12)

Intrahepatic gene profiling using microarrays in ethanol-fed baboons has identified increased expression of 14 different

annexin genes (including *A1* and *A2*) that were not previously implicated in the progression of fibrosis in ALD [89]. Furthermore, the intrahepatic transcriptome profile in alcoholism shares some similarity with lipopolysaccharide (LPS) administration but, in general, is significantly different from other forms of liver disease [89,90]. Cluster analysis has allowed differentiation of alcoholic hepatitis from alcoholic steatosis. Genes known to be involved in alcohol injury, such as alcohol dehydrogenases, acetaldehyde dehydrogenases, IL-8, *S*-adenosyl methionine synthetase, phosphatidylethanolamine N-transferase and several solute carriers, have been shown to be differentially expressed in alcoholic hepatitis vs. alcoholic steatosis. Many novel differentially expressed genes were identified, including claudins, osteopontin, *CD209*, selenoprotein and genes related to bile duct proliferation [89]. The most prominent categories of differentially expressed genes involved cell adhesion/extracellular matrix (ECM) proteins, oxidative stress and coagulation that were also common to endstage ALD. Overexpression of annexin A2 was also seen in alcoholic hepatitis. Genes associated with fibrosis/cell adhesion/ECM were the most prominent category in human advanced ALD, consistent with the fibrotic nature of ALD. However, these were not specific to alcohol and have been reported in primary biliary cirrhosis (PBC) and other forms of liver cirrhosis [80,91].

Non-alcoholic fatty liver disease (NAFLD) (see also Section 13)

Non-alcoholic steatohepatitis (NASH) is the clinicopathological syndrome in NAFLD that has been most widely studied using gene array analysis of transcript expression. Studies have identified differentially expressed genes in endstage NASH cirrhosis compared with other disease states [92–94]. Decreased expression of genes associated with mitochondrial function and increased expression of genes associated with the acute-phase response were observed [92]. The latter increases were speculated as being associated with insulin resistance, a feature of NAFLD [92]. Further differential expression of genes involved in lipid metabolism, ECM remodelling, regeneration, apoptosis and detoxification have all been observed in NASH following microarray analysis [93].

Primary biliary cirrhosis (see also Chapter 11.1)

One of the major findings in an array examination of PBC endstage liver disease was the identification of a subset of genes associated with the Wnt pathway [91]. In particular, Wnt13, Wnt5A and Wnt12 were shown to be differentially expressed. Other genes particularly upregulated in PBC included transcription initiation factor 250 kDa subunit (TAFII 250), PAX3/forkhead transcription factor and patched homologue (PTC). A consistent feature of the gene array analysis of PBC was the repeated identification of *Drosophila* gene homologues that were differentially expressed (Wnt genes, hedgehog pathway, notch pathway) [91].

Autoimmune hepatitis (AIH) (see also Chapter 11.2)

The only available data on AIH is a comparison between HCV- and AIH-associated cirrhosis [80]. One of the key findings in this study was the observation that three inhibitors of apoptosis (IAP) genes were selectively differentially expressed in AIH. This is an intriguing finding. If this gene expression was identified as being in the intrahepatic lymphocyte population, then lack of apoptosis of such cells may be an important pathogenic pathway in the perpetuation of AIH. In this comparison with HCV, AIH was associated with an inflammatory gene pathway that consisted of a mix of Th1- and Th2-associated genes. Also, there was a marked upregulation of a large number of transcription factors in AIH vs. other forms of cirrhosis [80].

Primary sclerosing cholangitis (PSC) (see also Chapter 11.3)

The only available data on PSC comes in a comparison with PBC [91]. There were a far greater number of genes showing differential expression in PSC vs. non-diseased liver compared with PBC and non-diseased liver. These include genes associated with epithelial biology (amphiregulin, bullous pemphigoid antigen), inflammation (T-cell secreted protein P I-309, CTLA4), apoptosis (Bcl-2 interacting killer, Bcl-x, death-associated protein 3) and intracellular kinases such as CDK7 and JAK1.

Biliary atresia (BA) (see Chapter 22.1)

A study comparing gene expression in embryonic vs. perinatal BA has been published [95]. Gene profiling clearly separated these two conditions. The most remarkable difference was in the expression of so-called regulatory genes. In embryonic BA, 45% of differentially expressed genes were in this category vs. 15% in the perinatal form. Included in these genes were imprinting genes, and genes associated with RNA processing and cell cycle regulation that were not present in the perinatal form of BA.

Cystic fibrosis (CF) (see also Chapter 16.4)

Gene array analysis of CF-related liver injury is yet to be published. Extrahepatic sites affected by this disease (lung, pancreas and intestine) have been studied [96–98]. Importantly, gene arrays using tiling oligonucleotides with corresponding sequence mismatches offer the promise of accurate screening of over 1200 known cystic fibrosis transmembrane conductance regulator (CFTR) gene mutations in a single experiment. The promise of gene array analysis in CF-related organ disease (especially lung, liver and intestine) is immense given the inexorable nature of the disease. It is envisaged that specialized gene arrays will be used selectively in many aspects of CF research.

Hepatocellular carcinoma (see also Chapter 18.2.1)

Neoplastic proliferation in HCV-associated HCC has been studied by array analysis. A plethora of potential novel tumour markers have been identified. These include the serine/threonine

kinase 15 (STK15) and phospholipase A2 (PLA2G13 and PLA2G7) that were increased in over half the tumours identified [81]. However, different studies identify different gene groups in HCV-associated HCC such as cytoplasmic dynein light chain, hepatoma-derived growth factor, ribosomal protein L6, TR3 orphan receptor and c-myc [99]. The clustering analysis in this study showed that the expression of 22 genes in HCC related to differentiation of the malignancy, with over half these genes being transcription factors or related to cell development or differentiation [99]. Although many of these genes can be implicated in HCC development, they are often identified in large gene sets in endstage disease. Therefore, whether these genes represent cause or effect is unknown. HBV-associated HCC has been studied by several groups [100–103]. Genes associated with cell proliferation, cell cycle, apoptosis and angiogenesis were deregulated in HCC tissues. Increased expression of cyclin-dependent kinases was seen, while several cell cycle negative regulators were decreased. Metastatic development has also been studied using gene arrays [104–107]. Genes identified with metastatic development included osteopontin [105]. The authors then demonstrated that neutralizing antibodies to osteopontin blocked tumour invasion *in vivo*. A study of unsupervised gene profiling of patients with HCC revealed a set of genes associated with decreased survival including RhoC [108]. These genes include a subset of proproliferative, antiapoptotic genes as well as genes involved in ubiquitination and histone modification. Gene profiles in HCC have also identified patterns of gene expression associated with tumour differentiation, vascular invasion as well as recurrence post surgery [107].

Cholangiocarcinoma (see also Chapter 19.9)
Obama *et al.* [109] used laser microdissection to compare gene expression in intrahepatic cholangiocarcinoma with noncancerous biliary epithelial cells. Over 50 upregulated genes were identified. These included forkhead and homeobox transcription factors, cadherin and survivin genes. Surprisingly, 421 genes were downregulated but not characterized in this study. Additionally, a group of 30 genes was identified as being associated with lymph node metastases. This study revealed some common findings with another studied aimed at identifying gene expression in a variety of biliary tract cancers [110].

Gene arrays in animal models

Animal models studied have included acute liver regeneration, drug toxicity, liver fibrosis, fatty liver, biliary obstruction, liver transplantation and carcinogenesis. Drug toxicity studies are numerous and include effects induced by clofibrate, PPARα agonists, carbon tetrachloride, amiodarone, arsenic and methotrexate [111–121]. In one study, a novel cDNA library highly enriched for genes expressed under a variety of hepatotoxic conditions was created and used to develop a custom oligonucleotide library [122].

An expression signature for rat liver fibrosis was identified using a cDNA 14 814 gene microarray [123]. The 'genetic fibrosis index' identified consisted of 95 genes (87 upregulated, 8 downregulated). These included genes associated with cytoskeletal proteins, cell proliferation and protein synthesis. Bile obstruction in the mouse identified three sequential main biological processes. At day 1, enzymes involved in steroid metabolism were overexpressed. This was followed by an increase in cell cycle/proliferation-associated genes at day 7, occurring at a time of maximum cholangiocyte proliferation. From days 14 to 21, genes associated with the inflammatory response and matrix remodelling were identified. Similar temporal gene expression was identified in the model of acute liver regeneration. Steroid and lipid metabolism genes were downregulated as early as 2 h post hepatectomy, whereas genes associated with cytoskeletal assembly and DNA synthesis became upregulated by 16 h and remained elevated at the 40-h time point at the peak of S phase.

Carcinogenic foci in experimental animals have been isolated and studied using gene array technology [124]. Approximately 8% of 2000 transcripts were differentially expressed in one study. These included genes with roles in signal transduction, detoxification and cytoskeletal assembly. Over 30 genes were identified as being dysregulated in these foci as well as in neonatal liver. Small-for-size liver allografts in rats showed upregulation of adhesion molecule, inflammatory mediators and apoptosis-associated genes together with downregulation of energy-metabolizing genes.

Alcoholic liver disease has been studied in the chronic enterogastric ethanol infusion model in a mouse; a total of 12 422 genes were analysed [90]. Several cytochrome P-450 genes were shown to be upregulated, while several genes involved in fatty acid metabolism (stearoyl CoA desaturase 3-hydroxyacetyl CoA dehydrogenase) and fatty acid synthetase were downregulated. In contrast, genes associated with glutathione *S*-transferase were markedly upregulated. Interestingly, a novel molecule intestinal factor was 50-fold downregulated. It was postulated that alcohol might be affecting the healthy intestinal epithelium, and downregulation of this gene might be associated with permeability changes in the intestine associated with chronic alcohol ingestion.

Proteomic data and liver disease

The liver proteome

The human proteome is complex and differs significantly depending on the organ or cell population being studied. Proteins can be subject to in excess of 100 different types of posttranslational modifications [22]. Therefore, the estimated 40 000 genes in the human genome may give rise to more than a million distinct proteins [33,54]. Utilizing an approach of parsing GenBank with keywords, we can gain insight into human

organ proteome complexity. [In June 2005, the GenBank protein entries were parsed with the keyword 'human' and one of the following: 'brain', 'liver', 'lung', 'kidney', 'bowel or colon', 'heart', 'kidney' and 'serum'. A total of 91 261 protein entries were identified across all these organs. The percentage for each organ was then calculated to give an estimate of relative protein abundance. The number of individual GenBank protein entries in each organ was: brain (35 834), liver (13 195), lung (12 770), kidney (11 997), bowel/colon (6045), heart (6011) and serum (5409).] Proteomes from human brain, liver, lung, kidney, bowel/colon, heart, kidney and serum express 39%, 14%, 14%, 13%, 7%, 7% and 6%, respectively, of the proteins found in all these organs. This highlights the complexity of the brain proteome. Furthermore, the liver has a complex organ proteome. In contrast, a prototype human cell such as a lymphoblast, with a mass of 670 pg, contains 67 pg of protein from a total of 10^9 polypeptide molecules from ~ 4000 different proteins [125,126]. Within a cell, approximately 90% of the cellular protein mass results from the 100 most abundant proteins, and a further 1200 proteins account for another 7% of the protein mass that is detectable by typical proteomic analysis (from a lysate of 10^6 cells) [125,126]. However, the remaining 3% of the protein mass includes 2800 proteins (over 50% of the different protein species) and is frequently below the detection limit of most proteomic methods [125,126]. Therefore, it is important to consider the frequency of protein expression within a homogeneous cellular sample (i.e. cell lines) compared with a heterogeneous cellular sample (i.e. organs). This is an especially important consideration for hepatologists using biopsy specimens in which the non-parenchymal cell subpopulation abundance is low and subject to sampling error [127,128].

Frequently, the underlying assumption of transcriptome analysis is that changes in mRNA expression reflect changes in protein expression. There are many examples in which protein expression or function is not controlled by mRNA expression. In the intact non-diseased liver tissue, approximately 25% of the changes in mRNA transcript expression are not accompanied by changes in the expression of the corresponding protein [129]. Studies comparing mRNA and protein expression in liver are few. Anderson and Seilhamer [129] showed a poor correlation between the liver tissue abundance of 19 proteins and corresponding mRNA transcripts (correlation coefficient of only 0.48). Furthermore, they isolated 50 abundant mRNA transcripts, of which 29 encoded secreted proteins [129]. However, of the 50 most abundant proteins they isolated, none was secreted [129]. There is a bias in mRNA pools, when compared with protein expression, towards an over-representation of both secreted protein transcripts and high-abundance mRNA transcripts such as *G3PDH* [129–133]. Ultimately, the protein expression in every cell is controlled by the transcriptome, although the relationship between individual gene transcripts and the corresponding protein expression may not be clear at first.

Proteomic studies of liver disease – general comments

Proteomic studies of liver disease have fallen into the following four groups: (i) discovery of previously unrecognized proteins in a cell population or disease state [134–136]; (ii) biomarker discovery [56,137]; (iii) hepatic toxicological prediction/profiling [138–147]; and (iv) studies of known proteins or classes of proteins [49,50] (see Tables 1 and 2). Proteomics has been used successfully in biodiscovery of proteins in hepatocytes, hepatic stellate cells [134–136], hepatocellular carcinoma [137] and viral hepatitis [148–153]. In these studies, tens to hundreds of proteins were identified. However, they are limited as they sample, rather than profile, the proteome. Further observed changes in protein expression may reflect weak associations rather than a direct role in the development of pathobiology. The biodiscovery approach has been used successfully in toxicological models and used to develop characteristic profiles of protein expression that may predict intrahepatic toxicology responses [138–147]. This is an area of intense focus for pharmaceutical companies as they strive to reduce development costs and aim to predict drug toxicity earlier in the drug development cycle. Biomarker discovery is another area receiving intense focus using proteomic methods. However, for years, there has not been a new Food and Drugs Administration (FDA)-approved serum marker as this is an immense challenge. Biological sample protein concentrations vary by 12–15 orders of magnitude. Furthermore, specific serum markers are likely to be expressed at nanomolar or lower concentrations. One approach to overcome these limitations is to use a combination of potential markers that are easier to detect but with each protein marker alone having a lower specificity but high sensitivity. This is an approach currently used in serum tests of hepatic fibrosis, and proteomic methods are being used to try and identify new serum markers of hepatic fibrogenesis [53,154,155]. One of the most promising approaches is the use of accurate mass tags (AMT) or suicide substrates that selectively and reproducibly target a subproteome [49,50,156,157]. This has the added advantage of aiding prefractionation and increasing the resolution of proteins as the tag can be captured on an affinity surface [49,50].

Proteomics in human liver disease

Hepatitis C virus infection (see also Section 9)

Proteomic methodologies have been applied to a number of aspects of HCV-related liver injury. These include the study of HCV-related HCC development in which overexpression of α-enolase was identified and correlated with poorly differentiated HCC [158,159]. The response of hepatocyte cell lines to IFNγ treatment has uncovered over 54 IFN-response genes including many novel targets, an approach that may pave the way for novel therapies. Examination of protein extracts that bind to the HCV internal ribosome entry site (IRES) has identified a number of novel protein targets such as Ewing sarcoma breakpoint 1 region

protein EWS and TRAF-3. The final aspect of HCV liver injury receiving attention is the study of potential biomarkers such as heat shock protein HSP-70 associated with HCV infection progression to HCC [160].

Hepatitis B virus infection (see also Section 9)

In contrast to gene array experiments, there are a number of studies that use proteomics on sera to examine different stages of chronic HBV infection. In one study, altered proteomic profiles were identified for haptoglobin β and α2 chain apolipoprotein (Apo)A-1 and A-1V, α-1 antitrypsin, transthyretin and DNA topisomerase 11β [161]. Some of these proteins are among the most abundant serum proteins secreted by the liver and are generally associated with acute-phase inflammatory responses. What was apparent in this study was that different isoforms of some of these proteins showed distinct changes in HBV infection itself and differed at times between patients with low inflammatory scores vs. high inflammatory scores. Some examples include a decrease in cleaved haptoglobin β peptides and ApoA-1 fragments in patients with higher inflammatory scores. In comparison, some α-1-antitrypsin fragments were increased in patients with higher inflammatory scores. In an attempt to simplify such studies, deglycosylation of serum was undertaken before analysis. An alternative approach studied serum protein profiles and correlated this with disease severity using a SELDI protein chip analysis and artificial neural network models [154]. They found six fragments with a positive and 24 with a negative prediction of fibrosis stage and subsequently developed a fibrosis index with excellent precise values for significant fibrosis and cirrhosis based on the Ishak fibrosis score. The inclusion of clinical biochemical parameters such as alanine aminotransferase (ALT), bilirubin, total protein, haemoglobin and international normalized ratio (INR) strengthened the study accuracy.

AIH-, PBC- and PSC-associated liver disease (see Section 11)

As far as we are aware, there are no published proteomic studies addressing the pathophysiology of these diseases. Cholangiocarcinoma that is associated with PSC has been studied using proteomics techniques [162]. Using tandem mass spectroscopy, Koopman *et al.* [162] identified Mac-2 binding protein (Mac-2BP) as a diagnostic marker in biliary carcinoma. The diagnostic accuracy of serum Mac-2BP expression in biliary carcinoma was superior to that of the established marker CA19-9. This study highlights the progression of proteomic research in liver disease: a focus initially on malignancy and biomarker discovery followed by studies of pathophysiology.

Alcoholic liver disease (ALD) and non-alcoholic fatty liver disease (NAFLD) (see Section 12 and Chapter 13)

Proteomic studies of alcoholism have, like the gene array studies, been an eclectic mix of research examining HCC development associated with alcohol, studies of hepatocyte alcohol-related biology and neural aspects of alcohol addiction. Studies of the intrahepatic toxic effects using proteomics have helped to outline toxicology profiles that can be used for screening as well as for trying to understand the alcohol-associated liver injury. Mitochondrial ethanol hepatotoxicity is thought to involve modification of protein thiol redox state. Using two-dimensional gel proteomic studies, Venkatraman *et al.* [163] were able to demonstrate a decrease in the reduced thiols on aldehyde dehydrogenase and glucose-regulated protein 78. The change in aldehyde dehydrogenase reduced thiols was accompanied by a reduction in the specific activity of the enzyme. The term 'alcoholomics' has been coined to refer to the study of those proteins (i.e. the subproteome) that are directly or indirectly affected by alcohol.

There is to date only a single proteomic study of NAFLD [93]. In this study, SELDI-TOF was used to profile serum samples from 91 patients with NAFLD compared with seven obese control subjects. Twelve unique protein peaks were identified that associated with NAFLD (four associated with steatosis, four with steatosis with non-specific inflammation and four with NASH). Unfortunately, although the peak mass is shown, SELDI-TOF lacks the accuracy required to give mass determination enabling unequivocal protein identification.

Hepatocellular carcinoma (HCC) (see Chapter 18.2.1)

To date, biomarker profiling has been applied predominantly to studies of malignant tissue [164–166]. In one study, HCC development in chronic HBV infection was characterized by a significant decrease in a fragment of complement-3 and an isoform of ApoA-1 [167]. In tissue studies, expression of variants of aldehyde dehydrogenase and tissue ferritin light chain have been identified in HCC, but not in surrounding tissues. Similar studies have also identified fructose-bisphosphatase arginosuccinate synthetase and cathepsin B preprotein as downregulated in HCC tissues. In an extensive study using laser capture microscopy, Li *et al.* [168] identified 261 proteins differentially expressed between HCC and non-HCC hepatocytes. Kinases in the Eph family were identified along with the Ras-like family of Rho proteins. In addition, a DED box polypeptide was downregulated while three members of the spliceosome and heterogeneous nuclear ribonucleoprotein K were upregulated. SELDI-TOF MS has also been used to examine the sera of 82 patients with cirrhosis (38 without and 44 with HCC). An algorithm including the six highest scoring peaks allowed the prediction of HCC in over 90% of cases [169]. The highest discriminating peak was a C-terminal peptide of vitronectin.

Proteomic analysis of blood as a marker of liver disease: 'next generation' liver function tests?

Several studies have evaluated proteomic analysis of serum protein as a diagnostic test to assess the severity of liver disease and, in particular, for non-invasive assessment of liver fibrosis. These studies are in their infancy, with basic methodologies still unresolved. However, the early studies show that the technique has

promise. In a pilot study of 46 patients with chronic hepatitis B, an artificial neural network (ANN) model was derived from the proteomic fingerprint and used to derive a fibrosis index [154]. The ANN fibrosis index correlated strongly with Ishak scores and stages of fibrosis. The areas under the receiver operating characteristic (ROC) curve for significant fibrosis (Ishak score > 2) and cirrhosis (Ishak score > 4) were both > 0.90. Inclusion of INR, total protein, bilirubin, ALT and haemoglobin in the ANN model improved the predictive power, giving accuracies > 90% for the prediction of fibrosis and cirrhosis. Another study found that pretreatment of serum proteins to remove N-glycosylation enhanced the resolution of serum polypeptide profiles [148]. This technique has the potential to improve diagnostic serum proteomics.

Chen and colleagues [170] developed a method of glycoproteomic analysis in an attempt to discover serum markers that can assist in the early detection of HBV-induced liver cancer. The authors showed that woodchucks diagnosed with HCC have dramatically higher levels of serum-associated core α-1, 6-linked fucose. One glycoprotein, Golgi protein 73 (GP73), was found to be elevated and hyperfucosylated in the serum of animals and humans with a diagnosis of HCC. Serum profiling was used to distinguish HCC from the earlier stages of HCV-related liver disease [56]. The proteomic model distinguished chronic HCV from HCV–HCC with moderate sensitivity and specificity. Inclusion of known serum markers α-fetoprotein, des-γ carboxyprothrombin and GP73 again improved the diagnostic accuracy significantly.

Proteomics in other liver disease

The metalloproteome is defined as the set of proteins that have metal binding capacity by being metalloproteins or having metal binding sites. The Cu and Zn metalloproteomes were defined in human hepatoma lines [171]. Although the gene for Wilson's disease has been identified, the mechanisms by which excess copper leads to oxidative stress and acute liver failure are not fully understood. Using an *in vitro* model of copper loading, novel copper binding proteins were isolated using proteomic techniques [140].

Although there has been limited proteomic analysis of liver tissue in models of disease, liver-associated pathobiological processes have been examined. In one study of the liver ageing process, 85 differentially expressed proteins were identified comprising antioxidation, glucose/amino acid metabolism, signal transduction and cell cycle systems [172]. In ageing, the antioxidation system showed a large increase in glutathione peroxidase and a decrease in glutathione *S*-transferase. Similarly, levels of glycolytic enzymes were decreased in the ageing animal. Furthermore, levels of proteins associated with signal transduction/apoptosis, for example cathepsin B, were decreased in the ageing process.

Proteomics has also been used to identify genes associated with LPS-induced liver injury. Proteins such as TRAIL receptor 2 were downregulated in the liver of LPS-treated mice whereas TNFAIP1 was significantly upregulated. Three different proteins were novel in the fatty liver proteome (aconitase succinate dehydrogenase, propanol CoA carboxylase α chain and 3-hydroxyanthrilate 3-4-dioxygenase).

Future studies

The future of 'omics' methodologies (genomics, proteomics and metabolomics) will address a number of technical and biological limitations of current techniques. Gene array analysis of mRNA transcript expression is the most developed functional genomics technique and has now been extended to the analysis of homogeneous cell populations from liver [173]. The last decade has seen this technique develop dramatically with the number of gene targets being included on arrays now enabling true transcriptome profiling as opposed to simply sampling the transcriptome. Additionally, the variability of the various gene array techniques is now better understood, with both technical and biological variability being addressed by the use of sample pooling, and technical and biological replicates. The adoption of MIAME standards for the presentation of results from gene array experiments promises better standardization, reproducibility and the ability to compare results [13,174]. The future will see the widespread development of specialized targeted gene arrays (such as fibrosis, cancer and iron metabolism arrays) as well as the use of gene arrays in clinical care. Gene array experiments that currently discriminate dissimilar cancer specimens will be able to discern much more closely related phenotypical stages in non-malignant disease progression. Additionally, the use of gene arrays covering multiple exons of an mRNA transcript will be able to detect alternative splicing, and the use of sequence mismatched oligonucleotides will detect multiple known and novel SNPs [175]. The bioinformatics analysis of gene expression data is now focused on outcome/phenotype prediction as well as uncovering biological pathway interactions, chromosomal loci identification and functional characterization in dynamic systems. These newer techniques are likely to become widely adopted research and then potentially clinically applicable methodologies.

Proteomic methods have lagged behind transcriptome analysis, and the immediate future heralds an increase in throughput, an increase in dynamic range/sensitivity and improved resolution of proteins within biological samples [35,36]. Sample preparation and prefractionation appear to be the key to improved resolution in the short term, with the use of proteomic methods to profile whole proteomes in a single specimen being a long-term distant research goal. Proteomic methods with future promise include the use of protein adjuncts to enable techniques such as DiGE and targeting of particular protein subclasses such as proteases. One particularly promising future technique is the use of imaging MS to perform a spatial profile of proteins in a tissue section (in a manner similar to SELDI-TOF but the laser actually rasters a tissue section) [176–178]. Another area of great

promise in proteomic research is its use in biomarker discovery. However, these techniques are still in their infancy as a result of differences in biological protein expression. The magnitude of the problems to be solved can be gauged by recent serum protein profiling that identified 3020 serum proteins by two or more tags but required 18 laboratories and failed to detect many of the low-abundance proteins (these are potential biomarkers) (www.hupo.org). Importantly, in this analysis, those laboratories that used very accurate MS analysis and prefractionation combined with multiple chromatographic separation methods were most successful. Additional improvements include the use of protein arrays on which antibodies or antigens are fixed to a membrane [179–183]. The initial experimental use of protein arrays is likely to involve studies of the immune system, given the number of antibodies available in this discipline. Studies such as the immunotyping of leukaemias with antibody arrays have demonstrated that the technology is available in a working format [184]. The study by Haab *et al.* [185] showed that a protein microarray could be produced allowing the detection of cognate ligands at an absolute concentration below 1 ng/mL. Unfortunately, only 20% of the arrayed antibodies and 50% of the arrayed antigen provided specific and accurate measurements of their cognate ligands at or below 1.6 μg/mL and 0.34 μg/mL respectively [185]. There are many commercial antibody and protein array sources that, along with academia, are developing these methodologies. Related technologies include the ability to capture proteins or antigens using technologies such as SELDI and BIAcore (biomolecular interaction analysis), both of which are available in chip formats. A newly emerging technology that promises to increase the initial 'downstream' characterization of differentially expressed genes is tissue arrays. Tissue arrays have been produced with over 600 individual tissue samples on a single glass slide; these are then analysed by immunohistochemistry, fluorescence *in situ* hybridization (FISH) and RNA/RNA *in situ* hybridization [186–191].

Finally, multiplexing is likely to be a key 'buzzword' in the future. The ability to conserve and process a sample in multiple ways, so that it can be subjected to many analytical methods, is an approach presently receiving a lot of attention [176–178]. The use of gene array platforms to profile transcriptomes, SNPs and promoter elements is readily possible on a single sample. Further protein analysis using chromatographic techniques with in-line parallel chromatographic sample treatments and separation is being adopted and can be readily automated. The adoption of cross-platform technologies is presently cost prohibitive for many institutions but likely to become more widespread with the adoption of core facilities in commercial and academic institutions and the focus on collaborations to use the inevitable deluge of data. This leaves us with new bioinformatic challenges. The future path for functional genomics/proteomics techniques appears to be bright and paved with almost endless data. Our ultimate challenge may be to make biological sense of these data!

References

1 Venter JC, Adams MD, Myers EW *et al.* (2001) The sequence of the human genome. *Science* 291 (5507), 1304–1351.

2 Kornblihtt AR (2005) Promoter usage and alternative splicing. *Curr Opin Cell Biol* 17 (3), 262–268.

3 Duyk GM (2002) Sharper tools and simpler methods. *Nature Genet* 32 (Suppl), 465–468.

4 Yano N, Habib NA, Fadden KJ *et al.* (2001) Profiling the adult human liver transcriptome: analysis by cDNA array hybridization. *J Hepatol* 35 (2), 178–186.

5 Shackel NA, Gorrell MD, McCaughan GW (2002) Gene array analysis and the liver. *Hepatology* 36 (6), 1313–1325.

6 Lee ML, Kuo FC, Whitmore GA *et al.* (2000) Importance of replication in microarray gene expression studies: statistical methods and evidence from repetitive cDNA hybridizations. *Proc Natl Acad Sci USA* 97 (18), 9834–9839.

7 Larkin JE, Frank BC, Gavras H *et al.* (2005) Independence and reproducibility across microarray platforms. *Nature Methods* 2 (5), 337–344.

8 Irizarry RA, Warren D, Spencer F *et al.* (2005) Multiple-laboratory comparison of microarray platforms. *Nature Methods* 2 (5), 345–350.

9 Churchill GA (2002) Fundamentals of experimental design for cDNA microarrays. *Nature Genet* 32 (Suppl) 490–495.

10 Yin JL, Shackel NA, Zekry A *et al.* (2001) Real-time reverse transcriptase-polymerase chain reaction (RT-PCR) for measurement of cytokine and growth factor mRNA expression with fluorogenic probes or SYBR Green I. *Immunol Cell Biol* 79 (3), 213–221.

11 Kendziorski C, Irizarry RA, Chen KS *et al.* (2005) On the utility of pooling biological samples in microarray experiments. *Proc Natl Acad Sci USA* 102 (12), 4252–4257.

12 Kendziorski CM, Zhang Y, Lan H *et al.* (2003) The efficiency of pooling mRNA in microarray experiments. *Biostatistics* 4 (3), 465–477.

13 Brazma A, Hingamp P, Quackenbush J *et al.* (2001) Minimum information about a microarray experiment (MIAME) – toward standards for microarray data. *Nature Genet* 29 (4), 365–371.

14 Feldman AL, Costouros NG, Wang E *et al.* (2002) Advantages of mRNA amplification for microarray analysis. *Biotechniques* 33 (4), 906–912, 914.

15 Eberwine J (1996) Amplification of mRNA populations using aRNA generated from immobilized oligo(dT)-T7 primed cDNA. *Biotechniques* 20 (4), 584–591.

16 Vernon SD, Unger ER, Rajeevan M *et al.* (2000) Reproducibility of alternative probe synthesis approaches for gene expression profiling with arrays. *J Mol Diagn* 2 (3), 124–127.

17 Zhu YY, Machleder EM, Chenchik A *et al.* (2001) Reverse transcriptase template switching: a SMART approach for full-length cDNA library construction. *Biotechniques* 30 (4), 892–897.

18 Seth D, Gorrell MD, McGuinness PH *et al.* (2003) SMART amplification maintains representation of relative gene expression: quantitative validation by real time PCR and application to studies of alcoholic liver disease in primates. *J Biochem Biophys Methods* 55 (1), 53–66.

19 Kohara Y, Noda H, Okano K *et al.* (2001) DNA hybridization using 'bead-array': probe-attached beads arrayed in a capillary in a predetermined order. *Nucleic Acids Res* 29 (Suppl. 1), 83–84.

20 Kohara Y, Noda H, Okano K *et al.* (2002) DNA probes on beads arrayed in a capillary, 'Bead-array', exhibited high hybridization performance. *Nucleic Acids Res* 30 (16), e87.

21 Noda H, Kohara Y, Okano K *et al.* (2003) Automated bead alignment apparatus using a single bead capturing technique for fabrication of a miniaturized bead-based DNA probe array. *Anal Chem* 75 (13), 3250–3255.

22 Cantin GT, Yates JR, 3rd (2004) Strategies for shotgun identification of post-translational modifications by mass spectrometry. *J Chromatogr A* 1053 (1–2), 7–14.

23 Resing KA, Ahn NG (2005) Proteomics strategies for protein identification. *FEBS Lett* 579 (4), 885–889.

24 Parent R, Beretta L (2005) Proteomics in the study of liver pathology. *J Hepatol* 43 (1), 177–183.

25 Colantonio DA, Chan DW (2005) The clinical application of proteomics. *Clin Chim Acta* 357, 151–158.

26 Lane CS (2005) Mass spectrometry-based proteomics in the life sciences. *Cell Mol Life Sci* 62 (7–8), 848–869.

27 Albala JS (2001) Array-based proteomics: the latest chip challenge. *Expert Rev Mol Diagn* 1 (2), 145–152.

28 Hanash S (2003) The emerging field of protein microarrays. *Proteomics* 3 (11), 2075.

29 Lauber WM, Carroll JA, Dufield DR *et al.* (2001) Mass spectrometry compatibility of two-dimensional gel protein stains. *Electrophoresis* 22 (5), 906–918.

30 Rodland KD (2004) Proteomics and cancer diagnosis: the potential of mass spectrometry. *Clin Biochem* 37 (7), 579–583.

31 Fountoulakis M, Juranville JF, Tsangaris G *et al.* (2004) Fractionation of liver proteins by preparative electrophoresis. *Amino Acids* 26 (1), 27–36.

32 Righetti PG, Castagna A, Herbert B *et al.* (2003) Prefractionation techniques in proteome analysis. *Proteomics* 3 (8), 1397–1407.

33 Righetti PG, Castagna A, Antonioli P *et al.* (2005) Prefractionation techniques in proteome analysis: the mining tools of the third millennium. *Electrophoresis* 26 (2), 297–319.

34 Kettman JR, Frey JR, Lefkovits I (2001) Proteome, transcriptome and genome: top down or bottom up analysis? *Biomol Eng* 18 (5), 207–212.

35 Kolch W, Mischak H, Chalmers MJ *et al.* (2004) Clinical proteomics: a question of technology. *Rapid Commun Mass Spectrom* 18 (19), 2365–2366.

36 Kolch W, Mischak H, Pitt AR (2005) The molecular make-up of a tumour: proteomics in cancer research. *Clin Sci (Lond)* 108 (5), 369–383.

37 Chernokalskaya E, Gutierrez S, Pitt AM *et al.* (2004) Ultrafiltration for proteomic sample preparation. *Electrophoresis* 25 (15), 2461–2468.

38 Nabi G, N'Dow J, Hasan TS *et al.* (2005) Proteomic analysis of urine in patients with intestinal segments transposed into the urinary tract. *Proteomics* 5 (6), 1729–1733.

39 Stasyk T, Huber LA (2004) Zooming in: fractionation strategies in proteomics. *Proteomics* 4 (12), 3704–3716.

40 Schirmer EC, Florens L, Guan T *et al.* (2003) Nuclear membrane proteins with potential disease links found by subtractive proteomics. *Science* 301 (5638), 1380–1382.

41 Murayama K, Fujimura T, Morita M *et al.* (2001) One-step subcellular fractionation of rat liver tissue using a Nycodenz density gradient prepared by freezing-thawing and two-dimensional sodium dodecyl sulfate electrophoresis profiles of the main fraction of organelles. *Electrophoresis* 22 (14), 2872–2880.

42 Lopez MF, Kristal BS, Chernokalskaya E *et al.* (2000) High-throughput profiling of the mitochondrial proteome using affinity fractionation and automation. *Electrophoresis* 21 (16), 3427–3440.

43 Zang L, Palmer Toy D, Hancock WS *et al.* (2004) Proteomic analysis of ductal carcinoma of the breast using laser capture microdissection, LC-MS, and 16O/18O isotopic labeling. *J Proteome Res* 3 (3), 604–612.

44 Tadros Y, Ruiz-Deya G, Crawford BE *et al.* (2003) In vivo proteomic analysis of cytokine expression in laser capture-microdissected urothelial cells of obstructed ureteropelvic junction procured by laparoscopic dismembered pyeloplasty. *J Endourol* 17 (5), 333–336.

45 Chignard N, Beretta L (2004) Proteomics for hepatocellular carcinoma marker discovery. *Gastroenterology* 127 (5 Suppl 1), S120–125.

46 Ahmed N, Barker G, Oliva KT *et al.* (2004) Proteomic-based identification of haptoglobin-1 precursor as a novel circulating biomarker of ovarian cancer. *Br J Cancer* 91 (1), 129–140.

47 Hanash S (2003) Disease proteomics. *Nature* 422 (6928), 226–232.

48 Mehta AI, Ross S, Lowenthal MS *et al.* (2003) Biomarker amplification by serum carrier protein binding. *Dis Markers* 19 (1), 1–10.

49 Greenbaum D, Baruch A, Hayrapetian L *et al.* (2002) Chemical approaches for functionally probing the proteome. *Mol Cell Proteomics* 1 (1), 60–68.

50 Joyce JA, Baruch A, Chehade K *et al.* (2004) Cathepsin cysteine proteases are effectors of invasive growth and angiogenesis during multistage tumorigenesis. *Cancer Cell* 5 (5), 443–453.

51 Barglow KT, Cravatt BF (2004) Discovering disease-associated enzymes by proteome reactivity profiling. *Chem Biol* 11 (11), 1523–1531.

52 Patton WF (2002) Detection technologies in proteome analysis. *J Chromatogr B Anal Technol Biomed Life Sci* 771 (1–2), 3–31.

53 Henkel C, Roderfeld M, Weiskirchen R *et al.* (2005) Identification of fibrosis-relevant proteins using DIGE (difference in gel electrophoresis) in different models of hepatic fibrosis. *Z Gastroenterol* 43 (1), 23–9.

54 Neverova I, Van Eyk JE (2005) Role of chromatographic techniques in proteomic analysis. *J Chromatogr B Anal Technol Biomed Life Sci* 815 (1–2), 51–63.

55 Steel LF, Haab BB, Hanash SM (2005) Methods of comparative proteomic profiling for disease diagnostics. *J Chromatogr B Anal Technol Biomed Life Sci* 815 (1–2), 275–284.

56 Schwegler EE, Cazares L, Steel LF *et al.* (2005) SELDI-TOF MS profiling of serum for detection of the progression of chronic hepatitis C to hepatocellular carcinoma. *Hepatology* 41 (3), 634–642.

57 Cordingley HC, Roberts SL, Tooke P *et al.* (2003) Multifactorial screening design and analysis of SELDI-TOF ProteinChip array optimization experiments. *Biotechniques* 34 (2), 364–365, 368–373.

58 Utz PJ (2005) Protein arrays for studying blood cells and their secreted products. *Immunol Rev* 204, 264–282.

59 Smyth GK, Yang YH, Speed T (2003) Statistical issues in cDNA microarray data analysis. *Methods Mol Biol* 224, 111–136.

60 Smyth GK, Speed T (2003) Normalization of cDNA microarray data. *Methods* 31 (4), 265–273.

61 Yang YH, Dudoit S, Luu P *et al.* (2002) Normalization for cDNA microarray data: a robust composite method addressing single and multiple slide systematic variation. *Nucleic Acids Res* 30 (4), e15.

62 Yang YH, Buckley MJ, Speed TP (2001) Analysis of cDNA microarray images. *Brief Bioinform* 2 (4), 341–349.

63 Yang MC, Ruan QG, Yang JJ *et al.* (2001) A statistical method for flagging weak spots improves normalization and ratio estimates in microarrays. *Physiol Genomics* 7 (1), 45–53.

64 Wu LF, Hughes TR, Davierwala AP *et al.* (2002) Large-scale prediction of *Saccharomyces cerevisiae* gene function using overlapping transcriptional clusters. *Nature Genet* 31 (3), 255–265.

65 Jain KK (2000) Applications of proteomics in oncology. *Pharmacogenomics* 1 (4), 385–393.

66 Hekkelman ML, Vriend G (2005) MRS: a fast and compact retrieval system for biological data. *Nucleic Acids Res* 33 (Web Server issue), W766–769.

67 Stuart JM, Segal E, Koller D *et al.* (2003) A gene-coexpression network for global discovery of conserved genetic modules. *Science* 302 (5643), 249–255.

68 Chaussabel D, Sher A (2002) Mining microarray expression data by literature profiling. *Genome Biol* 3 (10), RESEARCH0055.

69 Yuan J, Liu Y, Wang Y *et al.* (2001) Genome analysis with gene-indexing databases. *Pharmacol Ther* 91 (2), 115–132.

70 Coulouarn C, Lefebvre G, Derambure C *et al.* (2004) Altered gene expression in acute systemic inflammation detected by complete coverage of the human liver transcriptome. *Hepatology* 39 (2), 353–364.

71 Yamashita T, Hashimoto S, Kaneko S *et al.* (2000) Comprehensive gene expression profile of a normal human liver. *Biochem Biophys Res Commun* 269 (1), 110–116.

72 Yamashita T, Honda M, Takatori H *et al.* (2004) Genome-wide transcriptome mapping analysis identifies organ-specific gene expression patterns along human chromosomes. *Genomics* 84 (5), 867–875.

73 Yamashita Y, Shimada M, Harimoto N *et al.* (2004) cDNA microarray analysis in hepatocyte differentiation in Huh 7 cells. *Cell Transplant* 13 (7–8), 793–797.

74 Enard W, Khaitovich P, Klose J *et al.* (2002) Intra- and interspecific variation in primate gene expression patterns. *Science* 296 (5566), 340–343.

75 Bigger CB, Brasky KM, Lanford RE (2001) DNA microarray analysis of chimpanzee liver during acute resolving hepatitis C virus infection. *J Virol* 75 (15), 7059–7066.

76 Su AI, Pezacki JP, Wodicka L *et al.* (2002) Genomic analysis of the host response to hepatitis C virus infection. *Proc Natl Acad Sci USA* 99 (24), 15669–15674.

77 Karayiannis P (2005) The hepatitis C virus NS3/4A protease complex interferes with pathways of the innate immune response. *J Hepatol* 43 (4), 743–745.

78 Chen L, Borozan I, Feld J *et al.* (2005) Hepatic gene expression discriminates responders and nonresponders in treatment of chronic hepatitis C viral infection. *Gastroenterology* 128 (5), 1437–1444.

79 Honda M, Kaneko S, Kawai H *et al.* (2001) Differential gene expression between chronic hepatitis B and C hepatic lesions. *Gastroenterology* 120 (4), 955–966.

80 Shackel NA, McGuinness PH, Abbott CA *et al.* (2002) Insights into the pathobiology of hepatitis C virus-associated cirrhosis: analysis of intrahepatic differential gene expression. *Am J Pathol* 160 (2), 641–654.

81 Smith MW, Yue ZN, Korth MJ *et al.* (2003) Hepatitis C virus and liver disease: global transcriptional profiling and identification of potential markers. *Hepatology* 38 (6), 1458–1467.

82 Shackel NA, McGuinness PH, Abbott CA *et al.* (2003) Novel differential gene expression in human cirrhosis detected by suppression subtractive hybridization. *Hepatology* 38 (3), 577–588.

83 McCaughan GW, Xiao XH, Zekry A *et al.* (2003) The intrahepatic response to HCV infection. In: Jilbert AR, Grgacic EVL, Vickery K *et al.* (eds) *Proceedings of the 11th International Symposium on Viral Hepatitis and Liver Disease*. Sydney: Australian Centre for Hepatitis Virology, pp. 100–106.

84 Mansfield ES, Sarwal MM (2004) Arraying the orchestration of allograft pathology. *Am J Transplant* 4 (6), 853–862.

85 McCaughan GW, Zekry A (2004) Mechanisms of HCV reinfection and allograft damage after liver transplantation. *J Hepatol* 40 (3), 368–374.

86 McCaughan GW, Zekry A (2002) Pathogenesis of hepatitis C virus recurrence in the liver allograft. *Liver Transpl* 8 (10 Suppl 1), S7–S13.

87 Wieland S, Thimme R, Purcell RH *et al.* (2004) Genomic analysis of the host response to hepatitis B virus infection. *Proc Natl Acad Sci USA* 101 (17), 6669–6674.

88 Wieland SF, Chisari FV (2005) Stealth and cunning: hepatitis B and hepatitis C viruses. *J Virol* 79 (15), 9369–9380.

89 Seth D, Leo MA, McGuinness PH *et al.* (2003) Gene expression profiling of alcoholic liver disease in the baboon (*Papio hamadryas*) and human liver. *Am J Pathol* 163 (6), 2303–2317.

90 Deaciuc IV, Doherty DE, Burikhanov R *et al.* (2004) Large-scale gene profiling of the liver in a mouse model of chronic, intragastric ethanol infusion. *J Hepatol* 40 (2), 219–227.

91 Shackel NA, McGuinness PH, Abbott CA *et al.* (2001) Identification of novel molecules and pathogenic pathways in primary biliary cirrhosis: cDNA array analysis of intrahepatic differential gene expression. *Gut* 49 (4), 565–576.

92 Sreekumar R, Rosado B, Rasmussen D *et al.* (2003) Hepatic gene expression in histologically progressive nonalcoholic steatohepatitis. *Hepatology* 38 (1), 244–251.

93 Younossi ZM, Baranova A, Ziegler K *et al.* (2005) A genomic and proteomic study of the spectrum of nonalcoholic fatty liver disease. *Hepatology* 42 (3), 665–674.

94 Younossi ZM, Gorreta F, Ong JP *et al.* (2005) Hepatic gene expression in patients with obesity-related non-alcoholic steatohepatitis. *Liver Int* 25 (4), 760–771.

95 Zhang DY, Sabla G, Shivakumar P *et al.* (2004) Coordinate expression of regulatory genes differentiates embryonic and perinatal forms of biliary atresia. *Hepatology* 39 (4), 954–962.

96 Galvin P, Clarke LA, Harvey S *et al.* (2004) Microarray analysis in cystic fibrosis. *J Cyst Fibros* 3 (Suppl 2), 29–33.

97 Norkina O, Kaur S, Ziemer D *et al.* (2004) Inflammation of the cystic fibrosis mouse small intestine. *Am J Physiol Gastrointest Liver Physiol* 286 (6), G1032–1041.

98 Srivastava M, Eidelman O, Pollard HB (1999) Pharmacogenomics of the cystic fibrosis transmembrane conductance regulator (CFTR) and the cystic fibrosis drug CPX using genome microarray analysis. *Mol Med* 5 (11), 753–767.

99 Shirota Y, Kaneko S, Honda M *et al.* (2001) Identification of differentially expressed genes in hepatocellular carcinoma with cDNA microarrays. *Hepatology* 33 (4), 832–840.

100 Kim JW, Ye Q, Forgues M *et al.* (2004) Cancer-associated molecular signature in the tissue samples of patients with cirrhosis. *Hepatology* 39 (2), 518–527.

101 Kim BY, Lee JG, Park S *et al.* (2004) Feature genes of hepatitis B virus-positive hepatocellular carcinoma, established by its molecular discrimination approach using prediction analysis of microarray. *Biochim Biophys Acta* 1739 (1), 50–61.

102 Iizuka N, Oka M, Yamada-Okabe H *et al.* (2004) Molecular signature in three types of hepatocellular carcinoma with different viral origin by oligonucleotide microarray. *Int J Oncol* 24 (3), 565–574.

103 Iizuka N, Oka M, Yamada-Okabe H *et al.* (2002) Comparison of gene expression profiles between hepatitis B virus- and hepatitis C virus-infected hepatocellular carcinoma by oligonucleotide microarray data on the basis of a supervised learning method. *Cancer Res* 62 (14), 3939–3944.

104 Qin LX, Tang ZY (2004) Recent progress in predictive biomarkers for metastatic recurrence of human hepatocellular carcinoma: a review of the literature. *J Cancer Res Clin Oncol* 130 (9), 497–513.

105 Ye QH, Qin LX, Forgues M *et al.* (2003) Predicting hepatitis B virus-positive metastatic hepatocellular carcinomas using gene expression profiling and supervised machine learning. *Nature Med* 9 (4), 416–423.

106 Pan HW, Ou YH, Peng SY *et al.* (2003) Overexpression of osteopontin is associated with intrahepatic metastasis, early recurrence, and poorer prognosis of surgically resected hepatocellular carcinoma. *Cancer* 98 (1), 119–127.

107 Tang ZY, Ye SL, Liu YK *et al.* (2004) A decade's studies on metastasis of hepatocellular carcinoma. *J Cancer Res Clin Oncol* 130 (4), 187–196.

108 Wang W, Yang LY, Huang GW *et al.* (2004) Genomic analysis reveals RhoC as a potential marker in hepatocellular carcinoma with poor prognosis. *Br J Cancer* 90 (12), 2349–2355.

109 Obama K, Ura K, Li M *et al.* (2005) Genome-wide analysis of gene expression in human intrahepatic cholangiocarcinoma. *Hepatology* 41 (6), 1339–1348.

110 Hansel DE, Rahman A, Hidalgo M *et al.* (2003) Identification of novel cellular targets in biliary tract cancers using global gene expression technology. *Am J Pathol* 163 (1), 217–229.

111 Bulera SJ, Eddy SM, Ferguson E *et al.* (2001) RNA expression in the early characterization of hepatotoxicants in Wistar rats by high-density DNA microarrays. *Hepatology* 33 (5), 1239–1258.

112 Cunningham MJ, Liang S, Fuhrman S *et al.* (2000) Gene expression microarray data analysis for toxicology profiling. *Ann NY Acad Sci* 9 (19), 52–67.

113 Huang Q, Jin X, Gaillard ET *et al.* (2004) Gene expression profiling reveals multiple toxicity endpoints induced by hepatotoxicants. *Mutat Res* 549 (1–2), 147–167.

114 Jiang Y, Liu J, Waalkes M *et al.* (2004) Changes in the gene expression associated with carbon tetrachloride-induced liver fibrosis persist after cessation of dosing in mice. *Toxicol Sci* 79 (2), 404–410.

115 Jolly RA, Goldstein KM, Wei T *et al.* (2005) Pooling samples within microarray studies: a comparative analysis of rat liver transcription response to prototypical toxicants. *Physiol Genomics* 22 (3), 346–355.

116 Jung JW, Park JS, Hwang JW *et al.* (2004) Gene expression analysis of peroxisome proliferators- and phenytoin-induced hepatotoxicity using cDNA microarray. *J Vet Med Sci* 66 (11), 1329–1333.

117 Minami K, Saito T, Narahara M *et al.* (2005) Relationship between hepatic gene expression profiles and hepatotoxicity in five typical hepatotoxicant-administered rats. *Toxicol Sci* 87 (1), 296–305.

118 Shankar K, Vaidya VS, Corton JC *et al.* (2003) Activation of PPAR-alpha in streptozotocin-induced diabetes is essential for resistance against acetaminophen toxicity. *FASEB J* 17 (12), 1748–1750.

119 Ulrich RG, Rockett JC, Gibson GG *et al.* (2004) Overview of an interlaboratory collaboration on evaluating the effects of model hepatotoxicants on hepatic gene expression. *Environ Health Perspect* 112 (4), 423–427.

120 Waring JF, Ciurlionis R, Jolly RA *et al.* (2001) Microarray analysis of hepatotoxins *in vitro* reveals a correlation between gene expression profiles and mechanisms of toxicity. *Toxicol Lett* 120 (1–3), 359–368.

121 Waring JF, Jolly RA, Ciurlionis R *et al.* (2001) Clustering of hepatotoxins based on mechanism of toxicity using gene expression profiles. *Toxicol Appl Pharmacol* 175 (1), 28–42.

122 Waring JF, Cavet G, Jolly RA *et al.* (2003) Development of a DNA microarray for toxicology based on hepatotoxin-regulated sequences. *EHP Toxicogenomics* 111 (1T), 53–60.

123 Utsunomiya T, Okamoto M, Hashimoto M *et al.* (2004) A gene-expression signature can quantify the degree of hepatic fibrosis in the rat. *J Hepatol* 41 (3), 399–406.

124 Iida M, Anna CH, Hartis J *et al.* (2003) Changes in global gene and protein expression during early mouse liver carcinogenesis induced by non-genotoxic model carcinogens oxazepam and Wyeth-14,643. *Carcinogenesis* 24 (4), 757–770.

125 Lefkovits I, Kettman JR, Frey JR (2001) Proteomic analysis of rare molecular species of translated polypeptides from a mouse fetal thymus cDNA library. *Proteomics* 1 (4), 560–573.

126 Lefkovits I, Kettman JR, Frey JR (2000) Global analysis of gene expression in cells of the immune system I. Analytical limitations in obtaining sequence information on polypeptides in two-dimensional gel spots. *Electrophoresis* 21 (13), 2688–2693.

127 Ratziu V, Charlotte F, Heurtier A *et al.* (2005) Sampling variability of liver biopsy in nonalcoholic fatty liver disease. *Gastroenterology* 128 (7), 1898–1906.

128 Regev A, Berho M, Jeffers LJ *et al.* (2002) Sampling error and intraobserver variation in liver biopsy in patients with chronic HCV infection. *Am J Gastroenterol* 97 (10), 2614–2618.

129 Anderson L, Seilhamer J (1997) A comparison of selected mRNA and protein abundances in human liver. *Electrophoresis* 18 (3–4), 533–537.

130 ter Kuile BH, Westerhoff HV (2001) Transcriptome meets metabolome: hierarchical and metabolic regulation of the glycolytic pathway. *FEBS Lett* 500 (3), 169–171.

131 Miklos GL, Maleszka R (2001) Integrating molecular medicine with functional proteomics: realities and expectations. *Proteomics* 1 (1), 30–41.

132 Miklos GL, Maleszka R (2001) Protein functions and biological contexts. *Proteomics* 1 (2), 169–178.

133 Jansen R, Gerstein M (2000) Analysis of the yeast transcriptome with structural and functional categories: characterizing highly expressed proteins. *Nucleic Acids Res* 28 (6), 1481–1488.

134 Kristensen DB, Kawada N, Imamura K *et al.* (2000) Proteome analysis of rat hepatic stellate cells. *Hepatology* 32 (2), 268–277.

135 Kawada N, Kristensen DB, Asahina K *et al.* (2001) Characterization of a stellate cell activation-associated protein (STAP) with peroxidase activity found in rat hepatic stellate cells. *J Biol Chem* 276 (27), 25318–25323.

136 Eng FJ, Friedman SL (2000) Fibrogenesis I. New insights into hepatic stellate cell activation: the simple becomes complex. *Am J Physiol Gastrointest Liver Physiol* 279 (1), G7–G11.

137 Seow TK, Liang RC, Leow CK *et al.* (2001) Hepatocellular carcinoma: from bedside to proteomics. *Proteomics* 1 (10), 1249–1263.

138 Kaplowitz N (2004) Drug-induced liver injury. *Clin Infect Dis* 38 (Suppl 2), S44–48.

139 Fella K, Gluckmann M, Hellmann J *et al.* (2005) Use of two-dimensional gel electrophoresis in predictive toxicology: identification of potential early protein biomarkers in chemically induced hepatocarcinogenesis. *Proteomics* 5 (7), 1914–1927.

140 Roelofsen H, Balgobind R, Vonk RJ (2004) Proteomic analyzes of copper metabolism in an *in vitro* model of Wilson disease using surface enhanced laser desorption/ionization-time of flight-mass spectrometry. *J Cell Biochem* 93 (4), 732–740.

141 Low TY, Leow CK, Salto-Tellez M *et al.* (2004) A proteomic analysis of thioacetamide-induced hepatotoxicity and cirrhosis in rat livers. *Proteomics* 4 (12), 3960–3974.

142 Nordvarg H, Flensburg J, Ronn O *et al.* (2004) A proteomics approach to the study of absorption, distribution, metabolism, excretion, and toxicity. *J Biomol Tech* 15 (4), 265–275.

143 Merrick BA, Bruno ME (2004) Genomic and proteomic profiling for biomarkers and signature profiles of toxicity. *Curr Opin Mol Ther* 6 (6), 600–607.

144 Guzey C, Spigset O (2002) Genotyping of drug targets: a method to predict adverse drug reactions? *Drug Safety* 25 (8), 553–560.

145 Meneses-Lorente G, Guest PC, Lawrence J *et al.* (2004) A proteomic investigation of drug-induced steatosis in rat liver. *Chem Res Toxicol* 17 (5), 605–612.

146 Gao J, Ann Garulacan L, Storm SM *et al.* (2004) Identification of *in vitro* protein biomarkers of idiosyncratic liver toxicity. *Toxicol In Vitro* 18 (4), 533–541.

147 Fountoulakis M, Suter L (2002) Proteomic analysis of the rat liver. *J Chromatogr B Anal Technol Biomed Life Sci* 782 (1–2), 197–218.

148 Comunale MA, Mattu TS, Lowman MA *et al.* (2004) Comparative proteomic analysis of de-N-glycosylated serum from hepatitis B carriers reveals polypeptides that correlate with disease status. *Proteomics* 4 (3), 826–838.

149 Garry RF, Dash S (2003) Proteomics computational analyses suggest that hepatitis C virus E1 and pestivirus E2 envelope glycoproteins are truncated class II fusion proteins. *Virology* 307 (2), 255–265.

150 Kim W, Oe Lim S, Kim JS *et al.* (2003) Comparison of proteome between hepatitis B virus- and hepatitis C virus-associated hepatocellular carcinoma. *Clin Cancer Res* 9 (15), 5493–5500.

151 Lu H, Li W, Noble WS *et al.* (2004) Riboproteomics of the hepatitis C virus internal ribosomal entry site. *J Proteome Res* 3 (5), 949–957.

152 Rosenberg S (2001) Recent advances in the molecular biology of hepatitis C virus. *J Mol Biol* 313 (3), 451–464.

153 Scholle F, Li K, Bodola F *et al.* (2004) Virus–host cell interactions during hepatitis C virus RNA replication: impact of polyprotein expression on the cellular transcriptome and cell cycle association with viral RNA synthesis. *J Virol* 78 (3), 1513–1524.

154 Poon TC, Hui AY, Chan HL *et al.* (2005) Prediction of liver fibrosis and cirrhosis in chronic hepatitis B infection by serum proteomic fingerprinting: a pilot study. *Clin Chem* 51 (2), 328–335.

155 Xu C, Chang C, Yuan J *et al.* (2004) Identification and characterization of 177 unreported genes associated with liver regeneration. *Genomics Proteomics Bioinformatics* 2 (2), 109–118.

156 Pasa-Tolic L, Masselon C, Barry RC *et al.* (2004) Proteomic analyses using an accurate mass and time tag strategy. *Biotechniques* 37 (4), 621–624, 626–633, 636 passim.

157 Bogdanov B, Smith RD (2005) Proteomics by FTICR mass spectrometry: top down and bottom up. *Mass Spectrom Rev* 24 (2), 168–200.

158 Takashima M, Kuramitsu Y, Yokoyama Y *et al.* (2005) Overexpression of alpha enolase in hepatitis C virus-related hepatocellular carcinoma: association with tumor progression as determined by proteomic analysis. *Proteomics* 5 (6), 1686–1692.

159 Kuramitsu Y, Nakamura K (2005) Current progress in proteomic study of hepatitis C virus-related human hepatocellular carcinoma. *Expert Rev Proteomics* 2 (4), 589–601.

160 Takashima M, Kuramitsu Y, Yokoyama Y *et al.* (2003) Proteomic profiling of heat shock protein 70 family members as biomarkers for hepatitis C virus-related hepatocellular carcinoma. *Proteomics* 3 (12), 2487–2493.

161 He QY, Lau GK, Zhou Y *et al.* (2003) Serum biomarkers of hepatitis B virus infected liver inflammation: a proteomic study. *Proteomics* 3 (5), 666–674.

162 Koopmann J, Thuluvath PJ, Zahurak ML *et al.* (2004) Mac-2-binding protein is a diagnostic marker for biliary tract carcinoma. *Cancer* 101 (7), 1609–1615.

163 Venkatraman A, Landar A, Davis AJ *et al.* (2004) Oxidative modification of hepatic mitochondria protein thiols: effect of chronic alcohol consumption. *Am J Physiol Gastrointest Liver Physiol* 286 (4), G521–527.

164 Liu AY, Zhang H, Sorensen CM *et al.* (2005) Analysis of prostate cancer by proteomics using tissue specimens. *J Urol* 173 (1), 73–78.

165 Wong YF, Cheung TH, Lo KW *et al.* (2004) Protein profiling of cervical cancer by protein-biochips: proteomic scoring to discriminate cervical cancer from normal cervix. *Cancer Lett* 211 (2), 227–234.

166 Wiesner A (2004) Detection of tumor markers with ProteinChip technology. *Curr Pharm Biotechnol* 5 (1), 45–67.

167 Steel LF, Shumpert D, Trotter M *et al.* (2003) A strategy for the comparative analysis of serum proteomes for the discovery of biomarkers for hepatocellular carcinoma. *Proteomics* 3 (5), 601–609.

168 Li C, Hong Y, Tan YX *et al.* (2004) Accurate qualitative and quantitative proteomic analysis of clinical hepatocellular carcinoma using laser capture microdissection coupled with isotope-coded affinity tag and two-dimensional liquid chromatography mass spectrometry. *Mol Cell Proteomics* 3 (4), 399–409.

169 Paradis V, Degos F, Dargere D *et al.* (2005) Identification of a new marker of hepatocellular carcinoma by serum protein profiling of patients with chronic liver diseases. *Hepatology* 41 (1), 40–47.

170 Chen J, Kahne T, Rocken C *et al.* (2004) Proteome analysis of gastric cancer metastasis by two-dimensional gel electrophoresis and matrix assisted laser desorption/ionization-mass spectrometry for identification of metastasis-related proteins. *J Proteome Res* 3 (5), 1009–1016.

171 She YM, Narindrasorasak S, Yang S *et al.* (2003) Identification of metal-binding proteins in human hepatoma lines by immobilized metal affinity chromatography and mass spectrometry. *Mol Cell Proteomics* 2 (12), 1306–1318.

172 Cho YM, Bae SH, Choi BK *et al.* (2003) Differential expression of the liver proteome in senescence accelerated mice. *Proteomics* 3 (10), 1883–1894.

173 Schnabl B, Purbeck CA, Choi YH *et al.* (2003) Replicative senescence of activated human hepatic stellate cells is accompanied by a pronounced inflammatory but less fibrogenic phenotype. *Hepatology* 37, 653–664.

174 Killion PJ, Sherlock G, Iyer VR (2003) The Longhorn Array Database (LAD): an open-source, MIAME compliant implementation of the Stanford Microarray Database (SMD). *BMC Bioinformatics* 4 (1), 32.

175 Mockler TC, Ecker JR (2005) Applications of DNA tiling arrays for whole-genome analysis. *Genomics* 85 (1), 1–15.

176 Rohner TC, Staab D, Stoeckli M (2005) MALDI mass spectrometric imaging of biological tissue sections. *Mech Ageing Dev* 126 (1), 177–185.

177 Maddalo G, Petrucci F, Iezzi M *et al.* (2005) Analytical assessment of MALDI-TOF imaging mass spectrometry on thin histological samples. An insight in proteome investigation. *Clin Chim Acta* 357, 210–218.

178 McDonnell LA, Piersma SR, MaartenAltelaar AF *et al.* (2005) Subcellular imaging mass spectrometry of brain tissue. *J Mass Spectrom* 40 (2), 160–168.

179 Borrebaeck CA, Ekstrom S, Hager AC *et al.* (2001) Protein chips based on recombinant antibody fragments: a highly sensitive approach

as detected by mass spectrometry. *Biotechniques* 30 (5), 1126–1130, 1132.

180 Kodadek T (2001) Protein microarrays: prospects and problems. *Chem Biol* 8 (2), 105–115.

181 Zhu H, Snyder M (2001) Protein arrays and microarrays. *Curr Opin Chem Biol* 5 (1), 40–45.

182 Walter G, Bussow K, Cahill D *et al.* (2000) Protein arrays for gene expression and molecular interaction screening. *Curr Opin Microbiol* 3 (3), 298–302.

183 Nagayama K (1997) Protein arrays: concepts and subjects. *Adv Biophys* 34, 3–23.

184 Belov L, de la Vega O, dos Remedios CG *et al.* (2001) Immunophenotyping of leukemias using a cluster of differentiation antibody microarray. *Cancer Res* 61 (11), 4483–4489.

185 Haab BB, Dunham MJ, Brown PO (2001) Protein microarrays for highly parallel detection and quantitation of specific proteins and antibodies in complex solutions. *Genome Biol* 2 (2), RESEARCH0004.

186 Hoos A, Urist MJ, Stojadinovic A *et al.* (2001) Validation of tissue microarrays for immunohistochemical profiling of cancer specimens using the example of human fibroblastic tumors. *Am J Pathol* 158 (4), 1245–1251.

187 Gillett CE, Springall RJ, Barnes DM *et al.* (2000) Multiple tissue core arrays in histopathology research: a validation study. *J Pathol* 192 (4), 549–553.

188 Ibarrola N, Pandey A (2001) Integrating DNA and tissue microarrays for cancer profiling. *Trends Biochem Sci* 26 (10), 589.

189 Andersen CL, Hostetter G, Grigoryan A *et al.* (2001) Improved procedure for fluorescence in situ hybridization on tissue microarrays. *Cytometry* 45 (2), 83–86.

190 Dhanasekaran SM, Barrette TR, Ghosh D *et al.* (2001) Delineation of prognostic biomarkers in prostate cancer. *Nature* 412 (6849), 822–826.

191 Moch H, Kononen T, Kallioniemi OP *et al.* (2001) Tissue microarrays: what will they bring to molecular and anatomic pathology? *Adv Anat Pathol* 8 (1), 14–20.

192 Bigger CB, Guerra B, Brasky KM *et al.* (2004) Intrahepatic gene expression during chronic hepatitis C virus infection in chimpanzees. *J Virol* 78 (24), 13779–137792.

193 Shackel NA, McGuinness PH, Abbott CA *et al.* (2002) Insights into the pathobiology of hepatitis C virus associated cirrhosis: analysis of intrahepatic differential gene expression. *Am J Pathol* 160 (2), 641–654.

194 Girard S, Vossman E, Misek DE *et al.* (2004) Hepatitis C virus NS5A-regulated gene expression and signaling revealed via microarray and comparative promoter analyses. *Hepatology* 40 (3), 708–718.

195 Smith MW, Yue ZN, Geiss GK *et al.* (2003) Identification of novel tumor markers in hepatitis C virus-associated hepatocellular carcinoma. *Cancer Res* 63 (4), 859–864.

196 Kondoh N, Wakatsuki T, Ryo A *et al.* (1999) Identification and characterization of genes associated with human hepatocellular carcinogenesis. *Cancer Res* 59 (19), 4990–4996.

197 Yamashita T, Kaneko S, Hashimoto S *et al.* (2001) Serial analysis of gene expression in chronic hepatitis C and hepatocellular carcinoma. *Biochem Biophys Res Commun* 282 (2), 647–654.

198 Liu K, Lei XZ, Zhao LS *et al.* (2005) Tissue microarray for high-throughput analysis of gene expression profiles in hepatocellular carcinoma. *World J Gastroenterol* 11 (9), 1369–1372.

199 Kang YK, Hong SW, Lee H *et al.* (2004) Overexpression of clusterin in human hepatocellular carcinoma. *Hum Pathol* 35 (11), 1340–1346.

200 Tackels-Horne D, Goodman MD, Williams AJ *et al.* (2001) Identification of differentially expressed genes in hepatocellular carcinoma and metastatic liver tumors by oligonucleotide expression profiling. *Cancer* 92 (2), 395–405.

201 Obama K, Ura K, Satoh S *et al.* (2005) Up-regulation of PSF2, a member of the GINS multiprotein complex, in intrahepatic cholangiocarcinoma. *Oncol Rep* 14 (3), 701–706.

4 Pathology

4.1 Histological features

Valeer J. Desmet, Tania Roskams and Miguel Bruguera

Hepatocellular changes

The ground-glass hepatocyte [1] displays a more homogeneous, paler eosinophilic staining than the normal hepatocyte in all or part of its cytoplasm (see Plates 4.1.1 and 4.1.29, facing p. 72). It is most typically observed in carriers of hepatitis B virus (HBV), in whom its appearance is due to hypertrophy of the endoplasmic reticulum, loaded with HBsAg.

A more or less similar appearance of hepatocytes may be observed in drug induction, in myoclonal epilepsy (Lafora's disease), in alcoholics treated with aversion drugs (cyanamide) [2], in glycogenosis type 4 (Andersen's disease), in fibrinogen storage disease [3] and in immunosuppressed transplanted patients [4,5]. In HBV-infected patients, HBsAg can be demonstrated in ground-glass hepatocytes by special stains (Shikata's orcein stain, Victoria blue), immunohistochemical techniques, and regular and immunoelectron microscopy [6–8].

Acidophil condensation refers to a hepatocyte of reduced size, with increased density and eosinophilia of its cytoplasm, and usually pyknosis of the nucleus. The cell may assume a rhomboid outline [6,9].

Ballooning or hydropic swelling describes hepatocytes characterized by an increased volume with pale, 'empty' appearance of most of their cytoplasm; the remaining cytoplasm appears condensed in the perinuclear region (see Plates 4.1.2 and 4.1.8, facing p. 72). This lesion is thought to represent a precursor stage of lytic necrosis. It is observed in viral, toxic and ischaemic liver damage, predominantly in acinar zone 3 [6,9].

Alcoholic clear cells ('hépatite alcoolique à cellules claires' [10]) are enlarged and rounded hepatocytes with pale, rarefied cytoplasm; nuclei may be enlarged with prominent nucleoli. The cell borders are usually distinct, accentuated by pericellular fibrosis. Mallory bodies often occur in 'alcoholic clear cells' [7].

Feathery degeneration of hepatocytes is seen in cholestasis, mostly of longer duration. This lesion resembles 'hydropic swelling' with, in addition, bilirubin impregnation of the visible threads of cytoplasm. Ultrastructurally, such cells display whorls of membranous material, thought to result from intracellular membrane damage due to the detergent action of retained bile acids [11,12].

Alcoholic hyaline or Mallory body refers to an intracellular inclusion in hepatocytes, which are often pale and swollen (alcoholic clear cells). In its typical form, the Mallory body is an irregular, intensely eosinophilic mass (see Plate 4.1.3, facing p. 72). The lesion corresponds to clumps of aggregated cytokeratin filaments. Small Mallory bodies are better identified by immunostaining for cytokeratins.

The term alcoholic hyaline may be misleading because the lesion occurs in numerous other diseases besides alcoholic liver damage, especially in chronic cholestasis [13] and in non-alcoholic steatohepatitis.

In alcoholic liver disease, Mallory body-containing hepatocytes may be encircled by polymorphonuclear and/or mononuclear inflammatory cells; this lesion is known as satellitosis [7].

Megamitochondria (giant mitochondria) appear as round or cigar-shaped, intensely eosinophilic inclusions of variable size, up to the size of a nucleus (see Plate 4.1.3, facing p. 72); they are negative on periodic acid–Schiff (PAS)–diastase stained sections, in contrast to α_1-antitrypsin inclusions and phagolysosomes, with which they might be confused [7]. Their presence suggests a heavy alcohol consumption [14].

Mitochondriosis (oxyphil or oncocytic change) [15] corresponds to an increase in the number of mitochondria in hepatocytes, rendering the latter more granular and strongly eosinophilic than normal parenchymal cells. Oncocytic hepatocytes are often found in clusters.

Sanded nuclei [16] are hepatocellular nuclei stuffed with hepatitis B core particles causing peripheral margination of the chromatin. In light microscopy, the central part of the nucleus appears to be occupied by faintly eosinophilic, finely granular ('sand') material. They may be found in small numbers during the viral replicative phase of chronic viral hepatitis B. Sanded nuclei should not be confused with nuclear vacuolation [6,7].

Cytomegalovirus (CMV) inclusions may be found in all types of cells in the liver, most often in hepatocytes and bile duct cells. These are characterized by cytomegaly and the development of

intranuclear basophilic inclusions, surrounded by a clear halo. The cytoplasm may be strongly basophilic. Appropriate immunostaining reveals CMV antigens [17].

Herpes simplex viral inclusions occur as two types. The more common type renders the nucleus homogeneously basophilic, with effacement of the nucleolus and most of the chromatin granules. The second type corresponds to the classic Cowdry type A inclusion: an eosinophilic, rounded or irregular inclusion surrounded by a clear halo with margination of the chromatin. Viral antigens can be identified by appropriate immunostaining [7,18].

Nuclear vacuolation corresponds to hepatocellular nuclei that appear empty on light microscopy. The vacuolation may be due to glycogen (e.g. in diabetics) or to invagination of cytoplasm or accumulation of lipid into the nucleus. This change is not very helpful in diagnosis [7,9,18].

Atrophy of hepatocytes is reflected in reduced size and increased cytoplasmic density and lipofuscin content of hepatocytes (see Plate 4.1.19, facing p. 72).

Hypoxic vacuoles are formed in anoxic conditions by invagination of the cell membrane of hepatocytes with engulfment of plasma proteins. They occur in acinar zone 3 and appear as pale-staining smaller or larger vacuoles. Appropriate immunostaining reveals the presence of albumin, fibrinogen and other plasma proteins. Electron microscopy shows that the membrane surrounding the vacuoles is not part of the endoplasmic reticulum, which differentiates the lesion from 'endoplasmic reticulum storage disorders' such as α_1-antitrypsin or fibrinogen storage [19].

Necrosis and inflammation

Acidophil body (*single cell acidophil necrosis*; *coagulation necrosis*) refers to a rounded clump of intensely eosinophilic cytoplasm, with or without a pyknotic nucleus, corresponding to necrosis of a single hepatocyte. The acidophil body is disconnected from the liver cell plate and becomes phagocytosed by Kupffer cells. The lesion is often incorrectly referred to as a Councilman (-like) body [6,9,18].

Apoptosis represents a physiological, preprogrammed mode of cell death, characterized by budding and fragmentation of a liver cell into smaller and larger 'acidophil bodies' (see Plates 4.1.2 and 4.1.4, facing p. 72). Apoptosis is an essential and vital component in liver development and growth, in physiology and in the most diverse pathological conditions. It is the way in which senescent cells are eliminated in normal liver; it plays a role in embryonic development of intrahepatic bile ducts, in regression of ductular reaction and in vanishing bile duct diseases. Apoptosis is part and parcel of focal necrosis and piecemeal necrosis in chronic hepatitis; it is a common feature in acute and fulminant hepatitis and in liver allograft rejection. Furthermore, apoptosis is a key phenomenon in several forms of toxic liver injury, in carcinogenesis and in the cell kinetics of hepatocellular carcinoma [20].

Coagulative necrosis is a form of cell death in which hepatocytes lose cohesion from surrounding cells and have a deeply eosinophilic cytoplasm. This change is typical of anoxic injury.

Lytic necrosis represents a mode of liver cell death followed by rapid disappearance of the dead cells; it is histologically recognized by lack of cells [21,22].

Confluent (*lytic*) *necrosis* refers to the disappearance of groups of contiguous hepatocytes, resulting in denudation of the reticulin framework. According to the extent of confluent necrosis, it is graded as focal or zonal, the latter occupying an entire acinar zone, usually zone 3, occasionally zone 1 (for example in severe viral hepatitis A).

Bridging hepatic necrosis represents more extensive degrees of confluent necrosis, leading to necrotic 'bridges' between adjacent vascular structures.

Central–central bridging necrosis links adjacent central veins; it corresponds to confluent necrosis in the microcirculatory periphery of a complex acinus [23].

Portal–central bridging necrosis links portal tracts and central veins; it corresponds to confluent necrosis in the microcirculatory periphery of the simple acinus.

Still higher degrees of confluent necrosis are described as panlobular, multilobular, submassive and massive necrosis [21,22].

Surgical necrosis [24] is observed in liver specimens taken during abdominal surgical interventions. It appears as acidophil necrosis of hepatocytes surrounded by neutrophil polymorphs (see Plate 4.1.5, facing p. 72). It is usually observed in acinar zone 3; the extent of the lesion increases with the duration of the operation and the degree of manipulation of the liver. This lesion is often observed after revascularization of the donor liver in liver transplantation.

Piecemeal necrosis occurs at the interface between mesenchyme (portal tracts or septa) and parenchyma (interface hepatitis). Mononuclear lymphoid cells infiltrate the mesenchyme and extend into the adjacent parenchyma, associated with progressive apoptotic cell death and disappearance of hepatocytes, thus leading to an unsharp mesenchymal–parenchymal border and gradual expansion of the mesenchymal area (see Plate 4.1.6, facing p. 72) [22].

Lymphocytic piecemeal necrosis represents the 'classic' lesion and is characterized by a predominance of lymphocytes and plasma cells (see Plate 4.1.6) [7,25].

Biliary piecemeal necrosis occurs in periportal (zone 1) locations in chronic biliary disease; it is characterized by cholate stasis of zone 1 hepatocytes, periportal ductular reaction and infiltration by inflammatory cells, including neutrophils. This lesion also creates an unsharp mesenchymal–parenchymal interphase, and thus resembles classic piecemeal necrosis architecturally, but not cytologically [7,9,25].

Fibrous piecemeal necrosis apparently represents a late stage of (biliary) piecemeal necrosis, in which connective tissue strands surround entrapped groups of hepatocytes with little cellular inflammation. Around portal tracts, it leads to the formation

of new limiting plates that border seemingly enlarged portal tracts [25].

Ductular piecemeal necrosis describes a lesion that is close to biliary piecemeal necrosis, with less emphasis on periportal or paraseptal cholate stasis [25].

Liver cell rosettes [26] correspond to small groups of hepatocytes in lymphocytic or fibrous piecemeal necrosis; the cells appear hydropic and are often arranged around a central lumen [27] (see Plate 4.1.7, facing p. 72).

Focal necrosis describes cell death (usually apoptotic in nature) of a small group of hepatocytes, associated with local accumulation of mononuclear cells (lymphocytes, histiocytes); apoptotic liver cell fragments are not always identifiable between the infiltrating cells [9,28].

Spotty necrosis is virtually synonymous with focal necrosis, referring to involvement of single or very small groups of parenchymal cells (see Plate 4.1.4, facing p. 72) [9].

Emperipolesis refers to the intracellular location of a cell (usually a lymphocyte) inside a hepatocyte (see Plate 4.1.8, facing p. 72). The lymphocyte is often surrounded by a narrow clear halo. Peripolesis describes the close association between a lymphocyte and a hepatocyte; the former may be located in an indentation of the latter [7].

Biliary and cholestatic lesions

Parenchymal changes

In its histological meaning, the term cholestasis used to refer to a microscopically visible deposition of bilirubin in the liver tissue. In a strict sense, it corresponds to bilirubinostasis. As cholate stasis (see below) is another important parenchymal feature in chronic cholestatic conditions, it is more appropriate to replace the histological term cholestasis with the more precise term bilirubinostasis [7,29].

Hepatocellular bilirubinostasis corresponds to intracellular accumulation of bilirubin-stained granules in the parenchymal cells, especially in toxic cholestasis (e.g. resulting from drugs and endotoxinaemia) (see Plates 4.1.9 and 4.1.14, facing p. 72) [6,11].

Canalicular bilirubinostasis is recognized as inspissated bile plugs in more or less dilated intercellular bile canaliculi. It first occurs in acinar zone 3, but may extend up to acinar zone 1 in cholestasis of long duration (see Plate 4.1.9) [12].

Kupffer cell bilirubinostasis is represented by smaller and coarser bilirubin-stained inclusions in hypertrophic Kupffer cells. It is only observed in cholestasis of several days' duration (see Plate 4.1.9) [12].

Ductular bilirubinostasis corresponds to inspissated, bilirubin-stained concrements in more or less dilated bile ductules. It is occasionally seen in longstanding extrahepatic bile duct obstruction, especially in extrahepatic bile duct atresia in the neonate. It also occurs in severely necrotizing hepatitis [30]. In septicaemia, large bile concrements are formed in unusually dilated periportal ductules [31] (see Plate 4.1.10, facing p. 72).

Cholate stasis is a lesion of zone 1 hepatocytes in longlasting cholestasis [7,9,29]. The parenchymal cells are pale, swollen and coarsely granular. Some of the granules correspond to copper accumulation and stain with rhodamine (copper) and orcein or Victoria blue (copper-binding protein or metallothionein). Later on, bilirubin granules may also accumulate, and Mallory bodies may develop. The term cholate stasis refers to the presumed intracellular accumulation of bile salts as the suspected mechanism for this lesion.

The appearance of *cholestatic liver cell rosettes* [27] is a sign of longlasting cholestasis. It may be particularly pronounced in contraceptive steroid-induced cholestasis. Scattered through the parenchyma, groups of liver cells are arranged in a tubular fashion around a smaller or larger lumen, which may appear empty or filled with eosinophilic or bilirubin-stained material (see Plate 4.1.11, facing p. 72). The composing hepatocytes express bile duct-type cytokeratins, indicating an intermediate differentiation of these hepatocytes [29].

Xanthomatous cells (*foam cells*) occur as single cells or in clusters, in the parenchyma or portal tracts or both, in the case of longlasting cholestasis. They correspond to lipid-laden histiocytes, related to hyperlipidaemia and hypercholesterolaemia [32].

Bile infarct (*Charcot–Gombault infarct*) represents an area of paraportal necrosis of liver parenchyma; the central part of the necrotic zone, in particular, is impregnated with bilirubin (which has affinity for necrotic tissue) (see Plate 4.1.12, facing p. 72). With time, the necrotic mass becomes organized in a fibrous scar. This lesion is mainly (but not exclusively) observed in longstanding extrahepatic bile duct obstruction [32].

Bile lake refers to a large mass (larger than the usual extracellular bile plug of canalicular bilirubinostasis) in the parenchyma of a cholestatic liver [26,32].

Portal and periportal changes

Bile extravasates are mainly seen in the late stages of large duct obstruction; they represent inspissated bile concrements in ducts associated with erosion and necrosis of the epithelial lining of the duct. The bile mass in contact with portal connective tissue may incite a foreign body giant cell reaction.

Lymphocytic cholangitis [25] describes a normal or damaged portal bile duct in a dense lymphocytic infiltrate, sometimes organized as a lymph follicle (e.g. early primary biliary cirrhosis).

Pleomorphic cholangitis [25] refers to a normal or altered portal bile duct surrounded (or even infiltrated) by a mixed inflammatory infiltrate (e.g. in liver allograft rejection and graft-versus-host disease).

Granulomatous cholangitis [25] indicates the presence of a non-caseating epithelioid cell granuloma close to or around a damaged portal bile duct (e.g. in primary biliary cirrhosis and sarcoidosis with chronic cholestasis) (see Plate 4.1.13, facing p. 72). This lesion is also referred to as a florid bile duct lesion in primary biliary cirrhosis.

Fibro-obliterative cholangitis [25] corresponds to prominent layers of concentric dense connective tissue ('onion-skinning') around a portal bile duct, which may show features of atrophy and epithelial damage. The lesion indicates chronic irritation of the duct, but is not disease specific.

Purulent (*suppurative*) *cholangitis* [25] is characterized by the accumulation of polymorphs in the lumen and in the wall of bile ducts; destruction of the epithelial lining may proceed to the formation of cholangitic abscesses.

Paucity of intrahepatic bile ducts (*ductopenia*) is morphometrically defined as a portal bile duct to portal tract ratio of less than 0.5 (normal value 0.9–1.8) [33]. The disappearance of the ducts seems to result from pleomorphic cholangitis. The entity is part of the 'vanishing bile duct' disorders [34].

'Vanishing bile duct' disorders are recognized by the occurrence of portal tracts in which a portal bile duct of approximately the same size as the accompanying hepatic artery branch is missing [35]. These disorders include extrahepatic bile duct atresia, paucity of intrahepatic bile ducts, idiopathic adulthood ductopenia, primary biliary cirrhosis, autoimmune cholangiopathy, Hodgkin's disease, sarcoidosis with chronic cholestasis, primary sclerosing cholangitis, hepatic graft-versus-host disease, liver allograft rejection and some rare forms of prolonged drug-induced cholestasis [25,34].

The ductal plate is the primitive shape of intrahepatic bile ducts during embryonic development [34]. It corresponds to a partly double layer of bile duct epithelium around the primitive portal tracts (see Plate 4.1.14, facing p. 72). Its normal fate is to become remodelled into the normal network of portal bile ducts [36].

The ductal plate malformation represents a lack of remodelling of the embryonic ductal plate, with persistence of primitive bile duct structures [37]. It is observed in infantile polycystic disease, congenital hepatic fibrosis, Caroli's disease, Meckel syndrome and Von Meyenburg complexes (see Plate 4.1.15, facing p. 72). Ductal plate malformation associated with features of duct destruction and inflammation (pleomorphic cholangitis) is also part of early, severe forms of so-called extrahepatic bile duct atresia [34,38].

Ductular reaction ('*cholangiolitis*') refers to a periportal increase in the number of ductular profiles in histological sections. The ductules are accompanied by oedema and neutrophil polymorphs (inflammation of the ductules or cholangioles) (see Plate 4.1.16, facing p. 72). It is observed to a variable extent in all varieties of biliary disease [26,29,39].

In the case of acute, complete mechanical obstruction of larger bile ducts, the ductular reaction is mainly the result of ductular proliferation (so-called 'typical ductules', 'elongation type' of ductular proliferation or 'marginal bile duct proliferation') [40], resulting from multiplication of pre-existing ductules at the margin of portal tracts [39].

In the case of chronic, incomplete obstruction of larger bile ducts (e.g. in primary biliary cirrhosis, primary sclerosing cholangitis), the ductular reaction results from ductular metaplasia of zone 1 hepatocytes and from activation, proliferation and differentiation of 'facultative stem cells' or progenitor cells (so-called 'atypical' or 'sprouting type' of ductular proliferation) [39].

Pericholangitis [41], reported as a hepatic complication of ulcerative colitis, corresponds to the 'isolated small duct sclerosing cholangitis' variant of primary sclerosing cholangitis [25].

Fibrosis

The term fibrosis indicates an increase in connective tissue in the liver; it may occur in various patterns.

Portal fibrosis describes increased density and fibrous enlargement of portal tracts.

Concentric periductal fibrosis is a synonym of fibro-(obliterating) cholangitis.

Periportal fibrosis refers to fibrous extensions radiating from portal tracts.

Centrolobular (*acinar zone 3*) *fibrosis* describes fibrous scarring around the terminal hepatic venules. When conspicuous, as in some forms of alcoholic liver disease, it has been described as 'sclerosing hyaline necrosis' [42].

Perivenular fibrosis [43] indicates a fibrous thickening of the wall of the terminal hepatic venule. The lesion comprises a fibrotic rim more than 4 mm in thickness involving at least two-thirds of the perimeter of hepatic venules.

In *pericellular or perisinusoidal fibrosis*, collagen is laid down around single liver cells or small groups of hepatocytes. It occurs mostly in acinar zone 3. In alcoholic liver disease, this pattern was described as 'chicken-wire fibrosis' [7,26].

Septal fibrosis indicates fibrosis in the form of fibrous sheets. It occurs in various topographical patterns (portal–portal septa, portal–central septa, central–central septa, incomplete septa, etc.) according to the type of vascular canals linked by the connective tissue membranes [22].

Active septa represent connective tissue sheets that are infiltrated by mononuclear inflammatory cells, with imprecise delineation from the adjacent parenchyma. They can be conceived as extensive degrees of piecemeal necrosis (see Plate 4.1.6, facing p. 72) [22].

Passive septa are fibrous membranes that are rich in fibres and poor in cells, with sharp delineation from the adjacent parenchyma (see Plate 4.1.17, facing p. 72). They derive from post-necrotic collapse and scarring after extensive confluent lytic necrosis [7,22]. Older (more than 6 months) passive septa contain elastic fibres, demonstrable by orcein or Victoria blue staining [44].

Primary collapse indicates post-necrotic collapse and scarring after confluent necrosis in a previously normal parenchyma; the topographical spacing of the approximated portal tracts and terminal hepatic veins is more or less preserved [9].

Secondary collapse refers to post-necrotic scarring following necrosis in abnormal parenchymal territories (e.g. in

cirrhosis), resulting in irregular spacing of afferent and efferent vessels [9].

Hepatoportal sclerosis corresponds to phlebosclerosis of portal vein branches, as a result of organized mural thrombi or of portal hypertension, usually associated with some degree of portal and periportal fibrosis [7,9,12,26].

Biliary fibrosis is often confused with true biliary cirrhosis. It represents an advanced but potentially reversible state of chronic bile duct disease, characterized by periportal or portal–portal septa and garland-shaped parenchymal nodules; the basic lobular architecture and vascular relationships are preserved [9,25,29].

Cirrhosis is a diffuse type of septal fibrosis of the liver, associated with regenerative parenchymal nodules and disturbed intrahepatic circulation (see Chapter 7.1) [45].

Vascular changes

Hepatic artery

Obliterative endarteritis is a feature of chronic vascular rejection of a liver allograft. It consists of the obstruction of arteries by subintimal fibrosis or the accumulation of foamy lipid-loaded cells [12].

Afferent and efferent veins

Endothelialitis consists of lymphocytic infiltration of the portal or central vein endothelium, which appears to be damaged and lifted from its basement membrane. Endothelialitis is a helpful diagnostic feature in graft-versus-host disease and in acute liver allograft rejection [46].

Endophlebitis of the (terminal) hepatic veins consists of lymphocytic infiltration in the intima of the vessels. It is seen in acute (sub)massive necrosis in fulminant hepatitis. A lymphocytic phlebitis has been described in the (pre)cirrhotic stages of alcoholic liver disease [18].

Veno-occlusive disease corresponds to narrowing of the lumen of terminal hepatic venules and larger draining hepatic veins, due to subintimal fibrosis. First observed in bush tea intoxication (senecio and crotalaria alkaloids), it may result from several drugs, such as methotrexate and chemotherapy drugs used before a bone marrow transplantation, alcohol and irradiation [12,18,26].

Phlebosclerosis corresponds to fibrous thickening of the walls of veins, with or without an increase in elastic fibres. Phlebosclerosis of terminal hepatic venules occurs in several conditions, for example chronic passive congestion, alcoholic liver disease and graft-versus-host disease. Phlebosclerosis of portal vein branches is part of the lesion of hepatoportal sclerosis [12,18,26].

Prolapse of hepatocytes into terminal hepatic venules may result in partial occlusion and disruption of the wall of terminal hepatic venules. It has been reported in long-term anabolic–androgenic steroid therapy [18].

Sinusoids and the space of Disse

The space of Disse lies between the sinusoidal wall and the sinusoidal surface of the hepatocyte, from which abundant microvilli project into the space. The sinusoidal endothelium is discontinuous, extensively fenestrated and lacks a basement membrane. Therefore, the space of Disse is freely permeable to blood plasma and constitutes the immediate exchange area between blood and hepatocytes. The space of Disse contains collagen type 1 and 3, constituting the 'reticulin' framework of the liver. However, several other extracellular matrix components are also present, for instance collagen type 4, laminin and perlecan, in spite of the absence of a morphologically recognizable basement membrane.

Sinusoidal congestion occurs in acinar zone 3 as a result of venous outflow block; the sinusoids appear dilated and the parenchymal cells atrophic with pericellular fibrosis (see Plate 4.1.18, facing p. 72); all changes are variable according to the degree or duration, or both, of the venous congestion.

Sinusoidal dilatation in acinar zone 1 [47] may occur in patients using contraceptive steroids. It is often accompanied by slight perisinusoidal fibrosis in that area [48]. Sinusoidal dilatation lacking any particular zonal localization can be associated with neoplasms, mainly Hodgkin's disease, and granulomatous diseases [49].

Peliosis indicates irregular blood-filled cavities corresponding to sinusoidal dilatation without constant zonal topography. The dilatation may be huge, creating blood pools in which liver cells are missing [12,18,26].

Fibrin deposition in sinusoids is typically seen in acinar zone 1 in eclampsia (see Plate 4.1.19, facing p. 72) and in irregular topography in disseminated intravascular coagulopathy.

Capillarization of the sinusoids refers to important modifications of the space of Disse in fibrotic liver, as a morphologically distinct basement membrane-like structure appears, containing collagen type 4 and laminin. In addition, increased amounts of collagen types 1, 3, 5 and 6, fibronectin, tenascin and undulin are deposited along the sinusoids. These changes are associated with loss of fenestrations of endothelial cells, further impairing exchange between blood and hepatocytes [50]. Hepatic stellate cells (Ito cells) increase in number and acquire an activated myofibroblast-like phenotype.

Hairy cell leukaemia may produce a characteristic 'angiomatous' picture, consisting of dilated sinusoids lined by leukaemic cells that have replaced the sinusoidal lining cells. Hairy cells display a clear rim of cytoplasm and are positive for tartrate-resistant acid phosphatase and non-specific esterase [18].

Extramedullary haematopoiesis is recognized by the occurrence in sinusoids of clusters of haematopoietic precursor cells of the erythropoietic, granulopoietic and thrombopoietic series. Normoblasts and megakaryocytes are the most easily identifiable precursor cells [18].

Amyloidosis is characterized by the linear deposition of homogeneous eosinophilic material in vessel walls and in spaces of

Disse. Occasionally, globular deposition occurs. Advanced linear deposition of amyloid in parenchymal territories leads to atrophy of parenchymal cells. Amyloid is identified by the special stains Congo red and Sirius red, displaying characteristic green dichroism in polarized light [18].

Light chain (*deposit*) *disease* resembles amyloidosis with granular and fibrillar material in the spaces of Disse; the deposited material is PAS positive but does not stain as amyloid. Immunohistochemical stains for κ and λ light chains identify the deposits (see Plate 4.1.20, facing p. 72) [18].

Kupffer cell reaction and granuloma

Sinusoidal cell activation refers to excess sinusoidal cells, often of different type, including activated Kupffer cells and increased endothelial cells admixed with lymphocytes, monocytes and plasma cells [9].

Epithelioid granuloma. The term granuloma is not strictly defined; it refers to a focal accumulation of histiocytic cells, assuming epithelioid and multinucleated giant cell appearance in its most typical form (epithelioid granuloma). Histiocytic and epithelioid granulomas, with or without associated significant parenchymal inflammation (hepatitis), occur in numerous conditions [51].

Lipogranuloma describes the accumulation of histiocytes and mononuclear cells around a parenchymal cell with large droplet steatosis [47].

Mineral oil granulomas are a special form of foreign body granuloma, consisting of histiocytes and vacuolated macrophages around clear spaces (mineral oil deposits) in portal tracts and near terminal hepatic venules [18].

Doughnut granuloma (*fibrin ring granuloma*) has a characteristic appearance with a central empty-appearing fat globule surrounded by a collar of histiocytes sprinkled with some lymphocytes, neutrophils and sometimes eosinophils, and encircled by a ring of fibrin. Although highly characteristic of Q fever, this lesion is also observed in other conditions (for instance Hodgkin's disease, allopurinol hypersensitivity) [18].

Storage phenomena

Several metabolic diseases (storage diseases) are associated with deposition of metabolites in liver tissue [52]. Many of them require ultrastructural investigation for adequate identification. Their description is beyond the scope of this chapter.

Fat storage (*steatosis*, *fatty metamorphosis*) in hepatocytes is a feature common to numerous liver diseases. Neutral fat can be stained with oil red O or Sudan black in frozen sections; in paraffin-embedded tissue, fat appears as clear holes in parenchymal cells. The fat droplets may be small (microvesicular steatosis) with retained central position of the nucleus (see Plate 4.1.21, facing p. 72) or large (macrovesicular steatosis), in which case the nucleus is pushed to one side of the cell (see Plate 4.1.22, facing p. 72). The simultaneous presence of macro- and microvesicular steatosis indicates the presence of the inciting agent until the time of biopsy (e.g. alcohol abuse). Exclusive macrovesicular steatosis indicates a steady state of fat overload. Some special conditions with almost exclusive microvesicular steatosis have been emphasized (microvesicular fat diseases) [53], including Reye syndrome, acute fatty liver of pregnancy, Jamaican vomiting sickness and tetracycline and valproate intoxication.

Acute alcoholic foamy degeneration is a type of severe alcoholic liver damage with nearly exclusive microvesicular steatosis [54].

Morula cells or spongiocytes correspond to hepatocytes with microvesicular steatosis, observed in Labrea fever in the Amazon river basin, which appears to represent delta hepatitis superinfection of HBV carriers [9,55], perhaps by a more pathogenic strain [56].

Phospholipidosis is reflected in light microscopy in very small clear droplets and eosinophilic fine granules, often associated with Mallory bodies in some drug reactions (amiodarone, perhexiline maleate) [9,18].

Hepatic stellate cell hyperplasia (*Ito cell hyperplasia*) is recognized by an increased number of hepatic stellate cells (Ito cells, perisinusoidal cells); they appear as sinusoidal cells containing smaller or larger fat droplets indenting the nucleus (see Plate 23, facing p. 72). It is a diagnostic feature of vitamin A intoxication [8].

Iron storage (*siderosis*) is reflected in the accumulation of Prussian blue-positive haemosiderin granules in hepatocytes (parenchymal siderosis) (see Plate 4.1.24, facing p. 72) and/or in Kupffer cells and macrophages (reticuloendothelial siderosis) (see Plate 4.1.25, facing p. 72).

Copper storage is recognized by the accumulation of intrahepatocellular granules that stain positively with rhodamine (copper) and orcein or Victoria blue (copper-binding protein or metallothionein) [12,26].

Glycogen storage is reflected by a clear appearance of enlarged hepatocytes with accentuated cell walls (plant cell-like appearance), often associated with glycogen vacuolation of the nucleus [52].

α_1-Antitrypsin storage in the endoplasmic reticulum appears as eosinophilic inclusions of variable size in zone 1 hepatocytes. The inclusions are strongly PAS positive and diastase resistant (see Plate 4.1.26, facing p. 72), and can be identified by immunohistochemical stains and electron microscopy [52].

Fibrinogen storage may take the appearance of eosinophilic inclusions (resembling α_1-antitrypsin inclusions) or of ground-glass hepatocytes. The fibrinogen nature of the inclusions is ascertained by immunohistochemical staining [57].

Lipofuscin (*wear and tear pigment*) appears as brownish pericanalicular granules in acinar zone 3 hepatocytes, which represent the ageing cells of the liver acinus. The amount of lipofuscin may increase (lipofuscinosis), for example in abuse of analgesics.

The pigment in Dubin–Johnson syndrome (see Plate 4.1.27,

facing p. 72) resembles lipofuscinosis. The nature of this pigment (possibly melanin) is still debated [58].

Malaria pigment accumulates as dark granules in Kupffer cells in chronic malaria and schistosomiasis. The pigment is Prussian blue negative and birefringent in polarized light [18].

Ceroid pigment is an ill-defined material, appearing as granules and coarse clumps in hypertrophic Kupffer cells and macrophages ('ceroid macrophages') in all conditions associated with hepatocellular necrosis. The material represents phagocytosed debris from necrotizing liver cells. Ceroid macrophages thus attest to liver cell damage. They lie in the parenchyma in the early stages and migrate to portal tracts later on. Ceroid pigment is PAS positive, diastase resistant, stains partly with fat stains and is fluorescent under ultraviolet light.

Erythropoietic protoporphyria causes deposition of protoporphyrin as dark granules in hepatocytes and Kupffer cells and larger clumps of black material in dilated canaliculi and ductules. Under polarized light, the material is birefringent (appearing red in Maltese cross configuration in the larger deposits) and autofluorescent under ultraviolet light (see Plate 4.1.28, facing p. 72) [18].

Uroporphyrin crystals accumulate in hepatocytes in porphyria cutanea tarda. Difficult to recognize on haematoxylin- and eosin-stained sections, they are best visualized in unstained sections examined by polarizing microscopy (birefringence) or under ultraviolet light (red autofluorescence) [18].

Foreign material which may be stored in Kupffer cells includes talc, cellulose (in drug abusers), silica and anthracitic pigment (in coal workers), polyvinyl pyrrolidone (from plasma expanders), silicone (for instance from prosthetic heart valve devices) and thorotrast (a former contrast medium) [18].

Hepatitis (inflammation)

The term *liver cell pleomorphism* summarizes the complex set of histological changes of the liver parenchyma in several forms of acute viral- and drug-induced hepatitis (ballooning, acidophil condensation, apoptosis, regeneration). It is usually most marked in acinar zone 3 (see Plates 4.1.2 and 4.1.8, facing p. 72) [6].

Lobular disarray refers to the disruption of the normal regular arrangement of liver cell plates caused by liver cell pleomorphism and focal necrosis in acute hepatitis (see Plate 4.1.2 facing p. 72) [9].

Acute hepatitis is characterized by mononuclear cell infiltration in portal tracts (portal hepatitis) and in the parenchyma, associated with signs of parenchymal damage (see Plates 4.1.2 and 4.1.8, facing p. 72). The last depends on the severity of the hepatitis, corresponding to lobular disarray, liver cell pleomorphism and spotty necrosis in milder forms and various extents of confluent necrosis in severe cases [6].

Portal hepatitis refers to mononuclear cell infiltration in portal tracts. Portal hepatitis without significant parenchymal damage is the hallmark of mild chronic hepatitis, although of itself, it is a non-specific lesion [22].

Periportal hepatitis describes necroinflammatory changes in acinar zone 1 parenchyma around the portal tracts. It is a feature of viral hepatitis A. As a morphological descriptive term, it also refers to piecemeal necrosis (e.g. in moderate and severe chronic hepatitis) [59].

Central (*centrolobular*) *hepatitis* refers to necroinflammatory lesions in acinar zone 3.

Non-specific reactive hepatitis indicates mild inflammatory changes, combining portal hepatitis and mild focal necrosis without a demonstrable causative agent in the liver. It is observed in systemic and extrahepatic diseases, apparently due to circulating toxins and breakdown products [9,60].

Chronic lobular hepatitis is not a morphological entity. Histologically, it corresponds to a picture of mild acute hepatitis. The notion of chronicity relies on the clinical history [9,26].

Hepatitis B can be recognized in several cases by the presence of ground-glass hepatocytes. In acute episodes, liver cell pleomorphism is often marked, and hepatocyte degeneration tends to be of a ballooning or lytic type and is localized in acinar zone 3.

Features suggestive of *hepatitis C* include portal lymphoid aggregates or lymph follicles, bile duct damage, intra-acinar necroinflammatory changes with numerous apoptotic bodies, some steatosis and a mild degree of piecemeal necrosis [61].

Hepatitis D superinfection of chronic hepatitis B is usually characterized by severe lobular lesions with extensive piecemeal necrosis and rapid progression to cirrhosis. Marked panacinar inflammation with a morphology similar to hepatitis C is typical [62,63]. 'Morula cells' (hepatocytes with microvesicular steatosis) have been described in some instances [64].

Fibrosing cholestatic hepatitis, a peculiar morphological pattern of hepatitis B, was first observed after liver transplantation [65]. It is characterized by unusually high-level expression of intracytoplasmic HBsAg and HBcAg associated with only mild necrosis and inflammation. In addition, there is severe bilirubinostasis and a characteristic perisinusoidal fibrosis, encasing groups of liver cells or entire liver cell plates. It is apparently related to the immunosuppressed state of the patient, as it has also been reported in coinfection by HBV and human immunodeficiency virus (HIV) [66] and in renal transplant recipients [67,68].

Drug-induced chronic hepatitis can be suspected in some cases from the presence of small granulomas, eosinophilic infiltration and bile duct damage involving the finest biliary radicles.

Autoimmune hepatitis admittedly has no specific histopathology; however, a picture of severely active hepatitis including extensive piecemeal necrosis, bridging confluent necrosis, hepatitic liver cell rosettes and abundance of plasma cells is quite suggestive.

Wilson's disease is the result of tissue injury due to copper overload in the liver and other organs. Clinically as well as histopathologically, it may manifest itself as acute hepatitis mimicking acute viral hepatitis, as fulminant hepatitis, as chronic hepatitis indistinguishable from that due to viral and

other aetiologies or as cirrhosis. Helpful differential clues in the diagnosis of Wilson's disease include the presence of steatosis, glycogenated nuclei, the presence of Mallory bodies in periportal liver cells and moderate to marked copper storage (best seen on rhodamine stain).

α_1-Antitrypsin deficiency can histologically resemble chronic hepatitis of viral and other aetiologies. Recently, a high prevalence of hepatotrophic viral infection (HCV and HBV) has been documented in predominantly heterozygote patients with chronic liver disease [69]. However, other studies suggest that α_1-antitrypsin deficiency *per se* may be the cause of chronic liver disease [70].

Immunohistochemical stains (immunofluorescence and immunoperoxidase methods) are based on the binding of antibodies to specific antigens in tissue sections. Several procedures are available, the two most commonly used at present being the peroxidase–antiperoxidase immune complex method and the biotin–avidin immunoenzymatic technique. In the latter procedure, the high affinity of avidin for biotin is used to couple the peroxidase label to the primary antibody. Their use in demonstrating viral antigens has enormously increased the diagnostic impact of liver biopsy in confirming or establishing the viral aetiology of hepatitis. Some of the most frequently used are for hepatitis B (HBsAg, HBcAg), C and D, herpes and cytomegalovirus. Demonstration of HBsAg and HBcAg on paraffin sections of liver biopsies from patients with chronic hepatitis B is helpful in determining whether the patient is still in the viral replicative phase, and hence a potential candidate for interferon therapy, or whether the patient has already evolved into the so-called viral integration phase [63].

In situ hybridization finds increasing application in diagnostic pathology in general [71]. It is applied to liver tissue for the assessment of viral replication in hepatitis A, B, C and D, cytomegalovirus hepatitis and Epstein–Barr viral hepatitis [72]. Combination of the *polymerase chain reaction* with *in situ* hybridization becomes possible, providing the pathologist with an extremely sensitive detection method.

Acute alcoholic hepatitis (*acute hepatitis of the alcoholic type*, *fatty liver hepatitis*, *steatohepatitis*) comprises several changes; there is no general agreement on minimum requirements. Usually, the histological changes comprise steatosis, Mallory bodies and satellitosis. In most cases, some degree of fibrosis (periportal, pericentral, pericellular) is also present. In the face of continuing alcohol abuse, the lesions may persist in the cirrhotic stage. It must be realized that, in a minority of cases, this lesion is not due to alcohol (e.g. diabetes and obesity, amiodarone and perhexiline maleate toxicity, abetalipoproteinaemia) [7,18] (see also Chapters 12.3 and 13).

Regeneration

Parenchymal giant cells (*multinucleated hepatocytes*) correspond to huge, often pale parenchymal cells with multiple nuclei; they result from fusion rather than from incomplete division of hepatocytes. They occur most typically in neonatal cholestasis (so-called neonatal hepatitis and bile duct atresia), but are occasionally observed in adults, for example in viral hepatitis C and some forms of drug-induced hepatitis [9].

Anisokaryosis refers to unequal size of the liver cell nuclei. It increases with advancing age, due to increasing ploidy of liver cell nuclei.

Liver cell dysplasia (*dysplastic liver cells*) [73] usually occurs in groups of hepatocytes. They are characterized by unequal size and shape and increased staining density (hyperchromatism) of their nuclei (see Plate 4.1.29, facing p. 72). Dysplasia seems to be related to HBV and HCV infection [74]; its presence heralds an increased risk of hepatocellular carcinoma [75]. Two types of liver cell dysplasia, small cell dysplasia and large cell dysplasia, are recognized.

Twin-cell plates. In the normal liver beyond the age of 5 years, hepatocytes are arranged in single-cell plates (muralium simplex). Plates of two or more cells in thickness (muralium duplex or multiplex) indicate regeneration (see Plate 4.1.17, facing p. 72).

Nodular regeneration refers to regenerative expansion of smaller or larger parenchymal territories.

Micronodules are conventionally defined as 3 mm or less in diameter. They comprise regenerative parenchymal masses that may correspond to different parts or combinations of architectural liver units, as follows [12,18,26,45]:

1 segments of simple acini dissected by portal–central septa (pseudolobular nodules without vascular landmarks);
2 segments of simple acini encircled by portal–portal septa, carrying a central draining venule (monolobular nodules in biliary fibrosis and cirrhosis);
3 complex acini delineated by central–central septa and centred by a portal tract (in congestive or cardiac cirrhosis).

Macronodules (more than 3 mm in diameter) consist of large areas of parenchyma equivalent to several acini, presumably regenerating acinar agglomerates (multilobular nodules). A macronodule reveals a substructure, identified by draining veins, often in excess of portal tracts, which may appear diminutive; these anatomical landmarks show a less regular distribution than in normal liver parenchyma [12,18,26,45].

Nodular regenerative hyperplasia is characterized by diffuse nodularity of the liver parenchyma, due to regeneration and hyperplasia of acinar zones 1 and 2, associated with parenchymal atrophy and compression in the intervening acinar zones 3, without obvious internodular septum formation [12,18,26].

References

1 Hadziyannis S, Gerber MA, Vissoulis C *et al*. (1973) Cytoplasmic hepatitis B antigen in 'ground-glass' hepatocytes of carriers. *Arch Pathol* 96, 327–330.
2 Bruguera M, Lamar C, Bernet M, Rodes J (1986) Hepatic disease associated with ground-glass inclusions in hepatocytes after cyanamide therapy. *Arch Pathol Lab Med* 110, 906–910.

3 Callea F, de Vos R, Togni R *et al.* (1986) Fibrinogen inclusions in liver cells: a new type of ground-glass hepatocyte. Immune light and electron microscopic characterization. *Histopathology* 10, 65–73.
4 Wisell J, Boitnott J, Haas M *et al.* (2006) Glycogen pseudoground glass change in hepatocytes. *Am J Surg Pathol* 30, 1085–1090.
5 Lefkowitch JH, Lobritto SJ, Brown RS Jr *et al.* (2006) Ground-glass, polyglucosan-like hepatocellular inclusions: A 'new' diagnostic entity. *Gastroenterology* 131, 713–718.
6 Bianchi L (1983) Liver biopsy interpretation in hepatitis. Part II: histopathology and classification of acute and chronic viral hepatitis/differential diagnosis. *Pathol Res Pract* 178, 180–213.
7 Bianchi L (1983) Liver biopsy interpretation in hepatitis. Part I. Presentation of critical morphologic features used in diagnosis (Glossary). *Pathol Res Pract* 178, 2–19.
8 Phillips MJ, Poucell S, Patterson J *et al.* (1987) *The Liver. An Atlas and Text of Ultrastructural Pathology*. New York: Raven Press, p. 524.
9 Popper H (1986) General pathology of the liver: light microscopic aspects serving diagnosis and interpretation. *Semin Liver Dis* 6, 175–184.
10 Albot G, Schlumberger CS, Faye CM *et al.* (1956) Enlarged liver in alcoholics: biological formula and two histological aspects. *Sem Hop 32*, 1705–1722.
11 Desmet VJ (1986) Current problems in diagnosis of biliary disease and cholestasis. *Semin Liver Dis* 6, 233–245.
12 MacSween RNM, Anthony PP, Scheuer PJ *et al.* (1994) *Pathology of the Liver*. Edinburgh: Churchill Livingstone.
13 Desmet VJ (1985) Alcoholic liver disease. Histological features and evolution. *Acta Med Scand Suppl* 703, 111–126.
14 Bruguera M, Bertran A, Bombi JA *et al.* (1977) Giant mitochondria in hepatocytes: a diagnostic hint for alcoholic liver disease. *Gastroenterology* 73, 1383–1387.
15 Lefkowitch JH, Arborgh BA, Scheuer PJ (1980) Oxyphilic granular hepatocytes. Mitochondrion-rich liver cells in hepatic disease. *Am J Clin Pathol* 74, 432–441.
16 Bianchi L, Gudat F (1976) Sanded nuclei in hepatitis B: eosinophilic inclusions in liver cell nuclei due to excess in hepatitis B core antigen formation. *Lab Invest* 35, 1–5.
17 Vanstapel MJ, Desmet VJ (1983) Cytomegalovirus hepatitis: a histological and immunohistochemical study. *Appl Pathol* 1, 41–49.
18 Ishak KG (1987) New developments in diagnostic liver pathology. In: Farber E, Phillips MJ, Kaufman N (eds) *Pathogenesis of Liver Diseases*. Baltimore: Williams & Wilkins, pp. 223–373.
19 Nakanuma Y, Ohta G, Matsubara F *et al.* (1982) Cytoplasmic blood plasma inclusions in human hepatocytes. *Liver* 2, 212–221.
20 Patel T, Gores GJ (1995) Apoptosis and hepatobiliary disease. *Hepatology* 21, 1725–1741.
21 Bianchi L (1986) Necroinflammatory liver diseases. *Semin Liver Dis* 6, 185–198.
22 International Group (1977) Acute and chronic hepatitis revisited. *Lancet* ii, 914–919.
23 Desmet VJ (1988) Liver lesions in hepatitis B viral infection. *Yale J Biol Med* 61, 61–83.
24 Christoffersen P, Poulsen H, Skeie E (1970) Focal liver cell necroses accompanied by infiltration of granulocytes arising during operation. *Acta Hepatosplenol* 17, 240–245.
25 Ludwig J (1987) New concepts in biliary cirrhosis. *Semin Liver Dis* 7, 293–301.
26 Scheuer PJ, Lefkowitch JH (1994) *Liver Biopsy Interpretation*, 5th edn. London: WB Saunders.
27 Nagore N, Howe S, Boxer L *et al.* (1989) Liver cell rosettes: structural differences in cholestasis and hepatitis. *Liver* 9, 43–51.
28 Desmet VJ, De Vos R (1984) Structural analysis of acute liver injury. In: Keppler D, Bianchi L, Reutter W (eds) *Mechanisms of Hepatocyte Injury and Death*. Lancaster: MTP Press, pp. 11–30.
29 Desmet VJ (1986) Current problems in diagnosis of biliary disease and cholestasis. *Semin Liver Dis* 6, 233–245.
30 Schmid M, Cueni B (1972) Portal lesions in viral hepatitis with submassive hepatic necrosis. *Hum Pathol* 3, 209–216.
31 Lefkowitch JH (1982) Bile ductular cholestasis: an ominous histopathologic sign related to sepsis and 'cholangitis lenta'. *Hum Pathol* 13, 19–24.
32 International Group (1983) Histopathology of the intrahepatic biliary tree. *Liver* 3, 161–175.
33 Alagille D, Odievre M, Gautier M *et al.* (1975) Hepatic ductular hypoplasia associated with characteristic facies, vertebral malformations, retarded physical, mental, and sexual development, and cardiac murmur. *J Pediatr* 86, 63–71.
34 Desmet VJ (1987) Cholangiopathies: past, present and future. *Semin Liver Dis* 7, 67–76.
35 Nakanuma Y, Ohta G (1979) Histometric and serial section observations of the intrahepatic bile ducts in primary biliary cirrhosis. *Gastroenterology* 76, 1326–1332.
36 Van Eyken P, Sciot R, Callea F *et al.* (1988) The development of the intrahepatic bile ducts in man: a keratin-immunohistochemical study. *Hepatology* 8, 1586–1595.
37 Jorgensen MJ (1977) The ductal plate malformation. *Acta Pathol Microbiol Scand Suppl* 257, 1–87.
38 Desmet VJ, Callea F (1996) Cholestatic syndromes of infancy and childhood. In: Zakim D, Boyer TD (eds) *Hepatology. A Textbook of Liver Disease*, Vol. 2, 3rd edn. Philadelphia: WB Saunders, pp. 1649–1698.
39 Desmet V, Roskams T, Van Eyken P (1995) Ductular reaction in the liver. *Pathol Res Pract* 191, 513–524.
40 Christoffersen P, Poulsen H (1970) Histological changes in human liver biopsies following extrahepatic biliary obstruction. *Acta Pathol Microbiol Scand Suppl* 212(Suppl.), 150.
41 Mistilis SP (1965) Pericholangitis and ulcerative colitis. I. Pathology, etiology, and pathogenesis. *Ann Intern Med* 63, 1–16.
42 Edmondson HA, Peters RL, Reynolds TB *et al.* (1963) Sclerosing hyaline necrosis of the liver in the chronic alcoholic. A recognizable clinical syndrome. *Ann Intern Med* 59, 646–673.
43 Van Waes L, Lieber CS (1977) Early perivenular sclerosis in alcoholic fatty liver: an index of progressive liver injury. *Gastroenterology* 73, 646–650.
44 Scheuer PJ, Maggi G (1980) Hepatic fibrosis and collapse: histological distinction by orecin staining. *Histopathology* 4, 487–490.
45 Anthony PP, Ishak KG, Nayak NC *et al.* (1978) The morphology of cirrhosis. *J Clin Pathol* 31, 395–414.
46 Snover DC, Freese DK, Sharp HL *et al.* (1987) Liver allograft rejection. An analysis of the use of biopsy in determining outcome of rejection. *Am J Surg Pathol* 11, 1–10.
47 Poulsen H, Christoffersen P (1979)*Atlas of Liver Biopsies*. Copenhagen: Munksgaard.
48 Winkler K, Poulsen H (1975) Liver disease with periportal sinusoidal dilatation. A possible complication to contraceptive steroids. *Scand J Gastroenterol* 10, 699–704.
49 Bruguera M, Aranguibel F, Ros E *et al.* (1978) Incidence and clinical significance of sinusoidal dilatation in liver biopsies. *Gastroenterology* 75, 474–478.

50 Martinez-Hernandez A, Martinez J (1991) The role of capillarization in hepatic failure: studies in carbon tetrachloride-induced cirrhosis. *Hepatology* 14, 864–874.

51 Denk H, Scheuer PJ, Baptista A *et al.* (1994) Guidelines for the diagnosis and interpretation of hepatic granulomas. *Histopathology* 25, 209–218.

52 Ishak KG (1986) Hepatic morphology in the inherited metabolic diseases. *Semin Liver Dis* 6, 246–258.

53 Sherlock S (1983) Acute fatty liver of pregnancy and the microvesicular fat diseases. *Gut* 24, 265–269.

54 Uchida T, Kao H, Quispe-Sjogren M *et al.* (1983) Alcoholic foamy degeneration – a pattern of acute alcoholic injury of the liver. *Gastroenterology* 84, 683–692.

55 Buitrago B, Popper H, Hadler SC *et al.* (1986) Specific histologic features of Santa Marta hepatitis: a severe form of hepatitis delta-virus infection in northern South America. *Hepatology* 6, 1285–1291.

56 Parana R, Gerard F, Lesbordes JL *et al.* (1995) Serial transmission of spongiocytic hepatitis to woodchucks (possible association with a specific delta strain). *J Hepatol* 22, 468–473.

57 Callea F (1987) In: Lowe GDO *et al.* (eds) *Fibrinogen 2, Biochemistry, Physiology and Clinical Relevance.* Amsterdam: Elsevier Science Publishers (Biomedical Division), p. 75.

58 Kitamura T, Alroy J, Gatmaitan Z *et al.* (1992) Defective biliary excretion of epinephrine metabolites in mutant (TR-) rats: relation to the pathogenesis of black liver in the Dubin-Johnson syndrome and Corriedale sheep with an analogous excretory defect. *Hepatology* 15, 1154–1159.

59 Baptista A, Bianchi L, De Groote J *et al.* (1988) The diagnostic significance of periportal hepatic necrosis and inflammation. *Histopathology* 12, 569–579.

60 Gerber MA, Thung SN (1987) Histology of the liver. *Am J Surg Pathol* 11, 709–722.

61 Dhillon AP, Dusheiko GM (1995) Pathology of hepatitis C virus infection. *Histopathology* 26, 297–309.

62 Bianchi L, Gudat F (1994) Chronic hepatitis. In: MacSween RNM, Anthony PP, Scheuer PJ *et al.* (eds) *Pathology of the Liver*, 3rd edn. Edinburgh: Churchill Livingstone, pp. 349–395.

63 Desmet VJ (1991) Immunopathology of chronic viral hepatitis. *Hepato-Gastroenterology* 38, 14–21.

64 Buitrago B, Popper H, Hadler SC *et al.* (1986) Specific histologic features of Santa Marta hepatitis. A severe form of hepatitis delta-virus infection in northern South America. *Hepatology* 6, 1285.

65 Davies SE, Portmann BC, O'Grady JG *et al.* (1991) Hepatic histological findings after transplantation for chronic hepatitis B virus infection, including a unique pattern of fibrosing cholestatic hepatitis. *Hepatology* 13, 150–157.

66 Fang JW, Wright TL, Lau JY (1993) Fibrosing cholestatic hepatitis in patient with HIV and hepatitis B. *Lancet* 342, 1175.

67 Chen CH, Chen PJ, Chu JS *et al.* (1994) Fibrosing cholestatic hepatitis in a hepatitis B surface antigen carrier after renal transplantation. *Gastroenterology* 107, 1514–1518.

68 Booth JC, Goldin RD, Brown JL *et al.* (1995) Fibrosing cholestatic hepatitis in a renal transplant recipient associated with the hepatitis B virus precore mutant. *J Hepatol* 22, 500–503.

69 Propst T, Propst A, Dietze O (1992) High prevalence of viral infection in adults with homozygous and heterozygous a1-antitrypsin deficiency and chronic liver disease. *Ann Intern Med* 117, 641–645.

70 Geller SA, Nichols WS, Kim S *et al.* (1994) Hepatocarcinogenesis is the sequel to hepatitis in Z#2 alpha 1-antitrypsin transgenic mice: histopathological and DNA ploidy studies. *Hepatology* 19, 389–397.

71 Crocker J (1994) *Molecular Biology in Histopathology*. Chichester: John Wiley & Sons.

72 Desmet V, Fevery J (1995) Liver biopsy. *Baillières Clin Gastroenterol* 9, 811–828.

73 Anthony PP, Vogel CL, Barker LF (1973) Liver cell dysplasia: a premalignant condition. *J Clin Pathol* 26, 217–223.

74 Lefkowitch JH, Schiff ER, Davis GL *et al.* (1993) Pathological diagnosis of chronic hepatitis C: a multicenter comparative study with chronic hepatitis B. *Gastroenterology* 104, 595–603.

75 Borzio M, Bruno S, Roncalli M *et al.* (1995) Liver cell dysplasia is a major risk factor for hepatocellular carcinoma in cirrhosis: a prospective study. *Gastroenterology* 108, 812–817.

4.2 Classifications, scoring systems and morphometry in liver pathology

Pierre Bedossa and Valerie Paradis

The changing pattern of liver biopsy reports: from a detailed analytical report to classification and scoring systems

Liver biopsy is a useful diagnostic tool for the hepatologist [1]. It can assess the effects of a noxious agent on the liver at a level of detail that cannot be reached by any other means including imaging techniques [2]. In addition to providing help in diagnosis or establishing the aetiology of a liver disease (complementary to clinical, biological and serological data), liver biopsy provides valuable information about the intensity of parenchymal destruction or any other direct effect of the noxious agent that governs the immediate prognosis. It also provides information about lobular disorganization and architectural disturbance that is of major importance for long-term prognosis in chronic liver diseases. All these data are usually put together in a comprehensive and detailed biopsy report, and some of them should also be included in an easily accessible and more understandable manner for the hepatologist, namely a scoring system. The development of efficient treatment in chronic liver diseases has also stimulated pathologists, in close association with hepatologists, to develop classifications and scoring systems that summarize the most important lesions in a standardized form, providing a useful tool for treatment decisions and for assessing treatment efficacy. However, these scoring systems should not replace an analytical biopsy report but must complement and summarize in a concise and easy-to-access manner those features of importance.

Advantages of scoring liver biopsy

Dissection of the mental process that leads the pathologist to the elaboration of a histopathologic diagnosis gives some clues to the advantages and limits of scoring systems. When evaluating a liver biopsy, the first step is the identification of elementary histopathologic features (steatosis, Mallory bodies, hyaline bodies, apoptotic bodies, etc.). Once recognized, these features must be quantified (percentage, semi-quantification). Then, these lesions have to be integrated into a pathological diagnosis according to clinical and biological data. In order to achieve these goals, the pathologist needs experience in shape recognition, objectivity for quantification and guidelines to integrate the features into a diagnosis. Scoring systems can provide the pathologist with the objectivity to score lesions and the guidelines to make a diagnosis. By providing clear and detailed descriptions for each each elementary lesion and details on how to associate them, any pathologist should, in theory, be able to recognize a particular lesion and evaluate it. That is probably why histological scores have been adopted so widely; there is no chronic liver disease for which a scoring system has not been proposed, including chronic viral hepatitis, cholestatic liver diseases, alcoholic steatohepatitis (ASH) and non-alcoholic steatohepatitis (NASH), iron overload and even cancerous and precancerous lesions.

A scoring system provides major advantages both for cohort studies and also for individuals:

- Scores are very useful for cohort studies. Scoring a disease allows standardization of lesion evaluation that increases the reliability of multicentre studies. By categorizing patients into homogeneous groups with the same extent and severity of a disease, scoring adds to the validity of large multicentric epidemiological studies or clinical trials.
- In clinical practice and at the level of individual patients, scoring systems are very useful to support medical decisions. The best example is the simplification of treatment decisions provided by scores of chronic viral hepatitis. In addition, scoring liver damage allows the follow-up of the disease progression in a given patient spontaneously or under treatment. The semi-quantification provided by scores renders the comparison of biopsies performed in the same patient easier than comparing detailed reports.
- A score makes a liver biopsy report more accessible to non-specialized physicians and also to non-specialized pathologists. A score is easier to understand than a formal report: it does not require knowledge of the underlying liver histopathology.

• Finally, numerical scores are also very useful for setting up and validating surrogate markers, and it must be borne in mind that non-invasive markers of fibrosis are ultimately surrogates of histological scores.

In this context, it is important to emphasize that although scoring simplifies statistical calculations, restrictions do apply. Even when expressed in numerical values, scores are only semi-quantitative categorical data and not continuous variables. Although they refer to the progression in the severity of a histopathological feature or of a group of features, scores should not be used as quantitative variables in statistical analysis.

Limitations of scoring systems in liver biopsies

Although very useful, scoring systems have some drawbacks that have to be borne in the minds of both clinicians and pathologists. Some are related to the liver biopsy procedure itself while others are related directly to scoring systems.

Scores and sampling variability

Even for chronic diseases supposed to be diffuse within the liver, sampling variability remains a major drawback and sampling error strongly influences the performance of a scoring system. Sampling variability refers to the possible heterogeneous distribution of a histopathological feature within the liver. A liver biopsy represents a very limited part (<0.0001–0.00002%) of the whole organ. Such a tiny piece might give a wrong reflection of any lesion if this feature is not uniformly distributed in the liver. This variability depends on the type of pathological feature. Taking chronic hepatitis as an example, inflammation and steatosis are relatively homogeneously distributed within the liver, fibrosis is much more heterogeneous [3]. To limit the extent of sampling variation, the use of biopsy samples of sufficient size plus a scoring system that is not 'overprecise' is recommended. It has been shown that when the biopsy is long, the risk of sampling variability is reduced [4]. The recommended minimum sample size is a length of 15 mm; the optimum size should be around 25 mm [4,5]. Even with these thresholds, and taking the whole liver as the reference, 25–30% of biopsies are wrongly scored when fibrosis is concerned [4]. Fortunately, most discrepancies are only one stage different from the reference value. It is noteworthy that the complexity of a scoring system increases the risk of sampling error. A scoring system in which histopathological features are too rarely represented or too accurately evaluated does not work well with the sampling limitations of a liver biopsy core. However, a too simplistic score, although less sensitive to sampling error, will not provide enough information for the clinician. Therefore an efficient score will be the one that has reached a delicate equilibrium between the amount of information in the scoring system and the sampling variability.

Scores and observer variation

Observer variation refers to differences in scoring between pathologists. Interobserver variation is a major limitation in semi-quantitative histopathology and is highly dependent on the scoring system [6,7]. Observer variation must be tested for any new classification or scoring system, and only scores with low or acceptable interobserver variation should be retained [8,9]. Evaluation of observer variation should include both interobserver (i.e. the divergence of scores between different pathologists assessing the same biopsy) and intraobserver variation (i.e. the divergence when one pathologist scores the same biopsy at two different times). In general, intraobserver variation is lower than interobserver variation. Observer variation is closely related to the scoring system. For observer variation to be low, the scoring system must relate to unambiguously well-defined pathological items with accurate definitions of each grade on the scale. Observer variation increases with the complexity of the scoring system. In order to rule out observer variation, scoring by two observers in a collective lecture or by two observers independently with resolution of discordances in a dual lecture are the methods of choice especially in the context of clinical trials. When several biopsies have been performed in the same patient, scoring of more recent ones should be performed in conjunction with rereading of the older ones. Finally, it is recommended that in the context of clinical trials, all biopsies should be scored by the same referent pathologist. A recent study from France has shown that observer variation is related not only to the scoring system but also to pathologist experience [10]. Observer variation is lower between senior pathologists specialized in liver pathology and working in an academic environment than between junior or general pathologists. Biopsy size or staining does matter but is less important.

Chronic hepatitis C as a paradigm of scoring systems

The worldwide prevalence of hepatitis C virus infection and its frequent evolution towards chronicity has provided an instructive demonstration of the advantages and limits of scoring systems of liver biopsy [11]. It has also demonstrated how a score can evolve with time according to better knowledge of the natural history of the disease, to the expectations of hepatologists and to a clearer understanding of the limitations of the liver biopsy procedure [12].

The international classification that was proposed by an international panel of pathologists in 1968 has been used for years. It made a distinction between chronic persistent and chronic aggressive (active) hepatitis [13,14]. This classification has been utilized worldwide due to its clarity and simplicity. However, it has several limitations:

• Low information value, with only two classes (chronic persistent and chronic aggressive hepatitis).

• A systematic link between the stage and the grade: chronic persistent hepatitis shows no (or low) activity and no fibrosis whereas aggressive hepatitis shows both. We now know that the intensity of grade and stage are often dissociated, especially in chronic hepatitis C where fibrosis is common and activity generally low.
• In clinical practice, 'persistent' and 'active' hepatitis have been associated with two different diseases; however, it is now well known that these two lesions are simply two stages of the same disease with possible evolution from one to another [15].

Because the different histopathological features in chronic hepatitis can display a linear spectrum in intensity and can change either spontaneously or because of treatment, it was therefore of major importance to have a semi-quantitative scoring system [16]. The histological index of activity (Knodell score) responded in part to this aim and has been widely introduced [17]. This was a major step forward because it was the first scoring system that dissociated the different histopathological features that make up chronic hepatitis. It provides a numerical score (from 0 to 22) that is easy to computerize, and this index has been well utilized in clinical trials. However, several criticisms have been raised [18–20]:
• a lack of reproducibility for some items;
• an inappropriate grading system for mild chronic hepatitis;
• a non-linearity in score: values should be considered as categorical not nominal in statistical evaluations.
• addition of scores in different categories ignores their different pathogenic mechanisms and prognostic significance.

In recent years, a great amount of literature has addressed these concerns, and other new classifications have been proposed [21,22]. Although they differ somewhat in their content and methods of evaluation, there is a consensus among pathologists on the following points:
• The classification of chronic hepatitis must be reproducible. Any scoring system must take into account sampling variability. A histological feature that shows a high sampling variability must be assessed with a global, not overaccurate, scoring system, or assessed only on a biopsy of sufficient size.
• Any classification of chronic hepatitis should assess separately the grade and the stage of the disease. Grading evaluates the intensity of necroinflammation (or activity) and staging the degree of liver fibrosis. These two features must be dissociated because they correspond to two different mechanisms in term of pathogenesis, chronology, disease evolution and drug sensitivity. Whether scoring of fibrosis is easy to define unambiguously, there is more uncertainty in the grading of necroinflammation.
• The accuracy of a scoring system of chronic hepatitis should only reflect what the pathologist can reliably evaluate by light microscopy. However, it must be informative enough to be useful in the management of patients.
• A classification of chronic hepatitis must be applicable to all the aetiologies, whether infectious, autoimmune or toxic.

Based on these guidelines, the classifications that were commonly used in chronic hepatitis have been critically reassessed and new guidelines and classifications have been proposed [16,18,19,23,24]. They all satisfactorily meet the main criticisms outlined previously and differ only on minor points.

Table 1 METAVIR scoring system with algorithm for evaluation of grade of activity.

Stage of fibrosis
F0 = No fibrosis
F1 = Stellate enlargement of portal tract without septa
F2 = Stellate enlargement of portal tract with few septa (at least one on the biopsy)
F3 = Septal fibrosis without cirrhosis (more septa than portal tract without septa)
F4 = Cirrhosis
Grade of activity (a combination of periportal and lobular necrosis but not portal inflammation)
A0 = None
A1 = Mild activity
A2 = Moderate activity
A3 = Severe activity

PPN = 0	LN = 0	A = 0 no activity
	LN = 1	A = 1 mild activity
	LN = 2	A = 2 moderate activity
PPN = 1	LN = 0, 1	A = 1 mild activity
	LN = 2	A = 2 moderate activity
PPN = 2	LN = 0, 1	A = 2 moderate activity
	LN = 2	A = 3 severe activity
PPN = 3	LN 0, 1, 2	A = 3 severe activity

PPN, periportal necrosis; LN, lobular necrosis.

The METAVIR scoring system assesses fibrosis and necroinflammation separately and linearly [22]. A detailed algorithm that enables a global score of activity according to two elementary features (interface hepatitis and lobular inflammation) has been defined [25,26]. These scores have shown good reproducibility (excellent for score of fibrosis and acceptable for activity) and are widely adopted among pathologists and hepatologists. The detailed METAVIR scores are shown in Table 1. The simplicity and reproducibility of the METAVIR score make it useful both for routine practice and for clinical trials.

The Ishak scoring system is also commonly used [27]. It is a modification of the Knodell system that takes into account the major criticisms raised before. Both grade and stage are more detailed, which provides more information but to the detriment of reproducibility [28]. The Ishak scoring system is given in Table 2.

Although very useful, all these systems have limits. None of these scores assesses perisinusoidal fibrosis, and progress is still needed as regards the definition of activity. Which histological features are relevant to prognosis and to predicting response to treatment? A major criterion of acceptance for any classification will be its prognostic value, and data for this are still lacking. Better knowledge of the pathogenesis and natural history of liver

Table 2 The Ishak scoring system for grading and staging [27].

GRADING: Necroinflammatory scores	Score
A. Periportal or periseptal interface hepatitis (piecemeal necrosis)	
Absent	0
Mild (focal, few portal areas)	1
Mild/moderate (focal, most portal areas)	2
Moderate (continuous around 50% of tracts or septa)	3
Severe (continuous >50% of tracts or septa)	4
B. Confluent necrosis	
Absent	0
Focal confluent necrosis	1
Zone 3 necrosis in some areas	2
Zone 3 necrosis in most areas	3
Zone 3 necrosis + occasional portal–central (P-C) bridging	4
Zone 3 necrosis + multiple P-C bridging	5
Panacinar or multiacinar necrosis	6
C. Focal (spotty) lytic necrosis, apoptosis and focal inflammation	
Absent	0
One focus or less per 10× objective	1
Two to four foci per 10× objective	2
Five to ten foci per 10× objective	3
More than ten foci per 10× objective	4
D. Portal inflammation	
None	0
Mild, some or all portal areas	1
Moderate, some or all portal areas	2
Moderate/marked, all portal areas	3
Marked, all portal areas	4
STAGING: Architectural changes, fibrosis and cirrhosis	**Score**
No fibrosis	0
Fibrous expansion of some portal areas with or without short fibrous septa	1
Fibrous expansion of most portal areas with or without short fibrous septa	2
Fibrous expansion of most portal areas with occasional portal–portal bridging	3
Fibrous expansion of portal areas with marked portal–portal (P-P) and portal–central (P-C) bridging	4
Marked bridging (P-P and/or P-C) with occasional nodules (incomplete cirrhosis)	5
Cirrhosis, probable or definite	6

fibrosis and cirrhosis in chronic hepatitis would provide a firmer basis for a definitive classification of chronic hepatitis.

Scoring systems in other chronic hepatitides

The scoring systems described above have been developed mainly for chronic hepatitis C but they are also widely used for hepatitis B, although the pattern of necroinflammation is slightly different.

For autoimmune hepatitis, combined clinical and histopathological scoring systems have been proposed and recently reviewed [29]. They are useful to ascertain the diagnosis of autoimmune hepatitis and, to a lesser extent, to assess the severity. The various scores of chronic hepatitis described previously are also usable for this purpose.

Scoring systems in other chronic liver diseases

Alcoholic and non-alcoholic steatohepatitis (ASH and NASH)

Until the rise of metabolic syndrome and related liver diseases, there was no universal scoring system for alcoholic and non-alcoholic steatohepatitis [30]. Most authors used, for either clinical trials or research purposes, homemade scores or scores of fibrosis derived from the score of chronic hepatitis. Although this approach has been successful in several aspects, the physiopathology as well as key prognostic features of ASH and NASH are clearly different, rendering the use of these scores partly inappropriate. As an example, zone 3 and perisinusoidal fibrosis, which are cardinal features of ASH and NASH, are rarely encountered in the context of chronic hepatitis and never considered in scoring systems of chronic hepatitis [31]. In an attempt to take these features into account, a system for semi-quantitative evaluation of fibrosis that is more adapted to the unique lesions recognized in NASH was proposed by Brunt *et al.* and recently reviewed by Kleiner *et al.* (Table 3) [32,33].

The grading of liver cell lesions in NASH is far from easy mainly because the natural history of the disease remains partly unknown [34–36]. Therefore the choice of lesions to score and their quantification system remains uncertain and has to be tested and validated in prospective studies.

Cholestatic liver diseases

The scoring systems proposed by P. Scheuer and J. Ludwig *et al.* for primary biliary cirrhosis are the ones most widely accepted [37,38]. These two systems largely overlap. They are used both for individuals and for cohorts in clinical trials and are divided into four stages (Table 4). Because one characteristic of these diseases is the focal distribution of lesions, different stages might be present in a single liver simultaneously, thus diminishing the role of staging in cholestatic chronic liver diseases.

Table 3 Score of fibrosis in NASH [33].

0	None
1a	Mild zone 3 perisinusoidal fibrosis
1b	Moderate zone 3 perisinusoidal fibrosis
1c	Portal fibrosis only
2	Zone 3 perisinusoidal fibrosis and portal/periportal fibrosis
3	Bridging fibrosis (any bridging: i.e. central–central, central–portal, portal–portal)
4	Cirrhosis (probable and definite)

Table 4 Score of fibrosis in primary biliary cirrhosis [37].

Stage I	Florid lesion. Bile duct damage with inflammatory reaction
Stage II	Periportal fibrosis. Vanished bile ducts, portal and periportal inflammation and ductular proliferation
Stage III	Fibrosis. Portal fibrosis with periportal expansion and bridging fibrosis, typically without bile ducts
Stage IV	Cirrhosis

Morphometry as a step forward in scoring systems

When studying a liver biopsy, the hepatopathologist has two major tasks: shape recognition and shape quantification. Whereas shape recognition is an achievable goal with experience, quantification of individual histopathological items is more difficult, less suited to the working of the pathologist's eyes and brain. In order to gain more accuracy and objectivity in this matter, pathologists have developed a more sophisticated approach (i.e. morphometry) where the subjectivity of the eye–brain connection is replaced by a more objective and complex system that relies on image analysis [39]. Less expensive computer and image analysis hardware and better software and morphometric algorithms have been developed within the past 10 years and these developments have made morphometry more accessible and useful to pathologists [40]. It is of note that, even when using fully automated techniques, morphometry is very time-consuming and not recommended for routine practice. One of its most powerful applications is the evaluation of a drug in clinical trials.

There are several reasons to quantify features by morphometry:

- To decrease variability in quantifying features. Semi-quantification of morphological changes is dependent on observer variability. The sources of variability include the use of different visual templates, which arise from different educational or experiential backgrounds, and the fact that different pathologists emphasize the features differently. Morphometry potentially decreases this variability.
- To provide a finite quantitative scale. Scores are ordinal semi-quantitative assessments of changes to which numbers are typically assigned. However, these different scores are categories. Morphometric approaches to evaluating changes in tissue are linear and quantitative.
- To increase sensitivity in identifying minimal changes in features. Morphometry also offers the possibility of stratifying a disease process by an infinite number of categories, which cannot be done by visual estimation of the extent of change. This would permit a greater number of management and treatment options.
- To use as a research tool. Certain morphometric abnormalities, e.g. chromatin texture, area of fibrosis, correlate with biochemical and molecular changes [41,42].

Technical considerations

Morphometric studies are currently based on the analysis of two-dimensional structures – sections of cells and of tissue [43]. Three-dimensional (stereological) information can also be obtained from two-dimensional data, either by making assumptions about the three-dimensional structure regarding object size and shape or by directly assessing the third dimension by different means, such as confocal microscopy, or by reconstruction of serial sections or using computer-based image convolution techniques [44].

The choice of technique depends on the nature of the cells or tissue being analysed, the type of measurement being undertaken and the cost, measured in both time and money. Techniques can be categorized as manual, partially automated, automated with user interaction and fully automated. The rapid development of image analysis systems allowing fully automated analysis is now the method of choice. The principles are as follows:

- Obtain a digitized image from a histological slide. This is easily achieved through high-definition digital cameras or with software able to digitize analogue images obtained through high-definition video cameras. In some cases the digitized images are processed with the interaction of the pathologist to yield more accurate results.
- Thresholding the digitized image according to greyscale values provides the basis for segmenting the objects of interest.
- Segmentation to divide an image into two regions: the region that contains objects of interest for analysis (e.g. steatosis or fibrous tissue) and background data. In general, segmentation is based on the optical density of stained objects. Therefore highly contrasted staining is mandatory (such as picrosirius red for fibrosis).
- Measuring the structure of interest. Methods include point counting using a grid superimposed on microscopic sections or measuring the fractional area of interest using image analysis software, which provides a very high level of accuracy and allows complete automation of the process.

The main applications of morphometry are to measure linear distances (e.g. distance from a malignant tumour to a margin, or maximal two-dimensional size of a malignancy); object counting (e.g. counting mitoses or quantifying proliferation using immunohistochemistry to identify cycling cells for estimating the prognosis of tumours) [45]; measurement of fractional area (the fraction of tissue that consists of a particular structure or process); measurement of form factors – size and shape (sizes and shape of nuclei to identify disease and to predict the behaviour of cancer); and complex measurements (measure anisotropic biological structures that are not randomly oriented in tissue). For this approach, fractal geometry is the technique of choice [46]. Fractals are geometric patterns that retain their form at different scales of measurement [47]. Complex shapes, such as tumoral cell surfaces or areas of fibrosis, can be expressed as fractal dimensions [48,49].

Morphometry in liver diseases

In liver pathology, morphometry has been applied to quantify different but simple histological features. Despite the recent development of completely automated procedures, morphometry remains time-consuming, which prevents its use in routine practice. Therefore, morphometry has been used mainly for research purposes or to evaluate drug effects in clinical trials.

Steatosis

In several studies, objective computer-assisted methods and stereological point counting have been used to quantify the degree of steatosis [50,51]. The technique is simple and can be performed either by feeding images into the computer and using an overlay lattice, or supplying one eyepiece of the microscope with a graticule incorporating a point lattice and counting directly in the microscope [52].

Fibrosis

Digital image analysis rapidly provides objective quantitative results similar to but more precise than those determined by semi-quantitative scoring methods. With this approach the relative area of fibrosis is measured [53,54]. To be valuable, an interactive procedure with an experienced pathologist is needed before measuring to eliminate physiological fibrous tissue (e.g. Glisson's capsule, large proximal portal tracts). Falling costs and improvements in electronic and computer technology have enabled the implementation on personal computers of specific automatic applications for histology morphometry and fibrosis quantification [55,56]. Pilette *et al.* have demonstrated that the area of fibrosis, as determined by image analysis, and the semi-quantitative score are well correlated [54]. In addition to portal or septal fibrosis, morphometry allows rapid, reproducible and sensitive quantifications of perisinusoidal and perivenular fibrosis, features that are not usually assessed in semi-quantitative scores of fibrosis [57–60].

Another approach to assess fibrosis is fractal geometry. The fractional dimension of its irregular shape defines fibrosis as a natural fractal structure. The complex distribution of its components can be optimally quantified using a single numerical score that seems to be a better alternative to the semi-quantitative methods adopted so far [61,62].

A major advantage of morphometry in liver fibrosis is in the evaluation of antifibrotic treatments [63–65]. Because the changes induced by antifibrotic treatment are expected to be mild, the precision of fibrosis evaluation by morphometry is helpful [66]. However, because sampling error is a major drawback in fibrosis evaluation, morphometry should be performed in biopsies of at least 20mm in length [4]. Finally, due to its linearity and accuracy, measuring fibrosis with morphometry is the perfect reference to evaluate the performance of non-invasive methods.

Cirrhosis

In this context, three-dimensional structure reconstitution is of great interest in exploring the architectural reorganization accompanying cirrhosis. Several studies have used this approach to clarify the morphogenesis of cirrhotic nodules [67,68]. Morphometry enabled the demonstration that parenchyma consists of cirrhotic nodules centrifugally formed around the portal veins, and that their flows drain into the hepatic veins inside and around the nodule and nodule derived from the first. The latter was divided into the former by bridging fibrosis-induced intranodular septation.

Regeneration, benign and malignant liver tumours

Morphometric characterization of a variety of nuclear features provides the basis for distinguishing carcinoma cells from benign cells in liver tumours [69]. Combinations of morphometric features can be used for diagnosis and classification of tumours and especially hepatocellular carcinoma [70–73]. Morphological features of nuclei, including skewness of area, length of the major axis and nuclear roundness, provide the basis for distinguishing hepatocellular carcinoma from regenerative nodules. Based on these parameters, the positive predictive value of a neural net classifier of nuclear dimensions was 100%, and the negative predictive value was 85% in one study [74].

Cholestasis

Two- and three-dimensional reconstructions have been used to explore bile duct and bile-duct remodelling in several conditions including secondary biliary cirrhosis and bile duct ischaemia [75–77].

The limits of morphometry

There are many potential sources of error in morphometry. Some of the most important are:

- Error in identifying the object of interest. There is marked variability in the consistency with which observers identify objects. However, an image analysis system, which identifies objects by segmenting images, is also subject to variability. This can result either from the staining procedure, where staining can be too weak or lacking sufficient contrast or specificity to form a reliable basis for greyscale-based separation of object and background, or from the observer, who sets the threshold.
- Tissue processing. This involves multiple steps in which tissue components are chemically modified. The nature of the fixative and the conditions of fixation alter the dimensions of tissue components, which can lead to errors in counting objects. Whether such steps influence the relative fractional area of objects should be evaluated for each tissue constituent that is to be analysed.
- Errors in sampling. Is the sample size sufficiently large to obtain meaningful results? A morphometric analysis should sample the specimen to an extent sufficient to minimize variability [78,79]. The distribution of objects of interest is a consideration in sampling. Tissue-based studies have shown greater heterogeneity in feature distribution. Fibrosis or tumour vascularity is not uniformly distributed throughout a given section.

Conclusion

Semi-quantitative scoring systems are valuable tools for histopathological evaluation. They have been widely used in several chronic liver diseases although chronic viral hepatitis is probably the one that benefits most from this approach. Quantification techniques, which so far remain in the realm of research, might yield increasingly valuable information if the numerous problems inherent with the techniques can be solved.

References

1 Smetana HF (1954) The histologic diagnosis of viral hepatitis by needle biopsy. *Gastroenterology* 26, 612–625.
2 Bravo AA, Sheth SG, Chopra S (2001) Liver biopsy. *N Engl J Med* 344, 495–500.
3 Regev A, Berho M, Jeffers LJ *et al.* (2002) Sampling error and intra-observer variation in liver biopsy in patients with chronic HCV infection. *Am J Gastroenterol* 97, 2614–2816.
4 Bedossa P, Dargère D, Paradis V (2003) Sampling variability of liver fibrosis in chronic hepatitis C. *Hepatology* 38, 1449–1457.
5 Colloredo G, Guido M, Sonzogni A *et al.* (2003) Impact of liver biopsy size on histological evaluation of chronic viral hepatitis: the smaller the sample, the milder the disease. *J Hepatol* 39, 239–244.
6 Bedossa P, Poynard T, Naveau S *et al.* (1988) Observer variation in assessment of liver biopsies of alcoholic patients. *Alcoholism: Clin Exp Res* 12, 173–178.
7 Rozario R, Ramakrishna B (2003) Histopathological study of chronic hepatitis B and C: a comparison of two scoring systems. *J Hepatol* 38, 223–229.
8 METAVIR (1994) Quelle classification pour les hépatites chroniques? Les leçons du virus C. *Gastroentérol Clin Biol* 18, 403–406.
9 Brunt EM (2000) Grading and staging the histopathological lesions of chronic hepatitis: the Knodell histology activity index and beyond. *Hepatology* 31, 241–246.
10 Rousselet MC, Michalak S, Dupre F *et al.* (2005) Sources of variability in histological scoring of chronic viral hepatitis. *Hepatology* 41, 257–264.
11 Perrillo RP (1997) The role of liver biopsy in hepatitis C. *Hepatology* 26 Suppl., 57S–61S.
12 Goodman ZD, Ishak KG (1995) Histopathology of hepatitis C virus infection. *Semin Liver Dis* 15, 70–81.
13 DeGroote J, Desmet V, Gedigk P *et al.* (1968) A classification of chronic hepatitis. *Lancet* ii, 626–628.
14 Anon (1977) Review by an international group. Acute and chronic hepatitis revisited. *Lancet* ii, 914–919.
15 Fattovich G, Brollo L, Alberti A (1990) Chronic persistent hepatitis B can be a progressive disease when associated with sustained virus replication. *J Hepatol* 11, 29–33.
16 Scheuer PJ (1991) Classification of chronic viral hepatitis: a need for reassessment. *J Hepatol* 13, 372–374.
17 Knodell KG, Ishak KG, Black WC *et al.* (1981) Formulation and application of a numerical scoring system for assessing histological activity in asymptomatic chronic active hepatitis. *Hepatology* 1, 431–435.
18 Czaja AJ (1993) Chronic active hepatitis: the challenge for a new nomenclature. *Ann Intern Med* 119, 510–517.
19 Ludwig J (1993) The nomenclature of chronic active hepatitis: an obituary. *Gastroenterology* 105, 274–278.
20 Scheuer PJ (1995) The nomenclature of chronic hepatitis: time for a change. *J Hepatol* 22, 112–114.
21 Ludwig L (1994) Terminology of chronic hepatitis. *Am J Gastroenterol* 89, S177–1.
22 METAVIR cooperative group (1994) Inter- and intra-observer variation in the assessment of liver biopsy of chronic hepatitis C. *Hepatology* 20, 15–20.
23 Desmet VJ, Gerber M, Hoofnagle JH *et al.* (1994) Classification of chronic hepatitis: diagnosis, grading and staging. *Hepatology* 19, 1513–1519.
24 Ishak K (2000) Pathologic features of chronic hepatitis. A review and update. *Am J Clin Pathol* 113, 40–55.
25 METAVIR (1993) Proposition d'une grille de recueil des lésions histopathologiques dans l'hépatite chronique virale C. *Ann Pathol* 13, 260–265.
26 METAVIR cooperative study group (1996) An algorithm for the grading of activity in chronic hepatitis. *Hepatology* 24, 289–293.
27 Ishak K, Baptista A, Bianchi L *et al.* (1995) Histological grading and staging of chronic hepatitis. *J Hepatol* 22, 696–699.
28 Westin J, Lagging LM, Wejstal R *et al.* (1999) Interobserver study of liver histopathology using the Ishak score in patients with chronic hepatitis C virus infection. *Liver* 19, 183–187.
29 Czaja AJ, Carpenter HA (1996) Validation of a scoring system for the diagnosis of autoimmune hepatitis. *Dig Dis Sci* 41, 305–314.
30 Ludwig J, Viggiano TR, McGill DB *et al.* (1980) Nonalcoholic steatohepatitis: Mayo Clinic experiences with a hitherto unnamed disease. *Mayo Clin Proc* 55, 434–438.
31 Brunt EM (2004) Nonalcoholic steatohepatitis. *Semin Liver Dis* 24, 3–20.
32 Brunt EM, Janney CG, Di Bisceglie AM *et al.* (1999) Nonalcoholic steatohepatitis: a proposal for grading and staging the histological lesions. *Am J Gastroenterol* 94, 2468–2474.
33 Kleiner DE, Brunt EM, Van Natta M *et al.* (2005) Design and validation of a histological scoring system for nonalcoholic fatty liver disease. *Hepatology* 41, 1313–1321.
34 Angulo P, Keach JC, Batts KP *et al.* (1999) Independent predictors of liver fibrosis in patients with nonalcoholic steatohepatitis. *Hepatology* 30, 1356–1362.
35 Matteoni CA, Younossi ZM, Gramlich T *et al.* (1999) Nonalcoholic fatty liver disease: a spectrum of clinical and pathological severity. *Gastroenterology* 116, 1413–1419.
36 Dixon JB, Bhathal PS, O'Brien PE (2001) Nonalcoholic fatty liver disease: predictors of nonalcoholic steatohepatitis and liver fibrosis in the severely obese. *Gastroenterology* 121, 91–100.
37 Scheuer PJ (1967) Primary biliary cirrhosis. *Proc Roy Soc Med* 60, 1257–1260.
38 Ludwig J, Dickson ER, McDonald GS (1978) Staging of chronic non-suppurative destructive cholangitis. *Virchows Arch A* 379, 103–112.
39 Weibel ER (1979) *Stereological Methods: Practical Methods for Biological Morphometry*. San Diego, CA: Academic Press.
40 Dahab GM, Kheriza MM, El-Beltagi HM *et al.* (2004) Digital quantification of fibrosis in liver biopsy sections: description of a new method by Photoshop software. *J Gastroenterol Hepatol* 19, 78–85.
41 Liautaud RF, Teyssier JR, Ferre D *et al.* (1992) Can chromatin texture predict structural karyotypic changes in diploid cells from thyroid cold nodules? *Anal Cell Pathol* 4, 421–428.
42 Mulder J-WR, Offerhaus GJA, Feyter EP de *et al.* (1992) The relationship of quantitative nuclear morphology to molecular genetic alterations in the adenoma-carcinoma sequence of the large bowel. *Am J Pathol* 141, 797–804.
43 Wied CL, Bartels PH, Bibbo M *et al.* (1989) Image analysis in quantitative cytopathology and histopathology. *Hum Pathol* 20, 549–571.

44 Zhu Q, Tekola P, Baak JP *et al* (1994) Measurement by confocal laser scanning microscopy of the volume of epidermal nuclei in thick skin sections. *Anal Quant Cytol Histol* 16, 145–152.

45 Quinn CM, Wright NA (1990) The clinical assessment of proliferation and growth in human tumours: Evaluation of methods and applications as prognostic variables. *J Pathol* 160, 93–102.

46 Cross SS (1994) The application of fractal geometric analysis to microscopic images. *Micron* 25, 101–113.

47 Barnsley MF, Massopust P, Strickland H *et al.* (1987) Fractal modeling of biological structures. *Ann NY Acad Sci* 504, 179–194.

48 Keough KMW, Hyam P, Pink DA *et al.* (1991) Cell surfaces and fractal dimensions. *J Microsc* 163, 95–99.

49 Cross SS, Cotton DWK (1992) The fractal dimension may be a useful morphometric discriminant in histopathology. *J Pathol* 166, 409–411.

50 Auger J, Schoevaert D, Martin ED (1986) Comparative study of automated morphometric and semiquantitative estimations of alcoholic liver steatosis. *Anal Quant Cytol Histol* 8, 56–62.

51 Zaitoun AM, Al Mardini M, Record CO (1998) Stereology and morphometry of steatosis in human alcoholic (ALD) and non-alcoholic liver disease (NALD). *Acta Stereol* 17, 49–56.

52 Zaitoun AM, Al Mardini H, Awad S *et al.* (2001) Quantitative assessment of fibrosis and steatosis in liver biopsies from patients with chronic hepatitis C. *J Clin Pathol* 54, 461–465.

53 Ryoo JW, Buschmann RJ (1989) Morphometry of liver parenchyma in needle biopsy specimens from patients with alcoholic liver disease: Preliminary variables for the diagnosis and prognosis of cirrhosis. *Mod Pathol* 2, 382–389.

54 Pilette C, Rousselet MC, Bedossa P *et al.* (1998) Histopathological evaluation of liver fibrosis: quantitative image analysis vs semi-quantitative scores. Comparison with serum markers. *J Hepatol* 28, 439–446.

55 O'Brien MJ, Keating NM, Elderiny S *et al.* (2000) An assessment of digital image analysis to measure fibrosis in liver biopsy specimens of patients with chronic hepatitis C. *Am J Clin Pathol* 114, 712–718.

56 Masseroli M, Caballero T, O'Valle F *et al.* (2000) Automatic quantification of liver fibrosis: design and validation of a new image analysis method: comparison with semi-quantitative indexes of fibrosis. *J Hepatol* 32, 453–464.

57 Promrat K, Lutchman G, Uwaifo GI *et al.* (2004) A pilot study of pioglitazone treatment for nonalcoholic steatohepatitis. *Hepatology* 39, 188–196.

58 Imamura H, Kawasaki S, Bandai Y *et al.* (1994) Morphometry of sinusoids and portal hypertension in non-alcoholic cirrhosis. *J Hepatol* 21, 167–173.

59 Moragas A, Allende H, Sans M (1998) Characteristics of perisinusoidal collagenization in liver cirrhosis: computer-assisted quantitative analysis. *Anal Quant Cytol Histol* 20, 169–177.

60 Zimmermann A, Zhao D, Reichen J (1999) Myofibroblasts in the cirrhotic rat liver reflect hepatic remodeling and correlate with fibrosis and sinusoidal capillarization. *J Hepatol* 30, 646–652.

61 Dioguardi N, Grizzi F, Bossi P *et al.* (1999) Fractal and spectral dimension analysis of liver fibrosis in needle biopsy specimens. *Anal Quant Cytol Histol* 21, 262–266.

62 Moal F, Chappard D, Wang J *et al.* (2002) Fractal dimension can distinguish models and pharmacologic changes in liver fibrosis in rats. *Hepatology* 36, 840–849.

63 Baroni GS, D'Ambrosio L, Curto P *et al.* (1996) Interferon gamma decreases hepatic stellate cell activation and extracellular matrix deposition in rat liver fibrosis. *Hepatology* 23, 1189–1199.

64 Bruck R, Hershkoviz R, Lider O *et al.* (1996) Inhibition of experimentally-induced liver cirrhosis in rats by a nonpeptidic mimetic of the extracellular matrix-associated Arg-Gly-Asp epitope. *J Hepatol* 24, 731–738.

65 Alpini G, Elias I, Glaser S *et al.* (1997) Gamma-interferon inhibits secretin-induced choleresis and cholangiocyte proliferation in a murine model of cirrhosis. *J Hepatol* 27, 371–380.

66 Neef M, Ledermann M, Saegesser H *et al.* (2006) Oral imatinib treatment reduces early fibrogenesis but does not prevent progression in the long term. *J Hepatol* 44, 167–175.

67 Sakata A, Takasaki S, Kawakami M (1999) Three-dimensional image analysis of the hepatic restructuring process in chronic active hepatitis. *Anal Quant Cytol Histol* 21, 245–249.

68 Vizzotto L, Vertemati M, Gambacorta M *et al.* (2002) Analysis of histological and immunohistochemical patterns of the liver in post-hepatitic and alcoholic cirrhosis by computerized morphometry. *Mod Pathol* 15, 798–806.

69 Rubin EM, Martin AA, Thung SN *et al.* (1995) Morphometric and immunohistochemical characterization of human liver regeneration. *Am J Pathol* 147, 397–404.

70 Herman CJ, Vooijs GP, Baak JPA *et al.* (1984) Quantitative cytologic and histologic techniques to assist in cancer evaluation. *Methods Achiev Exp Pathol* 11, 73–95.

71 Hall TL, Fu YS (1985) Applications of quantitative microscopy in tumor pathology. *Lab Invest* 53, 5.

72 Ueda K, Terada T, Nakanuma Y, Matsui O (1992) Vascular supply in adenomatous hyperplasia of the liver and hepatocellular carcinoma: A morphometric study. *Hum Pathol* 23, 619–626.

73 Terayama N, Terada T, Nakanuma Y (1996) A morphometric and immunohistochemical study on angiogenesis of human metastatic carcinomas of the liver. *Hepatology* 24, 816–819.

74 Erler BS, Hsu L, Truong HM *et al.* (1994) Image analysis and diagnostic classification of hepatocellular carcinoma using neural networks and multivariate discriminant functions. *Lab Invest* 71, 446–451.

75 Ohara N, Schaffner T, Reichen J (1993) Structure-function relationship in secondary biliary cirrhosis in the rat: Stereologic and hemodynamic characterization of a model. *J Hepatol* 17, 155–162.

76 De Craemer D, Pauwels M, Van Den Branden C (1995) Regression of bile duct damage and bile duct proliferation in the non-rearterialized transplanted rat liver is associated with spontaneous graft rearterialization. *Hepatology* 21, 1353–1360.

77 Beaussier M, Wendum D, Fouassier L *et al.* (2005) Adaptative bile duct proliferative response in experimental bile duct ischemia. *J Hepatol* 42, 257–265.

78 Mathieu O, Cruz-Grive LM, Hoppeler H *et al.* (1981) Measuring error and sample variation in stereology: Comparison of the efficiency of various methods for planar image analysis. *J Microsc* 121, 75–88.

79 Collan Y, Torkkeli T, Kosma V-M *et al.* (1987) Sampling in diagnostic morphometry: The influence of variation sources. *Pathol Res Pract* 182, 401–406.

5 Investigation of hepatobiliary disease

5.1 Signs and symptoms of liver disease

Jürg Reichen

Signs and symptoms are nonspecific for either liver disease *per se* or for differentiating disease of the liver from that of other systems. Nevertheless, an adequate history, review of systems and physical examination can yield the clue to the diagnosis even in this age of advanced immunological, virological and biochemical testing – let alone the array of wonderful imaging techniques.

Symptoms

Weakness, fatigue and resulting decrease in quality of life

Close to 80% of the patients in my outpatient clinic complain of fatigue regardless of their underlying diagnosis. This is particularly frustrating for both patient and clinician as this symptom is notoriously difficult to treat.

This nonspecific symptom is said to be particularly prevalent in hepatitis C; an early study into this topic concluded that hepatitis C patients – as compared with healthy controls and patients with hepatitis B – had marked impairment in quality of life [1]. Changes in ^{1}H-magnetic resonance spectroscopy correlate well with cognitive impairment and decreased quality of life [2]. However, when other factors associated with fatigue such as depression, intravenous drug abuse and advanced liver disease are removed, the clinical relevance of impaired cognition becomes relatively minor [3].

Fatigue is also a relevant symptom in cholestatic liver disease, in particular in primary biliary cirrhosis [4]; rat experiments pioneered by Mark Swain have laid a pathophysiological basis for this phenomenon suggesting a central origin [5]. In a recent study, fatigue was present, albeit to a lesser degree, in patients with primary biliary cirrhosis but the impact on quality of life was minor; of particular interest was the fact that weakness (as assessed by grip strength) was not correlated with the self-assessment of fatigue by validated questionnaires [6]; indeed, a population-based survey has demonstrated a clear central effect for this symptom [7]. In contrast to primary biliary cirrhosis, patients with primary sclerosing cholangitis appear not to be fatigued [8].

Anorexia, dysgeusia and dysosmia

Lack of appetite is a prevalent symptom of acute liver disease of any cause. In endstage liver disease, anorexia is also prevalent. The reason(s) for anorexia are poorly understood. Research into satiety hormones may advance the field in the next few years. Support for this contention is the observation that the organism tries to correct reduced food intake by upregulating ghrelin [9].

Disordered taste and smell acuity are frequent in patients with acute and chronic liver disease but the reasons for this phenomenon remain unclear. Zinc defiency would be a plausible candidate for dysgeusia but this has not been borne out by a thorough investigation of different micronutrients [10]. Recently, a central origin for alterations in the sense of taste has been proposed [11].

Sicca syndrome

Dry gland syndrome is often not spontaneously reported and should be asked for. Measurement of tear flow with Schirmer's test or salivary flow should be performed in the appropriate settings. Although sicca syndrome is obviously strongly associated with primary biliary cirrhosis it can be seen in any cholestatic disorder resulting in ductopenia, including sarcoidosis [12] or drug-induced intrahepatic cholestasis. Another condition where sicca syndrome is quite frequent is chronic hepatitis C; Cacoub *et al.* reported an incidence of 11% [13]. Conversely, the presence of hepatitis C in patients presenting with sicca syndrome is also high at 19% [14]. Sicca syndrome can also be seen in chronic hepatitis B, albeit less frequently [15].

Abdominal pain and discomfort

Abdominal pain, particularly when it is localized to the right upper quadrant, may reflect stretching of the liver capsule.

This occurs when there is a rapid increase in liver volume due to, for example, swelling in right heart failure, hepatic vein occlusion in Budd–Chiari syndrome or the occurrence of a primary or metastatic liver tumour. Patients with chronic liver disease, in particular hepatitis C but also haemochromatosis, will often report a dull ache, which often occurs postprandially; one might speculate that this is due to swelling of the liver as a result of the osmotic load of a meal. This symptom often appears only once the patient has been told that there is something wrong with his or her liver. A careful history is of paramount importance when right upper quadrant pain is present; it might guide further evaluation by ultrasonography and/or oesophagogastroscopy.

A completely different issue is biliary pain – often misnamed biliary colic. The so-called biliary colic is not colicky at all but a constant pain lasting 30 min or more [16]. A meta-analysis clearly demonstrated that dyspeptic symptoms and fat intolerance are not related to gallstones [17]. Acute obstruction by gallstones in either the cystic duct or choledochus will last as long as the obstruction persists; biliary pain is often associated with nausea. In contrast, slowly developing obstruction is usually devoid of pain because the ducts are able to accommodate the slow increase in pressure by dilatation.

Abdominal discomfort with a feeling of abdominal swelling is most often due to intestinal gas, in particular when it is of short duration and/or waxing and waning. However, persistent discomfort with increased girth leading to changes in the size of clothes is most often due to ascites or marked organomegaly. In the latter case, the patient will also report a mass effect.

Bowel habits, stools and flatulence

Constipation is not a feature of liver disease but may aggravate or precipitate hepatic encephalopathy in patients with advanced liver disease.

Diarrhoea – a common symptom – should not be primarily attributed to acute or chronic liver disease but properly evaluated. It is, however, a frequently encountered presenting symptom in acute liver disease of viral or, particularly, alcoholic aetiology. Diarrhoea is seen in only 14% of patients with amoebic liver abscess [18]. In patients referred for workup of abnormal liver enzymes or a change in bowel habits to increased frequency and/or stool volume, several autoimmune diseases including primary sclerosing cholangitis, primary biliary cirrhosis, Behçet's disease and coeliac disease ought to be considered. A rare cause of liver disease and diarrhoea is amyloidosis – biopsy the intestine rather than the liver if suspicion is high!

Diarrhoea is of particular interest in the transplanted patient; there, nosocomial infections, antibiotic-induced diarrhoea and drug-induced diarrhoea ought to be considered [19]. Similar considerations apply to the HIV-positive patient. A classical but rare phenomenon is diarrhoea, sepsis and liver abscess due to iron-dependent microorganisms such as *Yersinia enterocolitica* in iron overload.

Changes in micturition and urine

Patients often notice that their urine gets darker before noticing scleral icterus; when questioning, one should ask whether the urine is like coca cola – lesser darkening is usually due to concentrated urine in dehydrated patients.

In the review of systems, symptoms of urinary tract infection (UTI) ought to be sought because UTIs are the second most frequent cause of bacterial infection in patients with endstage liver disease [20]. In contrast to some earlier reports, patients with primary biliary cirrhosis appear not to be prone to UTIs in precirrhotic stages [21].

Jaundice and pruritus

Profound jaundice will not be missed by patients; if it is accompanied by dark urine (see above), a hepatobiliary cause is very likely. Intermittent jaundice in a young patient with normally coloured urine is most probably the result of Gilbert syndrome.

Pruritus is an important sign of cholestatic liver disease but can also be seen in acute and chronic viral hepatitis. Pruritus is quite frequent in hepatitis C; different skin diseases – in particular eczema, urticaria, atopic dermatitis, cryoglobulinaemia and lichen planus – are often associated with hepatitis C [22,23].

The aetiology of pruritus of cholestasis has recently been reviewed by Bergasa [24]. Typically, it is more severe at night and affects the extremities more than the trunk. Painless jaundice together with pruritus in the elderly patient is often due to malignant obstruction but can also be caused by stones and even intrahepatic cholestasis, in particular primary biliary cirrhosis.

Muscle cramps

Cramps are a frequent symptom in endstage liver disease, occurring in close to two-thirds of patients with cirrhosis as compared with 7% in matched controls [25]. This symptom should be asked for and treatment considered because it is a major factor for the decreased quality of life in patients with endstage liver disease [26]. For such a frequent and painful symptom, amazingly little research has been done to elucidate the cause and optimal treatment.

Fever and shaking chills (rigors)

Fever is a frequent symptom in acute and chronic liver disease whereas shaking chills are rather rare. The latter – if liver is the leading diseased organ – should make you consider suppurative cholangitis or liver abscess.

Liver biopsy should be considered in all patients with fever of unknown origin and negative imaging studies.

Irritability, confusion, difficulties in concentration and sleep disturbance

The confused, disoriented patient with asterixis and known

cirrhosis is easily recognized as suffering from portosystemic encephalopathy (PSE). More subtle signs of PSE include a reversal in the diurnal rhythm [27], changes in personality – in particular irritability – which are often not recognized by the patient but can be elicited by asking close relatives.

Bleeding and bruising

Easy bruising and spontaneous bleeding from the nose or gums is a frequent symptom in endstage liver disease. Bleeding time in cirrhosis is prolonged concomitant with impairment of hepatic dysfunction and should therefore be measured in patients with advanced liver disease before invasive procedures [28].

Massive upper or lower gastrointestinal bleeding is, of course, a frequent first presentation of chronic liver disease and will be covered extensively in other chapters. Intra-abdominal bleeding can be a first manifestation of hepatocellular cancer and other malignant or even benign liver tumors.

Past medical history, family history and review of systems

Past medical history

I trust that all hepatologists will obtain a careful history of events that have occurred previously in the patient's life. Of particular interest for hepatology are previous episodes of jaundice, abdominal surgery and, in women, the course of pregnancy and the onset of menopause.

Family history

A history of relatives dying from liver disease may point to inherited diseases such as haemochromatosis, alpha-1-antitrypsin deficiency and others. Of note is that nonalcoholic steatohepatitis may run in families. Acquired liver diseases, in particular hepatitis B, might be revealed by an appropriate family history.

Review of systems

A thorough review of systems is mandatory. Particular attention should be paid to drugs and medicinal plants. It has to be realized that often megavitamins, a 'tea against the cold' (which in Europe may contain paracetamol) or phytotherapeutics are not considered 'drugs' by the patient. The heavily muscled young man who spends 6 hours per day in the gym will not tell you that he has been ingesting anabolic steroids. The elderly lady who has been taking a benzodiazepine for sleep for decades does not consider this a drug because she has been with it forever.

The review of systems should also consider work, hobbies and pets because these can be associated with exposure to toxins or infectious agents of which the patient is not aware.

Signs

Although modern imaging techniques have rendered many bedside skills 'obsolete', a thorough inspection and physical examination will still reveal many clues to the presence and even the aetiology of the underlying disease.

General appearance and vital signs

It goes without saying that the general appearance and the nutritional state should be recorded. Malnutrition – part of the original Child classification – has been shown to be related to the degree of liver failure [29]; onset of malnutrition is particularly important when considering the need for liver transplantation. Conversely, an elevated body mass index (BMI) will lead the physician to consider the presence of nonalcoholic fatty liver disease or steatohepatitis (NAFLD/NASH).

Decreased arterial pressure and a high heart rate are part of the hyperdynamic circulation syndrome in portal hypertension [30,31]. With liver function decreasing, pre-existing arterial hypertension often disappears. Conversely, arterial hypertension is part of the metabolic syndrome and therefore associated with NAFLD/NASH.

Dyspnoea and tachypnoea are frequent findings in advanced liver disease as a result of elevation and compression of the diaphragm by an enlarged liver, ascites or the presence of pleural effusions. Cystic fibrosis and alpha-1-antitrypsin deficiency obviously can affect both the lung and the liver; patients with alcoholic liver disease often smoke, and alcoholic liver disease is often associated with chronic obstructive pulmonary disease (COPD). Dyspnoea can also be a sign of portopulmonary hypertension; this will be covered in more depth in Chapter 7.7.

Fever is a hallmark of many acute viral and bacterial liver diseases, covered in Sections 9 and 10 respectively. Other liver infections usually associated with fever include suppurative cholangitis and liver abscess. Fever should be taken seriously in any patient with cirrhosis because infections are a leading cause of death in this population. Similarly, alarm bells should ring in the transplanted patient with fever (see Chapter 25.6). In the absence of infection, fever can be an accompanying symptom of any chronic liver disease, in particular of alcoholic hepatitis (see Chapter 12.4), hepatitis C and autoimmune liver diseases.

A particularly interesting situation is fever of unknown origin (FUO). A recent systematic review demonstrated that liver biopsy can be revealing in 14–17% of cases in this setting even when liver enzymes are normal [32]. My personal algorithm for this condition is to scan thorax and abdomen and, if this is negative, to proceed with liver biopsy.

Eyes

The obvious sign of liver disease to be sought in the eyes is scleral jaundice, which can be detected when serum bilirubin exceeds ~35 μmol/L. Red and dry conjunctivae might hint at the

presence of sicca syndrome and should elicit further questioning and performance of Schirmer's test.

Rare, but delightful if you see it because it allows you to make a rapid diagnosis, is the presence of a Kayser–Fleischer ring – golden-brown to greenish pigment deposition in Descemet's membrane – which obviously makes you think of Wilson's disease [33]. In advanced cases, this might proceed to sunflower cataracts by copper deposition on the anterior capsule of the lens. Kayser–Fleischer ring is not pathognomonic for Wilson's disease but might be found in other conditions with severe copper overload.

Cataracts in young patients should make you think of galactosaemia, cerebrotendinous xanthomatosis or familial hyperferritinaemia [34]. A posterior embryotoxon is found in 95% of patients with Alagille syndrome where other ocular abnormalities also prevail [35].

Skin

The discussion of the skin is restricted to the most important and general signs of liver disease; for a more thorough discussion of this fascinating topic, the reader is referred to Chapter 21.6.

A thorough inspection of the whole integument can yield valuable clues; a pale skin can indicate anemia, in particular when verified by pallor of the lips and conjunctivae. Jaundice – initially best seen in the sclerae and frenulum of the tongue – is an obvious sign. Neil McIntyre, who wrote the first and second editions of this chapter, considered enoral jaundice an epiphenomenon of little clinical value; our hospital unfortunately puts our patients on yellow bed linen – using a white lamp, I find enoral jaundice a good sign and can detect the usual visual limit of 35 μmol/L.

Many plant dyes – mostly carotenes and lycopenes – can cause pseudojaundice; such substances are abundant in carrots, tomatoes and papaya. Differentiation can be made chemically or by inspection of the sclerae: these are spared in pseudojaundice. Longstanding jaundice leads to a characteristic grey-greenish discoloration of the whole integument.

Cyanosis is most often thought of as being associated with cardiac or pulmonary disease. Either can also affect the liver and lead to hepatomegaly and disturbed liver function tests. In the patient with known cirrhosis, cyanosis should lead to diagnostic workup of potential hepatopulmonary syndrome [36].

Haemochromatosis is labelled in old textbooks as 'bronze diabetes'; nowadays the diagnosis should be made earlier. The increased skin pigmentation in extreme iron overload is due to iron and melanin deposition [37].

Vitiligo – patchy discoloration of the skin due to local destruction of melanocytes – can be associated with autoimmune liver disease and chronic hepatitis C. Whether vitiligo can be provoked by interferon treatment has been claimed but not proven because it is clearly associated with hepatitis C *per se* [38].

Xanthelasmata and excoriations hint at a chronic cholestatic liver disease, most often primary biliary cirrhosis.

Palmar erythema

Palmar erythema is not specific for liver disease but is also associated with rheumatoid arthritis, haematological malignancies and pregnancy. Furthermore, certain drugs – in particular cytostatic agents – are well known to induce palmar erythema; in this case, there is often dysaesthesia, which is absent in patients with liver disease or other causes of palmar erythema. The origin of the phenomenon is postulated to be capillary dilatation, presumably as a consequence of the hyperdynamic circulation syndrome; however, blood flow to the skin in the forearm of cirrhotic patients is not increased.

Spider naevi

Spider naevi are considered a hallmark of alcoholic liver disease. They are typically lesions measuring 1 mm to 1 cm with a central artery and a spider's web of capillaries radiating from them, and they disappear with pressure applied by a transparent spatula. Most spiders (>99%) are seen above the waist. Certain investigators consider palmar erythema and spider naevi as common manifestations of hyperdynamic circulation and/or a hormonal imbalance. The latter is supported by the fact that spider naevi can also appear rapidly and in great number in pregnant women (who also exhibit a hyperdynamic circulation). The evidence for and history of spider naevi is amply referenced and, as always, thoughtfully and scholarly discussed in the series by Professor Adrian Reuben in *Hepatology* [39]. The number of spider naevi should be recorded, because some find their presence and number to be of prognostic importance [39–42].

Extremities

An inspection of the extremities can yield valuable clues to the presence and even aetiology of liver disease and associated conditions.

Dupuytren's disease

This is a thickening of the palmar and digital fascia that can lead to contracture of the digits. In a prospective study in the late 1980s, a clear association with alcohol consumption – but not alcoholic liver disease – was found [43]. However, the presence of Dupuytren's disease in a liver clinic should not prompt labelling of the patient as an alcoholic because the disease is fairly common, increasing from 4% in the general population to 20% in those older than 65. Moreover, clear associations also exist between Dupuytren's disease and diabetes and epilepsy; furthermore, there must be a genetic basis because it is seen almost exclusively in Caucasians [44].

Nails

Inspection of the fingernails or toenails may yield valuable clues to the presence of liver disease. Muehrcke's line – a white transverse line on the nail – was initially described as revealing

nephrotic syndrome but can also be seen in cirrhosis. Terry's nails is a white discoloration of the nail bed with a pink distal band, initially described in cirrhotic patients; it is also seen in heart failure, diabetes and with increasing age; it is thought to reflect telangiectasias [45] and therefore is probably a manifestation of the hyperdynamic circulation syndrome. Grey or blue discoloration of the lunulae may hint at an excess heavy metal burden, namely Wilson's disease or argyrosis.

Clubbing – a sign well known to pneumologists – can also be seen in cirrhosis and other diseases with portal hypertension. It should lead the physician to further explore the presence of pulmonary arterial hypertension [46].

Cardiopulmonary examination

The effect of cardiovascular disease on the liver is reported in Chapter 20.1; the converse, the effect of liver disease on the cardiovascular system, is detailed in Chapter 21.1. I would just state here that a thorough cardiopulmonary examination in a liver clinic is mandatory. Congested neck veins, wet rales or a third heart sound are clues to congestive heart failure, which might explain abnormal liver function tests for which the patient has been referred to the liver clinic. A paradoxical pulse may indicate constrictive pericarditis – a frequently overlooked cause of transsudative ascites [47].

The same holds true for percussion and auscultation of the lungs; pulmonary complications of portal hypertension are covered in Chapter 7.7. I am puzzled by young physicians searching for pleural effusions with ultrasound: they are easily detected by percussion and, in a liver clinic (and any other clinic), one should consider the possibility of hepatic hydrothorax – which accounts for 5–10% of pleural effusions [48]. A pronounced P2 should evoke the possibility of pulmonary hypertension, a not so rare complication of portal hypertension (see Chapter 7.7). Physical signs of COPD should be taken into consideration because liver tests are frequently abnormal in severe COPD and sleep apnoea [49,50].

Physical signs of emphysema in young patients should evoke the presence of alpha-1-antitrypsin deficiency or cystic fibrosis.

Inspection, palpation and percussion of the abdomen

Inspection

Inspection of the abdomen can reveal striae as signs of recent distension due to ascites, weight gain or, more joyfully in the appropriate sex, pregnancy. Fresh striae are also seen in patients on corticosteroids and patients with autoimmune hepatitis.

Dilatation of the epigastric veins hints at portal hypertension, particularly if the flow is in the physiological direction, that is, upwards above the umbilicus and downwards below it. Massive venous dilatation of epigastric veins, in particular on the side of the abdomen, is a clue to obstruction of the vena cava; in this condition, the flow is upwards throughout the venous system and there is often pronounced leg oedema. Collaterals are also often seen on the back of the patient.

Umbilical hernia may be an early indicator of ascites formation; if it is associated with a venous hum (Cruveilhier–Baumgarten syndrome), it indicates recanalization of the umbilical vein and portal hypertension. This syndrome is rather rare – but blue discoloration around the umbilicus due to distended veins is not.

Flank distension can indicate the presence of ascites. Some very big and hard livers (and spleens) can be seen with appropriate lighting. This is particularly true for metastatic and polycystic liver disease, but I have also 'seen' hepatic amyloidosis.

Palpation and percussion of the liver

The whole abdomen should be palpated in a liver clinic because masses can yield a clue to metastatic liver disease. You recognize an old-fashioned hepatologist by the fact that he or she will stand at the right side of the patient's bed. With respect to palpation of the liver and spleen, both should initially be sought in the pelvic area: massive hepatomegaly and/or splenomegaly can be missed if palpation is begun a handbreadth or two below the costal margin; this is particularly true if the organ is soft. Riedel's lobe is notoriously missed if you do not start palpation in the pelvic area and to the right of the midclavicular line. Riedel's lobe is a normal variant apparently increasing with age [51] and not deserving further workup.

I palpate the liver just to the right of the rectus sheet leading with my index finger; try to exert some pressure, in particular in muscular patients. Then, ask for a deep breath and you will feel the liver flipping over your leading finger. Once you have felt the edge to the right of the rectus abdominis, it will be easy to follow the remainder of the liver edge into the left side of the belly. In muscular patients, this might be impossible across the rectus abdominis. Palpation fares reasonably well in patients with liver cirrhosis: in a prospective study, correlation between palpation and sonography regarding liver span was excellent in patients with cirrhosis but poor in controls [52] (where liver span is not that interesting anyhow). Palpation will tell you something about the firmness of the organ. Personally, I cannot feel 'nodularity', for which ultrasound is certainly better. However, superficial tumors or cysts can often be palpated and might direct further workup.

The scratch test and liver percussion do not stand up to scrutiny when compared with imaging procedures for assessing organ size [53,54]. Personally, I still find them helpful in following patients, for instance with fulminant hepatic failure or congestive heart failure, where a decrease or increase, respectively, might indicate worsening of the condition. With the wide availability of ultrasonography, however, these tests are, or soon will be, history.

Pulsatile livers are reported to occur in tricuspid insufficiency [55] and constrictive pericarditis [56]. It is a rare event and you can call your students to observe a phenomenon they'll never see

again. But kindly do not write a case report if you see it: it has been seen before.

The gallbladder may be palpated in cases of biliary obstruction (Courvoisier's sign). In such cases, it is most often a cystic, soft mass yielding to pressure in the right upper quadrant tending toward the umbilicus. In these days where a computerized tomography (CT) scan is obtained before a history is taken, the sign has probably lost its clinical usefulness as a clue to pancreatic/ampullary cancer in a patient with painless jaundice. Moreover, the gallbladder is enlarged to the same extent in patients with benign, as those with malignant, biliary obstruction [57].

Murphy's sign will be covered in the section on gallstone diseases (Chapter 19.3). Briefly, Murphy's sign can be suggestive of acute cholecystitis but, in this age of early imaging, more accurate results are obtained by ultrasound or CT. The sonographer, however, should report elicitation of the typical pain when touching the gallbladder. This may be a helpful sign in recurrent right upper quadrant pain, in particular in gallbladder dysfunction when the imaging techniques – except for biliary scintigraphy – are not revealing.

Palpation and percussion of the spleen

As for the liver, a spleen ought first to be sought in the pelvis. Big spleens are often reported by the patient as a mass. In the asymptomatic patient, single-handed palpation of the hypochondrium is not revealing in my experience: I prefer to start with a bimanual examination where the right hand is placed below the margin of the rib cage and exerts an upward and inward pressure. The right hand – with all digits deployed – is used to feel the spleen descending on a deep inspiration, accompanied by the mentioned movement of the left hand. This manoeuvre should be repeated with several different starting positions of the right hand. You will feel the spleen tip flipping over the most sensitive part of your right hand – the fingertips.

Other methods advocated in the times when clinical examination was still cherished included palpation with a similar position of the right hand as described above and moving the patient to a right lateral decubitus making use of gravity. If the first manoeuvre is unsuccessful and, if I have the time, I still use this method.

A nice study prospectively comparing different methods [58] concluded that percussion of Traube's space was best for raising suspicion of splenomegaly; if positive, it should be followed by any of the manoeuvres described above and a positive finding would be most likely in lean patients. Interestingly, ultrasound is also most revealing in lean patients. On the other hand, percussion is felt to be worthless for assessment of spleen size based on a critical analysis of the literature [54]. I beg to disagree – but I realise that clinical skills will be replaced by more objective imaging techniques.

Loins, kidneys and testicles

Kidneys can occasionally be felt in the loins – in particular if they are of the transplanted variety. Enlarged hard kidneys in either loin and, in particular, if they are also felt in the back are usually diagnostic of polycystic disease. I have given up on examining exactly how the organs move with inspiration to differentiate a big spleen from a big kidney – this is better answered by ultrasound.

Inguinal hernias should be sought in each and every patient, particularly in those with ascites. You'll miss them if you look for them with the patient lying down comfortably. Because you have moved to the nether regions of urinary tract organs, you might as well assess testicular size. 'Small testicles' are in the eye (hand?) of the beholder. But, if the patient confirms that they have shrunk, you should further explore alcohol consumption and rule out haemochromatosis.

Auscultation

Auscultation of the whole abdomen should be performed to check for bowel sounds or absence thereof, arterial bruits, venous hums and friction rubs.

Arterial bruits

Arterial bruits should be listened for while palpating the pulse and – because they are usually quite faint – during a breath-hold. Arterial bruits during systole in the epigastrium are frequent, particularly in young, lean subjects, and often disappear with a change in position. Occasionally, they can reflect stenosis of the superior mesenteric artery; such bruits are louder and longer, extending into diastole. Arterial bruits may be due to aortic disease such as aneurysms and aortitis. Splenic arterial bruits are located over the left hypochondrium or below the left ribcage. Such bruits can be heard with splenic artery compression due to pancreatic disease.

Arterial bruits over the liver are rare and usually due to aortovenous fistulae after trauma [59], including liver biopsy [60], in tumours [61] or in Osler–Weber–Rendu disease with hepatic involvement [62]. The prevalence of arterial bruits in hepatocellular cancer must be low although good data are missing – but, when you hear it in a patient with cirrhosis, the odds are high that imaging will reveal a hepatocellular cancer.

Venous hum

Even more difficult to hear, less frequent and probably completely unimportant in practice are venous hums. They are continuous, of low frequency and heard over the umbilicus in Cruveilhier–Baumgarten syndrome (see above) or occasionally over the portal vein. I still listen for them – and, when I hear one, I am pleased and call the medical students to listen for it. I also tell them that they probably will not hear it again and that they can forget it for the qualifying exams.

Rubs

Rubs can be heard over the liver in Fitz-Hugh–Curtis syndrome – pelvic inflammatory disease most often due to chlamydial infection [63] but also seen in other venereal and nonvenereal

diseases including tuberculosis. Rubs can also be heard in uraemia and with hepatocellular cancer. The sign is rare in my experience and should be noted when present.

Ascites

Massive ascites is seen on inspection and does not require imaging or further clinical testing. In my experience, there is only one more or less unequivocal clinical sign of ascites, namely shifting dullness by percussion: have the patient lie supine and percuss on both sides and mark the region where dullness goes to resonance (due to floating bowels). Then, have the patient shift on one side, wait for about half a minute and percuss again. If there is more than 2 cm in shifting dullness you can be quite certain that there is ascites. This is supported by a 25-year-old study of a very limited number of patients [64].

I find 'fluid thrill' useless in detecting ascites (it is elicited by tapping the lateral abdominal wall on one side with the other hand waiting for the 'thrill' to arrive on the other side). Cattau and colleagues [64] have already called for ultrasound to prove the presence of ascites; it has to be pointed out, however, that the Child–Pugh classification is based on clinical detection of ascites.

Neurological examination

I have never had the patience to perform a thorough neurological examination on my patients – if I have the impression that something is wrong, I ask for a neurology consultation and have the big thinkers sort out what is wrong. This attitude is probably wrong because reversible focal deficits can be found in ~15% of patients with hepatic coma [65].

A few tests definitively belong in the hepatology clinic, namely signs hinting at hepatic encephalopathy, Wilson's disease (covered in Chapter 16.1.) and subtle signs of neuropathy – in particular loss of sense of vibration – which are frequent in endstage liver disease, particularly that originating from alcohol toxicity.

Encephalopathy

The time-proven sign of hepatic encephalopathy is flapping tremor or asterixis. It is elicited by having the patient dorsiflex his or her hands in prone rotation. Asterixis is seen as a rhythmic loss of tone appearing as a flapping movement of the hands, reminding one of flapping bird wings. In very weak patients, asterixis can be felt by asking the patient to hold both of your hands or by looking at the tongue, again asking for a lifting of the tongue. Further testing for hepatic encephalopathy is described in Chapter 7.8.

Neuropathy

Peripheral neuropathy is frequent in patients abusing alcohol [66] but also in advanced liver disease of any atiology [67]. It should be sought in hepatitis C patients with cryoglobulinaemia. In patients with longstanding cholestasis, it can be related to vitamin E deficiency.

References

1 Foster GR, Goldin RD, Thomas HC (1998) Chronic hepatitis C virus infection causes a significant reduction in quality of life in the absence of cirrhosis. *Hepatology* 27, 209–212.
2 Weissenborn K, Krause J, Bokemeyer M *et al.* (2004) Hepatitis C virus infection affects the brain – evidence from psychometric studies and magnetic resonance spectroscopy. *J Hepatol* 41, 845–851.
3 McAndrews MP, Farcnik K, Carlen P *et al.* (2005) Prevalence and significance of neurocognitive dysfunction in hepatitis C in the absence of correlated risk factors. *Hepatology* 41, 801–808.
4 Poupon RE, Chrétien Y, Chazouillères O *et al.* (2004) Quality of life in patients with primary biliary cirrhosis. *Hepatology* 40, 489–494.
5 Swain MG (2000) Fatigue in chronic disease. *Clin Sci* 99, 1–8.
6 Stanca CM, Bach N, Krause C *et al.* (2005) Evaluation of fatigue in US patients with primary biliary cirrhosis. *Am J Gastroenterol* 100, 1104–1109.
7 Goldblatt J, Taylor PJS, Lipman T *et al.* (2002) The true impact of fatigue in primary biliary cirrhosis: A population study. *Gastroenterology* 122, 1235–1241.
8 Björnsson E, Simren M, Olsson R, Chapman RW (2004) Fatigue in patients with primary sclerosing cholangitis. *Scand J Gastroenterol* 39, 961–968.
9 Marchesini G, Bianchi G, Lucidi P *et al.* (2004) Plasma ghrelin concentrations, food intake, and anorexia in liver failure. *J Clin Endocrinol Metab* 89, 2136–2141.
10 Madden AM, Bradbury W, Morgan MY (1997) Taste perception in cirrhosis: its relationship to circulating micronutrients and food preferences. *Hepatology* 26, 40–48.
11 Bergasa NV (1998) Hypothesis: taste disorders in patients with liver disease may be mediated in the brain: potential mechanisms for a central phenomenon. *Am J Gastroenterol* 93, 1209–1210.
12 Drosos AA, Constantopoulos SH, Psychos D *et al.* (1989) The forgotten cause of sicca complex: sarcoidosis. *J Rheumatol* 16, 1548–1551.
13 Cacoub P, Poynard T, Ghillani P *et al.* (1999) Extrahepatic manifestations of chronic hepatitis C. *Arthritis Rheum* 42, 2204–2212.
14 Jorgensen C, Legouffe MC, Perney P *et al.* (1996) Sicca syndrome associated with hepatitis C virus infection. *Arthritis Rheum* 39, 1166–1171.
15 Cacoub P, Saadoun D, Bourlière M *et al.* (2005) Hepatitis B virus genotypes and extrahepatic manifestations. *J Hepatol* 43, 764–770.
16 Diehl AK, Sugarek NJ, Todd KH (1990) Clinical evaluation for gallstone disease: usefulness of symptoms and signs in diagnosis. *Am J Med* 89, 29–33.
17 Kraag N, Thijs C, Knipschild P (1995) Dyspepsia—how noisy are gallstones? A meta-analysis of epidemiologic studies of biliary pain, dyspeptic symptoms, and food intolerance. Scand J Gastroenterol 30, 411–421.
18 Misra SP, Misra V, Dwivedi M *et al.* (2004) Factors influencing colonic involvement in patients with amebic liver abscess. *Gastrointest Endosc* 59, 512–516.
19 Ginsburg PM, Thuluvath PJ (2005) Diarrhea in liver transplant recipients: etiology and management. *Liver Transpl* 11, 881–890.
20 Navasa M, Rimola A, Rodés J (1997) Bacterial infections in liver disease. *Semin Liver Dis* 17, 323–333.
21 O'Donohue J, Workman MR, Rolando N *et al.* (1997) Urinary tract infections in primary biliary cirrhosis and other chronic liver diseases. *Eur J Clin Microbiol Infect Dis* 16, 743–746.

22 Cribier B, Samain F, Vetter D *et al.* (1998) Systematic cutaneous examination in hepatitis C virus infected patients. *Acta Derm Venereol (Stockh)* 78, 355–357.
23 Dega H, Frances C, Dupin N *et al.* (1998) Pruritus and the hepatitis C virus. The MULTIVIRC Unit. *Ann Dermatol Venereol* 125, 9–12.
24 Bergasa NV (2005) The pruritus of cholestasis. *J Hepatol* 43, 1078–1088.
25 Baskol M, Ozbakir O, Coskun R *et al.* (2004) The role of serum zinc and other factors on the prevalence of muscle cramps in non-alcoholic cirrhotic patients. *J Clin Gastroenterol* 38, 524–529.
26 Marchesini G, Bianchi G, Amodio P *et al.* (2001) Factors associated with poor health-related quality of life of patients with cirrhosis. *Gastroenterology* 120, 170–178.
27 Steindl PE, Finn B, Bendok B *et al.* (1995) Disruption of the diurnal rhythm of plasma melatonin in cirrhosis. *Ann Intern Med* 123, 274–277.
28 Blake JC, Sprengers D, Grech P *et al.* (1990) Bleeding time in patients with hepatic cirrhosis. *Br Med J* 301, 12–15.
29 Merli M, Riggio O, Dally L *et al.* (1996) Does malnutrition affect survival in cirrhosis? *Hepatology* 23, 1041–1046.
30 Abelmann WH (1994) Hyperdynamic circulation in cirrhosis: a historical perspective. *Hepatology* 20, 1356–1358.
31 Kowalski HJ, Abelmann WH (1953) The cardiac output at rest in Laennec's cirrhosis. *J Clin Invest* 32, 1025–1033.
32 Mourad O, Palda V, Detsky AS (2003) A comprehensive evidence-based approach to fever of unknown origin. *Arch Intern Med* 163, 545–551.
33 Kitzberger R, Madl C, Ferenci P (2005) Wilson disease. *Metab Brain Dis* 20, 295–302.
34 Beaumont C, Leneuve C, Deveaux I *et al.* (1995) Mutation in the iron responsive element of the L ferritin mRNA in a family with dominant hyperferritinemia and cataract. *Nature Genet* 11, 444–446.
35 Hingorani M, Nischal KK, Davies A *et al.* (1999) Ocular abnormalities in Alagille syndrome. *Ophthalmology* 106, 330–337.
36 Rodriquez-Roisin R, Krowka MJ, Herve P, Fallon MB (2005) Highlights of the ERS Task Force on pulmonary-hepatic vascular disorders (PHD). *J Hepatol* 42, 924–927.
37 Milman N (1991) Hereditary haemochromatosis in Denmark 1950–1985. Clinical, biochemical and histological features in 179 patients and 13 preclinical cases. *Dan Med Bull* 38, 385–393.
38 El-Serag HB, Hampel H, Yeh C, Rabeneck L (2002) Extrahepatic manifestations of hepatitis C among United States male veterans. *Hepatology* 36, 1439–1445.
39 Reuben A (2002) Along came a spider. *Hepatology* 35, 735–736.
40 Orrego H, Israel Y, Blake JE, Medline A (1983) Assessment of prognostic factors in alcoholic liver disease: toward a global quantitative expression of severity. *Hepatology* 3, 896–905.
41 Foutch PG, Sullivan JA, Gaines JA, Sanowski RA (1988) Cutaneous vascular spiders in cirrhotic patients: correlation with hemorrhage from esophageal varices. *Am J Gastroenterol* 83, 723–726.
42 Pilette C, Oberti F, Aubé C *et al.* (1999) Non-invasive diagnosis of esophageal varices in chronic liver diseases. *J Hepatol* 31, 867–873.
43 Attali P, Ink O, Pelletier G *et al.* (1987) Dupuytren's contracture, alcohol consumption, and chronic liver disease. *Arch Intern Med* 147, 1065–1067.
44 Hart MG, Hooper G (2005) Clinical associations of Dupuytren's disease. *Postgrad Med J* 8, 425–428.
45 Holzberg M, Walker HK (1984) Terry's nails: revised definition and new correlations. *Lancet* i, 896–899.
46 Martínez GP, Barberà JA, Visa J *et al.* (2001) Hepatopulmonary syndrome in candidates for liver transplantation. *J Hepatol* 34, 651–657.
47 Van der Merwe S, Dens J, Daenen W *et al.* (2000) Pericardial disease is often not recognised as a cause of chronic severe ascites. *J Hepatol* 32, 164–169.
48 Cardenas A, Kelleher T, Chopra S (2004) Review article: hepatic hydrothorax. *Aliment Pharmacol Ther* 20, 271–279.
49 Henrion J, Colin L, Schapira M, Heller FR (1997) Hypoxic hepatitis caused by severe hypoxemia from obstructive sleep apnea. *J Clin Gastroenterol* 24, 245–249.
50 Tanné F, Gagnadoux F, Chazouillères O *et al.* (2005) Chronic liver injury during obstructive sleep apnea. *Hepatology* 41, 1290–1296.
51 Gillard JH, Patel MC, Abrahams PH, Dixon AK (1998) Riedel's lobe of the liver: fact or fiction? *Clin Anat* 11, 47–49.
52 Zoli M, Magalotti D, Grimaldi M *et al.* (1995) Physical examination of the liver: is it still worth it? *Am J Gastroenterol* 90, 1428–1432.
53 Tucker WN, Saab S, Rickman LS, Mathews WC (1997) The scratch test is unreliable for detecting the liver edge. *J Clin Gastroenterol* 25, 410–414.
54 McGee SR (1995) Percussion and physical diagnosis: separating myth from science. *Dis Mon* 41, 641–692.
55 Cha SD, Desai RS, Gooch AS *et al.* (1982) Diagnosis of severe tricuspid regurgitation. *Chest* 82, 726–731.
56 Manga P, Vythilingum S, Mitha AS (1984) Pulsatile hepatomegaly in constrictive pericarditis. *Br Heart J* 52, 465–467.
57 Chen JJ, Changchien CS, Tai DI, Kuo CH (1994) Gallbladder volume in patients with common hepatic duct dilatation – an evaluation of Courvoisier's sign using ultrasonography. *Scand J Gastroenterol* 29, 284–288.
58 Barkun AN, Camus M, Green L *et al.* (1991) The bedside assessment of splenic enlargement. *Am J Med* 91, 512–518.
59 Isik FF, Greenfield AJ, Guben J *et al.* (1989) Iatrogenic arterioportal fistulae: diagnosis and management. *Ann Vasc Surg* 3, 52–55.
60 Okuda K, Musha H, Nakajima Y *et al.* (1978) Frequency of intrahepatic arteriovenous fistula as a sequela to percutaneous needle puncture of the liver. *Gastroenterology* 74, 1204–1207.
61 Clain D, Wartnaby K, Sherlock S (1966) Abdominal arterial murmurs in liver disease. *Lancet* ii, 516–519.
62 Bernard G, Mion F, Henry L *et al.* (1993) Hepatic involvement in hereditary hemorrhagic telangiectasia – clinical, radiological, and hemodynamic studies of 11 cases. *Gastroenterology* 105, 482–487.
63 Zeger W, Holt K (2003) Gynecologic infections. *Emerg Med Clin North Am* 21, 631–648.
64 Cattau EL, Benjamin SB, Knuff TE, Castell DO (1982) The accuracy of the physical examination in the diagnosis of suspected ascites. *J Am Med Assoc* 247, 1164–1166.
65 Cadranel JF, Lebiez E, Di Martino V *et al.* (2001) Focal neurological signs in hepatic encephalopathy in cirrhotic patients: an underestimated entity? *Am J Gastroenterol* 96, 515–518.
66 Zambelis T, Karandreas N, Tzavellas E *et al.* (2005) Large and small fiber neuropathy in chronic alcohol-dependent subjects. *J Peripher Nerv Syst* 10, 375–381.
67 Chaudhry V, Corse AM, O'Brian R *et al.* (1999) Autonomic and peripheral (sensorimotor) neuropathy in chronic liver disease: a clinical and electrophysiologic study. *Hepatology* 29, 1698–1703.

5.2 Biochemical investigations in the management of liver disease

Igino Rigato, J. Donald Ostrow and Claudio Tiribelli

Introduction

Due to the complex and multiple metabolic functions of the liver, there is no single, ideal biochemical test that can fully assess the nature and severity of hepatic dysfunction. Rather, individual biochemical tests can be applied to assess specific aspects of hepatic function. Thus, necrosis of hepatocytes can be assessed by measuring enzymes that have leaked into the blood through the damaged plasma membranes of the liver cells. The ability of the liver to synthesize plasma proteins produced selectively by the liver can be assessed from the plasma concentrations of these proteins, keeping in mind that the concentration of each protein is influenced also by its catabolism. Impairment of the excretory functions of the liver, including bile secretion and flow, can be indirectly assessed from increases in the plasma levels of endogenous compounds (e.g. bile salts and bilirubin) that are normally cleared by the liver and secreted in bile. The plasma levels, however, may also be affected by changes in the rates of production, intestinal absorption and enterohepatic circulation, and renal excretion of these compounds.

These distinctions among classes of 'liver function' tests are somewhat arbitrary, but examining the results of all of these markers together often reveals patterns typical of different pathophysiological conditions, and allows some assessment of the severity of the liver disease. In this chapter, we will describe tests for plasma constituents that are commonly measured in the evaluation of patients with hepatobiliary diseases. For each of them, we will describe the following features, when available: description of rationale and biochemical reactions for the test; a critical comparison of available methods; interpretation of the results; and clinical relevance.

Markers of hepatocellular damage

Aminotransferases: aspartate aminotransferase (AST) and alanine aminotransferase (ALT)

Nature of the enzymes and their reactions

The most frequently used indices of hepatocellular necrosis are activities in the serum of aspartate aminotransferase (AST, previously known as glutamic–oxaloacetic transaminase, GOT) and alanine aminotransferase (ALT, previously known as glutamic–pyruvic transaminase, GPT). These enzymes, which are involved in the pathways of gluconeogenesis, catalyse the enzymatic transfer of the α-amino group from an amino acid, aspartate or alanine, to the oxo- group of α-ketoglutarate, yielding glutamate plus, respectively, oxaloacetate or pyruvate.

Distribution and localization of the enzymes

ALT is localized exclusively in the cytosol and essentially restricted to the hepatocytes and renal tubular epithelium, although there is also slight activity in skeletal muscle and heart [1]. By contrast, AST is widely distributed throughout the body, with highest activity in the heart, liver, skeletal muscle, brain, gastric mucosa, kidney, pancreas, spleen and lung [2]; it is also detectable in erythrocytes. Inside the liver cell, AST is localized mainly in the mitochondrial membrane (80%), with the remainder in the cytosol [3]. In normal healthy people, cytosolic AST is the source of more than 90% of total serum AST activity [3]. The two isoforms (cytosolic and mitochondrial) can be separated by immunochemical methods or by chromatographic and electrophoretic techniques, but, as those methods are not available in most laboratories, the distinction in the activity of the two isoenzymes is seldom used clinically.

The aminotransferases are released into the blood when enzyme-containing cells are damaged, resulting in an increase in their concentrations and activity in plasma. AST is not detectable in the urine except during renal ischaemia [4]: measurement of urine AST was formerly used to detect kidney failure after renal tubular necrosis, but other enzymes are now more reliably employed for this purpose. AST and ALT were formerly assayed by colorimetric methods, which have now been superseded completely by spectrophotometric techniques.

Assays of enzyme activity

The older colorimetric methods involved addition of the substrates α-ketoglutarate plus aspartate (for AST) or alanine (for ALT) to a buffered plasma sample. Pyruvate, formed directly from ALT, or produced by subsequent decarboxylation of the

oxaloacetate product of AST by addition of aniline citrate, was then treated with 2,4-dinitrophenylhydrazine. The hydrazone product turned brown in an alkaline solution, and was measured colorimetrically. The modern spectrophotometric AST method, recommended by the International Federation of Clinical Chemistry [5], is based on a simultaneous double reaction: reduction, with NADH and H^+, of the oxaloacetate formed by the aminotransferase reaction is catalysed by adding malate dehydrogenase, yielding L-malate and NAD^+. The absorbances at 365, 340 or 334 nm are used to quantify the loss of NADH or formation of NAD^+, which correlates directly with the content of AST in the sample. The spectrophotometric ALT assay utilizes a method analogous to that described for AST: L-alanine and α-ketoglutarate are transformed by ALT into pyruvate and L-glutamate. The pyruvate is then enzymatically converted to lactate by addition of lactic dehydrogenase and NADH, and the loss of NADH or formation of NAD^+ is monitored spectrophotometrically, as with the AST method.

Normal values and influencing factors

The normal serum transaminase levels in adults are below 40 U/L. Transaminases in serum specimens are stable for 3 days at room temperature and for 3 weeks in the refrigerator. In whole blood, by contrast, AST (but not ALT) increases during storage due to its release from spontaneous haemolysis of red cells.

The half-life of total AST in the blood is 17 ± 5 h whereas that of ALT is 47 ± 10 h. Within the normal range, the activities of AST and ALT in plasma vary with age and sex. AST and ALT activities increase from childhood to adulthood, then plateau at a steady level between the ages of 30 to 60. In adults, the enzymatic activity is higher in males than in females, and plasma levels of AST tend to be lower than ALT. Above age 60, AST levels rise slowly, whereas ALT levels decline after 60 [6]. AST is 15% higher in African–American men.

Abnormal values in hepatobiliary diseases

Aminotransferases in serum are usually elevated during hepatocellular injury of any cause. Marked elevations (8–20-fold above normal) suggest acute hepatocellular necrosis, due to viral hepatitis, drug- or toxin-induced liver damage or ischaemic hepatitis; ischaemic necrosis may lead to extreme elevations in aminotransferase levels (up to 100-fold). The degree of increase of serum levels, however, does not correlate with the extent of liver damage observed on liver biopsy, and does not predict mortality. Persistent, fluctuating, usually mild elevations of serum aminotransferase activities are observed during chronic liver injury caused by chronic viral hepatitis, alcoholic liver disease, nonalcoholic fatty liver disease (NAFLD), autoimmune hepatitis, haemochromatosis, Wilson's disease or liver cirrhosis. ALT and AST increase during extrahepatic obstruction, typically associated with elevation in serum of markers of cholestasis [alkaline phosphatase, γ-glutamyltransferase (γ-GT) and bilirubin].

Several patterns of increased aminotransferases have been touted as markers of specific liver diseases or different prognoses (Fig. 1). It was suggested that an AST/ALT ratio above 0.6 is associated with a poor outcome in cases of severe acute hepatitis [7]. The AST/ALT ratio is also increased in alcoholic liver damage (see below), exposure to various organic compounds (i.e. toluene, furan, methylene chloride), and in liver fibrosis. However, due to the wide spectrum of liver diseases associated with mildly elevated levels of aminotransferases, the AST/ALT ratio is of weak predictive value in defining the aetiology of liver disease. It is important to remember that, although elevations in aminotransferase levels may be the first or only marker of liver damage, significant liver damage may be present without any elevation of either AST or ALT, for example in chronic viral hepatitis, haemochromatosis or liver cirrhosis [8].

Drug-related hepatotoxicity engenders a significant increase in serum aminotransferase activity that usually is characterized by an elevated AST/ALT ratio; this aetiology should be considered every time an increased AST/ALT ratio is found in patients who do not consume alcohol. For this reason, aminotransferases are good markers of chemotherapy-induced hepatocellular necrosis. Aminotransferase activities are increased in 11–28% of patients undergoing anticonvulsant therapy [2].

Elevations of AST and/or ALT activity in alcoholic patients are generally mild (2–4 times the upper normal limits), but may be higher in acute alcoholic hepatitis. Intake of 3–4 g/kg body weight of alcohol by healthy subjects leads to an increase of aminotransferases within 24–48 h. In alcoholic liver disease, AST tends to be higher than ALT activity [9]. This is due to release of AST as a result of alcoholic damage to red cells, inhibition of the ALT reaction by alcohol and an increase in mitochondrial AST (mAST) during excessive alcohol consumption. It has been suggested that serum mAST activity, or the ratio of mAST/total AST activity, could be used to screen for excessive alcohol intake in the general population. In this setting, however, the specificity and sensitivity were low, and these indices have proven to be useful markers of alcoholic liver disease only in an inpatient setting [9].

Interestingly, although AST and ALT are both increased in NAFLD, serum aminotransferase activity is logarithmically related to body mass index irrespective of the aetiology of liver disease [10].

An inverse relationship has been described between serum AST activity and serum creatinine concentration. In uraemic patients, for unknown reasons, the AST level is decreased, irrespective of the analytical method and whether or not the patient is undergoing dialysis. Furthermore, in uraemic patients, AST may not increase when hepatic disease supervenes, rendering the AST determination an unreliable marker of hepatobiliary disease in such patients [11].

Abnormal values in other diseases

AST, in particular, is usually elevated in many nonhepatic diseases. AST is increased in acute myocardial infarction and with acute muscle damage that occurs in Duchenne's type muscular dystrophy, dermatomyositis, muscle trauma or surgery and

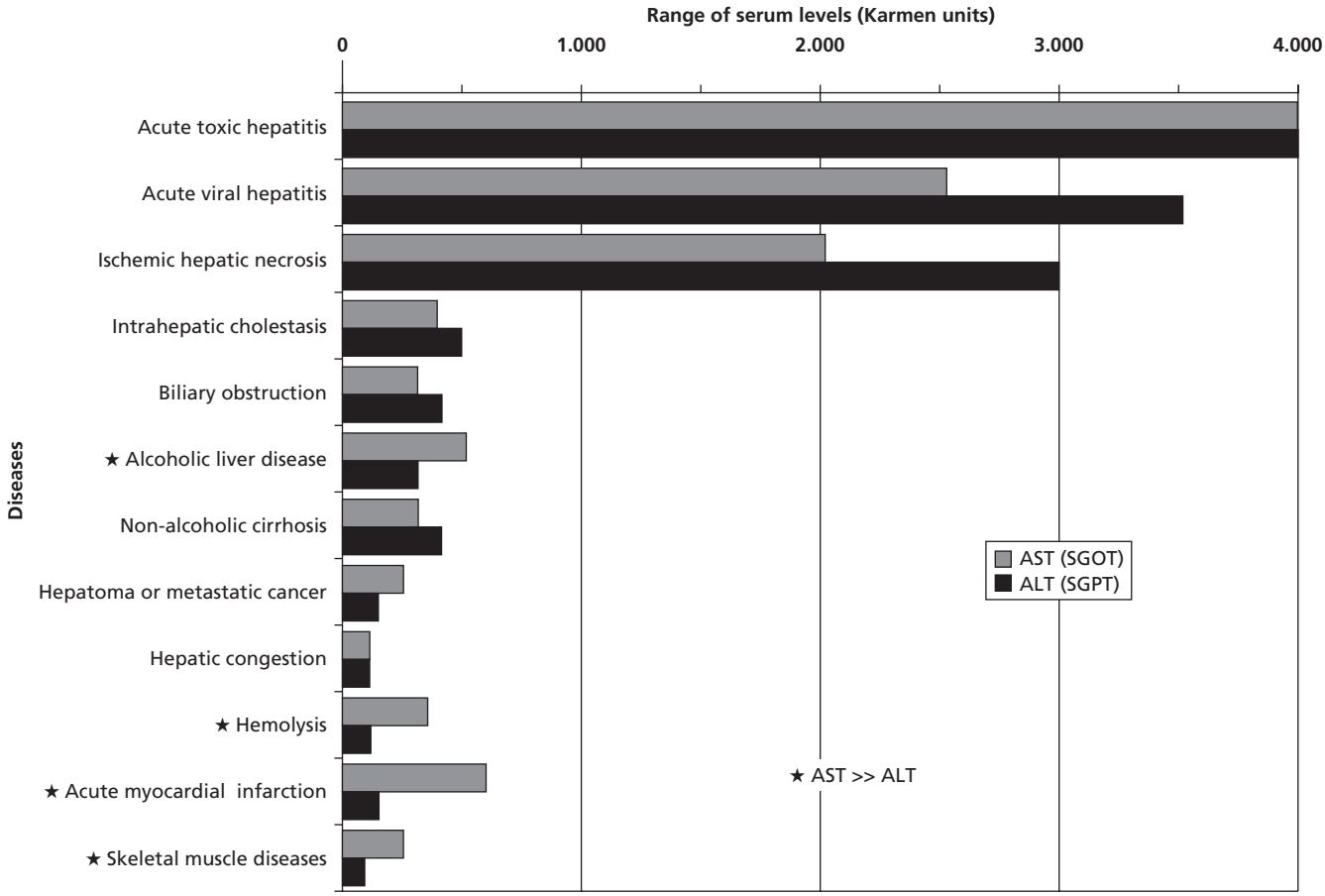

Fig. 1 Elevations of aspartate aminotransferase (AST) and alanine aminotransferase (ALT) in various diseases.

gangrene of the toes [12]. In children affected by rotaviral gastroenteritis, AST of enterocyte origin can be increased in serum [13]. Elevated serum aminotransferases are typically observed in pre-eclampsia and HELLP (haemolysis, elevated liver enzymes, low platelets) syndrome during pregnancy.

Several other factors can affect the AST and ALT plasma activity: exercise can increase (up to threefold) the AST levels while ALT levels may decrease. The day-to-day variation is similar in liver disease and health, and is around 5–10% for AST and 10–30% for ALT [14]. Even if both AST and ALT activities are higher in red blood cells than in plasma, only severe haemolysis causes a significant increase in serum aminotransferase activity [2]. By an unknown mechanism, aminotransferase activity, especially ALT, is increased by heparin therapy, more frequently in males than females [2]. The mAST isoenzyme was suggested to be useful to assess myocardial damage after thrombolysis as it is not influenced by the reperfusion of the damaged tissue [15].

Lactate dehydrogenase

Nature of the enzyme and its reaction

Lactic dehydrogenase (LDH), an enzyme of the glycolytic cycle, catalyses the reversible conversion of lactate to pyruvate, utilizing NAD^+/NADH as a cofactor. LDH also catalyses the reduction of other α-keto or α-γ-diketo groups. LDH enzyme is a tetramer that is constructed from two monomeric isoforms: type H from heart muscle and type M from liver. Various combinations of these two isoforms can yield five different isoenzymes, which have different tissue distributions. Increased release of LDH from damaged, dying or metabolically deranged cells in any of these tissues may cause an elevated serum LDH concentration.

Distribution and localization of the enzyme

LDH is highly expressed in kidney but it is also expressed in heart, skeletal muscle, spleen, liver, lung and erythrocytes. In liver, only LDH type 5 (the MMMM tetramer) is expressed. LDH5 is, however, also expressed in kidney, skeletal muscles and pancreas.

Assays of enzyme activity

Of the many different LDH assay techniques described, the most used and most accurate one for automated analysis is the photometric assessment of the oxidation rate of NADH, measured at 365 or 340 nm. The serum sample is incubated with standard concentrations of pyruvate and NADH, and the results are

expressed as arbitrary units per litre. For greater tissue specificity, the different isoenzymes can be separated by electrophoresis on cellulose acetate membranes, and the individual protein bands incubated with lactate and NAD^+; the NADH product is then reacted with a tetrazolium salt to produce a coloured dye (formazan), which is quantitated by densitometry.

Normal values and influencing factors

Each laboratory must determine its own normal values. Age influences the serum LDH activity: the normal range is higher in children than adults, and it decreases progressively with aging, reaching an adult range at about age 14 years [16]. The proportions of the five isoenzymes detected in normal serum are:

- LDH1 (HHHH) 18–33%
- LDH2 (HHHM) 28–40%
- LDH3 (HHMM) 18–30%
- LDH4 (HMMM) 6–16%
- LDH5 (MMMM) 2–13%.

Abnormal values in hepatobiliary diseases

An increase in serum LDH activity is often observed during acute hepatitis or hepatocyte necrosis of any aetiology.

Abnormal values in other diseases

Because of its wide tissue distribution, serum LDH can be increased with myocardial diseases, haemolytic anaemia, myopathies, leukaemias and lymphomas, acute pancreatitis and nephropathies.

Summary of clinical usefulness

Elevations in serum LDH are not specific for active liver disease, and are less sensitive and specific than the elevations in serum transaminases in this situation. It may be useful in jaundiced subjects to determine if haemolysis is contributory, because elevations in LDH, AST and indirect bilirubin are usually more striking than elevations in ALT in this situation. It is more often used to evaluate myocardial damage in patients with suspected myocardial infarction, in which case electrophoretic analysis of isoenzyme activity is essential to pinpoint the source of the serum enzyme elevation.

Markers to assess hepatic synthetic function

Albumin

Nature of the protein and its function

Albumin is a single, unglycosylated polypeptide chain of 575 amino acids (molecular mass 69 kDa). It is synthesized exclusively by hepatocytes at a rate of about 14 g/day [17], and secreted into the plasma [18], where it normally constitutes 58–64% of total serum proteins. It has two principal functions in plasma: maintenance of osmotic pressure and reversible, non-covalent binding of a variety of substances, both endogenous (e.g. bilirubin, bile salts, fatty acids and other organic anions and metal cations) and exogenous (drugs, contrast media). This transport function is essential for hydrophobic compounds that have low aqueous solubility.

The half-life of albumin in human serum is 14–21 days [19]. Hyperalbuminaemia is observed only with haemoconcentration during dehydration, whereas hypoalbuminaemia is a frequent condition, related to decreased synthesis, increased catabolism or excessive losses in the urine or stool (see below).

Assays

Many methods exist for measurement of the serum albumin concentration, including: precipitation, electrophoresis, immunochemical procedures and binding of dyes. Due to the ease of automation, binding of dyes, particularly bromocresol green (BCG), is most frequently used. In acid solution (pH 4.15), BCG has high affinity for albumin and little interaction with other serum proteins. The albumin–BCG complex has an absorbance maximum at 630 nm that avoids interference from the spectral peaks of haemoglobin or bilirubin. Some laboratories prefer bromocresol purple, which is more specific, because it reacts even less with serum globulin or transferrin [20]. With either dye, falsely low albumin levels may be obtained with jaundiced or haemolysed samples due to displacement of the dye from albumin by bilirubin or haemoglobin respectively.

Immunoassay techniques can be automated, but are more expensive. Electrophoresis on cellulose acetate membranes permits simultaneous measurement of the concentrations of all classes of serum proteins, but is difficult to automate.

Normal values

Serum albumin levels are typically low in neonates (2.8–4.4 g/dL), increasing progressively during the first week of life to normal adult concentrations (3.7–5.0 g/dL). By age 6 years, the values increase further (4.5–5.4 g/dL) and remain stable through young adulthood before decreasing again to the normal adult values. Further mild declines in serum albumin levels occur in old age, principally due to more rapid catabolism [19]. There is no significant difference between genders.

Influencing factors

Several conditions may influence albumin synthesis by a healthy liver. Despite adequate caloric intake, a strict vegetarian diet can impair albumin synthesis if it is not supplemented with soy proteins. High altitude can increase albumin synthesis, especially if the high altitude is reached by climbing. In addition, recovery from a period of intense physical exercise, in an upright position, can increase albumin synthesis. Albumin synthesis can increase by up to 30% when normoalbuminaemic patients are treated with haemodialysis [21].

Abnormal values in hepatobiliary diseases

The albumin concentration is decreased in liver cirrhosis, due to impaired hepatic synthesis, often aggravated by losses into

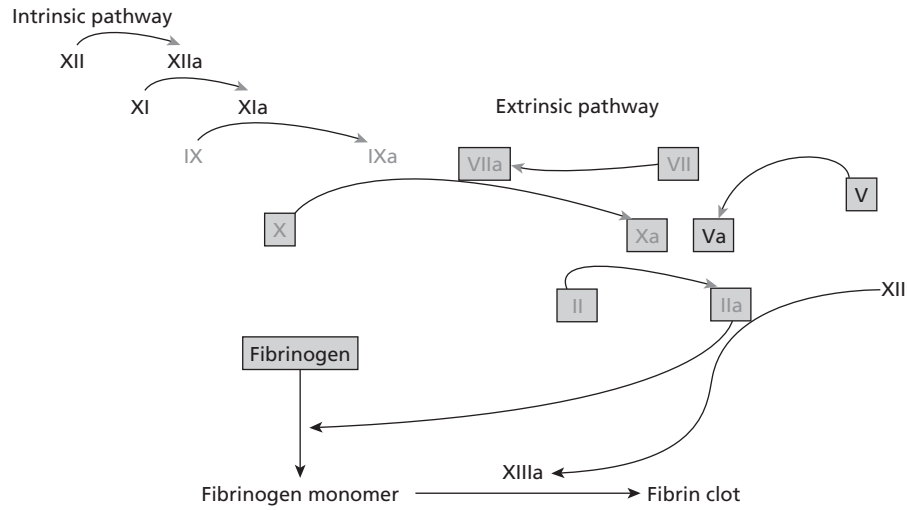

Fig. 2 The coagulation pathway. Highlighted factors are produced by the liver; vitamin K-dependent factors are shaded grey.

ascitic fluid due to leakage from hepatic lymphatics or exudation across the capsule of the liver [22].

Abnormal values in other diseases

Decreased albumin synthesis is also observed during malnutrition, and begins after only 24–48 hours of fasting [19]; for this reason, it is considered to be a good parameter to evaluate malnutrition, despite its poor sensitivity [23]. Every kind of 'stress' condition (major surgery, injury, severe infection or almost any severe, acute disease) may be associated with a decline in the serum albumin levels due to the release of cytokines and hormones (i.e. cortisone, thyroid hormones, growth hormone, insulin and sex hormones) that inhibit synthesis of this protein [23].

Hypoalbuminaemia may also result from excessive losses of serum albumin in the urine or stool. The nephrotic syndrome is characterized, by definition, by the presence of over 3.5 g/day of protein in the urine [24], the majority of which is represented by albuminuria. Leakage of protein from plasma into the gut lumen, with excessive faecal losses, characterizes protein-losing enteropathy, seen with Crohn's disease, sprue, kwashiorkor, Ménétrier's disease, eosinophilic gastroenteritis and radiation enteritis, among others [25]. Excessive intestinal protein loss may also occur secondary to high pressure in the portal capillaries, as in Budd–Chiari syndrome and constrictive pericarditis; it contributes to the hypoalbuminaemia of cirrhosis. With extensive burns or bed sores, exudation of albumin from the damaged skin can lead to severe hypoalbuminaemia [26].

Summary of clinical usefulness

Serum albumin concentration is one of the most important indices of residual hepatocytic synthetic function. When serum albumin concentration is decreased (<3.0 g/dL) in patients with liver disease, it strongly suggests the presence of cirrhosis. Serum albumin is an important parameter in both the Child–Pugh and MELD (model for end-stage liver disease) scores, the two most widely used systems to evaluate prognosis in chronic liver disease.

Prothrombin time (PT) and the international normalized ratio (INR)

Nature of the reaction

The one-stage prothrombin time (PT) reflects the presence or functional absence of those factors involved in the extrinsic clotting system. The cascade that leads to clot formation through the activation of the extrinsic pathway involves factors I, II, V, VII and X (Fig. 2). All those factors are produced in the liver and three of them (II, VII, X) require vitamin K as a cofactor for their synthesis. Low plasma levels of factors II, V and VII have been reported in patients with liver disease and therefore the PT can be considered an index of hepatocyte synthetic function [27].

Assay

The assay is based on the original method of Quick [28]. Sodium citrate is added to a blood sample, preventing coagulation by binding calcium. Afterwards tissue thromboplastin and calcium are added and the time to form a fibrin clot is registered. The results are expressed as the interval (in seconds) between the addition of calcium and the clot formation, compared with the time required for clot formation when the same reagents are added to a citrated pool of normal blood samples (control).

Normal values and influencing factors

The normal prothrombin time is usually below 12 s, with a ratio to the control time that is above 0.7. Storage in a refrigerator falsely shortens the PT, whereas storage at room temperature for up to 3 days does not influence the result. It is very important to completely fill the blood sample tube, because incomplete filling increases the PT. A high haematocrit leads to an increase in the PT [29].

The determination of PT is highly sensitive to the type of thromboplastin used (human-brain- or rabbit-brain-derived) and the PT may be 30–100% longer with different batches [30]. The PT is frequently used for monitoring subjects treated with anticoagulant drugs (warfarin, acenocoumarol). Because these

drugs are administered for prolonged periods and patients may move from one lab to another, it is extremely important to be able to compare results from different laboratories in order to safely adjust the dose of the medicine. For this reason, the World Health Organization (WHO) introduced the international normalized ratio (INR) as a unit for comparison of results among laboratories everywhere. Each batch of commercial thromboplastin is assigned an international sensitivity index (ISI), which is derived by comparison of the PT obtained with the commercial batch with a standard thromboplastin. The PT of the laboratory sample is then multiplied by the ISI, yielding the INR, which, like the PT, is an index of residual hepatocytic synthetic function (see below). Correction of the PT using the ISI has a greater effect on the PT obtained during anticoagulant treatment than in subjects with liver disease, and a decrease in the ISI of the thromboplastin used may not engender a significant increase in the PT. This is probably related to different isoforms of prothrombin produced during vitamin K deficiency and/or liver failure [14]. The general recommendation, therefore, is to use the INR for monitoring anticoagulant therapy and the PT to assess hepatic synthetic function.

Abnormal values in hepatobiliary diseases

During liver disease, several pathological mechanisms may affect the coagulation cascade, lengthening the PT, including: (i) decreased synthesis of coagulation factors and (ii) decreased intake and/or absorption of vitamin K. The latter cofactor is lipid soluble and requires adequate concentrations of bile salts in the intestinal lumen in order to be absorbed. Decreased synthesis of bile salts in hepatocellular diseases, and/or decreased biliary secretion of bile salts in cholestatic disorders, may decrease the luminal concentration of bile salts below the critical micellar concentration necessary for normal absorption of lipids, including vitamin K. A third cause of a prolonged PT in liver failure is related to impaired ability of the hepatic Kupffer cells to remove activated clotting factors from the circulation. This may lead to intravascular coagulation, with consumption of clotting factors [31].

Impairment of the PT is roughly proportional to the degree of liver damage, so the PT is an excellent prognostic index of liver disease [32]. The sensitivity of the PT as a marker of acute as well as chronic liver disease is related to the fact that this test assesses the extrinsic coagulation pathway that begins with the activation of factor VII. Factor VII has the shortest half-life (3–5.5 h) of any of the coagulation factors, and so is the first to decline when synthesis of coagulation factors is impaired, either due to hepatocellar damage or vitamin K deficiency [31].

The injection of 10 mg of vitamin K for three consecutive days can help to discriminate between a decreased absorption of vitamin K (due to cholestasis or other causes) and decreased hepatic protein synthesis: if the PT returns to the normal range, the reduced availability of vitamin K was the cause of the prolonged coagulation time; if the PT decreases but still is above the upper normal limit, then a double cause (reduced absorption and reduced liver synthetic function) should be considered; and if the PT hardly changes, it means that the PT was prolonged because of impaired liver function.

Abnormal values in other diseases

The PT may be prolonged in coeliac sprue due to malabsorption of vitamin K. It may, for unknown reasons, be abnormal in hepatic congestion related to right-sided heart failure.

Clinical usefulness

PT is an excellent prognostic factor in either acute or chronic liver failure. During acute viral or alcoholic hepatitis, the degree of elevation of the PT ratio is the best predictor of the risk of death. With paracetamol (acetaminophen) toxicity, however, only a persistent increase in the PT ratio heralds a fatal outcome [1]. In cirrhotic patients, the PT ratio is an important component of two commonly used prognostic indices, the Child–Pugh and MELD score; in both algorithms the PT ratio strongly influences the total score.

Although a key prognostic index in both acute and chronic liver disease, the PT has no value as a screening marker for liver disease. Rather it should be reserved to assess residual hepatic synthetic function for patients with known liver disease [33].

Plasma fibrinogen

Nature of the compound and its distribution

Fibrinogen is a homodimeric plasma protein that is synthesized in hepatocytes; each monomer is formed by three polypeptide chains: α, β and γ. In the final step of the coagulation cascade, fibrinogen is converted to fibrin monomers by the peptidase activity of thrombin. These in turn aggregate to form the insoluble polymer, fibrin gel, which is stabilized by activated factor XIII [34].

Assays for detection

The two most useful assays for quantitation of plasma fibrinogen are a clotting rate assay and an enzyme immunosorbent assay (EIA). Sodium citrate is used as anticoagulant to collect the plasma specimen. For the clotting rate assay, the plasma sample, diluted 10-fold, is incubated with thrombin; the resultant fibrin clot is suspended in 6.7 M alkaline urea, and the fibrinogen concentration is derived from the optical density at 280 nm, compared with standards containing known concentrations of fibrinogen. The EIA assay is performed using an immobilized monoclonal antibody against the carboxyl-terminal end of the fibrinogen α-chain to capture the fibrinogen. A monoclonal antibody against the amino-terminal end of the α-chain, complexed with horse radish peroxidase (HRP), is then added. The clot and EIA methods yield comparable results [35].

Normal values, factors influencing them and abnormal values in organ diseases other than liver

The normal range in plasma is 200–400 mg/dL, and this can

be influenced by several different pathological states. Fibrinogen is an 'acute phase protein', concentrations of which are often elevated in: severe infections, postsurgical states, collagenoses, rheumatoid arthritis and pregnancy. Decreases in the plasma concentration of fibrinogen can be due to a hereditary dysfibrinogenaemia, or to acquired conditions that decrease synthesis or increase consumption. Genetic hypofibrinogenaemia, present from birth, is related to gene mutations in either the α, β or γ chain [34]. Increased consumption of fibrinogen occurs in the syndrome of disseminated intravascular coagulation (DIC), in which fibrinogen levels are decreased due to increased degradation of fibrinogen to split products.

Abnormal values in hepatobiliary diseases

Plasma fibrinogen concentration is usually increased during fulminant hepatitis as an acute phase response. In such patients, the prognosis is poor if the fibrinogen concentration fails to rise or decreases, reflecting severely impaired protein synthesis [36] or development of DIC [37]. With chronic liver disease, fibrinogen levels usually remain within the normal range, decreasing only when severe liver dysfunction develops (Child class C patients) [35]. The decrease in plasma fibrinogen is a result of decreased protein synthesis and/or increased peripheral intravascular coagulation [38]. The latter is distinguished by increased plasma levels of fibrin split products.

Summary of clinical usefulness

Because plasma fibrinogen concentration decreases mainly in endstage liver failure, it has very limited predictive value in chronic liver disease [39] but suggests a poor prognosis in acute hepatic failure.

Pseudocholinesterase

Nature of the enzyme and its reaction

Pseudocholinesterase (PChE), or serum cholinesterase, is a family of 11 enzymes that hydrolyse acetylcholine and other choline esters to choline and an organic acid, for example acetic acid.

Distribution and localization of the enzyme

It is expressed in liver and to a lesser extent in small intestine, smooth muscle cells, heart, pancreas and adipocytes and it is present in plasma [40].

Assays of enzyme activity

Many different tests have been developed to detect PChE activity:

- detection of CO_2 produced (manometric method);
- assessment of the amount of acetic acid produced by monitoring the decrease in pH;
- direct measurement of acetic acid (titrimetric assay) by colorimetric or voltammeter detection.

In all of these techniques, the serum sample is incubated with 10 mM acetylcholine. This high concentration has two purposes: (i) to produce sufficient concentrations of thiocholine and acetate to be detected by colorimetric methods, and (ii) to inhibit a different acetylcholinesterase in serum that can contribute to the enzymatic activity. This cholinesterase, which originates in erythrocytes, utilizes acetyl-β-methylcholine as its specific substrate.

Normal values and factors influencing them

Normal values are between 4000 and 12 000 U/L. Normal values in females are on average 15% lower than in males and fall even further during pregnancy [41]. PChE concentration can be lower in subjects without any disease who carry one or two atypical alleles (polymorphism) that have much less activity (serum levels <3000 U/L). Treatment with steroids (corticosteroids) can reduce the serum PChE activity [42].

Abnormal values in hepatobiliary diseases

PChE is an index of liver synthetic function and is depressed during either acute or chronic liver damage. During acute hepatitis, the degree of decrease is mild, but it may be lowered by 30–50% during severe necrosis. In liver cirrhosis, PChE decreases progressively to values as low as 50–70% of normal. In patients affected by chronic liver disease, this test is more sensitive than estimation of plasma albumin to detect impairment of protein synthesis in the liver [43].

Abnormal values in other diseases

Starvation and malnutrition can reduce the serum PChE activity as part of the general impairment in protein synthesis; the same effect is observed in patients with intestinal malabsorption, sepsis or severe burns [44]. Mild reduction of PChE activity is observed during myocardial infarction. A severe decrease (up to 60% lower than normal values) occurs with intoxication by organophosphate and carbamate pesticides. High serum activity is observed in obese patients, and in diabetic patients activity is positively correlated with high levels of triglycerides and inversely with insulin sensitivity; the reasons are unknown [40]. One person in 1500 has a deficit of PChE activity due to inheritance of an atypical variant of the enzyme; such subjects may suffer prolonged apnoea after treatment with succinylcholine during surgical procedures.

Summary of clinical usefulness

Serum PChE activity is an index of liver function although its advantage versus serum albumin is not proven. Therefore the routine use of PChE is not recommended.

Ammonia

Nature of the compound and its distribution

Ammonia (NH_3) is present in normal blood and derives from the metabolism of amino acids by the kidney and of amino acids and urea by intestinal bacteria. At the near neutral pH values of body fluids and cells, ammonia ($pK_a = 9.25$) exists mainly in the form of ammonium ions (NH_4^+), which cannot diffuse passively

across membranes. Thus, only the small fraction of ammonia in the form of NH_3 is diffusible, and it will passively move along a pH gradient from a compartment with higher pH to a compartment with lower pH, due to being trapped as NH_4^+ in the lower pH compartment. Thus, the lower pH of the tissues compared with the blood favours diffusion of NH_3 into tissues, and the lower pH of the colon compared with blood tends to limit absorption of NH_3 from the intestine.

In the fasting state, the intestine (50%) and kidney (40%) are the two major sources of blood ammonia. The greatest fraction originates by passive absorption of NH_3 from the intestinal lumen, where it is derived from three sources: (i) NH_3 present in foods like meat and cheese; (ii) the deamination of ingested amino acids and deamidation of glutamine by the activity of intestinal bacteria; and (iii) the formation of NH_3 and CO_2 from urea, about 25% of which diffuses from the blood into the intestinal lumen on each circulation. The absorbed ammonia passes via the portal venous blood to the liver, where it is normally metabolized to produce urea or ligated to glutamate to produce glutamine. Skeletal muscles can also reversibly form glutamine from ammonia + glutamate.

Assays of blood ammonia

Two different principles are used to extract ammonia from the blood: one involves isothermal diffusion of NH_3, and the other utilizes ion-exchange resins. The former is performed in a vial with two chambers separated by a microfilter: after addition of potassium carbonate to the blood sample chamber, NH_4^+ is converted to NH_3, which diffuses across the microfilter and is trapped as NH_4^+ in the second chamber containing HCl. After 45 min, the remaining HCl is precipitated as $BaCl_2$ by addition of 0.01 N barium hydroxide. Measurement of the precipitated $BaCl_2$ by this method allows calculation of the amount of HCl consumed, and thus the quantity of ammonia that neutralized it. The other method is based on the reversible enzymatic reaction of glutamate dehydrogenase (GDH). In this method, the ammonium, trapped in the ion-exchange resin, is incubated with GDH, α-ketoglutarate and NADPH, resulting in the formation of L-glutamate and $NADP^+$; the decrease of spectral absorbance of NADPH at 340 nm is directly related to the concentration of ammonia.

Normal values and factors influencing them

The normal blood ammonia concentration is quite low: 40–80 μg/dL (23–46 μM). The blood ammonia determination is very sensitive to outside influences and variations in technique, so must be performed with extreme care. The blood sample should be arterial rather than venous. Red blood cells rapidly deaminate labile compounds (like glutamine). Studies with an ammonia electrode show that generation of ammonia by erythrocytes occurs rapidly from the moment the blood sample is drawn. To minimize spurious increases in ammonia concentration from this source, the sample must be put in ice immediately and analysed within 2 h. Cigarette smoke contains considerable ammonia, so the laboratory and technician must be smoke-free and the patient should not smoke during the previous 8 h [44].

Blood ammonia rises markedly after eating protein and after gastrointestinal bleeding, both of which provide increased substrate for generation of ammonia by the intestinal flora. Acidosis increases renal ammonia synthesis and vigorous exercise increases the formation of ammonia from adenylic acid and glutamine in muscle.

Abnormal values in hepatobiliary diseases

Patients affected by either acute liver failure or chronic liver disease may suffer a decrease in hepatic urea synthesis and shunting of portal blood around the liver, resulting in increased ammonia concentrations in the peripheral blood. The consequent elevations in ammonia levels in the central nervous system may engender hepatic encephalopathy through both direct and indirect mechanisms [45]. There is, however, a poor correlation between arterial ammonia concentrations and the symptoms or severity of encephalopathy [46]. This may be related to the multiplicity of factors, other than ammonia, that may also affect CNS function in patients with hepatic failure or cirrhosis, as well as the technical problems with measurement of ammonia, discussed above.

Abnormal values in other diseases

Few other conditions increase blood ammonia concentrations. Infants may suffer encephalopathy due to rare congenital hyperammonaemias, caused by genetic deficiencies of enzymes involved in urea synthesis. The deficient enzymes are carbamoylphosphate synthase (type 1) and ornithine transcarbamylase (type 2). An increase of ammonia is occasionally observed in patients affected by severe pulmonary emphysema or carbon monoxide (CO) intoxication.

Summary of clinical usefulness

Blood ammonia is widely used to confirm the diagnosis of hepatic encephalopathy in patients with liver dysfunction. Its sensitivity and specificity for the diagnosis of hepatic encephalopathy are, however, only 85% and 29%, respectively, so this test is used less frequently now than in the past.

Cholesterol, phospholipids and triglycerides

All of these lipids are both synthesized and catabolized by the liver, as well as by other organs.

Abnormal values in hepatobiliary diseases

Modifications of both the amount and composition of plasma lipoproteins are common in all forms of hepatobiliary diseases, with different patterns according to the aetiology of the disease. In cholestatic disorders, either intra- or extrahepatic, there is commonly elevation of free cholesterol and phospholipids in plasma. This is due to: (i) inhibition of the conversion of cholesterol to bile salts; and (ii) regurgitation of cholesterol/lecithin

vesicles from the bile, which combine with plasma albumin to form the abnormal lipoprotein, LP-X [47]. LP-X is specific for cholestasis and familial LCAT (lecithin-cholesterol acyltransferase) deficiency. Characteristically, in both intra- and extrahepatic cholestasis, plasma high-density lipoprotein (HDL), apolipoprotein A-I (ApoA-I) and apolipoprotein A-II (ApoA-II) are increased also [48]. Treatment of primary biliary cirrhosis (PBC) with ursodiol usually decreases the plasma cholesterol concentration [49]. In patients with chronic excessive alcoholic intake, either with or without hepatic steatosis, it is common to observe hypertriglyceridaemia related to an increase of VLDL (very-low-density lipoproteins); increases in plasma cholesterol and phospholipids are frequent also. After alcohol withdrawal, triglyceride clearance is rapid while the cholesterol and phospholipid concentrations decrease more slowly. In cirrhosis, serum cholesterol and ApoB levels are progressively decreased in concert with the impairment of the liver function. The decrease in serum cholesterol concentration is mainly at the expense of the esterified fraction, associated with decreased concentrations of α- and pre-β-lipoproteins [50].

Summary of clinical usefulness

Measurement of plasma cholesterol can be useful in two different clinical situations: (i) an increase as a marker for the diagnosis and severity of cholestatic disorders, such as PBC; and (ii) a decrease as a marker of impaired liver function in cirrhosis. Triglycerides can be used as a marker for the follow-up of patients with suspected abuse of alcohol.

Markers to assess hepatic excretory function

Bilirubin

Structure and properties of bilirubin

Bilirubin is a yellow pigment present in serum in two different forms: unconjugated bilirubin (UCB), also called indirect bilirubin (see below), and conjugated bilirubin (CB), also called direct bilirubin. Both forms of bilirubin are potent antioxidants at low concentrations, and may play a role in protecting cells against diseases caused by oxidant damage [51]. At higher concentrations, however, the unconjugated form, which readily diffuses across cell membranes, may be cytotoxic.

UCB is produced in adults at a rate of approximately 3.8 mg/kg/day as the final product of the catabolism of the porphyrin ring of haem. It is a tetrapyrrole with two substituent propionic acid groups, each internally hydrogen-bonded to the >C=O and >N–H groups of the opposite dipyrrole half of the molecule. This endows the molecule with very low water solubility (<0.1 μM), requiring that it be transported in blood 99.9% bound to plasma albumin (90%) and apolipoprotein D (10%).

Distribution, transport and metabolism of bilirubin

UCB is produced mainly in the spleen from the catabolism of haem released when senescent red cells are destroyed by the reticuloendothelial cells. About one-fourth of UCB derives from ineffective erythropoiesis in the bone marrow and catabolism of other haem proteins, particularly cytochromes in the liver and myoglobin in muscle. UCB, delivered from the spleen via the splenic vein, undergoes uptake across the basolateral membrane of the hepatocyte by a facilitated diffusion process; the responsible carrier remains unclear [52]. In the hepatocyte cytosol, UCB is bound to ligandin and then diffuses into the microsomes, where it is conjugated with one or two molecules of glucuronic acid by a specific UDP-glucuronosyl transferase (UGT1A1). This renders the bilirubin soluble in water and CB is actively secreted in the bile by the multidrug resistance–associated protein 2 (MRP2) [53] membrane transporter at the canalicular membrane. After passing through the biliary tree and the small intestine, CB is deconjugated by coliforms in the small intestine and anaerobic bacteria in the terminal ileum and colon. The anaerobes then reduce UCB to form colourless urobilinogens that are mostly expelled with faeces. In adults and older children, small proportions of UCB and urobilinogens are reabsorbed from the intestine into the portal venous blood and return to the liver (enterohepatic circulation). The absence of the appropriate flora in newborns precludes formation of urobilinogens and enhances greatly the enterohepatic circulation of UCB.

Assays

The 'gold standard' is high-performance liquid chromatography of bilirubins in plasma, either native or after derivatization. Though very accurate and specific, these methods are expensive and not easily automated, and are thus not routinely available clinically. The method most commonly used is based on the reaction of bilirubin with diazotized sulfanilic acid, which splits the molecule into two dipyrroles, each coupled with the diazo reagent [54]. These azopigments, which are red in neutral solution and blue or green in strongly acid or alkaline solution, are measured spectrophotometrically. Due to the internal hydrogen-bonding, UCB couples only slowly with the diazo reagent, and the reaction essentially measures only 'direct-reacting' CB. Addition of an 'accelerator' (caffeine or diphylline) that breaks the hydrogen bonds of UCB, allows the UCB to react also, yielding the total bilirubin concentration. The total-direct bilirubin = 'indirect-reacting' bilirubin, which is a rough measure of UCB in the sample.

The method used nowadays was originally developed by Jendrassik and Grof. The serum or plasma sample is added to a solution of sodium acetate and caffeine–sodium benzoate, which stabilizes the bilirubin and buffers the pH when the very acid diazo-reagent is added; for the direct reaction, the caffeine is omitted. The diazo reagent, freshly prepared by addition of HCl and sodium nitrite to sulfanilic acid, is then added. After 10 min, addition of an alkaline solution stops the reaction and changes the colour of the azopigments from pink to blue–green, shifting the absorption maximum to 600 nm, well away from the absorption maxima of other coloured compounds in serum. Inclusion

of ascorbic acid in the alkaline stop solution helps arrest the reaction and stabilize the azopigments. Unreactive blanks, prepared without nitrite or with ascorbic acid added before the diazo reagent, are used to correct for other coloured compounds in serum. The net A_{600} is then converted to bilirubin concentration by comparison with a standard curve prepared from a stock solution of bilirubin in serum.

A commercial modification of the diazo method (Kodak Ektachem, Rochester, NY) utilizes multilayered filters/adsorbants to separate the UCB, CB and δ-bilirubin (bilirubin covalently linked to albumin in cholestatic disorders), then measures the azopigments formed in each layer by reflectance spectroscopy.

In newborns, due to the very small amount of blood sample available, a direct spectrophotometric determination is often used. A blood sample is collected in heparinized capillary tubes; after centrifugation the plasma is removed and diluted in Tris buffer. The absorbance of this solution is measured spectrophotometrically at 453 and 575 nm or at 436 and 578 nm. The lower wavelength is near the peak of bilirubin absorbance, and the higher wavelength detects one of the multiple absorbance peaks of haem, which is commonly present in neonatal plasma due to haemolysis. Using constants determined from standard samples, total bilirubin concentration is calculated from the difference between the two absorbances:

$$\text{bilirubin (mg/dL)} = \text{dilution factor} \times (1.3A_{453} - 1.37A_{575}).$$

This method is feasible only in newborns because yellow carotenoids, which have absorbance maxima similar to bilirubin, are almost absent from plasma in the first week of life [55]. With this method it is not possible to differentiate between conjugated and unconjugated bilirubin.

Normal values and influencing factors

Normal serum bilirubin levels in adults range from 0.15 to 1.2 mg/dL (3–21 μM). Some factors may influence the accuracy of the measurement: it is important that the blood sample is collected after 8–12 h fasting, as the postprandial presence of chylomicrons and lipids in plasma renders the sample turbid, impairing the absorbance measurement. Haemolysed samples give falsely low values due to interference of haem with the diazo reaction. The sample should be kept in the dark or protected from direct light to minimize photo-oxidation of bilirubins to products that do not react with the diazo reagent.

It is also important to note that virtually all the bilirubin present in normal serum is in the unconjugated form [56]; the low level of direct-reacting bilirubin (<15% of the total) results from slow reaction of UCB even in the absence of added accelerator and possibly from endogenous accelerators in the plasma (caffeine, urea, bile salts). Unidentified diazo-reactive compounds present in the serum may falsely elevate the direct-reacting fraction [57].

Abnormal values in hepatobiliary diseases

The metabolism and excretion of bilirubin is impaired in almost all hepatobiliary disorders, giving rise to retention of the yellow pigments in the plasma and tissues (jaundice or icterus). Jaundice can be divided into two major classes: an increase of (i) UCB, or (ii) CB + UCB. Type (ii) is readily distinguished by the presence of bilirubin in the urine, because the conjugated bilirubins are less tightly bound to plasma proteins and can filter at the glomerulus. Making this distinction is the first step in the differential diagnosis of jaundice.

Unconjugated hyperbilirubinaemia (<15% direct-reacting) may be caused by overproduction of bilirubin (haemolysis), shunting around the liver of portal blood (including the UCB-rich blood in the splenic vein), impaired hepatic uptake of UCB, and/or genetic deficiencies of the conjugating enzyme, UGT1A1. Almost all newborns are 'physiologically' jaundiced because of increased haemolysis and enterohepatic circulation of UCB, increasing the load on immature mechanisms for uptake and conjugation of UCB by the liver. Genetic impairment of conjugation by 60–70%, accompanied by impaired hepatic uptake and/or overproduction of UCB, causes Gilbert syndrome. Seen in 6–10% of adults, this harmless syndrome is characterized by mild indirect hyperbilirubinaemia without overt haemolysis or evidence of structural liver disease. The rare Crigler–Najjar syndromes (types 1 and 2) are due to the genetic absence (I) or very low (<10%) activity (II) of UGT1A1. Type 1 patients show very high serum levels of indirect bilirubin (20–30 mg/dL) without direct bilirubin; type 2 patients usually have 8–12 mg/dL indirect bilirubin in serum, with small proportions of direct bilirubin [58].

Conjugated hyperbilirubinaemia is accompanied by bilirubinuria, and is almost always indicative of significant hepatobiliary disease, even if as little as 30% of the serum bilirubin is direct-reacting. The retention of bilirubin conjugates is due to impaired canalicular secretion or biliary flow, with regurgitation of the bilirubin conjugates from the liver cell or bile back into the plasma. The significant concomitant elevation of indirect-reacting (unconjugated) bilirubin is due to: (i) deconjugation of the retained CB by β-glucuronidases in the tissues; and (ii) accompanying defects leading to retention of UCB, including impairment of hepatocytic uptake, portosystemic shunting, and haemolysis. It is important to realize that bilirubin conjugation is little impaired in hepatobiliary diseases except with severe acute or chronic liver failure.

Once conjugated hyperbilirubinaemia has been detected, the next step is to determine whether the problem is primarily due to hepatocellular injury or to impaired bile secretion and/or flow (cholestasis). Initial clues come from the age of the patients, the history of exposure to drugs, toxins or hepatitis viruses, the presence of biliary colic, and the symptom of pruritus (itching), which occurs in 75% of patients with cholestasis.

Elevations of serum transaminases and/or low levels of serum albumin point to hepatocellular diseases, and the diagnosis is further established by other serological and biochemical tests, often followed by liver biopsy. By contrast, an increase in serum alkaline phosphatase levels to more than three times the upper limit of normal values favours a cholestatic disorder; in this case, the next step is to distinguish between intrahepatic cholestasis and extrahepatic obstruction. This is usually achieved by

visualization of the biliary tree, most often by endoscopic cholangiography. Because some hepatocellular diseases (e.g. drug-induced) may affect biliary secretion, and persistent cholestasis secondarily damages the hepatocytes (e.g. in primary biliary cirrhosis), a mixed clinical and laboratory picture is not uncommon. Nonetheless, 85–90% of cases of conjugated hyperbilirubinaemia can be correctly classified as primarily hepatocellular disease vs cholestasis, and intra- vs extra-hepatic cholestasis, utilizing only history, physical examination and routine serum biochemical tests.

Hereditary defects in MRP2, the canalicular exporter of conjugated bilirubins, cause the Dubin–Johnson and Rotor syndromes [53], typically marked by direct hyperbilirubinaemia with little or no increase of alkaline phosphatase and the other serum markers of cholestasis. Hereditary conjugated hyperbilirubinemias, due to genetic abnormalities in the canalicular transporters of bile salts or phospholipids, cause the syndromes of progressive familial intrahepatic cholestasis (PFIC) types 1–3, benign recurrent intrahepatic cholestasis, or cholestasis of pregnancy. Some of these defects are accompanied by significant elevations of γ-GT, which assists in their classification: PFIC type 3 is distinguished from the other familial cholestasis by significant elevations of the γ-GT levels in serum.

Abnormal values in other diseases

Serum UCB can be increased by haemolysis, due to increased production of bilirubin from the catabolism of haem. Haemolytic anaemia, by itself, rarely raises the total serum bilirubin above 4 mg/dL (68 μM). There is no increase of cholestatic markers (γ-GT, alkaline phosphatase or 5′-nucleotidase) or ALT, but release of LDH and AST from the damaged red cells can increase these enzymes in serum. The diagnosis is made from examination of erythrocyte ± bone marrow morphology, plus increases in serum haptoglobin and reticulocytes.

Clinical usefulness

Although the proportion of direct/total bilirubin tends to be higher in cholestatic than hepatocellular jaundice, it has been known for half a century that the overlap among disease categories is so great that the direct/total bilirubin ratio is of no diagnostic value except to distinguish unconjugated (<15%) from conjugated (>30%) hyperbilirubinaemia.

Total serum bilirubin is an important parameter in assessing the prognosis of both acute and chronic liver failure and in the decision to propose liver transplantation; an increased total serum bilirubin concentration is associated with a shorter life expectancy. In acute viral hepatitis, a serum total bilirubin concentration higher than 384 μM (22.5 mg/dL) predicts mortality with a positive predictive value of 0.80 and sensitivity of 0.80. Combination with total serum cholic acid and glycocholic acid levels enhances the predictive value even further [59]. In cirrhosis of the liver of any cause, total serum bilirubin is a key variable in the Child–Pugh and MELD scores, the two most widely used to predict long-term survival. The endstage of primary biliary cirrhosis (PBC), an autoimmune cholangiolitis, is characterized by an increasing rise of serum bilirubin concentration. Total serum bilirubin greater than 150 μmol/L (8.8 mg/dL) is the best single indicator for orthotopic liver transplantation [60].

Alkaline phosphatase (ALP)

Nature of the enzyme and tissue distribution

Alkaline phosphatases constitute a group of membrane-bound, glycosylated metalloenzymes with low substrate specificity that catalyse the hydrolysis of a phosphoester bond at an alkaline pH, with the release of inorganic phosphate. The ALPs, whose physiological functions are unknown, comprise four classes of isoenzymes (tissue-nonspecific, intestinal, germ-cell and placental ALP), encoded by at least four different gene loci. Posttranslational modifications (e.g. in glycosylation) yield further isoforms, the most important of which are produced in bone and liver [61]. In normal subjects, the serum ALP activity is represented mainly by the intestinal, bone and liver isoenzymes, with at least half the activity represented by the liver isoforms. The placental isoenzyme becomes a major component during pregnancy. In the liver, ALP is expressed in both the sinusoidal and canalicular membranes of the hepatocyte, principally in the latter [62]. It is also localized in the brush borders of the epithelial cells of the renal proximal convoluted tubules, small intestine, pulmonary alveoli and the membrane bordering the bile canaliculus [63].

Assays of detection

ALP activity is assayed enzymatically, utilizing one of a panoply of phosphate esters that are substrates for ALP. The analytical methods can be divided into two general categories: detection of the released phosphate (from phosphate esters as β-glycerolphosphate), or measurement of the liberated alcohol (e.g. phenol from phenylphosphate).

Values obtained on individual specimens agree poorly among the various methods (Table 1), due to several factors: (i) different substrates vary in their affinity for the different isoenzymes; (ii) activities of the various isoforms and isoenzymes are profoundly and differently affected by reaction conditions (pH, temperature, type of phosphate ester, the concentration and nature of the metal activator, etc.) [63]. Conversion factors for comparison of average values from one test to another are poorly applicable to individual specimens. Thus, in everyday clinical practice, ALP activities obtained from different laboratories are best compared by expressing the results as the ratio to the upper limit of normal range of values for that facility.

Distinguishing isoenzyme activities

Several different physicochemical, electrophoretic and immunochemical techniques have been developed to distinguish the contributions of the different isoenzymes and isoforms to total ALP activity. Among the most common are:

- differences in sensitivity of isoenzymes to inactivation by elevated temperatures, alterations in pH, or concentratons of urea;

Table 1 Some assays used for determination of serum ALP activity. Modified from ref. 63 with permission of Williams & Wilkins Co.

Method	Substrate	Temp. (°C)	pH	Buffer	Unit	Normal range
Bessey–Lowry–Brock	*p*-Nitrophenyl phosphate	39	10.5	Glycine	1 mmol *p*-nitrophenol/L/60 min	0.8–3.0
Bodansky	β-Glycerophosphate	37	8.6	Diethyl barbiturate	1 mg Pi/100 mL/60 min	1.5–4.0
International	*p*-Nitrophenyl phosphate	37	10.5	2-Amino-2-methyl-1-propanol	1 μmol *p*-nitrophenol/L/min	21.0–85.0
International	Phenylphosphate	37	10.0	Sodium carbonate	1 mg phenol/100 mL/30 min	3.0–13.0
King–Armstrong	Phenylphosphate	37	9.3	Diethyl barbiturate	1 mg phenol/100 mL/30 min	3.0–13.0
Klein–Read–Babson	Phenolphthalein diphosphate	37	9.3	Tris	1 mg phenolphthalein/100 mL/30 min	1.0–4.0
Shinowara–Jones–Reinhart	β-Glycerolphosphate	37	9.3	Diethyl barbiturate	1 mg phenol/100 mL/60 min	2.2–8.6

Pi, inorganic phosphate.

- comparative reactivity to a panel of specific substrates;
- electrophoretic separation according to molecular weight or isoelectric point;
- removal of isoenzymes by specific immunoprecipitation.

These techniques are not commonly used because many: (i) are too cumbersome for a routine use; (ii) have low sensitivity; (iii) don't yield a quantitative result; and (iv) poorly resolve the bone and the liver isoforms (the most important distinction in clinical practice). For those reasons, the origin of the ALP activity in patients is usually inferred from the contemporaneous determination of serum γ-GT and/or 5′-nucleotidase activities, enzymes that originate mainly from the liver (see below). The absence of a contemporaneous increase of γ-GT [64] or 5′-nucleotidase activities suggests that the elevated serum ALP activity originates from bone or placenta; a pregnancy test can help confirm the latter possibility.

Influencing factors

Serum ALP activity increases markedly during the pubertal increase in height and bone growth, between 5 and 14 years of age in males and 5 and 12 years of age in females [65]. African American boys and girls, who have larger skeletal mass, have higher values than Caucasaians of the same age [66]. After puberty, activities decrease towards adult values, but tend to remain higher in males than in females [67].

In the elderly, the serum total ALP activity of both sexes increases with increasing age, especially above age 60 years. The same trends are seen in the non-bone isoforms (assumed to be largely from liver) (Fig. 3). By contrast, the activity of the bone isoenzyme (b-ALP) increases in women and decreases in men. The reason for the postmenopausal increase of b-ALP in women has been attributed to loss of the inhibitory effects of estrogen on bone turnover. In men, the decline in b-ALP activity with age correlates with decreases in the histomorphometric markers of bone formation [68].

Abnormal values in hepatobiliary diseases

Total ALP activity is increased in hepatobiliary diseases due to three mechanisms: (i) cleavage of the membrane-bound enzyme from its glycophospholipid anchor in the sinusoidal membrane

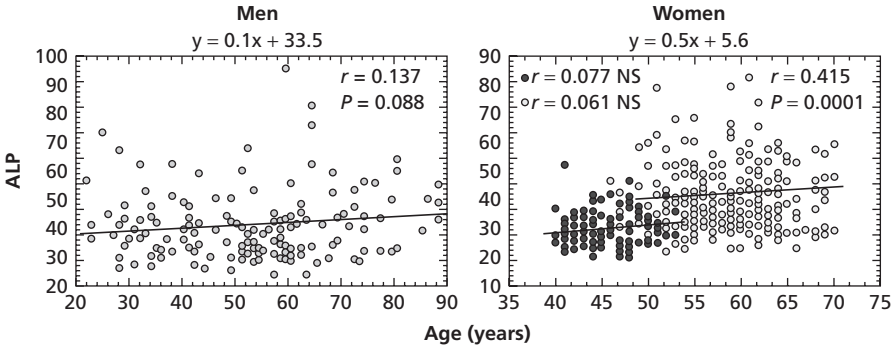

Fig. 3 Increase in total serum alkaline phosphatase (ALP) with age. The two *r* values at the left upper corner of the right panel for women are for (●) pre- and (○) post-menopausal women respectively. From ref. 68 with permission of American Association for Clinical Chemistry, Inc.

of the damaged hepatocyte; (ii) impaired trafficking of the enzyme from the sinusoidal to the apical membrane of the hepatocyte; and (iii) enhanced enzyme synthesis in the hepatocyte due to induction by retained bile acids [69]. The former concept that biliary secretion of the enzymes was impaired in cholestatic diseases has been negated by evidence that the hepatocyte does not excrete ALP into the bile [70].

The ALP activity is most strikingly increased in cholestatic and infiltrative liver diseases, less so in hepatocellular diseases. If ALP is not increased, the presence of cholestasis is unlikely, except for the cholestasis related to therapy with oestrogens or anabolic steroids; it is not known why there is little or no elevation of the serum ALP in the majority of such cases. With biliary tract obstruction, ALP activity is almost never normal and is at least three times the upper normal limit in over 90% of such cases. Elevation of the ALP is often the only abnormal 'liver function' test in patients with partial biliary obstruction (e.g. due to pancreatic or bile duct carcinomas, or sclerosing cholangitis) or multifocal intrahepatic duct obstruction by infiltrative diseases (e.g. hepatocellular or metastatic carcinoma, sarcoidosis, amyloidosis, or abscesses). ALP activity reportedly has a high sensitivity (90%) to detect metastatic malignancy [71].

It is important to understand that increased ALP activity is of no value in differentiating between intra- vs extrahepatic cholestasis, as it can be increased whenever bile flow is impaired, whether from obstructive lesions (tumours, primary biliary cirrhosis, sclerosing cholangitis) or hepatocellular damage (viral, drug or alcoholic hepatitis) [72].

Abnormal values in other diseases

Mild elevation of ALP levels of hepatic origin may occur in patients with stage I or II Hodgkin's disease, hypernephroma, congestive heart failure, myeloid metaplasia, peritonitis, diabetes, subacute thyroiditis or uncomplicated gastric ulcer [72].

During pregnancy, ALP activity of placental origin starts rising beyond the second trimester and reaches a peak of up to four times the normal range at the ninth month, then subsides to normal levels within 20 days after delivery.

Increased ALP activity originating from bone is observed in bone diseases whenever osteoblastic activity is increased (Paget's syndrome, healing fractures, rickets, osteomyelitis, bone metastases, osteoporosis, osteomalacia, primary hyperparathyroidism, etc.). Distinctively, in all those diseases, γ-GT and/or 5′-nucleotidase are usually normal. Patients affected by chronic renal failure, especially if treated with haemodialysis or peritoneal dialysis, can develop an increase of ALP activity related to the secondary bone or liver disease.

Several medications (Table 2) interfere directly with the measurement of ALP because they inhibit its enzymatic activity. Artefactual elevation of ALP activity has been described after albumin infusion because of the concomitant infusion of the active enzyme as a contaminant. This is possible because one of the sources of human albumin for infusion is the placenta and the ALP isoform in the placenta is resistant to the sterilization process [73]. ALP can be increased after drug treatment because of induction of liver damage (e.g. paracetamol, azathiaprine, methotrexate, oral contraceptives) or by inactivation of vitamin D (as it occurs in 25% of children receiving anticonvulsant therapy).

Table 2 Drugs that can inhibit enzymatic activity of serum alkaline phosphatase (ALP). From ref. 73 with permission of Adis International.

Arsenicals	Lithium	Serum phosphorus
Beryllium salts	Serum magnesium	Potassium
Ethionamide	Nitrofurantoin	Sulfhydryl compounds
Fluorides	Oxalates	Zinc salts

As a curiosity we refer to a family with autosomal dominant inheritance of a 2–4× increase of serum ALP activity in the absence of disease [74]; the mechanism is unknown.

Gamma-glutamyltransferase (γ-GT)

Nature of the enzyme

γ-GT is a cell-surface glycoprotein that cleaves γ-glutamyl amide bonds. It catalyses the transfer of the γ-glutamyl group from the γ-glutamylpeptide to another peptide or amino acid. The most abundant physiological substrates for the enzyme are glutathione and glutathione conjugates.

Tissue distribution

γ-GT is expressed most strongly in the kidney (brush border membranes of proximal convoluted tubules), moderately in the liver and pancreas, and to some degree in the heart, intestine, lung and spleen [75]. In the liver, its activity is located mainly in the microsomal fraction of the intra- and extrahepatic bile duct epithelium.

Assays of detection

The method recommended by the International Federation of Clinical Chemistry is based on the original procedure, using γ-glutamyl-3-carboxy-4-nitroanilide as a substrate and glycylglycine as the acceptor of the γ-glutamyl group. The final products are L-glutamyl-glycylglycine and 5-amino-2-nitrobenzoate. The latter compound is chromogenic (yellow) and is measured spectrophotometrically at a wavelength of 405 nm [76].

Normal serum levels and factors affecting them

The reference range for serum γ-GT is 12–32 IU/L. Within the normal range, values are influenced by:

- sex (higher in male);
- age (increases with age above 40–50 years) [77];
- race (higher values in black people);
- smoking (higher levels in smokers);
- childbirth (higher levels at 5–10 days postpartum and greater increase after caesarean section).

Physical exercise does not influence the serum activity [78].

Serum levels in hepatobiliary diseases

Serum γ-GT activity may be increased in all types of liver disease, but is most strikingly increased with obstruction of either intra- or extrahepatic bile ducts, although not directly correlated with the serum bilirubin levels. In cholestasis, it is more liver-specific than alkaline phosphatase (ALP), but its sensitivity may be less. The main clinical value of γ-GT activity is that it is not elevated when the increased serum ALP activity is of osseous or placental origin [79]. Its activity is increased in viral acute hepatitis, usually reaching a peak from the second to the third week, whereas it remains slightly elevated in chronic viral hepatitis and cirrhosis, and it can be considered as an expression of intrahepatic cholestasis during hepatitis. During acute hepatitis, however, the aminotransferase levels are disproportionally increased suggesting that an ALT/γ-GT ratio may help in the discrimination between hepatitis and obstructive hepatic disease (<1.8) [79]. The detection of elevated γ-GT activity in patients with proven malignancy is highly suggestive for the presence of metastatic lesions localized in the liver [80]. Elevation in γ-GT activity may be useful to distinguish PFIC type 3 from types 1 and II.

Abnormal values in other diseases and clinical situations

Serum γ-GT activity can be increased by treatment with drugs, such as the anticonvulsants phenytoin and phenobarbitone, that induce microsomal enzymes; the γ-GT levels are only weakly correlated with the drug concentrations in plasma [81]. Other drugs (i.e. oral contraceptives, carbamazepine, valproate) or chemicals (i.e. DDT, hexachlorobenzene) likewise may increase serum γ-GT activity [64].

Persistent alcohol consumption engenders a progressive, dose-related increase in γ-GT levels, but a single dose of alcohol has no effect [82]. The apparent half-life of serum γ-GT after abstention from alcohol varies from 5 to 17 days [83], being longer in patients with chronic liver disease. In decompensated cirrhosis, γ-GT levels can remain elevated despite abstinence, because of severe liver fibrosis [84]. For the detection of alcohol intake, the sensitivity and specificity of elevated γ-GT levels range from 33 to 58% and from 70 to 87% respectively. Thus, γ-GT alone is inadequate to screen for excessive alcohol intake, but it can be useful for serially monitoring alcohol abuse by individual patients [64].

γ-GT increases with increases in body weight, and in particular body mass index or hip/waist ratio. γ-GT is frequently elevated in patients affected by the metabolic syndrome, especially in patients affected by hypertriglyceridaemia, hypercholesterolaemia and insulin resistance, and in most patients with nonalcoholic fatty liver disease (NASH). γ-GT is increased also in 20% of diabetic patients – particularly noninsulin-dependent diabetes mellitus (NIDDM). In all these situations, the increased serum levels of γ-GT may be related to the associated fatty liver. Amyloidosis is another infiltrative hepatic disorder in which γ-GT activity can be raised [85].

Other causes of elevated serum γ-GT activity are myocardial infarction, congestive heart failure, acute pancreatitis, obstructive lung disease and chronic kidney failure.

Summary of clinical usefulness

Elevated serum γ-GT activity is a highly sensitive marker of hepatobiliary disease, but its usefulness is limited because of low specificity, related to the wide spectrum of diseases in which this enzyme activity is elevated. In our opinion, measurement of γ-GT activity is of value only to exclude a hepatobiliary source for an increased serum ALP, and to monitor the response to treatment in patients with uncomplicated alcoholic liver disease or other liver disorders who presented initially with an increased γ-GT activity. It is also useful in the differential diagnosis of PFIC.

5′-Nucleotidase

Nature of the enzyme

5′-Nucleotidase is an alkaline phosphatase that specifically catalyses the hydrolysis of the phosphopurine nucleotides by releasing inorganic phosphate from carbon 5 of the ribose (pentose) ring.

Assays of detection

Two different techniques are available: the first is based on the measurement of the total ALP activity (as previously described) after adding adenosine-5′-monophosphate to the sample as a specific substrate, and again after inhibiting the 5′-nucleotidase activity by adding Ni^{2+} or Zn^{2+}. The difference between the two values represents the activity of the 5′-nucleotidase. The second method consists of measuring the total phosphatase activity with added nonspecific substrates (i.e. phenylphosphate or β-glycerolphosphate) ± the specific substrate (adenosine-5′-monophosphate). The difference is taken as the 5′-nucleotidase activity. The first method is preferred, because of the greater influence of the unpredictable activity of nonspecific phosphatases on the second method.

Distribution

5′-Nucleotidase is present in most tissues and cells but the serum enzyme activity is increased only during cholestasis. This specificity is supposedly related to the highly hydrophobic nature of the enzyme, which results in its tight binding to plasma membranes; it then becomes soluble only upon treatment with detergents, such as bile salts. The markedly higher levels of retained bile salts in the liver during cholestasis presumably explains the specificity of high levels of serum 5′-nucleotidase for cholestatic disorders [86].

Normal serum levels, factors affecting them and clinical usefulness

The normal values are from 2 to 17 U/L and are not altered by age or sex [42], nor elevated by pregnancy or bone diseases.

These features make this assay valuable in infancy, pregnancy or subjects with bone diseases to discriminate whether an increase of serum ALP activity is related in part to underlying hepatobiliary disease. Because serum γ-GT can discriminate if the ALP increase is related or not to a biliary disorder except in paediatric patients, 5′-nucleotidase activity should be used in anicteric or icteric infants and children when cholestasis is suspected. In adults, 5′-nucleotidase activity is more specific than γ-GT, but the sensitivity is lower. Thus, in subjects with an elevated serum ALP, 5′-nucleotidase is useful only to prove the presence of hepatobiliary disease when positive, whereas γ-GT is useful only to exclude hepatobiliary disease when it is normal.

Overall take-home message

Unlike the lucky nephrologists, we hepatologists don't have creatinine for liver diseases. This means that we need to combine different tests to figure out what is wrong in the liver. In addition, although several of the tests described above have been used for more than 30 years, we still lack a precise correlation between the test result and its value for prognosis of the underlying liver disease, bar a few exceptions (albumin and prothrombin time for cirrhosis and bilirubin for biliary disorders). Therefore, decisions about what test to use and when must be driven by clinical suspicion and the results interpreted within the same frame.

References

1 Dufour DR, Lott JA, Nolte FS *et al.* (2000) Diagnosis and monitoring of hepatic injury. II. Recommendations for use of laboratory tests in screening, diagnosis, and monitoring. *Clin Chem* 46, 2050–2068.

2 Rej R (1989) Aminotransferases in disease. *Clin Lab Med* 9, 667–687.

3 Rej R (1978) Aspartate aminotransferase activity and isoenzyme proportions in human liver tissues. *Clin Chem* 24, 1971–1979.

4 Kempe E, Laursen T (1960) Investigations of the excretion of enzymes in urine. *Scand J Clin Lab Invest* 12, 463–471.

5 Bergmeyer HU, Horder M, Rej R (1986) International Federation of Clinical Chemistry (IFCC) Scientific Committee, Analytical Section: approved recommendation (1985) on IFCC methods for the measurement of catalytic concentration of enzymes. Part 3. IFCC method for alanine aminotransferase (L-alanine:2-oxoglutarate aminotransferase, EC 2.6.1.2). *J Clin Chem Clin Biochem* 24, 481–495.

6 Siest G, Schiele F, Galteau MM *et al.* (1975) Aspartate aminotransferase and alanine aminotransferase activities in plasma: statistical distributions, individual variations, and reference values. *Clin Chem* 21, 1077–1087.

7 Gitlin N (1982) The serum glutamic oxaloacetic transaminase/serum glutamic pyruvic transaminase ratio as a prognostic index in severe acute viral hepatitis. *Am J Gastroenterol* 77, 2–4.

8 Chopra S, Griffin PH (1985) Laboratory tests and diagnostic procedures in evaluation of liver disease. *Am J Med* 79, 221–230.

9 Sharpe PC (2001) Biochemical detection and monitoring of alcohol abuse and abstinence. *Ann Clin Biochem* 38, 652–664.

10 Salvaggio A, Periti M, Miano L *et al.* (1991) Body mass index and liver enzyme activity in serum. *Clin Chem* 37, 720–723.

11 Warnock LG, Stone WJ, Wagner C (1974) Decreased aspartate aminotransferase ('SGOT') activity in serum of uremic patients. *Clin Chem* 20, 1213–1216.

12 Wroblewski F (1959) The clinical significance of transaminase activities of serum. *Am J Med* 27, 911–923.

13 Grimwood K, Coakley JC, Hudson IL *et al.* (1988) Serum aspartate aminotransferase levels after rotavirus gastroenteritis. *J Pediatr* 112, 597–600.

14 Dufour DR, Lott JA, Nolte FS *et al.* (2000) Diagnosis and monitoring of hepatic injury. I. Performance characteristics of laboratory tests. *Clin Chem* 46, 2027–2049.

15 Panteghini M (1990) Aspartate aminotransferase isoenzymes. *Clin Biochem* 23, 311–319.

16 Bierman HR, Hill BR, Reinhardt L, Emory E (1957) Correlation of serum lactic dehydrogenase activity with the clinical status of patients with cancer, lymphomas, and the leukemias. *Cancer Res* 17, 660–667.

17 Peters T Jr (1977) Serum albumin: recent progress in the understanding of its structure and biosynthesis. *Clin Chem* 23, 5–12.

18 Campbell PN (1975) The biosynthesis of serum albumin. *FEBS Lett* 54, 119–121.

19 Rothschild MA, Oratz M, Schreiber SS (1988) Serum albumin. *Hepatology* 8, 385–401.

20 Hill PG (1985) The measurement of albumin in serum and plasma. *Ann Clin Biochem* 22, 565–578.

21 De Feo P, Lucidi P (2002) Liver protein synthesis in physiology and in disease states. *Curr Opin Clin Nutr Metab Care* 5, 47–50.

22 Rothschild MA, Oratz M, Schreiber SS (1972) Albumin synthesis (second of two parts). *N Engl J Med* 286, 816–821.

23 Doweiko JP, Nompleggi DJ (1991) The role of albumin in human physiology and pathophysiology, Part III: Albumin and disease states. *J Parenter Enteral Nutr* 15, 476–483.

24 Lewith G, Gabriel R (1975) Biochemical anomalies of the nephrotic syndrome. *Curr Med Res Opin* 3, 199–202.

25 Murch S (2005) Protein-losing disorders of the gastrointestinal tract. In: Wilfred M, Weinstein CJ, Bosch J (eds) *Clinical Gastroenterology and Hepatology*. London: Elsevier Mosby, pp. 309–314.

26 Kim GH, Oh KH, Yoon JW *et al.* (2003) Impact of burn size and initial serum albumin level on acute renal failure occurring in major burn. *Am J Nephrol* 23, 55–60.

27 Walls WD, Losowsky MS (1971) The hemostatic defect of liver disease. *Gastroenterology* 60, 108–119.

28 Quick AJ (1949) The coagulation mechanism, with specific reference to the interpretation of prothrombin time and a consideration of the prothrombin consumption time. *Am J Clin Pathol* 19, 1016–1023.

29 Baglin T, Luddington R (1997) Reliability of delayed INR determination: implications for decentralized anticoagulant care with off-site blood sampling. *Br J Haematol* 96, 431–434.

30 Munoz SJ (1991) Prothrombin time in fulminant hepatic failure. *Gastroenterology* 100, 1480–1481.

31 Roberts HR, Cederbaum AI (1972) The liver and blood coagulation: physiology and pathology. *Gastroenterology* 63, 297–320.

32 Rybak M, Dyrhon V, Losticky C *et al.* (1988) Effect of liver damage on the level of coagulation factor II, X and VII in human and bovine plasma. *Thromb Res* 52, 79–85.

33 Eisenberg JM, Goldfarb S (1976) Clinical usefulness of measuring prothrombin time as a routine admission test. *Clin Chem* 22, 1644–1647.

34 Roberts HR, Stinchcombe TE, Gabriel DA (2001) The dysfibrinogenaemias. *Br J Haematol* 114, 249–257.

35 de Maat MP, Nieuwenhuizen W, Knot EA *et al.* (1995) Measuring plasma fibrinogen levels in patients with liver cirrhosis. The occurrence of proteolytic fibrin(ogen) degradation products and their influence on several fibrinogen assays. *Thromb Res* 78, 353–362.

36 Izumi S, Hughes RD, Langley PG *et al.* (1994) Extent of the acute phase response in fulminant hepatic failure. *Gut* 35, 982–986.

37 Mammen EF (1994) Coagulation defects in liver disease. *Med Clin North Am* 78, 545–554.

38 Coccheri S, Mannucci PM, Palareti G *et al.* (1982) Significance of plasma fibrinopeptide A and high molecular weight fibrinogen in patients with liver cirrhosis. *Br J Haematol* 52, 503–509.

39 Ballmer PE, Reichen J, McNurlan MA *et al.* (1996) Albumin but not fibrinogen synthesis correlates with galactose elimination capacity in patients with cirrhosis of the liver. *Hepatology* 24, 53–59.

40 Rustemeijer C, Schouten JA, Voerman HJ *et al.* (2001) Is pseudocholinesterase activity related to markers of triacylglycerol synthesis in Type II diabetes mellitus? *Clin Sci (Lond)* 101, 29–35.

41 Sanz P, Rodriguez-Vicente MC, Diaz D *et al.* Red blood cell and total blood acetylcholinesterase and plasma pseudocholinesterase in humans: observed variances. *J Toxicol Clin Toxicol* 29, 81–90.

42 Breen KJ, Schenker S (1971) Liver function tests. *CRC Crit Rev Clin Lab Sci* 2, 573–599.

43 Wilson A, Calvert RJ, Geoghegan H (1952) Plasma cholinesterase activity in liver disease: its value as a diagnostic test of liver function compared with flocculation tests and plasma protein determinations. *J Clin Invest* 31, 815–823.

44 Viby-Mogensen J, Hanel HK, Hansen E *et al.* (1975) Serum cholinesterase activity in burned patients. I: biochemical findings. *Acta Anaesthesiol Scand* 19, 159–168.

45 Butterworth RF (2000) Complications of cirrhosis III. Hepatic encephalopathy. *J Hepatol* 32(1 Suppl.), 171–180.

46 Lockwood AH (2004) Blood ammonia levels and hepatic encephalopathy. *Metab Brain Dis* 19, 345–349.

47 Simon JB, Poon RW (1978) Lipoprotein-X levels in extrahepatic versus intrahepatic cholestasis. *Gastroenterology* 75, 177–180.

48 Miller JP (1990) Dyslipoproteinaemia of liver disease. *Baillières Clin Endocrinol Metab* 4, 807–832.

49 Szalay F (2001) Treatment of primary biliary cirrhosis. *J Physiol Paris* 95, 407–412.

50 Baraona E, Lieber CS (1979) Effects of ethanol on lipid metabolism. *J Lipid Res* 20, 289–315.

51 Rigato I, Ostrow JD, Tiribelli C (2005) Bilirubin and the risk of common non-hepatic diseases. *Trends Mol Med* 11, 277–283.

52 Persico M, Persico E, Bakker CT *et al.* (2001) Hepatic uptake of organic anions affects the plasma bilirubin level in subjects with Gilbert's syndrome mutations in UGT1A1. *Hepatology* 33, 627–632.

53 Paulusma CC, Kothe MJ, Bakker CT *et al.* (2000) Zonal down-regulation and redistribution of the multidrug resistance protein 2 during bile duct ligation in rat liver. *Hepatology* 31, 684–693.

54 Gambino R (1965) Bilirubin (modified Jendrassik and Grof). In: Meites S (ed.) *Standard Methods of Clinical Chemistry*. New York and London: Academic Press, pp. 55–64.

55 Richterich R (1969) Total bilirubin in the newborn: direct spectrophotometry. In: Karger S. (ed.) *Clinical Chemistry. Theory and Practice*. New York and London: Academic Press, pp. 416–418.

56 Blanckaert N, Kabra PM, Farina FA *et al.* (1980) Measurement of bilirubin and its monoconjugates and diconjugates in human serum by alkaline methanolysis and high-performance liquid chromatography. *J Lab Clin Med* 96, 198–212.

57 Lumeng L, O'Connor K (1986) Differential diagnosis of jaundice. In: Ostrow JD (ed.) *From Bile Pigments to Jaundice*. New York: Marcell Dekker, pp. 475–538.

58 Cekic D, Rigato I, Tiribelli C (2005) Disturbances of bilirubin metabolism. In: Weinstein WM, Hawkey CJ, Bosch J (eds) *Clinical Gastroenterology and Hepatology*. London: Elsevier Mosby, pp. 693–698.

59 Christensen E, Bremmelgaard A, Bahnsen M *et al.* (1984) Prediction of fatality in fulminant hepatic failure. *Scand J Gastroenterol* 19, 90–96.

60 Neuberger J (1997) Transplantation for primary biliary cirrhosis. *Semin Liver Dis* 17, 137–146.

61 Van Hoof VO, De Broe ME (1994) Interpretation and clinical significance of alkaline phosphatase isoenzyme patterns. *Crit Rev Clin Lab Sci* 31, 197–293.

62 Hagerstrand I (1975) Distribution of alkaline phosphatase activity in healthy and diseased human liver tissue. *Acta Pathol Microbiol Scand* [A] 83, 519–526.

63 Kaplan MM (1972) Alkaline phosphatase. *Gastroenterology* 62, 452–468.

64 Whitfield JB, Pounder RE, Neale G, Moss DW (1972) Serum-glutamyl transpeptidase activity in liver disease. *Gut* 13, 702–708.

65 Cherian AG, Hill JG (1978) Age dependence of serum enzymatic activities (alkaline phosphatase, aspartate aminotransferase, and creatine kinase) in healthy children and adolescents. *Am J Clin Pathol* 70, 783–789.

66 Bennett DL, Ward MS, Daniel WA Jr (1976) The relationship of serum alkaline phosphatase concentrations to sex maturity ratings in adolescents. *J Pediatr* 88, 633–636.

67 Eastman JR, Bixler D (1977) Serum alkaline phosphatase: normal values by sex and age. *Clin Chem* 23, 1769–1770.

68 Hsu SH, Tsai KS (1997) Different age-related trends of bone and nonbone forms of alkaline phosphatase in Chinese men and women. *Clin Chem* 43, 186–188.

69 Hatoff DE, Hardison WG (1979) Induced synthesis of alkaline phosphatase by bile acids in rat liver cell culture. *Gastroenterology* 77, 1062–1067.

70 Kaplan MM (1972) Alkaline phosphatase. *N Engl J Med* 286, 200–202.

71 Schaefer J, Schiff L (1965) Liver function tests in metastatic tumor of the liver: study of 100 cases. *Gastroenterology* 49, 360–363.

72 Breen KJ, Schenker S (1971) Liver function tests. *CRC Crit Rev Clin Lab Sci* 2, 573–599.

73 Sher PP (1982) Drug interference with clinical laboratory tests. *Drugs* 24, 24–63.

74 Wilson JW (1979) Inherited elevation of alkaline phosphatase activity in the absence of disease. *N Engl J Med* 301, 983–984.

75 Jacobs WL (1972) Gamma-glutamyl-transpeptidase in diseases of the liver, cardiovascular system and diabetes mellitus. *Clin Chim Acta* 38, 419–434.

76 Szasz G (1969) A kinetic photometric method for serum gamma-glutamyl transpeptidase. *Clin Chem* 15, 124–136.

77 Schiele F, Guilmin AM, Detienne H, Siest G (1977) Gamma-glutamyltransferase activity in plasma: statistical distributions, individual variations, and reference intervals. *Clin Chem* 23, 1023–1028.

78 Whitfield JB (2001) Gamma glutamyl transferase. *Crit Rev Clin Lab Sci* 38, 263–355.

79 Lum G, Gambino SR (1972) Serum gamma-glutamyl transpeptidase activity as an indicator of disease of liver, pancreas, or bone. *Clin Chem* 18, 358–362.

80 Cooper EH, Turner R, Steele L *et al.* (1975) The contribution of serum enzymes and carcinoembryonic antigen to the early diagnosis of metastatic colorectal cancer. *Br J Cancer* 31, 111–117.

81 Braide SA, Davies TJ (1987) Factors that affect the induction of gamma glutamyltransferase in epileptic patients receiving anti-convulsant drugs. *Ann Clin Biochem* 24, 391–399.

82 Nagaya T, Yoshida H, Takahashi H *et al.* (1999) Dose-response relationships between drinking and serum tests in Japanese men aged 40–59 years. *Alcohol* 17, 133–138.

83 Lamy J, Baglin MC, Aron E, Weill J (1975) Decrease in serum gamma-glutamyltranspeptidase following abstention from alcohol in cirrhotics. *Clin Chim Acta* 60, 97–101.

84 Silva IS, Ferraz ML, Perez RM *et al.* (2004) Role of gamma-glutamyl transferase activity in patients with chronic hepatitis C virus infection. *J Gastroenterol Hepatol* 19, 314–318.

85 McKenna JP, Moskovitz M, Cox JL (1989) Abnormal liver function tests in asymptomatic patients. *Am Fam Physician* 39, 117–126.

86 Goldberg DM (1973) 5′-Nucleotidase: recent advances in cell biology, methodology and clinical significance. *Digestion* 8, 87–99.

5.3 Hepatic removal kinetics: importance for quantitative measurements of liver function

Susanne Keiding and Michael Sørensen

Quantitative measurements of specific liver functions have been a challenge for hepatologists for many years. The many vital functions of the liver are not directly measurable, mainly because of the inaccessibility of sampling blood from the liver vessels. Several indirect tests have been proposed but few have proved clinically useful. A number of quantitative tests, each measuring particular metabolic functions or biliary excretory processes, are needed [1]. For successful design of such tests, it is most important to take into account the unique characteristics of liver structure, microcirculation, intracellular metabolism and biliary excretion.

The liver is ideally evolved for removal of substances from the circulation. Blood flows from the portal vein and the hepatic artery to the liver veins through a highly interconnected, spongelike system of sinusoids lined by hepatocytes. The endothelial cells are fenestrated, allowing large molecules, but not the corpuscular elements of the blood, direct access to the hepatocyte membrane, where numerous microvilli extend into the space of Disse. Bloodborne substances have direct access to a large area of the sinusoidal surface of the hepatocytes.

From a functional point of view, the bloodstream is unidirectional from the inlet to the outlet of the sinusoids. Substrate removal from the blood creates concentration gradients along the flow direction. This is in contrast to the *in vitro* test-tube experiment where all enzyme molecules are exposed to a uniform substrate concentration.

When describing the dynamics of hepatic removal of substances from the circulation, concepts developed *in vitro* must be adapted to the sinusoidal arrangement of hepatocyte anatomy and microcirculation. Model concepts should adequately express the complex physiological conditions in the intact organ. Parameters should, however, be limited to a few pertinent variables until experimental results justify the inclusion of further terms.

This review starts from enzyme kinetics *in vitro* and then transposes those concepts to the liver structure in terms of mathematical–physiological models. We describe *in vivo* Michaelis–Menten kinetics and discuss clearance measurements because these may be convenient estimates of liver blood flow or removal capacity for particular substances. Finally, we introduce the use of functional imaging by positron emission tomography (PET) as a unique technique for quantitative 3-D measurements of regional liver haemodynamics and metabolism.

In vitro Michaelis–Menten kinetics

In test-tube experiments, the enzymatic conversion of a substrate to a metabolite, viz. substrate removal, is characterized by Michaelis–Menten saturation kinetics; the relation between the conversion rate V and the substrate concentration c depends on the maximal conversion rate V_{max} and the half-saturation substrate concentration K_m (Fig. 1):

$$V = V_{max}\, c/(K_m + c) \qquad (1)$$

At low substrate concentrations, that is $c \ll K_m$, an increase in c causes a proportional increase in V; the kinetics is first-order. At high concentrations, that is $c \gg K_m$, an increase in c causes only a small increase in V; the metabolism approximates saturation, and the kinetics is zero-order.

In vivo Michaelis–Menten kinetics

For the intact liver, we first consider the simplest possible physiological approach, the single equivalent sinusoidal perfusion model [2,3]: all sinusoids contain the same amount of enzyme and they are perfused by identical flow rates. Substrate is given as a constant intravenous (i.v.) infusion so that blood concentrations are constant with time (steady-state), and there is complete presinusoidal mixing of blood from the portal vein and the hepatic artery. Red blood cells have about the same diameter as the sinusoid and this causes complete mixing of the substrate within each cross-section of the sinusoid. Diffusion from the sinusoidal bulk through the space of Disse up to the hepatocyte membrane is much faster than the removal rate. The substrate concentration accordingly is similar throughout each transverse section of the sinusoid.

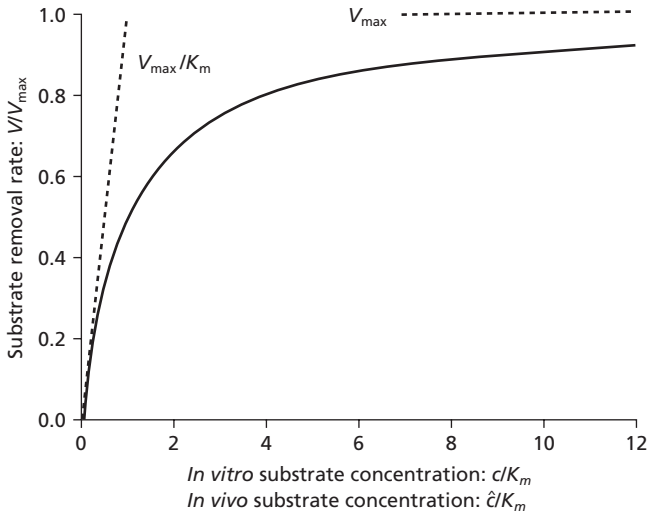

Fig. 1 Michaelis–Menten steady-state removal kinetics: $V = V_{max}c/(c + K_m)$, where V is the removal rate, c the substrate concentration, V_{max} the maximal substrate removal rate, and K_m is the half-saturation concentration. In the figure, V is normalized in respect to V_{max}, and c in respect to K_m. *In vitro*, all enzymes are exposed to the same concentration. *In vivo*, the hepatocytes lining the sinusoids are exposed to substrate concentration gradients along the blood-flow direction, decreasing from the inlet (c_i) to the outlet (c_o). In the sinusoidal perfusion model, $V = V_{max}\hat{c}/(\hat{c} + K_m)$, where the logarithmic average concentration $\hat{c} = (c_i - c_o)/\ln(c_i/c_o)$ accounts for the sinusoidal substrate gradient. At high concentrations, V approximates *in vivo* to V_{max}. At low concentrations, $V/\hat{c}$ approximates *in vivo* to V_{max}/K_m.

For the sinusoid, steady-state substrate removal rate, V, is:

$$V = F(c_i - c_o) \tag{2}$$

where F is the blood flow rate, and c_i and c_o are the inlet and outlet substrate concentrations respectively. This relation is model-independent, being based on Fick's principle of mass conservation only.

Removal of substrate by the hepatocytes is assumed to be governed by irreversible Michaelis–Menten kinetics of the rate-limiting step, either due to transport into the cell, metabolic conversion within the cell, or biliary excretion. The removal kinetics is described in relation to the local sinusoidal blood (or rather plasma water) substrate concentration pertaining to the rate-limiting step. During the passage of blood through the sinusoid, substrate removal by the hepatocytes gradually depletes the substrate, and a concentration gradient develops along the flow direction [3].

For the whole liver, integration of Equations 1 and 2 for all sinusoids gives [2,3]:

$$V = V_{max}\hat{c}/(K_m + \hat{c}) \tag{3}$$

where V, V_{max} and K_m now are parameters for the whole liver and $\hat{c} = (c_i - c_o)/\ln(c_i/c_o)$. As illustrated in Fig. 1, this is an *in vivo* Michaelis–Menten relation where the concentration $\hat{c}$ is the logarithmic mean of steady-state values of c_i and c_o; $\hat{c}$ is smaller than $(c_i + c_o)/2$ and larger than the integrated mean [3] and accounts for decreasing sinusoidal concentration gradients. It is seen that the flow F does not appear in Equation 3. This flow-independence of the relation between V and $\hat{c}$ is a salient feature of the model and has been validated experimentally [4–7].

Direct *in vivo* estimates of V_{max} and K_m were obtained from sets of steady-state values of c_i, c_o and F (Equations 2 and 3) for galactose [3,8,9], ethanol [10], antipyrine [11] and the parathyroid hormone [12].

Approximate estimates of V_{max} can be obtained at near-saturating substrate concentrations since for $\hat{c} \gg K_m$, Equation 3 reduces to $V \approx V_{max}$. Such estimates of galactose V_{max} were obtained in humans, using constant i.v. infusion of galactose and liver vein blood samples, and confirmed the flow-independence of these V_{max} estimates [13]. The measurement of the galactose elimination capacity (GEC) is another example. In this test, galactose is injected intravenously and GEC calculated from the decreasing blood galactose concentration [14]. GEC is measured at quasi-steady-state galactose concentrations higher than 2 mmol/L [14,15]. At these concentrations, $c_i \approx \hat{c} > 10K_m$ [3,9], and GEC approximates galactokinase V_{max} by 85% or more. GEC has been shown to contain prognostic information for both acute liver failure [16] and chronic liver disease [17–20].

Urea is produced nearly exclusively in the liver, and the excretion into the urine during constant i.v. infusion of alanine at near-saturating concentrations is used to quantify the V_{max} of hepatic urea synthesis [21,22]. This value is reduced during liver disease [21,23] and is used in studies of liver nitrogen metabolism [23,24].

Clearance

It is not always possible to determine V_{max}, because high concentrations may be toxic or have unwanted haemodynamic effects. In this case, clearance measurements can be useful, employing lower concentrations. Clearance of a substance from the blood is defined as the substrate removal rate (V) divided by the substrate concentration (c) at first-order kinetics, that is $\hat{c} \ll K_m$, viz. $V \ll V_{max}$ (see Fig. 1). Before a substance is chosen for clearance measurements, its removal kinetics must be evaluated to ensure that it follows first-order at the concentrations used. The consequence of using a substance with kinetics deviating from first-order is that the calculated clearance value depends on the dose given and, furthermore, that it varies with changes in liver function in a not easily comprehensive way [29,30]. In the present context it is useful to distinguish between intrinsic and systemic clearance.

Intrinsic hepatic clearance

Intrinsic hepatic clearance, Cl_{int}, is a flow-independent clearance that depends only on the 'intrinsic' transport/enzymatic removal processes. It is defined in relation to the $\hat{c}$ substrate concentration, and for $\hat{c} \ll K_m$, Equation 3 reduces to:

$$Cl_{int} = V/\hat{c} \approx V_{max}/K_m \quad (4)$$

It is seen that replacing V in Equation 4 by the term in Equation 2 and $\hat{c}$ by the term in Equation 3, we get:

$$Cl_{int} = -F \ln(1 - E) \quad (5)$$

where $E = (c_i - c_o)/c_i$ is the hepatic extraction fraction related to the rate-limiting metabolic step at steady state. E is flow-dependent (see Equation 7 below) in such a way that Cl_{int} (Equation 5) is flow-independent. It is mathematically identical to that used in capillary physiology [25] but in the present context applies to steady-state substrate removal.

For some substances, intrinsic clearance may be used to assess liver function. For $\hat{c} \ll 0.1K_m$, the first-order approximation of intrinsic clearance Cl_{int} to V_{max}/K_m is 90% or better (Equations 3 and 4). Intrinsic clearance of indocyanine (ICG) may be used as a measure of the biliary excretion function [6] and its flow-independence has been validated in human [6]. As seen from Equation 4, intrinsic hepatic clearance reflects V_{max} of the rate-limiting step of the particular metabolic or biliary excretory process studied, provided K_m is not changed by the experimental or pathophysiological conditions studied. The importance of this requirement is illustrated by findings in the isolated perfused pig liver, where experimental hypoxia was followed by parallel reductions of galactose V_{max} and K_m, yielding unchanged Cl_{int} values in spite of reduction of V_{max} to 2/3 of control values [26].

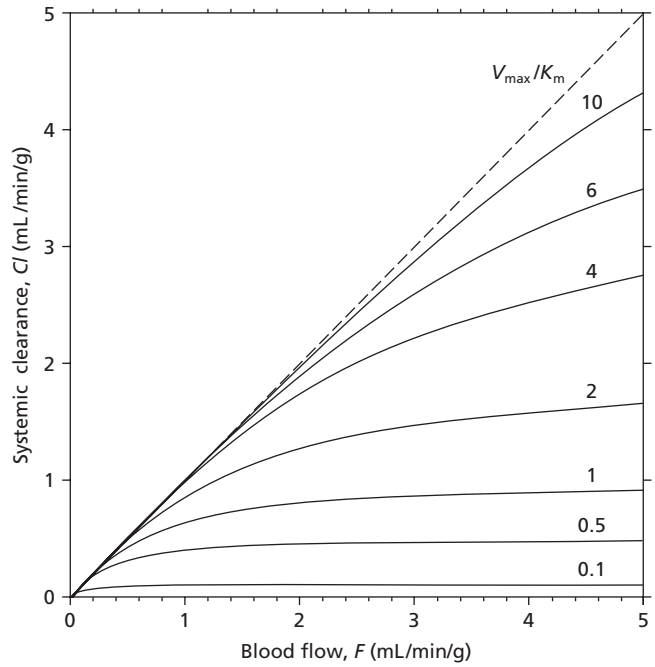

Fig. 2 Clearance of substances removed by the liver, Cl, in relation to liver blood flow, F, at different values of V_{max}/K_m. Clearance is flow-determined when $V_{max}/K_m \gg F$: $Cl \approx F$. Clearance is enzyme-determined when $V_{max}/K_m \ll F$: $Cl \approx V_{max}/K_m$ (see Table 1).

Systemic clearance: classification according to V_{max}/FK_m

Systemic clearance (Cl) is based on measurements of peripheral blood concentration (c_i). This clearance expression is of special interest in many experimental and clinical situations because it is based on substrate concentration measurements in peripheral blood only. This advantage is, however, gained at the expense of introducing a number of theoretical and practical limitations [27]. As a first approach, we consider cases with steady-state concentrations, no extrahepatic removal, and complete presinusoidal mixing of blood from the hepatic artery and the portal vein. Then, the sinusoidal inlet concentration c_i equals the peripheral (arterial) blood concentration. For $V \ll V_{max}$ or $V/FK_m \ll 1$, Equations 2 and 3 give for the systemic clearance:

$$Cl = V/c_i \approx F(1 - e^{-V_{max}/FK_m}) \quad (6)$$

It is seen that systemic clearance in general depends on both the removal capacity, in terms of V_{max}/K_m, and the liver blood flow F (Fig. 2). Depending on the specific test substance, blood flow and the physiological/pathophysiological conditions, systemic clearance can be used as an approximate estimate of either F or V_{max}/K_m.

Classification of substances for clearance measurements depends on the V_{max}/K_m ratio in relation to the blood flow, F. For substrates with high values of V_{max}/FK_m, Cl approximates F, and for low values of V_{max}/FK_m, Cl approximates V_{max}/K_m. The value of V_{max}/FK_m accordingly can be used for an unambiguous classification of clearance substances [27,28] (Fig. 3 and Table 1). For a substance with V_{max}/FK_m larger than 2.3, Cl approximates F by 90% or more (Equation 6). Systemic clearance is flow-determined and may be used as an estimate of F. For a substance with V_{max}/FK_m less than 0.10, Cl approximates V_{max}/K_m by 90% or more. Systemic clearance is enzyme-determined and may be used as an estimate of intrinsic clearance. For substances with V_{max}/FK_m within these limits, clearance depends on both F and V_{max}/K_m; the substance belongs to the intermediate clearance regime [27].

Previously, many test substances were classified according to their hepatic extraction fraction [31]. It is true that a high E generally indicates a high degree of flow-dependence, and that a low E indicates a high degree of enzyme-dependence. However, the effects of V_{max}/K_m and F cannot be separated, as seen from:

$$E = 1 - e^{-V_{max}/FK_m} \quad (7)$$

Hence, E is not a suitable basis for classification of hepatic clearance substances.

Enzyme-determined systemic clearance

When V_{max} of a given substance is small in relation to FK_m, the general clearance relation (Equation 6) reduces to $Cl \approx V_{max}/K_m$, which is identical to intrinsic clearance (Equation 4). This enzyme-determined clearance does not vary with flow and is

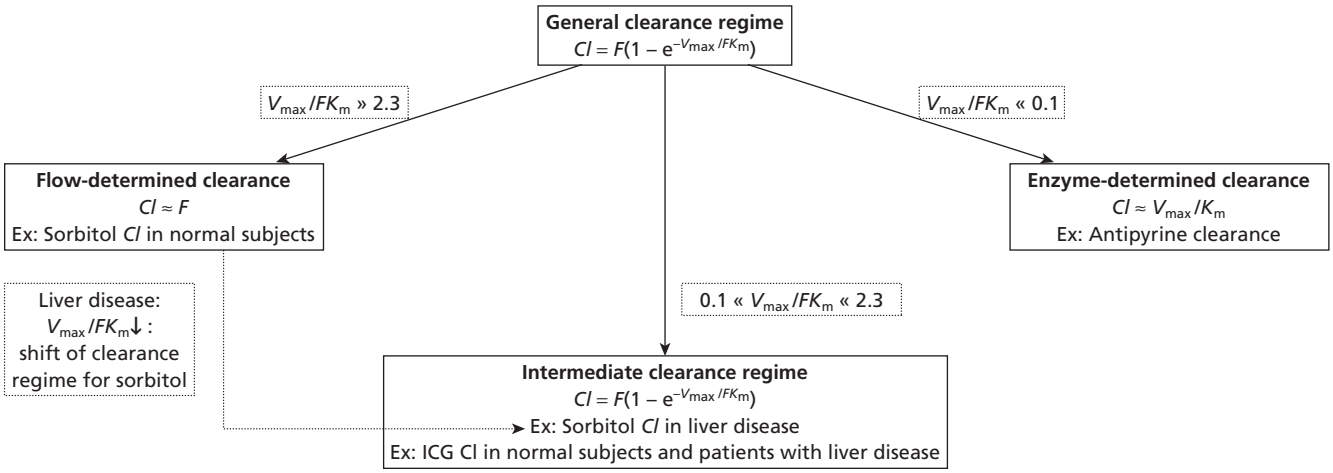

Fig. 3 Diagram of clearance regimes with example of shift of clearance regime for sorbitol during liver disease (dotted line).

Table 1 Clearance classification of substrates removed by the liver according to V_{max}/FK_m.

Test substrate	Experimental model	V_{max}/FK_m Mean (range)	Reference
Enzyme-determined clearance regimen: $V_{max}/FK_m < 0.1$			
Antipyrine (phenazone)	Normal pig, liver perfusion[a]	0.05 (0.03–0.08)	11
Caffeine	Normal human, breath test[c]	0.002	30
Caffeine	Cirrhosis human, breath test[c]	0.001	30
Flow-determined clearance regimen: $V_{max}/FK_m > 2.3$			
Sorbitol	Normal human, liver vein cath.[b]	3.6	38
Sorbitol	Normal human, liver vein cath.[b]	2.9	36
Sorbitol	Normal human, liver vein cath.[b]	2.8 (2.3–4.2)	35
Ethanol	Normal human, liver vein cath.[a]	7.4 (3.2–9.7)	10
Ethanol	Normal pig, liver vein cath.[a]	4.6 (1.9–11)	10
Galactose	Normal human, liver vein cath.[b]	2.5 (1.9–4.6)	40
Galactose	Normal pig, liver vein cath.[a]	4.1 (2.1–6.7)	9
Galactose	Normal cat, liver vein cath.[a]	3.2 (2.0–6.3)	8
Intermediate clearance regimen: $0.1 < V_{max}/FK_m < 2.3$			
Sorbitol	Cirrhosis human, liver vein cath.[b]	0.57	36
Sorbitol	Cirrhosis human, liver vein cath.[b]	1.9 (0.4–2.8)	35
Indocyanine green	Normal human, liver vein cath.[b]	0.70	36
Indocyanine green	Cirrhosis human, liver vein cath.[b]	0.20	36
Indocyanine green	Normal human, liver vein cath.[b]	0.9	34
Indocyanine green	Cirrhosis human, liver vein cath.[b]	0.4	34
Indocyanine green	Normal human, liver vein cath.[b]	1.7 (0.8–3.1)	35
Indocyanine green	Cirrhosis human, liver vein cath.[b]	0.9 (0.2–2.7)	35
Ethanol	Normal pig, liver perfusion[a]	1.5 (0.7–2.9)	10
Galactose	Normal pig, liver perfusion[a]	2.3 (1.5–3.6)	3

[a]Measurements of sets of steady-state c_i, c_o and F (Equation 3).
[b]Constant infusion at first-order kinetics with measurements of steady-state c_i and c_o: $E = (c_i - c_o)/c_i$; $V_{max}/FK_m = -\ln(1 - E)$ (Equation 5).
[c]Calculation of clearance from dose and concentration curve; liver flow assumed 1.2 L/min/70 kg body weight: $E = Cl/F$; $V_{max}/FK_m = -\ln(1 - E)$ (Equation 5).

proportional to V_{max}. Antipyrine (phenazone) is the only substance that has been thoroughly evaluated kinetically for its use as an enzyme-determined clearance substance. It is metabolized in the microsomes with first-order kinetics, has negligible extrahepatic elimination, and V_{max}/FK_m is about 0.05 in pigs [32] (Table 1). Antipyrine clearance was reduced in cirrhotic rats [33], and may provide prognostic information in patients with acute liver failure [16].

Flow-determined systemic clearance

When a substrate is removed in the liver by a process with a large amount of enzyme and a high affinity (low K_m) relative to hepatic blood flow, that is $V_{max}/FK_m \gg 1$, the general clearance relation (Equation 6) reduces to $Cl \approx F$. The removal is now entirely determined by the perfusion; all substrate is removed in a single pass. In subjects with no liver disease, V_{max}/FK_m for steady-state removal of sorbitol (corrected for urinary excretion) is >2.3 (Table 1) and extrahepatic metabolism is negligible [35–38]. In agreement with this, sorbitol clearance showed good agreement with flow measurements using ICG–Fick's principle (Equation 4) [35]. Sorbitol thus is an ideal test substance for clearance measurements of liver blood flow in healthy subjects. In subjects with liver disease, however, V_{max}/K_m is reduced [35,37] and sorbitol clearance shifts to the intermediate clearance regime (Table 1 and Fig. 2).

Galactose has been proposed as a clearance substance for measurement of liver blood flow because of a very high hepatic extraction fraction [39], but its use is hampered by significant extrahepatic elimination relative to that in the liver at low galactose concentrations [40]. The same is true for ethanol [10] (Table 1).

Some studies use systemic ICG clearance as a flow measurement, others as a measure of liver cell function. Neither is justified because ICG belongs to the intermediate clearance regime (Table 1).

PET measurements of regional liver metabolism

Positron emission tomography (PET) is an imaging modality that is new in the context of quantitative measurements of liver functions. The technique provides unique possibilities for measurements of regional liver blood perfusion and metabolism by means of i.v. injected radiolabelled tracers. PET tracers are positron-labelled natural substances, analogues thereof, drugs or receptor ligands. Combined PET/CT (computed tomography) cameras have the advantage of depicting functional PET images in CT-defined structures and allowing for noninvasive measurement of tracer supply through the liver blood vessels.

Clinical studies usually use PET images of the mean radioactivity concentration in a given time interval after tracer injection. Such images yield a visual impression of possible differences of metabolism between specific regions in the tissue. This provides the basis for the much used diagnostic detection of increased glucose metabolism in cancer nodules. Quantification of regional metabolic processes requires *dynamic* PET scanning, that is recordings of the time courses of tissue and blood radioactivity concentrations following tracer administration. Analysis of dynamic PET data comprises definition of a tissue region of interest (ROI) and analysis of the time course of tissue radioactivity concentrations in that region in relation to that in blood supplying the organ (see below). The kinetic modelling is based on a mathematical model of the metabolic diagram for the specific tracer used. In the case of ^{18}F-deoxy-2-glucose (FDG), metabolism can be described as illustrated in Figure 4.

Hepatic dual-input function

Following an i.v. injection of a tracer, the tracer is supplied to the liver via its dual blood supply. As seen in Figure 5, tracer radioactivity concentration in the hepatic artery rises steeply, reaches a peak and then decreases; the portal venous concentration curve is delayed and dispersed compared with that in the artery. The concentration resulting from the dual blood supply can be calculated as the flow-weighted average of the radioactivity concentrations in the hepatic artery and the portal vein. In experimental pig studies, estimates of kinetic parameters for the FDG kinetics (Fig. 4) using the liver dual-input function and nonlinear regression of the model to pig liver data gave parameter values that were comparable with independent estimates of flow and blood volume [41].

Because of difficulties in measuring the portal venous concentration, most PET studies of the liver ignore the dual blood supply, and kinetic parameter estimates rely on the use of an arterial input function. However, the importance of using dual-input function for determination of the kinetic parameters in the metabolic diagram (Figure 4) was demonstrated in pig studies using two glucose analogues, FDG [41,42] and ^{11}C-methylglucose [41].

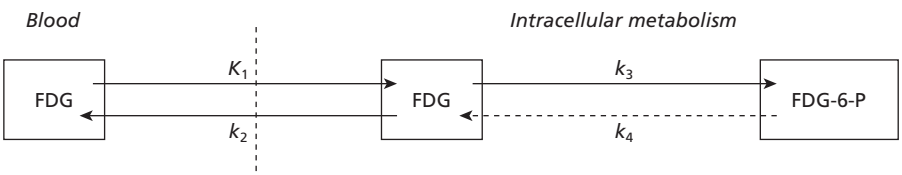

Fig. 4 Compartmental metabolic diagram for FDG (a glucose analogue) in the liver. Arrows indicate transport/metabolism of FDG. K_1 is the unidirectional clearance of FDG from blood to cell and k_2 the rate constant for the backflux; k_3 and k_4 are rate constants for phosphorylation and dephosphorylation. If the metabolism is irreversible, that is, k_4 is negligible, then the net metabolic clearance $K = K_1k_3/(k_2 + k_3)$.

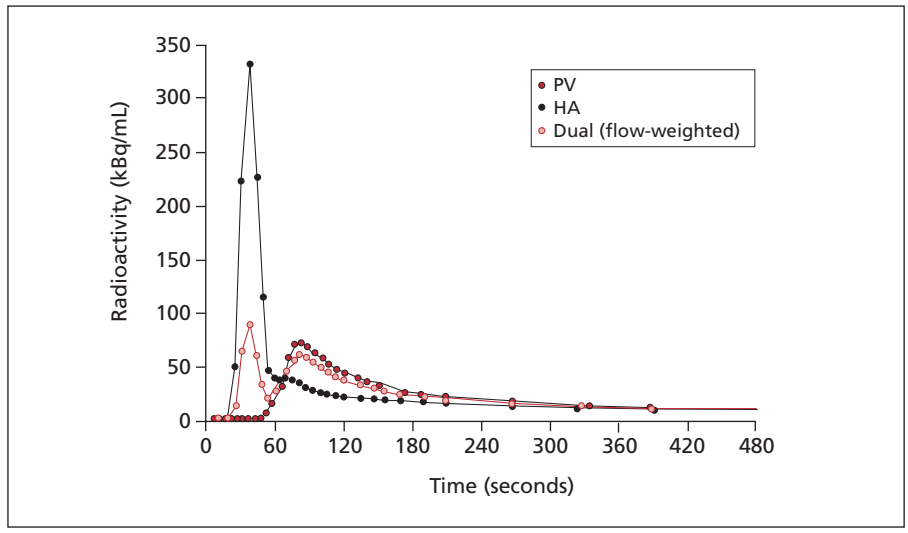

Fig. 5 Typical time-activity-curves for FDG in hepatic artery (HA), portal vein (PV) and flow-weighted dual-input blood. Initial 7 min are shown, when differences in shapes are most pronounced. The PV concentration is delayed and dispersed compared with the HA concentration as the result of the bolus passage through the intestinal vascular bed. After a few minutes, the three blood curves are similar. Blood data points are connected by straight lines.

In humans it is not possible to obtain successive blood samples from the portal vein or to measure the blood flow rates of the two supplying blood vessels. Work is in progress towards estimating the time courses of the radioactivity concentrations and the relative flow rates in the portal vein and hepatic artery by combined dynamic PET and contrast-CT for complete noninvasive measurement of the dual input [43–45]. However, a simpler but less informative analysis provided by the Gjedde–Patlak plot [46,47], using arterial concentration measurements only, can be very useful [41]. For substances with irreversible liver metabolism and negligible net removal in the intestines, the 'net metabolic clearance', *K*, can be used to describe steady-state irreversible clearance from blood to cell due to metabolism or biliary excretion. *K* is a simple mathematical combination of the kinetic rate constants as shown in Figure 4. *K* of FDG was used in experimental clinical studies to quantify differences in glucose metabolism between cholangiocarcinoma and nonmalignant liver tissue [48,49]. This relation has been used to measure pig liver metabolism of ammonia [55] and ^{18}F-deoxygalactose (M. Sørensen, unpublished data) as well as brain metabolism of ammonia during hepatic encephalopathy [56].

In routine clinical work it may be difficult to obtain series of arterial blood samples, and radioactivity concentration measurements from the abdominal aorta obtained from dynamic liver PET images may be used instead [43,50]. Furthermore, parametric images depicting pixel-by-pixel *K* values will often better distinguish between areas with increased metabolism due to tumour tissue or focal inflammation [49]. Thus, clinically useful parametric images of the net metabolic clearance can be produced based on totally noninvasive dynamic scans.

Compartment and microvascular models

Today, the standard kinetic model used for analysis of dynamic PET scans is most often a compartmental model (Fig. 4). This model regards tracer input to be instantaneously distributed in the capillaries/sinusoids and the transport/metabolism to take place at an identical input concentration all along the vascular path; it is an 'arterial equilibration model'. According to this modelling, mass is exchanged between well-mixed compartments as a function of time, and model parameters are rate constants that describe this exchange (Fig. 4). From a practical point of view, these models are often useful [41,51] but deviate obviously from liver physiology. Uncritical use of such models may lead to unphysiological parameter estimates [52,53]. We therefore have developed microvascular models to interpret PET data with a more physiological approach. When a tracer bolus passes through the capillary, time- and space-dependent concentration gradients develop [53], and by external detection the PET camera sees the spatial integral of the concentration at any time. These new microvascular models have been used to determine regional liver blood perfusion by dynamic $C^{15}O$ PET of pigs, validated by independent measurements using ultrasound transit-time flow-meters [53,54]. The models have not yet been developed for more complex metabolic diagrams, for example including backflux from cell to blood. In the next sections, we therefore restrict the discussion to the traditional 'hybrid' of using compartmental models but including expressions from classical capillary physiology to estimate flow and clearances (see also Chapter 5.8).

Physiological complexities

Sinusoidal heterogeneity

In the intact liver, the sinusoids form a highly interconnected, labyrinthine system. The sinusoids are not 'equivalent sinusoids'. Enzyme content of the hepatocytes may vary along the sinusoid, a phenomenon called sinusoidal zonation [57]. This phenomenon has been shown for metabolism of various amino acids [58], glucose [59] and ammonia [57,60], with ammonia metabolism being quantified *in vivo* by pig liver PET studies [61].

Heterogeneity between the sinusoids [62] lead to diminished efficiency of the overall removal, namely a diminished V_{max} as described in the distributed sinusoidal perfusion model [63].

Distribution of hepatic artery branches into acini is heterogeneous even in the normal liver as shown in rat studies [64]. In accordance with this, there was a remarkably higher variation of ^{13}N-ammonia trapped in the liver tissue as ^{13}N-glutamine in pig livers following ^{13}N-ammonia injection into the hepatic artery than following tracer injection into the portal or caval vein [65]. Thus, metabolic consequences of vascular heterogeneity could be quantified by dynamic liver PET. Similarly, measurements of the hepatic venous pressure gradient in two liver veins in subjects without liver disease showed a larger variation than can be attributed to measurement uncertainties [66]. The physiological importance of these variations remains to be elucidated.

Liver blood flow varies under different physiological conditions or pharmacological interventions. Food intake increases total flow [34,67] and e.g. vasopressin decreases it [13]. In agreement with the predicted flow-independence of V_{max}, neither of these flow changes changed the estimates of galactose V_{max} [13] or ICG intrinsic clearance [6]. Similarly, in perfused rat liver studies, galactose V_{max} was not influenced by flow changes as long as the perfusion rate was above 0.9 mL blood/min/g liver [68]. Similar results were found in the intact cat liver [8]. As the flow rate was gradually reduced, the effect of sinusoidal heterogeneity became more significant [69,70].

Hepatic first-pass elimination and systemic availability during saturation kinetics

The location of the liver between the portal and the systemic circulation means that substances absorbed from the gut have to pass through the liver before reaching the systemic circulation [61,71]. This constitutes the basis for the hepatic first-pass filter function.

For many orally taken drugs, for example acetylsalicylic acid [72], hepatic removal follows saturation kinetics and the systemic availability (the fraction of the absorbed dose that reaches the systemic circulation) depends on the dose (Fig. 6). Systemic availability approximates to unity at doses (V) approximating (or exceeding) the maximal removal capacity (V_{max}). In general, the lower the V_{max}/FK_m, the higher the systemic availability.

Systemic availability is very difficult to quantify *in vivo* because of the inaccessibility of portal venous blood. The dynamic PET/CT methods for noninvasive measurements of the hepatic dual-input function, as mentioned above, provide a promising methodological basis for a much-needed breakthrough in this research area.

Binding to circulating plasma proteins

Hydrophobic substances, such as long-chain fatty acids and organic anions like bilirubin and ICG, circulate in plasma bound to plasma proteins. It has been shown for several substances,

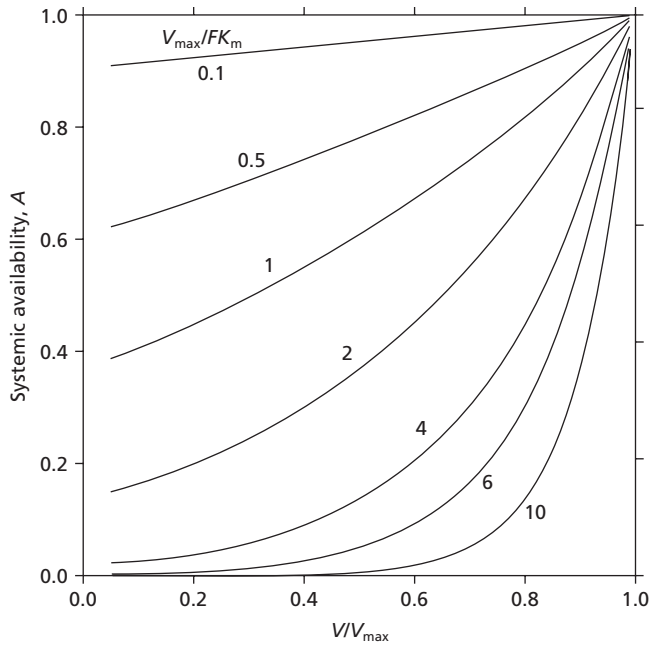

Fig. 6 Systemic availability at saturation removal kinetics: A = 1 – E = e^{-V_{max}/FK_m}. Curves show systemic availability in relation to dose, namely, V/V_{max} for different values of V_{max}/FK_m.

however, that more substrate is removed than corresponds to the unbound fraction [73–78]. This may be explained by diffusion barriers in the unstirred water layer adjacent to the hepatocyte plasma membrane [79,80]. The uptake of unbound substrate by the hepatocytes creates disequilibrium between bound and unbound substrate and the rate of dissociation of the protein–substrate complex becomes higher than the rate of complex formation within the unstirred water layer. Binding protein is not taken up by the hepatocytes: after unloading the drug, it returns to the sinusoidal bulk, where equilibrium between bound and unbound substrate molecules replenishes protein–substrate complex [81]. This model assumes no membrane binding of plasma proteins, but for free fatty acids there seems to be some albumin-mediated facilitation of the uptake process [82]. In liver vein catheterization studies using a constant i.v. infusion of ICG, experimental changes of plasma protein changed the removal of ICG in agreement with the codiffusion model in intact pigs [74] and in humans [77].

In perfused rat liver studies, backflux of dibromosulphthalein from the cells to the perfusate increased with increasing albumin concentration in the perfusate [83], which is also accounted for by the codiffusion phenomena.

Liver disease

Impaired liver-cell function

When hepatic metabolic functions are impaired due to liver disease, concepts of using V_{max} or enzyme-determined clearance

measurements are still valid (Fig. 3). Diminished GEC [84,85], antipyrine clearance [32] and urea synthesis capacity [21] in liver patients reflect reduced liver cell metabolism. However, when transposing flow-determined clearance measurements to pathological conditions, it must be ensured that the requirements for flow-determined clearance remain fulfilled. The shift of sorbitol clearance from being flow-determined in healthy subjects to being in the intermediate clearance in cirrhotic patients illustrates this question [35] (Fig. 3).

Intra- and extrahepatic vascular shunting

Patients with cirrhosis often develop extra- and intrahepatic portal–hepatic venous vascular shunts [86] and capillarization of the sinusoids [87]. Loss of metabolic liver function and both types of shunts will diminish the hepatic first-pass removal of substances. Systemic availability will increase and may lead to drug toxicity or hepatic encephalopathy. The effect of extrahepatic shunting can be assessed by dynamic magnetic resonance (MR) scans or catheterization of the azygos vein, which drains oesophageal varices [88,89]. At present, the effects of intrahepatic shunting cannot be distinguished from reduced liver cell function [37].

Clinical use of quantitative liver function measurements

Hepatic failure is ultimately the major cause of death in patients with liver disease. It is, therefore, reasonable to assume that quantitative measurements of various specific liver functions as outlined above, or serial measurements thereof, may provide clinically valuable prognostic information. Table 2 gives an overview of tests used today. Numerous tests have been proposed, but unfortunately most have not proved clinically useful. This is probably related to the fact that they have not been founded on proper physiological and pathophysiological grounds. Also, properly performed prognostic studies are astonishingly scarce.

PET or PET/CT measurements of regional liver haemodynamics and metabolism have the potential of being clinically useful prognostic quantitative tests [49].

Acute liver disease

In fulminant hepatic failure, quantitative tests of liver function may provide information on short-term survival. GEC was of prognostic value in patients with acute liver failure due to viral hepatitis [90] or paracetamol intoxication [91]. Following an overdose of paracetamol, the aminopyrine breath test was also able to predict fatal outcome [92]. In alcoholic hepatitis, the aminopyrine breath test predicted survival with reasonable accuracy [93].

Chronic liver disease

In chronic liver disease, GEC provides information on long-term survival [17–20,94–96]. In patients with primary biliary cirrhosis, serial determinations of GEC provided prognostic information [85]. The aminopyrine breath test was one of the statistically significant predictors of death in patients with cirrhosis [97] or chronic hepatitis [98].

Assessment of surgical risk

Liver resection in patients with chronic liver disease is associated with an increased risk of severe postoperative liver impairment. In a large prospective study of the predictive value of various preoperative liver tests, GEC was a strong independent and valuable predictor for short- and long-term outcome in patients with primary and secondary hepatic tumours undergoing resection [99]. In the treatment of patients with primary liver tumours or liver metastases, it is often impossible to predict if the patient will tolerate treatment with resection, radiofrequency, stereotactic radiotherapy or chemotherapy.

Assessment of therapeutic response

Only a few studies have attempted to evaluate treatment effects and prognostic value of quantitative liver function measurements. Jansen and co-workers (100) found that following liver resection, the liver regained 75% of the volume and 100% of the galactose elimination capacity after 120 days. In two studies,

Table 2 Quantitative liver function tests.

Test	Provides an estimate of:	Reference
Galactose elimination capacity	V_{max} of cytosolic enzyme galactokinase	[15]
Urea synthesis capacity	V_{max} of alanine to urea synthesis	[21]
Antipyrine clearance	V_{max}/K_m of microsomal metabolism	[11,105]
Intrinsic clearance of indocyanine green	V_{max}/K_m of biliary excretion	[6,35]
Sorbitol clearance	Liver blood flow in healthy subjects	[35–38]
Caffeine clearance	Microsomal function	[29,30]
Aminopyrine breath test	Microsomal demethylation	[106]
Ketoisocaproic acid breath test	Mitochondrial decarboxylation	[107]

FDG PET was found to be useful for prediction of treatment response in patients treated with chemotherapy for colorectal metastases to the liver [101,102]. Recent FDG PET studies successfully evaluated the effect of experimental radiotherapy [103] and radiofrequency treatment [104] of pig livers. Quantitative dynamic PET studies may be of significant benefit for the patients and more studies need to be done.

References

1 Tygstrup N. (1990) Assessment of liver function: principles and practice. *J Gastroenterol Hepatol* 5, 468–482.
2 Bass L, Keiding S, Winkler K *et al.* (1976) Enzymatic elimination of substrates flowing through the intact liver. *J Theor Biol* 61, 393–409.
3 Keiding S, Johansen S, Winkler K *et al.* (1976) Michaelis-Menten kinetics of galactose elimination by the isolated perfused pig liver. *Am J Physiol* 230, 1302–1313.
4 Keiding S, Chiarantini E. (1978) Effect of sinusoidal perfusion on galactose elimination kinetics in perfused rat liver. *J Pharmacol Exp Ther* 205, 465–470.
5 Keiding S, Priisholm K. (1984) Current models of hepatic pharmacokinetics: flow effects on kinetic constants of ethanol elimination in perfused rat liver. *Biochem Pharmacol* 33, 3209–3212.
6 Keiding S, Skak C. (1988) Methodological limitations of the use of intrinsic hepatic clearance of ICG as a measure of liver cell function. *Eur J Clin Invest* 18, 507–511.
7 Krarup N, Larsen JA. (1976) The influence of dye infusion rate and hepatic plasma flow on indocyanine green clearance. *Scand J Clin Lab Invest* 36, 183–188.
8 Greenway CV, Burczynski FJ. (1987) Effects of liver blood flow on hepatic uptake kinetics of galactose in anesthetized cats: parallel tube model. *Can J Physiol Pharmacol* 65, 1193–1199.
9 Keiding S, Johansen S, Winkler K. (1982) Hepatic galactose elimination kinetics in the intact pig. *Scand J Clin Lab Invest* 42, 253–259.
10 Keiding S, Johansen S, Midtboll I *et al.* (1979) Ethanol elimination kinetics in human liver and pig liver *in vivo*. *Am J Physiol* 237, E316–E324.
11 Andreasen B, Tonnesen K, Rabol A *et al.* (1977) Michaelis–Menten kinetics of phenazone elimination in the perfused pig liver. *Acta Pharmacol Toxicol* 40, 1–13.
12 D'Amour P, Huet PM. (1989) Ca^{2+} concentration influences the hepatic extraction of bioactive human PTH-(1–34) in rats. *Am J Physiol* 256, E87–E92.
13 Jacobsen KR, Ranek L, Tygstrup N. (1969) Liver function and blood flow in normal man during infusion of vasopressin. *Scand J Clin Lab Invest* 24, 279–284.
14 Tygstrup N. (1977) Effect of sites of blood sampling in determination of the galactose elimination capacity. *Scand J Clin Lab Invest* 37, 333–338.
15 Tygstrup N. (1966) Determination of the hepatic elimination capacity (Lm) of galactose by single injection. *Scand J Clin Lab Invest Suppl* 18, 118–125.
16 Ranek L, Andreasen PB, Tygstrup N. (1976) Galactose elimination capacity as a prognostic index in patients with fulminant liver failure. *Gut* 17, 959–964.
17 Merkel C, Bolognesi M, Angeli P *et al.* (1989) Prognostic indicators of survival in patients with cirrhosis and esophageal varices, without previous bleeding. *Am J Gastroenterol* 84, 717–722.
18 Merkel C, Gatta A, Zoli M *et al.* (1991) Prognostic value of galactose elimination capacity, aminopyrine breath test, and ICG clearance in patients with cirrhosis. Comparison with the Pugh score. *Dig Dis Sci* 36, 1197–1203.
19 Merkel C, Marchesini G, Fabbri A *et al.* (1996) The course of galactose elimination capacity in patients with alcoholic cirrhosis: possible use as a surrogate marker for death. *Hepatology* 24, 820–823.
20 Jepsen P, Vilstrup H, Sørensen HT *et al.* (2004) Galactose elimination capacity and prognosis of patients with liver cirrhosis – a Danish registry-based cohort study with complete long-term follow-up. *J Hepatol* 40 (Suppl. 1), 69A.
21 Vilstrup H. (1980) Synthesis of urea after stimulation with amino acids: relation to liver function. *Gut* 21, 990–995.
22 Hamberg O, Vilstrup H. (1994) A rapid method for determination of hepatic amino nitrogen to urea nitrogen conversion ('the Functional Hepatic Nitrogen Clearance'). *Scand J Clin Lab Invest* 54, 377–383.
23 Hamberg O, Nielsen K, Vilstrup H. (1992) Effects of an increase in protein intake on hepatic efficacy for urea synthesis in healthy subjects and in patients with cirrhosis. *J Hepatol* 14, 237–243.
24 Grofte T, Wolthers T, Jorgensen JO *et al.* (1999) Hepatic amino- to urea-N clearance and forearm amino-N exchange during hypoglycemic and euglycemic hyperinsulinemia in normal man. *J Hepatol* 30, 819–825.
25 Crone C. (1963) The permeability of capillaries in various organs as determined by use of the 'indicator dilution' method. *Acta Physiol Scand* 58, 292–305.
26 Keiding S, Johansen S, Tygstrup N. (1990) Galactose removal kinetics during hypoxia in perfused pig liver: reduction of Vmax, but not of intrinsic clearance Vmax/Km. *Eur J Clin Invest* 20, 305–309.
27 Winkler K, Bass L, Keiding S *et al.* (1979) The physiologic basis for clearance measurements in hepatology. *Scand J Gastroenterol* 14, 439–448.
28 Keiding S. (1976) Hepatic elimination kinetics: the influence of hepatic blood flow on clearance determination. *Scand J Clin Lab Invest* 36, 113–118.
29 Bonati M, Latini R, Galletti F *et al.* (1982) Caffeine disposition after oral doses. *Clin Pharmacol Ther* 32, 98–106.
30 Renner E, Wietholtz H, Huguenin P *et al.* (1984) Caffeine: a model compound for measuring liver function. *Hepatology* 4, 38–46.
31 Wilkinson GR, Shand DG. (1975) Commentary: a physiological approach to hepatic drug clearance. *Clin Pharmacol Ther* 18, 377–390.
32 Andreasen PB, Ranek L, Statland BE *et al.* (1974) Clearance of antipyrine-dependence of quantitative liver function. *Eur J Clin Invest* 4, 129–134.
33 Buters JT, Zysset T, Reichen J. (1993) Metabolism of antipyrine *in vivo* in two rat models of liver cirrhosis. Its relationship to intrinsic clearance *in vitro* and microsomal membrane lipid composition. *Biochem Pharmacol* 46, 983–991.
34 Skak C, Keiding S. (1987) Methodological problems in the use of indocyanine green to estimate hepatic blood flow and ICG clearance in man. *Liver* 7, 155–162.
35 Keiding S, Engsted E, Ott P. (1998) Sorbitol as a test substance for measurements of liver plasma flow in humans. *Hepatology* 28, 50–56.
36 Molino G, Avagnina P, Ballare M *et al.* (1991) Combined evaluation of total and functional liver plasma flows and intrahepatic shunting. *Dig Dis Sci* 36, 1189–1196.
37 Ott P, Clemmesen O, Keiding S. (2000) Interpretation of simultaneous measurements of hepatic extraction fractions of indocyanine

green and sorbitol: evidence of hepatic shunts and capillarization? *Dig Dis Sci* 45, 359–365.

38 Zeeh J, Lange H, Bosch J *et al.* (1988) Steady-state extrarenal sorbitol clearance as a measure of hepatic plasma flow. *Gastroenterology* 95, 749–759.

39 Henderson JM, Kutner MH, Bain RP. (1982) First-order clearance of plasma galactose: the effect of liver disease. *Gastroenterology* 83, 1090–1096.

40 Keiding S. (1988) Galactose clearance measurements and liver blood flow. *Gastroenterology* 94, 477–481.

41 Munk OL, Bass L, Roelsgaard K *et al.* (2001) Liver kinetics of glucose analogs measured in pigs by PET: importance of dual-input blood sampling. *J Nucl Med* 42, 795–801.

42 Brix G, Ziegler SI, Bellemann ME *et al.* (2001) Quantification of [(18)F]FDG uptake in the normal liver using dynamic PET: impact and modeling of the dual hepatic blood supply. *J Nucl Med* 42, 1265–1273.

43 Keiding S, Munk OL, Schiott KM *et al.* (2000) Dynamic 2-[18F]fluoro-2-deoxy-D-glucose positron emission tomography of liver tumours without blood sampling. *Eur J Nucl Med* 27, 407–412.

44 Munk OL, Keiding S, Bass L. (2003) Impulse-response function of splanchnic circulation with model-independent constraints: theory and experimental validation. *Am J Physiol Gastrointest Liver Physiol* 285, G671–G680.

45 Munk OL. (2005) Hepatic metabolism of glucose analogs measured by dynamic positron emission tomography and interpreted by compartment models. PhD thesis, Faculty of Health Sciences, University of Aarhus, Denmark.

46 Gjedde A. (1982) Calculation of cerebral glucose phosphorylation from brain uptake of glucose analogs *in vivo*: a re-examination. *Brain Res* 257, 237–274.

47 Patlak CS, Blasberg RG. (1985) Graphical evaluation of blood-to-brain transfer constants from multiple-time uptake data. Generalizations. *J Cereb Blood Flow Metab* 5, 584–590.

48 Keiding S, Hansen SB, Rasmussen HH *et al.* (1998) Detection of cholangiocarcinoma in primary sclerosing cholangitis by positron emission tomography. *Hepatology* 28, 700–706.

49 Prytz H, Keiding S, Björnsson E *et al.* (2006) Dynamic FDG PET is useful for detection of cholangiocarcinoma in patients with PSC listed for liver transplantation. *Hepatology* 44, 1572–1580.

50 Germano G, Chen BC, Huang SC *et al.* (1992) Use of the abdominal aorta for arterial input function determination in hepatic and renal PET studies. *J Nucl Med* 33, 613–620.

51 Munk OL, Keiding S. (2002) Quantification of (18)F-FDG uptake in the liver using dynamic PET. *J Nucl Med* 43, 439–441.

52 Becker G, Müller-Schauenburg W, Spilker ME *et al.* (2005) *A priori* identifiability of a one-compartment model with two input functions for liver blood flow measurements. *Phys Med Biol* 50, 1393–1404.

53 Munk OL, Keiding S, Bass L. (2003) Capillaries within compartments: microvascular interpretation of dynamic positron emission tomography data. *J Theor Biol* 225, 127–141.

54 Munk OL, Bass L, Feng H *et al.* (2003) Determination of regional flow by use of intravascular PET tracers: microvascular theory and experimental validation for pig livers. *J Nucl Med* 44, 1862–1870.

55 Sørensen M, Keiding S. (2006) Ammonia metabolism in cirrhosis. In: Häussinger D, Kircheisi G, Schless F (eds) *Proceedings of the 12th International Symposium of Hepatic Encephalopathy and Nitrogen Metabolism*. Springer Verlag, pp. 406–419.

56 Keiding S, Sørensen M, Bender D *et al.* (2006) Brain metabolism of ^{13}N-ammonia during acute hepatic encephalopathy in cirrhosis measured by PET. *Hepatology* 43, 42–50.

57 Haussinger D, Stoll B, Stehle T *et al.* (1989) Hepatocyte heterogeneity in glutamate metabolism and bidirectional transport in perfused rat liver. *Eur J Biochem* 185, 189–195.

58 Stoll B, McNelly S, Buscher HP *et al.* (1991) Functional hepatocyte heterogeneity in glutamate, aspartate and alpha-ketoglutarate uptake: a histoautoradiographical study. *Hepatology* 13, 247–253.

59 Gumucio JJ. (1989) Hepatocyte heterogeneity: the coming of age from the description of a biological curiosity to a partial understanding of its physiological meaning and regulation. *Hepatology* 9, 154–160.

60 Haussinger D, Lamers WH, Moorman AF. (1992) Hepatocyte heterogeneity in the metabolism of amino acids and ammonia. *Enzyme* 46, 72–93.

61 Keiding S, Munk OL, Roelsgaard K *et al.* (2001) Positron emission tomography of hepatic first-pass metabolism of ammonia in pig. *Eur J Nucl Med* 28, 1770–1775.

62 Lautt WW, Schafer J, Legare DJ. (1993) Hepatic blood flow distribution: consideration of gravity, liver surface, and norepinephrine on regional heterogeneity. *Can J Physiol Pharmacol* 71, 128–135.

63 Bass L, Robinson P, Bracken AJ. (1978) Hepatic elimination of flowing substrates: the distributed model. *J Theor Biol* 72, 161–184.

64 Richter S, Vollmar B, Mucke I *et al.* (2001) Hepatic arteriolo-portal venular shunting guarantees maintenance of nutritional microvascular supply in hepatic arterial buffer response of rat livers. *J Physiol* 531, 193–201.

65 Keiding S, Munk OL, Vilstrup H *et al.* (2005) Hepatic microcirculation assessed by positron emission tomography of first-pass ammonia metabolism in porcine liver. *Liver Int* 25, 171–176.

66 Keiding S, Vilstrup H. (2002) Intrahepatic heterogeneity of hepatic venous pressure gradient in human cirrhosis. *Scand J Gastroenterol* 37, 960–964.

67 Hansen HJ, Engell HC, Ring-Larsen H *et al.* (1977) Splanchnic blood flow in patients with abdominal angina before and after arterial reconstruction. A proposal for a diagnostic test. *Ann Surg* 186, 216–220.

68 Keiding S, Vilstrup H, Hansen L. (1980) Importance of flow and haematocrit for metabolic function of perfused rat liver. *Scand J Clin Lab Invest* 40, 355–359.

69 Brauer RW. (1963) Liver circulation and function. *Physiol Rev* 43, 115–213.

70 Lautt WW. (1977) Hepatic vasculature: a conceptual review. *Gastroenterology* 73, 1163–1169.

71 Keiding S. (1995) Drug administration to liver patients: aspects of liver pathophysiology. *Semin Liver Dis* 15, 268–282.

72 Levy G. (1965) Pharmacokinetics of salicylate elimination in man. *J Pharm Sci* 54, 959–967.

73 Forker EL, Luxon BA. (1983) Albumin-mediated transport of rose bengal by perfused rat liver. Kinetics of the reaction at the cell surface. *J Clin Invest* 72, 1764–1771.

74 Ott P, Keiding S, Bass L. (1992) Intrinsic hepatic clearance of indocyanine green in the pig: dependence on plasma protein concentration. *Eur J Clin Invest* 22, 347–357.

75 Weisiger RA, Zacks CM, Smith ND *et al.* (1984) Effect of albumin binding on extraction of sulfobromophthalein by perfused elasmobranch liver: evidence for dissociation-limited uptake. *Hepatology* 4, 492–501.

76 Weisiger RA. (1985) Dissociation from albumin: a potentially rate-limiting step in the clearance of substances by the liver. *Proc Natl Acad Sci USA* 82, 1563–1567.
77 Keiding S, Ott P, Bass L. (1993) Enhancement of unbound clearance of ICG by plasma proteins, demonstrated in human subjects and interpreted without assumption of facilitating structures. *J Hepatol* 19, 327–344.
78 Sorrentino D, Licko V, Weisiger RA *et al.* (1987) Phenobarbital specifically increases the hepatocellular uptake of sulfobromophthalein-glutathione. *Biochem Biophys Res Commun* 149, 921–926.
79 Bass L, Keiding S. (1988) Physiologically based models and strategic experiments in hepatic pharmacology. *Biochem Pharmacol* 37, 1425–1431.
80 Pond S, Bass L. (1988) The puzzle of rates of cellular uptake of protein-bound ligands. In: Pecile A, Rescigno A (eds) *Pharmacokinetics: Mathematical Approaches to Metabolism and Distribution of Chemicals and Drugs*. New York, London: Plenum Publishing, pp. 245–269.
81 Ott P, Weisiger RA. (1997) Nontraditional effects of protein binding and hematocrit on uptake of indocyanine green by perfused rat liver. *Am J Physiol* 273, G227–G238.
82 Weisiger RA, Pond SM, Bass L. (1989) Albumin enhances unidirectional fluxes of fatty acid across a lipid-water interface: theory and experiments. *Am J Physiol* 257, G904–G916.
83 Nijssen HM, Pijning T, Meijer DK *et al.* (1992) Influence of albumin on the net sinusoidal efflux of the organic anion dibromosulfophthalein from rat liver. *Hepatology* 15, 302–309.
84 Tygstrup N. (1964) The galactose elimination capacity in relation to clinical and laboratory findings in patients with cirrhosis. *Acta Med Scand* 175, 291–300.
85 Reichen J, Widmer T, Cotting J. (1991) Accurate prediction of death by serial determination of galactose elimination capacity in primary biliary cirrhosis: a comparison with the Mayo model. *Hepatology* 14, 504–510.
86 Popper H, Elias H, Petty DE. (1952) Vascular pattern of the cirrhotic liver. *Am J Clin Pathol* 22, 717–729.
87 Huet PM, Goresky CA, Villeneuve JP *et al.* (1982) Assessment of liver microcirculation in human cirrhosis. *J Clin Invest* 70, 1234–1244.
88 Sugano S, Yamamoto K, Takamura N *et al.* (1999) Azygos venous blood flow while fasting, postprandially, and after endoscopic variceal ligation, measured by magnetic resonance imaging. *J Gastroenterol* 34, 310–314.
89 Bendtsen F, Henriksen JH, Sorensen TI. (1991) Long-term effects of oral propranolol on splanchnic and systemic haemodynamics in patients with cirrhosis and oesophageal varices. *Scand J Gastroenterol* 26, 933–939.
90 Ramsoe K, Andreasen PB, Ranek L. (1980) Functioning liver mass in uncomplicated and fulminant acute hepatitis. *Scand J Gastroenterol* 15, 65–72.
91 Schmidt LE, Ott P, Tygstrup N. (2004) Galactose elimination capacity as a prognostic marker in patients with severe acetaminophen-induced hepatotoxicity: 10 years' experience. *Clin Gastroenterol Hepatol* 2, 418–424.
92 Saunders JB, Wright N, Lewis KO. (1980) Predicting outcome of paracetamol poisoning by use of 14C-aminopyrine breath test. *Br Med J* 280, 279–280.
93 Schneider JF, Baker AL, Haines NW *et al.* (1980) Aminopyrine N-demethylation: a prognostic test of liver function in patients with alcoholic liver disease. *Gastroenterology* 79, 1145–1150.
94 Merkel C, Bolognesi M, Finucci GF *et al.* (1989) Indocyanine green intrinsic hepatic clearance as a prognostic index of survival in patients with cirrhosis. *J Hepatol* 9, 16–22.
95 Merkel C, Bolognesi M, Bellon S *et al.* (1992) Aminopyrine breath test in the prognostic evaluation of patients with cirrhosis. *Gut* 33, 836–842.
96 Merkel C, Morabito A, Sacerdoti D *et al.* (1998) Updating prognosis of cirrhosis by Cox's regression model using Child-Pugh score and aminopyrine breath test as time-dependent covariates. *Ital J Gastroenterol Hepatol* 30, 276–282.
97 Villeneuve JP, Infante-Rivard C, Ampelas M *et al.* (1986) Prognostic value of the aminopyrine breath test in cirrhotic patients. *Hepatology* 6, 928–931.
98 Lashner BA, Jonas RB, Tang HS *et al.* (1988) Chronic hepatitis: disease factors at diagnosis predictive of mortality. *Am J Med* 85, 609–614.
99 Redaelli CA, Dufour JF, Wagner M *et al.* (2002) Preoperative galactose elimination capacity predicts complications and survival after hepatic resection. *Ann Surg* 235, 77–85.
100 Jansen PL, Chamuleau RA, van Leeuwen DJ *et al.* (1990) Liver regeneration and restoration of liver function after partial hepatectomy in patients with liver tumors. *Scand J Gastroenterol* 25, 112–118.
101 Bender H, Bangard N, Metten N *et al.* (1999) Possible role of FDG-PET in the early prediction of therapy outcome in liver metastases of colorectal cancer. *Hybridoma* 18, 87–91.
102 Dimitrakopoulou-Strauss A, Strauss LG, Rudi J. (2003) PET-FDG as predictor of therapy response in patients with colorectal carcinoma. *Q J Nucl Med* 47, 8–13.
103 Antoch G, Kaiser GM, Mueller AB *et al.* (2004) Intraoperative radiation therapy in liver tissue in a pig model: monitoring with dual-modality PET/CT. *Radiology* 230, 753–760.
104 Antoch G, Vogt FM, Veit P *et al.* (2005) Assessment of liver tissue after radiofrequency ablation: findings with different imaging procedures. *J Nucl Med* 46, 520–525.
105 Poulsen HE, Loft S. (1988) Antipyrine as a model drug to study hepatic drug-metabolizing capacity. *J Hepatol* 6, 374–382.
106 Bircher J, Kupfer A, Gikalov I *et al.* (1976) Aminopyrine demethylation measured by breath analysis in cirrhosis. *Clin Pharmacol Ther* 20, 484–492.
107 Lauterburg BH, Liang D, Schwarzenbach FA *et al.* (1993) Mitochondrial dysfunction in alcoholic patients as assessed by breath analysis. *Hepatology* 17, 418–422.

5.4 Immunological investigations in liver diseases

Elmar Jaeckel and Michael P. Manns

Introduction to the hepatic immune system

The hepatic immune system is capable of responding to and eliminating pathogenic microorganisms, toxins and tumour cells. At the same time, hepatic defence mechanisms are so tightly regulated that the induction of tolerance is favoured over the induction of immunity. The hepatic immune system is equipped with a specialized repertoire of cells that can selectively modulate various immune effector functions or tolerance. Hepatic antigen-presenting cells (APCs), such as Kupffer cells (liver-resident macrophages), dendritic cells and liver sinusoidal endothelial cells, can induce either tolerance or immunity via the selective release of proinflammatory cytokines, such as interleukin (IL)-6 or IL-12, or regulatory cytokines such as IL-10 or transforming growth factor (TGF)-β [1]. Additionally, hepatocytes, biliary epithelial cells and other liver cells release a complex array of lymphocyte growth, differentiation and activation factors. The presence of lymphocytes within the liver has, until recently, largely been dismissed as inflammatory infiltrates that enter the liver via the blood to respond to pathogenic stimuli. They were used, in part, to diagnose inflammatory conditions such as autoimmune and viral liver disease. However, recent studies have shown that healthy human liver contains large numbers of lymphocytes (approximately 10^{10}) that appear to be resident rather than circulating [2]. The liver contains various conventional lymphocytes such as αβ-T cells, B cells and natural killer (NK) cells. Many express mature/activated phenotypes, suggesting that, even in the healthy liver, they are mediating routine immunosurveillant functions [2,3]. Besides these, there are a large number of unconventional lymphocytes such as αβ- or γδ-natural killer T cells (NKT), which are much more abundant in the liver than in peripheral blood (Fig. 1) [2,4]. Many of these cells have roles in innate immunity, as evidenced by their ability to recognize common, conserved antigenic structures, their ability to mediate killing of target cells and/or their capacity to release cytokines that activate and regulate subsequent adaptive immune responses.

Immune responses against viruses, pathogens, toxins and self usually involve both the innate and the adaptive immune response. One problem in examining this immune response stems from the fact that we usually just have access to peripheral blood mononuclear cells and not to the site of inflammation. Even when analysing a patient's liver biopsy, this is restricted to the surface phenotype of infiltrating leukocytes. Although this might be helpful in assessment of the activity of viral hepatitis, autoimmune hepatitis and in the diagnosis of acute transplant rejection and/or graft-versus-host disease, most of

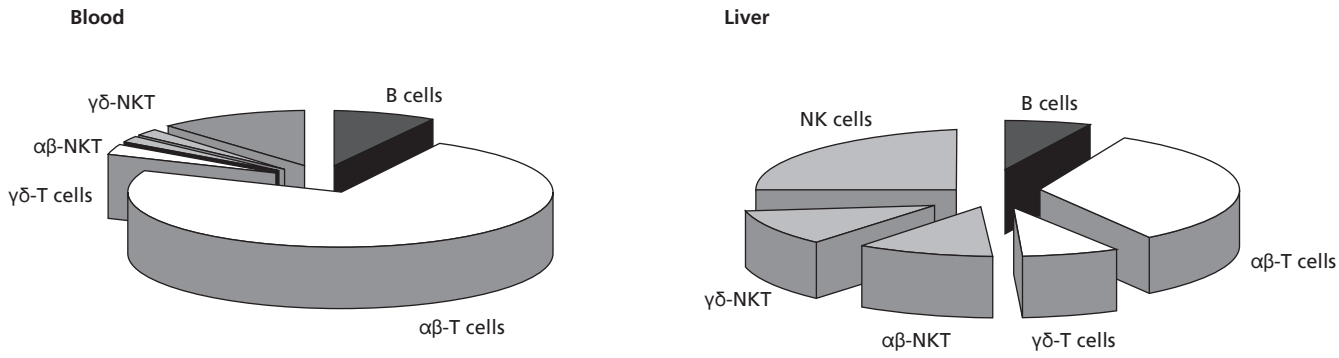

Fig. 1 Distribution of lymphocyte subpopulations in healthy human blood and liver.

the histopathological patterns are unspecific. Furthermore, specific immunological tests cannot be performed on fixed tissue specimens. Systemic cytokine levels have been evaluated in various hepatic disease conditions and especially after liver transplantation to identify acute rejection. However, cytokine levels simply reflect the extent of the immune activation, and no cytokine pattern has yet been described to be disease specific. Therefore, systemic measurement of cytokine levels – besides the problem of preanalytical stability of the serum sample – has no role in clinical hepatology so far [5]. Likewise, measurement of caspase activity in serum has been used to evaluate the extent of hepatic inflammation in steatosis, hepatitis C virus (HCV) infection and autoimmunity, but the source of the caspases (lymphocytes or hepatocytes) and their clinical significance remains uncertain [6,7].

On the other hand, the analysis of T-cell responses against hepatitis B virus (HBV) and HCV has provided interesting insights into the pathophysiology of acute and chronic viral infections of the liver [8]. Similarly, analysis of T-cell responses was crucial in our understanding of autoimmune liver diseases [9]. However, because of the large variability of the human major histocompatibility complex (MHC), the heterogeneity of the hepatotropic viruses and the variation in the antigen experience of the human T-cell repertoire between individuals, there is no clinical role for the analysis of T-cell responses in clinical practice.

The most constant and easiest to determine immunological measures in human viral and autoimmune liver diseases are provided by the humoral immune response [10]. Antibodies produced during HBV infection are markers of the immune status, and antibodies in hepatitis A virus (HAV) and HCV infection are important signs of the contact of the pathogen with the host's immune system (described elsewhere in this book). Besides this humoral immune response against viral proteins, measurement of response against self-antigens is a valuable scientific and clinical tool for our understanding of autoimmune liver diseases [10]. This response may also accompany inflammation caused by pathogens or toxins.

Autoantibodies and autoantigens in autoimmune hepatitis

Autoimmune hepatitis (AIH) represents a chronic, mainly periportal, hepatitis upon histology, which is characterized by female predominance, hypergammaglobulinaemia and circulating autoantibodies and benefits from immunosuppressive treatment (Table 1). The diagnosis of AIH is based on clinical, serological and immunological features as well as on the exclusion of other hepatobiliary diseases with and without autoimmune phenomena. These include disease entities such as chronic viral hepatitis, primary biliary cirrhosis (PBC), primary sclerosing cholangitis (PSC) and the so-called overlap or outlier syndromes. The revised AIH diagnostic score contributes to the establishment of the diagnosis in difficult cases by calculating a probability expressed as a numeric score [11].

Ever since the first description of AIH in 1950 by Waldenström [12], serological findings have attracted considerable attention, not only for the diagnosis of this chronic liver disease but also as a means of studying and eventually understanding its pathophysiology [13–15]. Waldenström described a disease predominantly affecting women and characterized by amenorrhoea, jaundice and elevated gammaglobulins leading to cirrhosis of the liver. It was recognized that patients with AIH displayed antinuclear antibodies (ANA), which led to the designation 'lupoid' hepatitis [16,17]. However, the term lupoid hepatitis has long been abandoned as AIH is not part of the syndrome of systemic lupus erythematosus (SLE). Autoantibodies have been the driving force of research aimed at elucidating the underlying mechanisms of AIH. They also serve as a means of serological subclassification of AIH [18,19].

Table 1 Prevalence of autoantibodies in autoimmune liver diseases.

Criterion	AIH	PBC	PSC
Female:male ratio	4:1	9:1	1:2
Serum Ig elevation	IgG	IgM	Variable
Autoantibodies			
ANA	60–85%	20–50%	7–77%
SMA	60–80%	10%	13–20%
LKM-1	5%	–	–
SLA	30–58%	0%	0%
pANCA	30–75%	18%	26–87% (atypical)
AMA	20%	95%	–
Diagnosis	AIH score > 15	AMA-M2, cholestatic serum enzyme pattern, histology	Cholangiography, cholestatic serum enzyme pattern, ulcerative colitis, pANCA

AIH, autoimmune hepatitis; PBC, primary biliary cirrhosis; PSC, primary sclerosing cholangitis; Ig, immunoglobulin; ANA, antinuclear antibody; SMA, smooth muscle antibody; LKM, Liver–kidney microsomal antibody; SLA, soluble liver antigen; AMA, antimitochondrial antibody; pANCA, perinuclear antineutrophil cytoplasmic antibody.

Table 2 Characterization of the major autoantibodies in autoimmune hepatitis.

Antibody	kDa	Target antigen	Disease
Autoantigens of the endoplasmic reticulum (microsomal autoantigens)			
LKM-1	50	Cytochrome P-450 2D6	Autoimmune hepatitis type 2, hepatitis C
LKM-2	50	Cytochrome P-450 2C9	Ticrynafen-induced hepatitis
LKM-3	55	UGTIA	Hepatitis D-associated autoimmunity
LKM	50	Cytochrome P-450 2A6	Autoimmune hepatitis type 2
			Autoimmune polyendocrine syndrome type 1 (APS-1)
			Hepatitis C
LM	52	Cytochrome P-450 1A2	Dihydralazine-induced hepatitis
			Hepatitis with autoimmune polyendocrine syndrome type 1 (APS-1)
	57	Disulphidisomerase	Halothane hepatitis
	59	Carboxylesterase	Halothane hepatitis
	35	?	Autoimmune hepatitis
	59	?	Chronic hepatitis C
	64	?	Autoimmune hepatitis
	70	?	Chronic hepatitis C
Soluble autoantigens of the cytoplasm			
LC-1	58–62	Formiminotransferase	Autoimmune hepatitis type 2
		cyclodeaminase	Autoimmune hepatitis
			Hepatitis C?
SLA/LP	50	UGA repressor tRNA-associated protein	Autoimmune hepatitis (type 3)

LC-1, anti-cytosol type 1; LM, liver microsomal.

Although this classification remains controversial, three subtypes can be distinguished based on the presence of serum autoantibodies. The classic form of AIH, AIH type 1, displays ANA. Research in the 1970s and 1980s led to the realization that autoantibodies in some patients are directed against antigens expressed in the endoplasmic reticulum (ER) [20–24]. These antimicrosomal autoantibodies were later identified as possessing specificity against cytochrome P-450 (CYP) mono-oxygenases expressed in the ER, which were identifiable in the microsomal fraction of cells (Table 2). Antimicrosomal antibodies directed against CYP 2D6, expressed not only in the liver but also in the kidney (LKM), characterized a second form of AIH (LKM-1) [24]. Finally, the analysis of serum from a patient with AIH by radioimmunoassay identified an antibody directed against a protein present in the 100 000-*g* supernatant of liver homogenate that was termed anti-SLA/LP [25–27]. These autoantibodies have recently been identified as being directed against a UGA repressor tRNA-associated protein [28–31]. The third serological group of AIH (AIH type 3) is clinically similar to AIH type 1 and, therefore, some researchers believe it does not represent a distinct subentity of its own [32]. The serological diversity of autoantibodies found in AIH supports the aforementioned subclassification and provides a framework for the scientific analysis of this heterogeneous disease group [33]. It also demonstrates that AIH is not a single disease with a single underlying mechanism, but is most likely a group of diseases with a similar clinical presentation.

Autoantibodies in autoimmune hepatitis type 1

When AIH is classified according to the presence of serological markers, ANA characterize AIH type 1. In most cases, smooth muscle autoantibodies (SMAs) are also present. The clinical profile of ANA-positive AIH shows hypergammaglobulinaemia in 97% of patients with an elevated immunoglobulin G. This form of AIH represents 80% of all cases of AIH, making it the most prevalent subclass. ANA-positive AIH was first described as lupoid, classical or idiopathic AIH by Cowling and colleagues [16]. Seventy per cent of patients are women, with a peak incidence between the ages of 16 and 30 years. It is noteworthy that 50% are older than 30 years. An association with other immune syndromes is observed in 48% of cases, with autoimmune thyroid disease, synovitis and ulcerative colitis as leading associations. The clinical course is usually not fulminant or clinically spectacular, and an acute onset is very rare. However, in rare cases, AIH may start as fulminant hepatitis. About 25% of patients have cirrhosis at the time of diagnosis.

ANA

ANA show specificity for both functional and structural proteins in the cell nucleus. They can be directed against nuclear membranes or even DNA [34–38]. Unfortunately, for diagnostic reasons, the target antigens are heterogeneous and incompletely defined, and heterogeneous even within a single disease such

Table 3 Differentiation between pANCA, cANCA and ANA.

Autoantibody	Ethanol-fixed granulocytes	Formalin-fixed granulocytes	Hep-2 cell
cANCA	Cytoplasmic	Cytoplasmic	None
pANCA	Nuclear/perinuclear	Nuclear/perinuclear	None
ANA	Nuclear/perinuclear	Reduced/none	Nuclear

as AIH. For the diagnostic workup of AIH, the molecular characterization of target antigen specificity does not supply important additional information to increase diagnostic precision. Screening determinations of ANA are routinely performed by indirect immunofluorescence on cryostat sections of rat liver and on Hep2 cell slides. Most commonly, a homogeneous or speckled immunofluorescence pattern is demonstrable. ANA have been found to be reactive with an array of antigens that include centromeres, ribonucleoproteins and cyclin A. They represent the most common autoantibody in AIH and occur in high titres, usually exceeding 1:160. However, the titre does not correlate with disease course, prognosis, progression, requirement for transplantation or disease activity.

SMA

SMA autoantibodies are also determined by indirect immunofluorescence on cryostat sections of rat stomach and kidney [39]. SMA are directed against cytoskeletal proteins such as actin, troponin and tropomyosin [40,41]. They frequently occur in high titres in association with ANA. They are not highly specific for AIH and have been shown to occur in advanced liver diseases of other aetiologies and in infectious diseases and rheumatic disorders (Table 1). In these cases, titres are often lower than 1:80. In paediatric patients, SMA autoantibodies may be the only marker of AIH type 1. When present in very young patients with AIH type 1, the titres may be as low as 1:40. SMAs have been found to be generally associated with the human leukocyte antigen (HLA) A1-B8-DR3 haplotype and, possibly as a reflection of this HLA status, the affected patients are younger and have a poorer prognosis [42]. Moreover, antibodies to actin identify a subgroup of patients with SMA who have disease at an earlier age and a poorer response to corticosteroid therapy [40].

Asialoglycoprotein receptor

The asialoglycoprotein receptor (ASGPR) is a liver-specific glycoprotein of the cell membrane. Autoimmunity targeting this antigen is observed in 88% of AIH patients [43]. However, anti-ASGPR antibodies are also found in chronic hepatitis B and C, alcoholic liver disease and PBC. The levels of anti-ASGPR antibodies vary according to inflammatory activity of the disease and could play a role as a marker to monitor therapeutic efficacy [44]. Anti-ASGPR appears to be a general marker of liver autoimmunity, and routine clinical determination is not recommended on account of the low specificity.

Antineutrophil cytoplasmic autoantibodies

Antineutrophil cytoplasmic autoantibodies (ANCA) are detected in 30–75% of sera [45,46]. Care has to be taken that high titres of ANAs are not misdiagnosed as perinuclear antineutrophil cytoplasmic autoantibodies (pANCA) on ethanol-fixed granulocytes. Additional stainings on formalin-fixed granulocytes and Hep2 cells can usually solve this problem (Table 3). pANCAs are rare in AIH type 2. The role of ANCA in AIH is not clear, and their routine determination is not recommended. However, these antibodies can be of diagnostic value for those patients with AIH type 1 who have been tested negative for ANA/SMA.

Autoantibodies in autoimmune hepatitis type 2

AIH type 2 is a rare disorder that affects up to 20% of AIH patients in Europe but only 4% in the United States [22,47]. There is a predominance in women. The average age at onset is around 10 years, but AIH type 2 is also observed in adults, especially in Europe. AIH type 2 carries a higher risk of progression to cirrhosis and of a fulminant course. When AIH type 2 is diagnosed in children, cirrhosis is very frequently present at the time of diagnosis.

LKM-1

The ER of the cell harbours two critical enzyme families that are the main players in phase I and phase II metabolism: the CYPs and the uridine diphosphate (UDP)-glucuronosyltransferases (UGT) [48]. Phase I metabolism leads to the oxidative modification of compounds, usually by the addition of functional groups such as hydroxylation [49]. Phase II metabolism leads to the conjugation with polar prosthetic groups such as glucuronic acid (glucuronidation) [50]. In the case of the UGTs, glucuronidation leads to a water-soluble glucuronide that is targeted for renal or biliary elimination [51]. Both enzyme families are preferred targets of a B-cell response in autoimmune liver diseases (Fig. 2, Table 2). Indirect immunofluorescence first led to the description of autoantibodies reactive with the proximal renal tubule and the hepatocellular cytoplasm in 1973 [52]. These autoantibodies, termed LKM-1, were associated with a second form of ANA-negative AIH. Between 1988 and 1991, the 50-kDa antigen of LKM-1 autoantibodies was identified as CYP 2D6 [20–25]. LKM-1 autoantibodies recognize a major linear epitope between amino acids 263 and 270 of the CYP 2D6 protein [53]. These autoantibodies inhibit CYP 2D6 activity

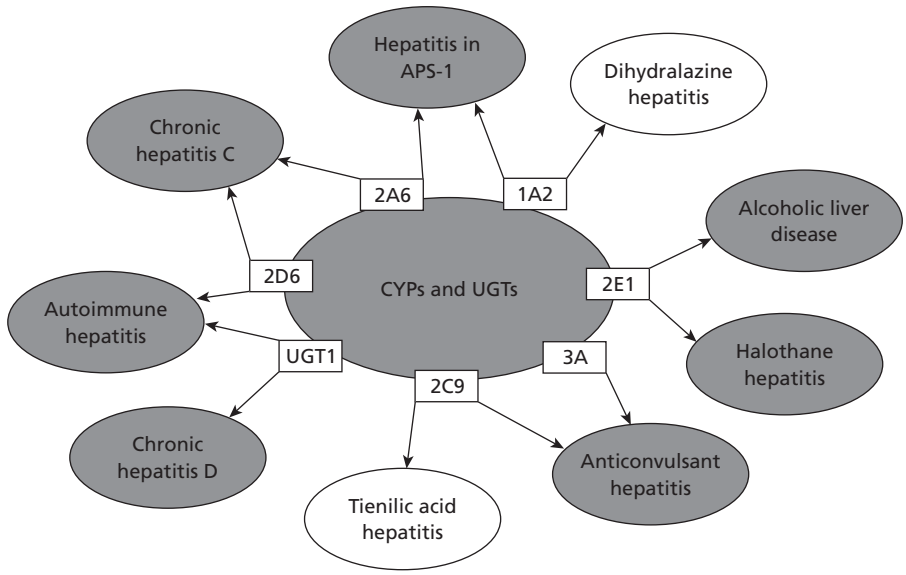

Fig. 2 Autoantibodies against enzymes of phase I and II metabolism in autoimmune liver disease. APS-1, autoimmune polyglandular syndrome type 1.

in vitro and are capable of activating liver-infiltrating T lymphocytes [54, 55], indicating the combination of B- and T-cell activity is involved in the autoimmune process. In addition to linear epitopes [53], LKM-1 autoantibodies have also been shown to recognize conformation-dependent epitopes [56]. However, the recognition of epitopes located between amino acids 257 and 269 appears to be a specific autoimmune reaction of AIH and is discriminatory against LKM-1 autoantibodies associated with chronic HCV infection [57–59].

LKM-3

LKM-3 autoantibodies are directed against UGT proteins with a molecular weight of 55 kDa. They occur in 10% of patients with AIH type 2 (Table 2). They are described further below.

LC-1

Anti-cytosol type 1 (anti-LC-1) antibodies are viewed as a second marker of AIH type 2, in which they have been detected in up to 50% of LKM-positive sera [62]. Other data indicate their occurrence in combination with ANA and SMA autoantibodies and also in chronic hepatitis C [63]. In contrast to LKM autoantibodies, LC-1 autoantibodies appear to correlate with disease activity. The molecular antigen target has been identified as formiminotransferase cyclodeaminase [64]. Their clinical significance is not yet completely defined, but some rare cases may present with anti-LC-1 as the sole marker of AIH.

Autoantibodies in autoimmune hepatitis type 3

AIH type 3 is serologically defined by the presence of soluble liver antigen (SLA)/liver–pancreas (LP) autoantibodies (Table 2). However, 74% of patients also have other serological markers of autoimmunity, including SMA and ANA. AIH type 3 has a lower prevalence than AIH type 2, affects female patients in 90% of cases and has an age maximum between 20 and 40 years. This subclass of AIH is based solely on the autoantibody profile and clinically resembles AIH type 1 [17]. Autoantibodies that target a soluble liver and pancreas antigen (anti-SLA/LP) exhibit a high specificity for AIH. They are detectable in about 10–30% of all patients with AIH [26,29–31]. In 1992, specific autoantibodies were identified in patients with a severe form of autoimmune chronic active hepatitis. These antibodies precipitated a UGA suppressor serine tRNA–protein complex that is likely to be involved in co-translational selenocysteine incorporation in human cells [29]. The screening of cDNA expression libraries confirmed these findings and identified a previously unknown amino acid sequence, which presumably encodes a UGA suppressor tRNA-associated protein, as target antigen of SLA antibodies [30,31]. In addition, it was demonstrated that anti-SLA and the independently described anti-LP are identical, and the designation anti-SLA/LP has replaced anti-SLA and anti-LP [27,30]. Recent data confirmed the previous finding that patients with anti-SLA/LP display a more severe course of AIH [65–67]. Regarding the disease specificity, anti-SLA/LP may be linked to the pathogenesis of the autoimmune process; however, the exact function and its role in autoimmunity are so far unclear.

Autoantibodies in primary biliary cirrhosis

Primary biliary cirrhosis (PBC) is an inflammatory, primarily T cell-mediated, chronic destruction of intrahepatic small bile

ducts of unknown aetiology. In 90% of cases, it affects women who exhibit elevated immunoglobulin M, antimitochondrial antibodies (AMAs) directed against the E2 subunit of pyruvate dehydrogenase (PDH-E2) and a cholestatic liver enzyme profile leading to cirrhosis over the course of years or decades (Table 1). A prominent feature is the presence of extrahepatic immune-mediated disease associations, including autoimmune thyroid disease, Sjögren syndrome, rheumatoid arthritis, inflammatory bowel disease and, less frequently, coeliac disease and CREST syndrome (calcinosis, Raynaud's disease, oesophageal motility disorders, sclerodactyly and telangiectasis). Extrahepatic syndromes frequently precede hepatic disease manifestation [68,69].

AMA

Antimitochondrial antibodies are found in approximately 95% of patients with PBC and are considered a serological hallmark of this disease. The targets of AMAs in PBC sera are members of an enzyme family, the 2-oxo acid dehydrogenase complexes (2-OADC, AMA-M2), which are located on the inner membrane of the mitochondria and catalyse the oxidative decarboxylation of various α-keto acid substrates. Components of 2-OADC include the E2 subunit of PDC (PDC-E2), the E2 subunit of the 2-oxoglutarate dehydrogenase complex (OGDC-E2), the E2 subunit of the branched-chain 2-oxo acid dehydrogenase complex (BCOADC-E2) and the dihydrolipoamide dehydrogenase-binding protein (E3BP) [70]. The most predominant reactivity of AMAs in sera from PBC patients is directed against PDC-E2. Reactivity against OGDC-E2 and BCOADC-E2 is lower, around 50–70%. Antibodies to PDC-E1-α are present in lower titres. Approximately 10% of patients react only to OGDC-E2 or BCOADC-E2, or to both [71,72].

ANA

Antinuclear antibodies (ANAs) have been identified in more than 50% of patients with PBC, and some ANA reactivities have a high specificity for PBC. In AMA-negative patients, they can be the only diagnostic marker suggestive of PBC [34]. These include antibodies against the nuclear pore protein, gp120, which are found in 25% of patients with AMA-positive PBC and in up to 50% of patients with AMA-negative PBC. The disease specificity for the detection of such antibodies by immunoblotting is more than 90% [73]. Other autoantigens include the nuclear pore protein p62, which is recognized by PBC sera in 32% of cases [74]. In about 20–30% of PBC patients, autoantibodies are directed against the nucleoprotein Sp100, which appears to have a high specificity for PBC [75]. Less than 1% of PBC patients present antibodies to the lamin B receptor (LBR), an inner nuclear membrane protein. These autoantibodies, although rare, also have a high disease specificity for PBC [76]. In summary, the presence of PBC-associated ANAs in AMA-negative patients may be the only immunological finding for establishing the diagnosis of PBC.

Autoantibodies in primary sclerosing cholangitis

Primary sclerosing cholangitis (PSC) is a chronic cholestatic liver disease involving the destruction of larger biliary ducts, which is frequently associated with ulcerative colitis [77]. A cholestatic liver enzyme pattern, typical cholangiographic findings and a compatible histology are mandatory to establish the diagnosis (Table 1). Autoantibodies can be helpful in early cases in which cholangiographic findings are mild [78]. However, it is unclear whether PSC represents a classical autoimmune disease with lack of adaptive tolerance to a disease-specific antigen, as there are no disease-specific autoantibodies and no response to immunosuppressive therapies [77]. The alternative hypothesis on the pathogenesis proposes PSC as an immune-mediated inflammatory disease. In this model, tissue destruction would result from an interplay between innate and adaptive immune effector mechanisms, resulting in the generation of proinflammatory cytokines such as tumour necrosis factor (TNF)α [77,79]. Tissue specificity in this model would be explained by continued homing of inflammatory cells to target tissue secreting specific chemokines.

pANCA

Between 30% and 88% of PSC patients, with or without ulcerative colitis, have atypical perinuclear-staining, antineutrophil cytoplasmic antibodies (pANCAs) [77,80]. Autoantibodies in PSC, irritable bowel disease (IBD) and AIH are rather atypical, in that they are not reacting with cytoplasmic actin, catalase or enolase antigens [81]. Instead, they react with the nuclear envelope and not cytoplasmic antigens. Therefore, the term peripheral antineutrophil nuclear antibodies (pANNAs) was introduced [81]. Western blotting has shown that 92% of atypical pANCAs in patients with IBD or hepatobiliary diseases react with a 50-kDa myeloid-specific nuclear envelope protein [82]. The putative autoantigen was identified as tubulin-β isotype 5. The role of pANNAs in the immunopathogenesis of PSC remains speculative as the myeloid-specific tubulin autoantigen is recognized by autoantibodies from patients with either PSC or AIH. The presence of atypical pANNAs also correlates with certain clinical features of PSC, including biliary complications [83] and intrahepatic rather than extrahepatic strictures [84], and higher titres are associated with cirrhosis [45]. However, none of these studies was appropriately powered to assess clinical correlations.

Autoantibodies in autoimmune polyglandular syndrome type 1

Autoimmune polyglandular syndrome type 1 [APS-1, autoimmune polyendocrinopathy–candidiasis–ectodermal dystrophy (APECED)] combines hypoparathyroidism, mucocutaneous fungal infections, adrenal insufficiency and a number of other

immune-mediated syndromes, such as nail dystrophy, vitiligo and alopecia. AIH is found in 10% of patients with APS-1 [85–87]. LKM autoantibodies against CYP 1A2 and CYP 2A6 are found in patients with APS-1 and hepatic involvement [86–88]. Anti-CYP 2A6 autoantibodies also occur in HCV infection [57,89]. LM autoantibodies, which are characterized by an immunofluorescence pattern selectively staining the hepatocellular cytoplasm but not the kidney, have been found to be directed against CYP 1A2 [90–92]. These autoantibodies are also found in APS-1 syndrome with hepatic involvement and occur in dihydralazine-induced hepatitis [86,93] (Fig. 2). APS-1 is associated with the presence of mutations within a single gene, the autoimmune regulator gene (*AIRE*) [94,95]. However, patients with AIH in the absence of APS-1 do not display mutations of the *AIRE* gene and are therefore genetically distinct from this form of AIH [96].

Autoantibodies in chronic HCV infection

Hepatitis C is associated with an array of extrahepatic manifestations, including mixed cryoglobulinaemia, membranoproliferative glomerulonephritis, polyarthritis, porphyria cutanea tarda, Sjögren syndrome and autoimmune thyroid disease [97–100]. Not surprisingly, numerous autoantibodies are associated with chronic hepatitis C. Similar to AIH, ANA, SMA, LKM and antithyroid antibodies are found with a high prevalence. An HCV-specific autoantibody, designated anti-GOR, that is present in at least 80% of sera from patients with hepatitis C, has been described [101]. However, anti-GOR seems to be anti-hepatitis C core antibodies cross-reacting with a nuclear self-antigen rather than being a proper autoantibody. This assumption is based on the fact that anti-GOR disappears once HCV replication has stopped. The examination of LKM autoantibodies in HCV patients revealed that, although anti-CYP 2D6 titres are similar to titres in AIH type 2, differences exist regarding the epitopes recognized by LKM autoantibodies [58,102–104]. In patients with AIH type 2, the epitope of amino acids 257–269 is recognized with a significantly higher prevalence than in chronic hepatitis C [103]. In addition, the immune reaction seems to be more heterogeneous than in AIH, as indicated by recognized protein targets of 59 kDa and 70 kDa [105]. The presence of anti-LKM-1 autoantibodies may also represent a HCV infection in patients with underlying AIH-2. In such cases, interferon (IFN)-α therapy can exacerbate the disease, and immunosuppression should be considered instead [57].

Another autoantibody was detected in patients infected with HCV and the hepatitis G virus (HGV)/GB virus subtype C. About 2% of HCV-positive sera in general and 7.5% of LKM-1-positive HCV sera recognize CYP 2A6. This autoantibody appears to occur more frequently in HCV-infected patients with LKM-1 autoantibodies. Interestingly, anti-CYP 2A6 autoantibodies are not detected in patients with AIH type 2 who exhibit high titres of LKM-1 autoantibodies. The clinical relevance of this finding remains to be determined [89]. Anti-CYP 2A6 autoantibodies have also been detected in patients with APS-1 [86].

Autoantibodies in chronic HDV infection

LKM-3 autoantibodies are directed against UGT proteins with a molecular weight of 55 kDa. They occur in 6–14% of patients with hepatitis D in addition to 10% of patients with AIH type 2. In contrast to LKM-1 and LKM-2 autoantibodies, which, on immunofluorescence, stain liver and kidney tissue only, with LKM-3 autoantibodies, additional fluorescence signals may be present in tissue from the pancreas, adrenal gland, thyroid and stomach. Western blot assay revealed several molecular targets around 55 kDa [60,61]. The molecular targets of the LKM-3 autoantibody were identified as UGTs of family 1 [60,61]. LKM-3 autoantibodies are not detected in sera from patients with chronic hepatitis B, chronic hepatitis C, PBC, PSC or lupus erythematosus [60]. Autoantibody titres in patients with chronic HDV infection are usually lower than they are in patients with AIH type 2 [61].

Overlap syndromes

The term overlap syndrome describes variant forms of the major hepatobiliary autoimmune diseases AIH, PBC and PSC. Patients present with both hepatitic and cholestatic biochemical patterns and histological features of AIH/PBC and/or PSC [106]. Autoantibodies characteristic of more than one of the disease phenotypes may strengthen the diagnosis. AIH/PBC overlaps have been reported in 10% of adult patients. Up to 8% of patients have an overlap of AIH and PSC. It remains unclear whether these overlaps represent distinct disease entities or just variants of AIH, PBC or PSC [107,108]. A standardization of diagnostic criteria does not exist, and the term overlap syndrome is often misused in clinical practice.

Conclusions

Much progress has been made in characterizing autoantibody/autoantigen systems in chronic liver diseases, and particularly in autoimmune liver diseases. Despite the fact that none of the autoantigenic targets discussed is expressed in a tissue-specific fashion and just a few are disease specific, their occurrence is very important for the diagnosis and classification of autoimmune liver diseases. Although the classification of AIH based on serological findings is still controversial, it does indicate the diversity of the mechanisms underlying AIH and gives us an indication of a complex aetiology. Autoantigen/autoantibody characterization continues to be an attractive model to gain insight into the as yet unresolved mystery of how tolerance of the liver is given up and autoimmunity ensues.

References

1 Doherty DG, O'Farrelly C (2001) Dendritic cells: regulators of hepatic immunity or tolerance? *J Hepatol* 34, 156–160.
2 Norris S, Collins C, Doherty DG *et al.* (1998) Resident human hepatic lymphocytes are phenotypically different from circulating lymphocytes. *J Hepatol* 28, 84–90.
3 Doherty DG, O'Farrelly C. (2000) Innate and adaptive lymphoid cells in the human liver. *Immunol Rev* 174, 5–20.
4 Tsukahara A, Seki S, Iiai T *et al.* (1997) Mouse liver T cells: their change with aging and in comparison with peripheral T cells. *Hepatology* 26, 301–309.
5 Maher JJ (1999) Cytokines: overview. *Semin Liver Dis* 19, 109–115.
6 Seidel N, Volkmann X, Langer F *et al.* (2005) The extent of liver steatosis in chronic hepatitis C virus infection is mirrored by caspase activity in serum. *Hepatology* 42, 113–120.
7 Bantel H, Lugering A, Heidemann J *et al.* (2004) Detection of apoptotic caspase activation in sera from patients with chronic HCV infection is associated with fibrotic liver injury. *Hepatology* 40, 1078–1087.
8 Rehermann B, Nascimbeni M (2005) Immunology of hepatitis B virus and hepatitis C virus infection. *Nature Rev Immunol* 5, 215–229.
9 Ichiki Y, Aoki CA, Bowlus CL *et al.* (2005) T cell immunity in autoimmune hepatitis. *Autoimmun Rev* 4, 315–321.
10 Moritoki Y, Lian ZX, Ohsugi Y *et al.* (2006) B cells and autoimmune liver diseases. *Autoimmun Rev* 5, 449–457.
11 Alvarez F, Berg PA, Bianchi FB *et al.* (1999) International Autoimmune Hepatitis Group Report: review of criteria for diagnosis of autoimmune hepatitis. *J Hepatol* 31, 929–938.
12 Waldenström J (1950) Leber, Blutproteine und Nahrungseiweisse. *Dtsch Gesellsch Verd Stoffw* 15, 113–119.
13 Manns MP, Vogel A (2006) Autoimmune hepatitis, from mechanisms to therapy. *Hepatology* 43, S132–144.
14 (2000) *Immunology and the Liver*. Boston, MA: Kluwer.
15 Strassburg CP, Obermayer-Straub P, Manns MP (2000) Autoimmunity in liver diseases. *Clin Rev Allergy Immunol* 18, 127–139.
16 Cowling DC, Mackay IR, Taft LI (1956) Lupoid hepatitis. *Lancet* 271, 1323–1326.
17 Mackay IR (1983) Immunological aspects of chronic active hepatitis. *Hepatology* 3, 724–728.
18 Manns MP, Strassburg CP (2001) Autoimmune hepatitis: clinical challenges. *Gastroenterology* 120, 1502–1517.
19 Czaja AJ, Manns MP (1995) The validity and importance of subtypes in autoimmune hepatitis: a point of view. *Am J Gastroenterol* 90, 1206–1211.
20 Zanger UM, Hauri HP, Loeper J *et al.* (1988) Antibodies against human cytochrome P-450db1 in autoimmune hepatitis type II. *Proc Natl Acad Sci USA* 85, 8256–8260.
21 Gueguen M, Meunier-Rotival M, Bernard O *et al.* (1988) Anti-liver kidney microsome antibody recognizes a cytochrome P450 from the IID subfamily. *J Exp Med* 168, 801–806.
22 Homberg JC, Abuaf N, Bernard O *et al.* (1987) Chronic active hepatitis associated with antiliver/kidney microsome antibody type 1: a second type of 'autoimmune' hepatitis. *Hepatology* 7, 1333–1339.
23 Manns M, Meyer zum Buschenfelde KH, Slusarczyk J *et al.* (1984) Detection of liver–kidney microsomal autoantibodies by radioimmunoassay and their relation to anti-mitochondrial antibodies in inflammatory liver diseases. *Clin Exp Immunol* 57, 600–608.
24 Manns MP, Johnson EF, Griffin KJ *et al.* (1989) Major antigen of liver kidney microsomal autoantibodies in idiopathic autoimmune hepatitis is cytochrome P450db1. *J Clin Invest* 83, 1066–1072.
25 Manns M, Gerken G, Kyriatsoulis A *et al.* (1987) Characterisation of a new subgroup of autoimmune chronic active hepatitis by autoantibodies against a soluble liver antigen. *Lancet* 1, 292–294.
26 Berg PA, Stechemesser E, Strienz J (1981) Hyper-gammglobulinaemische chronisch aktive Hepatitis mit Nachweis von Leber-Pankreas-spezifischen komplementbindenden Antikörpern. *Verh Dtsch Ges Inn Med* 87.
27 Stechemesser E, Klein R, Berg PA (1993) Characterization and clinical relevance of liver-pancreas antibodies in autoimmune hepatitis. *Hepatology* 18, 1–9.
28 Costa M, Rodriguez-Sanchez JL, Czaja AJ *et al.* (2000) Isolation and characterization of cDNA encoding the antigenic protein of the human tRNP(Ser)Sec complex recognized by autoantibodies from patients withtype-1 autoimmune hepatitis. *Clin Exp Immunol* 121, 364–374.
29 Gelpi C, Sontheimer EJ, Rodriguez-Sanchez JL (1992) Autoantibodies against a serine tRNA-protein complex implicated in cotranslational selenocysteine insertion. *Proc Natl Acad Sci USA* 89, 9739–9743.
30 Wies I, Brunner S, Henninger J *et al.* (2000) Identification of target antigen for SLA/LP autoantibodies in autoimmune hepatitis. *Lancet* 355, 1510–1515.
31 Volkmann M, Martin L, Baurle A *et al.* (2001) Soluble liver antigen: isolation of a 35-kd recombinant protein (SLA-p35) specifically recognizing sera from patients with autoimmune hepatitis. *Hepatology* 33, 591–596.
32 Kanzler S, Weidemann C, Gerken G *et al.* (1999) Clinical significance of autoantibodies to soluble liver antigen in autoimmune hepatitis. *J Hepatol* 31, 635–640.
33 Obermayer-Straub P, Strassburg CP, Manns MP (2000) Autoimmune hepatitis. *J Hepatol* 32, 181–197.
34 Strassburg CP, Manns MP (1999) Antinuclear antibody (ANA) patterns in hepatic and extrahepatic autoimmune disease. *J Hepatol* 31, 751.
35 Strassburg CP, Alex B, Zindy F *et al.* (1996) Identification of cyclin A as a molecular target of antinuclear antibodies (ANA) in hepatic and non-hepatic autoimmune diseases. *J Hepatol* 25, 859–866.
36 Tan EM (1991) Autoantibodies in pathology and cell biology. *Cell* 67, 841–842.
37 Czaja AJ, Nishioka M, Morshed SA *et al.* (1994) Patterns of nuclear immunofluorescence and reactivities to recombinant nuclear antigens in autoimmune hepatitis. *Gastroenterology* 107, 200–207.
38 Czaja AJ, Ming C, Shirai M *et al.* (1995) Frequency and significance of antibodies to histones in autoimmune hepatitis. *J Hepatol* 23, 32–38.
39 Bottazzo GF, Florin-Christensen A, Fairfax A *et al.* (1976) Classification of smooth muscle autoantibodies detected by immunofluorescence. *J Clin Pathol* 29, 403–410.
40 Czaja AJ, Cassani F, Cataleta M *et al.* (1996) Frequency and significance of antibodies to actin in type 1 autoimmune hepatitis. *Hepatology* 24, 1068–1073.
41 Toh BH (1979) Smooth muscle autoantibodies and autoantigens. *Clin Exp Immunol* 38, 621–628.
42 Strassburg CP, Manns MP (2002) Autoantibodies and autoantigens in autoimmune hepatitis. *Semin Liver Dis* 22, 339–352.
43 Poralla T, Treichel U, Lohr H *et al.* (1991) The asialoglycoprotein receptor as target structure in autoimmune liver diseases. *Semin Liver Dis* 11, 215–222.

44 Treichel U, Gerken G, Rossol S *et al.* (1993) Autoantibodies against the human asialoglycoprotein receptor: effects of therapy in autoimmune and virus-induced chronic active hepatitis. *J Hepatol* 19, 55–63.

45 Mulder AH, Horst G, Haagsma EB *et al.* (1993) Prevalence and characterization of neutrophil cytoplasmic antibodies in autoimmune liver diseases. *Hepatology* 17, 411–417.

46 Targan SR, Landers C, Vidrich A *et al.* (1995) High-titer antineutrophil cytoplasmic antibodies in type-1 autoimmune hepatitis. *Gastroenterology* 108, 1159–1166.

47 Czaja AJ, Manns MP, Homburger HA (1992) Frequency and significance of antibodies to liver/kidney microsome type 1 in adults with chronic active hepatitis. *Gastroenterology* 103, 1290–1295.

48 Obermayer-Straub P, Strassburg CP, Manns MP (2000) Target proteins in human autoimmunity: cytochromes P450 and UDP-glucuronosyltransferases. *Can J Gastroenterol* 14, 429–439.

49 Tukey RH, Johnson EF (1990) Molecular aspects of drug metabolizing enzymes. In: Pratt W, Taylor P (eds) *Principles of Drug Action*. New York: Churchill Livingstone, pp. 423–468.

50 Tukey RH, Strassburg CP (2000) Human UDP-glucuronosyltransferases: metabolism, expression, and disease. *Annu Rev Pharmacol Toxicol* 40, 581–616.

51 Tukey RH, Strassburg CP (2001) Genetic multiplicity of the human UDP-glucuronosyltransferases and regulation in the gastrointestinal tract. *Mol Pharmacol* 59, 405–414.

52 Rizzetto M, Swana G, Doniach D (1973) Microsomal antibodies in active chronic hepatitis and other disorders. *Clin Exp Immunol* 15, 331–344.

53 Manns MP, Griffin KJ, Sullivan KF *et al.* (1991) LKM-1 autoantibodies recognize a short linear sequence in P450IID6, a cytochrome P-450 monooxygenase. *J Clin Invest* 88, 1370–1378.

54 Manns M, Zanger U, Gerken G *et al.* (1990) Patients with type II autoimmune hepatitis express functionally intact cytochrome P-450 db1 that is inhibited by LKM-1 autoantibodies in vitro but not in vivo. *Hepatology* 12, 127–132.

55 Lohr HF, Schlaak JF, Lohse AW *et al.* (1996) Autoreactive CD4+ LKM-specific and anticlonotypic T-cell responses in LKM-1 antibody-positive autoimmune hepatitis. *Hepatology* 24, 1416–1421.

56 Duclos-Vallee JC, Hajoui O, Yamamoto AM *et al.* (1995) Conformational epitopes on CYP2D6 are recognized by liver/kidney microsomal antibodies. *Gastroenterology* 108, 470–476.

57 Dalekos GN, Wedemeyer H, Obermayer-Straub P *et al.* (1999) Epitope mapping of cytochrome P4502D6 autoantigen in patients with chronic hepatitis C during alpha-interferon treatment. *J Hepatol* 30, 366–375.

58 Ma Y, Peakman M, Lobo-Yeo A *et al.* (1994) Differences in immune recognition of cytochrome P4502D6 by liver kidney microsomal (LKM) antibody in autoimmune hepatitis and chronic hepatitis C virus infection. *Clin Exp Immunol* 97, 94–99.

59 Yamamoto AM, Cresteil D, Boniface O *et al.* (1993) Identification and analysis of cytochrome P450IID6 antigenic sites recognized by anti-liver-kidney microsome type-1 antibodies (LKM1). *Eur J Immunol* 23, 1105–1111.

60 Philipp T, Durazzo M, Trautwein C *et al.* (1994) Recognition of uridine diphosphate glucuronosyl transferases by LKM-3 antibodies in chronic hepatitis D. *Lancet* 344, 578–581.

61 Strassburg CP, Obermayer-Straub P, Alex B *et al.* (1996) Autoantibodies against glucuronosyltransferases differ between viral hepatitis and autoimmune hepatitis. *Gastroenterology* 111, 1576–1586.

62 Lenzi M, Manotti P, Muratori L *et al.* (1995) Liver cytosolic 1 antigen-antibody system in type 2 autoimmune hepatitis and hepatitis C virus infection. *Gut* 36, 749–754.

63 Martini E, Abuaf N, Cavalli F *et al.* (1988) Antibody to liver cytosol (anti-LC1) in patients with autoimmune chronic active hepatitis type 2. *Hepatology* 8, 1662–1666.

64 Lapierre P, Hajoui O, Homberg JC *et al.* (1999) Formiminotransferase cyclodeaminase is an organ-specific autoantigen recognized by sera of patients with autoimmune hepatitis. *Gastroenterology* 116, 643–649.

65 Baeres M, Herkel J, Czaja AJ *et al.* (2002) Establishment of standardised SLA/LP immunoassays: specificity for autoimmune hepatitis, worldwide occurrence, and clinical characteristics. *Gut* 51, 259–264.

66 Ma Y, Okamoto M, Thomas MG *et al.* (2002) Antibodies to conformational epitopes of soluble liver antigen define a severe form of autoimmune liver disease. *Hepatology* 35, 658–664.

67 Czaja AJ, Donaldson PT, Lohse AW (2002) Antibodies to soluble liver antigen/liver pancreas and HLA risk factors for type 1 autoimmune hepatitis. *Am J Gastroenterol* 97, 413–419.

68 Giorgini A, Selmi C, Invernizzi P *et al.* (2005) Primary biliary cirrhosis: solving the enigma. *Ann NY Acad Sci* 1051, 185–193.

69 Jones DE, Watt FE, Metcalf JV *et al.* (1999) Familial primary biliary cirrhosis reassessed: a geographically-based population study. *J Hepatol* 30, 402–407.

70 Ishibashi H, Shimoda S, Gershwin ME (2005) The immune response to mitochondrial autoantigens. *Semin Liver Dis* 25, 337–346.

71 Manns MP, Kruger M (1994) Immunogenetics of chronic liver diseases. *Gastroenterology* 106, 1676–1697.

72 Nishio A, Keeffe EB, Gershwin ME (2002) Immunopathogenesis of primary biliary cirrhosis. *Semin Liver Dis* 22, 291–302.

73 Bandin O, Courvalin JC, Poupon R *et al.* (1996) Specificity and sensitivity of gp210 autoantibodies detected using an enzyme-linked immunosorbent assay and a synthetic polypeptide in the diagnosis of primary biliary cirrhosis. *Hepatology* 23, 1020–1024.

74 Wesierska-Gadek J, Hohenuer H, Hitchman E *et al.* (1996) Autoantibodies against nucleoporin p62 constitute a novel marker of primary biliary cirrhosis. *Gastroenterology* 110, 840–847.

75 Szostecki C, Krippner H, Penner E *et al.* (1987) Autoimmune sera recognize a 100 kD nuclear protein antigen (sp-100). *Clin Exp Immunol* 68, 108–116.

76 Courvalin JC, Lassoued K, Worman HJ *et al.* (1990) Identification and characterization of autoantibodies against the nuclear envelope lamin B receptor from patients with primary biliary cirrhosis. *J Exp Med* 172, 961–967.

77 O'Mahony CA, Vierling JM (2006) Etiopathogenesis of primary sclerosing cholangitis. *Semin Liver Dis* 26, 3–21.

78 Charatcharoenwitthaya P, Lindor KD (2006) Primary sclerosing cholangitis: diagnosis and management. *Curr Gastroenterol Rep* 8, 75–82.

79 Mayer L (2003) Redefining autoimmunity. *Gastroenterology* 125, 1574.

80 Worthington J, Cullen S, Chapman R (2005) Immunopathogenesis of primary sclerosing cholangitis. *Clin Rev Allergy Immunol* 28, 93–103.

81 Terjung B, Worman HJ (2001) Anti-neutrophil antibodies in primary sclerosing cholangitis. *Best Pract Res Clin Gastroenterol* 15, 629–642.

82 Terjung B, Spengler U, Sauerbruch T *et al.* (2000) 'Atypical p-ANCA' in IBD and hepatobiliary disorders react with a 50-kilodalton nuclear envelope protein of neutrophils and myeloid cell lines. *Gastroenterology* 119, 310–322.
83 Pokorny CS, Norton ID, McCaughan GW *et al.* (1994) Anti-neutrophil cytoplasmic antibody: a prognostic indicator in primary sclerosing cholangitis. *J Gastroenterol Hepatol* 9, 40–44.
84 Bansi DS, Bauducci M, Bergqvist A *et al.* (1997) Detection of anti-neutrophil cytoplasmic antibodies in primary sclerosing cholangitis: a comparison of the alkaline phosphatase and immunofluorescent techniques. *Eur J Gastroenterol Hepatol* 9, 575–580.
85 Obermayer-Straub P, Perheentupa J, Braun S *et al.* (2001) Hepatic autoantigens in patients with autoimmune polyendocrinopathy–candidiasis–ectodermal dystrophy. *Gastroenterology* 121, 668–677.
86 Clemente MG, Obermayer-Straub P, Meloni A *et al.* (1997) Cytochrome P450 1A2 is a hepatic autoantigen in autoimmune polyglandular syndrome type 1. *J Clin Endocrinol Metab* 82, 1353–1361.
87 Clemente MG, Meloni A, Obermayer-Straub P *et al.* (1998) Two cytochromes P450 are major hepatocellular autoantigens in autoimmune polyglandular syndrome type 1. *Gastroenterology* 114, 324–328.
88 Gebre-Medhin G, Husebye ES, Gustafsson J *et al.* (1997) Cytochrome P450IA2 and aromatic L-amino acid decarboxylase are hepatic autoantigens in autoimmune polyendocrine syndrome type I. *FEBS Lett* 412, 439–445.
89 Dalekos G, Obermayer-Straub P, Maeda T *et al.* (1998) Antibodies against cytochrome P450 2A6 in patients with chronic viral hepatitis are mainly linked to hepatitis C virus infection. *Digestion* 59, S36.
90 Manns MP, Griffin KJ, Quattrochi LC *et al.* (1990) Identification of cytochrome P450IA2 as a human autoantigen. *Arch Biochem Biophys* 280, 229–232.
91 Bourdi M, Larrey D, Nataf J *et al.* (1990) Anti-liver endoplasmic reticulum autoantibodies are directed against human cytochrome P-450IA2. A specific marker of dihydralazine-induced hepatitis. *J Clin Invest* 85, 1967–1973.
92 Sacher M, Blumel P, Thaler H *et al.* (1990) Chronic active hepatitis associated with vitiligo, nail dystrophy, alopecia and a new variant of LKM antibodies. *J Hepatol* 10, 364–369.
93 Bourdi M, Gautier JC, Mircheva J *et al.* (1992) Anti-liver microsomes autoantibodies and dihydralazine-induced hepatitis: specificity of autoantibodies and inductive capacity of the drug. *Mol Pharmacol* 42, 280–285.
94 Aaltonen J, Bjorses P, Sandkuijl L *et al.* (1994) An autosomal locus causing autoimmune disease: autoimmune polyglandular disease type I assigned to chromosome 21. *Nature Genet* 8, 83–87.
95 Rinderle C, Christensen HM, Schweiger S *et al.* (1999) AIRE encodes a nuclear protein co-localizing with cytoskeletal filaments: altered sub-cellular distribution of mutants lacking the PHD zinc fingers. *Hum Mol Genet* 8, 277–290.
96 Vogel A, Liermann H, Harms A *et al.* (2001) Autoimmune regulator AIRE: evidence for genetic differences between autoimmune hepatitis and hepatitis as part of the autoimmune polyglandular syndrome type 1. *Hepatology* 33, 1047–1052.
97 Agnello V, Chung RT, Kaplan LM (1992) A role for hepatitis C virus infection in type II cryoglobulinemia. *N Engl J Med* 327, 1490–1495.
98 Cacoub P, Lunel-Fabiani F, Du LT (1992) Polyarteritis nodosa and hepatitis C virus infection. *Ann Intern Med* 116, 605–606.
99 Haddad J, Deny P, Munz-Gotheil C *et al.* (1992) Lymphocytic sialadenitis of Sjogren's syndrome associated with chronic hepatitis C virus liver disease. *Lancet* 339, 321–323.
100 Johnson RJ, Gretch DR, Yamabe H *et al.* (1993) Membrano-proliferative glomerulonephritis associated with hepatitis C virus infection. *N Engl J Med* 328, 465–470.
101 Michel G, Ritter A, Gerken G *et al.* (1992) Anti-GOR and hepatitis C virus in autoimmune liver diseases. *Lancet* 339, 267–269.
102 Yamamoto AM, Cresteil D, Homberg JC *et al.* (1993) Characterization of anti-liver-kidney microsome antibody (anti-LKM1) from hepatitis C virus-positive and -negative sera. *Gastroenterology* 104, 1762–1767.
103 Muratori L, Lenzi M, Ma Y *et al.* (1995) Heterogeneity of liver/kidney microsomal antibody type 1 in autoimmune hepatitis and hepatitis C virus related liver disease. *Gut* 37, 406–412.
104 Yamamoto AM, Johanet C, Duclos-Vallee JC *et al.* (1997) A new approach to cytochrome CYP2D6 antibody detection in autoimmune hepatitis type-2 (AIH-2) and chronic hepatitis C virus (HCV) infection: a sensitive and quantitative radioligand assay. *Clin Exp Immunol* 108, 396–400.
105 Durazzo M, Philipp T, Van Pelt FN *et al.* (1995) Heterogeneity of liver-kidney microsomal autoantibodies in chronic hepatitis C and D virus infection. *Gastroenterology* 108, 455–462.
106 Beuers U, Rust C (2005) Overlap syndromes. *Semin Liver Dis* 25, 311–320.
107 Poupon R (2003) Autoimmune overlapping syndromes. *Clin Liver Dis* 7, 865–878.
108 Czaja AJ (1996) The variant forms of autoimmune hepatitis. *Ann Intern Med* 125, 588–598.

5.5 Biopsy and laparoscopy

Arthur Zimmermann

Liver biopsy: its indications and contraindications

The issues of liver biopsy and laparoscopy have been extensively addressed in several recent textbooks and reviews [1–5]. As liver biopsy is an invasive manoeuvre planned subsequent to previous clinical, functional and imaging procedures, biopsy candidates must be carefully selected in accordance with distinct indications. An indication for biopsy should not only be based on a suspected liver disorder, but also on knowing what can reasonably be detected in a small liver tissue sample, and how findings can be interpreted [6–7]. The main indications for a liver biopsy (nongrafted livers) are summarized in Table 1.

In addition to the indications listed in Table 1, biopsy in the case of chronically elevated liver enzymes may be considered [8–12], but it will frequently be nondiagnostic. The main contraindications of liver biopsies include impaired haemostasis, severe anaemia, tense ascites, high-grade extrahepatic biliary obstruction with or without bacterial cholangitis, local infections, hepatic lesions with suspected high risk of bleeding, certain tumours (risk of seeding), suspected echinococcal cysts and cystic lesions that may cause bile leakage upon puncture, and severely sick or uncooperative patients. Hepatic amyloidosis is now regarded as a relative contraindication only [13].

Table 1 Indications for a liver biopsy.

Chronic fibrosing liver disease/liver cirrhosis
Chronic viral hepatitis (grading and staging)
Unexplained hepatomegaly
Suspected fatty liver disease (including ALD and NASH)
Cholestasis of unknown origin
Grading and staging of autoimmune biliary disorders
Diagnosis of space-occupying liver lesions (hyperplastic, dysplastic, neoplastic)
Unexplained multifocal liver disease (mainly granulomatous hepatitis and metastases)
Metabolic liver disease (haemochromatosis)
Specific infections (in particular mycobacterioses, fungi, CMV and EBV)
Hepatic venous outflow disorders
Suspected multisystem disease with liver involvement
Liver injury due to drugs or toxins
Fever of unknown origin (FUO)
Staging of malignancy
Assessment of response to treatment

ALD, alcoholic liver disease; CMV, cytomegalovirus; EBV, Epstein–Barr virus; NASH, non-alcoholic steatohepatitis.

What is an adequate, and what is a normal, liver biopsy?

A needle biopsy of the liver is a 'sample' in the proper sense of this term, usually representing about 1/50 000 of the organ mass, which of course raises concern about how representative a needle biopsy can be [14]. Against the background of such a limited sample, three major lesional patterns can be represented and visualized: diffuse lesions (e.g. steatosis); focal lesions (in part with anisotropic distribution, e.g. granulomas, multiple metastases and microabscesses; Fig. 1); and structural lesions (fibrosing hepatopathy with remodelling/cirrhosis). The presence of one of these patterns, or combinations thereof, has a marked impact on the required sample size. In the case of chronic hepatitis it has been shown that 'the smaller the sample, the milder the disease' [15]. The diagnostic yield of the sample also depends on the puncture sites – for example, inflammation may vary between the two liver lobes [16,17]. Furthermore, the interpretation of a sample of variable size is subject to intra-observer and interobserver variations, specifically in grading and staging [18].

What, then, is an adequate liver biopsy? Although a consensus has not been reached so far, a biopsy specimen should be at least 2.5 cm in length and contain at least 10 completely represented portal tract areas. Should more than one pass be recommended? Obtaining more than one core of liver tissue can augment the diagnostic yield, but morbidity increases with the number of passes, in particular when three or more consecutive samples are taken [19], and in the presence of older age and malignancy [20].

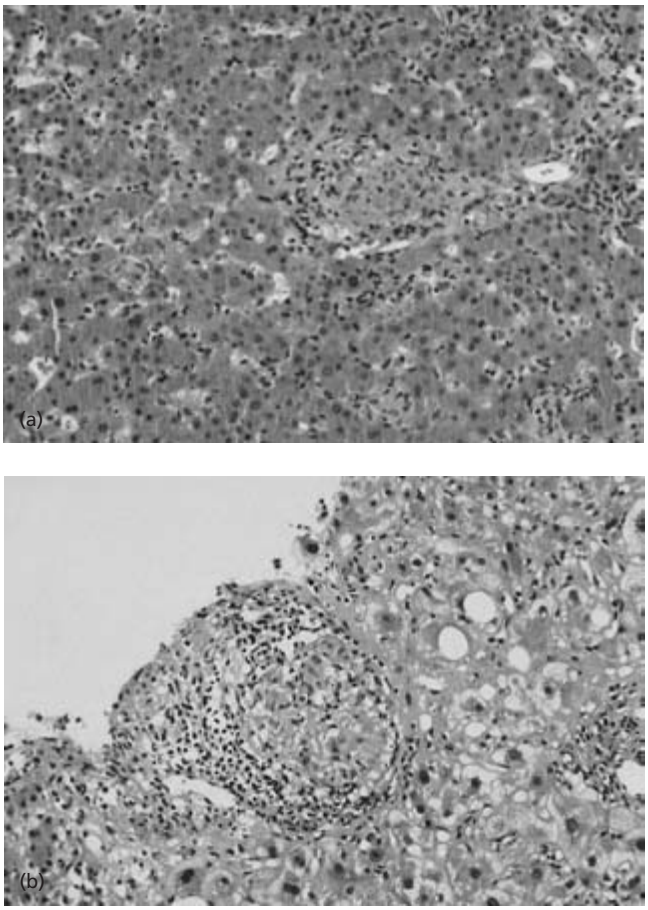

Fig. 1 Sampling of small focal liver lesions. (a) There is a small (early) granuloma in the parenchyma (to the right of the middle). Such intralobular granulomas seem to be randomly distributed, and their detection in biopsies depends on their number in relation to the sample size. It has been estimated that many millions of these lesions must be present in the liver for them to be reliably represented in a tissue section. (b) Granuloma located near a portal tract space. In contrast to (a), the spatial distribution of such granulomas depends on a pre-existent, highly ordered hepatic structure.

What is a normal liver biopsy? Liver biopsies present the interpreter with the question of what is normal, and what the range of normality is. This refers to several parameters, such as the overall tissue geometry and the mutual relationship of tissue compartments (portal tracts vs. elements of the vascular outflow tract), the configuration of liver cell plates, sinusoids and the perisinusoidal space, normal fat and other constituents in hepatocytes, the amount of connective tissue in portal tracts, the number of ducts and ductules (see Plate 5.5.1, facing p. 000), and the physiological amount of infiltrated cells (the liver-associated lymphoid tissue). Biopsies erroneously classified as normal frequently concern macronodular cirrhosis, regenerative nodular hyperplasia, and noncirrhotic portal hypertension; avoiding such errors requires sufficient knowledge of normal histological tissue relationships. However, data on normal liver histology are relatively sparse, owing to the difficulty of obtaining reference material that is not biased in regard to selection of individuals with apparently undamaged livers [21]. The shapes, diameters and densities of portal tracts detected in needle biopsies have systematically been studied [22]. This study has shown that there is a significant correlation of aggregate biopsy length with the number of portal tracts. In regard to 'normal' infiltrates, one study observed grade 1 or 2 inflammatory lesions in two-thirds of biopsies of patients with Gilbert's disease only [23], suggesting that there is a background of infiltrates that has to be taken into account.

Liver biopsy techniques and methods of processing

Liver biopsies are obtained percutaneously as a core with distinct biopsy needles, as needle biopsies performed during laparoscopy or laparotomy, as a wegde biopsy, or transvenously, usually via a transjugular route. Percutaneous liver biopsies are classified according to the site of entry, whether performed blind or guided, and whether the track is plugged after entry. A transjugular liver biopsy is chiefly indicated for patients with severly compromised haemostasis, liver failure, and/or marked ascites. Each method has advantages and disadvantages, and criteria for choosing a given technique, the different yields to be expected, and issues of imaging assistance for performing a biopsy have been discussed in detail [24,25].

The percutaneous approach is, in regard to the size and quality of the sample thus obtained, preferable. Transjugular biopsy specimens are thinner than Menghini cores, are advanced only 1–2 cm into liver substance, are sometimes fragmented, and contain fewer assessable portal tracts, but they may excellently serve to analyse parenchymal disease and the extent of hepatocyte damage. In contrast, wedge biopsies are not recommended, except for instances where a focal lesion is seen during laparoscopy or laparotomy. The reason is that, although the sample may be impressive as to its size, it will only represent a peripheral (subcapsular) part of the liver that is usually not representative. For instance, connective tissue pillars that normally extend from the capsule into the liver substance may mimic septal fibrosis, lymphoid cells are known to accumulate in the subcapsular compartment in the absence of relevant liver inflammation, and hepatocyte iron distribution is different in core vs. peripheral areas of the liver [26]. Therefore, a needle biopsy should also be performed during laparoscopy or laparotomy.

Upon harvesting, the biopsy should promptly be transferred into buffered neutral formalin (ideally 4%), as any delay will rapidly cause drying and then severe autolytic change of liver tissue. In case electron microscopy is planned, small samples must be preserved in glutaraldehyde, in accordance with the local laboratory's requirements. Samples must not be placed on

paper or cloth towel, or gauze, which rapidly dehydrate the sample, but in a saline-moisturized plastic foil. Immersion of samples in saline must be avoided, as this causes extraction of cellular constituents and cell swelling.

Recommendations for staining vary considerably in the literature, but minimum requirements for adequate diagnosis include the haematoxylin and eosin stain, a reliable connective tissue stain (trichrome stains; a stain containing sirius red; or chromotrope aniline stains), a reticulin stain (Gomori stain; essential for the assessment of liver cell plate thickness and the recognition of nodular regenerative hyperplasia), the periodic acid–Schiff (PAS) stain (preferably with and without diastase pretreatment), and an iron stain (Perls stain). As so much depends on the high quality of histology stains, staining procedures should be subjected to quality management programmes. It is highly advisable to produce sufficient extra sections in the first run of cutting (preferably on Superfrost Plus slides or a similar product), as any secondary cutting will inevitably result in tissue loss from the blocks. Apart from paraffin-embedded biopsies, frozen sections of native or fixed tissue may be required in distinct situations, but this approach requires special skill to produce thin sections based on sparse material. Intraoperative frozen sections are mainly indicated for the assessment of liver graft quality (in particular steatosis and small focal lesions), and for the typing of (unexpected) smaller nodular lesions during liver resections. Frozen sections also hold a crucial place in the reliable diagnosis of microvesicular fatty change.

Although an adequate evaluation of biopsies will be possible by use of conventionally stained preparations in most instances, immunohistochemistry (IHC) plays an increasing role. IHC is nowadays, with few exceptions, performed employing formalin-fixed tissue. Particularly important and helpful immunostains comprise those for microbial antigens – mainly hepatitis B virus (HBV)-, cytomegalovirus (CMV)- and herpes simplex virus (HSV)-associated antigens – the selective demonstration of bile duct and ductular cells (cytokeratins 7 and 19), the assessment of proliferative activity (e.g. Ki-67) and ubiquitin (detection of Mallory bodies) (Fig. 2 and Plates 5.5.2 and 5.5.3, facing p. 72). Tumour typing (primary or secondary hepatic neoplasms) will require an extended palette of antibodies, as in other tumour locations.

Liver biopsies are increasingly used for molecular biology examinations, specifically *in situ* hybridization (ISH; e.g. for EBV and CMV), fluorescence *in situ* hybridization (FISH), and polymerase chain reaction (PCR). As, for example, PCR may require several tissue sections of increased thickness (typically 10 μm) in order to obtain a sufficient amount of DNA, it is advisable to clarify the requirements before the biopsy is performed and processed. The same organizational steps have to be planned in case part of the biopsy material should be preserved for tissue banking, which usually requires tissue freezing in liquid nitrogen, and/or the storage of DNA, RNA or proteins (proteomics).

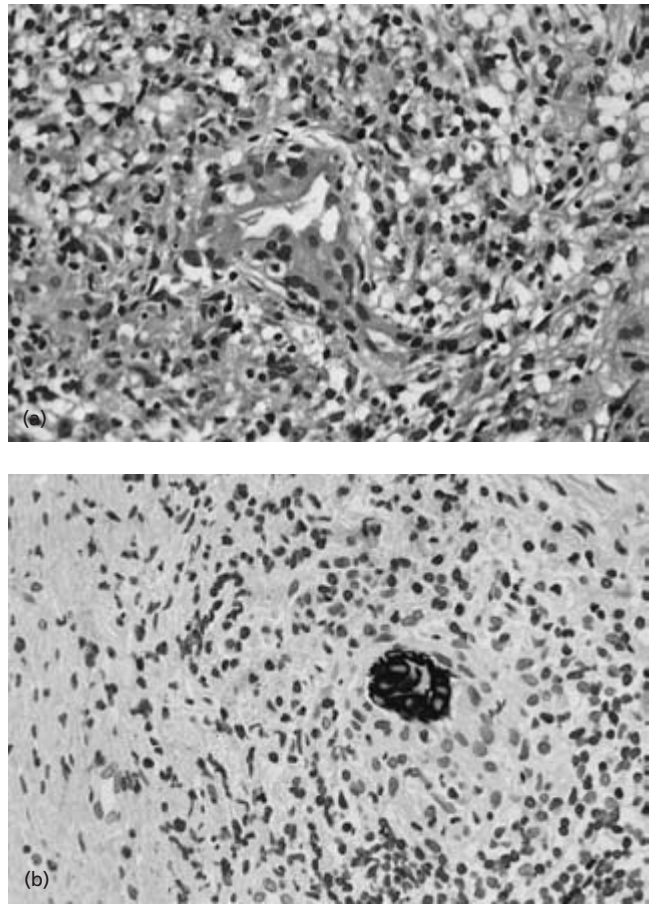

Fig. 2 Immunohistochemistry in liver biopsies: assessment of bile duct injury. (a) In this H&E-stained preparation, a florid bile duct lesion occurring in primary biliary cirrhosis (PBC) is seen (centre of the figure). (b) Bile duct lesion in PBC, demonstrated by cytokeratin-19 immunostaining. The details of the duct lesion are better seen, and this stain may uncover discrete changes that are not easily detectable in routine stains. Note the ductocentric granuloma.

Selected situations for bioptic assessment of disease

Alcoholic and non-alcoholic fatty liver disease

Macrovesicular steatosis (macrosteatosis; fatty liver disease, FLD; Fig. 3), defined as visible steatosis exceeding 5%, is increasingly prevalent, mainly related to obesity and excessive weight (body mass index ≥ 25 kg/m^2), type 2 (non-insulin-dependent) diabetes mellitus and hyperlipidaemia, and is a frequent indication for liver biopsy. FLD is broadly classified into two categories, namely, alcoholic liver disease (ALD; or alcoholic fatty liver disease, AFLD; see Plate 5.5.4, facing p. 72) and non-alcoholic fatty liver disease (NAFLD). It is estimated that NAFLD affects 10–25% of the general population in various countries. The histological criteria for the diagnosis of these major groups have been defined and reviewed [27]. The histological

Fig. 3 Fatty liver disease. (a) Macroscopic features of marked diffuse fatty liver disease. In regard to biopsy sampling it is easily seen that steatosis will be represented histologically irrespective of the place of the biopsy. (b) Macrovesicular steatosis of the liver (macrosteatosis). In this biopsy, steatosis is a single pathological feature, resulting in a rather broad differential diagnosis (H&E stain).

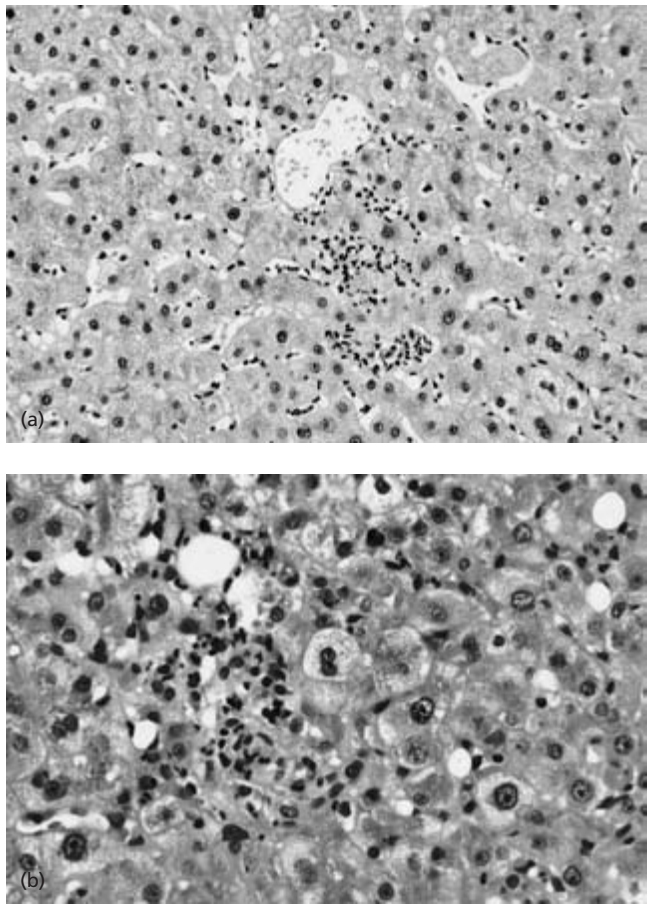

Fig. 4 Viral hepatitis. (a) The histology of acute viral hepatitis is characterized by cell damage and a lymphocyte-predominant lobular infiltrate, indicating the immune response directed against viral antigens (H&E stain). (b) At higher magnification, the features of the infiltrate are better resolved. Note that some of the lymphocytes look distorted, owing to their polarization in the course of locomotion/migration to antigen-containing cells. In this case, marked cholestasis is in evidence (cholestatic variant of acute viral hepatitis) (H&E stain).

spectrum of macrosteatosis comprises non-alcoholic fatty liver (NAFL), alcoholic fatty liver (AFL) and steatohepatitis (alcoholic steatohepatitis, ASH; see Plate 5.5.4a, facing p. 72; and nonalcoholic steatohepatitis, NASH). NASH is recognized as the progressive form of NAFLD with histological similarities to ASH [28]. NASH is associated with obesity, hyperlipidaemia and insulin resistance syndromes (and hence is a hepatic manifestation of syndrome X), but also causes progressive fibrotic liver disease [29]. In the latter context, and similar to chronic viral liver disease, grading and staging of NASH is necessary, grading reflecting the degree of steatosis and associated necroinflammatory changes, and staging estimating the extent of fibrosis and remodelling [30]. Several systems for grading and staging of NASH have been proposed [31]. In regard to biopsy requirements for the diagnosis of these disorders, the confirmation of fatty liver and early steatohepatitis as diffuse lesions is possible with small samples, while fibrosing lesions require the same staging samples as chronic viral hepatitis [32].

Chronic viral hepatitis: grading and staging

Liver biopsy has a central role in the assessment of disease activity and progression in chronic viral hepatitis [33]. A first reproducible semiquantitative approach to score liver biopsies with chronic hepatitis goes back to 1981, which resulted in a histological activity index (HAI) [34]. Later systems more clearly separated grade from stage, grade referring to the degree of inflammatory activity (or the immune reaction directed against viral antigens), and stage to the degree of fibrosis and hepatic remodelling. The histological features that should be included in grading and staging (Figs 4–9 and Plates 5.5.5 and 5.5.6, facing p. 72) have been reviewed in detail [35]. As the manifestations of chronic viral hepatitis are markedly heterogeneous within the liver, sampling to obtain an adequate biopsy specimen is particularly crucial in grading and staging; for example, it has been suggested that

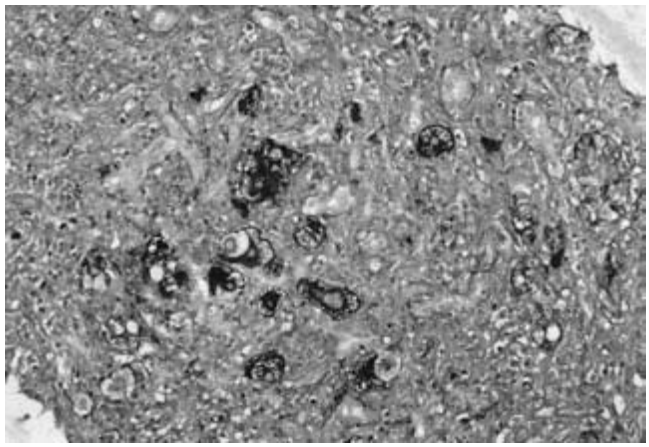

Fig. 5 Fulminant viral hepatitis (massive necrosis). In this periodic acid–Schiff (PAS) stain, the hepatic architecture is completely effaced, and only a few PAS-positive, viable-looking hepatocytes are still present.

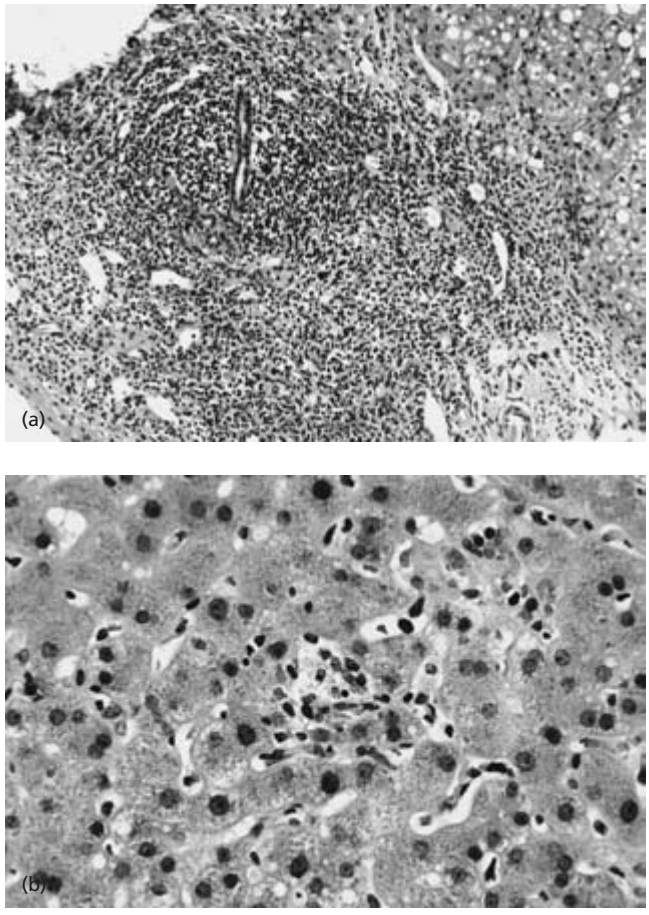

Fig. 6 Chronic viral hepatitis. (a) Chronic hepatitis C. The activity of the process manifests in the form of a dense portal tract infiltration, in part ductocentric. Around the bile duct (upper half), a lymph follicle has developed (H&E stain). (b) The intralobular component of the inflammation may be more discrete, and presents in the form of a focal macrophage and lymphocyte reaction (H&E stain).

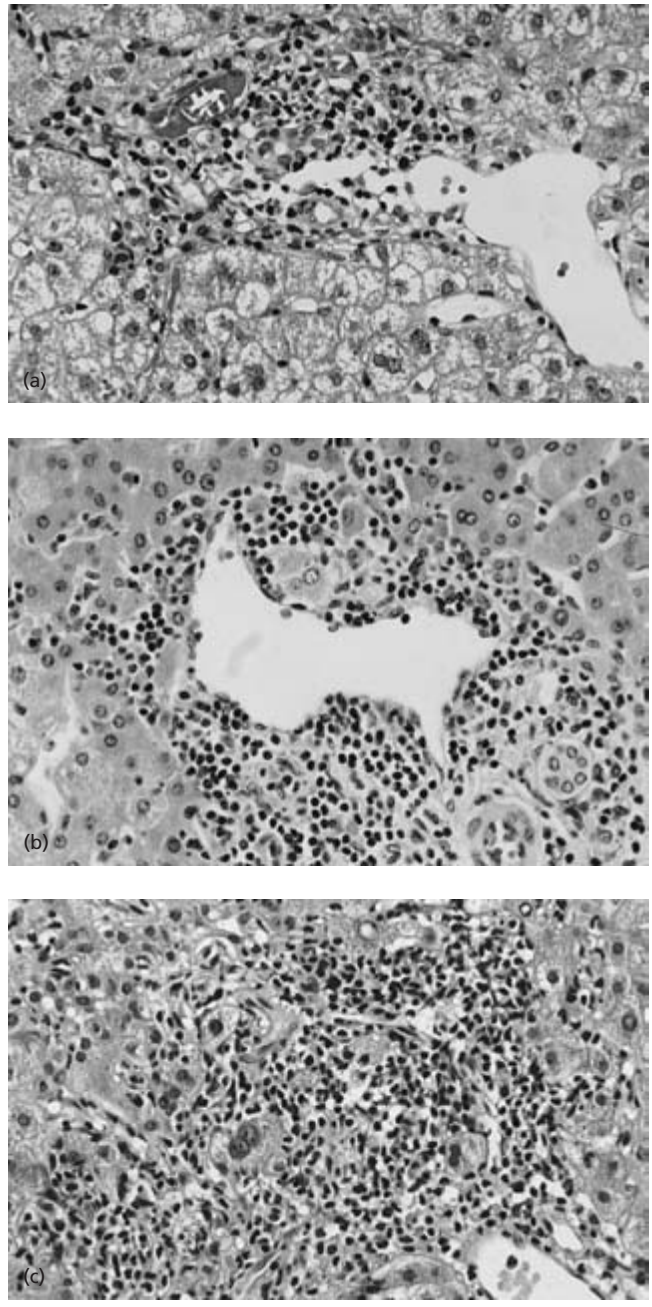

Fig. 7 Chronic viral hepatitis: grading. (a–c) Increasing levels of inflammatory activity in portal tracts and periportal parenchyma. These and other visible features of the immune reactions and their sequelae form the grading of lesions.

adequacy entails a sample that is 2.5 cm or more in length containing more than 10 complete portal tracts, but there is still no consensus [14]. The earlier Knodell classification has, over the past decade, been replaced by other systems, although what is the 'best' assessment procedure remains unresolved [36]. Well-known systems now include the Ishak modification of HAI, the Scheuer system, the Ludwig system, and the algorithm devised by the METAVIR group in France (for review see ref. 35). As any

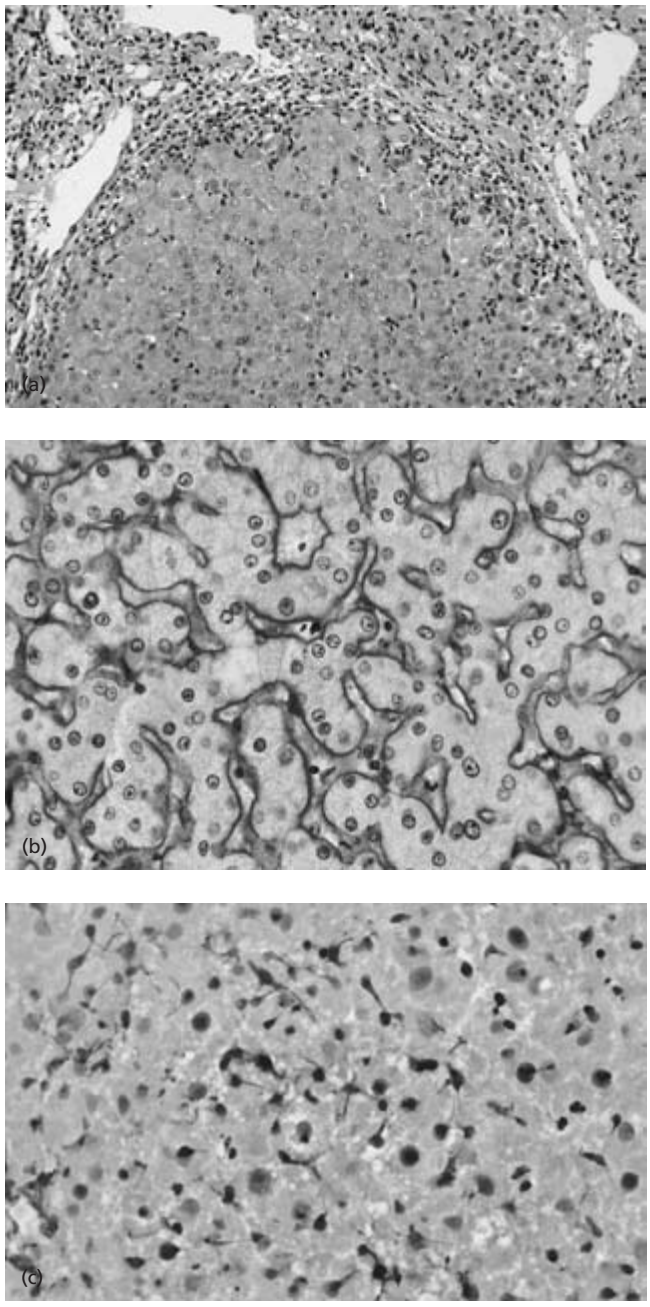

Fig. 8 Chronic viral hepatitis: staging. (a) A cirrhotic nodule representing a stage 4 lesion is seen (upper half). Note that interface lesions indicating activity of the process involve this nodule (H&E stain). (b) Cirrhosis is associated with a distinct change of the perisinusoidal matrix. In this collagen type 4 immunostain, the perisinusoidal space shows a linear red contour representing the establishment of a sinusoidal basement membrane (capillarization). (c) Cells critical for the fibrosing process are hepatic stellate cells (HSC), here demonstrated by use of a desmin immunostain (frozen section).

such scoring approach will be prone to intra- and interobserver errors, the systems should have an appropriate sensitivity together with an acceptably low level of complexity, plus well-defined and easily identifiable histological criteria.

Metabolic liver disease

Apart from fatty liver, hepatic iron storage disorders are the most important metabolic conditions to be assessed by biopsy. Among these, the now diverse forms of hereditary haemochromatosis [37] are regularly approached using biopsies, liver biopsy still being regarded as the gold standard for grading and, in particular, staging of disease (Fig. 10). In addition to haemochromatosis and other, much rarer, hereditary disorders, any interpretation of liver biopsies with hepatocyte iron overload has to consider an increasing spectrum of acquired disorders. A rather novel hepatic iron overload situation is observed in patients with NASH and insulin resistance, the so-called metabolic syndrome or syndrome X [38]. The assessment of biopsies with hepatocyte iron overload requires a biopsy from deeper parts of the liver (as iron is not uniformly distributed in this organ), a description of stainable iron distribution, and an estimation of the amount of iron that has progressively accumulated. Frequently employed semiquantitative estimations of iron overload include the Brissot score [39] and the Deugnier score/histological hepatic iron index [40]. For a quantitative assessment, the reference limits for iron in liver biopsies have been defined [41]. This allows the determination of the hepatic iron index (HII) calculated by the hepatic iron concentration (μg iron per gram dry weight) divided by the atomic weight of iron (55.846) times the patient's age in years, or μmol/g dry weight divided by the patient's age in years. An HII greater than 1.9 strongly suggests haemochromatosis, but not all haemochromatosis patients have an HII >1.9, related to the timing of biopsy and the variable penetrance of the disease. In case fresh tissue is employed for quantitative iron determination, the samples must be transported in iron-free containers, and not in saline, as this may extract part of the iron. Does the determination of the HII always require fresh tissue? It has been shown that an accurate measurement of the iron concentration in deparaffinized biopsy specimens is possible, provided the sample is ≥ 0.4 mg [42].

The role of the biopsy in liver transplantation

Because in the context of liver transplantation (LTX), clinical signs and liver function tests do not reflect well the status of the graft, liver biopsy has a significant place in graft monitoring and in the timely detection of complications [43]. The most frequent biopsies in LTX are usually termed 'null', 'protocol' and 'indicated' biopsies. So-called null biopsies, i.e. needle biopsies performed during or immediately after LTX, serve in some centres as a measure to assess eventual pre- or peritransplantation liver lesions (such as preservation injury), the identification of donor lesions (unrecognized inflammatory or fibrotic lesions), and as a baseline for comparing later histological findings with the original status of the graft. There is still no consensus as to whether, and when, such biopsies should be performed. Indicated graft biopsies are performed at any time when

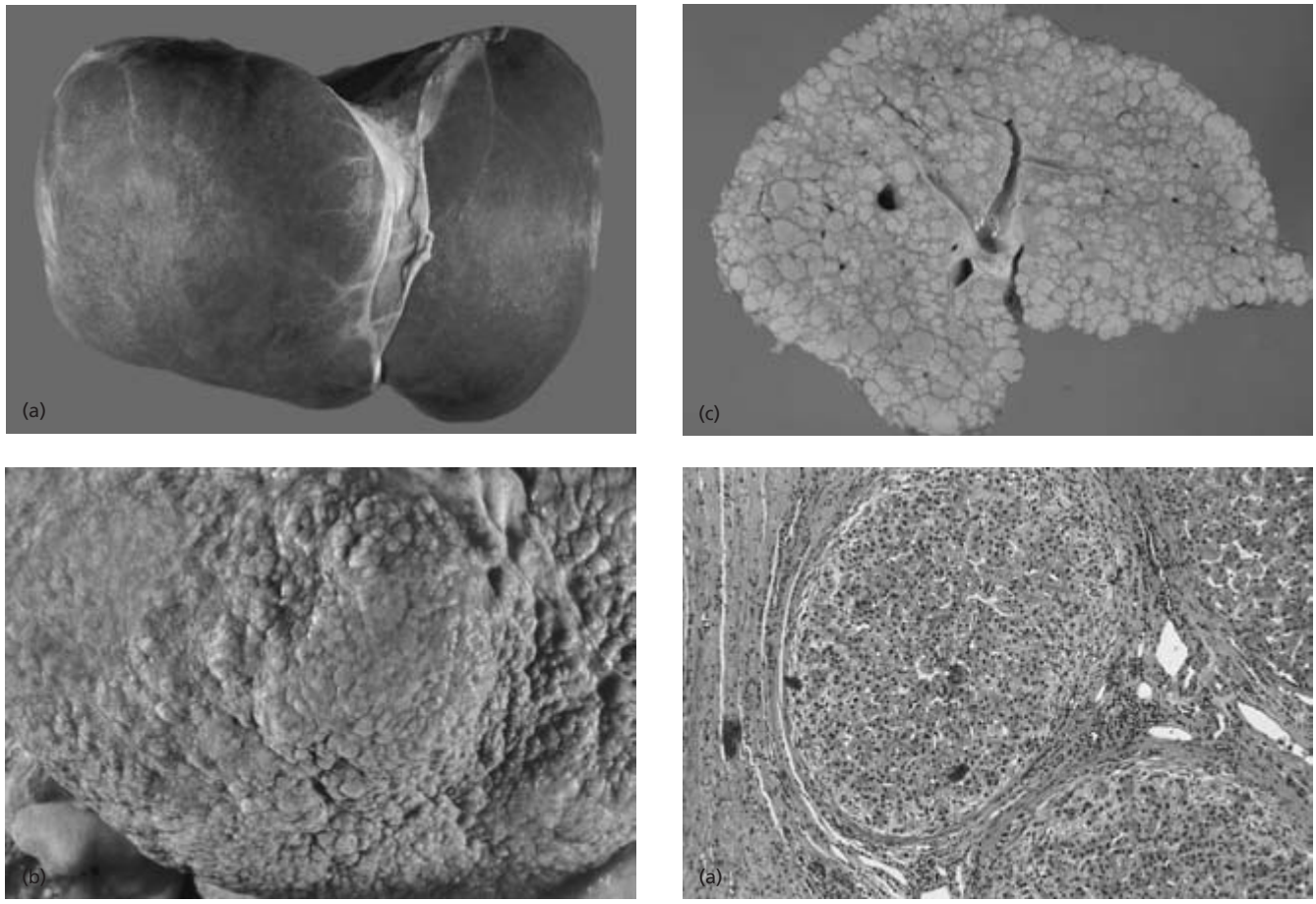

Fig. 9 Gross and histological features of established cirrhosis. (a) Normal liver. (b) Gross features of diffuse micronodular cirrhosis. The entire organ is replaced by densely placed regenerative nodules. (c) Cut surface of fully developed cirrhosis in chronic viral hepatitis. (d) Histology of the liver shown in (c). Note that a needle biopsy will need to be big enough to represent adequately both the nodules and their spatial relation to fibrotic areas (H&E stain).

abnormal graft function requires histological assessment. Conversely, the indications and the timing of so-called protocol biopsies (if performed) seem to still be controversial. A fourth, but not systematically performed, type of biopsy, is the donor organ biopsy, done in order to assess graft quality, specifically in regard to macrosteatosis, which is now established to adversely affect graft function, or in case of other suspected grossly identifiable lesions of unknown significance. Such biopsies can be processed as an intraoperative frozen section.

The histopathological alterations detectable in post-LTX liver biopsies may be divided into four main groups:

- changes directly associated with grafting (sequelae of ischaemia; rejection; Fig. 11a); infections (Figs 11b, 11c); adverse drug reactions; sequelae of technical complications;
- recurrence of the original liver disease (particularly viral hepatitis);
- *de novo* hepatic disease;
- unexpected donor lesions not recognized so far.

In the context of graft lesions related to preservation injury and rejection, grading systems have been developed. Acute rejection is graded according to the rejection activity score (RAI), and European and Banff classifications are available [44]. Similarly, criteria for staging chronic rejection have been worked out [45]. If microbiological examinations using hepatic biopsy material are planned, these procedures should be organized according to the local microbiology laboratory's requirements.

Complications of liver biopsy

Several large series (>20 000 interventions) have summarized the prevalence of minor and major complications directly related to liver biopsy. Overall, relevant or severe morbidity is estimated at 0.1–0.2%, while fatality rates range from 0% to 0.2%. Most complications (about 60%) become manifest within the first 3 hours after biopsy [46–48]. The most frequent adverse event is pain (usually resolving in 1–2 days), reported to occur in up to 50% of the patients, but only about half of them will require analgesia. Whereas minor bleeding is frequent, significant haemorrhage, sometimes requiring transfusion, is

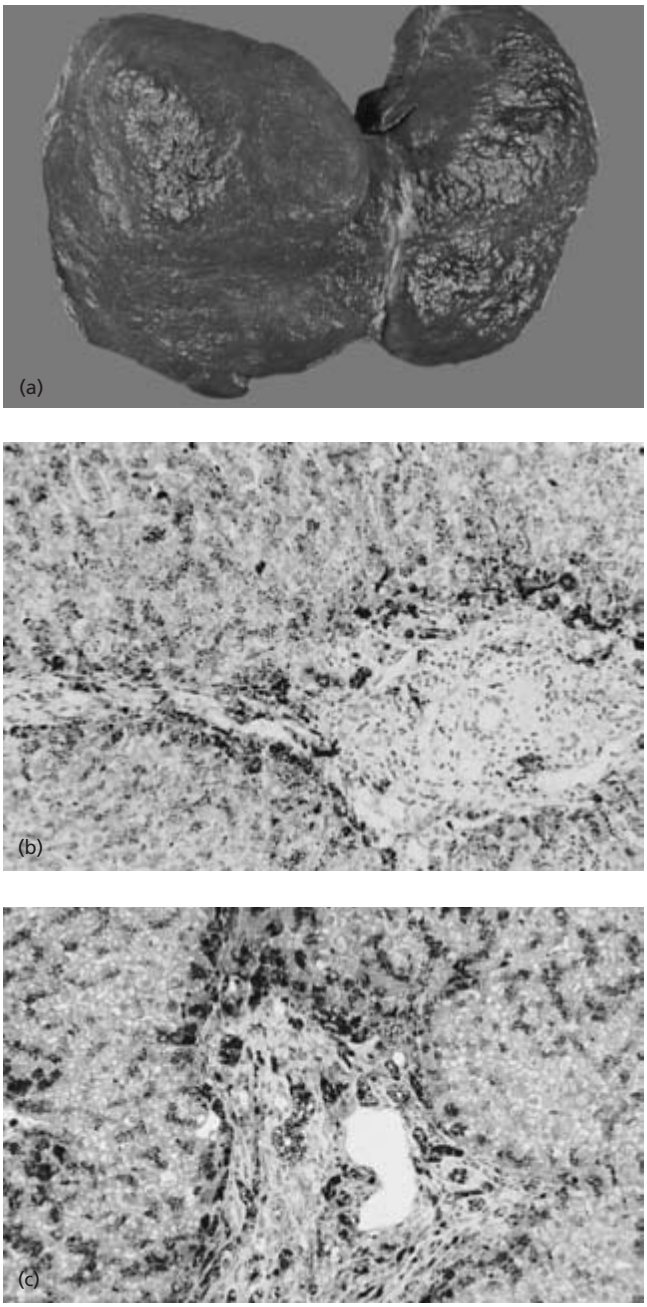

Fig. 10 Haemochromatosis. (a) Gross features of liver cirrhosis in haemochromatosis. This cirrhotic liver shows diffuse discoloration caused by the massive iron overload (pigment cirrhosis). (b) In an iron stain, the preferential localization of stainable iron (darker areas) in hepatocytes is seen. Note the typical zonation of iron overload. (c) At higher magnification, iron overload in cell systems other than hepatocytes (bile ducts, macrophages) is in evidence.

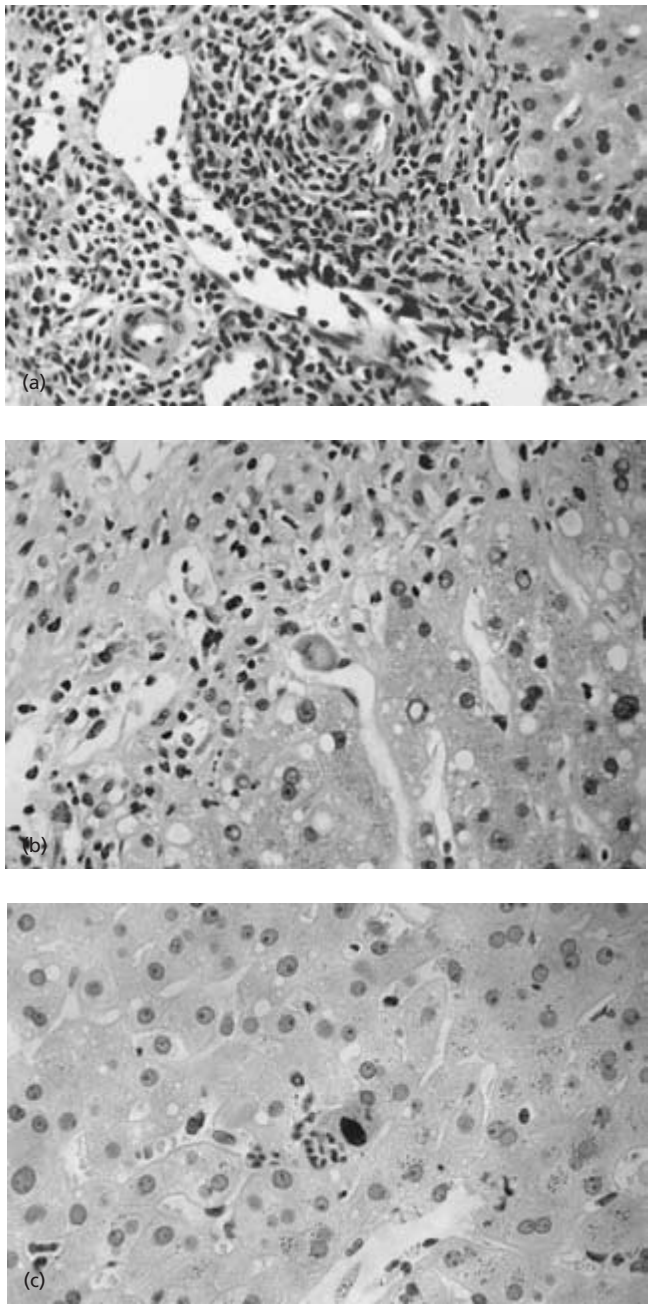

Fig. 11 Biopsy in liver transplantation. (a) Acute graft rejection. Three key features – a marked infiltration of portal tracts, venous endothelitis, and bile duct damage are observed (H&E stain). (b) Cytomegalovirus infection of a liver allograft. Note the markedly enlarged (cytomegalic) endothelial cell in the middle of the figure (H&E stain). (c) Immunostaining is particularly suited to detect cytomegalovirus (CMV) hepatitis. In this liver allograft, a typical nuclear (dark spot) inclusion body is seen, associated with a neutrophil accumulation (microabscess).

estimated to occur in 0.2% only, but is the most common cause of biopsy-associated death. Bile leakage with subsequent bile peritonitis is a high-risk complication, but should be avoidable if the typical contraindication of high-grade extrahepatic bile duct obstruction is respected. Other complications include right-sided pneumothorax or haemothorax (<0.5%), haemobilia (<0.2%), hepatic arteriovenous fistula (up to 5%), sepsis (<0.1%), subcutaneous emphysema (<0.2%), adverse anaesthetic reactions (<0.3%), needle break (≈0.02%), and puncture

Table 2 Indications for diagnostic laparoscopy.

Chronic fibrosing liver disease (in particular, staging)
Primary hepatic tumours, both benign and malignant
Nodular precursor lesions of the liver
Metastatic liver disease
Lymphomatous involvement of the liver
Evaluation of unclear abdominal masses
Staging of primarily extrahepatic malignancies
Ascites of unknown cause
Infection of the peritoneal cavity
Hepatic parasitoses
Chronic abdominal pain
Hepatomegaly or hepatosplenomegaly of unknown cause
Liver disease in renal failure
Liver involvement in multiorgan failure
Subfulminant liver failure
Assessment for liver transplantation
Patients at increased risk for other bioptic procedures

injury to other intra-abdominal organs (overall <0.5%). Intra-abdominal seeding of neoplastic cells upon puncture of hepatic malignancy is a possible complication that caused reluctance to perform such biopsies. In recent studies, needle tract implantation of hepatocellular carcinoma was found to range in prevalence from 1.6% to 5.1% [49,50], hence requiring a careful risk–benefit analysis when planning a tumour biopsy.

Laparoscopy

Diagnostic laparoscopy has an important place in the assessment of liver disease, albeit for a restricted spectrum of indications [51]. These are summarized in Table 2. Diagnostic laparoscopy is probably one of the most accurate measures for the diagnostic evaluation of specific forms of chronic liver disease. In this approach, the surgeon becomes a visual anatomist [52] whose macroscopic information will help the pathologist in the histopathological diagnosis (Fig. 12). Laparoscopic liver

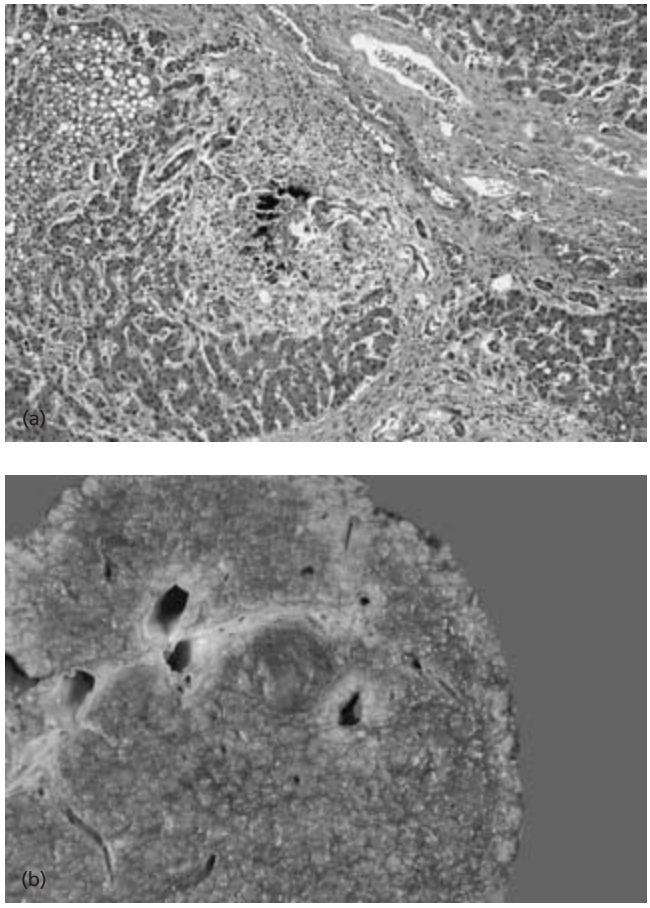

Fig. 12 Laparoscopic liver biopsy. (a) Laparoscopic biopsy is indicated in lesions of uncertain aetiology and in patients with increased risk (e.g. bacterial infection). In this case, a patient with infectious cholangitis and small focal liver lesions, the biopsy shows purulent cholangitis with bile duct rupture and leakage of bile (H&E stain). (b) Precursor lesions of hepatocellular carcinoma can be reliably assessed by use of laparoscopy. This excision shows a so-called bulging nodule, histologically representing a dysplastic nodule.

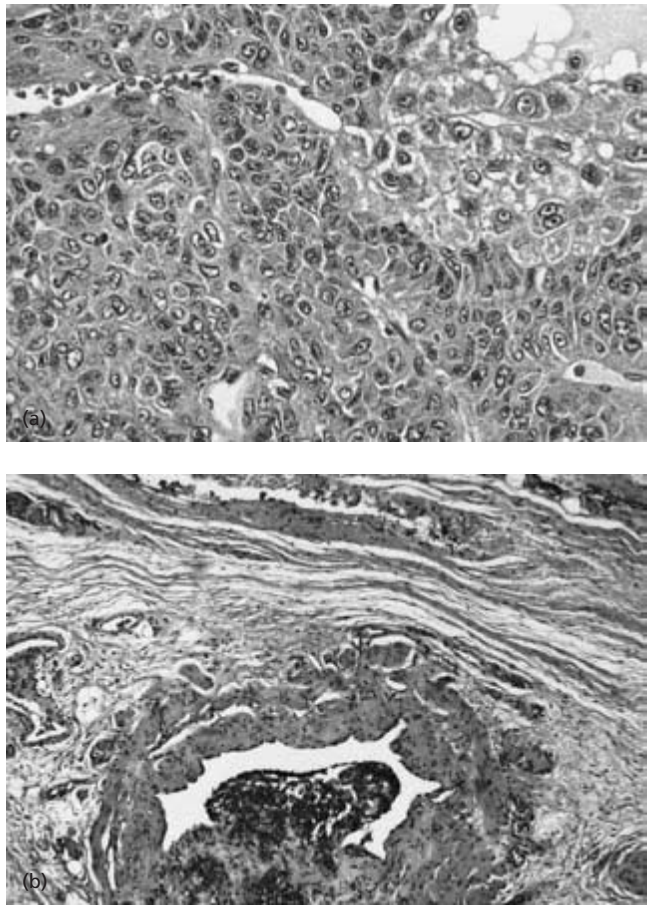

Fig. 13 Laparoscopic liver biopsy. (a) Hepatocellular carcinoma (HCC), trabecular type. Owing to their highly aggressive and invasive phenotype, HCC are regarded as a risk factor for needle biopsies (needle tract seeding), therefore laparoscopic biopsy is preferable (H&E stain). (b) In an excisional biopsy, the prognostically important feature, angioinvasion, has an increased chance of being detected (H&E stain).

biopsy is frequently used, in particular for patients with compromised haemostasis and for whom the transjugular procedure is not available. In some centres it is performed on an outpatient basis, and it seems to have a similar complication rate and mortality as percutaneous liver biopsy [51,53]. For certain lesions, this procedure seems to be more specific, in particular for staging chronic fibrosing liver disease in case of macronodularity [54,55]. Even minilaparoscopy (laparoscopy with a small-diameter telescope) offers the possibility of assessing macroscopic liver features and of coagulation of the biopsy site [56,57]. Laparoscopy associated with laparoscopic ultrasonography and biopsy plays an increasing role in the evaluation of patients with suspected liver tumours and hepatic tumour staging procedures [58,59,60,61], and allows better control of the circumstances that may favour tumour cell seeding (Fig. 13), but it also offers an approach for the treatment of liver tumours [62].

References

1 McGill DB (2001) Liver biopsy: when, how, by whom, and where? *Curr Gastroenterol Rep* 3, 19–23.

2 Geller SA, Pitman MB (2002) Morphological diagnostic procedures (liver biopsy). In: MacSween RNM, Burt AD, Portmann BC *et al.* (eds) *Pathology of the Liver*, 4th edn. London: Churchill Livingstone, pp. 943–960.

3 Reddy KR, Mallat DB, Jeffers LJ (2003) Evaluation of the liver: Liver biopsy and laparoscopy. In: Schiff ER, Sorrell MF, Maddrey WC (eds) *Schiff's Disease of the Liver*, 9th edn. Philadelphia: Lippincott Williams & Wilkins, Vol. 1, pp. 257–280.

4 Campbell MS, Reddy KR (2004) Review article: the evolving role of liver biopsy. *Aliment Pharmacol Ther* 20, 249–259.

5 Siegel CA, Silas AM, Suriawinata AA *et al.* (2005) Liver biopsy 2005: when and how? *Cleve Clin J Med* 72, 199–201.

6 Grant A, Neuberger J (1999) Guidelines on the use of liver biopsy in clinical practice. *Gut* 45 (Suppl. IV), IV1–IV11.

7 Bravo AA, Sheth SG, Chopra S (2001) Liver biopsy. *N Engl J Med* 344, 495–500.

8 Spycher C, Zimmermann A, Reichen J (2001) The diagnostic value of liver biopsy. *BMC Gastroenterol* 1, 12.

9 Friedman LS (2004) Controversies in liver biopsy: Who, where, when, how, why? *Curr Gastroenterol Rep* 6, 30–36.

10 Van Ness NM, Diehl AM (1989) Is liver biopsy useful in the evaluation of patients with chronically elevated liver enzymes? *Ann Intern Med* 111, 473–478.

11 Sorbi D, McGill DB, Thistle JL (2000) An assessment of the role of liver biopsies in asymptomatic patients with chronic liver test abnormalities. *Am J Gastroenterol* 95, 3206–3210.

12 Bianchi L (2001) Liver biopsy in elevated liver function tests? An old question revisited. *J Hepatol* 35, 290–294.

13 Stauffer MH, Gross JB, Foulk WT *et al.* (1961) Amyloidosis: diagnosis with needle biopsy of the liver in 18 patients. *Gastroenterology* 41, 92–96.

14 Guido M, Rugge M (2004) Liver biopsy sampling in chronic viral hepatitis. *Semin Liver Dis* 24, 89–97.

15 Colloredo G, Guido M, Sonzogni A *et al.* (2003) Impact of liver biopsy size on histological evaluation of chronic viral hepatitis: the smaller the sample, the milder the disease. *J Hepatol* 39, 239–244.

16 Regev A, Berho M, Jeffers LJ *et al.* (2002) Sampling error and intraobserver variation in liver biopsy in patients with chronic HCV infection. *Am J Gastroenterol* 97, 2614–2618.

17 Siddique I, El-Naga HA, Madda JP *et al.* (2003) Sampling variability on percutaneous liver biopsy in patients with chronic hepatitis C virus infection. *Scand J Gastroenterol* 38, 427–432.

18 METAVIR Cooperative Study Group (1994) Intraobserver and interobserver variations in liver biopsy interpretation in patients with chronic hepatitis C. *Hepatology* 20, 15–20.

19 Maharaj B, Bhoora IG (1992) Complications associated with percutaneous needle biopsy of the liver when one, two, or three specimens are taken. *Postgrad Med J* 68, 964–967.

20 McGill DB, Rakela J, Zinsmeister AR *et al.* (1990) A 21-year experience with major haemorrhage after percutaneous liver biopsy. *Gastroenterology* 99, 1396–1400.

21 Hilden M, Christoffersen P, Juhl E *et al.* (1977) Liver histology in a 'normal' population – examination of 503 consecutive fatal traffic casualties. *Scand J Gastroenterol* 12, 593–597.

22 Cawford AR, Lin XZ, Crawford JM (1998) The normal adult human liver biopsy: a quantitative reference standard. *Hepatology* 28, 323–331.

23 Kay EW, O'Dowd J, Thomas R *et al.* (1997) Mild abnormalities in liver histology associated with chronic hepatitis: distinction from normal liver histology. *J Clin Pathol* 50, 929–931.

24 Lebrec D (1996) Various approaches to obtaining liver tissue – choosing the biopsy technique. *J Hepatol* 25 (Suppl. 1), 20–24.

25 McCormack G, Nolan N, McCormack PA (2001) Transjugular liver biopsy: a review. *Ir Med J* 94, 11–12.

26 Petrelli M, Scheuer PJ (1967) Variation in subcapsular liver structure and its significance in the interpretation of wedge biopsies. *J Clin Pathol* 20, 743–748.

27 Sanyal AJ (2002) AGA technical review on nonalcoholic fatty liver disease. *Gastroenterology* 123, 1705–1725.

28 Brunt EM, Tiniakos DG (2002) Pathology of steatohepatitis. *Best Pract Res Clin Gastroenterol* 16, 691–707.

29 Neuschwander-Tetri BA, Caldwell SH (2003) Nonalcoholic steatohepatitis: summary of an AASLD single topic conference. *Hepatology* 37, 1202–1219.

30 Zafrani ES (2004) Non-alcoholic fatty liver disease: an emerging pathological spectrum. *Virchows Arch* 444, 3–12.

31 Mendler MH, Kanel G, Govindarajan S (2005) Proposal for a histological scoring and grading system for non-alcoholic fatty liver disease. *Liver International* 25, 294–304.

32 Goldstein NS, Hastah F, Galan MV *et al.* (2005) Fibrosis heterogeneity in nonalcoholic steatohepatitis and hepatitis C virus needle core biopsy specimens. *Am J Clin Pathol* 123, 382–387.

33 Gebo KA, Herlong HF, Torbenson MS *et al.* (2002) Role of liver biopsy in management of chronic hepatitis C – a systematic review. *Hepatology* 36, S161–S172.

34 Knodell RG, Ishak KG, Black WC *et al.* (1981) Formulation and application of a numerical scoring system for assessing histological activity in asymptomatic chronic active hepatitis. *Hepatology* 1, 431–435.

35 Brunt EM (2000) Grading and staging the histopathological lesions of chronic hepatitis: the Knodell histology activity index and beyond. *Hepatology* 31, 241–246.

36 Scheuer PJ (2003). Assessment of liver biopsies in chronic hepatitis: how is it best done? *J Hepatol* 38, 240–242.

37 Franchini M, Veneri D (2005) Recent advances in hereditary hemochromatosis. *Ann Hematol* 84, 347–352.

38 Moirand R, Mendler MH, Guillygomarc'h A *et al.* (2000) Non-alcoholic steatohepatitis with iron: part of insulin resistance-associated hepatic iron overload? *J Hepatol* 33, 1024–1026.
39 Brissot P, Bourel M, Herry D *et al.* (1981) Assessment of liver iron content in 271 patients: a reevaluation of direct and indirect methods. *Gastroenterology* 80, 557–565.
40 Deugnier YM, Turlin B, Powell LW *et al.* (1993) Differentiation between heterozygotes and homozygotes in genetic hemochromatosis by means of a histological hepatic iron index: a study of 192 cases. *Hepatology* 17, 30–34.
41 Nuttall KL, Palaty J, Lockitch G (2003) Reference limits for copper and iron in liver biopsies. *Ann Clin Lab Sci* 33, 443–450.
42 Olynyk JK, O'Neill R, Britton RS *et al.* (1994) Determination of hepatic iron concentration in fresh and paraffin-embedded tissue: diagnostic implications. *Gastroenterology* 106, 674–677.
43 Sebagh M, Samuel D (2004) Place of the liver biopsy in liver transplantation. *J Hepatol* 41, 897–901.
44 Demetris AJ (1997) International Panel. Banff schema for grading liver allograft rejection: an international consensus document. *Hepatology* 25, 658–663.
45 Demetris A, Adams D, Bellamy C *et al.* (2000) Update of the International Banff Schema for liver allograft rejection: working recommendations for the histopathologic staging and reporting of chronic rejection. An International Panel. *Hepatology* 31, 792–799.
46 Piccinino F, Sagnelli E, Pasquale G *et al.* (1986) Complications following percutaneous liver biopsy. A multicentre retrospective study on 68276 biopsies. *J Hepatol* 2, 165–173.
47 Garcia-Taso G, Boyer JL (1993) Outpatient liver biopsy: how safe is it? *Ann Intern Med* 118, 150–153.
48 Terjung B, Lemnitzer I, Dumoulin FL *et al.* (2003) Bleeding complications after percutaneous liver biopsy. An analysis of risk factors. *Digestion* 67, 138–145.
49 Takamori R, Wong LL, Dang C *et al.* (2000) Needle-tract implantation from hepatocellular cancer: is needle biopsy of the liver always necessary? *Liver Transpl* 6, 67–72.
50 Kosugi C, Furuse J, Ishii H *et al.* (2004) Needle tract implantation of hepatocellular carcinoma and pancreatic carcinoma after ultrasound-guided percutaneous puncture: clinical and pathologic characteristics and the treatment of needle tract implantation. *World J Surg* 28, 29–32.
51 Haydon GH, Hayes PC (1997) Diagnostic laparoscopy by physicians: we should do it. *QJM* 90, 297–304.
52 Schwaitzberg SD (2002) Diagnostic laparoscopy. *Semin Laparoscop Surg* 9, 10–23.
53 Lightdale CJ, Das L (1997) Difficult liver biopsies: only for radiologists? *Am J Gastroenterol* 92, 364–365.
54 Jalan RJ, Hayes PC (1995) Laparoscopy in the diagnosis of chronic liver disease. *Br J Hosp Med* 53, 81–86.
55 Helmreich-Becker I, Schirmacher P, Denzer U *et al.* (2003) Minilaparoscopy in the diagnosis of cirrhosis: superiority in patients with Child-Pugh A and macronodular disease. *Endoscopy* 35, 55–60.
56 Orlando R, Lirussi F (2003) Laparoscopy and guided liver biopsy in the diagnosis of cirrhosis: conventional technique vs. minilaparoscopy. *Endoscopy* 35, 1079–1080.
57 Denzer U, Helmreich-Becker I, Galle PR *et al.* (2003) Liver assessment and biopsy in patients with marked coagulopathy: value of minilaparoscopy and control of bleeding. *Am J Gastroenterol* 98, 893–900.
58 Berber E, Garland AM, Engle KL *et al.* (2004) Laparoscopic ultrasonography and biopsy of hepatic tumors in 310 patients. *Am J Surg* 187, 213–218.
59 White RR, Pappas TN (2004) Laparoscopic staging for hepatobiliary carcinoma. *J Gastrointest Surg* 8, 920–922.
60 Kim RD, Nazarey P, Katz E *et al.* (2004) Laparoscopic staging and tumor ablation for hepatocellular carcinoma in Child C cirrhotics evaluated for orthotopic liver transplantation. *Surg Endosc* 18, 39–44.
61 Grobmeyer SR, Fong Y, D'Angelica M *et al.* (2004) Diagnostic laparoscopy prior to planned hepatic resection for colorectal metastases. *Arch Surg* 139, 1326–1330.
62 Teramoto K, Kawamura T, Takamatsu S *et al.* (2005) Laparoscopic and thoracoscopic approaches for the treatment of hepatocellular carcinoma. *Am J Surg* 189, 474–478.

5.6 Imaging of the liver

5.6.1 Ultrasonography

Luigi Bolondi, Valeria Camaggi and Fabio Piscaglia

Ultrasonography (US) is the first-line imaging technique for the examination of the hepatobiliary system and other abdominal organs. The main advantages of US are low cost, broad availability, non-invasiveness, safety, repeatability and efficacy. US guidance provides an easy way for performing interventional procedures, such as percutaneous treatments for hepatic malignancies and biopsy. Its weakness is the difficulty in exploring the entire liver in cases of abundant intestinal gas and in obese or uncooperative patients. It is an operator-dependent technique, especially Doppler US, which requires thorough training to obtain good intra- and interobserver reproducibility.

Overview of the physical principles of US

The properties of ultrasound are used to create a real-time image of the insonated structures. Ultrasound consists of sound waves of frequencies beyond the range of human hearing (>20 kHz). When an ultrasound beam, generated by the US transducer, crosses an interface between two structures with different acoustic impedance, waves are partially reflected and received by the transducer, which translates them into electric pulses. A bidimensional real-time image is obtained by coding these pulses into a grey-scale panel of signals.

Human organs contain several acoustic interfaces both at a macroscopic (vessels, masses, etc.) and microscopic level (differences in cellular content and mesenchymal stroma) that are the basis for the US representation of the human body. A big difference in acoustic impedance between two adjacent structures (i.e. parenchyma and gas or bones) causes the near complete reflection of the US beam thereby preventing evaluation of the structures behind. This 'posterior acoustic shadowing' hampers liver examination when generated by ribs or intestinal gas, but may aid the correct diagnosis in other cases (e.g. gallstones). The key terms in the description of conventional US features are reported in Table 1.

Doppler US allows a non-invasive assessment of blood flow by the application of the Doppler physical principle: when

Table 1 Key terms in conventional US.

Term	Description	Examples
Anechoic or echo-free	Homogenous structure without internal interfaces, so that no echoes are returned. It appears black	Liquid filled structures (vessels, gallbladder, cysts), ascites
Echoic or reflective	Every structure that returns echoes. It can assume every gradation of grey up to white	Parenchyma, biliary sludge
Hypoechoic	A structure that is less echoic than the background, so that it appears darker	Several types of liver lesion (neoplasm, abscesses)
Hyperechoic	A structure that is more echoic than the background, so that it appears brighter	Small haemangiomas, some HCC, some metastases
Isoechoic	A structure that is as echoic as the background	Some liver masses (typically FNH)
Posterior acoustic shadowing	Absence of echoes behind a structure that reflects the US beam almost completely	Gallstones, bones, intestinal gas, calcifications
Posterior acoustic enhancement	Increased echogenicity behind a homogeneous structure that presents low attenuation of the US beam	Liquid-filled structure (cysts), fluid-rich lesions (haemangiomas)

FNH, focal nodular hyperplasia; HCC, hepatocellular carcinoma.

Table 2 Indications for US.

Indication	What to evaluate
Alteration in liver laboratory exams	Signs of diffuse liver disease Mass liver lesions Bile-duct dilatations, gallbladder pathology
Signs of PTH (ascites, oesophageal varices)	Signs of cirrhosis, portal and hepatic vein patency Doppler evaluation of splanchnic circulation
Jaundice	Bile-duct dilatations and cause of biliary obstruction Signs of diffuse liver disease
Abdominal pain	Biliary tract disease Portal thrombosis Extrahepatic causes of pain
Abdominal trauma	Hepatic haematoma Lesions of other abdominal organs (especially spleen)
Staging of known chronic hepatitis	Signs of progression to cirrhosis and PTH
Surveillance of cirrhotic patients (every 6 months)	Detection and characterization of mass lesions (HCC?)
Staging and follow-up in patients with known extrahepatic neoplasm	Detection and characterization of mass lesions (metastases?) Routine CEUS can be useful to disclose small lesions
Characterization of mass liver lesions	Conventional US appearance, presence and characteristics of vascular signals, pattern at CEUS. Assessment of resectability
Presurgical assessment for OLT	Confirmation of endstage liver disease Detection of HCC, portal thrombosis, wide collaterals
Follow-up after OLT	Vascular and biliary complications

HCC, hepatocellular carcinoma; OLT, orthotopic liver transplantation; PTH, portal hypertension.

ultrasound is reflected by a moving target, such as blood cells flowing in the vessels, the frequency of the reflected waves differs from that of the incident waves: it increases when the target is moving towards the transducer and decreases when the target is moving away. The difference between the incident and the reflected frequency is the *Doppler frequency*.

The Doppler frequencies can be represented by different modalities: *colour Doppler* displays a map of vascular structures in a selected portion of the real-time US scan, providing qualitative information about the presence and direction of blood flow by means of a colour code. Sensitivity in detecting slow flow can be increased by using *power Doppler*, which displays the integrated amplitude of the Doppler signal instead of its frequency. *Doppler spectral analysis* visualizes the velocity distribution of blood cells in a time function, giving quantitative and semiquantitative information about flow velocity and features. Impedance indices (i.e. resistance index, RI) and frequency peak are important in the characterization of mass liver lesions and splanchnic haemodynamics. Unfortunately, very small vessels (as in tumoral lesions) and deeply located structures are poorly recognized by Doppler US.

A revolutionary advance in US was the introduction of *contrast-enhanced US* (CEUS). US contrast media are gas-filled microbubbles dissolved in water. After injection in a peripheral vein, microbubbles reach the liver through both the hepatic artery and portal vein in subsequent phases, so that an arterial (10–30 s after injection), a portal (30–120 s) and a late phase are recognizable.

As no enhancement is detectable with conventional US, CEUS requires contrast-specific imaging modes, known as harmonic imaging techniques, that visualize exclusively the nonlinear tissue echoes generated by microbubbles, nullifying the linear tissutal echoes. Whereas the first-generation contrast media, i.e. Levovist (Schering AG, Berlin, Germany), permit only intermittent visualization of focal lesions, the second-generation contrast media, such as SonoVue (Bracco, Milan, Italy), allow continuous, real-time evaluation of hepatic structures. Thanks to this advantage, real-time CEUS, or perfusional angiosonography, has become the reference standard in this setting [1]. Clinical indications for US are summarized in Table 2.

Diffuse liver disease

Normal liver parenchyma gives a homogeneous pattern of low-level echoes in which vessels appear as anechoic tubular structures (Fig. 1). The size, morphology, echo-pattern and surface characteristics of the liver have to be assessed.

US has a sensitivity of up to 95% in distinguishing normal from abnormal liver, but the accuracy in discriminating different stages of chronic liver diseases is limited, with the exception of overt cirrhosis [2].

Acute hepatitis

Acute hepatitis does not produce specific US findings. The 'starry-night liver pattern', resulting from a decreased parenchymal

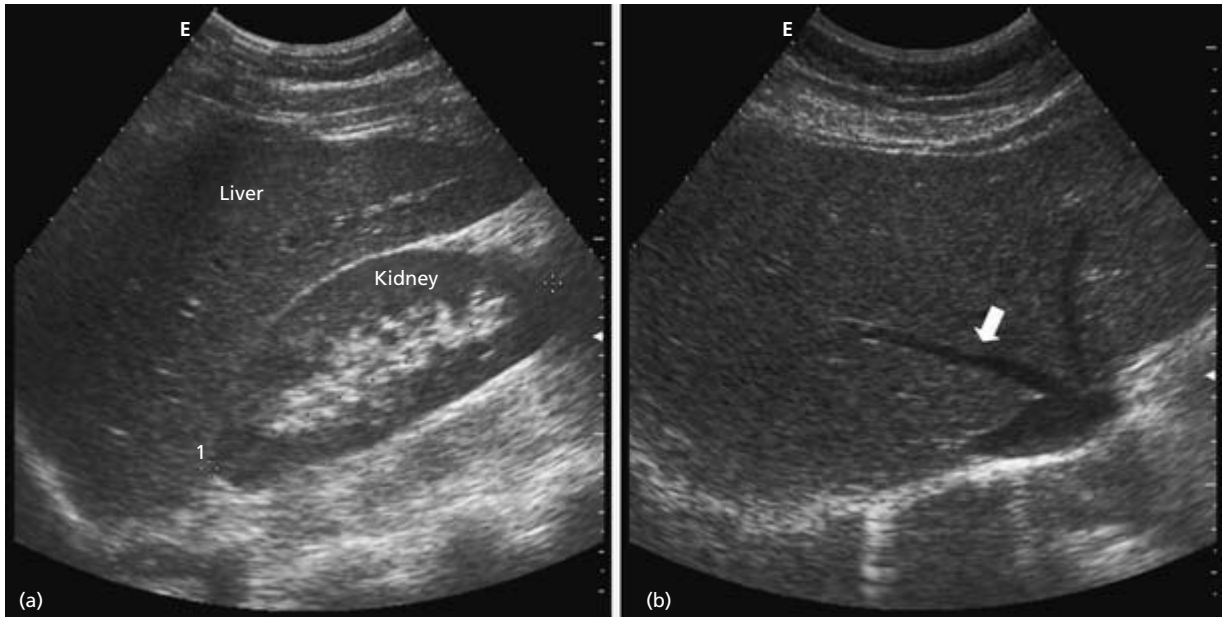

Fig. 1 The normal liver parenchyma is isoechoic or slightly hyperechoic in comparison with the right renal cortex (a); it is crossed by vessels, which appear anechoic (b, arrow).

echogenicity enhancing the hyperechoic periportal structures, has been associated with acute hepatitis, but its specificity and sensitivity are low. Hepatomegaly is a frequent finding.

Hepatic steatosis

Fatty infiltration produces an increased reflectivity of hepatic parenchyma, known as 'bright liver pattern' (Fig. 2). This feature can be assessed by comparing liver parenchyma with the right kidney's cortex, which normally presents an echogenicity equal to or slightly lower than that of the liver (Fig. 1a). Severe steatosis produces a strong attenuation in the deepest liver sections, resulting in poor explorability. The liver is frequently enlarged, with rounded profiles. US is unable to differentiate simple fatty liver from steatohepatitis.

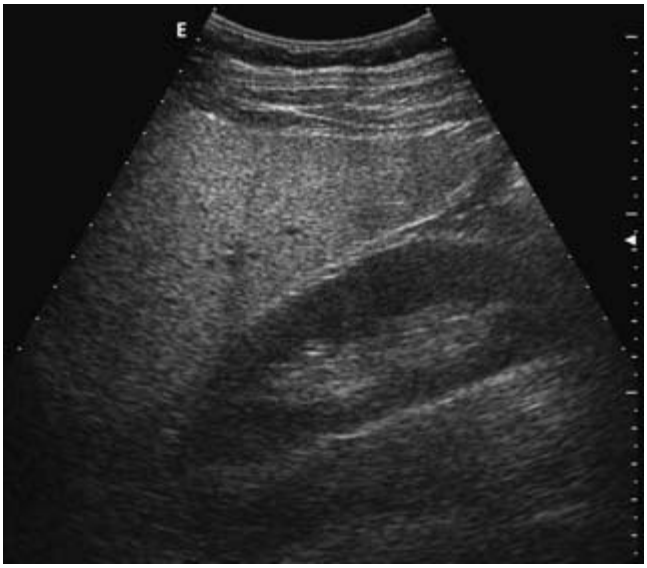

Fig. 2 Hepatic steatosis: the liver is brighter than the cortex of the right kidney.

Steatosis frequently presents an inhomogeneous distribution, appearing as 'patchy' hyperechoic areas, sometimes with a segmental distribution, or as hypoechoic areas frequently located near the gallbladder or the portal bifurcation. CEUS may help in distinguishing inhomogeneous steatosis from mass lesions by disclosing an isoechoic pattern in all the perfusional phases.

Chronic liver disease: from chronic hepatitis to cirrhosis

Chronic liver disease produces a broad continuous spectrum of US anomalies, from a near normal aspect in mild chronic hepatitis to overt alterations in cirrhosis. The progression from chronic hepatitis to compensated cirrhosis is difficult to evaluate with biochemical parameters, imaging techniques or even hepatic biopsy, as an underestimation is possible due to sampling error. Nevertheless, the diagnosis of cirrhosis at an early stage is useful because specific follow-up programmes are instituted for cirrhotic patients (i.e. surveillance for hepatocellular carcinoma and endoscopic evaluation for oesophageal varices).

As fibrosis progresses, US shows an increasingly coarsened echo-pattern and an increased echogenicity of the liver. A relative enlargement of the left lobe may take place, but the liver

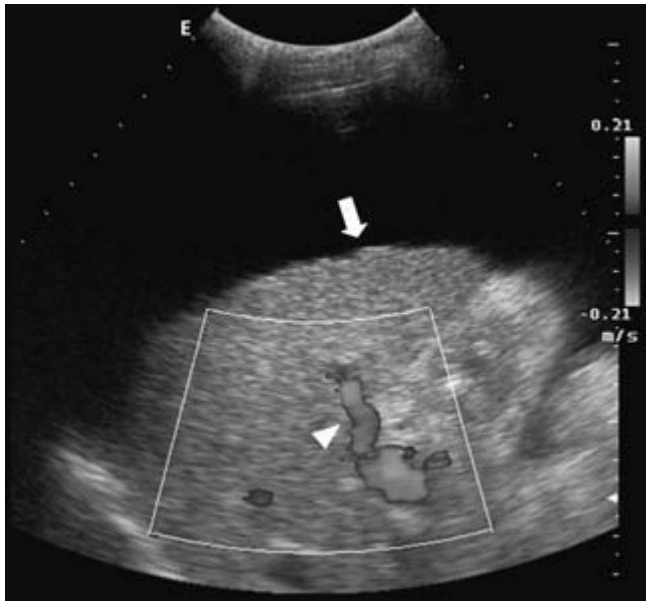

Fig. 3 Decompensated cirrhosis. Ascites enhances the visualization of the nodular liver surface (arrow). Colour Doppler shows a patent portal system with hepatopetal flow (arrow head).

surface still appears smooth and no signs of portal hypertension are detectable. Small lengthened adenopathies are often detected at the hepatic hilum in viral and autoimmune hepatitis.

The more sensitive and specific sign of progression to cirrhosis is the emergence of an irregular or nodular liver surface (Fig. 3), especially when associated with a reduction in portal flow velocity at Doppler examination [3]. Other findings suggesting cirrhosis are marked hypertrophy of the left and caudate lobes, atrophy of the right lobe and the onset of ascites. Doppler US can show signs of portal hypertension, as described below.

Portal hypertension

Doppler US and upper gastrointestinal endoscopy are the first-line exams when portal hypertension (PHT) is suspected. The aim of Doppler US is to disclose signs suggesting PHT and its cause.

US diagnosis of PHT

Many conventional US signs of PHT, namely splenomegaly and enlargement of the portal, splenic and superior mesenteric veins, present poor sensitivity and specificity. Instead, the absence of the normal calibre variation of splenic and superior mesenteric veins during forced inspiration–expiration (<40% reduction) is sensitive (up to 80%) and specific [4].

Doppler examination adds a significant contribution to the diagnosis of PHT by characterizing splanchnic haemodynamics. A reduction in portal flow velocity suggests PHT, but is not totally specific. The normal postprandial increase in portal flow velocity is reduced. An inversion in portal flow direction is rare but specific for PHT [4].

Collateral portosystemic pathways are a highly specific sign of PHT. They can be visualized by conventional US as tortuous channels, but Doppler US greatly increases the confidence in their recognition, confirming their vascular nature and showing traces indicative of turbulent venous flow. One of the most frequent collaterals is the recanalization of umbilical or paraumbilical veins, running from the left intrahepatic portal branch to the abdominal wall. Spontaneous splenorenal shunts connecting the splenic vein with the left renal vein are located at the lower spleen pole and are generally massive. Other sites of portosystemic shunts are the left gastric vein behind the left hepatic lobe (considered a sign of PHT only in case of reversed flow), the short gastric veins near the upper spleen pole, the gallbladder wall and retroperitoneum. Direct visualization of oesophageal varices is rare.

The width and location of collaterals can affect the flow characteristics in the portal system. Large splenorenal shunts reduce or even reverse the flow in the splenic and portal veins, probably decreasing the gastro-oesophageal bleeding risk. Umbilical vein patency can increase portal flow, which is mainly diverted into the collateral with a reduction or inversion of the right portal branch flow.

PHT affects the impedance of several arterial vessels [4]. The intraparenchymal branches of the splenic artery show increased impedance indices at Doppler evaluation (RI > 0.63), irrespective of spleen size. Impedance indices can also increase in intrarenal arterioles (RI > 0.70), due to renal vasoconstriction. In contrast, the superior mesenteric artery impedance is reduced as a consequence of cirrhotic hyperdynamic circulation.

Causes of PHT

US can identify the cause of PHT by showing signs of advanced chronic liver disease (intrahepatic PHT), portal thrombosis or splenic arteriovenous fistulae (prehepatic PHT), Budd–Chiari syndrome or cardiac liver (posthepatic PHT). US findings in cirrhosis, the most frequent cause of PHT, have been already described.

Portal vein thrombosis is frequently related to intrahepatic PHT, but it can be the primary cause. A recent thrombus is generally echo-poor, so that it may be undetectable at conventional US. Colour Doppler shows the absence of flow in the whole vessel (complete thrombosis) or in part of it (partial or mural thrombosis). The optimal setting of the equipment and the use of power Doppler allow the detection of very slow flow in the portal system that could have raised the suspicion of thrombosis at a first examination. As the thrombus organizes, it becomes visible as echoic material filling the lumen. Cavernous transformation in longstanding portal thrombosis appears as several tortuous vessels with turbulent flow at the porta hepatis.

Budd–Chiari syndrome is characterized by occlusion of the hepatic veins. Conventional US shows hepatomegaly, enlargement

Table 3 US features of the commonest liver masses.

Lesion	Conventional US	Colour Doppler signals	Spectral analysis of arterial signals		Contrast-enhanced US	
			Resistance index	Peak frequency	Arterial phase	Portal-late phase
Cysts	Anechoic with posterior enhancement	Absent	–	–	Anechoic	Anechoic
Haemangioma	Hyperechoic	Scarce or absent	Low	Low	Centripetal globular filling (slow)	Isoechoic
Focal nodular hyperplasia	Isoechoic with central scar	Rich spoke-wheel vascularization	Low	High	Early CE from central artery	Isoechoic
Dysplastic nodules on cirrhotic liver	Generally hypoechoic	Scarce or absent	Low	Low	Isoechoic	Isoechoic
Hepatocellular carcinoma	Variable	Present	Very high	High	Early CE	Slightly hypoechoic or isoechoic
Metastasis	Variable	Scarce or absent	High	High	Peripheral CE	Markedly hypoechoic

CE, contrast enhancement.

of the caudate lobe and ascites. Hepatic veins are not detectable or appear as fibrotic bands. In other cases, they are dilated and tortuous with nonvisualization of their confluence with the inferior vena cava (IVC), and Doppler examination discloses a flat waveform without the normal phasic variations. The latter sign is nonspecific, as it can also be found in advanced cirrhosis. Reversed flow in hepatic veins is pathognomonic albeit rare. The IVC is often obstructed or narrowed, with continuous and sometimes reversed flow in its lower portion.

Liver masses

US is the first-line exam for suspected liver masses and often detects incidental lesions when performed for other indications. Most benign and clinically irrelevant lesions (i.e. cyst, haemangioma and focal nodular hyperplasia) can often be diagnosed solely by using Doppler US and ultimately CEUS (Table 3). In other instances, US represents a complementary source of information, used in addition to other imaging techniques. Moreover, US can guide biopsy and visualizes the relationship between lesions and vascular and biliary structures, which is fundamental in assessing the resectability of liver tumours.

The clinical setting is useful in suggesting diagnosis (e.g. cirrhosis and hepatocellular carcinoma [5], a known extrahepatic malignancy and metastases, oral contraceptive use and adenoma, otherwise healthy subjects and haemangioma or focal nodular hyperplasia).

Liver cyst

Simple liver cyst is a common incidental US finding without any clinical relevance. Conventional US is diagnostic: cysts appear as anechoic, round-to-oval lesions with posterior acoustic enhancement.

Polycystic liver disease is an inherited condition characterized by multiple cysts throughout the liver, often associated with autosomal dominant polycystic kidney disease. Hepatic cysts generally arise in puberty and increase in number and size with time. In the case of very numerous or large cysts, the patient may become symptomatic for abdominal discomfort, early satiety or dyspnoea.

Echinococcal cyst

The liver is the most frequent site of hydatid disease. Echinococcal cysts are characterized by a thick wall, sometimes with two distinct layers and focal or circumferential calcifications. Inner daughter cysts and intraluminal debris may be present. Inactive lesions appear completely calcified or display the so-called 'waterlily sign', characterized by linear echoes floating into the cyst.

A classification based on the US appearance has been approved by the World Health Organization to guide the approach to treatment.

Liver abscess

Pyogenic liver abscesses present a great variability in US appearance even in the same patient, as their aspect may change over time. They frequently appear as slightly irregular hypoechoic lesions with distal enhancement. A hyperechoic pattern is possible especially in the initial phases.

Amoebic abscesses produce similar features, but they are generally round, and in a subcapsular location. Occasionally, a cystic area persists after recovery.

Haematoma

Haematoma, related to abdominal trauma or to interventional procedures such as biopsy, is usually hyperechoic in the very early phase and then becomes hypoechoic. Large subcapsular haematomas can appear hypo- to anechoic even in the early phase. A residual fibrous scar or a cystic area may persist after resolution.

Haemangioma

Haemangioma, the commonest benign hepatic tumour, is generally an incidental finding. Haemangiomas <3 cm in diameter typically appear as hyperechoic, well-demarcated lesions, often adjacent to liver vessels. Such lesions can cast a posterior acoustic enhancement. Larger lesions can present atypical features, for example an inhomogeneous or hypoechoic texture. If steatosis is present, haemangioma can be less evident or even appear hypoechoic.

Doppler US detects little or no blood flow within the lesion, because of the low flow velocity inside it.

Haemangioma presents a typical CEUS pattern, namely a peripheral globular enhancement with centripetal filling, so that in the late phase it appears isoechoic or even hyperechoic [6]. Large haemangiomas may present thrombosed areas that remain hypoechoic.

Focal nodular hyperplasia (FNH)

FNH generally appears as an isoechoic mass at conventional US. The presence of a central hyperechoic scar is infrequent, but highly suggestive for FNH.

Colour Doppler discloses a highly vascularized pattern often with a distinctive 'spoke-wheel' distribution. Spectral analysis shows both central and peripheral arterial waveforms characterized by high peak frequencies and low impedance [7]. The differential diagnosis with other hypervascular lesions (i.e. hepatocellular carcinoma or adenomas) is based on the central scar and the above-mentioned Doppler features.

At CEUS, FNH presents an early homogeneous filling in the arterial phase. It subsequently becomes isoechoic [6].

Hepatocellular adenoma

Adenoma is a rare lesion, more common in females using oral contraceptives. Its recognition is important despite the benign nature, as adenoma can cause significant morbidity (e.g. haemorrhage). In particular, adenoma should be differentiated from FNH, which shows similar features but is clinically irrelevant. If diagnostic clues for FNH are lacking, differential diagnosis is difficult and not always possible even for experienced US operators. Guided biopsy may be required.

Adenoma appears as an isohypoechoic inhomogeneous lesion characterized by rich peri- and intralesional vascularization without the spoke-wheel distribution observed in FNH. Both venous and arterial signals are detectable, the latter with high peak frequency and low impedance.

No large series are available about the accuracy of CEUS in adenoma. Like FNH, it usually presents an early flush-like enhancement in the arterial phase and an isoechoic aspect in the portal-late phase.

Metastases

Metastases are the most common malignant liver lesions in developed countries. Unfortunately, US appearance is extremely variable and does not show a significant relationship with the primary tumour. A hypoechoic mass is the most frequent presentation and may be seen in any type of malignancy. Hyperechoic lesions, often with a peripheral hypoechoic halo or a target aspect, are more frequently related to gastrointestinal or urogenital cancers.

Vascular signals are absent or rare with both colour and power Doppler US. Where observed, vascularization is irregular with high impedance and high peak frequency arterial signals.

Conventional US sensitivity in detecting hepatic metastases is relatively poor compared with contrast-enhanced computerized tomography (CT) and magnetic resonance imaging (MRI). In contrast, CEUS visualizes small metastases missed at conventional US and is thought to have a sensitivity similar or even slightly superior to CT in detecting small lesions [8].

The typical pattern of metastases at CEUS is a markedly hypoechoic aspect in the portal-late phase, due to poor contrast uptake with respect to the surrounding parenchyma. A peripheral or homogeneous enhancement is sometimes detected during the arterial phase.

Lymphoma

Both Hodgkin's and non-Hodgkin's lymphomas can affect the liver, assuming a diffuse or more rarely a focal pattern. Occasionally the liver can be the primary and unique site. A generalized decrease in hepatic echogenicity can be detected in diffuse infiltration. Circumscribed lymphoma appears as a markedly hypoechoic focal lesion with rare vascular signals. After contrast medium injection it is hypoechoic in the portal-late phase.

Cholangiocellular carcinoma (CCC)

No characteristic US and Doppler appearance is described for CCC. It appears as a mass located at the hepatic hilum with intrahepatic bile duct dilatation (Klatskin tumour) or as a focal lesion within the liver parenchyma (peripheral CCC), often with small satellite nodules. Portal invasion is a frequent finding.

Generally, CCC appears hypervascularized in the arterial phase and hypoechoic in the portal-late phase at CEUS.

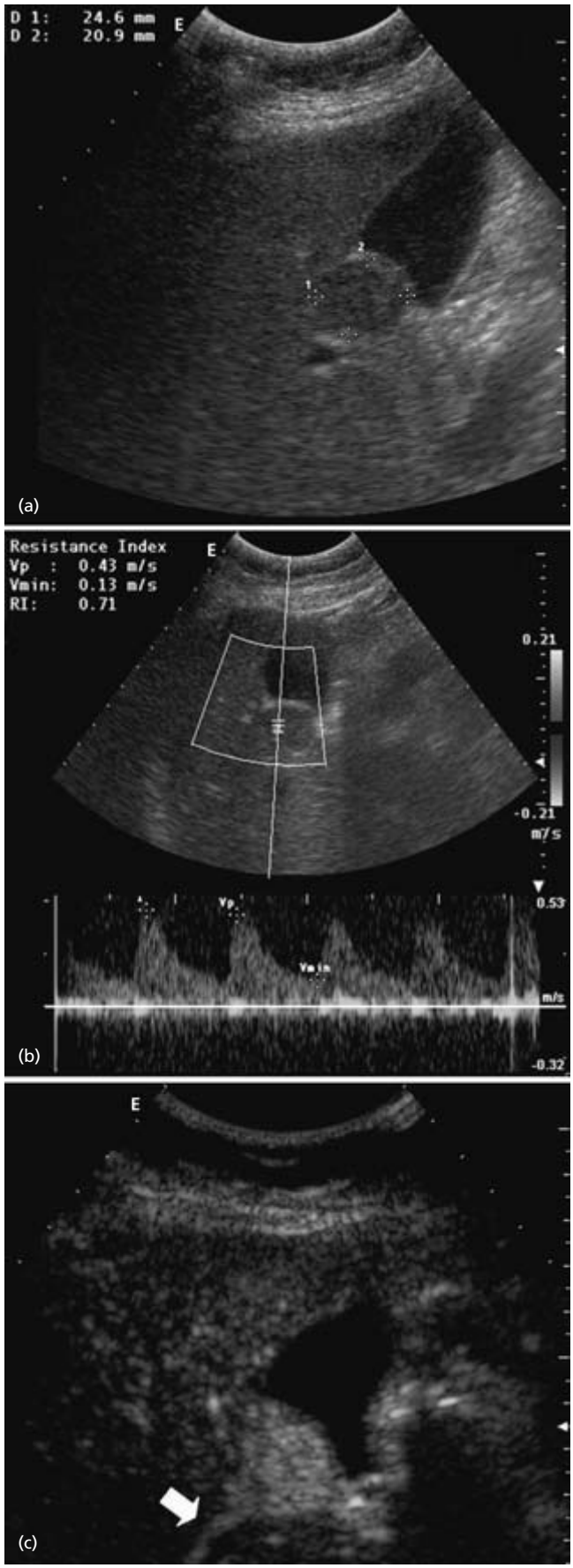

Mass lesions on cirrhotic liver: hepatocellular carcinoma (HCC) and non-malignant nodules

Surveillance programmes for cirrhotic patients have made the US detection of small nodules on cirrhotic liver a frequent event [5], pointing out the problem of differential diagnosis between HCC and nonmalignant macronodules [9]. Arterial hypervascularization is the hallmark of HCC [10] and differentiates it from large regenerative and dysplastic nodules. More recently, contrast medium washout in the portal–late phase has been recognized as a characteristic feature of HCC. The AASLD guideline [11] stated that, in the case of a nodule >2 cm found on US screening of a cirrhotic liver, the detection of both arterial contrast enhancement and venous washout on one imaging technique (out of CE, MRI, and CEUS) is diagnostic for HCC. Two concordant imaging techniques showing this pattern are required if the nodule is 1–2 cm in diameter.

Even if a cirrhotic patient may be affected by any one of the already described lesions, the detection of a nodule on cirrhotic liver should always raise the suspicion of HCC. It presents variable features at conventional US. HCCs <5 cm are usually hypoechoic, while larger lesions are hyperechoic or have a mixed echo-pattern. Nevertheless, up to 20–30% of HCCs <2 cm are hyperechoic.

The aim of Doppler and CEUS is the disclosure of arterial hypervascularization (Fig. 4). Doppler examination shows arterial signals with high peak frequencies and high impedance within or at the periphery of the nodule [7]. CEUS is more sensitive than Doppler US in detecting hypervascularization in small nodules: HCC appears hyperechoic in the early arterial phase and becomes isoechoic or slightly hypoechoic in the portal-late phase due to contrast medium washout [6]. Non-neoplastic nodules are isoechoic in all the phases.

HCC has a strong tendency to infiltrate portal vessels, which appear filled by echoic tissue. The detection of arterial signals within the thrombus at Doppler US or hypervascularization at CEUS confirms the suspicion of neoplastic thrombosis.

Biliary disease

In fasting patients, the gallbladder is distended by anechoic bile, which facilitates the detection of stones and wall abnormalities. The gallbladder wall appears as a single smooth reflective line <2 mm thick.

Gallstones

A stone in the gallbladder appears as a hyperechoic intraluminal structure with posterior acoustic shadowing [12]. Its position is gravity-dependent, so that it moves as the patient changes their decubitus. Changing a patient's position can reveal small stones previously hidden in the gallbladder neck. If the gallbladder is

Fig. 4 (*opposite*) Hepatocellular carcinoma: appearances on (a) conventional US, (b) Doppler US and (c) CEUS (arterial phase). Note the feeding artery (arrow) disclosed by CEUS.

scleroatrophic, gallstones appear separated from the gallbladder wall by only a thin hypoechoic rim.

Gravity-dependent echoes lacking distal shadowing within the gallbladder are named biliary sludge or echogenic bile. Aggregations of biliary sludge can mimic a soft-tissue mass. Differential diagnosis is aided by the absence of Doppler signals and by movement of the echoes under gravity.

Acute cholecystitis

The prompt recognition of acute cholecystitis is important due to the recent spread of early cholecystectomy within 72 hours of admission. There is no single absolutely specific US sign for acute cholecystitis [12], but the simultaneous finding of several signs increases US specificity up to 88–94%.

Thickened gallbladder wall is a common finding, but it can be present in several other conditions (i.e. PHT, haematological diseases or physiologically in the postprandial phase). The detection of an echo-poor halo around the gallbladder or focal hypoechoic zones in the wall, both ascribed to oedema, is more specific and is regarded as a major sign of acute cholecystitis. Other major signs are the presence of gallstones (acute cholecystitis is acalculous only in 5–10% of cases, generally related to severe systemic illnesses), the 'ultrasonic Murphy's sign' (compression of the gallbladder fundus by the US transducer elicits pain), and the presence of gas in the gallbladder wall (suggesting emphysematous cholecystitis). Minor signs are gallbladder wall thickening (>4 mm) without oedema, enlargement of the gallbladder, which assumes a rounded shape (transverse diameter >4.5 cm), the presence of pericholecystic fluid or intraluminal nonshadowing echoes related to pus or debris.

Gallbladder polyps and carcinoma

Cholesterol polyps appear as small (few millimetres) hyperechoic masses fixed to the gallbladder wall, without acoustic shadowing.

Gallbladder carcinoma is usually discovered in an advanced stage. In case of early, generally incidental, diagnosis, it appears as an irregular thickening of the gallbladder wall or an inhomogeneous echoic mass that partly or almost totally fills the lumen. In more advanced stages the gallbladder is hardly recognizable and a solid mass is instead visualized in the gallbladder fossa. The presence of stones within the mass facilitates the diagnosis [12].

Bile duct dilatation

US is essential in the diagnostic workup of jaundice as it promptly recognizes bile duct dilatation, the hallmark of obstructive jaundice, and can reveal the cause of obstruction (e.g. a mass at the porta hepatis, a stone within the common bile duct or a pancreatic neoplasm).

When investigating the common bile duct, it should be considered that its diameter increases with age (the upper normal value in millimetres is equal to the patient's decades of life) and after cholecystectomy.

Intrahepatic bile ducts are normally too small to be visualized. When dilated, they appear as anechoic tubular structures running adjacent to portal vein branches. This is known as the 'parallel channel sign'. Dilated bile ducts can be distinguished from vessels as they do not display flow at Doppler examination and converge towards the porta hepatis with a stellate pattern (whereas portal vessels present a branching pattern).

Liver transplant

US examination is useful both in the preoperative assessment of candidates for orthotopic liver transplantation (OLT) and in the postoperative follow-up.

Preoperative assessment

Firstly, US examination can confirm the indication for OLT by showing signs of endstage liver disease and PHT, fulminant hepatitis, or Budd–Chiari syndrome. The detection and staging of HCC is particularly important, as it should not exceed the accepted transplantation criteria, and many transplant centres grant a priority in the waiting list in case of HCC. Vascular and biliary invasion must be ruled out, as they are absolute contraindications to OLT. US also provides a guide for percutaneous treatments to prevent tumour growth beyond transplantation criteria.

Another important task of US examination is to assess portal vein patency. In case of portal occlusion, vascular anastomosis can be accomplished onto the superior mesenteric vein; if this vessel is also obstructed, OLT is not feasible according to the classical procedure and most centres reject such candidates.

Finally, the presence of wide portosystemic collaterals, especially splenorenal shunts, has to be assessed, because they can dramatically decrease portal perfusion after OLT.

Postoperative follow-up

The aim of post-transplantation US follow-up is the prompt recognition of vascular and biliary complications [13]. Moreover, US shows the disappearance of many haemodynamic alterations observed in decompensated cirrhosis [14]. Portal vein flow velocity and renal and splenic impedance return to normal. Spleen size decreases but generally does not return to normal values. Collateral vessels persist long after OLT.

Early arterial occlusion is the most frequent and threatening vascular complication [15], as it causes massive hepatic necrosis. Right and left intrahepatic branches of the hepatic artery and, if possible, the extrahepatic artery should be investigated with colour Doppler and spectral analysis. Failure to identify arterial signals requires urgent angiography to confirm the occlusion. A dampened spectrum with very low velocity flow and increased time between the beginning of systole and systolic peak (known

as 'tardus-parvus' profile) is suspicious for either thrombosis or critical upstream stenosis. Angiography is advised to confirm the diagnosis, and eventually percutaneous angioplasty can be performed. US can show further complications caused by ischaemic damage, such as intrahepatic abscess and biliary leaks or strictures. Biliary strictures are disclosed by the presence of bile duct dilatations.

The portal vein should be studied to exclude portal thrombosis or significant anastomotic stenosis, which causes a focal flow acceleration. The portal vein flow velocity is typically increased over the normal value in the first month after OLT [14]. It subsequently decreases to normal levels.

The classical surgical procedure for OLT includes resection of the recipient's retrohepatic IVC and double anastomosis with the donor's vena cava. In the case of superior anastomosis stenosis, a focal flow acceleration is observed and hepatic vein flow is flattened.

Piggy-back OLT is a technical variant that preserves the recipient's IVC. An anastomotic stenosis or kinking causes an obstacle to outflow through hepatic veins; in this case Doppler US will disclose accelerated and turbulent flow through piggy-back anastomosis.

There are no reliable conventional and Doppler US signs related to acute or chronic rejection.

References

1 Albrecht T, Blomley M, Bolandi L *et al.* (2004) Guidelines for the use of contrast agents in ultrasound. *Ultrashall Med* 25, 249–256.

2 Tchelepi H, Ralls PW, Radin R *et al.* (2002) Sonography of diffuse liver disease. *J Ultrasound Med* 21, 1023–1032.

3 Gaiani S, Gramantieri L, Venturoli N *et al.* (1997) What is the criterion for differentiating chronic hepatitis from compensated cirrhosis? A prospective study comparing ultrasonography and percutaneous liver biopsy. *J Hepatol* 27, 979–985.

4 Piscaglia F, Donati G, Serra C *et al.* (2001) Value of splanchnic Doppler ultrasound in the diagnosis of portal hypertension. *Ultrasound Med Biol* 27, 893–899.

5 Bolondi L, Sofia S, Siringo S *et al.* (2001) Surveillance programme of cirrhotic patients for early diagnosis and treatment of hepatocellular carcinoma: a cost-effectiveness analysis. *Gut* 48, 251–259.

6 Von Herbay A (2004) Real-time imaging with the sonographic contrast agent SonoVue. *J Ultrasound Med* 23, 1557–1568.

7 Gaiani S, Volpe L, Piscaglia F *et al.* (2001) Vascularity of liver tumors and recent advances in Doppler ultrasound. *J Hepatol* 34, 474–482.

8 Hohmann J, Albrecht T, Oldenburg A *et al.* (2004) Liver metastases in cancer: detection with contrast-enhanced ultrasonography. *Abdom Imaging* 29, 669–681.

9 Bolondi L, Gaiani S, Selli N *et al.* (2005) Characterization of small nodules in cirrhosis by assessment of vascularity. The problem of hypovascular hepatocellular carcinoma. *Hepatology* 42, 27–34.

10 Bruix J, Sherman M, Liovet JM *et al.* (2001) Clinical management of hepatocellular carcinoma. Conclusions of the Barcelona-2000 EASL conference. *J Hepatol* 35, 421–430.

11 Bruix J, Sherman M (2005) Management of hepatocellular carcinoma. *Hepatology* 42, 1208–1236.

12 Gandolfi L, Torresan F, Solmi L *et al.* (2003) The role of ultrasound in biliary and pancreatic diseases. *Eur J Ultrasound* 16, 141–159.

13 Kok T, Slooff MJ, Thijn CJ *et al.* (1998) Routine Doppler ultrasound for the detection of clinically unsuspected vascular complications in the early postoperative phase after orthotopic liver transplantation. *Transpl Int* 11, 272–276.

14 Piscaglia F, Zironi G, Gaiani S *et al.* (1999) Systemic and splanchnic hemodynamic changes after liver transplantation for cirrhosis: a long-term prospective study. *Hepatology* 30, 58–64.

15 De Gaetano AM, Cotroneo AR, Maresca G *et al.* (2000) Colour Doppler sonography in the diagnosis and monitoring of arterial complications after liver transplantation. *J Clin Ultrasound* 28, 373–380.

5.6.2 Computerized tomography imaging of the liver

Daniel T. Cohen and Dushyant V. Sahani

The exponential advance in computerized tomography (CT) imaging technology over the last decade, arguably, has been faster than improvements in any other imaging modality. The pixelated single-slice axial images from the first CT scanner in 1972 have progressed to 64-detector helical scanners with true isotropic resolution [1]. More importantly, CT is also the temporally fastest modality with cross-sectional capabilities (compared with ultrasound or magnetic resonance imaging). The addition of multiphase contrast enhancement to CT allows superior lesion characterization compared with non-contrast ultrasound. Although magnetic resonance imaging (MRI) may provide superior contrast resolution and tissue characterization capabilities even compared with CT, MRI remains a 'problem-solving' modality because of its high cost and long imaging times. The combination of ready availability, speed and high spatial resolution with three-dimensional capabilities has made CT imaging the *de facto* workhorse of liver imaging.

The indications for CT imaging of the hepatobiliary system can be classified as either targeted or non-targeted and incidental. For example, if a patient has a known hepatoma, CT may be performed for targeted liver evaluation and assessment of tumour size and multiplicity. Alternatively, if a patient presents to the emergency department with episodic right upper quadrant-flank pain and suspected renal colic, a CT scan may be performed for evaluation of the abdominal pelvic urinary tract. This examination will also necessarily image the liver and potentially discover incidental hepatic pathology (Fig. 1). This latter example represents non-targeted, or incidental, imaging of the liver. This distinction is not merely 'academic'. With the marked advances in CT technology, the CT protocol and the technical parameters of an individual examination can vary dramatically depending on indication. In this way, the clinical history provided at the time of imaging can significantly alter the CT protocol and the technical parameters that must be optimized to answer the clinical question.

As illustrated by the thickness of this entire volume, the pathophysiology of the liver is both broad and complex. Most of these hepatic conditions are amenable to radiological imaging,

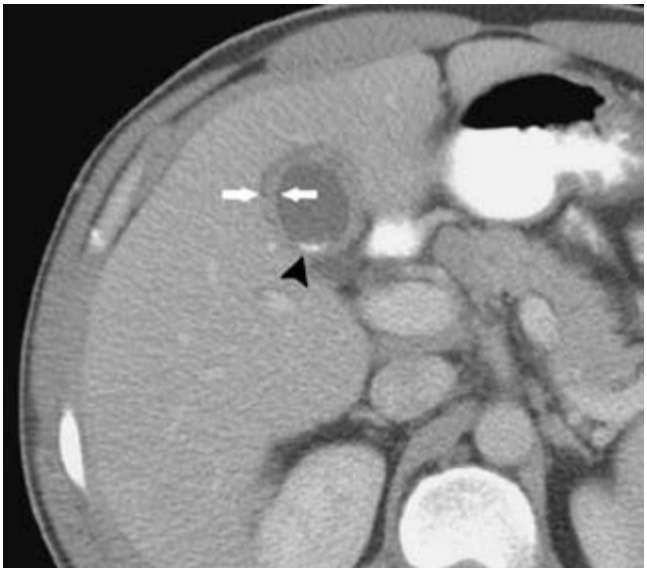

Fig. 1 Contrast-enhanced axial computerized tomography (CT) image. Arrowhead denotes hyperdense (white) calcified gallstones layering in the gallbladder. Gallbladder wall thickening is denoted by the white arrows. Pericholecystic low-density fluid is also present.

Fig. 2 Contrast-enhanced axial CT image degraded by respiratory motion. Black arrows denote blurring of the liver edges caused by liver motion secondary to diaphragmatic movement. In contrast, the vertebral body, which does not move during respiration, shows crisp edges.

frequently with CT. A comprehensive discussion of computerized tomography imaging techniques, protocols, normal variant and pathological imaging is beyond the scope of this chapter. This chapter will introduce several key concepts of CT technology and technique so that the non-imaging clinician can appreciate the benefits and limitations of a CT examination when utilizing hepatic CT imaging as part of clinical care. CT imaging can not only detect many hepatic abnormalities but also often characterize them into benign or malignant aetiologies. The latest generation of multidetector CT also provides angiographic quality assessment of the hepatic vasculature. In addition to presenting classic examples of benign lesions that can be confidently characterized by hepatic CT imaging, this chapter will also focus on detection and characterization of hepatocellular carcinoma (hepatoma) and hepatic metastases. Common hepatic metastases frequently present with either hypervascular or hypo-enhancing characteristics and thus require different imaging techniques.

CT imaging technique

At the basic level, computerized tomography still relies on the physical principles that govern plain radiography, the attenuation of an X-ray beam by the relative density differences within a patient. However, CT imaging has the marked advantage of cross-sectional depiction of the body. Early-generation scanners would generate 'thick slices'; each CT image represented a relatively large amount of body tissue and often appeared coarse [1]. Long imaging times made the images susceptible to motion; respiratory movements would frequently cause significant blurring of the liver (Fig. 2). Current scanners have multiple detector elements acquiring X-rays simultaneously (detector numbers range from 4 to 64). Additionally, all multidetector computerized tomography (MDCT) scanners also operate with a helical motion; this allows rapid overlapping coverage of the patient. Improvements in hardware and software capabilities have led to dramatic reductions in imaging times. During a patient's breath hold, the liver can be imaged multiple times (approximately 5–10 s per pass) allowing multiphase contrast imaging. This spatial resolution and rapid imaging speed must be coupled with intravenous (i.v.) contrast to allow appropriate opacification of and distinction between hepatic arteries, portal and hepatic veins, and the hepatic parenchyma; this is known as 'contrast resolution'. Intravenous contrast is unambiguously required for the detection and characterization of nearly all hepatic lesions.

Iodinated i.v. contrast is categorized based on its osmolarity relative to plasma. Most radiology departments utilize low osmolar or iso-osmolar contrast agents because of the reduced risk of allergic reaction and contrast-induced nephropathy [2]. For dedicated liver imaging, the i.v. contrast must be injected at a rapid rate to allow for separate imaging of the hepatic arteries without portal venous opacification on the initial series. With an injection of the standard 150 mL at a rate of approximately 2 mL/s and a modern MDCT, this hepatic arterial phase (HAP) occurs at approximately 30 s after the end of bolus injection. At approximately 60–70 s, there is peak opacification of the portal veins, hepatic veins and interposed liver parenchyma; this is the portal-venous phase (PVP). At longer time intervals, often 2 min, 'delayed' phase images can be obtained that represent additional recirculation of the intravascular i.v. contrast and more homogeneous opacification of the liver parenchyma. This sequence of arterial, portal-venous and delayed phase series

constitutes the 'triple phase' protocol liver CT (see Figs 11 and 19). An unenhanced series of the liver before contrast injection may demonstrate calcification or acute haemorrhage, which are hyperdense relative to the unopacified liver. The diagnostic role of these multiple phases will be discussed in the following sections as they apply to hepatic pathology detection and characterization.

The high spatial resolution of MDCT imaging allows for isotropic data sets; imaging resolution is nearly equivalent in all directions. The images can be presented in any coordinate system (sagittal, coronal and three-dimensional re-formations) in addition to the traditional axial image sets. CT angiography with three-dimensional (3-D) re-formations now replaces diagnostic catheter angiography in many institutions. With arterial phase imaging, the aorto-coeliac-hepatic arterial tree can be optimally opacified without venous contamination. Three-dimensional manipulation can present these data in various forms to aid surgeons in preoperative planning. The relationship of intrahepatic tumours to major vascular structures can be easily visualized in multiple planes (Figs 3 and 4). Additional 3-D techniques include surface and volume rendering for assessment of relative hepatic lobar volumes (Fig. 5). MDCT with multiphase imaging and 3-D data reconstruction provides comprehensive presurgical imaging for living related liver donors and hepatic tumour patients assessed for partial hepatectomy [3,4].

Continued dramatic improvements in CT technology are expected. CT perfusion, a technique pioneered in cerebral imaging of occlusive stroke patients, can also be utilized to assess any pathological state that causes alterations in liver parenchyma vascularity. In the future, CT perfusion will probably play a role in assessing tumour treatment therapy by monitoring changes in tumour neovascularity [5].

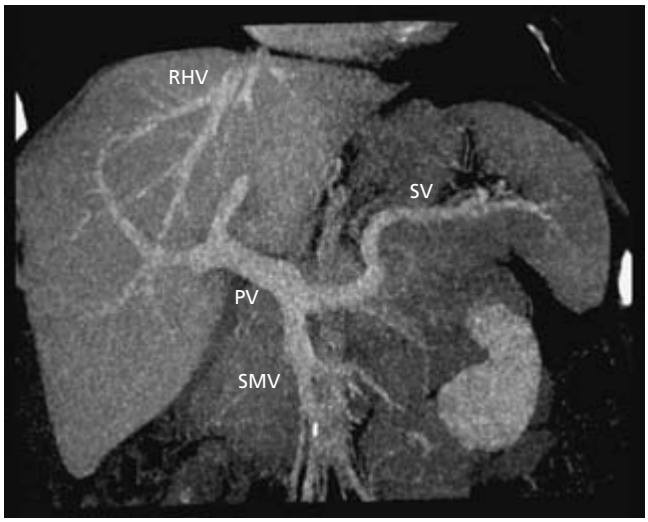

Fig. 3 Coronal maximum intensity projection from MDCT axial data demonstrates the portal–venous system. RHV, right hepatic vein; PV, portal vein; SMV, superior mesenteric vein; SV, splenic vein.

Fig. 4 Coronal maximum intensity projection from MDCT axial data. Black arrow denotes a large metastatic (colon cancer) lesion in the inferior right liver lobe. The relationship of the tumour to the hepatic artery (white arrow) is clearly seen. Prominent tumour neovascularity is also identified (asterisk).

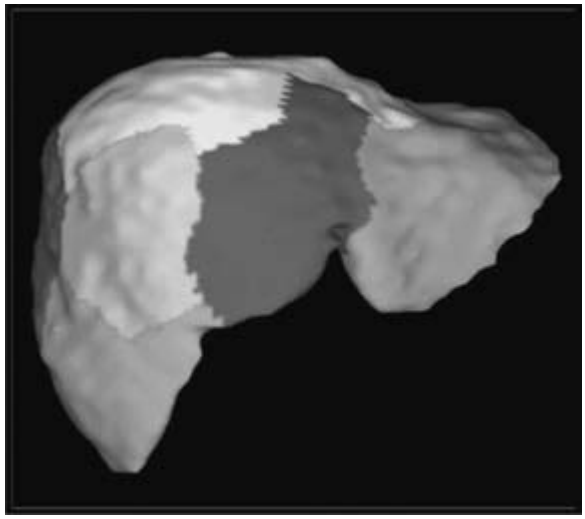

Fig. 5 Three-dimensional volume render of MDCT axial data, originally with colour coding of liver volumes. Subtle surface nodularity can be seen suggesting cirrhosis.

Normal hepatic anatomy

The unenhanced liver demonstrates intermediate density compared with other soft tissues of the body, between 50 and 75 Hounsfield units. (A Hounsfield unit, HU, is the standard CT measurement of density ranging from –1000 to 1000, with water measuring 0 HU and cortical bone approximately 300 HU.) The normal liver density closely matches the spleen. This liver–spleen relationship can provide a qualitative reference standard for assessing diffuse hepatic parenchymal changes on an unenhanced CT. The major vascular structures are hypodense to the

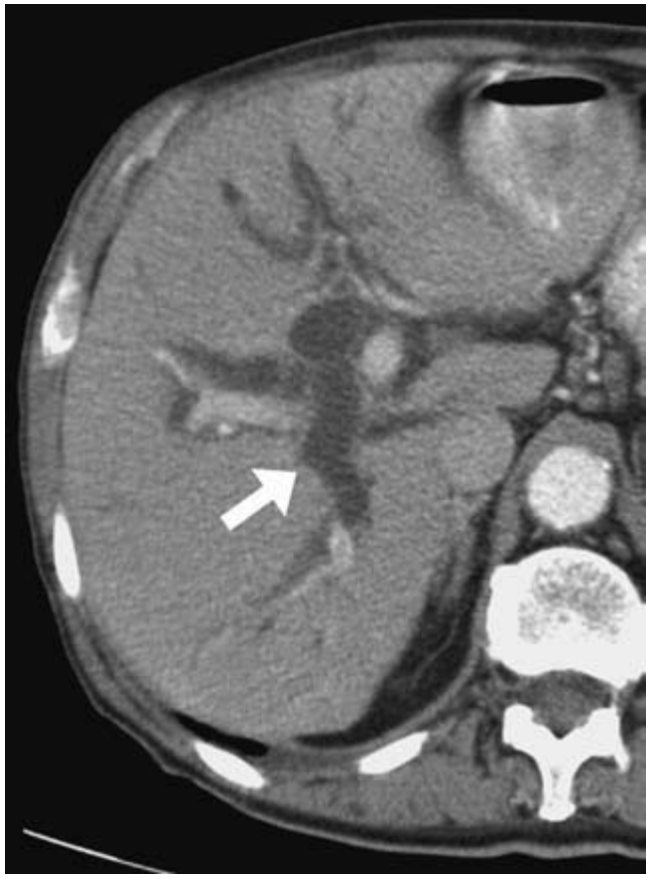

(a)

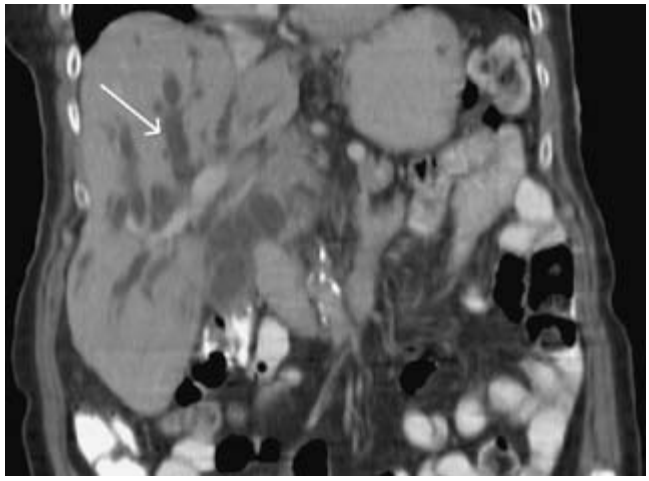

(b)

Fig. 6 (a) Contrast-enhanced axial CT image. (b) Coronal maximum intensity projection from MDCT axial data. Arrows denote low-density dilated intrahepatic biliary ducts adjacent to contrast-enhanced portal veins. Biliary dilatation was secondary to a pancreatic head mass (not pictured).

normal unenhanced liver. On contrast injection, the common hepatic artery (HA) and its major branches can be identified as they ramify into the liver. Peak HA enhancement occurs around 30 s after standard contrast injection, the HA phase. Variant hepatic arterial branches, such as a replaced right hepatic artery from the coeliac artery, are easily identified, especially with 3-D re-formations. Portal venous (PV) and hepatic venous (HV) opacification is less pronounced than HA and peaks at around 70 s, the PV phase. Seventy per cent of liver blood flow is via the portal venous system. In this way, liver parenchyma enhancement is maximized when PV and HV enhancement is optimal. Thus, the PV phase is the default imaging time for most liver and general abdominal pelvic imaging indications. The main portal and hepatic veins are key landmarks in localizing a hepatic lesion according to the eight Couinaud segments (Figs 3–5).

Computerized tomography provides an excellent rapid assessment of the biliary tree including the gallbladder. The density of bile is low, approximately 0–20 HU. Biliary dilatation, intra- or extrahepatic, is easily seen and measured especially following contrast administration (Fig. 6). Often, CT will identify the aetiology of biliary obstruction as well. Many of the classic ultrasound 'signs' of acute cholecystitis can be assessed with MDCT including gallbladder wall thickening, pericholecystic fluid and radio-opaque gallstones (Fig. 1). Nevertheless, rapid acquisition time and large field of view allow CT to rival ultrasound (US) in cholecystitis assessment, especially in an uncooperative, obtunded or obese patient.

Diffuse hepatic disease

Diffuse, or non-focal, hepatic disease must induce gross, detectable morphological change in order to be successfully diagnosed or monitored by CT. Along with the rise in body mass index in western society, there has been a similar rise in the frequency of steatohepatitis [6]. Steatohepatitis, or 'fatty liver', is also seen with alcohol and medication use. From a CT imaging perspective, the aetiology is rarely apparent. On an unenhanced examination, the liver with steatohepatitis will demonstrate lower density compared with the 'internal standard', the spleen (a >10 HU difference) [7]. Qualitatively, if there is sufficient fatty infiltration, the liver parenchyma will appear less dense than the blood vessels, mimicking contrast enhancement (Fig. 7). Fatty infiltration of the liver can also present as focal geographic areas of hypodensity, particularly adjacent to the falciform ligament and gallbladder fossa (Fig. 8). Conversely, when there is a background of steatohepatitis, these same areas can demonstrate relative absence of the fatty infiltration and will appear relatively hyperdense compared with the remainder of the liver. This is termed 'focal fatty sparing'. The location, geographical nature and absence of mass effect are often nearly diagnostic for these 'inverse' entities. Magnetic resonance with fat saturation techniques can provide the most definitive non-invasive imaging of steatohepatitis as well as focal fatty infiltration and sparing.

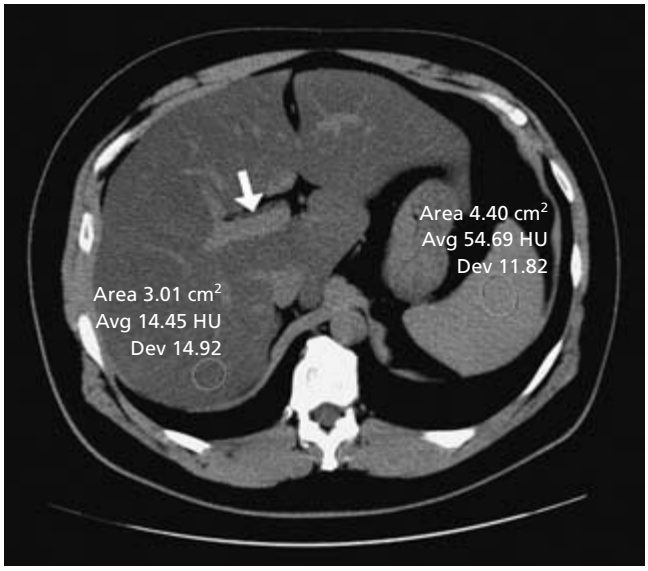

Fig. 7 Unenhanced axial CT image. Qualitatively, the liver is less dense compared with the spleen. Quantitatively, the liver measures 14 HU compared with 55 HU of the spleen consistent with diffuse fatty infiltration. Hepatic vasculature appears dense (arrow) mimicking contrast enhancement.

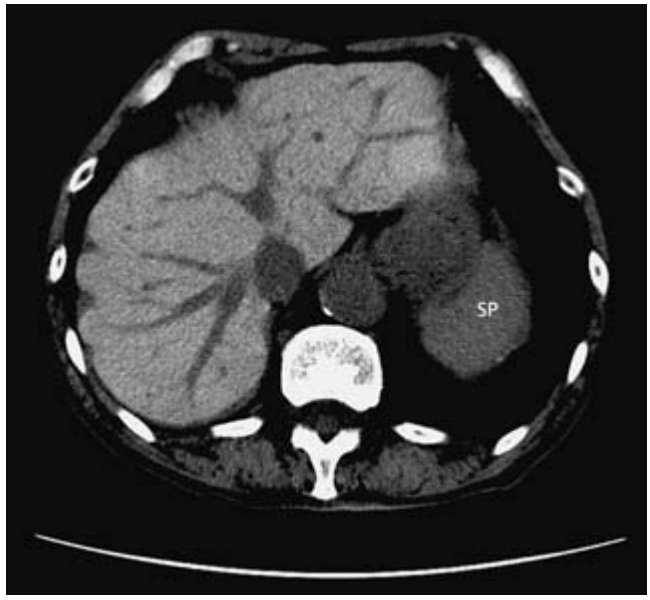

Fig. 9 Unenhanced axial CT image. In this patient with long-term amiodarone use, the liver parenchyma demonstrates marked hyperdensity compared with the superior portion of the spleen (SP).

Fig. 8 Contrast-enhanced axial CT image. Focal area of hypodensity (arrows) adjacent to falciform ligament and portal vein is consistent with focal fatty infiltration.

Acute and chronic hepatitis, regardless of aetiology, can often be undetectable by CT. When the hepatitis is fulminant in severity, the liver may demonstrate overall decreased density with the influx of excess oedema water into the hepatic extracellular space. Accompanying periportal oedema may present as a low-density halo surrounding the portal venous tributaries. Generalized, upper abdominal ascites may be present and is reactive in nature.

Most common diffuse hepatic parenchymal diseases present on CT as hepatic hypodensity. In contrast, the relatively short differential diagnosis for diffuse increased hepatic density includes haemochromatosis, Gaucher's disease, Wilson's disease and amiodarone toxicity (Fig. 9). Haemochromatosis represents abnormal accumulation of iron in the hepatocytes. This dense metal raises the native liver density to greater than 75 HU on an unenhanced scan and is the 'inverse' of steatohepatitis; the liver appears markedly denser than the spleen. In Gaucher's disease, secondary to glucocerebrosidase deficiency, abnormal accumulation of ceramide in reticuloendothelial cells raises the liver density, and hepatomegaly and splenomegaly will also be present. Focal hypodense lesions typically represent infarcts. When there is hepatic involvement, the myriad glycogen storage diseases can increase hepatic CT density. In Wilson's disease, abnormal copper accumulation leads to hyperdensity. Finally, long-term amiodarone use can lead to increased iodine deposition in hepatocytes with resultant diffuse hepatic CT hyperdensity [8]. In comparison with the other aetiologies for hyperdense liver parenchyma, amiodarone does not generally lead to gross morphological changes in the liver [9].

Benign focal liver lesions

'Non-targeted' contrast-enhanced imaging of the abdomen is routinely performed during the portal–venous phase of contrast enhancement. This PVP provides homogeneous enhancement

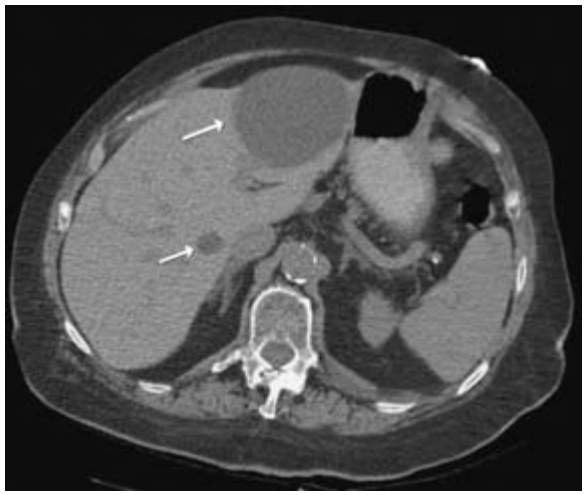

(a)

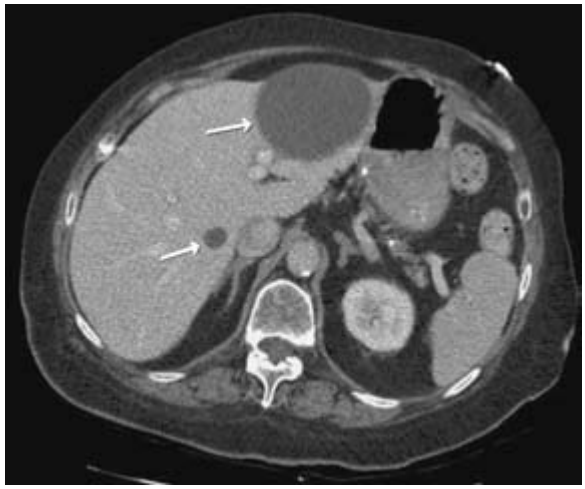

(b)

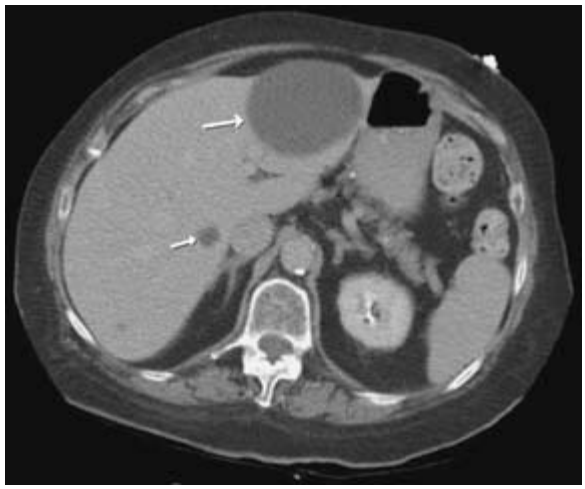

(c)

of the liver, the other abdominal parenchymal organs and the bowel wall. Although this phase of enhancement is generally sensitive for both liver and extrahepatic pathology, it often lacks specificity. Many radiologists will recommend 'targeted' multiphase hepatic CT imaging for further characterization despite adequate visualization of a lesion with portal venous CT imaging. The addition of non-contrast, arterial and delayed phase imaging can often triage a lesion between benign, malignant and indeterminate aetiologies.

Hepatic cysts are frequent incidental findings on CT. With low-density appearance (<20 HU), they appear as well-circumscribed, homogeneous masses without enhancement. Delayed phase imaging is necessary to ensure the absence of late enhancement, which suggests a solid internal structure (Fig. 10). Small cysts may appear to have higher density because of partial volume averaging with denser adjacent liver parenchyma; often, these small lesions may be too small to characterize by any imaging modality (CT, MR or US). If clinically relevant, watchful waiting and repeat imaging may be the only option. Unlike renal cyst classification, the presence of septations generally does not predict a higher risk of malignancy. However, some infectious aetiologies can present with septated cystic lesions, for example echinococcal hydatid cyst. Patients with polycystic syndromes may demonstrate dramatic macroscopic replacement of the liver with cysts with amazingly preserved hepatic function [10].

The rapid imaging speed of modern CT scanners now allows confident diagnosis of most hepatic haemangiomas by multiphase contrast-enhanced imaging. Cavernous haemangiomas are the most common liver tumour and frequently are incidental findings on both 'targeted' hepatic CT and 'non-targeted' abdominal pelvic CT. Haemangiomas appear as well-circumscribed lesions that are hypodense to surrounding unenhanced liver and may appear similar to benign cysts. Calcification within a haemangioma is unusual and can have a myriad of appearances [11]. Cavernous haemangiomas have a typical enhancement pattern (on both CT and MR), which allows confident diagnosis by imaging. On arterial phase imaging, the haemangiomas demonstrate peripheral, but discontinuous, nodular enhancement. There is progressive centripetal contrast filling of the entire lesion on the PV and delayed phases of contrast imaging. This 'fill-in' combined with nodular enhancement is considered pathognomonic for a typical cavernous haemangioma (Fig. 11). The discontinuous nodularity of haemangiomas allows for confident distinction between this benign lesion and hepatic metastasis, which can demonstrate a continuous peripheral rim of enhancement and also delayed homogeneous enhancement,

Fig. 10 (*opposite*) (a) Non-contrast axial CT image. (b) Portal–venous phase contrast-enhanced axial CT image. (c) Delayed phase contrast-enhanced axial CT image. Hepatic cysts (arrows) are low density on non-contrast imaging and show no evidence of vascular enhancement on contrast administration. Delayed imaging confirms absence of late tumour enhancement.

(a)

(b)

(c)

Fig. 11 (a) Hepatic arterial phase (HAP) contrast-enhanced axial CT image. (b) Portal–venous phase (PVP) contrast-enhanced axial CT image. (c) Delayed phase contrast-enhanced axial CT image. Classic haemangioma (white arrow) demonstrates characteristic peripheral nodular appearance on arterial phase, with progressive central fill on PVP and homogeneous enhancement on delayed phase (c). A small right liver lobe enhancing focus (black arrow) is also probably a small haemangioma but is too small to characterize by imaging and is without the classic peripheral nodular enhancement. A non-enhancing cyst is seen (asterisk).

or 'fill', of the lesion. Qualitatively, the degree of vascular enhancement within the haemangioma characteristically matches that of the aorta. In the early arterial phase, the peripheral nodular areas demonstrate intense arterial enhancement. During the portal–venous phase, the 'fill' of the haemangioma is slightly less intense, matching both the portal vein and the aorta density.

Small haemangiomas will frequently show intense and uniform enhancement during the arterial phase and persistent homogeneous density during the PV phase [12]. Unfortunately, without the classic peripheral nodular enhancement, these small haemangiomas may be confused with other hypervascular liver tumours such as hepatoma, focal nodular hyperplasia, adenoma and hypervascular metastases (Fig. 11). In these cases, the absence of a history of cirrhosis or primary malignancy is an important factor in suggesting haemangioma, and short-interval follow-up imaging documenting stability in size may obviate the need for invasive biopsy. The relatively rare giant haemangioma generally measures >5 cm. Giant haemangiomas will often show atypical enhancement patterns such as persistent central hypodense areas even on delayed phases and may show central calcification (Fig. 12). Capsular retraction secondary to haemangioma is possible, although this feature generally suggests a malignant lesion [13].

Focal nodular hyperplasia (FNH), a benign entity without malignant potential, is the second most common tumour of the

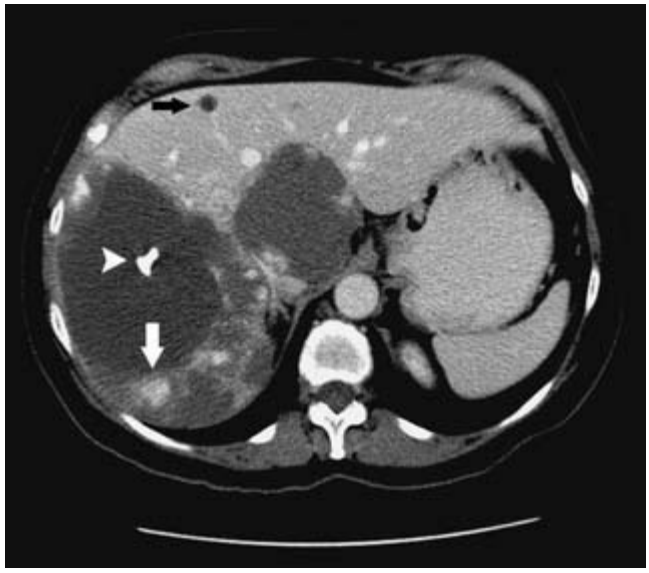

Fig. 12 Contrast-enhanced axial CT image. The giant haemangioma of the right liver lobe demonstrates some areas of peripheral nodular enhancement (white arrow). There is central tumour calcification (arrowhead). An incidental non-enhancing cyst is seen (black arrow).

(a)

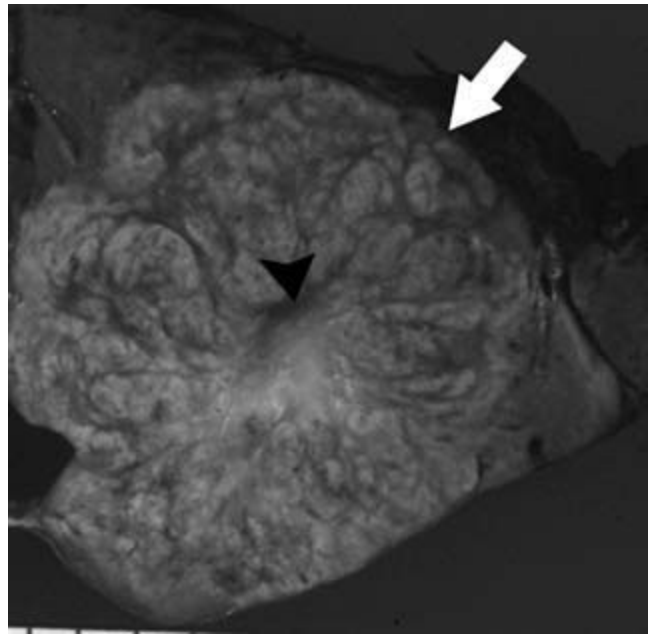

(b)

Fig. 13 (a) Contrast-enhanced axial CT image. Right liver lobe focal nodular hyperplasia (arrow) demonstrates classic peripheral enhancement with hypodense central scar (arrowhead). (b) Photograph from gross resection. Pathological findings mimic the CT imaging appearance: white arrow denotes tumour edge and black arrowhead shows the pearly white fibrosis of central scar region.

liver, generally asymptomatic and usually found incidentally as a solitary lesion. The classic distinguishing feature of FNH, both radiologically and pathologically, is the presence of a central scar of fibrous tissue (Fig. 13). On non-contrast examination, FNH is hypodense or isodense and may show occasional mass effect and lobulated contours. On multiphase contrast enhancement (Fig. 14), the classic FNH shows transient intense enhancement of the lesion during the arterial phase with rapid change to isodensity of the lesion during PV and delayed phases [14]. In this way, the lesion can easily be obscured by surrounding hepatic parenchyma if an arterial phase series is not performed. The key to characterization lies in identifying the central scar, which will be hypodense on arterial phase with progressive enhancement until the scar becomes hyperdense compared with the surrounding lesion and liver on delayed phase. When possible, classic FNH lesions should be characterized by triple-phase contrast imaging so as to avoid unnecessary biopsy and follow-up imaging. Atypical FNH may be larger than classic FNH or present as multiple lesions. An atypical FNH may show less arterial enhancement, absence of a central scar and the presence of an enhancing pseudocapsule. In these situations, a broader differential diagnosis must be considered and biopsy or excision may be indicated.

Hepatic adenomas are rare liver tumours composed of atypical hepatocytes (without bile ducts or Kupffer cells as seen in FNH). With a strong association with oral contraceptives, anabolic steroids and glycogen storage diseases, adenomas are most often found in young women. Large adenomas may cause symptoms secondary to mass effect. Clinically, adenomas carry a risk of spontaneous intraperitoneal haemorrhage with hypovolaemic shock. Intratumoral haemorrhage can cause acute right upper quadrant pain. Adenomas, even those stable over many years, may degenerate into hepatocellular carcinoma [15]. Adenomas are usually 5–10 cm in diameter and present as hypodense or isodense lesions on non-contrast imaging. An adenoma

Fig. 14 Portal–venous phase contrast-enhanced axial CT image. Homogeneous enhancement of the left liver lobe hepatic adenoma (arrow) appears more prominent because of the background diffuse fatty infiltration of the liver (asterisk). The density of this liver is so low as to match the low-density bile seen in the gallbladder (GB).

is generally well circumscribed because of the presence of a capsule. Prior haemorrhage may show focal areas of precontrast hyperdensity. During the arterial phase of contrast imaging and owing to subcapsular feeding arterioles, there may be peripheral intense enhancement with centripetal 'fill' of contrast. Unlike haemangiomas, this peripheral enhancement is not nodular in character. Because the adenomas are composed of hepatocytes, they subsequently match the surrounding liver enhancement on portal–venous and delayed phases. As with FNH, larger adenomas can give atypical presentations leading to diagnostic uncertainty. Because of the overlap of imaging characteristics between adenoma, fibrolamellar hepatoma, atypical FNH and hypervascular metastasis, most lesions will eventually require percutaneous biopsy or excision.

Cysts, haemangioma, FNH and adenoma account for a large portion of the benign focal lesions that will be encountered either incidentally or on targeted liver imaging. The clinical history will often dictate the appropriate differential diagnosis; for example, multiple hypodense lesions in a febrile immunocompromised patient will add abscess to the list of possibilities. Magnetic resonance imaging, with improved contrast resolution compared with CT, will occasionally provide additional characterization of lesions that are indeterminate by CT. Finally, the morbidity associated with image-guided focal liver biopsy is generally low and, on occasion, definitive characterization may require a pathologist.

Fig. 15 Contrast-enhanced axial CT image. Liver surface nodularity (arrows) consistent with cirrhosis is easily seen. Incidental non-enhancing cyst is noted (asterisk).

Cirrhosis, nodular hyperplasia and hepatocellular carcinoma

The anatomical resolution of MDCT is well suited to diagnosing the three main pathological characteristics of moderately advanced cirrhosis: fibrosis, nodular regeneration and hepatic architecture distortion [16]. Classic segmental lobar hypertrophy and atrophy can be easily appreciated; in fact, 3-D re-formations can provide accurate hepatic volume measurements (Fig. 5). A caudate to right lobe ratio >0.65 is suggestive of cirrhosis. The liver surface appears irregular and nodular (Fig. 15). The wide field of view afforded by MDCT will illustrate many of the secondary changes of cirrhosis and portal hypertension including portosystemic collateral varices, splenomegaly and ascites (Figs 16–18). Additionally, multiphase MDCT, particularly with thin-section series, can confidently diagnose portal vein thrombosis, a common and unfortunate complication of portal hypertension and cirrhosis [17]. Hepatic fibrosis and architectural distortion lead to alterations in hepatic perfusion, which can be seen as geographical, segmental and focal areas of either hyperperfusion/enhancement or hypoperfusion/hypodensity on contrast administration. These perfusion abnormalities, often in the absence of an underlying focal lesion, can create diagnostic uncertainty when searching for arterially enhancing hepatomas.

The two main types of cirrhosis, chronic sclerosing and nodular, demonstrate different morphological and, thus, CT appearances. In the former, the liver is small with minimal regenerative hepatocyte activity. In nodular cirrhosis, the liver may hypertrophy as a result of the innumerable small regenerating nodules or larger macronodules. The nodules represent foci of hypertrophied liver parenchyma surrounded by areas of fibrosis. Siderotic, iron-containing, regenerative nodules may be noted as hyperdense areas on the non-contrast examination. Macroregenerating nodules (>3 mm in size) may be visualized

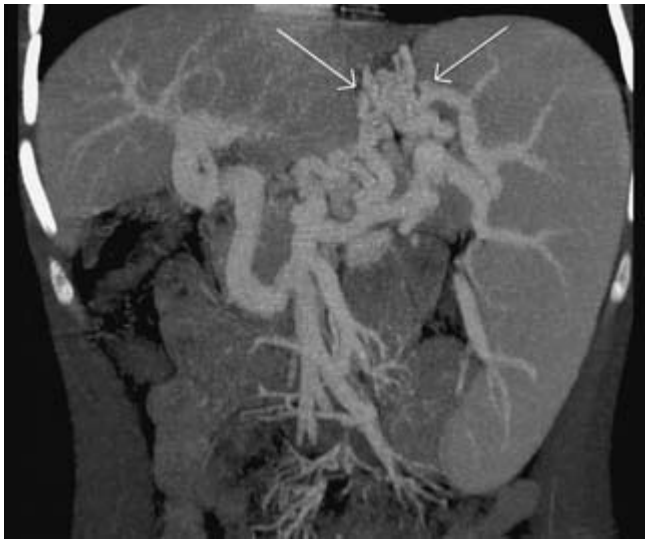

Fig. 16 Coronal maximum intensity projection from MDCT axial data. Arrows denote the prominent and tortuous gastrosplenic varices resulting from portal hypertension. Massive splenomegaly is also present.

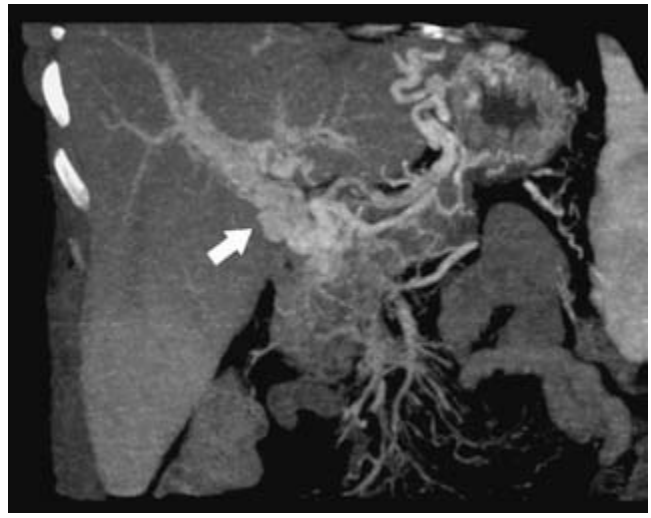

Fig. 18 Coronal maximum intensity projection from MDCT axial data. Arrow denotes the prominent and tortuous portal vein radicals resulting from portal hypertension and cavernous transformation of the hepatic hilum.

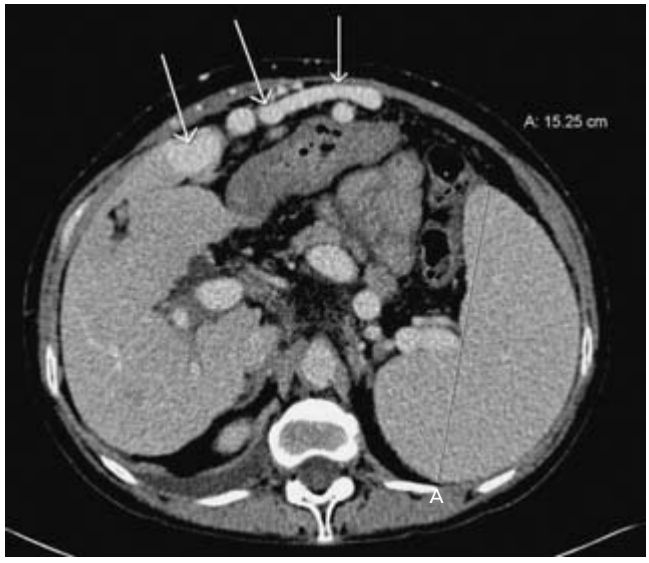

Fig. 17 Contrast-enhanced axial CT image. A recanalized umbilical vein is present secondary to liver cirrhosis and portal hypertension (arrows). Splenomegaly at 15 cm is noted.

by distortion of the liver capsule or intrahepatic vasculature (Fig. 15). However, the enhancement of regenerating nodules mimics that of the surrounding fibrotic liver and these nodules do not show arterial hyperenhancement. Thus, small regenerating nodules are rarely confidently diagnosed by MDCT, even with multiphase imaging [18].

Dysplastic nodules differ from regenerating nodules by the presence of cellular atypia and non-triadal arterial vessels [19]. Despite this increased arterialization on imaging, many dysplastic nodules do not show discernible arterial enhancement above the baseline surrounding liver parenchyma and otherwise match hepatic density on other phases. Thus, as with regenerating nodules, most dysplastic nodules cannot be distinguished from the cirrhotic liver background with MDCT. Comparatively, magnetic resonance offers superior hepatocellular nodular detection through utilization of multiple pulse sequences (e.g. T1- and T2-weighted series) in addition to similar i.v. contrast multiphase imaging with gadolinium enhancement. Unfortunately, a minority of small dysplastic nodules may show a mild degree of arterial enhancement similar to hepatocellular carcinoma [20].

When the arterial–portal venous perfusion ratio shifts even further away from portal flow, multiphase MDCT can detect the arterial neovascularization that is characteristic of classic hepatocellular carcinoma (HCC) (Fig. 19). With the majority of blood flow to the HCC from hepatic artery radicals, these, now frankly malignant, lesions classically demonstrate marked arterial enhancement compared with the cirrhotic liver background. On portal–venous phase, the HCC will be hyperdense – or isodense to the liver – and is frequently hypodense on delayed phase. This transition from hyper- to hypoenhancement has been called 'washout'. More than 90% of HCC lesions will show this arterial enhancement and approximatley three-quarters will demonstrate contrast 'washout' [21]. Whether employing CT or MR imaging for the detection of HCC, a rapid contrast bolus injection and fast imaging speed are necessary to confidently detect the HCC arterial blush. About 15% of HCCs will also demonstrate an enhancing capsular lesion; in some cases, this capsule may help to distinguish HCC from FNH, which is usually without a capsule. These 'classic' imaging characteristics apply more frequently to small HCC foci (<1.5 cm). As the

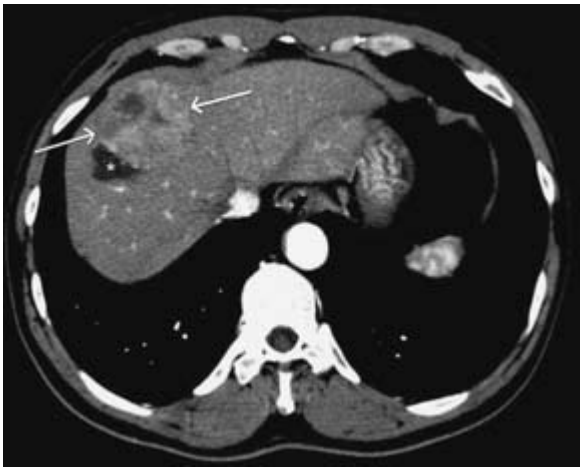

(a)

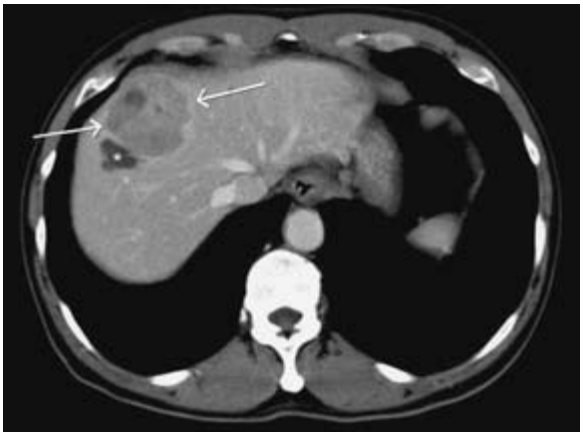

(b)

(c)

Fig. 19 (a) Hepatic arterial phase (HAP) contrast-enhanced axial CT image. (b) Portal–venous phase (PVP) contrast-enhanced axial CT image. (c) Delayed phase contrast-enhanced axial CT image. The hepatocellular carcinoma (HCC; arrows) shows arterial enhancement (a, HAP) and is isodense on PVP (b). The HCC is hypodense relative to the surrounding liver on delayed phase but shows delayed enhancement of its capsule (arrows). Incidental non-enhancing cyst is noted (asterisk).

Fig. 20 Contrast-enhanced axial CT image. A small left liver lobe fibrolamellar HCC is seen. The central scar is hypodense (arrowhead) and internal calcification is present (white arrow).

lesions grow in size, 'non-classic' features such as mosaic patterns of enhancement as well as central necrosis may be seen. Diffuse infiltration by HCC may be difficult to detect on a background of cirrhotic fibrosis with altered hepatic perfusion. Calcification is also present in about 25% of HCC lesions with an increased frequency (40%) in the fibrolamellar subtype. Fibrolamellar HCC typically presents in a younger and non-cirrhotic patient population as a lobulated heterogeneous mass with a central scar (Fig. 20). Other hepatic lesions with scar must also be considered in the differential diagnosis, as discussed previously. MR may be an adjuvant modality to differentiate these possibilities.

Despite optimization of modern contrast-enhanced MDCT techniques, CT studies with pathological correlation in transplant patients demonstrate an overall sensitivity of approximately 65% for the presence of HCC and approximately 40% for the total number of lesions [18]. It is clinically important to identify and characterize these focal lesions as accurately as possible. Outcomes from treatment of small HCC lesions are superior to larger, more conspicuous lesions. The Milan criteria, discussed in Section 23, govern a patient's ranking on the US United Network for Organ Sharing (UNOS) transplantation lists. The presence, size and number of HCC lesions can both elevate a patient's rank and also disqualify a patient from transplant. MDCT can accurately screen the post-transplant patient for disease recurrence and transplant complication.

Hepatic metastasis

Metastatic disease is the most common neoplasm in the adult liver and is the second most common focal liver lesion following

hepatic cysts. The liver may be the only metastatic site in some colorectal carcinomas, HCC and neuroendocrine tumours. Most metastases (~70%) present as multiple foci in both lobes with only approximately 10% as single foci [22]. They are generally iso- or hypodense to the surrounding liver in the non-contrast, arterial and portal–venous phases. A peripheral, complete ring of arterial enhancement may be seen. During the PV phase, a slightly thicker rind of enhancement can be noted; but this rind is still hypodense compared with the surrounding liver. Late enhancement of the centre of the metastatic lesion, isodense to liver on delayed phase, is common. This delayed, 'centripetal' fill-in is also a characteristic of haemangiomas. However, as discussed above, the classic haemangioma can be distinguished by its peripheral, nodular enhancement. The margins of metastasis may be irregular or illdefined; this is not a strict criterion, and a surrounding capsule is unusual. Central necrosis may account for the low-density centre in larger lesions, which outstrip their neovascular blood supply (Fig. 21). Mucinous gastrointestinal, ovarian, breast, lung, renal and thyroid cancer metastases may demonstrate variable degrees of calcification. Similarly, all metastases may show dystrophic calcification following active therapy.

A subset of hepatic metastases are hypervascular and will show homogeneous hyperenhancement relative to the liver during arterial phase imaging. The primary tumours include melanoma, renal cell carcinoma, sarcoma, neuroendocrine (carcinoid and pancreatic islet cell), choriocarcinoma and thyroid cancers (Fig. 22). Often, these metastases will be isodense or hypodense to the surrounding liver on all other, non-arterial, imaging phases. In this way, they are only detectable with MDCT or MR arterial phase contrast imaging. These hypervascular metastases, particularly when solitary, can create a diagnostic dilemma [23]. Many small haemangiomas demonstrate a homogeneous arterial enhancement, without the classic peripheral nodular rim. These haemangiomas also show a washout similar to hypervascular metastasis [24]. Capsular retraction adjacent to a mass is highly suggestive of malignancy [25] (Fig. 23).

Fig. 21 Contrast-enhanced axial CT image. Right liver lobe cholangiocarcinoma (arrow) demonstrates prominent central low density consistent with central necrosis.

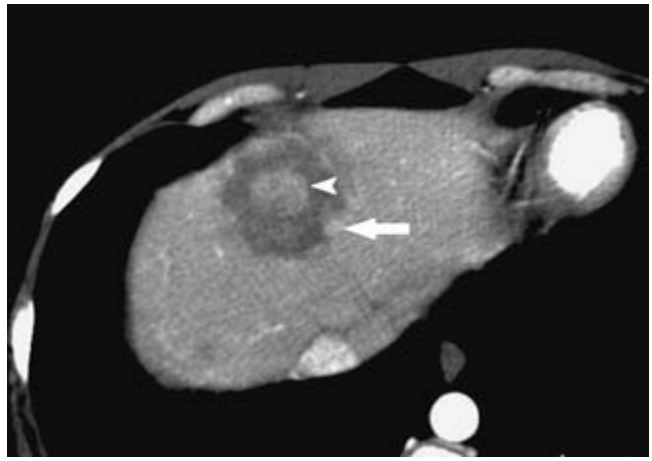

Fig. 22 Hepatic arterial phase contrast-enhanced axial CT image. Carcinoid hepatic metastasis demonstrates both central (arrowhead) and peripheral (arrow) arterial hyperenhancement.

Fig. 23 Delayed phase contrast-enhanced axial CT image. Large primary liver lymphoma (black arrow denotes tumour edge) shows delayed enhancement (arrowhead) adjacent to an area of central necrosis. There is also retraction of the right liver lobe capsule (white arrow).

Colorectal carcinoma hepatic metastasis

Colorectal carcinoma (CRC) metastases deserve special mention. Although CRC metastasis imaging features are not significantly

Fig. 24 Contrast-enhanced axial CT image. A right liver lobe colon cancer metastasis (arrows) demonstrates mild peripheral enhancement and central low density. Incidental splenic calcifications are seen, possibly from prior granulomatous disease.

different from other hepatic metastases, the clinical management of metastatic CRC has evolved (Fig. 24). Previously, hepatic CRC metastases were treated solely with chemotherapy with a dismal 5-year survival of approximately 5%. Patients who undergo hepatic CRC metastasis resection now experience 5-year survival ranging from 25% to 48%, with long-term disease-free survival approaching 12–19% [26]. These survival figures are predicated on primary colonic tumour removal and technically successful CRC hepatic metastasis resection, as well as the absence of known additional metastatic sites. Currently, many oncology surgeons will resect single CRC metastases or even multiple foci if they are confined to a localized hepatic region; adequate margins of resection must allow for preserved liver function following surgery (e.g. all foci confined to one lobe or resectable segment). MDCT remains the dominant imaging modality for screening for CRC metastasis both within the liver as well as extrahepatic abdominal pelvic sites. MDCT can achieve a sensitivity of >90% for hepatic CRC metastasis >1 cm in diameter and a sensitivity of 56% for smaller lesions [27]. The combination of positron emission tomography (PET) with MDCT 'fuses' the specificity of MDCT anatomical resolution to the sensitivity of PET physiological metabolic imaging [28]. It is important to identify the total number and sites of CRC metastasis in order to spare patients from a futile and potentially morbid hepatic resection in the presence of extensive hepatic or extrahepatic metastases. Conversely, as mentioned in the section on imaging technique, MDCT with appropriate angiographic technique and 3-D re-formation can provide all the necessary anatomical information for the oncology surgeon to plan a complete and safe CRC metastasis resection when appropriate.

Conclusion

Modern multidetector computerized tomography with isotropic high-resolution imaging is a highly sensitive modality for detecting both diffuse and focal hepatic pathology. Rapid imaging speed and multiphase intravenous contrast-enhanced imaging allow for characterization of many focal liver lesions. Benign hepatic lesions such as cysts, haemangiomas, focal nodular hyperplasia and adenomas can frequently be distinguished from hepatocellular carcinoma and hepatic metastases. Atypical lesions can be triaged between follow-up imaging and biopsy or excision. Advanced computer techniques yield three-dimensional display of hepatic pathology for non-invasive hepatic vascular assessment and presurgical planning. Of the advanced radiological imaging modalities, multidetector computerized tomography with multiphase contrast enhancement provides the most consistent, rapid and, overall, comprehensive assessment of liver pathology.

References

1 Husband J, Dombrowe G (2005) X-ray computed tomography – a truly remarkable medical development. *Br J Radiol* 78, 97–98.

2 Michael A, Bettmann MD (2004) Frequently asked questions: iodinated contrast agents. *Radiographics* 24, S3–S10.

3 Sahani D, Mehta A, Blake M *et al.* (2004) Preoperative hepatic vascular evaluation with CT and MR angiography: implications for surgery. *Radiographics* 24, 1367–1380.

4 Pomfret EA, Pomposelli JJ, Lewis WD *et al.* (2001) Live donor adult liver transplantation using right lobe grafts: donor evaluation and surgical outcome. *Arch Surg* 136, 425–433.

5 Pandharipande PV, Krinsky GA, Rusinek H, Lee VS (2005) Perfusion imaging of the liver: current challenges and future goals. *Radiology* 234, 661–673.

6 Bray GA (2004) Medical consequences of obesity. *J Clin Endocrinol Metab* 89, 2583–2589.

7 Jacobs JE, Birnbaum BA, Shapiro MA *et al.* (1998) Diagnostic criteria for fatty infiltration of the liver on contrast-enhanced helical CT. *Am J Roentgenol* 171, 659–664.

8 Goldman IS, Winkler ML, Raper SE *et al.* (1985) Increased hepatic density and phospholipidosis due to amiodarone. *Am J Roentgenol* 144, 541–546.

9 Mergo PJ, Ros PR (1998) Imaging of diffuse liver disease. *Radiol Clin North Am* 36, 365–375.

10 Everson GT, Scherzinger A, Berger-Leff N *et al.* (1988) Polycystic liver disease: quantitation of parenchymal and cyst volumes from computed tomography images and clinical correlates of hepatic cysts. *Hepatology* 8, 1627–1634.

11 Mitsudo K, Watanabe Y, Saga T *et al.* (1995) Nonenhanced hepatic cavernous hemangioma with multiple calcifications: CT and pathologic correlation. *Abdom Imaging* 20, 459–461.

12 Vilgrain V, Boulos L, Vullierme MP *et al.* (2000) Imaging of atypical hemangiomas of the liver with pathologic correlation. *Radiographics* 20, 379–397.

13 Yang DM, Yoon MH, Kim HS *et al.* (2001) Capsular retraction in hepatic giant hemangioma: CT and MR features. *Abdom Imaging* 26, 36–38.

14 Carlson SK, Johnson CD, Bender CE, Welch TJ (2000) CT of focal nodular hyperplasia of the liver. *Am J Roentgenol* 174, 705–712.
15 Foster JH, Berman MM (1994) The malignant transformation of liver cell adenomas. *Arch Surg* 129, 712–717.
16 Gupta AA, Kim DC, Krinsky GA, Lee VS (2004) CT and MRI of cirrhosis and its mimics. *Am J Roentgenol* 183, 1595–1601.
17 Kang HK, Jeong YY, Choi JH *et al.* (2002) Three-dimensional multidetector row CT portal venography in the evaluation of portosystemic collateral vessels in liver cirrhosis. *RadioGraphics* 22, 1053–1061.
18 Baron RL, Peterson MS (2001) Screening the cirrhotic liver for hepatocellular carcinoma with CT and MR imaging: opportunities and pitfalls. *RadioGraphics* 21, S117–S132.
19 International Working Party (1995) Terminology of nodular hepatocellular lesions. *Hepatology* 22, 983–993.
20 Jeong YY, Mitchell DG, Kamishima T (2002) Small (<20 mm) enhancing hepatic nodules seen on arterial phase MR imaging of the cirrhotic liver: clinical implications. *Am J Roentgenol* 178, 1327–1334.
21 Lee KH, O'Malley ME, Haider MA, Hanbidge A (2004) Triple-phase MDCT of hepatocellular carcinoma. *Am J Roentgenol* 182, 643–649.
22 Sica GT, Ji H, Ros PR (2000) CT and MR imaging of hepatic metastases. *Am J Roentgenol* 174, 691–698.
23 Hanafusa K, Ohashi I, Himeno Y *et al.* (1995) Hepatic hemangioma: findings with two-phase CT. *Radiology* 196, 465–469.
24 Leslie DF, Johnson CD, Johnson CM *et al.* (1995) Distinction between cavernous hemangiomas of the liver and hepatic metastases on CT: value of contrast enhancement patterns. *Am J Roentgenol* 164, 625–629.
25 Soyer P, Bluemke DA, Vissuzaine C *et al.* (1994) CT of hepatic tumors: prevalence and specificity of retraction of the adjacent liver capsule. *Am J Roentgenol* 162, 1119–1122.
26 Headrick JR, Miller DL, Nagorney DM *et al.* (2001) Surgical treatment of hepatic and pulmonary metastases from colon cancer. *Ann Thorac Surg* 71, 975–979.
27 Kuszyk BS, Bluemke DA, Urban BA *et al.* (1996) Portal-phase contrast-enhanced helical CT for the detection of malignant hepatic tumors: sensitivity based on comparison with intraoperative and pathologic findings. *Am J Roentgenol* 166, 91–95.
28 Cohade C, Osman M, Leal J, Wahl RL (2003) Direct comparison of (18)F-FDG PET and PET/CT in patients with colorectal carcinoma. *J Nucl Med* 44, 1797–1803.

5.6.3 Magnetic resonance imaging

Christoforos Stoupis

The major advantage of magnetic resonance imaging (MRI) compared with the other cross-sectional imaging techniques is its ability to detect as well to characterize focal liver lesions due to the superior soft-tissue contrast of this modality compared with irradiating and other non-irradiating imaging techniques [1].

Technical aspects

The MR equipment and its field strength is the first important hardware issue for liver imaging. Soft-tissue contrast between hepatic lesions and the normal hepatic parenchyma correlates with the field strength. The most acceptable field strength is 1.5 T (tesla).

The second most important issue regarding the equipment is the coils. For many years MRI of the liver has been commonly performed using a whole-volume body coil; however, phased-array surface multicoil systems have been developed for improved signal-to-noise ratio and high-resolution MR liver imaging. The phased-array technology has demonstrated the potential to significantly improve lesion-to-liver contrast, lesion detection and image definition.

The imaging protocol must be tailored to the clinical problem being considered. Both T1-weighted and T2-weighted image sequences are essential and justified for liver imaging [1]. T1-weighted imaging analyses the normal anatomy whereas T2-weighted imaging is of major importance for the characterization of focal lesions. Both sequences are generally used for transvessel imaging of the liver using a slice thickness ranging from 4 to 8 mm to cover the whole organ. Today, fast spin echo sequences are used mainly with breath-hold imaging techniques in order to obtain multiple images in one breath hold similar to the techniques used in computerized tomography (CT). Breath-hold T1- and T2-weighted images of the liver enable shorter imaging time with a higher contrast:noise ratio compared with conventional techniques.

In case of diffuse liver diseases, specifically in case of focal or diffused steatosis, a specific imaging technique has been developed called fat-suppressed imaging. The most commonly used technique is the chemical shift imaging method, which is sensitive to differences in resonance frequency between water and triglyceride protons. The opposed phase imaging technique is the most commonly used chemical shift imaging method; it is based on signal cancellation within a voxel that contains both water and triglyceride. This means that areas that contain both water and triglycerides (such as steatotic liver areas) will reduce their signal intensity in the opposed phase sequence while areas of malignancy, containing only water, will not change their signal. This imaging technique is proposed in case of focal or diffused steatosis of the liver in order to differentiate inhomogeneous parenchyma from metastatic disease. A second technique for faster imaging is the short time inversion recovery technique (STIR); remember, however, that this sequence suppresses signals from any tissue that has relaxation values similar to that of fat. Although the signal-to-noise ratio in the sequence is relatively low, in case of a focal liver lesion there is high lesion-to-liver contrast value available, and therefore it could be used for lesion detection.

An important technical advantage of MRI is the potential for vascular imaging using flow-sensitive MR sequences in order to depict and image hepatic vessels. The time of flight imaging angiography allows non-invasive imaging of the portal and the hepatic venous system without administration of contrast agent; using a flow-sensitive sequence, blood flowing into an image section that has higher longitudinal magnetization than the partially saturated stationary tissues within the section can easily be

detected. Phase-contrast angiographic imaging is based on the detection of changes in phase secondary to flow; however, this complicated encoding process is time consuming and the images are sensitive to motion artifacts. Therefore, phase-contrast imaging is not in daily use.

Three-dimensional contrast-enhanced MR angiography (MRA) is nowadays available for regular application; it uses a three-dimensional (3-D) gradient echo sequence on magnets with high-performance gradient systems; high-resolution 3-D volume of image data acquisition can be accomplished in a single breath hold of the patient (Fig. 1). A paramagnetic contrast medium is injected intravenously and the image data are collected as the contrast circulates through the vascular territory of interest using different phases and acquisition of contrast agent circulation (early and late arterial phase, hepatic parenchymal phase, etc.). Compared with other angiography techniques, contrast-enhanced MRA has the advantage of non-iodinated contrast agent with less risk of anaphylactic reactions. There is no nephrotoxicity and the volume injected for angiography is 20–30 mL as opposed to 80–100 mL with computerized tomography angiography. The reconstruction of images from MRA is similar to other imaging techniques.

MR liver imaging has the advantage of allowing 'all-in-one imaging', including transverse sectional imaging of the liver (MRI), magnetic resonance angiography in different phases (MRA) and MR cholangiopancreatography (MRCP; see Chapter 5.6.5), all in the same imaging session in a non-invasive way.

Contrast enhancement

Several contrast agents have been investigated and are in use for specific MR imaging of the liver. These contrast agents can be categorized as paramagnetic (increasing signal intensity in T1-weighted images) or superparamagnetic (decreasing the signal density of the normal hepatic parenchyma in T2-weighted images). According to their biochemical behaviour, they can be characterized as extracellular, reticuloendothelial system-directed agents or hepatocyte-specific contrast agents [2].

Extracellular agents

The gadolinium chelates are the most widely used MR contrast agents. These agents include gadoterate dimeglumine and gadopentetate dimeglumine (ionic agents), as well as gadodiamide and gadoteridol (non-ionic contrast agents). Because these extracellular agents display a rapid equilibration in the interstitial spaces, a dynamic MR imaging technique (bolus injection, rapid acquisition) that provides a high temporary resolution is essential to demonstrate differences in enhancement pattern between the normal hepatic parenchyma and the potential focal liver lesion. Similar to CT during arterial portography, gadolinium chelates have also been delivered to the liver via the superior mesenteric artery (MR imaging during arterial portography) providing the highest parenchymal enhancement,

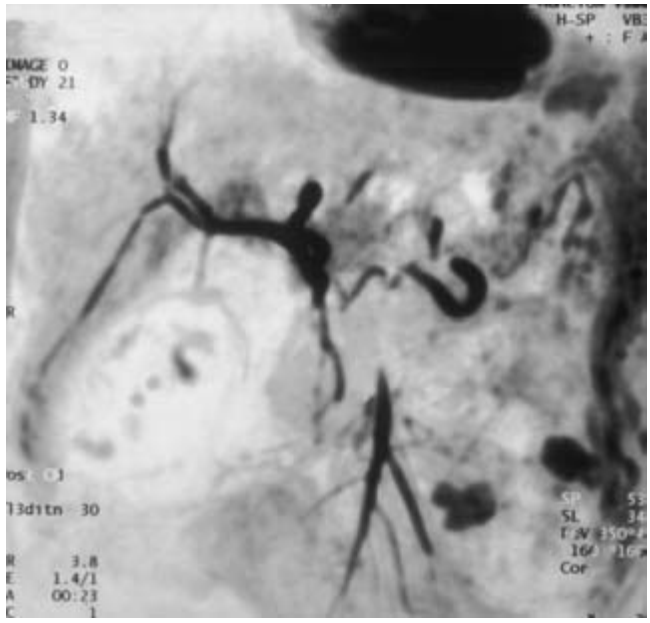

(a)

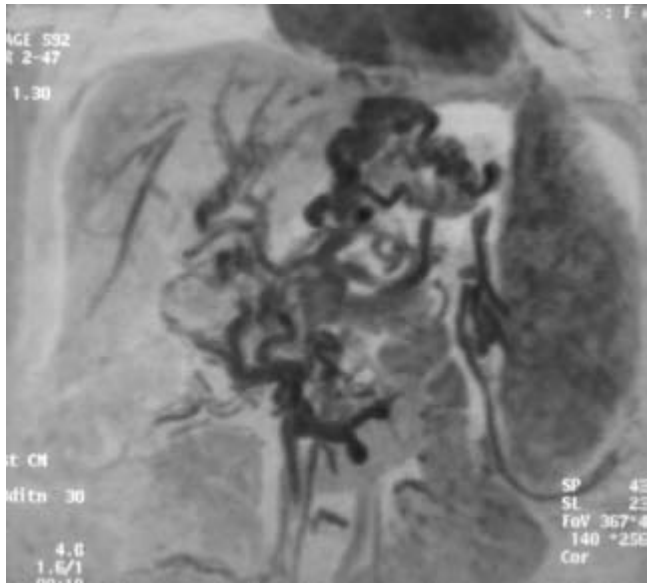

(b)

Fig. 1 MR angiography. (a) 3-D contrast-enhanced MR angiography after intravenous administration of gadolinium demonstrates the vessels in the arterial and early portal inflow phase. Note active bleeding within the gallbladder. This examination was done in a patient with renal insufficiency. (b) Contrast-enhanced MR angiography in hepatic parenchymal phase demonstrates collaterals by portal hypertension along the common ways of portosystemic circulation. Note the splenomegaly.

excellent lesion-to-liver contrast and high sensitivity for lesion detection although non-tumoral perfusion abnormalities and invasiveness are drawbacks of this technique. Extracellular gadolinium chelates, if given with the power injector, can be used in the initial injection phase for MR angiography acquisition,

again demonstrating the potential for both angiographic and late arterial hepatic phase and hepatic venous phase of the liver parenchyma similar to the phases seen by multidetector CT.

Superparamagnetic contrast agents such as Endorem (Advanced Magnetics Inc., Cambidge, MA, USA) or Resovist (Schering AG, Berlin, Germany) are phagocytes by the reticuloendothelial system. Because signal reduction of normal hepatic parenchyma, secondary to the administration of superparamagnetic contrast agent, is more pronounced on T2-weighted gradient echo images than on conventional T2-weighted images, gradient echo sequences (so called T*) are more sensitive in demonstrating focal liver lesion diseases. Lesions that do not contain reticuloendothelial system cells will not demonstrate a signal intensity drop as opposed to the normal hepatic parenchyma.

Hepatobiliary agents

Several hepatocyte-specific paramagnetic contrast agents are available. Mangafodipir trisodium (Mn-DPDP) is a typical example of this group. T1-weighted images are essential after the administration of these contrast agents because they affect the T1 relaxation times and therefore the T1 contrast (high signal intensity in the area of contrast accumulation). Two gadolinium chelates (gadolinium BOPTA and gadolinium EOB-DTPA) can also be used as hepatobiliary contrast agents. These two agents display extracellular activity; however, there is uptake by the hepatocytes followed by hepatobiliary secretion. Representative commercial products include Multihance (Bracco, Milan, Italy) and Primovist (Schering AG, Berlin, Germany) [3,4].

MR imaging of focal liver lesions

Benign hepatic tumours

Benign tumours of the liver are classified pathologically by their cell origin. Lesions of mesenchymal origin include haemangiomas, angiomyolipomas and lipomas. Lesions of epithelial origin include focal nodular hyperplasia (FNH), hepatocellular adenomas, hepatic cysts and biliary hamartomas. Determination of tumour extent and tissue characterization is provided by T1- and T2-weighted images as well as after intravenously administered contrast agents such as extracellular agents, reticuloendothelial system (RES)-directed contrasts or hepatobiliary secreted agents. Knowledge of the underlying gross and microscopic pathological features of benign liver masses leads to a better understanding of their MR imaging appearances [1,5].

Hepatic cysts are common and mostly asymptomatic, representing incidental finding by MR imaging of the liver. Most are unilocular but occasionally they have a multilocular appearance. On MR imaging they have a homogeneous well-defined appearance demonstrating low signal intensity on T1-weighted and high signal intensity on T2-weighted images reflecting their simple nature. After gadolinium administration cysts do not demonstrate any enhancement (Fig. 2). Complicated cysts

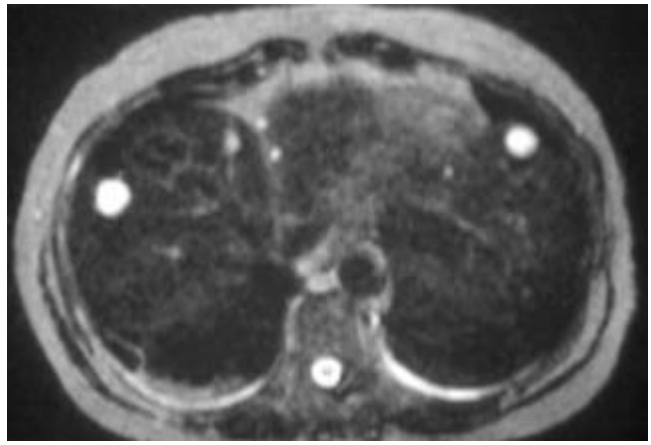

(a)

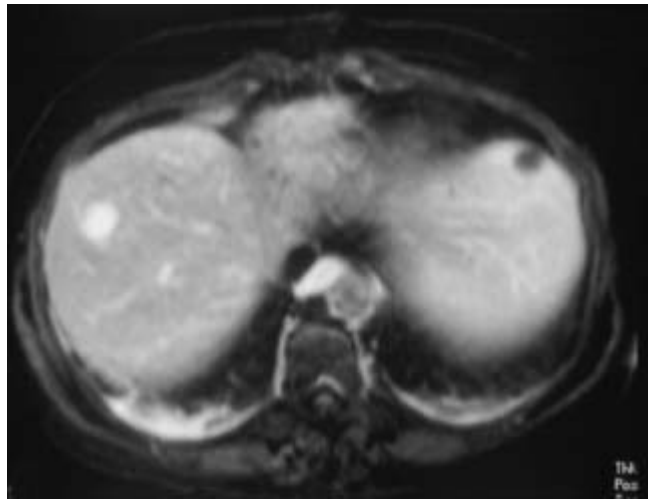

(b)

Fig. 2 Use of contrast agent to differentiate cystic from other lesions. (a) T2-weighted image demonstrates multiple lesions in the liver with high signal intensity. Further differentiation of those lesions is not possible. (b) T1-weighted image after gadolinium administration demonstrates that the lesion in the right lobe of the liver is a haemangioma whereas the other lesions do not enhance, representing simple cysts.

might demonstrate high signal intensity on T1- and low signal intensity on T2-weighted images.

Biliary hamartomas are benign, solitary or multiple biliary malformations of small size (<1 cm). Similar to cysts, they have low signal intensity on T1- and high signal intensity on T2-weighted images. However, after contrast administration they demonstrate rim enhancement; this feature might cause difficulties in differentiating them from metastatic lesions.

Angiomyolipoma of the liver is an uncommon tumour of mesenchymal origin often seen in patients with tuberous sclerosis. On MR imaging they often demonstrate high signal intensity on T1-weighted images due to their fatty content, which is well suppressed on T1 fat-suppressed images. Usually they do have moderate to high signal intensity on T2-weighted images. They demonstrate diffuse and heterogeneous enhancement

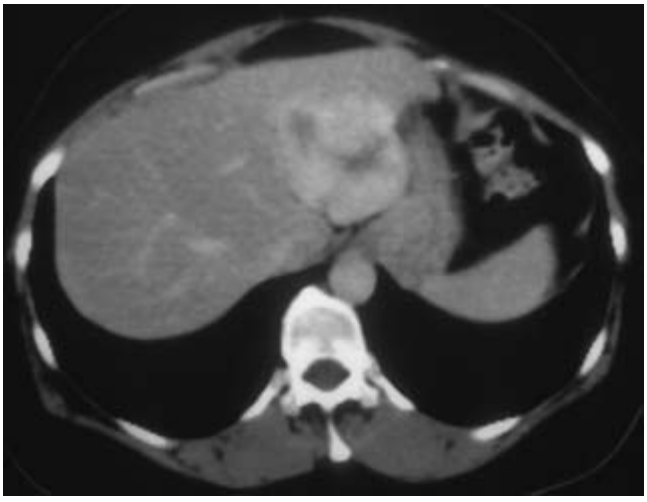

(a)

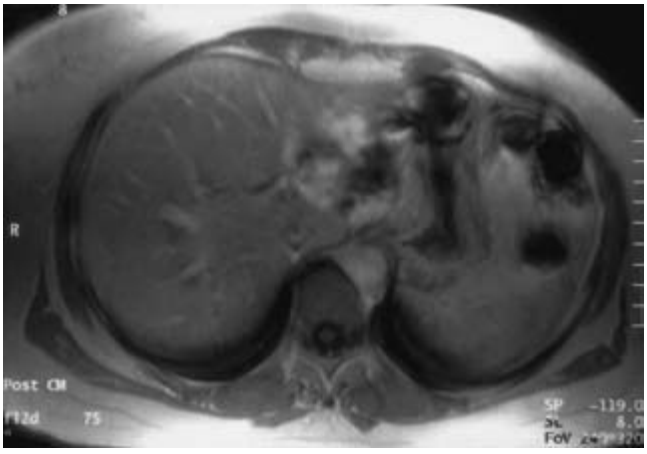

(b)

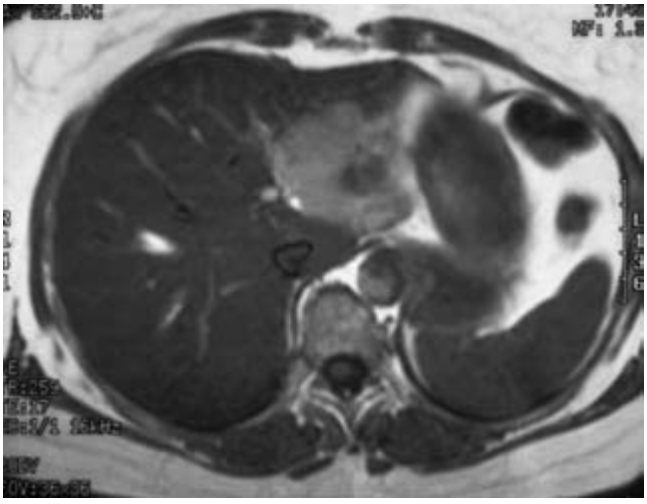

(c)

Fig. 3 Behaviour of contrast agents in haemangiomas. (a) Typical enhancement pattern by CT after injection of iodinated contrast agent. (b) The same patient after administration of gadolinium chelates with a typical peripheral enhancement of the lesion. (c) The same patient after superparamagnetic contrast agent administration with typical high signal intensity within the lesion because of pooling of the agent.

after gadolinium administration, which poses difficulties in differentiating them from hepatocellular carcinomas.

Haemangioma is the most common benign tumour of the liver; symptoms and complications are discussed in Chapter 18.1.1. Haemangiomas are well-defined round or lobular lesions with low signal intensity on T1-weighted and high signal intensity on T2-weighted images. Due to their large vascular lakes and channels they demonstrate peripheral enhancements with a typical cottonwool appearance (Fig. 3). If they are large they might contain central areas of fibrosis, which do not enhance after contrast administration. Unfortunately, areas of calcifications that can be seen by CT cannot be demonstrated by means of MRI. If the haemangioma is small and hypervascular, the typical features of peripheral nodular enhancement with centripetal progression to homogeneity are not seen. Instead immediate homogeneous enhancement might be present, which can be difficult to differentiate from hypervascular metastases. Haemangiomas can be differentiated from metastases by RES-directed contrast agents (SPIO, superparamagnetic iron oxide). In haemangioma there is pooling of the contrast agent in T2-weighted imaging. Signal intensity is high in T2 images before and after contrast administration, whereas the pooling produces a high signal intensity in T1-weighted images after contrast administration (Fig. 3). Metastases remain hypointense in T1-weighted images after SPIO administration. In case of hepatobiliary-directed contrast agents there is enhancement due to the vascularity of the lesion in the late arterial phase; however, in the delayed phase there is no pooling of this agent, similar to the metastatic lesions where no enhancement is seen. Giant haemangiomas might be difficult to differentiate from aggressive malignant lesions due to their large size. However, even with the presence of fibrosis, with the typical persistent central hypointense area after gadolinium administration, the peripheral nodular enhancement with a centripetal progression is typical and well demonstrated in those lesions [6].

Liver cell adenomas are benign tumours of hepatocellular origin; their clinical presentation is discussed in Chapter 18.1.2. Liver cell adenomas are composed of hepatocytes that might contain substantial amounts of glycogen or fat; therefore, T1-weighted images produce high signal intensity, which can be suppressed in fat-suppressed T1 images. If any complications are present, such as haemorrhage, causing high signal intensity in T1-weighted images similar to that of fat, differentiation between blood and fat can be accomplished by fat-suppressed techniques (blood remains bright, fat darkens its signal intensity). On T2-weighted images adenomas are seen as intermediate signal intensity lesions. After contrast administration they demonstrate a high vascularity; this sometimes produces difficulties in distinguishing adenomas from hepatocellular carcinomas. Therefore, if imaging appearance suggests adenoma and the lesion is solitary, surgical resection is suggested. Hepatocyte-specific contrast agents as well as iron oxide particulate agents demonstrate uptake, because adenomas accumulate contrast agents due to the presence of hepatocytes and RES cells [6,7].

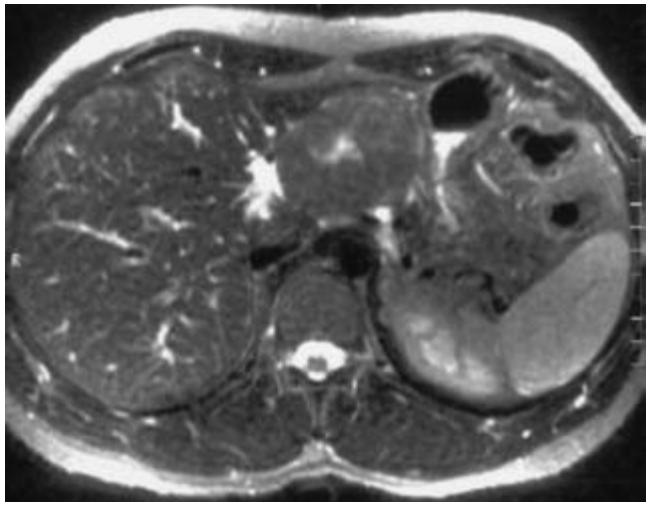

(a)

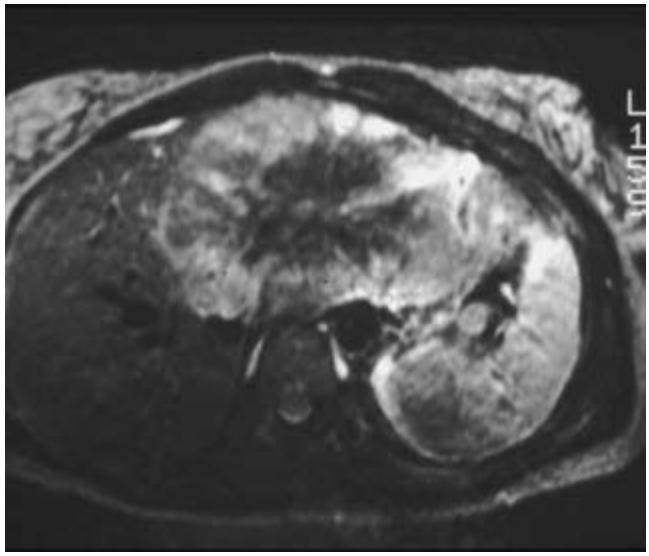

(b)

Fig. 4 Differentiation of focal nodular hyperplasia (FNH) from fibrolamellar carcinoma using the T2-weighted image. (a) Typical flow within the central scar of the FNH with high signal intensity on T2-weighted image. (b) In case of fibrolamellar carcinoma there is no flow within the central scar, which represents fibrous tissue. Around the fibrotic tissue note septae and necrotic oedematous changes with high signal intensity.

Focal nodular hyperplasia (FNH) is the second most common benign hepatic tumour after haemangioma. It is thought to be a hyperplastic response to an underlying congenital arterial venous malformation. The central fibrous scar contains the arterial venous malformation; this feature demonstrates high signal intensity on T2-weighted images (Fig. 4). Various appearances on T1- and T2-weighted images are described. After intravenous administration of gadolinium the lesions demonstrate prompt and marked enhancement higher than that of the liver, particularly in the late arterial phase. If the extracellular contrast agents do not reveal the underlying pathology in a small hypervascular lesion suspected of being FNH, cell-specific contrast agents can demonstrate the benign origin of the lesion. This can also be used to distinguish them from other lesions with a central scar such as fibrolamellar carcinoma. A specific type of FNH has been described as a telangiectatic focal nodular hyperplasia, an entity that does not demonstrate the typical scar and has an appearance similar to that of hepatocellular adenoma or carcinoma. Cell-specific contrast agents demonstrate the typical hepatocyte and Kupffer cell activities and allow for differentiation from carcinoma and adenoma.

Malignant hepatic tumours

Fibrolamellar carcinoma (FLC) is a malignant hepatocellular tumour with clinical and pathological features distinct from HCC. On MR imaging fibrolamellar carcinomas are typically of low signal intensity on T1-weighted images with the exception of bleeding, where hyperintense areas are seen. On T2-weighted images signal intensity is low; this low-intensity central scar differentiates FLC from FNH, where a high signal intensity on T2-weighted images within the scar is seen (Fig. 4). Radiating septae with low signal intensity in both T1- and T2-weighted images are also seen (Fig. 4). After gadolinium enhancement there is a heterogeneous enhancement of the lesion as opposed to the homogeneous enhancement of FNH. The central scar is due to true fibrotic tissue and remains hypointense after contrast administration [1].

Hepatocellular carcinoma (HCC) occasionally arises in patients without any pre-existing hepatic abnormalities; however, it is mostly seen in a previously damaged liver as in the case of hepatitis or fibrosis and cirrhosis (Figs 5 and 6). On MRI HCC generally has a variable appearance depending on its growth pattern. Vascular invasion, if present, is well displayed with thrombosis of the hepatic or portal vein branches. The ability of MRI to depict vascular invasion makes this technique essential for the diagnosis of a suspected lesion. On T1-weighted images, hepatocellular carcinoma has a variable appearance, depending on the presence of haemorrhage or steatosis, which produce high signal intensity. Haemorrhage can be differentiated from fat by the fat-suppression technique. On T2-weighted images the lesions may demonstrate a hyperintensity relative to the normal liver with areas of increased signal intensity in case of necrosis. In case of encapsulated HCC there is often a low signal intensity rim on T1-weighted images representing the fibrotic tumour capsule. After intravenous extracellular agent administration the tumours demonstrate enhancement due to their hypervascular nature [8,9].

Diagnostic problems abound when imaging of liver cirrhosis demonstrates regenerative and dysplastic nodules, as opposed to HCC. There are many studies and papers demonstrating the potential of MRI to differentiate between regenerative and dysplastic nodules and HCC; however, in general, the majority of HCC nodules are of slightly higher signal intensity

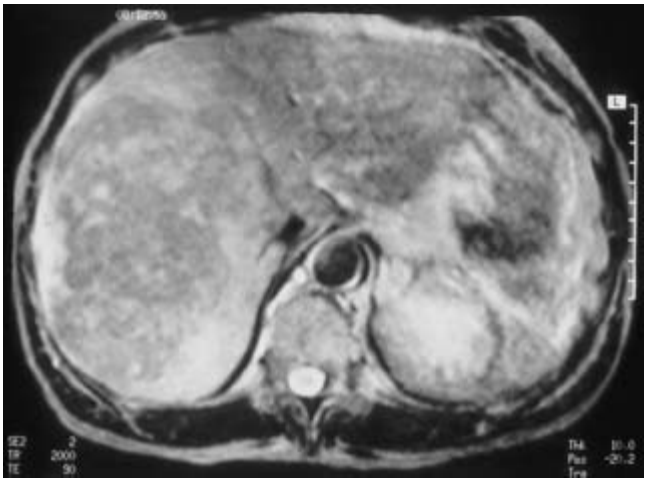

(a)

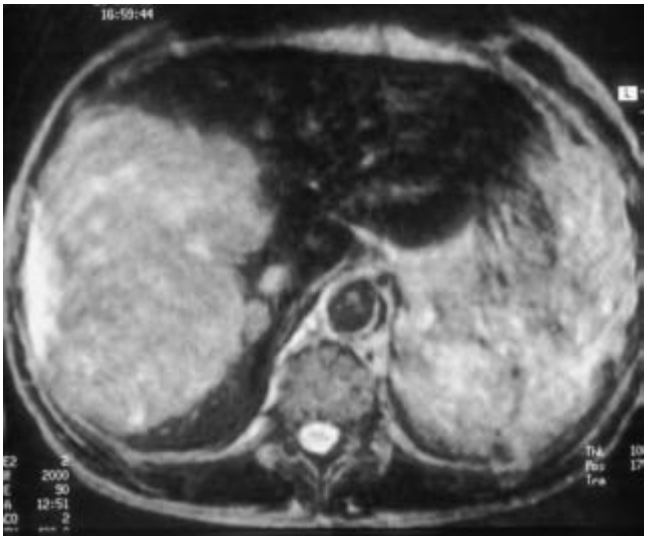

(b)

Fig. 5 Superparamagnetic contrast agent for detection of liver lesions. (a) T2-weighted image without contrast administration is unable to clearly delineate the HCC lesions in this patient. (b) After contrast administration note the darkening of the normal hepatic parenchyma. The HCC, which contains no reticuloendothelial system (RES) cells in this case, retains high signal intensity and therefore can be easily detected and delineated.

and regenerative nodules are of lower signal intensity on T2-weighted images, compared with the liver parenchyma. The degree of vascularity might be useful in demonstrating the high vascularity of HCC and the very fast washout compared with the other lesions. A published study demonstrated that, in the case of cirrhotic liver, many areas of hypervascularity could be seen in the late arterial phase. Of those areas that were visualized, only those whose size exceeded 2 cm were suspected hepatocellular carcinoma. Lesions in the periphery smaller than 1 cm were often due to intrahepatic shunts. Lesions between 1 and 2 cm should be followed up by re-examination; most often they are of benign regenerative origin [10].

Although the use of hepatospecific contrast agents (hepatocyte- or Kupffer cell-directed) suggested a higher degree of characterization of HCC, this remains problematic in the case of well-differentiated HCC, where both phagocytosis of SPIO particles and hepatocytic activity with uptake is demonstrated. In general, in the case of hypervascular lesions in a cirrhotic patient, even if these lesions are of low signal intensity on T2-weighted images, hepatocellular carcinoma must be considered in the differential diagnosis, and follow-up examination is essential. On the other hand attention needs to be paid in case the hepatocellular carcinoma is not hypervascular; other imaging features such as the high signal intensity in T2-weighted images and the presence of a pseudocapsule might guide the correct diagnosis.

Intrahepatic cholangiocarcinoma is the second most common primary malignant hepatic neoplasm after HCC. As opposed to the vascular enhancement of HCC, in cholangiocarcinoma there is encasement of large vessels without invasion. Areas of necrosis and haemorrhage can been seen with the typical changes on T1- and T2-weighted images. On MR imaging intrahepatic cholangiocarcinoma appears as a large heterogeneous mass, often encasing large vessels such as the portal vein and the hepatic veins without tumour thrombus as seen in HCC. On T1-weighted images the lesion is hypointense compared with the normal liver and on T2-weighted images the variable periphery is hyperintense with respect to normal liver, with central areas of hypointensity corresponding to fibrosis [1,11]. The use of gadolinium chelates demonstrates concentric enhancement with sparing of central areas due to the presence of central fibrosis (Fig. 7).

In extrahepatic cholangiocarcinoma, unlike intrahepatic cholangiocarcinoma, there is no space-occupying lesion but a stenosis of the involved bile duct segment (Fig. 8), while the additional use of gadolinium might demonstrate a rim enhancement in the area of the stenotic bile duct. MRCP is essential in the diagnosis and 'all-in-one MRI' could help in the further evaluation of the disease.

Biliary cystadenoma and cystadenocarcinoma represent two points on a disease spectrum; they are uncommon and present as large multilocular intrahepatic cystic masses that contain proteinaceous fluid material. On MR imaging the multilocular cystic masses have an irregular wall. On T1-weighted images the locules appear with variable signal intensity depending on their protein content. A similar appearance is seen in T2-weighted images, where the signal intensity seen is not that of clear fluid, demonstrating locules with lower signal intensity due to the content, that is, tinged bile. After gadolinium administration there is a variable enhancement seen in the irregular septae. The presence of solid components and mural nodules demonstrates cystadenocarcinoma [1]. Again, unlike CT, calcifications cannot be demonstrated by means of MRI.

Angiosarcoma is a rare malignancy seen specifically after exposure to different toxins. Haemorrhage and a heterogeneous appearance of the lesions is commonly seen. On MR imaging

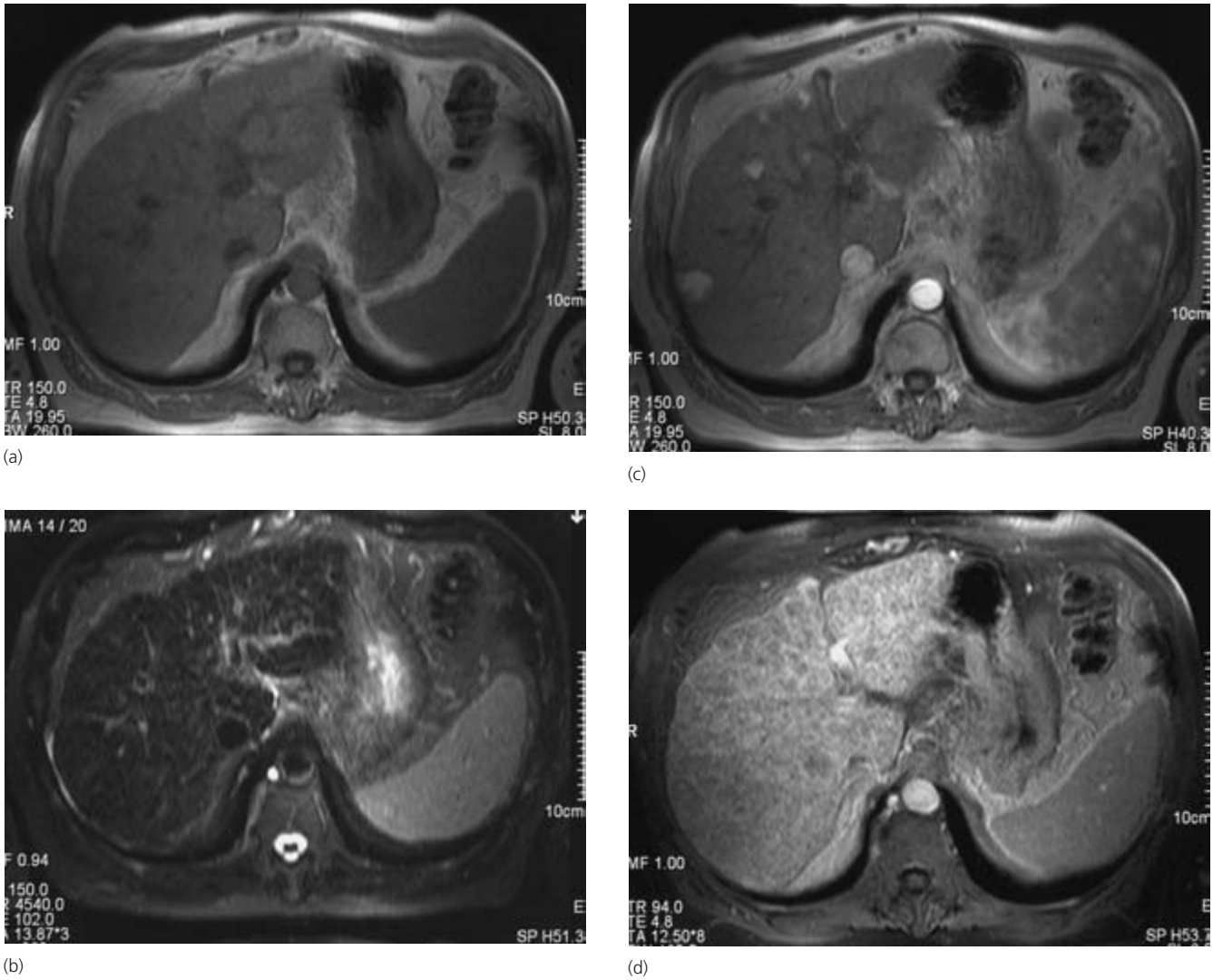

Fig. 6 Use of dynamic imaging to depict and characterize lesions in case of hepatic cirrhosis. (a) Non-enhanced T1-weighted image of the liver does not demonstrate any focal liver lesions. Note the irregular surface of the liver parenchyma due to cirrhosis. (b) T2-weighted image is unable to detect any liver lesions. (c) Arterial phase after intravenous administration of gadolinium. Note several lesions in the right and left lobes of the liver; based on the size of the lesions the one in the right lobe must be suspected HCC. (d) Late parenchymal phase reveals multiple lesions; however, regenerative nodules and HCC cannot be differentiated in this phase.

angiosarcoma is hypointense in relation to the normal liver parenchyma on T1-weighted images although areas of haemorrhage represent hyperintensity, similar to that of adenoma. An inhomogeneous appearance can be seen on T2-weighted images where normally, if not complicated, the lesion demonstrates high signal intensity. The intravenous administration of extracellular contrast agents demonstrates peripheral enhancement, sometimes similar to that seen with haemangioma [1].

Liver metastases

Examination for liver metastasis is one of the most common indications for liver MR imaging. However, differentiation of detected lesions in an oncology patient is necessary to exclude liver metastases specifically if, after chemotherapy, diffuse fatty change of the liver has occurred. Similarly to CT, depending upon the pattern of vascularization, liver metastases have been classified as hypovascular or hypervascular. A specific group has been described that is known to be of near isovascularity and demonstrates the particular appearance of those lesions if imaging targets to the vascularization pattern [3,4].

Hypovascular metastases have a non-specific pattern in MRI, demonstrating low signal intensity on T1-weighted images and similar signal intensity to the normal hepatic parenchyma on T2-weighted images. Because of the characteristic signal and relaxation changes after gadolinium enhancement, even hypovascular metastases demonstrate a peripheral rim enhancement

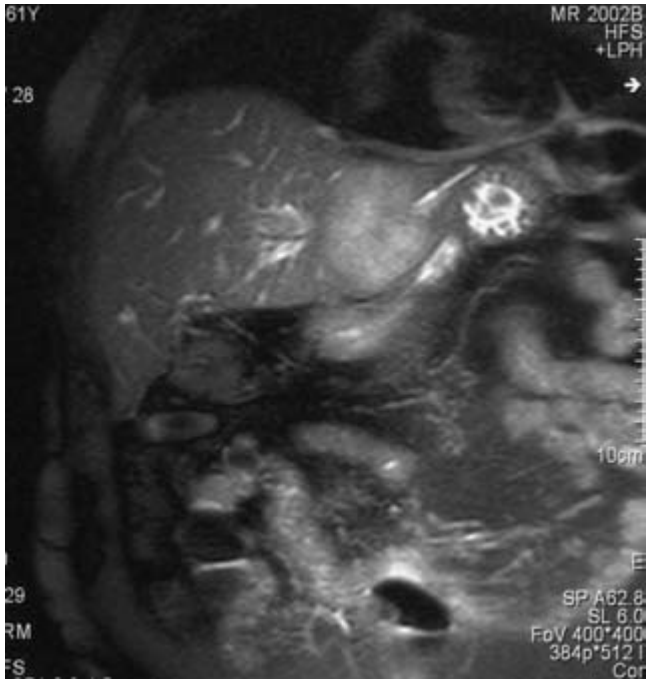

(a)

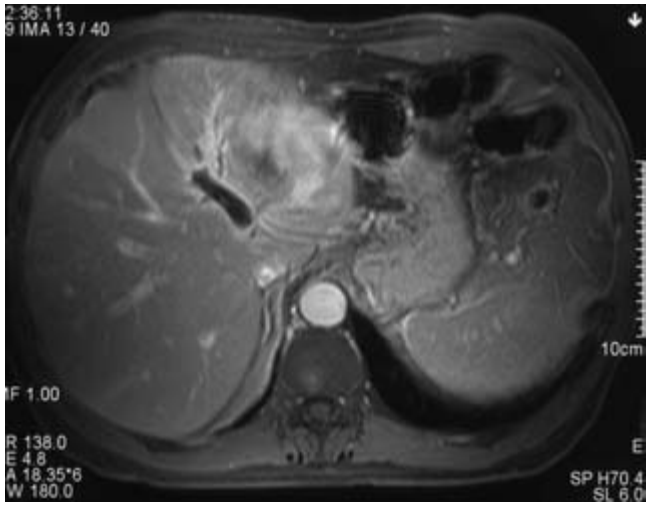

(b)

Fig. 7 Intrahepatic cholangiocarcinoma. (a) Coronal T2-weighted image demonstrates a space-occupying lesion within the left lobe. The adjacent intrahepatic bile ducts are dilated. (b) Contrast-enhanced T1-weighted image demonstrates the lesion in the left lobe with obstruction of the intrahepatic bile ducts.

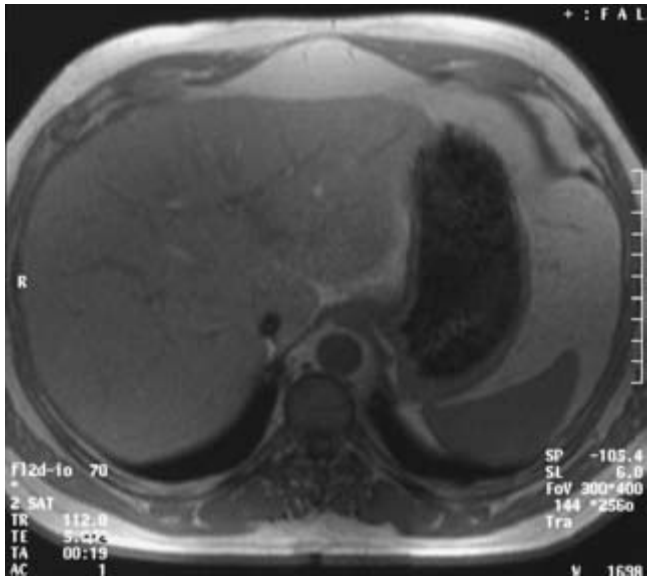

(a)

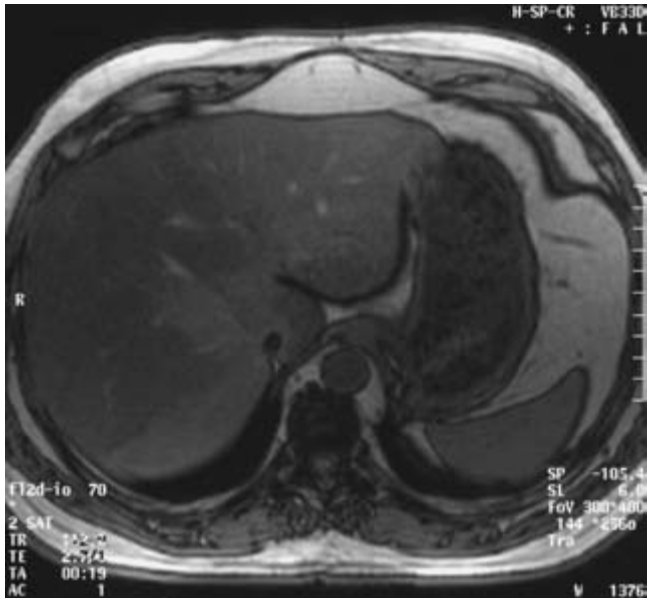

(b)

Fig. 8 Diffuse hepatic liver steatosis. Chemical shift imaging. (a) T1-weighted in-phase image demonstrates no abnormalities of the liver parenchyma. (b) T1-weighted out-of-phase image demonstrates drop of signal intensity in the areas where steatosis is evident. Liver segment I and part of the left lobe do not demonstrate a signal intensity decrease; hence there is no steatosis.

in the late arterial hepatic phase; however; these lesions typically demonstrate low signal intensity in the hepatic venous phase. Although hypovascular metastases may sometimes mimic hepatic cysts, delayed enhancement of the liver demonstrates a slightly peripheral enhancement in the metastases, a finding that is not seen with cysts.

Hypervascular metastases, similar to CT, are seen in the early and late hepatic arterial phases, therefore dynamic MR imaging must be applied in the case of suspected hypervascular metastasis even if there is no high signal intensity on T2-weighted images.

Near isovascular metastases, as the name implies, do enhance when using an extracellular contrast agent, and appear similar to

the liver in early and late arterial phases. Because of this peculiar pattern of enhancement, attention needs to be paid to the non-enhanced T1-weighted images, where the lesions are conspicuous and there is at least the potential of differentiation from other lesions.

As discussed previously, the use of extracellular contrast agents to detect and differentiate metastases from other lesions might produce diagnostic problems because of the different vascularity patterns of metastases. Therefore, in this situation, agents other than gadolinium chelates can be applied in order to demonstrate the number, location and extent of metastatic disease in the liver. One group of substances that can be administered intravenously and can be used for specific detection of metastases of a known primary tumour are the superparamagnetic contrast agents, which can be given either by drip infusion (Endorem) or by means of a bolus technique (Resovist). These agents target the absence of reticuloendothelial system cells within the metastatic lesions. On T2-weighted images there is a signal intensity increase in the normal liver compared with the non-enhanced images while metastatic lesions remain unchanging in their signal intensity and therefore appear much brighter in the post-contrast images as opposed to the precontrast images. Superparamagnetic contrast agents demonstrate a higher sensitivity than CT in detecting metastatic lesions, independent of the vascularity of those metastases. In addition to the superparamagnetic contrast agents, a specific extracellular contrast agent that demonstrates partial hepatocyte uptake and excretion through the biliary system can also be used for detection of metastases [12,13]. Two products are used routinely: Multihance and Primovist. Both agents can be used initially as extracellular agents to detect vascularity; thereafter, some 20–40 min after injection, a proportion of the contrast agent is taken up by the hepatocytes. Hence, in T1-weighted images, the normal liver becomes more intense compared with the images before the contrast administration, whereas metastatic lesions do not take up contrast and are darker than in the precontrast images. A similar contrast characteristic is produced after the use of Mn-DPDP. Although various different contrast agents have been introduced for detecting metastatic liver disease, attention needs to be paid to their utility in differentiating metastases from other focal liver lesions, specifically benign hypervascular lesions such as hypervascular haemangiomas and FNH. Furthermore, differentiation of small hypervascular lesions and small intrahepatic vessels is not always easy. Finally, the imaging of small capsular liver metastases in the case of peritoneal metastatic disease is an unsolved issue.

MR imaging of diffuse liver disease

Hepatic steatosis

Diffuse hepatic steatosis is not uncommon. It is known that CT examination of the liver can detect fatty liver changes if non-enhanced imaging is performed. The most sensitive MR technique to detect fatty change of the liver is the use of specific gradient echo pulse sequences, particularly chemical shift imaging (Fig. 8). Using 1.5 T at an echo time of 4.2 ms, water and lipid protons are in phase and their signal intensities are additive. However, using an echo time of half this value (i.e. 2.1 ms), water and lipid protons are out of phase and their signal intensities cancel each other. Hence, in steatotic areas of the liver the signal intensity decreases when out of phase compared to when in phase, whereas in areas of the liver with less fat the signal intensity out of phase remains similar to that when in phase. This simple imaging technique can be used not only to detect fatty changes of the liver parenchyma but also to differentiate fatty changes from other focal or diffuse entities of the liver such as liver metastases. This technique can be used to differentiate specific focal lesions that could mimic liver masses such as focal fatty infiltration and/or focal fatty sparing, specifically in liver segment IV. These changes are more pronounced in T1-weighted sequences; however, they can be manifest in T2-weighted images specifically with a fast spin echo technique. Therefore, in and out (opposed) phase gradient echo images must be used in every liver MRI examination in order to detect or to exclude focal changes and differentiate those from other potential focal liver lesions [14–16].

Hepatic iron deposition

Haemochromatosis of the liver can be genetic in origin or be caused by transfusional iron overload. In both entities the iron deposition within the liver decreases the signal intensity in both T1- and T2-weighted images. However, the findings are more pronounced in T2-weighted images, where the liver appears very dark. Differentiation between genetic and transfusional iron overload can be accomplished using the signal intensity of the spleen: in the first case the spleen is spared because it comprises dysfunctional reticuloendothelial cells, whereas with transfusional iron overload, iron is found in the Kupffer cells of the spleen and therefore the spleen decreases its signal intensity. A specific sequence, called a T2-weighted gradient echo image, is employed to detect and semi-quantify abnormal iron deposition in the liver, specifically exploiting the sensitivity of iron in the magnetic field. The same sequence can be used to detect hepatocellular carcinoma in patients with haemochromatosis, because iron does not accumulate in hepatoma and therefore those lesions can be seen within the liver using this T2-weighted gradient echo sequence [17,18].

Inflammatory liver diseases

Hepatic abscess

Ultrasonography and CT are the primary diagnostic tools for detecting pyogenic and amoebic abscesses in the liver with high sensitivity, and to guide treatment by means of interventional radiology and drainage of abscesses. Therefore MR imaging

should not be the first imaging choice where a liver abscess is suspected. MR imaging is used as a secondary tool for this diagnosis. Biogenic abscesses have a non-specific appearance on MR imaging and may mimic malignant neoplasms. On T1-weighted images the lesions are of low signal intensity and in T2 they have high signal intensity. Following administration of gadolinium an abscess shows a peripheral rim of enhancement surrounding the centre filled with necrotic debris of low signal intensity. In the case of amoebic abscess, similar to the findings on CT, a zone of hyperintensity might be seen around the abscess on T2-weighted images with enhancement after gadolinium administration, demonstrating the surrounding oedematous non-infected liver parenchyma [19].

Hydatid disease

As with other infectious diseases, MR imaging is not a primary tool for detecting and evaluating hepatic echinococcosis. Due to the inability of MRI to detect calcifications, this technique is not suggested as a primary tool to detect and differentiate cystic lesions, specifically echinococcosis, from other cystic lesions of the liver. The MR imaging features of hydatid cysts are those of hypointense lesions on T1-weighted imaging and of hyperintense lesions on T2-weighted images. In case of calcification a low signal intensity is evident on T1- or T2-weighted images. Dotted cysts may be seen within the lesion with similar signal intensity on T1- and T2-weighted images, hence they cannot be easily detected by MRI. A specific entity that may produce differential diagnostic problems is echinococcus alveolaris. In this case the lesion presents as a mass of low signal intensity in T1-weighted images and intermediate to high signal intensity in T2-weighted images, mimicking malignant tumours, whereas after contrast administration the lesion does not enhance, appearing as a necrotic area similar to that of a tumour. Therefore in cases where hydatid disease is suspected the method of choice is CT examination and not MRI because, specifically in case of echinococcus alveolaris, MRI may suggest the wrong differential diagnosis.

MR imaging of the bile system

One of the major advantages of MRI is the potential for imaging the bile duct system due to the signal intensity of slow-moving liquid within the intra- and extrahepatic bile ducts. Using T2-weighted images it is possible to darken the signal intensity of the liver, to avoid the appearance of the hepatic vessels and to demonstrate only the branches of the intra- and extrahepatic ducts depending upon the quantity of bile within the biliary system. This technique enables the delineation of the anatomy of the biliary system, demonstrating specifically potential variations of the bile duct system, an important issue before surgery. It is the method of choice to detect intra- and extrahepatic stones, although compared with endoscopic retrograde cholangiopancreatography (ERCP), it might miss stones that are smaller than 3 mm. However, MRCP has the potential to detect cholangiocarcinoma of the extrahepatic bile ducts (Fig. 9). Irregular changes of the intrahepatic bile duct system with additional periductal enhancement from contrast agent help to detect primary sclerosing cholangitis and differentiate this entity from other diffuse diseases of the liver that might deform the hepatic parenchyma.

In the future, the implementation of stronger and faster gradient systems, as in 3 T units, ushers in the potential for faster

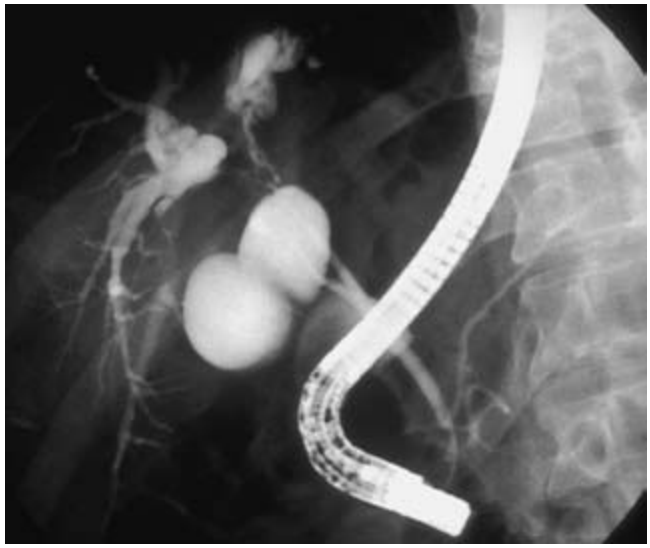

(a)

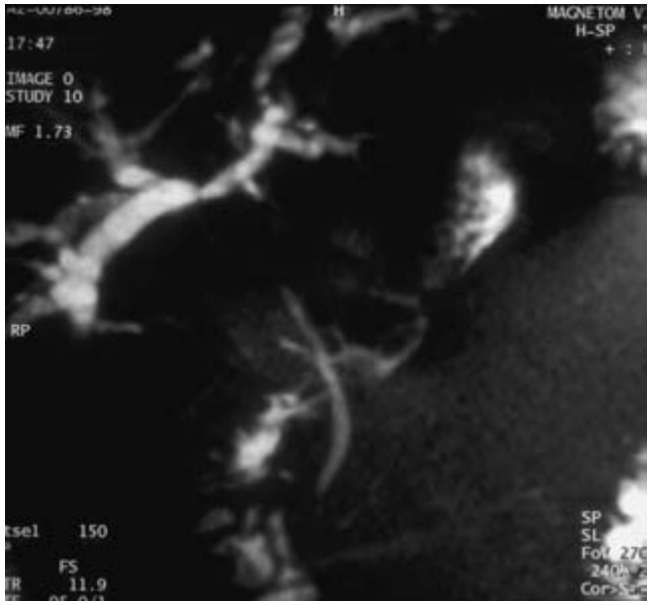

(b)

Fig. 9 Extrahepatic cholangiocarcinoma. Correlation of two different imaging techniques. (a) ERCP demonstrates the stenosis in the proximal part of the extrahepatic bile duct. Note the intrahepatic bile duct dilatation. (b) In the same patient MRCP reveals similar findings with proximal stenosis of the bile duct due to extrahepatic cholangiocarcinoma.

acquisition times and acquisition of a complete data set in one measurement (single-shot techniques). Echo planar imaging and diffusion imaging are potential imaging techniques that could be applied to specific aspects of liver imaging, targeting perfusional and functional features of the hepatic parenchyma. However, these exciting techniques are still under development.

References

1 Powers C, Ros PR, Stoupis C *et al.* (1994) Primary liver neoplasms: MR imaging with pathologic correlation. *Radiographics* 14, 459–482.
2 Semelka RC, Helmberger TK (2001) Contrast agents for MR imaging of the liver. *Radiology* 218, 27–38.
3 Ji H, Ros PR (2002) Magnetic resonance imaging. Liver-specific contrast agents. *Clin Liver Dis* 6, 73–90.
4 Balci NC, Semelka RC (2005) Contrast agents for MR imaging of the liver. *Radiol Clin North Am* 43, 887–898.
5 Motohara T, Semelka RC, Nagase L (2002) MR imaging of benign hepatic tumors. *Magn Reson Imaging Clin North Am* 10, 1–14.
6 Kim MJ, Kim JH, Chung JJ *et al.* (2003) Focal hepatic lesions: detection and characterization with combination gadolinium- and superparamagnetic iron oxide-enhanced MR imaging. *Radiology* 228, 719–726.
7 Scharitzer M, Schima W, Schober E *et al.* (2005) Characterization of hepatocellular tumors: value of mangafodipir-enhanced magnetic resonance imaging. *J Comput Assist Tomogr* 29, 181–190.
8 Hussain SM, Zondervan PE, IJzermans JN *et al.* (2002) Benign versus malignant hepatic nodules: MR imaging findings with pathologic correlation. *Radiographics* 22, 1023–1036.
9 Taouli B, Losada M, Holland A, Krinsky G (2004) Magnetic resonance imaging of hepatocellular carcinoma. *Gastroenterology* 127, S144–S152.
10 Shimizu A, Ito K, Koike S *et al.* (2003) Cirrhosis or chronic hepatitis: evaluation of small (≤2-cm) early-enhancing hepatic lesions with serial contrast-enhanced dynamic MR imaging. *Radiology* 226, 550–555.
11 Park MS, Kim TK, Kim KW *et al.* (2004) Differentiation of extrahepatic bile duct cholangiocarcinoma from benign stricture: findings at MRCP versus ERCP. *Radiology* 233, 234–240.
12 Ros PR, Freeny PC, Harms SE *et al.* (1995) Hepatic MR imaging with ferumoxides: a multicenter clinical trial of the safety and efficacy in the detection of focal hepatic lesions. *Radiology* 196, 481–488.
13 Tanimoto A, Wakabayashi G, Shinmoto H *et al.* (2005) Superparamagnetic iron oxide-enhanced MR imaging for focal hepatic lesions: a comparison with CT during arterioportography plus CT during hepatic arteriography. *J Gastroenterol* 40, 371–380.
14 Mergo PJ, Ros PR, Buetow PC, Buck JL (1994) Diffuse disease of the liver: radiologic-pathologic correlation. *Radiographics* 14, 1291–1307.
15 Itai Y, Saida Y (2002) Pitfalls in liver imaging. *Eur Radiol* 12, 1162–1174.
16 Siegelman ES, Rosen MA (2001) Imaging of hepatic steatosis. *Semin Liver Dis* 21, 71–80.
17 Siegelman ES, Mitchell DG, Rubin R *et al.* (1991) Parenchymal versus reticuloendothelial iron overload in the liver: distinction with MR imaging. *Radiology* 179, 361–366.
18 Gandon Y, Guyader D, Heautot JF *et al.* (1994) Hemochromatosis: diagnosis and quantification of liver iron with gradient-echo MR imaging. *Radiology* 193, 533–538.
19 Ralls PW, Henley DS, Colletti PM *et al.* (1987) Amebic liver abscess: MR imaging. *Radiology* 165, 801–804.

5.6.4 Hepatic angiography

Sanjeeva P. Kalva and Dushyant V. Sahani

The current role of angiography in the investigation of liver disease is limited due to technical advances in cross-sectional imaging. Computerized tomography (CT) and magnetic resonance imaging (MRI) are very useful in the diagnosis of hepatic parenchymal and vascular disorders. However, angiography is useful in a few specific circumstances and is part of various interventional procedures. This chapter summarizes the current indications, techniques and findings of hepatic angiography in liver disease. Angiography of the liver can be divided into three sections: hepatic arteriography, portal venography and hepatic venography.

Hepatic arteriography

Hepatic arteriography, the study of hepatic arteries by catheter angiography, is indicated in the following circumstances [1].

- To study the hepatic arterial anatomy before liver resection and intra-arterial chemotherapy pump placement.
- As part of various interventional procedures such as chemoembolization, embolization following trauma and as a part of planning before intra-arterial therapy with radioactive particles (such as SIRSpheres, Sirtex Medical, Lake Forest, IL, USA).
- Assessment of hepatic vascular disorders such as vasculitis, aneurysms, arteriovenous fistulae.
- To diagnose the source of haemobilia.
- Rarely to diagnose primary or metastatic neoplasms.
- As a part of CT arterioportography.
- Evaluation of vascular complications following hepatic transplantation.

Technique

With a transfemoral antegrade approach, a Cobra or Sidewinder catheter is used to cannulate the coeliac axis. If an axillary or brachial arterial approach is used, a Davis or multipurpose catheter can be used to cannulate the coeliac axis. In general, a coeliac arteriogram is performed to obtain a global view of coeliac axis anatomy. Then, selective cannulation of hepatic artery is performed using a hydrophilic guide wire or a coaxial technique. Cannulation of branches of the proper hepatic artery usually requires coaxial catheters. The complications of hepatic arteriography include injury to hepatic arteries (dissection, rupture, occlusion) due to catheter manipulation, access site complications such as haematoma, pseudoaneurysm and infection, and contrast material-related complications.

Standard hepatic arterial anatomy

A standard hepatic arterial anatomy is found in 55–60% of the population [2,3]. The common hepatic artery (CHA) arises

from the coeliac axis (CA) and divides into the proper hepatic artery (PHA) and gastroduodenal arteries (GDA). The proper hepatic artery divides into right and left hepatic arteries. The right hepatic artery (RHA) supplies the right lobe of the liver through right ventrocranial and right dorsocaudal branches. The caudate lobe receives blood supply from the right hepatic artery. The left hepatic artery supplies the left lobe through medial and lateral segmental branches. The lateral branch bifurcates into superior and inferior segmental arteries, which give the characteristic fork-like configuration to the left hepatic artery. The artery supplying the medial segment of the left lobe is often called the middle hepatic artery (segment IV artery).

Variant hepatic arterial anatomy

A variant hepatic arterial anatomy occurs in 40–45% of the population. In general, the following comments can be made. A portion of or the entire right lobe or the entire liver can get its blood supply from the superior mesenteric artery. Similarly, part or all of the left lobe may be supplied from the left gastric artery (LGA). The proper or common hepatic artery can arise directly from the aorta or from the superior mesenteric artery (Fig. 1). The segmental arteries may arise directly from the common hepatic artery in 25% of individuals. A maximum of three hepatic arteries supply the liver. The variations and their incidence are listed in Table 1 [4].

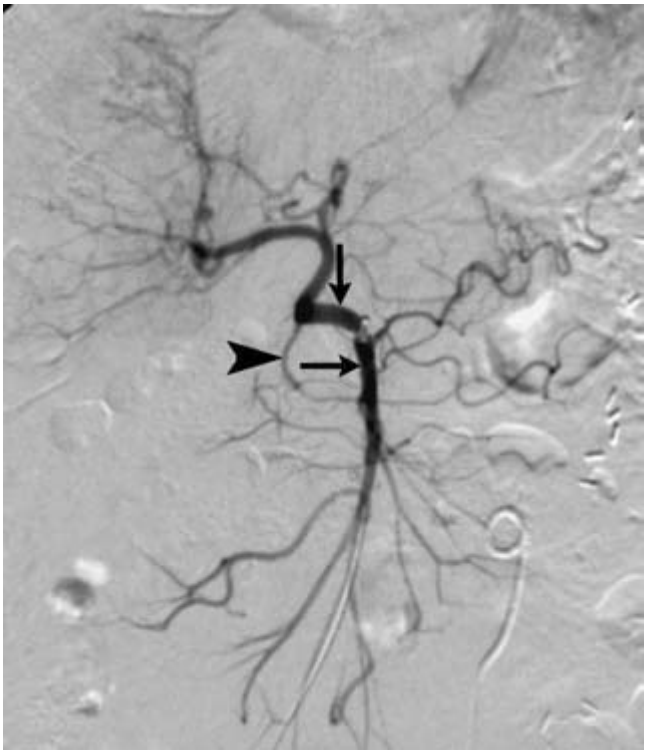

Fig. 1 Variant hepatic arterial anatomy. Superior mesenteric arteriogram demonstrates common hepatic artery (vertical arrow) arising from proximal superior mesenteric artery (horizontal arrow). The gastroduodenal artery is marked with an arrowhead.

Table 1 Variations in hepatic artery anatomy and their incidence.

Anatomical variation	Incidence (%)
Variant common hepatic artery (CHA)	
Origin from SMA	2.5
Origin from aorta	2.0
Variant proper hepatic artery	
Replaced RHA from SMA	12–14
Accessory RHA from SMA	6–8
RHA from aorta or CA or CHA	<2
Replaced LHA from LGA	11–12
Accessory LHA from LGA	11–12
LHA/LGA common trunk from aorta	1–2

CA, coeliac axis; LGA, left gastric artery; LHA, left hepatic artery; RHA, right hepatic artery; SMA, superior mesenteric artery.

Collateral pathways for the hepatic artery

In the event of stenosis or occlusion of the coeliac axis or the common hepatic artery, the proper hepatic artery is perfused through retrograde flow from the gastroduodenal artery through the pancreatico-duodenal arcades. Similarly, the accessory or replaced hepatic arteries provide excellent collateral pathways. Additionally, collateral pathways exist between phrenic and hepatic arteries at the liver capsule. Hepatocellular carcinomas can derive blood supply from the internal mammary, gastroepiploic, intercostal, phrenic and oesophageal arteries. The intrahepatic arteries are end arteries and collateral pathways within the intrahepatic segments are scant and imperfect [5].

Portal venography

Portal venography can be performed by placing a catheter in the portal vein (direct portal venography) or by other means without directly cannulating the portal vein (indirect portal venography). Portal vein patency and flow direction can be reliably imaged on colour Doppler sonography. CT and MRI are also useful in the detection of portal vein thrombus or tumour in the portal vein. The current indications for indirect portal venography are as follows:

- To assess patency of the portal vein before portosystemic shunt surgery.
- To assess patency of a portosystemic shunt (such as a splenorenal shunt).
- To study the portal haemodynamics (hepatopetal vs hepatofugal flow) when other imaging studies are inconclusive.
- Evaluation of portal vein for suspected vascular compromise following liver transplantation.

The indications for direct portal venography are as follows:

- All the indications of indirect portal venography when the results of indirect portal venography are inconclusive.
- To obtain portal vein pressures.
- As part of other interventional procedures such as portal vein embolization before liver surgery, autologous islet cell transplantation, embolization of gastric and oesophageal varices, and as part of transjugular intrahepatic portosystemic shunt (TIPS) procedure.
- Venous sampling for localization of endocrine tumours.

Techniques of portal venography

Direct portal venography can be performed via a percutaneous transhepatic approach, a transjugular transhepatic venous approach or by cannulating a patent umbilical vein in retrograde fashion. These are discussed in separate sections. The methods of indirect portal venography are arterial portography, splenoportography and wedged hepatic venography in patients with portal hypertension.

Arterial portography

During this study, either the superior mesenteric or the splenic artery is catheterized (through a femoral artery or brachial artery approach) and imaging is continued during the venous phase of arteriography (Fig. 2) [6]. This study requires a large volume of contrast material (40–60 mL injected at a rate of 6–8 mL/s) and filming is continued for 30–60 s. The drawbacks of this procedure include poor or inadequate opacification of the portal vein in patients with splenomegaly or due to hepatofugal flow in the portal vein. Another limitation is that a partial filling defect may be seen in the portal vein simulating a thrombus due to inflow from splenic vein during superior mesenteric artery (SMA) arterial portography or vice versa.

Splenoportography

Percutaneous splenoportography is performed by puncturing the spleen in the posterior axillary line with a 20–22 G needle and injecting contrast material into the spleen [7]. Portal pressures can be obtained by directly connecting the needle to a manometer as the splenic pulp pressure corresponds to portal pressure. During contrast injection the splenic and portal veins are opacified. The presence of portosystemic collaterals, oesophageal or fundal varices or hepatofugal flow may result in inadequate opacification of the portal vein. In addition, inflow of non-opacified blood from superior mesenteric or inferior mesenteric veins may simulate a thrombus in the splenic or portal veins. The main complications of this procedure are bleeding, which may require transfusions or splenectomy, injury to bowel, kidney or lung, and splenic artery aneurysms or arteriovenous fistulae. Embolization of the needle tract with Gelfoam (Pfizer Inc., New York, USA) decreases bleeding complications [8].

Fig. 2 Arterial portography. The superior mesenteric artery is catheterized (white arrow). The venous phase of the arteriogram depicts the portal vein (horizontal black arrow). The coronary vein (vertical black arrow) and gastric varices are also seen. The right portal vein is occluded (arrowhead) due to thrombus from a hepatoma.

Wedged hepatic venography

In patients with portal hypertension, wedged hepatic venography provides good opacification of the portal vein. This procedure is performed by placing a catheter in a hepatic vein tributary (through either a transjugular or femoral vein approach), such that the catheter wedges in the lumen of the hepatic vein, and contrast material is injected through the catheter. As an alternative, a balloon catheter can be used to occlude the hepatic vein. In patients with no portal hypertension, the contrast material opacifies other hepatic veins through hepatic venous collaterals. However, in patients with portal hypertension, the portal vein is opacified (Fig. 3). A hepatofugal flow may opacify the splenic, mesenteric veins and portosystemic collaterals. The degree of portal vein opacification depends on portal venous pressure and flow direction. In addition, the use of less viscous contrast material (such as CO_2) rather than the highly viscous iodinated contrast material provides better opacification of the portal vein [9]. The normal wedged hepatic venous pressure is <10 mmHg. The wedged hepatic venous pressure roughly equals the portal vein pressure. However, in patients with well-developed portosystemic collaterals, the wedged hepatic venous pressure may be less than the portal vein pressure. The wedged hepatic venous pressure is normal in patients with presinusoidal or extrahepatic types of

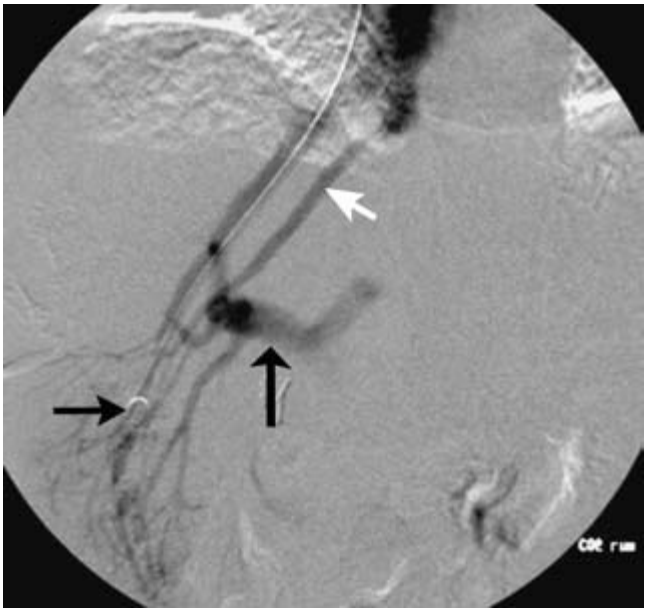

Fig. 3 Wedged hepatic venography in a patient with moderate portal hypertension. A balloon occlusion catheter is placed in the right hepatic vein (horizontal black arrow) and CO_2 venography is performed. There is opacification of the right (vertical black arrow) and left portal veins. There is also opacification of other hepatic veins (white arrow).

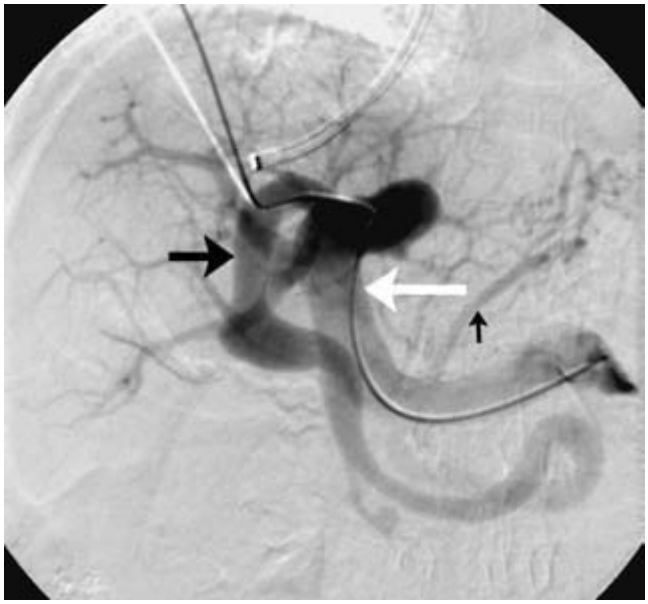

Fig. 4 Portography through umbilical vein catheterization. The umbilical vein (horizontal black arrow) is catheterized and the catheter tip is in the splenic vein. The coronary vein (vertical black arrow) and the portal vein (white arrow) are well seen.

portal hypertension. A falsely elevated wedged hepatic venous pressure may be recorded if pressure measurements are obtained after contrast material injection. The complications of wedged hepatic venography are minimal and include access site haematoma, injury to hepatic veins, haemorrhagic infarction and hepatic perforation [10].

Portal venography through patent umbilical vein

A patent umbilical vein, especially in patients with portal hypertension, provides a route for direct access to the portal vein [11]. The umbilical vein can be catheterized through the anterior abdominal wall under ultrasound guidance. Direct pressure measurements in the portal vein and portography can be performed (Fig. 4). The main limitation is that the umbilical vein is patent in only a few patients with portal hypertension. The complications are minimal and include bleeding and injury to liver, pleura and pericardium.

Percutaneous transhepatic portal venography

Percutaneous transhepatic portal venography is performed from the right midaxillary line at the 9–10th intercostal space using a 22 G Chiba needle. Generally, the right portal vein is opacified and the needle is exchanged for a catheter, which is placed in the main portal vein. Pressure measurements are obtained and portal venography undertaken. The catheter tract is usually embolized with Gelfoam upon completion of the study [12]. The main complications of the procedure are haemorrhage, injury to the pleura or intestine, traumatic pseudoaneurysm of the hepatic artery, and infection.

Transjugular transhepatic portal venography

Transjugular transhepatic portal venography is usually a part of the TIPS (transjugular intrahepatic portosystemic shunt) procedure [13]. Once the hepatic vein is cannulated through a transjugular route, access to the portal vein is obtained using a Colapinto needle. The portal vein is opacified and the needle is exchanged for a catheter over a wire. Portal venography and pressure measurements are performed (Fig. 5). The complications of this procedure are bleeding, traumatic pseudoaneurysm of the hepatic artery, injury to gallbladder, bile leak, injury to intestine and infection.

Normal portal venous anatomy

The splenic and superior mesenteric veins join at the pancreatic head to form the main portal vein. In the porta hepatis the main portal vein lies anterior to the common bile duct and to the right of the hepatic artery. As it enters the liver, it divides into right and left portal veins. The branching pattern is dichotomous and follows the branching pattern of the hepatic artery.

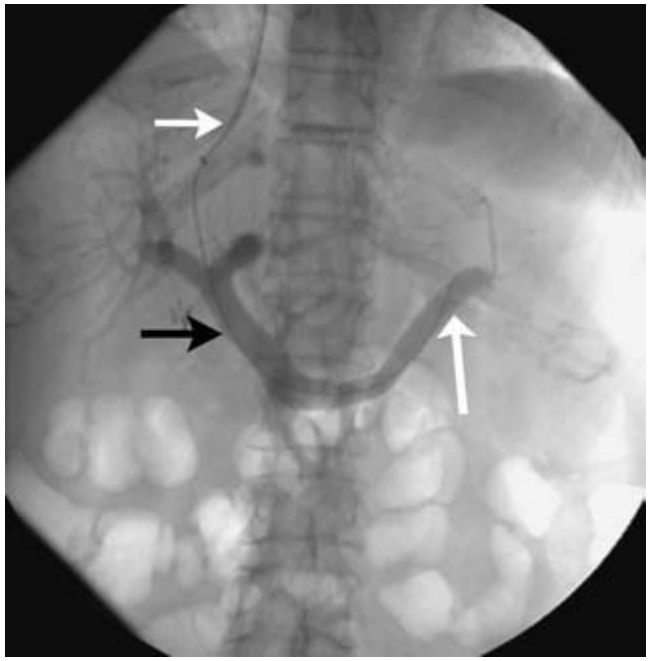

Fig. 5 Transjugular portography. The portal vein (black arrow) was catheterized through transjugular access. There is a large sheath in the hepatic vein (horizontal white arrow) and the catheter's tip is in the splenic vein (vertical white arrow).

Portosystemic collateral pathways

Multiple communications exist between the portal venous circulation and systemic veins that serve as collateral pathways in patients with portal hypertension [14]. These are listed in Table 2.

Hepatic venography

Hepatic vein catheterization and venography are indicated in the following circumstances.

- Measurement of free hepatic vein pressure and wedged hepatic vein pressure in patients with portal hypertension.
- During wedged hepatic venography to document patency and flow reversal in patients with portal hypertension.
- To detect occlusion or thrombus in hepatic veins.
- As a part of other interventional procedures such as transjugular liver biopsy and transjugular intrahepatic portosystemic shunt procedure.

Techniques of hepatic venography

There are several methods to opacify the hepatic veins.

- The hepatic veins can be catheterized through either the transjugular approach or femoral vein approach. Other approaches include subclavian vein or antecubital vein.
- Inferior venacavography with the Valsalva manoeuvre results in reflux of the contrast material into the hepatic veins.
- Percutaneous transhepatic venography can be performed if other methods are unsuccessful. In this method, a 22 G Chiba needle is used to inject 10–15 mL of contrast material into the hepatic parenchyma. In normal liver, this produces a dense parenchymal stain and, later, multiple hepatic veins are opacified. The portal vein radicals and hepatofugal flow may be seen in patients with portal hypertension.

Complications of hepatic venography

Hepatic venography is a safe procedure and complications are minimal. The complications include intrahepatic haematoma, focal haemorrhagic infarcts and hepatic perforation with subcapsular injection of contrast medium (especially during wedged hepatic venography).

Pathology

Angiography is rarely performed as a diagnostic test for evaluation of focal or diffuse liver disease. However, lesions may be detected on angiography performed for other indications, and it is important to know the angiographic appearances of various focal and diffuse liver diseases. The following sections describe briefly the imaging appearances of various diseases on angiography.

Table 2 Connections between the portal venous system and systemic veins that can serve as collaterals in portal hypertension.

Portal vessels	Connect to
Portal vein tributary (normally drains into the portal vein)	Systemic vein tributary (drains into SVC/IVC)
Oesophageal, gastric cardiac veins	Oesophageal veins of azygos, hemiazygos veins
Oesophageal, gastric cardiac veins	Left phrenic vein, which drains into left renal vein
Superior haemorrhoidal veins of inferior mesenteric vein	Middle and inferior rectal haemorrhoidal veins, which drain into internal pudendal veins
Splenic vein	Retroperitoneal veins such as renal, adrenal and phrenic veins
Recanalized umbilical vein (communicates with left portal vein)	Epigastric veins in the anterior abdominal wall
Mesenteric vein tributaries	Retroperitoneal veins
Patent ductus venosus (communicates left portal vein directly to IVC)	IVC

IVC, inferior vena cava; SVC, superior vena cava.

Neoplasms

Angiography plays an important role in the management of liver malignancies. It is part of interventional procedures such as transcatheter tumour embolization, and portal vein embolization to induce liver hypertrophy before liver resection. Angiography may also be used to detect focal hypervascular liver tumours that are not visible or incompletely characterized on other modalities. Angiography is also useful in characterizing suspected perfusion abnormalities detected on CT or MRI. Angiography may also be used to evaluate the hepatic arterial anatomy before chemotherapy pump placement or hepatic resection. CT arteriography and CT arterioportography require selective cannulation of the hepatic artery and splenic or mesenteric artery respectively. These two procedures are performed for the workup of hepatomas and metastases and for detecting small tumours in the liver.

Hepatic tumours are of either hepatocyte origin or non-hepatocyte origin. Tumours can also be divided into benign and malignant. Tumours of hepatocyte origin are supplied by the hepatic artery and tend to be hypervascular. The angiographic appearance depends on the size of the tumour, presence of haemorrhage or necrosis within the tumour and prior therapy. The angiographic findings of tumours (Fig. 6) in general are as follows:

- tumour neovascularity;
- arteriovenous shunting;
- tumour stain;
- contrast pooling or 'lakes';
- displacement of vessels;
- enlargement of feeding artery;
- vascular ingrowth or invasion or occlusion.

The angiographic appearances of various liver tumours are listed in Table 3 [15,16].

Trauma

CT is the initial imaging test for blunt and penetrating trauma. CT is useful for diagnosing subcapsular haematoma, liver contusion and laceration. Angiography is indicated in suspected major arterial injury in patients with acute trauma, for evaluation of haemobilia following trauma (especially following biliary interventions), suspected traumatic pseudoaneurysm on CT, and in the evaluation of traumatic haematoma in the liver. Hepatic arteriography may show active extravasation of contrast material at the site of laceration or amputation or occlusion of hepatic arteries, pseudoaneurysm (Fig. 7) or arterioportal or arteriobiliary fistulae [17]. Intrahepatic haematoma appears as a focal defect during the parenchymal phase with displacement of hepatic arteries. An infected haematoma may show peripheral rim enhancement. Mycotic aneurysms may be seen in association with infected haematomas. Subcapsular haematomas result in characteristic curvilinear configuration to the liver edge during the parenchymal phase. Embolization of the hepatic artery can be successfully performed for traumatic injuries using Gelfoam, particles or coils [18]. Portal vein patency should be assessed prior to embolizing the hepatic artery. Injuries to the portal vein are rarely encountered in practice as these result in profound haemodynamic instability and such patients are usually taken for immediate surgery. In major trauma, inferior vena cavography should also be performed to assess injury to the intrahepatic portion of the inferior vena cava.

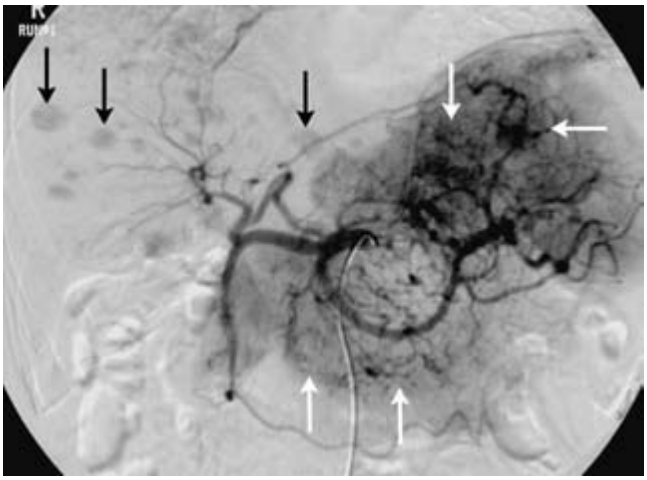

Fig. 6 Multicentric hepatoma. Coeliac axis angiogram shows multiple hypervascular liver lesions in the right lobe (black arrows). A large lesion in the left lobe (white arrows) demonstrates neovascularity, arteriovenous shunting and tumour stain.

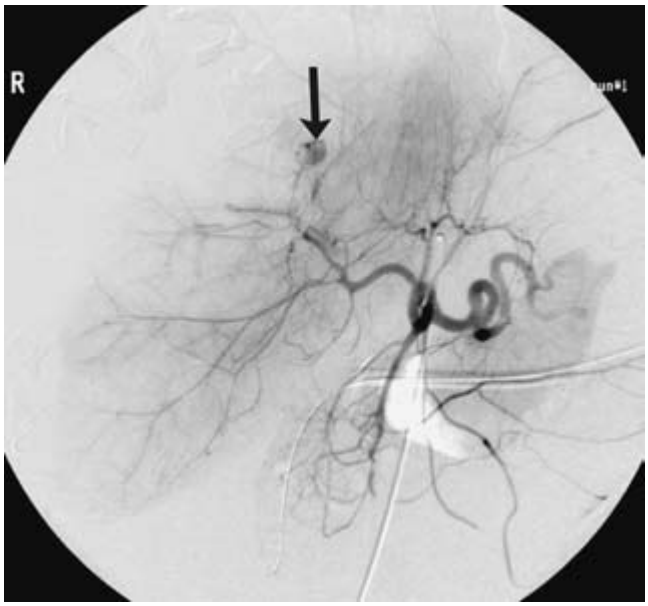

Fig. 7 Post-traumatic hepatic artery pseudoaneurysm. Coeliac axis angiogram in a 20-year-old male with hepatic laceration on CT following a motor vehicle accident. There is a pseudoaneurysm (arrow) arising from a branch of the right hepatic artery. This was successfully embolized.

Table 3 Angiographic appearances of liver tumours.

Tumour	Appearance during hepatic arteriography
Hepatic adenoma	Round, well-circumscribed hypervascular lesion with enlarged hepatic artery that is displaced to the periphery of the tumour; tumour vessels in the periphery of the lesion; diffuse parenchymal stain; focal areas of hypovascularity if the lesion is complicated by haemorrhage and necrosis
Focal nodular hyperplasia	Well-circumscribed hypervascular liver lesion that is subcapsular in location; 'spoke-wheel pattern' in small tumours as the hepatic artery enters the tumour centrally and divides into branches; enlarged displaced hepatic artery in large lesions; fine granular appearance in parenchymal phase with radiolucent septae or scar
Capillary haemangioma	Enlarged hepatic artery that divides into a capillary network; tumour stain
Cavernous haemangioma	Normal sized hepatic artery, splaying of hepatic artery if the tumour is large; irregular, nodular contrast pooling ('lakes') occurring in the periphery of the lesion and progressively moving towards the centre of the lesion and persisting during the venous phase; occasional phleboliths
Peliosis hepatis	Appearance similar to cavernous haemangioma; however, the 'contrast pooling' is not as dense and nodular as in cavernous haemangioma, and does not progress to the centre of the lesion
Regenerating nodule	No neovascularity; lesions isodense or hypodense to liver in parenchymal phase; hepatic artery branch at the centre of the lesion; displaced portal vein and hepatic vein branches if the lesion is large
Haemangioendothelioma	Enlarged hepatic artery; hypervascular lesion with no neovascularity; contrast pooling similar to haemangiomas with early washout; arteriovenous shunting
Hepatocellular carcinoma	Solitary or multicentric or diffuse; enlarged hepatic artery; hypervascular lesion with neovascularity; dense tumour stain; arterioportal shunting (Fig. 6); vascular encasement; vascular ingrowth into the portal vein or the hepatic vein; extrahepatic arterial supply from phrenic, intercostal, internal mammary and gastroduodenal arteries
Metastases	Angiographic appearance depends on the size and histology of the tumour; hypervascular metastases (carcinoid, islet cell, choriocarcinoma, renal cell, thyroid) demonstrate neovascularity, tumour stain and vascular encasement Hypovascular metastases demonstrate vascular displacement, tumour stain. Portal venography may show amputation or encasement of portal vein branches
Cholangiocarcinoma	Encasement; displacement of hepatic artery branches and portal vein; absent or minimal tumour stain
Hepatoblastoma	Enlarged hepatic artery; hypervascular tumour with neovascularity; tumour stain and arteriovenous shunting

Infections and inflammatory disorders

Angiography is rarely performed in the evaluation of hepatic infections and inflammatory disorders. Ultrasound and CT are the imaging tests for diagnosis of various focal infections. Angiographic appearances of abscesses and hepatitis are of historic interest. Abscesses may show displacement of vessels with focal defects in the parenchymal phase of the hepatic arteriogram. A peripheral rim enhancement may be seen. A few abscesses are hypervascular and show dilated tortuous vessels in the periphery with arteriovenous shunting. In acute hepatitis, the intrahepatic arteries are stretched and splayed with slow flow and dense inhomogeneous hepatogram.

Cirrhosis

Although angiography is not a diagnostic test in the evaluation of cirrhosis of the liver, angiographic appearances are characteristic and may help stage the disease [19]. The morphological changes in vessels and flow patterns are secondary to parenchymal fibrosis and increased portal venous pressure. During the early stage, hepatic arterial flow may be normal or the arteries may demonstrate delayed filling. The arteries may show stretching with a normal hepatogram. The portal venous flow is hepatopetal with normal morphology. Wedged hepatic venography shows an inhomogeneous sinusoidal pattern with no portal vein opacification. During the advanced stages, the arteries show enlargement with increased flow to the liver and occasional portal vein filling during the venous phase. The intrahepatic arteries demonstrate a corkscrew appearance (Fig. 8) with dense hepatogram. The portal vein radicals show change in calibre with tortuosity and hepatofugal or bidirectional flow pattern. The umbilical vein may be recanalized (Cruveilhier–Baumgarten syndrome) and other portosystemic collaterals may be seen. Wedged hepatic venography shows preferential filling of the portal vein with minimal or no opacification of hepatic veins.

Portal hypertension

Portal hypertension is classified based on the location of obstruction to normal portal venous flow. The types are presinusoidal (either extrahepatic or intrahepatic), sinusoidal or postsinusoidal. The indications for angiographic evaluation of portal hypertension are as follows [19]:

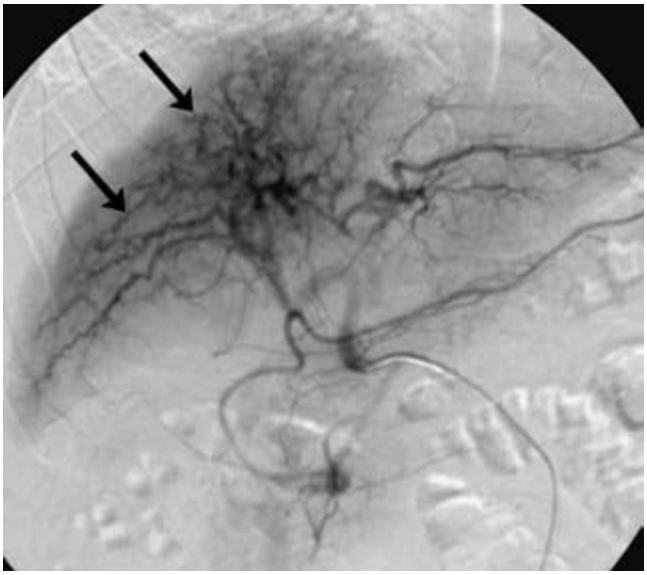

Fig. 8 Arteriographic appearance of cirrhotic liver. Late phase common hepatic arteriogram demonstrates corkscrew appearance (arrows) of intrahepatic arteries with dense hepatogram predominantly affecting the right lobe.

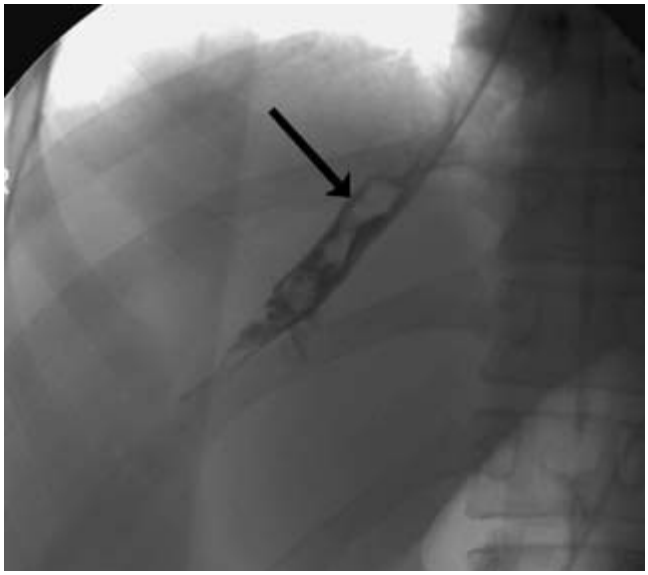

Fig. 9 Hepatic vein thrombosis in a patient with Budd–Chiari syndrome. Hepatic venography with catheter in the right hepatic vein demonstrates multiple filling defects (arrow) consistent with thrombus.

• To assess the severity of portal hypertension by pressure measurements and haemodynamic evaluation.
• To differentiate various types of portal hypertension.
• To evaluate patency of the portal venous system, surgical portosystemic shunts and TIPS.
• To demonstrate and embolize gastric and oesophageal varices.

The classification of portal hypertension is covered in Chapter 7.2. and its assessment is considered in Chapter 7.4

Budd–Chiari syndrome

Budd–Chiari syndrome is due to hepatic venous outflow obstruction. The obstruction may be in the hepatic veins – due to thrombus (Fig. 9) or tumour – or suprahepatic either in the inferior vena cava (thrombus, web, tumour) or in the heart (right heart failure, constrictive pericarditis). The intrahepatic type is common in women. Hepatic venography fails to demonstrate a main hepatic vein and multiple venous collaterals may be seen in spiderweb fashion during percutaneous hepatic venography [20,21]. Thrombi in the hepatic veins may be seen as filling defects. The hepatic wedge pressure is elevated. A web, thrombus, tumour or extrinsic impression may be demonstrable during inferior vena cavography. Portal venography shows bidirectional or hepatofugal flow with portosystemic collaterals. Hepatic arteriography may show stretching and splaying of hepatic arterial branches with inhomogeneous hepatogram due to congestive hepatomegaly.

Portosystemic shunts

Angiography of portosystemic shunts or TIPS is indicated when shunt malfunction is suspected and endovascular therapy is planned. During the evaluation of these shunts, pressure gradients across the anastomosis and contrast venography are obtained. Angioplasty and stent insertion may be performed whenever indicated.

Diseases of blood vessels

Aneurysms, arteriovenous fistulae, atherosclerosis, emboli, dissection and vasculitis may affect the hepatic arteries. Aneurysms are often post-traumatic and are usually intrahepatic. Atherosclerotic hepatic aneurysms affect the extrahepatic arteries (Fig. 10) and have a high risk of rupture [22]. Mycotic aneurysms are secondary to infected haematomas or abscesses. Multiple intrahepatic aneurysms may be seen in systemic vasculitis syndromes such as polyarteritis nodosa. Arteriography is indicated for diagnosis and treatment planning. Endovascular therapy may be attempted in intrahepatic aneurysms using particles or coils. Extrahepatic aneurysms are usually treated surgically. Atherosclerotic disease of the hepatic arteries is part of systemic arterial disease, and calcified and non-calcified plaques, vessel narrowing and occlusions may be seen affecting the extrahepatic arteries. Embolic occlusion is rare and is often due to emboli from the heart. Dissection of hepatic arteries is iatrogenic during catheter manipulation during selective hepatic arteriography. These dissections appear as focal or diffuse

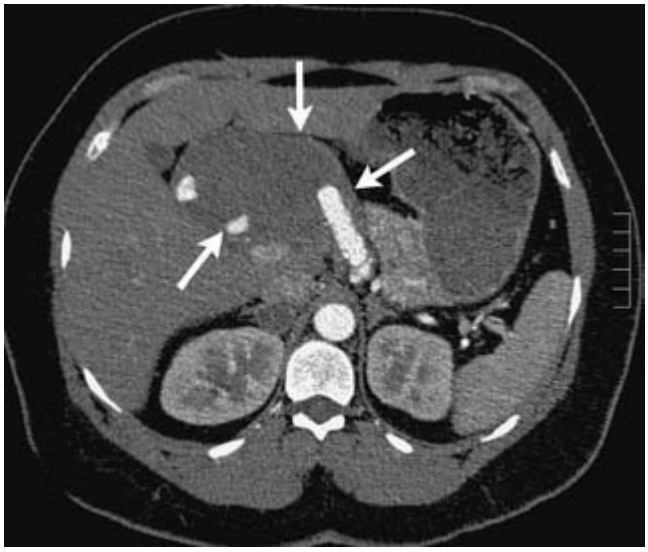

(a)

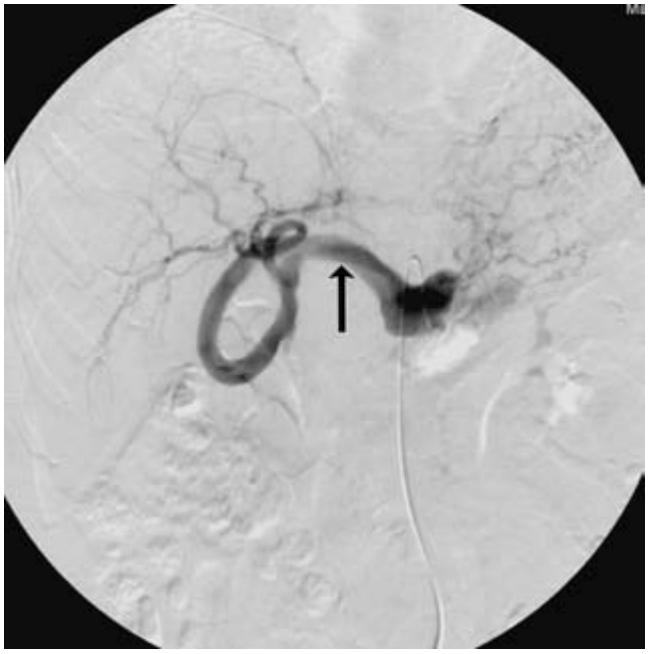

(b)

(c)

Fig. 10 Aneurysm of common hepatic artery. (a) CT scan of the abdomen shows a large aneurysm (arrows) affecting the common hepatic artery. There is thrombus within the aneurysm. (b) Angiography with catheter in the common hepatic artery shows a large false lumen (arrow) that communicates with the true lumen and fills intrahepatic arteries. (c) After embolization with coils (black arrows), the aneurysm is no longer filling. The intrahepatic arteries are seen (vertical white arrow) filling through capsular collaterals (arrowheads) from the right phrenic artery (horizontal white arrow).

narrowing, vessel occlusion and may resolve without any treatment. Fibromuscular dysplasia may affect the common hepatic artery, and the artery appears 'beaded' with multiple areas of focal narrowing and dilatation on arteriography. Various systemic vasculitis syndromes may affect the hepatic arteries and the angiographic appearance is non-specific with areas of diffuse or focal smooth narrowing and multiple aneurysms [23].

Evaluation of transplanted liver

Angiographic evaluation of a transplanted liver is indicated when liver function tests are abnormal and vascular compromise is suspected. Angiographic evaluation is usually preceded by non-invasive evaluation with ultrasound or MRI [24]. Aortography and selective arteriography are performed when arterial anastomotic stenosis or hepatic artery thrombosis is suspected. A pressure gradient across the anastomosis may be obtained. In the immediate postoperative period, treatment is surgical. Transluminal angioplasty may be performed during the late postoperative period [25]. When hepatic venous anastomotic stricture is suspected, MRI is usually sufficient; however, selective hepatic venography may be performed and the pressure gradient may be measured when MRI results are equivocal. Transjugular liver biopsy may be performed in acute and chronic rejections.

References

1 Dittman W (1982) Hepatic angiography. *Semin Liver Dis* 2, 41–48.
2 Covey AM, Brody LA, Maluccio MA *et al.* (2002) Variant hepatic arterial anatomy revisited: digital subtraction angiography performed in 600 patients. *Radiology* 224, 542–547.
3 Jones RM, Hardy KJ (2001) The hepatic artery: a reminder of surgical anatomy. *J R Coll Surg Edinb* 46, 168–170.
4 Bonn J (1996) Diagnostic visceral normal and variant anatomy – celiac, superior mesenteric and inferior mesenteric arteries. In: Haskal ZJ, Kerlan RK, Trerotola SO (eds) *Thoracic and Visceral Vascular Interventions*. SCVIR syllabus. Fairfax, VI: Society of Cardiovascular and Interventional Radiology, pp. 153–163.
5 Charnsangavej C, Chuang VP, Wallace S *et al.* (1982) Angiographic classification of hepatic arterial collaterals. *Radiology* 144, 485–494.
6 Herlinger H (1978) Arterioportography. *Clin Radiol* 29, 255–275.
7 Zamir O, Mogle P, Lernau O, Nissan S (1984) Splenoportography – a reappraisal. *Am J Gastroenterol* 79, 283–286.
8 Brazzini A, Hunter DW, Darcy MD *et al.* (1987) Safe splenoportography. *Radiology* 162, 607–609.
9 Martinez-Cuesta A, Elduayen B, Vivas I *et al.* (2000) CO(2) wedged hepatic venography: technical considerations and comparison with direct and indirect portography with iodinated contrast. *Abdom Imaging* 25, 576–582.
10 Castaneda-Zuniga WR, Jauregui H, Rysavy JA *et al.* (1978) Complications of wedge hepatic venography. *Radiology* 126, 53–56.
11 Pochaczevsky R, Calem WS, Richter RM (1967) Umbilical vein portography. Its value in the diagnosis of extrahepatic portal vein obstruction and in other applications. *Radiology* 89, 868–873.
12 Burcharth F (1979) Percutaneous transhepatic portography. I. Technique and application. *AJR Am J Roentgenol* 132, 177–182.
13 Stanley AJ, Jalan R, Forrest EH *et al.* (1996) Longterm follow up of transjugular intrahepatic portosystemic stent shunt (TIPSS) for the treatment of portal hypertension: results in 130 patients. *Gut* 39, 479–485.
14 Ahn J, Cooper JM, Silberzweig JE, Mitty HA (1997) Venographic appearance of portosystemic collateral pathways. *Br J Radiol* 70, 1302–1306.
15 Freeny PC (1983) Angiography of hepatic neoplasms. *Semin Roentgenol* 18, 114–122.
16 Watson RC, Baltaxe HA (1971) The angiographic appearance of primary and secondary tumors of the liver. *Radiology* 101, 539–548.
17 Schorn L, Coln D (1977) Hepatic angiographic changes after trauma. *Am J Surg* 134, 754–757.
18 Mohr AM, Lavery RF, Barone A *et al.* (2003) Angiographic embolization for liver injuries: low mortality, high morbidity. *J Trauma* 55, 1077–1081.
19 Kadir S (1986) Angiography of the liver, spleen and pancreas. In: Kadir S (ed.) *Diagnostic Angiography*. Philadelphia: WB Saunders.
20 Maguire R, Doppman JL (1977) Angiographic abnormalities in partial Budd-Chiari syndrome. *Radiology* 122, 629–635.
21 Wilson MW, Ring EJ, LaBerge JM *et al.* (1996) Percutaneous transhepatic venography in the delineation and treatment of Budd-Chiari syndrome. *J Vasc Interv Radiol* 7, 133–138.
22 Abbas MA, Fowl RJ, Stone WM *et al.* (2003) Hepatic artery aneurysm: factors that predict complications. *J Vasc Surg* 38, 41–45.
23 Herskowitz MM, Flyer MA, Sclafani SJ (1993) Percutaneous transhepatic coil embolization of a ruptured intrahepatic aneurysm in polyarteritis nodosa. *Cardiovasc Intervent Radiol* 16, 254–256.
24 Nghiem HV, Tran K, Winter TC 3rd *et al.* (1996) Imaging of complications in liver transplantation. *Radiographics* 16, 825–840.
25 Abbasoglu O, Levy MF, Vodapally MS *et al.* (1997) Hepatic artery stenosis after liver transplantation – incidence, presentation, treatment, and long term outcome. *Transplantation* 63, 250–255.

5.6.5 Endoscopic retrograde cholangiopancreatography

Alan J. Wigg and James Toouli

Introduction

Since the first descriptions of therapeutic endoscopic retrograde cholangiography (ERCP) in 1975, this technique has gained rapid and widespread acceptance in the diagnosis and management of a variety of biliary and pancreatic diseases. With advances in alternative techniques, the role of ERCP has changed now mostly to a therapeutic one. However, it should be noted that expertise in ERCP remains the most widely available, and newer approaches to therapy and diagnosis described below remain unavailable in many centres. In this chapter, we focus on the role of ERCP in the diagnosis and therapy of some common biliary diseases and also on important current controversies. The role of ERCP in sphincter of Oddi dysfunction is covered elsewhere in this book, and its role in pancreatic diseases is not discussed in this chapter.

ERCP in diagnosis

Bile duct stones

The sensitivity and specificity of clinical, biochemical and transabdominal ultrasound variables (fever, cholangitis, pancreatitis, abnormal liver function tests, dilated bile ducts) is poor. Mathematical models using combinations of these variables may improve the ability to predict the presence of bile duct stones, but they remain too imprecise for routine clinical use [1]. This problem has previously led to the routine use of ERCP in the diagnosis of suspected bile duct stones. Although ERCP has the obvious advantage of enabling definitive therapy to be performed immediately following the diagnosis of bile duct stones, this approach exposes a significant number of patients, without bile duct stones, to the risks associated with this invasive procedure. In the commonly encountered clinical situation in which there are associated gallstones, our approach is to proceed to laparoscopic cholecystectomy and use intraoperative cholangiography for diagnosis of suspected common bile duct stones. However, in instances in which the gallbladder stones may not be the primary candidate for suspecting bile duct pathology or where patient comorbidities make laparoscopic cholecystectomy high risk, a less invasive approach for diagnosis

is justified. The emergence of sensitive and specific non-invasive biliary imaging modalities including magnetic resonance cholangiopancreatography (MRCP), endoscopic ultrasound (EUS) and computerized tomographic cholangiography (CTC) are now changing the role of diagnostic ERCP in this setting.

The performance characteristics of these new modalities have been compared with ERCP by multiple investigators. However, a number of problems hamper the interpretation of these studies. First, ERCP has frequently been used as the gold standard to measure sensitivity, specificity, positive predictive and negative predictive values of the alternative diagnostic test. As ERCP may also have false-positive and false-negative findings in the diagnosis of bile duct stones, most of these studies measure only concordance with ERCP findings, and the results can only be worse than ERCP. Most studies have also suffered from small size and therefore inadequate power to detect what appear to be small differences in performance characteristics between the various tests.

MRCP, using state of the art technology, experienced radiologists and single breath-hold techniques, has demonstrated good concordance with ERCP in the diagnosis of bile duct stones (see Fig. 1). Sensitivities and specificities for MRCP in this setting have both been higher than 90% in most studies [2,3]. In one study, where endoscopic or surgical stone extraction was used as the gold standard rather than ERCP images, the sensitivity of ERCP (100%) was shown to be superior to that of MRCP (91%), but specificities were the same (both 100%) [4]. As the resolution of MRCP currently remains less than that of good-quality fluoroscopic ERCP images, a reduced sensitivity of MRCP due to lack of detection of smaller bile duct stones (< 5 mm) has been suggested by several authors [4–6].

The use of EUS in the diagnosis of bile duct stones was first described in 1992 [7]. The superior sensitivity of EUS compared with conventional transabdominal ultrasound and computerized tomography (CT) has been demonstrated [8], and nine reasonable quality studies have reported results comparing the performance characteristics of EUS vs. ERCP in the detection of bile duct stones [2]. In most of these studies, independent gold standards have been available as a result of endoscopic or surgical stone removal following both EUS and ERCP. The sensitivities of both techniques have been similar in these studies ranging from 84% to 96% for EUS and 79% to 100% for ERCP. Specificities have also been very similar in all studies ranging from 97% to 100% for EUS and 87% to 100% for ERCP. Significantly different differences in performance characteristics between the tests have not been reported.

CTC has also been proposed as a non-invasive alternative to ERCP for the diagnosis of bile duct stones. Comparison studies with ERCP are difficult to interpret because of differences in the choice of gold standard and the variety of contrast techniques used (none, oral, intravenous). In studies with independent reference standards, sensitivities appear to be lower than those for ERCP, ranging from 71% to 88% [9–12]. Specificities were 95% and above for three of these four studies. These studies provide an impression of lower sensitivity of CTC for the detection of bile duct stones, but more rigorous comparison is not possible.

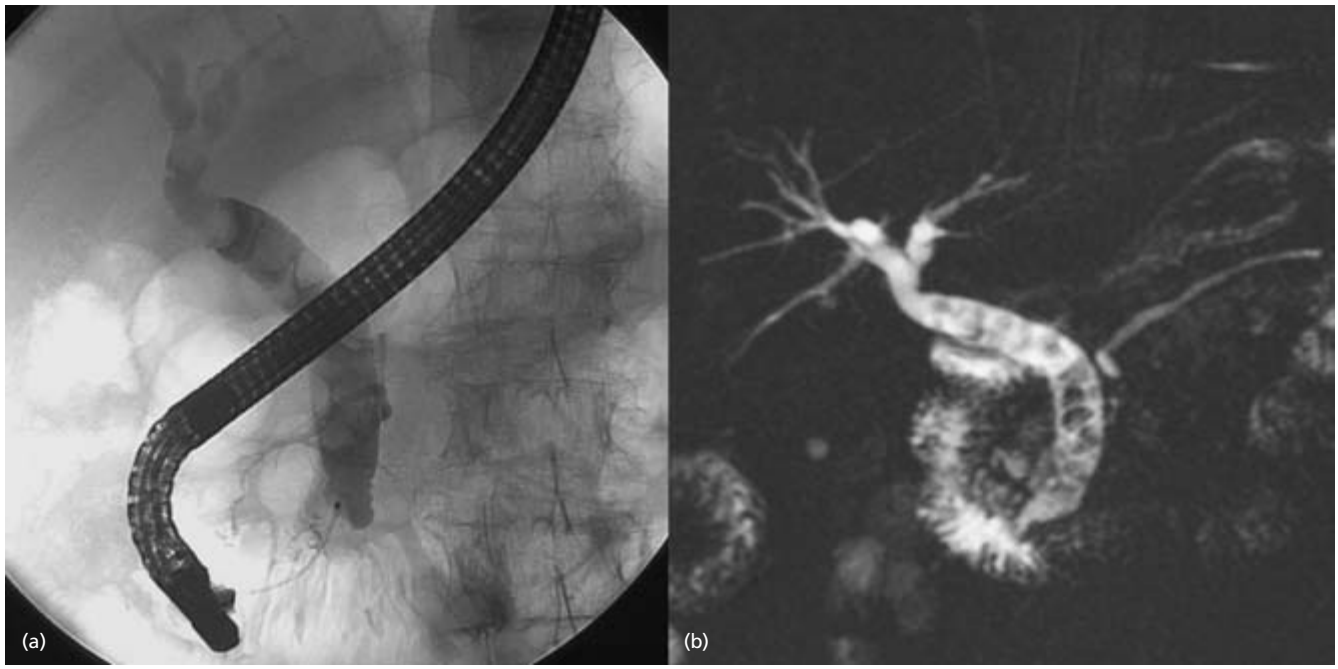

Fig. 1 Cholangiography of the same patient with ERCP (a) and MRCP (b) showing multiple filling defects due to bile duct stones.

On the basis of current evidence, the diagnostic performance of ERCP, MRCP and EUS appears to be equivalent in patients with suspected bile duct stones. However, the use of these tests is also determined by other important factors, including the probability of therapy and local expertise. In situations in which the probability of therapy is high, non-invasive diagnostic tests are likely to increase the expense and time required to treat patients with bile duct stones. Conversely, where the probability of therapy is lower, the use of non-invasive diagnostic tests has been shown to reduce the numbers of unnecessary ERCPs, morbidity and costs associated with the investigation of suspected bile duct stones [5,13,14]. The choice of non-invasive diagnostic test will vary according to available expertise. Proponents of EUS have advocated an approach in which EUS is performed immediately prior to ERCP, thus enabling avoidance of ERCP in those without stones demonstrated by EUS [13]. For most institutions, the logistics of such an approach are prohibitive. We favour MRCP in this setting as the technique is more widely available, is non-invasive with negligible morbidity and mortality and can be performed in an outpatient setting. The greatest use of MRCP in the diagnosis of bile duct stones is likely to be in the evaluation of patients with low to intermediate probability of bile duct stones who do not require cholecystectomy. Neither MRCP nor ERCP should be used routinely to rule out stones prior to laparoscopic cholecystectomy, as intraoperative cholangiography in this setting is the most cost-effective and efficient means.

Biliary strictures

Biliary strictures causing obstruction have a variety of benign (inflammatory, chronic pancreatitis) and malignant causes (pancreatic and gallbladder cancer, cholangiocarcinoma, portal metastases). Definitive diagnosis of such strictures and differentiation between a benign and a malignant process is a common challenge confronting clinicians. The role of ERCP in diagnosis appears to be changing following the introduction of several alternative diagnostic techniques.

Studies investigating the ability of MRCP and direct cholangiography to differentiate benign from malignant pancreaticobiliary strictures that have used independent reference standards (subsequent histology or follow-up) have demonstrated equivalent accuracy [15,16]. Initial MRCP also has a number of advantages in the setting of biliary obstruction. It avoids the risk of infection following contrast injection and incomplete subsequent drainage at ERCP. In conjunction with abdominal magnetic resonance imaging (MRI), it can provide useful information about surrounding abdominal structures that is not provided by ERCP. Proximal ducts beyond a stricture may be more easily seen, allowing more careful planning of future stent placements. Failure to obtain a cholangiogram is rare with MRCP and occurs less commonly than unsuccessful ERCP. MRCP can also be performed in patients with Roux-en-Y choledochojejunostomy or Bilroth II gastroenterostomy.

Multislice or multidetector CT, in which rapid 1- to 1.5-mm sections are performed, is another technique that is useful in the assessment of biliary obstruction due to strictures. It has been widely used in the evaluation of pancreatic neoplasms and their resectability. It may also be a reasonable alternative or complementary to MRCP in the evaluation of malignant obstruction, with high sensitivity and specificity for malignant obstruction reported in one study [17].

With suspected malignant strictures, tissue sampling techniques using ERCP have been the mainstay of definitive diagnosis. Such techniques have included brush cytology, bile or pancreatic juice aspiration for cytology, forceps biopsy and fine-needle aspiration (FNA) cytology. The technical difficulties associated with forceps biopsy and FNA cytology and the poor sensitivity of juice aspiration cytology have meant that most endoscopists use brush cytology alone. The sensitivity of brush cytology alone, however, remains poor with most studies reporting sensitivities between 30% and 70%. Techniques such as the use of microsatellite markers or DNA image analysis, when combined with brush cytology, may have the potential to improve the sensitivity of this technique, but are not currently widely available [18,19].

To improve the accuracy of tissue sampling, EUS-guided FNA of biliary strictures has been evaluated by a number of groups, with varying reported sensitivities for the diagnosis of malignancy. In one study directly comparing ERCP and brush biopsy with EUS-guided FNA, sensitivities were similar for both modalities (46% and 43% respectively) [20]. It is likely that EUS-guided FNA will be more useful as an adjunct to ERCP, following non-diagnostic ERCP intraductal tissue sampling. Higher sensitivities (86–89%) for the diagnosis of malignancy, leading to significant impacts on patient management, have been described using such an approach [21,22].

Intraductal ultrasound (IDUS) has also been proposed as a useful adjunct during ERCP to improve sensitivity in the diagnosis of malignant bile duct strictures. With this technique, a high-frequency ultrasound catheter is passed over a guidewire and into the bile duct during ERCP. Although this technique does not provide tissue, a number of ultrasonographic criteria have been proposed which suggest malignancy. In the hands of enthusiasts, the combination of ERCP and IDUS has been reported to be as sensitive than ERCP and ERCP biopsy techniques alone for the diagnosis of malignant strictures [23,24].

In summary, the diagnosis of biliary strictures often remains difficult. Where available, the use of abdominal MRI and MRCP is a useful initial strategy with less morbidity and equivalent diagnostic performance to ERCP. It also frequently enables proper planning of subsequent therapeutic procedures. Diagnostic (to obtain tissue specimens) and therapeutic ERCP will also frequently be required. Failure to obtain a tissue diagnosis with intraluminal biopsy techniques is a common problem due to the low sensitivity of ERCP tissue sampling methods. In this setting, the use of complementary testing including EUS-guided FNA or IDUS should be considered if available.

ERCP in therapy

Bile duct stones

Bile duct stones (choledocholithiasis) are associated with symptomatic gallbladder stones in 10–15% of cases. The majority of bile duct stones are formed in the gallbladder and then migrate to the bile duct. Bile duct stones may also form in the bile duct. These 'primary' bile duct stones are more common in Asian populations and may be associated with biliary stasis and infection. Symptoms and complications from bile duct stones are more frequent than with gallstones so, when discovered, their removal is usually indicated. Common clinical manifestations of bile duct stones and the role of ERCP in each are discussed below. ERCP removal of bile duct stones is performed following endoscopic sphincterotomy using balloon catheters or baskets (see Figs 2 and 3).

Fig. 2 Endoscopic sphincterotomy of the ampulla of Vater.

Synchronous gallbladder and bile duct stones

A common clinical scenario is that of a patient with symptomatic gallstones requiring cholecystectectomy and with a high suspicion of bile duct stones. A number of options exist in this setting including split therapeutic approaches (pre- or postoperative ERCP and cholecystectomy) or a one-stage laparoscopic cholecystectomy and bile duct clearance. Laparoscopic common duct exploration techniques have evolved rapidly since their introduction in the 1990s. The bile duct can be visualized intraoperatively via insertion of catheters into the cystic duct and subsequently explored usually by the transcystic route. Exploration via the more invasive transductal route (choledochotomy) is usually reserved for when removal of larger stones is being considered. Using a variety of techniques, similar to endoscopic stone removal, successful duct clearance has been reported in approximately 95% of cases in most recent large series with morbidity and mortality similar to the range described for ERCP [25]. Limited randomized control data comparing split and one-stage approaches have shown similar rates of duct clearance and morbidity [26,27]. Cost-effectiveness

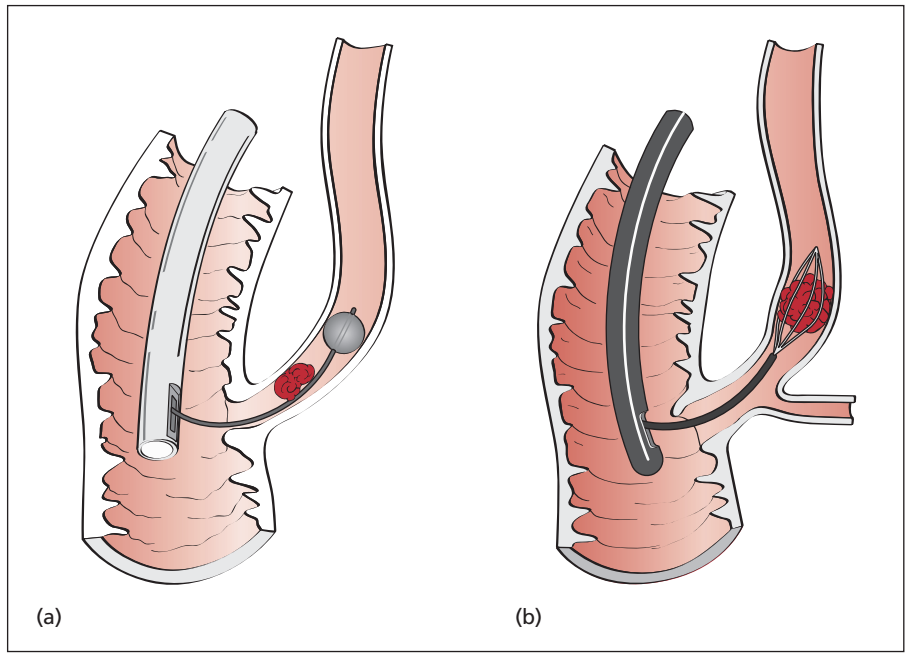

Fig. 3 Methods of endoscopic stone extraction using a balloon (a) or a basket (b).

data, however, appear to favour a one-stage laparoscopic approach [28]. Therefore, in situations in which patients require laparoscopic cholecystectomy and there is a suspicion of bile duct stones, we favour the one-stage laparoscopic cholecystectomy with intraoperative cholangiography (IOC) and laparoscopic bile duct clearance of visualized stones.

A number of important caveats exist to the routine use of this approach. The most significant obstacle to the widespread adoption of this one-stage laparoscopic approach is its lack of availability. In addition, outcomes by inexperienced surgeons are likely to be less impressive than those described by experienced, high-volume centres. Therefore, in the many centres without access to surgeons experienced in laparoscopic bile duct clearance techniques, other treatment options must be considered. Patient comorbidity can also influence the approach to synchronous gallbladder and bile duct stones. Patients with significant comorbidities, which increase the risks associated with laparoscopic cholecystectomy, should be considered for ERCP and sphincterotomy alone, particularly if bile duct stones are primarily responsible for symptoms.

Important indications for urgent preoperative ERCP include severe cholangitis and severe gallstone pancreatitis, and these are discussed below. However, in the absence of these indications, the role of preoperative ERCP for bile duct stones appears to be limited. While the routine use of preoperative ERCP should be discouraged, its use in situations where there is a high suspicion of bile duct stones also remains problematic. Efforts to tighten the selection criteria for suspected bile duct stones using models based on clinical, radiological and ultrasound variables still remain imprecise, and as many as 50% of ERCPs in this setting will not demonstrate stones [1,29]. Avoiding the morbidity and cost of unnecessary ERCPs is best achieved by selecting patients for postoperative ERCP using IOC. When bile duct stones are discovered at IOC and cannot be dealt with laparoscopically, an alternative to postoperative ERCP is conversion to an open duct exploration. However, this surgery is associated with added morbidity, and postoperative ERCP should be favoured in centres with expert endoscopists. To facilitate postoperative ERCP extraction of bile duct stones, a biliary stent may be placed in the bile duct and through the sphincter of Oddi into the duodenum. The stent can subsequently be used by the ERCP endoscopist to gain access to the bile duct prior to sphincterotomy and stone removal. Good-quality data examining the cost and risk benefits of the above algorithms for the management of bile duct stones around the time of laparoscopic cholecystectomy are lacking and are an important priority for future research.

Post-cholecystectomy stones

Another common clinical scenario is of symptomatic retained or recurrent bile duct stones in patients following cholecystectomy. In this setting, ERCP is the most practical option and avoids the morbidity and expense of surgery. Although such an approach is routine in clinical practice, prospective randomized trials confirming the superiority of ERCP over surgery in post-cholecystectomy patients are lacking. It is unlikely that such trials will be done as the differences between these two approaches are marked and obvious.

Cholangitis

Cholangitis is frequently associated with bile duct stones, which enhance bacterial colonization and become coated with a bacterial biofilm. This bacterial biofilm on stones is often activated by cytokines from the bile duct epithelium when stones cause obstruction of bile ducts [30]. The severity of cholangitis varies greatly. In mild to moderate cases, patients can often be treated conservatively with appropriate resuscitation and antibiotics and bridged to elective, definitive procedures involving both laparoscopic cholecystectomy and laparoscopic or endoscopic bile duct clearance. A proportion of patients with more severe cholangitis (hypotension on presentation, deterioration despite conservative therapy) will require urgent biliary decompression. Controlled trial data have established ERCP as the preferred treatment for urgent biliary decompression in the setting of severe cholangitis, with significantly less mortality than open biliary surgery [31].

Gallstone pancreatitis

The role of early ERCP in gallstone pancreatitis has been investigated by four randomized controlled studies. In two of these studies, significant reductions in complications were observed in the endoscopically treated group compared with the conservatively treated group, and the benefit was greatest in those with more severe pancreatitis [32,33]. Non-significant trends towards reduced mortality were also observed in these studies. A third study, published in abstract form only, found significant reductions in both complications and mortality for patients with gallstone pancreatitis who were treated with early ERCP and stone removal [34]. In this study, benefits of early ERCP were seen for both mild and severe pancreatitis. In the most recent study, early ERCP was not associated with any reduction in either complications or mortality [35]. An important difference between this study and previous randomized controlled trials was the exclusion of patients likely to benefit from ERCP (including those with associated cholangitis or jaundice). Two meta-analyses of these trials have reached slightly different conclusions. The first suggested that early ERCP and endoscopic sphincterotomy when required reduced both morbidity and mortality in acute biliary pancreatitis [36]. A more recent meta-analysis, which excluded the unpublished study by Nowak, found that ERCP with or without sphincterotomy reduced complications in severe gallstone pancreatitis but had no benefit in milder pancreatitis or on mortality in any subgroup [37].

On the basis of the above data, those patients presenting with severe pancreatitis (based on modified Glasgow scale, APACHE scores or Ranson criteria) should undergo early ERCP with

sphincterotomy and stone removal when present. Patients with associated biliary obstruction or who deteriorate in hospital despite an initial mild attack should also be considered for urgent ERCP. Biliary sphincterotomy disconnects the pancreatic and bile ducts and may provide some protection from recurrent bouts of gallstone pancreatitis. However, unless contraindications exist, most patients should also undergo cholecystectomy during the same admission to prevent further stone formation in the gallbladder (the usual site of origin of stones), with subsequent migration to the bile duct. Milder forms of pancreatitis are best managed conservatively with spontaneous improvement due to passage of stones occurring in the majority of such patients. Owing to the high recurrence rate of biliary pancreatitis in those with persistent gallstones, patients with milder forms of pancreatitis should also be considered for elective laparoscopic cholecystectomy with intraoperative cholangiography at the time of surgery to confirm passage of bile duct stones.

Malignant biliary obstruction

Malignant biliary obstruction may result from a variety of causes including pancreatic and gallbladder carcinoma, cholangiocarcinomas, hilar metastases and ampullary neoplasia. Frequently, malignancies in this region are unresectable, and therapeutic ERCP has an important palliative role in this setting via the relief of symptoms (jaundice, pruritus, pain) and improvement in the quality of life. Important controversies surrounding therapeutic ERCP in the management of malignant biliary obstruction are discussed below.

Preoperative biliary decompression

Owing to its widespread availability, ERCP and stenting are frequently performed early in the evaluation of patients with malignant jaundice. In those patients who, on subsequent staging, are shown to have resectable disease, the value of preoperative biliary decompression has been examined by multiple studies [38,39]. Studies comparing outcomes following preoperative decompression with no decompression have been of generally poor quality and have given conflicting results. While preoperative stent insertion has consistently demonstrated an improvement in bilirubin and liver function tests, it has not demonstrated improvements in significant clinical outcomes such as perioperative mortality. Concerns about increased infectious complications following ERCP and implantation metastases due to stenting have also been raised. On the basis of currently available data, it therefore seems unnecessary to decompress patients who are about to undergo surgery, which highlights the need for thorough staging investigations before ERCP is contemplated. Preoperative decompression may be more appropriate in a number of situations other than cholangitis. Decompression in patients with prolonged waiting times for surgery because of preoperative chemoradiotherapy may permit improvements in nutritional status. Patients with prolonged, severe jaundice may also be at higher risk of poorer postoperative outcomes [40]. Patients with poor cardiac function may also benefit from biliary decompression via decreases in levels of atrial natriuretic peptide and reductions in left ventricular systolic work [41]. However, clinical data demonstrating improvements in these subsets of patients following preoperative decompression are currently lacking.

Endoscopic vs. surgical palliation

Palliation of malignant biliary obstruction can be achieved with endoscopic stenting or surgical bypass, usually performed with hepaticojejunostomy. Percutaneous transhepatic stenting can also be performed, but increased mortality and less frequent technical success rates have been reported when compared with the less invasive endoscopic approach [42]. Five studies (three randomized controlled trials, two retrospective studies) have compared outcomes between endoscopic and surgical bypass [38]. These data have not demonstrated a survival advantage for either approach. An increased perioperative morbidity in the surgery group and an increased need for readmission and stent changes in the ERCP group have been consistent findings. More relevant trials, comparing minimally invasive surgical bypass techniques with longer patency expandable metal stents, have not been done and would be helpful in defining the preferred approach. In the absence of such definitive data, patient management needs to be individualized. A reasonable approach is to perform stenting with an expandable metal stent and to reserve surgical bypass for those patients in whom stenting cannot be achieved or who have unresectable disease found at the time of operation. In addition, patients who may have difficulty accessing expert endoscopic services, such as those from remote locations, may be better served by the surgical approach.

Plastic vs. metal stents

A significant drawback associated with the use of plastic (polyethylene) stents is stent occlusion due to bacterial biofilms clogging the internal stent lumen. Consequently, the median plastic stent patency is only around 4 months. Stent occlusion is usually heralded by recurrent jaundice and cholangitis. To avoid stent occlusion, many endoscopists will schedule elective stent changes 3- to 6-monthly, an approach that increases the costs of care. An alternative approach has been to perform stent changes only when clinically indicated; however, this approach may expose the patient to the risks of cholangitis.

The most promising current strategy to reduce the problem of stent occlusion is the use of expandable metal stents. Several controlled trials have compared the use of metal vs. plastic stents [43–46]. Conclusions from these studies have been that metal stents are associated with significantly longer patency rates and a reduction in costs associated with stent dysfunction. Median patency rates for metal stents are reported to be from

8 to 12 months in most studies. Therefore, in patients with an anticipated longer life expectancy, the higher initial costs of metallic stent insertion seem justifiable. In those patients with life expectancies less than 4 months, usually because of liver metastases, the use of plastic stents is more appropriate [46].

Although the use of metal stents appears to represent an advance in some settings, a number of problems associated with their use have been described. Tumour ingrowth and overgrowth are common causes of metal stent occlusion. As metal stents are not removable, further stent placement inside the initial stent is then required. Efforts to overcome such problems are being actively pursued and include the use of covered stents, removable metal stents and metal stents with antitumour activity.

Proximal lesions

Effective palliation of malignant obstruction involving the hilum or proximal extrahepatic bile ducts (see Fig. 4) is more difficult to achieve endoscopically than for distal lesions [47]. The use of multiple stents to provide adequate drainage to both liver lobes and prevent cholangitis following ERCP has been advocated. Despite the increased difficulties, proximal lesions can frequently be managed successfully with the use of single metal stents and careful preprocedure planning. Using unilateral metal stents, successful palliation of hilar obstruction has been reported in 97% of cases in one study and in 77% in another [48,49]. MRI can be particularly useful in helping to identify which lobes or segments require decompression and to avoid stenting atrophic segments. Although encouraging, some caution is required, as such an approach requires a high degree of technical expertise and stent occlusion rates are also higher for proximal lesions compared with distal lesions [47]. Percutaneous stenting using expandable metal stents is an alternative option in these patients and one that we usually prefer. In patients with very poor life expectancies, avoiding the expense and potential morbidity of biliary stenting can also be a sensible option.

Fig. 4 Malignant hilar stricture at the bifurcation of the left and right hepatic ducts.

References

1 Soltan HM, Kow L, Toouli J (2001) A simple scoring system for predicting bile duct stones in patients with cholelithiasis. *J Gastrointest Surg* 5(4), 434–437.

2 Mark DH, Flamm CR, Aronson N (2002) Evidence-based assessment of diagnostic modalities for common bile duct stones. *Gastrointest Endosc* 56(Suppl. 6).

3 Fulcher AS (2002) MRCP and ERCP in the diagnosis of common bile duct stones. *Gastrointest Endosc* 56(Suppl. 6).

4 Sugiyama M, Atomi Y, Hachiya J (1998) Magnetic resonance cholangiography using half-Fourier acquisition for diagnosing choledocholithiasis. *Am J Gastroenterol* 93(10), 1886–1890.

5 Griffin N, Wastle ML, Dunn WK *et al.* (2003) Magnetic resonance cholangiopancreatography versus endoscopic retrograde cholangiopancreatography in the diagnosis of choledocholithiasis. *Eur J Gastroenterol Hepatol* 15(7), 809–813.

6 Laokpessi A, Bouillet P, Sautereau D *et al.* (2001) Value of magnetic resonance cholangiography in the preoperative diagnosis of common bile duct stones. *Am J Gastroenterol* 96(8), 2354–2359.

7 Edmundowicz SA, Aliperti G, Middleton WD (1992) Preliminary experience using endoscopic ultrasonography in the diagnosis of choledocholithiasis. *Endoscopy* 24(9), 774–778.

8 Amouyal P, Amouyal G, Levy P *et al.* (1994) Diagnosis of choledocholithiasis by endoscopic ultrasonography (see comment). *Gastroenterology* 106(4), 1062–1067.

9 Ishikawa M, Tagami Y, Toyota T *et al.* (2000) Can three-dimensional helical CT cholangiography before laparoscopic cholecystectomy be a substitute study for endoscopic retrograde cholangiography? *Surg Laparosc Endosc Percutan Techn* 10(6), 351–356.

10 Polkowski M, Palucki J, Regula J *et al.* (1999) Helical computed tomographic cholangiography versus endosonography for suspected bile duct stones: a prospective blinded study in non-jaundiced patients. *Gut* 45(5), 744–749.

11 Neitlich JD, Topazian M, Smith RC *et al.* (1997) Detection of choledocholithiasis: comparison of unenhanced helical CT and endoscopic retrograde cholangiopancreatography (see comment). *Radiology* 203(3), 753–757.

12 Jimenez Cuenca I, del Olmo Martinez L, Pérez Homs M *et al.* (2001) Helical CT without contrast in choledocholithiasis diagnosis. *Eur Radiol* 11(2), 197–201.

13 Buscarini E, Tansini P, Vallisa D *et al.* (2003) EUS for suspected choledocholithiasis: do benefits outweigh costs? A prospective, controlled study. *Gastrointest Endosc* 57(4), 510–518.
14 Kaltenthaler E, Vergel YB, Chilcott J *et al.* (2004) A systematic review and economic evaluation of magnetic resonance cholangiopancreatography compared with diagnostic endoscopic retrograde cholangiopancreatography. *Health Technol Assess* 8(10), 1–89.
15 Rosch T, Meining A, Fruhmorgen S *et al.* (2002) A prospective comparison of the diagnostic accuracy of ERCP, MRCP, CT, and EUS in biliary strictures. *Gastrointest Endosc* 55(7), 870–876.
16 Park MS, Kim TK, Kim KW *et al.* (2004) Differentiation of extrahepatic bile duct cholangiocarcinoma from benign stricture: findings at MRCP versus ERCP. *Radiology* 233(1), 234–240.
17 Ahmetoglu A, Kosucu P, Kul S *et al.* (2004) MDCT cholangiography with volume rendering for the assessment of patients with biliary obstruction. *Am J Roentgenol* 183(5), 1327–1332.
18 Khalid A, Pal R, Sasatomi E *et al.* (2004) Use of microsatellite marker loss of heterozygosity in accurate diagnosis of pancreaticobiliary malignancy from brush cytology samples (see comment). *Gut* 53(12), 1860–1865.
19 Krishnamurthy S, Katz RL, Shumate A *et al.* (2001) DNA image analysis combined with routine cytology improves diagnostic sensitivity of common bile duct brushing. *Cancer* 93(3), 229–235.
20 Rosch T, Hofrichter K, Frimberger E *et al.* (2004) ERCP or EUS for tissue diagnosis of biliary strictures? A prospective comparative study. *Gastrointest Endosc* 60(3), 390–396.
21 Eloubeidi MA, Chen VK, Jhala NC *et al.* (2004) Endoscopic ultrasound-guided fine needle aspiration biopsy of suspected cholangiocarcinoma (see comment). *Clin Gastroenterol Hepatol* 2(3), 209–213.
22 Fritscher-Ravens A, Broering DC, Knoefel WT *et al.* (2004) EUS-guided fine-needle aspiration of suspected hilar cholangiocarcinoma in potentially operable patients with negative brush cytology. *Am J Gastroenterol* 99(1), 45–51.
23 Farrell RJ, Agarwal B, Brandwein SL *et al.* (2002) Intraductal US is a useful adjunct to ERCP for distinguishing malignant from benign biliary strictures. *Gastrointest Endosc* 56(5), 681–687.
24 Domagk D, Poremba C, Dietl KH *et al.* (2002) Endoscopic transpapillary biopsies and intraductal ultrasonography in the diagnostics of bile duct strictures: a prospective study. *Gut* 51(2), 240–244.
25 Dorman JP, Franklin ME Jr, Glass JL (1998) Laparoscopic common bile duct exploration by choledochotomy. An effective and efficient method of treatment of choledocholithiasis. *Surg Endosc* 12(7), 926–928.
26 Cuschieri A, Croce E, Faggioni A *et al.* (1996) EAES ductal stone study. Preliminary findings of multi-center prospective randomized trial comparing two-stage vs single-stage management (see comment). *Surg Endosc* 10(12), 1130–1135.
27 Sgourakis G, Karaliotas K (2002) Laparoscopic common bile duct exploration and cholecystectomy versus endoscopic stone extraction and laparoscopic cholecystectomy for choledocholithiasis. A prospective randomized study. *Minerva Chir* 57(4), 467–474.
28 Urbach DR, Khajanchee YS, Jobe BA *et al.* (2001) Cost-effective management of common bile duct stones: a decision analysis of the use of endoscopic retrograde cholangiopancreatography (ERCP), intraoperative cholangiography, and laparoscopic bile duct exploration. *Surg Endosc* 15(1), 4–13.
29 Tham TC, Lichtenstein DR, Vandervoort J *et al.* (1998) Role of endoscopic retrograde cholangiopancreatography for suspected choledocholithiasis in patients undergoing laparoscopic cholecystectomy. *Gastrointest Endosc* 47, 50–56.
30 Ko CW, Lee SP (2002) Epidemiology and natural history of common bile duct stones and prediction of disease. *Gastrointest Endosc* 56(Suppl. 6).
31 Lai EC, Mok FP, Tan ES *et al.* (1992) Endoscopic biliary drainage for severe acute cholangitis (see comment). *N Engl J Med* 326(24), 1582–1586.
32 Neoptolemos JP, Carr-Locke DL, London NJ *et al.* (1988) Controlled trial of urgent endoscopic retrograde cholangiopancreatography and endoscopic sphincterotomy versus conservative treatment for acute pancreatitis due to gallstones. *Lancet* 2(8618), 979–983.
33 Fan ST, Lai EC, Mok FP *et al.* (1993) Early treatment of acute biliary pancreatitis by endoscopic papillotomy (see comment). *N Engl J Med* 328(4), 228–232.
34 Nowak A, Nowakowska-Dulawa E, Marek T *et al.* (1995) Final results of a prospective, randomized, controlled study on endoscopic sphincterotomy versus conventional management in acute biliary pancreatitis. *Gastroenterology* 108, A380.
35 Folsch UR, Nitsche R, Ludtke R *et al.* (1997) Early ERCP and papillotomy compared with conservative treatment for acute biliary pancreatitis. The German Study Group on Acute Biliary Pancreatitis (see comment). *N Engl J Med* 336(4), 237–242.
36 Sharma VK, Howden CW (1999) Metaanalysis of randomized controlled trials of endoscopic retrograde cholangiography and endoscopic sphincterotomy for the treatment of acute biliary pancreatitis. *Am J Gastroenterol* 94(11), 3211–3214.
37 Ayub K, Imada R, Slavin J (2004) Endoscopic retrograde cholangiopancreatography in gallstone-associated acute pancreatitis. *Cochrane Database Syst Rev* 4.
38 Flamm CR, Mark DH, Aronson N (2002) Evidence-based assessment of ERCP approaches to managing pancreaticobiliary malignancies. *Gastrointest Endosc* 56(Suppl. 6).
39 Strasberg SM (2002) ERCP and surgical intervention in pancreatic and biliary malignancies. *Gastrointest Endosc* 56(Suppl. 6).
40 Su CH, Tsay SH, Wu CC *et al.* (1996) Factors influencing postoperative morbidity, mortality, and survival after resection for hilar cholangiocarcinoma. *Ann Surg* 223(4), 384–394.
41 Padillo J, Puente J, Gomez M *et al.* (2001) Improved cardiac function in patients with obstructive jaundice after internal biliary drainage: hemodynamic and hormonal assessment. *Ann Surg* 234(5), 652–656.
42 Speer AG, Cotton PB, Russell RC *et al.* (1987) Randomised trial of endoscopic versus percutaneous stent insertion in malignant obstructive jaundice. *Lancet* 2(8550), 57–62.
43 Knyrim K, Wagner HJ, Pausch J *et al.* (1993) A prospective, randomized, controlled trial of metal stents for malignant obstruction of the common bile duct. *Endoscopy* 25(3), 207–212.
44 Davids PH, Groen AK, Rauws EA *et al.* (1992) Randomised trial of self-expanding metal stents versus polyethylene stents for distal malignant biliary obstruction (see comment). *Lancet* 340(8834–8835), 1488–1492.
45 Prat F, Chapat O, Ducot B *et al.* (1998) A randomized trial of endoscopic drainage methods for inoperable malignant strictures of the common bile duct (see comment). *Gastrointest Endosc* 47(1), 1–7.
46 Kaassis M, Boyer J, Dumas R *et al.* (2003) Plastic or metal stents for malignant stricture of the common bile duct? Results of a randomized prospective study. *Gastrointest Endosc* 57(2), 178–182.

47 Becker CD, Glattli A, Maibach R *et al*. (1993) Percutaneous palliation of malignant obstructive jaundice with the Wallstent endoprosthesis: follow-up and reintervention in patients with hilar and non-hilar obstruction. *J Vasc Interv Radiol* 4(5), 597–604.

48 De Palma GD, Pezzullo A, Rega M *et al*. (2003) Unilateral placement of metallic stents for malignant hilar obstruction: a prospective study. *Gastrointest Endosc* 58(1), 50–53.

49 Freeman ML, Overby C (2003) Selective MRCP and CT-targeted drainage of malignant hilar biliary obstruction with self-expanding metallic stents. *Gastrointest Endosc* 58(1), 41–49.

5.7 Interventional radiology in hepatobiliary diseases

José Ignacio Bilbao Jaureguízar, Concepció Bru, Joan Falcó Fages and Lluís Donoso

Unlike other applications of diagnostic imaging, the main emphasis in interventional radiology is on the procedure, and this makes it especially amenable to innovation. Image-guided, minimally invasive therapies will continue to grow in importance as current techniques of delivering various forms of energy for ablation evolve towards non-invasiveness and methods are developed to deliver genes, gene products and drugs to specific target sites in order to control angiogenesis and other biological processes.

Percutaneous techniques have proved their usefulness in the management of hepatic pathology and have become the treatment of choice in a wide variety of diseases. The next few paragraphs will explain to what extent and in which situations interventional techniques are useful in treating problems deriving from hepatic haemorrhaging, hepatic tumours (in particular hepatocellular carcinoma) and bile duct obstruction.

Gastrointestinal bleeding of hepatic origin

Introduction

From the vascular viewpoint, the liver is unique in its double afferent vascularization. The hepatic artery, a branch of the coeliac trunk with a wide range of anatomical variants, accounts for 30% of the vascular flow to the liver. Apart from supplying the bile tract, this artery practically exclusively feeds liver tumours, whether primary or metastatic in origin. The portal vein, which supplies the remaining 70% of flow, is a closed system made up of mesenteric and splenic veins, and is connected to the systemic circulation through multiple collateral (fundamentally gastro-oesophageal, splenorenal and haemorrhoidal) vessels. The venous drainage of the liver is achieved through a single system (hepatic veins), which, like the arteries, can present multiple anatomical variants.

Arterial haemorrhaging

A lesion in the hepatic artery can manifest itself by bleeding freely into the peritoneal cavity, as in intrahepatic, subcapsular lesions or haemobilia, which may ultimately lead to gastrointestinal haemorrhage. This type of bleeding can be difficult to identify and distinguish from other types of intestinal haemorrhages. If the lesion is in the extravisceral part of the common hepatic artery, the haemorrhage is usually massive and difficult to control. It is normally caused by a pseudoaneurysm related to previous surgery (e.g. liver transplant) with or without associated infection. Percutaneous treatment consists of selective embolization, stopping the bleeding in the affected area. It is highly recommended that the permeability of the gastroduodenal artery should be maintained to ensure hepatic arterial perfusion. If embolization is not possible, for whatever reason, then, in isolated cases, the repair of the lesion should be done by placing a covered endovascular stent, which will seal the point of haemorrhage but at the same time maintain the hepatic arterial flow.

Morphologically speaking, vascular lesions causing gastrointestinal haemorrhage can be divided into four types [1–4]:

1 Small terminal vessel lesions. Usually caused by biopsy needles or biliary catheters, these can lead to major haemorrhage.

2 Vascular lacerations, almost always caused by a drainage catheter, injury or laceration trauma. Such cases need to be treated at both the proximal and the distal levels. The artery should be embolized using coils, first in the distal part of the lesion to avoid reperfusion through intrahepatic collaterals, after which the proximal artery should be embolized.

3 Vascular lesions with arterial–portal shunt – the traumatic/iatrogenic arterial–portal shunt is sometimes the only angiographic manifestation of intermittent haemobilia. The closing of the connection between the portal vein and hepatic artery will also seal the point of bleeding.

4 Vascular laceration with a pseudoaneurysm. The example most frequently seen is a lesion in the right hepatic artery or the common hepatic artery after surgery, especially after a laparoscopic cholecystectomy. In large pseudoaneurysms, just as in vascular lacerations, the most adequate percutaneous treatment is the occlusion of both the distal and the proximal arteries with the aim of excluding the arterial lesion and preserving the distal

flow. Occasionally, this procedure is not technically possible or is ineffective and, for that reason, it is better to resort to other possibilities such as the direct treatment of the lesion by direct puncture and thrombosis using coils, fibrin sponges or thrombin.

Haemorrhage due to portal hypertension

Whatever the circumstances that increase the gradient of the portal system (the difference in pressure between the portal system and the central blood pressure), more than a 10–15 mmHg increase will develop into a possible rupture of the collateral vessels, which leads to the fluid from the portal system entering the systemic vascularization. The cause of this increase in gradient has multiple aetiologies and depends upon a number of factors. The origin may be in the liver parenchyma (e.g. cirrhosis) or in the venous outflow, as in the Budd–Chiari syndrome, or in the venous inflow as in portal vein thrombosis.

The endovascular procedures applied in interventional radiology have shown their effectiveness in the three abovementioned cases. We continue to discuss the different possible techniques (palliative as well as curative) using interventional radiology in the treatment of patients with portal hypertension and bleeding.

Venous outflow obstruction

This can be due to Budd–Chiari syndrome, congenital membranous obstructive disease or postsurgical complications, particularly those arising after liver transplantation (Fig. 1). In these cases, the percutaneous transhepatic access – guided by echography – of the blocked or obstructed vein followed by angioplasty or the placement of a metallic endoprosthesis offers good long-term results and may sometimes be curative. The rate of restenosis of the treated lesion is very low (permeability at 3 years is 90%), and complications of the procedure are infrequent but severe when thy occur [5].

Treatment of diseases causing portal hypertension by affecting liver parenchyma

Independent of whether the lesion is presinusoidal, sinusoidal or postsinusoidal, the percutaneous treatment in these cases is palliative. The transjugular intrahepatic portosystemic shunt (TIPS) procedure involves a percutaneous approach that connects the hepatic with the portal vein [6]. When it was first described in 1969, it opened up new and different possibilities for percutaneous intervention, which allowed direct connection between the two blood vessels. Since then, it has been incorporated into various different technical aspects and has become a widely used procedure for treating patients with portal hypertension. The success rate of the technique is 90%; patients with acute haemorrhage have a survival rate of more than 70% after 1 month when the liver function is maintained (Child–Pugh A/B) [7–9]. The most frequent complications are hepatic encephalopathy (13%) and intraprosthetic stenosis, which often recurs.

(a)

(b)

Fig. 1 Liver transplant performed 2 months ago. Patient with ascites; ultrasound (US) shows a severe slowing down of hepatic vein flow. (a) After the percutaneous catheterization of the right and middle hepatic veins, a phlebography is performed showing moderate stenosis of the surgical venous connection. Stenosis is crossed with angiographical wires. Hepatic vein–right atrial pressure gradient is 7 mmHg. (b) Image obtained after co-locating two metallic autoexpandible prostheses. The pressure gradient has diminished to 1 mmHg.

(a)

(b)

Fig. 2 Patient with cirrhosis and recurrent bleeding due to gastro-oesophageal varices, in spite of being treated with endoscopic sclerotherapy. (a) Transjugular portography using catheters placed in a transparietal approach. Portosystemic gradient is 21 mmHg. Note hepatofugal flow into gastro-oesophageal varices. (b) Metallic prosthesis covered with PTFE between portal and right hepatic veins. Gradient is now 8 mmHg.

The uncovered prostheses are very effective in creating a channel deriving directly from the portal vein, but they have a tendency to occlusion. There are a variety of reasons, one of which is the intraductal 'contamination' of biliary material due to the transection of the biliary canaliculus in the TIPS procedure. To avoid restenosis, two alternative approaches have been developed: first, the creation of extrahepatic portosystemic percutaneous connections and, secondly, the implanting of a covered prosthesis of a non-permeable material [polytetrafluoroethylene (PTFE)] [10] (Fig. 2). With these advances, the permeability of TIPS has changed radically, from 50% to 90% in the year 2005. Therefore, in patients with portal hypertension and gastrointestinal bleeding, in whom pharmacological and endoscopic treatments have failed, treatment with TIPS is the best alternative.

Lesions of the portal vein

There are various causes that can generate portal hypertension as result of alterations in the portal vein and its tributaries. Among these are inflammatory stenosis and obstructions (pancreatic, pylophlebitis, etc.) as well as surgical causes (e.g. after liver transplant). In the absence of associated liver disease, the most appropriate treatment is angioplasty, preferably with the placement of an endoprosthesis, with direct transhepatic portal access (Fig. 3). There is a high permeability rate in the following 3–5 years after placement [11,12].

Hepatocellular carcinoma percutaneous treatment

Introduction

Hepatocellular carcinoma (HCC) develops in liver cirrhosis of any aetiology, being more frequent in advanced cirrhosis and the final cause of death in more than 50% of these patients.

The possibility of detecting the tumour at an early stage [13], when curative treatments can be applied, will represent the possibility of increasing survival in patients with HCC, who will otherwise have a really dismal prognosis.

To propose one or other therapy, we use the BCLC system [14], which links staging with treatment indication. Classification as well as diagnosis criteria are explained in Chapter 18.2.1.

Unfortunately, curative therapies can be applied only in 30–40% of the patients corresponding to stage A [15]. Most of the patients with HCC are diagnosed at stage B, and the only option that has been shown to have a positive impact on survival is transarterial chemoembolization (TACE).

Percutaneous treatments

Destruction or ablation of tumour cells can be achieved by the injection of chemical substances [ethanol (PEI), acetic acid (PAI)] or by inserting a probe that modifies local tumour

(a)

(b)

Fig. 3 A 45-year-old patient with recurrent pancreatitis requiring several surgical interventions with actual large varices due to a portal vein occlusion. (a) After a percutaneous transparietal puncture of the portal vein, a vascular introducer is placed in the right portal vein and a catheter, crossing the obstruction in the splenic vein. (b) Images obtained after co-locating a prosthesis in the obstructed area. It corresponds to an indirect portography after the administration of contrast into the splenic artery. It shows a good inner flow through the prosthesis without opacity of collateral veins.

temperature [cryotherapy, laser, radiofrequency (RF) and microwaves (MW)].

Percutaneous ablation is considered the best option for patients with early HCC who are ineligible for resection or transplantation [5] or who are on a waiting list for a liver transplant.

A few years ago, PEI was the most frequently employed technique as it is inexpensive, requires simple technology and – with expertise in fine-needle puncture of the liver – has a low rate of complications: < 3% morbidity with 0.5% mortality [16,17]. PEI aims at imbibing the tumour completely with ethanol, resulting in coagulative necrosis of the tissue and thrombosis of the small surrounding vessels. PEI is usually performed under ultrasound (US) guidance, which allows control of the diffusion of the alcohol by observing small bright spots spreading into the tumour and flowing in the nearby vessels. This permits exact control of the diffusion and change in the position of the needle if the tissue does not retain the alcohol. This characteristic can only be detected with US when injecting alcohol, which preserves a small amount of air that acts as a contrast. When using computerized tomography (CT), the diffusion of alcohol cannot be controlled, and a large amount of alcohol can reach a vessel producing non-desired thrombosis. PEI has to be repeated on separate days, and it achieves complete tumour necrosis in 90–100% of HCCs < 2 cm in diameter. This is reduced to 70% in tumours of 2–3 cm and to 50% in tumours of 3–5 cm. The 5-year survival of Child–Pugh A candidates with a complete response is more than 50% [16,17,29]. The presence of septa prevents the diffusion of ethanol into the whole tumour volume and, hence, complete necrosis is rarely achieved in tumours larger than 3 cm [17].

The injection of acetic acid (PAI) represents an alternative. It is painless, and comparative studies have shown that PAI needed fewer sessions than PEI, producing wide areas of necrosis. PAI has been employed mainly in China and Japan [18,19].

The introduction of RF in the late 1990s replaced PEI/PAI in most instances, PEI/PAI being reserved for some selected cases or as an adjuvant to RF [20] or TACE. This is particularly true for tumours near great vessels; vessels larger than 3 mm result in rapid dissipation of the heat by blood flow. In such cases, PEI in the area close to the vessel permits the achievement of complete necrosis. In superficial lesions, or those close to the gallbladder or intestinal structures, the risk of complications such as seeding or perforation is increased, but they are easily treated with PEI.

In a recent series [22,26], there are almost no criteria of exclusion for RF, but the incidence of complications is not negligible. RF is nowadays the ablative therapy used most frequently (Fig. 4). It can be applied through different kinds of electrodes, percutaneously, laparoscopically or intraoperatively. The main drawbacks of RF ablation are its higher cost, a morbidity of 8–10% and a mortality of close to 1% [23–25]. Studies comparing antitumoral efficacy of RF and PEI showed a clear advantage for RF [21–22]. RF is usually performed under US guidance, but CT or magnetic resonance imaging (MRI) with adequate needles can be used.

While PEI can be performed in an outpatient setting, RF needs a minimum of 24 hours in hospital and strong sedation or anaesthesia to support the therapy.

A post-RF syndrome consisting of pain, malaise and fever related to necrosis can appear, but should be over after 1 week. If it persists, the presence of complications must be suspected.

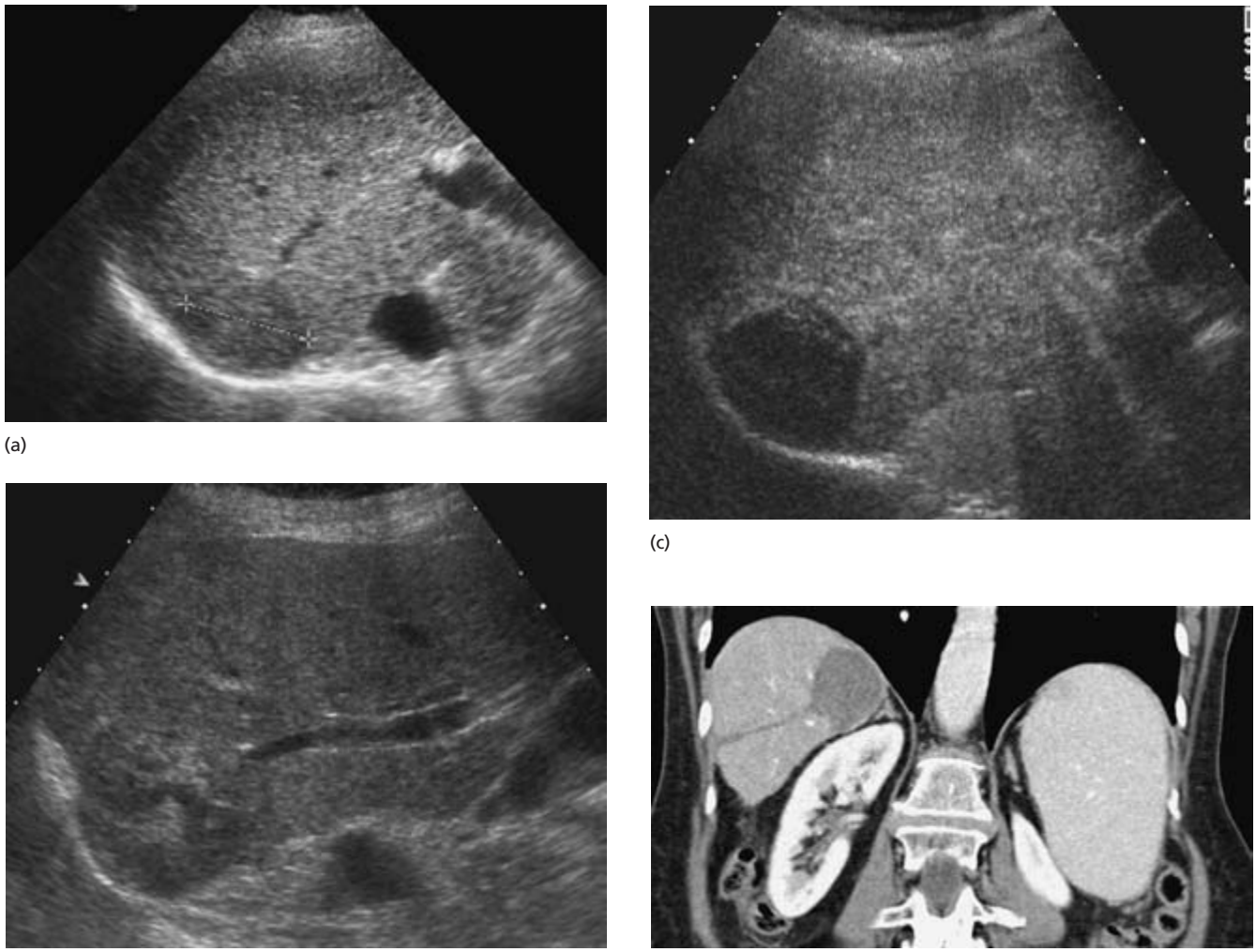

Fig. 4 (a) Ultrasound imaging of a 4 cm HCC in the right lobe of the liver. (b) Changes in echostructure after radiofrequency ablation performed with US control. (c) In the arterial phase of ultrasound contrast, no perfusion of the treated area is detected. (d) Coronal plane of CT showing the ablated area and the coagulation of the needle traject.

Control of efficacy

The degree of ablation is assessed at 1 month by dynamic contrast-enhanced ultrasound (CEUS), CT or MRI. The absence of contrast uptake in the tumour reflects tumour necrosis, while the recognition of contrast uptake indicates incomplete treatment. CEUS is useful during treatment as it detects persistence of tumour in areas that have not been reached by alcohol, or 24 hours after RF to assess technical adequacy or complications [27,28].

If CT or MRI is performed early after the treatment, the hyperaemia induced by the therapy all round the tumour can generate confusion with respect to the efficacy of the intervention: persistence of tumour or recurrence are usually partial and in a nodular shape; also, any enlargement of the lesion will suggest tumoral growth. CT or MRI will be useful in detecting new lesions and should be performed every 4 months in the first 2 years.

The recurrence rate after percutaneous ablation is similar to that detected after surgical resection and can occur within the vicinity of the treated nodule or in separate segments of the liver. Tumours initially classified as completely necrosed may present intratumoral recurrence later on, and this should be considered as a treatment failure that was not detectable in the early follow-up on imaging techniques. Nevertheless, initial complete necrosis obtained with either alcohol or RF will produce a significant increase in survival in Child A or B patients [29].

Other percutaneous therapies

Microwave ablation (MW) is an emerging modality [30,31] that

consists of introducing a special needle (antennas) – usually under sonographic guidance – generating microwaves inside the tumour. Thereby, wide areas of complete necrosis similar to those obtained with RF are attained for single tumours < 3 cm. Newer antennas with different shapes or combination with embolization have been tried to increase efficacy for larger tumours. There are no limitations in terms of proximity to large vessels, but prospective studies are needed to establish the safety of the procedure.

High-intensity focused ultrasound (HIFU)

This method is well established for prostate cancer. The advantages of this method include non-invasiveness and preservation of the nearby structures. Recently, this method has been reported in a series of patients with HCC [32]. The main limitation is the small area of necrosis produced, which can mean up to 8 hours' treatment for small lesions.

Transarterial chemoembolization (TACE) for HCC treatment

Occlusion of hepatic artery blood flow to HCC results in extensive tumour necrosis and has been a therapeutic option for years. Extrahepatic disease and absence of portal blood flow (secondary to portal vein obstruction with thrombosis or tumour, portosystemic anastomosis or hepatofugal flow) constitute the main contraindications. Patients with advanced disease (Child–Pugh C) should also be excluded because of the risk of acute liver failure.

Gelfoam is the most frequently used agent for arterial obstruction, but polyvinyl alcohol, beads, alcohol, starch microspheres, blood clots and metallic coils have also been used. Hepatic artery occlusion (transarterial embolization; TAE) is an angiographic procedure in which the catheter is advanced into the hepatic artery, attempting interruption of arterial inflow as close to the tumour as possible. In the treatment of multifocal HCC involving both hepatic lobes, the main branches of the hepatic artery may be safely occluded in patients with well-preserved liver function. During injection, it is important to avoid the backward flow of particles to avoid embolization of arterial vessels outside the liver (e.g. ischaemic cholecystitis).

TAE has been largely abandoned in favour of TACE, i.e. transarterial chemoembolization, in which the arterial occlusion is combined with injection of cytostatic drugs such as doxorubicin, mitomycin or cisplatin. The chemotherapeutic agents are suspended in lipiodol; some centres inject 25% of chemotherapy into the remaining liver, in the hope of eliminating undetected tumour cells.

The main side-effect of TACE is the 'post-embolization syndrome' observed in 50% of patients; it consists of fever, abdominal pain and a moderate degree of ileus. It is usually self-limited, and most patients can be discharged within 48–72 hours. Prophylactic antibiotics are not routinely used as post-procedure fever reflects tumour necrosis. If fever persists, severe infectious complications such as a hepatic abscess or cholecystitis associated with ischaemia should be ruled out.

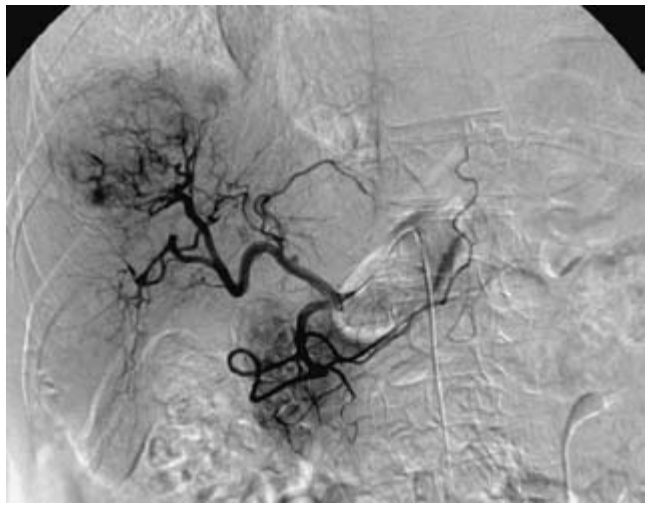

(a)

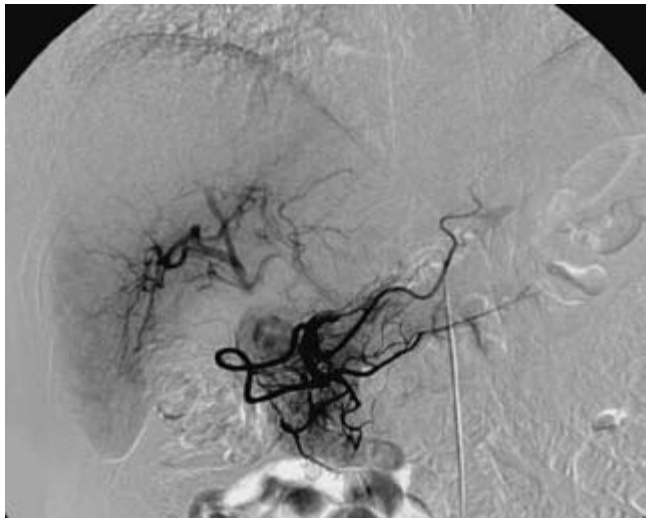

(b)

Fig. 5 (a) Arteriography performed prior to TACE. Hypervascularized big nodule in the right lobe of the liver and a daughter nodule in the periphery. (b) After two sessions of TACE, complete ischaemia of the tumoral area is obtained, preserving the arterial vascularization of the remaining non-tumoral liver.

Therapeutic efficacy is 15–55%, as defined by delayed tumour progression and vascular invasion. However, the residual tumour typically recovers its blood supply, and repeated treatments are necessary (Fig. 5). The results of two randomized trials show a beneficial effect of TACE in selected patients [33,34]; however, patient selection and the most active agents remain to be defined.

PEI, RF and, more recently, MW have been used prior to or after TACE to add the effects of both therapies, suggesting that they can be employed in patients with intermediate stage tumours [14,35].

Local radiation therapy

The potential of conventional radiation therapy of the liver is limited because of the high sensitivity of hepatocytes. The potential of local application of iodine-131, yttrium-90, rhenium-188 or holmium-166 incorporated into lipiodol or microspheres through TAE appears to be promising, but formal trials have yet to be performed before such interventions can be incorporated into clinical practice.

Percutaneous management of bile duct obstruction due to malignant or benign strictures

Since the early 1970s, percutaneous techniques such as percutaneous transhepatic cholangiography (PTC) [39] and percutaneous treatment of cholecystolithiasis [40,41] have become popular. Recent developments such as polyurethane endoprostheses or expandable metallic stents have changed the palliative management of tumours causing obstructive jaundice [42–44].

Stenting in obstructive jaundice due to malignancy

Biliary obstruction due to a tumour in the biliary tree should be diagnosed by non-invasive modalities such as multidetector computerized tomography (MDCT), magnetic resonance cholangiography (MRCP) or endoscopic ultrasound (EUS). Invasive techniques such as PTC or endoscopic retrograde cholangiopancreatography (ERCP) should be reserved for therapeutic interventions.

The main indication for the use of endoprostheses or stents is the palliation of obstructive jaundice due to biliary malignancy where resection is not possible, which applies to 70–80% of patients at the time of diagnosis [45]. Although some authors believe that surgery is the best palliative technique [46], the use of stents has become more popular [47].

The choice between PTC and ERCP to access the extrahepatic biliary tree should be determined by expertise and local availability. Only in complex high-level obstruction is the percutaneous radiological approach the first-line option.

For some authors, the only indication for surgical intervention is the presence of both malignant biliary and duodenal obstruction. Combined self-expandable metal stenting for simultaneous palliation of malignant biliary and duodenal obstruction may provide a safe and less invasive alternative to surgical palliation and should be considered as a treatment option for patients who are poor candidates for surgery [48] (Fig. 6).

Palliation – who are the right candidates?

Both procedures, percutaneous biliary drainage (PBD) and bil-

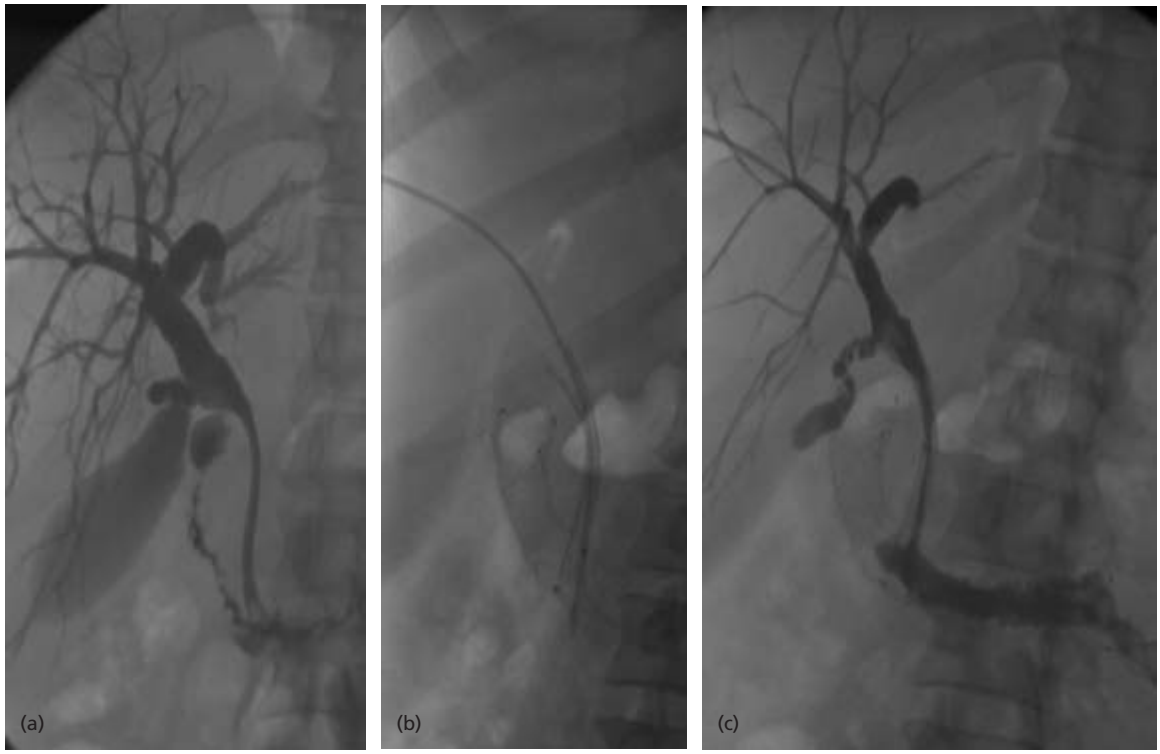

Fig. 6 Neoplasm of the pancreas with duodenal involvement. (a) Incomplete resolution of biliary obstruction after percutaneous implantation of biliary stent. Marked infiltration of duodenum. (b and c) Complete resolution after peroral implantation of duodenal stent.



Fig. 7 Metallic stents. (a) Autoexpandable Wallstent. (b) Absolute nitinol stent. (c) Gianturco Z-stent. (d) Covered Wallstent.

iary endoprosthesis, can be considered for adequate palliation. The main objection to the use of an endoprosthesis has been the fact that they are likely to become occluded in patients with a relatively long life expectancy [42]. The use of PBD is associated with an increase in infection, biliary leakage and pain at the skin entry site.

In the past, the endoprostheses used were plastic stents made of polyethylene or polyurethane. Their high obstruction rate and other complications were due to the use of large-bore devices; the main reason for obstruction was not tumour growth but bile encrustation [50]. Neither Teflon, hydrourethane nor hydrophilic coating could improve the patency [51].

This was changed by the introduction of metallic stents in the late 1980s. There are basically two broad categories, i.e. balloon-expandable stents (Palmaz or Strecker stents) or autoexpandable stents (Wallstent, Gianturco Z-stent, Zilver stent or Absolute nitinol stents; Fig. 7).

Their main advantage is that they can be introduced through a very small-calibre track (6 Fr), but can be expanded to a large internal lumen of 10 mm. However, they are still prone to obstruction; the true incidence of occlusion is difficult to establish because follow-up of patients in many series is incomplete. In a recent series of 142 consecutive patients managed with Wallstent, mean survival was 186 days with a need for reintervention in 12% [47]. Similar results were reported with nitinol alloy devices [52] or with drug-eluting or covered stents.

Achieving clinical success

We insist on aggressively achieving normalization of coagulation and broad-spectrum antibiotic coverage. Accurate selection of the puncture site and a decision about uni- or bilobar drainage is based on MRCP. Real-time ultrasound permits the identification of the most appropriate entry site (Fig. 8). To avoid haemobilia, selection of the most peripheral intrahepatic duct is mandatory. In our centre, we always use a micropuncture set, Acoustic (Boston Scientific Corporation) or Cruiser (PBN Medicals Denmark) with a coaxial sheath and a 0.38-inch stiff guidewire.

In biliary strictures without involvement of the ampulla of Vater, a stent with the end 1–2 cm above the ampulla is preferable to prevent ascending cholangitis [53]. In high-level obstruction, a bilobar drainage is accomplished with a single puncture and two stents in a Y arrangement, but our preference is a double puncture with two stents side by side (Fig. 9). When the ampulla is involved, a long stent from the hilum through the ampulla projecting just 1 cm into the duodenum is recommended to avoid mucosal damage.

Stent occlusion

Despite large-bore stents and new materials now available, stent occlusion remains a major problem. With plastic endoprostheses, bile incrustation and infection were the main problems. With the metal stents, problems of tumour growth are a major problem, but also fibrotic mucosal hyperplasia is well documented. In a palliative situation, the placement of a new stent provides adequate palliation.

Percutaneous treatment of benign biliary strictures

The treatment of benign strictures is no longer dependent on surgical techniques, with radiological and endoscopic approaches being used as alternatives, in particular for the following groups:

Fig. 8 PBD performed with peripheral puncture under US guidance. Note correlation between US image and cholangiography.

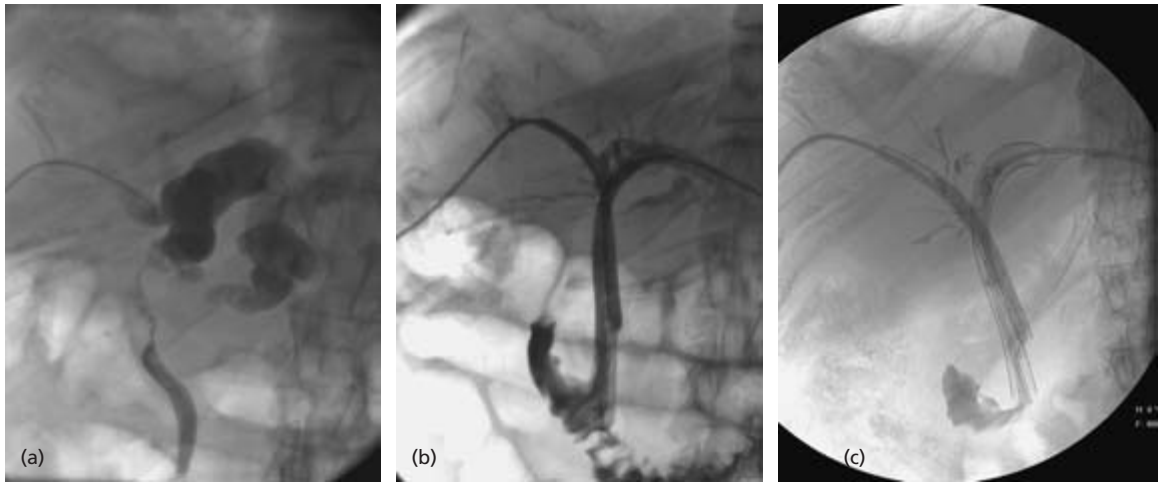

Fig. 9 (a) Cholangiocarcinoma with hilar involvement. (b and c) Bilateral bile duct puncture with a double stent in a side-by-side arrangement. Good drainage through the papilla.

1 Iatrogenic or traumatic bile duct lesions after cholecystectomy or liver transplantation.
2 Non-traumatic: sclerosing cholangitis, recurrent pyogenic cholangitis and Mirizzi syndrome. In this group, imaging diagnosis can be difficult, and histology is mandatory to differentiate benign causes from malignant strictures.

Criteria for selection of a radiological approach

The best results for surgical treatment are better than any published results for radiological management and, in specialist surgical centres, the treatment of choice for strictures of the extrahepatic ducts should be surgery.

Apart from local expertise, the following factors adversely affect the outcome of surgical stricture repair [55]. The presence of one or more of these factors favours the selection of a radiological approach:

1 Multiple previous operative attempts at repair.
2 Stricture of intrahepatic ducts or their confluence, associated or not with stones.
3 Presence of portal hypertension.

Access and technique for percutaneous dilation

The transhepatic route provides the most adequate access to repair biliary strictures, in particular in the presence of a biliodigestive anastomosis with a Roux loop. An alternative approach without hepatic puncture is possible when a surgical superficially fixed Roux loop is fixed to the anterior abdominal wall. The afferent fixed loop is marked with metal clips to facilitate radiological puncture and retrograde access to the biliary tree [56]. The technique for gaining transhepatic access is the standard for PTC.

Strictures are dilated using angioplasty balloon catheters with a diameter between 6 and 12 mm and a length of 2–6 cm. Inflation pressures of 12 atm are usual, but there is sometimes extensive fibrosis requiring high-pressure balloons with a pressure of 17–20 atm. The number and duration of inflations are variable, and the endpoint of the procedure is to restore a normal lumen with no residual wasting of the balloon. In our experience, the best results are accomplished with a catheter or plastic stent left in place for 4–6 weeks after dilation. Following this, the catheter is removed if there is no evidence of restenosis at cholangiographic control. Approximately 20–30% of benign stenoses will present a restenosis at follow-up [57]. Recently, the use of commercially available cutting balloons (Fig. 10) with small blades has increased the technical success rate of percutaneous management of transplant biliary strictures, with only 10% restenosis [58].



Fig. 10 Expandable balloon angioplasty into which four longitudinally orientated small blades are incorporated.

Is the use of metallic stents advisable in benign biliary strictures?

In spite of relatively good initial results with Gianturco stents [59,60], long-term follow-up of metallic stents is not encouraging with a high failure rate of more than 50% [60]. Metallic biliary stents should be used only for the treatment of benign biliary strictures in selected cases, where repeated balloon dilation has failed and the patient is a poor candidate for surgery.

References

1 Bilbao JI, Torres E, Martínez-Cuesta A (2002) Non-traumatic abdominal emergencies: imaging and intervention in gastrointestinal hemorrhage and ischemia. *Eur Radiol* 12, 2161–2171.
2 Hidalgo F, Narvaez JA, Rene M *et al.* (1995) Treatment of hemobilia with selective hepatic artery embolization. *J Vasc Interv Radiol* 6, 793–798.
3 Tarazov PG (1993) Intrahepatic arterioportal fistulae: role of transcatheter embolization. *Cardiovasc Interv Radiol* 16, 368–373.
4 Nicholson T, Travis S, Ettles D *et al.* (1999) Hepatic artery angiography and embolization for hemobilia following laparoscopic cholecystectomy. *Cardiovasc Interv Radiol* 22, 20–24.
5 Zhang CO, Fu LN, Xu L *et al.* (2003) Long-term effect of stent placement in 115 patients with Budd–Chiari syndrome. *World J Gastroenterol* 9, 2587–2591.
6 Bilbao JI, Quiroga J, Herrero JI *et al.* (2002) Transjugular intrahepatic portosystemic shunt (TIPS): current status and future possibilities. *Cardiovasc Interv Radiol* 25, 251–269.
7 Rossle M, Olschewski M, Siegerstetter V *et al.* (2004) The Budd–Chiari syndrome: outcome after treatment with the transjugular intrahepatic portosystemic shunt. *Surgery* 135, 394–403.
8 Boyer TD, Haskal ZJ (2005) The role of transjugular intrahepatic portosystemic shunt in the management of portal hypertension. *Hepatology* 41, 386–400.
9 Rossle M, Grandt D (2004) TIPS: an update. *Best Pract Res Clin Gastroenterol* 18, 99–123.
10 Bureau C, García-Pagán JC, Otal P *et al.* (2004) Improved clinical outcome using polytetrafluoroethylene-coated stents for TIPS: results of a randomized study. *Gastroenterology* 126, 469–475.
11 Rossle M, Mullen KD (2004) Long-term patency is expected with covered TIPS stents: this effect may not always be desirable! *Hepatology* 40, 495–497.
12 Wang JF, Zhai RY, Wei BJ *et al.* (2006) Percutaneous intravascular stents for treatment of portal venous stenosis after liver transplantation: midterm results. *Transplant Proc* 38, 1461–1462.
13 Sangiovanni A, Del Ninno E, Fasani P *et al.* (2004) Increased survival of cirrhotic patients with a hepatocellular carcinoma detected during surveillance. *Gastroenterology* 126(4), 1005–1014.
14 Llovet JM, Bru C, Bruix J (1999) Prognosis of hepatocellular carcinoma: the BCLC staging classification. *Semin Liver Dis* 19(3), 329–338.
15 Llovet JM, Bruix J (2003) Systematic review of randomized trials for unresectable hepatocellular carcinoma: chemoembolization improves survival. *Hepatology* 37(2), 429–442.
16 Ebara M, Akabe S, Kita K *et al.* (2005) Percutaneous ethanol injection for small hepatocellular carcinoma: therapeutic efficacy based on 20-year observation. *J Hepatol* 43, 458–464.

17 Vilana R, Bruix J, Bru C *et al.* (1993) Tumor size determines the efficacy of percutaneous ethanol injection for the treatment of small hepatocellular carcinoma. *Hepatology* 16, 353–357.

18 Ohnishi K (1998) Comparison of percutaneous acetic acid injection and percutaneous ethanol injection for small hepatocellular carcinoma. *Hepatogastroenterology* 45, 1254–1258.

19 Lin SM, Lin CJ, Lin CC *et al.* (2005) Randomised controlled trial comparing percutaneous radiofrequency thermal ablation, percutaneous ethanol injection, and percutaneous acetic acid injection to treat hepatocellular carcinoma of 3 cm or less. *Gut* 54, 1151.

20 Vallone P, Catalano O, Izzo F *et al.* (2006) Combined ethanol injection therapy and radiofrequency ablation therapy in percutaneous treatment of hepatocellular carcinoma larger than 4 cm. *Cardiovasc Interv Radiol* 29, 544–541.

21 Livraghi T, Goldberg SN, Lazzaroni S *et al.* (1999) Small hepatocellular carcinoma: treatment with radio-frequency ablation versus ethanol injection. *Radiology* 210(3), 655–661.

22 Shiina S, Teratami T, Obis S *et al.* (2005) A randomized controlled trial of radiofrequency ablation with ethanol injection for small HCC. *Gastroenterology* 129, 122–130.

23 Rhim HYK, Lee JM *et al.* (2003) Major complications after radiofrequency thermal ablation of hepatic tumors: spectrum of imaging findings. *RadioGraphics* 23, 123–136.

24 de Baere T, Risse O, Kuoch V *et al.* (2003) Adverse events during radiofrequency treatment of 582 hepatic tumors. *AJR Am J Roentgenol* 181, 695–700.

25 Jaskolka JD, Asch MR, Kachiura JR *et al.* (2005) Needle tract seeding after radiofrequency ablation of hepatic tumors. *J Vasc Interv Radiol* 16, 485–491.

26 Teratani T, Yoshida H, Shiina S *et al.* (2006) Radiofrequency ablation for hepatocellular carcinoma in so-called high-risk locations. *Hepatology* 43, 1101–1108.

27 Vilana R, Bianch IL, Varela M *et al.* (2006) Is microbubble-enhanced ultrasonography sufficient for assessment of response to percutaneous treatment in patients with early hepatocellular carcinoma? *Eur Radiol* 16, 2454–2462.

28 Meloni MF, Livraghi T, Filice C *et al.* (2006) RF ablation of liver tumors: the role of microbubble ultrasound contrast agents. *Ultrasound Quarterly* 22, 41–47.

29 Sala M, Llovet JM, Vilana R *et al.* (2004) Initial response to percutaneous ablation predicts survival in patients with hepatocellular carcinoma. *Hepatology* 40(6), 1352–1360.

30 Lu MD, Xu HX, Xie XY *et al.* (2005) Percutaneous microwave and radiofrequency ablation for hepatocellular carcinoma: a retrospective study. *J Gastroenterol* 40, 1054–1060.

31 Dong B, Liang P, Yu X *et al.* (2003) Percutaneous sonographically guided microwave coagulation therapy for HCC: results in 234 patients. *AJR Am J Roentgenol* 180, 1547–1555.

32 Wu F, Wang ZB, Chem WZ *et al.* (2004) Extracorporeal high intensity focused ultrasound ablation in the treatment of patients with large hepatocellular carcinoma. *Am Surg Oncol* 11, 1061–1069.

33 Llovet JM, Real MI, Montanya X *et al.* (2002) Arterial embolization, chemoembolization versus symptomatic treatment in patients with unresectable hepatocellular carcinoma: a randomized controlled trial. *Lancet* 359, 1734–1739.

34 Lo CM, Ngan H, Tso WK *et al.* (2002) Randomized controlled trial of transarterial lipiodol chemoembolization for unresectable hepatocellular carcinoma. *Hepatology* 35(5), 1164–1171.

35 Livraghi T, Meloni F, Morabito A (2004) Multimodality image-guided tailored therapy of early and intermediate hepatocellular carcinoma: long-term survival in the experience of a single radiological referral centre. *Liver Transpl* 10, S98–106.

36 Veltri A, Moretto P, Doriguzzi A *et al.* (2006) Radiofrequency thermal ablation (RFA) after transarterial chemoembolization (TACE) as a combined therapy for unresectable non-early hepatocellular carcinoma (HCC). *Eur Radiol* 16, 661–669.

37 Lu DS, Lu NC, Raman SS *et al.* (2005) Percutaneous radiofrequency ablation for hepatocellular carcinoma as a bridge for liver transplantation. *Hepatology* 41, 130–137.

38 Bruix J, Hessheimer AJ, Forner A *et al.* (2006) New aspects of diagnosis and therapy of hepatocellular carcinoma. *Oncogene* 25, 3848–3856.

39 Ferrucci JT Jr, Wittenberg J, Sarno RA *et al.* (1976) Fine needle transhepatic cholangiography: a new approach to obstructive jaundice. *AJR Am J Roentgenol* 127(3), 403–407.

40 Mazzariello RM (1976) Residual biliary tract stones: nonoperative treatment of 570 patients. *Surg Annu* 8, 113–144.

41 Burhenne HJ (1980) Percutaneous extraction of retained biliary tract stones: 661 patients. *AJR Am J Roentgenol* 134(5), 889–898.

42 Mueller PR, Ferrucci JT Jr, Teplick SK *et al.* (1985) Biliary stent endoprosthesis: analysis of complications in 113 patients. *Radiology* 156(3), 637–639.

43 Lammer J (1985) [Percutaneous transhepatic bile duct endoprosthesis. Choice of material, technique, clinical results]. *Rofo* 142(3), 243–253 (in German).

44 Coons HG, Carey PH (1983) Large-bore, long biliary endoprostheses (biliary stents) for improved drainage, *Radiology* 148(1), 89–94.

45 Connolly MM, Dawson PJ, Michelassi F *et al.* (1987) Survival in 1001 patients with carcinoma of the pancreas. *Ann Surg* 206, 366–376.

46 Blumgart LH, Hadjis NS, Benjamín IS *et al.* (1984) Surgical approaches to cholangiocarcinoma. At confluence of hepatic ducts. *Lancet* 14, 66–70.

47 Adam A, Cheetty N, Roddie M *et al.* (1991) Self-expandable stainless steel endoprostheses for the treatment of malignant bile duct obstruction. *Am J Radiol* 156, 321–325.

48 Kaw M, Singh S, Gagneja H (2003) Clinical outcome of simultaneous self-expandable metal stents for palliation of malignant biliary and duodenal obstruction. *Surg Endosc* 17(3), 457–461.

49 Sohn TA, Yeo CJ, Cameron JL *et al.* (2000) Do preoperative biliary stents increase postpancreaticoduodenectomy complications? *J Gastrointest Surg* 4(3), 258–267; discussion 267–268.

50 Moss AC, Morris E, MacMathuna P (2006) Palliative biliary stents for obstructing pancreatic carcinoma. *Cochrane Database Syst Rev* 19(2).

51 Han YH, Kim MY, Kim SY *et al.* (2006) Percutaneous insertion of Zilver stent in malignant biliary obstruction. *Abdom Imaging* 20, [epub ahead of print].

52 Okamoto T, Fujioka S, Yanagisawa S *et al.* (2006) Placement of a metallic stent across the main duodenal papilla may predispose to cholangitis. *Gastrointest Endosc* 63(6), 792–796.

53 Park do H, Kim MH, Choi JS *et al.* (2006) Covered versus uncovered wallstent for malignant extrahepatic biliary obstruction: a cohort comparative analysis. *Clin Gastroenterol Hepatol* 4(6), 790–796.

54 Blumgart LH, Kelley CJ, Benjamin IS (1984) Benign bile duct stricture following cholecystectomy: critical factors in management. *Br J Surg* 71(11), 836–843.

55 Hutson DG, Russell E, Schiff E *et al.* (1984) Balloon dilation of biliary strictures through a choledochojejuno-cutaneous fistula. *Ann Surg* 199(6), 637–647.

56 Gibson RN, Adam A, Yeung E *et al.* (1988) Percutaneous techniques in benign hilar and intrahepatic benign biliary strictures. *J Interv Radiol* 3, 125–130.
57 Saad WE, Davies MG, Saad NE *et al.* (2006) Transhepatic dilation of anastomotic biliary strictures in liver transplant recipients with use of a combined cutting and conventional balloon protocol: technical safety and efficacy. *J Vasc Interv Radiol* 17(5), 837–843.
58 Rossi P, Bezzi M, Salvatori FM *et al.* (1997) Clinical experience with covered wallstents for biliary malignancies: 23-month follow-up. *Cardiovasc Interv Radiol* 20(6), 441–447.
59 Irving JD, Adam A, Dick R *et al.* (1989) Gianturco expandable metallic biliary stents: results of a European clinical trial. *Radiology* 172(2), 321–326.
60 Hausegger KA, Kugler C, Uggowitzer M *et al.* (1996) Benign biliary obstruction: is treatment with the Wallstent advisable? *Radiology* 200(2), 437–441.

5.8 Positron emission tomography of the liver

Michael Sørensen and Susanne Keiding

For the hepatologist, positron emission tomography (PET) provides unique possibilities for the direct quantification of regional liver blood perfusion and metabolism of substances *in vivo*. Furthermore, PET is used in the clinical management of patients with malignancies in the liver.

Before a PET scan the patient inhales or receives an intravenous injection of a positron-labelled tracer. Tracers are natural substances, analogues hereof, drugs or receptor ligands. The most commonly used positron-emitters with different physical half-lives are: ^{15}O (2 min), ^{13}N (10 min), ^{11}C (20 min) and ^{18}F (109 min). Within the body, an emitted positron travels a few millimetres and then is annihilated by an electron, which leads to simultaneous emission of two 511-keV photons travelling in 180° opposing directions. The photons are recorded by the PET camera and data reconstructed into three-dimensional images of tracer concentrations in Bq/mL tissue.

Contemporary PET cameras are available as whole-body cameras, high-resolution brain cameras, small animal PET systems, and PET cameras combined with computerized tomography (CT). Combined PET/CT cameras have the advantage of aligning PET images of metabolic processes with detailed CT images of anatomical structures. For most purposes, PET/CT is performed with a low-dose CT scan, but, if indicated, it may comprise diagnostic CT, contrast-enhanced CT and respiratory-gated recordings. At present, combined PET/magnetic resonance (MR) cameras are being developed.

Regional liver metabolism

Dynamic PET recordings are used for quantification of metabolic processes. Starting at the time of tracer injection, data acquisition comprises recordings of the time courses of radioactivity concentrations in tissue and in the blood supply to the organ. The time course of the tissue concentration is analysed as a function of the time course of the blood input radioactivity concentration by fitting a kinetic model of the metabolic scheme for the tracer to the data. This provides clearance values and rate constants for the metabolic processes.

The dual tracer input to the liver has to be taken into account when performing detailed calculations of the kinetic parameters [1–3]. The time course of the blood radioactivity concentration in the hepatic artery following an i.v. bolus injection shows a high, narrow peak, whereas in the portal vein the peak is dispersed and delayed due to the passage of the bolus through the intestinal vascular bed (see Fig. 5 in Chapter 5.3). However, for a substance with irreversible liver metabolism and negligible elimination in the intestines, calculation of the net metabolic clearance of the tracer, K (mL blood/min/mL tissue) using arterial blood concentrations, can be used [1]. The constant K characterizes irreversible steady-state net transfer of the tracer from blood into intracellular metabolites. Munk *et al.* [1] showed that this calculation was applicable for the metabolism of the glucose analogue, 2-deoxy-2-[^{18}F]fluoro-deoxy-glucose (^{18}FDG) in the pig liver. The method can be made non-invasive by replacing arterial blood sampling by scan data of arterial blood radioactivity concentration from the aorta [4–5]. This makes the procedure completely non-invasive. In order to estimate the dual tracer input from both supplying vessels, current studies are exploring the use of combined dynamic PET and dynamic contrast-enhanced CT scans [6]. This will allow for non-invasive evaluation of kinetic properties of the initial tracer distribution, such as blood perfusion and blood-to-cell transfer processes.

The PET camera measures only total radioactivity concentration in the tissue. Kinetic models must embody the fact that the PET camera cannot separate un-metabolized tracer from possible radio-labelled metabolites. The models accordingly are based on metabolic schemes understood from biochemistry but may be validated by measurements of radio-labelled metabolites in tissue samples following tracer injection [7–8]. Similarly, the blood may contain both un-metabolized tracer and radio-labelled metabolites. However, these can often be accounted for by direct measurements in blood samples [9–11].

Table 1 shows examples of metabolic processes in the liver that have been studied by PET. Glucose analogues were used to study the importance of the dual tracer supply to the liver, using ^{18}FDG [1–3] as a substance transported across the cell membrane and metabolized within the cells and ^{11}C-methyl-glucose,

Table 1 Examples of PET studies of liver metabolism.

PET tracer	Experimental model	Metabolism studied	References
^{18}FDG	Pig and human liver	Glucose	[1–3,12,13]
^{11}C-methyl-glucose	Pig liver	Glucose	[1]
^{124}I-iodoinsulin	Rat liver	Insulin receptors	[14]
^{13}N-ammonia	Pig and human liver	Ammonia	[16–19]
^{11}C-glutamate	Rat liver	Amino acid	[15]
^{11}C-glutamine			
^{11}C-aspartate			
L-methyl-^{11}C-methionine	Rat, pig, and human liver	Protein synthesis	[9,20]
L-[1-^{11}C]-methionine			
14(R,S)-[^{18}F]-6-thia-heptadecanoic acid	Rat, pig, and human liver	Fatty acid	[21–26]
15-^{18}F-fluoro-3-oxa-entadecanoate			
1-^{11}C-octanoate			
^{15}O-CO	Pig liver	Blood perfusion	[28]

which is transported across the cell membrane in a similar way to ^{18}FDG but not metabolized. Other studies of liver glucose metabolism have shown that glucose ingestion inhibits the ^{18}FDG uptake by the liver [12] and that insulin increases hepatic glucose uptake [13]. In agreement with these findings, Iozzo *et al.* [14] demonstrated insulin receptors in rat liver PET studies, using ^{124}I-labelled human insulin.

Transport of three amino acids across the liver cell membrane was studied in rats [15]. The high first-pass liver metabolism of ammonia was quantified in pigs by means of a kinetic model of zonation sinusoidal distribution, with periportal urea production and perivenous glutamine production [16]. In a subsequent paper [17], comparison of the first-pass metabolism of ^{13}N-ammonia into the portal vein or the hepatic artery suggested that heterogeneous distribution of the arterial branches gives rise to heterogeneous tissue ammonia metabolism. Interestingly, a human study [18] found that liver ^{13}N-ammonia net metabolic clearance of ammonia, K, was similar in patients with cirrhosis and healthy subjects, may be of pathogenetic importance. Contrary to what was believed hitherto, recent dynamic ^{13}N-ammonia brain studies have shown that the permeability of the blood–brain membrane barrier is not significantly changed in patients with hepatic encephalopathy when compared with patients with cirrhosis without hepatic encephalopathy and healthy controls [10,19]. Brain metabolism of ammonia was increased corresponding to the increased blood ammonia [10]. PET studies may give new insight into the role of ammonia in the development of hepatic encephalopathy and catabolic stress in patients with liver failure.

Liver protein synthesis [9,20] and fatty acid oxidation [21–26] are important liver functions that have also been measured by PET (Table 1). Figure 1 gives an example of the PET measurements of ^{11}C-methionine uptake in a pig liver with production of ^{11}C-labelled protein released into the blood after a delay of approx. 15 min (S. Lausten, unpublished data, December 2006).

Metabolic schemes are most often represented by compartmental models in which tracer input concentration throughout the capillaries is assumed to equal the input concentration, i.e. in the present context, that in the mixed hepatic arterial and portal venous inlet. Such models ignore substrate concentration gradients along the vascular paths of the organ and in surrounding cells. By utilizing the high spatial and temporal resolution of contemporary PET technology, Munk *et al.* recently [27], developed models of microcirculation that account for the concentration gradients of a vascular tracer along the blood flow direction as a tracer bolus passes through the capillary. Application of the model in subsequent pig experiments with dynamic ^{15}O-CO PET gave values of the liver blood perfusion comparable with independent measurements [28] (see also Chapter 5.3).

Liver tumours

PET, with the glucose analogue ^{18}FDG, has proven very successful in the diagnostic evaluation of patients with cancer, and it is currently used routinely worldwide [29]. This is based on the fact that most malignant cells have increased glucose metabolism. ^{18}FDG enters the cells through the same Glut-1 membrane transporters as glucose and is phosphorylated by the rate-limiting hexokinase or, in the hepatocytes, by glucokinase to ^{18}FDG-6-phosphate. Both membrane transport and phosphorylation are up-regulated in cancer cells (Fig. 2). ^{18}FDG-6-phosphate is not a substrate for hexose-6-P-isomerase and therefore it accumulates in the cells. In the hepatocytes, but not in non-hepatocyte-derived tumour cells and bile duct cells, ^{18}FDG-6-phosphate can be de-phosphorylated by glucose-6-phosphatase. Compared with surrounding non-malignant liver tissue, ^{18}FDG-6-phosphate accumulates in cholangiocarcinoma and metastases in the liver. Hence, these metabolic characteristics make ^{18}FDG PET especially suitable for detection of such tumours (Fig. 2). Consequently, tumour nodules are seen as

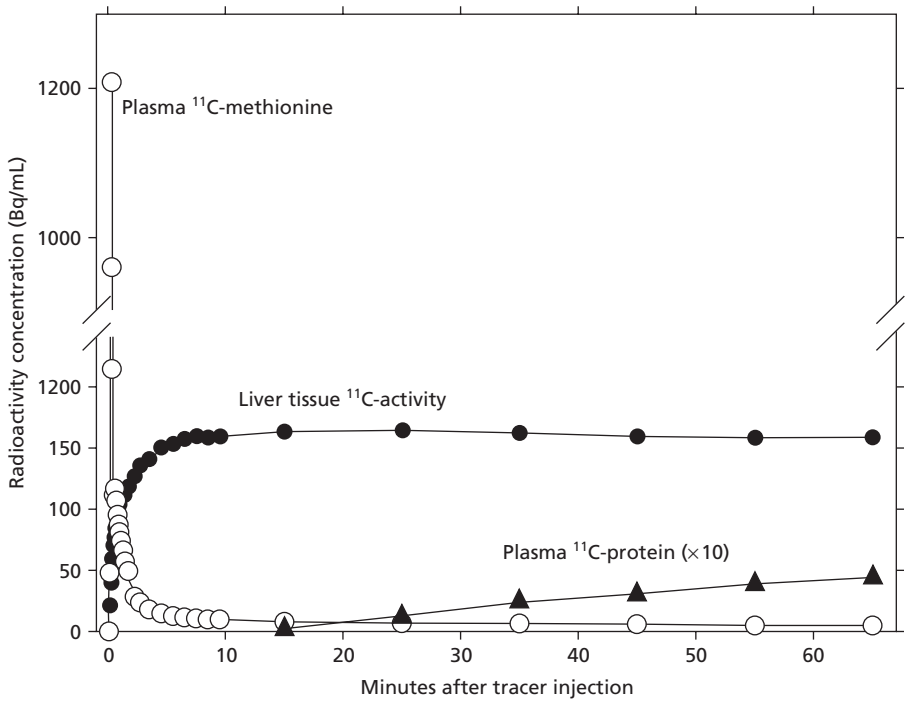

Fig. 1 Time courses of ^{11}C-radioactivity concentrations in pig liver tissue (PET) and plasma after intravenous injection of ^{11}C-methionine. Plasma radioactivity was separated into ^{11}C-methionine and ^{11}C-protein (radio HPLC).

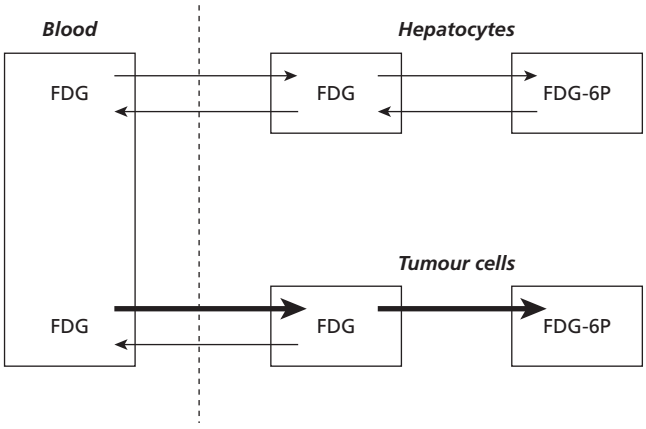

Fig. 2 Compartmental model showing the key differences between ^{18}FDG metabolism in hepatocytes and tumour cells, which form the basis for using ^{18}FDG PET in the diagnosis of liver metastases. Bold arrows indicate enhanced membrane transport and enzymatic phosphorylation of ^{18}FDG in malignant cells.

focal areas of increased radioactivity concentrations, so-called hotspots (Fig. 3).

Because the tumour-to-liver background tissue ratio is higher during fasting than after food intake, ^{18}FDG PET is usually performed after a fasting period of 6–8 h [30]. This is of especial importance for liver studies, as physiologic hyperinsulinemia stimulates ^{18}FDG uptake in normal liver tissue [13]. Furthermore, PET recordings typically take place at least 1 h after the ^{18}FDG injection, as the contrast between tumour and surrounding tissue is higher than at earlier time points [31–33]. This so-called static scan yields images of the mean radioactivity concentrations in the time period of the recordings. The concentrations are often normalized with respect to injected dose and body weight, yielding images of the standardized uptake value (SUV). This normalization procedure may be useful for defining criteria for ascribing hotspots to malignancies [33–34] and for comparison of PET results between individuals and evaluation of response to treatment in individual patients. The diagnostic accuracy for tumour diagnostics is better in combined PET/CT than in PET or contrast-enhanced CT alone [35]. The radiation dose given to the patient is in of the order of the yearly background radiation.

Cholangiocarcinoma

^{18}FDG PET is useful for the detection of cholangiocarcinoma. In a series of 36 consecutive patients who underwent ^{18}FDG PET for suspected cholangiocarcinoma [36], 31 patients had cholangiocarcinoma and five did not. Sensitivity for nodular morphology (mass 1 cm) was 85% but only 18% for infiltrating morphology. Reinhardt *et al.* [33] found a cutoff SUV of 3.6 for the detection of malignancy. In the study by Delbeke *et al.* [34], each of eight cholangiocarcinomas was classified correctly compared to pathological diagnosis. Similarly, each of eight cholangiocarcinomas was clearly visualised in an early ^{18}FDG PET study by our group [37].

Patients with primary sclerosing cholangitis (PSC) are at risk of developing cholangiocarcinoma [38] and a simple, reliable screening method for early detection of tumours would benefit these patients considerable. A key question is, if ^{18}FDG PET can

(a)

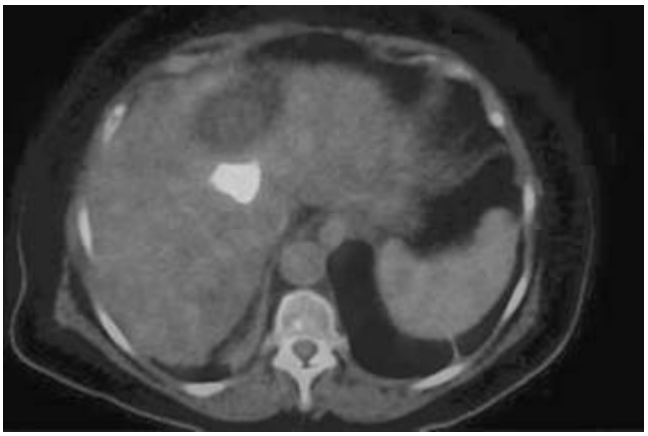

(b)

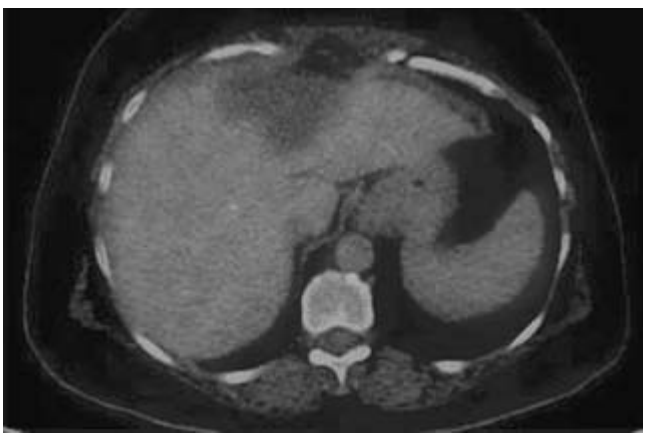

(c)

Fig. 3 ^{18}FDG PET/CT scan of a patient treated for colorectal cancer revealed synchronous liver metastases (a). The patient was treated with radiofrequency ablation (RFA). ^{18}FDG PET/CT 4 weeks later showed RFA-induced necrosis but also residual tumour (b). The patient was treated with RFA again, this time resulting in complete ablation of the tumour tissue (c).

distinguish between malignant tissue and local cholangitis. In a recent study, Prytz *et al.* [39] performed dynamic ^{18}FDG PET scans of 24 consecutive PSC patients listed for liver transplantation and with no signs of liver malignancies on CT or ultrasonography. PET results were compared with pathological diagnosis of the explanted liver in a double-blind study design. The scans were performed as dynamic studies, and parametric images of the net metabolic clearance K of ^{18}FDG were retrieved. By using a cutoff value of lesion-to-normal liver tissue ratio of K, PET diagnosed three out of four cholangiocarcinomas correctly, and it correctly classified hotspots with smaller K-ratios as being caused by local cholangitis. The procedure missed one case with high-grade hilar bile duct dysplasia. However, this was diagnosed by endoscopic cholangiography with brush cytology. Thus, dynamic ^{18}FDG PET seems to have a role as a supplement to CT in pre-transplant diagnostic work-up of liver patients. Dynamic ^{18}FDG PET may further prove to be useful in surveillance programs of patients with PSC.

Hepatocellular carcinoma

Similar to ultrasonography and CT, ^{18}FDG PET detects only two-thirds of known hepatocellular carcinoma (HCC) [40–43]. This is ascribed to similarities between ^{18}FDG metabolism in normal and malignant hepatocytes [42]. Nevertheless, in a study comprising 91 HCC patients, Wudel *et al.* [43] found that ^{18}FDG PET had significant impact on treatment in half of the patients with positive PET results, corresponding to 28% of all patients. Furthermore, ^{18}FDG PET was found useful for detection of extrahepatic metastases [44]. Even so, there is a need for improved diagnostic methods, and in order to comply with this, multi-tracer PET approaches have been investigated. In a PET study comprising 39 patients with HCC [45], ^{11}C-acetate was found to complement ^{18}FDG for the detection of hotspots. However, the ^{11}C-radioactivity tumour-to-reference tissue ratio was relatively low and highly variable, on average 1.96 ± 0.63 ($\pm$SD). Similarly, PET using ^{13}N-ammonia did not supplement ^{18}FDG PET well enough to be clinically useful [46, S. Keiding, unpublished data, December 2006]. Consequently the search for more useful PET tracers needs to continue.

Colorectal cancer liver metastases

^{18}FDG PET is an established tool in the clinical management of liver metastases from colorectal cancers [47–59]. Delbeke and co-workers [34] found that, validated by pathology, static ^{18}FDG PET correctly classified each of 60 colorectal cancer liver metastases and each of 23 benign hepatic lesions by using a cut-off value of 2 for the lesion-to-liver background tissue or a cutoff SUV of 3.5. PET changed diagnostic or therapeutic management of patients with colorectal cancer liver metastases in 20–50% [51–54], mainly by detecting previously unknown extrahepatic and/or hepatic disease. The utility of ^{18}FDG PET in patients with rising or elevated blood carcinoembryogenic antigen (CEA) is

discussed by Wiering *et al.* [49] and Liu *et al.* [50]. ^{18}FDG PET/CT does not replace CT and MR for preoperative anatomical evaluation of primary colorectal cancer but is a useful tool for pre-treatment evaluation of possible spread of the disease of known or suspected recurrence.

^{18}FDG PET is suitable for differentiating between benign and malignant lesions, viz. residual or relapse malignancy versus scarred liver tissue following resection or local ablative treatment [55]. Figure 3 shows an example of ^{18}FDG PET/CT findings in the course of a series of radiofrequency ablation (RFA) of a patient with colorectal liver metastases. Finally, comparison of ^{18}FDG PET results before and after chemotherapy of patients with colorectal liver metastases was predictive for outcome [56,57]. Thus, ^{18}FDG PET or PET/CT may prove useful for early detection of treatment failure and lead to revision of the therapeutic strategy.

Liver metastases from other tumours

Systematic studies of the use of ^{18}FDG PET or PET/CT in the therapeutic management of patients with tumour spread to the liver are scarce, but the technique seems suitable for the diagnosis and staging of liver metastases from breast, malignant melanoma, pancreatic, gastric and oesophageal cancer [58,59]. Liver metastases from neuroendocrine tumours cannot be unambiguously visualized by ^{18}FDG, but ^{11}C-hydroxy-tryptophan or ^{18}F-DOPA seem to be promising PET tracers [60].

References

1 Munk OL, Bass L, Roelsgaard K *et al.* (2001) Liver kinetics of glucose analogs measured in pigs by PET: importance of dual-input blood sampling. *J Nucl Med* 42, 795–801.

2 Brix G, Ziegler SI, Bellemann ME, Doll J *et al.* (2001) Quantification of [(18)F]FDG uptake in the normal liver using dynamic PET: impact and modeling of the dual hepatic blood supply. *J Nucl Med* 42, 1265–1273.

3 Munk OL, Keiding S (2002) Quantification of (18)F-FDG uptake in the liver using dynamic PET. *J Nucl Med* 43, 439–441.

4 Germano G, Chen BC, Huang SC *et al.* (1992) Use of the abdominal aorta for arterial input function determination in hepatic and renal PET studies. *J Nucl Med* 33, 613–620.

5 Keiding S, Munk OL, Schiott KM *et al.* (2000) Dynamic 2-[^{18}F]fluoro-2-deoxy-D-glucose positron emission tomography of liver tumours without blood sampling. *Eur J Nucl Med* 27, 407–412.

6 Munk OL (2005) Hepatic metabolism of glucose analogs measured by dynamic positron emission tomography and interpreted by compartment models. PhD thesis, Faculty of Health, University of Aarhus, Aarhus, Denmark.

7 Bender D, Munk OL, Feng HQ *et al.* (2001) Metabolites of (18)F-FDG and 3-O-(11)C-methylglucose in pig liver. *J Nucl Med* 42, 1673–1678.

8 Ishiwata K, Yamaguchi K, Kameyama M *et al.* (1989) 2-Deoxy-2-[^{18}F]fluoro-D-galactose as an in vivo tracer for imaging galactose metabolism in tumors with positron emission tomography. *Int J Rad Appl Instrum B* 16, 247–254.

9 Ishiwata K, Vaalburg W, Elsinga PH *et al.* (1988) Comparison of L-[1–^{11}C]methionine and L-methyl-[^{11}C]methionine for measuring in vivo protein synthesis rates with PET. *J Nucl Med* 29, 1419–1427.

10 Keiding S, Sørensen M, Bender D *et al.* (2006) Brain metabolism of ^{13}N-ammonia during acute hepatic encephalopathy in cirrhosis measured by PET. *Hepatology* 43, 42–50.

11 Nieves E, Rosenspire K, Filc-Dericco S *et al.* (1986) High-performance liquid chromatographic on-line flow-through radioactivity detector system for analyzing amino acids and metabolites labeled with nitrogen-13. *J Chromatogr* 383, 325–337.

12 Choi Y, Hawkins RA, Huang SC *et al.* (1994) Evaluation of the effect of glucose ingestion and kinetic model configurations of FDG in the normal liver. *J Nucl Med* 35, 818–823.

13 Iozzo P, Geisler F, Oikonen V *et al.* (2003) Insulin stimulates liver glucose uptake in humans: an ^{18}F-FDG PET Study. *J Nucl Med* 44, 682–689.

14 Iozzo P, Osman S, Glaser M *et al.* (2002) In vivo imaging of insulin receptors by PET: preclinical evaluation of iodine-125 and iodine-124 labelled human insulin. *Nucl Med Biol* 29, 73–82.

15 Wu F, Orlefors H, Bergstrom M *et al.* (2000) Uptake of ^{14}C- and ^{11}C-labeled glutamate, glutamine and aspartate in vitro and in vivo. *Anticancer Res* 20, 251–256.

16 Keiding S, Munk OL, Roelsgaard K *et al.* (2001) Positron emission tomography of hepatic first-pass metabolism of ammonia in pig. *Eur J Nucl Med* 28, 1770–1775.

17 Keiding S, Munk OL, Vilstrup H *et al.* (2005) Hepatic microcirculation assessed by positron emission tomography of first-pass ammonia metabolism in porcine liver. *Liver Int* 25, 171–176.

18 Sørensen M, Keiding S (2006) Ammonia metabolism in cirrhosis. In Häussinger D, Kircheis G, Schliess F (eds) *Hepatic Encephalopathy and Nitrogen Metabolism*. Dordrecht, The Netherlands: Springer, pp. 406–419.

19 Ahl B, Weissenborn K, van den Hoff J *et al.* (2004) Regional differences in cerebral blood flow and cerebral ammonia metabolism in patients with cirrhosis. *Hepatology* 40, 73–79.

20 Keiding S, Lausten S, Buus S *et al.* (2006) Liver protein synthesis measured in humans by dynamic ^{11}C-methionine PET: Validation of methodology in rat and pig studies. *Hepatology* 44 (Suppl.1), 488A.

21 Yamamura N, Magata Y, Kitano H *et al.* (1998) Evaluation of [1–^{11}C]octanoate as a new radiopharmaceutical for assessing liver function using positron emission tomography. *Nucl Med Biol* 25, 467–472.

22 DeGrado TR, Wang S, Rockey DC (2000) Preliminary evaluation of 15-[^{18}F]fluoro-3-oxa-pentadecanoate as a PET tracer of hepatic fatty acid oxidation. *J Nucl Med* 41, 1727–1736.

23 Iozzo P, Turpeinen AK, Takala T *et al.* (2003) Liver uptake of free fatty acids in vivo in humans as determined with 14(R, S)-[^{18}F]fluoro-6-thia-heptadecanoic acid and PET. *Eur J Nucl Med Mol Imaging* 30, 1160–1164.

24 Iozzo P, Takala T, Oikonen V *et al.* (2004) Effect of training status on regional disposal of circulating free fatty acids in the liver and skeletal muscle during physiological hyperinsulinemia. *Diabetes Care* 27, 2172–2177.

25 Iozzo P, Turpeinen AK, Takala T *et al.* (2004) Defective liver disposal of free fatty acids in patients with impaired glucose tolerance. *J Clin Endocrinol Metab* 89, 3496–3502.

26 Guiducci L, Järvisalo M, Kiss J *et al.* (2006) [^{11}C]palmitate kinetics across the splanchnic bed in arterial, portal and hepatic venous plasma during fasting and euglycemic hyperinsulinemia. *Nucl Med Biol* 33, 521–528.

27 Munk OL, Keiding S, Bass L (2003) Capillaries within compartments: microvascular interpretation of dynamic positron emission tomography data. *J Theor Biol* 225, 127–141.

28 Munk OL, Bass L, Feng H *et al.* (2003) Determination of regional flow by use of intravascular PET tracers: microvascular theory and experimental validation for pig livers. *J Nucl Med* 44, 1862–1870.

29 Reske SN, Kotzerke J (2001) FDG-PET for clinical use. Results of the 3rd German Interdisciplinary Consensus Conference, 'Onko-PET III', 21 July and 19 September 2000. *Eur J Nucl Med* 28, 1707–1723.

30 Choi Y, Hawkins RA, Huang SC *et al.* (1994) Evaluation of the effect of glucose ingestion and kinetic model configurations of FDG in the normal liver. *J Nucl Med* 35, 818–823.

31 Chen YK, Kao CH (2005) Metastatic hepatic lesions are detected better by delayed imaging with prolonged emission time. *Clin Nucl Med* 30, 455–456.

32 Nishiyama Y, Yamamoto Y, Monden T *et al.* (2005) Evaluation of delayed additional FDG PET imaging in patients with pancreatic tumour. *Nucl Med Commun* 26, 895–901.

33 Reinhardt MJ, Strunk H, Gerhardt T *et al.* (2005) Detection of Klatskin's tumor in extrahepatic bile duct strictures using delayed 18F-FDG PET/CT: preliminary results for 22 patient studies. *J Nucl Med* 46, 1158–1163.

34 Delbeke D, Martin WH, Sandler MP *et al.* (1998) Evaluation of benign vs malignant hepatic lesions with positron emission tomography. *Arch Surg* 133, 510–515.

35 Roman CD, Martin WH, Delbeke D (2005) Incremental value of fusion imaging with integrated PET-CT in oncology. *Clin Nucl Med* 30, 470–477.

36 Anderson CD, Rice MH, Pinson CW *et al.* (2004) Fluorodeoxyglucose PET imaging in the evaluation of gallbladder carcinoma and cholangiocarcinoma. *J Gastrointest Surg* 8, 90–97.

37 Keiding S, Hansen SB, Rasmussen HH *et al.* (1998) Detection of cholangiocarcinoma in primary sclerosing cholangitis by positron emission tomography. *Hepatology* 28, 700–706.

38 Boberg KM, Bergquist A, Mitchell S *et al.* (2002) Cholangiocarcinoma in primary sclerosing cholangitis: risk factors and clinical presentation. *Scand J Gastroenterol* 37, 1205–1211.

39 Prytz H, Keiding S, Björnsson E *et al.* (2006) Dynamic FDG PET is useful for detection of cholangiocarcinoma in patients with PSC listed for liver transplantation. *Hepatology* 44, 1572–1580.

40 Jeng LB, Changlai SP, Shen YY *et al.* (2003) Limited value of 18F-2-deoxyglucose positron emission tomography to detect hepatocellular carcinoma in hepatitis B virus carriers. *Hepatogastroenterology* 50, 2154–2156.

41 Khan MA, Combs CS, Brunt EM *et al.* (2000) Positron emission tomography scanning in the evaluation of hepatocellular carcinoma. *J Hepatol* 32, 792–797.

42 Torizuka T, Tamaki N, Inokuma T *et al.* (1995) In vivo assessment of glucose metabolism in hepatocellular carcinoma with FDG-PET. *J Nucl Med* 36, 1811–1817.

43 Wudel LJ, Jr., Delbeke D, Morris D *et al.* (2003) The role of [18F]fluorodeoxyglucose positron emission tomography imaging in the evaluation of hepatocellular carcinoma. *Am Surg* 69, 117–124.

44 Sugiyama M, Sakahara H, Torizuka T *et al.* (2004)18F-FDG PET in the detection of extrahepatic metastases from hepatocellular carcinoma. *J Gastroenterol* 39, 961–968.

45 Ho CL, Yu SC, Yeung DW (2003) ^{11}C-acetate PET imaging in hepatocellular carcinoma and other liver masses. *J Nucl Med* 44, 213–221.

46 Shibata T, Yamamoto K, Hayashi N (1988) Dynamic positron emission tomography with ^{13}N-ammonia in liver tumors. *Eur J Nucl Med* 14, 607–611.

47 Boykin KN, Zibari GB, Lilien DL *et al.* (1999) The use of FDG-positron emission tomography for the evaluation of colorectal metastases of the liver. *Am Surg* 65, 1183–1185.

48 Delbeke D, Martin WH (2004) PET and PET-CT for evaluation of colorectal carcinoma. *Semin Nucl Med* 34, 209–223.

49 Wiering B, Ruers TJ, Oyen WJ (2004) Role of FDG-PET in the diagnosis and treatment of colorectal liver metastases. *Expert Rev Anticancer Ther* 4, 607–613.

50 Liu FY, Chen JS, Changchien CR *et al.* (2005) Utility of 2-fluoro-2-deoxy-D-glucose positron emission tomography in managing patients of colorectal cancer with unexplained carcinoembryonic antigen elevation at different levels. *Dis Colon Rectum* 48, 1900–1912.

51 Wiering B, Krabbe PF, Jager GJ *et al.* (2005) The impact of fluor-18-deoxyglucose-positron emission tomography in the management of colorectal liver metastases. *Cancer* 15, 2658–2670.

52 Lejeune C, Bismuth MJ, Conroy T (2005) Use of a decision analysis model to assess the cost-effectiveness of 18F-FDG PET in the management of metachronous liver metastases of colorectal cancer. *J Nucl Med* 46, 2020–2028.

53 Selzner M, Hany TF, Wildbrett P *et al.* (2004) Does the novel PET/CT imaging modality impact on the treatment of patients with metastatic colorectal cancer of the liver? *Ann Surg* 240, 1027–1034.

54 Truant S, Huglo D, Hebbar M *et al.* (2005) Prospective evaluation of the impact of [18F]fluoro-2-deoxy-D-glucose positron emission tomography of resectable colorectal liver metastases. *Br J Surg* 92, 362–369.

55 Bender H, Bangard N, Metten N *et al.* (1999) Possible role of FDG-PET in the early prediction of therapy outcome in liver metastases of colorectal cancer. *Hybridoma* 18, 87–91.

56 Vitola JV, Delbeke D, Meranze SG *et al.* (1996) Positron emission tomography with F-18-fluorodeoxyglucose to evaluate the results of hepatic chemoembolization. *Cancer* 78, 2216–2222.

57 Dimitrakopoulou-Strauss A, Strauss LG *et al.* (2004) Prognostic aspects of 18F-FDG PET kinetics in patients with metastatic colorectal carcinoma receiving FOLFOX chemotherapy. *J Nucl Med* 45, 1480–1487.

58 Khandani AH, Wahl RL (2005) Applications of PET in liver imaging. *Radiol Clin North Am* 43, 849–860.

59 Kinkel K, Lu Y, Both M *et al.* (2002) Detection of hepatic metastases from cancers of the gastrointestinal tract using noninvasive imaging methods (US, CT, MR imaging, PET): a meta-analysis. *Radiology* 224, 748–756.

60 Mottaghy FM, Reske SN (2006) Functional imaging of neuroendocrine tumours with PET. *Pituitary* 9, 237–242.

5.9 Splanchnic haemodynamic investigations

Didier Lebrec and Richard Moreau

Introduction

In general, the circulatory system is evaluated by determination of blood flow, pressure and volume. In the splanchnic territory, portal pressure and splanchnic blood flow may be measured; vascular resistance is calculated by the ratio between pressure and blood flow. Portal pressure depends on two factors: portal intrahepatic vascular resistance (and vascular resistance of the portosystemic collateral when portal hypertension is present); and portal tributary blood flow (the sum of gastrointestinal, colic, splenic, mesenteric and pancreatic blood flow). Splanchnic blood flow or hepatic blood flow is the sum of portal tributary blood flow and hepatic arterial blood flow. In portal hypertension, splanchnic blood flow may be higher than hepatic blood flow as only a fraction of the portal blood reaches the systemic circulation by passing through the liver.

The haemodynamic investigation of the splanchnic circulation consists of the measurements of pressure and blood flow. In man, while pressures may be measured, there is no simple method for measuring either portal and hepatic arterial blood flows or the circulation in the collateral vessels. Regional blood flow can, however, be measured in animals. Finally, as it is altered in portal hypertension, the systemic circulation must also be evaluated.

In this chapter, the main haemodynamic methods used in man are described. It must be emphasized, however, that the results reported are those measured in fasted, conscious patients in a supine position. Results obtained in other conditions may differ widely from those reported below.

Measurement of portal pressure

The measurement of pressure in the portal venous system is the main method used to define and characterize portal hypertension. Normally, portal pressure ranges from 7 to 12 mmHg, and the pressure gradient between portal pressure and vena cava territory pressure ranges from 1 to 4 mmHg. Portal hypertension is present when portal pressure is higher than 12 mmHg or when the pressure gradient is higher than 4 mmHg. If the pressure in the vena cava territory increases, portal hypertension develops, but not collateral circulation. Portal pressure may be evaluated either directly or indirectly. Direct measurement of portal pressure is more invasive than the indirect method but is more valid, especially with cases of presinusoidal or extrahepatic portal hypertension.

Direct methods

During abdominal surgery, portal pressure may be measured directly by introducing a needle into the lumen of the portal vein or by inserting a catheter into a small ileal vein. These values differ from those measured without surgery, however, as anaesthetic agents modify splanchnic and systemic circulation. The catheterization of the umbilical vein also allows direct measurement of portal pressure. As the last invasive technique necessitates both general anaesthesia and surgery, it is not used regularly.

The most common direct technique is the percutaneous transhepatic puncture of the portal vein with a thin needle (Chiba needle). The portal vein may be located by ultrasonography [1]. Larger needles may also be used and, in this case, a catheter may be inserted in the lumen of the portal vein in order to cannulate different veins. If ascites or coagulation defects are present, these methods are contraindicated. The portal vein may be catheterized through a hepatic vein in the same manner as with a transvenous liver biopsy procedure [2]. This method allows measurement of the pressure in the inferior vena cava. It may cause abdominal pain.

Indirect methods

Intrasplenic pressure

Although splenic pressure, measured with a needle, has been widely used, this technique has a high risk of intraperitoneal haemorrhage. Splenic pulp pressure is similar to splenic vein pressure.

Intrahepatic pressure

It has been claimed that pressure in the hepatic tissue reflects sinusoidal pressure. This intrahepatic pressure measurement is performed blindly by introducing a needle percutaneously in the hepatic parenchyma [3]. While this pressure may be 'sinusoidal', it may also be intra-arterial, portal or that of the hepatic vein or the biliary tract.

Hepatic venous pressures

As it is simple and safe, measurement of wedged and free hepatic venous pressure is the most common procedure used to evaluate portal pressure indirectly. A radio-opaque catheter is introduced into a hepatic vein (usually the right vein) with an approach through a jugular, femoral or humeral vein under local anaesthesia. This procedure is performed under radioscopic control [4]. The tip of the catheter is wedged to block the circulation in a small hepatic venule. The wedged position is verified by the absence of reflux of radio-opaque dye. Wedged hepatic venous pressure is similar to the occluded pressure obtained with a balloon catheter. Free hepatic venous pressure is measured with the tip of the catheter placed in the hepatic vein close to the inferior vena cava. Recently, a divergence of pressure measurements between different hepatic veins has been demonstrated [5]. The investigator's experience plays a major role in ensuring that the technique is performed properly [6].

The hepatic venous pressure gradient (wedged minus free hepatic venous pressure) ranges from 1 to 4 mmHg in normal subjects. The hepatic venous pressure gradient remains normal in cases of extrahepatic portal hypertension and in certain cases of presinusoidal portal hypertension such as schistosomiasis [7]. In presinusoidal portal hypertension, the pressure gradient may be elevated, in general to no more than 13 mmHg, thus indicating two blocks (presinusoidal and sinusoidal). In chronic liver disease with extensive fibrosis, as well as in non-cirrhotic portal hypertension, the hepatic venous pressure gradient is increased from 5 to 20 mmHg but remains lower than portal pressure. This increase in the pressure gradient is also observed in several acute liver diseases such as fulminant hepatitis [8].

In alcoholic cirrhosis and in hepatitis-B-related cirrhosis, wedged hepatic venous pressure is similar to portal pressure [4]. The hepatic venous pressure gradient exhibits a circadian variation with two peaks (09.00 h and 23.00 h), and it may also increase during physical exercise. Among these patients, the hepatic venous pressure gradient may differ widely from 10 to 30 mmHg. This value is correlated with the severity of cirrhosis as estimated by the Child–Pugh classification [9]. Liver lesions of acute alcoholic hepatitis increase the hepatic venous pressure gradient [10]. The value for hepatic venous pressure gradient is correlated with the extent of fibrosis and the amount of liver cell necrosis. In patients with cirrhosis, it has also been observed that the presence of hepatocellular carcinoma may markedly increase the hepatic venous pressure gradient to more than 30 mmHg, and that it may be heterogeneous from one vein to another [11]. In patients with alcoholic cirrhosis with a hepatic venous pressure gradient of more than 12 mmHg, the pressure gradient is not associated with either the development of oesophageal varices or the risk of gastrointestinal bleeding [12]. When the hepatic venous pressure gradient is less than 12 mmHg, it has been established that rupture of oesophageal varices does not occur.

A hepatic venous pressure gradient of more than 4 mmHg indicates sinusoidal portal hypertension, but the mechanism causing this increase is not clear. It depends mainly on the reduction in hepatic vascular space, which increases intrahepatic vascular resistance [13]. This pressure gradient also depends on several other factors such as portal pressure, portal tributary blood flow and hepatic arterial blood flow.

Finally, in patients with alcoholic cirrhosis, a pharmacological decrease in the hepatic venous pressure gradient indicates a reduction in portal pressure [4]. In this case, however, the reduction in hepatic venous pressure gradient may be more marked than the decrease in portal pressure.

Oesophageal variceal pressures

In patients with portal hypertension and oesophageal varices, during oesophageal endoscopy, variceal pressures may be measured by different techniques. A first approach consists of puncturing the lumen of a varix with a needle [14]. This procedure should be performed before sclerotherapy because it may precipitate variceal bleeding. When measured by this technique, variceal pressure is elevated in cases with portal hypertension, but no correlation with portal pressure or hepatic venous pressure gradient has been reported. Intravariceal pressure seems to correlate with the size of the varix and with a previous history of ruptured oesophageal varices.

A second approach uses an endoscopic gauge allowing the measurement of variceal pressure without puncturing varices [15]. This non-invasive method uses a hemispheric pressure gauge with a small chamber fed with a constant flow of gas. This chamber is covered by a latex membrane. When the gauge is placed over a varix, the pressure needed to fill the gauge, as measured by a pressure transducer, is equal to the variceal pressure. It is assumed that the pressure needed to compress a varix equals the pressure inside the varix. It has been demonstrated recently that this technique is reproducible and can be used to assess variceal pressure regularly and evaluate the effects of pharmacological therapy [16].

A third endoscopic method has been described more recently using a transparent plastic balloon fixed to the tip of a gastroscope and observation of the pressure equilibrium between varices and the balloon [17]. The pressure values obtained with this technique correlate well with those measured by needle puncture or with direct portal pressure measurements [18].

Measurement of blood flow

Portal and hepatic arterial blood flows

During abdominal surgery, portal and hepatic arterial blood flow

may be measured separately by means of an electromagnetic flow-meter. The results of this invasive method are erroneous because it is performed under general anaesthesia. The ratio between portal and hepatic arterial blood flows can also be calculated by measuring hepatic radioactivity after the injection of a radioactive substance into a peripheral vein. A gamma camera may evaluate both hepatic arterial and the portal radioactivity. This method cannot be widely used because renal and pulmonary radioactivity interferes with hepatic and portal radioactivity; moreover, it is difficult to dissociate arterial and portal curves.

Measurement of hepatic blood flow

Indicator dilution method

Hepatic blood flow can be estimated with the indicator dilution method [19]. The indicator is injected into either the hepatic artery or the portal vein, and blood is drawn into a hepatic vein. Analysis of the hepatic curve gives the hepatic blood flow. This invasive technique is not widely used because there is inadequate mixing between the indicator and the blood. This method has been used, however, to evaluate hepatic microcirculation, transit time and distribution volume [20].

Hepatic clearance method

The clearance method is the most widely used technique at present for estimating hepatic blood flow in man. It is based on the Fick principle [21]. The hepatic clearance (Cl) depends on hepatic blood flow (HBF) and the extraction (E) of a substance by the liver:

$$Cl = HBF \times E$$

Hence:

$$HBF = Cl/E$$

Absolute hepatic clearance can be calculated by the continuous infusion method. When the peripheral concentration (C_p) of the substance has reached a plateau, the amount of substance removed by the liver is equal to the amount of perfused solution Q:

$$Cl = Q/C_p$$

Extraction depends on afferent (C_{aff}) and efferent (C_{eff}) concentrations of the substance. Thus:

$$E = (C_{aff} - C_{eff})/C_{aff}$$

If this substance is captured only by the liver, afferent concentration is equal to peripheral vein or arterial concentration of this substance. Efferent concentration is obtained from blood drawn from a hepatic vein. Therefore, hepatic vein catheterization is necessary to measure hepatic blood flow by the clearance method. Hepatic clearance is hepatic blood flow only if extraction reaches 100%. If extraction is lower than 10%, the values of hepatic blood flow are not calculated as it is considered that a slight change in extraction induces large variation in hepatic blood flow. Thus, the clearance method cannot evaluate hepatic blood flow in patients with severe liver disease. Moreover, a decrease in hepatic clearance does not indicate a decrease in hepatic blood flow as extraction may also decrease, leaving hepatic blood flow constant.

Fraction clearance (K) may also be used for the calculation of hepatic blood flow:

$$K = Cl/\text{Blood volume}$$

This method, using a bolus injection, is similar to the continuous infusion method.

Substances used for the clearance method should meet three criteria: they should be devoid of toxicity, should diffuse only within the vascular space and should be removed only by the liver. Two types of substance can be used: those cleared by hepatocytes [bromsulphthalein (BSP), indocyanine cardiogreen (ICG)] and those cleared by the Kupffer cells (colloid labelled with radiogold, denaturated labelled albumin).

Galactose clearance has been proposed for the estimation of hepatic blood flow as hepatic extraction of this substance is more than 90% in normal subjects [22]. In patients with liver disease, however, this extraction is markedly decreased and, hence, hepatic blood flow is not properly evaluated by galactose clearance. Moreover, it has been demonstrated recently that extrahepatic uptake of galactose occurs in cirrhotic patients. These findings clearly indicate that galactose clearance can be used neither for measurement of hepatic blood flow nor for studying variations in hepatic blood flow.

Values of hepatic blood flow

In normal fasted conscious subjects in the supine position, hepatic blood flow ranges from 1 to 2 L/min, i.e. 1 mL/min per g of liver tissue. In man, it is accepted, but has not been clearly demonstrated, that one-third of hepatic blood flow comes from the hepatic artery and two-thirds from the portal vein. In patients with liver diseases, hepatic blood flow may differ widely from one patient to another [23]. In patients with cirrhosis, hepatic blood flow may be low, normal or elevated. In particular, acute alcoholic hepatitis increases hepatic blood flow [24]. In patients with acute hepatitis, hepatic blood flow may be increased, while hepatic blood flow is low in patients with extrahepatic portal hypertension [25]. In patients with cirrhosis, no correlation has been found between hepatic blood flow and liver failure, nor has hepatic blood flow been correlated with portal pressure [26]. This observation is not surprising as, in portal hypertensive patients, a certain percentage of the portal blood does not reach the liver but bypasses this organ through the collateral circulation. Hence, portal pressure may decrease without a change in hepatic blood flow. In this case, the reduction in portal pressure depends on a decrease in portal tributary blood flow.

Measurement of portal blood flow

Several invasive methods have been described for measuring portal blood flow. However, they necessitate the insertion of a catheter into the lumen of the portal vein. Portal blood flow can be measured by the continuous thermodilution method or by means of a catheter with an electromagnetic flow-meter.

The most common method for the evaluation of portal blood flow is by Doppler sonography [27]. This non-invasive procedure measures the velocity of red blood cells. At present, however, the pulsed Doppler method is not accurate in man for the following reasons:

1 The mean angle between the Doppler beam and the axis of the portal vein may be too large, reaching up to 60°. In this case, a slight error in the angle results in a large variation in the cosine angle, which is related to flow velocity.

2 The ultrasound diffraction between the skin and the portal vein is not taken into consideration.

3 The measurement of maximal velocity in one area of the portal vein may differ from one position to another.

4 As the measurement of blood flow depends on the cross-sectional area of the portal vein, a slight error in the estimated diameter of the portal vein results in a large variation in this value.

The pulsed Doppler method has not yet been validated in man. The Doppler technique may, however, be used to assess the presence and direction of portal blood flow. In addition, in the same individual, physiological or pharmacological variations in blood velocity in the portal vein may be evaluated. Its accuracy and reproducibility are still in question [28].

In normal subjects, the portal blood flow goes towards the liver and has a continuous spectrum, with mild waves. In patients with portal hypertension, there is a continuous flow towards the liver. In some cases, alterations in portal blood flow appear as an absence of end-diastolic, arterialized flow or bidirectional flow. Reversed flow is rarely observed in the portal vein. Portal vein diameter and blood flow changes are not, however, correlated with the hepatic venous pressure gradient in patients with cirrhosis [29].

Estimation of blood flow in the collateral circulation

Quantification of portosystemic circulation

The percentage of portal venous inflow shunted through portosystemic collaterals may be estimated by comparing the area of an isotope dilution curve recorded from the hepatic vein after injecting an isotope into the superior mesenteric or splenic artery with the curve obtained after injecting an isotope into the hepatic artery [30]. In normal subjects, no shunting was detected but, in patients with cirrhosis, shunting of mesenteric or splenic flow ranged from zero to 100%. A similar estimation may be obtained after intrasplenic injection of a radioactive indicator.

The comparison of bioavailability of drugs after oral and intravenous administration allows the measurement of the shunt fraction of portal inflow [31]. The liver must remove 100% of these substances. The systemic availability of oral glyceryl trinitrate has been used. In this case, drug concentrations in plasma were replaced by assessments of pharmacological effects using digital plethysmography [32]. None of these invasive and non-invasive methods, however, could be used to predict the complication of portal hypertension.

Azygos blood flow

The superior portosystemic collateral circulation can be estimated by measuring blood flow in the azygos vein [33]. This vein essentially drains the splenogastric collateral circulation. Azygos blood flow is measured by the local continuous thermodilution method. Under fluoroscopic control, a continuous thermodilution catheter with a curved tip is introduced into the azygos vein up to approximately 5 cm from its junction with the superior vena cava. Its position is verified by injection of a contrast medium into the catheter. During routine haemodynamic investigation, catheterization of the azygos vein may be performed either from the femoral vein or from the right internal jugular vein. In normal subjects, azygos blood flow is approximately 100 mL/min. In patients with portal hypertension, azygos blood flow is six times higher than in normal subjects and ranges from 200 to 1500 mL/min.

An elevated azygos blood flow indirectly confirms the increased portal tributary blood flow observed in portal hypertensive animals. Azygos blood flow is correlated with portal pressure and depends on the severity of cirrhosis. Azygos blood flow is not correlated with either the presence and size of the oesophageal varices or the risk of ruptured varices [34]. Finally, azygos blood flow is a more sensitive measurement than the hepatic venous pressure gradient for evaluating the change in splanchnic circulation after portal hypotensive drug administration. Thus, the measurement of azygos blood flow seems to be the most viable method for the evaluation of portal hypertension.

Preliminary results showed that cine phase-contrast magnetic resonance angiography is a practical non-invasive method for measuring absolute azygos blood flow and provides a non-invasive method of monitoring portal hypertension [35].

References

1 Burcharth F, Joyce F (1987) Percutaneous transhepatic catheterization of the portal venous system. *J Gastroenterol Hepatol* 2, 569–587.

2 Lebrec D, Goldfarb G, Degott C *et al.* (1982) Transvenous liver biopsy. An experience based on 1000 hepatic tissue samplings with this procedure. *Gastroenterology* 83, 338–340.

3 Fenyves D, Pomier-Layrargues G, Willems B *et al.* (1988) Intrahepatic pressure measurement: not an accurate reflection of portal vein pressure. *Hepatology* 8, 211–216.

4 Valla D, Bercoff E, Menu Y *et al.* (1984) Discrepancy between wedged hepatic venous pressure and portal venous pressure after acute propranolol administration in patients with alcoholic cirrhosis. *Gastroenterology* 86, 1400–1403.

5 Keiding S, Vilstrup H (2002) Intrahepatic heterogeneity of hepatic venous pressure gradient in human cirrhosis. *Scand J Gastroenterol* 37, 960–964.

6 Groszmann RJ, Wongcharatrawee S (2004) The hepatic venous pressure gradient: Anything worth doing should be done right. *Hepatology* 39, 280–282.

7 Lebrec D, Benhamou JP (1986) Noncirrhotic intrahepatic portal hypertension. *Semin Liver Dis* 6, 332–340.

8 Valla D, Fléjou JF, Lebrec D *et al.* (1989) Portal hypertension and ascites in acute hepatitis. Clinical, hemodynamic and histological correlations. *Hepatology* 10, 482–487.

9 Braillon A, Calès P, Valla D *et al.* (1986) Influence of the degree of liver failure on systemic and splanchnic haemodynamics and on response to propranolol in patients with cirrhosis. *Gut* 27, 1204–1209.

10 Poynard T, Degott C, Munoz C *et al.* (1987) Relationship between degree of portal hypertension and liver histologic lesions in patients with alcoholic cirrhosis. Effect of acute alcoholic hepatitis on portal hypertension. *Dig Dis Sci* 32, 337–344.

11 Lee SS, Koshy A, Hadengue A *et al.* (1990) Heterogeneous hepatic venous pressures in patients with liver cancer. *J Clin Gastroenterol* 12, 53–56.

12 Lebrec D, de Fleury P, Rueff B *et al.* (1980) Portal hypertension size of esophageal varices, and risk of gastrointestinal bleeding in alcoholic cirrhosis. *Gastroenterology* 79, 1139–1144.

13 Lee SS, Hadengue A, Girod C *et al.* (1987) Reduction of intrahepatic vascular space in the pathogenesis of portal hypertension. In vitro and in vivo studies in the rat. *Gastroenterology* 93, 157–161.

14 Staritz M, Poralla T, Meyer Zum Buschenfelde H (1985) Intravascular oesophageal variceal pressure (IOVP) assessed by endoscopic fine needle puncture under basal conditions, Valsalva's manoeuvre and after glyceryltrinitrate application. *Gut* 26, 525–530.

15 Bosch J, Bordas JM, Rigau J *et al.* (1986) Noninvasive measurement of the pressure of esophageal varices using an endoscopic gauge: comparison with measurements by variceal puncture in patients undergoing endoscopic sclerotherapy. *Hepatology* 6, 667–672.

16 Nevens F, Sprengers D, Feu F *et al.* (1996) Measurement of variceal pressure with an endoscopic pressure sensitive gauge: validation and effect of propranolol therapy in chronic conditions. *J Hepatol* 24, 66–73.

17 Gertsch P, Fischer G, Kleber G *et al.* (1993) Manometry of esophageal varices: comparison of an endoscopic balloon technique with needle puncture. *Gastroenterology* 105, 1159–1166.

18 Brensing KA, Neubrand M, Textor J *et al.* (1998) Endoscopic manometry of esophageal varices: evaluation of a balloon technique compared with direct portal pressure measurement. *J Hepatol* 29, 94–102.

19 Cohn JN, Khatri IM, Groszmann RJ *et al.* (1972) Hepatic blood flow in alcoholic liver disease measured by an indicator dilution technique. *Am J Med* 53, 704–722.

20 Huet P-M, Pomier-Layrargues G, Villeneuve J-P *et al.* (1986) Intrahepatic circulation in liver disease. *Semin Liver Dis* 6, 277–286.

21 Caesar J, Shaldon S, Chiandussi L *et al.* (1961) The use of indocyanine green in the measurement of hepatic blood flow and as a test of hepatic function. *Clin Sci* 21, 43–57.

22 Keiding S (1988) Galactose clearance measurements and liver blood flow. *Gastroenterology* 94, 477–481.

23 Gadano A, Hadengue A, Vachiery F *et al.* (1997) Relationship between hepatic blood flow, liver tests, haemodynamic values and clinical characteristics in patients with chronic liver disease. *J Gastroenterol Hepatol* 12, 167–171.

24 Cohn JN, Khatri IM, Groszmann RJ *et al.* (1972) Hepatic blood flow in alcoholic liver disease measured by an indicator dilution technique. *Am J Med* 53, 704–722.

25 Lebrec D, Bataille C, Bercoff E *et al.* (1983) Hemodynamic changes in patients with portal venous obstruction. *Hepatology* 3, 550–553.

26 Lebrec D, Sicot C, Benhamou JP (1973) Débit sanguin hépatique, hypertension portale et insuffisance hépatocellulaire chez les malades atteints de cirrhose alcoolique. *Arch Fr Mal App Dig* 62, 465–471.

27 Burns p, Taylor K, Blei AT (1987) Doppler flowmetry and portal hypertension. *Gastroenterology* 92, 824–826.

28 Bolondi L, Gaiani S, Barbara L (1991) Accuracy and reproducibility of portal flow measurement by Doppler US. *J Hepatol* 13, 269–273.

29 Choi YJ, Baik SK, Park DH *et al.* (2003) Comparison of Doppler ultrasonography and the hepatic venous pressure gradient in assessing portal hypertension in liver cirrhosis. *J Gastroenterol Hepatol* 18, 424–429.

30 Groszmann R, Kotelanski B, Cohn JN *et al.* (1972) Quantitation of portasystemic shunting from the splenic and mesenteric beds in alcoholic liver disease. *Am J Med* 53, 715–722.

31 Nordlinger R, Parquet M, Infante R *et al.* (1982) Noninvasive measurement of nutrient portal blood shunting: an experimental study with [^{14}C]ursodeoxycholic acid. *Hepatology* 2, 412–419.

32 Porchet H, Bircher J (1982) Noninvasive assessment of portal-systemic shunting: evaluation of a method to investigate systemic availability of oral glyceryl trinitrate by digital plethysmography. *Gastroenterology* 92, 629–637.

33 Bosch J, Groszmann RJ (1984) Measurement of azygos venous blood flow by a continuous thermal dilution technique: an index of blood low through gastroesophageal collaterals in cirrhosis. *Hepatology* 4, 424–429.

34 Calès P, Braillon A, Jiron MI *et al.* (1984) Superior portosystemic collateral circulation estimated by azygos blood flow in patients with cirrhosis. Lack of correlation with oesophageal varices and gastrointestinal bleeding. Effect of propranolol. *J Hepatol* 1, 37–46.

35 Lomas DL, Hayball MP, Jones DP *et al.* (1995) Non-invasive measurement of azygos venous blood flow using magnetic resonance. *J Hepatol* 22, 399–403.

5.10 The Cochrane Hepatobiliary Group

*Christian Gluud, on behalf of the Cochrane Hepatobiliary Group**

Introduction

On 20 May 1747, the Scottish naval surgeon James Lind studied six interventions for 12 sailors with scurvy. The patients all had putrid gums, spots and lassitude. They shared a room and meals. Lind divided them into six groups: two patients were given sea water, two cider, two vinegar, two elixir vitriol, two a concoction of spices, garlic and mustard seeds, and two oranges and lemons. Within six days, the two patients given oranges and lemons became fit for duty or well enough to be appointed nurse for the remaining patients – see The James Lind Library (http://www.jameslindlibrary.org) and the European Clinical Research Infrastructures Network (http://www.ecrin.org). Lind reported this clinical trial in 1753. It took about another 150 years until we discovered vitamin C and understood the effect of oranges and lemons in scurvy. It took about another 200 years until we rediscovered the idea of conducting bias-free comparative trials (http://www.jameslindlibrary.org). Researchers began to use randomization at the time of the Second World War. The methods of conducting randomized trials have been refined since then. Such trials remain the most reliable way to test the effects of interventions [1].

Hepatobiliary randomized trials started to appear in 1955 [2]. Thomas C Chalmers and co-workers conducted the first two factorial-designed trials on diet, rest and physical reconditioning for acute infectious hepatitis [2]. In these trials, 260 patients and 200 patients were randomized [2]. Several other early trials in liver diseases have been reviewed [3]. It took a while before hepatobiliary controlled trials started to appear regularly (Fig. 1). Presently about 550 publications on hepatobiliary randomized trials are published each year (Fig. 1). This corresponds to about three publications per working day appearing in more than 1000 different journals. Nobody can any longer claim to be a specialist in all hepatobiliary diseases. The workload of keeping up to date has become so heavy that we have to collaborate and divide the tasks among ourselves. The first task is to conduct the randomized trials. The second task is to systematically review these trials. The third task is to implement the evidence from the systematic reviews into clinical practice.

In this chapter we describe the evidence hierarchy that may guide evidence-based clinical practice. We assess the proportion of hepatobiliary randomized trials with sample size estimation, the achieved sample size, and the proportion with adequate quality components. We compare the quality of hepatobiliary randomized trials to that of trials from all medical fields. Finally, The Cochrane Collaboration and the Cochrane Hepatobiliary Group (CHBG) are described.

The evidence hierarchy

The hierarchy of evidence is well established [4–6]. It is based on the estimated risks of bias in the different study designs. Randomized trials are internationally considered the gold standard for intervention comparisons [1–13]. The results from randomized trials form the basis for determining which drugs and devices are effective. Historically controlled studies, cohort studies and case–control studies are unreliable designs unless the intervention effect is dramatic [13,14]. Dramatic intervention effects are rare. Expert opinions, case reports and experimental models may be misleading and rank lowest in the evidence hierarchy [4–6]. Study designs other than randomized trials remain important for diagnostic [6,15] and prognostic [16,17] studies as well as for assessing rare adverse events [18,19] – but they cannot replace randomized trials in assessing beneficial effects of interventions.

Randomized trials are increasingly being used to guide evidence-based clinical practice. You need to address a central question before you consider using the results for patient care:

* Members of the Cochrane Hepatobiliary Group Editorial Team are: Bodil Als-Nielsen, Editor (Denmark), Gennaro D'Amico, Editor (Italy), Christian Gluud, Co-ordinating Editor (Denmark), Lise Lotte Gluud, Editor (Denmark), Saboor Khan, Editor (UK), Sarah L. Klingenberg, Hand Search Coordinator (Denmark), Ronald L. Koretz, Editor (USA), Rob Myers, Editor (Canada), Luigi Pagliaro, Editor (Italy), Rosanna Simonneti, Editor (Italy), Robert Sutton, Editor (UK), Dimitrinka Nikolova, Review Group Co-ordinator (Denmark) and Nader Salas, Data Manager (Denmark).

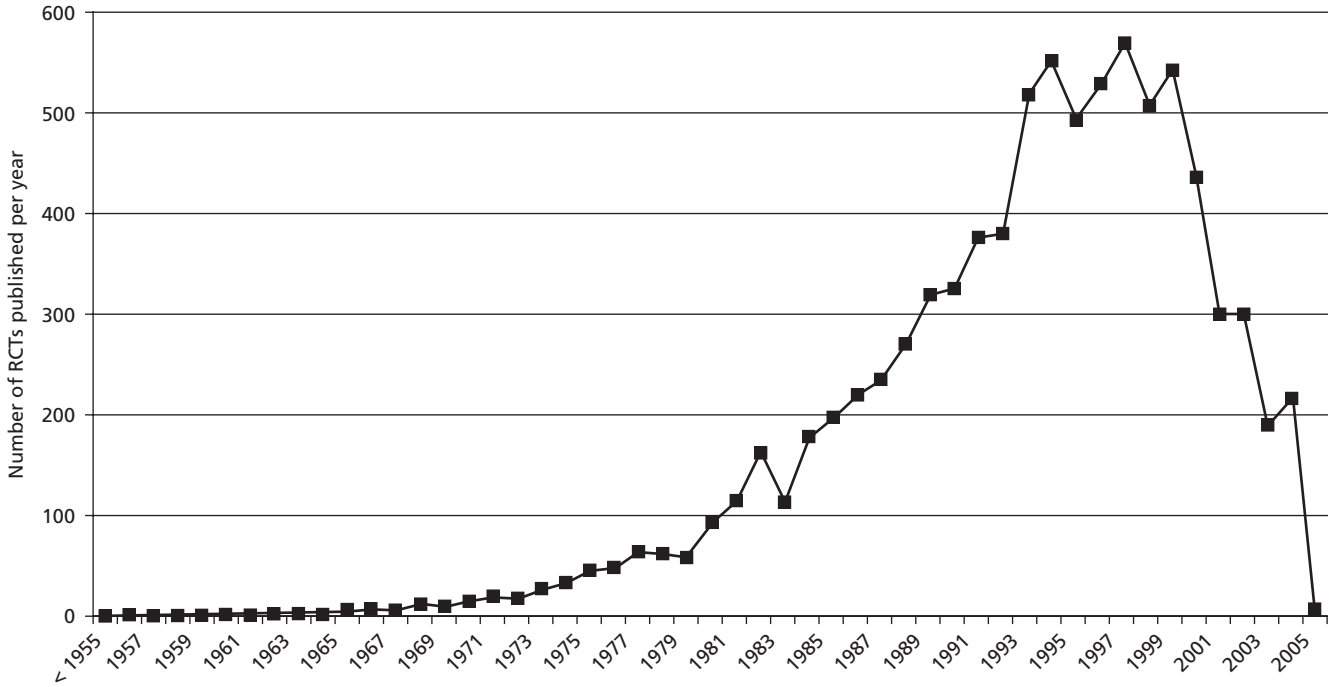

Fig.1 Number of publications on randomized trials and controlled clinical trials during the period 1955 to 2005 according to the Cochrane Hepatobiliary Group Controlled Trial Register [56]. The decline since 2001 is most likely due to a backlog in identification and registration. RCT, randomized controlled trial.

Table 1 Components used to assess the methodological quality of randomized trials

	Adequate	Inadequate
Generation of allocation sequence	Computer-generated random numbers, table of random numbers, or similar	Not described or inadequate methods
Allocation concealment	Central randomization, sealed envelopes, or similar	Not described or inadequate (by an open table or similar)
Double blinding	Identical placebo tablets or similar	Inadequate (e.g. tablets versus injection), not described, or no double blinding

are the results valid? The validity depends on the internal validity of the trial. The internal validity of a trial depends on the risks of *random errors* [10,20] and the risks of *systematic errors* (i.e. bias) [8–13,20,21]. Conducting randomized trials with many participants and outcomes decreases the risks of random errors [10,20]. Conducting randomized trials with high methodological quality, avoiding selection, performance, assessment, attrition and other biases, decreases the risks of systematic errors [8–13,20,21]. Methodological quality has been defined as 'the confidence that the trial design, conduct, and analysis has minimized or avoided biases in its treatment comparison' [9]. The methodological quality of a trial can be assessed as described in Table 1. The external validity of a trial should only be considered if the internal validity is considered adequate. If the internal validity is inadequate, the external validity becomes irrelevant.

A single randomized clinical trial may give misleading results due to random errors or bias. It is essential that independent groups conduct trials on the same therapeutic question, to establish firm evidence for an intervention effect [22–26]. Several trials on the same intervention for the same type of patients may reach more or less concurring conclusions. Conducting a meta-analysis will increase power and increase precision [27–29]. Systematic reviews with meta-analyses of several randomized trials have become an important tool for clinical decision-making [30] – see also The Cochrane Collaboration website (www.cochrane.org). The tendency not to publish trials with neutral or negative intervention effects leads to publication bias [31–34]. It is important that all trials are registered before inclusion of the first patient [35]. Here, details of the trial protocol as well as any amendments to the protocol should be registered. After the end of follow-up of the last patient and analysis, anonymous data from the trial should also be registered [35]. This reduces publication bias [31–34], bias due to post hoc changes of primary outcomes [36,37], and other biases.

Table 2 Number of randomized trials, the proportion of randomized trials reporting sample size calculations, and number of participants per intervention arm in four hepatobiliary journals [7,38–40]

	Liver	*Journal of Hepatology*	*Hepatology*	*Gastroenterology*[a]
Number of trials	32	171	235	383
Sample size calculations	7%	19%	26%	ND[b]
Number of participants per intervention arm				
Median	18	19	26	23
Interquartile range	10–36	11–31	14–44	10–50
Range	2–169	5–519	3–542	1–1107

[a]Includes trials on both hepatobiliary and other gastroenterology topics. There were no major differences between hepatobiliary trials and trials on other gastroenterology topics regarding sample size, but sample size varied significantly between the different disease areas examined (Kjaergard LL, Frederiksen S, Gluud C, unpublished observations).
[b]ND, not determined.

Table 3 Number of randomized trials and the proportion of randomized trials with adequate generation of the allocation sequence, allocation concealment, and double blinding in four journals publishing many hepatobiliary trials [7,38–40]

	Liver	*Journal of Hepatology*	*Hepatology*	*Gastroenterology*[a]
Number of trials	32	171	235	383
Adequate generation of the allocation sequence	21%	28%	52%	42%
Adequate allocation concealment	5%	13%	34%	39%
Adequate double blinding	28%	30%	34%	62%

[a]Includes trials on both hepatobiliary and other gastroenterology topics. There were no major differences between hepatobiliary randomized trials and randomized trials on other gastroenterology topics regarding methodological quality, but methodological quality varied significantly between the different disease areas examined (Kjaergard LL, Frederiksen S, Gluud C, unpublished observations).

Table 4 Comparison of 616 hepatobiliary randomized trials from 12 journals on MEDLINE [41] and 519 randomized trials from PubMed [44] regarding sample size and adequacy of methodological components

Variable	**Randomized hepatobiliary clinical trials published from 1985 to 1996 [41]**	**Randomized trials from all disease areas published in December 2000 [44]**
Median number of participants per intervention arm (10th to 90th percentiles participants per intervention arm)	23 participants (7–102 participants)	32 participants (12–159 participants)
Proportion with adequate generation of the allocation sequence	48%	21%
Proportion with adequate allocation concealment	38%	18%
Proportion with adequate double blinding	34%	38%

Most hepatobiliary randomized trials are too small and have methodological deficiencies [7,14,38–41] (Tables 2–4). Cumulative meta-analyses (i.e. adding each new trial to the meta-analyses when the trial is published) of interventions preventing oesophageal variceal bleeding and rebleeding, and of other interventions, have demonstrated that therapeutic recommendations in textbooks lag behind the available evidence [42,43]. Therefore we need a regular systematic review of the intervention literature.

Sample size estimation in randomized trials

In a trial with a dichotomous primary outcome, the sample size is determined from four pieces of information [20]:

- prior knowledge of the intervention effect (expected minimal relevant difference);
- the expected proportion of patients with the primary outcome during the trial in the control arm;

• alpha or the risk of committing a type 1 error (usually set to 0.05);
• beta or the risk of committing a type 2 error (usually set to 0.20 or 0.10) [20].

The sample size in a trial with a continuous outcome measure is determined from knowledge of the mean and standard deviation of the outcome instead of the expected proportion in the control arm [20]. Sample size estimation should be based on the primary outcome measure of the trial [20,36,37].

It is important to know the targeted sample size when we evaluate the internal validity of a randomized trial. Otherwise, we do not know whether the data of the trial are reported before, at, or after the targeted sample size was reached.

Some 7–26% of hepatobiliary randomized trials report a sample size calculation, depending on the journal in which they were published (Table 2). In a study including PubMed-indexed randomized trials from all disease areas, the figure was 27% [44].

Sample size of randomized trials

The number of patients included in hepatobiliary randomized trials varied only a little depending on the journal in which they were published (Table 2). The median number of participants per intervention arm was 23 (10th to 90th percentiles from 7 to 102) in hepatobiliary trials published in 12 different journals during 1985 to 1996 [41] (Table 4). In PubMed-indexed randomized trials from all disease areas, the median number was 32 participants per intervention arm (10th to 90th percentiles from 12 to 159) [44] (Table 4).

Small sample sizes are worrying, because they are connected with large risks of type 1 and type 2 errors [20,41,44]. With a small sample size, important prognostic variables may be unevenly distributed. This could lead to observation of significant 'intervention effects' simply due to the distribution of prognostic variables. A two-group comparison with 23 patients in each arm has 26% power to detect a difference between event rates of 30% in the control group and 10% in the experimental group at the 0.05 significance level. The difference in intervention effect corresponds to a relative risk of 0.33 or a relative risk reduction of 67%. Such intervention effects are rarely discovered. The power to detect smaller differences is less than 26%.

Random errors are a real problem in hepatobiliary and other types of randomized trials. These problems can only be overcome by developing more effective interventions (the molecular-genetic 'revolution' may give some hope) or by clinical researchers realizing that being a small part of a large trial is more important than being a large part of a small trial.

Methodological quality of randomized trials

Conducting randomized trials with high methodological quality, avoiding selection, performance, assessment, attrition and other biases, decreases the risks of systematic errors [8–13,20,21]. We have examined the methodological quality of hepatobiliary randomized trials (Tables 3 and 4), and have found that several trials have methodological deficiencies [7, 38–41,44–46].

The low methodological quality raises the question of whether biased estimates of intervention effects have occurred. A systematic review of the evidence may answer this question. The methodological quality of a trial is related to the number of centres involved [7], the therapeutic area [7,38,40,41] and whether the trial was sponsored [41]. We found no significant difference between the quality of trials sponsored by for-profit or not-for-profit organizations [41].

The proportion of hepatobiliary randomized trials with adequate generation of the allocation sequence varies from 21% to 52%, depending on the journal in which they were published (Table 3). About every second trial reported adequate generation of the allocation sequence among hepatobiliary trials published in 12 different journals during 1985–1996 [41]. The proportion was 21% in PubMed-indexed randomized trials from all disease areas [44] (Table 4).

The proportion of hepatobiliary randomized trials with adequate allocation concealment varies from 5% to 39%, depending on the journal in which they were published (Table 3). A total of 38% of trials reported adequate allocation concealment among hepatobiliary trials published in 12 different journals during 1985–1996 [41]. This proportion was higher in some areas of hepatology (e.g. primary biliary cirrhosis) and lower in others (e.g. hepatitis B and C) [41]. The proportion was 18% in PubMed-indexed randomized trials from all disease areas [44] (Table 4). Trials with unclear or inadequate allocation concealment are associated with a 20–30% exaggeration of the intervention effect [8–12,21]. Some studies have found that unclear reporting of allocation concealment does not necessarily mean inadequate conduct of allocation concealment, but these studies have been on small and select groups of trials [47–49]. Other studies observed unclear reporting of allocation concealment connected with unclear or inadequate methodology in about 80% of trials [50,51].

The proportion of hepatobiliary trials with adequate double blinding varies from 28% to 62%, depending on the journal in which they were published (Table 3). A total of 34% of trials were double blind among hepatobiliary randomized trials published in 12 different journals during 1985–1996 [41]. In PubMed-indexed randomized trials from all disease areas, 38% were double blind [44] (Table 4). Due to the nature of many interventions (e.g. endoscopy for portal hypertension, gallbladder surgery), double blinding (i.e. blinding of both patient and caregivers) may not be feasible. Only blinding of all involved in a trial can secure that reporting bias, performance bias, assessment bias, attrition bias and other biases do not occur. In trials where control interventions cannot be blinded with a placebo or a sham, you can always use blinded outcome assessment. This may reduce assessment and attrition bias.

The Cochrane Collaboration

The Cochrane Collaboration works to facilitate the preparation, maintenance and dissemination of systematic reviews of randomized trials and systematic reviews of other evidence evaluating health care. The Cochrane Collaboration is named after Archie Cochrane (1909–1988), the epidemiologist who first emphasized that reliable information from randomized trials is vital for making sound decisions in health care and research [52].

The Cochrane Collaboration started in 1993 and has since grown rapidly [52,53]. By 2005, 12 Cochrane Centres and 49 collaborative review groups were registered as part of the Collaboration. The infrastructure for covering all areas of health care is now in place. The tasks of the collaborative review groups are to:

- search the specialist literature for randomized trials, controlled clinical trials, and meta-analyses;
- establish and continuously update databases of these articles;
- prepare protocols for the systematic reviews;
- prepare the systematic reviews as well as continually updating them.

The protocols and the systematic reviews are peer-refereed by international experts before acceptance. Once accepted, the protocols and the systematic reviews are included in the Cochrane Database of Systematic Reviews in The Cochrane Library (http://www.cochrane.org). The Cochrane Library is disseminated electronically on CD-ROMs and via the internet (http://www.cochrane.org). The Cochrane Library contains the Cochrane Central Register of Controlled Trials. This register contains more than 450 000 references to abstracts or articles on controlled clinical trials. Further, The Cochrane Library contains about 20 reviews on methodology, a register of about 7000 articles on methodological issues, and references to different Methods Groups and Fields.

In 2005, more than 4000 protocols for systematic reviews and 2500 systematic reviews were published in The Cochrane Library. The Library also offers the *Cochrane Handbook for Systematic Reviews of Interventions* [29]. This *Handbook* describes the steps one has to take during formulating a protocol for a systematic review and when conducting the systematic review. It is available free of charge from http://www.cochrane.org or as part of the free software RevMan Analyses.

The Cochrane systematic review process is dynamic. The review is modified, as new information becomes available. If you want to contest something in a Cochrane review, you may send an e-mail to the Editorial Team and the authors. In this way, mistakes can be corrected and additional information included. The Cochrane Collaboration still has much to improve [53,54].

The scope of the Cochrane Hepatobiliary Group

The CHBG is one of the 49 collaborative review groups of The Cochrane Collaboration. The CHBG became registered in 1996 [55,56], and its scope is to perform the tasks of the Cochrane Collaboration within hepatobiliary diseases [55,56].

By 2005, the CHBG comprised more than 900 hepatologists, gastroenterologists, hepatobiliary surgeons and biostatisticians from more than 80 countries. Its members have expertise in clinical trials, clinical epidemiology and clinical practice related to hepatobiliary diseases.

The CHBG has the task of full-text searching the specialist journals for randomized trials and controlled clinical trials. Members of the CHBG are involved in searching 26 out of 159 identified specialist journals that need hand searching.

The productivity of the Cochrane Hepatobiliary Group

The CHBG has performed searches in a number of databases for randomized trials, controlled clinical trials, and meta-analyses pertinent to patients with hepatobiliary disorders. Millions of references have been identified and scanned. About 20 000 of these seem relevant for the work of the CHBG (Fig. 2). Of these, almost 9000 are articles on randomized trials (Fig. 2), published from 1955 until now (Fig. 1). These references are submitted to The Collaboration and included in the Cochrane Central Register of Controlled Trials in The Cochrane Library.

More than 200 titles for systematic reviews have been registered with the CHBG and more than 120 CHBG protocols have been published in The Cochrane Library. Of these protocols, 50 have turned into CHBG systematic reviews. Abstracts of these reviews are available free of charge via PubMed or http://www.cochrane.org. Total reviews are available free of charge in Australia, South Africa, a number of European countries, and in low-income countries via the WHO Health InterNetwork Access to Research Initiative.

How you can participate

You can participate as a hand searcher for randomized trials, an author of systematic reviews, or peer-referee of reviews by contacting the Editorial Team office. Interested parties can obtain information as to which specialist journals need full-text searching or which titles need to be reviewed or updated. You can also register a title for a new systematic review. For further information, please contact the CHBG Editorial Team Office, Copenhagen Trial Unit, Center for Clinical Intervention Research, Department 7102, Rigshospitalet, Copenhagen University Hospital, Blegdamsvej 9, DK-2100 Copenhagen, Denmark. Tel. +45 35457175; fax +45 35457101; e-mail dnikolov@ctu.rh.dk; home page http://inet.uni2.dk/~ctucph/chbg/.

The past and the future of clinical research

We have witnessed a dramatic increase in the number of randomized trials during the last 50 years (Fig. 1). The trial size and

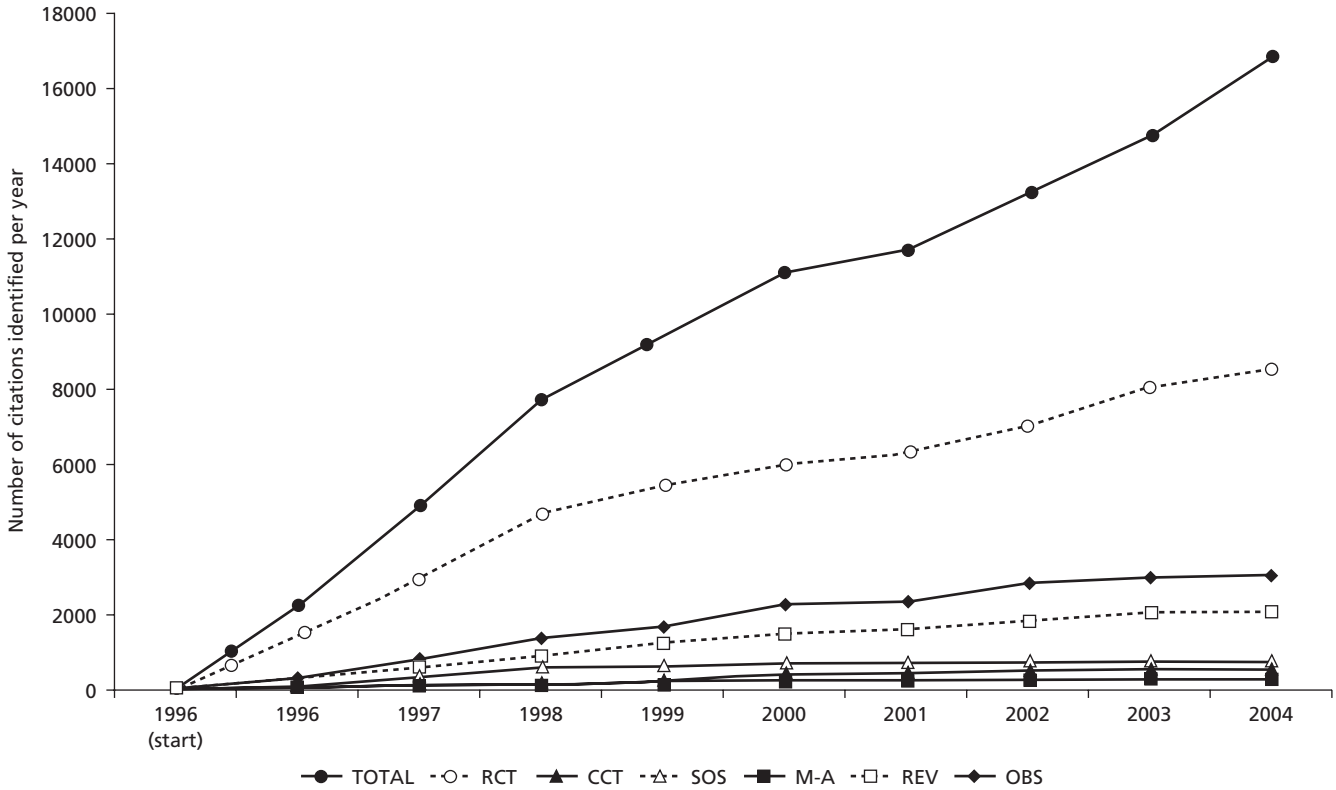

Fig. 2 Total number of publications (TOTAL) and number of publications on randomized trials (RCT), controlled clinical trials (CCT), second opinion ought to be sought (SOS), meta-analysis (MA), reviews (REV), and observational studies (OBS) registered in the Cochrane Hepatobiliary Group Controlled Trial Register from 1996 to 2005 [56].

methodological quality seem to leave a lot to be desired – and progress on this front has been slow or absent [7–13,29,38–41,44–46,52]. We need to improve education in clinical epidemiology and systematic reviewing. We need to pay more attention to adequate statistical power and adequate design of randomized trials. The recommendations of the CONSORT statement (http://www.consort-statement.org) and the Cochrane Collaboration [54] may serve as guides to future research. We need more research into how to organize large randomized trials and how to reduce dropouts and insufficient follow-up. We need more research into analyses of randomized clinical trials. For example, logistic regression analyses seem to dramatically increase rather than decrease the risks of over- and underestimation of intervention effects [13]. We also need more independent evaluation of interventions [22–26]. Additional research in methods for systematic reviewing is also important, for instance how best to conduct trial sequential analysis with trial sequential boundaries in order to reduce the risk of committing type 1 errors [57–59]. Finally, we need to bridge the gaps between clinical research and clinical practice [60,61]. These tasks may be achieved – with investment and dedicated collaboration.

References

1 Chalmers I (2001) Comparing like with like: some historical milestones in the evolution of methods to create unbiased comparison groups in therapeutic experiments. *Int J Epidemiol* 30, 1156–1164.
2 Chalmers TC, Eckhardt RD, Reynolds WE *et al.* (1955) The treatment of acute infectious hepatitis. Controlled studies of the effects of diet, rest, and physical reconditioning on the acute course of the disease and on the incidence of relapses and residual abnormalities. *J Clin Invest* 34, 1163–1235.
3 Chalmers TC (1976) Randomized controlled clinical trials in diseases of the liver. *Prog Liver Dis* 5, 450–456.
4 Sackett DL, Straus SE, Richardson WS *et al.* (2000) *Evidence-Based Medicine; How to Practise and Teach EBM*, 2nd edn. Edinburgh: Churchill Livingstone.
5 Hayward R (ed.) (2002) Users' Guides Interactive. Chicago: JAMA Publishing Group. URL http://www.usersguides.org.
6 Gluud C, Gluud LL (2005) Evidence based diagnostics. *Br Med J* 330, 724–726.
7 Kjaergard LL, Nikolova D, Gluud C (1999) Randomized trials in hepatology: predictors of quality. *Hepatology* 30, 1134–1138.
8 Schulz KF, Chalmers I, Hayes RJ, Altman DG (1995) Empirical evidence of bias. Dimensions of methodological quality associated with estimates of treatment effects in controlled trials. *JAMA* 273, 408–412.

9 Moher D, Pham B, Jones A *et al.* (1998) Does quality of reports of randomized trials affect estimates of intervention efficacy reported in meta-analyses? *Lancet* 352, 609–613.

10 Kjaergard LL, Villumsen J, Gluud C (2001) Reported methodological quality and discrepancies between large and small randomized trials in meta-analyses. *Ann Intern Med* 135, 982–989.

11 Balk EM, Boris PA, Moskowitz H *et al.* (2002) Correlation of quality measures with estimates of treatment effect in meta-analyses of randomized controlled trials. *JAMA* 287, 2973–2982.

12 Als-Nielsen B, Chen W, Gluud LL *et al.* (2004) Are trial size and quality associated with treatment effects in randomized trials? Observational study of 523 randomized trials [abstract]. 12th International Cochrane Colloquium. Ottawa: The Cochrane Collaboration, pp. 102–103. http://www.cochrane.org/colloquia/abstracts/ottawa/P-003.htm

13 Deeks JJ, Dinnes J, D'Amico R *et al.* (2003) Evaluating non-randomized intervention studies. *Health Technol Assess* 7, 1–173.

14 Kjaergard LL, Liu J, Als-Nielsen B, Gluud C (2003) Artificial and bioartificial support systems for acute and acute-on-chronic liver failure: a systematic review. *JAMA* 289, 217–222.

15 Tatsioni A, Deborah AZ, Aronson N *et al.* (2005) Challenges in systematic reviews of diagnostic technologies. *Ann Intern Med* 142, 1048–1055.

16 D'Amico G, Morabito A, Pagliaro L, Marubini E (1986) Survival and prognostic indicators in compensated and decompensated cirrhosis. *Dig Dis Sci* 31, 468–475.

17 Christensen E (2004) Prognostic models including the Child-Pugh, MELD and Mayo risk scores – where are we and where should we go? *J Hepatol* 41, 344–350.

18 Ioannidis JP, Evans SJ, Gotzsche PC *et al.* (2004) Better reporting of harms in randomized trials: an extension of the CONSORT statement. *Ann Intern Med* 141, 781–788.

19 Chou R, Helfand M (2005) Challenges in systematic reviews that assess treatment harms. *Ann Intern Med* 142, 1090–1099.

20 Pocock SJ (1996) *Clinical Trials – A Practical Approach*. Chichester: John Wiley & Sons.

21 Als-Nielsen B, Gluud LL, Gluud C (2004) Methodological quality and treatment effects in randomized trials – a review of six empirical studies [abstract]. 12th International Cochrane Colloquium. Ottawa: The Cochrane Collaboration, pp. 88–89. http://www.cochrane.org/colloquia/abstracts/ottawa/O-072.htm

22 Kjaergard LL, Als-Nielsen B (2002) Association between competing interests and authors' conclusions: epidemiological study of randomized trials published in the BMJ. *Br Med J* 325, 249–252.

23 Als-Nielsen B, Chen W, Gluud C, Kjaergard LL (2003) Association of funding and conclusions in randomized drug trials: a reflection of treatment effect or adverse events? *JAMA* 290, 921–928.

24 Bekelman JE, Li Y, Gross CP (2003) Scope and impact of financial conflicts of interest in biomedical research: a systematic review. *JAMA* 289, 454–465.

25 Lexchin J, Bero LA, Djulbegovic B, Clark O (2003) Pharmaceutical industry sponsorship and research outcome and quality: systematic review. *Br Med J* 326, 1167–1170.

26 House of Commons Health Committee (2005) *The Influence of the Pharmaceutical Industry. Fourth Report of Session 2004–05*, Vol. I. URL http://www.publications.parliament.uk/pa/cm200405/cmselect/cmhealth/42/4202.htm.

27 Friedman HP, Goldberg JD (1996) Meta-analysis: An introduction and point of view. *Hepatology* 23, 917–928.

28 Egger M, Jüni P, Bartlett C *et al.* (2003) How important are comprehensive literature searches and the assessment of trial quality in systematic reviews? Empirical study. *Health Technol Assess* 7, 1–76.

29 Higgins JPT, Green S (eds) (2005) *Cochrane Handbook for Systematic Reviews of Interventions 4.2.4* [updated March 2005]. In: The Cochrane Library, Issue 2, 2005. Chichester: John Wiley & Sons.

30 Santaguida PL, Helfand M, Raina P (2005) Challenges in systematic reviews that evaluate drug efficacy or effectiveness. *Ann Intern Med* 142, 1066–1072.

31 Simes RJ (1986) The case for an international registry of clinical trials. *J Clin Oncol* 4, 1529–1541.

32 Dickersin K (1988) Report from the panel on the case for registers of clinical trials at the Eighth Annual Meeting of the Society for Clinical Trials. *Control Clin Trials* 9, 76–81.

33 Gluud C (1998) 'Negative trials' are positive! *J Hepatol* 28, 731–733.

34 Dickersin K, Rennie D (2003) Registering clinical trials. *JAMA* 290, 516–523.

35 Krleza-Jeric K, Chan A-W, Dickersin K *et al.* (2005) Principles for international registration of protocol information and results from human trials of health related interventions: Ottawa statement (part 1). *Br Med J* 330, 956–958.

36 Chan A-W, Hrobjartsson A, Haahr MT *et al.* (2004) Empirical evidence for selective reporting of outcomes in randomized trials: comparison of protocols to published articles. *JAMA* 291, 2457–2465.

37 Chan A-W, Krleza-Jeric K, Schmid I, Altman DG (2004) Outcome reporting bias in randomized trials funded by the Canadian Institutes of Health Research. *CMAJ* 171, 735–740.

38 Gluud C (1999) Evidence based medicine in liver. *Liver* 19, 1–2.

39 Gluud C, Nikolova D (1998) Quality assessment of reports on clinical trials in the Journal of Hepatology. *J Hepatol* 29, 321–327.

40 Kjaergard LL, Frederiksen SL, Gluud C (2002) Validity of randomized trials in Gastroenterology from 1964–2000. *Gastroenterology* 122, 1157–1160.

41 Kjaergard LL, Gluud C (2002) Funding, disease area, and internal validity of hepatobiliary randomized trials. *Am J Gastroenterol* 97, 2708–2713.

42 Pagliaro L, D'Amico G, Pasta L *et al.* (1996) Efficacy and efficiency of treatments in portal hypertension. In: De Franchis R (ed.) *Portal Hypertension II. Proceedings of the Second Baveno International Consensus Workshop on Definitions, Methodology and Therapeutic Strategies.* Oxford: Blackwell Science, pp. 159–179.

43 Antman EM, Lau J, Kupelnick B *et al.* (1991) A comparison of results of meta-analyses of randomized control trials and recommendations of clinical experts. Treatments for myocardial infarction. *JAMA* 268, 240–248.

44 Chan A-W, Altman DG (2005) Epidemiology and reporting of randomized trials published in PubMed journals. *Lancet* 365, 1159–1162.

45 Gluud C (1999) Trials and errors in clinical research. *Lancet* 354, SIV59.

46 Wang J, Gluud C (eds) (2002) *Evidence-Based Medicine and Clinical Practice.* Beijing: Science Publisher.[in Chinese].

47 Hill CL, LaValley MP, Felson DT (2002) Discrepancy between published report and actual conduct of randomized trials. *J Clin Epidemiol* 55, 783–786.

48 Devereaux PJ, Choi PT, El-Dika S *et al.* (2004) An observational study found that authors of randomized controlled trials frequently use concealment of randomization and blinding, despite the failure to report these methods. *J Clin Epidemiol* 57, 1232–1236.

49 Soares HP, Daniels S, Kumar A *et al*. (2004) Bad reporting does not mean bad methods for randomized trials: observational study of randomized controlled trials performed by the Radiation Therapy Oncology Group. *Br Med J* 328, 22–24.

50 Liberati A, Himel HN, Chalmers TC (1986) A quality assessment of randomized control trials of primary treatment of breast cancer. *J Clin Oncol* 4, 942–951.

51 Pildal J, Chan A-W, Hróbjartsson A *et al*. (2005) Comparison of descriptions of allocation concealment in trial protocols and the published reports: cohort study. *Br Med J* 330, 1049.

52 Maynard A, Chalmers I (eds) (1997) *Non-random Reflections on Health Services Research. On the 25th Anniversary of Archie Cochrane's Effectiveness and Efficiency*. London: BMJ Publishing Group.

53 Olsen O, Middleton P, Ezzo J *et al*. (2001) Quality of Cochrane reviews: assessment of sample from 1998. *Br Med J* 323, 829–832.

54 Moja LP, Telaro E, D'Amico R *et al.* (2005) Assessment of methodological quality of primary studies by systematic reviews: results of the metaquality cross sectional study. *Br Med J* 330, 1053.

55 Gluud C, on behalf of the Cochrane Hepatobiliary Editorial Team (1999) The Cochrane Hepatobiliary Group. In: Bircher J, Benhamou JP, McIntyre N *et al.* (eds) *Oxford Textbook of Clinical Hepatology*, 2nd edn. Oxford: Oxford University Press, pp. 2145–2148.

56 Gluud C, Als-Nielsen B, D'Amico G *et al*. (2005) *The Cochrane Hepatobiliary Group. About The Cochrane Collaboration (Collaborative Review Groups (CRGs))*. The Cochrane Library, Issue 2. Chichester: John Wiley & Sons.

57 Wetterslev J, Thorlund K, Brok J, Gluud C (2005) Trial sequential analyses of six Cochrane Neonatal Review Group meta-analyses using actual information size (I). Abstract 24. *Clinical Trials* 2 (Suppl. 1), 32–33.

58 Brok J, Thorlund K, Gluud C, Wetterslev J (2005) Trial sequential analyses of six Cochrane Neonatal Review Group meta-analyses considering adequacy of allocation concealment (II). Abstract P35. *Clinical Trials* 2 (Suppl. 1), 61–62.

59 Thorlund K, Wetterslev J, Brok J, Gluud C (2005) Trial sequential analyses of six Cochrane Neonatal Review Group meta-analyses considering heterogeneity and trial weight (III). Abstract P36. *Clinical Trials* 2 (Suppl. 1), 62.

60 Gluud C, Afroudakis AP, Caballeria J *et al*. (1993) Diagnosis and treatment of alcoholic liver disease in Europe. First report. *Gastroenterol Int* 6, 221–230.

61 Kürstein P, Gluud LL, Kjellberg J *et al*. (2005) Agreement between reported use of interventions for liver diseases and research evidence in Cochrane systematic reviews. *J Hepatol* 43, 984–989.

6 Cirrhosis

6.1 The evolution of cirrhosis

John P. Iredale and I. Neil Guha

Introduction

Fibrosis is part of the innate wound healing response that occurs in injured tissues. Within the liver, fibrosis is characterized by the deposition of extracellular matrix. Current evidence indicates that net deposition of matrix is the result of a balance between synthesis and degradation and constitutes a dynamic process. The progression of fibrosis to cirrhosis has a number of sequelae. First, it will distort hepatic architecture and vasculature; second, it will have a deleterious effect on hepatic function; and third, it will increase the propensity for neoplastic transformation. Therefore, the evolution of fibrosis to cirrhosis represents a change in the morphology, haemodynamics and function of the liver. This chapter will focus on the mechanisms of progression and whether this process is potentially reversible.

Defining cirrhosis

The detailed histological description of fibrosis and cirrhosis can be found in Chapter 1.2. The definition of cirrhosis remains morphological, described by a working party for the World Health Organization (WHO) in 1978 as: 'a diffuse process characterized by fibrosis and the conversion of normal liver architectures into structurally abnormal nodules' [1]. Although nodularity is a prerequisite for the definition, regeneration is not. Regeneration is an important process in the development of cirrhosis but also occurs following virtually any insult to the liver that results in hepatocellular death. Another important aspect of the definition is that it does not include vascular changes associated with cirrhosis. However, these changes are an important component of the pathophysiology and progression of cirrhosis, and may determine the reversibility of fibrosis and cirrhosis, as discussed later in this chapter.

Mechanisms of progression

Iterative injury

It is self evident that iterative injury is an important and common mechanism by which fibrosis progresses to cirrhosis. This is exemplified by clinical paradigms in which the injurious insult is removed. In alcoholic liver disease, abstinence from alcohol not only prevents disease progression but may be associated with regression. Similarly, antiviral treatment in hepatitis B and hepatitis C infection and venesection in haemochromatosis are therapeutic strategies that can prevent the development of cirrhosis.

Apoptosis and collapse

Reduced hepatic cell mass is a key feature of advancing liver disease; apoptosis and collapse both contribute to this.

Toxic injury to hepatocytes can initiate 'programmed' cell death, a process known as apoptosis. However, apoptosis may also augment inflammation by the direct release of cellular contents such as cytokines or by the signals that induce apoptosis also co-stimulating inflammatory cascades [2]. Apoptosis results in the fragmentation of cells into membrane-bound bodies called apoptotic bodies. The clearance of apoptotic bodies has classically been viewed as not inducing inflammation but, in certain liver models, it has been shown to be fibrogenic [3]. Additionally, secondary necrosis can supervene in the context of massive apoptosis when clearance mechanisms are overwhelmed. Therefore, apoptosis not only causes a loss of hepatocytes but also contributes to inflammation and fibrosis, which in turn leads to further apoptosis. Finally, the complex interaction between apoptosis and fibrosis is highlighted by the role of apoptosis in the resolution of fibrosis, as discussed below.

Collapse of architecture results in the approximation of portal veins to hepatic veins, and it has been postulated that this results from vascular obstruction. A study of non-alcoholic hepatitis has demonstrated that 20% of hepatic veins were obstructed in fibrosis stage 0. This increased to 45% in stage 3–4 fibrosis [4]. These figures suggest that vascular obstruction is an important pathological process even in the milder stages of disease. Furthermore, collapse of architecture and disruption of sinusoidal blood flow results in hypoxia of the hepatic parenchyma

with resulting accentuation of inflammation and fibrosis (see section below on angiogenesis).

Inflammation

Inflammation involves the processes of cellular exudation and increased vascular permeability. The presence or absence of inflammation in the liver is usually determined by histology. While the majority of chronic liver diseases are associated with inflammation, in others, e.g. haemochromatosis, histological evidence of inflammation may not be prominent. To subdivide fibrosis into 'inflammatory' and 'non-inflammatory' processes is oversimplistic as the two processes have a great deal of overlap. Furthermore, histological examination offers a 'snapshot' view of events and is also limited by sample size. Moreover, there may be evidence of release of cytokines associated with injury and inflammation even in the absence of a cellular infiltrate. Therefore, the absence of inflammatory cells on a biopsy does not always exclude an inflammatory aetiology. However, by using this classification, one can highlight some of the proposed mechanisms for the development and progression of fibrosis.

Inflammatory mechanisms of progression

Tissue fibrosis is mediated by fibroblasts and myofibroblasts. Potential contributors to the hepatic myofibroblast population in areas of inflammation include the hepatic stellate cell (HSC), portal myofibroblast and myofibroblast derived from stem cells. Of these, the HSC is the most thoroughly studied.

The HSC represents one of the principal components in the initiation, orchestration, progression and resolution of liver fibrosis (see Chapter 1.6). We will recap some of the important aspects of HSC activation and perpetuation below.

Stellate cell activation

Activation involves the transdifferentiation of the quiescent, retinoid-storing HSC, lying in the space of Disse, into the activated, contractile 'myofibroblast'. In the activated state, HSCs enter the cell cycle, leading to an accumulation of HSCs in areas of injury. There are a number of potential initiators for HSC activation, including soluble signals released by sinusoidal endothelium, hepatocytes, Kupffer cells, platelets and leukocytes. They are able to interact with the HSC using a variety of mediators ranging from fibronectin release from damaged endothelium [5] to platelet-derived growth factor (PDGF), transforming growth factor (TGF)-β1 and epidermal growth factor from platelets [6].

Kupffer cells, which are resident macrophages in the liver, have a significant interaction with HSCs. They are able to activate stellate cells and stimulate matrix synthesis via the release of cytokines, in particular TGF-β1, and reactive oxygen intermediates. Kupffer cells also secrete matrix metalloproteinases (MMPs), tissue inhibitors of metalloproteinases (TIMPs) and anti-inflammatory cytokines such as interleukin (IL)-10, which may be important in fibrosis resolution (see below).

Perpetuation of stellate cell activation

The activation and proliferation of stellate cells has a number of effects. First, there is a direct increase in the amount of matrix produced, in particular collagen I but also collagen IV and collagen III.

Secondly, the HSC is a source of both MMPs and TIMPs. Studies in animal and human models have indicated that interstitial collagenase activity decreases with progression of liver fibrosis, an effect mediated by TIMPs. Therefore, activation of HSCs not only results in matrix accumulation, but matrix degradation is prevented through the expression of TIMPs. Proliferation of HSCs is promoted by PDGF released in a paracrine fashion from macrophages [7] and also in an autocrine manner from HSCs [8]. Other mitogens present in the inflammatory lesion include thrombin, insulin growth factor 1, TGF-α, endothelin-1, fibroblast growth factor (FGF) and vascular endothelial growth factor (VEGF) [9,10].

Studies have demonstrated a positive correlation between the degree of fibrosis and the accumulation of activated HSCs in the damaged liver [11,12]. Conversely, the resolution of acute liver injury following paracetamol overdose has been shown to be associated with a reduction in α-smooth muscle actin-positive activated HSCs [13].

A number of additional mechanisms may mediate both the activation and the perpetuation of activated HSCs, including chemotactic loops, retinoid loss and signalling and cytokine release. These are discussed in greater detail in Chapters 1.6 and 6.2.

The HSC has a central role in the inflammatory process, but there is a complex interaction with the other cell types, including Kupffer cells and T-lymphocyte cells, largely through cytokine mediators. T-cell subtype has been demonstrated to be important; for example, a type 2 T helper (Th2) response, in comparison to a Th1 response, promotes fibrogenesis [14]. This dichotomy of response may have evolved as a response to parasites, which classically elicit a Th2-driven response. Finally, there is emerging interest in the relative contribution to fibrosis from other myofibroblasts, i.e. portal myofibroblasts and myofibroblasts of bone marrow origin [15].

Extracellular matrix

The matrix components present in hepatic fibrosis include collagens (predominantly interstitial but including other collagen components, e.g. type 4 collagen), proteoglycans and matrix glycoproteins (see Chapter 2.4.3). In turn, this neomatrix may regulate progression. The normal basement membrane-type matrix (rich in collagen IV) and its replacement with a matrix rich in type I collagen, associated with inflammation and fibrosis, is likely to critically alter cell–matrix interactions, resulting in

activation and perpetuation of activation of HSCs. Some studies demonstrate increased activation of HSCs cultured on the EDA isoform of fibronectin [5], whereas there is inhibition of activation of HSCs cultured on a membrane analogous to normal basement membrane [16].

Recent evidence indicates that contact with the type I collagen-rich matrix and specific integrin-derived signals associated with the turnover of type I collagen in a pericellular manner may be associated with stellate cell survival and proliferation respectively. In contrast, degradation of type I-rich matrix may be associated with stellate cell apoptosis; indeed, disruption of specific integrin signals has also been demonstrated to result in stellate cell apoptosis. Thus, aspects of the activated stellate cell–matrix interaction in the presence of established fibrosis can be viewed as perpetuating the fibrotic response in a manner that leads to the persistence of fibrosis.

The matrix may also provide a reservoir for the mediators of fibrogenesis/fibrolysis, for example by binding cytokines, MMPS and TIMPs [17].

Non-inflammatory mechanisms of progression

Contractility

The teleological reason for contractility is the necessity for the body to close wounds, an integral part of healing. In common with wound healing processes in other tissues, the myofibroblast population in hepatic areas determines contractile activity. The contraction of activated myofibroblasts may have a contributory role in the development of portal hypertension. Endothelin concentrations, a powerful stimulation for contraction of HSCs, rise after fibrotic injury. To confound this, nitric oxide, which antagonizes the effect of endothelin and is derived from endothelial cells, is reduced in injury. Receptors for endothelin-1 and other less potent factors, including eicosanoids, prostaglandins, vasopressin, adenosine, thrombin, platelet-activating factor (PAF) and angiotensin 11, have been found on activated HSCs [18].

Angiogenesis

The endothelial lining of sinusoids becomes non-fenestrated with the development of perisinusoidal fibrosis. This 'capillarization' of the sinusoids leads to functional shunting of the blood across the lobule, resulting in a deficient supply of nutrients and oxygen. Relative hypoxia of the parenchyma can result in the release of angiogenic factors, as evidenced by animal models [19,20]. The release of these factors may then contribute to the development of vascular structures within the fibrous tissue connecting portal to portal tract or, more significantly, connecting portal tract to central vein. Therefore, both functional and anatomic shunting of blood occurs within the lobule, causing the development of a vicious circle encompassing hypoxia and fibrosis. Furthermore, vascular thrombosis also contributes to the vascular insufficiency. Imaging studies have demonstrated a significant proportion of portal vein thrombosis in cirrhotic patients [21–23] and, when explanted livers of this group are examined at autopsy, occlusion of the portal and hepatic vein is found in 36% and 70% of patients respectively [24].

Models of non-inflammatory progression

The most widely used example of non-inflammatory progression is haemochromatosis. Pronounced inflammatory cell infiltration is not a frequent feature seen in liver biopsy specimens from patients with genetic haemochromatosis. Therefore, other mechanisms of hepatic fibrogenesis have been proposed. Iron is involved in lipid peroxidation resulting in reactive oxygen species (ROS). Products of ROS, including isoprostanes and malondialdehyde, have been found in hepatic tissue in animal and human models of iron overload respectively [25,26]. These products of ROS may cause Kupffer cell activation or act directly on stellate cells. However, despite the absence of overt inflammation, an immunological/inflammatory aetiology cannot be entirely excluded. Studies have shown differences in immunological phenotypes including T-cell subsets and cytokine expression of IL-10 and interferon (IFN)-γ in patients with haemochromatosis [27,28]. Additionally, at least one study has shown that areas of intense iron deposition do not correspond with HSC activation as determined by immunostaining for α-smooth muscle actin [28]. Thus, the relative contribution of the immunological and oxidative stress pathways in producing fibrosis has yet to be definitively elucidated.

Studies of liver histology from patients with alcoholic liver disease have demonstrated that steatosis alone may be associated with the development of fibrosis [29]. There is some evidence that acetaldehyde, produced by the metabolism of ethanol, could also be directly fibrogenic by stimulating collagen production in HSCs [30]. However, this effect may require the stellate cells to be activated initially by an independent mechanism [31]. Furthermore, there is clear evidence that the development of inflammation in the context of alcoholic injury is associated with the progression to fibrosis and cirrhosis in comparison with individuals in whom alcoholic hepatitis does not supervene.

Taken together, these examples suggest that inflammation is a powerful stimulus for the fibrotic response and, as noted above, represents the most prevalent interactive injury in worldwide terms. However, there is significant overlap and synergy of the different mechanisms responsible for the progression of fibrosis.

Clinical factors influencing progression

In general, the progression of fibrosis requires the presence of ongoing stimulus over months to years. There are exceptions to this including neonatal fibrosis and veno-occlusive disease, which follow a more fulminant course for reasons that are not entirely clear [32,33]. The rate of progression varies within and between diseases. In hepatitis C, factors found to influence the

progression of fibrosis include male sex, duration of infection, acquisition of infection at an older age (> 40 years), long-term excessive alcohol intake, immunosuppression, co-infection with human immunodeficiency virus (HIV) or hepatitis B virus (HBV) and non-response to antiviral therapy. Additionally, longitudinal studies have suggested that the degree of necroinflammation at the first biopsy may predict future fibrosis [34,35] and have added weight to the concept that fibrosis progresses in a non-linear fashion. In hepatitis B, ongoing inflammation, influenced by host and viral factors, correlates with fibrosis [36,37]. The risk factors for progression in non-alcoholic steatohepatitis (NASH) are still being defined but include obesity, insulin resistance and age [38].

While some of the risk factors are intuitive, such as continuing inflammation and dual pathology, others are less so. In hepatitis C virus (HCV) and NASH, why does the age of acquisition of disease influence fibrosis progression? Is there a significant difference in the wound healing response with increasing age, perhaps determined by cellular senescence, or does this simply reflect a higher starting point resulting from subclinical fibrosis? Large studies to date have not shown that viral genotype has a role in fibrosis progression in HCV, yet this clearly influences response to treatment [39]. There is, however, increasing evidence for the role of the host genotype in fibrosis, e.g. polymorphisms including TGF-β and angiotensinogen [40] (see also Chapters 3.3.1 and 3.3.3). Recently, the genetic factor V Leiden mutation has also been shown to be associated with rapid progression of fibrosis in hepatitis C [41].

The progression of fibrosis may therefore be through a series of common pathways, but a multitude of factors determine to what extent and how quickly the final stage of cirrhosis is reached.

Cell and molecular events mediating perpetuation of the fibrotic response

While iterative injury and the persistence of inflammation will clearly continue to drive fibrosis, there are certain aspects of activated stellate cell behaviour and phenotype, described above, that will perpetuate the response and, in turn, may perpetuate fibrosis even in the absence of injury. Additionally, stellate cells can mediate inflammation. One recent observation is that senescent stellate cells may develop a proinflammatory phenotype. Senescence develops after prolonged periods of replication when critical shortening of telomeres prevents further replication and induces a specific phenotype of a given cell. One might anticipate that, in iterative injury in which stellate cells are driven to relentless cycles of proliferation, the development of senescence might indeed supervene and, in turn, be associated with the perpetuation of the inflammatory and fibrotic response.

Is fibrosis reversible?

The reversibility of fibrosis has been demonstrated in a spectrum of diseases including autoimmune hepatitis treated with steroids, haemochromatosis responding to venesection, hepatitis C treated with antiviral therapy and biliary decompression for secondary biliary fibrosis [42–46].

Animal models demonstrating the reversal of fibrosis also exist including biliary obstruction and carbon tetrachloride toxicity [47]. In the carbon tetrachloride model, biological mechanisms for this reversal have been proposed. Rats previously exposed to carbon tetrachloride for 4 weeks demonstrated evidence of loss of activated HSCs mediated by apoptosis in the recovery phase of fibrosis. Additionally, mRNA levels of the metalloprotease inhibitors, TIMP-1 and TIMP-2, decreased during the recovery phase in comparison with collagenase levels, which remained relatively constant. These findings, in conjunction with other experiments, suggest that the reversal of fibrosis is a result of reduced inhibition of collagenases, secondary to HSC apoptosis, thus tipping the balance towards matrix degradation [48]. Proof of concept is demonstrated by administration of gliotoxin, a fungal metabolite that induces apoptosis in activated HSCs, causing an improvement in the severity of fibrosis in the carbon tetrachloride rat model [49].

The role of macrophages/Kupffer cells in fibrosis is complex. Macrophages may play opposing roles in fibrosis during injury and recovery. Using an animal model in which macrophages are selectively depleted, fibrosis was attenuated and associated with reduced numbers of HSCs when depletion occurred during injury. In contrast, if depletion occurred during recovery, there was a failure of fibrosis resolution but not a significant diminution in HSCs [50]. The question remains whether the resolution of fibrosis was due to macrophage-mediated HSC fibrolysis or HSC-mediated fibrolysis in combination with direct matrix degradation by macrophages.

Is cirrhosis reversible?

This is a controversial area and opinions on this topic are certainly not united. There are clinical examples of 'reversal' of fibrosis within cirrhosis in a number of diseases. Poynard *et al.* [51] demonstrated a reduction in metavir scoring in patients with HCV infection, including patients with stage F4 representing cirrhosis, following combination treatment with pegylated interferon and ribavarin. However, whether this represents 'reversal' of cirrhosis is open to question. A major problem lies in the obvious propensity of needle biopsy to result in a sampling error, an effect potentially confounded by the limitations of semi-quantitative histological scoring. There is a body of evidence in both animal and clinical models that resolution of cirrhosis is associated with the transformation of micronodular cirrhosis into macronodular cirrhosis. As the fibrous bands surrounding macronodules are often not included in the biopsy specimen, the more subtle aspects of regenerating parenchyma can be misinterpreted as normal or near normal hepatic architecture. When larger specimens of liver are examined, such as liver explants, there is evidence of regression of micronodular cirrhosis into not only macronodular cirrhosis but also

incomplete septal fibrosis [52]. Remodelling has also been shown in a rat model of cirrhosis, studied over 366 days of recovery [53]. This model confirmed both a retreat from a micronodular to an attenuated macronodular cirrhosis as well as demonstrating that elements of the macronodular cirrhosis were essentially irreversible. Residual septae that were not remodelled were characterized by matrix cross-linking and, in certain cases, neoangiogenesis. This raises the intriguing possibility that cross-linking of collagen is a factor in determining the reversibility of cirrhosis. These examples also highlight the difficulty in trying to characterize a process that can take a prolonged and variable length of time. Certainly there is evidence for an improvement in fibrosis, although the balance of current evidence suggests that true cirrhosis is not entirely reversible. Whether this partial regression is sufficient to restore effective hepatocyte function is at present unknown.

A further problem with demonstrating reversal of cirrhosis lies in its definition. It is a morphological definition, yet cirrhosis also encompasses haemodynamic changes depicted above, and whether an improvement in fibrosis within the context of cirrhosis is associated with reversal of neovasculature is also unknown.

If histological reversal of cirrhosis is so contentious, is there any evidence of functional improvement in hepatocellular function as a surrogate measure? Clearly, no single surrogate marker will indicate reversal of cirrhosis in its entirety. For example, it may be possible to demonstrate an improvement in hepatic synthetic function but, in the presence of continued portal hypertension, this change is unlikely to represent a reversal of cirrhosis. In patients with cirrhosis secondary to hepatitis B, investigators have found an improvement in histological scores and clinical parameters of portal hypertension following treatment with lamivudine [54]. Similarly, in the HCV treatment trial quoted above, reduced rates of bleeding in association with improved liver parameters were found in patients treated with combination therapy. Using functional assessment is a useful tool for patients and clinicians alike, but alone cannot substitute for a histological definition for the reversal of cirrhosis.

Conclusion

The evolution of fibrosis to cirrhosis is critically dependent on the perpetuation/resolution of the underlying injury, the type of disease and host factors including specific genetic traits. A greater understanding of which factors have the greatest influence on progression and how they interact will give us insights into the prevention of this process.

Fibrosis is a dynamic process, and there is strong evidence that elements of fibrosis are completely reversible. The activation of hepatic stellate cells and the recruitment of other myofibroblast cells and the interaction of these cells with their environment and the inflammatory milieu may all determine the propensity of a given fibrotic lesion to resolve. Current evidence indicates that there are certain irreversible components of cirrhosis and, while there can be significant histological improvement with regression of cirrhosis, complete resolution with a return to normal architecture seems unlikely. Whether the improvements that may occur spontaneously or as a result of antifibrotic intervention would cause sufficient regression of fibrosis to be associated with clinical change in hepatic function is currently unknown. It is intriguing to suggest that the effect of antifibrotic therapy might be sufficient to obviate the need for liver transplantation by leaving a patient with adequate hepatocellular function. In this patient, complications such as portal hypertension could be managed piecemeal by band ligation or shunts introduced by radiological or surgical means.

References

1 Anthony PP, Ishak KG, Nayak NC *et al.* (1978) The morphology of cirrhosis. Recommendations on definition, nomenclature, and classification by a working group sponsored by the World Health Organization. *J Clin Pathol* 31(5), 395–414.

2 Canbay A, Friedman S, Gores GJ (2004) Apoptosis: the nexus of liver injury and fibrosis. *Hepatology* 39(2), 273–278.

3 Canbay A, Taimr P, Torok N *et al.* (2003) Apoptotic body engulfment by a human stellate cell line is profibrogenic. *Lab Invest* 83(5), 655–663.

4 Wanless IR, Shiota K (2004) The pathogenesis of nonalcoholic steatohepatitis and other fatty liver diseases: a four-step model including the role of lipid release and hepatic venular obstruction in the progression to cirrhosis. *Semin Liver Dis* 24(1), 99–106.

5 Jarnagin WR, Rockey DC, Koteliansky VE *et al.* (1994) Expression of variant fibronectins in wound healing: cellular source and biological activity of the EIIIA segment in rat hepatic fibrogenesis. *J Cell Biol* 127(6 Pt 2), 2037–2048.

6 Bachem MG, Melchior R, Gressner AM (1989) The role of thrombocytes in liver fibrogenesis: effects of platelet lysate and thrombocyte-derived growth factors on the mitogenic activity and glycosaminoglycan synthesis of cultured rat liver fat storing cells. *J Clin Chem Clin Biochem* 27(9), 555–565.

7 Nagaoka I, Honma S, Someya A *et al.* (1992) Differential expression of the platelet-derived growth factor-A and -B genes during maturation of monocytes to macrophages. *Comp Biochem Physiol B* 103(2), 349–356.

8 Marra F, Choudhury GG, Pinzani M *et al.* (1994) Regulation of platelet-derived growth factor secretion and gene expression in human liver fat-storing cells. *Gastroenterology* 107(4), 1110–1117.

9 Friedman SL (2000) Molecular regulation of hepatic fibrosis, an integrated cellular response to tissue injury. *J Biol Chem* 275(4), 2247–2250.

10 Pinzani M, Marra F (2001) Cytokine receptors and signaling in hepatic stellate cells. *Semin Liver Dis* 21(3), 397–416.

11 Ballardini G, Degli ES, Bianchi FB *et al.* (1983) Correlation between Ito cells and fibrogenesis in an experimental model of hepatic fibrosis. A sequential stereological study. *Liver* 3(1), 58–63.

12 Knittel T, Kobold D, Piscaglia F *et al.* (1999) Localization of liver myofibroblasts and hepatic stellate cells in normal and diseased rat livers: distinct roles of (myo-)fibroblast subpopulations in hepatic tissue repair. *Histochem Cell Biol* 112(5), 387–401.

13 Mathew J, Hines JE, James OF *et al.* (1994) Non-parenchymal cell responses in paracetamol (acetaminophen)-induced liver injury. *J Hepatol* 20(4), 537–541.

14 Shi Z, Wakil AE, Rockey DC (1997) Strain-specific differences in mouse hepatic wound healing are mediated by divergent T helper cytokine responses. *Proc Natl Acad Sci USA* 94(20), 10663–10668.

15 Forbes SJ, Russo FP, Rey V *et al.* (2004) A significant proportion of myofibroblasts are of bone marrow origin in human liver fibrosis. *Gastroenterology* 126(4), 955–963.

16 Friedman SL, Arthur MJ (1989) Activation of cultured rat hepatic lipocytes by Kupffer cell conditioned medium. Direct enhancement of matrix synthesis and stimulation of cell proliferation via induction of platelet-derived growth factor receptors. *J Clin Invest* 84(6), 1780–1785.

17 Benyon RC, Arthur MJ (2001) Extracellular matrix degradation and the role of hepatic stellate cells. *Semin Liver Dis* 21(3), 373–384.

18 Rockey DC (2001) Hepatic blood flow regulation by stellate cells in normal and injured liver. *Semin Liver Dis* 21(3), 337–349.

19 Corpechot C, Barbu V, Wendum D *et al.* (2002) Hypoxia-induced VEGF and collagen I expressions are associated with angiogenesis and fibrogenesis in experimental cirrhosis. *Hepatology* 35(5), 1010–1021.

20 Rosmorduc O, Wendum D, Corpechot C *et al.* (1999) Hepatocellular hypoxia-induced vascular endothelial growth factor expression and angiogenesis in experimental biliary cirrhosis. *Am J Pathol* 155(4), 1065–1073.

21 Okuda K, Ohnishi K, Kimura K *et al.* (1985) Incidence of portal vein thrombosis in liver cirrhosis. An angiographic study in 708 patients. *Gastroenterology* 89(2), 279–286.

22 Belli L, Romani F, Sansalone CV *et al.* (1986) Portal thrombosis in cirrhotics. A retrospective analysis. *Ann Surg* 203(3), 286–291.

23 Gaiani S, Bolondi L, Li BS *et al.* (1991) Prevalence of spontaneous hepatofugal portal flow in liver cirrhosis. Clinical and endoscopic correlation in 228 patients. *Gastroenterology* 100(1), 160–167.

24 Wanless IR, Wong F, Blendis LM *et al.* (1995) Hepatic and portal vein thrombosis in cirrhosis: possible role in development of parenchymal extinction and portal hypertension. *Hepatology* 21(5), 1238–1247.

25 Houglum K, Ramm GA, Crawford DH *et al.* (1997) Excess iron induces hepatic oxidative stress and transforming growth factor beta1 in genetic hemochromatosis. *Hepatology* 26(3), 605–610.

26 Dabbagh AJ, Mannion T, Lynch SM *et al.* (1994) The effect of iron overload on rat plasma and liver oxidant status *in vivo*. *Biochem J* 300 (Pt 3), 799–803.

27 Porto G, Vicente C, Teixeira MA *et al.* (1997) Relative impact of HLA phenotype and CD4–CD8 ratios on the clinical expression of hemochromatosis. *Hepatology* 25(2), 397–402.

28 Ramm GA, Crawford DH, Powell LW *et al.* (1997) Hepatic stellate cell activation in genetic haemochromatosis. Lobular distribution, effect of increasing hepatic iron and response to phlebotomy. *J Hepatol* 26(3), 584–592.

29 Reeves HL, Burt AD, Wood S *et al.* (1996) Hepatic stellate cell activation occurs in the absence of hepatitis in alcoholic liver disease and correlates with the severity of steatosis. *J Hepatol* 25(5), 677–683.

30 Moshage H, Casini A, Lieber CS (1990) Acetaldehyde selectively stimulates collagen production in cultured rat liver fat-storing cells but not in hepatocytes. *Hepatology* 12(3 Pt 1), 511–518.

31 Friedman SL (1990) Acetaldehyde and alcoholic fibrogenesis: fuel to the fire, but not the spark. *Hepatology* 12(3 Pt 1), 609–612.

32 Sato Y, Asada Y, Hara S *et al.* (1999) Hepatic stellate cells (Ito cells) in veno-occlusive disease of the liver after allogeneic bone marrow transplantation. *Histopathology* 34(1), 66–70.

33 El Youssef M, Mu Y, Huang L *et al.* (1999) Increased expression of transforming growth factor-beta1 and thrombospondin-1 in congenital hepatic fibrosis: possible role of the hepatic stellate cell. *J Pediatr Gastroenterol Nutr* 28(4), 386–392.

34 Ryder SD, Irving WL, Jones DA *et al.* (2004) Progression of hepatic fibrosis in patients with hepatitis C: a prospective repeat liver biopsy study. *Gut* 53(3), 451–455.

35 Fontaine H, Nalpas B, Poulet B *et al.* (2001) Hepatitis activity index is a key factor in determining the natural history of chronic hepatitis C. *Hum Pathol* 32(9), 904–909.

36 Lindh M, Horal P, Dhillon AP *et al.* (2000) Hepatitis B virus DNA levels, precore mutations, genotypes and histological activity in chronic hepatitis B. *J Viral Hepat* 7(4), 258–267.

37 Merican I, Guan R, Amarapuka D *et al.* (2000) Chronic hepatitis B virus infection in Asian countries. *J Gastroenterol Hepatol* 15(12), 1356–1361.

38 Angulo P, Keach JC, Batts KP *et al.* (1999) Independent predictors of liver fibrosis in patients with nonalcoholic steatohepatitis. *Hepatology* 30(6), 1356–1362.

39 Poynard T, Bedossa P, Opolon P (1997) Natural history of liver fibrosis progression in patients with chronic hepatitis C. The OBSVIRC, METAVIR, CLINIVIR, and DOSVIRC groups. *Lancet* 349(9055), 825–832.

40 Powell EE, Edwards-Smith CJ, Hay JL *et al.* (2000) Host genetic factors influence disease progression in chronic hepatitis C. *Hepatology* 31(4), 828–833.

41 Wright M, Goldin R, Hellier S *et al.* (2003) Factor V Leiden polymorphism and the rate of fibrosis development in chronic hepatitis C virus infection. *Gut* 52(8), 1206–1210.

42 Dufour JF, DeLellis R, Kaplan MM (1998) Regression of hepatic fibrosis in hepatitis C with long-term interferon treatment. *Dig Dis Sci* 43(12), 2573–2576.

43 Shiratori Y, Imazeki F, Moriyama M *et al.* (2000) Histologic improvement of fibrosis in patients with hepatitis C who have sustained response to interferon therapy. *Ann Intern Med* 132(7), 517–524.

44 Dufour JF, DeLellis R, Kaplan MM (1997) Reversibility of hepatic fibrosis in autoimmune hepatitis. *Ann Intern Med* 127(11), 981–985.

45 Hammel P, Couvelard A, O'Toole D *et al.* (2001) Regression of liver fibrosis after biliary drainage in patients with chronic pancreatitis and stenosis of the common bile duct. *N Engl J Med* 344(6), 418–423.

46 Powell LW, Kerr JF (1970) Reversal of 'cirrhosis' in idiopathic haemochromatosis following long-term intensive venesection therapy. *Australas Ann Med* 19(1), 54–57.

47 Abdel-Aziz G, Lebeau G, Rescan PY *et al.* (1990) Reversibility of hepatic fibrosis in experimentally induced cholestasis in rat. *Am J Pathol* 137(6), 1333–1342.

48 Iredale JP, Benyon RC, Pickering J *et al.* (1998) Mechanisms of spontaneous resolution of rat liver fibrosis. Hepatic stellate cell apoptosis and reduced hepatic expression of metalloproteinase inhibitors. *J Clin Invest* 102(3), 538–549.

49 Wright MC, Issa R, Smart DE *et al.* (2001) Gliotoxin stimulates the apoptosis of human and rat hepatic stellate cells and enhances the resolution of liver fibrosis in rats. *Gastroenterology* 121(3), 685–698.

50 Duffield JS, Forbes SJ, Constandinou CM *et al.* (2005) Selective depletion of macrophages reveals distinct, opposing roles during liver injury and repair. *J Clin Invest* 115(1), 56–65.

51 Poynard T, McHutchison J, Manns M *et al.* (2002) Impact of pegylated interferon alfa-2b and ribavirin on liver fibrosis in patients with chronic hepatitis C. *Gastroenterology* 122(5), 1303–1313.

52 Wanless IR, Nakashima E, Sherman M (2000) Regression of human cirrhosis. Morphologic features and the genesis of incomplete septal cirrhosis. *Arch Pathol Lab Med* 124(11), 1599–1607.

53 Issa R, Zhou X, Constandinou CM *et al.* (2004) Spontaneous recovery from micronodular cirrhosis: evidence for incomplete resolution associated with matrix cross-linking. *Gastroenterology* 126(7), 1795–1808.

54 Villeneuve JP, Condreay LD, Willems B *et al.* (2000) Lamivudine treatment for decompensated cirrhosis resulting from chronic hepatitis B. *Hepatology* 31(1), 207–210.

6.2 Cellular and molecular pathobiology of liver fibrosis and its pharmacological intervention

Scott L. Friedman

Introduction

Many significant advances in the investigation of hepatic fibrosis have led to a new understanding of how the liver generates scar in response to injury, and pointed to new approaches to its treatment. These advances have included the isolation and characterization of fibrogenic cell types in liver, elucidation of pathogenic mechanisms and clarification of mediators. This chapter will review the substantial progress in understanding the pathophysiology of hepatic fibrosis, and how this has led to a rational new template for antifibrotic therapy. Mechanisms underlying reversibility of fibrosis are summarized in Chapter 6.1 (Evolution of cirrhosis), whereas clinical features of cirrhosis are detailed in Chapter 6.3 (Clinical aspects of cirrhosis). In addition, emerging genetic determinants of fibrosis progression are reviewed in Chapters 3.3.1 (Polymorphisms) and 3.3.3 (Genetic determinants).

Hepatic fibrosis refers to the accumulation of interstitial or 'scar' extracellular matrix that follows either acute or chronic liver injury. Cirrhosis, the endstage of progressive fibrosis, is characterized by septum formation and scar surrounding nodules of hepatocytes. The composition of extracellular matrix molecules in fibrotic liver is similar to those of other fibrosing parenchyma including lung and kidney, and also similar among different aetiologies of liver disease. Typically, fibrosis requires years or decades to become clinically apparent, but notable exceptions in which cirrhosis develops over months may include paediatric liver disease (e.g. biliary atresia), drug-induced liver disease and viral hepatitis associated with immunosuppression following liver transplantation.

Cellular sources of extracellular matrix in normal and fibrotic liver

The *hepatic stellate cell* (previously called lipocyte, Ito, fat-storing or perisinusoidal cell) is the primary source in normal and fibrotic liver. In addition, related mesenchymal cell types from a variety of sources may also make minor contributions to total matrix accumulation, including classical portal fibroblasts [1–3] (especially in biliary fibrosis), bone marrow-derived cells [4], as well as fibroblast-derived epithelial–mesenchymal transition (EMT) [5]. EMT is a well-characterized response of the kidney [5] to injury, but its role in liver injury has been less convincing.

Hepatic stellate cells are resident perisinusoidal cells in the subendothelial space between hepatocytes and sinusoidal endothelial cells (for reviews, see [6,7]). As the primary storage site for retinoids (vitamin A compounds), stellate cells can be recognized by their vitamin A autofluorescence, perisinusoidal orientation and by expression of the cytoskeletal proteins desmin and glial acidic fibrillary protein.

The concept of 'stellate cells' may actually represent a heterogeneous population of mesenchymal cells with respect to cytoskeletal phenotype, vitamin A content and localization [8]. Moreover, remarkable plasticity of stellate cell phenotype has been documented *in vivo* and in culture, precluding a strict definition based only on cytoskeletal phenotype [9,10]. In addition, stellate cells with fibrogenic potential are not confined to liver and have been identified in pancreas, for example, where they contribute to desmoplasia in chronic pancreatitis [11] and carcinoma [12]. A common origin of hepatic and pancreatic stellate cells is strongly suggested by the remarkable similarity of their transcriptional profiles [13].

Stellate cell activation, a central event in hepatic fibrosis

'*Activation*' of stellate cells refers to a continuum of cellular and molecular changes in which stellate cells undergo a transition from a quiescent vitamin A-rich cell to a highly fibrogenic cell characterized by enlargement of rough endoplasmic reticulum, diminution of vitamin A droplets, ruffled nuclear membrane, appearance of contractile filaments and proliferation. Cells with features of both quiescent and activated cells are often called 'transitional cells'. Stellate cells have now been characterized in many human liver diseases. Alcoholic liver disease is the best studied example, with numerous reports documenting features of activation *in situ* (for review, see [14]); activation may even occur in the presence of steatosis alone without inflammation

[15]. Activated stellate cells have also been identified in viral hepatitis [16] and hepatocellular carcinoma, where they contribute to the deposition of tumour-associated stroma [17]. Stellate cells have additionally been characterized in a number of other human diseases, including vascular disease, haematological malignancy, biliary disease, mucopolysaccharidosis, paracetamol overdose, leishmaniasis and allograft rejection, and in drug abusers.

Extracellular matrix production by sinusoidal endothelial cells, while less than that of stellate cells, is nonetheless an important component of early fibrosis. Like stellate cells, there is considerable heterogeneity of sinusoidal endothelium in normal and fibrotic liver. Endothelial cells from normal liver produce types 3 and 4 collagen, laminin, syndecans and fibronectin [18]. Following acute liver injury, increased expression of cellular isoforms of fibronectin by these cells is a key early event [19], because their appearance creates a microenvironment that activates stellate cells.

Pathways of stellate cell activation (Fig. 1)

Stellate cell activation is conceptualized in two major phases of progression, *initiation* (also called a *preinflammatory stage*) and *perpetuation* [6], as well as a key stage of resolution (see Chapter 6.1). *Initiation* refers to early changes in gene expression and phenotype that render the cells responsive to other cytokines and stimuli, whereas perpetuation results from the effects of these stimuli on maintaining the activated phenotype and generating fibrosis. Initiation is largely due to paracrine stimulation, whereas perpetuation involves autocrine as well as paracrine loops.

Initiation of stellate cell activation

The earliest changes in stellate cells are likely to result from paracrine stimulation by all neighbouring cell types, including sinusoidal endothelium, Kupffer cells, hepatocytes and platelets. As noted above, early injury to endothelial cells stimulates the production of cellular fibronectin, which has an activating effect on stellate cells [20]. Endothelial cells are also likely to participate in the conversion of transforming growth factor (TGF)-β from the latent to the active, profibrogenic form. Sinusoidal endothelial cells, normally fenestrated to allow rapid bidirectional transport of solutes between sinusoidal blood and parenchymal cells, may rapidly lose their fenestrations upon injury and express proinflammatory molecules including intercellular adhesion molecule (ICAM)-1, vascular endothelial growth factor (VEGF) and adhesion molecules [21,22]. Together with stellate cells, they activate angiogenic pathways in response to hypoxia associated with local injury or malignancy [22–25].

Early stimulation of stellate cells by lipid peroxides contributes to many forms of liver fibrosis, particularly hepatitis C, non-alcoholic steatohepatitis (NASH) and iron overload [26]. In fact, there is an increased prevalence of heterozygosity for mutation of the haemochromatosis gene in patients with NASH, suggesting a potentially synergistic relationship between fat and iron overload [27]. Additionally, fibrosis is more likely among

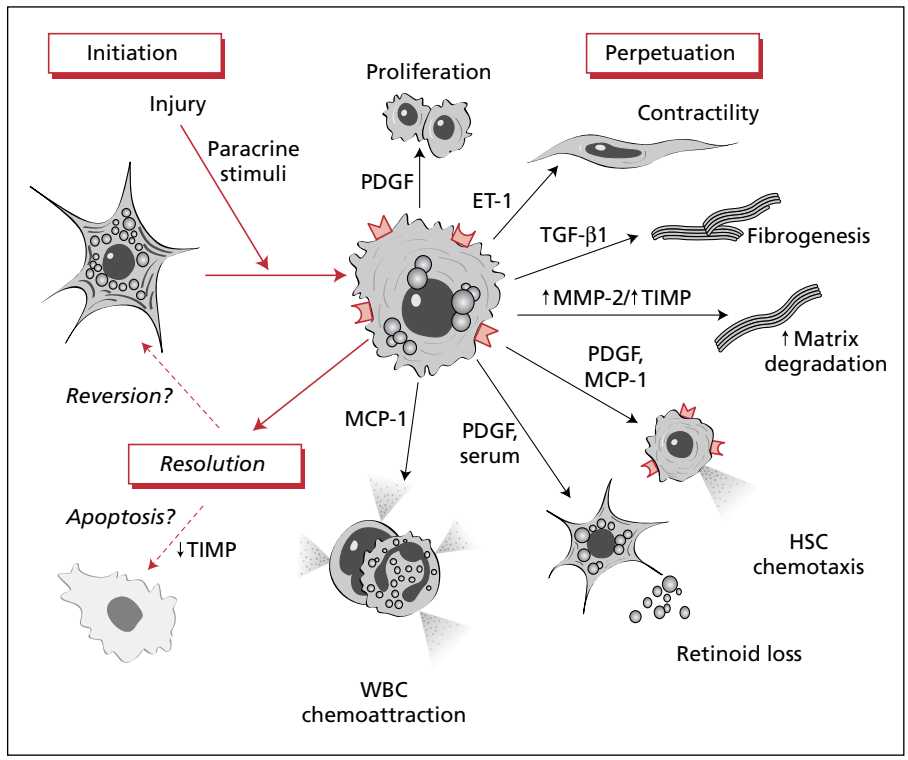

Fig. 1 Phenotypical features of hepatic stellate cell activation during liver injury and resolution. Following liver injury, hepatic stellate cells undergo 'activation', during which they are transformed from quiescent vitamin A-rich cells into proliferative, fibrogenic and contractile myofibroblasts. The major phenotypical changes after activation include proliferation, contractility, fibrogenesis, matrix degradation, chemotaxis, retinoid loss and white blood cell (WBC) chemoattraction. Key mediators underlying these effects are shown. The fate of activated stellate cells during the resolution of liver injury is uncertain but may include reversion to a quiescent phenotype or selective clearance by apoptosis. ECM, extracellular matrix; cFn, cellular fibronectin; PDGF, platelet-derived growth factor; ET-1, endothelin-1; TGF-β1, transforming growth factor β1; MMP-2, matrix metalloproteinase-2; MCP-1, monocyte chemoattractant protein-1; HSC, hepatic stellate cell (from ref. 94, with permission.)

patients with NASH who are obese, which correlates with increased hepatic steatosis [28]. Panels of biochemical markers have been developed to enhance the prediction of fibrosis in patients with NASH [29,30]. Because antioxidant levels are typically depleted in cirrhotic liver, as fibrosis advances, their loss could further amplify the injurious effects of lipid peroxides.

Hepatocytes, as the most abundant cell type in liver, are a potent source of these fibrogenic lipid peroxides. There is a correlation *in situ* between the presence of aldehyde adducts and collagen gene expression by stellate cells [31], and peroxides stimulate collagen synthesis by cultured stellate cells [32]. Steatosis in NASH and hepatitis C virus (HCV) infection correlates with increased stellate cell activation and fibrogenesis [33], possibly because fat represents an enhanced source of lipid peroxides. In culture, activation of stellate cells is provoked by the generation of free radicals and is blocked by antioxidants [34].

Whereas hepatocyte necrosis associated with lipid peroxidation is considered a classical inflammatory and fibrogenic stimulus, recent findings also implicate apoptosis, or programmed cell death, in the fibrogenic response [35]. Apoptotic fragments released from hepatocytes are fibrogenic towards cultured stellate cells, in part through induction of nicotinamide adenine dinucleotide phosphate hydrogenase (NADPH) oxidase [36,37], and also activate Kupffer cells [38]. Additionally, Fas-mediated hepatocyte apoptosis *in vivo* in experimental animals is fibrogenic [39].

Platelets are a potent source of growth factors in liver injury [40], yet their potential contribution has been largely overlooked. Potentially important platelet mediators include platelet-derived growth factor (PDGF), TGF-β1 and epidermal growth factor (EGF).

Perpetuation of stellate cell activation

Perpetuation of stellate cell activation reflects distinct alterations in cell behaviour that include: (i) proliferation; (ii) chemotaxis; (iii) fibrogenesis; (iv) contractility; (v) matrix degradation; (vi) retinoid loss; (vii) white blood cell (WBC) chemoattractant and cytokine release. Either directly or indirectly, the net effect of these changes is to increase the accumulation of extracellular matrix. For example, proliferation and chemotaxis lead to increased numbers of collagen-producing cells, but there is also more matrix production per cell. Cytokine release by stellate cells can amplify the inflammatory and fibrogenic tissue responses, and matrix proteases may hasten the replacement of normal matrix with one typical of the wound 'scar'.

Proliferation

PDGF is the most potent stellate cell mitogen that has been identified [41]. Induction of PDGF receptors early in stellate cell activation increases responsiveness to this potent mitogen [42]. Downstream pathways of PDGF signalling have been well characterized in stellate cells [43]. PDGF also stimulates Na^+/H^+ exchange, providing a potential site for therapeutic intervention by blocking ion transport [44]. Transgenic expression of PDGF-C in mice leads to both hepatic fibrosis and carcinoma [45], raising a potential role for the cytokine in carcinogenesis as well as fibrosis. Other compounds with mitogenic and/or fibrogenic activity in stellate cells include VEGF [24], thrombin and its receptor [46,47], EGF, TGF-β, keratinocyte growth factor [48] and basic fibroblast growth factor (bFGF) [49]. Signalling pathways for these and other mitogens have been greatly clarified in stellate cells [43].

Chemotaxis

Stellate cells can migrate towards cytokine chemoattractants [23,43] mediated by a number of transmembrane receptors [43,50–53], which is characteristic of wound-infiltrating mesenchymal cells in other tissues as well. Chemotaxis of stellate cells explains in part why stellate cells align within inflammatory septae *in vivo*.

Fibrogenesis

Increased matrix production by each fibrogenic cell contributes significantly to matrix accumulation in hepatic fibrosis. Regulation of the collagen I gene in stellate cells provides an important paradigm for understanding the pathophysiology of stellate cell fibrogenesis (see also Chapter 2.4.3, Function and metabolism of collagen and other extracellular matrix proteins). The most potent stimulus to collagen I production is TGF-β1, which is derived from both paracrine and autocrine sources; TGF-β1 also stimulates the production of other matrix components, including cellular fibronectin and proteoglycans [54]. TGF-β1 stimulates collagen in stellate cells through a hydrogen peroxide-, p38 MAPK- and C/EBPβ-dependent mechanism [55,56]. TGF-β expression is increased in patients with chronic hepatitis C, emphasizing the potential importance of this cytokine in chronic liver disease [57]. Similarly, serum levels of TGF-β correlate with the risk of veno-occlusive disease following bone marrow transplantation [58]. Also, stellate cell responsiveness to TGF-β1 is increased during activation by enhanced ligand binding to its cognate receptors [54].

Signals downstream of TGF-β1 include a family of bifunctional molecules known as Smads, upon which many extracellular and intracellular signals converge to fine tune and additionally enhance TGF-β's effects during fibrogenesis, downstream of its receptors [59,60]. The response of Smads in stellate cells differs between acute and chronic injury to further favour matrix production [61,62]. Smads 2 and 3 elicit distinct signalling responses that promote stellate cell activation and fibrogenesis [43], whereas Smad 7 is inhibitory, making it an attractive molecule to use in antifibrotic therapies [63] (see section on Pharmacological intervention in hepatic fibrosis).

Continued understanding of collagen gene transcription, translation and mRNA stability have emphasized the many sites of regulation that may affect collagen production [64–67].

Lipid peroxidation products are recognized as important stimuli for extracellular matrix production [68], particularly when derived from hepatocytes [34]. Their effects may be amplified by loss of antioxidant capacity of stellate cells as they become

activated [69]. These important insights have provoked efforts to use antioxidants as therapy for hepatic fibrosis (see section on Pharmacological intervention in hepatic fibrosis). Stimulation of fibrogenesis may be especially critical in the pathogenesis of NASH, in which fat provides a large reservoir of potential reactive oxygen species [70–72]. In addition to TGF-β1, connective tissue growth factor (now referred to as CCN2) is also a potent TGF-β-regulated fibrogenic cytokine [73,74].

Contractility

Contractility of stellate cells may be a major determinant of early and late increases in portal resistance during liver fibrosis. Activated stellate cells impede portal blood flow by both constricting individual sinusoids and contracting the cirrhotic liver, as the collagenous bands typical of endstage cirrhosis contain large numbers of activated stellate cells [75].

As stellate cells become contractile, expression of the cytoskeletal protein α-smooth muscle actin is increased. Detection of α-actin appears to be an important clinical predictor of subsequent fibrosis, particularly in NASH [76] or following liver transplantation [77–79].

The major contractile stimulus for stellate cells is endothelin-1, whose receptors are expressed on both quiescent and activated stellate cells but whose subunit composition may vary [75]. Unlike PDGF receptors, endothelin receptor expression does not increase with stellate cell activation, but there is a shift in the type of endothelin receptor that predominates, combined with increased sensitivity to autocrine endothelin-1 [80,81]. Increased endothelin levels result from increased endothelin-converting enzyme (ECE) activity resulting from stabilization of the ECE mRNA [82]. Contractility of stellate cells in response to endothelin-1 has also been documented *in vivo* as well as in culture [83].

Another key contractile mediator in activated stellate cells is angiotensin II, which is synthesized by activated stellate cells in an NADPH-dependent pathway [84–86]. These findings are particularly relevant to human disease, because antagonism of this pathway is an attractive antifibrotic therapy using a variety of safe, well-tolerated medications that are already available (see below) [87]. Contraction may also be induced in activated stellate cells by vasopressin [88], substance P [89] and atrial natriuretic peptide [90].

Locally produced vasodilator substances may counteract the constrictive effects of endothelin-1 [91,92]. Nitric oxide, which is also produced by stellate cells, is a well-characterized endogenous antagonist to endothelin. During acute endotoxaemia, stellate cell production of nitric oxide is increased. *In vivo* studies suggest that carbon monoxide also mediates sinusoidal relaxation through its effects on stellate cells [81,93].

Matrix degradation

Quantitative and qualitative changes in matrix protease activity play an important role in extracellular matrix remodelling accompanying fibrosing liver injury and resolution (for details, see Chapter 6.1).

Retinoid loss and nuclear receptor signalling

As stellate cells activate, they lose their characteristic perinuclear retinoid (vitamin A) droplets and acquire a more fibroblastic appearance. In culture, retinoid is stored as retinylesters, whereas stellate cells activate the retinoid released outside the cell as retinol, suggesting that there is intracellular hydrolysis of esters prior to export [94]. However, it is unknown whether retinoid loss is required for stellate cells to activate, and which retinoids might accelerate or prevent activation *in vivo*.

Several nuclear retinoid receptors have been identified in stellate cells [95–98]. This class of molecules binds intracellular retinoid ligands and regulates gene expression, but it is uncertain what regulatory role they play in fibrogenesis. This question has important clinical implications, as methods to use retinoids therapeutically are being considered (see below).

Recently, peroxisome proliferator-activated receptors (PPAR), in particular PPARγ, have been identified in stellate cells, and their expression increases with activation [96]. Ligands for this newly identified nuclear receptor family downregulate stellate cell activation [96,99]. Similarly, farnesoid X receptor (FXR) not only regulates a range of genes involved in choleresis but, in stellate cells, may drive antifibrotic pathways alone or by converging with PPARγ signalling [95,100,101]. In contrast, PPARβ ligands stimulate stellate cell proliferation [97].

Inflammatory signalling and WBC chemoattraction

Stellate cells are assuming an increasingly central role in our understanding of hepatic inflammation. They can amplify the inflammatory response by inducing infiltration of mono- and polymorphonuclear leukocytes, and chemokines secreted by bile duct epithelium may accelerate stellate cell activation during cholestasis [102]. Activated stellate cells produce chemokines that include MCP-1 [91], CCL21 [16] RANTES and CCR5 [103]. They also express Toll-like receptors (TLR) [104], indicating a capacity to interact with bacterial lipopolysaccharide and other exogenous ligands including possibly viral proteins and/or nucleic acids. TLR activation stimulates stellate cells [105], and a complete characterization of this receptor family and their potential roles in stellate cell biology is anticipated.

Stellate cells can also function as antigen-presenting cells [106] which can stimulate lymphocyte proliferation or apoptosis [107]. Stellate cells produce neutrophil chemoattractants including CINC [108], which could contribute to the neutrophil accumulation characteristic of alcoholic liver disease.

In addition to regulating leukocyte behaviour, stellate cells may in turn be affected by specific lymphocyte populations. For example, CD8 cells harbour more fibrogenic activity towards stellate cells than CD4 cells [109], which may explain in part the increased hepatic fibrosis seen in patients with hepatitis C virus (HCV)/HIV coinfection, in whom CD4/CD8 ratios are reduced, than in patients monoinfected with HCV alone. Apoptosis of hepatic stellate cells through stimulation by intrahepatic natural

killer (NK) cells has also been identified and could reduce stellate cell numbers during resolution of fibrosis [110].

Transcriptional regulation of stellate cell activation

There have been significant advances in understanding intracellular signalling and transcriptional gene regulation in activated hepatic stellate cells [111,112]. A growing number of transcription factors and signalling molecules may regulate stellate cell behaviour, including p70S6K [113], PPARα, β and γ [97,114,115], CRP-2 [116], retinoid receptors [117], NFκB [104], Jun D [111], Krüppel-like factor 6 [118], Foxf1 [119], Lhx2 [120] and MEF2 [121], among others [111,114].

Disease-specific mechanisms regulating hepatic fibrosis – NASH and HCV

NASH is associated with an increasing incidence of advanced fibrosis and cirrhosis with accelerated mortality [28,122]. Leptin, a circulating adipogenic hormone whose serum concentration reflects adipose mass, has been clearly tied to stellate cell fibrogenesis [123–125] and requires sympathetic neurotransmission [126]. Sources are likely to be both endocrine and autocrine, associated with enhanced signalling through the leptin receptor, which is upregulated during stellate cell activation [123,127].

In contrast to leptin, downregulation of adiponectin in obesity, a counter-regulatory hormone, may amplify the fibrogenic activity of leptin. Rapid advances in our understanding of these adipokines in liver disease reflect their growing significance in liver fibrosis, particularly NASH [127–129]. For example, mice lacking adiponectin have enhanced fibrosis following toxic liver injury [130], and patients with NASH have reduced expression of adiponectin and its receptors [131].

Advances in HCV biology have uncovered a potential direct fibrogenic activity of the virus. Activated stellate cells might be infectable by HCV because they express candidate viral receptors, including CD80, LDL receptor and C1q [132]. Additionally, adenoviral transduction of HCV non-structural and core proteins induces stellate cell proliferation and release of inflammatory signals [132]. The E2 protein of HCV can interact directly with CD81, a stellate cell plasma membrane receptor [133]. Moreover, hepatocytes in culture that support HCV replication generate paracrine factors that also stimulate stellate cells [134]. In HCV-infected liver, chemokines and their receptors are upregulated, stimulating lymphocyte recruitment [16].

HCV proteins may also interact directly with sinusoidal endothelium [135]. A ductular reaction with portal expansion also correlates with fibrosis progression [136]. Steatosis and apoptosis in HCV may accelerate fibrosis [137], even in patients without NASH, and steatosis has emerged as an important determinant of fibrosis progression in HCV [138,139].

Pharmacological intervention in hepatic fibrosis

Thus far, no drugs are approved as antifibrotic agents in humans, although a number of agents are in clinical trials. There are several essential considerations in developing a safe, effective antifibrotic to be approved for clinical use: (i) therapies will need to be well tolerated over decades; (ii) there must be good targeting to liver and few adverse effects on other tissues; (iii) combination therapies may prove synergistic rather than additive, but agents must first be tested individually to establish safety and 'proof-of-principle'; (iv) it is uncertain whether antifibrotic therapies will require intermittent or continuous administration; (v) for potentially effective agents, evidence of a direct antifibrotic effect must be established in experimental models rather than only an indirect effect by attenuating the injury that drives the fibrogenic response; (vi) candidate therapies must be effective in a liver that is already damaged (as in clinical liver disease) rather than only before the onset of injury; (vii) antifibrotic therapies also carry the theoretical concern that inhibiting the scarring response will prevent the encapsulation of injured regions, leading to extension of tissue damage. In reality, however, antifibrotic therapies need only downregulate the scar response to be effective and, in patients with cirrhosis, it is the scarring, not injury, which usually leads to liver failure.

Antifibrotic therapies – rationale and specific agents

The paradigm of stellate cell activation provides an important framework to define sites of antifibrotic therapy (Table 1) (for review, see [6]). These include: (i) curing the primary disease to prevent injury; (ii) reducing inflammation or the host response in order to avoid stimulating stellate cell activation; (ii) directly downregulating stellate cell activation; (iv) neutralizing proliferative, fibrogenic, contractile and/or proinflammatory responses of stellate cells; (v) stimulating apoptosis of stellate cells; (vi) increasing the degradation of scar matrix by stimulating cells that produce matrix proteases, downregulating their inhibitors or by direct administration of matrix proteases.

Curing the primary disease

The most effective way to eliminate hepatic fibrosis is to clear the primary cause of liver disease. This includes abstinence in alcoholic liver disease, removal of excess iron or copper in precirrhotic genetic haemochromatosis or Wilson's disease, clearance of HBV or HCV in chronic viral hepatitis, eradication of organisms in schistosomiasis or decompression in mechanical bile duct obstruction. Not to be overlooked, weight loss in patients with NASH [140], or even those with HCV who are overweight, may improve histology and is a simple recommendation. Similarly, reversal of jejunoileal bypass-related hepatic fibrosis and cessation of methotrexate may also prevent progression to cirrhosis. Identification of the pathogenetic mechanisms

Table 1 Current and proposed pharmacological interventions for hepatic fibrosis.

Reducing injury and inflammation
Antiviral therapy for viral hepatitis
Antihelminthic therapy for schistosomiasis
Chelation/venesection, treatment of metabolic disease
Angiotensin II type 1 receptor antagonists, ACE inhibitors
Hepatoprotectants:
Caspase inhibitors
HGF/HGF mimetics
Attenuating stellate cell activation
Alpha interferon
Antioxidants
Vitamin E, PDTC
Angiotensin II type 1 receptor antagonists
Cytokine-directed therapy
TGF-β antagonists
Endothelin receptor antagonists
HGF
PPARγ agonists
FXR agonists
Aldosterone antagonists
Pentoxifylline
Inhibiting properties of activated stellate cells
Antiproliferative
PDGF receptor antagonists
Sodium exchange inhibitors
HMG CoA reductase inhibitors
Plasmin/thrombin receptor antagonists
Anticontractile
Endothelin/endothelin receptor antagonists
Nitric oxide donors
Antifibrogenic
Collagen synthesis inhibitors
TGF-β inhibitors (soluble receptors, neutralizing antibodies)
HGF/HGF mimetics
AT receptor antagonists
ACE inhibitors
Integrin
CTGF/CCN antagonists
Smad 7 agonists
Promoting specific apoptosis of hepatic stellate cells
Gliotoxin
NGF agonists
TIMP antagonists
Degrading scar matrix
Direct collagenase administration
Inhibitors of transglutaminase or collagen cross-linking
TIMP antagonists
TGF-β inhibitors

ACE, angiotensinogen-converting enzyme; AT, angiotensin; CCN, cysteine-rich 61/connective tissue growth factor, neuroblastoma overexpressed; FXR, farnesyl X receptor; HGF, hepatocyte growth factor; HMG CoA, 3-hydroxy-3-methyl-glutaryl coenzyme A; NGF, nerve growth factor; NOV, nephroblastoma overexpressed; PDGF, platelet-derived growth factor; PDTC, pyrrolidine dithiocarbamate; PPAR, peroxisome proliferator-activated receptor; Smad, mothers against DPP homologue 7; TIMP, tissue inhibitor of metalloproteinase; TGF-β, transforming growth factor beta.

underlying primary biliary cirrhosis and sclerosing cholangitis could lead to elimination of bile duct injury and periductular fibrosis.

Reducing inflammation and immune response

Reduced fibrosis has been reported in HCV patients successfully treated with pegylated α-interferon and ribavirin [141], presumably through their effect on viral replication and liver injury. Sustained viral clearance will probably be associated with marked regression of fibrosis, so that long-term follow-up of patients successfully cleared of HCV may show more dramatic reversal of disease than at early time points. Importantly, some antifibrotic effect is observed even in the absence of viral clearance [142]. In experimental biliary fibrosis, α-interferon also reduces fibrosis [143], raising the possibility of a direct antifibrotic mechanism in addition to its antiviral effect.

A number of agents have anti-inflammatory activity *in vitro* and *in vivo*, which may eliminate the stimuli necessary for stellate cell activation. Corticosteroids have been used for decades to treat several types of liver disease, in particular autoimmune hepatitis [144]. Their activity is solely as anti-inflammatory agents, with no direct antifibrotic effect on stellate cells. Antagonists to tumour necrosis factor (TNF)α, or NFκB modulators have some rationale, as do a growing number of biologically active agents currently used in other chronic inflammatory diseases, in particular inflammatory liver disease. Pentoxifylline may exert its antifibrotic activity by downregulating TNFα signalling [145]. Other efforts to neutralize inflammatory cytokines include RGD (Arg-Gly-Asp) antagonists, which may limit immunological injury [146,147].

The renin–angiotensin system may also amplify inflammation through the generation of oxidative stress and, therefore, either angiotensin-converting enzyme antagonists and/or angiotensinogen II type 1 receptor antagonists may have anti-inflammatory as well as antifibrogenic activity [148,149].

Ursodeoxycholic acid has a beneficial effect on fibrosis in primary biliary cirrhosis [150,151], possibly in part because of its anti-inflammatory activity. Similarly, a nitric oxide-releasing derivative of ursodeoxycholic acid reduces inflammation, fibrosis and portal pressure in an animal model [152].

A new class of drugs, broadly referred to as 'hepatoprotectants', is showing considerable promise in preclinical and clinical studies, including hepatocyte growth factor (HGF), HGF deletion variants and HGF synthetic mimetics [153–155], as well as insulin-like growth factor [156] and a small-molecule caspase inhibitor that improves aspartate aminotransferase (AST) levels in patients with chronic HCV and is currently in clinical trials [157]. The exact mechanism of HGF's antifibrotic activity is uncertain, but may include inhibition of TGF-β1 activity or upregulation of bone morphogenic proteins (BMPs). Trials in large animals are under way, and those in humans are anticipated, with careful monitoring planned to screen for potential hepatocarcinogenesis, as HGF is a hepatocyte mitogen.

Inhibiting stellate cell activation

Reducing the transformation of quiescent stellate cells to activated myofibroblasts is a particularly attractive target given its central role in the fibrotic response. The most practical approach is to reduce oxidative stress, which is an important stimulus for activation. Antioxidants, including alpha-tocopherol (vitamin E) suppress fibrogenesis in some [158], but not all [159], studies of experimental fibrogenesis. Other antioxidants can also reduce stellate cell activation in culture [160], which provides a rationale for antioxidant trials in humans although, as noted above, more potent formulations than those currently available may be required.

Silymarin, a natural flavonoid component of the milk thistle *Silybum marianum*, has sparked interest as a potential antifibrotic therapy. The compound functions as an antioxidant and may decrease hepatic injury via both cytoprotection and inhibition of Kupffer cell function [160,161]. A single human trial in cirrhotics has reported a slight survival advantage in alcoholic cirrhotics in those with Child's A disease [162], but larger, carefully controlled studies are under way to assess its efficacy.

The cytokine definitive γ-interferon has inhibitory effects on stellate cell activation in animal models of fibrosis [163]. A clinical trial of γ-interferon did not show the expected antifibrotic benefit in patients with HCV, however, possibly because only patients with advanced fibrosis were enrolled and the treatment period (1 year) may have been too short.

Alpha-interferon, in addition to its antiviral effect, can downregulate stellate cell activation and fibrogenesis directly through well-defined molecular pathways and suppress experimental fibrosis [164]. Current long-term, low-dose α-interferon trials in HCV non-responders, including HALT-C [165], are based in part on this mechanism of action and, if these trials succeed, the drug may emerge as the first *bona fide* antifibrotic in humans. Inhibition of collagen gene expression in experimental models may also be accomplished using synthetic olignucleotides to inhibit collagen promoter activity [166].

Great excitement was generated by an uncontrolled trial of IL-10, which reported an antifibrotic effect in patients with advanced HCV [167]. The finding was particularly exciting because of parallel studies in animals and cultured stellate cells suggesting a direct antifibrotic activity for this agent [168–171]. However, a controlled clinical trial showed no benefit, possibly because the drug markedly increased HCV viral load [172].

PPARγ nuclear receptors are expressed in stellate cells, and synthetic PPARγ ligands (thiazolidinediones) downregulate stellate cell activation [96,173]. Given their widespread use in diabetes, second- and third-generation thiazolidinediones (i.e. lacking the hepatotoxicity seen with first-generation agents such as troglitazone) are now being tested in clinical trials in both NASH and other fibrotic liver diseases. FXR ligands appear to have similar effects, and small-molecule agonists are under study in preclinical models with evidence of antifibrotic activity [100].

Leptin is produced by activated stellate cells [174], which not only affects lipid metabolism, but can directly influence wound healing. In fact, animals deficient in leptin have reduced hepatic injury and fibrosis [175,176]. Based on this finding, the discovery of adiponectin, a natural counter-regulator to leptin, may lead to the use of this agent in fibrosis, particularly associated with NASH [127,130].

Progress in understanding transcriptional regulation has offered the opportunity to block stellate cell activation by inhibiting the activity of histone deacetylases (HDACs), enzymes critical for modifying chromatin during gene transcription [177]. Highly specific HDAC inhibitors offer the potential for selective blocking of stellate cell activation with tolerable safety and good efficacy [178], but none has reached clinical use. Similarly, modulation of intracellular proteins including transcription factors remains an elusive target for antifibrotic therapy.

Herbal therapies and products derived from natural compounds that are commonly used in the Far East are increasingly being tested under controlled, scientifically rigorous conditions [179], and some show promise of efficacy, in particular Sho-Saiko-To [180], salvia miltiorrhiza [181] and a green tea polyphenol [182].

Neutralizing proliferative, fibrogenic, contractile and/or proinflammatory responses of stellate cells

Significant advances in growth factor biology will benefit the treatment of hepatic fibrosis through the development of antagonists to cytokines and their receptors. In particular, many proliferative cytokines including PDGF, FGF and TGF-α signal through tyrosine kinase receptors, inhibitors of which are already undergoing clinical trials in other tissues [183]. Because the intracellular signalling pathways for these receptors are well understood, inhibitors to signalling models are being explored *in vivo* or in cultured stellate cells, including γ-linoleic acid and lipoxygenase inhibitors [184], and PPARγ pathway inhibitors (see above). Others include inhibitors of HMG CoA reductase [185], pentoxifylline, which inhibits PDGF receptor signalling [186], and compounds that elevate intracellular cyclic adenosine monophosphate (AMP) [187] or block ion transporters, including perfenidone [44,188].

The recent success in developing Gleevec, a safe, effective small-molecule tyrosine kinase antagonist in human leukaemia and mesenchymal cell tumours [189,190], augurs well for the potential of oral small-molecule therapies for other indications, including liver fibrosis. In fact, Gleevec is antifibrotic in experimental liver fibrosis [191,192]. Other orally available, low-molecular-weight small molecules to block cytokine receptor or intracellular signalling are under development. One such compound is a selective inhibitor of Rho-mediated focal adhesions, which can reduce experimental liver fibrosis [193]. Antisense mRNA to the PDGF B-chain as well as dominant-negative or soluble PDGF beta receptors also block stellate cell activation or experimental hepatic fibrosis [194–196]. As siRNA (small interfering RNA) technology has become clinically applicable, this approach will also merit further evaluation.

Inhibition of matrix production has been the primary target of most antifibrotic therapies to date. This has been attempted directly by blocking matrix synthesis and processing or indirectly by inhibiting the activity of TGF-β1, the major fibrogenic cytokine. Inhibitors of collagen synthesis such as HOE 077, which blocks the enzyme prolyl hydroxylase, were among the first antifibrotic compounds tested in liver, but success with this agent has been modest. The emerging importance of translational regulation of collagen gene expression [64,197–199] could lead to specific translational inhibitors with therapeutic value. Colchicine generated excitement at one time because of its apparent efficacy in a small group of patients [200]; however, a more recent study in alcoholic cirrhosis showed no benefit [201].

TGF-β antagonists are being tested extensively because neutralizing this potent cytokine would have the dual effect of inhibiting matrix production and accelerating its degradation (see [54]). Animal and culture studies using soluble TGF-β receptors or other means of neutralizing the cytokine including monoclonal antibodies and protease inhibitors to block TGF-β activation have established proof-of-principle [6,202,203]. Concerns that inhibiting TGF-β may alter hepatocellular growth or apoptosis will need to be considered as these antagonists reach clinical trials but, in other tissues, there is great promise for this approach. A number of even newer TGF-β antagonists are also being developed and may undergo testing soon. These could include recombinant Smad 7, which antagonizes TGF-β activity in stellate cells [204].

Rapamycin, an immunosuppressive drug used following liver transplantation, has the added benefit of inhibiting stellate cell proliferation [205], which could attenuate the accelerated fibrosis progression in patients with recurrent HCV; however, enthusiasm for using rapamycin has been tempered by a reported increase in hepatic artery thrombosis [206].

Relaxin, a natural peptide hormone that mediates parturition, has been developed as an agent to decrease collagen synthesis by stellate cells and increase matrix degradation *in vitro* and *in vivo* [207]. Stellate cells also express relaxin receptors [208], which might represent an attractive target for antagonism.

Because endothelin-1 is an important regulator of wound contraction and blood flow regulation mediated by stellate cells, antagonists have been tested as both antifibrotic and portal hypotensive agents. Bosentan, a mixed endothelin A and B receptor antagonist, has antifibrotic activity and reduces stellate cell activation in experimental hepatic fibrosis [209]. This and other endothelin antagonists remain attractive drug development targets [210]. Alternatively, delivery of nitric oxide to injured liver may have the same therapeutic effect as inhibiting endothelin-1 [152,211].

Halofuginone, an anticoccidial compound, has antifibrotic activity by blocking collagen expression and has been used in a number of models of tissue fibrosis, including liver [212].

The potential utility of retinoids (vitamin A) as antifibrotic therapy has been limited by inadequate knowledge about their regulatory role in stellate cell activation and by toxicity concerns. Although stellate cells export retinoid as they activate, it does not follow that restoration of cellular retinoid will prevent activation. In fact, some retinoids may accelerate fibrosis by augmenting membrane injury as in hypervitaminosis A [213].

Stimulating stellate cell apoptosis (see also Chapter 6.1)
Attention is increasingly focused on how liver fibrosis regresses and, in particular, the fate of activated stellate cells as fibrosis recedes. Mounting evidence indicates that both reversal of the activated stellate cell phenotype and apoptosis are possible. In particular, as liver fibrosis is decreased, there is selective cell death of activated stellate cells [214]. This exciting observation has led to animal studies using gliotoxin, which provokes selective apoptosis of stellate cells in culture and *in vivo*, leading to reduced fibrosis [215,216]. A TIMP-1 neutralizing antibody has antifibrotic activity in experimental liver fibrosis [217]. Similarly, inhibition of Ikk, whose net effect is to increase NFκB signalling in stellate cells, may accelerate apoptosis [218]. Apoptosis can also be provoked by disruption of integrin-mediated adhesion [147] or through the use of TRAIL ligands [219]. Stellate cells contain several families of apoptotic mediators, including Fas/FasL, TNF receptors, nerve growth factor receptors [220] and Bcl/Bax, so that additional targets for promoting apoptosis will probably be exploited in the future [221].

Increasing the degradation of scar matrix

This component of treatment is very important, because antifibrotic therapy in human liver disease will need to provoke resorption of existing matrix in addition to preventing the deposition of new scar. As noted above, TGF-β antagonists have the advantage of stimulating matrix degradation by downregulating TIMPs and increasing the net activity of interstitial collagenase (for review, see [222]). Retinoids may also stimulate matrix degradation, but concerns over toxicity limit their utility. Relaxin can directly increase matrix degradation [223].

Direct expression of metalloproteinases in animal models of hepatic fibrosis has begun to confirm that matrix can be resorbed by the expression of exogenous enzymes [224,225]. While this may seem impractical in humans, the data establish an important proof-of-principle that matrix is responsive to degradation. Moreover, an experimental study has affirmed the importance of matrix degradation in the regression of hepatic fibrosis by demonstrating that a genetically altered mouse expressing mutant collagen resistant to degradation displays delayed regression of fibrosis following liver injury [226].

Conclusions

While the prospect of treating fibrosis is not new, current strategies of antifibrotic therapies are far more rational and mechanism based. In view of mounting proof of fibrosis regression in humans following successful treatment of the underlying liver disease, continued progress is certain. Therapies will

increasingly be tailored to host genotype and disease-specific features, and given in combination. Methods of defining fibrosis progression risk and the likelihood of treatment response will be established. The two most immediate hurdles – the development of better diagnostics to clarify endpoints in clinical trials and the need to establish that an antifibrotic can halt or regress fibrosis even when the underlying disease is unchecked – will be important milestones for future trials of antifibrotic therapies.

References

1 Wells RG, Kruglov E, Dranoff JA (2004) Autocrine release of TGF-beta by portal fibroblasts regulates cell growth. *FEBS Lett* 559, 107–110.

2 Kinnman N, Housset C (2002) Peribiliary myofibroblasts in biliary type liver fibrosis. *Front Biosci* 7, D496–503.

3 Kruglov EA, Jain D, Dranoff JA (2002) Isolation of primary rat liver fibroblasts. *J Invest Med* 50, 179–184.

4 Forbes SJ, Russo FP, Rey V *et al.* (2004) A significant proportion of myofibroblasts are of bone marrow origin in human liver fibrosis. *Gastroenterology* 126, 955–963.

5 Kalluri R, Neilson EG (2003) Epithelial-mesenchymal transition and its implications for fibrosis. *J Clin Invest* 112, 1776–1784.

6 Friedman SL (2004) Mechanisms of hepatic fibrosis and therapeutic implications. *Nature Clin Pract Gastroenterol Hepatol* 1, 98–105.

7 Friedman SL (2003) Liver fibrosis – from bench to bedside. *J Hepatol* 38 (Suppl 1), S38–53.

8 Geerts A (2001) History, heterogeneity, developmental biology, and functions of quiescent hepatic stellate cells. *Semin Liver Dis* 21, 311–335.

9 Magness ST, Bataller R, Yang L *et al.* (2004) A dual reporter gene transgenic mouse demonstrates heterogeneity in hepatic fibrogenic cell populations. *Hepatology* 40, 1151–1159.

10 Friedman SL (2004) Stellate cells: a moving target in hepatic fibrogenesis. *Hepatology* 40, 1041–1043.

11 Apte MV, Wilson JS (2004) Mechanisms of pancreatic fibrosis. *Dig Dis* 22, 273–279.

12 Bachem MG, Schunemann M, Ramadani M *et al.* (2005) Pancreatic carcinoma cells induce fibrosis by stimulating proliferation and matrix synthesis of stellate cells. *Gastroenterology* 128, 907–921.

13 Buchholz M, Kestler HA, Holzmann K *et al.* (2005) Transcriptome analysis of human hepatic and pancreatic stellate cells: organ-specific variations of a common transcriptional phenotype. *J Mol Med* 83, 795–805.

14 Friedman SL (ed.) (2001) *The Hepatic Stellate Cell*. New York: Thieme.

15 Reeves HL, Burt AD, Wood S *et al.* (1996) Hepatic stellate cell activation occurs in the absence of hepatitis in alcoholic liver disease and correlates with the severity of steatosis. *J Hepatol* 25, 677–683.

16 Bonacchi A, Petrai I, Defranco RM *et al.* (2003) The chemokine CCL21 modulates lymphocyte recruitment and fibrosis in chronic hepatitis C. *Gastroenterology* 125, 1060–1076.

17 Faouzi S, Lepreux S, Bedin C *et al.* (1999) Activation of cultured rat hepatic stellate cells by tumoral hepatocytes. *Lab Invest* 79, 485–493.

18 Arthur MJ (2000) Fibrogenesis II. Metalloproteinases and their inhibitors in liver fibrosis. *Am J Physiol Gastrointest Liver Physiol* 279, G245–249.

19 George J, Wang SS, Sevcsik AM *et al.* (2000) Transforming growth factor-beta initiates wound repair in rat liver through induction of the EIIIA-fibronectin splice isoform. *Am J Pathol* 156, 115–124.

20 Jarnagin WR, Rockey DC, Koteliansky VE *et al.* (1994) Expression of variant fibronectins in wound healing: cellular source and biological activity of the EIIIA segment in rat hepatic fibrogenesis. *J Cell Biol* 127, 2037–2048.

21 LeCouter J, Moritz DR, Li B *et al.* (2003) Angiogenesis-independent endothelial protection of liver: role of VEGFR-1. *Science* 299, 890–893.

22 Olaso E, Salado C, Egilegor E *et al.* (2003) Proangiogenic role of tumor-activated hepatic stellate cells in experimental melanoma metastasis. *Hepatology* 37, 674–685.

23 Marra F (2002) Chemokines in liver inflammation and fibrosis. *Front Biosci* 7, d1899–1914.

24 Yoshiji H, Kuriyama S, Yoshii J *et al.* (2003) Vascular endothelial growth factor and receptor interaction is a prerequisite for murine hepatic fibrogenesis. *Gut* 52, 1347–1354.

25 Ankoma-Sey V, Wang Y, Dai Z (2000) Hypoxic stimulation of vascular endothelial growth factor expression in activated rat hepatic stellate cells. *Hepatology* 31, 141–148.

26 Parola M, Robino G (2001) Oxidative stress-related molecules and liver fibrosis. *J Hepatol* 35, 297–306.

27 Bonkovsky HL, Jawaid Q, Tortorelli K *et al.* (1999) Non-alcoholic steatohepatitis and iron: increased prevalence of mutations of the HFE gene in non-alcoholic steatohepatitis. *J Hepatol* 31, 421–429.

28 Angulo P (2002) Nonalcoholic fatty liver disease. *N Engl J Med* 346, 1221–1231.

29 Imbert-Bismut F, Ratziu V, Pieroni L *et al.* (2001) Biochemical markers of liver fibrosis in patients with hepatitis C virus infection: a prospective study. *Lancet* 357, 1069–1075.

30 Ratziu V, Giral P, Charlotte F *et al.* (2000) Liver fibrosis in overweight patients. *Gastroenterology* 118, 1117–1123.

31 Paradis V, Mathurin P, Kollinger M *et al.* (1997) In situ detection of lipid peroxidation in chronic hepatitis C: correlation with pathological features. *J Clin Pathol* 50, 401–406.

32 Nieto N, Friedman SL, Cederbaum AI (2002) Stimulation and proliferation of primary rat hepatic stellate cells by cytochrome P450 2E1-derived reactive oxygen species. *Hepatology* 35, 62–73.

33 Clouston AD, Jonsson JR, Purdie DM *et al.* (2001) Steatosis and chronic hepatitis C: analysis of fibrosis and stellate cell activation. *J Hepatol* 34, 314–320.

34 Nieto N, Friedman SL, Cederbaum AI (2002) Cytochrome P450 2E1-derived reactive oxygen species mediate paracrine stimulation of collagen I protein synthesis by hepatic stellate cells. *J Biol Chem* 277, 9853–9864.

35 Canbay A, Friedman S, Gores GJ (2004) Apoptosis: the nexus of liver injury and fibrosis. *Hepatology* 39, 273–278.

36 Canbay A, Taimr P, Torok N *et al.* (2003) Apoptotic body engulfment by a human stellate cell line is profibrogenic. *Lab Invest* 83, 655–663.

37 Zhan S-S, Wu J, Halsted C *et al.* (2006) Phagocytosis of apoptotic bodies by hepatic stellate cells induces NADPH oxidase and is associated with liver fibrosis in vivo. *Hepatology* 43, 435–443.

38 Canbay A, Feldstein AE, Higuchi H *et al.* (2003) Kupffer cell engulfment of apoptotic bodies stimulates death ligand and cytokine expression. *Hepatology* 38, 1188–1198.

39 Canbay A, Higuchi H, Bronk SF *et al.* (2002) Fas enhances fibrogenesis in the bile duct ligated mouse: a link between apoptosis and fibrosis. *Gastroenterology* 123, 1323–1330.

40 Bachem MG, Melchior R, Gressner AM (1989) The role of thrombocytes in liver fibrogenesis: effects of platelet lysate and thrombocyte-derived growth factors on the mitogenic activity and glycosaminoglycan synthesis of cultured rat liver fat storing cells. *J Clin Chem Clin Biochem* 27, 555–565.

41 Pinzani M (2002) PDGF and signal transduction in hepatic stellate cells. *Front Biosci* 7, d1720–1726.

42 Wong L, Yamasaki G, Johnson RJ *et al.* (1994) Induction of beta-platelet-derived growth factor receptor in rat hepatic lipocytes during cellular activation in vivo and in culture. *J Clin Invest* 94, 1563–1569.

43 Pinzani M, Marra F (2001) Cytokine receptors and signaling in hepatic stellate cells. *Semin Liver Dis* 21, 397–416.

44 Di Sario A, Bendia E, Taffetani S *et al.* (2003) Selective Na+/H+ exchange inhibition by cariporide reduces liver fibrosis in the rat. *Hepatology* 37, 256–266.

45 Campbell JS, Hughes SD, Gilbertson DG *et al.* (2005) Platelet-derived growth factor C induces liver fibrosis, steatosis, and hepatocellular carcinoma. *Proc Natl Acad Sci USA* 102, 3389–3394.

46 Marra F, Grandaliano G, Valente AJ *et al.* (1995) Thrombin stimulates proliferation of liver fat-storing cells and expression of monocyte chemotactic protein-1: potential role in liver injury. *Hepatology* 22, 780–787.

47 Marra F, DeFranco R, Grappone C *et al.* (1998) Expression of the thrombin receptor in human liver: up-regulation during acute and chronic injury. *Hepatology* 27, 462–471.

48 Steiling H, Muhlbauer M, Bataille F *et al.* (2004) Activated hepatic stellate cells express keratinocyte growth factor in chronic liver disease. *Am J Pathol* 165, 1233–1241.

49 Yu C, Wang F, Jin C *et al.* (2003) Role of fibroblast growth factor type 1 and 2 in carbon tetrachloride-induced hepatic injury and fibrogenesis. *Am J Pathol* 163, 1653–1662.

50 Efsen E, Grappone C, DeFranco RM *et al.* (2002) Up-regulated expression of fractalkine and its receptor CX3CR1 during liver injury in humans. *J Hepatol* 37, 39–47.

51 Mazzocca A, Carloni V, Sciammetta S *et al.* (2002) Expression of transmembrane 4 superfamily (TM4SF) proteins and their role in hepatic stellate cell motility and wound healing migration. *J Hepatol* 37, 322–330.

52 Ikeda K, Wakahara T, Wang YQ *et al.* (1999) In vitro migratory potential of rat quiescent hepatic stellate cells and its augmentation by cell activation. *Hepatology* 29, 1760–1767.

53 Kinnman N, Hultcrantz R, Barbu V *et al.* (2000) PDGF-mediated chemoattraction of hepatic stellate cells by bile duct segments in cholestatic liver injury. *Lab Invest* 80, 697–707.

54 Gressner AM, Weiskirchen R, Breitkopf K *et al.* (2002) Roles of TGF-beta in hepatic fibrosis. *Front Biosci* 7, D793–807.

55 Varela-Rey M, Montiel-Duarte C, Oses-Prieto JA *et al.* (2002) p38 MAPK mediates the regulation of alpha1(I) procollagen mRNA levels by TNF-alpha and TGF-beta in a cell line of rat hepatic stellate cells (1). *FEBS Lett* 528, 133–138.

56 Garcia-Trevijano ER, Iraburu MJ, Fontana L *et al.* (1999) Transforming growth factor beta1 induces the expression of alpha1(I) procollagen mRNA by a hydrogen peroxide-C/EBPbeta-dependent mechanism in rat hepatic stellate cells. *Hepatology* 29, 960–970.

57 Marek B, Kajdaniuk D, Mazurek U *et al.* (2005) TGF-beta1 mRNA expression in liver biopsy specimens and TGF-beta1 serum levels in patients with chronic hepatitis C before and after antiviral therapy. *J Clin Pharm Ther* 30, 271–277.

58 Anscher MS, Peters WP, Reisenbichler H *et al.* (1993) Transforming growth factor beta as a predictor of liver and lung fibrosis after autologous bone marrow transplantation for advanced breast cancer. *N Engl J Med* 328, 1592–1598.

59 Tsukada S, Westwick JK, Ikejima K *et al.* (2005) SMAD and p38 MAPK signaling pathways independently regulate alpha1(I) collagen gene expression in unstimulated and transforming growth factor-beta-stimulated hepatic stellate cells. *J Biol Chem* 280, 10055–10064.

60 Bonacchi A, Romagnani P, Romanelli RG *et al.* (2001) Signal transduction by the chemokine receptor CXCR3: activation of Ras/ERK, Src, and phosphatidylinositol 3-kinase/Akt controls cell migration and proliferation in human vascular pericytes. *J Biol Chem* 276, 9945–9954.

61 Tahashi Y, Matsuzaki K, Date M *et al.* (2002) Differential regulation of TGF-beta signal in hepatic stellate cells between acute and chronic rat liver injury. *Hepatology* 35, 49–61.

62 Uemura M, Swenson ES, Gaca MD *et al.* (2005) Smad2 and Smad3 play different roles in rat hepatic stellate cell function and {alpha}-smooth muscle actin organization. *Mol Biol Cell* 16, 4214–4224.

63 Dooley S, Hamzavi J, Breitkopf K *et al.* (2003) Smad7 prevents activation of hepatic stellate cells and liver fibrosis in rats. *Gastroenterology* 125, 178–191.

64 Stefanovic B, Stefanovic L, Schnabl B *et al.* (2004) TRAM2 protein interacts with endoplasmic reticulum Ca2+ pump Serca2b and is necessary for collagen type I synthesis. *Mol Cell Biol* 24, 1758–1768.

65 Yata Y, Scanga A, Gillan A *et al.* (2003) DNase I-hypersensitive sites enhance alpha1(I) collagen gene expression in hepatic stellate cells. *Hepatology* 37, 267–276.

66 Novitskiy G, Potter JJ, Rennie-Tankersley L *et al.* (2004) Identification of a novel NF-kappaB-binding site with regulation of the murine alpha2(I) collagen promoter. *J Biol Chem* 279, 15639–15644.

67 Dranoff JA, Ogawa M, Kruglov EA *et al.* (2004) Expression of P2Y nucleotide receptors and ectonucleotidases in quiescent and activated rat hepatic stellate cells. *Am J Physiol Gastrointest Liver Physiol* 287, G417–424.

68 Galli A, Svegliati-Baroni G, Ceni E *et al.* (2005) Oxidative stress stimulates proliferation and invasiveness of hepatic stellate cells via a MMP2-mediated mechanism. *Hepatology* 41, 1074–1084.

69 Whalen R, Rockey DC, Friedman SL *et al.* (1999) Activation of rat hepatic stellate cells leads to loss of glutathione S-transferases and their enzymatic activity against products of oxidative stress. *Hepatology* 30, 927–933.

70 George J, Pera N, Phung N *et al.* (2003) Lipid peroxidation, stellate cell activation and hepatic fibrogenesis in a rat model of chronic steatohepatitis. *J Hepatol* 39, 756–764.

71 MacDonald GA, Bridle KR, Ward PJ *et al.* (2001) Lipid peroxidation in hepatic steatosis in humans is associated with hepatic fibrosis and occurs predominately in acinar zone 3. *J Gastroenterol Hepatol* 16, 599–606.

72 Carmiel-Haggai M, Cederbaum AI, Nieto N (2005) A high-fat diet leads to the progression of non-alcoholic fatty liver disease in obese rats. *FASEB J* 19, 136–138.

73 Rachfal AW, Brigstock DR (2003) Connective tissue growth factor (CTGF/CCN2) in hepatic fibrosis. *Hepatol Res* 26, 1–9.

74 Gao R, Brigstock DR (2003) Low density lipoprotein receptor-related protein (LRP) is a heparin-dependent adhesion receptor for connective tissue growth factor (CTGF) in rat activated hepatic stellate cells. *Hepatol Res* 27, 214–220.

75 Housset C, Rockey DC, Bissel DM (1993) Endothelin receptors in rat liver: lipocytes as a contractile target for endothelin 1. *Proc Natl Acad Sci USA* 90, 9266–9270.

76 Kim WR, Gores GJ, Benson JT *et al.* (2005) Mortality and hospital utilization for hepatocellular carcinoma in the United States. *Gastroenterology* 129, 486–493.

77 Gawrieh S, Papouchado BG, Burgart LJ *et al.* (2005) Early hepatic stellate cell activation predicts severe hepatitis C recurrence after liver transplantation. *Liver Transpl* 11, 1207–1213.

78 Carpino G, Morini S, Ginanni Corradini S *et al.* (2005) Alpha-SMA expression in hepatic stellate cells and quantitative analysis of hepatic fibrosis in cirrhosis and in recurrent chronic hepatitis after liver transplantation. *Dig Liver Dis* 37, 349–356.

79 Russo MW, Firpi RJ, Nelson DR *et al.* (2005) Early hepatic stellate cell activation is associated with advanced fibrosis after liver transplantation in recipients with hepatitis C. *Liver Transpl* 11, 1235–1241.

80 Shao R, Rockey DC (2002) Effects of endothelins on hepatic stellate cell synthesis of endothelin-1 during hepatic wound healing. *J Cell Physiol* 191, 342–350.

81 Rockey DC (2003) Vascular mediators in the injured liver. *Hepatology* 37, 4–12.

82 Shao R, Yan W, Rockey DC (1999) Regulation of endothelin-1 synthesis by endothelin-converting enzyme-1 during wound healing. *J Biol Chem* 274, 3228–3234.

83 Zhang JX, Pegoli W, Jr, Clemens MG (1994) Endothelin-1 induces direct constriction of hepatic sinusoids. *Am J Physiol* 266, G624–632.

84 Bataller R, Sancho-Bru P, Gines P *et al.* (2003) Activated human hepatic stellate cells express the renin-angiotensin system and synthesize angiotensin II. *Gastroenterology* 125, 117–125.

85 Bataller R, Gines P, Nicolas JM *et al.* (2000) Angiotensin II induces contraction and proliferation of human hepatic stellate cells. *Gastroenterology* 118, 1149–1156.

86 Bataller R, Schwabe R, Choi Y *et al.* (2003) NADPH oxidase signal transduces angiotensin II in hepatic stellate cells and is critical in hepatic fibrosis. *J Clin Invest* 112, 1383–1394.

87 Bataller R, Brenner DA (2005) Liver fibrosis. *J Clin Invest* 115, 209–218.

88 Bataller R, Nicolas JM, Gines P *et al.* (1997) Arginine vasopressin induces contraction and stimulates growth of cultured human hepatic stellate cells. *Gastroenterology* 113, 615–624.

89 Sakamoto M, Ueno T, Kin M *et al.* (1993) Ito cell contraction in response to endothelin-1 and substance P. *Hepatology* 18, 978–983.

90 Gorbig MN, Gines P, Bataller R *et al.* (1999) Atrial natriuretic peptide antagonizes endothelin-induced calcium increase and cell contraction in cultured human hepatic stellate cells. *Hepatology* 30, 501–509.

91 Marra F, Pinzani M (2002) Role of hepatic stellate cells in the pathogenesis of portal hypertension. *Nefrologia* 22 (Suppl 5), 34–40.

92 Svegliati-Baroni G, Saccomanno S, van Goor H *et al.* (2001) Involvement of reactive oxygen species and nitric oxide radicals in activation and proliferation of rat hepatic stellate cells. *Liver* 21, 1–12.

93 Suematsu M, Goda N, Sana T *et al.* (1995) Carbon monoxide: an endogenous mediator of sinusoidal tone in the perfused liver. *J Clin Invest* 96, 2431–2437.

94 Friedman SL (2000) Molecular regulation of hepatic fibrosis, an integrated cellular response to tissue injury. *J Biol Chem* 275, 2247–2250.

95 Fiorucci S, Rizzo G, Antonelli E *et al.* (2005) Crosstalk between farnesoid X-receptor (FXR) and peroxisome proliferator-activated receptor (PPAR){gamma} contributes to the anti-fibrotic activity of FXR ligands in rodent models of liver cirrhosis. *J Pharmacol Exp Ther* 315, 58–68.

96 Marra F, Efsen E, Romanelli RG *et al.* (2000) Ligands of peroxisome proliferator-activated receptor gamma modulate profibrogenic and proinflammatory actions in hepatic stellate cells. *Gastroenterology* 119, 466–478.

97 Hellemans K, Michalik L, Dittie A *et al.* (2003) Peroxisome proliferator-activated receptor-beta signaling contributes to enhanced proliferation of hepatic stellate cells. *Gastroenterology* 124, 184–201.

98 Ohata M, Lin M, Satre M *et al.* (1997) Diminished retinoic acid signaling in hepatic stellate cells in cholestatic liver fibrosis. *Am J Physiol* 272, G589–596.

99 Hazra S, Xiong S, Wang J *et al.* (2004) Peroxisome proliferator-activated receptor gamma induces a phenotypic switch from activated to quiescent hepatic stellate cells. *J Biol Chem* 279, 11392–11401.

100 Fiorucci S, Antonelli E, Rizzo G *et al.* (2004) The nuclear receptor SHP mediates inhibition of hepatic stellate cells by FXR and protects against liver fibrosis. *Gastroenterology* 127, 1497–1512.

101 Fiorucci S, Rizzo G, Antonelli E *et al.* (2005) A FXR-SHP regulatory cascade modulates TIMP-1 and MMPs expression in HSCs and promotes resolution of liver fibrosis. *J Pharmacol Exp Ther* 314, 584–595.

102 Kruglov EA, Nathanson RA, Nguyen T *et al.* (2005) Secretion of MCP-1/CCL2 by bile duct epithelia induces myofibroblastic transdifferentiation of portal fibroblasts. *Am J Physiol Gastrointest Liver Physiol* 290, G765–G771.

103 Schwabe RF, Bataller R, Brenner DA (2003) Human hepatic stellate cells express CCR5 and RANTES to induce proliferation and migration. *Am J Physiol Gastrointest Liver Physiol* 285, G949–958.

104 Paik YH, Schwabe RF, Bataller R *et al.* (2003) Toll-like receptor 4 mediates inflammatory signaling by bacterial lipopolysaccharide in human hepatic stellate cells. *Hepatology* 37, 1043–1055.

105 Brun P, Castagliuolo I, Pinzani M *et al.* (2005) Exposure to bacterial cell wall products triggers an inflammatory phenotype in hepatic stellate cells. *Am J Physiol Gastrointest Liver Physiol* ??, 000–000.

106 Vinas O, Bataller R, Sancho-Bru P *et al.* (2003) Human hepatic stellate cells show features of antigen-presenting cells and stimulate lymphocyte proliferation. *Hepatology* 38, 919–929.

107 Kobayashi S, Seki S, Kawada N *et al.* (2003) Apoptosis of T cells in the hepatic fibrotic tissue of the rat: a possible inducing role of hepatic myofibroblast-like cells. *Cell Tissue Res* 311, 353–364.

108 Maher JJ, Lozier JS, Scott MK (1998) Rat hepatic stellate cells produce cytokine-induced neutrophil chemoattractant in culture and in vivo. *Am J Physiol* 275, G847–853.

109 Safadi R, Ohta M, Alvarez CE *et al.* (2004) Immune stimulation of hepatic fibrogenesis by CD8 cells and attenuation by transgenic interleukin-10 from hepatocytes. *Gastroenterology* 127, 870–882.

110 Melhem A, Mohanna N, Bishara A *et al.* (2006) Anti-fibrotic activity of NK cells in experimental liver injury through killing of activated HSC. *J Hepatol* 45, 60–71.

111 Mann DA, Smart DE (2002) Transcriptional regulation of hepatic stellate cell activation. *Gut* 50, 891–896.

112 Rippe RA (1999) Role of transcriptional factors in stellate cell activation. *Alcohol Clin Exp Res* 23, 926–929.

113 Gabele E, Reif S, Tsukada S *et al.* (2005) The role of p70S6K in hepatic stellate cell collagen gene expression and cell proliferation. *J Biol Chem* 280, 13374–13382.

114 She H, Xiong S, Hazra S *et al.* (2005) Adipogenic transcriptional regulation of hepatic stellate cells. *J Biol Chem* 280, 4959–4967.

115 Yavrom S, Chen L, Xiong S *et al.* (2005) Peroxisome proliferator-activated receptor gamma suppresses proximal alpha1(I) collagen promoter via inhibition of p300-facilitated NF-I binding to DNA in hepatic stellate cells. *J Biol Chem* 280, 40650–40659.

116 Weiskirchen R, Moser M, Weiskirchen S *et al.* (2001) LIM-domain protein cysteine- and glycine-rich protein 2 (CRP2) is a novel marker of hepatic stellate cells and binding partner of the protein inhibitor of activated STAT1. *Biochem J* 359, 485–496.

117 Hellemans K, Verbuyst P, Quartier E *et al.* (2004) Differential modulation of rat hepatic stellate phenotype by natural and synthetic retinoids. *Hepatology* 39, 97–108.

118 Ratziu V, Lalazar A, Wong L *et al.* (1998) Zf9, a Kruppel-like transcription factor up-regulated in vivo during early hepatic fibrosis. *Proc Natl Acad Sci USA* 95, 9500–9505.

119 Kalinichenko VV, Bhattacharyya D, Zhou Y *et al.* (2003) Foxf1+/– mice exhibit defective stellate cell activation and abnormal liver regeneration following CCl4 injury. *Hepatology* 37, 107–117.

120 Wandzioch E, Kolterud A, Jacobsson M *et al.* (2004) Lhx2–/– mice develop liver fibrosis. *Proc Natl Acad Sci USA* 101, 16549–16554.

121 Wang X, Tang X, Gong X *et al.* (2004) Regulation of hepatic stellate cell activation and growth by transcription factor myocyte enhancer factor 2. *Gastroenterology* 127, 1174–1188.

122 Adams LA, Lymp JF, St Sauver J *et al.* (2005) The natural history of nonalcoholic fatty liver disease: a population-based cohort study. *Gastroenterology* 129, 113–121.

123 Ikejima K, Takei Y, Honda H *et al.* (2002) Leptin receptor-mediated signaling regulates hepatic fibrogenesis and remodeling of extracellular matrix in the rat. *Gastroenterology* 122, 1399–1410.

124 Leclercq IA, Farrell GC, Schriemer R *et al.* (2002) Leptin is essential for the hepatic fibrogenic response to chronic liver injury. *J Hepatol* 37, 206–213.

125 Saxena NK, Saliba G, Floyd JJ *et al.* (2003) Leptin induces increased alpha2(I) collagen gene expression in cultured rat hepatic stellate cells. *J Cell Biochem* 89, 311–320.

126 Oben JA, Roskams T, Yang S *et al.* (2004) Hepatic fibrogenesis requires sympathetic neurotransmitters. *Gut* 53, 438–445.

127 Ding X, Saxena NK, Lin S *et al.* (2005) The roles of leptin and adiponectin: a novel paradigm in adipocytokine regulation of liver fibrosis and stellate cell biology. *Am J Pathol* 166, 1655–1669.

128 Schaffler A, Scholmerich J, Buchler C (2005) Mechanisms of disease: adipocytokines and visceral adipose tissue – emerging role in nonalcoholic fatty liver disease. *Nature Clin Pract Gastroenterol Hepatol* 2, 273–280.

129 Musso G, Gambino R, Durazzo M *et al.* (2005) Adipokines in NASH: postprandial lipid metabolism as a link between adiponectin and liver disease. *Hepatology* 42, 1175–1183.

130 Kamada Y, Tamura S, Kiso S *et al.* (2003) Enhanced carbon tetrachloride-induced liver fibrosis in mice lacking adiponectin. *Gastroenterology* 125, 1796–1807.

131 Jonsson JR, Moschen AR, Hickman IJ *et al.* (2005) Adiponectin and its receptors in patients with chronic hepatitis C. *J Hepatol* 43, 929–936.

132 Bataller R, Paik YH, Lindquist JN *et al.* (2004) Hepatitis C virus core and nonstructural proteins induce fibrogenic effects in hepatic stellate cells. *Gastroenterology* 126, 529–540.

133 Mazzocca A, Cappadona Sciammetta S, Carloni V *et al.* (2004) Binding of hepatitis C virus envelope protein E2 to CD81 up-regulates MMP-2 in human hepatic stellate cells. *J Biol Chem* 280, 11329–11339.

134 Schulze-Krebs A, Preimel D, Popov Y *et al.* (2005) Hepatitis C virus-replicating hepatocytes induce fibrogenic activation of hepatic stellate cells. *Gastroenterology* 129, 246–258.

135 Pohlmann S, Zhang J, Baribaud F *et al.* (2003) Hepatitis C virus glycoproteins interact with DC-SIGN and DC-SIGNR. *J Virol* 77, 4070–4080.

136 Clouston AD, Powell EE, Walsh MJ *et al.* (2005) Fibrosis correlates with a ductular reaction in hepatitis C: roles of impaired replication, progenitor cells and steatosis. *Hepatology* 41, 809–818.

137 Walsh MJ, Vanags DM, Clouston AD *et al.* (2004) Steatosis and liver cell apoptosis in chronic hepatitis C: a mechanism for increased liver injury. *Hepatology* 39, 1230–1238.

138 Monto A (2002) Hepatitis C and steatosis. *Semin Gastrointest Dis* 13, 40–46.

139 Harrison SA (2005) Steatosis and chronic hepatitis C infection: mechanisms and significance. *Clin Gastroenterol Hepatol* 3, S92–96.

140 Dixon JB, Bhathal PS, Hughes NR *et al.* (2004) Nonalcoholic fatty liver disease: improvement in liver histological analysis with weight loss. *Hepatology* 39, 1647–1654.

141 Poynard T, McHutchison J, Manns M *et al.* (2002) Impact of pegylated interferon alfa-2b and ribavirin on liver fibrosis in patients with chronic hepatitis C. *Gastroenterology* 122, 1303–1313.

142 Shiratori Y, Imazeki F, Moriyama M *et al.* (2000) Histologic improvement of fibrosis in patients with hepatitis C who have sustained response to interferon therapy. *Ann Intern Med* 132, 517–524.

143 Moreno MG, Muriel P (1995) Remission of liver fibrosis by interferon-alpha 2b. *Biochem Pharmacol* 50, 515–520.

144 Czaja AJ, Carpenter HA (2004) Progressive fibrosis during corticosteroid therapy of autoimmune hepatitis. *Hepatology* 39, 1631–1638.

145 Raetsch C, Jia JD, Boigk G *et al.* (2002) Pentoxifylline downregulates profibrogenic cytokines and procollagen I expression in rat secondary biliary fibrosis. *Gut* 50, 241–247.

146 Kotoh K, Nakamuta M, Kohjima M *et al.* (2004) Arg-Gly-Asp (RGD) peptide ameliorates carbon tetrachloride-induced liver fibrosis via inhibition of collagen production and acceleration of collagenase activity. *Int J Mol Med* 14, 1049–1053.

147 Iwamoto H, Sakai H, Kotoh K *et al.* (1999) Soluble Arg-Gly-Asp peptides reduce collagen accumulation in cultured rat hepatic stellate cells. *Dig Dis Sci* 44, 1038–1045.

148 Ramalho LN, Ramalho FS, Zucoloto S *et al.* (2002) Effect of losartan, an angiotensin II antagonist, on secondary biliary cirrhosis. *Hepatogastroenterology* 49, 1499–1502.

149 Kurikawa N, Suga M, Kuroda S *et al.* (2003) An angiotensin II type 1 receptor antagonist, olmesartan medoxomil, improves experimental liver fibrosis by suppression of proliferation and collagen synthesis in activated hepatic stellate cells. *Br J Pharmacol* 139, 1085–1094.

150 Degott C, Zafrani ES, Callard P *et al.* (1999) Histopathological study of primary biliary cirrhosis and the effect of ursodeoxycholic acid treatment on histology progression. *Hepatology* 29, 1007–1012.

151 Pares A, Rodes J (2003) Natural history of primary biliary cirrhosis. *Clin Liver Dis* 7, 779–794.

152 Fiorucci S, Antonelli E, Morelli A (2003) Nitric oxide and portal hypertension: a nitric oxide-releasing derivative of ursodeoxycholic acid that selectively releases nitric oxide in the liver. *Dig Liver Dis* 35(Suppl), 61–69.

153 Kim WH, Matsumoto K, Bessho K *et al.* (2005) Growth inhibition and apoptosis in liver myofibroblasts promoted by hepatocyte growth factor leads to resolution from liver cirrhosis. *Am J Pathol* 166, 1017–1028.

154 Ueki T, Kaneda Y, Tsutsui H *et al.* (1999) Hepatocyte growth factor gene therapy of liver cirrhosis in rats. *Nature Med* 5, 226–230.

155 Masunaga H, Fujise N, Shiota A *et al.* (1998) Preventive effects of the deleted form of hepatocyte growth factor against various liver injuries. *Eur J Pharmacol* 342, 267–279.

156 Sanz S, Pucilowska JB, Liu S *et al.* (2005) Expression of insulin-like growth factor I by activated hepatic stellate cells reduces fibrogenesis and enhances regeneration after liver injury. *Gut* 54, 134–141.

157 Valentino KL, Gutierrez M, Sanchez R *et al.* (2003) First clinical trial of a novel caspase inhibitor: anti-apoptotic caspase inhibitor, IDN-6556, improves liver enzymes. *Int J Clin Pharmacol Ther* 41, 441–449.

158 Pietrangelo A, Borella F, Casalgrandi G *et al.* (1995) Antioxidant activity of silybin in vivo during long-term iron overload in rats. *Gastroenterology* 109, 1941–1949.

159 Brown KE, Poulos JE, Li L *et al.* (1997) Effect of vitamin E supplementation on hepatic fibrogenesis in chronic dietary iron overload. *Am J Physiol* 272, G116–123.

160 Kawada N, Seki S, Inoue M *et al.* (1998) Effect of antioxidants, resveratrol, quercetin, and N-acetylcysteine, on the functions of cultured rat hepatic stellate cells and Kupffer cells. *Hepatology* 27, 1265–1274.

161 Dehmlow C, Erhard J, de Groot H (1996) Inhibition of Kupffer cell functions as an explanation for the hepatoprotective properties of silibinin. *Hepatology* 23, 749–754.

162 Ferenci P, Dragosics B, Dittrich H *et al.* (1989) Randomized controlled trial of silymarin treatment in patients with cirrhosis of the liver. *J Hepatol* 9, 105–110.

163 Rockey DC, Chung JJ (1994) Interferon gamma inhibits lipocyte activation and extracellular matrix mRNA expression during experimental liver injury: implications for treatment of hepatic fibrosis. *J Invest Med* 42, 660–670.

164 Inagaki Y, Nemoto T, Kushida M *et al.* (2003) Interferon alfa down-regulates collagen gene transcription and suppresses experimental hepatic fibrosis in mice. *Hepatology* 38, 890–899.

165 Lee WM, Dienstag JL, Lindsay KL *et al.* (2004) Evolution of the HALT-C Trial: pegylated interferon as maintenance therapy for chronic hepatitis C in previous interferon nonresponders. *Control Clin Trials* 25, 472–492.

166 Cheng K, Ye Z, Guntaka RV *et al.* (2005) Biodistribution and hepatic uptake of triplex-forming oligonucleotides against type alpha1(I) collagen gene promoter in normal and fibrotic rats. *Mol Pharm* 2, 206–217.

167 Nelson DR, Lauwers GY, Lau JY *et al.* (2000) Interleukin 10 treatment reduces fibrosis in patients with chronic hepatitis C: a pilot trial of interferon nonresponders. *Gastroenterology* 118, 655–660.

168 Louis H, Van Laethem JL, Wu W *et al.* (1998) Interleukin-10 controls neutrophilic infiltration, hepatocyte proliferation, and liver fibrosis induced by carbon tetrachloride in mice. *Hepatology* 28, 1607–1615.

169 Thompson K, Maltby J, Fallowfield J *et al.* (1998) Interleukin-10 expression and function in experimental murine liver inflammation and fibrosis (see comments). *Hepatology* 28, 1597–1606.

170 Wang SC, Tsukamoto H, Rippe RA *et al.* (1998) Expression of interleukin-10 by in vitro and in vivo activated hepatic stellate cells. *J Biol Chem* 273, 302–308.

171 Mathurin P, Xiong S, Kharbanda KK *et al.* (2002) IL-10 receptor and coreceptor expression in quiescent and activated hepatic stellate cells. *Am J Physiol Gastrointest Liver Physiol* 282, G981–990.

172 Nelson DR, Tu Z, Soldevila-Pico C *et al.* (2003) Long-term interleukin 10 therapy in chronic hepatitis C patients has a proviral and anti-inflammatory effect. *Hepatology* 38, 859–868.

173 Galli A, Crabb DW, Ceni E *et al.* (2002) Antidiabetic thiazolidinediones inhibit collagen synthesis and hepatic stellate cell activation in vivo and in vitro. *Gastroenterology* 122, 1924–1940.

174 Saxena NK, Titus MA, Ding X *et al.* (2004) Leptin as a novel profibrogenic cytokine in hepatic stellate cells: mitogenesis and inhibition of apoptosis mediated by extracellular regulated kinase (Erk) and Akt phosphorylation. *FASEB J* 18, 1612–1614.

175 Saxena NK, Ikeda K, Rockey DC *et al.* (2002) Leptin in hepatic fibrosis: evidence for increased collagen production in stellate cells and lean littermates of ob/ob mice. *Hepatology* 35, 762–771.

176 Ikejima K, Honda H, Yoshikawa M *et al.* (2001) Leptin augments inflammatory and profibrogenic responses in the murine liver induced by hepatotoxic chemicals. *Hepatology* 34, 288–297.

177 Wade PA (2001) Transcriptional control at regulatory checkpoints by histone deacetylases: molecular connections between cancer and chromatin. *Hum Mol Genet* 10, 693–698.

178 Niki T, Rombouts K, De Bleser P *et al.* (1999) A histone deacetylase inhibitor, trichostatin A, suppresses myofibroblastic differentiation of rat hepatic stellate cells in primary culture. *Hepatology* 29, 858–867.

179 Geerts A, Rogiers V (1999) Sho-saiko-To: the right blend of traditional Oriental medicine and liver cell biology. *Hepatology* 29, 282–284.

180 Sakaida I, Hironaka K, Kimura T *et al.* (2004) Herbal medicine Sho-saiko-to (TJ-9) increases expression matrix metalloproteinases (MMPs) with reduced expression of tissue inhibitor of metalloproteinases (TIMPs) in rat stellate cell. *Life Sci* 74, 2251–2263.

181 Oh SH, Nan JX, Sohn DW *et al.* (2002) *Salvia miltiorrhiza* inhibits biliary obstruction-induced hepatocyte apoptosis by cytoplasmic sequestration of p53. *Toxicol Appl Pharmacol* 182, 27–33.

182 Sakata R, Ueno T, Nakamura T *et al.* (2004) Green tea polyphenol epigallocatechin-3-gallate inhibits platelet-derived growth factor-induced proliferation of human hepatic stellate cell line LI90. *J Hepatol* 40, 52–59.

183 Wiedmann MW, Caca K (2005) Molecularly targeted therapy for gastrointestinal cancer. *Curr Cancer Drug Targets* 5, 171–193.

184 Beno DW, Mullen J, Davis BH (1995) Lipoxygenase inhibitors block PDGF-induced mitogenesis: a MAPK-independent mechanism that blocks fos and egr. *Am J Physiol* 268, C604–610.

185 Rombouts K, Kisanga E, Hellemans K *et al.* (2003) Effect of HMG-CoA reductase inhibitors on proliferation and protein synthesis by rat hepatic stellate cells. *J Hepatol* 38, 564–572.

186 Preaux AM, Mallat A, Rosenbaum J *et al.* (1997) Pentoxifylline inhibits growth and collagen synthesis of cultured human hepatic myofibroblast-like cells. *Hepatology* 26, 315–322.

187 Shimizu E, Kobayashi Y, Oki Y *et al.* (1999) OPC-13013, a cyclic nucleotide phosphodiesterase type III inhibitor, inhibits cell proliferation and transdifferentiation of cultured rat hepatic stellate cells. *Life Sci* 64, 2081–2088.

188 Di Sario A, Bendia E, Svegliati Baroni G *et al.* (2002) Effect of pirfenidone on rat hepatic stellate cell proliferation and collagen production. *J Hepatol* 37, 584–591.

189 Demetri GD, von Mehren M, Blanke CD *et al.* (2002) Efficacy and safety of imatinib mesylate in advanced gastrointestinal stromal tumors. *N Engl J Med* 347, 472–480.

190 Druker BJ, Sawyers CL, Kantarjian H *et al.* (2001) Activity of a specific inhibitor of the BCR-ABL tyrosine kinase in the blast crisis of chronic myeloid leukemia and acute lymphoblastic leukemia with the Philadelphia chromosome. *N Engl J Med* 344, 1038–1042.

191 Kinnman N, Goria O, Wendum D *et al.* (2001) Hepatic stellate cell proliferation is an early platelet-derived growth factor-mediated cellular event in rat cholestatic liver injury. *Lab Invest* 81, 1709–1716.

192 Yoshiji H, Noguchi R, Kuriyama S *et al.* (2005) Imatinib mesylate (STI-571) attenuates liver fibrosis development in rats. *Am J Physiol Gastrointest Liver Physiol* 288, G907–913.

193 Tada S, Iwamoto H, Nakamuta M *et al.* (2001) A selective ROCK inhibitor, Y27632, prevents dimethylnitrosamine-induced hepatic fibrosis in rats. *J Hepatol* 34, 529–536.

194 Borkham-Kamphorst E, Herrmann J, Stoll D *et al.* (2004) Dominant-negative soluble PDGF-beta receptor inhibits hepatic stellate cell activation and attenuates liver fibrosis. *Lab Invest* 84, 766–777.

195 Borkham-Kamphorst E, Stoll D, Gressner AM *et al.* (2004) Inhibitory effect of soluble PDGF-beta receptor in culture-activated hepatic stellate cells. *Biochem Biophys Res Commun* 317, 451–462.

196 Borkham-Kamphorst E, Stoll D, Gressner AM *et al.* (2004) Antisense strategy against PDGF B-chain proves effective in preventing experimental liver fibrogenesis. *Biochem Biophys Res Commun* 321, 413–423.

197 Stefanovic B, Schnabl B, Brenner DA (2002) Inhibition of collagen a1(I) expression by the 5' stem-loop as a molecular decoy. *J Biol Chem* 277, 18229–18237.

198 Lindquist JN, Parsons CJ, Stefanovic B *et al.* (2004) Regulation of alpha1(I) collagen messenger RNA decay by interactions with alphaCP at the 3'-untranslated region. *J Biol Chem* 279, 23822–23829.

199 Stefanovic L, Stephens CE, Boykin D *et al.* (2005) Inhibitory effect of dicationic diphenylfurans on production of type I collagen by human fibroblasts and activated hepatic stellate cells. *Life Sci* 76, 2011–2026.

200 Kershenobich D, Vargas F, Garcia-Tsao G *et al.* (1988) Colchicine in the treatment of cirrhosis of the liver. *N Engl J Med* 318, 1709–1713.

201 Cortez-Pinto H, Alexandrino P, Camilo ME *et al.* (2002) Lack of effect of colchicine in alcoholic cirrhosis: final results of a double blind randomized trial. *Eur J Gastroenterol Hepatol* 14, 377–381.

202 George J, Roulot D, Koteliansky VE *et al.* (1999) In vivo inhibition of rat stellate cell activation by soluble transforming growth factor beta type II receptor: a potential new therapy for hepatic fibrosis. *Proc Natl Acad Sci USA* 96, 12719–12724.

203 Okuno M, Akita K, Moriwaki H *et al.* (2001) Prevention of rat hepatic fibrosis by the protease inhibitor, camostat mesilate, via reduced generation of active TGF-beta. *Gastroenterology* 120, 1784–1800.

204 Dooley D, Hamzavi J, Breitkopf K *et al.* (2003) Smad7 prevents activation of hepatic stellate cells and liver fibrosis in rats. *Gastroenterology* 125, 178–191.

205 Zhu J, Wu J, Frizell E *et al.* (1999) Rapamycin inhibits hepatic stellate cell proliferation in vitro and limits fibrogenesis in an in vivo model of liver fibrosis. *Gastroenterology* 117, 1198–1204.

206 Trotter JF (2003) Sirolimus in liver transplantation. *Transplant Proc* 35, 193S-200S.

207 Williams EJ, Benyon RC, Trim N *et al.* (2001) Relaxin inhibits effective collagen deposition by cultured hepatic stellate cells and decreases rat liver fibrosis in vivo. *Gut* 49, 577–583.

208 Bennett RG, Mahan KJ, Gentry-Nielsen MJ *et al.* (2005) Relaxin receptor expression in hepatic stellate cells and in cirrhotic rat liver tissue. *Ann NY Acad Sci* 1041, 185–189.

209 Rockey DC, Chung JJ (1996) Endothelin antagonism in experimental hepatic fibrosis. Implications for endothelin in the pathogenesis of wound healing. *J Clin Invest* 98, 1381–1388.

210 Rockey DC (2005) Antifibrotic therapy in chronic liver disease. *Clin Gastroenterol Hepatol* 3, 95–107.

211 Fiorucci S, Antonelli E, Morelli O *et al.* (2001) NCX-1000, a NO-releasing derivative of ursodeoxycholic acid, selectively delivers NO to the liver and protects against development of portal hypertension. *Proc Natl Acad Sci USA* 98, 8897–8902.

212 Gnainsky Y, Spira G, Paizi M *et al.* (2004) Halofuginone, an inhibitor of collagen synthesis by rat stellate cells, stimulates insulin-like growth factor binding protein-1 synthesis by hepatocytes. *J Hepatol* 40, 269–277.

213 Geubel AP, De Galocsy C, Alves N *et al.* (1991) Liver damage caused by therapeutic vitamin A administration: estimate of dose-related toxicity in 41 cases. *Gastroenterology* 100, 1701–1709.

214 Iredale JP, Benyon RC, Pickering J *et al.* (1998) Mechanisms of spontaneous resolution of rat liver fibrosis. Hepatic stellate cell apoptosis and reduced hepatic expression of metalloproteinase inhibitors. *J Clin Invest* 102, 538–549.

215 Dekel R, Zvibel I, Brill S *et al.* (2003) Gliotoxin ameliorates development of fibrosis and cirrhosis in a thioacetamide rat model. *Dig Dis Sci* 48, 1642–1647.

216 Wright MC, Issa R, Smart DE *et al.* (2001) Gliotoxin stimulates the apoptosis of human and rat hepatic stellate cells and enhances the resolution of liver fibrosis in rats. *Gastroenterology* 121, 685–698.

217 Parsons CJ, Bradford BU, Pan CQ *et al.* (2004) Antifibrotic effects of a tissue inhibitor of metalloproteinase-1 antibody on established liver fibrosis in rats. *Hepatology* 40, 1106–1115.

218 Oakley F, Meso M, Iredale JP *et al.* (2005) Inhibition of inhibitor of kappaB kinases stimulates hepatic stellate cell apoptosis and accelerated recovery from rat liver fibrosis. *Gastroenterology* 128, 108–120.

219 Taimr P, Higuchi H, Kocova E *et al.* (2003) Activated stellate cells express the TRAIL receptor-2/death receptor-5 and undergo TRAIL-mediated apoptosis. *Hepatology* 37, 87–95.

220 Elsharkawy AM, Oakley F, Mann DA (2005) The role and regulation of hepatic stellate cell apoptosis in reversal of liver fibrosis. *Apoptosis* 10, 927–939.

221 Fallowfield JA, Iredale JP (2004) Targeted treatments for cirrhosis. *Expert Opin Ther Targets* 8, 423–435.

222 Iredale JP (2001) Hepatic stellate cell behavior during resolution of liver injury. *Semin Liver Dis* 21, 427–436.

223 Unemori EN, Pickford LB, Salles AL *et al.* (1996) Relaxin induces an extracellular matrix-degrading phenotype in human lung fibroblasts in vitro and inhibits lung fibrosis in a murine model in vivo. *J Clin Invest* 98, 2739–2745.

224 Siller-Lopez F, Sandoval A, Salgado S *et al.* (2004) Treatment with human metalloproteinase-8 gene delivery ameliorates experimental rat liver cirrhosis. Gastroenterology 126, 1122–1133; discussion 1949.

225 Iimuro Y, Nishio T, Morimoto T *et al.* (2003) Delivery of matrix metalloproteinase-1 attenuates established liver fibrosis in the rat. *Gastroenterology* 124, 445–458.

226 Issa R, Zhou X, Trim N *et al.* (2003) Mutation in collagen-1 that confers resistance to the action of collagenase results in failure of recovery from CCl4-induced liver fibrosis, persistence of activated hepatic stellate cells, and diminished hepatocyte regeneration. *FASEB J* 17, 47–49.

6.3 Clinical and diagnostic aspects of cirrhosis

I. Neil Guha and John P. Iredale

Definition

Cirrhosis is defined as the pathological findings of diffuse fibrosis and conversion of normal liver architecture into nodules. In the fifth century BC, Hippocrates recognized that hardening of the liver was a poor prognostic sign in the presence of icterus. The term cirrhosis is credited to René Laënnec and derived from the Greek kirrhos, meaning orange-yellow. It described the autopsy appearance of the liver in a patient with cirrhosis that also demonstrated nodules and an irregular edge. The definition has been refined over the years, notably by a consensus conference in La Habana 1956 and a working party sponsored by the World Health Organization (WHO) in 1978 [1], to give us the basis for the present definition. Despite its morphological definition, cirrhosis also implies a disturbance of hepatic and posthepatic haemodynamics, which may play a significant role in the evolution of fibrosis (see Chapter 6.1) and the clinical sequelae.

Classification

Cirrhosis may be classified by three differing morphologies: micronodular cirrhosis, macronodular cirrhosis and mixed (see also Section 4).

- *Micronodular:* this is characterized by small nodules, usually less than 3 mm in size, distributed uniformly throughout the liver and contained by thick, regular septa. An example of micronodular cirrhosis is that induced by alcohol.
- *Macronodular:* this term is used to describe the presence of septa and nodules of varying size. The larger nodules may contain portal tracts; the close proximity of three or more portal tracts is suggestive of architectural collapse.
- *Mixed:* the combination of micronodular and macronodular cirrhosis is termed mixed cirrhosis. The proportion of each subtype may vary but is usually equal. There are examples of micronodular cirrhosis converting to macronodular cirrhosis in time [2].

Aetiology

The causes of cirrhosis are legion and Table 1 lists the major underlying diseases and disease associations. More detailed descriptions of these diseases may be found in specific chapters.

Epidemiology

The number of deaths from cirrhosis in different regions is graphically illustrated in Figure 1. These figures are based on estimates made by the WHO report for 2002.

The precise prevalence of cirrhosis is difficult to ascertain for a number of reasons. Firstly, cirrhosis is often clinically silent and a significant proportion of patients with undiagnosed cirrhosis have been found at autopsy studies [3,4]. Secondly, the reliance on death certification for the rates of cirrhosis is dependent on having the infrastructure to collect these data. Additionally, even if these resources are in place, the stigmata of documenting cirrhosis and its aetiology will influence reporting. Differences in prevalence exist not only between continents but also within individual countries. For example, Corrao *et al.* found a difference in mortality between northern and southern Europe [5] whilst Lessa reported different prevalence rates within Brazil [6].

Autopsy studies, even when randomized, have an inherent bias because cirrhosis carries a risk of mortality. Furthermore, death rate may not always be a valid surrogate for prevalence and the relationship is not always linear. For example, if treatment significantly improves, the prevalence of the condition in the community will rise but the death rate from the condition, depending on how data are collected and documented, may appear to fall if these subjects subsequently die from an unrelated condition. Currently, the absence of accurate, validated, noninvasive tools for the diagnosis of cirrhosis makes population screening a difficult proposition (see Chapter 6.2).

The epidemiology of individual aetiologies of cirrhosis will be discussed in greater detail in the relevant chapters. Generally, viral hepatitis is the leading cause of cirrhosis in the developing world. Alcohol, hepatitis C and, more recently, nonalcoholic steatohepatitis associated with the metabolic syndrome are the most significant causes of cirrhosis in the developed world.

Table 1 Main causes of cirrhosis.

Aetiology	Examples
Infectious	Hepatitis B, C, D
	Schistosomiasis
	Syphilis
	HIV (sclerosing cholangitis)
Metabolic/inherited	Nonalcoholic steatohepatitis (NASH) in association with the metabolic syndrome
	Wilson's disease
	Haemochromatosis
	Alpha-1-antitrypsin deficiency
	Glycogen storage disease
	Cystic fibrosis
	Tyrosinaemia
	Galactosaemia
	Fructose intolerance
	Byler's disease
	Mucopolysaccharidosis
	Abetalipoproteinaemia
	Porphyria
	Wolman's disease
Biliary disease	Extrahepatic obstruction
	Intrahepatic obstruction
Immunological	Autoimmune hepatitis
	Primary biliary cirrhosis
	Primary sclerosing cholangitis
Vascular	Veno-occlusive disease
	Budd–Chiari syndrome
	Cardiac failure
	Hereditary haemorrhagic telangiectasia
Drugs and toxins	Alcohol
	Amiodarone
	Dantrolene
	Halothane
	Isoniazid
	Methotrexate
	Methyldopa
	Aflatoxin
	Diclofenac
	Hypervitaminosis A
Miscellaneous	Indian childhood
	Malnutrition
	Sarcoidosis
	Ischaemia
	Graft vs. host disease

Clinical features of cirrhosis

The visible signs and symptoms of cirrhosis are summarized in Table 2.

Compensated cirrhosis

Cirrhosis may progress insidiously without clinical signs or symptoms, giving rise to the term compensated cirrhosis. Compensated cirrhosis can continue for a variable length of time before the development of complications, hepatocellular carcinoma or hepatic failure. The appearance of these complications is referred to as decompensated cirrhosis. As stated earlier in this chapter, quantifying the numbers of asymptomatic cirrhotics is difficult because of the bias of autopsy studies and lack of noninvasive diagnostic tools.

Decompensated cirrhosis (see also Section 7)

Portal hypertension

Portal hypertension is defined by an elevated portal pressure greater than the normal value of 1–5 mmHg. In general, portal pressure becomes clinically significant above a level of 12 mmHg. The major complications of portal hypertension include ascites, gastrointestinal haemorrhage and renal dysfunction. Of these, gastrointestinal haemorrhage is the most dramatic and occurs frequently. Prospective studies suggest that 90% of patients with cirrhosis will develop oesophageal varices and a third of these will bleed [7]. Furthermore, gastrointestinal haemorrhage has been reported to carry a short-term mortality rate as high as 50% in the group with most severe liver dysfunction [8].

Ascites

In the presence of ascites, a diagnostic tap may help distinguish the possible aetiologies. Traditionally, these were subdivided into exudative and transudative on the basis of protein in ascites being greater than 25 g/L. More recently, a newer classification based on the serum–ascites albumin gradient has been proposed [9]. A gradient greater than 1.1 g/dL suggests nonperitoneal disease, including portal hypertension. This can help exclude some of the peritoneal causes of ascites, which have a gradient less than 1.1 g/dL, including malignancy, granulomatous peritonitis and vasculitis. For a more detailed account see Chapter 7.5.

Hypersplenism

This occurs in the context of portal hypertension and results in a variable pancytopenia with sequestration of red blood cells, white blood cells and platelets in the splenic tissues. This will affect oxygen delivery, coagulation and the immune response. The extent of thrombocytopaenia does not correlate directly with splenic size and rarely leads to spontaneous bleeding, but it may complicate bleeding from other sites such as varices.

Renal dysfunction

In cirrhosis there is abnormal renal handling of sodium and this in combination with abnormal haemodynamics results in a spectrum of disease culminating in hepatorenal syndrome (HRS). Patients with cirrhosis who are free of ascites, termed preascitic cirrhotics, have been shown to have a positive sodium balance after being fed a high-salt diet for one week compared with normal healthy controls [10]. There is increasing evidence from vascular studies in the supine and upright position that abnormal salt retention is the initiating event rather than a

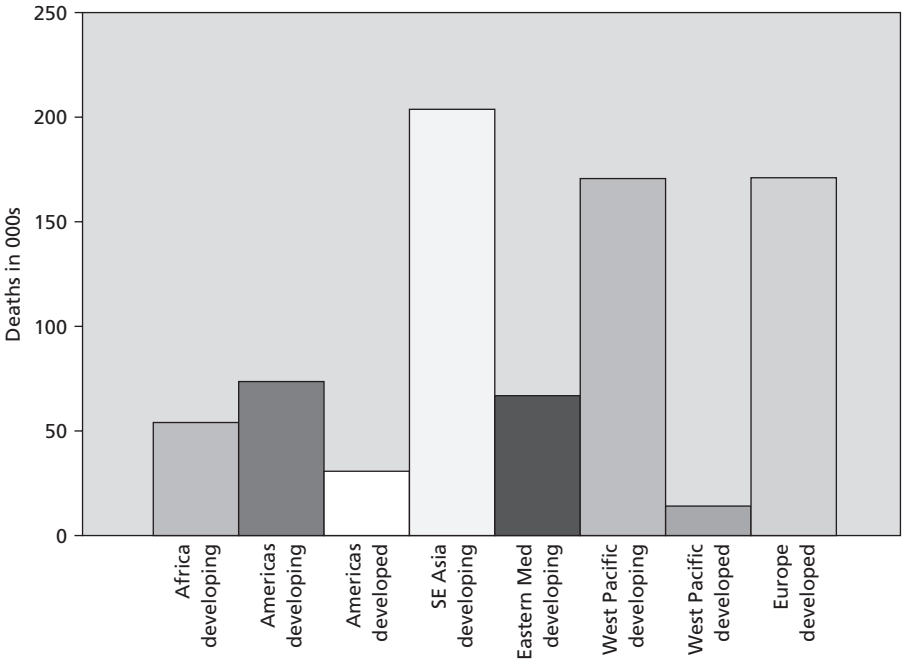

Fig. 1 Number of deaths from cirrhosis of the liver according to region. Data taken from www.who.int/healthinfo/bodgb2002original/en/

consequence of the hyperdynamic circulation [11,12]. The progression to hepatorenal syndrome is associated with splanchnic vasodilatation, increased cardiac output, decreased peripheral resistance and renal vasoconstriction, as discussed in detail in Chapter 7.6.

Prognosis is dependent on the subtype of HRS, as defined by the International Ascites Club, with type 2 HRS developing more insidiously and being associated with increased survival compared with type 1 (Table 3). Treatment options include pharmacological intervention with albumin and vasopressors, transjugular intrahepatic portosystemic shunts (TIPS), dialysis procedures and orthotopic liver transplantation (OLT) as discussed in Chapter 7.6.

Clinical features of portal hypertension

Clinical manifestations of portal hypertension include ascites, collateral circulation and splenomegaly (see Table 2).

The collateral circulation can manifest on the abdominal surface. For example, dilated veins around the umbilicus are known as caput medusae, and are derived from portal blood via the recannalized umbilical vein and paraumbilical veins. The distribution of blood flow on the abdominal surface is away from the umbilicus in all directions, a feature that can help differentiate this diagnosis from occlusion of the inferior vena cava.

Splenomegaly in the context of portal hypertension can lead to a pancytopenia with consequences for immunity and coagulation as discussed previously. Ascites may be clinically detectable after the accumulation of 2 L of fluid. Where clinical doubt remains, ultrasound can be a useful investigation. Abdominal distension will generally cause discomfort with large volumes of ascites. The presence of underlying infection should be excluded by performing a diagnostic ascitic tap. Pleural effusions can be associated with ascites in approximately 10% of cases [13]; the majority of effusions are right sided and are due to defects in the diaphragm.

Gastrointestinal haemorrhage from gastric or oesophageal varices will usually be self-evident. Endoscopy will provide a diagnostic and therapeutic tool. Rarely, bleeding is from other sites of portosystemic anastomoses including rectal and periumbilical varices. These can be more difficult to treat and often require radiological embolization and/or TIPS insertion.

Hepatopulmonary syndrome (HPS)

This is a disorder of pulmonary oxygenation occurring in the context of liver disease or portal hypertension. It is not exclusive to cirrhosis but, in this setting, studies have shown HPS has a prevalence of 24% and is an independent risk factor for mortality [14]. The pathophysiology is thought to relate to nitric oxide production as evidenced by increased levels of endothelial nitric oxide synthetase (eNOS) and inducible nitric oxide synthetase (iNOS) [15,16]. This may cause microvasular dilatation and contribute to intrapulmonary shunts with resultant hypoxaemia. Diagnosis involves the exclusion of other causes of cardiopulmonary disease and the demonstration of dependent hypoxaemia and pulmonary shunts using microbubble echocardiography. Hitherto, there have only been anecdotal or case reports or small uncontrolled trials of success with medical treatment. OLT remains the only effective long-term treatment [17,18], although HPS will also increase the anaesthetic risks associated with transplantation.

Clinical features

Patients with HPS may complain of dyspnoea on exertion and have objective evidence of decreased oxygen saturation.

Table 2 Clinical stigmata directly or indirectly associated with cirrhosis.

Stigmata	Comments
Palmar erythema	This condition also occurs in pregnancy, rheumatoid arthritis, leukaemia, chronic febrile illness and thyrotoxicosis
Leuconychia	Related to hypoalbuminaemia
Finger clubbing	Not specific to cirrhosis
Dupuytren's contracture	Thickening of the palmar fascia; occurs in, but not exclusive to, excess alcohol intake
Asterixis	Suggests underlying hepatic encephalopathy
Spider angiomas	Related to disturbance of oestrogen metabolism
Foetor hepaticus	Distinctive aroma thought to be of intestinal origin
Jaundice	May be the result of endstage liver disease, decompensation, cholestasis or haemolysis
Collateral veins and caput medusae	Direction of flow will differentiate portal hypertension from inferior vena caval (IVC) obstruction
Bruising	Results from abnormalities in platelets, coagulation pathways or both
Parotid gland enlargement	Raises the suspicion of alcohol as aetiology of cirrhosis
Kayser–Fleischer rings	Occurs in the context of Wilson's disease. Absence does not exclude diagnosis
Xanthelasma	May occur in hyperlipidaemia associated with primary biliary cirrhosis
Wernicke's encephalopathy	Triad of symptoms including ophthalmoplegia, ataxia and confusion caused by thiamine deficiency and invariably associated with alcoholic liver disease
Splenomegaly	Caused by portal hypertension; often the first clinical sign of cirrhosis.
Ascites	Can be clinically detected after approximately 2 L
Cachexia	Occurs in the context of malnutrition in cirrhosis but may also be associated with the development of HCC
Muscle cramps	Nonspecific feature and often difficult to treat
Hypertrophic osteoarthropathy	Occurs in cirrhosis but classically associated with carcinoma of the bronchus
Arthritis	Rheumatoid arthritis may indicate underlying autoimmune disease; haemochromatosis can cause chondrocalcinosis and osteoarthritis
Pigmentation	'Bronze diabetes' caused by excess ACTH following pituitary failure in haemochromatosis
Hypotension, bounding pulse and warm peripheries	Reduced peripheral resistance in the context of the hyperdynamic circulation
Striae	May be related to steroid use for autoimmune hepatitis; also occurs in pregnancy
Central obesity with raised waist to hip ratio	These patients are at increased risk of developing NASH and subsequent fibrosis/cirrhosis
Pulsatile liver	Classically found in tricuspid regurgitation. Long-term hepatic congestion may lead to cirrhosis
Gynaecomastia	Result from oestrogen imbalance but also a side effect of spironolactone
Scratch marks	Consequence of pruritus; if irretractable, an indication for OLT in PBC
Testicular atrophy	Occurs as a result of cirrhosis but also a direct effect of alcohol
Cyanosis	Raises the suspicion of underlying hepatopulmonary syndrome
Hair loss	As part of the loss of secondary sexual characteristics
'Emphysematous' chest	Exclude alpha-1-antitrypsin deficiency
Cushingoid appearance	Related to steroid therapy
Telangiectasia	Hereditary haemorrhagic telangiectasia is a rare cause of cirrhosis

ACTH, adrenocorticotropic hormone; HCC, hepatocellular carcinoma; NASH, nonalcoholic steatohepatitis; OLT, orthotopic liver transplantation; PBC, primary biliary cirrhosis.

Significant disease will result in central cyanosis. Other contributory factors to dyspnoea in the cirrhotic patient include anaemia, marked ascites and intrinsic pulmonary disease.

Cirrhotic cardiomyopathy

The affect of alcohol and iron on cardiac function have long been recognized. More recently, there has been increasing evidence of the effect of cirrhosis *per se* on the myocardium and the term 'cirrhotic cardiomyopathy' was described in 1989 by Lee [19]. The features include increased baseline cardiac output, attenuated systolic contractility and diastolic relaxation in response to inotropic and chronotropic stimuli and the absence of florid left ventricular failure. There can be associated electrophysiological abnormalities such as repolarization anomalies but morphological changes are often not pronounced. The exact pathophysiology is not completely understood but possibilities include alterations in beta-adrenergic receptors, membrane function, calcium channels, nitric oxide and carbon monoxide [20]. OLT has been shown to improve this condition [21].

Clinical features

The absence of overt signs of heart failure, which forms part of the definition, makes this a difficult clinical diagnosis. The condition is sometimes revealed when the patient undergoes acute

Table 3 Classification of hepatorenal syndrome (HRS).

Subtypes of HRS
Type 1: Progressive renal impairment defined by a doubling of initial serum creatinine above 2.5 mg/dL in less than 2 weeks
Type 2: Stable or slowly progressive renal impairment
Critical exclusions/features for the above:
Absence of shock, ongoing bacterial infection, fluid loss and no treatment with nephrotoxic drugs
Absence of obstructive uropathy and intrinsic renal disease
Serum creatinine concentration >1.5 mg/dL or 24-hour creatinine clearance <40 mL/min
No sustained improvement following removal of diuretic and fluid challenge

haemodynamic changes such as major surgery or TIPS insertion. An attenuated response to inotropic agents in the intensive care setting can also be a clue but in this situation there are often confounding factors, such as sepsis, causing alterations to myocardial function. A low index of suspicion and awareness of the condition are therefore key to making the diagnosis.

Hepatocelluar carcinoma (see also Chapter 18.2.1)

Cirrhosis remains the commonest cause for the development of hepatocellular carcinoma (HCC); it has been estimated that 80% of tumours occur in this setting [22]. The aetiology and the global location of disease are important determinants of the risk of cirrhosis progressing to HCC. For example, the annual risk of developing HCC in patients with hepatits C virus (HCV) is estimated to be 3–8% [23]. The 5-year cumulative incidence of HCC on the background of HCV is reported to be as high as 30% in Japan compared with 17% in the West. Comparing aetiologies, the rates decrease in the following order: haemochromatosis, hepatitis B infection, alcohol and biliary disease [24]. Interestingly, HCC is an uncommon complication of autoimmune hepatitis [25]. Regardless of aetiology, independent risk factors for HCC include gender, age, severity of compensated cirrhosis at presentation and sustained activity of liver disease [24].

The development of HCC may be heralded by symptoms of pain, bleeding, general decompensation or screening (see 'Follow-up and screening' below). The pathology and management of HCC will be discussed in greater detail in Chapter 18.2.1.

Clinical features

Right upper quadrant pain and abdominal distension with bloody ascites, on the background of cirrhosis, are very suggestive of rupture of an underlying HCC into the peritoneal cavity. However, this occurs infrequently and usually late in the disease. Often there are few signs of underlying malignancy; for example, cachexia may not change the physical appearance of the patient because of the underlying malnutrition. Cirrhotic patients that decompensate suddenly, either clinically or biochemically, without obvious cause, should always prompt the search for HCC.

Encephalopathy

Hepatic encephalopathy (HE) on the background of cirrhosis can occur in a subclinical, acute or chronic setting. The prevalence of subclinical encephalopathy (SCE) in patients with cirrhosis has reached 84% in some studies [26]. As there may be no compromise in routine daily life, SCE may only come to light upon psychometric testing using number connection tests, block reception tests and reaction times. Acute hepatic encephalopathy can be precipitated by sepsis, sedatives, dehydration, haemorrhage, etc. but it may also occur with no obvious precipitants in the presence of terminal liver failure. Chronic encephalopathy is usually due to the formation of portosystemic shunts, as part of the disease or iatrogenically as a consequence of TIPS insertion. In 2002, a working party created a new classification of hepatic encephalopathy (Table 4) [27]. Encephalopathy occurring in chronic liver disease was defined as episodic or persistent, and subclinical encephalopathy replaced with the term minimal encephalopathy. For a more detailed description of the pathophysiology, diagnosis and treatment of encephalopathy see Chapter 7.8.

Clinical features

Reversal of the day/night sleep pattern and somnolence during the day is a subtle clinical sign of underlying HE. As the HE progresses, the patient may become withdrawn, confused and

Table 4 Proposed nomenclature of hepatic encephalopathy (HE) by working party at 11th World Congress of Gastroenterology, 1998.

HE type	Nomenclature	Subcategory	Subdivisions
A	Encephalopathy associated with acute liver failure		
B	Encephalopathy associated with portosystemic shunts and no intrinsic hepatic disease		
C	Encephalopathy associated with cirrhosis and portal hypertension/or portosystemic shunts	Episodic HE	Precipitated
			Spontaneous
			Recurrent
		Persistent HE	Mild
			Severe
			Treatment dependent
		Minimal HE	

agitated before finally becoming unconscious. The clinical sign of asterixis (Table 2) usually represents established HE. The waveforms demonstrated by an electroencephalogram (EEG) in hepatic encephalopathy are not highly specific to this condition, as they can also occur in the context of other metabolic encephalopathies, but nonetheless can be a useful investigation. The presence of new HE should prompt the clinician to exclude precipitating factors such as new medications, underlying sepsis, occult haemorrhage and electrolyte disturbances. In severe cases of HE, the patient may need to be ventilated, especially if there is compromise to respiratory function.

Malnutrition

Cirrhosis is a catabolic state and, in combination with dietary insufficiency, can lead to significant malnutrition. Additionally, malabsorption, hypermetabolism and resistance to growth factors such as insulin and growth factor contribute to the pathophysiology. In hospitalized patients with liver disease, the prevalence of malnutrition is estimated to be as high as 20% in compensated disease rising to 60% with severe liver insufficiency [28]. Studies have shown that nourishment, measured by parameters such as skin-fold thickness and midarm muscle circumference, is an independent predictor of survival at 2 years [29].

Measures of anthropometry, such as skin-fold thickness, may be distorted by fluid retention and occur late in malnutrition. Thus, there has been interest in finding accurate tools for assessing nutritional status. This has led to the creation of measures such as the subjective global assessment tool (SGA), prognostic nutritional index (PNI) and hand grip strength (HGS). A recent study found that the prevalence of malnutrition was 63% in patients with Childs A cirrhosis using HGS, compared with a prevalence of 28% and 19% detected by SGA and PNI respectively [30].

Clinical features

In severe cases the patient will appear cachectic. Profound muscle wasting may manifest by a proximal myopathy and the inability of the patient to stand up. Diagnosis of less advanced cases requires objective assessment using one or more of the tools discussed above. Relying on simple weight measurements may be inaccurate – for example, the presence of ascites may disguise muscle weight loss.

Sepsis

It has been estimated that sepsis is present in 30–50% of hospital admissions due to cirrhosis [31]. Once sepsis has developed there is a higher rate of mortality, up to 30%, and this is independent of the severity of liver disease [32,33].

There are a number of reasons for increased susceptibility to sepsis in this group. Bacterial translocation (BT) is the migration of bacteria or their products from the intestinal lumen to mesenteric lymph nodes. BT has been shown to be significantly increased in patients with Childs C cirrhosis compared with the less severe Childs stages [34]. Moreover, not only does the antigen load increase but also there are changes in immunity, both within the local lymph nodes and systemically, which also determine whether there is progression to sepsis. Studies have shown a reduced phagocytic and killing capacity of the immune system [35,36] and reduced opsonization relating to low complement levels in ascites [37].

Sepsis results in a spectrum of physiological outcomes including the systemic inflammatory response syndrome (SIRS), septic shock and multiorgan failure [38]. The inflammatory response associated with sepsis is mediated by the cytokine cascade. Activation of Toll-like receptors by bacterial products, including lipopolysaccharide (LPS), is one such mechanism of activating the innate immune system. Investigators have found that the expression of Toll-like receptor 2 (TLR2) is increased on peripheral blood mononuclear cells in patients with cirrhosis but Toll-like receptor 4 (TLR4) is unaltered or downregulated [39,40]. Furthermore, the same study showed raised serum levels of tumour necrosis factor alpha (TNFα) levels correlating with TLR2. Thus, the cytokine response may be influenced by the amount and type of bacterial product presented and also the relative expression of the corresponding receptors.

It has been postulated that sepsis has a major aetiological role in disturbances of coagulation, haemodynamics and variceal bleeding. It is a predictor of variceal rebleeding, and patients with controlled bleeding have lower rates of sepsis than those with uncontrolled bleeding [41]. In the presence of variceal haemorrhage, cirrhotic patients given prophylactic antibiotic therapy have been shown to have improved survival rates [42]. Optimizing haemodynamic state is also important in cirrhotics with sepsis. In spontaneous bacterial peritonitis, survival has been shown to improve if albumin is administered with intravenous antibiotic compared with antibiotics alone [43]. Additionally, parameters of haemodynamics such as renin levels and renal function also improved in the group administered albumin. The alterations in coagulation may be due to increased amounts of heparinoid substances [44] and may augment the deficiencies in clotting factors because of hepatic insufficiency.

Clinical features

The characteristic features of sepsis in the previously healthy individual, such as hypotension, tachycardia and warm peripheries, often occur in cirrhotics with no evidence of sepsis because of the hyperdynamic circulation (see Table 2). Additionally, aetiologies such as alcoholic hepatitis cause the release of inflammatory cytokines, resulting in a low-grade pyrexia and raised peripheral white cell count. Thus, supervening sepsis in these individuals can be difficult to distinguish. The possibility of sepsis should be explored in unexplained decompensation or patients slow to respond to treatment with supportive measures. Often, confirmation of microbial infection by culture is not possible, particularly in the context of fungal sepsis, necessitating the use of broad-spectrum antibiotics. Expert advice should be sought at an early stage in these situations.

Haematological complications

Reduced platelets

The reduction of platelet count in cirrhosis is largely due to the effects of hypersplenism causing increased splanchnic pooling as discussed above. In health, 30% of the total platelet population is sequestered in the spleen but this can rise to 90% in portal hypertension. Additionally, there may be reduced bone marrow production particularly in alcoholic liver disease and viral hepatitis. Not only are absolute numbers of platelets reduced but also there may be deficiencies in function, particularly aggregation, and membrane composition.

Anaemia

A macrocytic, microcytic or normochromic anaemia can be found in cirrhosis. Macrocytic anaemia, secondary to folate deficiency, is often due to poor nutrition particularly in the context of alcoholic liver disease. Macrocytosis also occurs as a result of poor membrane function and is associated with advanced cirrhosis. Increased destruction of red blood cells occurs because of increased fragility, as a consequence of membrane defects. Damaged red blood cells are then extracted by the spleen. Haemolysis is also associated with certain autoimmune liver diseases, Wilson's disease, Zieve syndrome (alcoholic hepatitis and hypercholesterolaemia) and following the placement of uncovered stents inserted at TIPS. Reduced bone marrow production further contributes to lower red cell numbers.

Impaired coagulation

The liver is responsible for the production of both coagulants and anticoagulants. Disruption of synthetic function can disturb the homeostatic balance of these two pathways. Commonly, patients have impaired coagulation and, in combination with quantitative and qualitative deficiencies in platelets, this leads to complications of bleeding. Factors II, VII, IX and X, labile factor V, factor VIII, contact factors XI and XII, fibrinogen and fibrin-stabilizing factor XIII are vitamin K dependent. Vitamin K is produced by the intestinal bacteria and requires bile salts for absorption. Therefore, cholestatic conditions, in particular biliary obstruction, will also contribute to impaired coagulation.

Clinical features of haematological disturbance

Bruising in a patient with cirrhosis will often signify an underlying bleeding diathesis. In some cases, the bruising also may bring to light less obvious causes of internal bleeding. For example, a subdural haemorrhage in a patient with alcoholic liver disease may cause the patient to have further falls and external bruising. Haemolysis will cause a rise in unconjugated bilirubin and, if significant, result in jaundice (see Table 2).

Endocrine disturbance

Because the liver plays a major role in the metabolism of hormones it is unsurprising that cirrhosis affects a variety of endocrine pathways.

Feminization and hypogonadism

Feminization in men is reflected by a loss of libido, reduced secondary sexual hair and gynaecomastia. Testicular atrophy may be a consequence of alcohol rather than liver disease itself. In women, hypogonadism manifests as sterility, erratic or absent menstruation and loss of feminine characteristics in premenopausal women. Although there may be changes in plasma testosterone and oestradiol, they are insufficient to account for the degree of feminization or hypogonadism. Thus, a variety of mechanisms may be important.

Dysfunction of the hypothalamic–pituitary axis is suggested by normal levels of gonadotropins even in the presence of testicular or ovarian failure [45]. Oestradiol and testosterone are bound to sex hormone-binding globulin (SHBG); increasing levels of SHBG seen in cirrhosis can lead to a lower unbound fraction and subsequent decreased biological effect. The liver is responsible for the uptake and metabolism of oestrogen and testosterone; the concentration of receptors, blood delivery and conjugation process will all be altered by cirrhosis. Finally, increased peripheral conversion of the androgenic hormones into oestrogens may account for local effects.

The metabolic syndrome (see also Chapter 13)

The link between liver disease and the metabolic syndrome, previously known as syndrome X, has become more clearly established over recent years. The metabolic syndrome is characterized by insulin resistance, obesity, hyperlipidaemia and hypertension. Its associated liver condition, nonalcoholic fatty liver disease (NAFLD), represents a spectrum of disease from steatosis to hepatic necroinflammation (nonalcoholic steatohepatitis, or NASH) to cirrhosis. The diagnosis requires the presence of hepatic steatosis, usually macrovesicular, and the absence of excessive alcohol consumption. The progression of fibrosis within NAFLD has been estimated at 30% and evolution of NASH to cirrhosis estimated at 10–20% [46–48]. The true incidence of cirrhosis related to NAFLD is difficult to know precisely because of the indolent and asymptomatic nature of the disease. Moreover, with advancing disease, the steatosis is replaced by fibrotic tissue and therefore there may be few clues of NAFLD histologically. It is thought that a significant proportion of patients provisionally diagnosed with cryptogenic cirrhosis have underlying NAFLD. This is evidenced by studies showing a greater incidence of diabetes and obesity in cryptogenic cirrhosis compared with cirrhosis of other causes [49–51].

The exact pathophysiological mechanisms of NAFLD are incompletely understood. The interplay of insulin resistance and hepatic steatosis has a major role, with one worsening the other. Triglyceride accumulation is thought to result from excess free fatty acid influx into the liver. The 'second hit' may come from a variety of sources, including oxidative stress, endotoxins and cytokines, and leads to necroinflammation.

The production of hormones and cytokines from fat depots, termed adipokines, is also thought to have a role in the evolution

of NASH. Individuals with NASH have been shown to have low levels of adiponectin and high levels of TNFα [52]. Whilst TNFα promotes insulin resistance and liver inflammation, adiponectin antagonizes fatty acid oxidation and reduces the production and activity of TNFα. In addition, adiponectin is antifibrotic. The hormone leptin has been shown to be important in the development of fibrogenesis in animal models. The fibrotic response, absent in leptin-deficient mice, becomes apparent once leptin is restored by exogenous injection [53]. Also, higher serum leptin concentrations are found in patients with NASH compared with controls [54]. Research continues into the pathogenic roles of the adipokines and how they interact in patients with NASH. A more comprehensive review of the pathophysiology, treatment and management of NAFLD is given in Chapter 13.

Clinical features of endocrine disturbance

The endocrine stigmata of cirrhosis include spider angiomas and palmar erythema (Table 2). Spider angiomas are classically described as lying in the distribution of the vascular territory of the superior vena cava, but occasionally they occur outside this area. They consist of a central arteriole surrounded by smaller vessels. When sufficiently large, they can be seen or felt to pulsate. The lesion can be seen to disappear by applying pressure to the central region. Occasionally they may grow to cover a large area when the diagnosis may be mistaken. Their aetiology is thought to be related to oestrogen metabolism and can occur in other conditions including pregnancy, rheumatoid arthritis and oestrogen therapy.

Palmar erythema manifests with a bright-red coloration of the thenar and hypothenar eminences and pulps of the fingers. The soles of the feet may also be affected. Palmar erythema can coexist with spider angiomas but the two conditions also appear independently. The reason for the development of palmar erythema is obscure. White nails (leuconychia) occur due to an opacity of the nail bed. A small pink zone at the tip of the nail is preserved. The condition occurs bilaterally.

Foetor hepaticus is a sweet, faecal smell on the breath. It may represent a failure of hepatic detoxication function and is likely to have an intestinal origin, being more pronounced when there is an extensive collateral circulation and lessening after the use of broad-spectrum antibiotics.

In patients with the clinical suspicion of NASH, certain phenotypic features may be present. A history of type 2 diabetes and hypertension is suggestive of the presence of the underlying metabolic syndrome. Central obesity, and in particular an enlarged waist to hip ratio, is a risk factor for the presence of underlying steatohepatitis. Striae can occur with the use of steroids and pregnancy, but may also occur in rapid weight loss; the latter is a risk factor for NASH.

Miscellaneous features of cirrhosis

The patient with cirrhosis may have nonspecific symptoms such as fatigue, weight loss and depression. Furthermore, conditions such as gallstones and peptic ulcers have been reported to be higher in this patient subgroup [55,56].

Finger clubbing, hypertrophic osteoarthropathy, Dupuytren's contractures, parotid gland enlargement and muscle cramps may also be seen in cirrhosis although they are not specific to this condition (Table 2).

Diagnosis

The diagnosis of cirrhosis is based on a histological definition and therefore liver biopsy has been regarded as the 'gold standard'. But liver biopsy is not without its problems (see below). In practical clinical terms, a diagnosis of 'cirrhosis' is sometimes made in the presence of indicative clinical features, with serum and imaging results which map to a diagnosis (e.g. primary biliary cirrhosis). Therefore, the utilization of clinical, biochemical, haematological, endoscopic and radiological tools is vital in the diagnosis of cirrhosis and its associated complications (see also Chapter 6.2).

Clinical

A careful history and examination is important to ascertain aetiological clues and assess the severity of disease. A history of thyroid disease or family history of autoimmune conditions may suggest a predisposition to autoimmune liver disease. Medication is of relevance as certain drugs may directly cause hepatotoxicity (see Table 1) or may be prescribed for conditions that can be associated with fibrosis and cirrhosis: for example, oral hypoglycaemics prescribed in the context of type 2 diabetes. Furthermore, a thorough clinical examination will not only give rise to aetiological clues but may also indicate how far fibrosis has progressed. For example, a middle-aged man presenting with a history of intravenous drug abuse and signs of portal hypertension raises the clinical suspicion of chronic hepatitis C that has progressed to possible cirrhosis. In the history, careful attention to ethnic background, occupation, family history, blood transfusions, history of sexual contacts, history of participation in mass inoculation programmes, recreational drug use, alcohol consumption and medications is important. These details will influence the diagnostic tests requested and augment their findings.

Biochemical and haematological investigations in the clinical setting

A detailed description of blood tests used to diagnose and monitor liver disease is given in Chapter 5.2. The following section will address investigations of particular relevance to cirrhosis. It should be stated that individual haematological and biochemical tests are not diagnostic of cirrhosis but certain patterns do suggest significant underlying disease. The term 'liver function tests', traditionally used for the biochemical description of transaminases, γ-glutamyl transferase and alkaline phosphatase,

is something of a misnomer. It could be argued that serum albumin and prothrombin time are a better reflection of underlying synthetic function and hence truer liver function tests.

Transaminases

Alanine aminotransferase (ALT) and aspartate aminotransferase (AST) can be depressed, normal or elevated in cirrhosis. It has been proposed that an AST/ALT ratio of >1 can be helpful in diagnosing cirrhosis in nonalcoholic liver disease [57]. In hepatitis C, the specificity of this ratio appears to be better than the sensitivity [58]. In alcoholic liver disease, the ratio of AST/ALT is >1, independent of the development of cirrhosis. Although usually elevated in cirrhosis, both AST and ALT can be normal in up to 10% and 35% of cases respectively [59].

γ-Glutamyltransferase (γ-GT)

This test is often nonspecifically raised in cirrhosis. Alcoholic liver disease and cholestasis are thought to have a more profound effect on this enzyme compared with other aetiologies.

Alkaline phosphatase

This enzyme is not infrequently raised in cirrhosis; a level greater than threefold the upper limit of normal suggests either intra- or extrahepatic cholestatic aetiology.

Serum albumin

Diminished serum albumin levels are a hallmark of cirrhosis. Hypoalbuminaemia results from a combination of decreased synthesis, haemodilution and decreased secretion. However, care needs to be taken in the interpretation of hypoalbuminaemia. For example, intervening sepsis can produce fluctuations in serum albumin.

Hypoglycaemia

This usually is associated with fulminant liver failure, but also with acute alcohol ingestion.

Renal dysfunction

Hyponatraemia is a common finding in cirrhosis. The intrinsic water- and salt-handling abilities of the kidneys are impaired in cirrhosis (Table 5); the appearance of hyponatraemia represents a poor prognostic sign [60]. The injudicious, inappropriate or insufficient use of fluids during hospital admission and use of diuretics will additionally influence serum sodium levels.

Urea and creatinine levels are influenced by underlying muscle mass and protein metabolism. Both urea and creatinine levels can be depressed in cirrhosis. This has particular relevance in monitoring renal function, because a serum creatinine within the 'normal range' may be indicative of significant deterioration in glomerular function.

Table 5 Features of hyponatraemia in cirrhosis.

Splanchnic arterial vasodilatation
Arterial underfilling
Nonosmotic release of vasopressin
Impaired water excretion
Dilutional hyponatraemia

Serum globulin

There is a polyclonal increase in immunoglobulins in cirrhosis. The subtype of immunoglobulins increased will depend on the aetiology of disease, for example, increased IgA in alcoholic cirrhosis, IgG in autoimmune cirrhosis and IgM in biliary cirrhosis.

Prothrombin time

This is a useful marker of synthetic function in cirrhosis. Alone or in combination with other serum tests it has been used in screening tests for cirrhosis. The prothrombin time (PT) is the best day-to-day parameter of hepatic function because of the half-life of clotting factors. The PT is also exquisitely sensitive to conditions of vitamin K deficiency, and this may supervene in the ill cirrhotic patient, particularly after extensive malnourishment. Thus, the PT should be measured in the context of replete vitamin K levels.

The above are general biochemical and haematological investigations. In addition, specific investigations to find the cause of the underlying liver disease may be required, for example antimitochondrial antibody in primary biliary cirrhosis, urinary copper excretion in Wilson's disease, transferrin saturation in haemochromatosis, antibodies to and RNA levels of hepatitis C virus, etc. (see Chapter 5.4 for more details).

Imaging techniques valuable in cirrhosis

(see also Chapter 6.2)

Ultrasound

Ultrasound is a relatively noninvasive method of assessing the size, texture and vascular patency of the liver and for detecting space-occupying lesions in the liver. The former parameters may change in cirrhosis, but unfortunately are not specific to the condition. The cirrhotic liver may be enlarged (e.g. nonalcoholic steatohepatitis), normal or reduced in size. The echo pattern of the liver is frequently described as coarse (increased irregular echogenicity) in cirrhosis but can alternatively be small and nodular. Care must be taken in the interpretation of these findings as they are subjective and, additionally, conditions such as fatty infiltration, granulomatous disease and diffuse malignant infiltration can produce a similar textural appearance. Ultrasound is able to detect certain complications of cirrhosis, such as ascites and splenomegaly. Additionally, it is a useful, initial investigation in the patient with liver disease and jaundice to exclude extrahepatic causes of biliary obstruction.

Doppler ultrasound provides a technique to measure blood flow in the portal vein, hepatic artery and hepatic veins. It measures the frequency differences between the ultrasound signal emitted from the transducer and returned from the vessel to

Fig. 2 CT image of a hepatocellular carcinoma, enhanced by lipiodal, on the background of a cirrhotic liver.

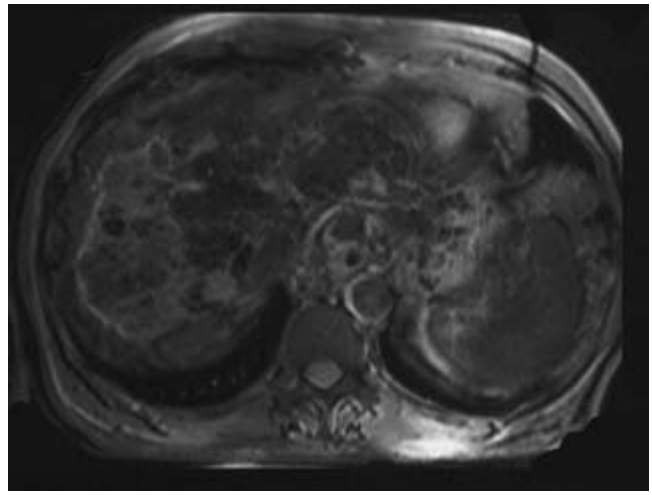

Fig. 3 MRI image of a liver showing dense uptake of Resovist® by a nodule on the background of cirrhosis.

generate direction and velocity of flow. The major vascular changes seen in cirrhosis reflect underling portal hypertension. They include reversal of portal vein blood from hepatopetal to hepatofugal, flattening of the Doppler waveform in hepatic veins and enlargement of the portal vein to greater than 15 mm.

Ultrasound has a further role in detecting the development of HCC on the background of cirrhosis. Isolated nodules larger than 2 cm are detected with good sensitivity but lower specificity. In combination with an elevated alpha-fetoprotein, the presence of HCC can be suspected (see 'Follow-up and screening' below). The performance of ultrasound in the presence of diffuse malignancy is poor.

Computed tomography (CT)

CT also has a role in assessing parenchymal disease in cirrhosis. The density of liver parenchyma is usually within the normal range but can vary depending on aetiology – for instance, it increases in haemochromatosis and decreases in fatty infiltration. The advantage of CT is that it provides cross-sectional anatomy. With the advent of multislice CT scanning, detailed information about space-occupying lesions can be gleaned. Furthermore, the addition of contrast agents such as lipiodal may improve detection of HCC. Helical CT can also visualize vascular anomalies of lesions by obtaining images in the arterial or portal phase. For example, HCC typically will have a brisk enhancement during the arterial phase (Fig. 2) but appears hypodense during the portal phase. Direct catheterization of the superior mesenteric artery and hepatic artery can also be used in combination with CT to improve diagnostic accuracy. Therefore, CT in isolation or in combination with arteriography is able to provide a 'road map', highlighting the blood supply of lesions or vascular anomalies that occur in the context of cirrhosis.

Magnetic resonance imaging (MRI)

This modality represents an emerging tool in liver disease. Dramatic and remarkably clear images of cirrhosis can be obtained in advanced disease (Fig. 3). There is evidence for the use of MRI in assessing hepatic iron concentration [61] and differentiating small benign nodules and HCC [62]. Injection of Resovist® may help distinguish lesions of focal nodular hyperplasia and HCC. MRI spectroscopy is currently an experimental tool but may yet emerge to provide a measure of metabolic changes within the liver; its role in the assessment of cirrhosis is hitherto unproven.

Arteriography

Arteriography does not a have a major diagnostic role in cirrhosis *per se*. It may be a useful additional investigation for HCC and remains the gold standard for the delineation of hepatic vasculature. Occasionally, the attenuated and tortuous arterial patterns seen in cirrhosis are observed when arteriography is performed for another indication, a finding that can be diagnostically useful.

Miscellaneous

Radionuclide scans and positron emission tomography (PET) scans are both emerging examples of other imaging modalities for cirrhosis. Neither technique has yet become widespread. PET imaging based on metabolic changes, particularly in ammonia and glucose metabolism, has been effectively focused on changes in the brain related to encephalopathy.

The role of radiology also extends to the diagnosis of complications arising in the presence of cirrhosis. For example, patients with cirrhosis have a higher incidence of gallstones. Gallstones within the common bile duct are not adequately visualized by ultrasound and mild intrahepatic biliary duct dilatation may be

more difficult to detect within a cirrhotic liver. Thus, magnetic resonance cholangiopancreatography (MRCP) is a useful non-invasive tool. If gallstones are found, patients can then be selected for endoscopic retrograde cholangiopancreatography (ERCP) or cholecystectomy for therapeutic intervention. Radiology is also valuable in the diagnosis of specific malignant complications of fibrotic and cirrhotic processes, such as the presence of a dominant stricture or cholangiocarcinoma on the background of primary sclerosing cholangitis. A combination of investigations including helical CT, MRCP and ERCP may be required, depending on the site of the lesion, to reach a diagnosis.

Endoscopy

It is not uncommon for the cirrhosis to present initially with gastrointestinal haemorrhage. Portal hypertension may be suspected at endoscopy by the presence of varices. Although these can occur at the site of any collateral circulation, they commonly occur in the lower oesophagus and gastric fundus. Bleeding, particularly in the context of a coaguloapthy, may also occur from portal gastropathy, which typically gives a 'snake-skin appearance' to the gastric mucosa. It is important to remember that approximately 50% of upper gastrointestinal bleeding episodes in a patient with cirrhosis may arise from lesions other than varices.

Histology

As alluded to earlier in this chapter, histological analysis remains the 'gold standard', and arguably from the purist's standpoint, the only method of diagnosing cirrhosis. Various histological classifications exist for the grading of fibrosis and cirrhosis including Scheuer, Ishak, Knodell and Metavir [63–65]; the majority of scores were originally validated for hepatitis C. A more detailed account of histological analysis and classification is given in Section 4.

The method for obtaining a liver biopsy can vary from the blind versus image-guided transabdominal approach, transjugular approach, laparoscopic approach and open approach at operation or post mortem. The choice of route will depend on factors such as body habitus, clotting abnormalities, the presence of ascites, available expertise and the quantity of specimen required (see Chapter 5.5 for more details).

The biopsy provides information in three major areas. Firstly, it can elucidate aetiology: for example, marked accumulation of iron in the hepatic parenchyma suggests haemochromatosis whereas biliary duct damage associated with granulomas raises the suspicion of primary biliary cirrhosis. Secondly, it stages the severity of fibrosis and presence of cirrhosis. Thirdly, it can also act as a prognostic indicator. For example, in the context of hepatitis C, inflammation in the biopsy is suggestive of future fibrosis [66].

Liver biopsy does have its limitations and some have questioned whether it truly represents a 'gold standard' reference test. In large studies of patients undergoing biopsy, pain has been reported in 20% and severe complications reported in 0.57% [67]. Sampling error exists, which is unsurprising considering the average biopsy specimen represents just 1/50 000th of the organ. Studies have shown discordance rates of up to 30% or more when right and left lobes are sampled laparoscopically, even in homogeneously distributed disease [68]. Interpretation of the biopsy is open both to intra- and interobserver error [69,70]. Morphometry allows an automated assessment of fibrosis, but hitherto the finer points of staging disease by pathologists have been difficult to replicate.

Surrogate markers

There has been considerable interest in finding surrogate markers of cirrhosis and liver fibrosis as an alternative to liver biopsy. Serum tests include markers of matrix turnover such as hyaluronic acid and procollagen of PIIINP [71–73]; more recently, panels of serum tests that produce a continuous score using algorithms have been published [74–78]. A systematic review of serum tests in the context of hepatitis C suggested that these markers, particularly panel markers, showed promise [79]. The tests in general are more robust in distinguishing cirrhosis from mild disease whereas they are less effective in differentiating more subtle variations such as moderate versus mild fibrosis.

The surrogate markers, however, still have significant limitations even in the context of cirrhosis. They are unable to provide aetiological clues to disease and, whilst this may not be required in diseases with good diagnostic tests such as hepatitis C, it may be more relevant in cases of cryptogenic cirrhosis or where there is a question concerning dual aetiology. The subtle aspects of architectural disturbance, fibrosis distribution and neovascular formation can only be seen on biopsy. On the positive side, surrogate markers largely offer a continuous scale for the diagnosis of fibrosis and cirrhosis, although the thresholds with high sensitivities and specificities tend to occur at the extremes of the scale and are not applicable to the majority of the population tested. The correlation of serum markers to clinical outcomes may overcome some of the limitations of using liver biopsy as a gold standard. Furthermore, surrogate markers may prove most useful in the serial monitoring of an individual or in the assessment of the effectiveness of intervention (e.g. antifibrotic trial).

Despite reservations, there is a continuing search for surrogate markers using more powerful technologies and varying combinations of markers. For example, it may be possible to bring serum markers together with imaging in an algorithm that gives clinically valuable sensitivities and specificities for the diagnosis and monitoring of cirrhosis.

Differential diagnosis

The differential diagnosis will depend on the mode of presentation. This is best illustrated by the use of clinical examples.

A patient presents with marked jaundice and signs of portal hypertension. The causes of jaundice are multiple (see Table 2)

and include haemolysis, biliary obstruction, decompensated liver disease and fulminant liver failure. Tests that will diagnose haemolysis include unconjugated/conjugated bilirubin, reticulocyte count, haptoglobulin, a Coombs test and blood film. The presence of signs of encephalopathy – decreased conscious level, rapidly deteriorating synthetic function (occasionally seen early after presentation) and hypoglycaemia – is highly suggestive of fulminant hepatic failure. Finally, radiological investigation with ultrasound, CT and MRCP may be required to exclude the presence of a supervening HCC, cholangiocarcinoma or biliary tract disease.

A patient presents with ascites and deranged liver function tests. The causes of ascites need to be considered. A diagnostic ascitic tap is required for microbiology, cytology and the serum–ascites albumin gradient to be calculated. A gradient of 2 g/dL with findings of portal hypertension on ultrasound may then narrow the diagnosis to cirrhosis, veno-occlusive disease (VOD), congestive heart failure and constrictive pericarditis. The last two differentials potentially could be excluded by clinical findings or, where doubt remains, by echocardiography. This leaves VOD and cirrhosis, which may require more detailed radiology or a liver biopsy to disentangle.

The final example is a patient presenting with an acute upper gastrointestinal haemorrhage and jaundice. An endoscopy shows bleeding oesophageal varices suggesting portal hypertension. Clinical findings of emaciation and parotid gland enlargement accompanying biochemical test results of a raised γ-GT and AST/ALT ratio of >1 would further suggest alcohol as the major aetiological factor. If this patient also had recurrent attacks of pancreatitis, the possibility of portal vein thrombosis would need to be excluded by radiological investigation. If portal vein thrombosis was present, three differentials could still exist: alcoholic cirrhosis with secondary portal vein thrombosis, portal vein thrombosis secondary to pancreatic inflammation and/or liver disease but not cirrhosis, and cirrhosis accompanying a portal vein thrombosis caused by pancreatic inflammation. Detailed histological and radiological assessment will therefore be required to reach the final diagnosis.

Prognosis

The prognosis will depend on the underlying aetiology of disease, the continuing presence or cessation of aetiological factors, stage of disease progression and underlying residual capacity of the liver. For example, in patients with alcoholic liver disease, if they are able to maintain abstinence over time they will have a prognosis similar to healthy individuals. If symptoms of decompensation have occurred, prognosis is adversely affected. In alcoholic liver disease, 5-year survival is 90% in compensated cirrhosis but falls to 30% in decompensated disease [80].

Prognostic models are either generalized or more disease specific. Examples of disease-specific prognostic scores include the Mayo model of primary biliary cirrhosis. Generalized prognostic models include the Child–Turcotte score and the modified Child–Pugh score [81]. The original purpose of the score was to assess the operative risks of patients undergoing

Table 6 Criteria for Child–Turcotte classification.

	A	B	C
Serum bilirubin (mg/100 mL)	<2.0	2.0–3.0	>3.0
Serum albumin (g/100 mL)	>3.5	3.0–3.5	<3.0
Ascites	None	Easily controlled	Poorly controlled
Neurological disorders	None	Minimal	Severe, coma
Nutrition	Excellent	Good	Poor, 'wasting'

Table 7 Criteria for modified Child–Pugh.

	1	2	3
Serum bilirubin (mg/100 mL)	<2.0	2.0–3.0	>3.0
Serum albumin (g/100 mL)	>3.5	2.8–3.5	<2.8
Prothrombin (seconds prolonged)	1–4	4–6	>6
Encephalopathy (grade)	None	1 and 2	3 and 4
Ascites	Absent	Slight	Moderate
For primary biliary cirrhosis:			
Bilirubin (mg/100 mL)	1–4	4–10	>10
Bilirubin (μmol/L)	17–68	68–170	>170

Each parameter is assigned a score from 1 to 3:
Child's A: 0–6
Child's B: 7–9
Child's C: 10–15

portosystemic shunts, but it has evolved into a model for assessing prognosis in liver disease. Tables 6 and 7 show the parameters that constitute the score.

More recently the Model for End-Stage Liver Disease (MELD) has been developed to guide prioritization in liver transplantation. There are parallels to the Child–Pugh score as the MELD was originally developed to predict survival in patients undergoing TIPS. It has subsequently been validated in different disease aetiologies and centres [82,83]. The formula for the MELD score is:

$$3.8 \log_e[\text{bilirubin (mg/dL)}] + 11.2 * \log_e(\text{INR}) + 9.6 \log_e[\text{creatinine (mg/dL)}] + 6.4 \text{ (aetiology: 0 cholestatic or alcoholic, 1 otherwise)}$$

The advantages of MELD over the Child–Pugh score include the use of objective parameters and its greater discriminatory ability; it is rapidly gaining acceptance as a method for prioritizing patients awaiting transplantation.

Treatment

General

Ultimately the goal in cirrhotic liver disease is identification of the aetiology and, when possible, to treat the underlying disease to prevent the progression and promote the reversal of disease. Patients generally present when disease is advanced and important supportive measures may be required.

Nutrition

Nutritional management must be active. As discussed above and in Chapter 23.2, patients with cirrhosis are catabolic and, particularly alcoholics, may have profound nutritional deficiencies. In the short term, a reduction in caloric intake has been shown to be an independent risk factor for mortality [84]. This study observed that enteral feeding was often initiated late and to patients who had advanced liver dysfunction. Overnight nasogastric feeding (ng) can be a useful measure, allowing patients to eat meals during the day. By feeding patients in an upright position, gastro-oesophageal reflux and pulmonary aspiration can be reduced. Enteral nutrition may be in the form of a polymeric diet, hypercaloric diet, hyperproteinic diet or a combination of these depending on nutritional requirements. Previously, there was a school of thought advocating the avoidance of high-protein diets in cirrhotic patients to prevent hepatic encephalopathy. This view is no longer widely held and nutritional repletion should be considered paramount. In individuals for whom protein feeding is associated with encephalopathy, the dietary/supplemental intake can be adjusted.

Nutritional support has also been shown to have beneficial effects in specific conditions. For example, in a randomized controlled trial of patients with alcoholic hepatitis, patients in the enteral nutrition arm had similar short-term survival and improved 1-year survival compared with the corticosteroid arm [85].

Haemodynamic consequences of cirrhosis

The complications of variceal haemorrhage will require endoscopic, pharmacological and radiological intervention in isolation or combination as discussed in Chapter 7.3. The prevention of ascites by vigilance over salt and water intake may be possible during the earlier stages of disease. However, in more advanced disease, specific intervention may be required in the form of large volume paracentesis or TIPS. Large multicentre controlled trials are divided about the benefit of TIPS versus paracentesis [86–89], as discussed in Section 7.5, but it seems likely that a consensus on TIPS as a treatment for ascites will emerge in the near future.

Orthotopic liver transplant (see Section 25)

The indications for liver transplantation will depend on the underlying aetiology and presence of complications such as diuretic resistance ascites, encephalopathy, hepatorenal syndrome, etc. Liver transplantation offers potentially curative treatment in toxic and metabolic conditions such as alcoholic liver disease and Wilson's disease. However, in the context of viral hepatitis or NASH, recurrence can frequently occur and may take a more aggressive form with rapid progression to fibrosis. There are also limits on resources, even when the evolving practice of living donor transplantation is taken into consideration. The complications listed above, which may be the indication for orthotopic liver transplantation (OLT), will also influence the success and postoperative recovery. Thus, OLT, whilst still offering the best available treatment for endstage liver disease, is not universally available, or without its problems, including those associated with long-term immunosuppression. See Chapter 25 for a more detailed review.

Antifibrotic drugs

There are a number of antifibrotic agents, as discussed in detail in Section 6.2. There have been a small number of published trials utilizing specific antifibrotic strategies (e.g. colchicine, interferon-gamma and peroxisome proliferator-activated receptor (PPAR) ligands) in patients with fibrosis [90]. Although the data from these trials are encouraging, the consensus opinion is that an effective, inexpensive and safe antifibrotic is so far unavailable. There are ongoing randomized controlled trials looking at novel targets, both in the context of fibrosis and cirrhosis. Patients with established cirrhosis are the most difficult to treat yet they may have the most to gain because of dwindling hepatic reserve. The other interesting question posed is what constitutes a success in treatment in this group – reversal in histological parameters, clinical outcomes, or both (see Chapter 6.1 for discussion of reversal of cirrhosis).

Follow-up and screening

Patients with compensated cirrhosis are at risk of developing the complications listed above. Careful follow-up may help to prevent or detect them at an early stage. Of particular relevance are the issues of upper gastrointestinal varices and HCC. Elective endoscopy to detect varices remains the gold standard diagnostic test, although there has been interest in noninvasive tests [91]. In the presence of varices, primary prophylaxis is recommended by either pharmacological means (e.g. beta-blockers) or band ligation in those intolerant to medication.

Screening for HCC remains controversial (see Chapter 18.2). The majority of HCC (80–90%) arise on the background of cirrhosis [92], and it has been estimated that the annual risk of developing HCC in this context is 1–5% per year. Therefore, it could be argued that this represents a good population to screen. Additionally, the screening tools of ultrasound and alpha-fetoprotein (AFP) are widely available and have a negligible morbidity. The sensitivity and specificity of these tests varies from 60 to 90%. Ultrasound has a subjective element and is operator dependent whilst the specificity of AFP is reduced by regeneration, which occurs in the context of cirrhosis and fluctuating viral replication. However, there is no substantive evidence that screening using ultrasound and AFP reduces mortality and there is no consensus that screening is cost effective [93]. The reasons for this may be due to, firstly, the inability to detect tumours at a stage that is amenable to treatment. Secondly, although there are a number of treatment modalities, including resection, chemoembolization and radiotherapy ablation, only OLT prevents *de novo* HCC from arising in the future. The latter is limited by resources, and by the time an appropriate graft is available the disease may have progressed. Despite the lack of firm evidence, many clinicians choose to screen patients with cirrhosis on a 6-monthly basis with ultrasound and AFP. With improving diagnostics and therapy, there may be stronger evidence for screening in the future.

The transition from compensated disease into decompensated disease will usually be self-evident and often requires emergency admission. There will also be cases of insidious progression with reducing reservoirs of hepatic function. In these cases, the timing of liver transplantation is crucial and careful attention to clinical, nutritional and biochemical trends is required over a period of time.

References

1 Anthony PP, Ishak KG, Nayak NC *et al.* (1978) The morphology of cirrhosis. Recommendations on definition, nomenclature, and classification by a working group sponsored by the World Health Organization. *J Clin Pathol* 31, 395–414.

2 Chedid A (2000) Regression of human cirrhosis. *Arch Pathol Lab Med* 124, 1591–1593.

3 Graudal N, Leth P, Marbjerg L, Galloe AM (1991) Characteristics of cirrhosis undiagnosed during life: a comparative analysis of 73 undiagnosed cases and 149 diagnosed cases of cirrhosis, detected in 4929 consecutive autopsies. *J Intern Med* 230, 165–171.

4 Haellen J, Norden J (1964) Liver cirrhosis unsuspected during life: a series of 79 cases. *J Chronic Dis* 17, 951–958.

5 Corrao G, Ferrari P, Zambon A *et al.* (1997) Trends of liver cirrhosis mortality in Europe, 1970–1989: age-period-cohort analysis and changing alcohol consumption. *Int J Epidemiol* 26, 100–109.

6 Lessa I (1996) [Liver cirrhosis in Brazil: mortality and productive years of life lost prematurely]. *Bol Oficina Sanit Panam* 121, 111–122.

7 The North Italian Endoscopic Club for the Study and Treatment of Esophageal Varices (1988) Prediction of the first variceal hemorrhage in patients with cirrhosis of the liver and esophageal varices. A prospective multicenter study. *N Engl J Med* 319, 983–989.

8 D'Amico G, Pagliaro L, Bosch J (1995) The treatment of portal hypertension: a meta-analytic review. *Hepatology* 22, 332–354.

9 Runyon BA, Montano AA, Akriviadis EA *et al.* (1992) The serum-ascites albumin gradient is superior to the exudate-transudate concept in the differential diagnosis of ascites. *Ann Intern Med* 117, 215–220.

10 Wong F, Liu P, Allidina Y, Blendis L (1995) Pattern of sodium handling and its consequences in patients with preascitic cirrhosis. *Gastroenterology* 108, 1820–1827.

11 Bernardi M, Trevisani F, Gasbarrini G (1993) Hyperdynamic circulation in cirrhosis: physiology or pathophysiology? *Gastroenterology* 104, 1579–1580.

12 Pozzi M, Grassi G, Redaelli E *et al.* (2001) Patterns of regional sympathetic nerve traffic in preascitic and ascitic cirrhosis. *Hepatology* 34, 1113–1118.

13 Johnston RF, Loo RV (1964) Hepatic hydrothorax: studies to determine the source of the fluid and report of thirteen cases. *Ann Intern Med* 61, 385–401.

14 Schenk P, Schoniger-Hekele M, Fuhrmann V *et al.* (2003) Prognostic significance of the hepatopulmonary syndrome in patients with cirrhosis. *Gastroenterology* 125, 1042–1052.

15 Fallon MB, Abrams GA, Luo B *et al.* (1997) The role of endothelial nitric oxide synthase in the pathogenesis of a rat model of hepatopulmonary syndrome. *Gastroenterology* 113, 606–614.

16 Nunes H, Lebrec D, Mazmanian M *et al.* (2001) Role of nitric oxide in hepatopulmonary syndrome in cirrhotic rats. *Am J Respir Crit Care Med* 164, 879–885.

17 Taille C, Cadranel J, Bellocq A *et al.* (2003) Liver transplantation for hepatopulmonary syndrome: a ten-year experience in Paris, France. *Transplantation* 75, 1482–1489.

18 Swanson KL, Wiesner RH, Krowka MJ (2005) Natural history of hepatopulmonary syndrome: impact of liver transplantation. *Hepatology* 41, 1122–1129.

19 Lee SS (1989) Cardiac abnormalities in liver cirrhosis. *West J Med* 151, 530–535.

20 Liu H, Song D, Lee SS (2002) Cirrhotic cardiomyopathy. *Gastroenterol Clin Biol* 26, 842–847.

21 Myers RP, Lee SS (2000) Cirrhotic cardiomyopathy and liver transplantation. *Liver Transpl* 6(4 Suppl. 1), S44–S52.

22 Velazquez RF, Rodriguez M, Navascues CA *et al.* (2003) Prospective analysis of risk factors for hepatocellular carcinoma in patients with liver cirrhosis. *Hepatology* 37, 520–527.

23 Tsukuma H, Hiyama T, Tanaka S *et al.* (1993) Risk factors for hepatocellular carcinoma among patients with chronic liver disease. *N Engl J Med* 328, 1797–1801.

24 Fattovich G, Stroffolini T, Zagni I, Donato F (2004) Hepatocellular carcinoma in cirrhosis: incidence and risk factors. *Gastroenterology* 127(5 Suppl. 1), S35–S50.
25 Park SZ, Nagorney DM, Czaja AJ (2000) Hepatocellular carcinoma in autoimmune hepatitis. *Dig Dis Sci* 45, 1944–1948.
26 Quero JC, Schalm SW (1996) Subclinical hepatic encephalopathy. *Semin Liver Dis* 16, 321–328.
27 Ferenci P, Lockwood A, Mullen K *et al.* (2002) Hepatic encephalopathy – definition, nomenclature, diagnosis, and quantification: final report of the working party at the 11th World Congresses of Gastroenterology, Vienna, 1998. *Hepatology* 35, 716–721.
28 Italian Multicentre Cooperative Project on Nutrition in Liver Cirrhosis (1994) Nutritional status in cirrhosis. *J Hepatol* 21, 317–325.
29 Alberino F, Gatta A, Amodio P *et al.* (2001) Nutrition and survival in patients with liver cirrhosis. *Nutrition* 17, 445–450.
30 Alvares-da-Silva MR, Reverbel DS (2005) Comparison between handgrip strength, subjective global assessment, and prognostic nutritional index in assessing malnutrition and predicting clinical outcome in cirrhotic outpatients. *Nutrition* 21, 113–117.
31 Navasa M, Fernandez J, Rodes J (1999) Bacterial infections in liver cirrhosis. *Ital J Gastroenterol Hepatol* 31, 616–625.
32 Borzio M, Salerno F, Piantoni L *et al.* (2001) Bacterial infection in patients with advanced cirrhosis: a multicentre prospective study. *Dig Liver Dis* 33, 41–48.
33 Caly WR, Strauss E (1993) A prospective study of bacterial infections in patients with cirrhosis. *J Hepatol* 18, 353–358.
34 Cirera I, Bauer TM, Navasa M *et al.* (2001) Bacterial translocation of enteric organisms in patients with cirrhosis. *J Hepatol* 34, 32–37.
35 Hassner A, Kletter Y, Jedvab M *et al.* (1979) Impaired monocyte function in liver cirrhosis. *Lancet* i, 329–330.
36 Rajkovic IA, Williams R (1986) Abnormalities of neutrophil phagocytosis, intracellular killing and metabolic activity in alcoholic cirrhosis and hepatitis. *Hepatology* 6, 252–262.
37 Runyon BA, Morrissey RL, Hoefs JC, Wyle FA (1985) Opsonic activity of human ascitic fluid: a potentially important protective mechanism against spontaneous bacterial peritonitis. *Hepatology* 5, 634–637.
38 Wong F, Bernardi M, Balk R *et al.* (2005) Sepsis in cirrhosis: report on the 7th meeting of the International Ascites Club. *Gut* 54, 718–725.
39 Riordan SM, Skinner N, Nagree A *et al.* (2003) Peripheral blood mononuclear cell expression of toll-like receptors and relation to cytokine levels in cirrhosis. *Hepatology* 37, 1154–1164.
40 Iredale JP (2003) Regulating hepatic inflammation: pathogen-associated molecular patterns take their toll. *Hepatology* 37, 979–982.
41 Bernard B, Cadranel JF, Valla D *et al.* (1995) Prognostic significance of bacterial infection in bleeding cirrhotic patients: a prospective study. *Gastroenterology* 108, 1828–1834.
42 Bernard B, Grange JD, Khac EN *et al.* (1999) Antibiotic prophylaxis for the prevention of bacterial infections in cirrhotic patients with gastrointestinal bleeding: a meta-analysis. *Hepatology* 29, 1655–1661.
43 Sort P, Navasa M, Arroyo V *et al.* (1999) Effect of intravenous albumin on renal impairment and mortality in patients with cirrhosis and spontaneous bacterial peritonitis. *N Engl J Med* 341, 403–409.
44 Goulis J, Patch D, Burroughs AK (1999) Bacterial infection in the pathogenesis of variceal bleeding. *Lancet* 353, 139–142.
45 Bannister P, Handley T, Chapman C, Losowsky MS (1986) Hypogonadism in chronic liver disease: impaired release of luteinising hormone. *Br Med J* (*Clin Res Ed*) 293, 1191–1193.
46 Powell EE, Cooksley WG, Hanson R *et al.* (1990) The natural history of nonalcoholic steatohepatitis: a follow-up study of forty-two patients for up to 21 years. *Hepatology* 11, 74–80.
47 Caldwell SH, Crespo DM (2004) The spectrum expanded: cryptogenic cirrhosis and the natural history of non-alcoholic fatty liver disease. *Journal of Hepatology* 40(4), 578–584.
48 Harrison SA, Torgerson S, Hayashi PH (2003) The natural history of nonalcoholic fatty liver disease: a clinical histopathological study. *Am J Gastroenterol* 98, 2042–2047.
49 Caldwell SH, Oelsner DH, Iezzoni JC *et al.* (1999) Cryptogenic cirrhosis: clinical characterization and risk factors for underlying disease. *Hepatology* 29, 664–669.
50 Poonawala A, Nair SP, Thuluvath PJ (2000) Prevalence of obesity and diabetes in patients with cryptogenic cirrhosis: a case-control study. *Hepatology* 32, 689–692.
51 Sakugawa H, Nakasone H, Nakayoshi T *et al.* (2003) Clinical characteristics of patients with cryptogenic liver cirrhosis in Okinawa, Japan. *Hepatogastroenterology* 50, 2005–2008.
52 Hui JM, Hodge A, Farrell GC *et al.* (2004) Beyond insulin resistance in NASH: TNF-alpha or adiponectin? *Hepatology* 40, 46–54.
53 Leclercq IA, Farrell GC, Schriemer R, Robertson GR (2002) Leptin is essential for the hepatic fibrogenic response to chronic liver injury. *J Hepatol* 37, 206–213.
54 Chitturi S, Farrell G, Frost LC *et al.* (2002) Serum leptin in NASH correlates with hepatic steatosis but not fibrosis: a manifestation of lipotoxicity? *Hepatology* 36, 403–409.
55 Bouchier IA (1969) Postmortem study of the frequency of gallstones in patients with cirrhosis of the liver. *Gut* 10, 705–710.
56 Kirk AP, Dooley JS, Hunt RH (1980) Peptic ulceration in patients with chronic liver disease. *Dig Dis Sci* 25, 756–760.
57 Williams AL, Hoofnagle JH (1988) Ratio of serum aspartate to alanine aminotransferase in chronic hepatitis. Relationship to cirrhosis. *Gastroenterology* 95, 734–739.
58 Park GJ, Lin BP, Ngu MC *et al.* (2000) Aspartate aminotransferase: alanine aminotransferase ratio in chronic hepatitis C infection: is it a useful predictor of cirrhosis? *J Gastroenterol Hepatol* 15, 386–390.
59 Ellis G, Goldberg DM, Spooner RJ, Ward AM (1978) Serum enzyme tests in diseases of the liver and biliary tree. *Am J Clin Pathol* 70, 248–258.
60 Borroni G, Maggi A, Sangiovanni A *et al.* (2000) Clinical relevance of hyponatraemia for the hospital outcome of cirrhotic patients. *Dig Liver Dis* 32, 605–610.
61 Gandon Y, Olivie D, Guyader D *et al.* (2004) Non-invasive assessment of hepatic iron stores by MRI. *Lancet* 363, 357–362.
62 Macdonald GA, Peduto AJ (2000) Magnetic resonance imaging (MRI) and diseases of the liver and biliary tract. Part 1. Basic principles, MRI in the assessment of diffuse and focal hepatic disease. *J Gastroenterol Hepatol* 15, 980–991.
63 Bedossa P, Poynard T (1996) An algorithm for the grading of activity in chronic hepatitis C. The METAVIR Cooperative Study Group. *Hepatology* 24, 289–293.
64 Knodell RG, Ishak KG, Black WC *et al.* (1981) Formulation and application of a numerical scoring system for assessing histological activity in asymptomatic chronic active hepatitis. *Hepatology* 1, 431–435.
65 Scheuer PJ, Standish RA, Dhillon AP (2002) Scoring of chronic hepatitis. *Clin Liver Dis* 6, 335–347, v–vi.
66 Ryder SD, Irving WL, Jones DA *et al.* (2004) Progression of hepatic fibrosis in patients with hepatitis C: a prospective repeat liver biopsy study. *Gut* 53, 451–455.

67 Cadranel JF, Rufat P, Degos F (2000) Practices of liver biopsy in France: results of a prospective nationwide survey. For the Group of Epidemiology of the French Association for the Study of the Liver (AFEF). *Hepatology* 32, 477–481.
68 Regev A, Berho M, Jeffers LJ *et al.* (2002) Sampling error and intra-observer variation in liver biopsy in patients with chronic HCV infection. *Am J Gastroenterol* 97, 2614–2618.
69 Bedossa P, Dargere D, Paradis V (2003) Sampling variability of liver fibrosis in chronic hepatitis C. *Hepatology* 38, 1449–1457.
70 The French METAVIR Cooperative Study Group (1994) Intraobserver and interobserver variations in liver biopsy interpretation in patients with chronic hepatitis C. *Hepatology* 20, 15–20.
71 Patel K, Lajoie A, Heaton S *et al.* (2003) Clinical use of hyaluronic acid as a predictor of fibrosis change in hepatitis C. *J Gastroenterol Hepatol* 18, 253–257.
72 Pares A, Deulofeu R, Gimenez A *et al.* (1996) Serum hyaluronate reflects hepatic fibrogenesis in alcoholic liver disease and is useful as a marker of fibrosis. *Hepatology* 24, 1399–1403.
73 Nojgaard C, Johansen JS, Christensen E *et al.* (2003) Serum levels of YKL-40 and PIIINP as prognostic markers in patients with alcoholic liver disease. *J Hepatol* 39, 179–186.
74 Imbert-Bismut F, Ratziu V, Pieroni L *et al.* (2001) Biochemical markers of liver fibrosis in patients with hepatitis C virus infection: a prospective study. *Lancet* 357, 1069–1075.
75 Forns X, Ampurdanes S, Llovet JM *et al.* (2002) Identification of chronic hepatitis C patients without hepatic fibrosis by a simple predictive model [see comment]. *Hepatology* 36, 986–992.
76 Wai CT, Greenson JK, Fontana RJ *et al.* (2003) A simple noninvasive index can predict both significant fibrosis and cirrhosis in patients with chronic hepatitis C [see comment]. *Hepatology* 38, 518–526.
77 Sud A, Hui JM, Farrell GC *et al.* (2004) Improved prediction of fibrosis in chronic hepatitis C using measures of insulin resistance in a probability index. *Hepatology* 39, 1239–1247.
78 Rosenberg WM, Voelker M, Thiel R *et al.* (2004) Serum markers detect the presence of liver fibrosis: a cohort study. *Gastroenterology* 127, 1704–1713.
79 Gebo KA, Herlong HF, Torbenson MS *et al.* (2002) Role of liver biopsy in management of chronic hepatitis C: a systematic review. *Hepatology* 36(5 Suppl. 1), S161–S172.
80 Alexander JF, Lischner MW, Galambos JT (1971) Natural history of alcoholic hepatitis. II. The long-term prognosis. *Am J Gastroenterol* 56, 515–525.
81 Pugh RN, Murray-Lyon IM, Dawson JL *et al.* (1973) Transection of the oesophagus for bleeding oesophageal varices. *Br J Surg* 60, 646–649.
82 Kamath PS, Wiesner RH, Malinchoc M *et al.* (2001) A model to predict survival in patients with end-stage liver disease. *Hepatology* 33, 464–470.
83 Botta F, Giannini E, Romagnoli P *et al.* (2003) MELD scoring system is useful for predicting prognosis in patients with liver cirrhosis and is correlated with residual liver function: a European study. *Gut* 52, 134–139.
84 Campillo B, Richardet JP, Scherman E, Bories PN (2003) Evaluation of nutritional practice in hospitalized cirrhotic patients: results of a prospective study. *Nutrition* 19, 515–521.
85 Cabré E, Rodriguez-Iglesias P, Caballerzia J *et al.* (2000) Short- and long-term outcome of severe alcohol-induced hepatitis treated with steroids or enteral nutrition: a multicenter randomized trial. *Hepatology* 32, 36–42.
86 Rossle M, Ochs A, Gulberg V *et al.* (2000) A comparison of paracentesis and transjugular intrahepatic portosystemic shunting in patients with ascites. *N Engl J Med* 342, 1701–1707.
87 Gines P, Uriz J, Calahorra B *et al.* (2002) Transjugular intrahepatic portosystemic shunting versus paracentesis plus albumin for refractory ascites in cirrhosis. *Gastroenterology* 123, 1839–1847.
88 Sanyal AJ, Genning C, Reddy KR *et al.* (2003) The North American Study for the Treatment of Refractory Ascites. *Gastroenterology* 124, 634–641.
89 Salerno F, Merli M, Riggio O *et al.* (2004) Randomized controlled study of TIPS versus paracentesis plus albumin in cirrhosis with severe ascites. *Hepatology* 40, 629–635.
90 Rockey DC (2005) Antifibrotic theapy in chronic liver disease. *Clin Gastroenterol Hepatol* 3, 95–107.
91 Pilette C, Oberti F, Aube C *et al.* (1999) Non-invasive diagnosis of esophageal varices in chronic liver diseases. *J Hepatol* 31, 867–873.
92 Simonetti RG, Camma C, Fiorello F *et al.* (1991) Hepatocellular carcinoma. A worldwide problem and the major risk factors. *Dig Dis Sci* 36, 962–972.
93 Di Bisceglie AM (2004) Issues in screening and surveillance for hepatocellular carcinoma. *Gastroenterology* 127(5 Suppl. 1), S104– S107.

7 Portal hypertension and its complications

7.1 Anatomy of the portal venous system in portal hypertension

J. Michael Henderson

Normal anatomy of the portal system

Embryology [1]

The development of the portal circulation builds around the two vitelline veins bringing blood from the yolk sac and the two umbilical veins returning the blood from the placenta. The vitelline veins intercommunicate in the septum transversum which is the site of development of the liver sinusoids. The extrahepatic portal venous system develops primarily from the left vitelline vein, which is later joined by the splenic vein to join the portal vein. Portions of both the right and left vitelline veins disappear and the remnant of the right vitelline vein continues as the right branch of the intrahepatic portal vein, while the left branch of the intrahepatic portal vein is formed from the left vitelline vein. The right umbilical vein atrophies; the left maintains its patency and communicates with the liver sinusoids but is directly connected to the sinus venosus. The ductus venosus communicates directly to a large common hepatic vein, bypassing much of the hepatic sinusoids in the fetal circulation, allowing most of the placental blood to bypass the developing liver. Despite this complex development, there are surprisingly few congenital anomalies of the portal venous system.

Gross anatomy [2]

The adult portal venous system includes all the veins that collect blood from the abdominal portion of the alimentary tract, the spleen and the pancreas. The portal vein itself is formed behind the neck of the pancreas by the confluence of the superior mesenteric and splenic veins. It is approximately 6–8 cm long, 1–1.2 cm in diameter, and passes superiorly from the upper margin of the pancreas, behind the duodenum, in the free edge of the lesser omentum, to terminate at the right end of the portahepatis.

The superior mesenteric vein is primarily formed by all the veins draining the small bowel, with significant further contributions of the ileocolic, right colic and middle colic veins. It runs in the root of the mesentery, in front of the third portion of the duodenum to unite with the splenic vein behind the neck of the pancreas. The splenic vein originates at the splenic hilus and runs on the posterior surface of the pancreas transversely to join the superior mesenteric vein behind the neck of the pancreas. The splenic vein receives numerous small feeding branches from the body and tail of the pancreas. The short gastric veins enter the spleen pulp superior to the origin of the splenic vein as does the left end of the gastroepiploic arcade. The third vein to contribute to portal venous inflow is the inferior mesenteric vein which drains blood from the rectum and the left colon. It enters the splenic vein in approximately two-thirds of patients within 1–2 cm of the splenic veins union with the superior mesenteric vein. In one-third of subjects, the inferior mesenteric vein enters directly into the superior mesenteric vein or at its confluence with the splenic vein. Finally, the left gastric, or coronary vein, has a variable entry into the portal venous system usually within 1–2 cm of the confluence, entering the splenic vein approximately 50% of the time and the portal vein in the other 50%.

The portal system carries all the blood from the alimentary tract to the liver and, thus, in the normal subject, all of the above named veins have blood flow directed towards the liver. This is of particular pertinence in portal hypertension because, in these patients, some of these vessels show reversal of blood flow with blood going away from the liver to collateral veins, which shunt directly to the systemic circulation [3].

The gastro-oesophageal junction

The normal venous anatomy of the gastro-oesophageal junction and lower oesophagus is particularly relevant to this chapter on portal hypertension [4–7]. This has been extensively studied by Vianna and colleagues [4]. Their work used the three techniques of radiological study, corrosion casting and morphometry. These studies were performed in specimens of a block of tissue that comprised the lower two-thirds of the oesophagus and the entire intra-abdominal portal circulation. Injections for corrosion casting and for radiographic studies were made by cannulating the splenic vein, ligating obviously leaking sites in the tissue block and proceeding to injection with the test substance.

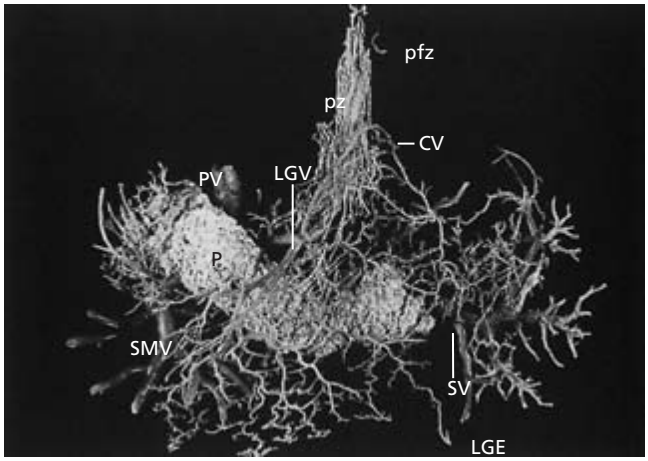

Fig. 1 A corrosion cast of the portal venous system, with emphasis of the upper stomach and lower oesophagus. P, pancreas; SMV, superior mesenteric vein; PV, portal vein; LGV, left gastric vein; LGE, left gastric epiploeic vein; SV, splenic vein; pz, palisade zone; pfz, perforating zone. This corrosion cast of normal blood vessels illustrates how the portal venous system condenses at the gastric fundus to form a tight longitudinal plexus of veins through the lower oesophagus in the palisade zone. (From ref. 4, with permission)

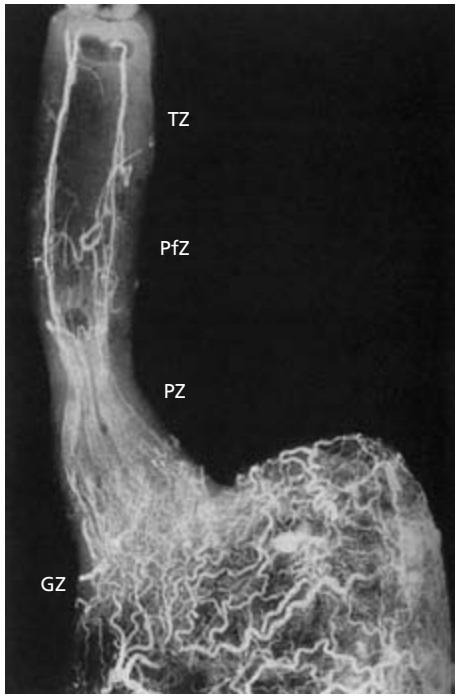

Fig. 2 A postmortem radiograph study of the venous anatomy at the gastro-oesophageal junction in a normal subject. The vessels have been injected with a barium gelatine solution to demonstrate the venous anatomy. GZ, gastric zone; PZ, palisade zone; PfZ, perforating zone; TZ, truncal zone. The network of veins in the gastric fundus condense just below the gastro-oesophageal junction and come together with longitudinal channels in the palisade zone. The perforating veins in the perforating zone can be identified. (From ref. 4, with permission.)

The morphometric studies examined 1-cm slices in the region of interest to document luminal areas of the main venous channels.

These studies documented four distinct zones of venous drainage:

1 The gastric zone, which extends for 2–3 cm just below the gastro-oesophageal junction, is the junctional zone between the stomach and lower oesophagus; the veins are longitudinal rather than the irregular network seen in the rest of the stomach. These veins are in the submucosa and lamina propria and come together at the lower (gastric) end to drain into the short gastric and left gastric veins. This configuration can be seen in Figures 1 and 2 marked as GZ.

2 The palisade zone extends 2–3 cm superiorly from the gastric zone into the lower oesophagus. The veins are uniformly distributed, parallel and run longitudinal in four groups which correspond to the oesophageal mucosal folds. The corrosion casting and radiological imaging of this zone (PZ) are illustrated in Figures 1 and 2. There are multiple anastomoses between these veins, which occupy the lamina propria as illustrated in Figure 3. There are no perforating veins in the palisade zone linking the intrinsic and extrinsic veins of the distal oesophagus. Morphometric study shows that the cross sectional area of the veins at this level is increased compared to other levels. These observations strongly support the palisade zone as being the watershed between the portal and systemic circulation. This is the anatomic location of the lower oesophageal sphincter – a region of the oesophagus of major physiological importance in swallowing and in control of gastro-oesophageal reflux.

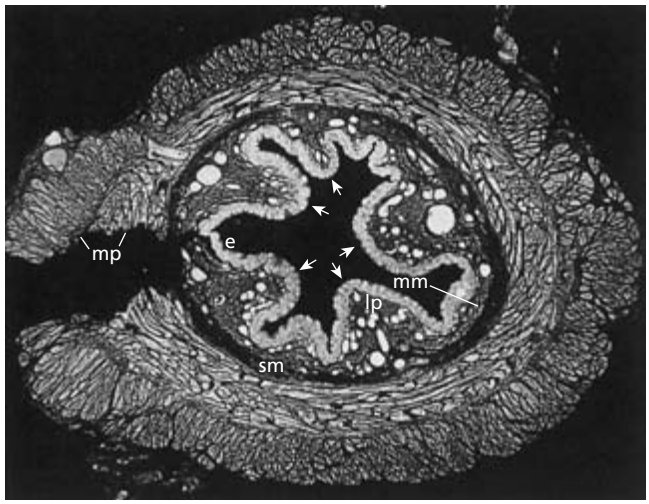

Fig. 3 A morphometric study of a transverse section of the distal oesophagus in a normal subject. This specimen has been injected with barium gelatine and transected 3 cm above the gastro-oesophageal junction. lp, lamina propria; sm, submucosa; mm, muscularis mucosa; e, epithelium; mp, muscularis propria. The white channels in the lamina propria represent the venous channels of the palisade zone which can clearly be seen to congregate in the longitudinal folds of the oesophagus. (From ref. 4, with permission.)

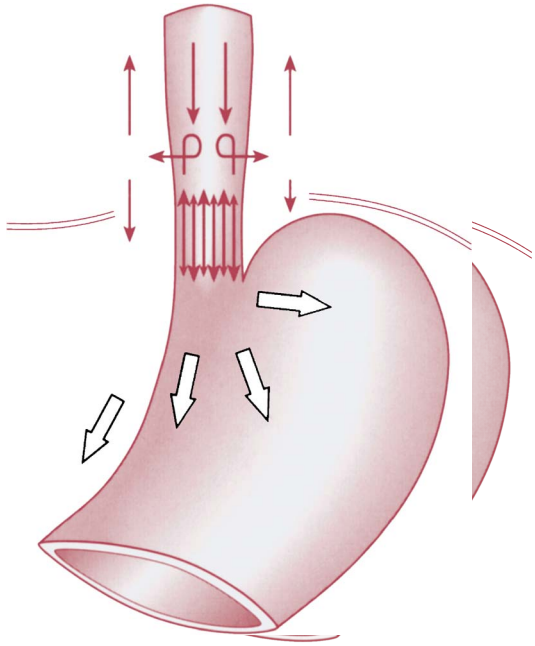

Fig. 4 Diagrammatic representation of the postulated pattern of normal venous drainage of the lower oesophagus. Venous drainage from the gastric fundus and lesser curvature is inferiorly to the portal vein. In the palisade zone, there is to/fro flow that is probably respiration dependent. The perforating veins connect the intrinsic and extrinsic oesophageal plexuses. Flow in the truncal zone is inferior to the perforating zone. (From ref. 4, with permission.)

Fig. 5 Venous phase of a superior mesenteric artery injection in a patient with cirrhosis. PV, portal vein; IMV, inferior mesenteric vein. The inferior mesenteric vein fills in a retrograde pattern indicating blood flow away from the liver in this patient with portal hypertension. This large inferior mesenteric vein fills pararectal varices and anastomosis to the haemorrhoidal veins.

3 The perforating zone extends approximately 2 cm further up the oesophagus above the palisade zone. The organized longitudinal structure is lost, with veins looping and forming a network. The main feature of this zone is perforating veins through the muscle wall of the oesophagus linking the internal and external veins. These perforating veins occur circumferentially around the oesophageal wall and are best illustrated in Figure 2.

4 The truncal zone is 8–10 cm long and is characterized by four or five longitudinal veins in the lamina propria, as illustrated in Figure 2. Perforating veins penetrate from the submucosa at irregular intervals to the external oesophageal venous plexus.

The summary of these zones is schematically illustrated in Figure 4, as conceptualized by Vianni and colleagues [4]. This diagram represents the blood flow directions in the four zones described above.

Changes with portal hypertension

Obstruction of portal venous flow, whatever the aetiology, results in a rise in portal venous pressure. The first response to increased venous pressure is the development of a collateral circulation diverting the obstructed portal flow to the systemic veins [8]. The sites and extent of these collaterals' paths vary and are illustrated in some of the following figures. While some of these collaterals are relatively 'benign', clinically the most important and dangerous are gastro-oesophageal varices. The patterns of development and anatomic variations of these will be described in more detail.

Collateral pathways

Figure 5 illustrates a large inferior mesenteric vein shown at angiography in a patient with cirrhosis and portal hypertension. The flow in this vein is away from the liver towards the rectum and anal canal, which is one of the natural portal–systemic collateral sites. Retrograde flow in the inferior mesenteric vein is a consistent finding in portal hypertension, but only occasionally does the vein enlarge to the size illustrated in this figure.

Figure 6 illustrates a large umbilical vein in a patient with cirrhosis and portal hypertension. The umbilical vein can enlarge from its vestigial size up to 2 cm in diameter and this always communicates with the left portal vein. It runs in the falciform ligament and may give rise to the clinical finding of a caput medusae at the umbilicus. Although the umbilical vein may not always be visualized at angiography, a prominent dye pattern in

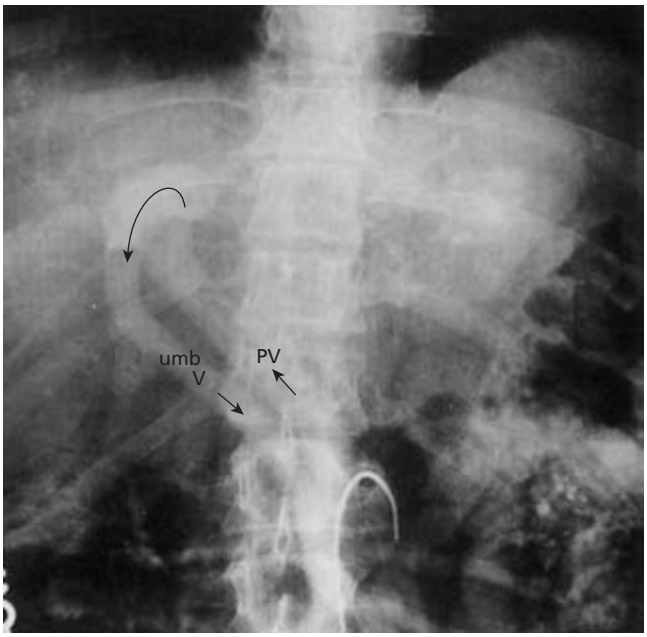

Fig. 6 This venous phase superior mesenteric artery injection demonstrates prograde flow in the portal vein (PV) and hepatofugal flow in the umbilical vein (umb V) carrying blood away from the liver towards the umbilicus. This patient had a caput medusae fed by this large umbilical vein.

Fig. 8 Venous phase superior mesenteric artery study of cavernous transformation of the portal vein in a patient with portal vein thrombosis. Three large collateral venous channels can be seen in the region of the portal vein and have developed from the obstructed superior mesenteric vein to the low pressure sinusoids in this normal liver.

Fig. 7 Venous phase of a superior mesenteric artery injection showing large retroperitoneal collaterals around the terminal ileum, cecum and the right pelvis.

the left portal vein is usually due to the origin of an umbilical vein. Flow in this is again away from the liver depriving the liver sinusoids of portal flow.

Figure 7 illustrates retroperitoneal collaterals with spontaneous shunting to the gonadal vessels. This is more common in female patients where the retroperitoneal collaterals will often communicate with larger ovarian vessels and spontaneously shunt into the iliac veins.

Figure 8 illustrates a patient with portal vein thrombosis and cavernous transformation of the portal vein. Rather than a single portal vein going to this liver, there are three or four very large channels, which demonstrate the preferred collateralization route when there is portal vein thrombosis. It is easier for the obstructed, high pressure superior mesenteric vein to collateralize to the low pressure sinusoids in the liver than to seek the more complex routes illustrated above. A clinical correlation with this abnormality is that an ultrasound exam may demonstrate an apparently good portal flow to the liver, when in reality one is only visualizing one of the large collateral vessels.

Gastro-oesophageal varices

This collateral pathway is of particular clinical importance because of the propensity of these abnormal veins to bleed. In total, 30% of patients identified with compensated cirrhosis and 60% of patients with decompensated cirrhosis have gastro-oesophageal varices at the time of presentation. The risk of

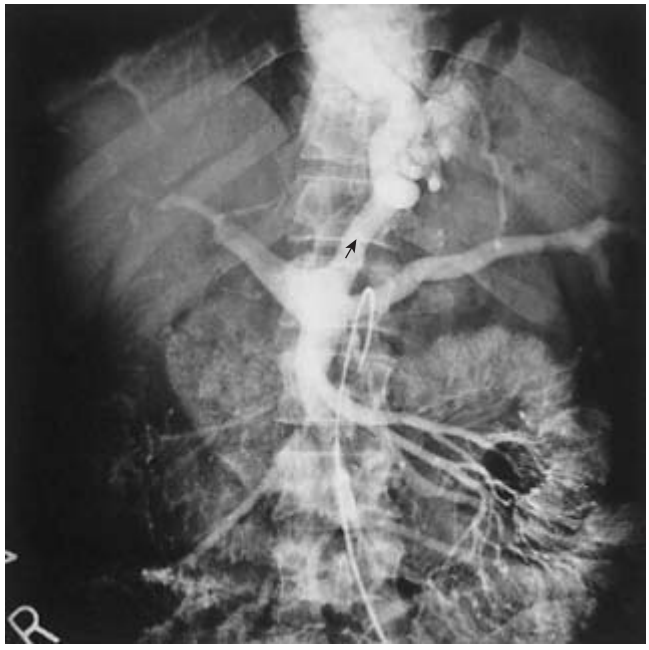

Fig. 9 Superior mesenteric artery injection in a patient with cirrhosis in whom there is no prograde portal flow into the liver although the portal vein is patent. Virtually all of the superior mesenteric venous flow is diverted into a large left gastric vein (↑) filling varices at the gastric fundus (gastric zone) and large paraoesophageal varices around the oesophagus. Note that there is also retrograde filling of the splenic vein.

Fig. 10 Superior mesenteric venous phase study in a patient with cirrhosis who still has good prograde portal flow to the liver. The increased density in the left branch of the portal vein is probably the origin of a large umbilical vein. The arrow indicates a small left gastric vein filling small gastric fundal varices. It should be noted that this patient had significant variceal bleeding.

bleeding from gastro-oesophageal varices is 30% in the first year after their identification [9]. An understanding of the pathophysiology leading to the development of varices and of the anatomic changes around the gastro-oesophageal junction provide some basis for therapies used to reduce the risk of bleeding.

There are two main inflows to gastro-oesophageal varices. The first of these is the left gastric or coronary vein. This may be a major contributor to variceal inflow as illustrated in Figure 9 where virtually all the portal venous flow is diverted into the left gastric vein to gastric fundal and oesophageal varices. In contrast, the patient illustrated in Figure 10 also had a major bleed from gastro-oesophageal varices, yet the left gastric vein is of a very small calibre.

The other major route of inflow for gastro-oesophageal varices is from the splenic hilus through the short gastric veins. This is illustrated in Figure 11, where the dominant venous outflow from the spleen is into gastric varices. The splenic vein is open in this patient with cirrhosis. However, the finding of isolated gastric fundus varices raises the question of isolated splenic vein thrombosis, where all the splenic outflow traverses the short gastric veins to the gastric fundus. The importance of identifying these patients is that they have a normal liver and are

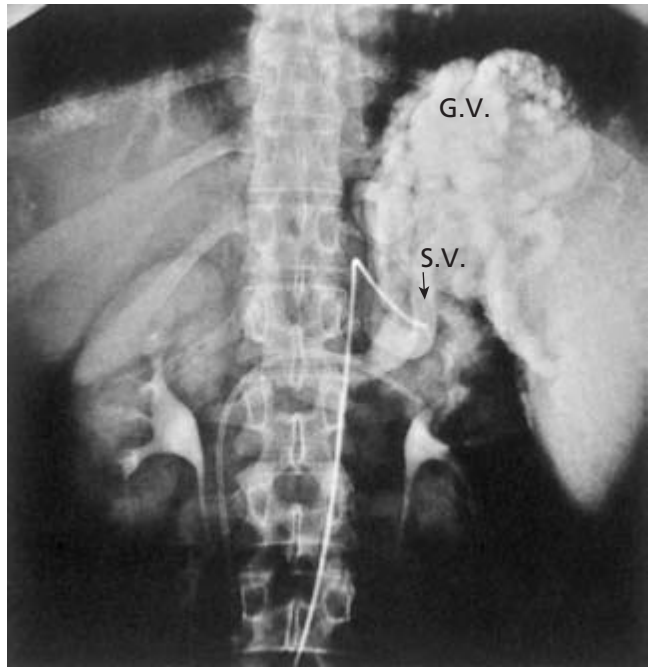

Fig. 11 The venous phase of a splenic artery injection in this patient with cirrhosis demonstrates a tortuous splenic vein (S.V.) and large gastric fundal varices (G.V.). It should be noted that these gastric varices drain through the retroperitoneum into a spontaneous splenorenal shunt with faint visualization of the inferior vena cava. The lower catheter is in the left renal vein which can be seen to drain some of the contrast on this venous phase study.

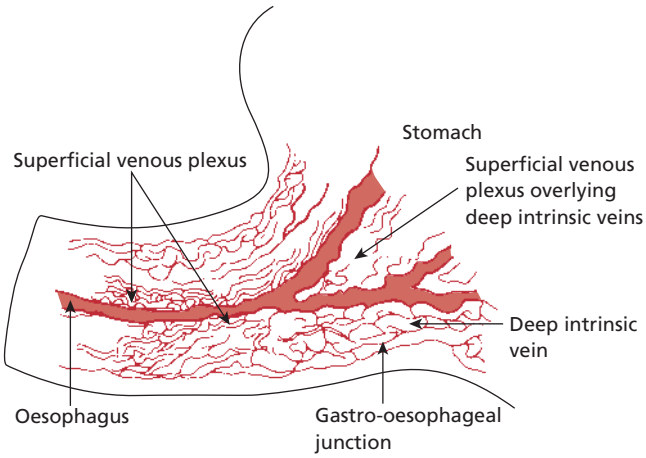

Fig. 12 Schematic representation of a resin cast of the lower oesophagus and upper stomach in a patient with portal hypertension. This cast has been partially dissected with the anterior wall removed to demonstrate the enlarged superficial venous plexus of veins as well as large deep intrinsic veins. These intercommunicate in the gastric zone. (Reprinted from ref. 10, with permission.)

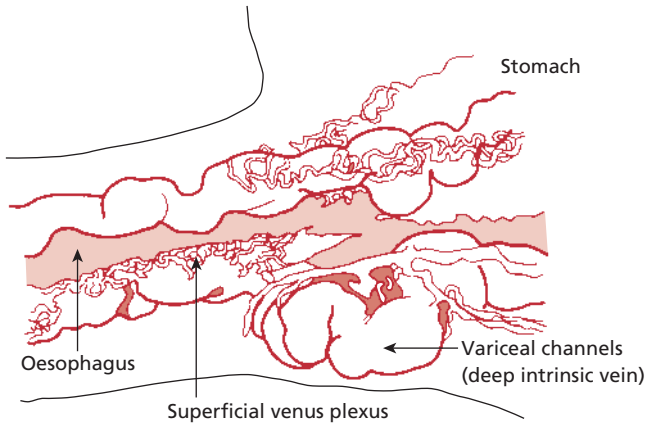

Fig. 13 A resin cast of the lower oesophagus and upper stomach at a later stage of dissection. Two very large, tortuous deep intrinsic variceal channels are demonstrated with overlying superficial venous plexus. For this dissection, some of the superficial venous plexus illustrated in the previous figure has been removed. (Reprinted from ref. 10, with permission.)

cured by splenectomy. The impact of these inflow changes on the venous anatomy at the gastro-oesophageal junction has been studied with the same techniques as those described previously for normal anatomy. The gastric, palisade perforating and truncal zones can again be identified, but undergo significant change in portal hypertension. The two main features of adaptation are dilatation and tortuosity, which are highly variable and do not occur in any constant or regular manner. Dilatation of the veins in the palisade zone is the most clinically problematic as this is the commonest site of rupture and bleeding. In contrast, enlargement of the paraoesophageal varices has less clinical consequence in terms of bleeding risk, but has physiological significance in terms of diverting portal flow.

Resin cast studies by Kitano and coworkers [10] demonstrate the dilatation and tortuosity of both the deep and superficial venous plexuses and are illustrated in Figures 12 and 13. When the deep veins become very large, they can displace the superficial veins and lie immediately beneath the mucosa as illustrated in Figure 13.

Further interesting data were generated by Spence *et al.* [11] who showed blood-filled channels in the oesophageal squamous epithelium as illustrated in Figure 14. These are apparently fed by communicating channels which erode into the epithelium. The precise relationship of each of these anatomic abnormalities to the event of variceal bleeding has not been fully clarified.

The main vascular patterns that develop in portal hypertension, demonstrated by these various studies, can be summarized as:

1 Varices in the fundus of the stomach are predominantly fed by the short gastric veins but may also be fed by the left gastric vein. From a clinical perspective, gastric varices may either occur 'in continuity' with oesophageal varices or be 'isolated' in the fundus. The latter group have a higher propensity to bleed and are particularly problematic in management.

2 Varices in the gastric and palisade zones form most of the varices seen in clinical practice, are markedly tortuous, numerous and dilated. They run longitudinally in these two zones and are usually in continuity. Because there are no perforating veins in the palisade zone, the submucosal veins are particularly prone to rupture and bleeding. This is the main anatomical site for the clinical problem of bleeding gastro-oesophageal varices.

3 Varices at the perforating and truncal zones – the perforating vessels above the palisade zone – provide a communication between the paraoesophageal varices and the submucosal varices. These perforating pathways can increase the pressure in the submucosal varices and in some patients flow to submucosal vessels will increase the risk of bleeding. Doppler ultrasound studies of perforating veins in patients with portal hypertension have suggested that these may be incompetent and there may be bidirectional flow through the perforators [12]. It has been speculated that turbulence of flow through these incompetent perforators is a risk factor in further bleeding.

4 Paraoesophageal varices are not at risk of bleeding but may develop as very large veins with significant flow. This flow can be measured clinically as azygos blood flow. These channels become important when there are incompetent perforators allowing this high flow to increase submucosal venous pressure and flow.

Anatomic studies of the portal circulation, and particularly the detailed studies of the gastro-oesophageal junction, have increased knowledge as to why and how gastro-oesophageal varices form. This information also provides pointers as to the therapeutic options.

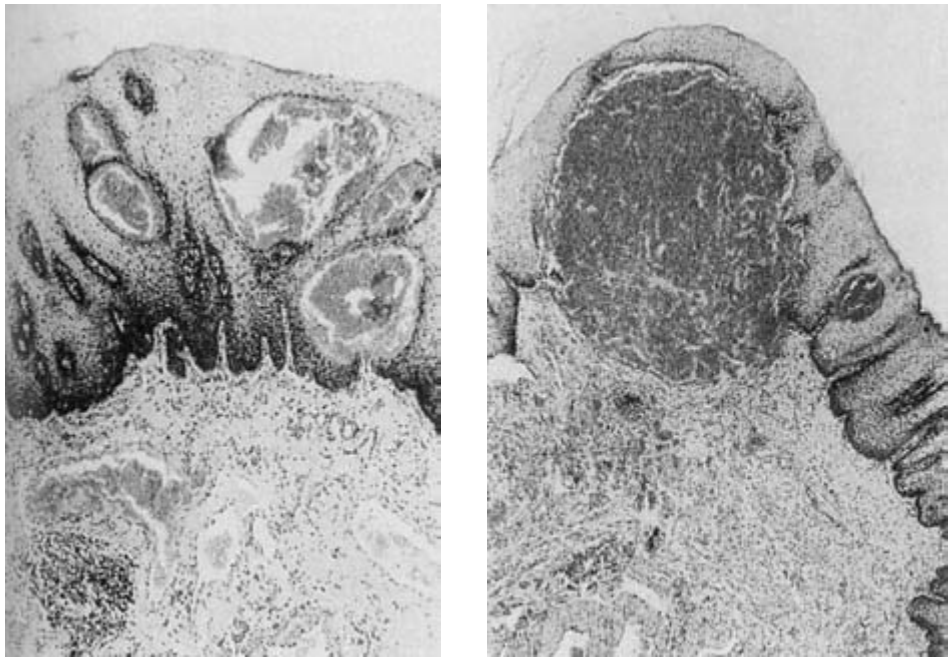

(a) (b)

Fig. 14 (a) Blood-filled channels in the oesophageal epithelium in a patient with portal hypertension. In addition, there are dilated vessels in the lamina propria. Magnification × 40. (b) A large subepithelial blood-filled channel in a patient with portal hypertension. The smaller intraepithelial channel appears to be arising from papillary capillary present to the right of the larger lesions. Magnification × 26. (Reproduced from ref. 11, with permission.)

References

1 Davies DV, Davies F (1962) *Gray's anatomy – descriptive and applied.* Longmans, Green and Co.

2 Douglas BE, Baggenstoss AH, Hollinshead WH (1979) The anatomy of the portal vein and its tributaries. *Surg Gynecol Obstet* 91, 562–576.

3 Salam AA, Warren WD (1974) Anatomic basis of the surgical treatment of portal hypertension. *Surg Clin North Am* 54(6), 1247–1257.

4 Vianna A, Hayes PC, Moscoso G *et al.* (1987) Normal venous circulation of the gastroesophageal junction. A route to understanding varices. *Gastroenterology* 93(4), 876–889.

5 Butler H (1951) The veins of oesophagus. *Thorax* 6, 276–96.

6 Kegaries D (1934) The venous plexus of the oesophagus. *Surg Gynecol Obstet* 58, 46–51.

7 Noda T (1984) Angioarchitectural study of esophageal varices. With special reference to variceal rupture. *Virchows Archiv A Pathol Anat Histopathology* 404(4), 381–392.

8 Sikuler E, Kravetz D, Groszmann RJ (1985) Evolution of portal hypertension and mechanisms involved in its maintenance in a rat model. *Am J Physiol* 248, G618–625.

9 The North Italian Endoscopic Club for the Study and Treatment of Esophageal Varices (1988) Prediction of the first variceal hemorrhage in patients with cirrhosis of the liver and esophageal varices. A prospective multicenter study. *N Engl J Med* 319(15), 983–989.

10 Kitano S, Terblanche J, Kahn D *et al.* (1986) Venous anatomy of the lower oesophagus in portal hypertension: practical implications. *Br J Surg* 73(7), 525–531.

11 Spence RA, Sloan JM, Johnston GW (1984) Histologic factors of the esophageal transection ring as clues to the pathogenesis of bleeding varices. *Surg Gynecol Obstet* 159(3), 253–259.

12 McCormack TT, Rose JD, Smith PM *et al.* (1983) Perforating veins and blood flow in oesophageal varices. *Lancet* ii, 1442–1444.

7.2 Pathogenesis of portal hypertension

Roberto J. Groszmann and Juan G. Abraldes

Introduction

Portal hypertension is the haemodynamic abnormality most frequently associated with cirrhosis of the liver, although it is also recognized less commonly in a variety of hepatic and extrahepatic diseases. Many of the most lethal complications of liver cirrhosis are related to the presence of portal hypertension, including haemorrhage from gastro-oesophageal varices, hepatic encephalopathy, ascites and functional renal failure, bacterial infections and hepatopulmonary syndrome. A thorough knowledge of the pathogenesis leading to portal hypertension sets the framework for a rational approach to treatment and is, therefore, central in the management of the patient with liver cirrhosis and in devising rational investigational strategies. This chapter is an overview of the basic pathophysiological mechanisms of the intrahepatic, splanchnic and systemic circulatory derangements involved in the genesis of portal hypertension.

Pathogenesis of portal hypertension: resistance and flow

Ohm's law states that changes in pressure ($P1$–$P2$) along a blood vessel are a function of the interplay between blood flow (Q) and vascular resistance (R):

$$P1 - P2 = Q \times R$$

It follows that portal hypertension may develop as the result of an increase in portal blood flow, an increase in resistance to portal blood flow, or both. The pathophysiology of portal hypertension is best approached by analysing these components separately, although mathematical formulas necessarily oversimplify the complex and dynamic interactions that exist in biological systems. Resistance to the flow in vessels can be expressed by Poiseuille's law:

$$R = (8\mathrm{n}L)/\pi r^4$$

where n is the coefficient of viscosity, L the length of the vessel and r its radius. Under physiological conditions, resistance is mainly a function of changes in r, which have a dramatic influence because these are taken to the fourth power. In contrast, L and n are basically constant because neither the length of a vessel nor the viscosity of blood vary greatly under usual circumstances. The liver is the main site of resistance to portal blood flow, but the liver itself has no active role in regulating portal inflow; this function is provided by resistance vessels at the splanchnic arteriolar level. Hence, the normal liver is a passive recipient of fluctuating amounts of blood flow that, because of its huge and distensible vascular network, can encompass a wide range of portal blood flow with minimal effect on pressure in the portal system. Thus, an increase in portal venous inflow, *per se*, does not induce portal hypertension. This means that the primary and necessary factor for the development of portal hypertension is an increased resistance to portal blood flow [1]. However, once portal hypertension develops, a series of mechanisms (not yet fully characterized) leads to an increase in portal venous inflow, which contribute to perpetuate and aggravate portal hypertension.

Hepatic vascular resistance

In liver cirrhosis, the most frequent cause of portal hypertension in western countries, marked morphological aberrations, characterized by fibrous tissue and regenerative nodules, result in vascular obliteration that leads to increased resistance to blood flow. In the early stages of liver fibrosis, sinusoidal capillarization is probably the initial factor that induces portal hypertension. Capillarized sinusoids are characterized by the accumulation of extracellular matrix in the space of Disse, and sinusoidal endothelial cells that lose their fenestrations and their typical phenotype. This, *per se*, may limit the ability of the sinusoids to accommodate variations in blood flow. In viral hepatitis, this occurs initially in the periportal area, while in alcoholic liver disease, it is predominant at the pericentral area. Later, the development of fibrous septae and regenerative nodules markedly alters the hepatic angioarchitecture. Additionally, it was suggested recently that thrombosis of the small portal and hepatic venules [2] could contribute to increase hepatic resistance and could

be an important factor in the progression of the architectural disturbances of cirrhosis. Although these morphological changes are undoubtedly the most important factor, functional factors leading to an increase in intrahepatic vascular tone also contribute to increased hepatic resistance in cirrhosis. The initial demonstration that vasodilators could decrease hepatic resistance in cirrhosis was the key study by Bhathal and Grossman [3], in which the use of the isolated and perfused liver model allowed the evaluation of the changes in hepatic resistance independently from the changes in systemic haemodynamics. It was suggested that up to 30% of the increase in hepatic resistance in cirrhosis is due to an increased vascular tone. There are no convincing studies that have quantified the magnitude of this functional component in patients with cirrhosis, and it is not well known whether its importance changes during the natural history of cirrhosis. This finding set the rationale for the treatment of portal hypertension with vasodilators.

The dynamic component in the increase in hepatic resistance reflects the existence of contractile structures in the liver that modulate hepatic resistance in response to endogenous or pharmacological vasoactive substances. In the normal liver, it has been demonstrated that the hepatic sinusoids can contract, and that changes in sinusoidal calibre colocalize with hepatic stellate cells (HSCs) [4]. These cells, located in the space of Disse, normally act as a deposit for retinoids and regulate the extracellular matrix turnover, but their contractile properties allow HSCs to behave as tissue pericytes that regulate microcirculation through capillary contraction [5]. The contractile capacity of HSCs, already present in the normal liver [4], is particularly important after liver injury, when HSCs acquire an activated phenotype, with increased proliferative, synthetic and contractile capacity, behaving as myofibroblasts [5]. Also, in the normal liver, it has been demonstrated that portal venules contract in response to vasoactive substances [6], but it is unknown whether this contributes to the increased hepatic resistance in cirrhosis. In that regard, data from a rat model of cirrhosis suggest that presinusoidal resistance is decreased in cirrhosis [7]. The same study suggests that the contraction of the postsinusoidal vascular bed could contribute to the increase in hepatic resistance and to ascites formation in cirrhosis. It is uncertain whether these results could be generalized to human cirrhosis.

Several vasoconstrictors and vasodilators have been shown to modify hepatic resistance. These substances can be of hepatic origin and act in a paracrine fashion [nitric oxide (NO), prostacyclin, endothelin, locally produced angiotensin II, thromboxane and leukotrienes], can arrive in the liver from the systemic circulation (circulating angiotensin II, vasopressin or norepinephrine) or can be of neural origin (norepinephrine). It is not known which of these systems is more relevant, but it is clear that in cirrhosis there is an imbalance between vasoconstrictive and vasodilating forces, characterized by an abundance of vasoconstrictors and a deficient production of and deficient response to vasodilators. These abnormalities are amplified by the fact that, compared with the normal liver, the hepatic vascular bed of the cirrhotic liver exhibits an increased response to vasconstrictors and a deficient response to vasodilators. In addition, most vasoconstrictors have profibrogenic actions, whereas vasodilators have antifibrogenic properties, so the effects of this imbalance go beyond the increase in intrahepatic vascular tone.

Deficit and hyporesponse to vasodilators

In the early 1990s, it was demonstrated that NO regulates intrahepatic resistance in the normal liver [8]. In the normal liver, sinusoidal endothelial cells respond to increases in shear stress with an increase in NO production. This allows the normal liver to accommodate physiological changes in portal blood flow with minimal changes in portal pressure. In contrast, the cirrhotic liver exhibits endothelial dysfunction, characterized by an insufficient production of NO, that contributes to an increase in hepatic vascular tone (and, thus, to the development and progression of portal hypertension) and a decreased capacity to accommodate increases in flow [9–11] (Fig. 1). The physiological increases in portal blood flow, such as those occurring after the ingestion of a meal, result in marked increases in portal pressure in cirrhotic patients [12]. Recent work in experimental models of cirrhosis have validated hepatic NO deficiency as a useful therapeutic target in cirrhosis, showing that it is possible to improve portal haemodynamics by increasing NO bioavailability in the liver circulation, either by transfection of the liver with adenovirus encoding nitric oxide synthase (NOS) [13] or by the administration of a liver-selective NO donor [14].

The mechanisms leading to the insufficient production of NO in cirrhosis have not been fully clarified. Endothelial nitric oxide synthase (eNOS) expression has been found to be normal [10,11] or decreased [13], while eNOS activity has been found to be consistently decreased. This is due to abnormalities in the complex posttranslational regulation of the enzyme, which include protein–protein interactions, phosphorylation and intracellular localization. Among other mechanisms, interaction with caveolin-1 reduces the activity of eNOS, while Akt-dependent eNOS phosphorylation increases eNOS activity. In the cirrhotic liver, an increase in caveolin-1 expression has been found and increased interaction of this protein with eNOS, with ensuing decreased activity of eNOS [11]. Also, a decrease in Akt-dependent eNOS phosphorylation has been found in the cirrhotic rat liver [15]. The status in the cirrhotic liver of other posttranslational regulatory mechanisms of eNOS has not been explored so far.

On the other hand, the response of the liver circulation to NO is impaired [16]. The mechanisms involved in this abnormality are not well understood, but could involve increased degradation of NO before the molecule reaches its targets (i.e. by increased oxidative stress and superoxide production [17]) or abnormalities at the downstream signal pathways of NO (the most relevant being the cGMP pathway) [18].

Carbon monoxide is another endogenous vasodilator that has been shown to modulate hepatic resistance in the normal

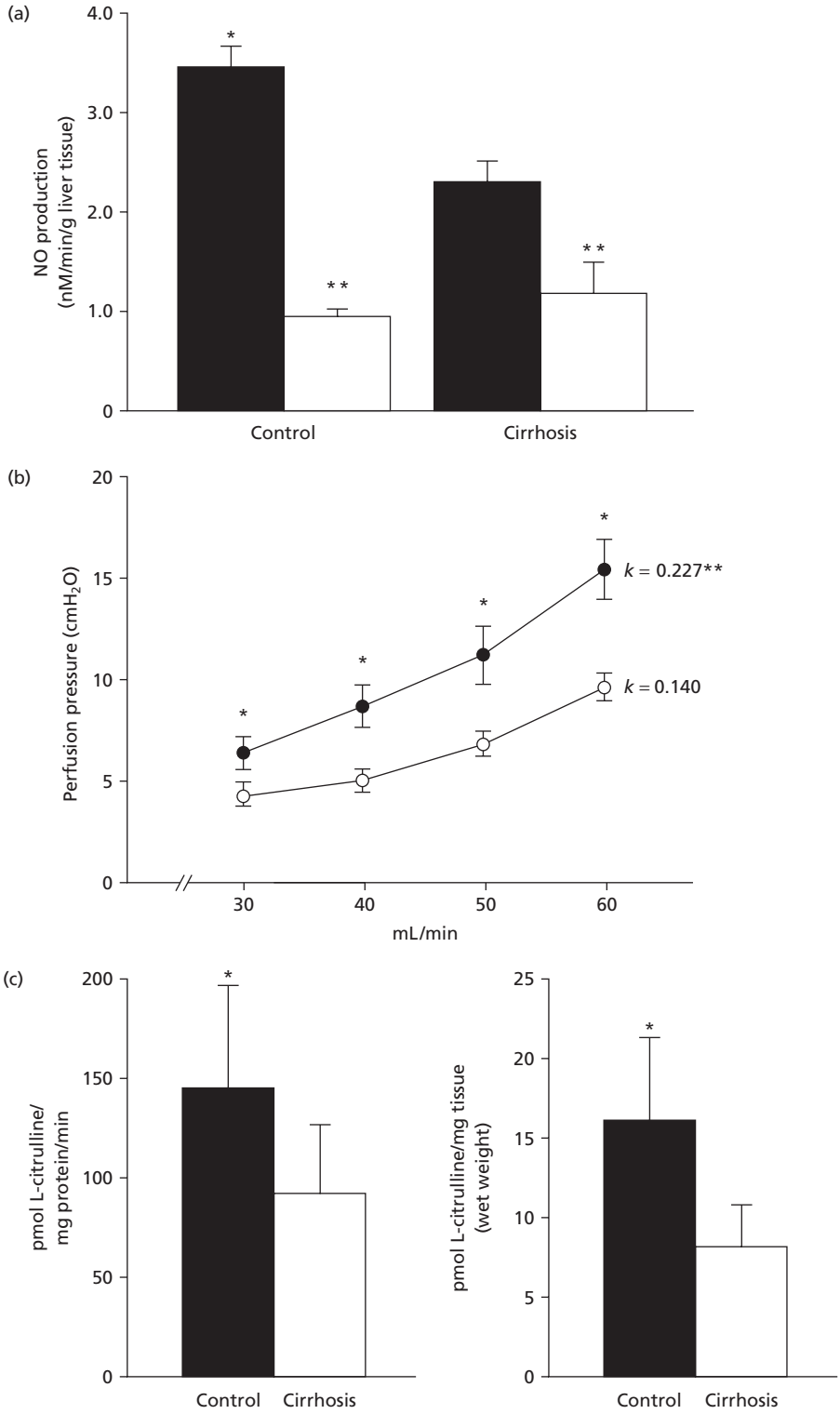

Fig. 1 Impaired NO production, pressure regulation and NOS activity in cirrhotic liver. (a) NO in the perfused liver was significantly lower in cirrhotic than in control animals (black bars). The addition of L-NMMA to the perfusate significantly inhibited NO production in both groups (white bars). (b) Flow-induced increases in perfusion pressure in both experimental groups. The increase in perfusion pressure was greater in cirrhotic animals (closed circles), as demonstrated by a significantly greater perfusion pressure at each flow rate and a significantly greater pressure–flow slope (*k*). (c) NOS activity was significantly reduced in liver tissue from cirrhotic animals compared with parallel control animals when normalized per milligram of protein (left) and per milligram of liver tissue (right) (from ref. 11, with permission).

liver [19]. In the cirrhotic liver, an increased expression of haemoxygenase-1 (the enzyme responsible for carbon monoxide synthesis) has been demonstrated [20], but its relevance in the pathogenesis of portal hypertension has not been addressed so far.

Increased production and response to vasoconstrictors

As discussed previously, both the normal and the cirrhotic liver vasculatures have contractile capacity. Consequently, infusion of vasoconstrictors increases intrahepatic resistance in the

isolated liver [21–23]. In the cirrhotic liver, there is an increase both in local vasoconstrictors produced in the liver itself and in circulating levels of vasoconstrictors [24–26]. Further, the cirrhotic liver exhibits an enhanced response to certain vasoconstrictors with respect to normal liver [7,21,23,27]. This hyperresponse has been attributed to different abnormalities, namely an increase in the amount of contractile tissue (proliferation of myofibroblast and activation of HSCs), a deficient production of vasodilators, changes in the expression and sensitivity of the receptors and amplification of the vasoconstrictive response by secondary production of vasoconstrictors. While the first two mechanisms would be non-specific and apply to every vasoconstrictor, the other two would be associated with changes in the signalling pathways of specific vasoconstrictors.

Endothelin

This is the vasoconstrictor that has been most thoroughly studied in the hepatic circulation. However, its role in portal hypertension remains unclear. There is evidence that circulating and intrahepatic levels of endothelin are increased in cirrhosis [25,28], and that endothelin can increase intrahepatic resistance in the isolated liver [29]. Endothelin acts through two receptors: ET-A and ET-B. The former mediates vasoconstriction, while the latter can mediate both vasoconstriction and vasodilation. The vasoconstrictive response of the cirrhotic liver vasculature to endothelin has been found to be both increased [29] and decreased [22] compared with the normal liver, while the vasoconstrictive response to selective ET-B agonists has been shown to be uniformly increased in cirrhosis [22]. On the other hand, activation of HSCs is associated with a change in endothelin receptor pattern from a predominance of ET-A receptors in normal subjects to a predominance of ET-B receptors in cirrhosis [25], which could suggest a change in the sensitivity of HSCs to endothelin. *In vivo* studies have not contributed to the clarification of the role of endothelin in portal hypertension. Acute administration of a mixed ET-A/ET-B receptor blocker seems to decrease portal pressure, whereas chronic administration does not modify portal pressure. On the contrary, chronic selective blockade of ET-A receptor decreases collagen accumulation in a secondary biliary cirrhosis model, whereas acute ET-A blockade to cirrhotic rats does not lower portal pressure [30]. Preliminary results in humans have shown that neither ET-A nor ET-B blockers are able to decrease portal pressure in cirrhotic patients, and that ET-A blockers induce marked hypotension [31]. Therefore, although these results suggest that endothelin might regulate hepatic resistance in the normal and cirrhotic liver, endothelin does not seem to be a useful pharmacological target in portal hypertension in cirrhosis.

Angiotensin II

In patients with advanced cirrhosis, there is a marked activation of the renin–angiotensin system (RAS), which correlates with the severity of portal hypertension [26]. In experimental studies in the isolated liver, angiotensin II infusion increases intrahepatic resistance [21,22], and infusion of angiotensin II through the portal vein of cirrhotic patients increases portal pressure and decreases hepatic blood flow. These effects are probably mediated by the contraction of HSCs which, once activated, express angiotensin II type 1 receptors and contract in response to angiotensin II [32]. Further, HSCs express all the components of the RAS [33], which suggests that not only circulating angiotensin but also locally produced angiotensin II has a role in the increased resistance in cirrhosis. Activation of RAS, however, is a homeostatic process that contributes to maintaining arterial pressure in advanced cirrhosis [34] and, therefore, RAS blockade induces marked hypotension in these patients without a significant decrease in portal pressure [35]. This means that angiotensin II is probably not a useful target for the treatment of portal hypertension, at least in advanced cirrhosis.

Cysteinyl-leukotrienes

These are potent vasoconstrictors that are derived from arachidonic acid through the 5-lipoxygenase (5-LO) pathway. Cysteinyl-leukotriene production is increased in livers from cirrhotic rats, which show an increase in 5-LO expression [24,27]. The isolated cirrhotic liver responds to leukotrienes with a marked increase in intrahepatic resistance, and 5-LO blockade decreases hepatic resistance in cirrhotic livers [27]. There is no information on the *in vivo* haemodynamic effects of 5-LO blockers.

Alpha-adrenergic stimulus

This increases hepatic resistance [21], and this effect is higher in cirrhotic than in normal liver [7,9,23]. This finding cannot be fully explained by a decreased production of NO in the cirrhotic liver [23]. A recent study demonstrated that the cirrhotic liver responds to alpha-adrenergic agonists with an increased endothelial production of thromboxane A_2 mediated by COX-1, which amplifies its vasoconstrictive effect [23,36]. This expands the concept of endothelial dysfunction in cirrhosis, characterized not only by insufficient production of NO but also by increased production of vasoconstrictive prostanoids (Fig. 2). *In vivo* studies have shown that alpha-adrenergic blockade decreases intrahepatic resistance in patients with cirrhosis, but the use of these agents in portal hypertension is hampered by the fact that, like most vasodilators, they not only act in the hepatic circulation, but also induce hypotension [30].

In summary, the cirrhotic liver exhibits a dysregulation in the production of and response to a number of vasconstrictors and vasodilators, and it is likely that more than a single target needs to be hit to effectively decrease intrahepatic resistance in cirrhosis.

Collateral resistance

The development of collaterals in portal hypertension is the key event that leads to severe complications such as variceal bleeding and hepatic encephalopathy. Collaterals develop as a consequence of the pressure increase in the portal system,

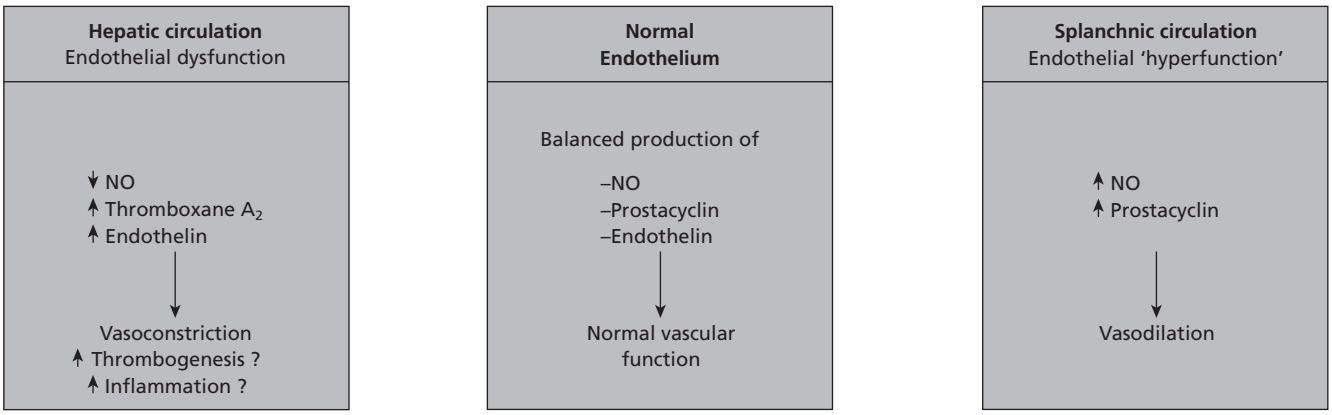

Fig. 2 The endothelium has a central role in the pathophysiology of portal hypertension. In the normal endothelium, a balanced production of vasoconstrictive and vasodilatory substances maintains a normal vascular tone and an anti-inflammatory and antithrombotic environment. In cirrhosis, endothelial dysfunction develops in the intrahepatic circulation, characterized by a decreased production of nitric oxide and an increased production of vasoconstrictive prostanoids and endothelin. This results in an increase in the intrahepatic vascular tone, and probably contributes to create a prothrombogenic and proinflammatory environment. In contrast, in the splanchnic circulation, there is an increase in the endothelial production of nitric oxide, which contributes to splanchnic vasodilation and the ensuing increase in portal blood inflow that maintains and worsens portal hypertension.

allowing the decompression of the portal territory to vascular beds of low pressure. However, this decompression is ineffective, not because these collaterals have a very high resistance but because, in parallel with the development of collaterals, an increase in portal blood inflow maintains portal hypertension.

Collateral formation results in part from the opening and dilation of preformed channels. Additionally, an active angiogenesis process intervenes in collateral formation, and this process is vascular endothelial growth factor (VEGF) dependent. VEGF expression increases in the intestine and mesentery of rats with prehepatic portal hypertension, and VEGF blockade reduces by 50% the development of collaterals in this model [37]. Additional studies showed that collateral formation is also NO dependent [38], raising the possibility that VEGF acts upstream of NO in the collateralization process.

Because as much as 90% of portal blood flow could be shunted through portosystemic collaterals in advanced portal hypertension, changes in collateral resistance can modify portal pressure. A number of studies performed in a model in which the collateral bed is perfused *in situ* have demonstrated that these vessels have functional receptors for vasopressin, endothelin, serotonin and alpha- and beta-adrenergic receptors, and respond to NO with vasodilation [39,40].

Increase in hepatic blood flow: the hyperdynamic circulation

In 1953, Kowalski and Abelman first demonstrated that cirrhosis is associated with a hyperdynamic circulatory syndrome, characterized by a marked decrease in systemic vascular resistance, arterial hypotension and increased cardiac output. These profound alterations in peripheral circulation in liver cirrhosis contribute to the development of complications such as ascites, hepatorenal syndrome and hepatopulmonary syndrome. Additionally, in the 1970s, a series of studies in patients with liver cirrhosis suggested that the splanchnic circulation was also hyperdynamic, and that not only an increase in hepatic resistance but also an increase in portal blood flow contributed to portal hypertension in cirrhosis [41]. This was unequivocally demonstrated in subsequent studies in rodent models of portal hypertension [42], and set the rationale for the use of vasoconstrictors in the treatment of portal hypertension. The hyperdynamic circulatory state in portal hypertension is the consequence of two pathophysiological phenomena: arterial vasodilation and plasma volume expansion. The presence of both is required for the expression of the hyperdynamic state [34,43,44].

Splanchnic and peripheral vasodilation

At least three mechanisms are thought to contribute to vasodilatation in portal hypertension: (i) increased concentration of circulatory vasodilators; (ii) increased endothelial production of local vasodilators; and (iii) decreased vascular responsiveness to endogenous vasoconstrictors. The last mechanism is probably due to the effect of the first two components.

Circulatory vasodilators

Glucagon Initial studies focused on circulating mediators that would be increased as a result of deficient removal by the liver because of deteriorated liver function and/or portosystemic shunting. Glucagon is probably the humoral vasodilator for which there is the most evidence of a significant role in promoting splanchnic hyperaemia in portal hypertension. Many studies have demonstrated that plasma glucagon levels are elevated in cirrhosis. Hyperglucagonism results, in part, from decreased hepatic clearance but, more importantly, from an increased

secretion by pancreatic alpha cells [45]. Support for a role for glucagon in modulating the splanchnic blood flow comes from studies showing that the normalization of the circulating levels of glucagon partially reverses the increased splanchnic blood flow, and this can be prevented by a concomitant glucagon infusion [46]. However, some studies showed no correlation between glucagon levels and splanchnic blood flow, thus questioning a major role for hyperglucagonism in portal hypertension. Glucagon release is clearly implicated in postprandial hyperaemia which, in patients with cirrhosis, is associated with marked increases in portal pressure [47]. Collectively, these data provided the rationale for the use of somatostatin and octreotide in the treatment of patients with portal hypertension, although it has been demonstrated recently that these drugs promote vasoconstriction by mechanisms independent of those of glucagon inhibition [48].

Endocannabinoids In rats and in patients with advanced cirrhosis, there is an increase in the production of the endogenous cannabinoid anandamide by monocytes [49,50], and the specific blockade of the peripheral cannabinoid receptor CB1 attenuates the hyperdynamic circulation [49,50] and decreases portal pressure [49]. It has been postulated that cannabinoids would act through an increase in NO production [49], but results are contradictory [50]. The mechanisms that would induce anandamide production are not clear, but could be related to the frequent endotoxaemia observed in cirrhosis.

Several other circulating vasodilators, such as calcitonin gene-related peptide (CGRP), adrenomedullin and carbon monoxide, have also been linked to the pathogenesis of vasodilation in portal hypertension, but evidence is still scarce.

Local vasodilators

The implication of NO in portal hypertension was initially suggested by Vallance and Moncada [51]. Several lines of evidence confirmed the central role of NO in the development of the hyperdynamic circulation. On one hand, patients with cirrhosis have increased levels of nitrites and nitrates [52], the degradation products of NO. In experimental animals, it was demonstrated that NO production is increased in the splanchnic vascular bed of portal hypertensive rats, and this accounts for the hyporesponse to vasoconstrictors characteristic of portal hypertension [53]. Furthermore, inhibition of NO production reduces portal pressure, portosystemic shunting and prevents (although not completely) the development of the hyperdynamic circulation [54,55]. This last finding, together with the fact that double eNOS/inducible NOS (iNOS) knockout mice still develop the hyperdynamic circulation after the induction of portal hypertension [56], suggests that NO is the principal, but not the only, mediator of vasodilation.

A number of studies have characterized at the molecular level the mechanisms leading to increased NO production in portal hypertension. At odds with the original hypothesis, which suggested that endotoxaemia present in cirrhosis would upregulate iNOS [51], overwhelming data suggest that increased NO in portal hypertension is mediated by eNOS [57]. Preliminary data suggest that neuronal NOS (nNOS) activation could also have a role in the increased NO production that occurs in portal hypertension [58], but this role would be far outweighed by that of eNOS [59].

The most powerful stimulus for eNOS upregulation is shear stress. Indeed, shear stress is increased in portal hypertension once the hyperdynamic circulation is established. Furthermore, the superior mesenteric vascular bed from portal hypertensive rats shows an enhanced production of NO in response to shear stress [53]. Bacterial translocation also contributes to increased NO production in advanced cirrhosis, but the mechanism involves an upregulation of eNOS, not iNOS [60]. Finally, portosystemic shunt, *per se*, can induce NO-mediated vasodilation [61]. However, sequential studies in the portal vein ligated model have shown that eNOS activation occurs before any of these three mechanisms is present [62,63]. This indicates, on the one hand, that increased eNOS production is a primary factor in the development of vasodilation and, on the other hand, that different mechanisms from those mentioned above activate eNOS in the very early phases of portal hypertension. Recent data indicate that the initial eNOS upregulation occurs at the small arterioles of the intestinal mucosa, and that it is secondary to VEGF upregulation [64], raising the possibility that the first stimulus that upregulates eNOS is intestinal hypoxia secondary to congestion or to superior mesenteric artery (SMA) reflex vasoconstriction in response to increased portal pressure [63]. In keeping with these findings, it was demonstrated recently that blocking VEGF action from the onset of portal hypertension markedly attenuates the development of the hyperdynamic circulation and decreases portal blood inflow by 50% [65]. Whether these mechanisms account for the development of the hyperdynamic circulation in human cirrhosis needs to be confirmed.

When looking at the signalling level, molecular studies have shown that, in the early stages of portal hypertension, increased eNOS activity is detected before the increase in eNOS expression. This is due to activation of eNOS at the posttranslational level, mediated by increased Akt-dependent eNOS phosphorylation [66]. In the more advanced stages of portal hypertension, NO production increases as a result of both an increase in eNOS expression [60] and an increase in eNOS activity related to changes at the posttranslational level. This latter mechanism involves an increased interaction of eNOS with the molecular chaperone Hsp90 [67]. Also, it has been shown that bacterial translocation activates eNOS through a tumour necrosis factor (TNF)α-dependent increase in tetrahydrobiopterin (BH_4) [60,68], an essential cofactor of eNOS. Taken together, these studies show that different mechanisms upregulate eNOS (Fig. 3) and that the relative importance of these mechanisms varies during the evolution of portal hypertension.

In summary, in striking contrast to what occurs in the intrahepatic circulation, in which there is a deficit in NO production,

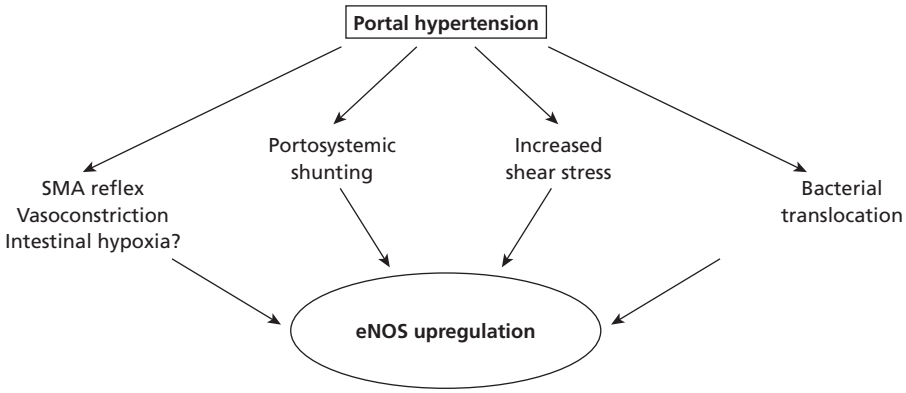

Fig. 3 Portal hypertension activates different mechanisms that ultimately lead to eNOS upregulation.

in the splanchnic circulation, there is an increase in NO production (Fig. 2) [57]. This paradox poses enormous difficulties in developing NO-based therapies for portal hypertension. However, it must be taken into account that the primary defect is the increase in intrahepatic resistance, and splanchnic vasodilation is a secondary alteration. Therefore, it is likely that, by improving the increase in hepatic resistance, some of the alterations in the splanchnic circulation can be reverted [15].

Another local vasodilator that has been linked to splanchnic hyperaemia in portal hypertension is prostacyclin [69,70], but the available evidence is less extensive than that for NO. Systemic and splanchnic production of prostacyclin is increased in portal hypertension as a consequence of an increased expression of COX-1 and COX-2 [71]. Blocking any of the two isoforms increases the response of the splanchnic vasculature to vasoconstrictors, but the effect of COX-2 blockade is more intense [71]. Further, COX blockade has been shown to attenuate the hyperdynamic circulation in portal hypertension [72,73].

Plasma volume expansion

For many years, plasma volume expansion has been recognized in a wide variety of portal hypertensive liver diseases. In conditions of constant peripheral vascular resistance, an increase in circulatory blood volume results in increased venous return and cardiac output. However, expansion of blood volume leads to stress relaxation of the vasculature and, after this initial increase, cardiac output returns to normal. This demonstrates that blood volume expansion alone is not sufficient in itself to maintain a hyperkinetic circulatory state. It is the combination of arterial vasodilation and blood volume expansion that produces optimal conditions for maintaining the hyperdynamic circulatory state in portal hypertension.

Sodium retention is the earliest and most frequent abnormality of renal function associated with portal hypertension. Sodium restriction markedly attenuates the development of the hyperdynamic circulation in portal hypertensive rats, normalizing cardiac output and portal venous inflow [74]. On the other hand, it has been demonstrated that diuretics such as spironolactone decrease (although mildly) portal pressure [75]. The initial stimulus for sodium retention is arterial vasodilation [76,77], which leads to arterial underfilling and subsequent activation of baroreceptors. This leads to the activation of the sympathetic nervous system, renin–angiotensin system and vasopressin secretion. The final result is sodium and water retention by the kidneys and plasma volume expansion (Fig. 4).

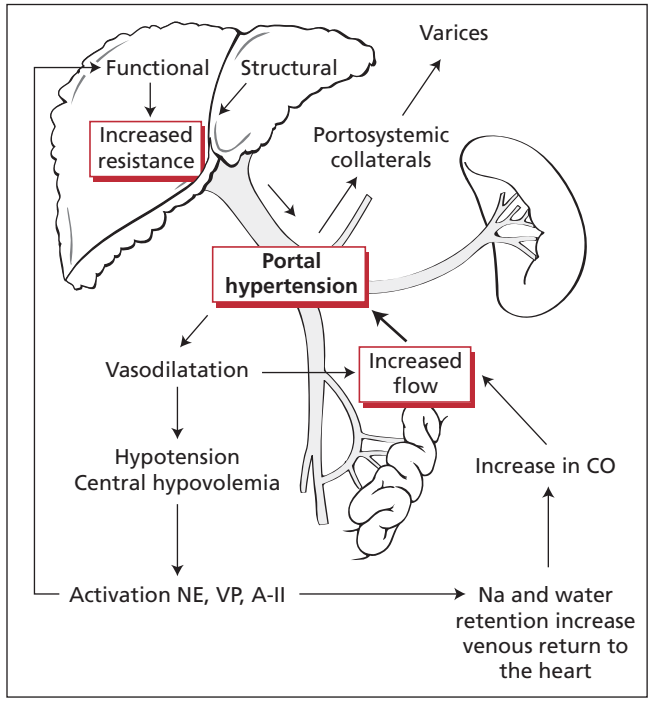

Fig. 4 Summary of the pathophysiology of portal hypertension. The increase in hepatic resistance leads to an increase in portal pressure. This leads to a cascade of disturbances in the splanchnic and systemic circulation characterized by vasodilation, sodium and water retention and plasma volume expansion, which are major players in the pathogenesis of ascites and hepatorenal syndrome. Additionally, these alterations lead to an increase in portal blood inflow that contributes to maintaining and aggravating portal hypertension. Another characteristic feature is the development of portosystemic collaterals that are responsible for complications such as variceal bleeding and hepatic encephalopathy. CO, cardiac output; NE, norepinephrine; VP, vasopressin; A-II, angiotensin II; Na, sodium.

This has been called the peripheral arterial vasodilation hypothesis [34], and not only explains the pathophysiology of the hyperdynamic circulation in portal hypertension, but also many aspects of other complications of portal hypertension such as ascites and hepatorenal syndrome [43].

Summary and conclusions

The primary event leading to portal hypertension in liver cirrhosis is increased hepatic resistance. This is due not only to the architectural disturbances in liver vasculature associated with the cirrhotic process, but also to an increased intrahepatic vascular tone that results from an imbalance between excessive vasoconstrictors and deficient vasodilators. Besides, portal hypertension induces marked alterations in the systemic and splanchnic circulation, characterized by a decrease in systemic vascular resistance, arterial hypotension, increased cardiac output and plasma volume expansion, and is known as the hyperdynamic circulatory state. This leads to an increase in portal blood inflow that contributes to maintain and aggravate portal hypertension (Fig. 4). These concepts provide the rationale for understanding the pharmacological treatments of portal hypertension in cirrhosis.

References

1 Sikuler E, Groszmann RJ (1986) Interaction of flow and resistance in maintenance of portal hypertension in a rat model. *Am J Physiol* 250, G205–G212.

2 Wanless IR, Wong F, Blendis LM *et al.* (1995) Hepatic and portal vein thrombosis in cirrhosis: possible role in development of parenchymal extinction and portal hypertension. *Hepatology* 21, 1238–1247.

3 Bhathal PS, Grossman HJ (1985) Reduction of the increased portal vascular resistance of the isolated perfused cirrhotic rat liver by vasodilators. *J Hepatol* 1, 325–337.

4 Zhang JX, Pegoli W Jr, Clemens MG (1994) Endothelin-1 induces direct constriction of hepatic sinusoids. *Am J Physiol (Gastrointest Liver Physiol)* 29, G624–G632.

5 Pinzani M, Gentilini P (1999) Biology of hepatic stellate cells and their possible relevance in the pathogenesis of portal hypertension in cirrhosis. *Semin Liver Dis* 19, 397–410.

6 Kaneda K, Sogawa M, Matsumara A *et al.* (1998) Endothelin-1 induced vasoconstriction causes a significant increase in portal pressure of rat liver: localized constrictive effect on the distal segment of preterminal portal venules as revealed by light and electron microscopy and serial reconstruction. *Hepatology* 27, 735–747.

7 Loureiro-Silva MR, Cadelina GW, Groszmann RJ (2003) Deficit in nitric oxide production in cirrhotic rat livers is located in the sinusoidal and postsinusoidal areas. *Am J Physiol Gastrointest Liver Physiol* 284, G567–G574.

8 Mittal MK, Gupta TK, Lee FY *et al.* (1994) Nitric oxide modulates hepatic vascular tone in normal rat liver. *Am J Physiol* 267, G416–G422.

9 Gupta TK, Toruner M, Chung MK *et al.* (1998) Endothelial dysfunction and decreased production of nitric oxide in the intrahepatic microcirculation of cirrhotic rats. *Hepatology* 28, 926–931.

10 Rockey DC, Chung JJ (1998) Reduced nitric oxide production by endothelial cells in cirrhotic rat liver: endothelial dysfunction in portal hypertension. *Gastroenterology* 114, 344–351.

11 Shah V, Toruner M, Haddad F *et al.* (1999) Impaired endothelial nitric oxide synthase activity associated with enhanced caveolin binding in experimental cirrhosis in the rat. *Gastroenterology* 117, 1222–1228.

12 Bellis L, Berzigotti A, Abraldes JG *et al.* (2003) Low doses of isosorbide mononitrate attenuate the postprandial increase in portal pressure in patients with cirrhosis. *Hepatology* 37, 378–384.

13 Van de CM, Omasta A, Janssens S *et al.* (2002) In vivo gene transfer of endothelial nitric oxide synthase decreases portal pressure in anaesthetised carbon tetrachloride cirrhotic rats. *Gut* 51, 440–445.

14 Loureiro-Silva MR, Cadelina GW, Iwakiri Y *et al.* (2003) A liver-specific nitric oxide donor improves the intra-hepatic vascular response to both portal blood flow increase and methoxamine in cirrhotic rats. *J Hepatol* 39, 940–946.

15 Morales-Ruiz M, Cejudo-Martn P, Fernandez-Varo G *et al.* (2003) Transduction of the liver with activated Akt normalizes portal pressure in cirrhotic rats. *Gastroenterology* 125, 522–531.

16 Dudenhoefer AA, Loureiro-Silva MR, Cadelina GW *et al.* (2002) Bioactivation of nitroglycerin and vasomotor response to nitric oxide are impaired in cirrhotic rat livers. *Hepatology* 36, 381–385.

17 Van De Casteele M, Van Pelt JF, Nevens F *et al.* (2003) Low NO bioavailability in CCl4 cirrhotic rat livers might result from low NO synthesis combined with decreased superoxide dismutase activity allowing superoxide-mediated NO breakdown: a comparison of two portal hypertensive rat models with healthy controls. *Comp Hepatol* 2, 2.

18 Loureiro-Silva MR, Iwakiri Y, Abraldes JG *et al.* (2006) Increased phosphodiesterase-5 expression is involved in the decreased vasodilator response to nitric oxide in cirrhotic rat livers. *J Hepatol* 44, 886–893.

19 Suematsu M, Goda N, Sano T *et al.* (1995) Carbon monoxide: an endogenous modulator of sinusoidal tone in the perfused rat liver. *J Clin Invest* 96, 2431–2437.

20 Makino N, Suematsu M, Sugiura Y *et al.* (2001) Altered expression of heme oxygenase-1 in the livers of patients with portal hypertensive diseases. *Hepatology* 33, 32–42.

21 Ballet F, Chretien Y, Rey C *et al.* (1988) Differential response of normal and cirrhotic liver to vasoactive agents. A study in the isolated perfused rat liver. *J Pharmacol Exp Ther* 244, 233–235.

22 Rockey DC, Weisiger RA (1996) Endothelin induced contractility of stellate cells from normal and cirrhotic rat liver: implications for regulation of portal pressure and resistance. *Hepatology* 24, 233–240.

23 Graupera M, Garcia-Pagan JC, Abraldes JG *et al.* (2003) Cyclooxygenase-derived products modulate the increased intrahepatic resistance of cirrhotic rat livers. *Hepatology* 37, 172–181.

24 Titos E, Claria J, Bataller R *et al.* (2000) Hepatocyte-derived cysteinyl leukotrienes modulate vascular tone in experimental cirrhosis. *Gastroenterology* 119, 794–805.

25 Pinzani M, Milani S, De Franco R *et al.* (1996) Endothelin 1 is overexpressed in human cirrhotic liver and exerts multiple effects on activated hepatic stellate cells. *Gastroenterology* 110, 534–548.

26 Bosch J, Arroyo V, Betriu A *et al.* (1980) Hepatic hemodynamics and the renin-angiotensin-aldosterone system in cirrhosis. *Gastroenterology* 78, 92–99.

27 Graupera M, Garcia-Pagan JC, Titos E *et al.* (2002) 5-lipoxygenase inhibition reduces intrahepatic vascular resistance of cirrhotic rat livers: a possible role of cysteinyl-leukotrienes. *Gastroenterology* 122, 387–393.

28 Asbert M, Gines A, Gines P *et al.* (1993) Circulating levels of endothelin in cirrhosis. *Gastroenterology* 104, 1485–1491.

29 Elliot AJ, Vo LT, Grossman VL *et al.* (1997) Endothelin-induced vasoconstriction in isolated perfused liver preparations from normal and cirrhotic rats. *J Gastroenterol Hepatol* 12, 314–318.

30 Bosch J, Abraldes JG, Groszmann RJ (2003) Current management of portal hypertension. *J Hepatol* 38, S54–S68.

31 Tripathi D, Therapondos G, Ferguson JW *et al.* (2006) Endothelin-1 contributes to the maintenance of systemic but not portal haemodynamics in patients with early cirrhosis: a randomised controlled trial. *Gut* 55, 1290–1295.

32 Bataller R, Gines P, Nicolas JM *et al.* (2000) Angiotensin II induces contraction and proliferation of human hepatic stellate cells. *Gastroenterology* 118, 1149–1156.

33 Bataller R, Sancho-Bru P, Gines P *et al.* (2003) Activated human hepatic stellate cells express the renin–angiotensin system and synthesize angiotensin II. *Gastroenterology* 125, 117–125.

34 Schrier RW, Arroyo V, Bernardi M *et al.* (1988) Peripheral arterial vasodilation hypothesis: a proposal for the initiation of renal sodium and water retention in cirrhosis. *Hepatology* 8, 1151–1157.

35 Gonzalez-Abraldes J, Albillos A, Banares R *et al.* (2001) Randomized comparison of long-term losartan versus propranolol in lowering portal pressure in cirrhosis. *Gastroenterology* 121, 382–388.

36 Graupera M, March S, Engel P *et al.* (2005) Sinusoidal endothelial COX-1-derived prostanoids modulate the hepatic vascular tone of cirrhotic rat livers. *Am J Physiol Gastrointest Liver Physiol* 288, G763–G770.

37 Fernandez M, Vizzutti F, Garcia-Pagan JC *et al.* (2004) Anti-VEGF receptor-2 monoclonal antibody prevents portal-systemic collateral vessel formation in portal hypertensive mice. *Gastroenterology* 126, 886–894.

38 Sieber CC, Sumanovski LT, Stumm M *et al.* (2001) In vivo angiogenesis in normal and portal hypertensive rats: role of basic fibroblast growth factor and nitric oxide. *J Hepatol* 34, 644–650.

39 Mosca P, Lee FY, Kaumann AJ *et al.* (1992) Pharmacology of portal–systemic collaterals in portal hypertensive rats: role of endothelium. *Am J Physiol* 263, G544–G550.

40 Chan CC, Wang SS, Lee FY *et al.* (2001) Endothelin-1 induces vasoconstriction on portal–systemic collaterals of portal hypertensive rats. *Hepatology* 33, 816–820.

41 Kotelanski B, Groszmann R, Cohn JN (1972) Circulation times in the splanchnic and hepatic beds in alcoholic liver disease. *Gastroenterology* 63, 102–111.

42 Vorobioff J, Bredfeldt J, Groszmann RJ *et al.* (1983) Hyperdynamic circulation in a portal hypertensive rat model: a primary factor for maintenance of chronic portal hypertension. *Am J Physiol* 244, G52–G56.

43 Groszmann RJ (1994) Hyperdynamic circulation of liver disease 40 years later: pathophysiology and clinical consequences. *Hepatology* 20, 1359–1363.

44 Iwakiri Y, Groszmann RJ (2006) The hyperdynamic circulation in chronic liver diseases: from the Patient to the Molecule. *Hepatology* 43(2 Suppl. 1), S121–131.

45 Gomis R, Fernandez-Alvarez J, Pizcueta P *et al.* (1994) Impaired function of pancreatic islets from rats with portal hypertension resulting from cirrhosis and partial portal vein ligation. *Hepatology* 19, 1257–1261.

46 Kravetz D, Bosch J, Arderiu MT *et al.* (1988) Effects of somatostatin on splanchnic hemodynamics and plasma glucagon in portal hypertensive rats. *Am J Physiol* 254, G322–G328.

47 Albillos A, Rossi I, Iborra J *et al.* (1994) Octreotide prevents postprandial splanchnic hyperemia in patients with portal hypertension. *J Hepatol* 21, 88–94.

48 Wiest R, Tsai MH, Groszmann RJ (2001) Octreotide potentiates PKC-dependent vasoconstrictors in portal-hypertensive and control rats. *Gastroenterology* 120, 975–983.

49 Batkai S, Jarai Z, Wagner JA *et al.* (2001) Endocannabinoids acting at vascular CB1 receptors mediate the vasodilated state in advanced liver cirrhosis. *Nature Med* 7, 827–832.

50 Ros J, Claria J, To-Figueras J *et al.* (2002) Endogenous cannabinoids: a new system involved in the homeostasis of arterial pressure in experimental cirrhosis in the rat. *Gastroenterology* 122, 85–93.

51 Vallance P, Moncada S (1991) Hyperdynamic circulation in cirrhosis: a role for nitric oxide? *Lancet* 337, 776.

52 Guarner C, Soriano G, Tomas A *et al.* (1993) Increased serum nitrite and nitrate levels in patients with cirrhosis: relationship to endotoxemia. *Hepatology* 18, 1139–1143.

53 Hori N, Wiest R, Groszmann RJ (1998) Enhanced release of nitric oxide in response to changes in flow and shear stress in the superior mesenteric arteries of portal hypertensive rats. *Hepatology* 28, 1467–1473.

54 Lee FY, Colombato LA, Albillos A *et al.* (1993) Administration of N omega-nitro-L-arginine ameliorates portal-systemic shunting in portal-hypertensive rats. *Gastroenterology* 105, 1464–1470.

55 García-Pagán JC, Fernandez M, Bernadich C *et al.* (1994) Effects of continued nitric oxide inhibition on the development of the portal hypertensive syndrome following portal vein stenosis in the rat. *Am J Physiol* 30, 984–990.

56 Iwakiri Y, Cadelina G, Sessa WC *et al.* (2002) Mice with targeted deletion of eNOS develop hyperdynamic circulation associated with portal hypertension. *Am J Physiol Gastrointest Liver Physiol* 283, G1074–G1081.

57 Wiest R, Groszmann RJ (2002) The paradox of nitric oxide in cirrhosis and portal hypertension: too much, not enough. *Hepatology* 35, 478–491.

58 Jurzik L, Froh M, Straub RH *et al.* (2005) Up-regulation of nNOS and associated increase in nitrergic vasodilation in superior mesenteric arteries in pre-hepatic portal hypertension. *J Hepatol* 43, 258–265.

59 Kwon SY, Groszmann RJ, Iwakiri Y (2007) Increased neuronal nitric oxide synthase interaction with soluble guanylate cyclase contributes to the splanchnic arterial vasodilation in portal hypertensive rats. *Hepatol Res* (in press).

60 Wiest R, Das S, Cadelina G *et al.* (1999) Bacterial translocation in cirrhotic rats stimulates eNOS-derived NO production and impairs mesenteric vascular contractility. *J Clin Invest* 104, 1223–1233.

61 Bernadich C, Bandi JC, Piera C *et al.* (1997) Circulatory effects of graded diversion of portal blood flow to the systemic circulation in rats: role of nitric oxide. *Hepatology* 26, 262–267.

62 Wiest R, Shah V, Sessa WC *et al.* (1999) NO overproduction by eNOS precedes hyperdynamic splanchnic circulation in portal hypertensive rats. *Am J Physiol* 276, G1043–G1051.

63 Tsai MH, Iwakiri Y, Cadelina G *et al.* (2003) Mesenteric vasoconstriction triggers nitric oxide overproduction in the superior mesenteric artery of portal hypertensive rats. *Gastroenterology* 125, 1452–1461.

64 Abraldes JG, Iwakiri Y, Loureiro-Silva *et al.* (2006) Mild increases in portal pressure upregulate vascular endothelial growth factor and endothelial nitric oxide synthase in the intestinal microcirculatory bed, leading to a hyperdynamic state. *Am J Physiol Gastrointest Liver Physiol* 290, G980–G987.

65 Fernandez M, Mejias M, Angermayr B *et al.* (2005) Inhibition of VEGF receptor-2 decreases the development of hyperdynamic splanchnic circulation and portal-systemic collateral vessels in portal hypertensive rats. *J Hepatol* 43, 98–103.
66 Iwakiri Y, Tsai MH, McCabe TJ *et al.* (2002) Phosphorylation of eNOS initiates excessive NO production in early phases of portal hypertension. *Am J Physiol Heart Circ Physiol* 282, H2084–H2090.
67 Shah V, Wiest R, Garcia-Cardena G *et al.* (1999) Hsp90 regulation of endothelial nitric oxide synthase contributes to vascular control in portal hypertension. *Am J Physiol* 277, G463–G468.
68 Wiest R, Cadelina G, Milstien S *et al.* (2003) Bacterial translocation up-regulates GTP-cyclohydrolase I in mesenteric vasculature of cirrhotic rats. *Hepatology* 38, 1508–1515.
69 Guarner C, Soriano G, Such J *et al.* (1992) Systemic prostacyclin in cirrhotic patients. Relationship with portal hypertension and changes after intestinal decontamination. *Gastroenterology* 102, 303–309.
70 Sitzmann JV, Bulkley GB (1989) Role of prostacyclin in the splanchnic hyperemia contributing to portal hypertension. *Ann Surg* 209, 322–327.
71 Potenza MA, Botrugno OA, De Salvia MA *et al.* (2002) Endothelial COX-1 and -2 differentially affect reactivity of MVB in portal hypertensive rats. *Am J Physiol Gastrointest Liver Physiol* 283, G587–G594.
72 Fernandez M, Garcia-Pagan JC, Casadevall M *et al.* (1996) Acute and chronic cyclooxygenase blockade in portal hypertensive rats. Influence on nitric oxide biosynthesis. *Gastroenterology* 110, 1529–1535.
73 Bruix J, Bosch J, Kravetz D *et al.* (1985) Effects of prostaglandin inhibition on systemic and hepatic hemodynamics in patients with cirrhosis of the liver. *Gastroenterology* 88, 430–435.
74 Genecin P, Polio J, Groszmann RJ (1990) Na restriction blunts expansion of plasma volume and ameliorates hyperdynamic circulation in portal hypertension. *Am J Physiol* 259, G498–G503.
75 Garcia-Pagan JC, Salmeron JM, Feu F *et al.* (1994) Effects of low-sodium diet and spironolactone on portal pressure in patients with compensated cirrhosis. *Hepatology* 19, 1095–1099.
76 Albillos A, Colombato LA, Groszmann RJ (1992) Vasodilatation and sodium retention in prehepatic portal hypertension. *Gastroenterology* 102, 931–935.
77 Colombato LA, Albillos A, Groszmann RJ (1996) The role of central blood volume in the development of sodium retention in portal hypertensive rats. *Gastroenterology* 110, 193–198.

7.3 Clinical manifestations and management of bleeding episodes in cirrhotics

Jaime Bosch, Juan G. Abraldes and Juan Carlos García-Pagán

Introduction

Variceal bleeding is one of the commonest and most severe complications of liver cirrhosis. Even with the current best medical care, mortality from variceal bleeding is still around 20%. Moreover, variceal bleeding often leads to deterioration in liver function, and it is a common trigger for other complications of cirrhosis, such as bacterial infections or hepatorenal syndrome. In this chapter, we will review the natural history of varices in patients with cirrhosis, the primary and secondary prevention of acute variceal bleeding, and the medical management of the bleeding episode.

The natural history and clinical course of variceal bleeding

Development of oesophageal varices

When cirrhosis is diagnosed, varices are present in about 30–40% of compensated patients and in 60% of those who present with ascites [1]. In those cirrhotic patients who present without varices, the annual incidence of new varices is about 5–10% [2–6]. An hepatic venous pressure gradient (HVPG) over 10 mmHg [6] is a strong predictor for the development of varices. This is in keeping with the role of portal pressure as the driving force for the development of collaterals. No other factors have been associated with the development of varices [5,7].

Progression of oesophageal varices from small to large

Once developed, varices increase in size from small to large before they eventually rupture and bleed. Studies assessing the progression from small to large varices are controversial, showing rates of progression of varices ranging from 5% to 30% per year [1,5,8,9]. The most likely reason for such variability is the different patient selection and follow-up endoscopy schedule across studies (7). The factor that has been most consistently associated with variceal progression is baseline Child–Pugh or its worsening during follow-up [5,8,10]. Other reported factors were alcoholic aetiology of cirrhosis and the presence of red wale markings [5]. It has been shown that changes in HVPG [either 'spontaneous' or caused by drug therapy or transjugular intrahepatic portosystemic shunts (TIPS)] are usually accompanied by parallel variations in the size of the oesophageal varices, which are significantly reduced when HVPG falls below 12 mmHg [11,12]. Thus, an increased HVPG plays a key role in both the development and the progression of the varices.

Incidence and risk indicators of first bleeding from oesophageal varices

Once varices have been diagnosed, the overall incidence of variceal bleeding is of the order of 25% at 2 years in non-selected patients [13]. Many efforts have been made to define risk criteria for the development of variceal bleeding. The most important predictive factors are variceal size, severity of liver dysfunction expressed by the Child–Pugh classification and red wale marks [14]. These risk indicators have been combined in the North Italian Endoscopic Club (NIEC) index, which allows the classification of patients into different groups with predicted 1-year bleeding risk ranging from 6% to 76% [14]. Overall, variceal size remains the most useful predictor for variceal bleeding [15]. This is the variable used in clinical practice to decide whether a patient should be given prophylactic therapy or not. The risk of bleeding is very low (between 1% and 2%) in patients without varices at the first examination, and increases to about 5% per year in those with small varices, and to 15% per year in those with medium or large varices at diagnosis [1].

The course of the acute bleeding episode

Prognostic factors

Ruptured oesophageal varices cause 70% of all upper gastrointestinal bleeding episodes in patients with portal hypertension [16]. Thus, in any cirrhotic patient with acute upper gastrointestinal bleeding, a variceal origin should be suspected. Clinical features are those of upper gastrointestinal bleeding (often

massive), combined with those of liver cirrhosis. The incidence of variceal bleeding shows a diurnal rhythm, with two peak incidences at 08.00–10.00 and 20.00–22.00 [17,18]. This rhythmicity is probably related to circadian variations in portal pressure [18]. Variceal bleeding is often intermittent, which should be taken into account in its diagnostic approach. Diagnosis is established at emergency endoscopy based on observing one of the following: (i) active bleeding from a varix (observation of blood spurting or oozing from the varix) (nearly 20% of patients); (ii) white nipple or clot adherent to a varix; (iii) presence of varices without other potential sources of bleeding.

Initial control of bleeding

Because variceal bleeding is frequently intermittent, it is difficult to assess when the bleeding stops and when a new haematemesis or melaena should be considered an episode of rebleeding. Several consensus conferences have addressed this issue and set definitions for events and timing of events related to episodes of variceal bleeding [19]. By using these definitions, data from placebo-controlled clinical trials have shown that variceal bleeding is spontaneously controlled in 40–50% of patients [13]. With currently available treatments, control of bleeding increases to about 80% of the patients [16].

Early rebleeding

The incidence of early rebleeding ranges between 30% and 40% in the first 6 weeks. The risk peaks in the first 5 days, with 40% of all rebleeding episodes occurring in this very early period, remains high during the first 2 weeks and then declines slowly in the next 4 weeks. After 6 weeks, the risk of further bleeding becomes virtually equal to that before bleeding [20]. Currently available treatments have reduced 6-week rebleeding to 20% [16]. Early rebleeding is a strong predictor of death within 6 weeks, indicating that its prevention should be a priority in the management of variceal bleeding. Prognostic indicators for early rebleeding were assessed in most studies together with initial failure to control bleeding and 5-day risk of death, confirming a composite endpoint referred to as '5-day failure'. Bacterial infection [21–23], active bleeding at emergency endoscopy [16,22,24], Child–Pugh class or score [16,22], aspartate aminotransferase (AST) levels [16], the presence of portal vein thrombosis [16] and an HVPG > 20 mmHg measured shortly after admission [25,26] have been reported as significant predictors of risk for 5-day failure.

Mortality

Mortality from variceal bleeding has greatly decreased in the last two decades from 42% mortality registered in the Graham and Smith study in 1981 [20] to the current 15–20% [16,27]. This decrease results from the implementation of effective treatments, such as endoscopic and pharmacological therapies and TIPS, as well as improved general medical care (i.e. antibiotic prophylaxis). As it may be difficult to assess the true cause of death (i.e. bleeding vs. liver failure or other adverse events), the general consensus is that any death occurring within 6 weeks from hospital admission for variceal bleeding should be considered as a bleeding-related death [19].

Immediate mortality from uncontrolled bleeding is in the range of 4–8% [3,4,16]. Prehospital mortality from variceal bleeding might be around 3% [28]. Like the risk of rebleeding, the risk of mortality peaks in the first days after bleeding, slowly declines thereafter and, after 6 weeks, becomes constant and virtually equal to that before bleeding [13,20]. Nowadays, only 40% of deaths are directly related to bleeding, while 50% are caused by liver failure and hepatorenal syndrome [16]. Thus, although there is still room for improving haemostatic treatments to substantially decrease mortality from variceal bleeding, therapies should be able to prevent liver and renal function deterioration.

Accurate indicators of risk of early death, available at hospital admission, could allow selection of patients for more aggressive therapies, such as emergency shunt or TIPS, before their conditions deteriorate, hampering further therapy. Unfortunately, the indicators of risk so far identified are also indicators of poor outcomes after derivative treatments and, consequently, are of limited clinical value. On hospital admission, the most consistently reported death risk indicators are Child–Pugh classification or its components, blood urea nitrogen (BUN) or creatinine, active bleeding on endoscopy, hypovolaemic shock and hepatocellular carcinoma [16,20,21,29–31]. Additionally, an HVPG > 20 mmHg [25] has been reported as a strong indicator of treatment failure. Conceivably, it is also associated with a higher risk of death, although its specific prognostic role for 6-week mortality has not been assessed. Prognostic indicators gathered in the early follow-up period are of no help in selecting immediate therapy, but do aid in developing a more focused and rational management of the patient. The most important among late prognostic indicators are early rebleeding [24,30], bacterial infection [23] and renal failure [30,31]. From these data, it is clear that management of the bleeding cirrhotic patient should be aimed not only at controlling the bleeding, but also at preventing early rebleeding, infection and renal failure.

Long-term recurrent bleeding from oesophageal varices and mortality

Patients surviving a first episode of variceal bleeding have a very high risk of rebleeding and death. Median rebleeding incidence within 1–2 years in untreated patients is around 60%, while mortality is around 33% [13]. Because of these high risks, all patients surviving a variceal bleeding should be treated for prevention of rebleeding independently of other risk indicators [32,33]. Randomized controlled trials (RCTs) for the prevention of rebleeding suggest that risk indicators of rebleeding and death are variceal size, Child–Pugh class, continued alcohol abuse and hepatocellular carcinoma [13]. An HVPG > 20 mmHg is significantly associated with a higher risk of 1-year mortality [25]. A spontaneous decrease in portal pressure after alcohol abstinence or the pharmacological reduction of portal pressure by

more than 20% of baseline values or below 12 mmHg are associated with a sustained decrease in the risk of rebleeding [11,34,35], indicating that effective portal pressure reduction can reverse the natural history of portal hypertension [35] (see below).

The management of portal hypertension

Rational basis for the treatment of portal hypertension

A very important concept, which has been strongly substantiated in recent years, is that the major factor determining the development of the complications and the clinical significance of portal hypertension is that portal pressure (assessed in clinical practice by the HVPG) increases above a critical threshold value. Varices do not develop until HVPG increases to ≥ 10 mmHg, and the HVPG should be of at least 12 mmHg for the appearance of other complications, such as variceal bleeding and ascites [36–38]. Implicit in this concept is that preventing the HVPG from increasing above these values will prevent the development of the complications of portal hypertension. Further, if HVPG is reduced below these thresholds by means of pharmacological treatment [12,34] or spontaneously as a result of an improvement in liver disease [11], variceal bleeding is totally prevented and varices decrease in size. Besides, even if this target is not achieved, a 20% decrease from baseline HVPG offers an almost total protection from variceal bleeding [34,35,39–43]. Such a reduction in HVPG, below 12 mmHg or of more than 20% of baseline, is now accepted as a therapeutic target in the treatment of portal hypertension. Achievement of these targets has also been shown to be associated with a decreased risk of developing ascites, spontaneous bacterial peritonitis, hepatorenal syndrome and death [35]. This provides the proof-of-concept of the reversibility of the portal hypertensive syndrome by means of portal pressure reduction.

A basic knowledge of the pathophysiology of portal hypertension is required to understand the pharmacological treatment of portal hypertension (Fig. 1). The initial factor that leads to portal hypertension is the increase in vascular resistance to portal blood flow. In cirrhosis, this increase in resistance occurs at the hepatic microcirculation (sinusoidal portal hypertension). It is important to emphasize that, contrary to what was traditionally thought, increased hepatic vascular resistance in cirrhosis is not only a mechanical consequence of the hepatic architectural disorder caused by the liver disease, but there is also a dynamic (and therefore reversible) component secondary to an increased intrahepatic vascular tone. This provides a rationale for the use of vasodilators in portal hypertension. Another way of

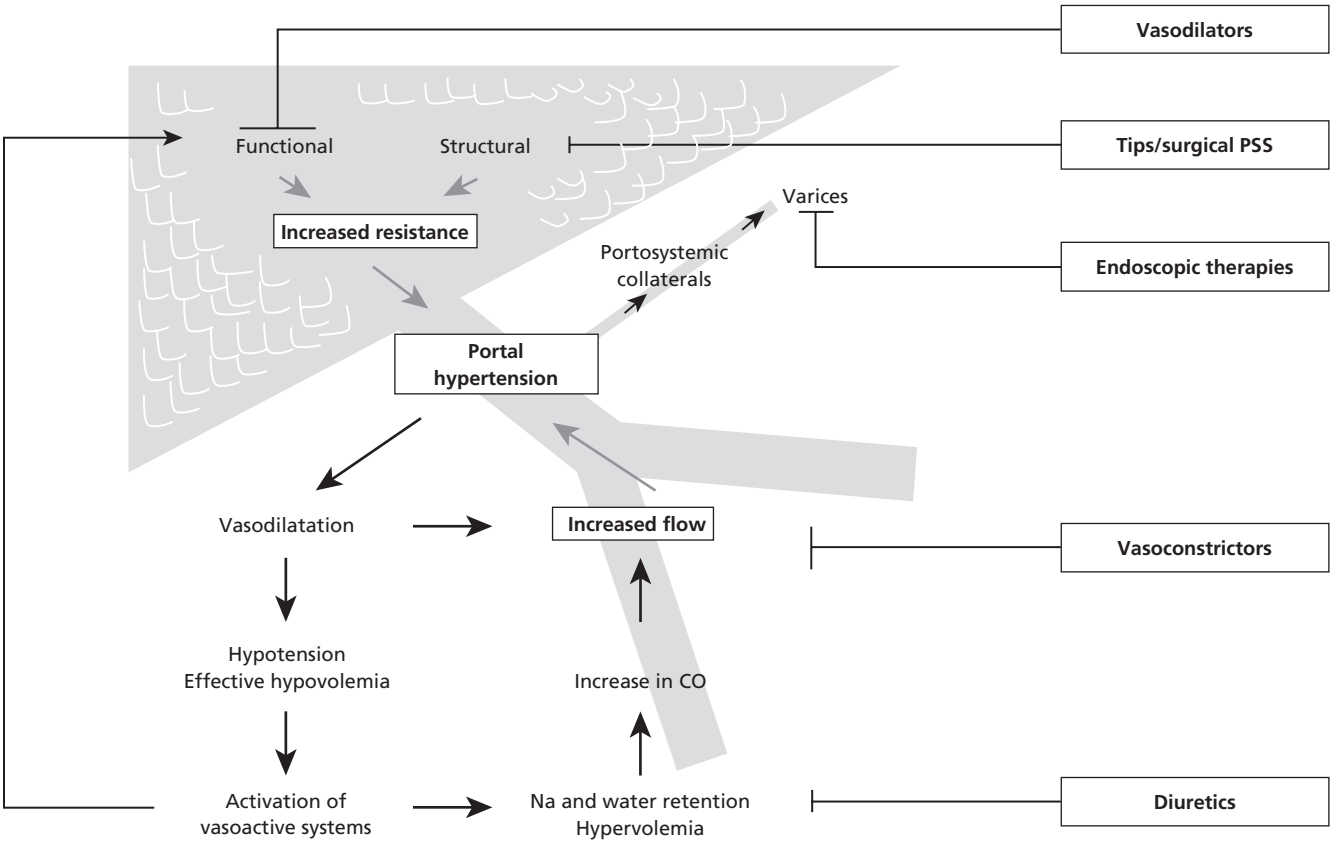

Fig. 1 Rationale for the treatment of portal hypertension (see text for details). CO, cardiac output; Na, sodium; PSS, portosystemic shunt.

overcoming the increased resistance through the cirrhotic liver is by means of portosystemic shunt surgery and TIPS. These procedures are highly effective in decreasing portal pressure, but have the detrimental effect that, by further decreasing portal blood flow through the liver and by increasing portosystemic shunting, they may enhance liver failure and facilitate hepatic encephalopathy.

A second factor contributing to portal hypertension is an increased blood flow through the portal venous system due to splanchnic arteriolar vasodilatation. Splanchnic hyperaemia contributes by aggravating the increase in portal pressure, and this explains why portal hypertension persists despite the establishment of an extensive network of portosystemic collaterals that may divert over 80% of the portal blood flow. The increased portal venous inflow can be corrected pharmacologically by means of splanchnic vasoconstrictors, such as vasopressin and its derivatives, somatostatin and its analogues and non-selective beta-adrenergic blockers, which are the drugs that have been more widely used in the treatment of portal hypertension. Splanchnic vasodilatation is accompanied by increased cardiac index and hypervolaemia, representing the hyperkinetic circulatory syndrome associated with portal hypertension [44,45]. An expanded blood volume is necessary to maintain the hyperdynamic circulation, which provides a rationale for the use of a low-sodium diet and spironolactone to attenuate the hyperkinetic syndrome and the portal pressure elevation in patients with cirrhosis [46].

Combined pharmacological therapy consists of associating vasoconstrictive drugs, which act by decreasing portal blood inflow, and vasodilators, which reduce the intrahepatic and portocollateral vascular resistance, in an attempt to enhance the reduction in portal pressure caused by the former.

Local treatments at the varices complete the spectrum of treatments for complications of portal hypertension. These treatments do not decrease portal pressure and therefore have no potential for preventing other complications of portal hypertension. Endoscopic therapy is directed at 'eradicating' the varices either by injecting a variety of irritating substances into or around the varices to promote thrombosis and fibrosis or by ligating the varices using elastic bands. It is possible that the efficacy of endoscopic therapy could be enhanced if combined with an agent that effectively lowers portal pressure [47]. Finally, haemostatic agents, such as recombinant activated factor VII, are being explored as adjuvants to conventional therapy to arrest variceal bleeding [48].

Prevention and treatment of the bleeding episodes

The treatment of portal hypertension includes the prevention of variceal haemorrhage in patients who have varices but never bled, the treatment of the acute bleeding episode and the prevention of rebleeding in patients who have survived a bleeding episode from oesophageal or gastric varices. So far, there is no effective treatment to prevent the development of varices ('preprimary prophylaxis') [6].

The main difference between these scenarios is that natural history and prognosis are very different from one to another. The previous considerations about the natural history of each of these situations should guide the selection of therapies, as the haemostatic or prophylactic efficacy of the available treatments are inversely proportional to their invasiveness and adverse effects.

Prevention of first bleeding from oesophageal varices

Screening for oesophageal varices

The aim of screening for oesophageal varices is to detect those patients with varices that will benefit from prophylactic treatment. The current consensus is that every cirrhotic patient should be screened endoscopically for varices at the time of diagnosis [19]. Although several studies indicate that non-invasive tests (particularly platelet count and data obtained from abdominal ultrasound) may have a potential use in selecting a group of patients with a high risk of varices [49–52], so far none of these has proved to be accurate enough in independent samples so that endoscopy can safely be omitted in patients with negative non-invasive indicators.

Cost-effectiveness decision analysis has challenged universal endoscopy screening in cirrhosis [53,54]. In these reports, it is suggested that empiric beta-blocker therapy for all patients without endoscopic screening is more cost-effective than universal screening and primary prophylaxis only in patients with large varices. A third study also suggested that empiric beta-blocker therapy is more cost-effective, but only in patients with decompensated cirrhosis [55]. However, the major drawbacks of beta-adrenergic blockers are patient adherence and side-effects (and thus quality of life), which are difficult to account for fully in decision analysis studies. The lack of effectiveness of beta-adrenergic blockers in preventing the development of varices and the high rate of side-effects observed even in well-compensated patients [6] severely compromise the use of beta-adrenergic blockers without screening.

In patients without varices on initial endoscopy, a second (follow-up) evaluation should be performed after 2–3 years to detect the development of varices before these bleed [19]. In those centres in which hepatic haemodynamic studies are available, it is advisable to measure HVPG. An HVPG over 10 mmHg indicates a more rapid progression to complications of cirrhosis and calls for shorter surveillance intervals [6]. In patients with small varices on initial endoscopy, the aim of subsequent evaluations is to detect the progression of small to large varices because of the important prognostic and therapeutic implications. Based on an expected 10–15% per year rate of progression of variceal size, endoscopy should be repeated every 1–2 years in patients with small varices [19]. In patients with advanced cirrhosis, red wale marks or alcoholic aetiology of cirrhosis, a 1-year interval

might be recommended [5,7]. Once the patient is started on beta-adrenergic blockers, there is no need for further endoscopic surveillance.

Treatments for the prevention of first bleeding

Pharmacological therapy The modern era of drug therapy for portal hypertension started in 1980 with the first publication of the use of propranolol for the prevention of recurrent variceal bleeding [56]. Since then, the efficacy of non-selective beta-adrenergic blockers has been assessed in a number of RCTs that consistently showed a significant reduction in the bleeding risk, both in the prophylaxis of first bleeding and in the prevention of rebleeding.

Non-selective beta-adrenergic blockers reduce portal pressure by decreasing portal venous inflow. Also, by reducing portal blood inflow, these drugs reduce portocollateral blood flow. This means that beta-adrenergic blockers can be beneficial in the prevention of variceal bleeding even in the absence of a decrease in portal pressure. The decrease in splanchnic blood flow is the result of a decrease in cardiac output due to the blockade of cardiac beta-1 adrenoceptors, and of splanchnic vasoconstriction due to the beta-2 receptor blockade, which leads to unopposed alpha-adrenergic activity [57].

Both propranolol and nadolol have been proven effective in the prevention of variceal bleeding [13]. Nadolol may be more convenient as it is administered once a day and, on account of its low lipid solubility, may have lower potential for central side-effects [58]. Timolol also has low liposolubility [58] and has the greatest beta-2 adrenoceptor blocking effect [59], but this drug was only tested in one randomized trial evaluating the prevention of the development of varices, with negative results [6]. Therefore, there is no evidence to support the use of timolol for the prevention of variceal bleeding.

The dose of beta-adrenergic blockers is determined by stepwise increases in dose until reaching the maximum tolerated. This approach is probably more effective than titrating against heart rate to achieve a reduction of about 25% [35]. Propranolol is commonly initiated at a dose of 20–40 mg b.i.d., while nadolol is initiated at a dose of 40 mg/day. The most common side-effects are lightheadedness, fatigue, shortness of breath, impotence and sleep disorders. Although severe events are rare, these side-effects often result in lack of compliance. About 10–15% of patients develop intolerance that results in treatment withdrawal [60]. In addition, up to 15–20% of cirrhotic patients with varices present contraindications that preclude the use of beta-blockers [61]. Absolute contraindications are congestive heart failure, asthma, chronic obstructive pulmonary disease, second- or third-degree heart block and peripheral vascular disease. Insulin-dependent diabetes and portopulmonary hypertension are relative contraindications.

A total of 12 trials have been conducted assessing beta-adrenergic blockers for the prevention of first bleeding. Meta-analysis of these studies shows that continued propranolol or nadolol therapy markedly reduces the bleeding risk, from 25% with non-active treatment to 15% with beta-adrenergic blockers over a median follow-up period of 2 years [13]. Mortality was only slightly reduced from 27% to 23%; this effect barely approached the level of statistical significance. The benefit of therapy has been proved in patients with moderate/large varices (> 5 mm), either with or without ascites or with good or poor liver function [13,62]. A recent trial demonstrated that beta-adrenergic blockers reduce the rate of progression from small to large varices, and decrease the incidence of variceal bleeding in patients with small varices [9]. Although confirmatory double-blind trials are required before a definite recommendation can be given [63], this suggests that the indication of beta-adrenergic blockers could be extended to patients with small varices, especially to those in Child class B and C. Therapy with beta-adrenergic blockers should be maintained indefinitely because, when they are withdrawn, the risk of variceal haemorrhage returns to what would be expected in an untreated population [64].

The addition of isosorbide mononitrate increases the portal pressure reduction of beta-adrenergic blockers [65,66]. However, it is not clear whether this translates into a greater clinical efficacy. An open trial comparing nadolol vs. nadolol plus isosorbide mononitrate demonstrated a significantly lower rate of first bleeding in the combination group, which was maintained after 55 months of follow-up, without survival advantage [67,68]. However, a large, randomized, double-blind study failed to confirm these results [60]. The current consensus does not recommend this combination therapy in primary prophylaxis [19]. Isosorbide mononitrate administered alone, despite its mild portal pressure-lowering effect, is ineffective in the prevention of variceal bleeding [61].

Endoscopic therapy Endoscopic band ligation is also effective in preventing the first variceal bleeding in patients with medium to large varices [69]. Twelve trials have compared endoscopic band ligation with beta-adrenergic blockers as first-line option for primary prophylaxis of variceal bleeding [70–81]. The meta-analysis of theses trials shows a clear but marginal advantage of endoscopic band ligation over beta-adrenergic blockers in terms of prevention of first bleeding, with no differences in mortality (Figs 2 and 3). However, the performance of beta-adrenergic blockers in the two trials showing a significant benefit of endoscopic band ligation was extremely poor [74,78]. Five of these trials are only available in abstract form, which makes it difficult to evaluate their quality. An additional concern is that, in the largest study [72], there was a 7% incidence of bleeding from ligation-induced ulcers, and two patients died as a direct consequence of this complication (treatment-related mortality of 2.6%). Further, because of the short duration of follow-up in most of these studies, the long-term safety and benefits of prophylactic endoscopic band ligation are still uncertain. On the contrary, the long-term safety and efficacy of prophylactic therapy using non-selective beta-adrenergic blockers has been established in a large number of trials [64,82]. On this basis, the current recommendation is to restrict

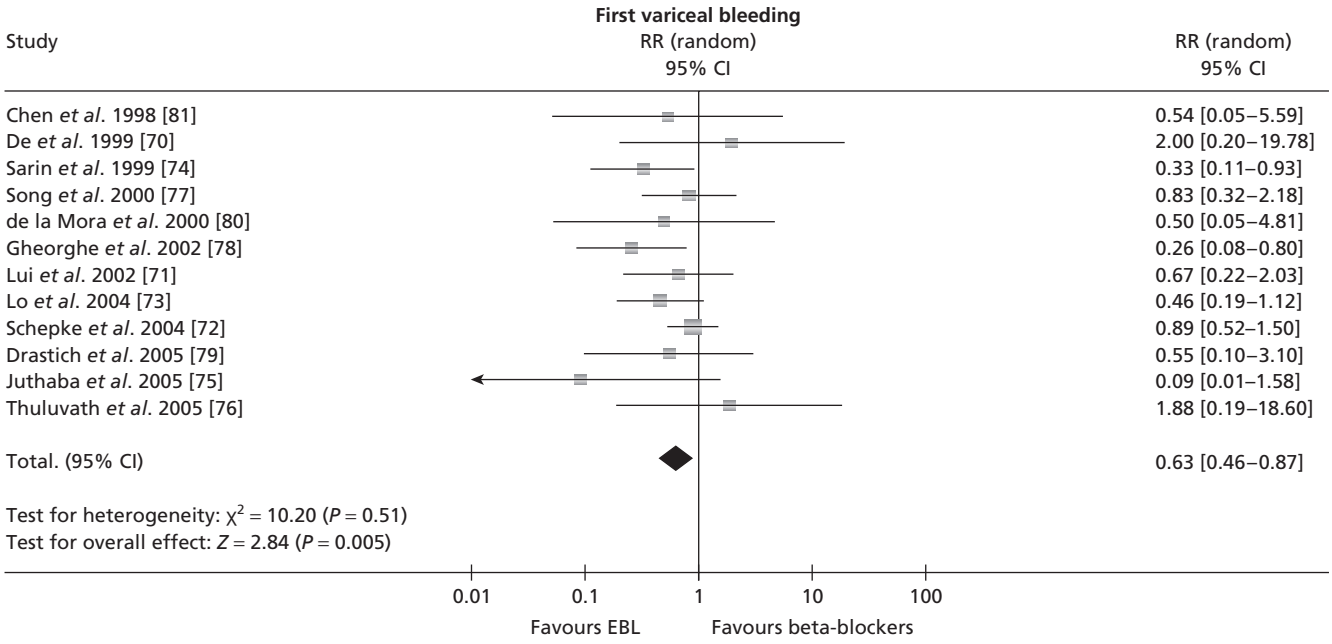

Fig. 2 Prevention of first variceal bleeding. Meta-analysis (random effects model) of randomized controlled trials comparing endoscopic band ligation (EBL) with beta-adrenergic blockers in the prevention of first variceal bleeding. EBL achieves a marginal improvement in the risk of developing a first variceal bleeding. RR, relative risk.

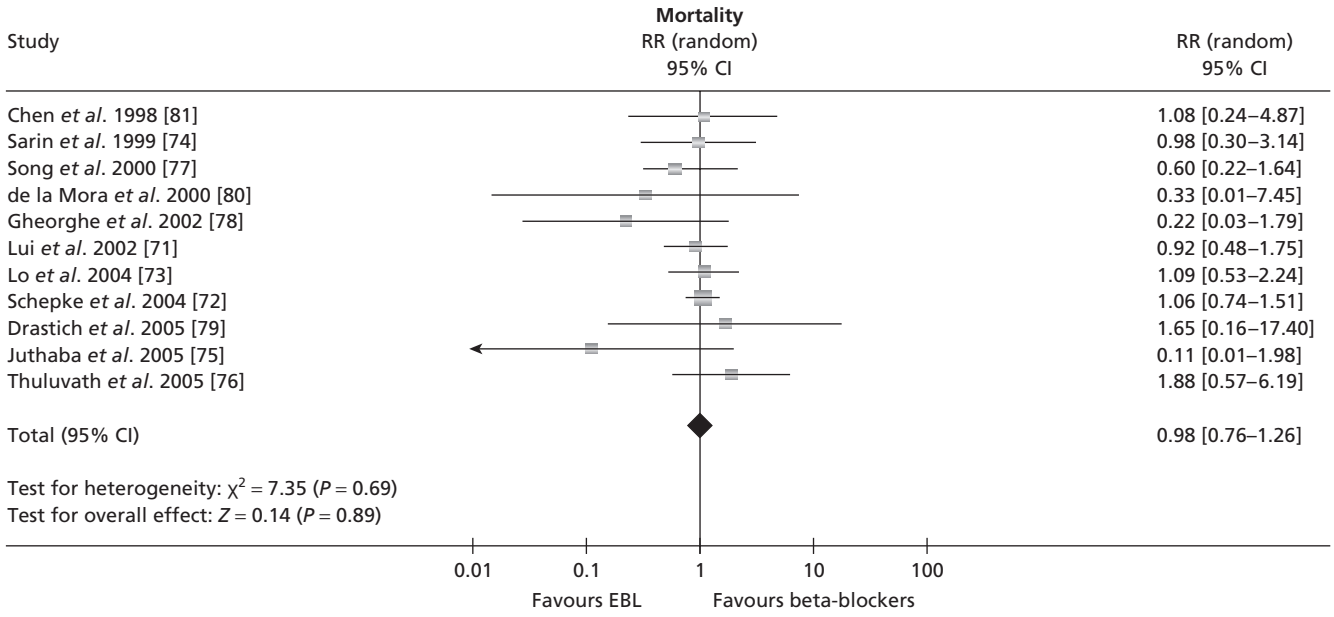

Fig. 3 Prevention of first variceal bleeding. Meta-analysis (random effects model) of randomized controlled trials comparing endoscopic band ligation (EBL) with beta-adrenergic blockers in the prevention of first variceal bleeding. EBL does not improve mortality. RR, relative risk.

the use of endoscopic band ligation to those patients with contraindications or intolerance to beta-adrenergic blockers (Fig. 4) [19]. Even in this case, the use of band ligation is controversial, as a recent trial comparing band ligation with no treatment in this subgroup of patients was stopped because of a high rate (12%) of iatrogenic bleeding in the band ligation group [83].

The combination of endoscopic band ligation plus beta-adrenergic blockers appears to offer no benefit in terms of prevention of first bleeding when compared with endoscopic band ligation alone, but more studies are required [84]. There is a lower rate of recurrence of varices in patients treated with endoscopic band ligation plus propranolol, but at the expense of more side-effects.

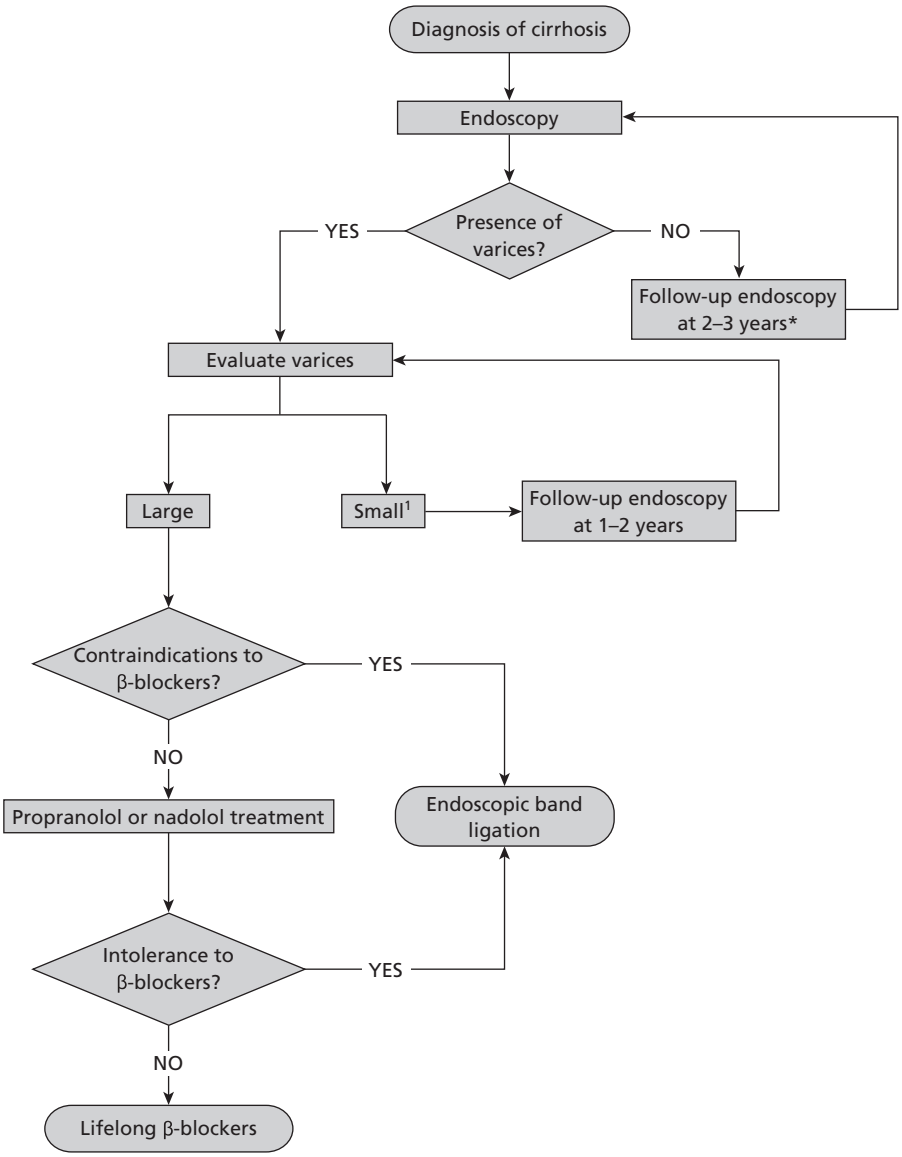

Fig. 4 Algorithm with recommendations for the prevention of first variceal bleeding in patients with cirrhosis. *Beta-adrenergic blockers might be initiated in patients with small varices. This would be especially indicated in patients in Child class B and C or with red signs at the varices.

Prevention of recurrent bleeding from oesophageal varices

Because of the extremely high risk of rebleeding in untreated patients, all patients surviving a variceal bleeding should receive active treatments for the prevention of rebleeding [19,32,85]. In addition, those with poor liver function or with other recurrent complications of portal hypertension should be considered for liver transplantation.

Drug therapy

Pharmacological treatment is based on the use of non-selective beta-adrenergic blockers [86]. Meta-analyses consistently found a marked benefit from beta-adrenergic blockers, in terms of both rebleeding (from 63% in control subjects to 42% under beta-adrenergic blockers) and mortality (from 27% to 20%) [13]. Controversy exists over whether nitrates should be added to beta-adrenergic blockers. Two trials are available [87,88], with one of them double-blind and placebo-controlled, but only published in abstract form [87]. These studies failed consistently to show a benefit from combination therapy in terms of rebleeding or survival. However, combination therapy has been used as 'optimal' pharmacological therapy for comparisons with band ligation. Whenever possible, it is recommended to assess the haemodynamic response to beta-adrenergic blockers. If a 20% decrease in baseline HVPG or a decrease to ≤ 12 mmHg is not achieved, isosorbide mononitrate may be added, which results in achieving the target reduction in portal pressure in a third of non-responders to beta-adrenergic blockers alone ('à la carte' treatment) [89].

Endoscopic therapy

Endoscopic injection sclerotherapy of oesophageal varices also

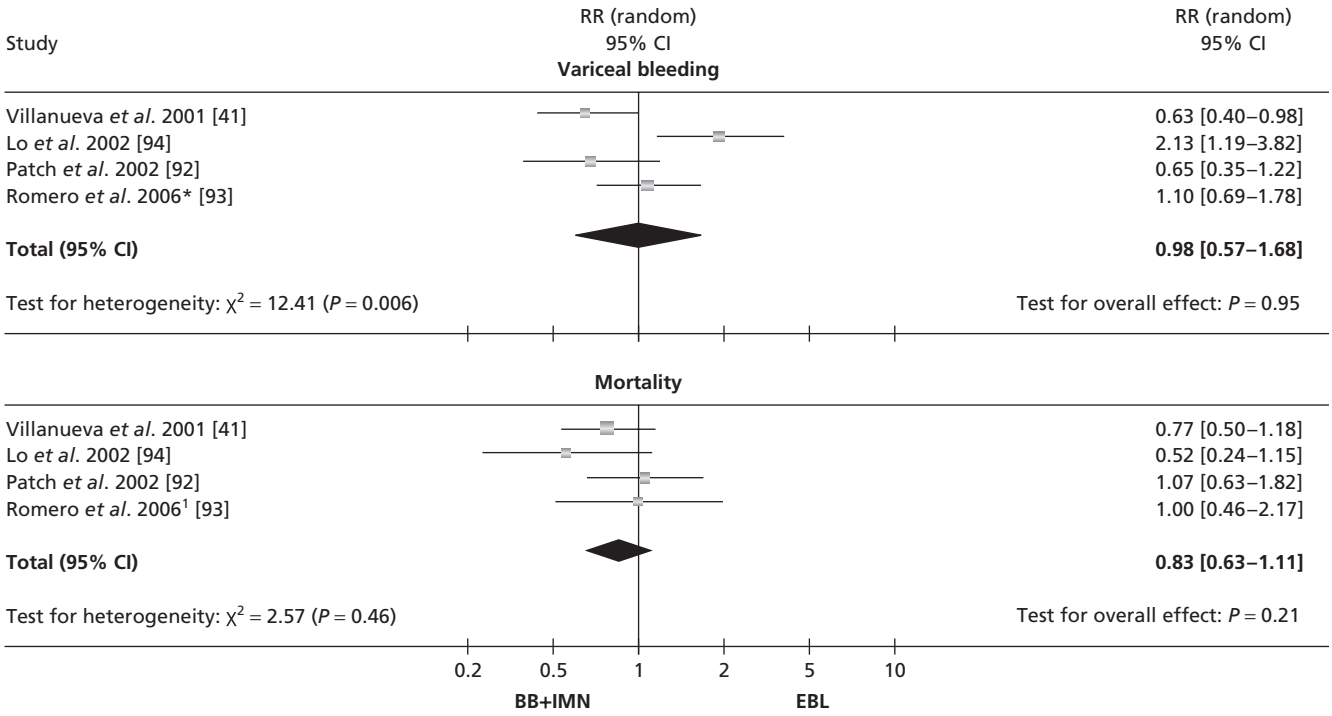

Fig. 5 Meta-analysis of available randomized controlled trials comparing pharmacological treatment [beta-adrenergic blockers plus nitrates (BB + IMN)] with endoscopic banding ligation (EBL) to prevent rebleeding. There were no differences between the two therapies in terms of variceal rebleeding and survival. *In the trial by Romero *et al.* [93], low-volume sclerotherapy was added to banding ligation.

reduces both rebleeding and death [90], but has been replaced by endoscopic band ligation, which is superior to sclerotherapy in terms of efficacy and complications [90,91]. The meta-analysis of the four available trials comparing optimal endoscopic treatment (band ligation) vs. optimized pharmacological treatment (the combination of beta-blockers and isosorbide mononitrate) [41,92–94] shows comparable results with the two therapies, but significant heterogeneity exists in the reported risk of variceal rebleeding (Fig. 5). Therefore, both beta-adrenergic blockers ± nitrates or banding ligation can be used as first-line treatments for the prevention of variceal rebleeding. If the patient bleeds while on primary prophylaxis with beta-adrenergic blockers, then the choice should be to add banding ligation, maintaining beta-adrenergic blockers (Fig. 6).

Two recent trials have shown that the association of beta-adrenergic blockers and endoscopic band ligation fares better than band ligation alone [47,95], suggesting that treatment with band ligation alone should be restricted to patients with contraindications to beta-adrenergic blockers.

Transjugular intrahepatic portosystemic shunt (TIPS)

A large corpus of consistent data indicates that TIPS is more effective than endoscopic therapy in preventing rebleeding [96]. A single trial demonstrated that it is also better than pharmacological therapy with propranolol and isosorbide mononitrate [97]. However, TIPS is associated with an increased rate of encephalopathy, does not increase survival [96] and is more expensive than drug therapy [97]. Thus, TIPS should only be used as rescue therapy for patients experiencing repeated or significant episodes of rebleeding while being treated with beta-adrenergic blockers ± isosorbide mononitrate or endoscopic band ligation. An open question is whether TIPS should be preferred to surgical shunts in patients with good liver function (Child A or 'good' B). Two RCTs have addressed this issue so far. One compared TIPS with an 8-mm prosthetic H-graft portocaval shunt, showing a lower rate of rebleeding, death and liver transplantation in the surgical group [98]. Another trial including 140 patients compared TIPS and distal splenorenal shunt in endoscopic and/or pharmacological failures [99]. There were no significant differences in rebleeding, hepatic encephalopathy or death. Patients with TIPS required more reinterventions to maintain portal decompression, on account of the well-known tendency of TIPS to dysfunction over time. The use of polytetrafluoroethylene (PTFE)-covered stents has dramatically decreased the rate of TIPS dysfunction, clinical relapses and the need for reinterventions [100], overcoming the main drawback of traditional bare stents without increasing the risk of hepatic encephalopathy and liver failure. Therefore, PTFE-covered stents should be the choice for TIPS placement.

Treatment of acute variceal bleeding

The management of acute variceal bleeding should be undertaken in an intensive care setting by a team of experienced

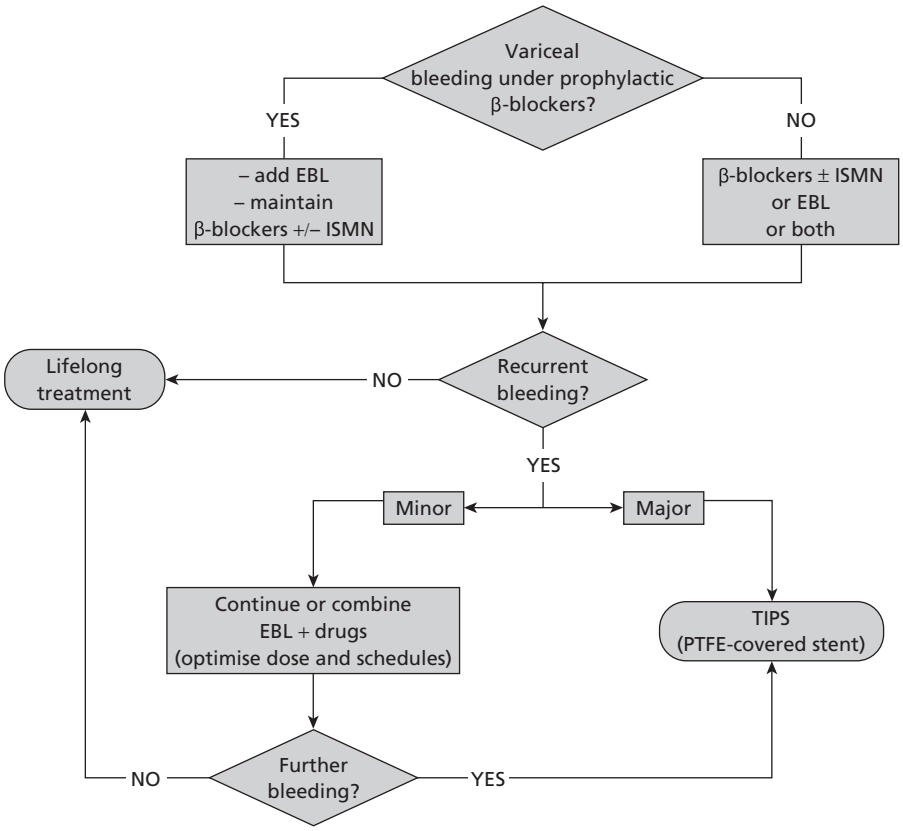

Fig. 6 Algorithm with recommendations for the prevention of rebleeding in patients who had recovered from an episode of acute variceal bleeding. EBL, endoscopic band ligation; ISMN, isosorbide mononitrate.

medical staff, including well-trained nurses, clinical hepatologists, endoscopists, interventional radiologists and surgeons. Lack of these facilities demands immediate referral. Decision-making should follow the guidelines set up in a written protocol developed to optimize the resources of each centre.

Acute variceal bleeding is defined as either active bleeding at endoscopy (emanating blood from a varix oozing or sprouting) or signs of an upper gastrointestinal bleeding (haematemesis, intragastric blood or coagulated blood, melaena) when active bleeding cannot be detected by endoscopy.

General management

The general management of the bleeding patient is aimed at correcting hypovolaemic shock (with judicious volume replacement and transfusion) and preventing complications associated with gastrointestinal bleeding (such as renal failure, hepatic decompensation, hepatic encephalopathy and bacterial infections). These goals, which are independent of the cause of the haemorrhage, demand immediate management.

Blood volume replacement should be initiated as soon as possible, aiming at maintaining the haematocrit around 24% (haemoglobin 8 g/L). The avoidance of prolonged hypovolaemic shock is particularly important in preventing complications such as infection and renal failure, which are associated with the risk of rebleeding and death [4,31]. Overtransfusion should be avoided, not only because of the risks inherent with blood transfusion, but also because there may be a rebound increase in portal pressure with a consequent risk of continued bleeding or rebleeding [101,102]. Although the role of transfusion of platelets in patients with a platelet count less than 50 000/μL and of administration of fresh frozen plasma in patients with coagulopathy has not been assessed in clinical studies, these agents are frequently used. Initial reports demonstrated that recombinant activated factor VII (rVIIa, Novoseven) corrects prothrombin time in cirrhotics, both in non-bleeders [103] and in the acute variceal bleeding setting [104]. A recent double-blind, multicentre RCT showed that rFVIIa administration may significantly improve the results of conventional therapy in patients with moderate and advanced liver failure (stages B and C of the Child–Pugh classification), in whom variceal bleeding carries a more severe prognosis, without increasing the incidence of adverse events [48], but these results must be confirmed in new trials focusing on this target population.

Infection is a strong prognostic indicator in acute variceal bleeding [22,105]. The more frequent infections are spontaneous bacterial peritonitis (50%), urinary tract infections (25%) and pneumonia (25%). The use of antibiotics in acute variceal bleeding has been shown to reduce both the risk of rebleeding [106] and mortality [107]. Therefore, antibiotics should be given to all patients from admission. Norfloxacin, 400 mg/12 h, is the first choice on account of its simpler administration and lower cost [108]. In high-risk patients (hypovolaemic

shock, ascites, jaundice or malnutrition), intravenous ceftriaxone has recently been shown to be superior to oral norfloxacin [109].

Bronchial aspiration of gastric contents and blood is a particular risk, especially in encephalopathic patients, which may be further exacerbated by endoscopic procedures. Endotracheal intubation is mandatory if there is any concern about the safety of the airway. Variceal bleeding can trigger hepatic encephalopathy. Lactulose can be given orally or by enema to prevent hepatic encephalopathy, although this has not been evaluated in randomized trials.

Specific therapy for control of bleeding

Specific therapy for acute variceal bleeding includes vasoactive drugs, endoscopic therapy and portosystemic shunts, either surgical or TIPS.

Pharmacological therapy

The action of vasoactive drugs is to reduce variceal pressure by decreasing variceal blood flow. The selection of the drug depends on the local resources. Terlipressin should be the first choice if available, as it is the only drug shown to improve survival [110]. Somatostatin, octreotide or vapreotide are the second choice [13,111]. If these drugs are not available, vasopressin plus transdermal nitroglycerin is an acceptable option [13].

Vasopressin was the first drug used, but was abandoned 25 years ago because of the severity of its cardiovascular adverse events. The association of vasopressin infusion plus nitroglycerin resulted in an enhanced fall in portal pressure and less marked systemic effects, and has been shown to be more effective and safer than vasopressin [13]. Vasopressin is started at 0.2–0.4 units/min and can be increased to a maximum of 0.8 units/min. Nitroglycerin is most commonly administered transdermally (20 mg/12 h). This combination is still used in countries were neither terlipressin nor somatostatin is available, but should not be maintained for more than 48 h because of an increased incidence of side-effects.

Terlipressin is a long-acting triglycyl lysine derivative of vasopressin. On top of its own vasoactive effects, terlipressin is slowly transformed to vasopressin by enzymatic cleavage of the triglycyl residues by tissue peptidases [112]. Clinical studies have consistently shown less frequent and severe side-effects with terlipressin than with vasopressin, even when vasopressin is associated with nitroglycerin. It has been speculated that this increased safety may be related to the combination of high tissue concentration with low circulating levels consequent to the slow release of vasopressin [112]. Terlipressin should be used with great caution in the rare cirrhotic patient with ischaemic heart disease or peripheral vascular disease. The most common side-effects are abdominal pain and hyponatraemia. Serious side-effects such as peripheral or myocardial ischaemia occur in less than 3% of patients [113].

Terlipressin may be initiated as early as variceal bleeding is suspected at a dose of 2 mg/4 h for the first 48 h, and it may be maintained for up to 5 days at a dose of 1 mg/4 h to prevent rebleeding [113]. Compared with placebo or non-active treatment, terlipressin significantly improves the rate of control of bleeding and survival [114]. This is the only treatment that has been shown to improve the prognosis of variceal bleeding in placebo-controlled RCTs and meta-analysis [13,114]. Terlipressin is as effective as any other effective therapy, including endoscopic injection sclerotherapy (EIS), and is safer than vasopressin plus nitroglycerin and EIS [13,113,114]. The overall efficacy of terlipressin in controlling acute variceal bleeding at 48 h is 75–80% across trials [114] and 67% at 5 days [113]. Terlipressin is also useful in hepatorenal syndrome [115]. Thus, the use of terlipressin for variceal bleeding may prevent renal failure, which is frequently precipitated by variceal bleeding [31].

Somatostatin has been used for over two decades [116] in the treatment of acute variceal bleeding, based on its ability to decrease portal pressure and collateral blood flow [117]. The usual scheme for somatostatin administration is an initial bolus of 250 μg followed by a 250 μg/h infusion that is maintained until the achievement of a 24-h bleed-free period. The bolus injection can be repeated up to three times in the first hour if bleeding is uncontrolled. Therapy may be maintained for up to 5 days to prevent early rebleeding [118]. The use of higher doses (500 μg/h) has been shown to translate into increased clinical efficacy in the subset of patients with more difficult bleedings (those with active bleeding at emergency endoscopy) [119]. Major side-effects with somatostatin are negligible. Minor side-effects, such as nausea and vomiting, occur in up to 25% of patients [120] and hyperglycaemia in 2–4% [118,119,121]. Several RCTs have shown that somatostatin significantly improves the rate of control of bleeding compared with placebo or non-active treatment [13,111]. However, despite the beneficial effect on control of bleeding, somatostatin did not reduce mortality [13]. Somatostatin has been compared with terlipressin, and no differences were found for failure to control bleeding, rebleeding, mortality or in the incidence of adverse events in both treatment groups [13].

Octreotide is a somatostatin analogue with a longer half-life. However, this is not associated with longer haemodynamic effects than somatostatin [122]. The optimal doses are not well determined. It is usually given as an initial bolus of 50 μg, followed by an infusion of 25 or 50 μg/h [111]. As with somatostatin, therapy can be maintained for 5 days to prevent early rebleeding. The safety profile of octreotide is similar to that of somatostatin. The efficacy of octreotide as a single therapy for variceal bleeding is controversial. No benefit from octreotide was found in the only trial using octreotide or placebo as initial treatment [123], which may be due to rapid development of tachyphylaxis [122]. However, RCTs using octreotide on top of sclerotherapy or ligation have shown a significant benefit in terms of reducing early rebleeding [124]. It has been speculated that this may be related to its sustained ability to prevent postprandial increase in portal pressure [111]. However, mortality was not affected [13,124]. These results suggest that octreotide may improve the results of endoscopic therapy but has no or

little effect if used alone. When compared with other vasoactive drugs, octreotide was better than vasopressin and equivalent to terlipressin, again suggesting a clinical value from the use of octreotide [13]. Side-effects were less frequent and severe with octreotide than with either vasopressin or terlipressin, but the difference was significant only for vasopressin [13].

Endoscopic therapy

Both sclerotherapy and band ligation have been shown to be effective in the control of acute variceal bleeding [90]. Two randomized trials specifically compared band ligation and sclerotherapy in acute variceal bleeding [125,126]. In one of them, all patients received pharmacological therapy (somatostatin) [126]. Additional information can be drawn from eight trials in which these two modalities were compared for both acute bleeding and the prevention of rebleeding [90]. The meta-analysis of these data shows that endoscopic band ligation is better than sclerotherapy in the initial control of bleeding and is associated with less adverse events and improved mortality (Fig. 7). Additionally, it has been shown that sclerotherapy, but not band ligation, induces a sustained increase in portal pressure [127], a factor associated with increased risk of treatment failure [25]. Therefore, band ligation should be the endoscopic therapy of choice in acute variceal bleeding, although injection sclerotherapy is acceptable if band ligation is not available or is technically difficult. Endoscopic therapy can be performed at the time of diagnostic endoscopy, soon after admission. However, if there is no active bleeding and the patient is stable, endoscopic treatment can probably be delayed until the next working day. This approach allows endoscopic therapy to be performed in the best conditions by a skilled endoscopist and an experienced nursing team, instead of the commonly less skilled physicians on duty. This may reduce the complications and the burden from emergency endoscopic procedures.

Current recommendations for initial treatment

The current recommendation is to combine these two approaches, starting vasoactive drug therapy early (ideally during the transfer to the hospital, even if active bleeding is only suspected) and performing endoscopic band ligation (or injection sclerotherapy if band ligation is technically difficult) after initial resuscitation (Fig. 8a). The rationale for this comes from a number of RCTs demonstrating that early administration of a vasoactive drug facilitates endoscopy and improves the control of bleeding and 5-day rebleeding [110,128,129]. Drug therapy also improves the results of endoscopic treatment if started just

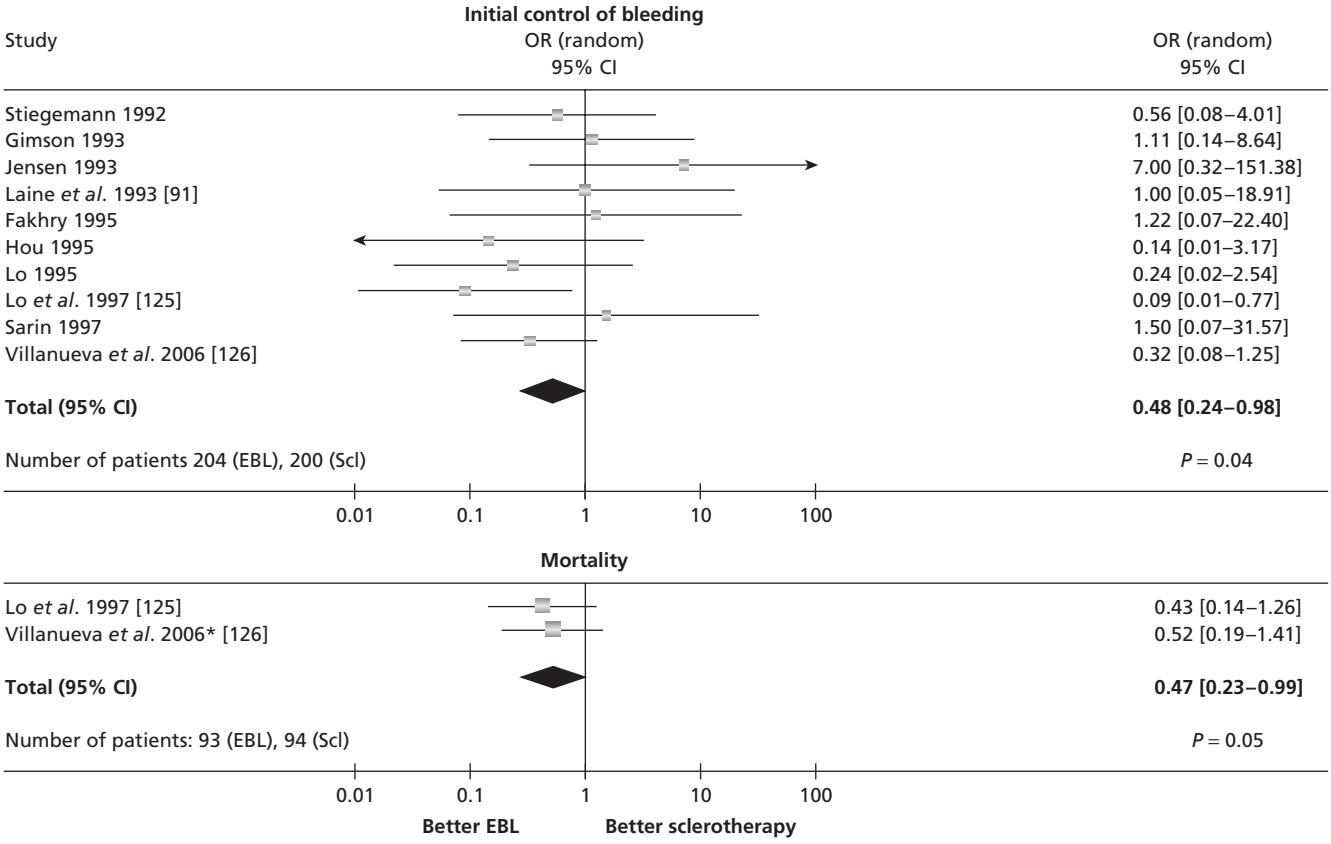

Fig. 7 Endoscopic therapy in acute variceal bleeding. Meta-analysis of studies comparing endoscopic band ligation (EBL) with endoscopic injection sclerotherapy (EIS). Note than EBL is better than sclerotherapy in terms of initial control of bleeding and mortality (update of the meta-analysis by de Franchis and Primignani [90]). OR, odds ratio.
*All patients received somatostatin.

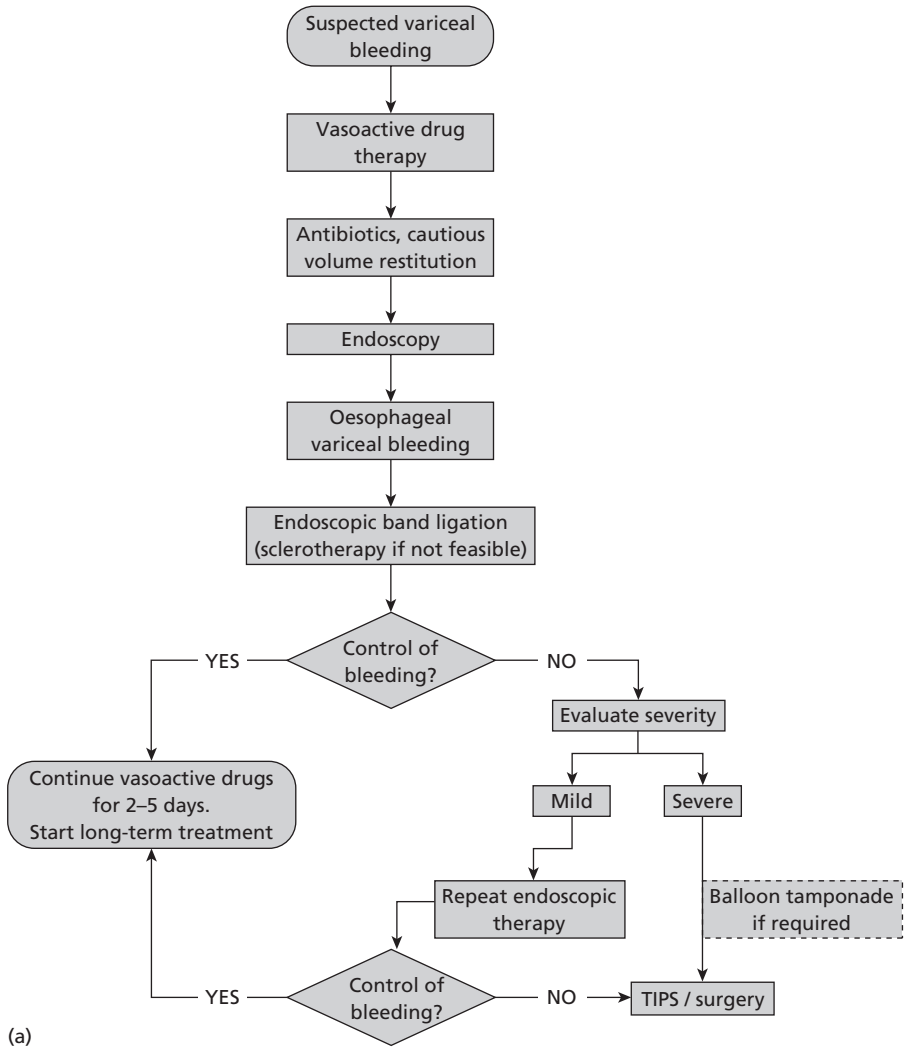

Fig. 8 Algorithm with recommendations for the treatment of acute variceal bleeding. (a) Bleeding from oesophageal varices.

after sclerotherapy or band ligation [13,111,124]. Moreover, the association with endoscopic therapy may improve the efficacy of vasoactive treatment [121]. However, this combined approach failed to improve 6-week mortality compared with endoscopic therapy [130] or a vasoactive drug [121] alone. On the other hand, single vasoactive therapy is as effective as endoscopic therapy, but with significantly fewer side-effects [131]. The optimal duration of drug therapy is not well established and requires evaluation. The current recommendation is to maintain the drug for 2–5 days. The rationale for this would be to cover the period of maximum risk of rebleeding [19].

Rescue therapies: tamponade, surgery and TIPS

In 10–20% of patients, variceal bleeding is unresponsive to initial endoscopic and/or pharmacological treatment. If bleeding is mild and the patient is stable, a second endoscopic therapy might be attempted. If this fails, or bleeding is severe, the patient should be promptly offered a derivative treatment before further deterioration in the clinical status of the patient occurs. Balloon tamponade achieves haemostasis in 60–90% of variceal bleedings [85] but should only be used in the case of massive bleeding, for a short period of time (less than 24 h) as a temporary 'bridge' until definite treatment is instituted. These treatments include implantation of a TIPS and surgical shunts. Both are extremely effective in controlling variceal bleeding (control rate approaches 95%), but invasiveness and side-effects (mainly encephalopathy and worsening of liver function) result in high mortality [85,132,133]. TIPS is the first choice, as most patients have advanced liver disease [134]. In patients with sepsis, inotropic support, ventilation after aspiration and deterioration of liver and renal function [132], mortality after TIPS placement is nearly 100%. This clearly indicates that some patients do not benefit from TIPS in this setting, and it is usually not difficult to make a clinically based decision. Rarely, if ever, will a patient with a Child–Pugh score over 13 survive TIPS. Prognostic scores [135] may provide objective parameters to ease the decision of not offering invasive treatments in some cases.

It was suggested recently that some high-risk patients might benefit from TIPS implantation as a first-line therapy. This suggestion comes from a single study showing that patients with high portal pressure (> 20 mmHg) who underwent early TIPS

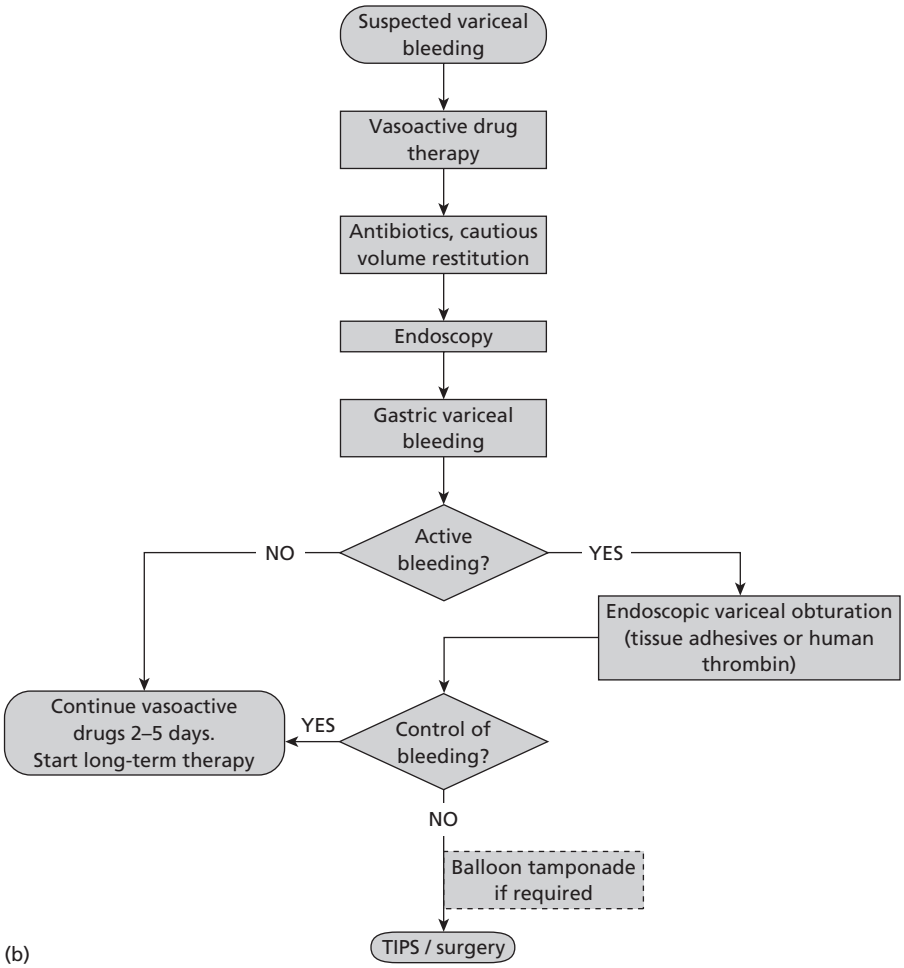

(b)

Fig. 8 (b) Bleeding from gastric varices.

placement after endoscopy had significantly fewer treatment failures and lower mortality rates than patients undergoing standard therapy [26]. If further studies, preferably with clinical criteria of high risk of failure, confirm this finding, TIPS may become an integral part of treatment for acute variceal bleeding according to individual risk factors.

Gastric varices

Gastric varices develop in approximately 20% of patients with portal hypertension [136]. They are the source of 5–10% of all upper digestive bleeding episodes in patients with cirrhosis. The risk of gastric variceal bleeding is lower than that of oesophageal variceal bleeding, but gastric variceal bleeding, in particular that from fundal varices, tends to be more severe, to require more transfusions and to have a higher mortality rate [136].

The optimal treatment of gastric varices has not been determined, as there are only a few RCTs and most data come from retrospective series and case reports. Although no RCT has been conducted until now, it seems reasonable to use non-selective beta-adrenergic blockers in patients with gastric varices to prevent the first bleeding episode. Also, the optimal treatment of acute gastric variceal bleeding is not known. The initial treatment is similar to that of oesophageal variceal bleeding, including the administration of a vasoactive drug (terlipressin, somatostatin or a somatostatin analogue) and general management for haemodynamic stabilization and the prevention of complications (Fig. 8b). However, the efficacy of vasoactive drugs has not been assessed. Balloon tamponade, with the Linton–Nachlas tube, has been used with limited success [137,138], but may serve as a bridge to derivative treatments in massive bleedings.

Some endoscopic therapies are promising, but quality information is scarce. Sclerotherapy, glue injection, thrombin, elastic band ligation and ligation with large detachable snares have been reported [139]. In most uncontrolled series, cyanoacrylate is highly effective, in the order of 90% [140–142]. A recent RCT confirmed that endoscopic obturation using cyanoacrylate was more effective and safer than band ligation in the management of bleeding gastric varices [143]. Also, in another RCT by Sarin and coworkers, cyanoacrylate was better than alcohol injection at achieving initial haemostasis and at achieving faster variceal obliteration [144]. Novel endoscopic therapies are under evaluation. Among them, the use of human thrombin injection [145,146] seems the most promising, as this treatment does not

cause mucosal damage and ulceration. These techniques need expertise and may not be feasible in massive bleedings.

TIPS is very effective in the treatment of bleeding gastric varices, with a more than 90% success rate for initial haemostasis and a low rebleeding rate [147,148]. In these patients, many centres associate TIPS with the embolization of the collateral vessels that feed the varices. Derivative and devascularization surgery is also effective, but with limited applicability in advanced cirrhosis.

The authors' recommendation is to start with a vasoactive drug. If bleeding is not controlled and an expert endoscopist is available, endoscopic treatment (cyanoacrylate or human thrombin) should be attempted. In cases of massive bleeding or after failure of previous therapies, TIPS (or surgical shunt in Child A patients) is mandatory. In some patients, especially in those with massive initial bleeding or in centres with reduced endoscopic experience in the treatment of gastric varices, TIPS may be used even before attempting endoscopic therapy.

Portal hypertensive gastropathy (PHG)

Portal hypertensive gastropathy is a macroscopic finding of a characteristic mosaic-like pattern of the gastric mucosa ('mild' PHG), red point lesions, cherry red spots and/or black–brown spots ('severe' PHG) [149]. However, these lesions are not entirely specific, i.e. they can occur in the absence of portal hypertension. In PHG, there is marked dilatation of the vasculature of the gastric mucosa and submucosa, together with an increased blood flow and a tendency towards decreased acid secretion. PHG is unrelated to *Helicobacter pylori* infection. In the largest study on the natural history of PHG, the overall prevalence of this condition was 80% in patients with cirrhosis [149]. Its prevalence is strongly correlated with the severity of portal hypertension and ranges between 11% and 80%. The incidence of acute bleeding is low (< 3% at 3 years) with a mortality of 12.5%; for chronic bleeding, the incidence is around 10–15% at 3 years. Chronic PHG bleeding usually manifests as chronic iron deficiency anaemia. Iron supplementation might be enough to keep a normal haemoglobin level. If not, beta-adrenergic blockers are the only treatment that has proved effective in these patients [150]. In acute PHG bleeding, beta-adrenergic blockers, somatostatin, octreotide, vasopressin, terlipressin and estrogens have been proposed based on their ability to decrease gastric perfusion in this condition [151–154]. However, only one uncontrolled study has so far evaluated one of these drugs (somatostatin) in the treatment of acute bleeding from PHG [155], achieving haemostasis in all patients. Propranolol has been found to reduce recurrent bleeding from PHG in a randomized trial [150]. The role of derivative treatments is controversial. Reported results with shunt surgery and TIPS suggest that these treatments are effective [156–158] but, because of a lack of randomized studies, the fluctuating nature of PHG and, possibly, unreported failures, both TIPS and shunt surgery should be considered only as rescue therapies for the uncommon patient who has repeated bleeding from PHG despite propranolol treatment. Liver transplantation reverses portal hypertension and therefore effectively treats PHG.

References

1 D'Amico G (2004) Esophageal varices: from appearance to rupture; natural history and prognostic indicators. In: Groszmann RJ, Bosch J (eds) *Portal Hypertension in the 21st Century*. Dordrecht: Kluwer Academic Publishers, pp. 147–154.

2 Christensen E, Fauerholdt L, Schlichting P *et al.* (1981) Aspects of the natural history of gastrointestinal bleeding in cirrhosis and the effect of prednisone. *Gastroenterology* 81, 944–952.

3 D'Amico G, Luca A (1997) Natural history. Clinical–haemodynamic correlations. Prediction of the risk of bleeding. *Baillieres Clin Gastroenterol* 11, 243–256.

4 de Franchis R, Primignani M (2001) Natural history of portal hypertension in patients with cirrhosis. *Clin Liver Dis* 5, 645–663.

5 Merli M, Nicolini G, Angeloni S *et al.* (2003) Incidence and natural history of small esophageal varices in cirrhotic patients. *J Hepatol* 38, 266–272.

6 Groszmann RJ, Garcia-Tsao G, Bosch J *et al.* (2005) Beta-blockers to prevent gastro-esophageal varices in patients with cirrhosis. *N Engl J Med* 353, 2254–2261.

7 De Franchis R (2003) Evaluation and follow-up of patients with cirrhosis and oesophageal varices. *J Hepatol* 38, 361–363.

8 Zoli M, Merkel C, Magalotti D *et al.* (2000) Natural history of cirrhotic patients with small esophageal varices: a prospective study. *Am J Gastroenterol* 95, 503–508.

9 Merkel C, Marin R, Angeli P *et al.* (2004) A placebo-controlled clinical trial of nadolol in the prophylaxis of growth of small esophageal varices in cirrhosis. *Gastroenterology* 127, 476–484.

10 Cales P, Desmorat H, Vinel JP *et al.* (1990) Incidence of large oesophageal varices in patients with cirrhosis: application to prophylaxis of first bleeding. *Gut* 31, 1298–1302.

11 Vorobioff J, Groszmann RJ, Picabea E *et al.* (1996) Prognostic value of hepatic venous pressure gradient measurements in alcoholic cirrhosis: a 10-year prospective study. *Gastroenterology* 111, 701–709.

12 Groszmann RJ, Bosch J, Grace ND *et al.* (1990) Hemodynamic events in a prospective randomized trial of propranolol versus placebo in the prevention of a first variceal hemorrhage (see comments). *Gastroenterology* 99, 1401–1407.

13 D'Amico G, Pagliaro L, Bosch J (1999) Pharmacological treatment of portal hypertension: an evidence-based approach. *Semin Liver Dis* 19, 475–505.

14 NIEC (1988) Prediction of the first variceal hemorrhage in patients with cirrhosis of the liver and esophageal varices. A prospective multicenter study. The North Italian Endoscopic Club for the Study and Treatment of Esophageal Varices (see comments). *N Engl J Med* 319, 983–989.

15 Merkel C, Zoli M, Siringo S *et al.* (2000) Prognostic indicators of risk for first variceal bleeding in cirrhosis: a multicenter study in 711 patients to validate and improve the North Italian Endoscopic Club (NIEC) index (in process citation). *Am J Gastroenterol* 95, 2915–2920.

16 D'Amico G, De Franchis R (2003) Upper digestive bleeding in cirrhosis. Post-therapeutic outcome and prognostic indicators. *Hepatology* 38, 599–612.

17 Merican I, Sprengers D, McCormick PA *et al.* (1993) Diurnal pattern of variceal bleeding in cirrhotic patients. *J Hepatol* 19, 15–22.

18 Garcia-Pagan JC, Feu F, Castells A *et al.* (1994) Circadian variations of portal pressure and variceal hemorrhage in patients with cirrhosis. *Hepatology* 19, 595–601.

19 de Franchis R (2005) Evolving consensus in portal hypertension. Report of the Baveno IV Consensus Workshop on methodology of diagnosis and therapy in portal hypertension. *J Hepatol* 43, 167–176.

20 Graham D, Smith J (1981) The course of patients after variceal hemorrhage. *Gastroenterology* 80, 800–806.

21 Bernard B, Cadranel JF, Valla D *et al.* (1995) Prognostic significance of bacterial infection in bleeding cirrhotic patients: a prospective study. *Gastroenterology* 108, 1828–1834.

22 Goulis J, Armonis A, Patch D *et al.* (1998) Bacterial infection is independently associated with failure to control bleeding in cirrhotic patients with gastrointestinal hemorrhage. *Hepatology* 27, 1207–1212.

23 Vivas S, Rodriguez M, Palacio MA *et al.* (2001) Presence of bacterial infection in bleeding cirrhotic patients is independently associated with early mortality and failure to control bleeding. *Dig Dis Sci* 46, 2752–2757.

24 Ben Ari Z, Cardin F, McCormick AP *et al.* (1999) A predictive model for failure to control bleeding during acute variceal haemorrhage. *J Hepatol* 31, 443–450.

25 Moitinho E, Escorsell A, Bandi JC *et al.* (1999) Prognostic value of early measurements of portal pressure in acute variceal bleeding. *Gastroenterology* 117, 626–631.

26 Monescillo A, Martinez-Lagares F, Ruiz-del-Arbol L *et al.* (2004) Influence of portal hypertension and its early decompression by TIPS placement on the outcome of variceal bleeding. *Hepatology* 40, 793–801.

27 Carbonell N, Pauwels A, Serfaty L *et al.* (2004) Improved survival after variceal bleeding in patients with cirrhosis over the past two decades. *Hepatology* 40, 652–659.

28 Nidegger D, Ragot S, Berthelemy P *et al.* (2003) Cirrhosis and bleeding: the need for very early management. *J Hepatol* 39, 509–514.

29 Gatta A, Merkel C, Amodio P *et al.* (1994) Development and validation of a prognostic index predicting death after upper gastrointestinal bleeding in patients with liver cirrhosis: a multicenter study. *Am J Gastroenterol* 89, 1528–1536.

30 del Olmo JA, Pena A, Serra MA *et al.* (2000) Predictors of morbidity and mortality after the first episode of upper gastrointestinal bleeding in liver cirrhosis. *J Hepatol* 32, 19–24.

31 Cardenas A, Gines P, Uriz J *et al.* (2001) Renal failure after upper gastrointestinal bleeding in cirrhosis: incidence, clinical course, predictive factors, and short-term prognosis. *Hepatology* 34, 671–676.

32 Grace ND, Groszmann RJ, Garcia-Tsao G *et al.* (1998) Portal hypertension and variceal bleeding: an AASLD single topic symposium. *Hepatology* 28, 868–880.

33 de Franchis R (2000) Updating consensus in portal hypertension: report of the Baveno III Consensus Workshop on definitions, methodology and therapeutic strategies in portal hypertension. *J Hepatol* 33, 846–852.

34 Feu F, Garcia-Pagan JC, Bosch J *et al.* (1995) Relation between portal pressure response to pharmacotherapy and risk of recurrent variceal haemorrhage in patients with cirrhosis. *Lancet* 346, 1056–1059.

35 Abraldes JG, Tarantino I, Turnes J *et al.* (2003) Hemodynamic response to pharmacological treatment of portal hypertension and long-term prognosis of cirrhosis. *Hepatology* 37, 902–908.

36 Viallet A, Marleau D, Huet M *et al.* (1975) Hemodynamic evaluation of patients with intrahepatic portal hypertension. Relationship between bleeding varices and the portohepatic gradient. *Gastroenterology* 69, 1297–1300.

37 Garcia-Tsao G, Groszmann RJ, Fisher RL *et al.* (1985) Portal pressure, presence of gastroesophageal varices and variceal bleeding. *Hepatology* 5, 419–424.

38 Casado M, Bosch J, Garcia-Pagan JC *et al.* (1998) Clinical events after transjugular intrahepatic portosystemic shunt: correlation with hemodynamic findings. *Gastroenterology* 114, 1296–1303.

39 Merkel C, Bolognesi M, Sacerdoti D *et al.* (2000) The hemodynamic response to medical treatment of portal hypertension as a predictor of clinical effectiveness in the primary prophylaxis of variceal bleeding in cirrhosis. *Hepatology* 32, 930–934.

40 Villanueva C, Balanzo J, Novella MT *et al.* (1996) Nadolol plus isosorbide mononitrate compared with sclerotherapy for the prevention of variceal rebleeding. *N Engl J Med* 334, 1624–1629.

41 Villanueva C, Minana J, Ortiz J *et al.* (2001) Endoscopic ligation compared with combined treatment with nadolol and isosorbide mononitrate to prevent recurrent variceal bleeding. *N Engl J Med* 345, 647–655.

42 Escorsell A, Bordas JM, Castaneda B *et al.* (2000) Predictive value of the variceal pressure response to continued pharmacological therapy in patients with cirrhosis and portal hypertension. *Hepatology* 31, 1061–1067.

43 Villanueva C, Lopez-Balaguer JM, Aracil C *et al.* (2004) Maintenance of hemodynamic response to treatment for portal hypertension and influence on complications of cirrhosis. *J Hepatol* 40, 757–765.

44 Schrier RW, Arroyo V, Bernardi M *et al.* (1988) Peripheral arterial vasodilation hypothesis: a proposal for the initiation of renal sodium and water retention in cirrhosis. *Hepatology* 8, 1151–1157.

45 Groszmann RJ (1994) Hyperdynamic circulation of liver disease 40 years later: pathophysiology and clinical consequences. *Hepatology* 20, 1359–1363.

46 Garcia-Pagan JC, Salmeron JM, Feu F *et al.* (1994) Effects of low-sodium diet and spironolactone on portal pressure in patients with compensated cirrhosis. *Hepatology* 19, 1095–1099.

47 de la Pena J, Brullet E, Sanchez-Hernandez E *et al.* (2005) Variceal ligation plus nadolol compared with ligation for prophylaxis of variceal rebleeding: a multicenter trial. *Hepatology* 41, 572–578.

48 Bosch J, Thabut D, Bendtsen F *et al.* (2004) Recombinant factor VIIa for upper gastrointestinal bleeding in patients with cirrhosis: a randomized, double-blind trial. *Gastroenterology* 127, 1123–1130.

49 Zaman A, Hapke R, Flora K *et al.* (1999) Factors predicting the presence of esophageal or gastric varices in patients with advanced liver disease. *Am J Gastroenterol* 94, 3292–3296.

50 Chalasani N, Imperiale TF, Ismail A *et al.* (1999) Predictors of large esophageal varices in patients with cirrhosis. *Am J Gastroenterol* 94, 3285–3291.

51 Madhotra R, Mulcahy HE, Willner I *et al.* (2002) Prediction of esophageal varices in patients with cirrhosis. *J Clin Gastroenterol* 34, 81–85.

52 Giannini E, Botta F, Borro P *et al.* (2003) Platelet count/spleen diameter ratio, proposal and validation of a non-invasive parameter to predict the presence of oesophageal varices in patients with liver cirrhosis. *Gut* 52, 1200–1205.

53 Saab S, DeRosa V, Nieto J *et al.* (2003) Costs and clinical outcomes of primary prophylaxis of variceal bleeding in patients with hepatic cirrhosis: a decision analytic model. *Am J Gastroenterol* 98, 763–770.

54 Spiegel BM, Targownik L, Dulai GS *et al.* (2003) Endoscopic screening for esophageal varices in cirrhosis: is it ever cost effective? *Hepatology* 37, 366–377.

55 Arguedas MR, Heudebert GR, Eloubeidi MA *et al.* (2002) Cost-effectiveness of screening, surveillance, and primary prophylaxis strategies for esophageal varices. *Am J Gastroenterol* 97, 2441–2452.

56 Lebrec D, Nouel O, Corbic M *et al.* (1980) Propranolol – a medical treatment for portal hypertension? *Lancet* 2, 180–182.

57 Kroeger RJ, Groszmann RJ (1985) Effect of selective blockade of beta 2-adrenergic receptors on portal and systemic hemodynamics in a portal hypertensive rat model. *Gastroenterology* 88, 896–900.

58 Gengo FM, Huntoon L, McHugh WB (1987) Lipid-soluble and water-soluble beta-blockers. Comparison of the central nervous system depressant effect. *Arch Intern Med* 147, 39–43.

59 Wang T, Kaumann AJ, Brown MJ (1996) (–)-Timolol is a more potent antagonist of the positive inotropic effects of (–)-adrenaline than of those of (–)-noradrenaline in human atrium. *Br J Clin Pharmacol* 42, 217–223.

60 Garcia-Pagan J, Morillas RM, Bañares R *et al.* (2003) Propranolol plus placebo vs propranolol plus isosorbide-5-mononitrate in the prevention of the first variceal bleed. A double blind RCT. *Hepatology* 37, 1260–1266.

61 Garcia-Pagan JC, Villanueva C, Vila MC *et al.* (2001) Isosorbide mononitrate in the prevention of first variceal bleed in patients who cannot receive beta-blockers. *Gastroenterology* 121, 908–914.

62 Poynard T, Cales P, Pasta L *et al.* (1991) Beta-adrenergic-antagonist drugs in the prevention of gastrointestinal bleeding in patients with cirrhosis and esophageal varices. An analysis of data and prognostic factors in 589 patients from four randomized clinical trials. Franco-Italian Multicenter Study Group. *N Engl J Med* 324, 1532–1538.

63 Bosch J (2005) Is treatment with nadolol effective against the growth of small esophageal varices in patients with cirrhosis? *Nature Clin Pract Gastroenterol Hepatol* 2, 18–19.

64 Abraczinskas DR, Ookubo R, Grace ND *et al.* (2001) Propranolol for the prevention of first esophageal variceal hemorrhage: a lifetime commitment? *Hepatology* 34, 1096–1102.

65 Garcia-Pagan JC, Feu F, Bosch J *et al.* (1991) Propranolol compared with propranolol plus isosorbide-5-mononitrate for portal hypertension in cirrhosis. A randomized controlled study. *Ann Intern Med* 114, 869–873.

66 Merkel C, Sacerdoti D, Bolognesi M *et al.* (1997) Hemodynamic evaluation of the addition of isosorbide-5-mononitrate to nadolol in cirrhotic patients with insufficient response to the beta-blocker alone. *Hepatology* 26, 34–39.

67 Merkel C, Marin R, Enzo E *et al.* (1996) Randomised trial of nadolol alone or with isosorbide mononitrate for primary prophylaxis of variceal bleeding in cirrhosis. Gruppo-Triveneto per L'ipertensione portale (GTIP) (see comments). *Lancet* 348, 1677–1681.

68 Merkel C, Marin R, Sacerdoti D *et al.* (2000) Long-term results of a clinical trial of nadolol with or without isosorbide mononitrate for primary prophylaxis of variceal bleeding in cirrhosis. *Hepatology* 31, 324–329.

69 Imperiale TF, Chalasani N (2001) A meta-analysis of endoscopic variceal ligation for primary prophylaxis of esophageal variceal bleeding. *Hepatology* 33, 802–807.

70 De BK, Ghoshal UC, Das T *et al.* (1999) Endoscopic variceal ligation for primary prophylaxis of oesophageal variceal bleed: preliminary report of a randomized controlled trial. *J Gastroenterol Hepatol* 14, 220–224.

71 Lui HF, Stanley AJ, Forrest EH *et al.* (2002) Primary prophylaxis of variceal hemorrhage: a randomized controlled trial comparing band ligation, propranolol, and isosorbide mononitrate. *Gastroenterology* 123, 735–744.

72 Schepke M, Kleber G, Nurnberg D *et al.* (2004) Ligation versus propranolol for the primary prophylaxis of variceal bleeding in cirrhosis. *Hepatology* 40, 65–72.

73 Lo GH, Chen WC, Chen MH *et al.* (2004) Endoscopic ligation vs. nadolol in the prevention of first variceal bleeding in patients with cirrhosis. *Gastrointest Endosc* 59, 333–338.

74 Sarin SK, Lamba GS, Kumar M *et al.* (1999) Comparison of endoscopic ligation and propranolol for the primary prevention of variceal bleeding (see comments). *N Engl J Med* 340, 988–993.

75 Jutabha R, Jensen DM, Martin P *et al.* (2005) Randomized study comparing banding and propanolol to prevent initial variceal hemorrhage in cirrhotics with high-risk esophageal varices. *Gastroenterology* 128, 870–881.

76 Thuluvath PJ, Maheshwari A, Jagannath S *et al.* (2005) A randomized controlled trial of beta-blockers versus endoscopic band ligation for primary prophylaxis: a large sample size is required to show a difference in bleeding rates. *Dig Dis Sci* 50, 407–410.

77 Song H, Shin JW, Kim HI *et al.* (2000) A prospective randomized trial between the prophylactic endoscopic variceal ligation and propranolol administration for prevention of first bleeding in cirrhotic patients with high risk esophageal varices. *J Hepatol* 32 (Suppl. 2), 41A.

78 Gheorghe C, Gheorghe L, Vadan R *et al.* (2002) Prophylactic banding ligation of high-risk esophageal varices in patients on the waiting list for liver transplantation: an interim analysis. *J Hepatol* 36 (Suppl. 1), 38A.

79 Drastich P, Lata J, Petrtyl J *et al.* (2005) Endoscopic variceal band ligation in comparison with propranolol in prophylaxis of first variceal bleeding in patients with liver cirrhosis. *J Hepatol* 42, 202a.

80 de la Mora, Farca-Belsaguy AA, Uribe M *et al.* (2000) Ligation vs propranolol for primary prophylaxis of variceal bleeding using multiple band ligator and objective measurements of treatment adequacy: preliminary results. *Gastroenterology* 118, 6511A.

81 Chen CY, Sheu MZ, Su SY (1998) Prophylactic endoscopic variceal ligation for esophageal varices. *Gastroenterology* 114, 1224A.

82 Turnes J, García-Pagán JC, Abraldes JG *et al.* (2003) Pharmacological reduction of portal pressure and long term risk of first variceal bleeding in patients with cirrhosis. *Hepatology* 38, 219A.

83 Triantos C, Vlachogiannakos J, Armonis A *et al.* (2005) Primary prophylaxis of variceal bleeding in cirrhotics unable to take beta-blockers: a randomized trial of ligation. *Aliment Pharmacol Ther* 21, 1435–1443.

84 Sarin SK, Wadhawan M, Agarwal SR *et al.* (2005) Endoscopic variceal ligation plus propranolol versus endoscopic variceal ligation alone in primary prophylaxis of variceal bleeding. *Am J Gastroenterol* 100, 797–804.

85 D'Amico G, Pagliaro L, Bosch J (1995) The treatment of portal hypertension: a meta-analytic review. *Hepatology* 22, 332–354.

86 Lebrec D, Nouel O, Bernuau J *et al.* (1981) Propranolol in prevention of recurrent gastrointestinal bleeding in cirrhotic patients. Lancet 1, 920–921.

87 Pasta L, D'Amico G, Patti R (1999) Isosorbide mononitrate (IMN) with nadolol compared with nadolol alone for prevention of recurrent bleeding in cirrhosis. a double-blind placebo-controlled randomised trial. *J Hepatol* 30, 81A.

88 Gournay J, Masliah C, Martin T *et al.* (2000) Isosorbide mononitrate and propranolol compared with propranolol alone for the prevention of variceal rebleeding. *Hepatology* 31, 1239–1245.
89 Bureau C, Peron JM, Alric L *et al.* (2002) 'A la carte' treatment of portal hypertension: adapting medical therapy to hemodynamic response for the prevention of bleeding. *Hepatology* 36, 1361–1366.
90 de Franchis R, Primignani M (1999) Endoscopic treatments for portal hypertension. *Semin Liver Dis* 19, 439–455.
91 Laine L, el Newihi HM, Migikovsky B *et al.* (1993) Endoscopic ligation compared with sclerotherapy for the treatment of bleeding esophageal varices. *Ann Intern Med* 119, 1–7.
92 Patch D, Sabin CA, Goulis J *et al.* (2002) A randomized, controlled trial of medical therapy versus endoscopic ligation for the prevention of variceal rebleeding in patients with cirrhosis. *Gastroenterology* 123, 1013–1019.
93 Romero G, Kravetz D, Argonz J *et al.* (2006) Comparative study between nadolol and 5-isosorbide mononitrate vs. endoscopic band ligation plus sclerotherapy in the prevention of variceal rebleeding in cirrhotic patients: a randomized controlled trial. *Aliment Pharmacol Ther* 24, 601–611.
94 Lo GH, Chen WC, Chen MH *et al.* (2002) Banding ligation versus nadolol and isosorbide mononitrate for the prevention of esophageal variceal rebleeding. *Gastroenterology* 123, 728–734.
95 Lo GH, Lai KH, Cheng JS *et al.* (2000) Endoscopic variceal ligation plus nadolol and sucralfate compared with ligation alone for the prevention of variceal rebleeding: a prospective, randomized trial. *Hepatology* 32, 461–465.
96 Burroughs AK, Vangeli M (2002) Transjugular intrahepatic portosystemic shunt versus endoscopic therapy: randomized trials for secondary prophylaxis of variceal bleeding: an updated meta-analysis. *Scand J Gastroenterol* 37, 249–252.
97 Escorsell A, Banares R, Garcia-Pagan JC *et al.* (2002) TIPS versus drug therapy in preventing variceal rebleeding in advanced cirrhosis: a randomized controlled trial. *Hepatology* 35, 385–392.
98 Rosemurgy AS, Serafini FM, Zweibel BR *et al.* (2000) Transjugular intrahepatic portosystemic shunt vs. small-diameter prosthetic H-graft portacaval shunt: extended follow-up of an expanded randomized prospective trial. *J Gastrointest Surg* 4, 589–597.
99 Henderson JM, Boyer TD, Kutner MH *et al.* (2006) Distal splenorenal shunt versus transjugular intrahepatic portal systematic shunt for variceal bleeding: a randomized trial. *Gastroenterology* 130, 1643–1651.
100 Bureau C, Garcia-Pagan JC, Otal P *et al.* (2004) Improved clinical outcome using polytetrafluoroethylene-coated stents for tips: results of a randomized study. *Gastroenterology* 126, 469–475.
101 McCormick PA, Jenkins SA, McIntyre N *et al.* (1995) Why portal hypertensive varices bleed and bleed: a hypothesis. *Gut* 36, 100–103.
102 Castaneda B, Morales J, Lionetti R *et al.* (2001) Effects of blood volume restitution following a portal hypertensive-related bleeding in anesthetized cirrhotic rats. *Hepatology* 33, 821–825.
103 Bernstein DE, Jeffers L, Erhardtsen E *et al.* (1997) Recombinant factor VIIa corrects prothrombin time in cirrhotic patients: a preliminary study. *Gastroenterology* 113, 1930–1937.
104 Ejlersen E, Melsen T, Ingerslev J *et al.* (2001) Recombinant activated factor VII (rFVIIa) acutely normalizes prothrombin time in patients with cirrhosis during bleeding from oesophageal varices. *Scand J Gastroenterol* 36, 1081–1085.
105 Vivas S, Rodriguez M, Palacio MA *et al.* (2001) Presence of bacterial infection in bleeding cirrhotic patients is independently associated with early mortality and failure to control bleeding. *Dig Dis Sci* 46, 2752–2757.
106 Hou MC, Lin HC, Liu TT *et al.* (2004) Antibiotic prophylaxis after endoscopic therapy prevents rebleeding in acute variceal hemorrhage: a randomized trial. *Hepatology* 39, 746–753.
107 Bernard B, Grange JD, Khac EN *et al.* (1999) Antibiotic prophylaxis for the prevention of bacterial infections in cirrhotic patients with gastrointestinal bleeding: a meta-analysis. *Hepatology* 29, 1655–1661.
108 Rimola A, Garcia-Tsao G, Navasa M *et al.* (2000) Diagnosis, treatment and prophylaxis of spontaneous bacterial peritonitis: a consensus document. International Ascites Club. *J Hepatol* 32, 142–153.
109 Fernandez J, Ruiz del Arbol L, Serradilla R *et al.* (2006) Norfloxacin vs ceftriaxone in the prophylaxis of infections in cirrhotics with advanced cirrhosis and hemorrhage. *Gastroenterology* 131, 1049–1056.
110 Levacher S, Letoumelin P, Pateron D *et al.* (1995) Early administration of terlipressin plus glyceryl trinitrate to control active upper gastrointestinal bleeding in cirrhotic patients. *Lancet* 346, 865–868.
111 Abraldes JG, Bosch J (2002) Somatostatin and analogues in portal hypertension. *Hepatology* 35, 1305–1312.
112 Bosch J, Lebrec D, Jenkins SA (1998) Development of analogues: successes and failures. *Scand J Gastroenterol Suppl* 226, 3–13.
113 Escorsell A, Ruiz d'A, Planas R *et al.* (2000) Multicenter randomized controlled trial of terlipressin versus sclerotherapy in the treatment of acute variceal bleeding: the TEST study. *Hepatology* 32, 471–476.
114 Ioannou GN, Doust J, Rockey DC (2003) Systematic review: terlipressin in acute oesophageal variceal haemorrhage. *Aliment Pharmacol Ther* 17, 53–64.
115 Uriz J, Gines P, Cardenas A *et al.* (2000) Terlipressin plus albumin infusion: an effective and safe therapy of hepatorenal syndrome. *J Hepatol* 33, 43–48.
116 Tyden G, Sammegard H, Thulin L *et al.* (1978) Treatment of bleeding esophageal varices with somatostatin. *N Engl J Med* 299, 1466–1467.
117 Bosch J, Kravetz D, Rodes J (1981) Effects of somatostatin on hepatic and systemic hemodynamics in patients with cirrhosis of the liver: comparison with vasopressin. *Gastroenterology* 80, 518–525.
118 Escorsell A, Bordas JM, del Arbol LR *et al.* (1998) Randomized controlled trial of sclerotherapy versus somatostatin infusion in the prevention of early rebleeding following acute variceal hemorrhage in patients with cirrhosis. Variceal Bleeding Study Group. *J Hepatol* 29, 779–788.
119 Moitinho E, Planas R, Bañares R *et al.* (2001) Multicenter randomized controlled trial comparing different schedules of somatostatin in the treatment of acute variceal bleeding. *J Hepatol* 35, 712–718.
120 Valenzuela JE, Schubert T, Fogel MR *et al.* (1989) A multicenter, randomized, double-blind trial of somatostatin in the management of acute hemorrhage from esophageal varices (see comments). *Hepatology* 10, 958–961.
121 Villanueva C, Ortiz J, Sabat M *et al.* (1999) Somatostatin alone or combined with emergency sclerotherapy in the treatment of acute esophageal variceal bleeding: a prospective randomized trial. *Hepatology* 30, 384–389.
122 Escorsell A, Bandi JC, Andreu V *et al.* (2001) Desensitization to the effects of intravenous octreotide in cirrhotic patients with portal hypertension. *Gastroenterology* 120, 161–169.
123 International Octreotide Varices Study Group and Burroughs AK (1996) Double blind RCT of 5 day octreotide versus placebo, associated with sclerotherapy for trial failures. *Hepatology* 24, 352A.

124 Corley DA, Cello JP, Adkisson W *et al.* (2001) Octreotide for acute esophageal variceal bleeding: a meta-analysis. *Gastroenterology* 120, 946–954.
125 Lo GH, Lai KH, Cheng JS *et al.* (1997) Emergency banding ligation versus sclerotherapy for the control of active bleeding from esophageal varices. *Hepatology* 25, 1101–1104.
126 Villanueva C, Morales J, Lionetti R *et al.* (2001) A randomized controlled trial comparing ligation and sclerotherapy as emergency endoscopic treatment added to somatostatin in acute variceal bleeding. *J Hepatol* 45, 560–567.
127 Avgerinos A, Armonis A, Stefanidis G *et al.* (2004) Sustained rise of portal pressure after sclerotherapy, but not band ligation, in acute variceal bleeding in cirrhosis. *Hepatology* 39, 1623–1630.
128 Avgerinos A, Nevens F, Raptis S *et al.* (1997) Early administration of somatostatin and efficacy of sclerotherapy in acute oesophageal variceal bleeds: the European Acute Bleeding Oesophageal Variceal Episodes (ABOVE) randomised trial. *Lancet* 350, 1495–1499.
129 Cales P, Masliah C, Bernard B *et al.* (2001) Early administration of vapreotide for variceal bleeding in patients with cirrhosis. French Club for the Study of Portal Hypertension. *N Engl J Med* 344, 23–28.
130 Banares R, Albillos A, Rincon D *et al.* (2002) Endoscopic treatment versus endoscopic plus pharmacologic treatment for acute variceal bleeding: a meta-analysis. *Hepatology* 35, 609–615.
131 D'Amico G, Pietrosi G, Tarantino I *et al.* (2003) Emergency sclerotherapy versus vasoactive drugs for variceal bleeding in cirrhosis: a Cochrane meta-analysis. *Gastroenterology* 124, 1277–1291.
132 Burroughs AK, Patch D (1999) Transjugular intrahepatic portosystemic shunt. *Semin Liver Dis* 19, 457–473.
133 Bosch J (2001) Salvage transjugular intrahepatic portosystemic shunt: is it really life-saving? *J Hepatol* 35, 658–660.
134 Henderson JM (2001) Salvage therapies for refractory variceal hemorrhage. *Clin Liver Dis* 5, 709–725.
135 Patch D, Nikolopoulou V, McCormick A *et al.* (1998) Factors related to early mortality after transjugular intrahepatic portosystemic shunt for failed endoscopic therapy in acute variceal bleeding. *J Hepatol* 28, 454–460.
136 Sarin SK, Lahoti D, Saxena SP *et al.* (1992) Prevalence, classification and natural history of gastric varices: a long-term follow-up study in 568 portal hypertension patients. *Hepatology* 16, 1343–1349.
137 Teres J, Cecilia A, Bordas JM *et al.* (1978) Esophageal tamponade for bleeding varices. Controlled trial between the Sengstaken–Blakemore tube and the Linton–Nachlas tube. *Gastroenterology* 75, 566–569.
138 Panes J, Teres J, Bosch J *et al.* (1988) Efficacy of balloon tamponade in treatment of bleeding gastric and esophageal varices. Results in 151 consecutive episodes. *Dig Dis Sci* 33, 454–459.
139 Sarin SK, Agarwal SR (2001) Gastric varices and portal hypertensive gastropathy. *Clin Liver Dis* 5, 727–767, x.
140 Huang YH, Yeh HZ, Chen GH *et al.* (2000) Endoscopic treatment of bleeding gastric varices by N-butyl-2-cyanoacrylate (Histoacryl) injection: long-term efficacy and safety. *Gastrointest Endosc* 52, 160–167.
141 Lee YT, Chan FK, Ng EK *et al.* (2000) EUS-guided injection of cyanoacrylate for bleeding gastric varices. *Gastrointest Endosc* 52, 168–174.
142 Kind R, Guglielmi A, Rodella L *et al.* (2000) Bucrylate treatment of bleeding gastric varices: 12 years' experience. *Endoscopy* 32, 512–519.
143 Lo GH, Lai KH, Cheng JS *et al.* (2001) A prospective, randomized trial of butyl cyanoacrylate injection versus band ligation in the management of bleeding gastric varices. *Hepatology* 33, 1060–1064.
144 Sarin SK, Jain AK, Jain M *et al.* (2002) A randomized controlled trial of cyanoacrylate versus alcohol injection in patients with isolated fundic varices. *Am J Gastroenterol* 97, 1010–1015.
145 Heneghan MA, Byrne A, Harrison PM (2002) An open pilot study of the effects of a human fibrin glue for endoscopic treatment of patients with acute bleeding from gastric varices. *Gastrointest Endosc* 56, 422–426.
146 Yang WL, Tripathi D, Therapondos G *et al.* (2002) Endoscopic use of human thrombin in bleeding gastric varices. *Am J Gastroenterol* 97, 1381–1385.
147 Chau TN, Patch D, Chan YW *et al.* (1998) 'Salvage' transjugular intrahepatic portosystemic shunts: gastric fundal compared with esophageal variceal bleeding. *Gastroenterology* 114, 981–987.
148 Barange K, Peron JM, Imani K *et al.* (1999) Transjugular intrahepatic portosystemic shunt in the treatment of refractory bleeding from ruptured gastric varices. *Hepatology* 30, 1139–1143.
149 Primignani M, Carpinelli L, Preatoni P *et al.* (2000) Natural history of portal hypertensive gastropathy in patients with liver cirrhosis. The New Italian Endoscopic Club for the study and treatment of esophageal varices (NIEC). *Gastroenterology* 119, 181–187.
150 Perez-Ayuso RM, Pique JM, Bosch J *et al.* (1991) Propranolol in prevention of recurrent bleeding from severe portal hypertensive gastropathy in cirrhosis. *Lancet* 337, 1431–1434.
151 Panes J, Bordas JM, Pique JM *et al.* (1993) Effects of propranolol on gastric mucosal perfusion in cirrhotic patients with portal hypertensive gastropathy. *Hepatology* 17, 213–218.
152 Panes J, Pique JM, Bordas JM *et al.* (1994) Reduction of gastric hyperemia by glypressin and vasopressin administration in cirrhotic patients with portal hypertensive gastropathy. *Hepatology* 19, 55–60.
153 Panes J, Pique JM, Bordas JM *et al.* (1994) Effect of bolus injection and continuous infusion of somatostatin on gastric perfusion in cirrhotic patients with portal-hypertensive gastropathy. *Hepatology* 20, 336–341.
154 Panes J, Casadevall M, Fernandez M *et al.* (1994) Gastric microcirculatory changes of portal-hypertensive rats can be attenuated by long-term estrogen–progestagen treatment. *Hepatology* 20, 1261–1270.
155 Kouroumalis EA, Koutroubakis IE, Manousos ON (1998) Somatostatin for acute severe bleeding from portal hypertensive gastropathy. *Eur J Gastroenterol Hepatol* 10, 509–512.
156 Orloff MJ, Orloff MS, Orloff SL *et al.* (1995) Treatment of bleeding from portal hypertensive gastropathy by portacaval shunt. *Hepatology* 21, 1011–1017.
157 Urata J, Yamashita Y, Tsuchigame T *et al.* (1998) The effects of transjugular intrahepatic portosystemic shunt on portal hypertensive gastropathy. *J Gastroenterol Hepatol* 13, 1061–1067.
158 Kamath PS, Lacerda M, Ahlquist DA *et al.* (2000) Gastric mucosal responses to intrahepatic portosystemic shunting in patients with cirrhosis. *Gastroenterology* 118, 905–911.

7.4 Haemodynamic assessment of portal hypertension

Juan Carlos García-Pagán, Juan Turnes and Jaime Bosch

Portal hypertension is a frequent clinical syndrome defined by a pathological increase in the portal venous pressure, which is responsible for the more frequent and severe complications of cirrhosis: gastrointestinal bleeding from gastro-oesophageal varices, ascites, renal dysfunction and hepatic encephalopathy. Because of the combined impact of these complications, portal hypertension represents the main cause of death and liver transplantation in patients with cirrhosis [1].

Measurement of portal pressure

Introduction and scientific basis

Measurement of the portal pressure is still the single most important haemodynamic measurement in portal hypertension. Other methods, such as the endoscopy assessment of the existence of oesophageal or gastric varices or the visualization of portal collateral circulation by imaging techniques, provide additional information but are not substitutes for the measurement of portal pressure.

The first published measurement of portal pressure in humans was that of Thompson *et al.* in 1937 [2] who recorded portal venous pressure during abdominal surgery. But it was in 1951 that Myers and Taylor [3], inspired by Dexter *et al.*'s experience with pulmonary capillary pressure for measuring left auricular pressure [4], developed the measurement of wedged hepatic venous pressure (WHVP) as an indirect index of portal venous pressure. The scientific basis is that, when blood flow in a hepatic vein is stopped by a 'wedged' small catheter, a continuous column of blood between the catheter and the sinusoid is formed, resulting in a pressure reading that is equal to the sinusoidal pressure. Thus, WHVP is a measurement of the hepatic sinusoidal pressure and not of the portal pressure itself. However, many studies have demonstrated that WHVP adequately reproduces portal pressure in alcoholic liver disease and hepatitis C- and hepatitis B-related cirrhosis [5,6]. These entities are by far the most frequent aetiologies of chronic liver disease in developed countries. It was soon evident that hepatic vein catheterization constituted a safe and relatively simple technique for performing accurate measurements of portal pressure in patients with liver disease [7,8]. However, it took five decades of broad experience with the technique before hepatic vein pressure measurements were recognized as a useful tool in the clinical management of patients with cirrhosis and portal hypertension. A limitation of this technique is that it does not reproduce the portal pressure in presinusoidal causes of portal hypertension such as portal vein thrombosis, early primary biliary cirrhosis, idiopathic portal hypertension or schistosomiasis. In these cases, a direct assessment of the portal pressure is mandatory.

Portal pressure should be expressed in terms of the portal pressure gradient, defined as the difference between WHVP and free hepatic venous pressure (FHVP), the so-called hepatic venous pressure gradient or HVPG, which has the advantage of not being modified by changes in intra-abdominal pressure such as those occurring in the presence of tense ascites or after total-volume paracentesis [9]. Increased intra-abdominal pressure will increase both the WHVP and the FHVP, but will not significantly modify the HVPG.

Description of the technique

Portal pressure may be measured by either direct or indirect methods.

Direct measurements of portal pressure

Direct measurement of portal pressure involves invasive techniques based on the surgical, percutaneous transhepatic or transvenous (transjugular) catheterization of the portal vein. In these techniques, except for the transjugular approach, the measurement of inferior vena cava (IVC) pressure requires the additional, simultaneous puncture of a hepatic vein to be able to determine the portal pressure gradient [10]. Because of this inconvenience and the associated surgical or haemorrhagic risk, direct measurements of portal pressure are reserved for cases of suspected presinusoidal portal hypertension.

The safety of either the percutaneous transhepatic or transjugular catheterization of the portal vein may be increased by

(a)

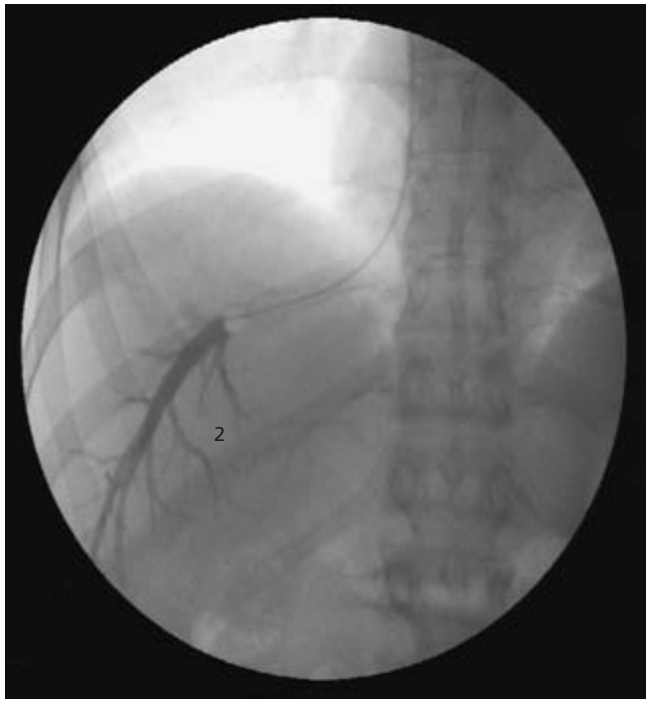

(b)

Fig. 1 The catheter (a) is advanced until it becomes 'wedged' into a small branch of the hepatic vein. Injection of contrast dye shows a small area of liver parenchyma draining to the vein where the catheter is wedged (1). The balloon-tipped catheter (b) allows occlusion of the blood flow in a larger segment of the liver (2), and allows repeat measurements of WHVP and FHVP in the same position.

performing the procedures under ultrasonographic guidance. The haemorrhagic risk is greater in the percutaneous procedure, which precludes its use in patients with impaired coagulation. This can be partly overcome by using a thin needle and by occluding the intrahepatic tract with gelatine sponge particles or coils passed through the catheter while withdrawing it from the liver.

Other drawbacks of the technique are the risk of causing portal vein thrombosis due to local trauma, capsular laceration with haemoperitoneum and subcapsular haematoma.

Indirect measurements of portal pressure: hepatic vein catheterization

This is the most commonly used technique to evaluate portal pressure [11] and has become a routine test in many hospitals. Basically, it consists of introducing, by the Seldinger technique, a venous introducer into the femoral or jugular vein under local anaesthesia and conscious sedation. A 5 or 7 French balloon-tipped catheter is then advanced into a hepatic vein, usually the main right hepatic vein, under fluoroscopic control. Before balloon inflation, the pressure measured is the FHVP, which reflects the IVC pressure (indeed, the difference between both should be less than 2 mmHg). WHVP is measured by occluding the hepatic vein, either by inflating the balloon at the tip of the catheter ('occluded' pressure) or by advancing the catheter until it becomes 'wedged' into a small branch of a hepatic vein (Fig. 1). The wedged/occluded position is confirmed by a slow injection of 5 mL of contrast dye through the catheter. If wedging is complete, the contrast outlines a portion of the hepatic venous tree distal to the catheter tip. Otherwise, the contrast flows back along the catheter or washout through communications with other hepatic veins (Fig. 2). The catheter should be carefully rinsed with 5% dextrose before measuring pressures. The balloon catheter is preferred on account of the lower variability of measurements as the pressure obtained represents the average of a wider vascular area of the liver [12]. In addition, the balloon catheter technique has the advantage of allowing repeated measurements from the same hepatic vein, which otherwise requires advancing and withdrawing the catheter for each HVPG measurement.

Although it is easy and simple to perform, accurate HVPG measurements require specific training, because the procedure differs from that used in heart catheterization laboratories and intensive care units. The following are useful tips to ensure adequate measurements:

- The transducer should be calibrated against known external pressures before starting measurements (e.g. 13.6 cmH_2O should read 10 mmHg and 27.2 cmH_2O should read 20 mmHg). Transducers that do not calibrate exactly should be discarded.
- The transducer should be placed at the level of the right atrium (midaxillary line), and the 'zero' pressure (the atmospheric pressure with the transducer open to the air) should match the 'zero' line in the pressure tracing.

Fig. 2 In the presence of a communicating hepatic vein (1), WHVP will not reflect the actual portal pressure in this patient unless in a different hepatic vein there are no communicating vessels. This finding is more frequent in instances of presinusoidal intrahepatic portal hypertension, such as 'idiopathic' portal hypertension.

• Use an appropriate scale to be able to sense small changes. The scales used for arterial pressure measurements are not adequate. The scale should be set, at least, at 1 mmHg = 1 mm of paper.
• Digital readings on the screen are instantaneous readings and may not reliably reflect the true pressure. Therefore, paper recordings should be used, allowing for the independent review of pressure tracings (Fig. 3).
• Venous pressures should be allowed to stabilize over a period of at least 1 min for WHVP and 15 s for FHVP (some patients may require longer). A slow paper speed (< 5 mm/s) should be used in the recorder.
• FHVP should be measured with the catheter tip introduced less than 5 cm into the hepatic vein. FHVP should not be more than 2 mmHg greater than the IVC pressure, measured at the level of the hepatic veins. If the difference is greater, a hepatic outflow problem should be investigated.
• Check that inflating the distal balloon totally occludes the hepatic vein before measuring WHVP.
• For each measurement, also obtain a 'mean' pressure by 'filtering' the tracing or by selecting this option in the recorder.
• Do all measurements in duplicate (or triplicate if the pressures differ by more than 1 mmHg).
• Any event that may cause an artifact, such as coughing or moving, should be noted.

In addition to pressure measurements, hepatic vein catheterization allows for the performance of a wedged hepatic retrograde portography using CO_2 as a contrast agent (Fig. 4). This will demonstrate the portal vein in most instances. In fact, an inability to demonstrate the portal vein on CO_2 retrograde portography strongly suggests the presence of presinusoidal portal hypertension [13]. Hepatic vein catheterization also allows for the performance of a transjugular liver biopsy, which adds very little time, discomfort and risk to the procedure, and can be done on a day-hospital basis.

Indications

The principal applications of HVPG measurements are discussed below.

Classification of portal hypertension

Findings at hepatic vein catheterization may help to identify the cause of portal hypertension. Causes of portal hypertension may be classified into presinusoidal, sinusoidal or postsinusoidal. In patients with clinical manifestations of portal hypertension who have normal WHVP, a presinusoidal source of portal hypertension should be suspected. In these cases, WHVP underestimates the true portal pressure because the catheter is recording the pressure of the normal sinusoid but not of the obstructed area. In liver cirrhosis, the increased WHVP is nearly equal to portal venous pressure [5,6]. In postsinusoidal portal hypertension resulting from Budd–Chiari syndrome, IVC obstruction, right heart failure or constrictive pericarditis, both FHVP and WHVP are increased, while HVPG remains usually normal [14] (Fig. 5).

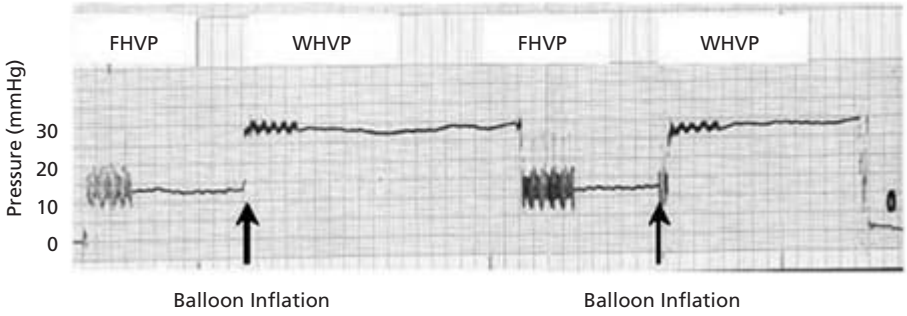

Fig. 3 Typical reading of correct measurements of hepatic venous pressures before (FHVP) and after balloon inflation (WHVP).

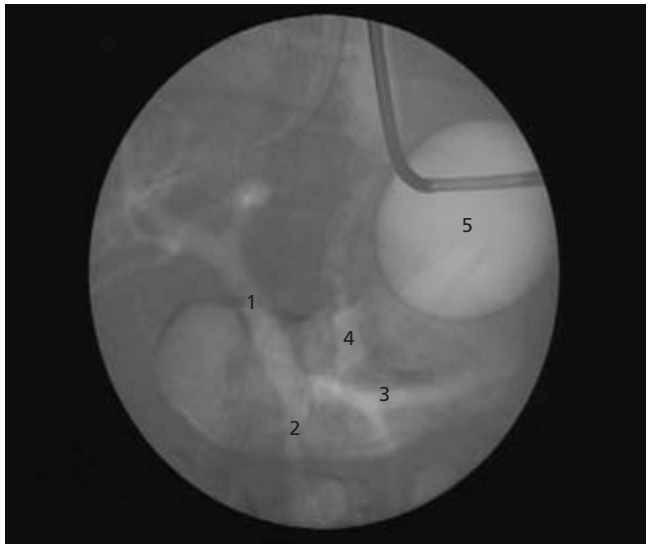

Fig. 4 Wedged retrograde portography using CO_2 as a contrast agent showing patent portal (1), mesenteric (2) and splenic veins (3). Retrograde portography also showed an extensive collateralization (4) in a patient with HCV-related cirrhosis in which a Sengstaken tube (5) was placed to treat a variceal bleeding episode.

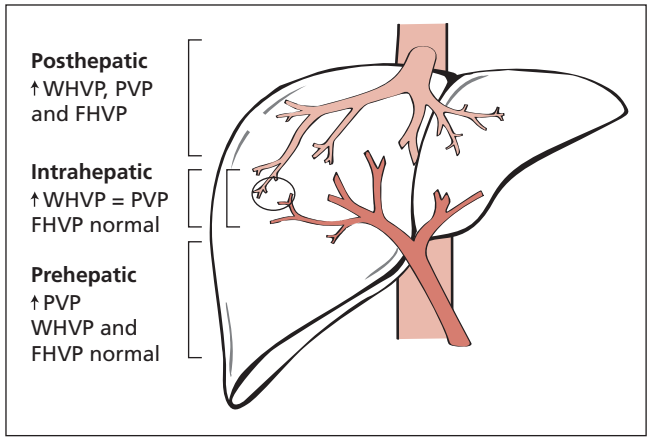

Fig. 5 Intrahepatic causes of portal hypertension may be classified into presinusoidal, sinusoidal or postsinusoidal according to the position of blood flow obstruction.

Evaluation of portal hypertension and assessment of the response to pharmacological therapy

The normal HVPG value is up to 5 mmHg. Oesophageal varices do not develop until the HVPG increases to 10–12 mmHg, and the HVPG should be at least 12 mmHg for the appearance of complications of portal hypertension, such as variceal bleeding and ascites [15,16]. Furthermore, longitudinal studies have demonstrated that, if HVPG is decreased below 12 mmHg by means of pharmacological treatment [17,18] or spontaneously due to an improvement in liver disease [19], variceal bleeding is totally prevented and varices may decrease in size. Therefore, patients with a HVPG below 12 mmHg are at negligible or no risk of experiencing portal hypertension-related complications. Besides, even if this target is not achieved, a decrease in HVPG of at least 20% [18] from baseline levels offers an almost total protection from variceal bleeding. Lack of achievement of these targets (reduction below 12 mmHg or more than 20% from baseline) constitutes the strongest independent predictor of variceal bleeding or rebleeding [18,20–22]. Therefore, tailoring the treatment of portal hypertension by measuring the individual portal pressure response to therapy would allow us to predict whether the treatment is likely to offer optimal or adequate protection from the risk of bleeding at short- and long-term (up to 8 years) follow-up [22,23]. However, whether the HVPG response to 'à la carte' treatment is cost-effective must be evaluated in specifically designed clinical trials [24].

Prognostic evaluation during variceal bleeding

Early measurements of HVPG within 48 h of admission for acute variceal bleeding provides useful prognostic information regarding the outcome of the bleeding episode and 1-year survival [25]. Patients with an HVPG > 20 mmHg are five times more likely to experience failure to control acute variceal bleeding or early rebleeding, require significantly more blood transfusions and days in the intensive care unit and have a higher mortality on follow-up. In addition, recent work has suggested that the early use of transjugular intrahepatic portosystemic shunts (TIPS) in these high-risk patients improves the control of bleeding and reduces early rebleeding and mortality [26].

Preoperative evaluation of resection risk in patients with small hepatocellular carcinoma

HVPG measurement may provide useful prognostic information in patients undergoing partial hepatectomy for small (< 5 cm) hepatocellular carcinoma. Patients with an HVPG > 10 mmHg and/or increased bilirubin levels have an increased risk of hepatic decompensation after surgical resection of hepatocellular carcinoma [27], even in cases with well-preserved liver function (Child–Pugh A). In a recent study, more than 50% of Child–Pugh class A patients had hepatic decompensation after surgery. This decompensation not only affected quality of life but was also associated with reduced long-term survival [27,28]. Surgical resection should therefore be restricted to patients with an HVPG below 10 mmHg. Otherwise, liver transplantation or local ablative therapies should be preferred.

Evaluation of progression of chronic liver disease

It has been suggested that, in the setting of severe chronic hepatitis C, HVPG could be considered a dynamic marker of fibrosis progression [29]. Thus, HVPG measurements may be considered as an adjunctive for the therapeutic evaluation of the response to antiviral therapy [29,30]. However, prospective trials in this area are needed to clarify the role of HVPG in the management of these patients.

Contraindications

Past episodes of allergic reaction to radiographic contrast medium constitute the only major contraindication to hepatic vein catheterization. Coagulation disorders are usually seen in cirrhotic patients, but the evidence of complications associated with severe thrombocytopenia or low prothrombin time is limited. Therefore, we do not use supportive therapy for routine HVPG measurements.

Complications

The measurement of the HVPG is a reproducible method that can be repeated because it carries very little discomfort. Performed under slight conscious sedation that does not modify haemodynamic measurements (midazolam 0.02 mg/kg i.v.) [31], its acceptability is comparable to that of upper gastrointestinal endoscopy, and the cost is similar to that of conventional venography. The complications reported occur in less than 1% of patients [32], and major complications are usually limited to local injury of the femoral or jugular vein (arteriovenous fistulae, leakage or rupture of venous introducers), Horner syndrome and transient brachial paralysis. These complications are greatly reduced by performing the venous puncture under Doppler ultrasonography guidance. Passage of the catheter through the right atrium may cause arrhythmias that are usually transient or easily corrected. Transjugular liver biopsies may rarely be complicated by intraperitoneal bleeding due to capsular perforation and subcapsular haematomas. The authors have observed no fatalities in over 10 000 studies. Because of the many clinical applications, hepatic vein catheterization is becoming a routine test in many hospitals.

Hepatic blood flow

The portal hypertension syndrome is characterized by the development of a hyperdynamic circulation with increased cardiac output and decreased systemic vascular resistance that leads to splanchnic vasodilatation with increased portal blood flow. Under normal circumstances, total hepatic blood flow represents approximately 25% of the cardiac output; a third is supplied by the hepatic artery and the remainder by the portal venous system. A reduction in portal blood flow results in an increase in hepatic artery flow up to 100% from baseline. This 'hepatic artery buffer response' is very important in cases in which portal blood flow decreases dramatically, such as in portal vein thrombosis or portocaval shunts. In contrast, the portal venous system is thought to be a passive vascular bed receiving the venous blood draining from the stomach, intestines, pancreas, spleen and omentum. Therefore, factors that regulate portal venous flow are those that control the arterial supply of blood to these organs. Contrary to what happens in the hepatic artery, there is no portal venous buffer hyperaemia in response to decreased hepatic arterial flow.

Measurement of hepatic blood flow is usually performed by means of clearance techniques. These techniques require the injection of dyes or radiolabelled particles that are avidly extracted by the liver. If a substance is totally extracted by the liver in a single pass, its plasma clearance will be equal to total hepatic blood flow. However, no substance possesses this property. Because of that, it is necessary to measure the hepatic extraction of the test compound directly (the fractional uptake in a single passage through the liver), which requires sampling blood simultaneously from a hepatic vein and a peripheral artery once the steady-state concentration for this substance has been reached. This is particularly true in the setting of clinical liver disease, in which extraction of the indicator is frequently diminished [33]. The most commonly used indicator is the albumin-bound dye indocyanine green, which is removed only by the liver, and its plasma clearance rate represents the hepatic clearance of the compound [34]. The extrarenal sorbitol clearance has been reported to be a safe, non-invasive and reliable means of measuring 'parenchymal' or 'effective' liver blood flow in patients with normal or diseased livers [35]. Other techniques have been described such as the indicator dilution technique and the inert gas washout, but these are invasive methods requiring catheterization of the hepatic artery and/or the portal vein, as well as of the hepatic vein.

The main application of measurements of hepatic blood flow is in the setting of studies aimed at assessing changes in the hepatic blood flow following the administration of vasoactive drugs and evaluating the accommodation of the hepatic vascular bed to increases in blood flow such as that produced by meals.

Measurement of azygos blood flow

Superior portal–systemic collaterals, including gastro-oesophageal varices, drain mainly into the azygos venous system. Therefore, measurement of the azygos blood flow represents an index of blood flow through the gastro-oesophageal collaterals and oesophageal varices in portal hypertension [36]. Patients with portal hypertension have an increased portocollateral blood flow, leading to an increased azygos blood flow. Values in normal subjects range from 100 to 250 mL/min, whereas mean values in patients with portal hypertension average 650–700 mL/min [36]. The azygos blood flow is also increased in patients with non-cirrhotic portal hypertension. Measurement of azygos blood flow requires the retrograde catheterization of the azygos vein using a continuous thermal dilution catheter. The procedure is simple and may be done in the course of routine haemodynamic investigations. Blood flow is measured by the thermodilution technique, applying Fick's principle.

It is important to note that this technique does not allow the separation of how much of the increase in azygos blood flow is contributed by oesophageal varices and how much by peri-oesophageal collaterals, which also drain into the azygos vein. In addition, in 25% of the cases, these gastro-oesophageal collaterals drain into other thoracic veins (subclavian, innominate and pulmonary), different from the azygos vein. Therefore, a normal

azygos blood flow does not necessarily indicate the absence of oesophageal varices.

The main application of measurements of azygos blood flow is in the monitoring of the effects of pharmacological therapy in portal hypertension. Azygos blood flow is markedly reduced by the use of vasoconstrictive drugs such as vasopressin [37], somatostatin [38], octreotide [39–41], terlipressin [40] and beta-blockers [42]. The ability of the technique to quantify changes in portocollateral blood flow has allowed a better understanding of the beneficial effects of vasoactive drugs currently used in the medical treatment of portal hypertension. It has been demonstrated that some splanchnic vasoconstrictors, such as propranolol, cause greater decreases in azygos blood flow than in portal pressure [42], suggesting that they may have specific effects at the collaterals, which cannot be evaluated by the isolated measurement of portal pressure [42,43].

Finally, promising results have been obtained measuring portal and azygos blood flow non-invasively using phase-contrast magnetic resonance imaging (MRI) angiography [44,45] and, recently, with dynamic contrast material-enhanced MRI [46]. Endoscopic ultrasonography has also been proposed [47], although it is less accurate.

Measurement of variceal pressure

Several endoscopic findings, such as the size of the varices and the presence of red colour signs, show a significant correlation with the risk of bleeding [48]. These are some of the main determinants of variceal wall tension [49], which is believed to play a key role in determining variceal rupture [50,51]. According to Laplace's law, variceal wall tension is directly related to the radius of the varix and inversely related to its wall thickness [49]. The other direct determinant of variceal wall tension is the transmural pressure at the varices, the difference between intravariceal pressure and oesophageal luminal pressure.

Variceal pressure can be accurately measured at endoscopy by puncturing the varices or by means of pressure gauges or low-resistance balloons [52–54]. The endoscopic pressure gauge is the method that has been used most commonly in prospective studies. The technique is based on the assumption that, because of their thin walls and lack of external tissue support, the varices behave as an elastic structure; thus, the pressure needed to compress a varix equals the pressure inside the varix. It consists of using a pressure-sensitive capsule, attached to the tip of an endoscope, that has a small chamber covered by a thin latex membrane, which is continuously perfused with a constant flow of nitrogen. It is assumed that, when the gauge is applied to the varix, the pressure needed to perfuse the gauge equals the pressure inside the varix. The difference between the pressure measured when applying the gauge over a varix and the pressure recorded when the gauge is free in the oesophageal lumen equals the transmural variceal pressure, which is the value used to express the results using this technique [50,53,55].

Variceal pressure correlates significantly with portal pressure [53]. Despite this correlation, variceal pressure is significantly lower than portal pressure, probably because a significant resistance along the collaterals feeding the varices causes a pressure drop from the portal vein to the varix [50]. Variceal pressure is of clinical interest because patients who have bled from varices have significantly greater variceal pressure than those who have not [56,57]. Several clinical studies have demonstrated that variceal pressure measurements using the endoscopic pressure gauge have prognostic value with regard to the evolution of an acute variceal bleeding episode [58], the development of the first variceal haemorrhage [59] and the risk of variceal rebleeding in patients receiving pharmacological therapy [60]. In addition, variceal pressure measurement may be used to assess the effects of pharmacological treatment [57,60,61]. A fall in variceal pressure after pharmacological therapy of at least 20% from baseline was associated with a very low risk of variceal bleeding on follow-up (the actuarial probability of variceal bleeding was only 7% at 3 years, whereas this was 46% in patients failing to achieve this target [60]). The prognostic value of the variceal pressure response to treatment was as powerful as that of the HVPG response. The two methods identify different populations of patients with a favourable outcome; therefore, they should be considered complementary rather than mutually exclusive [60].

Unfortunately, measurements of variceal pressure are difficult and prone to artifacts resulting from oesophageal peristalsis. In addition, the technique is not feasible in every patient; about 25% of patients initially scheduled to have variceal pressure measurements must be excluded because of technical difficulties, mainly in patients with small varices [60]. Variceal pressure measurements are considered satisfactory only when fulfilling the following predetermined criteria: (i) stable intra-oesophageal pressure; (ii) absence of artifacts caused by oesophageal peristalsis; and (iii) correct placement of the capsule over the varix, as shown by the fine fluctuations of the pressure tracing according to heart cycle and respiration, for at least 12 s [60]. These conditions are easily met when the procedure is performed by a skilled endoscopist in a cooperative patient. However, it should be kept in mind that endoscopic measurements are not exactly non-invasive, although certainly less so than HVPG measurements. Finally, the variability of the measurement and the training required for correct measurements exceed, by far, those of HVPG. Because of these limitations, it is highly unlikely that it might be used in routine clinical practice.

References

1 Bosch J, Abraldes JG, Groszmann RJ (2003) Current management of portal hypertension. *J Hepatol* 38, S54–S68.

2 Thompson W, Caughey J, Whippel A *et al.* (1937) Splenic vein pressure in congestive splenomegaly (Banti's syndrome). *J Clin Invest* 16, 571.

3 Myers JD, Taylor WJ (1951) An estimation of portal venous pressure by occlusive catheterization of an hepatic venule. *J Clin Invest* 30, 662.

4 Dexter L, Dow J, Haynes F (1950) Studies of the pulmonary circulation in man at rest, normal variations and the inter-relations between increased pulmonary blood flow, elevated pulmonary arterial pressure, and high pulmonary 'capillary' pressure. *J Clin Invest* 29, 602–613.

5 Perello A, Escorsell A, Bru C *et al.* (1999) Wedged hepatic venous pressure adequately reflects portal pressure in hepatitis C virus-related cirrhosis. *Hepatology* 30(6), 1393–1397.

6 Deplano A, Migaleddu V, Pischedda A *et al.* (1999) Portohepatic gradient and portal hemodynamics in patients with cirrhosis due to hepatitis C virus infection. *Dig Dis Sci* 44(1), 155–162.

7 Reynolds TB, Geller HM, Kuzma OT *et al.* (1960) Spontaneous decrease in portal pressure with clinical improvement in cirrhosis. *N Engl J Med* 263, 734–739.

8 Viallet A, Joly JG, Marleau D *et al.* (1970) Comparison of free portal venous pressure and wedged hepatic venous pressure in patients with cirrhosis of the liver. *Gastroenterology* 59(3), 372–375.

9 Luca A, Feu F, Garcia-Pagan JC *et al.* (1994) Favorable effects of total paracentesis on splanchnic hemodynamics in cirrhotic patients with tense ascites. *Hepatology* 20(1 Pt 1), 30–33.

10 Pomier-Layrargues G, Kusielewicz D, Willems B *et al.* (1985) Presinusoidal portal hypertension in non-alcoholic cirrhosis. *Hepatology* 5(3), 415–418.

11 Groszmann RJ, Glickman M, Blei AT *et al.* (1979) Wedged and free hepatic venous pressure measured with a balloon catheter. *Gastroenterology* 76(2), 253–258.

12 Groszmann RJ, Wongcharatrawee S (2004) The hepatic venous pressure gradient: anything worth doing should be done right. *Hepatology* 39(2), 280–282.

13 Debernardi-Venon W, Bandi JC, Garcia-Pagan JC *et al.* (2000) CO(2) wedged hepatic venography in the evaluation of portal hypertension. *Gut* 46(6), 856–860.

14 Groszmann RJ, Atterbury CE (1982) The pathophysiology of portal hypertension: a basis for classification. *Semin Liver Dis* 2(3), 177–186.

15 Garcia-Tsao G, Groszmann RJ, Fisher RL *et al.* (1985) Portal pressure, presence of gastroesophageal varices and variceal bleeding. *Hepatology* 5(3), 419–424.

16 Casado M, Bosch J, Garcia-Pagan JC *et al.* (1998) Clinical events after transjugular intrahepatic portosystemic shunt: correlation with hemodynamic findings. *Gastroenterology* 114(6), 1296–1303.

17 Groszmann RJ, Bosch J, Grace ND *et al.* (1990) Hemodynamic events in a prospective randomized trial of propranolol versus placebo in the prevention of a first variceal hemorrhage. *Gastroenterology* 99(5), 1401–1407.

18 Feu F, Garcia-Pagan JC, Bosch J *et al.* (1995) Relation between portal pressure response to pharmacotherapy and risk of recurrent variceal haemorrhage in patients with cirrhosis. *Lancet* 346(8982), 1056–1059.

19 Vorobioff J, Groszmann RJ, Picabea E *et al.* (1996) Prognostic value of hepatic venous pressure gradient measurements in alcoholic cirrhosis: a 10-year prospective study. *Gastroenterology* 111(3), 701–709.

20 Merkel C, Bolognesi M, Sacerdoti D *et al.* (2000) The hemodynamic response to medical treatment of portal hypertension as a predictor of clinical effectiveness in the primary prophylaxis of variceal bleeding in cirrhosis. *Hepatology* 32(5), 930–934.

21 Abraldes JG, Tarantino I, Turnes J *et al.* (2003) Hemodynamic response to pharmacological treatment of portal hypertension and long-term prognosis of cirrhosis. *Hepatology* 37(4), 902–908.

22 Bureau C, Peron JM, Alric L *et al.* (2002) 'A la carte' treatment of portal hypertension: adapting medical therapy to hemodynamic response for the prevention of bleeding. *Hepatology* 36, 1361–1366.

23 Bosch J, Garcia-Pagan JC (2003) Prevention of variceal rebleeding. *Lancet* 361(9361), 952–954.

24 de Franchis R (2005) Evolving Consensus in Portal Hypertension Report of the Baveno IV Consensus Workshop on methodology of diagnosis and therapy in portal hypertension. *J Hepatol* 43(1), 167–176.

25 Moitinho E, Escorsell A, Bandi JC *et al.* (1999) Prognostic value of early measurements of portal pressure in acute variceal bleeding. *Gastroenterology* 117(3), 626–631.

26 Monescillo A, Martinez-Lagares F, Ruiz-del-Arbol L *et al.* (2004) Influence of portal hypertension and its early decompression by TIPS placement on the outcome of variceal bleeding. *Hepatology* 40(4), 793–801.

27 Bruix J, Castells A, Bosch J *et al.* (1996) Surgical resection of hepatocellular carcinoma in cirrhotic patients: prognostic value of preoperative portal pressure. *Gastroenterology* 111(4), 1018–1022.

28 Llovet JM, Fuster J, Bruix J (1999) Intention-to-treat analysis of surgical treatment for early hepatocellular carcinoma: resection versus transplantation. *Hepatology* 30(6), 1434–1440.

29 Burroughs AK, Groszmann R, Bosch J *et al.* (2002) Assessment of therapeutic benefit of antiviral therapy in chronic hepatitis C: is hepatic venous pressure gradient a better end point? *Gut* 50(3), 425–427.

30 Groszmann RJ (1996) The hepatic venous pressure gradient: has the time arrived for its application in clinical practice? *Hepatology* 24(3), 739–741.

31 Steinlauf AF, Garcia-Tsao G, Zakko MF *et al.* (1999) Low-dose midazolam sedation: an option for patients undergoing serial hepatic venous pressure measurements. *Hepatology* 29(4), 1070–1073.

32 Trejo R, Alvarez W, Garcia-Pagan JC *et al.* (1996) [The applicability and diagnostic effectiveness of transjugular liver biopsy]. *Med Clin (Barc)* 107(14), 521–523.

33 Navasa M, Bosch J, Mastai R *et al.* (1991) Measurement of hepatic blood flow, hepatic extraction and intrinsic clearance of indocyanine green in cirrhosis. Comparison of a non-invasive pharmacokinetic method with measurements using hepatic vein catheterization. *Eur J Gastroenterol Hepatol* 3, 305–312.

34 Groszmann RJ (1983) The measurement of liver blood flow using clearance techniques. *Hepatology* 3(6), 1039–1040.

35 Zeeh J, Lange H, Bosch J *et al.* (1988) Steady-state extrarenal sorbitol clearance as a measure of hepatic plasma flow. *Gastroenterology* 95(3), 749–759.

36 Bosch J, Feu F, Garcia-Pagan JC (1991) Measurement of azygos blood flow. In: Okuda K, Benhamou JP (eds) *Portal Hypertension*. Tokyo: Springer-Verlag, pp. 139–150.

37 Bosch J, Mastai R, Kravetz D *et al.* (1985) Measurement of azygos venous blood flow in the evaluation of portal hypertension in patients with cirrhosis. Clinical and haemodynamic correlations in 100 patients. *J Hepatol* 1(2), 125–139.

38 Cirera I, Feu F, Luca A *et al.* (1995) Effects of bolus injections and continuous infusions of somatostatin and placebo in patients with cirrhosis: a double-blind hemodynamic investigation. *Hepatology* 22(1), 106–111.

39 McCormick PA, Biagini MR, Dick R *et al.* (1992) Octreotide inhibits the meal-induced increases in the portal venous pressure of cirrhotic patients with portal hypertension: a double-blind, placebo-controlled study. *Hepatology* 16(5), 1180–1186.

40 Escorsell A, Bandi JC, Moitinho E *et al.* (1997) Time profile of the haemodynamic effects of terlipressin in portal hypertension. *J Hepatol* 26(3), 621–627.

41 Escorsell A, Bandi JC, Andreu V *et al.* (2001) Desensitization to the effects of intravenous octreotide in cirrhotic patients with portal hypertension. *Gastroenterology* 120(1), 161–169.
42 Bosch J, Mastai R, Kravetz D *et al.* (1984) Effects of propranolol on azygos venous blood flow and hepatic and systemic hemodynamics in cirrhosis. *Hepatology* 4(6), 1200–1205.
43 Mastai R, Bosch J, Navasa M *et al.* (1987) Effects of alpha-adrenergic stimulation and beta-adrenergic blockade on azygos blood flow and splanchnic haemodynamics in patients with cirrhosis. *J Hepatol* 4(1), 71–79.
44 Debatin J, Zahner B, Meyenberger C *et al.* (1996) Azygos blood flow: phase contrast quantitation in volunteers and patients with portal hypertension pre- and postintrahepatic shunt placement. *Hepatology* 24, 1109–1115.
45 Wu MT, Pan HB, Chen C *et al.* (1996) Azygos blood flow in cirrhosis: measurement with MR imaging and correlation with variceal hemorrhage. *Radiology* 198(2), 457–462.
46 Annet L, Materne R, Danse E *et al.* (2003) Hepatic flow parameters measured with MR imaging and Doppler US: correlations with degree of cirrhosis and portal hypertension. *Radiology* 229(2), 409–414.
47 Nishida H, Giostra E, Spahr L *et al.* (2001) Validation of color Doppler EUS for azygos blood flow measurement in patients with cirrhosis: application to the acute hemodynamic effects of somatostatin, octreotide, or placebo. *Gastrointest Endosc* 54(1), 24–30.
48 NIEC (1988) Prediction of the first variceal hemorrhage in patients with cirrhosis of the liver and esophageal varices. A prospective multicenter study. The North Italian Endoscopic Club for the Study and Treatment of Esophageal Varices. *N Engl J Med* 319(15), 983–989.
49 Polio J, Groszmann RJ (1986) Hemodynamic factors involved in the development and rupture of esophageal varices: a pathophysiologic approach to treatment. *Semin Liver Dis* 6(4), 318–331.
50 Rigau J, Bosch J, Bordas JM *et al.* (1989) Endoscopic measurement of variceal pressure in cirrhosis: correlation with portal pressure and variceal hemorrhage. *Gastroenterology* 96(3), 873–880.
51 Escorsell A, Bosch J (2004) Pathophysiology of variceal bleeding. In: Groszmann RJ, Bosch J (eds) *Portal Hypertension in the 21st Century*. Dordrecht: Kluwer Academic Publishers, pp. 155–166.
52 Mosimann R (1982) Nonaggressive assessment of portal hypertension using endoscopic measurement of variceal pressure. Preliminary report. *Am J Surg* 143(2), 212–214.
53 Bosch J, Bordas JM, Rigau J *et al.* (1986) Noninvasive measurement of the pressure of esophageal varices using an endoscopic gauge: comparison with measurements by variceal puncture in patients undergoing endoscopic sclerotherapy. *Hepatology* 6(4), 667–672.
54 Gertsch P, Fischer G, Kleber G *et al.* (1993) Manometry of esophageal varices: comparison of an endoscopic balloon technique with needle puncture. *Gastroenterology* 105(4), 1159–1166.
55 Escorsell A, Bordas JM, Feu F *et al.* (1997) Endoscopic assessment of variceal volume and wall tension in cirrhotic patients: effects of pharmacological therapy. *Gastroenterology* 113(5), 1640–1646.
56 Nevens F, Sprengers D, Feu F *et al.* (1996) Measurement of variceal pressure with an endoscopic pressure sensitive gauge: validation and effect of propranolol therapy in chronic conditions. *J Hepatol* 24(1), 66–73.
57 Feu F, Bordas JM, Luca A *et al.* (1993) Reduction of variceal pressure by propranolol: comparison of the effects on portal pressure and azygos blood flow in patients with cirrhosis. *Hepatology* 18(5), 1082–1089.
58 Ruiz del Arbol L, Martin de Argila C, Vázquez M *et al.* (1992) Endoscopic measurement of variceal pressure during hemorrhage from esophageal varices. *Hepatology* 16, 147.
59 Nevens F, Bustami R, Scheys I *et al.* (1998) Variceal pressure is a factor predicting the risk of a first variceal bleeding: a prospective cohort study in cirrhotic patients. *Hepatology* 27(1), 15–19.
60 Escorsell A, Bordas JM, Castaneda B *et al.* (2000) Predictive value of the variceal pressure response to continued pharmacological therapy in patients with cirrhosis and portal hypertension. *Hepatology* 31(5), 1061–1067.
61 Bosch J, Bordas JM, Mastai R *et al.* (1988) Effects of vasopressin on the intravariceal pressure in patients with cirrhosis: comparison with the effects on portal pressure. *Hepatology* 8(4), 861–865.

7.5 Pathogenesis, diagnosis and treatment of ascites in cirrhosis

Vicente Arroyo, Carlos Terra and Luis Ruiz-del-Arbol

Aetiology and diagnosis of ascites

Causes

Many diseases are known to lead to the formation of free fluid within the peritoneal cavity. Basically, the causes of ascites may be grouped into those conditions in which the pathological process does not directly affect the peritoneum and those in which the peritoneum itself is involved. The first group includes diseases associated with sinusoidal portal hypertension, hypoalbuminaemia and a variety of disorders that may cause ascites through different mechanisms, such as myxoedema, ovarian diseases, chronic pancreatitis, biliary tract leakage, diseases affecting the lymphatic system of the splanchnic area and chronic renal failure. In the second group, ascites is formed as a consequence of primary peritoneal disease or as a result of peritoneal involvement in systemic processes; tuberculous, fungal, parasitic and granulomatous peritonitis, primary or metastatic peritoneal tumours, vasculitis, eosinophilic gastroenteritis and Whipple's disease are the most characteristic causes of ascites in this group. By far the most frequent cause of ascites in Europe and in North America is hepatic cirrhosis, followed by neoplasms and, to a lesser extent, congestive heart failure and tuberculous peritonitis. These four conditions account for more than 90% of the ascites in these areas [1].

Detection

The diagnosis of ascites is simple when large amounts of fluid accumulate in the peritoneal cavity. However, the diagnosis is much more difficult by physical examination when there is a small volume of ascitic fluid. It has been suggested that minimal amounts of ascites (less than 500 mL) can be detected by an exploratory manoeuvre that combines percussion and auscultation of the abdomen [2]. After 5 min in the prone position, the patient is asked to assume a position on hands and knees so that the middle portion of the abdomen is dependent. One flank is percussed by repeated, light flicking at a constant intensity, with the stethoscope being over the most dependent portion of the abdomen (the area of the ascitic 'puddle'). The stethoscope is then gradually moved towards the flank opposite the percussion site. A positive sign indicating the presence of ascites consists of a marked change in the intensity and character of the percussion note as the stethoscope is moved from the ascitic puddle to the flank opposite the point of percussion, where ascites is not present. A point of demarcation between the ascitic puddle and the area without intraperitoneal fluid can be obtained, correlating with the amount of ascitic fluid present. Nevertheless, in a prospective study in which five physical signs (bulging flanks, flank dullness, shifting dullness, fluid wave and puddle sign) were compared with the ultrasonographic demonstration of ascites (which can detect as little as 100–200 mL of intraperitoneal fluid) in patients in whom the bedside diagnosis of ascites was in question, the puddle sign did not show greater specificity and sensitivity for the detection of intra-abdominal fluid than the other signs of ascites [3].

Peripheral oedema (oedema in the lower extremities) is common in patients with cirrhosis. In many cases, it precedes the development of ascites by weeks or months, but it may also appear simultaneously with, or following, the accumulation of fluid within the abdomen. Massive peripheral oedema without ascites is occasionally seen in cirrhotic patients with severe hepatic insufficiency and a surgical portocaval shunt. Peripheral oedema in cirrhosis decreases or disappears with nocturnal rest and increases with ambulation. It is postulated that hypoalbuminaemia and increased venous pressure in the lower extremities due to constriction of the intrahepatic segment of the inferior vena cava or to the high intra-abdominal pressure caused by the presence of ascites are the main factors causing peripheral oedema in cirrhosis.

Ultrasonography, computerized tomography (CT) and magnetic resonance imaging (MRI) are very useful in the assessment of patients with ascites [4–7]. In addition to their sensitivity in detecting minimal amounts of ascites, they may suggest its cause, based on the characteristics of the intra-abdominal organs and vessels and the appearance of the intra-abdominal fluid. Ultrasonography is the best of these methods as it is not expensive, is as reliable as CT and is free of radiation hazards.

Intraperitoneal fluid resulting from portal hypertension appears as homogeneous, echo-free areas surrounding and interposed between the loops of bowel and viscera in a relatively uniform manner. When the amount of ascites is small, the fluid tends to collect in the flanks and the superior right paracolic gutter, around the liver and in the lowest peritoneal reflection in the pelvis. Rectal and transvaginal echography are particularly sensitive in the detection of small volumes of intra-abdominal fluid, the transvaginal approach being able to detect less than 50 mL of ascitic fluid [8]. Atypical sonographic characteristics, such as the presence of multiple fine echoes (indicating the presence of debris) or septations and fibrous strands within the ascitic fluid, may be seen in exudative ascites. Matted loops of bowel, plastering of the liver to surrounding structures and loculation of fluid, when present, are very suggestive of malignant ascites [9]. Peritoneal thickening, lymphadenopathy and bowel thickening in the ileocaecal junction are suggestive of a tuberculous aetiology [10].

Characteristics of cirrhotic ascites

The ascitic fluid in cirrhotics is transparent and yellow/amber in colour. Traditionally, ascites in these patients is considered to have the characteristics of a transudate, with a total protein concentration of less than 2.5 g/dL and with relatively few cells. However, cirrhotics with ascites do not constitute a homogeneous population with respect to the characteristics of the ascitic fluid. Total ascitic protein concentration ranges between 0.5 and more than 6 g/dL [11] and is greater than 3 g/dL ('exudative ascites') in up to 30% of patients with otherwise uncomplicated cirrhosis [12–14]. The proportions of albumin and globulins in the total protein concentration are approximately 45% and 55% respectively [12,14]. There is a close, direct correlation between ascitic albumin and globulin concentrations, indicating that proteins in ascitic fluid in cirrhosis derive from capillaries with relatively large pores, such as the hepatic sinusoids [14,15]. This contention is also supported by the observation of a similar ascites:plasma ratio for albumin and globulins (approximately 0.3 for both types of proteins) [12,14,15]. However, although ascitic proteins may come mainly from the extremely permeable hepatic sinusoids, the relative contribution of the hepatic microvasculature and the splanchnic capillaries to the formation of ascites may vary markedly from patient to patient, as the ascitic fluid:plasma ratios for total proteins, albumin and globulins range between 0.04 and 1.03 in patients with cirrhosis and ascites [12,14–16]. The total protein, albumin and globulin concentrations in ascitic fluid in cirrhosis correlate directly with the corresponding plasma concentrations and inversely with portal pressure [14]. The mobilization of ascites with diuretics increases the concentration of proteins in the ascitic fluid [17]. The total protein concentration in ascitic fluid in cirrhosis is an important predictive factor for spontaneous bacterial peritonitis. Spontaneous bacterial peritonitis usually occurs in cirrhotics with a low total protein concentration in ascitic fluid (< 1 g/dL), whereas it is infrequent in cirrhotics with higher protein concentrations in ascitic fluid and in patients with cardiac or malignant ascites, who generally have a protein concentration over this limit. The ascitic fluid has opsonic and bactericidal activity, which seems to be mediated by complement and fibronectin [18,19]. The total protein concentration in ascitic fluid correlates with the concentration of these proteins with antibacterial activity; the predictive value of the total protein concentration in ascitic fluid for the development of spontaneous bacterial peritonitis is probably a consequence of this relation [20,21].

The ascitic fluid in the cirrhotic without spontaneous bacterial peritonitis usually has fewer than 300–500 white blood cells/μL; nevertheless 10–15% may have more than 500 cells and 5% more than 1000 cells [12,22,23]. More than 70% of these white cells are mononuclear leukocytes. In contrast, in cirrhotic patients with spontaneous bacterial peritonitis, the ascitic fluid usually contains more than 500 white blood cells/μL (frequently more than 2000), with more than 70% of them being polymorphonuclear leukocytes [23,24]. The pH and the concentration of lactate in ascitic fluid in otherwise uncomplicated cirrhosis is similar to that in plasma [25]. Patients with spontaneous bacterial peritonitis have a significantly lower pH and higher lactate concentration in ascitic fluid than in plasma [26,27]. As with the total protein concentration, the absolute concentration of white cells in ascitic fluid increases during diuretic treatment, while the concentration of polymorphs remains unchanged [28]. Therefore, the percentage of polymorphs over the total leukocyte content of the ascitic fluid actually decreases during the mobilization of ascites with diuretics. The concentration of red blood cells in cirrhotic ascites is usually lower than 1000 cells/μL, although higher concentrations may occasionally be detected. In fact, bloody ascitic fluid, which indicates more than 50 000 red cells/μL (haematocrit of about 0.5%), occurs in approximately 2% of cirrhotics [22]. In one-third of these patients, bloody ascites is secondary to a superimposed hepatocellular carcinoma bleeding into the peritoneal cavity [29]. However, in as many as 50% of patients, no apparent cause of bloody ascites can be detected. The hepatic and the thoracic lymph of cirrhotics is often bloody also [30]. The mechanism of bloody ascites in cirrhotics without hepatocellular carcinoma could, therefore, be related to the leakage of bloody lymph from the liver lymphatics.

Alterations in the coagulation-related proteins in ascites have been reported in cirrhotic patients. The concentration of fibrinogen and plasminogen in ascitic fluid is lower than that expected from their molecular weights, whereas the concentrations of plasminogen activators and fibrin/fibrinogen degradation products are higher than in plasma [31]. This suggests that fibrinolysis is occurring within the peritoneal cavity. In addition, there is apparently intraperitoneal coagulation in cirrhotic patients as the concentration of fibrin monomers in ascitic fluid is almost 10 times higher than in plasma [32]. Therefore, the alterations in the coagulation-related proteins in cirrhotic ascites are probably the consequence of a complex coagulation

disturbance within the ascitic fluid, resulting in intraperitoneal coagulation and primary and secondary fibrinolysis. The infusion of ascitic fluid into the general circulation, either directly or by the insertion of a peritoneovenous shunt, is often associated with disseminated intravascular coagulation, as manifested by a marked reduction in platelet count, prothrombin time and fibrinogen concentration, and an increase in the plasma concentrations of fibrin degradation products, thus confirming the procoagulant activity of ascitic fluid [33,34]. This coagulopathy is clinically significant in 20–50% of patients treated with a peritoneovenous shunt and sometimes requires ligation of the prosthesis. Several substances present in the ascites, such as tissue thromboplastin, endotoxin, collagen, activated clotting factors and fibrin degradation products, have been implicated in the procoagulant activity of the ascitic fluid.

Cirrhotic patients with ascites have a very high concentration of interleukin (IL)-6 in ascitic fluid. The ascitic fluid:plasma concentration ratio of IL-6 is approximately 100 in these patients, indicating intra-abdominal production of this cytokine [35,36]. The concentration of tumour necrosis factor (TNF) is also higher in ascitic fluid than in plasma in cirrhotic patients, although the differences are much less impressive than with IL-6 [36]. Significant concentrations of soluble TNF receptors have also been detected in the ascitic fluid of cirrhotic patients with and without spontaneous bacterial peritonitis, the significance of which is still unknown. Activated peritoneal macrophages could be the origin of the intra-abdominal production of cytokines. Spontaneous bacterial peritonitis is associated with a marked increase in cytokines in the ascitic fluid [37]. Intra-abdominal cytokines escape into the systemic circulation, and this may explain some of the complications observed in patients with spontaneous bacterial peritonitis, particularly the impairment in circulatory and renal function [37]. The concentration of leptin and vascular endothelial growth factor (VEGF) is also higher in ascitic fluid than in plasma [38,39].

The biochemical and cytological characteristics of ascitic fluid in other diseases causing intrahepatic sinusoidal portal hypertension, such as acute alcoholic hepatitis, fulminant or subacute viral or toxic hepatitis and massive metastatic infiltration of the liver, are similar to those found in cirrhotic ascites.

Differential diagnosis of cirrhotic ascites

Malignant ascites

The macroscopic appearance of malignant ascites is generally similar to that of cirrhotic ascites (less than 10% of malignant ascites are macroscopically bloody) [40]. Thus, the differential diagnosis must be based on exploratory findings and laboratory tests. Measurement of the total protein concentration of the ascitic fluid (generally over 3 g/dL in malignant ascites) and its cytological examination for malignant cells, which were the laboratory tests first used to differentiate malignant ascites from that secondary to portal hypertension, are still the most common methods used [40,41].

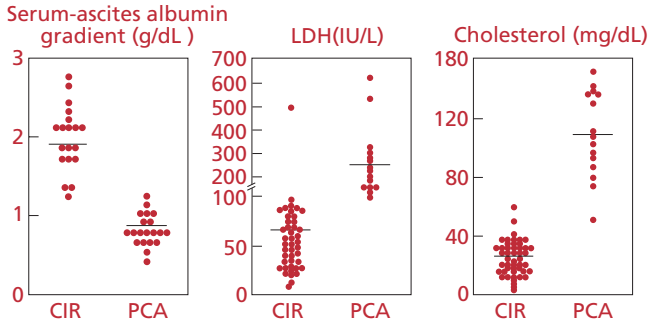

Fig. 1 Serum–ascites albumin gradient and ascitic fluid concentration of lactic dehydrogenase (LDH) and cholesterol in patients with cirrhosis (CIR) and peritoneal carcinomatosis (PCA).

Standard cytological examination is 60–90% accurate in the diagnosis of malignant ascites, especially when adequate volumes of fluid (at least several hundred millilitres) and concentration techniques are used [42]. False-positive results are rare in skilled hands. The greatest source of confusion is the differentiation of malignant cells from atypical mesothelial cells. The use of immunocytochemical techniques with monoclonal or polyclonal antibodies against numerous tumour markers is helpful in differentiating malignant from non-malignant ascites in these cases. These techniques may also help to differentiate primary (mesothelioma) from metastatic peritoneal malignancy. False-negative results on standard cytological examinations are the rule when ascites is due to portal hypertension secondary to massive liver metastases with little peritoneal involvement [40]. In this type of ascites, the total ascitic protein concentration is usually lower than 2.5 g/dL.

The serum–ascitic fluid gradient for albumin improves the diagnostic accuracy of the total protein concentration in ascitic fluid (Fig. 1) [40,41,43]. The concentration of lactic dehydrogenase in malignant ascites is higher than the corresponding values in plasma because of leakage of the enzyme from the malignant cells lining the peritoneum, whereas the reverse is the rule for cirrhotic ascites [44]. The concentration of lactic dehydrogenase in ascitic fluid and its ascitic fluid:plasma ratio are, therefore, useful for differentiating malignant from cirrhotic ascites, although they do not improve the results obtained with the ascitic fluid:plasma albumin gradient (Fig. 1) [40,44]. Other measurements in ascitic fluid that have proved to be of value in differentiating malignant from cirrhotic ascites include total lipids, free fatty acids, cholesterol, fibronectin, carcinoembryonic antigen and other tumour-associated antigens, urokinase, tissue plasminogen activator, plasminogen activator inhibitor and fibrin/fibrinogen degradation products, and human chorionic gonadotropin-β [40,43–48]. Of these, the cholesterol concentration of ascitic fluid, which is higher in most malignant ascites than in cirrhotic ascites owing to higher permeability to lipoproteins (Fig. 1), seems to be the most interesting because of its simplicity and cost-effectiveness [43,44]. Laparoscopy and direct biopsy of the peritoneal metastases is a useful approach to

confirm the diagnosis of malignant ascites in those cases with negative cytology [49].

Chylous ascites

Chylous ascites is an infrequent feature in patients with cirrhosis. In some cases, it develops in the postoperative period after splenorenal shunt but, in most instances, it appears spontaneously [50]. Chylous ascites is macroscopically turbid and white ('milky' ascites), and separates into layers on standing. These characteristics are due to a high concentration of chylomicrons very rich in triglycerides. The diagnosis of chylous ascites is based on triglyceride concentration in ascitic fluid, which is usually over 110 mg/dL and always higher than the corresponding value in plasma [51]. The concentration of cholesterol and phospholipids in ascitic fluid is, however, similar to that of non-chylous ascites. Gross milkiness of chylous ascites correlates poorly with absolute triglyceride concentrations because turbidity also reflects the size of the chylomicrons [51]. The proportion of lipids in chylous ascites is very similar to that in human intestinal and thoracic duct lymph after the ingestion of a fat meal [52]. As patients with cirrhosis usually have elevated pressure within the splanchnic lymph vessels, it has been suggested that spontaneous chylous ascites in these patients may be a consequence of the rupture of these lymph vessels, leading to the leakage of whole intestinal lymph into the peritoneal cavity [52]. Chylous ascites after splenorenal shunt is probably secondary to injury to retroperitoneal lymphatics [53]. In fact, chylous ascites is a well-recognized postoperative complication in patients submitted for renal transplantation, aortic aneurysmectomy, retroperitoneal lymph adenectomy and pancreatoduodenectomy [51]. Hepatic cirrhosis is a relatively infrequent cause of chylous ascites. Primary abnormalities of the lymphatics (lymphangiectasia) and the obstruction of the lymphatic system due to malignancies, especially lymphomas, are by far the most common causes in adults [51]. Other diseases associated with chylous ascites in adults include portal vein thrombosis, sarcoidosis, nephrotic syndrome, tuberculosis, pancreatitis, abdominal trauma, constrictive pericarditis, encapsulating peritonitis and pulmonary fibrosis with thoracic duct obstruction. Congenital malformations of the lymphatic system, including stenosis or atresia of the lymphatics and lymphatic mesenteric cysts, are the main causes of chylous ascites in children. Chylous ascites should be differentiated from pseudochylous ascites in which, although the macroscopic appearance may be identical, the triglyceride concentration is lower than 110 mg/dL. Clinically, chylous ascites is usually silent except for the distension of the abdomen.

Tuberculous peritonitis

The differential diagnosis between cirrhotic ascites and ascites due to tuberculous peritonitis is particularly important as alcoholic cirrhosis may predispose to peritoneal tuberculosis. Clinically, tuberculous peritonitis is characterized by fever, abdominal pain, anorexia, weight loss, abdominal tenderness and ascites. However, none of these symptoms is invariably present. The proportion of patients with pleural or pulmonary tuberculosis or with a reactive tuberculin skin test ranges between 21% and 78% and between 30% and 89%, respectively, in the different series [54,55]. In females without active pulmonary tuberculosis, peritoneal tuberculosis may represent the local extension of a tuberculous salpingitis. However, in many cases, no active focus of tuberculosis, apart from the peritoneal disease, can be detected. Ultrasonography and CT may suggest the diagnosis of tuberculous peritonitis. Findings frequently seen in tuberculous peritonitis include diffuse, regular peritoneal thickening, infiltration of the greater omentum, ascites with fine, mobile septation or floating debris on ultrasonography, loculation of ascites, bowel thickening, particularly in the ileocaecal area, retroperitoneal lymph node enlargement, lesions in solid organs (pelvic, adrenal, hepatic, splenic), cold abscesses and adhesions [55]. Results of examination of the peritoneal fluid are also suggestive of tuberculous infection if there is an increased concentration of proteins (over 3 g/dL) and lymphocytes. However, it has been shown that the ascitic fluid may be a transudate, particularly in cirrhotics with ascites and tuberculous peritonitis [56]. Ziehl–Nielsen-stained smears usually fail to show acid-fast bacilli. The proportion of cultures of ascitic fluid positive for *Mycobacterium tuberculosis* varies markedly from series to series (from 8% to 69%), probably reflecting technical differences. It has been suggested that the proportion of positive cultures may be increased up to 80% by concentrating 1 L of the fluid by centrifugation. Nevertheless, the diagnosis of tuberculous peritonitis cannot be based on cultures of ascitic fluid as the usual techniques of culturing acid-fast bacilli may require several weeks to obtain a definite result. The activity of lactic dehydrogenase in ascitic fluid is greater in tuberculous peritonitis than in cirrhosis. As in malignant ascites, the concentration of this enzyme in tuberculous ascites is higher than in plasma [56]. The activity of adenosine deaminase in the peritoneal fluid is a proven sensitive and specific test for tuberculous peritonitis [54,57] (Fig. 2). This is an enzyme involved in the catabolism of purine bases (catalysing the deamination of adenosine with the formation of inosine). It participates in the proliferation and differentiation of lymphocytes, and increases in tuberculous effusions, probably as a consequence of the stimulation of cell-mediated immunity and T lymphocytes. The concentration of adenosine deaminase in ascitic fluid in tuberculous peritonitis correlates directly with the total protein concentration in ascites. It is therefore not surprising that the number of false-negative results for adenosine deaminase in tuberculous peritonitis is higher in cirrhotic patients than in patients without chronic liver diseases [58].

Open peritoneal biopsy during a laparotomy or minilaparotomy, blind needle biopsy of the peritoneum and laparoscopy with direct biopsy of the affected areas have been used to confirm the diagnosis of tuberculous peritonitis [59,60]. Laparoscopy with direct peritoneal biopsy is the best of these methods [61]. The peritoneum characteristically shows scattered or confluent miliary nodules of uniform size, with

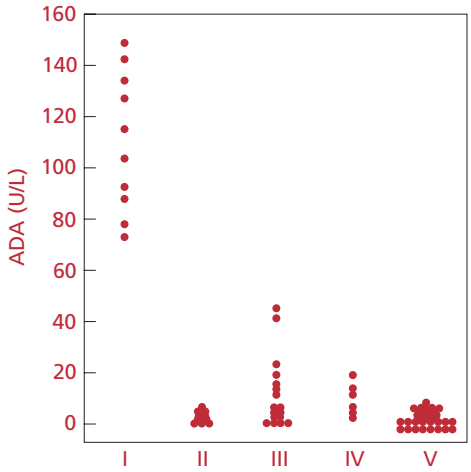

Fig. 2 Ascitic fluid concentration of adenosine deaminase (ADA) in different groups of patients with ascites: group I, tuberculous peritonitis; group II, non-tuberculous septic peritonitis; group III, malignant ascites; group IV, miscellaneous; group V, cirrhosis (reproduced with permission from ref. 56).

adhesions between bowel loops, liver capsule and abdominal walls. The histological appearance is characterized by the presence of caseating granulomas. In some instances, tubercle bacilli may be seen by staining with auramine–rhodamine and microscopy under ultraviolet light. *Mycobacterium tuberculosis* can be cultured from the biopsy specimen of the peritoneum. The macroscopic and microscopic appearances of tuberculous peritonitis are similar to those of other conditions causing granulomatous peritonitis, such as sarcoidosis, Crohn's disease and iatrogenic granulomatous peritonitis. The last condition occurs after 0.15% of abdominal operations and is usually caused by a cell-mediated immune response to starch, talc, cotton fibres and wood fibres originating from disposable surgical gowns and drapes [62]. Iatrogenic granulomatous peritonitis appears 2–9 weeks postoperatively and is characterized by abdominal pain, tenderness and fever, and frequently by the accumulation of ascites. The observation of starch granules in the ascitic fluid obtained by paracentesis can be diagnostic.

The detection of DNA of *Mycobacterium tuberculosis* by means of polymerase chain reaction (PCR) assay of ascitic fluid is very rapid and appears to be as sensitive as culture. To date, however, there are no controlled studies of PCR in patients with tuberculous peritonitis. Moreover, false-negative results have been reported, justifying the administration of antituberculous treatment in patients with clinical and histological features characteristic of peritoneal tuberculosis, even in cases with negative results from culture and PCR analysis [63]. The ligase chain reaction (LCR) DNA amplification method has recently been introduced into practice. This assay provides rapid information for the diagnosis of extrapulmonary tuberculosis with a higher diagnostic accuracy than PCR [64]. Further studies are needed to determine the clinical use of PCR and/or LCR in the diagnosis of tuberculous peritonitis.

Ascites due to hepatic venous outflow block

Ascites secondary to postsinusoidal portal hypertension generally shows a total protein concentration and ascitic fluid:plasma albumin gradient similar to that reported in malignant ascites and tuberculous peritonitis [65]. The diagnosis can, however, be established by considering the clinical condition of the patient and the concentrations of leukocytes, lactic dehydrogenase, cholesterol and adenosine deaminase in the ascitic fluid, which are lower in ascites secondary to hepatic outflow block. Patients with ascites due to constrictive pericarditis often lack symptoms of congestive heart failure. It is therefore important to seek physical findings characteristic of this entity in any patient with exudative ascites and no evidence of liver disease. Clear lung fields on radiographic examination and low voltage of the electrocardiogram suggest constrictive pericarditis. The diagnosis is confirmed by cardiac echography or catheterization. In patients with ascites due to a congenital web in the inferior vena cava, a cava-to-cava collateral circulation can be observed on the abdomen or back. The final diagnosis is based on inferior vena cavography. The differential diagnosis between chronic Budd–Chiari syndrome and cirrhosis is often difficult on clinical grounds. The protein concentration in ascitic fluid may be low in some of these patients as a result of the capillarization of the hepatic sinusoids. On the other hand, they may have hepatic stigmata, abnormal liver function tests, splenomegaly and oesophageal varices. If major hepatic veins are not visualized by CT and ultrasonography, this may suggest Budd–Chiari syndrome. The liver scintiscan sometimes shows a marked increase in isotope uptake centrally, possibly because of hypertrophy of the caudate lobule related to its autonomous venous drainage directly into the vena cava. However, in most cases, the diagnosis is made by liver biopsy. Ascites with a high protein concentration is frequently found in the postoperative period of liver transplantation. It is usually due to postsinusoidal portal hypertension secondary to deficient venous drainage from the implanted liver. Ascites due to obstructed hepatic venous outflow has also been reported in patients with polycystic liver disease.

Bile ascites

The leakage of bile into the peritoneal cavity may lead to two different clinical pictures [66]. Some patients develop signs and symptoms of acute peritonitis. Others have essentially no symptoms other than those caused by the accumulation of large quantities of bile ascites in the abdominal cavity. In both circumstances, paracentesis yields a green ascitic fluid with a bilirubin concentration considerably higher than in plasma. Between these two extremes, there is a wide spectrum of symptoms. Why intraperitoneal leakage of bile induces these two clinical pictures is unknown. Bile ascites usually occurs after biliary tract surgery (mainly cholecystectomy), percutaneous diagnostic procedures (liver biopsy and percutaneous transhepatic cholangiography) and trauma with injuries to the gallbladder, common bile duct, hepatic duct or liver. In contrast, the most common cause of bile

peritonitis is spontaneous perforation of the gallbladder or bile ducts due to erosion by stones or cholecystitis [66].

Pancreatic ascites

Pancreatic ascites occurs in approximately 3% of patients with chronic pancreatitis as a result of the leakage of fluid from a ruptured pancreatic duct, or from a pancreatic pseudocyst, into the peritoneal cavity [67]. Other, less frequent causes include acute haemorrhagic pancreatitis, abdominal trauma and pancreatic cancer [68]. As most patients with chronic pancreatitis are alcoholics and may develop massive ascites with little or no abdominal tenderness, the differential diagnosis of pancreatic from cirrhotic ascites may be difficult on clinical grounds. Laboratory analyses are therefore essential to establish a correct diagnosis. In virtually all cases, ascitic fluid amylase and lipase are dramatically increased. The concentration of pancreatic enzymes in ascitic fluid is between 5 and 20 times greater than the plasma concentrations obtained simultaneously. The protein concentration in ascitic fluid is generally over 3 g/dL, and the fluid is usually serous, but can be serosanguineous, turbid or chylous. The concentration of methaemalbumin in ascites is markedly increased in patients with haemorrhagic pancreatitis and has prognostic significance. The concentration of leukocytes in ascitic fluid ranges between 70 and 2200/μL, 80% being lymphocytes [69]. Ultrasonography and CT are important diagnostic procedures for pancreatic ascites as they may detect the presence of a pseudocyst. Pseudocysts in patients with pancreatic ascites are usually small, due to continuous leakage of the cystic fluid into the peritoneal space.

Other types of ascites

Other causes of ascites easily differentiated from cirrhotic ascites include nephrogenic ascites, myxoedema and Meig syndrome. Nephrogenic ascites may become a severe problem in approximately 5% of patients maintained on chronic haemodialysis [70]. The pathogenesis of ascites in these patients is unknown. The protein concentration in ascitic fluid is usually over 3 g/dL, and the white blood cell count ranges between 30 and 1500/μL. The amylase and lactic dehydrogenase activities in ascitic fluid are lower than the plasma concentrations obtained simultaneously. Peritoneal biopsies show only minor inflammation or fibrosis. The diagnosis of nephrogenic ascites is one of exclusion, so that it is important to rule out other causes.

Myxoedema is an infrequent cause of gross ascites (about 3–4% of cases of myxoedema develop significant ascites). As the systemic changes of myxoedema may be mild, it may not be identified as the cause of the ascites, thus leading to unnecessary diagnostic procedures. The ascitic fluid in myxoedema may be serous or gelatinous and characteristically has a high protein concentration. The pathogenesis of myxoedematous ascites is unknown.

Meig syndrome consists of the association of ascites and hydrothorax with various types of benign ovarian tumours (fibroma, cystadenoma, struma ovarii). A 'modern' type of Meig syndrome is the ovarian hyperstimulation syndrome occurring in patients treated with clomiphene and human menopausal gonadotrophins to induce ovulation. This syndrome is characterized by massive ascites, pleural effusions, signs of hypovolaemia (tachycardia, haemoconcentration, oliguria), enlarged ovaries (more than 10 cm in diameter), marked arterial vasodilation and activation of the renin–aldosterone and sympathetic nervous systems and antidiuretic hormone [71].

Cirrhotic hydrothorax

Pleural effusions, in the absence of primary pulmonary, pleural or cardiac disease, occur in approximately 5% of patients with hepatic cirrhosis [72]. Clinical ascites is almost always evident, and the pleural effusion is usually right-sided. Occasionally, however, effusion develops in the left pleura, on both sides or in the absence of detectable ascites. The pathogenesis of cirrhotic hydrothorax involves, in most cases, the direct passage of ascitic fluid from the abdomen through acquired defects in the diaphragm into the pleural space (Fig. 3) [73,74]. The driving force leading to the peritoneal–pleural transfer of fluid is the hydrostatic gradient between the positive intra-abdominal pressure and the negative intrathoracic pressure. In cases of cirrhotic hydrothorax without detectable ascites, the transport of fluid into the pleural space probably equals the rate of production of ascites. The presence of direct communications between the peritoneal and pleural cavities can be demonstrated by radioisotopic studies. The intraperitoneal injection of tracer amounts of [^{99m}Tc]sulphur colloid is followed by the rapid appearance of the isotope in the pleural cavity. The communications can be visualized by ultrafast echo MRI. The biochemical and cytological characteristics of the pleural fluid are similar to those of the ascitic fluid obtained simultaneously. It is not unusual, however, to find slightly higher concentrations of total protein, albumin, cholesterol and total lipids in pleural than in ascitic fluid, probably related to a higher rate of water reabsorption from the pleural compartment. However, if there are marked differences in

Fig. 3 Hole of 1 mm diameter in the right hemidiaphragm in a cirrhotic patient with right pleural effusion (reproduced with permission from ref. 74).

the biochemical or cytological characteristics between the pleural and the ascitic fluids, one should search for another cause of the pleural effusion. Spontaneous bacterial empyema due to Gram-negative bacilli is a frequent complication in patients with cirrhotic hydrothorax. The pathogenesis of this complication is similar to that of spontaneous bacterial peritonitis [75]. Videothoracoscopy has been used effectively to localize and close the diaphragmatic defects causing cirrhotic hydrothorax [76].

Factors involved in ascites formation in cirrhosis

Portal hypertension

In patients with liver disease, portal hypertension is essential for the formation of ascites. The accumulation of fluid within the peritoneal cavity is a common complication in diseases causing sinusoidal portal hypertension, for example Budd–Chiari syndrome, hepatic veno-occlusive disease, cirrhosis and severe acute hepatitis of toxic, viral or alcoholic origin. In contrast, it is extraordinarily infrequent in liver diseases in which the block to portal flow occurs before the sinusoids. Similarly, when portal hypertension develops as a consequence of an extrahepatic blockage of the hepatic or portal blood flow, ascites only occurs in those circumstances in which the vascular blockade increases sinusoidal pressure (right heart failure, constrictive pericarditis, obstruction of the inferior vena cava by congenital membranous webs), but not when the portal or the splenic veins are occluded. The relation between sinusoidal portal hypertension and the formation of ascites is also evident from experimental studies. Obstruction of the thoracic inferior vena cava or the hepatic veins is followed by rapid accumulation of fluid within the abdominal cavity. Ascites also occurs in several experimental models of cirrhosis (induced by carbon tetrachloride, dimethylnitrosamine or chronic ligation of the bile duct). In contrast, partial or even complete obstruction of the portal vein is not followed by the formation of ascites.

Effect of sinusoidal portal hypertension on trans-sinusoidal fluid exchange

Differences in anatomical and functional characteristics between the hepatic and splanchnic microvasculature have been proposed to explain why ascites only develops in circumstances of sinusoidal portal hypertension. The hepatic sinusoids are structurally unique among microvessels as they do not have a basement membrane. They are lined by three main types of cells: endothelial, Kupffer and fat storing (Ito or stellate cells). The endothelial cells are by far the main component of the sinusoidal wall. Kupffer cells also contribute to the wall, although they are most often found within the lumen, attached by processes to the endothelial cells. Ito cells are found in the space of Disse, between the endothelial and liver cells. The endothelial cells form a very porous sinusoidal wall with large apertures, ranging

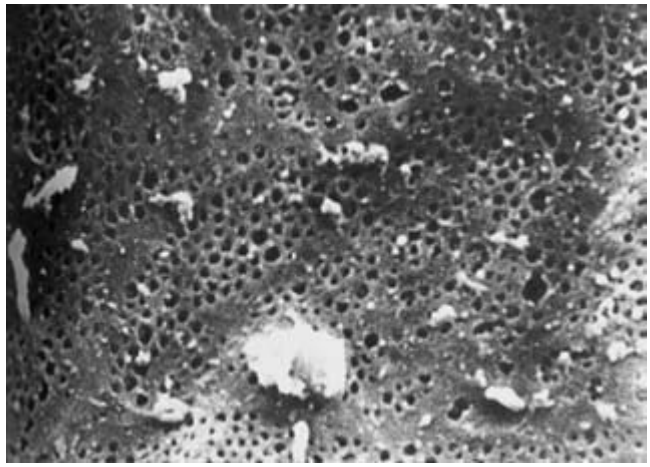

Fig. 4 Surface view of the endothelial lining of a liver sinusoid, as seen by scanning electron microscopy. Numerous fenestrae, with a pore size of 100–500 nm radius, are observed.

from 100 to 500 nm in radius (Fig. 4). Occasionally, microvilli from the hepatocytes cross the space of Disse and pass through these gaps in the endothelial membrane, thus reaching the sinusoidal lumen. This extremely porous membrane is almost completely permeable to macromolecules, including plasma proteins. These special characteristics of the sinusoidal wall are not surprising considering that the main function of the hepatic sinusoids is to promote intimate contact between the blood entering the liver and the hepatocytes. The space of Disse is relatively inconspicuous in normal conditions. It includes sparse bundles of collagen, glycosaminoglycans, occasional particles of very-low-density lipoprotein, Ito cells and hepatocyte microvilli. As no lymph vessels can be identified within the hepatic lobule, it has been suggested that the fluid in the space of Disse, in free communication with the interstitial spaces at the portal and central venous ends of the sinusoid, enters the lymphatics present in the portal tracts and in the central venous area as liver lymph. The highly porous nature of the sinusoidal wall explains why, in the normal liver, the protein concentration of hepatic lymph is approximately 95% that of plasma measured simultaneously [77]. A consequence of this high permeability is that the trans-sinusoidal oncotic gradient is virtually zero. Liver lymph is principally drained by vessels leaving at the liver hilus, although a small proportion passes through vessels accompanying the hepatic veins into the chest [78]. Lymph from the hilus, as well as that from other organs including the pancreas, spleen, kidney, adrenals, stomach, large and small intestines, gallbladder and mesentery, all drains via the para-aortic plexus and cisterna chyli into the thoracic duct [78]. This duct is a lymphatic channel 36–45 cm long that begins at the upper end of the cisterna chyli near the lower border of the 12th thoracic vertebra, passes through the diaphragm and ascends in the posterior mediastinum in close relation to the aorta and azygos vein. It passes into the neck behind the aortic arch and then curves laterally, joining the left subclavian or internal jugular vein. The

anatomical arrangement of the terminal thoracic duct is extremely variable. Only occasionally does it drain into the right jugular or subclavian vein alone. Usually, there are many anastomotic sites between it and the venous system in the left side of the neck. In normal humans, the thoracic lymph flow may reach 800–1000 mL/day.

Constriction of the suprahepatic inferior vena cava or the hepatic veins in experimental animals has been the model most frequently used to investigate the effect of sinusoidal portal hypertension on fluid exchange through the sinusoidal wall. The increased pressure in the hepatic veins is almost completely transmitted back to the hepatic sinusoids, indicating that capillary pressure is not autoregulated in the liver [79]. In addition, because of the high permeability to plasma proteins of the sinusoidal wall, no oncotic force opposes the increase in hydrostatic sinusoidal pressure. Consequently, elevation of hepatic venous pressure is followed by a dramatic increase in the passage of fluid with a protein concentration similar to that of plasma, from the sinusoidal lumen to the space of Disse [79–81]. The relation between sinusoidal pressure and the hepatic production of lymph is such that an increase of 60% in lymph production occurs for every millimetre rise in sinusoidal pressure [80]. The macroscopic consequence of this phenomenon is a marked enlargement of the liver. However, the compliance of the liver, that is the relation between interstitial pressure and interstitial volume, is very low [82]. This means that little interstitial fluid can accumulate without altering interstitial pressure. It has been estimated that, for venous pressures between zero and 30 mmHg, approximately 65% of the rise in hepatic venous pressure is transmitted to the hepatic interstitium [83]. The remaining 35% is absorbed by the increase in intravascular and interstitial volume. This high interstitial pressure explains the two major consequences of experimental sinusoidal portal hypertension: a striking increase in lymph flow through the liver lymphatics and thoracic duct; and the direct passage of hepatic lymph with very high protein concentrations from the liver surface into the peritoneal cavity, forming ascites [79,81].

Results of studies in cats with experimental constriction of the thoracic inferior vena cava strongly support the hypothesis that the ascitic fluid produced during acute experimental blockage of the hepatic outflow is mainly derived from the hepatic microvascular compartment. Greenway and Lautt [80] investigated the effect of increasing hepatic venous pressure on the formation of hepatic lymph in anaesthetized cats. The livers of these animals, with venous and arterial inflow intact, were inserted into a plethysmograph. The sequence of events occurring after the elevation in hepatic venous pressure consisted of a transient increase in hepatic volume, followed by a rapid accumulation of fluid with a protein concentration of approximately 80% of the plasma concentrations within the plethysmograph. With obstruction of the hepatic lymphatics, the rate of fluid filtration through the liver surface was directly proportional to the sinusoidal pressure. Freeman [84] and Mallet-Guy *et al.* [85] repositioned the liver supradiaphragmatically and subsequently constricted the thoracic inferior vena cava. Ascites only developed in the thoracic cavity. When a cellophane bag was placed around the liver, ascitic fluid only accumulated in the bag.

Effects of portal hypertension on splanchnic transmicrovascular fluid exchange

The structural and functional characteristics of the microvasculature of the stomach and small and large intestines are very different from those of the liver. First, the splanchnic capillaries are much less porous than the hepatic sinusoids and have a well-defined basement membrane. Although most splanchnic capillaries are fenestrated, the estimated pore size, 3.7–12 nm in radius, is between 50 and 100 times less than that of the hepatic sinusoids. The oncotic reflection coefficient (ORC), which describes the fraction of the total protein oncotic pressure generated across a capillary membrane (impermeable proteins generate 100% of their maximum oncotic pressure, ORC = 1, whereas freely permeable proteins generate no oncotic pressure, ORC = 0) has been estimated as 0 in the normal liver and 0.78, 0.92 and 0.85 in the stomach, small intestine and colon respectively [80,86]. Consequently, any increase in filtration in the splanchnic capillaries is quickly counterbalanced by an increase in the oncotic pressure difference between the capillary lumen and interstitial space. This may explain the infrequency of ascites in presinusoidal portal hypertension.

Three other factors may contribute to the infrequency of ascites when the blockage to portal flow occurs before the sinusoids. First, the gastric and intestinal interstitium is much more compliant than the hepatic interstitium, and considerable interstitial fluid can accumulate in these organs without causing any major changes in interstitial pressure [82]. Secondly, the intestines have a very efficient lymphatic system for removing interstitial oedema. In this respect, it is interesting that, in normal conditions, approximately 20% of the fluid absorbed by the small intestine is carried out into the general circulation by the lymphatics. The abrupt elevation in portal venous pressure increases lymph flow from the stomach, small intestine and colon [86,87]. Because of the low permeability of intestinal capillaries to plasma proteins, the ratio between protein concentrations in the intestinal lymph and in plasma in conditions of portal hypertension is characteristically low (20%) [77]. Finally, as most splanchnic capillaries are located within the submucosa [82] and the hydraulic conductance (permeability to submucosal interstitial fluid) of the muscular and serosal layers of the stomach, small bowel and colon is probably low, it is not surprising that partial occlusion of the portal vein produces marked accumulation of fluid in the submucosa with no major changes in the serosal and muscular layers. This also explains why transudation of fluid out of the gut in this condition occurs mainly into the lumen and not into the intraperitoneal space. In fact, net fluid and electrolyte secretion into the lumen of the small bowel occurs in animal models following acute elevation of portal pressure [83].

Source of ascites in cirrhosis

All the findings discussed above offer a rational explanation for the absence of ascites in patients and experimental animals with presinusoidal portal hypertension. They also suggest that an imbalance between hepatic lymph production and the capacity of the lymphatic system of the liver and thoracic duct to return the hepatic lymph to the general circulation may be the predominant mechanism of ascites formation in experimental blockade of the hepatic venous outflow and in patients with constrictive pericarditis, Budd–Chiari syndrome and hepatic veno-occlusive disease, who have increased lymph flow in the thoracic duct and ascites with a high protein content [82,88]. However, as hepatic cirrhosis differs in many respects from experimental blockade of the hepatic venous outflow, the pathogenesis of ascites in patients with chronic liver disease may vary from that in experimental sinusoidal portal hypertension.

First, it is well established that there are marked structural changes in the hepatic microvasculature in cirrhosis, the most characteristic being capillarization of the hepatic sinusoids. This abnormality has been extensively investigated by Huet *et al.* [89]. These workers showed that the marginal areas of the regenerative nodules were perfused with capillaries rather than sinusoids, whereas sinusoids were present in the central areas of the micronodules. The sinusoids were fenestrated in a normal fashion and lacked a basement membrane. In contrast, capillaries exhibited a continuous endothelial lining lacking fenestrae, supported by a basement membrane and collagenous tissue. The structure was such that, along a single vascular pathway, capillary and sinusoidal structures were encountered in sequence. Variations in the degree of capillary change were found from patient to patient. Huet *et al.* also investigated the functional consequences in cirrhotic patients of this alteration in liver microcirculation by using a multiple indicator dilution technique. Labelled red blood cells and albumin were injected simultaneously into the portal vein or hepatic artery and the outflow dilution pattern was obtained from hepatic venous blood. In the normal liver, labelled red cells occupy the intravascular compartment, whereas the volume of distribution of albumin, which gains access to the space of Disse, includes both the intravascular and the interstitial compartments. This explains why, in normal livers, the volume of distribution of albumin exceeds that of red cells by 60%. In contrast, in organs with less permeable capillaries in which no significant albumin exchange occurs during the time of a single passage, the difference between the volume of distribution of these two markers is only 7%. In cirrhotic patients, the calculated volume of distribution of albumin within the liver exceeded that of red cells by 7–60%. Some patients showed a pattern similar to that expected in the normal liver, while in others the hepatic sinusoids were almost impermeable to albumin.

Second, there is evidence that, contrary to what occurs in other vascular territories, the intestinal microvasculature does not autoregulate its capillary pressure or the capillary filtration coefficient in cirrhosis. Portal hypertension in cirrhotic patients and in animals with experimental cirrhosis is not associated with an increased splanchnic arteriolar resistance but, rather, with a generalized splanchnic arteriolar vasodilation [90]. As discussed later, the simultaneous occurrence of increased portal venous pressure and arterial blood inflow to the splanchnic microcirculation leads to a marked increase in splanchnic microvascular hydrostatic pressure and permeability, explaining why interstitial oedema in the mucosal, muscular and serosal layers is prominent in human cirrhosis. The serosal oedema is manifested by a fivefold increase in the thickness of the jejunal peritoneum in cirrhotic patients compared with control subjects [91].

Third, the total protein content in hepatic and thoracic duct lymph and in ascitic fluid is remarkably lower in cirrhosis than in experimental blockage of the hepatic outflow. Increased flow of thoracic duct lymph (usually 8–9 L/day) is a characteristic finding in cirrhosis, whether or not ascites is present [92]. This is associated with a marked enlargement of the thoracic duct and an elevation in duct pressure, which has been attributed to the presence of valves and endothelial folds at the duct–venous junction, making the flow of lymph into the venous system of the neck difficult. The number, size and thickness of lymphatics in the hilum of the liver, and in the mucosal and serosal layers of the intestine and mesentery, are markedly increased in cirrhosis. The hepatic lymph:plasma ratio for total proteins in cirrhosis with ascites ranges between 20% and 80% [93]. This low protein concentration of hepatic lymph is probably a consequence of the capillarization of hepatic sinusoids. The total protein content of intestinal lymph in cirrhotics with ascites is generally under 20% of that in plasma [93]. Finally, the thoracic duct lymph and the total protein concentration of ascitic fluid in these patients are between those of the hepatic and intestinal lymph [77,93]. It is therefore very likely that ascites in cirrhosis derives from both hepatic and splanchnic vascular compartments.

Studies evaluating the escape of radiolabelled albumin from the intravascular to the extravascular compartment and to the intraperitoneal space (which estimates the fluid dynamics through the capillary wall and peritoneum and liver surface respectively) indicate that the lymphatic system is extremely efficient in returning most of the excessive hepatic and splanchnic lymph to the general circulation in cirrhotic patients with ascites [16]. The transvascular escape rate of radiolabelled albumin in these patients is remarkably high (8.5% of the total intravascular mass of albumin per hour). The fraction of the transvascular escape of albumin passing into the peritoneal cavity is, however, very low (0.21%). Ascites formation is therefore the consequence of a small spillover of the increased rate of formation of hepatic and splanchnic lymph, most of which is returned directly to the circulation through the lymphatic system.

Effects of portal hypertension on splanchnic arteriolar circulation

In addition to increasing hepatic and splanchnic lymph production, portal hypertension induces a profound alteration in the

splanchnic circulation. Classically, portal hypertension was considered to be due solely to an increased resistance to portal venous flow. However, it is now clear that the pathogenesis of portal hypertension is much more complex and that increased portal venous inflow secondary to a generalized splanchnic arteriolar vasodilation also plays an important part in the increased portal pressure [90,94–98]. This high portal venous inflow may explain why, in experimental animals, portal pressure remains increased despite the development of a marked collateral circulation. The mechanism by which portal hypertension induces splanchnic arteriolar vasodilation and increased portal venous inflow is not entirely understood. There is strong evidence suggesting that an increased local production of vasodilatory substances (i.e. nitric oxide) is the most probable mechanism of splanchnic arterial vasodilation associated with portal hypertension. This enhanced production of local vasodilators also explains the decreased sensitivity of the gastric and intestinal microvasculature to endogenous vasoconstrictor systems, which also contribute to the splanchnic hyperaemia associated with portal hypertension [99].

There is indirect evidence that splanchnic arteriolar vasodilation also occurs in patients with cirrhosis and portal hypertension. Under normal conditions, almost all the flow circulating in the splanchnic bed reaches the liver, so the hepatic equals the splanchnic blood flow. In patients with cirrhosis and portal hypertension, because there is important shunting of blood through the portosystemic collateral circulation, the hepatic blood flow represents only a part of the splanchnic blood flow. Between 60% and 80% of the mesenteric and splenic blood flow is shunted through the collateral circulation in cirrhotic patients [100,101]. As several investigations have shown that the hepatic blood flow is normal or even increased in most such patients [102–104], it follows that in these there must be a marked increase in splanchnic blood flow secondary to arteriolar vasodilation. The observation that the mean transit time in the splanchnic vascular bed is substantially reduced in alcoholic cirrhotics further indicates the occurrence of splanchnic arteriolar vasodilation in these patients [105].

Renal functional abnormalities

Sodium retention is the most common abnormality of renal function in cirrhosis. It is constantly present in patients with ascites and plays a major role in the pathogenesis of this complication. Ascites disappears in most patients when sodium retention is inhibited by diuretics. Conversely, diuretic withdrawal or a high sodium diet leads to the reaccumulation of ascites. The degree of sodium retention in cirrhosis with ascites varies considerably from one patient to another, being practically nonexistent in some patients, but relatively high in others [106]. The observation that ascites might disappear in the latter patients only by reducing sodium intake below sodium excretion is a further argument for the importance of sodium retention in the pathogenesis of ascites. Experimental studies have shown that sodium retention precedes ascites formation in cirrhosis [107]. The impairment of sodium excretion in most cirrhotics occurs in the setting of a normal glomerular filtration rate. Therefore, the predominant mechanism for sodium retention in these patients is an increased tubular sodium reabsorption.

Patients with compensated cirrhosis do not have sodium retention. However, they present subtle abnormalities of sodium metabolism. For example, these patients are unable to excrete an acute intravenous salt load normally [108–110]. On the other hand, compensated cirrhotics with severe portal hypertension may not 'escape' from an exogenously administered mineralocorticoid hormone. If a normal individual ingesting a diet containing a constant amount of sodium is given a salt-retaining mineralocorticoid daily, a transient period of sodium retention is experienced, and limited weight gain occurs, reflecting the expansion of the extracellular fluid volume. After 3–5 days, however, sodium excretion increases and equals dietary intake, so that no further weight gain or extracellular volume expansion occurs. In contrast, compensated cirrhotics with high portal pressure may not escape from the sodium-retaining effect of mineralocorticoids, and they develop continuous renal fluid and sodium retention, leading to the formation of ascites and oedema [111,112]. Finally, it has been shown that compensated cirrhotics retain sodium while they are in an upright posture, whereas they show an exaggerated natriuresis during bedrest [113,114].

The oral or the intravenous (as 5% glucose solution) administration of a water overload of 20 mL/kg body weight over 45 min to a normal individual is followed after a period of between 30 and 60 min by the excretion of hypotonic urine (60–110 mosm/kg), at a rate of 8–14 mL/min. The volume of water excreted per minute by this individual can ideally be divided into two parts. The first consists of water, which dissolves urinary solutes iso-osmotically with respect to plasma (osmolar clearance). The second part consists of water free of solutes (free-water clearance, C_{H_2O}). As osmolar clearance in normal individuals is 1.5–2.5 mL/min, free-water clearance after a water overload in these subjects ranges between 6 and 12 mL/min. This means that a healthy person is able to maintain total body water within normal limits even if water ingestion is 10 L or more per day.

C_{H_2O} after a water overload is normal in compensated cirrhotics and reduced in most patients with cirrhosis and ascites [115–117]. The degree of impairment of water excretion in cirrhosis with ascites also varies markedly from patient to patient (Fig. 5). Thus, whereas in some cirrhotics with ascites, C_{H_2O} after a water overload is only slightly reduced, others present very low C_{H_2O} or may be unable to dilute the urine after the water load (negative C_{H_2O}). These patients with very low (< 1 mL/min) or negative C_{H_2O} retain most water taken in with the diet, causing a dilution of the interior milieu, hyponatraemia and hypo-osmolality [118]. Hyponatraemia in cirrhosis with ascites is, therefore, a consequence of an excess of water and not of sodium deficiency. This concept is important from a

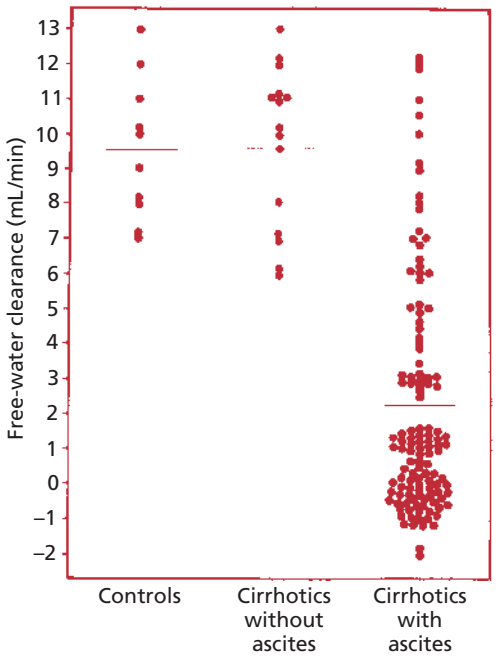

Fig. 5 Free-water clearance after an oral water overload of 20 mL/kg body weight in normal subjects and in patients with hepatic cirrhosis with and without ascites.

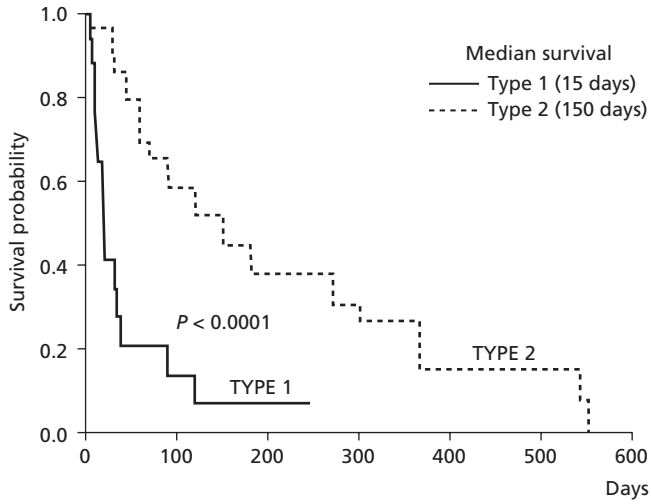

Fig. 6 Survival of patients with cirrhosis after the diagnosis of type 1 or type 2 HRS [reproduced with permission from Ginès P (2003) *Lancet* 362, 1819–1827].

therapeutic point of view. The incidence of hyponatraemia in cirrhotic patients with ascites is approximately 35% [118].

Hepatorenal syndrome is a peculiar type of functional renal failure that occurs in patients with acute liver failure and cirrhosis with ascites. It is due to reduced renal perfusion and, in most cases, renal histology is normal or presents minor abnormalities. Retrospective studies indicate that it is present in approximately 17% of patients admitted to hospital with ascites and in more than 50% of the cirrhotics who die [119]. The probability of developing hepatorenal syndrome 2 and 5 years after the onset of ascites in patients with cirrhosis is 32% and 41% respectively [120]. Hepatorenal syndrome represents the most accurate prognostic index in patients with cirrhosis and ascites: most of these patients die within weeks or months after the onset of the syndrome, independently of the degree of hepatic insufficiency [121,122]. There are two distinct types of hepatorenal syndrome in cirrhosis [122,123]. Type 1 hepatorenal syndrome is characterized by a rapid increase in blood urea nitrogen (BUN) and serum creatinine, which reach extremely high levels within days after the onset of renal failure (over 100 mg/dL and 5 mg/dL respectively). Most of these patients also present progressive oliguria, dilutional hyponatraemia (often below 120 mEq/L) and hyperkalaemia. This rapidly progressive renal impairment always occurs in patients with extremely poor hepatic function who, in addition to ascites, often present other complications of the underlying cirrhosis, such as jaundice or hepatic encephalopathy. Type 1 hepatorenal syndrome is commonly observed in alcoholic cirrhotics with superimposed severe alcoholic hepatitis or in any aetiological type of cirrhosis with ascites in which hepatic function deteriorates rapidly as a consequence of a serious bacterial infection, gastrointestinal haemorrhage or a major surgical procedure. The development of type 1 hepatorenal syndrome carries an ominous prognosis as most of these patients die within days or weeks after the onset of the syndrome. Type 2 hepatorenal syndrome is characterized by a moderate increase in BUN and serum creatinine (usually lower than 60 mg/dL and 2 mg/dL respectively), which remains steady for months [122,123]. It is important to realize, however, that in cirrhosis a small increase in BUN or serum creatinine represents a marked fall in glomerular filtration rate (GFR). In fact, GFR in patients with type 2 hepatorenal syndrome is reduced by more than 50%. Type 2 hepatorenal syndrome usually occurs in cirrhotics with a relatively preserved hepatic function, whose main clinical problem is an ascites refractory to diuretic treatment [122]. Survival of these patients, however, is considerably less than that of non-azotaemic cirrhotics with ascites (Fig. 6).

Mechanisms of renal function abnormalities in cirrhosis

Several neurohumoral systems and endogenous substances with sodium- or water-retaining activities, or vasoactive properties, have been implicated in the pathogenesis of renal dysfunction in cirrhosis, including the renin–angiotensin–aldosterone and the sympathetic nervous systems, antidiuretic hormone, prostaglandins, leukotrienes, natriuretic peptides, endothelin, nitric oxide, carbon monoxide, endogenous cannabinoids, natriuretic hormone, the renal–kallikrein–kinin system, glomerulopressin, endotoxin, false neurotransmitters, platelet-activating factor, estrogens and vasoactive intestinal peptide. It is important to point out, however, that more than 100 different compounds with significant effects on renal function have been isolated in human urine. Therefore, the systems and substances

cited above probably represent only a small fraction of the neurohumoral factors that may affect renal function in cirrhotics with ascites. In addition, alterations in intrarenal haemodynamics may also participate in the pathogenesis of sodium and water retention in these patients. Here, we summarize the extensive data presently available implicating the renin–angiotensin–aldosterone system, sympathetic nervous system, antidiuretic hormone and arachidonic acid metabolites in the pathogenesis of renal dysfunction in cirrhosis. Readers should consult other articles and chapters to review the potential role of other vasoactive substances, such as natriuretic peptides, nitric oxide and endothelin.

The renin–angiotensin–aldosterone system

Through the secretion of renin, the kidney exerts powerful control over arterial pressure, extracellular fluid volume (including blood volume), sodium and potassium excretion and the electrolyte composition of the body [124]. Renin is produced in the kidney by specialized cells of the juxtaglomerular apparatus, the granular cells of the wall of the afferent arteriola, which are in intimate contact with the macula densa in the ascending limb of the loop of Henle. The vascular and tubular components of the juxtaglomerular apparatus are richly innervated by sympathetic nerves. Renin is an enzyme with no biological activity and acts on an α-globulin (renin substrate or angiotensinogen), synthesized by the liver, releasing the inactive decapeptide angiotensin I (A-I).

Three major mechanisms control renin release from the kidney: the renal baroreceptor mechanism sensitive to changes in renal perfusion pressure; the macula densa mechanism, which responds to changes in sodium delivery or transport within the ascending limb of the loop of Henle; and the renal sympathetic nervous activity, which directly stimulates renin release by operating upon β1-receptors present in the juxtaglomerular apparatus. These three mechanisms operate in concert, as they are influenced in the same direction when there are changes in effective circulating blood volume or arterial pressure.

A-I is subsequently transformed to the octapeptide A-II by the action of the specific converting enzyme dipeptidyl carboxypeptidase. As the largest concentration of this converting enzyme is found in the lung, it was believed that conversion of A-I to A-II was primarily systemic rather than intrarenal. However, the converting enzyme is also present in the juxtaglomerular apparatus, and significant amounts of A-II are generated locally within the kidney.

A-II is one of the active components of the renin–angiotensin–aldosterone system. It is among the most active of the endogenous vasoconstrictors so far identified. The renal vasculature is especially sensitive to the vasoconstrictor effect of A-II because a striking reduction in renal blood flow occurs with doses of A-II well below those required to induce a pressor response. A-II also reduces the glomerular filtration rate. The latter effect is related to both a decrease in renal perfusion and a direct contractile effect on glomerular mesangial cells. Finally, the interaction of A-II with AT1 receptors in the adrenal glomerulosa cells stimulates the aldosterone biosynthetic pathway and increases the release of this hormone to the circulation [124].

The second active component of the renin–angiotensin–aldosterone system is aldosterone, an important regulator of sodium, potassium and acid–base balance [124]. The collecting tubule is the nephron segment responsive to aldosterone. The principal cells, located predominantly in the cortical segments, probably mediate the aldosterone-regulated sodium reabsorption and potassium secretion, whereas the intercalated cells, which predominate in the inner stripe of the outer medulla, participate in the aldosterone-regulated hydrogen ion transport. Aldosterone diffuses freely across the basolateral membrane of the principal cells and binds to a cytoplasmic receptor. The steroid–receptor complex is transported into the nuclear compartment and binds to specific promoters of a number of genes that are under aldosterone regulation. The interaction of the steroid–receptor complex with the promoter leads to the transcription of mRNAs which are, in turn, translated into their respective proteins, mediators of the sodium transport process. Among these proteins, the amiloride-sensitive sodium channel and the Na^+-K^+ATPase are of particular importance in the antinatriuretic effect of aldosterone. The sodium channels are inserted into the luminal membrane and favour the passive transport of sodium from the tubular lumen to the intracellular space. The Na^+-K^+ATPase (or sodium pump) molecules are located in the basolateral membrane and promote the active transport of intracellular sodium to the extracellular compartment and the entry of potassium from the extracellular to the intracellular space. The kaliuretic effect of aldosterone is related to its stimulatory effect on Na^+-K^+ATPase and probably also to the activation of luminal membrane potassium channels. The synthesis of the proteins activated by aldosterone takes time, and the half-life of these proteins is relatively prolonged. This explains the delay between the administration or withdrawal of spironolactone, a drug that competitively inhibits the binding of aldosterone to the cytosolic receptor, and the onset or finalization of the diuretic action.

The renin–angiotensin–aldosterone system is activated in most cirrhotics with ascites with marked sodium retention (urinary sodium excretion lower than 5 mEq/L) and in all patients with hepatorenal syndrome (Fig. 7). In many of these patients, the plasma levels of renin and aldosterone reach extraordinarily high values. In cirrhotic patients with ascites and moderate sodium retention, the plasma levels of renin and aldosterone may be normal or only slightly elevated (Fig. 7). Plasma renin activity and aldosterone are normal or reduced in compensated cirrhotics [125,127]. Several lines of evidence indicate that aldosterone plays a major role in the pathogenesis of sodium retention in cirrhosis. Urinary sodium excretion in cirrhotics with ascites correlates closely with the degree of hyperaldosteronism, plasma aldosterone levels being higher in cirrhotics with marked sodium retention [128]. On the other hand, sodium retention can be reversed in most of these patients following the

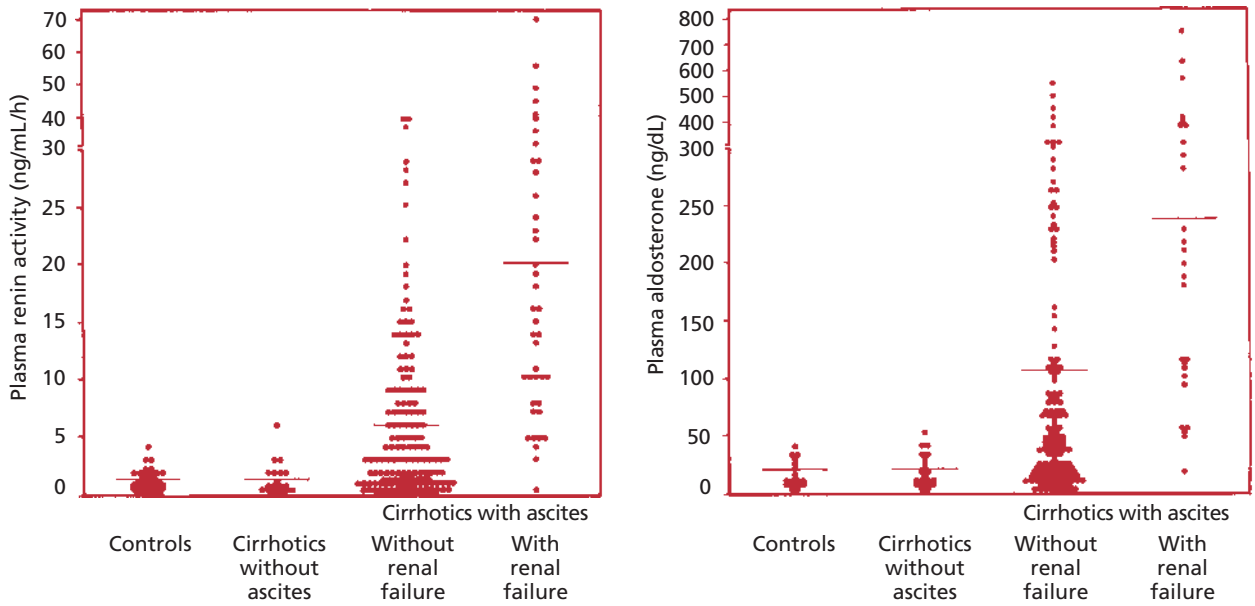

Fig. 7 Plasma renin activity and plasma aldosterone concentration in healthy subjects, cirrhotic patients without ascites and cirrhotic patients with ascites with and without hepatorenal syndrome. Measurements were made after 5 days on a 50-mEq sodium diet and without diuretics. Plasma renin activity was measured after incubating for 1 h.

blockade of the renal tubular effect of aldosterone with spironolactone [129]. The observation that cirrhotics with ascites may present sodium retention in the absence of hyperaldosteronism is generally considered to be an indication that factors other than aldosterone are involved in the excessive tubular sodium reabsorption [126]. However, cirrhotics with moderate sodium retention and normal plasma aldosterone concentration are extremely sensitive to spironolactone [128]; these patients may have an increased tubular sensitivity to aldosterone.

Studies using pharmacological agents that interrupt the renin–angiotensin–aldosterone system (inhibitors of the converting enzyme and structural analogues that competitively antagonize A-II at the vascular AT1 receptor) have been important in our understanding of the activation of the renin–angiotensin–aldosterone system in patients with cirrhosis and ascites. These patients present a systemic circulatory dysfunction characterized by low arterial pressure, hypervolaemia, high cardiac output and low peripheral resistance, findings consistent with marked arteriolar vasodilation [122,129–132]. Inhibition of the endogenous renin–angiotensin–aldosterone system in cirrhotic patients with increased plasma levels of renin by the intravenous injection of saralasin, a specific antagonist of A-II, or by converting enzyme inhibitors is associated with a further decrease in arterial pressure and peripheral resistance; this may be striking in patients with marked overactivity of the renin–angiotensin–aldosterone system [133]. The systemic circulatory disturbance of these patients would, therefore, be much more intense if endogenous A-II was not acting at the peripheral vasculature to maintain arterial pressure at normal or near-normal levels. Renin release in cirrhotics with ascites is, therefore, a homeostatic mechanism to maintain systemic haemodynamics, with arterial hypotension being the most likely mechanism of hyper-reninism in these patients.

Plasma renin activity is particularly elevated in patients with hepatorenal syndrome (Fig. 7) [134,135]. On the other hand, plasma renin activity in non-azotaemic cirrhotic patients with ascites is an independent predictor of hepatorenal syndrome development [120]. Therefore, it is reasonable to presume that endogenous A-II is involved in the pathogenesis of the active vasoconstriction, causing hepatorenal syndrome in cirrhosis.

The sympathetic nervous system

The sympathetic nervous system is another important endogenous mechanism controlling systemic haemodynamics and renal function in man. This system is influenced by high-pressure baroreceptors located in the carotid sinus and aortic arch and low-pressure baroreceptors (volume receptors) present in the cardiac atria and pulmonary veins. High-pressure baroreceptors are quiescent below an arterial pressure of 80 mmHg and show a progressive excitation with increasing arterial pressure up to approximately 180 mmHg. The activity from these receptors elicits a reflex inhibition of the sympathetic outflow and thus provides the afferent limb of the buffer reflexes that stabilize arterial pressure. When compared with the sympathetic activity directed to other visceral structures, efferent renal nerve activity appears to be particularly sensitive to inhibition by arterial baroreceptors [136]. Low-pressure baroreceptors are activated by distension of the cardiac atria and pulmonary veins and, therefore, function as intravascular volume receptors. Afferent impulses arising from high- and low-pressure baroreceptors

travel via the glossopharyngeal and vagus nerves to an integrative site in the medulla, which alters the sympathetic nervous outflow according to the information received. Afferent impulses from high- and low-pressure baroreceptors are also sent to the supraoptic and paraventricular nuclei of the hypothalamus, thus modifying antidiuretic hormone secretion [137]. Therefore, three neurohormonal vasoactive systems, the sympathetic nervous system, the renin–angiotensin–aldosterone system and antidiuretic hormone, are closely interrelated and operate simultaneously to regulate arterial pressure and intravascular volume.

The kidney is richly innervated by sympathetic noradrenergic fibres, which reach the afferent and efferent arterioles, juxtaglomerular apparatus, proximal and distal convoluted tubules, thick ascending limb of the loop of Henle and distal and collecting tubules [138]. In contrast, there is neither physiological nor anatomical evidence supporting the existence of sympathetic cholinergic vasodilator fibres in the kidney. Direct electrical stimulation of the renal nerves produces a decrease in renal blood flow and GFR, and stimulates sodium reabsorption in the proximal tubule, loop of Henle and distal nephron [139]. These effects, which can also be demonstrated when the renal sympathetic nervous system is reflexively activated through high- and low-pressure baroreceptors, are mediated by α1-adrenoreceptors [139]. The effect of the sympathetic nervous system on renal sodium metabolism is independent of its haemodynamic effect, as it can be observed with subpressor nerve stimulation in the absence of changes in renal perfusion and GFR.

The most commonly used method to assess sympathetic nervous activity in man is by measuring the plasma levels of noradrenaline (nonepinephrine), as most noradrenaline circulating in plasma is derived from that released as a transmitter at postsynaptic sympathetic nerve terminals. Many studies have been performed using this method in patients with cirrhosis with and without ascites or hepatorenal syndrome; they demonstrate that the plasma noradrenaline concentration in peripheral venous samples is normal in compensated cirrhosis, and usually increased in patients showing sodium retention and ascites (see Fig. 8) [130,134,135,140,141]. In normal subjects, the plasma concentration of noradrenaline in renal vein samples is similar to, or lower than, that in arterial samples, the renal venous–arterial difference, therefore, being zero or slightly negative. In contrast, in cirrhotics with ascites, this difference is usually positive, indicating an increased activity of the renal sympathetic nervous system [141]. By using radiotracer techniques, it has been shown that both total body and renal release of noradrenaline was elevated in parallel in these patients [142]. Direct evidence of a generalized overactivity of the sympathetic nervous system in cirrhosis has been provided by measuring the sympathetic nerve discharge rates from a peripheral muscular nerve. Muscular sympathetic nerve activity is markedly increased in patients with ascites and normal in patients without ascites, and correlates directly with plasma noradrenaline.

As the sympathetic nervous activity stimulates sodium reabsorption and is a vasoconstrictor in the renal circulation, it has

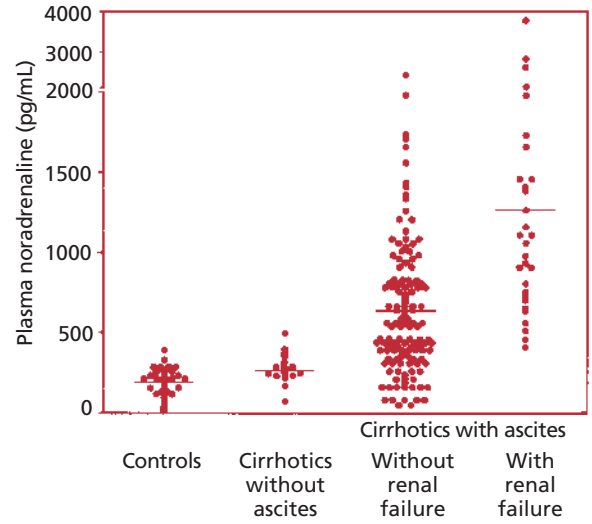

Fig. 8 Plasma noradrenaline concentration in healthy subjects, cirrhotic patients without ascites and cirrhotic patients with ascites with and without hepatorenal syndrome. Measurements were made after 5 days on a 50-mEq sodium diet without diuretics.

been implicated in the pathogenesis of sodium retention and hepatorenal syndrome in cirrhosis. There is evidence supporting this contention. Plasma noradrenaline and total noradrenaline spillover are normal in compensated cirrhotics, and usually increased in patients with ascites and sodium retention. In the latter group, sodium excretion correlates inversely with these measurements [140]. Acute bilateral renal surgical denervation is followed by increased urine volume and sodium excretion in bile duct-ligated miniature swine with cirrhosis and ascites; in conscious cirrhotic rats with ascites, it improves renal excretion of both an intravenous and an oral sodium load. Such direct evidence has also been presented in patients with cirrhosis, in whom anaesthetic blockade of the lumbar sympathetic nervous system, a manoeuvre that reduces the renal sympathetic nervous activity, improves sodium excretion [143]. Among cirrhotics with ascites, patients with hepatorenal syndrome have the highest plasma concentration of noradrenaline (Fig. 8) [131]. Moreover, the acute inhibition of the renal sympathetic outflow with clonidine in patients with cirrhosis is associated with a reduction in renal vascular resistance and an increase in GFR, indicating that the activation of the sympathetic nervous system participates in the pathogenesis of the renal vasoconstriction of cirrhosis.

Factors other than the sympathetic nervous activity and aldosterone are involved in sodium retention in cirrhosis [126]. A series of non-azotaemic patients with ascites, moderate to intense sodium retention and normal recumbent levels of plasma renin activity, aldosterone and noradrenaline were studied in an upright position and during moderate physical exercise and compared with a group of normal subjects and a group of patients with compensated cirrhosis. There were no significant differences in plasma renin activity, aldosterone and noradrenaline

between the three groups in any of the study conditions. Interestingly enough, the cirrhotic patients with ascites showed high circulating levels of atrial natriuretic peptide, indicating that sodium retention may occur in cirrhosis in the absence of detectable activation of the renin–angiotensin–aldosterone system and sympathetic nervous system and despite increased circulating levels of natriuretic peptides.

Antidiuretic hormone

Antidiuretic hormone (ADH) is produced by magnocellular neurones arising bilaterally in the supraoptic nuclei of the hypothalamus [137]. These neurones project medially to merge in the pituitary stalk and continue to form the posterior lobe of the pituitary gland. The neurones terminate as bulbous enlargements on capillary networks scattered through the stalk and body of the neurohypophysis. Biosynthesis of ADH occurs from the peptide precursor propressophysin, which is composed of ADH and the vasopressin-binding protein neurophysin. The precursor is synthesized in cell bodies in the supraoptic nuclei, packed in secretory granules and cleaved progressively as it moves down to the axon to yield neurophysin and ADH. In the nerve terminals, ADH and neurophysin are stored in secretory granules and secreted.

The most important physiological stimulus for ADH secretion is the osmotic pressure of body water, which induces changes in the water content of a group of neurones (osmoreceptors) concentrated in the anterior hypothalamus near the supraoptic nuclei [137]. The functional properties of these neurones resemble those of a set-point receptor. Plasma osmolality below a threshold level suppresses ADH to low or undetectable levels. Above that point, plasma ADH rises steeply in direct proportion to plasma osmolality. Secretion of ADH is also affected by changes in systemic haemodynamics [137]. Small decreases (< 10%) in blood volume or arterial pressure have little effect on plasma ADH. However, beyond that point, plasma ADH rises at a rapidly increasing rate. The ADH responses to haemodynamic changes are mediated by neurogenic stimuli that arise from high- and low-pressure baroreceptors. Changes in blood volume or pressure large enough to affect ADH secretion do not interfere with osmoreceptor regulation of the hormone but, rather, raise or lower the threshold level of hormone secretion. For example, in the presence of hypovolaemia, plasma ADH secretion can be suppressed if plasma osmolality falls, but the set-point at which ADH decreases in response to hypo-osmolality is lower than under normal conditions. This concept is of importance in explaining the relationship between ADH and plasma osmolality in circumstances, such as cirrhosis, with simultaneous changes in systemic haemodynamics and extracellular osmolality.

The two major biological effects of ADH are to increase water permeability in the cortical and medullary collecting tubules (hydro-osmotic effect), thus allowing water to be reabsorbed passively from the tubular lumen to the isotonic cortical and hypertonic medullary interstitium, and to produce contraction of the vascular smooth muscle cells (vasoconstrictor effect) [137]. The hydro-osmotic effect of ADH is mediated by the insertion of water channels (aquaporin-2), which are stored in cytoplasmic vesicles near the tubular lumen, in the luminal membrane of the collecting tubule epithelial cells [144,145]. In the unstimulated state, this membrane is almost impermeable to water because of a lack of water channels. In contrast, the basocellular membrane, which is very rich in aquaporin-3 (a different water channel that also transports non-ionic solutes such as urea), is highly permeable to water. The hydro-osmotic effect of ADH is initiated by the binding of the hormone to a V_2 receptor on the basolateral membrane of the collecting duct epithelial cells. This receptor is coupled to adenylate cyclase by a guanine nucleotide-binding protein (Gs), which stimulates the enzyme. Adenylate cyclase stimulation results in the insertion of aquaporin-2 molecules into the luminal membrane. The vasoconstrictor effect of ADH is initiated by the interaction of the hormone with V_1 receptors placed in the plasma membrane of the vascular smooth muscle cells. The vascular effect of ADH is particularly striking in the splanchnic, muscular and cutaneous vasculature, with renal circulation being much less sensitive to its vasoconstrictor action.

The production of free water within the kidney occurs in the ascending limb of the loop of Henle by a process involving the reabsorption of sodium chloride without a concomitant reabsorption of water (this segment of the nephron is almost impermeable to water) [146]. Free-water formation is, therefore, the result of a reabsorption of electrolytes from the tubular fluid rather than of an addition of water. In normal conditions, the kidney is continuously producing a hypotonic tubular fluid in the ascending limb of the loop of Henle. The final osmolality of the urine, therefore, depends on the degree of water reabsorption in the cortical and medullary collecting tubules, which is influenced by ADH [146].

Impairment in free-water excretion in cirrhosis was initially considered to be the result of reduced delivery of sodium chloride to the ascending limb of the loop of Henle due to low GFR and increased sodium reabsorption in the proximal tubule. Recent studies, however, have presented data indicating that ADH plays a major role in the impairment of free-water excretion in cirrhosis. Plasma levels of ADH are increased in most cirrhotics with ascites and correlate closely with the reduction in free-water excretion (Fig. 9) [140,147]. Longitudinal studies in rats with experimental cirrhosis and ascites have shown that impairment of water excretion appears in close chronological relationship to the onset of ADH hypersecretion. Brattleboro rats (rats with a congenital deficiency of ADH) with cirrhosis do not develop an impairment in water excretion [148]. Kidneys from cirrhotic rats with ascites show increased gene expression of aquaporin-2, the ADH-regulated water channel. The blockade of V_2 receptors with specific peptide and non-peptide ADH antagonists returns the impaired renal water excretion to normal in rats with carbon tetrachloride-induced cirrhosis and ascites [149] and in patients with cirrhosis, ascites and dilutional hyponatraemia [150–152]. This effect has also been observed

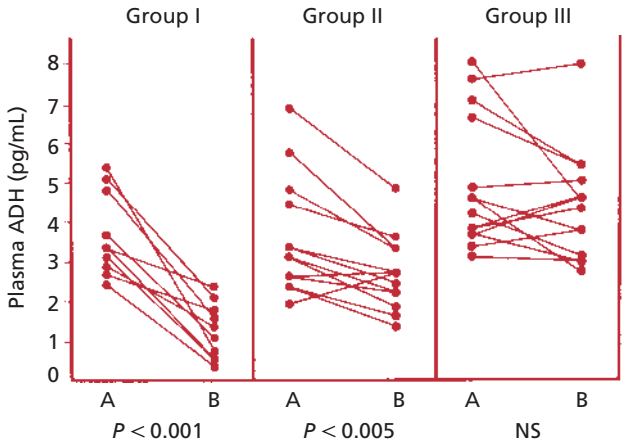

Fig. 9 Plasma antidiuretic hormone (ADH) concentration after 16 h of water restriction (A) and following a water overload of 20 mL/kg body weight (B). Group I includes normal subjects (free-water clearance 9.6 ± 0.8 mL/min). Group II includes cirrhotic patients with ascites who were able to generate free water after the overload (free-water clearance 3.6 ± 0.6 mL/min). Group III includes cirrhotic patients with ascites who were unable to generate free water after the overload (free-water clearance 0.37 ± 0.07 mL/min). (Reproduced with permission from ref. 147.) NS, not significant.

following the administration of niravoline (RU-51599), a kappa opioid agonist that inhibits the release and the tubular effect of ADH, to rats with cirrhosis and patients with ascites [153]. Plasma levels of ADH in patients with cirrhosis and ascites also correlate with renal perfusion and GFR, patients with hepatorenal syndrome having higher levels of ADH [147]. Therefore, ADH might contribute to the active renal vasoconstriction in hepatorenal syndrome.

The increased plasma ADH concentration in cirrhosis is due to an increased hypothalamic synthesis and not to a reduced systemic clearance of the peptide. Evidence indicates that this increased synthesis of ADH is related to a non-osmotic haemodynamic stimuli. Most patients with high plasma levels of ADH have a degree of hyponatraemia that would suppress the release of this hormone in normal subjects [147]. Moreover, ADH in cirrhotic patients with ascites correlates with plasma renin activity and noradrenaline, and is suppressed by manoeuvres that increase effective arterial blood volume, such as head-out water immersion or peritoneovenous shunting [140,147]. Finally, the blockade of V_1 receptors with specific ADH antagonists in rats with experimental cirrhosis, ascites and ADH hypersecretion is followed by a significant decrease in arterial pressure, an effect not observed in control animals [149]. This indicates that ADH hypersecretion contributes to the maintenance of arterial pressure in cirrhotics and suggests that the most likely mechanism of ADH hypersecretion in decompensated cirrhosis is arterial hypotension.

Arachidonic acid metabolites

The kidneys are able to synthesize substances that act locally to regulate renal function. Among these substances, the most extensively studied are prostaglandins (PGs), which are derived from arachidonic acid metabolism. The initial step in the formation of these compounds is the interaction of a stimulus, commonly a hormone, with a receptor on the cell surface, leading to an activation of phospholipase A_2. The net effect of this process is an increase in free arachidonic acid concentration, normally quite low, within the cell. The second step is the synthesis of the endoperoxides PGG_2 and PGH_2 from arachidonic acid. This is a complex process catalysed by a cyclo-oxygenase. Cyclo-oxygenase exists in two isoforms. Cyclo-oxygenase-1 (COX-1) is constitutively expressed in most of the tissues and is involved in the physiological production of PGs. Activation of COX-1 leads, for instance, to the production of PGI_2 which, when released by the renal vasculature, contributes to the maintenance of renal perfusion and GFR and, when released by the gastric mucosa, is cytoprotective [154]. The inducible form, cyclo-oxygenase-2 (COX-2), is present in cells exposed to pro-inflammatory agents, including cytokines, and is expressed during certain inflammatory processes. Inhibition of inducible COX-2 by non-steroidal anti-inflammatory drugs (NSAIDs) explains the therapeutic utility of these drugs as anti-inflammatory agents, whereas inhibition of constitutive COX-1 explains their unwanted side-effects on the stomach and the kidneys. The recent development of new drugs with selective action on COX-2 has opened a new field in the pharmacology of the inflammatory process, particularly in patients who require PGs to maintain vital functions. PGG_2 and PGH_2 are extremely unstable intermediates that are rapidly converted through various enzymes to the active compounds $PGF_{2\alpha}$, PGE_2, PGI_2 (or prostacyclin), PGD_2 and thromboxane A_2 by the action of specific enzymes.

The kidney contains several structures capable of synthesizing PGs. Glomeruli predominantly produce PGI_2 with lesser amounts of PGE_2, thromboxane A_2 and $PGF_{2\alpha}$; afferent and efferent arterioles produce PGI_2 and PGE_2, and medullary interstitial cells and collecting duct epithelial cells produce PGE_2. PGs are rapidly metabolized to products with no biological activity. Because of their rapid degradation, their biological actions are exerted at the site of synthesis. Therefore, PGI_2 and PGE_2 synthesized by the arterioles and glomeruli are thought to regulate renal perfusion and GFR; PGE_2 synthesized by the collecting duct epithelial cells is involved in the tubular handling of sodium and water in the distal nephron [155].

PGs are involved in the control of renal haemodynamics. PGE_2 and PGI_2 have powerful vasorelaxant effects on the renal arterioles and the glomerular mesangium [156]. In contrast, thromboxane A_2 and leukotrienes C4 and D4 produce contraction of the mesangial cells and possibly also the renal arterioles [156]. A-II and ADH, by interacting with ATI and V1 receptors, respectively, in vascular smooth muscle and mesangial cells, stimulate phospholipase A_2, which releases arachidonic acid from membrane phospholipids and enhances the renal synthesis of PGI_2 and PGE_2. Noradrenaline and efferent renal nerve activity also stimulate the renal synthesis of PGs, an effect that

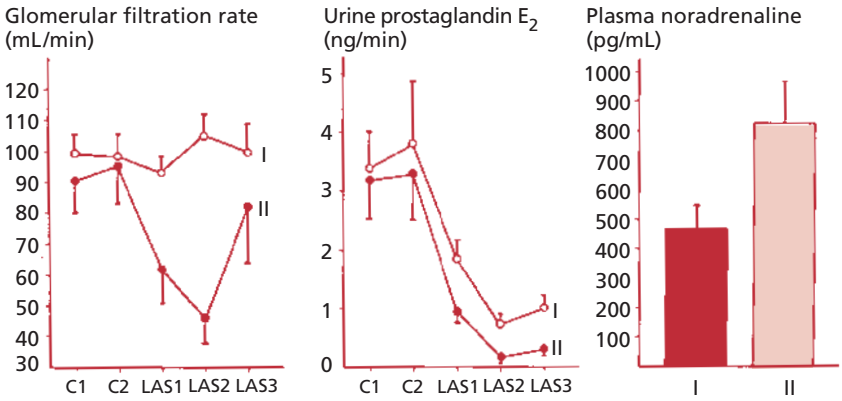

Fig. 10 Glomerular filtration rate and urinary excretion of prostaglandin E_2 (mean ± SEM) before and after the intravenous injection of 450 mg of lysine acetylsalicylate in 19 patients with cirrhosis and ascites. Patients were divided into two groups according to whether they developed renal insufficiency (II; 11 patients) or not (I; 8 patients) after the administration of the drug. C1 and C2 represent two 30-min periods before the administration of lysine acetylsalicylate. LAS1, LAS2 and LAS3 represent three 30-min periods after the administration of lysine acetylsalicylate. Values of plasma noradrenaline correspond to those of samples obtained before lysine acetylsalicylate injection. (Reproduced with permission from ref. 135.)

is mediated by α-receptors. PGE_2 and PGI_2 antagonize the renal vasoconstrictor effect of these endogenous vasoactive compounds. Finally, cyclo-oxygenase inhibition by NSAIDs potentiates the renal vasoconstrictor effect of A-II, noradrenaline, ADH and renal nerve stimulation, and impairs renal blood flow and GFR in circumstances of low effective blood volume, in which there is activation of the renin–angiotensin–aldosterone system, sympathetic nervous system and ADH. In these conditions, the renal production of PGs is increased, probably as a homeostatic response to antagonize the renal vascular effects of these systems. Renal PGE_2 and PGI_2 therefore regulate renal haemodynamics by modulating the renal vascular effects of endogenous vasoconstrictors.

PGE_2 also modulates the renal tubular action of ADH [156]. ADH stimulates the production of PGE_2 by cortical and medullary collecting duct epithelial cells. This effect appears to be secondary to the interaction of ADH with V1 receptors present in these cells. On the other hand, PGE_2 inhibits the hydro-osmotic effect of ADH. Finally, inhibition of PGs with NSAIDs enhances the tubular effect of ADH. A negative feedback therefore exists, in which ADH itself stimulates the synthesis of its antagonist PGE_2 in the collecting duct epithelial cells.

The following points support the suggestion that PGs play an important role in the homeostasis of renal blood flow and GFR in cirrhotic patients with ascites:

1 The urinary excretion of PGE_2 and 6-keto-$PGF_{1\alpha}$ (a stable metabolite of PGI_2), which is thought to estimate the renal production of PGE_2 and PGI_2, respectively, is increased in non-azotaemic cirrhotics with ascites, whereas it is reduced in patients with hepatorenal syndrome [134,135,157,158].

2 Non-azotaemic cirrhotics with ascites also show high urinary excretion of thromboxane B_2 (a stable metabolite of thromboxane A_2) and $PGF_{2\alpha}$ [157,158], which suggests that the stimulus promoting synthesis of PGs in these patients acts at the initial step of the arachidonic acid cascade, thus increasing the synthesis of all prostaglandins.

3 The administration of NSAIDs induces a profound decrease in renal blood flow and GFR in non-azotaemic cirrhotics with increased activity of the renin–angiotensin–aldosterone system and sympathetic nervous system and marked sodium retention. In contrast, PG inhibition with these drugs in patients with ascites and normal plasma renin activity and plasma noradrenaline is not associated with significant changes in renal perfusion and GFR (Fig. 10) [15,159,160]. These findings are the most persuasive arguments indicating that renal PGs are important factors in the maintenance of renal blood flow and GFR in non-azotaemic cirrhotics with ascites, and that an equilibrium between the degree of activity of endogenous vasoconstrictors and the renal synthesis of vasodilator PGs is of crucial importance in the homeostasis of renal haemodynamics in these patients.

4 In patients with compensated cirrhosis, the urinary excretion of PGs is similar to that in normal subjects [135,158,161]. On the other hand, there have been several studies showing that renal perfusion and GFR are normal in these patients and that PG inhibition with NSAIDs is not associated with significant changes in renal function [135,159,162]. These studies therefore indicate that PGs are not involved in the regulation of renal perfusion during the initial phases of cirrhosis, prior to the appearance of ascites. This feature is not surprising as it is well known that PGs are important in the maintenance of renal perfusion only in conditions of activated endogenous renal vasoconstrictors.

The increased renal production of PGE_2 in non-azotaemic cirrhotics with ascites, by antagonizing the hydro-osmotic effect of ADH, also contributes to the maintenance of free-water excretion in these patients. Most cirrhotic patients with ascites can dilute the urine after a water load despite inadequate suppression of ADH, indicating a relative resistance to the tubular effect of this hormone [147]. This renal resistance to ADH is related to increased renal production of PGE_2, as PG inhibition in these patients is associated with marked impairment in free-water excretion, occurring in the absence of changes in plasma ADH and independent of changes in renal blood flow and GFR [147].

Studies in experimental animals with cirrhosis and ascites and a recent investigation in patients with cirrhosis, ascites and

increased activity of the renin–angiotensin system show that COX-2 inhibitors do not impair renal function in decompensated cirrhosis [163]. The PG synthetic pathway participating in the maintenance of renal function in decompensated cirrhosis is, therefore, that related to COX-1.

Circulatory dysfunction in cirrhosis: role in the pathogenesis of renal function abnormalities in cirrhosis

Splanchnic arterial vasodilation: the peripheral arterial vasodilation hypothesis of renal dysfunction in cirrhosis

Renal dysfunction in patients with cirrhosis occurs in the setting of a circulatory dysfunction characterized by a marked arterial vasodilation [104,164] (Fig. 11). There is evidence that the site of this arterial vasodilation is the splanchnic circulation as there is vasoconstriction in all the other major vascular territories such as the kidneys, muscle and skin and brain [142,165,166]. In contrast, in the splanchnic circulation, there is vasodilation, which increases the inflow of blood into the portal venous system [167].

The mechanism of the decreased splanchnic arterial vascular resistance associated with portal hypertension in cirrhosis is not completely understood. For many years, arterial vasodilation in cirrhosis has been attributed to increased circulating plasma levels of vasodilators such as glucagon, prostaglandins, adrenomedullin and natriuretic peptide. However, because the site of arterial vasodilation is the splanchnic circulation, a local mechanism (increased release of a vasodilator substance within the splanchnic area) is a more likely hypothesis. Results of subsequent studies suggesting that nitric oxide, a vasodilator substance that acts in a paracrine manner, is important in the pathogenesis of splanchnic arterial vasodilation in cirrhosis is consistent with this hypothesis. Increased activity of nitric oxide synthase in the splanchnic circulation has been reported in experimental cirrhosis [168–170]. On the other hand, inhibition of nitric oxide normalizes circulatory function in experimental cirrhosis [170]. Two hypotheses have been raised to explain the mechanism of the increased production of nitric oxide in the splanchnic circulation. The first is that it is secondary to bacterial translocation from the intestinal lumen to the interstitial intestinal space. Endotoxin and the increased cytokine production would stimulate the activity of nitric oxide synthase in the endothelial and vascular smooth muscle cells [169,171]. The second hypothesis considers that there is a stimulation of the non-adrenergic, non-cholinergic nervous system secondary to portal hypertension [169,172]. This is a sensitive system that, when activated, releases numerous vasodilatory neurotransmitters, including nitric oxide, calcitonin gene-related peptide, substance P and vasoactive intestinal peptide [173,174]. Non-adrenergic, non-cholinergic terminals are abundant not only in the gastrointestinal smooth muscle but also in the vascular smooth muscle cells. It may be possible that portal hypertension induces changes in the intestinal wall (increase in interstitial pressure and interstitial oedema) that stimulate this system and cause splanchnic arterial vasodilation and an inhibitory effect on the gastrointestinal smooth muscle cells. In fact, the gastrointestinal transit time is greatly prolonged in patients with cirrhosis [175].

At the initial stages of cirrhosis, the circulatory dysfunction induced by the splanchnic arterial vasodilation is compensated by the development of a hyperdynamic circulation. Plasma volume, cardiac output and heart rate increase and the circulatory

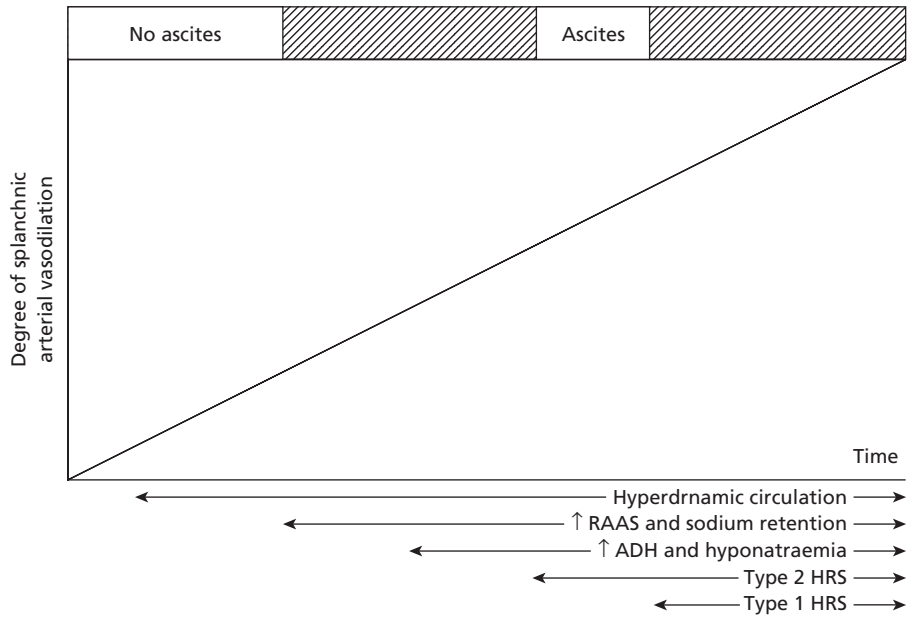

Fig. 11 Time course of the circulatory, neurohormonal and renal function abnormalities in cirrhosis. ADH, antidiuretic hormone; HRS, hepatorenal syndrome; RAAS, renin–angiotensin–aldosterone system.

transit time decreases. The incidence of arterial hypertension in cirrhotic patients with portal hypertension is very low because of this circulatory abnormality. With the progression of the liver disease and the accentuation of portal hypertension and splanchnic arterial vasodilation, patients develop sodium retention and ascites. In the initial phases of ascites, the renin–angiotensin and the sympathetic nervous systems are not stimulated, and the mechanism of sodium retention in this period is unknown. Later during the course of the disease, the renin–angiotensin–aldosterone system and the sympathetic nervous system become progressively activated in parallel with a more intense reduction in urinary sodium excretion. Patients with ascites and normal plasma renin activity and aldosterone concentration, in general, have urinary sodium excretion over 10 mEq/day, and they easily respond to low diuretic dosage. In contrast, most patients with high renin and aldosterone show a urinary sodium excretion lower than 5 mEq/day (in many cases almost zero) and need high diuretic dosage to achieve a natriuretic response. Hypersecretion of antidiuretic hormone occurs at later stages of the disease. This explains why hyponatraemia is a late event in decompensated cirrhosis. This is probably related to the fact that antidiuretic hormone is less sensitive than the sympathetic nervous system and the renin–angiotensin system to changes in the effective circulating blood volume. Hepatorenal syndrome (HRS) develops in the very late stages of the disease, always in the setting of a significant arterial hypotension and an intense activation of the renin–angiotensin and sympathetic nervous systems and antidiuretic hormone.

These different phases of circulatory and renal dysfunction in cirrhosis correlate closely with the progression of portal hypertension and splanchnic arterial vasodilation. In patients with cirrhosis, there is a strong direct relationship between the degree of portal hypertension, plasma levels of renin, aldosterone and norepinephrine and the intensity of sodium retention. Arterial pressure is lower in patients with cirrhosis and ascites than in those with compensated cirrhosis. Finally, among patients with ascites, those with HRS present the lowest arterial pressure and the highest plasma levels of renin, norepinephrine and antidiuretic hormone.

Renal and other extrasplanchnic regional circulations in cirrhosis

Traditional studies with para-aminohippurate clearance and recent investigations with the echo Doppler technique have shown increased intrarenal vascular resistance in patients with cirrhosis and ascites prior to the development of HRS. HRS is therefore the extreme expression of an impairment in renal circulatory function starting at earlier stages. Renal plasma flow, intrarenal vascular resistance and GFR in cirrhosis with ascites correlate closely with the degree of stimulation of the renin–angiotensin system and the sympathetic nervous system [135]. Patients with normal or moderately increased plasma levels of renin and norepinephrine usually show normal renal perfusion and GFR, whereas these substances are markedly increased in patients with HRS. These data have led to the contention that HRS in cirrhosis is caused by renal vasoconstriction related to the activation of these systems [176]. However, this hypothesis is too simple and, at present, there is evidence that intrarenal mechanisms may also participate in the regulation of renal perfusion.

The kidneys synthesize vasodilator substances. As discussed previously, renal PGE_2 and prostacyclin antagonize the vasoconstrictor effect of angiotensin II and norepinephrine and, by this mechanism, play an essential role in the maintenance of renal perfusion and GFR in decompensated cirrhosis. A syndrome similar to HRS can be produced in patients with non-azotaemic cirrhosis and ascites by the administration of NSAIDs, which inhibit prostaglandin synthesis [135,159]. Investigations in experimental animals with cirrhosis and ascites have shown that the renal production of nitric oxide also participates in the maintenance of renal perfusion [177]. Finally, the administration of antagonists of the vascular receptors of natriuretic peptides in animals with cirrhosis and ascites induces an impairment in renal function that mimics HRS [178]. Therefore, intrarenal and circulating vasodilatory substances contribute to the maintenance of renal perfusion in cirrhosis with ascites. HRS would develop when the renal production of these substances is insufficient to antagonize the renal effects of the endogenous vasoconstrictor systems. This can occur when there is a stimulation of the vasoconstrictor systems, a reduction in the synthesis of vasodilators or both.

The kidney produces vasoconstrictor substances, such as angiotensin-II, endothelin and adenosine. The production of these substances is stimulated in conditions of renal hypoperfusion. Therefore, these substances could also participate in the pathogenesis of HRS. If fact, it has been proposed that, when severe renal hypoperfusion develops in cirrhosis with ascites, there could be a reduction in the intrarenal synthesis of vasodilators and a stimulation of the renal synthesis of vasoconstrictors secondary to renal ischaemia, thus creating vicious circles that lead to a rapidly progressive impairment in renal perfusion and GFR (type 1 HRS).

Doppler studies of the brachial and femoral arteries, which supply blood mainly to skin and muscles, and of the middle cerebral artery, which supplies approximately 75% of the blood in the cerebral hemispheres, in patients with cirrhosis and ascites have also shown the presence of vasoconstriction in these vascular territories [165]. This vasoconstriction is correlated with the renal blood flow (Fig. 12). Because cutaneous, muscular and cerebral vascular resistance in patients with cirrhosis and ascites parallels renal vascular resistance and correlates closely with the degree of activity of the renin–angiotensin and sympathetic nervous systems, it is clear that changes in these regional circulations in decompensated cirrhosis represent a homeostatic response to maintain the arterial pressure.

Finally, the circulatory dysfunction induced by the splanchnic arterial vasodilation could contribute to the increased resistance

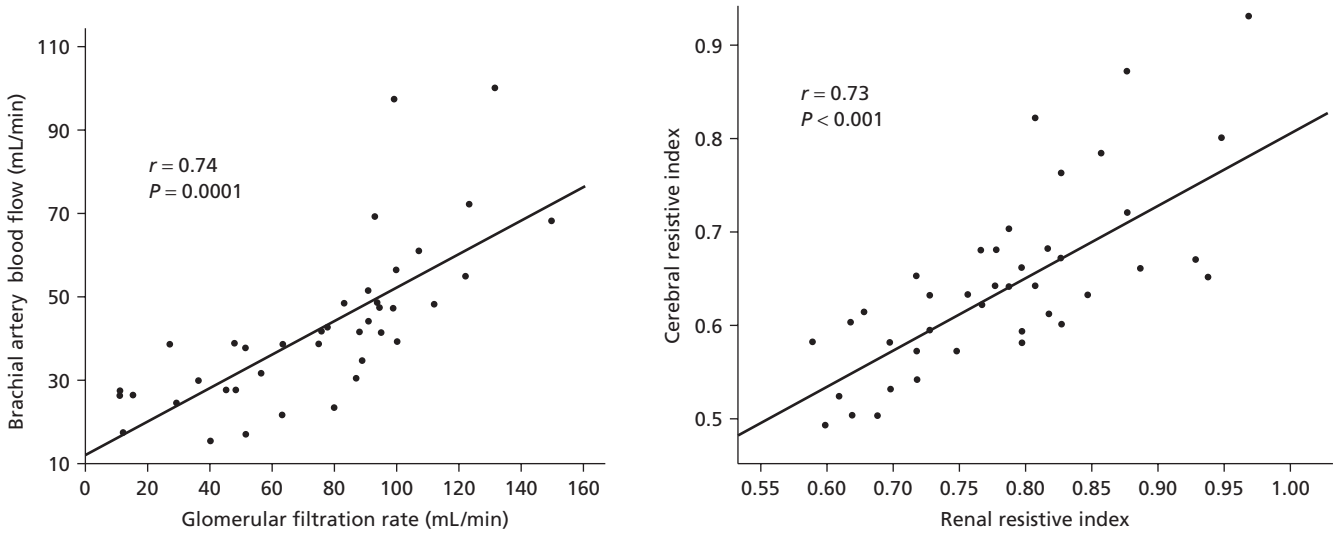

Fig. 12 Left graph: relationship between brachial artery blood flow and glomerular filtration rate. Right graph: relationship between renal resistive index and the resistive index in the middle cerebral artery in cirrhotic patients (reproduced with permission from refs 140 and 166).

to the portal venous flow and to portal hypertension. It is well known that, although the distortion of the liver vascular architecture caused by fibrosis and nodule formation is the most important mechanism in the increased intrahepatic vascular resistance in cirrhosis, there is a functional component of portal hypertension due to an increase in the intrahepatic vascular tone. The contractile intrahepatic vascular elements include the vascular smooth muscle cells from the small hepatic and portal venules and the hepatic stellate cells that surround the sinusoids. In cirrhosis, these stellate cells undergo a phenotypical transformation acquiring receptors for numerous endogenous vasoactive substances, including angiotensin II, norepinephrine, antidiuretic hormone and endothelin, and contractile properties. Therefore, the circulatory dysfunction in cirrhosis and the secondary activation of these endogenous vasoactive substances may result in an increase in the intrahepatic resistance to the portal venous flow and portal pressure. Three types of evidence support this contention. First, portal pressure in cirrhosis correlates closely with the plasma levels of renin and norepinephrine. Second, angiotensin-II blockage is associated with a decrease in portal pressure in the absence of changes in hepatic blood flow, indicating a decrease in intrahepatic vascular resistance. Finally, circulatory dysfunction associated with spontaneous bacterial peritonitis (SBP)-related type 1 HRS induces an acute and marked increase in portal pressure and a reduction in hepatic blood flow [176,179].

Splanchnic arterial vasodilation persists in decompensated cirrhosis despite the marked stimulation of the renin–angiotensin and sympathetic nervous systems and the non-osmotic hypersecretion of antidiuretic hormone. This phenomenon is related to a marked resistance of the splanchnic arterioles to the vasoconstrictor effect of angiotensin II, noradrenaline and vasopressin. Data on experimental cirrhosis suggest that the resistance is caused by increased local synthesis of nitric oxide, because inhibition of nitric oxide synthase normalizes the response of the splanchnic circulation to these vasoconstrictors. Therefore, splanchnic arterial vasodilation in cirrhosis progresses with the increase in portal hypertension, increases the activity of the endogenous vasoconstrictor systems and leads to vasoconstriction in the extrasplanchnic vascular territories. Because the splanchnic circulation in cirrhosis has little capacity to participate in the homeostasis of arterial pressure due to the lack of response vasoconstrictors, muscular and cutaneous blood flow is very low under resting conditions, and the cerebral circulation is regulated by a very effective mechanism, the maintenance of circulatory function in cirrhosis relies mainly on the renal circulation. This explains why cirrhotic patients with ascites are very prone to the development of renal impairment and HRS in conditions associated with an impairment in circulatory function, such as bacterial infections, paracentesis, haemorrhage and diuretic treatment.

Cardiac dysfunction in cirrhosis: a second important mechanism of circulatory and renal dysfunction and ascites

Research on circulatory function in cirrhosis has been focused for many years on the peripheral arterial circulation. However, recent studies suggest that, in cirrhosis, there is also a cardiac dysfunction that could be of major importance in the deterioration of circulatory and renal function and in the pathogenesis of ascites and HRS [176,179]. As indicated previously, arterial vasodilation in the splanchnic circulation increases during the course of the disease, leading to homeostatic activation of the

Table 1 Chronological changes in vasoactive systems and cardiovascular function from non-azotaemic cirrhosis with ascites (NA) to type 2 HRS.

	NA-1	NA-2	Type 2 HRS
Mean arterial pressure (mmHg)*	88 ± 9	86 ± 10	79 ± 7
Plasma renin activity (ng/mL/h)*	3 ± 2	7.5 ± 3.7	11.9 ± 4.8
Norepinephrine (pg/mL/h)*	221 ± 256	412 ± 155	628 ± 320
Systemic vascular resistance (dyn/s/cm^{-5})	962 ± 256	1058 ± 265	1014 ± 276
Cardiac output (L/min)*	7.2 ± 1.8	6.2 ± 1.4	5.8 ± 1.2
Heart rate (b.p.m.)	87 ± 15	84 ± 12	80 ± 14

NA-1: Baseline measurement in non-azotaemic cirrhotic patients who did not develop hepatorenal syndrome in the follow-up.
NA-2: Baseline measurement in non-azotaemic cirrhotic patients who developed type 2 hepatorenal syndrome in the follow-up.
*$P < 0.01$.

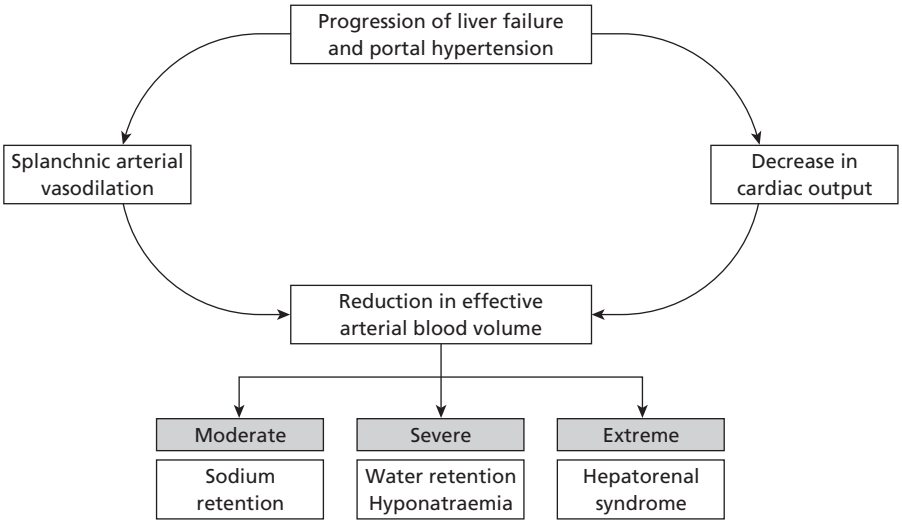

Fig. 13 Liver failure and portal hypertension.

renin–angiotensin and sympathetic nervous systems to maintain arterial pressure. This progressive decrease in cardiac afterload should be followed by an increase in cardiac output and heart rate. However, this is not the case (Table 1). Heart rate in patients with non-azotaemic cirrhosis, ascites and normal or slightly increased activity of the renin–angiotensin and sympathetic nervous systems is similar to that in non-azotaemic patients with increased activity of these systems or with HRS, indicating a severe impairment in cardiac chronotropic function. On the other hand, the cardiac output, although higher than normal in most cases, decreases progressively during the course of the disease. The mechanisms of circulatory dysfunction in cirrhosis may, therefore, be more complex than that proposed by the peripheral arterial vasodilation hypothesis (Fig. 13). In patients with compensated cirrhosis, the splanchnic arterial vasodilation would be compensated by an appropriated cardiac response, with increased heart rate, left ventricular systolic ejection fraction and cardiac output. However, with the progression of liver failure and portal hypertension, this compensatory mechanisms fails. The increased arterial vasodilation is not followed by an increase in heart rate. On the other hand, the cardiac output decreases rather than increases. Arterial pressure homeostasis is, therefore, solely dependent on the stimulation of the endogenous vasoconstrictor systems (renin–angiotensin system, sympathetic nervous system and antidiuretic hormone), which has deleterious effects on renal perfusion and on the perfusion of other organs and produces sodium retention and ascites formation.

Cardiac chronotropic dysfunction in cirrhosis is probably related to a downregulation of β-adrenergic receptors owing to the overactivity of the sympathetic nervous system. The decrease in cardiac output is probably related to a reduction in cardiac preload [176]. There is a cirrhotic cardiomyopathy characterized by an impaired left ventricular diastolic function and cardiac hypertrophy [180]. However, it is unlikely that it plays a significant role in the decrease in cardiac function because,

in decompensated cirrhosis, cardiac output increases following manoeuvres that expand the central blood volume (head-out water immersion, plasma volume expansion, therapeutic paracentesis and insertion of a peritoneovenous or a transjugular intrahepatic portocaval shunt), indicating a preserved cardiac reserve. Cardiac dysfunction in cirrhosis, therefore, appears to be a functional disorder unrelated to the structural changes in the heart.

Pathogenesis of ascites

The forward theory

The traditional concept of ascites formation in cirrhosis considers hepatic oedema to be a direct consequence of the 'backward' increase in hydrostatic pressure in the hepatic sinusoids and splanchnic capillaries due to the sinusoidal portal hypertension [92,93,181]. This feature, together with the hypoalbuminaemia, would alter the Starling equilibrium within the hepatic and splanchnic microcirculation, leading to the accumulation of fluid in the interstitial space of these vascular territories. Leakage of fluid from the interstitial space to the peritoneal cavity would occur when the formation of interstitial oedema overcomes the capacity of the abdominal lymphatic system to return the hepatic and splanchnic lymph to the systemic circulation. Renal dysfunction in cirrhosis would be a consequence of a reduction in the circulating blood volume secondary to the formation of ascites. The fact that the blood volume is constantly increased in patients with cirrhosis would not invalidate this hypothesis, as the effective blood volume would be reduced as a result of an enlargement of the intravascular venous compartment promoted by the increased portal pressure. During the last decade, data have been presented indicating that ascites formation in cirrhosis could be better explained on a 'forward' basis, as follows:

1 As indicated above, splanchnic arteriolar vasodilation is a constant finding in cirrhosis with ascites and portal hypertension. It is the primary event in the hyperdynamic circulation (hypervolaemia, high cardiac output, low peripheral vascular resistance, arterial hypotension) that characterizes patients with compensated and decompensated cirrhosis prior to HRS. Arteriolar vasodilation is also the primary event in the stimulation of the renin–aldosterone and sympathetic nervous systems and ADH, and renal dysfunction (sodium and water retention and HRS) in patients with ascites [182].

2 Investigations on portal vein-ligated rats have demonstrated that the increased hydrostatic pressure in the splanchnic microcirculation in chronic portal hypertension is predominantly due to the increased inflow of blood to this vascular territory, secondary to the splanchnic arteriolar vasodilation [97,183,184]. This increased inflow of blood into the splanchnic microcirculation increases not only the capillary hydrostatic pressure but also the filtration coefficient, leading to a marked increase in intestinal lymph flow [97]. Splanchnic arteriolar vasodilation is therefore the predominant mechanism of increased lymph formation during chronic portal hypertension.

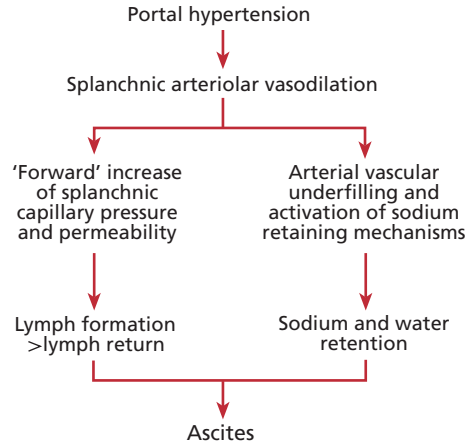

Fig. 14 The forward theory of ascites formation.

3 Portal hypertension is higher in cirrhosis than in prehepatic portal hypertension. In experimental animals with chronic ligation of the portal vein, portal pressure averages 15 mmHg, whereas it approaches 25–30 mmHg in experimental cirrhosis [97]. Among cirrhotic patients, the degree of portal hypertension is also higher in those with rather than without ascites [104]. Splanchnic arteriolar vasodilation is also higher in patients with decompensated than compensated cirrhosis, as they have a similar decrease in peripheral vascular resistance in the setting of marked overactivity of endogenous vasoconstrictor systems [104].

These data suggest that the pathogenesis of ascites could be satisfactorily explained on the basis of the changes in the arterial circulation induced by portal hypertension (Fig. 14) [185]. The hypothesis (forward theory of ascites formation) considers that the accumulation of fluid within the abdomen is a consequence of the splanchnic arteriolar vasodilation, which would simultaneously produce arteriolar vascular underfilling and a 'forward' increase in the splanchnic capillary pressure and filtration coefficient. In patients with compensated cirrhosis or with prehepatic portal hypertension, the degree of portal hypertension and of splanchnic arteriolar vasodilation is moderate. Their arterial vascular underfilling can be compensated for by transient and undetectable episodes of sodium and water retention that increase the plasma volume and cardiac index and refill the dilated arterial vascular bed [182]. The lymphatic system is able to return the moderate increase in lymph produced to the systemic circulation, thus preventing leakage of fluid into the abdominal cavity. As cirrhosis progresses, however, portal hypertension and the secondary fall in splanchnic vascular resistance are more intense and, on the other hand, the heart is unable to maintain an appropriate hyperdynamic circulation to compensate for the progression in the splanchnic hyperaemia. The maintenance of arterial pressure then requires persistent

activation of the renin–aldosterone system, the sympathetic nervous system and ADH, which produces continuous water and sodium retention. The retained fluid is, however, ineffective in refilling the dilated arterial vascular bed because it escapes from the intravascular compartment, due to an imbalance between the excessive lymph production and the ability of the lymphatic system to return it to the systemic circulation. The final consequence of both disorders is continuous leakage of fluid into the abdominal cavity and the formation of ascites.

Reabsorption of ascites

Although the above discussion has exclusively emphasized factors involved in the formation of ascites, the amount of ascites present at any given time reflects the balance between the rates of formation and reabsorption. Information on reabsorption is limited. It appears that the lymphatics on the undersurface of the diaphragm are especially important in removing ascitic fluid from the peritoneal cavity. Electron microscopic studies of the diaphragmatic peritoneum have demonstrated an anatomical arrangement that facilitates absorption from the peritoneal cavity. The peritoneal surface of the diaphragm is covered by a single layer of two different populations of mesothelial cells (cuboidal and extremely flattened) [186,187]. These cells rest on a connective tissue matrix within which lies a rich plexus of terminal lymphatic vessels (lymphatic lacunae). Cuboidal mesothelial cells are usually over the lymphatic lacunae, and the submesothelial connective tissue between them is scant or even absent. The remaining areas of the diaphragm, which lack submesothelial lymphatic lacunae, are mainly covered by flattened cells. Areas with cuboidal and flattened cells differ markedly in the structure of their intercellular (lateral) surfaces. Flattened cells form a layer with no discontinuity between adjacent cells. In contrast, numerous gaps are present between the cuboidal mesothelial cells, large enough to allow the passage of particles of Indian ink, colloidal carbon and of erythrocytes. Basically, two types of structurally different intercellular gaps may be found between the cuboidal cells. One type, which is formed by interlacing filamentous processes from adjacent mesothelial cells, represents a 'true intercellular gap' and overlies a thin layer of connective tissue. The other type, which represents a 'stoma', consists of a circular pore formed among several mesothelial cells whose cell membranes form adhesions with the underlying lymphatic endothelium. This results in a well-defined channel leading directly from the peritoneal cavity to the lumen of the lymphatic lacunae. The submesothelial plexus of lymphatic vessels intercommunicates at regular intervals by way of transverse anastomoses that drain into a deeper plexus of valved collecting vessels, which penetrate connective tissue septa of the muscular fibres of the diaphragm. Drainage from the deeper lymphatics of the diaphragm is mainly via parasternal trunks on the ventral thoracic wall, right lymphatic duct and right subclavian or internal jugular veins [188]. The lymphatic drainage of the diaphragm is therefore independent of the thoracic duct. The periodic respiratory movements of the diaphragm may be important in the passage of ascites into the lymphatic system and general circulation [188]. During inspiration, intercellular gaps and stomata close, intraperitoneal pressure is increased, and the lacunae are emptied through the combined effects of local compression and increased intra-abdominal and reduced intrathoracic pressures. During expiration, the gaps and stomata are opened, and free communication is re-established. The importance of diaphragmatic lymphatics in the reabsorption of intraperitoneal fluid has been demonstrated in animal studies showing that particles and cells of various sizes are rapidly removed from the peritoneal cavity by the lymphatics of the diaphragm; the obliteration of these diaphragmatic lymphatics by abrasion significantly delays the absorption of serum from the peritoneal cavity and increases the propensity of portal hypertension to produce ascites [186].

Reabsorption of ascites from the peritoneal cavity into the general circulation is a rate-limited phenomenon. The average fractional reabsorption rate of radiolabelled albumin from the peritoneal cavity into the general circulation in cirrhotics with ascites has been estimated as 1.27% of the intraperitoneal protein mass per hour, corresponding to a rate of ascitic fluid reabsorption of 1.4 L/24 h [16]. The rate of reabsorption of ascitic fluid, as estimated by the transport of radiolabelled proteins from the abdominal cavity into the circulating plasma, varies markedly from patient to patient [16,189]. Henriksen *et al.* [16] reported a range of reabsorption rates of 0.57–4.42 L/24 h in six cirrhotics with a mean ascitic fluid volume of 6.2 L. The values obtained by Buhac *et al.* [189] in 12 patients with an average volume of ascitic fluid of 9.95 L ranged from 1.0 to 5.3 L/24 h (mean 2.25 L/24 h). The time of appearance of radioactivity in plasma after the injection of radiolabelled albumin into the ascitic fluid in these patients was, on average, 0.5 h (range 0.1–1.2 h). This time lag between the intraperitoneal injection of tracer and the appearance of tracer in plasma suggests that the transport of ascitic fluid into the general circulation is slow and through tubes (lymphatic vessels) and not a transperitoneal absorption [16]. There are very few data on the factors influencing the reabsorption rate of ascitic fluid. Animal studies have demonstrated a positive relation between intra-abdominal pressure and reabsorption of intraperitoneal fluid. However, this relation was not observed in cirrhotic patients, in whom a decrease in intra-abdominal pressure did not lead to significant changes in the reabsorption of ascitic fluid from the peritoneal cavity [189]. The low rates of ascites formation and reabsorption of ascitic fluid in cirrhotics with ascites should not be taken as an indication that, in these patients, the intraperitoneal cavity is a segregated compartment isolated from the rest of the body. In fact, the transperitoneal exchange of water and water-soluble substances (for example antibiotics not bound to proteins) by diffusion is very rapid in cirrhotics with ascites. It has been demonstrated that the water content of ascitic fluid enters and leaves the peritoneal cavity very rapidly, approximating 40–80%/h.

Prognosis of patients with cirrhosis and ascites

The appearance of ascites in patients with cirrhosis carries a poor prognosis. The probability of survival 1 and 5 years after the first episode of ascites has been estimated as 50% and 20% respectively [190]. Among cirrhotics with ascites, those with hepatorenal syndrome have the shortest survival. They usually die within weeks or months after the onset of renal failure, independent of the degree of hepatic insufficiency [120]. Studies in non-azotaemic cirrhotics with ascites have shown that sodium excretion and plasma renin activity have prognostic significance [191]. Non-azotaemic cirrhotics with elevated plasma renin activity or with marked sodium retention (urinary sodium excretion lower than 10 mEq/day) have a significantly lower survival than those with normal plasma renin concentrations or relatively high urinary sodium excretion. Two investigations have evaluated the prognostic value in cirrhotics with ascites of numerous variables based on history, physical examination, hepatic biochemical tests (including galactose elimination capacity), renal function tests, systemic and splanchnic haemodynamics and endogenous vasoactive systems. Among 38 variables considered in the series by Llach *et al.* [121], composed of 139 patients in hospital for the treatment of an episode of ascites, only seven had independent prognostic value, including mean arterial pressure, plasma noradrenaline, glomerular filtration rate, urinary sodium excretion, nutritional status, hepatomegaly and serum albumin (Fig. 15). In the multivariate analysis by Tage-Jensen *et al.* [192] in 81 alcoholic cirrhotics with and without ascites, among the 25 variables considered, only the presence of ascites, the plasma noradrenaline concentration, portal pressure and serum bilirubin were independent predictors of survival. Thus, both studies indicate that measures estimating systemic and portal haemodynamics and renal function are better predictors of survival than those used to estimate hepatic function in patients with cirrhosis and ascites. Other variables with prognostic significance in cirrhotic patients with ascites include the Child–Pugh score, the ascitic protein concentration, a history of spontaneous bacterial peritonitis, the presence of dilutional hyponatraemia and the resistance of the ascites to diuretic therapy [118,193–198].

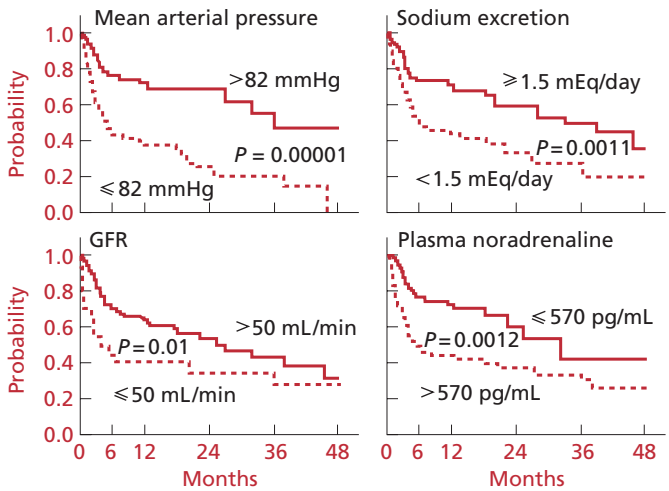

Fig. 15 Probability of survival in 136 cirrhotic patients with ascites classified according to mean arterial pressure, plasma noradrenaline concentration, urinary sodium excretion and glomerular filtration rate (GFR) (reproduced with permission from ref. 121).

Treatments for ascites

Bedrest and low-sodium diet

The assumption of an upright posture by patients with cirrhosis and ascites is associated with a striking activation of the renin–angiotensin–aldosterone and sympathetic nervous systems, a reduction in GFR and sodium excretion and a decreased response to loop diuretics. These effects are even more striking when upright posture is associated with moderate physical exercise [126,199]. Therefore, from a theoretical point of view, bedrest could be useful for the treatment of ascites in cirrhosis, particularly in patients who respond poorly to diuretics.

The aim of the medical treatment of ascites is to mobilize the intra-abdominal fluid by creating a net negative balance of sodium. In approximately 10–20% of cirrhotics with ascites, those who spontaneously excrete relatively high amounts of sodium in the urine, this can be obtained simply by reducing the sodium content in the diet to 60–90 mEq/day [106,200,201]. A more intense dietary sodium restriction is not practical, as it is difficult to accomplish and may worsen the anorexia and malnutrition commonly present in these patients. In the remaining cases with marked sodium retention, a negative sodium balance cannot be obtained without the aid of diuretics to increase urinary sodium excretion over intake. However, even in these patients, dietary sodium restriction is very important as it reduces the diuretic requirements. In cirrhotics responding poorly to diuretic treatment, a negative sodium balance cannot be obtained unless sodium intake is limited. A frequent cause of diuretic-resistant ascites is inadequate sodium restriction. This 'apparently intractable' ascites should be suspected in any patient whose ascites does not decrease despite a good natriuretic response to diuretics. In this respect, it is important to note that many drugs, particularly antibiotics, may contain relatively high amounts of sodium. Once ascites has disappeared, many cirrhotics continue to require a strict sodium diet and diuretics to avoid its reaccumulation. Other cases can, however, be maintained without ascites by moderate sodium restriction and low doses of diuretics. Finally, some patients may even recover their ability to excrete sodium normally and may be free of ascites despite normal sodium intake and no diuretics. Therefore, the long-term management of cirrhotics with ascites varies markedly from patient to patient, and every effort should be made to adjust sodium intake and diuretic dosage to individual requirements during the course of the disease.

Diuretics

Loop diuretics, in particular furosemide, and distal diuretics, especially spironolactone, are the drugs most commonly used in the treatment of ascites in cirrhosis. Loop diuretics inhibit chloride and sodium reabsorption in the ascending limb of the loop of Henle but have no effect on the distal nephron (distal and collecting tubules) [202,203]. They must reach the tubular lumen to be effective. Loop diuretics are all organic acids and are highly bound to plasma proteins. As a consequence, they can only reach the lumen by being actively secreted from the blood into the urine via the organic acid transport pathway of the straight segment of the proximal tubule. Once in the luminal compartment, furosemide is carried with the luminal fluid to the ascending limb of the loop of Henle, where it inhibits a specific cotransport system, the Na^+-$2Cl^-$-K^+ carrier, located in the luminal membrane of the ascending limb cells. It is therefore not surprising that the urinary concentration of furosemide correlates best with the response. Loop diuretics also increase the renal synthesis of prostaglandins, and anti-inflammatory drugs reduce their natriuretic effect. Renal prostaglandins therefore appear to be involved in the natriuretic response to loop diuretics.

Loop diuretics such as furosemide are the most powerful diuretics presently available. High dosage of furosemide can increase sodium excretion up to 30% of the filtered sodium in normal individuals. This high natriuretic potency can be attributed to two features. Firstly, between 20% and 50% of the filtered sodium is reabsorbed in the loop of Henle. Secondly, in the absence of hyperaldosteronism, the distal and collecting tubules, which are downstream from the loop of Henle, have a limited capacity for sodium reabsorption and are not capable of mitigating the diuresis induced by loop diuretics. Furosemide is rapidly absorbed from the gut. The onset of action is extremely rapid (within 30 min of oral administration), with peak effects occurring within 1–2 h; most of the natriuretic activity has finished in 3–4 h.

Spironolactone and other distal diuretics (triamterene, amiloride) have a much lower intrinsic natriuretic potency than loop diuretics. They are able to increase sodium excretion up to 2% of the filtered sodium in normal individuals [202,203]. Spironolactone undergoes extensive metabolism in man, leading to numerous biologically active compounds, including canrenone, 6-β-hydroxy-7-α-thiomethylspironolactone and 7-α-thiomethylspironolactone [204]. The antimineralocorticoid effect of spironolactone has traditionally been attributed to its major metabolite, canrenone. However, recent studies show that canrenone only accounts for 10–25% of the antimineralocorticoid activity. Other metabolites are therefore important in its diuretic effect. Spironolactone metabolites are tightly bound to plasma proteins, from which they are released slowly to the kidney and other target organs; the half-life of these metabolites in healthy individuals has been estimated to range between 10 and 35 h after single or multiple doses of spironolactone. This explains the 24- to 48-h delay between drug withdrawal and the end of the natriuretic effect. Spironolactone metabolism is impaired in cirrhosis, so that the terminal half-lives of spironolactone and its metabolites are increased when compared with values in normal individuals [205].

Spironolactone metabolites act by competitively inhibiting the tubular effect of aldosterone on the distal nephron. The activity of spironolactone and spironolactone metabolites does not depend on their filtration or tubular secretion but, rather, on their plasma concentrations because they act on the capillary side of the collecting tubular cells. They enter the basolateral membrane and interact with the mineralocorticoid cytosolic receptor. However, contrary to what occurs with aldosterone, the interaction of spironolactone with the receptor does not result in the exposure of the high-affinity DNA region. Therefore, spironolactone acts as a specific antagonist of aldosterone. This explains why spironolactone is effective in increasing sodium excretion in patients with primary or secondary hyperaldosteronism and in healthy people on a low-sodium diet; however, it has no effect on patients with adrenalectomy or healthy people on a high-sodium diet. The half-life of the aldosterone-induced proteins (sodium channels and Na^+-K^+ATPase molecules) is relatively prolonged, explaining the lag of 2 days between the beginning of spironolactone treatment and the onset of the natriuretic effect. The effective dosage of spironolactone depends on the plasma aldosterone concentration. Patients with moderately increased plasma aldosterone require low doses (100–150 mg/day), but as much as 500 mg/day may be required to antagonize the tubular effect of aldosterone in cases with marked hyperaldosteronism [128].

The administration of standard doses of loop diuretics to non-azotaemic cirrhotics with ascites gives rise to a good natriuretic response in only 50% of patients [128]. The mechanism of this poor diuretic effect is not well established. The bioavailability of furosemide is reportedly normal in cirrhotics with ascites, indicating that the renal resistance to the drug cannot be explained by impaired intestinal absorption [206]. On the other hand, although there is one study that shows impaired tubular secretion of furosemide in cirrhotics with ascites [207], others suggest that the pharmacokinetics and renal handling of furosemide in such patients are similar to those in healthy individuals [206–209]. Therefore, the most likely mechanism for diuretic resistance to furosemide in cirrhosis with ascites is pharmacodynamic in nature; that is, furosemide does not increase sodium excretion either because the delivery of fluid to the loop of Henle is reduced, owing to enhanced proximal sodium reabsorption [210], or because most sodium not reabsorbed in the loop of Henle by the action of furosemide is subsequently taken up in the convoluted distal and collecting tubules, owing to secondary hyperaldosteronism. The latter proposal is supported by several studies showing that non-azotaemic cirrhotics with ascites who have renal resistance to furosemide or other loop diuretics are those with higher plasma aldosterone concentrations [128,206].

Treatment of non-azotaemic cirrhotics with ascites with spironolactone is followed by a good natriuretic response in most patients. Therefore, contrary to what would be expected on the basis of their intrinsic natriuretic potencies, spironolactone is more effective than furosemide in non-azotaemic cirrhotics with ascites, which was also the conclusion in the only published, randomized study comparing furosemide with spironolactone in these patients [128]. The most rational treatment of cirrhotics with ascites is spironolactone alone or with furosemide. The simultaneous administration of furosemide and spironolactone increases the natriuretic effect of both drugs and reduces the incidence of the hypo- or hyperkalaemia frequently observed when these agents are given alone.

Two different approaches are commonly employed in the treatment of cirrhotic ascites with diuretics. The 'step care' medical treatment consists of progressive implementation of the therapeutic measures currently available [210,211]. Treatment is begun with a low-sodium diet; if there is no response, spironolactone is given at increasing dosage (starting with 100 mg/day) until a satisfactory diuresis is achieved. Where there is no response to the highest dosage of spironolactone (400 mg/day), furosemide is added, also at increasing dosage (40–160 mg/day). A more rapid therapeutic schedule, which may be particularly indicated in patients with tense ascites and avid sodium retention, is the 'combined treatment' [212]. It begins with the simultaneous administration of 40 mg/day furosemide and 100 mg/day spironolactone. If there is no response after 4–5 days, the dosage is increased stepwise up to 160 mg/day furosemide and 400 mg/day spironolactone. A recent randomized controlled trial has shown that the step care and the combined treatment approaches are similar regarding response rate, rapidity of ascites mobilization and incidence of complications [213]. There is general agreement that patients not responding to this programme should be considered to have diuretic-resistant ascites (see below). The best way to assess the effectiveness of diuretic therapy is by monitoring body weight. The goal of diuretic treatment should be to achieve a weight loss of 300–500 g/day. Once ascites has been mobilized, diuretic treatment should be adjusted to maintain the patient free of ascites. In most non-azotaemic cirrhotics, this can be achieved with low doses of spironolactone (100–200 mg/day). The most important predictor of diuretic response in cirrhotic patients with ascites is the degree of impairment of circulatory and renal function. Patients with a low glomerular filtration rate and/or high plasma concentrations of renin, aldosterone and noradrenaline require a high diuretic dosage or do not respond to medical treatment [128,210,211].

Complications of diuretic treatment in cirrhosis

The use of diuretics in cirrhotics with ascites may be associated with complications related to the effect of these drugs on the kidney and on extrarenal organs. Approximately 20% of these patients develop azotaemia due to depletion of intravascular volume [122]. This diuretic-induced renal failure is usually moderate and always reversible after diuretic withdrawal; it is the consequence of an imbalance between the intravascular fluid loss caused by the diuretics and the net passage of fluid (ascites reabsorption minus ascites formation) from the peritoneal cavity into the general circulation [214]. If diuretic therapy produces a loss of fluid above the net passage of ascitic fluid into the intravascular compartment, a contraction in circulating blood volume and a concomitant decrease in glomerular filtration rate will occur. Interstitial fluid accumulated as oedema is more easily reabsorbed than ascites. This explains why diuretic-induced renal failure occurs less frequently in patients with both ascites and oedema than in those with only ascites.

Hyponatraemia, occasionally severe, is another common complication of diuretic therapy in cirrhotics with ascites [215,216]. Although the pathogenesis of this abnormality is multifactorial, impairment of the renal ability to excrete free water induced by these drugs is probably the most important mechanism. Free-water formation in the kidney occurs in the ascending limb of the loop of Henle, where sodium chloride is reabsorbed without a concomitant reabsorption of water, leading to hypotonic urine. The second factor in water excretion is ADH, which regulates water reabsorption in the collecting tubules. Loop diuretics inhibit chloride and sodium reabsorption in the ascending limb of the loop of Henle. Moreover, the intravascular volume depletion produced by diuretic therapy increases fluid reabsorption in the proximal tubule, thus diminishing the delivery of sodium chloride to the loop of Henle. Both mechanisms impair the formation of free water in the diluting segment of the nephron. Finally, diuretic-induced hypovolaemia stimulates the release of ADH.

The distal nephron (distal and collecting tubules) plays a critical part in regulating acid balance. Sodium reabsorption in this segment generates a lumen-negative voltage that promotes passive potassium and H^+ excretion into the lumen. In cirrhotics with ascites, the inhibition of sodium reabsorption by spironolactone or other distally acting diuretics, such as triamterene or amiloride, may therefore produce metabolic acidosis. The administration of loop diuretics alone markedly increases potassium excretion and may produce serious hypokalaemia. This is not due to a specific direct effect on potassium transport but to increased potassium secretion by the distal nephron promoted by a high delivery of fluid to this segment. Spironolactone, triamterene and amiloride increase the serum potassium and may produce severe hyperkalaemia when used at high doses. This complication is particularly common in cirrhotics with hepatorenal syndrome. Spironolactone-induced hyperkalaemia is generally considered to be due to a reduction in urinary potassium excretion secondary to the inhibition of distal sodium reabsorption. However, studies on cirrhotics with ascites have shown that spironolactone produces a small but significant increase in potassium excretion [128]. An alternative mechanism may be a shift of potassium from the intracellular to extracellular space due to inhibition of the aldosterone effect on internal potassium balance or to metabolic acidosis.

The most important complication of diuretic therapy is hepatic encephalopathy, which has been estimated to occur in approximately 25% of cirrhotic patients admitted to hospital with tense ascites and treated with diuretics [215,216]. Diuretic-induced hepatic encephalopathy was traditionally considered to be secondary to hyperammonaemia because of increased renal ammonia production following diuretic-induced hypokalaemia and alkalosis. However, more recent studies show that some diuretics may also impair the urea cycle, leading to reduced hepatic transformation of ammonia to urea. Finally, other more recent studies suggest that, in cirrhotic patients with ascites, there is an increase in arteriolar vascular resistance in the cerebral circulation that may result in a reduction in cerebral blood flow. As cerebral arterial vascular resistance correlates closely with renal vascular resistance in these patients, the hypothetical mechanism of cerebral vasoconstriction in decompensated cirrhosis is arterial vascular underfilling. Because diuretic therapy may impair effective arterial blood volume, a further deterioration in cerebral blood flow could contribute to diuretic-induced hepatic encephalopathy.

Perhaps the most frequent side-effects of spironolactone in cirrhotics with ascites are those related to its antiandrogenic activity. Chronic spironolactone treatment is often associated with decreased libido, impotence and gynaecomastia in men, and menstrual irregularities in women. The origin of these abnormalities is probably related to alterations in sex steroid metabolism. At high dosage, spironolactone reduces testosterone biosynthesis and increases the peripheral conversion of testosterone to estradiol. In addition, *in vitro* experiments have shown that spironolactone inhibits the binding of testosterone to the cytosolic and nuclear receptors in the target organs.

Finally, cirrhotic patients treated with diuretics over a long period frequently complain of intense muscle cramps. They usually appear during the night, affect both the lower extremities and the hands and disappear rapidly either following assumption of the upright position or spontaneously. The mechanism of diuretic-induced muscle cramps is unknown. They are clearly related to the reduced effective arterial blood volume present in these patients as muscle cramps occur particularly in cases with low mean arterial pressure and high plasma renin activity, and their frequency can be drastically reduced if diuretic treatment is combined with plasma volume expansion with albumin [217]. The oral administration of quinine reduces the frequency of muscle cramps [218].

Refractory ascites

Although the term refractory ascites (or intractable ascites, resistant ascites or problematic ascites) was introduced in the 1950s to define ascites not responding to sodium restriction and diuretics, there has been major confusion concerning the use of this term during the last few decades. For this reason, the International Ascites Club recently organized a consensus conference to elaborate a new definition and the diagnostic criteria for refractory ascites in cirrhosis [123]. This conference extended the concepts proposed by a consensus conference held in Rome during the 13th International Congress of Gastroenterology in 1988.

According to this organization, 'refractory ascites' is that which cannot be mobilized or the early recurrence of which (i.e. after therapeutic paracentesis) cannot be satisfactorily prevented by medical therapy. Two different subtypes of refractory ascites can be identified: (i) 'diuretic-resistant ascites' is that which cannot be mobilized or the early recurrence of which cannot be prevented because of a lack of response to dietary sodium restriction and intensive diuretic treatment; (ii) 'diuretic-intractable ascites' is that which cannot be mobilized or the early recurrence of which cannot be prevented because of the development of diuretic-induced complications that preclude the use of an effective diuretic dosage.

The following criteria were considered to be important for the diagnosis of refractory ascites:

1 Ascites: the term ascites in these definitions refers to grade 2 or 3 clinically detectable ascites (grade 1, mild; grade 2, moderate; grade 3, massive or tense).

2 Mobilization of ascites: decrease of ascites to at least grade 1.

3 Treatment period to define refractory ascites: patients must have been on intensive diuretic treatment for at least 1 week.

4 Lack of response: mean loss of body weight of less than 200 g/day during the past 4 days on intensive diuretic therapy and urinary sodium excretion of less than 50 mEq/day.

5 Dietary sodium restriction: a 60- to 90-mEq sodium diet.

6 Intensive diuretic treatment: spironolactone, 400 mg/day, plus furosemide, 160 mg/day (bumetanide, 4 mg/day, or equivalent doses of other loop diuretics).

7 Early ascites recurrence: reappearance of grade 2–3 ascites within 4 weeks of initial mobilization; reaccumulation of ascites within 2–3 days of paracentesis must not be considered as early recurrence because it represents a shift of interstitial fluid into the intraperitoneal space.

8 Diuretic-induced complications: diuretic-induced hepatic encephalopathy is the development of hepatic encephalopathy in the absence of other precipitating factors. Diuretic-induced renal failure is an increase in serum creatinine by greater than 100% to a value above 2 mg/dL in patients with ascites responding to diuretic treatment. Diuretic-induced hyponatraemia is a decrease in serum sodium by greater than 10 mEq/L to a concentration lower than 125 mEq/L. Diuretic-induced hypo- or hyperkalaemia are, respectively, a decrease in serum potassium to less than 3 mEq/L or an increase to more than 6 mEq/L despite appropriate measures to normalize potassium concentrations.

'Recidivant ascites' is defined as ascites that recurs frequently (on three or more occasions within a 12-month period) despite dietary sodium restriction and adequate diuretic dosage, and is not to be considered as a true refractory ascites [123].

Most cirrhotics with diuretic-resistant ascites have type 2 hepatorenal syndrome [123], or lesser, although significant, degrees of impairment in renal perfusion and glomerular

filtration rate (increased serum creatinine to between 1.2 and 1.5 mg/dL) [106,200,203] It is important to stress that the inverse relation between glomerular filtration rate and serum creatinine concentration is hyperbolic. This means that a small increase in creatinine over normal represents a marked impairment of renal haemodynamics and glomerular filtration rate. The mechanism whereby ascites is resistant to diuretic therapy in cirrhotics with renal failure is probably related to alterations in both the pharmacokinetics and the pharmacodynamics. The access of loop diuretics to the organic acid secretory site, and of spironolactone to the aldosterone receptors, which is mainly determined by the amount of blood flowing to the proximal tubule and distal nephron, respectively, may be impaired in cirrhotics with functional renal failure due to the low renal perfusion. Moreover, the delivery of sodium chloride to the loop of Henle and distal nephron, the sites where furosemide and spironolactone inhibit sodium reabsorption, may be markedly reduced in cirrhotics with functional renal failure secondary to a low glomerular filtration rate and enhanced sodium reabsorption in the proximal tubule [210]. Therefore, both impaired access of diuretics to the effective sites on the tubular cells and a reduced substrate for the diuretic action are presumably the most important mechanisms of refractory ascites in cirrhosis. Additional factors that may contribute to the renal resistance to diuretics in cirrhotics with functional renal failure are hypoalbuminaemia, which reduces the delivery of diuretics to the kidney, and the increased activity of endogenous systems with sodium-retaining effects (renin–angiotensin–aldosterone and sympathetic nervous systems), which may inhibit the natriuretic effect of diuretics.

NSAIDs depress the diuretic response to furosemide and spironolactone in cirrhotics with ascites by a mechanism unrelated to the impairment in renal haemodynamics [219,220]. Evidence for the possible use of these agents should therefore be carefully sought in any cirrhotic patient not responding to sodium restriction and an adequate diuretic regimen.

Therapeutic paracentesis

Treatment with a low-sodium diet and diuretics is very effective in mobilizing ascites in cirrhosis. However, it has several limitations. First, approximately 10–20% of patients do not respond to diuretics (diuretic-resistant ascites). Second, diuretic treatment is frequently associated with complications, particularly when high doses of diuretics have to be used. Finally, the mobilization of ascites with diuretics is a slow process. This problem, which is not relevant in the care of patients with moderate ascites, who are usually treated as outpatients, is very important in patients with massive ascites, most of whom need prolonged hospitalization for diuretic therapy.

The demonstration in 1987 that large-volume paracentesis associated with plasma volume expansion is a rapid, effective and safe treatment for ascites in cirrhosis has considerably simplified the treatment of patients admitted to hospital with tense ascites [221]. Therapeutic paracentesis is considered to be the therapy of choice for tense ascites in cirrhosis [201]. It considerably shortens hospital stay and therefore the cost of treatment, and the incidence of complications during hospitalization is significantly lower among patients treated with paracentesis than among patients treated with diuretics [221–223]. In patients with moderate ascites, diuretics should be preferred to paracentesis.

Although paracentesis is a very simple procedure, several precautions should be taken to avoid complications. Therapeutic paracentesis can be performed either as repeated large-volume paracentesis (4–6 L/day until complete disappearance of ascites) or as total paracentesis (complete removal of ascites in only one paracentesis session). Total paracentesis is the best method because it is faster and associated with a lower incidence of local complications [221–223]. Ascites leakage through the skin or within the abdominal wall is relatively frequent after partial paracentesis, because a significant volume of ascites remains in the peritoneal cavity after the procedure. On the other hand, although complications related to the insertion of the needle are exceptional, the incidence increases with the number of taps. Paracentesis should be performed under strictly sterile conditions with specially designed needles. There are commercial kits for paracentesis using different types of needles with blunt-edged cannulas and side holes. With the patient under local anaesthesia, the needle is inserted into the left lower abdominal quadrant. The inner part is removed, and the cannula is connected to a large-capacity suction pump. The physician should remain at the bedside throughout the procedure. With this technique, the duration of treatment ranges from 30 to 60 min, depending on the amount of ascitic fluid removed. Total paracentesis procedures are finished when the flow from the cannula becomes intermittent despite gentle mobilization of the cannula within the peritoneal cavity and turning the patient to the left side. Peripheral oedema is rapidly reabsorbed after the mobilization of ascites in most patients and usually disappears within the first 2 days after treatment. Most of the fluid goes to the abdominal cavity as ascites. It is therefore not infrequent for patients with marked peripheral oedema to need a second procedure after complete mobilization of ascites at the initial paracentesis. Patients treated by means of repeated large-volume paracentesis should recline for 2 h on the side opposite the paracentesis site to prevent the leakage of ascitic fluid.

When paracentesis is performed without plasma volume expansion, there are no apparent major changes in circulatory function. Arterial pressure decreases slightly, but this also occurs when paracentesis is performed with plasma volume expansion. The pulse rate does not increase, and the patient does not experience any symptoms other than those related to the disappearance of ascites [222,224]. In addition, if serum creatinine and serum electrolytes are measured within the first days after paracentesis, no changes are observed in most patients. For this reason, some investigators have suggested that therapeutic paracentesis does not adversely affect circulatory function and that, consequently, plasma volume expansion is not necessary

in the care of patients with cirrhosis and ascites treated with this procedure.

However, when circulatory function is assessed by sensitive direct and indirect measures, marked changes are detected [222]. Immediately after paracentesis, circulatory function improves with a marked increase in cardiac output and stroke volume, a reduction in cardiopulmonary pressure and a suppression of the renin–angiotensin and sympathetic nervous systems [222]. These effects, which persist for approximately 12 h and have been attributed to mechanical factors (reduction in intrathoracic pressure and increase in venous return), are followed by opposing haemodynamic changes, including a reduction in cardiac output to baseline value and marked activation of the renin–angiotensin and sympathetic nervous systems over levels before paracentesis [224]. Renal function also improves during the first hours after paracentesis and may worsen 24–48 h after the procedure. The impairment in circulatory function induced by paracentesis is not related, as proposed initially, to a decrease in circulating blood volume secondary to a rapid reaccumulation of ascites, but rather to an accentuation of the arterial vasodilation already present in these patients (Fig. 16). The mechanism by which paracentesis induces reduction in peripheral vascular resistance and the site where this vasodilation occurs are unknown. An important observation is that the circulatory dysfunction induced by paracentesis is not spontaneously reversible [223]. Once plasma renin activity and plasma norepinephrine concentration increase, they remain elevated throughout the course of the disease. The cause of this phenomenon is unknown.

Plasma renin activity is a very sensitive marker of circulatory function and is the parameter used to detect impairment in circulatory function after paracentesis in most studies. Paracentesis-induced circulatory dysfunction has been defined as a 50% increase in plasma renin activity over baseline on the sixth day after treatment up to a value greater than 4 ng/mL/h (upper normal limit) [223,224]. According to this criterion, the incidence of spontaneous circulatory dysfunction among patients with cirrhosis admitted to hospital because of tense ascites and not receiving any treatment during 1 week of hospitalization was 16% (unpublished observations). The incidence of paracentesis-induced circulatory dysfunction has been estimated to be 75% among patients not undergoing plasma volume expansion, 33–38% in patients receiving polygeline (saline solution, 8 g/L ascitic fluid removed), dextran-70 (dextrose solution, 8 g/L ascitic fluid removed) or saline and 11–18% among patients receiving albumin (salt-poor solution, 8 g/L ascitic fluid removed) [223]. Similar findings have been reported in a recent trial comparing albumin with saline in patients with ascites treated by total paracentesis [225]. The incidence of paracentesis-induced circulatory dysfunction was 33.3% in patients receiving saline and 11.4% in those receiving albumin.

The amount of ascitic fluid removed is a predictor of paracentesis-induced circulatory dysfunction (Fig. 17). When the amount of ascitic fluid removed is less than 5 L, the incidence of circulatory dysfunction is similar among patients treated with albumin and those treated with synthetic plasma expanders (16% vs. 18%). However, when the amount is between 5 and 9 L, the incidence of circulatory dysfunction is higher among patients receiving synthetic plasma expanders (19% vs. 30%). Differences are particularly marked when the volume of paracentesis is greater than 9 L. In this case, the incidence of paracentesis-induced circulatory dysfunction is 21% among patients receiving albumin and 60% in those receiving synthetic plasma expanders [223].

These data indicate the following: (i) paracentesis-induced circulatory dysfunction is very frequent when the plasma volume is not expanded; (ii) plasma volume expansion with synthetic colloids is effective in reducing the incidence of circulatory dysfunction after paracentesis; (iii) plasma volume expansion with albumin almost totally prevents paracentesis-induced

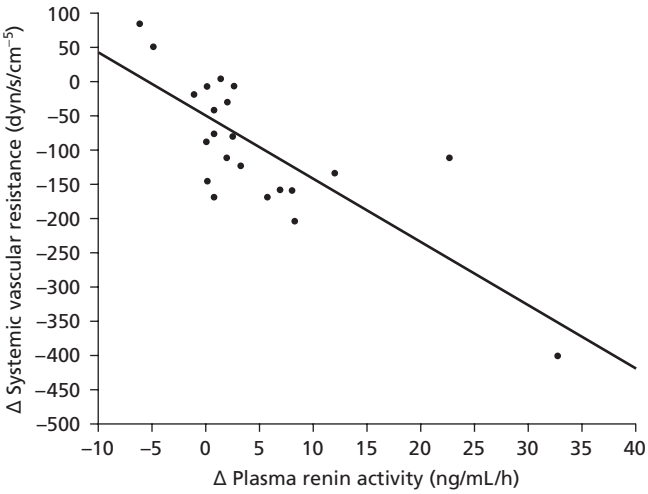

Fig. 16 Direct negative correlation between the increase in plasma renin activity (Δ PRA) and the decrease in systemic vascular resistance (Δ SVR) following therapeutic paracentesis in cirrhosis (reproduced with permission from ref. 224).

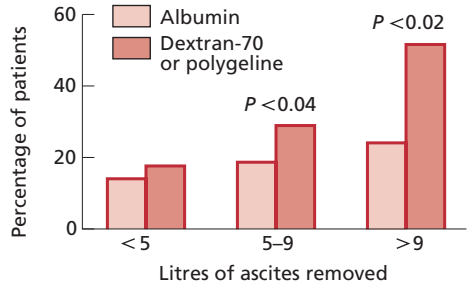

Fig. 17 Incidence of paracentesis-induced circulatory dysfunction in cirrhotic patients with ascites divided according to the volume of ascitic fluid removed and the type of plasma expander used (reproduced with permission from ref. 223).

circulatory dysfunction; (iv) among patients with an ascitic fluid volume of less than 5 L, the incidence of paracentesis-induced circulatory dysfunction is low and independent of the type of plasma expander used; (v) when the amount of ascitic fluid volume removed is more than 5 L, the incidence of circulatory dysfunction increases with the volume of paracentesis in patients receiving synthetic plasma expanders but not in patients receiving albumin.

Despite being asymptomatic, paracentesis-induced circulatory dysfunction adversely affects the clinical course of the disease. The incidence of hyponatraemia (3.8% vs. 17%) and renal impairment (0 vs. 11%) within a few days after paracentesis is significantly lower among patients receiving albumin infusions than among those not receiving plasma expanders. The time to first readmission to hospital is significantly shorter for patients with circulatory dysfunction after paracentesis than among those who do not have this complication. Finally, the probability of survival is also lower among patients with circulatory dysfunction after paracentesis [223].

The mechanism by which deterioration in circulatory function impairs the clinical course and the prognosis for patients with cirrhosis and ascites is probably multifactorial. Circulatory dysfunction is associated with an increase in circulating levels of vasoconstrictors that impair renal haemodynamics and the renal response to diuretics. Angiotensin-II and norepinephrine are important mechanisms of HRS, which is associated with poor survival. These substances also induce vasoconstriction of intrahepatic vascular resistance, which may reduce liver perfusion, impair hepatic function and increase portal pressure. These changes may further deteriorate circulatory function and create vicious circles that accelerate the course of the disease. One study has shown that the hepatic venous pressure gradient (an estimation of the intrahepatic vascular resistance) increases after paracentesis in patients in whom circulatory dysfunction develops but not in patients who do not have this complication [224].

Therefore, there is substantial evidence indicating that paracentesis-induced circulatory dysfunction is a relevant complication that should be prevented. The best way to do this is to expand the plasma volume with albumin when the volume of ascitic fluid removed is more than 5 L. When the volume is less than 5 L, less expensive synthetic plasma expanders can be used. The amount of albumin given in most centres is 8 g/L ascitic fluid removed, which represents the approximate amount of albumin removed with the paracentesis. We infused 50% of the dose immediately after paracentesis and 50% 6 h later. The patient may then leave hospital with diuretics to prevent the reaccumulation of ascites. Patients with normal BUN and serum creatinine require a standard diuretic dosage (200 mg/day spironolactone or 40 mg/day furosemide plus 100 mg/day spironolactone). However, higher diuretic dosages are required in patients with abnormal BUN or serum creatinine concentration, or in patients with ascites that is refractory before treatment.

Peritoneovenous shunting

In 1974, LeVeen and associates [226] introduced the peritoneovenous shunt for the treatment of cirrhotics with diuretic-resistant ascites. This device consists of a perforated intra-abdominal tube connected through a one-way, pressure-sensitive valve to a silicone tube that traverses the subcutaneous tissue up to the neck, where it enters one of the jugular veins (usually the internal jugular). The tip of the intravenous tube is located in the superior vena cava near the right atrium or in the right atrium itself. The aim of the shunt is to produce sustained expansion of the circulating blood volume by the continuous passage of ascites from the peritoneal cavity to the general circulation. Whenever a pressure gradient of 3 cmH_2O or more exists between the abdominal cavity and the superior vena cava, the valve remains open, and ascitic fluid flows into the central venous system. If this gradient diminishes, the valve closes, thus preventing blood from reflushing into the venous limb of the shunt. The insertion of a LeVeen shunt is technically simple and can be performed under local anaesthesia. It is advisable to assess the correct placement of the venous tip by chest radiography in the operating room. Although the LeVeen is the most widely used peritoneovenous shunt, other types are available. The Denver shunt has a valvular system with a pumping mechanism. The valvular system opens at low pressure gradients (1 cmH_2O) or when the pump chamber, placed in an intercostal space, is pressed externally. The Denver shunt was designed to reduce the high incidence of shunt obstruction observed with the LeVeen. It was thought that the compression of the pump chamber would avoid the formation of thrombi at, and within, the tip of the intravenous segment and the deposition of fibrin within the valve. However, a randomized study comparing LeVeen and Denver shunts in cirrhotics with medically intractable ascites showed a higher probability of shunt obstruction in patients treated with the Denver shunt, probably as a consequence of the reflux of blood into the valve during the release phase of the pumping cycle [227]. To avoid this problem, a double-valve Denver shunt was later developed. Whether this new valvular system is effective in preventing shunt obstruction is unknown.

Numerous studies show that the peritoneovenous shunt is capable of correcting most abnormalities thought to be involved in the pathogenesis of ascites. It produces a striking increase in circulating blood volume and cardiac output. As arterial pressure does not rise, there is a concomitant reduction in peripheral vascular resistance. These haemodynamic changes are associated with an increase in the plasma concentration of atrial natriuretic factor and a suppression of the plasma concentrations of renin, aldosterone, noradrenaline and ADH. Urine volume and free-water clearance increase in most patients, as is seen with the serum sodium in cases with dilutional hyponatraemia. However, there is significant natriuresis in less than half the patients. In cirrhotics with moderate functional renal failure, the peritoneovenous shunt may improve renal blood flow and glomerular filtration rate [228]. Finally, a marked reduction in

portal pressure and intrahepatic vascular resistance, as estimated by the wedged-to-free hepatic venous pressure gradient, has been reported after the insertion of a peritoneovenous shunt. The mechanism of this last effect is unknown. Follow-up studies show that these haemodynamic and hormonal changes persist in most cases and that a significant proportion of patients remain with minimal or no ascites despite a moderate sodium restriction and low diuretic dosage. Additionally, the nutritional status, as estimated by the arm muscle circumference, improved significantly in patients successfully treated with a peritoneovenous shunt.

Unfortunately, the procedure is associated with a high rate of complications, which may occur early in the postoperative period or at any time during follow-up. Acute bacterial infection, generally caused by *Staphylococcus* spp., is the most serious early complication [229]. The prosthesis is usually colonized and, in most cases, the infection cannot be eradicated unless the shunt is removed. The prophylactic administration of anti-staphylococcal antibiotics 24 h before and for 48 h after surgery reduces the incidence of early postoperative infections [229]. Postoperative fever, probably related to the passage of endotoxin contained in the ascitic fluid into the general circulation, is almost inevitable and disappears spontaneously within the second postoperative week [230]. Practically every cirrhotic patient treated with a peritoneovenous shunt develops biochemical signs of intravascular coagulation within the early postoperative period, including a decrease in plasma fibrinogen and platelets, prolongation of prothrombin, thrombin and partial thromboplastin times and a rise in the plasma concentrations of fibrin and fibrinogen degradation products [231,232]. The mechanism of this complication is unknown, but it may possibly be secondary to the massive passage of tissue thromboplastin and clotting factors, plasminogen activators, endotoxin, fibrin split products and collagen, which are present in the ascitic fluid, into the general circulation. The incidence of symptomatic intravascular coagulation was relatively high (25%) within the years immediately following the introduction of the shunt when the shunt was inserted without prior removal of ascitic fluid. At that time, the mortality rate attributed to intravascular coagulation was 5%. However, at present, with the widespread acceptance of the need to evacuate ascitic fluid preoperatively, or during surgery before inserting the shunt, the rate of symptomatic intravascular coagulation after peritoneovenous shunting has decreased dramatically. Some investigators have suggested the removal of all ascitic fluid and its replacement with normal saline before insertion of the prosthesis. Antiplatelet therapy with aspirin (300 mg/day) and dipyridamole (400 mg/day) in the immediate pre- and postoperative periods prevented intravascular coagulation after peritoneovenous shunting [233]. Other postoperative complications, such as bleeding from oesophagogastric varices and congestive heart failure, which are related to the acute expansion in the circulating blood volume, can also be prevented by reducing the volume of ascitic fluid before inserting the shunt. Postoperative mortality (within the first month after surgery) ranges between 0% and 26% [229].

Obstruction of the shunt is the most common complication during follow-up [229]. It occurs in more than 30% of patients and is usually due to deposition of fibrin within the valve or around the intravenous catheter, thrombotic obstruction of the venous limb of the prosthesis or thrombosis of the superior vena cava or right atrium initiated at the venous end of the shunt or in damaged endothelium [229]. Although the thrombosis of the superior vena cava is usually incomplete, total occlusion may occur, resulting in the development of a superior vena cava syndrome. Vascular thrombosis may result in pulmonary embolism. Obstruction of the shunt is frequently, but not necessarily, followed by reaccumulation of ascites. In these cases, Doppler ultrasonography or ^{99m}Tc scintigraphy after intraperitoneal injection of radioisotope will show the absence of flow through the shunt. When obstruction is confirmed by these techniques, a shuntogram after the injection of contrast medium into the proximal subcutaneous limb of the shunt should be performed in order to identify its exact site. Patients with obstruction at the venous limb of the shunt require venography or digital angiography to rule out vascular thrombosis. It has been suggested that the insertion of a titanium tip 3 cm long into the venous end of the LeVeen shunt prevents thrombotic obstruction of its venous limb and the development of thrombosis in the superior vena cava. Titanium is highly thromboresistant, a characteristic that has been exploited extensively in intravascular devices such as prosthetic heart valves. The titanium tip was also designed to provide gradual, streamlined flow convergence of ascites and blood. Finally, the weight and design of the tip may limit endothelial damage and mural thrombus formation in the superior vena cava. Unfortunately, in a study on a large series of patients, Ginès *et al.* [234] were not able to confirm that the titanium tip reduces the incidence of obstruction in peritoneovenous shunts.

Bacterial infections, particularly bacteraemia and spontaneous peritonitis, are also common complications during follow-up [229]. Bacteraemia can be successfully treated with antibiotics. Early recurrence indicates colonization of the shunt or bacterial endocarditis. Removal of the shunt has been recommended in patients with peritonitis, although some have successfully treated patients with bacterial peritonitis without this [229]. To prevent bacterial infections in patients with peritoneovenous shunts, prophylactic antibiotics should be administered whenever an invasive manoeuvre is to be performed.

Finally, another long-term complication of peritoneovenous shunting is small bowel obstruction, which occurs in approximately 10% of patients [235]. The small bowel is compressed and kinked inside multiple 'cocoons' and cysts consequent to marked peritoneal fibrosis. The shunt is usually not ensnared in the fibrosed areas but remains free. The cause is unknown.

Because of the high incidence of shunt-related complications, peritoneovenous shunting should be restricted to patients with refractory ascites. However, these patients often have endstage

liver disease and an extremely poor prognosis, which cannot be modified by successful treatment of ascites. In fact, an overall analysis of the four prospective, randomized trials comparing peritoneovenous shunting with conventional medical treatment in patients with refractory ascites does not disclose any benefit in terms of survival [236–239]. The role of peritoneovenous shunting in the management of patients with hepatorenal syndrome is also unclear: a beneficial effect has been observed in single cases, but the results obtained in the only two randomized trials published so far seem to indicate that peritoneovenous shunting, although preventing the progression of functional renal failure, does not improve the chances of survival. The reintroduction of therapeutic paracentesis has led to a decline in the use of peritoneovenous shunting. In the two randomized, controlled trials comparing paracentesis with the LeVeen shunt in patients with refractory ascites, shunting was superior in the long-term control of ascites, as estimated by the time to first readmission for ascites, the number of readmissions for ascites and diuretic requirements [234,240]. However, these advantages had little impact on the natural course of the disease as patients treated in both groups did not differ significantly in their time to first readmission for any reason, total time in hospital during follow-up and probability of survival. Furthermore, frequent reoperations were required in the surgical group because of shunt obstruction. At present, many groups consider paracentesis to be the treatment of choice in patients with refractory ascites, peritoneous shunting being indicated only in those intolerant of frequent paracentesis. The morbidity and survival of cirrhotics treated with the LeVeen shunt correlate with the degree of impairment of liver and renal function, patients with severe hepatic and renal failure having a higher incidence of complications and lower survival. Therefore, the best results with this procedure should be expected in those very few patients with diuretic-resistant ascites and preserved hepatic function.

Surgical portocaval anastomosis and transjugular intrahepatic portacaval shunt (TIPS)

Ascites and its complications (hepatorenal syndrome and spontaneous bacterial peritonitis) are rare in cirrhotic patients submitted to end-to-side portocaval anastomosis for the treatment of variceal bleeding, and the surgical relief of portal hypertension, either by end-to-side or side-to-side portocaval anastomosis, is an apparently effective treatment for ascites. It is therefore not surprising that portocaval anastomosis has been proposed as a treatment for refractory ascites. In 1970, Orloff [241], reviewing the literature on the surgical treatment of ascites, was able to collect data for 71 cirrhotics with ascites treated with end-to-side portocaval anastomoses and for 131 patients treated with side-to-side portocaval shunts. In most of these cases, ascites was refractory to diuretic treatment. Twenty-three patients treated with end-to-side shunts (32%) and 24 treated with side-to-side anastomoses (18%) died in the postoperative period. Of the surviving patients, 39 (81%) in the end-to-side group and 100 (90%) in the side-to-side group remained free of ascites during a follow-up period ranging from months to more than 10 years, despite a normal sodium diet and no diuretics. Subsequently, it was shown that, in cirrhotics treated with end-to-side portocaval shunts, the development of ascites during follow-up usually occurs in those cases who maintain a relatively high sinusoidal pressure and hepatic arterial blood flow. More recently, Franco [242] reported his experience with 41 patients submitted to side-to-side or end-to-side portocaval anastomoses for the treatment of refractory ascites. Almost all these patients had previously been treated with a LeVeen shunt that had to be removed because of complications such as thrombosis of the superior vena cava, infections or gastrointestinal haemorrhage. The operative mortality (within 2 months of surgery) was exceptionally low (two patients, 4.8%), probably related to the relatively well-preserved hepatic function presented by most cases. Every patient reaccumulated ascites in the immediate postoperative period, and 12 developed renal failure. However, ascites and renal impairment disappeared a few days after the operation in all but two cases. Only one of the survivors developed ascites during follow-up. The probability of survival 1 and 3 years after surgery was 73% and 39% respectively. However, the incidence of severe chronic hepatic encephalopathy (36%) was very high. Other studies have shown that side-to-side portocaval shunting may be followed by a return to normal renal function in patients with hepatorenal syndrome. The disappearance of ascites and renal failure in patients treated with portocaval shunts is associated with a return to normal plasma concentrations of renin and aldosterone. These data suggest that, although portocaval anastomosis is an effective treatment for refractory ascites in patients with cirrhosis and preserved hepatic function, it is associated with a high postoperative mortality and a high incidence of incapacitating chronic hepatic encephalopathy. As no controlled trials have compared the portocaval shunt with other treatments such as the LeVeen shunt or therapeutic paracentesis, its role in the management of refractory ascites is unconfirmed. Nevertheless, it is important to point out that only a few patients with refractory ascites are suitable candidates for surgical portocaval shunts as they usually present with a severe hepatic insufficiency that precludes any major surgical procedure.

The development of the transjugular intrahepatic portacaval shunt (TIPS) for the treatment of gastrointestinal haemorrhage in cirrhosis has reintroduced the idea of treating ascites and its complications (hepatorenal syndrome and refractory ascites) by reducing portal pressure. TIPS works as a side-to-side portocaval shunt and, from a theoretical point of view, it should correct the two principal mechanisms in the pathogenesis of ascites [243]. By doing so, it should suppress the endogenous vasoconstrictor system, improve renal perfusion and GFR and increase the response to diuretics. On the other hand, by decompressing both the splanchnic and the hepatic microcirculation, TIPS should decrease the formation of lymph both in the liver and in the other splanchnic organs.

A review of the records of the first 358 reported patients with refractory ascites treated with TIPS clearly indicated that this therapeutic procedure is extremely effective in improving circulatory and renal function and in the management of ascites in these patients [243]. TIPS induces a marked increase in cardiac output, a decrease in systemic vascular resistance and an elevation in right atrial pressure, pulmonary artery pressure and pulmonary wedge pressure [243]. These changes, which are similar to those following peritoneovenous shunting, are probably caused by an increase in venous return resulting from the presence of portocaval fistulas. The decrease in systemic vascular resistance, which is also a constant feature in patients treated by peritoneovenous shunting, is probably a physiological response to accommodate the increase in cardiac output.

Because it increases the hyperdynamic circulation, it has been suggested that TIPS impairs the systemic haemodynamics in cirrhosis. However, the results of studies of the effects of TIPS on the endogenous vasoactive systems do not support this concept. The results indicate that effective arterial blood volume is markedly improved following TIPS in patients with cirrhosis and ascites. As indicated earlier, the maintenance of arterial pressure in patients with advanced cirrhosis and ascites is critically dependent on a marked overactivity of the renin–angiotensin system, sympathetic nervous system and antidiuretic hormone. If TIPS enhances arterial vasodilation, a further increase in the degree of stimulation of these vasoconstrictor systems should occur. In contrast, TIPS insertion is associated with marked suppression of the plasma levels of renin, aldosterone, norepinephrine and antidiuretic hormone [243]. Suppression of the renin–angiotensin–aldosterone system occurs within the first week following TIPS insertion and persists during the follow-up period. Suppression of norepinephrine and antidiuretic hormone appears to require a longer period of time.

Deterioration in circulatory function should also be associated with a further impairment in renal function after TIPS; however, TIPS insertion induces a rapid increase in urinary sodium excretion, which is already observed within the first 1–2 weeks and persists during the follow-up period [243]. A significant increase in serum sodium concentration and GFR is also observed, indicating an improvement in renal perfusion and free-water clearance. However, these changes require 1–3 months to occur.

TIPS induces a marked decrease in the portocaval gradient. In the aforementioned review of the care of 358 patients with refractory ascites treated by TIPS, the mean decrease was from 20.9 to 10 mmHg [243]. Portal venous pressure also decreased markedly, from 29.4 to 21.8 mmHg. However, TIPS only partially decompresses the portal venous system; portal venous pressure in most healthy subjects is less than 5 mmHg. Although suppression of the renin–aldosterone system is evident, the plasma levels of renin and aldosterone do not decrease to normal levels. Improvement in splanchnic and systemic haemodynamics is associated with disappearance of ascites or partial response (no need for paracentesis) in most patients. Only 10% of cases do not respond to TIPS. Ascites characteristically resolves very slowly (within 1–3 months). Continuous diuretic treatment is required in more than 95% of cases, either for the management of ascites or to reduce the peripheral oedema that frequently occurs in patients treated with TIPS. The persistence of portal hypertension and hyperaldosteronism may be the explanation for this phenomenon.

Hepatic encephalopathy is the most important complication among patients with cirrhosis with refractory ascites managed with TIPS [243]. More than 40% of patients have this complication. In most cases, hepatic encephalopathy responds to standard therapy. However, it occasionally requires a decrease in stent size. Although hepatic encephalopathy before TIPS is a predictor of encephalopathy after TIPS, new or worsening hepatic encephalopathy develops in approximately 30% of cases. Shunt dysfunction is also a major problem, occurring in approximately 40% of cases within the first year. This is an important limitation of TIPS requiring frequent retreatments. However, the recent introduction of covered stents, which is associated with a very low rate of shunt dysfunctions, has solved this problem. The 1-year probability of survival among patients with cirrhosis with refractory ascites treated with TIPS is extremely poor. Early mortality (within 30 days after TIPS) is approximately 12% and late mortality 40%. Predictors of survival are the Child–Pugh score, age and the presence of HRS prior to TIPS [243].

Five randomized, controlled trials have been reported comparing TIPS and therapeutic paracentesis [244–248] (Table 2). Two included patients with recidivant and refractory ascites, and three included only patients with refractory ascites. The five trials clearly show that TIPS is better than paracentesis in the long-term control of ascites. Three trials showed significantly higher incidence of hepatic encephalopathy in patients treated

Table 2 TIPS vs. paracentesis for refractory ascites: a summary.

	Control	HRS	Hepatic encephalopathy	Cost	Survival
Lebrec *et al.* [244]	Better with TIPS	–	No difference	–	Worse with TIPS
Rossle *et al.* [245]	Better with TIPS	–	No difference	–	Better with TIPS?
Gines *et al.* [247]	Better with TIPS	Less frequent with TIPS	Worse with TIPS	Greater with TIPS	No difference
Sanyal *et al.* [248]	Better with TIPS	–	Worse with TIPS	–	No difference
Salerno *et al.* [246]	Better with TIPS	–	Worse with TIPS	–	Better with TIPS

with TIPS. An improvement in survival in the TIPS group was only observed in the trials including patients with recidivant ascites. The total time in hospital during follow-up was similar in both groups owing to the high incidence of shunt obstruction requiring new hospitalization for the treatment of complications related to portal hypertension and/or restenting. In one of these trials, the quality of life was assessed, and changes were similar in the two therapeutic groups [249]. These results indicate that TIPS changes the course of cirrhosis from ascites to hepatic encephalopathy without improving the overall results of paracentesis in relation to length of hospitalization and survival.

Treatment of hyponatraemia in cirrhosis with ascites

Aquaretic drugs

Dilutional hyponatraemia is the most common abnormality of serum electrolytes in patients with cirrhosis and ascites. Traditionally, hyponatraemia has been considered a minor problem in cirrhosis, as it is usually asymptomatic, even in patients with a markedly reduced serum sodium. On the other hand, the presence of hyponatraemia does not contraindicate diuretic treatment in patients with cirrhosis and ascites. In fact, most cirrhotics with ascites and hyponatraemia respond satisfactorily to diuretics without a further reduction in serum sodium. For these reasons, the use of aggressive procedures for the treatment of hyponatraemia in cirrhosis, such as the insertion of a LeVeen shunt or a TIPS, has never been justified. However, recent studies suggest that hyponatraemia may be more relevant than previously thought. It is associated with very poor prognosis. The probability of hepatic encephalopathy is significantly higher in patients with hyponatraemia than in those with comparable deterioration of hepatic function but with normal serum sodium concentration. Finally, the incidence of severe neurological events after liver transplantation in patients with dilutional hyponatraemia, probably related to the rapid correction of extracellular osmolality during the operation, is relatively high [250]. Therefore, treatment of hyponatraemia could be beneficial in patients with decompensated cirrhosis.

Studies using isotopic techniques have shown that total body sodium is markedly increased in cirrhotic patients with ascites and hyponatraemia, indicating that the reduced serum sodium is the result of a dilution of body fluids secondary to the impairment of free-water excretion. Consequently, the treatment of hyponatraemia should be directed towards reducing total body water. The administration of sodium may produce a transient increase in serum sodium, but at the expense of increasing the rate of ascites formation. Classically, the treatment of dilutional hyponatraemia consisted of water restriction. However, this therapy is difficult to carry out and is rarely effective. Demeclocycline, a tetracycline that inhibits the tubular effect of ADH, has been shown to correct water retention and hyponatraemia in cirrhotics with ascites, but its usefulness in these patients is limited by the high incidence of renal failure that it produces [251,252].

During the last two decades, a great effort has been made to develop specific antagonists of the tubular effect of ADH that could act as aquaretic agents and be used for the treatment of dilutional hyponatraemia in cirrhosis with ascites, and in congestive heart failure. The initial approach was to develop analogues of the ADH molecule with affinity for the V_2 receptors but lacking hydro-osmotic activity. Unfortunately, although several peptides with aquaretic activity in experimental animals were developed, they disclosed ADH agonistic activity when given to humans. It is interesting that the administration of one of these analogues to rats with carbon tetrachloride-induced cirrhosis, ascites and dilutional hyponatraemia was associated with a normalization of renal water metabolism with polyuria and an increase in free-water excretion [149].

The investigation of non-peptidic substances with aquaretic effects has had very promising results, and several types of aquaretic agents have been developed that are effective in experimental animals as well as in man. The first renal ADH antagonist identified was a benzazepine derivative named OPC-31260, which is 100 times more selective for V_2 receptors than for V_1 receptors. It is active after oral and intravenous administration, has no agonistic effect and increases the urine volume in normal rats and in rats treated with ADH without increasing urinary solute excretion, but not in Brattleboro rats with congenital diabetes insipidus. In normal man, OPC-31260 also induces a marked increase in urine volume (it may be as high as that obtained with furosemide) with a decrease in urine osmolality towards very low values (it may reach concentrations below 100 mosmol/kg), resulting in a remarkable increase in free water, with minor effects on electrolyte excretion [253]. The peak effects on urine volume and osmolality are observed between 1 and 2 h and last for 4 h. With the highest single dose used in normal individuals, the aquaretic effect is so marked that it is associated with a significant increase in serum osmolality and sodium. The plasma ADH also increases in these individuals. Other non-peptide V_2 antagonists have been developed (VPA-985, SR-121463, OPC-41061 and YMD-087) and are currently being investigated.

There are several studies assessing the effects of V_2 antagonists in human and experimental cirrhosis. Tsuboi *et al.* [254] examined the role of OPC-31260 in rats with carbon tetrachloride-induced cirrhosis and control rats. Water excretion after a water load increased fourfold and minimal urinary osmolality decreased by 30% after the administration of this agent. Additionally, serum sodium and urinary sodium excretion increased significantly when compared with the control group. However, in another study by Bosch-Marcé *et al.* [255], the maximum effect of this drug was limited to the first 2 days of treatment, probably due to the development of tachyphylaxis. Jimenez *et al.* [256] reported the long-term (10 days) efficacy of SR-121463 in cirrhotic rats with ascites and impaired water excretion after a water load. The administration of the drug led

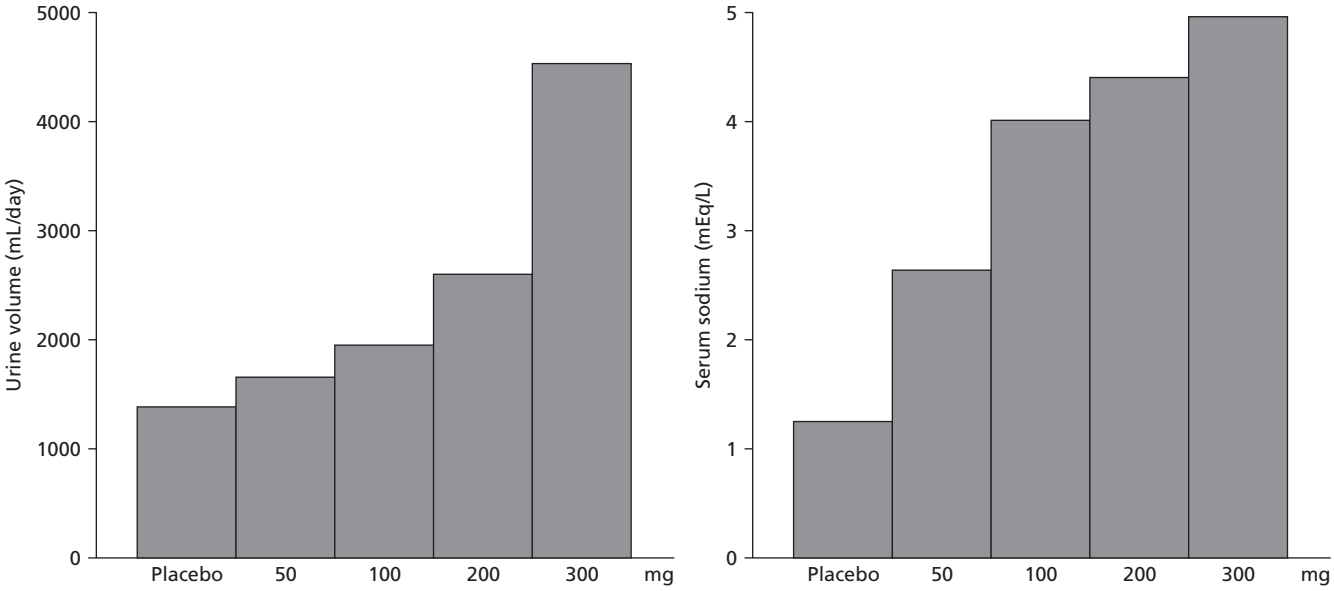

Fig. 18 Urine volume and serum sodium after a single dose of VPA-985 in cirrhotic patients with ascites (reproduced with permission from ref. 264.

to a significant increase in urine volume and reduced urine osmolality when compared with a vehicle. This also resulted in a great renal ability to excrete a water load and normalization of serum sodium and osmolality. In contrast to OPC-31260, the effects of SR-121463 were sustained, and there was no tachyphylaxis. Finally, Fernández-Varo *et al.* [257] in 2003 reported the effects of conivaptan, a combined receptor V_{1a}/V_2 antagonist, on renal water handling and systemic haemodynamics in cirrhotic rats with ascites. In this study, the chronic administration (10 days) of this agent to rats with severe water retention and ascites produced an acute increase in urine volume and a reduction in urine osmolality; the aquaretic effect lasted for only 5 days. Interestingly, there was a remarkable improvement in sodium excretion, which was probably due to the effect of conivaptan on the renin–angiotensin system. Most importantly, these effects occurred without affecting creatinine clearance or arterial pressure, an effect that could be expected because of the vasoactive action that the V_{1a} receptor exerts over blood vessels mediating vasoconstriction.

Inoue *et al.* [258] reported in 1998 the first study in humans examining the therapeutic effect of OPC-31260 in patients with cirrhosis and ascites. The administration of 30 mg/day p.o. to eight patients with cirrhosis and ascites without hyponatraemia was associated with an increase in the urine volume and solute-free water clearance at 2 and 4 h, respectively, and a decrease in urine osmolality at 2 h after administration. However, as patients did not have hyponatraemia at baseline, the effect on serum sodium was not assessed. Furthermore, neither the normal serum sodium rise nor urinary sodium excretion changed. In 2002, Guyader *et al.* [259] reported the pharmacodynamics, safety and pharmacokinetics of ascending single doses of VPA-985 (25–300 mg) in 27 patients with cirrhosis and ascites in a phase II randomized, double-blind, placebo-controlled trial. VPA-985 produced a marked dose-related rise in urinary output and a dose-related decrease in urine osmolality when given at 300 mg/day. Urine volume increased significantly with the 300-mg dose. Solute-free water clearance increased to levels greater than 3 mL/min for doses of 100 mg and higher. In addition, significant increases in urine sodium excretion and serum osmolality, sodium and vasopressin levels were observed (Fig. 18). In this pharmacodynamic study, the authors only demonstrated the potential of VPA-985 as a therapeutic agent for water retention in cirrhosis. But, as the main endpoint was to evaluate the safety and efficacy of this compound, they did not examine its role in managing patients with dilutional hyponatraemia; in fact, all patients had serum sodium levels above 130 mEq/L. Both agents (VPA-985 and OPC-31260) in the above studies were clinically well tolerated and did not produce any significant side-effects or changes in systemic haemodynamics.

Two multicentre, randomized, placebo-controlled trials published in 2003 evaluated the use of VPA-985 in cirrhotic patients with dilutional hyponatraemia. In the first trial, Wong *et al.* [260] investigated the effects of VPA-985 on serum sodium during a 7-day period in 44 hospitalized patients with dilutional hyponatraemia [33 with cirrhosis, five with congestive heart failure and five with syndrome of inappropriate secretion of ADH (SIADH)]. Patients with cirrhosis and congestive heart failure were kept on diuretics, and an escalating dose of VPA-985 ranging from 50 to 500 mg/day was given. VPA-985 had a significant aquaretic response compared with placebo in those on diuretic therapy as well as in patients not on diuretics (SIADH group). There was a dose-related increase in the net fluid volume (urine output-minus fluid intake) and solute-free water clearance, leading to significant increases in serum sodium and serum

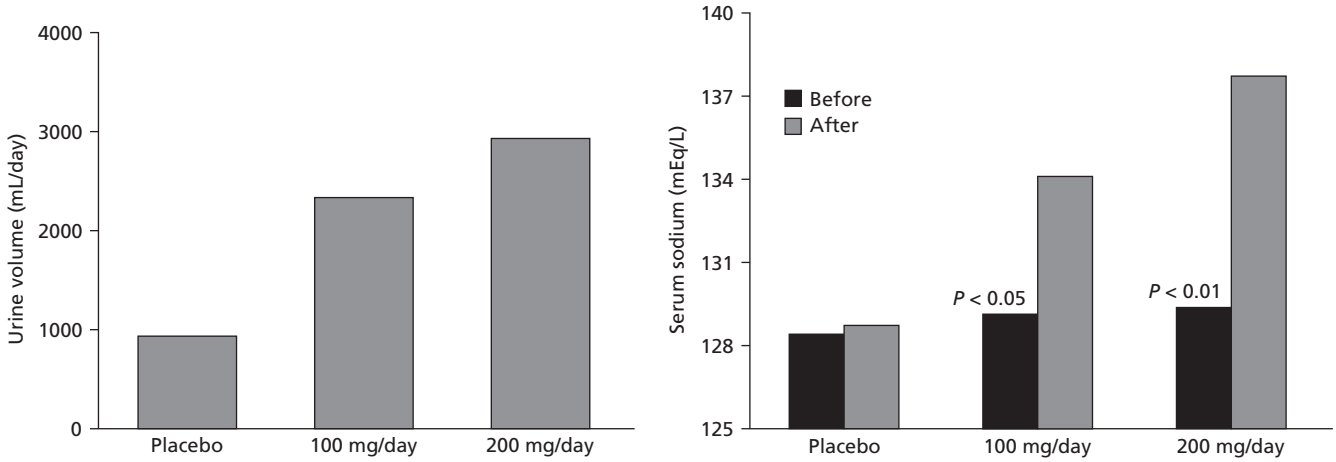

Fig. 19 Effects of V_2 receptor antagonist (VPA-985) on urine volume and serum sodium in patients with cirrhosis and hyponatraemia (reproduced with permission from ref. 261).

osmolality. Unfortunately, there was a high dropout rate (12 patients or 27%; six due to dehydration and the other half for other reasons). The highest doses of the drug (250–500 mg/day) were poorly tolerated and associated with dehydration, as assessed by systemic postural hypotension, increased thirst and marked sodium elevation. As a result, half the patients on the 500-mg/day dose had the medication withheld on several occasions. VPA-985 was most effective and safe when given at a dose of 125–250 mg/day. The second study by Gerbes *et al.* [261] included 60 patients with cirrhosis and dilutional hyponatraemia on fluid restriction who were randomly assigned to receive 100 or 200 mg/day VPA-985 or placebo for 7 days. There was a significant dose-dependent increase in serum sodium concentration and urine volume as well as a significant reduction in urine osmolality and body weight in both groups receiving VPA-985, whereas no changes in these parameters were found in the placebo arm (Fig. 19). Complete response, defined by reaching serum sodium ≥ 136 mEq/L, was observed in 27% on the 100-mg dose and 50% on the 200-mg dose. Thirst sensation was the main side-effect in the 200-mg group, but not in the other groups. Two problems with this study were the small number of patients in each group (around 20) and the effects of VPA-985 were only evaluated until serum sodium normalized with no information on long-term response.

A recent report in abstract form of the use of satavaptan (SR-12146) in patients with cirrhosis, ascites and dilutional hyponatraemia at baseline showed that it had significant effects on improvement in serum sodium [152]. In this randomized, double-blind, placebo-controlled study, the drug was administered in fixed doses of 5, 12.5 and 25 mg in 110 cirrhotic patients with ascites who received spironolactone treatment (100 mg/day). The percentage of patients with improvement in serum sodium at day 5 (defined as serum sodium ≥ 135 mEq/L or an increase of ≥ 5 mEq/L) was higher for the 5-mg, 12.5-mg and 25-mg doses (61%, 54% and 64% respectively) compared with the placebo (19%; $P < 0.05$ for all).

The findings of these studies suggest that the effects of V_2 receptor antagonists seem to be independent of sodium reabsorption proximal to the renal collecting tubules. This compound was administered in combination with diuretics without any significant problems. In fact, other aquaretics such as tolvaptan and conivaptan have a significant natriuretic effect in disease states such as congestive heart failure. This makes V_2 receptor antagonists attractive drugs for potential combination therapy with diuretics in diseases where there is concomitant sodium retention and dilutional hyponatraemia, such as cirrhosis and ascites. Nonetheless, caution would be needed when administering V_2 receptor antagonists and diuretics such as furosemide because this combination could produce a marked diuretic effect and lead to volume depletion and subsequent dehydration and/or renal failure. Currently, studies with V_2 receptor antagonists in patients with cirrhosis and dilutional hyponatraemia demonstrate that these drugs have a dose-related response when correcting hyponatraemia over 1 week. Results of further phase III trials will certainly help to define the usefulness of V_2 receptor antagonists in clinical practice.

A second type of aquaretic agent that may be relevant for the treatment of dilutional hyponatraemia in oedematous conditions are the κ-opioid agonists (ketazocine, ethylketazocine, bremazocine, R-84760, E-2078, U-62,066E, CI-997 and RU-51599), which increase urine volume in man and experimental animals with a reduction in urine osmolality and without changes in electrolyte excretion. The mechanism of this aquaretic effect is complex but clearly mediated through κ-receptors as it is blocked by κ-opioid receptor antagonists. The κ-opioid agonists act on the central nervous system, inhibiting the release of ADH from the neurohypophysis. The observation that these substances increase urine flow in the isolated perfused kidney suggests the existence of a local, intrarenal mechanism of action. The efficacy of κ-opioid agonists in the treatment of water retention in human and experimental cirrhosis was recently evaluated by Gadano *et al.* [262] and by Bosch-Marcé *et al.*

[153]. The acute subcutaneous administration of RU-51599 (niravoline) to rats with cirrhosis, ascites and impaired free-water excretion was associated with normalization of renal water metabolism. The plasma concentrations of ADH decreased after the administration of the drug, but did not reach normal values The acute intravenous administration of RU-51599 to patients with cirrhosis and ascites induced a marked (five to seven times) increase in urine volume during the first 2–3 h, associated with a reduction in urine osmolality to values lower than plasma osmolality and a significant increase in serum sodium. Personality disorders and mild confusion were detected in only two of the eight patients treated and disappeared within 8 h.

There is only one study assessing the effect of these two different types of aquaretic drugs given long term (10 days). This is a comparative study of OPC-31260 and RU-51599 in rats with experimental cirrhosis [255]. The aquaretic effect of OPC-31260 was transitory, occurring only during the first 2 days. In contrast, RU-51599 showed an aquaretic effect throughout the whole study period. There are no such studies recorded in humans.

Drug-induced renal impairment in cirrhosis

Antibiotics

Patients with cirrhosis and ascites are predisposed to aminoglycoside nephrotoxicity, the reported incidence of which (32%) [263] is much higher than that found by other investigators in the general population (3–11%). In that study, aminoglycoside nephrotoxicity was associated with a marked deterioration in renal function. A study of the risk factors in aminoglycoside toxicity found that the presence of liver disease was an independent predictor of nephrotoxicity [264]. The mechanism of this high incidence of aminoglycoside nephrotoxicity in cirrhosis is not known. In the study by Cabrera *et al.* [263], gentamicin or tobramycin was administered in association with cephalothin, which is known to increase the nephrotoxicity of aminoglycosides. However, this was not the case in the study by Moore *et al.* [264]. Another possibility is that patients with decompensated cirrhosis are prone to develop this complication; they frequently have impaired renal blood flow and glomerular filtration rates, and renal accumulation of aminoglycosides is greater with renal impairment. Cabrera *et al.* [263] found that aminoglycoside nephrotoxicity was five times more frequent in patients with renal failure before treatment than in those with a normal baseline serum creatinine.

The diagnosis of aminoglycoside nephrotoxicity in cirrhotics with serious infection is difficult because these patients may also develop functional renal failure. The determination of urinary sodium concentration, fractional sodium excretion and urine:plasma osmolality and creatinine ratios is not useful in differentiating functional renal failure from acute tubular necrosis in cirrhotic patients with ascites. The differential diagnosis, however, is of clinical importance. Aminoglycosides must be interrupted when nephrotoxicity develops, whereas careful dosage adjustment is necessary in the presence of functional renal failure. Furthermore, dialysis is indicated in cirrhotics with acute tubular necrosis, but not in patients with functional renal failure. The measurement of other urinary markers of tubular damage, such as β_2-microglobulin and tubular enzymes, may help in differentiating these disorders. The urinary concentration of β_2-microglobulin in alcoholic cirrhotics with superimposed acute alcoholic hepatitis, severe renal failure and deep jaundice (serum bilirubin greater than 20 mg/dL) may be similar to that commonly observed in acute tubular necrosis, suggesting a spontaneous development of tubular damage in these patients. Therefore, urinary β_2-microglobulin and tubular enzymes may not be useful in the diagnosis of aminoglycoside nephrotoxicity in patients with terminal hepatic and renal failure.

Non-steroidal anti-inflammatory drugs

The initial studies showing that patients with cirrhosis and ascites develop renal failure after cyclo-oxygenase inhibition with NSAIDs were made almost 20 years ago [159,265,266]. The first group of investigators observed that the oral administration of indomethacin (50 mg every 6 h for a total of four doses) produced a significant reduction in renal plasma flow and glomerular filtration rate in a large series of cirrhotics with ascites, but not in patients without ascites. Zipser *et al.* [266] gave indomethacin (200 mg for 1 day) or ibuprofen (2 mg for 1 day) to 12 cirrhotics with ascites and eight normal individuals; both drugs induced a marked decrease in urinary PGE_2 excretion and creatinine clearance in all patients, but they caused no change in creatinine clearance in normal individuals. Finally, Arroyo *et al.* [265] gave an intravenous bolus of 450 mg of lysine acetylsalicylate (equivalent to 250 mg of acetylsalicylic acid) to five normal individuals, nine cirrhotics who had never had ascites and 19 cirrhotics with ascites; it did not alter renal function in normal individuals and cirrhotics without ascites, but it reduced the glomerular filtration rate in 11 of the 19 patients with ascites. Urinary PGE_2 was decreased in all individuals after lysine acetylsalicylate. In these three studies, the degree of impairment in renal function after NSAIDs correlated with baseline values of urine sodium excretion and plasma renin and noradrenaline; patients with lower sodium excretion and higher plasma renin activity and noradrenaline concentrations developed greater reductions in renal plasma flow and glomerular filtration rate. These studies therefore indicate that cirrhotics with increased activity of the renin–angiotensin and sympathetic nervous systems and marked sodium retention are especially predisposed to develop renal failure after cyclo-oxygenase inhibition. The results of these three studies have been confirmed by subsequent investigations in cirrhotic patients with ascites receiving indomethacin, naproxen, lysine acetylsalicylate and sulindac, and in dogs with cirrhosis secondary to common bile duct ligation. The decline in glomerular filtration rate and renal blood flow in the dogs with ligated common bile ducts and

cirrhosis was preventable by prior administration of saralasin or captopril [267], confirming that overactivity of endogenous vasoconstrictor systems as well as inhibition of renal prostaglandin synthesis is a major determinant of renal failure after NSAID administration.

Some investigators have suggested that non-acetylated salicylates are less effective in inhibiting renal synthesis of prostaglandins than other NSAIDs, and do not impair renal function or the renal response to furosemide in patients and experimental animals with cirrhosis and ascites. On the other hand, there are several experimental studies and one investigation in human cirrhosis showing that pharmacological doses of COX-2 inhibitors (celecoxib), given during a short period of time (3 days), do not affect renal function or the renal response to diuretics in patients with ascites and increased plasma renin activity [268–270]. Further studies are needed to confirm these findings.

The most important practical conclusion of these investigations is that NSAIDs should be used with great caution, if ever, in patients with cirrhosis and ascites because they may induce renal failure, water retention and dilutional hyponatraemia, and diuretic-resistant ascites. Although these adverse renal effects have always been rapidly reversible after drug withdrawal, it is important to note that, in these studies, NSAIDs were given as an investigative tool, at low dosage and for 1 or 2 days only. Whether renal impairment would also be quickly reversible after long-term treatment with therapeutic dosages of these drugs is unknown.

Drugs used in the treatment of portal hypertension

Reports on the renal effects of somatostatin, a drug used for the treatment of acute variceal bleeding, are conflicting. One study [271] shows a significant decrease in glomerular filtration rate, sodium excretion and free-water clearance during the acute infusion of somatostatin. Conversely, another study [272] shows an increase in urine volume and creatinine clearance in patients with ascites who received octreotide, a synthetic analogue of somatostatin.

Propranolol, the drug used most extensively in the prophylaxis of variceal bleeding and rebleeding, has significant effects on systemic and splanchnic haemodynamics and on the endogenous vasoactive systems. It reduces cardiac output, increases systemic vascular resistance and circulating noradrenaline and reduces plasma renin activity and aldosterone in patients with cirrhosis with and without ascites. However, it has no significant effects on renal function in these patients [273].

Nitrates have been introduced for the prophylaxis of variceal rebleeding, given alone or in combination with propranolol. They reduce portal pressure mainly by decreasing hepatic vascular resistance, whereas propranolol is effective by reducing portal venous inflow and acting on the portocollateral circulation. This difference might explain the additive effects of the combined treatment in reducing portal pressure. The acute oral administration of isosorbide-5-mononitrate in cirrhotic patients with and without ascites is associated with a significant reduction in cardiac output, systemic vascular resistance and arterial pressure, an increase in plasma renin activity and aldosterone concentration, a suppression of the plasma concentrations of atrial natriuretic peptide and a reduction in renal blood flow, glomerular filtration rate, free-water clearance and sodium excretion [274]. These effects were particularly marked in the patients with ascites. These findings were later confirmed [275] in a study that observed the same changes after the acute administration of isosorbide-5-mononitrate in 21 patients with and without ascites. Interestingly, Salerno *et al.* [275] also found a significant reduction in arterial pressure, urine volume and sodium excretion during long-term administration of the drug in the patients with ascites. Therefore, acute and chronic administration of nitrates alone impairs renal function in decompensated cirrhosis. The effect of the combined treatment (propranolol plus nitrates) on renal function is more controversial. Vorobioff *et al.* [276] compared patients chronically treated with propranolol alone with those treated with propranolol plus isosorbide dinitrate. Eight of the 14 patients with ascites or a history of ascites receiving propranolol plus isosorbide dinitrate showed impairment in renal function and sodium metabolism, as reflected by the clinical development or worsening of ascites and a need for higher diuretic dosage. This high frequency of renal impairment did not occur in patients receiving propranolol alone, In contrast, others did not observe any detrimental effects on renal function after 3 or 6 months of therapy with a combination of isosorbide-5-mononitrate and β-blockers [277,278].

Prazosin is another drug investigated as a possible treatment for portal hypertension. It is an α-adrenergic blocker that reduces portal pressure by decreasing intrahepatic vascular resistance. Long-term administration of prazosin to compensated cirrhotic patients with portal hypertension caused vasodilation of the systemic circulation, which led to ascites or oedema formation in a significant number of patients [279].

References

1 Berner C, Davis JS, Riggs S *et al.* (1964) Diagnostic probabilities in patients with conspicuous ascites. *Arch Intern Med* 113, 687–690.

2 Lawson JD, Weissbein AS (1959) The puddle sign – an aid in the diagnosis of minimal ascites. *N Engl J Med* 260, 652–654.

3 Cattau EL, Benjamin SB, Knuff TE *et al.* (1982) The accuracy of the physical examination in the diagnosis of suspected ascites. *JAMA* 247, 1164–1166.

4 Branney SW, Wolfe RE, Moore EE *et al.* (1995) Quantitative sensitivity of ultrasound in detecting free intraperitoneal fluid. *J Trauma Injury Infect Crit Care* 39, 375–380.

5 Huning R (1973) Ultrasonic diagnosis of Wilms tumor. *Fortschritte Gebiete Rontgenstrahl Nuklearmed* 158–159.

6 Wall SD, Hricak H, Bailey GD *et al.* (1986) MR imaging of pathological abdominal fluid collections. *J Comp Assist Tomogr* 10, 746–750.

7 Proto AV, Lane EJ (1976) Visualization of differences in soft-tissue densities – liver in ascites. *Radiology* 121, 19–23.
8 Steinkampf MP, Blackwell RE, Younger JB (1991) Visualization of free peritoneal fluid with transvaginal sonography – a preliminary study. *J Reprod Med* 36, 729–730.
9 Edell SL, Gefter WB (1979) Ultrasonic differentiation of types of ascitic fluid. *Am J Roentgenol* 133, 111–114.
10 Kedar RP, Shah PP, Shivde RS *et al.* (1994) Sonographic findings in gastroenterology and peritoneal tuberculosis. *Clin Radiol* 49, 24–29.
11 Runyon BA, Montano AA, Akriviadis EA *et al.* (1992) The serum ascites albumin gradient is superior to the exudate–transudate concept in the differential diagnosis of ascites. *Ann Intern Med* 117, 215–220.
12 Wilson JAP, Suguitan EA, Cassidy WA *et al.* (1979) Characteristics of ascitic fluid in the alcoholic cirrhotic. *Dig Dis Sci* 24, 645–648.
13 Sampline RE, Iber FL (1974) High protein ascites in patients with uncomplicated hepatic cirrhosis. *Am J Med Sci* 267, 275–279.
14 Hoefs JC (1983) Serum protein concentration and portal pressure determine the ascitic fluid protein concentration in patients with chronic liver disease. *J Lab Clin Med* 102, 260–273.
15 Henriksen JH (1983) Permselectivity of the liver blood lymph (ascitic fluid) barrier to macromolecules in decompensated cirrhosis – relation to calculated pore size. *Clin Physiol* 3, 163–171.
16 Henriksen JH, Lassen NA, Parving HH *et al.* (1980) Filtration as the main transport mechanism of protein exchange between plasma and the peritoneal-cavity in hepatic cirrhosis. *Scand J Clin Lab Invest* 40, 503–513.
17 Runyon BA, Vanepps DE (1986) Diuresis of cirrhotic ascites increases its opsonic activity and may help prevent spontaneous bacterial peritonitis. *Hepatology* 6, 396–399.
18 Fromkes JJ, Thomas FB, Mekhjian HS *et al.* (1977) Antimicrobial activity of human ascitic fluid. *Gastroenterology* 73, 668–672.
19 Simberkoff MS, Moldover NH, Weiss G (1978) Bactericidal and opsonic activity of cirrhotic ascites and nonascitic peritoneal fluid. *J Lab Clin Med* 91, 831–839.
20 Runyon BA, Morrissey RL, Hoefs JC *et al.* (1985) Opsonic activity of human ascitic fluid – a potentially important protective mechanism against spontaneous bacterial peritonitis. *Hepatology* 5, 634–637.
21 Such J, Guarner C, Enriquez J *et al.* (1988) Low C-3 in cirrhotic ascites predisposes to spontaneous bacterial peritonitis. *J Hepatol* 6, 80–84.
22 Barmeir S, Lerner E, Conn HO (1979) Analysis of ascitic fluid in cirrhosis. *Dig Dis Sci* 24, 136–144.
23 Conn HO, Fessel JM (1971) Spontaneous bacterial peritonitis in cirrhosis – variations on a theme. *Medicine* 50, 161–197.
24 Hoefs JC, Runyon BA (1985) Spontaneous bacterial peritonitis. *Disease-A-Month* 31, 1–48.
25 Gitlin N, Stauffer JL, Silvestri RC (1982) The Ph of ascitic fluid in the diagnosis of spontaneous bacterial peritonitis in alcoholic cirrhosis. *Hepatology* 2, 408–411.
26 Stassen WN, McCullough AJ, Bacon BR *et al.* (1986) Immediate diagnostic-criteria for bacterial-infection of ascitic fluid – evaluation of ascitic fluid polymorphonuclear leukocyte count, Ph, and lactate concentration, alone and in combination. *Gastroenterology* 90, 1247–1254.
27 Garciatsao G, Conn HO, Lerner E (1985) The diagnosis of bacterial peritonitis – comparison of Ph, lactate concentration and leukocyte count. *Hepatology* 5, 91–96.
28 Hoefs JC (1981) Increase in ascites white blood cell and protein concentrations during diuresis in patients with chronic liver disease. *Hepatology* 1, 249–254.
29 Desitter L, Rector WG (1984) The significance of bloody ascites in patients with cirrhosis. *Am J Gastroenterol* 79, 136–138.
30 Dumont AE, Mulholland JH (1960) Flow rate and composition of thoracic-duct lymph in patients with cirrhosis. *N Engl J Med* 263, 471–474.
31 Buo L, Karlsrud TS, Dyrhaug G *et al.* (1995) The fibrinolytic system in human ascites. *Scand J Gastroenterol* 30, 1101–1107.
32 Hoefs J, Barnes T, Halle P (1981) Intraperitoneal coagulation in chronic liver disease ascites. *Dig Dis Sci* 26, 518–522.
33 Wilkinson SP, Henderson J, Davidson AR *et al.* (1975) Ascites reinfusion using rhodiascit apparatus – clinical experience and coagulation abnormalities. *Postgrad Med J* 51, 583–587.
34 Leveen HH, Ahmed N, Hutto RB *et al.* (1987) Coagulopathy post peritoneovenous shunt. *Ann Surg* 205, 305–311.
35 Bac DJ, Pruimboom WM, Mulder PGH *et al.* (1995) High interleukin-6 production within the peritoneal-cavity in decompensated cirrhosis and malignancy-related ascites. *Liver* 15, 265–270.
36 Zeni F, Tardy B, Vindimian M *et al.* (1993) High levels of tumor necrosis factor alpha and interleukin-6 in the ascitic fluid of cirrhotic patients with spontaneous bacterial peritonitis. *Clin Infect Dis* 17, 218–223.
37 Navasa M, Follo A, Filella X *et al.* (1998) Tumor necrosis factor and interleukin-6 in spontaneous bacterial peritonitis in cirrhosis: relationship with the development of renal impairment and mortality. *Hepatology* 27, 1227–1232.
38 Cejudo P, Jimenez W, Ros J *et al.* (2001) Increased production of vascular endothelial growth factor in peritoneal macrophages of cirrhotic patients with spontaneous bacterial peritonitis. *Hepatology* 34, 184A.
39 Giannini E, Romagnoli P, Tenconi GL *et al.* (2004) High ascitic fluid leptin levels in patients with decompensated liver cirrhosis and sterile ascites: relationship with TNF-alpha levels. *Dig Dis Sci* 49, 275–280.
40 Runyon BA, Hoefs JC, Morgan TR (1988) Ascitic fluid analysis in malignancy-related ascites. *Hepatology* 8, 1104–1109.
41 Rector WG, Reynolds TB (1984) Superiority of the serum ascites albumin difference over the ascites total protein concentration in separation of transudative and exudative ascites. *Am J Med* 77, 83–85.
42 Garcia LW, Ducatman BS, Wang HH (1994) The value of multiple fluid specimens in the cytological diagnosis of malignancy. *Mod Pathol* 7, 665–668.
43 Prieto M, Gomezlechon MJ, Hoyos M *et al.* (1988) Diagnosis of malignant ascites – comparison of ascitic fibronectin, cholesterol, and serum-ascites albumin difference. *Dig Dis Sci* 33, 833–838.
44 Gerbes AL, Jungst D, Xie YN *et al.* (1991) Ascitic fluid analysis for the differentiation of malignancy-related and nonmalignant ascites – proposal of a diagnostic sequence. *Cancer* 68, 1808–1814.
45 Castaldo G, Oriani G, Cimino L *et al.* (1994) Total discrimination of peritoneal malignant ascites from cirrhosis-associated and hepatocarcinoma-associated ascites by assays of ascitic cholesterol and lactate dehydrogenase. *Clin Chem* 40, 478–483.
46 Hafter R, Klaubert W, Gollwitzer R *et al.* (1984) Crosslinked fibrin derivatives and fibronectin in ascitic fluid from patients with ovarian cancer compared to ascitic fluid in liver cirrhosis. *Thromb Res* 35, 53–64.

47 Gerbes AL, Hoermann R, Mann K *et al.* (1996) Human chorionic gonadotropin-beta in the differentiation of malignancy-related and nonmalignant ascites. *Digestion* 57, 113–117.

48 Lee CM, Changchien CS, Shyu WC *et al.* (1992) Serum ascites albumin concentration gradient and ascites fibronectin in the diagnosis of malignant ascites. *Cancer* 70, 2057–2060.

49 Chu CM, Lin SM, Peng SM *et al.* (1994) The role of laparoscopy in the evaluation of ascites of unknown origin. *Gastrointest Endosc* 40, 285–289.

50 Rector WG (1984) Spontaneous chylous ascites of cirrhosis. *J Clin Gastroenterol* 6, 369–372.

51 Press OW, Press NO, Kaufman SD (1982) Evaluation and management of chylous ascites. *Ann Intern Med* 96, 358–364.

52 Malagela JR, Iber FL, Linschee WG (1974) Origin of fat in chylous ascites of patients with liver cirrhosis. *Gastroenterology* 67, 878–886.

53 Maywood BT, Goldstein L, Busuttil RW (1978) Chylous ascites after a Warren shunt. *Am J Surg* 135, 700–702.

54 Lingenfelser T, Zak J, Marks IN *et al.* (1993) Abdominal tuberculosis – still a potentially lethal disease. *Am J Gastroenterol* 88, 744–750.

55 Lundstedt C, Nyman R, Brismar J *et al.* (1996) Imaging of tuberculosis. 2. Abdominal manifestations in 112 patients. *Acta Radiol* 37, 489–495.

56 Shakil AO, Korula J, Kanel GC *et al.* (1996) Diagnostic features of tuberculous peritonitis in the absence and presence of chronic liver disease: a case control study. *Am J Med* 100, 179–185.

57 Martinezvazquez JM, Ocana I, Ribera E *et al.* (1986) Adenosine deaminase activity in the diagnosis of tuberculous peritonitis. *Gut* 27, 1049–1053.

58 Hillebrand DJ, Runyon BA, Yasmineh WG *et al.* (1996) Ascitic fluid adenosine deaminase insensitivity in detecting tuberculous peritonitis in the United States. *Hepatology* 24, 1408–1412.

59 Wolfe JHN, Behn AR, Jackson BT (1979) Tuberculous peritonitis and role of diagnostic laparoscopy. *Lancet* 1, 852–853.

60 Delope CR, Joglar GSM, Romero FP (1982) Laparoscopic diagnosis of tuberculous ascites. *Endoscopy* 14, 178–179.

61 Bhargava DK, Shriniwa S, Chopra P *et al.* (1992) Peritoneal tuberculosis – laparoscopic patterns and its diagnostic accuracy. *Am J Gastroenterol* 87, 109–112.

62 Holmes EC, Eggleston JC (1972) Starch granulomatous peritonitis. *Surgery* 71, 85–90.

63 Schwake L, von Herbay A, Junghanss T *et al.* (2003) Peritoneal tuberculosis with negative polymerase chain reaction results: report of two cases. *Scand J Gastroenterol* 38, 221–224.

64 Gamboa F, Dominguez J, Padilla E *et al.* (1998) Rapid diagnosis of extrapulmonary tuberculosis by ligase chain reaction amplification. *J Clin Microbiol* 36, 1324–1329.

65 Runyon BA (1988) Cardiac ascites – a characterization. *J Clin Gastroenterol* 10, 410–412.

66 Ackerman NB, Sillin LF, Suresh K (1985) Consequences of intraperitoneal bile – bile ascites versus bile peritonitis. *Am J Surg* 149, 244–246.

67 Sankaran S, Walt AJ (1976) Pancreatic ascites – recognition and management. *Arch Surg* 111, 430–434.

68 Maringhini A, Ciambra M, Patti R *et al.* (1996) Ascites, pleural, and pericardial effusions in acute pancreatitis – a prospective study of incidence, natural history, and prognostic role. *Dig Dis Sci* 41, 848–852.

69 Boyer TD, Kahn AM, Reynolds TB (1978) Diagnostic value of ascitic fluid lactic-dehydrogenase, protein, and WBC levels. *Arch Intern Med* 138, 1103–1105.

70 Hammond TC, Takiyyuddin MA (1994) Nephrogenic ascites – a poorly understood syndrome. *J Am Soc Nephrol* 5, 1173–1177.

71 Balasch J, Arroyo V, Fabregues F *et al.* (1994) Neurohormonal and hemodynamic-changes in severe cases of the ovarian hyperstimulation syndrome. *Ann Intern Med* 121, 27–33.

72 Lieberman F, Hidemura R, Peters RL *et al.* (1966) Pathogenesis and treatment of hydrothorax complicating cirrhosis with ascites. *Ann Intern Med* 64, 341–351.

73 Lieberman F, Peters RL (1970) Cirrhotic hydrothorax. Further evidence that an acquired diaphragmatic defect is at fault. *Arch Intern Med* 125, 114.

74 Singer JA, Kaplan MM, Katz RL (1977) Cirrhotic pleural effusion in absence of ascites. *Gastroenterology* 73, 575–577.

75 Xiol X, Castellvi JM, Guardiola J *et al.* (1996) Spontaneous bacterial empyema in cirrhotic patients: a prospective study. *Hepatology* 23, 719–723.

76 Mouroux J, Perrin C, Venissac N *et al.* (1996) Management of pleural effusion of cirrhotic origin. *Chest* 109, 1093–1096.

77 Witte MH, Witte CL, Dumont AE (1981) Estimated net transcapillary water and protein flux in the liver and intestine of patients with portal-hypertension from hepatic cirrhosis. *Gastroenterology* 80, 265–272.

78 Gnepp D (1984) Lymphatics. In: Staub N, Taylor AE (eds) *Edema*. New York: Raven Press, pp. 263–298.

79 Laine GA, Hall JT, Laine SH *et al.* (1979) Trans-sinusoidal fluid-dynamics in canine liver during venous hypertension. *Circ Res* 45, 317–323.

80 Greenway CV, Lautt WW (1970) Effects of hepatic venous pressure on transsinusoidal fluid transfer in liver of anesthetized cat. *Circ Res* 26, 697–703.

81 Granger DN, Miller T, Allen R *et al.* (1979) Permselectivity of cat liver blood–lymph barrier to endogenous macromolecules. *Gastroenterology* 77, 103–109.

82 Granger DN, Barrowman J (1984) Gastroenterology and liver edema. In: Staub N, Taylor AE (eds) *Edema*. New York: Raven Press, pp. 615–656.

83 Iber FL (1974) Normal and pathologic physiology of the liver. In: Sodeman W, Sodeman WJ (eds) *Pathologic Physiology*. Philadelphia: Saunders, pp. 790–817.

84 Freeman S (1953) Recent progress in the physiology and biochemistry of the liver. *Med Clin N Am* 1, 109–124.

85 Mallet-Guy P, Devic G, Feroldi J *et al.* (1954) Experimental study of ascites: posthepatic venous stenosis and transposition of the liver into the thorax. *Lyon Chir* 49, 153–172.

86 Richardson PDI, Granger DN, Mailman D *et al.* (1980) Permeability characteristics of colonic capillaries. *Am J Physiol* 239, G300–G305.

87 Mortillaro NA, Taylor AE (1976) Interaction of capillary and tissue forces in cat small-intestine. *Circ Res* 39, 348–358.

88 Witte CL, Witte MH, Dumont AE (1980) Lymph imbalance in the genesis and perpetuation of the ascites syndrome in hepatic cirrhosis. *Gastroenterology* 78, 1059–1068.

89 Huet PM, Goresky CA, Villeneuve JP *et al.* (1982) Assessment of liver microcirculation in human cirrhosis. *J Clin Invest* 70, 1234–1244.

90 Vorobioff J, Bredfeldt JE, Groszmann RJ (1984) Increased blood flow through the portal system in cirrhotic rats. *Gastroenterology* 87, 1120–1126.

91 Buhac I, Jarmolych J (1978) Histology of intestinal peritoneum in patients with cirrhosis of liver and ascites. *Am J Dig Dis* 23, 417–422.

92 Witte MH, Witte CL, Dumont AE (1971) Progress in liver disease – physiological factors involved in causation of cirrhotic ascites. *Gastroenterology* 61, 742–750.

93 Witte CL, Witte MH, Cole WR *et al.* (1969) Dual origin of ascites in hepatic cirrhosis. *Surg Gynecol Obstet/Int Abstracts Surg* 129, 1027–1033.

94 Vorobioff J, Bredfeldt JE, Groszmann RJ (1983) Hyperdynamic circulation in portal-hypertensive rat model – a primary factor for maintenance of chronic portal-hypertension. *Am J Physiol* 244, G52–G57.

95 Bosch J, Enriquez R, Groszmann RJ *et al.* (1983) Chronic bile-duct ligation in the dog – hemodynamic characterization of a portal hypertensive model. *Hepatology* 3, 1002–1007.

96 Sugita S, Ohnishi K, Saito M *et al.* (1987) Splanchnic hemodynamics in portal hypertensive dogs with portal fibrosis. *Am J Physiol* 252, G748–G754.

97 Korthuis RJ, Kinden DA, Brimer GE *et al.* (1988) Intestinal capillary filtration in acute and chronic portal-hypertension. *Am J Physiol* 254, G339–G345.

98 Benoit JN, Granger DN (1986) Splanchnic hemodynamics in chronic portal hypertension. *Semin Liver Dis* 6, 287–298.

99 Kiel JW, Pitts V, Benoit JN *et al.* (1985) Reduced vascular sensitivity to norepinephrine in portal-hypertensive rats. *Am J Physiol* 248, G192–G195.

100 Benoit JN, Korthuis RJ, Granger DN *et al.* (1990) Splanchnic hemodynamics in acute and chronic portal hypertension. In: Bomzon A, Blendis L (eds) *Cardiovascular Complications of Liver Disease*. Boca Raton: CRC Press, pp. 179–206.

101 Groszmann RJ (1995) Mechanisms of portal hypertension. In: Arrovo V, Bosch J, Rodes J (eds) *Treatments in Hepatology*. Barcelona: Masson SA, pp. 3–8.

102 Huet PM, Pomierlayrargues G, Villeneuve JP *et al.* (1986) Intrahepatic circulation in liver disease. *Semin Liver Dis* 6, 277–286.

103 Bosch J, Mastai R, Kravetz D *et al.* (1985) Measurement of azygous venous blood flow in the evaluation of portal hypertension in patients with cirrhosis – clinical and hemodynamic correlations in 100 patients. *J Hepatol* 1, 125–139.

104 Bosch J, Arroyo V, Betriu A *et al.* (1980) Hepatic hemodynamics and the renin–angiotensin–aldosterone system in cirrhosis. *Gastroenterology* 78, 92–99.

105 Kotelanski B, Groszman R, Cohn JN (1972) Circulation times in splanchnic and hepatic beds in alcoholic liver disease. *Gastroenterology* 63, 102–111.

106 Arroyo V, Rodes J (1975) Rational approach to treatment of ascites. *Postgrad Med J* 51, 558–562.

107 Jimenez W, Martinezpardo A, Arroyo V *et al.* (1985) Temporal relationship between hyper-aldosteronism, sodium retention and ascites formation in rats with experimental cirrhosis. *Hepatology* 5, 245–250.

108 Caregaro L, Lauro S, Angeli P *et al.* (1985) Renal water and sodium handling in compensated liver-cirrhosis – mechanism of the impaired natriuresis after saline loading. *Eur J Clin Invest* 15, 360–364.

109 Naccarato R, Messa P, Dangelo A *et al.* (1981) Renal handling of sodium and water in early chronic liver-disease – evidence for a reduced natriuretic activity of the cirrhotic urinary extracts in rats. *Gastroenterology* 81, 205–210.

110 Wong F, Massie D, Hsu P *et al.* (1994) Renal response to a saline load in well-compensated alcoholic cirrhosis. *Hepatology* 20, 873–881.

111 Wilkinson SP, Smith IK, Moodie H *et al.* (1979) Studies on mineralocorticoid escape in cirrhosis. *Clin Sci* 56, 401–406.

112 Lavilla G, Salmeron JM, Arroyo V *et al.* (1992) Mineralocorticoid escape in patients with compensated cirrhosis and portal hypertension. *Gastroenterology* 102, 2114–2119.

113 Trevisani F, Bernardi M, Gasbarrini A *et al.* (1992) Bed-rest-induced hypernatriuresis in cirrhotic-patients without ascites – does it contribute to maintain compensation? *J Hepatol* 16, 190–196.

114 Bernardi M, Dimarco C, Trevisani F *et al.* (1993) Renal sodium retention during upright posture in preascitic cirrhosis. *Gastroenterology* 105, 188–193.

115 Papper S, Rosenbaum JD (1952) Abnormalities in the excretion of water and sodium in compensated cirrhosis of the liver. *J Lab Clin Med* 40, 523–530.

116 Shear L, Hall PW, Gabuzda GJ (1965) Renal failure in patients with cirrhosis of liver. 2. factors influencing maximal urinary flow rate. *Am J Med* 39, 199–209.

117 Epstein M (1985) Derangements of renal water handling in liver disease. *Gastroenterology* 89, 1415–1425.

118 Arroyo V, Rodes J, Gutierrezlizarraga MA *et al.* (1976) Prognostic value of spontaneous hyponatremia in cirrhosis with ascites. *Am J Dig Dis* 21, 249–256.

119 Rodes J, Brugera M, Teres J *et al.* (1970) Terminal functional renal insufficiency (TFRI) in liver cirrhosis with ascites. *Rev Clin Esp* 117, 475–482.

120 Gines A, Escorsell A, Gines P *et al.* (1993) Incidence, predictive factors, and prognosis of the hepatorenal-syndrome in cirrhosis with ascites. *Gastroenterology* 105, 229–236.

121 Llach J, Gines P, Arroyo V *et al.* (1988) Prognostic value of arterial pressure, endogenous vasoactive systems, and renal function in cirrhotic patients admitted to the hospital for the treatment of ascites. *Gastroenterology* 94, 482–487.

122 Rodes J, Arroyo V, Bosch J (1975) Clinical types and drug therapy of renal impairment in cirrhosis. *Postgrad Med J* 51, 492–497.

123 Arroyo V, Gines P, Gerbes AL *et al.* (1996) Definition and diagnostic criteria of refractory ascites and hepatorenal syndrome in cirrhosis. *Hepatology* 23, 164–176.

124 Laragh J, Sealey JE (1992) Renin–angiotensin–aldosterone system and the regulation of sodium, potassium and blood pressure homeostasis. In: Windhager E (ed.) *Handbook of Physiology: Renal Physiology*. New York: Oxford University Press, pp. 1409–1542.

125 Simon MA, Diez J, Prieto J (1991) Abnormal sympathetic and renal response to sodium restriction in compensated cirrhosis. *Gastroenterology* 101, 1354–1360.

126 Salo J, Gines A, Anibarro L *et al.* (1995) Effect of upright posture and physical exercise on endogenous neurohormonal systems in cirrhotic patients with sodium retention and normal supine plasma renin, aldosterone, and norepinephrine levels. *Hepatology* 22, 479–487.

127 Wilkinson SP, Jowett TP, Slater JDH *et al.* (1979) Renal sodium retention in cirrhosis – relation to aldosterone and nephron site. *Clin Sci* 56, 169–177.

128 Perezayuso RM, Arroyo V, Planas R *et al.* (1983) Randomized comparative study of efficacy of furosemide versus spironolactone in nonazotemic cirrhosis with ascites – relationship between the diuretic response and the activity of the renin–aldosterone system. *Gastroenterology* 84, 961–968.

129 Kotelanski B, Groszman R, Cohn JN (1972) Circulation times in splanchnic and hepatic beds in alcoholic liver disease. *Gastroenterology* 63, 102–111.

130 Nicholls KM, Shapiro MD, Vanputten VJ *et al.* (1985) Elevated plasma norepinephrine concentrations in decompensated cirrhosis – association with increased secretion rates, normal clearance rates, and suppressibility by central blood volume expansion. *Circ Res* 56, 457–461.
131 Henriksen J, Ring-Larsen H, Christensen N (1985) Circulating noradrenaline and central haemodynamics in patients with cirrhosis. *Scand J Gastroenterol* 20, 1185–1190.
132 Lieberman F, Reynolds TB (1967) Plasma volume in cirrhosis of liver – its relation to portal hypertension ascites and renal failure. *J Clin Invest* 46, 1297–1308.
133 Arroyo V, Bosch J, Mauri M *et al.* (1981) Effect of angiotensin-II blockade on systemic and hepatic hemodynamics and on the renin-angiotensin-aldosterone system in cirrhosis with ascites. *Eur J Clin Invest* 11, 221–229.
134 Perezayuso RM, Arroyo V, Camps J *et al.* (1984) Renal kallikrein excretion in cirrhotics with ascites – relationship to renal hemodynamics. *Hepatology* 4, 247–252.
135 Arroyo V, Planas R, Gaya J *et al.* (1983) Sympathetic nervous activity, renin–angiotensin system and renal excretion of prostaglandin-e2 in cirrhosis – relationship to functional renal failure and sodium and water excretion. *Eur J Clin Invest* 13, 271–278.
136 Tobey JC, Weaver LC (1987) Pressoreceptor modulation of renal but not splenic sympathetic reflexes. *Am J Physiol* 252, R26–R33.
137 Robertson GL (1992) Regulation of vasopressin secretion. In: Seldin D, Giebisch G (eds) *The Kidney: Physiology and Pathophysiology*. New York: Raven Press, pp. 1595–1614.
138 Barajas L, Muller J (1973) Innervation of juxtaglomerular apparatus and surrounding tubules – quantitative-analysis by serial section electron microscopy. *J Ultrastruct Res* 43, 107–132.
139 Kopp U, DiBona G (1992) Neural control of renal function. In: Seldin D, Giebisch G (eds) *The Kidney: Physiology and Pathophysiology*. New York: Raven Press, pp. 1157–1204.
140 Bichet DG, Vanputten VJ, Schrier RW (1982) Potential role of increased sympathetic activity in impaired sodium and water excretion in cirrhosis. *N Engl J Med* 307, 1552–1557.
141 Ringlarsen H, Hesse B, Henriksen JH *et al.* (1982) Sympathetic nervous activity and renal and systemic hemodynamics in cirrhosis – plasma norepinephrine concentration, hepatic extraction, and renal release. *Hepatology* 2, 304–310.
142 Maroto A, Gines P, Arroyo V *et al.* (1993) Brachial and femoral artery blood flow in cirrhosis – relationship to kidney dysfunction. *Hepatology* 17, 788–793.
143 Solisherruzo JA, Duran A, Favela V *et al.* (1987) Effects of lumbar sympathetic block on kidney function in cirrhotic patients with hepatorenal syndrome. *J Hepatol* 5, 167–173.
144 Ishikawa S, Schrier RW (2003) Pathophysiological roles of arginine vasopressin and aquaporin-2 in impaired water excretion. *Clin Endocrinol* 58, 1–17.
145 Ishikawa S, Saito T, Kasono K (2004) Pathological role of aquaporin-2 in impaired water excretion and hyponatremia. *J Neuroendocrinol* 16, 293–296.
146 Jamison R, Gehrig JJ (1992) Urinary concentration and dilution. In: Windhager E (ed.) *Handbook of Physiology: Section 8, Renal Physiology*. New York: Oxford University Press, pp. 1219–1280.
147 Perezayuso RM, Arroyo V, Camps J *et al.* (1984) Evidence that renal prostaglandins are involved in renal water metabolism in cirrhosis. *Kidney Int* 26, 72–80.
148 Linas SL, Anderson RJ, Guggenheim SJ *et al.* (1981) Role of vasopressin in impaired water-excretion in conscious rats with experimental cirrhosis. *Kidney Int* 20, 173–180.
149 Claria J, Jimenez W, Arroyo V *et al.* (1989) Blockade of the hydroosmotic effect of vasopressin normalizes water excretion in cirrhotic rats. *Gastroenterology* 97, 1294–1299.
150 Gerbes AL, Golberg V, Gines P *et al.* (2003) Therapy of hyponatremia in cirrhosis with a vasopressin receptor antagonist: a randomized double-blind multicenter trial. *Gastroenterology* 124, 933–939.
151 Wong F, Blei AT, Blendis LM *et al.* (2003) A vasopressin receptor antagonist (VPA-985) improves serum sodium concentration in patients with hyponatremia: a multicenter, randomized, placebo-controlled trial. *Hepatology* 37, 182–191.
152 Gines P, Wong F, Milutinovic S *et al.* (2006) Effects of satavaptan (SR121463B), a selective vasopressin V2 receptor antagonist, on serum sodium concentration and ascites in patients with cirrhosis and hyponatremia. *J Hepatol* 44(2), S270.
153 Bosch-Marcé M, Jimenez W, Angeli P *et al.* (1995) Aquaretic effect of the kappa-opioid agonist Ru-51599 in cirrhotic rats with ascites and water retention. *Gastroenterology* 109, 217–223.
154 Smith WL (1992) Prostanoid biosynthesis and mechanisms of action. *Am J Physiol* 263, F181–F191.
155 Schnermann J, Briggs JP (1981) Participation of renal cortical prostaglandins in the regulation of glomerular filtration rate. *Kidney Int* 19, 802–815.
156 Conrad K, Dunn M (1992) Renal prostaglandins and other eicosanoids. In: Windhager E (ed.) *Handbook of Physiology: Section 8, Renal Physiology*. New York: Oxford University Press, pp. 1708–1757.
157 Rimola A, Gines P, Arroyo V *et al.* (1986) Urinary excretion of 6-keto-prostaglandin F1-alpha, thromboxane B-2 and prostaglandin-E2 in cirrhosis with ascites – relationship to functional renal failure (hepatorenal syndrome). *J Hepatol* 3, 111–117.
158 Moore K, Ward PS, Taylor GW *et al.* (1991) Systemic and renal production of thromboxane-A2 and prostacyclin in decompensated liver disease and hepatorenal syndrome. *Gastroenterology* 100, 1069–1077.
159 Boyer TD, Zia P, Reynolds TB (1979) Effect of indomethacin and prostaglandin-A1 on renal function and plasma renin activity in alcoholic liver disease. *Gastroenterology* 77, 215–222.
160 Lianos EA, Alavi N, Tobin M *et al.* (1982) Angiotensin-induced sodium-excretion patterns in cirrhosis – role of renal prostaglandins. *Kidney Int* 21, 70–77.
161 Wong F, Massie D, Hsu P, Dudley F (1993) Indomethacin-induced renal dysfunction in patients with well-compensated cirrhosis. *Gastroenterology* 104, 869–876.
162 Lianos EA, Alavi N, Tobin M *et al.* (1982) Angiotensin-induced sodium-excretion patterns in cirrhosis – role of renal prostaglandins. *Kidney Int* 21, 70–77.
163 Claria J, Kent JD, Lopez-Parra M *et al.* (2005) Effects of celecoxib and naproxen on renal function in nonazotemic patients with cirrhosis and ascites. *Hepatology* 41, 579–587.
164 Abelmann WH (1994) Hyperdynamic circulation in cirrhosis – a historical perspective. *Hepatology* 20, 1356–1358.
165 Fernandez-Seara J, Prieto J, Quiroga J *et al.* (1989) Systemic and regional hemodynamics in patients with liver cirrhosis and ascites with and without functional renal-failure. *Gastroenterology* 97, 1304–1312.
166 Guevara M, Bru C, Gines P *et al.* (1998) Increased cerebrovascular resistance in cirrhotic patients with ascites. *Hepatology* 28, 39–44.

167 Morales-Ruiz M, Tugues S, Cejudo-Martin P *et al.* (2005) Ascites from cirrhotic patients induces angiogenesis through the phosphoinositide 3-kinase/Akt signaling pathway. *J Hepatol* 43, 85–91.

168 Wiest R, Das S, Cadelina G *et al.* (1999) Bacterial translocation in cirrhotic rats stimulates eNOS-derived NO production and impairs mesenteric vascular contractility. *J Clin Invest* 104, 1223–1233.

169 Xu LM, Carter EP, Ohara M *et al.* (2000) Neuronal nitric oxide synthase and systemic vasodilation in rats with cirrhosis. *Am J Physiol (Renal Physiol)* 279, F1110–F1115.

170 Martin PY, Ohara M, Gines P *et al.* (1998) Nitric oxide synthase (NOS) inhibition for one week improves renal sodium and water excretion in cirrhotic rats with ascites. *J Clin Invest* 101, 235–242.

171 Wiest R, Groszmann RJ (2002) The paradox of nitric oxide in cirrhosis and portal hypertension: too much, not enough. *Hepatology* 35, 478–491.

172 Li Y, Song D, Zhang Y *et al.* (2003) Effect of neonatal capsaicin treatment on haemodynamics and renal function in cirrhotic rats. *Gut* 52, 293–299.

173 Gupta S, Morgan TR, Gordan GS (1992) Calcitonin gene-related peptide in hepatorenal-syndrome – a possible mediator of peripheral vasodilation. *J Clin Gastroenterol* 14, 122–126.

174 Fernandezrodriguez CM, Prieto J, Quiroga J *et al.* (1995) Plasma levels of substance P in liver cirrhosis – relationship to the activation of vasopressor systems and urinary sodium excretion. *Hepatology* 21, 35–40.

175 Chang CS, Chen GH, Lien HC *et al.* (1998) Small intestine dysmotility and bacterial overgrowth in cirrhotic patients with spontaneous bacterial peritonitis. *Hepatology* 28, 1187–1190.

176 Ruiz-del-Arbol L, Monescillo A, Arocena C *et al.* (2005) Circulatory function and hepatorenal syndrome in cirrhosis. *Hepatology* 42, 439–447.

177 Ros J, Claria J, Jimenez W *et al.* (1995) Role of nitric oxide and prostacyclin in the control of renal perfusion in experimental cirrhosis. *Hepatology* 22, 915–920.

178 Angeli P, Jimenez W, Arroyo V *et al.* (1994) Renal effects of natriuretic peptide receptor blockade in cirrhotic rats with ascites. *Hepatology* 20, 948–954.

179 Ruiz-del-Arbol W, Urman J, Fernandez J *et al.* (2003) Systemic, renal, and hepatic hemodynamic derangement in cirrhotic patients with spontaneous bacterial peritonitis. *Hepatology* 38, 1210–1218.

180 Moller S, Henriksen JH (2002) Cirrhotic cardiomyopathy: a pathophysiological review of circulatory dysfunction in liver disease. *Heart* 87, 9–15.

181 Witte CL, Witte MH, Dumont AE (1980) Lymph imbalance in the genesis and perpetuation of the ascites syndrome in hepatic cirrhosis. *Gastroenterology* 78, 1059–1068.

182 Schrier RW, Arroyo V, Bernardi M *et al.* (1988) Peripheral arterial vasodilation hypothesis – a proposal for the initiation of renal sodium and water-retention in cirrhosis. *Hepatology* 8, 1151–1157.

183 Benoit JN, Barrowman JA, Harper SL *et al.* (1984) Role of humoral factors in the intestinal hyperemia associated with chronic portal-hypertension. *Am J Physiol* 247, G486–G493.

184 Benoit JN, Granger DN (1988) Intestinal microvascular adaptation to chronic portal hypertension in the rat. *Gastroenterology* 94, 471–476.

185 Arroyo V, Gines P (1992) Arteriolar vasodilation and the pathogenesis of the hyperdynamic circulation and renal sodium and water-retention in cirrhosis. *Gastroenterology* 102, 1077–1079.

186 Leak LV, Rahil K (1978) Permeability of diaphragmatic mesothelium – ultrastructural basis for stomata. *Am J Anat* 151, 557–593.

187 Tsilibary EC, Wissig SL (1977) Absorption from peritoneal-cavity – SEM study of mesothelium covering peritoneal surface of muscular portion of diaphragm. *Am J Anat* 149, 127–133.

188 Yoffey J, Courtice F (1970) Lymph flow and regional lymphatics. In: Arnold E (ed.) *Lymphatics, Lymph and Lymphomyeloid Complex*. New York: Academia, pp. 356–443.

189 Buhac I, Flesh L, Kishore R (1984) Intraabdominal pressure and resorption of ascites in decompensated liver cirrhosis. *J Lab Clin Med* 104, 264–270.

190 Arroyo V, Gines P, Planas R *et al.* (1986) Management of patients with cirrhosis and ascites. *Semin Liver Dis* 6, 353–369.

191 Arroyo V, Bosch J, Gayabeltran J *et al.* (1981) Plasma renin activity and urinary sodium excretion as prognostic indicators in nonazotemic cirrhosis with ascites. *Ann Intern Med* 94, 198–201.

192 Tage-Jensen U, Henriksen JH, Christensen E *et al.* (1988) Plasma catecholamine level and portal venous pressure as guides to prognosis in patients with cirrhosis. *J Hepatol* 6, 350–358.

193 Salerno F, Borroni G, Moser P *et al.* (1993) Survival and prognostic factors of cirrhotic patients with ascites – a study of 134 outpatients. *Am J Gastroenterol* 88, 514–519.

194 Guardiola J, Xiol X, Escriba JM *et al.* (1995) Prognosis assessment of cirrhotic patients with refractory ascites treated with a peritoneovenous shunt. *Am J Gastroenterol* 90, 2097–2102.

195 Ruf AE, Kremers WK, Chavez LL *et al.* (2005) Addition of serum sodium into the MELD score predicts waiting list mortality better than MELD alone. *Liver Transplant* 11, 336–343.

196 Heuman DM, Abou-assi SG, Habib A *et al.* (2004) Persistent ascites and low serum sodium identify patients with cirrhosis and low MELD scores who are at high risk for early death. *Hepatology* 40, 802–810.

197 Schepke M, Roth F, Koch L *et al.* (2003) Prognostic impact of renal impairment and sodium imbalance in patients undergoing transjugular intrahepatic portosystemic shunting for the prevention of variceal rebleeding. *Digestion* 67, 146–153.

198 Borroni G, Maggi A, Sangiovanni A *et al.* (2000) Clinical relevance of hyponatraemia for the hospital outcome of cirrhotic patients. *Dig Liver Dis* 32, 605–610.

199 Salo J, Guevara M, FernandezEsparrach G *et al.* (1997) Impairment of renal function during moderate physical exercise in cirrhotic patients with ascites: relationship with the activity of neurohormonal systems. *Hepatology* 25, 1338–1342.

200 Gines P, Arrovo V, Rodes J (1992) Pharmacotherapy of ascites associated with cirrhosis. *Drugs* 43, 316–332.

201 Moore KP, Wong F, Gines P *et al.* (2003) The management of ascites in cirrhosis: report on the consensus conference of the international ascites club. *Hepatology* 38, 258–266.

202 Suki W, Eknoyan G (1992) Physiology of diuretic action. In: Seldin D, Giebisch G (eds) *The Kidney: Physiology and Pathophysiology*, 2nd edn. New York: Raven, pp. 3629–3670.

203 Puschett J, Winaver J (1992) Effects of diuretics on renal function. In: Windhager E (ed.) *Handbook of Physiology: Section 8, Renal Physiology*. New York: Oxford University Press, pp. 2335–2407.

204 Karim A (1986) Spironolactone metabolism in man revisited. In: Brumer H (ed.) *Contemporary Trends in Diuretic Therapy*. Amsterdam: Excerpta Medica, pp. 23–27.

205 Sungaila I, Bartle WR, Walker SE *et al.* (1992) Spironolactone pharmacokinetics and pharmacodynamics in patients with cirrhotic ascites. *Gastroenterology* 102, 1680–1685.

206 Sawhney VK, Gregory PB, Swezey SE *et al.* (1981) Furosemide disposition in cirrhotic patients. *Gastroenterology* 81, 1012–1016.

207 Pinzani M, Daskalopoulos G, Laffi G *et al.* (1987) Altered furosemide pharmacokinetics in chronic alcoholic liver disease with ascites contributes to diuretic resistance. *Gastroenterology* 92, 294–298.

208 Traeger A, Hantze R, Penzlin M *et al.* (1985) Pharmacokinetics and pharmacodynamic effects of furosemide in patients with liver cirrhosis. *Int J Clin Pharmacol Therapeut* 23, 129–133.

209 Villeneuve JP, Verbeeck RK, Wilkinson GR *et al.* (1986) Furosemide kinetics and dynamics in patients with cirrhosis. *Clin Pharmacol Therapeut* 40, 14–20.

210 Gatta A, Angeli P, Caregaro L *et al.* (1991) A pathophysiological interpretation of unresponsiveness to spironolactone in a stepped-care approach to the diuretic treatment of ascites in nonazotemic cirrhotic patients. *Hepatology* 14, 231–236.

211 Bernardi M, Laffi G, Salvagnini M *et al.* (1993) Efficacy and safety of the stepped care medical treatment of ascites in liver cirrhosis – a randomized controlled clinical trial comparing 2 diets with different sodium content. *Liver* 13, 156–162.

212 Forns X, Gines A, Gines P *et al.* (1994) Management of ascites and renal failure in cirrhosis. *Semin Liver Dis* 14, 82–96.

213 Santos J, Planas R, Pardo A *et al.* (2003) Spironolactone alone or in combination with furosemide in the treatment of moderate ascites in nonazotemic cirrhosis. A randomized comparative study of efficacy and safety. *J Hepatol* 39, 187–192.

214 Shear L, Ching S, Gabuzda GJ (1970) Compartmentalization of ascites and edema in patients with hepatic cirrhosis. *N Engl J Med* 282, 1391-&.

215 Sherlock S, Senewira B, Scott A *et al.* (1966) Complications of diuretic therapy in hepatic cirrhosis. *Lancet* 1, 1049–1052.

216 Strauss E, de Sa M, Laut C (1985) Standardization of therapeutic approach for ascites due to chronic liver disease. A prospective study of 100 cases. *Gastroenterol Endosc Dig* 4, 79–86.

217 Angeli P, Albino G, Carraro P *et al.* (1996) Cirrhosis and muscle cramps: evidence of a causal relationship. *Hepatology* 23, 264–273.

218 Lee FY, Lee SD, Tsai YT *et al.* (1991) A randomized controlled trial of quinidine in the treatment of cirrhotic-patients with muscle cramps. *J Hepatol* 12, 236–240.

219 Planas R, Arroyo V, Rimola A *et al.* (1983) Acetylsalicylic acid suppresses the renal hemodynamic effect and reduces the diuretic action of furosemide in cirrhosis with ascites. *Gastroenterology* 84, 247–252.

220 Mirouze D, Zipser RD, Reynolds TB (1983) Effect of inhibitors of prostaglandin synthesis on induced diuresis in cirrhosis. *Hepatology* 3, 50–55.

221 Gines P, Arroyo V, Quintero E *et al.* (1987) Comparison of paracentesis and diuretics in the treatment of cirrhotics with tense ascites – results of a randomized study. *Gastroenterology* 93, 234–241.

222 Gines P, Tito L, Arroyo V *et al.* (1988) Randomized comparative study of therapeutic paracentesis with and without intravenous albumin in cirrhosis. *Gastroenterology* 94, 1493–1502.

223 Gines A, FernandezEsparrach G, Monescillo A *et al.* (1996) Randomized trial comparing albumin, dextran 70, and polygeline in cirrhotic patients with ascites treated by paracentesis. *Gastroenterology* 111, 1002–1010.

224 Ruiz-del-Arbol L, Monescillo A, Jimenez W *et al.* (1997) Paracentesis-induced circulatory dysfunction: mechanism and effect on hepatic hemodynamics in cirrhosis. *Gastroenterology* 113, 579–586.

225 Sola-Vera J, Minana J, Ricart E *et al.* (2003) Randomized trial comparing albumin and saline in the prevention of paracentesis-induced circulatory dysfunction in cirrhotic patients with ascites. *Hepatology* 37, 1147–1153.

226 LeVeen HH, Christou G, Ip M *et al.* (1974) Peritoneo-venous shunting for ascites. *Ann Surg* 180, 580–591.

227 Fulenwider JT, Galambos JD, Smith RB *et al.* (1986) Denver peritoneovenous shunts for intractable ascites of cirrhosis – a randomized, prospective trial. *Arch Surg* 121, 351–355.

228 Schroeder ET, Anderson GH, Smulyan H (1979) Effects of a portacaval or peritoneovenous shunt on renin in the hepatorenal syndrome. *Kidney Int* 15, 54–61.

229 Smadja C, Franco D (1985) The Leveen shunt in the elective treatment of intractable ascites in cirrhosis – a prospective study on 140 patients. *Ann Surg* 201, 488–493.

230 Lund RH, Moritz MW (1982) Complications of Denver peritoneovenous shunting. *Arch Surg* 117, 924–928.

231 Harmon DC, Demirjian Z, Ellman L *et al.* (1979) Disseminated intravascular coagulation with the peritoneovenous shunt. *Ann Intern Med* 90, 774–776.

232 Stein SF, Fulenwider JT, Ansley JD *et al.* (1981) Accelerated fibrinogen and platelet destruction after peritoneovenous shunting. *Arch Intern Med* 141, 1149–1151.

233 Tang HH, Salem HH, Wood LJ *et al.* (1992) Coagulopathy during ascites reinfusion – prevention by antiplatelet therapy. *Gastroenterology* 102, 1334–1339.

234 Ginès A, Planas R, Angeli P *et al.* (1995) Treatment of patients with cirrhosis and refractory ascites using leveen shunt with titanium tip – comparison with therapeutic paracentesis. *Hepatology* 22, 124–131.

235 Greenlee HB, Stanley MM, Reinhardt GF (1981) Intractable ascites treated with peritoneovenous shunts (LeVeen) – a 24-month to 64-month follow-up of results in 52 alcoholic cirrhotics. *Arch Surg* 116, 518–524.

236 Wapnick S, Grosberg SJ, Evans MI (1979) Randomized prospective matched pair study comparing peritoneovenous shunt and conventional therapy in massive ascites. *Br J Surg* 66, 667–670.

237 Bories P, Garcia Compean D, Michel H *et al.* (1986) The treatment of refractory ascites by the LeVeen shunt. A multi-centre controlled trial (57 patients). *J Hepatol* 3, 212–218.

238 Ringlarsen H, Siemssen O, Krintel JJ *et al.* (1988) Diuretic resistant ascites in cirrhosis treated with peritoneo-venous shunt – a randomized controlled trial. *Hepatology* 8, 1353.

239 Stanley MM, Ochi S, Lee KK *et al.* (1989) Peritoneovenous shunting as compared with medical-treatment in patients with alcoholic cirrhosis and massive ascites. *N Engl J Med* 321, 1632–1638.

240 Gines P, Arroyo V, Vargas V *et al.* (1991) Paracentesis with intravenous infusion of albumin as compared with peritoneovenous shunting in cirrhosis with refractory ascites. *N Engl J Med* 325, 829–835.

241 Orloff MJ (1970) Pathogenesis and surgical treatment of intractable ascites associated with alcoholic cirrhosis. *Ann NY Acad Sci* 170, 213.

242 Franco D (1983) Treatment of intractable ascites in cirrhotic-patients by portal–systemic shunt. *Gastroenterol Clin Biol* 7, 533–539.

243 Arrovo V, Cardenas A (1999) TIPS in the treatment of refractory ascites. In: Arrovo V, Bosch J, Bruguera M *et al.* (eds) *Treatment of Liver Diseases*. Barcelona: Masson, pp. 43–51.

244 Lebrec D, Giuily N, Hadengue A *et al.* (1996) Transjugular intrahepatic portosystemic shunts: comparison with paracentesis in patients with cirrhosis and refractory ascites: a randomized trial. *J Hepatol* 25, 135–144.

245 Rossle M, Ochs A, Gulberg V *et al.* (2000) A comparison of paracentesis and transjugular intrahepatic portosystemic shunting in patients with ascites. *N Engl J Med* 342, 1701–1707.

246 Salerno F, Merli M, Riggio O *et al.* (2004) Randomized controlled study of TIPS versus paracentesis plus albumin in cirrhosis with severe ascites. *Hepatology* 40, 629–635.

247 Gines P, Uriz J, Calahorra B *et al.* (2002) Transjugular intrahepatic portosystemic shunting versus paracentesis plus albumin for refractory ascites in cirrhosis. *Gastroenterology* 123, 1839–1847.

248 Sanyal AJ, Genning C, Reddy KR *et al.* (2003) The North American study for the treatment of refractory ascites. *Gastroenterology* 124, 634–641.

249 Campbell NS, Brensinger CM, Sanyal AJ *et al.* (2005) Quality of life in refractory ascites: transjugular intrahepatic portal–systemic shunting versus medical therapy. *Hepatology* 42, 635–640.

250 Londono MC, Guevara M, Rimola A *et al.* (2006) Hyponatremia impairs early posttransplantation outcome in patients with cirrhosis undergoing liver transplantation. *Gastroenterology* 130, 1135–1143.

251 Carrilho F, Bosch J, Arroyo V *et al.* (1977) Renal failure associated with demeclocycline in cirrhosis. *Ann Intern Med* 87, 195–197.

252 Perezayuso RM, Arroyo V, Camps J *et al.* (1984) Effect of demeclocycline on renal-function and urinary prostaglandin-E2 and kallikrein in hyponatremic cirrhotics. *Nephron* 36, 30–37.

253 Ohnishi A, Orita Y, Okahara R *et al.* (1993) Potent aquaretic agent – a novel nonpeptide selective vasopressin-2 antagonist (Opc-31260) in men. *J Clin Invest* 92, 2653–2659.

254 Tsuboi Y, Ishikawa SE, Fujisawa G *et al.* (1994) Therapeutic efficacy of the nonpeptide AVP antagonist Opc-31260 in cirrhotic rats. *Kidney Int* 46, 237–244.

255 Bosch-Marcé M, Poo JL, Jimenez W *et al.* (1999) Comparison of two aquaretic drugs (niravoline and OPC-31260) in cirrhotic rats with ascites and water retention. *J Pharmacol Exp Therapeut* 289, 194–201.

256 Jimenez W, Serradeil-Le Gal C, Ros J *et al.* (2000) Long-term aquaretic efficacy of a selective nonpeptide V-2-vasopressin receptor antagonist, SR121463, in cirrhotic rats. *J Pharmacol Exp Therapeut* 295, 83–90.

257 Fernández-Varol G, Ros J, Cejudo-Martin P *et al.* (2003) Effect of the V-1a/V-2-AVP receptor antagonist, conivaptan, on renal water metabolism and systemic hemodynamics in rats with cirrhosis and ascites. *J Hepatol* 38, 755–761.

258 Inoue T, Ohnishi A, Matsuo A *et al.* (1998) Therapeutic and diagnostic potential of a vasopressin-2 antagonist for impaired water handling in cirrhosis. *Clin Pharmacol Therapeut* 63, 561–570.

259 Guyader D, Patat A, Ellis-Grosse EJ *et al.* (2002) Pharmacodynamic effects of a nonpeptide antidiuretic hormone V2 antagonist in cirrhotic patients with ascites. *Hepatology* 36, 1197–1205.

260 Wong F, Blei AT, Blendis LM *et al.* (2003) A vasopressin receptor antagonist (VPA-985) improves serum sodium concentration in patients with hyponatremia: a multicenter, randomized, placebo-controlled trial. *Hepatology* 37, 182–191.

261 Gerbes AL, Golberg V, Gines P *et al.* (2003) Therapy of hyponatremia in cirrhosis with a vasopressin receptor antagonist: a randomized double-blind multicenter trial. *Gastroenterology* 124, 933–939.

262 Gadano A, Moreau R, Pessione F *et al.* (2000) Aquaretic effects of niravoline, a kappa-opioid agonist, in patients with cirrhosis. *J Hepatol* 32, 38–42.

263 Cabrera J, Arroyo V, Ballesta AM *et al.* (1982) Aminoglycoside nephrotoxicity in cirrhosis – value of urinary beta-2-microglobulin to discriminate functional renal failure from acute tubular damage. *Gastroenterology* 82, 97–105.

264 Moore RD, Smith CR, Lipsky JJ *et al.* (1983) Analysis of risk for development of aminoglycoside nephrotoxicity. *Clin Res* 31, A251.

265 Arroyo V, Perezayuso RM, Camps J *et al.* (1983) Evidence that renal prostaglandin-E2 (Pge2) plays a major role in the maintenance of water excretion in cirrhosis. *Hepatology* 3, 856.

266 Zipser RD, Hoefs JC, Speckart PF *et al.* (1979) Prostaglandins – modulators of renal function and pressor resistance in chronic liver disease. *J Clin Endocrinol Metab* 48, 895–900.

267 Levy M, Wexler MJ, Fechner C (1983) Renal perfusion in dogs with experimental hepatic cirrhosis – role of prostaglandins. *Am J Physiol* 245, F521–F529.

268 Bosch-Marce M, Claria J, Titos E *et al.* (1999) Selective inhibition of cyclooxygenase 2 spares renal function and prostaglandin synthesis in cirrhotic rats with ascites. *Gastroenterology* 116, 1167–1175.

269 Lopez-Parra M, Claria J, Planaguma A *et al.* (2002) Cyclooxygenase-1 derived prostaglandins are involved in the maintenance of renal function in rats with cirrhosis and ascites. *Br J Pharmacol* 135, 891–900.

270 Lopez-Parra M, Claria J, Titos E *et al.* (2005) The selective cyclooxygenase-2 inhibitor celecoxib modulates the formation of vasoconstrictor eicosanoids and activates PPAR gamma. Influence of albumin. *J Hepatol* 42, 75–81.

271 Gines A, Salmeron JM, Gines P *et al.* (1992) Effects of somatostatin on renal function in cirrhosis. *Gastroenterology* 103, 1868–1874.

272 Mountokalakis T, Kallivretakis N, Mayopoulousymvoulidou D *et al.* (1988) Enhancement of renal-function by a long-acting somatostatin analog in patients with decompensated cirrhosis. *Nephrol Dialys Transplant* 3, 604–607.

273 Bernardi M, Depalma R, Trevisani F *et al.* (1989) Renal function and effective beta-blockade in cirrhosis with ascites – relationship with baseline sympathoadrenergic tone. *J Hepatol* 8, 279–286.

274 Salmeron JM, Delarbol LR, Gines A *et al.* (1993) Renal effects of acute isosorbide-5-mononitrate administration in cirrhosis. *Hepatology* 17, 800–806.

275 Salerno F, Borroni G, Lorenzano E *et al.* (1996) Long-term administration of isosorbide-5-mononitrate does not impair renal function in cirrhotic patients. *Hepatology* 23, 1135–1140.

276 Vorobioff J, Picabea E, Gamen M *et al.* (1993) Propranolol compared with propranolol plus isosorbide dinitrate in portal-hypertensive patients – long-term hemodynamic and renal effects. *Hepatology* 18, 477–484.

277 Morillas RM, Planas R, Cabre E *et al.* (1994) Propranolol plus isosorbide-5-mononitrate for portal hypertension in cirrhosis – long-term hemodynamic and renal effects. *Hepatology* 20, 1502–1508.

278 Merkel C, Gatta A, Donada C *et al.* (1995) Long-term effect of nadolol or nadolol plus isosorbide-5-mononitrate on renal function and ascites formation in patients with cirrhosis. *Hepatology* 22, 808–813.

279 Albillos A, Lledo JL, Rossi I *et al.* (1995) Continuous prazosin administration in cirrhotic-patients – effects on portal hemodynamics and on liver and renal function. *Gastroenterology* 109, 1257–1265.

7.6 Hepatorenal syndrome

Pere Ginès and Mónica Guevara

Renal failure is a frequent complication of patients with advanced cirrhosis [1,2]. Its occurrence usually entails a poor prognosis because of the combined detrimental effect of renal and liver failure. In some instances, renal failure in cirrhosis is due to aetiological factors that may also lead to renal failure in patients without liver disease, such as volume depletion, shock or administration of nephrotoxic drugs, or it is the consequence of an intrinsic renal disease, such as glomerulonephritis. However, in other instances, renal failure in cirrhosis occurs in the absence of these aetiological factors and with a normal renal histology. This unique condition, known as hepatorenal syndrome (HRS), is due to marked abnormalities in circulatory function that lead to an intense vasoconstriction of the renal circulation, which causes a striking reduction in glomerular filtration rate (GFR) [1–5]. In recent years, significant advances have been made in the knowledge of HRS. The aim of this chapter is to provide an updated revision of HRS, with special emphasis on clinical features, diagnosis and management.

Definition

HRS is a clinical condition that usually occurs in patients with advanced liver disease and portal hypertension and is characterized by a combination of disturbances in circulatory and kidney functions [6]. The major abnormality in the systemic circulation is arterial hypotension due to markedly reduced total systemic vascular resistance. Kidney function is markedly impaired because of severe reduction of renal blood flow. HRS occurs predominantly in the setting of cirrhosis, but it may also develop in other types of severe chronic liver diseases, such as alcoholic hepatitis, or in acute liver failure [7–9].

Pathogenesis

The pathophysiological hallmark of HRS is vasoconstriction of the renal circulation [1,2,4,6,10–15]. The mechanism of this vasoconstriction is incompletely understood and possibly multifactorial, involving disturbances in the circulatory function and activity of systemic and renal vasoactive mechanisms. In the systemic circulation, there is severe arterial underfilling due to a marked arterial vasodilation located in the splanchnic circulation, which is related to the presence of portal hypertension. In contrast, in the kidney, there is marked vasoconstriction.

The theory that best fits with the observed alterations in the renal and circulatory function in HRS is the arterial vasodilation theory, which proposes that HRS is the result of the effect of vasoconstrictor systems (i.e. the renin–angiotensin and the sympathetic nervous systems) acting on the renal circulation activated as a homeostatic response to improve the extreme underfilling of the arterial circulation [6,15–17]. As a result of this increased activity of the vasoconstrictor systems, renal perfusion and GFR are markedly reduced, but tubular function is preserved. Most available data suggest that the arterial underfilling is due to a marked vasodilation of the splanchnic circulation related to an increased splanchnic production of vasodilator substances, particularly nitric oxide [18,19]. In the early phases of decompensated cirrhosis, renal perfusion is maintained within normal levels because of an increased synthesis of renal vasodilator factors (mainly prostaglandins). In later phases of the disease, renal perfusion is not maintained because of the extreme arterial underfilling causing maximal activation of vasoconstrictor systems and/or decreased production of renal vasodilator factors, and HRS develops. The marked activation of vasoconstrictor systems results in vasoconstriction of some vascular beds other than the kidneys, including lower and upper extremities and brain [20–23]. The splanchnic area escapes from the effect of vasoconstrictors probably because of a markedly enhanced local production of vasodilators. Several recent studies suggest a role for a decreased cardiac function in the pathogenesis of the arterial underfilling leading to HRS [24–27]. A schematic illustration of the proposed pathogenesis of HRS is shown in Figure 1.

Clinical and laboratory findings

HRS usually occurs in the late stages of cirrhosis when patients have developed some of the major complications of the disease, especially ascites. Low urine sodium and dilutional hyponatraemia are the major risk factors for the development of HRS in patients with ascites [28]. The presence of ascites is

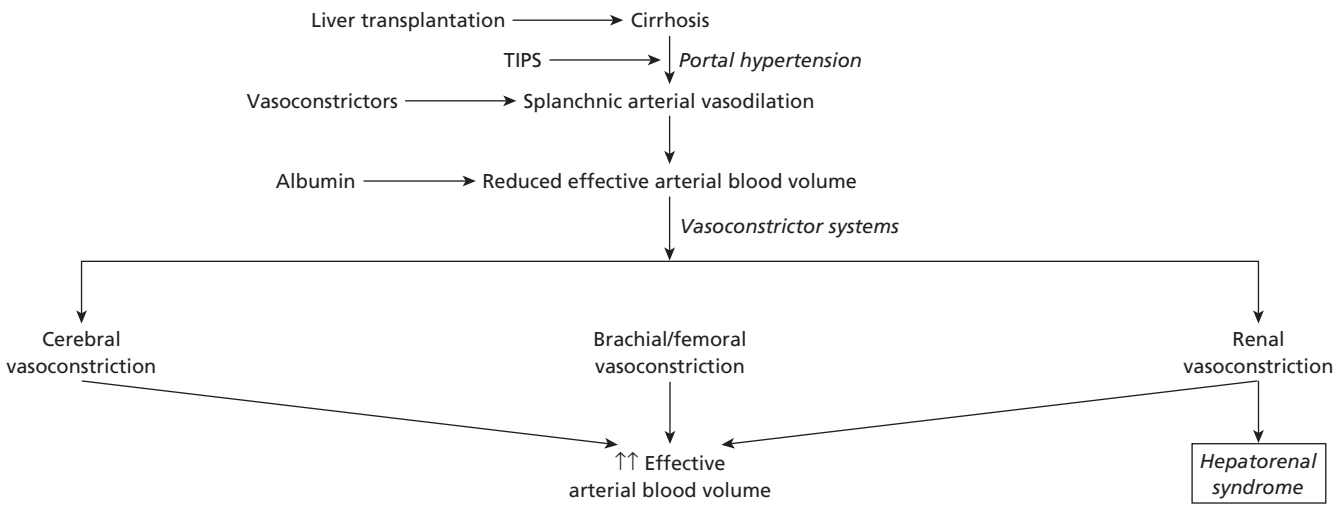

Fig. 1 Proposed pathogenesis of hepatorenal syndrome in cirrhosis according to the arterial vasodilation theory and effective therapeutic interventions. TIPS, transjugular intrahepatic portosystemic shunts.

universal in patients with HRS, so that the lack of ascites in a patient with cirrhosis and renal failure argues against HRS being the cause of renal failure and points towards other causes, particularly prerenal failure due to volume depletion because of excessive diuresis.

Precipitating factors

In some instances, HRS develops spontaneously without any apparent triggering event, whereas, in others, it occurs in close chronological relationship to some precipitating factors that can impair circulatory function [1,3,15,29]. The most common precipitating factors are bacterial infections, particularly spontaneous bacterial peritonitis (SBP), although the frequency of HRS after SBP has decreased markedly (from 33% to 10%) since the introduction of albumin in the management of patients with SBP (see below) [30,31]. Another well-known precipitating factor of HRS is large-volume paracentesis without plasma expansion [32]. Up to 15% of patients with ascites develop HRS when large volumes of ascitic fluid (more than 5 L) are removed without the administration of a plasma expander. Finally, renal failure occurs in about 10% of patients with cirrhosis and gastrointestinal bleeding [33,34]. However, it should be pointed out that a large proportion of episodes of renal failure after gastrointestinal bleeding are probably due to acute tubular necrosis related to hypovolaemic shock and not to HRS [34]. Intravascular volume depletion (i.e. diuretic-induced, extrarenal fluid losses) has been classically considered as a triggering factor for HRS [1], but no convincing evidence has been reported to support this pathogenetic relationship.

Renal function

In the past, HRS was generally diagnosed because of the development of oligoanuria [1,35–37]. Currently, however, with the widespread use of frequent biochemical monitoring for both outpatients and, especially, inpatients, HRS is most frequently first diagnosed by a finding of increased concentrations of serum creatinine and/or blood urea nitrogen (BUN). In some patients, there is a rapid rise in serum creatinine and BUN to very high values [3,37,38]. In other patients, the increases in serum creatinine and BUN levels are moderate with no (or very little) tendency to progress over time, at least in the short term [38–40]. These two different patterns of progression of renal failure define two different clinical types of HRS, type 1 and type 2 HRS [6,38]. The rate of progression used to define HRS type 1 has been arbitrarily set as a 100% increase in serum creatinine reaching a value greater than 2.5 mg/dL (221 μmol/L) in less than 2 weeks [6]. Patients not meeting these criteria of progression are considered to have type 2 HRS. Some patients with type 2 HRS eventually develop a sudden progression of renal failure after weeks or months of stable serum creatinine levels and may then meet the criteria for type 1 HRS. In patients with type 1 HRS, GFR is very low, commonly below 20 mL/min, and serum creatinine levels are high, with average values around 4 mg/dL – 356 μmol/L [38]. In contrast, patients with type 2 HRS have less severely abnormal GFR and creatinine concentrations (average around 2 mg/dL or 178 μmol/L) [38]. The predominant clinical feature of patients with type 1 HRS is severe renal failure, while that of patients with type 2 HRS is recurrent ascites because of poor or no response to diuretics due to the combination of reduced GFR and marked activation of antinatriuretic systems [6,38]. A major clinical difference between the two types of HRS is that patients with type 1 HRS have a very poor short-term outcome compared with that of patients with type 2 HRS (Fig. 2) [38].

Besides renal failure, patients with HRS have marked sodium retention with features of salt and water overload. Urine sodium is lower than 10 mEq/L in most patients [6,15,29,38]. The subsequently enhanced positive sodium balance results in weight gain due to an increase in ascites volume and peripheral oedema.

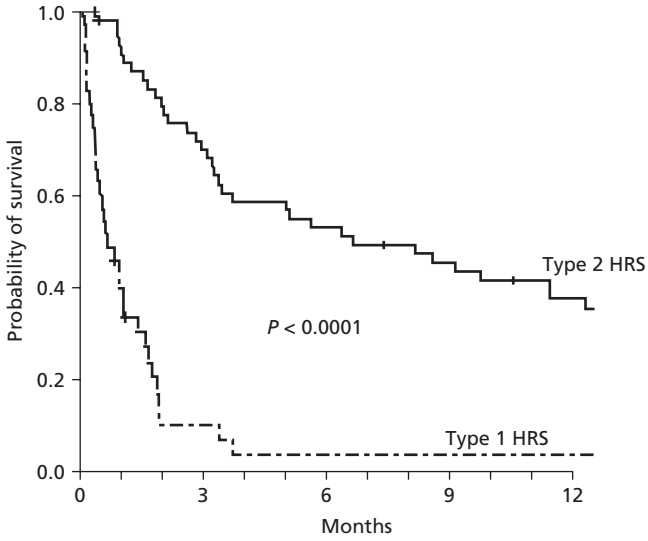

Fig. 2 Survival of patients with cirrhosis after the diagnosis of type 1 or type 2 hepatorenal syndrome (reproduced with permission from ref. 38).

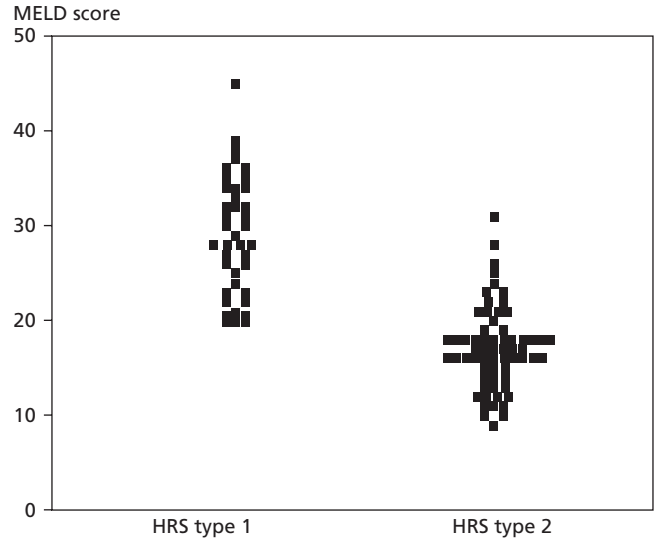

Fig. 3 Individual values of MELD score in patients with type 1 and type 2 hepatorenal syndrome (reproduced with permission from ref. 38).

Serum sodium concentration is low in patients with HRS, and most patients have hyponatraemia (serum sodium lower than 130 mEq/L) [6,38]. If serum sodium concentration in a patient with cirrhosis and renal failure is normal (> 135 mEq/L), the diagnosis of HRS is unlikely, and the patient should be investigated for a different cause of renal failure, particularly an intrinsic renal disease. Hyperkalaemia is also common but usually moderate. High rates of increase in plasma potassium levels are infrequent. Nevertheless, potassium levels should be monitored frequently and hyperkalaemia treated aggressively, if present, to avoid cardiac complications. Severe metabolic acidosis is also uncommon in HRS except for patients who develop a severe infection.

Cardiovascular function

Cardiovascular function is severely affected in patients with HRS. The total systemic vascular resistance is markedly reduced despite a striking activation of major vasoconstrictor systems, such as the renin–angiotensin and the sympathetic nervous systems [2,6,15–17,20,21,27,41–44]. Cardiac output may be increased, normal or reduced [15,20,21,27,42–45]. Recent studies have reported a reduction in cardiac output in some patients with HRS, which may be due to cardiomyopathy associated with cirrhosis [24–27]. Arterial pressure is usually low but stable (average mean arterial pressure around 70 mmHg). When haemodynamic instability exists, sepsis should be suspected. Except for arterial hypotension, the other cardiovascular abnormalities mentioned are not recognized unless invasive vascular monitoring is done and vasoconstrictor factors are measured. Nevertheless, these procedures are not required in the diagnosis or management of patients with HRS. Pulmonary oedema, which is a common and severe complication of acute renal failure in the absence of liver disease, is very rare in patients with HRS except in patients with very low urine volume who are treated aggressively with plasma expanders.

Liver function

Most patients with HRS show signs and symptoms of advanced liver failure and portal hypertension, particularly jaundice, coagulopathy, malnutrition and hepatic encephalopathy, yet a small proportion may develop HRS in the setting of only moderate liver insufficiency [38]. Because of this, most patients belong to the Child–Pugh C class, although some patients belong to class B. Model for Endstage Liver Disease (MELD) scores of patients with HRS are high (average MELD score 22) owing to the combined effect of liver and renal failure. Patients with type 1 HRS have MELD scores higher than those of patients with type 2 HRS (Fig. 3).

Severe bacterial infections, especially septicaemia (either spontaneous or related to intravenous catheters), SBP and pneumonia, are common in patients with HRS and constitute a frequent cause of death [28,38,46,47]. Both the renal failure and advanced liver disease probably account for an increased susceptibility to the infections.

Diagnosis

The initial step in the diagnosis of HRS is the demonstration of the existence of renal failure. The serum creatinine concentration is usually considered a better marker of GFR than the BUN concentration, but this has not been specially assessed. On the other hand, serum creatinine concentration is not an ideal marker of GFR in cirrhosis because it is usually lower than expected for any given level of GFR as a result of a low

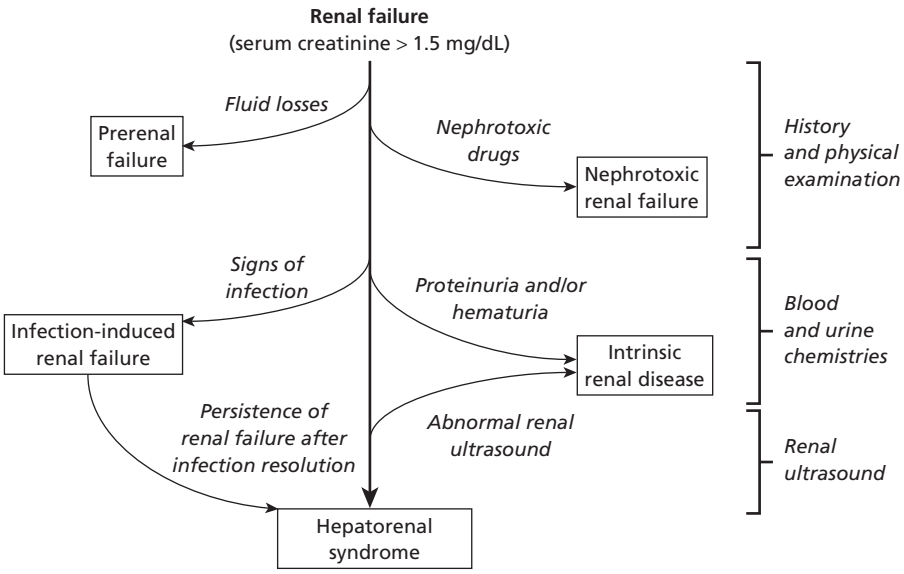

Fig. 4 Diagnostic flow chart of HRS (modified from ref. 75).

endogenous production of creatinine related to the reduced muscle mass that frequently occurs in advanced cirrhosis [48,49]. Nevertheless, as the use of more sensitive clearance techniques to evaluate GFR is expensive and not available in all settings, serum creatinine concentration is currently considered the method of choice to estimate GFR in cirrhosis [6]. There is consensus to establish the diagnosis of HRS when serum creatinine has increased above 1.5 mg/dL (133 μmol/L), which approximately corresponds to an average GFR of 30 mL/min [6,29]. In patients with increased serum creatinine concentration receiving diuretics, measurement of serum creatinine should be repeated after diuretic withdrawal because the use of diuretics may increase serum creatinine levels.

Because of the lack of specific diagnostic tests, the diagnosis of HRS must always be made after exclusion of other conditions that may cause renal failure in cirrhosis [6]. An algorithm for the diagnosis of HRS is shown in Figure 4. Acute renal failure of prerenal origin due to gastrointestinal fluid losses (vomiting, diarrhoea, nasogastric aspiration) or renal fluid losses (overdiuresis due to an excessive diuretic treatment) should be investigated by history and physical examination in all patients with cirrhosis and renal failure. If renal failure is secondary to volume depletion, renal function improves rapidly after volume expansion, whereas no improvement occurs in patients with HRS. The existence of shock before the onset of renal failure precludes the diagnosis of HRS and points towards the existence of acute tubular necrosis. Hypovolaemic shock due to gastrointestinal bleeding is easily recognized. However, septic shock may be more difficult to diagnose in the early phases because of the paucity of symptoms of bacterial infections in some patients with cirrhosis and because arterial hypotension due to sepsis may be erroneously attributed to the advanced liver disease. Therefore, a bacterial infection should always be ruled out by physical examination, laboratory tests and other procedures (i.e. chest X-ray) before the diagnosis of HRS is made. On the other hand, some patients with cirrhosis and bacterial infections (either SBP or sepsis) develop transient renal failure, which may resolve after resolution of the infection [30,50]. In these patients, the diagnosis of HRS should be made if renal failure persists after complete resolution of the infection. Patients with cirrhosis are at high risk of developing renal failure during treatment with non-steroidal anti-inflammatory drugs or aminoglycosides [51]. Therefore, treatment with these drugs in the previous days or weeks before the initiation of renal failure should always be ruled out before the diagnosis of HRS is made. Renal failure due to the administration of radiocontrast agents is very uncommon [52]. Finally, patients with cirrhosis may also develop renal failure due to intrinsic renal diseases, particularly glomerulonephritis [53,54]. These cases may be recognized by the existence of proteinuria and/or haematuria. The diagnosis may be confirmed by renal biopsy in selected cases.

No published information exists as to the comparative frequency of the different causes of renal failure in patients with cirrhosis. In a prospective ongoing study of renal failure in patients with cirrhosis being carried out at our unit, which so far includes 320 episodes of renal failure diagnosed over a 3-year period, the frequency of the different causes of renal failure is as follows: (i) bacterial infections, 38%; (ii) hypovolaemia, 26%; (iii) intrinsic renal diseases, 13%; (iv) HRS, 12%; (v) mixed, 7%; and (vi) nephrotic drugs, 3% (P. Ginès, unpublished).

Prognosis

Patients with type 1 HRS have an extremely poor outcome, with a median survival of only 1 month [38]. Survival in patients with type 1 HRS is independent of the MELD score. Patients with type 2 HRS have a better prognosis than that of patients with type 1, with a median survival of 7 months. In patients with type 2 HRS, survival is dependent on MELD score (Figs 2 and 5) [38].

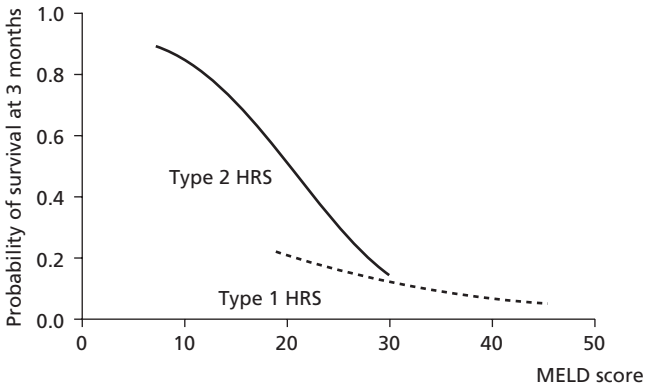

Fig. 5 Three-month survival probability in patients with type 1 and type 2 HRS according to MELD score (reproduced with permission from ref. 38).

Management

Type 1 hepatorenal syndrome

Patients with suspected type 1 HRS should have vital signs, urine output and blood chemistries monitored closely. Because most patients have dilutional hyponatraemia, total fluid intake [both oral and intravenous (i.v.) fluids] should be restricted to 1000 mL/day to avoid a positive fluid balance, which would cause a further reduction in serum sodium concentration. The administration of saline solutions may increase ascites and oedema markedly because of the presence of severe renal sodium retention, and therefore is not recommended. For this same reason and the lack of severe metabolic acidosis in most patients, the routine administration of sodium bicarbonate is also not advisable. Potassium-sparing diuretics should be withheld because of the risk of inducing severe hyperkalaemia. Early identification of infections and treatment with broad-spectrum antibiotics is fundamental, as severe infections are common and contribute to death in these patients. The efficacy of antibiotic prophylaxis for the prevention of infections in patients with HRS has not been assessed.

Several therapeutic approaches, which are discussed below, can be used in the management of type 1 HRS (Table 1).

Table 1 Recommendations for the management of type 1 hepatorenal syndrome.

Evaluate the patient for liver transplantation
Set up high priority for transplantation in candidate patients
Start vasoconstrictors plus i.v. albumin
Consider TIPS in patients without severe liver failure in whom vasoconstrictors have failed
Consider renal replacement therapy if there is pulmonary oedema, severe hyperkalaemia or metabolic acidosis not responding to medical therapy

TIPS, transjugular intrahepatic portosystemic shunt.

Liver transplantation

Liver transplantation is the treatment of choice for patients with cirrhosis and type 1 HRS because it allows the cure of both liver disease and the associated renal failure [55,56]. The most frequent contraindications for transplantation in these patients are advanced age, active alcoholism and infection. The main problem in the use of liver transplantation for type 1 HRS is that a significant proportion of patients die before transplantation is possible because of the short survival expectancy and prolonged waiting times in most transplant centres. This issue can be solved by assigning these patients a high priority for transplantation from a cadaveric donor. Because patients with type 1 HRS have high MELD scores (Fig. 3), the use of MELD score as a system for organ allocation for liver transplantation may improve the probability of transplantation in this patient population [57]. On the other hand, patients with type 1 HRS may probably benefit from treatment with vasoconstrictors before transplantation. This may improve renal function and help reduce the (moderately) higher morbidity and mortality reported in patients transplanted with HRS compared with those of patients transplanted without HRS [58–60]. In fact, patients with HRS treated with vasoconstrictors before transplantation have an outcome after transplantation that is no different from that of patients transplanted without HRS [61]. The use of combined liver–kidney transplantation for patients with HRS does not seem to improve the overall results obtained with liver transplantation alone and should not be used [62].

Vasoconstrictors

The administration of vasoconstrictors represents the only effective medical therapy currently available for the management of HRS. The rationale behind this therapy is to improve circulatory function by causing vasoconstriction of the extremely dilated splanchnic arterial bed, which subsequently improves arterial underfilling, suppresses the activity of the endogenous vasoconstrictor systems and increases renal perfusion (Fig. 1) [24]. Two types of drugs can be used, vasopressin analogues (terlipressin) or alpha-adrenergic agonists (noradrenaline or midodrine), which act on V_1 vasopressin receptors and α-1-adrenergic receptors, respectively, present in vascular smooth muscle cells (Table 2). In most studies, vasoconstrictors have been given in combination with i.v. albumin to further improve the arterial underfilling. Terlipressin is the vasoconstrictor that has been used more frequently in HRS [46,47,63–65]. The administration of terlipressin (0.5–2 mg/4–6 h i.v.) is associated with a complete renal response (reduction of serum creatinine below 1.5 mg/dL) in 50–75% of patients. The improvement in GFR occurs slowly over several days and, despite a marked improvement, GFR usually remains below normal values at the end of treatment. Recurrence of HRS after treatment withdrawal in responders is uncommon (approximately 15% of patients), and retreatment is usually effective. The incidence of ischaemic side-effects requiring the discontinuation of treatment ranges between 5% and 10%. The survival of responders to terlipressin

Table 2 Drugs used in the therapy of hepatorenal syndrome.

Drug	Dose range	Maximum duration of therapy (days)	Potential side-effects
Terlipressin[a]	0.5–2 mg/4 h i.v. bolus	15	Peripheral, splanchnic or cardiac ischaemia
Noradrenaline[b]	0.5–3 mg/h i.v. perfusion	15	Peripheral, splanchnic or cardiac ischaemia
Midodrine[c]	7.5–12.5 mg/8 h p.o.	Indefinite?	Not reported

[a]From refs 46, 47, and 63–65.
[b]From ref. 66.
[c]From refs 43 and 44.

is greater than that of non-responders [46,47]. There are two major shortcomings of the treatment with terlipressin, lack of availability in some countries and high cost, the latter being a major limiting factor for its use in some areas of the world. Alpha-adrenergic agonists (noradrenaline, midodrine) represent an attractive alternative to terlipressin because of their very low cost, wide availability and apparently similar efficacy compared with that of terlipressin [43,44,66]. However, information on the efficacy and side-effects of alpha-adrenergic agonists in patients with type 1 HRS is still very limited.

Transjugular intrahepatic portosystemic shunts

Only a few studies have reported the effects of transjugular intrahepatic portosystemic shunt (TIPS) in patients with type 1 HRS [67,68]. In patients with type 1 HRS, TIPS improves circulatory function and reduces the activity of vasoconstrictor systems. This is associated with a slow reduction in serum creatinine levels in approximately 60% of patients. Median survival after TIPS in patients with type 1 HRS ranges between 2 and 4 months [67,68]. TIPS is considered to be contraindicated in patients with severe liver failure (high serum bilirubin levels and/or Child–Pugh score greater than 12) or severe hepatic encephalopathy. Before comparative studies between TIPS and vasoconstrictors become available, it appears that vasoconstrictors are the treatment of choice in type 1 HRS because of an apparent similar efficacy, wider availability and lower costs compared with TIPS.

Other therapeutic methods

Renal replacement therapy (i.e. haemodialysis) is frequently used in the management of patients with type 1 HRS, especially in those who are candidates for liver transplantation, in an attempt to maintain patients alive until liver transplantation is performed or a spontaneous improvement in renal function occurs [69]. Unfortunately, the potential beneficial effect of this approach has not been unequivocally demonstrated. It is the clinical experience that most patients do not tolerate the haemodialysis and develop important side-effects, including arterial hypotension, bleeding and infections that may contribute to death during treatment. Moreover, findings that indicate the need for renal replacement therapy (severe fluid overload, acidosis or hyperkalaemia) are uncommon, at least in the early stages of type 1 HRS. Therefore, the initial therapy for these patients should probably include measures aimed at improving circulatory function (vasoconstrictors, TIPS) before haemodialysis is started.

Recently, extracorporeal albumin dialysis, a system that uses an albumin-containing dialysate that is recirculated and perfused through charcoal and anion-exchanger columns, has been reported to improve renal function and survival in a small series of patients with HRS, but these results require confirmation in larger series of patients [70].

Type 2 hepatorenal syndrome

Unlike patients with type 1 HRS, patients with type 2 HRS can be managed as outpatients unless they develop complications that require hospitalization. The most frequent clinical finding in these patients is refractory ascites. Diuretics should be given only if they cause a significant natriuresis (i.e. urine sodium > 30 mEq/day). Care should be taken with the use of spironolactone in these patients because of the risk of development of hyperkalaemia. Repeated paracentesis with i.v. albumin is probably the method of choice for the treatment of episodes of large ascites in these patients [71]. If dilutional hyponatraemia is present, total fluid intake should be restricted to approximately 1000 mL/day. Bacterial infections should be diagnosed and treated early because of the risk of precipitating type 1 HRS. The usefulness of prophylactic antibiotics in patients with type 2 HRS has not been assessed and would be worthy of study. Recommendations for the management of patients with type 2 HRS are outlined in Table 3.

Liver transplantation is the treatment of choice for candidate patients. As for patients with type 1 HRS, the use of MELD score for organ allocation in liver transplantation may be useful in reducing mortality on the waiting list. There is limited information on the use of vasoconstrictors in the treatment of patients with type 2 HRS, but it appears that their administration improves renal function in these patients [47,72]. However, more information is required before a definitive conclusion about this therapeutic approach can be drawn. The use of TIPS in patients with type 2 HRS is associated with an improvement in renal function, better control of ascites and reduced risk of progression from type 2 to type 1 HRS [71,73]. However, TIPS

Table 3 Recommendations for the management of patients with type 2 hepatorenal syndrome.

Evaluate the patient for liver transplantation. Establish priority for transplantation
Use diuretics for management of ascites only if they cause significant natriuresis (> 30 mEq/day). Restrict dietary sodium intake
Use repeated paracentesis plus i.v. albumin to treat recurrent large/tense ascites
Restrict fluid intake if hyponatraemia is present
Consider vasoconstrictors or TIPS before liver transplantation

does not improve survival in these patients compared with treatment with repeated paracentesis and i.v. albumin [74]. Therefore, the beneficial effects of TIPS in reducing ascites recurrence rate and progression to type 1 HRS in patients with type 2 HRS should be weighed against the lack of improvement in survival, increased risk of encephalopathy and high costs.

Prevention

Until very recently, no effective methods for the prevention of HRS existed. However, two recent studies have shown that HRS can be prevented effectively in two specific clinical settings: SBP and alcoholic hepatitis. In patients with SBP, the administration of albumin (1.5 g/kg i.v. at the diagnosis of the infection and 1 g/kg i.v. 48 h later) together with antibiotics markedly reduces the occurrence of HRS compared with the standard treatment with antibiotics alone (10% in the albumin group vs. 33% in the non-albumin group) [31]. Moreover, hospital mortality is also lower in patients receiving albumin (10% vs. 29% respectively). The beneficial effect of albumin is probably related to its capacity to prevent arterial underfilling and subsequent activation of vasoconstrictor systems during the infection. In patients with alcoholic hepatitis, the administration of pentoxifylline (400 mg t.i.d.) reduces the occurrence of HRS and mortality (8% and 24% respectively) with respect to a control group (35% and 46% respectively) [9]. The beneficial effect of pentoxifylline is probably related to its capacity to inhibit tumour necrosis factor production. Although the beneficial effects obtained in these two clinical trials require confirmation in other studies, they represent the first big step forward towards effective prevention of HRS in patients with endstage liver disease.

References

1 Papper S (1983) Hepatorenal syndrome. In: Epstein M (ed.) *The Kidney in Liver Disease*. New York: Elsevier Biomedical, pp. 87–106.

2 Ginès P, Rodes J (1999) Clinical disorders of renal function in cirrhosis with ascites. In: Arroyo V, Ginès P, Rodes J *et al.* (eds) *Ascites and Renal Dysfunction in Liver Disease, Pathogenesis, Diagnosis and Treatment*. Malden: Blackwell Science, pp. 36–62.

3 Hecker R, Sherlock S (1956) Electrolyte and circulatory changes in terminal liver failure. *Lancet* 271 (6953), 1121–1125.

4 Epstein M, Berk DP, Hollenberg NK *et al.* (1970) Renal failure in the patient with cirrhosis. The role of active vasoconstriction. *Am J Med* 49 (2), 175–185.

5 Arroyo V, Hecker R, Sherlock S (2002) Electrolyte and circulatory changes in terminal liver failure [*Lancet* (1956) 2, 1221–1225]. *J Hepatol* 36 (3), 315–320.

6 Arroyo V, Ginès P, Gerbes AL *et al.* (1996) Definition and diagnostic criteria of refractory ascites and hepatorenal syndrome in cirrhosis. International Ascites Club. *Hepatology* 23(1), 164–176.

7 Wilkinson SP, Blendis LM, Williams R (1974) Frequency and type of renal and electrolyte disorders in fulminant hepatic-failure. *Br Med J* 1 (5900), 186–189.

8 O'Grady JG (2005) Clinical disorders of renal function in acute liver failure. In: Arroyo V, Ginès P, Rodes J *et al.* (eds) *Ascites and Renal Dysfunction in Liver Disease*. Malden: Blackwell Publishing, pp. 383–393.

9 Akriviadis E, Botla R, Briggs W *et al.* (2000) Pentoxifylline improves short-term survival in severe acute alcoholic hepatitis: a double-blind, placebo-controlled trial. *Gastroenterology* 119 (6), 1637–1648.

10 Schroeder ET, Shear L, Sancetta SM *et al.* (1967) Renal failure in patients with cirrhosis of the liver. Evaluation of intrarenal blood flow by para-aminohippurate extraction and response to angiotensin. *Am J Med* 43 (6), 887–896.

11 Kew MC, Brunt PW, Varma RR *et al.* (1971) Renal and intrarenal blood-flow in cirrhosis of the liver. *Lancet* 2 (7723), 504–510.

12 Ring-Larsen H (1977) Renal blood flow in cirrhosis: relation to systemic and portal haemodynamics and liver function. *Scand J Clin Lab Invest* 37 (7), 635–642.

13 Platt JF, Marn CS, Baliga PK *et al.* (1992) Renal dysfunction in hepatic disease: early identification with renal duplex Doppler US in patients who undergo liver transplantation. *Radiology* 183 (3), 801–806.

14 Dagher L, Moore K (2001) The hepatorenal syndrome. *Gut* 49 (5), 729–737.

15 Arroyo V, Guevara M, Ginès P (2002) Hepatorenal syndrome in cirrhosis: pathogenesis and treatment. *Gastroenterology* 122 (6), 1658–1676.

16 Schrier RW, Arroyo V, Bernardi M *et al.* (1988) Peripheral arterial vasodilation hypothesis: a proposal for the initiation of renal sodium and water retention in cirrhosis. *Hepatology* 8 (5), 1151–1157.

17 Schrier RW, Niederberger M, Weigert A *et al.* (1994) Peripheral arterial vasodilatation: determinant of functional spectrum of cirrhosis. *Semin Liver Dis* 14 (1), 14–22.

18 Martin PY, Ginès P, Schrier RW (1998) Nitric oxide as a mediator of hemodynamic abnormalities and sodium and water retention in cirrhosis. *N Engl J Med* 339 (8), 533–541.

19 Wiest R, Groszmann RJ (1999) Nitric oxide and portal hypertension: its role in the regulation of intrahepatic and splanchnic vascular resistance. *Semin Liver Dis* 19 (4), 411–426.

20 Fernandez-Seara J, Prieto J, Quiroga J *et al.* (1989) Systemic and regional hemodynamics in patients with liver cirrhosis and ascites with and without functional renal failure. *Gastroenterology* 97 (5), 1304–1312.

21 Maroto A, Ginès P, Arroyo V *et al.* (1993) Brachial and femoral artery blood flow in cirrhosis: relationship to kidney dysfunction. *Hepatology* 17 (5), 788–793.

22 Guevara M, Bru C, Ginès P *et al.* (1998) Increased cerebrovascular resistance in cirrhotic patients with ascites. *Hepatology* 28 (1), 39–44.

23 Sugano S, Yamamoto K, Atobe T *et al.* (2001) Postprandial middle cerebral arterial vasoconstriction in cirrhotic patients. A placebo, controlled evaluation. *J Hepatol* 34 (3), 373–377.

24 Ginès P, Guevara M (2002) Good news for hepatorenal syndrome. *Hepatology* 36 (2), 504–506.

25 Lee SS (2003) Cardiac dysfunction in spontaneous bacterial peritonitis: a manifestation of cirrhotic cardiomyopathy? *Hepatology* 38 (5), 1089–1091.

26 Ruiz-del-Arbol L, Urman J, Fernandez J *et al.* (2003) Systemic, renal, and hepatic hemodynamic derangement in cirrhotic patients with spontaneous bacterial peritonitis. *Hepatology* 38 (5), 1210–1218.

27 Ruiz-del-Arbol L, Monescillo A, Arocena C *et al.* (2005) Circulatory function and hepatorenal syndrome in cirrhosis. *Hepatology* 42 (2), 439–447.

28 Ginès A, Escorsell A, Ginès P *et al.* (1993) Incidence, predictive factors, and prognosis of the hepatorenal syndrome in cirrhosis with ascites. *Gastroenterology* 105 (1), 229–236.

29 Bataller R, Ginès P, Guevara M *et al.* (1997) Hepatorenal syndrome. *Semin Liver Dis* 17 (3), 233–247.

30 Follo A, Llovet JM, Navasa M *et al.* (1994) Renal impairment after spontaneous bacterial peritonitis in cirrhosis – incidence, clinical course, predictive factors and prognosis. *Hepatology* 20 (6), 1495–1501.

31 Sort P, Navasa M, Arroyo V *et al.* (1999) Effect of intravenous albumin on renal impairment and mortality in patients with cirrhosis and spontaneous bacterial peritonitis. *N Engl J Med* 341 (6), 403–409.

32 Ginès P, Tito L, Arroyo V *et al.* (1988) Randomized comparative study of therapeutic paracentesis with and without intravenous albumin in cirrhosis. *Gastroenterology* 94 (6), 1493–1502.

33 Del Olmo JA, Pena A, Serra MA *et al.* (2000) Predictors of morbidity and mortality after the first episode of upper gastrointestinal bleeding in liver cirrhosis. *J Hepatol* 32 (1), 19–24.

34 Cardenas A, Ginès P, Uriz J *et al.* (2001) Renal failure after upper gastrointestinal bleeding in cirrhosis: incidence, clinical course, predictive factors, and short-term prognosis. *Hepatology* 34, 671–676.

35 Epstein M (1996) Hepatorenal syndrome. In: Epstein M (ed.) *The Kidney in Liver Disease.* Philadelphia: Hanley & Belfus, pp. 75–108.

36 Papper S, Belsky JL, Bleifer KH (1959) Renal failure in Laennecs cirrhosis of the liver. 1. Description of clinical and laboratory features. *Ann Intern Med* 51 (4), 759–773.

37 Shear L, Kleinerman J, Gabuzda GJ (1965) Renal failure in patients with cirrhosis of the liver. I. Clinical and pathologic characteristics. *Am J Med* 39:184–198.

38 Alessandria C, Ozdogan O, Guevara M *et al.* (2005) MELD score and clinical type predict prognosis in hepatorenal syndrome: relevance to liver transplantation. *Hepatology* 41 (6), 1282–1289.

39 Rodes J, Arroyo V, Bosch J (1975) Clinical types and drug-therapy of renal impairment in cirrhosis. *Postgrad Med J* 51(598), 492–497.

40 Vesin P (1962) Late functional renal failure in cirrhosis with ascites: pathophysiology, diagnosis and treatment. In: Martinin GA, Sherlock S (eds) *Aktuelle Probleme der Hepatologie.* Stuttgart: Georg Thieme Verlag, pp. 98–109.

41 Maroto A, Ginès A, Salo J *et al.* (1994) Diagnosis of functional kidney failure of cirrhosis with doppler sonography – prognostic value of resistive index. *Hepatology* 20 (4), 839–844.

42 Guevara M, Ginès P, Fernandez-Esparrach G *et al.* (1998) Reversibility of hepatorenal syndrome by prolonged administration of ornipressin and plasma volume expansion. *Hepatology* 27 (1), 35–41.

43 Angeli P, Volpin R, Gerunda G *et al.* (1999) Reversal of type 1 hepatorenal syndrome with the administration of midodrine and octreotide. *Hepatology* 29 (6), 1690–1697.

44 Wong F, Pantea L, Sniderman K (2004) Midodrine, octreotide, albumin, and TIPS in selected patients with cirrhosis and type 1 hepatorenal syndrome. *Hepatology* 40 (1), 55–64.

45 Tristani FE, Cohn JN (1967) Systemic and renal hemodynamics in oliguric hepatic failure: effect of volume expansion. *J Clin Invest* 46 (12), 1894–1906.

46 Moreau R, Durand F, Poynard T *et al.* (2002) Terlipressin in patients with cirrhosis and type 1 hepatorenal syndrome: a retrospective multicenter study. *Gastroenterology* 122 (4), 923–930.

47 Ortega R, Ginès P, Uriz J *et al.* (2002) Terlipressin therapy with and without albumin for patients with hepatorenal syndrome: results of a prospective, nonrandomized study. *Hepatology* 36 (4 Pt 1), 941–948.

48 Caregaro L, Menon F, Angeli P *et al.* (1994) Limitations of serum creatinine level and creatinine clearance as filtration markers in cirrhosis. *Arch Intern Med* 154 (2), 201–205.

49 Papadakis MA, Arieff AI (1987) Unpredictability of clinical evaluation of renal function in cirrhosis – prospective study. *Am J Med* 82 (5), 945–952.

50 Terra C, Guevara M, Torre A *et al.* (2005) Renal failure in patients with cirrhosis and sepsis unrelated to spontaneous bacterial peritonitis: value of MELD score. *Gastroenterology* 129, 1944–1953.

51 Salerno F, Badalamenti S (2005) Drug-induced renal failure in cirrhosis. In: Arroyo V, Ginès P, Rodes J *et al.* (eds) *Ascites and Renal Dysfunction in Liver Disease*. Philadelphia: Blackwell Science Malden, pp. 372–382.

52 Guevara M, Fernandez-Esparrach G, Alessandria C *et al.* (2004) Effects of contrast media on renal function in patients with cirrhosis: a prospective study. *Hepatology* 40 (3), 646–651.

53 Lhotta K (2002) Beyond hepatorenal syndrome: glomerulonephritis in patients with liver disease. *Semin Nephrol* 22 (4), 302–308.

54 Poole B, Schrier RW, Jani A (2005) Glomerular disease in cirrhosis. In: Ginès P, Arroyo V, Rodes J *et al.* (eds) *Ascites and Renal Dysfunction in Liver Disease.* Malden: Blackwell Publishing, pp. 360–370.

55 Gonwa TA, Morris CA, Goldstein RM *et al.* (1991) Long-term survival and renal function following liver transplantation in patients with and without hepatorenal syndrome–experience in 300 patients. *Transplantation* 51 (2), 428–430.

56 Rimola A, Navasa M, Grande L *et al.* (2005) Liver transplantation for patients with cirrhosis and ascites. In: Arroyo V, Ginès P, Rodes J *et al.* (eds) *Ascites and Renal Dysfunction in Liver Disease*, 2nd edn. Oxford: Blackwell Publishing, pp. 271–285.

57 Wiesner R, Edwards E, Freeman R *et al.* (2003) Model for end-stage liver disease (MELD) and allocation of donor livers. *Gastroenterology* 124 (1), 91–96.

58 Rimola A, Gavaler JS, Schade RR *et al.* (1987) Effects of renal impairment on liver transplantation. *Gastroenterology* 93 (1), 148–156.

59 Gonwa TA, Klintmalm GB, Levy M *et al.* (1995) Impact of pretransplant renal-function on survival after liver-transplantation. *Transplantation* 59 (3), 361–365.

60 Nair S, Verma S, Thuluvath PJ (2002) Pretransplant renal function predicts survival in patients undergoing orthotopic liver transplantation. *Hepatology* 35 (5), 1179–1185.

61 Restuccia T, Ortega R, Guevara M *et al.* (2004) Effects of treatment of hepatorenal syndrome before transplantation on posttransplantation outcome. A case–control study. *J Hepatol* 40 (1), 140–146.

62 Jeyarajah DR, Gonwa TA, McBride M *et al.* (1997) Hepatorenal syndrome: combined liver kidney transplants versus isolated liver transplant. *Transplantation* 64 (12), 1760–1765.

63 Uriz J, Ginès P, Cardenas A *et al.* (2000) Terlipressin plus albumin infusion: an effective and safe therapy of hepatorenal syndrome. *J Hepatol* 33 (1), 43–48.
64 Mulkay JP, Louis H, Donckier V *et al.* (2001) Long-term terlipressin administration improves renal function in cirrhotic patients with type 1 hepatorenal syndrome: a pilot study. *Acta Gastroenterol Belg* 64 (1), 15–19.
65 Halimi C, Bonnard P, Bernard B *et al.* (2002) Effect of terlipressin (Glypressin) on hepatorenal syndrome in cirrhotic patients: results of a multicentre pilot study. *Eur J Gastroenterol Hepatol* 14 (2), 153–158.
66 Duvoux C, Zanditenas D, Hezode C *et al.* (2002) Effects of noradrenalin and albumin in patients with type I hepatorenal syndrome: a pilot study. *Hepatology* 36 (2), 374–380.
67 Brensing KA, Textor J, Perz J *et al.* (2000) Long term outcome after transjugular intrahepatic portosystemic stent-shunt in non-transplant cirrhotics with hepatorenal syndrome: a phase II study. *Gut* 47 (2), 288–295.
68 Guevara M, Ginès P, Bandi JC *et al.* (1998) Transjugular intrahepatic portosystemic shunt in hepatorenal syndrome: effects on renal function and vasoactive systems. *Hepatology* 28 (2), 416–422.
69 Wong LP, Blackley MP, Andreoni KA *et al.* (2005) Survival of liver transplant candidates with acute renal failure receiving renal replacement therapy. *Kidney Int* 68 (1), 362–370.
70 Mitzner SR, Stange J, Klammt S, *et al.* (2000) Improvement of hepatorenal syndrome with extracorporeal albumin dialysis MARS: results of a prospective, randomized, controlled clinical trial. *Liver Transpl* 3, 277–286.
71 Moore KP, Wong F, Ginès P *et al.* (2003) The management of ascites in cirrhosis: report on the consensus conference of the International Ascites Club. *Hepatology* 38 (1), 258–266.
72 Alessandria C, Venon WD, Marzano A *et al.* (2002) Renal failure in cirrhotic patients: role of terlipressin in clinical approach to hepatorenal syndrome type 2. *Eur J Gastroenterol Hepatol* 14 (12), 1363–1368.
73 Ginès P, Uriz J, Calahorra B *et al.* (2002) Transjugular intrahepatic portosystemic shunting versus paracentesis plus albumin for refractory ascites in cirrhosis. *Gastroenterology* 123 (6), 1839–1847.
74 Albillos A, Bañares R, Gonzalez M *et al.* (2005) A meta-analysis of transjugular intrahepatic portosystemic shunt versus paracentesis for refractory ascites. *J Hepatol* 43, 990–996.
75 Ginès P *et al.* (2003) Hepatorenal syndrome. *Lancet* 362, 1819–1827.

7.7 Pulmonary complications of portal hypertension

Michael J. Krowka

Introduction

Pulmonary complications of portal hypertension can be grouped broadly into two major categories: pulmonary vascular abnormalities and pleural/diaphragm effects of ascites. The pulmonary vascular abnormalities include hepatopulmonary syndrome, portopulmonary hypertension and pulmonary emboli. Ascites can result in pleural effusions (hepatic hydrothorax) and subsequent effects on pulmonary function test results. This chapter will focus on the clinical presentations, diagnostic essentials and important treatment considerations, especially for liver transplantation candidates, when these pulmonary complications exist.

Pulmonary vascular complications

Hepatopulmonary syndrome (HPS)

First reported by Hoffbauer and Rydell in 1956, the classic triad of chronic liver disease, arterial hypoxaemia on room air and intrapulmonary vascular dilatation characterizes HPS [1]. A consensus statement emanating from a task force co-sponsored by the European Respiratory Society (ERS) and the European Association for the Study of the Liver (EASL) has summarized current thinking regarding diagnosis, epidemiology, pathophysiology and therapeutic advances (Table 1) [2].

Table 1 Diagnostic criteria for hepatopulmonary syndrome (HPS).[a]

1. Liver disease (usually portal hypertension)
2. $P_aO_2 < 80$ mmHg or alveolar–arterial oxygen gradient > 15 mmHg
3. Pulmonary vascular dilatation documented by either
   a. 'positive' contrast enhanced transthoracic echocardiogram;[b] or
   b. brain uptake > 6% following lung perfusion scanning with ^{99m}Tc macroaggregated albumin

[a]Modified from the ERS–EASL task force report.
[b]Microbubbles were detected in the left atrium between three and six cardiac cycles after visualization of microbubbles in the right atrium.

The clinical presentation of HPS includes dyspnoea and fatigue (manifestations of hypoxaemia at rest, with exertion and during sleep) [2]. The physical examination findings associated with HPS are nail bed and lip cyanosis, as well as skin spider angiomas. Screening for arterial hypoxaemia can be accomplished by either finger pulse oximetry or arterial blood gas analysis. Patients with finger pulse oximetry saturations less than 94% or arterial blood gas $P_aO_2 < 80$ mmHg while breathing room air in the sitting position should undergo testing for pulmonary vascular dilatations [2]. It is common in HPS to document worsening dyspnoea (platypnoea) and arterial oxygen (orthodeoxia) as the patient moves from the supine to sitting to standing position [3]. This phenomenon is presumably due to a combination of decreasing cardiac output and redistribution of blood flow to vascular dilatations in the lung bases as one assumes the standing position.

With the evolution of HPS over months and years, profound hypoxaemia ($P_aO_2 < 50$ mmHg) is not uncommon [3]. Spontaneous resolution of the syndrome with normalization of arterial oxygenation can occur, but is rare. Although varying degrees of hypoxaemia are common (40–50%) in the setting of chronic liver disease, the reported prevalence of this uncommon syndrome as a reason for hypoxaemia has varied as a function of cutoffs for arterial hypoxaemia [4]. Approximately 5% of patients referred annually to the Mayo Clinic liver transplant programme have HPS (using criteria of $P_aO_2 < 70$ mmHg) due to documented pulmonary vascular dilatations by contrast echocardiography [3].

Non-invasive methods used to determine the existence of pulmonary vascular dilatations are based upon the concept of either microbubbles (10–90 μm in diameter) or technetium-labelled macroaggregated albumen (^{99m}Tc-MAA 20–90 μm in size) traversing dilated pulmonary vessels (> 8 μm) [2,5]. Following peripheral arm vein injection of hand-agitated saline, the microbubbles are created and can be detected in the left heart by transthoracic echocardiography. Similarly, peripherally injected ^{99m}Tc-MAA can be measured over the brain by radionuclide scintigraphy. The echocardiography test is qualitative and more sensitive in detecting pulmonary vascular dilatation than

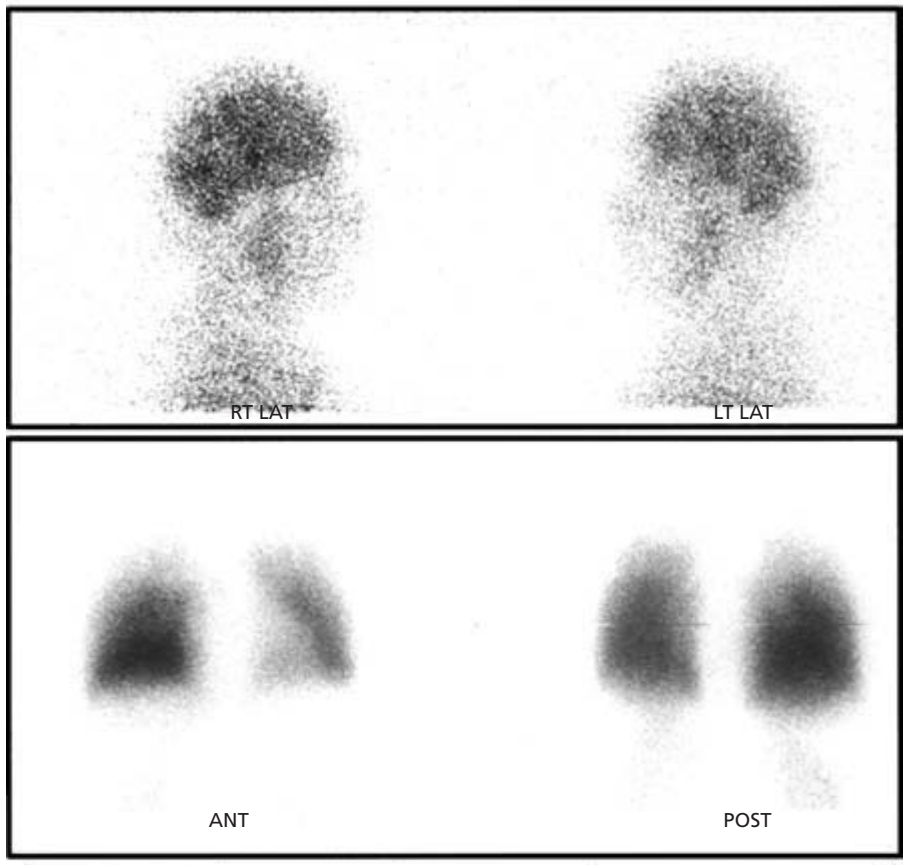

Geometric mean counts			
	Ant	Post	Geometric Mean
Lung	255244	368446	306665
	Left Lat	Right Lat	
Brain	15333	14876	15103
	Shunt index %	=	27.47
	Normal shunt index < 6%		

Fig. 1 Lung perfusion scan with ^{99m}Tc-MAA and quantitative measurement of uptake over the brain in a patient with HPS. Abnormal uptake estimated the intrapulmonary shunt to be 27.5% (normal < 6%).

the lung perfusion test [2,5]. However, the lung perfusion study with brain uptake gives a quantitative, reproducible measure of the degree of pulmonary vascular dilatation (Fig. 1).

Pulmonary angiography as a means of documenting (or further characterizing) pulmonary vascular dilatation is not necessary in most cases [3]. However, angiography is advised in HPS patients when the degree of hypoxaemia is severe (P_aO_2 < 50 mmHg) and the response to 100% inspired oxygen is poor (< 300 mmHg). The reason for proceeding to angiography is to identify and treat (with vascular embolization) discrete arteriovenous communications. Such discrete lesions are quite uncommon; most patients with HPS have either normal or diffuse, bilateral spongy lesions noted on pulmonary angiography that are not usually amenable to embolization.

Approximately 20–30% of HPS patients may have other comorbidities that can cause significant hypoxaemia [i.e. ascites, hydrothorax, pneumonia, pulmonary fibrosis and chronic obstructive pulmonary disease (COPD)] [3,6]. The ^{99m}Tc-MAA lung scan is extremely helpful in discerning vascular dilatation (abnormal brain uptake ≥ 6%) vs. non-vascular reasons (normal brain uptake < 6%) for hypoxaemia in the setting of liver disease. This distinction is of clinical importance when discussing expectations of modifying arterial hypoxaemia when liver transplantation is considered.

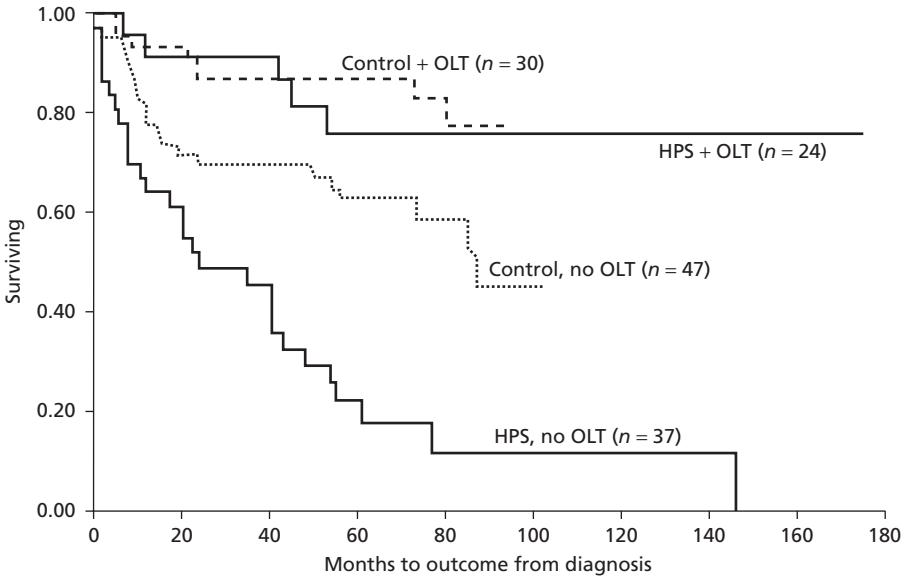

Fig. 2 Survival curves for patients with hepatopulmonary syndrome. Patients who underwent OLT had statistically similar baseline P_aO_2 levels, MELD scores and Child scores compared with those who did not undergo OLT. Survival for HPS patients who did not undergo OLT was significantly worse than for HPS patients who underwent OLT ($P < 0.001$).

Human and animal studies suggest that the pathophysiology of HPS may be related to circulating mediators that result in excess local effects of nitric oxide and bacterial translocation, upregulate pulmonary endothelium endothelin B receptors causing vasodilatation and pulmonary capillary proliferation via angiogenesis [2]. Yet, no proven medical treatments exist for HPS other than nasal cannula oxygen supplementation. There is no proven role for transjugular intrahepatic portosystemic shunts (TIPS). As the definitive treatment for HPS, orthotopic liver transplantation (OLT; cadaveric or living donor) is strongly advised assuming that no other major comorbidities complicate advanced liver disease [7–9]. Complications following OLT are not uncommon and appear to be related to the severity of hypoxaemia prior to transplantation. Some series have reported a 30–38% mortality within 12 months of OLT [5,6] and 16% transplant hospitalization mortality [7,10]. In addition, preliver transplant ^{99m}Tc-MAA lung perfusion scanning with brain uptake > 20% is associated with higher post-OLT mortality [11] However, complete resolution of HPS can occur even in the setting of severe hypoxaemia prior to OLT, and the time to resolution (usually many months) is related to the severity of hypoxaemia.

HPS alone is a risk factor for poor prognosis in patients with cirrhosis [11]. Long-term survival once the diagnosis of HPS has been established is related to the severity of hypoxaemia and whether liver transplantation can be successfully accomplished. The 5-year survivals with and without liver transplantation are 76% vs. 23% respectively. $P_aO_2 < 50$ mmHg with or without OLT is associated with worse survival compared with $P_aO_2 > 50$ mmHg (Fig. 2) [13]. Deterioration in P_aO_2 while awaiting OLT (approximately 5–10 mmHg per year) is well documented [13].

Portopulmonary hypertension (POPH)

Beginning with the 1951 report by Mantz and Craige, clinicians have recognized that patients with portal hypertension are predisposed to pulmonary arterial changes indistinguishable from those seen in idiopathic pulmonary artery hypertension [14]. The Venice 2003 Conference on Pulmonary Hypertension recognized POPH as one of the proven reasons for pulmonary artery hypertension [15]. The ERS–EASL consensus report estimated that fewer than 10% of patients referred for liver transplantation had true POPH based upon current right heart catheterization (RHC) diagnostic criteria (Table 2) [2].

Table 2 Diagnostic criteria for portopulmonary hypertension.

1. Presence of portal hypertension (clinical diagnosis)
2. Mean pulmonary artery pressure (MPAP) > 25 mmHg[a]
3. Pulmonary artery occlusion pressure (PAOP) < 15 mmHg[a]
4. Pulmonary vascular resistance (PVR) > 240 dynes/s/cm^5[b]

[a]MPAP and PAOP are measured pressures obtained during right heart catheterization (RHC). MPAP is the measured mean arterial pressure of the systolic and diastolic pressures obtained from a distal catheter transducer in the main pulmonary artery. PAOP is the pressure obtained via the distal catheter transducer when the catheter is advanced peripherally with balloon occlusion to impede arterial flow. This measurement provides an estimate of pulmonary venous pressure. Hence, a pressure gradient (MPAP–PAOP) is obtained. Cardiac output (CO) is measured to give an estimate of blood *flow*. The pressure gradient and flow are used to calculate the pulmonary vascular resistance to flow (PVR).

[b]PVR is a calculated number obtained via the following formula (multiplier 80 is used to keep units consistent):

PVR = [(MPAP–PAOP) × 80]/CO

Table 3 Mayo Clinic classification of pulmonary hypertension in the setting of portal hypertension.[a]

Type	MPAP	PAOP	CO	PVR
I. Pulmonary artery high flow state	↑	n or ↓	↑↑	↓
II. Excess pulmonary venous volume	↑	↑	↑	↓
III. Portopulmonary hypertension[b]				
a. pulmonary vascular obstruction; normal volume[c]	↑↑↑	n or ↓	↑	↑↑↑
b. pulmonary vascular obstruction; excess volume	↑↑	↑	↑	↑

[a]Based upon right heart catheterization measurements (MPAP, CO, PAOP) and calculations (PVR).
[b]All patients with portopulmonary hypertension have increased transpulmonary pressure gradients (MPAP–PAOP > 12 mmHg); most will have (a) normal (n) PAOP, but some will have (b) increased PAOP.
[c]PAOP < 15 mmHg.

RHC is essential to make the diagnosis of POPH as there are several reasons for increased pulmonary artery pressures in patients with portal hypertension (Table 3). For example, the high flow–hyperdynamic circulatory state (increased cardiac output) is common in portal hypertension. Such a state frequently results in increased pulmonary artery pressures, yet the actual resistance to flow is normal. In addition, increased central volume may contribute to increased pulmonary artery pressure [16]. It is the patient with increased pulmonary artery pressure (MPAP), increased pulmonary vascular resistance (PVR) to flow and normal central volume (PAOP) who is the most problematic [17]

The clinical presentation of POH includes exertional dyspnoea (the earliest symptom) and later complaints of chest pain, palpitations and even syncope. Signs and symptoms of hypoxaemia are uncommon in POPH [2]. Sudden death due to cardiovascular events is not uncommon. Chest radiographic abnormalities (enlarged central pulmonary arteries and cardiomegaly) and electrocardiogram changes (right ventricle strain with T-wave inversion in the anterior chest leads V1–V4) are late signs of at least moderate to severe POPH [2].

In the early liver transplant era, the diagnosis of POPH was initially made in the operating room in 65% of patients who underwent liver transplant surgery [18]. Subsequent mortality was 36% and was deemed unacceptable, and efforts began to screen all liver transplant candidates for POPH [18]. The American Association for the Study of Liver Diseases (AASLD) now advises transthoracic Doppler echocardiography to screen for pulmonary artery systolic pressures by estimating right ventricular systolic pressures (RVsys) as a practice guideline [19]. Patients with elevated pressures are advised to undergo RHC to confirm the diagnosis of POPH [2,19]. This is crucial for liver transplant candidates. Thresholds for proceeding to RHC have varied, but recent data suggest that up to 34% of those with RVsys > 50 mmHg simply have a high flow state (low calculated PVR at RHC) and do not satisfy accepted criteria for POPH (increased PVR); 66% have the true problem of POPH [20]. The correlation between Doppler echo and RHC pressures worsens when RVsys > 50 mmHg [21,22].

The pathophysiology of POPH is poorly understood. No animal models for POPH exist to date. Intuitively, it is suspected, but not proven, that circulating mediators (such as increased endothelin, a potent vasoconstrictor and stimulus for smooth muscle proliferation) associated with portal hypertension, and mediators resulting from abnormal hepatic metabolism, may initiate the pulmonary endothelium injury [2,23]. Endothelial proliferation, smooth muscle proliferation, *in situ* thromboses, platelet aggregation, vascular remodelling (plexogenic arteriopathy) and subsequent obstruction to pulmonary arterial flow results [2]. The natural history of POPH is that of progressive right heart failure and death. Unlike HPS, spontaneous resolution of POPH has never been reported. The resolution of hepatopulmonary and subsequent development of pulmonary artery hypertension has occurred both spontaneously and following the transplant resolution of HPS [2].

In the current era of liver transplantation, POPH has resulted in intraoperative death and increased transplant hospitalization mortality [17,24]. Multicentre, retrospective analysis evidence indicates that a preoperative MPAP > 35 mmHg serves as a threshold for increased risk of death. MPAP values between 35 and 50 mmHg predispose to a 50% increased risk of death [18]. Some investigators suggest that MPAP values alone should not be considered absolute and, in a recent multicentre study, patients with MPAP > 50 mmHg survived OLT without pre-OLT pulmonary vasodilator therapy; however, very few centres have transplanted patients in this range [10,25]. Despite poor outcomes, persistence of POPH and the *de novo* development of pulmonary artery hypertension after liver transplantation, many case reports of post-OLT improvement in POPH exist [2].

In the pre-OLT and prostacyclin therapy era, mean and median survival following diagnosis was 15 and 6 months, respectively, with half of the deaths related to pulmonary hypertension [26]. In the current OLT era, limited data suggest 5-year survivals of 53% and 28% for POPH patients with and without OLT respectively [26]. Worse survival trends appear to be associated with selected haemodynamic cutoffs such as the transpulmonary gradient (TPG = MPAP–PAOP > 30 mmHg), MPAP (> 50 mmHg) and PVR (> 400 dynes/s/cm^5). The role

of living donor OLT in the setting of POPH has yet to be determined [27].

Pre-OLT treatment with continuous intravenous infusions of prostacyclin may confer a survival advantage after OLT [28–31]. However, no large standardized protocols or randomized trials have addressed the issue of which agent may be the optimal pulmonary vasomodulating therapy in the setting of POPH or for those POPH patients considered for OLT. Single case reports and small series do suggest improved pulmonary haemodynamics with the use of newer pulmonary vascular modulating agents such as inhaled prostacyclin (iloprost) [32], dual endothelin receptor antagonists (bosentan) [33–35] and phosphodiesterase-5 inhibitors (sildenafil) [36]. Long-term survival data collection in cohorts of POPH patients treated with pulmonary vasodilators (with and without OLT) will be informative. It is likely that surrogate measures of right heart function (sequential echocardiography and plasma levels of B-type natriuretic peptide to assess right ventricular strain) will play an important role in patient prognosis and management [2].

Fig. 3 Hepatic hydrothorax associated with massive ascites. Compressive atelectasis of right lower lobe of the lung resulted in significant hypoxemia (P_aO_2 = 43 mmHg in the supine position).

Pulmonary emboli

Acute or chronic pulmonary emboli in the setting of portal hypertension are rare. Most case reports follow surgical procedures, prolonged bed rest or coagulopathies associated with Budd–Chiari syndrome. Although most patients with advanced liver disease have some component of coagulopathy due to hepatic synthetic dysfunction in synthesizing coagulation factors II, VII, IX and X, the increased risk of deep venous thrombosis and pulmonary embolism rarely exists as a result of inability to produce protein C, protein S and antithrombin III [37]. Post-mortem pulmonary arterial thromboses associated with portopulmonary hypertension are thought to be related to platelet aggregation, *in situ* clot formation due to low flow or emboli that have originated from portosystemic vascular shunts [2,15]. Asymptomatic radiopaque pulmonary emboli following endoscopic injection sclerotherapy for oesophagogastric variceal bleeding can occur. No management interventions are necessary [38].

Pleural/diaphragm effects of ascites

The effects of ascites can lead to clinically significant dyspnoea for two reasons. First, with massive ascites, the upward stretch and displacement of the hemidiaphragms cause a restrictive pulmonary physiology, in which the total lung capacity (TLC) and forced vital capacity (FVC) are reduced [39,40]. Ventilation of the lungs is restricted and dyspnoea follows. Within 2 h of performing large-volume paracentesis in patients with tense ascites, dyspnoea can be ameliorated as the diaphragms move to a more normal position followed by immeasurable, improved ventilatory function [40]. Secondly, when ascitic fluid traverses the hemidiaphragms with any degree of ascites and fills either or both the pleural spaces ('hepatic hydrothorax'), the underlying lung may become atelectatic, causing a physiological shunt (no ventilation with persistent perfusion) that leads to hypoxaemia (Fig. 3) [41]. The movement of ascitic fluid from the peritoneal cavity to the pleural space is thought to occur via lymphatic drainage and/or small hemidiaphragm anatomical defects. This movement is facilitated by the positive hydrostatic pressure in the peritoneal cavity combined with the negative pleural pressure with inspiration. If necessary to prove the abdominal origin of pleural fluid, scintigraphy can demonstrate the abnormal presence of thoracic activity within 90 min following intraperitoneal injection of ^{99m}Tc-sulphur-colloid radioisotope [41].

Hepatic hydrothorax (occurring in up to 12% of cases with portal hypertension) is usually transudative [low protein, low lactate dehydrogenase (LDH)], yellow in colour and not associated with pain or fever [41]. Chylous effusions (triglyceride levels > 110 mg/dL) are not infrequent [42]. A serum–pleural fluid albumen gradient of > 1.2 g/dL suggests a transudative pleural effusion in the setting of marked diuretic use. Although commonly bilateral, such pleural effusions can be right sided only, left sided only and may occur in the absence of clinical ascites on account of the negative pleural pressure that accompanies each inspiration. Most effusions occupy less than 25% of the hemithorax, but massive pleural effusions can occur causing a cardiac tamponade physiology as a result of collapse of the right ventricle. Infected hepatic hydrothorax (spontaneous bacterial empyema) is associated with 20% mortality without chest tube drainage; approximately 50% of cases are not associated with spontaneous bacterial peritonitis [43]. Aggressive medical management which includes dietary salt restriction and combination diuretics (including spironolactone) frequently reduces the symptoms resulting from hepatic hydrothorax.

Table 4 Summary of therapeutic and liver transplant considerations for hepatopulmonary syndrome (HPS) and portopulmonary hypertension (POPH). UNOS, United Network for Organ Sharing.

	HPS	POPH
High risk for OLT (↑mortality)	$P_aO_2 < 50$ mmHg ^{99m}Tc-MAA brain uptake > 20%	MPAP > 35 mmHg
UNOS 'indication' for OLT	Yes	No
Higher priority for OLT	Yes, if $P_aO_2 < 60$ mmHg	No
Syndrome deterioration awaiting OLT	Yes	Yes
Sudden death due to syndrome	No	25%
5-year survival without OLT	23%	30%
5-year survival with OLT	55%	No data
Pharmacological treatment without OLT prolongs survival	Not proven	Not proven
Pharmacologic treatment prior to OLT helpful	Not proven	Strongly suggested
Intraoperative death	Not reported	Yes
Transplant hospitalization mortality	16%	35%
Post-OLT syndrome resolution	Very common	Extremely variable

Therapeutic and diagnostic transthoracic thoracentesis may be necessary when dyspnoea is debilitating or if the clinical situation suggests neoplasm (pain) or infection within the pleural space (fever with or without pain). Chest tube insertion in the absence of infection for continual pleural fluid drainage is not advised because of the development of renal dysfunction, electrolyte imbalances and infection. Increased mortality in patients with prolonged chest tube drainage (> 5 days) has been associated with increased total bilirubin levels, encephalopathy and Child's C severity of liver disease [44].

When medical management fails, placement of a TIPS can reduce the amount of pleural fluid and improve symptoms in 60–80% of patients with hepatic hydrothorax [45,46]. TIPS can acutely worsen right heart function, but the effects usually improve within weeks [46]. Video-assisted thoracoscopy with hemidiaphragm defect closure can successfully eliminate the accumulation of pleural fluid in selected cases [41]. Refractory hepatic hydrothorax is considered to be an indication for liver transplantation [48].

Implications for liver transplantation

Understanding the distinctions between pulmonary vascular complications of portal hypertension are important, especially when OLT is considered (Table 4). No doubt, a subgroup of HPS patients poses a higher post-transplant risk of mortality (those with $P_aO_2 < 50$ mmHg breathing room air), but syndrome resolution over months is well documented even in those situations. For patients with POPH, the increased cardiopulmonary risk of the transplant procedure itself, transplant hospitalization complications and expected postliver transplant normalization of pulmonary haemodynamics remains problematic. Such patients remain an area of active clinical research with the advent of prospective screening [49] and POPH clinical trials that incorporate new pulmonary vasomodulating drugs. Complete resolution of hepatic hydrothorax and pulmonary effects of massive ascites can be expected within weeks of successful OLT.

The experience of several liver transplant centres has culminated in the recommendation to obtain chest radiographs, measures of arterial oxygenation (pulse oximetry or arterial blood gases) and sequential screening by transthoracic Doppler echocardiography for any patient being considered for liver transplantation [19]. In selected patients, complete pulmonary function testing should be accomplished: (i) in those with smoking histories and (ii) in any patient whose portal hypertension is associated with an abnormal antitrypsin phenotype.

Summary

Clinically significant pulmonary complications are estimated to occur in 5–10% of patients with portal hypertension. These pulmonary vascular complications result from the downstream effect of absent/excessive blood levels of circulating mediators (HPS and POPH) with poor correlation with the degree of portal hypertension. The pleural/diaphragm complications (hepatic hydrothorax and restrictive lung mechanics) result from direct anatomical effects of ascites production. Importantly, treating hepatic dysfunction (with combinations of diuretics, TIPS and OLT) and using pulmonary vasomodulating drugs (in the case of POPH) may dramatically improve the pulmonary symptoms and enhance survival associated with these complications.

References

1 Rydell R, Hoffbauer FW (1956) Multiple pulmonary atriovenous fistulas in juvenile cirrhosis. *Am J Med* 21, 450–459.

2 Rodrigeuz-Roisin R, Krowka MJ, Fallon MB *et al.* (2004) Pulmonary-hepatic vascular disorders: report of a task force. *Eur Respir J* 24, 861–880.

3 Krowka MJ, Wiseman GA, Burnett OL *et al.* (2000) Hepatopulmonary syndrome: a prospective study of relationships between severity of

liver disease, PaO2 response to 100% oxygen, and brain uptake after (99m)Tc MAA lung scanning. *Chest* 118, 615–624.
4 Schenk P, Fuhrmann V, Madl C *et al.* (2002) Hepatopulmonary syndrome: prevalence and predictive value of various cut offs for arterial oxygenation and their clinical consequences. *Gut* 51, 853–859.
5 Abrams GA, Nanda NC, Dubovsky EV *et al.* (1998) Use of macroaggregated albumin lung perfusion scan to diagnose hepatopulmonary syndrome: a new approach. *Gastroenterology* 114, 305–310.
6 Martinez G, Barbera JA, Navasa M *et al.* (1999) Hepatopulmonary syndrome associated with cardiorespiratory disease. *J Hepatol* 30, 882–889.
7 Krowka MJ, Porayko MK, Plevak D *et al.* (1997) Hepatopulmonary syndrome with progressive hypoxemia as an indication for liver transplantation: case reports and review of the literature. *Mayo Clin Proc* 72, 44–53.
8 Egawa H, Kasahara M, Inomata Y *et al.* (1999) Long-term outcome of living related liver transplantation for patients with intrapulmonary shunting and strategy for complications. *Transplantation* 67, 712–717.
9 Taille C, Cadranel J, Bellocq A *et al.* (2003) Liver transplantation for hepatopulmonary syndrome. A ten-year experience in Paris, France. *Transplantation* 75, 1482–1489.
10 Krowka MJ, Mandell MS, Ramsay MA *et al.* (2004) Hepatopulmonary syndrome and portopulmonary hypertension: a report of the multicenter liver transplant database. *Liver Transpl* 10, 174–182.
11 Arguedas M, Abrams G, Krowka M *et al.* (2003) Prospective evaluation of outcomes and predictors of mortality in patients with hepatopulmonary syndrome undergoing liver transplantation. *Hepatology* 37, 192–197.
12 Schenk P, Schoniger-Hekele M, Fuhrmann V *et al.* (2003) Prognostic significance of the hepatopulmonary syndrome in patients with cirrhosis. *Gastroenterology* 125, 1042–1052.
13 Swanson KL, Wiesner RH, Krowka MJ (2005) Natural history of hepatopulmonary syndrome: impact of liver transplantation. *Hepatology* 41, 1122–1129.
14 Mantz FA, Craige E (1951) Portal axis thrombosis with spontaneous portacaval shunt and resultant cor pulmonale. *Arch Pathol* 52, 91–97.
15 Simmoneau G, Galie N, Rubin LJ *et al.* (2004) Clinical classification of pulmonary hypertension. *J Am Coll Cardiol* 43 (Suppl), 5S–12S.
16 Castro M, Krowka MJ, Schroeder DR *et al.* (1996) Frequency and clinical implications of increased pulmonary artery pressures in liver transplant patients. *Mayo Clin Proc* 71, 543–551.
17 Ramsay M, Simpson B, Nguyen A *et al.* (1997) Severe pulmonary hypertension in liver transplant candidates. *Liver Transpl Surg* 3, 494–500.
18 Krowka MJ, Plevak DJ, Findlay JY *et al.* (2000) Pulmonary hemodynamics and perioperative cardiopulmonary-related mortality in patients with portopulmonary hypertension undergoing liver transplantation. *Liver Transpl* 6, 443–450.
19 Murray KF, Carithers RL (2005) AASLD Practice Guidelines: evaluation of the patients for liver transplantation. *Hepatology* 41, 1407–1432.
20 Krowka MJ, Swanson KL, Frantz RP *et al.* (2006) Portopulmonary hypertension: results of a 10-year screening algorithm. *Hepatology* 44, 1502–1510.
21 Kim W, Krowka M, Plevak D *et al.* (2000) Accuracy of Doppler echocardiography in the assessment of pulmonary hypertension in liver transplant candidates. *Liver Transpl* 6, 453–458.
22 Cotton C, Gandhi S, Vaitkus P *et al.* (2002) Role of echocardiography in detecting portopulmonary hypertension in liver transplant candidates. *Liver Transpl* 8, 1051–1054.
23 Benjaminov FS, Prentice M, Sniderman KW *et al.* (2003) Portopulmonary hypertension in decompensated cirrhosis with refractory ascites. *Gut* 52, 1355–1362.
24 DeWolf AM, Gasior T, Kang Y (1991) Pulmonary hypertension in a patient undergoing liver transplantation. *Transpl Proc* 23, 2000–2110.
25 Starkel P, Vera A, Gunson B *et al.* (2002) Outcome of liver transplantation for patients with pulmonary hypertension. *Liver Transpl* 8, 382–388.
26 Robalino BD, Moodie DS (1991) Association between primary pulmonary hypertension and portal hypertension: analysis of its pathophysiology and clinical, laboratory and hemodynamic manifestations. *J Am Coll Cardiol* 17, 492–498.
27 Swanson KL, McGoon MD, Krowka MJ (2003) Survival in portopulmonary hypertension with the use of intravenous epoprostenol. *Am J Respir Crit Care Med* 167, A683.
28 Plotkin J, Kuo P, Rubin L *et al.* (1998) Successful use of chronic epoprostenol as a bridge to liver transplantation in severe portopulmonary hypertension. *Transplantation* 65, 457–459.
29 Krowka MJ, Frantz RF, McGoon MD *et al.* (1999) Improvement if pulmonary hemodynamics during intravenous epoprostenol (prostacyclin): a study of 15 patients with moderate to severe portopulmonary hypertension. *Hepatology* 30, 641–648.
30 Tan HP, Markowitz JS, Montgomery RA *et al.* (2001) Liver transplantation in patients with severe portopulmonary hypertension treated with preoperative chronic intravenous epoprostenol. *Liver Transpl* 7, 745–749.
31 Minder S, Fischier M, Muelhaupt B *et al.* (2004) Intravenous iloprost bridging to orthotopic liver transplantation in portopulmonary hypertension. *Eur Respir J* 24, 703–707
32 Halank M, Marx C, Miehlke S *et al.* (2004) Use of inhaled iloprost in the treatment of portopulmonary hypertension. *J Gastroenterol* 39, 1222–1223.
33 Hoeper MM, Halank M, Marx G *et al.* (2005) Bosentan for the treatment of portopulmonary hypertension. *Eur Respir J* 25, 502–508.
34 Halank M, Miehlke S, Hoeffken G *et al.* (2004) Use of oral endothelin-receptor antagonist bosentan in the treatment of portopulmonary hypertension. *Transplantation* 77, 1775–1776.
35 Kuntzen C, Gulberg V, Gerbes AL (2005) Use of a mixed endothelin receptor antagonist in portopulmonary hypertension: a safe and effective therapy? *Gastroenterology* 128, 164–168.
36 Makisalo H, Koivusalo A, Vakkuri A *et al.* (2004) Sildenafil for portopulmonary hypertension in a patient undergoing liver transplantation. *Liver Transpl* 10, 945–950.
37 Espiritu JD (2000) Pulmonary embolism in a patient with coagulopathy from end-stage liver disease. *Chest* 117, 924–925.
38 Marco de Lucas E, Fifalgo I, Garcia-Baron PL *et al.* (2004) Radiopaque pulmonary arteries in chest radiology. *J Thorac Imag* 19, 264–266.
39 Angueira CE, Kadakia SC (1994) Effects of large-volume paracentesis on pulmonary function in patients with tense ascites. *Hepatology* 20, 825–828.
40 Chang SCX, Chang HI, Chen FJ *et al.* (1997) Therapeutic effects of diuretics and paracentesis on lung function in patients with non-alcoholic cirrhosis and tense ascites. *J Hepatol* 833–838.
41 Garcia N, Jr, Mihas AA (2004) Hepatic hydrothorax: pathophysiology, diagnosis, and management. *J Clin Gastroenterol* 38, 52–58.
42 Romero S, Martin C, Hernandez L *et al.* (1998) Chylothorax in cirrhosis of the liver: analysis of its frequency and clinical characteristics. *Chest* 114, 154–159.

43 Xiol X, Castellvi JM, Guardiola J *et al.* (1996) Spontaneous bacterial empyema. *Hepatology* 64, 341–351.
44 Liu LU, Haddadin HA, Bodian CA *et al.* (2004) Outcome analysis of cirrhotic patients undergoing chest tube placement. *Chest* 126, 142–148.
45 Gordon FD, Anastopoulus HT, Crenshaw W *et al.* (1997) The successful treatment of refractory hepatic hydrothorax with transjugular intrahepatic portosystemic shunt. *Hepatology* 25, 1366–1369.
46 Boyer T, Haskal (2005) AASLD practice guideline: the role of transjugular intrahepatic portosystemic shunt in the management of portal hypertension. *Hepatology* 41, 386–400.
47 Van der Linden P, Le Moine O *et al.* (1996) Pulmonary hypertension after transjugular intrahepatic shunt: effects on right ventricular function. *Hepatology* 23, 982–987.
48 Jeffries MA, Kazanjian S, Wilson M *et al.* (1998) Transjugular intrahepatic portosystemic shunts and liver transplantation for refractory hepatic hydrothorax. *Liver Transpl Surg* 4, 416–423.
49 Colle I, Moreau R, Godinho E *et al.* (2003) Diagnosis of portopulmonary hypertension in candidates for liver transplantation: a prospective study. *Hepatology* 37, 401–409.

7.8 Hepatic encephalopathy

Dieter Häussinger and Andres T. Blei

Definition and classification

Hepatic encephalopathy, defined in broad terms as changes in neurological function that result from liver disease, encompasses a wide range of neuropsychiatric signs and symptoms that are associated with both acute and chronic liver failure [1–3]. The term is not used when specific liver diseases exhibit discrete neurological findings (e.g. Wilson's disease, Zellweger syndrome or bilirubin encephalopathy in Crigler–Najjar syndrome). Rather, it focuses on the changes in mental state seen in cirrhosis and fulminant hepatic failure. The development of encephalopathy carries important prognostic implications in such patients. In acute liver failure, individuals with deep encephalopathy can succumb from neurological complications such as brain oedema and intracranial hypertension. In cirrhosis, the grade of encephalopathy is one of the five elements included in the Child–Pugh classification, a prognostic tool [4].

Two major alterations underlie the development of encephalopathy in acute and chronic liver disease: on the one hand, hepatic insufficiency and, on the other, portal–systemic shunting, in which the opening of collateral vessels as a result of portal hypertension allows elements in the portal blood to gain access to the systemic circulation. In acute liver failure, liver function is lost while extrahepatic portal–systemic shunting is not present. In patients with cirrhosis and hepatic encephalopathy, the degree of hepatic failure and the extent of portal–systemic shunts are variable. In addition, even with similar degrees of shunting, flow through larger and wider collaterals increases the rate of delivery of substances from the portal blood to the systemic circulation [5]. Still, the separation between liver function and portal–systemic shunting should not be a rigid one as there is an interplay between both elements: extensive and longstanding portal–systemic shunting (seen after a non-selective portocaval anastomosis) can result in liver atrophy, while the ability of the liver with cirrhosis to extract substances from the portal vein decreases with worsening liver function [6]. In acute liver failure, portal blood flowing through a necrotic liver can also be viewed as a total portal–systemic shunt.

These considerations have led to a classification of hepatic encephalopathy that is based on the clinical setting in which symptoms occur (Table 1) [7]. The encephalopathy of acute liver failure shares clinical characteristics with that of cirrhosis, but also exhibits unique features (see below). Although not fully proven, there is agreement that the pathogenesis of hepatic encephalopathy in both conditions has similar underpinnings. In cirrhosis, three major syndromes can be present:

Table 1 Classification of hepatic encephalopathy.

	Hepatic failure	Extrahepatic portal–systemic shunting	Special features
Acute liver failure	Maximal	Absent	Development of brain oedema and intracranial hypertension
Cirrhosis			Low-grade cerebral oedema without overt signs of intracranial hypertension
Episodic encephalopathy	Variable	Variable	Precipitant induced
Persistent encephalopathy	Variable	Generally large	Most often seen after portocaval surgery or TIPS
Minimal encephalopathy	Variable	Variable	Requires neuropsychological/neurophysiological testing

TIPS, transjugular intrahepatic portosystemic shunt.

1 Episodic (precipitant-induced) encephalopathy, commonly seen in the hospital setting, where a superimposed event is a key factor.
2 Persistent (chronic) encephalopathy, seen with extensive portal–systemic shunts and after portocaval shunt surgery or placement of transjugular intrahepatic portosystemic shunt (TIPS).
3 Minimal (subclinical) encephalopathy reflects alterations in cognitive function in patients who clinically exhibit a normal mental state. Its diagnosis requires the use of neuropsychological or neurophysiological testing; many subjects with cirrhosis (up to 70%) appear to exhibit such deficits.

With the advent of surgical techniques to decompress the portal hypertensive territory, the term 'portal–systemic encephalopathy' had been coined to highlight the importance of the anatomical rearrangement [8]. The term can also be applied to patients who exhibit clinical and structural changes in the brain with extensive portal–systemic shunts in the absence of parenchymal liver damage [9], also referred to as type B encephalopathy [7]. Patients with congenital portal-systemic shunts exhibit abnormalities of neuropsychological tests and magnetic resonance spectroscopy (MRS) similar to those observed in liver cirrhosis [10,11].

Pathogenesis

Seldom has an area of hepatology been so full of controversy as the study of the pathogenesis of hepatic encephalopathy. Several hypotheses have been postulated over several decades [12–15]. However, most of these hypotheses, such as the false neurotransmitter hypothesis [16] or the γ-aminobutyric acid (GABA) hypothesis [17,18], could only explain some, but not all, findings in hepatic encephalopathy. The difficulties in obtaining information on human neurochemistry have led to the use of animal models that reproduce some features of the human counterpart but do not replicate the picture in its entirety [19]. As in many other neurological conditions, the response to specific therapeutic measures has been one arbiter of the validity of a postulated hypothesis. However, with the availability of modern techniques of cell and molecular biology, on the one hand, and the advances in human non-invasive brain imaging and quantification. on the other, such as magnetic resonance imaging (MRI) and MRS, positron emission tomography (PET) scanning and magnetencephalography (MEG), considerable progress has been made in the understanding of the pathogenesis of hepatic encephalopathy. Although many questions are still open, the emerging pathogenetic picture largely integrates previous experimental findings with clinical observations. With regard to the latter, pathogenetic concepts need to explain the remarkable dynamics and diversity of encephalopathy symptoms and why episodes of hepatic encephalopathy are precipitated in patients with cirrhosis by very heterogeneous conditions such as drugs, electrolyte disturbances, bleeding, trauma or infections. The following cornerstones for the understanding of the pathogenesis of hepatic encephalopathy will be reviewed, before an attempt is made to integrate this knowledge into a pathogenetic picture:
1 ammonia and other circulating neurotoxins;
2 neuroanatomical changes;
3 brain water homeostasis;
4 neurotoxins, astrocyte swelling and astrocyte function;
5 oxidative and nitrosative stress;
6 energy metabolism;
7 alterations in neurotransmission; and
8 disturbances of oscillatory networks in the brain.

Ammonia and other circulating neurotoxins

In the 1950s, it was postulated that the liver synthesizes compounds that are critical for brain function, such as cytidine and uridine [20]. From this perspective, hepatic encephalopathy could be viewed as arising from the lack of production of such compounds by a diseased liver. However, experimental and clinical evidence does not support this concept. Cross-perfusion experiments in a rat model of hepatic liver failure showed that depuration of its blood through a normal liver is far more critical for an adequate mental state than the provision of liver-derived blood from a normal animal [21]. For many years, the controversy has centred around the nature of gut-derived toxins. The clinical evidence that supports the existence of such toxins can be surmised from the response to therapy in cirrhosis. They are of nitrogenous origin, as witnessed by the precipitation of encephalopathy with different nitrogenous substances [22]. While constipation can precipitate encephalopathy, increased catharsis is a cornerstone of treatment. The main source of this activity appears to be the colon, as drugs that act at that level (non-absorbable disaccharides) are used to improve mental state. Intestinal bacteria appear to be involved in the generation of the toxins, as non-absorbable antibiotics (e.g. neomycin) are used therapeutically. The toxins must be present in high concentrations in portal blood, as the construction of a portocaval anastomosis can precipitate encephalopathy. Several gut-derived neurotoxins have been implicated, of which ammonia plays a key role.

Ammonia

In the early 1930s, it had already been noted that ammonia salts would induce neurological changes in patients with cirrhosis [23]. A role for ammonia in the pathogenesis of encephalopathy has been evaluated extensively over many years, and much is known about its metabolism and mode of action.

Ammonia is generated in the intestine via two major mechanisms: as a result of the breakdown of urea by bacteria in the colonic lumen and from the metabolism of glutamine by small bowel mucosa [24]. It is absorbed via non-ionic diffusion and exhibits a high concentration in the portal vein, almost 10-fold higher than arterial levels [6]. In the liver, both portal-derived ammonia and that derived from amino acid metabolism are

taken up by periportal hepatocytes and used as a substrate for urea synthesis, in a reaction that exhibits a low affinity but a high capacity for ammonia metabolism. In downstream perivenous hepatocytes, ammonia combines with glutamate to form glutamine, a reaction catalysed by glutamine synthetase and exhibiting a high affinity but a low capacity for ammonia metabolism [25]. The cells that contain glutamine synthetase have been termed perivenous scavenger cells [26], because they eliminate with high affinity the ammonia not used by the upstream urea-synthesizing compartment. They are of crucial importance for the maintenance of non-toxic ammonia levels in the hepatic vein: selective damage of perivenous scavenger cells does not impair upstream urea synthesis, but leads to hyperammonaemia due to a failure of scavenger function [27]. The net effect of the two metabolic systems in series is a tight control of the levels of ammonia in the hepatic vein (see Chapter 2.3.7).

In patients with cirrhosis, multiple mechanisms contribute to the development of hyperammonaemia. The absorption rate from the intestine may be higher in view of the increased splanchnic inflow seen in the portal hypertensive state [28]. In view of the high hepatic extraction of ammonia, portal–systemic shunts, both extra- and intrahepatic, will result in an increased systemic bioavailability. A reduction in hepatic mass will decrease the capacity to synthesize urea [29] and glutamine [30]. Furthermore, extrahepatic sites also contribute to the development of hyperammonaemia. The synthesis of glutamine in muscle, an important alternative site for ammonia metabolism,[24,31], may be decreased in patients who lose muscle mass, a common finding in advanced cirrhosis with ascites. Generation of ammonia by the kidney may be increased in the face of respiratory alkalosis, an alteration that arises from primary hyperventilation seen in cirrhosis [32], and as a result of potassium deficiency [33], a frequent finding in cirrhosis irrespective of the use of diuretic therapy.

Studies using $^{13}NH_3$-PET scanning have shown an increased uptake of circulating ammonia into the brain in patients with cirrhosis, [34] and the increased permeability–surface product seen on PET scanning suggests that either the blood–brain barrier is more permeable to ammonia or an increased capillary surface is present, a finding that could be explained by cerebral vasodilatation and increased cerebral blood flow. Ammonia uptake by the brain may involve aquaporin 9, which is expressed in astrocytes [35] and was shown to mediate NH_3 and/or NH_4^+ uptake [36]. Ammonia taken up by the brain is trapped, at least in part, by glutamine synthesis, as evidenced by high glutamine signals in ^{1}H-MRS derived from the brain in patients with cirrhosis [37–39] and those with acute liver failure [40–41]. Ammonia-induced glutamine accumulation in the brain is probably one major event in the development of cerebral oedema in patients with hepatic encephalopathy (see below) [38,42,43]. Measurements of glutamine in the cerebrospinal fluid (CSF) of patients with hepatic encephalopathy correlate reasonably well with the degree of alteration in the mental state [44].

Once inside neural tissue, ammonia may exert deleterious effects at many levels [45–46]. Brain glucose and energy metabolism may be affected [47–51]. Specific alterations may be present in neurons, astrocytes and the interactions between both cell types [52,53]. Direct effects on cortical neurons include inhibition of chloride extrusion, affecting postsynaptic inhibitory potentials [54]. In addition, ammonia may decrease the activity of the tricarboxylic acid cycle via inhibition of α-ketoglutarate dehydrogenase [55]. The multiple effects of ammonia on astrocytes, which also involve changes in astrocyte hydration, morphology and the generation of oxidative/nitrosative stress, are discussed below.

A wide range of medical disorders that affect mental state are also associated with hyperammonaemia. These include urea cycle enzyme deficiencies, Reye syndrome and toxicity from drugs such as sodium valproate [53]. Medications that reduce ammonia levels (e.g. lactulose or sodium benzoate) or increase the activity of the urea cycle (zinc, ornithine–aspartate) have been reported to improve the altered mental state in all these conditions, including hepatic encephalopathy.

Although ammonia is widely accepted as a key factor in the pathogenesis of hepatic encephalopathy, hyperammonaemia cannot be equated with hepatic encephalopathy. Not all ammonium salts induce encephalopathy. Overt seizures, common in congenital hyperammonaemias [53], are seldom observed in subjects with cirrhosis and hepatic encephalopathy. The lack of correlation between circulating ammonia levels and the degree of encephalopathy has been a classic criticism; however, in the presence of an increased passage of ammonia into the brain, as seen in humans with hyperammonaemia [34], a direct relationship between blood and brain levels need not necessarily be present. A recent study showed a better correlation between mean values of PNH_3 and stages of encephalopathy [56], not confirmed by other authors [57].

Other neurotoxins

Other products of colonic bacterial metabolism may act synergistically with ammonia to aggravate encephalopathy. In experimental animals receiving intravenous doses of ammonia, the administration of mercaptans, such as methanethiol and dimethyldisulphide, reduced the dose of ammonia that resulted in coma [58]. Mercaptans are sulphur-containing products of methionine metabolism and have been implicated in the genesis of fetor hepaticus, a unique odour detected in the breath of encephalopathic patients. In one study, there was no relationship between the levels of methanethiol and the presence of encephalopathy [59]. However, administration of methionine to patients with cirrhosis can result in an altered mental state [60]. The mechanisms by which mercaptans may affect brain function have not been studied extensively. Phenols, derived from the catabolism of phenylalanine and tyrosine, are another category of compounds that may affect mental state [61]; their role is uncertain. Likewise, the role of indoles, which originate from bacterial tryptophan metabolism, remains to be settled.

Oxindol has neurodepressive effects [62], and its plasma levels are increased in acute liver failure in experimental animals [63].

Short-chain and medium-chain fatty acids may also potentiate the effects of ammonia on the brain [64]. Production of octanoic acid and C_3–C_5 short-chain fatty acids (such as propionate, butyrate and valerate) is reduced with therapy of hepatic encephalopathy using non-absorbable disaccharides [65].

Infections may synergistically modulate ammonia effects on the brain [66] in line with the longstanding experience that infections can trigger or exacerbate episodes of hepatic encephalopathy in patients with cirrhosis. Increased levels of inflammatory cytokines such as tumour necrosis factor α (TNFα), interleukin-1 and -6, oxidative stress and haemodynamic alterations may underlie this condition [67], as in sepsis-associated encephalopathy [68]. A relationship between plasma TNFα levels and the severity of hepatic encephalopathy was reported in cirrhotics [69].

Amino acid-derived neurotoxins may also be generated within the brain tissue itself. An increased transfer of neutral amino acids, such as phenylalanine and tryptophan, across the blood–brain barrier has been observed in experimental models [70]. It was explained by an increased exchange with glutamine [71], coupled with a plasma amino acid imbalance characterized by elevated plasma levels of aromatic amino acids (phenylalanine, tyrosine), but decreased levels of branched-chain amino acids [72] in chronic liver disease [73]. It was hypothesized that, in the presence of high aromatic amino acid levels in the brain, 'false neurotransmitters' such as octopamine, tyramine and β-phenylethanolamine are increasingly synthesized. However, measurements of brain catecholamines in postmortem samples from cirrhotic patients have shown a decrease in brain octopamine with normal noradrenaline/adrenaline (norepinephrine/epinephrine) values [74], and an increased entry of aromatic amino acids into brain was not confirmed in a group of patients with cirrhosis [75]. Also, clinical attempts at re-establishing the normal plasma aromatic/branched-chain amino acid ratio, which is also seen in patients without encephalopathy, have given inconclusive results.

Like the false neurotransmitter hypothesis, the 'gut-derived GABA hypothesis', proposed in the early 1980s [17,18] has essentially been abandoned. According to this view, GABA, a potent inhibitory neurotransmitter, which can also be generated within the intestine from the decarboxylation of glutamate, would gain access to the brain in the presence of liver failure and/or portal–systemic shunting and induce neuroinhibition after binding to GABA receptors, whose number is increased. Many tenets of this hypothesis have been refuted, as methodological problems were identified with regard to the measurements of GABA receptor density [76] and determination of GABA in plasma, hampered by cross-reactivity with other amino acids [77]. Furthermore, an increased permeability of the normally impermeable blood–brain barrier to GABA was not found in all animal models [78], and no alterations in GABA levels [79] or binding [80] were seen in human postmortem brain tissue.

Nonetheless, an alteration in GABAergic neurotransmission may still be present in hepatic encephalopathy. An increased concentration of compounds that bind to the GABA receptor (but not GABA itself) have been described in the plasma, CSF and brain of patients with acute and chronic liver failure [81]. These compounds have been termed 'endogenous' or 'natural' benzodiazepines, as they cross-react in a benzodiazepine radioreceptor assay but do not appear to exhibit the structure of this group of pharmacological agents. Animals without any lifetime exposure to exogenous benzodiazepines also have measurable levels of this activity [82,83]. A small fraction corresponds to known benzodiazepine compounds [84], but the source and nature of the greater fraction are unclear. It has been proposed that precursors of these compounds are produced by specific intestinal micro-organisms [85]. More recently, neurosteroids with positive allosteric modulatory properties at the $GABA_A$ receptor complex were identified in brain from patients with hepatic coma [86]. Animal studies showed that the synthesis of pregnenolone, which is a precursor of neurosteroids, is increased in hyperammonaemia and acute liver failure, probably as the result of activation of peripheral benzodiazepine receptors [87,88]. Ammonia may also synergistically interfere with GABAergic neurotransmission by increasing GABA-induced chloride currents in cultured neurons, ligand binding to the GABA receptor complex and inhibition of GABA uptake by astrocytes [89].

Neuroanatomical changes

With the exception of brain oedema, the brain of patients dying from acute liver failure in hepatic coma is surprisingly devoid of gross abnormalities. The only consistent change is the diffuse hyperplasia of astrocytes of the cerebral cortex, subcortical nuclei (such as the dentate and lenticular nucleus) and other brainstem nuclei [52]. Other parenchymal structures are minimally involved. In animal models of fulminant hepatic failure, astrocyte swelling (Fig. 1a) is a prominent pathological feature in practically all preparations [19,90,91]. Morphometric studies in patients with cirrhosis dying in hepatic coma indicate an increase in the size of astrocyte nuclei [92]. A characteristic appearance, the so-called Alzheimer type 2 astrocyte [93], is commonly observed in brains examined after immersion–fixation (Fig. 1b). It is characterized by enlarged pale nuclei with peripheral margination of chromatin and often prominent nucleoli. Human retinal glial cells undergo similar changes [94]. The changes can be reproduced in the experimental setting after administration of ammonia [95], and appear to be related to ammonia itself, as they can still be detected after inhibition of ammonia detoxification with methionine–sulphoximine, an inhibitor of glutamine synthetase [96]. They are also seen in congenital hyperammonaemic conditions [97]. Coupled with other evidence of astrocyte pathology, such as loss of glial fibrillary acidic protein, an intermediate filament [98,99], these changes highlight the need to consider a dysfunction of

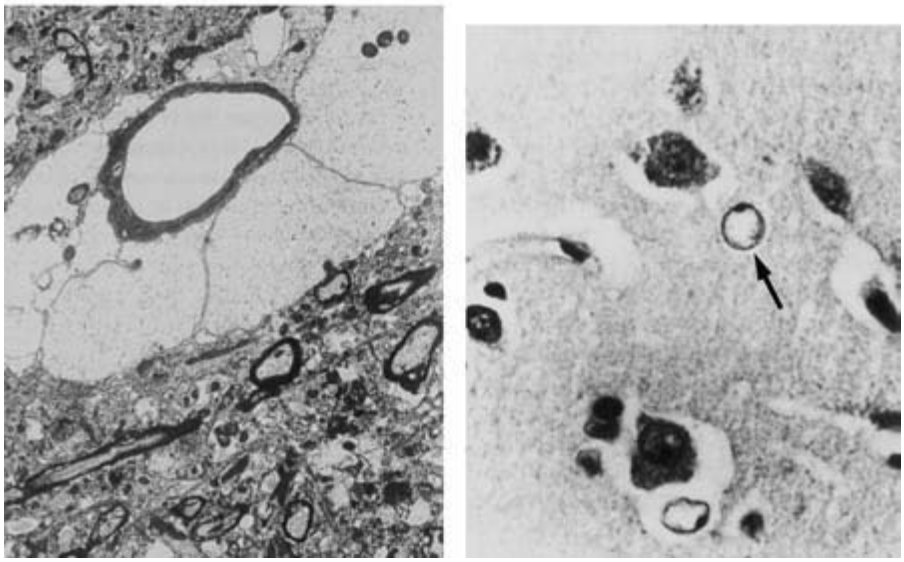

(a) (b)

Fig. 1 Alterations in astrocytic morphology in liver failure. (a) Hydropic foot processes of astrocytes surround a cerebral capillary from the cerebral cortex in a rabbit with galactosamine-induced fulminant hepatic failure (courtesy of Dr Mauro dal Canto, Northwestern University). (b) An Alzheimer type 2 astrocyte (arrow), with a large nucleus and its chromatin displaced to the side (courtesy of Dr Roger Butterworth, Université de Montreal, Canada).

this cell in any theory of the pathogenesis of encephalopathy [100].

Cortical atrophy can be seen on neuroradiological imaging [101,102], but may also reflect the additive effects of alcohol, ageing or other non-liver-related processes. It is viewed as a minor player, if any, in the symptomatology of hepatic encephalopathy. Discrete macroscopic changes can be detected in the so-called hepatocerebral degeneration [103]. This entity is characterized by a patchy but diffuse, spongy degeneration of the cortex, in which, histologically, neuronal degeneration of the deep cortical layer can be observed. Microcavitation can be seen in the striatum [104], a lesion that is also observed in Wilson's disease, and hence the term 'acquired hepatolenticular degeneration' is also used to define this condition. This is a feature of longstanding portal–systemic shunting, and can be seen many years after portocaval shunt surgery. Very rarely, spinal demyelination can occur after shunt surgery, with a symmetrical and variable loss of axons beginning in the spinal cord and becoming more conspicuous at lower levels. It predominates in the lateral pyramidal tracts and can give rise to a syndrome of spastic paraparesia [105].

More recently, MRI has raised the possibility that abnormalities of the basal ganglia may be more widespread than previously thought. A symmetrical hyperintense globus pallidus (Fig. 2) on T1-weighted MR spin echo sequences can be observed in more than 70% of stable subjects with cirrhosis, even without evidence of encephalopathy [106,107]. It has been related to plasma ammonia levels, portal–systemic shunting and liver function [108–110]. It persists (at least) over a 2-year period [111] and is reversible after hepatic transplantation. Quantitative T1 mapping with partial inversion recovery showed a relationship between T1 in the globus pallidus and the severity of hepatic encephalopathy; however, the signal is affected by both manganese and cerebral water content in opposite directions [112]. Direct measurements of the human brain at autopsy indicate that the accumulation of manganese could explain the hyperintensity seen on MR [113,114]. Manganese intoxication is a discrete neurological entity characterized by the development of similar changes in basal ganglia [115]. Manganese is neurotoxic, and possible pathogenic mechanisms include oxidative stress and excitotoxicity [116,117], inhibition of glutamate uptake in cultured astrocytes [118] and upregulation of binding sites for peripheral benzodiazepine receptor ligands [119]. In liver disease, portal–systemic shunting and biliary excretory failure could contribute to hypermanganesaemia [110,120]. The reasons for selective brain deposition of manganese are unclear, although a recent study suggests that hyperintensity seen at MR may be more widespread than a sole change in basal ganglia [121].

Brain water homeostasis

Whereas cerebral oedema is a frequent complication of fulminant liver failure [122], patients with cirrhosis and hepatic encephalopathy usually show no clinical signs of overt cerebral oedema and increased intracranial pressure, except for a few cases at the terminal stage [123]. Nonetheless, recent evidence suggests the presence of a low-grade cerebral oedema (without clinically overt signs of increased intracranial pressure) in patients with cirrhosis, which is even found in minimal hepatic encephalopathy and is considered to be of pathogenetic relevance [38–42]. The first indication for the presence of a low-grade cerebral oedema in patients with cirrhosis was derived from ^{1}H-MRS studies on the human brain *in vivo*, which identified the myoinositol signal as reflecting an osmosensitive myoinositol pool [38]. The brain from patients with hepatic

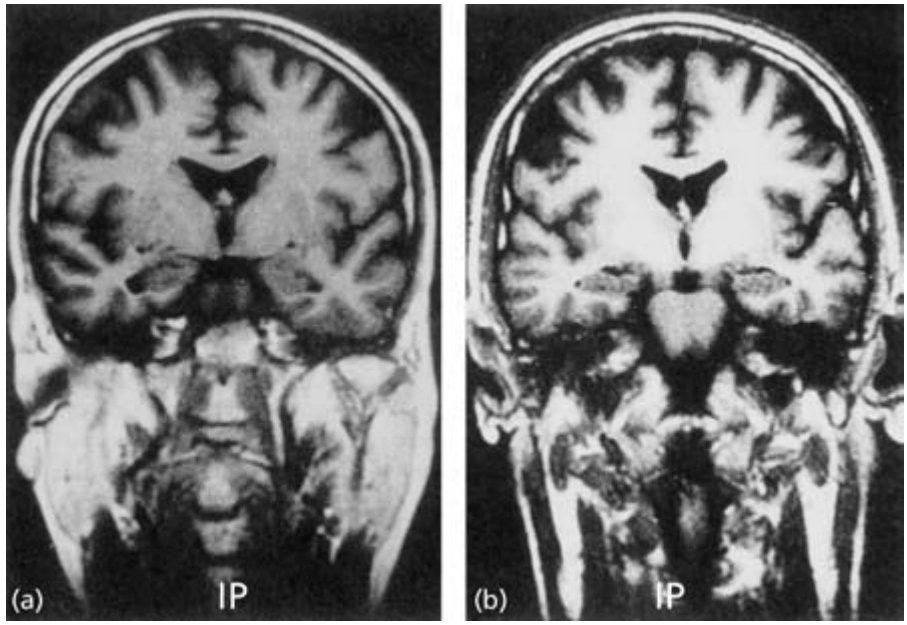

Fig. 2 Radiological alterations in cirrhosis. MR examination of a normal control subject (a) is compared with that of a cirrhotic individual (b), with conspicuous changes in the area of the basal ganglia. A hyper-resonant globus pallidus is seen (reproduced from ref. 108, with permission).

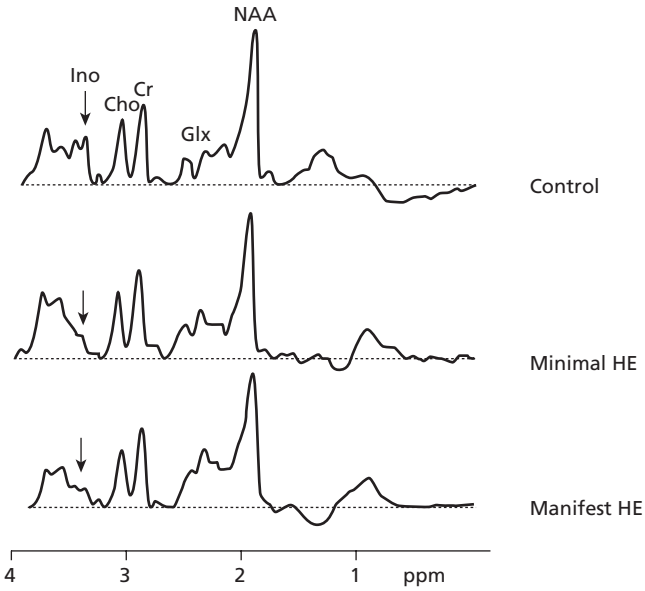

Fig. 3 Parietal ^{1}H-MR spectra from a healthy person (control) and patients with posthepatitic cirrhosis and minimal hepatic encephalopathy (HE) or manifest grade I–II HE. Note the decrease in myoinositol (Ino) signal and the increase in the glutamine/glutamate (Glx) signal. Other peaks refer to choline (Cho), creatine (Cr) and N-acetylaspartate (NAA) (reproduced from ref. 38, with permission).

encephalopathy consistently shows a depletion of this osmolyte (myoinositol) pool, which is accompanied by an increase in the glutamine/glutamate signal (Fig. 3) [38,124–126]. In view of the role of myoinositol as an organic osmolyte in astrocytes [127,128], these MRS findings suggested a disturbance of astrocyte volume homeostasis in the brain [43], supportive of a cellular (cytotoxic, but not vasogenic) oedema. This can be explained, at least in part, by an osmotically active intracellular accumulation of glutamine in response to hyperammonaemia and counteraction of the resulting astrocyte swelling by myoinositol depletion. In addition to myoinositol, other organic osmolytes such as taurine and α-glycerophosphorylcholine are also depleted in order to counteract astrocyte swelling [127,129,130]. However, ammonia-induced glutamine accumulation may not be the only mechanism by which astrocyte swelling is triggered in hepatic encephalopathy. Astrocyte swelling occurs *in vitro* not only under the influence of ammonia in a methionine–sulphoximine-sensitive way [131], but also in response to hyponatraemia [132,133], some neurotransmitters [132,134,135], cytokines [136] and benzodiazepines [137]. The above-mentioned ^{1}H-MRS findings are also induced in the rat following porto-caval shunting [138], are aggravated following institution of a TIPS [38] and largely normalize following liver transplantation [139,140]. There is a good correlation between the extent of these ^{1}H-MRS changes and the clinical severity of hepatic encephalopathy (Fig. 3) [124]. The existence of a low-grade cerebral oedema in patients with cirrhosis *in vivo* was meanwhile confirmed in studies on magnetization transfer ratios [140–141] and by quantitative cerebral water mapping based on a new MRI method for fast quantitative mapping of T1 and water content (see the chapter by Shah in ref. 3).

Whereas hepatic encephalopathy in patients with cirrhosis is characterized by a low-grade cerebral oedema without clinical signs of a rise in intracranial pressure, the development of severe brain swelling in acute liver failure is frequent and a major complication. Brain oedema in acute liver failure is thought to involve cytotoxic and vasogenic components. A cytotoxic (or cellular) oedema results from an increase in intracellular osmolarity, and sodium and glutamine have been proposed as possible osmolytes. In the case of sodium, circulating inhibitors

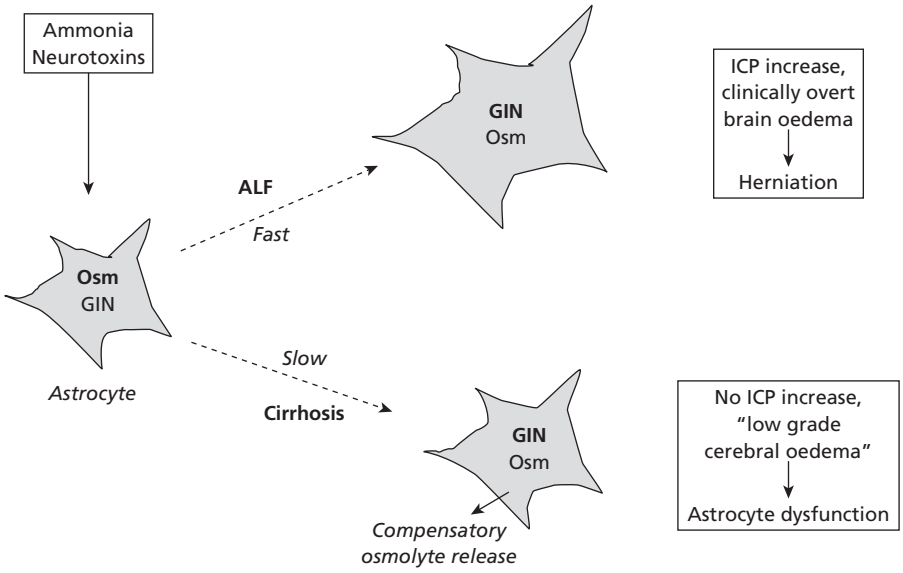

Fig. 4 Astrocyte volume homeostasis. Astrocyte swelling in acute liver failure (ALF) involves intracellular glutamine (GLN) accumulation, which is accompanied by an insufficient compensatory osmolyte release. Severe brain oedema with clinical signs of intracranial pressure (ICP) increase can develop. Glutamine also accumulates in the astrocytes of cirrhotic patients, but only a clinically inapparent low-grade cerebral oedema without signs of ICP increase develops due to a volume-regulatory osmolyte release. However, the mild increase in astrocyte water content may trigger astrocyte dysfunction.

of Na^+-K^+ATPase activity [142], whose presence can be determined indirectly, would enter brain tissue and prevent the exit of intracellular sodium. However, the existence of such inhibitors is controversial, and inhibition of brain Na^+-K^+ATPase has not been demonstrated convincingly in animal models. On the other hand, there is little doubt that the accumulation of glutamine, especially in astrocytes, plays a major role. Glutamine accumulation in the brain has been demonstrated in human postmortem tissue [79,143]. Inhibition of glutamine synthesis in animals infused with ammonia prevents the development of brain oedema [144,145]. There is clinical evidence that other acute conditions, such as chemotherapy-associated hyperammonaemia, are associated with brain swelling [146]. Interestingly, ^{1}H-MRS revealed that cerebral glutamine accumulation in acute liver failure was associated with unchanged myoinositol levels [141], while an increase in glutamine and a reduction in myoinositol are characteristic features of MRS in cirrhosis [37,38]. This suggests that, in contrast to the situation in liver cirrhosis, a compensatory osmolyte efflux in response to intracellular glutamine accumulation is compromised in the patient with acute liver failure, which results in more severe brain swelling (Fig. 4). The reasons underlying this difference between chronic and acute liver failure are unclear, but they may relate to different kinetics and time requirements of intracerebral glutamine accumulation, on the one hand, and the onset of volume-regulatory adaptations, on the other.

A vasogenic component ('vasogenic' oedema) would imply a disrupted blood–brain barrier. However, indirect evidence suggests that a gross disruption, as in cerebral tumours or trauma, is not seen in acute liver failure. Computerized tomography (CT) shows minimal changes [147] or, when present, subtle but diffuse changes in the cerebral cortex [148]; patchy involvement of both grey and white matter is noted in areas where the blood–brain barrier is broken. Brain biopsies of patients who had died with brain oedema showed intact tight junctions in the capillary endothelial cells [149]. On the other hand, there is evidence in experimental models of alterations of blood–brain barrier permeability towards the end of their clinical course [19]. It is unclear whether these arise from specific alterations in endothelial cell function or from changes in the cerebral circulation.

The fact that hepatic encephalopathy is associated with astrocyte swelling in both acute and chronic liver disease and that astrocytes are targets of neurotoxin action makes this cell type a central element in the pathogenesis of hepatic encephalopathy.

Neurotoxins, astrocyte swelling and astrocyte function

Astrocytes are the most abundant cellular element in the brain [150,151]. Their name reflects their stellar-like anatomy, with a small cellular body and extensive foot processes that surround capillary endothelial cells and neurons as well as axons. Functionally, this anatomical arrangement results in several key roles: neuronal function is optimized by controlling the extracellular environment (via mechanisms for the uptake of critical compounds such as CO_2, potassium and glutamate) [152,153]. Furthermore, astrocytes are components of the blood–brain barrier, which does not exhibit signs of gross disruption in liver disease [91,149,154]; however, alterations in distinct transport processes may be present [75]. Astrocytes also affect the function of the endothelial cells; in isolated preparations, coculturing with astrocytes allows endothelial cells to express blood–brain barrier properties, such as impermeable tight junctions [155]. Astrocytes are the only cellular elements containing glutamine synthetase, the sole mechanism that the brain possesses to detoxify ammonia [156].

Neurotoxin-induced alterations in astrocyte function have been studied in cultured astrocytes and experimental animals. Such alterations may be induced directly by neurotoxins and/or indirectly by the astrocyte swelling triggered by such neurotoxins. Changes in the cellular water content, i.e. cell hydration or the degree of cell swelling, have been identified in recent years as an independent signal that regulates function and gene expression through osmosensing and osmosignalling pathways in almost every cell type [157,158]. Thus, small increases in astrocyte water content, present in hepatic encephalopathy, may have important functional consequences despite the absence of clinically overt increases in intracranial pressure. Many, but not all, effects of ammonia on cultured astrocytes can be mimicked by swelling the astrocytes slightly in hypo-osmotic media. Like ammonia exposure, hypo-osmotic swelling of astrocytes activates extracellularly regulated protein kinases [132], upregulates the peripheral-type benzodiazepine receptor (PBR) [159], elevates the intracellular calcium concentration [160], affects multiple ion channels and amino acid transport [161] and increases the pH in endocytotic vesicles [162], i.e. a compartment that is involved in receptor/ligand sorting. Also, the increased deposition of glycogen in astrocytes in animal models of chronic hepatic encephalopathy can be explained by cell swelling [163]. Hyperammonaemia depresses glucose consumption in rat brain [164]. This and other metabolic effects of ammonia intoxication were shown to depend upon ammonia-induced glutamine synthesis, but not upon the presence of ammonia *per se* [165,166]. This points to a critical role for ammonia-induced astrocyte swelling, because inhibition of glutamine synthesis prevents ammonia-induced astrocyte swelling (see the chapter by Norenberg in ref. 167). Both ammonia and hypo-osmotic astrocyte swelling activate *N*-methyl-D-aspartate (NMDA) receptors and induce oxidative/nitrosative stress (see below). Astrocyte swelling leads to a release of cellular taurine, which has antioxidant properties. Taurine was shown to induce long-glasting enhancement of corticostriatal neurotransmission [168], and taurine depletion may therefore affect synaptic plasticity [169]. Further, taurine depletion in mice was shown to upregulate $GABA_A$ receptors in various brain regions [170], and increased GABAergic tone may be found in the brain of patients with hepatic encephalopathy.

However, not all ammonia effects on astrocytes are triggered by ammonia-induced cell swelling. For example, ammonia, but not hypo-osmotic exposure, induces haem oxygenase-1 expression in cultured astrocytes [171]. An increased haem oxygenase-1 expression was also found in the brains from ammonia-intoxicated [171] and portocaval-shunted rats [172] and may play a role in the pathogenesis of cerebral hyperaemia found in acute liver failure, through the increased formation of the vasodilator carbon monoxide [173].

Genechip studies have revealed profound effects of ammonia and portocaval shunting on gene expression in astrocytes and the cerebral cortex. The genes involved comprise components of signal transduction, antiapoptosis, oxidative stress defence and genes for various receptor and transport systems [172]. Ammonia effects on the expression of glutamate transport systems were studied in detail. Ammonia downregulates the astrocytic glutamate transporters GLAST and GLT-1 [174,175] and the activity of the neuronal glutamate transporter EAAT3 [176]. Thus, acute ammonia intoxication inhibits glutamate uptake and contributes to the established increase in extracellular brain glutamate, which may be responsible for hyperexcitability in acute liver failure or acute ammonia intoxication.

Ammonia impairs axonal growth in cultured embryonic rat brain cell aggregates, a finding not observed in mature cultures [177,178]. This disturbance is accompanied by a decrease in phosphocreatine and creatine, and is prevented by creatine supplementation. Such phenomena may contribute to the irreversible neurological damage that is observed in inborn hyperammonaemic syndromes, such as urea cycle defects.

Oxidative and nitrosative stress

A role for oxidative and nitrosative stress in the pathogenesis of hepatic encephalopathy is largely derived from *in vitro* and animal studies, whereas little direct evidence is available in humans. Indirect support arises from some beneficial therapeutic measures in hepatic encephalopathy that exhibit antioxidant properties together with the increased amounts of lipofuscin in the brains from patients who died with hepatic encephalopathy [133,179]. In cultured astrocytes, ammonia induces an oxidative stress response [180,181], which is also seen when astrocytes undergo hypo-osmotic swelling [182] or are treated with benzodiazepines [183] or inflammatory cytokines such as TNFα or interferons (newly published [406]). These oxidative stress responses are mediated by an activation of NMDA receptors, but the exact mechanism of this activation is unclear [133]. Possibilities include a swelling-induced glutamate release from astrocytes and a deinhibition of NMDA receptors due to a depolarization-induced Mg^{2+} removal. There is a close relationship between astrocyte swelling, NMDA receptor activation and oxidative stress. On the one hand, astrocyte swelling induces oxidative stress through an NMDA receptor and Ca^{2+}-dependent mechanism [182] and, on the other, NMDA receptor activation triggers astrocyte swelling [184]. This points to an autoamplification signalling loop allowing mutual amplification of cell swelling and oxidative stress [133]. Ammonia and astrocyte swelling also induce nitrosative stress, probably through an NMDA receptor and Ca^{2+}/calmodulin-dependent activation of constitutive nitric oxide synthases (NOS). In addition, in cultured astrocytes, ammonia (but not hyponatraemia) upregulates inducible NOS [181]. Increased cerebral NO formation may contribute to cerebral vasodilatation after ammonia intoxication [122], and a pathogenetic role for ammonia-induced oxidative/nitrosative stress is suggested by the finding that NMDA receptor antagonists and inhibitors of NOS ameliorate ammonia toxicity in animal models [185–187].

One consequence of oxidative/nitrosative stress induced by ammonia, astrocyte swelling, benzodiazepines and inflammatory cytokines is a covalent modification of tyrosine residues in astrocytic proteins through nitration in the 3-position of the aromatic ring. Protein tyrosine nitration (PTN) in astrocytes is also found *in vivo* in ammonia-intoxicated or portocaval-shunted rats [181]. Astrocytes located near the blood–brain barrier exhibit especially high levels of PTN. Peroxynitrite is involved in ammonia- and swelling-induced PTN [182], whereas benzodiazepine-induced PTN involves activation of the peripheral, but not the central, benzodiazepine receptor (PBR) [183]. Ammonia, benzodiazepines, inflammatory cytokines and swelling synergistically promote PTN in astrocytes [133]. PTN does not appear to be an unselective process, because only distinct proteins undergo PTN. Among these, glutamine synthetase, PBR, glyceraldehyde-3 phosphate dehydrogenase and the extracellular signal-regulated kinase Erk-1 were identified [181]. 3-Nitrotyrosines in proteins are poor substrates for tyrosine phosphorylation reactions with impairment of signal transduction cascades that depend on reversible tyrosine phosphorylation [188–90]. PTN of glutamine synthetase involves the catalytic centre of the enzyme [191] and is associated with its inactivation [181]. Although PTN interferes with enzyme activities and signal transduction, its role in the pathogenesis of hepatic encephalopathy is unclear, although inhibition of ammonia-induced PTN by NMDA receptor antagonists, inhibitors of glutamine synthetase or NOS is associated with an amelioration of ammonia toxicity in animals.

Also, a diminished oxidant defence may contribute to the ammonia-induced oxidative stress. Astrocyte swelling leads to the release of taurine, and ammonia downregulates Cu/Zn-dependent, but upregulates Mn-dependent, superoxide dismutase and haemoxygenase-1 [171,172].

Energy metabolism

Metabolic diseases can alter the level of consciousness as a result of brain energy failure, as exemplified by the encephalopathy that accompanies hypoglycaemia, where the lack of substrate results in a loss of the energy required to maintain transmembrane ionic gradients. Alterations in brain energy metabolism have been detected in patients with severe hepatic encephalopathy [192]. Recent studies measuring glucose utilization in rats after portocaval anastomosis using autoradiographic techniques have yielded conflicting results as both an increase and a reduction in this parameter have been noted in several brain regions [48,49]. Measurements of human glucose consumption with PET scanning have also yielded conflicting results (reviewed in [193]). In one study with special attention to statistical analysis, only a selective loss of glucose consumption was noted, specifically in the area of the cingulate gyrus [194]. This observation would be in line with a diminished blood oxygen level-dependent (BOLD) activation in this area in patients with cirrhosis who underwent examination with functional MRI [195]. Using ^{31}P-MRS, a reduction in the ratio of phosphomonoesters to adenosine triphosphate (ATP) was noted in human brain, a decrease that could reflect less breakdown of ATP to adenosine monophosphate (AMP) [196,197]; however, changes in other chemical compounds (such as choline) may explain these findings. Studies in animal models, in which a reduction in brain ATP was demonstrated [198], were performed at a late stage of the neurological picture. While newer technology may shed further light on this issue, a consensus has emerged that energy failure, although possibly present at the end of the clinical course, is not a primary pathogenic mechanism in hepatic encephalopathy [14].

Alterations in neurotransmission

Multiple neurotransmitter systems are altered in hepatic encephalopathy. This multiplicity is shared with other metabolic disorders of the brain and raises the question as to which changes are primarily responsible for symptoms and which are secondary to earlier modifications. In order to study this complex rearrangement, neurochemical measurements and behavioural testing are tools to probe such systems in the experimental animal. Recent technological advances, such as brain microdialysis, for example, have allowed measurements of transmitters in the extracellular space [199,200]. Improved methods for monitoring behaviour in small rodents are also becoming available [201]. A recent study on portocaval-shunted rats, which employed electrophysiological and behavioural approaches in the individual animal, showed deficits in cortico-striatal synaptic plasticity, which could be related to a disturbed processing of novel information and memory [202]. Correlations between synaptic plasticity and a variety of activity parameters in the open field were opposite for control and portocaval-shunted animals, indicating a disintegration of the relationship between synaptic plasticity and behaviour. The resulting habituation deficit in these animals may correspond to the cognitive and memory defects in patients with hepatic encephalopathy [203].

GABAergic neurotransmission

Several observations suggest that alterations in GABAergic neurotransmission may be present in hepatic encephalopathy. These include an excessive sedative response of cirrhotic patients to benzodiazepines [204] and the fact that the mental state improves in a subset of patients with hepatic encephalopathy after administration of flumazenil, a benzodiazepine receptor antagonist [205]. The lack of correlation between plasma levels of benzodiazepine receptor ligands and the clinical response to flumazenil suggested that the drug may also be working through other mechanisms. Recent observations implicate the PBR in the pathogenesis of hepatic encephalopathy [13,14]. In contrast to the central receptor, which is part of the neuronal $GABA_A$

complex, the PBR is located on the outer mitochondrial membrane of astrocytes, but is also found in most peripheral cell types. It has been implicated in many cellular functions [206,207]. One of the best characterized is the regulation of the synthesis of neurosteroids, such as allopregnenolone and allotetrahydrodeoxycorticosterone, which have positive $GABA_A$ receptor-modulatory activity and were identified in the brains of patients with hepatic coma [86].

In astrocytes, ammonia upregulates the PBR, increases its affinity for ligands [208] and induces tyrosine nitration of the PBR [181]; the functional relevance of these changes is unknown. Increased numbers of peripheral benzodiazepine receptors have been reported in rats after portocaval anastomosis [209] and, post mortem, in brains from patients with cirrhosis [87]. Such changes are also observed in a rat model of acute liver failure [88] and in hyperammonaemic mice with congenital ornithine transcarbamylase deficiency [210]. Another agonist of the peripheral receptor is the neuropeptide, diazepam-binding inhibitor [211], the levels of which are elevated in hepatic encephalopathy, and which exhibits antagonist activity at the level of the GABA receptor. The role of neurosteroids in the pathogenesis of hepatic encephalopathy is currently being explored. However, one must keep in mind that the PBR is also a component of the mitochondrial permeability transition pore, and its stimulation can induce apoptosis in some peripheral cell types [212]. Tyrosine nitration is known to inactivate the CD95 (Fas) death receptor [194] and, likewise, ammonia-induced PBR nitration may be protective. Activation of the PBR by benzodiazepines and synthetic ligands such as PK11195 or Ro5-4864 triggers an oxidative stress response and increases protein tyrosine nitration [183].

Glutamatergic neurotransmission

Glutamate is a major excitatory neurotransmitter in the brain. Profound alterations have been observed at many sites involved in glutamatergic neurotransmission. Total levels of brain glutamate are decreased in several animal models and in the tissue of patients with cirrhosis [46]; this reduction reflects its consumption in the formation of glutamine. However, increased levels in the CSF [213] and extracellular space [199,214] have been observed in animal models. Such an increase could be explained by an increased release, suggested from experimental preparations [215,216], and/or a defect in glial reuptake (see above). It should be noted that glutamate belongs to the osmolytes that are released from astrocytes in response to cell swelling [132].

This increased extracellular glutamate may explain the alterations in receptor binding reported in several models. Glutamate binds to ionotropic [NMDA, α-amino-3-hydroxy-5-methyl-4-isoxazolepropionic acid (AMPA) and kainate subtypes] and metabotropic receptors in postsynaptic membranes [217]. NMDA receptors are present on astrocytes [183,218]. As discussed above, NMDA receptor activation in astrocytes is a key trigger for the ammonia-, swelling-, benzodiazepine- and cytokine-induced oxidative stress response. A reduction in NMDA receptor number [219] and in the affinity of non-NMDA receptors [220] has been reported in animal models.

Dopaminergic neurotransmission

As in Parkinson's disease, the presence of extrapyramidal symptoms in patients with cirrhosis suggests that a dopamine deficiency may play a functional role. However, when dopamine levels in cirrhotic patients were increased by the administration of L-dopa, no clear improvement in clinical encephalopathy was noted [221].

Recent observations have rekindled interest in possible alterations in the dopaminergic system. Autopsied brain tissue has shown increased levels of homovanillic acid, a dopamine metabolite [222]. Levels of monoamine oxidase A, the enzyme responsible for dopamine degradation, were increased in the brains of individuals with cirrhosis [223]. The number of D_2 dopamine receptors was specifically decreased in human tissue [224]. Of even greater interest is the observation that manganese toxicity is exerted via its accumulation in the pallidum and neurodegenerative changes that result in a reduction in D_2 receptors [225].

Serotoninergic neurotransmission

In hepatic encephalopathy, cerebral levels of the stable metabolite of serotonin, 5-hydroxyindolacetic acid, are consistently elevated in animals [226] and human tissue [222]. This could reflect an increased turnover of serotonin metabolism [227]. More recent data have shown an increase in the activity of monoamine oxidase A, the enzyme that is involved in the degradation of serotonin [228], which would explain the increased levels of 5-hydroxyindolacetic acid. An increased number of HT_2 receptors has been noted in human postmortem tissue [229], a factor that could account for the precipitation of overt hepatic encephalopathy by ketanserin, an HT_2 receptor antagonist [230]. However, nothing is known about other HT receptor subtypes. Methysergide, a non-specific receptor antagonist, had some beneficial effects on behavioural parameters in an animal model (reviewed in ref. 231). More work is needed to assess the pathogenic implications of an altered serotoninergic system.

Histaminergic neurotransmission

There is a high prevalence of sleep disturbances and abnormalities in circadian rhythmicity in patients with liver cirrhosis [232,233]. The histaminergic hypothalamic tuberomammillary nucleus is a major waking system of the brain that can elicit synaptic plasticity [234]. Histamine inhibits glutamatergic corticostriatal synaptic transmission through presynaptic histamine H_3 receptors [235]. The histamine level in CSF in humans with hepatic encephalopathy is increased [236], and an increased density of histamine H_1 receptors was found in brains from patients with cirrhosis and portocaval-shunted rats [237],

whereas H_3 receptors are downregulated in patients who died in hepatic coma [238]. These findings seem consistent with changes in the histaminergic system and disturbances of sleep–waking regulation. In line with this concept, the histamine H_1 receptor blocker pyrilamine improved the spontaneous locomotor activity of portocaval-shunted rats and restored altered circadian rhythmicity [239]. In portocaval-shunted rats, corticostriatal synaptic plasticity is significantly impaired and also involves histamine H_3 receptor-mediated long-term depression [202].

Other neurotransmitter systems

Alterations in opioidergic neurotransmission may be involved in the alcohol preference of rats after portocaval anastomosis [240], an alteration that is accompanied by region-selective alterations in μ and δ receptors and responds to treatment with the opioid antagonist, naloxone [241]. Its role in hepatic encephalopathy, proposed as a result of altered levels of enkephalins and endorphins, is uncertain [242,243].

Receptor autoradiography was employed on brain slices from patients who died with hepatic encephalopathy (see Zilles, reported in ref. 3). Despite high regional and intersubject variabilities, the striatum of patients with hepatic encephalopathy presented lower kainate, $GABA_B$, muscarinic M_2, nicotinic, 5-HT_{1A} and adenosine A_1 and A_{2A} receptor densities compared with control subjects. In the primary somatosensory cortex of patients with hepatic encephalopathy, NMDA and 5-HT_{1A} receptors were upregulated, whereas benzodiazepine binding sites, nicotinic and adenosine A_1 receptors were downregulated. These findings support the view that multiple receptor systems are affected in hepatic encephalopathy.

Disturbances of oscillatory networks in the brain

Magnetoencephalography (MEG) allows for non-invasive assessment of information processing in the human brain with high spatial and temporal resolution [244,245]. This technique was employed together with simultaneous electromyography (EMG) in patients with cirrhosis and hepatic encephalopathy in order to obtain insight into the neurophysiological basis of mini-asterixis, i.e. a postural tremor of varying frequency (6–12 Hz), which is observed in patients with low-grade hepatic encephalopathy [246,247]. MEG analysis by dynamic imaging of coherent sources [248] was used to identify brain sources coherent to the EMG and for cerebrocerebral coherence. Patients with hepatic encephalopathy exhibited a stronger corticomuscular coherence with a shift to lower frequencies when compared with control subjects [246], indicating a pathologically slowed and synchronized motor cortical drive (Fig. 5). The extent of these changes correlated with the severity of hepatic encephalopathy. This pathological motor cortical drive in hepatic encephalopathy results from altered thalamocortical

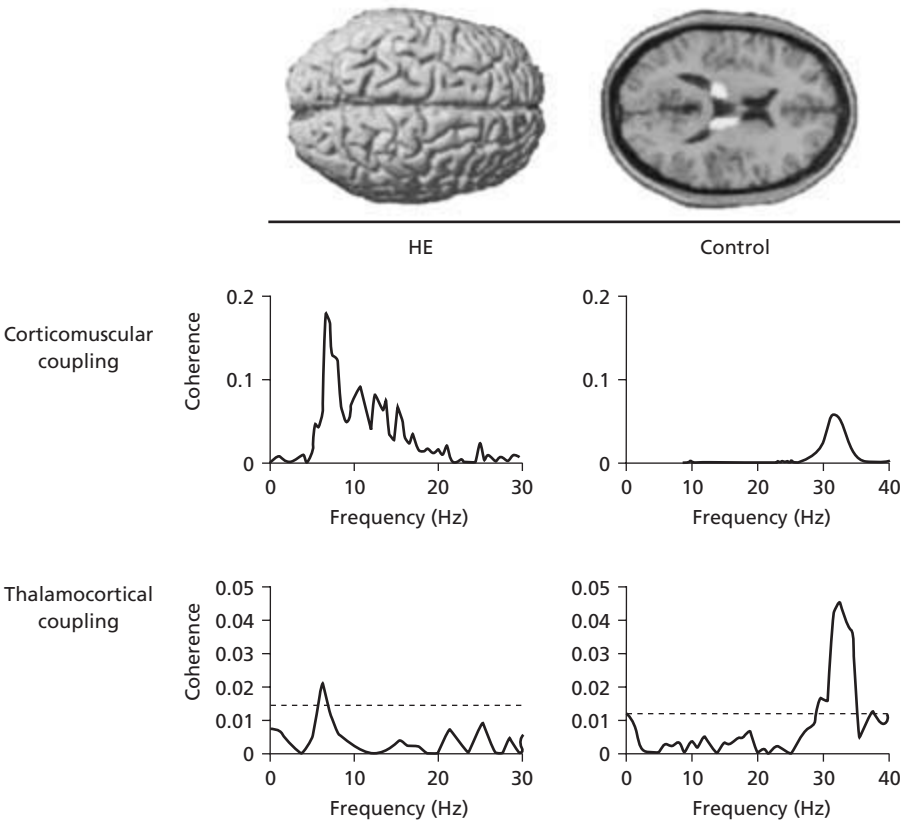

Fig. 5 Mini-asterixis in hepatic encephalopathy (HE) is induced by a pathologic thalamo–motorcortical coupling. Pathological oscillatory coupling in the motor system of a cirrhotic patient with HE. Cortical and muscular activities were recorded simultaneously by magnetencephalography and electromyography (EMG) (right extensor digitorum muscle) during forearm elevation with the right hand outstretched. Identification of brain sources coherent to each other or the peripheral EMG was performed by dynamic imaging of coherent sources. In both the healthy control subject and the cirrhotic HE patient with tremor (mini-asterixis), the M1 motor cortex is activated with electrical coupling to the thalamus (top). Corticomuscular coupling reveals a high-amplitude peak at the frequency of the tremor in the HE patient (centre), whereas coupling in the control patient is high frequency with a low amplitude. Thalamo-motor-cortical coupling in the HE patient occurs exactly at the individual tremor frequency, whereas in the control subject, thalamocortical coupling is at higher frequency, which also matches the frequency of corticomuscular coherence (bottom). Apparently, a pathologically rigid and slowed thalamocortical drive triggers mini-asterixis in HE (reproduced from ref. 247, with permission).

oscillatory coupling [247]. These findings point to a disturbance of cerebral oscillatory networks in hepatic encephalopathy that is triggered by possibly neurotoxin- and hydration-sensitive thalamic structures and results in an abnormally low frequency and rigid thalamocortical and corticomuscular coupling [249]. Such pathologically altered oscillatory networks may explain some motor and cognitive defects in patients with hepatic encephalopathy.

Current pathogenetic model

Based on the above considerations, a simplified pathogenetic model is presented (Fig. 6). In chronic liver disease, ammonia and other neurotoxins induce a low-grade cerebral oedema due to astrocyte swelling. This occurs without a clinically overt increase in intracranial pressure, but the hydration increase is sufficient to trigger multiple alterations in astrocyte function and gene expression and to induce oxidative/nitrosative stress with covalent protein modifications. An autoamplicatory loop between cell swelling and oxidative stress may be involved in these responses. In addition, there are direct, swelling-independent effects of neurotoxins on astrocyte and neuronal function. As a result of an altered astrocyte function, glioneuronal communication and multiple neurotransmitter systems become deranged, with an impact on synaptic plasticity and oscillatory cerebral networks. These changes may finally account for the symptoms of hepatic encephalopathy. Not only ammonia, but also inflammatory cytokines, benzodiazepines and hyponatraemia, can induce astrocyte swelling and synergistically act on oxidative/nitrosative stress. This offers an explanation as to why rather heterogeneous conditions, such as bleeding, infections, electrolyte disturbances or drugs, can precipitate episodes of hepatic encephalopathy in patients with cirrhosis. Thus, multiple factors act synergistically on a common pathogenetic endpoint, i.e. glial swelling with its functional consequences. Patients without cirrhosis may tolerate such precipitating factors without developing hepatic encephalopathy symptoms, because their osmolyte systems for counteraction of cell swelling are not exhausted. In cirrhosis, however, organic osmolytes are largely depleted in order to compensate for glial glutamine accumulation, and there may be little room for the action of these volume-regulatory mechanisms against further challenges in cell volume. This labile situation may explain the rapid kinetics of hepatic encephalopathy episodes and why severe brain oedema with fatal outcome can occasionally develop in subjects with endstage cirrhosis.

Similarities may exist with respect to the pathogenesis of hepatic encephalopathy in cirrhosis and that of acute liver failure, but differences in the kinetics, extent and cell volume-regulatory mechanisms counteracting glial swelling may be responsible for differences in the clinical picture in both settings. In acute liver failure, astrocyte swelling appears to be too rapid to allow for

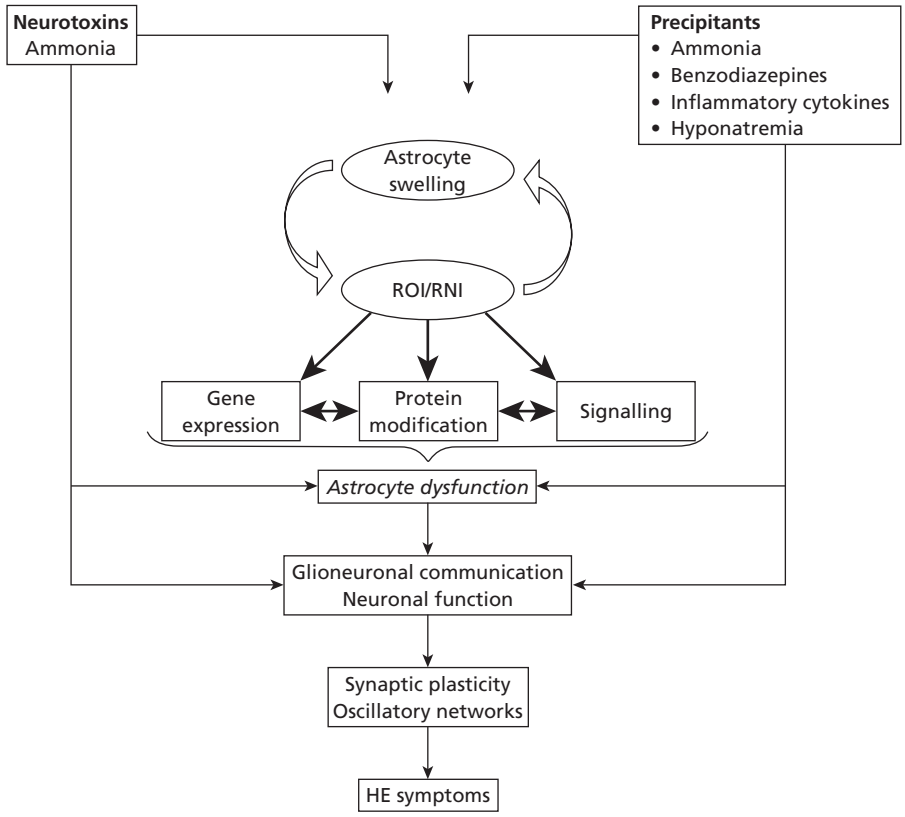

Fig. 6 Pathogenetic model for hepatic encephalopathy. Neurotoxins such as ammonia induce astrocyte swelling, which is aggravated synergistically by precipitants. Ammonia-induced osmolyte depletion reduces the volume-regulatory capacity and thus sensitizes astrocytes to swelling by precipitating factors. Astrocyte swelling involves NMDA receptor activation, Ca^{2+} and the generation of oxidative and nitrosative (ROI/RNI) stress. Swelling and oxidative stress are connected through an autoamplificatory loop. Sequelae of astrocyte swelling and oxidative/nitrosative stress are alterations in astrocyte function. Although astrocyte swelling is considered to be a major pathogenetic event, direct, swelling-independent effects of neurotoxins on astrocytes are also involved. Such alterations in astrocyte function involve gene expression and intracellular signal transduction as well as changes in transport, metabolism, neurotransmitter processing and the synthesis of neurosteroids. This astrocyte dysfunction is seen to reflect a major event, which affects glioneuronal communication. The latter is reflected by changes in synaptic plasticity and disturbances in oscillatory electrical networks in the brain as one basis for cerebral dysfunction in hepatic encephalopathy. This current model does not exclude direct neurotoxin effects on the neurons. ROI/RNI, reactive oxygen/nitrogen intermediates.

Table 2 Clinical features of HE in acute liver failure versus HE in chronic liver disease.

	Hepatic encephalopathy	
	Acute	**Chronic**
Overt brain oedema	Frequent	Very rare
Response to therapy	Poor	Acceptable
Agitation, seizures	20–30%	Very rare
Precipitating factors	Rare	Frequent
Short-term prognosis	Poor	Acceptable

efficient volume correction by volume-regulatory mechanisms, and clinical signs of increased intracranial pressure become evident.

Clinical manifestations

A wide range of symptoms and signs can be elicited in patients with hepatic encephalopathy. Some of them are seen throughout the spectrum of clinical syndromes; some are noted only in specific entities.

Encephalopathy of acute liver failure

The development of encephalopathy in a subject with an acutely failing liver is a serious prognostic sign. It can occur within 1 or 2 weeks after the onset of jaundice (hyperacute liver failure or fulminant hepatic failure) or after a more protracted time interval (subacute or subfulminant hepatic failure). The stages of encephalopathy have been well delineated, but some clinical manifestations are seldom seen in chronic liver disease (Tables 2 and 3). Periods of excitation and mania can be present in stage I, the prodromic phase of acute liver failure; this can be a difficult management problem, as pharmacological sedation obscures any spontaneous change in mental state. In stage II, coma is impending, with drowsiness and inability to maintain sphincter control; a flapping tremor can easily be elicited. Subclinical seizure activity, myoclonic or focal, can be a feature of the late stages of acute hepatic failure and is rarely seen in chronic liver disease. The progression of changes in mental state can be very rapid, counted in hours, and in stages III (stupor) and IV (coma), brain oedema and intracranial hypertension can complicate the clinical course.

Brain oedema is clinically silent but, once a critical point is reached, the normal intracranial pressure (0–10 mmHg) begins to rise within the limits of the rigid skull. Once brain compliance has been critically reduced, intracranial pressure can increase swiftly and reduce the cerebral perfusion pressure (mean arterial pressure–intracranial pressure) to the point at which brain ischaemia develops. The clinical course culminates with the development of 'pressure waves' that elevate the pressure to critical levels and result in the displacement of brain structures (Fig. 7). Herniation of the temporal or uncal lobe can be life-threatening. Brain oedema and intracranial hypertension are a major cause of death in acute liver failure.

An increased intracranial pressure can be clinically silent until high pressure values are reached. Patients are deeply encephalopathic, and a sudden respiratory arrest can be a clinical presentation. Frequent monitoring of signs that indicate a high pressure, such as loss of the caloric or pupillary reflexes, is not an effective screening tool. Papilloedema is not detected. With this diagnostic difficulty, alternative methods for clinical monitoring have been examined (see below).



Fig. 7 Elevation of intracranial pressure (ICP) in a rat model of acute liver failure (ALF). Pressure is recorded continuously from the onset of ALF, and initial higher values stabilize 1 h after surgery in both ALF (top) and control (bottom) subjects. Within the last 2 h of the course, intracranial pressure progressively rises in ALF and, in the last 30 min, episodic elevations occur with values above 50 mmHg. These culminate in brain herniation and demise of the animal [reproduced from Webster (1991) *Hepatology* 14, 715, with permission].

Table 3 Grading of encephalopathy.

Grade	Level of consciousness	Intellectual function	Neurological abnormalities	EEG abnormalities
0	Normal	Normal	None	None
I	Lack of awareness Change in personality Day/night reversal	Short attention span Easy forgetfulness	Slight tremor Uncoordination Asterixis	Symmetric slowing
II	Lethargy Unsuitable behaviour	Loss of orientation	Asterixis Abnormal reflexes	Symmetric slowing Triphasic waves
III	Asleep but rousable Confused when awake	Loss of interpersonal communication	Abnormal reflexes	Triphasic waves
IV	Unarousable	Absent	Babinski/clonus Decerebrate	Delta (very slow)

Episodic encephalopathy in cirrhosis

This is the most common presentation in the hospital setting: a patient with known chronic liver disease develops an alteration in mental state as a result of a precipitating factor. Gastrointestinal haemorrhage, uraemia, infections and the use of sedatives are most commonly incriminated. Less frequent, but clinically relevant, precipitants include constipation, hypokalaemia and excessive protein consumption. Removal or antagonism of the precipitant factor will result in neurological improvement.

Exploration of mental status (Table 3)

Difficulties can arise in the diagnosis of early encephalopathy. Subtle alterations in behaviour are first detected by family members. Abnormalities of sleep, including insomnia, hypersomnia or inversion of sleep, can be an initial complaint. A shortened attention span, irritability or depression can be detected. In individuals with defined activities, abnormalities in handwriting or subtly impaired computations can become apparent. As encephalopathy progresses, intellectual function may show a loss of orientation to time, while an overt change in personality can occur in some individuals. A lethargic state of consciousness can evolve into confusion, stupor and coma; a detailed classification of coma is available (Table 4), although it is designed for traumatic head injury.

Physical signs

Several physical signs can be detected in such patients. Asterixis ('liver flap'), the most conspicuous, was first described in 1953 [52]. It represents an intermittency of sustained muscle contraction with arrhythmic lapses of sustained posture. Under normal circumstances, a very short myoelectrical silence can be detected when maintaining a constant contraction of a muscle group; asterixis represents the prolongation of this myoelectrical silence, such that the contraction cannot be sustained. A mild form is probably the irregular postural tremor syndrome called 'mini-asterixis' [246,247]. It is most commonly elicited by asking the patient to extend his or her arm while retroflexing the wrist with separated digits. It is a feature of stages I and II encephalopathy; as the depth of encephalopathy progresses, the patient cannot cooperate with the request. In debilitated individuals, asterixis can also be elicited by asking the patient to extend the tongue or by having the examiner's fingers squeezed by the subject's hand; in both circumstances, the position cannot be maintained. Mini-asterixis and asterixis originate from derangements in central pathways rather than peripheral alterations, and reflect a pathologically slowed and synchronized motor cortical drive, which results from altered thalamocortical oscillatory coupling [246,247] (Fig. 5).

Asterixis is not a pathognomonic finding in hepatic encephalopathy; it can also be observed in other metabolic encephalopathies, such as uraemia, carbon dioxide narcosis, in hypomagnesaemia and with diphenylhydantoin intoxication. It can also be seen in focal neurological disease [250]. However, different mechanisms are involved in tremor generation in hepatic encephalopathy and Parkinson's disease [249].

Fetor hepaticus is a peculiar odour detected in the exhaled breath of patients with encephalopathy. It is difficult to define but, if sampled, it is easier to recognize in subsequent individuals. It is a pungent, somewhat sour, odour noted at all stages of encephalopathy. Volatile sulphur-containing compounds, such as mercaptans, may account for this finding [251].

A wide range of other neurological signs can be detected. Extrapyramidal abnormalities, including bradykinesia, dysarthria, rigidity and tremor, have been described in patients with cirrhosis [107]. Focal neurological findings can also be observed during the course of overt encephalopathy. Long-tract signs, such as Babinski and ankle clonus, can be unilateral or bilateral; they may be confusing in the individual who is stuporous or comatose but, in contrast to established neurological lesions, these focal signs characteristically wax and wane. Transient cortical blindness [252] and alternating gaze deviation [253] have been reported. It should be remembered that metabolic encephalopathies, such as hepatic encephalopathy, can result in the clinical expression of previously silent small focal lesions.

Table 4 Classification of coma (Glasgow coma scale).

Eyes open	
Spontaneously	4
To command	3
To pain	2
No response	1
Best motor response	
Obeys verbal command	6
Painful stimulus, localizes pain	5
Painful stimulus, flexion response	3
Painful stimulus, extension	2
No response	1
Best verbal response	
Oriented and conversant	5
Disoriented and conversant	4
Inappropriate words	3
Incomprehensible sounds	2
No response	1
Total score from 3 (worse) to 15 (best)	

Diagnosis (Table 5)

Detection of a precipitating event is a critical initial step, which may require examinations to exclude gastrointestinal bleeding or infection; encephalopathy can be a presenting symptom of spontaneous bacterial peritonitis.

There are two clinical circumstances that pose difficulties in diagnosis. The first is the rare circumstance in which encephalopathy is the presenting symptom of liver disease. As in other cases of a new abnormal mental state, a thorough physical and laboratory examination should provide diagnostic clues. In

Table 5 Diagnostic approach to overt encephalopathy in cirrhosis.

1. Exclude other causes of encephalopathy	
With fever and ↑WBC	Consider lumbar puncture
In active alcoholism	Consider subarachnoid haemorrhage
Alcoholism and confusion	Consider Wernicke's encephalopathy
	Obtain drug screen
Encephalopathy with asterixis	Rule out uraemia, CO_2 narcosis, ↓Mg
Decerebrate posturing	Consider brainstem lesions, but neuro-ophthalmological examination is normal in liver cases
Exclude dementia	Normal consciousness + global cognitive defect
	Long duration; insidious onset
Exclude psychosis	Normal consciousness + selective cognitive defect
	Short duration; acute onset
2. Search for precipitating factor of hepatic encephalopathy	
Most common	Gastrointestinal haemorrhage, uraemia, use of sedatives, diuretics, dehydration
Other causes	Dietary indiscretion, infection, constipation, hypokalaemia
Also consider	Hypoxia, anaemia, hyponatraemia and hypophosphataemia
	Large spontaneous portal–systemic collaterals
When none found	Acute deterioration of liver function
3. Obtain diagnostic tests	
Arterial ammonia	For diagnostic uncertainty, not needed for follow-up
EEG	For diagnostic uncertainty
Search for precipitant	Blood count and chemistry, blood/urine/ascites culture
	Rectal/nasogastric examination for occult blood
	Drug screen
Imaging	Brain CT for exclusion of other pathology

EEG, electroencephalogram.

this setting, measurement of plasma ammonia is useful; except for sedative-induced encephalopathy, many precipitating causes of encephalopathy are associated with an elevated ammonia level. Arterial blood provides a more accurate determination, as venous ammonia samples are influenced by the variable degree of peripheral metabolism. More recently, arterial and 'arterialized' samples (where the hand is warmed and the venous sample is drawn in a distal direction) or samples from the earlobe capillary [254] have been proposed, but their value has been questioned [57,255]. Immediate analysis and good laboratory practice are critical, as contamination should be rigorously avoided. Once the patient has been diagnosed as having hepatic encephalopathy, serial measurements of ammonia are unnecessary, as clinical examination is adequate to assess the evolution. In fact, as already discussed, mean blood ammonia levels correlate with stages of encephalopathy, but have poor predictive value in the individual case. Only in acute liver failure have arterial ammonia levels proved to potentially change management, as values > 200 mg/dL are associated with cerebral herniation [256].

The second diagnostic challenge is the exclusion of other causes of encephalopathy in patients with known liver disease. Alcoholic subjects may develop Wernicke's encephalopathy, in which a confusional state is associated with dysconjugate gaze. Fever and/or leucocytosis are not features of hepatic encephalopathy, and a lumbar puncture may be necessary to exclude meningitis; such patients may already exhibit a coagulopathy, and the procedure should be done by an experienced individual. If available, determination of glutamine in the CSF can assist in the diagnosis of hepatic encephalopathy. The presence of focal neurological signs may prompt neuroimaging with CT or MR. Brain atrophy may be seen, especially in alcoholic subjects [257], but its clinical relevance is questionable. A hyper-resonant globus pallidus is not diagnostic of hepatic encephalopathy [258]. Agitation and tremulousness, features of alcohol withdrawal, are seldom signs of hepatic encephalopathy. In other patients, extrapyramidal symptoms can be prominent; resistance to passive movements may increase with the velocity of limb displacement (*gegenhalten*). Parkinsonian features can be detected in up to 89% of subjects with advanced liver disease [120].

Persistent (chronic) encephalopathy

This category includes patients with recurrent episodes of encephalopathy as well as those in whom a persistent alteration in mental state can be detected clinically. In those with recurrent episodes, dietary indiscretion and constipation are more conspicuous precipitants than gastrointestinal haemorrhage and uraemia. In patients with cirrhosis and persistent abnormalities of mental state or in whom spontaneous episodes of encephalopathy recur, extensive spontaneous large-diameter

portal–systemic shunts (e.g. splenorenal) can be detected [259–261]. Such cases may explain how, occasionally, patients can be discovered in psychiatric or neurological wards.

Individuals subjected to surgical portal–systemic anastomoses are especially prone to chronic encephalopathy that can vary according to the type of anastomosis and the nature of liver function [262,263]. Patients may develop an acute hypomanic or paranoid–schizophrenic reaction in the first months after the operation, but persistent changes tend to develop 1 year after surgery. Approximately 30% of patients in whom endoscopic and/or pharmacological techniques have failed to control portal hypertension-related bleeding and who receive an emergency surgical anastomosis, or in whom a TIPS is placed [264], develop episodes of encephalopathy. TIPS-induced hepatic encephalopathy is usually mild [265], but shunt-narrowing/occlusion techniques are required in severe cases [266]. In non-alcoholic cirrhosis, persistent encephalopathy is more often seen with non-selective central shunts (end-to-side and side-to-side portocaval anastomoses, mesocaval shunt) than with selective derivations (distal splenorenal shunts) [267]. No single hepatic or neurological test has emerged as a clear predictor of encephalopathy after shunt surgery [268,269]. In the case of TIPS, the procedure is employed in older subjects, and this has emerged as a risk factor [264,270]. The role of a previous episode of encephalopathy in predicting post-TIPS encephalopathy may depend on whether it occurred spontaneously or as a result of a precipitant factor [271]. As expected, the risk of hepatic encephalopathy increases with the diameter of the TIPS shunt [272]. Interestingly, patients with cirrhosis and loss of portal perfusion before TIPS were protected against post-TIPS chronic hepatic encephalopathy [273].

Hepatocerebral degeneration will develop many years after the surgical anastomosis or in patients with large portal–systemic shunts [274]. Patients develop a variety of extrapyramidal symptoms, including disturbances of gait, tremor, chorea and ataxia [275]. Muscle rigidity can be conspicuous. The patients can appear as somewhat jovial in spite of their severe limitations. If spastic paraparesia develops, movement may be severely limited [105]; loss of bladder control can be prominent.

Minimal (subclinical) encephalopathy

A variable number of patients with cirrhosis, who appear to be clinically normal and whose neurological examination at the bedside appears unremarkable, exhibit cognitive deficits on neuropsychological examination [276–279]. The prevalence of these abnormalities is variable and, in the absence of a 'gold standard', a true prevalence may be difficult to define; up to 70% of patients have been reported to exhibit such changes. The relevance of minimal hepatic encephalopathy is derived from the findings that it may impair daily life [280–282] and is of prognostic relevance [283–285].

There is agreement that minimal hepatic encephalopathy is not a distinct pathogenetic entity but describes one end of the continuous symptom spectrum of hepatic encephalopathy [7]. Thus, minimal hepatic encephalopathy describes a poorly defined syndrome found in the 'grey zone' between normality and overt hepatic encephalopathy. In line with this concept, minimal hepatic encephalopathy can predict the development of overt hepatic encephalopathy [286]. Subcortical alterations were described as a possible anatomical site responsible for minimal changes, with involvement of basal ganglia [111,287,288]. However, these structures are also involved in overt hepatic encephalopathy [247]. A selective reduction in glucose consumption in the area of the cingulate gyrus, a nucleus involved in the attention process [289], was reported. However, as shown in recent functional MRI studies, judgement-related blood oxygen level-dependent (BOLD) activation was not only decreased in the cingulate cortex in minimal hepatic encephalopathy [195], but progressively decreased with severity of hepatic encephalopathy (see Kircheis in ref. 3). Also, the relation of subclinical changes to protein and amino acid metabolism [276], data from quantitative water mapping (see Shah in ref. 3), the reports of global reduction in cerebral blood flow noted in these patients [290], coupled with the response of neuropsychological tests to therapeutic manipulations which are applied in overt encephalopathy, suggest a global impact of the liver disease on brain function, as seen in cases of clinical encephalopathy.

Minimal encephalopathy probably has an impact on the daily life of patients. Proscription of automobile driving was recommended to patients who exhibit abnormal visual reaction times [278]. Subsequent studies confirmed an impaired fitness to drive [291,292], whereas a prior pilot study, in which the quality of automobile driving was assessed blindly in patients without prior episodes of overt encephalopathy, did not reveal differences between patients with and without abnormal neuropsychological tests or in their comparison with carefully matched control subjects [293]. In the absence of clear guidelines, it would appear prudent to fully evaluate patients who depend on driving or operating heavy machinery for their livelihood, and to examine the effects of therapy on their performance. If patients have already exhibited overt episodes of encephalopathy, limitation of driving may be necessary.

Sleep abnormalities are frequent in unselected patients with cirrhosis [232,294]. They may be related to alterations in circadian function [295], but could also reflect elements of anxiety and depression that may arise as a result of living with chronic disease. They are not necessarily related to abnormal neuropsychological test results [232].

Quantifying hepatic encephalopathy

With the variability that characterizes the clinical expression of hepatic encephalopathy, it is not surprising that many tools are available for patient follow-up. In subjects with overt changes in mental state, no test supersedes a clinical assessment. It is in the diagnosis of the earlier stages, such as minimal encephalopathy, that a large number of tests have been developed. Low grades of

encephalopathy can be viewed as a continuum and, ideally, tests will cover the spectrum of abnormalities currently divided into minimal, stage I and II encephalopathy.

Encephalopathy of acute liver failure

The development of brain oedema and intracranial hypertension poses diagnostic difficulties and influences the timing of liver transplantation. Brain swelling is not amenable to bedside clinical measurement as radiological techniques are imprecise and are not conducive to repeated measurements in these critically ill patients. Most of the effort is directed at measuring intracranial pressure. In the past few years, alternative non-invasive methods have been proposed, although none has emerged as a viable alternative.

Intracranial pressure monitoring

Patients with acute liver failure exhibit a severe coagulopathy, and placement of an intracranial pressure monitor may be associated with complications. A survey of clinical practice in the United States revealed a much lower incidence of haemorrhagic complications with the use of epidural transducers, while those monitors with which the dura mater was pierced (such as subdural bolts or intraventricular catheters) were associated with considerably more bleeding and even death [296]. Epidural monitors are less precise, and calibration can be problematic. The use of very thin transducers applied to the brain's surface has been suggested as an alternative, although complications do occur. Familiarity with the equipment and experience with such patients are important in reducing the complications. The procedure is mainly utilized in patients in whom liver transplantation is being considered, as evidence of increased survival by measurement of intracranial pressure has not been demonstrated [297]. Recent studies from the US Acute Liver Failure group indicate a 10% incidence of bleeding complications, including death [298]. Use of recombinant factor VII may decrease the incidence of complications [299].

Measurement of cerebral blood flow

Cerebral perfusion is decreased in the majority of patients with acute liver failure [300]. However, cerebral blood flow can increase prior to the development of intracranial hypertension [301] and, in the experimental animal, the signal for cerebral hyperaemia arises from the brain itself [302]. As mentioned, activation of haem oxygenase-1, as a result of oxidative stress, with generation of vasodilating carbon monoxide, is a leading candidate for the effect [173]. Furthermore, measurements of blood flow using radioactive xenon have shown that a subset of patients with acute liver failure may actually exhibit higher flows than would be expected for their cerebral metabolic rate, calculated as the product of cerebral blood flow and arteriovenous oxygen difference (the latter is estimated from measurements in a peripheral artery and in the jugular bulb). The term 'luxury perfusion' can describe this phenomenon [300], a change that can increase cerebral blood volume and facilitate the development of intracranial hypertension. In addition, these patients lose the capacity to autoregulate their cerebral blood flow in the face of variations in arterial pressure [303]. In this setting, an increase in arterial pressure may result in cerebral hyperaemia. These abnormalities in autoregulation appear to regress after liver transplantation and are not seen in the majority of patients with cirrhosis [304]. Cerebral vasodilatation *per se* may aggravate brain swelling, as shown recently with terlipressin [305].

Tools are being developed to monitor cerebral perfusion. Repeated measurements using radioactive xenon are not a practical alternative. Use of Doppler insonation of the middle cerebral artery may provide a non-invasive measurement [300], but it requires further validation. The sole measurement of the arteriovenous oxygen difference across the brain (arterial and jugular vein samples) is theoretically insufficient, as changes in perfusion and in cerebral metabolism can independently affect its value. Elevated jugular venous lactate has been demonstrated in some patients, raising the possibility that these individuals may be suffering from brain ischaemia [306]. Whether any of these measurements could replace intracranial pressure monitoring remains to be proven; they are more likely to provide complementary information.

Auditory evoked potentials and other approaches

In one study, serial recording of sensory evoked potentials in patients with acute liver failure provided prognostic information. Disappearance of the N70 wave was associated with the patient's demise or the lack of spontaneous recovery [307]. This experience awaits confirmation from other centres. Limited experience with the determination of critical flicker frequency in patients with acute liver failure suggests that this approach may be helpful for follow-up of the evolution of hepatic encephalopathy [308]. However, the technique is applicable to cooperative patients only.

Encephalopathy in cirrhosis

The PSE index

Many studies examining both precipitant-induced and persistent encephalopathy have utilized the portal–systemic encephalopathy (PSE) index (described in ref. [309]). This method combines clinical features with objective data, scored in a semi-quantitative fashion. For scoring, greater weight is given to mental state (factor of 3) than to arterial ammonia, asterixis, electroencephalogram (EEG) findings and score in the trailmaking test (factor of 1), each with scores of 1+ to 4+. Adding the contribution of these five parameters results in a PSE index value. The index has shortcomings, as separation into grades for some of its parameters (asterixis, trailmaking, ammonia) may be artificial; furthermore, repeated EEGs may not be readily available. A recent consensus statement has not supported its use for clinical trials in hepatic encephalopathy [7].

EEG

The EEG shows characteristic changes in hepatic encephalopathy [310]. These include the replacement of the normal background waves of 9–12 cycles/s by progressively slower waves, including φ waves, triphasic and δ waves (the last exhibit 2–3 cycles/s). These changes are not specific, as other metabolic encephalopathies and psychotropic agents can induce similar alterations. Quantitative and automated electroencephalographic analysis integrates the tracing and delineates the dominant signals [311]. Abnormalities have been associated with a poor prognosis. However, the use of the EEG has fallen behind other neurophysiological tools, mainly because of its low sensitivity. It still plays a role in patients in whom the diagnosis of the cause of encephalopathy is unclear.

Critical flicker frequency (CFF)

Recent data suggest that determination of the critical flicker frequency threshold could be an objective and reproducible technique for assessment of the severity of low-grade hepatic encephalopathy [308]. With this technique, which requires cooperation from the patient, a high-frequency flickering light is presented to the patient, which gives the impression of a steady light. After stepwise reduction in the frequency of the flickering light, the frequency is determined at which the flickering nature of the intrafoveally presented light is recognized by the patient. Healthy control subjects and patients with cirrhosis without evidence of encephalopathy in computer psychometric testing exhibit flicker frequencies (CFF) above 39 Hz, whereas those with manifest hepatic encephalopathy have values consistently below this threshold. The technique is largely free from training effects, does depend on the patient's educational status and can be performed rapidly as a bedside test, but is not applicable in patients with colour blindness, other severe ophthalmological disease and patients who are unable to fix the presented light. Functional MRI (fMRI) studies and correlations with psychometric tests have revealed that CFF determinations engage several brain areas [195] and integrate a broad variety of neuropsychological qualities [308]. CFF can also be used for follow-up of hepatic encephalopathy evolution and efficacy of treatment. However, up to now, experience with CFF measurements has been restricted to a few centres and the relation between CFF and quality of life is unclear.

Other neurophysiological testing

The integrated electrical response to visual, auditory or somatosensory stimuli is the rationale for the use of evoked potentials [312]. Several parameters can be determined, including peaks and latencies; as a result, the function of afferent pathways and of the cerebral cortex can be evaluated. Results are expressed as time (in milliseconds) to positive (P) or negative (N) deflections. They have been used to detect minimal encephalopathy as well as to follow subjects with overt changes in mental state. For the latter, their sensitivity and specificity are questionable [311,313]. Assessment of visual evoked potentials has been the tool most often evaluated, but differences in the type of light stimulus as well as in the liberal use of waves other than the P100 latency (100 ms between stimulation and peak) makes comparison between studies difficult.

For patients in whom minimal encephalopathy is suspected, endogenous event-related potentials may exhibit a greater sensitivity. In this test, two aspects are combined: visual or acoustic signals are presented but, in addition, the patient is asked to identify a predefined stimulus (such as a high-frequency sound). A prolongation of the P300 latency to acoustic stimuli was observed in patients with early encephalopathy [314,315]. Visual event-related potentials appeared to be superior to neuropsychological testing in detecting abnormalities in such individuals [316,317].

Neuropsychological testing

A large number of tests have been used in the diagnosis of minimal encephalopathy. The test most often utilized has been the number connection test (NCT). Although initially thought to reflect abnormalities corresponding to visuospatial perception, other neuropsychological areas appear to be involved in an abnormal result, including that of attention. The test is influenced by age and educational background, as well as being subject to the effects of repeated learning [319,320]. This may explain, in part, why single psychometric paper/pencil tests, such as NCT, digit symbol test and the line tracing test, are insufficiently sensitive to diagnose minimal hepatic encephalopathy [308]. Psychometric test batteries, as either paper/pencil tests or computer psychometry, were reported to be an accurate tool to diagnose subclinical encephalopathy [277,284]. One such battery, the psychometric hepatic encephalopathy score (PHES), simple to administer [320], is undergoing scrutiny at the present time. Other developments focus on the comparison between different neuropsychological domains as a useful diagnostic approach. However, in the absence of a 'gold standard', all these batteries require validation in the same patient over a period of time.

An important question is whether patients with alcoholic cirrhosis exhibit abnormalities as a result of the long-term neurological effects of alcohol. On a variety of neuropsychological tests, abstinent subjects with alcoholic cirrhosis perform comparably to their non-alcoholic counterparts [321]. After transplantation, the abnormalities in the alcohol group also improve [322].

Treatment of hepatic encephalopathy – general aspects

Several reviews on therapy have been published in recent years [323–326]. A rational therapeutic scheme for hepatic encephalopathy targets five possible non-mutually exclusive sites (Fig. 8):

1 the gut, decreasing the access of toxins to the systemic circulation;

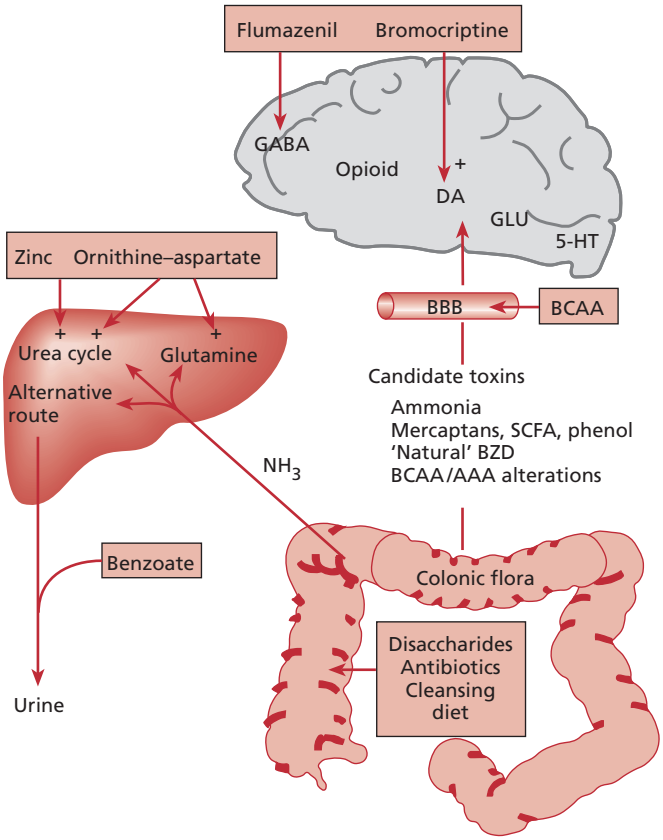

Fig. 8 Schematic diagram of therapeutic strategies in hepatic encephalopathy. Treatments reported to be successful are shaded. However, most effective therapy has been directed to the gut, where several options are available. The ability to increase urea and glutamine synthesis in a cirrhotic liver, as well as the activation of alternative pathways of nitrogen excretion (via the administration of benzoate), has not been fully evaluated. Branched-chain amino acids (BCAA) may work at the level of the blood–brain barrier (BBB), but their effectiveness is still a matter of conjecture. Two neurotransmitter systems have been manipulated pharmacologically, with limited results.

2 the liver, increasing the elimination of such toxins;
3 the muscle, as a possible alternative site for toxin disposal;
4 the blood–brain barrier, by interfering with toxin entry into the brain;
5 the brain itself, by attempting to restore the abnormalities of neurotransmission.

The gut

The therapeutic goal at this site is interference with the formation and/or absorption of nitrogenous compounds arising from bacterial metabolism in the colon, especially ammonia. Restriction of protein intake is one common approach to fulfilling this goal. However, malnutrition may arise from excessive protein restriction, and a recent study demonstrated no beneficial effect of protein restriction in episodic hepatic encephalopathy [327]. A positive nitrogen balance may actually benefit subjects with encephalopathy by increasing the ability of liver and muscle to carry out detoxification functions [328]. In the catabolic state of cirrhosis, a high protein intake, ~ 1.2 g/kg/day, may be necessary to accomplish this objective [329]. In addition, the type of ingested protein is important. Vegetable [330] and dairy-based protein [331] are better tolerated than animal-derived protein, as the high calorie to nitrogen ratio seen in the former reduces gluconeogenesis and has anabolic effects on the utilization of dietary proteins [332]. Vegetable-based diets have a high fibre content, which increases the elimination of nitrogen products in the stool [333]. For those intolerant of vegetable-based diets, administration of soluble forms of fibre can be added to a therapeutic regimen [324]. Protein-intolerant patients may benefit from oral supplements enriched with branched-chain amino acids [334–336] in order to reach a protein intake of at least 1 g/kg/day. The enteral route of nutrition is always preferred.

Bowel cleansing is another mainstay of therapy. Colonic cleansing reduces the luminal content of ammonia, decreases bacterial counts and lowers blood ammonia in cirrhotic patients. Although different laxatives could accomplish this effect, non-absorbable disaccharides have additional benefits and are widely used for this effect.

Since their original description, non-absorbable disaccharides have been widely used [337]. They include lactulose (β-galactosido-fructose) and lactitol (β-galactosido-sorbitol). When administered orally, they are not broken down by intestinal disaccharidases and thus reach the caecum, where enteric bacteria cleave the molecules and metabolize them, mainly to acetate; as a result, caecal pH drops [338,339]. In fact, acidification of the stool (pH < 6) can be used to monitor therapy, albeit it is not a very practical tool. The acidification results in a cathartic effect and favours non-ionic diffusion of ammonia into the lumen, where it is assimilated for bacterial metabolism. As a result, faecal nitrogen excretion is increased while plasma levels of ammonia and the total body pool of urea decrease [340].

Oral dosing (15–30 mL four times a day) is titrated to result in two or three soft bowel movements/day. In comatose patients, a more rapid onset of action may occur by administration via enema [341], with the patient in the Trendelenburg position to favour passage of the enema into the right colon. Complaints with oral administration include an excessively sweet taste, abdominal cramping and flatulence; these improve with continued administration. Excessive stool depositions as a result of overdosing can lead to loss of hypotonic colonic fluid with a resultant hypertonic dehydration with hypernatraemia, a factor that can by itself alter mental state.

Comparisons of lactitol with lactulose indicate similar effects but better palatability of the former agent [342]. The use of crystalline lactulose has been proposed to reduce potential contamination with other saccharides. In patients with known

intestinal lactase deficiency, oral lactose will have similar effects [343].

Although lactulose is frequently used for the treatment of hepatic encephalopathy, its efficacy has not been shown unequivocally. The study design of many trials has been criticized [344]. Most studies conducted so far have compared lactulose with non-absorbable antibiotics and found therapeutic equivalence of both treatments. A meta-analysis of studies that compared lactulose with placebo or no intervention gave insufficient evidence to support or refute the use of non-absorbable disaccharides in hepatic encephalopathy [344]. In this analysis, antibiotics were found to be somewhat superior to disaccharides, although the clinical relevance of this finding was questioned.

Antibiotics affect the intestinal flora that generate the putative toxins. In the case of neomycin, the most widely used antibiotic [345], non-bacterial effects may also be present at the level of the intestinal mucosa [346]. Although poorly absorbed, oto- and nephrotoxicity can develop (as with the use of other aminoglycosides), especially after chronic use. Thus, it is less commonly administered as a first line of therapy. The starting dose is 3–6 g/day, in divided doses, which is reduced to 1–2 g/day for maintenance. Other antibiotics have also been evaluated. Metronidazole, 800 mg/day in divided doses, has been shown to have similar effects to neomycin, although its bacterial spectrum of action is dissimilar [347]. Metronidazole is metabolized in the liver, and reduction of the dose is necessary with liver failure [348]. Growing experience with other poorly absorbable antibiotics, such as vancomycin [349] and rifaximin [350], also suggests beneficial effects.

Patients with cirrhosis frequently exhibit overgrowth of the colonic flora with potentially pathogenic *Escherichia coli* and staphylococcal species. Therapeutic modulation of the gut flora by probiotics enriched with non-urease-producing lactobacilli or fermentable fibre was reported to improve minimal hepatic encephalopathy in cirrhosis [352] and to reduce endotoxinaemia. Further studies are required to settle this issue.

Helicobacter pylori is a urease-producing pathogen and could theoretically contribute to intestinal/gastric ammonia production. However, no correlation was found between *H. pylori* infection and plasma ammonia concentration or hepatic encephalopathy in patients with cirrhosis [352]. Eradication of *H. pylori* did not result in improvement in neuropsychological or neurophysiological parameters in stable patients [353].

The liver and muscle

The potential of the diseased liver to increase its metabolic capacity is limited, as a reduction in hepatic mass, intrahepatic shunting and alterations in the sinusoidal architecture impose fixed restrictions. Nonetheless, improvement in the capacity of the liver to clear ammonia has been sought. Zinc is a cofactor for many enzymes in the urea cycle, and a deficiency may exist in cirrhosis as a result of malnutrition and increased urinary excretion. An improvement in the capacity to synthesize urea and in clinical status has been reported after administration of zinc acetate or sulphate, 600 mg/day in divided doses [354,355]. This has not been confirmed in other studies [356,357]. However, overt hepatic encephalopathy can be precipitated by overt zinc deficiency [358].

Ornithine–aspartate provides substrates for both urea and glutamine synthesis. It appears to prevent the rise of blood ammonia after a nitrogenous load [359], and therapeutic efficacy in patients with cirrhosis and hepatic encephalopathy has been shown [360,361]. Experimental studies have shown activity of the drug in the absence of a liver, indicating an effect on ammonia disposal by muscle [362]. Muscle is an important site for ammonia removal, where it is converted to glutamine via glutamine synthetase activity [24].

Children with urea cycle enzyme deficiencies are treated with drugs that allow an alternative pathway for nitrogen excretion. In the case of sodium benzoate, conjugation of one molecule of benzoyl-CoA with glycine results in one atom of nitrogen being excreted in the urine as hippurate. In one clinical trial, the drug was equally as effective as lactulose in the treatment of episodic encephalopathy in cirrhosis [363]. A second drug is phenylbutyrate; it is a precursor for the malodorous phenylacetate, which is conjugated in the liver with glutamine, and the product, phenylacetylglutamine, is excreted in the urine, resulting in the loss of two nitrogen atoms per molecule. Preliminary results are difficult to evaluate as patients were being treated with other medications [364]. The effectiveness of the hepatic conjugation process for both drugs in patients with advanced cirrhosis remains to be established.

The blood–brain barrier

Based on the (meanwhile abandoned) false neurotransmitter hypothesis, the effects of branched-chain amino acids, in both oral and intravenous forms, were tested. Numerous trials have been published in both precipitant-induced encephalopathy as well as in persistent encephalopathy [365]. Meta-analyses have yielded conflicting results [366,367]. Critical review of these studies did not find convincing evidence that branched-chain amino acids had a significant beneficial effect on patients with hepatic encephalopathy [368] but, given on a long-term basis, they may improve encephalopathy by increasing protein body stores [369]. They may provide a source of protein in patients with dietary protein intolerance. Even if beneficial for minimal encephalopathy, as suggested recently [335], their use is not justified in most patients on account of their relatively high cost.

The brain

As discussed above, multiple neurotransmitter systems are deranged in hepatic encephalopathy, and central effects of agonists/antagonists of these different systems could provide new therapeutic options as well as clues to the pathogenesis of

encephalopathy. However, only a few have received extensive evaluation.

Flumazenil is a selective antagonist of the benzodiazepine receptor. In several controlled studies in patients with moderate and severe encephalopathy, the mental state of a subset of individuals, about 40%, was improved with a bolus of intravenous flumazenil, albeit transiently [370–372]. The beneficial effect of flumazenil was confirmed in a meta-analysis including six randomized controlled trials (RCTs) [373]. A source of controversy is whether such patients had received exogenous benzodiazepines (a common occurrence in hospitalized patients) but, in some, no detectable benzodiazepines could be found in their serum. A favourable response typically occurs within a few minutes of administration, and a repeat injection is possible. An oral preparation is as yet unavailable. The drug undergoes hepatic clearance, and its elimination half-life is doubled in cirrhotics [374].

Enhancement of dopaminergic neurotransmission by increasing dopamine levels has been sought with the use of L-dopa and bromocriptine. With the latter and when used to improve consciousness, no major benefits were seen [375,376]. However, bromocriptine, in association with non-absorbable disaccharides, at a dose of 10 mg twice a day, resulted in an improvement in extrapyramidal symptoms [377]. Manipulation of glutamatergic and serotoninergic neurotransmission and of neurosteroid synthesis has been tried in experimental models of hepatic encephalopathy but, as yet, has not reached the stage of clinical testing. The same holds true for memantine, a non-competitive NMDA receptor antagonist, which improves hyperammonaemia-induced encephalopathy in rats [378].

Table 6 Therapeutic strategy in hepatic encephalopathy.

Episodic encephalopathy in cirrhosis
Identify, remove and treat precipitating event
Removal of blood from the gastrointestinal tract
Reversal of azotaemia
Specific antagonists for sedative-induced encephalopathy
Antibiotics for spontaneous bacterial peritonitis or other infections
Correct electrolyte disturbances
Bowel cleansing
Disaccharide enemas may be better than tap water enemas
Start oral non-absorbable disaccharides
Lactulose or lactitol 30 mL every 1–2 h until bowel evacuation
Then 15–45 mL every 6 h titrated to 2–3 soft bowel movements/day
Dietary management
Provide calories as intravenous glucose on the first day
Advance protein from 20 g/day to maximal tolerated
Persistant encephalopathy in cirrhosis
Search for precipitants
Dietary indiscretion and constipation more prominent than in episodic encephalopathy
Oral medications
If intolerance or ineffectiveness of non-absorbable disaccharides:
Replace with neomycin (2–6 g/day); monitor for toxicity
Replace with metronidazole (up to 800 mg/day); monitor for toxicity
Consider the addition of zinc sulphate or zinc acetate 600 mg/day
Consider the addition of neomycin to non-absorbable disaccharides
Dietary manipulation
Increase consumption of vegetable and dairy sources of protein
Feeding at bedtime (to decrease nocturnal gluconeogenesis)
For those intolerant to protein, consider branched-chain amino acid supplements
For problematic encephalopathy
Consider occlusion of large spontaneous portal–systemic shunt
Reduction of lumen of TIPS or portal–systemic shunt
Consider colonic exclusion in patient with reasonable liver function who is not a transplant candidate

Treatment of hepatic encephalopathy – specific strategies (Table 6)

Encephalopathy of acute liver failure

Many of the measures used in the episode of encephalopathy in cirrhosis are also applied in this setting, such as protein restriction and bowel cleansing with non-absorbable disaccharides. Their effectiveness, never tested in a controlled trial, may be marginal at best. Correction of other factors that may affect mental state, such as hypoglycaemia, pharmacological sedation or infection, is mandatory.

Tracheal intubation is recommended at the onset of grade III coma to minimize the risk of sudden respiratory arrest. Intracranial hypertension, defined as a persistent elevation in intracranial pressure above 25 mmHg for more than 5 min or the appearance of sudden elevations in pressure (the so-called 'pressure waves'), is treated with mannitol, 0.5–1 g/kg intravenously [379,380]. The drug should not be readministered at fixed doses, but bolused again when needed. In patients with renal failure, hyperosmolarity is a risk, and the patients may require dialysis. Recent studies indicate benefits of increasing serum osmolarity with hypertonic saline [381]. Emergency liver transplantation should be considered in the appropriate candidate. As a last resort, the patient can be treated with a barbiturate infusion, such as thiopental 180–500 mg administered intravenously over 15 min [382]. However, barbiturate coma is associated with arterial hypotension and requires EEG monitoring.

When liver transplantation is planned, moderate hypothermia (32°C) [383] may be an option in those patients with increased intracranial pressure that is resistant to standard medical therapy. The mechanisms by which hypothermia reduces the intracranial pressure are complex and may involve effects on cerebral blood flow, glutamate and lactate production [384]. Also, the methods of fractionated plasma separation and adsorption [385] as well as albumin dialysis [386] offer extracorporeal liver support devices, which were used successfully in preliminary studies to bridge patients with acute (on chronic) liver failure to transplantation.

Precipitant-induced (acute) encephalopathy in cirrhosis

Establishing the nature of the precipitating factor is critical, as removal or correction of the inciting cause is the most important therapeutic aspect. This point cannot be emphasized enough. Dietary protein intake is withheld for a few days only, and carbohydrates are administered intravenously. Oral protein is reintroduced once the mental state is improved, and enteral feeding provided for those patients in whom encephalopathy persists; oral supplements enriched in branched-chain amino acids are useful in highly protein-intolerant patients. Liver transplantation may be the ultimate solution of the problem, and the indications for this option have to be evaluated.

Regarding medical treatment, only a few approaches can be assumed to be effective on the basis of controlled randomized clinical trials, such as ornithine–aspartate and flumazenil (see above). Proof of treatment efficacy in most other cases is hampered by several problems. First, treatment of the precipitating factor leads to improvement in encephalopathy, making the efficacy of an additional medical treatment difficult to assess. Second, most previous clinical studies used endpoints such as mental state or results of paper/pencil tests, which do not allow (on account of inherent problems) accurate description of the evolution or resolution of hepatic encephalopathy. Neurophysiological tests of flicker frequency or evoked potentials are better suited to assess responses over short periods. Third, many previous trials were of insufficient quality or relied on case reports. Owing to the heterogeneous nature of the pathogenesis of hepatic encephalopathy and the many precipitants, only subgroups of patients may benefit from a given medical treatment. Finally, previous studies frequently used oral lactulose as a therapeutic gold standard and comparator for other treatment modalities, although the efficacy of oral lactulose is not really settled. There are only a few controlled studies comparing oral lactulose with placebo for this type of encephalopathy. As mentioned above, the ones that are available, especially those fulfilling the required quality standards, do not indicate a striking drug effect. Lactulose was as efficient as neomycin, but a combined treatment with lactulose and neomycin was not superior to placebo in the management of such episodes, with removal of the precipitating factor common to both groups [387].

It is difficult to interpret results in such patients, as allocation of precipitating factors during randomization cannot be fully controlled. Still, they highlight the importance of control of the precipitating factor as a key therapeutic step. Lactitol or lactose enemas appear to improve encephalopathy at a faster rate than cleansing enemas, as seen in a small group of 20 patients [341]. Nonetheless, clinical experience suggests that oral lactulose can be effective when given as 30–60 mL of syrup every 1–2 h until stooling occurs, at which time the dose is adjusted to 15–30 mL three or four times a day.

Flumazenil, 1 mg intravenous bolus, is certainly indicated for patients in whom benzodiazepines are identified or suspected as a precipitating factor. In a recent study, 6 of 13 patients in deep encephalopathy transiently improved their mental state with flumazenil, in contrast to none with placebo [370]. Similar results have been reported by other groups [388]. The effect is prompt but transient and, at 24 h, the two groups were indistinguishable. The impact of multiple dosing has not been evaluated. More information is needed on this type of agent.

Persistent (chronic) encephalopathy

Restriction of animal protein may be necessary to manage this type of patient, although high protein requirements may be needed for these catabolic patients. Consultation with a dietician should be considered in order to provide alternative sources, such as vegetable or casein-based protein or oral supplements enriched with branched-chain amino acids, in cases of severe protein intolerance. Non-absorbable disaccharides are also utilized. Although neither efficacy nor inefficacy has been shown in well-performed, randomized, placebo-controlled trials, these compounds are widely used. In crossover studies, reinstitution or switch to lactulose/lactitol is associated with an improvement in mental status. Results in this group are more easily interpretable, as the role of a precipitating factor is not as marked as in the acute precipitant-induced episode. However, neither disaccharides nor rifaximin were effective in the prophylaxis of hepatic encephalopathy during the first month after TIPS [389].

Oral, poorly absorbable antibiotics are seldom used as a first line of therapy, as concerns with long-term toxicity and bacterial resistance arise. If chronic neomycin is used, periodic auditory examinations and renal function testing are mandatory. For patients with difficulties in symptom control, zinc supplementation can be entertained, which also improves night-blindness, which can be observed in patients with cirrhosis. For those with prominent extrapyramidal symptoms, a trial of bromocriptine may be considered. Embolization of large spontaneous collaterals can be performed in patients with recurrent encephalopathy and good liver function [390,391].

Encephalopathy after portocaval anastomosis can be crippling and requires tight dietary control as well as the use of many drugs (preferably acting at different sites). Revision of the shunt [392], or narrowing or occlusion of the TIPS [393,394] are recommended for intractable cases. In suitable candidates, persistent encephalopathy is a clear indication for hepatic transplantation, although the procedure carries a greater mortality in patients with altered mental status at the time of the transplant. There are a few reports of improvement in the picture of hepatocerebral degeneration after the transplant procedure [395,396]. In non-transplant candidates with acceptable liver function, a surgical exclusion of the colon, preferably a colonic bypass, can provide relief from intractable encephalopathy [397].

Minimal hepatic encephalopathy

The indications to treat minimal encephalopathy would be clearer if the natural history of this condition was better defined. The indication for therapy should primarily take into account individual demands on the professional and daily life of the patient. Further, it may be prudent to separate patients according to a past history of an overt episode of encephalopathy. Consideration of the risk of driving an automobile may be more important if encephalopathy has been diagnosed previously. Sleep abnormalities, which cause considerable distress to patients, seldom respond, in the author's experience, to the usual measures employed to treat hepatic encephalopathy; general hygienic measures can be considered [398].

Neuropsychological tests do improve with many of the treatments that have been reviewed. These include protein restriction [399], non-absorbable disaccharides [400–402] and branched-chain amino acids [335,403]. The case of flumazenil is controversial, as one study showed benefit [404] while the other did not [405]; in the latter, patients with alcoholic cirrhosis developed more anxiety. Interpretation of these data is difficult, as techniques used to monitor the evolution of low-grade encephalopathy are not sensitive and objective enough. It is hoped that a recently suggested simplified grading system for the severity of hepatic encephalopathy (see Häussinger in ref. 3), which distinguishes only low- from high-grade encephalopathy and characterizes low-grade encephalopathy by means of an objective physical measure, such as critical flicker frequency, will provide a more reliable tool for future clinical studies assessing therapeutic options.

References

1 Conn HO, Lieberthal MM (1978) *The Hepatic Coma Syndromes and Lactulose*. Baltimore: Williams and Wilkins.

2 Conn HO, Bircher J (eds) (1994) *Hepatic Encephalopathy, Syndromes and Therapies*. Bloomington: Med-Ed Press.

3 Haussinger D, Kircheis G, Schliess F (eds) (2006) *Hepatic Encephalopathy and Nitrogen Metabolism*. Dordrecht: Springer Verlag.

4 Durand F, Valla D (2005) Assessment of the prognosis of cirrhosis: Child–Pugh vs MELD. *J Hepatol* 42 (Suppl. 1), S100–S107.

5 Coy DL, Srivastava A, Gottstein J *et al.* (1991) Postoperative course after portacaval anastomosis in rats is determined by the portacaval pressure gradient. *Am J Physiol* 261, G1072–G1078.

6 Nomura F, Ohnishi K, Terabayashi H *et al.* (1994) Effect of intrahepatic portal–systemic shunting on hepatic ammonia extraction in patients with cirrhosis. *Hepatology* 20, 1478–1481.

7 Ferenci P, Lockwood AR, Mullen K *et al.* (2002) Hepatic encephalopathy – definition, nomenclature, diagnosis, and quantification: Final Report of the Working Party at the 11th World Congress of Gastroenterology, Vienna 1998. *Hepatology* 35, 716–721.

8 Sherlock S, Sumerskill WH, White LP *et al.* (1954) Portal–systemic encephalopathy; neurological complication of liver disease. *Lancet* 267, 454–457.

9 McDermott WV Jr, Adams RD (1954) Episodic stupor associated with an Eck fistula in the human with particular reference to the metabolism of ammonia. *J Clin Invest* 33, 1–9.

10 Crespin J, Nemeck A, Rehkemper G *et al.* (2000) Intrahepatic portal-hepatic venous anastomosis: a portal–systemic shunt with neurological repercussions. *Am J Gastroenterol* 95, 1568–1571.

11 Ortiz M, Cordoba J, Alonso J *et al.* (2004) Oral glutamine challenge and magnetic resonance spectroscopy in three patients with congenital portosystemic shunts. *J Hepatol* 40, 552–557.

12 Ferenci P, Puspok A, Steindl P (1992) Current concepts in the pathophysiology of hepatic encephalopathy. *Eur J Clin Invest* 22, 573–581.

13 Mousseau DD, Butterworth RF (1994) Current theories on the pathogenesis of hepatic encephalopathy. *Proc Soc Exp Biol Med* 206, 329–344.

14 Butterworth RF (1996) The neurobiology of hepatic encephalopathy. *Semin Liver Dis* 16, 235.

15 Norenberg MD (1996) Astrocytic–ammonia interactions in hepatic encephalopathy. *Semin Liver Dis* 16, 245.

16 Fischer JE, Baldessarini RJ (1971) False neurotransmitters and hepatic failure. *Lancet* 2, 75–80.

17 Baraldi M, Zeneroli ZL (1982) Experimental hepatic encephalopathy: changes in the binding of gamma-aminobutyric acid. *Science* 216, 427–429.

18 Schafer DF, Jones EA (1982) Hepatic encephalopathy and the gamma-aminobutyric-acid neurotransmitter system. *Lancet* 1, 18–20.

19 Blei AT, Omary R, Butterworth RF (1992) Animal models of hepatic encephalopathies. In: Boulton AA, Baker GB, Butterworth RF (eds) *Animal Models of Neurological Disease, Neuromethods 22*. Clifton: Humana, pp. 183–222.

20 Geiger A, Magnes J, Taylor RM *et al.* (1954) Effect of blood constituents on uptake of glucose and on metabolic rate of the brain in perfusion experiments. *Am J Physiol* 177, 138–149.

21 Roche-Sicot J, Sicot C, Peignoux M *et al.* (1974) Acute hepatic encephalopathy in the rat: the effect of cross-circulation. *Clin Sci Mol Med* 47, 609–615.

22 Phillips GB, Schwartz R, Gabuzda GJ Jr *et al.* (1952) The syndrome of impending hepatic coma in patients with cirrhosis of the liver given certain nitrogenous substances. *N Engl J Med* 247, 239–246.

23 van Coulaert C, Deviller C, Halff M (1933) Troubles provoque par l'ingestion de sels ammoniacaux chez l'homme atteint de cirrhose de laennec. *CR Sci Soc Biol Ses Fil* 111, 739–740.

24 Olde-Damink SWM, Deutz NEP, Dejong CHC *et al.* (2002) Interorgan ammonia metabolism in liver failure. *Neurochem Int* 41, 177–188.

25 Haussinger D (1990) Nitrogen metabolism in liver: structural and functional organization and physiological relevance. *Biochem J* 267, 281–290.

26 Haussinger D, Stehle T (1988) Hepatocyte heterogeneity in response to icosanoids. The perivenous scavenger cell hypothesis. *Eur J Biochem* 175, 395–403.

27 Haussinger D, Gerok W (1984) Hepatocyte heterogeneity in ammonia metabolism: impairment of glutamine synthesis in CC14 induced liver cell necrosis with no effect on urea synthesis. *Chem Biol Interact* 48, 191–194.

28 Rikkers LF (1983) Portal hemodynamics, intestinal absorption, and postshunt encephalopathy. *Surgery* 94, 126–133.

29 Rudman D, DiFulco TJ, Galambos JT *et al.* (1973) Maximal rates of excretion and synthesis of urea in normal and cirrhotic subjects. *J Clin Invest* 52, 2241–2249.

30 Haussinger D, Lamers WH, Moorman AF (1992) Hepatocyte heterogeneity in the metabolism of amino acids and ammonia. *Enzyme* 46, 72–93.

31 Lockwood AH, McDonald JM, Reiman RE *et al.* (1979) The dynamics of ammonia metabolism in man. Effects of liver disease and hyperammonemia. *J Clin Invest* 63, 449–460.

32 Lustik SJ, Chhibber AK, Kolano JW *et al.* (1997) The hyperventilation of cirrhosis: progesterone and estradiol effects. *Hepatology* 25, 55–58.

33 Baertt JM, Sancetta SM, Gobuzda GJ (1964) Relation of acute potassium depletion to the renal ammonium metabolism in patients with cirrhosis. *N Engl J Med* 271, 1229–1235.

34 Lockwood AH, Yap EWH, Wong WH (1991) Cerebral ammonia metabolism in patients with severe liver disease and minimal encephalopathy. *J Cerebr Blood Flow Metabol* 11, 337–341.

35 Gunnarson E, Zelenina M, Aperia A (2004) Regulation of brain aquaporins. *Neuroscience* 129, 947–955.

36 Holm LM, Jahn TP, Moller AL *et al.* (2005) NH_3 and NH_4+ permeability in aquaporin-expressing *Xenopus* oocytes. *Pflugers Arch* 450, 415–428.

37 Kreis R, Ross BD, Farrow NA *et al.* (1992) Metabolic disorders of the brain in chronic hepatic encephalopathy detected with H-1 MR spectroscopy. *Radiology* 182, 19–27.

38 Häussinger D, Laubenberger J, vom Dahl S *et al.* (1994) Proton magnetic resonance spectroscopy on human brain myo-inositol in hypoosmolarity and hepatic encephalopathy. *Gastroenterology* 107, 1475–1480.

39 Laubenberger J, Haussinger D, Bayer S *et al.* (1997) Proton magnetic resonance spectroscopy of the brain in symptomatic and asymptomatic patients with liver cirrhosis. *Gastroenterology* 112, 1610–1616.

40 Bosman DK, Deutz NE, De Graaf AA *et al.* (1990) Changes in brain metabolism during hyperammonemia and acute liver failure: results of a comparative 1H-NMR spectroscopy and biochemical investigation. *Hepatology* 12, 281–290.

41 McConnell JR, Antonson DL, Ong CS *et al.* (1995) Proton spectroscopy of brain glutamine in acute liver failure. *Hepatology* 22, 69–74.

42 Cordoba J, Blei AT (1996) Brain edema and hepatic encephalopathy. *Semin Liver Dis* 16, 271.

43 Häussinger D, Kircheis G, Fischer R *et al.* (2000) Hepatic encephalopathy in chronic liver disease: a clinical manifestation of astrocyte swelling and low-grade cerebral edema. *J Hepatol* 32, 1035–1038.

44 Hourani BT, Hamilin EM, Reynolds TB (1971) Cerebrospinal fluid glutamine as a measure of hepatic encephalopathy. *Arch Intern Med* 127, 1033–1036.

45 Cooper AJL, Plum F (1987) Biochemistry and physiology of brain ammonia. *Physiol Rev* 2, 440–519.

46 Felipo V, Butterworth RF (2002) Neurobiology of ammonia. *Prog Neurobiol* 67, 259–279.

47 Hindfelt B, Plum F, Duffy TE (1977) Effect of acute ammonia intoxication on cerebral metabolism in rats with portacaval shunts. *J Clin Invest* 59, 386–396.

48 Lockwood AH, Ginsberg MD, Rhoades HM *et al.* (1986) Cerebral glucose metabolism after portacaval shunting in the rat. Patterns of metabolism and implications for the pathogenesis of hepatic encephalopathy. *J Clin Invest* 78, 86–95.

49 Hawkins RA, Mans AM (1993) Brain metabolism in hepatic encephalopathy and hyperammonemia. *Adv Exp Med Biol* 341, 13–19.

50 Lockwood AH (2002) Positron emission tomography in the study of hepatic encephalopathy. *Metab Brain Dis* 17, 431–435.

51 Barbiroli B, Gaiani S, Lodi R *et al.* (2002) Abnormal brain energy metabolism shown by *in vivo* phosphorus magnetic resonance spectroscopy in patients with chronic liver disease. *Brain Res Bull* 59, 75–82.

52 Adams RD, Foley JM (1953) The neurological disorder associated with liver disease. *Assoc Res Nerv Mental Dis Proc* 32, 198–237.

53 Bachmann C (2002) Mechanisms of hyperammonemia. *Clin Chem Lab Med* 40, 653–662.

54 Szerb JC, Butterworth RF (1992) Effect of ammonium ions on synaptic transmission in the mammalian central nervous system. *Prog Neurobiol* 39, 135–153.

55 Lai JC, Cooper AJ (1986) Brain alpha-ketoglutarate dehydrogenase complex: kinetic properties, regional distribution, and effects of inhibitors. *J Neurochem* 47, 1376–1386.

56 Kramer L, Tribl B, Gendo A *et al.* (2000) Partial pressure of ammonia versus ammonia in hepatic encephalopathy. *Hepatology* 31, 30–34.

57 Nicolao F, Efrati C, Masini A *et al.* (2003) Role of determination of partial pressure of ammonia in cirrhotic patients with and without hepatic encephalopathy. *J Hepatol* 38, 441–446.

58 Zieve L, Doizaki WM, Zieve J (1974) Synergism between mercaptans and ammonia or fatty acids in the production of coma: a possible role for mercaptans in the pathogenesis of hepatic coma. *J Lab Clin Med* 83, 16–28.

59 Blom HJ, Chamuleau RA, Rothuizen J *et al.* (1990) Methanethiol metabolism and its role in the pathogenesis of hepatic encephalopathy in rats and dogs. *Hepatology* 11, 682–689.

60 Phear EA, Ruebner B, Sherlock S *et al.* (1956) Methionine toxicity in liver disease and its prevention by chlortetracycline. *Clin Sci (Lond)* 15, 93–117.

61 Windus-Podehl G, Fyftogt C, Zieve L *et al.* (1983) Encephalopathic effect of phenol in rats. *J Lab Clin Med* 101, 586–592.

62 Mannaioni G, Carpenedo R, Pugliese AM *et al.* (1998) Electrophysiological studies on oxindole, a neurodepressant tryptophan metabolite. *Br J Pharmacol* 125, 1751–1760.

63 Carpenedo R, Mannaioni G, Moroni F (1998) Oxindole, a sedative tryptophan metabolite, accumulates in blood and brain of rats with acute hepatic failure. *J Neurochem* 70, 1998–2003.

64 Zieve L (1987) Pathogenesis of hepatic encephalopathy. *Metab Brain Dis* 2, 147–165.

65 Mortensen PB, Holtug K, Bonnen H *et al.* (1990) The degradation of amino acids, proteins, and blood to short-chain fatty acids in colon is prevented by lactulose. *Gastroenterology* 98, 353–360.

66 Shawcross DL, Davies NA, Williams R *et al.* (2004) Systemic inflammatory response exacerbates the neuropsychological effects of induced hyperammonemia in cirrhosis. *J Hepatol* 40, 247–254.

67 Blei AT (2004) Infection, inflammation and hepatic encephalopathy, synergism redefined. *J Hepatol* 40, 327–330.

68 Wilson JX, Young GB (2003) Progress in clinical neurosciences: sepsis-associated encephalopathy: evolving concepts. *Can J Neurol Sci* 30, 98–105.

69 Odeh M, Sabo E, Srugo I *et al.* (2004) Serum levels of tumor necrosis factor-alpha correlate with severity of hepatic encephalopathy due to chronic liver failure. *Liver Int* 24, 110–226.

70 Mans AM, Biebuyck JF, Shelly K *et al.* (1982) Regional blood–brain barrier permeability to amino acids after portacaval anastomosis. *J Neurochem* 38, 705–717.

71 Cangiano C, Cardelli-Cangiano P, James JH *et al.* (1983) Brain microvessels take up large neutral amino acids in exchange for glutamine. Cooperative role of Na^+-dependent and Na^+-independent systems. *J Biol Chem* 258, 894–954.

72 Morgan MY, Milsom JP, Sherlock S (1978) Plasma ratio of valine, leucine and isoleucine to tyrosine in liver disease. *Gut* 19, 1068–1073.

73 Fischer JE, Funovics JM, Aguirre A *et al.* (1975) The role of plasma amino acids in hepatic encephalopathy. *Surgery* 78, 276–290.

74 Cuilleret G, Pomier-Layargues G, Pons F *et al.* (1980) Changes in brain catecholamine levels in human cirrhotic hepatic encephalopathy. *Gut* 21, 565–569.

75 Knudsen GM, Schmidt J, Almdal T *et al.* (1993) Passage of amino acids and glucose across the blood-brain barrier in patients with hepatic encephalopathy. *Hepatology* 17, 987–992.

76 Rossle M, Mullen KD, Jones EA (1989) Cortical benzodiazepine receptor binding in a rabbit model of hepatic encephalopathy: the effect of Triton X-100 on receptor solubilization. *Metab Brain Dis* 4, 203–212.

77 Ferenci P, Ebner J, Zimmermann C *et al.* (1988) Overestimation of serum concentrations of gamma-aminobutyric acid in patients with hepatic encephalopathy by the gamma-aminobutyric acid-radioreceptor assay. *Hepatology* 8, 69–72.

78 Knudsen GM, Poulsen HE, Paulson OB (1988) Blood–brain barrier permeability in galactosamine-induced hepatic encephalopathy. No evidence for increased GABA-transport. *J Hepatol* 6, 187–192.

79 Lavoie J, Giguere JF, Layargues GP *et al.* (1987) Amino acid changes in autopsied brain tissue from cirrhotic patients with hepatic encephalopathy. *J Neurochem* 49, 692–697.

80 Butterworth RF, Lavoie J, Giguere JF *et al.* (1988) Affinities and densities of high-affinity [3H] muscimol (GABA-A) binding sites and of central benzodiazepine receptors are unchanged in autopsied brain tissue from cirrhotic patients with hepatic encephalopathy. *Hepatology* 8, 1084–1088.

81 Basile AS, Jones EA, Skolnick P (1991) The pathogenesis and treatment of hepatic encephalopathy: evidence for the involvement of benzodiazepine receptor ligands. *Pharmacol Rev* 43, 27–71.

82 Basile AS, Gammal SH, Jones EA *et al.* (1989) GABAA receptor complex in an experimental model of hepatic encephalopathy: evidence for elevated levels of an endogenous benzodiazepine receptor ligand. *J Neurochem* 53, 1057–1063.

83 Olesmaa M, Rothstein JD, Guidotti A *et al.* (1990) Endogenous benzodiazepine receptor ligands in human and animal encephalopathy. *J Neurochem* 55, 2015–2023.

84 Basile AS, Hughes RD, Harrison PM *et al.* (1991) Elevated brain concentrations of 1,4-benzodiazepines in fulminant hepatic failure. *N Engl J Med* 325, 473–478.

85 Yurdaydin C, Walsh TJ, Engler HD *et al.* (1995) Gut bacteria provide precursors of benzodiazepine receptor ligands in a rat model of hepatic encephalopathy. *Brain Res* 679, 42–48.

86 Ahboucha S, Pomier-Layargues G, Butterworth RF (2004) Increased brain concentrations of endogenous (non-benzodiazepine) GABA-A receptor ligands in human hepatic encephalopathy. *Metab Brain Dis* 19, 241–251.

87 Lavoie J, Layrargues GP, Butterworth RF (1990) Increased densities of peripheral-type benzodiazepine receptors in brain autopsy samples from cirrhotic patients with hepatic encephalopathy. *Hepatology* 11, 874–878.

88 Itzhak Y, Roig-Cantisano A, Dombro RS *et al.* (1995) Acute liver failure and hyperammonemia increase peripheral-type benzodiazepine receptor binding and pregnenolone synthesis in mouse brain. *Brain Res* 705, 345–348.

89 Jones EA (2002) Ammonia, the GABA neurotransmitter system, and hepatic encephalopathy. *Metab Brain Dis* 17, 275–281.

90 Livingstone AS, Potvin M, Goresky CA *et al.* (1977) Changes in the blood–brain barrier in hepatic coma after hepatectomy in the rat. *Gastroenterology* 73, 697–704.

91 Traber PG, Dal Canto M, Ganger DR *et al.* (1987) Electron microscopic evaluation of brain edema in rabbits with galactosamine-induced fulminant hepatic failure: ultrastructure and integrity of the blood–brain barrier. *Hepatology* 7, 1272–1277.

92 Martin H, Voss K, Hufnagl P *et al.* (1987) Morphometric and densitometric investigations of protoplasmic astrocytes and neurons in human hepatic encephalopathy. *Exp Pathol* 32, 241–250.

93 Hösslin CV, Alzheimer A (1912) Ein Betrag zur Klinik und patologischen Anatomie der Westphal-Strumpellachen Pseudosklerose. *Z Gesamte Neurol Psychiat* 8, 183–209.

94 Reichenbach A, Fuchs U, Kasper M *et al.* (1995) Hepatic retinopathy: morphological features of retinal glial (Muller) cells accompanying hepatic failure. *Acta Neuropathol (Berl)* 90, 273–281.

95 Cavanagh JB, Kyu MH (1971) Type II Alzheimer change experimentally produced in astrocytes in the rat. *J Neurol Sci* 12, 63–75.

96 Gutierrez JA, Norenberg MD (1975) Alzheimer II astrocytosis following methionine sulfoximine. *Arch Neurol* 32, 123–126.

97 Bruton CJ, Corsellis JA, Russell A (1970) Hereditary hyperammonaemia. *Brain* 93, 423–434.

98 Sobel RA, DeArmond SJ, Forno LS *et al.* (1981) Glial fibrillary acidic protein in hepatic encephalopathy. An immunohistochemical study. *J Neuropathol Exp Neurol* 40, 625–632.

99 Kretzschmar HA, DeArmond SJ, Forno LS (1985) Measurement of GFAP in hepatic encephalopathy by ELISA and transblots. *J Neuropathol Exp Neurol* 44, 459–471.

100 Norenberg MD (1995) Hepatic encephalopathy. In: Ketterman H, Ransom BR (eds) *Neuroglia*. New York: Oxford University Press, pp. 950–963.

101 Tarter RE, Hays AL, Sandford SS *et al.* (1986) Cerebral morphological abnormalities associated with non-alcoholic cirrhosis. *Lancet* 2, 893–895.

102 Zeneroli ML, Cioni G, Vezzelli C *et al.* (1987) Prevalence of brain atrophy in liver cirrhosis patients with chronic persistent encephalopathy. Evaluation by computed tomography. *J Hepatol* 4, 283–292.

103 Victor M, Adams RD, Cole M (1965) The acquired (non-Wilsonian) type of chronic hepatocerebral degeneration. *Medicine (Baltimore)* 44, 345–396.

104 Finlayson MH, Superville B (1981) Distribution of cerebral lesions in acquired hepatocerebral degeneration. *Brain* 104, 79–95.

105 Zieve L, Mendelson DF, Goepfert M (1960) Shunt encephalopathy. II. Occurrence of permanent myelopathy. *Ann Intern Med* 53, 53–63.

106 Pujol A, Graus F, Peri J *et al.* (1991) Hyperintensity in the globus pallidus on T1-weighted and inversion-recovery MRI: a possible marker of advanced liver disease. *Neurology* 41, 1526–1527.

107 Krieger S, Jauss M, Jansen O *et al.* (1996) Neuropsychiatric profile and hyperintense globus pallidus on T1-weighted magnetic resonance images in liver cirrhosis. *Gastroenterology* 111, 147–155.

108 Kulisevsky J, Pujol J, Balanzo J *et al.* (1992) Pallidal hyperintensity on magnetic resonance imaging in cirrhotic patients: clinical correlations. *Hepatology* 16, 1382–1388.
109 Pujol A, Pujol J, Graus F *et al.* (1993) Hyperintense globus pallidus on T1-weighted MRI in cirrhotic patients is associated with severity of liver failure. *Neurology* 43, 65–69.
110 Rose C, Butterworth FR, Zayed J *et al.* (1999) Manganese deposition in basal ganglia structures results from both portal-systemic shunting and liver dysfunction. *Gastroenterology* 117, 640–644.
111 Kulisevsky J, Pujol J, Deus J *et al.* (1995) Persistence of MRI hyperintensity of the globus pallidus in cirrhotic patients: a 2-year follow-up study. *Neurology* 45, 995–997.
112 Shah NJ, Neeb H, Zaitsev M *et al.* (2003) Quantitative T1 mapping of hepatic encephalopathy using magnetic resonance imaging. *Hepatology* 38, 1219–1226.
113 Pomier-Layargues G, Spahr L, Butterworth RF (1995) Increased manganese concentration in pallidum of cirrhotic patients. *Lancet* 345, 735.
114 Krieger D, Krieger G, Jansen O *et al.* (1995) Manganese and chronic hepatic encephalopathy. *Lancet* 346, 270–274.
115 Shinotoh H, Snow BJ, Hewitt KA *et al.* (1995) MRI and PET studies of manganese-intoxicated monkeys. *Neurology* 45, 1199–1204.
116 Brouillet EP, Shinobu L, McGarvey U *et al.* (1993) Manganese injection into the rat striatum produces excitotoxic lesions by impairing energy metabolism. *Exp Neurol* 120, 89–94.
117 Chen CJ, Liao SL (2002) Oxidative stress involves in astrocytic alterations induced by manganese. *Exp Neurol* 175, 216–225.
118 Hazell AS, Norenberg MD (1997) Manganese decreases glutamate uptake in cultured astrocytes. *Neurochem Res* 22, 1443–1447.
119 Hazell AS, Desjardins P, Butterworth RF (1999) Chronic exposure of rat primary astrocyte cultures to manganese results in increased binding sites for the 'peripheral-type' benzodiazepine receptor ligand 3H-PK 11195. *Neurosci Lett* 271, 5–8.
120 Spahr L, Butterworth RF, Fontaine S *et al.* (1996) Increased blood manganese in cirrhotic patients: relationship to pallidal magnetic resonance signal hyperintensity and neurological symptoms. *Hepatology* 24, 1116–1120.
121 Norton NS, McConnell JR, Zetterman RK *et al.* (1994) A quantitative evaluation of magnetic resonance image signal changes of the brain in chronic hepatic encephalopathy. *J Hepatol* 21, 764–770.
122 Blei AT, Larsen FS (1999) Pathophysiology of cerebral edema in fulminant hepatic failure. *J Hepatol* 31, 771–776.
123 Donovan JP, Schafer DF, Shaw BW Jr *et al.* (1998) Cerebral edema and increased intracranial pressure in chronic liver disease. *Lancet* 351, 719–721.
124 Kreis R, Farrow N, Ross BD (1990) Diagnosis of hepatic encephalopathy by proton magnetic resonance spectroscopy. *Lancet* 336, 635–636.
125 Ross BD, Jacobson S, Villamil F *et al.* (1994) Subclinical hepatic encephalopathy: proton MR spectroscopic abnormalities. *Radiology* 193, 457–463.
126 Shawcross DL, Balata S, Olde Damink SW *et al.* (2004) Low myo-inositol and high glutamine levels in brain are associated with neuropsychological deterioration after induced hyperammonemia. *Am J Physiol Gastrointest Liver Physiol* 287, G503–G509. Epub May 6 2004.
127 Zwingmann C, Brand A, Richter-Landsberg C *et al.* (1998) Multinuclear NMR spectroscopy studies on NH4C1-induced metabolic alteration and detoxification processes in primary astrocytes and glioma cells. *Dev Neurosci* 20, 417–426.
128 Paredes A, McManus M, Kwon HM *et al.* (1992) Osmoregulation of Na(+)-inositol cotransporter activity and mRNA levels in brain glial cells. *Am J Physiol* 263, 1282–1288.
129 Cordoba J, Gottstein J, Blei AT (1996) Glutamine, myo-inositol, and organic brain osmolytes after portocaval anastomosis in the rat: implications for ammonia-induced brain edema. *Hepatology* 24, 919–923.
130 Bluml S, Zuckerman E, Tan J *et al.* (1998) Proton-decoupled 31P magnetic resonance spectroscopy reveals osmotic and metabolic disturbances in human hepatic encephalopathy. *J Neurochem* 71, 1564–1576.
131 Norenberg MD, Baker L, Norenberg LO *et al.* (1991) Ammonia-induced astrocyte swelling in primary culture. *Neurochem Res* 16, 833–836.
132 Schliess F, Sinning R, Rischer R *et al.* (1996) Calcium-dependent activation of Erk-1 and Erk-2 after hypo-osmotic astrocyte swelling. *Biochem J* 320, 167–171.
133 Haussinger D, Schliess F (2005) Astrocyte swelling and protein tyrosine nitration in hepatic encephalopathy. *Neurochem Int* 47, 64–70.
134 Kimelberg HK (1995) Receptors on astrocytes – what possible functions? *Neurochem Int* 26, 27–40.
135 Kimelberg HK (1995) Current concepts of brain edema. Review of laboratory investigations. *J Neurosurg* 83, 1051–1059.
136 Bender AS, River IV, Norenberg MD (1992) Tumor necrosis factor alpha induces astrocyte swelling. *Trans Am J Neurochem*, 113.
137 Bender AS, Norenberg MD (1998) Effect of benzodiazepines and neurosteroids on ammonia-induced swelling in cultured astrocytes. *J Neurosci Res* 54, 673–680.
138 Moats RA, Lien YH, Filippi D *et al.* (1993) Decrease in cerebral inositols in rats and humans. *Biochem J* 295, 15–18.
139 Ross BD, Danielsen ER, Bluml S (1996) Proton magnetic resonance spectroscopy: the new gold standard for diagnosis of clinical and subclinical hepatic encephalopathy. *Dig Dis* 14, 30–39.
140 Cordoba J, Alonso J, Rovira A *et al.* (2001) The development of low grade cerebral edema in cirrhosis is supported by the evolution of (1) H-magnetic resonant abnormalities alter liver transplantation. *J Hepatol* 35, 598–604.
141 Miese F, Kircheis G, Wittsack HJ *et al.* (2006) ^{1}H-MR spectroscopy, magnetization transfer and diffusion-weighted imaging in alcoholic and nonalcoholic cirrhotic subjects with hepatic encephalopathy. *Am J Neuroradiol* 27, 1019–1026.
142 Sede HW, Gore CD, Hughes RD *et al.* (1984) Inhibition of rat brain Na^{+}, K^{+}-ATpase activity by serum from patients with fulminant hepatic failure. *Hepatology* 4, 74–79.
143 Record CO, Buxton B, Chase RA *et al.* (1976) Plasma and brain amino acids in fulminant hepatic failure and their relationship to hepatic encephalopathy. *Eur J Clin Invest* 6, 387–394.
144 Takahashi H, Koehler RC, Brusilow SW *et al.* (1991) Inhibition of brain glutamine accumulation prevents cerebral edema in hyperammonemic rats. *Am J Physiol* 261, H825–829.
145 Blei AT, Olafsson S, Therrien G *et al.* (1994) Ammonia-induced brain edema and intracranial hypertension in rats after portacaval anastomosis. *Hepatology* 19, 1437–1444.
146 Watson AJ, Chambers T, Karp JE *et al.* (1985) Transient idiopathic hyperammonemia in adults. *Lancet* 2, 1271–1274.
147 Munoz SJ, Robinson M, Northrup B *et al.* (1991) Elevated intracranial pressure and computed tomography of the brain in fulminant hepatocellular failure. *Hepatology* 13, 209–212.

148 Wijdicks EF, Plevak DJ, Rakela J *et al.* (1995) Clinical and radiological features of cerebral edema in fulminant hepatic failure. *Mayo Clin Proc* 70, 119–124.
149 Kato M, Hughes RD, Keays RT *et al.* (1992) Electron microscopic study of brain capillaries in cerebral edema from fulminant hepatic failure. *Hepatology* 15, 1060–1066.
150 Murphy S (ed.) (1995) *Astrocytes: Pharmacology and Function*. San Diego: Academic Press.
151 Kimelberg H, Ransom BR (eds) (1995) *Neuroglia*. New York: Oxford University Press.
152 Walz W (1989) Role of glial cells in the regulation of the brain ion microenvironment. *Prog Neurobiol* 33, 309–333.
153 Ransom BR, Sontheimer H (1992) The neurophysiology of glial cells. *J Clin Neurophysiol* 9, 224–251.
154 Sarna GS, Bradbury MW, Cavanagh J (1977) Permeability of the blood–brain barrier after portocaval anastomosis in the rat. *Brain Res* 138, 550–54.
155 Janzer RC, Raff MC (1987) Astrocytes induce blood–brain barrier properties in endothelial cells. *Nature* 325, 253–257.
156 Martinez-Hernandez A, Bell KP, Norenberg MD (1977) Glutamine synthetase: glial localization in brain. *Science* 195, 1356–1358.
157 Häussinger D (1996) The role of cellular hydration in the regulation of cell function. *Biochem J* 313, 697–710.
158 Lang F, Busch GL, Ritter M *et al.* (1998) Functional significance of cell volume regulatory mechanisms. *Physiol Rev* 78, 247–306.
159 Itzhak Y, Bender AS, Norenberg MD (1994) Effect of hypoosmotic stress on peripheral-type benzodiazepine receptors in cultured astrocytes. *Brain Res* 644, 221–225.
160 Fischer R, Schliess F, Haussinger D (1997) Characterization of the hypo-osmolarity-induced Ca^{2+} response in cultured rat astrocytes. *Glia* 20, 51–58.
161 Isaacks RE, Bender AS, Kim CY *et al.* (1999) Effect of osmolality and anion channel inhibitors on myo-inositol efflux in cultured astrocytes. *J Neurosci Res* 57, 866–871.
162 Busch GL, Wiesinger H, Gulbins E *et al.* (1996) Effect of astroglial cell swelling on pH of acidic intracellular compartments. *Biochim Biophys Acta* 1285, 212–218.
163 Dombro RS, Bender AS, Norenberg MD (2000) Association between cell swelling and glycogen content in cultured astrocytes. *Int J Dev Neurosci* 18, 161–169.
164 Jessy J, DeJoseph MR, Hawkins RA (1991) Hyperammonaemia depresses glucose consumption throughout the brain. *Biochem J* 277, 693–696.
165 Hawkins RA, Jessy J (1991) Hyperammonaemia does not impair brain function in the absence of net glutamine synthesis. *Biochem J* 277, 697–703.
166 Hawkins RA, Jessy J, Mans AM *et al.* (1993) Effect of reducing brain glutamine synthesis on metabolic symptoms of hepatic encephalopathy. *J Neurochem* 60, 1000–1006.
167 Häussinger D, Jungermann K (eds) (1998) *Liver and Nervous System*. Lancaster: Kluwer Academic Publishers.
168 Chepkova AN, Doreulee N, Yanovsky Y *et al.* (2002) Long-lasting enhancement of corticostriatal neurotransmission by taurine. *Eur J Neurosci* 16, 523–530.
169 Sergeeva OA, Chepkova AN, Doreulee N *et al.* (2003) Taurine induced long-lasting enhancement of synaptic transmission in mice: role of transporters. *J Physiol* 55, 911–919.
170 Oermann E, Warskulat U, Heller-Stilb B *et al.* (2005) Taurine-transporter gene knockout-induced changes in GABA (A), kainate and AMPA but not NMDA receptor binding in mouse brain. *Anat Embryol (Berl)* 210, 363–372.
171 Warskulat U, Görg B, Bidmon HJ *et al.* (2002) Ammonia-induced heme oxygenase-1 expression in cultured rat astrocytes and rat brain *in vivo*. *Glia* 40, 324–336.
172 Song G, Dhodda VK, Blei AT *et al.* (2002) Genechip analysis shows altered mRNA expression of transcripts of neurotransmitter and signal transduction pathways in the cerebral cortex of portocaval shunted rats. *J Neurosci Res* 68, 730–737
173 Vaquero J, Chung C, Blei AT (2004) Cerebral blood flow in acute liver failure: a finding in search of a mechanism. *Metab Brain Dis* 19, 177–194.
174 Zhou BG, Norenberg MD (1999) Ammonia downregulates GLAST mRNA glutamate transporter in rat astrocyte cultures. *Neurosci Lett* 276, 145–148.
175 Butterworth RF (2002) Glutamate transporters in hyperammonemia. *Neurochem Int* 41, 81–85.
176 Chan H, Zwingmann C, Pannunzio M *et al.* (2003) Effects of ammonia on high affinity glutamate uptake and glutamate transporter EAAT3 expression in cultured rat cerebellar granule cells. *Neurochem Int* 43, 137–146.
177 Braissant O, Henry H, Villard AM *et al.* (2002) Ammonium-induced impairment of axonal growth is prevented through glial creatine. *J Neurosci* 22, 9810–9820.
178 Bachmann C, Braissant O, Villard AM *et al.* (2004) Ammonia toxicity to the brain and creatine. *Mol Genet Metab* 81, S52–57.
179 Norenberg MD, Jayakumar AR, Rama Rao KV (2004) Oxidative stress in the pathogenesis of hepatic encephalopathy. *Metab Brain Dis* 19, 313–329.
180 Murthy CR, Rama Rao KV, Bai G *et al.* (2001) Ammonia-induced production of free radicals in primary cultures of rat astrocytes. *J Neurosci Res* 66, 282–288.
181 Schliess F, Görg B, Fischer R *et al.* (2002) Ammonia induces MK-801-sensitive nitration and phosphorylation of protein tyrosine residues in rat astrocytes. *FASEB J* 16, 739–741.
182 Schliess F, Foster N, Gorg B *et al.* (2004) Hyposmotic swelling increases protein tyrosine nitration in cultured rat astrocytes. *Glia* 47, 21–29.
183 Gorg B, Foster N, Reinehr R *et al.* (2003) Benzodiazepine-induced protein tyrosine nitration in rat astrocytes. *Hepatology* 37, 334–342.
184 Bender AS, Schousboe A, Reichelt W *et al.* (1998) Ionic mechanisms in glutamate-induced astrocyte swelling: role of K^+ influx. *J Neurosci Res* 52, 307–321.
185 Hermenegildo C, Marcaida G, Montoliu C *et al.* (1996) NMDA receptor antagonists prevent acute ammonia toxicity in mice. *Neurochem Res* 21, 1237–1244.
186 Vogels BA, Maas MA, Daalhuisen J *et al.* (1997) Memantine, a non-competitive NMDA receptor antagonist improves hyperammonemia-induced encephalopathy and acute hepatic encephalopathy in rats. *Hepatology* 25, 820–827.
187 Kosenko E, Kaminsky Y, Lopata O *et al.* (1998) Nitroarginine, an inhibitor of nitric oxide synthase, prevents changes in superoxide radical and antioxidant enzymes induced by ammonia intoxication. *Metab Brain Dis* 13, 29–41.
188 Klotz LO, Schroeder P, Sies H (2002) Peroxynitrite signaling: receptor tyrosine kinases and activation of stress-responsive pathways. *Free Radic Biol Med* 33, 737–743.
189 Saeki M, Maeda S (1999) p130cas is a cellular target protein for tyrosine nitration induced by peroxynitrite. *Neurosci Res* 33, 325–328.

190 Reinehr R, Gorg B, Hongen A *et al.* (2004) CD95-tyrosine nitration inhibits hyperosmotic and CD95 ligand-induced CD95 activation in rat hepatocytes. *J Biol Chem* 279, 10364–10373.
191 Gorg B, Wettstein M, Metzger S *et al.* (2005) LPS-induced tyrosine nitration of hepatic glutamine synthetase. *Hepatology* 42, 499.
192 Alman RW, Ehrmantraut WR, Fazekas JF *et al.* (1956) Cerebral metabolism in hepatic insufficiency. *Am J Med* 21, 843–849.
193 Morgan MY (1996) Non-invasive neuroinvestigation in liver disease. *Semin Liver Dis* 16, 293.
194 Lockwood AH, Yap EWH, Rhoades HM *et al.* (1991) Altered cerebral blood flow and glucose metabolism in patients with liver disease and minimal encephalopathy. *J Cerebr Blood Flow Metab* 11, 331–336.
195 Zafiris O, Kircheis G, Rood HA *et al.* (2004) Neural mechanism underlying impaired visual judgement in the dysmetabolic brain: an fMRI study. *Neuroimage* 22, 541–552.
196 Taylor-Robinson SD, Sargentoni J, Mallalieu RJ *et al.* (1994) Cerebral phosphorus-31 magnetic resonance spectroscopy in patients with chronic hepatic encephalopathy. *Hepatology* 20, 1173–1178.
197 Barbiroli B, Gaiani S, Lodi R *et al.* (2002) Abnormal brain energy metabolism shown by *in vivo* phosphorus magnetic resonance spectroscopy in patients with chronic liver disease. *Brain Res Bull* 59, 75–82.
198 Hindfelt B, Plum F, Duffy TE (1977) Effect of acute ammonia intoxication on cerebral metabolism in rats with portocaval shunts. *J Clin Invest* 59, 386–406.
199 deKnegt RJ, Schalm SW, van der Rijt CC *et al.* (1994) Extracellular brain glutamate during acute liver failure and during acute hyperammonemia simulating acute liver failure: an experimental study based on *in vivo* brain dialysis. *J Hepatol* 20, 19–26.
200 Rao VL, Audet RM, Butterworth RF (1995) Selective alterations of extracellular brain amino acids in relation to function in experimental portal-systemic encephalopathy: results of an *in vivo* microdialysis study. *J Neurochem* 65, 1221–1228.
201 Steindl PE, Coy DL, Finn B *et al.* (1996) A low-protein diet ameliorates disrupted locomotor activity in rats after portacaval anastomosis. *Am J Physiol* 271, G555–560.
202 Sergeeva OA, Schulz D, Doreulee N *et al.* (2005) Deficits in corticostriatal synaptic plasticity and behavioral habituation in rats with portocaval anastomosis. *Neuroscience* 134, 1091–1098.
203 Weissenborn K, Heidenreich S, Giewekemeyer K *et al.* (2003) Memory function in early hepatic encephalopathy. *J Hepatol* 39, 320–325.
204 Bakti G, Fisch HU, Karlaganis G *et al.* (1987) Mechanism of the excessive sedative response of cirrhotics to benzodiazepines: model experiments with triazolam. *Hepatology* 7, 629–638.
205 Pomier-Layrargues G, Giguere JF, Lavoie J *et al.* (1994) Flumazenil in cirrhotic patients in hepatic coma: a randomized double-blind placebo-controlled crossover trial. *Hepatology* 19, 32–37.
206 Zisterer DM, Williams DC (1997) Peripheral-type benzodiazepine receptors. *Genet Pharmacol* 29, 305–314.
207 Papadopoulos V (1993) Peripheral-type benzodiazepin/diazepam binding inhibitor receptor: biological role in steroidogenic cell function. *Endocrinol Rev* 12, 222–240.
208 Ducis I, Norenberg LO, Norenberg MD (1989) Effect of ammonium chloride on the astrocyte benzodiazepine receptor. *Brain Res* 493, 362–365.
209 Giguere JF, Hamel E, Butterworth RF (1992) Increased densities of binding sites for the peripheral-type benzodiazepine receptor ligand. [3H]PK 11195 in rat brain following portocaval anastomosis. *Brain Res* 585, 295–298.
210 Rao VL, Qureshi IA, Butterworth RF (1993) Increased densities of binding sites for the peripheral-type benzodiazepine receptor ligand [3H]PK 11195 in congenital ornithine transcarbamylase-deficient sparse fur mouse. *Pediatr Res* 34, 777–780.
211 Korneyev A, Pan BS, Polo A *et al.* (1993) Stimulation of brain pregnenolone synthesis by mitochondrial diazepam binding inhibitor receptor ligands *in vivo*. *J Neurochem* 61, 1515–1524.
212 Fischer R, Schmitt M, Bode JG *et al.* (2001) Expression of the peripheral-type benzodiazepine receptor and apoptosis induction in hepatic stellate cells. *Gastroenterology* 120, 1212–1226.
213 Swain MS, Bergeron M, Audet R *et al.* (1992) Monitoring of neurotransmitter amino acids by means of an indwelling cisterna magna catheter: a comparison of two rodent models of fulminant liver failure. *Hepatology* 16, 1028–1035.
214 Michalak A, Rose C, Butterworth J *et al.* (1996) Neuroactive amino acids and glutamate (NMDA) receptors in frontal cortex of rats with experimental acute liver failure. *Hepatology* 24, 908–913.
215 Moroni F, Lombardi G, Moneti G *et al.* (1983) The release and neosynthesis of glutamic acid are increased in experimental models of hepatic encephalopathy. *J Neurochem* 40, 850–854.
216 Tossman U, Delin A, Eriksson LS *et al.* (1987) Brain cortical amino acids measured by intracerebral dialysis in portacaval shunted rats. *Neurochem Res* 12, 265–269.
217 Cooper J, Bloom F, Roth RH (1996) *The Biochemical Basis of Neuropharmacology*. New York: Oxford University Press.
218 Schipke CG, Ohlemeyer C, Matyash M *et al.* (2001) Astrocytes of the mouse neocortex express functional N-methyl-D-aspartate receptors. *FASEB J* 15, 1270–1272.
219 Peterson C, Giguere JF, Cotman CW *et al.* (1990) Selective loss of N-methyl-D-aspartate-sensitive L-[3H] glutamate binding sites in rat brain following portocaval anastomosis. *J Neurochem* 55, 386–390.
220 Maddison JE, Watson WE, Dodd PR *et al.* (1991) Alterations in cortical [3H] kainate and alpha-[3H] amino-3-hydroxy-5-methyl-4-isoxazolepropionic acid binding in a spontaneous canine model of chronic hepatic encephalopathy. *J Neurochem* 56, 1881–1888.
221 Michel H, Solere M, Granier P *et al.* (1980) Treatment of cirrhotic hepatic encephalopathy with L-dopa. A controlled trial. *Gastroenterology* 79, 207–211.
222 Bergeron M, Reader TA, Layargues GP *et al.* (1989) Monoamines and metabolites in autopsied brain tissue from cirrhotic patients with hepatic encephalopathy. *Neurochem Res* 14, 853–859.
223 Rao VL, Giguere JF, Layargues GP *et al.* (1993) Increased activities of MAOA and MAOB in autopsied brain tissue from cirrhotic patients with hepatic encephalopathy. *Brain Res* 621, 349–352.
224 Mousseau DD, Perney P, Layargues GP *et al.* (1993) Selective loss of pallidal dopamine D2 receptor density in hepatic encephalopathy. *Neurosci Lett* 162, 192–196.
225 Butterworth RF, Spahr L, Fontaine S *et al.* (1995) Manganese toxicity, dopaminergic dysfunction and hepatic encephalopathy. *Metab Brain Dis* 10, 259–267.
226 Bengtsson F, Bugge M, Johansen KH *et al.* (1991) Brain tryptophan hydroxylation in the portacaval shunted rat: a hypothesis for the regulation of serotonin turnover *in vivo*. *J Neurochem* 56, 1069–1074.
227 Bugge M, Bengtsson F, Nobin A *et al.* (1987) The turnover of brain monoamines after total hepatectomy in rats infused with branched chain amino acids. *World J Surg* 11, 810–817.
228 Rao VL, Giguere JF, Layrargues GP *et al.* (1993) Increased activities of MAOA and MAOB in autopsied brain tissue from cirrhotic patients with hepatic encephalopathy. *Brain Res* 621, 349–352.

229 Rao VL, Butterworth RF (1994) Alterations of [3H]8-OH-DPAT and [3H] ketanserin binding sites in autopsied brain tissue from cirrhotic patients with hepatic encephalopathy. *Neurosci Lett* 182, 69–72.
230 Vorobioff J, Garcia-Tsao G, Groszmann R *et al.* (1989) Long-term hemodynamic effects of ketanserin, a 5-hydroxytryptamine blocker, in portal hypertensive patients. *Hepatology* 9, 88–91.
231 Ferenci P, Herneth A, Steindl P (1996) Newer approaches to therapy of hepatic encephalopathy. *Semin Liver Dis* 16, 329.
232 Cordoba J, Cabrera J, Lataif L *et al.* (1998) High prevalence of sleep disturbance in cirrhosis. *Hepatology* 27, 339–345.
233 Blei AT, Zee P (1998) Abnormalities of circadian rhythmicity in liver disease. *J Hepatol* 29, 832–835.
234 Haas H, Panula P (2003) The role of histamine and the tuberomamillary nucleus in the nervous system. *Nature Rev Neurosci* 4, 121–130.
235 Doreulee N, Yanovsky Y, Flagmeyer I *et al.* (2001) Histamine H(3) receptors depress synaptic transmission in the corticostriatal pathway. *Neuropharmacology* 40, 106–113.
236 Borg J, Warter JM, Schlienger JL *et al.* (1982) Neurotransmitter modifications in human cerebrospinal fluid and serum during hepatic encephalopathy. *J Neurol Sci* 57, 343–356.
237 Lozeva V, Tuomisto L, Sola D *et al.* (2001) Increased density of brain histamine H(1) receptors in rats with portacaval anastomosis and in cirrhotic patients with chronic hepatic encephalopathy. *Hepatology* 33, 1370–1376.
238 Lozeva V, Tuomisto L, Tarhanen J *et al.* (2003) Increased concentrations of histamine and its metabolite, tele-methylhistamine and down-regulation of histamine H3 receptor sites in autopsied brain tissue from cirrhotic patients who died in hepatic coma. *J Hepatol* 39, 522–527.
239 Lozeva V, Valjakka A, Lecklin A *et al.* (2000) Effects of the histamine H(1) receptor blocker, pyrilamine, on spontaneous locomotor activity of rats with long-term portacaval anastomosis. *Hepatology* 31, 336–344.
240 Martin JR, Porchet H, Buhler R *et al.* (1985) Increased ethanol consumption and blood ethanol levels in rats with portacaval shunts. *Am J Physiol* 248, G287–292.
241 de Waele JP, Audet RM, Leong DK *et al.* (1996) Portacaval anastomosis induces region-selective alterations of the endogenous opioid system in the rat brain. *Hepatology* 24, 895–901.
242 Panerai AE, Salerno F, Baldissera F *et al.* (1982) Brain beta-endorphin concentrations in experimental chronic liver disease. *Brain Res* 247, 188–190.
243 Yurdaydin C, Karavelioglu D, Onaran O *et al.* (1998) Opioid receptor ligands in human hepatic encephalopathy. *J Hepatol* 29, 796–801.
244 Lounasmaa OV, Hamalainen M, Hari R *et al.* (1996) Information processing in the human brain: magnetoencephalographic approach. *Proc Natl Acad Sci USA* 93, 8809–8815.
245 Schnitzler A, Gross J (2005) Normal and pathological oscillatory communication in the brain. *Nature Rev Neurosci* 6, 285–296.
246 Timmermann L, Gross J, Kircheis G *et al.* (2002) Cortical origin of mini-asterixis in hepatic encephalopathy. *Neurology* 58, 295–299.
247 Timmermann L, Gross J, Butz M *et al.* (2003) Mini-asterixis in hepatic encephalopathy induced by pathologic thalamo-motorcortical coupling. *Neurology* 61, 689–692.
248 Gross J, Kujala J, Hamalainen M *et al.* (2001) Dynamic imaging of coherent sources: studying neural interactions in the human brain. *Proc Natl Acad Sci USA* 98, 694–699.
249 Timmermann L, Gross J, Butz M *et al.* (2004) Pathological oscillatory coupling within the human motor system in different tremor syndromes as revealed by magnetoencephalography. *Neurol Clin Neurophysiol* 30, 2004–2026.
250 Rio J, Montalban J, Pujadas F *et al.* (1995) Asterixis associated with anatomic cerebral lesions: a study of 45 cases. *Acta Neurol Scand* 91, 377–381.
251 Chen S, Zieve L, Mahadevan V (1970) Mercaptans and dimethyl sulfide in the breath of patients with cirrhosis of the liver. Effect of feeding methionine. *J Lab Clin Med* 75, 628–635.
252 Miyata Y, Motomura S, Tsuji Y *et al.* (1988) Hepatic encephalopathy and reversible cortical blindness. *Am J Gastroenterol* 83, 780–782.
253 Averbuch-Heller L, Meiner Z (1995) Reversible periodic alternating gaze deviation in hepatic encephalopathy. *Neurology* 45, 191–192.
254 Huizenga JR, Gips CH, Conn HO *et al.* (1995) Determination of ammonia in ear-lobe capillary blood is an alternative to arterial blood ammonia. *Clin Chim Acta* 239, 65–70.
255 Ong JP, Aggarwal A, Krieger D *et al.* (2003) Correlation between ammonia levels and the severity of hepatic encephalopathy. *Am J Med* 114, 188–193.
256 Clemmesen JO, Larsen FS, Kondrup J *et al.* (1999) Cerebral herniation in patients with acute liver failure is correlated with arterial ammonia concentration. *Hepatology* 29, 648–653.
257 Barthauer L, Tarter R, Hirsch W *et al.* (1992) Brain morphologic characteristics of cirrhotic alcoholics and cirrhotic nonalcoholics: an MRI study. *Alcohol Clin Exp Res* 16, 982–985.
258 Thuluvath PJ, Edwin D, Yue NC *et al.* (1995) Increased signals seen in globus pallidus in T1-weighted magnetic resonance imaging in cirrhotics are not suggestive of chronic hepatic encephalopathy. *Hepatology* 21, 440–442.
259 Takashi M, Igarashi M, Hino S *et al.* (1985) Portal hemodynamics in chronic portal-systemic encephalopathy. Angiographic study in seven cases. *J Hepatol* 1, 467–476.
260 Ohnishi K, Sato S, Saito M *et al.* (1986) Clinical and portal hemodynamic features in cirrhotic patients having a large spontaneous splenorenal and/or gastrorenal shunt. *Am J Gastroenterol* 81, 450–455.
261 Riggio O, Efrati C, Catalano C *et al.* (2005) High prevalence of spontaneous portal-systemic shunts in persistent hepatic encephalopathy: a case–control study. *Hepatology* 42, 1158–1165.
262 Mutchnick MG, Lerner E, Conn HO (1974) Portal-systemic encephalopathy and portacaval anastomosis: a prospective, controlled investigation. *Gastroenterology* 66, 1005–1019.
263 Langer B, Taylor BR, Mackenzie DR *et al.* (1985) Further report of prospective randomized trial comparing distal splenorenal shunt with end-to-side portacaval shunt. An analysis of encephalopathy, survival, and quality of life. *Gastroenterology* 88, 424–429.
264 Sanyal AJ, Freedman AM, Shiffman ML *et al.* (1994) Portosystemic encephalopathy after transjugular intrahepatic portosystemic shunt: results of a prospective controlled study. *Hepatology* 20, 46–55.
265 Mamiya Y, Kanazawa H, Kimura Y *et al.* (2004) Hepatic encephalopathy alter transjugular intrahepatic portosystemic shunt. *Hepatol Res* 30, 162–168.
266 Madoff DC, Wallace MJ, Ahrar K *et al.* (2004) TIPS-related hepatic encephalopathy: management options with novel endovascular techniques. *Radiographics* 24, 21–36.
267 Langer B, Taylor BR, Greig PD (1990) Selective or total shunts for variceal bleeding. *Am J Surg* 160, 75–79.
268 Pomier-Layargues G, Huet PM, Infante-Rivard C *et al.* (1988) Prognostic value of indocyanine green and lidocaine kinetics for survival and chronic hepatic encephalopathy in cirrhotic patients

following elective end-to-side portocaval shunt. *Hepatology* 8, 1506–1510.
269 Planas R, Gomes-Vieira MC, Cabre E *et al.* (1992) Prognostic factors of hepatic encephalopathy alter portacaval anastomosis, a multivariate analysis in 50 patients. *Am J Gastroenterol* 87, 1792–1796.
270 Somberg KA, Riegler JL, LaBerge JM *et al.* (1995) Hepatic encephalopathy after transjugular intrahepatic portosystemic shunts: incidence and risk factors. *Am J Gastroenterol* 90, 549–555.
271 Blei, AT (1994) Hepatic encephalopathy in the age of TIPS. *Hepatology* 20, 249–252.
272 Rossle M, Piotraschke J (1996) Transjugular intrahepatic portosystemic shunt and hepatic encephalopathy. *Dig Dis* 1, 12–19.
273 Hassoun Z, Dechenes M, Lafortune M *et al.* (2001) Relationship between pre-TIPS liver perfusion by the portal vein and the incidence of post-TIPS chronic hepatic encephalopathy. *Am J Gastroenterol* 96, 1205–1209.
274 Summerskill WH, Davidson EA, Sherlock S *et al.* (1956) The neuropsychiatric syndrome associated with hepatic cirrhosis and an extensive portal collateral circulation. *Q J Med* 25, 245–266.
275 Mendoza G, Marti-Fabregas J, Kulisevsky J *et al.* (1994) Hepatic myelopathy: a rare complication of portacaval shunt. *Eur Neurol* 34, 209–212.
276 Rikkers L, Jenko P, Rudman D *et al.* (1978) Subclinical hepatic encephalopathy: detection, prevalence and relationship to nitrogen metabolism. *Gastroenterology* 75, 462–469.
277 Gitlin N, Lewis DC, Hinkley L (1986) The diagnosis and prevalence of subclinical hepatic encephalopathy in apparent healthy, ambulant, nonshunted patients with cirrhosis. *J Hepatol* 3, 75–82.
278 Schomerus H, Hamster W, Blunck H *et al.* (1981) Latent portasystemic encephalopathy. *Dig Dis Sci* 26, 622–660.
279 Ortiz M, Jacas C, Cordoba J (2005) Minimal hepatic encephalopathy: diagnosis, clinical significance and recommendations. *J Hepatol* 42, S45–53.
280 Groeneweg M, Quero JC, DeBruijn I *et al.* (1998) Subclinical hepatic encephalopathy impairs daily functioning. *Hepatology* 28, 45–49.
281 Marchesini G, Bianchi G, Amodio P *et al.* (2001) Italian Study Group for quality of life in cirrhosis. Factors associated with poor health-related quality of life of patients with cirrhosis. *Gastroenterology* 120, 170–178.
282 Arguedas MR, DeLawrence TG, McGuire BM (2003) Influence of hepatic encephalopathy on health-related quality of life in patients with cirrhosis. *Dig Dis Sci* 48, 1622–1626.
283 Bustamante J, Rimola A, Ventura PJ *et al.* (1999) Prognostic significance of hepatic encephalopathy in patients with cirrhosis. *J Hepatol* 30, 890–895.
284 Amodio P, Del Piccolo F, Marchetti P *et al.* (1999) Clinical features and survival of cirrhotic patients with subclinical cognitive alterations detected by the number connection test and computerized psychometric tests. *Hepatology* 29, 1662–1667.
285 Hartmann IJ, Groeneweg M, Quero JC *et al.* (2000) The prognostic significance of subclinical hepatic encephalopathy. *Am J Gastroenterol* 95, 2029–2034.
286 Romero-Gomez M, Boza F, Garcia-Valdecasas MS *et al.* (2001) Subclinical hepatic encephalopathy predicts the development of overt hepatic encephalopathy. *Am J Gastroenterol* 96, 2718–2723.
287 Kono I, Ueda Y, Nakajima K *et al.* (1994) Subcortical impairment in subclinical hepatic encephalopathy. *J Neurol Sci* 126, 162–167.
288 McCrea M, Cordoba J, Vessey G *et al.* (1996) Neuropsychological characterization and detection of subclinical hepatic encephalopathy. *Arch Neurol* 53, 758–763.
289 Lockwood AH, Murphy BW, Donnelly KZ *et al.* (1993) Positron-emission tomographic localization of abnormalities of brain metabolism in patients wit minimal hepatic encephalopathy. *Hepatology* 18, 1061–1068.
290 Rodriguez G, Testa R, Celle G *et al.* (1987) Reduction of cerebral blood flow in subclinical hepatic encephalopathy and its correlation with plasma-free tryptophan. *J Cerebr Blood Flow Metab* 7, 768–772.
291 Watanabe A, Tuchida T, Yata Y *et al.* (1995) Evaluation of neuropsychological function in patients with liver cirrhosis with special reference to their driving ability. *Metab Brain Dis* 10, 239–248.
292 Wein C, Koch H, Popp B *et al.* (2004) Minimal hepatic encephalopathy impairs fitness to drive. *Hepatology* 39, 739–745.
293 Srivastava A, Mehta R, Rothke SP *et al.* (1994) Fitness to drive in patients with cirrhosis and portal-systemic shunting: a pilot study evaluating driving performance. *J Hepatol* 21, 1023–1028.
294 Tarter RE, Hegedus AM, Van Thiel DH *et al.* (1984) Nonalcoholic cirrhosis associated with neuropsychological dysfunction in the absence of overt evidence of hepatic encephalopathy. *Gastroenterology* 86, 1421–1427.
295 Steindl PE, Finn B, Bendok B *et al.* (1995) Disruption of the diurnal rhythm of plasma melatonin in cirrhosis. *Ann Intern Med* 123, 274–277.
296 Blei AT, Olafsson S, Webster S *et al.* (1993) Complications of intracranial pressure monitoring in fulminant hepatic failure. *Lancet* 341, 157–158.
297 Keays RT, Alexander GJ, Williams R (1993) The safety and value of extradural intracranial pressure monitors in fulminant hepatic failure. *J Hepatol* 18, 205–209.
298 Vaquero J, Fontana RJ, Larson AM *et al.* (2005) Complications and use of intracranial pressure monitoring in patients with acute liver failure and severe encephalopathy. *Liver Transpl* 11, 1581–1589.
299 Shami VM, Caldwell SH, Hespenheide EE *et al.* (2003) Recombinant activated factor VII for coagulopathy in fulminant hepatic failure compared with conventional therapy. *Liver Transpl* 9, 138–143.
300 Larsen FS (1996) Cerebral circulation in liver failure: Ohm's law in force. *Semin Liver Dis* 16, 281.
301 Aggarwal S, Obrist W, Yonas H *et al.* (2005) Cerebral hemodynamic and metabolic profiles in fulminant hepatic failure: Relationship to outcome. *Liver Transpl* 11, 1353–1360.
302 Master S, Gottstein J, Blei AT (1999) Cerebral blood flow and the development of ammonia-induced brain edema in rats after portacaval anastomosis. *Hepatology* 30, 876–880.
303 Larsen FS, Ejlersen E, Hansen BA *et al.* (1995) Functional loss of cerebral blood flow autoregulation in patients with fulminant hepatic failure. *J Hepatol* 23, 212–217.
304 Strauss GI, Hansen BA, Herzog T *et al.* (2000) Cerebral autoregulation in patients with end-stage liver disease. *Eur J Gastroenterol Hepatol* 12, 767–771.
305 Shawcross DL, Davies NA, Mookerjee RP *et al.* (2004) Worsening of cerebral hyperemia by the administration of terlipressin in acute liver failure with severe encephalopathy. *Hepatology* 39, 471–475.
306 Wendon JA, Harrison PM, Keays R *et al.* (1994) Cerebral blood flow and metabolism in fulminant liver failure. *Hepatology* 19, 1407–1413.
307 Madl C, Grimm G, Ferenci P *et al.* (1994) Serial recording of sensory evoked potentials: a noninvasive prognostic indicator in fulminant liver failure. *Hepatology* 20, 1487–1494.
308 Kircheis G, Wettstein M, Timmermann L *et al.* (2002) Critical flicker frequency for quantification of low grade hepatic encephalopathy. *Hepatology* 35, 357–366.

309 Horst D, Grace ND, Conn HO *et al.* (1984) Comparison of dietary protein with an oral, branched chain-enriched amino acid supplement in chronic portal-systemic encephalopathy: a randomized controlled trial. *Hepatology* 4(2), 279–287.

310 Parsons-Smith B, Sumerskill W, Dawson AM *et al.* (1957) The electroencephalograph in liver disease. *Lancet* 2, 866–871.

311 van der Rijt CC, Schalm SW (1992) Quantitative EEG analysis and evoked potentials to measure (latent) hepatic encephalopathy. *J Hepatol* 14, 141–142.

312 Kullmann F, Hollerbach S, Holstege A *et al.* (1995) Subclinical hepatic encephalopathy: the diagnostic value of evoked potentials. *J Hepatol* 22, 101–110.

313 Sandford NL, Saul RE (1988) Assessment of hepatic encephalopathy with visual evoked potentials compared with conventional methods. *Hepatology* 8, 1094–1098.

314 Davies MG, Rowan MJ, MacMathuna P *et al.* (1990) The auditory P300 event-related potential: an objective marker of the encephalopathy of chronic liver disease. *Hepatology* 12, 688–694.

315 Weissenborn K, Scholz M, Hinrichs H *et al.* (1990) Neurophysiological assessment of early hepatic encephalopathy. *Electroencephalogr Clin Neurophysiol* 75, 289–295.

316 Kugler CF, Petter J, Taghavy A *et al.* (1994) Dynamics of cognitive brain dysfunction in patients with cirrhotic liver disease: an event-related P300 potential perspective. *Electroencephalogr Clin Neurophysiol* 91(1), 33–41.

317 Kugler CF, Lotterer E, Petter J *et al.* (1992) Visual event-related P300 potentials in early portosystemic encephalopathy. *Gastroenterology* 103, 302–310.

318 Zeneroli ML, Cioni G, Ventura P *et al.* (1992) Interindividual variability of the number connection test. *J Hepatol* 15, 263–264.

319 Weissenborn K, Ruckert N, Hecker H *et al.* (1998) The number connection tests A and B: interindividual variability and use for the assessment of early hepatic encephalopathy. *J Hepatol* 28, 646–653.

320 Weissenborn K, Ennen JC, Schomerus H *et al.* (2001) Neuropsychological characterization of hepatic encephalopathy. *J Hepatol* 34, 768–773.

321 Tarter RE, Van Thiel DH, Arria AM *et al.* (1988) Impact of cirrhosis on the neuropsychological test performance of alcoholics. *Alcohol Clin Exp Res* 12, 619–621.

322 Arria AM, Tarter RE, Starzl TE *et al.* (1991) Improvement in cognitive functioning of alcoholics following orthotopic liver transplantation. *Alcohol Clin Exp Res* 15, 956–962.

323 Córdoba J, Blei AT (1997) Treatment of hepatic encephalopathy. *Am J Gastroenterol* 92, 1429–1439.

324 Mullen KD, Weber FL Jr (1991) Role of nutrition in hepatic encephalopathy. *Semin Liver Dis* 11, 292–304.

325 Ferenci P, Müller C (1999) Hepatic encephalopathy treatment. In: McDonald J, Burroughs AK, Feagan BG (eds) *Evidence-based Gastroenterology and Hepatology*. London: BMJ Publisher, pp. 3–15.

326 Riordan SM, Williams R (1997) Treatment of hepatic encephalopathy. *N Engl J Med* 337, 473–479.

327 Cordoba J, Lopez-Hellin J, Planas M *et al.* (2004) Normal protein diet for episodic hepatic encephalopathy: results of a randomized study. *J Hepatol* 41, 38–43.

328 Morgan TR, Moritz TE, Mendenhall CL *et al.* (1995) Protein consumption and hepatic encephalopathy in alcoholic hepatitis. VA Cooperative Study Group #275. *J Am Coll Nutr* 14, 152–158.

329 Plauth M, Merli M, Kondrup J *et al.* (1997) ESPEN guidelines for nutrition in liver disease and transplantation. *Clin Nutr* 16, 43–55.

330 Uribe M, Marquez MA, Garcia Ramos G *et al.* (1982) Treatment of chronic portal–systemic encephalopathy with vegetable and animal protein diets. A controlled crossover study. *Dig Dis Sci* 27, 1109–1116.

331 Fenton JC, Knight EJ, Humpherson PL (1966) Milk-and-cheese diet in portal-systemic encephalopathy. *Lancet* 1, 164–166.

332 Zieve L, Zieve FJ (1987) The dietary prevention of hepatic coma in Eck fistula dogs. Ammonia and the carbohydrate to protein ration. *Hepatology* 7, 196–198.

333 Weber FL Jr, Minco D, Fresard KM *et al.* (1985) Effects of vegetable diets on nitrogen metabolism in cirrhotic subjects. *Gastroenterology* 89, 538–544.

334 Horst D, Grace ND, Conn HO *et al.* (1984) Comparison of dietary protein with an oral, branched chain-enriched amino acid supplement in chronic portal-systemic encephalopathy: a randomized controlled trial. *Hepatology* 4, 279–287.

335 Plauth M, Egberts EH, Hamster W *et al.* (1993) Long-term treatment of latent portosystemic encephalopathy with branched-chain amino acids. A double-blind placebo-controlled crossover study. *J Hepatol* 17, 308–314.

336 Marchesini G, Bianchi G, Merli M *et al.* (2003) Italian BCAA Study Group. Nutritional supplementation with branched-chain amino acids in advanced cirrhosis: a double-blind, randomized trial. *Gastroenterology* 124, 1792–1801.

337 Bircher J, Muller J, Guggenheim P *et al.* (1966) Treatment of chronic portal-systemic encephalopathy with lactulose. *Lancet* 1, 890–892.

338 Florent C, Flourie B, Leblond A *et al.* (1985) Influence of chronic lactulose ingestion on the colonic metabolism of lactulose in man (an *in vivo* study). *J Clin Invest* 75, 608–613.

339 Mortensen PB (1992) The effect of oral-administered lactulose on colonic nitrogen metabolism and excretion. *Hepatology* 16, 1350–1356.

340 Weber FL Jr, Fresard KM, Lally BR (1982) Effects of lactulose and neomycin on urea metabolism in cirrhotic subjects. *Gastroenterology* 82, 213–217.

341 Uribe M, Campollo O, Vargas F *et al.* (1987) Acidifying enemas (lactitol and lactose) vs. nonacidifying enemas (tap water) to treat acute portal-systemic encephalopathy: a double-blind, randomized clinical trial. *Hepatology* 7, 639–643.

342 Blanc P, Daures JP, Rouillon JM *et al.* (1992) Lactitol or lactulose in the treatment of chronic hepatic encephalopathy: results of a meta-analysis. *Hepatology* 15, 222–228.

343 Uribe M, Dibildox M, Malpica S *et al.* (1980) Treatment of chronic portal-systemic encephalopathy with lactose in lactase-deficient patients. *Dig Dis Sci* 25, 924–928.

344 Als-Nielsen B, Gluud LL, Gluud C (2004) Non-absorbable disaccharides for hepatic encephalopathy: systematic review of randomised trials. *Br Med J* 328, 1046.

345 Fisher CJ, Faloon WW (1957) Blood ammonia levels in hepatic cirrhosis: their control by the oral administration of neomycin. *N Engl J Med* 256, 1030–1035.

346 van Berlo CL, van Leeuwen PA, Soeters PB (1988) Porcine intestinal ammonia liberation. Influence of food intake, lactulose and neomycin treatment. *J Hepatol* 7, 250–257.

347 Morgan MH, Read AE, Speller DC (1982) Treatment of hepatic encephalopathy with metronidazole. *Gut* 23, 1–7.

348 Loft S, Sonne J, Dossing M *et al.* (1987) Metronidazole pharmacokinetics in patients with hepatic encephalopathy. *Scand J Gastroenterol* 22, 117–123.

349 Tarao K, Ikeda T, Hayashi K *et al.* (1990) Successful use of vancomycin hydrochloride in the treatment of lactulose resistant chronic hepatic encephalopathy. *Gut* 31, 702–706.

350 Mas A, Rodes J, Sunyer L *et al.* (2003) Spanish Association for the Study of the Liver Hepatic Encephalopathy Cooperative Group. Comparison of rifaximin and lactitol in the treatment of acute hepatic encephalopathy: results of a randomized, double-blind, double-dummy, controlled clinical trial. *J Hepatol* 38, 51–58.

351 Liu Q, Duan ZP, Ha da K *et al.* (2004) Symbiotic modulation of gut flora: effect on minimal hepatic encephalopathy in patients with cirrhosis. *Hepatology* 39, 1441–1449.

352 Huber M, Rossle M, Siegerstetter V *et al.* (2001) *Helicobacter pylori* infection does not correlate with plasma ammonia concentration and hepatic encephalopathy in patients with cirrhosis. *Hepatogastroenterology* 48, 541–544.

353 Vasconez C, Elizalde JI, Llach J *et al.* (1999) *Helicobacter pylori*, hyperammonemia and subclinical portosystemic encephalopathy: effects of eradication. *J Hepatol*, 260–264.

354 Reding P, Duchateau J, Bataille C (1984) Oral zinc supplementation improves hepatic encephalopathy. Results of a randomised controlled trial. *Lancet* 2, 493–495.

355 Marchesini G, Fabbri A, Bianchi G *et al.* (1996) Zinc supplementation and amino acid-nitrogen metabolism in patients with advanced cirrhosis. *Hepatology* 23, 1084–1092.

356 Riggio O, Ariosto F, Merli M *et al.* (1991) Short-term oral zinc supplementation does not improve chronic hepatic encephalopathy. Results of a double-blind crossover trial. *Dig Dis Sci* 36, 1204–1208.

357 Bresci G, Parisi G, Banti S (1993) Management of hepatic encephalopathy with oral zinc supplementation: a long-term treatment. *Eur J Med* 2, 414–416.

358 Van der Rijt CC, Schalm SW, Schat H *et al.* (1991) Overt hepatic encephalopathy precipitated by zinc deficiency. *Gastroenterology* 100, 1114–1118.

359 Staedt U, Leweling H, Gladisch R *et al.* (1993) Effects of ornithine aspartate on plasma ammonia and plasma amino acids in patients with cirrhosis. A double-blind, randomized study using a four-fold crossover design. *J Hepatol* 19, 424–430.

360 Kircheis G, Nilius R, Held C *et al.* (1997) Therapeutic efficacy of L-ornithine-L-aspartate infusions in patients with cirrhosis and hepatic encephalopathy: results of a placebo-controlled, double-blind study. *Hepatology* 25, 1351–1360.

361 Stauch S, Kircheis G, Adler G *et al.* (1998) Oral L-ornithine-L-aspartate therapy of chronic hepatic encephalopathy: results of a placebo-controlled double-blind study. *J Hepatol* 28, 856–864.

362 Rose C, Michalak A, Rao KV *et al.* (1999) L-ornithine-L-aspartate lowers plasma and cerebrospinal fluid ammonia and prevents brain edema in rats with acute liver failure. *Hepatology* 30, 636–640.

363 Sushma S, Dasarathy S, Tandon RK *et al.* (1992) Sodium benzoate in the treatment of acute hepatic encephalopathy: a double-blind randomized trial. *Hepatology* 16, 138–144.

364 Mendenhall CL, Rouster S, Marshall L *et al.* (1986) A new therapy for portal systemic encephalopathy. *Am J Gastroenterol* 81, 540–543.

365 Morgan MY (1990) Branched chain amino acids in the management of chronic liver disease. Facts and fantasies. *J Hepatol* 11, 133–141.

366 Eriksson LS, Conn HO (1989) Branched-chain amino acids in the management of hepatic encephalopathy: an analysis of variants. *Hepatology* 10, 228–246.

367 Naylor CD, O'Rourke K, Detsky AS *et al.* (1989) Parenteral nutrition with branched-chain amino acids in hepatic encephalopathy. A meta-analysis. *Gastroenterology* 97, 1033–1042.

368 Als-Nielsen B, Koretz RL, Kjaergard LL *et al.* (2003) Branched-chain amino acids for hepatic encephalopathy. *Cochrane Database Syst Rev* 2, CD001939.

369 Marchesini G, Dioguardi FS, Bianchi GP *et al.* (1990) Long-term oral branched-chain amino acid treatment in chronic hepatic encephalopathy. A randomized double-blind case-controlled trial. The Italian multicenter Study Group. *J Hepatol* 11, 92–101.

370 Pomier-Layrargues G, Giguere JF, Lavoie J *et al.* (1994) Flumazenil in cirrhotic patients in hepatic coma: a randomized double-blind placebo-controlled crossover trial. *Hepatology* 19, 32–37.

371 Barbaro G, Di Lorenzo G, Soldini M *et al.* (1998) Flumazenil for hepatic encephalopathy grade III and IVa in patients with cirrhosis: an Italian multicenter double-blind, placebo-controlled, cross-over study. *Hepatology* 28, 374–378.

372 Gyr K, Meier R, Haussler J *et al.* (1996) Evaluation of the efficacy and safety of flumazenil in the treatment of portal systemic encephalopathy: a double blind, randomised, placebo controlled multicentre study. *Gut* 39, 319–324.

373 Goulenok C, Bernard B, Cadranel JF *et al.* (2002) Flumazenil vs. placebo in hepatic encephalopathy in patients with cirrhosis: a meta-analysis. *Aliment Pharmacol Ther* 16, 361–372.

374 Pomier-Layrargues G, Giguere JF, Lavoie J *et al.* (1989) Pharmacokinetics of benzodiazepine antagonist Ro 15-1788 in cirrhotic patients with moderate or severe liver dysfunction. *Hepatology* 10(6), 969–972.

375 Uribe M, Farca A, Marquez MA *et al.* (1979) Treatment of chronic portal systemic encephalopathy with bromocriptine: a double-blind controlled trial. *Gastroenterology* 76, 1347–1351.

376 Als-Nielsen B, Gluud LL, Gluud C (2004) Dopaminergic agonists for hepatic encephalopathy. *Cochrane Database Syst Rev* 4, CD003047.

377 Morgan MY, Jakobovits AW, James IM *et al.* (1980) Successful use of bromocriptine in the treatment of chronic hepatic encephalopathy. *Gastroenterology* 78, 663–670.

378 Vogels BA, Maas MA, Daalhuisen J *et al.* (1997) Memantine, a noncompetitive NMDA receptor antagonist improves hyperammonemia-induced encephalopathy and acute hepatic encephalopathy in rats. *Hepatology* 25, 820–827.

379 Córdoba J, Blei AT (1995) Cerebral edema and intracranial pressure monitoring. *Liver Transpl Surg* 1, 187–194.

380 Muñoz SJ (1993) Difficult management problems in fulminant hepatic failure. *Semin Liver Dis* 13, 395–413.

381 Murphy N, Auzinger G, Bernel W *et al.* (2004) The effect of hypertonic sodium chloride on intracranial pressure in patients with acute liver failure. *Hepatology* 39, 464–470.

382 Forbes A, Alexander GJ, O'Grady JG *et al.* (1989) Thiopental infusion in the treatment of intracranial hypertension complicating fulminant hepatic failure. *Hepatology* 10, 306–310.

383 Jalan R, Olde Damink SW, Deutz NE *et al.* (2004) Moderate hypothermia in patients with acute liver failure and uncontrolled intracranial hypertension. *Gastroenterology* 127, 1338–1346.

384 Vaquero J, Blei AT (2005) Mild hypothermia for acute liver failure: a review of mechanisms of action. *J Clin Gastroenterol* 39 (Suppl. 2), S147–157.

385 Rifai K, Ernst T, Kretschmer U *et al.* (2003) Prometheus – a new extracorporeal system for the treatment of liver failure. *J Hepatol* 39, 984–990.

386 Heemann U, Treichel U, Loock J *et al.* (2002) Albumin dialysis in cirrhosis with superimposed acute liver injury: a prospective, controlled study. *Hepatology* 36, 949–958.

387 Blanc P, Daures JP, Liautard J *et al.* (1994) [Lactulose–neomycin combination versus placebo in the treatment of acute hepatic encephalopathy. Results of a randomized controlled trial] *Gastroenterol Clin Biol* 18, 1063–1068.

388 Cadranel JF, el Younsi M, Pidoux B *et al.* (1995) Flumazenil therapy for hepatic encephalopathy in cirrhotic patients: a double-blind pragmatic randomized, placebo study. *Eur J Gastroenterol Hepatol* 7, 325–329.

389 Riggio O, Masini A, Efrati C *et al.* (2005) Pharmacological prophylaxis of hepatic encephalopathy after transjugular intrahepatic portosystemic shunt: a randomized controlled study. *J Hepatol* 42, 674–679.

390 Uflacker R, Silva Ade O, d'Albuquerque LA *et al.* (1987) Chronic portosystemic encephalopathy: embolization of portosystemic shunts. *Radiology* 165, 721–725.

391 Vavasseur D, Duvoux C, Cherqui D *et al.* (1994) Chronic hepatic encephalopathy due to spontaneous splenorenal shunt: successful treatment by transhepatic shunt embolization. *Cardiovasc Intervent Radiol* 17, 298–300.

392 Dagenais MH, Bernard D, Marleau D *et al.* (1991) Surgical treatment of severe postshunt hepatic encephalopathy. *World J Surg* 15, 109–113.

393 Hauenstein KH, Haag K, Ochs A *et al.* (1995) The reducing stent: treatment for transjugular intrahepatic portosystemic shunt-induced refractory hepatic encephalopathy and liver failure. *Radiology* 194, 175–179.

394 Madoff DC, Wallace MJ, Ahrar K *et al.* (2004) TIPS-related hepatic encephalopathy: management options with novel endovascular techniques. *Radiographics* 24, 21–36; discussion 36–37. Erratum in *Radiographics* (2004) 24, 418.

395 Powell EE, Pender MP, Chalk JB *et al.* (1990) Improvement in chronic hepatocerebral degeneration following liver transplantation. *Gastroenterology* 98, 1079–1082.

396 Weissenborn K, Tietge UJ, Bokemeyer M *et al.* (2003) Liver transplantation improves hepatic myelopathy: evidence by three cases. *Gastroenterology* 124, 346–351.

397 Resnick RH, Ishihara A, Chalmers TC *et al.* (1968) A controlled trial of colon bypass in chronic hepatic encephalopathy. *Gastroenterology* 54, 1057–1069.

398 van Someren EJ, Mirmiran M, Swaab DF (1993) Non-pharmacological treatment of sleep and wake disturbances in aging and Alzheimer's disease: chronobiological perspectives. *Behav Brain Res* 57, 235–253.

399 de Bruijn KM, Blendis LM, Zilm DH *et al.* (1983) Effect of dietary protein manipulation in subclinical portal-systemic encephalopathy. *Gut* 24, 53–60.

400 McClain CJ, Potter TJ, Kromhout JP *et al.* (1984) The effect of lactulose on psychomotor performance tests in alcoholic cirrhotics without overt hepatic encephalopathy. *J Clin Gastroenterol* 6, 325–329.

401 Morgan MY, Alonso M, Stanger LC (1989) Lactitol and lactulose for the treatment of subclinical hepatic encephalopathy in cirrhotic patients. A randomised, cross-over study. *J Hepatol* 8, 208–217.

402 Salerno F, Moser P, Maggi A *et al.* (1994) Effects of long-term administration of low-dose lactitol in patients with cirrhosis but without overt encephalopathy. *J Hepatol* 21(6), 1092–1096.

403 Egberts EH, Schomerus H, Hamster W *et al.* (1985) Branched chain amino acids in the treatment of latent portosystemic encephalopathy. A double-blind placebo-controlled crossover study. *Gastroenterology* 88, 887–895.

404 Gooday R, Hayes PC, Bzeizi K *et al.* (1995) Benzodiazepine receptor antagonism improves reaction time in latent hepatic encephalopathy. *Psychopharmacology (Berl)* 119, 295–298.

405 Kapczinski F, Sherman D, Williams R *et al.* (1995) Differential effects of flumazenil in alcoholic and nonalcoholic cirrhotic patients. *Psychopharmacology (Berl)* 120, 220–226.

406 Görg B, Bidmon HJ, Foster N *et al.* (2006) Inflammatory cytokines induce protein-tyrosine nitration in rat astrocytes. *Arch Biochem Biophys* 449, 104–114.

7.9 Bacterial infections in portal hypertension

Javier Fernández and Miguel Navasa

Spontaneous bacterial peritonitis, urinary tract infections, respiratory infections and bacteraemia are the most frequent infective complications in cirrhosis. These infections are due to the concomitant presence of different facilitating mechanisms including changes in the intestinal flora and in the intestinal barrier, depression of activity of the reticuloendothelial system, decreased opsonic activity of the ascitic fluid, neutrophil leukocyte dysfunction and iatrogenic factors among others. Portal hypertensive patients with a high risk of developing bacterial infections are those with gastrointestinal haemorrhage, a past history of spontaneous bacterial peritonitis and low protein content in ascites fluid together with a poor hepatocellular function. Pathophysiology, treatment and prophylaxis of bacterial infections in these patients will be discussed in this chapter.

Spontaneous bacterial peritonitis

Spontaneous bacterial peritonitis (SBP) is defined as the infection of a previously sterile ascitic fluid, without any apparent intra-abdominal source of infection [1]. The prevalence of SBP in unselected cirrhotic patients with ascites admitted to a hospital ranges between 10% and 30% [2]. Diagnosis of SBP is established by a polymorphonuclear cell count in ascitic fluid equal to or higher than 250 cells/μL. In approximately 40–60% of cases, the organism responsible is isolated in ascitic fluid culture or in blood cultures [2,3]. The remaining cases are considered as a variant of SBP and are treated in the same way as those with a positive culture [4]. The outcome of cirrhotic patients with SBP has improved dramatically during the last 20 years. At present, the SBP resolution rate is approximately 90%, and hospital survival ranges between 70% and 90% [1–3]. An early diagnosis of SBP and especially the use of more adequate antibiotic therapy are the most likely reasons for the improvement in SBP prognosis. However, despite the resolution of the infection, the mortality rate of SBP is still high (10–30%), mainly due to the development of some complications such as renal impairment, gastrointestinal bleeding and progressive liver failure. Cirrhotic patients recovering from an episode of SBP should be considered as potential candidates for liver transplantation as the survival expectancy after this bacterial infection is very short.

Pathogenesis

Colonization of the ascitic fluid from an episode of bacteraemia is nowadays the most accepted hypothesis for the pathogenesis of SBP [2,4]. Although the passage of microorganisms from the bloodstream to ascites has never been documented, it can be assumed that bacteria present in the circulation may easily pass to the ascites because of the constant fluid exchange between these two compartments. Once bacteria have reached the ascites, the development of SBP depends on the antimicrobial capacity of the ascitic fluid. Patients with a decreased defensive capacity of ascitic fluid develop SBP.

As most organisms causing SBP are Gram-negative bacteria of enteric origin [2,4], several pathogenic mechanisms have been proposed to explain the passage of enteric organisms from the intestinal lumen to the systemic circulation:

1 Bacterial translocation, or the process by which enteric bacteria normally present in the gastrointestinal lumen can cross the mucosa, colonize the mesenteric lymph nodes and reach the bloodstream through the intestinal lymphatic circulation. Bacterial translocation could be the consequence of the intestinal bacterial overgrowth that leads to an increase in aerobic Gram-negative bacilli in the intestinal flora in cirrhosis and of the alteration in gut permeability due to portal hypertension or to circumstances decreasing mucosal blood flow (e.g. acute hypovolaemia or splanchnic vasoconstrictor drugs).

2 The depression of the hepatic reticuloendothelial system, which allows the free passage of microorganisms from the bowel lumen to the systemic circulation via the portal vein and prolongs bacteraemia. The skin and the urinary and upper respiratory tracts may be the sites by which non-enteric bacteria enter the circulation and cause SBP. This pathogenic mechanism is enhanced in many cases by diagnostic or therapeutic procedures that break the natural mucocutaneous barriers.

Whatever the source of the bacteria reaching the bloodstream, a bacteraemic event is more prolonged and, therefore, may more

readily become clinically significant in cirrhotic than in non-cirrhotic patients, because of the marked depression of the reticulendothelial system in the former. As indicated above, once microorganisms have colonized the ascites, the development of SBP depends on the defensive capacity of the ascitic fluid.

Bacterial translocation

It has been shown that, in CCl_4-induced cirrhotic rats with ascites, there is an increased passage of bacteria from the intestinal lumen to extraintestinal sites, including regional lymph nodes and the systemic circulation [5–10]. Causes for bacterial translocation are a disruption of the intestinal permeability barrier, bacterial overgrowth (IBO) and/or a decrease in host immune defences. The simultaneous presence of IBO and a severe disturbance in the intestinal barrier seem to be required for bacterial translocation to mesenteric lymph nodes (MLN) [6,7]. The alteration in gut permeability could be partially due to portal hypertension that causes marked oedema and inflammation in the submucosa of the caecum in cirrhotic rats with ascites, thus facilitating bacterial translocation [10]. Increased permeability of the intestinal mucosa has also been observed after haemorrhagic shock, sepsis, injury or administration of endotoxin. In portal hypertensive rats [10,11], it has been shown that haemorrhagic shock is followed by increased bacterial translocation to MLN, suggesting that haemorrhagic shock [11], a not infrequent event in cirrhotic patients, could alter the intestinal barrier in these animals. Gram-negative bacilli overgrowth has been demonstrated in the jejunal flora of cirrhotic patients [6,7]. The intestinal hypomotility caused by the sympathetic overactivity of cirrhotic patients could, at least partly, explain this fact [7]. The change in the intestinal flora may increase the chance of aerobic Gram-negative bacteria invading the bloodstream and causing infections of enteric origin in patients with cirrhosis. In patients with cirrhosis, bacterial translocation to MLN seems to be related to the presence of ascites and to the degree of hepatic insufficiency as it is significantly increased in Child C patients [12].

Depression of activity of the reticuloendothelial system

Although the reticuloendothelial system is widely distributed throughout the body, approximately 90% of this defensive system is in the liver, where Kupffer cells and endothelial sinusoidal cells are the major components [13]. Cirrhotic patients may have marked depression of reticuloendothelial system function. In addition, it has been shown that survival and the risk of acquiring bacteraemia and SBP in cirrhosis are directly related to the degree of dysfunction of the reticuloendothelial system in these patients [14,15].

Several mechanisms have been proposed to explain the impairment of the phagocytic activity of the reticuloendothelial system in cirrhosis including intrahepatic shunting, a reduction in the phagocytic capacity of monocytes, which are considered as the Kupffer cell precursors, and an impaired function of macrophage Fc gamma receptors in alcoholic cirrhosis [13,16,17]. Moreover, serum opsonic activity has been found to be markedly reduced in most cirrhotic patients, probably as a consequence of a decreased serum concentration of complement and fibronectin, substances that normally stimulate the phagocytosis of microorganisms by enhancing their adhesiveness to the reticuloendothelial cell surface.

Decreased opsonic activity of ascitic fluid

The non-specific antimicrobial capacity of ascitic fluid in cirrhosis varies greatly from patient to patient, and this variability may be involved in the pathogenesis of SBP. There is a highly inverse significant correlation between the opsonic activity of ascitic fluid and the risk of developing SBP in patients admitted to hospital with ascites [18].

The opsonic activity of ascitic fluid in cirrhosis is directly correlated with the total protein level in ascites and with the concentration of defensive substances, such as immunoglobulins, complement and fibronectin [18–23]. Interestingly, several investigators have found that the concentration of total protein in ascitic fluid, a very easy measurement in clinical practice, correlates directly with the risk of SBP in cirrhosis with ascites. Patients with protein concentrations in ascitic fluid below 10 g/L develop peritonitis during their hospital stay with a significantly higher frequency than those with a higher protein content in ascites (15% vs. 2% respectively) [19], and the cumulative 1-year probability of developing peritonitis during long-term follow-up is significantly greater in this subgroup of cirrhotic patients than in those with an ascitic protein concentration over 10 g/L (20% vs. 2% respectively) [21,22]. Finally, the probability of developing the first episode of SBP in cirrhotic patients with ascites is significantly influenced by the antimicrobial capacity of ascitic fluid and by hepatic function, with ascitic fluid protein levels, platelet count and serum bilirubin levels being the most useful indicators of high risk of SBP [23].

The variation in the antimicrobial properties could be related to: (i) the serum levels of the defensive proteins involved in antibacterial mechanisms of ascitic fluid; (ii) the degree of portal hypertension and hepatic insufficiency; and (iii) the volume of water diluting ascitic fluid solutes. This last possibility is supported by the finding that diuretic-induced reduction of water in ascitic fluid increases the total protein concentration and the antibacterial capacity of ascites, and by the common observation in clinical practice that SBP occurs predominantly in cirrhotic patients with large-volume ascites.

Neutrophil leukocyte dysfunction

A high proportion of cirrhotic patients show altered neutrophil leukocyte function at different levels. The most frequent disturbance is a marked reduction in chemotaxis, probably caused by the presence of chemotactic inhibitory substances in the serum. The nature of these substances has not yet been determined. Furthermore, the phagocytic and bacterial killing capacity of neutrophils has been found to be reduced in cirrhosis [24].

However, as infections developed by patients with congenital or acquired neutrophil function abnormalities, mainly chronic granulomatous diseases and recurrent staphylococcal and fungal infections, are very different from those developed by cirrhotic patients, it seems very unlikely that leukocyte dysfunction plays a major role in the susceptibility of cirrhosis to bacterial infections.

Iatrogenic factors

In addition to procedures well known to predispose to infection, such as intravenous or urethral catheters and tracheal intubation, cirrhotic patients are frequently subjected to other diagnostic or therapeutic manoeuvres that may alter the natural defence barriers and, therefore, increase the risk of bacterial infection. In that sense, a recent study by our group showed an increasing frequency of infections caused by Gram-positive cocci related to invasive procedures in recent years in cirrhosis [3]. Endoscopic sclerotherapy for bleeding oesophageal varices, particularly emergency sclerotherapy, is associated with bacteraemia, with an incidence ranging from 5% to 30% [25]. Although, in some cases, sclerotherapy has been implicated in the development of serious infectious complications such as purulent meningitis and bacterial peritonitis, bacteraemia is usually a transient phenomenon, and the use of prophylactic antibiotics is not recommended. Finally, there is a very low risk of clinically relevant infections with other invasive techniques often performed in these patients, such as diagnostic or therapeutic paracentesis, variceal band ligation, percutaneous ethanol injection or transcatheter arterial embolization, but the use of antibiotic prophylaxis in these procedures is not supported. In order to reduce nosocomial infections in patients with cirrhosis, urinary and central venous catheters should be used only when necessary and removed as soon as possible. In addition, measures to avoid colonization of venous lines should be strictly applied. At present, antibiotic prophylaxis with first- or second-generation cephalosporins is only advised prior to transjugular intrahepatic portosystemic shunt (TIPS) insertions and surgical interventions.

Diagnosis

Clinical characteristics

The clinical presentation of SBP probably depends on the stage at which the infection is diagnosed. Most patients present signs or symptoms clearly suggestive of peritoneal infection, although SBP may be asymptomatic, especially in the initial stages. Abdominal pain and fever are the most characteristic symptoms. Other signs and symptoms such as alterations in gastrointestinal motility (vomiting, ileus and diarrhoea), hepatic encephalopathy, gastrointestinal bleeding, renal impairment, septic shock and hypothermia may be present in a large number of patients [1,2]. Diagnostic paracentesis should be performed at hospital admission in all cirrhotic patients with ascites to investigate the presence of SBP, and in hospitalized patients with ascites whenever they present with any of the following: (i) abdominal pain, vomiting, diarrhoea, ileus or rebound tenderness; (ii) systemic signs of infection such as fever, leucocytosis, leucopenia or septic shock; and (iii) hepatic encephalopathy or impairment in renal function [1].

Laboratory and microbiological data

The diagnosis of SBP is based on clinical suspicion and on ascitic fluid analysis. An ascitic fluid polymorphonuclear (PMN) count ≥ 250 cells/μL is nowadays considered diagnostic of SBP and constitutes an indication to empirically initiate antibiotic treatment. In patients with haemorrhagic ascites, a subtraction of one PMN per 250 red blood cells should be made to adjust for the presence of blood in ascites [1].

The measurement of lactic dehydrogenase concentration, glucose levels and total protein concentration in ascitic fluid is important to establish a differential diagnosis between spontaneous and secondary peritonitis. A secondary peritonitis should be suspected when at least two of the following features are present in ascitic fluid: glucose levels < 50 mg/dL, protein concentration > 10 g/L, lactic dehydrogenase concentration > normal serum levels. Gram's stain of a smear of sediment obtained after centrifugation of ascitic fluid is frequently negative in SBP, as the concentration of bacteria is usually low (1 organism/mL or less). Nevertheless, it may be helpful in identifying patients with gut perforation in whom multiple types of bacteria can be seen [1].

Culture of ascitic fluid directly into blood culture bottles (aerobic and anaerobic media) at the bedside is positive in between 40% and 80% of cases. Moreover, blood cultures are positive in a significant proportion of patients with SBP. Table 1 shows the most common organisms isolated from patients with SBP.

Alterations in systemic laboratory parameters such as leucocytosis or leucopenia, azotaemia and acidosis can be seen in cirrhotic patients with SBP.

Treatment

Antibiotic therapy must be started once the diagnosis of SBP is established. Empirical treatment should cover all potential organisms responsible for SBP without causing adverse effects.

Table 1 Bacteria responsible for spontaneous bacterial peritonitis.

Culture-positive SBP	39–67%
Gram-negative bacilli	31–50%
Escherichia coli	25–37%
Klebsiella spp.	2–6%
Enterobacter spp.	1–2%
Others	3–7%
Gram-positive cocci	8–17%
Streptococcus pneumoniae	1–10%
Other streptococci	6%
Staphylococcus aureus	1%
Culture-negative SBP	33–61%

Table 2 Spontaneous bacterial peritonitis outcome depending on the different antibiotic therapy employed.

Antibiotic	Resolution rate (%)	Superinfection (%)	Hospital survival (%)
Cefotaxime (i.v.)			
2 g/4 h	86	0	73
2 g/6 h	77	1	69
2 g/12 h	79	1	79
2 g/8 h/5 days	93	0	67
2 g/8 h/10 days	91	0	58
Ceftriaxone (i.v.)	91	0	70
Cefonicid (i.v.)	94	0	63
Amoxicillin–clavulanic acid (i.v.)	85	7	63
Aztreonam (i.v.)	71	14	57
Ofloxacin (oral)	84	1	81

i.v. intravenously.

At present, third-generation cephalosporins are considered the gold standard in the treatment of SBP in cirrhosis. However, other antibiotics such as amoxicillin–clavulanic acid are also effective in the treatment of this infective complication [26–35]. Table 2 shows the SBP outcome depending on the antibiotic employed. At present, monotherapy with aztreonam is not recommended in the treatment of SBP as this antibiotic is only active against Gram-negative bacilli. Moreover, ofloxacin should not be employed in the treatment of SBP in patients submitted to long-term norfloxacin prophylaxis.

Intravenous albumin infusion in SBP

A randomized, multicentre, controlled trial has demonstrated that, in patients with SBP, treatment with intravenous albumin in addition to an antibiotic reduces the incidence of renal impairment and improves hospital survival [36]. The study included 126 patients with SBP, who were randomly assigned to treatment with intravenous cefotaxime (63 patients) or cefotaxime and intravenous albumin (63 patients). Albumin was given at a dose of 1.5 g/kg body weight at the time of diagnosis, followed by 1 g/kg body weight on day 3. Renal impairment developed in 21 patients in the cefotaxime group (33%) and in six in the cefotaxime plus albumin group (10%). The hospital mortality rate was 29% in the cefotaxime group compared with 10% in the cefotaxime plus albumin group. The results of this study suggest that cirrhotic patients with SBP should be expanded with albumin. However, it is important to identify those patients with SBP who may benefit from albumin infusion. In that sense, it should be noted that the incidence of renal impairment among patients with a baseline bilirubin level of less than 4 mg/dL and a creatinine level of less than 1 mg/dL was very low in both treatment groups (7% and 0% in the cefotaxime and cefotaxime + albumin groups respectively). Therefore, patients with abnormal renal function [blood urea nitrogen (BUN) > 30 mg/dL and/or creatinine > 1 mg/dL] and/or high bilirubin levels (> 4 mg/dL) appear to be the subgroup of patients with SBP who derive the most benefit from volume expansion with albumin. Further studies are needed to determine whether lower doses of albumin have the same effects on renal function and survival. A recent study by our group suggests that albumin cannot be substituted by artificial plasma expanders in SBP [37].

As renal dysfunction is a result of an aggravation in vasodilatation and a decrease in effective arterial blood volume [38], procedures that lead to a decreased effective blood volume should be avoided, such as the use of diuretics and large-volume paracentesis.

Prophylaxis

Current indications for selective intestinal decontamination in SBP prevention are summarized in Table 3. Cirrhotic patients with gastrointestinal haemorrhage are predisposed to develop severe bacterial infections during or immediately after the bleeding episode. Short-term intestinal decontamination is effective in preventing SBP in cirrhotic patients with gastrointestinal haemorrhage [39,40]. The usefulness of systemic antibiotics in cirrhotic patients with gastrointestinal haemorrhage has also

Table 3 Indications and duration of selective intestinal decontamination for the prevention of SBP in cirrhotic patients.

Indication	Duration of prophylaxis
Cirrhotic patients recovering from a previous episode of SBP (secondary prophylaxis)	Indefinitely or until liver transplantation
Cirrhotic patients with gastrointestinal bleeding	Seven days
Cirrhotic patients with ascites and low ascitic fluid protein levels (≤ 10 g/L)	During hospitalization (no consensus)

been investigated in four controlled studies. In these studies, the treated groups received ofloxacin (initially intravenously and then orally), ofloxacin (initially intravenously and then orally) plus amoxicillin–clavulanic acid (before each endoscopy), ciprofloxacin plus amoxicillin–clavulanic acid (first intravenously and then orally once the bleeding was controlled) and oral ciprofloxacin [41–44]. The incidence of bacterial infections was significantly lower in the treated groups (10–20%) than in the corresponding control groups (45–66%). A relative limitation in these studies was the inability to assess the effect of antibiotic prophylaxis specifically on SBP as the incidence of both SBP and bacteraemia was analysed together. Nevertheless, the marked decrease in the rate of overall infections and the improvement in survival in the groups receiving antibiotic prophylaxis support such prophylaxis [45], with it being strongly recommended in cirrhotic patients with gastrointestinal haemorrhage independently of their specific risk of SBP [1]. Furthermore, a meta-analysis including all the above-mentioned studies showed a significant benefit in the subgroup of cirrhotic patients with ascites and gastrointestinal haemorrhage: 95% of patients were free of SBP in the treated group vs. 87% in the control group [45].

Cases with low ascitic fluid total protein concentration may be a second group of cirrhotic patients who may benefit from selective intestinal decontamination. In 63 patients admitted to hospital for the treatment of an episode of ascites with an ascitic fluid total protein concentration lower than 15 g/L, some of whom had had a previous episode of SBP, the continuous administration of norfloxacin, 400 mg/day, throughout the hospitalization period (32 patients), decreased the in-hospital incidence of SBP from 22% in the control group to 0% in the treated group [46]. In cirrhotic patients with ascitic fluid protein concentrations < 15 g/L and no previous episodes of SBP, the 6-month incidence of SBP was 0% in the group of patients prophylactically treated with norfloxacin, 400 mg/day for 6 months, compared with 9% in patients treated with placebo. Nevertheless, the incidence of SBP caused by Gram-negative organisms (the only one that can theoretically be prevented by norfloxacin prophylaxis) in the two groups was not statistically significant: 0% in the norfloxacin-treated group and 5% in the placebo-treated group [47].

Other antibiotic regimes have been evaluated in the prevention of SBP in high-risk patients. A placebo-controlled study demonstrated that 6-month prophylaxis with ciprofloxacin, 750 mg weekly, was effective in reducing the incidence of SBP in cirrhotic patients with low protein concentrations in ascitic fluid: 4% in the treated group and 22% in the placebo control group [48]. In this study, patients with and without a prior history of SBP were included together, and no attempt was made to evaluate the development of SBP in these two subgroups of patients separately. Trimethoprim–sulphamethoxazole (one double-strength tablet 5 days a week) is also effective in the prevention of SBP in cirrhotic patients with ascites [49]. In a randomized controlled trial with a median follow-up of only 90 days, the incidence of SBP was 26.7% in the control group and 3.3% in the group of patients receiving trimethoprim–sulphamethoxazole prophylaxis. Again, patients with different risks for SBP were analysed together: patients with low and high ascitic fluid protein and patients who had and who had not had previous SBP episodes.

Patients recovering from an episode of SBP represent a unique population in which to assess the effect of long-term intestinal decontamination in the prophylaxis of SBP. In a double-blind, placebo-controlled trial including 80 cirrhotic patients who had recovered from an episode of SBP, the overall probability of SBP recurrence at 1 year of follow-up was 20% in the norfloxacin group and 68% in the placebo group, and the probability of SBP caused by aerobic Gram-negative bacilli at 1 year of follow-up was 3% and 60% respectively. Only one patient treated with norfloxacin experienced side-effects related to treatment (oral and oesophageal candidiasis) [50]. Therefore, long-term selective intestinal decontamination dramatically decreases the rate of SBP recurrence in patients with SBP. Three recent economic analyses have calculated that long-term antibiotic prophylaxis in cirrhotic patients is associated with a reduced cost compared with the 'diagnosis and treat' strategy, suggesting that prophylaxis is cost-effective when applied to patients at high risk of developing SBP [51–53].

Taking into account all these prophylactic studies, it can be assumed that antibiotic prophylaxis in cirrhotic patients with ascites is indicated in patients who have had a previous episode of SBP because they are at high risk of SBP recurrence and because prophylaxis is cost-effective. In patients with low protein content in ascitic fluid who have never had SBP, the recommendation is difficult to establish due to the heterogeneity of the published studies, which included patients with low and high risk of SBP together. This is the main reason for the lack of consensus because, despite the positive results of all the studies investigating different antibiotics in the prophylaxis of SBP in patients with cirrhosis, they have been unable to identify subsets of patients who clearly benefit from this therapy. In that sense, it should be noted that three studies have been performed assessing the incidence and predictive factors of the first episode of SBP in cirrhotic patients with ascites, and they may help in deciding whether a patient should initiate antibiotic prophylaxis. In a series of 127 patients admitted to hospital for the treatment of an episode of ascites, the probability of the appearance of the first episode of SBP was 11% at 1 year and 15% at 3 years of follow-up [21]. Five variables obtained at admission were significantly associated with a higher risk of SBP appearance during follow-up [poor nutritional status, increased serum bilirubin levels, decreased prothrombin activity, increased serum aspartate aminotransferase (AST) levels and low ascitic fluid protein concentration], but only one (low ascitic fluid protein concentration) showed an independent predictive value. The 1-year and 3-year probabilities of the first episode of SBP in patients with ascitic fluid protein content lower than 10 g/L were 20% and 24%, respectively, whereas in those with ascitic fluid

protein content equal to or greater than 10 g/L, they were 0% and 4% respectively. A clear conclusion from this study is that long-term prophylactic administration of antibiotics is not necessary in patients with high protein content in ascitic fluid, in whom the risk of developing SBP is negligible. In a similar study performed in 110 consecutive cirrhotic patients hospitalized for the treatment of an episode of ascites [22], six variables associated with a higher risk of first SBP appearance during follow-up (serum bilirubin > 2.5 mg/dL, prothrombin activity < 60%, ascitic fluid total protein concentration < 10 g/L, serum sodium concentration < 130 mEq/L, platelet count < 116 000/μL and serum albumin concentration < 26 g/L) were identified, but only two (ascitic fluid protein concentration and serum bilirubin) showed an independent predictive value. In a recent study, cirrhotic patients with low ascitic fluid protein levels (≤ 10 g/L) and high serum bilirubin level (> 3.2 mg/dL) and/or low platelet count (< 98 000/μL) presented a 1-year probability of developing a first SBP of 55% in comparison with 24% of patients with only low ascitic fluid protein levels [23]. Three studies, therefore, indicate that cirrhotic patients with ascites who are at risk of developing a first episode of SBP can be identified using routine biochemical parameters and might benefit from selective intestinal decontamination. However, the efficacy of antibiotic prophylaxis in these high-risk patients should be adequately investigated in prospective randomized trials.

A second reason for the lack of consensus in the prophylaxis of SBP, particularly in those patients who have never had a previous episode of SBP, is the problem of the development of quinolone-resistant enterobacteria. A review of the published data indicates that, from an initial stage when norfloxacin prophylaxis was considered effective and not associated with the development of quinolone-resistant bacteria, we have moved to a final stage in which quinolone-resistant bacteria may cause severe infections in these patients. Initial studies suggested that the risk of developing SBP or other infections caused by quinolone-resistant strains of Gram-negative bacilli was low, as the majority of SBP recurrences in patients on norfloxacin prophylaxis were caused by Gram-positive cocci, mainly streptococci [50,54,55]. Thereafter, a high incidence of quinolone-resistant strains of *Escherichia coli* in the stools of cirrhotic patients undergoing long-term quinolone prophylaxis was reported in several studies, although none of these studies reported any infection due to quinolone-resistant *E. coli* [56,57]. In 1997, the first study on long-term norfloxacin prophylaxis in SBP was published, showing a relevant emergence of infections, mainly mild urinary infections, caused by Gram-negative bacilli resistant to quinolones (90% of *E. coli* isolated were resistant to quinolones) [58]. More recently, it has been shown that 39 out of 106 infections caused by *E. coli* in hospitalized cirrhotic patients were quinolone resistant, with long-term norfloxacin prophylaxis being significantly associated with the development of infections (mainly urinary tract infections) caused by quinolone-resistant *E. coli*. However, the development of SBP due to quinolone-resistant *E. coli* in decontaminated patients was scarcely reported [59].

Data from a study performed in our liver unit, which prospectively evaluated all bacterial infections occurring in a 2-year period, show a clear relationship between the development of SBP caused by quinolone-resistant Gram-negative bacilli and long-term treatment with norfloxacin (Table 4). In patients on long-term norfloxacin prophylaxis, 50% of culture-positive SBP were caused by quinolone-resistant Gram-negative bacilli, whereas only 16% of culture-positive SBP in patients not receiving this prophylaxis were caused by these resistant bacteria. Although SBP caused by quinolone-resistant Gram-negative bacilli represented only 26% of the culture-positive SBP in this study, quinolone-resistant SBP seem to be emerging for the first time as a real problem in hepatology, and this will probably increase in the near future [3]. This study also showed a high rate of culture-positive SBP caused by trimethoprim–sulphamethoxazole-resistant Gram-negative bacteria in patients on long-term treatment with norfloxacin (44%), suggesting that this antibiotic is not an alternative to norfloxacin. These results suggest that the effectiveness of norfloxacin is decreasing in

Table 4 Antibiotic susceptibility of Gram-negative bacilli (GNB) isolated in cirrhotic patients submitted or not to long-term norfloxacin prophylaxis.

	Long-term norfloxacin	None
Total isolated GNB		
Quinolone-resistant strains	65%	29%
Trimethoprim–sulphamethoxazole-resistant strains	68%	44%
Cephalosporin-resistant strains	19%	16%
GNB isolated in SBP		
Quinolone-resistant strains	57%	21%
Trimethoprim–sulphamethoxazole-resistant strains	50%	24%
Cephalosporin-resistant strains	0	7%
GNB isolated in urinary infections		
Quinolone-resistant strains	92%	33%
Trimethoprim-sulphamethoxazole-resistant strains	92%	40%
Cephalosporin-resistant strains	8%	5%

the prevention of SBP in cirrhotic patients and, therefore, this should be considered as an alarm signal.

Our study also showed no significant differences in the resolution rate of infections caused by *E. coli* resistant to quinolones in comparison with the resolution rate of those due to sensitive strains. The absence of cross-resistance between quinolones and other antibiotics commonly used to treat these bacterial infections, such as third-generation cephalosporins, could explain this finding (SBP resolution rate 92% vs. 91%). The fact that none of the *E. coli* isolated in patients undergoing long-term quinolone prophylaxis was resistant to third-generation cephalosporins reinforces the idea that this antibiotic constitutes the elective treatment for bacterial infections not only in non-decontaminated cirrhotic patients but also in those undergoing selective intestinal decontamination with quinolones. On the other hand, the high incidence of quinolone- and trimethoprim–sulphamethoxazole-resistant strains of *E. coli* isolated in decontaminated cirrhotic patients underlines the necessity of restricting the administration of prophylactic antibiotics only to those patients at the greatest risk of SBP. The increasing emergence of infections caused by quinolone- and trimethoprim–sulphamethoxazole-resistant strains of Gram-negative bacilli also suggests that the effectiveness of these antibiotics may decrease with time on account of their widespread use. Thus, further studies are needed to evaluate alternative prophylactic measures such as other antibiotic regimes and non-antibiotic procedures in SBP prophylaxis. Finally, it should be kept in mind that SBP carries a poor prognosis. The 1-year and 2-year probabilities of survival after an episode of SBP are 30–50% and 25–30% respectively [2]. Therefore, patients recovering from an episode of SBP should be considered as potential candidates for liver transplantation.

Other bacterial infections

Urinary tract infections

Several predisposing factors have been recognized for urinary tract infections (UTIs) in cirrhosis: the presence of urethral catheters, ascites and female sex [60]. Most cases are oligo or asymptomatic, and bacteriuria alone can be present in 40% of cases [61]. The microorganisms usually responsible for UTI in cirrhosis are Gram-negative bacilli and enterococci in cases of urinary manipulation [2,3]. The empirical treatment should include third-generation cephalosporins or amoxicillin–clavulanic acid [62,63]. In cases of treatment failure, add ampicillin if urinary catheterization is present and perform ultrasonography to rule out other facilitating pathologies in the urinary tract.

Pneumonia

The distinction between community- and hospital-acquired (nosocomial) pneumonia is very useful. The causative organisms in cases of community-acquired pneumonia are the same as we can see in the general population: *Streptococcus pneumoniae*, *Haemophilus influenzae*, *Mycoplasma pneumoniae* or *Legionella* spp., and in addition Gram-negative bacilli, particularly *Klebsiella pneumoniae*, and anaerobic bacteria [3,64–66]. Empirical treatment should cover all these possibilities. The empirical use of third-generation cephalosporins or amoxicillin–clavulanic acid plus a macrolide (clarithromycin or azithromycin) or levofloxacin is at present recommended [66]. In case of treatment failure, the possibility of infection by *Staphylococcus aureus* and *Pseudomonas* spp. has to be considered.

Predisposing factors for nosocomial pneumonia are tracheal intubation, hepatic encephalopathy and oesophageal tamponade [67,68], with Gram-negative bacilli (*Pseudomonas* spp.) and *Staphylococcus* spp. being the bacteria most frequently responsible for infection in these cases [69–70]. Therefore, empirical treatment in patients with predisposing factors should include antipseudomonic antibiotics (i.e. ceftazidime or cefepime + ciprofloxacin), adding vancomycin in cases of tracheal intubation. In patients without predisposing factors for *Pseudomonas* spp. or Staphylococcus spp., third-generation cephalosporins are very effective and do not have significant adverse effects.

Spontaneous bacteraemia

The causative organisms are the same as those found in SBP because, in theory, spontaneous bacteraemia is a previous step in the colonization of ascitic fluid [3]. Therefore, the empirical treatment should cover Gram-negative bacilli and non-enterococcal streptococci, with third-generation cephalosporins being the most effective and safe treatment. Amoxicillin–clavulanic acid is another option. In case of treatment failure, blood cultures are very important to know the susceptibility of the bacteria. A secondary origin of the bacteraemia has to be excluded.

Secondary bacteraemia

The causative bacteria should be considered according to the origin of the bacteraemia. Catheter sepsis is usually caused by *Staphylococcus aureus* and *Staphylococcus epidermidis* [3]. Anaerobic facultative streptococci are usually involved in infectious complications after transcatheter arterial embolization [71]. Infections after TIPS insertion or revision are usually caused by Gram-positive cocci or enterobacteria [72]. Finally, both Gram-positive cocci and Gram-negative bacilli can cause infections after variceal sclerotherapy [25].

The recommended empirical treatment for catheter sepsis is vancomycin and removal of the catheter. Fever after transcatheter arterial embolization is frequent and does not necessarily mean infection. In case of bacteraemia, amoxicillin–clavulanic acid is a good antibiotic choice. Bacteraemia after TIPS insertion or revision should be treated with a third-generation cephalosporin plus vancomycin.

Endocarditis

Despite the initial suggestion of a high frequency of endocarditis in cirrhosis according to the observations in postmortem studies [73–75], this infection is rare in the absence of predisposing factors such as the presence of prosthetic valves and invasive procedures [3]. As a consequence, the most common causative organisms are Gram-positive cocci: *Staphylococcus aureus*, *S. epidermidis* and streptococci [75]. The 'classic' empirical treatment with ampicillin + gentamicin is very effective although, in the presence of prosthetic valves, ampicillin must be substituted by vancomycin.

Cellulitis and lymphangitis

Several predisposing factors have been implicated in these infections such as deficient hygienic standards, unapparent skin injuries and oedema [76]. The empirical treatment should cover Gram-positive cocci (*Staphylococcus aureus*, streptococci) and enterobacteria. Amoxicillin–clavulanic acid, a third-generation cephalosporin plus cloxacillin or ofloxacin are good options as empirical treatment.

Summary

Spontaneous bacterial peritonitis is a frequent and severe complication of cirrhotic patients with ascites. Its diagnosis is established on the basis of a polymorphonuclear cell count in ascitic fluid equal to or higher than 250 cells/μL. The routine use of diagnostic paracentesis whenever a cirrhotic patient with ascites is admitted to hospital usually allows early diagnosis of the infection. At present, third-generation cephalosporins are considered the gold standard in the treatment of SBP. Because of the high incidence of quinolone-resistant Gram-negative bacilli isolated in cirrhotic patients on long-term norfloxacin prophylaxis, SBP in these patients should not be treated with quinolones as empirical therapy. Although SBP prognosis has improved in recent years, the mortality rate associated with this bacterial infection is still high. The development of severe complications such as renal impairment and gastrointestinal bleeding is responsible for this poor prognosis. The mechanisms involved in the pathogenesis of these complications are under evaluation. Selective intestinal decontamination with quinolones has been demonstrated to be effective in SBP prophylaxis in patients who have recovered from a previous episode of SBP and in patients with gastrointestinal bleeding. The increasing emergence of quinolone-resistant organisms clearly establishes the necessity of restricting the primary prophylaxis to those subsets of patients at high risk of developing a first episode of SBP. The identification of these patients and the evaluation of alternative prophylactic measures such as other antibiotic regimes and no antibiotic procedures are still under investigation. Because of the poor survival expectancy after this bacterial infection, cirrhotic patients recovering from an episode of SBP should be considered as potential candidates for liver transplantation. Finally, other bacterial infections in cirrhosis and their most frequent causative organisms and empirical treatment are summarized.

References

1 Rimola A, Garcia-Tsao G, Navasa M *et al.* (2000) Diagnosis, treatment and prophylaxis of spontaneous bacterial peritonitis: a consensus document. *J Hepatol* 32, 142–153.

2 Navasa M, Rodés J (2004) Bacterial infections in cirrhosis. *Liver Int* 24, 277–280.

3 Fernández J, Navasa M, Gomez J *et al.* (2002) Bacterial infections in cirrhosis: epidemiological changes with invasive procedures and norfloxacin prophylaxis. *Hepatology* 35, 140–148.

4 Runyon BA, Hoefs JC (1984) Culture-negative neutrocytic ascites: a variant of spontaneous bacterial peritonitis. *Hepatology* 4, 1209–1211.

5 Runyon BA, Squier S, Borzio M (1994) Translocation of gut bacteria in rats with cirrhosis to mesenteric lymph nodes partially explains the pathogenesis of spontaneous bacterial peritonitis. *J Hepatol* 21, 792–796.

6 Casafont Morencos F, de las Heras Castaño G, Martín Ramos L *et al.* (1995) Small bowel bacterial overgrowth in patients with alcoholic cirrhosis. *Dig Dis Sci* 40, 1252–1256.

7 Perez-Paramo MP, Muñoz J, Albillos A *et al.* (2000) Effect of propranolol on the factors promoting bacterial translocation in cirrhotic rats with ascites. *Hepatology* 31, 43–48.

8 Sorell WT, Quigley EMM, Jin G *et al.* (1993) Bacterial translocation in the portal-hypertensive rat: studies in basal conditions and on exposure to haemorrhagic shock. *Gastroenterology* 104, 1722–1726.

9 Llovet JM, Bartoli R, Planas R *et al.* (1994) Bacterial translocation in cirrhotic rats. Its role in the development of spontaneous bacterial peritonitis. *Gut* 35, 1648–1652.

10 Garcia-Tsao G, Lee FY, Barden GE *et al.* (1995) Bacterial translocation to mesenteric lymph nodes is increased in cirrhotic rats with ascites. *Gastroenterology* 108, 1835–1841.

11 Llovet JM, Bartoli R, Planas R *et al.* (1996) Selective intestinal decontamination with norfloxacin reduces bacterial translocation in ascitic cirrhotic rats exposed to haemorrhagic shock. *Hepatology* 23, 781–787.

12 Cirera I, Bauer TM, Navasa M *et al.* (2001) Bacterial translocation of enteric organisms in patients with cirrhosis. *J Hepatol* 34, 32–37.

13 Jones EA, Summerfield JA (1988) Kupffer cells. In: Arias IM, Jakoby WB, Popper H *et al.* (eds) *The Liver: Biology and Pathobiology*, 2nd edn. New York: Raven Press, pp. 683–704.

14 Rimola A, Soto R, Bory F *et al.* (1984) Reticuloendothelial system phagocytic activity in cirrhosis and its relation to bacterial infections and prognosis. *Hepatology* 4, 53–58.

15 Bolognesi M, Merkel C, Bianco S *et al.* (1994) Clinical significance of the evaluation of hepatic reticuloendothelial removal capacity in patients with cirrhosis. *Hepatology* 19, 628–634.

16 Guarner C, Runyon BA (1995) Macrophage function in cirrhosis and the risk of bacterial infection. *Hepatology* 22, 367–369.

17 Gomez F, Ruiz P, Schreiber AD (1994) Impaired function of macrophage Fc gamma receptors and bacterial infection in alcoholic cirrhosis. *N Engl J Med* 331, 1122–1128.

18 Runyon BA (1988) Patients with deficient ascitic fluid opsonic activity are predisposed to spontaneous bacterial peritonitis. *Hepatology* 8, 632–635.

19 Runyon BA (1986) Low-protein-concentration ascitic fluid is predisposed to spontaneous bacterial peritonitis. *Gastroenterology* 91, 1343–1346.

20 Tito Ll, Rimola A, Gines P *et al.* (1988) Recurrence of spontaneous bacterial peritonitis in cirrhosis: frequency and predictive factors. *Hepatology* 8, 27–31.

21 Llach J, Rimola A, Navasa M *et al.* (1992) Incidence and predictive factors of first episode of spontaneous bacterial peritonitis in cirrhosis with ascites: relevance of ascitic fluid protein concentration. *Hepatology* 16, 724–727.

22 Andreu M, Solá R, Sitges-Serra A *et al.* (1993) Risk factors for spontaneous bacterial peritonitis. *Gastroenterology* 104, 1133–1138.

23 Guarner C, Sola R, Soriano G *et al.* (1999) Risk of a first community-acquired spontaneous bacterial peritonitis in cirrhotics with low ascitic protein levels. *Gastroenterology* 117, 414–419.

24 Garcia-Gonzalez M, Boixeda D, Herrero D *et al.* (1993) Effect of granulocyte–macrophage colony-stimulating factor on leukocyte function in cirrhosis. *Gastroenterology* 105, 527–531.

25 Rolando N, Gimson A, Philpott-Howard J *et al.* (1993) Infectious sequel after endoscopic sclerotherapy of oesophageal varices: role of antibiotic prophylaxis. *J Hepatol* 18, 290–294.

26 Felisart J, Rimola A, Arroyo V *et al.* (1985) Cefotaxime is more effective than is ampicillin–tobramycin in cirrhotics with severe infections. *Hepatology* 5, 457–462.

27 Runyon BA, McHutchison JG, Antillon MR *et al.* (1991) Short-course versus long-course antibiotic treatment of spontaneous bacterial peritonitis. A randomized controlled study of 100 patients. *Gastroenterology* 100, 1737–1742.

28 Rimola A, Salmeron JM, Clemente G *et al.* (1995) Two different dosages of cefotaxime in the treatment of spontaneous bacterial peritonitis in cirrhosis: results of a prospective, randomized, multicenter study. *Hepatology* 21, 674–679.

29 Mercader J, Gómez J, Ruiz J *et al.* (1989) Use of ceftriaxone in the treatment of bacterial infections in cirrhotic patients. *Chemotherapy* 35(Suppl. 2), 23–26.

30 Gómez-Jimenez J, Ribera E, Gasser I *et al.* (1993) Randomized trial comparing ceftriaxone with cefonicid for treatment of spontaneous bacterial peritonitis in cirrhotic patients. *Antimicrob Agents Chemother* 37, 1587–1592.

31 Ariza J, Xiol X, Esteve M *et al.* (1991) Aztreonam vs. cefotaxime in the treatment of gram-negative spontaneous peritonitis in cirrhotic patients. *Hepatology* 14, 91–98.

32 Grange JD, Amiot X, Grange V *et al.* (1990) Amoxicillin–clavulanic acid therapy of spontaneous bacterial peritonitis: a prospective study of twenty-seven cases in cirrhotic patients. *Hepatology* 11, 360–364.

33 Ricart E, Soriano G, Novella MT *et al.* (2000) Amoxicillin–clavulanic acid versus cefotaxime in the therapy of bacterial infections in cirrhotic patients. *J Hepatol* 32, 596–602.

34 Silvain C, Breux JP, Grollier G *et al.* (1989) Les septicémies et les infections du liquide d'ascite du cirrhotique peuvent-elles être traitées exclusivement par voie orale? *Gastroenterol Clin Biol* 13, 335–339.

35 Navasa M, Follo A, Llovet JM *et al.* (1996) Randomized, comparative study of oral ofloxacin versus intravenous cefotaxime in spontaneous bacterial peritonitis. *Gastroenterology* 111, 1011–1017.

36 Sort P, Navasa M, Arroyo V *et al.* (1999) Effect of intravenous albumin on renal impairment and mortality in patients with cirrhosis and spontaneous bacterial peritonitis. *N Engl J Med* 5, 403–409.

37 Fernández J, Monteagudo J, Bargalló X *et al.* (2005) A randomized unblinded pilot study comparing albumin versus hydroxyethyl starch in spontaneous bacterial peritonitis. *Hepatology* 42, 627–634.

38 Ruiz del Arbol L, Urman J, Fernández J *et al.* (2003) Cardiovascular, renal and hepatic hemodynamic derangement in cirrhotic patients with spontaneous bacterial peritonitis. *Hepatology* 38, 1210–1218.

39 Rimola A, Bory F, Terés J *et al.* (1985) Oral non-absorbable antibiotics prevent infection in cirrhosis with gastrointestinal haemorrhage. *Hepatology* 5, 463–467.

40 Soriano G, Guarner C, Tomás A *et al.* (1992) Norfloxacin prevents bacterial infection in cirrhotics with gastrointestinal haemorrhage. *Gastroenterology* 103, 1267–1272.

41 Blaise M, Pateron D, Trinchet J-C *et al.* (1994) Systemic antibiotic therapy prevents bacterial infection in cirrhotic patients with gastrointestinal haemorrhage. *Hepatology* 20, 34–38.

42 Pauwels A, Mostefa-Kara N, Debenes B *et al.* (1996) Systemic antibiotic prophylaxis after gastrointestinal haemorrhage in cirrhotic patients with a high risk of infection. *Hepatology* 24, 802–806.

43 Hsieh W-J, Lin H-C, Hwang S-J *et al.* (1998) The effect of ciprofloxacin in the prevention of bacterial infections in patients with cirrhosis after upper gastrointestinal bleeding. *Am J Gastroenterol* 93, 962–966.

44 Hou MC, Lin HC, Liu TT *et al.* (2004) Antibiotic prophylaxis after endoscopic therapy prevents rebleeding in acute variceal hemorrhage: a randomized trial. *Hepatology* 39, 746–753.

45 Bernard B, Grange JD, Khac EN *et al.* (1999) Antibiotic prophylaxis for the prevention of bacterial infections in cirrhotic patients with gastrointestinal bleeding: a meta-analysis. *Hepatology* 29, 1655–1661.

46 Soriano G, Guarner C, Teixidó M *et al.* (1991) Selective intestinal decontamination prevents spontaneous bacterial peritonitis. *Gastroenterology* 100, 477–481.

47 Grange J-D, Roulot D, Pelletier G *et al.* (1998) Norfloxacin primary prophylaxis of bacterial infections in cirrhotic patients with ascites: a double-blind randomised trial. *J Hepatol* 29, 430–436.

48 Rolanchon A, Cordier L, Bacq Y *et al.* (1995) Ciprofloxacin and long-term prevention of spontaneous bacterial peritonitis: results of a prospective controlled trial. *Hepatology* 22, 1171–1174.

49 Singh N, Gayowski T, Yu VL *et al.* (1995) Trimethoprim–sulfamethoxazole for the prevention of spontaneous bacterial peritonitis in cirrhosis: a randomized trial. *Ann Intern Med* 122, 595–598.

50 Ginès P, Rimola A, Planas R *et al.* (1990) Norfloxacin prevents spontaneous bacterial peritonitis recurrence in cirrhosis: results of a double-blind, placebo-controlled trial. *Hepatology* 12, 716–724.

51 Inadomi J, Sonnenberg A (1997) Cost-analysis of prophylactic antibiotics in spontaneous bacterial peritonitis. *Gastroenterology* 113, 1289–1294.

52 Younossi ZM, McHutchison JG, Ganiats TG (1997) An economic analysis of norfloxacin prophylaxis against spontaneous bacterial peritonitis. *J Hepatol* 27, 295–298.

53 Das A (1998) A cost analysis of long-term antibiotic prophylaxis for spontaneous bacterial peritonitis in cirrhosis. *Am J Gastroenterol* 93, 1895–1900.

54 Llovet JM, Rodríguez-Iglesias P, Moitinho E *et al.* (1997) Spontaneous bacterial peritonitis in patients with cirrhosis undergoing selective intestinal decontamination. *J Hepatol* 26, 88–95.

55 Campillo B, Dupeyron C, Richardet J-P *et al.* (1998) Epidemiology of severe hospital-acquired infections in patients with liver cirrhosis: effect of long-term administration of norfloxacin. *Clin Infect Dis* 26, 1066–1070.

56 Dupeyron C, Mangeney N, Sedrati L *et al.* (1994) Rapid emergence of quinolone resistance in cirrhotic patients treated with norfloxacin to prevent spontaneous bacterial peritonitis. *Antimicrob Agents Chemother* 38, 340–344.
57 Aparicio JR, Such J, Pascual S *et al.* (1999) Development of quinolone-resistant strains of *Escherichia coli* in stools of patients with cirrhosis undergoing norfloxacin prophylaxis: clinical consequences. *J Hepatol* 31, 277–283.
58 Novella M, Solà R, Soriano G *et al.* (1997) Continuous versus inpatient prophylaxis of the first episode of spontaneous bacterial peritonitis with norfloxacin. *Hepatology* 25, 532–536.
59 Ortiz J, Vila MC, Soriano G *et al.* (1999) Infections caused by *Escherichia coli* resistant to norfloxacin in hospitalized cirrhotic patients. *Hepatology* 29, 1064–1069.
60 Rabinivitz M, Prieto M, Gavaler JS *et al.* (1992) Bacteriuria in patients with cirrhosis. *J Hepatol* 16, 73–76.
61 Burroughs AK, Rosenstein IJ, Epstein O *et al.* (1984) Bacteriuria and primary biliary cirrhosis. *Gut* 25, 133–137.
62 Lipsky BA (1989) Urinary tract infections in men. Epidemiology, pathophysiology, diagnosis and treatment. *Ann Intern Med* 110, 138–150.
63 Westphal J-F, Jehl F, Vetter D (1994) Pharmacological, toxicologic, and microbiological considerations in the choice of initial antibiotic therapy for serious infections in patients with cirrhosis of the liver. *Clin Infect Dis* 18, 324–335.
64 Adams HG, Jordan C (1984) Infections in the alcoholic. *Med Clin North Am* 68, 179–200.
65 Bradsher RW (1983) Overwhelming pneumonia. *Med Clin North Am* 67, 1233–1250.
66 Levy M, Dromer F, Brion N *et al.* (1988) Community-acquired pneumonia. *Chest* 92, 43–48.
67 Panés J, Terés J, Bosch J *et al.* (1988) Efficacy of balloon tamponade in treatment of bleeding gastric and esophageal varices. Results in 151 consecutive patients. *Dig Dis Sci* 33, 454–459.
68 American Thoracic Society (1996) Hospital-acquired pneumonia in adults: diagnosis, assessment, initial severity and prevention. A consensus statement. *Am J Respir Crit Care Med* 153, 1711–1725.
69 Bodmann KF (2005) Current guidelines for the treatment of severe pneumonia and sepsis. *Chemotherapy* 51, 227–233.
70 Craven DE, De Rosa FG, Thornton D (2002) Nosocomial pneumonia: emerging concepts in diagnosis, management, and prophylaxis. *Curr Opin Crit Care* 8, 421–429.
71 Chen C, Chen PJ, Yang PM *et al.* (1997) Clinical and microbiological features of liver abscess after transarterial embolization for hepatocellular carcinoma. *Am J Gastroenterol* 92, 2257–2259.
72 Bouza E, Muñoz P, Rodriguez C *et al.* (2004) Endotipsitis: an emerging prosthetic-related infection in patients with portal hypertension. *Diagn Microbiol Infect Dis* 49, 77–82.
73 Snyder N, Atterbury CE, Correia JP *et al.* (1977) Increased occurrence of cirrhosis and bacterial endocarditis. A clinical and postmortem study. *Gastroenterology* 73, 1107–1113.
74 Denton JH, Rubio C, Velázquez J *et al.* (1981) Bacterial endocarditis in cirrhosis. *Dig Dis Sci* 26, 935–937.
75 Hsu RB, Chen RJ, Chu SH (2004) Infective endocarditis in patients with liver cirrhosis. *J Formos Med Assoc* 103, 355–358.
76 Swartz MN (1995) Cellulitis and subcutaneous tissue infections. In: Mandel GL, Bennett JE, Dolin R (eds) *Principles and Practice of Infectious Diseases*, 4th edn. New York: Churchill Livingstone, pp. 909–928.

7.10 Hypersplenism

P. Aiden McCormick

The spleen in liver disease

Splenomegaly is a frequent finding in patients with liver disease. The incidence of splenomegaly in cirrhotics varies from 36% to 92% in different series [1]. The cause of the liver disease influences the frequency of splenomegaly. Patients with idiopathic portal hypertension typically have large spleens, and it has been reported that patients with non-alcoholic cirrhosis tend to have larger spleens than patients with alcoholic cirrhosis [2]. A variable proportion of patients with liver disease and splenomegaly exhibit thrombocytopenia, anaemia and/or leucopenia (hypersplenism). Severe hypersplenism in cirrhotics is associated with a worsening of prognosis (see below). While passive venous congestion is believed to be the major cause of splenomegaly in portal hypertension, there is a poor correlation between portal venous pressure and spleen size [3]. The presence of splenomegaly, with an associated increase in splenic venous flow, may contribute to the maintenance of portal hypertension, particularly in idiopathic portal hypertension. If intrahepatic resistance is high enough to reverse blood flow in the splenic vein, prognosis is poor. In a prospective study of 50 patients with biopsy-proven severe alcoholic liver disease, survival at 1 year was significantly lower in patients with hepatofugal splenic blood flow than in those with hepatopetal blood flow in the splenic vein (41.7% vs. 82.4%; $P = 0.34$) [4]. The spleen may also contribute to increased intrahepatic resistance. Endothelin-1 is a potent vasoconstrictor, circulating levels of which are increased in cirrhotic patients, with higher levels in the superior mesenteric and splenic veins compared with the systemic circulation [5]. Immunostaining on surgically removed spleens in portal hypertensive patients has shown that endothelin-1 is produced by endothelial cells of the splenic sinus and lymphocytes in the marginal zones and germinal centres of the lymphoid sheaths and follicles.

Structure and functions of the spleen

The spleen is the largest lymphoid organ in the body and has important immunological and filtering functions. Resting splenic blood flow in animal studies is approximately 40–100 mL/min/100 g tissue [6]. This represents between 1% and 10% of cardiac output. In many species, the spleen is contractile and acts as a reservoir for blood cells. The human spleen is non-contractile, suggesting that this reservoir function is less important in man. The normal adult spleen weighs between 100 g and 174 g and becomes smaller in old age. It reaches its maximum size in late adolescence and may be palpable in up to 3% of apparently healthy young adults [7]. The spleen must double in size before it becomes palpable below the costal margin. It enlarges caudally and medially, and the spleen tip may be felt at the level of the 9th or 10th costal cartilage. In some patients with liver disease, it lies more posteriorly and may be missed unless palpation is performed in the left flank.

The spleen receives its arterial supply from the splenic artery and drains via the splenic vein into the portal vein. The spleen is divided into a variable number (3–7) of well-defined segments, each with its own blood supply and separated from each other by avascular planes [8]. Both splenic artery and vein lie close to the pancreas over much of their course and may be affected in conditions such as pancreatitis or pancreatic carcinoma. The cut surface of the spleen is characterized by red and white pulp. White pulp is visible as tiny white or grey spots (Malpighian corpuscles) seen against the dark background of the red pulp. The white pulp is lymphatic tissue which surrounds the splenic arterioles as a periarterial lymphatic sheath. It contains lymphocytes, monocytes and lymphoid follicles. The red pulp consists of a reticular meshwork, containing phagocytic reticular cells and endothelial macrophages, that lies between the splenic arterioles and the venous sinuses.

Microcirculation of the spleen

The microcirculation of the spleen is complex [6]. Microcirculatory studies suggest that there are two parallel functional blood flow pathways. Ninety per cent of blood flows through the fast pathway. Splenic arterioles lead to capillaries which, instead of leading into venules, empty into a reticular meshwork. The reticular network is not homogeneous. An area

called the marginal zone or marginal sinus at the junction of the red and white pulp appears to receive the majority of the blood flow. Open-ended venous sinuses exist in this area that drain rapidly into the venous circulation. Blood in the remaining red pulp exits the spleen through the walls of venous sinuses, which have a structure similar to blind-ending sacs. Formed blood elements must pass through openings in the sinus walls called interendothelial slits (IESs). *In vivo* microscopy studies in the rat spleen suggest that these slits are contractile, and only approximately 20% are open during any particular 5-min observation period with a calculated flow rate of approximately three red blood cells/IES/min. It is believed that the red pulp provides the filtration function in the spleen. In contrast, blood flow through the marginal zone is believed to facilitate traffic of lymphocytes and macrophages into the lymphatic structures, as part of the immunological function of the spleen.

Functions of the spleen

The spleen has important immunological and filtration functions [9]. Splenectomized patients are particularly at risk of overwhelming infection from encapsulated bacteria such as pneumococcus, *Haemophilus influenzae* and meningococcus. The spleen functions as both a particulate filter and a lymphoid organ that can mount an adaptive immune response. In contrast to the hepatic Kupffer cells, splenic phagocytosis is effective even with poorly opsonized particles. There appears to be a distinct subset of mature peripheral B cells in the spleen, which respond rapidly to antigen and polyclonal activators, termed marginal zone (MZ) B cells [10]. These cells appear to bridge the gap between the innate immune system and the classic adaptive follicular B cells. The spleen is important in host defence against protozoal infections. More severe and frequent infections with malaria and babesiosis have been reported following splenectomy, although it should be noted that most splenectomized patients survive these infections [11].

Hypersplenism

It is believed that the term hypersplenism was first introduced by Chauffard in 1907 but was not precisely defined [12]. A clinical definition of hypersplenism has been suggested by Bowdler [13]: 'Hypersplenism is a syndrome in which there is enlargement of the spleen, accompanied by a deficit in one or more of the circulating cell lines of the peripheral blood (anaemic, thrombocytopenia, and granulopenia), together with demonstrated active haematopoiesis of the affected cell line(s) in the bone marrow. Retrospectively, the syndrome is justified by correction of the deficit by splenectomy.' This definition implies that a bone marrow examination is necessary to make the diagnosis. This is rarely done in practice unless there is doubt about the diagnosis. A more practical definition was suggested by Liangpunsakul *et al.* [14]. They defined hypersplenism as 'the presence of platelet count < 150 000/μL and/or white blood cell count (WBC) < 3500/μL in conjunction with splenomegaly' [14]. Severe hypersplenism was defined as the presence of a platelet count of ≤ 75 000/μL and/or white cell count ≤ 2000/μL in conjunction with splenomegaly.

Incidence of hypersplenism

The reported incidence of hypersplenism in liver disease varies widely. Using the definitions shown above, Liangpunsakul *et al.* assessed the incidence of hypersplenism in 419 consecutive patients referred for liver transplantation [14]. Hypersplenism was present in 215 (51%) and severe hypersplenism in 108 (33%) patients. Decompensated liver disease and a history of excess alcohol consumption were independent risk factors. Interestingly, another 81 patients had either leucopenia or thrombocytopenia in the absence of splenomegaly. The incidence of hypersplenism may depend on the aetiology of the liver disease. Hypersplenism was present in 13/18 (72%) patients with cystic fibrosis-related cirrhosis [15]. In a study of 235 patients with non-alcoholic chronic liver disease, 64% of patients with severe fibrosis/cirrhosis had a platelet count of < 150 000/μL and 5% had leucopenia, with a circulating white cell count < 3500/μL [16]. In a retrospective study of 563 patients who had shunt surgery, El-Khishen *et al.* [17] found that 33 (6%) had a preoperative platelet count of < 50 000 μL and 30 (5%) had a white blood cell count < 2500 μL.

Mechanisms of hypersplenism

Thrombocytopenia in hypersplenism

The normal spleen stores between 30% and 45% of the circulating platelet pool, and this figure may rise of over 90% in patients with splenomegaly. There is a significant inverse correlation between the size of the spleen and the platelet count, although the relationship is very variable between individual patients (Fig. 1) [17]. Platelets are not irreversibly confined to the enlarged spleen, and a proportion may be released under conditions of stress or during an intravenous infusion of adrenaline (epinephrine) [18]. Thrombocytopenia in hypersplenism differs from idiopathic thrombocytopenia (ITP). In the former, it appears that the spleen contains the youngest and most haemostatically active platelets, which may be released at times of stress. Circulating platelets in ITP are larger, suggesting that the newly formed platelets are circulating in this condition [19]. Platelets transfused from asplenic donors appear to have a longer lifespan (~ 2 days) than those from normal donors, suggesting that young platelets are sequestered in the spleen before release into the circulation [20]. Exogenous platelets are also rapidly sequestered in the spleen. Approximately 20% of infused platelets are still present in the circulation 2 hours after infusion, compared with 60% in normal subjects (Fig. 2) [18].

In addition to increased sequestration of platelets, survival time appears to be decreased in cirrhotic patients. In one study,

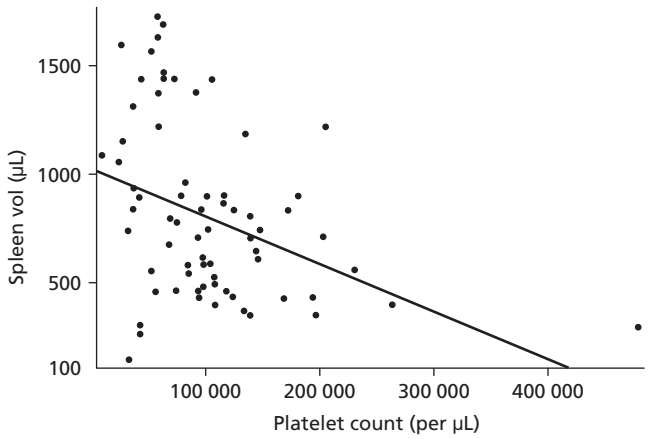

Fig. 1 Platelet count compared with spleen size. The platelet count is inversely related to spleen size, although the relationship is very variable between different patients. Reproduced from ref. 17: El-Khishen MA *et al*. (1985) Splenectomy is contraindicated for thrombocytopenia secondary to portal hypertension. *Surg Gynecol Obstet* (now *J Am Coll Surg*) 160, 233–238, with permission from the American College of Surgeons.

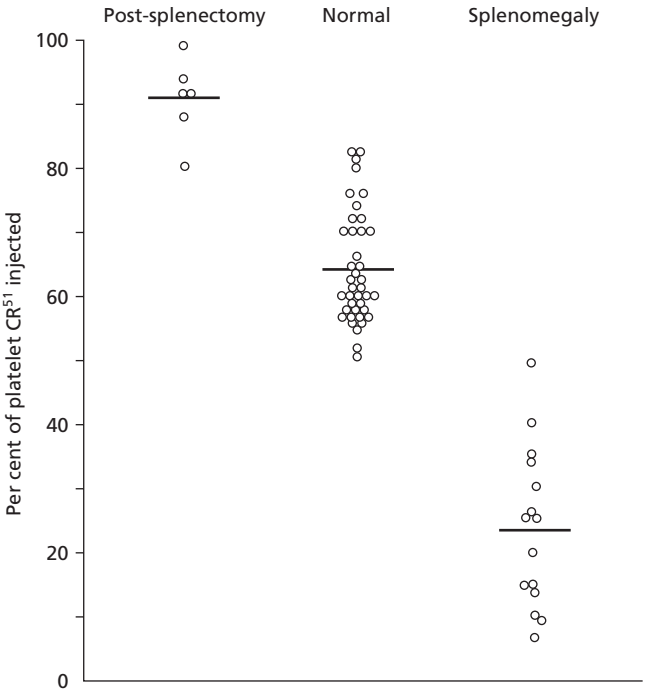

Fig. 2 Percentage of platelets remaining in the general circulation 2 hours after infusion. Reproduced from ref. 18: Aster RH (1966) Pooling of platelets in the spleen: role in the pathogenesis of 'hypersplenic' thrombocytopenia. *J Clin Invest* 45, 645, with permission from the American Society for Clinical Investigation.

mean survival was 5.8 days in cirrhotics compared with 9.5 days in normal control subjects [21]. The decreased survival time may be partially related to increased immune-related destruction. Platelet-associated immunoglobulin (PAIgG) is believed to render platelets more susceptible to immune-related destruction in the reticuloendothelial system. PAIgG is increased in cirrhotic patients with portal hypertension, and the level appears to correlate with shortened platelet survival time [22].

Platelet production may also be impaired in cirrhosis. Thrombopoietin is a 353-amino-acid peptide produced at a constant rate mainly in the liver. Platelets have receptors for thrombopoietin, and bound thrombopoietin is not active in the bone marrow. In thrombocytopenia, free circulating thrombopoietin increases and stimulates platelet production. In idiopathic thrombocytopenic purpura, there is thrombocytopenia, an increase in thrombopoietin levels and an increased proportion of reticulated (young) platelets in the circulation. In contrast, patients with aplasia have thrombocytopenia, decreased reticulated platelets and high thrombopoietin levels. Cirrhotics appear to have normal or low thrombopoietin levels and normal or low circulating reticulated platelets [23]. The relatively low thrombopoietin levels could be because of binding to platelets in the spleen and/or reduced production in the failing liver. Certainly, liver transplantation generally increases both platelet counts and thrombopoietin levels, suggesting that there is a significant production deficit in cirrhosis [24]. The relative importance of sequestration, decreased production and increased production in cirrhotic thrombocytopenia is still a matter of some debate [25,26]. In patients with relatively well-preserved liver function and hypersplenism, e.g. schistosomiasis, decreased thrombopoietin production is less likely to be a significant contributory factor to thrombocytopenia [27].

Granulocytopenia in hypersplenism

Granulocytopenia is less common than thrombocytopenia in patients with hypersplenism, and there is a relatively poor correlation between spleen size and neutrophil counts (Fig. 3) [17].

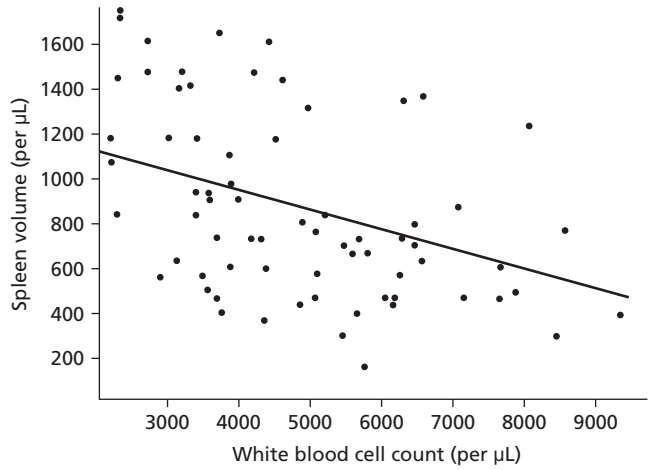

Fig. 3 Correlation between peripheral white blood cell count and spleen size. Reproduced from ref. 17: El-Khishen MA *et al*. (1985) Splenectomy is contraindicated for thrombocytopenia secondary to portal hypertension. *Surg Gynecol Obstet* (now *J Am Coll Surg*) 160, 233–238, with permission from the American College of Surgeons.

Radiolabelled studies suggest that there is a splenic pool of granulocytes that may be released under conditions of physiological stress, e.g. exercise [28]. Plasma myeloperoxidase levels are increased in cirrhotic patients compared with normal control subjects [29]. Myeloperoxidase is contained in the primary granules of neutrophils and released on activation or degradation. The high levels in cirrhosis are believed to be due to increased destruction or consumption of neutrophils along with decreased hepatic clearance. Levels are higher in patients with splenomegaly and correlate inversely with circulating neutrophil and platelet counts. This is indirect evidence that increased destruction along with splenic pooling may contribute to neutropenia in these patients. It has been suggested that plasma myeloperoxidase levels may be a possible marker of hypersplenism [30]. As well as splenic sequestration, neutropenia in cirrhosis may result from increased apoptosis in circulating polymorphonuclear leukocytes (PMNs). Ramirez *et al.* [31] demonstrated decreased viability on culture of PMNs from patients with decompensated liver disease compared with control subjects. These cells had morphological features of apoptosis and increased activity of caspase-3, an important transduction factor of apoptosis.

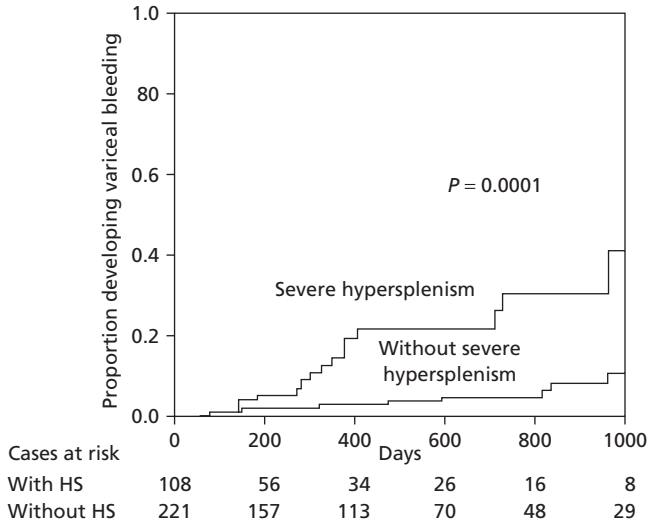

Fig. 4 Cumulative probability of variceal bleeding in patients with cirrhosis and severe hypersplenism compared with cirrhotics without hypersplenism (HS). Reproduced from ref. 14: Liangpunsakul S *et al*. (2003) Predictors and implications of severe hypersplenism in patients with cirrhosis. *Am J Med Sci* 326, 111–116, with permission from the Southern Society for Clinical Invesitagtion.

Anaemia in hypersplenism

Minor forms of anaemia are frequently seen in patients with liver disease and splenomegaly. The cause is often multifactorial and may include iron deficiency due to gastrointestinal bleeding, vitamin deficiencies, e.g. folate in alcoholic liver disease, haemolytic anaemia or the effects of toxins such as alcohol on the bone marrow. There is red cell pooling in the spleen, which may account for between 5% and 40% of the total red cell mass. The size of the splenic pool increases with spleen size, but the correlation is not close [32]. An additional factor contributing to anaemia is expansion of the plasma volume seen in cirrhosis. This expansion is probably secondary to the haemodynamic effects of cirrhosis and does not appear to be correlated with spleen size [33]. Increased red cell fragility may cause haemolysis in the spleen. Examples would be spur cell anaemia or the recently described haemolytic anaemia associated with a soluble variant of asialoglycoprotein receptor in the serum [34]. Both are usually seen in patients with alcoholic liver disease.

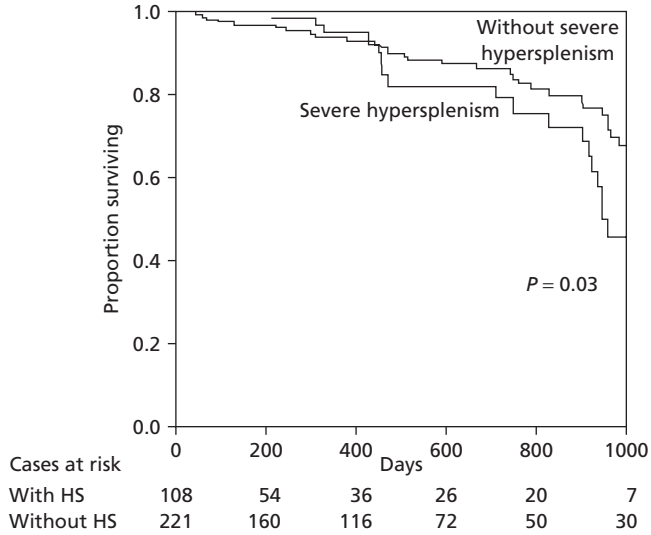

Fig. 5 Cumulative probability of survival in cirrhotic patients with severe hypersplenism compared with cirrhotics without severe hypersplenism (HS). Reproduced from ref. 14: Liangpunsakul S *et al*. (2003) Predictors and implications of severe hypersplenism in patients with cirrhosis. *Am J Med Sci* 326, 111–116, with permission from the Southern Society for Clinical Invesitagtion.

Clinical consequences of hypersplenism

Patients with severe hypersplenism (platelet count < 75 000/μL and/or white blood cell count < 2000/μL) appear to be at increased risk of variceal bleeding, spontaneous bacterial peritonitis and death compared with cirrhotic patients without severe hypersplenism [14]. In a study including 108 patients with and 221 patients without hypersplenism, the relevant figures for variceal bleeding were 19% vs. 5% ($P = 0.001$) (Fig. 4) and 16% vs. 3% for spontaneous bacterial peritonitis. The median survival was 32 months in the patients with severe hypersplenism compared with 47 months in those without ($P = 0.03$) (Fig. 5). It is likely that patients with more advanced liver disease will have an increased incidence of hypersplenism and increased risk of liver-related complications and mortality. However, severe hypersplenism remained an independent predictor in multivariate analysis. For mortality, the relationship

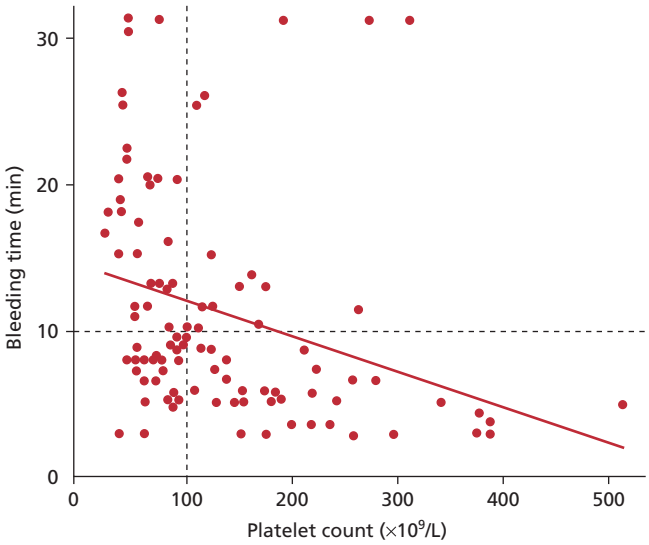

Fig. 6 Bleeding time compared with platelet count in cirrhotic patients. Overall, there is a weak but significant correlation between platelet count and bleeding time (RS = –0.048; $P < 0.001$). Reproduced from ref. 29: Blake JC *et al*. (1990) Bleeding time in patients with hepatic cirrhosis. *Br Med J* 301, 12–15, with permission from the BMJ Publishing Group.

between severe hypersplenism and mortality persisted even after controlling for Child–Pugh class [14].

It is easy to see that a low platelet count may increase the risk of variceal bleeding. In cirrhotics with thrombocytopenia, the bleeding time is prolonged and is significantly correlated with platelet count (Fig. 6) [29]. It is likely that bleeding may also be more severe or prolonged in patients with severe thrombocytopenia. In a large series of 695 cirrhotic patients admitted with variceal bleeding, platelet count was an independent predictor of early rebleeding [35]. Interestingly, platelet count was not an independent predictor of mortality in this study, although failure to control bleeding or early rebleeding was associated with higher mortality. Hypersplenism may also limit treatment options, particularly in patients with hepatitis C. A platelet count of < 50/mm^3 is regarded as a relative contraindication to treatment. Leucopenia is a frequent side-effect of treatment but may be effectively managed with granulocyte colony-stimulating factor (G-CSF).

Treatment of hypersplenism

It is important to realize that hypersplenism itself rarely requires specific treatment. The anaemia is seldom troublesome and, despite low granulocyte or platelet counts in the peripheral blood, cirrhotics with splenomegaly can usually mobilize granulocytes to deal with infection and platelets in the face of bleeding. If neutrophil counts are very low, therapy with G-CSF is often effective (see below). Thrombocytopenia is often more troublesome. Many patients with hypersplenism and thrombocytopenia receive platelet transfusions to cover surgery and invasive procedures or as part of the treatment of variceal haemorrhage. In a study by the American College of Gastroenterology GI bleeding registry, data on 725 patients with bleeding oesophageal varices was gathered. A median of 1.5 units of platelets was transfused per episode of variceal bleeding [36]. Infused platelets are rapidly sequestered in the enlarged spleen with only about 20% still present in the circulation at 2 hours compared with 60% in normal subjects (Fig. 2) [18]. This suggests that prophylactic platelet transfusions should be administered during or shortly before invasive elective procedures to maximize their effectiveness. Unfortunately, there has been little study of the efficacy of platelet transfusion in patients with cirrhosis and hypersplenism. Platelet transfusions are a relatively scarce resource, and new strategies to maximize their effectiveness in this situation would be helpful. Many situations in which thrombocytopenia is a problem are short term or self-limiting, e.g. elective surgical procedures or biopsies. In other situations, e.g. recurrent variceal haemorrhage or severe epistaxis, thrombocytopenia may be a significant precipitant. Even in these situations, treatment directed at the site of bleeding, e.g. banding of varices or transjugular intrahepatic portosystemic shunts (TIPS), may solve the problem rather than therapy directed specifically at hypersplenism.

Granulocyte colony-stimulating factor (G-CSF)

G-CSF has been used to increase neutrophil counts in patients with hypersplenism. It appears to be effective in the majority of patients but has little effect on platelet numbers [37]. G-CSF appears to be well tolerated after liver transplantation and may be particularly useful in patients with cytomegalovirus (CMV) disease [38]. One large randomized controlled trial looked at the effect of routine G-CSF for the first 21 days after liver transplantation irrespective of neutrophil count. There were significant increases in neutrophil counts in the treatment group but no beneficial effects on infection rates or survival. Interestingly, there was a non-significant increase in the incidence of biopsy-proven rejection and nosocomial pneumonia in the treatment group [39].

Neutropenia and thrombocytopenia are frequent side-effects during antiviral treatment for hepatitis C virus [40]. Interferon causes a 10–50% reduction in peripheral platelet count, which may be clinically important in patients with hypersplenism and pre-existing thrombocytopenia. A reduction in dose is recommended if total neutrophil counts fall below 750/μL. An alternative strategy is to use G-CSF to increase neutrophil counts and maintain antiviral treatment doses.

Erythropoietin

Erythropoietin has been used extensively in renal patients with anaemia. It appears to have a modest effect in increasing platelet number. In a small randomized study, including patients with

alcoholic cirrhosis and platelet counts < 120/μL, erythropoietin increased mean platelet count by about 25% [41].

Thrombopoietin

Thrombocytopenia causes most clinical problems in patients with cirrhosis and hypersplenism. The identification and purification of thrombopoietin in 1994 raised hopes that effective therapy might be at hand. To date, two forms have undergone extensive clinical testing, recombinant human thrombopoietin (rhTPO) and pegylated recombinant human megakaryocyte growth and development factor (PEG-rHuMGDF), mainly in oncology and haematology patients [42]. Both have been shown to stimulate megakaryocyte growth and platelet production and to ameliorate drug-induced thrombocytopenia. Results to date suggest that the peak response is delayed a few days and pretreatment is required. However, administration of multiple subcutaneous doses of PEG-rHuMGDF resulted in prolonged thrombocytopenia in 8–10% of patients. This appears to be due to the development of neutralizing antibodies that cross-react with native thrombopoietin. As a result, PEG-rHuMGDF was withdrawn from clinical trials. This effect has not been seen with rhTPO, which is given intravenously. In an analogous situation, cases of antibody-mediated pure red cell aplasia have been reported in renal patients following erythropoietin treatment [43]. They were attributed to subcutaneous rather than intravenous administration and to changes in stabilizers and storage methods. These problems were identified and resolved followed by the virtual disappearance of the clinical problem with erythropoietin. It is hoped that the similar problems with thrombopoietin will also be overcome. For the present, peptide thrombopoietin mimetics are being developed, designed to bind to and activate the thrombopoietin receptor. Thrombopoietin or thrombopoietin analogues would clearly be useful in patients with liver disease and thrombocytopenia, particularly for elective surgery or liver biopsy. Because of the delayed onset of action, they would be of limited value in emergency situations such as variceal haemorrhage.

Splenectomy

Splenectomy should cure hypersplenism. However, in patients with advanced liver disease, the procedure may be technically difficult and associated with considerable morbidity and mortality. Specific concerns include the risk of decompensation associated with surgery, postoperative portal vein thrombosis, increasing difficulty of subsequent liver transplantation and the increased risk of sepsis with encapsulated organisms such as pneumococcus. Splenectomy may be performed as part of the Sigiura procedure for patients with bleeding varices. This is now rarely performed in western countries as TIPS has superseded shunt surgery in many centres. Devascularization and splenectomy is still a major treatment option for patients with schistosomal portal hypertension and bleeding varices [44]. Splenectomy may also be indicated in the rare patient with 'sinistral' or left-sided portal hypertension complicated by variceal bleeding [45]. This is characterized by splenic vein thrombosis and gastric varices.

While splenectomy is generally not recommended in cirrhotic patients, there is a suggestion that it may be useful in patients with cirrhosis and hepatoma. Wu *et al.* [46] reported a series of 41 patients treated in this way in a cohort of 526 hepatoma resections. These patients had preoperative platelet counts of < 80 000/μL. Morbidity and mortality rates were similar in patients treated with and without splenectomy. The authors claimed that this technique allowed them to increase the patients suitable for surgical resection in this situation [46]. Another Chinese group reported on 94 hepatoma patients treated with partial hepatectomy and splenectomy compared with partial hepatectomy alone in 110 patients [47]. They reported significantly improved 5-year disease-free survival in the splenectomy group (37% vs. 27.3%; $P = 0.003$), although overall survival was similar. However, all patients in the splenectomy group completed adjuvant chemotherapy compared with 15% in the hepatectomy alone group, which may have contributed to the observed differences. Clearly, controlled data will be required to confirm the role of splenectomy in this patient group.

Laparoscopic splenectomy has now been described in patients with cirrhosis and hypersplenism. A recent report described 11 patients with hepatitis C and thrombocytopenia which limited interferon treatment [48]. Laparoscopic splenectomy was successful in all, with no major complications. Mean spleen weight was 1043 g, and mean platelet count increased from 55/μL to 439/μL following surgery. It is important to note that all patients in this study had Child's class A liver disease. Partial splenectomy may be possible particularly in patients with schistosomal or non-cirrhotic portal hypertension. In a long-term (1–12 years) follow-up study of 32 patients, increases in circulating white cell counts and platelets were seen in 31% and 22% respectively [49].

Partial splenic embolization

Partial splenic embolization has been shown to produce significant increases in peripheral white cell and platelet counts. Interestingly, platelet survival time appears to improve after this procedure [22]. Initial enthusiasm was tempered by a high incidence of side-effects including pain, fever, splenic abscess, splenic rupture, acute pancreatitis and septicaemia. Side-effects may be reduced by careful aseptic technique, administration of prophylactic intravenous antibiotics and embolization of less than 70% of splenic volume. The place for this technique in the management of hypersplenism is still not clear. Reasonable long-term efficacy has been demonstrated in paediatric patients [50]. One cohort study suggested that the combination of variceal band ligation and partial splenic embolization reduced the risk of bleeding and improved prognosis in patients with

varices and thrombocytopenia compared with band ligation alone [51]. Controlled studies will be required to confirm these findings. A recent variation on this technique is radiofrequency ablation of the spleen. A preliminary report of this technique in nine patients has appeared [52]. Improvement in hypersplenism and a low incidence of side-effects was described. There is an obvious potential for serious intraperitoneal haemorrhage with this technique, which may limit its applicability.

Transplantation

Successful liver transplantation replaces the failing liver, corrects portal hypertension and returns thrombopoietin production to normal. In the immediate post-transplant period, platelet levels may fall further as a result of consumption, immunosuppressive drugs or rejection. This can usually be managed conservatively with platelet transfusions as required. In very rare cases, severe symptomatic thrombocytopenia may persist following liver transplantation and require specific therapy, such as splenectomy [53]. Spleen size usually diminishes after transplantation, over time, but still remains somewhat enlarged in many patients. Platelet counts increase in the majority of patients, but many still have subnormal values on long-term follow-up [54].

Portosystemic shunts

Portosystemic shunt surgery and TIPS appear to have modest but somewhat unpredictably beneficial effects on hypersplenism. In two controlled studies of shunt surgery, splenomegaly diminished more often in the shunted patients [1,55]. However, only one study demonstrated an improvement in peripheral white cell and platelet counts [55]. The reported effect of TIPS on thrombocytopenia is also variable. An Austrian group noted a 19.7% increase in median platelet count over a 1-year period in 45 patients treated with TIPS [56]. There was a 17.1% drop in median platelet count in 110 control patients over the same time period. The percentage reduction in portosystemic gradient was not predictive of response. In contrast, an American group noted no significant change in platelet count in 60 patients treated with TIPS [57].

Venesection

An Italian group reported that phlebotomy caused increased platelet counts in cirrhotic patients with iron overload [58]. The aetiology of cirrhosis in this study was varied, including hepatitis C, alcohol and hereditary haemochromatosis. The increased platelet count was associated with improvements in alanine aminotransferase levels. Sixty-two patients were treated with an increase in mean platelet count from 110 to 168×10^9/L.

References

1 Mutchnick MG, Lerner E, Conn HO (1980) Effect of portocaval anastomosis on hypersplenism. *Dig Dis Sci* 25, 929–938.

2 Soper NJ, Rikkers LF (1982) Effect of operations for variceal hemorrhage on hypersplenism. *Am J Surg* 144, 700–703.

3 Shah SHA, Hayes PC, Allan PL *et al.* (1996) Measurement of spleen size and its relation to hypersplenism and portal hemodynamics in portal hypertension due to hepatic cirrhosis. *Am J Gastroenterol* 91, 2580–2583.

4 Duvoux C, Radier C, Roudot-Thoraval F *et al.* (2004) Low grade steatosis and major changes in portal flow as new prognostic factors in steroid-treated alcoholic hepatitis. *Hepatology* 40, 1370–1378.

5 Nagasue N, Dhar DK, Yamanoi A *et al.* (2000) Production and release of endothelin-1 from the gut and spleen in portal hypertension due to cirrhosis. *Hepatology* 31, 1107–1114.

6 Groom AC, MacDonald IC, Schmidt EE (2002) Splenic microcirculatory blood flow and function with respect to red blood cells. In: Bowdler AJ (ed.) *The Complete Spleen: Structure, Function and Clinical Disorders*. Totowa, NJ: Humana Press, pp. 23–50.

7 Ebaugh FG, McIntyre OR (1979) Palpable spleens: ten-year follow-up. *Ann Intern Med* 90, 130–131.

8 Redmond HP, Redmond JM, Rooney BP *et al.* (1989) Surgical anatomy of the human spleen. *Br J Surg* 76, 198–201.

9 Dailey MO (2002) The immune functions of the spleen. In: Bowdler AJ (ed.) *The Complete Spleen: Structure, Function and Clinical Disorders*. Totowa, NJ: Humana Press, pp. 51–69.

10 Lopes-Carvalho T, Kearney JF (2004) Development and selection of marginal zone B cells. *Immunol Rev* 197, 192–205.

11 Demar M, Legrand E, Hommel D *et al.* (2004) *Plasmodium falciparum* malaria in splenectomized patients: two case reports in French Guiana and a literature review. *Am J Trop Hyg* 71, 290–293.

12 Chauffard M (1907) Apropos de la communication de M Vaquez. *Bull Mem Soc Med Hop Paris* 24, 1201–1203.

13 Bowdler AJ (2002) The clinical significance of the spleen. In: Bowdler AJ (ed.) *The Complete Spleen*. Totowa, NJ: Humana Press, pp. 139–155.

14 Liangpunsakul S, Ulmer BJ, Chalasani N (2003) Predictors and implications of severe hypersplenism in patients with cirrhosis. *Am J Med Sci* 326, 111–116.

15 Psacharopolous HT, Howard ER, Portman B *et al.* (1981) Hepatic complications of cystic fibrosis. *Lancet* 2(8237), 78–80.

16 Bashour FN, Teran JC, Mullen KD (2000) Prevalence of peripheral blood cytopenias (hypersplenism in patients with nonalcoholic chronic liver disease. *Am J Gastroenterol* 95, 2936–2939.

17 El-Khishen MA, Henderson JM, Millikan WJ *et al.* (1985) Splenectomy is contraindicated for thrombocytopenia secondary to portal hypertension. *Surg Gynecol Obstet* 160, 233–238.

18 Aster RH (1966) Pooling of platelets in the spleen: role in the pathogenesis of 'hypersplenic' thrombocytopenia. *J Clin Invest* 45, 645.

19 Karpatkin S, Freedman ML (1978) Hypersplenic thrombocytopenia differentiated from increased peripheral destruction by platelet volume. *Ann Intern Med* 89, 200–203.

20 Shulman NR, Watkins SP Jr, Itscoitz SB *et al.* (1968) Evidence that the spleen retains the youngest and hemostatically most effective platelets. *Trans Assoc Am Physiol* 81, 302–313.

21 Stein SF, Harker LA (1982) Kinetic and functional studies of platelets, fibrinogen and plasminogen in patients with hepatic cirrhosis. *J Lab Clin Med* 99, 217–230.

22 Noguchi H, Hirai K, Aoki Y *et al.* (1995) Changes in platelet kinetics after a partial splenic arterial embolization in cirrhotic patients with hypersplenism. *Hepatology* 22, 1682–1688.

23 Adinolfi LE, Giordano MG, Andreana A *et al.* (2001) Hepatic fibrosis plays a central role in the pathogenesis of thrombocytopenia in patients with chronic viral hepatitis. *Br J Haematol* 113, 590–595.

24 Haeh M, Hauser SP, Nydegger UE (2001) Transient thrombopoietin peak after liver transplantation for end-stage liver disease. *Br J Haematol* 112, 493–498.
25 Giannini E, Borro P, Botta F *et al.* (2002) Serum thrombopoietin levels are linked to liver function in untreated patients with hepatitis C virus-related chronic hepatitis. *J Hepatol* 37, 638–644.
26 Sanjo A, Satoi J, Ohnishi A *et al.* (2003) Role of elevated platelet-associated immunoglobulin G and hypersplenism in thrombocytopenia of chronic liver diseases. *J Gastroenterol Hepatol* 18, 638–644.
27 Souza MR, Aguiar L, Goto JM *et al.* (2002) Thrombopoietin serum levels do not correlate with thrombocytopenia in hepatic schistosomiasis. *Liver* 22, 127–129.
28 Allsop P, Peters AM, Arnot RN *et al.* (2005) Intrasplenic blood cell kinetics in man before and after brief maximal exercise. *Clin Sci* 83, 47–54.
29 Blake JC, Sprengers D, Grech P *et al.* (1990) Bleeding time in patients with hepatic cirrhosis. *Br Med J* 301, 12–15.
30 Nakamuta M, Ohashi M, Tanabe Y *et al.* (1993) High plasma concentration of myeloperoxidase in cirrhosis: a possible marker of hypersplenism. *Hepatology* 18, 1377–1383.
31 Ramirez MJ, Titos E, Claria J *et al.* (2004) Increased apoptosis dependent on caspase-3 activity in polymorphonuclear leukocytes from patients with cirrhosis and ascites. *J Hepatol* 41, 44–48.
32 Christensen BE (1975) Red blood cell kinetics. *Clin Haematol* 4, 393–405.
33 Blendis LM, Ramboer C, Williams R (1970) Studies on the haemodilution anaemia of splenomegaly. *Eur J Clin Invest* 1, 54–64.
34 Hilgard P, Schreiter T, Stockert RJ *et al.* (2004) Asialoglycoprotein receptor facilitates hemolysis in patients with alcoholic liver cirrhosis. *Hepatology* 39, 1398–1407.
35 Ben-Ari Z, Cardin F, McCormick PA *et al.* (1999) A predictive model for failure to control bleeding during acute variceal haemorrhage. *J Hepatol* 31, 443–450.
36 Sorbi D, Gostout CJ, Peura D *et al.* (2003) An assessment of the management of acute bleeding varices: a multicenter prospective member-based study. *Am J Gastroenterol* 98, 2424–2434.
37 Gurakar A, Fagiuoli S, Gavaler JS *et al.* (1994) The use of granulocyte–macrophage colony-stimulating factor to enhance hematologic parameters of patients with cirrhosis and hypersplenism. *J Hepatol* 21, 582–586.
38 Turgeon N, Hovingh GK, Fishman JA *et al.* (2000) Safety and efficacy of granulocyte colony-stimulating factor in kidney and liver transplant recipients. *Transpl Infect Dis* 2, 15–21.
39 Winston DJ, Foster PF, Somberg KA *et al.* (1999) Randomized, placebo-controlled, double-blind, multicenter trial of efficacy and safety of granulocyte colony-stimulating factor in liver transplant recipients. *Transplantation* 15(1298), 1304.
40 Russo MW, Fried MW (2003) Side effects of therapy for chronic hepatitis C. *Gastroenterology* 124, 1711–1719.
41 Homoncik M, Jilma-Stohlawetz P, Schmic M *et al.* (2004) Erythropoietin increases platelet reactivity and platelet counts in patients with alcoholic liver cirrhosis: a randomized double-blind, placebo-controlled study. *Aliment Pharmacol Ther* 20, 437–443.
42 Kuter DJ, Begley CG (2002) Recombinant human thrombopoietin: basic biology and evaluation of clinical studies. *Blood* 100, 3457–3469.
43 Casadevall N, Rossert J (2005) Importance of biologic follow-ons: experience with EPO. *Best Pract Res Clin Haematol* 18, 381–387.
44 Ferraz AA, Bacelar TS, Silveira MJ *et al.* (2001) Surgical treatment of schistosomal portal hypertension. *Int Surg* 86, 1–8.
45 Koklu S, Yuksel O, Arhan M *et al.* (2005) Report of 24 left-sided portal hypertension cases: a single-center prospective cohort study. *Dig Dis Sci* 50, 976–982.
46 Wu CC, Cheng SB, Ho WM *et al.* (2004) Appraisal of concomitant splenectomy in liver resection for hepatocellular carcinoma in cirrhotic patients with hypersplenic thrombocytopenia. *Surgery* 136, 660–668.
47 Chen XP, Wu ZD, Huang ZY *et al.* (2005) Use of hepatectomy and splenectomy to treat hepatocellular carcinoma with cirrhotic hypersplenism. *Br J Surg* 92, 334–339.
48 Kercher KW, Carbonell AM, Heniford BT *et al.* (2004) Laparoscopic splenectomy reverses thrombocytopenia in patients with hepatitis C cirrhosis and portal hypertension. *J Gastrointest Surg* 8, 120–126.
49 Petroianu A, da Silva RG, Simal CJ *et al.* (1997) Late postoperative follow-up of patients submitted to subtotal splenectomy. *Am Surg* 63, 735–740.
50 Nio M, Hayashi Y, Sano N *et al.* (2003) Long-term efficacy of partial splenic embolization in children. *J Pediatr Surg* 38, 1760–1762.
51 Ohmoto K, Yamamoto S (2003) Prevention of variceal recurrence, bleeding, and death in cirrhosis patients with hypersplenism, especially those with severe thrombocytopenia. *Hepatogastroenterology* 50, 1766–1769.
52 Liu Q, Ma K, He Z *et al.* (2005) Radiofrequency ablation for hypersplenism in patients with liver cirrhosis: a pilot study. *J Gastrointest Surg* 9, 648–657.
53 Altaca G, Scigliano E, Guy SR *et al.* (1997) Persistent hypersplenism early after liver transplant: the role of splenectomy. *Transplantation* 64, 1481–1483.
54 Yanaga K, Tzakis AG, Shimada M *et al.* (1989) Reversal of hypersplenism following orthotopic liver transplantation. *Ann Surg* 210, 180–183.
55 Felix WR Jr, Myerson RM, Sigel B *et al.* (1974) The effect of portocaval shunt on hypersplenism. *Surg Gynecol Obstet* 139, 899–904.
56 Gschwantler M, Vavrik J, Gebuer A *et al.* (1999) Course of platelet counts in cirrhotic patients after implantation of a transjugular intrahepatic portosystemic shunt – a prospective, controlled study. *J Hepatol* 30, 254–259.
57 Sanyal A, Freedman AM, Purdum PP *et al.* (1996) The hematologic consequences of transjugular intrahepatic portosystemic shunts. *Hepatology* 23, 32–39.
58 Franchini M (2003) Platelet count increase following phlebotomy in iron overloaded patients with liver cirrhosis. *Hematology* 8, 259–262.

8 Congenital hepatic fibrosis and non-parasitic cystic lesions of the liver and bile ducts

8.1 Congenital conditions

8.1.1. Congenital hepatic fibrosis

Jean-Pierre Benhamou

Congenital hepatic fibrosis is an inherited, congenital malformation characterized by portal spaces enlarged by fibrosis and multiple bile ductules, the main consequence of which is portal hypertension. The disease was described as fibrocystic disease of the liver by Grumbach [1]. The denomination of congenital hepatic fibrosis was introduced by Kerr [2].

Pathology and pathogenesis

The lesion of congenital hepatic fibrosis consists of portal spaces markedly increased in size because of abundant connective tissue and numerous bile ductules, more or less ectatic, communicating with the biliary tree. It must be emphasized that congenital hepatic fibrosis is not simply fibrosis and that bile ductular proliferation is an essential component of the lesion. A few portal spaces may remain normal, which explains why congenital hepatic fibrosis may be unrecognized by histological examination of a small specimen taken by liver biopsy. Some clusters of multiple bile ductules surrounded with fibrosis may be present within the lobules, apart from the portal spaces. Some bile ductules are so markedly dilated that they form microcysts: these microcysts communicate with the biliary tree. Separation between the fibrotic portal spaces and the rest of the liver parenchyma is sharp. Architecture of the liver remains normal. There is no regenerative nodule.

The primary disorder of congenital hepatic fibrosis is likely to be ductular proliferation, fibrosis being secondarily induced by the multiple bile ductules. The initial lesion might be clusters of multiple bile ductules, i.e. von Meyenburgh complexes, resembling the initial lesion of the liver cyst associated with adult polycystic kidney disease; however, in congenital hepatic fibrosis, the abnormal bile ductules maintain their communications with the biliary tree and, as a result, only microcysts are formed. In adult polycystic kidney disease, the abnormal bile ductules loose their communications with the biliary tree and, as a result, dilate markedly and form large cysts.

The mechanism for the development of multiple bile ductules in congenital hepatic fibrosis is unknown. It has been suggested that the abnormal abundance of bile ductules might result from a defect in the involution of the so-called ductular plate [3]. Normal involution would result in the obstruction of a large part of the ductular plate. The residual, undestroyed parts of the ductular plate would form intrahepatic bile duct. Congenital hepatic fibrosis would be due to the undestroyed parts of ductular plate. A similar disorder affecting the epithelium of the large bile ducts might account for Caroli's syndrome associated with congenital hepatic fibrosis. A similar mechanism might explain the dilatation of the renal collecting tubules and the dilatation of the pancreatic ducts, two extrahepatic malformations which may be associated with congenital hepatic fibrosis.

Aetiology

Congenital hepatic fibrosis is an inherited malformation, transmitted as an autosomal recessive trait [2,4]. The parents, presumably heterozygous, are phenotypically normal. Males and females are equally affected. Several siblings may be affected. Consanguinity increases the risk of congenital hepatic fibrosis.

The prevalence of congenital hepatic fibrosis is not established, but is certainly very low and might be of the same order of magnitude as that of another autosomal recessive liver disease, Wilson's disease, i.e. about 1:100 000 [5]. There is no ethnic predominance.

Manifestations and diagnosis

The main consequence of congenital hepatic fibrosis is portal hypertension, which is likely to be present from birth. The disease is recognized at the first episode of gastrointestinal bleeding

resulting from ruptured oesophageal varices, which usually occurs between 5 and 20 years of age, but sometimes later. In a few patients, the disease is recognized before any gastrointestinal bleeding, because of blood disorders due to hypersplenism, abdominal discomfort resulting from an enlarged spleen, or the presence of abdominal collateral venous circulation.

At clinical examination, the liver is often, but not constantly, enlarged. Splenomegaly is present in most of the patients. Abdominal collateral venous circulation, Cruveilhier syndrome in some patients, is often visible. Ascites is absent. There is no symptom or sign indicating liver failure, in particular jaundice or spider naevi. The liver function tests are normal, except for moderately increased alkaline phosphatase and gammaglutamyl transpeptidase in a few patients. Endoscopic and/or radiographic examinations demonstrate oesophageal varices. Ultrasonography and/or computed tomography show that the liver is often enlarged, the portal vein is patent (which excludes extrahepatic portal hypertension), the spleen is enlarged, and portacaval collateral circulation is present; the venous phase of coeliac and mesenteric arteriography would provide similar information. Histological examination of an hepatic specimen taken by needle biopsy demonstrates the typical liver lesion in most patients; however, especially if the specimen is small, the lesion may be missed because, as mentioned above, some of the portal spaces may be normal.

Course and complications

The course of the disease is dominated by recurrent episodes of gastrointestinal bleeding, the frequency of which varies widely from patient to patient. The episodes of gastrointestinal bleeding are often well tolerated and are usually not followed by hepatic encephalopathy, ascites or jaundice. The patient's death is due to massive bleeding but not to liver failure. Thus, the course of congenital hepatic fibrosis resembles that of extrahepatic portal hypertension and differs from that of cirrhosis.

In a few patients, in the absence of Caroli's syndrome, congenital hepatic fibrosis is complicated by recurrent episodes of bacterial cholangitis. Uncontrolled, severe bacterial cholangitis may cause the death of such patients.

Thrombosis of the portal vein can complicate congenital hepatic fibrosis. This complication is often due to surgical operations on the portal vein or its branches, in particular splenectomy (which is unjustified in these patients).

Cholangiocellular carcinoma can complicate congenital hepatic fibrosis [6].

Associated malformations

Congenital hepatic fibrosis is often associated with Caroli's syndrome, either clinically silent or cholangitis determining (see below).

Congenital hepatic fibrosis is likewise often associated with a renal malformation consisting of ectatic collecting tubules resembling sponge kidney [7]; however, dilatation affects both the medullary and cortical portions of the collecting tubules in congenital hepatic fibrosis, whrereas dilatation is limited to the medullary portion in sponge kidney [8,9]. This renal malformation is clinically silent except for haematuria and/or urinary infection in a few patients. Dilatation of the collecting tubules can be demonstrated by intravenous pyelography showing enlarged kidneys and coarse striation of the medulla [7]. These radiological abnormalities are present in about two-thirds of the patients [4,7]; their presence is good evidence for, but their absence is not an argument against, the diagnosis of congenital hepatic fibrosis. In some patients with a normal intravenous pyelogram, histological examination of the kidneys may show ectatic collecting tubules [8].

In most patients, dilatation of collecting tubules remains stable. However, in some, the ectatic segments lose their communications with the urinary tract and transform into large renal cysts; the renal malformation then resembles adult polycystic kidney disease [10]. This transformation accounts for the large renal cysts detectable by intravenous pyelography or ultrasonography in a certain number of patients with congenital hepatic fibrosis [4]. This transformation may be rapid and take place in infancy or, more often, is more progressive, large renal cysts being formed only over 30 or 40 years. In patients with large renal cysts, the renal malformation may cause renal failure and/or arterial hypertension.

Other associated malformations are uncommon and include duplication of the intrahepatic portal vein branches [11], cystic dysplasia of the pancreas [2], intestinal lymphangectasia [12], pulmonary emphysema [13], cerebellar haemangioma [14], aneurysms of renal and cerebral arteries and cleft palate [2].

Treatment

Endoscopic sclerotherapy of oesophageal varices and/or non-selective beta blockers can be recommended for the prevention of recurrent bleeding, although these procedures have not been specifically evaluated in congenital hepatic fibrosis.

In patients in whom sclerotherapy and/or beta blockers are inefficient, a surgical portacaval shunt can be considered. Hepatic encephalopathy and liver failure after portacaval shunt is less common in patients with congenital hepatic fibrosis than in those with cirrhosis [4,15].

Splenectomy, which has been performed in a few patients in whom hypersplenism had not been related to congenital hepatic fibrosis, does not prevent occurrence or recurrence of gastrointestinal bleeding and may be followed by portal vein thrombosis, preventing subsequent surgical portacaval shunt (Benhamou, personal observation).

Operations or invasive investigations on the biliary tree, such as cholecystectomy, choledocotomy, T-tube drainage,

intraoperative cholangiography or endoscopic retrograde cholangiography, must be avoided because of the risk of inducing bacterial cholangitis.

References

1 Grumbach R (1954) *Arch Anat Cytol Pathol* 30, 74–77.
2 Kerr DN, Harrison CV, Sherlock S *et al.* (1961) Congenital hepatic fibrosis. *Q J Med* 30, 91–117.
3 Desmet VJ (1992) Congenital diseases of intrahepatic bile ducts: variations on the theme 'ductal plate malformation'. *Hepatology* 16, 1069–1083.
4 Alvarez F, bernard O, Brunelle F *et al.* (1981) Congenital hepatic fibrosis in children. *J Pediatr* 99, 370–375.
5 Scheinberg IH (1984) *Wilson's Disease*. Philadelphia: Saunders, p. 71.
6 Yamoto (1998) *J Hepatol* 28, 717–722.
7 Kerr DN, Warrick CK, Hart-Mercer J (1962) A lesion resembling medullary sponge kidney in patients with congenital hepatic fibrosis. *Clin Radiol* 12, 85–91.
8 Clermont RJ, Maillard JN, Benhamou JP (1967) [Congenital hepatic fibrosis.] *Can Med Assoc J* 97, 1272–1278.
9 Fauvert R (1974) *The Liver and its Diseases*. New York: IMS, pp. 283–288.
10 Dupont HL (1978) Etiologic diagnosis of acute diarrhea. *Ann Intern Med* 88, 514–515.
11 Odièvre M, Chaumont P, Gautier M (1977) Transient hepatic peliosisin a child. *Radiology* 122, 427–430.
12 Chagnon (1982) [Primary biliary cirrhosis associated with digestive scleroderma without CRST syndrome or cutaneous involvement.] *Gastroenterol Clin Biol* 6, 326–332.
13 Williams R, Scheuer PJ, Heard BE (1964) Congenital hepatic fibrosis with an unusual pulmonary lesion. *J Clin Path* 17, 135–142.
14 Wagenvoort CA, Baggenstoss AH, Love JG (1962) Subarachnoid hemorrhage due to cerebellar hemangioma associated with congenital hepatic fibrosis and polycystic kidneys: report of a case. *Mayo Clin Proc* 37, 301–306.
15 Kerr DN, Okonkwo S, Choa RG (1978) Congenital hepatic fibrosis: the long-term prognosis. *Gut* 19, 514–520.

8.1.2. Simple cyst of the liver

Valérie Vilgrain

The simple cysts of the liver are cystic formations containing serous fluid, which do not communicate with the intrahepatic biliary tree. Numerous terms have been used: biliary cyst, non-parasitic cyst of the liver, benign hepatic cyst, congenital hepatic cyst, unilocular cyst of the liver, solitary cyst of the liver (this last designation is inappropriate because, as mentioned below, the simple cysts are often multiple). Although frequent in the general population, most simple cysts are less than 3 cm in diameter, easily identified at ultrasound and asymptomatic. Symptoms, when present, are usually related to intracystic bleeding that changes the morphological appearance of the cyst and may mimic cystadenoma or hydatid disease.

Pathogenesis and pathology

Simple non-parasitic cysts of the liver are congenital. The pathogenesis of the simple cysts is still unclear, and it is usually considered that the pathogenesis is similar to that observed in polycystic diseases. During embryogenesis, abnormal or excessive numbers of intrahepatic ducts develop. These bile ducts fail to connect with the biliary tree and progressively dilate to form cysts. Despite this congenital origin, communication with the biliary tree is very rare. Liver cyst epithelial cells retain differentiated secretory function as they secrete fluid and generate a positive luminal pressure that may be greater than 30 cm H_2O. The composition of the fluid, which contains water and mineral electrolytes without bile acids and bilirubin, is close to that of the normal secretion of the epithelium of the bile ducts.

Macroscopically, simple cysts may be solitary or multiple, but are usually unilocular. Multilocular cysts are formed by the confluence of multiple adjacent cysts. They have a spherical or ovoid shape. The diameter ranges from a few millimetres to 20 cm or more. Up to five cysts can be observed, but the presence of multiple cysts should raise the possibility of adult polycystic kidney disease or adult polycystic liver disease. The presence of renal cysts or family history are key. The cystic fluid is usually clear yellow, but it may appear mucoid, bile stained or bloody because intracystic bleeding is relatively common. The inner surface is smooth. The small cysts are surrounded by normal hepatic tissue. The large cysts produce atrophy of the adjacent hepatic tissue: a huge cyst may result in complete atrophy of a hepatic lobe with compensatory hypertrophy of the other lobe. Atrophy respects the large bile ducts and blood vessels, which therefore appear to be abundant in the atrophic tissue in contact with the cyst. Large bile ducts and blood vessels persisting after atrophy may protrude and form folds over the inner surface of the cyst, which may mimic septae. Occasionally, von Meyenburg complexes can be present in the neighbouring liver.

Microscopically, the cystic epithelium is single cuboidal to columnar and resembles biliary epithelium. The cells are uniform, without any atypia. Epithelial cells contain small quantities of mucin and demonstrate weak immunostaining for epithelial antigen and carcinoembryonic antigen (CEA) [1].

Prevalence

Simple cysts have long been considered rare: up to 1971, only 350 cases had been reported [2,3], and early estimates of incidence from autopsy studies were less than 1% [4]. However, the development of imaging techniques has revealed that simple cysts are in fact much more frequent. Prevalence in ultrasonography studies is between 3% and 5% [5,6] and was as high as 18% in a recent spiral computerized tomography (CT) study of

an adult population [7]. These discrepancies are explained by the usually small size of most cysts that are only discovered with accurate imaging techniques.

The prevalence of simple cysts is age and gender related. Simple cysts are uncommon before the age of 40 years, and their prevalence increases sharply thereafter. Simple cysts are also larger in adults over 50 years than in younger individuals [4]. Most studies show a higher prevalence in women (1.5 to four times higher) [5,6,8], and the female-to-male ratio rises to 9:1 in symptomatic or complicated simple cysts [3]. Huge cysts almost exclusively affect women over 50 years of age. An association between simple hepatic cysts and simple renal cysts has been documented [7], but is unexplained yet.

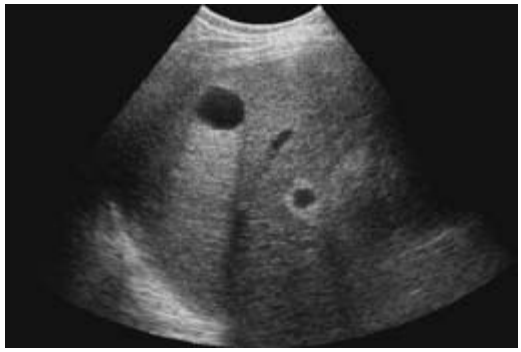

Fig. 1 Typical simple hepatic cyst at sonography. The lesion is strictly anechoic, with thin walls. Strong acoustic posterior enhancement is seen beyond the cyst.

Manifestations

In the vast majority of cases, simple cysts – all the small cysts, but also most of the large cysts – are asymptomatic and fortuitously demonstrated by ultrasonography or CT. Symptoms are usually due to space occupation by the cysts and pressure on the adjacent structures; therefore, only some of the large cysts produce symptoms, but the severity of the symptoms does not correlate with the size of the cyst. Symptoms generally include abdominal pain (right upper quadrant or epigastric), discomfort, abdominal fullness, early satiety, dyspnoea, increasing abdominal girth or vomiting [9]. Sharp pain is not observed unless intracystic haemorrhage has occurred. Rarely, patients present with obstructive jaundice or oedema of the lower extremities. Because of the high prevalence of simple cysts in adults, and the vague symptomatology, the causal relationship between symptoms and a simple cyst of the liver should only be accepted if the cyst is large or complicated and if other possible causes of the symptoms have been excluded.

At clinical examination, only the large cysts can be palpated as spherical tumours. The condition of individuals with a simple cyst of the liver is good. Liver function tests are normal; abnormal liver function tests in a patient with a simple cyst of the liver are not related to the cyst and are caused by another liver disease, except when the cysts compress bile ducts.

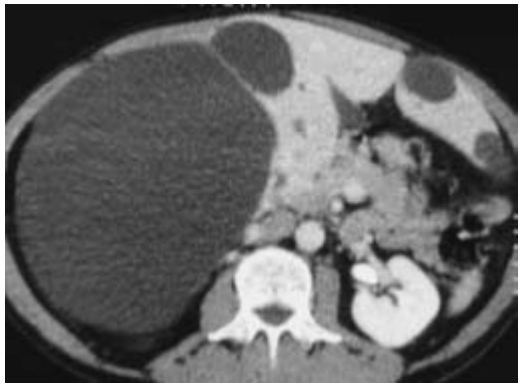

Fig. 2 Typical simple hepatic cysts on enhanced CT: homogeneous and hypoattenuating lesions that do not enhance after administration of contrast medium.

Imaging

Ultrasonography is the best procedure for recognizing cysts. All cysts are characterized by anechoic or hypoechoic content. But other criteria have to be found to characterize the cystic lesion as a simple cyst (Fig. 1): round or oval shape; totally anechoic lesion; sharp and smooth borders with thin walls; strong acoustic posterior enhancement, which reflects an accentuation of the echoes beyond the cyst compared with echoes at a similar depth transmitted through normal adjacent liver tissue [10].

The posterior enhancement is observed only when the deep tissue transmits ultrasound and is not seen when a total reflector, such as gas or bone, lies behind the cyst. In some patients, because of intracystic bleeding, intracystic echoes can be detected. Focal thickening and nodularity are absent in simple cysts. Calcifications rarely occur and, if present, are localized and not circumferential. True septations are not seen in simple cysts, but the interface of several adjacent cysts may mimic septae; in such cases, the lobulated circumference of a cluster of multiple cysts allows distinction.

The other imaging procedures are generally unnecessary in uncomplicated cysts. A simple cyst appears as a homogeneous and hypoattenuating lesion on non-enhanced CT scans, with no enhancement of its wall or content after the administration of contrast material [11] (Fig. 2). Cysts are round or oval, and are thin-walled. In small cysts, recognition of water density may be difficult (the average density of the cyst being obscured by the density of the adjacent liver tissue). At magnetic resonance imaging (MRI), simple cysts have homogeneous very low signal intensity on T1-weighted images and homogeneous very high signal intensity on T2-weighted images. Strong hyperintensity persists on heavily T2-weighted images, and this feature allows differentiation from metastatic lesions [11]. No enhancement is seen after administration of gadolinium chelates.

When the diagnosis remains uncertain after complete non-invasive examination including MRI, aspiration may be useful for confirming the diagnosis by showing a clear fluid and by demonstrating the absence of communication with the biliary tree after intracystic injection of contrast medium [12]. It may also be used to rule out the presence of scolex if hydatid disease is suspected. The adjunctive use of measurements of cyst fluid CEA and CA19-9 levels has been reported. CEA measurements on the supernatant by enzyme immunoassay show negative levels (< 5 ng/mL) in fluids from benign cysts and elevated levels (> 600 ng/mL) in fluids from biliary cystadenoma/cystadenocarcinoma and cystic metastases [13]. Only one case report of a simple cyst with markedly elevated CEA has been reported [14]. Because of the biliary epithelium, CA19-9 activity is very high in simple cysts, and this measurement may also be used to assess the effect of ethanol injection on a liver cyst [15].

Course and complications

In most cases, simple cysts remain silent; repeated ultrasonography usually shows no significant changes over years. In some patients, the cysts grow slowly (Fig. 3a and b). Why some simple cysts grow and others remain stable is not known. In a small number of patients, the size of the cysts increases rapidly: such a course, which may be associated with severe pain and discomfort, is observed almost exclusively in women over 50 years of age.

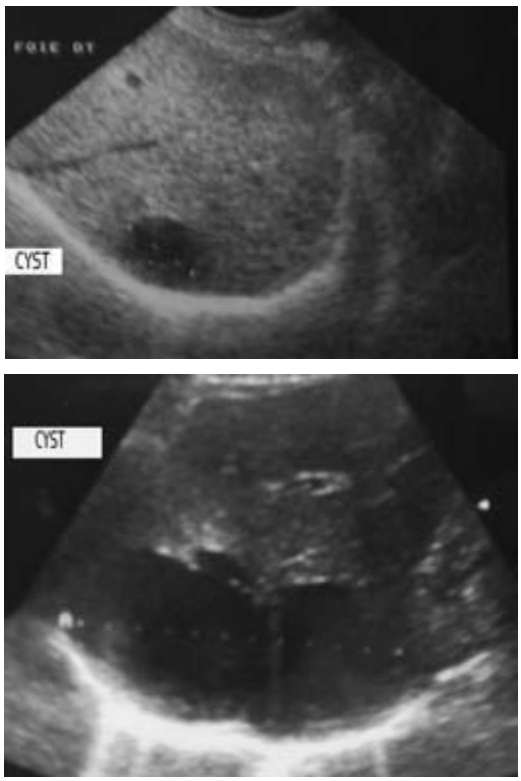

(a)

(b)

Fig. 3 Ultrasonography of a typical simple hepatic cyst which grew over a 10-year period: (a) first sonography; (b) sonography 10 years later.

Complications are uncommon. Intracystic bleeding is by far the most frequent [3,16]. It is presumed to result from the erosion of an artery adjacent to the cyst. The clinical manifestations consist of sudden, severe pain and increase in the size of the cyst. The pain resolves in a few days. There is no evidence of anaemia, and the liver tests can only show a moderate elevation of γ-glutamyltransferase. At ultrasonography, echoic and mobile material, corresponding to clots, is present in the dependent part of the cyst, but thin and mobile septations may also be observed in haemorrhagic cysts (Fig. 4a). CT is usually unable to detect intracystic bleeding. MRI is very specific (Figs 4b–d). The complicated cysts are hyperintense on both T1- and T2-weighted sequences [17]. In most cases, the signal is heterogeneous on T1-weighted sequences (Fig. 4b). Thickened wall and fluid level may be seen (Fig. 4d).

Other complications are very uncommon. Spontaneous rupture may occur in the peritoneal cavity [18] or, more rarely, in the pleural cavity or the duodenum [19]. Rupture may also result from trauma [20] (Fig. 5). Unlike hydatid cysts, peritoneal perforation of simple cysts is exceptional and self-limited. Severe haemoperitoneum has only been described in patients with polycystic liver disease undergoing dialysis. Bacterial infection, although rare, has been reported. Simple cysts can induce compression of the bile ducts [3,21–23]. Large size and proximity to the main bile ducts are predisposing factors. Patients present with rising alkaline phosphatase and abdominal pain, but jaundice is observed in some patients. At imaging, the cyst responsible for biliary abnormalities is usually centrally located and leads to bile duct dilatation (Fig. 6). Other structures may be compressed by simple cysts: the inferior vena cava [16], which could result in clot formation and pulmonary embolism [24], and the portal vein with portal hypertension [25]. Communication with an intrahepatic duct [26], cholestasis due to haemobilia and torsion [27] have also been reported.

Squamous cell carcinoma of the liver originating from simple cysts has been reported several times in the literature [28]. It is hypothesized that the squamous epithelium arises from chronic inflammation and metaplasia. Ultrasonography and CT show large and complex cystic masses containing a solid component. Calcifications may be seen in the solid components [28].

Differential diagnosis

Simple cysts are easily distinguishable from liver abscess, necrotic malignant tumour, large haemangioma and haematoma. The clinical background of these lesions is different. At ultrasonography and CT, these lesions rarely appear as purely fluid-filled with sharply defined areas. However, some cystic metastases of endocrine origin or secondary to sarcomas can sometimes be difficult to distinguish from liver cysts because these tumours can be purely cystic. Careful analysis of the cystic wall usually demonstrates wall thickening or wall enhancement.

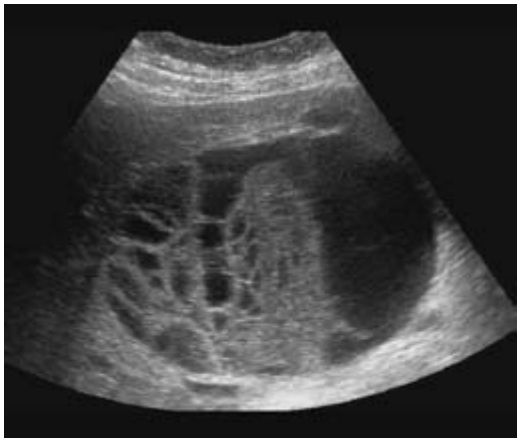

(a)

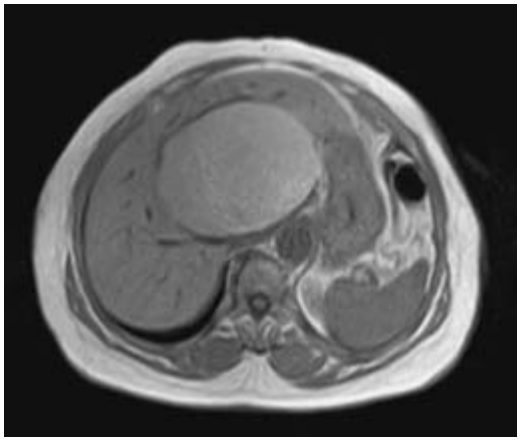

(b)

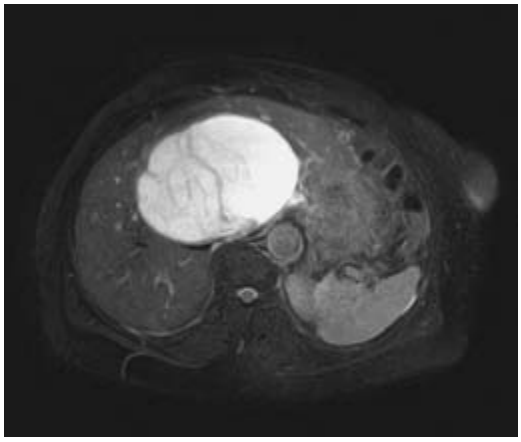

(c)

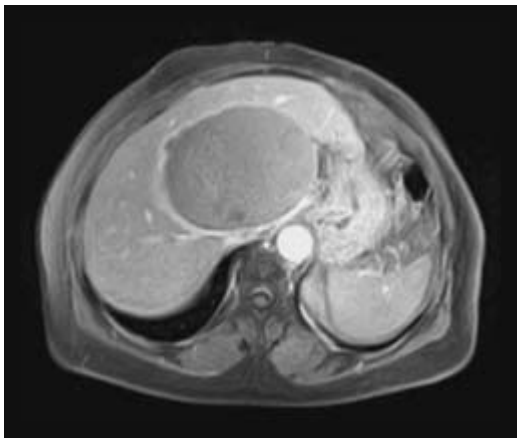

(d)

Fig. 4 (*opposite*) Haemorrhagic cyst. The cyst has a complex appearance mainly at ultrasonography and MRI. (a) Ultrasonography shows echoic and mobile material within a cystic lesion. (b–d) MRI. The cyst is strongly hyperintense on T1- (b) and T2-weighted images (c). Septations are often seen. In contrast to non-complicated cysts, the wall may enhance after administration of chelates of gadolinium (d).

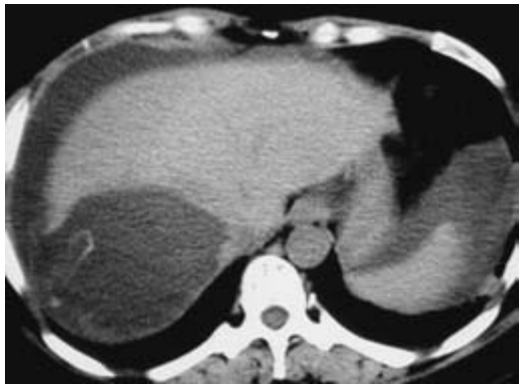

Fig. 5 Spontaneous rupture of a simple cyst on unenhanced CT. The cyst is ill-defined and communicates with peritoneal effusion.

Fig. 6 Large simple hepatic cyst causing intrahepatic bile duct dilatation on enhanced CT. Large size and central location are the main predisposing factors.

The distinction between simple cyst and hydatid disease can be more difficult. Several characteristics of the simple cyst and hydatid disease, listed in Table 1, usually allow a clear distinction between the two diseases. However, difficulties may result from the following: (i) hydatid disease may have been contracted in an area where this parasitic infection is not endemic; (ii) calcifications, septations and split walls may be absent in hydatid cysts; (iii) septations may be observed in complicated cysts with intracystic haemorrhage or caused by contiguous simple cysts; (iv) serological tests for hydatid disease may be negative in some patients with hydatid cyst. In doubtful cases, serological tests for

Table 1 Distinctive characteristics of simple hepatic cyst, hydatid cyst of the liver and biliary cystadenoma.

	Simple cyst	Hydatid cyst	Biliary cystadenoma
Septations	Absent	Common	Common
Calcifications	Absent	Common	Possible
Split wall	Absent	Possible	Absent
Papillary projections	Absent	Absent	Common
Communication with the biliary tree	Absent	Possible	Rare
Serological tests for hydatid disease	Negative	Positive[a]	Negative

[a] In most, but not in all, patients with hydatid disease.

this parasitic infection must be performed as well as microscopic examination of cystic fluid obtained by aspiration [29].

Distinction between a haemorrhagic cyst and a cystadenoma may be difficult too. The presence of associated typical hepatic cysts and the lack of enhancement of the septations after contrast injection in haemorrhagic cyst are helpful in suggesting the diagnosis of simple cyst (Table 1) [30].

Treatment

Asymptomatic liver cysts, even when large, need no treatment. When symptoms are present, treatment is indicated only if these symptoms are clearly related to the cyst. One should be very cautious before advocating any form of treatment in patients with cysts that are smaller than 8 cm and that do not protrude outside the liver surface. In case of doubt, an initial ultrasound-guided aspiration of the cyst is warranted to confirm that subsequent definitive treatment will resolve symptoms: if aspiration has no influence on the symptoms, an alternative source of symptoms should be investigated. Importantly, simple aspiration should never be used as definitive treatment because cyst recurrence is almost certain [31]. The treatment of simple cysts has changed over the last decades because of interventional procedures and the development of laparoscopy. Treatments include aspiration and sclerosis, laparoscopy and laparotomy for either resection or open fenestration. The choice depends on the cyst location, number and the complications. For instance, cysts in the dome of the liver can pose technical problems if the laparoscopic approach is used.

Percutaneous aspiration and sclerotherapy

This treatment is based on injection of a sclerosing agent into the cyst cavity, which aims at the destruction of the epithelium lining. The most frequently used sclerosing agent is ethanol. The cyst is punctured under ultrasound guidance. Cyst contents are aspirated, and biochemical analysis is performed in uncertain cases. A pigtail catheter is inserted into the cyst by a Seldinger technique. The volume of the aspiration is measured, and a cystogram is performed to check any vascular or biliary communication or perforation into the peritoneal cavity. After complete aspiration of the contrast medium, sterile absolute alcohol is injected depending on the cyst volume, but not exceeding a total amount of 100 mL. The posture of the patient varies to ensure complete exposure of the sclerosing agent to the cyst wall (a total of 40 min exposure is the rule). Then, the ethanol is aspirated and the catheter is removed. Complications include severe abdominal pain during intracystic injection (generally due to extravasation of alcohol into the peritoneal cavity; this explains why this procedure should be done under complete sedation), alcohol intoxication, hypotension, pleural effusion, peritoneal extravasation, infection and inflammatory changes of the cysts. Overall, morbidity is less than 10%. Minocycline hydrochloride has been used as an alternative to ethanol and seems to be associated with fewer side-effects, although it may require multiple injections [32]. Although sclerotherapy has been used for almost 15 years, there are few large studies with prolonged follow-up [32–36]. The success rates range between 70% and 95%. Repeat aspiration and sclerotherapy may be required. Large cysts could have two sessions of sclerotherapy with a 24-h interval with the catheter left in the cyst between the sessions. Contraindication to this treatment is the presence of bile in the cyst cavity or leakage of contrast media injected in the cyst into the bile duct.

Laparoscopy

The laparoscopic technique has evolved recently and is the preferred treatment for some authors [37–42]. The laparoscopic approach permits both partial excision (including fenestration) and total excision. The goal of the fenestration is to establish a large communication between the cyst and the peritoneal cavity. Fluid continues to be produced by the epithelium lining but is reabsorbed by the peritoneum. Laparoscopic management has some advantages: it is less invasive than laparotomy and involves a shorter hospital stay. However, it has drawbacks: limited access to deep-seated or posteriorly situated cysts, in patients with a history of previous abdominal surgery (because of adhesions), when haemorrhage or infection within a liver cyst results in changes that mimic a liver tumour or a parasitic cyst, and in patients with multiple cysts unless a large accessible cyst is symptomatic. Similar to the experience of percutaneous aspiration and sclerosis, the reported number of patients treated is small, and the duration of follow-up is short. Success ranges from 75% to 100%. Conversion to an

open laparotomy for treatment in these select patients may be required. The need for careful patient selection seems crucial [39,42–44]. Complications occur in 0–15% of patients and include shoulder pain, dyspnoea, pleural effusion, ascites (especially when the cyst is very large because fluid secretion may overflow the resorption capacity of the peritoneum), haemorrhage, infection and subhepatic bile collection. No mortality has been reported. Recurrence rate is less than 17% [42,43]. In patients with multiple cysts, the long-term outcome is similar to that in patients with single cysts [45].

Laparotomy

This was the treatment of choice for simple cysts before the percutaneous and laparoscopic techniques became widespread. The surgical technique was either partial or total cystectomy, and rarely hepatic resection. In contrast to total cystectomy or hepatic resection, partial cystectomy is associated with a risk of recurrence [9].

References

1 Terada T, Nakanuma Y, Ohta T *et al.* (1991) Mucin-histochemical and immunohistochemical profiles of epithelial cells of several types of hepatic cysts. *Virchows Arch A Pathol Anat Histopathol* 419, 499–504.

2 Flagg RS, Robinson DW (1967) Solitary non parasitic hepatic cysts. Report of oldest known case and review of the literature. *Arch Surg* 95, 964–973.

3 Moreaux J, Bloch P (1971) Les kystes biliaires solitaires du foie. *Arch Franç Mal Appar Dig* 60, 203–224.

4 Larsen KA (1961) Benign lesions affecting the bile ducts in the post-mortem cholangiogram. *Acta Pathol Microbiol Immunol Scand* 51, 47–62.

5 Gaines PA, Sampson MA (1989) The prevalence and characterization of simple hepatic cysts by ultrasound examination. *Br J Radiol* 62, 335–337.

6 Caremani M, Vincenti A, Benci A *et al.* (1993) Echographic epidemiology of non-parasitic hepatic cysts. *J Clin Ultrasound* 21, 115–118.

7 Carrim ZI, Murchison JT (2003) The prevalence of simple renal and hepatic cysts detected by spiral computed tomography. *Clin Radiol* 58, 626–629.

8 Hadad AR, Westbrook KC, Graham GG *et al.* (1977) Symptomatic non parasitic liver cysts. *Am J Surg* 134, 739–744.

9 Karavias DD, Tsamandas AC, Payatake AH (2000) Simple (non-parasitic) liver cysts: clinical presentation and outcome. *Hepato-Gastroenterology* 47, 1439–1443.

10 Spiegel RM, King DL, Green WM (1978) Ultrasonography of primary cysts of the liver. *Am J Roentgenol* 131, 235–238.

11 Mortele KJ, Ros PR (2001) Cystic focal liver lesions in the adult: differential CT and MR imaging features. *Radiographics* 21, 895–910.

12 Roemer CE, Ferrucci JT, Mueller PR *et al.* (1981) Hepatic cysts: diagnosis and therapy by sonographic needle aspiration. Am J Roentgenol 136, 1065–1070.

13 Pinto MM, Kaye AD (1988) Fine needle aspiration of cystic liver lesions. Cytologic examination and carcinoembryonic antigen assay of cyst contents. *Acta Cytol* 33, 852–856.

14 Sato T, Kokudo N, Seki M *et al.* (1999) A case of simple liver cyst with markedly elevated CEA level in the cystic fluid. *Nippon Shokakibyo Gakkai Zasshi* 96, 530–534.

15 Ikeda Y, Kawasaki K, Uchida H *et al.* (1996) Treatment of large cyst evaluated with CA 19-9 In the cystic fluid. *HepatoPancreatoBil Surg* 9, 179–182.

16 Frisell J, Röjdmark S, Arvidsson H *et al.* (1979) Compression of the inferior caval vein. A rare complication of a large non-parasitic liver cyst. *Acta Med Scand* 205, 541–542.

17 Vilgrain V, Silbermann O, Benhamou JP *et al.* (1993) MR imaging in intracystic hemorrhage of simple hepatic cysts. *Abdom Imaging* 18, 164–167.

18 Akriviadis EA, Steindel H, Ralls P *et al.* (1989) Spontaneous rupture of nonparasitic cyst of the liver. *Gastroenterology* 97, 213–215.

19 Williamson RCN, Ramus NI, Shorey BA (1978) Congenital solitary cysts of the liver and spleen. *Br J Surg* 65, 871–876.

20 Yamaguchi M, Kuzume M, Matsumoto T *et al.* (1999) Spontaneous rupture of a nonparasitic liver cyst complicated by intracystic hemorrhage. *J Gastroenterol* 34, 645–648.

21 Santman FW, Thijs LG, Van der Veen EA *et al.* (1977) Intermittent jaundice: a rare complication of solitary nonparasitic liver cyst. *Gastroenterology* 72, 325–328.

22 Clinkscales NB, Trigg LP, Poklepovic J (1985) Obstructive jaundice secondary to benign hepatic cyst. *Radiology* 154, 643–644.

23 Cappell MS (1988) Obstructive jaundice from benign, nonparasitic hepatic cysts: identification of risk factors and percutaneous aspiration for diagnosis and treatment. *Am J Gastroenterol* 83, 93–96.

24 Buyse S, Asselah T, Vilgrain V *et al.* (2004) Acute pulmonary embolism: a rare complication of a large non-parasitic hepatic cyst. *Eur J Gastroenterol Hepatol* 16, 1241–1244.

25 Lebon J, Bourgeon R, Claude R (1955) Kyste solitaire du foie. *Arch Franç Mal Appar Dig* 44, 1274–1277.

26 Perreau P, Guntz M, Renier JC (1965) Kyste solitaire non parasitaire du foie. Considérations anatomo-cliniques, diagnostiques et thérapeutiques. *Arch Franç Mal Appar Dig* 54, 881–888.

27 Soud SC, Watson A (1974) Solitary cyst of the liver presenting as an abdominal emergency. *Postgrad Med J* 50, 48–50.

28 Yagi H, Ueda M, Kawachi S *et al.* (2004) Squamous cell carcinoma of the liver originating from non-parasitic cysts after a 15 year follow-up. *Eur J Gastroenterol Hepatol* 16, 1051–1056.

29 Giuliante F, D'Acapito F, Vellone M *et al.* (2003) Risk for laparoscopic fenestration of liver cysts. *Surg Endosc* 1, 1735–1738.

30 Vuillemin-Bodaghi V, Zins M, Vullierme MP *et al.* (1997) Imaging of atypical cysts of the liver. Study of 26 surgically treated cases. *Gastroenterol Clin Biol* 21, 394–399.

31 Saini S, Mueller PR, Ferrucci JT, Jr *et al.* (1983) Percutaneous aspiration of hepatic cysts does not provide definitive therapy. *Am J Roentgenol* 141, 559–560.

32 Yamada N, Shinzawa H, Ukai K *et al.* (1994) Treatment of symptomatic hepatic cysts by percutaneous instillation of minocycline hydrochloride. *Dig Dis Sci* 39, 2503–2509.

33 Simonetti G, Profili S, Sergiocomi GL *et al.* (1993) Percutaneous treatment of hepatic cysts by aspiration and sclerotherapy. *Cardiovasc Intervent Radiol* 16, 81–84.

34 Montorsi M, Torzilli G, Fumagalli U *et al.* Percutaneous alcohol sclerotherapy of simple hepatic cysts. Results from a multicentre survey in Italy. HPB-Surgery (1994) 8, 89–94.

35 Tanaka Y, Ogino M, Tokuda H *et al.* (1996) Examination of percutaneous minocycline hydrochloride injection therapy for hepatic cyst by one puncture method. *Nippon Shokakibyo Gakkai Sasshi* 93, 828–836.

36 Tikkakoski T, Mäkelä JT, Leinonen S, *et al.* (1996) Treatment of symptomatic congenital hepatic cysts with single-session percutaneous drainage and ethanol sclerosis: technique and outcome. *J Vasc Interv Radiol* 7, 235–239.
37 Morino M, De Guili M, Festa V *et al.* (1994) Laparoscopic management of symptomatic nonparasitic cysts of the liver. Indications and results. *Ann Surg* 219, 157–164.
38 Gigot JF, Jadoul P, Que F *et al.* (1997) Adult polycystic liver disease: is fenestration the most adequate operation for long-term management? *Ann Surg* 225, 286–294.
39 Emmermann A, Zornig C, Lloyd DM *et al.* (1997) Laparoscopic treatment of nonparasitic cysts of the liver with omental transposition flap. *Surg Endosc* 11, 734–736.
40 Fabiani P, Mazzsa D, Toouli J *et al.* (1997) Laparoscopic fenestration of symptomatic non-parasitic cysts of the liver. *Br J Surg (London)* 84, 321–322.
41 Klingler PJ, Gadenstätter M, Schmid T *et al.* (1997) Treatment of hepatic cysts in the era of laparoscopic surgery (review). *Br J Surg* 84, 438–444.
42 Martin IJ, McKinley AJ, Currie EJ *et al.* (1998) Tailoring the management of nonparasitic liver cysts. *Ann Surg* 228, 167–172.
43 Gigot JF, Legrand M, Hubens G *et al.* (1996) Laparoscopic treatment of nonparasitic liver cysts: adequate selection of patients and surgical technique. *World J Surg* 20, 556–561.
44 Marks J, Mouiel J, Katkhouda N *et al.* (1998) Laparoscopic liver surgery: a report of 28 patients. *Surg Endosc* 12, 331–334.
45 Farges O, Bismuth H (1995) Fenestration in the management of polycystic liver disease. *World J Surg* 19, 25–30.

8.1.3. Polycystic kidney disease

Valérie Vilgrain

Autosomal dominant polycystic disease is a frequent inherited disorder involving the liver. It is genetically heterogeneous and most commonly predisposes to the development of renal and cystic cysts.

Pathology and pathogenesis

The liver cysts in patients with adult autosomal dominant polycystic kidney disease (ADPKD) are macroscopically and microscopically similar to simple cysts of the liver. The main difference between these two entities concerns the number of liver cysts: the liver cysts, when present, are multiple in all patients with ADPKD; in contrast, numerous cysts are found only in a few patients with simple cysts of the liver.

Grossly, the liver in ADPKD is enlarged and diffusely cystic, the cysts varying from < 1 mm to 12 cm or more in diameter (Fig. 1). Occasionally, one lobe, usually the left, is affected. Diffuse dilatation of the intra- and extrahepatic bile ducts has been reported in some cases. The cysts contain a clear, colourless or yellow fluid. Analysis of the cyst fluid discloses similarities to the 'bile salt-independent' fraction of human bile, suggesting that such cysts are lined by a functioning bile duct epithelium.

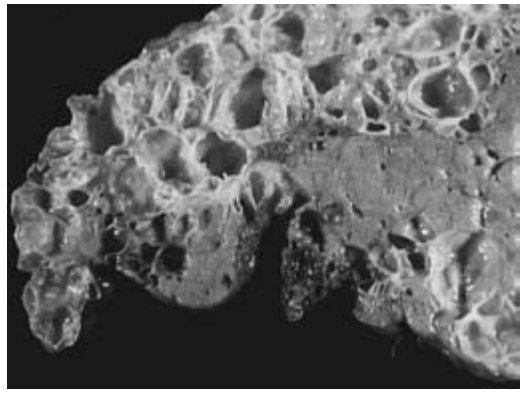

Fig. 1 Macroscopic view of multiple liver cysts in a patient with ADPKD.

Microscopically, the cysts are lined by columnar or cuboidal epithelium, but the larger cysts have a flat epithelium. Collapsed cysts resemble corpora atretica of the ovary. The supporting connective tissue is scanty except in relation to von Meyenburg complexes, a frequently associated lesion, where it may be dense and hyalinized. Inflammatory cells may infiltrate the stroma. Infected cysts contain pus and may rupture. Calcification of the wall of hepatic cysts in ADPKD has been reported.

Von Meyenburg complexes are considered to be part of the spectrum of ADPKD, and it is hypothesized that polycystic disease develops over the years by gradual cystic dilatation of these complexes [1]. It has also been suggested that the cystic dilatation of peribiliary glands may lead to the formation of the cysts in ADPKD.

Despite the large number and the large size of liver cysts, the hepatic parenchymal volume is preserved [2], which explains why normal hepatic function and normal intrahepatic circulation are maintained in most of these patients.

Genetics and molecular biology

The most common forms of ADPKD are linked to mutations in either *PKD1* or *PKD2* genes. *PKD1* [3] is localized on the short arm of chromosome 16. Transcription and translation of the *PKD1* gene produces polycystin-1, an integral membrane protein that may serve as an extracellular receptor. There are over 230 distinct mutations of the *PKD1* gene. The majority are missense or nonsense mutations, but splicing mutations and gene rearrangements have also been reported. Approximately 60% of all mutations introduce premature stop codons that result in truncated proteins [4]. It has been suggested that the type or position of mutations may predict the patient phenotype. Certain mutations are linked to intracranial aneurysms and more severe polycystic disease within individual ADPKD families [5]. Location of a mutation in the 5′ end of the gene predicts more rapid progression and greater severity of endstage renal disease [4]. *PKD1* mutations account for up to 90% of mutations in ADPKD families.

Most of the remaining are related to mutations in *PKD2* [6], localized on chromosome 4. The *PKD2* gene product, polycystin-2, is an integral membrane protein with molecular characteristics of a calcium-permeant cation channel. There are over 60 identified mutations of the *PKD2* gene, and mutations occur throughout the gene; severity of disease may vary with site of mutation in *PKD2* and the functional consequence on the resultant polycystin-2 protein. ADPKD at the cellular level is likely to be a 'molecular recessive' disease, requiring a second somatic mutation: the 'two-hit' model.

Molecular genetic testing may be considered in young (age < 30 years), presymptomatic individuals at risk of ADPKD, because ultrasonography may lack sensitivity and linkage analysis is impractical. The identification of a *PKD1* or *PKD2* mutation could affect family planning, monitoring and screening for associated conditions such as cerebral aneurysm or mitral valve prolapse.

Features of the cysts and their natural history are comparable whatever the mutation, although patients with *PKD2* mutations tend to have later onset of their disease than patients with *PKD1* mutations and approximately 16 years of increased life expectancy compared with patients who have mutations in *PKD1*. Two unrelated families have been described who, by genetic linkage analysis, lack mutations in either *PKD1* or *PKD2* [7,8]. These findings are controversial but suggest that mutations in at least a third gene may be responsible for ADPKD.

Natural history and risk factors for development and progression

Hepatic cysts, as for simple cysts, are rarely observed prior to puberty, and their prevalence increases thereafter. Kidney cysts in patients with ADKPD always precede the development of hepatic cysts. By the fifth decade of life, approximately 80% of patients with renal cysts have liver cysts [9] (Table 1). The number and size of the liver cysts are greater in females than in males, increase with the age of the patient, and are greater in patients with large renal cysts and severe kidney dysfunction than in patients with small renal cysts and mild renal insufficiency. As for simple cysts, men and women have an equal lifetime risk of developing hepatic cysts, but women experience greater numbers and larger sizes of hepatic cysts. Pregnancy and the use of female steroid hormones further increase the risk of severe hepatic cystic disease. One longitudinal study of anovulatory women with ADPKD treated with hormone replacement has suggested that estrogens may selectively increase the severity of hepatic cystic disease [10]. The pathological expansion of the liver cysts could be related to specific growth factors and cytokines contained in liver cyst fluid. Nichols *et al.* [11] have suggested an autocrine and paracrine model for ADPKD liver cyst growth. Local hypoxia induces the synthesis and release of cytokines and growth factors across the apical and basal membranes to signal to epithelial cells via apical domain receptors, endothelial cells and stellate and fibroblast cells [11].

Clinical features

Most patients with polycystic liver are asymptomatic or may note only a protuberant abdomen. Patients with ADPKD can be arbitrarily divided into two groups, massive or minimal, based on a definition of mass of total liver cyst/parenchymal volume ratio > 1 [2]. Most symptomatic cases are restricted to patients with massive hepatic cystic disease, with abdominal pain and discomfort and shortness of breath correlating with severity of hepatic cystic disease. Early postprandial fullness is mainly observed in patients with severe involvement of the left liver that compresses the stomach.

At clinical examination of patients with large cysts, the liver is enlarged, sometimes enormous; the cysts may be so tense that they can be confused with solid tumours. Usually, there are no signs or symptoms suggesting cholestasis, liver failure or portal hypertension. Liver tests are usually normal or show only a slight elevation in gamma-glutamyltransferase.

Imaging findings

Ultrasonography shows round, smooth-walled anechoic areas with marked distal echo enhancement. ADPKD typically appears as multiple homogeneous and hypoattenuating cystic lesions with a regular outline on non-enhanced computerized tomography (CT) with no wall or content enhancement on

Table 1 Age and prevalence of liver cysts demonstrated by liver scintiscan [48] and by computerized tomography [49] in patients with adult polycystic kidney disease.

	Series of Milutinovic *et al.* [48]		Series of Thomsen and Thaysen [49]	
Age (years)	No. of patients studied	Percentage of patients with liver cysts	No. of patients studied	Percentage of patients with liver cysts
10–19	12	0	0	
20–29	47	11	1	0
30–39	31	32	15	40
40–49	30	37	17	53
50–59	25	40	20	65
> 60	13	77	13	87
Total/mean	158	29	66	59

contrast-enhanced images (Figs 2a and b). Coalescence of cysts produces bizarre appearances. Coalescence of large cysts causes distortion of the shape of an individual cyst and may give a false appearance of a multiloculated or septated cystic lesion. Remaining hepatic parenchyma between the cysts may resemble mural nodules or thickened internal septa [12]. Calcification of the cysts has been reported, but is very rare [13,14] (Fig. 3a). On magnetic resonance imaging (MRI), hepatic cysts in ADPKD are homogeneously and strongly hyperintense on T2-weighted MR images owing to their pure fluid content (Fig. 3e) and strongly hypointense on T1-weighted images except when they are complicated by haemorrhage when they appear hyperintense on T1-weighted sequences. They do not enhance after administration of gadolinium contrast material.

In a series of 44 patients with ADPKD, CT showed many large liver cysts in 31.8% of patients, small liver cysts in 25% and no liver cysts in 43.2% [15]. Patients with many large cysts often showed increased liver volumes [2,15]. Splenic volumes did not differ significantly in patients with and without liver cysts, suggesting that portal hypertension is rarely associated with cystic liver disease. There was no correlation between severity of liver involvement and extent of renal cystic disease, as determined from urea nitrogen and creatinine levels and renal volumes.

In another series of 24 patients with ADPKD, an attempt was made to categorize these cysts into peribiliary cysts (located adjacent to larger portal triads or in the hepatic hilum) and intrahepatic cysts (within the liver parenchyma but not in

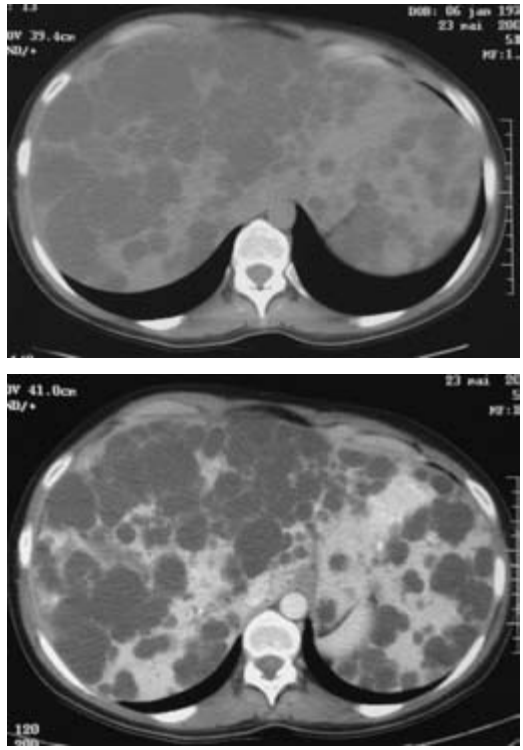

(a)

(b)

Fig. 2 Unenhanced (a) and enhanced (b) CT images of an ADPKD patient. CT shows multiple small cysts that do not enhance after the administration of contrast medium.

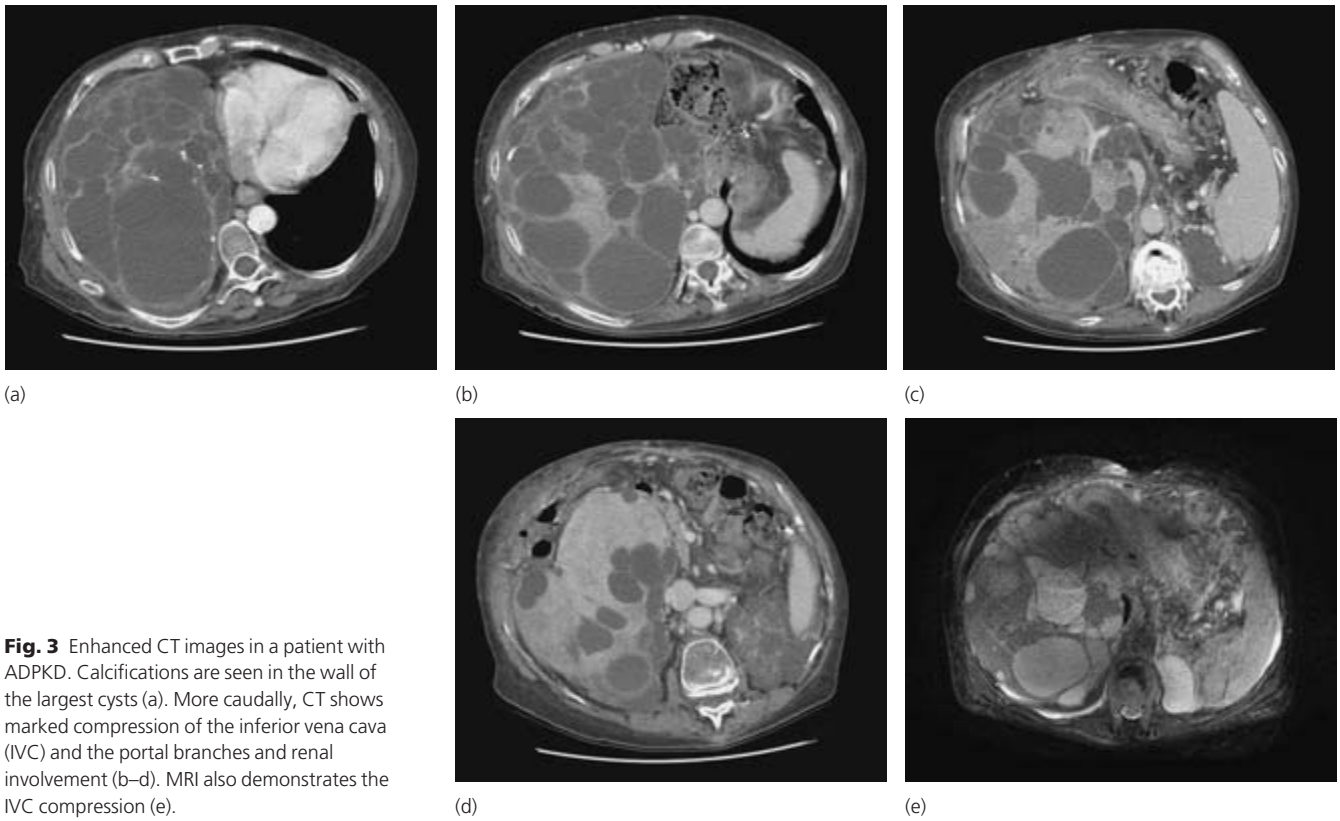

(a) (b) (c) (d) (e)

Fig. 3 Enhanced CT images in a patient with ADPKD. Calcifications are seen in the wall of the largest cysts (a). More caudally, CT shows marked compression of the inferior vena cava (IVC) and the portal branches and renal involvement (b–d). MRI also demonstrates the IVC compression (e).

contact with larger portal triads). Liver cysts were seen in 13 (54%) patients. Intrahepatic cysts were seen in 12 patients and were mainly peripheral in location with sizes ranging from less than 10 mm to 8 cm. Peribiliary cysts were seen in all 13 patients and were usually less than 10 mm in size. These cysts were seen as discrete cysts (eight patients), a string of cysts (10 patients) or as a tubular structure paralleling the portal vessels, mimicking biliary dilatation (11 patients). Twelve patients also showed indeterminate cysts, which defied definite categorization into either type; two common causes of confusion included large (more than 10 mm) discrete cysts in the hilar region and the presence of a vessel adjacent to peripheral cysts [16].

Although the diagnosis of polycystic disease is easily made with both CT and MRI, MRI is more sensitive for the detection of complicated cysts.

Complications

Liver cysts grow slowly. In some patients whose life has been prolonged by haemodialysis or renal transplantation, the size of liver cysts may become enormous.

The most common, clinically relevant complications arising from hepatic cysts are intracystic haemorrhage, infection or posttraumatic rupture (Table 2). Cystadenocarcinoma, biliary obstruction, Budd–Chiari syndrome, portal hypertension or hepatic failure are rarely reported.

Patients with haemorrhagic hepatic cysts usually present with a recent history of abdominal pain, but intracystic haemorrhage may also be detected fortuitously at imaging. CT is often unremarkable, whereas ultrasonography reveals heterogeneous content appearing as intracystic echogenic deposits or thin and mobile septations. In contrast to the septations observed in other tumours such as cystadenocarcinomas, these septations are not seen on CT images. MRI is key, demonstrating a hyperintensity on T1-weighted sequences (Fig. 4a) and a normal appearance on T2-weighted sequences (Fig. 4b) [17]. Theoretically, hyperintensity in cystic lesions on T1-weighted images could also suggest mucin, high protein content or fat, but the diagnosis of haemorrhagic hepatic cyst is easy because of the clinical context.

Table 2 Clinical complications of hepatic cysts in ADPKD.

Complications	Diagnostic tests
Cyst infection	Ultrasound Puncture
Cyst haemorrhage	Ultrasound MRI
Cyst rupture	Ultrasound CT
Portal hypertension	CT Endoscopy
Hepatic venous outflow obstruction	Ultrasound MRI Hepatic venous pressure
Biliary obstruction	MR cholangiography

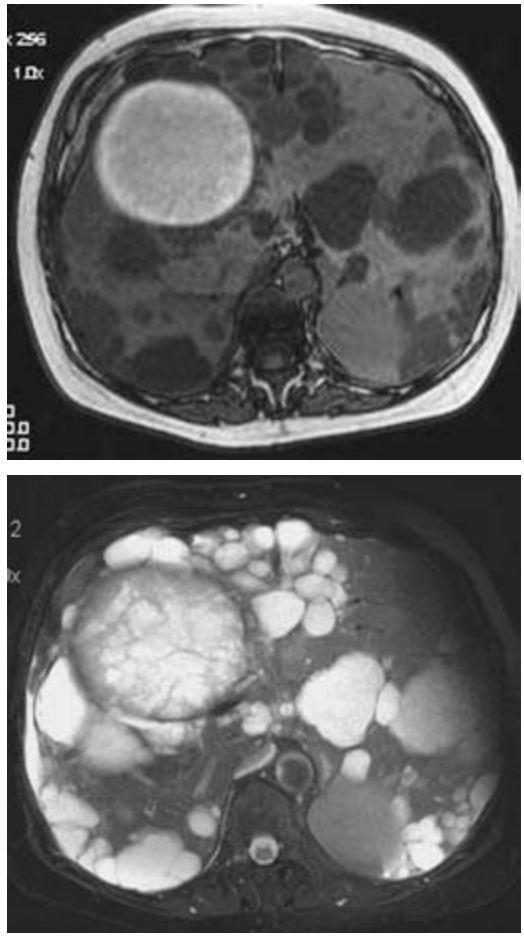

Fig. 4 MRI of an intracystic haemorrhage in an ADPKD patient. The complicated cyst has a signal intensity different from that of the non-complicated cysts: hyperintense on T1- (a) and hyperintense and heterogeneous on T2-weighted images (b).

Bacterial infection of a cyst [18,19] may be facilitated by immunosuppressive drugs administered to renal transplant recipients [20]. The clinical manifestations of patients with hepatic cyst infection are an acute (58%) or subacute (42%) febrile illness, typically associated with tenderness in the right upper quadrant, leucocytosis, a very high erythrocyte sedimentation rate, but minor abnormalities in liver function tests [19]. Bacteraemia is often present. Complex cysts are observed whatever the imaging modality: ultrasonography, CT and MRI. On CT scanning, the finding of fluid levels within cysts, cyst wall thickening, intracystic gas bubbles, cyst wall calcification and heterogeneous or increased density have all been correlated with infection of a hepatic cyst. Ultrasound imaging may show changes such as indistinct cyst margins or cystic wall changes as well as echogenic fluid. ^{111}In leukocyte scans are positive. An unfavourable outcome may be observed in patients

treated only with antibiotics, therefore the treatment of choice is a combination of percutaneous drainage and antimicrobial therapy.

Cystic rupture is rare, and patients usually present with an acute history of abdominal pain. Imaging findings show an irregular subcapsular cyst with liver capsule disruption and the presence of ascites, which is very infrequent in ADPKD patients.

Obstructive jaundice due to polycystic liver disease is rare [21,22]. Immense size and porta hepatis proximity are major risk factors for developing jaundice. Abdominal pain of recent onset and rising alkaline phosphatase levels are warning signs that this complication is developing. In these situations, treatment prior to developing jaundice is recommended, and relief of jaundice may be obtained by percutaneous cyst aspiration, sclerosis or resection [23,24].

Jaundice due to malignant obstruction from cholangiocarcinoma has been described rarely with a total of 10 cases in the English literature, although whether the abnormal biliary epithelium of the hepatic cysts predisposes to the development of cholangiocarcinoma is unknown [25]. A potential association between ADPKD and ampulla of Vater adenomas may exist given the report of two sisters diagnosed with symptomatic biliary obstruction due to ampullary adenomas. A more recent case of ampullary adenoma in the setting of ADPKD has also been reported [26]. These few cases notwithstanding, it would seem that an ampullary adenoma in the setting of ADPKD is more likely to be the case of a rare finding superimposed on a common genetic disorder such as ADPKD.

Hepatic venous outflow obstruction is a rare but major complication of polycystic liver disease. All patients present with severe exudative ascites [27]. Some possible predisposing factors may be identified such as recent abdominal surgery. All patients have extrinsic compression of the hepatic veins and the inferior vena cava by hepatic cysts (Fig. 3b and e), and some have proven thrombosis of the inferior vena cava and/or hepatic veins [28]. Ultrasound and MRI are helpful in determining the level of obstruction in the inferior vena cava and the patency of the hepatic and portal veins. The outcome is worse in patients with thrombosis but, in patients without thrombosis, recovery is observed after alcohol sclerosis of a large dominant cyst or after hepatic resection and cyst fenestration. Hepatic venous outflow obstruction has probably been under-recognized as a cause of portal hypertension, ascites and liver dysfunction in polycystic liver disease.

The other complications, which are less common, include portal hypertension by compression of the portal branches causing gastrointestinal bleeding (Fig. 3c) [29] or refractory ascites [30], right atrium compression causing hypotension and leg oedema [31], denutrition by compression of the stomach and cholangiocellular carcinoma [15].

Associated conditions may include cerebral aneurysm and mitral valve prolapse. Cerebral aneurysms may be linked to the *PKD1* mutation [4]. Most of these aneurysms are small and do not appear to be at increased risk of growth or rupture [32].

Differential diagnosis

Liver cysts associated with ADPKD must be distinguished from multiple simple cysts of the liver. First, as ADPKD is transmitted as an autosomal dominant trait, it is usual for one parent or sibling to have been recognized as suffering from the disease. In the case of simple cysts of the liver, which are non-inherited malformations, parents and siblings are not affected by the disease. However, the presentation of ADPKD varies, and affected individuals may be asymptomatic and therefore unrecognized. Secondly, multiple renal cysts are constantly associated with liver cysts in ADPKD (Fig. 3d), whereas renal cysts are absent in multiple simple cysts of the liver. However, as mentioned above, one or a few simple renal cysts may be fortuitously associated with simple cysts of the liver. Patients with this fortuitous association must not be regarded as affected with ADPKD.

Treatment

Medical treatment

There are no effective medical therapies for polycystic liver disease. Although secretin triggers secretion by normal intrahepatic bile duct cells, somatostatin analogues have failed to reduce hepatic cyst growth or size [33]. There is no strong evidence that estrogen replacement therapy should be avoided, when indicated.

Cyst aspiration and sclerosis

Symptomatic patients with one or a few dominant cysts may be considered for cyst aspiration and sclerosis. Most patients with polycystic disease either have too many cysts or their cysts are of insufficient size to warrant this approach. Cyst sclerotherapy requires ultrasonographic or CT-guided percutaneous puncture of the targeted cyst and placement of an intracystic drainage catheter. For large cysts (> 100 mL or a diameter of ≥ 6 cm), the catheter may be left in place for 24 h, and a second treatment may be performed the following day. Success in obliterating individual cysts in polycystic patients is approximately 70–90% [34].

Surgical treatments

Symptoms in polycystic liver disease are mainly related to the volume of the liver rather than to a specific cyst, and the aim of treatment is to decompress the whole liver or remove as many cysts as possible. These objectives can be achieved in highly symptomatic patients by open fenestration, liver resection or liver transplantation. The aim of fenestration is to unroof as many cysts as possible, starting from the superficial cyst followed by stepwise opening of the deeper cysts. The laparoscopic approach is debated. For some authors, it is an alternative surgical technique [35]. Advantages of laparoscopic surgery

include less morbidity, reduced hospital stay and the potential for outpatient surgical management. However, symptoms recur in approximately half of those cases. For others, the laparoscopic approach is contraindicated [36,37]. The vascular structures that are compressed by the cysts may be injured inadvertently.

Partial liver resection in combination with fenestration of the remnant liver has been proposed [38–40] in order to increase the regeneration of the non-cystic liver. Hepatic resection with cyst fenestration takes advantage of both operative techniques by removing diffusely cystic liver that cannot be adequately fenestrated and fenestrating cysts in relatively spared liver to preserve liver function.

Liver transplantation should be considered in patients in whom the above procedures have been unsuccessful, but it has only been performed in a very few patients [41–45]. Orthotopic liver transplantation for ADPKD is clearly indicated for patients with progressive ADPKD after resection/fenestration, in patients with concurrent liver dysfunction and renal failure and in those patients with diffuse ADPKD without segmental sparing. Operative mortality for orthotopic liver transplantation for ADPKD has approached 12%. Risk is increased by prior intervention, especially with open abdominal procedures. Orthotopic liver transplantation is particularly challenging in ADPKD. The massive size of the liver makes the access to the suprahepatic inferior vena cava extremely difficult.

All these treatments lack consensus on their respective indications. Available data indicate that: (i) open fenestration of the maximum number of cysts is associated with significant morbidity but provides long-term relief of symptoms in patients who do not have diffuse replacement of their liver by cysts [40,46,47]; (ii) liver resection, which often proves possible as a result of an asymmetry in cyst distribution, is a demanding procedure, associated with high morbidity rates, but achieves better results than fenestration alone; long-term sustained reduction in symptoms is observed in more than 90% of patients [39]; (iii) liver transplantation cures patients [45] but has its inherent mortality with 5-year survival of 69% (US scientific registry of transplant recipients). Despite its risk, transplantation is the only option in patients with kidney failure resulting from ADPKD or denutrition resulting from massive hepatomegaly. If liver transplantation is indicated *per se*, simultaneous renal transplantation should be considered if renal function is impaired. The rationale for a combined liver–kidney transplant using the grafts from the same donor are: (i) immunosuppression is difficult to manage in patients with renal failure; (ii) renal function may deteriorate further after liver transplantation because of the nephrotoxicity of immunosuppressive agents and/or progression of the kidney disease; (iii) rejection episodes seem to be fewer in patients receiving both organs from the same donor than from two donors.

Asymptomatic or paucisymptomatic patients should not be operated on. If kidney transplantation is indicated *per se*, simultaneous liver transplantation should be performed if liver cysts determine incapacitating manifestations. As immunosuppression following kidney transplantation is similar to that after liver transplantation, the additional risk of simultaneous liver transplantation is only related to surgical complications and not to immunosuppression.

References

1 Melnick PJ (1975) Polycystic liver. Analysis of seventy cases. *Arch Pathol Lab Med* 59, 162–172.

2 Everson GT, Scherzinger A, Berger-Leff N *et al.* (1988) Polycystic liver disease: quantitation of parenchymal and cyst volumes from computed tomography images and clinical correlates of hepatic cysts. *Hepatology* 8, 1627–1634.

3 Ward CJ, Turley H, Ong AC *et al.* (1996) Polycystin, the polycystic kidney disease 1 protein, is expressed by epithelial cells in fetal, adult, and polycystic kidney. *Proc Natl Acad Sci USA* 93, 1524–1528.

4 Rossetti S, Chauveau D, Kubly V *et al.* (2003) Association of mutation position in polycystic kidney disease 1 (PKD1) gene and development of a vascular phenotype. *Lancet* 361, 2196–2201.

5 Watnick TJ, Phakdeekitcharoen B, Johnson A *et al.* (1999) Mutation detection of PKD1 identifies a novel mutation common to three families with aneurysms and/or very-early-onset disease. *Am J Hum Genet* 65, 1561–1571.

6 Mochizuki T, Wu G, Hayashi T *et al.* (1996) PKD2, a gene for polycystic kidney disease that encodes an integral membrane protein. *Science* 272, 1339–1342.

7 deAlmeida S, deAlmeida E, Peters D *et al.* (1995) ADPKD: evidence for the existence of a third locus in a Portuguese family. *Hum Genet* 96, 83–88.

8 Ariza M, Alvarez V, Marin R *et al.* (1997) 96A family with a milder form of ADPKD is not linked to PKD1(16p) or PKD2(4q) genes. *J Med Genet* 34, 587–589.

9 Gabow PA, Johnson AM, Kaehny WD *et al.* (1990) Risk factors for the development of hepatic cysts in autosomal dominant polycystic kidney disease. *Hepatology* 11, 1033–1037.

10 Shrestha R, McKinley C, Russ P *et al.* (1997) Postmenopausal estrogen therapy selectively stimulates hepatic enlargement in women with autosomal dominant polycystic kidney disease. *Hepatology* 26, 1282–1286.

11 Nichols MT, Gidey E, Matzakos T *et al.* (2004) Secretion of cytokines and growth factors into autosomal dominant polycystic kidney disease liver cyst fluid. *Hepatology* 40, 836–846.

12 Wan SKH, Cochlin DL (1990) Sonographic and computed tomographic features of polycystic disease of the liver. *Gastrointest Radiol* 15, 310–312.

13 Kutcher R, Schneider M, Gordon DH (1977) Calcification in polycystic disease. *Radiology* 122, 77–80.

14 Coffin B, Hadengue A, Degos F *et al.* (1990) Calcified hepatic and renal cysts in adult dominant polycystic kidney disease. *Dig Dis Sci* 35, 1172–1175.

15 Levine E, Cook LT, Grantham JJ (1985) Liver cysts in autosomal-dominant polycystic kidney disease: clinical and computed tomographic study. *Am J Roentgenol* 145, 229–233.

16 Gupta S, Seith A, Dhiman RK *et al.* (1999) CT of liver cysts in patients with autosomal dominant polycystic kidney disease. *Acta Radiol* 40, 444–448.

17 Wilcox DM, Weinreb JC, Lesh P (1985) MR imaging of a hemorrhagic hepatic cyst in a patient with polycystic liver disease. *J Comput Assist Tomogr* 9,183–185.
18 Robson GB, Fenster F (1964) Fatal liver abscess developing in a polycystic liver. *Gastroenterology* 47, 82.
19 Telenti A, Torres VE, Gross JB Jr *et al.* (1990) Hepatic cyst infection in autosomal dominant polycystic kidney disease. *Mayo Clin Proc* 65, 933–942.
20 Bourgeois M, Kinneart P, Vereerstraeten P *et al.* (1983) Infection of hepatic cysts following kidney transplantation in polycystic disease. *World J Surg* 7, 629–631.
21 Howard RJ, Hanson RF, Delaney JP (1976) Jaundice associated with polycystic liver disease. Relief by surgical decompression of the cysts. *Arch Surg* 111, 816–817.
22 Ergün H, Wolf BH, Hissung SL (1980) Obstructive jaundice caused by polycystic liver disease. *Radiology* 136, 435–436.
23 Garber S, Mathieson J, Cooperberg PL (1993) Percutaneous sclerosis of hepatic cysts to treat obstructive jaundice in a patient with polycystic liver disease. *Am J Roentgenol* 161, 77–78.
24 Lerner ME, Roshkow JE, Smithline A *et al.* (1992) Polycystic liver disease with obstructive jaundice: treatment with ultrasound-guided cyst aspiration. *Gastrointest Radiol* 17, 46–48.
25 Arnold HL, Harrison SA (2005) New advances in evaluation and management of patients with polycystic liver disease. *Am J Gastroenterol* 100, 1–14.
26 Serafini FM, Carey LC (1999) Adenoma of the ampulla of Vater: a genetic condition? *HPB Surg* 11, 191–193.
27 Uddin W, Ramage JK, Portmann B *et al.* (1995) Hepatic venous outflow obstruction in patients with polycystic liver disease: pathogenesis and treatment. *Gut* 36, 142–145.
28 Torres VE, Rastogi S, King BF *et al.* (1994) Hepatic venous outflow obstruction in autosomal dominant polycystic kidney disease. *J Am Soc Nephrol* 5, 1186–1192.
29 Ratcliffe PJ, Reeders S, Theaker JM (1984) Bleeding oesophageal varices and hepatic dysfunction in adult polycystic kidney disease. *Br Med J* 288, 1330–1331.
30 McGarrity TJ, Koch KL, Rasbach DA (1986) Refractory ascites associated with polycystic liver disease. Treatment with peritoneovenous shunt. *Dig Dis Sci* 31, 217–220.
31 Lasic LB, DeVita MV, Spiegel PJ *et al.* (2004) Refractory hypotension and edema caused by right atrial compression in a woman with polycystic kidney disease. *Am J Kidney Dis* 43, 13–17.
32 Gibbs GF, Huston J 3rd, Qian Q *et al.* (2004) Follow-up of intracranial aneurysms in autosomal-dominant polycystic kidney disease. *Kidney Int* 65, 1621–1627.
33 Chauveau D, Martinez F, Grunfeld JP (1993) Evaluation of octreotide in massive polycystic liver disease. 12th International Congress of Nephrology Conference Program 487A.
34 Van Sonnenberg E, Wroblicka JT, D'Agostino HB *et al.* (1994) Symptomatic hepatic cysts: percutaneous drainage and sclerosis. *Radiology* 190, 387–392.
35 Everson GT, Taylor MRG, Doctor RG (2004) Polycystic disease of the liver. *Hepatology* 40, 774–782.
36 Morino M, De Guili M, Festa V *et al.* (1994) Laparoscopic management of symptomatic nonparasitic cysts of the liver. Indications and results. *Ann Surg* 219, 157–164.
37 Kabbej M, Sauvanet A, Chauveau D *et al.* (1996) Laparoscopic fenestration in polycystic liver disease. *Br J Surg* 83, 1697–1701.
38 Soravia C, Mentha G, Giostra E *et al.* (1995) Surgery for adult polycystic liver disease. *Surgery* 117, 272–275.
39 Que F, Nagorney DM, Gross JB *et al.* (1995) Liver resection and cyst fenestration in the treatment of severe polycystic liver disease. *Gastroenterology* 108, 487–494.
40 Vons C, Chauveau D, Martinod E *et al.* (1998) Résection hépatique chez les malades atteints de polykystose hépatique. *Gastroentérol Clin Biol* 22, 50–54.
41 Starzl TE, Reyes J, Tzakis A *et al.* (1990) Liver transplantation for polycystic liver disease. *Arch Surg* 125, 575–577.
42 Washburn WK, Johnson LB, Lewis WD *et al.* (1996) Liver transplantation for adult polycystic liver disease. *Liver Transpl Surg* 2, 17–22.
43 Swenson K, Seu P, Kinkhabwala M *et al.* (1998) Liver transplantation for adult polycystic liver disease. *Hepatology* 28, 412–415.
44 Jeyarajah DR, Gonwa TA, Testa G *et al.* (1998) Liver and kidney transplantation for polycystic liver disease. *Transplantation* 66, 529–544.
45 Pirenne J, Aerts R, Yoong K *et al.* (2001) Liver transplantation for polycystic liver disease. *Liver Transplant* 7, 238–245.
46 Farges O, Bismuth H (1995) Fenestration in the management of polycystic liver disease. *World J Surg* 19, 25–30.
47 Gigot JF, Jadoul P, Que F *et al.* (1997) Adult polycystic liver disease: is fenestration the most adequate operation for long-term management? *Ann Surg* 225, 286–294.
48 Milutinovic J, Fialkow PJ, Rudd TG *et al.* (1980) Liver cysts in patients with autosomal dominant polycystic kidney disease. *Am J Med* 68, 741–744.
49 Thomsen HS, Thaysen JH (1988) Frequency of hepatic cysts in adult polycystic kidney disease. *Acta Med Scand* 224, 381–384.

8.1.4. Polycystic liver disease

Valérie Vilgrain

Polycystic liver disease (PCLD) may also be observed in the absence of renal cystic disease and is a rare autosomal dominant human disorder that has been described in less than 50 families of Finnish, Dutch, American, Belgian and Spanish Belgian ancestry. The pathology is characterized by the presence of multiple scattered cysts of biliary origin in the liver parenchyma. The occurrence of PCLD independently from polycystic kidney disease has been known for a long time. Autopsy or surgical series of PCLD have shown that polycystic kidney disease was observed in 50–60% of cases) [1]. However, it has been difficult to separate PCLD and autosomal dominant polycystic kidney disease (ADPKD) because cystic liver is also found in about 30% of ADPKD patients, and the liver pathology is indistinguishable between PCLD and ADPKD. A large autopsy study from Finland has identified 22 cases with either PCLD or polycystic kidney disease, but macrocystic cysts in both organs were seen in only one case, supporting the idea that PCLD and polycystic kidney disease are separate entities [2]. There are still no exact epidemiological data regarding the incidence of PCLD in any

population. More recently, studies have demonstrated that isolated familial PCLD was unlinked to the *PKD1* and *PKD2* loci. Manifestations and complications (and management) are the same whether PCLD is isolated or associated with ADPKD [3].

Pathology and pathogenesis

The gross appearance of the resected liver is indistinguishable from that of those resected in patients with severe polycystic disease associated with ADPKD. All the specimens contain variable numbers of von Meyenburg complexes characterized by clusters of dilated bile ducts lined by a layer of cuboidal cells surrounded by a fibrous stroma. The epithelium of the complexes and most of the cysts is cytokeratin-7 positive, consistent with its origin from intrahepatic bile ducts. Small cysts often seem to arise from von Meyenburg complexes. Large cysts are lined by flattened epithelium. Peribiliary glands may be seen as well. The surrounding hepatic parenchyma is normal in most cases, but focal fibrosis may be seen near larger cysts [3]. Because both types of cysts (von Meyenburg complexes and peribiliary glands) are seen in ADPKD and PCLD, it suggests that both diseases have the same pathogenesis.

Genetics and molecular biology

The gene mutated in PCLD, known as protein kinase C (PKC) substrate 80K-H *(PRKCSH)*, has been identified recently [4,5]. The PCLD gene locus has been mapped to chromosome 19p13.2–13.1. The *PRKCSH* gene encodes hepatocystin, a protein that moderates glycosylation and fibroblast growth factor receptor signalling [4]. Mutations that affect messenger RNA splicing or truncate hepatocystin have been reported in PCLD families. However, the distribution of mutations within the gene as well as genotype–phenotype relationships remain speculative [6]. Most PCLD families are linked to chromosome 19p13.2–13.1, but there exists a second PCLD locus yet to be found [7]. Mutations in *SEC63*, another gene encoding products involved in intracellular protein transport, have also been found in association with PCLD [8].

Diagnosis

Surgical reviews have attempted to distinguish multicystic liver (> five cysts) from simple cystic liver disease (< five cysts) [9], whereas other authors have described PCLD as having six or more cysts per liver [10] or as cystic involvement of more than 50% of the hepatic parenchyma [11,12]. The age of the individual is also crucial.

This is why some authors have proposed clinical criteria which allow the diagnosis of PCLD: subjects with more than 20 liver cysts who do not fulfil the criteria for ADPKD; at-risk individuals aged 40 years or younger with any liver cysts; and at-risk individuals older than 40 years with four or more liver cysts [3].

The sensitivity and specificity of these criteria are 70% and 100%, respectively, in individuals younger than 40 years. Therefore, the presence of any cysts in at-risk individuals aged 40 years or younger is diagnostic of the disease; however, negative findings on ultrasonography are insufficient to exclude the diagnosis in this age group. The sensitivity and specificity of these criteria are 78.3% and 100%, respectively, in individuals older than 40 years. Therefore, other criteria have been proposed in those older than 40 years as follows: at-risk individuals between the ages of 40 and 65 years with more than one liver cyst; and at-risk individuals older than 65 years with more than three liver cysts [3].

Natural history and risk factors for development and progression

Isolated polycystic liver disease seems to be less penetrant in the liver than ADPKD, and the development of liver cysts in PCLD may not occur until late in life. As in ADPKD, PCLD is more severe in women than in men, and there is a positive correlation between the severity of the disease and the number of pregnancies.

Clinical features and complications

PCLD is most often asymptomatic and is frequently diagnosed incidentally during the workup of other clinical problems or complaints. This is the case even in the families of patients with highly symptomatic disease, in which relatives are more likely to be aware of the symptoms and to undergo diagnostic testing [3]. When symptoms develop in PCLD, the spectrum is similar to that observed in ADPKD patients.

Patients with PCLD have minimal elevations in serum alkaline phosphatase and total bilirubin levels and lower serum levels of total cholesterol and triglycerides compared with their unaffected relatives [3]. This could suggest that the hepatic lipid metabolism may be altered in patients with PCLD [13].

Whether patients with PCLD are at increased risk of intracranial aneurysms and valvular heart disease is not known. Qian *et al.* [3] noted a trend towards increased risk of intracranial aneurysms, with almost 6% of patients with linkage analysis-confirmed PCLD being found to have either intracranial aneurysm or dissection. The paucity of data prevents more definitive recommendations from being made on screening the PCLD patient for aneurysmal disease.

The higher prevalence of mitral valve abnormalities in patients with PCLD compared with their unaffected relatives indicates that PCLD, like ADPKD, is a systemic disorder [3].

Treatment

Most patients with PCLD require no treatment, but percutaneous cyst aspiration and sclerosis, cyst fenestration, partial hepatectomy and liver transplantation, depending on the extent,

distribution and anatomy of the cysts, may be indicated in highly symptomatic patients.

References

1 Melnick PJ (1954) Polycystic liver. Analysis of seventy cases. *Arch Pathol Lab Med* 59, 162–172.
2 Karhunen PJ, Tenhu M (1986) Adult polycystic liver and kidney diseases are separate entities. *Clin Genet* 30, 29–37.
3 Qian Q, Li A, King BF *et al.* (2003) Clinical profile of autosomal dominant polycystic liver disease. *Hepatology* 37, 164–171.
4 Drenth JP, Te Morsche RH, Smink R *et al.* (2003) Germline mutations in PRKCSH are associated with autosomal dominant polycystic liver disease. *Nature Genet* 33, 345–347.
5 Drenth JP, Martina JA, Te Morsche RH *et al.* (2004) Molecular characterization of hepatocystin, the protein that is defective in autosomal dominant polycystic liver disease. *Gastroenterology* 126, 1819–1827.
6 Everson GT, Taylor MRG, Doctor RG (2004) Polycystic disease of the liver. *Hepatology* 40, 774–782.
7 Tahvanianen P, Tahvanianen E, Reijonen H *et al.* (2003) Polycystic liver disease is genetically heterogeneous: clinical and linkage studies in eight Finnish families. *J Hepatol* 38, 39–43.
8 Davila S, Furu L, Gharavi AG *et al.* (2004) Mutations in SEC63 cause autosomal dominant polycystic liver disease. *Nature Genet* 36, 575–577.
9 Gigot JF, Metairie S, Etienne J *et al.* (2001) The surgical management of congenital liver cysts. *Surg Endosc* 15, 357–363.
10 Katkhouda N, Hurwitz M, Gugenheim J *et al.* (1999) Laparoscopic management of benign solid and cystic lesions of the liver. *Ann Surg* 229, 460–466.
11 Hansman MF, Ryan JA Jr, Holmes JH *et al.* (2001) Management and long-term follow-up of hepatic cysts. *Am J Surg* 181, 404–410.
12 Martin IJ, McKinley AJ, Currie EJ *et al.* (1998) Tailoring the management of nonparasitic liver cysts. *Ann Surg* 228, 167–172.
13 Luoma PV, Sotaniemi EA, Ehnholm C (1980) Low high-density lipoprotein and reduced antipyrine metabolism in members of a family with polycystic liver disease. *Scand J Gastroenterol* 15, 869–873.

8.1.5. Biliary hamartomas

Valérie Vilgrain

Biliary hamartomas, also called von Meyenburg complexes, are considered to be part of the spectrum of ductal plate abnormalities [1]. Multiple bile duct hamartomas are usually detected by pathologists as incidental findings, and have recently been better described in the radiological literature. They were first reported by Moschowitz in 1906 as aberrant intrahepatic bile ducts. Later, they were defined as hamartomatous lesions of bile ducts by Meyenburg in 1918. They may occur in an otherwise normal liver or in association with Caroli's disease, congenital hepatic fibrosis and autosomal dominant polycystic kidney or liver disease. Recognition of this entity is crucial because they often mimic liver metastases [2,3].



Fig. 1 Microscopic view of a biliary hamartoma showing dilated bile ducts embedded in a fibrous, sometimes hyalinized, stroma.

Pathology and pathogenesis

Biliary hamartomas are small (< 0.5 cm in diameter), greyish-white or green and are usually scattered in both lobes. Microscopically, the lesions are discrete, round to irregular in shape and typically paraportal in location. They comprise a variable number of dilated bile ducts embedded in a fibrous, sometimes hyalinized, stroma (Fig. 1). They are lined by low columnar or cuboidal epithelium and contain pink amorphous material that may be bile-stained or actual bile. On serial section examination, the bile duct lumina within a complex have been shown to be interconnecting [1]. Some of the duct structures may show polypoid projections in the lumen; others show, on section, a central island of connective tissue covered with the same type of epithelium as that lining the wall of the dilated duct. Rarely, in some biliary hamartomas, the bile duct profiles are involutive and seem to disappear in a hyalinized, scarring stroma. Classically, it is considered that the dilated ducts of the biliary hamartomas do not communicate with the rest of the biliary tree, but the presence of bile casts in the lumen of some cavities strongly supports the idea of a communication. Furthermore, a detailed serial reconstruction of a biliary hamartoma has demonstrated the communicating nature of these bile duct abnormalities [4].

The morphology of the biliary hamartoma suggests that the lesion represents a partially fibrosing and, on occasion, slowly involutive remnant of ductal plate malformation of the smaller, more peripheral, interlobular bile ducts. Owing to the embryology of intrahepatic bile ducts, which develop from the hilum of the liver to distal parts over time, it seems that the factor arresting or perturbing the remodelling of the ductal plates occurs in the later phases of embryological development of intrahepatic bile ducts [1]. Also, biliary hamartomas are often associated with other ductal plate abnormalities such as Caroli's disease, congenital hepatic fibrosis and polycystic diseases. Redston and Wanless examined the liver slides from 2843 autopsies in order to assess the prevalence of biliary hamartomas in both the general population and patients with adult polycystic kidney disease [5]. Biliary hamartomas were found in 5.6% of adults and in

0.9% of children. Among adults with adult polycystic kidney disease, biliary hamartomas were found in 97% and hepatic cysts in 88%. Because adult polycystic kidney disease could account for only 11% of the patients with biliary hamartomas, these authors suggest that biliary hamartomas, in the absence of adult polycystic kidney disease, are a manifestation of a different disease, which could be genetic or secondary to inflammation or ischaemia [5]. Then, biliary hamartomas seem to be at the origin of the development of adult polycystic kidney and liver disease by their progressive dilatation and fluid filling of the original clusters of bile duct structures [6].

The prevalence of biliary hamartomas varies according to the method of reference. In a study including 2000 liver needle biopsies, Thommesen examined the liver for the occurrence of biliary hamartomas and found 12 positive biopsies corresponding to 0.6% of the liver biopsies [7]. The prevalence is higher in autopsy studies, and the same author has reported biliary hamartomas in 2.8% of cases.

Sometimes, large numbers of duct profiles are in a biliary hamartoma, which may appear as a conglomerate of approximated ductal plate remnants, associated with an abnormal arborization pattern of the peripheral branches of the portal vein similar to that observed in early severe extrahepatic bile duct atresia and congenital hepatic fibrosis [6]. In our experience, biliary hamartomas were found at imaging in three of 18 adult patients with congenital hepatic fibrosis [8]. The paraportal location of some biliary hamartomas, fused to normal-appearing portal tracts, suggests that one of the branches may give rise to a normal portal tract with normal duct development, whereas the rest evolve into hypoplastic vein branches with fusion of adjacent portal tracts and clustering of their ductal plates.

Natural history and risk factors for development and progression

In patients with adult autosomal dominant polycystic kidney and liver disease, biliary hamartomas and peribiliary cysts are thought to be at the origin of the development of liver cysts. In patients with no history of fibrocystic disease, the natural history of biliary hamartomas is not known. Some cases of malignant transformation have been reported. The increased risk of malignancy has been attributed to the bile stasis and prolonged exposure of the parenchyma to potential carcinogens present in the bile [9]. Fewer than 15 cases have been reported in the literature [9,10–13]. The malignant transformation may be discovered fortuitously or revealed by biochemical or clinical abnormalities. Patients ranged in age from 35 to 80 years with a sex ratio of 1:1 [14]. Few patients had cirrhosis or genetic haemochromatosis [9,14,15]. Macroscopically, the liver contains biliary hamartomas and cholangiocarcinoma. Microscopically, there is evidence that the carcinoma evolves from biliary hamartoma through the intermediate stage of hyperplasia or adenomatous transformation and *in situ* carcinoma [9]. The adenomatous transformation may be seen in two forms: the formation of distinct nodules of proliferating biliary hamartoma-like glandular structures; or marked tumour-like concentric or eccentric proliferation of ductular structures surrounding hepatic nodules [9].

In addition, some specimens show poorly differentiated areas that could be interpreted as hepatocellular carcinoma. Immunohistochemical staining shows positivity for epithelial membrane antigen, carcinoembryonic antigen and keratins in tumour cells consistent with cholangiocarcinoma [9].

Clinical features

Patients with biliary hamartomas are generally asymptomatic, and diagnosis of the liver lesions is usually made fortuitously or in the management of patients with other ductal plate malformations. However, a case report has described a patient who suffered from fever, jaundice and right upper quadrant pain due to bile duct hamartomas with microabscess formation associated with biliary stones and biliary tract infection [16]. The blood liver tests are usually normal, but association with other ductal plate malformations may explain blood liver test abnormalities in some patients.

Imaging findings

Imaging manifestations of biliary hamartomas are various. The number of lesions varies from one or two circumscribed lesions to multiple lesions and innumerable lesions with a size ranging from 2 to 10 mm in diameter [3]. Although there have been numerous case reports, the number of studies evaluating the imaging features is low [3,17–20].

Ultrasound (US) findings have been described as hypoechoic, hyperechoic or mixed heterogenic echoic structures [19,21]. These variations might reflect the histological features of biliary hamartomas, including dilated bile ducts and fibrocollagenous stroma. Luo *et al.* [18] described the sign of multiple comet-tail echoes, and speculated that it might be a specific US finding. Zheng *et al.* [19] have found multiple small comet-tail echoes in all but one case, which manifested as posterior echo enhancement of the lesions. This artefact might be due to the cystic feature of dilated bile duct and therefore resulted in good transmission of the sound beam. This suggests that the presence of multiple small comet-tail echoes is a unique US feature of biliary hamartomas and may have a high diagnostic value [19]. Anechoic lesions suggesting typical cysts up to 20 mm in diameter are often observed [18]. In patients with microbiliary hamartomas, US may be normal [18].

On plain computerized tomography (CT) images, almost all biliary hamartomas that have been reported were demonstrated to be multiple small hypodense lesions, usually measuring between 0.5 and 1 cm in diameter (Fig. 2a), whereas on enhanced CT images, although homogeneous enhancement of the lesions has been noted, no enhancement of the lesions is observed in most of the reported cases after intravenous

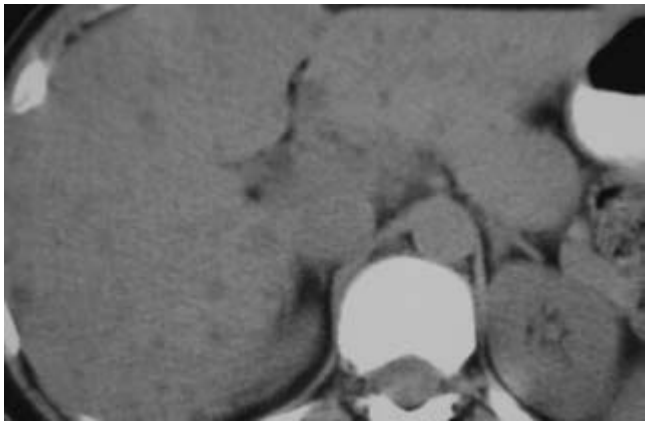

(a)

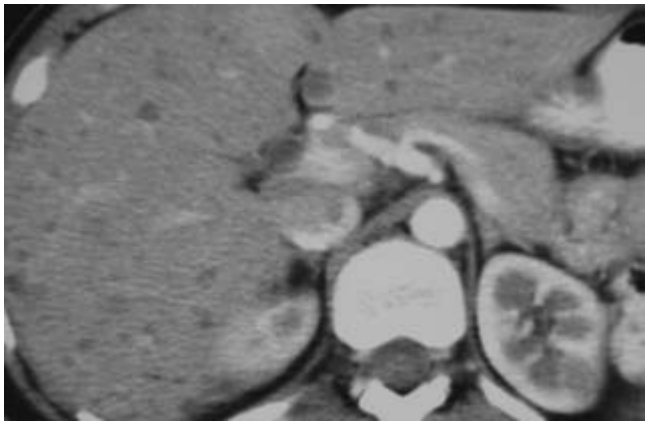

(b)

Fig. 2 Unenhanced (a) and enhanced (b) CT of biliary hamartomas. The lesions are much more conspicuous after administration of contrast medium.

administration of contrast medium [2,3,18–21] (Fig. 2b). The lesions usually increase in number on enhanced CT [18], meaning that, on unenhanced CT, approximately half the lesions are of isodensity or of far lesser conspicuity [18]. On enhanced CT, some lesions are noted to be located adjacent to the medium-sized portal veins (portal tracts, over fourth-order branches), but are to be found less frequently along the hepatic veins of similar size.

On magnetic resonance imaging (MRI), biliary hamartomas are hypointense on T1-weighted images and strongly hyperintense on T2-weighted images when compared with surrounding liver parenchyma [17–19,22,23] (Figs 3a and 4a and b). Usually, on account of the high lesion signal intensity, many more nodules are depicted on T2-weighted images than on T1-weighted images. On heavily T2-weighted images, the signal increases further, nearly reaching the signal of fluid [17]. Magnetic resonance cholangiopancreatography (MRCP) is considered to be highly sensitive in depicting intra- and extrahepatic bile duct anomalies and cystic lesions of the liver, and often displays the biliary hamartomas more clearly than CT and MRI in relation to both the lesion number and shape [19] (Fig. 3b). This may result in part from the relatively large slice thickness in CT and MRI, resulting in the overlooking of lesions smaller than the slice thickness. MRCP also shows that the lesions do not communicate with intrahepatic bile ducts and are not associated with bile duct abnormalities except in Caroli's disease patients (Fig. 4c). Absence of communication between biliary hamartomas and intrahepatic bile ducts may be confirmed after intravenous injection of hepatospecific contrast agents such as Mn-DPDP. The presence and type of biliary hamartoma enhancement is still debated in the literature. While some authors did not find any enhancement following gadolinium administration [17] (Fig. 3c), others have described a homogeneous enhancement or a rim enhancement on early and

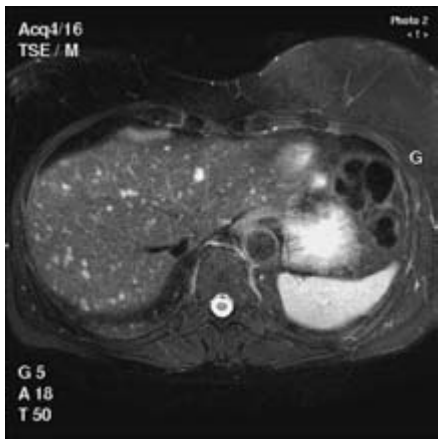

(a)

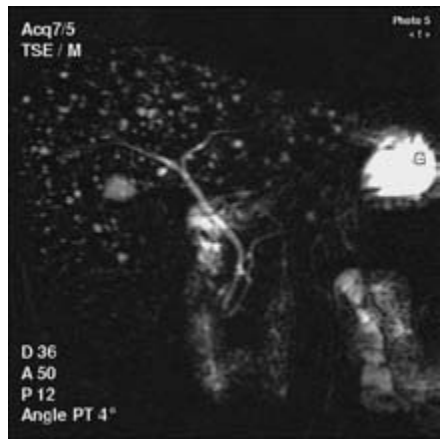

(b)

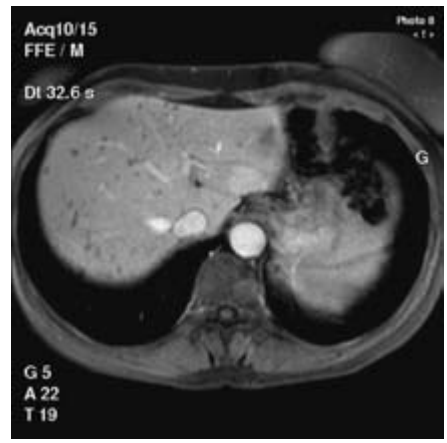

(c)

Fig. 3 MRI of biliary hamartomas. The lesions are strongly hyperintense on T2-weighted imaging (a) and even more intense on heavily T2-weighted sequences such as MRCP images (b). On T1-weighted images (c), after administration of chelates of gadolinium, the enhancement varies and is absent in this example.

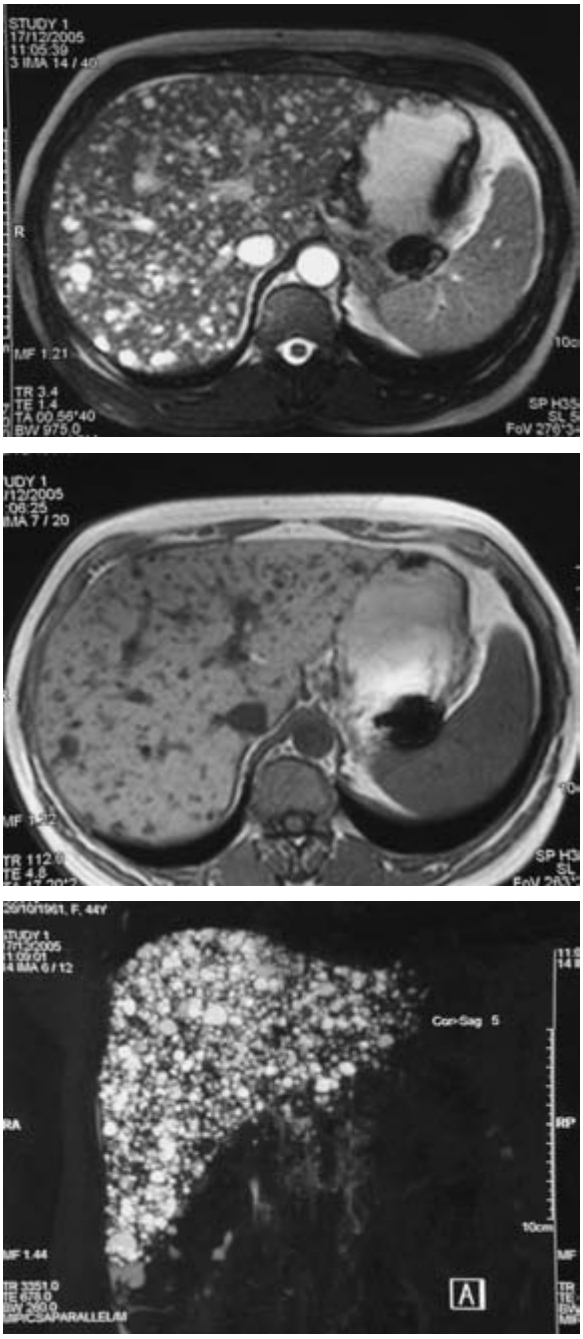

Fig. 4 MRI of multiple biliary hamartomas. The lesions are hypointense on T1- (a) and hyperintense on T2-weighted (b) images. Thick slab MRCP image shows innumerable lesions that do not communicate with the bile ducts (c).

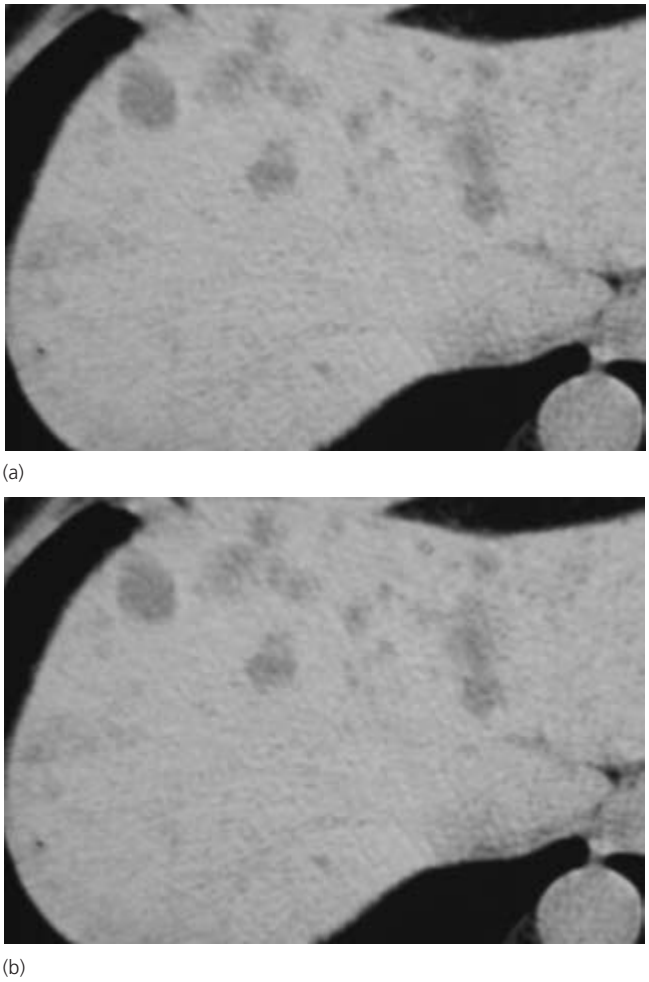

Fig. 5 Mural nodules in biliary hamartomas. Unenhanced (a) and enhanced (b) CT images demonstrating a mural nodule in the largest hamartoma, which enhances after the administration of contrast medium.

late postcontrast images [20,23]. On histopathology, the rim enhancement correlates with the compressed liver parenchyma surrounding the lesions [20]. Sometimes, biliary hamartomas exhibit mural nodules that have an intermediate signal on T2-weighted images and could be enhanced on portal and delayed-phase imaging [24] (Figs 5a and b). Interestingly, although angiography is not performed any more to characterize these lesions, a previous study has shown that biliary hamartomas appear as multiple areas of abnormal vascularity, which persist in the venous phase, but there is no evidence of tumour vessels leaking or arteriovenous shunting [25]. This difference in lesion enhancement may vary according to the lesion size, the connective tissue and the presence of an abnormal portal branch.

Diagnosis

Some authors claim that the imaging findings of biliary hamartomas are not specific and that liver biopsy is needed for a definitive diagnosis [3,26]. This is true with ultrasound even if multiple small comet-tail echoes could evoke the diagnosis. This is also true with CT because multiple tiny hypodense lesions scattered throughout the liver are not specific. However, with the use of advanced imaging modalities, especially MRI with heavily T2-weighted sequences and MRCP, it is possible to make a correct diagnosis of biliary hamartomas by imaging [17,19,20]. When typical imaging findings appear, such as

subcentimetric multiple lesions high signal intensity on T2-weighted images and a mural nodule with normal intrahepatic bile ducts on MRI and MRCP, a diagnosis of biliary hamartomas can be considered. Liver biopsy may have limitations such as sample errors and performance difficulties due to the very small size of the lesions. Furthermore, fine needle aspiration is not diagnostic.

Differential diagnosis

The spectrum of differential diagnosis of biliary hamartomas is fairly wide. However, the most important one is liver metastasis especially in patients with extrahepatic malignant tumours [3,20]. Usually, multiple small metastases are ill-defined on plain CT and show various degrees of enhancement (such as rim enhancement) after intravenous administration of contrast medium. Even if some biliary hamartomas display rim enhancement, the rim enhancement is thin and uniform, may persist on delayed images but does not progress centripetally, and these lesions have a fluid content. However, for patients who are difficult to diagnose, final exclusion of metastatic lesions should still depend on liver biopsy or follow-up imaging studies.

Simple hepatic cysts are variable in number, size and location, and usually round in shape. As biliary hamartomas may coexist with simple hepatic cysts or polycystic liver and kidney diseases, it is sometimes difficult to make a definitive differentiation especially from polycystic liver disease on imaging. Simple hepatic cysts should be considered when the lesions are larger than 10 mm in diameter and round in shape, as most biliary hamartomas are reported to be less than 10 mm in diameter.

Peribiliary cysts are multiple, small, cystic dilatations of the intrahepatic extramural peribiliary glands and should also be included in the differential diagnoses of biliary hamartomas. Both lesions could coexist in patients with adult autosomal dominant polycystic kidney or liver disease. However, they are located exclusively in the hepatic hilum and along the larger portal tract, in contrast to the biliary hamartomas, which have a scattered distribution and predominate near the liver capsula.

Bile duct adenoma may be confused with biliary hamartomas. The bile duct adenoma is usually subcapsular and presents as a solitary, white and fibrous nodule. The histological appearance consists of small ducts that are lined by a single layer of cuboidal cells that may secrete mucin. Bile is not seen in the lumen.

Microabscesses of the liver can be differentiated from biliary hamartomas by means of clinical and radiological data. Imaging features are more heterogeneous.

Intrahepatic bile duct anomalies such as dilated bile ducts and Caroli's disease can be readily distinguished from biliary hamartomas by imaging, especially with MRCP.

Follow-up and treatment

Follow-up of these lesions with imaging modalities shows no remarkable change in the lesions [18]. When the diagnosis of biliary hamartomas is firmly established, because of the benign condition and the very low risk of malignant transformation, no recommendation based on a follow-up can be made. Follow-up study is necessary when the diagnosis is doubtful at imaging or at pathology, especially for the patient with malignant disease elsewhere in the body.

References

1 Desmet VJ (1998) Pathogenesis of ductal plate abnormalities. *Mayo Clin Proc* 73, 80–89.

2 Iha H, Nakashima Y, Fukukura Y *et al.* (1996) Biliary hamartomas simulating multiple hepatic metastasis on imaging findings. *Kurume Med J* 43, 231–235.

3 Lev-Toaff AS, Bach AM, Wechsler RJ *et al.* (1995) The radiologic and pathologic spectrum of biliary hamartomas. *Am J Roentgenol* 165, 309–313.

4 Otha W, Ushio H (1984) Histological reconstruction of a von Meyenburg's complex on the liver surface. *Endoscopy* 16, 71–74.

5 Redston MS, Wanless IR (1996) The hepatic von Meyenburg complex with hepatic and renal cysts. *Mod Pathol* 9, 233–237.

6 Desmet VJ (1992) Congenital diseases of intrahepatic bile ducts: variations on the theme 'ductal plate malformation'. *Hepatology* 16, 1069–1083.

7 Thommesen N (1978) Biliary hamartomas (von Meyenburg complexes) in liver needle biopsies. *Acta Pathol Microbiol Scand (Sect A)* 86, 93–99.

8 Zeitoun D, Brancatelli G, Colombat M *et al.* (2004) Congenital hepatic fibrosis: CT findings in 18 adults. *Radiology* 231, 109–116.

9 Jain D, Sarode VR, Abdul-Karim F *et al.* (2000) Evidence for the neoplastic transformation of Von-Meyenburg complexes. *Am J Surg Pathol* 24, 1131–1139.

10 Burns CD, Kuhns JG, Wieman TJ (1990) Cholangiocarcinoma in association with multiple biliary microhamartomas. *Arch Pathol Lab Med* 114, 1287–1289.

11 Homer LW, White HJ, Read RC (1968) Neoplastic transformation of Von Meyenburg complexes of the liver. *J Pathol Bacteriol* 96, 499–502.

12 Dekker A, Ten Kate FJW, Terpstra OT (1989) Cholangiocarcinoma associated with multiple bile-duct hamartomas of the liver. *Dig Dis Sci* 34, 952–958.

13 Hasebe T, Sakamoto M, Mukai K *et al.* (1995) Cholangiocarcinoma arising in bile duct adenoma with focal area of bile duct hamartoma. *Virchows Archiv* 426, 209–213.

14 Yaziji N, Martin L, Hillon P *et al.* (1997) Cholangiocarcinome développé sur micro-hamartomes biliaires chez un malade atteint d'hémochromatose. *Ann Pathol* 17, 346–349.

15 Wiesniewski B, Tordjman G, Tran Van Nhieu J *et al.* (2002) Cholangiocarcinome sur complexes de von Meyenburg au cours d'une hémochromatose génétique. *Gastroenterol Clin Biol* 26, 922–924.

16 Chen YC, Chien RN, Chen MF *et al.* (2000) Biliary hamartomas associated with biliary stones presenting as multiple microabscesses. *Chang Gung Med J* 23, 560–565.

17 Mortelé B, Mortelé K, Seynaeve P *et al.* (2002) Hepatic bile duct hamartomas (von Meyenburg complexes): MR and MR cholangiography findings. *J Comput Assist Tomogr* 26, 438–443.

18 Luo T-Y, Itai Y, Eguchi N *et al.* (1998) von Meyenburg complexes of the liver: imaging findings. *J Comput Assist Tomogr* 22, 372–378.

19 Zheng RQ, Zhang B, Kudo M *et al.* (2005) Imaging findings of biliary hamartomas. *World J Gastroenterol* 11, 6354–6359.
20 Semelka RC, Hussain SM, Marcos HB *et al.* (1999) Biliary hamartomas: solitary and multiple lesions shown on current MR techniques including gadolinium enhancement. *J Magn Res Imag* 10, 196–201.
21 Eisenberg D, Hurwitz L, Yu AC (1986) CT and sonography of multiple bile duct hamartomas simulating malignant liver disease (case report). *Am J Roentgenol* 147, 279–280.
22 Slone HW, Bennett WF, Bova JG (1993) MR findings of multiple biliary hamartomas. *Am J Roentgenol* 161, 581–583.
23 Maher MM, Dervan P, Keogh B *et al.* (1999) Bile duct hamartomas (von Meyenburg complexes): value of MR imaging in diagnosis. *Abdom Imag* 24, 171–173.
24 Cheung YC, Tan CF, Wan YL *et al.* (1997) MRI of multiple biliary hamartomas. *Br J Radiol* 70, 527–529.
25 McLoughlin MJ, Phillips MJ (1975) Angiographic findings in multiple bile-duct hamartomas of the liver. *Radiology* 116, 41–43.
26 Cooke JC, Cooke DAP (1987) The appearances of multiple biliary hamartomas of the liver (von Meyenburg complexes) on computed tomography. *Clin Radiol* 38, 101–102.

8.1.6. Peribiliary cysts

Valérie Vilgrain

There are glands within and around the walls of the extrahepatic bile ducts in humans, and these glands have been described as tubuloalveolar glands [1]. Under some circumstances, these glands may become cystic. Recognition of this entity is important because this abnormality often mimics intrahepatic bile duct disease.

Pathology

Peribiliary glands

The glandular structures can be classified into two types: one is located within the bile duct wall, the so-called '*intramural glands*', and the glands are small in number and random in distribution; the other is found within the periductal connective tissue in the form of a lobule [1]. These glands are termed '*extramural glands*' and are located at both sides of the bile ducts and parallel to the hepatic parenchyma. The patterns of distribution of these glands along the biliary tracts are divided into three forms: only at the common bile duct, and left and right hepatic duct; at the common bile duct, left and right hepatic duct and in smaller ducts such as segmental ducts; between the two patterns mentioned above.

There is a greater extension of glandular distribution in the left side than in the right side [1].

Histologically, the lobules of the extramural glands consist of several acini, serous (72%), mucous (17%), or mixed (11%). The epithelium of serous acini is low columnar or cuboidal in shape with dark cytoplasm, while that of the mucous acini is columnar in shape with a clear cytoplasm. These lobules have their own excretory ducts, through which they communicate with the neighbouring bile duct lumen. The periductal glands are speculated to function as follows: the glandular mucus acts as a lubricant for the bile stream; the glands renew cells when epithelial loss occurs in the bile ducts; the glands concentrate the bile; the glandular mucus protects the mucosal surface from the bile and bacteria.

Heterotopic pancreas is found in 4.1% of the liver and is usually intermingled with intrahepatic peribiliary glands. It is situated exclusively in the large and medium-sized portal tracts [2].

Cystic dilatation

Some glands dilate to a grossly recognizable size, these markedly dilated glands being preferentially found along the edge of portal tracts. The cysts are usually unilocular, expanded, round, thin-walled and multiple, and contain serous fluid [3]. The largest cysts measure 2 cm in diameter.

Histologically, dilated cysts are lined by a cuboidal to columnar epithelia surrounded by thin fibrous tissue. These cysts are admixed with non-dilated or mildly dilated extramural glands. Inflammatory changes are seen in half the cases.

Pathogenesis

Most of the patients with peribiliary cysts have severe liver disease.

- Chronic liver disease and portal hypertension [4]. Nakanuma *et al.* [5] reported eight patients with peribiliary cysts and, among them, seven had oesophageal varices, five portal vein thrombosis, four had cirrhosis and three had hepatocellular carcinoma. Similarly, Wanless *et al.* [4] have described three cases. All three patients had portal vein thrombosis including two with alcoholic cirrhosis.
- Polycystic liver disease and polycystic kidney disease are also known to be associated with cystic dilatation of these glands to varying degrees, and these cystic changes in peribiliary glands may constitute part of the polycystic changes of the liver [3]. Peribiliary cysts seem to occur quite frequently in polycystic liver or kidney disease. In a series reported by Itai *et al.* [6], peribiliary cysts were definitely seen on computerized tomographic (CT) scans of 22/64 patients with autosomal dominant polycystic kidney disease and probably seen in 19 other patients, representing a total of 73% of all polycystic patients with hepatobiliary cysts.
- Other conditions have been described such as systemic infection and metastatic malignancy with or without obstructive jaundice.
- Hepatolithiasis. Terada *et al.* [7] reported a case of cholesterol hepatolithiasis with peribiliary cysts. In this observation, the

peribiliary cysts were present around the intrahepatic large bile ducts.

• Peribiliary cysts have been reported recently as a rare post-transplant biliary tract complication, occurring in 2.6% of 493 consecutive liver transplants, including three patients with obstructive jaundice. Two types were identified: large and unilocular cavities probably secondary to sequestered remnants of the cystic duct and cystically dilated peribiliary glands similar to those described [8].

Although peribiliary cysts are usually observed in patients with chronic liver disease, their pathogenesis is still unknown. These chronic liver diseases are various and could provide a bias for detection of peribiliary cysts; however, despite many liver abnormalities or tumours that are discovered fortuitously, this does not seem to happen with peribiliary cysts.

Several mechanisms have been suggested for cystic dilatation of intrahepatic peribiliary glands:

• It might be due to ischaemic changes because some cases are associated with portal hypertension and/or portal thromboembolism [5].

• It might be congenital, especially in patients with polycystic liver disease or polycystic kidney disease.

• It might be related to obstruction of ducts of the intrahepatic peribiliary glands due to cholangitis (retention cysts) and/or local peribiliary ischaemia resulting from pressure from stone impaction [8].

Clinical presentation

In most reported patients with peribiliary cysts, patients have severe liver disease, but the cysts are usually asymptomatic. Wanless *et al.* [4] have reported the case of a patient with peribiliary cysts presenting as obstructive jaundice. In this case, the jaundice was secondary to obstruction of the hepatic ducts by periductal cysts. To our knowledge, malignant transformation of these cysts has never been described.

Imaging

Whatever imaging modalities are used, peribiliary cysts are characterized by their peculiar distribution (predominantly perihilar and on both sides of the bile ducts) and small size [9]. They may appear as discrete cysts, as a tubular structure paralleling the portal structures and as a string of cysts that simulate abnormal bile ducts [10].

On ultrasound, the cysts are detected within the echogenic larger portal tract or seem to appear as anechoic areas adjacent to or connecting with the portal vein [9] (Fig. 1a). Sonography appears to be sensitive for detecting the thin septa [10].

CT demonstrates more clearly the distribution of hepatic peribiliary cysts and their relationship with the bile ducts. On unenhanced CT scans, the peribiliary cysts may mimic the periportal collar or appear as cysts along the larger portal tract. They are best depicted after administration of contrast medium because they do not enhance (Fig. 2a). The size of the cysts ranges from a millimetre to > 10 mm [9]. They do not enhance after administration of cholangiographic contrast agent.

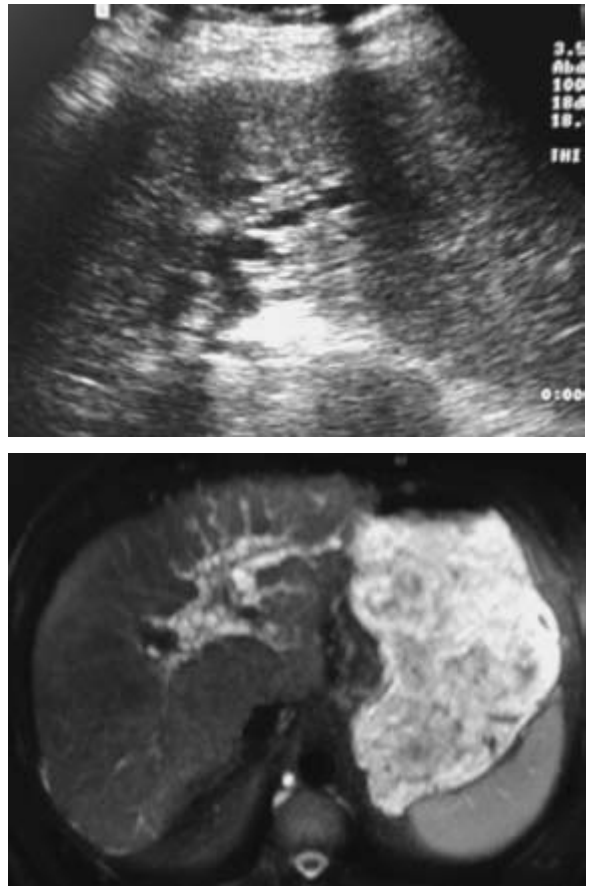

Fig. 1 Cystic dilatation of peribiliary glands. (a) Ultrasonography shows anechoic tubular structures paralleling the portal structures. (b) At MRI, they are strongly hyperintense on T2-weighted images and located on both sides of the bile ducts.

On MRI, the peribiliary cysts are hypointense on T1- (Figs 2b and 3b) and strongly hyperintense on T2-weighted imaging (Figs 1b, 2c, 3a) as well as on magnetic resonance cholangiopancreato-graphy (MRCP) images [10] (Fig. 2d). They can mimic intrahepatic bile duct dilatation, but they arise predominantly around the hilum and are not associated with dilatation of small intrahepatic ducts. Similarly, they do not enhance after administration of hepatospecific contrast agents such as Mn-DPDP.

Differential diagnosis

The differential diagnosis is mainly represented by diffuse or local dilatation of the intrahepatic bile ducts. An important feature is that dilatation of intrahepatic bile ducts always appears on one side of the portal vein, conversely to the peribiliary cysts. Caroli's disease is also a common differential diagnosis because

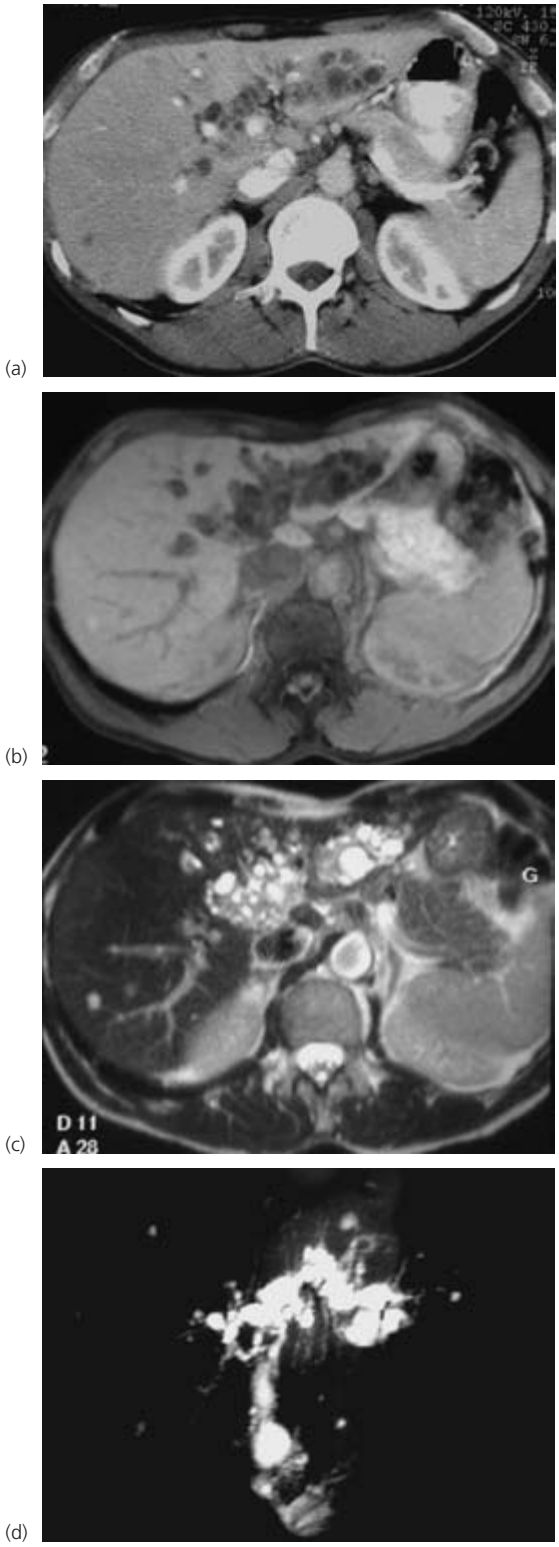

Fig. 2 Cystic dilatation of peribiliary glands. (a) Enhanced CT demonstrates multiple low-attenuation cysts along the left portal tract. The size of the cysts varies from a few millimetres to 1 cm. These cysts are hypointense on T1- (b) and strongly hyperintense on T2-weighted images (c). On MRCP images (d), the peribiliary cysts could mimic intrahepatic bile duct dilatation.

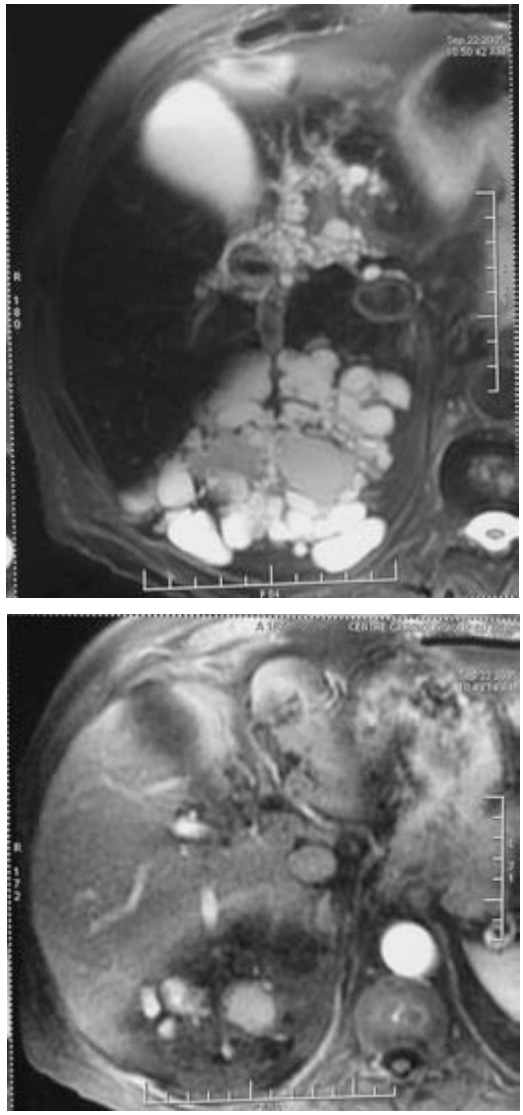

Fig. 3 Cystic dilatation of peribiliary glands in a patient with adult autosomal dominant polycystic kidney disease. T2- (a) and postcontrast T1-weighted (b) images demonstrate the peribiliary cysts, which do not enhance after administration of chelates of gadolinium. Multiple renal cysts are clearly seen; some of them are haemorrhagic. Interestingly, this patient had no liver cyst.

Caroli's disease may be localized. However, localized biliary dilatation that is limited to the larger ducts is rarely observed in Caroli's disease. Furthermore, the central dot sign, which is a key finding in Caroli's disease, is not described in peribiliary cysts [9]. Other differentials include von Meyenburg complexes (see Chapter 8.1.5), cholangitis and periportal collar. Cystic appearance and absence of communication with the bile ducts at imaging favour a diagnosis of peribiliary cysts.

In conclusion, hepatic peribiliary cysts are caused by the dilatation of the extramural peribiliary glands and are characterized by the presence of multiple tiny cysts seen exclusively within the larger portal tracts or hepatic hilum. Imaging is highly

characteristic. Because these lesions are benign, no treatment or follow-up is recommended.

References

1 Tedara T, Nakanuma Y, Ohta G (1987) Glandular elements around the intrahepatic bile ducts in man: their morphology and distribution in normal livers. *Liver* 7, 1–8.

2 Terada T, Nakanuma Y, Kakita A (1990) Pathologic observations of intrahepatic peribiliary glands in 1000 consecutive autopsy livers. Heterotopic pancreas in the liver. *Gastroenterology* 98, 1333–1337.

3 Nakanuma Y, Sasaki M, Terada T *et al.* (1994) Intrahepatic peribiliary glands of humans. II. Pathological spectrum. *J Gastroenterol Hepatol* 9, 80–86.

4 Wanless IR, Zahradnik J, Heathcote EJ (1987) Hepatic cysts of periductal gland origin presenting as obstructive jaundice. *Gastroenterology* 93, 894–898.

5 Nakanuma Y, Kurumaya H, Ohta G (1984) Multiple cysts in the hepatic hilum and their pathogenesis. *Virchows Arch (Pathol Anat)* 404, 341–350.

6 Itai Y, Ebihara R, Eguchi N *et al.* (1995) Hepatobiliary cysts in patients with autosomal dominant polycystic kidney disease. *Am J Roentgenol* 164, 339–342.

7 Terada T, Matsushita H, Tashiro J *et al.* (2003) Cholesterol hepatolithiasis with peribiliary cysts. *Pathol Int* 53, 716–720.

8 Colina F, Castellano VM, Gonzalez-Pinto I *et al.* (1998) Hilar biliary cysts in hepatic transplantation. Report of three symptomatic cases and occurrence in resected liver grafts. *Transpl Int* 11, 110–116.

9 Itai Y, Ebihara R, Tohno E *et al.* (1994) Hepatic peribiliary cysts: multiple tiny cysts within the larger portal tract, hepatic hilum, or both. *Radiology* 191, 107–110.

10 Baron RL, Campbell WL, Dodd III GD (1994) Peribiliary cysts associated with severe liver diseases: imaging-pathologic correlation. *Am J Roentgenol* 162, 631–636.

8.1.7. Caroli syndrome

Jean-Pierre Benhamou

Caroli syndrome is a congenital malformation characterized by multifocal dilatation of the segmental bile ducts. The main consequence of this malformation is recurrent bacterial cholangitis.

Pathology, classification and aetiology

The lesion of Caroli syndrome consists of multifocal dilatation of the segmental bile ducts. The ectatic portions form cysts of various sizes, separated by portions of bile ducts which are normal or regularly dilated. The multifocal dilatation may be diffuse, affecting the whole intrahepatic biliary tree (although it may be more marked in a part of the liver), or it may be confined to a part of the liver, often the left lobe or a segment of the left lobe [1]. The number of cysts is large in the diffuse form and limited, usually less than 10, in the localized form.

Multifocal dilatation of the segmental bile ducts is not a single entity. In the majority of cases, it is associated with congenital hepatic fibrosis [2].

Manifestations and diagnosis

Caroli syndrome, which is likely to be present at birth, usually remains asymptomatic for the first 5 to 20 years of the patient's life, and in a few cases for the patient's whole life. Asymptomatic Caroli syndrome is unrecognized, except in patients in whom congenital hepatic fibrosis has been diagnosed and multifocal dilatation of the segmental bile ducts has been suspected and demonstrated by ultrasonography or computed tomography.

In most patients, the first episode of cholangitis occurs in the absence of any apparent cause. In a few, the first episode of cholangitis is the consequence of a surgical operation or an invasive investigation on the biliary tree, such as cholecystectomy, choledochotomy, T-tube drainage, intraoperative cholangiography, or endoscopic retrograde cholangiography (Benhamou, personal observation; see also refs 3–5).

The main and often the only symptom of cholangitis due to Caroli syndrome is fever, in contrast to cholangitis complicating common bile duct stones in which fever is usually accompanied by pain and/or jaundice. As a consequence, the first episodes of fever may not be attributed to cholangitis.

At clinical examination, the liver is usually enlarged. There is no sign or symptom indicating liver failure. In patients with Caroli syndrome associated with congenital hepatic fibrosis, manifestations of portal hypertension are present. Liver function tests are normal except for alkaline phosphatase and gammaglutamyl transpeptidase which may be moderately increased.

The best procedures for the diagnosis of Caroli syndrome are ultrasonography, computerized tomography and magnetic resonance cholangiography which show cystic formations of various size, diffuse or limited to a part of the liver, associated or not associated with tubular dilatation of segmental bile ducts. Ultrasonography and computerized tomography show tiny dots within dilated intrahepatic bile ducts (the central dot sign); these intraluminal dots correspond to intraluminal portal vein; this finding indicates that the portal radicles are surrounded by dilated intrahepatic bile ducts [6]. Computerized tomography after intravenous injection of biliary contrast may show opacification of cysts and dilated segmental bile ducts. Cystic formations, communicating with intrahepatic biliary tract, may be demonstrated by intraoperative cholangiography, postoperative cholangiography through a T-tube or endoscopic retrograde cholangiography; these three procedures must not be used in patients with asymptomatic Caroli syndrome, but can be employed in patients with Caroli syndrome already complicated by cholangitis.

The other imaging procedures have less interest for the diagnosis of Caroli syndrome. Radiocolloid liver scans show cold areas corresponding to the large cysts. Hepatobiliary scans shows

cold areas in the early phase which become hot at a late phase of imaging [7].

Course and complications

The course of Caroli syndrome is dominated by recurrent episodes of cholangitis, the frequency of which varies widely: some patients experience 10 to 20 episodes a year, whereas others suffer only one or two episodes a year. In patients with frequent episodes of cholangitis, the prognosis is poor: generally, five to 10 years after the onset of recurrent cholangitis, such patients die from uncontrolled biliary bacterial infection.

Cholangitis may be complicated by liver abscesses, septicaemia, extrahepatic abscesses and secondary amyloidosis [8].

Cholangitis often induces the formation of intracystic stones [9], which are usually recognized at ultrasonography or endoscopic retrograde cholangiography but may be missed by computed tomography when not calcified. These stones can migrate from the cysts into the common bile duct and cause biliary pain and/or cholestasis and/or acute pancreatitis [10]. Cholangiocarcinoma develops in some patients with Caroli syndrome [11].

Associated malformations

In patients with Caroli syndrome and congenital hepatic fibrosis, the malformations associated with congenital hepatic fibrosis alone may obviously be present. In patients affected by Caroli syndrome with or, more often, without congenital hepatic fibrosis, associated choledocal cyst is relatively common [11]. Exceptionally, Caroli syndrome is associated with Laurence–Moon–Biedl syndrome [12].

Treatment

The treatment of the episodes of bacterial cholangitis is with appropriate antibiotics.

The prevention of recurrences of bacterial cholangitis is difficult. Periodic administration of antibiotics seems efficacious in some patients but completely inefficient in others. T-tube drainage is not effective and may be dangerous in patients with associated congenital hepatic fibrosis; large amounts of water and electrolytes, secreted by the multiple bile ductules, may be lost through the T-tube, which may result in severe dehydrattion [13]. Administration of ursodesoxycholic acid may be used for the prevention and treatment of intracystic stones [14] and has been recommended to be administered to all patients with Caroli syndrome [15]. Transhepatic intubation and drainage of the biliary tree have been used successfully in a small number of patients [16]. Surgical biliointestinal anastomoses or endoscopic papillotomy may facilitate the passage of stones into the intestine, but cannot be recommended because these procedures may increase the frequency and severity of the episodes of cholangitis [17]. In the localized form of Caroli syndrome, partial hepatectomy is indicated and excellent results can be expected [18]. In the diffuse form, if the cysts clearly predominate in a part of the liver, partial hepatectomy can also be envisaged; however, in such patients, partial hepatectomy is difficult because of associated congenital hepatic fibrosis and portal hypertension, and the long-term results may be compromised because multifocal dilatation affecting the remaining liver may be the source of recurrent cholangitis [18]. In the diffuse form without predominance of the cysts in any part of the liver and complicated by severe recurrent cholangitis, liver transplantation might be considered.

References

1 Caroli J, Couinaud C, Soupault R *et al.* (1958) [A new disease, undoubtedly congenital, of the bile ducts: unilobar cystic dilation of the hepatic ducts.] *Semin Hôp Paris* 34, 488–495.
2 Fauvert R (1974) *The Liver and its Diseases*. New York: IMS, pp. 283–288.
3 Clermont RJ, Maillard JN, Benhamou JP (1967) [Congenital hepatic fibrosis.] *Can Med Assoc J* 97, 1272–1278.
4 Erlinger (1969) [The angiocholitic forms of the congenital hepatic fibrosis.] *Presse Med* 77, 1189–1191.
5 Grumbach R (1954) *Arch Anat Cytol Pathol* 30, 74–77.
6 Choi IP, Berenstein A, Kagetsu NJ (1990) Irrigation device for neuroangiographic procedures. *Radiology* 174, 161–163.
7 Stillman AE (1981) *Gastroenterology* 80, 1295 (abstr.)
8 Fevery (1972) Congenital dilatation of the intrahepatic bile ducts associated with the development of amyloidosis. *Gut* 13, 604–609.
9 Mathias CG (1978) *Acta Hepatogastroenterol Belg* 25, 30–34.
10 Sahel (1976) [Caroli's disease with acute pancreatitis and angiocholitis. Diagnostic and therapeutic value of endoscopic choledochowirsungography.] *Nouv Presse Med* 5, 2067–2069.
11 Dayton MT, Longmire WP Jr, Tompkins RP (1983) Caroli's disease: a premalignant condition? *Am J Surg* 145, 41–48.
12 Tsuchiya R, Nishimur R, Ito T (1977) Congenital cystic dilation of the bile duct associated with Laurence–Moon–Biedl–Bardet syndrome. *Arch Surg* 112, 82–84.
13 Turnberg (1968) Biliary secretion in a patient with cystic dilation of the intrahepatic biliary tree. *Gastroenterology* 54, 1155.
14 Kutz K, Miederer SE, Paumgartner G (1978) Case report: chenodeoxycholic acid therapy of intrahepatic radiolucent gallstones in a patient with Caroli's syndrome. *ActaHepatogastroenterol Stuttg*. 25, 398.
15 Ros E, Navarro S, Bruc *et al.* (1993) Ursodeoxycholic acid treatment of primary hepatolithiasis in Caroli's syndrome. *Lancet* 342, 404.
16 Witlin LT, Gadacz TR, Zuidema GD *et al.* (1982) Transhepatic decompression of the biliary tree in Caroli's disease. *Surgery* 91, 205–209.
17 Watts DR, Lorenzo GA, Beal JM (1974) Proceedings: congenital dilatation of the intrahepatic biliary ducts. *Arch Surg* 108, 592.
18 Ramond MJ, Huguet C, Danan G *et al.* (1984) Partial hepatectomy in the treatment of Caroli's disease. Report of a case and review of the literature. *Dig Dis Sci* 29, 367–370.

8.1.8. Choledocal cyst

Jean-Pierre Benhamou

Choledocal cyst is a rare congenital condition that is characterized by a cystic dilatation of a segment of the biliary ductal system. The disease should be termed 'bile duct cyst' rather than 'choledocal cyst'. The prevalence is higher in Asia than in western countries. The disease is four times more common in females than in males. Most surgeons accept the Todani modification of the Alonso–Lej classification [1]. In this schema, patients with type 1 cyst (the most common) have an extrahepatic biliary dilatation that can be divided into three groups: (A) cystic dilatation of the entire common bile duct; (B) focal segmental dilatation of the common bile duct; and (C) fusiform dilatation of the extrahepatic biliary tree. Type 2 cyst consists of a diverticulum of the common bile duct. Type 3 cyst, also known as 'choledococoele', represents cystic dilatation of the intraduodenal portion of the biliary tree. Type 4 cyst is divided into two subtypes: type 4-A has multiple intrahepatic and extrahepatic cysts; type 4-B has multiple extrahepatic cysts. Type 5, also known as Caroli's disease, is isolated to intrahepatic bile ducts.

The pathogenesis is unknown. However, in most cases, an anomalous pancreaticobiliary ductal junction is present, which has suggested that reflux of pancreatic juice into the common bile duct could play a role in the pathogenesis of choledocal cyst.

Classically, the patient with a choledocal cyst type 1 is a female infant of Asian descent who has a palpable mass, abdominal pain and jaundice. In fact, in currently reported series, an increasing number of patients are adults, and the classical triad is absent. The diagnosis is established by ultrasound, magnetic resonance cholangiography, computerized tomographic scan and endoscopic retrograde cholangiopancreatography.

Many complications have been reported including cholangitis, cholelithiasis, jaundice, acute pancreatitis and rupture. Carcinoma of the biliary tree is the most serious complication of choledocal cyst; it mainly affects adults over 50 years.

Prior to the two most recent decades, cyst drainage was considered to be the appropriate treatment of choledocal cyst. In fact, cyst drainage is associated with two problems: first, there is a very high incidence of stricture, probably related to the often severe inflammation of the cyst epithelium; secondly, there is a risk of malignancy in the dilated cyst segment.

Resection of the choledocal cyst with reconstruction of the biliary tree is the treatment of choice. The entire cyst must be excised; incomplete excision exposes to the risk of carcinoma on the remaining portion of the cyst.

Reference

1 Lipsett PA, Cameron JL (1996) Choledocal cyst disease: a review. *J Hep Bil Pancr Surg* 3, 389–395.

8.1.9 Ciliated hepatic foregut cyst

Jean-François Cadranel

Wheeler and Edmonson first used the term ciliated hepatic foregut cyst (CHFC) to describe a benign liver lesion that apparently arises from the embryologic foregut [1]. CHFC is an uncommon entity. Fewer than 70 cases have been reported in the English, French and Japanese language literature [1–27]. The majority of CHFC cases have been reported in the last 20 years [2]. The increase in reported cases over the last two decades has coincided with the increased used of abdominal imaging techniques [2,11].

Pathology

Histologically [1,11,12,24], the CHFC is lined with a pseudostratified cylindrical epithelium with ciliated and mucin-secreting cells. It is surrounded by connective tissue and a band of smooth muscle fibres [1,11,12,24]. The cyst wall consists of the following four layers: (i) a pseudostratified, columnar ciliated epithelium; (ii) a subepithelial connective tissue; (iii) a layer composed of smooth muscle bundles; and (iv) a fibrous capsule (Fig. 1). Small bile ductules can occasionally be observed in the cyst wall, lined by columnar non-ciliated epithelium [18,25].

The cyst epithelium contains ciliated cells, the cilia of which are strongly labelled with tubulin [23,24]. Goblet cells of the cyst epithelium contain neutral, carboxylated and sulphated mucins, like the mucin-secreting cells of the respiratory epithelium [23,24]. Goblet cells stain with periodic acid–Schiff (PAS), Alcian blue and high-iron diamine [12].

Immunohistochemical studies showed that the cyst epithelium contained endocrine cells immunoreactive for chromogranin,

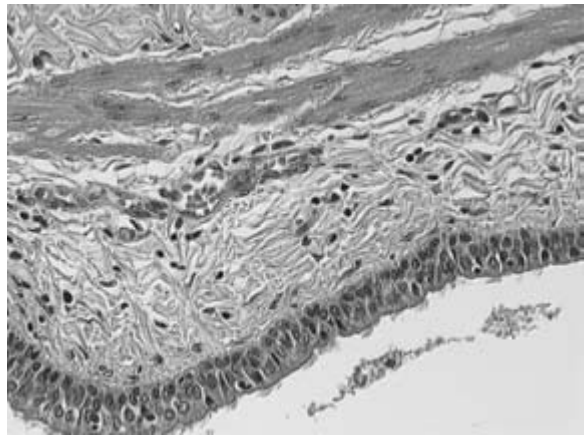

Fig. 1 Foregut ciliated cyst. Gross magnification. Note the four layers: (a) pseudostratified columnar ciliated epithelium; (b) subepithelial connective tissue: (c) smooth muscle bundles; (d) fibrous capsule (courtesy of Dr Valérie Paradis, Hôpital Beaujon, Clichy, France).

synaptophysin, calcitonin and bombesin [12]. This pattern is similar to that of endocrine cells present in the respiratory epithelium [14]. In contrast, endocrine cells were negative for serotonin, somatostatin, glucagon, insulin, gastrin and pancreatic polypeptide [12]. Immunoreactivity of some cells for CC10 strongly suggested the presence of Clara cells [12,23]. Ultrastructural observations revealed definite cilia arranged in a 9 + 2 pattern, as well as mucous cells [24].

Pathogenesis

The overall cellular features and architecture are similar to those of the respiratory bronchi and indicate that these cysts arise from abnormally developing ventral endoderm within the liver [1,12,24]. Mouse embryo studies have demonstrated that the ventral endoderm gives rise to the adult foregut structures, including the oropharynx down to the hepatic diverticulum [28]. CHFCs probably originated from embryogenic foregut remnants that persisted in the liver and differentiated towards bronchial structures [23,24].

Clinical presentation

Patients with CHFC average 52 years at presentation (range 5–82 years). The male to female ratio is 1.2:1. In two-thirds of patients, CHFC are found incidentally on imaging studies [11,12,17–19,23,24,27], at surgery or incidentally during autopsy [11]. About 25–30% of patients presented with abdominal pain [11,12,16,21–25,27] and abnormal liver function tests, but it is unclear how the cysts were discovered or whether they were responsible for the presenting signs and symptoms [11].

In one case, the cyst caused compression of the portal vein with resulting portal hypertension and splenomegaly [14]. One case has been reported in a cirrhotic patient [17]; we have also observed such a case (personal communication).

Imaging pattern

CFHC are more often located in the left lobe, especially in the medial segment (segment IV) [11,14,17,18,21,22,25,27]. A case has been reported in the left hepatic vein [4] and a few cases in the gallbladder wall [22]; one CHFC communicated with the gallbladder [3]. Most of the lesions were less than 4 cm (median 3 cm; range 0.4–9 cm) [1–27].

A larger size should raise suspicion of a malignant transformation. Indeed, three cases of squamous cell carcinoma arising in a CFHC were reported between 1999 and 2002 [29–31]. The sizes of the CFHC were 10 cm, 10 cm and 12 cm in these three cases [29–31]. CFHC appeared as well-delineated solitary, unilocular, hypoechoic small masses with or without posterior enhancement on ultrasonography [10,27]. Less frequently, CFHC are anechoic. They may occasionally have a pseudosolid pattern [13,25]. On computerized tomography (CT), CFHC appeared as well-defined, unilocular, isolated masses located beneath the hepatic surface in the subcapsular areas [10,21,26,27]. Calcifications of the cyst wall are rare [27]. On CT scan, because they contain various elements ranging from clear serous material to milky white to brown mucoid material, and have variable viscosities, the different CT attenuation numbers can be shown [26]. On enhanced CT, CFHC appeared with low density and can be hypoattenuating or isoattenuating relative to the surrounding liver parenchyma; these lesions remained with low density after contrast enhancement [10,21,26,27]. Occasionally, CFHC may appear with slightly higher density before contrast enhancement, mimicking a solid tumour [25]. On magnetic resonance imaging (MRI), lesions are hyperintense on T2-weighted spin images [13,21,26,27]. On T1-weighted spin image MRIs, CFHC are usually hyperintense [13,21,26,27]. However, they are sometimes isointense [16,21] or hypointense [26,27] on T1 sequences. These different imaging features depend on the fluid composition of the cyst, related to viscosity, mucin density and the presence of calcium or cholesterol crystals [25,26]. There is no contrast enhancement after gadolinium injection [26]. According to the imaging pattern, several diagnoses may be discussed: solitary non-parasitic cyst in cases of anechoic patterns on ultrasonography, solid tumour in cases of pseudosolid patterns [13,25] or cystadenoma when mucoid material is rich. Comparison of ultrasound, CT scan and MRI may help in achieving a precise diagnosis [32]. Guided fine needle aspiration [18,19] may be helpful by showing columnar cells with basally oriented nuclei and prominent apical terminal plates with cilia [18,19].

Treatment

Four to five per cent of CHFC may have malignant transformation [2,29–31]. As discussed, the major risk factor for malignant transformation appears to be the size of the cyst. Because of this potential risk, total surgical excision is necessary in patients who have a cyst greater than 4–5 cm, a symptomatic cyst, an enlarging cyst or when imaging studies show abnormalities in the cyst wall [29–31]. Vick *et al.* [29] recommend surgical excision even for asymptomatic patients.

References

1 Wheeler DA, Edmondson HA (1984) Ciliated hepatic foregut cyst. *Am J Surg Pathol* 8, 467–470.
2 Jakowski JD, Lucas JG, Seth S *et al.* (2004) Ciliated hepatic foregut cyst: a rare but increasingly reported liver cyst. *Ann Diagn Pathol* 8, 342–346.
3 Koletsa T, Tzioufa V, Michalopoulos A *et al.* (2005) Ciliated hepatic foregut cyst communicating with the gallbladder. *Virchows Arch* 446, 200–201.
4 Momin TA, Milner R, Sarmiento JM (2004) Ciliated hepatic foregut cyst of the left hepatic vein. *J Gastrointest Surg* 8, 601–603.
5 Cai XJ, Huang DY, Liang X *et al.* (2004) Ciliated hepatic foregut cyst: report of first case in China and review of literature. *J Zhejiang Univ Sci* 5, 483–485.

6 Del Poggio P, Jamoletti C, Mattiello M *et al.* (2003) Images in hepatology. Ciliated hepatic foregut cyst. *J Hepatol* 39, 1090.

7 Balducci G, Bellagamba R, De Siena T *et al.* (2003) Ciliated hepatic foregut cysts: a case report. *G Chir* 24, 189–192.

8 Horii T, Ohta M, Mori T *et al.* (2003) Ciliated hepatic foregut cyst. A report of one case and a review of the literature. *Hepatol Res* 26, 243–248.

9 Bogner B, Hegedus G (2002) Ciliated hepatic foregut cyst. *Pathol Oncol Res* 8, 278–279.

10 Hirata M, Ishida H, Konno K *et al.* (2001) Ciliated hepatic foregut cyst: case report with an emphasis on US findings. *Abdom Imaging* 26, 594–596.

11 Vick DJ, Goodman ZD, Deavers MT *et al.* (1999) Ciliated hepatic foregut cyst: a study of six cases and review of the literature. *Am J Surg Pathol* 23, 671–677.

12 Chatelain D, Chailley-Heu B, Terris B *et al.* (2000) The ciliated hepatic foregut cyst, an unusual bronchiolar foregut malformation: a histological, histochemical, and immunohistochemical study of 7 cases. *Hum Pathol* 31, 241–246.

13 Wu ML, Abecassis MM, Rao MS (1998) Ciliated hepatic foregut cyst mimicking neoplasm. *Am J Gastroenterol* 93, 2212–2214.

14 Harty MP, Hebra A, Ruchelli ED *et al.* (1998) Ciliated hepatic foregut cyst causing portal hypertension in an adolescent. *Am J Roentgenol* 170, 688–690.

15 Kajiya Y, Nakajo M, Ichinari N *et al.* (1997) Retroperitoneal foregut cyst. *Abdom Imaging* 22, 111–113.

16 Carnicer J, Duran C, Donoso L *et al.* (1996) Ciliated hepatic foregut cyst. *J Pediatr Gastroenterol Nutr* 23, 191–193.

17 Murakami T, Imai A, Nakamura H *et al.* (1996) Ciliated foregut cyst in cirrhotic liver. *J Gastroenterol* 31, 446–449.

18 Hornstein A, Batts KP, Linz IJ *et al.* (1996) Fine needle aspiration diagnosis of ciliated hepatic foregut cysts: a report of three cases. *Acta Cytol* 40, 576–580.

19 Zaman SS, Langer JE, Gupta PK (1995) Ciliated hepatic foregut cyst. Report of a case with findings on fine needle aspiration. *Acta Cytol* 39, 781–784.

20 Kakita A, Kimura T, Takahashi T (1995) Ciliated hepatic foregut cyst and hepatic foregut cyst. *Ryoikibetsu Shokogun Shirizu* 8, 128–131.

21 Shoenut JP, Semelka RC, Levi C *et al.* (1994) Ciliated hepatic foregut cysts: US, CT, and contrast-enhanced MR imaging. *Abdom Imaging* 19, 150–152.

22 Peltier E, Leger-Ravet MB, Franco D *et al.* (1993) Ciliated cysts of the liver. 2 cases. *Gastroenterol Clin Biol* 17, 859–862.

23 Terada T, Nakanuma Y, Ohta T *et al.* (1991) Mucin-histochemical and immunohistochemical profiles of epithelial cells of several types of hepatic cysts. *Virchows Arch A Pathol Anat Histopathol* 419, 499–504.

24 Terada T, Nakanuma Y, Kono N *et al.* (1990) Ciliated hepatic foregut cyst. A mucus histochemical, immunohistochemical, and ultrastructural study in three cases in comparison with normal bronchi and intrahepatic bile ducts. *Am J Surg Pathol* 14, 356–363.

25 Kimura A, Makuuchi M, Takayasu K *et al.* (1990) Ciliated hepatic foregut cyst with solid tumor appearance on CT. *J Comput Assist Tomogr* 14, 1016–1018.

26 Kadoya M, Matsui O, Nakanuma Y *et al.* (1990) Ciliated hepatic foregut cyst: radiologic features. *Radiology* 175, 475–477.

27 Benlolo D, Vilgrain V, Terris B *et al.* (1996) Imagerie des kystes ciliés hépatiques ou biliaires à revêtement cilié. *Gastroenterol Clin Biol* 20, 497–504.

28 Zaret KS (2002) Regulatory phases of early liver development: paradigms of organogenesis. *Nature Rev Genet* 3, 449–512.

29 Vick DJ, Goodman ZD, Ishak KG (1999) Squamous cell carcinoma arising in a ciliated hepatic foregut cyst. *Arch Pathol Lab Med* 123, 1115–1117.

30 De Lajarte-Thirouard AS, Rioux-Leclercq N, Boudjema K *et al.* (2002) Squamous cell carcinoma arising in a hepatic foregut cyst. *Pathol Res Pract* 198, 697–700.

31 Furlanetto A, Deil Tos AP (2002) Squamous cell carcinoma arising in a ciliated hepatic foregut cyst. *Virchows Arch* 441, 296–298.

32 Vuillemin-Bodaghi V, Zins M, Vullierme MP *et al.* (1997) Imaging of atypical cysts of the liver. Study of 26 surgically treated cases. *Gastroenterol Clin Biol* 21, 394–399.

8.2 Acquired conditions

8.2.1 Inflammatory cystic diseases

Jean-François Cadranel

Endometrial cysts of the liver

Endometriosis is characterized by the presence of functioning endometrial tissue outside the uterine cavity [1]. Ectopic endometrium has been described in almost every location, but is most frequently located in the pelvic organs. Unusual sites of involvement include the umbilicus, laparotomy or incisional scars, arms, legs, kidney, diaphragm, gastrointestinal tract, bladder wall, lung, pleura, pancreas, heart and bone [2]. The only organ in the abdominal cavity that is apparently refractory to the disease is the spleen [2].

Hepatic endometriosis is extremely rare [1,3]. The first case was reported by Finkel *et al.* in a 21-year-old woman who complained of epigastric pain, nausea and vomiting. She was found to have an endometrial cyst (EC) measuring 13 cm in the left lobe of the liver [4]. To date, fewer than 20 cases have been reported [1,3,4,12].

EC of the liver occurred in women with an age ranging from 21 to 62 years [1]. One-third of the patients had a history of abdominal endometriosis, whereas the other two-thirds showed no evidence of endometrial implants other than in the liver [1]. However, some of the women without a history of pelvic-associated endometriosis had difficulty in conceiving, suggesting possible Fallopian tube lesions [1]. Two-thirds of the women presented with acyclic gastric or right upper abdominal tenderness or pain [1,3]. Right upper abdominal mass can be noted when EC are large. EC of the liver are located in either the left or the right lobe of the liver [1,3]. In two cases, pleural endometriosis was associated with EC of the liver [12]. EC range in size from 3 to 24 cm and average 10 cm. EC were solitary in all but one of the reported cases [1,3]. One 62-year-old woman [9] who presented with right upper abdominal tenderness had two EC of 3.1 cm and 2.8 cm located in the right lobe and the falciform ligament respectively. The latter lesion was complicated by malignant transformation with moderately differentiated endometrioid adenosquamous carcinoma [9]. EC of the liver are either unilocular or multilocular and present with septations that are better seen during ultrasonography examination than during tomodensitometry examination [4,8]. Abdominal ultrasonography, computerized tomography (CT) scan and magnetic resonance imaging (MRI) showed cystic tumours that may be indistinguishable from a simple cyst. In some instances, however, irregularity of the cyst wall and septation led to a preoperative diagnosis of cystadenoma [8]. Large EC of the right lobe may be accompanied by a reactive enlargement of the left lobe [7]. Calcifications of the cyst wall have been reported occasionally [6,10]. Choledochal compression and communication with the biliary tract have been reported in one case each [7,8]. The content of EC is usually chocolate coloured and haemorrhagic-like, typical of endometriosis [1]; it may occasionally be clear [4]. Histologically, the cyst wall is lined by a single layer of cuboidal cells with occasional formation of endometrial glands. These glands are admixed with a well-vascularized mesenchymal stroma [8]. When performed, immunostaining is positive for estrogen and progesterone receptors [3]. The liver adjacent to EC is either normal or shows focal haemosiderin deposition [1]. A case of adenosarcoma arising in hepatic endometriosis has been reported. It presented as a huge heterogeneous mass containing septated thick-walled cystic lesions [11]; the patient was asymptomatic with no abnormalities on liver and abdominal CT scan after enlarged right hepatectomy at a 2-year follow-up. The treatment of EC of the liver is surgery; the median term results (when available) are good with no symptoms of recurrence after follow-up ranging from 10 to 22 months [1,5,6].

The pathogenesis of extra-abdominal endometriosis remains uncertain [3]. Many theories have been proposed, including coelomic metaplasia, retrograde menstruation, iatrogenic injury and haematogenous or lymphatic dissemination [13]. Metaplasia or differentiation from coelomic epithelium, triggered by many stimuli, has been observed frequently. Transportation of

endometrial fragments by one means or another is important to the histogenesis and has been described after surgical procedures that involve the endometrium. Endometrial fragments have been observed in the oviduct and in the peritoneal cavity. Regurgitated menstrual fluid is not rare and may be responsible for the development of pelvic endometriosis. Endometrial tissue has been observed in lymphatic and blood vessels; vascular dissemination probably occurs more frequently after surgical trauma than spontaneously [3,13,14].

Pancreatic pseudocysts of the liver

Although pancreatic pseudocysts can form anywhere in the abdomen, intrahepatic occurrence is rare [15,16]. Hepatic extrapancreatic pseudocysts have been reported in the setting of acute alcoholic [15,17] or biliary pancreatitis [18], chronic pancreatitis [19] or pancreatic injury [16,20]. Pancreatic pseudocyst is a collection of pancreatic juice confined by a non-epithelialized wall of granulation tissue [21] and requires a least 4 weeks to form [21]. Unusual location of pancreatic pseudocysts has been reported in 22.4% of patients in one study [22]. The first two cases of hepatic pancreatic pseudocysts were reported by Siegelman *et al.* in 1980 [23]. In a literature review, we found 26 reported cases of pancreatic pseudocysts of the liver up to 2000 [24]. Occasional case reports have been reported after 2000 [18,25]. Intrahepatic location of the pseudocyst has been document by ultrasonography, CT scan, MRI or surgical exploration [21,24,26,27]. Clinical symptoms are usually related to the underlying inflammatory pancreatic disease. Elevated serum lipase and/or elevated serum and urinary amylase levels should arouse suspicion of this condition [16]. Continuous epigastric pain after acute pancreatitis [28] or recurrence of abdominal pain after initial clinical resolution of pancreatitis may be observed [24]. A palpable upper abdominal mass has been reported rarely [28–30]. Hepatomegaly has been reported occasionally [15,17,26]. Jaundice is rarely observed [24,30]. Results of liver function tests are usually within the normal range [24]. Serum aminotransferase activities are usually not elevated despite digestion of liver cells [16]. Correct diagnosis is not difficult with imaging when other signs of acute pancreatitis are present [16]. On CT, a mature intrahepatic pseudocyst appears as a well-defined, subcapsular, homogeneous, hypoattenuating mass surrounded by a thin fibrous capsule [31]. In the setting of acute pancreatitis, the attenuation of the fluid within the cyst may be high as a result of haemorrhage and necrotic debris, and the lesion may be less distinctly defined [31,32]. On MRI [21], a pancreatic pseudocyst appears as a well-circumscribed subcapsular lesion with low signal intensity on T1-weighted images (T1 WI) and markedly high signal intensity on T2-weighted images (T2 WI) [21]. In mature cysts, an enhancing capsule is observed following intravenous administration of gadolinium chelates [31]. When performed for diagnostic purposes, puncture shows a yellowish fluid with high lipase and amylase activity. MRI is superior to CT for the prediction of drainability [21], allowing better visualization (on T2-weighted sequences) of fluid and solid components. Pancreatic pseudocyst percutaneous drainage has been reported to be an effective treatment method with a 90% cure rate [27], limiting the risks of major intra-abdominal surgery. Percutaneous drainage, when possible according to imaging results, permits treatment to be initiated rapidly [16,24,27], avoiding a wait of several weeks for cyst maturation prior to surgery. In addition, percutaneous catheter techniques may lower morbidity and mortality compared with surgical drainage [33]. Different hypotheses have been suggested to explain the extension of pancreatic pseudocysts in the liver, due to the proteolytic effect of pancreatic enzymes that reach the lesser sac and then the liver either directly through the liver capsule [20,34] or indirectly through the hepatic hilum vessels, the hepatogastric ligament [16,29,34] or, rarely, via the hepatoduodenal ligament [25]. These hypotheses account for the location of pancreatic pseudocysts in the left lobe. Ancel *et al.* [18] suggest that pancreatic enzymes could cause liver damage, through the pararenal anterior space, often infiltrated during acute pancreatitis, reaching the right hepatic lobe through the area nuda. This hypothesis may account for pseudocysts located in the right lobe.

Miscellaneous

Epidermoid cysts of the liver

Epidermoid cysts of the liver are extremely rare [35–40]. The origin of these cysts is unknown. It is postulated that they derive from accessory foregut buds [35]. They occur in children or young adults. They may be responsible for right upper quadrant abdominal pain or mass [35]. Liver tests may be normal or exhibit an increase in aminotransferase and alkaline phosphatase activities. Ultrasonography shows large solitary cystic lesions that may simulate a hydatid cyst [36]. Total enucleation is warranted as subtotal cystectomy may be followed by relapse [36]. Pathological examination of the cyst wall shows its epidermoid nature lined by stratified squamous epithelium. Occasional reports of squamous cell liver cancer arising from an epidermoid cyst have been noted [37,39,40]. Because of their malignant potential and tendency to reoccur, total excision should be performed.

Cystic hepatic peliosis

Peliosis hepatis is an uncommon condition characterized by numerous blood-filled cavities or cystic spaces. Although the cause is unknown, it has been reported in association with several disease states such as tuberculosis, malignancy, diabetes, sprue, postrenal and cardiac transplantation and medication, particularly androgenic steroids [41].

Peliosis hepatis may occasionally present a cystic appearance [42–45]; abdominal ultrasonography may demonstrate diffuse

mixed echogenic masses, some with cystic cavities [42]. MRI findings are the following [43]: heterogeneic signal intensity on T1 WI with areas of high–intermediate and low signal intensity; a cystic round mass with a slim hyperintensity has been noted on T1 WI images [42]; heterogeneic signal on T2 WI with the presence of numerous intralesional 'cystic' hyperintense areas with a hypointense border [43]; after intravenous administration of gadolinium, enhancement is observed in the portovenous and late phases [43].

Cystic inflammatory pseudotumour of the liver

Inflammatory pseudotumours (IPT) of the liver are uncommon begin lesions that have been reported to occur in various organs and tissues [46]. Causes and pathogenesis of the lesion remain unknown. The term 'pseudotumour' arises from the discrepancy between the macroscopic appearance, indicative of a malignant tumour, and the histological picture, which reveals its inflammatory nature [46,47]. IPT has been reported increasingly in the liver, in both children and adults, usually presenting with systemic symptoms and fever [46,47].

Cystic appearance of IPT of the liver that masquerades as either a malignant cystic tumour of the liver [48] or a complicated hydatid cyst [47] has been reported rarely.

Cystic hepatic lymphangiomatosis

Hepatic lymphangiomatosis is a rare disorder characterized by cystic dilatation of the lymphatic vessels in the hepatic parenchyma [49]. It can occur in the liver alone, in the liver and spleen or in multiple organs [49,52]. Isolated case reports have focused on the cystic form of hepatic lymphangiomatosis [49–52] that can mimic polycystic liver disease [49] or hydatid cyst [50]. Some of the cysts contained caseous material [52].

References

1 Tuech JJ, Rousselet MC, Boyer J *et al.* (2003) Endometrial cyst of the liver: case report and review. *Fertil Steril* 79, 1234–1236.
2 Markham SM, Carpenter SE, Rock JA (1989) Extrapelvic endometriosis. *Obstet Gynecol Clin North Am* 16, 193–219.
3 Huang WT, Chen WJ, Chen CL *et al.* (2002) Endometrial cyst of the liver: a case report and review of the literature. *J Clin Pathol* 55, 715–717.
4 Finkel L, Marchevsky A, Cohen B (1986) Endometrial cyst of the liver. *Am J Gastroenterol* 7, 576–578.
5 Rovati V, Faleschini E, Vercellini P *et al.* (1990) Endometrioma of the liver. *Am J Obstet Gynecol* 163, 1490–1492.
6 Cravello L, D'Erenle C, Le Treut YP *et al.* (1996) Hepatic endometriosis a case report. *Fertil Steril* 66, 657–659.
7 Verbeke C, Härle M, Sturm J (1996) Cystic endometriosis of the upper abdominal organs. Report of three cases and review of the literature. *Pathol Res Pract* 192, 300–301.
8 Chung CC, Liew CT, Hewitt PM *et al.* (1998) Endometriosis of the liver. *Surgery* 123, 106–108.
9 Weinfeld RM, Johnson SC, Lucas CE *et al.* (1998) CT diagnosis of perihepatic endometriosis complicated by malignant transformation. *Abdom Imaging* 23, 183–184.
10 Inal M, Bicabei K, Soyupak S *et al.* (2000) Hepatic endometrioma: a case report and review of the literature. *Eur Radiol* 10, 431–434.
11 N'Senda P, Wendum D, Balladur P *et al.* (2000) Adenosarcoma arising in hepatic endometriosis. *Eur Radiol* 10, 1287–1289.
12 Bhaumik J, Hefni MA (2002) Endometriosis of liver and diaphragm: is the diagnosis often missed? *Gynaecol Endosc* 11, 155.
13 Jenkins S, Olive DL, Haney AF (1986) Endometriosis: pathogenetic implications of the anatomic distribution. *Obstet Gynecol* 76, 335–338.
14 Marik JJ, Jenkins S (1997) Endometrious etiology. *J Reprod Med* 19, 301–302.
15 Aiza I, Barkin JS, Casillas VJ *et al.* (1993) Pancreatic pseudocysts involving both hepatic lobes. *Am J Gastroenterol* 8, 1450–1452.
16 Okuda K, Sugita S, Tsukada E *et al.* (1991) Pancreatic pseudocyst in the left hepatic lobe: a review of two cases. *Hepatology* 13, 359–363.
17 Lederman E, Cajot O, Canva-Delcambre V *et al.* (1997) Pseudocysts in the left hepatic lobe: an unusual complication of acute pancreatitis. *Gastroenterol Clin Biol* 2, 340–341.
18 Ancel D, Lefebvre M, Peyrin-Biroulet L *et al.* (2005) Pancreatic pseudocysts of the right lobe during acute biliary pancreatitis. *Gastroenterol Clin Biol* 29, 743–745.
19 Roche J, Frairot A, Volle L *et al.* (1987) Intrahepatic localization of pancreatic pseudocyst. Treatment by simple puncture under ultrasonography. *Presse Med* 16, 2230.
20 Epstein BM, Conidaris C (1982) Pseudocysts involving the left lobe of the liver. CT demonstration. *Br J Radiol* 55, 928–930.
21 Baron TH, Morgan DE (1997) The diagnosis and management of fluid collections associated with pancreatitis. *Am J Med* 102, 555–563.
22 Hamm VB, Franzen N (1993) Atypically located pancreatic pseudocysts in liver, spleen, stomach wall and mediastinum: their CT diagnosis. *Fortschr Rontgenstr* 159, 522–527.
23 Siegelman SS, Copeland BE, Saba GP *et al.* (1980) CT of fluid collections associated with pancreatitis. *Am J Roentgenol* 134, 1121–1132.
24 Mofredj A, Cadranel JF, Dautreaux M *et al.* (2000) Pancreatic pseudocyst located in the liver. *J Clin Gastroenterol* 30, 81–83.
25 Shibasaki M, Bandai Y, Ukai T (2002) Pancreatic pseudocyst extending into the liver via the hepatoduodenal ligament: a case report. *Hepatogastroenterology* 49, 1719–1721.
26 Atienza P, Couturier D, Grandjouan S *et al.* (1987) Intrahepatic liquid collection of pancreatic origin. One case and a review of the literature. *Presse Med* 16, 1195–1198.
27 Boyd-Kranis RL, Bonn J (1997) Transhepatic transduodenal drainage of a pancreatic pseudocyst. *J Vasc Interv Radiol* 8, 659–662.
28 Gautier-Benoit C, Luez J, Cecile JP (1974) Pseudocyst of the pancreas with intrahepatic development. *Semin Hôp Paris* 50, 1235–1237.
29 Wang SJ, Chen JJ, Changchien CS *et al.* (1993) Sequential invasions of pancreatic pseudocysts in pancreatic tail, hepatic left lobe, caudate lobe, and spleen. *Pancreas* 8, 133–136.
30 Hospitel S, Guinot B, Teyssou H *et al.* (1983) Intrahepatic false cysts of the pancreas. *J Radiol* 64, 355–358.

31 Murphy BJ, Cassillas J, Ros PR *et al.* (1989) The CT appearance of cystic masses of the liver. *Radiographics* 9, 307–322.
32 Lantink JA, Heggelman BGF, Geerdink RA (1989) Intrahepatic rupture of a pancreatic pseudocyst: sonographic and CT demonstration. *Am J Roentgenol* 152, 1129.
33 Gumaste VV, Dave PB (1991) Pancreatic pseudocyst drainage: the needle or the scalpel? *J Clin Gastroenterol* 13, 500–505.
34 Okuda K, Sugita S (1998) Hepatobiliary images pancreatic pseudocysts in the liver. *J Gastroenterol Hepatol* 13, 433–436.
35 Schullinger JN, Wigger HJ, Price JB *et al.* (1983) Epidermoid cysts of the liver. *J Pediatr Surg* 18, 240–243.
36 Fernandez-Castroagudin J, Bustamante Montalvo M, Delgado Blanco M *et al.* (2001) Epidermoid cyst: a rare cause of cystic liver disease. *Gastroenterol Hepatol* 24, 247–249.
37 Yagi H, Ueda M, Kawachi S *et al.* (2004) Squamous cell carcinoma of the liver originating from non-parasitic cysts after a 15 year follow-up. *Eur J Gastroenterol Hepatol* 16, 1051–1056.
38 Ganti AL, Sardi A, Gordon J (2002) Laparoscopic treatment of large true cysts of the liver and spleen is ineffective. *Am Surg* 68, 1012–1017.
39 Caratozzolo E, Massani M, Recordare A *et al.* (2001) Squamous cell liver cancer arising from an epidermoid cyst. *J Hepatobiliary Pancreat Surg* 8, 490–493.
40 Lombardo FP, Hertford DE, Tan LK *et al.* (1995) Epidermoid cyst of the liver complicated by microscopic squamous cell carcinoma: CT, ultrasound, and pathology. *J Comput Assist Tomogr* 19, 131–134.
41 De Leve LD (2003) Vascular liver diseases. *Curr Gastroenterol Rep* 5, 63–70.
42 Saatci I, Coskun M, Boyvat F *et al.* (1995) MR findings in peliosis hepatis. *Pediatr Radiol* 25, 31–33.
43 Verswijvel G, Janssens F, Colla P *et al.* (2003) Peliosis hepatis presenting as a multifocal hepatic pseudotumor: MR findings in two cases. *Eur Radiol* 13, 40–44.
44 Shim SG, Paik SW, Hyun JG *et al.* (2001) Lipiodol accumulation in focal peliosis hepatis with sinusoidal dilatation. *J Clin Gastroenterol* 32, 356–358.
45 Staub PG, Leibowitz CB (1996) Peliosis hepatis associated with oral contraceptive use. *Australas Radiol* 40, 172–174.
46 Chen KT (1984) Inflammatory pseudotumor of the liver. *Hum Pathol* 15, 694–696.
47 Uccheddu A, Faa G, Cois A *et al.* (1995) Inflammatory pseudotumor of the liver. A report of two cases with unusual histologic picture. *Tumori* 81, 151–156.
48 Akiyama T, Saito H, Kiriyama M *et al.* (1995) A case of gallbladder cancer associated with a common bile duct neuroma, and a cystic lesion of the liver with histologic findings similar to those of an inflammatory pseudotumor. *J Gastroenterol* 30, 408–412.
49 O'Sullivan DA, Torres VA, de Groen PC *et al.* (1998) Hepatic lymphangiomatosis mimicking polycystic liver disease. *Mayo Clin Proc* 73, 1188–1192.
50 Clerici D, Griffa B, Ceppi M *et al.* (1989) Cystic lymphangioma of the liver. Presentation of a clinical case. *Minerva Chir* 44, 1139–1141.
51 Haratake J, Koide O, Takeshita H (1992) Hepatic lymphangiomatosis: report of two cases, with an immunohistochemical study. *Am J Gastroenterol* 87, 906–909.
52 McQuown DS, Fishbein MC, Moran ET *et al.* (1975) Abdominal cystic lymphangiomatosis: report of a case involving the liver and spleen and illustration of two cases with origin in the greater omentum and root of the mesentery. *J Clin Ultrasound* 3, 291–296.

8.2.2 Neoplasms including cystadenoma

Peter Starkel and André P. Geubel

Cystadenoma and cystadenocarcinoma

Prevalence

Biliary cystadenomas are rare multiloculated cystic tumours that represent less than 5% of cystic lesions of the liver [1]. They are 100 to 200 times less frequent than simple cysts of the liver and represent 1/10 000 to 1/20 000 hepatic tumours. They occur predominantly in middle-aged women (mean age 38 years) and are considered premalignant lesions [1,2].

Aetiology, pathogenesis and pathology

Aetiology and pathogenesis are unknown. A congenital origin from abnormal intrahepatic bile ducts or from misplaced germ cells has generally been suspected. Alternatively, a pseudo-ovarian origin would better account for the mucinous epithelium that delineates the cysts. Macroscopically, a large multiloculated-appearing tumour limited by a thin wall is found (Fig. 1a). The lesions are predominantly intrahepatic, but extrahepatic localizations have been reported [3]. The tumour generally contains a mucinous fluid. At microscopy, a single layer of mucin-secreting cuboidal epithelial cells with round or oval nuclei delineates the inner space of the cysts. The epithelium is

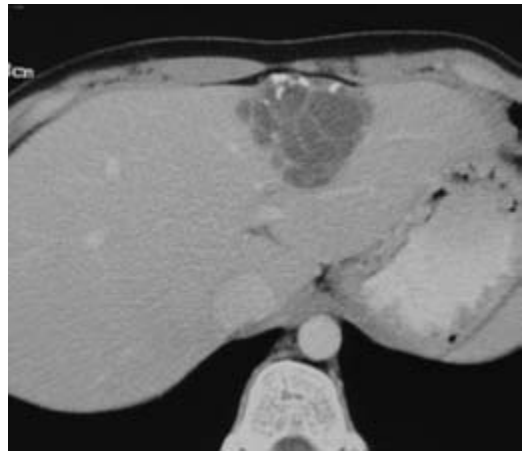

Fig. 1 Cystadenoma: tomodensitometry showing a multiloculated cystic lesion of the left lobe of the liver partly calcified in its anterior periphery. Morphological appearance of the columnar mucinous epithelium surrounded by a highly cellular mesenchymal tissue resembling ovarian stroma. Periodic acid–Schiff (PAS) mucus staining is shown in the lower right corner (see Plate 8.2.2.1, facing p. 72).

supported by a thick, cellular-rich, ovarian-like mesenchymal stroma (see Plate 8.2.2.1, facing p. 72) [4].

Clinical manifestations

Symptoms are usually related to the mass effect of the lesion and consist of intermittent abdominal discomfort, pain or swelling. Dyspepsia-like symptoms with nausea and anorexia may be encountered. A large hepatic mass can seldom be felt at abdominal examination. Signs of biliary tract obstruction may also be present.

Diagnosis

Liver function tests are usually normal. Diagnosis of cystadenoma relies on ultrasonography (US), computerized tomography (CT; Fig. 1a) and magnetic resonance imaging (MRI). At US, a large anechoic, fluid-filled globular area with irregular margins and internal echoes is seen corresponding to internal septa or papillary growths originating from the cystic wall [5]. CT shows a solitary cystic mass with a well-defined thick fibrous capsule, internal septa and mural nodules [2]. At MRI, a fluid-containing, multiloculated, septated mass is seen. Signal intensity of the content of the cysts is homogeneously low on T1-weighted images and high on T2-weighted images. Variable signal intensities on both T1- and T2-weighted images depend on the presence of solid components, haemorrhage or protein content. The portal–venous phase gadolinium-enhanced T1-weighted image shows enhancement of the capsule and septa [2]. Further imaging procedures [endoscopic retrograde cholangiopancreatography (ERCP), angiography, etc.] do not provide additional or useful information over the standard imaging techniques.

Course and complications

Cystadenomas are slow-growing tumours. Complications might result from various mass effects of the cyst that include compression of parts of the biliary tree leading to cholestasis. Intracystic haemorrhage, rupture or bacterial infections may also occur.

Cystadenomas have a clear malignant potential, and the most feared complication is transformation into cystadenocarcinoma. Malignant tumours almost exclusively arise in pre-existing cystadenomas, although rare cases of unusual origin have been reported [6,7]. Malignancy may affect the entire cyst but, more frequently, focal neoplastic transformation of the epithelium is observed. Intracystic haemorrhage in the absence of trauma, large projections protruding into the lumina of the lobules and calcification of the septa on imaging are arguments in favour of malignancy (Fig. 2a and b) [8,9]. Diagnosis of malignancy may require ultrasound-guided biopsy. Histologically, the malignant epithelium is multilayered with numerous papillary projections and dysmorphic epithelial cells invading the stroma. Cystadenocarcinoma's extension arises locally into the liver, with extrahepatic metastasis also being observed [10].

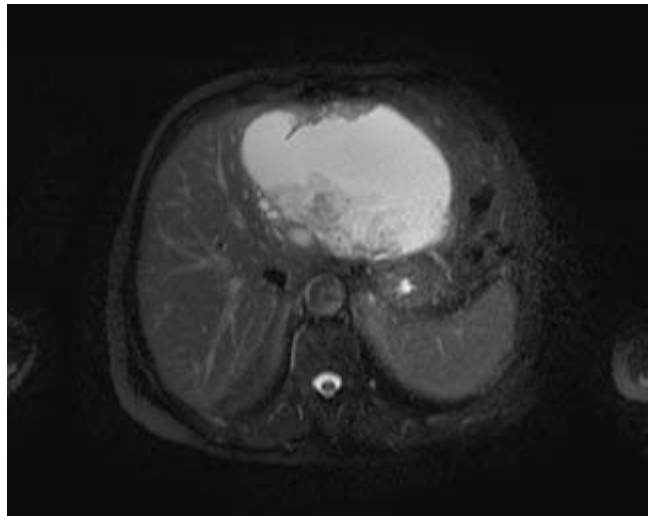

(a)

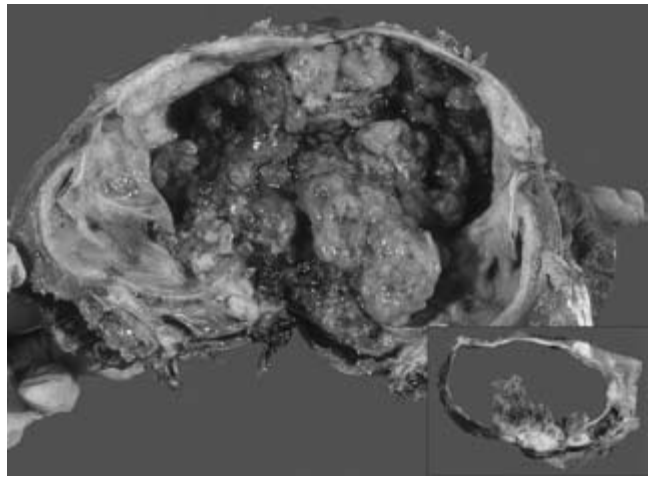

(b)

Fig. 2 Cystadenocarcinoma: T2-weighted MR image with fat suppression showing a voluminous cystic lesion in the left lobe with a heterogeneous signal at the posterior side of the lesion and a thickening of the anterior wall (a). Macroscopic appearance of the lesion together with a cut section seen in the lower right corner (b).

Differential diagnosis

Distinction between cystadenomas, simple liver cysts complicated by intracystic haemorrhage (Fig. 3) or even hydatid cysts, albeit important on clinical grounds, might be difficult. The presence of calcifications together with positive serology is a strong argument for hydatid disease. High levels of CA19-9 in a mucinous fluid obtained by percutaneous or echoendoscopic fine-needle aspiration seem to be suggestive of cystadenoma or cystadenocarcinoma and might be of help in distinguishing them from simple cysts [11,12]. The characteristics of other cystic neoplasms that may be relevant for the differential diagnosis will be discussed below.

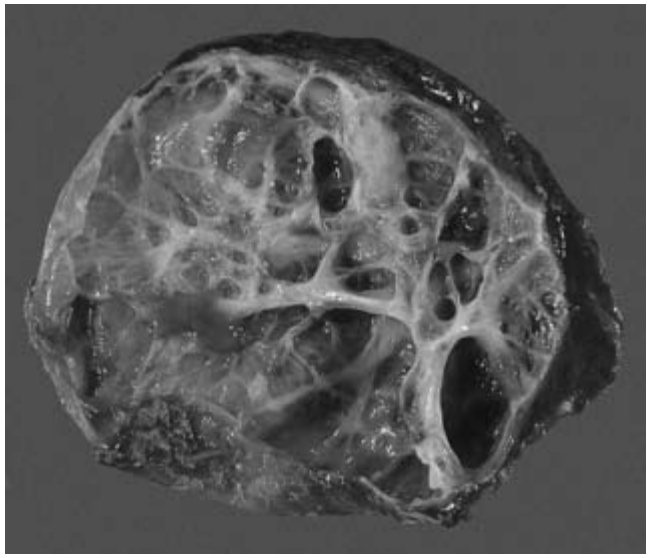

Fig. 3 Macroscopic aspect of a biliary cyst complicated by recurrent haemorrhagic episodes. Luminal scarring has the potential to induce a multiloculated appearance mimicking that of a cystadenoma (courtesy of Professor J.F. Gigot).

Treatment

When feasible, complete surgical excision, even in asymptomatic patients, is mandatory given the risk of recurrence after partial removal of the lesion and its potential for malignant transformation [13,14].

Cystic subtypes of primary liver neoplasms

Most of the primary liver neoplasms are solid lesions, and their cystic-like appearance is usually related to internal haemorrhage or necrosis following disproportionate growth.

Internal haemorrhage is the most frequent cause of a partially cystic appearance in hepatocellular adenoma. Rarely, cystic degeneration of adenomas has been reported [15].

Hepatocellular carcinoma may manifest as a partially cystic mass due to internal necrosis in large tumours or following locoregional treatment. Even in predominantly cystic tumours, the diagnosis of hepatocellular carcinoma may be suspected if CT or MRI shows features or complications suggestive of underlying liver cirrhosis. In addition, the presence of an encapsulated tumour with hypervascular solid parts on CT or MRI reinforces the diagnosis of hepatocellular carcinoma [2], especially when associated with elevated serum α-fetoprotein levels. Central cystic degeneration or extensive necrosis may result in a cyst-like presentation of giant cavernous haemangioma, the nature of which is generally easily recognized on CT and/or MRI. On contrast-enhanced imaging, their characteristic peripheral nodular enhancement together with a non-enhancing central cystic area is suggestive of the diagnosis [16,17].

Cystic metastases

Metastases to the liver are common, and some may exhibit a complete or partial cystic appearance. Rapid growth of hypervascular metastatic tumours leading to necrosis and cystic degeneration is frequently implicated in the cystic pattern of liver metastases from sarcoma, melanoma, lung and breast carcinoma. Contrast-enhanced CT and MRI usually demonstrate multiple, irregularly defined lesions with a strong enhancement of the peripheral viable tissue [18]. As the radiological picture is not specific for a particular primary tumour, the clinical circumstances and the determination of serum tumour markers such as carcinoembryonic antigen (CEA), CA15-3 and neuron-specific enolase (NSE) are useful in guiding additional diagnostic procedures.

The same pathophysiological mechanism and radiological appearances apply to cystic neuroendocrine tumours, particularly those of large size. However, in some instances, neoplasms may mimic benign cysts by their clinical and radiological appearances. In this particular situation, the various imaging modalities are rarely helpful in distinguishing between benign or neoplastic cysts [19]. If malignancy can be neither confirmed nor invalidated by standard diagnostic procedures including the neuroendocrine tumour markers chromogranin and NSE, a biopsy of the cyst wall for histological examination may be required to obtain a definite diagnosis.

Metastatic colorectal adenocarcinomas spread preferentially into the liver through the bloodstream and may present as intraparenchymal cystic metastases as a result of their mucinous secretions (Fig. 4) [20]. Their radiological appearances are similar to those of other cystic metastases. In contrast, cystic metastases originating from ovarian adenocarcinoma usually present as cystic serosal implants on both the peritoneal surface of the liver and the parietal peritoneum, as they spread predominantly by peritoneal seeding [2,21].

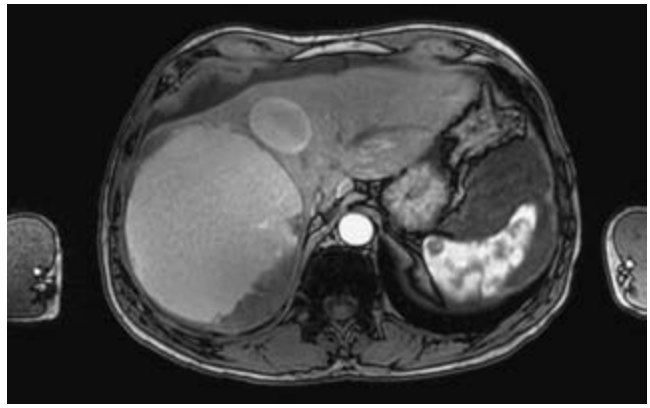

Fig. 4 Cystic metastases of the liver (adenocarcinoma of the colon): T1-weighted MR image with contrast injection showing two cystic lesions of the right lobe with a spontaneous hyperintense signal resulting from their high mucinous content. There is parietal thickening of the posterior wall of the largest lesion (courtesy of Professor B. Van Beers).

Miscellaneous and rare conditions

Neoplastic degeneration to squamous cell carcinoma has been described for solitary benign hepatic cysts. The tumour usually arises from metaplastic foci in pre-existing liver cysts that subsequently undergo neoplastic transformation [22].

Some rare forms of cholangiocarcinoma may present with a cyst-like appearance. Mucinous cholangiocarcinoma results from mucin production by adenocarcinoma cells that leads to the formation of multiple microcysts assembled in a honeycomb-like pattern [23]. Coexistence of solid cholangiocarcinoma with developmental liver cysts has also been reported. Whether this tumour arises directly from initially non-neoplastic cysts with atrophic epithelium and dysplastic changes remains unclear [24].

Although Von Meyenburg complexes are generally considered to be innocuous, their neoplastic transformation into cholangiocarcinoma has been described. Pathophysiology might involve a progressive transition through hyperplasia or adenomatous transformation. Several case reports in the literature describe a profoundly disturbed hepatic environment with extensive liver fibrosis and portal hypertension that might have contributed to neoplastic transformation [25].

Undifferentiated embryonal sarcoma is a rare malignant hepatic tumour that develops in older children, adolescents and, exceptionally, in young adults. At imaging, a large, solitary cystic mass is found with well-defined borders and, occasionally, a pseudocapsule. Given the high water content of the myxoid stroma of this tumour, hypointense signal on T1- and hyperintense signal on T2-weighted images are demonstrated in large portions of the tumoral tissue on MRI. Signs of intratumoral haemorrhage and a heterogeneous enhancement of the peripheral, solid parts of the mass may be present on contrast-enhanced CT or MRI [2].

References

1 Buetow PC, Midkiff RB (1997) Primary malignant neoplasms in the adult. *Magn Reson Imaging Clin N Am* 5, 289–318.
2 Mortelé KJ, Ros PR (2001) Cystic focal lesions in the adult: differential CT and MR imaging features. *Radiographics* 21, 895–910.
3 Palacios E, Shannon M, Solomon C *et al.* (1990) Biliary cystadenoma: ultrasound, CT and MRI. *Gastrointest Radiol* 15, 313–316.
4 Devaney K, Goodman ZD, Ishak KG (1994) Hepatobiliary cystadenoma and cystadenocarcinoma. A light microscopic and immunohistochemical study of 70 patients. *Am J Surg Pathol* 18, 1078–1091.
5 Forrest ME, Cho KJ, Shields JJ *et al.* (1980) Biliary cystadenomas: sonographic-angiographic-pathologic correlations. *Am J Roentgenol* 135, 723–727.
6 Devine P, Ucci AA (1985) Biliary cystadenocarcinoma arising in a congenital cyst. *Hum Pathol* 16, 92–94.
7 Horsmans Y, Laka A, van Beers BE *et al.* (1997) Hepatobiliary cystadenocarcinoma without ovarian stroma and normal CA19-9 levels. Unusually prolonged evolution. *Dig Dis Sci* 42, 1406–1408.
8 Stanley J, Vujic I, Schabel SI *et al.* (1983) Evaluation of biliary cystadenoma and cystadenocarcinoma. *Gastrointest Radiol* 8, 245–248.
9 Korobkin M, Stephen DH, Lee JK *et al.* (1989) Biliary cystadenoma and cystadenocarcinoma: CT and sonographic findings *Am J Roentgenol* 153, 507–511.
10 Iemoto Y, Kondo Y, Nakano T *et al.* (1983) Biliary cystadenocarcinoma diagnosed by liver biopsy performed under ultrasonographic guidance. *Gastroenterology* 84, 399–403.
11 Horsmans Y, Laka A, Gigot JF *et al.* (1996) Serum and cystic fluid CA19-9 determinations as a diagnostic help in liver cysts of uncertain nature. *Liver* 16, 255–257.
12 Bonnet S, Béchade D, Palazzo L *et al.* (2005) Ponction sous échoendoscopie d'un cystadénome hépatique. *Gastroenterol Clin Biol* 29, 607–609.
13 Lewis WD, Jenkins RL, Rossi RL *et al.* (1988) Surgical treatment of biliary cystadenoma. A report of 15 cases. *Arch Surg* 123, 563–568.
14 Kim J, Choi J, Park Y *et al.* (1998) Biliary cystadenoma of the liver. *Hepatobiliary Pancreat Surg* 5, 348–352.
15 Kobayashi M, Enzan H, Araki K *et al.* (1999) Spontaneous hepatocellular adenoma with marked cystic degeneration. *Hepatogastroenterology* 46, 2955–2958.
16 Vilgrain V, Boulos L, Vullierme MP *et al.* (2000) Imaging of atypical hemangiomas of the liver with pathologic correlation. *Radiographics* 20, 379–397.
17 Semelka RC, Sofka CM (1997) Hepatic hemangiomas. *Magn Reson Imaging Clin N Am* 5, 241–253.
18 Lewis KH, Chezmar JL (1997) Hepatic metastases. *Magn Reson Imaging Clin N Am* 5, 319–330.
19 Thompson NW, Eckhauser FE, Vinik AI *et al.* (1984) Cystic neuroendocrine neoplasms of the pancreas and liver. *Ann Surg* 199, 158–164.
20 Sugawara Y, Yamamoto J, Yamasaki S *et al.* (2000) Cystic liver metastases from colorectal cancer. *J Surg Oncol* 74, 148–152.
21 Lundstedt C, Holmin T, Thorvinger B (1992) Peritoneal ovarian metastases simulating liver parenchymal masses. *Gastrointest Radiol* 17, 250–252.
22 Monteagudo M, Vidal G, Moreno M *et al.* (1998) Squamous cell carcinoma and infection in a solitary hepatic cyst. *Eur J Gastroenterol Hepatol* 10, 1051–1053.
23 Sonobe H, Enzan H, Ido E *et al.* (1995) Mucinous cholangiocarcinoma featuring a unique microcystic appearance. *Pathol Int* 45, 292–296.
24 Azizah N, Paradinas FJ (1980) Cholangiocarcinoma coexisting with developmental liver cysts: a distinct entity different from liver cystadenocarcinoma. *Histopathology* 4, 391–400.
25 Jain D, Sarode VR, Abdul-Karim FW *et al.* (2000) Evidence for the neoplastic transformation of von-Meyenburg complexes. *Am J Surg Pathol* 24, 1131–1139.

8.2.3 Posttraumatic cystic diseases

Jean-François Cadranel

Biloma

Biloma is an abnormal fluid collection that can be intrahepatic or perihepatic [1,2]. Biloma results from rupture of the biliary system, which can be spontaneous, iatrogenic following surgery

or interventional procedures or traumatic [1–3]. Extravasation of bile into the liver parenchyma generates an intense inflammatory reaction, thus inducing the formation of a well-defined pseudocapsule [1–3]. Clinical manifestations depend on the location and size of the biloma [2,3]. Ultrasonography revealed an anechoic well-defined collection [1]. It is usually located in the right hypochondrium near the hepatic pedicle or gallbladder [1]. On both computerized tomography (CT) and magnetic resonance imaging (MRI), a biloma appears as a well-defined or slightly irregular cystic mass without septa or calcifications [2,3]. Also, the pseudocapsule is usually not readily identifiable [2,3]. This imaging appearance, in combination with the clinical history and location, should enable a correct diagnosis [2]. Puncture of the collection showed a high level of bilirubin concentration allowing for the biliary nature of the collection [3]. Owing to potential injury to the peritoneum, biloma should be evacuated [1].

Haematoma

Posttraumatic haematoma are unusual sequelae of hepatic trauma [2,4–6]. Symptomatic manifestations depend on the severity of the bleeding, the location and the time frame during which the haemorrhage occurred [2].

Cystic transformation of hepatic haematoma is usual after hepatic trauma. It can be located either subcapsulac or in the parenchyma [1]. Imaging pattern depends on the cause of the bleeding and the lag time [1,2]. In an acute or subacute setting, haematic collection is heterogeneous on ultrasonography and is followed by an anechoic pattern [1]. On CT, during the acute or subacute phases, haemorrhage has a higher attenuation value than pure fluid due to the presence of aggregated fibrin components [7]. In the chronic phase, a haematoma has attenuation identical to that of pure fluid [2]. On MRI, the aspect is variable according to the lag time between the traumatic event and the imaging procedure.

High signal intensity on T1-weighted images is highly suggestive of the haematic nature of the collection [1]. Margins are usually irregular [1]. Coexistent features such as hepatic lacerations, rib fractures or perihepatic fluid may be present [2]. Owing to the paramagnetic effect of methaemoglobin, MRI is even more suitable than CT for the detection and characterization of haemorrhage [2]. Diagnosis of hepatic haematoma is based on the history of trauma, surgery or radiological intervention [1,6].

References

1 Vilgrain V (2001) Cystic lesions of the liver. *Gastroenterol Clin Biol* 25, B167–B177.
2 Mortele KJ, Ros PR (2001) Cystic focal liver lesions in the adult: differential CT and MR imaging features. *Radiographics* 21, 895–910.
3 Murphy BJ, Cassillas J, Ros PR *et al.* (1989) The CT appearance of cystic masses of the liver. *Radiographics* 9, 307–322.
4 Ratan SK, Bhandar I, Grover S *et al.* (1999) Post-traumatic hepatic cyst. *Ind Pediatr* 36, 1048–1051.
5 Sugimoto T, Yoshioko T, Sawada Y *et al.* (1982) Post traumatic cyst of the liver found on CT-scan. A new concept. *J Trauma* 22, 797–800.
6 Chuang JH, Huang SC (1996) Post traumatic hepatic cyst. An unusual sequel of liver injury in the era of imaging. *J Pediatr Surg* 31:272–274.
7 Merrine D, Fishman EK, Zerhoumi EA (1988) Spontaneous hepatic hemorrhage: clinical and CT findings. *J Comput Assist Tomogr* 12, 397–400.

9 Viral infections of the liver

9.1 Viral hepatitis

9.1.1 Viral hepatitis

Mario Rizzetto and Fabien Zoulim

Although many viruses can affect liver function and morphology indirectly as a result of systemic infections, only a minority are truly hepatotropic, that is infectious to the liver itself, producing hepatitis as the major clinical manifestation. The term 'viral hepatitis' refers to disease caused by this subgroup.

Historical background and nomenclature

Although viral hepatitis is a disease of antiquity, and epidemic jaundice is mentioned in the Talmud, the infectious nature of the disease was not recognized until the end of the nineteenth century.

The first description of 'hepatitis B' dates back to 1885 when Lürman, a public health officer in Bremen, Germany, gave a detailed report of an outbreak of jaundice that developed among workers at a local company vaccinated against smallpox with glycerinized human serum [1].

Transmission studies in human volunteers in the late 1930s and during the Second World War provided the first information about the infectivity, mode of transmission and properties of the hepatitis agents; they suggested that two distinct viral agents, lacking cross-immunity, were responsible for military outbreaks, and MacCallum introduced the classic terminology of hepatitis A virus (HAV) and hepatitis B virus (HBV) [2].

Faeces were shown to induce hepatitis A (infectious hepatitis) by the oral route; the incubation period was 15–30 days. Acute-phase serum was shown to induce hepatitis B (serum hepatitis), after several months, when given by the parenteral route.

Transmission studies in humans by Krugman and associates in the late 1950s and early 1960s, using the newly discovered assays for serum transaminases, contributed significantly to the understanding of the characteristics of the two hepatitis 'viruses' (identified by Krugman as the MS1 strain, causing hepatitis A, and the MS2 strain, causing hepatitis B) [3].

The discovery of the Australia antigen, now called hepatitis B surface antigen (HBsAg), by Blumberg and his associates in the mid-1960s [4], and the recognition by Prince [5] of its specific relation to hepatitis B, started the contemporary era in the field of hepatitis. Intensive research quickly led to the identification of the hepatitis B virion [6], to the recognition of its antigenic and genomic complexity [7] and oncogenic potential and, later, to the development of a safe and effective vaccine [8]. The lessons learned from work on hepatitis B helped in the rapid discovery of HAV. Using an immunoelectron microscopic technique, previously applied to reveal the nucleocapsid of HBV, Feinstone and associates identified the HAV in 1973 in immunocomplexes from faeces to which serum of a patient convalescent from hepatitis A had been added [9]. Then, in 1977, a discrepancy in immunofluorescence testing for HBV antigens in the liver led Rizzetto and associates to the discovery of the delta antigen [10], which was subsequently shown to be related to a new RNA virus designated the hepatitis delta virus (HDV).

When testing for hepatitis A and B was made generally available, it became clear that the two viruses did not explain all causes of viral hepatitis, as many patients lacked markers of either infection. Thus, the concept emerged in the 1980s of a new variant of viral hepatitis, which was called 'non-A, non-B hepatitis' to highlight the fact that the diagnosis was based on exclusion criteria, not on specific positive evidence [11]. The magnitude of the problem was best seen in relation to blood transfusion: in the wake of the widespread and increasing application of blood transfusion and plasma substitution, hepatitis continued to occur in 5–10% of the recipients of blood products, despite almost total control of HBV.

However, efforts to identify the major aetiological agent of endemic non-A, non-B hepatitis met with failure or with spurious results until 1989. The breakthrough resulted from exhaustive research involving the use of sophisticated technological methods. Several thousand clones of genetic material from a serum containing a putative agent of non-A, non-B hepatitis were systematically analysed by Houghton and associates [12], who ultimately identified a clone that met the criteria for being a new viral genome and provided the key to the characterization of the

hepatitis C virus (HCV), alias transfusion-transmitted non-A, non-B virus. Meanwhile, a novel agent responsible for enterically transmitted outbreaks of epidemic non-A, non-B hepatitis in tropical and subtropical areas and named the hepatitis E virus (HEV) had been identified in the early 1980s by epidemiological analysis and human transmission studies [13].

The five viruses recognized by the end of the 1980s account for the great majority of viral hepatitides occurring at temperate latitudes. Since then, several new viruses, named the F, GB/HG, TT and SEN viruses, have been proposed as hepatitides agents, raising the hope that they might fill the remaining nosological gap. However, extensive scrutiny has failed to demonstrate that these agents play a causal role in acute or chronic liver disease, and they have not entered the differential diagnosis of viral liver disorders.

The enterically transmitted hepatitis F virus (HFV), described in 1994 [14] and thought to be responsible for sporadic non-A, non-E hepatitis, was probably a ubiquitous non-pathogenic intestinal resident that colonizes stools during liver injury.

The GB virus [15] C subtype and hepatitis G virus (HGV) [16] are a similar RNA flavivirus that is transmitted by blood transfusions; its prevalence is therefore high among groups with frequent parenteral exposures.

The TT virus (TTV) belongs to a large and heterogeneous DNA virus family classified as Circoviridae [17]; it shares a commensal non-pathogenic relationship with humans, is transmitted by parenteral routes and is prevalent in multiply-transfused subjects and in populations in Africa and South America.

The SEN virus (SENV), of which A–H variants have been described, was discovered using degenerate TTV primers; it shares properties with the latter, but is classified separately within the Circoviridae. It is transmitted by transfusion and probably by non-parenteral routes; its prevalence is high (20%) in healthy persons in Japan.

While the puzzle of the existence, if any, of other hepatitis viruses remains unresolved, the perspectives for the treatment of HBV and HCV disease have greatly increased in recent years. The advent of interferon in the mid-1980s [19] has provided the first valid, although limited, therapeutic panacea for all forms of chronic viral hepatitis. At the beginning of the third millennium, the combination of ribavirin with interferon and the advent of slow-release pegylated interferons have led to a significant improvement in the rate of HCV cure, while the tumultuous discovery of new synthetic antivirals is leading to better control of hepatitis B with better tolerance and less long-term resistance to the drugs. In parallel, the worldwide expansion of liver transplantation is offering a valid option for endstage cirrhotic disease with a risk of reinfection that has dramatically diminished for hepatitis B.

Further hope rests with the development of new treatments for hepatitis C based on protease and polymerase inhibitors, several of which are currently under clinical study.

While treatment strategies evolve and therapy is progressing from primarily treating a liver disease to the targeting of the viral disease via direct antiviral therapy, the worldwide implementation of the HBV vaccine represents the cornerstone for the global control of hepatitis B, and the development of a HCV vaccine remains the challenge for the next decade.

References

1 Lurman A (1885) Eine Icterusepidemie. *Berliner Klin Wochensch* 22, 20–23.

2 MacCallum FO (1947) Homologous serum jaundice. *Lancet* 2, 691–692.

3 Krugman S, Giles JP, Hammond J (1967) Infectious hepatitis: evidence for two distinctive clinical, epidemiological and immunological types of infection. *JAMA* 200, 365–373.

4 Blumberg BS, Gerstley BJS, Hungerford DA *et al.* (1967) A serum antigen (Australia antigen) in Down's syndrome, leukemia, and hepatitis. *Ann Intern Med* 66, 924–931.

5 Prince AM (1968) An antigen detected in the blood during the incubation period of serum hepatitis. *Proc Natl Acad Sci USA* 60, 814–821.

6 Dane DS, Cameron CH, Briggs M (1970) Virus-like particles in serum of patients with Australia-antigen-associated hepatitis. *Lancet* 1, 695–698.

7 Tiollais P, Charnay P, Vyas GN (1981) Biology of hepatitis B virus. *Science* 213, 406–411.

8 Szmuness W, Stevens CE, Harley EJ *et al.* (1980) Hepatitis B vaccine: demonstration of efficacy in a controlled clinical trial in a high-risk population in the United States. *N Engl J Med* 303, 833–841.

9 Feinstone SM, Kapikian AZ, Purcell RH (1973) Hepatitis A: detection by immune electron microscopy of a viruslike antigen associated with acute illness. *Science* 182, 1026–1028.

10 Rizzetto M, Canese MG, Aricò S *et al.* (1977) Immunofluorescence detection of new antigen-antibody system (delta/anti-delta) associated to hepatitis B virus in liver and in serum of HBsAg carriers. *Gut* 18, 997–1003.

11 Alter HJ, Purcell RH, Holland PV *et al.* (1975) Clinical and serological analysis of transfusion-associated hepatitis. *Lancet* 2, 838–841.

12 Choo Q-L, Kuo G, Weiner AJ *et al.* (1989) Isolation of a cDNA clone derived from a blood-borne non-A, non-B viral hepatitis genome. *Science* 244, 359–362.

13 Khuroo MS (1980) Study of an epidemic of non-A, non-B hepatitis. Possibility of another human hepatitis virus distinct from post-transfusion non-A, non-B type. *Am J Med* 68, 818–824.

14 Pillot J, Meng J, Maillard P *et al.* (1997) The "presumed" hepatitis F virus. In: Rizzetto M, Purcell RH, Gerin JL *et al.* (eds) *Viral Hepatitis and Liver Diseases*. Turin: Minerva Medica, pp. 399–401.

15 Simons JN, Leary TP, Dawson GJ *et al.* (1995) Isolation of novel virus-like sequences associated with human hepatitis. *Nature Med* 1, 564–569.

16 Linnen J, Wages J Jr, Zhang-Keck ZY *et al.* (1996) Molecular cloning and disease association of hepatitis G virus: a transfusion-transmissible agent. *Science* 271, 505–508.

17 Mushahwar IK, Erker JC, Muerhoff AS *et al.* (1999) Molecular and biophysical characterization of TT virus: evidence for a new virus family infecting humans. *Proc Natl Acad Sci USA* 96, 3177–3182.

18 Tanaka Y, Primi D, Wang RYH *et al.* (2001) Genomic and molecular evolutionary analysis of a newly identified infectious agent (SEN virus) and its relationship to the TT virus family. *J Infect Dis* 183, 359–367.

19 Hoofnagle JH, Mullen KD, Jones DB *et al.* (1986) Treatment of chronic non-A, non-B hepatitis with recombinant human alpha interferon. A preliminary report. *N Engl J Med* 315, 1575–1578.

9.1.2 The viruses of hepatitis

9.1.2.i Structure, replication and laboratory diagnosis of hepatitis B virus and hepatitis D virus

Stephan Schaefer and Wolfram H. Gerlich

Introduction

The stepwise discovery of hepatitis B virus (HBV) began with a serum antigen that was first detected in an Australian aborigine during genetic studies on serum protein polymorphisms. 'Australia antigen' was located on 20-nm large spherical lipoprotein particles. After several years, it was recognized that Australia antigen was not a genetic marker but an antigen acquired after infection with hepatitis type B. Australia antigen particles did not contain nucleic acid and were thus considered for a while to be an unconventional infectious agent like prions. However, in addition to the 20-nm particles, 42-nm large, double-shelled particles, known as Dane particles, were detected in sera from hepatitis B patients that carried Australia antigen on their surface and resembled viruses (Fig. 1). Soon afterwards, Robinson and coworkers detected an endogenous DNA polymerase within the Dane particles and, finally, a small circular DNA. Almeida and coworkers [1] released the core particles from the Dane particles using detergent, and were able to form immune complexes of these particles with antibodies from hepatitis B convalescents. These findings showed that Dane particles were the agent of hepatitis B with two antigen moieties: Australia antigen, which was renamed hepatitis B surface antigen (HBsAg), and hepatitis B core antigen (HBcAg). A third, non-structural HBV antigen in the serum of highly viraemic virus carriers was named HBeAg, in which 'e' has no specific meaning. Cloning, sequencing and expression of the DNA extracted from Dane particles allowed the identification of the viral genes. Since the early 1970s, the development of serological assays for the HBsAg helped to diagnose hepatitis B reliably and to screen for asymptomatic, but infectious, HBV carriers among blood and organ donors. Antibodies against HBcAg (anti-HBc) are present during the acute phase of hepatitis B and thereafter, but they do not protect against HBV. Antibodies against HBsAg (anti-HBs) are formed at resolution of acute hepatitis B and protect against infection. This observation opened the way to use HBsAg from virus carrier plasma as a vaccine against HBV. Later, the HBsAg was produced safely and in unlimited amounts in yeast cells transformed with the HBsAg gene. As HBV is the major cause of hepatocellular carcinoma, purified HBsAg serves as the first human antitumour vaccine with proven efficacy.

Two other hepatitis viruses (HCV and HDV) are also transmitted parenterally. Hepatitis D virus (HDV) was identified as an infectious agent that encoded delta antigen before the discovery of hepatitis C virus (HCV). Delta antigen was initially considered to be a new variant of HBV antigens, but it is the nucleoprotein of a completely different defective RNA virus that depends on envelopment by the HBV surface proteins.

Structure of HBV (Fig. 2)

HBV is enveloped and contains within its icosahedral core the viral DNA genome with a length varying from 3185 to 3248 basepairs (bp) depending on the HBV genotype (Table 1). Electron microscopy of negatively stained virions shows particles with a diameter of 42 nm but, in the hydrated state, the outer diameter is about 50 nm. The envelope of the virus is made up of an estimated 370–400 molecules of membrane-spanning HBV surface proteins, 160–200 of which show surface projections [2,3].

Taxonomy

HBV belongs to the family of Hepadnaviridae, which is made up of two genera [4,5]. The genus Avihepadnavirus is found

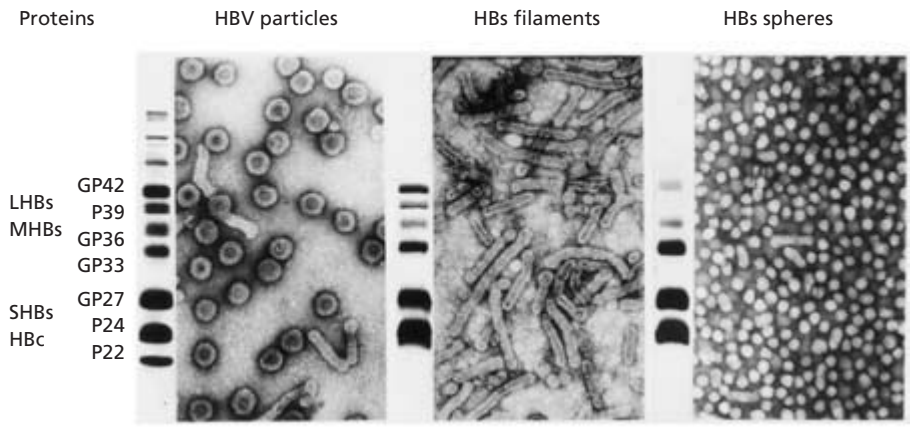

Fig. 1 HBV-associated particles purified from the plasma of a highly viraemic persistent HBV carrier. Electron micrographs and protein patterns in silver-stained gels after separation by denaturing sodium dodecyl sulphate (SDS) gel electrophoresis.

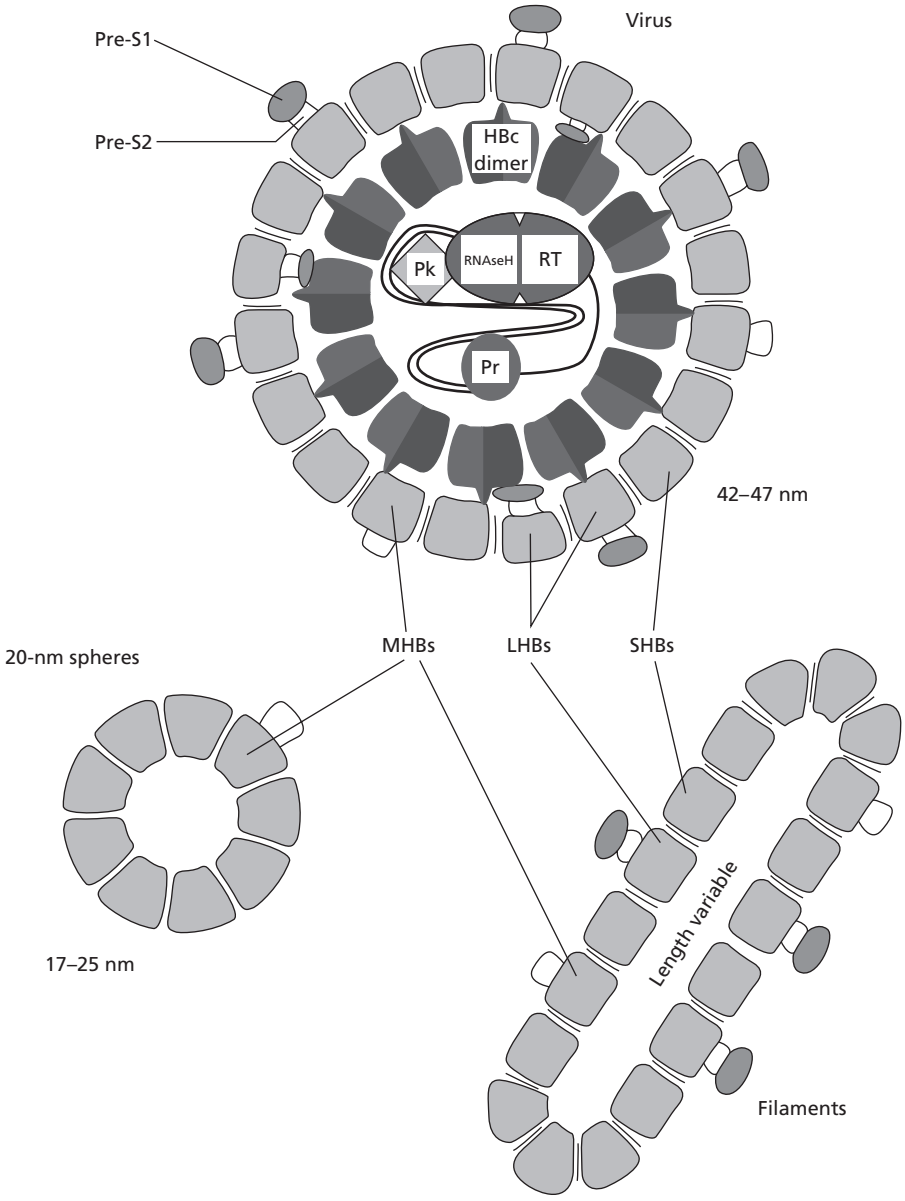

Fig. 2 Schematic model of HBV particles and subviral HBsAg particles. Pk, protein kinase; RT, reverse transcriptase; Pr, priming (or terminal) domain of the polymerase; L-, M-, SHBs, large, middle and small HBs protein with their domains, pre-S1, pre-S2.

in birds, and Orthohepadnavirus (Fig. 3) in mammals. Orthohepadnaviruses have been detected in rodents, the new world woolly monkey, in apes and in man [6,7].

Human HBV is subdivided into eight genotypes, called A–H, that differ by more than 8% from each other [8–10] (Fig. 3). HBV isolates found in apes form additional HBV genotypes in phylogenetic analyses and have been named HBVcpz, -oru, -gor and -gbn for their respective hosts chimpanzee, orang-utan, gorilla and gibbon (Fig. 3) [11].

HBV genotypes can be further subdivided into subgenotypes (Table 2), which differ by at least 4% from each other [12,13]. In HBV genotypes A, B and C, epidemiological data show that the respective subgenotype pairs A1/A2, B1/B2 [14] and C1/C2 [15–17] differ substantially in many virological, and probably some clinical, parameters. Subgenotypes also show distinct geographic distribution (Fig. 4).

Hepadnaviruses replicate their genome via reverse transcription of a pregenomic (pg) RNA. Thus, in spite of being DNA viruses, they share many features with retroviruses, including sensitivity to certain human immunodeficiency virus (HIV) drugs.

HBV DNA

The DNA encapsidated in the mature virion has an unusual structure (Fig. 5a). The two DNA strands are linear but, because of 5′ terminal overlaps of 234 bases, the genomic DNA acquires a relaxed circular (rc) form. The strand encoding the viral

Table 1 Genotype, genome length and differences of HBV genotypes.

Genotype	Genome length (bp)	ORF differences
A	3221	Insertion of aa 153 and 154 in HBc
B	3215	
C	3215	
D	3182	Deletion of aa 1–11 in pre-S1
E	3212	Deletion of aa 11 in pre-S1
F	3215	
G	3248	Insertion of 12 aa in HBc Deletion of aa 11 in pre-S1
H	3215	

Bp, basepair; ORF, open reading frame; aa, amino acid.
The normal length of the HBV genome seems to be 3215 bp. Differences in genome length arise from deletions of 33 nucleotides (nt) (genotype D) or insertions of 6 nt (genotype A) or 33 nt (genotype G) in different parts of the genome.

proteins is termed the minus strand because the mRNA transcribed from it is, by definition, plus stranded. The 5′ end of the minus strand is covalently linked via a phosphodiester bridge to the hydroxyl group of tyrosine 63 in the terminal protein domain of the polymerase protein. The 5′ end of the DNA plus strand is formed by the residual 18 bases of the pg RNA. In contrast to the minus strand, the plus strand is incomplete, leaving a single-stranded gap of several hundred up to 1500 bases. The rc DNA contains various elements required for replication, such as direct repeats DR1 and DR2, a short 3′ and 5′ terminal 9-bp redundancy r in the minus strand and sequence elements 5E, 3E and M for circularization. The covalently closed form of the DNA (Fig. 5b) is the template for transcription of the viral mRNAs. It encodes four conserved open reading frames: core (C), surface (pre-S1, pre-S2, S), X and pol. There are two enhancers (Enh I and II), four promoters (P), a negative regulatory element (NRE) and a glucocorticoid-responsive element (GRE).

Hepatitis B virus core protein

Most HBV genotypes code for a core protein (HBc) with 183 amino acids (aa) (185 aa for genotype A) [18]. The four C-terminal arginine-rich clusters bind the encapsidated viral nucleic acids. HBc forms dimers that are linked by cystine bridges after release from the reducing environment of the cytosol. During replication, core particles package a complex containing the viral pg RNA, the viral DNA polymerase, a cellular protein kinase and cellular chaperones. The interaction of the pg RNA with the basic arginine-rich clusters of HBc enhances assembly. However, HBc dimers may combine at high concentrations into trimers and assemble spontaneously into capsids even in the absence of other viral components [19]. Capsids are found in two populations of icosahedral particles with a T = 3

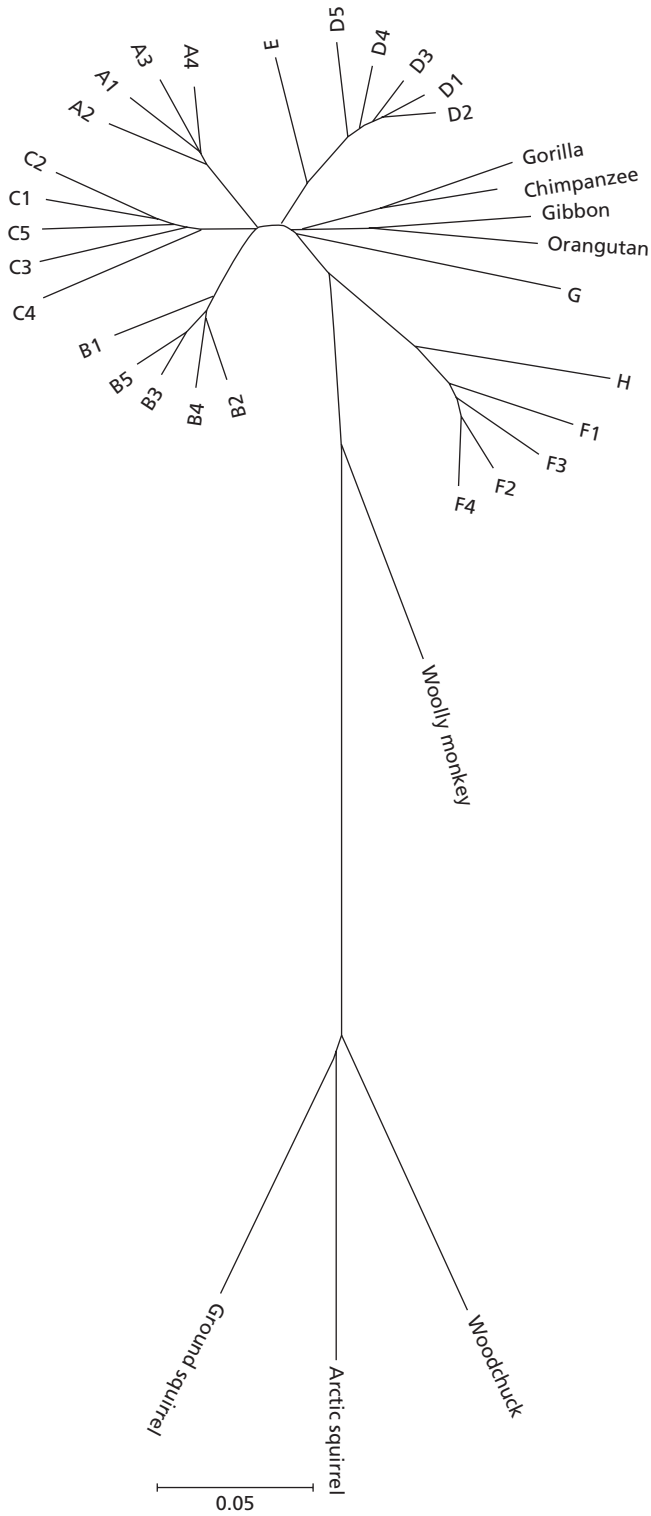

Fig. 3 Phylogenetic tree of complete orthohepadnaviral genomes. For human HBV sequences, only the designation of the subgenotype, e.g. A1, is indicated. For hepadnaviral genomes obtained from rodents or apes, the name of the host is given. The alignment of complete sequences was performed with Clustal W in the program DNAstar. The alignment was further analysed by bootstrapping using the neighbourhood-joining method contained in MEGA version 2.1 [153].

Table 2 HBV subgenotypes and geographical prevalence.

	Subgenotype	Synonyms	Geographical origin	References
A	A1	Aa, A′	Africa, (Asia, South America)	[122,154]
	A2	Ae, A–A′	Europe	
	A3	Ac	Gabon, Cameroon	[155,156]
	A4		Mali	[157]
	(A5)[a]		Nigeria	[157]
B	B1	Bj	Japan	[24,128]
	B2	Ba	Asia without Japan	
	B3		Indonesia, Philippines	[12]
	B4		Vietnam	[12]
	B5		Philippines	[158,159]
C	C1	Cs	South-east Asia (Vietnam, Myanmar, Thailand, southern China)	[15–17]
	C2	Ce	Far East (Korea, Japan, northern China)	
	C3		Micronesia	[12]
	C4		Australia	[160]
	C5		Philippines, Vietnam	[159,161]
D	D1		Mongolia, Europe	
	D2		India	
	D3		South Africa, East India, Europe, Serbia	[154,162]
	D4		Australia	[160]
	D5		East India	[162]
F	F1		South and Central America	[163,164]
	F2		South America	
	F3		Bolivia	[165,166]
	F4		Argentina	[165,166]

[a]No complete sequence available.

Fig. 4 Geographical distribution of HBV genotypes and subgenotypes. Modified from ref. 5.

and/or a T = 4 symmetry, having 180 or 240 subunits and a diameter of 32 or 36 nm respectively.

The immunodominant epitope of HBc has been mapped to residues 78–83 and requires the conformation of native core particles. Residues 78–83 are on the tip of the spikes that protrude from the capsid shell [20]. These spikes are four-helix bundles formed by the pairing of helix–turn–helix motifs from two subunits of the HBc dimer. Using monoclonal antibodies,

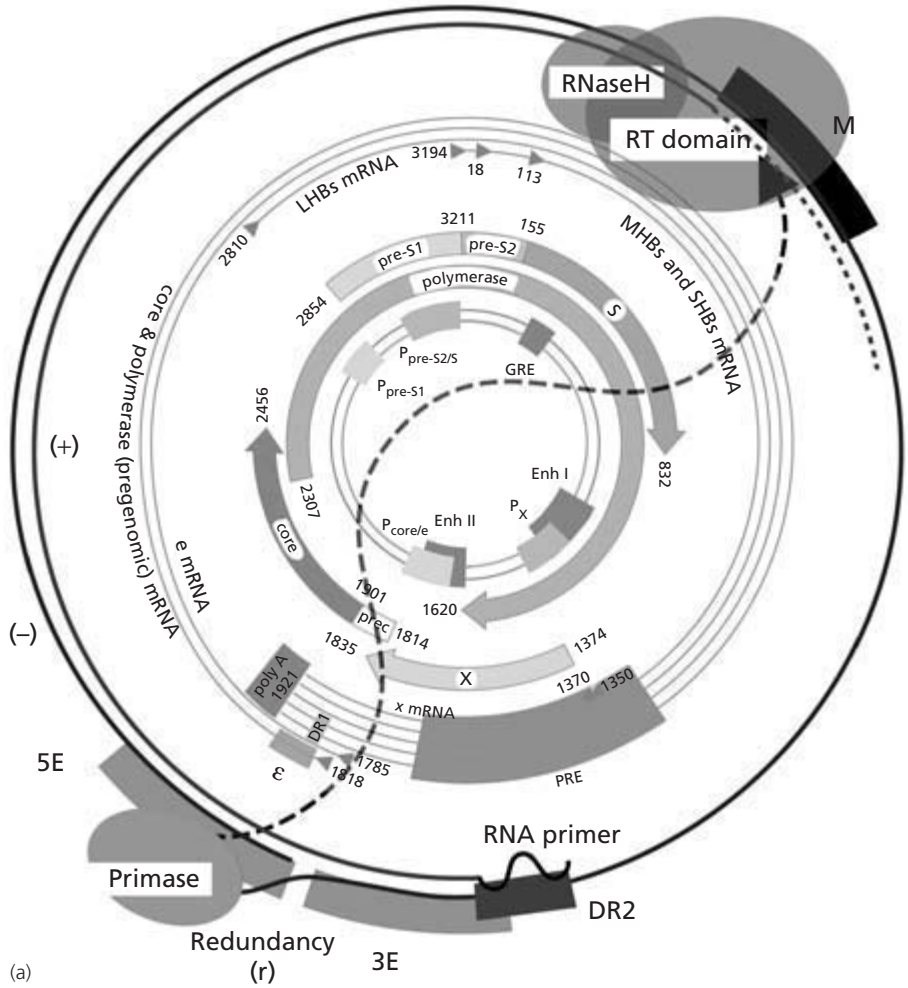

Fig. 5 Genome elements of HBV. (a) Virion-encapsidated DNA structure. M, 5E and 3E are sequence elements required for circularization of the genome. The priming (or terminal) domain of the polymerase is linked with the reverse transcription domain by the tether domain (broken line).

four or more possible epitopes were mapped on HBc capsids [21].

HBe protein

The nature of HBe protein remained enigmatic until 1982 when recombinant HBc particles, devoid of any other viral component, were converted into HBeAg by treatment with protease and ionic detergents. The reading frames and, hence, the immunological epitopes at T-cell level of HBc and HBeAg are almost identical. However, HBcAg and HBeAg are recognized distinctly by antibodies. An in-frame start codon upstream of the HBc start site results in a version of HBc with an extra 29 N-terminal amino acids. This additional 'precore' sequence serves as a signal peptide that directs the nascent peptide into the secretory pathway. After N-terminal cleavage by the signal peptidase at amino acid 19 [22], 10 amino acids of the precore sequence remain and interfere with the assembly of the core protein [23]. C-terminal cleavage at position 149 results in mature HBe, which is secreted into the bloodstream.

The function of HBeAg is not completely clear. The HBV genomes of many chronic HBV carriers harbour variants that prevent expression of HBeAg. HBe-negative HBV is infectious and has been associated with a fulminant course of hepatitis. While HBe-negative genomes replicate about 10-fold faster *in vitro*, patients with HBe-negative hepatitis B usually have lower concentrations of HBV DNA in serum compared with wild-type (wt) infections.

Evidence for the importance of HBeAg comes from HBV genotype G infection. Only HBV genotype G wt is unable to express HBeAg. But this may be compensated by the fact that genotype G is usually found together with other HBeAg-expressing HBV genotypes [24], although one case of transient low-level monoinfection has been described [25].

Apart from HBV genotype G, HBeAg is conserved in all hepadnaviruses including the avihepadnaviruses. This suggests that it provides an advantage for the survival and spread of the virus. Experimental infection of newborn woodchucks with an HBeAg-negative mutant led to acute but not chronic infection. Thus, HBeAg may suppress immune elimination of HBV and

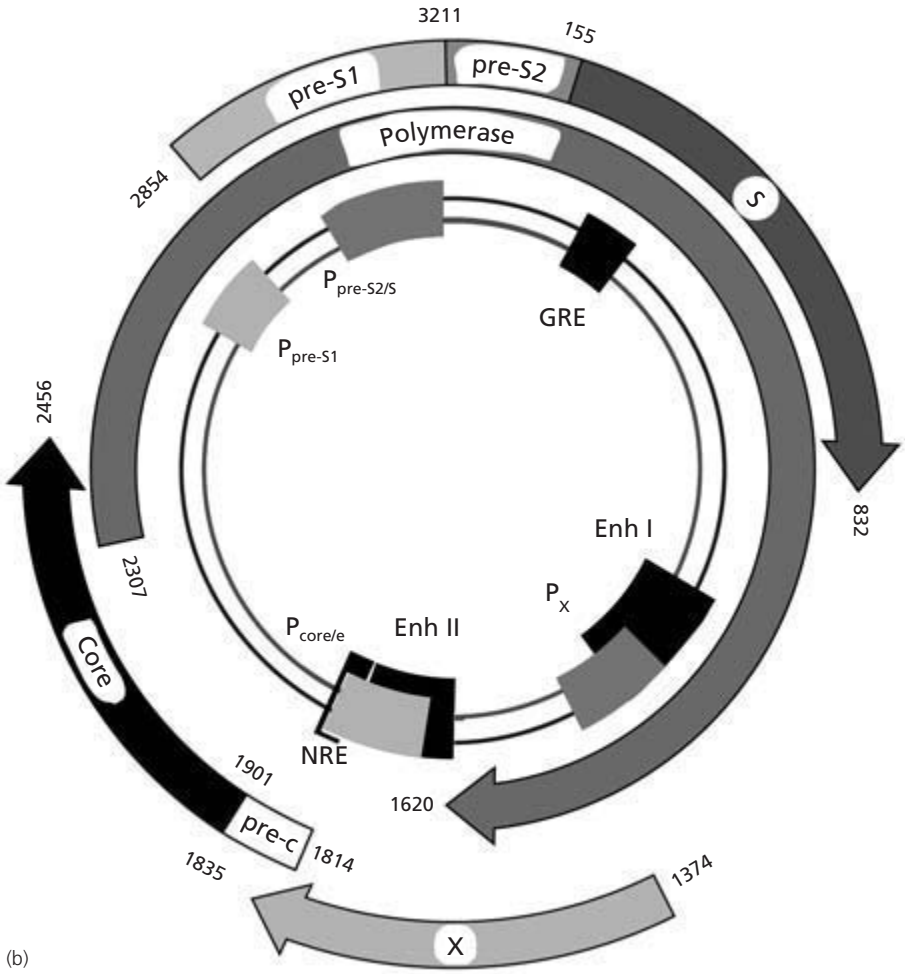

(b)

Fig. 5 (b) Open reading frames and transcription regulating elements in the ccc form of HBV DNA. P, promoter; NRE, negative regulatory element active in non-hepatic cells; GRE, glucocorticoid-responsive element. Numbering starts at the *Eco*RI site.

contribute to the development of the carrier state in newborns [26]. HBeAg accomplishes this by downregulating the host T-cell response to the nucleocapsid antigens via a variety of tolerance-inducing mechanisms [27].

Hepatitis B virus X protein

Hepatitis B virus X protein (HBx) is a viral regulatory protein with pleiotropic biochemical actions [28–34]. The HBx open reading frame (ORF) is conserved in all hepadnaviral species including avihepadnaviruses [35]. HBx protein is translated into a protein of 154 aa, with a short half-life of 30–120 min [36]. The concentration of X protein is low with $4–8 \times 10^4$ molecules per cell in the livers of infected woodchucks. Quantitative expression data for HBx in natural human infection are not available. However, the detection of HBx with a mainly cytoplasmic localization is possible by immunofluorescence in all stages of chronic HBV infection [37]. HBx has also been found in the nucleus of transfected cells.

HBx functions *in vitro* are:

- transactivation of a plethora of cellular and viral promoters;
- promiscuous binding to a multitude of cellular and viral proteins;
- interference with cellular DNA repair;
- inhibition of the cellular proteasome complex;
- positive and negative enhancement of regulated cell death;
- cofactor in tumour formation in HBx transgenic mice;
- malignant transformation of several cell lines.

In vitro, HBx is not essential, but increases virus production about 10-fold [38–40]. However, X-deficient genomes from the woodchuck HBV did not induce infection in animal experiments. Other studies showed that X-deficient genomes were not totally incapable of replication in woodchucks, but induced protective immunity against challenge with wt virus after low-level replication [41].

The activation of viral and cellular promoters by HBx as well as activation of viral replication appears to be mediated by an increased activity of cellular signalling cascades in the cytoplasm (for reviews, see refs 30,32). Activation of ras–raf signalling cascades [42] by tyrosine kinases, such as src or FAK (focal adhesion kinase) [30,43], with or without calcium release seems to

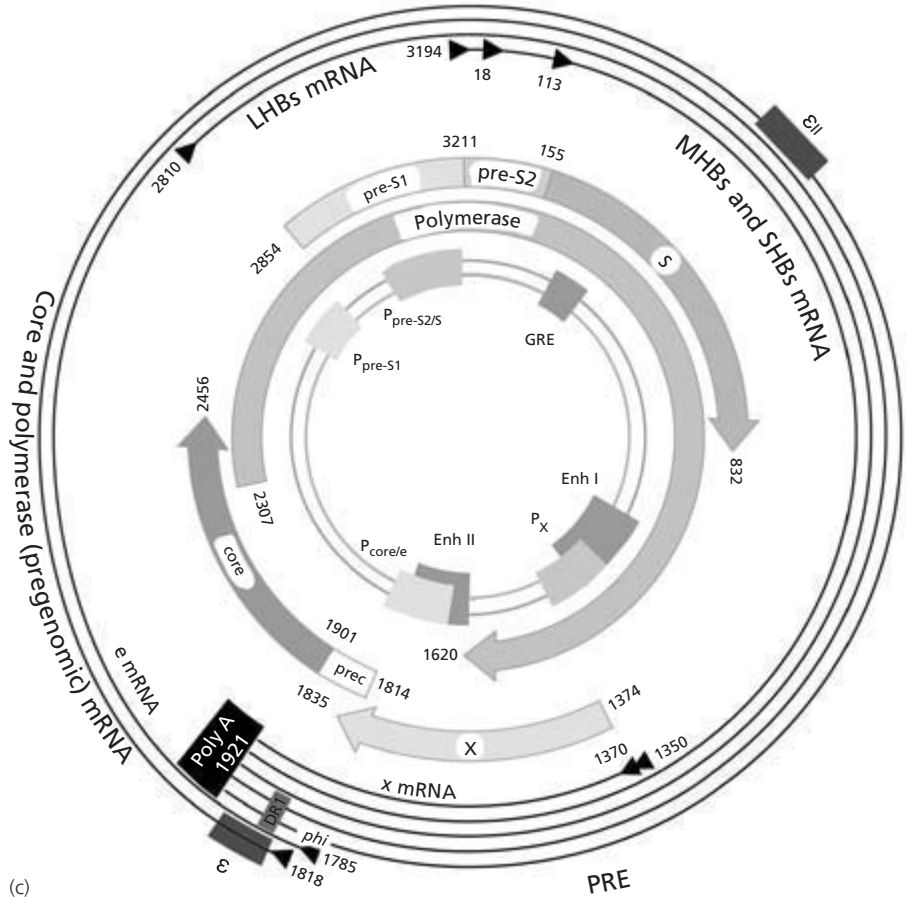

(c)

Fig. 5 (c) Elements of HBV mRNAs governing processing and reverse transcription. ε, encapsidation signal; ε II, phi, cofactors required for genome maturation; DR1, direct repeat 1; PRE, posttranscriptional regulatory element; poly A, polyadenylation site.

play a key role (for reviews, see refs 30,32). An important finding is that HBx regulates the phosphorylation of HBV capsids during replication [44]. Depending on the cell type, HBx has both proapoptotic and antiapoptotic activities [29,33] that are largely mediated by the transcription activation domains of HBx [45,46]. HBx-associated apoptosis and transcription activation is probably mediated by molecular mechanisms similar to calcium signalling [47].

HBx protein has been reported to bind to at least 28 cellular proteins with diverse functions in the cell. Only two of these proteins or protein complexes have been found by more than one group, and these two proteins give some insight into the molecular effects of HBx:

1 The HBx protein binds to proteasome subunits [48–50], which inhibits proteasomal activity *in vitro* [51] and *in vivo* [52,53] and enhances HBV replication [54]. In addition, the altered half-life of short-lived proteins, many of them proto-oncogenes or cell cycle regulators, may lead to disturbances of growth regulation.

2 The UV-damaged DNA binding protein 1 (DDB1) binds to HBx of HBV and WHV [55]. Binding of HBx to DDB1 seems to be necessary for transactivation [56,57], induction of apoptosis [58,59], infection [56] and stability of HBx [60]. The interaction of HBx with a subunit of the cellular DNA repair complex may explain the reduced DNA repair activity in HBx-expressing cells and may be a cofactor in HBV-associated carcinogenesis [33,40].

HBx, expressed alone or in the context of the viral genome, behaves like an oncogene in cell culture and in transgenic mice (for reviews, see refs 28,29,31,34). The amino-terminus of HBx is sufficient for transformation [61]. However, the oncogenic effect of HBx is weak and needs additional cocarcinogenic factors. HBx protein is expressed in certain, but not all, hepatocellular carcinomas (HCC) [37]. The coding region of HBx is often integrated in the chromosomes of hepatocytes from patients with chronic hepatitis or HCC [62,63].

HBV polymerase

The HBV polymerase is a multifunctional protein that consists of four domains (Fig. 6) with defined functions [64]:

- the terminal protein (TP) that serves as a primer for the DNA minus strand;
- a spacer or tether region with undefined function;
- the reverse transcriptase (RT) domain for RNA- and DNA-dependent DNA synthesis;
- the ribonuclease (RNaseH) that degrades hybrid DNA/RNA strands.

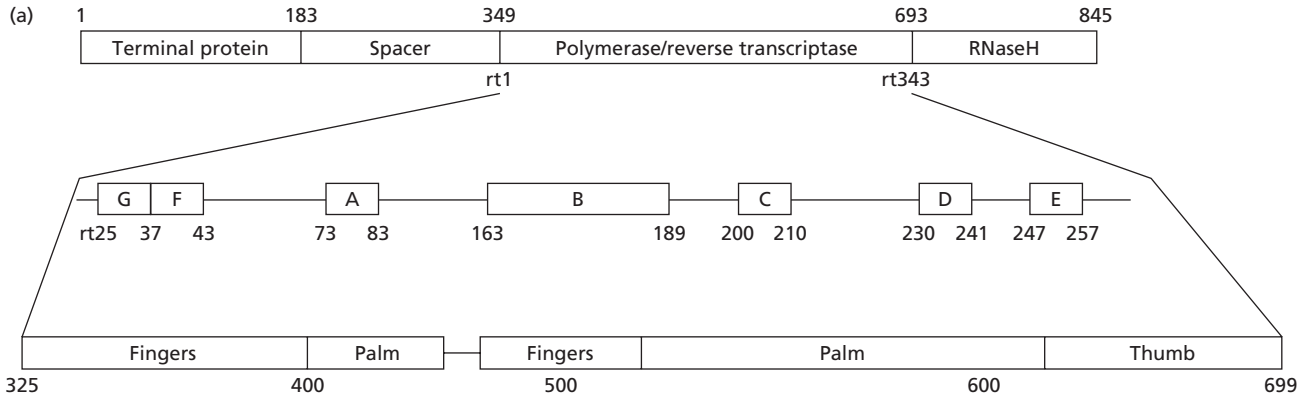

(b)

Genotype	Terminal protein	Spacer	Pol/RT	RNaseH
A	1 – 182	183 – 348	349 – 692	693 – 845
B	1 – 177	178 – 346	347 – 690	691 – 843
C	1 – 177	178 – 346	347 – 690	691 – 843
D	1 – 177	178 – 335	336 – 679	680 – 832
E	1 – 177	178 – 345	346 – 689	690 – 842
F	1 – 177	178 – 346	347 – 690	691 – 843
G	1 – 177	178 – 345	346 – 689	690 – 842
H	1 – 177	178 – 346	347 – 690	691 – 843

Fig. 6 Schematic representation of the HBV multifunctional polymerase protein (numbering for HBV genotype A). (a) Top: functional domains of the HBV polymerase. The numbering above delimits the borders of the domains with the methionine of the multifunctional protein set as 1. Below the scheme, the numbering following the new nomenclature [64] for the reverse transcriptase (RT) domain is indicated. Middle: domains A to G, numbered according to Sheldon *et al.* [135] and Stuyver *et al.* [64]. Bottom: domains involved in making up the three-dimensional conformation of the HBV polymerase, with amino acid coding according to Das *et al.* [70]. (b) Limits of the functional domains of the HBV polymerase of the eight HBV genotypes (modified from Stuyver *et al.* [64]).

Functional TP, RT [65] and RNaseH [66] domains can be expressed independently. TP and RT form a complex that is functional *in vitro* [65]. For the RT domain to function, most of the RNaseH domain is required [65], while RNaseH retains high activity when expressed independently [66].

The HBV RT domain is the prime target for antiviral therapy. Owing to differences in the length of the RT ORF between HBV genotypes, a nomenclature for drug-resistant HBV variants has been proposed [64], in which the first amino acid of the RT domain is a conserved E (glutamic acid) (Fig. 6b).

The structure of the HIV RT has been resolved by X-ray crystallography [67]. Based on the sequence homology of retroviral transcriptases, a three-dimensional model of the HBV RT domain has been derived [68–70]. The model assumes a right-handed conformation with thumb, palm and finger domains. The finger domains correspond structurally to deoxynucleoside triphosphate (dNTP) binding and catalysis sites (domains A, C and D). Thumb and palm domains most probably interact with the RNA template and the 3′ end (domains B and E) [71]. The C domain of the HBV RT contains the rt203YMDD motif, which is highly conserved in RTs. HBV RT is further divided into five subdomains, A–E, with additional domains F and G for RTs [72].

Crystallographic data show that the primary mechanism of resistance appears to be steric hindrance within the dNTP binding pocket [71]. Replacement of methionine in the YMDD motif with valine, isoleucine or serine leads to projections of the new amino acid side-chain into the dNTP binding site.

Other factors leading to resistance are caused by suboptimal nucleophilic attack geometry [73]. For the elongation of the DNA strand by incoming dNTP, a precise spatial arrangement of the 5′ phosphate and the 3′ hydroxyl group is important. Altered three-dimensional structures can reduce the efficiency of catalysis.

Hepatitis B virus surface proteins

Three HBs proteins, [L(arge), M(iddle) and S(mall)], are translated from one ORF using three in-frame start codons. Differences in size come from the amino-terminal domains added to the smallest protein SHBs. MHBs contains the pre-S2 region in addition to SHBs, whereas LHBs consists of the pre-S1 domain and the MHBs sequence. The pre-S (= pre-S1 + pre-S2) domain of LHBs exists in two orientations, facing either the outside or the interior of the viral particle [74,75]. About 50% of SHBs, 30% of MHBs and 90% of LHBs carry a complex glycan at position Asn146 of the S domain. The pre-S2 domain of MHBs contains a complex glycan at Asn4, whereas the same residue is glycan free in LHBs [76,77]. Thus, a very typical pattern of the

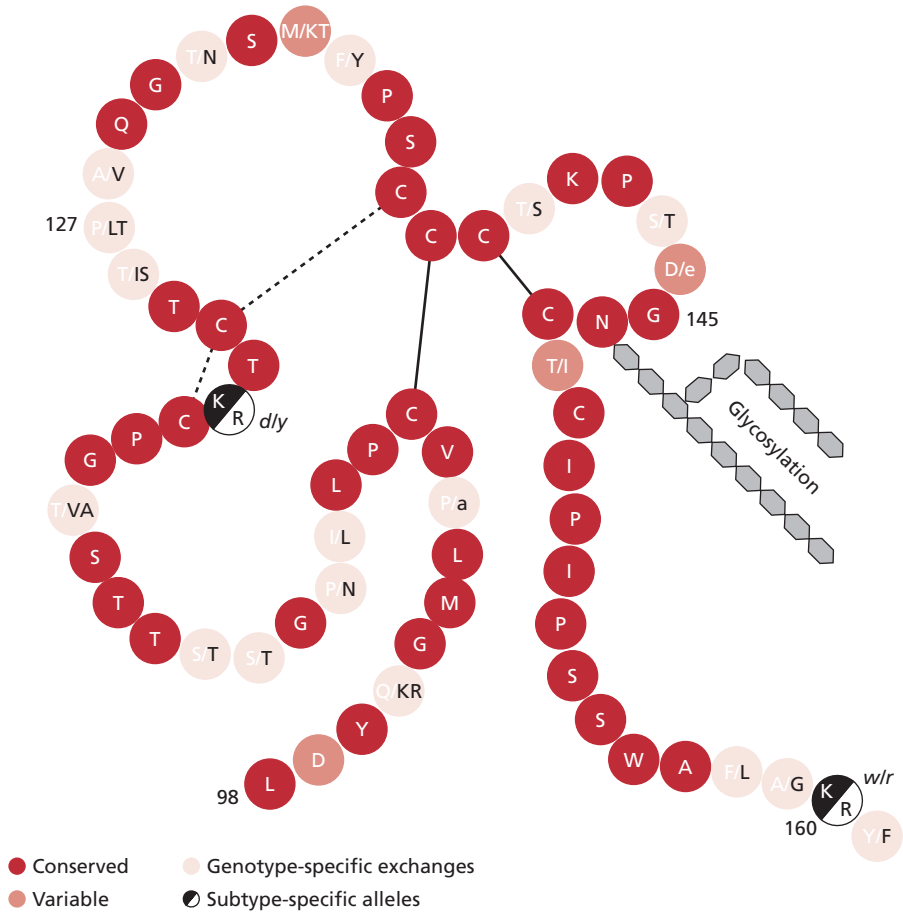

Fig. 7 Hypothetical model of the *a* determinant formed by the small surface protein. Residues 122 and 160, which confer subtype changes from *d/y* and *w/r*, respectively, are indicated in black and white. *w2* reactivity is determined by P127, *w3* by T127, *w4* by L/I127; I126 abolishes reactivity with *w* antisera and is linked to the *r* subdeterminant.

six different proteins can be distinguished in sodium dodecyl sulphate (SDS) gel electrophoresis (Fig. 1).

Infected hepatocytes secrete subviral HBsAg particles in large excess in addition to infectious HBV. Particles with low content of LHBs form spherical particles with a size of ca. 20 nm, whereas a higher content of LHBs induces the formation of filaments with varying length (Figs 1 and 2). In serum samples from highly viraemic individuals, these particles can be found in up to 1000-fold excess over virions.

LHBs with a cytosolic pre-S domain is essential for envelopment of mature DNA-containing core particles [78]. For secretion of virus or subviral HBsAg particles, an excess of SHBs over LHBs is required because LHBs alone are retained in the endoplasmic reticulum (ER) where it can lead to the ground glass-like appearance of hepatocytes. MHBs seem to be non-essential but are conserved in all orthohepadnaviruses. Hypoglycosylation of MHBs inhibits secretion of virus and HBs particles [79]. The surface exposure of the pre-S domain is necessary for infectivity of the virus. The translocation from the interior to the surface of the virus or subviral particles occurs posttranslationally [74], possibly in a Golgi compartment [77]. The pre-S domain is largely hydrophilic, probably unstructured and highly sensitive to proteases. In contrast, the S domain or SHBs is highly resistant against proteases and has at least two, possibly four, hydrophobic transmembrane domains creating an internal and an external hydrophilic loop. The external loop from amino acid 99 to about amino acid 170 carries the HBsAg epitopes. Most of these epitopes are conformational and require disulphide bridges (Fig. 7). All HBV strains are believed to share a set of common epitopes called determinant *a*, but they also express mutually exclusive subtype determinants *d* or *y* (K or R at amino acid 122) and *w* or *r* (K or R at amino acid 160). *w* may be further distinguished into *w1*, *w2* (P127), *w3*, (T127) and *w4* (L/I127). These determinants may be expressed in various combinations by the HBV genotypes.

The viral life cycle (Fig. 8)

For a long time, it was difficult to study the early steps in the viral life cycle *in vitro* because the available cell lines were not susceptible to HBV. Only primary hepatocyte cultures obtained from freshly excised human or primate liver could be infected with HBV and, even then, the efficiency of infection was low, and very little progeny virus could be obtained. Thus, most studies were done with rodent or avian hepadnaviruses. The late steps in the life cycle were easier to study because hepatoma cell lines could

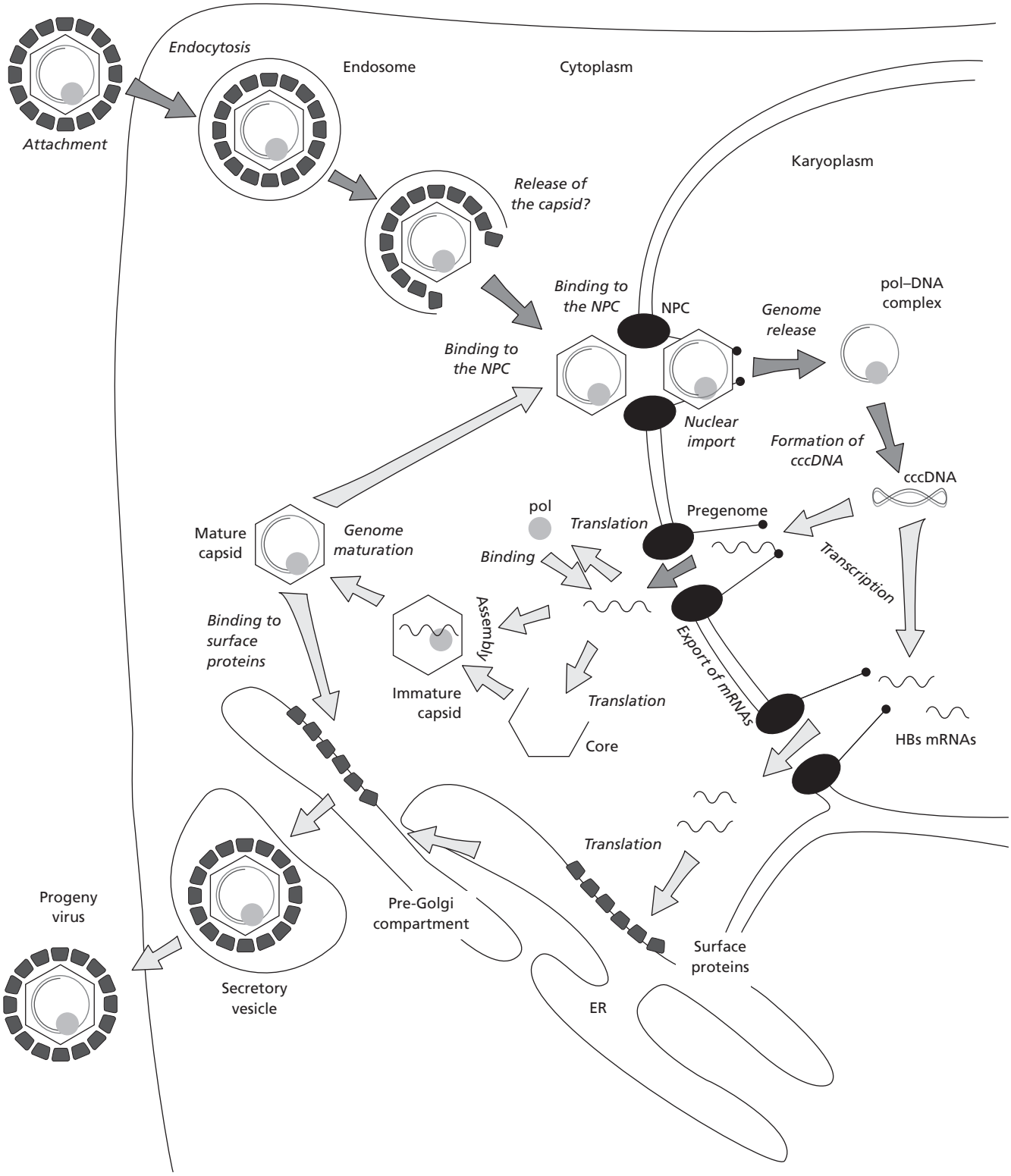

Fig. 8 Intracellular life cycle of HBV. NPC, nuclear pore complex. mRNAs are shown as wavy lines. Expression of X, subviral HBsAg and HBeAg is deleted for simplicity.

be transfected with cloned HBV DNA and were permissive for HBV production. Recently, two systems have become available for the study of the early steps in HBV replication: the redifferentiated hepatoma cell line Hepa RG [80] and cultures of primary tupaia hepatocytes [81]. Tupaias are small squirrel-like animals phylogenetically placed between primates and rodents.

Attachment and entry

HBV attaches via the amino-terminal sequence of the pre-S1 domain (9–48 in genotype D) first to sulphated glycosaminoglycans (D. Glebe, unpublished observations), and then via the same sequence to an unknown high-affinity receptor [82,83]. Thereafter, the S domain of LHBs mediates the uptake of virus and the release of core particles. Reductive cleavage of the disulphide bridges in the S domain prior to attachment destroys infectivity (D. Glebe, unpublished observations). The cysteines 121 and 124 are essential for infectivity [84]. In the duck hepatitis B virus (DHBV) system, the fusion peptide in the first transmembrane sequence of the large surface protein causes fusion of the viral envelope with the membrane of late endosomes [85]. A similar sequence is present in human HBV [86]. Surprisingly, the release of cores from the endosomes seems to be pH independent [87]. Attachment and entry limit the efficiency of infection and take 18 h.

Transport of the virus to endosomes [88] and of cores to the nucleus [89] requires microtubules but not actin filaments. Cytosolic core particles are rapidly transported within 1 h to the basket of the nuclear pore complex using the importing alpha-dependent pathway [90]. The cores are arrested there by the nuclear porin nup153, and finally release the viral genome to the nucleoplasma (Schmitz and Kann, unpublished observations). Ubiquitous cellular DNA repair enzymes (present even in *Escherichia coli*) remove the covalently bound polymerase, the RNA fragment, close the single-stranded gap and the nick, and thus convert the rc form into cccDNA. This is the first stable molecule generated during the life cycle and is, therefore, often taken as proof of infection.

Transcription and translation

The cccDNA is the template for the viral mRNAs. Liver enriched transcription factors are necessary for efficient and accurate transcription of mRNAs encoding core and LHBs, whereas transcription of M/SHBs and X also occurs efficiently in non-hepatic cells. Besides the promoters and enhancers, various activator or silencer elements are present on the DNA [91], e.g. the GRE (Fig. 5b). Transcription is regulated and seems to support viral expression optimally in resting, fully differentiated hepatocytes. Owing to the common polyadenylation site, four groups of mRNAs are generated that have an identical 3′ terminus (Fig. 5c). These encode HBeAg/core/pol, LHBs, M/SHBs and X. The mRNAs encoding core, small surface and X protein have heterogeneous 5′ ends. Thus, some of the largest mRNAs of 3.5 kb start upstream of the precore sequence and encode HBeAg, whereas others start downstream of the HBeAg start codon and encode core and pol. The expression of both RNAs is tightly coupled [91]; however, natural variants and point mutations [92] located in this transcriptional element can uncouple the transcription of the RNAs. Fine tuning of the core promoter and enhancer determines the ratio of HBeAg- to core/pol-encoding mRNAs. A similar situation occurs with the middle-sized 2.1-kb RNA, in which a part encodes MHBs and another part SHBs. No splicing is required for expression of the known essential viral proteins, but splicing is known to occur to a limited extent, (e.g. [93]) and generates proteins of unknown significance [94,95]. The transport and stability of the mRNAs is regulated by the posttranscriptional regulatory element (PRE) [96] (Fig. 5c). Cellular factors interacting with the PRE also seem to regulate the extent of splicing [97].

The expression of core, pol and X protein occurs at cytosolic polyribosomes, whereas HBeAg and the HBs protein are translated at the rough ER and directed to membrane compartments. The polymerase does not have its own mRNA but is translated by internal initiation in the core mRNA. Core protein assembles into core particles, which encapsidate their own mRNA together with the polymerase. The suboptimal sequence context of the MHBs start codon favours translation initiation at the SHBs sequence even in those mRNAs that contain the MHBs start codon. Thus, MHBs is usually a minor protein, whereas SHBs is the major surface protein. The three surface proteins insert into the ER membrane, aggregate and bud as subviral particles to the ER. The X protein is very unstable [36] and difficult to detect [37].

Replication and morphogenesis

The elements steering reverse transcription and circularization of the genome [98] are shown in Figure 9. The mRNA for the core and pol protein is truly multifunctional and also functions as the precursor for the viral genome within core particles (pregenomic RNA or pg RNA). pg RNA forms a secondary structure at the 5′ end, ε (epsilon), which interacts with the primase (or terminal) domain of pol after binding and activation by the cellular chaperones Hsc70 and Hsp40. This complex initiates encapsidation by the core protein. For priming of DNA synthesis, the first nucleotide of the minus strand DNA is linked to the hydroxyl of tyrosine 63 in the primase domain (tyrosine 96 in DHBV). After the addition of four nucleotides, the nascent DNA strand is shifted to a sequence element in the 3′ terminal copy of DR1 of the pg RNA. From there, the polymerase elongates the minus strand until the 5′ end of the pg RNA is reached, generating a short terminal redundancy r of 8–10 bases. The RNaseH of pol concomitantly degrades the already transcribed pg RNA, leaving only the 18 5′ terminal bases of pg RNA at DR1 uncleaved. This short RNA segment is shifted to the DR2 element in the minus strand DNA and serves as a primer for the plus strand DNA. The nick in the minus-strand template is

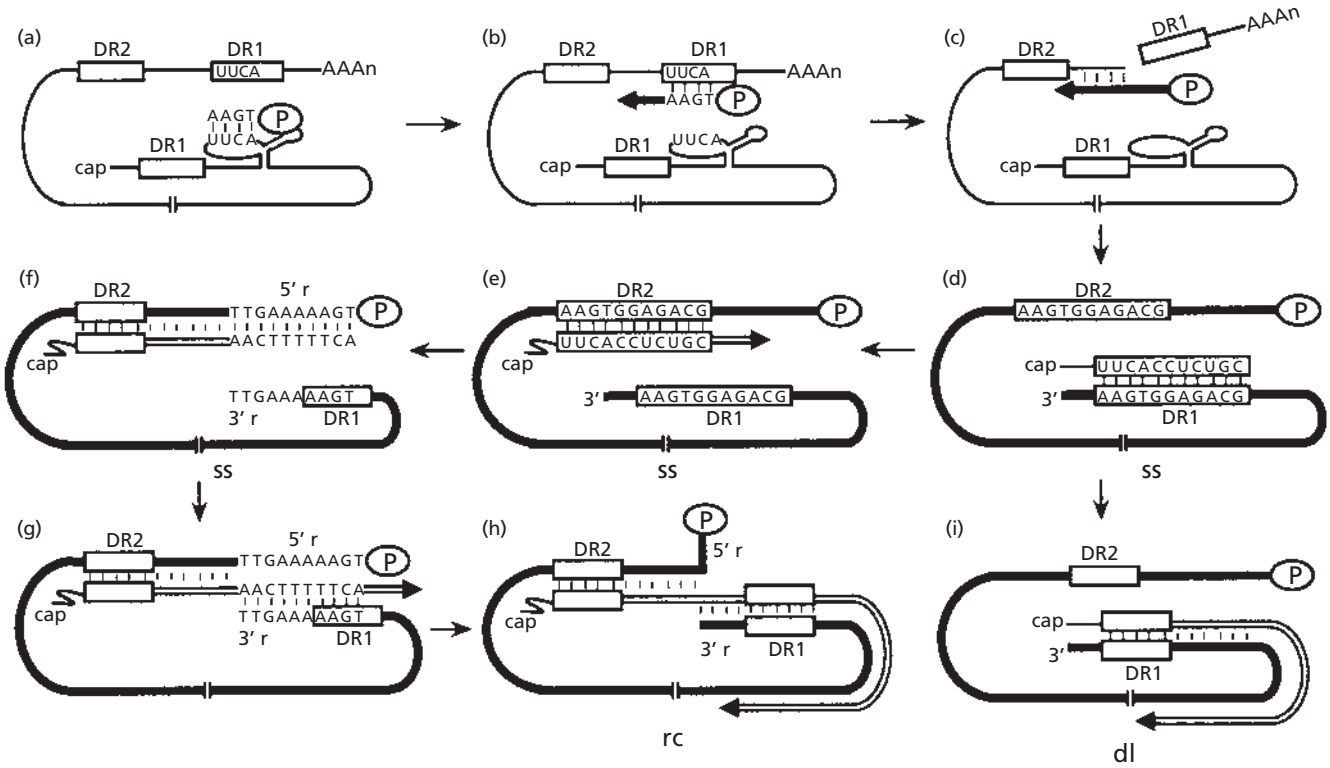

Fig. 9 Steps of genome maturation beginning (in a) with pregenome recognition by the priming domain (P) and ending (in h) with the relaxed circular (rc) form of HBV DNA. DR1, DR2, direct repeats 1 and 2; ss, single-stranded DNA; (i) shows double-stranded linear DNA (dl), which is a side-product of replication. From ref. 98 with permission.

bridged during plus strand synthesis with the aid of the redundancy r. The plus strand usually remains incomplete leaving a large gap. The entire replication occurs within the core particles. During this process, a series of phosphorylations modify the serines in the arginine-rich carboxy-terminal domain of the core protein. The nucleotide triphosphates necessary for replication and phosphorylation can enter the lumen of the cores via 2-nm large holes in the protein shell.

After completion of DNA synthesis (genome maturation), the core particles assume a different structure [99], and the C-terminal core domain becomes partially accessible at the surface. It contains a nuclear localization signal that mediates the transport of mature cores to the nuclear pore complex and the release of the viral DNA to the nucleus. In the early phase of infection, this reimport of viral genomes leads to the accumulation of cccDNA and establishes persistent infection of a cell. The generation and secretion of enveloped virus particles is regulated by the availability of LHBs with a cytosolic pre-S domain. The sequence between Arg103 and Ser124 of pre-S at the junction of pre-S1 and pre-S2 is essential for the interaction with mature cores. The interaction site on the core particles is formed by a ring-like groove around the spikes and by amino acids at the transition to the nucleic acid binding domain. Budding and secretion of enveloped virions requires an excess of SHBs over LHBs. Partial translocation of the pre-S domain to the surface of virions may occur before secretion in a mildly acidic cell compartment because low pH favours this process. Envelopment and egress of virus particles involves the ubiquitin ligase Nedd4 and a putative endosomal sorting adaptor, gamma2 adaptin [100]. Possibly, secretion of the virus follows an endosomal pathway, whereas the subviral HBsAg particle follows the Golgi pathway.

Immunopathogenesis and clinical course of infection

The entire biology and clinical course of HBV infections can be understood only by the variable interaction of the virus with the immune system. Depending on the strength and timing of the immune response of the host, clinical courses from asymptomatic to fulminant hepatitis and from self-limiting to chronic infection are possible (Fig. 10). This section describes briefly the pathogenesis of HBV. Several reviews have been published recently [101–103].

Acute hepatitis B

The existence of a weeks- or months-long incubation phase with increasing and finally very high viraemia but without clinical or biochemical signs of liver damage shows that replication and persistance of HBV is not cytopathic *per se*. Analysis of the hepatic cellular expression patterns in acutely HBV-infected

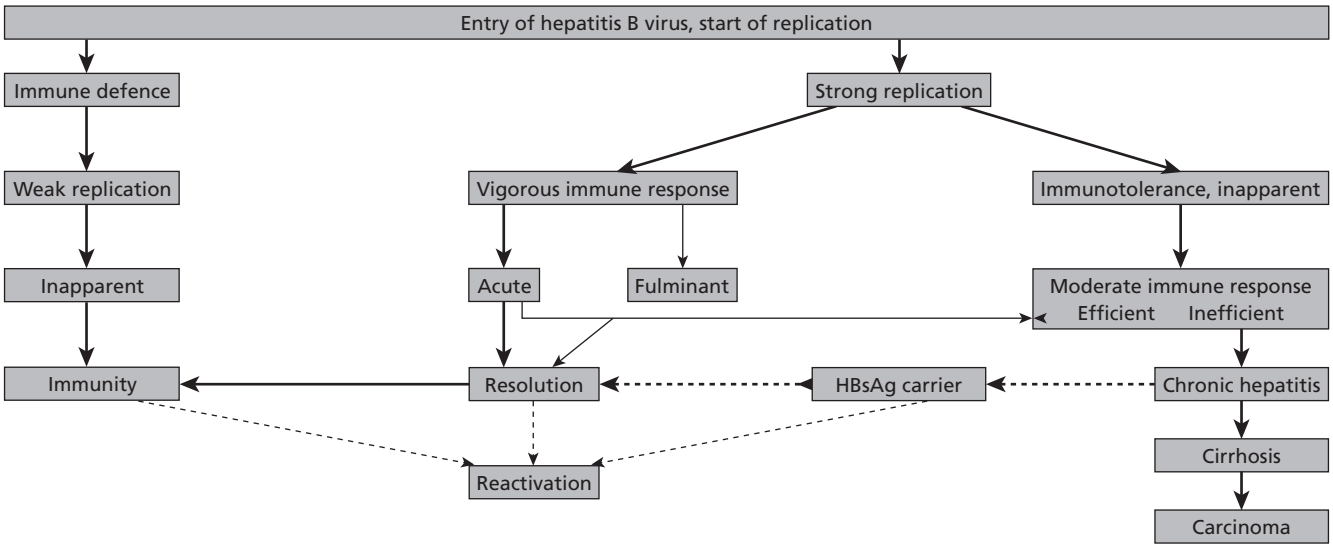

Fig. 10 Possible courses of HBV infection.

chimpanzees showed that no host response to viral replication occurred during the incubation phase. HBV behaved like a 'stealth virus' and did not stimulate the innate immune system which recognises pathogen-associated molecular patterns [104]. In contrast, later in the infection period, most of the effector molecules associated with the adaptive cellular immune response are induced, followed by HBV antibodies. HBV elimination starts several weeks before onset of the disease with T-cell-dependent noncytolytic mechanisms, but later cytolytic immune responses follow and generate the symptoms of acute hepatitis [105]. IFN-induced mechanisms seem to inhibit the maturation of pgRNA to cccDNA and to mediate its degradation both in the early and in the late phase [106]. During the acute disease, high numbers of cytolytic CD8+ T cells are present in the liver and these react with a multitude of HBV epitopes and eliminate the virus by destroying infected cells. High disease activity usually leads to clinical and serological resolution. However, even after serological resolution, small amounts of cccDNA persist in the liver for years, decades and possibly for life. T-cell immunity suppresses viral replication originating from these cccDNA copies to very low levels [107].

Anti-HBc appears with the onset of the disease as the first anti-HBV antibody, then anti-HBe, anti-pre-S and finally anti-SHBs. These antibodies probably contribute neither to virus elimination from the liver nor to the pathogenesis of hepatitis. However, anti-HBs formed during convalescence and later may enhance opsonisation of HBsAg and block *de novo* infection of hepatocytes by released HBV. In contrast to the other HBV antibodies, anti-HBc induction is partially T-cell independent. This explains the presence of anti-HBc even in those patients who do not build up an efficient immune response. Serological resolution is defined by disappearance of HBsAg which may take months after onset.

Inapparent transient infection

Most HBV infections worldwide remain asymptomatic and result in immmunity, as indicated by the presence of anti-HBs and anti-HBc. It is likely that the course of virus replication and elimination is similar to acute hepatitis B but that the immune reaction starts earlier at much lower levels of infection, thus resulting in minimal clinically asymptomatic liver damage. Factors favouring an unobtrusive course are a low dose of infecting virus, mucocutaneous entry and a mature, competent immune system. Viraemia and HBs antigenaemia are often short lived and may often go unnoticed, unless the person donates blood or organs. The benign course does, however, not exclude establishment of low-level persistance with small numbers of cccDNA in the liver that have the potential to activate under immune suppression. The term occult HBV infection has been coined for this condition.

Chronic HBV infection

HBV has the ability to persist in the liver in spite of effective elimination by the immune system. In contrast to this type of immune-controlled low-level persistance, frank chronicity is characterised by persistent HBs antigenaemia, indicating that T-cell activity and anti-HBs production were insufficient to overcome the expression of HBsAg. The inability of the immune system to cope with HBsAg may be based on the fact that it is produced to such great excess that it may induce a high dose tolerance. Furthermore, the antigen-presenting cells encounter HBsAg normally in the form of subviral particles without viral RNA or other danger signals. This may result in immunotolerance. These two and other factors may apply also to HBeAg as the secreted T-cell tolerance inducer for HBcAg. Furthermore, anti-HBV antibodies, particularly anti-HBc, may impair the T-cell response to the corresponding antigen. The state of immune

inertia and/or tolerance can be maintained for years, allowing high replication and viraemia in the absence of disease. The absence of immune selection is confirmed by the highly conserved HBV DNA sequences within immunotolerant long-term carriers and within an infection chain. A rare complication of the highly viraemic carrier state is extrahepatic immune complex disease causing periarteriitis nodosa or glomerulonephritis.

T-cell tolerance to HBe/c is much less stable than that to HBsAg and breaks down after years or decades in the majority of chronic HBV carriers, resulting in immune elimination and pathogenesis. This event is often associated with a significant decrease in viraemia, a transiently enhanced liver damage, disappearance of HBeAg and appearance of anti-HBe. Finally, the sufferer reaches the stable state of an almost healthy HBsAg carrier with low or absent infectivity.

Less fortunate patients develop a labile equilibrium between virus and immune defence, which results in chronic disease. Patients with chronic infection have detectable but small numbers of HBV-specific T cells targeted against a small number of epitopes. Episodes of active disease may alternate with sometimes long episodes without recognisable disease. The inflammation is maintained by active HBV replication and causes hepatocellular damage and fibrosis. HBeAg may be present, but very often expression of HBeAg is abolished by the selection of HBe-negative mutants. The constant immune pressure enhances mutations in many regions of the HBV genome. Hotspots of functionally important mutations are the precore region, the core promoter overlapping with the X gene, the aminoterminal part of pre-S2 and various regulatory elements. The resulting imbalanced expression of HBV proteins may contribute directly to pathogenicity: some HBe-negative variants replicate more strongly and express more HBcAg which cannot be exported and may exert direct cytotoxicity. An excess of LHBs over SHBs causes storage disease and enhanced sensitivity to apoptosis. Patients with advanced liver disease harbour often defective interfering virus particles with deletions in the core gene or spliced genomes. In summary, three types of chronic HBV carriers can be distinguished:

1 immunotolerant HBV carriers, HBeAg positive, asymptomatic, highly viremic and infectious;

2 chronic hepatitis patients with variable levels of replication and immune response (active infection);

3 healthy HBsAg carriers without HBeAg and with low viremia (inactive infection).

Intermediate forms and transitions between these types are possible (see Chapter 9.1.2.iv).

Integration of HBV DNA to the host genome

In contrast to orthoretroviruses, integration is not a necessary step in the life cycle of HBV. However, the incompletely double-stranded DNA intermediates, which are generated during genome maturation and released in the nucleus before formation of cccDNA, are prone to illegitimate recombination events with themselves and with cellular DNA. Integrated HBV DNA has been identified in most HBV-associated hepatocellular carcinomas (HCC) but it can also be found in seemingly normal hepatocytes. Virtually all integrated HBV DNA fragments are incomplete and often rearranged. Thus, integrated HBV DNA is not a source of viral replication, but complementation of defective replicons in trans by integrated HBV genes cannot be excluded. Viral integration points are frequently around the DR1 region at the nick in the minus strand. The core gene is usually absent, whereas the surface gene is often present. It appears possible that in HBsAg carriers without detectable HBV DNA in the serum, a portion or all of the HBsAg in the serum is expressed from integrated DNA. This presumption is supported by the fact that HBsAg carriers often have large amounts of non-secreted LHBs protein but no core protein in the hepatocytes (ground-glass cells). Clonal integrates from HCC encode often truncated pre-S/S proteins which gain transactivating and potentially oncogenic properties. The X gene is usually also present in integrated HBV DNA and is often mutated. It has been suggested that these mutations enhance the weak oncogenicity of HBx protein.

Integration occurs often within cellular transcription units but there is no other preference for integration sites except a limited sequence homology with the viral insertion site. In HCC, the integrated HBV DNA can act as a transcriptional enhancer element and may support malignant growth by activation of various cellular growth-promoting genes. Details have been reviewed [108].

Laboratory diagnosis

Diagnosis of acute or chronic HBV infection is complex on account of the wide spectrum of clinical outcomes ranging from inapparent transient infection as the most benign form to fulminant acute hepatitis. As pointed out above, two forms of asymptomatic infection are possible: (i) transient or persistent low-level infection with low or no viraemia; and (ii) immunotolerance to HBV with very high persistent viraemia. Chronic hepatitis B and its sequelae develop if the immune defence is active but unable sufficiently to suppress viral activity. Episodes of active disease may interchange with long episodes without recognizable disease. Healthy adults usually resolve the infection with or without apparent disease, whereas infants and immunosuppressed patients usually develop chronic infection. A battery of laboratory tests allows for the accurate diagnosis and prognosis if used and interpreted properly (Table 3 and Fig. 11).

HBsAg

Detection of HBsAg in the serum of patients corresponds to ongoing HBV infection with two exceptions: (i) after vaccination, HBsAg can be detected in serum for up to 1 week; (ii) rare case reports have shown that HBsAg can be expressed independently from viral replication from HBV DNA integrated into chromosomal DNA even after resolved infection. However,

Table 3 Selection of the HBV test programme according to the medical question.

Immune?	
Prior to vaccination	Anti-HBc
After vaccination	Anti-HBs
Acute hepatitis, type?	HBsAg
	Anti-HBc IgM
Previous exposure?	Anti-HBc
Potential of reactivation?	HBsAg, anti-HBc
Chronic hepatitis, type?	HBsAg, anti-HBc
Chronic hepatitis B, activity?	HBV DNA, qPCR
	HBeAg
Infectivity	
HBsAg carrier	HBV DNA, qPCR
Blood donor	HBsAg, anti-HBc[a], HBV DNA[a]
Organ donors	HBsAg, anti-HBc

[a]Optional in some countries. qPCR, quantitative polymerase chain reaction.

integrated HBV DNA will usually be accompanied by episomal, replication-competent DNA.

The high clinical sensitivity of HBsAg is due to the fact that it is secreted into the serum in about 100-fold or higher excess compared with viral particles. In serum from immune-tolerant carriers, up to 1 000 000 ng/mL HBsAg can be found; typical concentrations are 30 000–150 000 ng/mL. These high concentrations of HBsAg pose several problems. Today's immune assays have a detection limit of 0.1 ng/mL. Thus, contamination of 1 mL of negative serum with 0.1 nL of carrier serum can give false-positive results. Furthermore, the high concentrations found in early acute infections and immune-tolerant carriers are far beyond the linear range of today's commercial immune assays, which usually end at 10 ng/mL. Accurate quantification of HBsAg is possible with well-calibrated assays and is useful as a prognostic factor for successful interferon (IFN) therapy. High HBsAg concentrations above 30 000 ng/mL correlate with poor response to IFN therapy [109]. One accurately assayed ng of HBsAg corresponds to 1 Paul-Ehrlich unit or 2 international units (IU).

In acute infections, HBsAg concentrations rise logarithmically for weeks to months from undetectable to typical final concentrations of 10 000–100 000 ng/mL with 2–4 days of doubling time [110]. If the acute HBV infection is resolved, HBsAg decreases with an initial half-life of 8 days until it has been removed completely from serum after weeks to months. In about 25% of acute resolving hepatitis B cases, the elimination of HBsAg proceeds much faster, with the consequence that samples taken in the late acute phase may be HBsAg negative [111].

A decrease in HBsAg concentration by more than 50% within the first 4 weeks indicates resolving acute infection in > 95% of cases [112]. Hence, quantitative analysis of highly concentrated HBsAg is an excellent prognostic marker, indicating progression to chronicity if the values remain stable or increase.

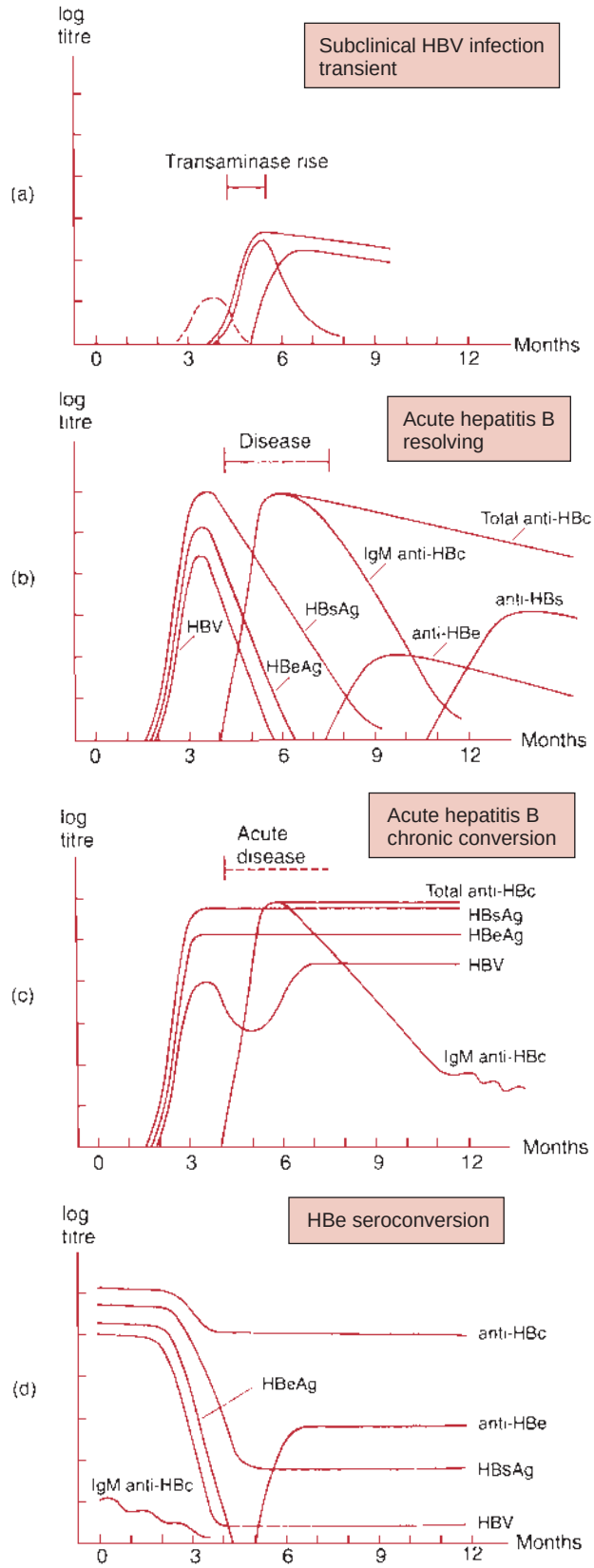

Fig. 11 Schematic serological profiles of various courses of HBV infections.

False-negative HBsAg results may be generated by natural variability, immune selection of variants or antiviral therapy [113]. As a consequence, the manufacturers have improved their assays with the inclusion of antibodies against assumed conserved epitopes from the *a* determinant of HBsAg. Nevertheless, new variants showing amino acid exchanges in the *a* determinant (Fig. 7) could not be detected by one or more commercial assays [113]. If false-negative HBsAg results are suspected, an analysis with the assay from another manufacture may give a correct positive result. Serologically undetectable HBsAg variants can usually be detected by amplification of the viral DNA with conserved primers.

Positive HBsAg screening results, e.g. at blood transfusion, should be reproduced by repetition in duplicate and, if reproduced, confirmed by assaying additional HBV markers, in particular anti-HBc and HBV DNA. If these markers are negative, the specificity should be tested by preincubation with anti-HBs and/or a second HBsAg assay.

HBeAg and anti-HBe

Testing for HBeAg is indicated only if HBsAg is positive in an immune assay. HBeAg is a marker of high replication activity and viral immune modulation. HBeAg-positive HBsAg carriers with mild or no liver disease often have higher viraemia than those with active hepatitis, because the immune reaction causing inflammation also suppresses virus replication [114]. HBeAg is an important marker for therapy monitoring. Loss of HBeAg suggests that a sustained resolution of disease has been achieved, and is one of the therapeutic targets in HBeAg-positive patients. Loss of HBeAg during acute hepatitis B is a good prognostic marker.

The absence of HBeAg does not exclude significant viraemia, particularly in HBsAg-positive patients with chronic hepatitis.

Testing for anti-HBe is useful to confirm a stable HBsAg carrier state with low viraemia and no inflammation. In subjects with anti-HBc, but without HBsAg and anti-HBs, a positive anti-HBe result supports the specificity of the anti-HBc result. During resolving acute hepatitis B, anti-HBe appears after anti-HBc but before anti-HBs. It usually disappears earlier than anti-HBs.

HBV DNA

Detection of HBV DNA is a central part of HBV diagnostics. In many instances, measurement of HBV DNA is a prerequisite for proper diagnosis and decision-making in chronic and, to a lesser extent, acute hepatitis B.

Highly sensitive (< 12.5 IU/mL) qualitative detection of HBV DNA is indispensable for:

- controlling the specificity of serological assays in patients with isolated anti-HBc or isolated HBsAg positivity without additional serological HBV signals;
- detection of the very early stages or occult forms of HBV infection.

Quantitative determination is necessary for:

- controlling antiviral treatment;
- estimating the infectivity of HBV-infected medical personnel.

These applications require DNA assays that reach a sensitivity of one genome per assay. However, available assays vary significantly in sensitivity (Table 4). With timely nucleic acid amplification techniques (NAT), the overall sensitivity of the assay is largely limited by the sample volume and the extraction method. Qualitative and quantitative detection of HBV DNA is preferably performed with the real-time polymerase chain reaction (PCR), in which the signal is generated *in situ* and measured after each amplification step [quantitative PCR (qPCR)]. qPCR offers the possibility of quantification over a very wide range of concentrations from < 100 to 10^{12} copies/mL. The risk of contamination by amplified DNA is reduced because amplification is carried out in closed systems. Furthermore, the specificity of the signal is obtained by interaction with HBV-specific probes, and the product is available for direct sequencing and cloning. Amplification of the S/RT region provides DNA that can be used simultaneously for genotyping and resistance analysis [115].

Standardized quantification of HBV DNA requires a standard sample with known concentration. The World Health Organization (WHO) has approved an international standard with a defined quantitative amount of HBV DNA [116]. The use of this standard for the quantification/standardization of in-house and commercial assays is encouraged.

Owing to variable results obtained with different methods of detection, the WHO has defined the amount of HBV DNA in international units (IU) and not in genome equivalents (g.e.)/mL or copies/mL. The observed variability in results comes mainly from losses during extraction. The HBV polymerase is covalently bound to the HBV DNA, and this protein alters the extraction properties of the DNA. Thus, for the standardization of HBV DNA assays, HB virion-derived DNA and not cloned DNA should be used. Furthermore, not all HBV genotypes may be amplified equally well.

With adequate extraction and calibration, 1 IU corresponds to 5 g.e./mL HBV DNA of genotype A2 [117]. One picogram (pg) of HBV DNA is 280 000 g.e./mL.

Antibody to the HB core antigen (anti-HBc)

Anti-HBc is present during ongoing or after previous HBV infection; it is therefore useful as a marker of HBV prevalence. Most assays use recombinant HBcAg as reagent and an inhibition format for detection. Both sensitivity and specificity are suboptimal. Most chronic HBsAg carriers are anti-HBc positive but, in perinatally infected carriers or immunodeficient patients, anti-HBc may be undetectable by less sensitive assays. Transient inapparent or previous infections may generate low levels of anti-HBc. On the other hand, anti-HBc assays may generate non-specific anti-HBc results.

The serological pattern 'anti-HBc only' is seen with varying prevalence in different countries [118]. In Germany, a country

Table 4 Commercially available quantitative HBV DNA assays (modified from ref. 167).

Assay	Manufacturer	Principle	Procedure	LDL (copies/mL)	Linearity	Genotypes detected
HBV Digene Hybrid Capture I	Digene Diagnostics	Hybridization	Manual	7×10^5	7×10^5–6×10^8	A–D
HBV Digene Hybrid Capture I	Digene Diagnostics	Hybridization with signal amplification	Manual	1×10^5	1×10^5–2×10^9	A–D
Ultra-sensitive HBV Digene Hybrid Capture II	Digene Diagnostics	Hybridization with signal amplification after centrifugation	Manual	5×10^3	5×10^3–6×10^7	A–D
VERSANT HBV DNA 1.0 assay	Bayer Diagnostics	Hybridization with signal amplification, bDNA	Manual	7×10^5	7×10^5–5×10^9	?
VERSANT HBV DNA 3.0 assay	Bayer Diagnostics	Hybridization with signal amplification, bDNA	Semi-automated	2×10^3	2×10^3–1×10^8	A–F
Amplicor HBV Monitor	Roche Diagnostics	PCR	Semi-automated	1×10^3	1×10^3–4×10^7	A–G
COBAS Amplicor HBV Monitor	Roche Diagnostics	PCR	Automated	2×10^2	2×10^2–2×10^5	A–F
TaqMan	Roche Diagnostics	PCR (real time)	Automated	2×10^1	2×10^2–1×10^{10}	A–F
RealArt HBV PCR	Artus	PCR (real time)	Automated	1	1–4×10^8	A–G

with relatively low prevalence of HBV, 1.4–2.2% of patients have only anti-HBc [118,119]. Demographic factors associated with an anti-HBc-only pattern are male sex and higher age [118,119]. Some 20% of anti-HBc-only patients in Germany [112] and up to 50% of intravenous drug abusers [118] are HCV-positive. Possible explanations for this serological status are:

- window phase, early after infection;
- resolved HBV infection;
- false-positive anti-HBc test;
- false-negative or absent anti-HBs or HBsAg.

Currently, non-specific results of anti-HBc seem to be rare. Anti-HBc-only patients showed a high concordance of test results with three different assays [120]. Thus, anti-HBc only is usually associated with HBV infections that resolved a long time ago, and the anti-HBs concentration has decreased below the detection limit. In patients with proven resolved infection, HBV DNA can be detected in the serum, and this is also true for about 10% of anti-HBc-only patients, 36% of whom have HBV DNA in liver biopsies [120]. Thus, these patients are a possible source of HBV transmission by blood transfusion or liver transplantation (for reviews, see [118,121]).

False-negative HBsAg results are a concern in HBV diagnostics. Some isolated anti-HBc-positive individuals may be low-level carriers of HBsAg, where the HBsAg concentration is below the detection limit of current tests. A further explanation for missing HBsAg detection may be variants of HBsAg undetected by one or more tests [113]. Anti-HBs testing may also produce false-negative results. Up to 14.4% of anti-HBc-only individuals showed discrepant results when comparing two different anti-HBs tests [122].

Anti-HBc immunoglobulin (Ig)M

This marker may be useful in two situations:

1 to distinguish an acute hepatitis caused by HBV from a hepatitis of different aetiology in a HBV carrier;

2 to identify an acute hepatitis in some hepatitis B patients, particularly those with fulminant hepatitis B or HDV coinfection, where HBsAg may have been eliminated very rapidly.

Tests should be quantitative because anti-HBc IgM is also positive in chronic active hepatitis B and during convalescence. Levels > 600 Paul-Ehrlich units/mL suggest an acute HBV infection with high inflammatory activity. In all other situations, concentrations are lower or undetectable. Inactive HBsAg carriers are usually negative [123].

Antibody to the HBsAg (anti-HBs)

The meaning of the term anti-HBs is somewhat ambiguous. Some understand it to mean antibodies only against the small HBsAg protein (SHBs), others the entire antibody spectrum against all three surface proteins including pre-S1 and pre-S2. During acute infection, anti-pre-S antibodies appear before anti-SHBs, and they often coexist with HBsAg.

Anti-HBs indicates previous contact with HBsAg and, if no HB vaccine was given, it suggests previous HBV infection as a rule. In this case, anti-HBc should also be positive but, in rare cases, anti-HBc may appear later and/or disappear earlier than anti-HBs. Furthermore, the possibility of non-specific anti-HBs results must be considered.

Some HBsAg-positive persons are also anti-HBs positive. In this case, the HBsAg result is more relevant if its specificity

is confirmed. Thus, screening for immunity against HBV by anti-HBs without prior anti-HBc and HBsAg testing may be misleading.

Anti-HBs protects against HBV infection. Persons who are found to be positive for anti-HBs need not be vaccinated, and vaccinated persons should be tested 4 weeks after the last dose to prove reliable protection. After active vaccination, 10 IU/L anti-HBs is considered to be the minimal protective level. For passive protection by hepatitis B immune globulin (HBIG), higher serum levels > 100 IU/L are necessary. One IU of anti-HBs binds about 900 ng of HBsAg. When a positive anti-HBs result is obtained, it should be documented even if it is < 10 IU/L.

Modern HB vaccines contain only small HBs protein of the European/US genotype A2. The anti-HBs induced by these vaccines does not contain anti-pre-S or HBsAg subtype-specific antibodies other than anti-HBs/adw2. Ninety-nine per cent of the HBV carriers worldwide have other HBsAg subtypes; the antibodies against the HBs subtype determinants are often present in larger amounts than the anti-*a* antibodies.

Different anti-HBs test kits use different types of HBsAg as reagent. Complete quantitative agreement between these assays should not be expected [124], but discordance is usually within a factor of 2.

Anti-HBs and particularly anti-pre-S1 neutralizes HBV infectivity *in vitro* and *in vivo*. However, it cannot suppress intracellular replication and spread of HBsAg escape mutants. Postexposure prophylaxis favours the selection of escape mutants.

Occult infection and reactivation

This term has been coined recently for HBV infections that are HBsAg negative for various reasons [121]. Very often, they are asymptomatic, of low replication activity and normally clinically irrelevant. However, there are three situations in which this condition is important:

1 The small amount of HBV present in these persons is sufficient to transmit full-blown HBV infection in recipients of blood or organ donations. Persistent occult infection is usually detectable by anti-HBc. Thus, liver donors and, in some countries, blood donors have to be screened for anti-HBc. HBV DNA assays, even if very sensitive, may be insufficient to detect such infections.

2 An occult HBV infection may reactivate in patients experiencing severe immunosuppression, e.g. during bone marrow or stem cell transplantation or aggressive leukaemia/lymphoma therapy. The reactivated virus may be wt or an escape mutant. In the latter case, HBsAg results may be false negative. Thus, monitoring of such patients is preferably done by HBV DNA assays.

3 Occult infections may represent the persistence of viral DNA after the serological cure and may be associated with liver cirrhosis and the development of hepatocellular carcinoma.

HBV genotypes, variants and mutants

HBV genotypes are important for the prognosis of interferon therapy [125–129], whereas therapy with RT inhibitors shows no clear genotype influence (for reviews, see [10,130]). Long-term prognosis of chronic HBV infection may be dependent on the genotypes. Furthermore, the genotypes give a hint to the origin of the infection. Genotyping methods based on various PCR techniques have been described, and test kits are available [11]. The most reliable method is sequencing. However, direct sequencing usually misses coinfections with two or more HBV genotypes [11]. Because coinfections with two genotypes have recently been reported to be of importance for the prognosis of the disease [131], hybridization-based [132] or multiplex PCR methods [133,134] appear to be advantageous. Recombinants of two genotypes have been described in some regions, but they are not predominant in Europe or the USA.

More important than genotypes and genosubtypes are probably the mutants that have been selected by the host's immune defence [135]. The primary target is expression of HBeAg, which may be suppressed by core promoter mutations, a stop codon in the precore region and/or other mutations affecting translation or processing of the HBe protein [114].

Another important target is MHBs, the start codon of which may be mutated. Alternatively, the pre-S1/S2 sequence around the amino acid 120 region may show small deletions [136]. Truncations of the S domain are often found in integrated HBV DNA fragments from hepatocellular carcinomas. X protein may be truncated by mutations/deletions in the core promoter. Deletions and truncations of the core protein have also been found in defective interfering genomes from kidney transplant recipients with terminal liver disease [137]. Such mutants are typically found in severely ill patients.

Escape mutations in the HBsAg loop may arise either on the background of profoundly altered genomes or in otherwise normal genomes [113]. Active or passive vaccination favours mutations in the SHBs region 120–145, with G145R being the most prominent. Naturally induced anti-HBs selects for a wider variety of mutations between amino acid 100 and 170. Detection of all these mutations is best accomplished by PCR and sequencing of the corresponding gene. Owing to morphogenesis and secretion defects, the genomes detected in the serum may not reflect the intrahepatic pattern of mutation.

A special case are resistance mutations under antiviral therapy [138]. If there is no decline or an increase in HBV DNA levels during therapy, this suggests that the therapy is ineffective; a genotypical resistance assay may help to find the polymerase gene mutation and allow the adaptation of antiviral therapy according to the known sensitivity of this mutant to antivirals. Hybridization of PCR products with selected probes is more sensitive than direct sequencing, but sequencing is able to detect new mutants as well.

Hepatitis D virus (HDV)

Taxonomy

HDV consists of an HBsAg envelope, an HDAg core and a small 1.7-kb RNA. After cloning and sequencing of the HDV RNA, a similarity of HDV with viroids and virusoids (plant pathogens) was recognized. Formally, HDV is now classified among negative-strand viruses as genus deltavirus without its own virus family [139]. However, it does not have much in common with other negative-strand viruses.

Virus structure (Fig. 12)

The structure and replication has been reviewed recently [140,141]. A nucleocapsid-like structure is formed by approximately 70 HD protein subunits together with the small RNA genome, but a (icosahedral) symmetry of this complex has not been identified and may in fact be absent. The HD protein exists in two forms: a small HD protein (SHD) with 195 amino acids and a collinear large form (LHD) with a carboxy-terminal extension of 19 amino acids. The envelope consists of SHBs, MHBs and LHBs. As with HBV, SHBs is the major component and MHBs a minor component. Assembled HDV particles have a size of 36–43 nm and a density in caesium chloride of 1.24–1.25 g/mL. HDAg can be released from HDV by treatment with non-ionic detergents. As the HBsAg envelope is required for infectivity, the stability of HDV is probably comparable to that of HBV.

Genome structure (Fig. 13)

HDV has a unique genome structure among the animal viruses. Its RNA forms a covalently closed single-stranded circle with 1670–1685 nucleotides depending on the isolate. On account of 70% self-complementarity within the RNA sequence, the circle folds to a double-stranded rod with covalently closed ends at base numbers 795 and 1638. In electron microscopy, the HDV genome appears as a short rod about 280 nm in length, which opens to a circle under denaturing conditions [142]. The minus-strand genome encodes the mRNA with one ORF for the two coterminal HD proteins.

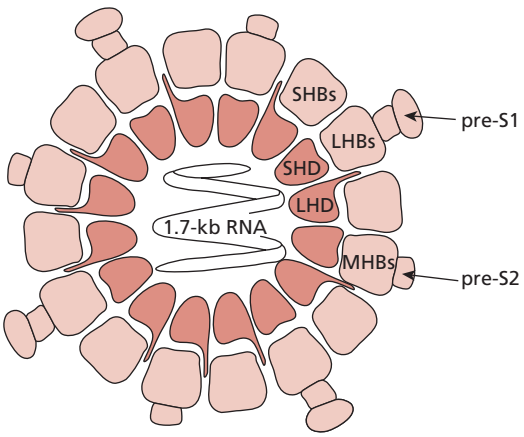

Fig. 12 Schematic model of hepatitis delta virus. The circular RNA genome is highly self-complementary and forms double-stranded rods. SHBs, MHBs, LHBs, small, middle and large hepatitis B surface protein; SHD, LHD, small and large hepatitis delta protein; pre-S1, pre-S2, domains of HBs proteins.

RNA editing

In order to encode the two forms of HD protein, HDV has evolved a unique strategy. The replication-competent form of the HDV genome encodes the SHD protein because SHD is required for HDV genome replication. This SHD genome carries a U at position 1015 and, in the antigenome or the mRNA, an A as part of a UAG (amber) stop codon for the 195-amino acid SHD protein. For envelopment and secretion of the HDV, LHD protein is required. In order to encode LHD, the SHD antigenome is mutated (edited) by the cellular enzyme, double-stranded RNA adenosine deaminase (ADAR1), at position 1015 from A to inosine [143]. This unusual base is transcribed during RNA replication to C in the genome strand and to G in the newly produced mRNA and antigenome sequence. Thus, codon 196 of HD protein is no longer a stop codon, but encodes tryptophan and allows for an extension of 19 amino acids until the next stop codon occurs [144]. As SHD protein is required for genome replication, an HDV infection can only be established by the SHD genome, but spread of HDV and establishment of HD viraemia require partial conversion of SHD to LHD genomes.

Ribozyme activity

Similar to viroids, the genome and the antigenome contain a ribozyme structure that is able to self-cleave and self-ligate its own sequence (i.e. *in cis*). The delta-type ribozymes have four short double helices and a similar space structure to viroids [145]. The self-cleavage of the viral RNA phosphodiester backbone requires both divalent cations and a cytidine nucleotide. The ribozyme structures in the pre- and post-cleavage states reveal conformational changes after cleavage [146]. The self-cleavage occurs at the 5′ end of this structure and may cleave off any sequence upstream. This property of the delta ribozyme has been used as a molecular tool to generate RNAs with exactly defined 3′ ends that are necessary for the generation of replication-competent minus-strand RNA viruses (e.g. measles virus or influenza virus).

Properties of HD proteins

A schematic presentation of their various identified functions is shown in Figure 14. A region between amino acid 31 and 52 forms coils that can interact with each other and mediate oligomerization of HD proteins. HD proteins contain a bipartite nuclear localization signal. Thus, HD proteins are predominantly

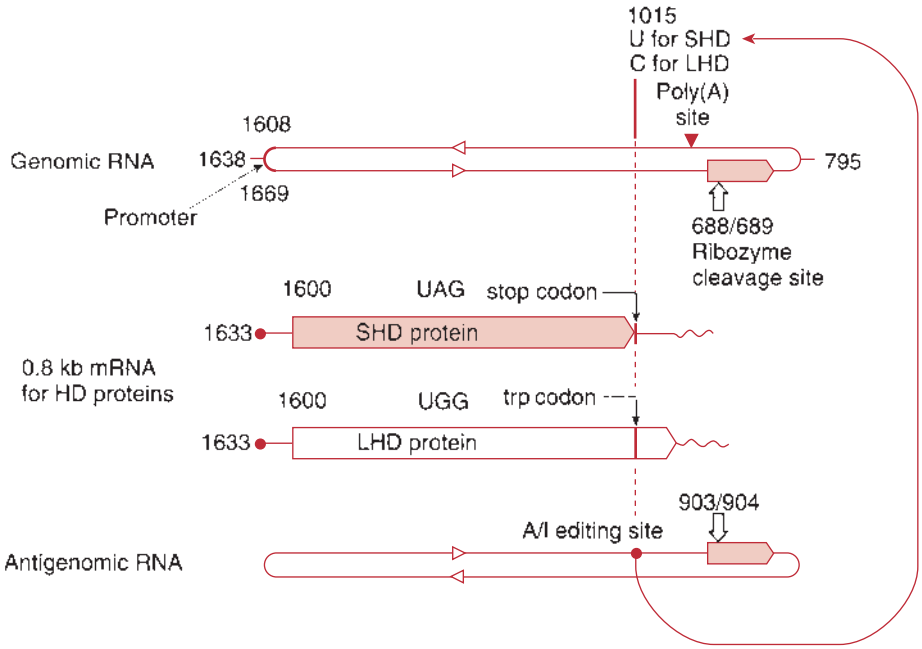

Fig. 13 Genome structure, RNA editing and expression products of HDV. U, uridine; C, cytidine; A, adenine; I, inosine.

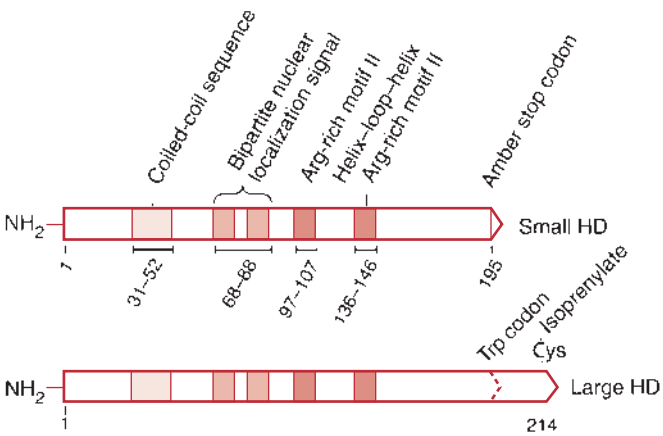

Fig. 14 Functions and motifs of the two HD proteins.

found in the nucleus. Two arginine-rich motifs support binding of RNA. They are specific for rod-like RNA structures with closed ends as in the HDV genome. All these features of SHD contribute to the replication of the HDV genome. LHD has an additional 19 amino acids, the sequence of which may be quite variable. A Cys-Arg-Pro-Glu motif is conserved at the carboxy end, which is a target for a linkage between the Cys and a 15-carbon farnesyl isoprenoid. This modification is required for the secretion of HD protein within the HBs envelope. LHD has a transdominant negative effect on the functions of SHD protein, which is mediated by the coil–coil interaction. LHD is possibly partially retained by the isoprenylate at the ER, whereas SHD functions only in the nucleus. Mature virions always contain a mixture of SHD and LHD. *In vivo*, the small and large delta antigens assemble as antiparallel coiled-coil dimers and assume an octameric quaternary structure *in vivo* [147]. Both HD proteins are phosphorylated by casein kinase II. In addition, SHD gets phosphorylated by protein kinase C (PKC) and PKR [148]. PKC activates SHD functions, but LHD is six times more phosphorylated and inhibits SHD functions.

HD proteins are moderately immunogenic. Antibodies react with the nuclear localization signal and the C-terminal sequences of SHD- and LHDAg [149]. Patients' antibodies react well with the HD nucleoprotein complex and with denatured HD proteins in Western blots.

Genotypes and variability

The major part of the HDV genome is variable with the exception of essential motifs. Initially, three genotypes, I–III, were identified, which differ as much as 40% in nucleotide sequence. Later studies found four further clades (or genotypes) in Africa suggesting an African origin of HDV [150]. Today, HDV is divided into eight major clades [151]. Recombinations between two genotypes/clades have been found *in vivo* and *in vitro* [152].

Genotypes seem to influence the course of disease. Genotype I is most frequent worldwide and has variable pathogenicity. In a recent study, patients infected with genotype I HDV had a lower remission rate and more adverse outcomes [153] than those with genotype II HDV. Genotypes II and IV have been found in East Asia causing relatively mild disease [154], whereas genotype III is associated with HBV genotype F and fulminant hepatitis in South America [155].

Replication

Host and organ tropism

HDV can infect humans and primates if HBV is also present. Infection of woodchuck hepatitis virus (WHV)-carrying woodchucks with HDV of human origin is also possible [156]. The envelope of WHV is acquired in this case. If brought into cells by transfection (e.g. of cloned cDNA), HDV RNA can replicate in various mammalian cells, provided HD protein is present to initiate the replication cycle. Spread from cell to cell and secretion is only possible in the presence of SHBs and LHBs. In transgenic mice, the HDV genome is best expressed in muscle cells [157]. Thus, the natural organ specificity is most probably due to the attachment and penetration mediated by the HBs envelope proteins [82].

Genome expression

After penetration, the HDV genome reaches the nucleoplasm, possibly guided by the nuclear localization signal of the HD ribonucleoprotein complex. As with viroids, the cellular RNA polymerase II (against all the rules of normal gene expression) is believed to accept the HDV RNA genome as a template [140,141]. The RNA-encoded promoter is formed by sequence 1608–1669, which forms a stem–loop region with two bulges. This secondary structure is required for HDV genome expression and replication [158]. Proximal to the 3′ end of the HD gene, the genome contains a leaky signal for termination of transcription and polyadenylation. Thus, a 0.8-kb mRNA encoding either SHD or LHD depending on base 1015 is generated.

Genome replication (Fig. 15)

In the presence of increasing amounts of SHD protein, the poly-A site is suppressed, and the entire circular genome is transcribed to a linear more-than-genome length antigenomic intermediate. The nascent antigenomic RNA strand has the ability to fold first into the ribozyme structure and to clip the continuously growing intermediate into genome-long units. This molecule folds back to the rod-like structure and undergoes self-ligation. Host factor(s) prevent first folding of the rod structure and stabilize the ribozyme. After generation of the circular structure, the ribozyme is inactivated by RNA sequences *in cis*, which prevent further self-cleavage of the genome. The clipping and self-ligation is (*in vitro*) reversible and independent of any protein and, thus, a true ribozyme reaction. The energy of the phosphodiester bond is conserved in the cleaved state by transesterification of the phosphate from the 5′ group to a 2′,3′cyclic monophosphate terminus. The same process now starts with the antigenome, thus generating progeny genomes. Interaction with SHD stabilizes the RNA and facilitates further cycles of replication. The basepaired region around base 1015 of the antigenome is subject to RNA editing, and a certain proportion of the genome will finally encode LHD and no longer contribute to replication, but to envelopment and secretion.

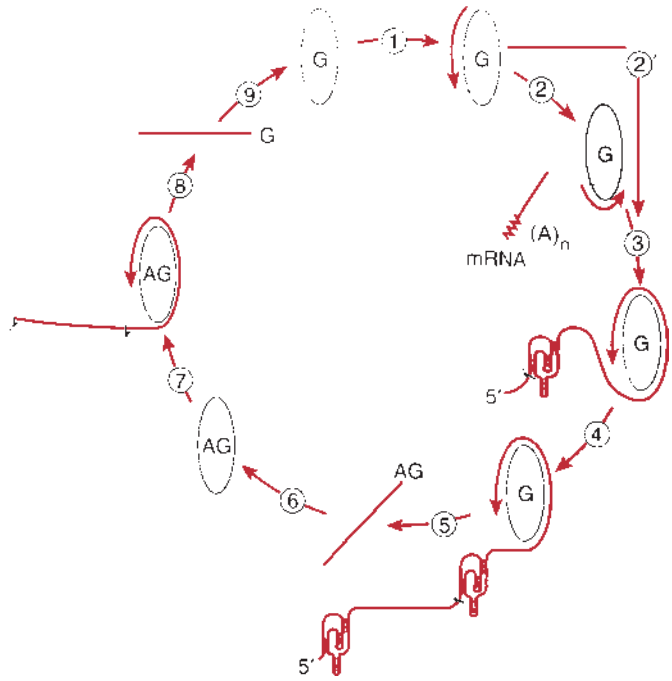

Fig. 15 HDV RNA replication cycle. The genomic (G) strand is transcribed (1) by RNA polymerase II to a short mRNA (2) and a long continuously growing strand (3), which cleaves itself by its ribozyme first at the 5′ end (4) and thereafter a second time resulting in a genome-long linear RNA (5). This antigenome (AG) is able to recircularize (6) and to repeat the cycle now with the genomic transcript (7–9). Courtesy of M.M.C. Lai.

Assembly

SHD has an affinity for the RNA rods of HDV, and it can also form mixed complexes with LHD. LHD interacts in the ER with SHBs. Isoprenylation is required for envelopment of LHD, but the oligomerization is dispensable for this function [159]. In contrast to HBV, LHBs is not required for envelopment of HDV nucleoprotein. However, mixed assembly of SHBs with LHBs is required for infectivity of HDV, whereas MHBs is dispensable (as is the case with HBV). The structure and function of the HBsAg envelope in HDV is different from that in the HBV envelope, because the host specificity of HDV is obviously not so narrow as for HBV and primary cell cultures can be infected more easily than with HBV.

Diagnosis of HDV infection

Course of the disease

Transmission occurs mainly by percutaneous contact with infectious blood and, less frequently than with HBV, by mucocutaneous contact. Two situations must be distinguished:

1 Coinfection in which the infectious material contains both HBV and HDV. HDV suppresses replication of HBV by unknown mechanisms; the course of infection is usually self-limiting, but the acute phase is of variable severity. The

infectivity titre of the inoculum is determined by either HBV or HDV, whichever is lower.

2 In superinfection, HDV infects an HBV carrier. Owing to the established colonization by HBV, HDV can replicate much more vigorously. Superinfection of HBV carriers usually leads to chronic HDV infection, and may cause fulminant hepatitis. The infectivity titre of the inoculum is determined only by HDV.

In both situations, the HD protein appears first in the liver after an incubation period of weeks or months. HDV is secreted to the blood before the onset of clinical disease, and starts to decrease during acute hepatitis. Infectivity titres of HDV may reach 10^{11}/mL of serum during the early acute phase, but are as a rule lower in persistent infection. Anti-HD antibodies appear during the acute phase, and may disappear within a few months after recovery. In persistent infection, titres remain high, as is also true for IgM anti-HD.

Anti-HD and HDAg

HDV infection occurs together with HBV infection. Thus, detection of HDV and anti-HD antibodies is normally indicated only for subjects with markers of ongoing HBV infection. HDV-infected patients who have received a liver transplant are exceptions. In such cases, the new liver can be infected in spite of seemingly absent HBV. As a general recommendation, an assay of anti-HD should be done as a screening test in all HBsAg-positive persons and in cases of HBsAg-negative acute hepatitis where no other agent can be identified. Owing to suppression of HBV by HDV, HBsAg may indeed be absent in some patients during acute HDV infection; usually, these patients have anti-HBc IgM. In drug abusers and recipients of blood products, testing for anti-HD may also be informative, even when HBsAg is absent.

During early acute hepatitis D as well as during the incubation period, anti-HD may still be negative; in this phase, HDAg may be detectable in detergent-treated serum samples. When anti-HD appears, direct testing for HDAg by immune assay is no longer useful unless HDV proteins are separated from anti-HD and detected by immunoblotting.

Disease activity and infectivity cannot be deduced from the presence of anti-HD, but only from the determination of HD protein in serum and liver or, preferably, from an assay of HDV RNA.

HDAg and anti-HD were first detected by immunofluorescence using liver biopsies from chronic HDV carriers as antigen and serum from the carriers as antibody. Currently, HDAg in serum is detected by sandwich immunoassays using high-titre IgG anti-HD as the capturing antibody and labelled anti-HD as the tracer. The inhibition of tracer binding to HDAg fixed on a solid phase indicates the presence of anti-HD in the serum sample. Several test kits for anti-HD and HDAg are available on the market. As with all inhibition assays, the analytical sensitivity is not high for anti-HD, but is sufficient to detect the great majority of productive HDV infections.

IgM anti-HD

The standard anti-μ capture assay is used for the detection of this antibody. The assay may be applied to diagnose acute infection, but patients with both acute and chronic disease have high titres of IgM anti-HD. IgM anti-HD may be considered as an indirect marker of active HDV infection and HDV-associated disease.

HDV RNA

No commercial assay is available for the detection of HDV RNA, but various methods have been published from specialized laboratories. Because of the high variability of the HDV genome, the choice of primers from a conserved site of the genome is crucial to avoid false-negative results.

At present, qPCR is the method of choice because it is sensitive and allows for quantification over a wide range [125]. The assay is indicated for confirmation and follow-up of a positive anti-HD result, and for monitoring chronic patients, especially when antiviral therapies are undertaken. In addition, the concentration of HDV RNA seems to be of prognostic significance because levels of HDV RNA in the serum of patients with chronic hepatitis or liver cirrhosis were reported to be higher than those in asymptomatic carriers [160].

References

1 Almeida JD, Rubenstein D, Stott EJ (1971) New antigen-antibody system in Australia-antigen-positive hepatitis. *Lancet* 2, 1225–1227.

2 Dryden KA, Wieland SF, Whitten-Bauer C *et al.* (2006) Native hepatitis B virions and capsids visualized by electron cryomicroscopy. *Mol Cell* 22, 843–850.

3 Kann M, Gerlich WH (2005) Hepatitis B virus and other Hepadnaviridae. Structure and molecular virology. In: Thomas H, Lemon S, Zuckerman A (eds) *Viral Hepatitis*, 3rd edn. Oxford: Blackwell, pp. 140–180.

4 Guo H, Mason WS, Aldrich CE *et al.* (2005) Identification and characterization of avihepadnaviruses isolated from exotic anseriformes maintained in captivity. *J Virol* 79, 2729–2742.

5 Schaefer S (2006) Hepatitis B virus taxonomy and hepatitis B virus genotypes. *World J Gastroenterol* 13, 14–21.

6 Dandri M, Burda H, Will H *et al.* (2000) Animal models of Hepadnavirus infection. A review. *J Viral Hepatitis Rev* 6, 29–45.

7 Schaefer S, Tolle T, Lottmann S *et al.* (1998) Animal models and experimental systems in hepatitis B virus research. In: Koshy R, Caselmann W (eds) *Hepatitis B Virus: Molecular Mechanisms in Disease and Novel Strategies for Therapy*. London: Imperial College Press, pp. 51–74.

8 Chu CJ, Lok AS (2002) Clinical significance of hepatitis B virus genotypes. *Hepatology* 35, 1274–1276.

9 Miyakawa Y, Okamoto H, Mayumi M (1997) The molecular basis of hepatitis B e antigen (HBeAg)-negative infections. *J Viral Hepat* 4, 1–8.

10 Schaefer S (2005) Hepatitis B virus – significance of genotypes. *J Viral Hepat* 12, 111–124.

11 Bartholomeusz A, Schaefer S (2004) Hepatitis B virus genotypes: comparison of genotyping methods. *Rev Med Virol* 14, 3–16.

12 Norder H, Couroucé A-M, Coursaget P *et al.* (2004) Genetic diversity of hepatitis B Virus strains derived worldwide: genotypes, subgenotypes, and HBsAg subtypes. *Intervirology* 47, 289–309.
13 Kramvis A, Kew M, Francois G (2005) Hepatitis B virus genotypes. *Vaccine* 23, 2409–2423.
14 Sugauchi F, Kumada H, Acharya SA *et al.* (2004) Epidemiological and sequence differences between two subtypes (Ae and Aa) of hepatitis B virus genotype A. *J Gen Virol* 85, 811–820.
15 Chan HL, Tsui SK, Tse CH *et al.* (2005) Epidemiological and virological characteristics of 2 subgroups of hepatitis B virus genotype C. *J Infect Dis* 191, 2022–2032.
16 Huy TT, Ushijima H, Quang VX *et al.* (2004) Genotype C of hepatitis B virus can be classified into at least two subgroups. *J Gen Virol* 85, 283–292.
17 Tanaka Y, Orito E, Yuen MF *et al.* (2005) Two subtypes (subgenotypes) of hepatitis B virus genotype C: A novel subtyping assay based on restriction fragment length polymorphism. *Hepatol Res* 33, 216–224.
18 Steven AC, Conway JF, Cheng N *et al.* (2005) Structure, assembly, and antigenicity of hepatitis B virus capsid proteins. *Adv Virus Res* 64, 125–164.
19 Zlotnick A, Johnson JM, Wingfield PW *et al.* (1999) A theoretical model successfully identifies features of hepatitis B virus capsid assembly. *Biochemistry* 38, 14644–14652.
20 Conway JF, Cheng N, Zlotnick A *et al.* (1998) Hepatitis B virus capsid: localization of the putative immunodominant loop (residues 78 to 83) on the capsid surface, and implications for the distinction between c and e-antigens. *J Mol Biol* 279, 1111–1121.
21 Belnap DM, Watts NR, Conway JF *et al.* (2003) Diversity of core antigen epitopes of hepatitis B virus. *Proc Natl Acad Sci USA* 100, 10884–10889.
22 Standring DN, Ou JH, Masiarz FR *et al.* (1988) A signal peptide encoded within the precore region of hepatitis B virus directs the secretion of a heterogeneous population of e antigens in Xenopus oocytes. *Proc Natl Acad Sci USA* 85, 8405–8409.
23 Wasenauer G, Köck J, Schlicht HJ (1992) A cysteine and a hydrophobic sequence in the noncleaved portion of the pre-C leader peptide determine the biophysical properties of the secretory core protein (HBe protein) of human hepatitis B virus. *J Virol* 66, 5338–5346.
24 Kato H, Orito E, Gish RG *et al.* (2002) Characteristics of hepatitis B virus isolates of genotype G and their phylogenetic differences from the other six genotypes (A through F) *J Virol* 76, 6131–6137.
25 Chudy M, Schmidt M, Czudai V *et al.* (2006) Hepatitis B virus genotype G monoinfection and its transmission by blood components. *Hepatology* 44, 99–107.
26 Milich D, Liang TJ (2003) Exploring the biological basis of hepatitis B e antigen in hepatitis B virus infection. *Hepatology* 38, 1075–1086.
27 Chen M, Sallberg M, Hughes J *et al.* (2005) Immune tolerance split between hepatitis B virus precore and core proteins. *J Virol* 79, 3016–3027.
28 Andrisani OM, Barnabas S (1999) The transcriptional function of the hepatitis B virus X protein and its role in hepatocarcinogenesis (review). *Int J Oncol* 15, 373–379.
29 Arbuthnot P, Capovilla A, Kew M (2000) Putative role of hepatitis B virus X protein in hepatocarcinogenesis: effects on apoptosis, DNA repair, mitogen-activated protein kinase and JAK/STAT pathways. *J Gastroenterol Hepatol* 15, 357–368.
30 Bouchard MJ, Schneider RJ (2004) The enigmatic X gene of hepatitis B virus. *J Virol* 78, 12725–12734.
31 Buendia MA (1998) Hepatitis B viruses and cancerogenesis. *Biomed Pharmacother* 52, 34–43.
32 Murakami S (1999) Hepatitis B virus X protein: structure, function and biology. *Intervirology* 42, 81–99.
33 Murakami S (2001) Hepatitis B virus X protein: a multifunctional viral regulator. *J Gastroenterol* 36, 651–660.
34 Schaefer S (2001) Hepatitis B virus in experimental carcinogenesis. In: Grand RJA (ed.) *Viruses, Cell Transformation and Cancer*. Amsterdam: Greenwich, Elsevier, pp. 193–228.
35 Chang SF, Netter HJ, Hildt E *et al.* (2001) Duck hepatitis B virus expresses a regulatory HBx-like protein from a hidden open reading frame. *J Virol* 75, 161–170.
36 Dandri M, Petersen J, Stockert RJ *et al.* (1998) Metabolic labeling of woodchuck hepatitis virus X protein in naturally infected hepatocytes reveals a bimodal half-life and association with the nuclear framework. *J Virol* 72, 9359–9364.
37 Su Q, Schröder CH, Hofmann WJ *et al.* (1998) Expression of hepatitis B virus X protein in HBV-infected human livers and hepatocellular carcinomas. *Hepatology* 27, 1109–1120.
38 Bouchard MJ, Wang LH, Schneider RJ (2001) Calcium signaling by HBx protein in hepatitis B virus DNA replication. *Science* 294, 2376–2378.
39 Hafner A, Brandenburg B, Hildt E (2003) Reconstitution of gene expression from a regulatory-protein-deficient hepatitis B virus genome by cell-permeable HBx protein. *EMBO Rep* 4, 767–773.
40 Tang H, Delgermaa L, Huang F *et al.* (2005) The transcriptional transactivation function of HBx protein is important for its augmentation role in hepatitis B virus replication. *J Virol* 79, 5548–5556.
41 Zhang Z, Torii N, Hu Z *et al.* (2001) X-deficient woodchuck hepatitis virus mutants behave like attenuated viruses and induce protective immunity in vivo. *J Clin Invest* 108, 1523–1531.
42 Benn J, Schneider RJ (1994) Hepatitis B virus HBx protein activates Ras–GTP complex formation and establishes a Ras, Raf, MAP kinase signaling cascade. *Proc Natl Acad Sci USA* 91, 10350–10354.
43 Bouchard MJ, Wang L, Schneider RJ (2006) Activation of focal adhesion kinase by hepatitis B virus HBx protein: multiple functions in viral replication. *J Virol* 80, 4406–4414.
44 Melegari M, Wolf SK, Schneider RJ (2005) Hepatitis B virus DNA replication is coordinated by core protein serine phosphorylation and HBx expression. *J Virol* 79, 9810–9820.
45 Bergametti F, Prigent S, Luber B *et al.* (1999) The proapoptotic effect of hepatitis B virus HBx protein correlates with its transactivation activity in stably transfected cell lines. *Oncogene* 18, 2860–2871.
46 Schuster R, Gerlich WH, Schaefer S (2000) Induction of apoptosis by the transactivating domains of the hepatitis B virus X gene leads to suppression of oncogenic transformation of primary rat embryo fibroblasts. *Oncogene* 19, 1173–1180.
47 Chami M, Ferrari D, Nicotera P *et al.* (2003) Caspase-dependent alterations of Ca2+ signaling in the induction of apoptosis by hepatitis B virus X protein. *J Biol Chem* 278, 31745–31755.
48 Fischer M, Runkel L, Schaller H (1995) HBx protein of hepatitis B virus interacts with the C-terminal portion of a novel human proteasome alpha-subunit. *Virus Genes* 10, 99–102.
49 Huang J, Kwong J, Sun EC *et al.* (1996) Proteasome complex as a potential cellular target of hepatitis B virus X protein. *J Virol* 70, 5582–5591.

50 Seeger C (1997) The hepatitis B virus X protein: the quest for a role in viral replication and pathogenesis. *Hepatology* 25, 496–498.

51 Hu Z, Zhang Z, Doo E *et al.* (1999) Hepatitis B virus X protein is both a substrate and a potential inhibitor of the proteasome complex. *J Virol* 73, 7231–7240.

52 Cui F, Wang Y, Wang J *et al.* (2006) The up-regulation of proteasome subunits and lysosomal proteases in hepatocellular carcinomas of the HBx gene knockin transgenic mice. *Proteomics* 6, 498–504.

53 Hu Z, Zhang Z, Kim JW *et al.* (2006) Altered proteolysis and global gene expression in hepatitis B virus X transgenic mouse liver. *J Virol* 80, 1405–1413.

54 Zhang Z, Protzer U, Hu Z *et al.* (2004) Inhibition of cellular proteasome activities enhances hepadnavirus replication in an HBX-dependent manner. *J Virol* 78, 4566–4572.

55 Sitterlin D, Lee TH, Prigent S *et al.* (1997) Interaction of the UV-damaged DNA-binding protein with hepatitis B virus X protein is conserved among mammalian hepadnaviruses and restricted to transactivation-proficient X-insertion mutants. *J Virol* 71, 6194–6199.

56 Sitterlin D, Bergametti F, Tiollais P *et al.* (2000) Correct binding of viral X protein to UVDDB-p127 cellular protein is critical for efficient infection by hepatitis B viruses. *Oncogene* 19, 4427–4431.

57 Wentz MJ, Becker SA, Slagle BL (2000) Dissociation of DDB1-binding and transactivation properties of the hepatitis B virus X protein. *Virus Res* 68, 87–92.

58 Bontron S, Lin-Marq N, Strubin M (2002) Hepatitis B virus X protein associated with UV-DDB1 induces cell death in the nucleus and is functionally antagonized by UV-DDB2. *J Biol Chem* 277, 38847–38854.

59 Lin-Marq N, Bontron S, Leupin O *et al.* (2001) Hepatitis B virus X protein interferes with cell viability through interaction with the p127-kDa UV-damaged DNA-binding protein. *Virology* 287, 266–274.

60 Bergametti F, Sitterlin D, Transy C (2002) Turnover of hepatitis B virus X protein is regulated by damaged DNA-binding complex. *J Virol* 76, 6495–6501.

61 Gottlob K, Pagano S, Levrero M *et al.* (1998) Hepatitis B virus X protein transcription activation domains are neither required nor sufficient for cell transformation. *Cancer Res* 58, 3566–3570.

62 Peng Z, Zhang Y, Gu W *et al.* (2005) Integration of the hepatitis B virus X fragment in hepatocellular carcinoma and its effects on the expression of multiple molecules: a key to the cell cycle and apoptosis. *Int J Oncol* 26, 467–473.

63 Schlüter V, Meyer M, Hofschneider PH *et al.* (1994) Integrated hepatitis B virus X and 3′ truncated preS/S sequences derived from human hepatomas encode functionally active transactivators. *Oncogene* 9, 3335–3344.

64 Stuyver L, Locarnini S, Lok A *et al.* (2001) Nomenclature for antiviral-resistant human hepatitis B virus mutations in the polymerase region. *Hepatology* 33, 751–757.

65 Lanford RE, Kim YH, Lee H *et al* (1999) Mapping of the hepatitis B virus reverse transcriptase TP and RT domains by transcomplementation for nucleotide priming and by protein–protein interaction. *J Virol* 73, 1885–1893.

66 Wei X, Peterson DL (1996) Expression, purification, and characterization of an active RNase H domain of the hepatitis B viral polymerase. *J Biol Chem* 271, 32617–32622.

67 Huang H, Chopra R, Verdine GL *et al.* (1998) Structure of a covalently trapped catalytic complex of HIV-1 reverse transcriptase: implications for drug resistance. *Science* 282, 1669–1675.

68 Allen MI, Deslauriers M, Andrews CW *et al.* (1998) Identification and characterization of mutations in hepatitis B virus resistant to lamivudine. Lamivudine Clinical Investigation Group. *Hepatology* 27, 1670–1677.

69 Bartholomeusz A, Groenen LC, Locarnini SA (1997) Clinical experience with famciclovir against hepatitis B virus. *Intervirology* 40, 337–342.

70 Das K, Xiong X, Yang H *et al.* (2001) Molecular modeling and biochemical characterization reveal the mechanism of hepatitis B virus polymerase resistance to lamivudine (3TC) and emtricitabine (FTC). *J Virol* 75, 4771–4779.

71 Gao HQ, Boyer PL, Sarafianos SG *et al.* (2000) The role of steric hindrance in 3TC resistance of human immunodeficiency virus type-1 reverse transcriptase. *J Mol Biol* 300, 403–418.

72 Bartholomeusz A, Tehan BG, Chalmers DK (2004) Comparisons of the HBV and HIV polymerase, and antiviral resistance mutations. *Antivir Ther* 9, 149–160.

73 Doo E, Liang TJ (2001) Molecular anatomy and pathophysiologic implications of drug resistance in hepatitis B virus infection. *Gastroenterology* 120, 1000–1008.

74 Bruss V, Lu X, Thomssen R *et al.* (1994) Post-translational alterations in transmembrane topology of the hepatitis B virus large envelope protein. *EMBO J* 13, 2273–2279.

75 Lambert C, Prange R (2001) Dual topology of the hepatitis B virus large envelope protein: determinants influencing post-translational pre-S translocation. *J Biol Chem* 276, 22265–22272.

76 Schmitt S, Glebe D, Alving K *et al.* (1999) Analysis of the pre-S2 N- and O-linked glycans of the M surface protein from human hepatitis B virus. *J Biol Chem* 274, 11945–11957.

77 Schmitt S, Glebe D, Tolle TK *et al.* (2004) Structure of pre-S2 N- and O-linked glycans in surface proteins from different genotypes of hepatitis B virus. *J Gen Virol* 85, 2045–2053.

78 Gerelsaikhan T, Tavis JE, Bruss V (1996) Hepatitis B virus nucleocapsid envelopment does not occur without genomic DNA synthesis. *J Virol* 70, 4269–4274.

79 Block TM, Lu X, Mehta AS *et al.* (1998) Treatment of chronic hepadnavirus infection in a woodchuck animal model with an inhibitor of protein folding and trafficking. *Nature Med* 4, 610–614.

80 Gripon P, Rumin S, Urban S *et al.* (2002) Infection of a human hepatoma cell line by hepatitis B virus. *Proc Natl Acad Sci USA* 99, 15655–15660.

81 Köck J, Nassal M, MacNelly S *et al.* (2001) Efficient infection of primary tupaia hepatocytes with purified human and woolly monkey hepatitis B virus. *J Virol* 75, 5084–5089.

82 Engelke M, Mills K, Seitz S *et al.* (2006) Characterization of a hepatitis B and hepatitis delta virus receptor binding site. *Hepatology* 43, 750–760.

83 Glebe D, Urban S, Knoop EV *et al.* (2005) Mapping of the hepatitis B virus attachment site by use of infection-inhibiting preS1 lipopeptides and tupaia hepatocytes. *Gastroenterology* 129, 234–245.

84 Jaoude GA, Sureau C (2005) Role of the antigenic loop of the hepatitis B virus envelope proteins in infectivity of hepatitis delta virus. *J Virol* 79, 10460–10466.

85 Chojnacki J, Anderson DA, Grgacic EV (2005) A hydrophobic domain in the large envelope protein is essential for fusion of duck hepatitis B virus at the late endosome. *J Virol* 79, 14945–14955.

86 Berting A, Fischer C, Schaefer S *et al.* (2000) Hemifusion activity of a chimeric influenza virus hemagglutinin with a putative fusion peptide from hepatitis B virus. *Virus Res* 68, 35–49.

87 Funk A, Mhamdi M, Hohenberg H *et al.* (2006) pH-independent entry and sequential endosomal sorting are major determinants of hepadnaviral infection in primary hepatocytes. *Hepatology* 44, 685–693.

88 Funk A, Hohenberg H, Mhamdi M *et al.* (2004) Spread of hepatitis B viruses in vitro requires extracellular progeny and may be codetermined by polarized egress. *J Virol* 78, 3977–3983.

89 Rabe B, Glebe D, Kann M (2006) Lipid-mediated introduction of hepatitis B virus capsids into nonsusceptible cells allows highly efficient replication and facilitates the study of early infection events. *J Virol* 80, 5465–5473.

90 Rabe B, Vlachou A, Pante N *et al.* (2003) Nuclear import of hepatitis B virus capsids and release of the viral genome. *Proc Natl Acad Sci USA* 100, 9849–9854.

91 Moolla N, Kew M, Arbuthnot P (2002) Regulatory elements of hepatitis B virus transcription. *J Viral Hepat* 9, 323–331.

92 Yu X, Mertz JE (1997) Differential regulation of the pre-C and pregenomic promoters of human hepatitis B virus by members of the nuclear receptor superfamily. *J Virol* 71, 9366–9374.

93 Sommer G, van Bommel F, Will H (2000) Genotype-specific synthesis and secretion of spliced hepatitis B virus genomes in hepatoma cells. *Virology* 271, 371–381.

94 Soussan P, Garreau F, Zylberberg H *et al.* (2000) In vivo expression of a new hepatitis B virus protein encoded by a spliced RNA. *J Clin Invest* 105, 55–60.

95 Soussan P, Tuveri R, Nalpas B *et al.* (2003) The expression of hepatitis B spliced protein (HBSP) encoded by a spliced hepatitis B virus RNA is associated with viral replication and liver fibrosis. *J Hepatol* 38, 343–348.

96 Huang J, Liang TJ (1993) A novel hepatitis B virus (HBV) genetic element with Rev response element-like properties that is essential for expression of HBV gene products. *Mol Cell Biol* 13, 7476–7486.

97 Heise T, Sommer G, Reumann K *et al.* (2006) The hepatitis B virus PRE contains a splicing regulatory element. *Nucleic Acids Res* 34, 353–363.

98 Liu N, Ji L, Maguire ML *et al.* (2004) cis-Acting sequences that contribute to the synthesis of relaxed-circular DNA of human hepatitis B virus. *J Virol* 78, 642–649.

99 Roseman AM, Berriman JA, Wynne SA *et al.* (2005) A structural model for maturation of the hepatitis B virus core. *Proc Natl Acad Sci USA* 102, 15821–15826.

100 Rost M, Mann S, Lambert C *et al.* (2006) {gamma}2-adaptin, a novel ubiquitin-interacting adaptor, and Nedd4 ubiquitin ligase control hepatitis B virus maturation. *J Biol Chem* 281, 29297–29308.

101 Thursz M (2004) Pros and cons of genetic association studies in hepatitis B. *Hepatology* 40, 284–286.

102 Visvanathan K, Lewin SR (2006) Immunopathogenesis: role of innate and adaptive immune responses. *Semin Liver Dis* 26, 104–115.

103 Wieland SF, Chisari F (2005) Stealth and cunning: hepatitis B and hepatitis C viruses. *J Virol* 79, 9369–9380.

104 Wieland S, Thimme R, Purcell RH *et al.* (2004) Genomic analysis of the host response to hepatitis B virus infection. *Proc Natl Acad Sci USA* 101, 6669–6674.

105 Murray JM, Wieland SF, Purcell RH *et al.* (2005) Dynamics of hepatitis B virus clearance in chimpanzees. *Proc Natl Acad Sci USA* 102, 17780–17785.

106 Wieland SF, Spangenberg HC, Thimme R *et al.* (2004) Expansion and contraction of the hepatitis B virus transcriptional template in infected chimpanzees. *Proc Natl Acad Sci USA* 101, 2129–2134.

107 Rehermann B, Ferrari C, Pasquinelli C *et al.* (1996) The hepatitis B virus persists for decades after patients' recovery from acute viral hepatitis despite active maintenance of a cytotoxic T-lymphocyte response. *Nat Med* 2, 1104–1108.

108 Cougot D, Neuveut C, Buendia MA (2005) HBV induced carcinogenesis. *J Clin Virol* 34(Suppl. 1), S75–S78.

109 Burczynska B, Madalinski K, Pawlowska J *et al.* (1994) The value of quantitative measurement of HBeAg and HBsAg before interferon-alpha treatment of chronic hepatitis B in children. *J Hepatol* 21, 1097–1102.

110 Whalley SA, Murray JM, Brown D *et al.* (2001) Kinetics of acute hepatitis B virus infection in humans. *J Exp Med* 193, 847–854.

111 Chulanov VP, Shipulin GA, Schaefer S *et al.* (2003) Kinetics of HBV DNA and HBsAg in acute hepatitis B patients with and without coinfection by other hepatitis viruses. *J Med Virol* 69, 313–323.

112 Gerlich W, Stamm B, Thomssen R (1977) [Prognostic significance of quantitative HBsAg determination in acute hepatitis B. Partial report of a cooperative clinical study of the DFG-focus of "virus hepatitis"]. *Verh Dtsch Ges Inn Med* 83, 554–557.

113 Gerlich WH (2004) Diagnostic problems caused by HBsAg mutants: a consensus report of an expert meeting. *Intervirology* 47, 310–313.

114 Funk ML, Rosenberg DM, Lok AS (2002) World-wide epidemiology of HBeAg-negative chronic hepatitis B and associated precore and core promoter variants. *J Viral Hepat* 9, 52–61.

115 Schildgen O, Sirma H, Funk A *et al.* (2006) Variant of hepatitis B virus with primary resistance to adefovir. *N Engl J Med* 354, 1807–1812.

116 Saldanha J (2001) Validation and standardisation of nucleic acid amplification technology (NAT) assays for the detection of viral contamination of blood and blood products. *J Clin Virol* 20, 7–13.

117 Heermann KH, Gerlich WH, Chudy M *et al.* (1999) Quantitative determination of hepatitis B virus DNA in two international reference plasmas. *J Clin Microbiol* 37, 68–73.

118 Grob P, Jilg W, Bornhak H *et al.* (2000) Serological pattern 'anti-HBc alone': report on a workshop. *J Med Virol* 62, 450–455.

119 Jilg W, Hottentrager B, Weinberger K *et al.* (2001) Prevalence of markers of hepatitis B in the adult German population. *J Med Virol* 63, 96–102.

120 Knoll A, Hartmann A, Hamoshi H *et al.* (2006) Serological pattern 'anti-HBc alone': characterization of 552 individuals and clinical significance. *World J Gastroenterol* 12, 1255–1260.

121 Allain JP (2004) Occult hepatitis B virus infection: implications in transfusion. *Vox Sang* 86, 83–91.

122 Weber B, Melchior W, Gehrke R *et al.* (2001) Hepatitis B virus markers in anti-HBc only positive individuals. *J Med Virol* 64, 312–319.

123 Gerlich WH, Uy A, Lambrecht F *et al.* (1986) Cutoff levels of immunoglobulin M antibody against viral core antigen for differentiation of acute, chronic, and past hepatitis B virus infections. *J Clin Microbiol* 24, 288–293.

124 Weber B (2006) Diagnostic impact of the genetic variability of the hepatitis B virus surface antigen gene. *J Med Virol* 78(Suppl. 1), S59–65.

125 Erhardt A, Gerlich W, Starke C *et al.* (2006) Treatment of chronic hepatitis delta with pegylated interferon-alpha2b. *Liver Int* 26, 805–810.

126 Flink HJ, van Zonneveld M, Hansen BE *et al.* (2006) Treatment with Peg-interferon alpha-2b for HBeAg-positive chronic hepatitis B: HBsAg loss is associated with HBV genotype. *Am J Gastroenterol* 101, 297–303.
127 Janssen HL, van Zonneveld M, Senturk H *et al.* (2005) Pegylated interferon alfa-2b alone or in combination with lamivudine for HBeApositive chronic hepatitis B: a randomised trial. *Lancet* 365, 123–129.
128 Kao JH, Wu NH, Chen PJ *et al.* (2000) Hepatitis B genotypes and the response to interferon therapy. *J Hepatol* 33, 998–1002.
129 Wai CT, Chu CJ, Hussain M *et al.* (2002) HBV genotype B is associated with better response to interferon therapy in HBeAg(+) chronic hepatitis than genotype C. *Hepatology* 36, 1425–1430.
130 Kramvis A, Weitzmann L, Owiredu WK *et al.* (2002) Analysis of the complete genome of subgroup A′ hepatitis B virus isolates from South Africa. *J Gen Virol* 83, 835–839.
131 Toan NL, Song le H, Kremsner PG *et al.* (2006) Impact of the hepatitis B virus genotype and genotype mixtures on the course of liver disease in Vietnam. *Hepatology* 43, 1375–1384.
132 Grandjacques C, Pradat P, Stuyver L *et al.* (2000) Rapid detection of genotypes and mutations in the pre-core promoter and the pre-core region of hepatitis B virus genome: correlation with viral persistence and disease severity. *J Hepatol* 33, 430–439.
133 Kirschberg O, Schuttler C, Repp R *et al.* (2004) A multiplex-PCR to identify hepatitis B virus-genotypes A–F. *J Clin Virol* 29, 39–43.
134 Naito H, Hayashi S, Abe K (2001) Rapid and specific genotyping system for hepatitis B virus corresponding to six major genotypes by PCR using type-specific primers. *J Clin Microbiol* 39, 362–364.
135 Sheldon J, Rodes B, Zoulim F *et al.* (2006) Mutations affecting the replication capacity of the hepatitis B virus. *J Viral Hepat* 13, 427–434.
136 Sugauchi F, Ohno T, Orito E *et al.* (2003) Influence of hepatitis B virus genotypes on the development of preS deletions and advanced liver disease. *J Med Virol* 70, 537–544.
137 Marschenz S, Endres AS, Brinckmann A *et al.* (2006) Functional analysis of complex hepatitis B virus variants associated with development of liver cirrhosis. *Gastroenterology* 131, 765–780.
138 Bartholomeusz A, Locarnini S (2006) Hepatitis B virus mutations associated with antiviral therapy. *J Med Virol* 78(Suppl. 1), S52–55.
139 Mason WS, Burrell CJ, Casey J *et al.* (2005) Hepadnaviridae. In: Fauquet CM, Mayo MA, Maniloff J *et al.* (eds) *Virus Taxonomy*, 8th Report of the International Committee on Taxonomy of Viruses. Philadelphia, PA: Elsevier.
140 Macnaughton TB, Lai MM (2006) HDV RNA replication: ancient relic or primer? *Curr Topics Microbiol Immunol* 307, 25–45.
141 Taylor JM (2006) Structure and replication of hepatitis delta virus RNA. *Curr Topics Microbiol Immunol* 307, 1–23.
142 Kos A, Dijkema R, Arnberg C *et al.* (1986) The hepatitis delta (delta) virus possesses a circular RNA. *Nature* 323, 558–560.
143 Wong SK, Lazinski DW (2002) Replicating hepatitis delta virus RNA is edited in the nucleus by the small form of ADAR1. *Proc Natl Acad Sci USA* 99, 15118–15123.
144 Polson AG, Bass BL, Casey JL (1996) RNA editing of hepatitis delta virus antigenome by dsRNA-adenosine deaminase. *Nature* 380, 454–456.
145 Ferre-D'Amare AR, Zhou K, Doudna JA (1998) Crystal structure of a hepatitis delta virus ribozyme. *Nature* 395, 567–574.
146 Ke A, Zhou K, Ding F *et al.* (2004) A conformational switch controls hepatitis delta virus ribozyme catalysis. *Nature* 429, 201–205.
147 Cornillez-Ty CT, Lazinski DW (2003) Determination of the multimerization state of the hepatitis delta virus antigens in vivo. *J Virol* 77, 10314–10326.
148 Chen CW, Tsay YG, Wu HL *et al.* (2002) The double-stranded RNA-activated kinase, PKR, can phosphorylate hepatitis D virus small delta antigen at functional serine and threonine residues. *J Biol Chem* 277, 33058–33067.
149 Bichko VV, Lemon SM, Wang JG *et al.* (1996) Epitopes exposed on hepatitis delta virus ribonucleoproteins. *J Virol* 70, 5807–5811.
150 Radjef N, Gordien E, Ivaniushina V *et al.* (2004) Molecular phylogenetic analyses indicate a wide and ancient radiation of African hepatitis delta virus, suggesting a deltavirus genus of at least seven major clades. *J Virol* 78, 2537–2544.
151 Deny P (2006) Hepatitis delta virus genetic variability: from genotypes I, II, III to eight major clades? *Curr Topics Microbiol Immunol* 307, 151–171.
152 Wang TC, Chao M (2005) RNA recombination of hepatitis delta virus in natural mixed-genotype infection and transfected cultured cells. *J Virol* 79, 2221–2229.
153 Su CW, Huang YH, Huo TI *et al.* (2006) Genotypes and viremia of hepatitis B and D viruses are associated with outcomes of chronic hepatitis D patients. *Gastroenterology* 130, 1625–1635.
154 Wu JC (2006) Functional and clinical significance of hepatitis D virus genotype II infection. *Curr Topics Microbiol Immunol* 307, 173–186.
155 Casey JL, Niro GA, Engle RE *et al.* (1996) Hepatitis B virus (HBV)/hepatitis D virus (HDV) coinfection in outbreaks of acute hepatitis in the Peruvian Amazon basin: the roles of HDV genotype III and HBV genotype F. *J Infect Dis* 174, 920–926.
156 Casey JL, Gerin JL (2006) The woodchuck model of HDV infection. *Curr Topics Microbiol Immunol* 307, 211–225.
157 Polo JM, Jeng KS, Lim B *et al.* (1995) Transgenic mice support replication of hepatitis delta virus RNA in multiple tissues, particularly in skeletal muscle. *J Virol* 69, 4880–4887.
158 Beard MR, MacNaughton TB, Gowans EJ (1996) Identification and characterization of a hepatitis delta virus RNA transcriptional promoter. *J Virol* 70, 4986–4995.
159 Sheu SY, Chen KL, Lee YW *et al.* (1996) No intermolecular interaction between the large hepatitis delta antigens is required for the secretion with hepatitis B surface antigen: a model of empty HDV particle. *Virology* 218, 275–278.
160 Yamashiro T, Nagayama K, Enomoto N *et al.* (2004) Quantitation of the level of hepatitis delta virus RNA in serum, by real-time polymerase chain reaction—and its possible correlation with the clinical stage of liver disease. *J Infect Dis* 189, 1151–1157.
153 Nei M, Kumar S (2000) *Molecular Evolution and Phylogenetics*. Oxford: Oxford University Press.
154 Kimbi GC, Kramvis A, Kew MC (2004) Distinctive sequence characteristics of subgenotype A1 isolates of hepatitis B virus from South Africa. *J Gen Virol* 85, 1211–1220.
155 Kurbanov F, Tanaka Y, Fujiwara K *et al.* (2005) A new subtype (subgenotype) Ac (A3) of hepatitis B virus and recombination between genotypes A and E in Cameroon. *J Gen Virol* 86, 2047–2056.
156 Makuwa M, Souquiere S, Telfer P *et al.* (2006) Identification of hepatitis B virus subgenotype A3 in rural Gabon. *J Med Virol* 78, 1175–1184.
157 Olinger CM, Venard V, Njayou M *et al.* (2006) Phylogenetic analysis of the precore/core gene of hepatitis B virus genotypes E and A in West Africa: new subtypes, mixed infections and recombinations. *J Gen Virol* 87, 1163–1173.

158 Nagasaki F, Niitsuma H, Cervantes JG *et al.* (2006) Analysis of the entire nucleotide sequence of hepatitis B virus genotype B in the Philippines reveals a new subgenotype of genotype B. *J Gen Virol* 87, 1175–1180.
159 Sakamoto T, Tanaka Y, Orito E *et al.* (2006) Novel subtypes (subgenotypes) of hepatitis B virus genotypes B and C among chronic liver disease patients in the Philippines. *J Gen Virol* 87, 1873–1882.
160 Sugauchi F, Mizokami M, Orito E *et al.* (2001) A novel variant genotype C of hepatitis B virus identified in isolates from Australian Aborigines: complete genome sequence and phylogenetic relatedness. *J Gen Virol* 82, 883–892.
161 Cavinta L, Sun J, Zarnekow M *et al.* (submitted) New hepatitis B virus subgenotype C5 from the Philippines.
162 Banerjee A, Kurbanov F, Datta S *et al.* (2006) Phylogenetic relatedness and genetic diversity of hepatitis B virus isolates in Eastern India. *J Med Virol* 78, 1164–1174.
163 Kato H, Fujiwara K, Gish RG *et al.* (2005) Classifying genotype F of hepatitis B virus into F1 and F2 subtypes. *World J Gastroenterol* 11, 6295–6304.
164 Norder H, Arauz-Ruiz P, Blitz L *et al.* (2003) The T(1858) variant predisposing to the precore stop mutation correlates with one of two major genotype F hepatitis B virus clades. *J Gen Virol* 84, 2083–2087.
165 Devesa M, Rodriguez C, Leon G *et al.* (2004) Clade analysis and surface antigen polymorphism of hepatitis B virus American genotypes. *J Med Virol* 72, 377–384.
166 Huy TT, Ushijima H, Sata T *et al.* (2006) Genomic characterization of HBV genotype F in Bolivia: genotype F subgenotypes correlate with geographic distribution and T(1858) variant. *Arch Virol* 151, 589–597.
167 Weber B (2005) Recent developments in the diagnosis and monitoring of HBV infection and role of the genetic variability of the S gene. *Expert Rev Mol Diagn* 5, 75–91.

9.1.2.ii Structure, replication and laboratory diagnosis of hepatitis C virus

Ralf Bartenschlager

Introduction

Persistent infection with the hepatitis C virus (HCV) is a major risk factor for the development of chronic liver disease. Although it was already known in the late 1970s that a non-A, non-B hepatitis virus must exist that frequently causes chronic liver disease after blood transfusion, it was not until 1988 that the genome of this virus could be cloned [1]. The availability of the cloned genome allowed the implementation of diagnostic tests to exclude HCV-contaminated blood products, resulting in a rapid and profound decline in the number of new infections [2]. One of the main routes of transmission is the use of HCV-contaminated needles; it is assumed that inadequately sterilized needles used during treatment of schistosomiasis from the 1960s to the 1980s account for the high prevalence of about 30% of HCV infections in Egypt [3].

Based on nucleotide sequence diversity of HCV genomes, six major genotypes and more than 100 subtypes have been defined. Viruses belonging to genotype 1 are distributed throughout the world, whereas other genotypes are primarily restricted to distinct geographical regions [4]. Apart from steatosis, which seems to be linked primarily to genotype 3 virus infections [5], no clear associations can be made between a distinct genotype and pathogenesis. However, sustained viral response rates are clearly associated with the genotype of the infecting virus because success of interferon (IFN)/ribavirin combination therapy with patients infected with genotype 2 and 3 viruses is in the range of 80% but only about 50% in genotype 1 and 4 virus infections [5]. The molecular details underlying this striking correlation are not yet understood, but it argues for viral determinants of IFN-α resistance (see below).

Clinical course of hepatitis C

The course and outcome of HCV infection are very variable [6,7]. In acute hepatitis C, only 30–35% of adults develop symptoms and these are fatal in less than 1%. The average incubation period of acute hepatitis C is about 50 days (Fig. 1). During this period, HCV RNA becomes detectable in serum with virus titres increasing to an average value of about 10^5 genome equivalents per mL (see below). Serum aminotransferase values typically rise 2–4 weeks after the appearance of viral RNA followed by rather non-specific symptoms such as malaise, weakness, nausea, poor appetite or muscle aches. In a fraction of patients, a typical icteric phase follows that may last 4–6 weeks. Concomitant with symptoms, HCV-specific antibodies become detectable and rise in titre during the following weeks. About 30% of patients mount an immune response that is sufficient to clear viral infection, accompanied by a resolution of symptoms. However, the majority of patients with an acute infection, in particular those who are asymptomatic, do not resolve the infection but, rather, develop chronic hepatitis C. In fact, about 75% of infected adults and 55% of infected children acquire a persistent infection. It is characterized by prolonged (usually 6 months and more) detection of viral RNA in the serum and, in about 50% of patients, elevated serum aminotransferases. However, there is significant fluctuation in both parameters, and persistently infected patients may have phases of normal serum aminotransferases and no detectable HCV RNA. Therefore, single time point measurements do not allow discrimination between acute resolved and chronic hepatitis C.

HCV genome organization and functions of the viral proteins

In silico analysis of the first HCV genome sequence revealed a genomic organization that is very similar to that of flaviviruses. Therefore, HCV was grouped in the family Flaviviridae to which the flaviviruses and the pestiviruses belong. These viruses have in common a single-stranded RNA genome of positive polarity

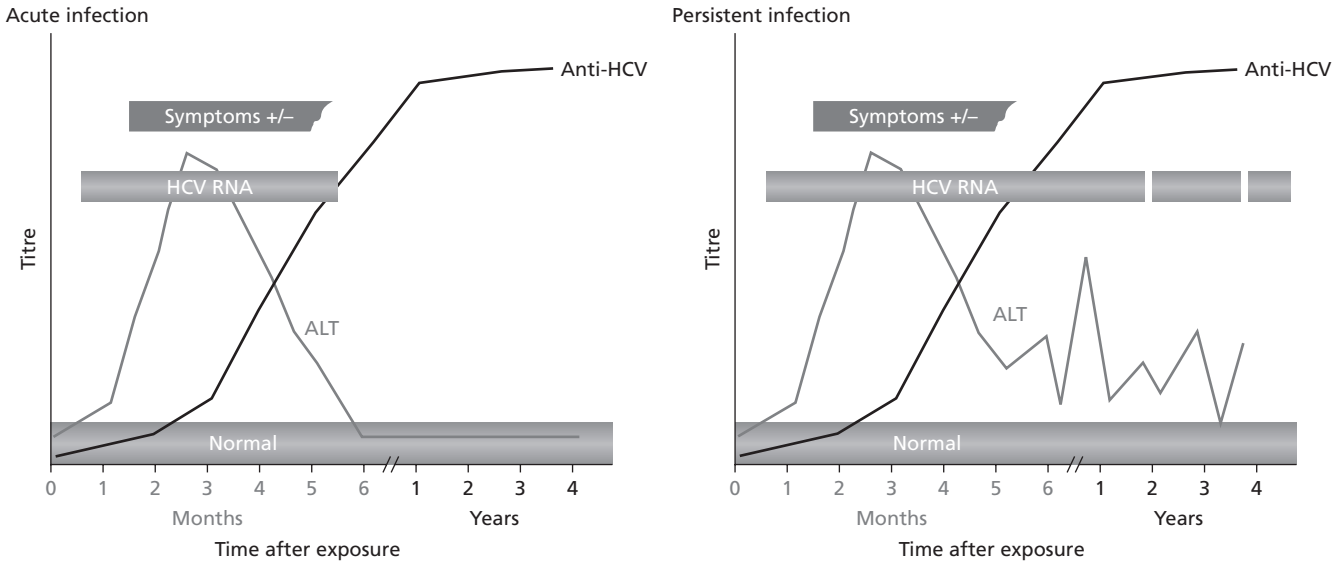

Fig. 1 Serological patterns of acute self-limiting HCV infection (left) or acute HCV infection leading to a persistent state (right). For details, see text. ALT, alanine aminotransferase.

that, in the case of HCV, has a length of about 9600 nucleotides (Fig. 2). It carries one long open reading frame (ORF) that is flanked at both ends by short non-translated regions (NTRs) that are essential for RNA translation and replication (reviewed in [8]). This ORF encodes an ~ 3000-amino-acid-long polyprotein that is cleaved co- and posttranslationally into at least 10 different products to which distinct functions could be ascribed (Fig. 2). The structural core proteins (core, E1 and E2) are the major constituents of the virus particle, and they reside in the amino (N)-terminal region of the polyprotein. p7 is a small hydrophobic protein that may act as a viroporin. It is essential for infectivity *in vivo*, can form oligomeric complexes in lipid membranes and is thought to form an ion channel. It was shown recently that p7 is required for assembly and release of virus particles from infected cells (E. Steinmann, R. Bartenschlager and T. Pietschmann, unpublished). NS2 is a bifunctional molecule. Its largely hydrophobic N-terminal domain that anchors this protein to intracellular membranes is involved in virus formation (N. Appel, T. Pietschmann and R. Bartenschlager, unpublished). In contrast, the NS2 carboxy (C)-terminal domain is part of the NS2/3 protease that is formed by this NS2 domain and the N-terminal NS3 domain. The NS2/3 protease catalyses cleavage at the NS2/3 site (reviewed in [8]). The protease is essential for RNA replication in cell culture and for infectivity *in vivo*. The N-terminal NS3 domain carries a serine-type protease that forms a tight complex with NS4A. The latter acts as a cofactor that, upon binding, activates the enzyme, which mediates cleavage at four sites at least (Fig. 2). The C-terminal NS3 domain binds to RNA and carries a nucleoside triphosphatase and a helicase activity. It is thought to catalyse unwinding of double-stranded (ds) RNA during replication and may also be involved in RNA translation. NS4B is a highly hydrophobic protein that can induce membrane alterations important for the formation of the viral replication complex. The highly phosphorylated NS5A is also crucially involved in RNA replication, but its exact role is not yet defined (reviewed in [9]). NS5A binds to RNA [10,11] and may control the transition from RNA replication to virus assembly. In addition, NS5A appears to be involved in IFN-α resistance [9]. NS5B is the RNA-dependent RNA polymerase (RdRp), which is the core enzyme of the viral RNA amplification machinery. An 11th protein is generated in low amounts by a ribosomal frameshift event or by internal translation initiation [8]. The resulting product(s) designated F or ARF protein(s) is an unstable and barely detectable protein. However, both a humoral and a cellular immune response against this protein was found in a fraction of infected patients, arguing that F/ARF-P is expressed *in vivo*. Its role in the viral life cycle is not known, but it is dispensable for HCV RNA replication in cell culture.

Translation of the HCV genome is mediated by the 5′ NTR which folds into a complex higher order RNA structure [12] (Fig. 2). It serves as an internal ribosome entry site (IRES) that allows translation of the HCV genome in the absence of a 5′ terminal cap structure. The cap is usually added to the 5′ end of cellular mRNAs by enzymes residing in the nucleus; as HCV replicates in the cytoplasm and does not encode the enzymes required for cap formation, its viral genome must be translated by some alternative strategy. Apart from serving as an IRES, the first about 130 nucleotides of the genome are required for RNA replication and most likely serve as a ‘core promoter’ for the synthesis of positive strand RNA [13].

The 3′ end of the HCV genome is also formed by an NTR (Fig. 2). It has a tripartite structure composed of a variable region, a poly U/UC tract and a highly conserved, 98-nucleotide-long

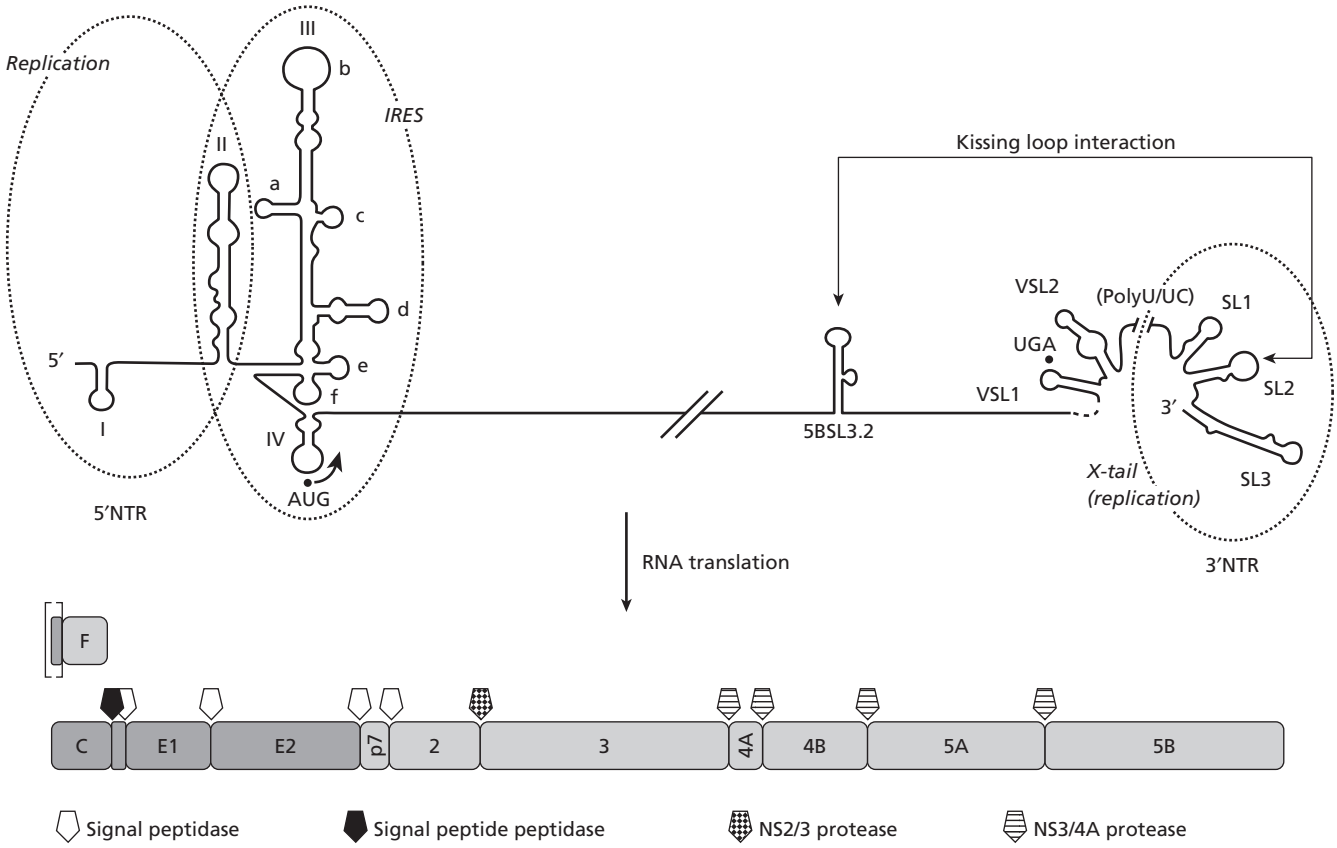

Fig. 2 Organization of the HCV genome and essential *cis*-acting RNA elements. The viral RNA with the secondary structures of the non-translated regions (NTRs) as well as 5BSL3.2 is given at the top. RNA elements in the NTRs required for translation and replication are encircled by dotted lines. The start and stop codons of the polyprotein are indicated by dots. The organization of the polyprotein with the individual cleavage products is drawn below. The F proteins generated by ribosomal frameshifting a few codons downstream of the core gene AUG start codon or by internal translation initiation are drawn above. Proteases responsible for polyprotein cleavage are given at the bottom. SL, stem–loop; VSL, stem–loop in the variable region; IRES, internal ribosome entry site.

sequence designated the X-tail [14,15]. Most of the 3′ NTR is essential for RNA replication and serves as a promoter for the synthesis of negative strand RNA.

A third RNA element that is essential for HCV replication was identified in the 3′ terminal coding region of NS5B [16] (Fig. 2). This element, designated 5BSL3.2, forms a stable stem–loop structure with the top loop sequence forming a basepairing interaction with the top loop region of SL2 in the 3′ NTR [17] (Fig. 2). It was found that 5BSL3.2 binds the NS5B RdRp with some specificity [18]. It is therefore plausible to speculate that, via binding of NS5B to this RNA structure, the polymerase is ‘captured’ and transferred to the 3′ NTR (for which the RNA–RNA interaction between the two stem–loops may be required) in order to initiate synthesis of negative strand viral RNA.

Structure of the virus particle

Owing to limiting amounts of HCV particles in infected tissues and, until very recently, the lack of efficient *in vitro* propagation systems, the molecular composition and structure of the virus particle could not be analysed in detail. Based on analogy with the well-solved structures of the envelope proteins of the flaviviruses, tick-borne encephalitis virus and Dengue virus, and intensive biochemical studies of the HCV glycoproteins, a model was proposed (reviewed in [19]) (Fig. 3). E1 and E2 are tethered to the viral envelope via their hydrophobic transmembrane domains residing in the C-termini of the proteins. The same domains are also required for the formation of heterodimeric E1/E2 complexes that may form higher order oligomers. It is assumed that the ectodomain of E2 (and probably also of E1) lies rather flat on the surface of the envelope that surrounds the nucleocapsid. So far, it remains unclear whether the capsid has a regular symmetry or forms some rather unstructured ribonucleoprotein complex.

By using a novel system that allows the production of infectious HCV particles in cell culture, a first characterization of the virions could be made [20–22] (Fig. 3). HCV particles are spherical with an average diameter of about 55 nm and an inner spherical structure of about 30 nm that may represent the nucleocapsid (Fig. 3). Cell culture-grown HCV particles are rather heterogeneous in density, but the majority of particles sediment to a density of about 1.10 g/mL, which is similar to what was

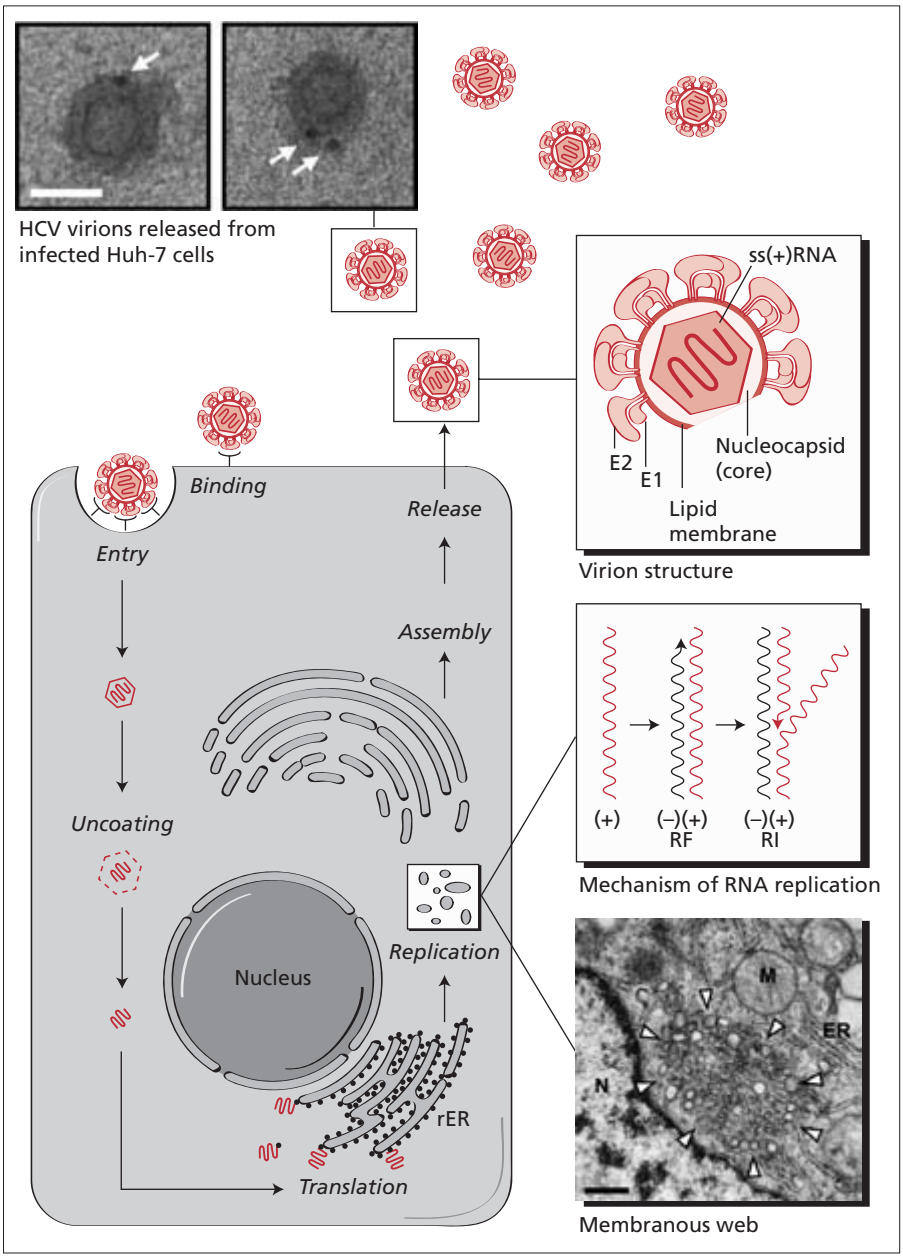

Fig. 3 Schematic diagram of the HCV replication cycle. Virus particles enter the host cell most likely by receptor-mediated endocytosis (binding and entry). The viral genome is liberated from the nucleocapsid (uncoating) and translated at the rough ER. Newly synthesized viral proteins induce the formation of membranous vesicles forming a membranous web, the site of HCV RNA replication (see electron micrograph at lower right; the arrowheads indicate the position of the web; note the close proximity of the web and ER membranes; N, nucleus; ER, endoplasmic reticulum, M, mitochondrium. bar = 500 nm). After genome amplification and further viral protein accumulation, progeny virions are assembled and released. The centre right part of the figure shows a model for the synthesis of negative (–) and positive (+) strand RNA via a replicative form (RF) and a replicative intermediate (RI). The upper right part shows a schematic representation of an HCV particle. The envelope proteins E1 and E2 are drawn according to the structure and orientation of the tick-borne encephalitis virus envelope proteins M and E respectively [46]. The two electron micrographs at the upper left corner of the figure show infectious HCV particles produced in the hepatoma cell line Huh-7 (arrows point to E2-specific immunogold particles; bar = 50 nm) (adapted from ref. 8 with permission from the publisher).

described for HCV in patient and chimpanzee sera. The heterogeneity is probably due to association of the viral particles with host cell components, most notably lipoproteins and antibodies.

The HCV replication cycle

HCV replicates primarily in hepatocytes, but there is convincing evidence that replication also occurs in lymphocytes, at least under laboratory conditions (reviewed in [8]). However, the importance of this extrahepatic reservoir for HCV persistence and success or failure of antiviral therapy is not clear. The recent demonstration of viral RNA in lymphocytes isolated from patients with spontaneous virus clearance or sustained viral response suggests that HCV can persist in lymphatic cells [23,24]. It is questionable whether the residual viral RNA detected in these patients is of clinical and epidemiological relevance, as relapses are very rare in patients with sustained response induced by therapy and the amounts of viral RNA detected in lymphatic cells are very low.

Infection of the host cell starts with HCV binding to one or more cell surface molecules. Candidate receptors are CD81, scavenger receptor BI (SR-BI), low-density lipoprotein receptor and dendritic cell-specific ICAM-3-grabbing non-integrin (DC-SIGN) and L-SIGN (reviewed in [8]) receptors. However, none of these molecules is sufficient on its own to mediate productive infection. It is therefore assumed that some as yet unidentified

molecule expressed preferentially on the surface of hepatocytes is also required for uptake of HCV into the host cell. The virus probably enters the cell by receptor-mediated endocytosis and, upon release of the RNA genome into the cytoplasm, the RNA is translated at the rough endoplasmic reticulum (ER) where processing of the structural proteins occurs (Fig. 3). It is assumed that NS4B, presumably in conjunction with some other viral and cellular protein(s), induces the formation of a distinct membranous compartment within the cytoplasm that has been designated the membranous web [25]. It carries most, if not all, viral proteins and is probably the site of HCV RNA replication. The positive strand RNA genome is amplified via a negative strand copy that may basepair with the positive strand RNA and form a double-stranded intermediate designated the 'replicative form' (RF) (Fig. 3). This RF would serve as a template for the production of excess amounts of positive strand RNA copies that can be used for translation (i.e. polyprotein synthesis), serve as a template for the production of new negative strand RNAs or become encapsidated into viral particles. The exact site of virus assembly and the underlying mechanisms are not known, but it is assumed that virus particles are formed at or in close proximity to the ER or ER-derived membranes. Interestingly, within a transfected or infected cell, the majority of the HCV core protein is associated with lipid droplets, raising the possibility that they play an important role in particle formation.

Recent achievements in cell-based HCV replication systems

With the availability of the first molecularly cloned HCV genome, initial progress was rapid and led to the elucidation of the viral genome structure and the characterization of several HCV proteins, most notably those enzymes that are prime targets for selective therapy (NS3 protease, NS3 helicase and NS5B RdRp). However, attempts to propagate HCV in cultured cells were of limited success and only in the past few years could this hurdle be overcome in a step-by-step process (reviewed in [26]). The first important achievement was the development of the HCV replicon system [27]. It is based on the self-replication of genetically engineered HCV 'minivariants' in which the region encoding core to NS2 is replaced by a selectable marker and a heterologous IRES (Fig. 4a). Synthetic RNAs produced from the cloned replicons were transfected into cells of the human hepatoma cell line Huh-7 and, after appropriate selection of the cells

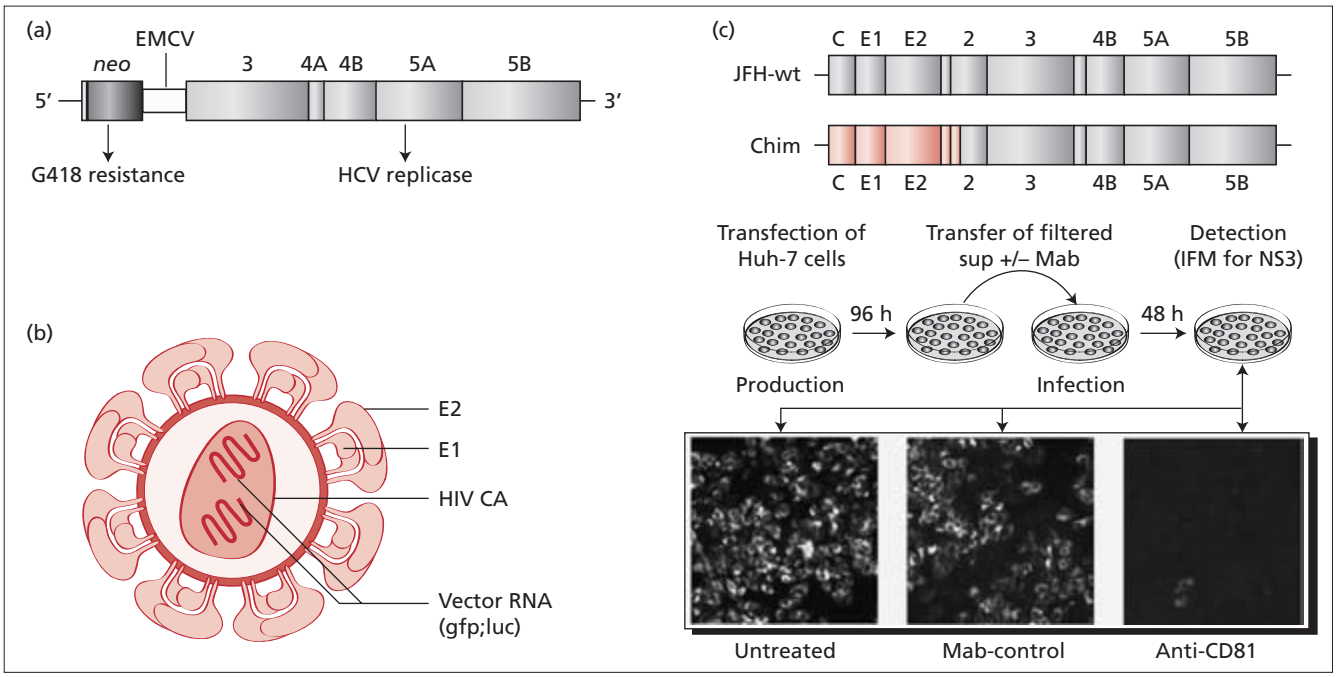

Fig. 4 Model systems for the study of HCV replication in cell culture. (a) Design of a selectable subgenomic HCV replicon carrying the selectable marker *neo* that confers resistance to the cytotoxic drug G418. The *neo* gene is translated via the HCV IRES, whereas the HCV replication factors NS3 to NS5B are translated from the EMCV IRES. (b) Structure of an HCVpp that is composed of a lipid envelope carrying the E1–E2 glycoprotein complexes, the HIV nucleocapsid (CA) and two copies of the HIV vector RNA, into which a marker gene has been inserted (most often the green fluorescent protein (gfp) or the luciferase (luc) gene). (c) Production of infectious HCV in cell culture. Huh-7 cells are transfected with genomic HCV RNA obtained by *in vitro* transcription from the cloned JFH-1 genome (top) or a JFH-1 chimera in which the region from core up to the N-terminus of NS2 (indicated by red) stems from another isolate of the same or a different genotype. Four days later, culture supernatant is harvested and used to inoculate naive Huh-7 cells. Forty-eight hours after inoculation, cells are analysed for infection using a NS3-specific immunofluorescence assay (bottom). Infection was performed directly with supernatant (left) or with supernatant containing either a CD81-specific antibody or a control antibody (right and centre respectively). Infection can be neutralized by CD81-specific antibodies, demonstrating that CD81 plays an important role in infection by HCV. Mab, monoclonal antibody.

(e.g. with G418 in the case of replicons carrying the *neo* gene), drug-resistant colonies were obtained that contained high amounts of self-replicating HCV RNAs. Subsequent studies confirmed and extended this observation, and it was found that the high level of HCV RNA replication in this system is due to cell culture adaptive mutations and the selection for cells that are highly permissive for HCV RNA replication (reviewed in [26]). The replicon system is in wide use nowadays both for basic research and for the development of antiviral compounds.

The next important achievement was the HCV pseudoparticle (pp) system [28,29]. HCVpps are composed of retroviral nucleocapsids (e.g. derived from HIV) that are surrounded by a lipid envelope into which native HCV glycoproteins are embedded (Fig. 4b). As infection [binding to the receptor(s), uptake into the cell and uncoating] is orchestrated primarily by the envelope glycoproteins, HCVpps are an ideal tool for the study of the early steps in the HCV replication cycle. In addition, they are also an important tool for characterizing the neutralizing capacity of antibodies directed against the HCV glycoproteins or cell surface molecules assumed to be required for infection. In fact, it was shown that antibodies directed against CD81, SR-B1 and LDL receptor interfere with infection by HCVpps, arguing that these cell surface molecules are critical for infection (reviewed in [8]). Moreover, it was shown that sera from hepatitis C patients contain (partially) neutralizing and even cross-neutralizing antibodies. However, the role of these antibodies in controlling an HCV infection is not clear.

Very recently, the first system for the production of infectious HCV in cell culture was established [20–22] (Fig. 4c). It is based on a distinct HCV genotype 2a isolate (designated JFH-1 because it was isolated from a Japanese patient with fulminant hepatitis) that, for unknown reasons, replicates to an unprecedentedly high level in Huh-7 cells and does not require cell culture adaptive mutations [30]. Upon transfection of these cells with RNA derived from the cloned JFH-1 genome, virus particles are released that are infectious for naive Huh-7 cells as well as for chimpanzees [20]. The latter observation confirms that cell culture-grown JFH-1 particles are authentic. Infectivity could be neutralized by CD81-specific antisera, antibodies against E2 and immunoglobulins isolated from chronically infected hepatitis C patients [20–22].

Apart from using the authentic JFH-1 genome, virus production could also be achieved using chimeric genomes in which the region from core to NS2 of JFH-1 is replaced by the analogous region from isolates of the same [21] or even a different genotype [31] (Fig. 4c). The production of such chimeras will greatly expand our arsenal of tools for studying the early steps of the viral life cycle, evaluating neutralizing and cross-neutralizing antibodies on a broad scale and developing compounds that interfere with the entry of most HCV genotypes into host cells.

HCV and innate immunity

Given the clear correlation between sustained viral response after IFN-α/ribavirin combination therapy and the genotype of the infecting HCV, it was assumed that viral factors contribute to IFN resistance. Based on comparative sequence analyses of HCV genomes isolated from IFN-α responders and non-responders as well as several biochemical and cell-based assays, the two viral proteins NS5A and E2 were identified as potential antagonists of the IFN-induced dsRNA-activated protein kinase PKR (reviewed in [32]). However, the results obtained in several follow-up studies were controversial, and it is still unclear whether and to what extent these viral factors contribute to IFN-α resistance.

Apart from a direct inhibition of a distinct effector molecule contributing to the IFN-induced antiviral state, there is increasing evidence that HCV interferes with signal transduction. One pathway that may be targeted by the HCV core protein is the Jak-STAT signalling pathway responsible for relaying the signal from the IFN-α receptor to the transcriptional activation of IFN-α-induced genes (reviewed in [8]).

The key player in blocking the induction of the early innate antiviral defence appears to be the NS3/4A protease that can interfere with the dsRNA-induced activation of IFN regulatory factor 3 (IRF-3) [33]. Within a cell, dsRNA is perceived by at least three different molecules: Toll-like receptor 3 (TLR3) and the RNA helicases retinoic acid-inducible gene I (RIG-I) and mda5 (also called Helicard) (reviewed in [34]). Upon activation by dsRNA binding, these molecules recruit adapter proteins, which are TRIF (also called TICAM-1) in the case of TLR3, and Cardif (also called IPS-1, MAVS or VISA) in the case of RIG-I. These adapter molecules relay their activation signal via induction of a kinase complex and phosphorylation of IRF-3, resulting in the transcriptional activation of IFN-β [34]. It was shown that both TRIF and Cardif can be cleaved by the NS3/4A protease, at least under various experimental conditions [35,36]. Although final proof for *in vivo* relevance is not yet available, Cardif is also cleaved by the NS3/4A protease in HCV-infected Huh-7 cells [35], suggesting that interference at least with the RIG-I pathway also occurs *in vivo*. This interference may contribute to the establishment of a persistent HCV infection.

HCV and adaptive immunity

As can be inferred from the high rate of persistent infections, HCV not only escapes innate immunity but also has the means to undermine adaptive immunity without globally affecting immune response to other infectious agents. It is generally accepted that the vigour and the breadth of the immune response mounted upon HCV infection determine the outcome of infection (reviewed in [37]). Therefore, a successful immune response targets multiple major histocompatibility complex (MHC) class I-restricted epitopes in the HCV polyprotein and induces rather large numbers of HCV-specific CD8+ T cells. In addition, a strong CD8+ T-cell response is usually accompanied by a strong and multispecific CD4+ T-cell proliferative response, and permanent loss of this response is a strong predictor of

persistence [38,39]. Resolved infections usually leave a durable memory response, lowering the chance of persistence upon reinfection [40]. This appears to be brought about mainly by CD4+ T cells [41].

Given the high frequency of persistence, in most cases T-cell responses either are rather poor or decline rapidly after an initially strong response. The underlying reasons are not well understood, but it should be kept in mind that HCV infection does not lead to a general immune suppression as is the case, for example, with HIV but, rather, induces a defect in cellular immunity that is HCV specific. It is assumed that an HCV-specific loss of T-cell help is the key event by which the virus escapes adaptive immunity [41]. One could imagine that the interference of HCV with the innate immunity (e.g. TLR3, RIG-I) results in a series of consecutive events that lead to CD4+ T-cell impairment. As T-cell help is important for CD8+ T cells, the degree of helper cell impairment would be a critical determinant of virus elimination or persistence. A weak T-cell response would also facilitate the emergence of T-cell escape variants in HCV epitopes and may lead to functional impairment (anergy) of CD8+ T cells.

Thus far, it is uncertain to what extent B-cell responses contribute to viral clearance. On the one hand, immune escape mutants in B-cell epitopes have been described, arguing that HCV adapts to immune selection pressure exerted by antibodies. On the other hand, antibodies developed during self-limited infection do not prevent reinfection, indicating that they are of limited efficacy. Moreover, HCV infection can be terminated in the absence of antibodies [42]. It is therefore assumed that T-cell immunity is the primary determinant in controlling HCV infection.

Laboratory diagnosis

Two types of laboratory tests are used for detection and monitoring of HCV infection: virological assays measuring viral components (RNA and core protein) and serological assays measuring HCV-specific antibodies (Fig. 1). First-generation assays developed for the detection of HCV-contaminated blood and blood products were based on an antibody-specific enzyme-linked immunosorbent assay (ELISA) using a recombinant HCV antigen derived from the NS3 to 4B coding region [2]. Later on, this assay was steadily improved by the inclusion of antigens derived from core and NS5. Current ELISAs have a specificity of more than 99%, and they are positive in more than 99% of immunocompetent patients with detectable HCV RNA [43]. However, antibody detection is problematic in immunocompromised and haemodialysis patients. RNA testing has therefore been recommended because of potentially false-negative antibody diagnosis in these individuals.

Anti-HCV antibodies can be detected in serum 2–4 months after infection, but seroconversion may take up to 6 months (Fig. 1). Given this large serological window (time from infection until the development of detectable antibodies), assays to detect anti-HCV IgM have been developed, but they do not narrow down the serological window significantly. Therefore, nucleic acid-based testing is used. To exclude false-positive ELISA results, confirmatory assays have been developed. The most commonly used is the recombinant immunoblot assay RIBA (Chiron Corporation, Emeryville, CA, USA), in which several recombinant peptide antigens are immobilized on a strip that is probed with a patient serum. This assay allows the detection of antibodies directed against individual HCV antigens.

Qualitative assays for RNA detection are based on target amplification using polymerase chain reaction (PCR) or transcription-mediated amplification (TMA) (reviewed in [44]). Two commercial kits are available: first, the PCR-based assay which has a detection cutoff of 50 international units (IU) of HCV RNA/mL (based on the HCV RNA IU as defined by WHO for standardization of HCV RNA quantification units); second, the TMA-based assay that is slightly more sensitive (~ 10 IU of HCV RNA/mL). Both assays have a specificity of about 99% and, because of their high sensitivity, are the gold standards for the detection of HCV. Qualitative RNA detection assays have been implemented in blood banks of, for example, the EU and the US in order to reduce the risk of transfusion-associated hepatitis C that arises as a result of the long serological window. Because of this rigorous screening, the risk of HCV transmission by this route has been reduced to less than 1 in 1 million blood donations.

Quantitative HCV RNA assays are based on branched (b)DNA technology, competitive reverse transcription (RT)-PCR or real-time RT-PCR. The broadest dynamic range of quantification is achieved with the last, which can cover a range from 30 to 2×10^8 IU/mL (Cobas TaqMan 48 HCV; Roche Molecular Systems, USA). The specificity of these assays is up to 99%, and they allow quantification of viral load independent of the genotype of the virus. The advantage of the bDNA assay is that no amplification of the target sequence is required, which reduces the risk of false-positive results, e.g. resulting from contamination, and false-negative results, e.g. on account of polymerase inhibitors present in the patient sample. The disadvantage of bDNA over RT-PCR-based methods is its lower sensitivity.

An alternative to qualitative and quantitative RNA detection methods is the detection of viral antigens, which is technically less challenging and less demanding for the instrumentation of the diagnostic laboratory. A core antigen-specific ELISA has been developed (Ortho-Clinical Diagnostics, USA), and it was shown that the core antigen titre correlates well with the HCV RNA level [45]. Core titres can therefore be used as a marker for viral RNA replication. However, given the lower sensitivity of this antigen ELISA compared with RNA detection methods, its clinical use is somewhat limited.

Determination of the genotype of the infecting virus is an important parameter for the design of antiviral combination therapy. Several commercial assays for genotyping are available that, with one exception (Murex HCV serotyping 1–6 assay; Murex Diagnostics, UK), are based on analysing viral RNA. One

assay uses hybridization of amplicons with genotype-specific oligonucleotides immobilized on strips and colorimetric detection (InnoLIPA or Versant genotyping assay; Innogenetics, Belgium). Other assays are based on direct sequence analysis of amplicons derived from the 5′ NTR and subsequent alignment with an HCV genotype sequence database (Truegene HCV 5′ NC genotyping kit; Bayer, USA). Finally, a genotyping system based on multiple real-time PCR amplifications of the 5′ NTR and part of the NS5B coding region using genotype-specific primers is commercially available (HCV Geno ASR; Abbott, USA). All assays can discriminate between the six major genotypes but not, or only insufficiently, differentiate between subtypes. This is, however, not of clinical relevance, because decisions for therapy are based on genotypes and not subtypes.

References

1 Choo QL, Kuo G, Weiner AJ *et al.* (1989) Isolation of a cDNA clone derived from a blood-borne non-A, non-B viral hepatitis genome. *Science* 244, 359–362.

2 Kuo G, Choo QL, Alter HJ *et al.* (1989) An assay for circulating antibodies to a major etiologic virus of human non-A, non-B hepatitis. *Science* 244, 362–364.

3 Rao MR, Naficy AB, Darwish MA *et al.* (2002) Further evidence for association of hepatitis C infection with parenteral schistosomiasis treatment in Egypt. *BMC Infect Dis* 2, 29.

4 Simmonds P (1998) Variability of the hepatitis C virus genome. *Curr Stud Haematol Blood Transfus* 62, 38–63.

5 Pawlotsky JM (2003) Hepatitis C virus genetic variability: pathogenic and clinical implications. *Clin Liver Dis* 7, 45–66.

6 Hoofnagle JH (1997) Hepatitis C: the clinical spectrum of disease. *Hepatology* 26, 15S–20S.

7 Seeff LB (2002) Natural history of chronic hepatitis C. *Hepatology* 36, S35–S46.

8 Bartenschlager R, Frese M, Pietschmann T (2004) Novel insights into hepatitis C virus replication and persistence. *Adv Virus Res* 63, 71–180.

9 Macdonald A, Harris M (2004) Hepatitis C virus NS5A: tales of a promiscuous protein. *J Gen Virol* 85, 2485–2502.

10 Tellinghuisen TL, Marcotrigiano J, Rice CM (2005) Structure of the zinc-binding domain of an essential component of the hepatitis C virus replicase. *Nature* 435, 374–379.

11 Huang L, Hwang J, Sharma SD *et al.* (2005) Hepatitis C virus nonstructural protein 5A (NS5A) is a RNA-binding protein. *J Biol Chem*. 280, 36417–36428.

12 Honda M, Beard MR, Ping LH *et al.* (1999) A phylogenetically conserved stem–loop structure at the 5′ border of the internal ribosome entry site of hepatitis C virus is required for cap-independent viral translation. *J Virol* 73, 1165–1174.

13 Friebe P, Lohmann V, Krieger N *et al.* (2001) Sequences in the 5′ nontranslated region of hepatitis C virus required for RNA replication. *J Virol* 75, 12047–12057.

14 Kolykhalov AA, Feinstone SM, Rice CM (1996) Identification of a highly conserved sequence element at the 3′ terminus of hepatitis C virus genome RNA. *J Virol* 70, 3363–3371.

15 Tanaka T, Kato N, Cho MJ *et al.* (1995) A novel sequence found at the 3′ terminus of hepatitis C virus genome. *Biochem Biophys Res Commun* 215, 744–749.

16 You S, Stump DD, Branch AD *et al.* (2004) A cis-acting replication element in the sequence encoding the NS5B RNA-dependent RNA polymerase is required for hepatitis C virus RNA replication. *J Virol* 78, 1352–1366.

17 Friebe P, Boudet J, Simorre JP *et al.* (2005) Kissing-loop interaction in the 3′ end of the hepatitis C virus genome essential for RNA replication. *J Virol* 79, 380–392.

18 Lee H, Shin H, Wimmer E *et al.* (2004) Cis-acting RNA signals in the NS5B C-terminal coding sequence of the hepatitis C virus genome. *J Virol* 78, 10865–10877.

19 Dubuisson J (2000) Folding, assembly and subcellular localization of hepatitis C virus glycoproteins. *Curr Topics Microbiol Immunol* 242, 135–148.

20 Wakita T, Pietschmann T, Kato T *et al.* (2005) Production of infectious hepatitis C virus in tissue culture from a cloned viral genome. *Nature Med* 11, 791–796.

21 Lindenbach BD, Evans MJ, Syder AJ *et al.* (2005) Complete replication of hepatitis C virus in cell culture. *Science* 309, 623–626.

22 Zhong J, Gastaminza P, Cheng G *et al.* (2005) Robust hepatitis C virus infection in vitro. *Proc Natl Acad Sci USA* 102, 9294–9299.

23 Pham TN, MacParland SA, Mulrooney PM *et al.* (2004) Hepatitis C virus persistence after spontaneous or treatment-induced resolution of hepatitis C. *J Virol* 78, 5867–5874.

24 Pham TN, MacParland SA, Coffin CS *et al.* (2005) Mitogen-induced upregulation of hepatitis C virus expression in human lymphoid cells. *J Gen Virol* 86, 657–666.

25 Gosert R, Egger D, Lohmann V *et al.* (2003) Identification of the hepatitis C virus RNA replication complex in huh-7 cells harboring subgenomic replicons. *J Virol* 77, 5487–5492.

26 Bartenschlager R, Kaul A, Sparacio S (2003) Replication of the hepatitis C virus in cell culture. *Antiviral Res* 60, 91–102.

27 Lohmann V, Körner F, Koch JO *et al.* (1999) Replication of subgenomic hepatitis C virus RNAs in a hepatoma cell line. *Science* 285, 110–113.

28 Bartosch B, Dubuisson J, Cosset FL (2003) Infectious hepatitis C virus pseudo-particles containing functional E1-E2 envelope protein complexes. *J Exp Med* 197, 633–642.

29 Hsu M, Zhang J, Flint M *et al.* (2003) Hepatitis C virus glycoproteins mediate pH-dependent cell entry of pseudotyped retroviral particles. *Proc Natl Acad Sci USA* 100, 7271–7276.

30 Kato T, Date T, Miyamoto M *et al.* (2003) Efficient replication of the genotype 2a hepatitis C virus subgenomic replicon. *Gastroenterology* 125, 1808–1817.

31 Pietschmann T, Kaul A, Koutsoudakis G *et al.* (2006) Construction and characterization of infectious intragenotypic and intergenotypic hepatitis C virus chimeras. *Proc Natl Acad Sci USA* 103, 7408–7413. Epub 1 May 2006.

32 Tan S-L, Katze MG (2001) How hepatitis C virus counteracts the interferon response: the jury is still out on NS5A. *Virology* 284, 1–12.

33 Foy E, Li K, Wang C *et al.* (2003) Regulation of interferon regulatory factor-3 by the hepatitis C virus serine protease. *Science* 300, 1145–1148.

34 Haller O, Kochs G, Weber F (2005) The interferon response circuit: induction and suppression by pathogenic viruses. *Virology*, 344, 119–130.

35 Meylan E, Curran J, Hofmann K *et al.* (2005) Cardif is an adaptor protein in the RIG-I antiviral pathway and is targeted by hepatitis C virus. *Nature* 437, 1167–1172

36 Li K, Foy E, Ferreon JC *et al.* (2005) Immune evasion by hepatitis C virus NS3/4A protease-mediated cleavage of the Toll-like receptor 3 adaptor protein TRIF. *Proc Natl Acad Sci USA* 102, 2992–2997.
37 Bowen DG, Walker CM (2005) Adaptive immune responses in acute and chronic hepatitis C virus infection. *Nature* 436, 946–952.
38 Diepolder HM, Zachoval R, Hoffmann RM *et al.* (1995) Possible mechanism involving T-lymphocyte response to non-structural protein 3 in viral clearance in acute hepatitis C virus infection. *Lancet* 346, 1006–1007.
39 Gerlach JT, Diepolder HM, Jung MC *et al.* (1999) Recurrence of hepatitis C virus after loss of virus-specific CD4(+) T-cell response in acute hepatitis C. *Gastroenterology* 117, 933–941.
40 Mehta SH, Cox A, Hoover DR *et al.* (2002) Protection against persistence of hepatitis C. *Lancet* 359, 1478–1483.
41 Grakoui A, Shoukry NH, Woollard DJ *et al.* (2003) HCV persistence and immune evasion in the absence of memory T cell help. *Science* 302, 659–662.
42 Post JJ, Pan Y, Freeman AJ *et al.* (2004) Clearance of hepatitis C viremia associated with cellular immunity in the absence of seroconversion in the hepatitis C incidence and transmission in prisons study cohort. *J Infect Dis* 189, 1846–1855.
43 Colin C, Lanoir D, Touzet S *et al.* (2001) Sensitivity and specificity of third-generation hepatitis C virus antibody detection assays: an analysis of the literature. *J Viral Hepatol* 8, 87–95.
44 Pawlotsky JM (2002) Molecular diagnosis of viral hepatitis. *Gastroenterology* 122, 1554–1568.
45 Bouvier-Alias M, Patel K, Dahari H *et al.* (2002) Clinical utility of total HCV core antigen quantification: a new indirect marker of HCV replication. *Hepatology* 36, 211–218.
46 Yagnik AT, Lahm A, Meola A *et al.* (2000) A model for the hepatitis C virus envelope glycoprotein E2. *Proteins* 40, 355–366.

9.1.2.iii Hepatitis A

Loriana Di Giammarino and Jules L. Dienstag

Definition and virology

Hepatitis A is an acute, self-limited, necroinflammatory disease of the liver resulting from infection with the enterically transmitted hepatitis A virus (HAV). HAV is a positive-stranded, non-enveloped, icosahedral, 27-nm RNA virus [1] now classified as a hepatovirus within the picornavirus family [2]. Unusually resistant to heat, ether and acid, HAV has an RNA genome of approximately 7500 nucleotides, the protein product of which is cleaved posttranslationally to yield three protein precursors of four capsid viral polypeptides, VP1–VP4. Non-structural proteins include a viral polymerase and proteases. Although genomic heterogeneity of up to 25% exists among virus strains, and although at least seven genotypes have been identified, all isolates appear to be immunologically indistinguishable, i.e. only a single serotype exists [3]. Unlike most of the human hepatitis viruses, HAV can be cultivated in cell culture [4]; however, most strains replicate slowly and, unlike many picornaviruses, HAV is not cytopathic in culture [5]. The entire genome has been cloned and characterized [6,7].

Although HAV can be detected in stools within 10 days to 2 weeks after infection, the clinical incubation period, measured to the onset of symptoms, is approximately 4 (range 2–6) weeks. During the late incubation period (10–14 days before the onset of clinically apparent illness), the virus is excreted in the stool, but faecal excretion wanes rapidly and rarely lasts beyond the first few days of clinical or subclinical illness [8]; viraemia is very limited, detectable for a few days towards the end of the incubation period. The consensus is that HAV replication is limited to the liver; from the liver, the virus is excreted through the bile into the intestine and shed in the stool.

Although HAV can be detected in the liver for weeks, and although circulating HAV antigen can be detected in serum by sensitive immunoassays for longer than a week after the onset of clinical illness, infectivity does not extend beyond the first few days of illness (except when it recurs in 'relapsing' cases – see below). A potential exception to such brief faecal shedding of HAV has been reported in a neonatal intensive care unit, in which neonates with hepatitis A were infectious, presumably shedding faecal virus, for 6 months [9]. Faecal shedding of HAV persisting for months has also been documented in patients undergoing liver transplantation for fulminant hepatitis A [10]. Protracted hepatitis A and faecal shedding have not been documented in immunocompetent persons.

The primary antibody response to HAV, which is of the immunoglobulin (Ig)M class (IgM anti-HAV), lasts only a few months and is replaced ultimately by anti-HAV of the IgG class (IgG anti-HAV). After infection with HAV, IgG antibody remains detectable indefinitely and correlates with lasting immunity.

History

The illness we categorize today as hepatitis A was probably recognized during antiquity, but its link to viral infection was not established until the 1940s [11]. Epidemiological and volunteer studies during and after the Second World War differentiated between 'infectious hepatitis' and 'serum hepatitis' [12] and established that infectious hepatitis was caused by a filterable agent, presumably a virus, that had a short incubation period and was spread predominantly by the faecal–oral route.

Volunteer studies were continued in the 1950s and 1960s [13,14] and were supplemented by studies suggesting successful transmission of a viral agent in marmoset monkeys (tamarins) [15,16]. Ultimately, clinical specimens generated in volunteer and experimental animal studies provided the reagents that were used to identify HAV.

In 1973, investigators at the National Institutes of Health, using immune electron microscopy, found 27-nm virus-like particles that were aggregated by convalescent but not by pre-infection serum in the stools of volunteers infected with HAV [1]. This discovery was followed rapidly by the development of serological tests, confirmation of the marmoset model and

Table 1 Epidemiology of hepatitis A virus.

Transmission in nature almost exclusively by the faecal–oral route
Percutaneous transmission very rare
Perinatal transmission unlikely
Endemic in developing countries (where infection is predominant in childhood)
Declining in developed countries
Mean age of exposure increasing
Frequency of clinically apparent disease increasing

establishment of the chimpanzee as an experimental model, the cultivation of HAV *in vitro* in 1979 [4] and the cloning [17] and sequencing [18,19] of the viral genome [20].

Epidemiology (Table 1)

Mode of transmission

Hepatitis A virus is transmitted in nature almost exclusively by the faecal–oral route. Although viraemia occurs, it is transient and does not contribute to transmission of HAV infection except in very unusual circumstances. As an enteric agent, hepatitis A is spread from person to person or is acquired when a susceptible person ingests food, water, milk, bivalve shellfish, etc. that has been contaminated with faecal material from an infected person, occasionally in the context of a food-borne outbreak traced to a foodhandler. Indeed, a massive shellfish-associated outbreak, involving more than 310 000 persons, occurred in Shanghai in 1988 [21].

Most recently, in 2003, HAV-contaminated green onions, imported from Mexico to a Pennsylvania restaurant, were the source of the largest outbreak of food-borne hepatitis A ever reported in the United States, involving at least 600 persons [22]; this report is an example of a series of recent food-borne outbreaks linked to ingestion in developed countries (where immunity is limited) of produce contaminated during harvest in developing countries (where water supplies are often contaminated with enteric agents).

Poor personal and environmental hygiene foster the spread of enteric agents such as HAV; both sporadic cases and outbreaks are common, and efficient intrafamilial spread accounts for secondary cases within the household of an infected person. Because infectivity peaks during the late incubation period, the risk of transmission is highest for those in contact with a patient just before clinically apparent illness, rather than for those exposed to the patient during or after the onset of clinical illness. Because HAV does not cause chronic infection and is not associated with a carrier state, perpetuation of infection within populations relies upon person-to-person transmission or environmental contamination; certainly, HAV has been shown to remain stable in the environment for many months [23]. In temperate climates, hepatitis A tended to occur in seasonal waves, concentrated in the late autumn and early winter, and in epidemic waves cycling every 5–20 years, relying on the emergence of new susceptible populations; however, in developed countries, the frequency of hepatitis A declined regularly during the second half of the twentieth century, and these seasonal and generational cycles are not as apparent. Unexpected outbreaks, however, continue to emerge in developed countries, as noted above, fostered by a global economy in which food items that cannot be heat inactivated are imported from HAV-endemic countries [24].

Groups traditionally recognized as being at high risk of HAV infection include travellers from non-endemic to endemic areas, whose risk has been estimated to be three cases per 1000 travellers per month [25]; military personnel stationed in endemic areas; persons working with non-human primates; children, employees and parents of children in daycare centres; and clients and employees of institutions for the developmentally disabled [26,27]. Persons who work as foodhandlers are not considered to be at increased risk of occupationally acquired hepatitis A [28], despite the key role that they may have played in the recent outbreaks associated with food [29,30]. In daycare centres, hepatitis A in the children is so mild that clinical recognition is rare; outbreaks become apparent when adults exposed to the children, daycare centre employees and parents become clinically ill [31]. Although the role of sexual transmission is not known, men who have sex with men have an increased risk of HAV infection [32], probably through faecal exposure. Similarly, injection drug users have been found to have an increased risk of HAV infection, not as a result of percutaneous exposure to contaminated needles but rather related to poor hygiene. Outbreaks have been reported in the past among staff of neonatal intensive care units, presumably infected by exposure to faecal material from infected neonates [9], and among recipients of clotting factors [33]. An outbreak of hepatitis A in oncology patients treated with interleukin-2 and lymphokine-activated killer (LAK) cells was attributed to contaminated plasma used to dilute the LAK cells [34]. Such rare cases in blood-product recipients notwithstanding, hepatitis A is rarely transmitted by transfusion. Hepatitis A is rarely, if ever, transmitted perinatally from mother to offspring, one case report [35] notwithstanding, and health workers do not have a higher prevalence of infection than that of the general population [36].

Distribution within populations

In the United States and other developed countries, HAV accounts for approximately a quarter of all reported cases of acute viral hepatitis. Indeed, in the United States, approximately 26 000 cases of acute hepatitis A were reported annually to the Centers for Disease Control and Prevention during the 1980s and 1990s. After adjusting for under-reporting and asymptomatic cases, the number of new cases per year during those decades was estimated to be in excess of 270 000 [37]. During the last 10 years, however, the rate of hepatitis A declined substantially and, in 2003, the annual frequency of hepatitis A in

the United States fell to the lowest ever recorded, 2.7 cases per 100 000 persons [38]. Exposure is inversely proportional to socioeconomic status, and seroprevalence surveys show an increase in anti-HAV frequencies with advancing age. The most compelling trend in the prevalence of HAV infection (reflected by anti-HAV frequencies) has been the regular decline in the frequency of infection in developed countries. When populations in the United States, western Europe and Australia are evaluated at intervals a decade apart, overall prevalences and age-specific prevalences have been documented to fall with each progressive decade.

In the United States, the most recent survey (Third National Health and Nutrition Examination Survey, NHANES-III, conducted between 1988 and 1994) revealed an anti-HAV prevalence of 33% [28], which is 5% lower than the 38% prevalence detected during the 1976–1980 NHANES-II survey [39] and 12% lower than the 45% prevalence reported in a serological survey of New York blood donors in 1976 [40]. In Europe, a north-to-south gradient exists in relative endemicity of hepatitis A, from negligible in northern Scandinavian countries to more common in southern Mediterranean countries.

In the United States, the frequency of acute hepatitis A was higher in western states as well as in certain populations, including Alaskan natives and native Americans [28]; however, following the 1999 recommendations for childhood vaccination, the frequency of hepatitis A declined steadily in these regions/populations to levels approximately equal to those in other regions and the general population of the US. An increasing proportion of cases now occur among high-risk populations. For example, the number of cases among men who have sex with men has increased from 1.5% in 1992 to 8.4% in 2002. Similarly, the proportion of hepatitis A cases attributed to travel rose from 1.3% (1992) to 9.4% (2002) [27].

Hepatitis A is primarily an infection of childhood, but the mean age of exposure increases with improvement in the levels of hygiene and sanitation. Thus, in developing countries, where HAV is endemic, e.g. Africa, Central and South America, Central Asia, Southeast Asia and Mediterranean countries, childhood exposure to HAV is almost universal, and almost all infections, and consequently immunity, are acquired by the age of 10 years. In highly developed countries, the overall prevalence of anti-HAV in the general population may be lower than 20% and the age of acquisition higher.

As infections in childhood decline, a population of adults emerges that, having escaped HAV infection in childhood, remains susceptible into adulthood. As this susceptible population matures into adulthood and becomes sufficiently affluent to travel, imported cases of acute hepatitis A begin to emerge in non-endemic areas.

Moreover, as infection with HAV becomes less frequent in a population, and as cases are shifted from younger to older segments of the population, a shift also occurs in clinical presentation. Because infections in young children tend to be subclinical (< 30% jaundiced), whereas infections in adults tend to be clinically apparent and even severe (> 70% jaundiced), paradoxically, as the frequency of hepatitis A infections decreases in a population, the occurrence of clinically apparent and severe cases increases [41,42]. Therefore, in developed countries, cases of acute hepatitis A sufficiently severe to require hospitalization, even fulminant cases, are more common today than they were several decades ago.

Table 2 Clinical features of HAV infection.

An acute, self-limited illness, with modest morbidity and negligible mortality
Incubation period 2–6 weeks, with a mean of 4 weeks
Occasional variants include cholestatic and relapsing hepatitis
Clinical severity and the likelihood of jaundice increase with age
Fatality rate (fulminant hepatitis) < 1/1000
No long-term sequelae, no chronic hepatitis A, no chronic carrier state

Clinical and laboratory features

Clinical features (Table 2)

Infection with HAV may be asymptomatic or may result in acute hepatitis of variable severity, including fulminant hepatitis. Although the severity and duration of acute hepatitis A may vary, hepatitis A does not cause chronic hepatitis, and no hepatitis A carrier state exists.

The symptoms and signs of acute hepatitis A are similar to those for the other types of viral hepatitis. After a clinical incubation period of approximately 4 weeks (range 2–6 weeks), patients may experience prodromal, non-specific, systemic symptoms, such as fatigue, malaise, headache, low-grade fever, myalgias, arthralgias, nausea and vomiting, loss of appetite, alteration in gustatory and olfactory senses and weight loss. Hepatitis-specific symptoms, such as right upper quadrant pain, dark urine, jaundice and acholic stools, occur later, as the clinical illness peaks. When jaundice is severe, pruritus may occur. Physical examination usually reveals mildly tender hepatomegaly and, in icteric cases, scleral icterus and jaundice. Signs of chronic liver disease, such as spider angiomata and splenomegaly, are rare but can be seen transiently.

Except in fulminant cases, which are very rare (in the order of 1:1000 cases), symptoms and signs subside within several weeks, after which recovery is complete and without sequelae. Clinical and laboratory recovery occurs in approximately half of otherwise healthy young adults within 3 weeks, and the remainder recover thereafter; rarely, laboratory abnormalities may persist for months to a year. In a small proportion of cases, fatigue may be prolonged and outlast all other symptoms, signs and laboratory abnormalities.

Laboratory features

Levels of alanine aminotransferase (ALT) tend to exceed those of aspartate aminotransferase (AST). Values of several hundred

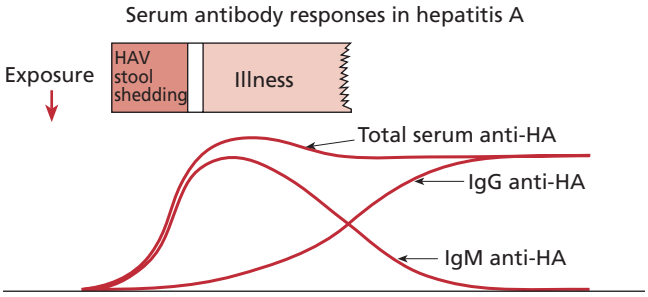

Fig. 1 Diagrammatic representation of the clinical, serological, and virological events that occur in HAV infection.

units are common but, occasionally, ALT and AST levels exceed 1000–2000 units. Elevations in aminotransferase activity tend to precede elevations in bilirubin, which may continue to climb even as aminotransferase levels decline.

Elevations in prothrombin time and reductions in serum albumin are rare, and alkaline phosphatase levels are normal or minimally elevated. Transient neutropenia and atypical lymphocytosis can occur, and an elevation in non-virus-specific serum IgM is a common feature, in addition to a mild increase in total gammaglobulin levels.

Diagnosis

Technically, a diagnosis of acute HAV infection can be made by demonstrating virus in stools or serum during the late incubation period; however, faecal shedding and viraemia have usually subsided by the time a patient presents clinically. In the same vein, diagnosis by cultivation of HAV *in vitro* is impractical because of the long latency of the virus in culture.

Therefore, a diagnosis is made by relying on serological detection of antibodies to HAV (anti-HAV) (Fig. 1). Antibodies to HAV appear early during acute illness, even while faecal shedding of virus is still occurring and while serum aminotransferase levels are elevated. The early antibody response is of the IgM class, and the presence of IgM anti-HAV establishes the diagnosis with 100% sensitivity and a specificity nearly as good, marred only by rare, confounding, non-specific immunoassay binding in the presence of rheumatoid factor. As tests for IgM anti-HAV are configured, this primary humoral immune response remains detectable for approximately 3 months in most patients, rarely lasting longer. Thereafter, beginning during convalescence and persisting indefinitely, IgG anti-HAV predominates and is associated with lifelong immunity to reinfection. In patients presenting with acute hepatitis whose serum contains IgG anti-HAV rather than IgM anti-HAV, the current acute hepatitis is not related to hepatitis A.

Because IgM anti-HAV persists for several months after acute infection, IgM anti-HAV testing can be used to make a retrospective diagnosis, for example in a person suspected as the source of a food-borne outbreak or in a traveller returning after recovery from acute illness.

Pathology

Liver biopsies are almost never indicated in patients with acute hepatitis A, a self-limited disease. Still, the histological hallmarks of acute hepatitis A have been described and share the typical features of all forms of acute viral hepatitis: ballooning of hepatocytes, coagulative necrosis, focal necrosis, portal expansion by a mononuclear infiltrate, periportal inflammation and Kupffer cell hyperplasia.

Cholestasis may be present and, in more severe cases, piecemeal necrosis or interface hepatitis (erosion of the limiting plate of periportal hepatocytes) and/or bridging necrosis (cell dropout that spans lobules) may be observed. Although periportal fibrosis may be seen in protracted cases, progression to cirrhosis has not been documented. When liver tissue is available, HAV can be localized by immunohistochemical staining to the hepatocyte cytoplasm [43].

Pathogenesis

HAV replicates predominantly in the liver; although the virus has been detected by some investigators in extrahepatic sites such as the gut [44,45] and, although virus replication has been identified in orally infected monkeys [46], the relative magnitude of intestinal HAV replication and its importance in the life cycle of the virus is not known.

HAV is not a cytopathic agent, and the virus is not cytolytic in cell culture, having no effect on the rate of host protein RNA synthesis [47]. Liver injury is almost certainly mediated by cellular immune responses to virus-infected hepatocytes. Cytolytic T-cell responses have been documented in acute hepatitis A [48–50], and T-cell epitopes, potential targets for cytolytic T cells, have been identified on HAV structural proteins [51].

A reasonable hypothesis is that CD8+ cytolytic T cells recognize HAV antigens complexed with hepatocyte cell surface host histocompatibility antigens and participate in the immunopathogenesis of hepatitis A by attacking and injuring HAV-infected hepatocytes.

Determinants of severity in acute hepatitis A are not well characterized. The size of the virus inoculum varies inversely with the length of the incubation period and does not affect the severity of acute hepatitis A. Age of infection is an important factor in the clinical expression of illness; the frequency of clinically apparent hepatitis increases with age [23]. Studies of candidate HAV vaccine strains after serial passage in cell culture have shown that the pathogenicity of the virus can be attenuated, and such attenuation has been linked to changes at the genome level [52–54]. Immune complex-mediated extrahepatic manifestations of acute hepatitis, such as rash (cutaneous vasculitis) and arthralgias/arthritis, have been reported only rarely in patients with acute hepatitis A [55,56]. Such manifestations have also been reported in patients with relapsing hepatitis A (see below) [55,57].

Complications

Patients with acute hepatitis A recover completely without any lasting sequelae. Neither chronic hepatitis A nor a chronic hepatitis A carrier state has been demonstrated to exist. In addition, recovery from acute hepatitis A is followed by lifelong immunity to reinfection. Fulminant hepatitis A, which occurs rarely, in approximately 1:1000 cases of acute hepatitis A can lead to death; based on an estimated (not the reported) number of deaths per year in the United States, the Centers for Disease Control and Prevention estimate a case fatality rate of 0.3% [27]. In patients older than 50 years, the case fatality rate is higher, 1.8% according to the Centers for Disease Control estimate and, in patients with underlying chronic liver disease, the risk of fulminant hepatitis A is increased [58].

Two variants of acute hepatitis A merit special attention, cholestatic hepatitis A and relapsing hepatitis A. Cholestatic hepatitis A, characterized by persistent jaundice and pruritus, with marked elevation of bilirubin levels, occurs rarely and can be misconstrued for extrahepatic biliary obstruction or chronic cholestatic liver disease. Although symptoms and biochemical abnormalities may persist for many months and even up to a year, cholestatic hepatitis A invariably resolves and is followed by complete recovery. Generally, liver biopsy is not required in this setting but, when obtained, liver tissue demonstrates profound centrolobular cholestasis as well as more typical portal inflammation [59].

Relapsing hepatitis A can occur in as many as 5–10% of patients with acute hepatitis A, usually reflected by an asymptomatic elevation in aminotransferases within weeks to months after apparent biochemical recovery [57,60–64]. In a proportion of cases, symptoms and jaundice recur during relapse, and resumption of faecal HAV excretion has been documented during relapse [65]. This variant, too, invariably resolves without any chronic sequelae.

Other complications during acute hepatitis A are rare, although a host of miscellaneous case reports link hepatitis A in rare instances to Guillain–Barré syndrome [66], pancreatitis [67], cholecystitis [68], aplastic anaemia, renal failure [69], encephalitis [70] and haemophagocytic syndrome [71].

Isolated cases have been described in which autoimmune hepatitis (with autoantibodies and substantial hyperglobulinaemia) followed acute hepatitis A [72–74].

Management

No specific therapy is required for acute hepatitis A or for its variants, cholestatic hepatitis A or relapsing hepatitis A. Because the disease is self-limited, specific antiviral therapy is not required, nor have any antiviral agents been shown to be clinically effective in hepatitis A. Management remains supportive, and hospitalization is rarely required, except for patients with other concurrent, serious medical problems, those who cannot maintain oral intake or those with incipient liver failure (e.g. coagulopathy, mental status changes).

Bedrest, restriction of physical activity or dietary restrictions are of no benefit [75], but abstaining from alcohol is a reasonable, common-sense approach, albeit one that has not been proven in clinical trials. Corticosteroids are not helpful and should be avoided. For the systemic symptoms of acute hepatitis A, patients may be instructed to take paracetamol or non-steroidal anti-inflammatory drugs in moderation; rarely, cholestyramine is required to manage severe pruritus. In patients with fulminant hepatitis A, meticulous, intensive supportive care is the only available intervention, short of liver transplantation. In a case report involving four patients with fulminant hepatitis A, interferon-β was administered and followed by recovery [76], but up to 80% of patients with fulminant hepatitis A managed with supportive care have been reported to survive. Both management of fulminant hepatitis and liver transplantation are addressed in other chapters in this volume.

Prevention

In areas of the world where hepatitis A is endemic, control of hepatitis A requires societal improvements in environmental hygiene, including a clean, safe water supply, adequate disposal of waste and improvements in living conditions. Although hepatitis A vaccines are now available in developed countries, simple, common sense hygienic measures such as handwashing, special training for foodhandlers, etc. play a role in limiting the spread of hepatitis A. Because HAV is spread by close person-to-person contact, no special precautions are required for classmates and co-workers of patients with acute hepatitis A.

Similarly, universal precautions currently practised in hospitals, clinics and physicians' offices are sufficient to prevent nosocomial hepatitis A; therefore, additional, cumbersome isolation in a private room as well as the use of gowns and gloves are not required. Travellers to endemic areas should avoid tap water and uncooked food and drinks potentially contaminated with water (salads, ice in drinks).

Currently, both passive immunization with immune globulin and active immunization with inactivated vaccines are available for prophylaxis against HAV infection. Active immunization with hepatitis A vaccine is discussed in Chapter 9.1.3.i.

Passive immunization

Before hepatitis A vaccines were developed, prophylaxis against hepatitis A relied upon passive immunization with immune globulin, prepared from large plasma pools, inactivated by cold ethanol fractionation and invariably containing anti-HAV. Cold alcohol fractionation has been shown to yield a safe product, free of infectious agents, including human immunodeficiency virus (HIV). Although the minimum protective concentration of anti-HAV in immune globulin is not known, all contemporary

lots of immune globulin contain sufficient anti-HAV (at least 100 IU/mL) to be protective. The efficacy of immune globulin was first demonstrated in an outbreak at a summer camp in 1944 [77] and confirmed in large-scale studies among American soldiers serving in Europe during the Second World War [78], as well as in persons residing in institutions for the mentally handicapped [79].

Now that hepatitis A vaccine has widely replaced immune globulin for pre-exposure prophylaxis, the role of immune globulin has been confined to postexposure prophylaxis or for passive pre-exposure immunization in pregnant or lactating women and immunosuppressed persons.

Until very recently, in the United States, immune globulin was also recommended for protection against hepatitis A in children younger than 2 years; since October 2005, the Advisory Committee on Immunization Practices (ACIP) of the United States Public Health Service has recommended that all children between the ages of 1 and 2 years receive a two-dose vaccination against hepatitis A virus [80].

In some settings (e.g. in a traveller who does not have sufficient time before embarking to complete a course of hepatitis A vaccine and who expects to travel for an extended period or to travel frequently in the future), a combination of passive immunization with immune globulin plus active immunization with hepatitis A vaccine, at different sites of administration, is suggested [19]. Although levels of anti-HAV following combination passive and active immunization may be lower than those achieved after vaccination alone [81], for all practical purposes, the two types of immunization do not interfere with the efficacy of the other. Immune globulin is not known to interfere with any other killed vaccines either but can interfere with immune responses to live, attenuated vaccines; therefore, administration of such live, attenuated vaccines should be delayed for 5 months or longer after immune globulin administration [28]. When given pre-exposure, immune globulin is administered intramuscularly at a dose of 0.02 mL/kg for brief expected exposures (1–2 months, such as for recreational travel) or 0.06 mL/kg for longer exposures (3–5 months). For prolonged exposure, repeat injections of immune globulin at 5- to 6-month intervals were recommended; however, the need for repeat immune globulin injections has been supplanted by the availability of hepatitis A vaccine. When administered within 2 weeks of exposure, immune globulin has been shown to be at least 85% effective in preventing acute hepatitis A [25]. Levels of measurable anti-HAV are low or undetectable after passive immunization, and protection lasts for several months [82].

The earlier after exposure that immune globulin can be given, the more effective it is likely to be. When administered sufficiently early after exposure, immune globulin prevents HAV infection entirely; however, if administration is delayed into the late incubation period, immune globulin may not abort infection entirely but, instead, attenuate it and render the infection clinically inapparent. Consequently, longlasting immunity resulting from subclinical infection occurs, rather than transient protection resulting from passive immunization, i.e. 'passive–active' immunity. Such postexposure prophylaxis should be given as soon after the exposure as possible (without prior anti-HAV testing, which would delay immunization unnecessarily and would add substantial expense) to household, sexual and institutional contacts of patients with acute hepatitis A; however, prophylaxis is not necessary for casual contacts (e.g. classmates, office and factory co-workers, hospital employees). Immune globulin has been given routinely to persons exposed to HAV in common-source (e.g. food-borne) outbreaks; however, by the time such outbreaks are recognized, a full incubation period has elapsed, and prophylaxis may be too late to prevent infection. On the other hand, prophylaxis this late may attenuate clinical illness in some recipients and/or potentially limit the number of secondary cases (Table 3).

Table 3 Postexposure prophylaxis against HAV infection with immune globulin.

Indications:	Close personal contacts
	Household contacts
	Sexual contacts
	Daycare centres with recognized cases of hepatitis A
	Staff
	Children attending the centre
	Household members of children attending the centre
	Common-source exposure
	Other foodhandlers besides index case
	Patrons – prophylaxis unlikely to be of benefit unless administered within 2 weeks after exposure
	Schools, factories, offices, hospitals – not routinely recommended
Regimen:	0.02 mL/kg, intramuscularly, as soon after exposure as possible, not beyond 2 weeks of exposure

References

1 Feinstone SM, Kapikian AZ, Purceli RH (1973) Hepatitis A: detection by immune electron microscopy of a viruslike antigen associated with acute illness. *Science* 182(116), 1026–1028.

2 Melnick JL (1992) Properties and classification of hepatitis A virus. *Vaccine* 10(Suppl. 1), S24–26.

3 Robertson BH, Jansen RW, Khanna B *et al.* (1992) Genetic relatedness of hepatitis A virus strains recovered from different geographical regions. *J Gen Virol* 73(Pt 6), 1365–1377.

4 Provost PJ, Hilleman MR (1979) Propagation of human hepatitis A virus in cell culture *in vitro*. *Proc Soc Exp Biol Med* 160(2), 213–221.

5 Lemon SM (1985) Type A viral hepatitis. New developments in an old disease. *N Engl J Med* 313(17), 1059–1067.

6 Ticehurst JR (1986) Hepatitis A virus: clones, cultures, and vaccines. *Semin Liver Dis* 6(1), 46–55.

7 Cohen JI (1989) Hepatitis A virus: insights from molecular biology. *Hepatology* 9(6), 889–895.

8 Dienstag JL, Feinstone SM, Kapikian AZ *et al.* (1975) Faecal shedding of hepatitis-A antigen. *Lancet* 1(7910), 765–767.

9 Rosenblum LS, Villarino ME, Nainan OV *et al.* (1991) Hepatitis A outbreak in a neonatal intensive care unit: risk factors for transmission and evidence of prolonged viral excretion among preterm infants. *J Infect Dis* 164(3), 476–482.

10 Fagan E, Yousef G, Brahm J *et al.* (1990) Persistence of hepatitis A virus in fulminant hepatitis and after liver transplantation. *J Med Virol* 30(2), 131–136.

11 Feinstone SM, Gust ID (1997) Hepatitis A virus. In: Livingstone C (ed.) *Clinical Virology*. New York, pp. 1049–1072.

12 MacCallum FO (1972) Early studies of viral hepatitis. *Br Med Bull* 28(2), 105–108.

13 Krugman S, Ward R, Giles JP (1962) The natural history of infectious hepatitis. *Am J Med* 32, 717–728.

14 Krugman S, Giles JP, Hammond J (1967) Infectious hepatitis. Evidence for two distinctive clinical, epidemiological, and immunological types of infection. *JAMA* 200(5), 365–373.

15 Deinhardt F, Holmes AW, Capps RB *et al.* (1967) Studies on the transmission of human viral hepatitis to marmoset monkeys. I. Transmission of disease, serial passages, and description of liver lesions. *J Exp Med* 125(4), 673–688.

16 Holmes AW, Wolfe L, Rosenblate H *et al.* (1969) Hepatitis in marmosets: induction of disease with coded specimens from a human volunteer study. *Science* 165(895), 816–817.

17 Ticehurst JR, Racaniello VR, Baroudy BM *et al.* (1983) Molecular cloning and characterization of hepatitis A virus cDNA. *Proc Natl Acad Sci USA* 80(19), 5885–5889.

18 Baroudy BM, Ticehurst JR, Miele TA *et al.* (1985) Sequence analysis of hepatitis A virus cDNA coding for capsid proteins and RNA polymerase. *Proc Natl Acad Sci USA* 82(7), 2143–2147.

19 Najarian R, Caput D, Gee W *et al.* (1985) Primary structure and gene organization of human hepatitis A virus. *Proc Natl Acad Sci USA* 82(9), 2627–2631.

20 Hollinger FB, Ticehurst JR (1996) Hepatitis A virus. In: Fields BN, Knipe DM, Howley PM *et al.* (eds) *Fields Virology*. Philadelphia: Lippincott-Raven, pp. 735–782.

21 Halliday ML, Kang LY, Zhou TK *et al.* (1991) An epidemic of hepatitis A attributable to the ingestion of raw clams in Shanghai, China. *J Infect Dis* 164(5), 852–859.

22 Anon (2003) Hepatitis A outbreak associated with green onions at a restaurant – Monaca, Pennsylvania, 2003. *MMWR Morb Mortal Wkly Rep* 52(47), 1155–1157.

23 Lednar WM, Lemon SM, Kirkpatrick JW *et al.* (1985) Frequency of illness associated with epidemic hepatitis A virus infections in adults. *Am J Epidemiol* 122(2), 226–233.

24 Di Giammarino L, Dienstag JL (2005) Hepatitis A – the price of progress. *N Engl J Med* 353(9), 944–946.

25 Steffen R, Kane MA, Shapiro CN *et al.* (1994) Epidemiology and prevention of hepatitis A in travelers. *JAMA* 272(11), 885–889.

26 Szmuness W, Purcell RH, Dienstag JL *et al.* (1977) Antibody to hepatitis A antigen in institutionalized mentally retarded patients. *JAMA* 237(16), 1702–1705.

27 Centers for Disease Control and Prevention (2004) *Hepatitis Surveillance Report No. 59*. Atlanta, GA: US Department of Health and Human Services. Centers for Disease Control and Prevention.

28 Anon (1999) Prevention of hepatitis A through active or passive immunization: Recommendations of the Advisory Committee on Immunization Practices (ACIP). *MMWR Recomm Rep* 48(RR-12), 1–37.

29 Hutin YJ, Pool V, Cramer EH *et al.* (1999) A multistate, foodborne outbreak of hepatitis A. National Hepatitis A Investigation Team. *N Engl J Med* 340(8), 595–602.

30 Wheeler C, Vogt T, Armstrong GL *et al.* (2005) An outbreak of hepatitis A associated with green onions. *N Engl J Med* 353, 890–897.

31 Hadler SC, Erben JJ, Francis DP *et al.* (1982) Risk factors for hepatitis A in day-care centers. *J Infect Dis* 145(2), 255–261.

32 Corey L, Holmes KK (1980) Sexual transmission of hepatitis A in homosexual men: incidence and mechanism. *N Engl J Med* 302(8), 435–438.

33 Soucie JM, Robertson BH, Bell BP *et al.* (1998) Hepatitis A virus infections associated with clotting factor concentrate in the United States. *Transfusion* 38(6), 573–579.

34 Weisfuse IB, Graham DJ, Will M *et al.* (1990) An outbreak of hepatitis A among cancer patients treated with interleukin-2 and lymphokine-activated killer cells. *J Infect Dis* 161(4), 647–652.

35 Watson JC, Fleming DW, Borella AJ *et al.* (1993) Vertical transmission of hepatitis A resulting in an outbreak in a neonatal intensive care unit. *J Infect Dis* 167(3), 567–571.

36 Gibas A, Blewett DR, Schoenfeld DA *et al.* (1992) Prevalence and incidence of viral hepatitis in health workers in the prehepatitis B vaccination era. *Am J Epidemiol* 136(5), 603–610.

37 Armstrong GL, Bell BP (2002) Hepatitis A virus infections in the United States: model-based estimates and implications for childhood immunization. *Pediatrics* 109(5), 839–845.

38 Centers for Disease Control and Prevention (2005) Summary of Notifiable Disease – United States, 2003. Report No. 54. *Morbidity and Mortality Weekly Report* 52, 1–88.

39 Shapiro CN, Coleman PJ, McQuillan GM *et al.* (1992) Epidemiology of hepatitis A: seroepidemiology and risk groups in the USA. *Vaccine* 10(Suppl. 1), S59–62.

40 Szmuness W, Dienstag JL, Purcell RH *et al.* (1976) Distribution of antibody to hepatitis a antigen in urban adult populations. *N Engl J Med* 295(14), 755–759.

41 Purcell RH (1994) Hepatitis viruses: changing patterns of human disease. *Proc Natl Acad Sci USA* 91(7), 2401–2406.

42 Shapiro CN, Margolis HS (1993) Worldwide epidemiology of hepatitis A virus infection. *J Hepatol* 18(Suppl. 2), S11–14.

43 Shimizu YK, Mathiesen LR, Lorenz D *et al.* (1978) Localization of hepatitis A antigen in liver tissue by peroxidase-conjugated antibody method: light and electron microscopic studies. *J Immunol* 121(5), 1671–1679.

44 Mathiesen LR, Feinstone SM, Purcell RH *et al.* (1977) Detection of hepatitis A antigen by immunofluorescence. *Infect Immun* 18(2), 524–530.

45 Karayiannis P, Jowett T, Enticott M *et al.* (1986) Hepatitis A virus replication in tamarins and host immune response in relation to pathogenesis of liver cell damage. *J Med Virol* 18(3), 261–276.

46 Asher LV, Binn LN, Mensing TL *et al.* (1995) Pathogenesis of hepatitis A in orally inoculated owl monkeys (*Aotus trivirgatus*). *J Med Virol* 47(3), 260–268.

47 Locarnini SA, Coulepis AG, Westaway EG *et al.* (1981) Restricted replication of human hepatitis A virus in cell culture: intracellular biochemical studies. *J Virol* 37(1), 216–225.

48 Vallbracht A, Gabriel P, Maier K *et al.* (1986) Cell-mediated cytotoxicity in hepatitis A virus infection. *Hepatology* 6(6), 1308–1314.

49 Vallbracht A, Maier K, Stierhof YD *et al.* (1989) Liver-derived cytotoxic T cells in hepatitis A virus infection. *J Infect Dis* 160(2), 209–217.

50 Fleischer B, Fleischer S, Maier K *et al.* (1990) Clonal analysis of infiltrating T lymphocytes in liver tissue in viral hepatitis A. *Immunology* 69(1), 14–19.

51 Wunschmann S, Vallbracht A, Flehmig B *et al.* (1997) Cytolytic T lymphocyte epitopes are present on hepatitis A virus structural proteins. In: Rizzetto M, Purcell RH, Gerin JL *et al.* (eds) *Viral Hepatitis and Liver Disease*. Turin: Edizione Minerva Medica, pp. 51–54.

52 Cohen JI, Rosenblum B, Feinstone SM *et al.* (1989) Attenuation and cell culture adaptation of hepatitis A virus (HAV): a genetic analysis with HAV cDNA. *J Virol* 63(12), 5364–5370.

53 Emerson SU, Huang YK, McRill C *et al.* (1992) Mutations in both the 2B and 2C genes of hepatitis A virus are involved in adaptation to growth in cell culture. *J Virol* 66(2), 650–654.

54 Zhang H, Chao SF, Ping LH *et al.* (1995) An infectious cDNA clone of a cytopathic hepatitis A virus: genomic regions associated with rapid replication and cytopathic effect. *Virology* 212(2), 686–697.

55 Inman RD, Hodge M, Johnston ME *et al.* (1986) Arthritis, vasculitis, and cryoglobulinemia associated with relapsing hepatitis A virus infection. *Ann Intern Med* 105(5), 700–703.

56 Scully LJ, Ryan AE (1993) Urticaria and acute hepatitis A virus infection. *Am J Gastroenterol* 88(2), 277–278.

57 Glikson M, Galun E, Oren R *et al.* (1992) Relapsing hepatitis A. Review of 14 cases and literature survey. *Medicine (Baltimore)* 71(1), 14–23.

58 Reiss G, Keeffe EB (2004) Review article: hepatitis vaccination in patients with chronic liver disease. *Aliment Pharmacol Ther* 19(7), 715–727.

59 Gordon SC, Reddy KR, Schiff L *et al.* (1984) Prolonged intrahepatic cholestasis secondary to acute hepatitis A. *Ann Intern Med* 101(5), 635–637.

60 Bamber M, Thomas HC, Bannister B *et al.* (1983) Acute type A, B, and non-A, non-B hepatitis in a hospital population in London: clinical and epidemiological features. *Gut* 24(6), 561–564.

61 Gruer LD, McKendrick MW, Beeching NJ *et al.* (1982) Relapsing hepatitis associated with hepatitis A virus. *Lancet* 2(8290), 163.

62 Jacobson IM, Nath BJ, Dienstag JL (1985) Relapsing viral hepatitis type A. *J Med Virol* 16(2), 163–169.

63 Chiriaco P, Guadalupi C, Armigliato M *et al.* (1986) Polyphasic course of hepatitis type A in children. *J Infect Dis* 153(2), 378–379.

64 Raimondo G, Longo G, Caredda F *et al.* (1986) Prolonged, polyphasic infection with hepatitis A. *J Infect Dis* 153(1), 172–173.

65 Sjogren MH, Tanno H, Fay O *et al.* (1987) Hepatitis A virus in stool during clinical relapse. *Ann Intern Med* 106(2), 221–226.

66 Tabor E (1987) Guillain–Barre syndrome and other neurologic syndromes in hepatitis A, B, and non-A, non-B. *J Med Virol* 21(3), 207–216.

67 Davis TV, Keeffe EB (1992) Acute pancreatitis associated with acute hepatitis A. *Am J Gastroenterol* 87(11), 1648–1650.

68 Mourani S, Dobbs SM, Genta RM *et al.* (1994) Hepatitis A virus-associated cholecystitis. *Ann Intern Med* 120(5), 398–400.

69 Geltner D, Naot Y, Zimhoni O *et al.* (1992) Acute oliguric renal failure complicating type A nonfulminant viral hepatitis. A case presentation and review of the literature. *J Clin Gastroenterol* 14(2), 160–162.

70 Thomas WJ, Bruno P, Holtzmuller K (1993) Hepatitis A virus anicteric encephalitis coexistent with hepatitis C virus infection. *Am J Gastroenterol* 88(2), 279–281.

71 Watanabe M, Shibuya A, Okuno J *et al.* (2002) Hepatitis A virus infection associated with hemophagocytic syndrome: report of two cases. *Intern Med* 41(12), 1188–1192.

72 Vento S, Garofano T, Di Perri G *et al.* (1991) Identification of hepatitis A virus as a trigger for autoimmune chronic hepatitis type 1 in susceptible individuals. *Lancet* 337(8751), 1183–1187.

73 Rahaman SM, Chira P, Koff RS (1994) Idiopathic autoimmune chronic hepatitis triggered by hepatitis A. *Am J Gastroenterol* 89(1), 106–108.

74 Huppertz HI, Treichel U, Gassel AM *et al.* (1995) Autoimmune hepatitis following hepatitis A virus infection. *J Hepatol* 23(2), 204–208.

75 Chalmers TC, Eckhardt RD, Reynolds WE *et al.* (1955) The treatment of acute infectious hepatitis. Controlled studies of the effects of diet, rest, and physical reconditioning on the acute course of the disease and on the incidence of relapses and residual abnormalities. *J Clin Invest* 34(7, Pt II), 1163–1235.

76 Yoshiba M, Inoue K, Sekiyama K (1994) Interferon for hepatitis A. *Lancet* 343(8892), 288–289.

77 Stokes J, Neefe JH (1945) The prevention and attenuation of infectious hepatitis by gamma-globulin. *JAMA* 127, 144–145.

78 Gellis SS, Stokes J, Brother GM *et al.* (1945) The use of human immune serum globulin (gamma-globulin) in infectious (epidemic) hepatitis in the Mediterranean theater of operations. I. Studies on prophylaxis in two epidemics of infectious hepatitis. *JAMA* 128, 1062–1023.

79 Krugman S (1976) Effect of human immune serum globulin on infectivity of hepatitis A virus. *J Infect Dis* 134(1), 70–74.

80 Charatan F (2005) US panel recommends young children receive hepatitis A vaccination. *Br Med J* 331(7525), 1102.

81 Wagner G, Lavanchy D, Darioli R *et al.* (1993) Simultaneous active and passive immunization against hepatitis A studied in a population of travellers. *Vaccine* 11(10), 1027–1032.

82 Fujiyama S, Iino S, Odoh K *et al.* (1992) Time course of hepatitis A virus antibody titer after active and passive immunization. *Hepatology* 15(6), 983–938.

83 World Health Organization. Department of Communicable Disease Surveillance and Response (2000) Hepatitis A. *Bull World Health Org* WHO/CDS/CSR/EDC/2000.7, 1–39.

84 Craig AS, Schaffner W (2004) Prevention of hepatitis A with the hepatitis A vaccine. *N Engl J Med* 350(5), 476–481.

85 Clemens R, Safary A, Hepburn A *et al.* (1995) Clinical experience with an inactivated hepatitis A vaccine. *J Infect Dis* 171(Suppl. 1), S44–49.

86 Tsai IJ, Chang MH, Chen HL *et al.* (2000) Immunogenicity and reactogenicity of the combined hepatitis A and B vaccine in young adults. *Vaccine* 19(4–5), 437–441.

87 Rothstein KD (2002) Hepatitis A vaccination in patients with chronic liver disease: to screen or not to screen? *Am J Gastroenterol* 97(7), 1590–1593.

88 Wasley A, Samandari T, Bell BP (2005) Incidence of hepatitis A in the United States in the era of vaccination. *JAMA* 294(2), 194–201.

89 Nainan OV, Armstrong GL, Han XH *et al.* (2005) Hepatitis A molecular epidemiology in the United States, 1996–1997: sources of infection and implications of vaccination policy. *J Infect Dis* 191(6), 957–963.

90 Dagan R, Leventhal A, Anis E *et al.* (2005) Incidence of hepatitis A in Israel following universal immunization of toddlers. *JAMA* 294(2), 202–210.

91 Connor BA (2005) Hepatitis A vaccine in the last-minute traveler. *Am J Med* 118(Suppl. 10A), 58S–62S.

92 Robertson BH, D'Hondt EH, Spelbring J *et al.* (1994) Effect of post-exposure vaccination in a chimpanzee model of hepatitis A virus infection. *J Med Virol* 43(3), 249–251.

93 D'Hondt E, Purcell RH, Emerson SU *et al.* (1995) Efficacy of an inactivated hepatitis A vaccine in pre- and postexposure conditions in marmosets. *J Infect Dis* 171(Suppl. 1), S40–43.
94 Bonanni P, Franzin A, Staderini C *et al.* (2005) Vaccination against hepatitis A during outbreaks starting in schools: what can we learn from experiences in central Italy? *Vaccine* 23(17–18), 2176–2180.

9.1.2.iv Hepatitis B

Geoffrey M. Dusheiko

Definition

Type B hepatitis is caused by the hepatitis B virus (HBV), a small, enveloped DNA virus that infects the liver causing hepatocellular necrosis and inflammation [1]. HBV infection can be either acute or chronic, and can range in severity from being asymptomatic to severe and symptomatic with progressive and even fatal illness.

Acute hepatitis B is defined as a self-limiting disease marked by acute inflammation and hepatocellular necrosis in association with a transient HBV infection. Chronic hepatitis B is defined as persistent HBV infection accompanied by evidence of hepatocellular injury and inflammation; the diagnosis is based upon the finding of abnormal concentrations of serum aminotransferases and hepatitis B surface antigen (HBsAg) in serum for 6 months or more. Chronic hepatitis B can enter a phase of remission with an improvement in serum aminotransferases despite the persistence of HBsAg [2]. However, these patients are at risk of reactivation of active hepatitis. Patients may ultimately develop cirrhosis, portal hypertension and hepatocellular failure. A proportion also develop hepatocellular carcinoma as a result of chronic HBV infection.

Introduction

After the identification of HBsAg, hepatitis B was clearly linked to the development of cirrhosis and hepatocellular carcinoma. Subtypes of HBsAg were described [3], the virus and subviral particles were identified in serum, a nucleocapsid core protein (HBcAg) and an associated DNA polymerase activity were described, and the genome of the virus was isolated and characterized as a small, circular molecule of DNA [4]. The identification of HBV led to the development of vaccines using HBsAg isolated from the serum of chronic carriers [5].

By 1978, the genome of the HBV had been cloned, and four open reading frames delineating the four gene products of HBV were identified [6]. Furthermore, identification of animal viruses resembling human HBV [7] led to the characterization of the replication cycle of this family of viruses, the so-called hepadnaviruses.

The virus exists as a 42-nm, double-shelled particle found in serum (see Chapter 9.1.2.i). HBV has an outer envelope component of HBsAg and an inner nucleocapsid component of HBcAg. In addition to actual virions, incomplete viral particles, 20-nm spheres and tubules, which consist entirely of HBsAg without HBcAg or nucleic acid, are present in serum and outnumber virions. HBsAg can also be detected in the liver. The nucleocapsid HBcAg is not found free in serum, but inside HBV virions. HBV DNA can be detected in serum and can be used to monitor viral replication. Hepatitis Be antigen (HBeAg), unlike HBsAg and HBcAg, is not particulate, but rather is detectable as a soluble, 17-kDa protein in serum. HBV replicates largely in the liver (see Chapter 9.1.2.i).

Transmission

Infection with HBV is a common problem worldwide [8]. Chronic hepatitis B is relatively uncommon in industrialized nations, affecting 1% or less of persons. In contrast, in undeveloped nations, HBV infection is an almost universal infection of childhood, and the HBsAg carrier state affects 5–15% of adults. Worldwide, approximately 5% of the population has chronic HBV infection, an estimated 300 million individuals. The ratio of males to females is usually between 1.5 and 2:1. The source of most HBV infection is probably exposure to blood secretions from chronic carriers. HBsAg carriers vary in their infectivity from less than 10 to more than 10^8 virions/mL of plasma. Patients with HBeAg in addition to HBsAg generally have 10^6 virions/mL and higher infectivity. However, anti-HBe-positive persons have virus in lower titre so that a larger volume exposure is necessary.

HBV has been transmitted by transfusion with HBsAg-negative, anti-HBc-positive blood, representing low levels of infection below the level of detection of HBsAg. HBV DNA has been detected in patients after clearance of HBsAg after the resolution of acute or chronic hepatitis B [9]. While HBsAg can occasionally be found in urine, breast milk, vaginal secretions, cerebrospinal fluid, sweat, tears, bile and faeces, the amounts are low.

The usual mode of transmission of hepatitis B is parenteral or percutaneous exposure such as blood transfusions, the use of unpasteurized plasma products, needlestick accidents and injections with unsterilized instruments such as in tattooing, acupuncture, ear piercing or dentistry. Outbreaks of nosocomial HBV infection have been ascribed to gynaecological surgery or dentistry. Recently, transmission from HBeAg-negative, HBV DNA-positive surgeons has also been reported. Hepatitis B from transfusion has become rare since the introduction of routine screening of blood donors for HBsAg. Routine nucleic acid testing of blood for anti-HBc (which was introduced as an indirect means of eliminating non-A, non-B hepatitis) may further decrease post-transfusion hepatitis B, but many countries have chosen not to include anti-HBc screening. Intravenous drug abuse is an increasing cause of hepatitis B in many areas of the world. Contaminated drug paraphernalia is often shared.

Careful investigation of cases of acute or chronic hepatitis B does not always uncover a potential parenteral source of transmission. In most developed countries of the world, the major mode of spread is probably sexual. This accounts for the very high rate of hepatitis B among male homosexuals and in promiscuous heterosexuals. Sexual spread of hepatitis B among heterosexuals also appears to occur, both female to male and male to female. Non-sexual intrafamilial spread is best described as inapparent parenteral spread, the vehicle perhaps being saliva, blood-tinged fluid and fluid from open sores, skin lesions or scratches. Thus, the non-sexual spread of hepatitis B in families, and particularly among small children, as appears to occur in underdeveloped areas of the world, is partially unexplained. The possible role of biting insects cannot be dismissed. Other cultural practices, such as tribal and witch doctor scarification and acupuncture, may spread hepatitis B. A splash of blood in the eye may also transmit the infection.

Perinatal spread is an important mode of transmission of hepatitis B. Newborns of mothers who are HBeAg positive are likely to develop HBV infection. The onset of infection is usually 3 months after birth. The acute phase of infection is typically mild, not associated with apparent illness and accompanied by minimal abnormalities in aminotransferases. However, infection during the neonatal period almost always leads to chronic infection. Maternal–infant spread is an important means by which this virus infection was sustained in populations prior to vaccination. Mothers with HBeAg in addition to HBsAg are the most infectious and, without vaccination, spread the chronic infection to their newborns in over 90% of cases.

Epidemiology

Low- (less than 2% of the population infected), intermediate- (2–8%) and high-prevalence (more than 8%) areas of hepatitis B infection are recognized. The disease is endemic in several regions: these include the Far East, more than 40 countries in the Pacific region and also large parts of Asia and sub-Saharan Africa. The disease is also prevalent in South America and in a number of foci in other regions, for example eastern Europe and the Arctic.

Some areas have an intermediate endemicity and appear to be in a state of transition from high to low. In some countries, such as Japan, countries of eastern Europe and in South America, the carrier rate among adults is 1–5%, and infections occur in both adults and children. In southern Europe, the incidence of HBV infections has consistently declined in the last decade.

The two extremes of endemicity could probably be accounted for in a prevaccination era by two separate major patterns of HBV transmission. In highly endemic areas, without vaccination, HBV was spread first by maternal–infant transmission, creating a cohort of children with chronic hepatitis B who were highly infectious. In turn, this pattern of childhood infection determined a high rate of chronic infection. Because infection occurred in childhood, the carrier rate was high, and the pool of infected individuals was sustained to the next generation. Because disease complications occur only after decades of chronic infection, the infectious carriers had offspring and continued the cycle of infection. Horizontal transmission, that is child–child, was equally important. In endemic areas in Africa, the prevalence in children is quite low at 1 year of age but increases rapidly thereafter and, in many countries in this region, the prevalence reaches a peak in children of 7–14 years of age.

Infection of neonates at birth from their infected mothers was common in the Far East and China, whereas horizontal transmission from child to child was more common in Africa [10,11]. The patterns of transmission are related to the higher prevalence of HBeAg and, hence, higher infectivity in Chinese (40%) compared with African mothers (15%).

In areas of low endemicity, hepatitis B is a disease of adults, typically those who are in high-risk occupations or have high-risk habits such as drug abuse or sexual promiscuity. Hepatitis B in adults more frequently leads to acute, icteric hepatitis and rarely causes chronic hepatitis. Epidemiological characterization of cases suggests that most are attributable to drug abuse, heterosexual contact, transfusion and occupational exposure. These percentages have been changing over time, probably due to the initiation of vaccination programmes, the growth of drug abuse as a social problem and changes in high-risk sexual practices by homosexual men. These rates will begin to change now that HBV vaccine is available and recommended for these groups. Behavioural changes because of concerns about acquired immunodeficiency syndrome (AIDS) have been influential. Epidemiological studies of the last decade indicate that the reported rates of hepatitis B infection have significantly declined or are declining in western and northern Europe and the United States; the decline is the result of a number of factors, including safer sexual practices, behavioural changes, safe needle practices and vaccination but not as a result of widespread adoption of immunization, blood-screening refinements and the use of viral-inactivated blood components. Treatment may have reduced the infectivity of a proportion of carriers. Universal rather than selective vaccination has been more advantageous [12].

Changing patterns of HBV infection

In parallel with the decline in the prevalence of HBV, the virological pattern of chronic hepatitis B is changing in the developed world and in parts of the developing world. A few decades ago the disease was characterized primarily by the wildtype HBV virus prototype, capable of secreting HBeAg. However, in recent years the prevalence of HBeAg-positive relative to HBeAg-negative infection has diminished and a substantial proportion of HBV infections are now characterized by HBV mutants unable to secrete HBeAg. The predominant mutation in HBeAg-defective HBV in the Mediterranean area is a point mutation at nucleotide 1896 in the pre-core region that converts codon 28 from a tryptophan residue to a stop codon (so called pre-core mutants) [13,14]. The most frequent mutation in the

basic core-promoter region is a double T to A and an A to G substitution at nucleotides 1762 and 1764, respectively, which reduces pre-core mRNA levels [15,16]. The two types of mutation can occur separately or together and can independently prevent the expression of HBeAg, through transcriptional inhibition in the case of basic core-promoter mutations or through translational inhibition in the case of pre-core mutations.

The 1896 stop codon mutant is associated with HBV genotypes harbouring a T at position 1858 (genotypes B, D, E and some of the genotype C and F strains); within these genotypes, the generation of the G to A mutation at nucleotide 1896 stabilizes the secondary structure of the encapsidation signal loop and the resulting mutants are viable [17]. In contrast, in genotypes A and some of genotype C and F strains, the presence of C at nucleotide 1858 would significantly reduce the possibility for G to A 1896 variants to be selected, because of lower replication fitness.

In the Asian Pacific area, the Mediterranean basin and North America/northern Europe, 15%, 33% and 14%, respectively, of HBsAg-positive infections currently exhibit the HBeAg-negative phenotype and, among HBeAg-negative HBV carriers from these areas (whether or not positive for anti-HBe), 36%, 24% and 22%, respectively, suffer from chronic hepatitis B [18]. These estimates would suggest that at least one-fifth of the HBsAg-positive population is HBeAg-negative in the various areas of the world [18].

Studies from clinical centres have shown that, in the Asian Pacific region, about 50% of chronic hepatitis B cases are infected with HBeAg-negative HBV, with a prevalence ranging from 45% in mainland China to 69% in Hong Kong [18,19]. Prevalence rates are distinctly higher in the Mediterranean basin, ranging from 63% in Spain to as high as 86% and 90.5% in Greece and Italy respectively [20,21]. Data are more variable in the few clinical series examined in northern Europe and North America, with only 9% and 22% of chronic hepatitis B cases being HBeAg-negative in the US, but with as many as 67% and 84% in Sweden and Germany respectively [21]; in France, the prevalence of HBeAg-negative chronic hepatitis B has increased from 22% in 1994 to 72% in 2005 [22].

Studies in Japan found the prevalence of mutant HBV in patients with chronic hepatitis B to range from 58% [23] to 83% [24], and in Korea [25] to be 38%. In that country, mutants were detectable in 86% of the patients with chronic hepatitis B-related hepatocellular carcinoma for whom DNA sequencing was possible. In India, 15% of chronic hepatitis B carriers were found to have mutant infection [26].

The median prevalence of pre-core variants in HBeAg-negative chronic hepatitis B was 50% (range 19–100%), 92% (range 67–100%) and 24% (range 0–53%), respectively, among patients in the Asian Pacific, Mediterranean and US/northern Europe regions and the median prevalence of basic core-promoter variants was 77% (range 59–98%) in the Asian Pacific.

Classification of HBV infections

The clinical outcome of HBV infection is the result of the level of replication attained by HBV and the efficacy of the host immune response against it. Upon exposure to HBV, individuals with a vigorous and broad immune response to the virus develop an acute self-limited infection which may result in acute hepatitis; an aberrant response can lead to fulminant hepatitis. Individuals who do not mount a broad and vigorous immune response do not clear the virus but develop persistent infection and become carriers of HBsAg. Chronic HBsAg carriers exhibit three clinical patterns (Fig. 1) [27–29]. A minority are immune tolerant and have subclinical or mild disease despite high replication of the virus; HBV DNA levels are elevated, typically > 10^5 copies/mL and alanine aminotransferase (ALT) levels are normal. The second pattern is that of active infection, i.e. sustained high replication of HBV, to which the host mounts an unsuccessful immume response. This response is unable to clear the virus but sustains its partial clearance with continuing inflammatory activity; HBV DNA levels are above 10^5 copies/mL, ALT levels are abnormal and liver disease is present on histological

	Immune tolerant	'Active'	'Inactive'
HBsAg	+	+/+	+
HBeAg	+	+/–	–
Anti-HBe	–	–/+	+
ALT	Normal	↑	Normal
HBV DNA (copies/mL)	$>10^5$	$>10^5/>10^4$[a]	$<10^{3-4}$
Histology	Normal/mild	Active	Normal

Fig. 1 Classification of HBV infections.
[a]Expert opinions on this value vary.

investigation. Active infections can be due either to infection in which wild-type HBeAg-positive HBV is predominant (chronic HBeAg-positive hepatitis B) or to infections in which mutant forms of HBV unable to secrete the HBeAg are predominant (chronic HBeAg-negative hepatitis B). Because the molecular identification of disease-specific mutations requires laborious genotyping, in practice, the lack of HBeAg together with the finding of HBV DNA > 10^4 copies/mL has become synonymous with mutant HBV infection without the need for further determining the precise viral sequence. The third pattern is that of inactive HBV infection, i.e. diminished HBV replication. Levels of HBV DNA are below 10^{3-4} copies/mL; the low level of viremia may denote immunological control; these individuals have normal levels of ALT.

These three phases are not static and can change one into the other; immunotolerant subjects may apparently develop a break in tolerance and develop active disease, carriers with inactive disease may develop active disease and high ALT levels, and vice versa, active disease may revert to inactive quiescent disease with no or minor disease upon therapy or spontaneously.

A fourth profile, of yet uncertain clinical significance, is occult HBV infection [30–34]. It is characterized by the persistence of HBV DNA in the liver tissue (± serum) of HBsAg-negative individuals. Recent evidence indicates that this particular form of HBV infection may be present not only in individuals with circulating anti-HBs and/or anti-HBc, but also in subjects negative for all HBV markers [35–37]; it may sometimes be associated with mutant viruses undetectable by commercial HBsAg assays [38]. The molecular bases of occult HBV infection appear to be related to the long-lasting persistence in the nuclei of the hepatocytes of the HBV cccDNA, an intermediate form of the virus life cycle that serves as template for gene transcription [39–41].

Occult HBV infection may have several clinical impacts. It is probably the main mechanism for the rare cases of transfusion-transmitted type B hepatitis that are still occasionally reported [42] and it may provoke HBV infection in recipients in cases of liver or other organ transplantation [43]. The development of an immunosuppressive status (for instance, chemotherapeutic treatments or HIV infection) may induce reactivation of occult HBV with the development of an acute hepatitis B that may have a fulminant course [44,45]. It is not certain whether occult HBV infection may by itself induce clinically significant chronic liver disease. Some studies have indicated its possible association also with cryptogenic liver disease [46] and with cirrhosis in chronic HCV carriers, suggesting that it might favour or accelerate the progression of the chronic hepatitis C [41]. There are data suggesting that occult HBV infection may also be a major risk factor for the development of hepatocellular carcinoma [47,48].

Pathogenesis

Hepatitis B is marked by necrosis of hepatocytes and an accompanying lymphocytic infiltrate. In acute hepatitis, the injury is diffuse, necrosis of individual cells is prominent, there is general cellular unrest, and inflammatory cells are found in the parenchyma and portal areas. Although serious or even fatal hepatitis may occur as a result of acute hepatitis B, the optimal outcome is eradication of infected hepatocytes, curtailment of viral replication and rapid hepatic regeneration. This process may occur in the absence of jaundice and symptoms. However, a proportion of patients exposed to HBV do not clear HBsAg but progress to chronic hepatitis. In chronic hepatitis, the cell injury and unrest are less severe, tend to be periportal, and focal and inflammatory cells are predominantly portal.

While acute and chronic infection are undoubtedly due to the viral infection, the nature and pattern of infection suggest that immunological factors are important [49,50].

In acute hepatitis B the cellular immune response is complex [49,50].

After acute hepatitis, low virus levels persist for decades after resolution of disease. Viral persistence is associated with the long-term persistence of CTL activation markers that maintain CTL response for life [51–54].

Recovery from acute hepatitis is thought to involve destruction of infected cells by CTL and NK cells, and apoptosis [55]. This killing is a T cell-dependent process.

Experiments to ascertain the relative contribution of CD4 and CD8 lymphocytes suggest that in CD8-depleted chimpanzees that CD8 T lymphocytes are the main effectors of viral clearance [56,57]. CTL recognition triggers apoptosis by physical engagement of CTL. Activated cells may produce inflammatory cytokines, especially interferon gamma, alpha, beta and TNF, to activate intracellular antiviral events that interrupt HBV infection. The inhibitory action of these cytokines implicates a non-cytolytic mechanism by which antigen-nonspecific immune responses in part regulate HBV replication in infected hepatocytes [58–60].

The elimination of virus-infected hepatocytes is dependent on the recognition of viral determinants in association with HLA proteins on the infected cells by cytotoxic T cells. In acute disease, a polyclonal and vigorous cytolytic T-cell response can occur [61]. HLA-restricted epitopes from the core, envelope and polymerase and, in particular, several HLA-A2-restricted, cytotoxic T-cell epitopes have been defined [51,62] The HBcAg epitope located between core amino acids 50–69 is most commonly recognised by class II-restricted lymphocytes in patients with acute hepatitis B [63]. Patients with acute, self-limiting hepatitis B also develop a polyclonal, HLA class I-restricted, cytotoxic T-cell response against numerous epitopes in the HBV envelope, nucleocapsid and polymerase proteins [49, 64].

HBV-specific T-cell responses are very weak or totally undetectable in the peripheral blood of patients with long-lasting chronic hepatitis B [65–67]. The persisting ineffective immune response appears to be responsible for liver damage. Chronic HBeAg-positive disease is not infrequently accompanied by acute exacerbations that lead to downregulation of HBV DNA, a decline in HBV DNA and seroconversion to anti-HBe. The

trigger to these exacerbations could conceivably involve a significant alteration in T-cell responsiveness to HBV. Available data suggest, therefore, that clonal deletion of T cells does not occur, albeit that antigen-specific T-cell responsiveness is difficult to discern in HBeAg-positive patients.

Varying levels of HBV replication may be found during chronic infection, but there is a spectrum of disease in patients, ranging from minimal hepatitis to rapidly progressive liver injury and cirrhosis. Patients with the highest concentrations of virus in liver and serum may have the mildest disease. These findings suggest that HBV is not cytopathic and that failure of clearance (establishment of chronic infection) is due to a failure of an adequate immune response. Chronic disease is unusual in patients with acute icteric hepatitis B, whereas the majority of cases of chronic hepatitis will not have been preceded by an episode of clinically apparent, icteric hepatitis, suggesting that the clearance of HBV requires a hepatitic illness.

The propensity to cause chronic infection is a property of hepadnaviral infections, particularly in those mammalian or avian hosts affected early in life. There is an inverse relation between age at infection and the probability of chronic disease.

In neonates, specific suppression of the cell-mediated immune response may favour infection, perhaps because of exposure to HBeAg inducing tolerance to epitopes that are usually the target of the cytotoxic T-cell response at a time when the immune system is ontogenically 'immature'. Clonal deletion of HBV-specific T cells may occur as as a consequence of transplacental infection of the developing fetus or transplacental passage of viral antigens. In murine transgenic experiments, non-transgenic progeny of HBeAg-positive transgenic mothers are known to be tolerant to both HBeAg and HBcAg at the T-cell level, perhaps owing to the thymic deletion of major histocompatibility complex (MHC) class II-restricted, HBV nucleocapsid-specific, helper T cells as a result of transplacental exposure to HBeAg [68].

In contrast with the vigorous, polyclonal, class I- and class II-restricted T-cell response that can be identified in patients with acute icteric hepatitis B, in chronic disease the HLA class II-restricted response in peripheral blood is relatively weak and focused (oligoclonal), and insufficient to clear replicating virus.

Mutations abrogating recognition of wild-type hepatitis B in patients infected by variants have been recognised. Natural variants of the HBcAg 18–27 core epitope that interfere with recognition of the wild-type epitope and act as T cell-receptor antagonists have been identified in two patients with chronic hepatitis [69]. This antagonism could lead, in theory, to an active inhibition of epitope recognition at T cell-receptor contact sites.

The mechanism of the immunological defect in otherwise healthy adult carriers is imprecisely understood. A B-lymphocyte defect may explain an impaired synthesis of anti-HBs after induction by non-specific mitogens; *in vitro* synthesis of anti-HBc and immunoglobulin remain normal in chronic carriers [70]. The high concentrations of HBsAg in the serum may lead to a state of tolerance.

Although the frequency of occurrence of HBV-specific, cytotoxic T-lymphocyte precursors is greatly diminished in the peripheral blood of chronically infected patients, such cells are nonetheless present at very low concentrations in the periphery and in the infected liver [67, 71–73]. This could explain both the continuing, indolent liver injury and exacerbations of the disease.

Acute hepatitis B

Acute hepatitis B resembles other forms of acute hepatitis clinically and cannot be distinguished by history, physical examination or routine serum biochemical tests. The course is divided into the incubation period, preicteric, icteric and convalescence phases. From the incubation period to the onset of symptoms or jaundice it averages 75 days (range 40–140 days).

The onset of hepatitis B is typically insidious, with non-specific symptoms of malaise, poor appetite, nausea and pain in the right upper quadrant. With the onset of the icteric phase, symptoms of fatigue and anorexia typically worsen. Jaundice can last from a few days to several months, the average being 2–3 weeks. Itching and pale stools may occur. Weight loss of 2–10 kg is typical. The convalescent phase of hepatitis B begins with the resolution of jaundice. Fatigue is generally the last symptom to abate and may persist for many months into convalescence.

The physical signs of typical acute hepatitis B are not prominent. Variable degrees of jaundice are present. The only other common physical finding in acute hepatitis B is a mild and slightly tender hepatomegaly. Mild enlargement of spleen or lymph nodes occurs uncommonly. Wasting, ascites, oedema, palmar erythema and prominent spider angiomas should suggest the presence of chronic liver disease.

As in other forms of acute hepatitis, the serum alanine and aspartate aminotransferases are usually markedly elevated and to the same extent (10- to 50-fold). The serum alkaline phosphatase and lactic dehydrogenase are usually only mildly elevated (less than threefold). The bilirubin is variably increased, in both direct and indirect fractions. Serum albumin rarely falls except with protracted severe disease. The prothrombin time can increase and is the most reliable marker of severity of injury. Blood counts do not usually change unless the disease is prolonged or fulminant. Various autoantibodies can appear during the course of acute hepatitis B, most typically to smooth muscle.

The results of serological testing provide the means for diagnosis of hepatitis B. The course of a 'typical' case of acute hepatitis B is shown in Figure 2. Tests for HBV DNA in serum are the most direct markers for assessing viral replication. The polymerase chain reaction technique for the detection of DNA has been adapted to the detection of HBV DNA in serum and liver. This technique is capable of detecting as few as 50–100 viral genomes per sample. In a number of patients with acute hepatitis B, the serological course may be atypical; these patients clear HBsAg rapidly and are negative for this viral marker when first seen by the physician. The diagnosis of acute hepatitis B can

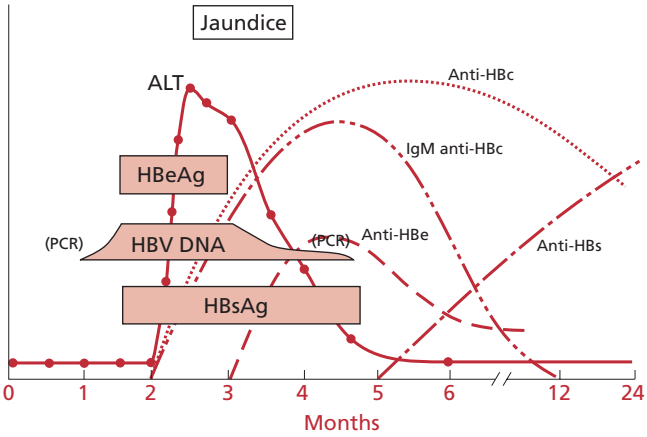

Fig. 2 Serological course of acute hepatitis B. ALT, alanine aminotransferase; PCR, polymerase chain reaction.

be made in these circumstances by detection of IgM anti-HBc, which is present in high titres.

In a small proportion of patients with acute hepatitis B, the disease may worsen over 1–3 months, with increasing jaundice, deteriorating coagulation, ascites, bleeding and encephalopathy. The serum aminotransferases may paradoxically improve as the disease worsens. Submassive hepatic necrosis, as the disease is also known, is more common in patients older than 40 years. Histopathological examination may reveal bridging or massive hepatic necrosis. The prognosis is poor.

Fulminant hepatitis refers to a clinical condition with rapid onset and development of acute hepatic failure, with encephalopathy, coma and death in more than 70% of cases. Fulminant hepatitis B is also an atypical course for this infection, occurring in less than 1% of icteric cases. Hepatitis D coinfection may predispose to fulminant hepatitis. The prevalence is approximately 2/1000 icteric cases. The mortality varies with the age of the patient. The onset of symptoms may also be insidious. Morphologically, the liver shows massive multilobular or bridging necrosis. The development of hepatic encephalopathy is the clinical criterion used for diagnosis of fulminant hepatitis. Encephalopathy may first be manifested by a subtle change in personality, abusive or violent behaviour, confusion or extreme lassitude. With progressive disease, stuporousness and then coma develop. Jaundice deepens progressively. With protracted disease, ascites may appear. Serum aminotransferases, while high at the onset of disease, may fall as the patient deteriorates. Serum bilirubin rises and albumin falls progressively. Most ominous, however, is a progressive rise in the prothrombin time, reflecting decreases in coagulation factors synthesized by the liver, particularly factors V and VII. Typically, in fulminant disease, HBV DNA and HBeAg become undetectable as hepatic failure supervenes. The pattern of serological markers during the course of fulminant hepatitis B suggests that this outcome is due to a sudden and extreme immunological response to HBV infection.

Chronic hepatitis B

The persistence of abnormal ALT activity for more than 6 months after the onset of acute hepatitis B is indicative of disease progression, and is usually accompanied by serological evidence of continued infection.

Prospective studies conducted by several groups have observed that 5–10% of adults exposed to the HBV may develop chronic type B viral liver disease [74]. The proportion of symptomatic patients who develop chronic liver disease after acute hepatitis B may be lower than this. In contrast, 90% of neonates infected perinatally will develop chronic hepatitis B. The incidence in children is inversely related to the age of onset. Males are more likely to become chronic carriers than females. Chronic hepatitis B is rather variable in its clinical course, presentation, progression and outcome. Two forms can be distinguished.

HBeAg-positive chronic hepatitis B

HBeAg-positive disease is typically associated with high levels of HBV replication for a prolonged period of time. The disease is found in young individuals with chronic hepatitis B, who have high levels of HBV DNA (usually > 10^7 copies/mL) in serum. Early on they may have been 'immunotolerant' of the disease, with normal serum aminotransferases (ALT), and have developed the ALT increase disease ('active infection') at a later stage. Spontaneous seroconversion rates are higher in patients with raised levels of ALT and genotype B (vs. C) and genotype D (vs. A) of HBV. The disease is not infrequently acquired in early childhood or the neonatal period in endemic areas. Patients may have normal or near normal ALT levels for decades, with little necroinflammatory disease. Importantly, patients with normal serum ALT levels and high circulating concentrations of HBV DNA display profound peripheral immunological tolerance. It is difficult to discern antigen-specific T cells in blood or in the liver. Treatment of these patients remains difficult, probably for this reason. These individuals are poor responders to interferon therapy and poor short-term responders to nucleoside or nucleotide antiviral drugs. Spontaneous seroconversion rates remain low in this group.

HBeAg-negative, anti-HBe-positive disease

This form of chronic hepatitis B is characterized by the absence of HBeAg in serum as a result of genotypic changes preventing expression of HBeAg. Viral replication continues and patients show an active disease course characterized typically by fluctuations in levels of HBV replication and, not infrequently, fluctuations in levels of serum ALT. These patients are HBsAg-positive and anti-HBe positive. HBV DNA concentrations are typically > 10^5 copies/mL but < 10^7 copies/mL. Liver biopsy shows necroinflammation and varying stages of fibrosis. Sustained antiviral responses are difficult to achieve with this group after both interferon and nucleoside analogue therapy.

Only a small percentage of patients with chronic infection give a history of acute hepatitis or jaundice. Thus, for the majority of patients with chronic hepatitis B, the time of onset is unknown, a circumstance that is typical of perinatal and childhood infection in endemic areas.

Most patients with uncomplicated chronic hepatitis B have no symptoms of liver disease. If symptoms are present, they are usually non-specific and mild. The most common symptom is fatigue. Myalgias, arthralgias and transient skin rashes are common extrahepatic manifestations of chronic hepatitis B, which may be due to immune complex deposition and occur more frequently in women than in men. With the development of cirrhosis, weight loss, weakness, wasting, abdominal swelling, oedema, dark urine and jaundice may become progressive problems. Many carriers may be detected through routine screening for HBsAg or through the presence of hepatomegaly and abnormal liver function tests. Older patients may present with complications of chronic active hepatitis and cirrhosis, or even with hepatocellular carcinoma, as typically occurs in Africa. A proportion of patients may present with an extrahepatic manifestation of HBV infection, for example glomerulonephritis, vasculitis or polyarteritis. HBV is an important cause of glomerulonephritis in tropical areas. Immunoelectron microscopy has been used to localize 'membrane attack complexes' and HBeAg to subepithelial deposits. With more severe disease, there may be spider angiomas and hepatomegaly. Wasting, ascites, peripheral oedema, palmar erythema, pale nails and bruising suggest advanced disease with cirrhosis. In patients with extrahepatic manifestations, there may be oedema from glomerulonephritis and hypoproteinaemia, fleeting urticarial or maculopapular rashes from mucocutaneous vasculitis, or mild tenderness, redness and synovial thickening from hepatitis B-related arthritis. The features of portal hypertension, such as ascites and bleeding oesophageal varices, are late features of a chronic active hepatitis accompanying cirrhosis.

Laboratory test results in typical, uncomplicated chronic hepatitis B are characteristic, demonstrating increases in alanine and aspartate aminotransferases with little or no increase in alkaline phosphatase, γ-glutamyltransferase or lactic dehydrogenase. The aminotransferases fluctuate over time, generally ranging from just above normal to between five- and eightfold elevated. Multiple ALT flares, accompanied by peaks of HBV viremia alternating with prolonged periods of biochemical and viral quiescence, are typical of chronic HBeAg-negative hepatitis B, occurring in as many as 60% of these patients.

Aspartate aminotransferase is usually lower than alanine aminotransferases. Serum bilirubin and albumin, the prothrombin time and the sedimentation rate are normal unless the disease is particularly severe. Serum immunoglobulins may demonstrate mild increases in IgG.

More emphasis is now placed on grading the degree of inflammation and staging the extent of fibrosis. Numerical assessments of liver biopsy findings have been developed as a tool for studying the course of chronic hepatitis B and for judging the efficacy of drugs in clinical therapeutic trials. There is consensus that scoring of the microinflammatory lesions should be separated from scoring of the architectural changes in the liver.

With progressive disease and the development of cirrhosis from chronic hepatitis B, the laboratory test results will change, becoming progressively more abnormal. By and large, the severity of the current injury and hepatitic disease activity is best reflected in the aminotransferase abnormalities, particularly aspartate. As cirrhosis develops, the ratio of aspartate aminotransferase:alanine aminotransferase will gradually increase; the finding of aspartate greater than alanine aminotransferase therefore suggests the presence of cirrhosis. In addition, alkaline phosphatase and γ-glutamyltransferase will increase, serum albumin will fall, and the prothrombin time will become prolonged with the onset of cirrhosis and worsening hepatocellular function. Autoantibodies, particularly smooth muscle autoantibodies and rheumatoid factor, may become detectable, and the immunoglobulins will increase in concentration, a raised IgA being particularly suggestive of cirrhosis. Hyperbilirubinaemia with depressed albumin and prolonged prothrombin time are poor prognostic findings.

A varying immune responsiveness plays a critical role in determining the outcome and pathogenesis of acute and chronic hepatitis B. It is likely that immune responses induced by antiviral therapy play a similar pivotal role. However, critical differences may occur in the two major forms of active chronic hepatitis B that usually require treatment: wild-type or HBeAg-positive chronic HBV infection and anti-HBe-positive or precore mutant disease. HBeAg seroconversion during antiviral therapy in HBeAg-positive disease may require an appropriate host T-cell response, which unfortunately is abrogated or dysfunctional in most patients.

Patients with an active infection and disease may revert to an inactive carrier state with remission of disease activity either spontaneusly or after antiviral therapy. These patients are HBeAg-negative, anti-HBe-positive with lower HBV DNA levels ($\leq 10^4$ copies/mL) and little or no necroinflammation or fibrosis, depending on the timing of seroconversion. The disease may be a retrospective–prospective diagnosis as inactive carriers show some propensity to reactivation.

The subsequent course of chronic hepatitis B is variable (Fig. 3). Patients with chronic infection may have a relatively benign outcome. Probably only 15–20% of patients who acquire this infection in adulthood ultimately develop cirrhosis and any chronic disability. Furthermore, the development of cirrhosis is usually slow, occurring over 5–20 years. Infection in childhood may have a different prognosis, with a higher percentage of persons ultimately developing cirrhosis and hepatocellular carcinoma. Typically, the infection is mild in childhood and associated with few symptoms and minimal elevations of the aminotransferases. However, the disease may change once adulthood is reached, with marked fluctuations in its activity and the development of cirrhosis in up to 40% of patients.

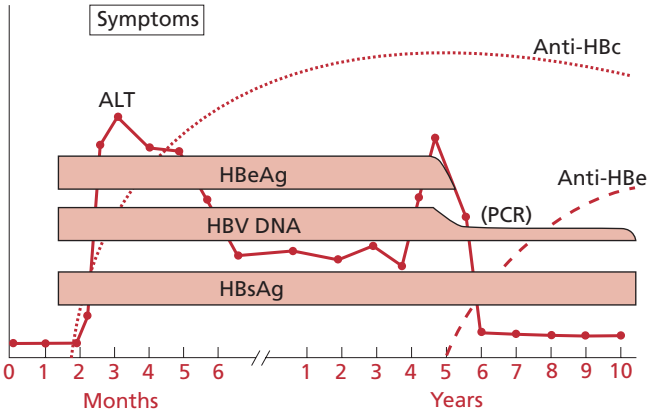

Fig. 3 Serological course of chronic hepatitis B. ALT, alanine aminotransferase; PCR, polymerase chain reaction.

Observations on large numbers of patients with chronic hepatitis B indicate that its course and outcome correlate with serological markers of viral replication. In a European analysis, 366 Caucasian HBsAg-positive patients with cirrhosis who had never had clinical manifestations of hepatic decompensation were enrolled and followed for a mean period of 72 months. Death occurred in 23%, mainly from liver failure or hepatocellular carcinoma. The probability of survival was 84% and 68% at 5 and 10 years respectively. The worst survival was in HBeAg- and HBV DNA-positive individuals (at diagnosis) [75]. Thus, progressive disease is associated with persistence of viral replication, and remission is associated with loss of active viral replication. The exacerbations associated with the decline in viral replication, or the reactivation of viral replication causing a recurrence of disease, can be severe and life-threatening. Indeed, the pattern of recurrent reactivation with multiple remissions and recurrences is a particularly severe form of this chronic infection, frequently leading to cirrhosis and, ultimately, hepatic failure.

Chronic hepatitis B can lead to hepatocellular carcinoma, which is a common form of cancer in many areas of the world where chronic hepatitis B is also common. Furthermore, a large percentage of patients with hepatocellular carcinoma have chronic HBV infection. Epidemiological and clinical studies suggest that hepatocellular carcinoma is a complication of prolonged HBV infection, most patients having had the disease for several decades before diagnosis of the carcinoma. Indeed, the majority of patients with this cancer also have cirrhosis, although it is often mild and inactive.

In a large European study, hepatocellular carcinoma developed during a mean follow-up of 6 years in 9% of 317 patients with compensated hepatic cirrhosis. Five years after diagnosis, the probability of hepatocellular carcinoma appearing was 6% (and that of decompensation 28%). After the first episode of decompensation, the 5-year probability of survival (35%) was poor [76].

Hepatocellular carcinoma is more common in men than in women and appears to be most common in patients who acquire HBV infection in childhood rather than in adulthood. Hepatocellular carcinoma is discussed elsewhere. In endemic areas of HBV infection, HBV carriers frequently have silent disease until the development of advanced hepatocellular carcinoma. For these reasons, ultrasonographic examinations and regular determinations of α-fetoprotein can be used to screen for hepatocellular carcinoma in high-risk populations. The populations at highest risk are men over the age of 40 years who acquired HBV infection during childhood and who have cirrhosis.

Although a large body of scientific evidence has confirmed a relation between chronic HBV infection and hepatocellular carcinoma, the mechanism of oncogenesis is not known. Exogenous factors may speed the process of oncogenesis, but chronic HBV infection must be considered as an important independent risk factor. The pathogenesis of HBV-associated hepatocellular carcinoma is unknown, however, and may be related to the phasic necrosis, regeneration and cirrhosis induced as a result of HBsAg infection. Although the molecular mechanism of HBV-associated carcinogenesis is unknown, HBV may have a direct cytogenetic role. Integration of the HBV genome into the hepatocyte DNA may be an important initiating factor. It is postulated that the development of hepatocellular carcinoma could be by insertional mutagenesis, or by the production of novel fusion genes, chromosomal deletions and translocations associated with HBV integration, or by loss of tumour-suppressor alleles or, as in woodchucks, by c-*myc* oncogene amplification. A retinoic acid receptor is expressed at high concentration in human hepatocellular carcinoma, in association with HBV integration [77]. Recent evidence has suggested that the translational product of the X gene, a 17-kDa protein, is a transactivating factor for viral enhancers and that, in cotransfection experiments, the X gene encodes a protein with the ability to stimulate transcription. The X-gene product does not bind DNA directly, but a number of effects of HBx on cell growth and cell cycle progression have been reported. Exposure to aflatoxin may be important in some geographical regions. A genetic susceptibility to hepatocellular carcinoma associated with genetic variation in enzymatic detoxification of aflatoxin has been reported.

In some parts of the world, codon 249 mutations in p53 are associated with aflatoxin exposure. The increased formation of carcinogen–DNA adducts may represent one mechanism adding to the association between chronic hepatitis B infection and the development of hepatocellular carcinoma [78,79].

References

1 Tiollais P, Pourcel C, Dejean A (1985) The hepatitis B virus. *Nature* 317, 489–495.
2 Hoofnagle JH, Shafritz DA, Popper H (1987) Chronic type B hepatitis and the 'healthy' HBsAg carrier state. *Hepatology* 7, 758–763.
3 Le Bouvier GL (1971) The heterogeneity of Australia antigen. *J Infect Dis* 123, 671–675.

4 Summers J, O'Connell A, Millman I (1975) Genome of hepatitis B virus: restriction of enzyme cleavage and structure of DNA extracted from Dane particles. *Proc Natl Acad Sci USA* 72, 4597–4601.
5 Szmuness W, Stevens CE, Harley EJ *et al.* (1980) Hepatitis B vaccine. Demonstration of efficacy in a controlled clinical trial in a high-risk population in the United States. *N Engl J Med* 303, 833–841.
6 Galibert F, Mandart E, Fitoussi F *et al.* (1979) Nucleotide sequence of the hepatitis B virus genome (subtype ayw) cloned in *E. coli*. *Nature* 281, 646–650.
7 Summers J, Smolec J, Snyder R (1978) A virus similar to human hepatitis B virus associated with hepatitis and hepatoma in woodchucks. *Proc Natl Acad Sci USA* 75, 4533–4537.
8 Alter MJ, Margolis HS (1990) The emergence of hepatitis B as a sexually transmitted disease. *Med Clin North Am* 74, 1529–1542.
9 Kaneko S, Miller RH, Feinstone SM *et al.* (1989) Detection of serum hepatitis B virus DNA in patients with chronic hepatitis using the polymerase chain reaction assay. *Proc Natl Acad Sci USA* 86, 312–316.
10 Botha JF, Ritchie MJ, Dusheiko GM *et al.* (1984) Hepatitis B virus carrier state in black children in Ovamboland: role of perinatal and horizontal infection. *Lancet* 1(8388), 1210–1212.
11 Dusheiko GM, Bowyer SM, Sjogren MH *et al.* (1985) Replication of hepatitis B virus in adult carriers in an endemic area. *J Infect Dis* 152, 566–571.
12 Anderson B, Bodsworth NJ, Rohrsheim RA *et al.* (1994) Hepatitis B virus infection and vaccination status of high risk people in Sydney: 1982 and 1991. *Med J Aust* 161, 368–371.
13 Carman WF, Jacyna MR, Hadziyannis S *et al.* (1989) Mutation preventing formation of hepatitis B e antigen in patients with chronic hepatitis B infection. *Lancet* 2, 588–591.
14 Brunetto MR, Stemler M, Shodell F *et al.* (1989) Identification of HBV variants which cannot produce pre-core derived HBeAg and may be responsible for severe hepatitis. *Ital J Gastroenterol* 21, 151–154.
15 Buckwold VE, Xu ZC, Chen M *et al.* (1996) Effects of a naturally occurring mutation in the hepatitis B virus basal core promoter on precore gene expression and viral replication. *J Virol* 70, 5845–5851.
16 Moriyama K, Okamoto H, Tsuda F *et al.* (1996) Reduced precore transcription and enhanced core-pregenome transcription of hepatitis B virus DNA after replacement of the precore-core promoter with sequences associated with e antigen-seronegative persistent infections. *Virology* 226, 269–280.
17 Lok ASF, Akarca U, Greene S (1994) Mutations in the pre-core region of hepatitis B virus serve to enhance the stability of the secondary structure of the pre-genome encapsidation signal. *Proc Natl Acad Sci USA* 91, 4077–4081.
18 Funk ML, Rosenberg DM, Lok AS (2002) World-wide epidemiology of HBeAg-negative chronic hepatitis B and associated precore and core promoter variants. *J Viral Hepat* 9, 52–61.
19 Yap I, Wee A, Guan R (1991) Chronic hepatitis B infection in Singapore. *Sing Med J* 32, 352–355.
20 Laras A, Koskinas J, Avgidis K *et al.* (1998) Incidence and clinical significance of hepatitis B virus precore gene translation initiation mutations in e antigen-negative patients. *J Viral Hepat* 5, 241–248.
21 Rizzetto M, Gaeta GB (2004) The expanding territory of HBeAg negative chronic hepatitis B. In: Jilbert AR (ed.) *Proceedings of the 11th International Symposium on Viral Hepatitis and Liver Disease.* Australian Centre for Hepatitis Virology, pp. 66–71.
22 Zazski JP, Marcellin P, Leroy V *et al.* (2006) Characteristics of patients with chronic hepatitis B in France: predominant frequency of HBe antigen negative cases. *J Hepatol* 45, 355–360.
23 Karasawa T, Shirasawa T, Okawa Y *et al.* (1997) Association between frequency of amino acid changes in core region of hepatitis B virus (HBV) and the presence of precore mutation in Japanese HBV carriers. *J Gastroenterol* 32, 611–622.
24 Nakahori S, Yokosuka O, Ehata T *et al.* (1995) Detection of hepatitis B virus precore stop codon mutants by selective amplification method: frequent detection of precore mutants in hepatitis B e antigen positive healthy carriers. *J Gastroenterol Hepatol* 10, 419–425.
25 Kim WH, Kim KH, Chung JP *et al.* (1993) Mutations in the pre-core region of hepatitis B virus DNA in patients with chronic liver diseases. *Yonsei Med J* 34, 158–165.
26 Guptan RC, Thakur V, Sarin SK *et al.* (1996) Frequency and clinical profile of precore and surface hepatitis B mutants in Asian–Indian patients with chronic liver disease. *Am J Gastroenterology* 91, 1312–1317.
27 Lai CL, Ratziu V, Yuen MF *et al.* (2003) Viral hepatitis B. *Lancet* 362(9401), 2089–2094.
28 Keeffe EB, Dieterich DT, Han SH *et al.* (2004) A treatment algorithm for the management of chronic hepatitis B virus infection in the United States. *Clin Gastroenterol Hepatol* 2, 87–106.
29 Lok AS, McMahon BJ (2004) Chronic hepatitis B: update of recommendations. *Hepatology* 39, 857–861.
30 Raimondo G, Balsano C, Craxi A *et al.* (2000) Occult hepatitis B virus infection. *Dig Liver Dis* 32, 822–826.
31 Brechot C, Thiers V, Kremsdorf D *et al.* (2001) Persistent hepatitis B virus infection in subjects without hepatitis B surface antigen: clinically significant or purely 'occult'? *Hepatology* 34, 194–203.
32 Hu KQ (2002) Occult hepatitis B virus infection and its clinical implications. *J Viral Hepat* 9, 243–257.
33 Torbenson M, Thomas DL (2002) Occult hepatitis B. *Lancet Infect Dis* 2, 479–486.
34 Liang TJ, Baruch Y, Ben-Porath E *et al.* (1991) Hepatitis B virus infection in patients with idiopathic liver disease. *Hepatology* 13, 1044–1051.
35 Cacciola I, Pollicino T, Squadrito G *et al.* (1999) Occult hepatitis B virus infection in patients with chronic hepatitis C liver disease. *N Engl J Med* 341, 22–26.
36 Zhang YY, Hansson BG, Kuo LS *et al.* (1993) Hepatitis B virus DNA in serum and liver is commonly found in Chinese patients with chronic liver disease despite the presence of antibodies to HBsAg. *Hepatology* 17, 538–544.
37 Carman W, Thomas H, Domingo E (1993) Viral genetic variation: Hepatitis B virus as a clinical example. *Lancet* 341, 349–353.
38 Pollicino T, Squadrito G, Cerenzia G *et al.* (2004) Hepatitis B virus maintains its pro-oncogenic properties in the case of occult HBV infection. *Gastroenterology* 126, 102–110.
39 Wieland SF, Spangenberg HC, Thimme R *et al.* (2004) Expansion and contraction of the hepatitis B virus transcriptional template in infected chimpanzees. *Proc Natl Acad Sci USA* 101, 2129–2134.
40 Werle-Lapostolle B, Bowden S, Locarnini S *et al.* (2004) Persistence of cccDNA during the natural history of chronic hepatitis B and decline during adefovir dipivoxil therapy. *Gastroenterology* 126, 1750–1758.
41 Raimondo G, Pollicino T, Squadrito G (2005) What is the clinical impact of occult hepatitis B virus infection? *Lancet* 365(9460), 638–640.

42 Allain JP (2004) Occult hepatitis B virus infection: implications in transfusion. *Vox Sang* 86, 83–91.

43 Chazouilleres O, Mamish D, Kim M *et al.* (1994) 'Occult' hepatitis B virus as source of infection in liver transplant recipients. *Lancet* 343(8890), 142–146.

44 Waite J, Gilson RJ, Weller IV *et al.* (1988) Hepatitis B virus reactivation or reinfection associated with HIV-1 infection. *AIDS* 2, 443–448.

45 Grumayer ER, Panzer S, Ferenci P *et al.* (1989) Recurrence of hepatitis B in children with serologic evidence of past hepatitis B virus infection undergoing antileukemic chemotherapy. *J Hepatol* 8, 232–235.

46 Chemin I, Zoulim F, Merle P *et al.* (2001) High incidence of hepatitis B infections among chronic hepatitis cases of unknown aetiology. *J Hepatol* 34, 447–454.

47 Brechot C, Gozuacik D, Murakami Y *et al.* (2000) Molecular bases for the development of hepatitis B virus (HBV)-related hepatocellular carcinoma (HCC). *Semin Cancer Biol* 10, 211–231.

48 Squadrito G, Pollicino T, Cacciola I *et al.* (2006) Occult hepatitis B virus infection is associated with the development of hepatocellular carcinoma in chronic hepatitis C patients. *Cancer* 106, 1326–1330.

49 Chisari FV, Ferrari C (1995) Hepatitis B virus immunopathogenesis. *Annu Rev Immunol* 13, 29–60.

50 Webster GJ, Reignat S, Maini MK *et al.* (2000) Incubation phase of acute hepatitis B in man: dynamic of cellular immune mechanisms. *Hepatology* 32, 1117–1124.

51 Rehermann B, Fowler P, Sidney J *et al.* (1995) The cytotoxic T lymphocyte response to multiple hepatitis B virus polymerase epitopes during and after acute viral hepatitis. *J Exp Med* 181, 1047–1058.

52 Rehermann B, Ferrari C, Pasquinelli C *et al.* (1996) The hepatitis B virus persists for decades after patients' recovery from acute viral hepatitis despite active maintenance of a cytotoxic T-lymphocyte response. *Nat Med* 2, 1104–1108.

53 Rehermann B (2003) Immune responses in hepatitis B virus infection. *Semin Liver Dis* 23, 21–38.

54 Rehermann B, Nascimbeni M (2005) Immunology of hepatitis B virus and hepatitis C virus infection. *Nat Rev Immunol* 5, 215–229.

55 Whalley SA, Murray JM, Brown D *et al.* (2001) Kinetics of acute hepatitis B virus infection in humans. Journal of Experimental Medicine 2001; 193, 847–853.

56 Guidotti LG, Ando K, Hobbs MV *et al.* (1994) Cytotoxic T lymphocytes inhibit hepatitis B virus gene expression by a noncytolytic mechanism in transgenic mice. *Proc Natl Acad Sci USA* 91, 3764–3768.

57 Guidotti LG, Rochford R, Chung J *et al.* (1999) Viral clearance without destruction of infected cells during acute HBV infection. *Science* 284, 825–829.

58 Romero R, Lavine JE (1996) Cytokine inhibition of the hepatitis B virus core promoter. *Hepatology* 23, 17–23.

59 Koziel MJ (1999) What once was lost, now is found: restoration of hepatitis B-specific immunity after treatment of chronic hepatitis B (Comments). *Hepatology* 29, 1331–1333.

60 Koziel MJ (1999) Cytokines in viral hepatitis. *Semin Liver Dis* 19, 157–169.

61 Van Hecke E, Paradijs J, Molitor C *et al.* (1994) Hepatitis B virus-specific cytotoxic T lymphocyte responses in patients with acute and chronic hepatitis B virus infection. *J Hepatol* 20, 514–523.

62 Rehermann B, Pasquinelli C, Mosier SM *et al.* (1995) Hepatitis B virus (HBV) sequence variation in cytotoxic T lymphocyte epitopes is not common in patients with chronic HBV infection. *J Clin Invest* 96, 1527–1534.

63 Ferrari C, Penna A, Bertoletti A *et al.* (1990) Cellular immune response to hepatitis B virus-encoded antigens in acute and chronic hepatitis B virus infection. *J Immunol* 145, 3442–3449.

64 Penna A, Chisari FV, Bertoletti A *et al.* (1991) Cytotoxic T lymphocytes recognize an HLA-A2-restricted epitope within the hepatitis B virus nucleocapsid antigen. *J Exp Med* 174, 1565–1570.

65 Jung MC, Pape GR (2002) Immunology of hepatitis B infection. *Lancet Infect Dis* 2, 43–50.

66 Ferrari C, Penna A, Bertoletti A *et al.* (1998) Antiviral cell-mediated immune responses during hepatitis B and hepatitis C virus infections. Recent Results Cancer Res 154, 330–336.

67 Webster GJ, Reignat S, Brown D *et al.* (2004) Longitudinal analysis of CD8+ T cells specific for structural and nonstructural hepatitis B virus proteins in patients with chronic hepatitis B: implications for immunotherapy. *J Virol* 78, 5707–5719.

68 Milich DR, Jones JE, Hughes JL (1990) Is a function of the secreted hepatitis B e antigen to induce immunologic tolerance *in utero*? *Proc Natl Acad Sci USA* 87, 6599–6603.

69 Bertoletti A, Costanzo A, Chisari FV *et al.* (1994) Cytotoxic T lymphocyte response to a wild type hepatitis B virus epitope in patients chronically infected by variant viruses carrying substitutions within the epitope. *J Exp Med* 180, 933–943.

70 Dusheiko GM, Hoofnagle JH, Cooksley WG *et al.* (1983) Synthesis of antibodies to hepatitis B virus by cultured lymphocytes from chronic hepatitis B surface antigen carriers. *J Clin Invest* 71, 1104–1113.

71 Barnaba V, Franco A, Alberti A *et al.* (1989) Recognition of hepatitis B virus envelope proteins by liver-infiltrating T lymphocytes in chronic HBV infection. *J Immunol* 143, 2650–2655.

72 Bertoletti A, Chisari FV, Penna A *et al.* (1993) Definition of a minimal optimal cytotoxic T-cell epitope within the hepatitis B virus nucleocapsid protein. *J Virol* 67, 2376–2380.

73 Maini MK, Boni C, Ogg GS *et al.* (1999) Direct *ex vivo* analysis of hepatitis B virus-specific $CD8^+$ T cells associated with the control of infection. Gastroenterology 117, 1386–1396.

74 Shah N, Ostrow D, Altman N *et al.* (1985) Evolution of acute hepatitis B in homosexual men to chronic hepatitis B. Prospective study of placebo recipients in a hepatitis B vaccine trial. *Arch Intern Med* 145, 881–882.

75 Realdi G, Fattovich G, Hadziyannis S *et al.* (1994) Survival and prognostic factors in 366 patients with compensated cirrhosis type B: a multicenter study. *J Hepatol* 21, 656–666.

76 Fattovich G, Giustina G, Schalm SW *et al.* (1995) Occurrence of hepatocellular carcinoma and decompensation in Western European patients with cirrhosis type B. *Hepatology* 21, 77–82.

77 Benbrook D, Lernhardt E, Pfahl M (1988) A new retinoic acid receptor identified from a hepatocellular carcinoma. *Nature* 333(6174), 669–672.

78 Kirk GD, Turner PC, Gong Y *et al.* (2005) Hepatocellular carcinoma and polymorphisms in carcinogen-metabolizing and DNA repair enzymes in a population with aflatoxin exposure and hepatitis B virus endemicity. *Cancer Epidemiol Biomarkers Prev* 14, 373–379.

79 Kirk GD, Camus-Randon AM, Mendy M *et al.* (2000) Ser-249 p53 mutations in plasma DNA of patients with hepatocellular carcinoma from the Gambia. *J Natl Cancer Inst* 92, 148–153.

9.1.2.v Hepatitis D

Antonella Smedile and Mario Rizzetto

Definition

Hepatitis D, also named hepatitis delta [1], is a disease caused by the hepatitis delta (D) virus (HDV), a unique hepatotropic human pathogen requiring obligatory helper functions provided by the hepatitis B virus (HBV) for *in vivo* infection. The virion of HDV is a particle of 36 nm diameter coated by the HB surface antigen (HBsAg), inside which are sequestered the RNA genome and the HD antigen (HDAg). The deltavirus genus includes at least eight major clades [2]. The three major genotypes, designated I, II and III, differ by as much as 40% over the entire genome and have different geographical prevalences [3,4]; two subgroups have been identified within genotypes I and II, named genotype IA and IB and genotype IIA and IIB.

Natural history

HDV can establish infection only in patients simultaneously infected by HBV [5]. It usually modifies the natural history of the underlying HBV infections upon which it thrives, aggravating pre-existent hepatitis B by adding HDV damage or creating hepatitis D in healthy carriers of HBV. Hepatitis D is a distinct medical entity that, as a rule, is more severe than disease caused by HBV alone [6–8]. Persons susceptible to HBV or already infected by it are susceptible to HDV and, therefore, hepatitis D occurs in two settings: in a normal person simultaneously infected by HDV–HBV (coinfection) or in a carrier of HBsAg superinfected by HDV (superinfection). Persons protected from HBV by the acquisition of antibody to HBsAg (anti-HBs) are protected from HDV.

Coinfection

In this setting, transmission of HDV is attained by infectious inocula containing both HBV and HDV (Fig. 1). Infection with HDV demands that the helper HBV be activated first, thus providing the functions (mainly the HBsAg) necessary for the activation of HDV [6–8].

As HDV cannot replicate until HBV has infected hepatocytes, the expression of the defective virus depends on (and is limited by) the virulence of the associated HBV. Slow spread of HBV to hepatocytes either fails to support HDV or supports only an abortive infection; rapid spread provides enough vulnerable hepatocytes for the defective virus to be activated to a clinically significant degree.

Because of the complex interactions between the two viruses, the expression of HDV is variable, ranging from incomplete to very virulent. However, as in normal individuals who are coinfected with the two viruses the background HBV infection is usually self-limiting and HDV cannot outlive the elimination of its helper virus, acute HBV–HDV coinfections are rarely progressive and cause chronic liver disease in only about 2% of cases.

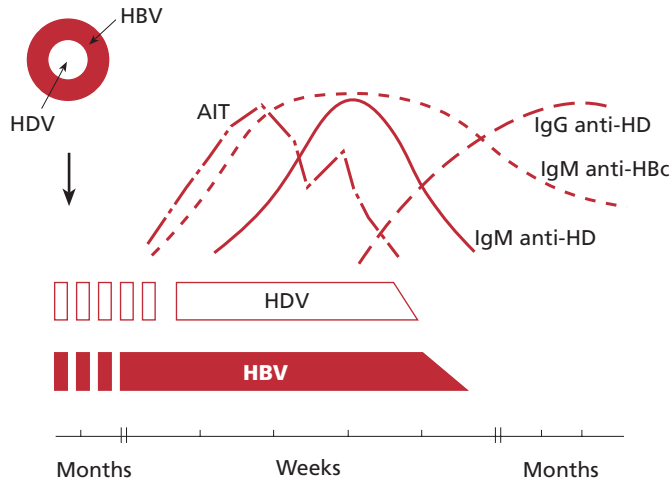

Fig. 1 Course of typical HBV–HDV coinfection; AIT, alanine aminotransferase. IgG anti-HD, IgG antibody to HDV; IgM anti-HD, IgM antibody to HDV; IgM anti-HBC, IgM antibody to hepatitis B core antigen.

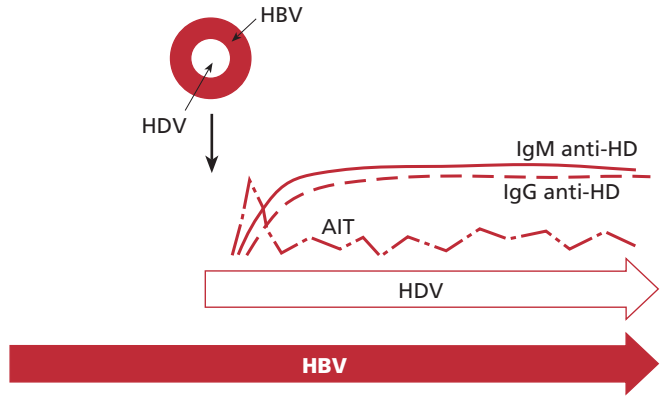

Fig. 2 Course of typical HDV superinfection in HBsAg carriers; AIT, alanine aminotransferase.

Superinfection

A pre-existing HBV infection (with production of HBsAg) provides the ideal background for the activation of the superinfecting HDV, affording a highly susceptible substrate that permits the rapid amplification of the defective pathogen (Fig. 2). In this setting, HDV establishes infection independently of the virulence of the HBV with which it was associated in the original inoculum; the helper function necessary for HDV replication is provided by the HBV colonizing the host. A pre-existing HBsAg state may rescue minimal amounts of HDV, and biological material containing HDV that is not infectious to the normal person (because the accompanying HBV is unable to establish

its own helper infection) can nevertheless transmit hepatitis D to the carrier of HBsAg [6–8].

With superinfection, HDV transcapsidates from the HBsAg coat worn in the original inoculum to the coat made available by the HBV of the superinfected host, a process that also takes place with interspecies passage of HDV to animals infected with hepadnaviruses different from HBV [9].

Although superinfection can be self-limiting, it most often results in chronic HDV infection. As continuing production of HBsAg secures the indefinite survival of HDV, providing the biological niche in which it can replicate and from which it can seed continuously, the chronic carrier of HBsAg/HDV represents the main epidemiological reservoir and source of the virus [10].

Diagnosis

Screening for HDV relies primarily on indirect antibody testing; this is the first step in diagnosing hepatitis D [11]. The immunoglobulin (Ig)M antibody to HDV (IgM anti-HD) is detected transiently in acute hepatitis D with a mean delay of 7–15 days from admission [12]. It may be the only serum marker of acute HDV infection and persists, increasing in titre as hepatitis D progresses to chronicity.

During primary infections, the IgM antibody consists of pentameric 19S molecules [13]; in chronic infections, monomeric 7S molecules become prevalent. The IgM antibody was considered to be an indicator of HDV-related liver damage, but this role has been questioned.

The IgG antibody to HDV (anti-HD) is not protective; in immunocompetent patients with ongoing HDV infection, it coexists with concurrent replication of HDV. It may also be present as a serological 'scar' in patients whose double HBV–HDV infection has resolved. It is raised in acute hepatitis D and increases to high titres as HDV infection progresses to chronicity [6].

The finding in serum or liver of HDV RNA or of hepatitis D antigen (HDAg) establishes the presence of active HDV infection. The intrahepatic antigen can be demonstrated by immunohistological techniques in frozen and in fixed liver specimens [11,14]; fixed material must be predigested with protease. HDV genotypes can also be determined in liver tissue by immunohistochemistry [15]. The intrahepatic expression of HDAg decreases as the disease progresses, thus increasing the probability of a false-negative result caused by sampling variation in needle liver biopsies.

The HDV genome can be detected in formalin-fixed, paraffin-embedded liver sections by radioactive and non-radioactive *in situ* hybridization techniques [16].

Solid-phase immunosorbent tests for the measurement of HDAg in serum can detect antigen only during the early stage of primary infection, before the development of anti-HD; when the antibody appears in blood, HDAg is masked in immune complexes that render it unavailable to the assay.

The introduction of reverse transcriptase and polymerase chain reaction (PCR)-based assays for the detection of HDV RNA has increased the limit of sensitivity to less than 10 genome molecules per assay [17]. The use of PCR assays has shown that virtually all HBsAg carriers with chronic hepatitis D have continuing HDV replication. The PCR assay is also useful in early diagnosis and in monitoring the effect of therapy with interferon [18]. The choice of suitable primers for the amplification of HDV RNA is difficult because of the extensive sequence heterogeneity of the different viral isolates; only a few conserved regions exist in the HDV genome, and secondary and tertiary constraints may further reduce the efficiency of reverse transcription. Amplification of the C-terminal half of the HDAg coding region ensures the highest degree of efficiency. A reverse transcription PCR and a quantitative PCR have been developed recently [19]. The HDV genotype may be determined in serum by restriction fragment length polymorphism analysis of PCR amplification products or by sequencing.

Epidemiology

HDV is maintained by transmission through superinfection from carrier to carrier of the HBsAg; secondary extension of the virus to normal, HBsAg-negative individuals occurs in direct proportion to the rate of HDV-infected HBsAg carriers in the population and in reverse proportion to the rate of HBV immunity (presence of anti-HBs) in contacts. Spread to non-carriers has no long-term epidemiological consequences as it results in self-limiting forms of HBV–HDV infection.

HDV infection is acquired by the parenteral route, either overt or covert, in the same way as HBV infection. However, the relative efficiency of HDV transmission differs from that of HBV. Direct inoculation of HDV by infected paraphernalia is the most efficient route of transmission, and the highest rates of hepatitis D were reported in HBsAg-positive drug addicts; in chimpanzees carrying the HBsAg, HDV has been transmitted by inoculation of HDV-positive human serum diluted 10^{-11} [20]. Transmission is efficient both by sexual [5,6,21] and household contacts [22,23], but vertical transmission is rarely documented, and spread of HDV has been inconspicuous among homosexual men [5]. The contemporary control of blood for HBsAg eliminates virtually all blood containing HDV.

Hepatitis D occurs worldwide, the most important factor influencing its spread being the rate of HBV infection within the population. Surveys in the 1980s [6] had shown that the prevalence of HDV was high among HBsAg carriers in tropical and subtropical areas of the African and South American continents and intermediate in the Mediterranean area, in correlation with high and intermediate local rates of HBV infection; however, rates of HDV were low in the Far East despite locally high rates of HBV. Genetic analysis of HDV worldwide has likewise shown wide geographical variations [2,3,24]. Genotype I predominates in Italy [25], USA, Europe, Russia [26], Turkey [27], the Middle East and Mongolia; genotype IA predominates in Asia, IB in the USA, both are common in the Mediterranean basin and a subgroup of genotype I has been isolated in Africa [28]. Genotype II

was found in Japan [29,30], Taiwan [31] and in Yakutia in Russia [32]. Genotype III has been identified in northern South America [33].

In northern Europe and North America, where the rates of HBV were low, HDV infection in the 1980s was confined to parenteral drug addicts and to immigrants from endemic areas [19]. In countries in the Mediterranean basin [34,35] and in Taiwan [36], the epidemiological pattern of infection was composite, resulting from endemic infection in the general populations and from epidemic outbreaks among drug addicts in urban areas. The infection peaked around the third to fourth decade of life, and endemic spreading occurred mainly in the household, facilitated by overcrowding and promiscuity. High rates of hepatitis D were found in Taiwanese and Greek HBsAg-positive prostitutes and in HBsAg-positive haemophiliacs [5].

Drug addicts are often also infected by the hepatitis C virus (HCV) and, in this setting, HDV infection was associated with high morbidity; clustered epidemics of fulminant hepatitis B were reported in drug-abusing communities of the United States and western Europe [6].

Important epidemiological changes have occurred in the last two decades in countries where HBV infection has been brought under control through better public health standards, universal HBV vaccination and measures to contain the spread of HIV, which is transmitted in the same way as HBV/HDV.

Paradigmatic are the changes that have occurred in Italy. In a baseline study performed in the country in the years 1978–1981, the prevalence of HDV infection in HBsAg carriers with liver disease, determined from the prevalence of anti-HD, was 24% [37]; it remained stable up to the second half of the 1980s [38] but, by the early 1990s, it had diminished to 14% [37] and, in nationwide surveys performed in the late 1990s, it has declined further to 7–8% [40,41].

In Spain, the rate of anti-HD in HBsAg carriers with chronic hepatitis diminished from 15% in 1975–1985 to 7.1% in 1986–1992 [42], and a significant decrease in the prevalence of HDV superinfection has been observed in Taiwan in both the general population and high-risk groups [43,44].

Information on the recent epidemiological trends in HDV infection from other countries is limited. However, it is unlikely that the pattern of HDV infection has changed in endemic areas of the developing world, unless the factors determining transmission and circulation of the helper HBV have been significantly modified in the last decades. Outbreaks of severe HDV hepatitis have continued to occur in the Amazon basin, extending from the Brazilian to the Peruvian and Ecuadorean areas [45]. The prevalence of HDV infection remains high in Turkey (33–59.4% prevalence of anti-HD in chronic HBsAg liver disease in Eastern Anatolia [46]) and in Albania [47]. Anti-HD has been detected in 8.6% of the HBsAg-positive chronic hepatitis patients in a recent large survey in Saudi Arabia [48]. Endemic HDV foci were reported from west Greenland and Mongolia [49], Tunisia [10] and Okinawa [10], and markers of HDV were found in a consistent proportion (18.35%) of HBsAg-positive pregnant women in Moldova as well as in 13.15% of hepatitis B patients in the Shandong province in China [10]. In contrast, from 1991 to 1997, the prevalence of anti-HD in patients with HBsAg-positive cirrhosis in Belarus [10] has decreased from 47.6% to 15.4%.

Hepatitis D is rare in Poland [50], apparently absent in the high Andean plateau [10] and Nigeria [10], low in patients with HBsAg-positive liver disease in sub-Saharan Africa and in HBsAg carriers in north-west Mexico (6.5% and 4% respectively) [10]. In Korea [51], the prevalence of anti-HD was 4%; the antibody was found mainly in HBsAg-positive patients with hepatocellular carcinoma. Conflicting data were reported from India: anti-HD was found in 21.4% of HBsAg-positive liver disease in Northern India [52], and HDV was implicated as a major risk factor for fulminant hepatitis in the country [53], but anti-HD was rarely found in hospital patients and mixed clinical HBsAg-positive populations in Calcutta [54]. HDV infection was observed among inhabitants of the Nicobar Islands but not in those inhabiting the Andaman Islands [55].

The infection has also declined among risk groups in developed countries. In Taiwan, the rate of anti-HD in HBsAg-positive drug addicts diminished from 79% in 1985 to 14% in 2004; in this population, the average rate of decrease in the prevalence of HDV infection was 4.7% per year [44,56]. No HDV case was found in intravenous drug users in Rio de Janeiro, Brazil, despite a 7.8% prevalence of serum HBsAg in this community [10], and a 14.7% prevalence rate was found in HBsAg-positive drug users in Jeddah, Saudi Arabia [10].

Disease

Although viral and host immune response are likely to interact in the pathogenesis of the liver damage associated with HDV, the mechanisms conducive to HDV liver damage in humans remain unknown. Early hypotheses suggesting that viral cytotoxicity could be caused directly by intrahepatic expression of the HDAg or by a disturbance of cell function induced by HDV RNA base-pairing to corresponding RNA regions of the signal recognition particle, a structure involved in the targeting of secretory and membrane proteins to the membrane of the endoplasmic reticulum, have not been substantiated [57]. It was suggested that the pathogenicity of HDV may be modulated by the degree of replication of the helper HBV and/or by the genotype of HDV [58]; genotype III was associated with outbreaks of fulminant hepatitis in South America [33], and Japanese patients with genotype IIB showed greater progression of chronic hepatitis to cirrhosis than those with genotype II [4].

Course of coinfection and superinfection hepatitis D

The clinical and histological features of acute and chronic hepatitis D are not specific and are non-distinctive from ordinary hepatitis B, and recognition of the disease is based on specific

serological testing [5,8,59]. In coinfections, the serological picture shows the features of acute HBV infection, including the IgM antibody to the hepatitis B core antigen (IgM anti-HBc) with superimposed markers of HDV. HD viraemia is usually transient and may be detected by PCR. Occasionally, HBV/HDV hepatitis acquired by coinfection may be severe; these forms exhibit a full serological response consisting of early HD antigenaemia followed by seroconversion to anti-HD, initially of the IgM and then of the IgG class.

The clinical presentation of HDV superinfection in patients chronically infected by HBV depends on whether they were asymptomatic carriers of HBsAg, or whether clinical features of type B hepatitis were present [5–8]. In the asymptomatic carrier, superinfection appears as an intercurrent hepatitis; in the patient with chronic type B hepatitis, it may be mistaken for an exacerbation of the underlying HBV disease. In asymptomatic carriers unaware of their HBsAg state, superinfection may mimic acute hepatitis B as a positive HBsAg test suggests this diagnosis if it is first performed after infection with HDV. Clues to the nature of the disease are a positive HDV serology and an incomplete or atypical HBV profile (superinfected carriers, unlike patients with acute hepatitis B, usually lack the IgM anti-HBc).

In superinfection, the antibody response is more uniform and consistent than in coinfection. There is a relatively brisk IgM and IgG anti-HD response; when superinfection progresses to chronicity, both antibodies increase rapidly in a few weeks, and persist in high titres as hepatitis D continues. In patients whose chronic hepatitis D resolves, the IgM antibody disappears, whereas IgG anti-HD declines slowly.

Whether acquired by coinfection with HBV or superinfection in a chronic HBsAg carrier, HDV can precipitate an episode of fulminant hepatitis [6]. In cases of fulminant hepatitis D in tropical areas, microscopic features of microvesicular steatosis and foamy degeneration were often observed; these aspects have rarely been observed in fulminant hepatitis D in developed countries [6].

Atypical acute hepatitis D

The course of HDV infection may be confounded by the inhibitory effect exerted by HDV on the replication of HBV. In coinfection, early repression of HBV can occasionally produce a picture of HBsAg-negative hepatitis resembling a non-B hepatitis. Sequential expression of HBV and HDV may result in a biphasic hepatitis.

HDV superinfection can occasionally terminate the HBsAg state with clearance of HBV and HDV. Clearance of the HBsAg occurs more frequently over the years in chronic HDV patients than in ordinary HBV patients [60], and prior delta infection may result in effective suppression of residual HBV infection [61].

Rarely, transient suppression of pre-existing HB viraemia can create diagnostic confusion because, with disappearance of HBsAg from serum caused by marked inhibition of HBV at the time of superinfection, anti-HBs may temporarily appear in these patients, simulating the resolution of an acute HBV hepatitis; the HBsAg, however, returns at the termination of florid HDV infection [5].

Chronic hepatitis D

Patients with chronic hepatitis D suffer from a disease that is more serious and progressive than ordinary hepatitis B. Studies conducted in the 1970s and 1980s in Europe and the United States have shown that markers of HDV were more prevalent in HBsAg carriers with chronic hepatitis than in apparently healthy carriers; in HBsAg carriers with liver damage, the prevalence of HDV was higher in those with chronic active hepatitis or cirrhosis than in those with chronic persistent hepatitis [5–8,59].

Superinfection hepatitis D often ran a rapidly progressive course to liver failure (within 2 years from exposure to HDV) in drug addicts with HBeAg-positive (wild-type) HBV infection. Triple HBV–HDV–HCV infection also occurred often in drug addicts; in studies from Europe and the USA, HDV [62–65] was the dominant virus inhibiting the other two; in a study from Taiwan [66], HCV was the dominant virus.

A survey of 148 Italian patients with chronic hepatitis from 1977 to 1994 [67] has shown two patterns of disease. In about 10%, the disease was mild, non-progressive and characterized at histology by portal inflammation only. In the other 90%, the disease was progressive and characterized by chronic active hepatitis or active cirrhosis. Progression to extensive fibrosis and cirrhosis was usually rapid, with about 30–40% of the patients with non-cirrhotic disease at baseline developing cirrhosis within 5 years of follow-up. However, the cirrhotic stage has often remained clinically stable for decades, and the course of cirrhosis has been asymptomatic over many years; these patients may exhibit a marked enlargement of the spleen. In Italian patients, infection with HDV increased the risk of hepatocellular carcinoma threefold and of mortality twofold in those with HBsAg-positive cirrhosis [68].

In oriental patients, the virological profile of progressive chronic hepatitis D consisted of an early phase following superinfection characterized by elevated alanine aminotransferase, active HDV replication and suppression of HBV, an intermediate phase characterized by moderately elevated alanine aminotransferase, decreasing HDV synthesis and reactivation of HBV, and a late cirrhotic phase characterized by marked reduction in the synthesis of both HBV and HDV [69].

In Mediterranean patients, the underlying HBV infection was most often inactive (HBV DNA negative by conventional hybridization assays or positive at low titre by PCR; HBeAg negative and anti-HBe positive in serum) [5–8], and a proportion of patients with early and florid disease raised a variety of autoantibodies, the most frequent of which was a liver–kidney microsomal antibody (LKM) similar in its immunofluorescence pattern to LKM of autoimmune type 2 hepatitis and directed against UDP glucuronyltransferase [70]. In children, the course

of chronic hepatitis D was also severe and progressive. In view of the young age of acquisition and the accelerated course of disease, hepatitis D was an important cause of juvenile cirrhosis in the Mediterranean area in the 1970s to 1980s [8,59].

HDV coinfection remains an important problem in patients with human immunodeficiency virus (HIV) infection. HDV-coinfected immunocompromised patients with acquired immune deficiency syndrome (AIDS) may have blunted antibody responses to HDV [5,8] and may exhibit persistent HD antigenaemia. Studies on the mutual clinical influence of HIV and HDV, performed before the era of highly active antiretroviral therapy (HAART), were contradictory; early studies reported that HIV coinfection worsened liver damage by HDV [71,72], but other studies [73–75] showed that the course of chronic hepatitis D was not influenced by concomitant HIV infection.

In the last 15 years, the clinical scenario of HDV infections has changed significantly in the developed world, in parallel with the control of HBV fostered by universal vaccination, improvement in sanitation measures and efforts to contain the HIV epidemic. Along with the decline in the circulation of HDV in southern Europe, clinical changes have been most impressive in this area. The majority of hepatitis D patients collected in Italy in the 1980s had a florid chronic active hepatitis, and inactive cirrhosis residual to burnt-out inflammation was seen in fewer than 20% of cases; in contrast, by the end of the 1990s [63], the proportion of cirrhotic patients has increased in Italy to 70%. These patients represent the survivors of the epidemic of hepatitis D in the 1970s to 1980s; a minority have a long-standing indolent infection, the majority have advanced cirrhosis for which there is no specific medical therapy and only liver transplantation offers a therapeutical perspective.

References

1 Rizzetto M, Canese MG, Arico S *et al.* (1977) Immunofluorescence detection of new antigen-antibody system (delta/anti-delta) associated to hepatitis B virus in liver and in serum of HBsAg carriers. *Gut* 18, 997–1003.

2 Deny P (2006) Hepatitis delta virus genetic variability; from genotypes I, II, III to eight major clades? *Curr Topics Microbiol Immunol* 307, 151–171.

3 Casey JL, Polson AG, Bass BL *et al.* (1997) Molecular biology of HDV: analysis of RNA editing and genotype variations. In: Rizzetto M, Purcell RH, Gerin JL *et al.* (eds) *Viral Hepatitis and Liver Disease*. Turin: Minerva Medica Torino, pp. 290–294.

4 Watanabe H, Nagayama K, Enomoto N *et al.* (2003) Chronic hepatitis delta virus infection with genotype IIb variant is correlated with progressive liver disease. *J Gen Virol* 84, 3275–3289.

5 Rizzetto M, Ponzetto A, Bonino F *et al.* (1988) Hepatitis delta virus infection: clinical and epidemiological aspects. In: Zuckerman AJ (ed.) *Viral Hepatitis and Liver Disease*. New York: Alan R. Liss, pp. 389–394.

6 Smedile A, Rizzetto M, Gerin JL (1994) Advances in hepatitis D virus biology and disease. In: Boyer JL, Ockner RK (eds) *Progress in Liver Disease*, Vol. 12. Philadelphia: W.B. Saunders, pp. 157–175.

7 Hadziyannis SJ (1997) Hepatitis delta: an overview. In: Rizzetto M, Purcell RH, Gerin JL (eds) *Viral Hepatitis and Liver Disease*. Turin: Minerva Medica pp. 283–289.

8 Farci P (2003) Delta hepatitis: an update. *J Hepatol* 39, S212–S219.

9 Ponzetto A, Cote PJ, Popper H *et al.* (1984) Transmission of the hepatitis B virus-associated delta agent to the eastern woodchuck. *Proc Natl Acad Sci USA* 81, 2208–2212.

10 Ciancio A, Rizzetto M (2002) Clinical patterns, epidemiology and disease burden of hepatitis D virus chronic liver disease. In: Margolis HS, Alter MJ, Liang TJ *et al.* (eds) *Proceedings of the 10th International Symposium on Viral Hepatitis and Liver Disease*. Atlanta, GA: International Medical Press, pp. 271–275.

11 Negro F, Rizzetto M (1995) Diagnosis of hepatitis delta virus infection. *J Hepatol* 22 (Suppl 1), 136–139.

12 Aragona M, Macagno S, Caredda F *et al.* (1987) Serologic response to the hepatitis Delta Virus in acute hepatitis D. *Lancet* 1, 478–480.

13 Macagno S, Smedile A, Caredda F *et al.* (1990) Monomeric (7S) immunoglobulin M antibodies to hepatitis delta virus in hepatitis type D. *Gastroenterology* 98, 1582–1586.

14 Abid K, Negro F (2004) Immunohistochemical detection of hepatitis delta antigen. In: *Methods in Molecular Medicine 95. Hepatitis B and D Protocols*, Vol. 1. *Detection, Genotypes and Characterization*. Humana Press, pp. 107–112.

15 Hsu SC, Syu WJ, Ting LT *et al.* (2000) Immunohistochemical differentiation of hepatitis D virus genotypes. *Hepatology* 32, 1111–1116.

16 Negro F (2004) Nonradioisotopic *in situ* hybridization for HDV RNA. In: *Methods in Molecular Medicine 95. Hepatitis B and D Protocols*, Vol. 1. *Detection, Genotypes and Characterization*. Humana Press, pp. 95–98.

17 Smedile A, Niro MG, Rizzetto M (2004) Detection of serum HDV-RNA by RT-PCR. In: *Methods in Molecular Medicine 95*, Vol. 1. *Detection, Genotypes and Characterization*. Humana Press, pp. 85–94.

18 Le Gal F, Gordien E, Affolabi D *et al.* (2005) Quantification of hepatitis delta virus RNA in serum by consensus real-time PCR indicates different patterns of virological response to interferon therapy in chronically infected patients. *J Clin Microbiol* 43, 2363–2369.

19 Yamashiro T, Nagayama K, Enomoto N *et al.* (2004) Quantitation of the level of hepatitis delta virus RNA in serum, by real-time polymerase chain reaction-and its possible correlation with the clinical stage of liver disease. *J Infect Dis* 189, 1151–1157.

20 Ponzetto A, Negro F, Popper H *et al.* (1988) Serial passage of hepatitis delta virus in chronic hepatitis B virus carrier chimpanzees. *Hepatology* 8, 1655–1661.

21 Wu JC, Chen CM, Sheen IJ *et al.* (1995) Evidence of transmission of hepatitis D virus to spouses from sequence analysis of the viral genome. *Hepatology* 22, 1656–1660.

22 Stroffolini T, Ferrigno L, Cialdea L *et al.* (1994) Incidence and risk factors of acute Delta hepatitis in Italy: results from a national surveillance system. SEIEVA Collaborating Group. *J Hepatol* 21, 1123–1126.

23 Niro GA, Casey JL, Gravinese E *et al.* (1999) Intrafamilial transmission of hepatitis delta virus: molecular evidence. *J Hepatol* 30, 564–569.

24 Shakil AO, Hadziyannis S, Hoofnagle JH *et al.* (1997) Geographic distribution and genetic variability of hepatitis delta virus genotype I. *Virology* 234, 160–167.

25 Niro GA, Smedile A, Andriulli A *et al.* (1997) The predominance of hepatitis delta virus genotype I among chronically infected Italian patients. *Hepatology* 25, 728–734.

26 Flodgren E, Bengtsson S, Knutsson M *et al.* (2000) Recent high incidence of fulminant hepatitis in Samara, Russia: molecular analysis of prevailing hepatitis B and D virus strains. *J Clin Microbiol* 38, 3311–3316.

27 Bozday AM, Aslan N, Bozday G *et al.* (2004) Molecular epidemiology of hepatitis B, C and D viruses in Turkish patients. *Arch Virol* 149, 2115–2129.
28 Zhang YY, Tsega E, Hansson BG (1996) Phylogenetic analysis of hepatitis D viruses indicating a new genotype I subgroup among African isolates. *J Clin Microbiol* 34, 3023–3030.
29 Sakugawa H, Nakasone H, Nakayoshi T *et al.* (1999) Hepatitis delta virus genotype IIb predominates in an endemic area, Okinawa, Japan. *J Med Virol* 58, 366–372.
30 Moriyama M, Taira M, Matsumura H *et al.* (2005) Full genomic analysis of hepatitis delta virus prevalent on Miyako Island, Japan. *Intervirology* 48, 246–254.
31 Kao JH, Chen PJ, Lai MY *et al.* (2002) Hepatitis D virus genotypes in intravenous drug users in Taiwan: decreasing prevalence and lack of correlation with hepatitis B virus genotypes. *J Clin Microbiol* 40, 3047–3049.
32 Ivaniushina V, Radjef N, Alexeeva M *et al.* (2001) Hepatitis delta virus genotypes I and II cocirculate in an endemic area of Yakutia, Russia. *J Gen Virol* 82, 2709–2718.
33 Nakano T, Shapiro CN, Hadler SC *et al.* (2001) Characterization of hepatitis D virus genotype III among Yucpa Indians in Venezuela. *J Gen Virol* 82, 2183–2189.
34 Rizzetto M, Hadziyannis S, Hansson BG *et al.* (1992) Hepatitis delta virus infection in the world, epidemiological patterns and clinical expression. *Gastroenterol Int* 5, 18–32.
35 Sagnelli E, Stroffolini T, Ascione A *et al.* (1992) The epidemiology of hepatitis delta infection in Italy. *Hepatology* 15, 211–215.
36 Liaw YF, Chiu KW, Chu CM *et al.* (1990) Heterosexual transmission of hepatitis delta virus in the general population of an area endemic for hepatitis B virus infection: a prospective study. *J Infect Dis* 162, 1170–1172.
37 Smedile A, Lavarini C, Aricò S *et al.* (1983) Epidemiological patterns of infection with the hepatitis B virus associated delta agent in Italy. *Am J Epidemiol* 117, 223–229.
38 Sagnelli E, Stroffolini T, Ascione A *et al.* (1993) The epidemiology of hepatitis delta infection in Italy over the last 18 years. *Prog Clin Biol Res* 382, 287–294.
39 Sagnelli E, Stroffolini T, Ascione A *et al.* (1997) Decrease in HDV endemicity in Italy. *J Hepatol* 26, 20–24.
40 Gaeta GB, Stroffolini T, Chiaramonte M *et al.* (2000) Chronic hepatitis D: a vanishing disease? An Italian multicenter study. *Hepatology* 32, 824–827.
41 Stroffolini T, Sagnelli E, Mele A *et al.* (2004) The aetiology of chronic hepatitis in Italy: results from a multicentre national study. *Dig Liver Dis* 36, 829–833.
42 Navascues CA, Rodriguez M, Sotorrio NG *et al.* (1995) Epidemiology of hepatitis D virus infection: changes in the last 14 years. *Am J Gastroenterol* 90, 1981–1984.
43 Huo TI, Wu JC, Lin RY *et al.* (1997) Decreasing hepatitis D virus infection in Taiwan: an analysis of contributory factors. *Gastroenterol Hepatol* 12, 745–746.
44 Huo TI, Wu JC, Wu SI *et al.* (2004) Changing seroepidemiology of hepatitis B, C, and D virus infections in high-risk populations. *J Med Virol* 72, 41–45.
45 Manock SR, Kelley PM, Hyams KC *et al.* (2000) An outbreak of fulminant hepatitis delta in the Waorani, an indigenous people of the Amazon basin of Ecuador. *Am J Trop Med Hyg* 63, 209–213.
46 Degertekin H, Yalcin K, Yakut M (2006) The prevalence of hepatitis delta virus infection in acute and chronic liver diseases in Turkey: an analysis of clinical studies. *Turk J Gastroenterol* 17, 25–34.
47 Dalekos GN, Zervou E, Karabini F *et al.* (1995) Prevalence of viral markers among refugees from southern Albania: increased incidence of infection with hepatitis A, B and D viruses. *Eur J Gastroenterol Hepatol* 7, 553–558.
48 Al-Traif I, Ali A, Dafalla M *et al.* (2004) Prevalence of hepatitis delta antibody among HBsAg carriers in Saudi Arabia. *Ann Saudi Med* 24, 343–344.
49 Inoue J, Takahashi M, Nishizawa T *et al.* (2005) High prevalence of hepatitis delta virus infection detectable by enzyme immunoassay among apparently healthy individuals in Mongolia. *J Med Virol* 76, 333–340.
50 Chlabicz S, Grzeszczuk A, Lapinski TW *et al.* (2003) Search for hepatitis delta virus (HDV) infection in hepatitis C patients in north-eastern Poland. Comparison with anti-HDV prevalence in chronic hepatitis B. *Eur J Epidemiol* 18, 559–561.
51 Jeong SH, Kim JM, Ahn HJ *et al.* (2005) The prevalence and clinical characteristics of hepatitis-delta infection in Korea. *Kor J Hepatol* 11, 43–50.
52 Singh V, Goenka MK, Bhasin DK *et al.* (1995) A study of hepatitis delta virus infection in patients with acute and chronic liver disease from northern India. *J Viral Hepat* 2, 151–154.
53 Narang A, Gupta P, Kar P *et al.* (1996) A prospective study of delta infection in fulminant hepatic failure. *J Assoc Phys India* 44, 246–247.
54 Bhattacharyya S, Dalal BS, Lahiri A (1998) Hepatitis D infectivity profile among hepatitis B infected hospitalised patients in Calcutta. *Ind J Public Health* 42, 108–112.
55 Murhekar MV, Murhekar KM, Arankalle VA *et al.* (2005) Hepatitis delta virus infection among the tribes of the Andaman and Nicobar Islands, India. *Trans R Soc Trop Med Hyg* 99, 483–484.
56 Kao J-H, Chen PV, Lai M-Y *et al.* (2002) Hepatitis D virus genotypes in intravenous drug users in Taiwan: decreasing prevalence and lack of correlation with hepatitis B virus genotypes. *J Clin Microbiol* 40, 3047–3049.
57 Negro F, Rizzetto M (1991) Pathobiology of hepatitis delta virus. In: Blaine Hollinger F, Lemon S, Margolis HS (eds) *Viral Hepatitis and Liver Disease*. Philadelphia, PA: Williams and Wilkins, pp. 477–480.
58 Smedile A, Rosina F, Saracco G *et al.* (1991) Hepatitis B virus replication modulates pathogenesis of hepatitis D virus in chronic hepatitis D. *Hepatology* 13, 413–416.
59 Smedile A, Ciancio A, Rizzetto M (2002) Hepatitis D, Hepatitis D virus. In: Richman DD, Whitley RJ, Hayden FG (eds) *Clinical Virology*. Washington, DC: ASM Press, pp. 1227–1240.
60 Niro GA, Gravinese E, Martini E *et al.* (2001) Clearance of hepatitis B surface antigen in chronic carriers of hepatitis delta antibodies. *Liver* 21, 254–259.
61 Chen PJ, Chen DS, Chen CR *et al.* (1988) Delta infection in asymptomatic carriers of hepatitis B surface antigen: low prevalence of delta activity and effective suppression of hepatitis B virus replication. *Hepatology* 8, 1121–1124.
62 Jardi R, Rodriguez F, Buti M *et al.* (2001) Role of hepatitis B, C, and D viruses in dual and triple infection: influence of viral genotypes and hepatitis B precore and basal core promoter mutations on viral replicative interference. *Hepatology* 34, 404–410.
63 Mathurin P, Thibault V, Kadidja K *et al.* (2000) Replication status and histological features of patients with triple (B, C, D) and dual (B, C) hepatic infections. *J Viral Hepat* 7, 15–22.

64 Raimondo G, Brunetto MR, Pontisso P *et al.* (2006) Longitudinal evaluation reveals a complex spectrum of virological profiles in hepatitis B virus/hepatitis C virus-coinfected patients. *Hepatology* 43, 100–107.
65 Eyster ME, Sanders JC, Battegay M *et al.* (1995) Suppression of hepatitis C virus (HCV) replication by hepatitis D virus (HDV) in HIV-infected hemophiliacs with chronic hepatitis B and C. *Dig Dis Sci* 40, 1583–1588.
66 Lu SN, Chen TM, Lee CM *et al.* (2003) Molecular epidemiological and clinical aspects of hepatitis D virus in a unique triple hepatitis viruses (B, C, D) endemic community in Taiwan. *J Med Virol* 70, 74–80.
67 Rosina F, Conoscitore P, Cuppone R *et al.* (1999) Changing pattern of chronic hepatitis D in Southern Europe. *Gastroenterology* 117, 161–166.
68 Fattovich G, Giustina G, Christensen E *et al.* (2000) Influence of hepatitis delta virus infection on morbidity and mortality in compensated cirrhosis type B. The European Concerted Action on Viral Hepatitis (Eurohep). *Gut* 46, 420–426.
69 Wu JC, Chen TZ, Huang YS *et al.* (1995) Natural history of hepatitis D viral superinfection: significance of viremia detected by polymerase chain reaction. *Gastroenterology* 108, 796–802.
70 Philip T, Durazzo M, Trautwein C *et al.* (1994) Recognition of uridine diphosphate glucuronosyl transferases by LKM-3 antibodies in chronic hepatitis D. *Lancet* 344, 578–581.
71 Novick DM, Farci P, Croxson TS *et al.* (1988) Hepatitis D virus and human immunodeficiency virus antibodies in parenteral drug abusers who are hepatitis B surface antigen positive. *J Infect Dis* 158, 795–803.
72 Housset C, Pol S, Camot F *et al.* (1992) Interactions between human immunodeficiency virus-1, hepatitis delta virus and hepatitis B virus infections in 260 chronic carriers of hepatitis B virus. *Hepatology* 15, 578–583.
73 Caredda F, Antinori S, Coppin P *et al.* (1991) The influence of human immunodeficiency virus infection on acute and chronic HBsAg-positive hepatitis. *Prog Clin Biol Res* 364, 365–375.
74 Pol S, Wesenfelder L, Dubois F *et al.* (1994) Influence of human immunodeficiency virus infection on hepatitis delta virus superinfection in chronic HBsAg carriers. *J Viral Hepat* 1, 131–137.
75 Buti M, Jardi R, Allende H *et al.* (1996) Chronic delta hepatitis: is the prognosis worse when associated with hepatitis C virus and human immunodeficiency virus infections? *J Med Virol* 49, 66–69.

9.1.2.vi Hepatitis C

Alfredo Alberti and Luisa Benvegnù

Definition

Hepatitis C is caused by the hepatitis C virus (HCV), an RNA virus that shares genomic similarities with the pestiviruses and has been classified within the Flaviviridae family [1].

Significant heterogeneity has been observed between different HCV isolates, leading to the classification of HCV into distinct genotypes, designated by Arabic numerals (i.e. HCV-1, HCV-2, HCV-3, etc), and subtypes, identified by lower case letters (i.e. HCV-1a, HCV-1b, HCV-1c, etc) [2]. HCV is a bloodborne agent that is transmitted parenterally. Before the discovery of HCV in 1989, blood transfusion was a frequent cause of hepatitis C transmission. With the implementation of screening of blood donations for HCV, the risk of post-transfusion hepatitis C has been dramatically reduced; however, infection continues to occur via other modes of apparent and inapparent parenteral transmission.

Hepatitis C has a global distribution. Infection with HCV often results in chronicity because of the high propensity of this virus to persist by evading control by the immune system. The incidence of new cases is declining in most countries of the civilized world, but the prevalence of chronically infected individuals is still high, with at least 170 million carriers of the HCV worldwide. Chronic HCV infection is particularly frequent in a number of risk groups, including intravenous drug users, patients with haemophilia who received clotting factors before 1990–92, those who received blood transfusions before 1992 and patients on haemodialysis.

The diagnosis of hepatitis C rests upon detection of a set of antiviral antibodies (anti-HCV) and viral genomic sequences (HCV RNA) in serum.

HCV causes acute and chronic hepatocellular damage of variable severity and evolution, and is the leading cause of cirrhosis and hepatocellular carcinoma and the main reason for liver transplantation in many western countries. Infection may also occur in extrahepatic cells and tissues, leading to a spectrum of extrahepatic disorders, including immunological abnormalities, autoimmune phenomena, production of autoantibodies, cryoglobulinaemia, vasculitis and other types of immunocomplex disease. A cause–effect relationship of HCV to other disorders, such as porphyria cutanea tarda, thyroiditis, sialadenitis, psoriasis and B-cell non-Hodgkin's lymphoma, is also suspected but not yet clearly proven. More recently, HCV has also been linked to the development of insulin resistance and type 2 diabetes.

Acute HCV infection is defined as an infection of less than 6 months duration. Most often, acute infections are asymptomatic and remain clinically unrecognized and, for this reason, it has been problematic to define the precise incidence of hepatitis C. Severe and fulminant hepatitis C is extremely rare in the immunocompetent host but may occur under immunosuppression. Only a minority of cases of acute hepatitis C recover completely, with spontaneous virus eradication; in most cases, the acute infection progresses to chronicity. Chronic HCV infection is defined as an infection that persists for more than 6 months, with or without clinical manifestations of hepatic or extrahepatic disease. Around 35–45% of HCV carriers in the general population have no overt signs or symptoms of liver disease and persistently normal levels of serum alanine aminotransferase (ALT), although many of them have some underlying chronic liver lesions on liver biopsy. The remaining carriers have varying profiles of ALT abnormalities. Liver biopsy in compensated chronic hepatitis C shows a wide range of histological lesions, from minimal–mild to severe–advanced necroinflammatory changes and fibrosis. Progression to cirrhosis occurs slowly and in an unpredictable way in a subgroup of patients who may ultimately die of portal hypertension, hepatic failure or

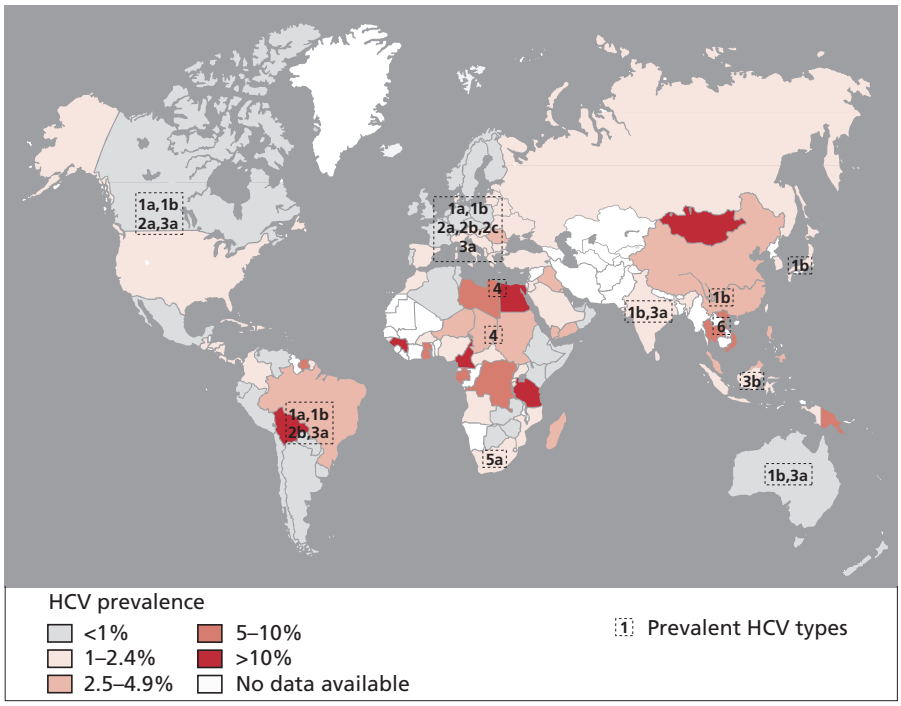

Fig. 1 Prevalence of HCV infection and HCV genotypes/subtypes in different geographical regions.

hepatocellular carcinoma. The downhill course of chronic liver disease is accelerated by a number of aetiological cofactors, including coinfection with the hepatitis B virus (HBV) and the human immunodeficiency virus (HIV), excess alcohol consumption and the presence of a number of metabolic abnormalities, such as obesity, insulin resistance, liver steatosis, diabetes and iron overload. Race, gender and age at infection also play a role in determining the course and outcome of chronic HCV infection. The management of chronic HCV infection needs to be individualized based on a number of virus and host parameters that result in the heterogeneous clinical features and outcome of hepatitis C.

Epidemiology

Prevalence in the general population and in risk groups

The World Health Organization (WHO) estimates that at least 3% of the world's population is chronically infected with HCV [3]. The prevalence of chronic HCV carriers varies greatly depending on geographical location and the characteristics of the population analysed (Fig. 1 and Table 1) [4]. Low rates are found in the general adult population in North America and western Europe, intermediate rates in Japan and higher rates in some areas of eastern Europe, the Middle East and South America [5,6]. The number of infected individuals is particularly high in Egypt. High rates have also been found in the elderly population in some Mediterranean areas, including southern Italy. In the general population, there is evidence for an age-related distribution of HCV infection, with prevalences that are minimal in childhood and progressively higher with increasing age. The prevalence of HCV infection is increased in several risk groups, which are listed in Table 1.

Table 1 Reported prevalence of HCV infection in risk groups.

Risk group	Anti-HCV positive (%)
Intravenous drug users	35–90
Haemophiliacs treated before 1990	50–90
Thalassaemics	42–83
Haemodialysis patients	10–45
Prisoners	15–46
Alcoholics	15–25
HIV-positive individuals	20–65
Patients with history of blood transfusion received before 1992	15–25
Tattooed individuals	11
Heath-care professionals (exposed by needlestick)	0–10 (3–12)
People with disabilities/institutionalized individuals	4–7
Prostitutes	0.7–6
Homosexuals	3–18
Heterosexual partners of HCV carriers	0–18
Household non-sexual contacts of HCV carriers	0–11
Children born to HCV-infected mothers	0–6

Incidence and prevalence in patients with liver disease

The incidence of acute symptomatic hepatitis C, which represents an underestimation of all cases of acute HCV infection as many cases remain asymptomatic, has been decreasing progressively since 1990 in most industrialized countries. HCV is the recognized cause of about 33% of cases of symptomatic acute hepatitis in the western world and 10% of cases in the Far East [7]. The prevalence of chronic HCV infection in patients with chronic hepatitis, cirrhosis and hepatocellular carcinoma is very high in southern Europe and Japan (60–90%), intermediate in other part of Europe, the United States, Australia and Africa (30–60%) and lower in China and other countries of the Far East (10–39%). HCV is the major cause, either alone or with other cofactors, of chronic liver disease, cirrhosis and hepatocellular carcinoma, and the main reason for liver transplantation in most countries of the western world, second only to alcohol-related diseases in a few geographical locations [8,9]. The prevalence of HCV infection is highest in patients who develop chronic liver disease after blood transfusion or who have a well-recognized risk for parenteral contamination in their previous history. The prevalence of HCV infection in patients with chronic liver disease or hepatocellular carcinoma varies around the world depending on the HBV endemicity. In areas of high HBV endemicity, HCV is relatively uncommon, whereas in areas of intermediate or low HBV endemicity, the prevalence of hepatitis C increases significantly. In areas of intermediate HBV endemicity, concurrent HBV and HCV infection is seen in patients with chronic liver disease and this association increases in frequency with the severity and stage of liver damage.

Transmission

HCV is efficiently transmitted in blood and blood products [10]. Currently, unsafe intravenous drug use is the main mode of transmission in most parts of the western world, whereas unscreened contaminated blood transfusion and folk-medicine practices still represent an important source of infection in underdeveloped countries [5,6]. Transmission of HCV between monogamous partners is thought to be rare; transmission increases significantly with multiple sexual partners [11]. Other documented sources of infection are needlestick exposure in health-care workers [12], sharing a razor or toothbrush with an infected individual [13], unsafe body piercing and tattooing [14]. There is also solid evidence of nosocomial transmission of HCV during invasive procedures. Major gynaecological and cardiovascular surgery carries a high risk; however, microsurgery, in particular, ophthalmic, has also been implicated. HCV is transmitted vertically to newborns by 3–5% of HCV-monoinfected mothers, but the risk increases significantly in the presence of HIV coinfection [15]. On the basis of these epidemiological data, recommendations for the prevention and control of HCV infection have been made (Table 2) [16,17]

Table 2 Recommendations for prevention and control of HCV infection.

HCV testing is highly recommended in:
Individuals with a risk factor (see list in Table 1)
Individuals with unexplained abnormalities of transaminases and/or other liver function tests
Individuals with signs or symptoms of liver disease
HCV-infected individuals should be counselled to:
Avoid sharing anything that might be contaminated by their own blood or body fluid
Not donate blood, body organs, other tissues or semen
Consider the risk of sexual transmission to be low but not absent

Diagnosis

Infection with HCV can be identified and staged with a variety of diagnostic tools that include (i) detection of antiviral antibodies (anti-HCV), a marker of past or ongoing infection; (ii) direct detection and quantification of the viral genome (HCV RNA) in serum, a marker of ongoing HCV infection and replicative activity; and (iii) analysis of the genomic sequences of the virus to define the genotype and subtype of the infecting HCV, an intrinsic characteristic of HCV genomic variability.

Detection of antiviral antibodies

Testing for anti-HCV antibodies is the primary tool to screen for HCV infection and to diagnose past or ongoing infection [18]. Anti-HCV antibodies can be detected by third-generation enzyme immunoassays (EIAs). These assays detect mixtures of antibodies directed against different HCV epitopes of the core and non-structural NS3, NS4 and NS5 proteins. The specificity of currently available commercial assays for anti-HCV antibodies is > 99%. In acute infection, detection of anti-HCV antibodies may be delayed compared with the appearance of HCV-RNA viraemia. In chronic infection, the sensitivity of anti-HCV antibody tests is excellent in immunocompetent individuals, whereas it is reduced in immunocompromized hosts, who may remain anti-HCV negative despite the presence of ongoing HCV replication. The interpretation of anti-HCV antibody results depends on the clinical setting (see below).

In clinical practice, the usual approach is to test initially for anti-HCV antibodies and, if the results are positive, assess for the presence of HCV RNA using a sensitive qualitative assay, to document viraemia and distinguish between ongoing and resolved infection.

Detection of serum HCV RNA

HCV replicates at low levels and, therefore, HCV RNA needs to be amplified to enable it to be detected in serum [19]. Two types of diagnostic assay are available for serum HCV-RNA testing: qualitative and quantitative. Qualitative assays are carried out

using the classical polymerase chain reaction (PCR), real-time PCR or transcriptase-mediated amplification (TMA). Several commercial assays are available, with a lower limit of detection in the range of 5 IU/mL (real-time PCR), 5–10 IU/mL (TMA-based assays) and 30–100 IU/mL (classic PCR). These qualitative assays represent the gold standard for the diagnosis of ongoing HCV infection. They are essential for the diagnosis of hepatitis C in immunocompromized individuals who do not produce significant levels of anti-HCV antibodies and in the early phase of acute hepatitis C before anti-HCV seroconversion. Quantitative serum HCV-RNA assays are based on target amplification techniques (competitive PCR or real-time PCR) or signal amplification [branched DNA (bDNA) assay]. These assays measure viral load in viraemic patients and provide tools to monitor antiviral therapy.

Determination of HCV genotype

The six major HCV genotypes can be detected using commercial assays [20]. They have different geographical distributions (Fig. 1) and their prevalence also varies according to the epidemiological setting; HCV-3 is often associated with intravenous drug usage. HCV genotyping is of clinical utility in patients who are candidates for antiviral therapy, to enable the dose and duration of treatment to be determined and to predict the probability of achieving a sustained virological response. In many parts of the world, the prevalence of the different HCV genotypes within the HCV-infected population has changed over the last decade. Most studies report a progressive reduction in the prevalence of HCV-1b-infected individuals, which is counterbalanced by an increase in HCV-1a- and HCV-3-infected individuals [21–23]; this trend has also been recently observed in HCV-infected children [24]. Other studies indicate a rapid increase in the spread of HCV-4 in many European countries [25, 26].

Clinical use of HCV markers and diagnostic algorithms [27]

Patients with acute hepatitis

When acute hepatitis C is suspected, patients should be tested for serum HCV RNA with a sensitive qualitative assay and for anti-HCV antibodies using an EIA. Serum HCV RNA is the first marker to become detectable during the acute phase; it can be demonstrated by sensitive PCR as early as 1 week after exposure [7]. Viraemia then persists without an antibody response for a period of a few weeks to months (window phase). Anti-HCV seroconversion usually occurs 4–8 weeks after exposure but may be delayed by up to several weeks or months, with large individual variations. Immunoglobulin (Ig)M anti-HCV tests have not shown adequate specificity and sensitivity for the identification of acute hepatitis C and their use is not recommended. Serum HCV RNA, but not anti-HCV antibodies, is eventually cleared in the minority of patients whose hepatitis C resolves; it persists, often with fluctuations, in patients who progress to chronic infection. The interpretation of different patterns of HCV serum markers in patients with acute hepatitis is described in Table 3.

Table 3 Interpretation of HCV marker profiles in patients with acute hepatitis.

Anti-HCV	HCV-RNA	Interpretation and follow-up
Negative	Negative	Acute hepatitis C excluded
Negative	Positive	Acute hepatitis C confirmed, follow-up for anti-HCV seroconversion
Positive	Negative	Acute hepatitis C unlikely (unless late testing)
Positive	Positive	Impossible to differentiate acute from reactivated chronic hepatitis C (follow-up and retesting needed)

Patients with chronic liver disease

The diagnosis of HCV infection in patients with overt evidence of chronic liver damage is initially based on anti-HCV antibody testing and confirmed by detection of serum HCV RNA by qualitative testing. However, serum HCV RNA should be tested in all immunocompromized or immunosuppressed patients with liver disease of unknown aetiology, even if negative for anti-HCV antibodies. This includes patients on chronic haemodialysis, those with HIV infection and recipients of organ transplants [27].

Detection of anti-HCV at occasional screening

Low-risk individuals with normal ALT levels and no evidence of liver disease, who are found to be anti-HCV antibody positive by EIA at occasional screening or at blood donation, should have serum HCV-RNA levels tested by sensitive qualitative assay to distinguish between ongoing and resolved infection. Repeated HCV-RNA testing (2–3 times at monthly intervals) is recommended for those individuals that are initially found to be HCV-RNA negative, to exclude intermittent viraemia.

Figure 2 describes the diagnostic algorithms that are used in clinical practice in anti-HCV-positive individuals to distinguish between (i) resolved HCV infection, (ii) chronic HCV infection with normal ALT and (iii) biochemically active chronic hepatitis C.

Natural history and clinical outcomes

The current knowledge of the natural history of acute and chronic hepatitis C infection is still incomplete because of the silent nature of many infections, which often impedes detection of the disease in its earliest stages, and also the slow, unpredictable and often discontinuous progression of liver damage, which takes at least one decade, but more frequently several decades, to produce serious chronic sequelae [28]. The outcome of HCV infection is influenced by many variables and cofactors that may significantly accelerate the natural course of liver

Fig. 2 Diagnostic algorithms in hepatitis C and interpretation of combined testing of viral markers and ALT. PNALT, persistently normal ALT levels.

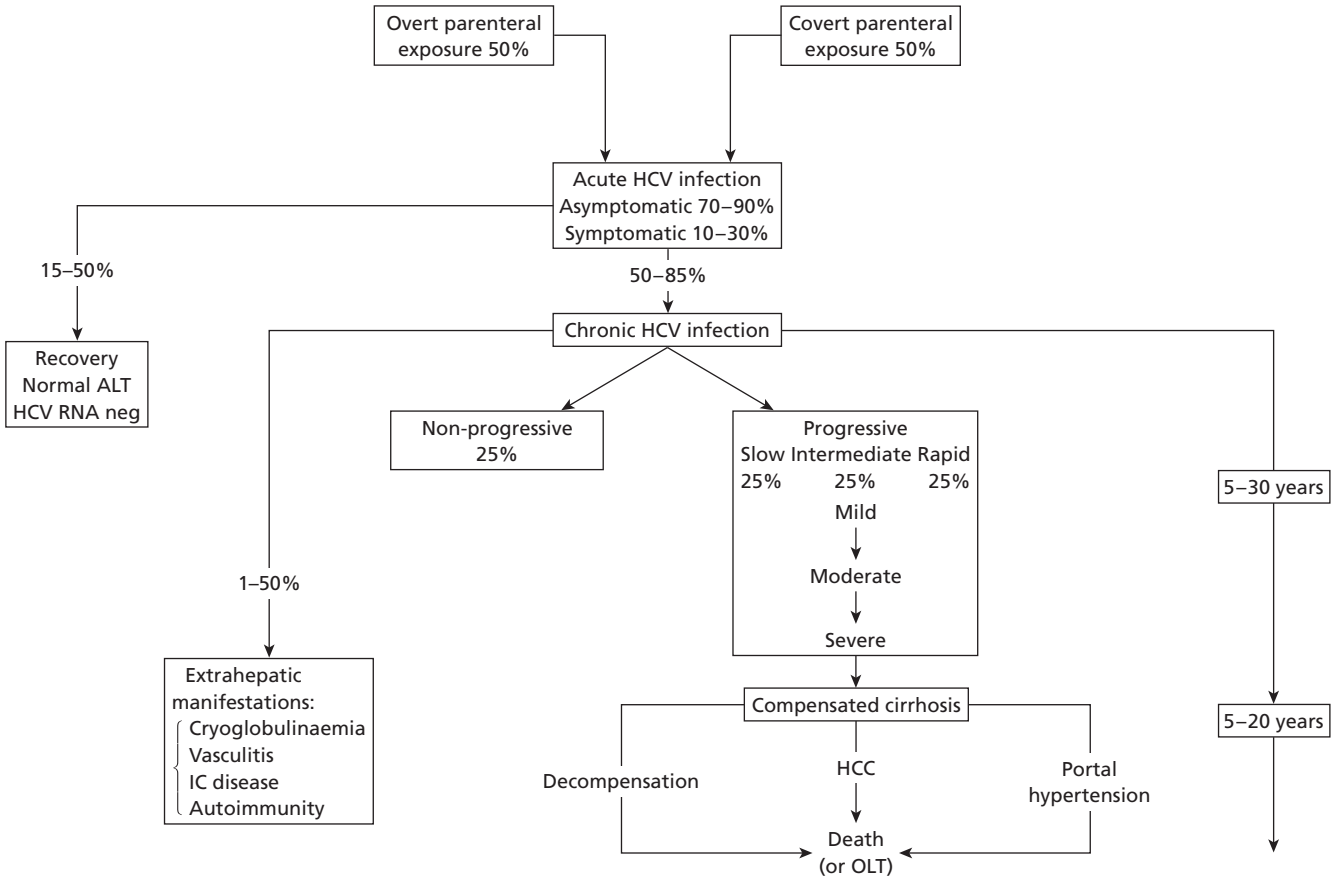

Fig. 3 Clinical spectrum and natural history of hepatitis C. Percentages indicate average prevalence/incidence of events. Wide variability of outcomes depends on many cofactors.

disease. For these reasons, the clinical course of hepatitis C is highly variable and the long-term prognostic assessment is problematic in the individual patient. Figure 3 describes the clinical spectrum of hepatitis C and the different stages and rates of progression.

Acute infection

The average incubation period of acute hepatitis C, as determined in prospective studies of post-transfusion hepatitis, is 7–8 weeks, but the range varies widely (from 2 to 26 weeks

or more) [29]. Shorter incubation periods have been reported in experimental infections and in haemophiliacs treated with factor VIII. HCV viraemia is the first marker to become detectable during acute hepatitis C; it is demonstrable by sensitive PCR as early as 1 week after exposure. Viraemia then persists without an antibody response for a variable window period before anti-HCV seroconversion [30,31].

The onset of liver damage, marked by variable ALT elevations, is always delayed with respect to the appearance of viraemia and may either precede or follow seroconversion to anti-HCV. Patients rarely have prodromic symptoms or fever. The acute phase of hepatitis C is often mild and usually less severe than hepatitis A and B; more than two-thirds of cases are asymptomatic and anicteric. A severe or fulminant course of acute hepatitis C rarely occurs, except in patients with immunodeficiency, pre-existing liver disease or the presence of other cofactors, such as hepatitis A or B or intravenous drug use. The clinical profile of symptomatic acute hepatitis C is the same as that of any type of viral hepatitis and is often indistinguishable from hepatitis A and B. Symptomatic cases present with malaise, dark urine, nausea (with or without vomiting), abdominal discomfort and/or jaundice.

Hepatitis C exhibits several patterns of ALT elevation. The most typical is polyphasic, with significant fluctuations in enzyme levels that may last for a few weeks or several months. Sometimes, periods of biochemical abnormality are separated by periods of ALT normality. Chronic hepatitis develops frequently in patients with a polyphasic ALT pattern [32].

The histological features of acute hepatitis C include a few peculiar morphological changes, in addition to the classic features that are common to viral hepatitis in general. Liver biopsy may show eosinophilic clamping of the cytoplasm, macrovescicular steatosis, marked activation of sinusoidal cells, peeling up of bile ductular cells in the lumen and a large number of acidophilic bodies. A liver biopsy is not recommended for routine diagnosis of acute hepatitis C, as none of the histological lesions is specific, and it is not essential for identifying progression to chronicity. This can be diagnosed by monitoring ALT levels and serum HCV-RNA levels in the months after the onset of acute disease. By definition, patients who have abnormal ALT values for more than 6–12 months are progressing to chronic hepatitis C [7]. These patients have evidence of chronic hepatitis of variable activity and severity on liver biopsy. Likewise, patients who remain serum positive for HCV RNA, despite the return of ALT levels to normal, often exhibit evidence of chronic hepatitis in the liver biopsy, usually with mild activity. A subacute course of hepatitis C with progressive hepatic failure is exceptional and should prompt a search for other causes of liver damage. The most frequent course seen after acute HCV infection is chronic evolution, with fluctuating ALT levels and persistently- or intermittently-positive serum HCV-RNA levels. The outcome of acute hepatitis C varies, depending on virus and host factors and on the size of the infecting inoculum. Minimal exposure may result in transient infection with recovery and development of some kind of T-cell immunity, even in the absence of anti-HCV seroconversion.

Three main outcome profiles can be seen after acute HCV infection:

1 Recovery with virus eradication: this occurs in 20–50% of cases, more frequently with smaller inocula. It is characterized by persistent ALT normalization and a repeatedly-confirmed negative HCV-RNA test in the presence of persistent anti-HCV reactivity, which remains positive in the serum for many years.

2 Evolution into a biochemically active chronic hepatitis C, with elevated and often fluctuating ALT levels.

3 Evolution into the asymptomatic HCV carrier state, with persistently normal ALT (PNALT) levels.

The different clinical outcomes seen in acute hepatitis C, their serological and biochemical profiles and the main determinants of HCV clearance versus persistence are described in Fig. 4.

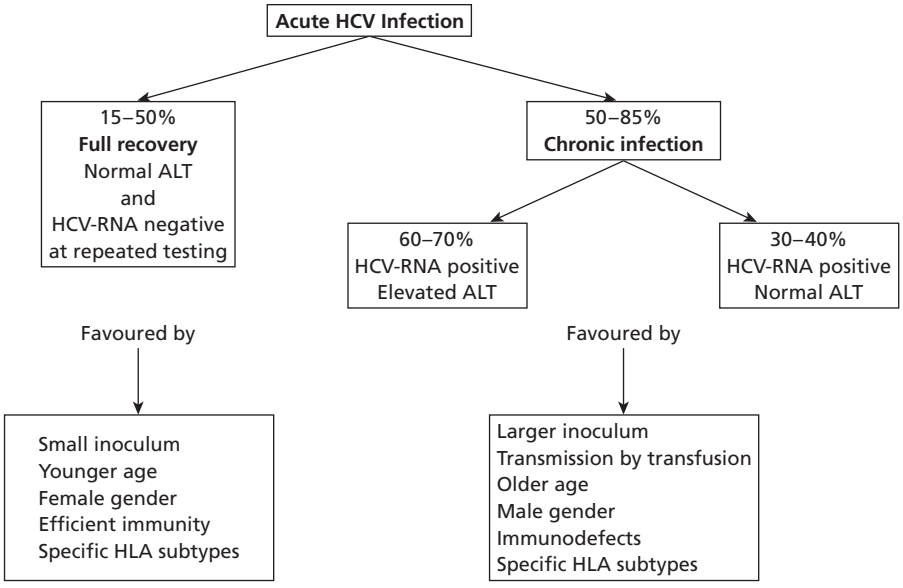

Fig. 4 Outcomes of acute HCV infection and predisposing variables. HLA, human leukocyte antigen.

Compensated phase of chronic HCV infection

Chronic HCV infection is defined as the persistence of serum HCV RNA for more than 6 months. It is usually not preceded by an overt acute onset. For this reason, patients with chronic HCV infection are usually diagnosed at different phases of the infection and may present at different stages of liver disease [9]. The main biochemical and clinical profiles are: (i) the typical form of chronic hepatitis C, with abnormal ALT levels and a wide spectrum of liver damage and progression rates; (ii) the HCV carrier state, with PNALT; and (iii) patients with extrahepatic manifestations of hepatitis C.

Biochemically active chronic hepatitis

The course of chronic hepatitis C with ALT elevations is often unpredictable in the individual patient. In a number of cases, it progresses slowly to more severe and active liver disease, with increasing fibrosis and, ultimately, transition to cirrhosis. Progression to cirrhosis may take years or decades. In other patients, the liver disease is minimal or mild and remains stable for decades, without significant worsening. The long-term outcomes of chronic HCV infection are schematically described in Fig. 3.

From chronic hepatitis C to compensated cirrhosis

Patients with biochemically active chronic hepatitis C have a persistently positive serum HCV-RNA test, and persistently or intermittently elevated ALT levels. Most are asymptomatic or have only mild and aspecific symptoms, such as chronic or parossistic fatigue, dyspepsia and myalgia. Chronic hepatitis C may be stable or progressive over time. Progression is marked by the worsening of liver fibrosis, a consequence of continuing necroinflammation and associated fibrogenesis [33,34]. Staging of liver fibrosis on liver biopsy is carried out using semiquantitative scoring systems: fibrosis is graded from 0 to 4 (METAVIR scoring system) [35] or from 0 to 6 (Ishak scoring system) [36]. Patients with chronic hepatitis C can be classified as being non-progressors, having stable disease, or being slow, intermediate or rapid progressors, with an estimated time interval between infection and development of cirrhosis of more than 50 years, 15–30 years or 3–10 years, respectively, and with about 25% of patients falling within each subgroup [37]. The risk of progression is dependent on a number of variables and cofactors, which are often interrelated. The stage of disease at presentation is obviously relevant for prognosis, and progression to cirrhosis is more frequent and imminent in those with more advanced liver disease [38]. The ALT levels and profile do correlate to some extent with disease activity and progression rate [39–41]. The age of the patient and mode of acquisition of HCV infection are important prognostic factors: older patients often have more rapid progression, although chronic HCV infection may also be benign and non-progressive in the elderly. Patients infected via a blood transfusion have more severe and progressive liver disease than those who acquire HCV by an inapparent source, possibly as a consequence of a larger virus inoculum, leading to higher virus spread and replication [42–46]. The role of HCV genotypes in determining disease outcomes is controversial. All HCV subtypes may be associated with mild, non-progressive, or severe and rapidly progressive liver disease. The actual viral loads are poorly correlated with disease severity and the measurement of serum HCV-RNA levels is not particularly useful in assessing disease outcomes in untreated patients. Alcohol [47], coinfection with HBV or HIV [38,48,49], impairment of the immune system and a coexisting malignancy have all been repeatedly and convincingly shown to aggravate the course of chronic hepatitis C. Metabolic factors are also important; obesity, insulin resistance and liver steatosis are associated with more rapid progression of liver fibrosis in hepatitis C [50–52].

Liver steatosis and metabolic abnormalities in hepatitis C

Liver steatosis is particularly frequent in hepatitis C; it is seen in more than 50% of cases and in more than 75% of those infected with HCV-3. The pathogenesis of liver steatosis in hepatitis C is multifactorial, being related to metabolic cofactors (insulin resistance) in some and to a more direct effect of HCV in others. The direct steatogenic effect of HCV has been attributed to the interference of the HCV core protein with mitochondrial function and apolipoprotein B-100 very-low-density lipoprotein (VLDL) secretion [53–55]; this results in the accumulation of triglycerides in hepatocytes, the induction of fatty acid oxidation and the release of cytokines, leading to steatosis and steatohepatitis [56,57]. In patients infected with HCV-3, the degree of fat infiltration appears to correlate with the level of HCV replication and protein expression, both in serum and in liver tissue [58], but not with liver fibrosis; in a recent study of over 3000 patients with HCV-related chronic hepatitis, the association between steatosis and fibrosis was confirmed in HCV-1-infected subjects but not in HCV-3-infected subjects [59]. Liver steatosis of the metabolic type should be corrected as it is more frequently associated with disease worsening and poor response to antiviral therapy. For this reason, hepatitis C is often more severe and progressive in overweight patients with type 2 diabetes. Liver iron overload is also associated with more advanced and progressive hepatitis C [60]. Other cofactors that have been associated with fibrosis progression in hepatitis C, including specific human leukocyte antigen (HLA) polymorphisms [61], are listed in Table 4.

HCV carrier state with persistently normal ALT

ALT levels may remain normal despite chronic HCV infection with ongoing HCV replication in the liver and a positive HCV-RNA serum test. This profile is characteristic of HCV carriers with PNALT. The number of HCV patients in this subgroup is consistent, representing around 20–45% of chronically infected individuals in the general population [62]. Many patients

Table 4 Cofactors and variables associated with more rapid evolution of chronic hepatitis C.

Larger inoculum
Acquisition by transfusion
Male gender
Older age at infection
Older age at diagnosis
Alcohol abuse
HBV coinfection
HIV coinfection
Obesity
Liver steatosis
Insulin resistance
Type 2 diabetes
Iron overload
Smoking
Malignancy
Immunosuppression/immunodefects
Organ transplantation
Some genetic polymorphisms
Some HLA subtypes

maintain PNALT levels over long-term follow-up, but a significant subgroup (around 20–25% over 3–5 years) develop biochemical reactivation, which may be transient or persistent and may be associated with disease worsening [63]. Most HCV carriers with PNALT have some degree of liver damage on liver biopsy, with the majority showing mild to moderate chronic hepatitis and fibrosis [64,65]. Liver disease is stable or progresses very slowly in these patients and the development of cirrhosis and endstage complications is rare. However, around 10–15% have advanced fibrosis or cirrhosis in the absence of biochemical (ALT) activity. Recently, the definition of ALT 'normality' has been challenged in patients with HCV, as the currently used upper limits of normality of ALT may underestimate a 'minimal' degree of liver cell necrosis. Therefore, liver biopsy remains the only tool to exactly define the degree and stage of liver disease in these patients. The indication to carry out a liver biopsy in HCV carriers with PNALT needs to be individualized, depending on the patient's age, life expectancy and motivation [63,66]. Currently, most international and national guidelines include liver biopsy in the clinical assessment of HCV carriers with normal ALT, particularly when a decision has to be made whether to treat with antiviral therapy. All patients presenting with chronic HCV infection and normal ALT should be monitored regularly (every 6–12 months) because of the possibility of ALT reactivation and liver disease worsening. Counselling regarding lifestyle and infectivity should be the same for these patients as it is for HCV-infected patients with elevated ALT.

The role of liver biopsy in assessing patients with chronic HCV infection

As in many other chronic liver diseases, liver biopsy is the gold standard for fibrosis staging in chronic hepatitis C. However, biopsy interpretation may be limited by sampling errors, resulting in underestimation of fibrosis stage, particularly when the size of the liver sample is small or inadequate [67–69]; laparoscopic studies have shown that cirrhosis is missed in up to 10–20% of percutaneous biopsies obtained from the same patients. For this reason, in practice, it may be more reasonable to distinguish patients with no or minimal fibrosis from those with significant and advanced fibrosis, as this simple separation has important prognostic value. Because liver biopsy is invasive and costly and requires hospitalization, non-invasive surrogate methods to predict liver fibrosis would be useful. A number of potential tools are currently under evaluation and include biochemical makers and panels of biochemical tests, and methods to measure liver stiffness by elastography. It is expected that some of these approaches will be used in the near future in the clinic to reduce the number of liver biopsies needed to correctly stage liver fibrosis in patients with chronic hepatitis C, as well as other forms of chronic liver disease [70,71].

From HCV-related compensated cirrhosis to endstage liver disease

When patients with chronic hepatitis C reach the stage of cirrhosis, the risk of developing severe and endstage complications becomes significant. The progressive impairment of liver function and the development of portal hypertension are responsible for most complications, which include ascites, variceal bleeding and hepatic encephalopathy. Several prospective studies have indicated that hepatic decompensation, defined as an episode of ascites, jaundice, variceal bleeding or hepatic encephalopathy, occurs relatively late in the natural course of HCV-related cirrhosis, with an estimated annual decompensation rate of around 3–4% and a 5-year cumulative incidence of 15–18% [72]. The same studies demonstrated that, in western countries and Japan, cirrhosis caused by chronic HCV infection is a major risk factor for hepatocellular carcinoma. In these areas, the prevalence of HCV infection ranges from 50% to 70% among patients with hepatocellular carcinoma. In chronic HCV infection, hepatocellular carcinoma occurs almost invariably with cirrhosis or advanced fibrosis. The annual incidence of hepatocellular carcinoma in HCV-related cirrhosis is estimated to be 1–6%, with a 5-year cumulative incidence ranging from 7% to 30%. Because hepatocellular carcinoma rarely develops in the absence of cirrhosis, this condition represents the major risk factor for hepatocellular carcinoma in chronic HCV infection. Older age and long-lasting liver disease, as well as the presence of active liver disease and regeneration shown by high ALT and alpha-fetoprotein (AFP) levels, represent high-risk conditions for hepatocellular carcinoma development. Several cofactors increase the risk of hepatocellular carcinoma in HCV-related cirrhosis, including HBV coinfection, heavy alcohol intake (above 50–80 g/day), iron overload and the presence of the metabolic syndrome and liver steatosis [73]. Complications of cirrhosis are the primary cause of death in patients with chronic HCV

infection. In patients with compensated cirrhosis, the 5-year survival rate is around 85–90%, whereas, after the first episode of decompensation, the 5-year survival rate is only 45–55%. In cohort studies, hepatocellular carcinoma was the primary cause of death in 47–72% of patients, followed by liver failure in 23–44% of cases and bleeding in 5–8% [74,75].

Extrahepatic manifestations of hepatitis C

Chronic HCV infection has been associated with a variety of extrahepatic manifestations (Table 5). These conditions may occur in the presence or absence of accompanying liver disease, which, if present, may be of variable severity. A direct cause–effect relationship is well established for mixed cryoglobulinaemia (MC) [76], vasculitis, membranoproliferative glomerulonephritis and a number of immune complex-associated disorders and some forms of low-grade malignant B-cell lymphoma. A relationship is suspected for porphyria cutanea tarda and some forms of autoimmune thyroiditis and diabetes mellitus; however, the association with HCV is weak or doubtful for the other conditions [77]. The association of HCV infection with an overt cryoglobulinaemic syndrome has clear geographical segregation (southern and eastern Europe), suggesting that genetic factors might be involved. The observation that the syndrome is more frequent in patients with long-standing infection suggests a role for chronic immune stimulation of B cells by HCV; this could also explain the production of autoantibodies and the risk of progression towards low-grade non-Hodgkin's B-cell lymphoma, which is reported in patients with chronic HCV. Many patients with chronic hepatitis C have detectable cryoglobulins in their serum but only small subgroups develop symptoms. Symptoms of HCV–MC are related to systemic vasculitis in small- and, less frequently, medium-sized vessels. Disease expression most often involves the skin and joints and, less frequently, the nerves and kidneys [78]. The main symptom is palpable purpura, which is reported in up to 90% of HCV–MC symptomatic patients; purpura begins in the lower extremities [79] and may extend to the abdomen and trunk and, less frequently, to the upper extremities. It subsides after 3–10 days, leaving a brownish discoloration that is particularly marked in the lower limbs. Purpura may be accompanied by Raynauds syndrome and acrocyanosis. Bilateral symmetrical arthralgias involving the great joints are reported in 60–90% of patients. Neither arthritis nor joint destruction is a feature. Distal sensory or sensory–motor asymmetrical polyneuropathies and multiple mononeuropathies develop in 40% of cases. Renal disease, usually membranoproliferative glomerulonephritis, accompanied by proteinuria and microscopic haematuria, occurs in 25% of patients. There is no clinical indication to search for cryoglobulins in the serum of HCV patients who have no signs or symptoms that are suggestive of the clinical syndrome.

Clinical course of hepatitis C in special subgroups

The course of acute and chronic hepatitis C is influenced by the immunocompetence of the host and by several cofactors. In the immunocompromized host, hepatitis C often runs a more severe course; this is the case in renal transplant recipients in whom HCV is an important cause of liver disease, which may significantly reduce survival [80]. Patients with HIV are frequently coinfected with HCV (at a rate of about 30% in Europe) and exhibit an accelerated progression to cirrhosis and endstage liver disease, particularly in the presence of low CD4 counts. With the improved therapeutic control of HIV infection and reduced mortality rates from acquired immune deficiency syndrome (AIDS), the endstage complications of hepatitis C have become a leading cause of mortality among HIV–HCV coinfected individuals. Coinfection with HCV and HBV is also common, particularly when both virus infections have significant prevalence in the population; coinfection is often associated with more severe histological liver lesions and a more

Table 5 Extrahepatic manifestations caused by or associated with chronic HCV infection.

Syndrome	Link to HCV infection
Mixed cryoglobulinaemia Vasculitis Membranoproliferative glomerulonephritis	Proven (HCV has a pathogenetic role)
Porphyria cutanea tarda Low-grade non-Hodgkin's lymphoma	Most likely (HCV may act as cofactor)
Autoimmune thyroiditis Type 2 diabetes Lichen planus	Possible (more data needed)
Sjogren syndrome Idiopathic pulmonary fibrosis Aplastic anaemia Polyarteritis nodosa Erythema nodosum	Weak (etiological role of HCV is unlikely)

rapid progression to cirrhosis and liver failure. In a study of bone marrow transplant recipients [81], the long-term outcome of chronic HCV infection was described as being particularly severe, with a cumulative rate of progression to cirrhosis of 10% and 25% at 15 and 20 years after bone marrow transplant respectively.

Chronic hepatitis C in children

HCV infection is uncommon in children because vertical transmission, which is responsible for most cases of paediatric infection in the western world, occurs in only about 3–5% of cases. Blood transfusions were a major route of infection of children before the implementation of HCV screening of blood donors. Intravenous drug use and high-risk sexual behaviour are currently maintaining the reservoir of infection in adolescents, particularly in large urban areas. Chronic hepatitis C in childhood has been characterized by an asymptomatic presentation, a variable biochemical pattern and mild liver lesions at histology [82]. Nevertheless, the spontaneous clearance of HCV and definitive ALT normalization were infrequently observed throughout childhood and adolescence, and increasing rates of fibrosis were documented in the liver in a proportion of cases that were followed prospectively with sequential liver biopsies [83]. As a consequence, there was an increased risk of developing cirrhosis and hepatocellular carcinoma in adult life, although the frequency and timing of these complications remain undefined.

Management of chronic HCV infection in clinical practice

Once chronic HCV infection has been identified by serological testing (the presence of anti-HCV antibodies and HCV RNA in serum), patients should be evaluated for the presence and stage of liver disease. This is best achieved by liver histology. Liver biopsy is not necessary if clinical and/or biochemical/haematological signs of overt cirrhosis are present. On the basis of histological findings, chronic hepatitis C is classified as minimal/mild (with no fibrosis or only minimal/mild fibrosis limited to the portal tracts or few and incomplete septa) or moderate/severe (with many septa or bridging necrosis). This broad distinction is clinically useful in terms of prognostic assessment. Patients who are not considered for antiviral therapy and those who fail treatment need to be monitored periodically for disease progression; they are usually monitored at 6- to 12-month intervals for biochemical markers of liver function and disease activity. Periodical ultrasound examination of the upper abdomen is recommended for those with moderate/severe liver disease. Histological re-evaluation is usually recommended after 5–6 years for patients who initially present with minimal/mild disease, and after 2–3 years for those with moderate/severe disease. Monitoring for liver fibrosis with non-invasive markers may enter clinical practice in the future, if better standardization can be achieved. All patients with chronic HCV infection should be evaluated for disease cofactors, particularly those that can be modified by intervention. Because a 'metabolic type' of liver steatosis may aggravate the course of hepatitis C, this condition should be investigated and, when detected, patients should be appropriately counseled to reduce the grade of fatty changes in the liver (by diet, exercise or reduction of body weight; see Chapter 13 for the clinical management of non-alcoholic fatty liver disease). Abstinence or avoidance of excess alcohol is also recommended in patients with chronic HCV, particularly when liver disease is active or advanced. Patients with chronic HCV should be encouraged to undergo testing for HBV and HIV markers, particularly when specific risk factors are identified. HBV vaccination should be recommended to HCV carriers who are negative for all HBV markers, including antibodies to hepatitis B surface antigen (anti-HBs). Hepatitis A virus vaccination is also recommended for non-immune individuals. Adequate counseling to reduce the risk of HCV transmission is mandatory for all HCV carriers, regardless of the viraemic load, HCV genotype and grade and stage of liver disease.

Because of the major role of direct percutaneous exposure in the transmission of HCV, educational programs and ensuring access to sterile needles and syringes for intravenous drug users are of paramount importance. Because of the low risk of HCV transmission, monogamous couples do not need to use barrier protection (condoms), although they should be advised that condoms may reduce the risk of transmission. On the other hand, HCV-infected individuals with multiple sexual partners should be advised to use barrier protection. Sharing common household items that may be contaminated with blood, such as razors and toothbrushes, should be avoided. The risk of HCV infection from a needlestick injury, an accident that frequently occurs in the health-care setting, is estimated to be around 2% and, at present, immunoglobulin prophylaxis is not recommended. Whenever possible, the source should be tested for HCV and the exposed individual followed for seroconversion to obtain early identification of HCV infection, which may be treated when appropriate. The risk of perinatal transmission is approximately 2–5% for infants of anti-HCV-positive mothers. High HCV-RNA levels at delivery, and HIV coinfection, significantly increase this risk. Elective caesarean section has not been shown to reduce the risk. Invasive fetal monitoring and prolonged labour after rupture of membranes should be avoided. Breastfeeding does not appear to transmit HCV [84].

References

1 Choo QL, Kuo G, Weiner AJ *et al.* (1989) Isolation of a cDNA clone derived from a blood-born non-A, non-B viral hepatitis genome. *Science* 244, 359–362.
2 Simmonds P (2001) The origin and evolution of hepatitis viruses in humans. *J Gen Virol* 82, 693–712.
3 Anonymous (1999) Global surveillance and control of hepatitis C. Report of a WHO consultation organized in collaboration with the Viral Hepatitis Prevention Board. *J Viral Hepat* 6, 35–47.

4 Memon MI, Memon MA (2002) Hepatitis C: an epidemiological review. *J Viral Hepat* 9, 84–100.
5 Alter MJ (1995) Epidemiology of hepatitis C in the West. *Semin Liver Dis* 15, 5–14.
6 Mansell CJ, Locarnini SA (1995) Epidemiology of hepatitis C in the East. *Semin Liver Dis* 15, 15–32.
7 Orland JR, Wright TL, Cooper S (2001) Acute hepatitis C. *Hepatology* 33, 321–327.
8 Kim WR (2002) The burden of hepatitis C in the United States. *Hepatology* 36(5 Suppl 1), S30–34.
9 Hoofnagle JH (2002) Course and outcome of hepatitis C. *Hepatology* 36(5 Suppl 1), S21–29.
10 Schreiber GB, Busch MP, Kleinman SH *et al.* (1996) The risk of transfusion-transmitted viral infections. The Retrovirus Epidemiology Donor Study. *N Engl J Med* 334(26), 1685–1690.
11 Terrault NA (2002) Sexual activity as a risk factor for hepatitis C. *Hepatology* 36(5 Suppl 1), S99–105.
12 Puro V, Petrosillo N, Ippolito G (1995) Risk of hepatitis C seroconversion after occupational exposures in health careworkers. Italian Study Group on occupational risk of HIV and other bloodborne infections. *Am J Infect Control* 23, 273–277.
13 Tumminelli F, Marcellin P, Rizzo S *et al.* (1995) Shaving as potential source of hepatitis C virus infection. *Lancet* 345, 658.
14 Sun DX, Zhang FG, Geng YQ *et al.* (1996) Hepatitis C transmission by cosmetic tattooing in women. *Lancet* 347, 541.
15 Jonas MM (2002) Children with hepatitis C. *Hepatology* 36(5 Suppl 1), S173–178.
16 Alter MJ (2002) Prevention of spread of hepatitis C. *Hepatology* 36(5 Suppl 1), S93–98.
17 Recommendations for prevention and control of hepatitis C virus (HCV) infection and HCV-related chronic disease. Centers for Disease Control and Prevention (1998). *MMWR Recomm Rep* 47(RR-19), 1–39.
18 Pawlotsky JM (2002) Use and interpretation of virological tests for hepatitis C. *Hepatology* 36(5 Suppl 1), S65–73.
19 Pawlotsky JM (2002) Molecular diagnosis of viral hepatitis. *Gastroenterology* 122, 1554–1568.
20 Nolte FS, Green AM, Fiebelkorn KR *et al.* (2003) Clinical evaluation of two methods for genotyping hepatitis C virus based on analysis of the 5′ noncoding region. *J Clin Microbiol* 41, 1558–1564.
21 van Soest H, Boland GJ, van Erpecum KJ (2006) Hepatitis C: changing genotype distribution with important implications for patient management. *Neth J Med* 64, 96–99.
22 Dal Molin G, Ansaldi F, Biagi C *et al.* (2002) Changing molecular epidemiology of hepatitis C virus infection in Northeast Italy. *J Med Virol* 68, 352–356.
23 Ross RS, Viazov S, Renzing-Kohler K *et al.* (2000) Changes in the epidemiology of hepatitis C infection in Germany: shift in the predominance of hepatitis C subtypes. *J Med Virol* 60, 122–125.
24 Bortolotti F, Resti M, Marcellini M *et al.* (2005) Hepatitis C virus (HCV) genotypes in 373 Italian children with HCV infection: changing distribution and correlation with clinical features and outcome. *Gut* 54, 852–857.
25 Matera G, Lamberti A, Quirino A *et al.* (2002) Changes in the prevalence of hepatitis C virus (HCV) genotype 4 in Calabria, Southern Italy. *Diagn Microbiol Infect Dis* 42, 169–173.
26 Echevarria JM, Leon P, Pozo F *et al.* (2006) Follow-up of the prevalence of hepatitis C virus genotypes in Spain during a nine-year period (1996–2004). *Enferm Infecc Microbiol Clin* 24, 20–25.
27 Pawlotsky JM, Lonjon I, Hezode C *et al.* (1998) What strategy should be used for diagnosis of hepatitis C virus infection in clinical laboratories? *Hepatology* 27, 1700–1702.
28 Seeff LB, Hoofnagle JH (2002) National Institutes of Health Consensus Development Conference: management of hepatitis C: 2002. *Hepatology* 36(5 Suppl 1), S1–2.
29 Barrera JM, Bruguera M, Ercilla MG *et al.* (1995) Persistent hepatitis C viremia after acute self-limiting post transfusion hepatitis C. *Hepatology* 21, 639–644.
30 Farci P, Alter HJ, Wong D *et al.* (1991) A long-term study of hepatitis C virus replication in non-A, non-B hepatitis. *N Engl J Med* 325, 98–104.
31 Alter MJ, Margolis HS, Krawczynski K *et al.* (1992) The natural history of community-acquired hepatitis C in the United States. The Sentinel Counties Chronic Non-A, Non-B Hepatitis Study Team. *N Engl J Med* 327, 1899–1905.
32 Villano SA, Vlahov D, Nelson KE *et al.* (1999) Persistence of viremia and the importance of long-term follow-up after acute hepatitis C infection. *Hepatology* 29, 908–914.
33 Marcellin P, Asselah T, Boyer N (2002) Fibrosis and disease progression in hepatitis C. *Hepatology* 36(5 Suppl 1), S47–56.
34 Yano M, Kumada H, Kage M *et al.* (1996) The long-term pathological evolution of chronic hepatitis C. *Hepatology* 23, 1334–1340.
35 Bedossa P, Poynard T (1996) An algorithm for the grading of activity in chronic hepatitis C. The METAVIR Cooperative Study Group. *Hepatology* 24, 289–293.
36 Ishak K, Baptista A, Bianchi L *et al.* (1995) Histological grading and staging of chronic hepatitis. *J Hepatol* 22, 696–699.
37 Poynard T, Bedossa P, Opolon P (1997) Natural history of liver fibrosis progression in patients with chronic hepatitis C. The OBSVIRC, METAVIR, CLINIVIR, and DOSVIRC groups. *Lancet* 349, 825–832.
38 Alberti A, Benvegnù L (2003) Management of hepatitis C. *J Hepatol* 38(Suppl 1), S104–118.
39 Boccato S, Pistis R, Noventa F *et al.* (2006) Fibrosis progression in initially mild chronic hepatitis C. *J Viral Hepat* 13, 297–302.
40 Pradat P, Alberti A, Poynard T *et al.* (2002) Predictive value of ALT levels for histologic findings in chronic hepatitis C: a European collaborative study. *Hepatology* 36, 973–977.
41 Hui CK, Belaye T, Montegrande K *et al.* (2003) A comparison in the progression of liver fibrosis in chronic hepatitis C between persistently normal and elevated transaminase. *J Hepatol* 38, 511–517.
42 Seeff LB (2002) Natural history of chronic hepatitis C. *Hepatology* 36(5 Suppl 1), S35–46.
43 Casiraghi MA, De Paschale M, Romano L *et al.* (2004) Long-term outcome (35 years) of hepatitis C after acquisition of infection through mini transfusions of blood given at birth. *Hepatology* 39, 90–96.
44 Kenny-Walsh E (1999) Clinical outcomes after hepatitis C infection from contaminated anti-D immune globulin. Irish Hepatology Research Group. *N Engl J Med* 340, 1228–1233.
45 Alter HJ, Seeff LB (2000) Recovery, persistence, and sequelae in hepatitis C virus infection: a perspective on long-term outcome. *Semin Liver Dis* 20, 17–35.
46 Wiese M, Berr F, Lafrenz M *et al.* (2000) Low frequency of cirrhosis in a hepatitis C (genotype 1b) single-source outbreak in Germany: a 20-year multicenter study. *Hepatology* 32, 91–96.
47 Harris DR, Gonin R, Alter HJ *et al.*, National Heart, Lung, and Blood Institute Study Group (2001) The relationship of acute transfusion-associated hepatitis to the development of cirrhosis in the presence of alcohol abuse. *Ann Intern Med* 134, 120–124.

48 Monga HK, Rodriguez-Barradas MC, Breaux K *et al.* (2001) Hepatitis C virus infection-related morbidity and mortality among patients with human immunodeficiency virus infection. *Clin Infect Dis* 33, 240–247. Epub 2001 Jun 15.
49 Graham CS, Baden LR, Yu E *et al.* (2001) Influence of human immunodeficiency virus infection on the course of hepatitis C virus infection: a meta-analysis. *Clin Infect Dis* 33, 562–569.
50 Adinolfi LE, Gambardella M, Andreana A *et al.* (2001) Steatosis accelerates the progression of liver damage of chronic hepatitis C patients and correlates with specific HCV genotype and visceral obesity. *Hepatology* 33, 1358–1364.
51 Ortiz V, Berenguer M, Rayon JM *et al.* (2002) Contribution of obesity to hepatitis C-related fibrosis progression. *Am J Gastroenterol* 97, 2408–2414.
52 Monto A, Alonzo J, Watson JJ *et al.* (2002) Steatosis in chronic hepatitis C: relative contributions of obesity, diabetes mellitus, and alcohol. *Hepatology* 36, 729–736.
53 Sabile A, Perlemuter G, Bono F *et al.* (1999) Hepatitis C virus core protein binds to apolipoprotein AII and its secretion is modulated by fibrates. *Hepatology* 30, 1064–1076.
54 Perlemuter G, Sabile A, Letteron P *et al.* (2002) Hepatitis C virus core protein inhibits microsomal triglyceride transfer protein activity and very low density lipoprotein secretion: a model of viral-related steatosis. *FASEB J* 16, 185–194.
55 Mirandola S, Realdon S, Iqbal J *et al.* (2006) Liver microsomal triglyceride transfer protein is involved in hepatitis C liver steatosis. *Gastroenterology* 130, 1661–1669. Epub 2006 Mar 6.
56 Barba G, Harper F, Harada T *et al.* (1997) Hepatitis C virus core protein shows a cytoplasmic localization and associates to cellular lipid storage droplets. *Proc Natl Acad Sci USA* 94, 1200–1205.
57 Moriya K, Yotsuyanagi H, Shintani Y *et al.* (1997) Hepatitis C virus core protein induces hepatic steatosis in transgenic mice. *J Gen Virol* 78, 1527–1531.
58 Kumar D, Farrell GC, Fung C *et al.* (2002) Hepatitis C virus genotype 3 is cytopathic to hepatocytes: reversal of hepatic steatosis after sustained therapeutic response. *Hepatology* 36, 1266–1272.
59 Leandro G, Mangia A, Hui J *et al.* (2006) Steatosis is independently associated with fibrosis in chronic hepatitis C: a meta-analysis of individual patient data. *Gastroenterology* 130, 1636–1642.
60 Smith BC, Gorve J, Guzail MA *et al.* (1998) Heterozygosity for hereditary hemochromatosis is associated with more fibrosis in chronic hepatitis C. *Hepatology* 27, 1695–1699.
61 Thursz M, Yallop R, Goldin R *et al.* (1999) Influence of MHC class II genotype on outcome of infection with hepatitis C virus. The HENCORE group. Hepatitis C European Network for Cooperative Research. *Lancet* 354, 2119–2124.
62 Alberti A (2005) Towards more individualised management of hepatitis C virus patients with initially or persistently normal alanine aminotransferase levels. *J Hepatol* 42, 266–274.
63 Alberti A, Noventa F, Benvegnù L *et al.* (2002) Prevalence of liver disease in a population of asymptomatic persons with hepatitis C virus infection. *Ann Intern Med* 137(12), 961–964. Summary for patients in *Ann Intern Med* (2002) 137(12), I36.
64 Alberti A, Morsica G, Chemello L *et al.* (1992) Hepatitis C viraemia and liver disease in symptom-free individuals with anti-HCV. *Lancet* 340, 697–698.
65 Gholson CF, Morgan K, Catinis G *et al.* (1997) Chronic hepatitis C with normal aminotransferase levels: a clinical histologic study. *Am J Gastroenterol* 92, 1788–1792.
66 National Institutes of Health (2002) National Institutes of Health Consensus Development Conference Statement: management of hepatitis C: 2002. *Hepatology* 36(5 Suppl 1), S3–20.
67 Garcia G, Keeffe EB (2001) Liver biopsy in chronic hepatitis C: routine or selective. *Am J Gastroenterology* 96, 3053–3055.
68 Dienstag JL, McHutchison JG (2006) American Gastroenterological Association Medical Position Statement on the Management of Hepatitis C. *Gastroenterology* 130, 225–230.
69 Regev A, Berho M, Jeffers LJ *et al.* (2002) Sampling error and intra-observer variation in liver biopsy in patients with chronic HCV infection *Am J Gastroenterol* 97, 2614–2618.
70 Afdhal NH, Nunes D (2004) Evaluation of liver fibrosis: a concise review. *Am J Gastroenterol* 99, 1160–1174.
71 Sebastiani G, Alberti A (2006) Non invasive fibrosis biomarkers reduce but not substitute the need for liver biopsy. *World J Gastroenterol* 12, 3682–3694.
72 Fattovich G, Giustina G, Degos F *et al.* (1997) Morbidity and mortality in compensated cirrhosis type C: a retrospective follow-up study of 384 patients. *Gastroenterology* 112, 463–472.
73 Benvegnù L, Fattovich G, Noventa F *et al.* (1994) Concurrent hepatitis B and C virus infection and risk of hepatocellular carcinoma in cirrhosis. A prospective study. *Cancer* 74, 2442–2448.
74 Niederau C, Lange S, Heintges T *et al.* (1998) Prognosis of chronic hepatitis C: results of a large, prospective cohort study. *Hepatology* 28, 1687–1695.
75 Benvegnù L, Gios M, Boccato S *et al.* (2004) Natural history of compensated viral cirrhosis: a prospective study on the incidence and hierarchy of major complications. *Gut* 53, 744–749.
76 Agnello V, Chung RT, Kaplan LM (1992) A role for hepatitis C virus infection in type II cryoglobulinemia. *N Engl J Med* 327, 1490–1495.
77 Zignego AL, Brechot C (1999) Extrahepatic manifestations of HCV infection: facts and controversies. *J Hepatol* 31, 369–376.
78 Cacoub P, Renou C, Rosenthal E *et al.* (2000) Extrahepatic manifestations associated with hepatitis C virus infection. A prospective multicenter study of 321 patients. *Medicine (Baltimore)* 79, 47–56.
79 Monti G, Galli M, Invernizzi F *et al.* (1995) Cryoglobulinaemias: a multi-centre study of the early clinical and laboratory manifestations of primary and secondary disease. GISC Italian Group for the study of cryoglobulinaemias. *QJ Med* 88, 115–126.
80 Mathurin P, Mouquet T, Poynard T *et al.* (1999) Impact of hepatitis B and C virus on kidney transplantation outcome. *Hepatology* 29, 257–263.
81 Peffault de Latour R, Levy V, Asselah T *et al.* (2004) Long term outcome of hepatitis C infection after bone marrow transplantation. *Blood* 103, 1618–1624.
82 Shepard CW, Finelli L, Alter MJ (2005) Global epidemiology of hepatitis C virus infection. *Lancet Infect Dis* 5, 558–567.
83 McHutchinson JG (2004) Understanding hepatitis C. *Am J Manag Care* 10, S21–29.
84 NIH Consensus Statement on management of hepatitis C: 2002 (2002) *NIH Consens State Sci Statements* 19, 1–46.

9.1.2.vii Hepatitis E

Rakesh Aggarwal and Krzysztof Krawczynski

Definition

Hepatitis E is a form of acute viral hepatitis aetiologically related to hepatitis E virus (HEV) infection. The disease is endemic in developing countries in the Indian subcontinent, central and south-east Asia, Africa and the Middle East, where it is a cause of significant morbidity and mortality.

Virology

Morphology and genomic organization

HEV is a small RNA virus, 32–34 nm in diameter, non-enveloped, icosahedral in symmetry, with indentations and spikes on its surface. The virus is currently classified in a separate genus *Hepevirus* in the family Hepeviridae. The HEV genome is a single-stranded, positive-sense and polyadenylated RNA of approximately 7200 bases [1]. The genome carries a 7-methylguanosine (m^7G) nucleotide cap [2] and is composed of discontinuous and partially overlapping open reading frames (ORFs) flanked by a 5′ untranslated region and a 3′ poly-A tail (Fig. 1) [1]. ORF1 encodes non-structural proteins (RNA-dependent RNA polymerase, helicase and methyl transferase) that are used in viral replication. ORF2 codes for the major structural (capsid) protein which contains a signal sequence at the 5′ end and three glycosylation sites. ORF3 overlaps ORF1 and ORF2 by 1 and 328 nucleotides, respectively, and encodes a small phosphoprotein that associates with the cytoskeleton in *in vitro* experiments. ORF3 may be involved in intracellular signal transduction and is associated with the assembly of virions. Details of HEV attachment and entry into hepatocytes, the primary target cells for the virus, HEV replication and release of mature virions remain unknown. Hypothetically, non-structural gene products are expressed from the full-length, positive-sense genome. Newly generated, negative-strand RNA may act as a template for the production of full-length genomic RNA that is packed into progeny virions or used for further expression of non-structural proteins. It is possible that host-derived proteins are involved in viral replication. Recently, infectious cDNA clones of HEV and a subgenomic replicon system were developed that allow the study of viral replication strategies [3], which had been hindered by the absence of a reliable tissue culture system for HEV and a small animal model of HEV infection.

Genotypes and genetic epidemiology

Various geographically distinct isolates of HEV have been classified into at least four genotypes, based on the phylogenetic relationship of their genomic sequences (Table 1) [4]. The various isolates included in genotype 1 ('Asian strain') have a nucleotide sequence homology of 92–99% (amino acid sequence homology 95–99%) with each other, but only a 75% nucleotide homology (86% amino acid homology) with the isolate included in genotype 2 ('Mexico strain'). Isolates from sporadic cases in the United States, a non-endemic region, classified as genotype 3, are 92% identical to each other but only 73.5–74.5% identical to isolates from genotypes 1 and 2. Genotype 4 comprises isolates from some parts of China and Taiwan. HEV isolates from Africa (Chad, Algeria, Egypt) are more closely related to the Burmese strain than to the Mexican strain; however a Nigerian isolate appears to be closer to the

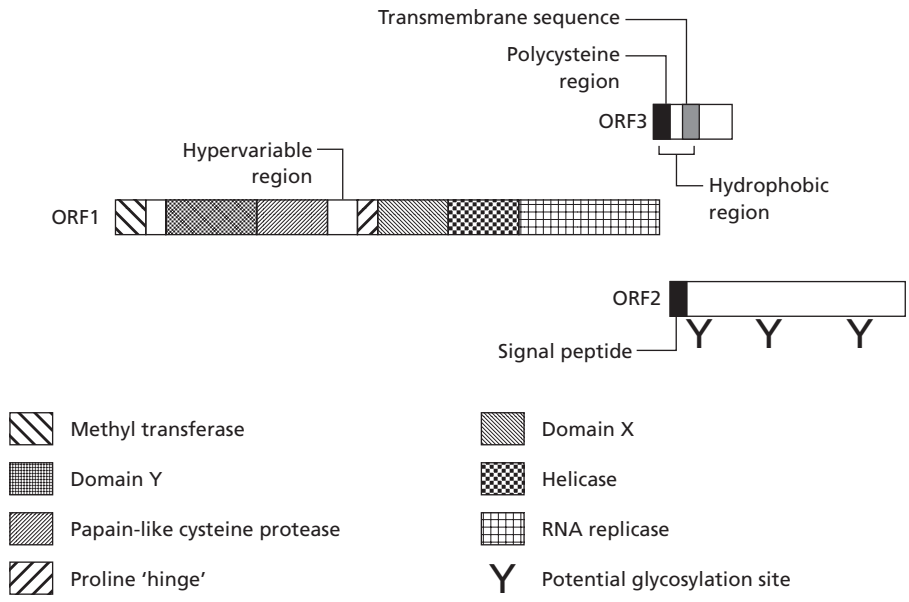

Fig. 1 A schematic diagram showing genomic organization of hepatitis E virus RNA, including its three open reading frames.

Table 1 Proposed genotype classification system for hepatitis E virus based on phylogenetic analysis of nucleotide sequences.

Genotype	Geographical origin of isolates
1	Asia
1A	India, Burma (Myanmar), Nepal
1B	China, Pakistan, former USSR
1C	Africa
1D	An isolate from a patient with fulminant hepatic failure and a few Indian isolates
2	Mexico and some African (Nigerian) strains
3	United States
4	China/Taiwan
5	Italy
6	Greece 1
7	Greece 2
8	Argentina (Argentina 1 and 2)

Based on ref. 4.

Mexican strain. Separate genotypes have been proposed for recently described single isolates from other non-endemic regions, such as Italy, Greece and Spain (genotypes 5–8). Despite significant genomic variability, all genotypes share at least one major serologically cross-reactive epitope.

Swine HEV, an HEV-like virus, was first identified in pigs in the midwestern United States [5], and later in other countries. It naturally infects pigs, inducing transient viraemia and antibodies that react with the capsid protein of human HEV strains. It has approximately 90.2–91.7% and 78.9–82.9% identity at the amino acid level with the Burmese and Mexican isolates of human HEV in the ORF2 and ORF3 regions respectively. In comparison, the US isolates of HEV share 92% identity with swine HEV and are more closely related to it than to the Burmese and Mexican strains. Similarly, swine HEV strains in Taiwan and Spain are more similar genetically to human HEV strains from these regions than to swine and human HEV isolates from other parts of the world. However, swine HEV identified in India, an HEV-endemic region, is genetically different from the HEV in patients from the same geographical region. Recently, an HEV-like virus was recovered from chickens; partial sequencing of its genome showed that it is genetically more diverse than isolates from mammalian species [6].

Clinical characteristics, pathology and pathogenesis

Clinical features

Clinical signs and symptoms in patients with symptomatic HEV infection are similar to those in persons with acute hepatitis A or B. Acute-phase symptoms include abdominal pain, anorexia, arthralgia, asthenia, malaise, flu-like symptoms, clay-coloured stools, dark or tea-coloured urine, diarrhoea, fever, jaundice, nausea, vomiting, aversion to smoking, pruritus and skin rash [7–9]. The most commonly reported symptoms have been jaundice (90–100%), malaise (95–100%), anorexia (66–100%), nausea/vomiting (29–100%), fever (23–97%) and itching (14–59%) [7–9]. Common clinical findings include jaundice, hepatomegaly (10–85%) and, at times, splenomegaly. Laboratory findings are also similar to those in patients with other forms of viral hepatitis and include elevated levels of serum bilirubin, alanine aminotransferase (ALT), aspartate aminotransferase, alkaline phosphatase and γ-glutamyltransferase.

The incubation period in human volunteers after oral exposure was 4–5 weeks; incubation periods of 15–60 days have been reported during hepatitis E outbreaks. Acute-phase symptoms are preceded by a prodromal phase characterized by fever and nausea that diminish with the onset of jaundice (icteric phase). Most patients with acute hepatitis E have a self-limited course, and resolution of hyperbilirubinaemia and elevated aminotransferase levels generally occurs within 3 weeks (range 1–6 weeks) after illness onset. A subset of patients has a prolonged illness with prominent cholestasis, which usually resolves spontaneously. A few patients have a particularly severe disease and develop liver failure. The overall case–fatality ratio for the general population in disease-endemic countries has been from 0.1% to 4% [10]. Case–fatality rates are much higher (up to 25%) among pregnant women infected with HEV, especially during the third trimester [11]. The reason for the particularly high disease severity and mortality among pregnant women is not yet known.

The ratio of clinical to subclinical infections has not been determined; however, lower disease rates reported in younger age groups during several outbreaks may be the result of anicteric and/or subclinical HEV infections. In most hepatitis E outbreaks, the highest rates of symptomatic disease (jaundice) have been in young to middle-aged adults. No evidence of chronic hepatitis or liver cirrhosis has been detected among patients followed up clinically and among those who had liver biopsies after acute hepatitis E [12]. HEV infection in patients with pre-existing liver cirrhosis has been associated with the occurrence of acute-on-chronic liver failure. These patients may have a particularly poor outcome, although a subset improves to an asymptomatic state with compensated liver function [13].

Treatment for hepatitis E is essentially supportive. No data are available to evaluate the efficacy of antiviral agents or other specific therapies. The role of termination of pregnancy in pregnant patients with hepatitis E and fulminant hepatic failure has not been studied.

Pathology

Two histopathological patterns were observed in specimens obtained from an outbreak in Delhi, India: an obstructive or cholestatic pattern in 58% of examined cases, and a pattern similar to other forms of acute viral hepatitis in 42% of cases [14]. The cholestatic type was characterized by bile stasis in canaliculi

and parenchymal cells, which were arranged in a gland-like fashion. Degenerative changes in liver cells (including acidophilic bodies) and focal necrosis were seen less frequently in the cholestatic type of hepatitis E. Polymorphonuclear leukocytes were observed in both intralobular infiltrate and portal tracts in larger amounts than those seen in classic acute viral hepatitis, although lymphomononuclear cells were the predominant cell type in portal tracts. Among the 'standard' changes typically observed in cases of viral hepatitis, ballooned hepatocytes, acidophilic degeneration of hepatocytes and acidophilic body formation were the most frequently encountered. The acidophilic type of hepatocytic degeneration was also a characteristic morphological feature of experimentally induced hepatitis E in cynomolgus macaques. Focal hepatocyte necrosis was observed in both patients and infected primates, with prominent accumulations of mononuclear macrophages and activated Kupffer cells and a much less striking presence of lymphocytes, which prevailed in portal infiltrates.

Elements of pathogenesis

Clinical and pathological features of HEV infection have been characterized based on surveys of patients involved in outbreaks of hepatitis E, studies of human volunteers and experimental models of infection in non-human primates. Data on virus replication in the liver, humoral immune response and liver pathology related to HEV infection were collected from these studies and used to develop a composite picture of the pathogenetic events of HEV infection (Fig. 2).

The pathogenic features associated with HEV infection have been characterized in rare volunteer studies [15]. In surveys of patients involved in outbreaks of acute hepatitis E, genomic sequences of HEV were identified in stools, bile and sera. HEV RNA has been detected in the faeces of most patients for about 2 weeks [16]; however, faecal HEV excretion for as long as 52 days has been reported. The relationship between HEV RNA detection and infectivity in stools has not been demonstrated. HEV RNA has been found in serum in virtually all patients within 2 weeks after illness onset [16]. Prolonged periods of HEV RNA positivity in serum ranging from 4 to 16 weeks have also been reported. Both immunoglobulin (Ig) M and IgG anti-HEV are generally detectable at the time of onset of illness, but the exact time course for the development of an antibody response is not known. It appears that the anti-HEV IgM response begins to develop just before the maximal ALT activity and disappears about 5 months into the convalescent phase of the disease [17,18]. The IgG response begins to develop shortly after the IgM response, and its titre increases throughout the acute phase and into the convalescent phase, remaining high from 1 to 4.5 years after the acute phase of the disease [17,18]. Virtually all patients have detectable IgG anti-HEV for at least 20 months after acute infection. In one study, nearly 50% of persons had detectable antibody approximately 14 years after infection [19], whereas the other half no longer had serological evidence of HEV infection. Recent data show that cellular immune responses are also activated during acute hepatitis E [20].

The experimental model of HEV infection is reproduced best in cynomolgus macaques and chimpanzees, although other non-human primates (rhesus, owl monkeys, tamarins) have been shown to be susceptible to HEV infection [21–23]. In macaques inoculated intravenously with HEV, expression of HEV antigen (HEVAg) in hepatocytes, indicative of viral replication, is first seen at about day 7 after infection [21]. HEVAg has been detected in 70–90% of hepatocytes at the peak of HEV replication, and decreases rapidly after the maximum ALT activity. HEVAg has been detected simultaneously in hepatocyte cytoplasm, bile and faeces during the second or third week after inoculation, and before and concurrently with the onset of ALT

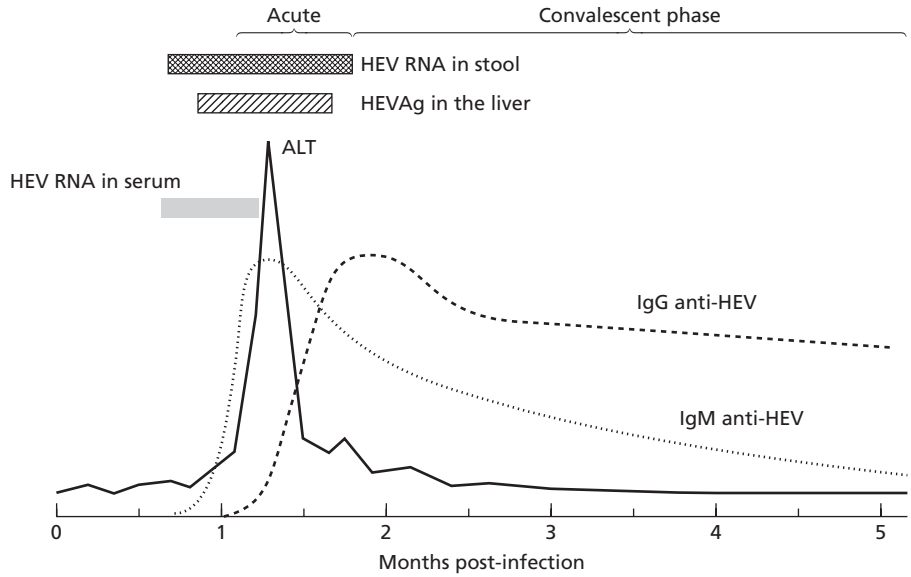

Fig. 2 Pathogenesis and clinical course of hepatitis E. A hypothetical graphical summary showing the course of events during HEV infection based on data from studies in human subjects and experimentally infected primates. The separation between the acute and convalescent phases of disease is arbitrary and is based on the alanine aminotransferase (ALT) levels.

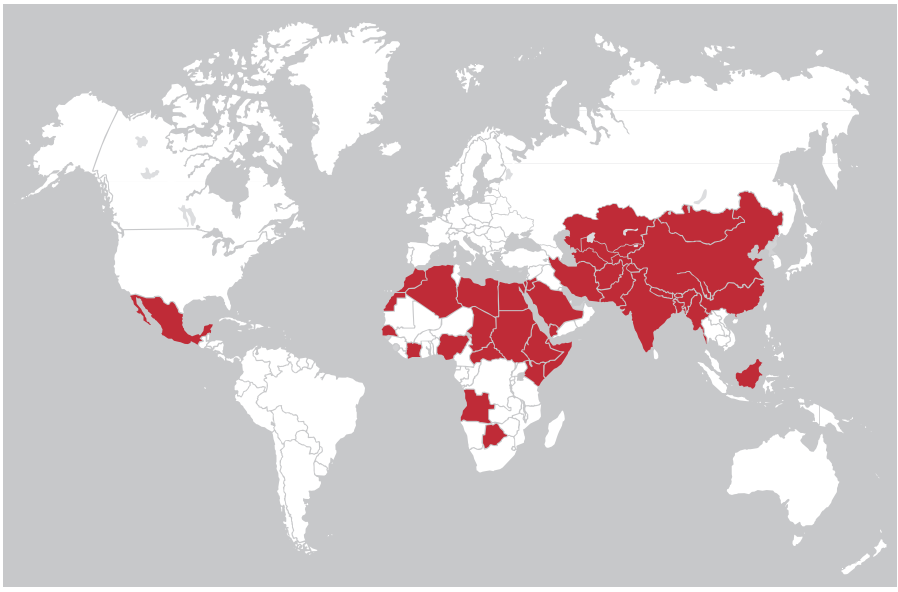

Fig. 3 Geographical distribution of HEV. The shaded areas represent disease-endemic regions.

elevation and histopathological changes in the liver [23]. These findings suggest that HEV may be released from hepatocytes into bile and, consequently, into faeces, before the peak morphological changes in the liver. The humoral immune response in infected animals resembles the pattern observed in humans. Both IgM and IgG anti-HEV are detected in serum in assays using immunoreactive epitopes of ORF2 and ORF3. As in humans, the IgM antibody level decreases rather precipitously, reaching negligible levels in the early convalescent phase. High titres of IgG anti-HEV are detected during convalescence. Anti-HEV has been observed as long as 10 years after inoculation and onset of liver injury in chimpanzees experimentally infected with serum specimens derived from HEV-infected patients in Tashkent, Pakistan and Mexico. In a challenge experiment that followed immunization of cynomolgus macaques with recombinant capsid proteins, the profile of the anti-ORF3 antibody response suggested that the presence of this antibody may be indicative of HEV replication. The mechanism responsible for the destruction of hepatocytes during HEV infection remains unknown. However, the onset of ALT elevation and histopathological changes in the liver generally corresponds with the detection of anti-HEV in serum and with decreasing levels of HEVAg in hepatocytes. In one study, infiltrating lymphocytes in the liver of HEV-infected cynomolgus macaques were found to have a cytotoxic/suppression immunophenotype [24], suggesting that liver injury may be immune mediated.

Inoculum titration experiments in cynomolgus macaques suggest that the size of the infectious dose may be related to the virological, immunological and pathological sequelae of infection [23,25]. Virus replication, anti-HEV immune response and acute hepatitis were all observed only after the administration of a high-titre inoculum. With decreasing amounts of inoculated HEV, biochemical and pathological evidence of liver injury and expression of HEVAg were absent; however, the subclinically infected animals excreted large amounts of viable HEV, capable of transmitting disease to naive animals, in their faeces [25]. The infection resulting from the endpoint dilution of the infectious inoculum (HEV Mexico strain) was marked only by seroconversion to anti-HEV.

Table 2 Epidemiology of hepatitis E outbreaks.

Occurrence in HEV-endemic regions	Large outbreaks involving thousands of cases, sporadic cases[a]
Mode of transmission	Faecal–oral
Vehicle of transmission in outbreaks	Faecally contaminated water
Peak of epidemic	6–7 weeks after primary exposure
Low secondary attack rate among exposed household members	
Highest attack rate among individuals between 15 and 40 years of age	
High case–fatality ratio among infected pregnant women (20%)	

[a]Sporadic cases are also observed in non-endemic regions, primarily in travellers to HEV-endemic regions.

Epidemiology

Epidemiology in HEV-endemic regions

Figure 3 shows the areas of the world where HEV infection is endemic. The characteristic epidemiological features of hepatitis E are summarized in Table 2. HEV is transmitted primarily by the faecal–oral route, and faecally contaminated drinking water has been identified as the likely vehicle of transmission in most reported outbreaks. Recurrent hepatitis E epidemics, with a periodicity of 5–10 years, have been observed in several parts of the world, including India, north-west China, Indonesia

and the Central Asian republics of the former Soviet Union [8,10,26–28]. Reasons for this periodicity have not been determined; however, several outbreaks have occurred in a seasonal pattern after heavy rains. Person-to-person transmission of HEV appears to be uncommon, even in settings with poor environmental sanitation such as refugee camps [26,29]. Reported secondary attack rates for households with hepatitis E cases have ranged from 0.7% to 2.2% compared with 50–75% among susceptible contacts in households with hepatitis A cases. Vertical transmission of HEV infection from mother to infant has been shown to occur frequently [30]. A recent study showed that HEV infection can be transmitted through blood transfusions in HEV-endemic regions [31]; the significance of this route in the epidemiology of the disease has not been determined.

Areas of the world can be classified as HEV endemic based on the occurrence of hepatitis E outbreaks, which have been reported throughout Asia, Africa, the Middle East and Central America. The first extensively studied outbreak of waterborne hepatitis, which involved 29 000 cases of icteric hepatitis, was observed in Delhi, India, in 1955–1956 [26] and was serologically documented as non-A, non-B hepatitis several years later. Subsequent outbreaks of epidemic and sporadic hepatitis E in this region occurred in Kashmir [8], Kanpur [29] and Nepal. Many hepatitis E outbreaks have consisted of several thousand cases; the largest outbreak reported to date, involving more than 100 000 cases, occurred in north-western China between 1986 and 1988 [28]. Finally, small outbreaks of hepatitis E have been reported from the North American continent in two villages located south of Mexico City [32]. During outbreaks, disease attack rates are much higher among pregnant women than among men and non-pregnant women.

In many areas in which hepatitis E outbreaks have been reported, HEV infection accounts for a substantial proportion of acute sporadic hepatitis in both children and adults. In seroprevalence studies conducted in HEV-endemic countries, anti-HEV has been detected in as many as 5% of children aged < 10 years and in 10–40% of adults aged > 25 years [10]. These rates appear to be somewhat low in view of the frequent occurrence of outbreaks and nearly ubiquitous opportunities for infection, and may reflect the disappearance of antibodies with time. Hepatitis E may also be endemic in several countries where outbreaks have not been reported, including Hong Kong, Turkey and Egypt, based on a high incidence of sporadic hepatitis E cases in these countries. Recent data suggest that a proportion of healthy persons in these regions has detectable IgM anti-HEV and HEV RNA in their blood [31]; the exact significance of these findings is not yet clear.

Epidemiology in HEV non-endemic regions

In most countries where hepatitis E is not endemic, the disease accounts for fewer than 1% of reported cases of acute viral hepatitis. Most cases of acute hepatitis E reported in these countries have been associated with travel to HEV-endemic regions [33]. However, cases of acute hepatitis E have also been reported among persons with no history of travel to disease-endemic countries. In recent years, a few small outbreaks of acute hepatitis E related to the consumption of undercooked boar or deer meat have been recognized in Japan [34].

Seroprevalence studies among blood donors in some non-endemic countries have found an anti-HEV prevalence of 1–5%, which is relatively high compared with the low rate of clinically evident disease associated with HEV in these areas. Possible reasons for these findings include subclinical and/or anicteric HEV infection, serological cross-reactivity with other agents and false-positive test results. The higher antibody prevalence rates observed among swine handlers and sewage workers in these regions may reflect true positivity related to occupational exposure.

Reservoirs of HEV

It is possible that an environmental reservoir exists in disease-endemic geographical regions due to the continuous presence of conditions that allow faecal contamination of water sources and the environment. Another potential reservoir for HEV in these regions may be serial transmission of infection among susceptible individuals. Sporadic cases of hepatitis E account for a substantial proportion of acute viral hepatitis in countries where hepatitis E outbreaks have been reported, and these infections may maintain transmission of the virus during interepidemic periods. Consequently, serial transmission could be in the form of subclinical infection. Finally, HEV-like viruses have been detected in the faeces of wild-caught pigs, and anti-HEV has been detected in the serum of pigs, cattle and sheep in disease-endemic regions, suggesting the possibility of a zoonotic reservoir [35]. Although the close genetic relationship of human and swine HEV isolates from non-endemic regions supports the zoonotic hypothesis, differences in human and animal isolates in HEV-endemic regions counter this possibility.

Prevention

Development of an inactivated or live attenuated virus vaccine is not currently possible because of the lack of an efficient culture system. Neither pre-exposure nor postexposure use of immunoglobulin manufactured in hepatitis E-endemic areas has been found to be effective. Moreover, the natural history of protective immunity after acute HEV infection has not been fully determined, although the presence of pre-existing IgG anti-HEV was found to prevent hepatitis E in young adults. In two separate studies, neutralization epitopes have been identified and shown to span amino acids 452–617 and 458–607, respectively, of the HEV capsid protein [36,37]. Importantly, different HEV genotypes showed serological cross-reactivity and cross-neutralization in these subregions of the capsid protein. Recombinant HEV proteins evaluated in experimental studies as potential candidates for a prototype hepatitis E vaccine have

been shown to attenuate HEV infection. In these studies, primates immunized with recombinant HEV proteins derived from HEV capsid protein and challenged either with the same strain of HEV or with a heterologous HEV strain divergent from the vaccine source were protected against liver injury, although faecal excretion of the virus was not prevented [38]. An experimental HEV DNA vaccine tested in cynomolgus macaques has been shown to induce levels of anti-HEV that are protective against heterologous HEV strain challenge [39]. One of the candidate vaccines has been shown to be safe and immunogenic in human subjects, but the results of efficacy trials are not yet available [40]. Modifications of the recombinant immunogen, the use of more efficient adjuvants and optimization of immunization schedules may help to induce higher levels of neutralizing antibodies and prolong the duration of protection. Further studies on HEV vaccines are needed because even short-term protection may be useful for travellers and pregnant women.

Given the lack of products to prevent hepatitis E, prevention relies primarily on the provision of clean drinking water. Limited data are available regarding the efficacy of chlorination of water in inactivating HEV, and studies are needed to identify other appropriate environmental control measures. Until such prevention measures are determined, the only prophylactic measures against HEV infection that can currently be recommended and applied are improved sanitation and sanitary handling of food and water. The best prophylaxis in disease-endemic areas is to drink water from safe sources, eat cooked vegetables and practise adequate personal hygiene.

References

1 Tsarev SA, Emerson SU, Reyes GR *et al.* (1992) Characterization of a prototype strain of hepatitis E virus. *Proc Natl Acad Sci USA* 89, 559–563.

2 Kabrane-Lazizi Y, Meng XJ, Purcell RH *et al.* (1999) Evidence that the genomic RNA of hepatitis E virus is capped. *J Virol* 73, 8848–8850.

3 Emerson SU, Nguyen H, Graff J *et al.* (2004) In vitro replication of hepatitis E virus (HEV) genomes and of an HEV replicon expressing green fluorescent protein. *J Virol* 78, 4838–4846.

4 Schlauder GG, Frider B, Sookoian S *et al.* (2000) Identification of 2 novel isolates of hepatitis E virus in Argentina. *J Infect Dis* 182, 294–297.

5 Meng XJ, Purcell RH, Halbur PG *et al.* (1997) A novel virus in swine is closely related to the human hepatitis E virus. *Proc Natl Acad Sci USA* 94, 9860–9865.

6 Haqshenas G, Shivaprasad HL, Woolcock PR *et al.* (2001) Genetic identification and characterization of a novel virus related to human hepatitis E virus from chickens with hepatitis-splenomegaly syndrome in the United States. *J Gen Virol* 82, 2449–2462.

7 Vishwanathan R, Sidhu AS (1957) Infectious hepatitis: clinical findings. *Indian J Med Res* 45 (Suppl.), 49–58.

8 Khuroo MS (1980) Study of an epidemic of non-A, non-B hepatitis: possibility of another human hepatitis virus distinct from post-transfusion non-A, non-B type. *Am J Med* 68, 818–823.

9 Tsega E, Krawczynski K, Hansson BG *et al.* (1991) Outbreak of acute hepatitis E virus infection among military personnel in northern Ethiopia. *J Med Virol* 34, 232–236.

10 Aggarwal R, Krawczynski K (2000) Hepatitis E: an overview and recent advances in clinical and laboratory research. *J Gastroenterol Hepatol* 15, 9–20.

11 Khuroo MS, Teli MR, Skidmore S *et al.* (1981) Incidence and severity of viral hepatitis in pregnancy. *Am J Med* 70, 252–255.

12 Khuroo MS, Saleem M, Teli MR *et al.* (1980) Failure to detect chronic liver disease after epidemic non-A, non-B hepatitis. *Lancet* ii, 97–98.

13 Kumar A, Aggarwal R, Saraswat V *et al.* (2004) Hepatitis E virus is responsible for decompensation of chronic liver disease in an endemic region. *Indian J Gastroenterol* 23, 59–62.

14 Gupta DN, Smetana HF (1957) The histopathology of viral hepatitis as seen in the Delhi epidemic (1955–56). *Indian J Med Res* 45 (Suppl.), 101–113.

15 Balayan MS, Andjaparidze AG, Savinskaya SS *et al.* (1983) Evidence for a virus in non-A, non-B hepatitis transmitted via the fecal–oral route. *Intervirology* 20, 23–31.

16 Aggarwal R, Kini D, Sofat S *et al.* (2000) Duration of viraemia and faecal viral excretion in acute hepatitis E. *Lancet* 356, 1081–1082.

17 Favorov MO, Fields HA, Purdy MA *et al.* (1992) Serologic identification of hepatitis E virus infections in epidemic and endemic settings. *J Med Virol* 36, 246–250.

18 Dawson GJ, Chau KH, Cabal CM *et al.* (1992) Solid-phase enzyme-linked immunosorbent assay for hepatitis E virus IgG and IgM antibodies utilizing recombinant antigens and synthetic peptides. *J Virol Methods* 38, 175–186.

19 Khuroo MS, Kamili S, Dar MY *et al.* (1993) Hepatitis E and long-term antibody status. *Lancet* 341, 1355.

20 Naik S, Aggarwal R, Naik SR *et al.* (2002) Evidence for activation of cellular immune responses in patients with acute hepatitis E. *Indian J Gastroenterol* 21, 149–152.

21 Krawczynski K, Bradley DW (1989) Enterically transmitted non-A, non-B hepatitis: identification of virus-associated antigen in experimentally infected cynomolgus macaques. *J Infect Dis* 159, 1042–1049.

22 Bradley DW, Krawczynski K, Cook EH *et al.* (1987) Enterically transmitted non-A, non-B hepatitis: serial passage of disease in cynomolgus macaques and tamarins and recovery of disease-associated 27–34 nm viruslike particles. *Proc Natl Acad Sci USA* 84, 6277–6281.

23 Tsarev SA, Emerson SU, Tsareva TS *et al.* (1993) Variation in course of hepatitis E in experimentally infected cynomolgus monkeys. *J Infect Dis* 167, 1302–1306.

24 Soe S, Uchida T, Suzuki K *et al.* (1989) Enterically transmitted non-A, non-B hepatitis in cynomolgus monkeys: morphology and probable mechanism of hepatocellular necrosis. *Liver* 9, 135–145.

25 Aggarwal R, Kamili S, Spelbring J *et al.* (2001) Experimental studies on subclinical hepatitis E virus infection in cynomolgus macaques. *J Infect Dis* 184, 1380–1385.

26 Vishwanathan R (1957) Infectious hepatitis in Delhi (1955–56): a critical study: epidemiology. *Indian J Med Res* 45 (Suppl. 1), 1–29.

27 Naik SR, Aggarwal R, Salunke PN *et al.* (1992) A large waterborne viral hepatitis E epidemic in Kanpur, India. *Bull WHO* 70, 597–604.

28 Zhuang H, Cao X-Y, Liu C-B *et al.* (1991) Enterically transmitted non-A, non-B hepatitis in China. In: Shikata T, Purcell RH, Uchida T (eds) *Viral Hepatitis C, D and E*. Amsterdam: Excerpta Medica, pp. 277–285.

29 Aggarwal R, Naik SR (1994) Hepatitis E: intrafamilial transmission versus waterborne spread. *J Hepatol* 21, 718–723.

30 Khuroo MS, Kamili S, Jameel S (1995) Vertical transmission of hepatitis E virus. *Lancet* 345, 1025–1026.
31 Khuroo MS, Kamili S, Yattoo GN (2004) Hepatitis E virus infection may be transmitted through blood transfusions in an endemic area. *J Gastroenterol Hepatol* 19, 778–784.
32 Valazquez O, Stetler HC, Avila C *et al.* (1990) Epidemic transmission of enterically transmitted non-A, non-B hepatitis in Mexico, 1986–1987. *JAMA* 263, 3281–3285.
33 Centers for Disease Control and Prevention (1993) Hepatitis E among US travelers, 1989–1992. *MMWR – Morb Mort Wkly Rep* 42, 1–4.
34 Tei S, Kitajima N, Takahashi K *et al.* (2003) Zoonotic transmission of hepatitis E virus from deer to human beings. *Lancet* 362, 371–373.
35 Meng XJ (2000) Novel strains of hepatitis E virus identified from humans and other animal species: is hepatitis E a zoonosis? *J Hepatol* 33, 842–845.
36 Meng J, Dai X, Chang JC *et al.* (2001) Identification and characterization of the neutralization epitope(s) of the hepatitis E virus. *Virology* 288, 203–211.
37 Zhou YH, Purcell RH, Emerson SU (2004) An ELISA for putative neutralizing antibodies to hepatitis E virus detects antibodies to genotypes 1, 2, 3, and 4. *Vaccine* 22, 2578–2585.
38 Zhang M, Emerson SU, Nguyen H *et al.* (2001) Immunogenicity and protective efficacy of a vaccine prepared from 53 kDa truncated hepatitis E virus capsid protein expressed in insect cells. *Vaccine* 20, 853–857.
39 Kamili S, Spelbring J, Carson D *et al.* (2004) Protective efficacy of hepatitis E virus DNA vaccine administered by gene gun in the cynomolgus macaque model of infection. *J Infect Dis* 189, 258–264.
40 Purcell RH, Nguyen H, Shapiro M *et al.* (2003) Pre-clinical immunogenicity and efficacy trial of a recombinant hepatitis E vaccine. *Vaccine* 21, 2607–2615.

9.1.3 Prevention and treatment of viral hepatitis

9.1.3.i Vaccines against hepatitis A

Pierre Van Damme, Koen Van Herck and Philippe Beutels

Introduction

Hepatitis A is one of the most common vaccine-preventable infectious diseases causing significant morbidity and mortality, with 1.5 million documented cases worldwide each year.

While no effective treatment is available against hepatitis A, vaccination of individuals implemented for more than 10 years according to selected strategies at international and national levels, together with improved sanitary conditions, have contributed to a substantial reduction in the economic burden associated with disease management. A selected number of countries with intermediate hepatitis A virus (HAV) endemicity are currently considering universal hepatitis A vaccination for their younger age population.

Currently available hepatitis A vaccines: composition, method of production, route of administration, dosage and schedule

Several inactivated and live attenuated vaccines against hepatitis A were developed in the 1980s and licensed for use in the early 1990s. These vaccines are safe and well tolerated, they are highly immunogenic, and they provide longlasting protection against hepatitis A disease in children and adults. Four formalin-inactivated, cell culture-produced, whole-virus vaccines are available internationally: Havrix (HM 175 strain, GlaxoSmithKline Biologicals, Rixensart, Belgium) [1,2], Vaqta (CR326F strain, Merck & Co., West Point, PA, USA) [3–5], Epaxal (RG SB strain, Berna Biotech Ltd, Bern, Switzerland) [6–8] and Avaxim (GBM strain, Sanofi Pasteur, Lyon, France) [9,10]. These have been approved for use in most parts of the world, and Havrix and Vaqta are also licensed in the US.

Other hepatitis A vaccines are produced with limited distribution. These include a Chinese live attenuated vaccine (H2 strain, Zhejiang Academy of Medical Sciences, Hangzhou, People's Republic of China) [11], a vaccine manufactured by Vaccine and Bio-product Company 1 in Vietnam since 2004 [12] and Nothav, an inactivated vaccine manufactured by Chiron Behring GmbH and distributed in Italy only [13].

Several types of combination vaccines containing an inactivated hepatitis A vaccine have been developed in order to protect individuals against more than one infectious disease when travelling to endemic countries. Such vaccines include Twinrix [14] (GlaxoSmithKline Biologicals, Rixensart, Belgium), the only combined vaccine against both hepatitis A and hepatitis B infections, licensed since 1996; other combined vaccines include Hepatyrix [15] (GlaxoSmithKline Biologicals, Rixensart, Belgium) and Viatim [9] (Sanofi Pasteur, Lyon, France), both protecting against hepatitis A and typhoid fever.

Inactivated hepatitis A vaccines all contain HAV antigen, but the content per vaccine dose is expressed in different units by manufacturers (Table 1). Recommended vaccination schedules, ages for which the vaccine is licensed and whether there is a paediatric and adult formulation also vary. All vaccines are licensed from 1 year of age in most countries, including the United States since September 2005 [16,17], except in Australia [18,19], where vaccines are licensed from 2 years, and in China where Epaxal is licensed from 6 months onwards. The inactivated vaccines are produced according to similar manufacturing processes involving whole-virus preparations of HAV strains growing in human MRC-5 diploid cell cultures, with subsequent virus purification and inactivation with formaldehyde. Havrix (HM 175 strain), Vaqta (CR326F strain) and Avaxim (GBM strain) are adjuvanted with alum, whereas Epaxal (RG SB strain) contains a liposome adjuvant in the form of immunopotentiating reconstituted influenza virosomes (IRIV). Havrix and Avaxim contain 2-phenoxyethanol as a preservative, while the other vaccines are preservative-free formulations [2,3,6,10]. All vaccines are

Table 1 Dosage and schedule for inactivated monovalent hepatitis A vaccines (in chronological order).

Vaccine	Antigen content (HAV strain)	Volume (mL)	Two-dose schedule (months)
Havrix 720 Junior	720 El.U (HM 175)	0.5	0, 6–12
Havrix 1440 Adult	1440 El.U (HM 175)	1	0, 6–12
Vaqta	25 U (CR326 F)	0.5	0, 6–18
Vaqta	50 U (CR326 F)	1	0, 6–18
Epaxal Junior	12 IU (RG SB)	0.25	0, 6–12
Epaxal	24 IU (RG SB)	0.5	0, 6–12
Avaxim 80U Paediatric	80 antigen units (GBM)	0.5	0, 6–12
Avaxim 160U	160 antigen units (GBM)	0.5	0, 6–12

administered via intramuscular injection, according to varying dosages and schedules, as described in Table 1.

If medically indicated, such as in haemophiliacs or in patients under anticoagulation, all four vaccines can be given subcutaneously [20–23].

Vaccine tolerability

To date, several million doses of hepatitis A vaccines have been administered to children and adults worldwide, with no serious adverse event ever statistically linked to their use [24]. The safety profile of inactivated hepatitis A vaccines has been reviewed extensively, and results from clinical trials, as well as postmarketing surveillance studies, have demonstrated that the vaccines are all safe and well tolerated [2,25–27]. The most commonly reported adverse events have included mild and transient local site reactions, such as pain, swelling and redness (21% in children and 52% in adults); Epaxal has a two to three times lower rate of local reactions in comparison with alum-adsorbed hepatitis A vaccines [27,28]. General reactions such as fever, fatigue, diarrhoea, vomiting and headache were reported in less than 5% of subjects [19,29].

Vaccine immunogenicity and protective efficacy

The absolute minimum level of anti-HAV antibodies required to prevent HAV infection has not been defined. Experimental studies in chimpanzees have shown that low levels of passively transferred antibody (< 10 mIU/mL) obtained from vaccinated persons do not protect against infection but do prevent clinical hepatitis and virus shedding [30].

In the absence of an absolute lower protective level of antibody required to prevent HAV infection, the lower limit of detection of the specific assay used in a study is generally considered as an accepted correlate of protection, i.e. 20 or 33 mIU/mL by enzyme-linked immunosorbent assay (ELISA) in clinical studies with Havrix; 20 mIU/mL by ELISA with Avaxim and Epaxal, and 10 mIU/mL by ELISA for Vaqta [2,4,6,9].

Currently licensed inactivated hepatitis A vaccines have proved highly immunogenic in extensive clinical studies, conferring protective immunity against the disease 2–4 weeks after first dose administration. Recent data have shown that a vast majority of individuals seroconvert within 2–4 weeks of vaccination, with rates ranging from 95% to 100% in children and adults. Administration of the second dose of the primary schedule (6–18 months after the first dose) ensures long-term protection [7,31]. Review of the immunogenicity data for each vaccine as well as results from several comparative clinical trials demonstrate the equally high immunogenicity and interchangeability of hepatitis A vaccines [1,9,27,32].

The protective efficacy of inactivated hepatitis A vaccines against clinical disease has been documented in several controlled clinical efficacy trials. The cumulative protective efficacy of the vaccination course with Havrix in more than 40 000 Thai children aged 1–16 years was 95% [33]. The observed protective efficacy of Vaqta was 100% after one vaccine dose in a trial involving more than 1000 children aged 2–16 years from a highly endemic community in the United States [3]. In a recent trial involving 274 Nicaraguan children aged 1.5–6 years, the protective efficacy of a single dose of Epaxal was also 100% [34].

The presence of passively transferred antibodies from previous maternal HAV infection has been shown to result in reduced antibody response to hepatitis A vaccination in infants [35–37]. However, in spite of lower antibody concentrations observed after primary vaccination of infants born to anti-HAV seropositive mothers, several studies have indicated that priming and immune memory were induced, as demonstrated by the anamnestic response at the time of booster [35–41]. This was the case after a second vaccine dose administered at 12 months to 300 infants born to either anti-HAV seronegative or seropositive mothers in a study conducted in Israel [38]. Similarly, in a study conducted in Turkey with children who had received primary vaccination at 2, 4 and 6 months of age, all subjects showed anamnestic response after booster vaccination at 4 years of age [39]. At 15 months, protective levels of antibody were also present in 93% of American Indian infants born to

anti-HAV-positive mothers, who had received primary immunization at 2, 4 and 6 months or at 8 and 10 months of age [35]. Effective hepatitis A vaccination was also demonstrated in a study with 30 infants aged 6–7 months – half of them with maternal antibodies – and 30 children aged 6–7 years who were all seroprotected at month 1 and month 12 postvaccination and also showed a strong antibody response to booster vaccination [41].

Such findings relating to hepatitis A vaccine immunogenicity in children younger than 2 years of age, as well as studies that have shown that hepatitis A vaccine may be effectively and safely coadministered with other paediatric vaccines, such as diphtheria–tetanus–acellular pertussis, inactivated and oral polio, *Haemophilus influenzae* type b vaccine and hepatitis B vaccines [36,37], are of particular importance in the implementation of prevention strategies involving routine childhood vaccination programmes. Other studies in adults have demonstrated effective and safe coadministration of hepatitis A vaccine with traveller vaccines, including hepatitis B, polio, diphtheria, tetanus, typhoid fever, yellow fever, rabies, cholera and Japanese encephalitis [42–45].

In spite of an initially slower immune response observed in subjects over 40 years following administration of hepatitis A vaccines, response rates were similar to those observed in younger individuals on completion of the full vaccination course [46–48]. These data are confirmed by anti-HAV seroconversion rates of at least 98% in retrospective analyses of subjects ≥ 40 years of age who received a combined vaccine against hepatitis A and B [49,50].

Other conditions that may result in a lower immune response to hepatitis A vaccination include human immunodeficiency virus (HIV) infection and chronic liver disease. Limited data reported from studies conducted with HIV-infected male individuals have indicated that they had lower antibody concentrations than HIV-negative individuals and that approximately 75% had protective antibody levels on completion of the vaccination course [19]. Results from several trials evaluating the safety and immunogenicity of hepatitis A vaccine in chronic liver disease patients in the United States, Europe and Asia, including data collected in children, have been extensively reviewed and discussed elsewhere [2,19]. Mainly, these data indicate that hepatitis A vaccine was generally well tolerated and that the proportions of subjects with protective antibody levels were similar to those obtained in healthy individuals on completion of the vaccination course, while final antibody concentrations were substantially lower.

A few studies in transplant recipients also indicate a lower immune response following hepatitis A vaccination. While one study reported an acceptable 97% seropositivity in vaccinated liver transplant patients after two doses of hepatitis A vaccine on a 0- to 6 month schedule, compared with 100% in the control group, a third group of renal transplant recipients showed only 72% seropositivity. Moreover, seropositivity after the first dose was obtained in only 41% of liver transplant patients and 24% of renal transplant patients, compared with 90% in the control group. Therefore, the authors concluded that transplant recipients should receive a full vaccination course before potential exposure to hepatitis A virus [51]. Two years later, only 59% and 26% of the seroconverters maintained anti-HAV seropositivity in the groups of liver transplant and renal transplant patients respectively. The rate of antibody loss in transplant patients therefore seems to be substantially higher [52].

Another study in liver transplant patients reached only 26% seropositivity after a full hepatitis A vaccination schedule [53]. These data reveal a lower hepatitis A vaccine efficacy in transplant patients, especially in those with stronger immunosuppressive regimens.

Hepatitis A vaccine has a recommended two-dose schedule, with the second dose being administered at 6–12 months in the case of Havrix, Avaxim and Epaxal, and at 6–18 months in the case of Vaqta. However, timing of the second dose is flexible as an anamnestic response has been shown to be triggered by a second dose when administered several years after the first vaccine dose in children and adults [54–58]. Flexible two-dose vaccination schedules with a 'delayed' second dose are of critical importance because travellers often miss the second dose and present themselves some years later with a new/repeated indication for hepatitis A vaccination. In addition, a flexible schedule might help in introducing hepatitis A vaccines into established childhood routine vaccination programmes. For example, a vaccination schedule for infants/children with the first dose administered during the second year of life and a second dose given at school entry at the age of 5–6 years seems to be worth investigating. Also, additional long-term follow-up studies of individuals who have received a single vaccine dose should help to formulate future recommendations in terms of dosing schedule.

Early protection and duration of protection

Hepatitis A vaccines confer early protection, as confirmed by recent data showing that a majority of individuals seroconvert within 2 weeks of vaccination, well within the 28-day incubation period of the virus. Travellers receiving the vaccine any time before departure may thus be expected to be protected against the disease [7,9,31].

With regards to duration of immunity, long-term follow-up studies have shown persistence of protective anti-HAV antibodies for at least 5 years in children and up to more than 12 years in adults postvaccination [8,40,59–61]. The kinetics of antibody persistence 10 years after primary immunization of 313 seronegative healthy adults with a two-dose inactivated hepatitis A vaccine administered either on a 0–6 or 0–12 schedule is presented in Figure 1 [62].

A robust immune response was also demonstrated in 31 vaccinated adults challenged with a paediatric dose of hepatitis A vaccine antigen 12 years after primary vaccination, while

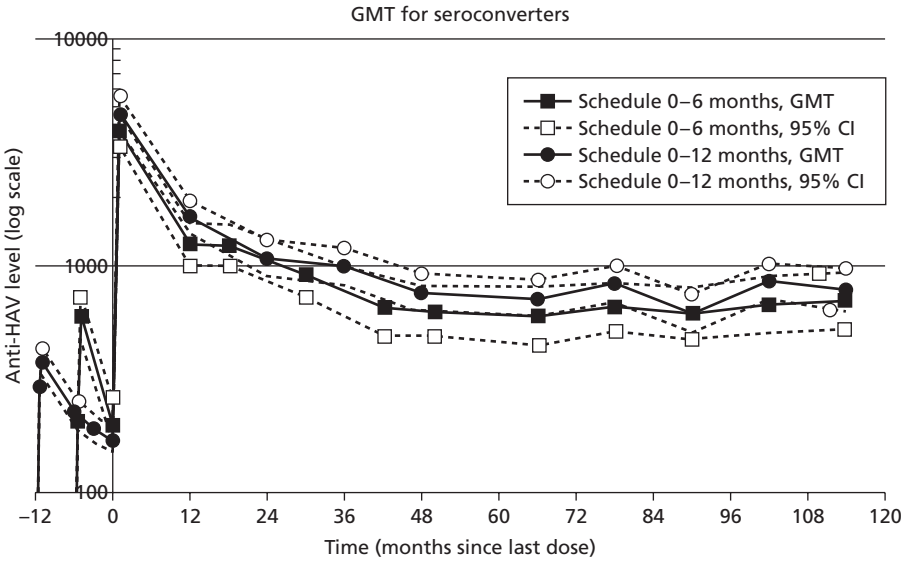

Fig. 1 Anti-HAV geometric mean titre (GMT) for the 0–6 and the 0–12-month schedules within their respective 95% confidence intervals (CI).

geometric mean anti-HAV antibody concentration was ≥ 15 IU/L before booster administration [63].

Mathematical models using data from vaccinated adults have estimated protective antibodies to persist for at least 25 years in more than 95% of vaccinees [8,9,64].

The role of immune memory in conferring protection for individuals vaccinated against hepatitis A was reviewed in 2002 by an International Consensus Group on HAV immunity [65]. The group concluded that evidence is accumulating that hepatitis A vaccines elicit immune memory persisting even after loss of detectable antibody. It recommended that reliance be placed on immune memory rather than booster doses to protect healthy individuals who received a full vaccination course. Based on the demonstrated persistence of protective antibodies for more than 10 years postvaccination, their estimated mathematical persistence for more than 25 years postvaccination and the presence of immune memory considered to confer protection even beyond detectable circulating antibodies, hepatitis A booster vaccination has been considered to be unnecessary in the healthy individual. Additional long-term follow-up studies should validate this expert consensus.

Field effectiveness of routine vaccination programmes

Hepatitis A routine immunization of young children has proved effective in rapidly reducing disease incidence and maintaining very low incidence levels among vaccine recipients as well as across all other age groups, thus demonstrating the development of herd immunity, in a number of settings. In the United States, the introduction of immunization programmes for children, with a primary focus on preschool children (i.e. 2–5 years), living in communities with the highest incidence rates, has resulted in a decrease in disease incidence to rates that are similar to the national average or even lower. In 2003, the overall incidence rate of hepatitis A disease in the United States was 2.6 cases per 100 000, representing an overall decline of 76%, while targeted states had a reduction of 88% (even with levels of vaccination coverage not exceeding 50%), and a 53% decrease was observed in non-targeted states [66–68]. A national toddler immunization programme in place in Israel since 1999 has also demonstrated vaccine effectiveness, with a decrease in the annual incidence rate of hepatitis A disease from 50.4 cases per 100 000 (1993–1998) to 2.2–2.5 per 100 000 (2002–2004), representing more than a 95% reduction. This marked decline was seen in targeted vaccine recipients (85–90% coverage), as well as in all other age groups, thus demonstrating the effectiveness of hepatitis A vaccination, as well as the development of herd immunity [69]. Mass vaccination programmes also proved effective in localized regions of intermediate to high HAV endemicity in industrialized nations with otherwise low endemicity levels, such as the Puglia region of Italy, the Catalonia region of Spain and in North Queensland, Australia [18,70–72].

The real impact and added value of such mass vaccination programmes will need to be confirmed by continued disease surveillance. Indeed, although vaccination was a major contributer to the marked declines observed in the incidence of hepatitis A disease in Israel and the United States, it is difficult to evaluate to what extent this reduction could be partly due to improved sanitation and hygiene or to the epidemic cycles that have characterized the hepatitis A virus in the past [66,69,73]. Furthermore, the long-term effects of herd immunity are yet to be observed. As widespread vaccination continues, the accumulation of susceptible persons [in unvaccinated (age) groups] due to reductions in natural exposure may, in the long run, for instance, influence the frequency and size of outbreaks [outbreaks were observed to become less frequent and smaller in size in the short run in some settings (e.g. see [18])]. The associated increase in the average age at infection may also increase the

occurrence of severe and fatal hepatitis A in adults and the elderly. These long-term effects ultimately depend on vaccine uptake, the duration of vaccine-induced protection (and therefore the realization of expectations regarding immunological memory) and concomitant improvements in safe water and sanitation in specific settings.

Field effectiveness of postexposure administration and in outbreak control situation

Studies in chimpanzees [74], further supported by randomized trials in humans [75,76], have shown that hepatitis A vaccine is effective in preventing HAV infection when administered postexposure. Although the postexposure window for successful vaccination has yet to be defined, there is increasing evidence of the efficacy of hepatitis A as a valid alternative to passive postexposure prophylaxis with immune globulin, allowing, in particular, for a better control of outbreak situations.

Results from studies conducted in chimpanzees have also shown that vaccinated animals did not shed hepatitis A virus once exposed to the wild-type virus, thus demonstrating that the use of vaccines is effective in controlling spread in the case of outbreak [30].

The effectiveness of hepatitis A vaccination in controlling outbreak situations has been reported in various settings in the United States, including rural communities from Alaska, and Europe, including Slovakia, Croatia, the UK and Italy [1,19]. Recent data have reported the successful use of hepatitis A vaccine to control an outbreak among intravenous drug users in Bristol, UK, in 2000 [77], while the duration of two outbreaks was also substantially shortened in a maternal school and a daycare centre in Tuscany, Italy, at the end of 2002 [78].

Indications for vaccination and current recommendations

Inactivated hepatitis A vaccine is indicated for active immunization of susceptible infants ≥ 1 or ≥ 2 years of age at risk of hepatitis A and, in regions of low to intermediate endemicity, it is particularly recommended in individuals at increased risk of infection, at increased risk of spreading infection or at risk of complications in case of infection (see Table 2). On the basis of these indications, hepatitis A vaccination is currently recommended by both national and international authorities. Official recommendations made by the Advisory Committee on Immunization Practices (ACIP) of the US Public Health Service, World Health Organization (WHO) and the Viral Hepatitis Prevention Board (VHPB) are summarized in Table 2.

Next, to recommendations of 'at risk' groups, both the WHO and the VHPB [80,81] recommend the implementation of universal hepatitis A vaccination programmes in order to prevent and control hepatitis A epidemics in countries with intermediate endemicity level.

Table 2 Summary of current ACIP, WHO and VHPB recommendations for hepatitis A vaccination.

Persons at increased risk for HAV who should be routinely vaccinated
Persons travelling to or working in countries that have high or intermediate endemicity of infection
Men who have sex with men
Intravenous drug users
Persons who have occupational risk for infection
Persons who have clotting factor disorders
Daycare centre children and staff
Persons in residential institutions
Food handlers
Health-care workers
Persons who have chronic liver disease
Susceptible persons who have chronic liver disease or who are either awaiting or have received liver transplants
During outbreaks
Vaccination for outbreak control should take into consideration the characteristics of hepatitis A epidemiology in the community and existing hepatitis A vaccination programmes

From refs 79–81.

Of note, although studies of age-specific seroprevalence have distinguished different possible infection patterns, there is currently no global consensus on a definition of low, intermediate and high endemicity [82–84]. The key characteristics of HAV infection, including disease incidence, usual ages of infection and pathways of disease transmission, can be described within endemicity patterns presented in Table 3.

Both the WHO and the VHPB recommend that the decision of a moderate endemicity country to include hepatitis A vaccine in routine childhood immunization programmes should take into consideration the prevalence and incidence of hepatitis A disease, frequency of outbreaks, health impact of hepatitis A compared with other health priorities, feasibility of hepatitis A vaccination programmes and an economic evaluation of the different hepatitis A prevention strategies [80,81]. In addition, the VHPB recommends that childhood hepatitis A vaccination programmes currently implemented in some regions of European countries should be followed up and evaluated.

Official recommendations for the use of hepatitis A vaccine in the USA were first issued by the ACIP in 1996 and were updated in 1999 [79]. They are articulated as a regional strategy according to which children living in states, countries and communities with an annual HAV incidence rate ≥ 20 cases per 100 000 population during the period 1987–1997 should be routinely vaccinated while children living in states, countries and communities with an annual HAV incidence rate ≥ 10 cases (but < 20 cases) per 100 000 population should be considered for routine vaccination. On 26 October 2005, the ACIP voted to recommend that all children in the US receive hepatitis A vaccination between 12 and 23 months of age [85].

Table 3 Pattern of hepatitis A infection in Europe and the United States.

HAV endemicity	Reported disease incidence (per 10^5/year)	Usual age of patients (years)	Risk groups
Very high	1–40	< 9	–
High	15–150	5–14	
Moderate	15–150	5–24	
Low	5–15	5–39	Many
Very low	< 5	> 20	Travellers, drug abusers

Adapted from ref. 82.

The future use of hepatitis A vaccines

Existing hepatitis A vaccines have an excellent safety profile, they are highly immunogenic and offer longlasting protection to individuals against all strains of HAV found in the community. Anti-HAV antibodies have been shown to persist for more than 12 years in vaccinated adults, and mathematical modelling has predicted their persistence in over 95% of vaccinees more than 25 years after immunization. Also, several studies have demonstrated the presence of longlasting immune memory induced by hepatitis A vaccination.

The field effectiveness of hepatitis A vaccines has been demonstrated in countries where routine vaccination programmes have been implemented. In addition to reinforcement of preventive measures including educational programmes, improved sanitation in countries of high HAV endemicity levels and improved surveillance systems in regions of low and intermediate endemicity, a review of current vaccination policy and strategies might be warranted by the global epidemiological shift towards lower endemicity experienced over the last decades, resulting in a growing pool of susceptible unprotected children, adolescents and adults, as well as an increased risk of epidemics and outbreaks.

Recommended universal vaccination programmes of children and adolescents in areas of HAV intermediate endemicity might be best implemented by the introduction of hepatitis A vaccine into existing programmes, with the first vaccine dose possibly administered at 1–2 years of age and the second at the first school health visit, at 5–6 years, in order to take advantage of existing childhood vaccination calendars.

The implementation of future hepatitis A prevention strategies, in particular universal vaccination programmes, warrants further investigations on co-administration of hepatitis A vaccines and flexibility of dosing schedules. Long-term protection studies should also be conducted, and vaccinated individuals should be followed up in order to assess the need for booster vaccinations and confirm the presence of immune memory, protecting individuals against the circulation of virus which could shift and allow infection to occur at an older age, causing intervention to convert an otherwise asymptomatic childhood infection into a symptomatic disease upon exposure later in life.

Continued disease surveillance will confirm the real impact of mass vaccination programmes on reduced hepatitis A incidence rates, as well as the indirect effect on non-vaccinated age groups, developing herd immunity.

Cost-effectiveness of hepatitis A vaccination

Model-based economic analyses assessing the cost-effectiveness of hepatitis A vaccination vary according to endemicity area, target group and model used (i.e. 'dynamic' models reflecting the disease transmission process and taking into account herd immunity vs. 'static' models which do not) [86].

In low and very low endemic regions, targeted hepatitis A vaccination has been shown to be cost-effective, depending on prophylaxis cost, previous exposure (mainly determined by age) and specific characteristics of the target group [87–91]. Postexposure prophylaxis and other outbreak control measures might prove potentially cost-effective in these areas too [89] (which is unlikely for universal childhood hepatitis A vaccination, from the perspective of both the health-care payer and society [86]). Cost-effectiveness of universal vaccination in low endemicity areas would be best assessed using a dynamic transmission model accounting for herd immunity effects (leading to reduced incidence in unvaccinated individuals and increased average age at infection). In areas of low and very low endemicity, there may be relatively small communities with an elevated incidence and disease burden from hepatitis A, such as immigrant families holidaying in their country of origin [92] or indigenous communities in Australia and Canada [93]. Childhood vaccination in such communities could have knock-on effects on the wider society, enhancing the cost-effectiveness of this option and yielding attractive results [92,93].

In areas of intermediate and high endemicity, the cost-effectiveness of universal childhood vaccination largely depends on the duration of vaccine-induced immunity, expected vaccine uptake and improvements in safe water and sanitation. The potential age shift caused by vaccination could have a more important impact on the cost-effectiveness than in low endemicity areas as the prevaccination average age at infection is very low when most infection is asymptomatic. In order to assess the cost-effectiveness in such areas, the use of dynamic

models of infectious disease transmission is therefore recommended [86].

Summary

Experience over more than 10 years has shown that hepatitis A vaccines are safe, highly immunogenic and that they induce lifelong protection, with no need for booster immunizations in healthy individuals. HAV vaccination has proved effective for prophylaxis and postexposure control of outbreaks, as well as in routine vaccination programmes. Many countries (in particular those with intermediate endemicity) have experienced a global epidemiological shift towards lower endemicity over the last decades. As a consequence, more adults and adolescents are put at risk of clinically severe disease, whereas the risk of epidemics and outbreaks has increased as a result of a growing number of susceptible individuals. For these reasons, universal vaccination programmes of children and adolescents are recommended in areas of intermediate endemicity, in addition to specific risk group vaccination. While completing the two-dose schedule within 6–18 months remains recommended, administering a delayed second dose a few years after the first one can be considered sufficient to complete the vaccination course.

References

1 Van Herck K, Van Damme P (2005) Prevention of hepatitis A by Havrix: a review. *Expert Rev Vaccines* 4(4), 459–471.

2 André F, Van Damme P, Safary A *et al.* (2002) Inactivated hepatitis A vaccine: immunogenicity, efficacy, safety and review of official recommendations for use. *Expert Rev Vaccines* 1, 9–23.

3 Werzberger A, Mensch B, Kuter B *et al.* (1992) A controlled trial of a formalin-inactivated hepatitis A vaccine in healthy children. *N Engl J Med* 327 (7), 453–457.

4 Werzberger A, Mensch B, Nalin DR *et al.* (2002) Effectiveness of hepatitis A vaccine in a former frequently affected community: 9 years' follow-up after the Monroe field trial of VAQTA®. *Vaccine* 20, 1699–1701.

5 Nalin DR, Kuter BJ, Brown L *et al.* (1993) Worldwide experience with the CR326F-derived inactivated hepatitis A virus vaccine in pediatric and adult populations: an overview. *J Hepatol* 18 (Suppl 2), S51–55.

6 Loutan L, Bovier P, Althaus B *et al.* (1994) Inactivated virosome hepatitis A vaccine. *Lancet* 343, 322–334.

7 Ambrosch F, Finkel B, Herzog C *et al.* (2004) Rapid antibody response after vaccination with a virosomal hepatitis A vaccine. *Infection* 32, 149–152.

8 Bovier PA, Bock J, Loutan L *et al.* (2002) Long-term immunogenicity of an inactivated virosome hepatitis A vaccine. *J Med Virol* 68, 489–493.

9 Vidor E, Dumas R, Porteret V *et al.* (2004) Aventis Pasteur vaccines containing inactivated hepatitis A virus: a compilation of immunogenicity data. *Eur J Clin Microbiol Infect Dis* 23 (4), 300–309.

10 Dagan R, Greenberg D, Goldenbertg-Gehtman P *et al.* (1999) Safety and immunogenicity of a new formulation of an inactivated hepatitis A vaccine. *Vaccine* 17 (15–16), 1919–1925.

11 Mao JS, Chai SA, Xie RY *et al.* (1997) Further evaluation of the safety and protective efficacy of live attenuated hepatitis A vaccine (H2-strain) in humans. *Vaccine* 15 (9), 944–947.

12 Rader RA (2005) Hepatitis A vaccine products. In: Rader RA (ed.) *Biopharmaceutical Products in the US and European Markets*, 4th edn. Rockville, MD: BioPlan Associates, 557 pp.

13 Minutello M, Zotti C, Orecchia S *et al.* (2000) Dose range evaluation of a new inactivated hepatitis A vaccine administered as a single dose followed by a booster. *Vaccine* 19 (1), 10–15.

14 Van Damme P, Van Herck K (2004) A review of the efficacy, immunogenicity and tolerability of a combined hepatitis A and B vaccine. *Expert Rev Vaccines* 3 (3), 249–267.

15 Beran J, Beutels M, Levie K *et al.* (2001) A single dose, combined vaccine against typhoid fever and hepatitis A: consistency, immunogenicity and reactogenicity. *J Travel Med* 7 (5), 246–252.

16 Merck (Press release, 15 August 2005) FDA Approves Expanded Age Indication for VAQTA® (Hepatitis A Vaccine, Inactivated), Merck's Hepatitis A Vaccine, to Children as Young as 12 Months of Age. Accessed at http://www.merck.com/newsroom/press_releases/product/2005_0815.html, 8 November 2005.

17 GlaxoSmithKline (2005) Havrix® (Hepatitis A vaccine, inactivated). Prescribing Information. Accessed at http://us.gsk.com/products/assets/us_havrix.pdf, 8 November 2005.

18 Hanna JN, Hills SL, Humphreys JL (2004) Impact of hepatitis A vaccination of indigenous children on notifications of hepatitis A in north Queensland. *Med J Aust* 181 (9), 482–485.

19 Bell BP, Feinstone SM (2004) Hepatitis A vaccine. In: Plotkin SA, Orenstein WA (eds) *Vaccines*, 4th edn. Philadelphia: W.B. Saunders, pp. 269–297.

20 Tilzey AJ, Palmer SJ, Harrington C *et al.* (1996) Hepatitis A vaccine responses in HIV-positive persons with haemophilia. *Vaccine* 14, 1039–1041.

21 Linglöf T, Van Hattum J, Kaplan KM *et al.* (2001) An open study of subcutaneous administration of inactivated hepatitis A vaccine (VAQTA) in adults: safety, tolerability, and immunogenicity. *Vaccine* 19, 3968–3971.

22 Steffen R, Lücking FP, Ciuera A *et al.* (2000) Subcutaneous versus intramuscular administration of a virosome formulated hepatitis A vaccine. Abstracts 10th Eur Congr Clin Microbiol Infect Dis (ECCMID), Stockholm; Abstract no. WeP307.

23 Fisch A, Cadilhac P, Vidor E *et al.* (1996) Immunogenicity and safety of a new inactivated hepatitis A vaccine: a clinical trial with comparison of administration route. *Vaccine* 14, 1132–1136.

24 World Health Organization (2000) Hepatitis A vaccines. WHO position paper. *Weekly Epidemiol Rec* 75, 38–44.

25 Black S, Shinefield H, Hansen J *et al.* (2004) A post-licensure evaluation of the safety of inactivated hepatitis A vaccine (VAQTA®, Merck) in children and adults. *Vaccine* 22, 766–772.

26 Zuckerman J, Peyron F, Wallon M *et al.* (1997) Comparison of the safety and immunogenicity of two inactivated hepatitis A vaccines. *Adv Ther* 14, 116–124.

27 Bovier PA, Farinelli T, Loutan L (2005) Interchangeability and tolerability of a virosomal and an aluminum-adsorbed hepatitis A vaccine. *Vaccine* 23, 2422–2427.

28 Clarke PD, Adams P, Ibanez R *et al.* (2005) Rate, intensity, and duration of local reactions to a virosome-adjuvanted versus an aluminium-adsorbed hepatitis A vaccine in UK travellers. Abstracts 9th Conference of the International Society of Travel Medicine (9th CISTM), Lisbon; Abstract no. PO 02.09.

29 Huang DB, Wu JJ, Tyring SK (2004) A review of licensed viral vaccines, some of their safety concerns, and the advances in the development of investigational viral vaccines. *J Infect* 49, 179–209.

30 Purcell RH, Dhondt E, Bradbury R *et al.* (1992) Inactivated hepatitis-A vaccine–active and passive immunoprophylaxis in chimpanzees. *Vaccine* 10 (Suppl 1), S148–S151.

31 Connor BA, Van Herck K, Van Damme P (2003) Rapid protection and vaccination against hepatitis A for travellers. *Biodrugs* 17 (Suppl 1), 19–21.

32 Bryan JP, Henry CH, Hoffman AG *et al.* (2001) Randomized, crossover, controlled comparison of two inactivated hepatitis A vaccines. *Vaccine* 19, 743–750.

33 Innis BL, Snitbhan R, Kunasol P *et al.* (1994) Protection against hepatitis A by an inactivated vaccine. *J Am Med Assoc* 271, 1328–1334.

34 Pérez OM, Herzog C, Zellmeyer M *et al.* (2003) Efficacy of virosome hepatitis A vaccine in young children in Nicaragua: randomized placebo-controlled trial. *J Infect Dis* 188, 671–677.

35 Letson GW, Shapiro CN, Kuehn D *et al.* (2004) Effect of maternal antibody on immunogenicity of hepatitis A vaccine in infants. *J Pediatr* 144, 327–332.

36 Kanra G, Yalcin SS, Ceyhan M *et al.* (2000) Clinical trial to evaluate immunogenicity and safety of inactivated hepatitis A vaccination starting at 2-month-old children. *Turk J Pediatr* 42 (2), 105–108.

37 Piazza M, Safary A, Vegnente A (1999) Safety and immunogenicity of hepatitis A vaccine in infants: a candidate for inclusion in the childhood vaccination programme. *Vaccine* 17, 585–588.

38 Dagan R, Amir J, Mijalovsky A *et al.* (2000) Immunization against hepatitis A in the first year of life: priming despite the presence of maternal antibody. *Pediatr Infect Dis* 19, 1045–1052.

39 Kanra G, Yalcin SS, Kara A *et al.* (2002) Hepatitis A booster vaccine in children after infant immunization. *Pediatr Infect Dis J* 21 (8), 727–730.

40 Fiore AE, Shapiro CN, Sabin K *et al.* (2003) Hepatitis vaccination of infants: effect of maternal antibody status on antibody persistence and response to a booster dose. *Pediatr Infect Dis J* 22 (4), 354–359.

41 Usonis V, Bakasénas V, Valentelis R *et al.* (2003) Antibody titres after primary and booster vaccination of infants and young children with a virosomal hepatitis A vaccine (Epaxal®). *Vaccine* 21, 4588–4592.

42 Bock HL, Kruppenbacher JP, Bienzle U *et al.* (2000) Does the concurrent administration of an inactivated hepatitis A vaccine influence the immune response to other travelers vaccines? *J Travel Med* 7 (2) 74–78.

43 Jong EC, Kaplan KM, Eves KA *et al.* (2002) An open randomized study of inactivated hepatitis A vaccine administered concomitantly with typhoid fever and yellow fever vaccines. *J Travel Med* 9 (2), 66–70.

44 Bovier PA, Althaus B, Glück R *et al.* (1999) Tolerance and immunogenicity of the simultaneous administration of virosome hepatitis A and yellow fever vaccines. *J Travel Med* 6 (4), 228–233.

45 Dumas R, Forrat R, Lang J *et al.* (1997) Safety and immunogenicity of a new inactivated hepatitis A vaccine in concurrent administration with a typhoid fever vaccine or a typhoid fever + yellow fever vaccine. *Adv Ther* 14 (4), 160–167.

46 Briem H, Safary A (1994) Immunogenicity and safety in adults of hepatitis A virus vaccine administered as a single dose with a booster 6 months later. *J Med Virol* 44, 443–445.

47 Reuman PD, Kubilis P, Hurni W *et al.* (1997) The effect of age and weight on the response to formalin inactivated, alum-adjuvanted hepatitis A vaccine in healthy adults. *Vaccine* 15 (10), 1157–1161.

48 D'Acremont V, Herzog C, Genton B (2006) Immunogenicity and safety of a virosomal hepatitis A vaccine (Epaxal) in the elderly. *J Travel Med* 13(2), 78–83.

49 Stoffel M, Lievens M, Dieussaert I *et al.* (2003) Immunogenicity of Twinrix in older adults: a critical analysis. *Expert Rev Vaccines* 2, 9–14.

50 Nothdurft HD (2004) Letter to the editor. *Vaccine* 22, 592–593.

51 Stark K, Gunther M, Neuhaus R *et al.* (1999) Immunogenicity and safety of hepatitis A vaccine in liver and renal transplant recipients. *J Infect Dis* 180, 2014–2017.

52 Gunther M, Stark K, Neuhaus R (2001) Rapid decline of antibodies after hepatitis A immunization in liver and renal transplant recipients. *Transplantation* 71, 477–479.

53 Arslan M, Wiesner RH, Poterucha JJ *et al.* (2001) Safety and efficacy of hepatitis A vaccination in liver transplantation recipients. *Transplantation* 72, 272–276.

54 Landry P, Tremblay S, Darioli R *et al.* (2001) Inactivated hepatitis A vaccine booster given ≥ 24 months after the primary dose. *Vaccine* 19, 399–402.

55 Iwarson S, Lindh M, Widerstrom L (2004) Excellent booster response 4 to 8 years after a single primary dose of an inactivated hepatitis A vaccine. *J Travel Med* 11, 120–121.

56 Williams JL, Bruden DA, Cagle HH *et al.* (2003) Hepatitis A vaccine: immunogenicity following administration of a delayed immunization schedule in infants, children and adults. *Vaccine* 21, 3208–3211.

57 Beck BR, Hatz C, Brönnimann R *et al.* (2003) Successful booster antibody response up to 54 months after single primary vaccination with virosome-formulated, aluminum-free hepatitis A vaccine. *Clin Infect Dis* 37, 126–128.

58 Beck BR, Hatz CF, Loutan L *et al.* (2004) Immunogenicity of booster vaccination with a virosomal hepatitis A vaccine after primary immunization with an aluminum-adsorbed hepatitis A vaccine. *J Travel Med* 11, 201–207.

59 Van Damme P, Thoelen S, Cramm M *et al.* (1994) Inactivated hepatitis A vaccine: reactogenicity, immunogenicity, and long-term antibody persistence. *J Virol Med* 44 (4), 446–451.

60 Wiens B, Bohidar N, Pigeon J *et al.* (1996) Duration of protection from clinical hepatitis A disease after vaccination with VAQTA. *J Med Virol* 49, 235–241.

61 Fan PC, Chang MH, Lee PI *et al.* (1998) Follow-up immunogenicity of an inactivated hepatitis A virus vaccine in healthy children: results after 5 years. *Vaccine* 16, 232–235.

62 Van Herck K, Van Damme P, Dieussaert I *et al.* (2004) Antibody persistence 10 years after immunisation with a two-dose inactivated hepatitis A vaccine. *11th International Congress on Infectious Diseases.* Cancun, Mexico. Poster 64.012:S225.

63 Van Herck K, Van Damme P, Lievens M *et al.* (2004) Hepatitis A vaccine: indirect evidence of immune memory 12 years after the primary course. *J Med Virol* 72, 194–196.

64 Van Herck K, Beutels P, Van Damme P *et al.* (2000) Mathematical models for assessment of long-term persistence of antibodies after vaccination with two inactivated hepatitis A vaccines. *J Med Virol* 60, 1–7.

65 Van Damme P, Banatvala J, Fay O *et al.* (2003) Consensus statement: hepatitis A booster vaccination: is there a need? *Lancet* 362, 1065–1071.

66 Wasley A, Samandari T, Bell B (2005) Incidence of hepatitis A in the United States in the era of vaccination. *J Am Med Assoc* 294, 194–201.

67 Averhoff F, Shapiro CN, Bell BP *et al.* (2001) Control of hepatitis A through routine vaccination of children. *J Am Med Assoc* 286, 2968–2973.

68 Bialek SR, Thoroughman DA, Hu D *et al.* (2004) Hepatitis A incidence and hepatitis A vaccination among American Indians and Alaska natives, 1990–2001. *Am J Public Health* 94 (6), 996–1001.
69 Dagan R, Leventhal A, Anis E *et al.* (2005) Incidence of hepatitis A in Israel following universal immunization of toddlers. *J Am Med Assoc* 294, 202–210.
70 MacIntyre CR, Burgess MA, Hull B *et al.* (2003) Hepatitis A vaccination options for Australia: review article. *J Paediatr Child Health* 39, 83–87.
71 Lopalco PL, Salleras L, Barbuti S *et al.* (2001) Hepatitis A and B in children and adolescents – what can we learn from Puglia (Italy) and Catalonia (Spain)? *Vaccine* 19, 470–474.
72 Dominguez A, Salleras L, Carmona G *et al.* (2003) Effectiveness of a mass hepatitis A vaccination program in preadolescents. *Vaccine* 21, 698–701.
73 Van Damme P, Van Herck K (2005) Effect of hepatitis A vaccination programs. *J Am Med Assoc* 294, 246–248.
74 Robertson BH, Dhondt EH, Spelbring J *et al.* (1994) Effect of postexposure vaccination in a chimpanzee model of hepatitis-A virus-infection. *J Med Virol* 43 (3), 249–251.
75 Sagliocca L, Amoroso P, Stroffolini T *et al.* (1999) Efficacy of hepatitis A vaccine in prevention of secondary hepatitis A infection: a randomized trial. *Lancet* 353, 1136–1139.
76 Furesz J, Scheifele DW, Palkonyay L (1995) Safety and effectiveness of the new inactivated hepatitis A virus vaccine. *Can Med Assoc J* 152 (3), 343–348.
77 Syed NA, Hearing SD, Shaw IS *et al.* (2003) Outbreak of hepatitis A in the injecting drug user and homeless populations in Bristol: control by a targeted vaccination programme and possible parenteral transmission. *Eur J Gastroenterol Hepatol* 15 (8), 901–906.
78 Bonanni P, Franzin A, Staderini C *et al.* (2005) Vaccination against hepatitis A during outbreaks starting in schools: what can we learn from experiences in central Italy? *Vaccine* 23, 2176–2180.
79 Centers for Disease Control and Prevention (1999) Prevention of hepatitis A through active or passive immunization: recommendations of the Advisory Committee on Immunization Practices (ACIP). *MMWR Recomm Rep* 48 (no. RR-12).
80 World Health Organization (1995) Public health control of hepatitis A: memorandum from a WHO meeting. *Bull WHO* 73 (1), 15–20.
81 Viral Hepatitis Prevention Board (1997) Hepatitis A: disease and epidemiology. Hepatitis A update. *Viral Hepatitis* 6, 5–14.
82 Hadler SC (1991) Global impact of hepatitis A virus infection: changing patterns. In: Hollinger FB, Lemon SM, Margolis HS (eds) *Viral Hepatitis and Liver Diseases*. Baltimore, MD: Williams & Wilkins, pp. 14–20.
83 Jacobsen KH, Koopman JS (2004) Declining hepatitis A seroprevalence: a global review and analysis. *Epidemiol Infect* 132, 1005–1022.
84 Jacobsen KH, Koopman JS (2005) The effects of socioeconomic development on worldwide hepatitis A virus seroprevalence patterns. *Int J Epidemiol* 34, 600–609.
85 ACIP (Press release, 28 October 2005). CDC's Advisory Committee on Immunization Practices Expands Hepatitis A Vaccination for Children: The recommendation for vaccination of children, between 1–2 years of age will be integrated into the routine childhood vaccination schedule. Accessed at http://www.cdc.gov/od/oc/media/pressrel/r051028.htm, 8 November 2005.
86 Beutels P, Edmunds WJ, Antoñanzas F *et al.* (2002) Economic evaluation of vaccination programmes: A consensus statement focusing on viral hepatitis. *PharmacoEconomics* 20 (1), 1–7.
87 Tormans G, Van Damme P, Van Doorslaer E (1992) Cost-effectiveness analysis of hepatitis A prevention in travellers. *Vaccine* 10 (Suppl 1), S88–S92.
88 Chodick G, Lerman Y, Wood F *et al.* (2002) Cost-utility analysis of hepatitis A prevention among health-care workers in Israel. *J Occup Environ Med* 44 (2), 109–115.
89 Péchevis M, Khoshnood B, Buteau L *et al.* (2003) Cost-effectiveness of hepatitis A vaccine in prevention of secondary hepatitis A infection. *Vaccine* 21 (25–26), 3556–3564.
90 Jacobs RJ, Rosenthal P, Meyerhoff AS (2004) Cost effectiveness of hepatitis A/B versus hepatitis B vaccination for US prison inmates. *Vaccine* 22 (9–10), 1241–1248.
91 Arguedas MR, Heudebert GR, Fallon MB *et al.* (2002) The cost-effectiveness of hepatitis A vaccination in patients with chronic hepatitis C viral infection in the United States. *Am J Gastroenterol* 97 (3), 721–728.
92 Postma MJ, Bos JM, Beutels P *et al.* (2004) Pharmaco-economic evaluation of targeted hepatitis A vaccination for children of ethnic minorities in Amsterdam (The Netherlands). *Vaccine* 22, 1862–1867.
93 Beutels P, MacIntyre R, McIntyre P (2005) Cost-effectiveness of childhood hepatitis A vaccination in Australia. 5th World Congress of the International Health Economics Association, Barcelona, Spain. Abstract no. 40.254 #1.

9.1.3.ii Hepatitis B vaccines and immunization

Daniel Lavanchy

Hepatitis B vaccines provide the best protection against HBV infection and its clinical sequelae, i.e. cirrhosis and hepatocellular carcinoma (HCC) [1–3]. They are therefore the first vaccines against cancer ever licensed [4].

Control and the eventual elimination of transmission of HBV infection is possible with the appropriate use of hepatitis B vaccines.

Vaccine preparations

Hepatitis B vaccines are highly purified preparations of the 22-nm spherical particles of hepatitis B surface antigen (HBsAg), containing aluminium salts as an adjuvant. Guiding principles for the public health purchase and use of vaccines have been published by the World Health Organization in *Vaccines and Biologicals. Ensuring the Quality of Vaccines at Country Level* (http://www.who.int/vaccinesdocuments/DocsPDF02/www693.pdf).

Plasma-derived vaccines

In the 1960s, it was shown that boiled serum from patients with 'serum hepatitis' could protect against clinical disease [5]. This led to the development of vaccines from highly purified preparations of HBsAg from the plasma of HBV carriers using various methods of purification and inactivation. These vaccines proved to be safe, highly immunogenic and effective in preventing

disease. Plasma-derived vaccines became commercially available in 1982 and have been used extensively worldwide [6–8]. Today, they have been replaced by recombinant DNA vaccines.

Recombinant DNA vaccines

DNA recombinant vaccines were developed in the 1980s by inserting plasmids containing the HBV gene coding for HBsAg (with or without the pre-S1 and pre-S2 components) into yeast or mammalian cells. These cells then produce self-assembling, immunogenic HBsAg particles, almost identical to those found in the plasma of chronic HBV carriers [9,10].

Combination vaccines

Today, hepatitis B vaccines are not only available in monovalent formulations that protect only against hepatitis B, but also in combination formulations that protect against hepatitis B and other diseases [e.g. diphtheria–tetanus–pertussis (DTP)–HepB; DTP–HepB + *Haemophilus* influenza B (Hib); Hib–HepB] [11–15]. Table 1 shows the formulations of hepatitis B vaccine currently available. The most obvious benefits of combination vaccines are the immunization of all children receiving DTP with an additional antigen, but without an additional injection, resulting in increased injection safety and fewer vaccine-related costs and waste.

As the DTP and Hib antigens have reduced immunogenicity when given before the age of 6 weeks, a combination vaccine with a hepatitis B component cannot be used for newborns and, therefore, the monovalent hepatitis B vaccine must be used for vaccination at birth.

Vaccine schedules

The main objective of hepatitis B immunization is to prevent chronic HBV infection and its serious consequences, including liver cirrhosis and hepatocellular cancer (HCC). Routine vaccination of all infants against HBV infection should become an integral part of national immunization strategies. A high coverage of the primary vaccine series among infants will have the greatest overall impact on the prevalence of chronic HBV infection in children and should be given the highest priority.

A variety of schedules may be used for hepatitis B immunization in national programmes, depending on the local epidemiological situation. However, in countries where a high proportion of HBV infections are acquired perinatally, the first dose of hepatitis B vaccine should be given as soon as possible (< 24 hours) after birth. In countries where a lower proportion of HBV infections are acquired perinatally, the relative contribution of perinatal HBV infection to the overall disease burden, and the feasibility and cost-effectiveness of providing vaccination at birth, should be carefully considered before a decision is made on the optimal vaccination schedule.

Catch-up strategies targeted at older age groups or groups with risk factors for acquiring HBV infection should be considered as a supplement to routine infant vaccination in countries of intermediate or low hepatitis B endemicity. In such settings, a substantial proportion of the disease burden may be attributable to infections acquired by older children, adolescents and adults. In countries of high endemicity, large-scale routine vaccination of infants rapidly will rapidly reduce the transmission of HBV. In these circumstances, catch-up vaccination of older children and adults has relatively little impact on chronic disease because most of them have already been infected.

There are multiple options for incorporating the hepatitis B vaccine into national immunization programmes (Table 2) The minimum recommended interval between doses is 4 weeks. Longer intervals may increase the final anti-HBs titres but not the seroconversion rates. More than three doses of the vaccine are not required, regardless of duration (> 4 weeks) of the interval between them.

Table 1 Formulations of hepatitis B vaccine.

Monovalent	Hepatitis B
DTwP–HepB	Diphtheria + tetanus + whole-cell pertussis + hepatitis B
DTwP–Hib–HepB	Diphtheria + tetanus + whole-cell pertussis + *Haemophilus* influenza type B + hepatitis B
DTaP–Hib–IPV–HepB	Diphtheria + tetanus + acellular pertussis + *Haemophilus* influenza type B + inactivated polio vaccine + hepatitis B
DTaP–IPV–HepB	Diphtheria + tetanus + acellular pertussis + inactivated polio vaccine + hepatitis B
Hib–HepB	*Haemophilus* influenza type B + hepatitis B
HepA–HepB	Hepatitis A + hepatitis B

Hepatitis B vaccine is available as monovalent formulations or in fixed combination with other vaccines, including DTwP, DTaP, Hib, hepatitis A and IPV. When immunizing against HBV at birth, only monovalent hepatitis B vaccine should be used: the other antigens found in combination vaccines are currently not approved for use at birth.

A heptavalent EPI vaccine (DTwP, HepB, Hib, meningo A/C) is currently under development.

Table 2 Hepatitis B vaccine schedules.

Newborn

Visit	Age	Other antigens				Hepatitis B vaccine options: No birth dose	With birth dose	
						I	II	III
0	Birth	BCG OPVO[a]					HepB1[b]	HepB1[b]
1	6 weeks		OPV1	DTP1		HepB1[c]	HepB2[b]	HepB2[c]
2	10 weeks		OPV2	DTP2		HepB2[c]	NA	HepB3[c]
3	14 weeks		OPV3	DTP3		HepB3[c]	HepB3[b]	HepB4[c]
4	9–12 months		NA	NA	Measles	NA	NA	NA

Adult

Visit	Schedule: Standard	Accelerated I[e]	Accelerated II[e]	Hepatitis B vaccine
1	0	0	0	HepB[c]
2	1 month	1 month	7 days	HepB[c]
3	6–12 months	2 months	21 days	HepB[c]
4[d]		6–12 months	6–12 months	HepB[c]

NA, not applicable; BCG, bacillus Calmette–Guérin (vaccine); OPV, oral polio vaccine.
[a]Given only given in highly polio-endemic countries.
[b]Monovalent vaccine.
[c]Monovalent or combination vaccine.
[d]A fourth dose of vaccine is recommended after an accelerated schedule.
[e]Not licensed in all countries.

Recommended schedules for vaccination can be divided into those that include a birth dose and those that do not. Schedules with a birth-dose call for the first vaccination at birth, followed by a second and third dose at the time of the first and third DTP vaccination, respectively (Table 2, column II). Alternatively, a four-dose schedule may be employed, whereby the dose at birth is followed by three additional doses; these doses may be given either as monovalent vaccine or as a combination (e.g. with DTP and/or Hib) following the schedules commonly used for those vaccines (Table 2, column III). These schedules will prevent most perinatally acquired infection.

Experimental vaccines

Although HBsAg vaccine is effective in preventing HBV infection, it is poorly immunogenic (if not adjuvanted). While most recipients of three doses of currently available hepatitis B vaccines produce a strong and longlasting anti-HBs response, 5–10% of healthy adults do not produce protective levels of anti-HBs and can be considered non-responders [16,17]. Therefore, strategies to overcome non- or poor responsiveness to hepatitis B vaccines have been devised.

One such strategy is to *add pre-S epitopes to HBsAg (S-only) vaccine* [18,19]. Early trials demonstrated that pre-S2-containing vaccines are safe and immunogenic but failed to show an advantage over the existing S-only vaccines [20]. Other trials, using pre-S1- and pre-S2-containing recombinant HBsAg vaccines, suggested that pre-S sequences do confer increased immunogenicity in proven non-responders [21–24 and recent reference 119]. These conflicting results may result from the incorporation of different pre-S1 and pre-S2 epitopes, the protease sensitivity and resulting instability of certain products or the cell line used for the production. These issues need to be clarified before definitive statements can be made on the usefulness of vaccines containing pre-S sequences.

Immunization using *DNA vaccines* encoding for HBsAg is another area currently under investigation [25–27]. It still remains to be determined whether DNA-based immunization will prove to be more effective, less expensive or safer than recombinant proteins.

Hepatitis B core antigen (HBcAg) is far more immunogenic than HBsAg, making it extremely attractive for use as a carrier of heterologous B-cell epitopes. As a result, chimeric particles containing recombinant HBcAg and HBsAg sequences have been constructed. These constructs have shown enhanced immunogenicity for the inserted HBsAg. Further research is needed before such a vaccine can be recommended for public health use [28,29].

Enhanced immunogenicity of vaccines can also be achieved by *changing the adjuvant* used for delivery rather than the protein composition. For currently licensed vaccines, the only adjuvants approved for use are aluminium salts and MF59 [30,31]. HBV envelope proteins formulated in several adjuvant systems turned out to be more immunogenic than their non-adjuvanted or aluminium-adjuvanted counterparts [31–38]. It is conceivable that a two-dose hepatitis B vaccine schedule could

be achieved using vaccines with enhanced immunogenicity, and eventually lead to reduced vaccine administration costs and improved compliance.

Vaccine efficacy

Immune response to vaccine

Hepatitis B vaccine schedules are flexible; there are various options for adding the vaccine to established national immunization schedules without requiring additional visits for vaccination. The most widely used vaccination schedule is 0, 1 and 6–12 months. Among immunocompetent infants, children and adults, a protective antibody response develops in 90–95% of vaccine recipients [16,17,39]. Protection lasts for as long as 15 years and outlasts the presence of detectable antibodies [40–42] because long-term protection relies on a T cell-based immunological memory, which provides an anamnestic response after exposure to HBV.

Studies in Alaska [16,50] have shown that titres of anti-HBs higher than 10 mIU/L persist in 75% and 65% of vaccinated individuals 10 and 15 years after vaccination respectively. Likewise 64% of Italians vaccinated at birth and 87% of those vaccinated at 12 years of age had titres of anti-HBs higher than 10 mIU/L 11 years aften vaccination; a booster dose in vaccinees that had lower antibody titres induced in all but 6% of individuals vaccinated at birth an ameliorative effect.

Booster doses

No data support the use of booster doses of hepatitis B vaccine among immunocompetent individuals who have responded to a complete primary vaccination series. Therefore, booster doses of vaccine are *not* recommended [42–45]. However, additional information is required to establish whether booster injections are needed for adults beyond 15 years after hepatitis B vaccination, for children immunized at birth (to determine whether the immunological memory persists into adolescence and adulthood) and for population groups at higher risk of infection with HBV. Booster doses are recommended for immunocompromised individuals.

Breakthrough infections after successful hepatitis B vaccination

A limited number of children have been infected with HBV after completing a full vaccination course [44]. These cases were attributed to HBV vaccine escape mutant strains carrying mutations on the antigenic *a* determinant of HBsAg [46–48]. The same phenomenon was also observed in almost 4% of babies born to HBsAg-positive mothers who received active and passive immunization at birth; some of the infected babies developed chronic hepatitis [49]. The risk of hepatitis B infection is inversely related to the titres of the anti-HBs generated by vaccination [50]. Almost all infections occurring in successfully vaccinated individuals are clinically silent [39,51]. Although long-term follow-up studies are needed to determine the impact of disease from breakthrough infections, current hepatitis B vaccines have been shown to effectively protect whole populations [41,52–54].

Postvaccination testing for anti-HBs

Monitoring of anti-HBs titres is recommended for vaccinated immunocompromised persons considered at risk of HBV infection (e.g. haemodialysis patients). Adult vaccinees with ≤ 10 mIU/mL anti-HBs after a full hepatitis B vaccination course, measured 1–3 months following vaccination, should be considered for revaccination [43].

Vaccine safety issues

Contraindications to vaccination

There are few contraindications to hepatitis B vaccination: (i) severe reactions to previous doses; (ii) hypersensitivity to one of the vaccine components; and (iii) fever above 38.5°C [39,47].

Multiple sclerosis (MS), acute lymphoblastic leukaemia (ALL), macrophagal myofasciitis (MMF) or other autoimmune diseases potentially associated with HBV vaccination

The issue of a possible association between hepatitis B vaccination and the development of MS, first raised in France, has not been confirmed by convincing scientific data [39,55–59].

Likewise, the hypothetical link between vaccination and ALL in children has not been confirmed [56,57].

In 1993, MMF was investigated through biopsies of the deltoid muscle in patients with general systemic complaints (myalgia, fatigue, arthralgia, muscle weakness, fever, asthenia) [56,57]. The conclusions of a recently performed case–control study noted that there is no basis to reports that aluminium-containing vaccines pose a serious health risk [57].

Although the prevalence of autoimmune disease (AID) is generally quite low, the incidence has increased in industrialized countries during recent years, affecting approximately 5% of the population [60]. However, no scientific data support the existence of a causal link or triggering association between the administration of hepatitis B vaccine and the onset of an autoimmune disease [57]. Considering the high levels of vaccination coverage resulting from immunization programmes worldwide, and given that more than 1 billion doses of vaccine have been used since 1982, the most likely explanation for the occurrence of MS, ALL, MMF or other autoimmune diseases linked to a vaccination against hepatitis B is a coincidental temporal association. There is currently enough evidence to

conclude that people suffering from autoimmune diseases can be vaccinated [57].

Thiomersal, also known as thimerosal, contains small amounts of ethyl mercury and has been used as a preservative in vaccines. Although the Institute of Medicine [61] found no evidence of a causal relationship between exposure to thiomersal and the development of autism, attention deficit hyperactivity disorder and speech or language delay, it has been eliminated from many preparations [56,62].

Addressing vaccine safety concerns

In a rapidly changing global environment, and as successful immunization programmes have led to less visible disease threats, many communities have lost the knowledge of the natural consequences of vaccine-preventable diseases that have disappeared (e.g. measles, diphtheria, acute viral hepatitis). In the absence of disease, the misconception arises that vaccination is no longer needed. Thus, interests may increasingly focus on vaccine adverse events rather than on the prevention and control of diseases, resulting in lower vaccine coverage and subsequent disease outbreaks.

Loss of public confidence in vaccination is one of the greatest threats to public health and needs to be addressed. Recent studies have indicated that the proven benefits of vaccination in general and, more specifically, those of hepatitis B vaccination are overwhelming and far outweigh any suggested risk. Consequently, immunization programmes should not stop while each hypothesis is investigated [63].

Injection safety issues

A real issue, unsafe injection practices, has aroused little interest and, therefore, its consequences are largely unknown to the public and to many health-care professionals. With approximately 16 billion injections administered worldwide each year (only 10% of them related to vaccination), it is estimated that 33% of injections in developing countries are unsafe, contributing annually to approximately 20 million new HBV infections (and also to 2 million hepatitis C virus (HCV) infections and 260 000 human immunodeficiency virus (HIV) infections). Promoting safer injection practices through education and the provision of autodisposable syringes is a global task [57,64,65].

Immunization strategies

For population-based immunizations, two strategies have been used [66,67]:

1 High-risk group targeting. Strategies aimed at vaccinating and changing behaviour in these high-risk groups (see Table 3) should be pursued. However, the targeted immunization of high-risk groups has failed to control hepatitis B infection in the general population [17,68–73].

Table 3 Groups at high risk of hepatitis B infection.

Injecting drug users
Persons engaging in unsafe sexual behaviour
Inmates and staff of prisons
Household contacts, other social contacts and sexual partners of persons with acute or chronic HBV infection
Babies born to mothers either with persistent HBV infection or suffering acute hepatitis B during pregnancy
Families adopting children originating from regions of intermediate or high hepatitis B endemicity
Immigrants or refugees from countries of intermediate or high hepatitis B endemicity
Workers whose occupation potentially involves exposure to blood and other body materials (e.g. health care workers and public safety workers)
Patients receiving frequently blood or blood products (e.g. haemophiliacs, haemodialysis patients, transplant patients and chronic liver disease patients)
Unimmunized or uninfected persons who travel to areas of intermediate or high hepatitis B endemicity

2 Universal vaccination programmes. Universal vaccination programmes are needed to eliminate hepatitis B infection, even in areas of low endemicity.

Targeted vaccination of risk groups

Persons with occupational risk

HBV infection is an occupational hazard for health-care workers and for public safety workers exposed to blood in the workplace. The risk of acquiring HBV infections depends on the frequency of percutaneous and permucosal exposure to blood or blood-contaminated body fluids. Therefore, workers who perform tasks involving contact with blood or blood-contaminated body fluid should be vaccinated, and vaccination should be completed during training in schools of medicine, dentistry, nursing, laboratory technology and other allied health professions before trainees have their first contact with blood [74–76].

Haemodialysis patients

Seroconversion rates and anti-HBs titres are lower (50–60%) in haemodialysis patients [77,78]. Vaccination of haemodialysis patients early in the course of renal disease is recommended because those who are vaccinated before entering dialysis are more likely to respond to the vaccine. Booster doses are necessary to maintain protective titres of anti-HBs [79–82].

Recipients of blood products

Patients receiving clotting factor concentrates, such as haemophiliacs or patients with β-thalassaemia major, are at greater risk of HBV infection, and they should be vaccinated as soon as their specific clotting disorder is identified [83,84].

Prevention of perinatal HBV transmission

Control of perinatal transmission can be achieved by delivering

the first dose of vaccine at birth. This prophylactic strategy is very efficient in preventing chronic infection, bearing in mind that 70–90% of infants born to HBsAg-positive mothers become infected, 90% of whom remain chronically infected [41,85–90].

The prevention of perinatal HBV transmission (from mother to neonate) by universal antenatal screening for HBV markers in pregnant women should be encouraged where possible. Women who present for delivery without having been screened for HBsAg should be tested immediately. Newborns from HBsAg-positive mothers should be vaccinated within 12 h of birth. In cases where hepatitis B immune globulin (HBIG, 0.06 mL/kg, not available in all countries) is given, it should be administered concurrently with hepatitis B vaccine, but at a different site. Recent evidence suggests that vaccine alone may be just as effective [91]. HBsAg-positive mothers should not be discouraged from breastfeeding [92–95].

Household contacts and sexual partners of persons with hepatitis B virus infection

Hepatitis B vaccine is indicated in infants if the mother or primary caregiver has acute HBV infection. Prophylaxis for other household contacts of persons with acute HBV infection is not indicated unless they have had identifiable blood exposure to the index case. All household and sexual contacts of persons identified as chronically HBsAg positive should receive hepatitis B vaccine after performing a screening for serum HBV markers. The vaccine is not recommended for persons who have casual contact with chronic carriers at schools and offices as they have little risk of catching HBV.

Susceptible sexually active homosexual and bisexual men should be vaccinated, as vaccination remains the most effective tool for preventing hepatitis B in homosexual men [96,97]. Vaccination is also recommended for men and women with other recently acquired sexually transmitted diseases, for prostitutes and for persons who have a history of high sexual promiscuity [98]. Administering the vaccine with HBIG may improve the efficacy of postexposure prophylaxis.

Adopted or fostered orphans or unaccompanied minors originating from countries where HBV infection is endemic should be screened for HBsAg and, if the children are HBsAg positive, the other family members should be vaccinated [99,100].

International travellers

Hepatitis B is less common than hepatitis A and particularly affects those who engage in sexual activity abroad or who are exposed occupationally. Vaccination should be considered for persons who plan to spend more than 6 months in areas with high rates of HBV infection or who will have close contact with the local population. Vaccination should begin at least 6 months before travel to allow for completion of the full vaccine schedule, although a partial schedule will offer some protection. Rapid schedules can also be considered for last-minute travellers (0, 7, 21 and 360 days) [101].

Injecting illicit substance users

All injecting substance users who are susceptible to HBV should be vaccinated as soon as their drug use begins. Because of the high rate of HBV infection in this population, prevaccination screening should be considered. Drug users who do not respond to vaccination should be counselled [99].

Long-term prisoners

In many facilities the rates of HBV and HCV infection among prison inmates are high [102]. Prison officials should consider undertaking screening and vaccination programmes directed at inmates with histories of high-risk behaviour [99,103]. It may be appropriate to use the accelerated vaccination schedules, which provide protective levels of anti-HBs relatively quickly.

Universal immunization

Selected vaccination strategies targeted to identifiable high-risk groups failed to control transmission in the population and to reduce the incidence and prevalence of hepatitis B. This stimulated the recommendation for universal immunization programmes. Universal vaccination of infants is the best option because vaccines can be delivered to babies with a very high coverage and it is more acceptable to parents [104]. The World Health Organization (WHO) recommended in 1992 that all countries should introduce universal hepatitis B vaccination for the immunization of infants and adolescents into their national immunization programmes by December 1997 [68].

The impact of mass hepatitis B immunization on the chronic consequences of infection was first demonstrated in Taiwan. The HBsAg prevalence in the population of < 15-year-olds decreased from 9.8% (1984) to 0.7% (1999) [105], and, in children aged 6–14 years, the incidence of primary liver cancer declined from 0.7/100 000 in the period 1981–1986 to 0.57/100 000 in 1986–1990 and to 0.36/100 000 in 1990–1996 [53].

Proof of the decreasing incidence of acute hepatitis B after vaccination is also available from Italy, the first industrialized country to introduce routine immunization in a double cohort of subjects, i.e. infants and 12-year-old adolescents, leading to an all-time low for acute hepatitis B infection [54].

Similar successes induced by the universal vaccination of neonates were reported from Bulgaria [106] and Alaska (an area of traditionally high endemicity) [16].

As of today, 151 (WHO 2005) countries have implemented universal infant and/or adolescent vaccination against hepatitis B. However, many low-income countries do not yet use the vaccine, because the price of the hepatitis B vaccine is too expensive. The Global Alliance for Vaccines and Immunization (GAVI) was created in 1999. GAVI is helping 74 low-income countries to reinforce their national vaccine programmes and introduce hepatitis B vaccines into their national immunization programmes.

Some industrialized countries administer the vaccine to adolescents as their primary immunization strategy [84,107–

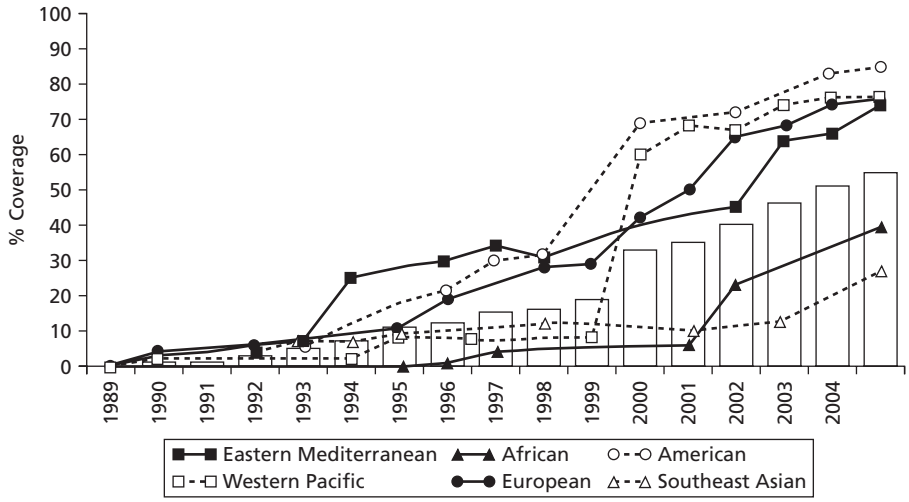

Fig. 1 Global and regional immunization at the third dose of hepatitis B vaccine in infants, 1989–2005. Bars show global coverage, symbols regional coverage as follows: Eastern Mediterranean (closed squares); Western Pacific (open squares); Europe (closed circles); the Americas (open circles); Africa (closed triangles); Southeast Asia (open triangles). Data courtesy of WHO and UNICEF.

109], either in addition to the universal infant immunization programme or as a catch-up vaccination for adolescents aged 9–18 years; combined universal early adolescent and infant vaccination programmes were shown to have the fastest impact on reducing levels of hepatitis B infection [110].

Combination vaccines serve as a vehicle to meet the goal of accelerating new vaccine use, although the process should be carefully managed to ensure affordability without jeopardizing the existing vaccination polices [11].

Immunization programme sustainability

To ensure that vaccine programmes are sustained over time, hepatitis B prevention programmes must be monitored, evaluated and updated. Efforts must focus on monitoring vaccination coverage and checking the incidence of acute disease [112,113].

Economic considerations

In industrialized countries, various economic evaluations have been performed in order to support decision-making; practically all evaluations have used models to predict the cost-effectiveness of immunization against hepatitis B. The complexity of HBV disease outcomes not only leads to a wide range of divergent cost-effectiveness ratios, but it also emphasizes unresolved methodological issues in economic evaluation, with discounting of health gains being one of the main factors of divergent opinions. These controversial results have raised suspicion about the validity and usefulness of economic evaluations among a number of policy-makers. However, the more frequent use of expensive therapies (including liver transplantation) and the sharp decrease in vaccination costs have made universal HBV vaccination strategies cost-effective when compared with other interventions in health care throughout most of the world [114–117].

In countries of very low HBV endemicity, doubts about universal immunization persist because of contradictory results from cost-effectiveness evaluations. Nevertheless, the decision to implement universal immunization should not just be based on economic considerations, particularly in the light of the insufficient credibility of economic evaluations.

Little academic research has been carried out on the economics of combined vaccines [118].

The current status of hepatitis B immunization

To date 158 countries have followed the WHO recommendation to incorporate hepatitis B vaccine as an integral part of their national infant immunization programmes. Figure 1 presents global and regional summaries based on official data from member states. In recent years, the significantly reduced price of hepatitis B vaccine in developing countries has facilitated its introduction into many HBV-endemic areas, to the extent that global immunization coverage in infants reached 55% in 2005. HepB3 coverage has steadily increased since 1990 as a result of the increasing number of countries introducing the vaccine into their routine immunization services, as well as increasing coverage in these countries. Despite this steady progress, there is still room for improvement.The cost-effectiveness of large-scale vaccination against hepatitis B has also been clearly demonstrated, except in countries of very low endemicity, where economic evaluations have given contradictory results, depending on the model used.

References

1 Lavanchy D (2005) Worldwide epidemiology of HBV infection, disease burden, and vaccine prevention. *J Clin Virol* 34, S1–S3.

2 Gay N, Edmunds W, Bah E *et al.* (2001) *Estimating the Global Burden of Hepatitis B*. Geneva: World Health Organization Department of Vaccines and Biologicals.

3 Parkin DM, Bray F, Ferlay J *et al.* (2001) Estimating the world cancer burden: Globocan 2000. *Int J Cancer* 94, 153–156.
4 Hall A (1998) We have a cancer vaccine – why don't we use it? *Trop Med Int Health* 3, 337–338.
5 Krugman S, Giles JP, Hammond J (1971) Viral hepatitis, type B (MS-2 strain). Studies on active immunization. *J Am Med Assoc* 217, 41–45.
6 Maupas P, Goudeau A, Coursaget P *et al.* (1976) Immunisation against hepatitis B in man. *Lancet* 1, 1367–1370.
7 Purcell RH, Gerin JL (1975) Hepatitis B subunit vaccine: a preliminary report of safety and efficacy tests in chimpanzees. *Am J Med Sci* 270, 395–399.
8 Hilleman MR, Buynak EB, Roehm RR *et al.* (1976) Purified and inactivated human hepatitis B vaccine. *Am J Med Sci* 270, 401–404.
9 Valenzuela P, Medina A, Rutter WJ *et al.* (1982) Synthesis and assembly of hepatitis B surface antigen particles in yeast. *Nature* 298, 347–350.
10 Andre FE, Safary A (1988) Clinical experience with a yeast derived hepatitis B vaccine. In: Zuckerman AJ (ed.) *Viral Hepatitis and Liver Disease*. New York: Alan R. Liss.
11 VHPB (Viral Hepatitis Prevention Board) (2002) Combined hepatitis B vaccines. *Viral Hepat* 10, 1–20.
12 Chunsuttiwat S, Biggs BA, Maynard JE *et al.* (2002) Comparative evaluation of a combined DTP-HB vaccine in the EPI in Chiangrai Province, Thailand. *Vaccine* 21, 188–193.
13 Ramkissoon A, Coovadia HM, Jugnundan P *et al.* (2001) A new combined DTP-HBV-Hib vaccine – strategy for incorporation of Hib vaccination into childhood immunisation programmes. *S Afr Med J* 91, 864–869.
14 Nolan T, Hogg G, Darcy MA *et al.* (2001) A combined liquid Hib (PRP-OMPC), hepatitis B, diphtheria, tetanus and whole-cell pertussis vaccine: controlled studies of immunogenicity and reactogenicity. *Vaccine* 19, 2127–2137.
15 Papaevangelou G (1998) Current combined vaccines with hepatitis B. *Vaccine* 16 (Suppl), 69–72.
16 Harpaz R, McMahon BJ, Margolis HS *et al.* (2000) Elimination of new chronic hepatitis B virus infections: results of the Alaska immunization program. *J Infect Dis* 181, 413–418.
17 Hsu HM, Chen DS, Chuang CH *et al.* (1988) Efficacy of a mass hepatitis B vaccination program in Taiwan. Studies on 3464 infants of hepatitis B surface antigen-carrier mothers. *J Am Med Assoc* 260, 2231–2235.
18 Heerman KH, Goldmann U, Schwartz W *et al.* (1984) Large surface proteins of hepatitis B virus containing the pre-S sequence. *J Virol* 52, 396–402.
19 Neurath AR, Kent SBH, Strick N *et al.* (1985) Hepatitis B virus contains pre-S gene-encoded domains. *Nature* 315, 154–156.
20 Milich DR, Thornton GB, Neurath AR *et al.* (1985) Enhanced immunogenicity of the pre-S region of hepatitis B surface antigen. *Science* 228, 1195–1199.
21 Suzuki H, Iino S, Shiraki K *et al.* (1994) Safety and efficacy of a recombinant yeast-derived pre-S2 + S-containing hepatitis B vaccine (TGP-943): phase 1, 2 and 3 clinical testing. *Vaccine* 12, 1090–1096.
22 Kuroda S, Fujisawa Y, Iino S *et al.* (1991) Induction of protection level of anti-pre-S2 antibodies in humans immunized with a novel hepatitis B vaccine consisting of M (pre-S2 + S) protein particles (a third generation vaccine). *Vaccine* 9, 163–169.
23 Yamada K, Kotani M, Eguchi T *et al.* (1998) Efficacy of hepatitis B vaccines with and without preS2-region product in Sumo wrestlers in Japan. *Hepatol Res* 12, 3–11.
24 Shapira MY, Zeira E, Adler R *et al.* (2001) Rapid seroprotection against hepatitis B following the first dose of a Pre-S1/Pre-S2/S vaccine. *J Hepatol* 34, 123–127.
25 Mancini-Bourgine M, Fontaine H, Scott-Algara D *et al.* (2004) Induction or expansion of T-cell responses by a hepatitis B DNA vaccine administered to chronic HBV carriers. *Hepatology* 40, 874–882.
26 Tacket CO, Roy MJ, Widera G *et al.* (1999) Phase 1 safety and immune response studies of a DNA vaccine encoding hepatitis B surface antigen delivered by a gene delivery device. *Vaccine* 17, 2826–2829.
27 Davis HL, McCluskie MJ, Gerin JL *et al.* (1996) DNA vaccine for hepatitis B: evidence for immunogenicity in chimpanzees and comparison with other vaccines. *Proc Natl Acad Sci USA* 93, 7213–7218.
28 Chen X, Li M, Le X *et al.* (2004) Recombinant hepatitis B core antigen carrying preS1 epitopes induce immune response against chronic HBV infection. *Vaccine* 22, 439–446.
29 Yang HJ, Chen M, Cheng T *et al.* (2005) Expression and immunoactivity of chimeric particulate antigens of receptor binding site-core antigen of hepatitis B virus. *World J Gastroenterol* 11, 492–497.
30 Podda A, Del Giudice G (2003) MF59-adjuvanted vaccines: increased immunogenicity with an optimal safety profile. *Expert Rev Vaccines* 2, 197–203.
31 Heineman TC, Clements-Mann ML, Poland GA *et al.* (1999) A randomized, controlled study in adults of the immunogenicity of a novel hepatitis B vaccine containing MF59 adjuvant. *Vaccine* 17, 2769–2778.
32 Yang HZ, Xu S, Liao XY *et al.* (2005) A novel immunostimulator, N-[alpha-O-benzyl-N-(acetylmuramyl)-L-alanyl-D-isoglutaminyl]-N6-trans-(m-nitrocinnamoyl)-L-lysine, and its adjuvancy on the hepatitis B surface antigen. *J Med Chem* 48, 5112–5122.
33 Elias F, Flo J, Rodriguez JM *et al.* (2005) PyNTTTTGT prototype oligonucleotide IMT504 is a potent adjuvant for the recombinant hepatitis B vaccine that enhances the Th1 response. *Vaccine* 23, 3597–3603.
34 Vandepapeliere P, Rehermann B, Koutsoukos M *et al.* (2005) Potent enhancement of cellular and humoral immune responses against recombinant hepatitis B antigens using AS02A adjuvant in healthy adults. *Vaccine* 23, 2591–2601.
35 Cooper CL, Davis HL, Morris ML *et al.* (2004) CPG 7909, an immunostimulatory TLR9 agonist oligodeoxynucleotide, as adjuvant to Engerix-B HBV vaccine in healthy adults: a double-blind phase I/II study. *J Clin Immunol* 24, 693–701.
36 Boland G, Beran J, Lievens M *et al.* (2004) Safety and immunogenicity profile of an experimental hepatitis B vaccine adjuvanted with AS04. *Vaccine* 23, 316–320.
37 Joseph A, Louria-Hayon I, Plis-Finarov A *et al.* (2002) Liposomal immunostimulatory DNA sequence (ISS-ODN): an efficient parenteral and mucosal adjuvant for influenza and hepatitis B vaccines. *Vaccine* 20, 3342–3354.
38 Thoelen S, De Clercq N, Tornieporth N (2001) A prophylactic hepatitis B vaccine with a novel adjuvant system. *Vaccine* 19, 2400–2403.
39 Mahoney F, Kane M (1999) Hepatitis B vaccine. In: Plotkin SA, Orenstein WA (eds) *Vaccines*, 3rd edn. Philadelphia: W.B. Saunders Co., pp. 158–182.

40 Liao SS, Li RC, Li H *et al.* (1999) Long-term efficacy of plasma-derived hepatitis B vaccine: a 15-year follow-up study among Chinese children. *Vaccine* 17, 2661–2666.

41 Chen HL, Chang MH, Ni YH *et al.* (1996) Seroepidemiology of hepatitis B virus infection in children: Ten years of mass vaccination in Taiwan. *J Am Med Assoc* 276, 906–908.

42 Zanetti AR, Mariano A, Romano L *et al.* (2005) Long-term immunogenicity of hepatitis B vaccination and policy for booster: an Italian multicentre study. *Lancet* 366, 1379–1384.

43 European Consensus Group on Hepatitis B Immunity (2000) Are booster immunisations needed for lifelong hepatitis B immunity? *Lancet* 355, 561–565.

44 FitzSimons D, Francois G, Hall A *et al.* (2005) Long-term efficacy of hepatitis B vaccine, booster policy, and impact of hepatitis B virus mutants. *Vaccine* 23, 4158–4166.

45 John TJ, Cooksley G (2005) Hepatitis B vaccine boosters: is there a clinical need in high endemicity populations? *J Gastroenterol Hepatol* 20, 5–10.

46 Harrison TJ, Hopes EA, Oon CJ *et al.* (1991) Independent emergence of a vaccine-induced escape mutant of hepatitis B virus. *J Hepatol* 13, S105–107.

47 Hollinger FB, Liang TJ (2001) Hepatitis B virus. In: Knipe DM, Hawley PM (eds) *Fields Virology*. Philadelphia, PA: Lippincott Williams & Wilkins, pp. 2971–3036.

48 Zuckerman AJ (2000) Effect of hepatitis B virus mutants on efficacy of vaccination. *Lancet* 355, 1382–1384.

49 Whittle H, Jaffar S, Wansbrough M *et al.* (2002) Observational study of vaccine efficacy 14 years after trial of hepatitis B vaccination in Gambian children. *Br Med J* 325, 569.

50 McMahon BJ, Bruden DL, Petersen KM *et al.* (2005) Antibody levels and protection after hepatitis B vaccination: results of a 15-year follow-up. *Ann Intern Med* 142, 333–341.

51 Yuen MF, Lim WL, Chan AO *et al.* (2004) 18-year follow-up study of a prospective randomized trial of hepatitis B vaccinations without booster doses in children. *Clin Gastroenterol Hepatol* 2, 941–945.

52 Mele A, Tancredi F, Romano L *et al.* (2001) Effectiveness of hepatitis B vaccination in babies born to hepatitis B surface antigen-positive mothers in Italy. *J Infect Dis* 184, 905–908.

53 Chang MH, Chen CJ, Lai MS *et al.* (1997) Universal hepatitis B vaccination in Taiwan and the incidence of hepatocellular carcinoma in children. Taiwan Childhood Hepatoma Study Group. *N Engl J Med* 336, 1855–1859.

54 Stroffolini T, Mele A, Tosti ME *et al.* (2000) The impact of the hepatitis B mass immunisation campaign on the incidence and risk factors of acute hepatitis B in Italy. *J Hepatol* 33, 980–985.

55 Marwick C, Mitka M (1999) Debate revived on hepatitis B vaccine value. *J Am Med Assoc* 282, 15–17.

56 Anon (2002) Global advisory committee on vaccine safety. *Weekly Epidemiol Rec* 77, 389–404.

57 VHPB (2003) Hepatitis B vaccination: safety issues. *Viral Hepat* 12, 1–14.

58 WHO (1997) Expanded programme on immunization (EPI). Lack of evidence that hepatitis B vaccine causes multiple sclerosis. *Weekly Epidemiol Rec* 72, 149–152.

59 Ascherio A, Zhang SM, Hernan MA *et al.* (2001) Hepatitis B vaccination and the risk of multiple sclerosis. *N Engl J Med* 344, 327–332.

60 Jacobson DL, Gange SJ, Rose NR *et al.* (1997) Epidemiology and estimated population burden of selected autoimmune diseases in the United States. *Clin Immunol Immunopathol* 84, 223–243.

61 Committee Board of Health Promotion and Disease Prevention (2001) Thimerosol-containing vaccines and neurodevelopmental disorders. In: National Academy Press (ed.) *Immunization Safety Review*. Washington, DC: Institute of Medicine.

62 Clements CJ (2004) The evidence for the safety of thiomersal in newborn and infant vaccines. *Vaccine* 22, 1854–1861.

63 WHO position paper (1998) Hepatitis B immunization. *Weekly Epidemiol Rec* 73, 329.

64 Kane A, Lloyd J, Zaffran M *et al.* (1999) Transmission of hepatitis B, hepatitis C and human immunodeficiency viruses through unsafe injections in the developing world: model-based regional estimates. *Bull WHO* 77, 801–807.

65 WHO (2005) Global status of immunization safety: report based on the WHO/UNICEF Joint Reporting. *Weekly Epidemiol Rec* 80, 361–368.

66 Kane M (1995) Global programme for control of hepatitis B infection. *Vaccine* 13, S47–S49.

67 Grosheide P, van Damme P (1996) Prevention and control of hepatitis B in the community. *Commun Dis Ser* 1, 1–60.

68 Scientific Advisory Group of Experts (SAGE) (1996) Hepatitis B control through immunization. *WHO Global Programme for Vaccines and Immunization*, GPV/SAGE.96/WP.02.

69 Prince AM (1990) Control of hepatitis B virus infection in Third-World countries. *Transfus Med Rev* 4, 187–190.

70 Mahoney FJ (1999) Update on diagnosis, management, and prevention of hepatitis B virus infection. *Clin Microbiol Rev* 12, 351–366.

71 Bonanni P, Pesavento G, Bechini A *et al.* (2003) Impact of universal vaccination programmes on the epidemiology of hepatitis B: 10 years of experience in Italy. *Vaccine* 21, 685–691.

72 van Steenbergen JE (2002) Results of an enhanced-outreach programme of hepatitis B vaccination in the Netherlands (1998–2000) among men who have sex with men, hard drug users, sex workers and heterosexual persons with multiple partners. *J Hepatol* 37, 507–513.

73 Zanetti AR, Tanzi E, Romano L *et al.* (1993) Vaccination against hepatitis B: the Italian strategy. *Vaccine* 11, 521–524.

74 Bonanni P, Bonaccorsi G (2001) Vaccination against hepatitis B in health care workers. *Vaccine* 19, 2389–2394.

75 Mast EE, Alter MJ (1992) Prevention of hepatitis B virus infection among healthcare workers. In: Ellis RS (ed.) *Hepatitis B Vaccines in Clinical Practice*. New York: Marcel Dekker, pp. 295–307.

76 Roggendorf M, Viazov S (2003) Health care workers and hepatitis B. *J Hepatol* 39, S89–92.

77 Mannucci PM, Zanetti AR, Gringeri A *et al.* (1989) Long-term immunogenicity of a plasma-derived hepatitis B vaccine in HIV seropositive and HIV seronegative hemophiliacs. *Arch Intern Med* 149, 1333–1337.

78 Stevens CE, Alter HJ, Taylor PE *et al.* (1984) Hepatitis B vaccine in patients receiving hemodialysis. Immunogenicity and efficacy. *N Engl J Med* 311, 496–501.

79 Busek SU, Baba EH, Tavares Filho HA *et al.* (2002) Hepatitis C and hepatitis B virus infection in different hemodialysis units in Belo Horizonte, Minas Gerais, Brazil. *Mem Inst Oswaldo Cruz* 97, 775–778.

80 Hutin YJ, Goldstein ST, Varma JK *et al.* (1999) An outbreak of hospital-acquired hepatitis B virus infection among patients receiving chronic hemodialysis. *Infect Control Hosp Epidemiol* 20, 731–735.

81 Alter MJ, Favero MS, Francis DP (1983) Cost benefit of vaccination for hepatitis B in hemodialysis centers. *J Infect Dis* 148, 770–771.

82 Zoulim F (1999) Hepatitis C virus infection in special groups. *J Hepatol* 31, 130–135.
83 Schreiber GB, Busch MP, Kleinman SH *et al.* (1996) The risk of transfusion-transmitted viral infections. *N Engl J Med* 334, 1685–1690.
84 Alter MJ (2003) Epidemiology and prevention of hepatitis B. *Semin Liver Dis* 23, 39–46.
85 Mast EE, Alter MJ, Margolis HS (1999) Strategies to prevent and control hepatitis B and C virus infections: a global perspective. *Vaccine* 17, 1730–1733.
86 Edmunds WJ, Medley GF, Nokes DJ (1996) The transmission dynamics and control of hepatitis B virus in The Gambia. *Stat Med* 15, 2215–2233.
87 Beasley RP, Hwang LY, Lee GC *et al.* (1983) Prevention of perinatally transmitted hepatitis B virus infections with hepatitis B virus infections with hepatitis B immune globulin and hepatitis B vaccine. *Lancet* 2, 1099–1102.
88 Zanetti AR, Dentico P, Del Vecchio Blanco C *et al.* (1986) Multicenter trial on the efficacy of HBIG and vaccine in preventing perinatal hepatitis B. Final report. *J Med Virol* 18, 327–334.
89 VHPB (1998) VHPB recommendations on prevention of perinatal HBV transmission. *Viral Hepat* 7, 1–12.
90 Tsebe KV, Burnett RJ, Hlungwani NP *et al.* (2001) The first five years of universal hepatitis B vaccination in South Africa: evidence for elimination of HBsAg carriage in under 5-year-olds. *Vaccine* 19, 3919–3926.
91 Yang YJ, Liu CC, Chen TJ *et al.* (2003) Role of hepatitis B immunoglobulin in infants born to hepatitis B e antigen-negative carrier mothers in Taiwan. *Pediatr Infect Dis J* 22, 584–588.
92 Burke J (2005) Breastfeeding. *Am J Nurs* 105, 15.
93 Hill JB, Sheffield JS, Kim MJ *et al.* (2002) Risk of hepatitis B transmission in breast-fed infants of chronic hepatitis B carriers. *Obstet Gynecol* 99, 1049–1052.
94 Wang JS, Zhu QR, Wang XH (2003) Breastfeeding does not pose any additional risk of immunoprophylaxis failure on infants of HBV carrier mothers. *Int J Clin Pract* 57, 100–102.
95 World Health Organization (1998) Hepatitis B and breastfeeding. *J Int Assoc Phys AIDS Care* 4, 20–21.
96 Gerbase AC, Rowley JT, Heymann DH *et al.* (1998) Global prevalence and incidence estimates of selected curable STDs. *Sex Transm Infect* 74, S12–16.
97 Piot P, Goilav C, Kegels E (1990) Hepatitis B: transmission by sexual contact and needle sharing. *Vaccine* 8, S37–40; discussion S41–33.
98 Alter MJ, Hadler SC, Margolis HS *et al.* (1990) The changing epidemiology of hepatitis B in the United States. Need for alternative vaccination strategies. *J Am Med Assoc* 263, 1218–1222.
99 Recommendations of the Immunization Practices Advisory Committee (ACIP) (1991) Hepatitis B virus: a comprehensive strategy for eliminating transmission in the United States through universal childhood vaccination:. *Morbidity Mortality Weekly Rep* 40, 1–19.
100 Hershow RC, Hadler SC, Kane MA (1987) Adoption of children from countries with endemic hepatitis B: transmission risks and medical issues. *Pediatr Infect Dis J* 6, 431–437.
101 Bock HL, Loscher T, Scheiermann N *et al.* (1995) Accelerated schedule for hepatitis B immunization. *J Travel Med* 2, 213–217.
102 Butler TG, Dolan KA, Ferson MJ *et al.* (1997) Hepatitis B and C in New South Wales prisons: prevalence and risk factors. *Med J Aust* 166, 127–130.
103 Spaulding AC, Lally M, Rich JD *et al.* (1999) Hepatitis B and C in the context of HIV disease: implications for incarcerated populations. *AIDS Read* 9, 481–491.
104 Zuckerman AJ (1996) Hepatitis viruses. In: Baron S. (ed.) *Medical Microbiology*, 4th edn. Galveston, TX: The University of Texas Medical Branch at Galveston, pp. 849–863.
105 Ni YH, Chang MH, Huang LM *et al.* (2001) Hepatitis B virus infection in children and adolescents in a hyperendemic area: 15 years after mass hepatitis B vaccination. *Ann Intern Med* 135, 796–800.
106 Gatcheva N, Vladimirova N, Kourtchatova A (1995) Implementing universal vaccination programmes: Bulgaria. *Vaccine* 13 (Suppl 1), S82–83.
107 Kammerlander R, Vaudaux B, Bourquin C *et al.* (1998) Vaccination contre l'hépatite B en Suisse: vers une stratégie globale. *Rev Med Suisse Romande* 118, 335–339.
108 Bonanni P (1998) Universal hepatitis B immunization: infant, and infant plus adolescent immunization. *Vaccine* 16, S17–22.
109 Tepper ML (1998) Universal hepatitis B immunization: young adolescent immunization. *Vaccine* 16, S23–26.
110 WHO (2001) Hepatitis B immunization. Introducing hepatitis B into national immunization services. *Fact sheet* WHO/V&B/01.
111 Stroffolini T, Cialdea L, Tosti ME *et al.* (1997) Vaccination campaign against hepatitis B for 12-year-old subjects in Italy. *Vaccine* 15, 583–585.
112 Henderson DA (1999) Lessons from the eradication campaigns. *Vaccine* 17 (Suppl 3), 53–55.
113 Bonanni P, Colombai R, Gasparini R *et al.* (1999) Impact of routine infant and adolescent hepatitis B vaccination in Tuscany, Central Italy. *Pediatr Infect Dis J* 18, 677–682.
114 Beutels P (2001) Economic evaluations of hepatitis B immunization: a global review of recent studies (1994–2000). *Health Econ* 10, 751–774.
115 Beutels P, Edmunds WJ, Antonanzas F *et al.* (2002) Economic evaluation of vaccination programs; a consensus statement focusing on viral hepatitis. *Pharmacoeconomics* 20, 1–7.
116 Da Villa G, Sepe A (1999) Immunization programme against hepatitis B virus infection in Italy: cost-effectiveness. *Vaccine* 17, 1734–1738.
117 Margolis HS, Coleman PJ, Brown RE *et al.* (1995) Prevention of hepatitis B virus transmission by immunization. An economic analysis of current recommendations. *J Am Med Assoc* 274, 1201–1208.
118 Lieu TA, Black SB, Ray GT *et al.* (2000) The hidden costs of infant vaccination. *Vaccine* 19, 33–41.
119 Rendi-Wagner P, Shouval D, Genton B *et al.* (2006) Comparative immunogenicity of a PreS/S hepatitis B vaccine in non- and low responders to conventional vaccine. *Vaccine* 24, 2781–2789.

9.1.3.iii Therapy of acute viral hepatitis

Markus Cornberg, Heiner Wedemeyer and Michael P. Manns

Introduction

Infection with the common hepatitis viruses A, B, C, D and E can cause acute inflammation in the liver. However, not all patients develop symptoms. For example, the typical symptom jaundice is present in less than one-third of patients with acute hepatitis C virus (HCV) infection. Fortunately, fulminant hepatitis is a rare event; however, acute hepatitis A virus (HAV) and hepatitis B virus (HBV) infection still represent frequent causes of acute liver failure in the US and Europe. While acute hepatitis D is a problem in the Mediterranean area, hepatitis E can cause severe disease, particularly in pregnant women. Two to five per cent of adult patients with acute HBV infection and 50–90% of patients with acute HCV infection develop a persistent infection. A good reason for submitting to antiviral treatment of acute viral hepatitis would be the potential prevention of a persistent infection. However, in this respect, there is no reason to treat acute hepatitis A, and treatment of acute hepatitis B may be questionable because the chance of developing a chronic HBV infection is rather low for immunocompetent adults. Another reason for antiviral therapy may be reduction in the severity of the acute disease. However, this only has a rationale if the available antiviral drug acts quickly and has few side-effects. As long as the role of antiviral therapies needs to be established, only the best supportive care is warranted for patients with acute viral hepatitis. The optimal management includes the timely referral of patients with impending liver failure to specialized centres that offer the option of emergency liver transplantation if fulminant hepatitis develops.

Supportive care for acute viral hepatitis

Patients with acute viral hepatitis need to be monitored to identify those who may develop fulminant hepatitis with the risk of liver failure. Severe acute viral hepatitis is more often caused by HAV and HBV than by HCV. Fulminant hepatitis develops in 0.4% of cases with HAV infection and in 1% of cases with HBV infection [1]. Acute liver failure is seen more often in patients with HBV and hepatitis D superinfection (2.5–6%). Hepatitis E can cause a dramatic course in the third trimester of pregnancy. Fulminant hepatitis due to an acute HCV infection is extremely rare and may only be seen in combination with additional factors (e.g. coinfection, drugs). Transaminases, bilirubin and liver synthesis markers [albumin, international normalized ratio (INR)] should be measured at least twice weekly during the first weeks of infection depending on the individual kinetics of the laboratory values. Patients with signs of severe flare of hepatitis or liver failure should be transferred to a hospital with the capability for liver transplantation. The mortality of fulminant hepatitis (thrombin time < 40%, encephalopathy) is up to 80%, and liver transplantation is the only curative option.

Antiviral therapy of acute hepatitis B

Antiviral therapy in acute hepatitis B can have two aims. First, it may reduce the severity of the disease. Second, treatment should prevent viral reinfection after liver transplantation in the case of fulminant hepatitis B. The course of disease is severe in about one-third of patients with acute hepatitis B infection. Many patients require hospitalization, and recovery is rather slow. Data on the treatment of acute hepatitis B are limited and, thus, recommendations for the treatment of acute hepatitis B vary. One might expect that the strong immune response that causes fulminant hepatitis should eradicate the virus efficiently. However, low levels of viraemia can be detected in most cases with fulminant hepatitis B with sensitive assays [2]. Tillmann and colleagues reported 37 patients with fulminant hepatitis who were treated with lamivudine in order to prevent reinfection after a potential liver transplantation; interestingly, most of the patients recovered in a short time, and only eight patients required liver transplantation (25%) [2]. This rate of terminal liver failure was lower compared with historical control subjects, among whom 70–100% of those with fulminant hepatitis B either died or were transplanted [2–4]. Treated patients had a rapid improvement in liver synthesis (INR) and inflammation (transaminases). The results of this study have led to the recommendation of the German consensus conference to treat fulminant hepatitis B with lamivudine [5]; this recommendation is further supported by several other reports [6,7].

Antiviral therapy of acute hepatitis C

The aim of acute hepatitis C treatment is the prevention of persistent HCV infection. Early therapy in order to reduce the severity of symptoms of acute hepatitis C infection has no justifiable rationale as severe symptoms occur infrequently, fulminant cases are extremely rare, and the only available therapy is based on interferon (IFN)-α and is therefore associated with significant side-effects. However, the reason to treat acute hepatitis C is the risk of progression to chronicity. The rate of chronic evolution is 50–90%, and chronic hepatitis C can progress to liver cirrhosis and hepatocellular carcinoma [8]. The social burden of the HCV infection can be high, particularly for health-care workers. Extrahepatic manifestations of HCV are often troublesome and may not be reversible with viral eradication later on [9]. As a specific vaccine is not yet available, the early treatment of acute HCV infection with IFN-α is the only option to prevent persistent HCV infection; however, the diagnosis of acute primary HCV infection may be difficult, and distinction from the exacerbation of an underlying unrecognized chronic HCV infection may be impossible [10].

Problems in the early treatment of acute hepatitis C

The overall impact of the early treatment of acute HCV infection to prevent chronic disease has limitations. A main problem is that primary HCV infection is usually asymptomatic, and most patients are not identified in the early stages of disease. Another reason is that a number of patients have medical contraindications for IFN or are not suitable for therapy because they frequently use intravenous (i.v.) drugs. There are two concerns in treating active drug addicts with IFN. One problem is the ongoing drug abuse. In cases of successful therapy, the risk of reinfection with HCV is high [11]. Another reason is the side-effect profile of IFN, especially the neuropsychiatric problems during therapy that may result in resuming the drug habit [12]; furthermore, it has been shown that the acceptance of and adherence to antiviral therapy by these patients is low because of side-effects such as depression [13] (Fig. 1).

Nevertheless, in certain circumstances (e.g. good compliance), early treatment may be a chance for a drug addict ultimately to get rid of both in the end, the HCV and the drugs.

Treatment modalities

Efficacy of therapy

Early therapy with IFN monotherapy can prevent chronic hepatitis C in about 90% of patients with symptomatic acute HCV infection. This was shown in many small single-centre studies (14). In an early study, 24 patients with acute HCV infection, most of them i.v. drug addicts, were treated with high daily doses of standard IFN until normalization of transaminases. Chronicity was prevented in 18 of 22 patients who completed therapy [15]. This gave the rationale for the first German multicentre acute HCV study in which 44 patients with acute HCV infection were treated for 24 weeks with standard IFN (see Fig. 2). All patients responded and were HCV-RNA-negative at the end of treatment, and only one patient demonstrated a relapse [16]. The sustained virological response was longlasting in those patients who could be followed for 52–224 weeks [17]. Several studies have investigated the efficacy of pegylated (PEG)-IFN in patients with acute hepatitis C (see Table 1).

The second German multicentre acute HCV study [12], supported by the German competence network for viral hepatitis [19], recruited twice as many patients in the same time as the first study by Jaeckel *et al.* [16]. The overall sustained viral response (SVR) rates were only 71% in the intention-to-treat analysis. However, patients who were adherent to treatment had a SVR of 89% [12]. Although previous drug abuse did not significantly influence adherence in our study, 6 out of 13 patients who were lost to follow-up had a history of drug abuse. In conclusion, early therapy of patients with acute hepatitis C with IFN or PEG-IFN can be highly successful if the patients are compliant and adherent to therapy; close monitoring during both therapy and follow-up is required, especially in patients

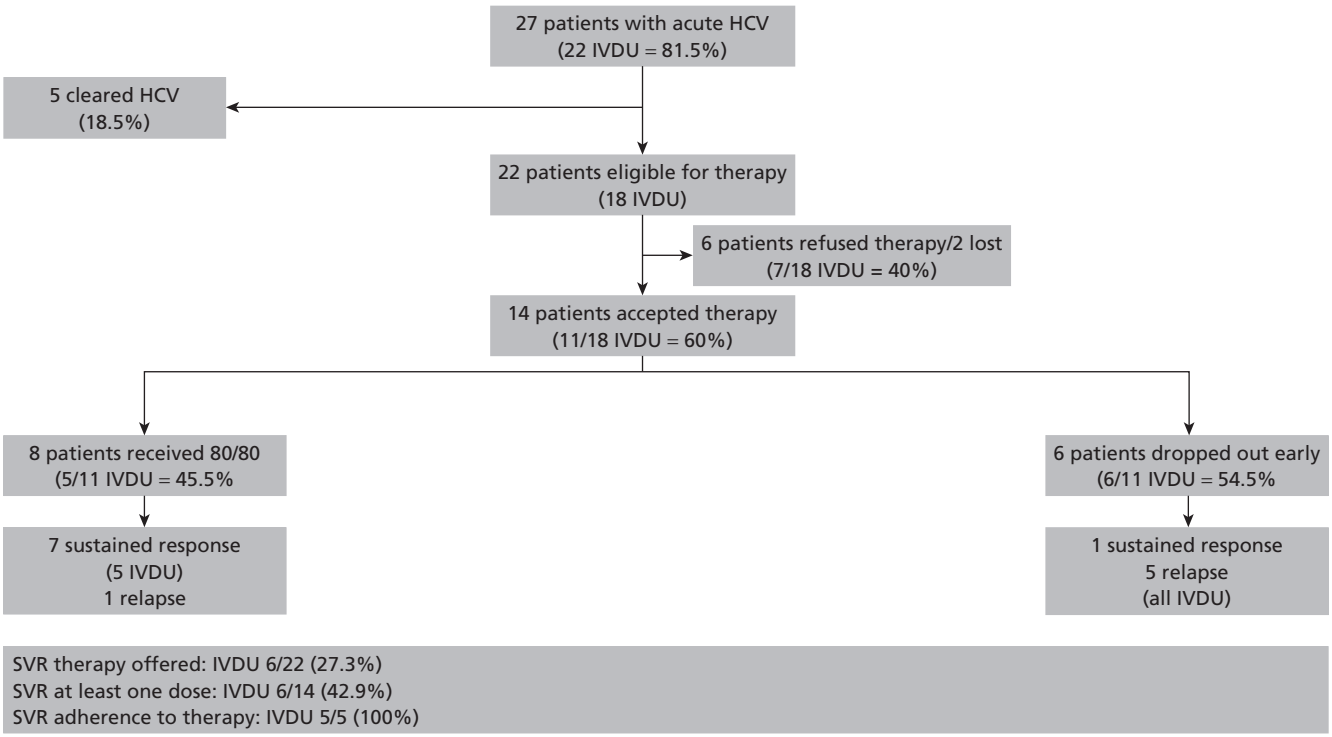

Fig. 1 Low acceptance of therapy and poor compliance of patients with a history of intravenous drug use (IVDU) limit the success of early treatment of acute HCV infection with PEG-IFN. Twenty-two patients with IVDU were eligible for acute HCV therapy: 40% refused therapy and, out of 14 who were treated, less than 50% were adherent to therapy. However, those patients who were compliant and adherent to therapy demonstrated a 100% sustained response.

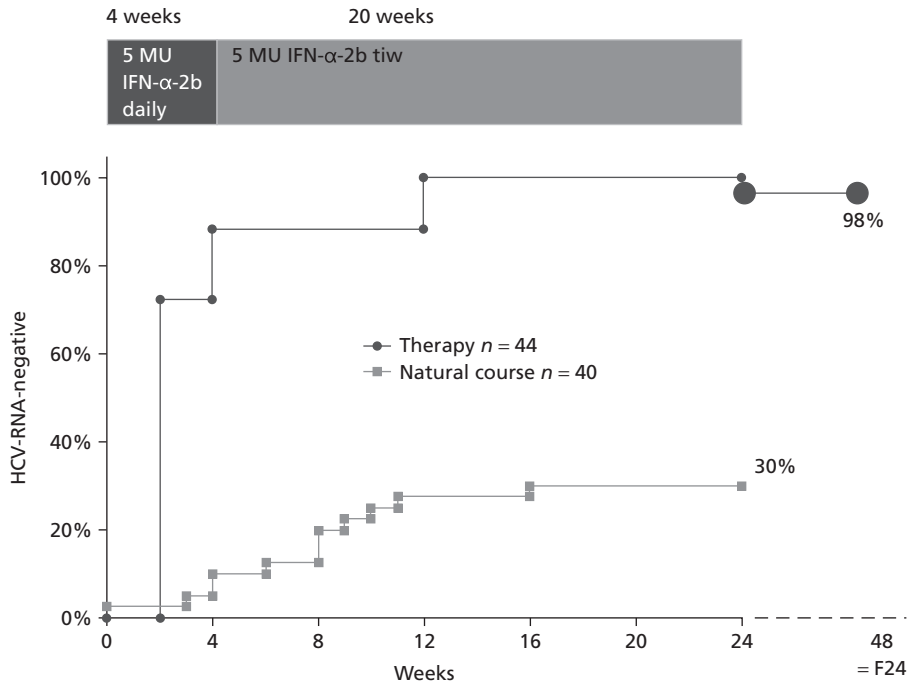

Fig. 2 Treatment schedule and cumulative incidence of undetectable serum HCV RNA during treatment (small circles) and follow-up (large circles). Natural-course patients (small squares) were not treated and demonstrated the expected rate of chronic evolution after 24 weeks of observation. tiw, three times a week.

Table 1 Results of three different studies with PEG-IFN.

Ref. no.	*n*	Treatment	Start of therapy	Duration	Efficacy
[18]	28	PEG-IFN-α-2b (1.5 μg/kg/week)	12 weeks after onset of disease (17/28 chronic, 16 were treated)	24 weeks	15/16 (94%)
[13]	27 (22 IVDU)	PEG-IFN-α-2b (1.5 μg/kg/week)	100 ± 82 days after onset of symptoms, 63 ± 82 days after diagnosis (asymptomatic) (22/27 chronic, 14 were treated)	24 weeks	8/14 (57%) 7/8 (88%) of adherent patients
[12]	89 recruited in 53 centres	PEG-IFN-α-2b (1.5 μg/kg/week)	76 days after infection (range 14–150 days), 27 days after onset of symptoms (range 5–131 days)	24 weeks	63/89 (71%) 58/65 (89%) of adherent patients

with a history of drug abuse [13]. For certain patients, e.g. those asymptomatic with low alanine aminotransferase (ALT) baseline levels, an induction as used in the Jaeckel study may be considered. The results of the major trials showed that there is no need for a combination with ribavirin [16,20]. Also, the only randomized trial so far demonstrated no further benefit of a ribavirin combination [21]. However, the recent studies with PEG-IFN showed that some patients experienced a relapse after the end of treatment. The question is whether we can avoid the relapse with ribavirin in those patients? Patients with baseline factors that are associated with a lower response (e.g. low ALT value) may require additional ribavirin.

Treatment duration

Most studies treated for 24 weeks [15,22,23]. As in chronic hepatitis C, viral kinetics may predict the response [24,25], and treatment duration can be individually tailored to the viral kinetics; it may also be possible to treat acute HCV infection for less than 24 weeks in individual cases. However, the treatment of acute HCV infection requires a simple algorithm to avoid complicated management of these difficult to manage patients. Strategies to enhance the adherence to treatment may be more important than further optimizing the already highly efficacious treatment strategy.

Timing of treatment

A most important question is whether the initiation of treatment can wait until one is certain that the patients will not recover spontaneously. This strategy would avoid the unnecessary inconvenience of IFN side-effects and costs in patients recovering spontaneously. A study by Hofer and colleagues demonstrated a high chance of spontaneous recovery from acute HCV infection in symptomatic patients [26]. The time from infection to spontaneous viral clearance was 77 ± 25 days and

35 ± 22 days from the onset of symptoms. The authors suggested that early and frequent HCV-RNA measurements may discriminate patients with spontaneous recovery from those with chronically evolving HCV infection. It appeared that only patients who failed to clear the virus within the first 35 days after the onset of symptoms needed treatment [26]. This information raises the question whether it is wise to wait for about 12 weeks until a chronic course becomes likely and then treat only the patients who are likely to progress to chronic hepatitis C. A study that adopted the wait-and-see strategy demonstrated that treatment of these patients who remain HCV-RNA-positive for more than 12 weeks after the onset of symptoms resulted in an overall SVR (self-limited and treatment induced) in 91% of patients [27,28]. In the natural (untreated) course of acute symptomatic hepatitis C, spontaneous clearance was observed in 52%, usually within 12 weeks after the onset of symptoms, whereas all asymptomatic patients developed chronic hepatitis C. The SVR to the subsequent IFN or IFN/ribavirin treatment started beyond 12 weeks after the onset of acute hepatitis C in those who developed chronic hepatitis C was 80%, independent of the severity of the acute HCV infection. In conclusion, the wait-and-see strategy avoided unnecessary treatment in half the symptomatic patients, but may not be adequate for asymptomatic patients.

Of note, a study from Japan showed that treatment of acute HCV infection may not be as effective after waiting too long. Treatment within 8 weeks after the onset of acute hepatitis resulted in a 100% SVR compared with only 40% when treatment was initiated after 1 year [23].

The treatment of acute hepatitis C is effective regardless of the genotype [16], but the genotype must be taken into account in treatment decisions. The data indicate that patients with HCV genotype 3 may resolve acute HCV infection more frequently than patients with HCV genotype 1 [29]. Considering the high chance of successful treatment of chronic HCV genotype 3 infection with 12–24 weeks of treatment with PEG-IFN-α and ribavirin, it may be wise to avoid early treatment in acute HCV genotype 3 infection, but rather consider the wait-and-see strategy. This concept may be considered in particular for patients with more than one of the factors associated with spontaneous clearance (see Table 2).

The important open questions on the treatment of acute hepatitis C are listed in Table 3.

Table 2 Factors potentially associated with spontaneous HCV clearance.

Factors associated with spontaneous clearance	Ref. no.
Symptomatic hepatitis C	[27]
Female gender	[27]
HCV kinetics early after infection	[26]
HCV genotype 3	[29]
HLA B27	[30]
Vigorous T-cell immunity	[31]

HLA, human leukocyte antigen.

Table 3 Questions and best possible answers regarding the therapy of acute HCV infection.

Question	Answer
Is early treatment with IFN effective?	≥ 90% sustained virological response possible
Which patients should be treated?	Asymptomatic > symptomatic? HCV genotype 1 > HCV genotype 2/3
When to start treatment?	Immediately in asymptomatic patients Symptomatic patients: immediate therapy vs. wait-and-see under investigation
Which drugs?	IFN-α (5 MU daily for first 4 weeks) or 1.5 μg/week PEG-IFN-α Ribavirin not necessary
Treatment duration?	24 weeks Shorter may be possible

Postexposure prophylaxis

Postexposure prophylaxis after contact with HCV-contaminated blood (e.g. needlestick) is not necessary. First, the early therapy or the wait-and-see strategy is effective in more than 90% of cases. Second, the use of IFN after exposure to HCV has been shown not to be superior [32].

Concluding remarks

Early identification of patients with acute viral hepatitis infection is important for their optimal management. Early referral to a transplant centre is mandatory if patients develop fulminant hepatitis, and best supportive care may prevent further complications in some patients. Antiviral treatment of fulminant hepatitis B with lamivudine can prevent liver failure and reduces the need for liver transplantation. Early measurement of HCV RNA is mandatory in cases of suspicion of acute hepatitis C. Asymptomatic patients have the highest chance of developing chronic hepatitis C and may thus benefit from early (PEG)-IFN-α monotherapy. Symptomatic patients have a high chance of clearing the HCV virus spontaneously. A study is under way to test whether a wait-and-see strategy may be as effective as immediate treatment. Postexposure prophylaxis is not indicated. The future may bring highly effective antiviral drugs that may allow short-term treatment for all acute HCV patients. HCV polymerase and protease inhibitors are the most promising drugs. The first drugs have already been tested in phase I/II trials, and the proof of concept has been demonstrated (reviewed in [33]). The ultimate goal for preventing chronic hepatitis C is a protective vaccine. The first studies in chimpanzees give hope. However, it may not be possible to induce sterilizing immunity, but a less severe course and the prevention of chronic infection may be possible (reviewed in [34]).

References

1 Hoofnagle JH, Carithers RL Jr, Shapiro C *et al.* (1995) Fulminant hepatic failure: summary of a workshop. *Hepatology* 21(1), 240–252.
2 Tillmann HL, Hadem J, Leifeld L *et al.* (2006) Safety and efficacy of lamivudine in patients with severe acute or fulminant hepatitis B, a multicenter experience. *J Viral Hepat* 13(4), 256–263.
3 Garfein RS, Bower WA, Loney CM *et al.* (2004) Factors associated with fulminant liver failure during an outbreak among injection drug users with acute hepatitis B. *Hepatology* 40(4), 865–873.
4 Bernuau J, Goudeau A, Poynard T *et al.* (1986) Multivariate analysis of prognostic factors in fulminant hepatitis B. *Hepatology* 6(4), 648–651.
5 Manns MP, Wedemeyer H, Meyer S *et al.* (2004) [Diagnosis, progression and therapy of hepatitis-B-virus infection – results of an evidenced based consensus conference of the German Society for Alimentary Metabolic Disorders and in cooperation with the Hepatitis Competence Network]. *Z Gastroenterol* 42(8), 677–678.
6 Clark FL, Drummond MW, Chambers S *et al.* (1998) Successful treatment with lamivudine for fulminant reactivated hepatitis B infection following intensive therapy for high-grade non-Hodgkin's lymphoma. *Ann Oncol* 9(4), 385–387.
7 Santantonio T, Mazzola M, Pastore G (1999) Lamivudine is safe and effective in fulminant hepatitis B. *J Hepatol* 30(3), 551.
8 Hoofnagle JH (2002) Course and outcome of hepatitis C. *Hepatology* 36(5 Suppl. 1), S21–S29.
9 Manns MP, Rambusch EG (1999) Autoimmunity and extrahepatic manifestations in hepatitis C virus infection. *J Hepatol* 31(Suppl. 1), 39–42.
10 Pawlotsky JM (2002) Use and interpretation of virological tests for hepatitis C. *Hepatology* 36(5 Suppl. 1), S65–S73.
11 Davis GL, Rodrigue JR (2001) Treatment of chronic hepatitis C in active drug users. *N Engl J Med* 345(3), 215–217.
12 Wiegand J, Buggisch P, Boecher W *et al.* (2006) Early monotherapy with pegylated interferon alfa-2b for acute hepatitis C infection: The HEP-NET Acute-HCV-II Study. *Hepatology* 43(2), 250–256.
13 Broers B, Helbling B, Francois A *et al.* (2005) Barriers to interferon-alpha therapy are higher in intravenous drug users than in other patients with acute hepatitis C. *J Hepatol* 42(3), 323–328.
14 Poynard T, Regimbeau C, Myers RP *et al.* (2002) Interferon for acute hepatitis C. *Cochrane Database Syst Rev* 1, CD000369.
15 Vogel W, Graziadei I, Umlauft F *et al.* (1996) High-dose interferon-alpha2b treatment prevents chronicity in acute hepatitis C: a pilot study. *Dig Dis Sci* 41(12 Suppl.), 81S–85S.
16 Jaeckel E, Cornberg M, Wedemeyer H *et al.* (2001) Treatment of acute hepatitis C with interferon alfa-2b. *N Engl J Med* 345(20), 1452–1457.
17 Wiegand J, Jackel E, Cornberg M *et al.* (2004) Long-term follow-up after successful interferon therapy of acute hepatitis C. *Hepatology* 40(1), 98–107.
18 Santantonio T, Fasano M, Sinisi E *et al.* (2005) Efficacy of a 24-week course of PEG-interferon alpha-2b monotherapy in patients with acute hepatitis C after failure of spontaneous clearance. *J Hepatol* 42(3), 329–333.
19 Manns MP, Meyer S, Wedemeyer H (2003) The German network of excellence for viral hepatitis (Hep-Net). *Hepatology* 38(3), 543–544.
20 Wedemeyer H, Jackel E, Wiegand J *et al.* (2004) Whom? When? How? Another piece of evidence for early treatment of acute hepatitis C. *Hepatology* 39(5), 1201–1203.
21 Kamal SM, Ismail A, Graham CS *et al.* (2004) Pegylated interferon alpha therapy in acute hepatitis C: relation to hepatitis C virus-specific T cell response kinetics. *Hepatology* 39(6), 1721–1731.
22 Delwaide J, Bourgeois N, Gerard C *et al.* (2004) Treatment of acute hepatitis C with interferon alpha-2b: early initiation of treatment is the most effective predictive factor of sustained viral response. *Aliment Pharmacol Ther* 20(1), 15–22.
23 Nomura H, Sou S, Tanimoto H *et al.* (2004) Short-term interferon-alfa therapy for acute hepatitis C: a randomized controlled trial. *Hepatology* 39(5), 1213–1219.
24 von Wagner M, Huber M, Berg T *et al.* (2005) Peginterferon alfa-2a (40KD) and ribavirin for 16 or 24 weeks in patients with genotype 2 or 3 chronic hepatitis C. *Gastroenterology* ??, 000–000.
25 Mangia A, Santoro R, Minerva N *et al.* (2005) Peginterferon alfa-2b and ribavirin for 12 vs. 24 weeks in HCV genotype 2 or 3. *N Engl J Med* 352(25), 2609–2617.
26 Hofer H, Watkins-Riedel T, Janata O *et al.* (2003) Spontaneous viral clearance in patients with acute hepatitis C can be predicted by repeated measurements of serum viral load. *Hepatology* 37(1), 60–64.
27 Gerlach JT, Diepolder HM, Zachoval R *et al.* (2003) Acute hepatitis C: high rate of both spontaneous and treatment-induced viral clearance. *Gastroenterology* 125(1), 80–88.
28 Pimstone NR, Pimstone D, Saicheur T *et al.* (2004) 'Wait-and-see': an alternative approach to managing acute hepatitis C with high-dose interferon-alpha monotherapy. *Ann Intern Med* 141(6), W91–W92.
29 Lehmann M, Meyer MF, Monazahian M *et al.* (2004) High rate of spontaneous clearance of acute hepatitis C virus genotype 3 infection. *J Med Virol* 73(3), 387–391.
30 Neumann-Haefelin C, McKiernan S, Ward S *et al.* (2006) Dominant influence of an HLA-B27 restricted CD8+ T cell response in mediating HCV clearance and evolution. *Hepatology* 43(3), 563–572.
31 Rehermann B, Nascimbeni M (2005) Immunology of hepatitis B virus and hepatitis C virus infection. *Nature Rev Immunol* 5(3), 215–229.
32 Chung H, Kudo M, Kumada T *et al.* (2003) Risk of HCV transmission after needlestick injury, and the efficacy of short-duration interferon administration to prevent HCV transmission to medical personnel. *J Gastroenterol* 38(9), 877–879.
33 Cornberg M, Manns MP (2005) New approaches and therapeutic modalities for the treatment of patients with chronic hepatitis C. *Ann Hepatol* 4(3), 144–150.
34 Houghton M, Abrignani S (2005) Prospects for a vaccine against the hepatitis C virus. *Nature* 436(7053), 961–966.

9.1.3.iv Antiviral therapy of chronic hepatitis B

Fabien Zoulim and Mario Rizzetto

Pathobiology background

As hepatitis B virus (HBV) replication does not lead by itself to a cytopathic effect, chronic hepatitis B is the result of an ongoing liver injury mediated by the T-cell immune response targeting hepatocytes that harbour HBV replication [1,2]. Our knowledge of the pathobiology of HBV infection has come from clinical

studies and from experimental investigations performed in animal models. Viral clearance requires the coordinated action of several components of the immune response [3–6]: (i) a cytotoxic T-helper 1 (Th1) response by CD8-positive cells recognizing infected hepatocytes expressing viral antigens; (ii) a non-cytolytic Th1 response whereby the CD8-positive cells produce Th1 cytokines such as interferon (IFN)-γ, tumour necrosis factor (TNF)α and interleukin (IL)-12, which exhibit a direct antiviral effect in the infected liver; (iii) the innate immune response mediated by natural killer (NK) and NKT cells; (iv) the production of neutralizing antibodies by B cells to prevent the infection of new hepatocytes by residual virions; (v) cell lysis and turnover to generate new uninfected cells that will repopulate the liver.

While there is a consensus on the role of these different effectors, the order of events is still debated. In transgenic mice and acutely infected chimpanzees, several studies have shown a major role for non-cytolytic processes in the immune-mediated clearance of viral infection. In contrast, in the woodchuck and duck models of acute infection, evidence has been obtained that cell lysis and hepatocyte turnover are required to clear infection.

In the setting of chronic infection, antivirals decrease viral production and thus prevent a new round of infection, but also restore the specific CD4- and CD8-mediated immune response following the decrease in viral load in the infected host [7,8]. An HBV load of 10^7 copies/mL appears to be a threshold below which circulating multispecific HBV-specific CD8+ T cells are consistently detected [9]. It is also possible that prolonged antiviral treatment may induce cell curing by inhibiting the intracellular recycling of viral cccDNA. It was also shown that viral persistence during long-term antiviral therapy in the duck and woodchuck models is linked to a long half-life of viral cccDNA [10,11]. Following the development of polymerase chain reaction (PCR)-based assays, the kinetics of viral cccDNA clearance from the liver have been studied in detail in chronically infected patients. The results suggest that viral cccDNA may persist over decades even after the serological clearance of viral infection and that resolution of infection may not occur via sterilizing immunity but by the continuous control of viral infection over time [12,13]. These data suggest that the reservoir of cccDNA may be the source of renewed viral replication and clinical reactivation in case of loss of immunological control, i.e. immunosuppression, organ transplantation, human immunodeficiency virus (HIV) coinfection. It also indicates that antiviral treatment should be maintained until the specific anti-HBV immune response controls the residual low levels of viral replication [13–15].

Unfortunately, long-term therapy exposes to the risk of selection of drug-resistant mutants [16]. Indeed, owing to the spontaneous viral genome variability, the pharmacological pressure may select for the viral species that exhibit the best replication capacity in this new treatment environment. The mutations conferring resistance to nucleoside analogues are located in the viral polymerase gene. The rapidity of selection of drug-resistant mutants depends on their replication capacity and fitness, their level of resistance and the free liver space available for infection by these mutants. This explains the differences in the rate of resistance for the different drugs that are clinically available.

Indication to antiviral therapy

Based on the present knowledge of the natural history of chronic HBV hepatitis and on the efficacy of antiviral drugs, treatment is indicated only in hepatitis B surface antigen (HBsAg) carriers with liver disease.

HBsAg carriers with chronic hepatitis B who should be treated

Antiviral therapy of chronic HBV infection is indicated in patients with chronic hepatitis B in the immunoactive phase. As this phase is characterized by high levels of viral replication and immunomediated damage of HBV-containing hepatocytes, these HBsAg-positive carriers usually have levels of viral DNA in serum higher than 10^4 copies/mL and exhibit elevated serum alanine aminotransferase (ALT) levels.

Liver histology usually shows inflammatory activity and variable degrees of liver fibrosis depending on the duration of the disease. As continuing HBV replication and elevation of ALT levels imply a significant risk of disease progression towards liver cirrhosis and hepatocellular carcinoma [17,18], antiviral therapy is indicated to decrease viral load, normalize ALT levels and induce a remission of the liver disease.

There are two main forms of chronic HBsAg-positive hepatitis [19]. The HBeAg-positive form is associated with a so-called wild-type virus infection, HBsAg and HBeAg positivity, high HBV DNA levels usually > 10^6 copies/mL and elevated ALT levels. The HBeAg-negative form is associated with precore mutant virus infection, HBsAg positivity and HBeAg negativity (most patients have anti-HBe antibody), HBV DNA levels that are fluctuating but usually > 10^4 copies/mL and elevated ALT levels that may also be fluctuating over time. Treatment endpoints differ depending on the form of chronic hepatitis B.

Chronic HBsAg carriers who should not be treated

Patients with chronic HBV infection who are in the immunotolerance phase should not be treated. These individuals represent a minority among chronic HBsAg carriers. They are defined serologically by HBsAg positivity, HBeAg positivity, high HBV DNA levels (usually higher than 10^8 copies/mL) and normal serum ALT levels. They usually have no liver damage or only minimal liver disease at liver biopsy examination, but they are highly infectious. The risk of disease progression is low as long as ALT levels remain within the normal range. The results of

clinical trials of IFN-α or nucleoside analogues indicate that patients with high HBV DNA load and normal ALT levels have almost no chance of responding to therapy, i.e. HBeAg seroconversion. However, patients should be monitored carefully on a regular basis to diagnose a break in immune tolerance characterized by an elevation in ALT levels and a decline in viral load. These events reflect the onset of liver damage and may represent an indication for antiviral therapy, unless HBeAg seroconversion (which is the ultimate goal of therapy, see below) occurs spontaneously.

A 6-monthly analysis of ALT levels and HBV DNA is recommended in chronic carriers who are in the immunotolerance phase. Patients' relatives and household contacts should be screened for HBV markers and vaccinated against HBV if not protected.

The other category of patients with chronic HBV infection who should not be treated is the HBsAg inactive carriers. These individuals are the majority among HBsAg carriers. They are characterized by HBsAg positivity, HBeAg negativity, anti-HBe antibody positivity, low HBV DNA levels (< 10^4 copies/mL) and normal ALT levels. Liver histology usually shows no or minimal damage, and the risk of progressive liver disease is considered to be minimal as long as ALT levels remain normal and viraemia remains below 10^4 copies/mL. It is currently recommended that these patients should not be treated, but followed carefully to diagnose reactivation of viral replication and ALT exacerbations promptly, should these occur. A 6-monthly follow-up of ALT levels and HBV DNA is suitable to make sure that the inactive state is maintained over time.

Goals of antiviral therapy

The main goal of antiviral therapy is to suppress HBV replication to induce the remission of liver disease activity. In addition, the inhibition of HBV replication decreases patients' infectivity and the risk of HBV transmission. This is especially important in health-care workers. Recent studies suggest that lamivudine therapy of chronically HBV-infected pregnant women during the last trimester of pregnancy increases the protection of newborns who receive hepatitis B immune globulin (HBIG) and vaccine at birth.

In patients with wild-type virus infection, the primary goal of antiviral therapy is to achieve seroconversion from HBeAg to the homologous anti-HBe antibody (referred to hereafter as HBe seroconversion) as this immunological event is associated with a reduction in the risk of progression of the liver disease. Of note, a prior decline in viral load is mandatory to obtain HBe seroconversion, which is subsequently required to achieve seroconversion from HBsAg to the homologous anti-HBs antibody (referred to hereafter as HBs seroconversion).

In patients with an HBeAg-negative chronic hepatitis B, available antiviral agents are effective in suppressing HBV replication but, in most cases, are not capable of eradicating the virus. Therefore, the main objective of therapy is to control viral replication to prevent ALT flares and/or induce remission of disease. The only event marking a sustained response to therapy would be HBs seroconversion to anti-HBs, which unfortunately occurs only seldom.

Different types of responses have been defined during the European Consensus Conference in 2002 [20], i.e. the initial response, the on-treatment or maintained response and the sustained response when antiviral treatment has been stopped. The virological response is defined by the decline in HBV DNA below 10^4 or 10^3 copies/mL, the biochemical response by the normalization of ALT levels and the histological response by improvement in the histological activity or fibrosis indices (Knodell or Ishak or METAVIR scores). The combined response is defined by improvement in ALT levels and decrease in viral load, while the complete response is characterized by the combination of a decrease in viral load, normalization of ALT levels, occurrence of an HBe or HBs seroconversion and histological improvement in liver disease.

The treatment response is also defined depending on the timing during therapy. The initial response is characterized by a decrease in viral load at week 12 of therapy by at least 1 log10 copies/mL compared with the baseline value. The maintained response is defined by a low viral load during therapy (Fig. 1).

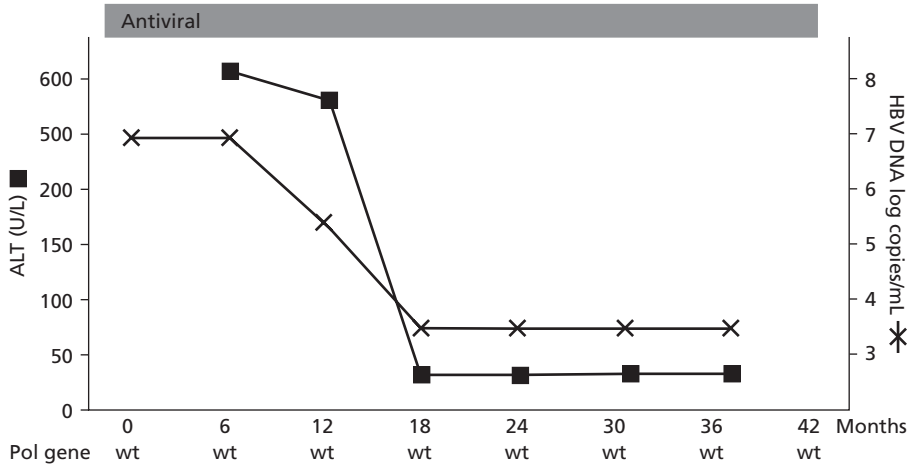

Fig. 1 Maintained antiviral response. wt, wild type HBV polymerase gene sequence.

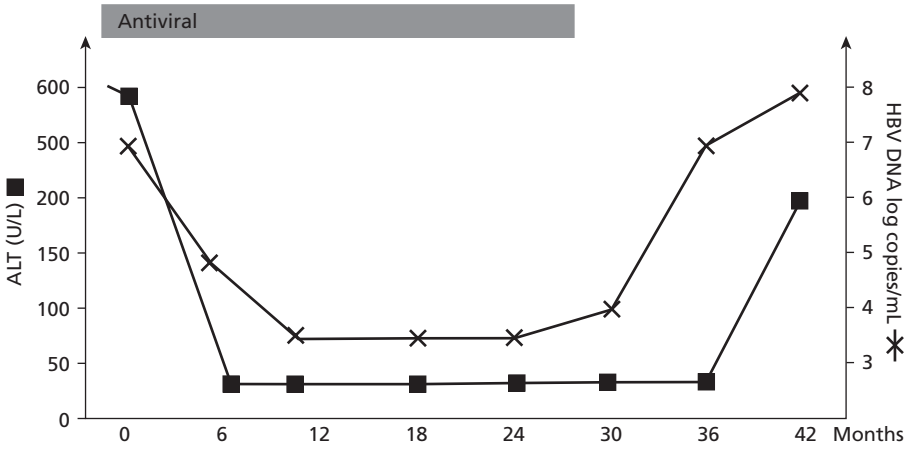

Fig. 2 Relapse after treatment cessation.

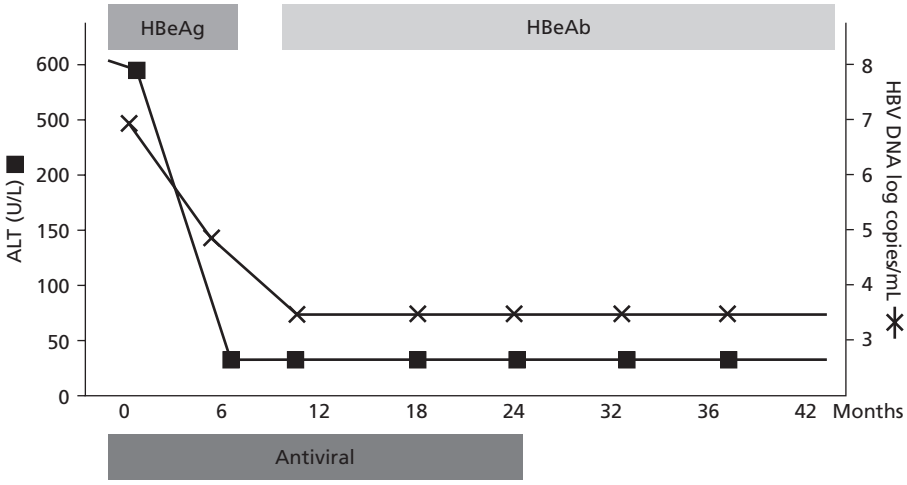

Fig. 3 Sustained antiviral response.

Depending on the use of nucleoside analogue or interferon, there is no agreed threshold to define the maintained response. Usually, a decrease in viral load below 10^4 copies/mL is associated with an improvement in liver histology. However, with nucleoside analogues, the lower the viral load, the less is the risk of developing viral drug resistance. For instance, it was shown that, during lamivudine therapy, the risk of further resistance to treatment was significantly lower when viral load was below 10^3 copies/mL. The end-of-treatment response is defined by the response observed at the end of therapy, if it was decided to stop treatment. A relapse is defined by the increase in viral load after treatment cessation (Fig. 2). The sustained response is defined conventionally by the maintenance of the response 6 months after drug withdrawal (Fig. 3).

Antiviral agents

IFN-α was introduced in clinical practice in the 1980s as initial therapy for chronic hepatitis B. In the 1990s, the advent of nucleoside analogues targeting specific viral functions has provided a therapeutic alternative. However, viral persistence and the emergence of resistance remain a major challenge to the use of nucleoside analogues, and research continues in an attempt to discover new agents that are more efficacious and less prone to induce viral resistance.

Study models of anti-HBV agents

Antiviral agents have been studied extensively in experimental models, *in vitro* in tissue culture and *in vivo* in ducks and woodchucks [16]. Infection and complete replication including formation of the viral minichromosome (cccDNA), which plays an essential role in the persistence of infection and in the long-term resistance to treatment, can be obtained only in primary cultures of hepatocytes and in the HepaRG cells. Cell culture systems, useful for the screening of anti-HBV compounds and study of their mode of action, are (i) stably transfected hepatoma lines HepG2.2.15 or HepAD38, (ii) transiently transfected hepatoma cell lines [HepG2 or Huh-7 human cells for HBV and LMH avian cells for duck HBV (DHBV)], and (iii) hepatoma cell lines infected via recombinant HBV baculovirus that allow full viral replication including cccDNA formation. Determination of the

mode of action has been investigated (i) in primary cultures of hepatocytes taken from the well-characterized animal models of HBV, the duck and the woodchuck, (ii) on endogenous viral DNA- and RNA-dependent DNA polymerase, which can be assayed in purified nucleocapsid or (iii) in a tube reconstituted assay for both priming and reverse transcription of the viral genome. The *in vivo* models allowed the study of the antiviral efficacy, the kinetics of viral clearance, the emergence of drug resistance, as well as the toxicity of the drugs [11,21–24]. All these *in vitro* and animal models contributed to the molecular characterization of the replication cycle of HBV and, consequently, to the identification of viral targets for antiviral therapy of HBV infection [25]: (i) neutralization of the virus–cell interaction with anti-envelope antibodies; (ii) cytokine and/or antisense inhibition of viral transcription and viral gene expression; (iii) packaging inhibition with peptides; (iv) RNA- or DNA-dependent DNA polymerase activity inhibition by nucleoside analogues or antisense; and (v) viral secretion with glucosidase inhibitors.

Immunomodulatory approaches

One strategy to eradicate viral infection consists of the enhancement of the specific immune response, using cytokines such as IFN-α, IFN-γ, TNFα, IL-12 or a viral recombinant protein or plasmid DNA-based vaccine approach. The combination of nucleoside analogues to inhibit viral production with immunomodulatory approaches to eradicate the residual infected hepatocytes (that may support the replication of escape mutants) warrants further evaluation in animal models of hepadnavirus infection and in clinical trials.

Interferon alpha and pegylated IFN

IFN-α belongs to a family of naturally occurring proteins that have antiviral and immunomodulatory actions. They bind to cellular receptors and activate secondary messengers in order to initiate the production of multiple proteins critical to the defence of the cell against viruses. The antiviral effects include degradation of viral mRNA, inhibition of viral protein synthesis and prevention of the viral infection of cells. The immunomodulating effects include enhancement of foreign antigen presentation by human leukocyte antigen (HLA) I and II to the immune system, activation of NK cells and other immune cells and increased cytokine production. IFN-α is obtained by two main methods. It can be either purified from human lymphoblastoid cells, which have been stimulated by Sendai virus, or produced using recombinant molecular biology in *Escherichia coli*. In the latter case, the gene encoding one of the human subtypes (α-2a or α-2b) of interferon is cloned into a bacterial expression vector and used for production. An important advance was the development of slow-release pegylated IFN-α-2a and -α-2b, which exhibit a better antiviral effect than standard interferon. Pegylated IFN is the result of a linkage between standard IFN and polyethylene glycol (PEG), which decreases the kidney clearance of IFN and therefore increases its half-life, allowing a single injection weekly. The side-effects of pegylated IFN-α-2a and -α-2b are similar to those of standard IFNs and have been described in Chapter 9.1.3.v. It is noteworthy that the rate of depression seems to be lower in patients with chronic hepatitis B than in those with chronic hepatitis C who receive pegylated IFN-α-2a or -α-2b.

Vaccine therapy

A new concept has emerged with the use of HBV vaccine as a therapeutic tool to break immune tolerance. The first attempts were made with recombinant HBsAg vaccines alone or in combination therapy. Early studies suggested a trend towards an increased rate of HBeAg seroconversion and some level of restoration of immune responses against HBV [26]. More recently, the use of a DNA vaccine approach relying on the administration of a DNA plasmid encoding for the viral envelope gene has been evaluated, as it was shown that this strategy may be more effective in the stimulation of the immune response via antigen presentation by dendritic cells [27,28]. A phase I clinical trial has been performed and will be followed by phase II evaluation [29].

Nucleoside/nucleotide analogues

Lamivudine

Lamivudine (β-L-2′,3′-dideoxy-3′thiacytidine or 3TC) is a cytidine analogue that belongs to the L-nucleoside analogue family. After cellular penetration, it is transformed into its triphosphate form by cytidine kinase. Lamivudine triphosphate has a poor affinity for cellular polymerases (i.e. mitochondrial and nuclear polymerases) and is preferentially targeted to viral polymerases, explaining its very good selectivity index [30]. This explains why lamivudine is very well tolerated by the patients and has no significant side-effects. Elimination occurs mainly by kidney filtration, explaining why lamivudine dosage should be adapted to creatinine clearance.

Lamivudine is a potent *in vitro* inhibitor of both duck and human hepadnaviruses, acts as a chain terminator of reverse transcription and has no mitochondrial toxicity. Lamivudine is a very effective inhibitor of DHBV in ducks, and HBV in chimpanzees, but only a moderate inhibitor of the woodchuck hepatitis virus (WHV) in woodchucks. Consistent with the last observation, it was observed that a prolonged 3TC treatment of primary woodchuck hepatocytes infected by WHV does not allow viral eradication. Lamivudine treatment promotes viral resistance [31]. Variants emerging during lamivudine therapy display mutations in the viral polymerase, within the catalytic domain (C-domain), which includes the YMDD motif (e.g. M204V or M204I), and within the B-domain (e.g. L180M or V173L). These mutants have a reduced replicative capacity compared with the wild-type virus. To find an alternative treatment for lamivudine-resistant patients, the susceptibility of these mutants to other drugs has been studied. Two categories of drug

have been characterized: those that present a cross-resistance pattern with lamivudine, such as the pyrimidine analogues, i.e. emtricitabine or clevudine, and those that are active against lamivudine-resistant mutants, such as the purine analogues, i.e. adefovir, tenofovir and entecavir. Details on these drugs follow.

Emtricitabine

Emtricitabine (β-L-2′3′-dideoxy-5′fluoro-3′thiacytidine or FTC) is a 5-fluoro-oxathiolane derivative, closely related to lamivudine [32]. Not surprisingly, it exhibits a similar potency as an inhibitor of HBV replication *in vitro* and *in vivo*. However, the same profile of resistance has been observed *in vitro*, as well as in patients treated with emtricitabine who select for the same drug-resistant mutants as those treated with lamivudine. The drug is currently in phase III trial for the treatment of chronic hepatitis B [33].

Clevudine

Clevudine (2′-fluoro-5-methyl-β-L-arabinofuranosyluracil or L-FMAU), a novel β-L-nucleoside analogue derived from deoxythymidine (TTP), is a potent inhibitor of HBV replication in HepG2.2.15 cells and has a low *in vitro* cytotoxicity [34]. In this cell line, L-FMAU inhibits HBV replication without affecting the host DNA synthetic machinery. In contrast to D-FMAU and D-FIAU, L-FMAU does not decrease mitochondrial DNA content and function and is not incorporated in cellular DNA. L-FMAU exhibits antiviral activity *in vivo* in the duck and woodchuck model. Interestingly, L-FMAU is a weak inhibitor of reverse transcriptase activity, but mainly an inhibitor of DNA-dependent DNA polymerase activity. Phase II clinical trials have been performed; the drug has been approved recently in Korea.

Adefovir dipivoxil

Adefovir dipivoxil [9-(2-phosphonolmethoxyethyl) adenine or PMEA] is an acyclic phosphonate nucleotide analogue of adenosine monophosphate. Unlike nucleoside analogues, it does not require the first of three phosphorylation steps for conversion to the active triphosphate form. Adefovir diphosphate, the active metabolite of adefovir, is a potent inhibitor of HBV polymerase activity and viral replication in human hepatoma cells lines stably transfected with HBV and in primary duck hepatocytes infected with DHBV [35]. The antihepadnaviral activity of adefovir dipivoxil was also demonstrated *in vivo*, in the duck model and in woodchucks chronically infected with WHV. Although adefovir dipivoxil is a more potent inhibitor of DHBV replication than lamivudine in experimentally infected ducklings and primary duck hepatocytes, it fails to prevent cccDNA synthesis and accumulation [36]. The most important feature of adefovir dipivoxil resides in its capacity to inhibit the replication of lamivudine-resistant mutants. However, with prolonged administration of the drug, resistant mutants may emerge: rtA181V and rtN236T in the polymerase gene [37,38].

Adefovir is also eliminated by the kidney. Clinical studies have shown a dose-dependent toxicity on kidney tubules, which causes hypophosphoraemia and increased blood creatinine level. Adefovir dipivoxil dosage should also be adapted to creatinine clearance.

Entecavir

Entecavir, also known as BMS-200475, is a cyclopentyl guanosine analogue. It is both a highly potent inhibitor of HBV replication in hepatoma cell lines and among the most potent antiviral agents against WHV [39]. In chronically infected woodchucks, long-term antiviral therapy with entecavir leading to control of viral replication allowed delay in the onset of hepatocellular carcinoma [40]. This compound inhibits the priming and elongation of minus strand DNA synthesis as well as DNA-dependent DNA polymerase by its incorporation in the DNA strand in exchange for the natural dGTP [41]. Cross-resistance testing in tissue culture showed that entecavir exhibits a reduced inhibitory activity against lamivudine-resistant mutants [42]. Furthermore, it was shown that the first cases of entecavir resistance occurred in patients who were treated for lamivudine failure, with the entecavir resistance mutations in the viral polymerase adding up on a background of lamivudine resistance [43].

Tenofovir

Tenofovir disoproxil fumarate is the prodrug of tenofovir (PMPA). Tenofovir is active *in vitro* and *in vivo* against both wild-type and lamivudine-resistant strains of HIV and HBV [44]. This antiviral profile makes its use very interesting in HIV–HBV coinfected patients.

Telbivudine

Telbivudine (β-L-2′-deoxythymidine) is an orally bioavailable L-nucleoside with potent anti-HBV activity *in vitro* and in the woodchuck hepadnavirus model, and a favourable preclinical toxicological profile [45,46].

Combination of drugs

The concept of combination therapy in chronic hepatitis B virus infection is becoming a critical issue to overcome the problem of persistence and selection of drug-resistant mutants [16,47]. To be suitable, combination of drugs must achieve at least an additive and, in the best case, a synergistic effect and prevent or delay the occurrence of drug resistance. The use of a combination should also allow reduction in the dosage of each drug, thus reducing the risk of toxicity. The combination of polymerase inhibitors is one of the potential approaches. To obtain a synergistic antiviral effect, a combination of nucleoside analogues exhibiting different mode of actions (antipriming, anti-elongation, purine analogues, pyrimidine analogues) is expected to be the best option. A few studies have shown that the combination of lamivudine with penciclovir and/or adefovir may synergistically inhibit DHBV replication in primary duck hepatocyte cultures. This should decrease on a statistical basis the risk of selection of polymerase mutants. The combination of compounds with different patterns of viral resistance will also be required to

further decrease the risk of selecting multiple drug-resistant mutants [48,49].

Treatment of the clinical forms of chronic hepatitis B

Wild-type virus infection, i.e. HBeAg-positive chronic hepatitis B

In this setting, the goal is to achieve HBe seroconversion, which usually results in remission of the liver disease. There are currently two treatment options: the use of a finite course of standard or pegylated IFN or long-term therapy with nucleoside analogues. The choice should depend on the evaluation of factors predictive of treatment response, the past history of the patient (contraindications to IFN for instance), his/her lifestyle, the desire for a pregnancy, as well as the personal choice of the patient (Table 1).

Results of standard IFN-α

Administration of standard IFN induces a sustained response, defined by HBe seroconversion 24 weeks after treatment, in 20–40% of patients depending on patient characteristics, while only 5–10% of patients seroconvert in the placebo group [50,51]. Patients with high ALT levels, a high histology activity index (HAI) score and low HBV DNA levels have a higher chance of HBe seroconversion (> 40%). Response is marked by the clearance of serum HBV DNA and an increase in ALT levels during the second or third month of therapy, which reflects the immunological response leading to clearance of the virus. Clearance of HBsAg and seroconversion to anti-HBs is a late event; the percentage of patients who became HBsAg negative after seroconverting to anti-HBe has varied widely (7–65%) for follow-ups of 3–4 years [52,53]. Studies on survival and the cost–benefit of therapy, based on models predictive of the likely clinical outcome and related medical expenses, have also shown that interferon is able to prolong life in patients with chronic hepatitis B who have HBeAg in their serum. Furthermore, benefits exceed costs when an evaluation of life expectancy is included in the analysis [54,55]. The European consensus conference recommended using a regimen of 5 MU daily or 10 MU thrice weekly for 24 weeks [20]. However, because of the frequency of side-effects at these high doses of IFN, 5–6 MU of IFN thrice weekly may be an optimal choice to allow the continuation of therapy. Several studies have suggested that, in patients who present a virological response with an HBV DNA level below 10^5 copies/mL, it is recommended to continue IFN therapy until HBe seroconversion. It was likewise suggested to continue therapy 2–3 months after seroconversion to limit the risk of reactivation after treatment withdrawal.

Side-effects are frequent and numerous, but usually mild and reversible after treatment withdrawal. The most frequent is a flu-like syndrome consisting of fever, arthralgia, headache and shivering; it is usually well controlled by paracetamol prescription. Other side-effects are asthenia, weight loss, alopecia, sleep disorders, mood disorders, concentration disorders and skin dryness. Psychiatric symptoms may be serious. Depression can occur in 10% of patients and should be treated as early as possible to avoid severe consequences (i.e. suicide attempt). Mental function may decompensate if the patient had a pre-existing psychosis. Thyroiditis with either hypo- or hyperthyroid syndrome may develop, although less frequently than in hepatitis C patients. Pregnancy is a contraindication for IFN therapy.

Results of pegylated IFN-α

In a phase II clinical trial, administration of pegylated IFN for 24 weeks was superior to that of standard IFN in terms of HBe seroconversion (37% vs. 25%) [56]. Subsequently, two other phase III trials have evaluated the antiviral effect of pegylated IFN-α-2a or -2b administration for 48 weeks and showed an HBe seroconversion rate of approximately 30% 6 months after treatment [57,58]. Interestingly, an HBs seroconversion rate of 3–5% was observed at the end of follow-up, while HBsAg negativity was observed in up to 7% of patients. Pretreatment predictive factors for HBe seroconversion were high ALT levels [> 5 × upper limit of normal (ULN)], low HBV DNA levels (< 10^7 copies/mL) and infection with HBV genotype A or genotype B.

Tolerance of pegylated IFN-α was generally similar to that of standard IFN, and side-effects were similar in nature and frequency. Flu-like syndrome, inflammatory skin reaction at the injection site and neutropenia were more frequent with pegylated IFN than with standard IFN. Depression appears to be less frequent in chronic hepatitis B patients than in hepatitis C patients receiving pegylated IFN.

Table 1 Treatment of HBeAg-positive chronic hepatitis B.

	PEG-IFN	Lamivudine	Adefovir	Entecavir
Viral suppression	4.5 log10 copies/mL	5–6 log10 copies/mL	3–4 log10 copies/mL	6–7 log10 copies/mL
HBe seroconversion	30%	15–20% at 1 year 25–30% at 2 years	10–15% at 1 year	20% at 1 year 30% at 2 years
Predictive factors	High ALT levels Low HBV DNA levels	High ALT levels	High ALT levels	?
Side-effects	+	–	–	–
Resistance	No resistance but non-response	20% per year	20% at 4 years	0% at 2 years

Results of lamivudine administration

Several phase III trials have evaluated the antiviral efficacy of lamivudine administration in patients with HBeAg-positive chronic hepatitis B [59–61]. Lamivudine presents several advantages: it is administered orally, associated with an excellent safety profile and rapid antiviral effect. Viral load declines by 3–5 log10 copies/mL after 1 year of therapy compared with baseline values. The antiviral effect is accompanied by a significant decrease in ALT levels and an improvement in the HAI. An improvement in liver fibrosis has also been observed during lamivudine therapy [62]. However, the primary goal of therapy, i.e. HBe seroconversion, is obtained in only approximately 20% of patients after 1 year of treatment. The rate of HBe seroconversion is significantly higher than in patients receiving placebo (5–10%).

Continuous lamivudine therapy is indicated in patients who do not seroconvert. It avoids rebounds of viral replication and exacerbations of liver disease. Prolonged lamivudine therapy is associated with an increased number of patients who undergo HBe seroconversion, reaching approximately 50% after 4 years of therapy [63]. In contrast to IFN, no ALT flares occur at HBe seroconversion induced by lamivudine. The durability of HBe seroconversion is tightly linked to the duration of lamivudine therapy after seroconversion. When lamivudine therapy is stopped just after seroconversion, most patients revert to HBeAg. In contrast, when lamivudine is continued for at least 6 months after seroconversion, viral reactivation and HBeAg reversion occur in only approximately 20% of the patients. The only predictive factor for HBe seroconversion at baseline is the level of serum ALT. In patients with ALT higher than $3 \times$ ULN or even $5 \times$ ULN, the likelihood of HBe seroconversion after 1 year of therapy is significantly increased [64].

The major problem with long-term lamivudine therapy is the occurrence of drug resistance. The spontaneous variability of the HBV genome and the slow kinetics of viral clearance are the biological basis for the selection of drug-resistant mutants. The main mutations conferring resistance are located within the YMDD motif in the C-domain of the viral polymerase: M204I or M204V mutants. These mutations can be accompanied by other mutations in the B-domain of the viral polymerase, i.e. V173L and L180M, named compensatory because they provide a higher replication capacity than the YMDD mutants [65]. The results of phase III clinical trials and of cohort studies have shown an incidence of lamivudine resistance of approximately 20% per year [66]. Lamivudine resistance develops in up to 70% of patients after 4 years of therapy [67]. Lamivudine resistance is associated with an increase in viral load (viral breakthrough), which is followed by an increase in ALT levels (biochemical breakthrough), a reduced HBe seroconversion rate and a progression of liver disease. The reactivation of HBV under therapy recapitulates disease; although the clinical/biochemical breakthrough is often delayed, ultimately, all patients who develop resistance exhibit a recrudescence of hepatitis within 24–32 months from the viral breakthrough. In some patients, especially those with liver cirrhosis or severe fibrosis, lamivudine resistance may be associated with a severe and acute exacerbation of liver disease, which may cause liver failure [67–69]. It is therefore necessary to make an early diagnosis of drug resistance to adapt antiviral therapy prior to the degradation of liver functions [69,70].

Results of adefovir dipivoxil administration

A large phase III trial has evaluated the antiviral efficacy of adefovir dipivoxil administration in 515 patients with HBeAg-positive chronic hepatitis B [71]. After 48 weeks of therapy, the median viral load decline was approximately 3.5 log10 copies/mL in comparison with pretreatment values. HBe seroconversion was achieved in only a minority of patients, i.e. 12% in the group of patients receiving adefovir dipivoxil 10 mg daily vs. 6% in the placebo group. Normalization of ALT levels was observed in 48% of patients receiving adefovir vs. 16% in the placebo group. An improvement in liver histology was observed in 53% of patients vs. 25% in the placebo group. With a daily dose of 10 mg, tolerance was comparable to placebo. After 48 weeks of therapy, no genotypical resistance was observed. Extended administration of adefovir dipivoxil showed an increased rate of HBe seroconversion over time, and an increasing number of patients showed a significant decline in viral load. However, a longer follow-up in patients with HBeAg-negative chronic hepatitis B has shown the occurrence of adefovir resistance starting from the second year of treatment (see below).

Recent data of adefovir administration for 5 years showed probabilities of HBeAg loss of 60% and HBe seroconversion of 48%. Four patients (2%) had an HBs seroconversion. HAI and fibrosis scores improved in 67% and 60% of patients, respectively. Adefovir resistance mutations developed in 20% of patients after 4 years.

Results of combination therapy

Several studies have evaluated the efficacy of a combination of PEG-IFN-α-2a or -2b with lamivudine in comparison with PEG-IFN alone and/or lamivudine alone [57,58]. Treatment was administered for 48 weeks, and endpoints were analysed 24 weeks after treatment. During therapy, there was a benefit in the combination by comparison with the single treatment in terms of viral load decline. The rate of lamivudine resistance was lower in patients who received the combination of lamivudine with PEG-IFN by comparison with lamivudine monotherapy. However, 24 weeks after therapy, the rate of HBe seroconversion was similar in patients who received PEG-IFN alone or the combination with lamivudine, i.e. approximately 30%. The HBe seroconversion rate was lower in patients who received lamivudine monotherapy, i.e. approximately 20%. These results are also in agreement with those of combination studies with standard IFN and lamivudine, which did not show an added benefit of the combination. New studies are clearly warranted to evaluate the combination of PEG-IFN and lamivudine or other antivirals with different schedules of administration.

The few published studies of the combination of lamivudine and adefovir dipivoxil in naive patients in comparison with lamivudine alone have analysed virological endpoints after a short-term treatment of 48 weeks. There was no significant difference in terms of viral load between the two groups. The rate of lamivudine resistance was lower in patients who received the combination of drugs. The major drawback of these studies is the absence of a comparative arm with adefovir dipivoxil monotherapy. Long-term combination studies are required to determine whether a combination of nucleoside analogues will show an added benefit in terms of prevention of drug resistance.

Results of new drugs: entecavir, telbivudine, tenofovir, emtricitabine

Entecavir

Entecavir was evaluated in phase II trials [73,74] and, more recently, in three controlled phase III trials involving 1633 patients with chronic HBV infection, detectable HBV DNA, persistently elevated ALT levels and chronic inflammation on liver biopsy. In two randomized studies involving nucleoside-naive patients, entecavir administered 0.5 mg orally once daily for 52 weeks was superior to lamivudine (100 mg orally once daily for 52 weeks) on the primary efficacy endpoint of histological improvement and on secondary endpoints, such as the reduction in viral load and normalization of ALT. After 2 years of treatment, 81% of patients receiving entecavir had a viral load below 300 copies/mL vs. only 39% of patients receiving lamivudine, 31% seroconverted to anti-HBe vs. 26% in the lamivudine group, and 5% showed a clearance of HBsAg vs. 3% in lamivudine-treated patients [75].

In lamivudine-refractory patients, entecavir administered at 1 mg once daily was superior to lamivudine in terms of viral load reduction and histological improvement. Entecavir was approved recently, first by the US Food and Drug Administration (FDA) and then in Europe, for the treatment of chronic HBV infection in adults with evidence of active viral replication and evidence of either persistent elevation in serum ALT or histologically active disease.

Entecavir resistance mutants have been rarely identified in treatment-naive patients; they have been described, mostly in patients with lamivudine resistance [43]. Approximately 9% of lamivudine-resistant patients treated with entecavir develop resistance to entecavir after 2 years of therapy. The resistant mutants are then resistant to both lamivudine and entecavir [76].

Telbivudine

Safety, antiviral activity and pharmacokinetics of telbivudine have been assessed in 43 adults with HBeAg-positive chronic hepatitis B [77]. This placebo-controlled, dose escalation trial investigated six telbivudine daily dosing levels (25, 50, 100, 200, 400 and 800 mg/day); treatment was given for 4 weeks. Telbivudine was well tolerated at all dosing levels, with no dose-related or treatment-related clinical or laboratory adverse events. Marked dose-related antiviral activity was evident, with a maximum at telbivudine doses of 400 mg/day or more. In the 800 mg/day cohort, the mean HBV DNA reduction was 3.75 log10 copies/mL at week 4, comprising a 99.98% reduction in serum viral load. Subsequently, large phase III studies have shown the superiority of telbivudine compared with lamivudine in the suppression of viral load (by 6.5 log10 vs. 5.5 log10) and improvement in liver histology [78]. Telbivudine resistance was observed in approximately 5% of patients after 1 year of therapy. The resistance mutations were the same as those responsible for lamivudine resistance, i.e. M204I mutation in the viral polymerase. Telbivudine has been approved in the US at the end of 2006.

Tenofovir

Tenofovir is already approved for the treatment of HIV infection. Its anti-HBV activity has been studied mainly in HIV–HBV coinfected patients. In this patient population, tenofovir administration significantly decreased HBV load in both lamivudine-naive and lamivudine-resistant patients [79–82]. Several non-randomized studies suggest that tenofovir may be more potent than adefovir in reducing HBV load [83]. Several phase III trials are ongoing to compare the anti-HBV activities of tenofovir and adefovir in HBV monoinfected patients and in HIV–HBV coinfected patients.

Emtricitabine

Emtricitabine was evaluated in phase II and phase III trials. Ninety-eight patients were randomized to receive emtricitabine at 25 mg, 100 mg or 200 mg daily for 48 weeks and then 200 mg until week 96. The dose of 200 mg daily gave the best results. After 2 years, 53% of patients had serum HBV DNA below 4700 copies/mL, 33% seroconverted to anti-HBe and 85% had normal ALT levels. Resistance mutations were observed in 18% of patients after 96 weeks of therapy [72].

Predictive factors of treatment response

Pretreatment factors predictive of therapy response have been identified. They may be useful for the decision to treat and the choice of drug to use. The results of clinical trials have shown that high ALT values ($> 3 \times$ ULN or $> 5 \times$ ULN) and low viral load ($< 10^7$ copies/mL) are predictive of a favourable response to standard or pegylated IFN. Recent studies suggested that HBV genotypes A (vs. D) and B (vs. C) are associated with a better response to IFN therapy. In patients treated with nucleoside analogues (lamivudine or adefovir), the only established baseline predictor of response is the level of ALT values. The chance of HBe seroconversion is significantly higher when ALT levels are greater than 3 or $5 \times$ ULN.

The collation of these predictive factors as well as the past history of the patient (previous non-response to IFN, side-effects to a previous course of IFN, contraindications to IFN, lifestyle of the patient and professional obligations, willingness

for a pregnancy) are critical for decision-making. In young patients, a finite course with PEG-IFN may be proposed especially for those who have predictive factors for a favourable response. In patients who present a low chance of response to IFN, long-term therapy with a nucleos(t)ide analogue should be proposed.

Precore mutant infection, i.e. HBeAg-negative chronic hepatitis B

Standard IFN administration was the only treatment available until the end of the 1990s. Trials using 6–12 months of IFN therapy showed that, regardless of IFN dosage, there was a good response while on therapy (inhibition of HBV DNA, normalization of ALT), but relapses after therapy were common and observed in a majority of patients. These initial studies therefore indicated that therapy should not rely on courses of IFN shorter than 1 year. Long-term administration for at least 2 years showed clinical benefit in terms of viral suppression and ALT normalization. Approximately 30% of patients may present a sustained response after treatment withdrawal when the IFN course was sufficiently long to maintain the suppression of viral replication [84,85]. However, side-effects and poor tolerance of IFN administration limit its prolonged use in this form of chronic hepatitis B.

Lamivudine administration has been evaluated in patients with HBeAg-negative chronic hepatitis B in randomized trials and in cohort studies. Lamivudine given at a dose of 100–150 mg daily for 52 weeks induces a marked suppression of serum HBV DNA accompanied by normalization of ALT in approximately 80% of patients, together with liver histology improvement. However, most treated patients do not clear HBsAg and, therefore, show disease reactivation after discontinuing therapy [86]. Long-term therapy is therefore recommended. Unfortunately, prolonged lamivudine therapy is hampered by the emergence of drug resistance. Long-term lamivudine studies have shown that, after reaching a peak between 6 and 12 months of therapy, the response rate decreases because of virological breakthroughs associated with the emergence of lamivudine-resistant HBV mutants. Resistance occurs through mutations at the YMDD locus, as for HBeAg-positive patients. In a study, the virological response diminished from 68% at month 12 to 52% and 41.6%, respectively, at months 18 and 24 of therapy [68]. The virological breakthroughs were not uneventful, as ALT flares were observed in 6 of 11 patients who experienced a virological breakthrough, and one of these patients became jaundiced. Long-term studies showed that the antiviral efficacy and histological improvement are progressively lost with time, as the prevalence of resistance mutations increases [87]. After 3–4 years of therapy, lamivudine resistance outweighs the initial clinical benefit [88–91]. In a single-centre study in Greece, ALT levels increased progressively with the duration of infection with the lamivudine-resistant mutants: no patient with lamivudine resistance mutations for 24 months had normal ALT levels [90]. Likewise, in a multicentre study, only 5% of the patients with lamivudine-resistant mutants for 12–24 months had normal ALT levels compared with 72% of those without YMDD mutants [91]. In a retrospective nationwide analysis of lamivudine therapy in Italy, the development of clinically important events after virological breakthroughs depended on the severity of the underlying liver disease; severe hepatitis flares at the emergence of lamivudine-resistant mutants were noted in patients with Child B and C cirrhosis but not in patients with non-cirrhotic chronic hepatitis [89]. These studies confirmed that severe exacerbations of liver disease may occur in patients with precore mutant infection in whom lamivudine resistance develops, especially in those who had liver cirrhosis prior to therapy [68,69].

In HBeAg-negative chronic hepatitis, adefovir dipivoxil administration has shown similar results after 1 year of therapy compared with the treatment of HBeAg-positive patients [92]. At week 48, 64% of patients had improvement in histological liver abnormalities, compared with 33% of patients in the placebo group ($P < 0.001$). Serum HBV DNA levels were reduced to < 400 copies/mL in 51% of patients in the adefovir dipivoxil group (63 of 123) and in 0% in the placebo group ($P < 0.001$). The median decrease in log-transformed HBV DNA levels was greater with adefovir dipivoxil treatment than with placebo (3.91 vs. 1.35 log10 copies/mL , $P < 0.001$). ALT levels had normalized at week 48 in 72% of patients receiving adefovir dipivoxil (84 of 116), compared with 29% of those receiving placebo (17 of 59, $P < 0.001$) [93]. A longer duration study for 144 weeks showed a median decrease in serum HBV DNA of 3.47 log10 copies/mL at 96 weeks and 3.63 log10 copies/mL at week 144 [93]. HBV DNA was below 1000 copies/mL in 71% and 79% of patients after 96 and 144 weeks respectively. Interestingly, in the majority of patients who were switched from adefovir to placebo, the benefit of treatment was lost, indicating that antiviral therapy with nucleoside analogues has to be prolonged in this patient population to avoid viral reactivation and ALT flares. Resistance mutations rtN236T and rtA181V were identified in 3% and 5.9% of patients after 96 and 144 weeks respectively. Side-effects after 144 weeks were similar to those observed at week 48. Recent studies showed the clinical response after 5 years of therapy: 70% of patients have a suppression of viral load accompanied by ALT normalization and histology improvement, while 29% of patients developed adefovir-resistant mutations [94].

Among patients with HBeAg-negative chronic hepatitis B who were not previously treated with a nucleoside analogue, the rates of histological improvement, virological response and normalization of ALT levels were significantly higher at 48 weeks with entecavir than with lamivudine. The safety profile of the two agents was similar, and there was no evidence of viral resistance to entecavir during the study period [95].

One study has evaluated the efficacy of a combination of PEG-IFN-α-2a with lamivudine in comparison with PEG-IFN alone and lamivudine alone [96]. Treatment was administered for 48 weeks, and endpoints were analysed 24 weeks after treatment.

Table 2 Treatment of HBeAg-negative chronic hepatitis B.

	PEG-IFN	Lamivudine (100 mg/day)	Adefovir (10 mg/day)	Entecavir
Long-term therapy	+	+ (continuous)	+ (continuous)	+ (continuous)
Side-effects	+	–	–	–
Resistance	–	20% per year	29% at 5 years	0% at 2 years
Sustained response	≤ 30%	30–35% at 3 years	> 70% at 5 years	> 90% at 2 years
Clearance of HBsAg	+	–	–	–
Cost	++	±	+	+

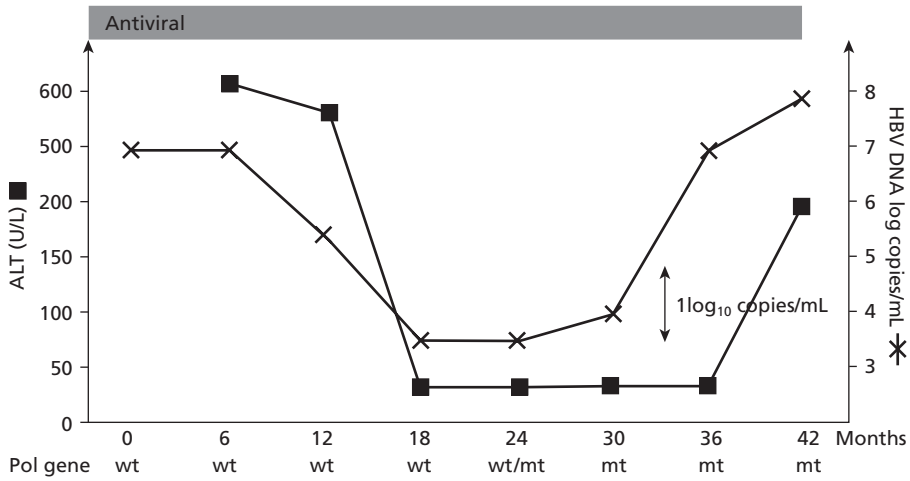

Fig. 4 Viral breakthrough and drug resistance. wt, wild-type HBV polymerase gene sequence; mt, drug-resistant HBV mutant.

During therapy, there was a benefit in the combination in comparison with the single treatment in terms of viral load decline. The rate of lamivudine resistance was lower in patients who received the combination of lamivudine with PEG-IFN in comparison with lamivudine monotherapy. However, 24 weeks after therapy, there was no difference in the rate of ALT normalization (approximately 60%) or virological response (approximately 20% of patients) between the groups who received PEG-IFN alone or in combination with lamivudine. The two groups of patients who received PEG-IFN had a better response rate 24 weeks after therapy than the group who received lamivudine alone. In view of the fluctuating nature of HBeAg-negative disease, long-term follow-up studies are necessary to determine whether sustained responses (maintained 6–12 months after therapy) herald permanent responses or represent spontaneous remissions of the disease.

A summary of treatment options in HBeAg-negative chronic hepatitis B is shown in Table 2.

Patients with drug resistance

The rescue treatment of patients with drug resistance has improved significantly in recent years. Indeed, new drugs are available, and the knowledge of the *in vitro* cross-resistance profile has provided the rationale for their use in patients with treatment failure. HBV resistance to antivirals can be defined at different levels (Fig. 4): (i) genotypic resistance is the detection of polymerase gene mutations known to confer resistance to the drug; (ii) virological breakthrough is defined by an increase in HBV DNA of at least 1 log10 copies/mL compared with the lower value during treatment, associated with the presence of resistance mutations; it usually follows genotypic resistance; (iii) clinical failure is defined by viral breakthrough, increase in ALT levels and subsequent progression of liver disease.

Lamivudine resistance

Mutations conferring resistance to lamivudine are mainly located in the C-domain of reverse transcriptase within the YMDD motif, i.e. M204V or M204I, and may be associated with compensatory mutations in the C-domain, i.e. V173L or L180M (Fig. 5). After 1 year of treatment, lamivudine-resistant mutants emerged in 32% of patients, increasing to 38% after 2 years, 53% after 3 years and 66% after 4 years [67] (see also Fig. 6). *In vitro* studies showed that the main lamivudine resistance mutants remain sensitive to adefovir and tenofovir and have a reduced susceptibility to entecavir [16,47]. Adefovir has a proven clinical benefit in the treatment of lamivudine resistance with a significant inhibition of viral mutant replication and improvement in liver function after 1 year of therapy. Several studies compared the addition of adefovir to ongoing lamivudine with the switch from lamivudine to adefovir [97,98]. After 48 weeks of therapy, there was no difference in viral load decline in these

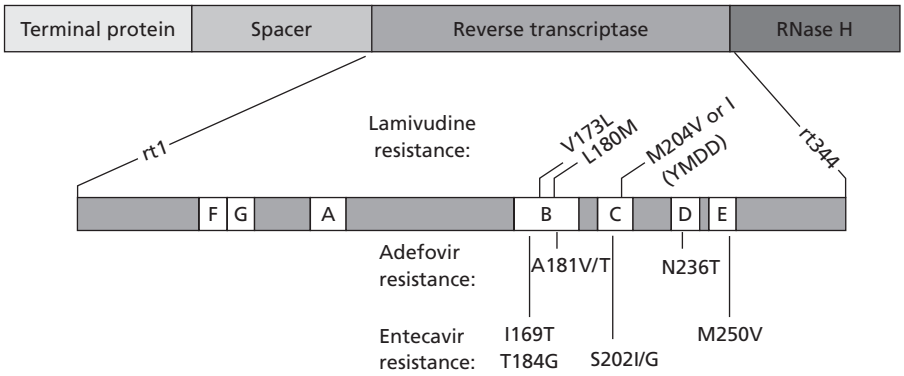

Fig. 5 Polymerase gene mutations conferring drug resistance.

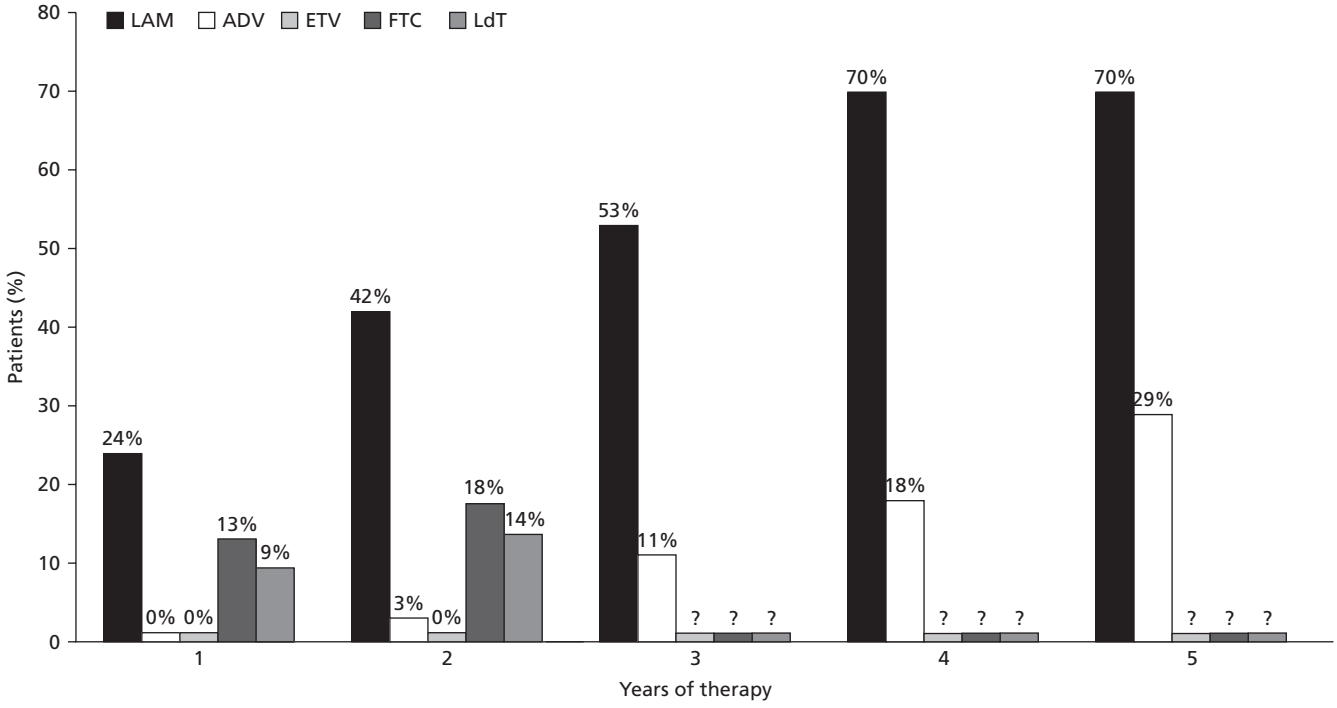

Fig. 6 Incidence of resistance in treatment-naive patients. LAM, lamivudine; ADV, adefovir; ETV, entecavir; FTC, emtricitabire; LdT, telbivudine.

two treatment groups. Indeed, in most clinical trials of adefovir administration for lamivudine failure, virogical endpoints were examined at week 48 of therapy, while adefovir resistance starts to occur during the second year. Because of the lack of cross-resistance between the two drugs, there is now a consensus among experts that adefovir should be added to lamivudine in patients with lamivudine failure to prevent or delay the subsequent selection of new resistant mutants.

Entecavir administration has also been evaluated in patients with lamivudine failure at a higher dose of 1 mg daily (compared with 0.5 mg in naive patients) because of the reduced susceptibility of the lamivudine resistance mutant to entecavir *in vitro*. Entecavir administration was associated with a significant decline in viral load in these lamivudine-refractory patients [98]. Of note, the only cases of entecavir resistance described so far have been observed in lamivudine-resistant patients, suggesting a certain level of cross-resistance between these two drugs, leading to the selection of mutants resistant to both drugs. With the current knowledge, it is therefore questionable to use entecavir in patients with prior lamivudine resistance, as subsequent selection of entecavir-resistant mutants may occur in as many as 38% of these patients after 3 years of therapy.

Adefovir resistance

Adefovir 10 mg/day is associated with the emergence of drug-resistant mutants in less than 3% of patients after 2 years of therapy, 11% after 3 years, 18% after 4 years and 29% after 5 years (Fig. 6). Resistance to adefovir is conferred by the selection of a N236T mutation in the D-domain of the HBV polymerase or a A181V mutation in the B-domain of the polymerase [37,38,48] (Fig. 5). *In vitro*, the N236T mutation is sensitive to both lamivudine and entecavir; the A181V showed

a decreased susceptibility to lamivudine. Few reports showed the benefit of lamivudine administration in patients with adefovir resistance.

Entecavir resistance

Entecavir resistance has so far been observed only during the therapy of lamivudine-refractory patients. The resistance rate appears to be approximately 10% per year in patients with lamivudine failure. The main resistance mutations are rtT184G, rtS202I and rtM250V on a background of lamivudine resistance mutations [43] (Fig. 5). These mutants are resistant to lamivudine. One *in vitro* study showed their susceptibility to adefovir and tenofovir. Clinical data are awaited to provide recommendations for the treatment of entecavir-resistant patients.

Monitoring of antiviral therapy

The risk of the emergence of drug resistance mandates the monitoring of antiviral therapy when patients are treated with nucleos(t)ides. The rationale for the timing of monitoring derives from the consideration that the biochemical breakthrough usually occurs with a delay of several weeks after the virological breakthrough and that the clinical impact is usually different in non-cirrhotic than in cirrhotic disease. In the former, the ALT breakthrough most usually has no major clinical consequences; in the latter, it may precipitate liver failure and death. Monitoring should be performed by measuring the viral load with quantitative HBV DNA testing whenever possible and affordable.

Early during therapy (week 8 or 12), viral load monitoring allows the assessment of the initial response, which may predict the treatment outcome. In HBeAg-positive patients treated with lamivudine or adefovir dipivoxil, the magnitude of HBV DNA decline early on during therapy is associated with a greater tendency towards HBe seroconversion [100]. The antiviral response at week 24 of therapy was also found to be a predictor of subsequent efficacy (HBeAg loss, HBV DNA < 200 copies/mL, ALT normalization and viral breakthrough) in patients treated with lamivudine or telbivudine [78]. In the 5-year study of adefovir dipivoxil administration in HBeAg-negative chronic hepatitis, patients with a viral load lower than 3 log10 copies/mL after 1 year of therapy had a significantly lower risk of developing resistance by year 3 of treatment (< 3%) compared with a risk of 26% and 66% for those having a viral load between 3 and 6 log10 copies and > 6 log10 copies/mL respectively [94].

During long-term treatment, a 3- or 6-monthly assessment of viral load and serological markers is required to monitor antiviral treatment efficacy and to determine whether the response is maintained or drug resistance is likely to occur. In patients with moderate liver disease, 6-monthly monitoring might be sufficient during the first 2 years of treatment when using drugs with a slow rate of resistance, but more frequent monitoring may be necessary thereafter when the risk of resistance increases significantly. In patients with advanced liver disease, 3-monthly monitoring is required to detect incoming viral drug resistance and thus provide immediate rescue with alternative antiviral therapy prior to a potentially dangerous flare of ALT levels.

HBV drug resistance is defined by the confirmed increase in viral load by at least 1 log10 by comparison with the nadir value during therapy [65] (Fig. 4). It is important to assess drug compliance, as any drug interruption may lead to a rebound of viral replication and ALT flares. The detection of polymerase mutations by sequencing, line probe assay, DNA chip technologies or other tools will be important in the future to target new treatment to the profile of mutations in the polymerase gene [69,101]. Indeed, the cross-resistance profile is different from one mutant to another [102,103].

New tools may become available in the future to monitor the efficacy of antiviral therapy, such as the quantification of intrahepatic cccDNA or the quantification of serum HBsAg as a surrogate marker [13–15]. Furthermore, with the development of new drugs and the increasing complexity of the resistance profile, phenotypic assays to determine the drug susceptibility of the clinical isolates may prove useful to tailor antiviral therapy to the virological situation of the patient, as already shown in HIV [102,103].

Special forms of chronic hepatitis B

Liver cirrhosis

In patients with compensated cirrhosis, the risk of the development of complications including decompensation and development of hepatocellular carcinoma is significantly higher in those who maintain a high level of viral replication and ALT [18]. The advent of nucleos(t)ide analogues that control HBV replication has significantly changed the management of these patients. It was demonstrated recently in a phase III trial of lamivudine in cirrhotics that control of viral replication decreases the risk of liver disease progression, as assessed by the Child–Pugh score and compared with the placebo group [104]. Furthermore, in patients who developed lamivudine resistance, there was a higher risk of liver disease progression, although it remained lower than in the placebo group, at least during the study period. Tolerance of the drug was very good. The results of this study demonstrate the clinical benefit of viral replication suppression and advocate treatment strategies aiming at maintaining viral suppression in the context of liver cirrhosis.

In patients with decompensated liver cirrhosis, the use of IFN-α is limited by the risk of severe side-effects including severe neutropenia and infection, thrombopenia and the hazard of ALT flares upon HBe seroconversion induced by IFN, which may lead to rapid liver failure. The development of nucleoside analogues, whose mode of action is mainly to control viral replication, for the therapy of chronic HBV infection has changed the management of these patients. Several studies have shown that lamivudine therapy of patients with decompensated liver

cirrhosis is associated with control of HBV replication, improvement in ALT levels and liver function tests (bilirubin, albumin and prothrombin time), as well as a significant clinical improvement assessed by the Child–Pugh score [105–107]. Tolerance was also very good in this setting. Many patients had a marked clinical improvement and, therefore, were withdrawn from the transplantation waiting list. However, it is important to note that lamivudine resistance may occur in the long term and may subsequently be associated with a new deterioration of liver functions. In these patients, it is therefore mandatory to monitor viral load closely and adapt antiviral therapy prior to the progression of the disease.

Adefovir dipivoxil administration was also evaluated in a large cohort of cirrhotic patients who were candidates for transplantation and had developed lamivudine resistance [108]. It was shown that adefovir dipivoxil therapy, by controlling viral replication, induces a significant improvement in liver function tests. Therefore, there is a large body of evidence that nucleos(t)ide analogues should be prescribed as early as possible in patients with decompensated HBV cirrhosis. First-line therapy in this group of patients may vary from country to country depending on administrative issues related to treatment reimbursement, but some centres favour the use of a combination of lamivudine and adefovir to reduce the risk of subsequent drug resistance. The place of entecavir in this population of patients remains to be determined.

Liver transplantation (see Chapter 25.1)

It is now recommended in patients with endstage liver cirrhosis who are candidates for liver transplantation to start nucleos(t)ide analogue administration prior to transplantation to lower viral load and thus decrease the risk of HBV recurrence after transplantation, and to maintain or improve liver function while the patient is on the waiting list [109,110]. Patients should be monitored closely to diagnose viral breakthrough and allow adefovir dipivoxil to be added as soon as possible to control viral replication and allow liver transplantation. Adefovir dipivoxil therapy may also be started as first-line treatment in the pretransplant setting as the risk of resistance is lower. However, some studies suggest a lag between the start of adefovir therapy and the control of viral replication and the subsequent clinical improvement. For this reason, several centres use a combination of lamivudine and adefovir dipivoxil to rapidly improve the clinical situation and delay the risk of drug resistance while the patient is on the waiting list.

After liver transplantation, administration of HBIG and the continuation of the nucleoside analogue is recommended. With such a prophylaxis regimen, the risk of HBV recurrence in the liver graft has decreased dramatically below 10% [111].

In patients with HBV recurrence after liver transplantation, liver disease may progress very rapidly. Antiviral therapy is recommended as soon as the diagnosis of recurrence has been made [112].

HIV–HBV coinfected patients

In these patients, HBV infection is becoming a major clinical problem, as the restoration of immune response induced by highly active antiretroviral therapy (HAART) may trigger liver damage. Furthermore, antivirals used in the HAART regimen may be hepatotoxic, and some of them exhibit both anti-HIV and anti-HBV activities. The increasing choice of drugs to treat coinfected patients will help to manage these patients especially when facing problems of HIV and/or HBV drug resistance. Several antivirals are effective against both HIV and HBV, such as lamivudine, emtricitabine and tenofovir. Other drugs such as adefovir and entecavir are active only against HBV. The decision of which drug to use for therapy of chronic HBV infeition depends also on the HIV status and the requirement or not of nucleoside RT inhibitors. A specific chapter is dedicated to HIV and the liver (see Chapter 9.3).

Coinfection with hepatitis delta virus

Interferon therapy

IFN-α has been most studied in this situation. In two controlled Italian therapeutic trials of chronic hepatitis D that have included a consistent number of patients [113,114], IFN-α induced biochemical responses (normalization of ALT) while the patients were on therapy but, in the majority of responders, there was a relapse after therapy discontinuation. There was no effect of therapy on the hepatitis D virus (HDV); in most patients, the level of HDV RNA was unaffected. Specifically, liver tests became normal or improved significantly after 4 months of therapy in 42% of the patients who received 5 MU/m^2 IFN-α-2b thrice weekly for 4 months followed by 3 MU/m^2 for 8 more months. However, only eight (25%) were in remission when IFN was discontinued, and there was a relapse in all but one (3%) during the post-therapy follow-up [114]. Better on-therapy results were obtained with a more aggressive therapeutic protocol [113]. ALT normalized in 10 of 14 (71%) patients receiving 9 MU of IFN-α-2a for 48 weeks compared with 4 of 14 (29%) treated with 3 MU and 1 of 13 untreated control subjects (8%). In patients treated with 9 MU, the normalization of ALT levels was associated with marked histological improvement, and no HDV RNA was detected while they where on therapy. In five patients, the biochemical response persisted for up to 4 years; however, there was no long-term effect on HDV as HDV RNA reappeared in the serum of all responders. Overall, the data from these studies and from other controlled and uncontrolled studies including limited numbers of patients have shown that liver chemistry ameliorates in about 50% of HDV patients while on therapy, but only a minority exhibits a sustained normalization of ALT levels with clearance of HDV; in these latter patients, IgM anti-HD disappears from serum and the HBsAg is cleared within months to years with seroconversion to anti-HBs [115]. Of note, there is no clear evidence that this minority benefited from a therapeutic advantage rather than from a more benign

course of the disease; no statistically significant long-term effect of IFN on HDV has been shown by controlled study, and spontaneous long-term remissions are known to occur in the natural history of HDV disease. Indeed, in a follow-up study, the rate of spontaneous HBsAg clearance over the years was increased in HDV-positive compared with HDV-negative HBsAg carriers [115].

Nevertheless, after 2–14 years of follow-up, complete fibrosis regression and loss of HDV RNA were reported in some of the patients who had achieved a persistent biochemical response and lost IgM anti-HD with high-dose IFN therapy, all of whom had an initial diagnosis of active cirrhosis [116]. Likewise, in another study, resolution of chronic hepatitis D was reported up to 12 years after continuous IFN therapy [117]. Few data are available for the treatment of other categories of HDV carriers such as children [115] or HIV-positive patients [118].

Nucleoside analogue therapy

Famciclovir, lamivudine and adefovir, which are inactive on HDV replication but efficacious in inhibiting the helper HBV, have been tested with discouraging results. No patients with chronic hepatitis D responded to famciclovir administered at 500 mg three times a day for 6 months and then followed up for 6 months after treatment [119].

Several small trials of lamivudine have been performed in chronic hepatitis D. Five patients received oral lamivudine 100 mg daily for 12 months [120]. HBV DNA became undetectable in four patients and decreased by 5 log10 in the other but, in all, ALT levels remained abnormal, HDV RNA detectable and HBsAg positive.

In another study, a 12-month vs. a 24-month course of lamivudine 100 mg/day were compared [121]. Thirty-one patients were randomized to treatment, 11 to placebo and 20 to lamivudine for 12 months; thereafter, all were given lamivudine on an open-label basis for 12 months and followed up for a further 16 weeks. At the end of treatment, HDV RNA was negative and ALT levels normal in three patients, but only two patients remained virus free at the end of follow-up. In another study [122], eight patients with chronic hepatitis D were treated with lamivudine for at least 24 weeks, and then lamivudine was combined with high-dose IFN followed by 9 MU of IFN thrice weekly; the patients were followed up for 12 weeks after therapy. The HBsAg concentration in serum decreased in two patients. There was no significant decrease in serum HDV RNA during treatment. At the end of treatment, ALT levels had normalized in one patient and decreased in three other patients, but three of these four patients showed a biochemical rebound after withdrawal of therapy.

Recommendations for therapy of HBV–HDV coinfection

There is as yet no established therapy for chronic hepatitis D. However, as IFN-α appears to be capable of controlling inflammation in a proportion of patients, this cytokine may be used in order to slow disease progression. To achieve biochemical responses, high dosages of IFN (between 6 and 9 MU) given thrice weekly for prolonged periods (over 12 months) are recommended. Treatment should be maintained for 12 months after normalization of ALT levels.

Treated patients can lose HDV markers from serum while on therapy, but may relapse when treatment is discontinued if they remain HBsAg positive; therefore, therapy should not be discontinued prematurely on the basis of the clearance of HDV. Loss of HBsAg is a reliable marker of resolution of hepatitis D [115]. Pegylated IFNs appear to represent a logical therapeutic option for the long-term treatment required for chronic hepatitis D. Preliminary results are encouraging. In a recent study [132], a sustained clearance of HDV-RNA was obtained in 6 out of 14 (43%) patients with chronic hepatitis D treated with PEG-IFN-α-2b (1.5 μg/kg per week). Viral kinetics were predictive of the response; after 3 months of therapy, HDV-RNA was significantly lower in responders than in non-responders.

Ferenci *et al.* [124] reported the clearance of HDV RNA and a sustained clinical amelioration in a patient with HDV cirrhosis treated for 6 months with PEG-IFN-α-2a and lamivudine. However, confirmation of the efficacy of PEG-IFN in the setting of HDV infection requires larger prospective studies.

The factors determining a biochemical response are not known. The type of underlying HBV infection, whether HBeAg positive or HBeAg negative, does not influence response. Indeed, although HDV patients with concomitant HBeAg-positive HBV infection seroconverted to anti-HBe during IFN therapy, the control of HBV infection had no impact on HDV infection or disease activity [115]. Whether response may depend on the HBV or HDV genotype is unknown.

Of note, a major factor influencing the response to therapy in chronic hepatitis D, as in all forms of viral hepatitis, is the duration of the viral infection and disease, with patients with early disease responding better than those with longstanding fibrosis or cirrhosis. Therefore, the prospects of therapy for HDV infection appear to be even less encouraging in the Mediterranean area as, in this area, the spectacular decline in HDV infection fostered by the control of HBV has led to an increase in IFN-resistant fibrotic and cirrhotic forms (representing longstanding disease) over more therapy-susceptible recent forms of the disease.

Liver transplantation

Liver transplantation is a valid treatment option for endstage HDV liver disease. The risk of spontaneous reinfection is lower for HDV than for HBV. The prospect of an uneventful clinical course after transplantation was improved by the long-term administration of hyperimmune serum against HBsAg. The 5-year survival rate of 76 patients transplanted in Paris for terminal delta cirrhosis was 88%, with reappearance of HBsAg in only 9% under long-term anti-HBs prophylaxis [125]. The addition of lamivudine also helps to decrease the risk of viral recurrence in patients with replicating HBV prior to transplantation. In

another series, none of 62 HDV patients transplanted experienced a viral recurrence, of whom 48 were given HBIG after transplantation and 14 were given lamivudine before transplantation and lamivudine together with HBIG after transplantation [126].

Extrahepatic manifestations of HBV infection

Extrahepatic manifestations of HBV infection, such as periarteritis nodosa (PAN), are due to immune complexes involving viral envelope proteins. As their formation is the consequence of active viral replication, treatment of HBV-associated PAN relies on the use of antiviral therapy. This may be combined initially, especially in patients with severe symptoms, with plasmapheresis and a short course of corticosteroids to decrease the effect of the deposit of immune complexes on the artery walls [127,128]. When the clinical situation is under control, prednisone and plasmapheresis can be stopped while antiviral therapy is continued until HBe or HBs seroconversion.

Several studies have shown the clinical benefit of anti-HBV agents, including vidarabine, IFN-α, lamivudine, famciclovir and adefovir [129–133]. Indeed, the control of viral replication is accompanied by a decrease in immune complex formation and improvement in the clinical signs of vasculitis. Clearance of HBsAg and cure of the vasculitis have been reported by several investigators.

Special cases

In health-care workers chronically infected with HBV, antiviral therapy may be indicated to suppress viral load and reduce the risk of nosocomial transmission to patients.

In pregnant women, the prevention of mother-to-baby transmission usually relies on HBIG and vaccine administration to newborns at birth. However, it was shown that, in highly viraemic mothers, this may not be sufficient to provide complete prophylaxis. One study showed that lamivudine administration during the last month of pregnancy, combined with vaccination of the newborn, prompted a significant decrease in the risk of vertical transmission [134].

In children, chronic hepatitis B is usually mild because of the immunotolerant status. This may explain the relatively poor rate of HBe seroconversion observed in children treated with lamivudine [135] or standard IFN [136,137]. However, in children with chronic active hepatitis and elevated ALT levels, both drugs have shown a beneficial effect.

Conclusions

A treatment algorithm is proposed in Figure 7. Currently, patients with minimal disease, whether in the immunotolerance phase or with inactive infection, should not be treated. In patients with chronic hepatitis proven by ALT elevation and abnormal liver histology, antiviral therapy is indicated because all studies have shown that antiviral therapy decreases the risk of liver disease progression compared with the natural history of the disease. In patients who are HBeAg positive, the primary goal of antiviral therapy is to obtain an HBe seroconversion. If the patient is young and has predictive factors of favourable response, a finite course of pegylated IFN should be tried as a first-line option. In other cases (including non-responders to IFN, patients intolerant to IFN and those with factors predictive of poor response to IFN), long-term therapy with nucleoside analogues is usually needed.

In patients who are HBeAg negative, long-term therapy is required. In this situation, nucleoside analogues are better tolerated than pegylated IFN, but the therapeutic choice has to take into account the risk of drug resistance. In patients with severe liver disease, i.e. decompensated liver cirrhosis or HBV recurrence on the liver graft, one might consider combining nucleoside analogues lacking cross-resistance to provide the best chance of long-term control of viral replication and disease progression. In the situation of treatment failure, knowledge of

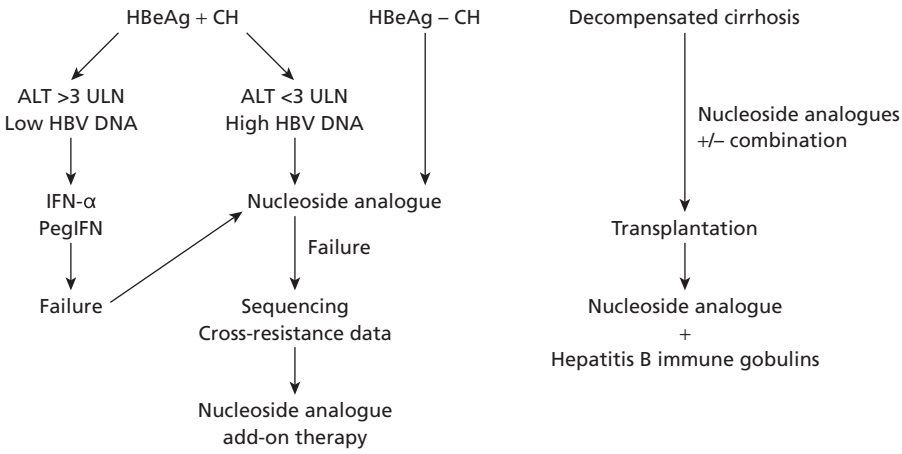

Fig. 7 Treatment algorithm. CH, chronic hepatitis.

the resistance profile is important to adapt antiviral therapy. One of the major questions in the future will be how to delay or prevent drug resistance. Combination therapy, although currently very expensive, will probably become part of the treatment paradigm.

Perspectives: can we prevent or delay drug resistance?

The rationale for combination therapy relies on experimental findings in the hepadnavirus models and on HIV therapy experience [138]: (i) simple mutants pre-exist as shown by longitudinal studies of viral polymerase gene sequence; (ii) genetic variants harbouring multiple mutations have less chance to pre-exist or to occur; (iii) retreatment leads to a rapid re-emergence of resistant mutants, although wild-type virus re-emerges after the first treatment interruption; the same applies to sequential treatment selecting for partially cross-resistant strains, i.e. lamivudine and entecavir; (iv) cccDNA represents a genetic archive for a more rapid reselection of resistance.

The optimal antiviral regimen may combine drugs with a different mechanism of action on viral replication, lacking cross-resistance and exhibiting antiviral synergy. These theoretical combinations should reduce the risk of the selection of drug-resistant mutants because of the inhibition of viral replication and the selective pressure exerted on the different viral strains that compose the quasi-species. For instance, it was shown that the combination of lamivudine and famciclovir accelerates the kinetics of viral clearance, although no long-term follow-up was available to determine its effect on the prevention of drug resistance [139].

With the development and evaluation of newer drugs acting at different steps in viral genome replication, it will be easier to choose the best combination relying on drugs with different mechanisms of action, for instance drugs with potent antipriming activity, drugs inhibiting viral minus strand DNA synthesis and others inhibiting plus strand DNA synthesis. The combination of such compounds was found to be either additive or, more rarely, synergistic in polymerase assays (reverse transcriptase activity) [147] as well as in tissue culture experiments (viral DNA synthesis) or in chronically infected woodchucks [140–144]. By more potently inhibiting viral DNA synthesis, such combinations may therefore delay the onset of viral resistance by limiting the chance of a given mutation occurring. Furthermore, results of cross-resistance studies on the main lamivudine-, adefovir- and entecavir-resistant strains are now becoming available [37,38,42,49,145–147]. This should allow the evaluation of rationale combinations, taking into account the mechanism of action of the drugs as well as their antiviral activity and cross-resistance profile, to better suppress viral replication and prevent the selection of resistant mutants within the viral quasi-species [47,148]. This should pave the way for future clinical trials and improved treatment of chronic hepatitis B.

References

1 Bertoletti A, Naoumov NV (2003) Translation of immunological knowledge into better treatments of chronic hepatitis B. *J Hepatol* 39, 115–124.

2 Ganem D, Prince AM (2004) Hepatitis B virus infection – natural history and clinical consequences. *N Engl J Med* 350, 1118–1129.

3 Guidotti LG, Rochford R, Chung J *et al.* (1999) Viral clearance without destruction of infected cells during acute HBV infection. *Science* 284, 825–829.

4 Summers J, Jilbert AR, Yang W *et al.* (2003) Hepatocyte turnover during resolution of a transient hepadnaviral infection. *Proc Natl Acad Sci USA* 100, 11652–11659.

5 Summers J, Mason WS (2004) Residual integrated viral DNA after hepadnavirus clearance by nucleoside analog therapy. *Proc Natl Acad Sci USA* 101, 638–640.

6 Wieland S, Thimme R, Purcell RH *et al.* (2004) Genomic analysis of the host response to hepatitis B virus infection. *Proc Natl Acad Sci USA* 101, 6669–6674.

7 Boni C, Bertoletti A, Penna A *et al.* (1998) Lamivudine treatment can restore T cell responsiveness in chronic hepatitis B. *J Clin Invest* 102, 968–975.

8 Boni C, Penna A, Ogg GS *et al.* (2001) Lamivudine treatment can overcome cytotoxic T-cell hyporesponsiveness in chronic hepatitis B: new perspectives for immune therapy. *Hepatology* 33, 963–971.

9 Webster GJ, Reignat S, Brown D *et al.* (2004) Longitudinal analysis of CD8+ T cells specific for structural and nonstructural hepatitis B virus proteins in patients with chronic hepatitis B: implications for immunotherapy. *J Virol* 78, 5707–5719.

10 Mason W, Cullen J, Saputelli J *et al.* (1994) Characterization of the antiviral activity of 2'carbodeoxyguanosine in ducks chronically infected with duck hepatitis B virus. *Hepatology* 19, 398–411.

11 Mason WS, Cullen J, Moraleda G *et al.* (1998) Lamivudine therapy of WHV-infected woodchucks. *Virology* 245, 18–32.

12 Maynard M, Parvaz P, Durantel S *et al.* (2005) Sustained HBs seroconversion during lamivudine and adefovir dipivoxil combination therapy for lamivudine failure. *J Hepatol* 42, 279–281.

13 Werle-Lapostolle B, Bowden S, Locarnini S *et al.* (2004) Persistence of cccDNA during the natural history of chronic hepatitis B and decline during adefovir dipivoxil therapy. *Gastroenterology* 126, 1750–1758.

14 Sung JJ, Wong ML, Bowden S *et al.* (2005) Intrahepatic hepatitis B virus covalently closed circular DNA can be a predictor of sustained response to therapy. *Gastroenterology* 128, 1890–1897.

15 Zoulim F (2005) New insight on hepatitis B virus persistence from the study of intrahepatic viral cccDNA. *J Hepatol* 42, 302–308.

16 Zoulim F (2004) Mechanism of viral persistence and resistance to nucleoside and nucleotide analogs in chronic Hepatitis B virus infection. *Antiviral Res* 64, 1–15.

17 Realdi G, Fattovich G, Hadzyiannis S *et al.* (1994) Survival and prognostic factors in 366 patients with compensated cirrhosis type B: a multicenter study. *J Hepatol* 21, 656–666.

18 Yang HI, Lu SN, Liaw YF *et al.* (2002) Hepatitis B e antigen and the risk of hepatocellular carcinoma. *N Engl J Med* 347, 168–174.

19 Lok AS, McMahon BJ (2001) Chronic hepatitis B. *Hepatology* 34, 1225–1241.

20 de Franchis R, Hadengue A, Lau G *et al.* (2003) EASL International Consensus Conference on Hepatitis B, 13–14 September, 2002,

Geneva, Switzerland. Consensus statement (long version). *J Hepatol* 39 (Suppl 1), S3–25.

21 Le Guerhier F, Pichoud C, Guerret S, *et al.* (2000) Characterization of the antiviral effect of 2′,3′-dideoxy-2′, 3′-didehydro-beta-L-5-fluorocytidine in the duck hepatitis B virus infection model. *Antimicrob Agents Chemother* 44, 111–122.

22 Le Guerhier F, Pichoud C, Jamard C *et al.* (2001) Antiviral activity of beta-L-2′,3′-dideoxy-2′,3′-didehydro-5-fluorocytidine in woodchucks chronically infected with woodchuck hepatitis virus. *Antimicrob Agents Chemother* 45, 1065–1077.

23 Zhou T, Saputelli J, Aldrich CE *et al.* (1999) Emergence of drug-resistant populations of woodchuck hepatitis virus in woodchucks treated with the antiviral nucleoside lamivudine. *Antimicrob Agents Chemother* 43, 1947–1954.

24 Zhu Y, Yamamoto T, Cullen J *et al.* (2001) Kinetics of hepadnavirus loss from the liver during inhibition of viral DNA synthesis. *J Virol* 75, 311–322.

25 Seeger C, Mason WS (2000) Hepatitis B virus biology. *Microbiol Mol Biol Rev* 64, 51–68.

26 Pol S, Nalpas B, Driss F *et al.* (2001) Efficacy and limitations of a specific immunotherapy in chronic hepatitis B. *J Hepatol* 34, 917–921.

27 Le Guerhier F, Thermet A, Guerret S *et al.* (2003) Antiviral effect of adefovir in combination with a DNA vaccine in the duck hepatitis B virus infection model. *J Hepatol* 38, 328–334.

28 Michel ML, Loirat D (2001) DNA Vaccines for prophylactic or therapeutic immunization against hepatitis B. *Intervirology* 44, 78–87.

29 Mancini-Bourgine M, Fontaine H, Scott-Algara D *et al.* (2004) Induction or expansion of T-cell responses by a hepatitis B DNA vaccine administered to chronic HBV carriers. *Hepatology* 40, 874–882.

30 Bridges E, Cheng Y (1995) Use of novel b-L(–)-nucleoside analogues for treatment and prevention of chronic hepatitis B virus infection and hepatocellular carcinoma. *Prog Liver Dis* 13, 231–245.

31 Allen MI, Deslauriers M, Andrews CW *et al.* (1998) Identification and characterization of mutations in hepatitis B virus resistant to lamivudine. *Hepatology* 27, 1670–1677.

32 Condreay L, Condreay J, Jansen R *et al.* (1996) (–)-cis-5-fluoro-1-(2-(hydroxymethyl)-1,3-oxathiolan-5-yl)cytosine (524W91) inhibits hepatitis B virus replication in primary human hepatocytes. *Antimicrob Agents Chemother* 40, 520–523.

33 Marcellin P, Mommeja-Marin H, Sacks SL *et al.* (2004) A phase II dose-escalating trial of clevudine in patients with chronic hepatitis B. *Hepatology* 40, 140–148.

34 Pai S, Liu S, Zhu Y *et al.* (1996) Inhibition of hepatitis B virus by a novel L-nucleoside, 2'-fluoro-5-methyl-b-L-arabinofuranosyl uracil. *Antimicrob Agents Chemother* 40, 380–386.

35 Xiong X, Flores C, Yang H *et al.* (1998) Mutations in hepatitis B DNA polymerase associated with resistance to lamivudine do not confer resistance to adefovir in vitro. *Hepatology* 28, 1669–1673.

36 Delmas J, Schorr O, Jamard C *et al.* (2002) Inhibitory effect of adefovir on viral DNA synthesis and covalently closed circular DNA formation in duck hepatitis B virus-infected hepatocytes in vivo and in vitro. *Antimicrob Agents Chemother* 46, 425–433.

37 Angus P, Vaughan R, Xiong S *et al.* (2003) Resistance to adefovir dipivoxil therapy associated with the selection of a novel mutation in the HBV polymerase. *Gastroenterology* 125, 292–297.

38 Villeneuve JP, Durantel D, Durantel S *et al.* (2003) Selection of a hepatitis B virus strain resistant to adefovir in a liver transplantation patient. *J Hepatol* 39, 1085–1089.

39 Innaimo SF, Seifer M, Bisacchi GS *et al.* (1997) Identification of BMS-200475 as a potent and selective inhibitor of hepatitis B virus. *Antimicrob Agents Chemother* 41, 1444–1448.

40 Colonno RJ, Genovesi EV, Medina I *et al.* (2001) Long-term entecavir treatment results in sustained antiviral efficacy and prolonged life span in the woodchuck model of chronic hepatitis infection. *J Infect Dis* 184, 1236–1245.

41 Seifer M, Hamatake RK, Colonno RJ *et al.* (1998) In vitro inhibition of hepadnavirus polymerases by the triphosphates of BMS-200475 and lobucavir. *Antimicrob Agents Chemother* 42, 3200–3208.

42 Levine S, Hernandez D, Yamanaka G *et al.* (2002) Efficacies of entecavir against lamivudine-resistant hepatitis B virus replication and recombinant polymerases in vitro. *Antimicrob Agents Chemother* 46, 2525–2532.

43 Tenney DJ, Levine SM, Rose RE *et al.* (2004) Clinical emergence of entecavir-resistant hepatitis B virus requires additional substitutions in virus already resistant to lamivudine. *Antimicrob Agents Chemother* 48, 3498–3507.

44 Ying C, De Clercq E, Neyts J (2000) Lamivudine, adefovir and tenofovir exhibit long-lasting anti-hepatitis B virus activity in cell culture. *J Viral Hepat* 7, 79–83.

45 Bryant ML, Bridges EG, Placidi L *et al.* (2001) Antiviral L-nucleosides specific for hepatitis B virus infection. *Antimicrob Agents Chemother* 45, 229–235.

46 Standring DN, Bridges EG, Placidi L *et al.* (2001) Antiviral beta-L-nucleosides specific for hepatitis B virus infection. *Antiviral Chem Chemother* 12 Suppl 1, 119–129.

47 Zoulim F (2004) Antiviral therapy of chronic hepatitis B: can we clear the virus and prevent drug resistance? *Antiviral Chem Chemother* 15, 299–305.

48 Brunelle MN, Jacquard AC, Pichoud C *et al.* (2005) Susceptibility to antivirals of a human HBV strain with mutations conferring resistance to both lamivudine and adefovir. *Hepatology* 41, 1391–1398.

49 Seigneres B, Pichoud C, Martin P *et al.* (2002) Inhibitory activity of dioxolane purine analogs on wild-type and lamivudine-resistant mutants of hepadnaviruses. *Hepatology* 36, 710–722.

50 Perillo, R, Schiff E, Davis G *et al.* (1990) A randomized, controlled trial of interferon alfa-2b alone and after prednisone withdrawal for the treatment of chronic hepatitis B. *N Engl J Med* 323, 295–301.

51 Wong DK, Cheung AM, O'Rourke K *et al.* (1993) Effect of alpha-interferon treatment in patients with hepatitis B e antigen-positive chronic hepatitis B. A meta-analysis (see comments). *Ann Intern Med* 119, 312–323.

52 Korenman J, Baker B, Waggoner J *et al.* (1991) Long-term remission of chronic hepatitis B after alpha-interferon therapy. *Ann Intern Med* 114, 629–634.

53 Lok AS, Chung HT, Liu VW *et al.* (1993) Long-term follow-up of chronic hepatitis B patients treated with interferon alfa. *Gastroenterology* 105, 1833–1838.

54 Dusheiko, GM, Roberts JA (1995) Treatment of chronic type B and C hepatitis with interferon alfa: an economic appraisal. *Hepatology* 22, 1863–1873.

55 Wong JB, Koff RS, Tine F *et al.* (1995) Cost-effectiveness of interferon-alpha 2b treatment for hepatitis B e antigen-positive chronic hepatitis B. *Ann Intern Med* 122, 664–675.

56 Cooksley WG, Piratvisuth T, Lee SD *et al.* (2003) Peginterferon alpha-2a (40 kDa): an advance in the treatment of hepatitis B e antigen-positive chronic hepatitis B. *J Viral Hepat* 10, 298–305.

57 Janssen HL, van Zonneveld M, Senturk H *et al.* (2005) Pegylated interferon alfa-2b alone or in combination with lamivudine for HBeAg-positive chronic hepatitis B: a randomised trial. *Lancet* 365, 123–129.

58 Lau GK, Piratvisuth T, Luo KX *et al.* (2005) Peginterferon Alfa-2a, lamivudine, and the combination for HBeAg-positive chronic hepatitis B. *N Engl J Med* 352, 2682–2695.

59 Dienstag JL, Schiff ER, Wright TL *et al.* (1999) Lamivudine as initial treatment for chronic hepatitis B in the United States. *N Engl J Med* 341, 1256–1263.

60 Lai CL, Chine RW, Leung NWY *et al.* (1998) A one year trial of lamivudine for chronic hepatitis B. *N Engl J Med* 339, 61–68.

61 Zoulim F (2002) A preliminary benefit-risk assessment of Lamivudine for the treatment of chronic hepatitis B virus infection. *Drug Safety* 25, 497–510.

62 Dienstag JL, Goldin RD, Heathcote EJ *et al.* (2003) Histological outcome during long-term lamivudine therapy. *Gastroenterology* 124, 105–117.

63 Leung NW, Lai CL, Chang TT *et al.* (2001) Extended lamivudine treatment in patients with chronic hepatitis B enhances hepatitis B e antigen seroconversion rates: results after 3 years of therapy. *Hepatology* 33, 1527–1532.

64 Chien RN, Liaw YF, Atkins M (1999) Pretherapy alanine transaminase level as a determinant for hepatitis B e antigen seroconversion during lamivudine therapy in patients with chronic hepatitis B. Asian Hepatitis Lamivudine Trial Group. *Hepatology* 30, 770–774.

65 Locarnini S, Hatzakis A, Heathcote J *et al.* (2004) Management of antiviral resistance in patients with chronic hepatitis B. *Antiviral Ther* 9, 679–963.

66 Zoulim F, Poynard T, Degos F *et al.* (2006) A prospective study of the evolution of lamivudine resistance mutations in patients with chronic hepatitis B treated with lamivudine. *J Viral Hepat* 13, 278–288.

67 Lai CL, Dienstag J, Schiff E *et al.* (2003) Prevalence and clinical correlates of YMDD variants during lamivudine therapy for patients with chronic hepatitis B. *Clin Infect Dis* 36, 687–696.

68 Hadziyannis SJ, Papatheodoridis GV, Dimou E *et al.* (2000) Efficacy of long-term lamivudine monotherapy in patients with hepatitis B e antigen-negative chronic hepatitis B. *Hepatology* 32, 847–851.

69 Nafa S, Ahmed S, Tavan D *et al.* (2000) Early detection of viral resistance by determination of hepatitis B virus polymerase mutations in patients treated by lamivudine for chronic hepatitis B. *Hepatology* 32, 1078–1088.

70 Lampertico P, Vigano M, Manenti E *et al.* (2005) Adefovir rapidly suppresses hepatitis B in HBeAg-negative patients developing genotypic resistance to lamivudine. *Hepatology* 42, 1414–1419.

71 Marcelli M, Chang TT, Lim SG *et al.* (2003) Adefovir dipivoxil for the treatment of hepatitis B e antigen-positive chronic hepatitis B. *N Engl J Med* 348, 808–816.

72 Gish RG, Trinh H, Leung N *et al.* (2005) Safety and antiviral activity of emtricitabine (FTC) for the treatment of chronic hepatitis B infection: a two-year study. *J Hepatol* 43, 60–66.

73 Lai CL, Rosmawati M, Lao J *et al.* (2002) Entecavir is superior to lamivudine in reducing hepatitis B virus DNA in patients with chronic hepatitis B infection. *Gastroenterology* 123, 1831–1838.

74 Wolters LM, Hansen BE, Niesters HG *et al.* (2002) Viral dynamics during and after entecavir therapy in patients with chronic hepatitis B. *J Hepatol* 37, 137–144.

75 Chang TT, Gish RG, de Man R *et al.* (2006) A comparison of entecavir and lamivudine for HBeAg-positive chronic hepatitis B. *N Engl J Med* 354, 1001–1010.

76 Colonno RJ, Rose R, Baldick CJ *et al.* (2006) Entecavir resistance is rare in nucleoside-naïve patients with hepatitis B. *Hepatology* 44, 1656–1665.

77 Lai C, Lim SG, Brown NA *et al.* (2004) A dose-finding study of once-daily oral telbivudine in HBeAg-positive patients with chronic hepatitis B virus infection. *Hepatology* 40, 719–726.

78 Lai CL, Gane E, Liaw Y-F *et al.* (2005) Telbivudine versus lamivudine for chronic hepatitis B: first year results from the international phase III globe trial (abstract LB01). *Hepatology* 42 (Suppl 1), 748A.

79 Bani-Sadr F, Palmer P, Scieux C *et al.* (2004) Ninety-six-week efficacy of combination therapy with lamivudine and tenofovir in patients coinfected with HIV-1 and wild-type hepatitis B virus. *Clin Infect Dis* 39, 1062–1064.

80 Benhamou Y, Tubiana R, Thibault V (2003) Tenofovir disoproxil fumarate in patients with HIV and lamivudine-resistant hepatitis B virus. *N Engl J Med* 348, 177–178.

81 Dore GJ, Cooper DA, Pozniak AL *et al.* (2004) Efficacy of tenofovir disoproxil fumarate in antiretroviral therapy-naive and -experienced patients coinfected with HIV-1 and hepatitis B virus. *J Infect Dis* 189, 1185–1192.

82 Lacombe K, Gozlan J, Boelle PY *et al.* (2005) Long-term hepatitis B virus dynamics in HIV-hepatitis B virus-co-infected patients treated with tenofovir disoproxil fumarate. *AIDS* 19, 907–915.

83 van Bommel F, Wunsche T, Mauss S *et al.* (2004) Comparison of adefovir and tenofovir in the treatment of lamivudine-resistant hepatitis B virus infection. *Hepatology* 40, 1421–1425.

84 Lampertico P, Del Ninno E, Manzin A *et al.* (1997) A randomized, controlled trial of a 24-month course of interferon alfa 2b in patients with chronic hepatitis B who had hepatitis B virus DNA without hepatitis B e antigen in serum. *Hepatology* 26, 1621–1625.

85 Manesis EK, Hadziyannis SJ (2001) Interferon alpha treatment and retreatment of hepatitis B e antigen-negative chronic hepatitis B. *Gastroenterology* 121, 101–109.

86 Tassopoulo, NC, Volpes R, Pastore G *et al.* (1999) Efficacy of lamivudine in patients with hepatitis B e antigen-negative/hepatitis B virus DNA-positive (precore mutant) chronic hepatitis B (in process citation). *Hepatology* 29, 889–896.

87 Rizzetto M, Tassopoulos NC, Goldin RD *et al.* (2005) Extended lamivudine treatment in patients with HBeAg-negative chronic hepatitis B. *J Hepatol* 42, 173–179.

88 Buti M, Cotrina M, Jardi R *et al.* (2001) Two years of lamivudine therapy in anti-HBe-positive patients with chronic hepatitis B. *J Viral Hepat* 8, 270–275.

89 Di Marco V, Marzano A, Lampertico P *et al.* (2004) Clinical outcome of HBeAg-negative chronic hepatitis B in relation to virological response to lamivudine. *Hepatology* 40, 883–891.

90 Papatheodoridis GV, Dimou E, Laras A *et al.* (2002) Course of virologic breakthroughs under long-term lamivudine in HBeAg-negative precore mutant HBV liver disease. *Hepatology* 36, 219–226.

91 Rizzetto M (2002) Efficacy of lamivudine in HBeAg-negative chronic hepatitis B. *J Med Virol* 66, 435–451.

92 Hadziyannis SJ, Tassopoulos NC, Heathcote EJ *et al.* (2003) Adefovir dipivoxil for the treatment of hepatitis B e antigen-negative chronic hepatitis B. *N Engl J Med* 348, 800–807.

93 Hadziyannis SJ, Tassopoulos NC, Heathcote EJ *et al.* (2005) Long-term therapy with adefovir dipivoxil for HBeAg-negative chronic hepatitis B. *N Engl J Med* 352, 2673–2681.
94 Hadzyiannis S, Tassopoulos N, Chang TT *et al.* (2005) Long-term adefovir dipivoxil treatment induces regression of liver fibrosis in patients with HBeAg-negative chronic hepatitis B: results after 5 years of therapy (abstract LB14). *Hepatology* 42 (Suppl 1), 745A.
95 Lai CL, Shouval D, Lok AS *et al.* (2006) Entecavir versus lamivudine for patients with HBeAg-negative chronic hepatitis B. *N Engl J Med* 354, 1011–1020.
96 Marcellin P, Lau GK, Bonino F *et al.* (2004) Peginterferon alfa-2a alone, lamivudine alone, and the two in combination in patients with HBeAg-negative chronic hepatitis B. *N Engl J Med* 351, 1206–1217.
97 Perrillo R, Hann HW, Mutimer D *et al.* (2004) Adefovir dipivoxil added to ongoing lamivudine in chronic hepatitis B with YMDD mutant hepatitis B virus. *Gastroenterology* 126, 81–90.
98 Peters MG, Hann HW, Martin P *et al.* (2004) Adefovir dipivoxil alone or in combination with lamivudine in patients with lamivudine-resistant chronic hepatitis B. *Gastroenterology* 126, 91–101.
99 Sherman M, Yurdaydin C, Sollano J *et al.* (2006) Entecavir for treatment of lamivudine-refractory HBeAg-positive chronic hepatitis B. *Gastroenterology* 130, 2039–2049.
100 Werle B, Cinquin K, Marcellin P *et al.* (2004) Evolution of hepatitis B viral load and viral genome sequence during adefovir dipivoxil therapy. *J Viral Hepat* 11, 74–83.
101 Lok AS, Zoulim F, Locarnini S *et al.* (2002) Monitoring drug resistance in chronic hepatitis B virus (HBV)-infected patients during lamivudine therapy: evaluation of performance of INNO-LiPA HBV DR assay. *J Clin Microbiol* 40, 3729–3734.
102 Durantel D, Carrouee-Durantel S, Werle-Lapostolle B *et al.* (2004). A new strategy for studying in vitro the drug susceptibility of clinical isolates of human hepatitis B virus. *Hepatology* 40, 855–864.
103 Yang H, Westland C, Xiong S *et al.* (2004) In vitro antiviral susceptibility of full-length clinical hepatitis B virus isolates cloned with a novel expression vector. *Antiviral Res* 61, 27–36.
104 Liaw YF, Sung JJ, Chow WC *et al.* (2004) Lamivudine for patients with chronic hepatitis B and advanced liver disease. *N Engl J Med* 351, 1521–1531.
105 Villeneuve JP, Condreay LD, Willems B *et al.* (2000) Lamivudine treatment for decompensated cirrhosis resulting from chronic hepatitis B. *Hepatology* 31, 207–210.
106 Yao FY, Bass NM (2000) Lamivudine treatment in patients with severely decompensated cirrhosis due to replicating hepatitis B infection (in process citation). *J Hepatol* 33, 301–307.
107 Yao FY, Terrault NA, Freise C *et al.* (2001) Lamivudine treatment is beneficial in patients with severely decompensated cirrhosis and actively replicating hepatitis B infection awaiting liver transplantation: a comparative study using a matched, untreated cohort. *Hepatology* 34, 411–416.
108 Schiff ER, Lai CL, Hadziyannis S *et al.* (2003) Adefovir dipivoxil therapy for lamivudine-resistant hepatitis B in pre- and post-liver transplantation patients. *Hepatology* 38, 1419–1427.
109 Buti M, Mas A, Prieto M *et al.* (2003) A randomized study comparing lamivudine monotherapy after a short course of hepatitis B immune globulin (HBIg) and lamivudine with long-term lamivudine plus HBIg in the prevention of hepatitis B virus recurrence after liver transplantation. *J Hepatol* 38, 811–817.
110 Perrillo RP, Wright T, Rakela J *et al.* (2001) A multicenter United States-Canadian trial to assess lamivudine monotherapy before and after liver transplantation for chronic hepatitis B. *Hepatology* 33, 424–432.
111 Zoulim F (2003) Towards an improved and cost-saving prophylaxis of hepatitis B virus recurrence after liver transplantation? *J Hepatol* 38, 850–852.
112 Perrillo R, Rakela J, Dienstag J *et al.* (1999) Multicenter study of lamivudine therapy for hepatitis B after liver transplantation. Lamivudine Transplant Group. *Hepatology* 29, 1581–1586.
113 Farci P, Mandas A, Coiana A *et al.* (1994) Treatment of chronic hepatitis D with interferon alfa-2a. *N Engl J Med* 330, 88–94.
114 Rosina F, Pintus C, Meschievitz C *et al.* (1991) A randomized controlled trial of a 12-month course of recombinant human interferon-alpha in chronic delta (type D) hepatitis: a multicenter Italian study. *Hepatology* 13, 1052–1056.
115 Niro GA, Rosina F, Rizzetto M (2005). Treatment of hepatitis D. *J Viral Hepat* 12, 2–9.
116 Farci P, Roskams T, Chessa L *et al.* (2004) Long-term benefit of interferon alpha therapy of chronic hepatitis D: regression of advanced hepatic fibrosis. *Gastroenterology* 126, 1740–1749.
117 Lau DT, Kleiner DE, Park Y *et al.* (1999) Resolution of chronic delta hepatitis after 12 years of interferon alfa therapy. *Gastroenterology* 117, 1229–1233.
118 Puoti M, Rossi S, Forleo MA *et al.* (1998) Treatment of chronic hepatitis D with interferon alpha-2b in patients with human immunodeficiency virus infection. *J Hepatol* 29, 45–52.
119 Yurdaydin C, Bozkaya H, Gurel S *et al.* (2002) Famciclovir treatment of chronic delta hepatitis. *J Hepatol* 37, 266–271.
120 Lau DT, Doo E, Park Y *et al.* (1999) Lamivudine for chronic delta hepatitis (see comments). *Hepatology* 30, 546–549.
121 Niro GA, Ciancio A, Tillman HL *et al.* (2005) Lamivudine therapy in chronic delta hepatitis: a multicentre randomized-controlled pilot study. *Aliment Pharmacol Ther* 22, 227–232.
122 Wolters LM, van Nunen AB, Honkoop P *et al.* (2000) Lamivudine-high dose interferon combination therapy for chronic hepatitis B patients co-infected with the hepatitis D virus. *J Viral Hepat* 7, 428–434.
123 Castelnau C, LeGal F, Ripault MP *et al.* (2006) Efficacy of Peginterferon alpha 2-b in chronic hepatitis delta: relevance of quantitative RT-PCR for follow-up. *Hepatology* 44, 728–735.
124 Ferenci P, Formann E, Romeo R (2005) Successful treatment of chronic hepatitis D with a short course of peginterferon alfa-2a. *Am J Gastroenterol* 100, 1626–1627.
125 Samuel D, Zignego AL, Reynes M *et al.* (1995) Long-term clinical and virological outcome after liver transplantation for cirrhosis caused by chronic delta hepatitis. *Hepatology* 21, 333–339.
126 Marzano A, Lampertico P, Mazzaferro V *et al.* (2005) Prophylaxis of hepatitis B virus recurrence after liver transplantation in carriers of lamivudine-resistant mutants. *Liver Transpl* 11, 532–538.
127 Prince AM, Trepo C (1971) Role of immune complexes involving SH antigen in pathogenesis of chronic active hepatitis and polyarteritis nodosa. *Lancet* 1, 1309–1312.
128 Trepo C, Thivolet J (1970) Hepatitis associated antigen and periarteritis nodosa (PAN). *Vox Sang* 19, 410–411.
129 Erhardt A, Sagir A, Guillevin L *et al.* (2000) Successful treatment of hepatitis B virus associated polyarteritis nodosa with a combination

of prednisolone, alpha-interferon and lamivudine. *J Hepatol* 33, 677–683.
130 Krüger M, Böker KHW, Zeidler H *et al.* (1997) Treatment of hepatitis B-related polyarteritis nodosa with Famciclovir and interferon alfa-2b. *J Hepatol* 26, 935–939.
131 Maclachlan D, Battegay M, Jacob AL *et al.* (2000) Successful treatment of hepatitis B-associated polyarteritis nodosa with a combination of lamivudine and conventional immunosuppressive therapy: a case report (letter). *Rheumatology (Oxford)* 39, 106–108.
132 Wartelle-Bladou C, Lafon J, Trepo C *et al.* (2001) Successful combination therapy of polyarteritis nodosa associated with a pre-core promoter mutant hepatitis B virus infection. *J Hepatol* 34, 774–779.
133 Wicki J, Olivieri J, Pizzolato G *et al.* (1999) Successful treatment of polyarteritis nodosa related to hepatitis B virus with a combination of lamivudine and interferon alpha (letter). *Rheumatology (Oxford)* 38, 183–185.
134 van Zonneveld M, van Nunen AB, Niesters HG *et al.* (2003) Lamivudine treatment during pregnancy to prevent perinatal transmission of hepatitis B virus infection. *J Viral Hepat* 10, 294–297.
135 Jonas MM, Kelly DA, Mizerski J *et al.* (2002) Clinical trial of lamivudine in children with chronic hepatitis B. *N Engl J Med* 346, 1706–1713.
136 Bortolotti F, Jara P, Barbera C *et al.* (2000) Long term effect of alpha interferon in children with chronic hepatitis B. *Gut* 46, 715–718.
137 Lai CL, Lok AS, Lin HJ *et al.* (1987) Placebo-controlled trial of recombinant alpha 2-interferon in Chinese HBsAg-carrier children. *Lancet* 2, 877–880.
138 Richman DD (2000) The impact of drug resistance on the effectiveness of chemotherapy for chronic hepatitis B. *Hepatology* 32, 866–867.
139 Lau GK, Tsiang M, Hou J *et al.* (2000) Combination therapy with lamivudine and famciclovir for chronic hepatitis B-infected Chinese patients: a viral dynamics study (see comments). *Hepatology* 32, 394–399.
140 Seigneres B, Martin P, Werle B *et al.* (2003) Effects of pyrimidine and purine analog combinations in the duck hepatitis B virus infection model. *Antimicrob Agents Chemother* 47, 1842–1852.
141 Colledge D, Civitico G, Locarnini S *et al.* (2000) In vitro antihepadnaviral activities of combinations of penciclovir, lamivudine, and adefovir (in process citation). *Antimicrob Agents Chemother* 44, 551–560.
142 Colledge D, Locarnini S, Shaw T (1997) Synergistic inhibition of hepadnaviral replication by lamivudine in combination with penciclovir in vitro. *Hepatology* 26, 216–225.
143 Korba BE (1996) In vitro evaluation of combination therapies against hepatitis B virus replication. *Antiviral Res* 29, 49–51.
144 Korba BE, Cote P, Hornbuckle W *et al.* (2000) Enhanced antiviral benefit of combination therapy with lamivudine and famciclovir against WHV replication in chronic WHV carrier woodchucks. *Antiviral Res* 45, 19–32.
145 Delaney WET, Edwards R, Colledge D *et al.* (2001) Cross-resistance testing of antihepadnaviral compounds using novel recombinant baculoviruses which encode drug-resistant strains of hepatitis B virus. *Antimicrob Agents Chemother* 45, 1705–1713.
146 Fu L, Cheng YC (2000) Characterization of novel human hepatoma cell lines with stable hepatitis B virus secretion for evaluating new compounds against lamivudine- and penciclovir-resistant virus (in process citation). *Antimicrob Agents Chemother* 44, 3402–3407.
147 Menne S, Roneker CA, Korba BE *et al.* (2002) Immunization with surface antigen vaccine alone and after treatment with 1-(2-fluoro-5-methyl-beta-L-arabinofuranosyl)-uracil (L-FMAU) breaks humoral and cell-mediated immune tolerance in chronic woodchuck hepatitis virus infection. *J Virol* 76, 5305–5314.
148 Zoulim F (2003) Treatment of pre- and post-liver transplantation HBV infection: Should we aim at combination therapy? *Hepatology* 38, 1353–1355.

9.1.3.v Therapy for chronic hepatitis C

Giorgio Saracco, Fabien Zoulim and Mario Rizzetto

Introduction

Interferon (IFN) was introduced as monotherapy for chronic hepatitis C at the end of the 1980s [1,2]. Different types of α- and beta-IFNs initially shared the therapeutic arena, with the recommended duration of therapy 24 weeks; this was later extended to 48 weeks [3]. The rates of sustained responses were initially limited, in the range of 12–16% [4]. A therapeutic advance was made with the introduction of ribavirin (RBV) in association with IFN in 1998 [5,6]; in all of the different clinical subsets of hepatitis C virus (HCV)-infected patients, this combination virtually doubled the rate of cure that was achieved with IFN monotherapy. In parallel, recombinant α-IFNs have emerged as the most efficacious among the different types of IFNs.

At the end of the 1990s, the development of pegylated IFN led to further improvements [7–9]; currently, about 50% of HCV patients treated with the combination of pegylated IFN and RBV are expected to be cured of infection.

The interferons

The IFNs are a family of cytokines that are produced by eukaryotic cells in response to a variety of stimuli [10]. They are biologically multivalent, possessing antiproliferative, antiviral and immunomodulant properties. There are three types of natural IFN: IFN-α, produced mainly by leukocytes, IFN-β, produced mainly by fibroblasts, and IFN-γ, produced mainly by T lymphocytes. IFN-α and -β interact with the same cellular receptor, whereas IFN-γ interacts with different receptors.

There are two major types of IFN-α available for therapeutic use, both produced by recombinant technology: IFN-α-2a and IFN-α-2b. Standard IFN-α are dosed in million units (MU). A hybrid bioengineered 'consensus' molecule (IFN-alfacon-1) is also available for therapy [11]; it is composed of the amino acids that are most frequently conserved at each position of the α IFNs and shares 89%, 30% and 60% identity with IFN-α, IFN-β and IFN-γ respectively. The optimal

dosing schedule is 9–15 μg daily; efficacy is similar to that of IFN-α-2b. In some European countries, leukocyte-derived IFN-α, produced by the stimulation of human leukocytes, is used in patients who are intolerant to recombinant IFN-α. IFN-beta is used in Japan; the use of lymphoblastoid-derived IFN-α has been dismissed.

The process of pegylation, by which an inert molecule of polyethylene glycol (PEG) is covalently linked to a protein, increases the molecular weight of IFN, thus inducing a slower absorption, reduced clearance and an increased serum half-life [12]. Two formulations of PEG-IFN are available: PEG-IFN-α-2b, in which IFN-α-2b is attached to a single 12 kDa PEG molecule, and PEG-IFN-α-2a, in which IFN-α-2a is attached to a branched 40 kDa methoxy-PEG moiety. Pegylated IFNs are dosed in micrograms (μg).

Both PEG-IFNs are administered subcutaneously at once-weekly intervals, and the serum concentrations of IFN are maintained throughout the dosing interval. PEG-IFN-α-2a is metabolized primarily in the liver by non-specific proteases; biodistribution is restricted predominantly to the blood and extracellular volume [13]. PEG-IFN-α-2b is eliminated primarily via the kidney and is widely distributed throughout body fluids and tissues, the volume distribution depending on body weight; weight-based dosing is recommended [13].

IFN-α-2b has also been fused with recombinant human serum albumin producing an 85.7 kDa protein (Albuferon). The more extended half-life of Albuferon permits dosing once every 2–4 weeks; the longer duration of therapeutic activity might improve the efficacy and tolerability compared with conventional IFNs and PEG-IFNs [14].

Ribavirin

RBV is a synthetic guanosine analogue that has been used for the treatment of respiratory syncytial virus infection in infants. It inhibits the RNA-dependent RNA polymerase of all six HCV subtypes as well as the subgenomic HCV replicon system *in vitro*, but has no clinically significant effect on viral replication [15]; although it exerts only an early, transient and moderate antiviral action *in vivo*, it may significantly decrease serum alanine aminotransferase (ALT) activity in approximately 50% of patients, with an improvement in liver histology [16,17]. Despite the lack of antiviral efficacy when used as monotherapy, in association with IFNs or PEG-IFNs, RBV significantly improves the rates of sustained virological responses, reducing virological relapses during follow-up. It is rapidly absorbed following oral administration and bioavailability is increased when it is administered with a fat meal. The drug accumulates with repeated administration; its concentration is several-fold higher in erythrocytes than in blood [15]. Excretion of RBV and its metabolites is by the renal route and it should not be used in patients with kidney failure.

RBV is currently used at dosages between 800 and 1200 mg/day, in two divided doses. Its mechanism of action remains unclear, but the lack of virological efficacy suggests that its beneficial effect may be immune-mediated [18]. Alternatively, it may act through the inhibition of HCV RNA-dependent RNA polymerase at the level of the catalytic site [19] or it may have mutagenic properties, leading to 'error catastrophe' and resulting in the generation of non-viable HCV quasi-species [20]. RBV may also inhibit inosine monophosphate dehydrogenase (IMPDH), resulting in depletion of the intracellular pool of dGTP, which may subsequently lead to decreased viral replication levels. RBV was also shown in mouse model experiments to modulate the immune response towards a T-helper 1 (Th1) response, which may account for its synergistic effect in combination with IFN-α.

Definition of response

The goal of therapy is the eradication of HCV. A biphasic HCV decay is seen with current antiviral therapies [21]. The HCV decline slopes differ among treated patients and can be distinguished as rapid, slow or flat. The type of slope correlates with the probability of a sustained virological response (SVR); patients with an initially rapid slope achieve the highest rate of sustained responses. In the rapid phase of the response, which occurs during the first 2 days of therapy, the serum titre of HCV declines quickly, reflecting the inhibition of virus replication by IFN and its degradation in serum. The decline of HCV titre starts 8–12 h after the first dose of IFN; the HCV-RNA serum titre diminishes by 0.5–1.5 logs within the next 48 h [22]. The slope pattern and viral decline depend on the type and dose of IFN. In the second slower phase, starting 2–3 days after therapy begins, the virus decline is slower, reflecting the clearance of infected cells; complete virus elimination requires several months of further therapy [23]. Usually, the clearance of the virus is accompanied by normalization of liver enzymes and an improvement of histology; if this does not occur despite virus elimination, a concomitant cause of liver damage other than HCV should be suspected. Occasionally, ALT may become normal in patients who remain viraemic, possibly because of a normalizing effect of RBV on ALT levels. Alternatively, ALT levels may remain elevated despite the clearance of viraemia and the lack of other risk factors for liver disease; this may particularly be the case in patients treated with PEG-IFN and in those with fibrosis and cirrhosis, and may be the result of a minor toxic effect of IFN [7,8]; the enzyme levels return to normal when therapy is terminated [6–8].

During therapy, the clearance of HCV follows defined time points that have prognostic significance and help to guide the management of the patient [24,25]. The end-of-therapy virological response (ETR) is defined as the clearance of HCV during therapy, which is maintained at the end of therapy. The achievement of a ETR is mandatory for the eradication of the virus. A virological relapse is defined as the reappearance of HCV RNA in serum during follow-up, after its apparent clearance following therapy. A virological breakthrough is defined as the early

disappearance of HCV RNA during therapy, followed by the reappearance of the virus before the end of therapy. Effective therapy is confirmed by the achievement of a SVR. This is defined as the maintenance of virus clearance 6 months after termination of therapy.

Long-term post-treatment follow-up studies have shown that HCV RNA remains undetectable in more than 95% of patients who achieve a SVR [26–28], and that SVR results in long-term histological improvement [28–31]; therefore, SVR is adopted as a surrogate marker of cure. Of note, hepatocellular carcinoma (HCC) may still develop in patients who originally presented with cirrhosis or fibrosis and who had a SVR to antiviral therapy [32,33]; however, the incidence of HCC in sustained responders is lower than that in untreated or non-responding patients.

Two additional interim response points have attracted clinical interest, the early virological response (EVR) [34], defined by the clearance of HCV RNA or a decrease of at least 2 log10 in the viraemic titre compared with baseline, 12 weeks after starting therapy, and the rapid virological response (RVR), defined as the clearance of HCV RNA, 4 weeks after starting therapy [35]. A SVR can be predicted with more than 70% probability by an EVR, and the failure to achieve an EVR predicts a lack of SVR with almost 98% probability; similarly, it has been reported that a RVR predicts a SVR with almost 90% probability. Therefore, EVR appears to be a strong negative and RVR a strong positive predictor of a virological response.

Unfortunately, differences in the sensitivity and dynamic ranges of currently available assays used to measure HCV-RNA levels in serum limit the usefulness of quantitative HCV-RNA testing and comparisons [36]. Standardization of all HCV-RNA assays to a World Health Organization standard, and expression of results as a common international unit has been proposed [37]. Assays with a wide dynamic range should be used, with a lower detection limit of at least 50 IU/mL. The use of the ultrasensitive transcription-mediated amplification (TMA) assay (with a detection limit of 10 IU/mL) may further help to determine the optimal duration of treatment. In the HALT-C study [38], patients who were negative at week 48 of therapy, based on the Roche COBAS Amplicor 2.0 assay (sensitivity ≥ 100 IU/mL), but who remained TMA-positive, had an 89% chance of post-treatment relapse. Therefore, TMA testing during, or at the end of, antiviral therapy might help to identify patients who could benefit from extended antiviral treatment.

Therapeutic protocols

The combination of PEG-IFN with RBV (PEG-IFN/RBV) has become the standard of care for chronic hepatitis C [7–9]. PEG-IFN/RBV is more effective than standard IFN at doses between 3 and 6 MU with RBV (IFN/RBV) (overall SVR rate of 54% versus 47% respectively) [5–9,39] or PEG-IFN alone (overall SVR rate of 54% versus 39% respectively) [40]. PEG-IFN alone is significantly superior to standard IFN alone (overall SVR rate of 39% versus 19%), particularly in cirrhotic patients (overall SVR rate of 30% versus 8%) [41].

The efficacy of PEG-IFN-α-2b was documented in a randomized controlled trial of 1530 patients [7]. The highest SVR rate (54%) was observed in patients treated with 1.5 μg/kg of PEG-IFN in combination with 800 mg daily of RBV. The SVR rate was 47% in patients treated with 0.5 μg/kg of PEG-IFN or standard IFN. The SVR rate among HCV-1-infected patients treated with PEG-IFN/RBV (42%) was significantly higher than that observed with standard IFN/RBV (33%) and significantly lower than the 80% SVR rate observed in patients with HCV-2 or -3 from all therapy groups.

The efficacy of PEG-IFN-α-2a/RBV was determined in two multicentre trials of 1121 [8] and 1311 [9] patients. In the first trial [8], a 56% SVR rate was obtained among patients treated with a 'flat' dose of PEG-IFN-α-2a (180 μg weekly) plus RBV (1000–1200 mg daily); the SVR rate was significantly higher in patients with HCV-2 or -3 (76%) than in those with HCV-1 (46%). In the second trial [9], among HCV-1 patients treated with 180 μg weekly of PEG-IFN-α-2a and 1000–1200 mg daily of RBV, the SVR rate was significantly higher in those treated for 48 weeks (52.2%) than in those treated for 24 weeks only (41%). Among HCV-2 and HCV-3 patients given PEG-IFN-α-2a at a dose of 180 μg weekly, those treated with a low dose (800 mg/day) of RBV for 24 weeks had the same SVR (80%) as those treated for 48 weeks or those treated for 24 weeks with higher RBV doses (1000–1200 mg/day).

There are few data available on the responsiveness of HCV-4 patients. A study that was targeted to these patients [42] found a SVR rate of 68%, with baseline predictive factors of response that were identical to those observed in HCV-1 patients. HCV-5 appears to be a relatively easy virus to treat, with response rates that are similar to those of HCV-2 and -3 after a 48-week course of therapy. Response rates in patients with HCV-6 may be intermediate between HCV-1 and HCV-2 or -3; the optimal duration of treatment (24 versus 48 weeks) for this genotype is unclear and under investigation [43].

The current treatment protocols recommended by the National Institutes of Health (NIH) consensus conference [44] are reported in Table 1. The dosage of PEG-IFN-α-2b should be tailored to the weight of the patient, i.e. 1.5 μg/kg/week; PEG-IFN-α-2a is administered at a fixed dose (180 μg/week). These recommendations may have to be revised according to the results of ongoing trials designed to assess whether 1 μg/kg/week of PEG-IFN-α-2b is as effective as 1.5 μg/kg/week [45]. A dose of PEG-IFN-α-2a of 135 μg/week may be as effective as 180 μg/week in HCV-2 and -3 patients [46].

In HCV-1-infected patients treated with PEG-IFN-α-2b, the dose of RBV should be adjusted according to weight (10.6 mg/kg). In contrast, in HCV-2 or -3 patients treated with both PEG-IFN-α-2b and PEG-IFN-α-2a, a flat RBV dose of 800 mg/day can be given [47]; preliminary data suggest that, in these patients, daily doses of 400 mg may be as effective [48]. Dosing may be determined by measuring RBV plasma

Table 1 Current recommended treatment schedules for naive patients.

Treatment schedule	Dosage	
	Genotype 1 (48 weeks)	Genotypes 2 and 3 (24 weeks)
PEG-IFN-α-2a + RBV	IFN: 180 μg/week; RBV: 1000 mg/day (< 75 kg) or 1200 mg/day (> 75 kg)	IFN: 180 μg/week; RBV: 800 mg/day
PEG-IFN-α-2b + RBV	IFN: 1.5 μg/kg/week; RBV: > 10.6 mg/kg/day	IFN: 1.5 μg/kg/week; RBV: 800 mg/day[a]

[a]Not proven by specific randomized trials.

concentrations using liquid chromatography; in one study [49], RBV plasma concentrations varied widely and were predictive of anaemia and early virological responses.

A more prolonged 72-week course of therapy may be of benefit in slow-responder patients who fail to clear HCV RNA early [50–54]. In one study [53], 326 patients who did not achieve a RVR were randomized to a 48- or a 78-week course of treatment; the SVR was significantly higher in the latter group (45% versus 32%, $P = 0.01$). In another study [54], the lack of an EVR appeared to be more critical in discriminating patients who might benefit from extended therapy; among patients who failed to achieve an EVR and who were randomized to a 48- or 72-week course of therapy, 29% (31 out of 106) of the latter group obtained a SVR compared with 17% (17 out of 100) of the former ($P = 0.04$).

Patients with the more favourable HCV-2 and -3 genotypes may respond to a short 12-week course of combination therapy, with SVR rates that are similar to those obtained after the standard 24-week course [55,56]; the efficacy of a short-term course appears to be higher in patients with a low viraemia titre before therapy (≤ 800 000 IU/mL). However, in a prospective study of 1469 patients [57], the overall 76% SVR rate in HCV-2 and -3 patients treated for 24 weeks with PEG-IFN-α-2a/RBV was significantly higher than the 65% rate achieved with 16 weeks of therapy; the difference was accounted for by the higher relapse rate in patients treated for the shorter time period. It is doubtful whether short treatment is efficacious in HCV-3 patients with a high viraemia titre (≥ 800 000 IU/mL) [58]; whether these patients should be treated for 24 weeks or even longer has to be addressed by further studies [59].

Similarly, a reduced 24-week course of combination therapy may be as effective as the standard 48-week course in HCV-1 patients with low baseline viraemia (< 600 000 IU/mL) [60] and in those who achieve a RVR at week 4 (HCV RNA < 50 IU/mL) [61].

Of note, although reduced therapy courses may be proposed to patients with the appropriate virological credentials who are at risk of side-effects or who are reluctant to undergo full therapy, neither the 12-week course for favourable genotypes nor the 24-week course for the difficult HCV-1 genotype has yet been recommended by consensus conferences.

Many other modified therapeutic protocols have been proposed over the years, including an early induction phase, with IFN given at a higher dosage and/or at more frequent intervals for the first 4–12 weeks [62], late IFN dose reductions after an initial full dose, or intermittent therapy or therapy targeted to the individual virological response [63]. Despite claims that some of these protocols are more efficacious or more cost-effective than the standard protocols, none has been recommended for general use.

Monitoring

Monitoring is important to assess the efficacy of therapy and the development of toxic drug effects. Baseline evaluation should include determinations of white and red blood cell counts, haemoglobin concentration, platelet counts, ALT levels, thyroid-stimulating hormone (TSH) levels, quantitative HCV viraemia and viral genotype. A serum sample should be frozen for possible further re-evaluation and comparison of HCV-RNA titres. Determinations of ALT, liver function tests, haemoglobin concentration, white blood cell count and platelet count should be performed every month to detect toxicity. TSH should be tested every 3 months in order to individuate hyper/hypothyroidism.

Monitoring of serum HCV-RNA levels should be performed at 12 and 24 weeks and at the end of therapy in patients treated for 48 weeks. No interim HCV-RNA monitoring during therapy is required for patients with HCV-2 or -3 who are treated for 6 months; in these patients, HCV-RNA levels should be determined at the end of therapy. A final HCV-RNA test is required at 6 months post-therapy to establish successful eradication of the virus.

Contraindications

Pregnancy

Pregnancy is an absolute contraindication to combination therapy. RBV was found to be teratogenic in animals [19] and fetal mortality was high in women who became pregnant during combination therapy. Patients of childbearing age are required to use stringent contraceptive methods during therapy and for 6 months after treatment suspension.

Ischaemic cardiac and cerebrovascular disease

Patients with ischaemic cardiac and cerebrovascular disease are unsuitable candidates for therapy because of the risk of acute ischaemia secondary to the sudden fall in haemoglobin levels induced by RBV [24,64–66]. Rarely, IFN may induce a reversible cardiac arrhythmia or cardiomyopathy.

Autoimmune disease

Because of the potential for IFN to enhance immune and autoimmune responses [66–69], combination therapy is not recommended for individuals with clinical autoimmune diseases. However, immune-mediated thyroiditis, diabetes, neuropathy and other autoimmune disorders develop in only 1% of treated patients. An increase in the level of autoantibodies during therapy does not imply that an autoimmune disease is developing [70]; in many patients, raised autoantibody levels disappear after therapy withdrawal.

Retinopathy

Ophthalmological side-effects have been reported during IFN therapy, particularly retinal lesions and neurovisual impairment. Patients with hepatitis C who have risk factors for retinopathy should undergo an ophthalmoscopical evaluation before starting treatment. In a study [71] of 156 patients with chronic viral hepatitis and without baseline risk factors for retinopathy who were treated with standard or PEG-IFN, signs of retinopathy and neurovisual impairment were common during therapy but were rarely symptomatic.

Dermatological diseases

Dryness, itching and a wide range of non-specific skin lesions, such as transient rashes, diffuse erythema and urticaria, have been reported during IFN/RBV therapy. Lichen planus and psoriasis may develop or worsen during therapy [72,73]. Both diseases may induce a premature discontinuation of therapy but do not represent an absolute contraindication to treatment.

Side-effects

The common and/or important side-effects of IFN/RBV therapy, their frequency and the methods used to control them are summarized in Table 2 [74–76]. Less common or rare adverse events caused by IFN/PEG-IFN and RBV are reported in Table 3. The 'flu-like' syndrome (fever, chills, headache, myalgias, arthralgia) occurs frequently during the first weeks of therapy, can be prevented by paracetamol and generally abates after the first month of therapy. Other IFN/PEG-IFN-induced symptoms are fatigue, loss of appetite, weight loss, diarrhoea, skin rash, hair loss and insomnia; erythema at the injection site occurs in about 40% of patients and is more frequent with PEG-IFN. Leukocyte IFN-α has been used for IFN retreatment in patients who are intolerant to other IFNs [77].

Haematological side-effects are frequent and may be important [78]. Anaemia usually complicates therapy, with an average

Table 2 Interferon and ribavirin therapy: frequent side-effects of combination therapy.

Side-effect	Frequency (%)	Solution
Flu-like symptoms	59	Paracetamol
Anaemia (> 10% decrease in baseline haemoglobin)	34	RBV dose reduction, epoetin
Alopecia	24	–
Dyspnoea	24	–
Rash	23	Antihistamines, topical steroids
Injection-site inflammation	23	Antihistamines
Dry skin	22	–
WBC count decrease (< 3000 cells/μL); platelet decrease (< 80 000 cells/μL)	21	PEG-IFN dose reduction, G-CSF, GM-CSF
Psychiatric symptoms	19	Antidepressants, diphenhydramine
Nausea	12	–
Anorexia	11	–
Vomiting	10	–
Diarrhoea	10	–
Abdominal pain	8	–
Thyroid disease	5	Substitution therapy
Pruritus	4	–
Cough	3	–

G-CSF, granulocyte colony-stimulating factor; GM-CSF, granulocyte–macrophage colony-stimulating factor; WBC, white blood cell.

Table 3 Interferon and ribavirin therapy: less common or rare adverse events.

Neuropsychiatric
Suicidal ideation or suicide attempt
Personality change
Confusion and coma
Memory loss
Substance-abuse relapse
Tinnitus
Hearing loss
Motor and sensory neuropathy
Seizures
Autoimmune
Type 1 diabetes mellitus
Addison's disease
Coeliac disease
Idiopathic thrombocytopenia
Myasthenia gravis
Autoimmune hepatitis
Pulmonary
Interstitial pneumonitis
Bronchiolitis obliterans organizing pneumonia
Sarcoidosis
Ocular
Retinal haemorrhage
Visual loss
Cotton wool spots
Retinal vein thrombosis
Dermatological
Photosensitivity
Psoriasis flare
Lichen planus
Cardiovascular
Arrhythmias
Congestive heart failure
Myocardial infarction
Angina
Transient ischaemic attack
Stroke
Miscellaneous
Acute renal failure
Exacerbation of hepatitis
Local abscess formation

haemoglobin drop of 2–3 g/dL; more pronounced anaemia (haemoglobin < 10 g/dL) occurs in 5–10% of patients. There is a gradual decline in haemoglobin levels during the first month of therapy, after which the haemoglobin level usually stabilizes. In one study [79], 54% of the patients on combination therapy experienced a haemoglobin decrease of > 3 g/dL. The cause is multifactorial, with RBV inducing a dose-dependent haemolytic anaemia [80,81] and IFN suppressing erythroid progenitor cells and red blood cell production [82]; the level of reticulocytes markedly increases as a response to anaemia. RBV withdrawal or dose reductions are mandatory when haemoglobin levels fall below 10 g/dL. RBV may also cause nausea, dry skin, pruritus, cough and hyperuricaemia. It may also result in an increase in the level of ferritin during therapy because of haemolysis; however, there is usually no need to remove iron.

Anaemia can be treated with erythropoietin (epoetin) [83–85]. A dose of epoetin of 40 000 IU/week subcutaneously increased the level of haemoglobin by approximately 2 g/dL in patients who developed anaemia, allowing the full RBV dose to be continued in about 90% of patients and improving the quality of life [85]. Common adverse effects of epoetin are headache and nausea; the drug can also result in the formation of thrombi.

Leukocytopenia with granulocytopenia and thrombocytopenia are also common side-effects of therapy; granulocytopenia occurs more frequently with PEG-IFN than with standard IFN. In about 10–20% of treated patients, neutropenia requires a dose reduction of PEG-IFN; however, therapy suspension – mandatory when the neutrophil count decreases to less than 500/μl – is rarely needed. Granulocyte–macrophage colony-stimulating factor can be used to raise the granulocyte count [86,87]. Thrombocytopenia is common but rarely causes symptoms (purpura) or forces dose reductions. Nevertheless, it is the most common cause for excluding cirrhotics from therapy: the exclusion threshold is usually 40 000–50 000 platelets/μl. RBV attenuates thrombocytopenia by stimulating megakaryocytes and thrombocytosis as a reaction to anaemia; therefore, thrombocytopenia is more pronounced in patients given IFN alone.

Treatment may induce dysthyroidism [88,89]; however, there is no association between thyroid dysfunction and IFN dosage or efficacy of therapy [90]. Female gender and the presence of antithyroid microsomes or antithyroperoxidase antibodies before beginning antiviral therapy are predictive of dysthyroidism during therapy [91].

Although the finding of thyroid autoantibodies may help to identify patients who are at risk for thyroid disease during therapy, these patients should not be excluded from therapy because only a minority will develop abnormalities of thyroid function. Likewise, therapy should not be suspended in patients who develop thyroid autoantibodies during therapy but maintain a normal TSH level. Thyroid IFN-related dysfunction is reversible in most, but not all, patients after stopping therapy; hypothyroidism may ensue [92].

Patients with spontaneous or IFN-related stable hypothyroidism (treated with thyroid hormone replacement) can be safely given or regiven IFN. Treatment should be discontinued in patients who develop hyperthyroidism; however, in cases in which there is significant HCV liver disease, it can be continued in association with antithyrotoxic therapy and supervision by an endocrinologist. Of note, the development of fatigue, anxiety and tachycardia during therapy should alert the clinician to thyroid dysfunction as well as to RBV-induced anaemia.

Therapy with IFN tends to aggravate a depressive personality; therefore, treatment should only be offered to depressed

patients who have severe liver disease, provided that psychiatric stabilization can be achieved [93–95]. Psychiatric side-effects during therapy may be severe, ranging from irritability and mood changes to profound depression and suicide attempts [96]. Side-effects occur more frequently during early than late therapy. Depression can be controlled by paroxetine (a serotonin reuptake inhibitor), initiated before and continued during treatment [97]. If IFN is absolutely contraindicated and liver disease is progressing, RBV monotherapy may be considered.

Epilepsy may be exacerbated by IFN therapy; however, epileptic patients who are undergoing drug treatment to achieve neurological control can be given antiviral therapy.

Rules for stopping treatment

The current recommendation is to discontinue treatment in patients who do not achieve a EVR or a reduction in HCV-RNA levels from baseline of at least 2 log10 by treatment week 12 (negative predictive value approaching 100%). In contrast, patients who achieve these endpoints have an increased probability (67–83%) of achieving a SVR and should be encouraged to continue treatment. However, the favourable prognostic significance of a viraemic decline that is short of complete virus clearance has been questioned; a recent analysis has shown that a distinct proportion of patients who had a reduced viraemic titre of lower than 2 log10 at 12 weeks of therapy failed to eradicate HCV and experienced viral rebounds during and after therapy [54].

Patients who achieve an EVR can complete therapy without further HCV-RNA testing, whereas those who remain HCV-RNA-positive (regardless of the 2 log10 reduction) should be retested for HCV RNA at 24 weeks. Patients who remain HCV-RNA-positive at 24 weeks should stop treatment, whereas those who are negative should complete the course of therapy.

These rules for stopping therapy do not apply to patients with HCV-2 or -3, who have a high probability of achieving a SVR and who do not require assessment of an EVR.

Factors predictive of a response to antiviral therapy

Both viral [65] and host [98] factors influence the probability of achieving a response to antiviral therapy; most factors are fixed, although a few may be correctable (Table 4). The most important factor is the HCV genotype; in each clinical category of hepatitis C patients, genotypes 2 and 3 are easier to treat, with SVR rates that are double those achieved with the difficult-to-treat genotype 1 [5,8,44,58,60,64,65,99]; genotype 1a may respond better than genotype 1b [100]. Genotypes 4, 5 and 6 appear to respond less well than genotypes 2 and 3, but better than 1a and 1b [42,43].

Patients with high serum viral loads respond less well than those with low viraemia [5,8]. However, what is considered a low or a high viral titre is arbitrary to a considerable degree; recent studies have individuated a cut-off of 600 000 IU/mL [58–60]. The prognostic impact of the viral load is currently considered marginal compared with the impact of the genotype.

Table 4 Baseline factors affecting the response to therapy.

Non-modifiable factors
Gender
Age
Ethnicity
Histology
Viral load
Genotype
Modifiable factors
Body mass index
Intrahepatic iron levels
Insulin resistance (?)

Host factors affecting the antiviral response are age, gender and ethnicity. Younger patients and women respond better than older patients and men. Despite the lower rate of response with increasing age and the higher percentage of side-effects, treatment is often appropriate in older patients because hepatitis C tends to progress more rapidly with advancing age. The response in HCV genotype 1 patients of Afro-American descent is poorer than that in Caucasians [101,102]; however, the response appears to be similar in both genotype 2 and 3 patients from these two ethnic groups [103].

Overweight patients respond less well, even after the dosages of IFN and RBV are adjusted according to weight [104]. About 50% of patients with HCV genotype 1 are insulin resistant, and insulin resistance was shown to be an independent predictor of a diminished response to antiviral therapy [105]. Liver steatosis secondary to insulin resistance also diminishes the response to antiviral therapy [106]. Steatosis observed in patients infected with HCV genotype 3 appears to be related to a viral mechanism; in these patients, the response to therapy is associated with reductions in hepatic fat [107] and the recurrence of infection is generally accompanied by the recrudescence of steatosis. In 1428 naive patients, the presence of steatosis was associated with a lower SVR rate than that seen in non-steatotic patients but, in patients who achieved a SVR, steatosis was most improved in those with HCV genotype 3; low baseline serum cholesterol was also corrected by IFN treatment in genotype 3 responders [106].

Patients with intrahepatic iron overload have a lower response rate to IFN [108,109], and iron removal by phlebotomy improves responses in these patients [110]. Adjuvant iron reduction also appears to improve the therapeutic response in patients with normal baseline ferritin and transferrin saturation [111–113].

The extent of liver fibrosis also has an impact on treatment outcome and may be taken into account as a secondary predictive factor, together with the above-mentioned criteria.

Adherence to therapy

Adherence to therapy is an important determinant of a SVR. In one study, a 3 × 80 adherence rule, i.e. administration of at least 80% of the originally prescribed dose of IFN and RBV for at least 80% of the planned duration of therapy, was considered to define compliance, resulting in the expected rate of efficacy [114]. HCV genotype 1 patients who did not reduce therapy below the 80% rule had a significantly higher SVR rate than patients who were unable to adhere to the full dose. However, further analysis indicated that early low adherence (during the first 12–20 weeks of therapy) diminished the SVR rate more significantly than late (20–48 weeks) non-compliance and that, during early therapy, keeping the full dose of RBV was more important than keeping the full dose of IFN. In the HALT-C study [38], dose reductions of PEG-IFN from greater than 80% to less than 60% of the target dose within the first 20 weeks of therapy did not diminish SVR rates, whereas reductions of the target dose of RBV to less than 60% resulted in a significant reduction in the SVR; a reduction of either drug after 20 weeks, when HCV-RNA levels had become undetectable, did not significantly effect the SVR.

As dose reductions of IFN and RBV are usually forced by treatment-related adverse events, management of side-effects is important to ensure compliance and achieve the highest possible SVR. The control of RBV-induced anaemia with epoetin may improve compliance [88,90]. Granulocyte growth factors may also be administered to combat IFN-induced leukopenia.

Compliance is a major problem in drug addicts because of a poor rate of acceptance of or adherence to therapeutic regimens; treatment with PEG-IFN/RBV is safe and sufficiently effective in patients on methadone maintenance [115].

Which HCV subject to treat?

All patients with chronic hepatitis C are potential candidates for antiviral therapy [44]. However, treatment may be associated with important side-effects and the results of current antiviral therapy are variable, depending on viral and individual factors. Therefore, the decision whether to treat a patient should be based on: (i) the risk of the underlying liver disease evolving into cirrhosis and HCC in the lifetime of the patient, (ii) the possible impact of treatment-related adverse effects on the patient's general health, and (iii) the probability of achieving a response, taking into consideration the HCV genotype and viral load and the clinical features and comorbidities of the patient. Of note, the data on which current antiviral drugs and treatment protocols were licensed have been collected from selected clinically homogeneous HCV patients without significant comorbidities; results may be less favourable in field practice in the general HCV population, in whom the epidemiological and clinical scenario is more disparate [75].

These issues need to be exhaustively discussed with the patients. Patients must be fully aware of the pros and cons of therapy and must participate in the decision-making process, ultimately deciding themselves whether the risk-to-benefit ratio of therapy is acceptable. Patients with no evidence of progressive disease, with HCV genotype 1 and with comorbid conditions may reasonably decide to delay therapy until more efficient and tolerable treatments become available.

The presence of elevated ALT levels is the main determinant in the decision to start therapy, as there is a correlation between ALT abnormalities and liver disease activity and progression. There is a consensus that liver biopsy is not necessary in the treatment of HCV-2 and -3 patients. Given that the indication to treat now extends to the whole spectrum of histological lesions, from initial fibrosis to established compensated cirrhosis, and that histological scores may grossly underestimate the extent of fibrosis because of sampling errors, the need to take a confirmatory liver biopsy in HCV patients willing to submit to therapy is currently being debated; a biopsy should be recommended for HCV-1 patients who are unwilling to undergo therapy or who have comorbid conditions that increase the risk of side-effects, in order to motivate treatment or justify its withdrawal. The role of non-invasive markers of liver fibrosis (serum markers and/or elastogram) in the treatment decision-making process is still to be determined.

Individuals with persistently normal ALT

The issue of whether HCV-RNA-positive subjects with persistently normal ALT levels should be treated is evolving. These subjects appear to respond as well as, and according to the same prognostic factors as, patients with abnormal ALT levels [116,117]; SVR rates of 40% and 72% were obtained in genotype 1 and 2/3 patients, respectively, when PEG-IFN plus RBV was given for 48 and 24 weeks respectively [116].

The decision to treat should be individualized and based not only on the clinical suspicion of underlying liver disease but also on the age and motivation of the patient; a major determinant of treatment may be the negative perception of the chronic infection and the psychological impact of being a potential source of HCV transmission. The need for a liver biopsy is controversial; young motivated patients at no increased risk, in particular those with HCV-2 and -3, may be treated without a biopsy [118]. A confirmatory liver biopsy may be useful in patients who are older than 50 and who have relative contraindications to therapy and genotypes that are difficult to treat; in these patients, the decision to treat should be based on the finding of significant fibrosis [118]. Hopefully, the introduction of non-invasive methods such as the liver elastogram will help to differentiate patients with and without fibrosis and enable liver biopsies to be targeted to those with a stiff liver.

Cirrhosis

There is indication to treat patients with compensated cirrhosis [119–121]. Although fibrosis has been considered to be an

important negative predictor of response to antiviral therapy, registrative PEG-IFN/RBV studies have shown that the rate of SVR in compensated patients with advanced fibrosis and cirrhosis is only marginally less than in patients without fibrosis (44% versus 54% [7]; 43% versus 56% [8]).

Although antiviral therapy is evolving in patients with decompensated cirrhosis, there is, as yet, no indication to treat such patients. The clinical status at the time of initiating antiviral therapy appears to be the major limiting factor; treatment must be avoided in patients with a Child–Turcotte–Pugh (CTP) score of > 11 or a model for endstage liver disease (MELD) score of > 25, as the risk of precipitating liver failure is high [122]. Published reports mostly describe patients undergoing liver transplantation. The series of patients included have been clinically heterogeneous and not comparable; most studies have considered a lack of HCV reinfection in the liver graft as evidence of treatment efficacy [123]. Treatment can be considered in patients with CTP scores of 8–11 (MELD scores 18–25); although SVR responses as high as 90% were reported in patients with HCV-2 and -3 and responses of 30% were reported in patients with HCV-1, treatment benefit was offset by severe complications related primarily to neutropenia, thrombocytopenia and anaemia [124–125]. Low initial escalating doses of IFN have been proposed for patients with blood cytopenia [120].

Children

In children, the course of chronic hepatitis C is usually benign and progression is slow; thus, in most paediatric patients, therapy is not necessary or can be delayed. Treatment may be considered in children who are viraemic and who have persistently abnormal ALT levels [126]. They are good candidates for therapy as the HCV infection is short-lived, they do not usually have advanced fibrosis and they appear to tolerate treatment well; however, therapy should be avoided in children of less than 3 years because it may adversely affect growth [127].

In various heterogeneous studies in which 336 children were treated with IFN monotherapy, the average SVR rate was 36% and, in several limited series in which children were treated with standard IFN/RBV, the SVR rate varied between 50% and 64% [128].

Among children treated with PEG-IFN-α-2b/RBV [129], a SVR was obtained in 47.8% of patients with HCV-1, 100% of patients with HCV-2 and -3, and 50% of patients with HCV-4. Treatment was generally well tolerated; however, three children required dose reductions and 10.3% developed thyroid autoantibodies and thyroid dysfunction.

Patients with autoantibodies

IFN therapy has occasionally been associated with hepatitic flares in patients with autoantibodies [130,131]. However, borderline antinuclear autoantibody (ANA) or smooth muscle autoantibody (SMA) reactivities often occur in hepatic as well as in all forms of liver disease, and their frequency increases with age and with the inflammatory activity of the underlying liver disease; in the absence of other signs of autoimmunity, these autoantibodies do not contraindicate the use of IFN or PEG-IFN. In patients with well-documented hepatitis C, the presence of liver–kidney microsomal (LKM) antibodies does not predict autoimmune hepatitis or hyporesponsiveness to IFN/RBV [132,133]. In patients with hepatitis C who have significant titres of autoantibodies, attention should be given to the presence of other autoimmune stigmata such as arthritis, haemolytic anaemia and a high level of immunoglobulin (Ig)G. In order to identify possible cases of autoimmune hepatitis, one can apply the International Autoimmune Hepatitis Group Scoring System [134], which was devised to identify autoimmune liver disease. If the aggregate score is non-diagnostic, therapy with IFN appears to be safe; if the score points to probable or definite autoimmune hepatitis, steroids should be considered.

Mixed cryoglobulinaemia

In a proportion of mixed cryoglobulinaemia (MC) patients, treatment with IFN monotherapy at doses of 3–6 MU three times a week for 6–12 months reduced the cryocrit, improved the cutaneous rash and joint symptoms and led to the clearance of HCV RNA [135,136]; in some studies, IFN was used in combination with low doses of steroids [137]. However, the virological and clinical response was lower and the relapse rate higher than in hepatitis C patients without MC. Variations in the biological markers of MC (cryocrit, rheumatoid factor, complement) may be independent of the virological or ALT response. In some patients with severe MC symptoms, long-term maintenance therapy is required because they respond well to IFN but promptly relapse at therapy withdrawal. The efficacy of IFN in treating MC-associated neuropathies is debated. Concomitant with HCV-RNA clearance, IFN therapy may lead to the disappearance of monoclonal B-cell infiltrates and to a lack of detection of circulating t(14:18) translocated B-cell clones; the latter reappear if serum HCV reactivates [138,139]. In a study of nine symptomatic and refractory HCV–MC patients, there was an improvement in the symptoms of the majority of the patients after treatment with standard IFN/RBV, even though HCV clearance was only obtained in a minority (22%) [140].

In two pilot studies of 9 and 18 MC patients [141,142], PEG-IFN-α-2b/RBV given for 12–13 months induced a virological and clinical response in the majority of patients (78%–83%) while on therapy; however, in one of the studies, the rate of relapse was high (44%) [142].

The persistence of MC despite the clearance of HCV RNA from serum may be associated with residual HCV infection in lymphocytes [143].

In patients who are non-responders to PEG-IFN/RBV combination therapy and who show clinically significant symptoms of

MC, administration of anti-CD20 monoclonal antibody (rituximab) against B-cell monoclonal proliferation may be considered.

Immunodepressed patients

Treatment of chronic hepatitis C in HIV and transplanted patients is discussed in Chapters 9.3 and 25.5 respectively.

HCV–HBV coinfected patients

Data on the long-term outcome for individuals coinfected with HCV and HBV suggest that these patients have higher rates of progressive liver disease and HCC; effective treatment for such individuals is, therefore, of particular importance. In general, in double infections such as these, one virus usually inhibits the other; therefore, it is essential to measure both HBV-DNA and HCV-RNA levels to determine which infection is dominant and treat accordingly. If both infections are active, initial therapy with IFN and RBV, according to the protocols used for the treatment of hepatitis C, may be the first option, as eradication of HCV is more likely than eradication of HBV, and IFN may also control HBV infection. To date, no specific randomized trials have addressed the issues of an optimal treatment protocol and therapeutic outcome in HCV–HBV coinfected patients.

Patients with comorbidities

Renal disorders

HCV infection is frequent in haemodialyzed patients with renal insufficiency [144]. The course of HCV disease in these patients is characterized by low or normal ALT values and viraemic levels that are lower than in non-uremic patients; viraemia may spontaneously become transiently negative.

The clearance of RBV is much reduced in patients with kidney failure and the drug is not removed by dialysis. Even a dosage of RBV of as low as 200 mg/day can precipitate serious anaemia [145–146] and, therefore, its use is contraindicated. The clearance of standard IFN is also reduced and dosages should be adapted to plasma creatinine values [147].

A review of 269 dialysis patients from 14 heterogeneous clinical trials showed that standard IFN monotherapy given for 4–12 months induced a SVR in 37% of patients, with a dropout rate of 17% [148]. The overall weighted estimate for a SVR in HCV-1 patients was 30.6%; a negative serum HCV-RNA test at 8–12 weeks correlated with a SVR. Tolerance was lower than in non-uremic patients and prolonged IFN monotherapy did not improve the SVR. In a further study of haemodialysis patients [149], the SVR was 34% in 29 patients who completed treatment (out of 46 who originally enrolled in the study). Finally, in a preliminary study [150], PEG-IFN-α-2b and low-dose RBV (target concentration of 10–15 mmol/L) were given to six haemodialysis patients; all patients became HCV-RNA-negative during therapy and three remained negative with extended follow-up.

Haematological disorders

Trials in hepatitis C patients with thalassemia have shown that treatment with IFN and RBV is safe and effective [151,152], as long as adequate haemoglobin levels can be maintained by transfusion.

Red blood cells of individuals with the Mediterranean form of glucose-6-phosphate dehydrogenase deficiency do not appear to be more susceptible to the haemolytic potential of RBV; 26 Sardinian HCV patients with severe glucose-6-phosphate dehydrogenase deficiency were safely treated with PEG-IFN/RBV, with responses that were similar to patients with HCV alone [153].

HCV patients with haemophilia have also been safely treated with standard IFN/RBV therapy [154]; the overall SVR rate was lower (29%) than in patients with HCV alone, but it was high among adolescents younger than 18 years (59%).

Diabetes

Although IFN may precipitate diabetic decompensation, particularly in patients with pancreatic autoantibodies [155–157], compensated diabetes is not a contraindication to therapy in chronic HCV hepatitis. In one study of a patient with pre-existing diabetes, the diabetes resolved after combination therapy [158].

Hepatitis C in liver transplants

(See Chapter 25.5)

Retreatment

Non-response to therapy is defined as the persistence of serum HCV RNA throughout, and at the end of, treatment. Relapse is defined as the recurrence of serum HCV RNA during the post-therapy follow-up, after apparent clearance of viraemia throughout therapy. As chronic hepatitis C is a curable disease, it is important to consider retreatment in patients who were previous non-responders or relapsers after a first course of antiviral therapy. In one study [159] of patients who previously relapsed after treatment with standard IFN monotherapy or standard IFN/RBV therapy, the overall SVR rate after retreatment with PEG-IFN/RBV was 60% and 53% respectively. Retreatment with combination therapy resulted in a SVR in about 25% of patients who were non-responders to IFN monotherapy but who had a partial biochemical or virological response during the monotherapy course [160–162].

New information is emerging from two large-scale studies whose aim is to retreat patients with advanced compensated liver disease (bridging fibrosis or cirrhosis) for 48 weeks with PEG-IFN/RBV (lead-in phase), and maintain long-term with low-dose PEG-IFN monotherapy those who fail to achieve a SVR with full antiviral therapy. Preliminary results from the lead-in phase of the HALT-C study [38] (designed to retreat non-responders to IFN monotherapy or standard IFN/RBV therapy with PEG-IFN-α-2a/RBV) have shown a 28% SVR rate in previous non-responders to IFN alone and a 12% SVR rate in non-responders to standard IFN/RBV. Similarly, preliminary

results from the EPIC3 study (designed to retreat relapsers and non-responders to IFN/RBV therapy with PEG-IFN-α-2b/RBV) [163] have shown SVR rates of 41% in relapsers and 14% in non-responders. In both studies, HCV genotypes 2 and 3 responded significantly better than HCV genotype 1 (54–65% versus 14%).

In a recent study [164], 19% of the genotype 1 patients who were retreated with PEG-IFN-α-2b/RBV after failing to respond to standard IFN/RBV therapy achieved a SVR; independent predictors of response were low γ-glutamyltransferase levels and low viral load. In another PEG-IFN/RBV retreatment study [165], an overall SVR rate of 23% was obtained in patients who had not previously responded to IFN monotherapy or IFN/RBV therapy. Among standard α IFN/RBV non-responders retreated with daily consensus IFN and RBV, 22% achieved a SVR [166].

These data suggest that it is reasonable to retreat patients who relapse to IFN monotherapy or standard IFN/RBV combination therapy with PEG-IFN/RBV, and to retreat patients who do not respond to IFN monotherapy with PEG-IFN/RBV. Although it also seems reasonable to retreat HCV genotype 2 and 3 patients who do not respond to standard IFN/RBV therapy with PEG-IFN/RBV, current retreatment SVR rates in HCV genotype 1 patients who do not respond to standard IFN/RBV therapy are lower than 20% and, therefore, the efficacy of treating these patients, who account for the larger proportion of non-responders, is doubtful.

The addition of histamine in triple combination with PEG-IFN and RBV was of no benefit and the efficacy of the addition of amantadine is debated [167]; this triple combination is not generally used. Large-scale studies are in progress to evaluate the efficacy of retreatment with high doses of PEG-IFN/RBV [168] and with triple combinations including thymosin or protease inhibitors.

Long-term maintenance monotherapy with reduced weekly dosages of PEG-IFN has been proposed to prevent progression of disease in patients with advanced disease who fail or do not tolerate full antiviral therapy [169]. Three major long-term trials are ongoing to assess the efficacy of maintenance therapy (COPILOT, HALT-C, EPIC3); preliminary results have been encouraging [170].

New treatments in development

Approximately 50–60% of patients with chronic HCV infection do not achieve a SVR with current therapy. Treatment failures are often considered to be the result of the virus being 'resistant' to therapy, with antiviral resistance being commonly defined as the mechanisms that a virus develops to continue replication and escape the antiviral effects of treatment and/or the immune response of the host. However, it is not known whether the failure to achieve a SVR can be entirely considered as being 'true' resistance according to this definition. Non-responders to current therapy show little or no decrease in serum HCV-RNA levels during therapy. In these patients, the lack of immune clearance of infected cells may be a key determinant in the lack of viral eradication [171]. In addition, the genetic heterogeneity or quasi-species nature of HCV raises important therapeutic implications, as the generation and selection of resistant variants can allow the virus to escape the antiviral pressure exerted by treatment [172].

New HCV inhibitors

With improved understanding of HCV molecular virology, new therapies that specifically target HCV replication are being developed. A number of protease or polymerase inhibitors directed against HCV genotype 1 enzymes have been identified. Several are now undergoing phase I/II clinical trials in monotherapy and in combination with pegylated IFN, in order to increase the virus clearance rate and decrease the resistance rate; amongst the most promising are the NS3 serine protease inhibitors [173] and the NS5B RNA-dependent RNA polymerase inhibitors.

New IFNs (Albuferon) are also being evaluated, as well as RBV derivatives (viramidine, etc.) that are less prone to induce haemolysis.

Drug resistance is a major consideration for novel direct antivirals

Because of the high mutation rate observed with HCV, it is likely that mutated viruses having a reduced sensitivity to antiviral therapies will emerge. In addition, the overall prevalence of individual mutations changes over time, indicating that the relative 'fitness' (ability to replicate) of a resistant variant will play a role in viral dynamics during treatment [174]. Potential resistance mutations in both the polymerase and protease enzymes have been identified. As the active site for protease inhibitors is a long shallow groove, a single point mutation in this enzyme may be sufficient to hinder the binding of antivirals, with different mutations conferring low-level or high-level resistance. There have been several studies reporting the selection of HCV mutants that are resistant against various protease inhibitors using the *in vitro* replicon system [174–180].

The active site of the NS5B RNA-dependent RNA polymerase is a highly conserved region in all HCV genotypes and any amino acid mutation in this region may inhibit the ability of the virus to replicate. This suggests that mutations in this enzyme, which could result in resistance to nucleoside polymerase inhibitors, may not readily develop. *In vitro* studies have shown that replicons carrying mutations showed decreased replication fitness [178–183]. The NS5B polymerase has also been targeted through the interaction of its thumb and palm structural domains with non-nucleoside analogues. *In vitro* resistance to this class of inhibitor arises through single mutations within the inhibitor binding site, which strongly reduces its affinity for the inhibitors [179,180]. The success of future HCV antiviral agents

will be heavily influenced by their ability to inhibit viral variants and prevent the emergence of escape mutants. Agents with different mechanisms of action show limited cross-resistance in laboratory studies, suggesting that these therapies may be used in combination. Thus, the ultimate pharmacological control of HCV may be best achieved with a combination of agents that are specifically designed to inhibit different virus-specific targets through complimentary mechanisms of action, e.g. protease inhibitors with polymerase inhibitors or nucleoside with non-nucleoside polymerase inhibitors [184]. Clinical trials are ongoing to determine if these new inhibitors will improve the rate of SVR in chronic hepatitis C.

References

1 Davis GL, Balart LA, Schiff ER *et al.* (1989) Treatment of chronic hepatitis C with recombinant interferon alfa. A multicenter randomized controlled trial. *N Engl J Med* 321, 1501–1506.

2 Di Bisceglie AM, Martin P, Kassianides C *et al.* (1989) Recombinant interferon alfa therapy for chronic hepatitis C. A randomized, double-blind, placebo-controlled trial. *N Engl J Med* 321, 1506–1510.

3 Poynard T, Leroy V, Cohard M *et al.* (1996) Meta-analysis of interferon randomized trials in the treatment of viral hepatitis C: effects of dose and duration. *Hepatology* 24, 778–789.

4 Carithers RL, Emerson SS (1997) Therapy of hepatitis C: meta-analysis of interferon alfa-2b trials. *Hepatology* 26(Suppl), S83–88.

5 McHutchison JG, Gordon SC, Schiff ER *et al.* (1998) Interferon alfa-2b alone or in combination with ribavirin as initial treatment for chronic hepatitis C. *N Engl J Med* 339, 1485–1492.

6 Poynard T, Marcellin P, Lee SS *et al.* (1998) Randomised trial of interferon alpha2b plus ribavirin for 48 weeks or for 24 weeks versus interferon alpha2b plus placebo for 48 weeks for treatment of chronic infection with hepatitis C virus. *Lancet* 352, 1426–1432.

7 Manns M, McHutchison J, Gordon S *et al.* (2001) Peginterferon alfa-2b plus ribavirin compared with interferon alfa-2b plus ribavirin for initial treatment of chronic hepatitis C: a randomised trial. *Lancet* 358, 958–965.

8 Fried MW, Shiffman ML, Reddy KR *et al.* (2002) Peg-Interferon alfa2a plus ribavirin for chronic hepatitis C virus infection. *N Engl J Med* 347, 975–982.

9 Hadziyannis SJ, Sette H Jr, Morgan TR *et al.* (2004) Peginterferon-alpha2a and ribavirin combination therapy in chronic hepatitis C: a randomized study of treatment duration and ribavirin dose. *Ann Intern Med* 140, 346–355.

10 Baron S, Tyring SK, Fleischmann WR Jr *et al.* (1991) The interferons. Mechanisms of action and clinical applications. *JAMA* 266, 1375–1383.

11 Blatt LM, Davis JM, Klein SB *et al.* (1996) The biologic activity and molecular characterization of a novel synthetic interferon-alpha species, consensus interferon. *J Interferon Cytokine Res* 16, 489–499.

12 Glue P, Fang JW, Rouzier-Panis R *et al.* (2000) Pegylated interferon-alpha2b: pharmacokinetics, pharmacodynamics, safety, and preliminary efficacy data. *Clin Pharmacol Ther* 68, 556–567.

13 Zeuzem S, Welsch C, Herrmann E (2003) Pharmacokinetics of peginterferons. *Semin Liver Dis* 23(Suppl 1), 23–28.

14 Bain VG, Kaita KD, Yoshida EM *et al.* (2006) A phase 2 study to evaluate the antiviral activity, safety, and pharmacokinetics of recombinant human albumin-interferon alfa fusion protein in genotype 1 chronic hepatitis C patients. *J Hepatol* 44, 671–678.

15 Glue P (1999) The clinical pharmacology of ribavirin. *Semin Liver Dis* 19(Suppl 1), 17–24.

16 Zoulim F, Haem J, Ahmed SS *et al.* (1998) Ribavirin monotherapy in patients with chronic hepatitis C: a retrospective study of 95 patients. *J Viral Hepat* 5, 193–198.

17 Hoofnagle JH, Lau D, Conjeevaram H *et al.* (1996) Prolonged therapy of chronic hepatitis C with ribavirin. *J Viral Hepat* 3, 247–252.

18 Lau JY, Tam RC, Liang TJ *et al.* (2002) Mechanism of action of ribavirin in the combination treatment of chronic HCV infection. *Hepatology* 35, 1002–1009.

19 Pawlotsky JM, Dahari H, Neumann AU *et al.* (2004) Antiviral action of ribavirin in chronic hepatitis C. *Gastroenterology* 126, 703–714.

20 Crotty S, Cameron CE, Andino R (2001) RNA virus error catastrophe: direct molecular test by using ribavirin. *Proc Natl Acad Sci USA* 98, 6895–6900.

21 Layden JE, Layden TJ (2002) Viral kinetics of hepatitis C: new insights and remaining limitations. *Hepatology* 35, 967–970.

22 Zeuzem S, Herrmann E, Lee JH *et al.* (2001) Viral kinetics in patients with chronic hepatitis C treated with standard or peginterferon alpha2a. *Gastroenterology* 120, 1438–1447.

23 Herrmann E, Lee JH, Marinos G *et al.* (2003) Effect of ribavirin on hepatitis C viral kinetics in patients treated with pegylated interferon. *Hepatology* 37, 1351–1358.

24 Heathcote J (2000) Antiviral therapy for patients with chronic hepatitis C. *Semin Liver Dis* 20, 185–199.

25 Strader DB, Wright T, Thomas DL *et al.* (2004) Diagnosis, management, and treatment of hepatitis C. *Hepatology* 39, 1147–1471.

26 Reichard O, Glaumann H, Fryden A *et al.* (1999) Long-term follow-up of chronic hepatitis C patients with sustained virological response to alpha-interferon. *J Hepatol* 30, 783–787.

27 Veldt BJ, Saracco G, Boyer N *et al.* (2004) Long term clinical outcome of chronic hepatitis C patients with sustained virological response to interferon monotherapy. *Gut* 53, 1504–1508.

28 Barnes E, Webster G, Jacobs R *et al.* (1999) Long-term efficacy of treatment of chronic hepatitis C with alpha interferon or alpha interferon and ribavirin. *J Hepatol* 31(Suppl 1), 244–249.

29 Poynard T, McHutchison J, Manns M *et al.* (2002) Impact of pegylated interferon alfa-2b and ribavirin on liver fibrosis in patients with chronic hepatitis C. *Gastroenterology* 122, 1303–1313.

30 Camma C, Di Bona D, Schepis F *et al.* (2004) Effect of peginterferon alfa-2a on liver histology in chronic hepatitis C: a meta-analysis of individual patient data. *Hepatology* 39, 333–342.

31 Shiratori Y, Imazeki F, Moriyama M *et al.* (2000) Histologic improvement of fibrosis in patients with hepatitis C who have sustained response to interferon therapy. *Ann Intern Med* 132, 517–524.

32 Yoshida H, Shiratori Y, Moriyama M *et al.* (1999) Interferon therapy reduces the risk for hepatocellular carcinoma: national surveillance program of cirrhotic and noncirrhotic patients with chronic hepatitis C in Japan. *Ann Intern Med* 131, 174–181.

33 Ikeda K, Saitoh S, Arase Y *et al.* (1999) Effect of interferon therapy on hepatocellular carcinogenesis in patients with chronic hepatitis type C: a long-term observation study of 1,643 patients using statistical bias correction with proportional hazard analysis. *Hepatology* 29, 1124–1130.

34 Davis GL, Wong JB, McHutchison JG *et al.* (2003) Early virologic response to treatment with peginterferon alfa-2b plus ribavirin in patients with chronic hepatitis C. *Hepatology* 38, 645–652.

35 Jensen D, Morgan T, Marcellin P *et al.* (2005) Rapid virologic response at week 4 (RVR) of peginterferon alfa-2a (40 KD) (Pegasys)

plus ribavirin (RBV, Copegus) treatment predicts sustained virological response (SVR) after 24 weeks in genotype 1 patients. *Hepatology* 42(Suppl 1), 650A.
36 Pradat P, Chossegros P, Bailly F *et al.* (2000) Comparison between three quantitative assays in patients with chronic hepatitis C and their relevance in the prediction of response to therapy. *J Viral Hepat* 7, 203–210.
37 Pawlotsky JM, Bouvier-Alias M, Hezode C *et al.* (2000) Standardization of hepatitis C virus RNA quantification. *Hepatology* 32, 654–659.
38 Shiffman ML, Di Bisceglie AM, Lindsay KL *et al.* (2004) Peginterferon alfa-2a and ribavirin in patients with chronic hepatitis C who have failed prior treatment. *Gastroenterology* 126, 1015–1023.
39 Reichard O, Norkrans G, Fryden A *et al.* (1998) Randomised, double-blind, placebo-controlled trial of interferon alpha-2b with and without ribavirin for chronic hepatitis C. *Lancet* 351, 83–87.
40 Zeuzem S, Feinman SV, Rasenack J *et al.* (2000) Peginterferon alfa-2a in patients with chronic hepatitis C. *N Engl J Med* 343, 1666–1672.
41 Heathcote EJ, Shiffman ML, Cooksley WG *et al.* (2000) Peginterferon alfa-2a in patients with chronic hepatitis C and cirrhosis. *N Engl J Med* 343, 1673–1680.
42 Hasan F, Asker H, Al-Khaldi J *et al.* (2004) Peginterferon alfa-2b plus ribavirin for the treatment of chronic hepatitis C genotype 4. *Am J Gastroenterol* 99, 1733–1737.
43 Nguyen MH, Keefe EB (2005) Prevalence and treatment of hepatitis C virus genotypes 4,5, and 6. *Clin Gastroenterol Hepatol* 3(Suppl 2), S97–101.
44 NIH Consensus Statement (2002) Management of hepatitis C. *Hepatology* 19, 1–46.
45 Craxi A, Camma C (2006) Treating patients with HCV genotype 1 and low viraemia: more than meets the eye. *J Hepatol* 44, 4–7.
46 Weiland O, Schwarcz R, Mattsson L *et al.* (2006) 135 microg Peg-IFN alpha-2a in combination with weight-based ribavirin for genotype 2 and 3 is highly efficacious. *J Hepatol* 44(Suppl 2), S230.
47 Brown RS, Jacobson IM, Afdhal N *et al.* (2006) Differences in treatment outcome to antiviral therapy based on genotype and viral load in hepatitis C genotypes 2 and 3 in the WIN-R trial. *J Hepatol* 44(Suppl 2), S20.
48 Ferenci P, Brunner H, Laferl H *et al.* (2006) Further reduction of ribavirin dose in HCV genotype 2/3 patients receiving PegInterferon alpha-2a (40 kDa) (Pegasys) plus ribavirin (Copegus): interim results of a randomised controlled trial. *J Hepatol* 44(Suppl 2), S37.
49 Rendon A, Nunez M, Romero M *et al.* (2005) Early monitoring of ribavirin plasma concentrations may predict anemia and early virologic response in HIV/hepatitis C virus-coinfected patients. *J Acquir Immune Defic Syndr* 39, 401–405.
50 Fontana RJ (2006) Optimizing outcomes in hepatitis C: is treatment beyond 48 weeks ever justified? *Gastroenterology* 130, 1357–1362.
51 Drusano GL, Preston SL (2004) A 48-week duration of therapy with pegylated interferon alpha 2b plus ribavirin may be too short to maximize long-term response among patients infected with genotype-1 hepatitis C virus. *J Infect Dis* 189, 964–970.
52 Brouwer JT, Nevens F, Bekkering FC *et al.* (2004) Reduction of relapse rates by 18-month treatment in chronic hepatitis C. A Benelux randomized trial in 300 patients. *J Hepatol* 40, 689–695.
53 Sanchez-Tapias JM, Diago M, Escartin P *et al.* (2006) Peginterferon alfa-2a plus ribavirin for 48 weeks in patients with detectable hepatitis C virus RNA at week 4 of treatment. *Gastroenterology* 131, 451–460.
54 Berg T, von Wagner M, Nasser S *et al.* (2006) Extended treatment duration for hepatitis C virus type 1: comparing 48 versus 72 weeks of peginterferon-alfa-2a plus ribavirin. *Gastroenterology* 130, 1086–1097.
55 Mangia A, Santoro R, Minerva N *et al.* (2005) Peginterferon alfa-2b and ribavirin for 12 vs. 24 weeks in HCV genotype 2 or 3. *N Engl J Med* 352, 2609–2617.
56 Von Wagner, Huber M, Berg T *et al.* (2005) Peginterferon-alpha-2a (40KD) and ribavirin for 16 or 24 weeks in patients with genotype 2 or 3 chronic hepatitis C. *Gastroenterology* 129, 522–527.
57 Shiffman ML, Pappas S, Nyberg L *et al.* (2006) Peginterferon alpha-2a (Pegasys) plus ribavirin (Copegus) for 16 or 24 weeks in patients with genotype 2 or 3. *J Hepatol* 44(Suppl 2), S271.
58 Zeuzem S, Hultcrantz R, Bourliere M *et al.* (2004) Peginterferon alfa-2b plus ribavirin for treatment of chronic hepatitis C in previously untreated patients infected with HCV genotypes 2 or 3. *J Hepatol* 40, 993–999.
59 Alberti A (2004) Optimizing PEG-interferon and ribavirin combination therapy for patients infected with HCV-2 or HCV-3: is the puzzle completed? *J Hepatol* 40, 1032–1035.
60 Zeuzem S, Buti M, Ferenci P *et al.* (2006) Efficacy of 24 weeks treatment with peginterferon alfa-2b plus ribavirin in patients with chronic hepatitis C infected with genotype 1 and low pretreatment viraemia. *J Hepatol* 44, 97–103.
61 Ferenci P, Bergholz U, Laferl H *et al.* (2006) 24 weeks treatment regimen with peginterferon alpha-2a (40kD) (Pegasys) plus ribavirin (Copegus) in HCV genotype 1 or 4 'super-responders'. *J Hepatol* 44(Suppl 2), S6.
62 Ferenci P, Brunner H, Nachbaur K *et al.* (2001) Combination of interferon induction therapy and ribavirin in chronic hepatitis C. *Hepatology* 34, 1006–1011.
63 Neumann AU, Hagai E, Schalm SW *et al.* (2003) Early viral kinetics prediction of sustained virological response after 1 or 4 weeks of Peg-Interferon-alfa-2A and ribavirin therapy. *Hepatology* 38, 248A.
64 Booth JC, O'Grady J, Neuberger J (2001) Clinical guidelines on the management of hepatitis C. *Gut* 49(Suppl 1), 1–21.
65 Di Bisceglie AM, Hoofnagle JH (2002) Optimal therapy of hepatitis C. *Hepatology* 36(5 Suppl 1), S121–127.
66 Reddy KR, Wright TL, Pockros PJ *et al.* (2001) Efficacy and safety of pegylated (40-kd) interferon alpha-2a compared with interferon alpha-2a in noncirrhotic patients with chronic hepatitis C. *Hepatology* 33, 433–438.
67 Selmi C, Lleo A, Zuin M *et al.* (2006) Interferon alpha and its contribution to autoimmunity. *Curr Opin Investig Drugs* 7, 451–456.
68 Wilson LE, Widman D, Dikman SH *et al.* (2002) Autoimmune disease complicating antiviral therapy for hepatitis C virus infection. *Semin Arthritis Rheum* 32, 163–173.
69 Wesche B, Jaeckel E, Trautwein C *et al.* (2001) Induction of autoantibodies to the adrenal cortex and pancreatic islet cells by interferon alpha therapy for chronic hepatitis C. *Gut* 48, 378–383.
70 Muratori P, Muratori L, Guidi M *et al.* (2005) Clinical impact of non-organ-specific autoantibodies on the response to combined antiviral treatment in patients with hepatitis C. *Clin Infect Dis* 40, 501–507.
71 D'Alteroche L, Majzoub S, Lecuyer AI *et al.* (2006) Ophtalmologic side effects during alpha-interferon therapy for viral hepatitis. *J Hepatol* 44, 56–61.
72 Jubert C, Pawlotsky JM, Pouget F *et al.* (1994) Lichen planus and hepatitis C virus-related chronic active hepatitis. *Arch Dermatol* 130, 73–76.
73 Funk J, Langeland T, Schrumpf E *et al.* (1991) Psoriasis induced by interferon-alpha. *Br J Dermatol* 125, 463–465.
74 Fattovich G, Giustina G, Favarato S *et al.* (1996) A survey of adverse events in 11,241 patients with chronic viral hepatitis treated with alfa interferon. *J Hepatol* 24, 38–47.

75 Gaeta GB, Precone DF, Felaco FM *et al.* (2002) Premature discontinuation of interferon plus ribavirin for adverse effects: a multicentre survey in 'real world' patients with chronic hepatitis C. *Aliment Pharmacol Ther* 16, 1633–1639.

76 Russo MW, Fried MW (2003) Side effects of therapy for chronic hepatitis C. *Gastroenterology* 124, 1711–1719.

77 Cacopardo B, Benanti F, Brancati G *et al.* (1998) Leucocyte interferon-alpha retreatment for chronic hepatitis C patients previously intolerant to other interferons. *J Viral Hepat* 5, 333–339.

78 Maddrey WC (1999) Safety of combination interferon alfa-2b/ribavirin therapy in chronic hepatitis C-relapsed and treatment-naive patients. *Semin Liver Dis* 19(Suppl 1), 67–53.

79 Sulkowski MS, Wasserman R, Brooks L *et al.* (2004) Changes in haemoglobin during interferon alpha-2b plus ribavirin combination therapy for chronic hepatitis C virus infection. *J Viral Hepat* 11, 243–250.

80 Van Vlierbergh H, Delanghe JR, De Vos M *et al.* (2001) Factors influencing ribavirin-induced hemolysis. *J Hepatol* 34, 911–916.

81 De Franceschi L, Fattovich G, Turrini F *et al.* (2000) Hemolytic anemia induced by ribavirin therapy in patients with chronic hepatitis C virus infection: role of membrane oxidative damage. *Hepatology* 31, 997–1004.

82 Peck-Radosavljevic M, Wichlas M, Homoncik-Kraml M *et al.* (2002) Rapid suppression of hematopoiesis by standard or pegylated interferon-alpha. *Gastroenterology* 123, 141–151.

83 Brau N (2004) Epoetin alfa treatment for acute anaemia during interferon plus ribavirin combination therapy for chronic hepatitis C. *J Viral Hepat* 11, 191–197.

84 Di Fazio I, Motta M, Musumeci S *et al.* (2004) Efficacy of human recombinant erythropoietin plus IFN-alpha in patients affected by chronic hepatitis C. *J Interferon Cytokine Res* 24, 594–599.

85 Afdhal NH, Dieterich DT, Pockros PJ *et al.* (2004) Epoetin alfa maintains ribavirin dose in HCV-infected patients: a prospective, double-blind, randomized controlled study. *Gastroenterology* 126, 1302–1311.

86 Shiffman ML, Hofmann CM, Luketic VA *et al.* (1998) Use of granulocyte macrophage colony stimulating factor alone or in combination with interferon-alpha-2b for treatment of chronic hepatitis C. *J Hepatol* 28, 382–389.

87 Carreno V, Martin J, Pardo M *et al.* (2000) Randomized controlled trial of recombinant human granulocyte-macrophage colony-stimulating factor for the treatment of chronic hepatitis C. *Cytokine* 12, 165–170.

88 Kee KM, Lee CM, Wang JH *et al.* (2006) Thyroid dysfunction in patients with chronic hepatitis C receiving a combined therapy of interferon and ribavirin: incidence, associated factors and prognosis. *J Gastroenterol Hepatol* 21, 319–326.

89 Prummel MF, Laurberg P (2003) Interferon-alpha and autoimmune thyroid disease. *Thyroid* 13, 547–551.

90 Dalgard O, Bjoro K, Hellum K *et al.* (2002) Thyroid dysfunction during treatment of chronic hepatitis C with interferon alpha: no association with either interferon dosage or efficacy of therapy. *J Intern Med* 251, 400–406.

91 Moncoucy X, Leymarie F, Delemer B *et al.* (2005) Risk factors and long-term course of thyroid dysfunction during antiviral treatments in 221 patients with chronic hepatitis C. *Gastroenterol Clin Biol* 29, 339–345.

92 Doi F, Kakizaki S, Takagi H *et al.* (2005) Long-term outcome of interferon-alpha-induced autoimmune thyroid disorders in chronic hepatitis C. *Liver Int* 25, 242–246.

93 Zdilar D, Franco-Bronson K, Buchler N *et al.* (2000) Hepatitis C, interferon alfa, and depression. *Hepatology* 31, 1207–1211.

94 Hauser P, Khosla J, Aurora H *et al.* (2002) A prospective study of the incidence and open-label treatment of interferon-induced major depressive disorder in patients with hepatitis C. *Mol Psychiatry* 7, 942–947.

95 Asnis GM, De La Garza R (2006) Interferon-induced depression in chronic hepatitis C: a review of its prevalence, risk factors, biology, and treatment approaches. *J Clin Gastroenterol* 40, 322–335.

96 Schaefer M, Schmidt F, Folwaczny C *et al.* (2003) Adherence and mental side effects during hepatitis C treatment with interferon alfa and ribavirin in psychiatric risk groups. *Hepatology* 37, 443–451.

97 Musselman, Lawson DH, Gumnick JF *et al.* (2001) Paroxetine for the prevention of depression induced by high-dose interferon alfa. *N Engl J Med* 344, 961.

98 Gao B, Hong F, Radaeva S (2004) Host factors and failure of interferon-alpha treatment in hepatitis C virus. *Hepatology* 39, 880–890.

99 Craxì A, Cammà C (2006) Treating patients with HCV genotype 1 and low viraemia: more than meets the eye. *J Hepatol* 44, 4–7.

100 Alberti A, Colombo M, Craxi A *et al.* (2006) HCV-1 subtypes and response to pegylated interferon plus ribavirin therapy. *J Clin Virol* 36 (Suppl 2), S132.

101 McHutchison JG, Poynard T, Pianko S *et al.* (2000) The impact of interferon plus ribavirin on response of therapy in black patients with chronic hepatitis C. *Gastroenterology* 119, 1317–1323.

102 Muir AJ, Bornstein JD, Killenberg PG (2004) Peginterferon alfa-2b and ribavirin for the treatment of chronic hepatitis C in blacks and non-Hispanic whites. *N Engl J Med* 350, 2265–2271.

103 Brau N, Bini EJ, Currie S *et al.* (2006) Black patients with chronic hepatitis C have a lower sustained viral response rate than non-blacks with genotype 1, but the same with genotypes 2/3, and this is not explained by more frequent dose reductions of interferon and ribavirin. *J Viral Hepat* 13, 242–249.

104 Bressler BL, Guindi M, Tomlison G *et al.* (2003) High body mass index is an independent risk factor for nonresponse to antiviral treatment in chronic hepatitis C. *Hepatology* 38, 639–644.

105 Romero-Gomez M, Del Mar Viloria M, Andrade RJ *et al.* (2005) Insulin resistance impairs sustained response rate to peginterferon plus ribavirin in chronic hepatitis C patients. *Gastroenterology* 128, 636–641.

106 Poynard T, Ratziu V, McHutchison J *et al.* (2003) Effect of treatment with peginterferon or interferon alfa-2b and ribavirin on steatosis in patients infected with hepatitis C. *Hepatology* 38, 75–85.

107 Rubbia-Brandt L, Giostra E, Mentha G *et al.* (2001) Expression of liver steatosis in hepatitis C virus infection and pattern of response to alpha-interferon. *J Hepatol* 35, 307.

108 Bonkovsky HL (2002) Iron as a comorbid factor in chronic viral hepatitis. *Am J Gastroenterol* 97, 1–4.

109 Olynyk JK, Reddy KR, Di Bisceglie AM *et al.* (1995) Hepatic iron concentration as a predictor of response to interferon alfa therapy in chronic hepatitis C. *Gastroenterology* 108, 1104–1109.

110 Rulyak SJ, Eng SC, Patel K *et al.* (2005) Relationships between hepatic iron content and virologic response in chronic hepatitis C patients treated with interferon and ribavirin. *Am J Gastroenterol* 100, 332–337.

111 Di Bisceglie AM, Bonkovsky HL, Chopra S *et al.* (2000) Iron reduction as an adjuvant to interferon therapy in patients with chronic hepatitis C who have previously not responded to interferon: a

multicenter, prospective, randomized, controlled trial. *Hepatology* 32, 135–138.
112 Fontana RJ, Israel J, LeClair P *et al.* (2000) Iron reduction before and during interferon therapy of chronic hepatitis C: results of a multicenter, randomized, controlled trial. *Hepatology* 31, 730–736.
113 Fargion S, Fracanzani AL, Rossini A *et al.* (2002) Iron reduction and sustained response to interferon-alpha therapy in patients with chronic hepatitis C: results of an Italian multicenter randomized study. *Am J Gastroenterol* 97, 1204–1210.
114 McHutchison JG, Manns M, Patel K *et al.* (2002) Adherence to combination therapy enhances sustained response in genotype-1-infected patients with chronic hepatitis C. *Gastroenterology* 123, 1061–1069.
115 Mauss S, Berger F, Goelz J *et al.* (2004) A prospective controlled study of interferon-based therapy of chronic hepatitis C in patients on methadone maintenance. *Hepatology* 40, 120–124.
116 Zeuzem S, Diago M, Gane E *et al.* (2004) Peginterferon alfa-2a (40 kilodaltons) and ribavirin in patients with chronic hepatitis C and normal aminotransferase levels. *Gastroenterology* 127, 1724–1732.
117 Zehnter E, Mauss S, John C *et al.* (2006) Efficacy and safety of Peginterferon alpha-2a (40KD) [PEG] plus ribavirin (RBV) 1000/1200 mg/d in genotype 1 patients with chronic hepatitis C and 'normal' ALT levels. *J Hepatol* 44(Suppl 2), S622.
118 Alberti A (2005) Towards more individualised management of hepatitis C virus patients with initially or persistently normal alanineaminotransferase levels. *J Hepatol* 42, 266–274.
119 Arenas JI, Vargas HE (2004) Hepatitis C virus antiviral therapy in patients with cirrhosis. *Gastroenterol Clin North Am* 33, 549–562.
120 Everson GT, Trotter J, Forman L *et al.* (2005) Treatment of advanced hepatitis C with a low accelerating dosage regimen of antiviral therapy. *Hepatology* 42, 255–262.
121 Fontana RJ, Everson GT, Tuteja S *et al.* (2004) Controversies in the management of hepatitis C patients with advanced fibrosis and cirrhosis. *Clin Gastroenterol Hepatol* 2, 183–197.
122 Everson GT (2004) Treatment of chronic hepatitis C in patients with decompensated cirrhosis. *Rev Gastroenterol Disord* 4(Suppl 1), S31–38.
123 Forns X, Garcia-Retortillo M, Serrano T *et al.* (2003) Antiviral therapy of patients with decompensated cirrhosis to prevent recurrence of hepatitis C after liver transplantation. *J Hepatol* 39, 389–396.
124 Crippin JS, McCashland T, Terrault N *et al.* (2002) A pilot study of the tolerability and efficacy of antiviral therapy in hepatitis C virus-infected patients awaiting liver transplantation. *Liver Transpl* 8, 350–355.
125 Thomas RM, Brems JJ, Guzman-Hartman G *et al.* (2003) Infection with chronic hepatitis C virus and liver transplantation: a role for interferon therapy before transplantation. *Liver Transpl* 9, 905–915.
126 Elisofon SA, Jonas MM (2006) Hepatitis B and C in children: current treatment and future strategies. *Clin Liver Dis* 10, 133–148.
127 Pembrey L, Newell M, Tovo P (2005) The management of HCV infected pregnant women and their children. *J Hepatol* 43, 515–525.
128 Gonzalez-Peralta RP, Kelly DA, Haber B *et al.* (2005) Interferon alfa-2b in combination with ribavirin for the treatment of chronic hepatitis C in children: efficacy, safety, and pharmacokinetics. *Hepatology* 42, 1010–1018.
129 Wirth S, Pieper-Boustani H, Lang T *et al.* (2005) Peginterferon alfa-2b plus ribavirin treatment in children and adolescents with chronic hepatitis C. *Hepatology* 41, 1013–1018.
130 Papo T, Marcellin P, Bernau J *et al.* (1992) Autoimmune chronic hepatitis axacerbated by alpha interferon. *Ann Int Med* 116, 51–53.
131 Muratori L, Lenzi M, Cataleta M *et al.* (1994) Interferon therapy in liver/kidney microsomal antibody type 1-positive patients with chronic hepatitis C. *J Hepatol* 21, 199–203.
132 Todros L, Saracco G, Durazzo M *et al.* (1995) Efficacy and safety of interferon alfa therapy in chronic hepatitis C with autoantibodies to liver-kidney microsomes. *Hepatology* 22, 1374–1378.
133 Monti V, Aghemo A, Rumi MG *et al.* (2005) The prevalence, clinical features and response to antiviral therapy of patients with chronic hepatitis C who are seropositive for liver-kidney microsome type 1 antibodies. *Antivir Ther* 10, 715–720.
134 Alvarez F, Berg PA, Bianchi FB *et al.* (1999) International Autoimmune Hepatitis Group report: review of criteria for diagnosis of autoimmune hepatitis. *J Hepatol* 31, 929–938.
135 Ferri C, Marzo E, Longombardo G *et al.* (1993) Interferon-alpha in mixed cryoglobulinemia patients: a randomized, crossover-controlled trial. *Blood* 81, 1132–1136.
136 Misiani R, Bellavita P, Fenili D *et al.* (1994) Interferon alfa-2a therapy in cryoglobulinemia associated with hepatitis C virus. *N Engl J Med* 330, 751–756.
137 Casato M, Agnello V, Pucillo LP *et al.* (1997) Predictors of long-term response to high-dose interferon therapy in type II cryoglobulinemia associated with hepatitis C virus infection. *Blood* 90, 3865–3873.
138 Zuckerman E, Zuckerman T, Sahar D *et al.* (2001) The effect of antiviral therapy on t(14;18) translocation and immunoglobulin gene rearrangement in patients with chronic hepatitis C virus infection. *Blood* 97, 1555–1559.
139 Giannelli F, Moscarella S, Giannini C *et al.* (2003) Effect of antiviral treatment in patients with chronic HCV infection and t(14;18) translocation. *Blood* 102, 1196–1201.
140 Zuckerman E, Keren D, Slobodin G *et al.* (2000) Treatment of refractory, symptomatic, hepatitis C virus related mixed cryoglobulinemia with ribavirin and interferon-alpha. *J Rheumatol* 27, 2172–2178.
141 Cacoub P, Saadoun D, Limal N *et al.* (2005) PEGylated interferon alfa-2b and ribavirin treatment in patients with hepatitis C virus-related systemic vasculitis. *Arthritis Rheum* 52, 911–915.
142 Mazzaro C, Zorat F, Caizzi M *et al.* (2005) Treatment with peg-interferon alfa-2b and ribavirin of hepatitis C virus-associated mixed cryoglobulinemia: a pilot study. *J Hepatol* 42, 632–638.
143 Giannini C, Giannelli F, Zignego AL (2006) Association between mixed cryoglobulinemia, t(14;18) translocation, and persistence of occult HCV lymphoid infection after treatment. *Hepatology* 43, 1166–1167.
144 Meyers CM, Seeff LB, Stehman-Breen CO *et al.* (2003) Hepatitis C and renal disease: an update. *Am J Kidney Dis* 42, 631–657.
145 Bruchfeld A, Stahle L, Andersson J *et al.* (2001) Ribavirin treatment in dialysis patients with chronic hepatitis C virus infection – a pilot study. *J Viral Hepat* 8, 287–292.
146 Tan AC, Brouwer JT, Glue P *et al.* (2001) Safety of interferon and ribavirin therapy in haemodialysis patients with chronic hepatitis C: results of a pilot study. *Nephrol Dial Transplant* 16, 193–195.
147 Bruchfeld A, Lindahl K, Stahle L *et al.* (2003) Interferon and ribavirin treatment in patients with hepatitis C-associated renal disease and renal insufficiency. *Nephrol Dial Transplant* 18, 1573–1580.
148 Fabrizi F, Dulai G, Dixit V *et al.* (2003) Meta-analysis: interferon for the treatment of chronic hepatitis C in dialysis patients. *Aliment Pharmacol Ther* 18, 1071–1081.
149 Rocha CM, Perez RM, Ferreira AP *et al.* (2006) Efficacy and tolerance of interferon-alpha in the treatment of chronic hepatitis C in end-stage renal disease patients on hemodialysis. *Liver Int* 26, 305–310.

150 Bruchfeld A, Lindahl K, Reichard O *et al.* (2006) Pegylated interferon and ribavirin treatment for hepatitis C in haemodialysis patients. *J Viral Hepat* 13, 316–321.
151 Inati A, Taher A, Ghorra S *et al.* (2005) Efficacy and tolerability of peginterferon alpha-2a with or without ribavirin in thalassaemia major patients with chronic hepatitis C virus infection. *Br J Haematol* 130, 644–646.
152 Butensky E, Pakbaz Z, Foote D *et al.* (2005) Treatment of hepatitis C virus infection in thalassemia. *Ann NY Acad Sci* 1054, 290–299.
153 Demelia L (2007) Tolerability of Peg interferon (alpha) 2b and ribavirin therapy in patients with chronic hepatitis C and glucose-6-phosphate dehydrogenase deficiency. *J Hepatol*, 46, 171–173.
154 Fried MW, Peter J, Hoots K *et al.* (2002) Hepatitis C in adults and adolescents with hemophilia: a randomized, controlled trial of interferon alfa-2b and ribavirin. *Hepatology* 36, 967–972.
155 Fabris P, Betterle C, Fioreani A *et al.* (1992) Development of type 1 diabetes mellitus during interferon alpha therapy for chronic HCV hepatitis. *Lancet* 340, 548.
156 Cozzolongo R, Betterle C, Fabris P *et al.* (2006) Onset of type 1 diabetes mellitus during peginterferon alpha-2b plus ribavirin treatment for chronic hepatitis C. *Eur J Gastroenterol Hepatol* 18, 689–692.
157 Primo Vera J (2004) Pegylated-interferon-induced diabetes mellitus type 1 in two patients with chronic hepatitis C. *Gastroenterol Hepatol* 27, 69.
158 Tahrani A, Bowler L, Singh P *et al.* (2006) Resolution of diabetes in type 2 diabetic patient treated with IFN-alpha and ribavirin for hepatitis C. *Eur J Gastroenterol Hepatol* 18, 291–293.
159 Krawitt EL, Ashikaga T, Gordon SR *et al.* (2005) Peginterferon alfa-2b and ribavirin for treatment-refractory chronic hepatitis C. *J Hepatol* 43, 243–249.
160 Shiffman ML, Hofmann CM, Gabbay J *et al.* (2000) Treatment of chronic hepatitis C in patients who failed interferon monotherapy: effects of higher doses of interferon and ribavirin combination therapy. *Am J Gastroenterol* 95, 2928–2935.
161 Saracco G, Ciancio A, Olivero A *et al.* (2001) A randomized 4-arm multicenter study of interferon alfa-2b plus ribavirin in the treatment of patients with chronic hepatitis C not responding to interferon alone. *Hepatology* 34, 133–138.
162 Di Marco V, Vaccaro A, Ferraro D *et al.* (2001) High-dose prolonged combination therapy in non-responders to interferon monotherapy for chronic hepatitis C. *Aliment Pharmacol Ther* 15, 953–958.
163 Poynard T, Schiff E, Terg R *et al.* (2004) High early viral response (EVR) with Peg-Intron Rebetol (PR) weight based dosing (WBD) in previous interferon/ribavirin HCV treatment failures; early results of the epic trial. *Hepatology*, 40(Suppl 1), 170A.
164 Taliani G, Gemignani G, Ferrari C *et al.* (2006) Pegylated interferon alfa-2b plus ribavirin in the retreatment of interferon–ribavirin non-responder patients. *Gastroenterology* 130, 1098–1106.
165 Sherman M, Yoshida EM, Deschenes M *et al.* (2006) Peginterferon alfa-2a (40KD) plus ribavirin in chronic hepatitis C patients who failed previous interferon therapy. *Gut*, 55, 1631–1638.
166 Cornberg M, Hadem J, Herrmann E *et al.* (2006) Treatment with daily consensus interferon (CIFN) plus ribavirin in non-responder patients with chronic hepatitis C: a randomized open-label pilot study. *J Hepatol* 44, 291–301.
167 Maynard M, Pradat P, Bailly F *et al.* (2006) Amantadine triple therapy for non-responder hepatitis C patients. Clues for controversies. *J Hepatol* 44, 484–490.
168 Jensen DM, Marcellin P (2005) Rationale and design of the REPEAT study: a phase III, randomized, clinical trial of peginterferon alfa-2a (40 kDa) plus ribavirin in non-responders to peginterferon alfa-2b (12 kDa) plus ribavirin. *Eur J Gastroenterol Hepatol* 17, 899–904.
169 Kelleher TB, Afdhal N (2005) Maintenance therapy for chronic hepatitis C. *Curr Gastroenterol Rep* 7, 50–53.
170 Afdhal N, Freilich B, Levine R *et al.* (2004) Colchicine versus Peg-Intron long-term (COPILOT) trial: interim analysis of clinical outcomes at year 2. *Hepatology*, 40(Suppl 1), 180A.
171 Pawlotsky JM (2003) The nature of interferon-alpha resistance in hepatitis C virus infection. *Curr Opin Infect Dis* 16, 587–592.
172 Martell M, Esteban JI, Quer J *et al.* (1992) Hepatitis C virus (HCV) circulates as a population of different but closely related genomes: quasispecies nature of HCV genome distribution. *J Virol* 66, 3225–3229.
173 Reesink HW, Zeuzem S, Weegink CJ *et al.* (2006) Rapid decline of viral RNA in hepatitis C patients treated with VX-950: a phase Ib, placebo-controlled, randomized study. *Gastroenterology* 131, 997–1002.
174 Tong X, Chase R, Skelton A *et al.* (2006) Identification and analysis of fitness of resistance mutations against the HCV protease inhibitor SCH 503034. *Antivir Res* 70, 28–38.
175 Lin C, Lin K, Luong Y-PB *et al.* (2004) In vitro resistance studies of hepatitis C virus serine protease inhibitors, VX-950 and BILN 2061: structural analysis indicates different resistance mechanisms. *J Biol Chem* 279, 17508–17514.
176 Lin K, Perni RB, Kwong AD *et al.* (2006) VX-950, a novel hepatitis C virus (HCV) NS3–4A protease inhibitor, exhibits potent antiviral activities in HCV replicon cells. *Antimicrob Agents Chemother* 50, 1813–1822.
177 Lu L, Pilot-Matias TJ, Stweart KD *et al.* (2004) Mutations conferring resistance to a potent hepatitis C virus serine protease inhibitor *in vitro*. *Antimicrob Agents Chemother* 48, 2260–2266.
178 Trozzi C, Bartholomew L, Ceccacci A *et al.* (2003) In vitro selection and characterization of hepatitis C virus serine protease variants resistant to an active-site peptide inhibitor. *J Virol* 77, 3669–3679.
179 Tomei L, Altamura S, Paonessa G *et al.* (2005) HCV antiviral resistance: the impact of *in vitro* studies on the development of antiviral agents targeting the viral NS5B polymerase. *Antivir Chem Chemother* 16, 225–245.
180 De Francesco R, Migliaccio G (2005) Challenges and successes in developing new therapies for hepatitis C. *Nature* 436, 953–960.
181 Seiwert S, Andrews SW, Tan H *et al.* (2006) Generation and characterization of HCV replicons with reduced sensitivity to Itmn 191, a macrocyclic inhibitor of NS3/4a. *Gastroenterology* 130(Suppl 2), A195.
182 Migliaccio G, Tomassini JE, Carroll SS *et al.* (2003) Characterization of resistance to non-obligate chain-terminating ribonucleoside analogs that inhibit hepatitis C virus replication *in vitro*. *J Biol Chem* 278, 49164–49170.
183 Le Pogam S, Kang H, Harris SF *et al.* (2006) Selection and characterization of replicon variants dually resistant to thumb- and palm-binding non-nucleoside polymerase inhibitors of the hepatitis C virus. *J Virol* 80, 6146–6154.
184 Mo H, Lu L, Pilot-Matias T *et al.* (2005) Mutations conferring resistance to a hepatitis C virus (HCV) RNA-dependent RNA polymerase inhibitor alone or in combination with an HCV serine protease inhibitor *in vitro*. *Antimicrob Agents Chemother* 49, 4305–4314.

9.2 Systemic virosis producing hepatitis

Alberto Biglino and Mario Rizzetto

Introduction

Many viral agents may induce liver damage as part of a systemic infection or an infection primarily involving other organs. Although hepatic involvement with these agents is usually mild and the clinical picture is dominated by systemic complications or complications in other organs, severe hepatitis with acute liver failure or fulminant hepatitis may occur, either as part of disseminated disease or, less frequently, as the main clinical manifestation.

These viral agents include the herpesviruses (herpes simplex virus, varicella-zoster virus, Epstein–Barr virus, cytomegalovirus and the human herpesviruses types 6, 7 and 8), the adenoviruses, human parvovirus B19, the measles and rubella viruses, and the enteroviruses.

Herpesviruses

The herpesviruses are a family of about 150 large enveloped DNA-containing viruses that are infectious to a wide range of invertebrate and vertebrate hosts. The eight known human herpesviruses (HHV) are classified into three subfamilies (Alpha-, Beta- and Gammaherpesvirinae) according to genome homology, host range and cell tropism. Herpesviruses vary widely in their ability to infect different types of cells, including epithelial and nerve cells, fibroblasts and lymphocytes. Following primary infection, all herpesviruses undergo lifelong latency in their natural hosts, either as extrachromosomal or integrated DNA, or as slowly replicating forms. Latency is maintained in 'immunologically privileged' sites, such as sensory nerve ganglia, secretory glands or B and T lymphocytes, because of the capacity of the virus to interfere with major histocompatibility complex (MHC)-I-driven immune recognition and cytotoxic T-lymphocyte-mediated destruction of infected cells. Reactivation, leading to recurrent disease or invasive infection, may be induced by immune suppression or by other poorly defined stimuli. Herpesviruses may induce disease by direct tissue damage, immune-mediated cytolysis or neoplastic transformation.

Alphaherpesvirinae subfamily

In both primary and recurrent infections, tissue tropism in the immunocompetent host involves mucocutaneous epithelia and neuronal cells. Visceral infections, including hepatitis, pneumonia, encephalitis and retinitis, or disseminated disease may occur in neonates and immunocompromised hosts. Latency is established primarily, but not exclusively, in sensory ganglia.

Herpes simplex virus

Herpes simplex virus (HSV) types 1 and 2 (HSV-1 and HSV-2) are double-stranded DNA viruses belonging to the Alphaherpesvirinae subfamily. HSV has a worldwide distribution; the seroprevalence in the general population of Europe and the United States is about 13% and 22%, respectively, and rates between 25% and 64% are found in people attending clinics for sexually transmitted diseases [1]. Infection is spread through close contact with peripheral lesions on the skin or mucosae; however, asymptomatic shedding is common with both HSV-1 and HSV-2 [2], and so oropharyngeal and genital secretions are important sources of infection in the absence of typical lesions. The virus enters the human host through mucosal surfaces (oropharynx, cervix, conjunctivae) or the damaged epidermis and replicates within the nuclei of epithelial cells. Infection leads to the formation of typical vesicles, which may rupture leaving shallow or confluent ulcers. Primary HSV infection may be either subclinical or accompanied by significant systemic and local symptoms such as fever, headache, myalgias, irritability and wide local mucocutaneous involvement with satellite lymphadenopathy (both in orofacial and genital localizations). The virus is transported intra-axonally along peripheral sensory nerves to the nerve cell bodies in dorsal root ganglia, where it replicates and from where it spreads to the mucosal or skin surface by centrifugal migration through the same sensory nerves [3]. Latency is established in sensory nuclei; upon reactivation, the virus returns to the mucocutaneous surfaces by anterograde axonal movement [4].

Visceral HSV infection usually follows viraemia; multiple-organ involvement is common, including oesophagitis, pneumonitis,

acute respiratory distress syndrome, adrenalitis and hepatitis with disseminated intravascular coagulation. Neonatal HSV-1 and HSV-2 infection, and primary infection in immunosuppressed subjects (particularly children), are associated with visceral infections. Prompt diagnosis of HSV-related liver damage is critical, as this is one of the very few treatable causes of acute hepatitis. The disease has a high mortality rate (41–79%); the liver lesions are severe and lead to rapid hepatic failure [5].

Neonatal HSV hepatitis occurs in the setting of disseminated infection; it affects 25% of HSV-infected neonates, with an incidence of one case per 2000–5000 deliveries per year [6], and is the most common of the infectious causes of neonatal acute liver failure [7]. Besides the liver, other organs that are involved include the central nervous system (CNS), lungs, adrenal glands, skin, eyes and/or mouth. Diagnosis may be difficult because 60–80% of women who deliver an HSV-infected infant have no evidence of genital HSV infection at delivery, or a past history of genital herpes or sexual partner(s) with genital HSV [8]. Without appropriate antiviral therapy and liver transplantation, the prognosis is poor.

HSV hepatitis in healthy adults is a rare, but potentially fatal, disease, occurring mainly during primary infection; no definite case of acute hepatitis has been reported during recurrent infection in immunocompetent hosts, although HSV may affect the liver in this setting [9]. Mortality rates in untreated patients with severe HSV hepatitis may be as high as 80% [10].

The clinical picture of acute HSV-related hepatitis includes fever, upper right abdominal quadrant tenderness, abrupt elevations of bilirubin and serum aminotransferase levels and leukopenia (< 4000 white blood cells/μL). Disseminated intravascular coagulation may also develop, rapidly followed by oliguria, encephalopathy and coma.

HSV hepatitis during pregnancy may result from primary or reactivated infections caused by both HSV-1 and HSV-2. The differential diagnosis includes severe preeclampsia, preeclampsia/haemolysis, elevated liver function and low platelets (HELLP syndrome) and acute fatty liver of pregnancy, as well as hepatitis caused by other viral pathogens or exposure to exogenous substances, such as drugs [11]. Mucocutaneous lesions are absent in nearly half of the cases [12]. Maternal and neonatal mortality rates from HSV hepatitis may be as high as 39% [13].

Diagnosis is difficult because disseminated HSV infection is rarely suspected in apparently immunocompetent, otherwise healthy, subjects. Initial symptoms are non-specific; mucocutaneous oral/genital lesions are evident in 40–70% of cases [9,14]. In a review of HSV hepatitis [15], herpes simplex was considered in the differential diagnosis in only 33% of patients, although the reported cases included 26 pregnant women and 15 patients receiving immunosuppression for a variety of diagnoses. Fatal HSV hepatitis has also been reported after corticosteroid treatment in a neoplastic patient [16].

A high index of suspicion is required in order to ask for more specific tests (HSV-DNA detection in blood or biopsy specimens). Given the potential for cure, the diagnostic workup should proceed even in the presence of severe liver failure with coagulopathy; prompt diagnosis via transjugular liver biopsy should be undertaken and empirical treatment with aciclovir also considered, even in the absence of typical cutaneous manifestations.

Immunocompromised hosts, such as bone marrow and solid-organ transplant patients, patients undergoing chemotherapy and those with extensive burns or who are severely malnourished, are at greater risk of severe HSV infection. In these subjects, HSV causes extensive mucocutaneous infections and may disseminate.

HSV-related disease in immunosuppressed patients is usually the consequence of the reactivation of a latent infection [17]. The majority of patients awaiting liver transplantation are HSV-antibody positive [18]. In the immediate postoperative period, the risk of HSV reactivation is high because of the induction of immunosuppression at the time of surgery. Most recipients of kidney, liver and bone marrow transplants excrete HSV-1 in saliva during the first 2–3 weeks after grafting. HSV-1-seropositive recipients of a bone marrow transplant from an HSV-seronegative donor are at higher risk for recurrence and are more likely to develop aciclovir-resistant strains of HSV than those who receive marrow from HSV-1-positive donors [19]. Mucocutaneous infection is the most common manifestation of HSV reactivation, but HSV pneumonia and fatal hepatitis have also been documented. Prophylaxis against HSV infection in liver transplant recipients is not performed routinely, possibly because data regarding the incidence and significance of HSV reactivation in this population are lacking. In one study, ganciclovir was shown to reduce the incidence of symptomatic HSV infections after liver transplantation to 3.5%, compared with 23.5% in transplant recipients given placebo [20].

Liver histology of fulminant HSV hepatitis reveals large areas of necrosis, with HSV-DNA-positive hepatocytes detected using *in situ* hybridization. Occasionally, Cowdry's type A intranuclear inclusions are seen, which disappear after starting antiviral treatment; numerous hepatocytes show DNA accumulation beneath the nuclear membrane [21]. Massive liver infiltration with mononuclear cells is not consistent with fulminant HSV hepatitis; in addition to necrosis, apoptosis may play a significant role in liver damage [22].

Diagnosis

Antibodies to purified HSV-1 and HSV-2 proteins are readily detectable in serum of HSV-infected individuals but are of no use for diagnosing acute infection; the presence of serum immunoglobulin (Ig)M antibodies, as well as fourfold increases in the IgG antibody titre, are not patognomonic of primary infection because they may arise during reactivation. Nevertheless, serology is an accurate tool for identifying subjects with longstanding HSV infection [23]. Type-specific IgG antibodies to the glycoproteins gG1 (HSV-1) and gG2 (HSV-2), which are antigenically distinct, may be detected in serum, and

HSV-2 screening is recommended in selected groups at risk [24]; Western blotting may distinguish HSV-1 from HSV-2 infections, with a sensitivity and specificity that is greater than 98% [25].

Herpes simplex should be considered in the differential diagnosis of acute hepatitis when other viral or toxic causes are ruled out. Patients should be asked about sore throat, odynophagia, dysuria or genital discharge to determine the most likely location of vesicles. Both exposed and unexposed skin surfaces should be examined, searching for mucocutaneous lesions; a pelvic examination may be necessary as vesicles on the cervix may not be accompanied by vulvar or vaginal vesicles. If lesions are identified, Giemsa or Wright staining of scrapings from their base (Tzanck test) allows a rapid microscopic diagnosis, with demonstrations of multinucleated giant cells with the characteristic ground-glass nuclear inclusion bodies (Cowdry's type A). Viral antigens may also be demonstrated on cytological preparations using fluorescent antibody staining [5]. HSV infection can be confirmed by viral culture or by polymerase chain reaction (PCR) detection of HSV DNA in blood and tissue specimens. Cultures should always be undertaken because they provide a virus isolate that can be typed. A scraping of skin vesicles should be taken from any skin lesions and transferred in appropriate virus transport media to a virology laboratory for inoculation onto a susceptible cell culture. A cytopathic effect usually develops 24–48 h after inoculation; antiviral treatment should not be delayed while awaiting cultural diagnosis [18].

Therapy

Aciclovir, a synthetic acyclic purine nucleoside analogue, is the standard first-line therapy for HSV infection. The precursor drugs valaciclovir and famciclovir have better oral bioavailability than their activated forms aciclovir and penciclovir respectively. Renal dysfunction can occur, especially with rapid intravenous infusion of large doses of aciclovir, but this is rare and usually reversible. The risk of nephrotoxicity can be reduced by slow infusion and by ensuring adequate hydration. The intravenous administration of aciclovir has also been linked to disturbances of the CNS (agitation, hallucinations, disorientation, tremors and myoclonus). Oral aciclovir has been associated with renal failure in elderly individuals [26]. Because aciclovir crosses the placenta and is concentrated in amniotic fluid, there is concern about potential fetal nephrotoxicity; however, none has been observed [27].

In immunocompromised patients, particularly after induction chemotherapy or transplantation, aciclovir prophylaxis reduces the rate of symptomatic HSV infection; famciclovir and valaciclovir have similar effects [6].

Resistance to aciclovir can develop and is often associated with clinical failure; this is an important issue in allogeneic bone marrow transplant recipients [28]. Resistance most often occurs via mutations in the gene for viral thymidine kinase (TK), which is required for phosphorylation of the drug; resistance was reported in 0.28–0.33% of HSV isolates recovered from normally immunocompetent subjects in the general population [29]. Higher resistance rates were observed in subjects with a depressed immune function (6–7.6%), in bone marrow graft recipients (7.0–15.4%) [28] and in subjects with human immunodeficiency virus (HIV) infection (4.2–7.1%) [30]. Factors that increase the development of aciclovir resistance include previous treatment with aciclovir, HIV-1 infection and graft-versus-host disease (GVHD).

Foscarnet and cidofovir retain activity against TK-deficient strains of HSV. Foscarnet is the treatment of choice for aciclovir-resistant HSV infection; mutations in the HSV-DNA polymerase occur less frequently but may confer resistance to either foscarnet or aciclovir [31]. Infections with HSV strains that are resistant to both aciclovir and foscarnet can be treated with cidofovir, a nucleotide analogue that is active against a wide range of DNA viruses, including HSV [32]. HSV resistance to cidofovir has also been reported [28].

Ganciclovir, a synthetic analogue of 2′-deoxyguanosine, inhibits the replication of HSV-1 and HSV-2 *in vitro*, but it has not been used in HSV infections in humans; HSV strains that are resistant to aciclovir appear to also be resistant to ganciclovir.

Varicella-zoster virus

Humans are the only host and reservoir of varicella-zoster virus (VZV). Primary infection is spread via the respiratory route; the virus replicates in the nasopharynx and is transferred to migrating T cells, with dissemination to the lymphoreticular organs and the skin, resulting in chickenpox with a rash (varicella). After primary infection, VZV becomes latent within the dorsal root ganglia; when latency is disrupted, the virus is transported along neuronal axons to the skin and this reactivaction leads to herpes zoster. VZV is endemic in the population but becomes epidemic among susceptible individuals during seasonal periods (late winter and early spring).

Clinical hepatitis is not observed in healthy children with uncomplicated primary varicella, although 28% of them may show abnormal aminotransferase levels [33]; however, in one study [34], only 1.4% of healthy children showed an increase in the alanine aminotransferase level that was at least two times greater than the upper limit of normality. In apparently immunocompetent infants of less than 12 months, primary varicella may result in high mortality rates [35] because of complications such as pneumonitis, encephalitis and haemorrhagic manifestations (but not severe hepatitis). Reye syndrome, an abrupt mitochondrial failure manifesting as acute encephalopathy and liver dysfunction with fatty infiltration, is often preceded by varicella.

Perinatal varicella is associated with mortality rates that are as high as 30% when maternal disease develops between 5 days before delivery and 48 h postpartum.

Primary varicella may run a severe course in apparently immunocompetent adults and may be complicated by pneumonia (occurring in about 1 in 400 cases), viral encephalitis, haemorrhagic conditions and secondary infections. However,

even in these cases, severe hepatitis with liver failure is exceptional, although liver enzyme elevations of up to three times the upper normal level or higher are common (particularly in men) [36,37].

In immunocompromised children and adults, primary varicella may be life-threatening. Most cases of VZV-related hepatitis and acute liver failure were reported in patients who were immunocompromised because of acute leukaemia, [38,39], bone marrow [40–42] or solid-organ transplantation [43,44], or acquired immune deficiency syndrome (AIDS) [45].

The use of systemic corticosteroids greatly increases the risk of fatal primary varicella hepatitis, even in the absence of underlying pathological conditions [46,47].

VZV reactivation is common after haematopoietic stem cell transplantation (HSCT), as T-cell immunity against VZV, which is crucial for the re-establishment of latency, recovers slowly [48]. The incidence of herpes zoster in children following HSCT has been reported to be in the range of 23–67% in the 5 years post-HSCT [49].

The infection may be confined to the skin; however, visceral involvement, including hepatitis, pneumonitis and meningoencephalitis, can also occur. Visceral involvement occurs in approximately 1% of adults [40] and in around 7% of paediatric bone marrow transplant recipients with VZV reactivation [50]; pneumonitis and hepatic failure are the most important causes of death. Visceral involvement is probably underdiagnosed, as immunosuppressed patients may fail to develop the skin rash in the early phase of the infection; nevertheless, aminotransferases are frequently slightly elevated before development of the rash in cases in which herpes zoster involves visceral abdominal organs [51]. Therefore, an otherwise unexplained aminotransferase elevation might serve as a potential marker for preclinical herpes zoster infection [52]. Visceral VZV infection often presents as poorly localized abdominal pain accompanying pancreatitis, hepatitis and paralytic ileus. In a series of patients [40], the pain was epigastric, occasionally involving the right upper quadrant or radiating to the back. Fever and skin rash may be initially absent and may develop up to 5 days or later after abdominal pain. [53]. VZV reactivation should be included in the differential diagnosis of the many causes of elevated alanine and aspartate aminotransferases post-HSCT; in one study [42], the majority of patients with elevated alanine aminotransferase levels preceding herpes zoster did not have concomitant GVHD, which can independently cause liver dysfunction.

The diagnosis of VZV hepatitis is based on PCR and immunohistochemical analysis of liver tissue obtained by biopsy or postmortem. PCR analysis of blood may be of diagnostic value in visceral VZV before the signs of infection appear on the skin, enabling early diagnosis and treatment [54].

Therapy

Prevention of VZV infection/reactivation has been attempted in immunocompromised (mostly transplanted) patients using both antiviral drugs and vaccines. Aciclovir, either at low (400 mg/day) or high (1600 mg/day) doses, taken for up to 6–12 months after bone marrow transplantation, was shown to delay, but not prevent, disseminated herpes zoster [55,56]; ganciclovir showed similar results [55].

Inactivated varicella vaccine is immunogenic; it significantly reduced the incidence of herpes zoster when four doses, the first given 30 days before transplant, were administered to patients with lymphoma who received an autologous HSCT [57].

Betaherpesvirinae subfamily

The Betaherpesvirinae subfamily includes human cytomegalovirus (CMV; HHV-5), HHV-6 and HHV-7.

Cytomegalovirus

Virology

CMV or HHV-5 is the largest known HHV, with a linear double-stranded DNA of about 230 kDa. The viral DNA is wrapped in a nucleoprotein core and is surrounded by a proteinaceous matrix and the pp65 antigen, which can be detected in host cells by immunofluorescence, immunoperoxidase and other antigen detection methods. The viral matrix is surrounded by a lipid bilayer containing viral glycoproteins. Glycoprotein B (gB) is the major envelope glycoprotein of CMV; it is implicated in host-cell entry, cell-to-cell virus transmission and fusion of infected cells and is also an important target for both humoral and cellular immune responses [58]. Latency of CMV depends on mechanisms that are still unknown; the downregulation of human leukocyte antigen (HLA)-1 expression at the cell surface may play a role by preventing immune recognition and destruction of infected cells. Disease most often follows the reactivation of CMV induced by HIV- or drug-mediated immunosuppression.

Diagnosis of CMV infection

Serology is useful only for the determination of a patient's serostatus, as in pretransplant workup; it is of limited value in the diagnosis of acute CMV infection, with the exception of infection in immunocompetent adults. The presence of IgM antibodies to CMV immediate-early and tegument proteins, as well as to membrane glycoproteins, is usually associated with acute infection in immunocompetent subjects [59]; however, they are also reported in about one-third of recurrent infections in transplanted patients. On the other hand, specific IgM antibodies may be absent in AIDS patients with generalized CMV infection. Primary acute infection in immunocompetent adults can be diagnosed by IgG antibody seroconversion (i.e. IgG serology changing from negative to positive) to both non-structural and structural CMV antigens. A low avidity of IgG antibodies is also significantly associated with recent primary infection.

In all other situations, only the direct demonstration of the virus or its components is of diagnostic value. This is particularly the case in immunocompromised patients, in whom the

diagnosis of 'CMV infection' requires isolation of CMV or detection of viral proteins/nucleic acid in body fluids or tissue specimens. [60]. Traditional viral cultures on human fibroblast cells are too time-consuming and insensitive to be of diagnostic use in acute disease. Modern culture techniques using 'shell vial' cell monolayers and monoclonal antibodies to immediate-early CMV antigens can result in the detection of viral growth after overnight incubation. Virus may be grown from semen or cervical swabs from healthy subjects, as well as from throat swabs and urine from patients with asymptomatic infection or during recovery from acute primary infection. Viraemia, defined as the isolation of CMV from blood by standard or 'shell vial' rapid culture techniques, is highly suggestive of pathogenic infection in immunocompetent subjects. Rapid viral culture for diagnosing acute systemic infection is best carried out using tissue, bronchoalveolar lavage (BAL) fluid and urine; however, CMV growth from these specimens taken from immunocompromized subjects is often positive in the absence of invasive disease. In viraemic patients, viral antigens, such as the matrix phosphoprotein pp65, are detectable in peripheral blood granulocytes using a monoclonal antibody (CMV antigenaemia). As with viraemia, the presence of antigenaemia in an immunocompetent subject is suggestive of clinically relevant infection.

In immunocompromised patients, antigenaemia resulting from recurrent CMV infection is frequent, regardless of the clinical features, and cannot be used to diagnose end-organ disease. However, as the rate of antigen-carrying cells correlates with both viraemia and CMV mRNA levels in leukocytes, counts of pp65-positive cells exceeding six per 200 000 granulocytes are predictive of the development of clinical disease [61].

To assess the viral load in immunocompromised patients, many laboratories are now using molecular techniques based on the detection of CMV DNA by signal or DNA amplification or on the detection of late-CMV mRNA. Some of these techniques allow a true quantitative definition of the 'CMV viral load' (CMV DNAemia) in samples of plasma, whole blood or peripheral blood buffy-coat specimens. Viral load can be used as a predictor for the development of CMV end-organ disease in AIDS [62] and transplant patients [63,64]; trends are more useful than individual assay results, as the rate of rise of viral load and initial quantitative viral load assessment are independent indicators of CMV disease risk [65]. In liver transplant patients, the optimal cutoff for CMV viral load that can be used to predict disease is around 5000 copies/mL, with a sensitivity of 85.7% and a specificity of 86.8% [66]. Determination of the CMV viral load appears to be the key diagnostic tool for patient surveillance and management of CMV disease if pre-emptive approaches are used, i.e. the use of antiviral therapy to lower CMV-DNA levels to prevent end-organ disease. The detection of CMV pp65 mRNA in plasma, whole blood or buffy-coat specimens using nucleic acid sequence-based amplification (NASBA) or reverse transcriptase PCR ('RNAemia') has been found to be predictive for the development of symptomatic disease, although with a lower sensitivity [67].

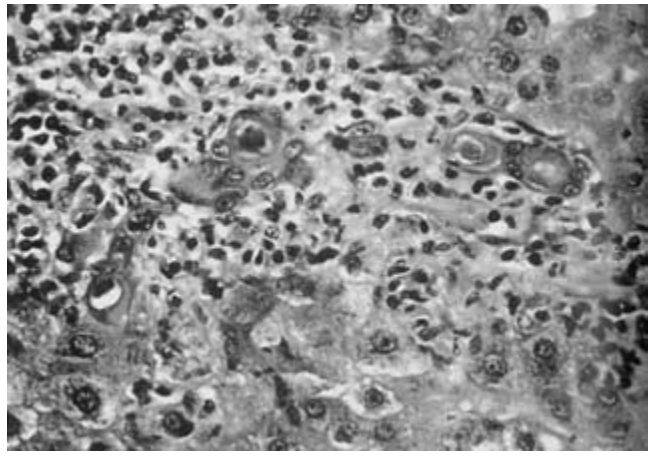

Fig. 1 CMV liver infection. 'Owl's eye' inclusions in bile duct cells within portal inflammation (× 400).

Histopathological examination of tissue is important in diagnosing invasive disease, as virus cultivation from tissue and body fluids may be the consequence of viraemia and not of tissue invasion. Single large intranuclear inclusions, which give the cell an 'owl's eye' appearance, may be found in lung, hepatocytes, Kupffer cells and biliary tract epithelium (Fig. 1). The use of immunohistochemistry with monoclonal antibodies and/or *in situ* hybridization to identify CMV-infected cells results in more sensitive morphological analysis.

Epidemiology and pathogenesis

Primary infection may be acquired at any age via saliva, sexual contact, placental transfer, breastfeeding, blood transfusion or solid-organ transplantation or HSCT. Congenital infection follows intrauterine transmission; this can occur in about 40–45% of pregnant women who acquire a primary CMV infection during the first trimester of gestation, and in about 8% of women who have preconceptional primary infections [68].

The rate of CMV infection increases steadily with age, resulting in a seroprevalence of 30–70% in young adults in developed countries, and of nearly 100% in some African regions. Primary infection is frequent during adolescence, and rates of congenital CMV infection are higher among infants born to mothers younger than 20 years of age [69]. In socially disadvantaged groups – particularly in developing countries – and homosexual men, seroprevalence rates may exceed 90% [70].

After a primary infection, the virus persists in the body and is harboured mainly in leukocytes, cells of the myeloid lineage and endothelial cells, from where recurrent infection may develop [71].

'Recurrent infection' is defined as the new detection of CMV infection in a patient with a previously documented infection, in whom the virus was not detected for an interval of at least 4 weeks during active surveillance. Recurrent infection may result from reactivation of the latent virus (endogenous) or reinfection

(exogenous). 'Reinfection' is defined as the detection of a CMV strain which is different from the strain that caused the patient's original infection, and may be documented by sequencing specific regions of the viral genome. In immunocompetent subjects, primary infections, as well as reactivations and reinfections, are usually asymptomatic; however, there are rare reports of severe and even fatal CMV infections in previously healthy children and adults. In contrast, immunosuppressed patients and, particularly, organ transplant recipients have significant mortality and morbidity rates as a result of primary CMV infection from donated organs or blood products, as well as from reactivation [72] or reinfection.

CMV hepatitis

'CMV hepatitis' is defined by the presence of elevated liver enzyme and/or bilirubin levels, the absence of other causes of hepatitis and the detection of CMV in a liver biopsy specimen (by culture, immunohistochemical analysis or *in situ* hybridization). Detection of CMV by PCR analysis of serum is not sufficient, as it only implies the presence of viraemia; the finding of CMV within liver tissue is required.

In neonatal hepatitis, newborns may display hepatosplenomegaly, cholestatic jaundice, thrombocytopenia, petechiae and elevated liver enzymes in a setting of intrauterine growth retardation and severe neurological symptoms; the hepatitis tends to be self-limiting, although mortality may be as high as 10% and neurological sequelae persist [73].

Primary CMV infection in young adults may cause an infectious mononucleosis-like syndrome with fever, weakness, lymphadenopathy, pharyngitis and lymphocytosis. It is estimated that 79% of infectious mononucleosis is caused by the Epstein–Barr virus (EBV) and the other 21% by acute CMV infection. [73]. Patients with acute CMV are usually older than those with EBV mononucleosis (more than 30 years of age compared with 15–20 years) and have longer durations of fever and malaise (up to 32 weeks, with a mean duration of 7–8 weeks). Pharyngeal exudates, lymphadenopathy and peripheral leukocytosis are less common in CMV than in EBV infection; atypical lymphocytosis may be delayed by several weeks, but may persist for months. Although symptomatic hepatitis is rare in immunocompetent patients with CMV mononucleosis, liver function abnormalities are found in 69% of acute CMV infections [74]. Frank jaundice is seen in only about 10% of patients, with haemolytic anaemia sometimes contributing to the icterus [75,76].

A diagnosis of CMV hepatitis is very likely in this clinical setting; it is confirmed by high CMV IgM levels (> 300 U/mL) and IgG seroconversion [71]. CMV pp65 antigenaemia is of little help in diagnosis because it has poor sensitivity in immunocompetent patients (about 50%); in addition, the CMV-DNA viral load is usually low and does not correlate with the severity of clinical disease. Liver histology reveals mononuclear cells infiltrating the portal areas, along with giant cells, microscopic granulomas and few foci of necrosis. 'Owl's eye' cells are rare or may be absent in hepatocytes but are more frequent in the bile duct epithelium. Acute hepatitis in the setting of acute primary CMV infection generally resolves.

CMV hepatitis in immunocompromised subjects is usually a manifestation of disseminated disease in AIDS patients or after transplantation. As recurrent infection is common, it may be difficult to distinguish between CMV reactivation with viraemia and end-organ disease.

In solid-organ transplantation, the risk of developing clinically significant CMV disease depends primarily on the CMV serostatus of both the donor and recipient. Seronegative recipients of an allograft from a seropositive donor are at greatest risk [77]; without effective prophylaxis, 50–75% will develop CMV disease [78]. If the donor is CMV-seronegative, CMV transmission – particularly in stem-cell transplantation – occurs mainly via blood products; the use of blood products from seronegative donors or of leukocyte-depleted blood products is recommended. The risk of CMV disease is also dependent on age, occurring in 5–16% of adult and 6% of paediatric transplant recipients, and on the type of organ transplanted. Steroids, the monoclonal antibody OKT-3 and polyclonal antilymphocyte globulins have been associated with an increased risk of disease, whereas ciclosporin and tacrolimus were not found to be of risk; conflicting data exist on the risk of mycophenolate mofetil. The risk associated with newer agents, such as sirolimus and the interleukin (IL)-2-receptor antibody, is unknown. The overall intensity of immunosuppression appears to be more important in determining risk than the use of any specific immunosuppressive agent [79]. Higher and more rapid increases in CMV viral load, as well as the presence of multiple CMV gB genotypes rather than a single gB genotype, are associated with an increased risk of CMV infection/disease [80] and with acute graft rejection (in renal transplantation) or chronic graft dysfunction.

Hepatitis is the most common organ-specific complication of CMV infection after liver transplantation. In a study of 253 liver transplantations, CMV hepatitis was diagnosed in 11% of patients; the incidence was higher among seronegative (26%) than seropositive recipients (9%), and most cases (70%) occurred during reactivation rather than primary infection. The histological alterations associated with CMV infection may cause problems in the differential diagnosis of acute rejection, in particular, mild forms of rejection. The ballooning of hepatocytes, a marked Kupffer cell reaction and the presence of microabscesses are typical of CMV hepatitis. Findings of portal lymphocytic infiltration, endotheliitis and cholestasis may not be distinguishable from findings in mild forms of acute rejection. Evidence of graft dysfunction, together with minor but confusing histological findings, may lead to unnecessary antirejection treatments, which may further aggravate CMV infection. Of note, it has been suggested that CMV infection may trigger a mild subclinical rejection [81]. CMV significantly increased the expression of ICAM-1/VCAM-1 adhesion molecules and their ligands (LFA-1, VLA-4), as well as MHC class II- and IL-2-receptor-positive lymphocytes in the graft. CMV hepatitis had

no influence on the long-term outcome of the graft, but biliary complications were common [81].

CMV infection has been associated with cirrhosis and graft failure after liver transplantation, and with a more aggressive relapse of hepatitis C with rapid progression of fibrosis. CMV-induced immunosuppression may increase the risk of opportunistic (particularly fungal) infections, as well as EBV-related post-transplant lymphoproliferative disorders [82]. Infection is diagnosed by monitoring CMV pp65 antigenaemia; liver histology is required for definite diagnosis, including the demonstration of CMV antigens on immunohistochemistry and CMV DNA by *in situ* hybridization. CMV antigens are mainly located in the inflammatory cells of portal infiltrates, but can also be found within a few infected hepatocytes. No CMV-positive endothelial or bile duct epithelial cells have been recorded.

Therapy

Ganciclovir, foscarnet and cidofovir are the antiviral drugs that are currently used for the treatment of systemic CMV disease. Ganciclovir remains the preferred first-line agent; the other two drugs may be nephrotoxic when combined with ciclosporin. Appropriate drug dosing is important because subtherapeutic drug levels in the face of high viral loads promote resistance; however, the majority of documented cases of recurrent CMV disease have been caused by incomplete suppression of viral replication rather than drug resistance.

Symptomatic CMV disease is generally treated with a 2–4 week course of intravenous ganciclovir; the risk of relapse is estimated to be about 25–30% [83]. Factors such as pretransplant donor/recipient CMV serostatus, the presence of multisystem disease, treatment of rejection and intensity of immunosuppression (e.g. antilymphocyte therapy) may influence the risk of relapse. Patients who relapse have significantly higher initial CMV viral loads, lower rates of CMV clearance and are significantly more likely to have CMV viral loads that are detectable in peripheral blood or plasma at the end of therapy [84]. Thus, viral load kinetics (i.e. rate of change of viral load) seems to be an early predictor of both an increased risk of developing CMV disease, which is associated with a faster rate of viral load increase [65], and a good response to treatment, which is associated with a faster rate of viral load decrease (mean half-life of 3.17 days, compared with 8.8 days in non-responders).

Foscarnet and cidofovir are alternative treatments when drug-resistant strains emerge during ganciclovir therapy. Drug resistance may also appear during treatment with foscarnet or cidofovir; cidofovir cross-resistance can result from prolonged therapy with ganciclovir alone. CMV drug resistance mutations map to the UL97 phosphotransferase (kinase) sequence at codons 460, 520 and 591–607, which confer resistance only to ganciclovir, or to the DNA polymerase gene between codons 300 and 1000; resistance to each of the three drugs has been mapped within this codon range [85], and appears to be significantly associated with drug-resistant CMV with high peak virus loads. The genotypic drug resistance assay is the test of choice for guiding treatment strategy, as rapid results may be obtained and many different mutations are detectable by automated sequencing of PCR products amplified from DNA extracted from viral cultures.

CMV-seronegative recipients of a liver graft from CMV-seropositive donors have the greatest risk for CMV disease. A prophylaxis trial of sequential intravenous and oral ganciclovir versus prolonged intravenous ganciclovir in high-risk CMV-seronegative liver transplant recipients with CMV-seropositive donors did not show significant differences between the two groups. All cases of CMV occurred more than 90 days after transplantation and there were no deaths from CMV in either study group. Both oral and intravenous ganciclovir were generally well tolerated. This study indicates that, after induction with 14 days of intravenous ganciclovir, oral treatment can be as effective as intravenous for the long-term prophylaxis of CMV disease [77].

Human herpesvirus types 6 and 7

HHV-6 and HHV-7 are lymphotropic viruses with high tropism for human CD4+ T lymphocytes; they may infect monocytes/macrophages and embryonic glial cells, as well as EBV-transformed B lymphocytes. About 64–83% of all humans are already infected with HHV-6 by 13 months of age, and more than 96% are infected by the age of 2 years [86]; HHV-7 infection is acquired later, over the first 5–6 years of life. After primary infection, both viruses persist for life and are shed in saliva, which is the major route of transmission [87]. Liver involvement was not observed in a large series of acutely ill, febrile children with culture-proven HHV-6 primary infection [88], but a few anecdotal cases of severe or fulminant hepatitis at the time of primary HHV-6 infection have been reported in newborns or infants [89,90], as well as in adults [91]. However, although HHV-6 infection appeared to be well-documented in these cases, the involvement of the virus in episodes of clinically relevant hepatitis remains questionable. As HHV-6 is ubiquitous, its long-lasting persistence or reactivation may be concomitant with an acute hepatitis episode but may not necessarily cause it; even the detection of viral DNA in tissue using PCR cannot be considered as definite proof of virus-related organ disease, as circulating lymphocytes carrying latent HHV-6 may be trapped within the liver in viraemic patients. More convincing data on the relationship between HHV-6 primary infection and severe acute hepatitis has arisen from recent studies employing real-time quantitative PCR analysis of liver tissue [92]. This technique, which allows a precise assessment of tissue viral HHV-6 DNA levels normalized for the number of hepatocytes examined [93], has led to the detection of liver viral loads exceeding 270 000 copies/10^5 hepatocytes, ruling out the possibility of 'incidental' lymphocytes or other mononuclear cells within the liver carrying the virus.

Virus reactivation with viraemia is common after transplantation, occurring in one-third of solid-organ and half of bone

marrow recipients within 4 weeks of transplantation; however, no definite role of reactivation has been documented, so far, in organ disease (including post-transplant hepatitis) [94]. Symptomatic HHV-6 reactivation with fever or rash may be temporally associated with pneumonia, encephalitis and GVHD. These conditions are usually caused by reactivation of other, more overwhelming, opportunistic agents like CMV [95,96].

Treatment

The *in vitro* sensitivity of both HHV-6 and -7 to anti-herpetic drugs parallels that of CMV: cidofovir and foscarnet are inhibitory at pharmacologically suitable concentrations, ganciclovir activity is variable and aciclovir is inactive.

Both ganciclovir and foscarnet have been reported to be effective for prophylaxis or treatment of HHV-6 infections in transplanted patients [97].

Gammaherpesvirinae subfamily

The gammaherpesvirinae subfamily is characterized by a relatively restricted host range. Gamma-1 herpesviruses (lymphocryptoviruses) include EBV and EBV-like viruses, which infect humans and nonhuman primates respectively; gamma-2 herpesviruses (rhadinoviruses) may infect humans (Kaposi's sarcoma-associated herpesvirus; KSHV or HHV-8), as well as rodents and old- and new-world monkeys. Specific cell tropism, including B and T lymphocytes (*in vivo*) and lymphoblastoid cells (*in vitro*), latency in either B or T cells, and cell-transformation capabilities with frank oncogenic potentials, are typical of this subfamily.

Epstein–Barr virus

EBV (HHV-4) is a ubiquitous HHV; it is the causative agent of heterophile-positive infectious mononucleosis (whereas the heterophile-negative form is mainly caused by CMV). EBV is associated with the development of malignancies, including Burkitt's lymphoma, Hodgkin's lymphoma, nasopharyngeal carcinoma and immunosuppression-related lymphomas, such as post-transplant lymphoproliferative disease (PTLD) and the AIDS-related diffuse large-cell (B-cell) lymphoma, primary CNS lymphoma and primary effusion lymphoma of body cavities.

Virology and serology

EBV has a double-stranded DNA genome encased in a protein nucleocapsid, which is surrounded by a lipid envelope with embedded viral glycoproteins. Primary infection results from the exposure of susceptible individuals to oropharyngeal secretions of seropositive subjects through kissing, intimate contact or sharing of food; it is debated whether productive (lytic) replication in epithelial cells precedes virus spreading to the B-cell compartment [98]. B lymphocytes are driven to rapid and continuous proliferation by EBV, resulting in indefinite *in vitro* propagation (immortalization) [99]; *in vivo*, these cells are usually removed from the circulation in immunocompetent hosts as a result of a strong T-cell adaptive response [100].

Viral persistence is established by switching to latency, in which the genome circularizes in the nucleus and is replicated as an episome by the host-cell enzyme machinery. Although complete virions are not produced, this in not true latency; limited gene transcription continues, with the expression of different proteins such as the EBV nuclear antigens (EBNAs) and latent infection membrane proteins (LMP-1 and LMP-2) [101]. EBNAs promote the replication of the latent viral genome in the episomal state by host-cell machinery, ensure proper segregation of the EBV genome in daughter cells and activate expression of remaining nuclear proteins and of LMP-1 and LMP-2 [102]. LMP-1 is the major EBV oncogene, whose expression results in B-cell lymphomas [103]. EBV accounts for 1% of the global cancer burden and 5.6% of all infection-related malignancies [104]; most EBV-associated malignancies are associated with latent infection and latent gene expression.

Lytic infection, with active production of virions and cell death, may be the consequence of either primary infection or reactivation. Reactivation of latent infection is induced by different stimuli, particularly by antibodies to surface immunoglobulins (B-cell receptors) after antigenic stimulation. As a consequence, expression of immediate-early genes is induced, leading to production of early antigens (EAs) involved in viral replication (thymidine kinase, DNA polymerase), followed by expression of late genes encoding structural (capsid) antigens (viral capsid antigens, VCAs) [105].

The humoral immune response to EBV is characterized by the production of specific antibodies to the lytic infection-associated antigens (VCA and EA) and latency-associated nuclear antigens [EBNA-1, -2 and -3, and the EBV nuclear leader protein (EBNALP)], as well as to some antigens found on sheep, horse and beef red cells (heterophile antibodies).

Heterophile agglutinating antibodies (mostly IgM) to sheep and horse red cells are detectable in 90% of patients at some point during infectious mononucleosis, and persist for 1 year in 70–75% of cases. Heterophile antibodies may also be present in normal serum (naturally occurring Forssman's antibodies), leading to false-positive results. The differential absorption of serum with guinea pig kidney cells (which remove Forssman's and serum sickness-associated antibodies, but not mononucleosis-associated heterophile antibodies) and with beef red cells (which remove mononucleosis-associated but not Forssman's antibodies) increases the test specificity. Titres of 40 or more after guinea pig absorption are compatible with infectious mononucleosis, although false-positive results may be found in 7–12% of patients, and false-negative results are common in paediatric age groups or in the very early phase of disease, warranting later retesting in the course of the illness.

Specific antibodies to structural VCAs and nonstructural EAs expressed during the lytic cycle, as well as antibodies to latent EBNAs, are detectable by indirect immunofluorescence or enzyme immunoassays. Anti-VCA IgG antibody levels are

usually close to peak at the time of presentation, so that a four-fold rise in titre, which is required to confirm acute infection, is detectable in only 10–20% of patients with mononucleosis or related complications. As IgG antibodies to VCAs persist for life, their detection is only useful for an assessment of serostatus. Conversely, IgM antibodies to VCAs at titres of 1/32 or greater are detectable in 90% of early acute infections, but are present in no more than 10% of patients after 4 months; their presence is therefore diagnostic of acute EBV infection. IgM antibodies to VCAs may be absent in 10–20% of acute infections. This diagnostic dilemma may be solved by measuring the avidity of IgG antibodies, i.e. the stability of binding to the antigen in the presence of urea; recent infection is characterized by low IgG avidity values.

Antibodies to EAs are found in about 70% of patients with acute infectious mononucleosis, peak at 3–4 weeks after disease onset and disappear after 3–6 months; in contrast, antibodies to EBNAs are not detectable until 3–4 weeks after disease onset, but persist for life in about 100% of infected patients. Thus, the appearance of antibodies to EBNAs in patients who were negative at the beginning of the illness is diagnostic of acute primary EBV infection.

In view of the high sensitivity and specificity of the serological tests, and the intermittent virus shedding by healthy seropositive subjects, virus detection by culture of oropharyngeal washings or circulating mononuclear cells is of little value in immunocompetent subjects with acute infection. The detection of virus in tissues by PCR amplification of viral DNA or by EBV-encoded RNA *in situ* hybridization (EBER-RISH) is also of limited clinical use when employed alone, because of the ubiquitous presence of virus-infected B lymphocytes trapped in peripheral organs [106]. When obtained in combination, serological data consistent with active infection and suggestive histopathological features and tissue detection of viral DNA by PCR may be useful.

Epidemiology and pathogenesis

Antibodies to EBV are detectable in more than 90% of the world's adult population, without predilection for sex, ethnicity and socioeconomic status. In the western world, only 50% of primary infections occur before the age of 5 years, with a second wave of infections occurring in the second decade of life. EBV is labile when exposed to the environment, and may be spread only by intimate contact with virus shedders (kissing in adolescents/young adults or transfer of saliva to susceptible children within families through shared objects or food).

Most signs and symptoms of acute primary EBV infection (infectious mononucleosis) in immunocompetent subjects are produced by immune activation, aimed at both EBNA-expressing B cells and EBV-transformed mononuclear cells, which represent 20% of circulating B cells and 0.5% of mononuclear cells respectively. Antigen-activated CD8+ cytotoxic T lymphocytes (CTLs) that are highly specfic for EBV lytic antigens or EBNA proteins are the major effectors of removal of proliferating or transformed mononuclear cells during acute infection and suppression of EBV-infected B-lymphocyte growth during subsequent viral latency respectively [107].

EBV hepatitis

Typical infectious mononucleosis is characterized clinically by fever, sore throat, lymphadenopathy and splenomegaly, by the appearance of heterophile antibodies and by mononuclear leukocytosis with atypical lymphocytes. Transient and self-limited liver enzyme elevations are found in the majority of patients (80–90%) [108]. In adults over the age of 40, abdominal pain with fever and transaminase/akaline phosphatase alterations may predominate. Jaundice with a frank cholestatic picture may be present in 5–7% of cases [108–111]. Histopathology shows minimal swelling and vacuolization of hepatocytes and bile ducts, with pleomorphic lymphocyte and monocyte portal infiltration; biliary stasis is rare.

Severe hepatitis is rare in immunocompetent individuals with infectious mononucleosis and only a few lethal cases have been reported [112,113]. The majority of cases of severe and potentially lethal liver damage are observed in immunocompromised subjects with either X-linked (Duncan's) lymphoproliferative disease (frequently resulting in fulminant hepatitis at the time of primary EBV infection) or post-transplant lymphoproliferative disease, especially after liver transplantation (as a result of primary EBV infection or reactivation).

'Chronic' hepatitis has been tentatively linked to primary infection [114] or chronic EBV infection [115]; liver histology in these patients shows portal and intrasinusoidal mononuclear inflammatory cell infiltrates (mostly B and T lymphocytes, with rare plasma cells) and fatty changes, without significant hepatocyte necrosis or liver structure disarray.

Autoimmune chronic hepatitis triggered by EBV through the continuous proliferation of asialoglycoprotein receptor-specific B lymphocytes has been reported [116]. Histopathology reveals active lobular hepatitis with portal and sinusoidal mononuclear cell infiltration, piecemeal necrosis and portal or bridging fibrosis [117,118]. Anti-smooth muscle antibodies may be present [119].

In these patients, serology is generally consistent with latent EBV infection, with absent or low-level antibodies typical of lytic infection (IgG antibodies to EAs and IgM antibodies to VCAs), but with significant titres of IgG antibodies to both VCAs and EBNAs. Molecular techniques have revealed the presence of EBV in liver tissue; however, the specificity of these techniques may be weakened by the presence of circulating EBV-carrying B lymphocytes 'trapped' within the liver at the moment of biopsy. The paradox of viral latency in the lymphocytes infiltrating the liver but not in the hepatocytes, which lack the CD21 epithelial cell receptor for EBV and have not been found to contain EBV sequences, remains unexplained [120].

As the mechanisms underlying EBV-related hepatitis are poorly understood, reliable diagnostic criteria for EBV hepatitis are lacking. Recent data suggest that the diagnosis of acute and chronic EBV hepatitis should be based on the combination of

four parameters: elevated liver enzymes, serology indicating active EBV infection, typical histopathological changes and demonstration of the viral genome in liver tissue by PCR or EBER-RISH [121]. None of these parameters alone is sufficient for a reliable diagnosis of EBV hepatitis outside infectious mononucleosis. In all other situations, quantification of EBV DNA should be carried out with highly standardized procedures, such as real-time PCR [122,123], to establish clinically significant thresholds for differentiating EBV-associated liver damage from non-specific amplification of viral genomes in circulating B cells trapped within the liver.

Treatment

Adenine arabinoside, aciclovir and ganciclovir inhibit EBV replication *in vitro*; these drugs are active only during lytic and not latent infection, as they target the EBV DNA polymerase. A decrease or suppression of viral excretion in pharyngeal secretions may be obtained in infectious mononucleosis, without affecting the course of disease. In fact, no significant benefit of aciclovir in the treatment of mild, moderate and severe infectious mononucleosis was demonstrated in a meta-analysis of five randomized controlled trials [124].

Severe post-transplant EBV-related hepatitis is treated with aciclovir or ganciclovir [125,126]. As the majority of cells in lymphoproliferative disease are latently infected and do not express the EBV DNA polymerase, they should not be sensitive to aciclovir and ganciclovir; however, these drugs may act on lytic EBV replication occurring in a small number of cells, limiting cell-to-cell spread of EBV and, thus, reducing the pool of infected B cells [127].

Human herpesvirus type 8

HHV-8 (KSHV) is the only known human gamma-2 herpesvirus (rhadinovirus). Transmission is via sexual and non-sexual routes; in adults from developed countries, 15–20% of HIV-negative and 40% of HIV-infected male homosexuals are HHV-8 seropositive, whereas 10–20% of children in the subendemic/endemic areas of the Mediterranean Basin [128] and up to 50% of the general population of sub-Saharan Africa are seropositive [129]. Saliva is likely to be the principal vehicle of transmission [130]. HHV-8 DNA is detectable in tissues and peripheral blood mononuclear cells from patients with HHV-8-related diseases. The virus induces both latent and lytic infection; latent infection is the basis for the lifelong persistence of the virus in human hosts, and latency-associated antigens induce tumorigenesis by promoting cell growth and inhibiting apoptosis [131].

HHV-8 is the cause of Kaposi's sarcoma (KS), a proliferation of virus-infected malignant dermal spindle cells with mononuclear cell infiltration. The classic form of KS typically affects elderly men of Mediterranean descent, with an indolent or slowly progressive course involving the skin of the lower limbs. The endemic KS of sub-Saharan Africa behaves similarly to the classic form in adults but, in children under 10 years of age, it may show an aggressive multifocal lymphadenopathic course, which is usually fatal. The AIDS-associated KS observed in HIV-infected adults predominates in homosexual men; it shows a rapidly progressive and wide dissemination involving the skin of the face and trunk, as well as the gastrointestinal and respiratory tract. Invasive manifestations in other organs are less frequent. The iatrogenic form of KS is reported with increasing frequency in transplanted patients and patients who are on immunosuppressive or cytostatic treatment for autoimmune and neoplastic diseases respectively. Primary HHV-8 infection in immunocompetent hosts is usually asymptomatic; however, a mild self-limited illness with fever and a maculopapular rash spreading from face to trunk and limbs may be seen in children [132], whereas fever, diarrhoea, localized rash and cervical lymphadenopathy may be seen in immunocompetent adults [133].

Primary infection in immunocompromised patients shows a different clinical picture and may have significant consequences. In HIV-positive subjects, HHV-8 seroconversion may be followed after some weeks by high fever, arthralgia, lymphadenopathy, splenomegaly and skin lesions showing foci of KS and angiolymphoid hyperplasia; lesions have not recurred after starting antiretroviral treatment. Disseminated KS with plasmacytosis and bone marrow failure or fatal HHV-8-positive lymphoproliferative disease has occurred in recipients a few weeks after transplant of renal [134] or liver allografts, respectively, from HHV-8 seropositive donors [135,136].

Significant liver involvement has not been reported in immunocompetent subjects with HHV-8 primary infection. In contrast, liver tissue may be involved in KS and other HHV-8-related malignancies in immunocompromised patients, particularly in the setting of primary acute disseminated infection – as in transplant recipients from an infected donor – or, less frequently, during HHV-8 reactivation in HIV-positive patients.

Treatment

Ganciclovir, cidofovir, foscarnet and adefovir, but not aciclovir, show significant activity *in vitro* against HHV-8 lytic replication but, similarly to other anti-herpetic drugs, not against latent viral forms, which predominate in all HHV-8-associated diseases; their use in this setting, therefore, seems unreasonable. Only anecdotal reports exist on the treatment of acute infections with disseminated disease following seroconversion in transplanted patients [137]; further studies are needed to elucidate the role of antivirals in this setting, as well as in the prophylaxis/pre-emptive treatment of graft recipients from HHV-8-positive donors.

Measles

Measles is an acute, highly contagious, febrile illness caused by the rubeola virus, a morbillivirus belonging to the family Paramyxoviridae.

Diagnosis is based on the demonstration of a serological response, virus isolation (particularly in immunosuppressed

patients in whom the antibody response is impaired) and identification of viral antigens or RNA in tissue specimens. The current standard serological diagnosis is based on the enzyme-linked immunosorbent assay (ELISA) detection of specific IgM antibodies alongside the rash, or on a fourfold or higher IgG antibody titre increase in convalescent serum.

Clinically significant hepatitis in measles is rarely observed; overt jaundice has been reported in only a few cases [138], although increases in liver enzyme levels are seen in up to 80% of patients, particularly young adults [139]. In a small series of patients with uncomplicated measles and asymptomatic liver dysfunction, maximum alanine aminotransferase levels ranged from 46 to 2910 IU/L; liver histology showed small foci of hepatocyte necrosis, but no piecemeal necrosis, cellular infiltration or portal fibrosis were observed. Electron microscopy showed no virus particles, and immunohistochemistry was negative, although measles virus RNA was detectable in one case [140]. The pathogenesis of liver injury in measles is poorly understood; immune-mediated or antipyretic-induced damage have been hypothesized [141].

Secondary bacterial superinfections should be vigorously treated as they are correlated with the severity of liver damage. The efficacy of parenteral, as well as aerosolized, ribavirin in complicated measles remains unclear.

Rubella

Rubella (German measles) is a febrile exanthem of children and adults that is caused by a togavirus and is spread by droplets from respiratory secretions of infected patients.

Mild hepatitis has been reported as an unusual manifestation of postnatal rubella [142]. In the few cases reported in the literature, the age of the patients ranged from the second to the sixth decade; aminotransferases did not exceed 350 IU/mL, whereas lactate dehydogenase (LDH) levels were greatly increased [143]. Liver histology revealed focal hepatocellular necrosis, cellular swelling and mononuclear infiltration of portal spaces [144]; inflammatory cells within the liver were mainly CD8-positive/CD16-negative mononuclear cells (T-cytotoxic lymphocytes), suggesting that cell-mediated immune responses may play a role in liver injury [145]. Thrombocytopenic purpura, meningoencephalitis, hepatosplenomegaly, jaundice and hepatitis are transient manifestations that are observed at birth; type 1 diabetes may develop in late childhood. Cholestatic jaundice with high levels of alkaline phosphatase and bilirubin, and less significant alterations of aminotransferases, are observed immediately after birth; true hepatitis may occasionally occur, with focal hepatocyte necrosis, giant-cell hepatitis and viral colonization of the liver.

Enteroviruses

The non-poliovirus enteroviruses (coxsackieviruses and echoviruses) are responsible for febrile syndromes and exanthems in immunocompetent children and adults.

They commonly infect newborns, with consequences ranging from asymptomatic infection and benign illness to life-threatening generalized disease and death [146]; however, they are rarely associated with hepatitis in adults. Clinical manifestations of neonatal enteroviral infections include meningoencephalitis, pneumonia, myocarditis, coagulopathy and hepatitis.

Fulminant hepatitis may develop in disseminated coxsackievirus B infections in newborns and young infants, dominating the clinical picture. In a small series, coxsackievirus B1 infection was diagnosed in four patients with hepatitis and coxsackievirus B3 in one; hepatic involvement progressed rapidly to jaundice and coagulopathy [147]. Severe neonatal hepatitis has also been reported in association with coxsackievirus B5 [148], echovirus 11 [149] and echovirus 18 infection [150]. Echovirus 33, a relatively uncommon enterovirus, led to 75 virologically-confirmed cases of infection during the winter of 2000 in New Zealand; two infants died of systemic disease, including a neonate with fulminant hepatitis [151]. In a series of 61 neonatal echovirus infections, the mortality rate in infants with severe hepatitis was 83% [152].

Diagnosis

The mainstay of diagnosis has traditionally been viral isolation from tissue culture; however, PCR analysis is more sensitive than viral culture, highly specific and rapid [153]. Histology may show a syncytial giant-cell hepatitis with mixed lymphocytic and neutrophilic infiltrates; however, syncytial giant-cell hepatitis in the neonatal period has also been associated with CMV, rubella virus, HSV, HHV-6, varicella virus, reovirus 3, parvovirus B19 and paramyxovirus infections [154].

Treatment

Immunoglobulin has been used to treat neonates with enterovirus disease, but its efficacy is not proven. Specific antiviral therapy for enteroviruses is in development; pleconaril is an investigational agent that inhibits viral attachment to host cell receptors and uncoating of viral nucleic acid. Three newborns presenting at 4–5 days of age with neonatal echovirus infection, fulminant hepatic failure and severe coagulopathy were treated with 5 mg/kg of pleconaril every 8 h by nasogastric tube; two recovered fully [155]. A benefit of pleconaril was also shown in children and adults with enteroviral meningitis, and in adults with upper respiratory tract infections caused by picornaviruses (rhinoviruses or enteroviruses) [153].

Adenoviruses

The adenoviruses (ADV) include non-enveloped double-stranded DNA viruses that infect humans via the respiratory, faecal–oral or conjunctival routes [156]. Infection in immunocompetent hosts is usually subclinical (in about 50% of cases) or characterized by mild to moderate upper respiratory disease.

Manifestations are relatively common in paediatric age groups, in whom infection is endemic, causing 10% of respiratory infections [156].

Liver involvement in immunocompetent adults and children with primary ADV infection is unusual and characterized by mild enzyme abnormalities. Severe hepatic damage has been reported in a few paediatric cases, one of which presented with fulminant hepatic failure, pancreatitis and encephalopathy; this patient was treated with cidofovir and recovered without transplantation [157].

Invasive multiorgan disease, including hepatitis, is a frequent and often fatal complication of ADV infection in immunocompromized individuals [158]. Definition of invasive disease requires the identification of positive viral cultures with the addition of either the finding of ADV at the corresponding site (definite case) or a compatible clinical picture (probable case) [159]. Invasive or disseminated (> two organ systems) disease is particularly frequent in immunocompromised paediatric patients, but has also been shown to occur in 1.1% of immunocompetent children during epidemics, particularly with serotypes 3, 5, 7 and 21 [160], and, exceptionally, in immunocompetent adults [161]. Since the 1960s, ADV infection in children with congenital immune deficiencies has been reported to result in severe hepatitis with a high mortality rate [162].

In acquired immunodeficiencies, severe ADV hepatitis with liver failure is rare as an initial manifestation, but is a deadly complication of disseminated disease [163].

ADV-related disease occurs in about 11% of all transplanted patients [164,165]. Invasive disease has been reported in 6–9.6% of paediatric bone marrow transplant/HSCT recipients [159,166,167], with evidence of severe hepatitis in 0.5–1.5%. Fulminant hepatitis as the sole manifestation of invasive disease after bone marrow transplant is rare [168]. Among adult bone marrow transplant recipients, the incidence of invasive disease was 2.6–4.2%, with evidence of hepatitis in 0.25% [169].

In solid-organ transplant recipients, the most common manifestation of invasive disease is pneumonia, although transplanted organs – particularly liver and kidney – are often targets. The overall rate of ADV infection following liver transplantation is 5.8–11%, with higher rates in paediatric patients [163], and the incidence of hepatitis ranges from 1.9% to 4%; half of the patients die from massive liver necrosis [170]. Hepatitis may be caused either by reactivation of disease or by transmission from a seropositive donor liver; ADV-seropositive recipients have a better prognosis.

Induction chemotherapy used for the treatment of acute leukaemias has been rarely associated with fulminant ADV hepatitis [171,172].

Diagnosis

Direct fluorescent assays (DFA) of nasal washes have limited sensitivity. ADV isolation from cell culture is very sensitive but requires several days unless the shell vial technique is employed [173]. Immunohistochemistry with type-specific monoclonal antibodies can be used to detect ADV in the cytoplasm of exfoliated cells from BAL fluid or urine sediment [174], as well as in tissue specimens [175]. ADV-DNA detection by PCR analysis of peripheral blood predicts disseminated disease, allowing earlier diagnosis and treatment [176]. A quantitative PCR technique, which measures the ADV viral load, has been developed [177].

Histopathology demonstrates multifocal or widespread hepatocyte necrosis involving both periportal and centrolobular areas [178], macrovesicular fat distributed in hepatocyte cytoplasm with minimal inflammation, and 'smudgy' cells containing eosinophilic nuclear inclusions.

Treatment

Vidarabine, ribavirin and cidofovir have been used to treat severe ADV diseases [175,179–184]. Cidofovir inhibits viral DNA polymerase and ADV replication in animal models [185], but its use may be limited by renal toxicity. Cidofovir has been employed with apparent benefit in stem-cell transplant recipients, at doses ranging from 1 mg/kg three times weekly to 5 mg/kg once weekly [186,187], and in solid-organ transplant recipients [188]. Recent data suggest that optimal therapeutic responses may be achieved by combining antiviral therapy with immunotherapeutic approaches [189].

Human parvovirus B19

Human parvovirus B19 (HPV-B19) is a small DNA virus that can induce the erythematous 'fifth disease' in children, arthritis in the presence of acute infections and a variety of blood dyscrasias in predisposed patients, such as those with chronic haemolytic anaemia and AIDS [190]. Diagnosis is based on the finding of the IgM antibody to HPV-B19 by immunoassay or of viral DNA by PCR [191]. Most infections are subclinical, benign and self-limited and result in lifelong immunity [190]; liver enzyme levels may transiently rise without signs of liver dysfunction.

The prevalence of infection increases with age; in the United Kingdom, up to 80% of subjects older than 70 have IgG antibodies to HPV-B19 [191]. Infection prevalence was reported to be higher in HCV-positive than in HCV-negative subjects [192].

HPV-B19 has been implicated in cases of fulminant hepatitis that are unrelated to the hepatitis A, B and C viruses [193,194]; many of these patients had aplastic anaemia and, in young children, the recovery from the HBV-B19-related severe liver disease was significantly more frequent and rapid than in patients with fulminant hepatitis of other origin [195].

References

1 Corey L, Wald A, Celum CL *et al.* (2004) The effects of herpes simplex virus-2 on HIV-1 acquisition and transmission: a review of two overlapping epidemics. *J Acquir Immune Defic Syndr* 35, 435–445.

2 Wald A, Zeh J, Selke S *et al.* (2000) Reactivation of genital herpes simplex virus type 2 infection in asymptomatic seropositive persons. *N Engl J Med* 342, 844–850.

3 Sawtell NM (2003) Quantitative analysis of herpes simplex virus reactivation *in vivo* demonstrates that reactivation in the nervous system is not inhibited at early times postinoculation. *J Virol* 77, 4127–4138.

4 Whitley RJ, Kimberlin DW, Roizman B (1998) Herpes simplex viruses. *Clin Infect Dis* 26, 541–555.

5 Sharma S, Shobha S, Mosunjac M (2004) Herpes simplex hepatitis in adults: a search for muco-cutaneous clues. *J Clin Gastroenterol* 38, 697–704.

6 Whitley RJ, Roizman B (2001) Herpes simplex virus infections. *Lancet* 357, 1513–1518.

7 Squires RH Jr, Shneider BL, Bucuvalas J *et al.* (2006) Acute liver failure in children: the first 348 patients in the pediatric acute liver failure study group. *J Pediatr* 148, 652–658.

8 Verma A, Dhawan A, Zuckerman M *et al.* (2006) Neonatal herpes simplex virus infection presenting as acute liver failure: prevalent role of herpes simplex virus type I. *J Pediatr Gastroenterol Nutr* 42, 282–286.

9 Velasco M, Llamas E, Guijarro-Rojas M *et al.* (1999) Fulminant herpes hepatitis in a healthy adult: a treatable disorder? *J Clin Gastroenterol* 28, 386–389.

10 Farr RW, Short S, Weissman D (1997) Fulminant hepatitis during herpes simplex virus infection in apparently immunocompetent adults: report of two cases and review of the literature. *Clin Infect Dis* 24, 1191–1194.

11 Corey L (2005) Herpes simplex virus. In: Mandell GJ, Bennett JE, Dolin R (eds) *Mandell, Douglas and Bennett's Principles and Practice of Infectious Diseases*, 6th edn. Philadelphia, PA: Elsevier, p. 1771.

12 Allen RH, Tuomala RE (2005) Herpes simplex virus hepatitis causing acute liver dysfunction and thrombocytopenia in pregnancy. *Obstet Gynecol* 106, 1187–1189.

13 Kang AH, Graves CR (1999) Herpes simplex hepatitis in pregnancy: a case report and review of the literature. *Obstet Gynecol Surv* 54, 463–468.

14 Kaufman B, Gandhi SA, Louie E *et al.* (1997) Herpes simplex virus hepatitis: case report and review. *Clin Infect Dis* 24, 334–338.

15 Sharma S, Mosunjac M (2004) Herpes simplex hepatitis in adults: a search for muco-cutaneous clues. *J Clin Gastroenterol* 38, 697–704.

16 Mariani P, Paul MD, Vilenski LMD (2005) Fulminant hepatitis due to herpes simplex virus: a case report. *Infect Dis Clin Pract* 13, 274–276.

17 Griffiths WJH, William JH, Wreghitt TG *et al.* (2005) Reactivation of herpes simplex virus after liver transplantation. *Transplantation* 80, 1353–1354.

18 Peters DJ, Greene WH, Ruggiero F *et al.* (2000) Herpes simplex-induced fulminant hepatitis in adults: a call for empiric therapy. *Dig Dis Sci* 45, 2399–2404.

19 Nichols WG, Boeck M, Carter RA *et al.* (2003) Transferred herpes simplex virus immunity after stem-cell transplantation: clinical implications. *J Infect Dis* 187, 801–808.

20 Gane E, Faouzi S, Valdecasas GJC *et al.* (1997) Randomised trial of efficacy and safety of oral ganciclovir in the prevention of cytomegalovirus disease in liver-transplant recipients. *Lancet* 350, 1729–1733.

21 Jacques SM, Quresci F (1992) Herpes simplex virus hepatitis in pregnancy: a clinicopathologic study of three cases. *Hum Pathol* 23, 183–187.

22 Prétet JL, Pelletier L, Bernard B *et al.* (2003) Apoptosis participates to liver damage in HSV-induced fulminant hepatitis. *Apoptosis* 8, 655–663.

23 Cowan FM, French RS, Mayaud P *et al.* (2003) Seroepidemiological study of herpes simplex virus types 1 and 2 in Brazil, Estonia, India, Morocco, and Sri Lanka. *Sex Transm Infect* 79, 286–290.

24 Guerry SL, Bauer HM, Klausner JD *et al.* (2005) Recommendations for the selective use of herpes simplex virus type 2 serological tests. *Clin Infect Dis* 40, 38–45.

25 Golden MR, Ashley-Morrow R, Swenson P *et al.* (2005) Herpes simplex virus type 2 (HSV-2) Western blot confirmatory testing among men testing positive for HSV-2 using the focus enzyme-linked immunosorbent assay in a sexually transmitted disease clinic. *Sex Transm Dis* 32, 771–777.

26 Yavuz BB, Cankurtaran M, Halil M *et al.* (2005) Renal dysfunction after oral acyclovir treatment in a geriatric woman: a case report. *Scand J Infect Dis* 37, 611–613.

27 Stone KM, Reiff-Eldridge R, White AD *et al.* (2004) Pregnancy outcomes following systemic prenatal acyclovir exposure: conclusions from the international acyclovir pregnancy registry, 1984–1999. *Birth Defects Res A Clin Mol Teratol* 70, 201–207.

28 Chen Y, Schieux C, Garrait V *et al.* (2000) Resistant herpes simplex virus type 1 infection: an emerging concern after allogeneic stem cell transplantation. *Clin Infect Dis* 31, 927–935.

29 Danve-Szatanek C, Aymard M, Thouvenot D *et al.* (2004) Surveillance network for herpes simplex virus resistance to antiviral drugs: 3-year follow-up. *J Clin Microbiol* 42, 242–249.

30 Levin MJ, Bacon TH, Leary JJ (2004) Resistance of herpes simplex virus infections to nucleoside analogues in HIV-infected patients. *Clin Infect Dis* 39, S248–257.

31 Wyles DL, Patel A, Madinger N *et al.* (2005) Development of herpes simplex virus disease in patients who are receiving cidofovir. *Clin Infect Dis* 41, 676–680.

32 Martinez CM, Luks-Golger DB (1997) Cidofovir use in acyclovir-resistant herpes infection. *Ann Pharmacother* 31, 1519–1521.

33 Pitel PA, McCormick KL, Fitzgerald E *et al.* (1980) Subclinical hepatic changes in varicella infection. *Pediatrics* 65, 631–633.

34 Peterson CL, Mascola S, Chao SM *et al.* (1996) Children hospitalized for varicella: a prevaccine review. *J Pediatr* 129, 529–536.

35 Meyer PA, Seward JF, Jumaan AO *et al.* (2000) Varicella mortality: trends before vaccine licensure in the United States, 1970–1994. *J Infect Dis* 182, 383–390.

36 Anderson DR, Schwartz J, Hunter NJ *et al.* (1994) Varicella hepatitis: a fatal case in a previously healthy, immunocompetent adult. Report of a case, autopsy, and review of the literature. *Arch Intern Med* 154, 2101–2106.

37 Vartian CV (1999) Varicella-zoster virus infection associated with acute liver failure. *Clin Infect Dis* 28, 412–413.

38 Kavaliotis J, Loukou I, Trachana M *et al.* (1998) Outbreak of varicella in a pediatric oncology unit. *Med Pediatr Oncol* 31, 166–169.

39 Mantadakis E, Anagnostatou N, Danilatou V *et al.* (2005) Fulminant hepatitis due to varicella zoster virus in a girl with acute lymphoblastic leukemia in remission: report of a case and review. *J Pediatr Hematol Oncol* 27, 551–553.

40 David DS, Tegtmeier BR, O'Donnell MR *et al.* (1998) Visceral varicella zoster after bone marrow transplantation: report of a case series and review of the literature. *Am J Gastroenterology* 93, 810–813.

41 Kim SH, Haycox C (1999) Primary disseminated varicella presenting as an acute abdomen. *Pediatr Dermatol* 16, 208–210.

42 Grant RM, Weitzman SS, Sherman CG *et al.* (2002) Fulminant disseminated varicella zoster virus infection without skin involvement. *J Clin Virol* 24, 7–12.

43 Dits H, Frans E, Wilmer A *et al.* (1998) Varicella-zoster virus infection associated with acute liver failure. *Clin Infect Dis* 27, 209–210.

44 Os I, Strom EH, Stenehjem A *et al.* (2001) Varicella infection in a renal transplant recipient associated with abdominal pain, hepatitis, and glomerulonephritis. *Scand J Urol Nephrol* 35, 330–333.

45 Vafai A, Berger M (2001) Zoster in patients infected with HIV: a review. *Am J Med Sci* 321, 372–380.

46 Dowell SF, Bresee JS (1993) Severe varicella associated with steroid use. *Pediatrics* 92, 223–228.

47 Hyvernat H, Roger PM, Pereira C *et al.* (2005) Fatal varicella hepatitis in an asthmatic adult after short-term corticosteroid treatment. *Eur J Intern Med* 16, 361–362.

48 Redman RL, Nader S, Zerboni L *et al.* (1997) Early reconstitution of immunity and decreased severity of herpes zoster in bone marrow transplant recipients immunized with inactivated varicella vaccine. *J Infect Dis* 176, 578–585.

49 Koc Y, Miller KB, Schenkein DP *et al.* (2000) Varicella zoster virus infections following allogeneic bone marrow transplantation: frequency, risk factors, and clinical outcome. *Biol Bone Marrow Transplant* 6, 44–49.

50 Berman JN, Wang M, Berry W *et al.* (2006) Herpes zoster infection in the post-hematopoietic stem cell transplant pediatric population may be preceded by transaminitis: an institutional experience. *Bone Marrow Transplant* 37, 73–80.

51 Rogers SY, Irving W, Harris A *et al.* (1995) Visceral varicella zoster infection after bone marrow transplantation without skin involvement and the use of PCR for diagnosis. *Bone Marrow Transplant* 15, 805–807.

52 Leung TF, Chik KW, Li CK *et al.* (2000) Incidence, risk factors and outcome of varicella-zoster virus infection in children after haemapoietic stem cell transplantation. *Bone Marrow Transplant* 25, 167–172.

53 Leena M, Ville V, Veli-Jukka A (2006) Visceral varicella zoster virus infection after stem cell transplantation: a possible cause of severe abdominal pain. *Scand J Gastroenterol* 41, 242–244.

54 de Jong MD, Weel JF, van Oers MH *et al.* (2001) Molecular diagnosis of visceral herpes zoster. *Lancet* 357, 2101–2102.

55 Steer CB, Szer J, Sasadeusz J *et al.* (2000) Varicella-zoster infection after allogenic bone marrow transplantation: incidence, risk factors and prevention with low-dose acyclovir and ganciclovir. *Bone Marrow Transplant* 25, 657–664.

56 Thomson KJ, Hart DP, Banerjee L *et al.* (2005) The effects of low-dose acyclovir on reactivation of varicella-zoster virus after hematopoietic stem cell transplant. *Bone Marrow Transplant* 35, 1065–1069.

57 Hata A, Asanuma H, Rinki M *et al.* (2002) Use of an inactivated varicella vaccine in recipients of hematopoietic-cell transplants. *N Engl J Med* 347, 26–34.

58 Coaquette A, Bourgeois A, Dirand C *et al.* (2004) Mixed cytomegalovirus glycoprotein B genotypes in immunocompromised patients. *Clin Infect Dis* 39, 155–161. Available: http://www.journals.uchicago.edu/CID/journal/issues/v39n2/32984/32984.text.html – fn1#fn1

59 Wreghitt TG, Teare EL, Sule O *et al.* (2003) Cytomegalovirus infection in immunocompetent patients. *Clin Infect Dis* 37, 1607–1608.

60 Ljungman P, Griffiths P, Paya C (2002) Definitions of cytomegalovirus infection and disease in transplant recipients. *Clin Infect Dis* 34, 1094–1097.

61 Humar A, Gregson D, Caliendo AM *et al.* (1999) Clinical utility of quantitative cytomegalovirus viral load determination for predicting cytomegalovirus disease in liver transplant recipients. *Transplantation* 68, 1305–1311.

62 Shinkai M, Bozzette SA, Powderly W *et al.* (1997) Utility of urine and leukocyte cultures and plasma DNA polymerase chain reaction for identification of AIDS patients at risk for developing human cytomegalovirus disease. *J Infect Dis* 175, 302–308.

63 Imbert-Marcille BM, Cantarovich D, Ferre-Aubineau V *et al.* (1997) Usefulness of DNA viral load quantification for cytomegalovirus disease monitoring in renal and pancreas/renal transplant recipients. *Transplantation* 63, 1476–1481.

64 Flexman J, Kay I, Fonte R *et al.* (2001) Differences between the quantitative antigenemia assay and the cobas amplicor monitor quantitative PCR assay for detecting CMV viraemia in bone marrow and solid organ transplant patients. *J Med Virol* 64, 275–282.

65 Emery VC, Sabin CA, Cope AV *et al.* (2000) Application of viral-load kinetics to identify patients who develop cytomegalovirus disease after transplantation. *Lancet* 355, 2032–2036.

66 Piiparinen H, Hockerstedt K, Lappalainen M *et al.* (2002) Monitoring of viral load by quantitative plasma PCR during active cytomegalovirus infection of individual liver transplant patients. *J Clin Microbiol* 40, 2945–2952.

67 Gerna G, Lilleri D, Baldanti F *et al.* (2003) Human cytomegalovirus immediate-early mRNAemia versus pp65 antigenemia for guiding pre-emptive therapy in children and young adults undergoing hematopoietic stem cell transplantation: a prospective, randomized, open-label trial. *Blood* 101, 5053–5060.

68 Revello MG, Zavattoni M, Furione M *et al.* (2006) Preconceptional primary human cytomegalovirus infection and risk of congenital infection. *J Infect Dis* 193, 783–787.

69 Pass RF (2004) A key role for adolescents in the epidemiology of cytomegalovirus and genital herpes infection. *Clin Infect Dis* 39, 1439–1440.

70 Stanberry LR, Rosenthal SL, Mills L *et al.* (2004) Longitudinal risk of herpes simplex virus (HSV) type 1, HSV type 2, and cytomegalovirus infections among young adolescent girls *Clin Infect Dis* 39, 1433–1438.

71 Gandhi MK, Khanna R (2004) Human cytomegalovirus: clinical aspects, immune regulation, and emerging treatments. *Lancet Infect Dis* 4, 725–738.

72 Kytö V, Vuorinen T, Saukko P *et al.* (2005) Cytomegalovirus infection of the heart is common in patients with fatal myocarditis. *Clin Infect Dis* 40, 683–688.

73 Crumpacker CS, Wadhwa S (2005) Cytomegalovirus. In: Mandell GJ, Bennett JE, Dolin R (eds) *Mandell, Douglas and Bennett's Principles and Practice of Infectious Diseases*, 6th edn. Philadelphia, PA: Elsevier, pp. 1786–1800.

74 Wreghitt TG, Teare EL, Sule O *et al.* (2003) Cytomegalovirus infection in immunocompetent patients. *Clin Infect Dis* 37, 1603–1606.

75 Revello MG, Zavattoni M, Sarasini A *et al.* (1998) Human cytomegalovirus in blood of immunocompetent persons during

primary infection: prognostic implications for pregnancy. *J Infect Dis* 177, 1170–1175.
76 Amory JK, Rosen H, Sukut C *et al.* (2006) Clinical problem-solving. A jaundiced eye. *N Engl J Med* 354, 1516–1520.
77 Winston DJ, Busuttil RW (2004) Randomized controlled trial of sequential intravenous and oral ganciclovir versus prolonged intravenous ganciclovir for long-term prophylaxis of cytomegalovirus disease in high-risk cytomegalovirus-seronegative liver transplant recipients with cytomegalovirus-seropositive donors. *Transplantation* 77, 305–308.
78 Paya CV (2001) Prevention of cytomegalovirus disease in recipients of solid-organ transplants. *Clin Infect Dis* 32, 596–603.
79 Preiksaitis JK, Brennan DC, Fishman J *et al.* (2005) Canadian society of transplantation consensus workshop on cytomegalovirus management in solid organ transplantation final report. *Am J Transplant* 5, 218–227.
80 Cope AV, Sabin C, Burroughs A *et al.* (1997) Interrelationships among quantity of human cytomegalovirus (HCMV) DNA in blood, donor-recipient serostatus, and administration of methylprednisolone as risk factors for HCMV disease following liver transplantation. *J Infect Dis* 176, 1484–1490.
81 Lautenschlager I, Halme L, Hockerstedt K *et al.* (2006) Cytomegalovirus infection of the liver transplant: virological, histological, immunological, and clinical observations. *Transpl Infect Dis* 8, 21–30.
82 Moutaftsi M, Mehl AM, Borysiewicz LK *et al.* (2002) Human cytomegalovirus inhibits maturation and impairs function of monocyte-derived dendritic cells. *Blood* 99, 2913–2921.
83 Falagas ME, Snydman DR, Griffith J *et al.* (1997) Clinical and epidemiological predictors of recurrent cytomegalovirus disease in orthotopic liver transplant recipients. Boston Center for Liver Transplantation CMVIG Study Group. *Clin Infect Dis* 25, 314–317.
84 Sia IG, Wilson JA, Groettum CM *et al.* (2000) Cytomegalovirus (CMV) DNA load predicts relapsing CMV infection after solid organ transplantation. *J Infect Dis* 181, 717–720.
85 Lurain NS, Bhorade SM, Pursell KJ *et al.* (2002) Analysis and characterization of antiviral drug-resistant cytomegalovirus isolates from solid organ transplant recipients. *Clin Infect Dis* 186, 760–768.
86 Huang LM, Lee CY, Chen JY *et al.* (1992) Primary human herpesvirus 6 infections in children: a prospective serologic study. *J Infect Dis* 165, 1163–1164.
87 Ward KN (2005) The natural history and laboratory diagnosis of human herpesviruses-6 and -7 infections in the immunocompetent. *J Clin Virol* 32, 183–193.
88 Hall CB, Long CE, Schnabel KC *et al.* (1994) Human herpesvirus-6 infection in children. A prospective study of complications and reactivation. *N Engl J Med* 331, 432–438.
89 Aita K, Jin Y, Irie H *et al.* (2001) Are there histopathologic characteristics particular to fulminant hepatic failure caused by human herpesvirus-6 infection? A case report and discussion. *Hum Pathol* 32, 887–889.
90 Ohashi M, Yoshikawa T, Asonuma K *et al.* (2004) Human herpesvirus 6 fulminant hepatic failure treated by living donor liver transplantation. *Pediatr Int* 46, 730–732.
91 Harma M, Hockerstedt K, Lautenschlager I (2003) Human herpesvirus-6 and acute liver failure. *Transplantation* 76, 536–539.
92 Safronetz D, Humar A, Tipples GA (2003) Differentiation and quantitation of human herpesviruses 6A, 6B and 7 by real-time PCR. *J Virol Methods* 112, 99–105.
93 Cacheux W, Carbonell N, Rosmorduc O *et al.* (2005) HHV-6-related acute liver failure in two immunocompetent adults: favourable outcome after liver transplantation and/or ganciclovir therapy. *J Intern Med* 258, 573–578.
94 Feldstein AE, Razonable RR, Boyce TG *et al.* (2003) Prevalence and clinical significance of human herpesviruses 6 and 7 active infection in pediatric liver transplant patients. *Pediatr Transplant* 7, 125–129.
95 Mendez JC, Dockrell DH, Espy MJ *et al.* (2001) Human betaherpesvirus interactions in solid organ transplant recipients. *J Infect Dis* 183, 179–184.
96 Clark DA, Griffiths PD (2003) Human herpesvirus 6: relevance of infection in the immunocompromised host. *Br J Haematol* 120, 384–395.
97 Tokimasa S, Hara J, Osugi Y *et al.* (2002) Ganciclovir is effective for prophylaxis and treatment of human herpesvirus-6 in allogeneic stem cell transplantation. *Bone Marrow Transplant* 29, 595–598.
98 Tugizov SM, Berline JW, Palefsky JM (2003) Epstein-Barr virus infection of polarized tongue and nasopharyngeal epithelial cells. *Nat Med* 9, 307–314.
99 Cohen JI (2000) Epstein-Barr virus infection. *N Engl J Med* 343, 481–492.
100 Tsurumi T, Fujita, Kudoh A (2005) Latent and lytic Epstein-Barr virus replication strategies. *Rev Med Virol* 15, 3–15.
101 Kieff E, Rickinson AB (2001) Epstein-Barr virus and its replication. In: Knipe DM, Howley PM (eds) *Fields' Virology*, 4th edn. Philadelphia, PA: Lippincott Williams & Wilkins, pp. 2511–2574.
102 Harada S, Kieff E (1997) Epstein-Barr virus nuclear protein LP stimulates EBNA-2 acidic domain-mediated transcriptional activation. *J Virol* 71, 6611–6618.
103 Kulwichit W, Edwards RH, Davenport EM *et al.* (1998) Expression of the Epstein-Barr virus latent membrane protein 1 induces B cell lymphoma in transgenic mice. *Proc Natl Acad Sci USA* 95, 11963–11968.
104 Parkin DM (2002) The global health burden of infection-associated cancers in the year 2002. *Int J Cancer* 118, 3030–3044.
105 Ragoczy T, Heston L, Miller G (1998) The Epstein-Barr virus Rta protein activates lytic cycle genes and can disrupt latency in B lymphocytes. *J Virol* 72, 7978–7984.
106 Middeldorp JM, Brink AA, Van den Brule AJ *et al.* (2003) Pathogenic roles for Epstein-Barr virus (EBV) gene products in EBV-associated proliferative disorders. *Crit Rev Oncol Hematol* 45, 1–36.
107 Klenerman P, Hill A (2005) T cells and viral persistence: lessons from diverse infections. *Nat Immunol* 6, 873–879.
108 Markin RS (1994) Manifestations of Epstein-Barr virus-associated disorders in liver. *Liver* 14, 1–13.
109 Shaukat A, Tsai HT, Rutherforth R *et al.* (2005) Epstein-Barr virus induced hepatitis: An important cause of cholestasis. *Hepatol Res* 33, 24–26.
110 Kimura H, Nagasaka T, Hoshino Y *et al.* (2001) Severe hepatitis caused by Epstein-Barr virus without infection of hepatocytes. *Human Pathol* 32, 757–762.
111 Hinedi TB, Koff RS (2003) Cholestatic hepatitis induced by Epstein-Barr virus infection in an adult. *Dig Dis Sci* 48, 539–541.
112 Markin RS, Linder J, Zuerlein K *et al.* (1987) Hepatitis in fatal infectious mononucleosis. *Gastroenterology* 93, 1210–1217.
113 Jimenez-Saenz M, Perez-Pozo JM, Leal-Luna A *et al.* (2002) Lethal liver failure in an elderly patient with hepatitis B superinfected with Epstein-Barr virus. *Eur J Gastroenterol Hepatol* 14, 1283–1284.
114 SakamotoT, Uemura M, Fukui K *et al.* (1992) Chronic active Epstein-Barr virus infection in an adult. *Intern Med* 31, 1190–1196.

115 Yuge A, Kinoshita E, Moriuchi M *et al.* (2004) Persistent hepatitis associated with chronic active Epstein-Barr virus infection. *Pediatr Infect Dis J* 23, 74–76.

116 Vento S, Guella L, Mirandola F *et al.* (1995) Epstein-Barr virus as a trigger for autoimmune hepatitis in susceptible individuals. *Lancet* 346, 608–606.

117 Chiba T, Goto S, Yokosuka O *et al.* (2004) Fatal chronic active Epstein-Barr virus infection mimicking autoimmune hepatitis. *Eur J Gastroenterol Hepatol* 16, 225–228.

118 Vento S, Cainelli F (2004) Is there a role for viruses in triggering autoimmune hepatitis? *Autoimmun Rev* 3, 61–69.

119 Nobili V, Comparcola D, Sartorelli MR *et al.* (2003) Autoimmune hepatitis type 1 after Epstein-Barr virus infection. *Pediatr Infect Dis J* 22, 387.

120 Negro F (2006) The paradox of Epstein-Barr virus-associated hepatitis. *J Hepatol* 44, 839–841.

121 Drebber U, Kasper HU, Krupacz J *et al.* (2006) The role of Epstein-Barr virus in acute and chronic hepatitis. *J Hepatol* 44, 879–885.

122 Ruiz G, Pena P, de Ory F *et al.* (2005) Comparison of commercial real-time PCR assays for quantification of Epstein-Barr virus DNA. *J Clin Microbiol* 43, 2053–2057.

123 Stevens SJ, Verkuijlen SA, Middeldorp JM (2005) Quantitative detection of Epstein-Barr virus DNA in clinical specimens by rapid real-time PCR targeting a highly conserved region of EBNA-1. *Methods Mol Biol* 292, 15–26.

124 Torre D, Tambini R (1999) Acyclovir for treatment of infectious mononucleosis: a meta-analysis. *Scand J Infect Dis* 31, 543–547.

125 Andreone P, Gramenzi A, Lorenzini S *et al.* (2003) Posttransplantation lymphoproliferative disorders. *Arch Intern Med* 163, 1997–2004.

126 Preiksaitis JK, Keay S (2001) Diagnosis and management of post-transplant lymphoproliferative disorder in solid-organ transplant recipients. *Clin Infect Dis* 33(Suppl 1), S38–46.

127 Gershburg E, Pagano JS (2005) Epstein-Barr virus infections: prospects for treatment. *J Antimicrob Chemother* 56, 277–281.

128 Ablashi DV, Chatlynne LG, Whitman JE Jr *et al.* (2002) Spectrum of Kaposi's sarcoma-associated herpesvirus, or human herpesvirus 8, diseases. *Clin Microbiol Rev* 15, 439–464.

129 Chatlynne LG, Ablashi DV (1999) Seroepidemiology of Kaposi's sarcoma-associated herpesvirus (KSHV). *Semin Cancer Biol* 9, 175–185.

130 Verna SC, Robertson ES (2003) Molecular biology and pathogenesis of Kaposi sarcoma-associated herpesvirus. *FEMS Microbiol Lett* 222, 155–163.

131 Dourmishev LA, Dourmishev AL, Palmieri D *et al.* (2003) Molecular genetics of Kaposi's sarcoma-associated herpesvirus (human herpesvirus-8) epidemiology and pathogenesis. *Microbiol Mol Biol Rev* 67, 175–212.

132 Andreoni M, Sarmati L, Nicastri E *et al.* (2002) Primary human herpesvirus 8 infection in immunocompetent children. *JAMA* 287, 1295–1300.

133 Wang QJ, Jenkins FJ, Jacobson LP *et al.* (2001) Primary human herpesvirus 8 infection generates a broadly specific CD8(+) T-cell response to viral lytic cycle proteins. *Blood* 9, 2366–2373.

134 Luppi M, Barozzi P, Schulz TF *et al.* (2000) Bone marrow failure associated with human herpesvirus 8 infection after transplantation. *N Engl J Med* 343, 1378–1385.

135 Verucchi G, Calza L, Trevisani F *et al.* (2005) Human herpesvirus-8-related Kaposi's sarcoma after liver transplantation successfully treated with cidofovir and liposomal daunorubicin. *Transpl Infect Dis* 7, 34–37.

136 Marcelin AG, Roque-Afonso AM, Hurtova M *et al.* (2004) Fatal disseminated Kaposi's sarcoma following human herpesvirus 8 primary infections in liver-transplant recipients. *Liver Transpl* 10, 295–300.

137 Boeckle E, Boesmuller C, Wiesmayr S *et al.* (2005) Kaposi sarcoma in solid organ transplant recipients: a single center report. *Transplant Proc* 37, 1905–1909.

138 Odeh M, Oliven A, Potasman I (1995) Hepatitis with overt jaundice in acute measles infection. *J Clin Gastroenterol* 20, 345–346.

139 Khatib R, Siddique M, Abbass M (1993) Measles associated hepatobiliary disease: an overview. *Infection* 21, 112–114.

140 Satoh A, Kobayashi H, Yoshida T *et al.* (1999) Clinicopathological study on liver dysfunction in measles. *Intern Med* 38, 454–457.

141 Ackerman Z, Flugelman MY, Wax Y *et al.* (1989) Hepatitis during measles in young adults: possible role of antipyretic drugs. *Hepatology* 10, 203–206.

142 Zeldis JB, Miller JD, Dienstag JL (1985) Hepatitis in an adult with rubella. *Am J Med* 79, 515–516.

143 Arai M, Wada N, Maruyama N *et al.* (1995) Acute hepatitis in an adult with acquired rubella infection. *J Gastroenterol* 30, 539–542.

144 Tameda Y, Kosaka Y, Shiraki K *et al.* (1993) Hepatitis in an adult with rubella. *Intern Med* 32, 580–583.

145 Gershon AA (2005) Rubella virus. In: Mandell GJ, Bennett JE, Dolin R (eds) *Mandell, Douglas and Bennett's Principles and Practice of Infectious Diseases*, 6th edn. Philadelphia, PA: Elsevier, pp. 1921–1926.

146 Verboon-Maciolek MA, Krediet TG, van Loon AM *et al.* (2002) Epidemiological survey of neonatal non-polio enterovirus infection in the Netherlands. *J Med Virol* 66, 241–245.

147 Wang SM, Liu CC, Yang YJ *et al.* (1998) Fatal coxsackievirus B infection in early infancy characterized by fulminant hepatitis. *J Infect* 37, 270–273.

148 Clavell M, Barkemeyer B, Martinez B *et al.* (1999) Severe hepatitis in a newborn with coxsackievirus B5 infection. *Clin Pediatr* 38, 739–741.

149 Hsiao CC, Tsao LY, Chen HN (2003) Echovirus 11 sepsis in a neonate: report of one case. *Acta Paediatr Taiwan* 44, 104–105.

150 Shah SS, Gallagher PG (1997) Neonatal sepsis due to echovirus 18 infection. *J Perinat Med* 25, 311–384.

151 Huang QS, Carr JM, Nix WA *et al.* (2003) An echovirus type 33 winter outbreak in New Zealand. *Clin Infect Dis* 37, 650–657.

152 Modlin JF (1986) Perinatal echovirus infection: insights from a literature review of 61 cases of serious infection and 16 outbreaks in nurseries. *Rev Infect Dis* 8, 918–926.

153 Abzug MJ (2004) Presentation, diagnosis, and management of enterovirus infections in neonates. *Paediatr Drugs* 6, 1–10.

154 Hicks J, Barrish J, Zhu SH (2001) Neonatal syncytial giant cell hepatitis with paramyxoviral-like inclusions. *Ultrastruct Pathol* 25, 65–71.

155 Aradottir E, Alonso EM, Schulman ST (2001) Severe neonatal enteroviral hepatitis treated with pleconaril. *Pediatr Infect Dis J* 20, 457–459.

156 Baum SG (2005) Adenovirus. In: Mandell GJ, Bennett JE, Dolin R (eds) *Mandell, Douglas and Bennett's Principles and Practice of Infectious Diseases*. 6th edn. Philadelphia, PA: Elsevier, 1835–1841.

157 Rocholl C, Gerber K, Daly J *et al.* (1992) Adenoviral infections in children: the impact of rapid diagnosis. *Pediatrics* 113, 51–56.

158 Hierholzer JC (1992) Adenoviruses in the immunocompromised host. *Clin Microbiol Rev* 5, 262–274.

159 Flomenberg P, Babbitt J, Drobyski WR *et al.* (1994) Increasing incidence of adenovirus disease in bone marrow transplant recipients. *J Infect Dis* 169, 775–781.

160 Munoz FM, Piedra PA, Demmler GJ (1998) Disseminated adenovirus disease in immunocompromised and immunocompetent children. *Clin Infect Dis* 27, 1194–1200.

161 Two fatal cases of adenovirus-related illness in previously healthy young adults–Illinois, 2000 (2001) *MMWR Morb Mortal Wkly Rep* 50, 553–555.

162 Wigger HJ, Blanc WA (1966) Fatal hepatic and bronchial necrosis in adenovirus infection with thymic alymphoplasia. *N Engl J Med* 275, 870–874.

163 Kojaoghlanian T, Flomenberg P, Horwitz MS (2003) The impact of adenovirus infection on the immunocompromised host. *Rev Med Virol* 13, 155–171.

164 Blanke C, Clark C, Broun ER *et al.* (1995) Evolving pathogens in allogeneic bone marrow transplantation: increased fatal adenoviral infections. *Am J Med* 99, 326–328.

165 Howard DS, Phillips II GL, Reece DE *et al.* (1999) Adenovirus infections in hematopoietic stem cell transplant recipients. *Clin Infect Dis* 29, 1494–1501.

166 Bordigoni P, Carret AS, Venard V *et al.* (2001) Treatment of adenovirus infections in patients undergoing allogeneic hematopoietic stem cell transplantation. *Clin Infect Dis* 32, 1290–1297.

167 Hale GA, Heslop HE, Krance RA *et al.* (1999) Adenovirus infection after pediatric bone marrow transplantation. *Bone Marrow Transplant* 23, 277–282.

168 Bertheau P, Parquet N, Ferchal F *et al.* (1996) Fulminant adenovirus hepatitis after allogeneic bone marrow transplantation. *Bone Marrow Transplant* 17, 295–298.

169 La Rosa AM, Champlin RE, Mirza N *et al.* (2001) Adenovirus infections in adult recipients of blood and marrow transplants. *Clin Infect Dis* 32, 371–376.

170 Michaels MG, Green M, Wald ER *et al.* (1992) Adenovirus infection in pediatric liver transplant recipients. *J Infect Dis* 165, 170–174.

171 Kaur B, Gottardo NG, Keil AD *et al.* (2002) A rare case of adenovirus fulminant hepatic necrosis after chemotherapy. *Pediatr Hematol Oncol* 19, 361–371.

172 Hough R, Chetwood A, Sinfield R *et al.* (2005) Fatal adenovirus hepatitis during standard chemotherapy for childhood acute lymphoblastic leukemia. *J Pediatr Hematol Oncol* 27, 67–72.

173 Shih SR, Tsao KC, Ning HC *et al.* (1999) Diagnosis of respiratory tract viruses in 24 h by immunofluorescent staining of shell vial cultures containing Madin-Darby Canine Kidney (MDCK) cells. *J Virol Methods* 81, 77–81.

174 Grandien M, Pettersson CA, Gardner PS *et al.* (1985) Rapid viral diagnosis of acute respiratory infections: comparison of enzyme-linked immunosorbent assay and the immunofluorescence technique for detection of viral antigens in nasopharyngeal secretions. *J Clin Microbiol* 22, 757–760.

175 Gavin P, Katz BZ (2002) Intravenous ribavirin treatment for severe adenovirus disease in immunocompromised children. *Pediatrics* 110, e9.

176 Echavarria M, Forman M, van Tol MJD *et al.* (2001) Prediction of severe disseminated adenovirus infection by serum PCR. *Lancet* 358, 384–385.

177 Lankester AC, van Tol MJ, Claas EC *et al.* (2002) Quantification of adenovirus DNA in plasma for management of infection in stem cell graft recipients. *Clin Infect Dis* 34, 864–867.

178 Charles AK, Caul EO, Porter HJ *et al.* (1995) Fatal adenovirus 32 infection in a bone marrow transplant recipient. *J Clin Pathol* 48, 779–781.

179 Kitabayashi A, Hirokawa M, Kuroki J *et al.* (1994) Successful vidarabine therapy for adenovirus type II-associated acute hemorrhagic cystitis after allogeneic bone marrow transplantation. *Bone Marrow Transplant* 14, 853–854.

180 La Rosa AM, Champlin RE, Mirza N *et al.* (2001) Adenovirus infections in adult recipients of blood and marrow transplants. *Clin Infect Dis* 32, 871–876.

181 Miyamura K, Hamaguchi M, Taji H *et al.* (2000) Successful ribavirin therapy for severe adenovirus hemorrhagic cystitis after allogeneic marrow transplant from close HLA donors rather than distant donors. *Bone Marrow Transplant* 25, 545–548.

182 Arav-Boger R, Echavarria M, Forman M *et al.* (2000) Clearance of adenoviral hepatitis with ribavirin therapy in a pediatric liver transplant recipient. *Pediatr Infect Dis J* 19, 1097–1100.

183 Aebi C, Hendrick CL, McCracken GH *et al.* (1997) Intravenous ribavirin therapy in a neonate with disseminated adenovirus infection undergoing extracorporeal oxygenation. *J Pediatr* 130, 612–615.

184 Wulffraat NM, Geelen SP, van Dijken PJ *et al.* (1995) Recovery from adenovirus pneumonia in a severe combined immunodeficiency patient treated with intravenous ribavirin. *Transplantation* 59, 927.

185 de Oliveira CB, Stevenson D, LaBree L *et al.* (1996) Evaluation of Cidofovir (HPMPC, GS-504) against adenovirus type 5 infection *in vitro* and in a New Zealand rabbit ocular model. *Antiviral Res* 31, 165–172.

186 Legrand F, Berrebi D, Houhou N *et al.* (2001) Early diagnosis of adenovirus infection and treatment with cidofovir after bone marrow transplantation in children. *Bone Marrow Transplant* 27, 621–626.

187 Hoffman JA, Shah AJ, Ross LA *et al.* (2001) Adenoviral infections and a prospective trial of cidofovir in pediatric hematopoietic stem cell transplantation. *Biol Blood Marrow Transplant* 7, 388–394.

188 Ison MG (2006) Adenovirus infections in transplant recipients. *Clin Infect Dis* 43, 331–339.

189 Lenaerts L, Naesens L (2006) Antiviral therapy for adenovirus infections. *Antiviral Res* 71, 172–180.

190 Clewley JP (2006) Polymerase chain reaction assay of parvovirus B19 DNA in clinical specimens. *J Clin Microbiol.* 27, 2647–2651.

191 Anderson LS (2002) Human parvovirus B19. In: Richman DD, Whitley RS, Hayden FG (eds) *Clinical Virology*. Washington, DC: American Society for Microbiology (ASM) Press, pp. 597–612.

192 Cacoub P, Boukli N, Hausfater P *et al.* (1998) Parvovirus B19 infection, hepatitis C virus infection, and mixed cryoglobulinaemia. *Ann Rheum Dis* 57, 422–424.

193 Langnas A, Markin RS, Cattral LS *et al.* (1995) Parvovirus B19 as a possible causative agent of fulminant liver failure and associated aplastic anemia. *Hepatology* 22, 1661–1665.

194 Karetnyi Y, Beck PR, Markin PR *et al.* (1999) Human parvovirus B19 infection in acute fulminant liver failure. *Arch Virol* 144, 1713–1724.

195 Sokal E, Melchior M, Comu C *et al.* (1998) Acute parvovirus B19 infection associated with fulminant hepatitis of favourable prognosis in young children. *Lancet*, 35, 1739–1741.

9.3 Human immunodeficiency virus and the liver

Vincent Soriano, Pablo Barreiro, Javier García-Samaniego, Luz Martín-Carbonero and Marina Nuñez

Liver damage in patients with human immunodeficiency virus (HIV) infection can result from multiple factors, including HIV itself, coinfection with hepatitis viruses, hepatic involvement during the course of systemic infections, drug toxicities and tumours (Table 1). Since the advent of highly active antiretroviral therapy (HAART), severe HIV-related immunodeficiency is only rarely seen in the developed world. Accordingly, the spectrum of liver complications in HIV+ persons has changed dramatically. Liver involvement due to opportunistic infections (i.e. cytomegalovirus, toxoplasmosis, tuberculosis, etc.) or neoplasms (i.e. Kaposi's sarcoma, lymphomas, etc.) is no longer an important issue. In contrast, chronic hepatitis B and C have emerged as one of the leading causes of hospital admission and death among HIV+ patients in the new millennium.

Hepatitis B

Introduction

The prevalence of chronic hepatitis B virus (HBV) infection among HIV+ individuals varies according to geography and risk category. In western countries, chronic hepatitis B is overall 10-fold more frequent among HIV+ individuals than in the general population [1]. Men infected through homosexual contacts tend to show the highest rates (6–10%); rates are slightly lower among intravenous drug users (IDUs) and much lower among persons infected through heterosexual contacts [1].

Table 1 Aetiology of liver damage in HIV-infected patients.

1 Chronic viral hepatitis: HBV and HCV
2 Other hepatitis viruses: A, E, G, EBV, CMV
3 Infections of the liver: tuberculosis, toxoplasmosis, cryptococcosis, others
4 Liver tumours: hepatocarcinoma, lymphomas, Kaposi's sarcoma
5 Drug-related liver toxicity: antiretrovirals, other medications
6 Biliary disease

HBV, hepatitis B virus; HCV, hepatitis C virus; EBV, Epstein–Barr virus; CMV, cytomegalovirus.

HIV infection has a deleterious effect on the outcome of chronic viral hepatitides, and complicates their management. Mortality is higher in HIV-positive individuals with chronic hepatitis, either B and/or C, than in those with HIV alone [1–3], with the highest rates being reported among those with multiple hepatitides [3]. In one study conducted before 2000, HBV coinfection was associated with a nearly 13-fold higher risk of liver-related mortality in HIV-positive patients, and this negative impact was more prominent in subjects with low CD4 counts [2]. There are scarce data on the outcome of HBV infection in the HAART era [1,4].

The reciprocal interferences between HIV and HBV infections result in specific problems in coinfected patients [4]. Poorer response to interferon alpha (IFN-α), and faster selection of lamivudine (3TC)-resistant HBV strains have been reported [4]. The higher risk of selecting drug-resistant HIV and/or HBV argues against monotherapy with nucleos(t)ide analogues in this population. Thus, the management of both infections should be carefully coordinated.

For a long time, 3TC has been the only available oral drug with dual activity against HIV and HBV. However, since the approval of tenofovir disoproxil fumarate (TDF) and emtricitabine (FTC) for the treatment of HIV infection, chronic HBV infection in HIV-coinfected patients may also benefit from using these new drugs, even though they have not yet been approved for the treatment of HBV monoinfection. In addition, the new pegylated IFN-αs, which may be administered subcutaneously once a week, have recently attracted attention, as they are more convenient and potent.

Efficacy of anti-HBV drugs in HIV-coinfected patients

Four drugs have been approved so far for the treatment of chronic hepatitis B: IFN-α, 3TC, adefovir dipivoxil (ADV) and entecavir (ETV). However, other compounds showing anti-HBV activity have already been approved as therapy against either HIV (i.e. TDF and FTC) or hepatitis C (i.e. pegylated IFN-α). Although not yet approved against HBV, these drugs

Table 2 HBV arsenal in HIV-infected patients.

Drug	Anti-HIV activity	Anti-HBV potency	Resistance barrier	Comments
Pegylated interferon	Yes	High	No	Weekly subcutaneous administration Contraindicated in ESLD 6–12 months' treatment duration
Lamivudine	Yes	Intermediate	Low	> 30% resistance at 12 months Excellent tolerance
Emtricitabine	Yes	Intermediate	Low	Equivalent to lamivudine Co-formulated with tenofovir
Adefovir[a]	No	Intermediate	Intermediate	Useful in ESLD and 3TC failures 15% resistance at 4 years
Tenofovir	Yes	High	High	Good tolerance Useful in 3TC and adefovir failures
Entecavir	No	High	High	Useful but less potent in 3TC failures Good tolerance

[a]Adefovir at doses of 10 mg daily.
ESLD, endstage liver disease; 3TC, lamivudine.

are often used in HBV/HIV-coinfected patients. Table 2 summarizes the current therapeutic armamentarium against HBV [5].

IFN-α

While responses in HIV+ patients are superior compared with no treatment, they tend to be lower than in HIV-negative individuals. Higher CD4+ counts and higher baseline transaminase levels are predictors of IFN response. The therapeutic response to IFN-α in HBV is worse when HCV and/or HDV coinfections are present, a common situation in HIV+ IDUs. Therefore, several reasons may account for the lower response to IFN-α seen in HBV/HIV-coinfected patients, such as low CD4 counts, low transaminase levels and frequent HCV coinfection.

Lamivudine (3TC)

Although the inhibitory dosage for blocking HBV replication is lower (100 mg/day) than that needed for inhibiting HIV, 300 mg/day of the drug should be given when treating HBV/HIV-coinfected patients, and 3TC should always be combined with at least two other anti-HIV agents. Otherwise, 3TC monotherapy would rapidly select HIV resistance mutations [5].

Anti-HBe seroconversion occurs in only a minority of patients treated with 3TC, but many show improvements in liver histology; reversal of liver decompensations is common in those with advanced cirrhosis. However, the downside of 3TC monotherapy is the relatively high incidence of HBV resistance mutations over time (~20% per year) [6].

Emtricitabine (FTC)

This cytosine analogue, closely related to 3TC, has been approved for the treatment of HIV infection. FTC should not be used as monotherapy in this population due to the high risk of selecting HIV resistance mutations. FTC is not indicated after 3TC failure, as both drugs show cross-resistance.

Adefovir (ADV)

The dose recommended is 10 mg daily, which does not show clinical activity against HIV. In a study conducted in 35 HIV/HBV-coinfected patients with 3TC-resistant HBV strains, the addition of ADV to 3TC provided a significant reduction in serum HBV DNA, which was maintained for 192 weeks, along with normalization of transaminases in most cases [7]. ADV-resistant mutations were not selected in HBV or in HIV. However, in other studies, mutations rtN236T and rtA181V were shown to be selected in 29% of HBV-monoinfected individuals treated with ADV monotherapy for 5 years.

Tenofovir (TDF)

Lamivudine is no longer a protagonist in the treatment of HBV in HIV-coinfected patients since the approval of TDF for the treatment of HIV infection. TDF is a nucleotide analogue with both anti-HIV and anti-HBV activity; it is a very potent inhibitor of HBV replication *in vitro*, even in the presence of 3TC resistance. The results of retrospective studies assessing the efficacy of TDF against HBV in HIV-coinfected patients are shown in Table 3. Serum HBV DNA levels declined on average 4 log10, despite most patients carrying 3TC-resistant mutations [8–13].

Entecavir (ETV)

This is one of the most potent anti-HBV agents examined so far and shows a relatively good safety profile. It lacks any anti-HIV activity. Data have been released from a randomized and double-blind study performed on 68 HIV/HBV-coinfected patients failing 3TC. Either a 2 $\log_{10}$ reduction in viral load from baseline or undetectable HBV DNA (< 400 copies/mL) were achieved at 24 weeks by 84% of ETV-treated patients. Virological responses to ETV are seen in patients with 3TC-resistant HBV, although they tend to be lower than in 3TC-naive

Table 3 Efficacy of tenofovir against HBV in HIV-coinfected patients.

Author [ref.]	No.	YMDD mutants	Mean ↓HBV DNA (log10) at 24 weeks	Seroconversion	Seroconversion
				Anti-HBe	Anti-HBs
Núñez *et al.* [8]	12	8	−3.8[a]	1/9	1/12
Van Bömmel *et al.* [9]	5	5	−4.5	0/4	0/5
Ristig *et al.* [10]	6	3	−4.3	0/6	0/6
Nelson *et al.* [11]	20	11	−4.0[a]	2/20	0/20
Benhamou *et al.* [12]	12	10	−3.8	0/?	0/12
Dore *et al.* [13]	12	7	−4.9	1/10	0/10

[a]Median.

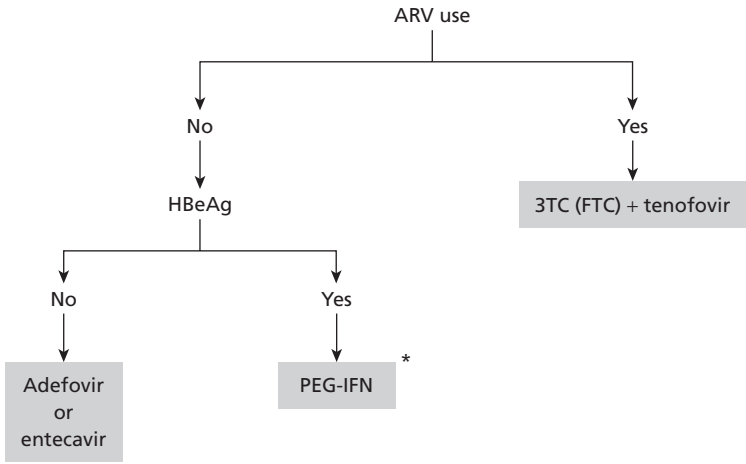

* With caution in cirrhotics

Fig. 1 Preferred anti-HBV agents in HBV/HIV-coinfected patients in distinct situations. ARV, antiretroviral.

patients. Resistance to ETV results from the accumulation of multiple changes in the HBV polymerase, including those linked to 3TC resistance. For this reason, ETV doses of 0.5 mg daily are recommended in drug-naive patients, but doses of 1.0 mg daily are preferred for patients with 3TC-resistant HBV strains. In HBV/HIV-coinfected patients, doses of 1.0 mg/day are preferred at first, given the overall higher HBV viraemia seen in this population [5].

HBV resistance to nucleos(t)ide analogues

On average, YMDD mutations develop at a rate of 15–20% per year of 3TC treatment, but are more rapidly selected in HBV/HIV-coinfected subjects, with incidences of 50% and 90% after 2 and 4 years of 3TC therapy, respectively [6]. Selection of HBV resistance to FTC seems to occur more slowly than with 3TC, with rates of 19% after 2 years of FTC treatment.

Hepatitis B surface antigen (HBsAg) should be screened in all HIV-infected individuals. If positive, full serological assessment of HBV infection should be performed, including testing for HBeAg and anti-HBe antibody and plasma HBV DNA measurement [5]. HBV treatment is generally indicated for those patients with active disease and viral replication.

The HIV/HBV-coinfected population is unique in the sense that some nucleos(t)ide analogues frequently used as antiretrovirals also have anti-HBV activity. If HIV needs to be treated, in the presence of an active HBV infection, drugs such as TDF and 3TC (FTC), preferentially in combination, should be considered as the best option (Fig. 1). The problem of when to treat HBV in HIV-coinfected patients becomes more relevant when there is no need to initiate antiretroviral therapy. Most recent guidelines do not support the requirement for a liver biopsy, relying more on serum markers such as alanine aminotransferase (ALT) levels, HBV DNA and HBeAg serostatus to decide whether HBV treatment should be initiated or may be delayed [5,14]. However, liver biopsy may be convenient in patients with no indication for antiretrovirals when ALT levels are normal but serum HBV DNA is greater than 10^4 copies/mL (Fig. 2) [5]. The advent of non-invasive techniques to assess liver fibrosis, such as serum biochemical markers and liver elastography, might be

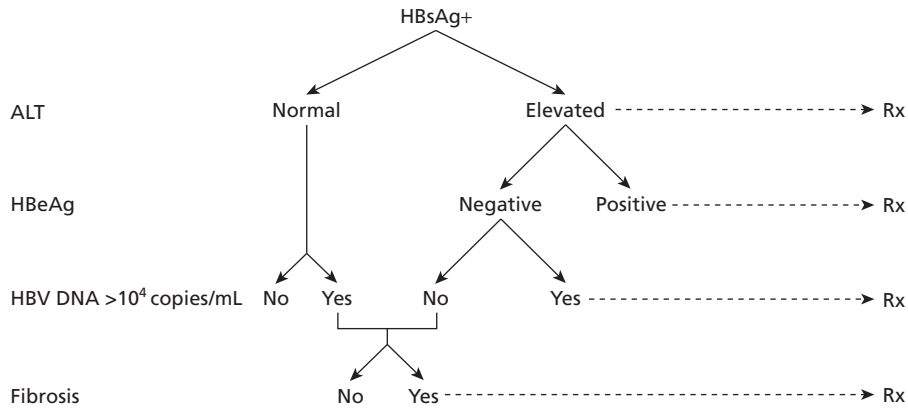

Fig. 2 HBV treatment (Rx) decision algorithm in HIV/HBV-coinfected patients.

useful to stage liver fibrosis in chronic hepatitis B, avoiding the performance of liver biopsy [15]. Liver biopsy could be left only for discordant cases.

While recent guidelines in HIV-negative individuals with chronic hepatitis B have recommended that treatment should be considered for patients with serum HBV DNA above 10^5 copies/mL in HBeAg-positive patients [16], a lower threshold could be appropriate for HBeAg-negative patients and those with decompensated cirrhosis (thresholds of 10^4 and 10^3 copies/mL respectively) [16]. At this time, the recommendations for treating HBV in the setting of HIV coinfection should be taken individually and based on the consideration of aspects related to the HIV situation [5]. The coexistence of HIV infection along with chronic hepatitis B makes an integrated approach necessary for the appropriate management of both infections.

Table 4 summarizes the treatment options for HIV-infected subjects with chronic hepatitis B. A major issue is the indication to give or not to give antiretroviral therapy. If HBV is the only virus to be treated, the pegylated forms of IFN-α could be a valid option [5]. The presence of HBeAg is one of the most important determinants in favour of IFN-α. The proportion of patients achieving HBeAg seroconversion using IFN-α is higher than with nucleos(t)ide analogues. An advantage of IFN-α is that it is given for a limited period of time (6–12 months). However, IFN-α should not be used in patients with decompensated cirrhosis, as necroinflammatory flares accompanying HBeAg clearance may lead to liver decompensation. IFN-α appears to be safe in patients with compensated cirrhosis, although there is still a risk of hepatic decompensation with prolonged therapy [16]. Given the lack of data on the use of pegylated IFN-α in HBV/HIV-coinfected subjects, these patients should be treated within clinical trials.

Table 4 HBV treatment options in HIV/HBV-coinfected patients.

HBV treatment only	Pegylated interferon
HBeAg-positive	ETV
	ADV
HBeAg-negative	ETV
	ADV
HIV and HBV treatment	HAART including TDF ± (3TC or FTC)
	HAART + (ADV or ETV)
HIV treatment only	Consider including at least one anti-HBV drug in the HAART regimen to avoid flares due to immune reconstitution

ADV, adefovir; ETV, entecavir; HAART, highly active antiretroviral therapy; 3TC, lamivudine; FTC, emtricitabine; TDF, tenofovir.

The choice of oral anti-HBV drugs should be based on their efficacy in the clinical setting. ETV is a good choice in HBV/HIV-coinfected patients who do not need antiretroviral therapy and may be the best option for HBeAg-negative hepatitis B. ADV may be considered as a reasonable alternative choice, although the potential selection of resistance mutations in the HIV genome has been a matter of concern [5]; however, this does not seem to represent a major problem [17].

The use of 3TC, FTC or TDF in monotherapy should be avoided in HIV/HBV-coinfected patients, as it would favour the selection of HIV resistance mutations. Antiretroviral therapy including either 3TC (FTC) and TDF could be discontinued in patients who achieve a response, i.e. anti-HBe seroconversion, but it should be stopped no earlier than 6 months after the response in order to minimize the risk of relapses upon drug discontinuation [16].

In patients who meet the criteria for antiretroviral therapy as well as for HBV treatment, triple regimens containing 3TC (or FTC) and TDF should be the preferred option [5]. Although the role of combination therapy for HBV is unclear at this time, 3TC (FTC) along with TDF appears at present to be an appropriate backbone, and their combination appears therefore to be the first choice [5]. In cases of no clear indication for anti-HBV treatment, the inclusion of active drug(s) against HBV in the HAART regimen may be considered to avoid hepatic flares in the context of immune reconstitution [5].

HBV resistance should be suspected in patients with detectable HBV viraemia who have already received 3TC. FTC is not useful in this setting, and switching to or adding TDF is recommended. If HIV replication is already suppressed, adding ADV or ETV is a reasonable option.

Finally, HBV/HIV-coinfected patients not treated for HBV should regularly undergo biochemical and virological follow-up (every 3–6 months) to re-evaluate the need for anti-HBV treatment. Biannual α-fetoprotein and ultrasound are recommended in cirrhotics. There has been no agreement as to the time for repeating liver biopsies in patients with no or minimal activity in a first biopsy. However, the availability of the new non-invasive tools for assessing liver fibrosis may overcome this problem. Periodic monitoring with these techniques is particularly helpful in HBV/HIV-coinfected patients in whom progression to endstage liver disease may be accelerated [18].

Hepatitis C

Introduction

Chronic HCV infection has been the focus of particular attention in HIV-positive patients over the last few years. HCV-related liver disease is now a leading cause of morbidity and mortality among HIV-infected individuals in areas with a high prevalence of IDUs [19]. This increased rate of liver complications among HIV-infected patients is due to the dramatic decrease in opportunistic infections as a result of the widespread use of HAART, to the accelerated course of HCV-related liver disease in the HIV setting and to the enhanced risk of liver toxicity using antiretroviral agents in the presence of underlying chronic hepatitis C.

The bidirectional interferences between HCV and HIV infections have clinical consequences and make the management of coinfected individuals complex [14,20].

Epidemiology of HIV/HCV coinfection

Given that HIV and either hepatitis B and C viruses share similar routes of transmission, coinfection is relatively frequent (Fig. 3).

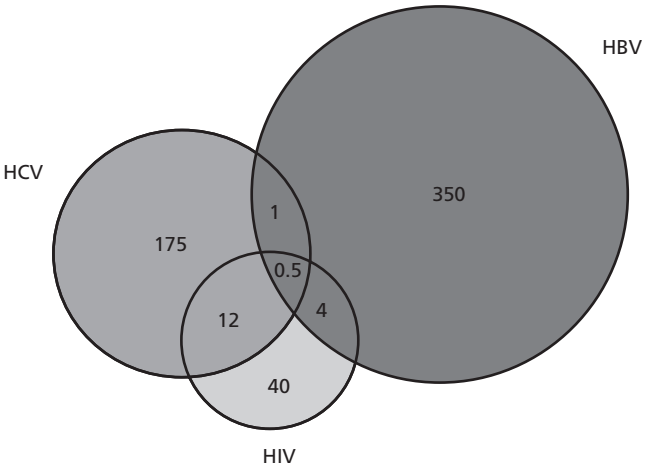

Fig. 3 Estimated number of individuals (in millions) with HIV, HBV and HCV worldwide.

In the United States and western Europe, around one-third of HIV-infected individuals are coinfected with HCV [21]. HCV and HIV are both transmitted by whole blood and blood products, with HCV being 10 times more infectious than HIV. Coinfection with HIV and HCV is therefore frequent in persons with increased blood exposure such as IDUs and haemophiliacs, who have a prevalence of coinfection > 75%. Sexual transmission of HCV is infrequent; this explains the low rate of HCV coinfection among homosexual HIV+ patients. Nevertheless, recent outbreaks of acute HCV infection have been described in association with some homosexual practices.

Laboratory markers and diagnosis of hepatitis C in the HIV setting

Current guidelines recommend that all HIV-infected individuals should be screened for HCV antibodies by enzyme-linked immunosorbent assay (ELISA) [14,20]. More than 85% of anti-HCV antibody-positive patients have detectable HCV RNA in the setting of HIV infection, whereas HCV RNA is detectable in only 75% of HIV-negative patients with HCV antibody. Patients with repeatedly elevated aminotransferases of unclear cause (HCV antibody negative) should also be tested for HCV RNA, given that rare cases of silent HCV infection have been reported, mainly among subjects with profound immunodeficiency [20].

In all HCV RNA-positive patients, the HCV genotype should be determined before making any therapeutic decision. Finally, around 20% of HIV+ patients with active HCV replication may show repeatedly normal transaminases. At present, the management of this subset of patients is unclear. HIV/HCV-coinfected patients should be vaccinated against hepatitis A virus if they have not been previously exposed or immunized, because acute hepatitis A may be more severe in the presence of underlying chronic hepatitis C. Likewise, HBV vaccination should not be forgotten in these patients, as up to 20% of HIV-infected individuals may lack markers of ongoing and/or past HBV infection.

Natural history of HIV/HCV coinfection

The coexistence of HIV and HCV in the same individual results in complex interactions between both infections, leading to changes in their respective natural histories. With HAART, HCV-related liver disease might progress less rapidly than in severely immunosuppressed individuals who have no control of HIV replication.

Influence of chronic hepatitis C on the course of HIV infection

Clinical studies of the influence of HCV on HIV disease progression are conflicting. In the Swiss cohort, HIV-positive individuals with HCV infection progressed faster to AIDS and death than HCV-negative patients [22] whereas, in an American

cohort, the progression rates to AIDS and survival were similar in both groups [23].

Results are also conflicting on the possible negative influence of HCV infection in HIV patients who recover immunity using antiretroviral therapy. Although CD4 gains seem to be blunted in HCV/HIV-coinfected individuals recruited in some studies [22], similar gains in CD4 cell counts compared with HCV-negative patients have been seen by others [23]. If the deleterious effect exists, a successful treatment of HCV infection might contribute to higher CD4 gains using HAART in the coinfected population.

HCV may negatively influence HIV disease through indirect pathways, such as forcing antiretroviral treatment discontinuation more frequently because of an increased risk of liver toxicity. Up to one-quarter of coinfected patients who initiate HAART stop therapy on account of drug-related hepatotoxicity [24]; an increased risk ratio of 3.7 times for developing liver toxicity was found in one study [25]. This risk might be even more pronounced in patients carrying HCV genotype 3, given that baseline steatosis is associated with this HCV variant [26]. Liver toxicity is most often asymptomatic, but occasionally it may lead to acute liver failure [27].

Influence of HIV infection on the course of chronic hepatitis C

Acute HCV infection evolves more easily into chronic hepatitis in HIV-infected individuals, especially in those with a more advanced immune deficiency. HCV RNA levels are much higher in HIV-coinfected patients than in HCV-monoinfected individuals, both in plasma and in the liver. The reason for the higher level of HCV replication in HIV-coinfected patients seems to be the poorer control of HCV infection, mainly due to a decrease in anti-HCV-specific CD8 responses, which are more evident in patients with lower CD4 counts. Although the implications of these findings on the natural history of HCV infection are uncertain, patients with high levels of HCV replication may have lower chances of response to IFN-based treatments [28].

The progression of liver fibrosis is accelerated in HIV/HCV-coinfected patients, especially when immune deficiency is profound. In a recent multicentre European study that assessed liver biopsies from 914 patients coinfected with hepatitis C and HIV, the distribution of METAVIR liver fibrosis stages was F0 in 10% of patients, F1 in 33%, F2 in 22%, F3 in 22% and F4 in 13%, highlighting the high degree of liver fibrosis in this population [29]. Nearly half of patients had advanced liver fibrosis (F3–F4) after the age of 40 years. Clearly, progression to endstage liver disease occurs faster in the HIV/HCV-coinfected population, including the development of hepatocellular carcinoma at younger ages [30]. Overall, 25% of the HIV/HCV-coinfected patients will develop cirrhosis within 15 years after HCV exposure, whereas this occurs in only 5% of those without HIV infection [31].

HAART might be associated with better survival through decreasing HIV-related and also liver-related deaths [32]. The improved prognosis in HIV/HCV-coinfected patients conferred by HAART could be related to a slower progression of liver fibrosis. Several studies have reported significantly reduced fibrosis scores in patients on protease inhibitor (PI)-based HAART. HAART may reverse at least partially the negative effect of HIV infection on HCV-related liver disease, in particular when the immune deficiency is more profound.

Treatment of hepatitis C in the HIV setting

Until the advent of HAART, liver disease associated with HCV had minimal impact on the outcome of HIV+ individuals, and classical opportunistic illnesses were the main concern, particularly at advanced stages of immunosuppression. However, since 1996, potent antiretroviral therapy has permitted the reversal of the immune deficiency in most HIV-infected individuals and, therefore, the risk of developing opportunistic infections. As a consequence, other illnesses such as chronic viral hepatitis have become much more relevant.

Rationale

The treatment of hepatitis C in HIV+ patients has become a priority for two main reasons. First, progression to endstage liver disease due to HCV occurs more rapidly in the HIV setting. Second, the tolerance of antiretroviral agents is much poorer in the presence of underlying chronic hepatitis C, with a greater risk of developing hepatotoxicity [20].

Current results

Pegylated IFN (PEG-IFN) plus ribavirin (RBV) should be considered as the current treatment of choice in this population [14,20]. However, treatment responses are lower than in HCV-monoinfected patients. Because both PEG-IFN and RBV act, at least in part, as immunomodulatory agents, immune defects driven by HIV infection might negatively affect the performance of these drugs.

Most of the studies assessing the efficacy and safety of peg-IFN plus RBV in coinfected patients provided treatment for 12 months to all patients, irrespective of their HCV genotype [33–36]. Because of concerns about drug interactions and further toxicities, lower (800 mg daily) than recommended doses of RBV were prescribed. Only patients with a relatively good immunological status were recruited. Table 5 summarizes the treatment schedules and the results obtained in the main prospective randomized trials.

The high rate of HCV treatment discontinuation in some trials may reflect a higher frequency of serious adverse events in HIV-positive compared with HIV-negative patients; it might also reflect fears by some HIV physicians not familiar enough with the management of side-effects of anti-HCV therapy. Thus, efforts to minimize side-effects with symptomatic treatments and appropriate management of complications are critical to ensure completion of HCV therapy [20].

Table 5 Response to PEG-IFN plus ribavirin in HCV/HIV-coinfected patients in four studies.

	ACTG 5071 [33]	RIBAVIC [34]	APRICOT [35]	Laguno *et al.* [36]
No. of patients	66	205	289	52
Type of PEG-IFN	Roche	Schering-Plough	Roche	Schering-Plough
RBV dose	Escalating 600→1000 mg/day	800 mg/day	800 mg/day	800–1200 mg/day
IDU	80%	81%	62%	75%
Cirrhosis	11%	18%	15%	11%
Genotypes 1–4	77%	69%	67%	63%
Median CD4 count	492 cells/μL	525 cells/μL	520 cells/μL	624 cells/μL
With ARV	85%	82%	84%	94%
Premature stop	12%	36%	25%	25%
ETR (ITT)	41%	36%	49%	52%
SVR (ITT)	27%	27%	40%	44%

ETR, end-of-treatment response; SVR, sustained virological response; ARV, antiretroviral therapy; PEG-IFN, pegylated interferon; RBV, ribavirin; ITT, intention to treat; IDU, intravenous drug user.

Selection of candidates for HCV therapy

Histology

The value of liver biopsy before prescribing anti-HCV therapy has lost importance as anti-HCV therapy has become more efficacious. Outside academic purposes, many experts feel that it is no longer needed in most cases [20,37]. Liver histology allows staging of HCV hepatic damage and may predict the development of cirrhosis. It may also provide information to rule out other causes of liver damage. However, the reproducibility is quite low and largely affected by the size of the hepatic fragment and the expertise of the pathologist.

The controversy on the need for a liver biopsy may be even less justified in HCV/HIV-coinfected patients, in whom the fibrosis progression rate is faster than in HCV-monoinfected persons. Nearly half of coinfected patients may show cirrhosis or precirrhosis after 40 years of age [29]; it should be noted that the mean age of HCV/HIV-coinfected patients currently seen in clinics in the USA and western Europe is above 40 years of age.

CD4 counts

The efficacy of HCV therapy depends somewhat on the baseline CD4 cell count [28]. Candidates to receive HCV therapy should ideally have more than 200–350 CD4+ T cells/μL, a feasible threshold for most patients if antiretroviral therapy is used appropriately [20]. That figure is also currently the immunological threshold for initiating HAART in drug-naive patients.

In patients with CD4 counts below 200 cells/μL and already under HAART, the decision to treat HCV infection must take into account other factors, such as the estimated length of HCV infection, the severity of liver disease, the extent of HIV suppression and classical predictors of response to HCV therapy such as HCV genotype and viral load. Toxicities of IFN and/or RBV as well as poorer responses may be more frequent in this subset of patients. In general, HCV therapy should be deferred in individuals with less than 200 CD4+ T cells/μL, as the risk of toxicity is increased and the response may be poorer. IFN-based therapies cause a decline in the CD4 count, which may put patients at risk of developing opportunistic infections if baseline counts are low. Therefore, in drug-naive coinfected patients, antiretroviral therapy should be considered at first. Once the CD4 count has risen and plasma HIV RNA is under control, the prescription of HCV therapy should be reassessed [20].

Conversely, in antiretroviral-naive individuals with HCV/HIV coinfection, hepatitis C should be treated first if the CD4 count does not warrant immediate antiretroviral therapy. It is debated whether, in patients with CD4 counts above 350 cells/μL but with high plasma HIV RNA levels, suppression of HIV replication should be attempted first, deferring HCV therapy until undetectable HIV viraemia is attained [20]. Finally, the greater efficacy of HCV therapy in patients with higher CD4 counts should be balanced against a higher risk of interactions between antiretrovirals and anti-HCV drugs [14,20].

Contraindications and special populations

Contraindications to the use of IFN or RBV are the same as in HIV-negative patients (see Chapter 5.1.3.v).

Patients on methadone are acceptable candidates for anti-HCV therapy. However, up to one-third of them may need adjustments in methadone dosage. This is generally due to psychological demands rather than to pharmacological interactions between anti-HCV drugs and methadone. Ideally, a multidisciplinary team, including experts in addiction medicine and psychologists/psychiatrics, should take care of these patients.

Patients with repeated normal liver enzymes, particularly those infected with HCV genotypes 2 or 3, might benefit from anti-HCV therapy. However, more information on liver damage in this subset of HCV/HIV-coinfected patients is needed to balance the cost–benefit of HCV therapy in them [14,20]. In the RIBAVIC trial [33], significant liver fibrosis was recognized in a substantial proportion of coinfected patients with normal ALT levels, but treatment responses were lower in this population.

In summary, all HIV+ persons with chronic HCV infection should be considered as potential candidates for HCV therapy, given their higher risk of progression to endstage liver disease compared with HIV-negative patients and their increased risk of liver toxicity after beginning antiretroviral therapy. The timing for anti-HCV treatment should be decided on an individual basis. Severe neuropsychiatric disorders [38] and alcohol and drug abuse generally contraindicate current HCV treatment. However, methadone use and non-decompensated cirrhosis are not contraindications for therapy. Treatment of patients with CD4 counts below 200 cells/μL is risky and should generally not be advised.

Monitoring and duration of HCV therapy in coinfected patients

Despite a possible slower initial HCV RNA decay in HIV-coinfected patients, all patients who attain a sustained viral response (SVR) showed a decline greater than 2 logs at week 12 of therapy [32–34]. Therefore, the predictive roles of early virological response (EVR) also apply to HCV/HIV-coinfected patients (see Chapter 5.1.3.v). Furthermore, one recent report has demonstrated the negative predictive value of the 2 log rule at week 12 in coinfected patients [39], showing that the only difference between HIV-positive and HIV-negative patients with hepatitis C was the proportion of patients reaching virological responses at any given time point (lower in the coinfected population, although this could be due to the relatively low doses of RBV used in that study); using adequate RBV doses, HCV kinetics do not seem to differ much in HIV-positive and HIV-negative subjects, except that baseline HCV RNA is much higher in coinfected individuals and, therefore, it may take longer to reach undetectable viraemia [40,41]. Thus, the principles guiding anti-HCV therapy in HIV-negative patients may equally apply to HIV-coinfected patients.

Patients with high HCV loads may show a good EVR but may fail to clear viraemia at week 24, and may clear the virus later on. This subset of patients represents less than 3% of HCV-monoinfected individuals, but it is larger in HIV-coinfected patients, given their higher baseline HCV RNA levels and possible slower HCV RNA decays on therapy. Therefore, extending treatment beyond 6 months may be advisable in coinfected patients who showed more than 2 log HCV RNA falls at week 12 but are still HCV RNA positive at week 24. If HCV RNA is still detectable at month 9, therapy should be discontinued.

The second phase of clearance of HCV RNA on HCV therapy, which accounts for the steady destruction of infected liver cells, may also be delayed in HIV/HCV-coinfected patients, and could explain the more frequent relapse rate in early virological responders seen in HIV-coinfected patients [42]. Therefore, HIV/HCV-coinfected patients who carry genotypes 2 or 3 should be treated for 12 months.

The use of high doses of RBV seems to enhance substantially the virological response, and this may be even more apparent in the setting of HIV coinfection. Therefore, an effort to keep patients on adequate doses of the drug should be attempted. The administration of recombinant erythropoietin has been proposed as a useful strategy in the management of RBV-related anaemia.

Patients not achieving HCV eradication with treatment might benefit from long-term therapy with PEG-IFN alone. Maintenance therapy with PEG-IFN may provide histological improvement and even reduce the risk of hepatocellular carcinoma; this approach is currently being investigated as an alternative strategy in large trials (i.e. HALT-C and EPIC) in HCV-monoinfected patients. Whether this strategy may also be applicable to non-responding HIV/HCV-coinfected individuals with advanced liver fibrosis remains to be elucidated. However, the potential benefit of this approach should be balanced against the compromise in the quality of life and the reduced CD4+ T cell count caused by PEG-IFN [43].

Interactions between antiretroviral agents and HCV medications

HCV treatment in the presence of HIV infection may be complicated by the interactions between RBV and some antiretrovirals. The intracellular levels of some HIV nucleoside analogues may be decreased by RBV, but the interactions seem to have no clinical consequences. However, a higher toxicity was noted with the concomitant use of didanosine (ddI) and RBV; toxicity is further increased using stavudine (d4T) and ddI together with RBV due to the enhancement of mitochondrial toxicity. Hepatitis C, HIV, RBV and HIV nucleoside analogues may all cause mitochondrial dysfunction and act synergistically [44]. Hepatic decompensation, sometimes with fatal outcome [45], was described with the co-administration of these drugs in cirrhotic patients. Lactic acidosis and pancreatitis have also been reported with the combined use of RBV and ddI; therefore ddI should be avoided in patients receiving anti-HCV therapy [20].

It is also advisable to avoid zidovudine (AZT) when anti-HCV therapy is initiated, because anaemia is more frequent and severe in patients taking AZT along with RBV [46]. A recent study showed a correlation between RBV plasma levels and anaemia, with higher RBV concentrations in patients receiving AZT compared with other nucleoside analogues [46].

How to improve HCV treatment responses

Multiple factors may account for the lower response to HCV therapy seen in HIV-coinfected vs. HCV-monoinfected patients. In view of the low eligibility and applicability of HIV/HCV-coinfected subjects to receive anti-HCV treatment, the first effort needed is to increase the population of candidates for therapy. Poor compliance with follow-up visits was one of the most common causes for excluding HIV/HCV-coinfected patients from therapy. Drugs and alcohol abuse are also often reported as barriers to treating hepatitis C in this population. Special efforts should be made to follow very closely and to manage appropriately the side-effects derived from anti-HCV

medications in coinfected patients to avoid unnecessary discontinuations.

Recent reports have shown the achievement of higher early and sustained responses in HIV/HCV-coinfected subjects with more elevated RBV plasma levels, suggesting that, in this setting, it is also important to maximize the exposure to RBV [40,46].

In contrast to HCV-monoinfected patients, treatment should be given for 48 weeks to HIV/HCV-coinfected patients with HCV genotype 3, as this schedule seems to decrease the number of relapsers after the initial response. Relapses in HIV-positive patients coinfected with HCV genotypes 1 or 4 treated for 12 months occur in 20–30% of patients. In this population, the benefit of prolonged periods of therapy, at least among early virological responders, should be investigated [47]. Tailoring the duration of treatment according to early kinetics might be another strategy to maximize the proportion of SVR. Thus, patients with slower declines during the first weeks of therapy could benefit from receiving more prolonged therapy than those showing a rapid decline in HCV RNA levels [48]. However, extending the duration of treatment in patients who had not attained an adequate virological response at week 12 (> 2 log10) did not increase SVR in HIV/HCV-coinfected subjects.

Management of endstage liver disease in HCV/HIV-coinfected patients

Owing to the accelerated progression of the histological liver damage in the HIV setting, the time to evolve to endstage liver disease (ESLD) is shortened in coinfected patients. Individuals with ESLD have a very poor prognosis, and liver transplant is the only change of survival for them. Results of studies evaluating the outcome of liver-transplanted HIV-infected subjects suggest that HIV should no longer be considered an absolute contraindication for orthotopic liver transplantation (OLT) in coinfected patients [49]. Early evaluation of candidates is critical in this population [50]. Patients with ESLD due to viral hepatitis are also at high risk of developing hepatocellular carcinoma.

Liver transplantation in HCV/HIV-coinfected patients

Given the improved survival and quality of life achieved with HAART, OLT is currently being proposed for HIV/HCV-coinfected patients with ESLD. The first OLT attempts, before the introduction of HAART, provided very poor results, with only a small percentage of transplanted HIV+ recipients achieving a satisfactory outcome. However, more recently, short- and mid-term survival has improved significantly in HIV-infected OLT recipients, although the management of liver transplant entails major difficulties in HIV/HCV-coinfected patients.

The criteria used for OLT are relatively similar worldwide, including CD4 counts above 100 cells/μL, undetectable plasma HIV RNA on HAART or available antiretrovirals for the post-OLT period if the HIV load is detectable, and absence of prior history of AIDS-defining conditions other than pulmonary tuberculosis. The risk of opportunistic infections in the post-transplant period is low as long as HIV replication is well controlled with antiretrovirals. Furthermore, CD4 cell counts remain stable or even increase after transplantation. Therefore, the use of standard immunosuppressive therapy in patients with well-controlled HIV infection seems to be safe and does not increase the risk of developing opportunistic infections.

There are, however, a number of issues involved in both the pre- and post-transplant period that make it more difficult to achieve satisfactory OLT outcomes in the HIV population. First, the selection of HIV-infected candidates for transplantation, because patients with ESLD often present a poor profile (alcohol abuse, drug addiction, prior AIDS-defining conditions, etc.). Second, the priority of organ allocation, as most HIV-infected patients, because of their rapid clinical deterioration, will not survive sufficiently long to receive a liver transplant if they are not prioritized. Therefore, new approaches to make liver transplantation available sooner after the assignment of HIV patients to the waiting list should be assessed [50].

Intolerance to HAART and drug-to-drug interactions between antiretrovirals and immunosuppressive agents create further difficulties. Some antiretrovirals may produce liver toxicity, which makes the interpretation of liver enzyme elevations more complicated. Low doses of ritonavir (RTV) or non-nucleoside analogues (nevirapine or efavirenz) should be used with caution because of their effects on cytochrome P-450 and P-glycoprotein, which may cause important pharmacokinetic interactions with immunosuppressive agents, such as ciclosporin A and tacrolimus. Administration of lower doses of calcineurin inhibitors and/or ciclosporin are needed in patients on protease inhibitors (PIs), and their plasma levels should be closely monitored. Episodes of acute rejection have been reported in patients who stopped PIs without adapting doses of calcineurin inhibitors. Patients taking HIV non-nucleoside reverse transcriptase inhibitors may show reduced plasma levels of immunosuppressive drugs, which may make them prone to graft rejection. The use of higher levels of immunosuppressive drugs may favour fibrocholestatic hepatitis C and rapid progression to ESLD in patients with HCV relapse after transplantation. Therapeutic drug monitoring of immunosuppressive agents is mandatory when taking antiretrovirals.

HIV coinfection and hepatitis A, D and G viruses

Hepatitis A virus (HAV) vaccine should be recommended to all HIV-infected adults who have no HAV antibodies. The safety and efficacy has already been proven in this population; immunogenicity is only slightly reduced in subjects with very low CD4 counts [51].

As in HIV-negative subjects, hepatitis D may be acquired coincident with exposure to HBV or, in HIV-positive patients, appear as a superinfection in a patient with chronic hepatitis B.

Progression of liver fibrosis occurs rapidly in chronic hepatitis D, and response to IFN therapy is low, even using high doses of IFN, such as 9 MU t.i.w, particularly in the setting of HIV coinfection [52]. In patients with advanced HIV immunosuppression, the Delta antigen can be recognized in the serum and not only in the liver.

A study suggested that the course of HIV infection is less progressive in HIV patients coinfected with the hepatitis G virus or GB virus (a lymphotropic virus replicating in B and T lymphocytes) than in HIV-monoinfected patients [53]; this issue has also raised debate as to whether IFN therapy of hepatitis C in HIV/HCV/hepatitis G-coinfected patients might accelerate progression of HIV disease due to the clearance of the hepatitis G virus that is sensitive to IFN. Neither assumption has been confirmed.

Other infections of the liver

Cytomegalovirus

All herpesviruses and particularly cytomegalovirus (CMV) cause disseminated disease in severely immunosuppressed patients. Although chorioretinitis is the most frequent CMV-related complication in HIV-infected individuals with less than 100 CD4+ T cells/μL, lung, gastrointestinal and liver involvement is also frequent in these patients.

Tuberculosis

Infection with *Mycobacterium tuberculosis* is one of the most frequent illnesses in HIV-infected patients in developing regions and among IDUs in North America and western Europe. It may develop in subjects without severe immunodeficiency as pulmonary tuberculosis (TB), although it tends to present as disseminated TB in patients with low CD4 counts. In the latter situation, hepatic involvement is frequent. It complicates treatment management as most anti-TB drugs are hepatotoxic to some degree (mainly rifampin, isoniazid and pirazinamid). Characteristic large and multiple hepatosplenic abscesses have been reported in association with intra-abdominal lymphadenopathies in HIV-infected immunosuppressed patients, mimicking lymphomas [55]. They may also develop as a result of an immune reconstitution syndrome following initiation of HAART. Hepatic TB may be part of miliary disease, featuring granulomatous hepatitis in the liver biopsy and fever of apparently unknown origin.

Mycobacterium avium complex (MAC)

Atypical mycobacteria of the *M. avium–intracellulare* complex are among the most common opportunistic organisms identified in the liver biopsy of severely immunosuppressed HIV-infected patients. Their presence is usually associated with fever, night sweats and weight loss, as well as elevated serum alkaline phosphatase and transaminases [56]. Infection is usually disseminated, and examination and culture of bone marrow, lymph node aspirates or blood will often give the diagnosis, avoiding the need for liver biopsy. Granuloma formation is often scanty, and the examination of smears and culture of biopsy tissue are essential. Response to treatment, particularly in patients with advanced disease, is often poor, and maintenance therapy is required to prevent relapse. However, since the advent of HAART, the improvement in the immune status in most patients on therapy has dramatically reduced the incidence of this complication. Conversely, immune reconstitution syndromes with lymph node enlargement and fever have been described following initiation of HAART in subjects with subclinical atypical mycobacterial infections.

Toxoplasmosis

Symptomatic infection with *Toxoplasma gondii* in HIV-positive patients generally manifests as cerebral toxoplasmosis. However, in severely immunosuppressed individuals, disseminated toxoplasmosis may appear with lung and/or hepatic involvement [57].

Drug-related liver toxicity

Background

Liver enzyme elevations are often seen following initiation of antiretroviral therapy. Liver toxicity is an important cause of morbidity, mortality and treatment discontinuation in HIV-infected patients. Drug liver toxicity has affected the recommendations for antiretroviral therapy in certain scenarios, as in the case of nevirapine in post-exposure prophylaxis [58], which should be avoided in women with CD4 counts > 250 cells/μL.

Definition of hepatotoxicity

There is a broad variability across studies in the criteria used to categorize the severity of hepatotoxicity. We propose as the most accepted, the AIDS Clinical Trials Group (ACTG) scale of liver toxicity. Accordingly, patients with transaminases within normal limits at baseline are considered to develop hepatotoxicity when ALT and/or aspartate aminotransferase (AST) rise above the upper limits of normal. Severe hepatic injury (the primary study outcome) is defined as grade 3 or 4, a > fivefold or > 10-fold change in AST and/or ALT levels during antiretroviral treatment respectively.

To avoid an over-representation of individuals with chronic hepatitis at baseline experiencing liver toxicity, changes in transaminase levels should be recorded based on baseline values. Therefore, transaminase level elevation is scored as grade 1 (1.25–2.5 × baseline), grade 2 (2.6–3.5 × baseline), grade 3 (3.6–5 × baseline) and grade 4 (> 5 × baseline) in subjects with abnormal liver enzyme values at baseline [24].

Incidence and risk factors

The reported incidence of severe liver toxicity after initiating HAART ranges from 2% to 18%. Differences in study populations, as well as in the methods used, account for this wide range. Liver toxicity is more frequent among subjects with chronic hepatitis C and/or B than in those without underlying liver disease. A higher risk of hepatotoxicity has been found in patients carrying HCV genotype 3 compared with other genotypes [26].

Among the PIs, full-dose RTV is more hepatotoxic than other drugs [25]; it has caused fatal acute hepatitis. The use of two PIs, often including RTV at low doses as a booster for the second PI, does not increase the risk of liver toxicity. The incidence of liver toxicity with lopinavir (LPV), which is given with fixed low doses of RTV (200 mg/day), is low. Atazanavir also has a good liver safety profile, even if used with low-dose RTV. In contrast, tipranavir, the last approved PI, appears to be more hepatotoxic, possibly because it is given with higher doses of RTV (400 mg/day) as a booster.

Some nucleoside reverse transcriptase inhibitors (NRTIs), such as 3TC and TDF, have a low incidence of hepatotoxicity. The mitochondrial damage is thought to be the mechanism involved in the development of liver injury by other NRTIs [24]. Cases of hepatic failure have been reported in patients taking AZT, although ddI and d4T are the most common agents causing severe hepatotoxicity. Abacavir (ABC) and TDF, which have a low potential for mitochondrial damage, have a safer liver profile.

Non-nucleoside reverse transcriptase inhibitors (NNRTIs) may cause liver toxicity by several mechanisms [24]. Cases of severe liver toxicity have been reported, some of them fatal, in subjects receiving nevirapine (NVP) as part of a post-exposure prophylaxis regimen [58]. Likewise, in a trial assessing the NRTI emtricitabine (FTC), a higher incidence of hepatotoxicity was observed among patients taking NVP [59]. Of interest, in both the post-exposure prophylaxis and the FTC trial, hepatotoxicity developed early following initiation of treatment and predominated among black African women in the FTC study. These data suggest a hypersensitivity reaction causing the liver abnormalities. However, in other reports, the hepatotoxicity of NVP-containing regimens had a later onset (beyond the fourth month), with an increase in the cumulative incidence over time [60,61]. Therefore, it is likely that NVP causes liver toxicity through a second mechanism, more common than the hypersensitivity syndrome. More importantly, while the allergic phenomenon might not be favoured by underlying hepatitis B or C, the toxic cumulative mechanism could be more frequent in patients with chronic viral hepatitis.

Several retrospective studies have evaluated the development of hepatotoxicity linked to the use of NNRTIs. In general, the incidence of liver toxicity is higher compared with other antiretrovirals, particularly in populations with a high prevalence of chronic HCV infection and with NVP rather than efavirenz.

Table 6 Mechanisms of liver toxicity of antiretroviral drugs.

Mitochondrial toxicity
Exclusive to NRTI, particularly d4T and ddI
Tends to occur after prolonged exposure
Hypersensitivity reaction
Associated with nevirapine and abacavir
Occurs early, often within the first 12 weeks
HLA-linked
Often associated with rash and fever
Not favoured by HCV or HBV
Direct damage
With PI and NNRTI
Favoured by HCV and/or HBV
Two modalities:
Intrinsic toxicity: dose-dependent, early onset
Idiosyncratic: not dose-dependent, latent period often long
Immune reconstitution
Mainly in patients with low CD4 counts and high viral load
Only in patients with HCV and/or HBV

HLA, human leukocyte antigen.

Mechanisms of liver toxicity

The possible mechanisms involved in the development of hepatotoxicity associated with the use of antiretrovirals are summarized in Table 6. Four main pathogenic mechanisms of hepatotoxicity of antiretrovirals exist, including direct drug toxicity, immune reconstitution in the presence of HCV and/or HBV coinfections, hypersensitivity reactions with liver involvement and mitochondrial toxicity. It is probable that multiple pathogenic pathways occur simultaneously in some patients. Other pathogenic mechanisms may also be involved, such as insulin resistance, which is favoured by several antiretrovirals and may contribute to the development of steatohepatitis [24].

Therapeutic management

The three main considerations necessary for the adequate management of transaminase elevations following the introduction of HAART are severity, clinical impact and aetiological mechanism. The suspicion of hypersensitivity reactions or lactic acidosis, and the development of liver decompensation, are all reasons for stopping treatment immediately [20]. Severe liver toxicity (grades 3–4), even in the absence of symptoms, similarly warrants discontinuation of antiretroviral therapy.

If fatty liver is present, the removal of factors predisposing to steatosis is indicated. If the patient is taking an antiretroviral with higher hepatotoxic potential (i.e. NVP), replacement of this drug is an option. The continuation of the same regimen, with spontaneous decrease in transaminase values, has been reported in immune reconstitution cases. Liver enzyme elevations may persist in some patients; the long-term consequences are unknown, yet sporadic cases of severe liver disease potentially

linked to prolonged antiretroviral exposure have been reported recently.

Liver tumours

Neoplasias involving the liver are not uncommon in HIV-infected individuals. Primary tumours are mainly represented by hepatocellular carcinoma, lymphomas and Kaposi's sarcoma. Metastatic lesions are seen in subjects with colorectal cancer. While the incidence of hepatocellular carcinoma seems to be on the rise in HIV-infected patients with chronic hepatitis B and/or C, other hepatic tumours are declining since the introduction of HAART.

Hepatocarcinoma

Concurrent HIV infection may increase the incidence of hepatocellular carcinoma in cirrhotic patients with either HBV and/or HCV. In a study, six cases of hepatocellular carcinoma in a cohort of 2383 HIV-infected patients were identified, with an incidence ratio of 13.95, higher than expected in the general population [30]. A more aggressive course was also identified as a distinctive feature of chronic hepatitis C-associated hepatocellular carcinoma in the HIV setting.

HIV-infected cirrhotic patients should be screened for hepatocellular carcinoma at 6-month intervals using ultrasonography and measurement of alpha-fetoprotein levels [14,20]. Percutaneous ethanol injection can be indicated for small tumours in patients who are not candidates for surgery. Chemoembolization may improve survival in cases with late-stage hepatocellular carcinoma. In general, HIV-infected patients with hepatocellular carcinoma do not qualify for liver transplantation.

Lymphomas

The incidence of non-Hodgkin's lymphoma (NHL) is increased in HIV-infected individuals, but has declined significantly since the introduction of HAART. Hepatic involvement is frequently seen in NHL, but almost always as part of a systemic disease and very rarely as a primary tumour [62]. Hodgkin's disease is less frequent, but may likewise involve the liver at presentation or thereafter in the absence of response to chemotherapy.

Kaposi's sarcoma

Infection with human herpesvirus type 8 (HHV-8) is associated with three different clinical entities: (i) Kaposi's sarcoma (KS); (ii) primary effusive lymphomas; and (iii) multicentre Castleman's disease. Symptomatic HHV-8 infection was particularly frequent among homosexual men until the advent of HAART. Since then, the incidence of these neoplasias has declined dramatically. Vascular lesions of KS in the liver were common in subjects with visceral disease, and almost always accompanied cutaneous lesions.

HIV-associated biliary disease

The biliary tract may be involved in HIV disease as a result of infection with *Cryptosporidium*, *Microsporidium*, *Cyclospora*, MAC and tuberculosis. Chronic sclerosing cholangitis often results in cholestasis, jaundice and pruritus. In some HIV-infected subjects, the cholangiopathy has been limited to the distal choledochus, resulting in a dilated bile duct; resolution was obtained with endoscopic retrograde cholangiography followed by resection. As with other opportunistic infections, HAART has almost eliminated HIV-related cholangiopathy.

References

1 Konopnicki D, Mocroft A, de Wit S *et al.* (2005) Hepatitis B and HIV: prevalence, AIDS progression, response to HAART and increased mortality in the EuroSIDA cohort. *AIDS* 19, 593–602.

2 Thio C, Seaberg E, Skolasky RD *et al.* (2002) HIV-1, hepatitis B virus, and risk of liver-related mortality in the Multicenter AIDS Cohort Study (MACS). *Lancet* 360, 1921–1926.

3 Bonacini M, Bzowej N, Louie S *et al.* (2004) Survival in patients with HIV infection and viral hepatitis B or C. *AIDS* 18, 2039–2045.

4 Nuñez M, Puoti M, Camino N *et al.* (2003) Treatment of chronic hepatitis B in the HIV-infected patient: present and future. *Clin Infect Dis* 37, 1678–1685.

5 Soriano V, Puoti M, Bonacini M *et al.* (2005) Care of patients with chronic hepatitis B and HIV coinfection: recommendations from an international HBV/HIV Panel. *AIDS* 19, 221–240.

6 Benhamou Y, Bochet M, Thibault V *et al.* (1999) Long term incidence of hepatitis B virus resistance to lamivudine in HIV-infected patients. *Hepatology* 30, 1303–1306.

7 Benhamou Y, Thibault V, Vig P (2006) Long-term treatment with adefovir dipivoxil 10 mg in patients with lamivudine-resistant HBV and HIV co-infection results in significant and sustained clinical improvement. *J Hepatol* 44, 62–67.

8 Núñez M, Pérez-Olmeda M, Díaz B *et al.* (2002) Activity of tenofovir on hepatitis B virus replication in HIV-co-infected patients failing or partially responding to lamivudine. *AIDS* 16, 2352–2354.

9 Van Bömmel F, Wünsche T, Schürmann D *et al.* (2002) Tenofovir treatment in patients with lamivudine-resistant hepatitis B mutants strongly affects viral replication. *Hepatology* 36, 507–508.

10 Ristig MB, Crippin J, Aberg J *et al.* (2002) Tenofovir disoproxil fumarate therapy for chronic hepatitis B in HIV/hepatitis B virus-coinfected individuals for whom interferon-α and lamivudine therapy have failed. *J Infect Dis* 186, 1844–1847.

11 Nelson M, Portsmouth S, Stebbing J *et al.* (2003) An open-label study of tenofovir in HIV-1 and hepatitis B virus co-infected individuals. *AIDS* 17, F7–F10.

12 Benhamou Y, Tubiana R, Thibault V (2003) Tenofovir disoproxil fumarate in patients with HIV and lamivudine-resistant hepatitis B virus. *N Engl J Med* 348, 177–178.

13 Dore G, Cooper D, Pozniak A *et al.* for 903 and 907 Study Teams (2004) Efficacy of tenofovir disoproxil fumarate in antiretroviral therapy-naïve and -experienced patients coinfected with HIV-1 and hepatitis B virus. *J Infect Dis* 189, 1185–1192.

14 Alberti A, Clumeck N, Collins S *et al.* (2005) Short statement of the first European Consensus Conference on the treatment of chronic hepatitis B and C in HIV co-infected patients. *J Hepatol* 42, 615–624.

15 Castera L, Vergniol J, Foucher J *et al.* (2005) Prospective comparison of transient elastography, Fibrotest, APRI, and liver biopsy for the assessment of fibrosis in chronic hepatitis C. *Gastroenterology* 128, 343–350.
16 Keeffe E, Dieterich D, Han S-H, *et al.* (2004) A treatment algorithm for the management of chronic hepatitis B virus infection in the United States. *Clin Gastroenterol Hepatol* 2, 87–106.
17 Sheldon J, Corral A, Rodes B *et al.* (2005) Risk of selecting K65R in antiretroviral-naïve HIV-infected individuals with chronic hepatitis B treated with adefovir. *AIDS* 19, 2036–2038.
18 Colin J, Cazals-Hatem D, Loriot M (1999) Influence of HIV infection on chronic hepatitis B in homosexual men. *Hepatology* 29, 1306–1310.
19 Martín-Carbonero L, Soriano V, Valencia E *et al.* (2001) Increasing impact of chronic viral hepatitis on hospital admissions and mortality among HIV-infected patients. *AIDS Res Hum Retroviruses* 17, 1467–1472.
20 Soriano V, Puoti M, Sulkowski M *et al.* (2004) Care of patients with hepatitis C and HIV co-infection. Updated recommendations from the HIV-HCV International Panel. *AIDS* 18, 1–12.
21 Rockstroh J, Mocroft A, Soriano V *et al.* (2005) Influence of hepatitis C on HIV disease progression and response to antiretroviral therapy. *J Infect Dis* 192, 992–1002.
22 Greub G, Ledergerber B, Battegay M *et al.* (2000) Clinical progression, survival, and immune recovery during antiretroviral therapy in patients with HIV-1 and HCV coinfections. *Lancet* 356, 1800–1805.
23 Sulkowski M, Moore R, Mehta S *et al.* (2002) Hepatitis C and progression of HIV disease. *JAMA* 288, 199–206.
24 Nuñez M, Soriano V (2005) Hepatotoxicity of antiretrovirals: incidence, mechanisms and management. *Drug Safety* 28, 53–66.
25 Sulkowski M, Thomas D, Chaisson R *et al.* (2000) Hepatotoxicity associated with antiretroviral therapy in adults infected with HIV and the role of hepatitis C or B virus infection. *JAMA* 283, 74–80.
26 Núñez M, Ríos P, Martín-Carbonero L *et al.* (2002) Role of hepatitis C virus genotype in the development of severe transaminase elevation after the introduction of antiretroviral therapy. *J Acquir Immun Defic Syndr* 30, 65–68.
27 Nuñez M, Soriano V (2005) Risks and benefits of antiretroviral therapy in HIV-HCV co-infected patients. *J Hepatol* 42, 290–292.
28 Soriano V, García-Samaniego J, Bravo R *et al.* (1996) Interferon alpha for the treatment of chronic hepatitis C in patients infected with HIV. *Clin Infect Dis* 23, 585–591.
29 Martin-Cabonero L, Benhamou Y, Puoti M *et al.* (2004) Incidence and predictors of severe liver fibrosis in HIV infected patients with chronic hepatitis C – a European collaborative study. *Clin Infect Dis* 38, 128–133.
30 Puoti M, Bruno R, Soriano V *et al.* (2004) Hepatocellular carcinoma in HIV-infected patients: epidemiological features, clinical presentation and outcome. *AIDS* 18, 2285–2293.
31 Soto B, Sanchez-Quijano A, Rodrigo L *et al.* (1997) HIV infection modifies the natural history of chronic parenteral acquired hepatitis C with an unusually rapid progression to cirrhosis. *J Hepatol* 26, 1–5.
32 Qurishi N, Kreuzberg C, Lüchters G *et al.* (2003) Effect of antiretroviral therapy on liver-related mortality in patients with HIV and hepatitis C coinfection. *Lancet* 362, 1708–1713.
33 Chung R, Andersen J, Volberding P *et al.* (2004) Peginterferon Alfa-2a plus ribavirin versus interferon alfa-2a plus ribavirin for chronic hepatitis C in HIV-coinfected persons. *N Engl J Med* 351, 451–459.
34 Carrat F, Bani-Sadr F, Pol S *et al.* (2004) Pegylated interferon alfa-2b vs standard interferon alfa-2b, plus ribavirin, for chronic hepatitis C in HIV-infected patients. *JAMA* 292, 2839–2848.
35 Torriani F, Rodriguez-Torres M, Rockstroh J *et al.* (2004) Peginterferon Alfa-2a plus ribavirin for chronic hepatitis C virus infection in HIV-infected patients. *N Engl J Med* 351, 438–450.
36 Laguno M, Murillas J, Blanco JL *et al.* (2004) Peginterferon alfa-2b plus ribavirin compared with interferon alfa-2b plus ribavirin for treatment of HIV/HCV co-infected patients. *AIDS* 18, F27–36.
37 Soriano V, Martín-Carbonero L, García-Samaniego J (2003) Treatment of chronic hepatitis C virus infection: we must target the virus or liver fibrosis? *AIDS* 17, 751–753.
38 Soriano V, Maida I, Garcia-Samaniego J *et al.* (2004) Long-term follow-up of HIV-infected patients with chronic hepatitis C virus infection treated with interferon-based therapies. *Antivir Ther* 9, 987–992.
39 Soriano V, Nuñez M, Camino N *et al.* (2004) Hepatitis C virus-RNA clearance in HIV-coinfected patients with chronic hepatitis C treated with pegylated interferon plus ribavirin. *Antivir Ther* 9, 505–509.
40 Nuñez M, Camino N, Ramos B *et al.* (2005) Impact of ribavirin exposure on early virological response to hepatitis C therapy in HIV-infected patients with chronic hepatitis C. *Antivir Ther* 10, 657–662.
41 Sherman K, Shire N, Rouster S *et al.* (2005) Viral kinetics in hepatitis C or hepatitis C/HIV-infected patients. *Gastroenterology* 128, 313–327.
42 Soriano V, Pérez-Olmeda M, Ríos P *et al.* (2004) Hepatitis C virus (HCV) relapses after anti-HCV therapy are more frequent in HIV-infected patients. *AIDS Res Hum Retroviruses* 20, 351–354.
43 Soriano V, Bravo R, García-Samaniego J *et al.* (1994) CD4+ T lymphocytopenia in HIV-infected patients receiving interferon therapy for chronic hepatitis C. *AIDS* 8, 1621–1622.
44 De Mendoza C, Sánchez-Conde M, Timmermans E *et al.* (2005) Mitochondrial DNA depletion in HIV-infected patients is more pronounced with chronic hepatitis C and enhanced following treatment with pegylated interferon plus ribavirin. *Antivir Ther* 10, 557–561.
45 Mauss S, Valenti W, DePamphilis J *et al.* (2004) Risk factors for hepatic decompensation in patients with HIV/HCV coinfection and liver cirrhosis during interferon therapy. *AIDS* 18, F21–25.
46 Rendon A, Nuñez M, Romero M *et al.* (2005) Early monitoring of ribavirin plasma concentrations may predict anemia and early virological response in HIV/hepatitis C virus-coinfected patients. *J Acquir Immune Defic Syndr* 39, 401–405.
47 Brouwer J, Nevens F, Bekkering F *et al.* (2004) Reduction of relapse rates by 18-month treatment in chronic hepatitis C: a Benelux randomised trial in 300 patients. *J Hepatol* 40, 689–695.
48 Drusano G, Preston S (2004) A 48-week duration of therapy with pegylated interferon alpha 2b plus ribavirin may be too short to maximize long-term response among patients infected with genotype-1 hepatitis C virus. *J Infect Dis* 189, 964–970.
49 Neff G, Shire N, Rudich S (2005) Outcomes among patients with end-stage liver disease who are coinfected with HIV and hepatitis C virus. *Clin Infect Dis* 41(Suppl. 1), 50–55.
50 Maida I, Núñez M, González-Lahoz J *et al.* (2005) Liver transplantation in HIV-HCV coinfected candidates: what is the most appropriate time for evaluation? *AIDS Res Hum Retroviruses* 21, 599–601.
51 Wallace M, Brandt C, Earhart K *et al.* (2004) Safety and immunogenicity of an inactivated hepatitis A vaccine among HIV-infected subjects. *Clin Infect Dis* 39, 1207–1213.
52 Puoti M, Rossi S, Forleo M *et al.* (1998) Treatment of chronic hepatitis D with interferon alpha 2b in patients with HIV infection. *J Hepatol* 29, 45–52.

53 Tillmann H, Heiken H, Knapick-Botor A *et al.* (2001) Infection with GB virus C and reduced mortality among HIV-infected patients. *N Engl J Med* 345, 715–724.
54 Kaiser T, Tillmann H (2005) GB virus C infection: is there a clinical relevance for patients with the HIV? *AIDS Rev* 7, 3–12.
55 Soriano V, Tor J, Gabarre E *et al.* (1991) Multifocal splenic abscesses caused by *Mycobacterium tuberculosis* in HIV-infected drug users. *AIDS* 5, 901–902.
56 Poles M, Dieterich D, Schwarz E *et al.* (1996) Liver biopsy findings in 501 patients infected with HIV. *J Acquir Immun Defic Syndr* 11, 170–177.
57 Rabaud C, May T, Amiel C *et al.* (1994) Extracerebral toxoplasmosis inpatients infected with HIV: a French national survey. *Medicine (Baltimore)* 73, 306–314.
58 CDC (2001) Serious adverse events attributed to nevirapine regimens for post-exposure prophylaxis after HIV exposures-worldwide, 1997–2000. *Morb Mortal Wkly Rep* 49, 1153–1156.
59 Sanne I, Mommeja-Marin H, Hinkle J *et al.* (2005) Severe hepatotoxicity associated with nevirapine use in HIV-infected subjects. *J Infect Dis* 191, 825–829.
60 Martínez E, Blanco J, Arnáiz J *et al.* (2001) Hepatotoxicity in HIV-infected patients receiving nevirapine-containing antiretroviral therapy. *AIDS* 15, 1261–1268.
61 Gonzalez de Requena D, Nuñez M, Jimenez-Nacher I *et al.* (2002) Liver toxicity caused by nevirapine. *AIDS* 16, 290–291.
62 Antinori S, Ridolfo A, Esposito R *et al.* (1994) Liver involvement in AIDS-associated malignancies. *J Hepatol* 21, 1145–1146.

9.4 Exotic virus infections of the liver

Viral haemorrhagic fevers

Pierre E. Rollin and Thomas G. Ksiazek

Patients with viral haemorrhagic fevers frequently present with similar and non-specific clinical signs resembling malaria, typhoid fever and pharyngitis. A detailed travel history, coupled with a high index of suspicion and the availability of definitive virological tools, should facilitate a rapid diagnosis and the timely implementation of appropriate patient isolation, clinical management procedures and public health measures.

Lassa fever and other arenaviruses

Arenaviruses cause chronic infections of wild and peridomestic rodents indigenous to Europe, Africa and the Americas. When these asymptomatically infected animals come into contact with man, human disease may result. Arenavirus infections of humans are common and, in some cases, cause severe haemorrhagic fevers.

Aetiological agent and epidemiology

Arenaviruses are spherical enveloped viruses that have a sandy, granular appearance by thin-section electron microscopy. The lipid envelope of arenaviruses makes them susceptible to organic solvents and detergents. The arenavirus genome consists of two single-stranded RNA molecules, which are designated S (small) and L (large). Two genes are encoded in an ambisense orientation on each RNA. The family Arenaviridae is divided into two complexes [1]. The lymphocytic choriomeningitis (LCM) or Old World complex contains LCM virus and the Lassa viruses, and also includes a number of related and apparently benign viruses (Mopeia, Mobala and Ippy). All have been isolated from rodents of the family Muridae. The Tacaribe or New World complex includes several severe human pathogens (Junin, Machupo, Guanarito, Sabia, Flexal and Chapare viruses), some viruses that are responsible for mild laboratory infections (Pichinde, Tacaribe) and some that are not associated with human disease (Amapari, Bear Canyon, Cupixi, Latino, Parana, Oliveros, Pirital, Tamiami and Whitewater Arroyo viruses).

In nature, arenaviruses are maintained by association with specific rodent hosts, in whom they produce chronic viraemia and/or viruria; they are routinely isolated from blood and urine samples. Naturally occurring human disease can usually be traced to direct or indirect contact with infected rodents. Aerosol infectivity is thought to be an important natural route of human infection [1,2]. Attempts to implicate arthropod vectors have been unsuccessful, but ectoparasites taken from viraemic mammalian hosts have occasionally yielded arenavirus isolates. Rodents serve as a food source in Lassa fever-endemic regions and handling of these animals is a risk factor for Lassa virus infection.

Lassa fever is endemic in several countries of West Africa: Sierra Leone, Guinea, Liberia and Nigeria. The rodent reservoir, and certainly the virus, is also present in other West African countries. The natural host species of Lassa virus are African rodents of the genus *Mastomys* [1,2].

The Argentine haemorrhagic fever (AHF)-endemic region is limited to the Pampa area of Argentina, but has shown a continuing northward extension since the first description of the disease, now covering 150 000 square kilometers. The peak incidence occurs during harvesting in May and is correlated with the population density of the reservoir, the drylands vesper mouse (*Calomys musculinus*). Male rural workers were the population at risk; however, health education and recent intensive human vaccination have changed the epidemiological pattern. AHF, caused by the Junin virus, is not usually contagious, although person-to-person transmission by sexual contact has been described [1].

Bolivian haemorrhagic fever (BHF; caused by Machupo virus) has been described in the Beni department of Bolivia. The reservoir of the virus is *Calomys callosus*. BHF is a seasonal disease, with more cases occurring in the dry season. The cases are sporadic, with small clusters of cases caused by human-to human transmission. In the past, large epidemics in towns have been described following unusually high rodent density levels [1].

Since its description in 1989, Venezuelan haemorrhagic fever (VHF; caused by Guanarito virus) has been restricted to the municipality of Guanarito, in the southern tip of Portuguesa state in Venezuela, with *Zygodontomys brevicauda* being the reservoir. As is often the case with arenaviral haemorrhagic fevers, the seasonal incidence and agricultural activity peaks coincide. Person-to-person transmission has not been observed [1].

The epidemiology of Sabia and Flexal viruses is not known, but severe, or even fatal, laboratory infections have been described for these two viruses.

Pathology and pathogenesis

Arenavirus pathogenesis is difficult to understand from pathological examination of tissues from animal models or humans. The observed lesions cannot explain the severity of the disease and arenaviruses are not highly cytopathic. In Lassa fever, the virus can be isolated from all organs and the liver is consistently affected, as confirmed by aspartate aminotransferase (AST) elevation and pathological examination of liver biopsies or post-mortem tissues [3]. Levels of coagulation factors are slightly decreased and functional disturbances have been found in platelets [4]. In Lassa fever patients, a fatal outcome correlates with low levels of circulating interleukin (IL)-8 and interferon-inducible protein (IP)-10. This down-regulation of the immune system is also associated with an impaired B-cell response: there is a low or absent antibody response in fatal cases. Proinflammatory cytokines are elevated and, in AHF, there is a correlation between mortality and the levels of tumour necrosis factor (TNF)-α and interferon (IFN). In arenavirus infections, haemorrhages result from the activation and dysregulation of infected macrophages, endothelial and inflammatory cells. The levels of virus replication are important and are indirectly correlated with the patient's outcome of infection via a pathophysiological cascade [1].

Clinical manifestations

Lassa fever patients usually present with fever, sore throat, severe lower back pain, cough and conjunctivitis. In tropical areas, this syndrome can easily be misdiagnosed and is very often labeled as malaria. During the second week of infection, digestive signs include nausea, vomiting, diarrhoea and abdominal pain. In most patients, the disease is self-limiting; however, in a small percentage, the disease is more severe and patients are hospitalized. A maculopapular rash, bleeding from the gums and the nose, haematemesis and oedema of the face may develop, but frank haemorrhage is seen in only a proportion of the most severe cases. Pleural and pericardial effusions are common and can be massive. Respiratory distress, hypovolemic shock and bleeding are usually associated with fatal cases, which is the outcome in 15–20% of patients with Lassa fever who are hospitalized. Central nervous system involvement (seizures and encephalopathy) is frequent [5]. Lassa fever is a particularly severe disease among pregnant women, and fetal loss occurs in more than 80% of cases [6]. Ataxia and deafness are not uncommon sequelae. In infants, swollen-baby syndrome, which is characterized by anasarca, abdominal distension and bleeding, is also typical [2].

The clinical pictures of AHF, BHF and VHF are similar. Incubation periods range from 7 to 14 days and the onset is generally gradual, with fever, anorexia and malaise occurring over several days. The disease is multisystemic, including the gastrointestinal, cardiovascular and central nervous systems. On initial examination, flushing of the face, neck and chest and bleeding from the gums with enanthem are common. Other complications include extensive petechial haemorrhages, oozing from puncture wounds, melena and haematemesis. In addition, among the 15% of patients who die from these conditions, hypotension and shock may develop. During the second week of illness, clinical improvement may begin or complications may develop. Neurological involvement ranges from mild irritability and lethargy to coma, delirium and convulsions in severely ill patients, with or without any haemorrhagic manifestations. Recovery is slow; weakness, fatigue and mental difficulties may last for weeks. In AHF, a significant proportion of patients relapse with a 'late neurological syndrome', which includes headache, cerebellar tremor and cranial nerve palsies; deafness has also been described as a sequela [1].

Laboratory findings

In Lassa fever, patients are frequently dehydrated and have high haematocrits. Proteinuria is usually present, and lymphopenia and relative or absolute neutrophilia is the rule. Platelet numbers are reduced but, most importantly, an inhibitor of platelet function (e.g. aggregation) is present [4,5]. A serum AST level of 150 units/mL or higher on admission is associated with a high risk of mortality [7]. The impact of infection on liver function is limited (glucose and bilirubin are normal) and cannot be responsible for the severity of the disease [8,9]. In contrast to Lassa fever, clinical laboratory studies in cases of Junin virus infection are frequently useful for diagnosis. Proteinuria is constant. Total leukocyte counts usually fall to 1000–2000 cells/μL, although the differential remains normal. Platelet counts fall precipitously, usually to between 25 000 and 100 000 cells/μL. Routine clotting parameters are usually normal or slightly abnormal; however, patients with severe cases of disease may show evidence of disseminated intravascular coagulation (DIC). Transaminases generally remain normal [1].

Diagnosis

The specific diagnosis of arenavirus haemorrhagic fever requires biological containment and is limited to only a few laboratories in the world. Acute human infections are associated with viraemia. Viral antigen, viral RNA or virus can easily be

identified by antigen detection enzyme-linked immunosorbent assay (ELISA), reverse transcriptase-PCR (RT-PCR) or isolation respectively [10,11]. In the rapidly fatal forms of Lassa or Machupo haemorrhagic fevers, patients may often die without any detectable antibodies. Specific antibodies become detectable in the second week of the disease and can be detected using IgM capture ELISA and IgG ELISA tests. Immunohistochemical assays can be used to detect virus antigen in liver biopsies or tissues collected during post-mortem.

Treatment and prevention

Barrier nursing is very important in arenavirus haemorrhagic fever and should be implemented as early as possible. Numerous episodes of nosocomial infection have been described for Lassa and Machupo haemorrhagic fever. Specimens collected for diagnosis and management of the patient should also be handled with extreme precautions. Variable results have been observed in the treatment of Lassa fever with immune plasma. Convalescent immune plasma, selected on the basis of neutralizing antibody concentration, has been used with success for the treatment of AHF [1]. About 10% of the recipients developed a transient neurological syndrome. Intravenous ribavirin, a broad-spectrum antiviral, is the treatment of choice for Lassa fever [6,7]. Its efficacy is particularly evident when used early in the disease. Treatment starts with a loading dose of 30 mg/kg (with a maximum of 2 g), followed by 16 mg/kg every 6 h for 4 days and 8 mg/kg every 8 h for 6 days. Ribavirin is also likely to be an effective therapy for South American arenavirus infections.

No vaccine is currently available for Lassa fever. A Junin vaccine has been developed and is used in the endemic area. This vaccine also protects non-human primates against Machupo virus.

Rift Valley fever

The Rift Valley fever (RVF) virus is a mosquito-borne agent that is mainly responsible for disease in domestic ruminants (sheep, goats and cattle). The virus was though to be enzootic in East Africa only, but has been found in virtually all sub-Saharan countries. The virus was responsible for massive animal and human epidemics that occurred in 'virgin soil', including Egypt, and, more recently, Saudi Arabia and Yemen [3].

Aetiological agent and epidemiology

The RVF virus is a negative-sense, trisegmented, single-stranded RNA enveloped virus belonging to the family Bunyaviridae. The virus was first isolated in 1930 during an outbreak of disease in sheep in the Rift Valley of Kenya. For many years, heavy rainy seasons in this area were regularly followed by small epidemics in ruminants. The virus was also found to be present in other countries, but the human impact was very limited with a few cases of self-limiting febrile illness. However, in 1977, a massive epidemic occurred in Egypt, with more than 200 000 people infected and nearly 600 deaths. Because of the large number of cases, a more complete clinical spectrum of human disease was reported. Since the Egyptian outbreak, there have been several sites of considerable outbreaks in animals and humans, including Mauritania in 1987, Madagascar in 1990, and Saudi Arabia and Yemen in 2000 [12,13]. Although the enzootic maintenance and transmission cycle is not entirely understood, heavy rains and flooding, irrigated farming and water management (dams) have an obvious impact on the populations of *Culex* and *Aedes* mosquitoes before and during outbreaks. Susceptibility to the virus among breeds of animals is variable, but the abortion rate can reach 100% in afffected pregnant animals and mortality in young animals is also very high. Because of the lack of effective animal disease surveillance systems, severe human disease has very often been the initial indicator revealing epizootics.

Pathology and pathogenesis

A viraemic phase, corresponding to an initial febrile period, is the first step in infection and leads to dissemination of the virus, with secondary replication in endothelial cells and hepatocytes. RVF virus is very cytolytic and infection results in hepatocellular degeneration, necrosis that is mainly centrizonal and scattered lobular foci of necrosis [3]. Massive necrosis associated with the loss of hepatic architecture is seen in the severe form of disease, as demonstrated by immunohistochemistry of post-mortem specimens. Intrathecal replication of the virus is at the origin of RVF encephalitis. The pathogenesis of retinal lesions is not understood, but is coincidental with the onset of antibody circulation. In non-human primate models, the late onset of the IFN response is associated with more severe disease and DIC, suggesting that the early production of IFN is influential in limiting the severity of disease; in the same model, prophylactic administration of recombinant IFN-α limited viraemia, hepatocellular damage and haemostatic derangement [14].

Clinical manifestations

The most frequent clinical manifestations include the sudden onset of fever, myalgia, headache and anorexia of a week's duration, followed by a complete recovery. Three other clinical syndromes have been seen, particularly in large outbreaks of disease. Some patients develop an acute decrease in visual acuity about 5–15 days after the onset of disease. Retinal lesions can be uni- or bilateral and are characterized by macular lesions, edema, vasculitis and haemorrhage. Recovery is often not complete and half of these patients have some permanent loss of vision [12,15,16]. The other two severe complications have been described in approximately 1% of the total number of cases. In the haemorrhagic fever form of the disease, haemorrhagic manifestations become evident in the few days following onset of disease, with epistaxis, gingival bleeding, haematemesis and melena. The prognosis is very bad, frequently with DIC and hepatic and renal failure. A few other patients develop headache, meningismus and confusion, 7–10 days after onset. In this

meningoencephalitic form of the disease, the mortality rate is high and residual sequelae are frequent. Human-to-human transmission has never been described, although laboratory infections commonly occur in individuals.

Laboratory findings

In acute uncomplicated RVF, clinical laboratory tests show leukopenia, but liver function tests and platelet counts are within the normal range. In the severe syndromes, half of the patients show anaemia with evidence of DIC. The most obvious abnormal findings are marked abnormal liver function tests [elevated alanine aminotransferase (ALT) and AST]; lactic dehydrogenase and creatine phosphokinase levels are also elevated [13,15,17,18]. Hepatic failure is frequent and may lead to fatal hepatic encephalopathy. Renal failure with high creatinine and urea levels is also common and may require haemodialysis [12]. In patients with encephalitis, the cerebrospinal fluid shows pleocytosis (mostly lymphocytes) and normal glucose and protein concentrations.

Diagnosis

At the very acute stage of RFV disease, viraemia is very significant and it is easy to detect viral antigen (by antigen capture ELISA), viral RNA (by RT-PCR) or virus (by isolation) [11,13]. After 1–2 days, the virus or antigen can no longer be detected because of the presence of detectable IgM and IgG antibodies. As for other diseases, it is best to use a combination of the available assays for diagnosis. The same tests can be applied to confirm a clinical suspicion of disease in animals. Specific immunohistochemical assays can detect viral antigen in post-mortem human and animal specimens (liver being the optimal specimen).

Treatment and prevention

There is no specific antiviral treatment for RVF disease. Most patients with severe disease should receive supportive care, including intravenous fluids and, when indicated, blood and freshly frozen plasma transfusions, mechanical ventilation, haemodialysis and antimicrobial therapy for secondary bacterial or fungal infections [12,13]. Ribavirin is effective against RVF virus in cell culture but, during one human trial, there was no suggestion of any benefit for patients and a suggestion of adverse effects. Very effective inactivated vaccines against RVF have been developed by the US Department of Defense, but they are not available for the general population. Proper vaccination of domestic animals in the endemic area is possible and important, as livestock usually serve as the amplificatory step.

Marburg and Ebola virus diseases

The Marburg and Ebola viruses, which are filoviruses, are responsible for severe disease in Central Africa. Although case fatality rates vary between the viruses, the symptomatology, progression of disease, pathogenesis and epidemiology are very similar, and only specific laboratory testing allows a specific diagnosis to be made.

Aetiological agent and epidemiology

The viral genomes of the Marburg and Ebola viruses consist of nonsegmented, negative-sense, single-stranded RNAs. These viruses contain seven virus-specific structural proteins that are expressed from seven genes [19]. The Marburg and Ebola viruses are easy to identify by electron microscopy because of the characteristic combination of the size and shape of the virions: they have widely variable lengths, as well as branching circular or '6' shapes. Phylogenetic analysis clearly separates the Marburg and Ebola viruses into two genera, *Marburgvirus* and *Ebolavirus*, with one species for the Marburg virus and four for the Ebola virus: Zaire *Ebolavirus* (EBO-Z), Sudan *Ebolavirus* (EBO-S), Reston *Ebolavirus* (EBO-R) and Tai forest *Ebolavirus* (formerly known as Ivory Coast *Ebolavirus*) [19]. Heat, lipid solvents, β-propiolactone, formaldehyde, ultraviolet light and gamma radiation can be used to inactivate these viruses.

The Marburg virus was the first filovirus to be recognized: in 1967, 31 individuals in Germany and Yugoslavia became infected following contact with monkeys or their tissues or with other patients. In 1976, Ebola virus was responsible for two simultaneous outbreaks in Zaire and Sudan. Around 500 cases were reported, with case-fatality rates of 88% in Zaire and 53% in Sudan. Despite the simultaneous emergence, these viruses (EBO-Z and EBO-S) are distinct species by serological and sequence analysis criteria. More recently, two additional distinct Ebola virus species have been isolated. In 1989, a new strain of Ebola virus (EBO-R) was isolated from monkeys held in quarantine in Virginia (USA), following importation from the Philippines. No human disease was recorded, although several animal handlers at the quarantine facility seroconverted. EBO-R reappeared in monkeys exported from the same facility in the Philippines to Siena, Italy, in 1992 and to Alice, Texas, in 1996. In 1994, the fourth genetically distinct species of Ebola virus (Tai forest *Ebolavirus*) was associated with disease in a human and deaths among chimpanzees in West Africa.

In 1995, EBO-Z was responsible for a massive outbreak in Zaire and, subsequently (1996, 2001–2005), a number of outbreaks occurred in Gabon and adjacent areas of the Republic of Congo among apes and humans; several of the human cases were exposed to infected non-human primates. In 2000, EBO-S was responsible for a large outbreak of disease in Gulu, in the north-west of Uganda. More than 400 people were infected and 53% of them died. In 2004, in Yambio (Sudan), 17 individuals were infected with EBO-S and seven of them died. From 1999 to 2000, an outbreak of disease caused by the Marburg virus occurred in the eastern Democratic Republic of Congo. In the spring of 2005, a large outbreak of Marburg occurred in Uige, northern Angola, with a total of 252 cases and 227 deaths reported by the end of August of that year. Following every large outbreak, a search for the animal reservoirs of filoviruses have

been made without success. Non-human primates, the source of many human infections, are not considered to be a likely reservoir. The real reservoirs have not yet been found, although recent data have implicated fruit bats [20].

Pathology and pathogenesis

The understanding of the pathogenesis of these diseases is derived from animal-model studies and from the very few human specimens, including tissues, collected during outbreaks. Extensive and disseminated infection and necrosis is obvious in major organs such as the liver, spleen, lung and kidney. Extensive hepatocellular necrosis is associated with the formation of characteristic intracytoplasmic viral inclusions; lymphoid depletion is particularly obvious in the spleen; and virus replication in endothelial cells and macrophages plays a role in vascular dysregulation and permeability, cytokine induction and haemostatic balance [19].

Clinical manifestations

Marburg and Ebola virus infections are clinically similar. The incubation period varies from 4 to 16 days. The onset is sudden and marked by a non-specific syndrome, including fever, chills, headache, anorexia, and myalgia. Digestive signs and symptoms follow: nausea, vomiting, sore throat, abdominal pain and diarrhoea. On examination, patients are usually dehydrated, apathetic and disoriented. Pharyngeal and conjunctival injection is usual. After 3–4 days, a characteristic maculopapular rash over the trunk, petechiae and mucous membrane haemorrhages appear; however, they may be difficult to see on dark-skinned patients. Gastrointestinal bleeding is common, accompanied by intense epigastric pain. Severe cases can develop petechiae and bleeding from puncture wounds and mucous membranes [21,22]. Multiorgan failure with shock usually precedes death, which occurs in 80–90% and 51% of cases of EBO-Z and EBO-S respectively. The case-mortality rates in Marburg virus infection have varied from 30% in the original outbreak to 90% in the recent outbreak in Angola.

Laboratory findings

Clinical laboratory studies usually reveal an early and profound leukopenia, which is sometimes moderately elevated at a later stage. Platelet counts decline to 50 000–100 000 cells/μL during the haemorrhagic phase. Elevated liver enzyme (AST and ALT) values reflect the gravity of the syndrome [21]. Abnormalities in coagulation parameters include fibrin split products and prolonged prothrombin and partial thromboplastin times, suggesting that DIC is a terminal event and usually associated with multiorgan failure. More recent studies have shown that D-dimers are detectable early in the disease. During the terminal stages, kidney failure is confirmed by high creatinine and blood urea nitrogen values. Ebola or Marburg viral antigens are present at high levels in all tissues, including the skin, allowing a specific diagnosis to be made post-mortem by immunohistochemistry.

Diagnosis

The specific diagnosis of filovirus infection requires tests that are not usually available in the endemic areas of these viruses, or in any hospital in the western world. Diagnosis initially requires the elimination of a number of viral haemorrhagic fevers. In general, viraemia and antigenaemia are present during the acute phase of the disease. The best approach is to use a combination of tests, including antigen detection ELISA assay, RT-PCR (usually more sensitive but subject to artifacts and contamination) and IgM capture ELISA [11,23,24]. RT-PCR has the advantage of allowing genetic analysis of the products. Virus can be isolated, but this requires time and adequate levels of containment (BSL-4 level). During rapid fatal disease, patients may often die without any detectable antibodies; however, ELISA tests can be used to detect IgM antibodies, which may be present during illness and usually appear early in convalescence. IgG ELISA tests play little role in establishing acute diagnosis, but can be used for retrospective or epidemiological studies. Post-mortem diagnosis can be carried out using specific immunohistochemical analysis of tissues, including skin biopsies, collected after deaths that are suspected to be caused by filovirus infection; this is a distinct advantage in highly fatal diseases [25].

Treatment and prevention

Barrier nursing and the avoidance of parenteral exposure of hospital staff are important in the management of filovirus infections because of the frequency with which nosocomial transmission is seen. Symptomatic and supportive management, with careful maintenance of fluid balance, is the only available treatmtent option at this time. No antiviral drugs or vaccines are currently available for human use, but several candidate vaccines have shown potential in animal models.

Crimean–Congo haemorrhagic fever

Crimean–Congo haemorrhagic fever (CCHF) was first recognized in the Crimean peninsula (former USSR) at the end of the Second World War. In 1969, the causal virus was found to be identical to a virus isolated from a febrile child in 1956 in Stanleyville, a town in the former Belgian Congo [26,27]. Since then, the virus has been found from Africa to the western provinces of China.

Aetiological agent and epidemiology

The CCHF virus, a tick-borne virus found in Africa, eastern Europe and Asia, belongs to the genus *Nairovirus* of the family Bunyaviridae. The genome is composed of three segments

of negative-sense, single-stranded RNA. Virions contain two envelope glycoproteins, a nucleocapsid protein and a RNA polymerase. The CCHF virus is an enveloped virus.

CCHF virus has been isolated from 30 species of ixodid ticks and, with the exception of Madagascar, the distribution of the virus overlaps with the distribution of *Hyalomma* ticks. These ticks feed on different hosts during their life-cycle, from rodents and birds to small ruminants and cattle. Transovarial transmission of virus from female ticks to progeny occurs [27]. Although several species of mammal can be infected, disease only develops in humans. The virus is usually contracted through the bite of an infected tick, or by contact with blood or tissue from a viraemic animal or a patient at home or in a hospital setting. The number of human cases during outbreaks is usually small and, frequently, those in contact with animals (farm or slaughterhouse workers) are at the origin of the infection; health-care personnel who take care of infected patients are involved secondarily in small clusters [13].

Pathology and pathogenesis

Because of the lack of an animal model, the occurrence of the disease in remote areas and the limited number of specialized laboratories, the pathogenesis of CCHF is poorly understood. Few tissues collected during necropsies have been made available for analysis. Pathological examination of liver tissue reveals hepatocellular necrosis with prominent Councilman bodies, hypertrophic Kupffer cells and lack of inflammatory mononuclear cell infiltrates. Abundant immunostaining of CCHF virus antigens reveals replication of the virus in hepatocytes, mononuclear phagocytes and endothelial cells [28]. The infection of endothelial cells plays an important role in the vascular leakage and haemostasis that are observed in the disease [13].

Clinical manifestations

The incubation period can be as short as 3 days but is usually around 7 days. Onset is characterized by the sudden appearance of headache, dizziness, fever, nausea, vomiting and abdominal pain. Behavioural changes, such as somnolence or depression, are frequent; some patients are confused or even aggressive [29,30]. During the clinical examination, conjunctival injection and enanthem are usually obvious and lymphadenopathies and hepatomegaly may be present, as well as tenderness of the right upper quadrant of the abdomen. A petechial rash on the trunk and limbs may be seen by the end of the first week of illness [27,30,31]. In some patients, large ecchymoses and bruises are indications of the haemorrhagic tendencies of CCHF infections. Epistaxis, haematemesis and melena are common. The most severely ill patients develop multiorgan failure, coma and DIC [27,29,31,32]. In mild forms of the disease, defervescence is observed during the second week, with progressive general improvement; convalescence is usually prolonged.

Laboratory findings

Leukopenia is only transient, but thrombocytopenia is an early and consistent feature of CCHF. Elevations of blood urea nitrogen and creatinine levels are accompagnied by proteinuria. All patients have abnormal liver functions, with elevated levels of serum AST, ALT and gamma-glutamyltransferase [18,29]. Most patients show a decline in haemoglobin levels [27,31,32]. During the course of fatal infections, elevations of the prothrombin ratio, activated partial thromboplastin time, fibrin degradation products and D-dimers, and low fibrinogen levels, are typical of DIC.

Diagnosis

Laboratory diagnosis of the infection at the early stage of the disease is carried out by detection of the CCHF virus, antigen or RNA. This is achieved using an antigen detection ELISA or by RT-PCR analysis of serum or blood [11,27,29]. Virus isolation from cell cultures or suckling mice is sensitive but requires several days and a laboratory with adequate levels of containment. Tissues collected during necropsies are also suitable for CCHF antigen, RNA or virus isolation [13,28]. In addition, immunohistochemical assays can specifically confirm the aetiological diagnosis [28]. IgM and IgG antibodies, detectable by ELISA, may often be absent in fatal cases and appear later in the disease process.

Treatment and prevention

Most of the facilities where CCHF patients are hospitalized have no diagnostic capabilities and the treatment is symptomatic. Good barrier-nursing practices should be initiated in areas where disease is present [13]. Ribavirin is effective against the CCHF virus in cell cultures and, although no rigorous clinical trials have been carried out, intravenous and oral ribavirin have been used in South Africa, Pakistan, Iran and Turkey with apparent success [31–33].

Disclaimer

The findings and conclusions in this report are those of the authors and do not necessarily represent the views of the funding agency.

References

1 Enria D, Mills JA, Flick R *et al.* (2006) Arenavirus infections. In: Guerrant RL, Walker DH, Weller PF (eds) *Tropical Infectious Diseases. Principles, Pathogens and Practice*, 2nd edn. Philadelphia, PA: Elsevier Churchill Livingstone, pp. 734–755.

2 Gunther S, Lenz O (2004) Lassa virus. *Crit Rev Clin Lab Sci* 41, 339–390.

3 Walker DH, McCormick JB, Johnson KM *et al.* (1982) Pathologic and virologic study of fatal Lassa fever in man. *Am J Pathol* 107, 349–356.

4 Cummins D, Fisher-Hoch SP, Walshe KJ *et al.* (1989) A plasma inhibitor of platelet aggregation in patients with Lassa fever. *Br J Haematol* 72, 543–548.
5 Cummins D (1992) Lassa fever encephalopathy: clinical and laboratory findings. *J Trop Med Hyg* 95, 197–201.
6 McCormick JB, King IJ, Webb PA *et al.* (1987) A case-control study of the clinical diagnosis and course of Lassa fever. *J Infect Dis* 155, 445–455.
7 Johnson KM, McCormick JB, Webb PA *et al.* (1987) Clinical virology of Lassa fever in hospitalized patients. *J Infect Dis* 155, 456–464.
8 McCormick JB, Walker DH, King IJ *et al.* (1986) Lassa virus hepatitis: a study of fatal Lassa fever in humans. *Am J Trop Med Hyg* 35, 401–407.
9 Schmitz H, Kohler B, Laue T *et al.* (2002) Monitoring of clinical and laboratory data in two cases of imported Lassa fever. *Microbes Infect* 4, 43–50.
10 Bausch DG, Rollin PE, Demby AH *et al.* (2000) Diagnosis and clinical virology of Lassa fever as evaluated by enzyme-linked immunosorbent assay, indirect fluorescent-antibody test, and virus isolation. *J Clin Microbiol* 38, 2670–2677.
11 Drosten C, Gottig S, Schilling S *et al.* (2002) Rapid detection and quantification of RNA of Ebola and Marburg viruses, Lassa virus, Crimean-Congo hemorrhagic fever virus, Rift Valley fever virus, Dengue virus, and Yellow fever virus by real-time reverse transcription-PCR. *J Clin Microbiol* 40, 2323–2330.
12 Madani TA, Al-Mazrou YY, Al-Jeffri MH *et al.* (2003) Rift Valley fever epidemic in Saudi Arabia: epidemiological, clinical, and laboratory characteristics. *Clin Infect Dis* 37, 1084–1092.
13 Watts DM, Flick R, Peters CJ *et al.* (2006) Bunyaviral fevers: Rift Valley fever and Crimean-Congo hemorrhagic fever. In: Guerrant RL, Walker DH, Weller PF (eds) *Tropical Infectious Diseases. Principles, Pathogens and Practice*. Philadelphia, PA: Elsevier Churchill Livingstone, pp. 756–761.
14 Morrill JC, Jennings JB, Johnson AL *et al.* (1990) Pathogenesis of Rift Valley fever in rhesus monkeys: role of interferon response. *Arch Virol* 110, 195–212.
15 van Velden DJ, Meyer JD, Olivier J *et al.* (1977) Rift Valley fever affecting humans in South Africa: a clinicopathological study. *South African Med J* 51, 867–871.
16 Al-Hazmi M, Ayoola EA, Abduraman M *et al.* (2003) Epidemic Rift Valley fever in Saudi Arabia: a clinical study of severe illness in humans. *Clin Infect Dis* 36, 245–252.
17 Adam F, Jouan A, Philippe B *et al.* (1992) Biological parameters of patients infected by the Rift Valley fever virus in Rosso (Mauritania). *Presse Medicale – Paris* 21, 1731.
18 Ayoola AE, Al-Hazmi MH, Michail NT *et al.* (2003) Liver involvement in patients with moderately severe Rift Valley fever. *Am J Gastroenterol* 98(9 Suppl), S92.
19 Sanchez A, Khan AS, Zaki SR *et al.* (2001) Filoviridae: Marburg and Ebola viruses. In: *Fields' Virology*, 4th edn. Philadelphia, PA: Lippincott Williams & Wilkins, pp. 1279–1304.
20 Leroy EM, Kumulungui B, Pourrut X *et al.* (2005) Fruit bats as reservoirs of Ebola virus. *Nature* 438, 575–576.
21 Martini GA (1971) Marburg virus disease. Clinical syndrome. In: Martini GA, Siegert R (eds) *Marburg Virus Disease*. New York: Springer-Verlag, pp. 1–9.
22 Bwaka M, Bonnet M-J, Calain P *et al.* (1999) Ebola hemorrhagic fever in Kikwit, Democratic Republic of Congo (former Zaire): clinical observations. *J Infect Dis* 179(Suppl 1), S1–7.
23 Ksiazek TG, Rollin PE, Williams AJ *et al.* (1999) Clinical virology of Ebola hemorrhagic fever (EHF) virus: virus, virus antigen, and IgG and IgM findings among EHF patients in Kikwit, Democratic Republic of Congo, 1995. *J Infect Dis* 179(Suppl), S177–187.
24 Towner JS, Rollin PE, Bausch DG *et al.* (2004) Rapid diagnosis of ebola hemorrhagic fever by reverse transcription-PCR in an outbreak setting and assessment of patient viral load as a predictor of outcome. *J Virol* 78, 4330–4341.
25 Zaki SR, Shieh W-J, Greer PW *et al.* (1999) A novel immunohistochemical assay for detection of Ebola virus in skin: implications for diagnosis, spread, and surveillance of Ebola hemorrhagic fever. *J Infect Dis* 177(Suppl 1), S36–47.
26 Casals J (1969) Antigenic similarity between the virus causing Crimean hemorrhagic fever and Congo virus. *Proc Soc Exp Biol Med* 131, 2333–2336.
27 Hoogstraal H (1979) The epidemiology of tick-borne Crimean-Congo hemorrhagic fever in Asia, Europe, and Africa. *J Med Entomol* 15, 307–417.
28 Burt FJ, Swanepoel R, Shieh W-J *et al.* (1997) Immunohistochemical and in situ localization of Crimean-Congo hemorrhagic fever (CCHF) virus in human tissues and implications for CCHF pathogenesis. *Arch Pathol Lab Med* 121, 839–846.
29 Swanepoel R, Gill DE, Shepherd AJ *et al.* (1989) The clinical pathology of Crimean-Congo hemorrhagic fever. *Rev Infect Dis* 11(Suppl 4), 794–800.
30 Athar MN, Baqai HZ, Ahmad M *et al.* (2003) Crimean-Congo hemorrhagic fever outbreak in Rawalpindi, Pakistan, February 2002. *Am J Trop Med Hyg* 69, 284–287.
31 Jamil B, Hasan RS, Sarwari AR *et al.* (2005) Crimean-Congo hemorrhagic fever: experience at a tertiary care hospital in Karachi, Pakistan. *Trans Royal Soc Trop Med Hyg* 99, 577–584.
32 Ozkurt Z, Kiki I, Erol S *et al.* (2006) Crimean-Congo hemorrhagic fever in Eastern Turkey: clinical features, risk factors and efficacy of ribavirin therapy. *J Infect* 52, 207–215.
33 Mardani M, Jahromi MK, Naieni KH *et al.* (2003) The efficacy of oral ribavirin in the treatment of Crimean-Congo hemorrhagic fever in Iran. *Clin Infect Dis* 36, 1613–1618.

Dengue and yellow fever

Alberto Queiroz Farias and Flair José Carrilho

Dengue

Aetiological agent and epidemiology

Dengue infection is currently ranked as the most important mosquito-borne viral disease worldwide. The disease is endemic in more than 100 countries and affects 100 million people, mainly in tropical and subtropical regions, with 450 000 annual cases of the haemorrhagic form of the disease. The vector is the day-biting mosquito of the genus *Aedes*, usually *Aedes aegypti*, although *A. albopictus* and *A. polynesensis* may also have epidemiological relevance depending on the geographical location.

A. aegypti breeds in small collections of water and the eggs are resistant to desiccation. Transovarial virus transmission may account for the maintenance of a reservoir without human participation. The dengue virus is a single-stranded RNA virus of the Flaviviridae family with a genome of 11 kb. The disease is caused by any of the four dengue virus serotypes (DEN-1 to DEN-4). The infection induces specific, but not cross-protective, immunity [1,2].

Pathology and pathogenesis

The dengue virus replicates within cells of the mononuclear phagocyte system and in mast, dendritic and endothelial cells. Bone marrow suppression occurs in dengue infection and contributes to low lymphocyte and platelet counts [3,4]. Occasionally, the dengue virus crosses the blood–brain barrier and causes encephalitis. The viraemic and infective phase lasts for up to 5 days after the onset of symptoms and is followed by the appearance of specific IgM antibodies around the sixth day [5]. Most of the patients recover, but a small percentage of cases progress to dengue haemorrhagic fever (DHF), which is characterized by plasma leakage. The risk of severe disease is highly increased in cases of sequential infection by a different serotype. Circulating cross-reacting non-neutralizing antibodies, either from previous dengue episodes or from acquired maternal IgG in the neonatal period, are implicated in DHF. During secondary infection, the Fc portion of those antibodies forms complexes with the dengue virus and enhances cell-surface binding and entry of the second virus serotype into macrophages, leading to DHF [6]. The underlying pathophysiological process in DHF is increased capillary permeability, producing plasma leakage; microscopically, there is no necrosis or inflammation of capillary vessels. Higher levels of cytokines and other markers of activated T cells support the role of these mediators in increasing capillary permeability.

The liver in dengue virus infection

Liver involvement is characterized by focal midzonal necrosis of varying degrees of severity and by microvesicular steatosis. Focal perivenular necrosis and dropout of hepatocytes are common findings. Low-grade inflammation is usually found and residual parenchymal calcification may occur. Plate 9.4.1 (facing p. 72) shows immunohistochemical staining of dengue virus antigen in liver tissue.

Clinical manifestations

The incubation period is 4–7 days. Dengue infection may be asymptomatic. According to the World Health Organization (WHO), symptomatic infections can be classified into three categories [1,7,8]:

1 Undifferentiated fever – usually seen in primary infection and indistinguishable from other acute viral disorders.

2 Dengue fever – characterized by sudden onset of high fever (40°C or 104°F) with a biphasic course and including two or more of the following manifestations: intense myalgia ('break-bone fever'), arthralgia, headache, retro-orbital pain, leukopenia and haemorrhagic diathesis. Manifestations such as flushing, coryza, rash and seizure may also occur. The tourniquet test may be positive in some subjects, presumably because of capillary fragility.

3 DHF – the WHO case definition must fulfill all of the following four criteria:

- acute sudden onset of high fever for 2–7 days;
- haemorrhagic manifestations demonstrated by spontaneous bleeding or positive tourniquet test;
- platelet count $< 100 \times 10^9$ cells/L;
- plasma leakage shown by a raised packed cell volume of > 20% in serial measurements or by the development of ascites or pleural effusions.

DHF is classified into four grades of severity based on the presence of spontaneous bleeding and the severity of plasma leakage. Dengue shock syndrome includes DHF grades III and IV. Although rare, DHF may be complicated by myocarditis, haemolytic uremic syndrome, acute renal failure, encephalopathy, encephalitis and fulminant liver failure.

Laboratory findings and diagnosis

Laboratory findings are variable and more conspicuous in DHF. The most common findings are a decreased platelet count, leukopenia, atypical lymphocytosis, an abnormal coagulation profile and reduced serum complement levels. Liver enzymes are elevated in most infected individuals. Infections with DEN-3 or DEN-4 serotypes are believed to induce a higher increase in liver enzymes than other genotypes. Other findings include low albumin levels and acid–base and electrolyte disturbances.

A definite diagnosis of dengue virus infection depends on the detection of specific circulating antibodies, viral isolation and detection of viral RNA in tissue or serum samples. The monoclonal antibody-based capture enzyme-linked immunosorbent assay (ELISA) is still the most commonly used serological test. However, antibodies are not detectable until at least 5 days after infection, and cross-reactivity with other flaviviruses is possible. Inoculation on mosquito cell cultures (mainly the C6/36 clone of *A. albopictus*) has become the standard technique for dengue virus isolation. Viral RNA detection by reverse transcriptase-polymerase chain reaction (RT-PCR) may be used; however, it still needs to be internationally standardized [9–11].

Treatment, prognosis and prevention

Most cases are self-limited and hospitalization is not required. Treatment is merely symptomatic. Antiviral drugs are not effective, but therapy with paracetamol has been proposed. Acetylsalicylic acid (aspirin) should be avoided because of the

risks of bleeding episodes and the development of Reye syndrome. In the case of DHF or dengue shock syndrome, the life-threatening forms of the infection, therapy is aimed at adequate and prompt fluid replacement. Although dengue fever is self-limited, DHF is associated with high mortality rates. Adequate supportive therapy for DHF has been reported to successfully decrease fatalities from 40% to less than 1%. Currently, no effective vaccine is commercially available. The most effective strategy for prevention of infection is vector control, which may be achieved by removing stagnant pools of water around houses, treating stored water with larvicide, the biological control of vectors (with the use of larvivorous fish or endotoxin-producing bacteria) and education [1,12].

Yellow fever

Aetiological agent and epidemiology

Yellow fever (YF) is a systemic mosquito-borne viral infection that affects approximately 200 000 individuals annually in tropical regions of Africa and Central and South America. The disease probably originated in Africa and was brought to the New World during the period of the slave trade. The infectious agent is a flavivirus of 25–65 nm in size, and there are seven strains that are infectious to man. In Africa, YF is endemic in 29 countries and both rural and urban outbreaks have occurred. In the Americas, YF has not been reported in urban areas for the last 50 years and is now restricted to the tropical rain forests. There are two cycles of YF in endemic regions: the forest (jungle or sylvatic) cycle and the urban cycle. In America, the forest cycle is maintained in monkeys and, probably, in rodents. The vectors are *Haemagogus* spp. and *Sabethes* spp. forest-dwelling mosquitoes. The *Aedes aegypti* mosquito is responsible for urban outbreaks. In Africa, infection in monkeys, mainly Cercopithecus monkeys (vervet), accounts for the jungle cycle, and a number of *Aedes* spp. mosquitoes play a role in virus transmission. Infected hosts transmit the YF virus to mosquitoes during the period of fever. The intrinsic cycle in the mosquito is 4–18 days, depending on environmental conditions, and the infection is lifelong in mosquitoes. Transovarial viral transmission contributes to YF virus maintenance during the dry seasons. Individuals entering the forest are bitten by mosquitoes that have acquired infection from primates; these individuals then serve as reservoirs when they return to urban areas. The peridomiciliar *A. aegypti* may disseminate the YF virus, beginning the urban cycle [3,13,14]. Interhuman transmission is unimportant. YF virus has also been isolated from the tick *Amblyomma variegatum*, but the epidemiological significance of this finding is unclear [15].

Pathology and pathogenesis

Initial replication probably takes place in the draining lymph nodes. During the subsequent haematogenous dissemination, the liver becomes the principal focus of infection. Kupffer cells are infected first, followed by hepatocytes. Pathogenesis is mediated by direct viral injury to hepatocytes. Stroma cells are not involved, and typical lesions may not be found in biopsy specimens during the recovery phase. Liver involvement is conspicuous and characterized by extensive midzonal necrosis with minimal inflammation. The more intense immunostaining of YF antigens in the midzonal region suggests a specific viral tropism toward zone 2.

Lesions in other organs are variable. Myocarditis is characterized by degenerative and focal fatty changes and may result in circulatory dysfunction and arrhythmias. Fatty changes may be seen in the sinoatrial node and in the bundle of His and are related to the clinical finding of bradycardia. Encephalitis, cerebral edema and perivascular haemorrhages can also occur. In the kidneys, the most important pathological findings are in the renal tubules, which show acute tubular necrosis and fatty changes. Haemorrhagic diathesis is characterized by decreased synthesis of clotting factors and disseminated intravascular coagulation. Haemorrhages occur in the digestive system, eyes, lungs, uterus, liver, spleen and kidneys. The number of spleen and lymph node lymphocytes decrease and adrenal lesions may be found. Death results from hepatorenal failure, although heart dysfunction may also contribute [16,17].

The liver in yellow fever

In the liver, the characteristic histopathological changes are seen between the third and eighth day of illness. The hallmark of liver infection is the clear preferential involvement of zone 2, as seen by midzonal necrosis of the parenchyma with degenerated hepatocytes forming eosinophilic Councilman bodies. Nuclei are pyknotic and have enlarged nucleoli and sometimes nuclear inclusions (Torres bodies). Villela bodies are similar structures, but are restricted to the cytoplasm of hepatocytes. Microvesicular steatosis and Kupffer cell hyperplasia also occur. Hepatocytes around the portal and centrolobular veins are spared, inflammatory cells are not prominent and the reticulin framework is preserved [18]. The pattern of midzonal injury, initially thought to represent a characteristic histopathological finding of YF, is also observed with relative frequency in infections by other viral haemorrhagic fevers, such as dengue and Rift Valley fever viruses. Plate 9.4.2 (facing p. 72) shows the major histological findings in the liver that are associated with YF.

Clinical manifestations

The incubation period is 3–6 days. The spectrum of infection is variable; in the majority of cases, the disease is mild or subclinical. Severe classic YF accounts for 10–20% of cases. The typical presentation of severe forms of YF is characterized by three distinct periods (Fig. 1) [13]:

1 Period of infection – this early period corresponds to the viraemic stage and lasts for 3 days. Prodromal symptoms are

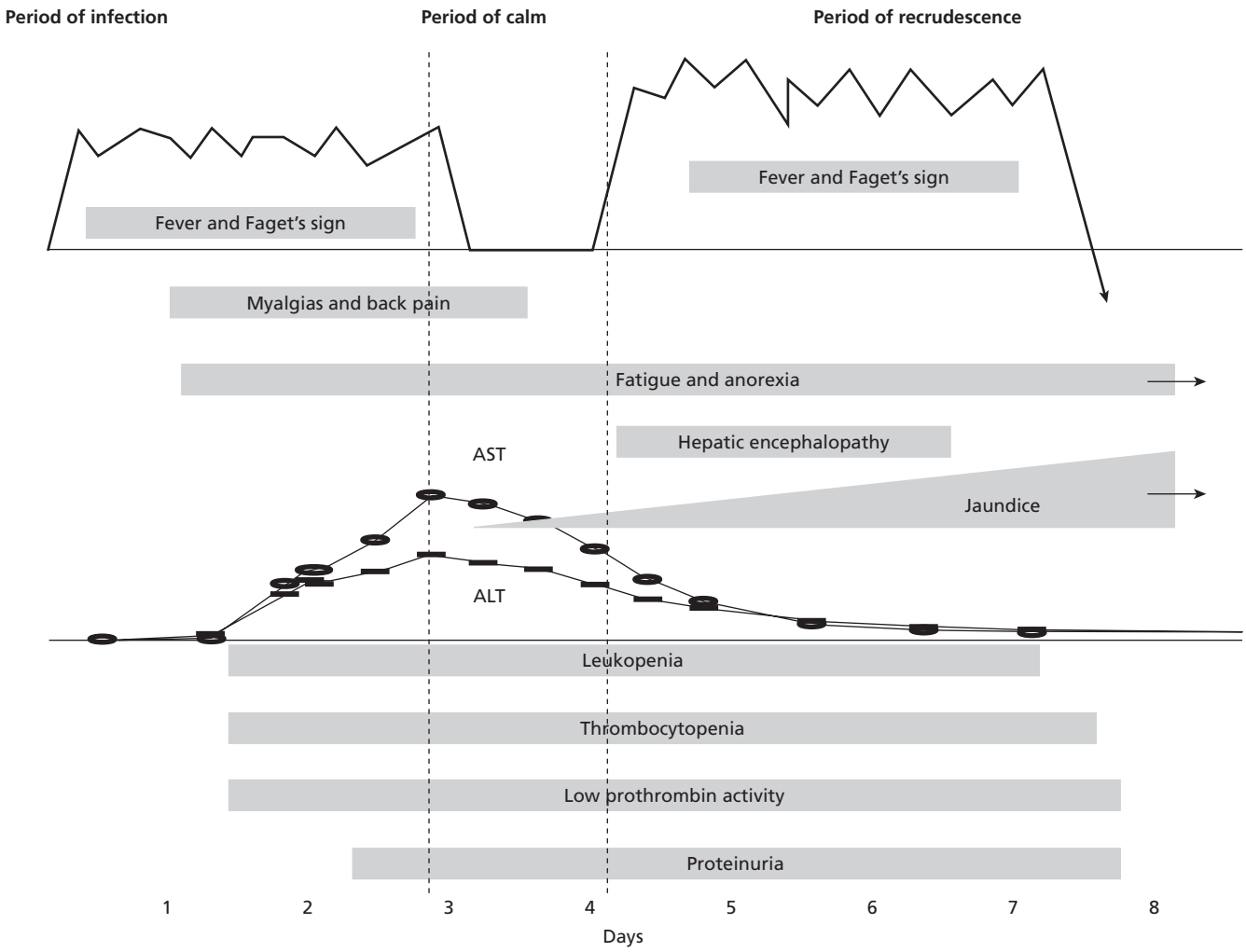

Fig. 1 Clinical course in a patient with yellow fever.

usually absent. There is an abrupt onset with a fever of up to 40°C, chills, headache, nausea, vomiting, abdominal pain, myalgia and lumbosacral pain. Conjunctival injection and hyperaemia along the edges of the tongue may be found. On the second day, despite a rising temperature, the pulse may decrease (Faget's sign). Nasal bleeding is a common finding.

2 Period of calm – this phase is characterized by the fall of fever; it lasts from several hours to a day, and the patient may enter clinical remission or progress to the following period.

3 Period of recrudescence – viraemia is no longer detectable and circulating antibodies may be present. The fever returns, Faget's sign reappears and the patient's condition deteriorates. Liver and kidney failure develop. Jaundice becomes evident but is never as deep as in viral hepatitis. As in other haemorrhagic fevers, bleeding from different organs may occur, in particular from the eyes, nose, mouth, bladder, uterus and digestive tract. The classical manifestation of coffee-ground haematemesis or 'black vomit' carries a dismal prognosis. In spite of severe proteinuria, ascites is rare. Myocardial dysfunctions are characterized by hypotension, heart failure, arrhythmias and ST segmental changes. Central nervous system involvement is suggested by signs of meningitis or encephalitis. Suppurative parotitis and pneumonia may complicate YF. Death usually occurs on the seventh to tenth day of illness, but the duration of the period of recrudescence is quite variable and may last for up to two weeks.

Laboratory findings and diagnosis

Clinical laboratory tests reveal leukopenia, thrombocytopenia and hypoglycaemia and elevated levels of conjugated bilirubin, serum aminotransferases [particularly aspartate aminotransferase (AST)], blood urea nitrogen and creatinine in endstage disease. Serological tests, such as haemaglutination inhibition,

complement fixation, indirect immunofluorescence, ELISA and radioimmunoassay, have been used as a supplementary tool for diagnosis. However, cross-reactivity to other flavivirus is a concern. An elevation in the titre of IgM antibodies indicates recent infection; paired acute and convalescent sera should be tested, with rising antibody titres providing a confirmatory diagnosis. Inoculation onto mosquito cell cultures is the method of choice for virus isolation. YF antigen may be demonstrated in formalin-fixed tissue from the liver, kidney and heart by immunohistochemical staining [17]. However, histopathological examination of the liver is not recommended because of the high risk of life-threatening bleeding from the biopsy site. A PCR-based test is available to detect the YF virus.

Treatment, prognosis and prevention

During the acute phase of YF, the patient should be protected from mosquito bites to avoid the spread of infection. Treatment is supportive and symptomatic. Inhibitors of gastric acid secretion are advisable to decrease the risk of gastric bleeding. Dialysis may be required. Heparin therapy is controversial and should be reserved for selected patients with documented severe disseminated intravascular coagulation. No specific antiviral drug is available. The overall case fatality rate during outbreaks is between 5% and 10%. The prognosis for patients with jaundice is poor, with up to 50% dying between the seventh and tenth day after onset. YF is a preventable disease and vaccination is mandatory for populations at risk and travellers to endemic areas. The live attenuated 17D vaccine, produced from chicken embryos and delivered by a single subcutaneous dose, induces long-lasting immunity in more than 95% of people. Immunity is probably lifelong but, for travel certification, revaccination is recommended every 10 years. The vaccine must not be given to infants of less than 6 months of age because of the risk of postvaccinal encephalitis; if possible, it is best to delay vaccination until 12 months of age. The rate of encephalitis is from 0.5 to 4.0 in 1000 in those younger than 9 months and one in eight million in those older than 9 months [19,20]. Immunization during pregnancy is contraindicated because of the fetal risk and poor maternal immune response. The YF vaccine is inexpensive and relatively safe. More than 400 million doses have been used since the implementation of the seed-lot system in 1945, and only 27 cases of postvaccinal encephalitis and 12 cases of viscerotropic complications have been reported. Six fatal vaccine-associated cases have been reported worldwide [21]. In Brazilian patients among these cases, the course resembled classic YF. [22]

The possibility of eradicating YF in endemic forest regions seems remote. The control of *A. aegypti* is the cornerstone strategy for the prevention of urban YF. This includes the removal of mosquito breeding sites in stagnant waters and the biological or chemical control of vectors.

References

1 Malavige GN, Fernando S, Fernando DJ *et al.* (2004) Dengue viral infections. *Postgrad Med J* 80, 588–601.

2 Pinheiro FP, Corber SJ (1997) Global situation of dengue and haemorrhagic fever, and its emergence in the Americas. *World Health Stat Q* 50, 161–169.

3 Solomon T, Mallewa M (2001) Dengue and other emerging flavivirus. *J Infect* 42, 104–115.

4 Ho LJ, Wang JJ, Shaio MF *et al.* (2001) Infection of human dendritic cells by dengue virus causes cell maturation and cytokine production. *J Immunol* 166, 1499–1506.

5 Vaughn DW, Green S, Kalayanorooj S *et al.* (2000) Dengue viremia titer, antibody response pattern, and virus serotype correlate with disease severity. *J Infect Dis* 181, 2–9.

6 Littaua R, Kurane I, Ennis FA (1990) Human IgG Fc receptor II mediates antibody-dependent enhancement of dengue virus infection. *J Immunol* 144, 3183–3186.

7 WHO (1997) *Dengue Hemorrhagic Fever, Diagnosis, Treatment, Prevention and Control*, 2nd edn. Geneva: World Health Organization.

8 Deen JL, Harris E, Wills B *et al.* (2006) The WHO dengue classification and case definition: time for a reassessment. *Lancet* 368, 170–173.

9 De Paula SO, Fonseca BAL (2004) Dengue: a review of the laboratory tests a clinician must know to achieve a correct diagnosis. *Braz J Infect Dis* 8, 390–398.

10 Telles FRR, Prazeres DMF, Lima-Filho JL (2005) Trends in dengue diagnosis. *Rev Med Virol* 15, 287–302.

11 Kao CL, King CC, Chao DY *et al.* (2005) Laboratory diagnosis of dengue virus infection: current and future perspectives in clinical diagnosis and public health. *J Microbiol Immunol Infect* 38, 5–16.

12 Kabra SK, Jain Y, Singhal T *et al.* (1999) Dengue hemorrhagic fever: clinical manifestations and management. *Indian J Pediatr* 66, 93–101.

13 Monath TP (2001) Yellow fever: an update. *Lancet Infect Dis* 1, 11–20.

14 Rogers DJ, Wilson AJ, Hay SI *et al.* (2006) The global distribution of yellow fever and dengue. *Adv Parasitol* 62, 181–220.

15 Cornet JP, Huard M, Camicas JL *et al.* (1982) Experimental transmission of the yellow fever virus by the tick *Amblyoma variegatum*. *Bull Soc Pathol Exot Filiales* 75, 136–140.

16 Monath TP, Barret AD (2003) Pathogenesis and pathophysiology of yellow fever. *Adv Virus Res* 60, 343–395.

17 De Brito T, Siqueira SAC, Santos RTM *et al.* (1992) Human fatal yellow fever. Immunohistochemical detection of viral antigens in the liver, kidney and heart. *Path Res Pract* 188, 177–181.

18 Vieira WT, Gayotto LC, de Lima CP *et al.* (1983) Histopathology of the human liver in yellow fever with special emphasis on the diagnostic role of the Councilman body. *Histopathology* 7, 195–208.

19 Monath TP (1999) Yellow fever. In: Protkin S, Orenstein W (eds) *Vaccines*. New York: WB Saunders, pp. 815–998.

20 Robertson SE (1993) The immunological basis for immunization. 8: yellow fever. Document WHO/EPI/GEN/93.18. Geneva: WHO.

21 Seligman SJ, Gould EA (2004) Live flavivirus vaccines: reasons for caution. *Lancet* 363, 2073–2075.

22 Vasconcelos PF, Luna EJ, Galler LJ *et al*, Brazilian Yellow Fever Vaccine Evaluation Group (2001) Serious adverse events associated with yellow fever 17DD vaccine in Brazil: a report of two cases. *Lancet* 358, 91–97.

10 Other infections of the liver

10.1 Bacterial, rickettsial and spirochaetal infections

José M. Sánchez-Tapias

Bacterial infection

Introduction

A large number of bacteria may affect the liver either as a result of parenchymal or biliary invasion or as a manifestation of bacteraemia or toxaemia. There is a wide spectrum of clinical manifestations, ranging from asymptomatic abnormalities of liver function tests to jaundice and, occasionally, severe liver failure.

Liver dysfunction in extrahepatic infection

Patients with extrahepatic infection often have clinical or biochemical signs of liver dysfunction [1]. Jaundice was described as early as 1836 in patients with pneumococcal pneumonia, but the overall prevalence of liver dysfunction in infected patients remains undefined. Liver disorder is more frequent in children than in adults, and its frequency increases with the severity of the underlying condition, being highest in patients with septic shock and multiple organ failure [2]. About half of patients with severe infection admitted to intensive care units may have bilirubin serum concentrations higher than 2 mg/dL. Liver dysfunction occurs mostly in patients with documented Gram-negative bacteraemia, especially *Escherichia coli* and *Klebsiella* spp., although Gram-positive organisms may be involved as well, especially *Streptococcus pneumoniae* and *Staphylococcus aureus*. The most common sources of bacteraemia in these patients are pneumonia, urinary tact infection and soft-tissue infection, although organisms may originate from other sources such as pelvic infection, diverticulitis, appendicitis, peritonitis, meningitis, lung abscess, septic abortion or others.

The severity of liver disorder is variable, ranging from subclinical evidence of cholestasis to deep jaundice. Pruritus is fairly uncommon. Symptoms are those of the underlying condition. Viral, drug-related and ischaemic hepatitis must be excluded. In severe infections, other complications may ensue, including renal failure, respiratory distress syndrome and coagulopathies. Prognosis is related to the underlying condition, and mortality seems to be related more closely to renal, neurological and coagulation complications than to hepatic impairment itself [3,4].

Pyogenic liver abscess

Pyogenic liver abscess results from bacterial infection of the liver parenchyma and subsequent infiltration of the area with neutrophils and other phagocytes to form a collection of pus. The wall of the abscess may be formed, for instance, by biliary epithelium or by the lining of a hydatid cyst, in cases secondary to infection of ectatic bile ducts or parasitic cyst respectively.

There have been changes in the epidemiology of pyogenic liver abscess in recent years. The age distribution now has a peak at around 60–70 years, and an increase in prevalence has been noted between 1977 and 2002 from 6 to 18 per one million, most probably as a result of using more sensitive diagnostic tools [5].

Biliary tract infection resulting from obstruction of the common bile duct accounts for about 40% of cases and is the most frequent of the known causes of pyogenic liver abscess, but no underlying cause can be identified in nearly one-third of cases [6,7]. Systemic bacteraemia is thought to be the most common cause in infants and young children and is responsible for 10–20% of cases in adults, sometimes by infection of pre-existing tumours or intrahepatic haematomas following blunt trauma. Portal bacteraemia caused by intra-abdominal infections, such as appendicitis, diverticulitis, abscesses, inflammatory bowel disease and others, may lead to liver abscess formation, but this is less frequent than in the pre-antibiotic era. Liver abscesses may also result from extension of septic processes in the vicinity of the liver, such as cholecystitis, pancreatitis or penetrating gastric or duodenal ulcers. Occasionally, treatment of liver tumours by transarterial embolization and, more rarely, by ethanol injection may cause abscess formation.

The causative organisms vary according to the primary site of infection. Abscesses following cholangitis or intra-abdominal sepsis are frequently polymicrobial and involve enteric Gram-negative organisms and anaerobes, whereas systemic bacteraemia causes abscesses with a single organism, such as *Staph. aureus*,

streptococci or aerobic Gram-negative organisms. *Escherichia coli* is classically the organism most frequently involved, but *Klebsiella pneumoniae* has increasingly been recovered from cultures in recent years, particularly among Asian patients [8,9], and a genetically determined increased tissue invasiveness has recently been recognized in involved strains [10].

Patients typically present with slow onset of fever and pain or tenderness in the right upper quadrant, loss of appetite and body weight. These symptoms may last for weeks before the diagnosis is made, but there may be rapid deterioration with signs of sepsis, jaundice and septic shock, particularly in cases associated with biliary obstruction.

Laboratory abnormalities are not specific. Increased erythrocyte sedimentation rate (ESR), elevated alkaline phosphatase, increased leukocyte count with neutrophilia, and mild anaemia are usually found. Blood cultures are positive in about half the cases. On chest X-rays, there may be elevation of the right hemidiaphragm, pleural effusion or a basal infiltrate, but abdominal ultrasonography, computerized tomography (CT) or magnetic resonance imaging (MRI) are essential for diagnosis. Modern imaging techniques are important because they can provide relevant information regarding underlying biliary or abdominal disorders, and facilitate aspiration of pus for diagnostic or therapeutic purposes.

The prognosis of pyogenic liver abscess has very much improved in recent years. Early diagnosis and appropriate management have reduced overall mortality to about 10% or less, although it remains high in patients with subjacent malignancies [5,11].

Treatment is based on the administration of appropriate antibiotics and evacuation of pus. In selected patients, antibiotic therapy alone may be an option. In view of the wide range of possible organisms, microbiological diagnosis is important in choosing the most effective antibiotics. Empiric therapy should include antibiotics active against Gram-negative bacteria, streptococci, including enterococci, and anaerobes. Duration of therapy depends on the response but, in general, antibiotics should be given intravenously (i.v.) for 2 weeks and by mouth for a further 4 weeks. Evacuation of pus must be done surgically in patients with large abscesses [12]; otherwise, percutaneous, ultrasound-guided drainage is less aggressive and very effective [13]. Percutaneous evacuation of pus can be done by continuous drainage via an inserted catheter or by intermittent needle aspiration. A recent controlled trial suggests that needle aspiration may be the procedure of choice as a first option [14].

Liver dysfunction following infection with specific organisms

Staphylococcus aureus and the toxic shock syndrome

The toxic shock syndrome is a severe multisystem disorder that occurs in patients infected with a strain of *Staph. aureus* producing a specific toxin called TSST-1. This syndrome was initially described in adult females at the onset of menstruation and was related to the use of specific tampons. Following adequate preventive measures, the incidence of this syndrome has markedly decreased in this setting, but still occurs as a complication of surgical procedures, trauma, burns and other local infections [15].

Clinically, it is characterized by high fever, hypotension, erythematous rash and multiorgan involvement affecting the gastrointestinal tract, kidney, central nervous system and liver. Liver dysfunction is characterized by a transient, moderate increase in bilirubin, transaminases and alkaline phosphatase. Diagnosis is based on clinical criteria. *Staph. aureus* is rarely recovered from blood but may be isolated from vaginal swabs or from other sites. Differential diagnosis is that of multisystem disease with fever, hypotension and rash and includes scarlet fever, meningococcaemia, erythema multiforme, drug eruption, leptospirosis and others. Treatment is based on supportive measures, drainage of infected sites, appropriate antibiotics and, in severe cases, intravenous immunoglobulin, which contains anti-TSST-1 antibodies, may be considered.

Clostridium perfringens

Clostridium perfringens may directly affect the liver in the form of an abscess or, very rarely, by causing diffuse, necrotizing, massive gas gangrene of the liver, leading to fulminant hepatic failure [16]. Patients with gas gangrene elsewhere, following septic abortion or wound infection, may be jaundiced mostly as a consequence of massive haemolysis.

Listeria monocytogenes

Listeria monocytogenes, a Gram-positive, aerobic bacillus, is widely distributed in nature but rarely causes symptomatic infection, except in pregnant women, immunocompromised subjects and neonates. Hepatic involvement with *L. monocytogenes* may occur as a solitary liver abscess or may be more widespread and present as an acute hepatitis with high transaminases. High fever, neutrophilia and the presence of granulomas in the liver may be valuable for distinction from viral hepatitis [17,18]. This organism has been recognized as a cause of spontaneous bacterial peritonitis in patients with cirrhosis [19]. Diagnosis is confirmed by isolation of the organism from blood, tissue or organic fluid cultures. Ampicillin is the drug of choice.

Legionella pneumophila

Legionella pneumophila causes Legionnaire's disease, which is a pneumonia with multisystem involvement. This disease has its highest incidence in the 40- to 70-year-old age group and is more frequent in men. Alcoholics, smokers and subjects with chronic diseases are at highest risk. Abnormalities of liver function test are quite common, but frank jaundice is rarer [20]. Histological changes of the liver are non-specific. The diagnosis is mostly based on serology, and the differential diagnosis includes other bacterial pneumonias, *Mycoplasma* infection, psittacosis and Q fever. Oral azithromycin or clarythromycin is the treatment of choice in the immunocompetent host, whereas

immunocompromised or patients with severe disease need i.v. therapy with azithromycin, levofloxacin or ciprofloxacin.

Brucella spp.

Brucellosis is a worldwide zoonosis that occasionally affects man. There are three important pathogenic species: *Br. abortus*, *Br. melitensis* and *Br. suis*, which have different geographic distributions and somewhat different clinical presentation [21]. Brucellosis is an occupational infection of farmers, veterinary surgeons, meat handlers and microbiology laboratory workers and is also transmitted by raw milk, particularly goat milk, and dairy products.

The presentation of the disease may be acute, subacute or chronic. Major features are fever, sweating, malaise, headache, rigors, arthralgia, myalgia and back pain. The liver, the spleen or both are enlarged in about one-third of cases, but significant liver damage with jaundice or liver abscess formation is infrequent, and chronic hepatosplenic suppurative brucellosis is rare [22,23]. Elevation of alkaline phosphatase, suggesting an infiltrative process within the liver, is the most prominent biochemical abnormality. Liver biopsy usually shows non-specific inflammation, reactive changes and small non-caseating granulomas, the last being found infrequently when the disease becomes chronic [24]. Large liver abscesses are rare, and symptoms are insidious, but imaging techniques characteristically show large, poorly defined, hypodense areas surrounding a patent central calcification [23,25]. Several serological tests [Bengala rose, Coombs, enzyme-linked immunosorbent assay (ELISA)] are available for diagnosis, but interpretation may be difficult, particularly in endemic areas or in chronic infection. Brucella can frequently be isolated from blood in the early stages of infection, but cultures are rarely positive at later stages, during non-febrile periods. Several days or weeks may be necessary for cultures to grow. Modified automated culture techniques and polymerase chain reaction (PCR)-based methods have increased sensitivity and are helpful in speeding diagnosis [26]. Therapy is based on prolonged administration of antibiotics, mostly doxycycline in combination with streptomycin or rifampicin. Surgical excision may be required for large liver abscesses.

Neisseria gonorrhoeae

Gonococcal perihepatitis, with the formation of violin-string fibrin adhesions between the liver capsule and the peritoneal wall, may result from direct spreading through the peritoneum of germs causing pelvic inflammatory disease in women or, rarely, by retroperitoneal lymphatic or haematogenous dissemination in men. Clinically, it is characterized by severe pain in the right upper quadrant and fever, and there may be a friction rub. Liver function tests are usually normal, although serum transaminases may be raised. CT scan or ultrasonography may show thickening of the peritoneum. Laparoscopy is useful to confirm the diagnosis and to relieve pain by section of the adhesions. This clinical picture (Fitz-Hugh and Curtis syndrome) may also be caused by *Chlamydia trachomatis*. Antibiotic therapy is based on a combination of doxycycline and ceftriaxone.

Burkholderia pseudomallei

Burkholderia pseudomallei, a Gram-negative aerobic bacillus, is a soil saprophyte that can easily be recovered from water and wet soils in endemic areas. Melioidosis is a very important cause of sepsis during the rainy seasons in northeastern Thailand and has also been recognized in other Southeast Asian countries, the north of Australia and Central America. Melioidosis mostly affects people who have direct contact with wet soils and have a predisposition to infection, such as diabetes or other chronic diseases. The skin is the portal of entry. The disease may present as severe sepsis, often fatal, or a chronic debilitating condition with abscess formation mostly in the lung, although virtually any organ, including the liver, spleen, kidney, brain, skeletal muscle, skin and, in children, parotid gland, may be involved [27]. On ultrasound examination, liver abscesses may present as multiple hypoechoic areas or large, multiloculated lesions [28]. Melioidosis should be considered in severely septic patients living in or coming from endemic areas. Rapid diagnosis and immediate therapy are important. Serologic tests are of little help in endemic areas. *B. pseudomallei* can readily be cultured from infected sites or from blood within 48–72 h. Indirect immunofluorescence of sputum, urine or pus is very specific and provides much more rapid diagnostic information [29]. Immunoperoxidase staining of fixed specimens may be useful as well [30]. Rapid and specific PCR techniques have been described [31], but their applicability is probably low in endemic areas. Initial intensive care management, intravenous ceftazidime followed by prolonged oral administration of chloramphenicol, doxycycline and trimethoprim–sulphamethoxazole is the therapy of choice [27].

Hepatic involvement in infections with bacterial enteric pathogens

Salmonella *spp.*

Several *Salmonella* species may cause cholangitis, cholecystitis and liver abscesses. *Salmonella typhi* and *S. paratyphi* cause enteric fever. Liver involvement, as indicated by enlarged liver and abnormal liver function tests, is frequent in patients with typhoid fever. Histological findings are non-specific. Occasionally, typhoid nodules, which consist of aggregates of Kupffer cells, may be found [32]. More serious liver injury and clinical jaundice, the so-called typhoid hepatitis, is rare but may resemble viral hepatitis. High fever, bradycardia, lower peak serum aminotransferases level, high peak alkaline phosphatase and low alanine aminotransferase (ALT) to lactate dehydrogenase (LDH) ratio suggest typhoid hepatitis, but culture of salmonella from blood stool is important for diagnosis [33]. Salmonella is able to colonize the gallbladder, leading to a chronic carrier state that causes prolonged shedding of the organism. Chloramphenicol was traditionally the first-line

antibiotic for the treatment of typhoid fever, but fluoroquinolones are more effective, as these drugs provide a rapid cure in most patients, with a very low rate of both relapse or faecal carriage of the organism [34].

Other bacterial enteric pathogens

Abnormalities of liver function tests and an enlarged, tender liver may frequently be found in infections with *Shigella* spp. and *Campylobacter* spp., but clinical hepatitis or jaundice is rare. A few cases of spontaneous peritonitis caused by *Campylobacter* have been reported in patients with cirrhosis. Liver abscesses caused by *Yersinia*, although uncommon, have mostly been reported in patients with genetic haemochromatosis or secondary iron overload.

Tularaemia

Franciscella tularensis is a Gram-negative coccobacillus that causes tularaemia in wild rodents. Infection may be transmitted to man directly from infected animals, by insect bites or by drinking contaminated water. *F. tularensis* is distributed worldwide, but human disease is rare and occurs mainly in persons in contact with infected animals [35]. Clinical manifestations are variable and include fever, malaise, headache and a local reaction at the entry site, causing several types of illness: glandular, ulceroglandular, oculoglandular, pulmonary, oropharyngeal and typhoidal. Elevation of aminotransferases is frequent, but clinically apparent liver involvement is rare, although hepatic abscesses and hepatic granulomas have been reported. *F. tularensis* is difficult to culture, and the handling of this bacterium poses risks to laboratory workers. Microagglutination and ELISA tests and PCR-based methods are being used for diagnosis [36]. Streptomycin and aminoglycosides are the antibiotics of choice for treatment

Q fever

Q fever is a worldwide distributed zoonosis with protean clinical manifestations [37,38]. The responsible agent is *Coxiella burnetti*, a pleomorphic, Gram-negative, strictly intracellular coccobacillus. Recent phylogenetic studies showed that *C. burnetti* belongs to the order of Legionellales rather than Rickettsiales. A wide variety of animals can be infected, including domesticated and wild mammals, reptiles, amphibians, fish and ticks. Most human infections occur in persons in direct contact with infected animals such as cattle, sheep or goats, but may also occur by indirect exposure in rural or urban areas, mostly by inhalation of wind-spread infectious aerosol particles or consumption of unpasteurized dairy products.

Q fever usually presents as a febrile influenza-like illness with pneumonitis, hepatitis or both. Jaundice is rare, but elevation of liver enzymes and hepatomegaly are very common. Pericarditis, myocarditis, neurological manifestations, such as meningitis, meningoencephalitis or peripheral neuropathies, and dermatological lesions may be present. Bradycardia is common. Fever of unknown origin and abnormal liver enzymes are a frequent form of presentation. Liver histology shows parenchymal granulomas with a characteristic ring of fibrinoid necrosis, which is surrounded by histocytes and lymphocytes and centred by a fat vacuole. This 'doughnut' or lipogranuloma lesion is highly suggestive of Q fever, but not pathognomonic, as it may be found in other granulomatous diseases such as typhoid fever, lymphoma, vasculitis and Epstein–Barr virus and cytomegalovirus infection [39]. Q fever is often autolimited, but may very occasionally be fatal. Endocarditis is by far the best characterized consequence of chronic infection. It has also been suggested that the chronic fatigue syndrome may be associated with protracted infection in some patients.

In patients with acute disease, the diagnosis can be confirmed by serology, with detection of rising antibodies against phase II antigens, but significant titres may take 3 or 4 weeks to appear. The diagnostic value of PCR assays in serum samples is limited, but may be useful for earlier diagnosis in some cases, as PCR may be positive within the first 2 weeks from the onset, when conventional serology is still negative [40]. Patients with chronic infection have high titres of antibodies against phase I antigen.

Doxycycline is the treatment of choice, but macrolides and fluoroquinolones have also been used. Several types of vaccines have been developed and may be efficacious in persons at risk.

Chlamydia

Chlamydia trachomatis

Infection with *C. trachomatis* is virtually restricted to humans and distributed worldwide. This pathogen causes a wide variety of disorders, including trachoma and conjunctivitis, sexually transmitted diseases in adults and pneumonia in the newborn. In males with lymphogranuloma venereum, increased liver enzymes and hepatic granuloma formation have been described. However, perihepatitis is the most typical hepatic disorder caused by *C. trachomatis*. Perihepatitis occurs mostly in young females via peritoneal spread of germs from the genital tract, although cases have been described in men, via blood or lymphatic dissemination. The disease results from localized inflammation, which leads to the formation of adhesions between the parietal and visceral peritoneum overlying the liver. In most cases, perihepatitis is associated with salpingitis and presents with fever and severe pain in the right upper quadrant, which exacerbates with deep breathing and coughing. Laparoscopy shows the typical fibrin 'violin-string' adhesions (Fitz-Hugh and Curtis syndrome). Perihepatitis may be found incidentally in non-symptomatic patients who undergo laparoscopic examination for other reasons [41]. *C. trachomatis* may be grown in cell culture or demonstrated by immunofluorescence from vaginal, endocervical or ureteral swabs. More recently, molecular procedures for amplification and hybridization of specific nucleic acid fragments have been developed and are commercially available [42]. This condition must be distinguished from acute cholecystitis and appendicitis, and from

perihepatitis caused by *N. gonorrhoeae*. Doxycycline and azithromycin are the antibiotics of choice.

Chlamydophila psittaci

Psittacosis is a worldwide distributed zoonosis that affects birds. *C. psittaci* is transmitted to man by the oral route, replicates in the liver and spleen and reaches the lung and other tissues following haematogenous dissemination. Symptoms are those of a non-specific atypical pneumonia: high fever, headache, malaise, dry cough; there may be some haemoptysis, but pleuritic pain is absent. Many patients have splenomegaly and enlarged liver, and a maculopapular rash may be present. Mild elevation of transaminases is frequent, but jaundice is rare, except in the most severe cases. Diagnosis is based on increasing titres of antibodies in sequential sera. Culture is difficult and hazardous for laboratory workers. PCR-based techniques are under development. Doxycycline is the antibiotic of choice, and macrolides and chloramphenicol may alternatively be used.

Chlamydophila pneumoniae

Chlamydophila pneumoniae has been recognized as an important aetiological agent in acute respiratory disorders and community-acquired pneumonia, mostly in young people. Over the past few years, there has been much debate about the possible role of this agent in atherosclerosis. Recently, *C. pneumoniae* antigen and RNA have been detected in explanted liver tissue from patients with primary biliary cirrhosis, and a controversy on its role in this disease has been opened [43].

Mycoplasma pneumoniae

Mycoplasma pneumoniae is a small Gram-negative eubacterium that does not have a cellular wall. It is distributed worldwide and produces pharyngitis and tracheobronchitis, and is a frequent cause of community-acquired pneumonia. Most infections are mild and do not require hospitalization. Symptoms are not specific. Some patients have a maculopapular rash or a bullous myringitis. Characteristically, respiratory physical signs are scarce, whereas chest X-ray shows prominent changes. Liver involvement is not frequent, but some patients may have elevated transaminases, and cholestatic hepatitis has been described in children. Cases of mild hepatitis in patients without pneumonia have also been reported [44]. Diagnosis is mostly based on serology. The antibiotic of choice is azithromycin.

Cat-scratch disease

Cat-scratch disease is an infection caused by *Bartonella henselae*, a small Gram-negative bacillus that infects cats, dogs and their fleas. Children and young adults are most frequently affected. In the majority of patients, cat-scratch disease is characterized by regional granulomatous lymphadenopathy following a cat scratch or bite. The site of inoculation is marked by a vanishing papular lesion. General symptoms such as low-grade fever or malaise may be present or not, and spontaneous, although slow, resolution is frequent. Liver involvement is rare. There are atypical cases in which the characteristic regional lymphadenitis and inoculation papule are absent. Granulomatous hepatic and splenic involvement has been reported in a few cases [45]. Diagnosis is based on serology and PCR amplification of bacterial DNA from tissue specimens. Therapy may not be necessary in localized, typical forms. Otherwise, a wide variety of antibiotics including fluoroquinolones, new macrolides such as azithromycin and co-trimoxazole may be useful.

In immunocompromised patients, *B. henselae* may cause severe granulomatous hepatitis and peliosis hepatis [46]. These patients have an enlarged and tender liver and appear seriously ill. Imaging techniques show multiple focal nodular hypodense lesions that must be differentiated from malignancies and a number of other granulomatous or infectious diseases that may affect the liver.

Mycobacteria

Involvement of the liver is frequent in patients with mycobacterial infections. Until recently, the incidence of tuberculosis has been declining in developed countries, but there is a recrudescence of mycobacterial infection due to immigration from underdeveloped countries and to the emergency of the acquired immune deficiency syndrome (AIDS). In this setting, in addition to *Mycobacterium tuberculosis*, other species such as *M. avium intracellulare* or, more rarely, *M. genavense*, may be involved. In addition, due to immune suppression, organ-transplanted patients are also at increased risk of developing tuberculosis. Liver-transplanted patients are prone to develop significant hepatotoxicity from standard antituberculous therapy, and alternative regimens should be considered [47].

The clinical spectrum of liver disease due to *Mycobacterium* spp. ranges from the absence of symptoms to severe hepatic disease, including liver failure. Multiple small granuloma formation within the parenchyma is the most common lesion. However, granulomas may also coalesce and form large tuberculomas, may affect the intrahepatic or extrahepatic biliary tree or the lymph nodes at the porta hepatis and cause biliary obstruction. Furthermore, patients with extrahepatic tuberculosis may have drug-induced hepatitis, non-specific lesions such as fatty infiltration or reactive hepatitis. Granulomatous hepatitis has been reported in patients undergoing bacille Calmette-Guérin (BCG) systemic immunization or local instillation in patients with carcinoma of the urinary bladder.

Tuberculosis is a frequent cause of liver granulomatosis. The number of granulomas is variable, being greater in patients with disseminated miliary tuberculosis. Hepatic tuberculosis occasionally occurs in the absence of apparent tuberculosis elsewhere [48]. Granulomatous hepatic tuberculosis does not usually cause symptoms, and the clinical manifestations are those of non-hepatic disease. Hepatomegaly and abnormal liver function tests, particularly elevation of alkaline phosphatase, are incidental findings. Jaundice and ascites are rare, and related to involvement of the biliary tree or the peritoneum respectively. Cases of liver failure mimicking fulminant viral hepatitis have

been reported. Suspicion of liver involvement arises from clinical symptoms or biochemical abnormalities. Plain X-ray may show multiple calcifications in the hepatic area. Imaging techniques do not provide specific data, but may be useful in ruling out other lesions. Liver biopsy demonstrates the presence of granulomas, which are formed by aggregates of epithelioid cells surrounded by mononuclear inflammatory cells and contain a few multinucleated giant cells. Caseation may be found in half the cases, but none of these features is specific. Acid-fast bacilli may be demonstrated by Ziehl–Nielsen staining in a minority of cases. *Mycobacteria* may be isolated in less than half the cases. Recently, several PCR-based assays have been developed for rapid and specific diagnosis of tuberculosis in clinical specimens, but the performance of these techniques in liver biopsies has not been fully evaluated in hepatic miliary tuberculosis.

Hepatic tuberculoma, tuberculous hepatic abscess, nodular or pseudotumoral hepatic tuberculosis are terms used to designate larger hepatic lesions resulting from the coalescence of tuberculous granulomas. They may be single or multiple and of variable size, although lesions greater than 3 cm in diameter are rare [49]. Abdominal pain, fever and weight loss are the most usual symptoms, but these may not be very apparent, and a tuberculous abscess may be discovered incidentally, when patients with abnormal liver function tests, particularly increased alkaline phosphatase, are investigated. Manifestations of pulmonary tuberculosis are often absent. Imaging techniques show a diversity of space-occupying lesions without specific features, which must be differentiated from primary or metastatic neoplasms or fungal infection. Histological examination of liver tissue obtained by percutaneous biopsy may show granulomas or non-specific inflammatory or fibrotic material. Staining for acid-fast bacilli, cultures and PCR-based DNA amplification are necessary for diagnosis. Most patients respond well to antituberculous regimens, but improvement may not be immediate and prolonged treatment is necessary.

Rickettsial infection

Rocky Mountain spotted fever

This condition is a tick-borne, multisystemic disease caused by *Rickettsia rickettsii* [50]. It is endemic in some areas in North, Central and South America, and has its highest incidence in children as they play outdoors and with dogs. Most patients have a mild or moderate illness, but the disease may be severe in some cases. High fever, malaise, headache, muscle aches, abdominal symptoms and an initially distal maculopapular rash are the first symptoms. A significant proportion of patients are not aware of having been bitten by a tick. Abnormal elevation of ALT is frequent, but clinical manifestations of liver involvement are rare. Prompt treatment is essential, as mortality in untreated patients may be high. Immunofluorescence assays and ELISA tests using specific antigens as well as PCR-based techniques are available, but treatment initiation must not await serological confirmation when there is a reasonable degree of clinical suspicion. Doxycycline is the drug of choice.

Mediterranean spotted fever (tick typhus, 'fievre boutonneuse')

This acute febrile illness is caused by *Rickettsia connorii*, which is transmitted to man mostly by a dog tick. It is endemic in the Mediterranean basin, the Middle East, India and South Africa, but a number of cases have been reported recently from central Europe. Initial symptoms are high fever, headache, myalgia, photophobia and a distal papular rash, which later extends onto the trunk and face. A characteristic black eschar, which is the inoculation site and where the tick may still be found, can be observed in a large proportion of patients. Hepatic involvement is very common and is manifested by liver enlargement, elevated transaminases, alkaline phosphatase and γ-glutamyl transpeptidase, and hepatic granulomas may be found [51]. Diagnosis can be based on clinical data. Rickettsias may be detected by direct immunofluorescence of cutaneous lesions, by increased specific antibody titres or by a positive Weil–Felix reaction. The course of the disease is usually benign. Doxycycline is very effective, but co-trimoxazole and chloramphenicol may also be used. Clarythromycin and azithromycin are effective in children. No vaccines are available.

Ehrlichioses and anaplasmosis

Human monocytotropic ehrlichiosis and human granulocytotropic anaplasmosis, formerly known as human granulocytotropic ehrlichioses, are tick-borne zoonoses caused by *Ehrlichia chaffeensis* and *Anaplasma phagocytophilum* respectively [50,52,53]. These conditions are characterized by infection of leukocytes, where the agents may form microcolonies within cytoplasmic vacuoles called morulae, which may be found in conventional smears of peripheral blood. Most patients have a moderately severe febrile illness with flu-like symptoms, and a cutaneous rash may be present, especially in patients with ehrlichiosis. Severe complications such as respiratory or renal failure, gastrointestinal haemorrhage or neurological complications may occur, mostly in patients of advanced age. Leukopenia (40%), thrombocytopenia (70%) and mildly increased aminotransferase serum levels (70%) are frequently found, and a few patients may be jaundiced. As symptoms are non-specific, a high index of suspicion is essential for early diagnosis. The presence of morulae in leukocytes is highly suggestive, but blood smear is quite insensitive, as morulae are found in a minority of cases. Immunofluorescence and ELISA assays are available, but these tests do not allow for early diagnosis because specific antibody response does not occur until the second week. Demonstration of rising IgG or IgM titres in serum specimens taken 2 or 3 weeks apart is required to confirm acute infection. PCR techniques can detect specific DNA sequences earlier, mostly in whole blood specimens, but a negative test does not rule out the diagnosis.

Culture is difficult. Antibiotic therapy must be initiated as soon as the diagnosis is suspected. Doxycycline is the drug of choice.

Spirochaetal infections

Treponema pallidum (syphilis)

Syphilis is a multisystem, sexually transmitted infection, which evolves through several clinical stages when left untreated. It may be transmitted to the fetus during pregnancy. Liver involvement may occur at every stage of the infection.

Besides the characteristic mucocutaneous lesions, osteitis and osteochondritis, babies with congenital syphilis have hepatitis with hepatosplenomegaly and jaundice [54]. Serum transaminases may reach very high levels, and aspartate aminotransferase (AST) is typically higher than ALT. Liver biopsies show multiple epithelioid granulomas and portal and pericellular fibrosis. Spirochaetes are localized mostly at the space of Disse and may be demonstrated by silver staining or electronic microscopy of liver tissue. Granulomas may evolve silently over the years and become manifest later in infancy or during adolescence as a hepar lobatum or hepatic gummas. Serological diagnosis may be difficult in the early stages because of the presence of maternal antibodies.

A resurgence of syphilis is being observed, particularly among human immunodeficiency virus (HIV)-infected individuals [55]. Liver involvement is relatively frequent in patients with secondary syphilis, but recognition may be obscured by coincidental, sexually transmitted, viral hepatitis. Patients present with anorexia, loss of weight, weakness, hepatomegaly and pruritus, but jaundice is uncommon [56]. In HIV-infected patients, neurological involvement seems to be more prominent than cutaneous or hepatic involvement [57]. A cutaneous rash, but not the primary chancre, is still present. Liver function tests are abnormal, and alkaline phosphatase is disproportionately elevated. A variety of histological changes have been described, including portal inflammation, areas of hepatocellular necrosis, granuloma formation, pericholangiolar inflammation, vasculitis and cholestasis. Spirochaetes are rarely found, and the pathogenesis of these liver lesions is unclear. Diagnosis is based on serology and on the demonstration of treponemes in cutaneous and mucous membrane lesions. All abnormalities subside rapidly with penicillin therapy.

In untreated patients, the clinical manifestations of secondary syphilis resolve spontaneously within a few weeks, and the infection enters into a state of latency. Recurrent secondary eruptions may occur but are rare. Latency may last for years and produce a variety of lesions leading to neurological, ocular, cardiovascular, skeletal, cutaneous or hepatic manifestations. Hepatic involvement is very rare and consists of the formation of gummas, which are granulomatous formations with no specific features. Gummas are space-occupying lesions that do not usually cause symptoms, but may be confounded with malignant lesions, mostly metastatic cancer [58]. Cases with pain over the right hypochondrium, loss of weight and presentation as a Budd–Chiari syndrome caused by compression of the inferior vena cava have been described. Percutaneous liver biopsy and specific treponemic tests are useful for diagnosis. Patients respond well to penicillin. Doxycycline has also been used successfully.

Borrelia burgdorferi (Lyme disease)

Lyme disease is a multisystem disorder caused by *B. burgdorferi*, a tick-borne microaerophilic spirochaete that is distributed worldwide. The distribution of the disease is related to the geographic prevalence of the tick vector. The disease follows three consecutive stages. Following inoculation, the organism multiplies locally and spreads into the regional lymph nodes and then to the organs and joints. The initial symptoms are those of a generalized infection, with fever, malaise, headache, lymphadenopathy, arthralgia, myalgia and a characteristic rash, named erythema chronicum migrans, a reddish macular or papular rash, which expands over time while fading centrally [59]. Neurological or cardiac abnormalities occur weeks or months later and may persist for several weeks. The late phase is characterized by the development of chronic erosive arthritis that may resemble rheumatoid arthritis. Hepatic involvement is very frequent in the early stage, when about half the patients have abnormal liver function tests resembling acute viral hepatitis. Liver lesions include portal inflammation, ballooning and microvesicular fatty degeneration of hepatocytes, abundant mitoses and infiltration of sinusoid with inflammatory cells [60,61]. Diagnosis is based on serological ELISA and immunofluorescence tests and, recently, on DNA amplification by PCR-based assays. Doxycycline is the drug of choice, but azithromycin is also effective.

Borrellia recurrentis

Relapsing fever is a louse-borne disease that is transmitted from man to man and occurs mostly in epidemics associated with very poor hygiene conditions. It is caused by *B. recurrentis*, a microaerophilic spirochaete that has no animal reservoir. The disease presents with rigors, high fever, arthralgia, myalgia, vomiting, photophobia and a cutaneous rash that may be petechial. Hepatosplenomegaly is present in most patients, jaundice is common, transaminasas are elevated, and there may be thrombocytopenia. Within less than 2 weeks, the initial episode abruptly subsides. At this time, death may occur as a consequence of cardiovascular collapse. Following an afebrile period that lasts several days, there is a relapse that resembles the initial episode [62]. Relapses are caused by the emergence of organisms able to evade protecting antibodies due to changing antigenicity. Diagnosis is made by direct demonstration of the organism in blood extension during a febrile episode. Tetracyclines and erythromycin are more effective than penicillin.

Leptospirosis

Leptospirosis results from infection with different serovars belonging to the species *Leptospira interrogans*, such as *L. icterohaemorrhagiae*, *L. canicola*, *L. pomona*, *L. andamana*, *L. autumnalis*, *L. copenhageni*, *L. gripptyphosa*, *L. hebdomadis* and others. Leptospirosis occurs worldwide, in rural and urban areas, but is more frequent in underdeveloped or developing countries and still remains an important public health problem [63]. There are many animal hosts, mostly rodents, which act as reservoirs and eliminate the leptospires in the urine. Stagnant water and warm temperature favour survival of the organisms. Humans are infected by contact of abraded skin with contaminated water or soil. Infection can also occur by penetration of the organisms through mucosal surfaces, including ingestion of contaminated food. The disease often results from occupational exposure in persons working in sewers, mines or rice and sugar cane plantations, as well as in persons who handle animal tissues or fluids.

The incubation period is 10 days on average. The severity of the illness varies widely, from asymptomatic cases to a severe disease with jaundice, renal failure and haemorrhages (Weil's disease). Most symptomatic patients have a biphasic disease. The first phase lasts several days and is characterized by sudden onset of high fever, rigors, severe headache, myalgia and abdominal complaints. There may be stiffness of the neck suggesting meningitis, and muscle pain is prominent. During this phase, leptospires are found in blood and in the cerebrospinal fluid. After a relatively asymptomatic interval lasting a few days, a second phase ensues, in which symptoms are variable, with a predominance of neurological manifestations, mostly meningitis and optical neuritis or iridocyclitis. Leptospires are excreted in the urine during this phase.

The manifestations of the second phase of leptospirosis may be severe. Weil's disease is characterized by marked jaundice, renal failure, haemorrhagic manifestation such as purpura or bleeding from the nose, gums or gastrointestinal tract, and neurological manifestations. Patients may have myocardial damage, which may cause arrythmias and heart failure. Typically, there is a moderate increase in serum transaminases in contrast to very high levels of bilirubin and γ-glutamyl transferase. Histology shows relatively little liver damage. Apart from prominent cholestatic features, the parenchyma appears well preserved, with some oedema and inflammation of the portal tracts, mitotic activity of the hepatocytes and hyperplasia of Kupffer cells.

Diagnosis should first be based on clinical and epidemiological suspicion. Leptospires can be isolated from blood or cerebrospinal fluid during the first phase and from urine during the second phase. Several methods are available for the detection of specific antibodies during the second phase, including macroscopic and microscopic agglutination, immunofluorescence and ELISA tests. Detection of leptospires in blood or urine by PCR amplification techniques allows early confirmation of the diagnosis during the initial phase of the illness [64].

Most patients with mild leptospirosis heal spontaneously. Doxycycline may reduce the duration of the illness in these patients, but there is no clear evidence that antibiotics are effective in modifying the illness in patients with severe disease, where doxycycline, cefotaxime and penicillin appear to be equally effective [65].

References

1 Gimson AES (1987) Hepatic dysfunction during bacterial sepsis. *Intensive Care Med* 13, 162–166.

2 Brienza N, Dalfino L, Cinnella G *et al.* (2006) Jaundice in critical illness: promoting factors of a concealed reality. *Intensive Care Med* 32, 267–274.

3 Russell JA, Singer J, Bernard GR (2000) Changing pattern of organ dysfunction in early human sepsis related to mortality. *Crit Care Med* 28, 3405–3411.

4 Gogos Lekkou A, Papageorgiou O *et al.* (2003) Clinical prognostic markers in patients with severe sepsis: a prospective analysis of 139 consecutive cases. *J Infect* 47, 300–306.

5 Jepsen P, Vilstrup H, Schonheyder HC *et al.* (2005) A nationwide study of the incidence and 30-day mortality of pyogenic liver abscess in Denmark, 1977–2002. *Aliment Pharmacol Ther* 15, 1185–1188.

6 Setto RK, Rockey DC (1996) Pyogenic liver abscess: changes in etiology, management and outcome. *Medicine (Baltimore)* 75, 99–113.

7 Johannsen EC, Sifri CD, Madoff LC (2000) Pyogenic liver abscesses: *Infect Dis Clin North Am* 14, 547–563.

8 Rahimian J, Wilson T, Oram V *et al.* (2004) Pyogenic liver abscess: recent trends in etiology and mortality. *Clin Infect Dis* 39, 1654–1659.

9 Lederman ER, Crum NF (2005) Pyogenic liver abscess with a focus on *Klebsiella pneumoniae* as a primary pathogen: an emerging disease with unique clinical characteristics. *Am J Gastroenterol* 100, 322–331.

10 Ma LC, Fang CT, Lee CZ *et al.* (2005) Genomic heterogeneity in *Klebsiella pneumoniae* strains is associated with primary pyogenic liver abscess and metastatic infection. *J Infect Dis* 192, 117–128.

11 Wong WM, Wong BC, Hui CK *et al.* (2002) Pyogenic liver abscess: retrospective analyses of 80 cases over 10-year period. *J Gastroenterol Hepatol* 17, 1001–1007.

12 Tan YM, Chung AY, Chow PK *et al.* (2005) An appraisal of surgical and percutaneous drainage for pyogenic liver abscesses larger than 5 cm. *Ann Surg* 241, 485–490.

13 Girogio A, Tarantino I, Mariniello N *et al.* (1995) Pyogenic liver abscesses: 13 years of experience in percutaneous needle aspiration with US guidance. *Radiology* 195, 122–124.

14 Yu SC, Ho SS, Lau WY *et al.* (2004) Treatment of pyogenic liver abscess: prospective randomized comparison of catheter drainage and needle aspiration. *Hepatology* 39, 932–938.

15 McCormick JK, Yarwood JM, Schlievert PM (2001) Toxic shock syndrome and bacterial superantigens: an update. *Annu Rev Microbiol* 55, 77–104.

16 Begert H, Illert T, Friedrich K *et al.* (2004) Fulminant liver failure following infection with *Clostridium perfringens*. *Surg Infect (Larchmt)* 5, 205–209.

17 Yu VL. Miller WP, Wing EJ *et al.* (1982) Disseminated listeriosis presenting as acute hepatitis. *Am J Med* 73, 773–777.

18 Vargas V, Aleman C, de Torres I *et al.* (1998) *Listeria monocytogenes*-associated acute hepatitis in a liver transplant recipient. *Liver* 18, 213–215.

19 Nolla-Salas J, Almela M, Gasser I *et al.* (2002) Spontaneous *Listeria monocytogenes* peritonitis. A population-based study of 13 cases collected in Spain. *Am J Gastroenterol* 97, 1507–1511.

20 Kirby BD, Snyder KM, Meyer RD *et al.* (1980) Legionnaire's disease: report of sixty-five nosocomially acquired cases and review of the literature. *Medicine* 59, 188–205.

21 Troy SB, Rickman LS, Davis CE (2005) Brucellosis in San Diego: epidemiology and species-related differences in acute clinical presentation. *Medicine (Baltimore)* 84, 174–187.

22 Colmenero JD, Reguera JM, Martos F *et al.* (1996) Complications associated with *Brucella melitensis* infection: a study of 530 cases. *Medicine (Baltimore)* 75, 195–211.

23 Ariza J, Pigrau C, Canas C *et al.* (2001) Current understanding and management of hepatosplenic suppurative brucellosis. *Clin Infect Dis* 32, 1024–1033.

24 Cervantes F, Bruguera M, Carbonell J *et al.* (1982) Liver disease in brucellosis. A clinical and pathological study of 40 cases. *Postgrad Med J* 58, 346–350.

25 Colmenero JD, Queipo-Ortuño MI, Reguera JM *et al.* (2002) Chronic hepatosplenic abscesses in brucellosis. Clinico-therapeutic features and molecular diagnostic approach. *Diagn Microbiol Infect Dis* 42, 159–167.

26 Queipo-Ortuño MI, Colmenero JD, Baeza G *et al.* (2005) Comparison between lightcycler real-time polymerase chain reaction (PCR) assay with serum and PCR-enzyme linked immunosorbent assay with whole blood samples for the diagnosis of human brucellosis. *Clin Infect Dis* 40, 260–264.

27 White NJ (2003) Melioidosis. *Lancet* 361, 1715–1722.

28 Vatcharapreechasakul T, Suputtamongkol Y, Dance DA *et al.* (1992) *Pseudomonas pseudomallei* liver abscess: a clinical, radiographic and ultrasonographic study. *Clin Infect Dis* 14, 412–417.

29 Walsh AL, Smith MD, Wuthiekanun V *et al.* (1994) Immunofluorescence microscopy for the rapid diagnosis of melioidosis. *J Clin Pathol* 47, 377–379.

30 Wong KT, Vadivelu J, Puthucheary SD *et al.* (1996) An immunohistochemical method for the diagnosis of melioidosis. *Pathology* 28, 188–191.

31 Ulrich MP, Norwood DA, Christensen DR *et al.* (2006) Using real-time PCR to specifically detect *Burkholderia pseudomallei*. *J Med Microbiol* 55, 551–559.

32 Koshla SN, Singh R, Singh GP *et al.* (1988) The spectrum of hepatic injury in enteric fever. *Am J Gastroenterol* 83, 413–416.

33 El-Newihi HM, Alamy ME, Reynolds TB (1999) Salmonella hepatitis: analysis of 27 cases and comparison with acute viral hepatitis. *Hepatology* 24, 516–519.

34 Bhan MK, Bahl R, Bhatnagar S (2005) Typhoid and para typhoid fever. *Lancet* 366, 749–762.

35 Eliasson H, Broman T, Forsman M *et al.* (2006) Tularemia: current epidemiology and disease management. *Infect Dis Clin North Am* 20, 289–311.

36 Ellis J, Oyston PC, Gree M *et al.* (2002) Tularemia. *Clin Microbiol Rev* 15, 631–646.

37 Raoult D, Tissot-Dupont H, Foucault C *et al.* (2000) Q fever 1985–1998: clinical and epidemiological features of 1383 infections. *Medicine (Baltimore)* 79, 109–123.

38 Parker NR, Barralet JH, Bell AM (2006) Q fever. *Lancet* 367, 679–688.

39 Bonilla MF, Kaul DR, Saint S *et al.* (2006) Ring around the diagnosis. *N Engl J Med* 354, 1937–1942.

40 Fournier PE, Raoult D (2003) Comparison of PCR and serology assay for early diagnosis of acute Q fever. *J Clin Microbiol* 41, 5094–5098.

41 Sharma JB, Malhotra M, Arora R (2002) Incidental Fitz-Hugh–Curtis syndrome at laparoscopy for benign gynecological conditions. *Int J Gynecol Obstet* 79, 237–240.

42 Johnson RE, Newhall WJ, Papp JR *et al.* (2002) Screening tests to detect *Chlamydia trachomatis* and *Neisseria gonorrhoeae* infections – 2002. *MMWR Recomm Rep* 51(RR-15), 1–38.

43 Abdulkarim AS, Petrovic LM, Kim WR *et al.* (2004) Primary biliary cirrhosis: an infectious disease caused by *Chlamydia pneumoniae*? *J Hepatol* 40, 380–384.

44 Romero Gómez M, Otero MA, Sánchez-Muñoz D *et al.* (2006) Acute hepatitis due to *Mycoplasma pneumoniae* without lung involvement in adult patients. *J Hepatol* 44, 827–828.

45 Le Tallec V, Abgueguen P, Pichard E *et al.* (2003) Localisations hépatospléniques de la maladie du griffe du chat chez l'adulte immunocompetent. Deux cas. *Gastroenterol Clin Biol* 27, 225–229.

46 Liston TE, Koehler JE (1996) Granulomatous hepatitis and necrotizing splenitis due to *Bartonella henselae* in a patient with cancer: case report and review of hepatosplenic manifestations of bartonella infection. *Clin Infect Dis* 22, 951–957.

47 Meyers BR, Papanicolau GA, Sheiner P *et al.* (2000) Tuberculosis in orthotopic liver transplant patients: increased toxicity of recommended agents: cure of disseminated infection with non conventional regimens. *Transplantation* 15, 64–69.

48 Mert A, Bilir M, Tabak-Ozaras R *et al.* (2001) Miliary tuberculosis: clinical manifestations, diagnosis and outcome in 38 adults. *Respirology* 6, 217–224.

49 Huang WT, Wang CC, Chen WJ *et al.* (2003) The nodular form of hepatic tuberculosis: a review with five additional cases. *J Clin Pathol* 56, 835–839.

50 Chapman AS, Bakken JS, Folk SM *et al.* (2006) Diagnosis and management of tickborne rickettsial diseases: Rocky Mountain spotted fever, ehrlichioses, and anaplasmosis, United States. A practical guide for physicians and other health-care and public health professionals. *MMWR Recomm Rep* 55(RR-4), 1–27.

51 Guardia J, Vilaseca J, Moragas A *et al.* (1981) Hepatitis in exanthematous Mediterranean fever. *Hepatogastroenterology* 28, 81–83.

52 Dumler JS (2005) *Anaplasma* and *Ehrlichia* infection. *Ann NY Acad Med Sci* 1063, 361–373.

53 Dumler JS, Choi KS, García-García JC *et al.* (2005) Human granulocytic anaplasmosis and *Anaplasma phagocytophilum*. *Emerg Infect Dis* 11, 1828–1834.

54 Woods CR (2005) Syphilis in children: congenital and acquired. *Semin Pediatr Infect Dis* 16, 245–257.

55 Mullick CJ, Liappis AP, Benator DA *et al.* (2004) Syphilitic hepatitis in HIV-infected patients: a report of 7 cases and review of the literature. *Clin Infect Dis* 39, 100–105.

56 Witkowski JA, Parish LC (2002) The great imitator: malignant syphilis with hepatitis. *Clin Dermatol* 20, 152–163.

57 Baughn RE, Musher DM (2005) Secondary syphilitic lesions. *Clin Microbiol Rev* 18, 205–216.

58 Maincent G, Labadie H, Fabre M *et al.* (1997) Tertiary hepatic syphilis: a treatable cause of multinodular liver. *Dig Dis Sci* 42, 447–450.

59 Wormser GP (2006) Early Lyme disease. *N Engl J Med* 354, 2794–2781.

60 Horowitz HW, Dworkin B, Forseter G *et al.* (1996) Liver function in early Lyme disease. *Hepatology* 23, 1412–1417.

61 Zaidi SA, Singer C (2002) Gastrointestinal and hepatic manifestations of tickborne diseases in the United States. *Clin Infect Dis* 34, 1206–1212.

62 Johnson WD, Golightly LM (2000) *Borrelia* species (relapsing fever). In: Mandell GL, Bennett JE, Dolin R (eds) *Mandell, Douglas and Bennett's Principles and Practice of Infectious Diseases*, 5th edn. Philadelphia: Churchill Livingstone, pp. 2502–2504.

63 Bharti AR, Nally JE, Ricaldi JN *et al.* (2003) Leptospirosis: a zoonotic disease of global importance. *Lancet Infect Dis* 3, 757–771.

64 Ahmad SN, Shah S, Ahmad FM (2005) Laboratory diagnosis of leptospirosis. *J Postgrad Med* 51, 195–200.

65 Suputtamongkol Y, Niwattayakul K, Suttinont C *et al.* (2004) An open, randomized, controlled trial of penicillin, doxycycline, and cefotaxime for patients with severe leptospirosis. *Clin Infect Dis* 39, 1417–1424.

10.2 Fungal infections affecting the liver

Roderick J. Hay

The liver becomes a target for infection in certain systemic fungal infections for several reasons. First, fungi of the appropriate size, such as *Histoplasma capsulatum*, are taken up by reticuloendothelial cells. Second, because of the volume of blood flow through the liver, fungi disseminated through the bloodstream commonly involve this organ. Third, certain fungi, notably *Candida albicans* and *Candida tropicalis*, are thought to penetrate the gastrointestinal mucosa in severely ill, neutropenic patients and spread directly to the liver via the portal vein before invading other organs. Despite this, the liver is not commonly reported as a site of fungal infection, possibly through simple oversight. It also reflects the fact that symptoms resulting from invasion of other sites such as the central nervous system or lung may dominate the clinical picture. The mycoses most frequently associated with invasion of the liver are shown in Table 1. They include the systemic fungal infections histoplasmosis, coccidioidomycosis penicillinosis due to *Penicillium marneffei*, paracoccidioidomycosis and, less frequently, blastomycosis. Of the opportunistic fungal pathogens, both *Aspergillus* and *Cryptococcus* may spread to this site, but liver infection is more often seen in disseminated candidosis as well as in rarer diseases such as trichosporonosis.

The other important way in which fungi may cause damage to hepatocytes is via mycotoxicosis produced by ingestion of fungal toxins. Many of the aflatoxins produced by a range of environmental fungi such as *Aspergillus* spp. may cause hepatic necrosis or cirrhosis. Other mycotoxins, such as patulin and ochratoxin A, affect the liver in laboratory animals, although the contribution made by these substances to human disease is largely unproven.

Table 1 Liver involvement has been reported in the following deep fungal infections.

Opportunistic mycoses
Candidosis – includes hepatosplenic candidosis
Cryptococcosis
Less common: aspergillosis, mucormycosis, trichosporonosis
Pathogenic mycoses
Histoplasmosis – disseminated (classical) histoplasmosis
Paracoccidioidomycosis
Less common: coccidioidomycosis, African histoplasmosis, blastomycosis, penicillinosis

Candidosis

Definition

Infections caused by fungi of the genus *Candida*, known as candidosis or candidiasis, may be either superficial or systemic [1]. Liver involvement follows dissemination via the circulation, either after direct introduction of the organisms through a contaminated intravenous line or intravenous injection in a drug abuser, or after invasion via the gastrointestinal tract. While hepatic infection may pass virtually unrecognized among the other manifestations of fulminant systemic candidosis, in certain patients, *Candida* infection of the liver and spleen produces a characteristic syndrome called hepatosplenic candidosis (chronic disseminated candidosis).

Introduction

In the last 30 years, systemic *Candida* infections have become a relatively frequent occurrence in certain groups such as neutropenic cancer or postoperative or intensive therapy unit (ITU) patients. Infection of the liver has been a consistent finding in many autopsy surveys of systemic candidosis.

Epidemiology

Candidosis has a worldwide distribution [1]. The most common species that causes human infection is *Candida albicans*, although others such as *C. tropicalis*, *C. parapsilosis* and *C. glabrata* may also be implicated. *Candida krusei* and *C. glabrata* are usually resistant to the antifungal drug fluconazole. Overall, there has been a change in the distribution of different *Candida* species in systemic infections, with a higher proportion of infections occurring in ITU and neutropenic patients being caused by species other than *C. albicans* such as *C. glabrata* or *C. parapsilosis*.

Candida spp. are common commensal organisms, being carried by a significant proportion of the healthy population in the mouth (25%), gastrointestinal tract (16%) and vagina (22%). The organisms become pathogenic under appropriate conditions, a change often associated with the development of hyphae. These conditions range from abnormalities of epithelial surfaces to physiological changes, endocrine or metabolic disease and primary or secondary immunodeficiency states.

Pathogenesis and pathology

Candida causes disease by invasion of tissue. There are various potential routes of systemic invasion. The organisms may be introduced directly into the bloodstream by injection, a form of disease seen in intravenous drug addicts, in whom fungi cause infection of the eyes, hair follicles and bones. *Candida* may also gain entry via an intravenous drip site by contamination of intravenous fluids or the skin. A major route of entry in neutropenic patients is via the gastrointestinal (probably jejunal) mucosa. This may follow invasion of the mucosa, or a process known as persorption in which particles such as *Candida* cells rapidly cross an intact mucosal wall. This is based on evidence in man that non-pathogenic yeasts can appear rapidly in the bloodstream after oral administration and, in neonatal mice, transfer of yeasts from the bowel lumen to the circulation appears to occur in the jejunum.

In tissue, *C. albicans* is normally found in both yeast and hyphal forms in small abscesses, and there are usually many organisms present. However, in patients with hepatosplenic candidosis, in whom the infection may persist for weeks despite a return of white cell counts to the normal range, few organisms are seen in the later stages of infection, and the tissue response may be granulomatous or mixed, with granulomas surrounding neutrophil abscesses. Hyphae are seldom produced in tissues by *Candida* spp. other than *C. albicans.* The pattern of disease associated with hepatosplenic candidosis has been described as an immunorestitution syndrome [not associated with human immunodeficiency virus (HIV)], a description that explains some of the features of the condition [2].

Clinical features and complications

Systemic candidosis usually has few clinical features that can be used to separate it from other septicaemic illnesses in severely ill patients. Patients present with pyrexia, usually after abdominal surgery or during neutropenia. Occasionally, there are helpful signs that may give a clue to the diagnosis, such as the appearance of multiple skin nodules, muscle pains or retinal deposits. The liver may be enlarged in such cases, but this is very variable. Hepatic lesions are usually found incidentally at autopsy. A number of risk factors have been associated with fungal liver infection in bone marrow transplant recipients. These include deep fungal infection after transplantation, colonization or superficial fungal infection after transplantation and severe liver dysfunction through veno-occlusive disease or graft-vs.-host disease [3].

Hepatosplenic candidosis

In recent years, increasing numbers of patients have been described with a syndrome whose principal feature is *Candida* infection of the liver and spleen [4]. The main characteristics of these patients were reviewed by Odds (Table 2) [1]. Most have leukaemia and have had a prolonged episode of neutropenia. The infection is most often caused by *C. albicans.* Unlike other forms of candidosis, the signs may appear after the patient appears to be in remission from the primary disease. The main clinical features are high, swinging pyrexia and chills, with right upper abdominal pain. Appetite is poor and patients show a variable degree of malaise. Progress is variable but, in untreated patients, the infection persists over weeks. It is also notoriously resistant to therapy [5–7]. The names hepatosplenic or chronic disseminated candidiasis have been used for this syndrome.

Diagnosis and differential diagnosis

Systemic candidosis may be difficult to diagnose, particularly in the immunocompromised patient. Blood cultures should be set up and repeated if necessary; cultures of intravenous line tips may also be helpful. Blood cultures are positive in a high proportion of patients after surgery, but in less than 20% of those with neutropenia. Other methods of diagnosis include serology, which is often only available in specialized centres. There are a few commercial kits available for the detection of *Candida* antibodies or antigen. These investigations may be contributory, but should not be regarded as diagnostic, particularly in the absence of any other evidence of *Candida* infection. The most reliable method of diagnosis is by biopsy and histopathological examination of appropriate lesions such as skin nodules. Percutaneous liver biopsy has not been widely used, except in hepatosplenic candidosis, where it is the definitive method of diagnosis [8].

Hepatosplenic candidosis

In this syndrome, a number of approaches to diagnosis in addition to biopsy may also be contributory. The most consistent results are seen with computerized tomography (CT) or magnetic resonance imaging (MRI) scans, which will show liver or spleen granulomas and abscesses [9,10]. The biphasic spiral liver CT technique shows specific patterns of enhancement, and the pattern is best seen in the arterial phase of perfusion [11]. MRI is a useful technique for following the course of infection. Ultrasonography has been less helpful, but is an alternative. Radionucleotide scanning with technetium-99 or gallium-67 has produced variable results. To prove the identity of the infection, it may be necessary to attempt liver biopsy with echo guidance or open biopsy at laparotomy. Serological tests may be positive in some of these patients and, in many such cases, antibody rather than antigen titres may be considerably elevated. The use of polymerase chain reaction (PCR) techniques can improve the diagnostic yield [12]. Liver enzymes are usually

Table 2 Clinical and pathological features of hepatosplenic candidosis.

Feature	Details	Percentage with feature
Sex distribution	Male:female	45.2:54.8
Age distribution (years)	<1	0
	1–9	25.0
	10–29	25.0
	30–49	34.1
	50–69	13.6
	>70	2.3
Underlying diseases	Acute leukaemia	86.3
	Aplastic anaemia	5.9
	Other	7.8
Diagnostic features	Fever	100.0
	Upper quadrant abdominal pain	96.3
	Raised alkaline phosphatase	100.0
	Blood leucocytosis	81.0
	CT scan abnormalities	93.8
	Ultrasound abnormalities	66.7
Sites affected	Liver alone	23.5
	Spleen alone	13.7
	Both liver and spleen	62.7
Causative organism	*Candida albicans*	88.2
	C. tropicalis	5.9
Outcome	Patient died	43.2

Data taken from Table 22.3 in Odds FC (1988) *Candida and Candidosis*. London: Baillière Tindall, pp. 196–205, with permission.

elevated, although the most consistent abnormality has been in alkaline phosphatase.

In hepatosplenic candidosis, the presence of a high, swinging pyrexia should alert the attending physician.

Treatment and prognosis

The mainstay of treatment for systemic *Candida* infections is intravenous amphotericin B (0.5–1.0 mg/kg body weight). Other choices include lipid-associated forms of amphotericin B [13], amphotericin B combined with flucytosine, itraconazole (oral), caspofungin and fluconazole (oral or intravenous). The range of treatment regimes employed suggests that these are difficult infections, possibly in keeping with their designation as part of an immune reconstitution syndrome. There is a high mortality in proven infections affecting neutropenic patients; therapy should be continued, where possible, until there is recovery of white cell numbers and, at any rate, for a minimum of 2–3 weeks. Treatment of hepatosplenic infections is also difficult, and many patients fail to respond to long courses of amphotericin B and flucytosine or fluconazole [5]. Some successes have been achieved with the lipid-associated forms of amphotericin B that are liposome based (AmBisome), a colloidal dispersion (ABCD or Amphocil) or a lipid complex (ABLC or Abelcet). Once again, there are few case reports on these compounds in hepatosplenic candidosis. Hepatosplenic candidosis is not necessarily a contraindication to bone marrow transplantation, provided that recipients are treated with antifungals both before and after engraftment until the graft is established [14]. There is little experience to date with voriconazole in this variety of candidosis.

Other opportunistic fungal infections

Invasive aspergillosis may be associated with solitary or multiple liver abscesses in 13–41% of cases [15]. The usual pattern of infection is the invasion of tissue, with scattered fungal hyphae penetrating necrotic liver parenchyma [16]. Occasionally, the fungus may form into a fungus ball, or aspergilloma, at this site [17]. Likewise, liver abscesses have been recorded with systemic infections caused by other fungi such as *Trichosporon beigelii* [18]. Mucormycosis, invasive zygomycosis and *Scedosporium* infections have only occasionally been recorded as causing liver disease, largely because they are often rapidly fatal even with localized infection of a distal site. All these infections are treated in much the same way as systemic candidosis, usually with amphotericin B in conventional or lipid-associated forms and/or flucytosine.

Cryptococcosis

Cryptococcosis is caused by *Cryptococcus neoformans*, a yeast

that is found in the environment in association with pigeon excreta [19]. There are two varieties of the organism: *C. neoformans neoformans*, which causes disease in Europe and parts of the United States in otherwise healthy people and immunocompromised patients including those with acquired immunodeficiency virus (AIDS); and *C. neoformans gattii*, which is seen mainly in non-AIDS patients in Africa and the Far East. The former is associated with pigeon excreta, the latter with certain species of Eucalyptus. Infection usually follows inhalation. Previously healthy individuals may be infected, particularly in the tropics but, in many parts of the world, cryptococcosis is seen mainly in patients with defective T-lymphocyte function, including those with Hodgkin's disease, AIDS, systemic lupus erythematosus, and in patients on steroid therapy as well as those receiving immunosuppression after organ transplants.

The primary focus of infection is the lung, but the most common clinical manifestation of the disease is meningitis. Skin or bone lesions may also occur. About 10–15% of patients have some evidence of pulmonary involvement, indicating that the primary focus often heals, despite dissemination. Liver infiltration during disseminated cryptococcosis is not common, but has been reported, particularly in patients with AIDS, where enlargement of the liver is not infrequent [20]. Patients may present with apparent biliary obstruction due to liver infiltration [21,22].

In non-AIDS patients, other patterns of liver infiltration have been recorded rarely. These include focal granulomatous hepatitis, which may mimic viral hepatitis and, on occasion, widespread infiltrates resulting in hepatic failure [23].

Another rare method of presentation is with obstructive jaundice secondary to sclerosing cholangitis, where the yeasts can be identified in the common bile duct [24]. In at least one such case, there has been histological evidence of pre-existing cirrhosis. Extensive hepatic necrosis associated with cryptococcal infection leading to liver failure has been described [25].

The best method of laboratory diagnosis is direct microscopic examination of smears, sputum or cerebrospinal fluid. The samples can be stained with India ink or nigrosin, both of which emphasize the yeast capsule. Cultures can also be taken and are usually positive in infected cases. There is a rapid antigen detection test using the agglutination of latex particles coated with antibody or an enzyme-linked immunosorbent assay (ELISA) that can be performed on serum or cerebrospinal fluid.

In most patients, the most appropriate therapy is amphotericin B with or without flucytosine given in doses of 0.3–0.6 mg/kg daily and 150 mg/kg daily respectively. Therapy in patients with AIDS is associated with a high relapse rate (over 70%), and it is usually necessary to give long-term treatment at weekly intervals after the induction of remission, the length of suppressive treatment depending on the response to highly active antiretroviral therapy (HAART). Fluconazole produces significant remissions at a dose of 400 mg daily in comparison with amphotericin B, but there may be a somewhat higher frequency of early relapse with fluconazole. Higher doses of fluconazole (600–800 mg daily) appear to be more effective. However, fluconazole is effective as a long-term treatment after initial remission.

Histoplasmosis

Definition

Histoplasmosis is a systemic infection caused by *Histoplasma capsulatum*, a dimorphic organism that can be found in the environment in soil or material contaminated with bird or bat excreta [19]. Infection follows inhalation and, in most people, this is asymptomatic. Occasionally, the infection may disseminate from the lungs to involve other organs, notably those rich in macrophages. The liver is affected in disseminated infections. This type of infection is known as classical or small-form histoplasmosis and is caused by a specific variant of the fungus, *H. capsulatum capsulatum*. The small-form disease is characterized by the presence of tiny yeasts (2–4 μm in diameter) in tissue macrophages; it has a worldwide distribution.

A second type of histoplasmosis, African or large-form histoplasmosis, caused by another variant of *H. capsulatum*, named *H. capsulatum* var. *duboisii*, is seen in central regions of Africa. Liver infection is not commonly recorded in this form of the disease. The tissue yeast forms in African histoplasmosis are large (10–12 μm in diameter) and are found in foreign-body giant cells; both forms of *H. capsulatum* are culturally indistinguishable. African histoplasmosis will be discussed separately.

Prevalence and epidemiology

Histoplasmosis (classical) has a well-defined endemic area, being found in the east and central regions of the United States as well as Central and South America, Africa, the Indian subcontinent and the Far East. Exposure, as assessed by conversion rates on the histoplasmin skin test, is highest in the United States and northern South America. In parts of the United States, over 90% of the healthy populace are skin test positive. A lower prevalence of positive skin test (under 20%) is seen in Africa and the Far East. These findings suggest that the infection is usually asymptomatic and self-healing. Infection follows inhalation of the organism, which is particularly associated with large accumulations of bird droppings in roosting sites and old buildings. In the tropics, important sites of potential exposure are bat-infested caves or buildings housing bat colonies.

Pathogenesis

Most of the systemic mycoses follow a common pattern of infection shown in Table 3. Subclinical infection is common, but the primary infection may be symptomatic where it is associated with massive exposure to a natural source of the fungus, for instance in a cave (cave fever). Chronic infection of the lungs may develop in those with pre-existing pulmonary disease, such as emphysema. The infection is a frequent, self-healing event,

Table 3 Scheme for clinical features of systemic mycoses due to endemic pathogenic fungi (histoplasmosis, blastomycosis, etc.).

Asymptomatic (sensitization)	Positive delayed-type hypersensitivity to fungal antigen
Acute pulmonary	Acute pulmonary infection after high-dose exposure
Chronic pulmonary	
Inactive	Asymptomatic pulmonary nodule(s)
Active	Chronic consolidation or cavitary lung disease
Disseminated[a]	
Acute	Widespread extrapulmonary dissemination
Chronic	Focal slowly progressive dissemination
Primary cutaneous	Skin lesion and lymphadenopathy following inoculation

[a]The progress and extent of dissemination in deep mycoses varies depending on the infection and the underlying condition of the patient.

even in subclinical cases because, in endemic areas, splenic or hepatic calcification of the site of healed metastatic lesions, some of which contain *H. capsulatum*, is common. In addition to this, dissemination may be progressive, particularly in patients with defective resistance. In rapidly disseminated forms of histoplasmosis, liver involvement may be more common, but it is also a feature of the indolent, chronic form of disseminated histoplasmosis in which the main clinical abnormalities are oral ulceration, hepatic enlargement or adrenal insufficiency [26].

Clinical features

The clinical features of histoplasmosis are largely determined by the site of infection. Acute and chronic pulmonary histoplasmosis are dominated by respiratory symptoms such as cough, weight loss, chest pain and fever. Disseminated disease is also associated with weight loss and fever but, in the chronic forms of infection, oral or laryngeal ulcers or adrenal insufficiency may appear [19].

Symptomatic hepatic involvement may be seen in the rapid-onset, disseminated form of *Histoplasma* infection. Studies indicate that as many as 66% of patients have hepatomegaly [27,28]. The enlarged liver may be tender, and the spleen is frequently enlarged also. Lesions are usually diffusely distributed through the liver, with multiple granulomas or parenchymal infiltration with many macrophages being stuffed with organisms [26]. Abnormalities of liver function may also occur. In patients with AIDS, liver enlargement has also been a common feature in those presenting with histoplasmosis [29–31].

The liver may also be involved in chronic disseminated forms of the infection. Here, there may be only slight hepatic enlargement. Interestingly, the most common pathological pattern is diffuse granuloma formation and, in many of these lesions, organisms cannot be found [32]. Infiltration of an allograft liver has also been reported [33].

Investigations

Histoplasma capsulatum is very small and difficult to demonstrate in pathological material without experience. Giemsa- or methenamine silver-stained sections or biopsies may show the organisms. *Histoplasma* can be cultured from such cases. Liver biopsies may also be a source of histopathological material [34]. Serological tests (immunodiffusion and complement fixation) are useful procedures for diagnosis and monitoring therapy. Two very specific precipitin bands, H and M, are found in histoplasmosis, the former being a more reliable indicator of active disease. Newer antigen detection tests are available and are particularly helpful for AIDS patients.

Therapy

The treatment of the patient with histoplasmosis affecting the liver is the same as that used for disseminated infections. Amphotericin B is the main treatment and is given in doses of 0.8–1.0 mg/kg daily. The duration of treatment varies, but it may need to be continued until a total dose of 2.0 g is achieved. Itraconazole is effective in some forms of histoplasmosis and is probably the treatment of choice in chronically disseminated forms of the disease; it is also effective in patients with AIDS both for initial therapy at 200–400 mg daily and for long-term suppressive therapy (cf. cryptococcosis) at 100–200 mg daily [35]. These regimens can be modified depending on the response to HAART.

African histoplasmosis

African histoplasmosis is an uncommon disease. Patients mainly present with disseminated lesions affecting the skin, bones and lymph nodes. Pulmonary involvement is rare. There are few reports of liver involvement in the course of African histoplasmosis [36].

Paracoccidioidomycosis

Definition

Paracoccidioidomycosis is a systemic fungal infection caused by the dimorphic fungus *Paracoccidioides brasiliensis* [37]. The infection is seen only in parts of South and Central America and Mexico. The organism causes either a widely disseminated infection or one localized to one or two sites, particularly the oral mucosa or lungs. Involvement of the liver is infrequently recognized, although it is probably common in widespread infections.

Epidemiology and pathogenesis

Paracoccidioidomycosis is a New World infection, although imported cases have been described outside this area in Japan and Europe. While it is believed that *P. brasiliensis* is found in

nature, it has only been identified in the natural environment on a few occasions and, therefore, its true ecological niche is unknown.

Cases of the infection are not common, even in endemic areas, and are mainly seen in adult males. This is thought to be due to an unusual effect of human androgens on the conversion of the organism to the yeast phase. There have been several surveys which suggest that exposure to the organism is fairly widespread in the population of endemic areas, although only occasionally have more than 20–25% of the community been found to be skin test positive to intradermal antigens of *P. brasiliensis*. Infection follows inhalation.

Clinical features

Paracoccidioidomycosis is a multisystem disease involving the lungs and the lymphatic system. It is often classified, as with the other systemic mycoses, into pulmonary and disseminated forms, or by location into pulmonary, lymphatic, mucocutaneous and mixed depending on the predominant site(s) of clinical involvement. Like histoplasmosis, a proportion of those exposed to this organism appear to develop asymptomatic infection, and the process resolves with the only evidence of infection being a positive skin test. Respiratory disease may also coexist with extrapulmonary infection, particularly ulcerative lesions of the oral or genital mucosa as well as adjacent skin. Lymph node involvement is also common.

Evidence for hepatic involvement is largely based on autopsy surveys, in which between 24% and 56% of those who die with paracoccidioidomycosis are found to have liver involvement [38,39]. In some series, over 40% of those with disseminated forms of infection have had hepatomegaly. The liver in these cases is said to be enlarged diffusely with unchanged consistency. Jaundice is rare and is found in less than 6% of cases [40]. Biopsy shows lesions ranging from small granulomas to diffuse infiltration of yeast forms and fibrosis. The bile ducts are commonly involved. The earliest signs are changes in aminotransferase concentrations; changes in alkaline phosphatase or bilirubin tend to occur in late disease.

Investigations

The diagnosis is confirmed by the demonstration of the organism in tissue and its isolation in culture. *Paracoccidioides brasiliensis* characteristically produces multipolar buds around the circumference of a yeast cell, and these can be seen in direct examination of smears. The organisms grow well in primary culture. Serodiagnosis may be very helpful, and immunodiffusion and complement fixation tests are available for this disease.

Therapy

The most appropriate therapy available at present is itraconazole, which is given in doses of 100–200 mg daily for 3–6 months or longer if necessary. The older azole antifungal, ketoconazole, is also very active. Other methods include intravenous amphotericin B and sulphonamides. Relapse after using the latter is very common.

Coccidioidomycosis

Coccidioidomycosis is an infection caused by *Coccidioides immitis*, a soil organism found in the arid western parts of the United States in California, Arizona, Texas and New Mexico, as well as in certain areas in South and Central America (northern Argentina, Colombia, Uruguay) [41]. Infection follows inhalation of the fungus and, like histoplasmosis, many of those exposed simply become sensitized without infection. Like histoplasmosis, acute or chronic pulmonary infections may result, or the disease may spread from the primary lung focus to involve other sites including the liver.

The main features of infection are therefore respiratory, and patients present with acute or chronic cough, malaise and fever. Dissemination often occurs in immunocompromised patients and is also more frequently seen in certain ethnic groups such as Indians or African Americans. The principal sites for dissemination are the meninges, joints and skin. In severe and widely disseminated infections, involvement of the liver is common, and one autopsy survey suggested that hepatic foci could be found in at least half of those with this type of disease [42]. The pattern of liver involvement ranges from focal granuloma formation to diffuse inflammatory infiltration [42,43]. Liver enlargement can occur together with changes in liver enzymes. Liver involvement has also been reported in patients with AIDS who develop coccidioidomycosis [44].

This infection is diagnosed by culture or by finding the characteristic *Coccidioides* spherules in smears or histologically. The organism grows well in laboratory culture. Laboratory staff should be warned about a possible diagnosis of coccidioidomycosis if they are attempting cultures. Serology (immunodiffusion, enzyme immunoassay or counter-immunoelectrophoresis) is very helpful in both establishing the diagnosis and monitoring the course of disease. Liver biopsy has been reported as a diagnostic procedure in coccidioidomycosis [43].

Although the management of some forms of coccidioidomycosis may be relatively simple, disseminated infections are difficult to treat. Amphotericin B is the mainstay of therapy, although some patients with soft-tissue disease may respond to ketoconazole, itraconazole or fluconazole.

Other systemic mycoses

Blastomycosis due to the dimorphic fungus, *Blastomyces dermatitidis*, is occasionally associated with liver infiltration in disseminated forms [45]. The geographical range of this disease is fairly wide, with cases being found in north and central United States and Canada, Africa, the Middle East and occasionally elsewhere. It is uncommon and has only occasionally been reported

in disseminated infections in immunocompromised patients [46]. In one study in such groups, two of six patients with chronic myeloid and chronic lymphocytic leukaemia, respectively, had diffuse infiltrations of leukaemic cells and *B. dermatitidis* in the liver at autopsy.

Penicillinosis due to *Penicillium marneffei* is a disease recently reported from Southeast Asia and in individuals who have visited that area. The organism naturally causes infection in bamboo rats. Its mode of transmission and pathogenesis is unknown, but widespread disseminated forms of the disease have been seen, with foci of infection in bone marrow, spleen, lung and liver [47]. The infection is generally associated with AIDS, and it is encountered regularly as an AIDS-related complication in endemic areas in Thailand, South China, Malaysia, Hong Kong and Myanmar. Patients generally present with disseminated disease in which there are widespread skin lesions and bone marrow infiltration with yeast cells. They are febrile and systemically unwell. Less frequently, patients may present without skin lesions and with tender hepatomegaly [48].

The organism can be recognized histologically and isolated in culture. In tissue, *P. marneffei* may resemble *Histoplasma* small forms, but it does not form buds and individual cells divide by transverse fission. Hepatic lesions are of one of three types: diffuse, granulomatous and mixed. The diffuse pattern showed a diffuse infiltration of foamy macrophages that contained numerous *P. marneffei*, whereas in the granulomatous pattern, true granulomas are seen with various degrees of inflammatory cell infiltration. The mixed pattern shows features of both forms. All show abnormal liver function, but there are no specific features that will distinguish the types, and there is usually a granulomatous response. This infection can be treated with itraconazole or amphotericin B.

Actinomycete infections

The actinomycetes are filamentous bacteria that may cause a variety of different diseases. By convention, two of these, actinomycosis and nocardiosis, are usually considered with the fungal infections.

Actinomycosis

Actinomycosis is an infection caused by actinomycetes of the genus *Actinomyces*, notably *A. israelii*, *A. bovis* and *A. naeslundii.* More rarely, other actinomycete species are involved. Infections often occur in specific sites such as the mouth (cervicofacial), abdomen, thorax or uterus (pelvic). In the pelvic site of infection, there has been an association with certain intrauterine contraceptive devices.

In many cases, it appears that aggregates of *Actinomyces* are associated with other bacteria such as coliforms. The part played by these bacteria in the pathogenesis of the infection is unknown. Actinomycosis is mainly seen in otherwise healthy patients. The hallmark of the infection is the formation of inflammatory masses containing granules. Such masses encroach on other structures, and multiple draining sinuses are formed. These may involve the jaw, the chest or the pelvis, and can be confused with a range of other conditions such as mycetoma or tumours. Infection of the liver is unusual but has been recorded.

In about 15% of cases of abdominal actinomycosis, itself a rare condition, the liver is affected [49]. The route of infection to this site is unknown, but it has been suggested that spread follows passage through the portal vein after appendicitis or surgery [50]. Most commonly, it presents as a solitary liver abscess and may spread to affect adjacent sites such as the bowel and the diaphragm. The liver may appear enlarged, but jaundice is rare [51]. The course of this infection may be very slow (over 2 years).

The diagnosis is made on the basis of cultures after needle aspiration or biopsy. CT scans show single or multiple, poorly defined areas of increased density [50]. The presumptive diagnosis is of liver abscess; aspirated material should be cultured. The main treatment is penicillin given parenterally ($2–12 \times 10^6$ units daily in adults), the dose depending on the site. Alternatives include erythromycin or tetracycline

Nocardiosis

Nocardia asteroides, *N. brasiliensis* and *N. caviae* are aerobic actinomycetes that may cause human disease [51]. There are two main clinical varieties: mycetoma, a subcutaneous infection resulting from implantation; and systemic nocardiosis, an invasive disease seen in both immunocompromised and healthy patients. Liver invasion is occasionally seen in disseminated nocardiosis. The primary portal of infection is thought to be the lung, and patients may present with primary lung disease and pulmonary infiltrates or with clinical lesions due to extrapulmonary dissemination, for instance to the brain or skin. The liver is a rare target in disseminated nocardiosis. In one survey of 230 cases of disseminated nocardiosis, only 3% of patients had proven hepatic lesions, either solitary or multiple abscesses. In one instance, the diagnosis was established by CT-guided needle aspiration of a subcapsular abscess [52]. Most patients with disseminated *Nocardia* infections have some form of underlying disease affecting T-lymphocyte function, such as lymphoma or AIDS, chronic granulomatous disease [53] or are receiving immunosuppressive regimens including corticosteroids.

The diagnosis is confirmed by culture, although the presence of partially acid-fast filaments in smears or histopathological sections is helpful. Nocardiosis often responds to treatment with co-trimoxazole. Alternative drugs include minocycline, ampicillin, amikacin and impipenem.

References

1 Odds FC (1988) *Candida and Candidosis*. London: Baillière Tindall, pp. 196–206.

2 Cheng VC, Yuen KY, Wong SS *et al.* (2001) Immunorestitution diseases in patients not infected with HIV. *Eur J Clin Microbiol Infect Dis* 20, 402–406.

3 Rossetti F, Brawner DL, Bowden R *et al.* (1995) Fungal liver infection in marrow transplant recipients: prevalence at autopsy, predisposing factors, and clinical features. *Clin Infect Dis* 20, 801–811.

4 Bodey GP, DeJongh D, Isassi A *et al.* (1969) Hypersplenism due to disseminated candidiasis in a patient with acute leukemia. *Cancer* 24, 417–420.

5 Tashjian LS, Abramson JS, Peacock JE Jr (1984) Focal hepatic candidiasis: a distinct clinical variant of candidiasis in immunocompromised patients. *Rev Infect Dis* 6, 689–703.

6 Linker CA, DeGregorio MW, Ries CA (1984) Computerized tomography in the diagnosis of systemic candidiasis in patients with acute leukemia. *Med Pediatr Oncol* 12, 380–385.

7 Sallah S, Semelka RC, Wehbie R *et al.* (1999) Hepatosplenic candidiasis in patients with acute leukaemia. *Br J Haematol* 106, 697–701.

8 Miller JH, Greenfield LD, Wald BR (1982) Candidiasis of the liver and spleen in childhood. *Radiology* 142, 375–380.

9 Bartley DL, Hughes WT, Parvey LS *et al.* (1982) Computed tomography of hepatic and splenic fungal abscesses in leukemic children. *Pediatr Infect Dis* 1, 317–321.

10 Linker CA, DeGregorio MW, Ries CA (1984) Computerized tomography in the diagnosis of systemic candidiasis in patients with acute leukemia. *Med Pediatr Oncol* 12, 380–385.

11 Rudolph J, Rodenwaldt J, Ruhnke M *et al.* (2004) Unusual enhancement pattern of liver lesions in hepatosplenic candidiasis. *Acta Radiologica* 45, 499–503.

12 Kirby A, Chapman C, Hassan C *et al.* (2004) The diagnosis of hepatosplenic candidiasis by DNA analysis of tissue biopsy and serum. *J Clin Pathol* 57, 764–765.

13 Sallah S, Semelka RC, Sallah W *et al.* (1999) Amphotericin B lipid complex for the treatment of patients with acute leukemia and hepatosplenic candidiasis. *Leukemia Research* 23, 995–999.

14 Bjerke JW, Meyers JD, Bowden RA (1994) Hepatosplenic candidiasis – a contraindication to marrow transplantation? *Blood* 84, 2811–2814.

15 Denning DW (1998) Invasive aspergillosis. *Clin Infect Dis* 26, 781–803.

16 Callister ME, Griffiths MJ, Nicholson AG *et al.* (2004) A fatal case of disseminated aspergillosis caused by a non-sporulating strain of *Aspergillus fumigatus*. *J Clin Pathol* 57, 991–992.

17 Baker RD (1962) Leukopenia and therapy in leukemia as factors predisposing to fatal mycoses. Mucormycosis, aspergillosis, and cryptococcosis. *Am J Clin Path* 37, 358–373.

18 Haupt HM, Merz WG, Beschorner WE *et al.* (1983) Colonization and infection with Trichosporon species in the immunosuppressed host. *J Infect Dis* 147, 199–203.

19 Perfect JR, Casadevall A (2002) Cryptococcosis. *Infect Dis Clin North Am* 16, 837–874.

20 Dismukes WE (1988) Cryptococcal meningitis in patients with AIDS. *J Infect Dis* 157, 624–628.

21 Goenka MK, Mehta S, Yachha SK *et al.* (1995) Hepatic involvement culminating in cirrhosis in a child with disseminated cryptococcosis. *J Clin Gastroenterol* 20, 57–60.

22 Kothari AA, Kothari KA (2004) Hepatobiliary dysfunction as initial manifestation of disseminated cryptococcosis. *Indian J Gastroenterol* 23, 145–146.

23 Sabesin SM, Fallon HJ, Andriole VT (1963) Hepatic failure as a manifestation of cryptococcosis. *Arch Intern Med* 111, 661–669.

24 Bucuvalas JC, Bove KE, Kaufman RA *et al.* (1985) Cholangitis associated with *Cryptococcus neoformans*. *Gastroenterology* 88, 1055–1059.

25 Lin JI, Kabir MA, Tseng HC *et al.* (1999) Hepatobiliary dysfunction as the initial manifestation of disseminated cryptococcosis. *J Clin Gastroenterol* 28, 273–275.

26 Sarosi GA, Voth DW, Dahl BA *et al.* (1971) Disseminated histoplasmosis: results of long-term follow-up. A Center for Disease Control cooperative mycoses study. *Ann Intern Med* 75, 511–516.

27 Schwarz J (1981) *Histoplasmosis*. New York: Praeger.

28 Deepe GS (2005) *Histoplasma capsulatum*. In: Mandell GL, Bennett JE, Dolin R (eds) *Principles and Practice of Infectious Diseases*. Philadelphia: Elsevier Churchill Livingstone, pp. 3013–3026.

29 Symmers WS (1972) Histoplasmosis in southern and south-eastern Asia. A syndrome associated with a peculiar tissue form of histoplasma: a study of 48 cases. *Ann Soc Belge Med Trop* 52, 435–452.

30 Mandell W, Goldberg DM, Neu HC (1986) Histoplasmosis in patients with the acquired immune deficiency syndrome. *Am J Med* 81, 974–978.

31 Huang CT, McGarry T, Cooper S *et al.* (1987) Disseminated histoplasmosis in the acquired immunodeficiency syndrome. Report of five cases from a nonendemic area. *Arch Intern Med* 147, 1181–1184.

32 Wheat LJ, Slama TG, Zeckel ML (1985) Histoplasmosis in the acquired immune deficiency syndrome. *Am J Med* 78, 203–210.

33 Sylvestre PB, Gonzalez-Koch AR, Ishitani MB (2000) *Liver Transpl* 6, 643.

34 Christian ER (1952) An evaluation of needle biopsy of the liver. *Am J Med* 13, 689–703.

35 Hecht FM, Wheat J, Korzun AH *et al.* (1997) Itraconazole maintenance treatment for histoplasmosis in AIDS: a prospective, multicenter trial. *J Acquir Immune Defic Syndr Hum Retrovirol* 16, 100–107.

36 Wheat J (2001) Laboratory diagnosis of histoplasmosis. Update 2000. *Semin Resp Infect* 16, 131–140.

37 Williams AO, Lawson EA, Lucas AO (1971) African histoplasmosis due to *Histoplasma duboisii*. *Arch Pathol* 92, 306–318.

38 Pinto HB (1961) La Paracoccidioidosis brasiliensis como enfermedad sistemica. *Mycopathologia* 15, 90–114 [in Portuguese].

39 Teixeira F, Gayotto LC, De Brito T (1978) Morphological patterns of the liver in South American blastomycosis. *Histopathology* 2, 231–237.

40 Raphael A, Campana AO, Waiman J (1964) [Hepatic coma in South America blastomycosis.] *Rev Assoc Med Bras* 10, 151–154 [in Portuguese].

41 Restrepo A (2003) Paracoccidioidomycosis. In: Dismukes WE, Pappas PG, Sobel JK (eds) *Clinical Mycology*. New York: Oxford University Press, pp. 328–345.

42 Stevens DA (ed.) (1981) *Coccidioidomycosis*. New York: Plenum.

43 Huntington RW, Waldman WJ, Sargent JA *et al.* (1967) Pathologic and clinical observations of fatal coccidioidomycosis with necropsy. In: Ajello L (ed.) *Coccidioiodomycosis*. Tucson: University of Arizona Press, pp. 143–163.

44 Dodd LG, Nelson SD (1990) Disseminated coccidioidomycosis detected by percutaneous liver biopsy in a liver transplant recipient. *Am J Clin Pathol* 93, 141–144.

45 Galgiani JN (1999) Coccidioidomycosis: A regional disease of national importance. Rethinking approaches for control. *Ann Intern Med* 130, 293–300.

46 Recht LD, Davies SF, Eckman MR *et al.* (1982) Blastomycosis in immunosuppressed patients. *Am Rev Resp Dis* 125, 359–362.

47 Supparatpinyo K, Khamwan C, Baosoung V *et al.* (1994) Disseminated *Penicillium marneffei* infection in southeast Asia. *Lancet* 344(8915), 110–113.
48 Kantipong P, Panich V, Pongsurachet V *et al.* (1998) Hepatic penicilliosis in patients without skin lesions. *Clin Infect Dis* 26, 1215–1217.
49 Bradsher RW (2003) Blastomycosis. In: Dismukes WE, Pappas PG, Sobel JD (eds) *Clinical Mycology*. New York: Oxford University Press, pp. 299–310.
50 Yousukh A, Jutavijittum P, Pisetpongsa P *et al.* (2004) Clinicopathologic study of hepatic *Penicillium marneffei* in Northern Thailand. *Arch Pathol Lab Med* 128, 191–194.
51 Felekouras E, Menenakos C, Griniatsos J *et al.* (2004) Liver resection in cases of isolated hepatic actinomycosis: case report and review of the literature. *Scand J Infect Dis* 36, 535–538.
52 Cockerill FR III, Edson RS, Roberts GD *et al.* (1984) Trimethoprim/sulfamethoxazole-resistant *Nocardia asteroides* causing multiple hepatic abscesses. Successful treatment with ampicillin, amikacin, and limited computed tomography-guided needle aspiration. *Am J Med* 77, 558–560.
53 Sereti I, Holland SM (2001) Disseminated nocardiosis in a patient with X-linked chronic granulomatous disease and human immunodeficiency virus infection. *Clin Infect Dis* 33, 235–239.

10.3 Protozoal infections affecting the liver

10.3.1 Amoebiasis, giardiasis and cryptosporidiosis

David Kershenobich, Guillermo Robles Díaz and Juan Miguel Abdo

Introduction

Amoebae, *Giardia* and *Cryptosporidium* are among the most common protozoa that can infect humans, mainly in the tropics. By far the most favourable sites for intestinal parasites are the duodenum, ileum, caecum and large intestine. To survive and to reproduce in the gastrointestinal tract, the parasites have to adapt to continuous physiological changes relative to the feeding habits of the host, the battery of protein, fat and carbohydrate-splitting enzymes, pH changes and the almost oxygen-free environment [1,2]. These protozoa can gain access to the bloodstream and biliary tract and eventually disseminate to extraintestinal organs, mainly the liver, leading to variable clinical manifestations [3,4]. Hepatic involvement is a frequent clinical presentation for amoeba infection, whereas *Giardia* and *Cryptosporidium* are uncommon aetiological agents of hepatobiliary damage and affect mainly selected populations, such as immunocompromised individuals [5–10].

Epidemiology

Amoebae, *Giardia* and *Cryptosporidium* can be found worldwide but are still more prevalent in tropical and subtropical regions. They affect persons in all age groups, and one of the diseases caused, giardiasis, has been considered the most common protozoan infection in humans with a worldwide incidence ranging between 20–60% and 2–7% in industrialized countries [11]. The implications of invasive amoebiasis and its extension to the liver causing liver abscess continue to stand out as the most consequential protozoan infection in the liver. Most of the estimates regarding the global magnitude of amoebiasis were assessed before the identification of *Entamoeba dispar* as a separate species that is non-invasive and does not cause disease (Fig. 1); however, among the estimated 500 million people infected each year with *Entamoeba histolytica*, there are approximately 48 million cases of colitis and liver abscess and 70 000 deaths [12–14] (Fig. 2).

About 200 million people have symptomatic giardiasis in Asia, Africa and Latin America with some 500 000 new cases reported each year [15]. Approximately 20 000 cases are reported annually in a Giardiasis surveillance programme in the United States [16]. In a meta-analysis conducted in the Nordic countries of Denmark, Finland, Norway and Sweden, which analysed the data from 13 clinically and methodologically non-heterogeneous studies published before 2004, the estimated prevalence of *Giardia* cases in an asymptomatic (i.e. no gastroenteric symptoms) population was 2.97% (2.64–3.31%) and in a symptomatic population 5.81% (5.34–6.30%) [17].

The proportion of the general population excreting *Cryptosporidium* oocysts is 1–3% in the developed countries and 10% in developing countries. Cryptosporidial infection

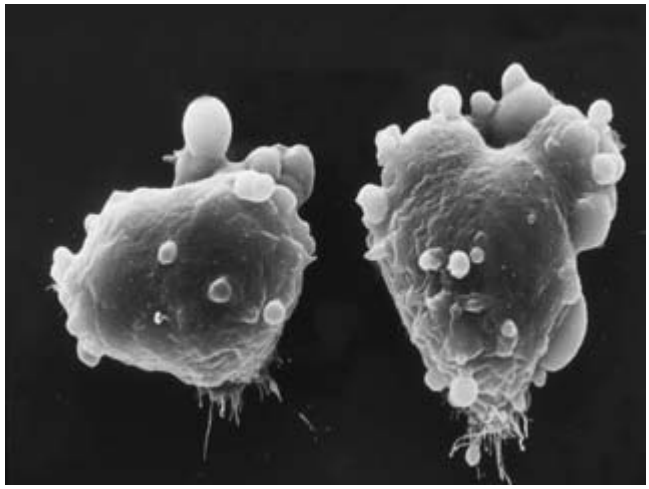

Fig. 1 *Entamoeba histolytica* and *Entamoeba dispar*. Both species are morphologically indistinguishable. Differentiation should be made by isoenzyme analysis, by monoclonal antibodies and by PCR.

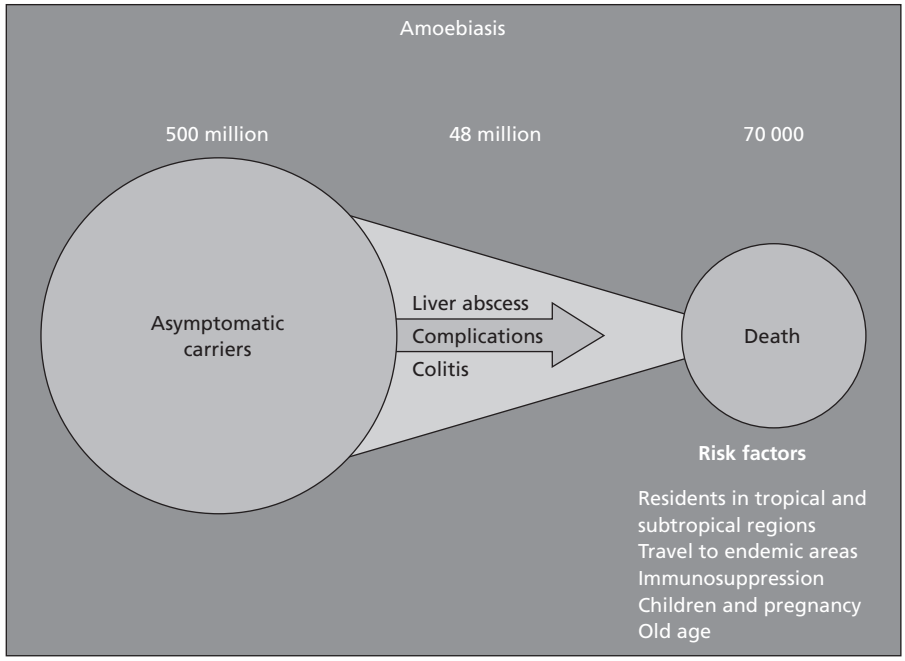

Fig. 2 Worldwide impact of amoebiasis.

accounts for 2.2% (0.26–22%) of cases of diarrhoea in immunocompetent persons in developed countries and 6.1% (1.4–4%) in immunocompetent persons in developing countries. In immunocompromised persons, cryptosporidiosis occurs in 14% (6–70%) of the population in developed countries and in 24% (8.7–48%) in developing countries [18].

Most giardiasis and cryptosporidiosis cases occur sporadically, but outbreaks are well documented, mainly linked to infected recreational or drinking water and also food-borne outbreaks [11,16,19–21].

Demographic changes have modified susceptibility to protozoan infections. The impact of parasitic infections in the developing countries is brought home to citizens of the developed countries when tourists, immigrants or soldiers returning or migrating from these less developed countries are infected with endemic parasites [22]. The clinical relevance of this phenomenon is exemplified in a study of 56 patients with an amoebic liver abscess (ALA) at two large San Francisco Hospitals from 1979 to 1994, in which the patients with a history of travel to an endemic area were a decade older and tended to have an insidious onset [23].

We have entered the twenty-first century with a new term introduced to our vocabulary, emergent risk factors, which include the increase in drug abusers, human immunodeficiency virus (HIV)-infected subjects, organ transplant recipients or drug-induced immunosuppressed patients (Table 1). The rapidly evolving context of host immune deficiency requires that biologists and health professionals maintain attentiveness and update their knowledge of the problem in the setting of parasitic infections. In the above-mentioned study of ALA in San Francisco [23], one-third of the patients studied had no associated travel history or endemic origin as risk factors. Of these, 63% had a condition consistent with severe immunosuppression, such as infection with HIV, malnourishment with severe hypoalbuminaemia or chronic infection. During the last 5 years of the study, one-third of all patients diagnosed with ALA were HIV positive. Also associated with a decrease in the immune system, sclerosing cholangitis due to cryptosporidiosis has been described in liver-transplanted children receiving immunosuppression with tacrolimus and prednisone [24]. Although *Cryptosporidium parvum*, in particular genotypes human type 1 and bovine type 2, are the most common species in humans, *C. felis*, *C. muris* and *C. meleagridis* have also been identified in immunocompromised persons [25,26].

Table 1 Risk factors for protozoan infections.

Travel history to an endemic area
Contamination of recreational or drinking water
Unsafe food-related habits
Drug abusers
HIV-infected patients
Organ transplant recipients
Drug-induced immunosuppression
Underlying systemic disease

Life cycle

Entamoeba histolytica

Humans are the primary reservoir for *E. histolytica*; the main source of transmission is the chronically infected human. Stools infected with the cysts from the parasites may contaminate food

or water. Another common source of transmission is oral–anal sexual contacts. There may be some animal reservoirs of *E. histolytica* (dogs, monkeys and probably pigs), but they represent a very small source of human infection. As humans are infected by ingesting infected cysts, they travel through the gut lumen to the small intestine where they excyst to form trophozoites. The trophozoite of *E. histolytica* can convert to a precyst form with a nucleus and mature into a tetranucleated cyst, which migrates down and out of the colon where it becomes a mature and infectious cyst [27,28].

Giardia lamblia

Giardia is found in humans and in other animals such as cats, dogs, beavers and cattle. The *Giardia* life cycle involves two stages: the cyst, which is the infectious form and is ingested in contaminated water, food, direct oral–faecal contact in children and sexual practices that include oral–anal contact. Once ingested, the low pH in the stomach and pancreatic proteases found in the proximal small intestine promote rapid excitation, giving rise to the trophozoites that are responsible for symptomatic illness. The trophozoites attach to the mucosa of the duodenum and proximal jejunum, where they multiply rapidly via binary division. Responding to unknown stimuli, possibly bile salts, some trophozoites encyst in the ileum and are eliminated in the stools of infected hosts [29–33].

Cryptosporidium

Various domestic animals and cattle are potential sources of human infection. Transmission occurs by the faecal–oral route (person to person and animal to person) and via contaminated food and water [34]. The developmental stages of *Cryptosporidium* originate in an intracellular, extracytoplasmic location within parasitophorous vacuoles of host cell origin; these vacuoles are found at the microvillous surface of the host cell. Humans are infected when they ingest *Cryptosporidium* oocysts. Once ingested, oocysts excyst in the gastrointestinal tract and release infective sporozoites that affix to the apical membrane of the host epithelial cell. Such attachment induces reorganization of the host cell actin cytoskeleton and swelling of the host cell membrane around the sporozoite to form a vacuole in which the organism remains intracellular but extracytoplasmic. The internalized sporozoite then matures and undergoes asexual reproduction (schizogony) to produce merozoites. After release into the intestinal lumen, merozoites can either infect other epithelial cells or mature into gametocytes, the sexual form of the parasite. The life cycle is repeated after fertilization occurs in the intestinal tract, producing thin-walled oocysts that sporulate to release sporozoites again; this can lead to autoinfection and heavy, persistent infections, with massive shedding of oocysts in the faeces of an infected patient. The presence of a thin-walled autoinfective oocyst can cause an overwhelming infection in a susceptible host and explains the persistent, life-threatening infections in immunocompromised patients in the absence of repeated exposure to oocysts [35,36].

Pathophysiology

Protozoan infections are usually brought to a halt by different pathophysiological mechanisms occurring mainly at the level of the intestine. Disease processes intrinsic to host–parasite interactions may, however, lead to more severe and life-threatening complications that affect the liver and biliary tract. Among these pathophysiological mechanisms, some of the most relevant are tissue inflammation, neutrophil adherence to endothelium, endothelial disruption, release of cytokines, release of active oxidants, changes in the permeability of plasma membranes, lysosomal disruption, release of proteolytic enzymes and cell death. Abnormalities in intestinal function can alter the secretion of products that undergo enterohepatic circulation and increase the synthesis of bile acids by the liver. In addition, bile acids that enter the colon induce water secretion by the colonic mucosa and cause diarrhoea. Understanding the mechanisms involved in the relation of protozoan infections and the liver is still an open issue, with some insights coming from the analysis of each particular infection (Table 2).

E. histolytica

An important factor contributing to the pathogenesis of *E. histolytica* is its highly effective actomyosin cytoskeleton, which allows fast morphological changes associated with amoebic

Table 2 Pathophysiological mechanisms involved in protozoan infections in the intestine and the liver.

Amoebiasis
Parasite motility
Cell adhesion
Cytoskeletal re-arrangement
Signal transduction
Cytolysis
Migration in the liver
Release of proteases
Necrosis, apoptosis
Giardiasis
Attachment to intestinal epithelium
Altered brush border, crypt hyperplasia
Decreased disaccharidase activity
Giardia–bile salt interactions
Epithelial damage/increased permeability
Cytokine-induced liver damage?
Cryptosporidiosis
Intestinal epithelial damage
Humoral and cell-mediated immunity
Invasion of biliary epithelial cells
Morphofunctional changes in hepatocytes

motility and spatial reorganization of cellular components [37]. The earliest observations of this protozoa noted that their motility involved force generation through either the microtubule- or the microfilament-based cytoskeletal elements. The amoeba is a protozoa that crawls along a solid substratum in a fashion known as 'amoeboid movement'. Amoeba projects out a pseudopodium, or false foot, from the cell body. The pseudopodium then attaches to the substratum and pulls the rest of the cell body forward. The force involved in this movement is generated by another cytoskeletal system, which is composed of actin and myosin. Actin forms long filaments, also known as microfilaments, and myosin is a motor protein that moves along the microfilaments in an adenosine triphosphate (ATP)-dependent manner [38,39]. Its motility, cell adhesion properties and aggressive behaviour are however variable and may depend on the host immune system and on the localization in the host.

Contact-dependent cytolysis of host cells by *E. histolytica* is an important event in the pathogenesis of amoebic liver abscess [40]. *E. histolytica* may be viewed as a cytotoxic effector cell with an extraordinary capacity for killing various target cells and also as a primitive actively phagocytosing eukaryotic cell that uses bacteria as a major nutrient source [41].

The coordinated action of the *E. histolytica* cytoskeleton and surface adhesion molecules is a key factor in pathogenesis [42–44]. Some of the best characterized parasite surface molecules involved in amoeba binding to host cells are the Gal/GalNac lectin [45] and myosin II [46], which enables adhesion of the trophozoite to intestinal epithelial cells by high-affinity interactions with cell surface glycoproteins. Experimental studies in hamsters show that the disruption of Gal/GalNac and myosin II impairs the area of contact between *E. histolytica* and the enterocytes. Intraportal delivery of these parasites to the liver leads to the formation of small abscesses with disorganized morphology that are localized in the vicinity of blood vessels. Successful invasion of the liver parenchyma requires that the trophozoite binds strongly to the endothelium to counteract the pressure imposed by the bloodstream, extravasation and migration through the three-dimensional structure of the hepatic tissue. The trophozoite has to survive the host inflammatory response at each of these steps. Adhesion to the host cells modulates the distribution of trophozoites in the liver and their capacity to migrate in the hepatic tissue [38].

Initial steps in tissue invasion may be aided by the release of proteases from trophozoites that degrade extracellular matrix components such as fibronectin and laminin [47]. In patients with invasive amoebiasis, *E. histolytica* causes vast tissue damage that is believed to be a direct result of its ability to induce necrosis and host cell apoptosis (Fig. 3). *In vitro* trophozoites of *E. histolytica* induce apoptosis of host cells including neutrophils, T lymphocytes and macrophages [48]. Nuclei of hepatocytes of murine amoebic liver abscess are positive by terminal deoxynucleotidyl transferase-mediated dUTP-biotin end labelling (TUNEL) staining [49]; treatment of mice with a pan-caspase inhibitor blocks the formation of amoebic liver abscesses [50].

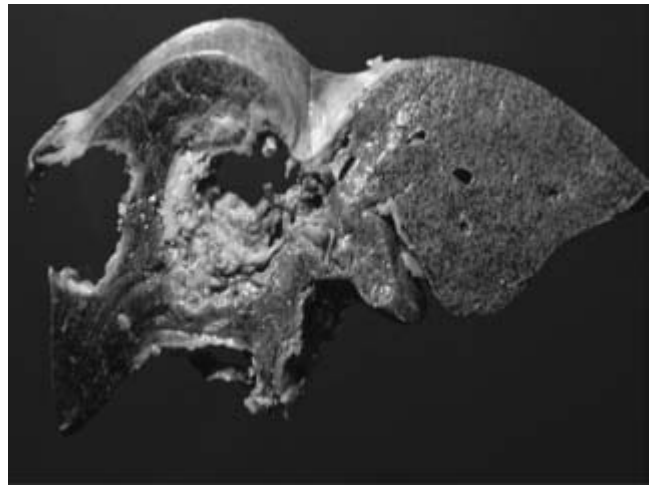

Fig. 3 Gross appearance of a huge amoebic liver abscess at autopsy.

Reactive oxygen species (ROS)-mediated activation of ERK1/2 is required for the entamoeba to induce neutrophil apoptosis [51]. In contrast to life in the anoxic colon, *E. histolytica* encounters a relatively high oxygen environment during invasive amoebiasis; ability to cope with this change is an important factor in determining its virulence. *E. histolytica* has four copies of flavoprotein E, which detoxifies nitric oxide and/or oxygen [52] and also contains rubrerythrin [53], which is protective against intracellular hydrogen peroxide in anaerobic bacteria. Taking all these observations together, it has been proposed that the regulatory mechanisms of redox signalling may be relevant in the amoebic-induced inflammatory response [51].

E. histolytica uses a complex mix of signal transduction systems in order to sense and interact with the different environments it encounters. The analysis of its genome has revealed almost 270 putative *E. histolytica* protein kinases representing members of all seven families of the eukaryotic protein kinase superfamily. These include tyrosine kinase with SH2 domains, tyrosine kinase-like protein kinases and 90 putative receptor SER/THR kinases. *E. histolytica* contains more than 100 protein phosphatases that dephosphorylate proteins. All these observations come from the analysis of the genome of *E. histolytica* [54], whose comparisons with other genomes will help to resolve fundamental issues relating to eukaryote and amoeba phylogeny.

Giardia

Giardia has a special disc located on its ventral surface, which is relevant to its attachment to the intestinal epithelium [55]. This process is mediated by specific lectins. During the process of attachment, intestinal damage can ensue. The brush border is altered, there is crypt hyperplasia and disaccharidase activity decreases [11]. In the small bowel, *Giardia* trophozoites harbouring peripheral bacterial endosymbionts are destroyed and lysed by the Paneth cells located at the base of the crypts of

Lieberkuhn, which leads to greater intestinal epithelial damage [56]. Bile specifically stimulates the growth of *Giardia* by unknown mechanisms, and it is avidly consumed by the parasite, leading to reduced intraluminal bile salt concentrations [57]. It seems that *Giardia* is unable to survive in the absence of bile acids, but it does not reside in the biliary tract where the pH and the absence of nutritional substrate do not allow its colonization [58]. The increase in intestinal epithelial permeability may allow the passage of toxic substances or cytokines that could eventually cause damage to the liver.

There is evidence for diversity in infectivity and host specificity of *Giardia* species. An ongoing genome project plans to obtain approximately 95% of the genome by a random approach, as well as a complete physical map using a bacterial artificial chromosome library. The *Giardia* genome project [59] promises to greatly increase our understanding of this interesting and enigmatic organism as well as its phylogenetic relationship to other primitive organisms. Also, an important role of variant-specific surface proteins (VSPs) in *Giardia lamblia*–host interactions has been demonstrated that exert both positive and negative selective pressures on the parasite, independent of the adaptive immune response [60].

Host defences against *Giardia* infection must act in the gut lumen in the absence of induction by classical inflammatory mediators. Secretory IgA antibodies have a major role in the control of infection [61], but other immunoglobulins and B cell-independent mechanisms also exist and can contribute to eradication of the parasite. Neither Th1 nor Th2 cells are strictly necessary for the clearance of *Giardia* infection, whereas mucosal T cells may have an important role, and T-cell cytokines may induce the production and release of anti-giardial defensins into the intestinal lumen [11,62].

Cryptosporidium

Cryptosporidium oocytes enter the brush border of intestinal epithelium, develop into merozoites and multiply, impairing absorption of glucose, electrolytes, water, fats and vitamin B12 [63]. There is a general consensus that the mechanisms responsible for clearing *Cryptosporidium* from the gastrointestinal tract involve a role for gamma interferon, although the mechanism by which this cytokine impairs resistance is unclear. After infection with *Cryptosporidium*, CD40 ligand and interferon gamma knockout mice develop a very aggressive type of liver damage [64], suggesting that the absence of the CD40–CD40 ligand interaction and/or the downregulation of interferon gamma may be related to the development of *Cryptosporidium*-associated sclerosing cholangitis, bile duct dysplasia and possibly neoplasms [65,66]. It is also clear that CD4 T lymphocytes are necessary for the resolution of both acute and chronic cryptosporidiosis [67]. The spectrum and severity of the disease in immunocompromised individuals with cryptosporidiosis reflect this importance, as individuals with a defect in T-cell response have more severe disease [68].

No difference has been found between cryptosporidiosis in normal and B cell-depleted neonatal mice, suggesting that antibody production may play a less important role in recovery from infection [69].

In an *in vitro* model of human biliary cryptosporidiosis during internalization of the parasite, numerous vacuoles covered by its plasma membrane are formed and cluster together to establish a preparasitophorous vacuole. This preparasitophorous vacuole comes into contact with host cell membrane to form a host cell–parasite membrane interface. Vacuole-like structures appear in the apical complex region of the attached sporozoite, which bud out into host cells. A tunnel directly connecting the parasite to the host cell cytoplasm forms during internalization and remains when the parasite is totally internalized [70].

C. parvum has the capacity to invade epithelial cells and induce survival signals. It activates the NFkappaB/I(kappa)B system in infected biliary epithelia, thus protecting infected cells from death and facilitating parasite survival and propagation [71]. *C. parvum* invasion of biliary epithelial cells requires host cell tyrosine phosphorylation of cortactin to induce actin polymerization at the attachment site, a process associated with microbial secretion but independent of host cell endocytosis [72].

In experimental animals, morphofunctional changes in hepatocytes have been demonstrated after infection with different doses of oocysts of *C. parvum*, which include an increase in multinuclear hepatocytes, a decrease in the quantity of glycogen and an increase in proteins and nuclear DNA [73].

Clinical manifestations

Amoebic liver abscess

This is the most common extraintestinal manifestation of amoebiasis. It occurs more frequently in tropical regions, in men between the ages of 20 and 40 years, although cases are found at both age extremes, the youngest patients having been described at 6 weeks of age. The characteristic clinical manifestations may vary in relation to the size, number and localization of the lesions as well as the development of possible complications secondary to rupture or communication of liver abscesses to neighbouring organs. Most frequently, patients with ALA present an abrupt onset of fever between 38°C and 40°C, accompanied by chills and profuse sweating, severe and progressive pain in the right upper abdominal quadrant radiating to the scapular region and right shoulder. The pain increases with movement, deep breathing or coughing. Patients usually refer with a history of malaise in the preceding days and weight loss. On physical examination, the liver is usually large and tender, ventilation in the right lung is restricted, and the respiratory sounds are reduced. Jaundice is present in less than 10% of the cases.

Although the colon is the portal of entry and colonic involvement is of considerable importance, there are surprisingly few studies of the colon with ALA. Colonic ulcers, when investigated, are found in approximately 55% of patients with ALA;

they are more likely to be present if the patient has diarrhoea as a presenting symptom or has had diarrhoea in the recent past. However, diarrhoea is observed in less than a third of patients with ALA [74]. It has been suggested that either the colon is involved minimally without symptoms or there is a considerable time interval between the colonic and liver involvement, allowing for healing of the colonic lesions, and presentation later with an ALA. Multiple, large and left-sided ulcers are more common in elderly patients and in those in whom diarrhoea is the presenting symptom [75].

Invasive amoebiasis as an emerging parasitic disease is being recognized more frequently among immunosuppressed patients. Investigators in Japan, Italy, Korea and Taiwan have found a higher prevalence of antibody to *E. histolytica* in homosexual men with or without HIV infection [5].

Giardiasis

In humans, clinical manifestations of giardiasis range from asymptomatic to symptoms such as chronic diarrhoea, weight loss, vomiting, abdominal distension and abdominal pain. The severity of symptoms may vary and has been found to be related to the number of cysts ingested, the age of the host and the state of the host immune system [76]. Malabsorption caused by disaccharidase deficiency has been described and is related to the parasite burden in the small intestine [77].

Overt involvement of the liver by *Giardia* is rare; however, when investigated intentionally, alterations in hepatic histology including steatosis, inflammatory lesions and data of chronic active hepatitis have been reported in patients with a diagnosis of giardiasis by duodenal intubation [8]. Cases of granulomatous hepatitis and cholangitis [78] or biliary giardiasis in HIV patients have been reported [79,80].

Cryptosporidiosis

Although *Cryptosporidium* has been described as causing a self-limited diarrhoeal illness in immunocompetent people, lasting between 2 and 4 weeks, it is a major problem in immunocompromised patients causing chronic debilitating diarrhoea [81].

Extraintestinal cryptosporidiosis may involve the respiratory system, middle ear, pancreas, stomach and biliary tract. Biliary cryptosporidiosis is the most common extraintestinal manifestation, causing gallbladder disease and sclerosing cholangitis [82–84]. Two distinct presentations are seen, papillary stenosis with extrahepatic ductal dilatation and sclerosing cholangitis or acalculous cholecystitis. These manifestations have also been described in patients with AIDS and intestinal cryptosporidiosis before retroviral treatment [85,86]. *C. parvum*-induced sclerosing cholangitis has been found in other immunodeficient states such as congenital immunodeficiency and X-linked immunodeficiency with hyper-IgM [87] and in renal or liver transplant recipients [82,83]. Besides diarrhoea, there is pain in the right upper quadrant, nausea, vomiting and fever.

Diagnosis

Imaging

Imaging plays a pivotal role in the workup of patients with suspected ALA and has reduced the delay in diagnosis. Studies include chest X-ray, liver ultrasound, computerized tomography (CT), magnetic resonance imaging (MRI) and ^{99}Tc liver scan. Ultrasonography is the first choice. A space-occupying lesion is seen in at least 75% of cases. The lesions tend to be round or oval, with well-defined margins. The lesions are primarily hypoechoic [88]. Within the lesion, there may be hyperechoic areas corresponding to necrotic conglomerates especially in the early phases; when this occurs, Doppler examination is useful as it fails to detect any signal in the interior of the abscess [89].

CT is indicated when the diagnosis has not been confirmed by other methods, when symptoms persist under medical treatment or when the need for differential diagnosis with other lesions arises. On contrast-enhanced CT, amoebic abscesses appear as lesions with attenuation values that indicate the presence of complex fluid (10–20 HU). An enhancing wall 3–15 mm in thickness and a peripheral zone of oedema around the abscess are common and somewhat characteristic. The central abscess cavity may show multiple septa or fluid debris levels and, rarely, air bubbles or haemorrhage [88,90].

On MRI, ALA has homogeneous low signal intensity and high signal intensity on T1- and T2-weighted images respectively. Perilesional oedema is seen on T2-weighted MR images in 50% of cases [91].

Chest X-ray abnormalities include atelectasis, pulmonary infiltrates and pleural effusion or elevated right diaphragm [92].

Ultrasonographic findings of biliary disease in cryptosporidiosis are the thickening of the biliary duct wall and/or dilatation of the gallbladder. Endoscopic retrograde cholangiopancreatography is indicated in these cases and can reveal papillary stenosis or long extrahepatic bile duct strictures [7]. Endoscopic ultrasonography can be useful in detecting papillary stenosis.

Laboratory findings

The majority of patients with ALA have an increased white blood cell count, with neutrophilia, elevated alkaline phosphatase, mild anaemia and increased erythrocyte sedimentation rate. Slight increases in bilirubin are seen in approximately one-third of patients.

Serological test methods for the detection of antiamoebic antibodies are useful for the diagnosis of ALA. Indirect haemagglutination (IHA) and enzyme-linked immunosorbent assay (ELISA) are the most often used. A cutoff value of 1:512 is considered diagnostic. Titres may persist after resolution of the amoebic abscess. Serology is often positive in areas of endemicity where circulating antibodies may reflect a past infection. In countries where amoebiasis is uncommon and its presence

may be an emerging pathology, antiamoebic serology is usually correlated with disease.

In those patients in whom an aspirate is obtained, the material should be sent for Gram stain, determination of the presence of neutrophils and culture. Amoebic culture and visualization of trophozoites can be done using the last 5 mL of aspirate [93].

Diagnosis of *Giardia lamblia* infection is established by the microscopic examination of stool for the parasite [94,95]. Detection of anti-*Giardia* salivary IgA antibodies is an excellent tool for screening *G. lamblia* in patients with longstanding symptoms of more than 1 month duration [96].

Cryptosporidium stains intensely red by modified acid-fast techniques on microscopic examination of stool [97] Serological testing using EIA has been described. Serological tests are of limited value as antibodies to *Cryptosporidium* can be found in previously exposed persons.

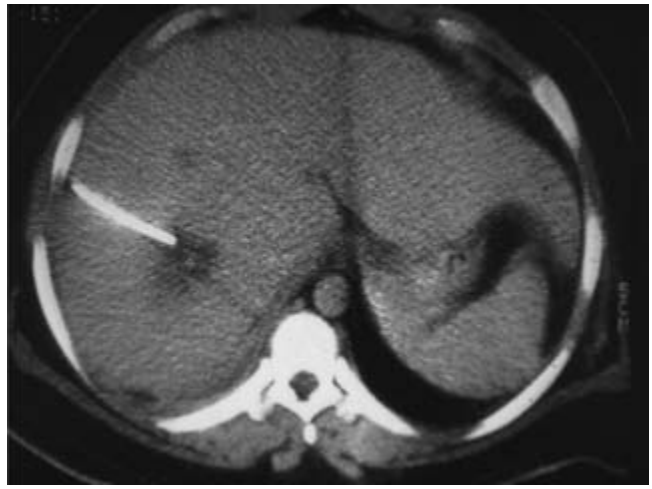

Fig. 4 Guided percutaneous aspiration of an amoebic liver abscess.

Treatment

Amoeba

The drugs of choice for invasive amoebiasis are tissue active agents, such as metronidazole, tinidazole and chloroquine, or the more toxic emetin derivatives, including dehydroemetine [98,99].

Metronidazole and tinidazole are derived from 5-nitroimidazole, which kills the trophozoites by alterations in the protoplasmic organelles of the amoeba [100]. Metronidazole is the drug of choice in the treatment of uncomplicated amoebic liver abscess. The oral dose is 1 g twice daily for 15 days in adults and 30–50 mg/kg daily for 10 days in three divided doses for children; intravenous metronidazole is given at a dose of 500 mg every 6 h in adults and 7.5 mg/kg every 6 h for children. Tinidazole is given orally 2 g daily for 15 days. While on treatment, patients should abstain from alcohol as these drugs have an antiabuse effect.

Chloroquine is derived from 4-aminoquinolines; it acts on the vegetative forms of the parasite and kills it by inhibiting DNA synthesis. Adults should receive 1 g/day orally for 2–5 days followed by 500 mg/day for 2–3 weeks; in children, the dose is 15 mg/kg orally, daily for 2–5 days followed by 5 mg/kg daily for 2 weeks [101].

Percutaneous aspiration/drainage can be used as a diagnostic or therapeutic tool and should be performed with imaging guidance (Fig. 4). Indications include the lack of clinical response to medical treatment, defined as no decrease in fever or pain, no reduction in the white cell count in a 5-day period following initiation of treatment. It is also indicated when less than 1 cm of rim liver tissue remains around a liquefied abscess or when it becomes necessary to rule out a pyogenic abscess.

Rupture of an abscess into the lungs, pleural space, pericardium or peritoneum has a severe rate of mortality and requires urgent surgical intervention.

Giardia

Therapy of diarrhoea caused by giardiasis includes a vast range of drugs, mainly nitroimidazoles, nitazoxanide, paromomycin, furazolidone, albendazole or quinacrine [102–104]. Of these, metronidazole has been the most thoroughly studied and also the most commonly used worldwide at a dose of 500 mg three times a day for 5 days [105]. Tinidazole at a single dose of 1.0–2.0 g has the advantage of compliance and has similar proven efficacy [106].

Resistance has been reported with all the different agents; strategies to overcome resistance are the use of higher doses of the original agent or using a different drug to avoid cross-resistance. Combination therapy may be necessary in immunosuppressed patients.

Cryptosporidium

Cryptosporidium carriage in liver-transplanted children with sclerosing cholangitis has been successfully treated with paromomycin, a non-absorbable aminoglycoside, while immunosuppression is decreased according to graft tolerance [107]. Paromomycin 500 mg three times daily for 2 weeks has been used to treat cryptosporidiosis in patients with AIDS, while these patients continue to receive antiretroviral therapy [108]. Recent reports suggest that, in the setting of *C. parvum* infection, sclerosing cholangitis may be completely reversible if the infection can be eradicated quickly. Protease inhibitors have a direct inhibitory effect on *Cryptosporidium* infection [109].

Nitazoxanide, paromomycin and azithromycin are commonly used to eradicate *Cryptosporidium* infection in both immunocompetent and immunosuppressed patients [110].

References

1 Cox FEG (2003) Taxonomy and classification of human parasites. In: Murray PR, Baron EJ, Jorgensen JH *et al.* (eds) *Manual of Clinical Microbiology*, 8th edn. Washington, DC: ASM Press, pp. 1897–1902.

2 Sleigh MA (1991) The nature of protozoa. In: Kreier JP (ed.) *Parasitic Protozoa*, 2nd edn, Vol. 1. San Diego, CA: Academic Press, pp. 1–53.

3 Bruckner DA (1992) Amebiasis. *Clin Microbiol Rev* 5, 356–369.

4 Barsoum RS (2004) Parasitic infections in organ transplantation. *Exp Clin Transplant* 2, 258–267.

5 Hung Ch Ch, Deng HY, Hsiao WH *et al.* (2005) Invasive amebiasis as an emerging parasitic disease in patients with human immunodeficiency virus type 1 infection in Taiwan. *Arch Intern Med* 165, 409–415.

6 Vakil NB, Schwartz SM, Buggy BP *et al.* (1996) Biliary cryptosporidiosis in HIV-infected people after the waterborne outbreak of cryptosporidiosis in Milwaukee. *N Engl J Med* 334, 19–23.

7 Schneiderman DJ, Cello JP, Laing FC (1987) Papillary stenosis and sclerosing cholangitis in the acquired immunodeficiency syndrome. *Ann Intern Med* 106, 546–549.

8 Sotto A, Gra B (1985) Hepatic manifestations in giardiasis. *Acta Gastroenterol Latinoam* 15, 89–94.

9 Roberts-Thomson IC, Anders RF, Bhathal PS (1982) Granulomatous hepatitis and cholangitis associated with giardiasis. *Gastroenterology* 83, 480–483.

10 Sotto A, Alvarez JL, Garcia B *et al.* (1990) Acute hepatic lesion caused by *Giardia lamblia*. *Rev Esp Enferm Dig* 77, 24–28.

11 Hawrelak J (2003) Giardiasis: pathophysiology and management. *Altern Med Rev* 8, 129–142.

12 Farthing MJG, Cevallos AM, Kelly P (2003) Intestinal protozoa. In: Cook GC, Zumla AL (eds). *Manson's Tropical Diseases*, 21st edn. Edinburgh: Elsevier Science, pp. 1373–1386.

13 World Health Organization (1998) *The World Health Report. Life in the 21st Century: A Vision for All*. Geneva: WHO.

14 World Health Organization (1997) Amoebiasis. *WHO Wkly Epidemiol Record* 72, 97–100.

15 World Health Organization (1996) *The World Health Report. Fighting Disease, Fostering Development*. Geneva: WHO.

16 Hlavsa MC, Watson JC, Beach MJ (2005) Giardiasis surveillance – United States, 1998–2002. *MMWR Surveill Summ* 54, 9–16.

17 Horman A, Korpela H, Sutinen J *et al.* (2004) Meta-analysis in assessment of the prevalence and annual incidence of *Giardia* spp. and *Cryptosporidium* spp. infections in humans in the Nordic countries. *Int J Parasitol* 34, 1337–1346.

18 Guerrant RL (1997) Cryptosporidiosis: an emerging, highly infectious threat. *Emerg Infect Dis* 3, 51–57.

19 Chen XM, Keithly JS, Paya CV *et al.* (2002) Cryptosporidiosis. *N Engl J Med* 346, 1723–1731.

20 Lavas MC, Watson JC, Beach MJ (2005) Cryptosporidiosis surveillance – United States 1999–2002. *MMWR Surveill Summ* 54, 1–8.

21 Cifuentes E, Suarez L, Espinosa M *et al.* (2004) Risk of *Giardia intestinalis* infection in children from an artificially recharged groundwater area in Mexico City. *Am J Trop Med Hyg* 71, 65–70.

22 Chistie JD, García LS (2004) Emerging parasitic infections. *Clin Lab Med* 24, 737–772.

23 Seeto RK, Rockey DC (1999) Amebic liver abscess: epidemiology, clinical features, and outcome. *West J Med* 170, 104–109.

24 Campos M, Jouzdani E, Sempoux C *et al.* (2000) Sclerosing cholangitis associated to cryptosporidiosis in liver-transplanted children. *Eur J Pediatr* 159, 113–115.

25 Coupe S, Sarfati C, Hamane S *et al.* (2005) Detection of *Cryptosporidium* and identification to the species level by nested PCR and restriction fragment length polymorphism. *J Clin Microbiol* 43, 1017–1023.

26 Carreno RA, Pokorny NJ, Lee H *et al.* (2001) Phenotypic and genotypic characterization of *Cryptosporidium* species isolates. *J Ind Microbiol Biotech* 26, 95–106.

27 Huston CHD, Haque R, William AP (1999) Molecular-based diagnosis of *Entamoeba histolytica* infection. *Expert Rev Mol Med* 1–11.

28 García LS (2001) *Diagnostic Medical Parasitology*, 4th edn. Washington, DC: ASM Press.

29 Rendtorff RC (1954) The experimental transmission of human intestinal protozoan parasites. II. *Giardia lamblia* cysts given in capsules. *Am J Hyg* 59, 209–220.

30 Rendtorff RC (1978) The experimental transmission of *Giardia lamblia* among volunteer subjects. In: Jacubowski W, Hoff JC (eds) *Waterborne Transmission of Giardiasis*. EPA 600/9-79-001. Washington, DC: US Environmental Protection Agency, pp. 64–81.

31 Rice EW, Schaefer FW (1981) Improved *in vitro* excystation procedure for *Giardia lamblia* cyst. *J Clin Microbiol* 14, 709–710.

32 Erlandsen SL, Macechko PT, Van Keulen H *et al.* (1996) Formation of the *Giardia* cyst wall: studies on extracellular assembly using immunogold labeling and high resolution field emission SEM. *J Eukaryot Microbiol* 43, 416–429.

33 Lujan HD, Mowatt MR, Nash TE (1997) Mechanism of *Giardia lamblia* differentiation into cysts. *Microbiol Mol Biol* 61, 294–304.

34 Tzipori S, Widmer G (2000) The biology of *Cryptosporidium*. *Contrib Microbiol* 6, 1–32.

35 O'Donoghue PJ (1995) *Cryptosporidium* and cryptosporidiosis in man and animals. *Int J Parasitol* 25, 139–195.

36 Ferreira MS, Borges AS (2002) Some aspects of protozoan infections in immunocompromised patients – a review. *Mem Inst Oswaldo Cruz* 97, 443–457.

37 Guillén, N (1996) Role of signaling and cytoskeletal rearrangements in the pathogenesis of *Entamoeba histolytica*. *Trends Microbiol* 4, 191–196.

38 Tavares P, Rigothier MCH, Khum H *et al.* (2005) Roles of cell adhesion and cytoskeleton activity in *Entamoeba histolytica* pathogenesis: a delicate balance. *Infect Immun* 73, 1771–1778.

39 Dominik M, Klopocka W, Pomorski P *et al.* (2005) Characterization of *Amoeba proteus* myosin VI immunoanalog. *Cell Motil Cytoskel* 61, 172–188.

40 Stanley SL Jr (2003) Amoebiasis. *Lancet* 361, 1025–1034.

41 Benkert C, Jacobs T, Berninghausen O *et al.* (1997) Molecular basis of aggressive and defensive functions of *Entamoeba histolytica*. *Arch Med Res* 28, S211–S213.

42 Wehrle-Haller B, Imhof B (2002) The inner lives of focal adhesions. *Trends Cell Biol* 12, 382–389.

43 Tsutsumi V, Mena-Lopez R, Anaya-Velásquez F *et al.* (1984) Cellular bases of experimental amebic liver abscess formation. *Am J Parasitol* 117, 81–91.

44 Tavares P, Sansonetti P, Guillen N (2000) Cell adhesion and polarization in a pathogenic protozoan: role of the *Entamoeba histolytica*. *Arch Med Res* 2, 643–649.

45 Rawal S, Majumdar S, Vohra H (2005) Activation of MAPK kinase pathway by Gal/GalNAc adherence lectin of *E. histolytica*: gateway to host response. *Mol Cell Biochem* 268, 93–101.

46 Arhets P, Olivo JC, Gounon P *et al.* (1998) Virulence and functions of myosin II are inhibited by overexpression of light meromyosin in *Entamoeba histolytica*. *Mol Biol Cell* 8, 1537–1547.

47 Stanley SL Jr (2001) Pathophysiology of amoebiasis. *Trends Parasitol* 17, 280–285.

48 Petri WA, Haque R, Mann BJ (2002) The bittersweet interface of parasite and host: lectin–carbohydrate interactions during human invasion by the parasite *Entamoeba histolytica*. *Annu Rev Microbiol* 56, 39–54.

49 Velázquez C, Shibayama-Sales M, Aguirre-García J *et al.* (1998) Role of neutrophils in innate resistance to *Entamoeba histolytica*. *Cell Microbiol* 20, 255–262.

50 Yan L, Stanley L (2001) Blockade of caspases inhibits amebic liver abscess formation in a mouse model of disease. *Infect Immun* 69, 7911–7914.

51 Sim S, Yong TS, Park SJ *et al.* (2005) NADPH oxidase-derived reactive oxygen species-mediated activation of ERL1/2 required for apoptosis of human neutrophils induced by *Entamoeba histolytica*. *J Immunol* 174, 4279–4288.

52 Gomes CM, Giuffre A, Forte E *et al.* (2002) A novel type of nitric-oxide reductase. *Escherichia coli* flavorubredoxin. *J Biol Chem* 277, 25273–25276.

53 Sztukowska M, Bugno M, Potempa J *et al.* (2002) Role of rubrerythrin in the oxidative stress response of *Porphyromonas gingivalis*. *Mol Microbiol* 44, 479–488.

54 Loftus B, Anderson I, Davies R *et al.* (2005) The genome of the protist parasite *Entamoeba histolytica*. *Nature* 433, 865–868.

55 Leber AL, Novak SM (2003) Intestinal and urogenital amebae, flagellates and ciliates. In: Murray PR, Baron EJ, Jorgensen JH *et al.* (eds) *Manual of Clinical Microbiology*, Vol. 2. Washington, DC: American Society for Microbiology, pp. 1990–2007.

56 El-Shewy KA, Eid RA (2005) In vivo killing of *Giardia* trophozoites harbouring bacterial endosymbionts by intestinal Paneth cells: an ultrastructural study. *Parasitology* 130, 269–274.

57 Halliday CE, Clark C, Farthing MJ (1988) *Giardia*–bile salt interactions *in vitro* and *in vivo*. *Trans R Soc Trop Med Hyg* 82, 428–432.

58 Vesy CJ, Peterson WL (1999) Review article: the management of giardiasis. *Aliment Pharmacol Ther* 13, 843–850.

59 McArthur AG, Morrison HG, Nixon JE *et al.* (2000) The *Giardia* genome project database. *FEMS Microbiol Lett* 189, 271–273.

60 Carranza PG, Feltes G, Ropolo A *et al.* (2002) Simultaneous expression of different variant-specific surface proteins in single *Giardia lamblia* trophozoites during encystation. *Infect Immun* 70, 5265–5268.

61 Tellez A, Palm D, Weiland M *et al.* (2005) Secretory antibodies against *Giardia intestinalis* in lactating Nicaraguan women. *Parasite Immunol* 27, 163–169.

62 Eckmann L (2003) Mucosal defences against *Giardia*. *Parasite Immunol* 25, 259–270.

63 Barbot L, Topouchian A, Capet C *et al.* (2001) *Cryptosporidium parvum*: functional study of the intestinal malabsorption syndrome. *Ann Pharm Fr* 59, 305–311.

64 Stephens J, Cosyns M, Jones M *et al.* (1999) Liver and bile duct pathology following *Cryptosporidium parvum* infection of immunodeficient mice. *Hepatology* 30, 27–35.

65 Stout RD, Suttles J, Xu J *et al.* (1996) Impaired T cell mediated macrophage activation in CD40 ligand deficient mice. *J Immunol* 156, 8–11.

66 Kline TJ, De las Morenas T, O'Brien M *et al.* (1993) Squamous metaplasia of extrahepatic biliary system in an AIDS patient with cryptosporidia and cholangitis. *Dig Dis Sci* 38, 960–962.

67 McDonald V, Smith R, Robinson H *et al.* (2000) Host immune responses against *Cryptosporidium*. *Contrib Microbiol* 6, 75–91.

68 Hunter PR, Nichols G (2002) Epidemiology and clinical features of *Cryptosporidium* infection in immunocompromised patients. *Clin Microbiol Rev* 15, 145–154.

69 Gomez Morales MA, Pozio E (2002) Humoral and cellular immunity against *Cryptosporidium* infection. *Curr Drug Targets Immune Endocr Metabol Disord* 2, 291–301.

70 Huang BQ, Chen XM, LaRusso NF (2004) *Cryptosporidium parvum* attachment to and internalization by human biliary epithelia *in vitro*: a morphologic study. *J Parasitol* 90, 212–221.

71 Chen XM, Levine SA, Splinter PL *et al.* (2001) *Cryptosporidium parvum* activates nuclear factor kappaB in biliary epithelia preventing epithelial cell apoptosis. *Gastroenterology* 120, 1774–1783.

72 Chen XM, Huang BQ, Splinter PL *et al.* (2003) *Cryptosporidium parvum* invasion of biliary epithelia requires host cell tyrosine phosphorylation of cortactin via c-Src. *Gastroenterology* 125, 216–228.

73 Beier TV, Anastskaia RAS, Sidorenko NV *et al.* (2002) Morphofunctional changes in hepatocytes during the early postnatal development of rats experimentally infected with the intestinal protozoan pathogen *Cryptosporidium parvum* (Coccidia, Sporozoa). *Tsitologiia* 44, 1046–1057.

74 Misra SP, Misra V, Dwivedi M *et al.* (2004) Factors influencing colonic involvement in patients with amebic liver abscess. *Gastrointest Endosc* 59, 512–516.

75 Sachdev GK, Dhol P (1997) Colonic involvement in patients with amebic liver abscess: endoscopic findings. *Gastrointest Endosc* 46, 37–39.

76 Farthing MJG (1996) Giardiasis. *Gastroenterol Clin North Am* 25, 493–515.

77 Jennings W, Rowl R, Hecker R *et al.* (1976) The significance of lowered jejunal disaccharidase levels. *Aust NZ J Med* 6, 556–560.

78 Roberts-Thomson IC, Anders RF, Bhathal PS (1982) Granulomatous hepatitis and cholangitis associated with giardiasis. *Gastroenterology* 83, 480–483.

79 Esfiandari A, Swartz J, Teklehaimanot S (1997) Clustering of giardiasis among AIDS patients in Los Angeles County. *Cell Mol Biol* 43, 1077–1083.

80 Aronson NF, Cheney C, Rholl V *et al.* (2001) Biliary giardiasis in a patient with human immunodeficiency virus. *J Clin Gastroenterol* 33, 167–170.

81 Current R, Bailey W, Heyman M *et al.* (1983) Human cryptosporidiosis in immunocompetent and immunodeficient persons. *N Engl J Med* 308, 1252–1257.

82 Abdo A, Klassen J, Urbansski S *et al.* (2003) Reversible sclerosing cholangitis secondary to cryptosporidiosis in a renal transplant patient. *J Hepatol* 38, 688–691.

83 Campos M, Jouzdani E, Sempoux C *et al.* (2000) Sclerosing cholangitis associated to cryptosporidiosis in liver transplanted children. *Eur J Pediatr* 159, 113–115.

84 Cordero E, Lopez Cortez LF, Belda O *et al.* (2001) Acquired immunodeficiency syndrome related cryptosporidial cholangitis: resolution with endobiliary prosthesis insertion. *Gastrointest Endosc* 53, 534–535.

85 Gross T, Wheat J, Bartlett M *et al.* (1986) AIDS and multiple system involvement with cryptosporidiosis. *Am J Gastroenterol* 81, 456–458.
86 Kaplan JE, Hanson D, Dworkin MS (2000) Epidemiology of human immunodeficiency virus associated opportunistic infections in the United States in the era of highly active retroviral therapy. *Clin Infect Dis* 30, S5–S14.
87 Levy J, Espanol-Boren T, Thomas C *et al.* (1997) Clinical spectrum of X-linked hyper-IgM syndrome. *J Pediatr* 131, 47–54.
88 Mortele KJ, Segatto E, Ros PR (2004) The infected liver: radiologic–pathologic correlation. *RadioGraphics* 24, 937–955.
89 Grant EG (1992) Liver. In: Mittelstaedt CA (ed.) *General Ultrasound*. New York: Churchill Livingstone, Ch. 5, pp. 208–211.
90 Radin DR, Ralls P, Coletti PM *et al.* (1988) CT of amebic liver abscess. *Am J Roentgenol* 150, 1297–1301.
91 Mortele KJ, Ross PR (2001) Cystic focal lesions in the adult: differential CT and MR imaging features. *RadioGraphics* 21, 895–910.
92 Shamsuzzaman SM, Hashiguchi Y (2002) Thoracic amebiasis. *Clin Chest Med* 23, 479–492.
93 Khanna D, Chaudhary D, Kumar A *et al.* (2005) Experience with aspiration in cases of amebic liver abscess in an endemic area. *Eur J Clin Microbiol Infect Dis* 24, 428–430.
94 Souza DS, Barreiros JT, Papp KM *et al.* (2003) Comparison between immunomagnetic separation, coupled with immunofluorescence, and the techniques of Faust *et al.* and of Lutz for the diagnosis of *Giardia lamblia* cysts in human feces. *Rev Inst Med Trop Sao Paulo* 45, 339–342.
95 Fedorko DP, Williams EC, Nelson NA *et al.* (2000) Performance of three enzyme immunoassays for detection of *Giardia lamblia* in stool specimens preserved in ECOFIX. *J Clin Microbiol* 38, 2781–2783.
96 Shatla HM, el-Hodhod MT, Mohsen DM *et al.* (2004) Potential diagnosis of *Giardia lamblia* infection through specific antibody detection in saliva. *J Egypt Soc Parasitol* 34, 621–630.
97 Didier ES, Orenstein JM, Aldra D *et al.* (1995) Comparison of three staining methods for detecting microsporidia in fluids. *J Clin Microbiol* 33, 3138–3145.
98 Hughes MA, Oetri WA Jr (2000) Amebic liver abscess. *Infect Dis Clin North Am* 14, 565–583.
99 Torre A, Kershenobich D (2002) Amebic liver abscess. *Ann Hepatol* 1, 45–47.
100 Rosenblatt JE, Edson RS (1987) Metronidazole. *Mayo Clin Proc* 62, 1013–1017.
101 Badalamenti S, Jameson JE, Reddy KR (1999) Amebiasis. *Curr Treat Options Gastroenterol* 2(2), 97–103.
102 Karabay O, Tamer A, Gunduz H *et al.* (2004) Albendazole versus metronidazole treatment for adult giardiasis: an open randomized clinical study. *World J Gastroenterol* 10, 1215–1217.
103 Wright JM, Dunn LA, Upcroft PJA (2003) Efficacy of antigiardial drugs. *Expert Opin Drug Safety* 2, 529–541.
104 Fox LM, Saravolatz LD (2005) Nitazoxanide: a new thiazolide antiparasitic agent. *Clin Infect Dis* 40, 1173–1180.
105 Petri WA (2005) Treatment of giardiasis. *Curr Treat Options Gastroenterol* 8, 13–17.
106 Gardner TB, Hill DR (2001) Treatment of giardiasis. *Clin Microbiol Rev* 14, 114–128.
107 Zardi EM, Picardi A, Afeltra A (2005) Treatment of cryptosporidiosis in immunocompromised hosts. *Chemotherapy* 51, 193–196.
108 Hommer V, Eichholz J, Petry F (2003) Effect of antiretroviral protease inhibitors alone, and in combination with paromomycin, on the excystation, invasion and *in vitro* development of *Cryptosporidium parvum*. *J Antimicrob Chemother* 52, 359–364.
109 Smith HV, Corcoran GD (2004) New drugs and treatment for cryptosporidiosis. *Curr Opin Infect Dis* 17, 557–564.
110 Giacometti A, Burzacchini F, Cirioni O *et al.* (1999) Efficacy of treatment with paromomycin, azithromycin, and nitazoxanide in a patient with disseminated cryptosporidiosis. *Eur J Clin Microbiol Infect Dis* 18, 885–889.

10.3.2 Malaria

Montse Renom and Pedro L. Alonso

Malaria, caused by *Plasmodium* protozoan parasites, represents a major global health problem [1]; it is the most important parasitic disease of man. Approximately 4% of the world's population is infected; the disease is endemic in more than 100 countries and 40% of the world's population is at risk. Every year, approximately 500 million people suffer the disease, of whom approximately 1–3 million die, 90% in sub-Saharan Africa and 75% of them children [1–3].

The disease is caused by an intracellular protozoan of the *Plasmodium* genus that is transmitted to humans by the bite of the female mosquito of the *Anopheles* genus. The infection can also be acquired by blood transfusion, through the placenta (congenital transmission) as well as by the use of contaminated needles or syringes.

In non-endemic areas, the disease should be suspected in all febrile patients with a travel history to endemic countries. Needless to say, malaria should be suspected in all febrile patients in endemic areas.

Four species of *Plasmodium* infect humans (*P. falciparum*, *P. vivax*, *P. ovale* and *P. malariae*). *P. falciparum* is encountered mainly in African countries and is responsible for the most severe forms of the disease. *P. vivax* and *P. ovale* are known to form resting stages in the liver (hypnozoites) that may reactivate and can cause clinical relapse many months after the initial clinical presentation [3].

Epidemiology

At present, malaria is found throughout the tropics in 103 countries in Africa, Latin America, Asia and Oceania. The epidemiology of the disease is complex and varies in different areas within the same geographical zone. The transmission depends on at least four interrelated factors: the vector (*Anopheles*), the parasite (*Plasmodium*), the human host and the environment [4,5].

In Africa, Papua Guinea and Haiti, *P. falciparum* is the predominant species; *P vivax* is more common in Central and South America, North Africa, the Middle East and the Indian subcontinent. The prevalence of both species is approximately equal in other parts of South America, East Asia and Oceania. *P. vivax* is rare in sub-Saharan Africa, whereas *P. ovale* is

relatively uncommon outside West Africa. *P. malariae* is found in most areas, but is less common outside Africa. *P. vivax* strains may still be found in China and adjacent countries.

Malaria was endemic in some areas of Europe and northern Asia, and was introduced to North America, but has been eradicated from these areas since the mid-nineteenth century.

The epidemiology of malaria is described as endemic (stable transmission) when the incidence is relatively constant annually; transmission may be seasonal or perennial. It is defined as epidemic (unstable transmission) when marked differences exist between different years. Endemic areas were further classified (from low to high) as hypoendemic, mesoendemic, hyperendemic and holoendemic depending on the intensity of transmission and the effects on the population. Epidemics occur when one or several of the following factors appear: (i) increase in the number of susceptible individuals in the population; (ii) increase in the gametocyte reservoir of the population; (iii) increased contact between human and vector; and (iv) increased effectiveness in vector transmission.

Epidemics often occur in hypoendemic and mesoendemic areas and are characterized by an elevated mortality affecting all age groups. In areas of high endemicity, mortality is mainly seen in the most vulnerable groups such as children under 5 years of age. Malaria infection also poses substantial risks to pregnant women and their fetuses and may result in spontaneous abortion and stillbirth. Most cases diagnosed in Europe and the USA are imported. More than 15 000 and 1200 cases are declared annually in Europe and the USA respectively.

Aetiology

There are 120 *Plasmodium* species that affect animals (primates, birds and reptiles), only four of which affect humans. The genomic sequence of *P. falciparum* has been described recently. The *Plasmodium* life cycle is complex and similar in the four species infecting humans: (i) a sexual exogenous phase in certain *Anopheles* mosquitoes (sporogony); and (ii) an asexual endogenous phase in humans, which includes an exoerythrocytic phase and an erythrocytic phase.

Humans may be infected through the bite of a female *Anopheles* mosquito which inoculates the sporozoites (infective form) into the dermis and the bloodstream. The blood drives the sporozoites to the liver where they invade the hepatocytes. This phase is known as the exoerythrocytic or hepatic schizogony phase. The circumsporozoite protein and TRAP (organelle protein translocated to the sporozoite surface) bind to hepatocytes through the heparan sulphate glycosaminoglycans (GAGs) specifically expressed on the hepatocyte surface. Malaria sporozoites actively enter the Kupffer cells prior to hepatocyte invasion [6–10]. In the hepatocyte, the sporozoite becomes schizont through schizogony and divides into several thousand merozoites. Up to this stage, there is no obvious effect on liver function, nor are signs and symptoms of the disease observed. Infection with *P. vivax* and *P. ovale* may lead to the persistence of pre-erythrocytic forms in the liver (hypnozoite), which can awake and mature into schizonts months after the initial infection. This is not seen with *P. falciparum* or *P. malariae* parasites.

After 6–16 days, depending on the species, merozoites are delivered into the bloodstream where they invade red blood cells (RBCs). At this point, the erythrocytic schizogony phase starts. In the initial stages, the parasite can be seen as annular rings or trophozoites and, in the following stages, the trophozoite absorbs haemoglobin resulting in the formation of haemozoin pigment. After a maturation period, the trophozoite undergoes multiple divisions forming the schizont. When the schizont becomes engorged with merozoites, the RBC is destroyed, and all merozoites are released into the bloodstream ready to infect other RBCs where the same process takes place. The duration of the erythrocytic phase varies between species being 48 h in *P. vivax*, *P. ovale* and *P. falciparu*m and 72 h in *P. malariae*. Many generations after the initial merozoites, a few of them evolve into differentiated sexual forms (gametocytes).

When a female *Anopheles* mosquito feeds from an infected individual, parasites are delivered into its stomach, the asexual forms and RBCs are destroyed and gametocytes continue with the maturation process. Fecundation takes place, giving rise to a zygote which evolves into oocytes that contain sporozoites. Sporozoites will accumulate in the mosquito salivary gland and enter the human host through a bite. The sexual cycle in the mosquito lasts approximately 10–20 days, and the ideal temperature for it to happen is between 15 and 32°C. It does not take place at altitudes above 2000 m.

Clinical manifestations

Malaria has a wide range of clinical manifestations which depend mainly on the species of *Plasmodium* and the previous immune status of the host; children less than 5 years, pregnant women and travellers from non-endemic areas are most vulnerable and suffer more severe forms.

The pathogenetic effect is the result of erythrocyte destruction, liberation of the parasite and RBC degradation products into the bloodstream and host responses to these events. Known physiopathological phenomena that have been recognized so far to cause damage are: (i) cytokine toxicity; (ii) cytoadherence phenomena in the blood vessels and organs with microcirculation occlusion; (iii) rosetting, non-infected erythrocytes adhere to parasitized RBCs; (iv) deformability, parasitized RBCs become more rigid. The organs most affected during malaria infection are the brain, spleen, liver [11], kidney, lungs and placenta. The incubation period varies between 8 and 30 days depending on the species: shorter for *P. falciparum* and longer for *P. malariae*. Nevertheless, some *P. vivax* may have an incubation period of almost a year. The clinical features of uncomplicated malaria are common in the four species and consist of fever, headache, muscle aches, abdominal discomfort, lethargy and anaemia. Diarrhoea and respiratory symptoms may be present.

Severe malaria, mainly caused by *P. falciparum*, is often classified as: cerebral malaria (which includes a Blantyre coma score ≤ 2), severe malarial anaemia (including a haematocrit ≤ 15) or other forms of severe malaria (which may include multiorgan failure, severe hypoglycaemia, respiratory distress, acidosis or circulatory collapse) [12–15].

Malaria hepatic dysfunction

Jaundice in malaria

Although jaundice is considered to be a frequent sign in malaria, there is a wide variation in its reported incidence ranging from 2.58% to 62% [16]. Possible reasons for this wide variation could include the level of endemicity (endemic vs. epidemic), age, the *Plasmodium* species (*vivax* vs. *falciparum*) and case definition used (e.g. inclusion of complicated cases only where the incidence of jaundice is higher).

Jaundice in malaria is multifactorial and mostly due to one or several of the following:

1 intravascular haemolysis due to destruction of parasitized and non-parasitized RBCs;
2 coexistent malnutrition;
3 shock and disseminated intravascular coagulation leading to microangiopathic haemolysis;
4 hepatocyte dysfunction.

Malarial hepatitis

Hepatocellular dysfunction is observed in falciparum malaria. This clinical picture may range from different degrees of conjugated hyperbilirubinaemia with or without mild elevation of transaminases to fulminant hepatic failure [16–18].

Several mechanisms conducive to hepatic have been described dysfunction Organ damage, including the liver, is believed to be related to cytoadherence of parasitized red blood cells (pRBCs) to the vascular and sinusoidal endothelium, leading to stagnant anoxaemia. Reduction in portal venous flow has been described as a consequence of micro-occlusion of portal venous branches by pRBCs. Liver function abnormalities have been reported in severe systemic infections and endotoxaemia; this has also been described, with or without concomitant bacterial infections, in complicated malaria. An additional mechanism is the intrahepatic cholestasis secondary to reticuloendothelial blockage and disturbances of the hepatic microvilli. In many cases, the biochemical and histological evidence of hepatocellular injury is minimal.

The traditional view that, besides jaundice, signs of hepatic dysfunction are unusual, and clinical signs of liver failure such as asterixis or 'liver flap' are never seen unless there is concomitant viral hepatitis [19], has been challenged in recent years by a number of reports describing the occurrence of hepatic encephalopathy in infections caused by falciparum malaria [20,21]. Other reports have also inappropriately used the term fulminant hepatic failure in malaria patients with coma, without ruling out a neurological involvement by malaria (cerebral malaria) rather than hepatic encephalopathy.

Malarial hepatopathy has a wide range of presentations that are classified in two large groups:

- type A involves a fulminant illness with coma, jaundice, purpura and multiorgan failure [19];
- type B, a milder illness with fever, headache and vomiting, resolving in 10–15 days [22].

Jaundice is the commonest sign of hepatic dysfunction; according to some classifications, it can be considered as a sign of severe malaria.

Anatomopathological findings

In acute falciparum malaria, the liver is enlarged and can weigh approximately 2.5 kg. It is congested and pigmented dark brown. A wide variety of histological changes have been reported in malaria which are not consistently found in all studies. By electron microscopy, Kupffer cells are hypertrophied and contain haemozoin pigment. The sinusoids are dilated, and the portal tracts may be infiltrated with inflammatory cells. The parasites are rarely demonstrable (seen in less than half the cases). Additional changes include steatosis, focal hepatocyte swelling and necrosis and focal accumulation of histiocytes forming non-granulomatous lesions. Parasitized red blood cells are seen in Kupffer cells and endothelial cells. Characteristically rectangular, crystalline malaria pigment granules are seen in these cells. The hepatocytes contain lipofuchsin and haemosiderin as well as fat droplets. There are changes in the endoplasmic reticulum and mitochondria. The spaces of Disse can become narrow with loss of microvilli in the hepatocytes and the bile canaliculi. Centrizonal necrosis has also been described and, of the other non-specific changes, it is a strong indicator of hepatocellular damage [23]. It still needs to be resolved whether this is due to malaria infection itself or to terminal hypotension artifacts.

Diagnosis

Malaria

The diagnostic gold standard remains the microscopic examination of a thick and thin blood smear stained with Giemsa, Leishman or Romanowsky–eosin. Thick smears have a greater sensitivity because erythrocytes are haemolysed, and intraerythrocytic parasites are then liberated. It provides a simpler method of counting parasites that allows formulation of the relative parasite count and gives the results in a semi-quantitative scale (one to five crosses). Thin smears have a better specificity because they keep the parasite morphology allowing the identification of species and stage. They allow parasite counting per microlitre (μL); this is based on the number of parasites per μL of blood, counted in relation to a predetermined number of leukocytes. An average of 8000 leukocytes/μL is taken as the standard. Despite inaccuracies due to variations in ill persons, this standard permits reasonable comparisons.

Other diagnostic methods are QBC (quantified buffy coat), DNA probes, detection of monoclonal antibodies. They still

do not have a role in clinical settings and are only used in epidemiological studies. Antibody determination is useless in acute episodes but may be useful in epidemiological studies to confirm past exposure.

Malarial hepatitis diagnosis

The diagnosis is made on clinical evidence of signs and symptoms of liver injury, confirmed by the appropriate laboratory tests of liver dysfunction. In 29 patients with malaria hepatitis [24], the ultrasound examination found hepatomegaly with low echogenicity and thick gallbladder similar to that seen in acute viral hepatitis. No data are available on the features of livers in malaria by computerized tomography or magnetic resonance imaging. It is therefore important to make the diagnosis of liver dysfunction in the context of an already made diagnosis of malaria, as well as to consider malaria as the cause of a suspected liver injury of varying degrees. In the context of malaria, unconjugated bilirubin is often elevated in association with intravascular haemolysis of multifactorial origin, but the finding of increased conjugated bilirubin with elevation in liver enzymes should lead to the diagnosis of malarial hepatopathy. Haemolysis alone does not cause severe jaundice or predominantly conjugated hyperbilirubinaemia. Therefore, major patients with serum bilirubin levels of more than 10 mg% and a are likely to suffer from proportion of conjugated bilirubin associated hepatocellular injury; these patients also have increased liver enzymes.

Malarial hepatitis: diagnostic criteria [16]

- Demonstration of *P. falciparum* infection by the detection of parasites in peripheral blood smear;
- Hyperbilirubinaemia > 10 mg% with elevated conjugated bilirubin;
- A minimum of a threefold rise in transaminases, especially alanine aminotransferase, on two consecutive blood samples taken 24 h apart with or without the presence of conjugated hyperbilirubinaemia;
- Absence of serological evidence suggesting viral infection;
- No intake of drugs that may affect liver function;
- Clinical response to antimalarials;

Malarial hepatitis differential diagnosis

Malaria must enter the differential diagnosis of patients with a history of travel to endemic areas who present with fever and jaundice or any sign of liver dysfunction. While the full-blown presentation with oligoanuria, disproportionate anaemia with normal and increased liver mass, as well as persistent fever and mild elevations in liver enzymes, should prompt consideration of malaria as a cause, it is important also to include malaria in the differential diagnosis of minor signs of liver dysfunction in travellers, as malarial disease is reversible if treated but may progress rapidly if unrecognized. In this regard, it should be noted that malarial hepatitis may mimic fulminant hepatic failure from whatever cause; it is vital to start antimalarial therapy immediately as severe malarial hepatitis may very rapidly lead to death if untreated or treated with delay. Thinking about malaria is important in developed countries where travel to endemic areas is becoming frequent, and medical professionals are not yet accustomed to include parasitic and/or other tropical diseases in their differential diagnosis of liver disorders. Imported falciparum malaria in the USA is often misdiagnosed as hepatitis and gastroenteritis or, in the severe presentations, as fulminant hepatic failure.

Fulminant hepatic failure (FHF), defined as the onset of encephalopathy within 8 weeks from the first symptom of hepatic injury, is commonly due to viral hepatitis and drug use. Infectious diseases such as sepsis or typhoid fever may also rarely present with FHF. Altered consciousness in malarial hepatitis, although uncommon, may make the distinction between malarial hepatitis and viral FHF very difficult. Malaria is treatable with numerous drugs, and the outcome, when prompt treatment is started, is often good. Mortality was 24% in cases of malarial hepatitis compared with 76% in the viral FHF group [20,25].

Jaundice induced by antimalarial drugs

A minimal elevation of liver enzymes has been described after exposure to mefloquine, especially in previously damaged livers. The drug should, therefore, be prescribed with caution in patients with known liver disease. Fatal acute hepatitis has been reported secondary to amodiaquine and hepatitis has been reported with chloroquine prophylaxis. Combination therapies, which are recommended to delay the development of resistance to *P. falciparum*, were also associated with hepatic alterations. An episode of acute asymptomatic hepatitis was described in two healthy volunteers after two doses of amodiaquine plus artesunate as well as after the administration of pyrimethamine–sulphadoxine; a case of granulomatous hepatitis has been attributed to pyrimethamine–chloroquine administered for prophylaxis.

Coexisting acute viral hepatitis

In endemic areas, it is important to differentiate whether jaundice is secondary to malaria *per se* or to acute viral hepatitis. In the former, it is characteristic to see a disproportionate hyperbilirubinaemia with mild elevation of the liver enzymes. Acute hepatitis E and malaria can commonly coexist in tropical countries [26,27]. Hepatic failure is mostly associated with viral infection or with severe falciparum malaria. Hepatitis A has also been reported in association with malaria [28].

Underlying chronic hepatitis

The overall prevalence of HBsAg was found to be higher (23.77%) than previously described (9.8%) among adult Vietnamese patients admitted for severe falciparum malaria [29]. HBsAg was present in a slightly greater proportion in patients admitted for cerebral malaria. However, no association was found between the risk of death and the coexistence of

severe malaria and HBsAg. Chronic infection with hepatitis B virus (HBV) may nevertheless be a risk factor for severe malaria. It has been suggested that the immunoresponse-raising anti-RESA (antibody against *P. falciparum* ring-infected erythrocytes surface antigen) could be suppressed in chronic HBsAg carriers [30]. There have also been reports of an association between HBsAg carriage and severe malaria in Gambian children [31]; this association, which could be explained by a reduced level of HLA class I antigen expression on hepatocytes infected by HBV, impairing the clearance of liver parasites, has not been shown in other studies in different endemic areas.

Vice versa, malaria infection might influence the course and pathogenesis of HBV infection and modulate viraemia in chronic hepatitis B [32]. Interestingly, severe flares of HBV hepatitis B with liver cell failure were seen after discontinuation of chloroquine given for malaria prophylaxis [33]. The proposed mechanism is through chloroquine inhibiton of the association of the major histocompatibility complex (MHC) type 2 with HBV, therefore inhibiting T cell-mediated lysis of infected cells.

Malarial hepatitis simulating FHF vs. fulminant hepatic failure [25,34]

Severe malaria due to *P. falciparum* may masquerade as FHF. Simple clinical and laboratory parameters together with a high index of suspicion can easily distinguish these entities. A detailed and focused medical history, physical examination and pattern of liver test abnormalities may help to distinguish both entities. The presence of hepatomegaly and normal prothrombin time (PT) are characteristic of malarial hepatitis. In contrast, a decreased liver size and prolonged PT are the hallmarks of FHF. In patients presenting with FHF, clinical suspicion of malaria and, in a non-endemic area, history of recent travel to an endemic area should prompt a peripheral blood smear to rule out malaria.

Treatment

Uncomplicated malaria

During the last 50 years, treatment has been based on chloroquine, a safe, efficacious, easy to take and cheap drug. However, during the past two decades, development by the parasite of resistance to chloroquine has increased so much that this drug is no longer recommended as first-line treatment (although it is still used in some countries, particularly in West Africa). The emergence and spread of resistance to sulphadoxine–pyrimethamine is also rendering this drug of limited value as a first-line substitute. The artemisinine derivative, especially in combination with other antimalarial drugs, is showing promising results and is being introduced in many countries. Its availability and cost are the main limitations as well as the limited availability of safety data in certain groups such as pregnant women [35]. Other options are quinine, mefloquine, halofantrine, doxycycline and clindamycin.

Complicated malaria

Current recommendations are parenteral quinine salt 20 mg/kg body weight infused over a 4-h period followed by 10 mg/kg infused over a 4-h period every 8 h. Once patient consciousness improves, medication is switched to oral quinine 650 mg every 8 h for a total duration of 7 days. Oral doxycycline should be added for 7 days when possible.

Treatment of the intrahepatic forms (*P. vivax* and *P. ovale*)

Primaquin 15 mg base/day (0.25 mg/kg) for 2 weeks. Contraindicated in pregnant women, in the breastfeeding period and for those with glucose-6-phosphate dehydrogenase deficiency.

Malarial hepatitis treatment

Measures should be addressed to correct the hepatocellular dysfunction if needed, as well as to appropriately treat malaria. Hepatocellular jaundice is indicative of severe malaria and, therefore, appropriate intravenous antimalarial treatment is indicated (described above). As quinine elimination half-life is prolonged and clearance is lower, current dosage regimens may need to be adjusted or followed closely in patients with acute hepatitis and/or renal dysfunction and in those who had an acute hepatitis within the previous 3 months.

Mild cases of liver disorders have improved with antimalarial therapy, with amelioration of liver function tests [21].

Prevention

At present, the malaria prevention strategies are vector control, the reduction of human–vector contact and drugs for its prevention and treatment [36]. Treatment in developing areas is hindered by the lack of effective, safe and cheap drugs. Intermittent preventive treatment in infants and pregnant women is being developed. A malaria vaccine, RTS,S/ASO2A, has shown promising results in endemic areas but is still under investigation [37,38].

References

1 Snow RW, Hay SI (2006) Comparing methods of estimating the global morbidity burden from *Plasmodium falciparum* malaria. *Am J Trop Med Hyg* 74(2), 189–190.
2 Guinovart C, Navia MM, Tanner M *et al.* (2006) Malaria: burden of disease. *Curr Mol Med* 6(2), 137–140.
3 Greenwood BM, Bojang K, Whitty CJ *et al.* (2005) Malaria. *Lancet* 365(9469), 1487–1498.
4 White NJ (2003) Malaria. In: Cook GC (ed.) *Manson's Tropical Diseases*, Philadelphia, PA: W.B. Saunders, pp. 1207–1295.
5 Menendez Santos C (1997) Paludismo. I, 1836–1841. In: *Medicina Interna*. J. Rodés Teixidor.

6 Barnwell JW (2001) Hepatic Kupffer cells: the portal that permits infection of hepatocytes by malarial sporozoites? *Hepatology* 33(5), 1331–1333.
7 Sinnis P (1996) The malaria sporozoite's journey into the liver. *Infect Agents Dis* 5(3), 182–189.
8 Pradel G, Frevert U (2001) Malaria sporozoites actively enter and pass through rat Kupffer cells prior to hepatocyte invasion. *Hepatology* 33(5), 1154–1165.
9 Mota MM, Pradel G, Vanderberg JP *et al.* (2001) Migration of *Plasmodium* sporozoites through cells before infection. *Science* 291(5501), 141–144.
10 Pradel G, Wagner C, Mejia C *et al.* (2005) *Plasmodium falciparum*: co-dependent expression and co-localization of the PfCCp multi-adhesion domain proteins. *Exp Parasitol* 112, 263–268.
11 Molyneux ME, Looareesuwan S, Menzies IS *et al.* (1989) Reduced hepatic blood flow and intestinal malabsorption in severe falciparum malaria. *Am J Trop Med Hyg* 40(5), 470–476.
12 Mackintosh CL, Beeson JG, Marsh K (2004) Clinical features and pathogenesis of severe malaria. *Trends Parasitol* 20(12), 597–603.
13 Krishnan A, Karnad DR (2003) Severe falciparum malaria: an important cause of multiple organ failure in Indian intensive care unit patients. *Crit Care Med* 31(9), 2278–2284.
14 Harris VK, Richard VS, Mathai E *et al.* (2001) A study on clinical profile of falciparum malaria in a tertiary care hospital in south India. *Ind J Malariol* 38(1–2), 19–24.
15 World Health Organization, Communicable Diseases Cluster (2000) Severe falciparum malaria. *Trans R Soc Trop Med Hyg* 94(Suppl. 1), S1–90.
16 Anand AC, Puri P (2005) Jaundice in malaria. *J Gastroenterol Hepatol* 20(9), 1322–1332.
17 Kochar DK, Singh P, Agarwal P *et al.* (2003) Malarial hepatitis. *J Assoc Phys India* 51, 1069–1072.
18 Anand AC (2001) Liver in malaria. *Ind J Gastroenterol* 20(Suppl. 1), C37–C38.
19 Murthy GL, Sahay RK, Sreenivas DV *et al.* (1998) Hepatitis in falciparum malaria. *Trop Gastroenterol* 19(4), 152–154.
20 Kochar DK, Agarwal P, Kochar SK *et al.* (2003) Hepatocyte dysfunction and hepatic encephalopathy in *Plasmodium falciparum* malaria. *Q J Med* 96(7), 505–512.
21 Anand AC, Ramji C, Narula AS *et al.* (1992) Malarial hepatitis: a heterogeneous syndrome? *Natl Med J India* 5(2), 59–62.
22 Ghoda MK (2002) Falciparum hepatopathy: a reversible and transient involvement of liver in falciparum malaria. *Trop Gastroenterol* 23(2), 70–71.
23 Mishra SK, Mohanty S, Das BS *et al.* (1992) Hepatic changes in *P. falciparum* malaria. *Ind J Malariol* 29(3), 167–171.
24 Kachawaha S, Pokharana R, Rawat N *et al.* (2003) Ultrasonography in malarial hepatitis. *Ind J Gastroenterol* 22(3), 110.
25 Devarbhavi H, Alvares JF, Kumar KS (2005) Severe falciparum malaria simulating fulminant hepatic failure. *Mayo Clin Proc* 80(3), 355–358.
26 Ghoshal UC, Somani S, Chetri K *et al.* (2001) *Plasmodium falciparum* and hepatitis E virus co-infection in fulminant hepatic failure. *Ind J Gastroenterol* 20(3), 111.
27 Bansal R, Kadhiravan T, Aggarwal P *et al.* (2002) *Plasmodium vivax* and hepatitis E co-infection – a rare cause of malarial jaundice. *Ind J Gastroenterol* 21(5), 207–208.
28 Katou K, Nakamura C, Amano F *et al.* (1982) [Hepatitis A and *Salmonella enteritis* complicated with malaria]. *Kansenshogaku Zasshi* 56(10), 872–876.
29 Barcus MJ, Hien TT, White NJ *et al.* (2002) Short report: hepatitis b infection and severe *Plasmodium falciparum* malaria in Vietnamese adults. *Am J Trop Med Hyg* 66(2), 140–142.
30 Souto FJ, Fontes CJ, Gaspar AM (2002) Relation between hepatitis B carrier status and antibody against synthetic *Plasmodium falciparum* erythrocyte surface. *Mem Inst Oswaldo Cruz* 97(2), 197–198.
31 Thursz MR, Kwiatkowski D, Torok ME *et al.* (1995) Association of hepatitis B surface antigen carriage with severe malaria in Gambian children. *Nature Med* 1(4), 374–375.
32 Brown AE, Mongkolsirichaikul D, Innis B *et al.* (1992) Falciparum malaria modulates viremia in chronic hepatitis B virus infection. *J Infect Dis* 166(6), 1465–1466.
33 Helbling B, Reichen J (1994) [Reactivation of hepatitis B following withdrawal of chloroquine]. *Schweiz Med Wochenschr* 124(18), 759–762.
34 Ahsan T, Rab SM, Shekhani MS (1993) Falciparum malaria or fulminant hepatic failure? *J Pak Med Assoc* 43(10), 206–208.
35 Newman RD, Parise ME, Slutsker L *et al.* (2003) Safety, efficacy and determinants of effectiveness of antimalarial drugs during pregnancy: implications for prevention programmes in *Plasmodium falciparum*-endemic sub-Saharan Africa. *Trop Med Int Health* 8(6), 488–506.
36 Alonso PL, Guinovart C (2004) Malaria: situation, control tools, resources and solutions. *Ars Med Rev Hum* 2, 166–179.
37 Alonso PL, Sacarlal J, Aponte JJ *et al.* (2004) Efficacy of the RTS,S/AS02A vaccine against *Plasmodium falciparum* infection and disease in young African children: randomised controlled trial. *Lancet* 364(9443), 1411–1420.
38 Alonso PL, Sacarlal J, Aponte JJ *et al.* (2005) Duration of protection with RTS,S/AS02A malaria vaccine in prevention of *Plasmodium falciparum* disease in Mozambican children: single-blind extended follow-up of a randomised controlled trial. *Lancet* 366(9502), 2012–2018.

10.3.3 Visceral leishmaniasis

Manuel Corachan

Introduction

The protozoan parasite responsible for visceral leishmaniasis (VL) was morphologically described by Laveran and Mesnil in 1903; it was given the name of *Leishmania donovani* when, almost simultaneously, Leishman in Calcutta and Donovan in Madras published a sketch of the parasite in the spleens of patients with remittent types of fevers.

The epidemiology, diagnostic approach and therapy of VL have changed significantly in the last two decades, as a result primarily of the increase in *Leishmania* coinfection with the human immunodeficiency virus (HIV virus). Coinfection has been brought under partial control in some areas, such as the the EU Mediterranean, zone thanks to the new therapeutic possibilities and preventive efforts targeted against drug addiction; however, in other places, it is still on the rise, as in Brazil. Besides representing an emerging risk for HIV-immunocompromised

subjects, *Leishmania* is also emerging as a risk for people who receive organ transplants.

Transmission occurs through phlebotomine arthropods with *Phlebotomus argentipes* in the Old World and *Lutzomia longipalpis* in the New World being the most prevalent among several hundred sandfly species described. The phlebotomines ingest the parasite from a human or canine reservoir which can be wild or domestic. The parasite inoculated by the sandfly colonizes the mononuclear phagocytic system throughout the body, stimulating a T-helper cell response that may contain disease despite the persistence of the infection. Infected people raise antibodies to *Leishmania*, but these are not protective. Infection includes a febrile illness that may result in marked organomegaly, cachexia and pancytopenia.

The overall annual incidence of infection by *Leishmania* species is estimated to be between 1.5 and 2 million; this includes the various types of clinical presentations (cutaneous, mucocutaneous or visceral). Visceral leishmaniasis is also known as 'kala-azar' from the Hindi language meaning dark fever.

Epidemiology

Leishmania infection is endemic in more than 60 countries with an estimated 500 000 new cases per year and around 41 000 deaths [1].

The sandflies have nocturnal feeding habits. Their precise breeding sites are still controversial, but it is known that they feed on several species of mammals including rodents, canines, marsupials and primates. In the Old World, the dog is the most important reservoir, and the animal itself may undergo a severe and often fatal disease.

Infection via blood transfusion or through neonatal transmission is extremely rare; however, the exchange of syringes among drug users has been responsible for the spread of *Leishmania* coinfection with HIV in Europe, especially in the Mediterranean basin. Infection can be transmitted by transplantation of infected organs.

In the last two decades, endemic areas have undergone considerable geographical extension for several reasons, among which war, famine, drought and economic migration were the most important [2].

A small outbreak of VL produced by *Leishmania tropica* (usually producing urban cutaneous leishmaniasis) affected the US troops during the Gulf War. The Indian subcontinent, Sudan and the northeast of Brazil register more than 80% of total cases. The epidemiology in India and Brazil shows a similar pattern in which the classical rural infection and the urban HIV pandemic are joining forces, thus resulting in significant numbers of coinfections. The spreading of coinfections produces a considerable increase in the human reservoir and complicates the diagnosis and therapy of the parasitic disease, which will be prone to frequent relapses [3]. In this setting therapeutic responses are poor, clinical manifestations atypical and *Leishmania* serology often negative, thus hampering the diagnostic approach.

Table 1 Visceral leishmaniasis.

Species	Geography	Reservoir
L. donovani	East Africa, India	Human
L. infantum	Mediterranean	Canine
L. chagasi[a]	Central and South America	Canine

[a]*L. chagasi* is currently considered as a synonym of *L. infantum*.

In East Africa and the Indian subcontinent humans are the reservoir of the parasite; most VL elsewhere are considered as zoonoses, and their geographical distribution coincides with that of the presence of the vector. The geographical distribution of the species and the nature of the reservoir are shown in Table 1 and Figure 1.

Clinical features

The incubation period ranges from a few weeks to several years (average 2–6 months).

Fever is the dominant feature, and the disease is classically considered in the differential diagnosis of pyrexia of unknown origin (PUO) syndrome. All types of fever have been described, bimodal being the most frequent; apyrexial periods are usually intercalated. There is progressive asthenia and weight loss accompanied by signs of anaemia, lymphadenopathy, occasional hepatomegaly and the almost constant finding of progressive splenomegaly that extends below the umbilicus producing a protuberant abdomen.

The size of the spleen correlates with the degree of pancytopenia and the duration of the illness. There is no convincing evidence that autoimmune haemolysis contributes to the severity of anaemia [4]. Liver laboratory abnormalities are not characteristic; aminotransferases and alkaline phosphatase may be increased, usually to a relatively minor degree. Overt ascites and liver failure occur rarely.

Pulmonary involvement and bleeding episodes can occur in advanced disease. The natural course of the chronic infection will be fatal in 90% of cases due to intercurrent infections or bleeding complications.

Clinical variants of these 'classical' features occur. Subclinical infections have been described in Kenya, Brazil and the Mediterranean. These subclinical cases may change to full-blown disease when the patient immune status changes. Immunosuppressive therapy or the development of acquired immunodeficiency syndrome (AIDS) may convert latent infections of long standing to overt VL. In the Mediterranean basin, the form of kala-azar caused by *Leishmania infantum* is predominant in the under 5-year age group compared with the adult form; however, at the peak of the AIDS epidemic in the European Mediterranean area, the prevalences of *L. infantum* infection became almost equal in children and adults. VL has

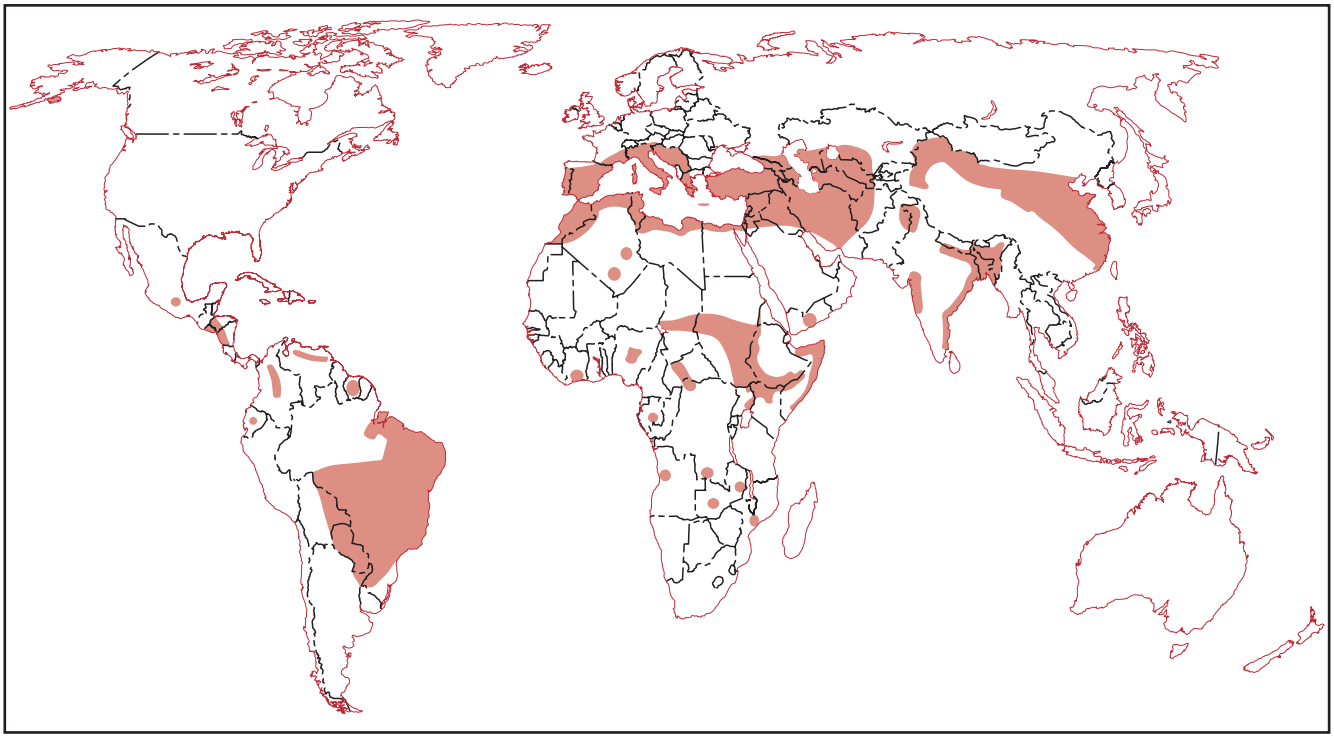

Fig. 1 Map showing geographical distribution of visceral leishmaniasis, showing the four main zones and sporadic human cases.

developed in patients who received liver, heart and kidney transplants.

Post-kala-azar dermal leishmaniasis (PKDL)

Between 5% and 60% (depending on the geographical area) of patients with VL develop PKDL during or years after receiving treatment. This complication was described many decades ago, but its importance and its epidemiological implications (especially in East Africa) have only recently been recognized. Usually, it appears during the first months after treatment of VL in East Africa but after 2–3 years in the Indian subcontinent and in Asia. PKDL is more severe, the shorter the interval between treatment and the development of the complication. Younger age is predictive of severity.

It presents as a macular, papular rash in a patient who is recovering from systemic illness, starting on the face and spreading over the rest of the body when severe. Biopsy of the lesions can show the parasites, although the clinical picture in a treated patient is the main diagnostic element. Serological tests and the leishmanin skin test are of no clinical value in this situation, but polymerase chain reaction (PCR) will detect the parasites in more than 80% of cases [5].

Laboratory parameters and diagnosis

Pancytopenia is accompanied by important changes in plasma proteins resulting in the classical profile of low albumin levels together with overproduction of polyclonal IgG; erythrocyte sedimentation rate (ESR) and C-reactive protein are increased due to the inflammatory syndrome.

Pancytopenia is a consequence of hypersplenism. Anaemia is the most visible sign. In chronic disease, neutropenia increases the risk of associated infections and thrombopenia is responsible for bleeding episodes if alteration of coagulation factors is also present.

The identification of the parasite through culture techniques or direct observation confirms the clinical suspicion. The parasite can be stained or cultured in aspirates of bone marrow, spleen, lymph node or liver. Most rewarding is the spleen aspirate used as a last measure in developed countries but as a routine diagnosis in field practice in Kenya and Sudan (Fig. 2).

In patients with *Leishmania*/HIV coinfection, the parasite can often be directly detected in peripheral blood. In immunocompromised patients, it is also possible to find parasites in unusual localizations such as the pleural fluid, cerebrospinal fluid and in the mucosa of the digestive tract.

The classical blood agar 3N medium is the most currently used, but other diphasic and liquid methods are also available; the strains involved in visceral leishmaniasis are less difficult to isolate and culture than the cutaneous strains, such as *Leishmania venezuelensis* or *Leishmania braziliensis*.

PCR evaluation is very sensitive, permitting the detection of very low levels of the parasite in the blood [6,7]. This technique is also useful in monitoring relapses of HIV coinfections, but

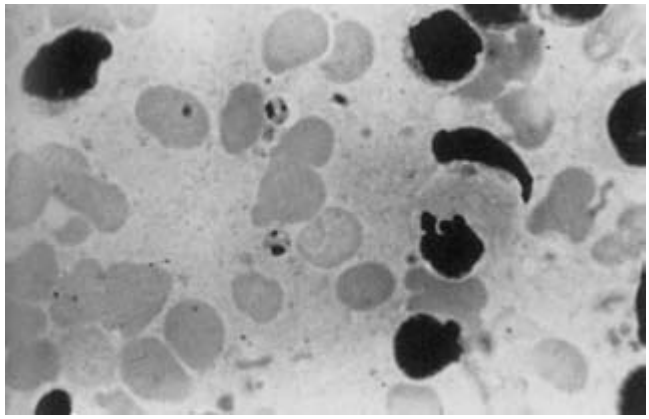

(a)

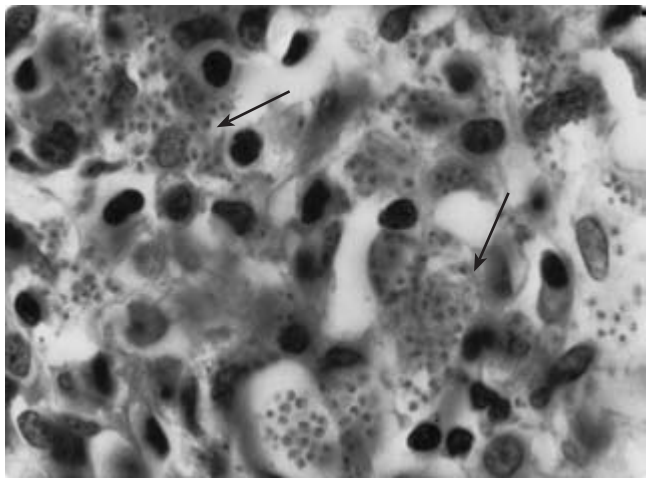

(b)

Fig. 2 (a) Two amastigotes of *L. donovani* in the spleen aspirate of a patient with visceral leishmaniasis. Parasites are usually extracellular in smears, because the macrophages that contain them rupture when the smear is made; they are intracellular in tissue sections. (b) *L. donovani* in Kupffer cells in the liver (× 1000).

it is still not available for fieldwork leishmaniasis in areas of high prevalence such as in the horn of Africa.

Serological techniques

Immunocompetent patients raise high levels of specific antibodies during active VL, but in immunocompromised patients, the antibody response is blunter. Direct and latex agglutination tests, Dot and fast enzyme-linked immunosorbent assay (ELISA) are usually available in most laboratories for the identification of antibodies. However, cross-reactions with other blood protozoa (malaria and trypanosomes) and helminths (schistosoma) do occur.

Research efforts are now devoted to the development of recombinant DNA-derived leishmania proteins of potential use in diagnosis and probably in future vaccines. A promising recombinant antigen is rK39, which is used to diagnose VL caused by *L. donovani*, *L. chagasi* or *L. infantum*. Serological testing showed that 98% of Brazilian and 100% of Sudanese VL patients have high levels of antibodies against this antigen, and this finding correlated with clinical disease [8,9].

High antibody titres of *L. donovani* hydrophilic acylated surface protein (HASPB1) and *L. major* gen B protein (GBP) are present in the serum of VL patients. Both can also induce antibodies that are detectable in patients with post-kala-azar dermal leishmaniasis (PKDL). Public health attention is also directed towards the identification of asymptomatic infected dogs (the main reservoir of the infection), as the control of the canine disease could have an impact in reducing transmission to humans.

Treatment

The earlier the treatment is started, the better is the response. It is worth remembering that there are many more subclinical than overt cases of VL [10]; generally speaking, the clinical response is slow whatever the drug used and often a second course of treatment is needed to complete the cure.

Antimonials (already in use for almost a century) are still the most widely used therapy in less developed countries because of economic constraints. An exception is northern India (Bihar state) where resistance to the antimonials has emerged. Table 2 shows the antileishmanial drugs currently utilized.

Antimonial therapy

Resistance to these widely used drugs (pentavalent anti-monials) is increasing, as suggested by studies in India [11] and Sudan. They have several disadvantages, mainly cardiotoxicity (at the repolarization conduction level) and other side-effects such as arthralgia, nausea and acute pancreatitis (the last is frequent in HIV coinfections). Relapses are frequent after inadequate or incomplete treatment with a single drug as monotherapy may select resistant mutants. Local pain at sites of injection due to the prolonged treatment diminishes acceptance of this drug in endemic areas. It has practically been abandoned in industrialized areas with fewer economic constraints.

Amphotericin B

Currently used for treating systemic fungal infections, it has become the first-line drug in areas of known resistance and in wealthy countries; the more expensive lipid-associated amphotericin B or the liposomal amphotericin are used as alternative treatments. Efficient plasma concentrations are achieved with its intravenous infusion. Fever, chills, thrombophlebitis, hypotension, vertigo and, exceptionally, cardiogenic shock are infusion related side-effects that can be lessened by a slow rate of infusion and the addition of corticosteroids at the infusion drip. The renal elimination is rather slow; nephrotoxicity is the most serious of the more frequent side-effects.

Table 2 Antileishmanial therapy.

Drug	Dose	Notes
Pentavalent antimonials Sodium stibogluconate (100-mL bottle: 100 mg Sb/mL) Meglumine antimoniate (5-mL ampoules: 85 mg Sb/mL	20 mg/kg/day for 3–6 weeks Depending on the geographical area, parenterally	Haematological and biochemistry controls as well as ECG controls are recommended during the period of treatment
Amphotericin B Formulated as a colloidal suspension	7–20 mg/kg as a total dose over 2–3 weeks	Slow (6–8 h) intravenous infusion Watch dose-limiting toxicity
Lipid-associated amphotericin B Liposomal Colloidal dispersion	10–20 mg/kg total dose. Given over 10 days (5–10 doses) i.v.	Retreatment of antimonial failures. First line in an HIV coinfection. First line in wealthy countries Optimum dosage needs to be defined
Miltefosine Alkyl phospholipid	100 mg/day over 4 weeks 2.5 mg/kg/day in children	First highly effective oral drug Most probably will need to be used in combination to avoid early development of resistance

In areas of India where it has become the drug of choice, amphotericin B achieved more than 97% cure rates with no evidence of resistance to date [12].

Lipid-associated amphotericin B

Liposomal amphotericin B is less toxic than the conventional amphotericin B and more efficient in immunocompetent as well as in immunocompromised patients; it has become first-line treatment in the developed countries.

A short course of treatment is currently used (see Table 2). For immunocompromised patients, the number of injections is increased to a total of 10.

Two other lipid-associated formulations, amphotericin B phospholipid complex and amphotericin B cholesterol dispersion, are not yet licensed for the treatment of visceral leishmaniasis.

Miltefosine

This alkyl phospholipid derives from oncology. Studies in India have shown a 100% cure rate with a dosage of 100 mg/day orally for 4 weeks. Gastrointestinal side-effects are frequent but do not usually interfere with treatment. Toxicity to male dog gonads has raised concern for teratogenicity, but in phase III trials in humans the drug did not affect male fertility [2].

The long half-life of this drug together with its narrow therapeutic index have a potential for the emergence of resistant mutants; combination therapy should be considered to delay this possibility.

Others

Paromomycin and aminosidine

These broad-spectrum aminoglycosides were used successfully in combination with pentavalent antimonials [13] in East Africa, India and in the UK in complicated cases. This valuable drug is at present undergoing a phase III clinical trial promoted by the Tropical Diseases Research (TDR) programme of the WHO as the traditional parenteral formulation is no longer available on the market.

Imidazoles

These have weak anti-leishmania activity when used as a single drug. In combination with allopurinol, isolated cases of cure have been reported, but there have been no formal clinical trials of the combination.

Allopurinol

This is another oral drug with weak anti-leishmania activity when used as monotherapy. Limited clinical trials have also shown a synergistic activity with pentavalent antimonials as well as with the imidazoles.

Interferon-γ

Because *Leishmania* infection depends on a defect in macrophage activation, the therapeutic use of this macrophage-activating cytokine has a rationale, but no convincing clinical studies have been carried out to date with this agent.

Treatment of PKDL

Most cases of PKDL undergo spontaneous healing, but this can take months. When treatment is required, the same drugs are used as for classical VL. Patients with mild clinical presentation can be left untreated. Patients with more severe forms, high serum antibody titres and a negative leishmanin skin test should receive treatment [5].

Cure rates of 62–90% were achieved with sodium stibogluconate at 20 mg/kg/day in India; this therapy needs to be administered for 3–4 months. Case reports are available on the efficacy of amphotericin B and liposomal amphotericin B; the latter is probably the best drug for the treatment of both VL and PKDL.

There is a need for testing of the new oral compound miltefosine. If proven beneficial, it could avoid the lengthy courses of daily parenteral treatment in countries where the amphotericin group of drugs are too expensive for the national health services.

References

1 WHO (2001) *The World Health Report 2001*. Geneva: WHO.

2 Guerin PhJ, Olliaro P, Sundar S *et al.* (2002) Visceral leishmaniasis: current status of control, diagnosis and treatment. *Lancet Infect Dis* 2, 494–501.

3 Pintado V, Lopez Velez R (2001) HIV-associated visceral leishmaniasis. *Clin Microbiol Infect* 7, 291–300.

4 Fleming AS, de Silva PS (2003) Haematological disease in the tropics. In: Cook GC, Zumla A (eds) *Manson's Tropical Diseases*, 21st edn. Philadelphia: Saunders, pp. 170–251.

5 Zijlstra EE, Musa AM, Khalil EAG *et al.* (2003) Post-kala-azar dermal leishmaniasis. *Lancet Infect Dis* 3, 87–98.

6 Salotra P, Sreenivas G, Pogue GP *et al.* (2001) Development of a species-specific PCR assay for detection of *Leishmania donovani* in clinical samples from patients with kala-azar and post kala-azar dermal leishmaniasis. *J Clin Microbiol* 39, 849–854.

7 Kubar J, Fragaki K (2005) Recombinant DNA-derived leishmania proteins: from the laboratory to the field. *Lancet Infect Dis* 5, 107–114.

8 Burns JM Jr, Shrefler WG, Benson DR *et al.* (1993) Molecular characterization of a kinesin-related antigen of *Leishmania chagasi* that detects specific antibody in African and American visceral leishmaniasis. *Proc Natl Acad Sci USA* 90, 775–779.

9 Ziljstra EE, Nur Y, Desjeux P *et al.* (2001) Diagnosing visceral leishmaniasis with the recombinant K39 strip test: experience from the Sudan. *Trop Med Int Health* 6, 108–113.

10 Ho M, Siongok TK, Lyerly WH *et al.* (1982) Prevalence and disease spectrum in a new focus of visceral leishmaniasis in Kenya. *Trans R Soc Trop Med Hyg* 76, 741–746.

11 Sundar S (2001) Drug resistance in Indian visceral leishmaniasis. *Trop Med Int Health* 6, 849–854.

12 Thakur CP, Sinha GP, Pandey AK (1996) Comparison of regimens of amphotericin B deoxycholate in kala-azar. *Ind J Med Res* 103, 259–263.

13 Thakur CP, Kanyok TP, Pandey AK (2000) A prospective randomised, comparative, open-label trial of the safety and efficacy of paromomycin (aminosidine) plus sodium stibogluconate versus sodium stibogluconate alone for the treatment of visceral leishmaniasis. *Trans R Soc Trop Med Hyg* 94, 429–431.

10.4 Helminthiasis

10.4.1 Blood flukes (schistosomes) and liver flukes

Flair Carrilho, Pedro Paulo Chieffi and Luiz Caetano Da Silva

Blood flukes

Blood flukes are trematode worms belonging to the genus *Schistosoma*, which inhabit either intestinal or vesical venous circulations in their definitive hosts. Among the five species of *Schistosoma* that infect humans, *Schistosoma mansoni*, *S. japonicum*, *S. intercalatum* and *S. mekongi* are found in the intestinal venous circulation, and *S. mansoni* and *S. japonicum* mainly affect the liver through the portal system, sometimes causing severe disease. *S. haematobium*, another important human parasite, inhabits the vesical venules and may damage the urinary bladder and the ureters.

The life cycle of *Schistosoma* species alternates between a sexual stage of adult schistosomes in the definitive vertebrate host and an asexual stage in a molluscan host. *S. mansoni* has snails of the genus *Biomphalaria* as intermediate hosts; *Oncomelania* and *Bulinus* are the molluscan intermediate hosts of *S. japonicum* and *S. haematobium*, respectively, and *S. intercalatum* and *S. mekongi* have the asexual stages in snails of the genus *Bulinus* and *Neotricula* respectively.

The life cycle of schistosomes begins with the shedding of eggs in the urine (*S. haematobium*) or stool (other *Schistosoma* species) of the vertebrate hosts. After reaching fresh water collections, the miracidium, a free-swimming stage, hatches from the egg and infects the snail intermediate host, giving rise to sporocysts that, at the end of 35–45 days, produce numerous free-swimming cercariae, the infective stage in vertebrate hosts. Both miracidium and cercariae are short-lived stages, keeping their infective properties for only 10–12 h.

Cercariae may actively enter human skin and give rise to schistosomulae, which mature to adult *Schistosoma*, reaching their normal habitat according to each species: the venous urinary system for *S. haematobium* and the mesenteric and portal venous systems for the other *Schistosoma* species. Approximately 45–60 days after infection, eggs are eliminated in either the urine or the stool of the infected vertebrate host.

Excluding *S. haematobium*, which infects humans almost exclusively, other *Schistosoma* species infecting man are zoonoses. *S. haematobium* has rarely been found to infect other vertebrates (primates or rodents), but this kind of infection is considered to be coincidental, without importance in the natural transmission to humans. *S. japonicum*, besides man, can infect several species of wild and domestic mammals; *S. mekongi* has only dogs as reservoir hosts. *S. mansoni* infects mainly humans, but it was frequently found to be a natural infection in several species of small rodents in Brazilian endemic areas.

Schistosomiasis mansoni

This section will discuss liver disease caused by *S. mansoni*, which is the most widely distributed schistosome in man and is found in both the Old and New Worlds. Mansonian schistosomiasis is endemic in the northeast of Brazil, where it affects around 2.5 million people [1]. The prevalence of *S. mansoni* is nowadays very low (below 1%) in some areas such as the Caribbean Islands, Venezuela and Suriname. This might be due, at least in part, to the predatory action of some snails (e.g. *Thiara granifera*) on the intermediate host *Biomphalaria glabrata* [2]. This hypothesis may be valid in restricted areas, but not where the *Biomphalaria* snails are distributed in vast territories. In Brazil, a big programme to control *S. mansoni* based on treatment with oxamniquine and snail control resulted in a sharp decrease in the hepatosplenic and other advanced forms of schistosomiasis [1].

Schistosomiasis is considered to be a 'man-made disease' because man is the victim and the source of infection at the same time. People's habits regarding defaecation in canal water and exposure to the polluted water by bathing, swimming for recreation and washing purposes characterize the endemic areas. Exposure starts as early as 6 months of age, and infection and its severity occur in early childhood (10–14 years) followed by progressive decrease with increasing age. The lower prevalence

in adults may be explained by less exposure to contaminated water and the development of concomitant acquired immunity [1].

Environmental changes that result from the development of water resources and the growth and migration of populations can facilitate the spread of schistosomiasis. For example, the construction of the Diama Dam led to the introduction of *S. mansoni* into Mauritania and Senegal [3].

Clinical forms and pathogenesis

Liver disease in schistosomiasis results from the entrapment of eggs that are not excreted but instead lodge in portal venules that match the smallest diameter of the eggs, about 50 μm. Eggs in the liver remain viable for about 3 weeks and secrete products that initially elicit a characteristic response, the schistosome egg granuloma. In some persons with heavy infections, the final result of hepatic schistosomiasis is a severe portal fibrosis (Fig. 1). Advanced schistosomal hepatic fibrosis gives a gross appearance of greatly enlarged fibrotic portal tracts, described by Symmers in 1904 as resembling clay pipestems thrust through the liver, and now termed Symmers' pipestem fibrosis.

Schistosome infection can be divided into distinct stages. The prepatent stage begins with cercarial invasion and ends with initiation of egg laying. The patent (acute) stage coincides with schistosome egg production and can be further divided into acute and chronic schistosomiasis [1].

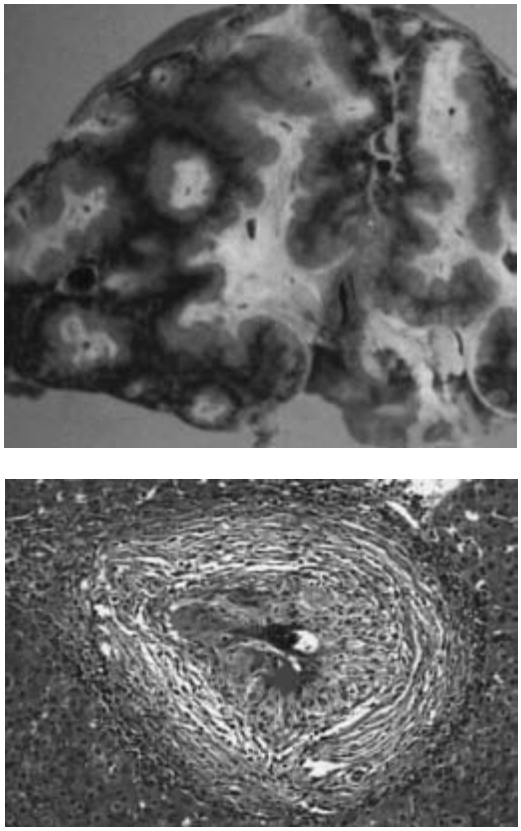

(a)

(b)

Fig. 1 Symmers' periportal fibrosis of the liver (a) with *Schistosoma mansoni* showing an egg at the centre of a granuloma (b).

Acute form (Katayama fever)

Acute schistosomiasis results from a new fresh infection. Clinical manifestations may be absent, particularly in individuals living in an endemic area. Occasionally, some individuals may develop the syndrome after exposure to water contaminated by *S. mansoni* cercariae. The most common manifestations are fever, chills, weakness, headache, anorexia, nausea, vomiting and general malaise. Severe watery diarrhoea, sometimes bloody stools, non-productive cough and rapid weight loss may develop [1].

Occasionally, patients with acute schistosomiasis mansoni are misdiagnosed as having typhoid fever, hepatitis, pancreatitis, miliary tuberculosis, myelitis and appendicitis. Hepatomegaly is virtually constant and frequently accompanied by slight right upper quadrant tenderness. Transitory generalized lymphadenopathy and splenomegaly appear frequently, but there is no jaundice. Laboratory examinations show leucocytosis with eosinophilia, which can reach 70%, and slight changes in serum aminotransferase [1].

Ultrasonography studies are scarce in patients with acute schistosomiasis, and the ultrasound and computerized tomography (CT) features of this form are unknown.

Acute schistosomiasis usually progresses to an asymptomatic infection and eventually to the chronic forms. In patients with acute schistosomiasis admitted to hospital with severe symptoms, treatment should be started with corticosteroids, followed by schistosomicides. However, this situation is quite uncommon.

Chronic forms

The life cycle of the parasite in the host explains why *S. mansoni* can produce damage in organs other than the intestines and the liver [4]. However, these localizations are by far the most frequent.

Intestinal and hepatointestinal forms

Intestinal manifestations may be diarrhoea and colicky pain, but asymptomatic forms are more frequent.

Rearrangement of the egg granuloma is observed during the transition of the acute form to the chronic form; this results in a less pathogenic effect on the liver cells. According to some authors, in patients who fail to remodel the granuloma, the disease tends to evolve to the hepatosplenic form [5].

As the intestinal form is frequently asymptomatic, the diagnosis is based on the finding of *S. mansoni* eggs in the stools of the patients.

Schistosomotic intestinal poliposis is uncommon in Brazil, but is frequently observed in Egypt [1].

The subdivision into an intestinal form and a hepatointestinal form is not uniformly accepted, but enlargement of the liver, mainly of the left lobe, may be seen in schistosomotic individuals living in highly endemic areas, and this characterizes the

hepatointestinal form. Recently, portal and splenic overflow was reported in both hepatointestinal and hepatosplenic forms of schistosomiasis by our group [1].

Hepatosplenic form and portal hypertension

Pathophysiology. Formation of the egg granuloma appears to be the main process responsible for the tissue damage in organs such as liver, intestines, lung and pancreas; however, immunocomplexes derived from parasite antigens are responsible for additional lesions such as glomerulopathy [4].

Hepatic granulomas initially form endovascularly in presinusoidal areas, usually at inlet venules or terminal portal venules. Following an initial endothelial proliferation, the blood vessels rapidly become occluded with eventual obliteration of the lumen and displacement of hepatocytes by the developing granuloma. Symmers' fibrosis of the liver, which may result in portal hypertension and congestive splenomegaly, predominates in the 6- to 20-year age group and occurs 5–15 years after the onset of infection. It is the most severe form and the most common cause of morbidity or death. However, in heavily infected young patients, there is a 'non-congestive' phase of the disease with splenomegaly but without signs of portal hypertension. Data from Brazil show that, in such cases, the spleen may become non-palpable after adequate chemotherapy. In young patients, a strong correlation has been shown repeatedly between the hepatosplenic form and the worm load. Furthermore, experimental studies suggest that massive infections during the initial exposure to cercariae may be important. The individual failure in the immunological modulation of the inflammatory reactions seems to play a role. These and other factors would explain the presence of hepatosplenic schistosomiasis (HSS) in only a small percentage of patients with heavy worm burden [4].

Hepatic periportal fibrosis is caused by the T cell-rich granuloma that develops around schistosome eggs. Experimental models of infection have shown that granuloma and fibrosis are regulated by cytokines. However, it is unknown why advanced periportal fibrosis occurs only in certain subjects.

In some patients with heavy infection, chemotherapy may produce a peculiar type of pulmonary lesions, 'the dead worm' pneumonitis; this event has been attributed to a hyperergic pulmonary reaction to the products of dead worms.

Family-based studies have found a highly significant concentration of hepatosplenic forms among children from the same nuclear family, particularly when the mother was affected by the same form of the disease. Furthermore, hepatosplenic schistosomiasis occurs with higher frequency in whites than in blacks, despite the fact that Brazilian whites have better social and economic conditions. This evidence would point to an as yet undetermined genetic component.

It is generally accepted that *S. mansoni* infection alone does not lead to cirrhosis. Hepatitis B and C virus infections are important pathogenic factors in causing progression of hepatic schistosomiasis to cirrhosis and decompensation.

Haemodynamic aspects. Intrahepatic angiographic changes suggestive of hepatosplenic schistosomiasis are the enlargement of the hepatic veins and a marked reduction in branching, along with a more pronounced arching of large branches [4]. In 50 patients studied by Mies *et al.* [6], the gradient between hepatic vein wedged and free pressures was at the upper limit of normal (9.1 ± 5.7 mmHg). In about 40% of cases, however, it was raised: the gradient ranged from 10.4 to 22.7 mmHg.

Contrast material injected into the portal system shows an intrahepatic pattern characterized by gross amputations of large branches, and by the appearance of a dense network of small-calibre vessels around portal branches. These aspects were described by Bogliolo in 1957 and are known as 'Bogliolo's sign'. Enlargement of splenic and portal veins is usually present. Portal pressure is raised to levels similar to those seen in liver cirrhosis.

Angiographic studies have shown a reduced diameter of the hepatic artery, with thin, arched branches outlining vascular gaps. The tortuous aspect characteristic of liver cirrhosis is not observed. These aspects suggest that the poor intrahepatic arterial vascularization demonstrated by selective arteriography in human hepatosplenic schistosomiasis is due to a 'functional deviation' of arterial blood to the splenic territory [4]. In advanced schistosomiasis, the hepatic artery may be hypertrophic [1].

Total liver blood flow, measured by different methods, is normal; this suggests that the increased portal blood flow is accompanied by a reduction in the arterial blood flow, pointing to an interaction between portal and arterial blood flow.

Dynamic studies have demonstrated that a high splenic blood flow may be responsible for the increased portal blood flow. It seems that the splenic component and the abundant network around portal branches ('Bogliolo's sign') may be preponderant (hyperflow component) over the obstruction of the intrahepatic portal branches produced by parasitosis (presinusoidal block), at least in cases of severe splenomegaly. However, ultrasound studies show that an extensive periportal thickening of the liver may be found in some patients without a palpable spleen, probably as a consequence of spontaneous shunts. Furthermore, schistosomic portal hypertension is not restricted to patients with splenic hyperdynamic circulation. Mies *et al.* [7] showed that, despite small changes in sinusoidal pressure and liver function, schistosomotic patients present with high cardiac index and low systemic vascular resistance compatible with a systemic hyperdynamic circulatory status similar to cirrhosis.

Clinical and laboratory changes. Schistosomiasis mansoni exhibits a wide range of clinical manifestations, varying from asymptomatic to several symptomatic forms. Occasionally, the disease is discovered accidentally, either by a routine stool examination or by enlargement of the liver or spleen on physical examination [4].

Hepatosplenic schistosomiasis can be divided clinically into compensated and decompensated forms. The latter is

characterized by muscular wasting, low serum albumin and, occasionally, chronic ascites. However, other causes, such as alcoholism and hepatitis B and C virus infection, are frequently responsible for the decompensation of liver funetion.

The main symptoms of the hepatosplenic form are related to splenomegaly and haemorrhage. Spontaneous ascites is uncommon; it usually appears after episodes of bleeding or infection or when schistosomiasis is associated with other causes of liver damage.

Spontaneous neuropsychiatric symptoms are very rare in hepatosplenic schistosomiasis, even with abundant collateral circulation. These symptoms are seen only after precipitating factors, mainly haemorrhage or infection. Anaemia with delayed somatic and sexual development may be observed in young people. Spider naevi, gynaecomastia and palmar erythema are rare in uncomplicated schistosomiasis. Leucopenia and thrombocytopenia are found in most cases of hepatosplenic schistosomiasis [4].

In hepatosplenic schistosomiasis, clotting defects result from an impaired rate of protein synthesis by the liver or localized consumption coagulopathy, or both. The relative role of these two factors is not well established. Changes in the plasma coagulation systems may be partially corrected by subcutaneous heparinization but the most effective correction is by splenectomy [8].

Diagnosis

Direct methods of diagnosis are based on the demonstration of eggs or of miracidia. Eggs may be found in the stools by the Kato–Katz quantitative method. The hatching test provides a simple, cheap and useful method, without the need for microscopy and is especially useful for the diagnosis of *S. haematobium*, whose eggs are eliminated into the urine. Rectal biopsy is used in suspected cases with negative parasitological tests.

Immunological methods, indirect immunofluorescence, indirect haemagglutination and enzyme-linked immunosorbent assay (ELISA) give a high degree of positivity.

Antibody titres are usually higher in the hepatosplenic form than in the hepatointestinal form. Titres increase early and significantly after chemotherapy as a consequence of the death of the worms.

A major diagnostic problem is the demonstration of periportal fibrosis at histology, even with wedged liver biopsies. Ultrasonography has however become a reliable and sensitive method of demonstrating this type of lesion [9]. Ultrasonography can provide reliable information on the state of internal organs in schistosomiasis as well as on regression of pathological changes after treatment.

Periportal fibrosis, seen in ultrasonography as echodense areas along the portal vein (Fig. 2), is an important diagnostic feature, and also an indicator of the possible existence of portal hypertension. Until fibrosis becomes advanced and generalized, thickened patches are typically scattered throughout the liver; the portal vein and the structures around it can best be visualized in the left liver lobule [9].

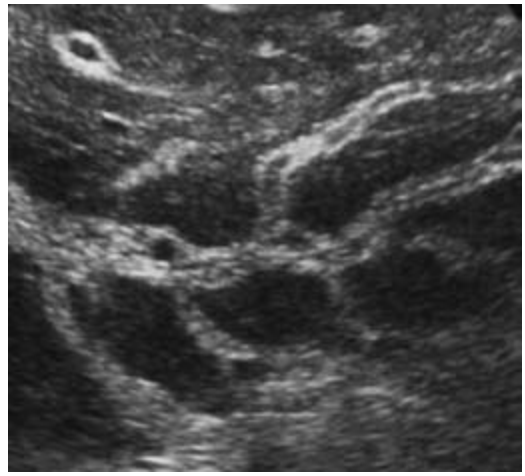

Fig. 2 Ultrasonographic features of periportal fibrosis in schistosomiasis mansoni.

Variceal bleeding in patients with hepatosplenic schistosomiasis correlates with endoscopic (variceal size, red signs, congestive gastropathy and fundic varices) and ultrasonographic (portal vein diameter and periportal thickness) parameters [10].

By Doppler ultrasonography, hepatic left lobe hypertrophy and right lobe atrophy are commonly observed in hepatosplenic schistosomiasis [9,11]. In summary, our group showed that portal overflow may be found in both forms of schistosomiasis.

Course and prognosis

The prognosis for hepatic schistosomiasis is good in the acute and hepatointestinal forms. The prognosis for the hepatosplenic forms depends on whether the liver disease is compensated or decompensated. Fortunately, most cases remain compensated: the prognosis is better than for patients with cirrhosis. Recovery after haematemesis is rapid and the patients live longer [5]. Hepatic coma and ascites after haemorrhage are less frequent and easier to control [4].

Treatment

Treatment of helminthiasis

The treatment of helminthiasis is indicated in all stages and clinical forms of mansonian schistosomiasis, but some patients with a very advanced form or with concomitant non-hepatic disorders may not tolerate chemotherapy.

There are two highly effective chemotherapeutic drugs: oxamniquine, used at different doses in Latin America and Africa, and praziquantel; both are given by the oral route.

Praziquantel can also be safely given to patients with compensated hepatosplenic forms of the disease.

Treatment of portal hypertension

Non-surgical treatment of bleeding oesophageal varices

The management of patients with oesophageal and gastric varices remains a challenge, particularly when prophylactic procedures are considered.

Endoscopic changes indicative of a high risk of bleeding include the finding of large varices, cherry-red spots, varices on varices, erosions on varices [10] and hypertensive gastropathy. These and ultrasonographic changes should be used in the identification of patients for prophylactic procedures, including drug therapy, sclerotherapy and surgery.

The utility of β-blockers such as propranolol, which are efficacious in liver cirrhosis, is not well established in chronic schistosomiasis.

Propranolol seems to protect patients with schistosomiasis against gastrointestinal rebleeding during the short periods of time that precede definitive surgical treatment. A single oral 'blockade dose' may induce a significant decrease in the azygous blood flow [12].

In a retrospective study of sclerotherapy of bleeding oesophageal varices in schistosomiasis, the eradication of varices was obtained in nearly 70% of patients during a follow-up period lasting between 48 and 132 months. Sclerotherapy was effective in the control of rebleeding in 97% of the patients previously submitted to portal hypertension surgery and in 73% of the patients without previous portal hypertension surgery, with a smaller number of sessions of sclerotherapy per patient in the former group [13]. A prospective non-randomized trial comparing elective sclerotherapy with a control group during a 5-year follow-up showed that the incidence of rebleeding was 28% and 45%, respectively, a difference that was not significant; however, the mortality from rupture of oesophageal varices was 3% in the sclerotherapy group and 28% in the control group, which was a significant difference [14].

Surgical treatment of portal hypertension

Until 1986, three major types of operations were used in Brazil: oesophagogastric devascularization plus splenectomy (EGDS), splenectomy with splenorenal shunt, selective portal decompression (SPD) or distal splenorenal shunt (DSS).

In a prospective randomized trial [15] comparing the results of the three surgical techniques, the proximal splenorenal shunt (SRS) induced portosystemic encephalopathy with a high frequency (39%). Later on, a long-term follow-up study (85.7 ± 33.1 months) in the same patients showed that gastrointestinal bleeding occurred in 24.1% of the patients, with no significant differences among the three groups, but rebleeding because of varices was more frequent after oesophagogastric devascularization with splenectomy (EGDS). Hepatic encephalopathy was significantly higher after proximal SRS (39.3%) compared with distal splenorenal shunting (DSS, 14.8%) and EGDS (0%). Mortality was also significantly higher after SRS (42.9%) compared with DSS (14.8%) and EGDS (7.1%). EGDS therefore appeared to be the best surgical option.

In our department, patients with schistosomiasis and bleeding oesophageal varices are treated with oesophagogastric devascularization with splenectomy and, if rebleeding occurs, by sclerosis of the varices [4].

Liver flukes

Definition

Liver flukes are trematode worms found in the bile ducts, where they may determine hepatic disease. Some species such as *Fasciola hepatica*, *F. gigantica*, *Opisthorchis felineus*, *O. viverrini* and *Clonorchis sinensis* can infect humans. Rarely, *Dicrocoelium dendriticum* and *Eurytreme pancreaticum* produce human infections.

Fasciola hepatica and *Fasciola gigantica*

The genus *Fasciola* comprises digenetic trematode parasites of herbivorous mammals such as livestock. Two species, *F. hepatica* and *F. gigantica*, are known, and the former is much more important as a human parasite because of its higher prevalence rate. *F. hepatica* infects sheep or cattle in Central and South America, some European countries, Australia, China and the Middle East. *F. gigantica* is endemic in Southeast Asia, some African countries and in the western Pacific [16].

The human infection by *F. hepatica* or *F. gigantica* depends on the ingestion of raw vegetables, especially common watercress (*Nasturtium officinale*), in the leaves of which the cercariae, having been eliminated by limnaeid snails of the genus *Lymnaea* or *Galba*, encyst as metacercariae. Less frequently, human infection may result from ingestion of contaminated water by floating metacercariae. In human bile ducts, adults of *Fasciola* can survive at least 10 years. Once in the duodenum, larvae emerge and burrow through the bowel wall into the peritoneal cavity. The larvae penetrate Glisson's capsule and migrate through the hepatic parenchyma to the bile ducts. The larvae mature into adult flukes within the larger intrahepatic bile ducts over 2–3 months and start producing eggs. The eggs are shed in the bile and enter the host intestinal tract through the ampulla of Vater. To complete the life cycle, the eggs must be shed into fresh water, hatch into miracidia and enter fresh water snails, where they develop into cercariae [16].

The pathogenesis of liver disease from fascioliasis results from the larval migration through the hepatic parenchyma and the chronic inflammatory changes induced within the biliary tract. As the larvae travel through the hepatic parenchyma, there is a marked local inflammatory reaction with eosinophilia, hepatocyte necrosis, haemorrhage and abscess formation, followed by fibrosis. The severity of the hepatic inflammation and damage is proportional to the parasite load; in Bolivia, approximately 17% of cases present with massive infestation. In the chronic biliary

phase of infestation, the adult fluke incites hyperplasia and desquamation of the biliary epithelial layer, resulting in thickened, dilated and fibrotic bile ducts. The adult fasciola and its ova, in addition to causing chronic intermittent obstruction, are a nidus for recurrent cholelithiasis. Secondary biliary cirrhosis and sclerosing cholangitis have been reported. The adult fluke is thought to feed on host hepatocytes and biliary epithelial cells while residing in the large intrahepatic and extrahepatic bile ducts [16,17].

The clinical manifestations of fascioliasis are reflective of the parasite life cycle. In 50% of cases, the initial presentation is subclinical. The acute hepatic phase begins within 12 weeks of exposure and is characterized by low-grade fever, tender hepatomegaly, anorexia, nausea and pruritus. A mild to moderate peripheral eosinophilia is common, but can become marked during larval migration through the liver. Elevated levels of alkaline phosphatase and γ-glutamyl transpeptidase are typical, with high aminotransferase levels seen only with significant hepatocellular necrosis. Jaundice, urticaria, weight loss, ascites formation and haemobilia have been reported in children with massive infestations [16,17].

During the chronic biliary phase, patients may be asymptomatic or complain of non-specific symptoms such as dyspepsia, dull right upper quadrant discomfort or diarrhoea. If the biliary tract becomes obstructed (with either flukes or gallstones), patients may present with typical biliary colic, ascending cholangitis, acute pancreatitis or cholecystitis (adult flukes occasionally migrate into the gallbladder). As mentioned previously, chronic inflammation and obstructation have been reported to lead to marked biliary dilatation, sclerosing cholangitis and biliary cirrhosis. In the chronic phase of infestation, peripheral eosinophilia may be mild or absent [16].

Detection of eggs in the faeces, bile or duodenal aspirate is the definitive test. However, multiple stool specimens and concentration techniques are often necessary in light infestations because egg production and shedding may be low. In a patient with the proper clinical presentation and travel history, a negative stool examination does not rule out fascioliasis. ELISA-based tests aid in diagnosis because of their extremely high sensitivity (> 95%) and specificity (97–100%). Serological tests are also useful in the acute phase of disease prior to the larvae maturing into adult liver flukes. Antibody titres should decline after successful therapy and can therefore be used to monitor treatment response [16,17].

Imaging techniques are also helpful in establishing the diagnosis, particularly in the chronic biliary phase. Hepatic ultrasound may demonstrate adult flukes in the bile ducts or gallbladder as well as hyperechoic lesions corresponding to the migrating larvae. CT scanning may also reveal characteristic 1- to 10-mm hypodense linear lesions in a 'radiating' pattern that corresponds to the larval burrows in the hepatic parenchyma. In addition, CT may show small peripheral hypodense nodules, calcifications and a thickened liver capsule. Endoscopic retrograde cholangiopancreatography (ERCP) plays an important role in diagnosis and therapy when biliary obstruction from adult flukes or choledocholithiasis is suspected [16,17].

The current therapy of choice is triclabendazole, 10–12 mg/kg/day. However, this drug is not widely available. The alternative therapy is biothionol, 30–50 mg/kg/day for 10–15 days. Intramuscular dehydroemetine, 1 mg/kg/day for 14 days, is another alternative. Praziquantel is also used for liver flukes but, because *F. hepatica* does not respond to this agent, it is not recommended. In biliary obstruction, ERCP with endoscopic sphincterotomy and antihelminthic therapy are recommended. In light infestation, a dormia basket or biliary balloon can be used to clear the bile ducts of adult flukes. In patients with heavy burden and resistance to oral therapy, intraductal endoscopic treatment with a fasciolicidal agent has been successful; a 10% povidine iodine solution (mixed with contrast) is instilled into the biliary system and left in place by occluding the distal common bile duct with a biliary balloon (for 10 min), after which the ducts can be swept free of the dead liver flukes [16–19].

Clonorchis sinensis, *Opisthorchis felineus* and *Opisthorchis viverrini*

Clonorchis sinensis is a trematode endemic in many oriental countries such as Taiwan, continental China, Japan, South and North Korea and Vietnam. Anecdotal human infections have been noticed in western countries as a consequence of imported contaminated food from endemic areas. *C. sinensis* shows a zoonotic behaviour, infecting several mammal species besides man. Dogs, cats, pigs, rats, badgers, mink and camels can harbour natural infections. In humans, the adult worms can survive for a long time (approximately 20 years). Humans and other mammal species may be infected by *C. sinensis* by ingestion of either raw or undercooked freshwater fish of the family Cyprinidae, in which metacercariae can be encysted. The fish usually become infected by ingesting snails of the genus *Parafossarulus*; less frequently, fish infection is caused by ingestion of snails of the genus *Thiara* or *Melanoides* [16,20].

Opisthorchis viverrini is the most common liver fluke infestation in Southeast Asia. The World Health Organization estimates that 16 million people worldwide are infested with *O. felineus* and another 10 million with *O. viverrini*. These three liver flukes are found in close association with fish-eating mammals and the human consumption of raw or pickled fish. As in fascioliasis, these liver flukes can survive for decades in the host biliary system [16,20].

The pathogenesis of hepatic disease in *Clonorchis* and *Opisthorchis* human infections depends on alterations in the biliary tract induced by their infestation, which may either be acute or, most commonly, chronic. The severity of the disease is, in the majority of cases, a consequence of the worm burden. The acute phases of *Clonorchis* and *Opisthorchis* infections are usually asymptomatic but, in 10% of the patients, fever, malaise and abdominal pain may be present. Patients with chronic heavy infections by *C. sinensis* usually complain of weakness, weight

loss, abdominal pain and diarrhoea. The development of intrahepatic gallstones is common and, sometimes, cholangitis and cholecystitis occur. The rate of cholangiocarcinoma is higher in these patients. Mild infections by *O. viverrini* are usually asymptomatic. When the worm burden is higher, there is loss of appetite, abdominal pain, flatulence, moderate fever and, more rarely, jaundice. Eventually, hepatic cirrhosis and cholangiocarcinoma may develop. In patients infected by *O. felineus* symptoms were the same as those with *O. viverrini*; however, rates of cholangiocarcinoma were not higher [21–23].

Detection of eggs in the faeces, bile or duodenal aspirate is the definitive test. However, multiple stool specimens and concentration techniques are often necessary in light infestations because egg production may be low. Serological tests are available for *Clonorchis* (immunoblot antigen assay and ELISA) and *O. viverrini* (ELISA) but are not routinely used except as an adjunct to stool studies or cholangiography [16,20].

Transabdominal ultrasonography detects abnormalities in approximately 50% of patients with liver fluke infestation. The findings may be consistent with chronic cholecystitis, biliary sludge, hepatomegaly or hydropic gallbladder. Liver flukes appear as non-shadowing echogenic material within the bile ducts. CT scanning may also reveal dilated or thickened intrahepatic bile ducts that are not appreciated on liver ultrasonography. Cholangiography may reveal duct wall irregularities, multiple cystic dilations of the intrahepatic ducts with tapering at the periphery and an overall decrease in intrahepatic radicles. If visible, *Clonorchis* appears as a wavy, elliptiform filling defect [16,20].

The treatment of choice is praziquantel, 75 mg/kg divided into three doses a day. Single dose therapy (praziquantel, 40 mg/kg) is not advocated in *Clonorchis* species because of low cure rates. The recommended alternative treatment is albendazole, 10 mg/kg/day for 7 days. As an adjunct to medical therapy, endoscopic management of acute and chronic complications may be necessary. Biliary decompression is often needed in patients with ascending cholangitis on an emergency basis. Chronic complications include recurrent intrahepatic pigment stones, biliary strictures and cholangiocarcinoma, which can be managed endoscopically or surgically depending upon regional availability and local expertise [16,24].

Dicrocoelium and *Eurytrema*

Dicrocoeliasis and eurytremiasis are infections of the bile and pancreatic ducts of herbivorous mammals caused, respectively, by the trematodes *Dicrocoelium dendriticum* and *Eurytrema pancreaticum*. Human infections have been reported, but are rare. Sometimes, the finding of eggs in human stool represents a spurious infection, due to ingestion of infected animal livers. The two trematodes have similar life cycles, and both require two intermediate hosts: the first is a snail (genus *Zebrina*, *Helicella*, *Cionella* or *Bradybaena* for *D. dendriticum* and *Ganesella* for *E. pancreaticum*). The second intermediate hosts for *D. dendriticum* are ants of the genus *Formica*; the grasshoppers (genus *Conocephalus*) or tree crickets (genus *Oecanthus*) are the second intermediate hosts for *E. pancreaticum*. Infection of the definitive hosts by these trematodes depends on the ingestion of metacercariae encysted on the insect second intermediate host tissues. The adults of both species produce and shed morphologically similar eggs, making specific diagnosis by faecal examination difficult. The definitive diagnosis depends on the recovery of adult worms at surgery or necropsy. Dicrocoeliasis and eurytremiasis usually cause mild symptoms in humans. However, heavy infections may produce biliary, pancreatic and gastrointestinal disturbances and, sometimes, jaundice. Occasionally, enlarged liver and systemic symptoms are found. Human infections by these trematodes should be treated with praziquantel; as second choice, the drug triclabendazole may be used [25,26].

References

1 Da Silva LC, Chieffi PP, Carrilho FJ (2005) Schistosomiasis mansoni – clinical features. *Gastroenterol Hepatol* 28, 30–39.

2 Giboda M, Malek EA, Correa R (1997) Human schistosomiasis in Puerto Rico: reduce prevalence rate and absence of *Biomphalaria glabrata*. *Am J Trop Med Hyg* 57, 564–568.

3 Ross AGP, Bartley PB, Sleigh AC *et al.* (2002) Schistosomiasis. *N Engl J Med* 346, 1212–1220.

4 Da Silva LC, Carrilho FJ (1992) Hepatosplenic schistosomiasis. Pathophysiology and treatment. *Gastroenterol Clin North Am* 21, 163–177.

5 Rezende SA, Lambertucci JR, Goes AM (1997) Role of immune complexes from patients with different clinical forms of schistosomiasis in the modulation of *in vitro* granuloma reaction. *Mem Inst Oswaldo Cruz* 92, 683–687.

6 Mies S, Mori T, Larsson E *et al.* (1980) A veia cava inferior e as veias supra-hepáticas na esquistossomose hepatoesplênica. Estudo angiográfico. *Rev Hosp Clin Fac Med São Paulo* 35, 136–142.

7 Mies S, Neto OB, Beer A Jr *et al.* (1997) Systemic and hepatic hemodynamics in hepatosplenic Manson's schistosomiasis with and without propranolol. *Dig Dis Sci* 42, 751–761.

8 Manoukian N, Borges DR (1984) Prealbumin, prekallikrein and prothrombin in hepatosplenic schistosomiasis: increased turnover of the clotting proteins? *Rev Inst Med Trop Sao Paulo* 26, 237–240.

9 Cerri GG, Alves VA, Magalhaes A (1984) Hepatosplenic schistosomiasis mansoni: ultrasound manifestations. *Radiology* 153, 777–780.

10 Martins RD, Szejnfeld J, Lima FG *et al.* (2000) Endoscopic, ultrasonographic, and US-Doppler parameters as indicators of variceal bleeding in patients with schistosomiasis. *Dig Dis Sci* 45, 1013–1018.

11 Paranagua-Vezozzo DC, Cerri GG (1992) Duplex hemodynamic evaluation of hepatosplenic mansoni schistosomiasis. *Mem Inst Oswaldo Cruz* 87(Suppl. 4), 149–151.

12 Neto OB, Beer A Jr, Baia CE *et al.* (1997) Systemic and hepatic hemodynamics in hepatosplenic manson's schistosomiasis with and without propranolol. *Dig Dis Sci* 42, 751–761.

13 Sakai P, Boaventura S, Ishioka S *et al.* (1990) Sclerotherapy of bleeding esophageal varices in schistosomiasis. Comparative study in patients with and without previous surgery for portal hypertension. *Endoscopy* 22, 5–7.

14 Cordeiro F (1990) Variceal sclerosis in schistosomotic patients: a five-year follow-up study. *Gastrointest Endosc* 36, 475–478.
15 Da Silva LC, Strauss E, Gayotto LCC *et al.* (1986) A randomized trial for the study of the elective surgical treatment of portal hypertension in mansonic schistosomiasis. *Ann Surg* 204, 148–153.
16 Pockros PJ, Capozza TA (2005) Helminthic infections of the liver. *Curr Infect Dis Rep* 7, 61–70.
17 Roig CV (2002) Hepatic fascioliasis in the Americas: a new challenge for therapeutic endoscopy. *Gastrointest Endosc* 56, 315–317.
18 Dowidar N, el Sayad M, Osman M *et al.* (1999) Endoscopic therapy of fascioliasis resistant to oral therapy. *Gastrointest Endosc* 50, 345–351.
19 Saba R, Korkmaz M, Inan D *et al.* (2004) Human fascioliasis. *Clin Microbiol Infect* 10, 385–387.
20 Bunnag D, Cross JH, Bunnag T (2000) Liver fluke infections. In: Strickland GT (ed.) *Hunter's Tropical Medicine and Emerging Infectious Disease*, 8th edn. Philadelphia: W.B. Saunders Co., pp. 840–847.
21 Acha PN, Szyfres B (2003) *Zoonosis y Enfermedades Transmisibles communes al Hombre ya a los Animales*, Vol. III, *Parasitosis*, 2nd edn. Publicación Científica y Técnica no. 580. Washington: Organización Mundial de la Salud.
22 Choi BI, Han JK, Hong ST *et al.* (2004) Clonorchiasis and cholangiocarcinoma: etiologic relationship and imaging diagnosis. *Clin Microbiol Rev* 17, 540–552.
23 Wang KX, Zhang RB, Cui YB *et al.* (2004) Clinical and epidemiological features of patients with clonorchiasis. *World J Gastroenterol* 10, 446–448.
24 Keiser J, Utzinger J (2004) Chemotherapy for major food-borne trematodes: a review. *Expert Opin Pharmacother* 5, 1711–1726.
25 Ishii Y, Koga M, Fujino T *et al.* (1983) Human infection with the pancreas fluke *Eurytrema pancreaticum*. *Am J Trop Med Hyg* 32, 1019–1022.
26 El-Shiekh-Mohamed AR, Mummery Y (1990) Human dicrocoeliasis. Report of 208 cases from Saudi Arabia. *Trop Geogr Med* 42, 1–7.

10.4.2 Echinococcosis of the liver

S. Bresson-Hadni, G.A. Mantion, J.P. Miguet and D.A. Vuitton

Cystic echinococcosis (CE, or hydatid disease) and alveolar echinococcosis (AE) are different in presentation, natural history and complications, and will be described separately; their immunodiagnosis and chemotherapy, which share many points, will be presented together [1].

Cystic echinococcosis

Epidemiology

Life cycle

The adult cestode develops in the small intestine of the definitive host, a carnivore. The last segments (proglottids) of this worm (3–5 mm long) contain eggs that are released into the intestine, and dispersed on the grass with the stools of the host. When eggs are eaten by the intermediate host (usually a mammal), the hexacanth embryo, released into the duodenum, passes through the intestinal wall and usually settles in the liver as 'cysts' ('hydatids'). Sheep, cattle, camels, swine or (accidentally) humans serve as intermediate hosts. Commonly, dogs are infected by eating raw infected offal containing hydatid larvae. Man becomes infected either by touching dogs with contaminated hair or by ingesting vegetables or water infected by dog stools [2]. Less commonly, the cycle involves a wild carnivore such as the wolf, jackal or coyote and a wild herbivore such as the elk, caribou or reindeer [3].

Prevalence

The disease is prominent in rural areas where humans, dogs and cattle coexist closely, with poor housing conditions and low levels of sanitation, and is most common in the regions of the world where raising livestock is a major industry: the entire Mediterranean littoral, the former USSR, China and parts of South America, particularly Uruguay, Argentina and Chile; New Zealand and Australia, highly endemic in the past, are now far less infected [2,4]. The highest prevalence is observed in western China (up to 5–10% of screened people) [4]. The disease remains frequent in Turkey and the Middle East countries, and is re-emerging in several countries where it had been partially controlled, especially in the endemic ex-USSR territories, e.g. Bulgaria and Romania, in Europe and the central Asian republics [5]. The diagnosis should thus be evoked for any suspect occupying lesion of the liver seen in immigrants from these countries.

Prevention and control

Control of *Echinococcus granulosus* is a realistic objective [2,4,5]; it has been achieved in islands where importation of animals was more easily controlled, such as Iceland, New Zealand and Tasmania. Eradication is much more difficult in continental areas, where reinfection of animals may occur easily from the surrounding regions. Cultural, economic and political factors may interfere with any control campaign, and these are the major pitfalls that preclude the theoretical 'easy control' of the disease [4–6].

Preventive measures include treatment of dogs with praziquantel and/or destruction of stray dogs, education campaigns, active measures to prevent access by dogs to infected offal and development of safe livestock slaughtering facilities [6]. Effective control must involve all approaches, including vaccination of animal intermediate hosts (mostly sheep) using the very efficient EG95 vaccine [7].

Pathogenesis

After ingestion of the eggs, the embryos of *E. granulosus* develop into a metacestode delimited by an inner, fertile membrane, the germinal layer, and an outer hyaline membrane, the laminated layer [1,2,8]. 'Brood capsules' containing numerous protoscolices (the future head of the adult cestode) develop by budding

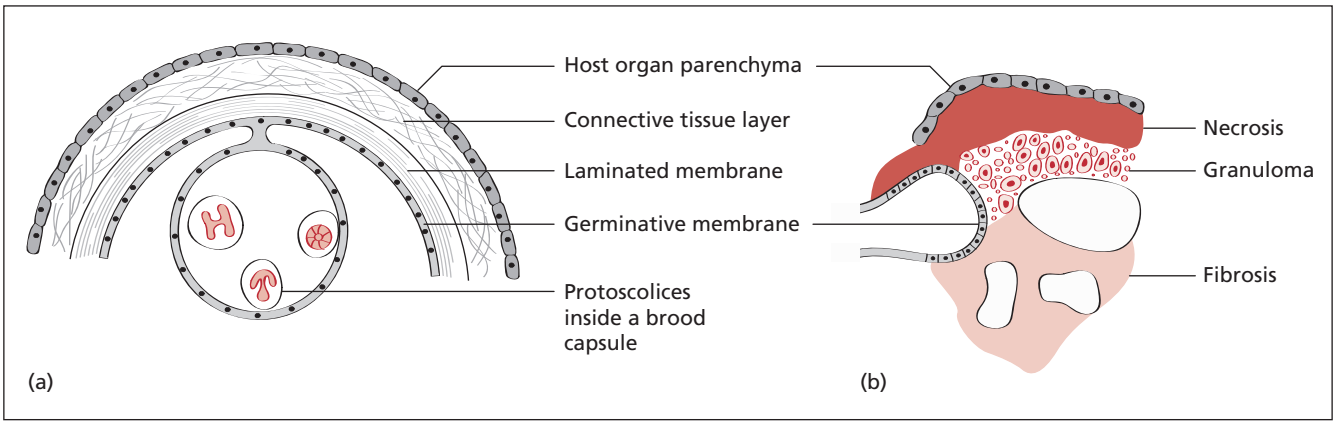

Fig. 1 (a and b) Diagrammatic structure of an *Echinococcus granulosus* cyst.

from the germinal layer. The laminated layer is surrounded by a fibrous wall, derived from host tissue, sometimes calcified, which limits the extension of the cyst. Outside this wall, the liver appears normal (Fig. 1a).

The cyst grows at a rate of about 0.3 cm/year. A significant proportion of cases either degenerate or never increase [9]. The cysts are filled with fluid under pressure and contain protoscolices (called 'hydatid sand' or 'granula', which gave the parasite the species name *granulosus*). Daughter cysts may develop inside or outside the germinal layer.

The cysts may be of any size, solitary or multiple, and located in any area of the liver. The right lobe is involved in 75% of cases; one-third of cysts are solitary [2]. Two-thirds of the lesions are located in the liver, a quarter in the lungs, 15% in muscle, 3% in bone, 2% in kidney, 1% each in spleen and brain [2]; multiple organs are involved in 20% of patients [2]. Bone, chest and brain localizations have been extensively studied; cysts may occur in the heart, biliary tract, thyroid and parotid gland, tongue, tooth, broad ligament, prostate, bladder, tonsil, pulmonary artery and inferior vena cava [1,8].

Clinical features and complications

The hydatid cyst remains clinically silent for a long time and is often discovered incidentally during routine abdominal ultrasound examination (US). The patient may complain of vague right upper quadrant pain, urticaria, episodes of itching or of a right upper quadrant tumoral mass. Clinical symptoms are usually absent until the cyst has reached 10 cm in diameter; a mass is rarely palpable until it reaches 20 cm. The diagnosis is usually made when a complication occurs, usually jaundice. In endemic areas, mass screening programmes using US and serology have shown that liver cysts, albeit far more numerous than lung cysts, were more frequently asymptomatic and remained so for a long period of time [9–13].

Physical examination of the liver may be normal or may disclose an enlarged and regular liver. If the cyst is located in the anterior liver, a round, painless tumour can be palpated with, exceptionally, a 'hydatid thrill' [1,8]. Compression of the common bile duct, portal or hepatic veins or inferior vena cava is uncommon. Rupture of the cyst (usually into the bile ducts) is more common: at diagnosis, 36–40% of cysts have ruptured or have become infected. Cysts can erode and perforate the diaphragm into the pleural and pericardial cavities, the lung or the bronchi, and the peritoneum into the peritoneal cavity or the duodenum, stomach, colon or right renal pelvis. This may lead to extrahepatic hydatic cysts, which favour the development of daughter cysts and may cause allergic symptoms (increase in blood eosinophils, itching urticaria and anaphylactic shock). More commonly, the rupture of hydatid cysts occurs into bile ducts and is revealed by cholestatic jaundice, cholangitis or biliary pain. Ruptures may be clinically silent, and are thus only disclosed during an operation.

Diagnosis

The two key procedures for diagnosis are US and serology.

Plain films of the abdomen and/or chest may show highly suggestive arc-shaped calcifications, characteristic deformation of the diaphragm and sometimes images in the lungs or mediastinum.

US can be used to recognize cysts as small as 1 cm in diameter. It can show one or several round masses with a well-defined contour, which may be empty or filled with echogenic structures corresponding to daughter cysts. It can be used to recognize the rupture of the germinative membrane by showing a folded, detached endocyst. When cysts become infected, they are diffusely hyperechogenic and no longer exhibit characteristic features. In 1981, a US classification was proposed by Gharbi *et al.* [10] based on a correlation between five US types and pathological findings. Several classifications have since been proposed with various aims and degrees of complexity. The WHO Informal Working Group on Echinococcosis (IWGE) has promoted a unified classification, shown in Table 1, which might be

Table 1 Ultrasonographic classification of hydatic cyst of the liver.

Gharbi *et al*. (1981) [10]	WHO classification [11]	Clinical correlation
–	CL	No pathognomonic signs of cystic echinococcosis
Type 1	CE1	Group 1: active lesions Evolutive cysts, usually fertile
Type 3	CE2	Group 2: transitional lesions
Type 2	CE3	Cysts becoming degenerated, but usual persistence of viable protoscolices with possible evolution to CE2 type
Type 4	CE4	Group 3: inactive lesions
Type 5	CE5	Degenerated cysts or partially/totally calcified. High probability of sterilization

CL, cystic lesion.

(a) (b) (c)

Fig. 2 CT images of cystic echinococcosis of the liver. (a) Two cysts located in the right lobe. The anterior one, corresponding to a type 1 (CE1), is characterized by a hypodense content and well-defined contour. The posterior one, totally calcified, corresponds to a type 5 (CE5). (b) Huge, well-delineated hydatid cyst in the top of the right liver classified as type 2 (CE3): detached membranes are well visualized inside the hydatid fluid. (c) Complicated cystic echinococcosis. The cyst in the left liver (containing multiple daughter cysts) has ruptured in the biliary duct and is responsible for a biliary obstruction (note the intrahepatic biliary duct dilatations).

used to compare data from mass screenings and therapeutic interventions as well [11]. This classification attempts to follow the natural history of the cyst; however, stage CE3 (Gharbi II), characterized by the detachment of membranes, may progress either to development of daughter cysts or to degeneration. When the classification is used to assess any therapeutic intervention, the diameter of cysts (in cm) rather than semi-quantitative values should be given [14].

On computerized tomography (CT) (Fig. 2a–c), the unilocular cyst with its spherical or oval structure of near water density is easily recognized [1,8]. Conversely, multilocular cysts may have several CT patterns depending on the space occupied by daughter cysts inside the mother cyst; however, the CT densities of viable daughter cysts are always lower than those of mother hydatid cysts. Abscesses or necrotic tumours may mimic hydatid cysts. In these cases, if serology is negative, only aspiration cytology can establish the diagnosis of hydatid cyst [15]. Hydatid cyst aspiration with a fine needle under US guidance is currently considered medically and ethically acceptable [15,16]. However, the procedure must be accompanied by appropriate precautions aimed at preventing and/or treating any anaphylactic complication and protoscolex spillage, and must be systematically followed by the puncture, aspiration, injection and reaspiration (PAIR) technique if the diagnosis of hydatid cyst is confirmed.

Treatment

Surgery has long been considered the first choice treatment for all cases of hydatid cysts. Current availability of alternative therapies has made this statement obsolete. In 1996, treatment guidelines published by the WHO-IWGE stated that the therapeutic strategy should consider chemotherapy and PAIR [17]. Since then, the results of long-term evaluation of these treatments have been made available, and surgery should always be discussed regarding cyst location in the liver, number of cysts, presence of other cysts in other organs, anatomical/clinical complications, clinical status of the patient, but also surgical facilities, expertise of the surgical team and quality of follow-up. New guidelines are currently being discussed by the WHO-IWGE and should be published soon. A recent meta-analysis

aimed at finding 'evidence-based' answers to the main questions about treatment strategy in cystic echinococcosis [18]. The main results, graded according the Cochrane system (level of evidence and grade of recommendation), were the following: (i) chemotherapy is not the ideal treatment for uncomplicated hydatid cysts of the liver when used alone; (ii) the level of evidence is too low to help in deciding between radical or conservative treatment; (iii) omentoplasty associated with radical or conservative treatment is efficient in preventing deep abscesses; (iv) the laparoscopic approach is safe; (v) drug treatment associated with surgery requires further studies; (vi) percutaneous drainage associated with albendazole therapy is safe and efficient in selected patients; the level of evidence is low concerning treatment of complicated cysts. This has led some authors to write this rather provocative statement: 'Surgery should be reserved for patients with hydatid cysts refractory to PAIR because of secondary bacterial infection or for those with difficult-to-manage cyst–biliary communication or obstruction' [19], whereas others still write: 'Although certain types of hydatid cysts are successfully treated by PAIR, surgery remains the treatment of choice' [20]. This discrepancy clearly indicates that further well-designed studies are in order.

Surgery

The goal of surgery is eradication, i.e. to remove all parasitic cysts and fluid completely; eradication achievable by surgery is a major advantage compared with other types of treatment. Controversies still exist about the best operative technique. The main surgical alternatives are cystectomy, with an appropriate management of the residual cavity, and hepatic resection. Despite the high number of hydatid cysts removed surgically worldwide, few large reviews of surgical cases with a significant follow-up are available. In a European non-endemic country, a recent retrospective study, in 84 patients followed up for a median of 8 years, showed that almost half the patients operated on for liver hydatid cysts had complicated disease [21]; after complete removal of cystic and pericystic tissue with simultaneous treatment of the fistulous tract, in 23% of the patients, there was postoperative morbidity, but no mortality and no recurrence of disease. In a highly endemic area in Kenya, among 663 patients managed with surgery, there was one intraoperative and one postoperative death, and 47 patients underwent repeated operations [22] for postoperative complications and/or recurrences. Recurrences are estimated to occur in 2–25% of cases, depending on the size, location, number or peroperative rupture of the original cysts, as well as on the expertise of the surgical team.

Various types of cystectomy permit the complete removal of the parasite without the risks of liver resection [1,8]. To avoid spillage of the contents of the hepatic cyst, the peritoneal cavity must be carefully protected during cyst evacuation. The contents of the cyst are first sterilized by the injection of scolicidal agents and then evacuated. Formalin and hypertonic saline should not be used because of the risk of caustic sclerosing cholangitis. Chlorehexidine, H_2O_2, 80% alcohol or 0.5% cetrimide are safer. Their intracystic injection should not be used if there is any evidence of biliary communication. Pretreatment of patients with antiparasitic drugs may make scolicidal agents obsolete; however, there is as yet no long-term study that has evaluated the efficacy of chemotherapy in preventing recurrence. After the liver overlying the cyst has been incised, attempts should be made to excise the laminated membrane intact; this may be done by cleaving through the virtual gap existing between the inner and outer fibrous layer surrounding the cyst ('total subadventitial cystectomy') [23].

Hepatic resection is usually only recommended for central cysts of a left lateral segment. Liver transplantation (LT) has exceptionally been performed in patients with acute Budd–Chiari syndrome and secondary biliary cirrhosis related to toxic sclerosing cholangitis [24].

Instrumental treatment: puncture–aspiration–injection–reaspiration (PAIR)

Since 1986, PAIR has been proposed as an alternative to surgery [25]. After percutaneous puncture under US guidance, aspiration is performed; the residual cavity is then completely filled with a scolicidal agent, usually ethanol, which is reaspirated 10 min later. Detailed practical guidelines for a wider use of the PAIR technique have been published by the WHO-IWGE [16]. A long-term follow-up of patients is now available [26]; a meta-analysis has confirmed that PAIR is efficacious, safe and useful in selected indications [27]. A very limited number of anaphylactic shocks, nearly always reversible with appropriate resuscitation, and no secondary dissemination have been reported. Recurrence of the cysts in most series is lower than after surgery. PAIR can be proposed for type CE1 and selected cases with CE2 and CE3 cysts. It is contraindicated if there is a communication of the cyst with the biliary tree, assessed through puncture of the cyst with cystocholangiography or, in disadvantaged settings, by checking bilirubin in the cyst content. The duration of pre- and postinterventional benzimidazole therapy necessary to avoid parasitic spillage has not been properly evaluated. In experienced hands, PAIR represents the first choice of treatment [28]; drainage may be associated with PAIR in treating large cysts [28]. To treat cysts with numerous daughter cysts, a PAIR-like technique ('percutaneous puncture drainage and curettage') [29], which uses larger tubes and vacuum aspiration through a small surgical incision, was first described in western China; similar procedures have since been published in Europe [30,31].

Laparoscopic aspiration and sterilization of the cysts is also feasible; however, it is more frequently complicated by spillage and recurrence [32].

Treatment of complications

Cholangitis is usually treated by biliary surgical drainage. In some instances, papillotomy during endoscopy may be proposed. The rupture of a hepatic cyst into the peritoneal cavity

remains difficult to cure. Despite the removal of cyst contents from the peritoneal cavity at surgery, residual protoscolices form daughter cysts that almost inevitably lead to recurrence. Benzimidazole–praziquantel combined therapy should be used in these situations.

Alveolar echinococcosis

Alveolar echinococcosis (AE) of the liver is an uncommon parasitic disease of the northern hemisphere which is due to the intrahepatic growth of the larva of *Echinococcus multilocularis* (*E.m.*). AE behaves as a liver cancer and is always fatal unless completely removed by surgery. The significant advances achieved in the management of AE during the past 20 years have led to a dramatic improvement in the prognosis of AE, even in inoperable cases.

Epidemiology

Life cycle

A cycle in wild animals allows the parasite to subsist in nature [33]. The adult cestode usually develops in the small intestine of the fox. The last segments (2–4 mm long) are released into the intestine, and their eggs are dispersed on the ground with the stools, contaminating the grass. Eggs are surrounded by an envelope that allows them to resist very low temperatures (down to −40°C); they die at +60°C. When eggs are eaten by the intermediate host, usually a wild rodent, the hexacanth embryo is released into the duodenum, enters the liver through the intestinal wall and can reach the lungs, brain and bones. In rodents, AE consists of a mass of small vesicles each lined by the germinal layer from which enormous numbers of protoscolices develop; lesions produced by several embryos may coalesce and can occupy a considerable part of the liver [2]. The life cycle is completed when the intermediate host, containing infected larvae, is eaten by foxes. Dogs are the most common definitive hosts in some areas, such as China. Less commonly, other carnivores including coyotes and cats can also serve as definitive hosts [33,34].

Prevalence

Humans become infected either by eating contaminated wild fruits or by touching infected foxes or pets. Risk factors for human AE in endemic regions include occupation in agriculture (or activity in gardening, foresting, hunting), a history of dog/cat ownership and residence in a rural upland landscape that favours high densities of small mammals, especially voles [35]. Because of immunogenetic (but also behavioural) factors, the wide distribution and generally high frequency of *E. multilocularis* in foxes is not reflected in disease prevalence in humans, which is low in most endemic areas [34,36]. Among European patients, 54% were female and 46% male with a median age at diagnosis of 56 years [37]; although AE was also disclosed in young children, a mean period of 15 years is usual between contamination and presenting symptoms. The average incidence, referred to the total population of a country, is rather low, ranging from 0.02 (Austria) to 0.10 (Switzerland) cases per 100 000 inhabitants per year in western Europe. However, because of the geographically focused epidemiology of the parasitic cycle, local incidence rates may be much higher. In a retrospective study of 559 European AE cases diagnosed between 1982 and 2000, 42% were in eastern France, 23.6% in southern Germany and 21% in northeast Switzerland [37]. The increase in fox populations and parasite prevalences and the increasing encroachment of foxes into urban areas, with spillover of *E. multilocularis* infection from wild carnivores to domestic dogs and cats, might point to the emergence of a new AE public health hazard in central Europe [34,37,38]. Neither human cases nor fox infection have ever been found in the British islands [39]. Other endemic regions for AE in humans are many areas of the former Soviet Union, eastern Turkey, northern Japan, China and Alaska. Reports of adult or larval cestodes in the wild fauna of north central America suggest that, in the United States, the parasite is still moving south and east [34]. In north and northwestern China, the prevalence of alveolar echinococcosis in humans can be as high as 16% in some villages [34,40].

Prevention and control

Mass surveys using US and serology are recommended in high-risk populations in endemic areas to monitor epidemiological trends and support health education [12,40,41]. Prevention measures are limited to educational programmes aimed at warning the population in endemic areas of the hazards of touching foxes and eating uncooked fruits and vegetables. It may be advisable to enclose a kitchen garden located near a forest. Extermination of foxes and/or rodents is not a realistic objective and could be deleterious. A third option consists of mass dosing of foxes with praziquantel-treated baits; pilot studies have been done to assess the feasibility and efficacy of this option in non-urban areas and are currently ongoing in urban areas [38,42]. Praziquantel provides a 100% elimination of the parasite from dogs when given at a dose of 5 mg/kg body weight; it should therefore be used for the deworming of domestic dogs in the endemic areas [2,5,38].

Pathogenesis

The hepatic lesions of humans generally consist of a unique mass of fibrous tissue that displays a multitude of cavities, ranging from a few millimetres to a few centimetres in size (Fig. 1b). *E. multilocularis* induces hepatic necrosis allowing the parasite to invade the liver step by step in a way similar to a liver carcinoma. The lesions are not limited by a fibrous shell. The parasitic tissue electively involves and destroys the bifurcation of intrahepatic bile ducts. It may also invade major hepatic vessels and the inferior vena cava [1,43,44]. The lesions are usually most prominent in the right lobe of the liver. Microscopically, they consist of

numerous parasitic vesicles (1 mm to 1 cm in diameter) lined by an inner germinal layer and an outer laminated layer. Protoscolices are observed in only 15% of cases, and the germinal layer is usually absent in 'old' vesicles embedded in a dense fibrosis. The parasitic vesicles are surrounded by concentric layers of 'epithelioid cells' of the macrophagic lineage, by a macrophagic/fibroblastic infiltrate and collagen bundles, and by peripheral lymphocytes (mostly CD8 T-cell lymphocytes), arranged in a granuloma [36,45]. The parasitic granuloma (absent in cystic echinococcosis) leads to a fibrotic scar which compresses and then destroys the hepatic vessels and the bile ducts. The resulting necrotic process leads to the formation of large cavities containing parasitic and hepatic debris, blood, bile and sometimes pus; the migration of necrotic fragments is responsible for cholangitis and systemic bacteraemia. The migration of parasitic material through the hepatic vessels may result in distant metastases [46].

Clinical features and complications

AE was frequently diagnosed at an advanced stage and mimicked neoplasia. Jaundice was the most frequent presenting symptom before the 1980s; it was observed in 43% in our series [44], either as a gradual-onset jaundice with pruritus related to hilum involvement or as intermittent jaundice with pain and fever related to superimposed bacterial biliary infection. Hard and massive hepatomegaly was classically the revealing symptom in about 25% of cases.

During the past 20 years, the symptoms at presentation have changed with the earlier diagnosis of less severe and asymptomatic cases. In a series of patients diagnosed between 1983 and 1993, only 25% presented with jaundice, and hepatomegaly was observed in 16%. Vague abdominal right upper quadrant pain is a presenting symptom in about one-third of cases. The contrast between a huge hepatomegaly mimicking a liver carcinoma and a good clinical status should raise suspicion of AE in endemic areas. Currently, a significant number of patients with AE are asymptomatic: they may be diagnosed by chance (during surgery or an ultrasonographic examination for other reasons) or as a result of mass screening in an endemic area.

Complications are rarely the first manifestations of the disease. The most frequent are biliary infection with septicaemia and septic shock and liver abscesses resulting from bacterial or fungal infection of the central necrotic area. Owing to locoregional extension or haematogenous spread of parasitic tissue to distant metastases (in approximately 12% of cases, mainly in the lungs) [37], symptoms ranging from dyspnoea and bile sputum to seizures and stroke as well as skin nodules [43,47] or bone pain may be the presenting clinical manifestations. Anaphylactic reactions are exceptional as initial symptoms [46]. Earlier diagnosis and prophylaxis of variceal bleeding with β-blockers have diminished bleeding from oesophagogastric varices related to portal hypertension, secondary to biliary cirrhosis or to chronic parasitic Budd–Chiari syndrome or portal thrombosis.

Diagnosis

Laboratory findings

Lymphopenia is frequent. Total and conjugated bilirubin are increased in proportion to the degree of jaundice; γ-glutamyl transferase and alkaline phosphatase are markedly increased in jaundiced patients as well as in patients without jaundice. Conversely, serum transaminases are usually normal except for the few patients with a necrotic process in the liver, in whom a two- to fourfold increase is usual. Eosinophilia greater than 7% is found in 10% of patients. A high level of C-reactive protein is suggestive of a latent biliary infection [43]. Prothrombin time and factor V are usually normal. In 80% of patients, serum gammaglobulins are over 30 g/L; electrophoresis shows a polyclonal, and only exceptionally a monoclonal, gammopathy. All three classes of immunoglobulins (G, A, M) are increased.

Morphological findings

US and CT remain the basic morphological imaging techniques in AE [47]. US is the current screening method of choice for diagnosis and regular follow-up in AE [48,49]. A typical US aspect is observed in 70% of cases: the lesion is characterized by irregular limits and heterogeneous content with juxtaposition of hyperechogenic and hypoechogenic areas (Fig. 3a). The hyperechogenic fibrous tissue often contains scattered calcifications. Another US aspect typical of AE is a huge lesion with large central necrosis surrounded by a hyperechogenic ring. However, in endemic AE areas, the following atypical US aspects account for 30% of cases: (i) a small haemangioma-like hyperechogenic nodule which corresponds to an early homogeneous nodular lesion; (ii) a pseudocystic form in the case of a huge AE lesion with massive necrosis; the irregular lining suggests the diagnosis of AE; (iii) a small calcified lesion that corresponds to an abortive form of the disease or a small developing AE [41,48]. US can also provide information on the biliary and vascular involvement.

The typical CT aspect is a lesion with irregular linings and heterogeneous contents of various densities: hyperdense scattered calcifications and hypodense areas corresponding to necrosis and active parasitic tissue (Fig. 3b). No significant enhancement is observed within the lesion after the intravenous bolus administration of contrast medium. The dilatation of the intrahepatic bile ducts in the contralateral lobe of the liver is the hallmark of an infiltration of the hilum by the parasitic process.

Magnetic resonance imaging (MRI) may facilitate the diagnosis in uncertain cases with non-calcified lesions. It is the best technique to characterize the different components of the parasitic lesion and to study the extension to adjacent structures. Cholangio-MRI has now advantageously replaced the classical percutaneous cholangiography. It is an important part of the preoperative evaluation, as it provides information on the relationship between the AE lesion and the biliary tree. Positron emission tomography using [18F]fluorodeoxyglucose has recently been developed for the follow-up of inoperable AE patients

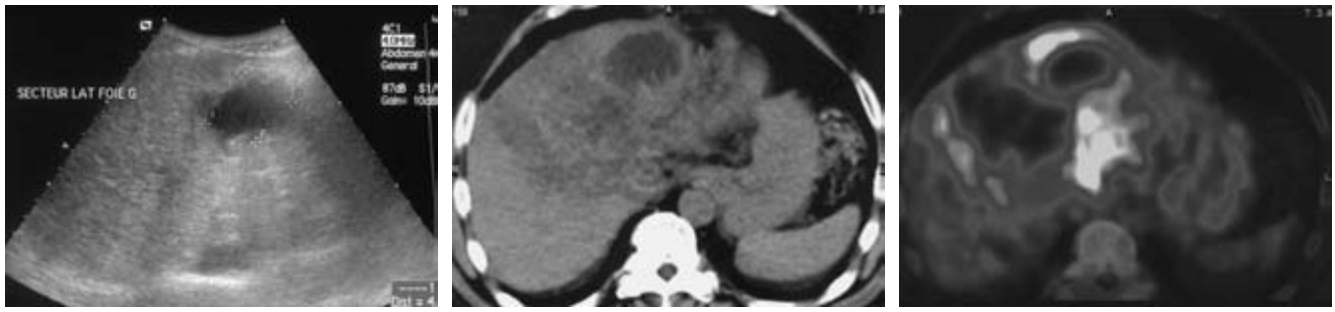

(a) (b) (c)

Fig. 3 Morphological aspects of alveolar echinococcosis (AE) of the liver. (a) Ultrasonic aspect of a huge AE lesion located in the left and the central part of the liver, characterized by irregular limits, a heterogeneous content with central hypoechogenic area (necrosis) surrounded by the hyperechogenic fibrous tissue containing scattered calcifications. (b) CT images of the same lesion: heterogeneous content with irregular border and hypodense central area. (c) Positron emission tomography using [18F]fluorodeoxyglucose in the same patient, before the introduction of albendazole therapy: very intense perilesional activity within the inflammatory reaction that indirectly traduces the parasitic viability.

under long-term benzimidazole therapy [50,51]. This approach seems to be promising in assessing inflammatory activity and thereby indirectly depicting parasitic activity (Fig. 3c).

Treatment

Modern treatment of AE clearly requires a multidisciplinary approach with benzimidazole therapy as a common denominator (see below). Depending on the size of the lesion, its location in the liver and vascular and biliary involvement, the option may be a curative resection, an interventional radiological procedure or, exceptionally, a liver transplant. Partial debulking resections followed by continuous administration of a benzimidazole must be avoided [52]. A classification system has been developed recently that could be useful in helping clinicians to choose the appropriate treatment [53].

The sole efficient treatment is partial hepatectomy when the lesions are sufficiently localized [53–55]. Because the intrahepatic common bile duct is usually involved, it is often necessary to remove the bifurcation and to reconstruct the biliary tract using a Roux-en-Y loop [56]. In our series from 1983 onwards, 35% of patients underwent a curative partial hepatectomy, compared with 10% before 1983.

For unresectable patients, palliative surgery is now advantageously replaced by instrumental treatment procedures [47,57,58], which consist of percutaneous radiological drainage of huge centroparasitic abscesses or a dilated intrahepatic bile duct above a hilar stenosis. The best option is to push the drain beyond the stenosis to obtain external/internal biliary drainage. Such drains may be maintained for years; with chemotherapy, they have allowed prolonged survival in initially very severe AE cases [59]. Biliary endoprosthesis could also be inserted, but the stent may become obstructed by necrotic plugs; it is far more difficult to change a stent than an external–internal drain.

A retrospective analysis of the results of LT for unresectable AE (45 cases from different European centres) has been published recently [60]. From this experience, LT is indicated only for incurable symptomatic biliary AE with life-threatening cholangitis and/or symptomatic secondary biliary cirrhosis; despite this major procedure, only half the patients have actually been definitively cured by LT. In other patients, parasitic residues were observed with accelerated progression related to immunosuppressive therapy [60,61]. The actuarial survival rate was 58% at 5 years.

Immunological and molecular diagnosis

Numerous immunodiagnostic tests have been developed for CE and AE, but there is currently no standard, highly sensitive and specific as well as cheap test available for antibody detection in either disease. Cross-reactivity is observed between both cestodes, and most tests for CE can be used for the diagnosis of AE and vice versa. In some endemic countries, both diseases may be found in the same area (this is especially the case in China, but also in Turkey and most central Asian countries), and a differential diagnosis could theoretically be useful. Cellular tests are interesting for research but have no value in the diagnosis of these diseases [36]. The intradermal 'Casoni' test is no longer used because of its lack of sensitivity and specificity as well as safety.

Serological tests

Assays for specific antibodies in serum have used natural antigens obtained from both *Echinococcus granulosus* (hydatid fluid or hydatid sand) and *Echinococcus multilocularis* (protoscolices or parasitic extracts) and/or purified antigens or recombinant proteins from either *Echinococcus* sp. [62]. The following considerations apply to serological testing; (i) complement fixation tests are no longer used because of poor sensitivity and specificity; (ii) indirect haemagglutination and latex tests, with

crude *Echinococcus* extracts, are both cheap and sensitive but poorly specific; (iii) immunoelectrophoresis or immunosyneresis is specific, but poorly sensitive and time-consuming; (iv) ELISA tests, using crude antigens from *E. granulosus* or *E. multilocularis*, are sensitive but poorly specific; (v) more specific are ELISA tests using purified antigenic fractions or recombinant antigens such as antigen 5 or antigen B of *Echinococcus granulosus*, the Em2 or the Em18 fractions of *Echinococcus multilocularis*, the specific alkaline phosphatase of *E. multilocularis*, the recombinant Em3/10 and Em18; (vi) Western blots use either crude extracts from *E. granulosus* or *E. multilocularis* (more sensitive) or purified fractions or recombinant antigens (more specific). The combination of antigens in a single test (such as the EM2+) or Western blot patterns have attempted to provide both the positive and the differential diagnosis. By comparing the 'best' serological tests with ultrasound- and/or CT-confirmed lesions, the overall sensitivity reaches 80% for liver hydatid cysts (it is lower for lung cysts, averaging 65%) and 90% for alveolar echinococcosis; specificity may reach 90% for both [62]. The diagnostic efficiency of serology is limited by the reduced capacity of some infected subjects to develop specific antibodies and the failure to release specific antigens by some hydatid cysts (decreased sensitivity) and the existence of infected non-diseased subjects in endemic areas (decreased specificity). Positive serological results in individuals account for at least five different situations: (i) 'patent', overt disease with symptoms; (ii) 'latent', non-apparent disease; (iii) calcified dead lesions in the liver; (iv) hydatid cyst in the lung or other organs and exceptional cases of isolated extrahepatic AE; and (v) no parasitic lesions at all [12,13,36,40,43,45]. Negative serology with patent CE or AE lesions has been found in all mass screenings and is the rule in all published hospital case series [13,40,43]. Serology should thus never be used as a 'first intent' test for mass screening; it should always be combined with ultrasound imaging, and used to confirm a diagnosis suspected on the basis of imaging techniques.

The predominant antibody response consists mainly of the IgG1 and IgG4 subclasses. Elevated total IgE and specific IgE against *Echinococcus* antigens, which may be found in the serum of CE patients, are significantly more elevated when a rupture or a fissuration of the cyst occurs; an increased eosinophil count may also be observed in these situations. Specific IgE antibodies against *E. multilocularis* antigens may be found in AE patients, and histamine release from circulating basophils stimulated with *Echinococcus* antigens is constant in AE patients [36].

In the post-surgery follow-up, after a temporary increase, antibody levels progressively decrease for 1–2 years before turning negative. The persistence of raised levels or a further increase is suggestive of residual disease or a recurrence; however, the long-term persistence of antibodies in some patients is not evidence against the eradication of the parasite. IgE, IgG4 and IgG2 antibodies seem to be associated with progressive and severe cases and are the first to disappear after surgery or efficient chemotherapy [62]. In AE patients with a recurrence after LT, antibodies detected using crude antigens (e.g. crude hydatid fluid) were observed at an early stage in recurrence, and more specific antibodies (e.g. against the *E. multilocularis* specific Em2 antigen) could only be detected later [63]. Similar observations have been made at mass screenings: early lesions were associated with antibodies against crude extracts and could thus be missed using more specific antigens/recombinant proteins [64].

Molecular tests

Molecular identification of both *E. granulosus* and *E. multilocularis* is mostly based on polymerase chain reaction (PCR) using mitochondrial DNA probes [64]. It may be used on liver needle aspiration (for CE) and/or liver biopsy (for AE), if echinococcosis is suspected despite negative serology. In addition, it may be useful in epidemiological studies to identify the subspecies of *E. granulosus* involved in human contamination from the animal cycle: more than 10 subspecies have been described, the most frequently involved in humans being the G1 ('sheep') and G6 ('camel') subspecies. Recent reports have shown that the latter is also infectious to humans [65]. *E. multilocularis* is far less heterogeneous, and only minor differences in geographical isolates may be disclosed.

Medical treatments of echinococcosis

Although no well-designed clinical trials have been performed for any medical treatment modality in either form of echinococcosis, two benzimidazole compounds have proved efficacious against both alveolar and cystic echinococcosis: mebendazole (MBZ) (4.5 g/day) and albendazole (ABZ) (10–15 mg/kg/day). Because of limited toxicological data, ABZ was originally administered intermittently. More recent data suggest that continuous treatment achieves equivalent or improved efficacy with no increased adverse effects [66].

Benzimidazoles (BZM) in cystic echinococcosis

Three randomized controlled trials showed that ABZ alone had a better effect on hydatid cysts than placebo [67,68] or MBZ [69]. One prospective controlled trial compared ABZ in combination with praziquantel (25 mg/kg/day) vs. ABZ alone [70] and concluded that the combined treatment was more effective than ABZ alone. However, complete disappearance of all cysts was never reached. Therefore, chemotherapy is not the ideal treatment when used alone. This therapeutic option is indicated for patients with multiple cysts in two or more organs and for patients with peritoneal cysts. ABZ is poorly absorbed by the gastrointestinal tract. To improve absorption, ABZ should be taken with a fatty meal [71].

Pre- and postintervention chemotherapy with BZM may reduce the risk of recurrence and intraperitoneal seeding. There is no optimal scheme, but the current recommendation is to

administer ABZ 3 weeks before and for 1–2 months after the intervention [18]. PAIR plus chemotherapy is associated with increased clinical and parasitological efficacy [27]. ABZ is to be given the day before and for 1 month after PAIR [72]; ABZ should not be administered when PAIR is performed during pregnancy.

Benzimidazoles in alveolar echinococcosis

MBZ and ABZ are the drugs of choice in the treatment of AE. However, these drugs only have a parasitostatic effect and do not kill the parasite in most cases. There are no comparative studies, but ABZ is currently preferred because it is > 40% less expensive, is easier to take and is now licensed for AE in many countries [73]. In case of extirpable AE lesions, it is recommended to initiate ABZ before the operation and to maintain ABZ for at least 2 years to avoid recurrence [17]. In inoperable cases, long-term chemotherapy may significantly prolong survival (10-year survival of approximately 80% in treated cases, compared with less than 25% in historical untreated control subjects) [74]. Recent reports emphasize the possibility of parasite death under long-term BZM therapy [74–76]. By assessing parasite viability, the combination of sequential PET-CT and new serological markers offers the prospect of a more personalized medical treatment of inoperable AE patients: discontinuation of BZM after many years of treatment could be feasible in selected cases using these new tools [51,74]. If LT is indicated, ABZ must be initiated before the operation and maintained after LT for at least 2 years (lifelong in case of metacestode remnants or new AE foci discovered during post-LT follow-up) [17].

Side-effects of BZM

Adverse events of BZM were reported in 5.8–20% of the patients treated. General complaints include headache, nausea, anorexia, vomiting, abdominal pain and itching. In the first weeks of treatment, a transient increase in liver enzymes may be observed; it usually appears to be the result of drug efficacy rather than evidence of drug toxicity [77]. Idiosyncratic reactions have been observed in a few cases [78]. Regular monitoring is therefore recommended: if aminotransferase levels rise to 200–300 IU/L, discontinuation of therapy should be considered. A significant but usually reversible alopecia occurs in about 5% of cases. In AE, this effect has been observed particularly in patients with portal hypertension and/or severe cholestasis. The risk, albeit small, of bone marrow depression (neutropenia or even rarely aplastic anaemia) should prompt regular checking of blood cell count [79]. ABZ has been shown to be teratogenic in rats and rabbits and, therefore, should be avoided, if possible, during pregnancy (in particular during the first trimester) and lactation [8]. Although they are closely related drugs, MBZ may be better tolerated by patients with ABZ side-effects and vice versa; a switch to the other drug can thus be tried before withdrawing chemotherapy definitively [43].

Future prospects in the treatment of echinococcosis of the liver

Research is in progress to increase the serum concentrations of ABZ. Studies with liposome-entrapped ABZ have given promising results [80,81]. Amphotericin B has been used as salvage treatment for AE patients with intolerance or resistance to BZM; although the drug is only parasitocidal [82], it effectively halted parasite progression in a small series of patients [83]. Nitazoxanide (NTX), a broad-spectrum antihelminthic agent, also used for enteric bacteria treatment, seems to be promising for AE treatment: a parasitocidal effect was demonstrated *in vitro* [84,85]. Immunomodulatory treatment with interferon-α might be a future treatment goal for AE [86,87]. Radiothermal ablation by radiofrequency is currently under investigation for cystic echinococcosis [88]. However, the best strategy to direct therapeutic options is to design controlled studies aimed at more clearly defining the respective place of surgery (and what type of surgery) and of PAIR [89,90].

References

1 Amman RW, Eckert J (1996) Cestodes. *Echinococcus*. In: *Parasitic Diseases of the Liver and Intestines*. *Gastroenterol Clin North Am* 25, 655–689.

2 Eckert JP, Deplazes PS, Craig M *et al.* (2001) Echinococcosis in animals: clinical aspects, diagnosis and treatment. In: Eckert J, Gemmell MA, Meslin F-X *et al.* (eds) *WHO/OIE Manual on Echinococcosis in Humans and Animals: a Public Health Problem of Global Concern*. Paris: World Organisation for Animal Health (OIE), pp. 72–99.

3 Jenkins DJ, Macpherson CN (2003) Transmission ecology of *Echinococcus* in wild-life in Australia and Africa. *Parasitology* 127, S63–72.

4 Torgerson PR, Budke C (2003) Echinococcosis – an international public health challenge. *Res Vet Sci* 74, 191–202.

5 Ito A, Urbani C, Jiamin Q *et al.* (2003) Control of echinococcosis and cysticercosis: a public health challenge to international cooperation in China. *Acta Trop* 86, 3–17.

6 Torgerson PR, Heath DD (2003) Transmission dynamics and control options for cystic echinococcosis. *Parasitology* 127, S143–S158.

7 Lightowlers MW, Heath DD (2004) Immunity and vaccine control of *Echinococcus granulosus* infection in animal intermediate hosts. *Parasitologia* 46, 27–31.

8 Kern P (2003) *Echinococcus granulosus* infection : clinical presentation, medical treatment and outcome. *Langenbecks Arch Surg* 388, 413–420.

9 Frider B, Larrieu E, Odriozola M (1999) Long-term outcome of asymptomatic liver hydatidosis. *J Hepatol* 30, 228–231.

10 Gharbi HA, Hassine W, Brauner MW *et al.* (1981) Ultrasound examination of the hydatic liver. *Radiology* 139, 459–463.

11 WHO Informal Working Group on Echinococcosis (2003) International classification of ultrasound images in cystic echinococcosis for application in clinical and field epidemiological settings. *Acta Trop* 85, 253–261

12 Macpherson CN, Bartholomot B, Frider B. (2003) Application of ultrasound in diagnosis, treatment, epidemiology, public health and control of *Echinococcus granulosus* and *E. multilocularis*. *Parasitology* 127, S21–35.

13 Larrieu EJ, Frider B (2001) Human cystic echinococcosis: contributions to the natural history of the disease. *Ann Trop Med Parasitol* 95, 679–687.

14 Wang Y, Zhang X, Bartholomot B *et al.* (2003) Classification, follow-up and recurrence of hepatic cystic echinococcosis using ultrasound images. *Trans R Soc Trop Med Hyg* 97, 203–211.

15 Hira PR, Lindberg LG, Francis I *et al.* (1988) Diagnosis of cystic hydatid disease: role of aspiration cytology. *Lancet* 2, 655–657.

16 WHO-Informal Working Group on Echinococcosis (2003) *PAIR: a New Option for the Treatment of Cystic Echinococcosis*. Geneva: WHO.

17 WHO-Informal Working Group on Echinococcosis (1996) Guidelines for treatment of cystic and alveolar echinococcosis in humans. *Bull World Health Org* 74, 231–242.

18 Dziri C, Haouet K, Fingerhut A (2004) Treatment of hydatid cyst of the liver: where is the evidence? *World J Surg* 28, 731–736.

19 Smego RA Jr, Sebanego P (2005) Treatment options for hepatic cystic echinococcosis. *Int J Infect Dis* 9, 69–76.

20 Sayek I, Tirnaksiz MB, Dogan R (2004) Cystic hydatid disease: current trends in diagnosis and management. *Surg Today* 34, 987–996.

21 Chautems R, Buhler LH, Gold B *et al.* (2005) Surgical management and long-term outcome of complicated liver hydatid cysts caused by *Echinococcus granulosus*. *Surgery* 137, 312–316.

22 Cooney RM, Flanagan KP, Zehyle E (2004) Review of surgical management of cystic hydatid disease in a resource limited setting: Turkana, Kenya. *Eur J Gastroenterol Hepatol* 16, 1233–1236.

23 Wu XW, Peng XY, Zhang SJ *et al.* (2004) Formation mechanisms of the fibrous capsule around hepatic and splenic hydatid cyst. *Zhongguo Ji Sheng Chong Xue Yu Ji Sheng Chong Bing Za Zhi* 22, 1–4 (in Chinese).

24 Moreno-Gonzalez E, Loinaz Segurola C, Garcia Urena MA *et al.* (1994) Liver transplantation for *Echinococcus granulosus* hydatid disease. *Transplantation* 58, 797–800.

25 Ben Amor N, Gargouri M, Gharbi HA *et al.* (1986) Trial therapy of inoperable abdominal hydatid cysts by puncture. *Ann Parasitol Hum Comp* 61, 689–692 (in French).

26 Akhan O, Ozmen MN, Dinçer A *et al.* (1996) Liver hydatid disease: long term results of percutaneous treatment. *Radiology* 198, 259–264.

27 Smego RA Jr, Bhatti S, Khaliq AA *et al.* (2003) Percutaneous aspiration-injection-reaspiration drainage plus albendazole or mebendazole for hepatic cystic echinococcosis: a meta-analysis. *Clin Infect Dis* 37, 1073–1083.

28 Felice C, Pirola F, Brunetti E *et al.* (1990) A new therapeutic approach for hydatid liver cysts. *Gastroenterology* 98, 1366–1368.

29 Wang XZ, Yongshou L, Sheng F *et al.* (1994) Clinical treatment of hepatic and abdominal hydatidosis with percutaneous puncture drainage and curettage (report of 869 cases). *Chin J Parasitol Parasitic Dis* 12, 285–287.

30 Schipper HG, Laméris JS, van Delden OM *et al.* (2002) Percutaneous evacuation (PEVAC) of multivesicular echinococcal cysts with or without cystobiliary fistulas which contain non-drainable material: first results of a modified PAIR method. *Gut* 50, 718–723.

31 Avtan L (2005) A new 'Perforator Grinder-Aspirator Apparatus (PGAA)' for the minimal access surgery of cystic liver hydatidosis. *Hepatogastroenterology* 52, 339–342.

32 Baskaran V, Patnaik PK (2004) Feasibility and safety of laparoscopic management of hydatid disease of the liver. *J Soc Laparoendosc Surgeons* 8, 359–363.

33 Craig P (2003) *Echinococcus multilocularis*. *Curr Opin Infect Dis* 16, 437–444.

34 Vuitton DA, Zhou H, Bresson-Hadni S *et al.* (2003) Epidemiology of alveolar echinococcosis with particular reference to China and Europe. *Parasitology* 127, S87–107.

35 Giraudoux P, Craig PS, Delattre P *et al.* (2003) Interactions between landscape changes and host communities can regulate *Echinococcus multilocularis* transmission. *Parasitology* 127, S121–131.

36 Vuitton DA (2003) The ambiguous role of immunity in echinococcosis: protection of the host or of the parasite? *Acta Trop* 85, 119–132.

37 Kern P, Bardonnet K, Renner E *et al.*; European Echinococcosis Registry (2003) European echinococcosis registry: human alveolar echinococcosis, Europe, 1982–2000. *Emerg Infect Dis* 9, 343–349.

38 Deplazes P, Hegglin D, Gloor S *et al.* (2004) Wilderness in the city: the urbanization of *Echinococcus multilocularis*. *Trends Parasitol* 20, 77–84.

39 Smith GC, Gangadharan B, Taylor Z *et al.* (2003) Prevalence of zoonotic important parasites in the red fox (*Vulpes vulpes*) in Great Britain. *Vet Parasitol* 118, 133–142.

40 Bartholomot B, Vuitton DA, Harraga S *et al.* (2002) Combined ultrasound and serologic screening for hepatic alveolar echinococcosis in central China. *Am J Trop Med Hyg* 66, 23–29.

41 Bresson-Hadni S, Laplante JJ, Lenys D *et al.* (1994) Seroepidemiologic screening of *Echinococcus multilocularis* in a European area endemic for alveolar echinococcosis. *Am J Trop Med Hyg* 5, 837–846.

42 Ito A, Romig T, Takahashi K (2003) Perspective on control options for *Echinococcus multilocularis* with particular reference to Japan. *Parasitology* 127, S159–172.

43 Bresson-Hadni S, Vuitton DA, Bartholomot B *et al.* (2000) A twenty-year history of alveolar echinococcosis: analysis of a series of 117 patients from eastern France. *Eur J Gastroenterol Hepatol* 12, 327–336.

44 Kasai Y, Koshino I, Kawanishi N *et al.* (1980) Alveolar echinococcosis of the liver. Studies on 60 operated cases. *Ann Surg* 191, 145–152.

45 Vuitton DA, Zhang SL, Yang YR *et al.* (2006) Survival strategy of *Echinococcus multilocularis* in the human host. *Parasitol Int* 55(Suppl.), 551–555.

46 Bresson-Hadni S, Vuitton D, Didier D *et al.* (1989) Metastases pulmonaires de l'echinococcose alveolaire. Frequence et mecanismes de survenue. *Presse Med* 18, 83.

47 Bresson-Hadni S, Humbert P, Paintaud G *et al.* (1986) Skin localization of alveolar echinococcosis of the liver. *J Am Acad Dermatol* 34, 873–877.

48 Bresson-Hadni S, Delabrousse E, Blagosklonov O *et al.* (2006) Imaging aspects and non-surgical interventional treatment in human alveolar echinococcosis. *Parasitol Int* 55(Suppl.), 5267–5272.

49 Craig PS, Giraudoux P, Shi D *et al.* (2000) An epidemiological and ecological study of human alveolar echinococcosis transmission in south Gansu, China. *Acta Trop* 77, 167–177.

50 Reuter S, Schirmeister H, Kratzer W *et al.* (1999) Pericystic metabolic activity in alveolar echinococcosis: assessment and follow-up by positron emission tomography. *Clin Infect Dis* 29, 1157–1163.

51 Reuter S, Buck A, Manfras S *et al.* (2004) Structured treatment interruption in patients with alveolar echinococcosis. *Hepatology* 39, 509–517.

52 Kadry Z, Renner EC, Bachmann LM *et al.* (2005) Evaluation of treatment and long-term follow-up in patients with hepatic alveolar echinococcosis. *Br J Surg* 92, 1110–1116.

53 Kern P, Gruener B, Sato N *et al.* (2006) WHO classification of alveolar echinococcosis: principles and application. *Parasitol Int* 55(Suppl.), 5283–5287.

54 Miguet JP, Bresson-Hadni S (1989) Alveolar echinococcosis of the liver. *J Hepatol* 8, 373–379.

55 Wilson JF, Rausch RL, Wilson FR (1995) Alveolar hydatid disease. Review of the surgical experience in 42 cases of active disease among Alaskan eskimos. *Ann Surg* 221, 315–323.

56 Gillet M, Bresson-Hadni S (1991) L'échinococcose alvéolaire hépatique. *Rev Prat* 41, 1805–1811.

57 Mosimann F (1980) Is alveolar hydatid disease of the liver incurable? *Ann Surg* 192, 118–123.

58 Bret PM, Paliard P, Partensky C *et al.* (1984) Le traitement de la cholestase par stenose des voies biliaires intrahepatiques au cours de l'echinococcose alveolaire. Essai de drainage biliaire par voie percutanée transhepatique. *Gastroenterol Clin Biol* 8, 308–313.

59 Bresson-Hadni S, Mantion GA, Vuitton DA *et al.* (2004) Echinococcose alvéolaire en région parisienne. *Gastroenterol Clin Biol* 28, 1147–2251.

60 Koch S, Bresson-Hadni S, Miguet JP *et al.* (2003) Experience of liver transplantation for incurable alveolar echinococcosis: a 45 case European collaborative report. *Transplantation* 75, 856–863.

61 Bresson-Hadni S, Koch S, Beurton I *et al.* (1999) Primary disease recurrence after liver transplantation for alveolar echinococcosis: long term evaluation in 15 patients. *Hepatology* 30, 857–864.

62 Craig PS, Rogan MT, Campos-Ponce M (2003) Echinococcosis: disease, detection and transmission. *Parasitology* 127, S5–20.

63 Bresson-Hadni S, Franza A, Miguet JP *et al.* (1991) Orthotopic liver transplantation for incurable alveolar echinococcosis of the liver: report of 17 cases. *Hepatology* 13, 1061–1070.

64 Ito A, Craig PS (2003) Immunodiagnostic and molecular approaches for the detection of taeniid cestode infections. *Trends Parasitol* 19, 377–381.

65 Bardonnet K, Piarroux R, Dia L *et al.* (2002) Combined eco-epidemiological and molecular biology approaches to assess *Echinococcus granulosus* transmission to humans in Mauritania: occurrence of the 'camel' strain and human cystic echinococcosis. *Trans R Soc Trop Med Hyg* 96, 383–386.

66 McManus D, Zhang W, Li J *et al.* (2003) Echinococcosis. *Lancet* 362, 1295–1304.

67 Gil-Grande LA, Rodriguez-Caabeiro F, Prieto JG *et al.* (1993) Randomized controlled trial of efficacy of albendazole in intra-abdominal hydatid disease. *Lancet* 342, 1269–1272.

68 Keshmiri M, Baharvahdat F, Fattahi SH *et al.* (2001) Albendazole versus placebo in the treatment of echinococcosis. *Trans R Soc Trop Med Hyg* 95, 190–191.

69 Franchi C, Di Vico B, Teggi A (1999) Long-term evaluation of patients with hydatidosis treated with benzimidazole. *Clin Infect Dis* 29, 304–309.

70 Mohamed AE, Yasawy MI, Al Karawi MA (1998) Combined albendazole and praziquantel versus albendazole alone in the treatment of hydatid disease. *Hepatogastroenterology* 45, 1690–1694.

71 Schipper HG, Kager PA (2004) Diagnosis and treatment of hepatic echinococcosis: an overview. *Scand J Gastroenterol* 39 (Suppl. 241), 50–55.

72 Vuitton DA, Bresson-Hadni S, Delabrousse E *et al.* (2004) Foie et maladies parasitaires. *Gastroenterol Clin Biol* 28, 1122–1137.

73 Reuter S, Jensen B, Buttenschoen K *et al.* (2000) Benzimidazoles in the treatment of alveolar echinococcosis: a comparative study and review of the literature. *J Antimicrob Chemother* 46, 451–456.

74 Ammann RW, Renner EC, Gottstein B *et al.* (2004) Immunosurveillance of alveolar echinococcosis by specific humoral and cellular immune tests: long-term analysis of the Swiss chemotherapy trial (1976–2001). *J Hepatol* 41, 551–559.

75 Ammann RW, Fleiner-Hoffmann A, Grimm F *et al.* (1998) Long-term mebendazole therapy may be parasitocidal in alveolar echinococcosis. *J Hepatol* 29, 994–998.

76 Ammann RW, Ilitsch N, Marincek B *et al.* (1994) Effect of chemotherapy on the larval mass and the long-term course of alveolar echinococcosis. *Hepatology* 19, 735–742.

77 Horton RJ (1997) Albendazole in treatment of human cystic echinococcosis: 12 years of experience. *Acta Trop* 6, 79–93.

78 Horton J (2003) Albendazole for the treatment of echinococcosis. *Fund Clin Pharmacol* 17, 205–212.

79 Opatrny L, Prichard R, Snell L *et al.* (2005) Death related to albendazole-induced pancytopenia: case report and review. *Am J Trop Med Hyg* 72, 291–294.

80 Wen H, New RRC, Muhmut M *et al.* (1996) Pharmacology and efficacy of liposome-entrapped albendazole in experimental secondary alveolar echinococcosis and effect of co-administration with cimetidine. *Parasitology* 113: 111–121.

81 Chai J, Menghebat T, Wei J *et al.* (2004) Observations on clinical efficacy of albendazole emulsion in 264 cases of hepatic cystic echinococcosis. *Parasit Int* 53, 3–10.

82 Reuter S, Merkle M, Brehm K *et al.* (2003) Effect of amphotericin B on larval growth of *Echinococcus multilocularis*. *Antimicrob Agents Chemother* 47, 620–625.

83 Reuter S, Buck A, Grebe O *et al.* (2003) Salvage treatment with amphotericin B in progressive human alveolar echinococcosis. *Antimicrob Agents Chemother* 47, 3586–3591.

84 Stettler M, Fink R, Walker M *et al.* (2003) In vitro parasiticidal effect of nitazoxanide against *Echinococcus multilocularis* metacestodes. *Antimicrob Agents Chemother* 47, 467–474.

85 Stettler M, Rossignol JF, Fink R *et al.* (2004) Secondary and primary murine alveolar echinococcosis: combined albendazole/nitazoxanide chemotherapy exhibits profound anti-parasitic activity. *Int J Parasitol* 34, 615–624.

86 Harraga S, Godot V, Bresson-Hadni S *et al.* (1999) Clinical efficacy of and switch from T helper 2 to T helper 1 cytokine profile after interferon alpha2a monotherapy for human echinococcosis. *Clin Infect Dis* 29, 205–206.

87 Godot V, Harraga S, Podoprigora G *et al.* (2003) IFN alpha-2a protects mice against a helminth infection of the liver and modulates immune responses. *Gastroenterology* 124, 1441–1450.

88 Brunetti E, Filice C (2001) Radiofrequency thermal ablation of echinococcal liver cysts. *Lancet* 358, 1464.

89 Buttenschoen K, Carli Buttenschoen D (2003) *Echinococcus granulosus* infection: the challenge of surgical treatment. *Langenbecks Arch Surg* 388, 218–230.

90 Kjossev KT, Losanoff JE (2005) Classification of hydatid liver cysts. *J Gastroenterol Hepatol* 20, 352–359.

10.4.3 Ascariasis, visceral larva migrans, strongyloidiasis, capillariasis and pentastomiasis

Marcelo Simão Ferreira and Edna Strauss

Introduction

Parasitic diseases of the liver and the biliary system are frequent in tropical and subtropical regions of the world and cause important morbidity and mortality. In general, the clinical and laboratory findings are not specific enough to lead to suspicion of hepatobiliary parasitosis and, in most cases, the presence of infection can only be confirmed with modern imaging methods and parasitological tests. In this section, we describe infections caused by *Ascaris lumbricoides* including the visceral larva migrans, by strongyloidiasis and by two other relatively rare parasitoses, namely capillariasis and pentastomiasis.

Ascariasis

Introduction

Infection by *A. lumbricoides* is widespread throughout the world, and is particularly prevalent in developing countries. The worm has been known to be a parasite of man since Ancient Greek times. The adults are yellowish-pink, round helminths, ranging from 15 to 35 cm in size and occasionally reaching 50 cm in length; the females are generally larger than the males, and the latter have a characteristic curved posterior end. They live in the small intestine of humans and feed on its contents. The nematode is extremely mobile and does not attach itself permanently to the mucosa. The number of parasites that an individual can host varies and can reach as many as 500–600 adult worms in some cases. The females release about 200 000 eggs a day, and their uterus can contain as many as 27 million eggs. These are round or oval shaped and yellowish-brown in colour, measuring 60 μm in length. They are covered with a wrinkled or mammilliform albuminous layer, which has a brown colour as a result of the biliary pigments absorbed from the faeces. The eggs are eliminated before embryonation and are highly resistant to environmental factors [1,2].

Epidemiology

Ascariasis is the most widespread intestinal parasitosis in the world, and recent figures from the World Health Organization show that one billion people are infected by this helminth. The high temperature and humidity in tropical parts of the world favour maturation of the eggs. Children, particularly those in rural areas, appear to be most affected. Populations living in poor hygienic conditions where potable water is not readily available are highly susceptible. Eggs present in the soil can survive for long periods (45–55 days) even at low temperatures (16–18°C), most notably in clay soils, which retain water and prevent the eggs becoming desiccated. Under favourable conditions, the eggs become infective in around 2 weeks, embryonate with third-stage larvae and can be found in different environments, including objects for personal use, furniture, swimming pools, fruit, vegetables, coins, notes and also drinking water [1,3].

Life cycle

After being ingested and reaching the duodenum, the infective eggs release the third-stage larvae, which migrate to the caecum, where they penetrate the wall and enter the bloodstream or the lymphatic system, through which they reach the liver and right heart, and then the lungs. They remain in the lungs for several days, undergoing two moults. They then pass through the bronchioles, bronchi and trachea to reach the epiglottis, where they are eliminated by the saliva or swallowed. After being swallowed, and on reaching the stomach and small intestine, they undergo the fourth moult and, at this stage, they are 10 times larger than their original size (about 2 mm). Approximately 60 days after being ingested, the parasites become adults and start oviposition. Many third-stage larvae are destroyed in the liver during the beginning of the life cycle, and only a small percentage reach the right heart.

The swine ascarid, *Ascaris suum*, although morphologically similar to the human one, is unable to complete its life cycle in a human host. Its larvae, however, can produce symptoms of visceral larva migrans when migrating erratically through the liver and lungs.

Pathogenesis and pathology

The migratory larvae do not normally produce an inflammatory reaction in the liver in individuals with a primary infection, but an inflammatory process rich in neutrophils and eosinophils does occur in individuals who are re-exposed to infection. If the larvae die, as is very often the case, their fragments can elicit a granulomatous reaction. Helminths can obstruct the choledochum and other intrahepatic biliary branches, leading to acute periductal inflammation (Fig. 1). The walls of the choledochum thicken and its diameter increases; many ducts are amputated; the damage can be observed at cholangiography (Fig. 2). The hepatic parenchyma may be invaded, and many helminths perforate the Glisson's capsule and enter the subdiaphragmatic space. The papilla of Vater, which is the helminth's point of entry into the biliary system, may show signs of papillitis. In cases of massive infection, all the intra- and extrahepatic ducts are ectasic, and there is periductal fibrosis, oedema, degenerative change in the biliary epithelium, ulcerated areas, epithelial hyperplasia and, less commonly, intraductal papillomas (Fig. 3). When the helminths die in the hepatobiliary system, the body of the parasite disintegrates, a large number of eggs

Fig. 1 Biliary ascariasis at autopsy. The bodies of adult worms are seen in the gallbladder and in the common bile duct (courtesy of Dr Luiz Carlos C. Gayotto).

are released, and suppurative cholangitis is produced. This very often involves the hepatic veins and circumadjacent hepatocytes. Multiple hepatic abscesses can be produced, and remnants of the parasites and their eggs are commonly found in the pus within the necrotic areas; in addition, enterobacteria and anaerobes may also be isolated from this material. Granulomas may occasionally be seen throughout the hepatic parenchyma and around the small intrahepatic biliary ducts, especially in areas where eggs and fragments of the worms are deposited and sometimes phagocytosed by large giant cells (Fig. 4). The presence of this material from degenerated nematodes appears to be essential for the formation of intrahepatic calculi (hepatolithiasis). This formation is facilitated by the high level of glycuronidase activity present in these helminths, which deconjugates bilirubin and contributes to the formation of pigmented calculi. The prolonged presence of *A. lumbricoides* in the biliary tree may cause ductal stenosis, chronic cholangitis, hepatolithiasis and secondary biliary cirrhosis [4–7].

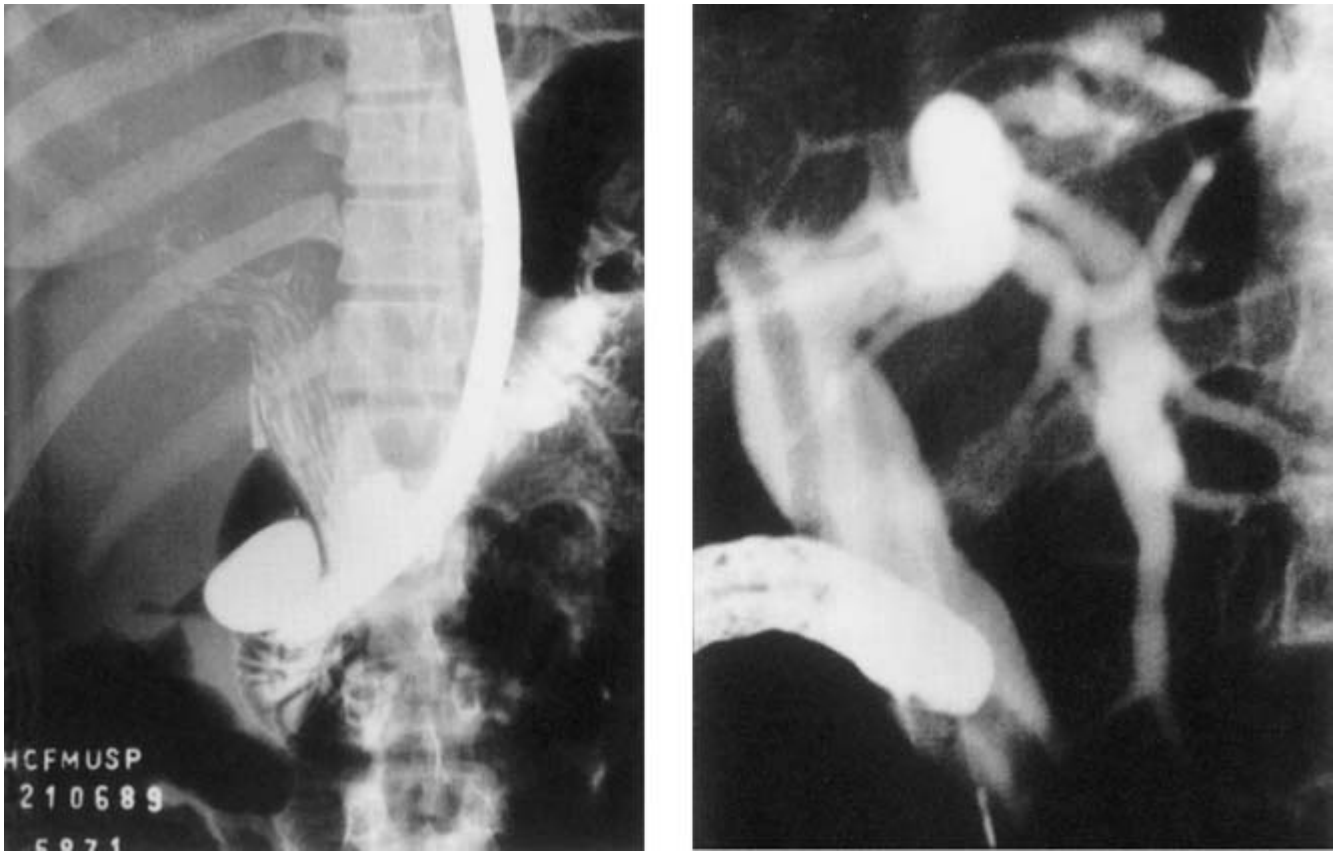

(a) (b)

Fig. 2 Endoscopic retrograde cholangiopancreatography in a case of biliary ascariasis showing filling defects corresponding to adult worms in a dilated common bile duct. There is amputation of several branches of the biliary tree (courtesy of Dr Ernesto Damerau). (a) Endoscopic retrograde cholangiopancreatography in a case of biliary ascariasis. (b) In a markedly dilated common bile duct, filling defects show many bodies of adult worms. Seventy-six worms were removed from the biliary tree (courtesy of Dr Marcel C. Machado).

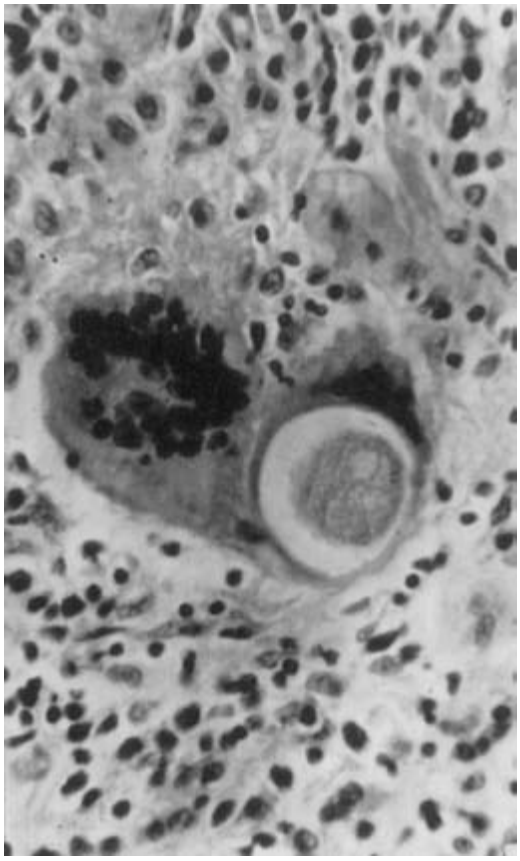

Fig. 3 Remnants of a dead worm mixed with cellular debris are tightly adherent to the hyperplastic epithelial lining of a bile duct. The portal tract shows fibrosis, inflammation and erosion of the limiting plate (Masson's trichrome) (courtesy of Dr Luiz Carlos C. Gayotto).

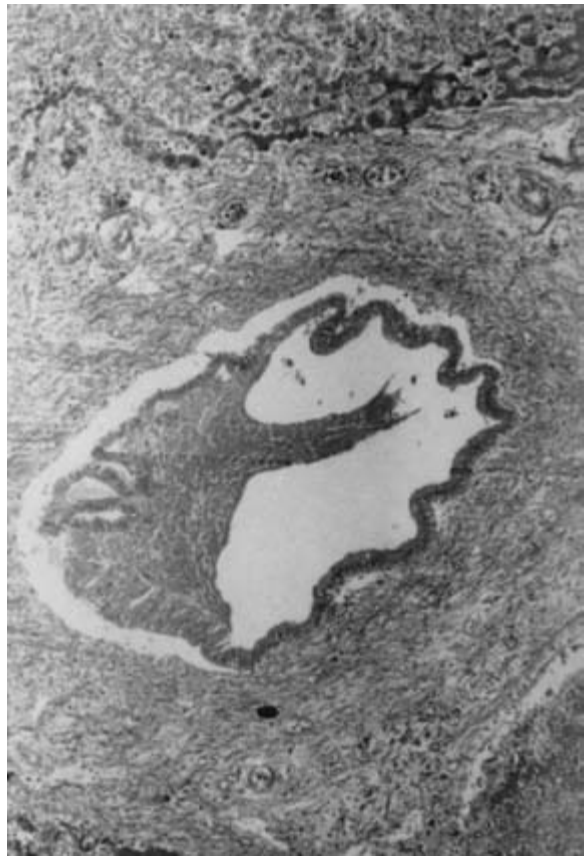

Fig. 4 An egg of *A. lumbricoides* is phagocytosed by a foreign body giant cell around which there is an eosinophilic infiltrate (haematoxylin and eosin) (courtesy of Dr Luiz Carlos C. Gayotto).

Clinical picture: hepatobiliary involvement

In the initial phase of ascariasis, the larvae may produce symptoms of asthmatiform bronchitis and pneumonitis as they pass through the lungs; symptoms are more severe during reinfections and massive infections. Blood eosinophilia is very often present during this phase. This set of symptoms is known as Loeffler syndrome; it can also be seen in infections caused by other nematodes with a pulmonary cycle (ancillostomides and *Strongyloides stercoralis*) [2,8].

The presence of adult worms in the small intestine may be asymptomatic, especially when few helminths are present. Some individuals, however, may complain of abdominal pain and intermittent cramps accompanied by nausea. The most common complication of the disease is obstruction of the intestine by an '*Ascaris*' bolus. This is particularly common in undernourished children with a low standard of living, and can evolve in some cases to ischaemic necrosis of the intestinal wall, perforation and peritonitis [2,8].

Penetration of the biliary system may initially be asymptomatic. However, depending on the number of worms in the biliary system, abdominal pain in the upper right quadrant, nausea and vomiting are present in most cases; fever with shivering and jaundice are present in up to 20–30% of patients and reflect concomitant acute suppurative cholangitis. At physical examination, hepatomegaly is the most important finding after jaundice [2]. Laboratory data show leucocytosis and eosinophilia, which can be very conspicuous in some cases (> 40%). It is not unusual in such cases for *Ascaris* to be eliminated orally or anally. Some authors recognize five clinical forms of hepatobiliary ascariasis: acute cholecystitis (sometimes with acute hepatitis), acute cholangitis, biliary colic, acute pancreatitis and hepatic abscess [2,5,8]. Another rare form of this liver parasitosis is the formation of a pseudotumour as a result of granulomas that coalesce around *A. lumbricoides* eggs [4,6]. The hepatic mass, simulating a malign tumour, can be detected with ultrasonography or computerized tomography (CT). The actual nature of the process can only be disclosed by histopathological examination [4,5,9,10].

Ascariasis-associated hepatolithiasis is very common in Asian countries and can lead to recurrent pyogenic cholangitis, multiple hepatic abscesses, secondary biliary cirrhosis and cholangiocarcinoma. The calculi are usually located in the intrahepatic biliary ducts close to the junction of the right and left

liver. The clinical picture results from biliary stasis and bacterial infections which ascend from the intestinal lumen [5–7,9–11].

Diagnosis

Intestinal ascariasis is easily diagnosed by detecting the parasite's eggs in faeces [12], using suitable methods such as those of Lutz (Hoffman, Pons and Janner) and of Kato–Katz. Coproscopic examinations can be negative if infection is sustained by a single parasite or by males alone, or if carried out in the preoviposition period (60 days after infection). The haemogram may show eosinophilia, particularly in the larval phase of the disease [5,9,10].

Helminths in the biliary system can be detected by ultrasonography; with this technique, it is possible to observe their movements in the gallbladder or in the larger ducts. The parasites appear as long, linear or curved, strongly echogenic structures, very often with an acoustic shadow. The imaging can also show dilatation of the biliary system, and can confirm the presence of gallbladder oedema, single or multiple hepatic abscesses or oedematous pancreatitis [5,13].

CT and retrogade endoscopic cholangiography are also useful in diagnosing hepatobiliary ascariasis. Liver histology can occasionally reveal granulomas around the helminth's eggs.

Treatment

Intestinal ascariasis can be treated with various anthelminthic drugs:

1 Mebendazole – oral dose of 100 mg twice daily for 3 days or a single dose of 600 mg orally, independently of body weight.

2 Albendazole – single oral dose of 400 mg for adults and a 10 mg/kg dose for children.

3 Levamisole (or tetramisole) – single oral dose of 150 mg for adults and 80 mg for children.

Any treatment results in a high cure rate, generally above 90%. In cases of intestinal obstruction, piperazine salts (50–100 mg/kg/day) delivered by nasogastric probe should be used; they act on the myoneural junction of the helminths, producing paralysis and facilitating elimination of the bolus by peristaltic movements. Treatment of the hepatolithiasis associated with biliary ascariasis involves the endoscopic extraction of the helminths and the calculi from the larger biliary ducts with or without sphincterotomy. A partial hepatectomy is sometimes required in cases with serious complications. Of note, in hyperendemic regions, sphincterotomy has the disadvantage that it allows the helminths to reach the biliary system more easily in future reinfections. Anthelminthic therapy over a prolonged period (with albendazole, for example) is needed in most cases of hepatobiliary ascariasis.

Prevention and control

Measures for controlling ascariasis are primarily aimed at reducing the prevalence and severity of infection by means of basic sanitation, health education, disinfection and treatment of carriers, which is essential to eliminate sources of infection in the population. The last procedure appears to be the simplest and most efficient for interrupting the epidemiological chain of the parasitosis. Campaigns against the parasite endemia should promote treatment on a widespread scale, primarily in small communities. It is important to administer the anthelminthic agent in a single dose every 1 or 2 months for at least 1 year in order to reduce the prevalence of the disease to reasonably acceptable levels.

Visceral larva migrans

Introduction

The 'larva migrans' syndrome was first identified and proposed as a term in 1952 by Beaver *et al.* when they described the clinical picture in American children of hepatomegaly, pulmonary manifestations, severe eosinophilia and ascarid larvae at liver biopsy. This syndrome is caused by the erratic migration of nematode larvae across the organs of non-natural (paratenic) hosts such as man, where the parasite's normal cycle is not completed and is blocked at the larval stage. Various helminths may be responsible for this syndrome. The most common are ascarid parasites of dogs and cats that belong to the genera *Toxocara* (*T. canis*, *T. cati*) and *Toxascaris*. In addition, *Gnathostoma spinigerum*, *Ancylostoma caninum* and *Angyostrongylus costaricencis* can cause the 'larva migrans' syndrome by erratic migration in man. *T. canis* is the most important agent of this disease in Latin American countries, and the term toxocariasis has become synonymous with visceral 'larva migrans' in the literature [14].

Epidemiology

T. canis infects a large percentage of canids throughout the world, particularly in tropical and subtropical regions. The transmission to man is by ingestion of the nematode's eggs containing third-stage larvae. Development of disease in humans depends on a high concentration of *T. canis* eggs in the soil, a situation commonly found in areas with large numbers of dogs. Public places frequented by large numbers of people and animals favour transmission of the disease, with children being particularly at risk as they have frequent contact with the soil while playing games. The eggs must remain in the soil for 2–5 weeks to become infective. Habits such as geophagia and onychophagia increase the risk of contracting the disease. The incidence of anti-*Toxocara* antibodies is higher in individuals who keep dogs at home. Population studies using serology (ELISA) have shown a prevalence of 1–5% in the general population, with a distinctly higher prevalence among children and adolescents. The ingestion of raw or poorly cooked meat and/or offal from animals that are paratenic hosts to *T. canis* (poultry

and rabbits) has been suspected as a means of transmission of the parasitosis to man [14].

Life cycle

The normal life cycle of the helminth is not completed in man. After ingestion, the larvae are released in the small intestine, penetrate the mucosa, enter the portal circulation, reach the liver and, from there, the lungs, heart, central nervous system and ocular globe. The eggs and larvae are not detectable in faeces [14,15].

Pathogenesis and pathology

The presence of the larvae causes local reactions of an immunoallergic nature in the different human organs, attributable mainly to their death. The parasites also stimulate a humoral and cellular immune response. The *Toxocara* antibodies appear at an early stage and belong to the IgM, IgG and IgE classes. Their appearance is accompanied by marked peripheral eosinophilia, reflecting a type Th_2 immunocellular response. Pathological changes are most common in the liver, although other organs can show significant changes as well. Macroscopically, the organ increases in volume, with sinuous lesions about 2–5 cm in size on the surface. Small nodules, spread throughout the liver, can sometimes be observed (Fig. 5). Microscopically, there is an extensive inflammatory process, with areas of necrosis and cellular infiltrate composed of eosinophils and Charcot–Leyden crystals; sometimes, real eosinophilic abscesses are formed.

An important inflammatory reaction also develops around the larvae, consisting of granulomas made up of histocytes, giant cells, lymphocytes, plasmocytes and eosinophils (Fig. 6). These lesions may occasionally progress to become fibrous nodules or even simulate neoplastic processes. Biliary ductopenia and cholestasis may be observed on rare occasions. The larvae (or their remnants) cannot easily be seen in ordinary histological preparations, and a large number of histological sections may be needed to detect their presence [11,14,16,17]. However, immunohistological techniques can reveal the presence of parasite antigens in liver cuts and can confirm the diagnosis.

Clinical picture: hepatobiliary involvement

The clinical picture of visceral 'larva migrans' varies depending on the parasitic load, length of infection and location of the larvae in the tissues. Most infections are asymptomatic and probably occur in all age groups. The symptomatology consists of fever, fatigue, pruriginous skin rash, abdominal pain, nausea, vomiting, diarrhoea, weight loss and hepatosplenomegaly [17]. Pulmonary symptoms such as coughing, dyspnoea and

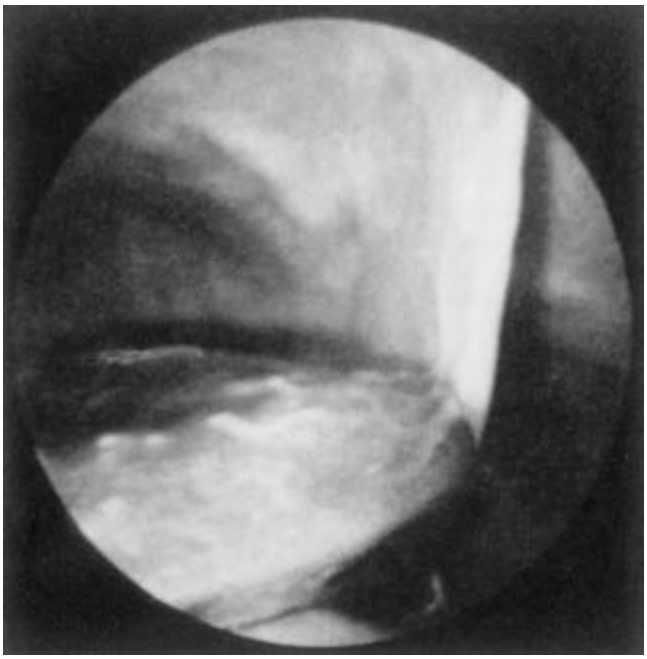

Fig. 5 Laparoscopic view of the liver surface in a case of visceral larva migrans. Typical serpiginous lesions (courtesy of Dr Raimundo Llanio).

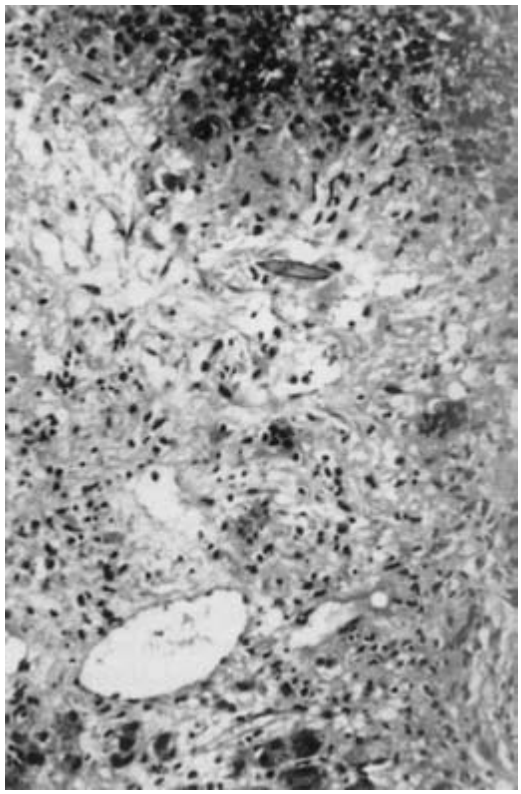

Fig. 6 Liver biopsy in a case of visceral larva migrans. Florid reaction made up of extensive necrosis of the liver parenchyma, an eosinophilic infiltrate and many fragments of larval bodies, some phagocytosed by foreign body giant cells (haematoxylin and eosin) (courtesy of Dr Luiz Carlos C. Gayotto).

expectoration are common and probably reflect migration of the larvae to the lungs. A picture of progressive cholestatic jaundice has been reported [16,18]. Less common manifestations include cardiac dysfunction, nephrotic syndrome and neurological manifestations (epilepsy, paresia and transverse myelitis). The association between visceral 'larva migrans' and deep abscesses has been confirmed in recent years in experimental and clinical studies. Hepatic, renal and muscular abscesses (tropical pyomyositis) have been attributed to toxocariasis in tropical areas where the parasitosis is common [16,19]. The lesions induced by the larvae can predispose to the appearance of staphylococcal infections. Larvae in the ocular globe can lead to loss of sight [11,14,17].

Laboratory findings include occasional anaemia, leucocytosis with intense eosinophilia, hypergammaglobulinaemia and an increase in hepatic enzymes, in particular alkaline phosphatase and γ-glutamyl-transferase [16]. Imaging methods can be used to demonstrate hepatic involvement [20]; ultrasonography shows single or multiple hypoechoic lesions in one or both lobes that can progress to hyperechoic lesions. On CT, these hepatic lesions appear as hypodense nodules and, in nuclear magnetic resonance, as lesions with a low-intensity signal on T1 and a high-intensity signal on T2. The differential diagnosis should include primary or secondary neoplastic lesions of the liver; other granulomatous diseases, such as tuberculosis and sarcoidosis, should also be considered [19,20].

Diagnosis

Visceral 'larva migrans' is not easy to diagnose. The larvae can be found in hepatic tissue obtained by biopsy, but it is often difficult to identify them. Immunohistochemical techniques applied to the tissue are extremely helpful in confirming the diagnosis [21].

Serological diagnosis is important, and enzyme-linked immunosorbent assay (ELISA) techniques using *Toxocara* larvae secretor/excretor antigens are widely used in clinical practice. In regions where ascariasis is endemic, sera must be treated with *Ascaris* antigens beforehand to increase the reaction's specificity [22,23].

Indirect haemagglutination and agar gel double diffusion have also been used to diagnose visceral 'larva migrans', but they have low sensitivity. Alternatively, the assay for *Toxocara* larva-specific IgE has good sensitivity. A Western blot technique has been developed and is a possible diagnostic option in daily clinical practice [22].

Treatment

One 50-mg/kg/day dose of thiabendazole taken orally for 10 days is the treatment of choice for visceral 'larva migrans'. This drug inhibits migration of the larvae through the tissues and contributes to an inflammatory reaction against the parasite. Symptomatic patients should be treated. There is controversy as to whether treatment should be given to patients with few or no symptoms. Other drugs such as diethylcarbamazine, albendazole, levamisole and ivermectin can also be used to kill or immobilize the helminth in the tissues [22]. Corticosteroids can be useful in serious cases involving the lungs, central nervous system or ocular globe. The signs and symptoms of disease usually disappear within a few weeks, but eosinophilia may persist for months after treatment. Deaths are rare and, in most patients, the course of the disease is benign [17].

Prevention and control

Prevention of visceral 'larva migrans' depends on the control of canine infection and contamination of the soil by *T. canis* eggs. Treatment of dogs and cats with imidazolic derivatives is very efficient; it should be carried out regularly in order to eradicate the adult parasites from animals. Puppies and kittens should also be treated from 3 weeks of age on. Various countries now adopt legislation which makes dog and cat owners responsible for removing and cleaning up pet wastes in public places. This step has been efficacious in reducing contamination of the soil with *T. canis* eggs. It is also important to eliminate stray dogs and cats from city streets and squares. Health education with information to the population of the risks of owning a dog carrying the nematodes in the house is fundamental in controlling this helminthiasis [17].

Strongyloidiasis

Introduction

Strongyloidiasis is a helminthiasis prevalent in some tropical areas of the world. Its importance, as an intestinal parasitosis, is related to the severity of its lesions and dissemination in multiple organs. Severe forms of the infection occur primarily in immunodepressed individuals.

Epidemiology

Strongyloidiasis is endemic in tropical areas of Africa, Asia and the Americas, in particular in populations from poor socioeconomic backgrounds. Strongyloidiasis is also endemic in some European countries and central areas of the United States, although the prevalence in these regions is low. Countries with the highest rates of parasitism in the Americas are Peru, Brazil, Chile and Colombia. Suitable environmental conditions, a temperature between 25°C and 30°C and sandy soil are essential for the development of the two different phases (free-living and parasitic stage) of the parasite life cycle.

Man plays an important role in transmitting the infection as he is the only host of *S. stercoralis*. Animals do not function as reservoirs of the human disease. Lack of sanitary facilities, defaecation in the peridomicile area, ingestion of contaminated food and water and the habit of not wearing shoes are essential factors in the transmission of this parasitosis [15].

Life cycle

The life cycle of this helminth has two different patterns. In the direct cycle, the filariform larvae, which are eliminated in the faeces of the carrier, penetrate the skin or mucosa, enter the circulatory system and cross the lungs, where they rupture into the pulmonary alveoli. They then ascend to the pharynx through the bronchi, are swallowed and subsequently mature into adult parthenogenetic females in the small intestine. Oviposition starts and rhabditoid larvae hatch from the eggs while in the intestinal lumen. The larvae are then eliminated in the faeces. They may sometimes transform into filariform larvae in the lumen of the small intestine, subsequently penetrating the mucosa and completing the pulmonary cycle. This type of life cycle is called internal autoinfection. In most cases, however, the rhabditoid larvae eliminated by the faeces to the soil develop into free-living males and females, which in turn produce rhabditoid larvae again. After two moults, rhabditoid larvae transform into filariform larvae which can infect man (indirect cycle). Filariform larvae that reach the perianal region when faeces are passed can cause autoinfection by penetrating the skin in this area [24].

Pathology

Autoinfection allows the parasitosis to persist for decades in the human body. Immunodepression can accelerate the life cycle of the parasite, increasing the parasitic load and disseminating filariform larvae to many organs. This 'hyperinfection' was reported in patients with severe malnutrition, those who use corticosteroids in large doses, transplant recipients, lymphoma and acquired immune deficiency syndrome (AIDS) patients. The presence of eggs and helminths in the mucosa and submucosa of the small intestine results in a significant inflammatory reaction, which may lead to extensive, usually superficial ulcerations. In massive infections, the stomach and colon can also be involved. Intestinal microorganisms may superinfect mucosal ulcerations and cause bacteraemia and remote infections.

In the liver, the larvae are found in the portal tracts, in the periportal areas and even inside the intrahepatic veins. They are generally surrounded by an eosinophilic infiltrate or by a granulomatous reaction rich in eosinophils. Miliary granulomas without the larva can also be found (Fig. 7). Although necrosis of hepatocytes is rare, areas of steatosis and discrete cholestasis are common. The larvae have a characteristic appearance, with double lateral alae, which is easily recognized at histology [24–26].

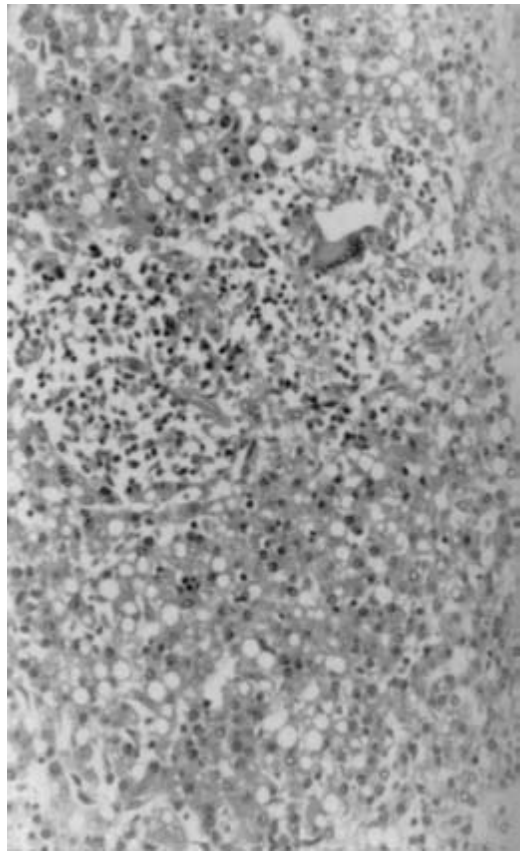

Fig. 7 Miliary granulomas in the liver of a patient with the disseminated form of strongyloidiasis: a giant cell, a few epithelioid cells, a dense eosinophilic infiltrate and fragments of the larva in a loose arrangement. There is fatty change in the parenchyma (haematoxylin and eosin) (courtesy of Dr Maria de Fatima Araujo).

Clinical picture: hepatobiliary involvement

Most individuals infected by *S. stercoralis* are asymptomatic or oligosymptomatic. Passage of the larvae through the lungs may result in pneumonitis, with asthmatiform manifestations and peripheral eosinophilia. The duodenum and proximal jejunum are the segments of the small intestine preferred by the parasite; it may also be found, sometimes in large numbers, in the terminal ileum and colon. Symptomatic patients complain of epigastric pain, anorexia, nausea, vomiting, abdominal distension and prolonged diarrhoea. In patients with a high parasitic load, diarrhoea may be intense, voluminous and malabsorptive in nature, with steatorrhoea and enteric protein loss. In the disseminated form of the disease ('hyperinfection syndrome'), bronchopulmonary symptoms and fever, the latter arising from the presence of larvae in multiple organs, can be observed in addition to gastrointestinal symptoms. Hepatobiliary manifestations include hepatomegaly and cholestatic jaundice. The latter can be the result of biliary obstruction due to papillary stenosis, which can resolve with specific treatment [25]. Usually, many larvae can be found in the bile. Laboratory tests demonstrate increases in alkaline phosphatase, γ-glutamyl-transferase and aminotransferases. Cross-infective hepatitis of bacterial origin and pyogenic hepatic abscesses can develop during disseminated strongyloidiasis because, on leaving the intestine, the larvae carry Gram-negative bacteria in their tegument that cause bacteraemia and severe sepsis [25,26].

Diagnosis

Strongyloidiasis can be diagnosed [27] by detecting the helminth larvae in the faeces using suitable methods such as the Baerman–Moraes or modified Rugai techniques. These techniques are very sensitive and are based on the thermotropism and hydrotropism of the parasite larvae. At least three samples of faeces are needed to achieve maximum sensitivity. Coproculture techniques are more sensitive and can be used to detect different phases of the helminth's life cycle. The best known are the Harada–Mori and agar plate techniques. Larvae can also be detected in other organic fluids such as the duodenal contents, obtained by endoscopy, and respiratory secretions collected during bronchoscopy procedures. Serology is rarely used and is useful only in epidemiological studies in endemic areas [23].

Treatment

Few drugs are available to treat strongyloidiasis. The most often used are:

1. thiabendazole – 50 mg/kg/day (maximum 3 g/day) for 3 days;
2. cambendazole – 5 mg/kg/single dose;
3. albendazole – 400 mg twice daily for 3–5 days;
4. ivermectin – 200 μg/kg/single dose.

These drugs have variable cure rates of between 85% and 95%. Patients with the disseminated form should take thiabendazole or albendazole for an extended period (up to 10 days). A 200 μg/kg dose of ivermectin on days 1, 2, 15 and 16 is recommended for patients with AIDS. Clinical and parasitological cure has been reported with this dosage in most cases. The therapeutic efficacy can be evaluated by parasitological examination on the 7th, 14th and 21st days after treatment.

In the systemic forms of the disease, broad-spectrum antibiotics (cephalosporins and quinolones) must be used in conjunction with anthelminthic agents to fight associated bacterial infections.

Capillariasis

Introduction

Hepatic capillariasis is caused by the nematode *Capillaria hepatica*. Another species of the genus, *Capillaria philippinensis*, is found in the small intestine of humans and can cause chronic and malabsorptive diarrhoea. The hepatic form of the disease is rare in humans, and few cases have been reported. The parasite can be found in the liver of rats, squirrels, dogs, beavers and some primates. Man is probably an accidental host.

Epidemiology

By the end of the twentieth century, only 32 cases of this disease had been published. This is somewhat surprising in view of the high prevalence of infection among domestic rodents, which are in close contact with human populations living in poor conditions. Many cases go undetected. Sometimes, the infection is discovered only at necropsy or biopsy of suspected cases. Cases of human infection have been described in different parts of the world, including Brazil [10].

Life cycle

The non-embryonated eggs of *C. hepatica* are released from the carcasses of infected animals; they may also be eliminated in the faeces of rodents or humans. The eggs embryonate in the environment and become infective to humans approximately 2–6 weeks later. Infection occurs mainly in small children, who occasionally practise geophagia. When the eggs reach the caecum, they release the larvae, which cross the intestinal mucosa, enter the portal system and lodge in the liver. They mature in this organ, become adults in around 3 weeks and start oviposition. When they die, they release a large number of eggs in the parenchyma [28–30].

Pathology

The liver is enlarged and its surface shows small 0.1–0.2 cm yellowish granulomatous nodules surrounded by an area of induration up to 3 cm in diameter. Granulomas made up of epithelioid and giant cells can be found surrounding the eggs and necrotic remains of the parasite [28]. Experimental studies in rodents indicate that the nematode can induce the formation of a long, thin, septal fibrosis in acinar zone III of the liver, starting about 30 days after the oral contamination with the embryonated eggs. The fibrosis increases progressively and can lead to cirrhosis. The presence of sequestered parasitic antigens, which are probably released slowly in the liver, appears to be the most important factor in the pathogenesis of septal fibrosis [29–31].

Clinical picture

Commonly observed clinical symptoms in hepatic capillariasis are persistent fever, hepatosplenomegaly and hypereosinophilia. Visceral larva migrans, acute schistosomiasis and the larval phase of some intestinal parasitoses (ascariasis, ancylostomiasis and strongyloidiasis) should be considered in the differential diagnosis. In most cases, liver function tests are altered, with pronounced increases in cholestatic enzymes (alkaline phosphatase and GGT) and aminotransferases [3,29,30].

Diagnosis and treatment

In exceptional cases, the diagnosis may be based on the identification of operculated and striated eggs of *C. hepatica* in faeces, but the vast majority are based on histopathology, on a liver biopsy. Granulomas surrounding the eggs and the remnants of the helminth, associated with extensive septal fibrosis, confirm the diagnosis [3,29–31].

There is no consensus regarding treatment because of the small number of cases published. Good results were described in Brazil and Germany with thiabendazole, albendazole and ivermectin. Adding corticosteroids can help to reduce the inflammatory reaction in the liver [3,29].

Pentastomiasis

Introduction

Pentastomiasis (or porocephalosis) is induced by haematophagous endoparasites of vermiform appearance that belong to the phylum Arthropoda. Two families are of medical interest: Linguatulidae, with the species *Linguatula serrata*, and Porocephalidae, with the species *Armillifer* (or *Porocephalus*) *armillatus* [32,33].

Epidemiology

The adult parasites live in the respiratory tract of carnivorous animals and snakes. The larval stage can occasionally be found in man. Human infection has been described in various countries. Cases have been confirmed in the Americas (the United States, Canada, Panama, Brazil, etc.), Europe (Switzerland and Germany), Southeast Asia and Africa (Zaire and Nigeria). Infestation can be found in up to 2.2% of autopsies in some areas of Malaysia and Africa [30–33].

Life cycle

Adult parasites attach with their hooks to the respiratory tract of the final host and feed on epithelial cells, blood, lymph and mucous. They are of different sex; males are smaller. The fertilized eggs are eliminated in the nasal secretions, saliva and faeces of carnivores and snakes, and may be ingested by various intermediate hosts, including man. The eggs release first-stage larvae in the intestine, which penetrate the bowel wall and reach the liver. There they undergo nine moults in 6 months and form third-stage larvae or infective nymphs which then become encysted. The larva grows progressively and can behave like a space-occupying lesion inside the parenchyma of the liver. The larva usually dies with time; occasionally, it can escape from the cyst and invade the peritoneal cavity [30,32,34].

Pathogenesis and pathology

The death of the larva may result in a prominent inflammatory reaction that subsequently undergoes calcification. The infection is usually discovered by chance during radiological investigations, surgery or autopsy. Nymphs may cause disease depending on their location, the number of parasites and where they have migrated to. The encysted nymph in the liver is surrounded by a dense fibrous tissue and is often calcified. Granulomas develop around the remnants of the disintegrated parasite and are generally necrotic. Pyogenic abscesses may occasionally form around the larvae [30,32,34].

Clinical picture

The clinical picture varies from subclinical to a serious illness presenting as pneumonitis, intestinal obstruction, biliary obstruction with cholestasis, hepatic abscess, meningitis and pericarditis. Calcifications are typically 5 mm in diameter, elongate or rounded; they may be found in several organs. Humans are highly tolerant to this infection. Peripheral eosinophilia is almost always present in all the clinical forms of the disease [33,34].

Diagnosis and treatment

Diagnosis of pentastomiasis is based on the detection of parasite nymphs in tissue during autopsy or surgery, or at biopsy. A serological test has been developed in France, but its role in diagnosis has yet to be determined [34,35].

Pentastomiasis does not need to be treated. Curative surgery can be carried out in cases where the lesions take up space in organ parenchymas. Antibiotics may be required for secondary pyogenic complications [32,35].

References

1 Crompton DW (2001) Ascaris and ascariasis. *Adv Parasitol* 48, 285–375.
2 Hsu FH (1962) Clinical observation on 110 cases of *Ascaris* invasion into the biliary tract. *Nagoya J Med Sci* 24, 215–233.
3 Pereira VG, França LCM (1983) Successful treatment of *Capillaria hepática* infection in an acutely ill adult. *Am J Trop Med Hyg* 32, 1272–1274.
4 Fogaça HS, Oliveira CS, Barbosa HT *et al.* (2000) Liver pseudotumor: a rare manifestation of hepatic granulomata caused by *Ascaris lumbricoides* ova. *Am J Gastroenterol* 95, 2099–2101.
5 Khuroo MS (2001) Hepatobiliary and pancreatic ascariasis. *Ind J Gastroenterol* 20, C 28–32.
6 Leung JW, Yu AS (1997) Hepatolithiasis and biliary parasites. *Baillières Clin Gastroenterol* 11, 681–706.
7 Pilankar KS, Amarapurkar AD, Joshi RM *et al.* (2003) Hepatolithiasis with biliary ascariasis – a case report. *BMC Gastroenterol* 3, 35–39.
8 Khuroo MS, Zargar SA (1985) Biliary ascariasis. A common cause of biliary and pancreatic disease in an endemic area. *Gastroenterology* 88, 418–423.
9 Khuroo MS, Zargar SA, Mahajan R *et al.* (1987) Sonographic appearances in biliary ascariasis. *Gastroenterology* 93, 267–272.
10 Khuroo MS, Zargar SA, Mahajan R (1990) Hepatobiliary and pancreatic ascariasis in India. *Lancet* 335, 1503–1506.
11 Ehrhard T, Kernbaum S (1979) *Toxocara canis* et toxocarose humaine. *Bull Inst Pasteur* 77, 225–287.
12 Hall A, Holland C (2000) Geographical variation of *Ascaris lumbricoides* fecundity and its implications for helminth control. *Parasitol Today* 16, 540–544.
13 Khuroo MS, Zargar SA, Yatoo GN *et al.* (1993) Worm extraction and

biliary drainage in hepatobiliary and pancreatic ascariasis. *Gastrointest Endosc* 39, 680–685.
14 Beaver PC (1969) The nature of visceral larva migrans. *J Parasitol* 55, 3–12.
15 Glickman LT, Schantz PM (1981) Epidemiology and pathogenesis of zoonotic toxocariasis. *Epidemiol Rev* 3, 230–250.
16 Gonzalez MT, Ibanez O, Balcarce N *et al.* (2000) Toxocariasis with liver involvement. *Acta Gastroenterol Latinoamer* 30, 187–190.
17 Zinkham WH (1978) Visceral larva migrans. A review and reassessment indicating two forms of clinical expression: visceral and ocular. *Am J Dis Child* 132, 627–633.
18 Hartleb M, Januszewski K (2001) Severe hepatic involvement in visceral larva migrans. *Eur J Gastroenterol Hepatol* 13, 1245–1249.
19 Rayes AA, Lambertucci JR (1999) The association between human toxocariasis and pyogenic abscesses. *Rev Soc Bras Med Trop* 32, 425–438.
20 Azuma K, Yashiro N, Kinoshita T *et al.* (2002) Hepatic involvement of visceral larva migrans due to *Toxocara canis*: a case report – CT and MR findings. *Radiat Med* 20, 89–92.
21 De Brito T, Chieffi PP, Peres BA *et al.* (1994) Immunohistochemical detection of toxocaral antigens in human liver biopsies. *Int J Surg Pathol* 2(2), 117–124.
22 Bahia V, Sarin SK (1994). Hepatic visceral larva migrans: evolution of the lesion, diagnosis and role of high-dose albendazole therapy. *Am J Gastroenterol* 89, 624–627.
23 Glickman L, Schantz P, Dombroske R *et al.* (1978) Evaluation of serodiagnostic tests for visceral larva migrans. *Am J Trop Med Hyg* 27, 492–498.
24 Haque AK, Schnadig V, Rubin SA *et al.* (1994) Pathogenesis of human strongyloidiasis: autopsy and quantitative parasitological analysis. *Mod Pathol* 7, 276–288.
25 Delaracque Astagnau E, Hadengue A *et al.* (1994) Biliary obstruction resulting from *Strongyloides stercoralis* infection: report of a case. *Gut* 35, 705–707.
26 Poltera AA, Katsimbura N (1974) Granulomatous hepatitis due to *Strongyloides stercoralis*. *J Pathol* 113, 241–245.
27 Siddigui AA, Berk SL (2002) Diagnosis of *Strongyloides stercoralis* infection. *Clin Infect Dis* 34, 1280–1281.
28 Galvão VA (1981) *Capillaria hepatica*: an evaluation of its pathogenic role in man. *Mem Inst Oswaldo Cruz* 76, 415–433.
29 Pannenbecker J, Miller TC, Muller J *et al.* (1990) Severe liver involvement by *Capillaria hepatica*. *Monastsschr Kinderheilkd* 138, 767–771.
30 Sawamura R, Fernandes MI, Peres LC *et al.* (1999) Hepatic capillariasis in children: report of 3 cases in Brazil. *Am J Trop Med Hyg* 61, 642–647.
31 Ferreira LA, Andrade ZA (1993) *Capillaria hepatica*: a cause of septal fibrosis of the liver. *Mem Inst Oswaldo Cruz* 88, 441–447.
32 Nzeh DA, Akinlemibola JK, Nzeh GC (1996) Incidence of *Armillifer armillatus* (pentastome) calcification in the abdomen. *Central Afr J Med* 42, 29–31.
33 Prathap K, Lau KS, Bolton JM (1969) Pentastomiasis: a common finding at autopsy among Malaysian aborigines. *Am J Trop Med Hyg* 18, 20–27.
34 Self JT, Hopps HC, Olufemi Williams A (1975) Pentastomiasis in Africans. *Trop Geogr Med* 27, 1–13.
35 Smith JA, Oladiran B, Lagundoye SB *et al.* (1975) Pentastomiasis and malignancy. *Ann Trop Med Parasitol* 69, 503–512.

11 Immune disorders of the liver

11.1 Primary biliary cirrhosis

E. Jenny Heathcote and Piotr Milkiewicz

Definition of primary biliary cirrhosis

Small intrahepatic bile ducts are progressively destroyed, probably by an immunological process. This results in progressive cholestasis, the rate of which varies between patients.

Introduction

The first descriptions were in 1851 by Addison and Gull [1] and in 1892 by Hanot [2]. In 1949, the association with high levels of serum cholesterol and skin xanthomas led to MacMahon and Thannhauser [3] coining the term 'xanthomatous biliary cirrhosis'.

In 1950, Ahrens and the group from the Rockefeller Institute in New York gave the first clear description of the condition, which they termed primary biliary cirrhosis (PBC) [4]. This we now recognize was a misnomer as not all patients are cirrhotic, at least on initial presentation. In 1964, Rubin *et al.* [5] from the Mount Sinai Hospital in New York described the disease as 'chronic non-suppurative destructive cholangitis'. This is a better term, although too cumbersome to replace the easier name 'primary biliary cirrhosis'.

The last decade of the twentieth and first decade of the twenty-first century have been witness to a major change in our understanding of PBC – it is now apparent that this disease affects all races worldwide. Today, it is most common for the diagnosis to be made when individuals are asymptomatic. The natural history of both symptomatic and asymptomatic patients is well described. Treatment has altered the course of the disease, and the enhanced availability of liver transplantation has meant that endstage PBC is rarely witnessed.

Epidemiology

The disease usually affects middle-aged women of all races between 40 and 59 years of age (range 15–80+ years) [6–8]. Reports on the prevalence of PBC suggest figures ranging from 51 to 400 cases per million [9–11]; the disease appears to be more common in temperate climates in the northern hemisphere. It has been estimated in Britain that approximately 1 in 900 women over 40 years of age [9] have PBC, with a 9:1 ratio of women to men affected. There are no particular distinguishing features when the disease affects men, except that men report less pruritus [12] and may be more at risk of hepatocellular carcinoma. Several factors may influence prevalence rates, the most obvious being the methods used for tracing cases and the criteria required to make a diagnosis. Thus, in Australia, when cases of PBC were traced only by mailing physicians, a prevalence of 19 per million was reported in 1995 [13]. When the same group repeated their epidemiological study in 2004 [11], a figure of 51 cases per million was reported, but their case-finding methods changed to include the methods used by investigators in Newcastle, i.e. tracing all individuals whose sera tested positive for antimitochondrial antibodies (AMA), the serological hallmark for PBC (this latter technique uncovered 127 of the total number of 249 cases identified in this series). The prevalence of PBC in Newcastle using these same tracing techniques was reported to be 334 per million [9]. As more sophisticated testing for AMA is developed, more cases may be identified. Cases of PBC recruited by identifying individuals tested for AMA for another reason appear to be older by 10 years than those cases of PBC recruited from the office of gastroenterologists. In a study in which the methodology for AMA testing remained the same, i.e. immunofluorescence, and in which cases were not recruited from laboratories screening for AMA, the incidence of PBC appeared to remain the same in a stable community in Olmsted County in the US [10]. Similarly, the incidence has not changed in Newcastle in the north of England, only the prevalence [9]. At this time, it is not clear whether the rising prevalence rates of PBC are due to the methods used for case recruitment of affected individuals and/or affected individuals living longer. Geographical clustering is described, and the reported rates of this disease cannot be explained only by closeness to an interested academic centre [14]. Extremely high rates of AMA positivity are reported in surviving individuals who have lived in close proximity to the Nagasaki atomic bomb explosion in Japan (8.3% AMA positive) [15]. Other geographical clusters have been described in related individuals, as in one

large First Nations family on Vancouver Island [16]. With our current state of knowledge of the genetics of PBC, it is impossible to separate the effect of environment and the host. A report from Australia suggests that migration influences the prevalence of PBC, as individuals of English extraction had significantly less PBC than that reported in the UK using the same methods of case collection [11]. The role of the environment in the development of PBC was first suggested by the development of the disease in a daughter, her mother and a close unrelated friend who nursed the daughter through her terminal illness [17].

There are a few published studies on the prevalence of AMA in healthy populations [18–20], all conducted in the northern hemisphere. The results are similar; about 0.5% test AMA positive, which suggests that only 1–10% of AMA-positive individuals are subsequently discovered to have PBC; this observation supports the notion that there may be several factors needed for the complete phenotype.

No cases of children with PBC have been described but, recently, two postpubertal girls of 15 have been reported to have PBC, one of whom's mother also had PBC [21]. The risk of PBC is highest in the daughters of index cases [22]. The rate of AMA positivity in family members of index cases of PBC is much disputed, perhaps because different methods are used for AMA testing; this will be ascertained in the future with much larger family studies. To date, any human leukocyte antigen (HLA) associations with PBC have been weak [23], and reports of gene-specific mutations altering immune responsiveness have not clearly shown any disease-specific associations; however, all genetic studies to date have been small.

Pathogenesis (Table 1)

PBC is almost universally associated with the presence of AMA. These antibodies react with the M2 family of mitochondrial antigens, which include components of three mitochondrial enzymes: pyruvate dehydrogenase complex (PDC), 2-oxoglutarate dehydrogenase complex (OGDC) and branched-chain 2-oxo-acid dehydrogenase complex (BCOADC) [24]. As shown in immunoblotting or enzyme-linked immunosorbent assay (ELISA) studies, serum autoantibodies from 95% of patients with PBC react with the E2 subunit of PDC, and sera from 50–70% of patients react with the E2 subunit of OGDC or BCOADC. Thus, if antibodies to all three antigens are checked, AMA can be detected in the sera of at least 95% of affected individuals and have been shown to be highly specific and sensitive for PBC [25–26] when present in individuals with liver disease.

Table 1 Possible aetiological factors in primary biliary cirrhosis.

Breakdown of immunological tolerance leading to recognition of mitochondrial self-antigens
'Molecular mimicry' of mitochondrial antigens by infectious particles (bacteria, viruses). Possibly impaired glutathionylation within interlobular bile ducts and salivary epithelial cells facilitates immunogenicity
Involvement of innate immune response to infection – induction of IgM, cytokines and chemokines
Genetic profile of a 'complex disease'

As the initial tissue damage is focused almost entirely on biliary epithelial cells (BEC), PBC can be included in the group of organ-specific autoimmune conditions. Inflammatory responses most probably result from a breakdown of immunological tolerance and recognition of aberrant expression of mitochondrial self-antigen, leading to the generation of specific T and B lymphocytes with subsequent production of proinflammatory cytokines [27].

It remains to be established how PDC-E2 and other epitopes, localized to the inner membrane of mitochondrium, become the subject of an autoimmune reaction in such a highly selective population of cells confined to the interlobular bile ducts and salivary duct cells. It has been suggested that apoptosis can increase the exposure of PDC-E2 to the immune system, leading to an autoimmune attack [28,29]. It has been demonstrated that a predominant epitope against which AMA is directed is localized to the lysine-lipoyl domain of PDC, with prefered recognition of reduced sulphydryl groups [30]. Unlike other apoptotic cells in which PDC-E2 is not recognized by AMA, in apoptotic rat cholangiocytes and human salivary gland epithelial cells, recognition of PDC-E2 by AMA remains [29]. This immunoreactivity is decreased by gluthathionylation and sustained by inhibition of glutathionylation [28]. These findings suggest that masking of sulphydryl groups with glutathionylation reduces the immunogenicity of PDC-E2, and it has been postulated that this process may be specifically impaired in cells primarily involved in the pathogenesis of PBC. Competition for the lysine residue between glutathionylation and ubiquitinylation has also been suggested as a potential source of impaired glutathionylation in BEC [29]. Studies in experimental models suggests that AMA belonging to the IgA but not the IgG subclass can enter cholangiocytes (via the pIgR transporter) and interact with intracellular PDC-E2, leading to activation of caspase and subsequent induction of apoptosis [31]. This observation may be relevant to the pathogenesis of PBC. Other authors have reported that apoptosis itself can cause aberrant expression of PDC-E2 on the cell surface [32].

The pathogenesis of PBC may be an example of 'molecular mimicry', a phenomenon in which 'self'-like immunogenic determinants from an exogenous factor (bacterium, virus, xenobiotic, etc.) may induce the production of antibodies or effector T cells that then erroneously interact with similar epitopes on a host cell or protein. A number of bacteria, including *Escherichia coli*, *Pseudomonas aeruginosa*, *Helicobacter pylori*, *Chlamydia pneumoniae* and *Haemophilus influenzae*, have been linked with triggering PBC via 'molecular mimicry'. The most convincing data so far are related to *Novosphingobium aromaticivorans*, a ubiquitous bacterium whose own PDC-E2 contains 12 of 13 contiguous amino acids of the core sequence identical to the human PDC-E2 sequence [33]. Furthermore, the *N.*

aromaticivorans PDC-E2 sequence resembles motifs crucial for T-cell recognition [34], and this microbe is detected more frequently in stools from individuals with PBC compared with healthy subjects [33]. However, stool-positive control subjects have undetectable serum autoantibodies to this microorganism, suggesting that intestinal permeability may be altered in PBC, as has been reported [35]. *N. aromaticivorans* is able to metabolize 17β-estradiol, the metabolites of which may interact with and/or modify lipoyl residues of PDC-E2 and trigger an autoimmune reaction. This may be relevant, considering the female preponderance of PBC. *Chlamydia pneumoniae* RNA has been identified in all of 25 explant liver tissues from patients with advanced PBC and in all 14 biopsy specimens from patients with early PBC analysed in one study, but in only 8.5% (9/105) of liver tissue specimens from patients with other liver diseases [36]. Whether these findings are aetiologically relevant and/or reflect molecular mimicry remains to be determined. The potential role of microorganisms in triggering PBC via their interaction with the innate immune system has also been postulated. IgM secretion is a vital part of innate immunity, being a first-line host defence against infectious agents. Bacterial DNA sequences containing CpG motifs can induce polyclonal B-cell activation associated with the production of IgM. Kikuchi *et al.* [37] found that bacterial CpG was able to induce increased production of IgM by CD27(+) memory B cells originating from patients with PBC but not in control subjects with other liver diseases. CpG motifs are recognized by cells via toll-like receptor 9 (TLR9) and play a pivotal role in innate immune mechanisms, which promote cellular proliferation and induction of IgM, interferons and proinflammatory cytokines and chemokines. This observation potentially implies an important role for innate immune mechanisms in the generation of immune responses in PBC.

Involvement of viruses in the pathogenesis of PBC, either directly or via molecular mimicry, has also been invoked. Viral particles, closely related to the mouse mammary tumour virus (MMTV), were detected in cholangiocytes and lymph nodes obtained from patients with PBC. Viral particles were also identified in 'normal' BEC once incubated with lymph node homogenates from patients with PBC. Induction of phenotypical features of PBC in these BEC, including membrane expression of PDC-E2, was also observed [38,39]. The role of MMTV in the pathogenesis of PBC has been questioned [40]. The authors of the reports suggesting that a betaretrovirus may play a role in the pathogenesis of PBC have also conducted a small pilot study which showed that oral administration of an antiretroviral agent, combivir, may induce an improvement in liver biochemistry and liver histology in patients with PBC [41]. Recurrence of PBC following liver transplantation occurs significantly earlier and more severely in overimmunosuppressed patients and happens more commonly in patients treated with tacrolimus rather than ciclosporin A (CyA)-based immunosuppression [42]. These findings may be relevant in the context of the potential role of viruses in the pathogenesis of PBC, as it has been shown recently that CyA may possess innate antiviral properties both *in vivo* and *in vitro* [43].

An immune response against liver cells can be triggered by changes in the molecular structure of self proteins induced by xenobiotics. Rabbits immunized with 6-bromohexanoate–bovine serum albumin conjugate not only produce antibodies directed against this xenobiotic but they also make self-reactive AMA [44]. Halothane may induce the production of antibodies against both its metabolite, called TFA, and also PDC-E2 [45]. The possible role of xenobiotics excreted in the biliary system is an attractive hypothesis, as it may provide an explanation as to why cholangiocytes are the cells that are preferentially damaged in PBC. However, recent work on genetic polymorphisms of proteins involved in the metabolism of xenobiotics, including CYP2E1, MDR1 or PXP, did not show a difference between patients with PBC and matched control subjects, although the CYP2E1 c1/c2 genotype was linked with more severe disease [46].

Epidemiological data strongly support an important role for genetics in the aetiology of PBC, which is considered to be a 'complex disease'. This expression has replaced previous terms used, such as 'polygenic', i.e. involving more than one gene, or 'multifactorial', i.e. alluding to interactions between host genome and environmental factor(s) [47]. Clusters of PBC within families are reported [16], and the prevalence of this disease in close relatives of affected subjects has been reported to be as high as 6.4% in one study [48]. Prevalence of PBC in first-degree relatives of propositi has been estimated at 0.72% and in the offspring of affected individuals at 1.2%. Notably, the sibling relative risk for PBC (λs or ratio of disease prevalence in siblings of affected subjects to the population prevalence of the disease) has been calculated to be 10.5 [22], which is higher than that observed in rheumatoid arthritis ($\lambda s = 8$), ulcerative colitis ($\lambda s = 8$) and many other diseases with a proven genetic predisposition. The highest relative risk is seen in daughters of affected females. Although familial clustering may, to some extent, reflect ascertainment bias (increased probability of relatives seeking medical attention) and some shared environmental factors, these relative risk data provide unquestionable support for an important genetic component in PBC [49].

Twin concordance data showed PBC concordance to be 0.63 in monozygotic and 0.00 in dizygotic twins [50] (numbers similar to those seen in Crohn's and coeliac disease), again indicating an important role for genetic susceptibility in PBC. Similarly, overlap with other autoimmune conditions, also thought to have a genetic aetiology, supports a genetic basis for PBC. Like some other genetic diseases, PBC may show genetic anticipation, the disease usually presenting earlier and more aggressively in daughters than in their affected mothers [48]. It is unclear, however, whether this observation reflects a genetic phenomenon or merely increased familial awareness of the classical symptoms. Unlike autoimmune hepatitis or other conditions with an autoimmune aetiology, PBC does not show a strong association with HLA molecules, and only a weak link with DR8 has been

established [23]. DRB1*0801 was found to be a susceptible allele in white patients [51,52], whereas it was found to be DRB1*0803 in Japanese subjects [53].

Diagnosis (Table 2)

Diagnostic features

The patient is usually a middle-aged woman, but initial presentation may be as young as 15 years and older than 80 years. In the twenty-first century, the diagnosis tends to be made early, and the patient is usually asymptomatic. But asymptomatic disease is not synonymous with early disease on liver histology. The individual is most commonly found to have a raised level of serum alkaline phosphatase with or without an elevation in total serum cholesterol, discovered at a routine check. Alternatively, the diagnosis may be made in patients undergoing investigation for a condition known to be associated with PBC, such as scleroderma. Abnormal physical signs are often absent whereas serum AMA are generally present. Most laboratories still use immunofluorescence as the initial screening test; a diagnostic titre is > 1:40. In some instances, AMA-positive subjects detected as part of a rheumatological workup may have no elevation in liver biochemistries. Measurement of serum immunoglobulins generally reveals an elevated IgM value. At initial diagnosis, the serum bilirubin is most often normal. Similarly, serum aminotransferases may be normal but are often mildly (× 2–3 ULN) elevated.

Liver biopsy has been reported to be abnormal in 26 of 29 individuals whose liver biochemistry was normal, their sole marker being AMA positivity [25]. Long-term (mean 10-year) follow-up of these individuals showed that most developed both biochemical abnormalities and typical symptoms of PBC, although often not until many years later [54].

Table 2 Diagnosis of primary biliary cirrhosis.

Clinical features
Female (15–80+ years)
Asymptomatic (60%)
Symptoms if present: fatigue and/or pruritus, right upper quadrant discomfort
Hepatomegaly ± splenomegaly
Jaundice (rare)
Sjögren syndrome
Xanthelasma
Biochemical features
Elevated alkaline phosphatase
Aminotransferase levels normal or mildly elevated
Bilirubin often normal
Elevated total cholesterol
Serological features
Elevated IgM
Positive for antimitochondrial antibody (immunofluorescence/ELISA)

It has been argued that AMA positivity in an individual with an elevated serum alkaline phosphatase (ALP) value is sufficient to make a diagnosis of 'probable' PBC, i.e. liver biopsy is not required [55]. But without a liver biopsy, the severity of the liver disease remains unknown. This may be irrelevant if the initial diagnosis is being made in an elderly person with other significant comorbidities. For a younger individual, it is important to know the severity of hepatic fibrosis [56], and recent data suggest that the degree of interface hepatitis seen on liver biopsy is helpful in predicting the future likelihood of progression to cirrhosis [57].

AMA-negative PBC

In the case where the patient is thought on history, physical and laboratory investigation to have PBC but AMA in serum are undetectable, a liver biopsy is essential, particularly if the highly sensitive and specific test using a triple-epitope ELISA is not available [26]. If the AMA test is persistently negative and the serum alkaline phosphatase remains elevated, other causes of cholestasis (or infiltrative liver disease) also need to be excluded on the liver biopsy, and radiological examination of the biliary tree should probably be performed. The introduction of reliable visualization of the biliary tree using magnetic resonance imaging (MRI) has almost eliminated the need for invasive, risky tests such as endoscopic retrograde cholangiography as an investigative tool. Whereas some individuals given a diagnosis of AMA-negative PBC may have AMA detected subsequently [58], most do not, but their natural history is otherwise no different [59].

Symptoms associated with PBC

Fatigue

Some individuals with PBC can almost give the exact date when they first developed fatigue; in others, the onset is more gradual – fatigue has generally been present long before the diagnosis is made, i.e. not due to 'labelling'. Fatigue affects up to one-third of the general population, has many aetiologies and its lack of specificity makes it hard to evaluate and easy to ignore (but not by the affected individual!). The only clear association of fatigue is with depression, but all depression scores include fatigue as an item so this 'overlap' is expected. The prevalence of fatigue in individuals given a diagnosis of PBC varies from 40% to 80% and does not correlate with the severity of liver disease or with age [60,61]. One study suggests that, in those with fatigue, there is an abnormality of manganese homeostasis in the brain and elevated manganese levels in the blood of subjects with PBC when compared with healthy control subjects [62], and another study suggests that there is an association of fatigue in PBC with elevated serum levels of tyrosine and phenylalanine and decreased tryptophan [63]. Although experimental studies in bile duct ligated animals suggested that 'fatigue' induced by this form of acute cholestasis was effectively inhibited by a serotonin

agonist, a recent trial of ondansetron, which alters serotonergic transmission, did not ameliorate fatigue in patients with PBC [64].

Pruritus

Pruritus is much easier to define than fatigue but just as difficult to measure. It is a very specific symptom of cholestatic liver disease. As partial biliary diversion eliminates the pruritus of cholestasis, clearly a component of bile is responsible for this symptom [65]. Likewise, the anion exchange resin cholestyramine, which binds bile in the gut, relieves the pruritus of cholestasis. However, the exact component of bile that causes pruritus is uncertain; both bile acids and endogenous opioids have been incriminated.

Pruritus is better in the sun and worse at night. It is usually generalized and not associated with any rash (unless caused by trauma to the skin secondary to scratching). Long-term cholestasis (even if anicteric) and pruritus gradually lead to both thickening and darkening of the skin, more marked in pruritic areas. Severe pruritus (whether acute or chronic) causes marked sleep disturbance and distress, sometimes leading to suicidal ideation. Despite the distress induced by this symptom, it is often inadequately managed by physicians. Patients may present *de novo* to dermatologists, who need to check AMA and liver biochemistry. Pruritus can start during pregnancy, and a few cases of PBC are first diagnosed during pregnancy when the pruritus usually fails to recede in the postpartum period.

Jaundice

As more cases of PBC are diagnosed and treated earlier, so fewer jaundiced cases are observed. Whereas in the past PBC was considered rare in some parts of the world, it is now being increasingly recognized, e.g. in India [66], as diagnostic tests for AMA become more accessible and physicians are more aware of the condition in both icteric and anicteric subjects. Jaundiced cases of PBC may still present where access to healthcare facilities is either not available or not affordable or in individual patients misdiagnosed or failing to seek medical help despite obvious jaundice. Otherwise, marked jaundice is only seen in individuals with PBC who, because of comorbidities, are not candidates for a liver transplant. Curiously, pruritus often lessens as jaundice progresses, as does xanthelasma.

There are many causes of hyperbilirubinaemia in PBC in addition to endstage disease; they include Gilbert syndrome, common duct stones, hyperthyroidism, sepsis, drug-induced liver disease and the wrong diagnosis such as PBC/autoimmune hepatitis (AIH) overlap.

Marked jaundice is associated with steatorrhoea and weight loss caused by malabsorption of fat. Overt fat-soluble vitamin deficiency is rarely noted nowadays but, if ignored, may cause osteomalacia, a coagulopathy and night blindness.

Other clinical features

Abdominal discomfort

Primarily located in the right quadrant, this is not unusual in PBC [67]. This may prompt more extensive investigations of the biliary tree. Gallstones are common in all patients with chronic liver disease, and it may be hard to distinguish symptoms of gallstones from those of PBC alone. In patients with an elevated bilirubin, it is particularly important to distinguish progressive liver disease from common duct stones (or superimposed Gilbert syndrome). The presence of fever clearly indicates that the cause of pain is not PBC.

Hepatocellular carcinoma

This is associated with severe PBC (stages III and IV) and is the only malignant tumour that is preferentially seen in individuals with PBC [68]. It is more common in the elderly and in men [69]. Some studies suggest that it is as common as in patients with severe chronic viral hepatitis [70].

Xanthelasma/xanthoma

These are now rarely seen in PBC – why is not clear, as their presence is not associated with disease severity. In most instances, high levels of serum cholesterol were seen in association with xanthomata, but this was not always the case.

Associated conditions

Osteoporosis

The issue of whether osteoporosis is or is not more common in patients with PBC is very controversial – in a large study of predominantly elderly individuals with early PBC, osteoporosis was no more common than in age- and gender-matched control subjects [71]. In another study published in the same year, the authors suggest that osteoporosis is a feature of PBC, particularly in those who are older, thinner and with more advanced liver disease [72]. One study suggests that menopausal status is not a risk factor for osteoporosis in PBC [73], but an earlier study claimed that the postmenopausal state was an independent factor in its development! [74]. Certainly, osteoporosis is not unusual in the population affected by PBC and needs attention in terms of appropriate preventive and therapeutic strategies.

Autoimmune associations

As patients with PBC are universally found to test positive for one autoantibody or another, it is not unexpected to observe the presence of other autoimmune diseases. Only recently has there been a detailed survey of patients with PBC from a single geographical area, and these authors employed very well-defined criteria for the diagnosis of specific autoimmune diseases when they examined their cases of PBC and healthy control subjects. This report from the north of England centred on a cohort of

160 patients – 108 with definite, i.e. AMA-positive and liver biopsy-proven PBC and 52 with 'probable' PBC, 19 of whom were AMA negative. The authors reported that 53% had one or more probable or definite autoimmune conditions and 20% had two or more. Other autoimmune disease was more common in those who tested positive for antinuclear antibodies (ANA) (75% vs. 50% in ANA negative) and more frequently observed in AMA-positive PBC (79% vs. 49%) [75]. This study suggested that both primary and secondary Sjögren syndrome is associated with PBC – together affecting 25%. Sicca symptoms can be elicited from up to 70% of patients with PBC [76]. Coeliac disease in association with PBC was not observed in the Newcastle study; only Sjögren syndrome (7.5%), Raynaud's phenomenon (2.4%), pernicious anaemia (4%) and systemic lupus erythematosus (SLE) (1.5%) were significantly higher than expected when compared with local control subjects [75]. Of note was that other autoimmune diseases such as rheumatoid arthritis (17%) and autoimmune thyroid disease (23%), although common, were no more common than in the local control population.

Renal associations

Renal complications reported in patients with PBC include IgM-associated membranous glomerulonephritis [77] and renal tubular acidosis attributed to copper deposits in the distal renal tubule [78]. Bacteriuria develops in 35% and is often asymptomatic [79]; it is unexplained, but it has been postulated that these urinary tract organisms might be involved in the pathogenesis of PBC.

Non-hepatic malignancy in PBC

There is controversy as to whether there is an increase in other malignancies. There are reports of an increased rate of breast cancer [80,81], but this has not been confirmed by others [68,82].

Investigations

Serum bilirubin values are very rarely elevated at the time of diagnosis (unless there is superimposed Gilbert syndrome) in asymptomatic patients, who account for 60% of new cases of PBC, as most, but not all, have early liver disease. Elevated levels of serum alkaline phosphatase (ALP) and γ-glutamyl-transpeptidase (GGT) are the usual biochemical abnormalities, often detected at a routine checkup and sometimes elevated to very high levels. The serum aminotransferase levels may or may not be elevated. The total serum cholesterol is often elevated (if facilities are available, it will be found that the cholesterol is predominantly lipoprotein X and thus quite harmless [83]). There appears to be no increased risk of atherosclerotic vascular disease in PBC [84]. The serum albumin level is nearly always normal at presentation, and the total serum globulin only moderately increased, but the serum IgM fraction is usually raised. As in all patients with a cholestatic profile (even if asymptomatic), ultrasound examination of the biliary tree is recommended as part of the baseline diagnostic workup. Only in individuals who test negative for AMA would magnetic resonance cholangiography be recommended (especially in men in whom primary sclerosing cholangitis is a more likely cause of chronic cholestasis).

Serum AMA tests

The standard immunofluorescence method for detection of AMA employs rat stomach or kidney and was the initial test used and remains that frequently used for the detection of AMA [85]. On occasions, immunostaining results seen in patients who have anti-LKM-positive autoimmune hepatitis are falsely reported as being AMA, as microsomes may be confused on the slide with mitochondria. ELISA testing for AMA is more specific and reliable, particularly if a hybrid recombinant molecule containing the three key epitopes of M2 is used [26]. Immunoblotting techniques for the detection of AMA are predominantly used for research purposes as this method is time consuming. Historically, approximately 5–10% of patients with elevated ALP and/or GGT and classical findings on liver biopsy for PBC have tested AMA negative, particularly if checked only by immunofluorescence. Many such sera subsequently test positive by ELISA, but still a small proportion of patients remain AMA negative. AMA can be detected in asymptomatic subjects with completely normal liver biochemistry, who may yet have the hepatic histological features compatible with PBC [25,54]. Titres of AMA do not correlate with either clinical presentation or progression of the disease [86]. Patients with PBC may test positive for ANA, particularly those antibodies belonging to the group that recognize nuclear pore antigens. These include anti-Sp100 and anti-gp210. They are considered to be highly specific for PBC and, when present, may potentially be associated with more rapid progression of the disease and worse outcome [87–89].

Liver histology (Table 3 and Plate 11.1, facing p. 1268)

As the diagnosis of PBC may be reliably established on the grounds of a positive AMA test and elevated ALP [55], liver biopsy is performed predominantly to assess disease severity rather than to confirm the diagnosis. Histologically, the disease begins with damage to the epithelium of just the interlobular bile ducts. Histometric examinations show that only bile ducts less than 70–80 Å in diameter are destroyed [90].

As the bile ducts become destroyed, their sites are marked by aggregates of lymphoid cells and bile ductular proliferation. Visualization of the damaged ducts may be facilitated using a cytokeratin stain, which shows the abnormal proliferating bile ducts very clearly [91]. Granulomas are present in a proportion of patients, particularly in those with early-stage disease. Unlike the granulomas of sarcoidosis, they are nearly always confined to the portal tracts in PBC and may just appear as small collections

Table 3 Liver histology of primary biliary cirrhosis.

Portal tracts	Lymphocytes invading bile ducts
	Plasma cells, eosinophils also found
	Granulomas/histiocytes
	Bile duct loss/proliferation (CK7 stain)
	Loss of portal venous radicles
Limiting plate	Lymphocytic 'hepatitis'
	Biliary 'hepatitis'
Parenchyma	Variable lymphocytic infiltrate
	No liver cell injury unless associated AIH
	Nodular regenerative hyperplasia
	'Jigsaw' pattern of fibrosis
THV	Venulitis

of histiocytoid cells. Absence of granulomas does not exclude PBC. Hepatic arterial branches can be easily identified in the portal zones, but accompanying bile ducts may be missing; unless specifically looked for, their absence may go unnoticed. Portal venous radicles may also be involved in the inflammatory process and become destroyed, and nodular regenerative hyperplasia (best depicted with a reticulin stain) is a consequence [92]. Hepatic fibrosis is induced by the retention of hydrophobic bile acids, caused by bile duct loss, and proinflammatory cytokines, secreted as part of the inflammatory response, and is seen extending from the portal tracts through the limiting cell plate (interface hepatitis). The severity of lymphoplasmacytic interface hepatitis may be an independent predictive factor for progression of early PBC to cirrhosis, even in patients treated with ursodeoxycholic acid (UDCA) [57]. As in any chronic cholestatic disease, substantial amounts of copper and copper-associated protein may be demonstrated histochemically in periportal zones. Fibrous septa gradually come to distort the architecture of the liver and regenerative nodules develop. These are often irregular in distribution, and cirrhosis may be seen in one part of a biopsy but not in another; this may be described as a 'jigsaw' pattern of cirrhosis. In some areas, zonal architecture may be preserved for some time. Hepatocellular hyaline deposits, similar to those of alcoholic liver disease, are found in hepatocytes in about 25% of cases of PBC.

The histological appearance has been divided into four stages: stage I, florid bile duct lesions; stage II, ductular proliferation; stage III, scarring (septal fibrosis and bridging); and stage IV, cirrhosis [93]. Such staging is of limited value as the changes in the liver are often focal and evolve at different speeds in different parts of the liver. Stages overlap, and it is particularly difficult to separate stages II and III. Thus, it is probably more or at least as important to examine the degree of bile duct loss and interface hepatitis, as these are the two major factors that seem to govern disease progression.

The disease has a very variable and often silent course, and advanced stage III lesions or even stage IV PBC may be seen in the asymptomatic patient; thus, asymptomatic PBC does not always mean early PBC.

Differential diagnosis (Table 4)

Initial clinical presentation of individuals subsequently given a diagnosis of PBC has changed dramatically over the last 40 years. The majority of patients diagnosed four decades ago were jaundiced, whereas jaundiced subjects comprise only about 4% of patients with PBC diagnosed today [94].

The presence of AMA is virtually diagnostic for PBC [when AMA are detected in patients with typical AIH (< 5%), this may represent an 'overlap syndrome']. A small proportion of patients with typical clinical, biochemical and histological features of PBC do not have detectable AMA, even when the most sophisticated methods are employed [59]. They have AMA-negative PBC. It is currently accepted that the natural history, clinical presentation and prognosis are not different from those of classical AMA-positive PBC.

Primary sclerosing cholangitis (PSC) may pose a diagnostic difficulty, but the AMA test is almost always negative, and cholangiography by either endoscopy (ERCP) or magnetic resonance cholangiography (MRC) demonstrates the typical bile duct irregularities. In early PSC, or in those who may have only small duct PSC [95], these typical cholangiographic findings may not be present. Other less common causes of 'vanishing bile ducts' are uncommon, and other clinical features will usually point to their aetiology. Idiopathic ductopenia may show histological features of bile duct damage that may be difficult to differentiate from PBC, although infiltration of the portal tract with chronic inflammatory cells is generally minimal in adult idiopathic ductopenia [96].

The cholestatic form of sarcoidosis can be indistinguishable from PBC; moreover, the coexistence of PBC and sarcoidosis is well established [97]. Lymphadenopathy seen on chest radiography tends to be present in sarcoidosis, whereas granulomas in PBC are rarely found outside the abdomen. In sarcoidosis, although granuloma are often present in the liver, they are mostly in the parenchyma and, unlike PBC granuloma, those in sarcoid become fibrotic with time. Increased levels of serum angiotensin-converting enzyme may be found in any person with significant liver disease and, therefore, its measurement is not helpful in this situation. Granulomatous disease of the lung can be observed in both PBC and sarcoid; bronchoalveolar lavage findings are similar [98]. The presence of AMA in serum is not a feature of sarcoidosis.

Drug-induced cholestasis, for example after chlorpromazine or antibiotics such as flucloxacillin or amoxicillin–clavulinic acid, can become chronic and produce a picture resembling PBC [99]. Serum ALP tests may remain abnormal for many years even though the jaundice fades. However, there is a history of taking the drug, and the initial presentation is with jaundice, whereas in PBC, once jaundice is present, it does not spontaneously resolve (unless caused by a superimposed condition such as choledocholithiasis, haemolysis or Gilbert syndrome).

Herbal remedies and products such as pyrrolizidine alkaloids, germander, chaparral leaf or Jin Bu Huan may give clinical and

Table 4 Differential diagnosis of primary biliary cirrhosis.

Disease	Features	Serum antimitochondrial antibody	Liver biopsy
Primary biliary cirrhosis	Female; pruritus; high serum alkaline phosphatase	Positive (5% negative)	Bile duct lesions, lymphoid aggregates; intact lobules; periseptal cholestasis
Primary sclerosing cholangitis	Males predominant; associated with ulcerative colitis; pruritus; cholangiography is diagnostic	Negative	Zone 1 ductular proliferation, fibrosis and cellularity; 'onion skin' duct fibrosis
Cholestatic sarcoidosis	Equal sexes; high alkaline phosphatase; pruritus; chest radiographic abnormalities	Negative	Many granulomas all zones/often fibrotic; modest bile duct changes
Cholestatic drug reaction	History of drug use, acute onset	Negative	Mononuclear zone 1 reaction, sometimes with eosinophils and granulomas; modest piecemeal necrosis may be followed by duct paucity
Autoimmune hepatitis	Female; high serum aminotransferases and gammaglobulin; positive serum anti-smooth muscle and antinuclear antibodies or anti-liver–kidney microsomal antibodies – overlap with PSC or PBC possible	Negative or low titre	Zone 1 mononucleosis and fibrosis; marked piecemeal necrosis; bridging necrosis; rosettes of liver cells; plasma cell infiltrates; rare bile duct loss
Other vanishing bile duct syndromes	Pruritus; high serum alkaline phosphatase	Negative	Ductopenia rather than inflammatory cell invasion of ducts
Turner syndrome	Persistently elevated alkaline phosphatase ± bilirubin	No reports	No reports

biochemical symptoms of acute cholestasis and features of bile duct damage on histology. As in many cases of drug-induced cholestasis, the onset of herbal-induced cholestasis is usually rapid, associated with elevated transaminases but, in the majority of patients, symptoms resolve after withdrawal of the causative agent, although cholestatic drug reactions may take several months to resolve. Concomitant estrogen use will enhance cholestasis with any liver injury.

Chronic cholestasis is an increasingly recognized problem in women with Turner syndrome. As many as 80% of patients with Turner syndrome who are older than 35 years present with features of chronic, anicteric cholestasis [100]. Although cases of PBC in patients with Turner syndrome have been described [101,102], chronic cholestasis in these patients requires further investigation.

Patients with AIH may have biochemical cholestasis and some are AMA positive. Bile duct lesions are occasionally found on liver biopsy in AIH [103]. Overlaps of PBC and AIH are discussed in detail in Chapter 11.5.

Complications

Bone changes

Chronic cholestasis is associated with an increased risk of osteopenia and osteoporosis. It can be reliably diagnosed and monitored with serial measurements of bone mineral density (BMD) using non-invasive, dual-energy X-ray absorptiometry (DEXA scan). Osteoporosis is usually classified as 'low-turnover' with normal resorption but reduced synthesis and slow mineralization of matrix and 'high-turnover' with increased resorption secondary to increased activity of osteoblasts. It seems that both mechanisms play a role in the development of osteoporosis in PBC. Contributing factors may include inherited predisposition associated with particular genetic polymorphisms [104,105], deficiency of vitamin K [106], impaired osteoblastic function as well as increased bone resorption. In patients with PBC, who are mostly postmenopausal females, this process may additionally be exacerbated by hormonal deficiency and low body mass index (BMI). In addition, malabsorption (coexistent coeliac disease and/or jaundice) may also play a role. Environmental factors such as excessive smoking, alcohol intake, lack of exercise and low calcium intake may exacerbate osteopenia. Newton and colleagues [71] suggested that osteoporosis in patients with PBC could merely be a consequence of postmenopausal changes and older age; however, these findings were not confirmed by other studies, which clearly demonstrated an increased risk of osteoporosis in patients with advanced PBC [72]. The explanation for these differences may be in the method of patient recruitment – many patients in the Newton study were individuals identified by screening blood work with only mild liver disease, whereas other

cohorts were from patients referred to liver clinics. Menon *et al.* [72] studied 176 patients with PBC and found that the prevalence of osteoporosis was 20%, representing a 30-fold increase in the relative risk of having osteoporosis when compared with a well-matched control group. The authors found that age above 57 years, BMI less than 24, features of advanced disease on liver histology and past history of bone fractures were independent predictors for osteoporosis. Guanabens *et al.* [73] studied a group of 142 female patients with PBC and found that the prevalence of osteoporosis was 32% compared with 11% in well-matched control subjects. Risk factors for the development of osteoporosis identified by regression analysis were as follows: older age, higher Mayo risk score, lower BMI and features of advanced histological disease. Menopause in itself was not found to be an independent risk factor in this group of patients. Both the above-mentioned studies emphasize the role of the severity of cholestasis (both clinical and histological) as the main contributory factor in the development of osteoporosis in PBC. In patients who undergo liver transplantation for PBC, significant bone mass loss is usually observed within 3 months after surgery, although improvement in BMD is described once the new liver has been in place for more than 6 months. The overall risk of skeletal fractures in these patients is estimated to be between 17% and 65% [107]. Whereas in the past, osteomalacia was a recognized complication of PBC, the introduction of liver transplantation for endstage PBC means that this form of metabolic bone disease is only seen in patients unsuitable for transplantation, who have marked jaundice causing steatorrhoea with vitamin D and calcium malabsorption.

Malabsorption

Overt malabsorption of fat and fat-soluble vitamins is a consequence of chronic, icteric cholestasis when the delivery of bile salts to the intestine is markedly reduced. Phillips *et al.* [108] have recently studied vitamin deficiency in 180 patients with PBC and found that as many as 33.5% showed some degree of vitamin A deficiency. With regard to other vitamins, abnormally low levels of vitamin D were found in 13.2%, vitamin E in 1.9% and vitamin K in 7.8% of patients in this study. By univariate analysis, high Mayo risk score, older age, lower triglycerides, low albumin, elevated bilirubin and aspartate aminotransferase (AST) levels were associated with vitamin A deficiency. High Mayo risk score, elevated bilirubin and low albumin were associated with vitamin D and K deficiency (vitamin K was not measured directly and prothrombin time was used as a surrogate marker). No risk factors for vitamin E deficiency were identified in this study. A Mayo risk score ≥ 5 was found to have the highest sensitivity and specificity in recognizing patients at increased risk for vitamin A deficiency. Kowdley *et al.* [109] studied a cohort of 77 patients with PBC and found that 22% of them had vitamin A deficiency. This is the only study so far in which vitamin K was measured directly and low levels were seen in 23%.

Portal hypertension

Portal hypertension may be associated with complications when the pressure in the portal venous system exceeds 8 mmHg. With increasing pressure, splenomegaly, the formation of ascites and/or oesophageal/gastric varices develop. Bleeding oesophageal varices may be a presenting feature in patients with PBC, even in the absence of cirrhosis. This is most probably related to the portal tract inflammation, which causes localized vascular injury and the subsequent formation of venous microthrombi in the portal venous radicles. This cascade of events may lead to the development of nodular regenerative hyperplasia (NRH), giving rise to presinusoidal portal hypertension. Thus, variceal haemorrhage in a patient with PBC is not necessarily a sign of endstage liver disease and should not automatically provoke workup for a liver transplant. The disappearance of oesophageal varices in non-cirrhotic patients with PBC, correlating with improvement in histology, has been reported after treatment with UDCA [110]. Before the introduction of UDCA therapy for PBC, Gores *et al.* [111] studied 265 patients with PBC who had no oesophageal varices at baseline. During a mean follow-up of 5.6 years, 31% developed varices and almost half had at least one episode of variceal bleeding. However, these patients with PBC had a significantly better survival rate than patients with a variceal bleed resulting from other liver disorders. Laboratory parameters can be used for predicting the detection of oesophageal varices in patients with PBC. Bressler *et al.* [112] demonstrated that oesophageal varices are present in 85% of patients with PBC who have a platelet count $\leq 200 \times 10^9$/L, low albumin and elevated bilirubin. On the other hand, varices were present in only 7% of patients in whom these three parameters were normal and the platelet count was $\geq 200 \times 10^9$/L.

Natural history

When PBC was first formally recognized in the 1950s, patients were most often diagnosed only once they presented with jaundice, although a few anicteric asymptomatic cases were recognized by Sherlock [113] in the first case series she described in 1959. Since that time, the number of asymptomatic and generally early cases of PBC, often identified as a result of routine screening tests for liver biochemistries and/or AMA either at a routine medical checkup or as part of a workup for another disease, has continued to increase. Asymptomatic PBC now accounts for up to 60% of newly diagnosed cases.

Thus, the natural history of PBC very much depends on the starting point and the method of initial detection. In a case series of 29 individuals who, as part of a screening workup, were found to test AMA positive [25] but with consistently normal liver biochemistry, liver biopsy revealed that all but a few had either diagnostic features of PBC or features compatible with a diagnosis of PBC. Of the five with no features of PBC on biopsy, four had undetectable AMA when rechecked by ELISA. Of these initial 29 cases, five died of non-hepatic causes, the remaining 24 all

developed abnormal liver tests (16, raised ALP; seven, raised aminotransferase levels; and one with low serum albumin), and 22 of these 24 became symptomatic. On average, it took 5 years from initial recognition of AMA positivity to the development of a raised ALP. On repeat liver biopsy 10 years later in 10 individuals – all but one of whom had originally had a diagnostic liver biopsy – only four showed evidence of histological progression (median 11.4 years), from stage I to II in two and from stage I to III in another two [54]. The median age of these individuals was 67 years, a decade older than the usual age of presentation of overt PBC. These are the only data available that describe the very early phase of PBC in the absence of any therapeutic intervention. Also, this study is the only reported follow-up with serial liver histology of individuals who only had detectable AMA at baseline and would suggest that all who test positive for AMA have PBC but, if this is the case, PBC is much more common than currently appreciated, as the prevalence of AMA in healthy individuals is about 0.5% [18–20].

Asymptomatic PBC

As outlined above, the natural history of asymptomatic PBC is also very dependent on the case finding method. Case series have been retrieved from such diverse routes as referral of cases to tertiary centres, letter writing campaigns to specialist offices and sometimes retrieval from immunology laboratories testing for AMA.

The largest series reported to date are from the north of England (Newcastle) and include cases recruited by all the above methods. The first description of their 770 cases of PBC [14] reported that 61% were asymptomatic at their presentation/diagnosis; however, 10 years later, only 17% remained asymptomatic, and symptoms became evident within 5 years in 50%. The mean age of this entire cohort was almost a decade older than in most other case series, probably a reflection of their case finding methods. This observation explains in part why, in a subsequent report of the same patient population [114], the survival of their asymptomatic cases was no different from that of the symptomatic cases. This is contrary to most other studies and is likely to be a reflection of the older age at initial diagnosis of their patient population. These authors also noted that the standardized mortality ratio (SMR), which was 2.87 for the entire cohort, was still greater than expected when the deaths from liver disease were excluded (1.73). Of the 469 initially asymptomatic cases, 31% died a liver death (compared with 57% of those with initially symptomatic disease). The SMR for asymptomatic PBC was 2.64 and, in those who did not die a liver death, it was still elevated at 1.86.

There have been several other case series of asymptomatic PBC; all but the series from Newcastle are small (the largest reported comprised 91 cases) [115–120]. In these smaller studies, in which the cases were mostly collected from tertiary centres, both median and mean survival were considerably longer than that reported by the Newcastle group. Most series indicate that, as long as the individual remains asymptomatic, patient survival is no different from that of an age- and sex-matched control population. The 50% survival ranged from 12.5 to 16 years in these series, whereas it was 9.6 for the Newcastle series, probably because their patient population was older than is typical for PBC reported from elsewhere.

Symptomatic PBC

Data on the expected outcome in patients with symptomatic disease who have not received any treatment can only be gleaned from case series published more than 20 years ago. An extended follow-up of the Yale series indicates that the median survival is only 6.8 years [119]. Unless liver transplantation is contraindicated, it is unusual nowadays to witness liver failure in PBC. The Mayo model, which was developed from data obtained from patients with PBC prior to the routine availability of liver transplantation, remains a valid prognostic marker for survival even for PBC patients being treated with UDCA [121]. Although not initially developed for asymptomatic PBC, the Mayo model has also been reported to be reliable in the asymptomatic population. The Mayo model requires age, prothrombin time, albumin and the presence or absence of oedema ± diuretics for calculation. Because this score does not require information from a liver biopsy, it can be used with greater ease than the other prognostic scores developed (Table 5).

It has become clear that the course of PBC is very heterogeneous. Thus, cases of liver failure developing prior to the onset of cirrhosis are reported; such individuals have been shown to have marked ductopenia causing severe cholestasis [122]. There are now several reports suggesting that the presence of subspecies of ANA – Sp100 and, more recently, gp210 – are markers for more rapidly progressive disease. A recent study suggests that those with a high titre have the worst outcome [89].

To date, there have been few genetic studies of a 'respectable' size in PBC. Donaldson *et al.* [123] suggested in one study of 164 cases that those with non-progressive PBC were unlikely to be DRB1*0801 positive or DQB1*0401 positive, whereas 24% and 23%, respectively, were positive for these HLA patterns if they had progressive disease (88 cases).

In a study from France, the authors identified that the E4 allele of the apolipoprotein E gene, when present, was found significantly more often in patients with PBC who were younger and had a higher bilirubin and IgG and lower prothrombin index than E2 or E3 homozygous carriers [124]. The same authors have extensively examined serially collected liver tissue from individuals with PBC and have shown that the rate of progression to cirrhosis is dependent on the degree of interface hepatitis. When there is minimal inflammation, progression to cirrhosis within the next 5 years is very unlikely, whereas the risk is 50% at 5 years of follow-up in those with severe interface hepatitis at baseline [57].

Table 5 Independent clinical variables predictive of survival in primary biliary cirrhosis from several prognostic models.

Yale	European	Mayo	Oslo	Glasgow	Australian
Age	Age	Age	Variceal bleed	Age	Age
Bilirubin	Bilirubin	Bilirubin	Bilirubin	Bilirubin	Bilirubin
Hepatomegaly	Albumin	Albumin		Ascites	Albumin
Fibrosis/cirrhosis	Cirrhosis	Prothrombin time		Fibrosis	
	Cholestasis	Oedema		Cholestasis	
				Mallory bodies	

From Wiesner *et al.*, *Hepatology* 1992; 16, 1290.

Liver failure

Decompensated liver disease occurs late in the course of PBC. It is marked by increasing jaundice and may be associated with the disappearance of both xanthomata and pruritus. The levels of serum albumin and total cholesterol usually fall, and features of advanced portal hypertension with oedema and ascites develop. Occasionally, ascites may appear prior to the onset of jaundice, particularly now when most patients are treated with UDCA, which reduces bilirubin levels. Terminal events include episodes of hepatic encephalopathy and uncontrollable bleeding, usually from oesophageal varices. An intercurrent infection leading to septicaemia is often the terminal event.

The issue of liver transplantation should be discussed with patients who are observed to have a steady increase in serum bilirubin, certainly by the time it has reached 6 mg/dL (100 μmol/L) [125]. It is important to know the length of the local waiting list for liver transplantation to calculate the optimal time to refer patients for this procedure unless the patient has a willing living donor. Indications for liver transplantation are discussed in another section of this chapter.

Treatment (Table 6)

Several aspects of therapy for PBC should be considered: symptomatic, preventative and therapeutic.

Symptomatic treatment

The most common symptom of PBC is fatigue, and this is associated with considerable impairment of quality of life [60,61,126]. It has not been determined whether fatigue is caused by the associated depression leading to sleep dysfunction or vice versa. Fatigue not infrequently accompanies other chronic inflammatory diseases. Therapies evaluated but not found to be effective include the antioxidant Q210 [127], the 5HT3 serotonin receptor subtype antagonist ondansetron [64] and the antidepressant fluvoxamine [128]. A reported series of five cases suggests that modafinil, a central nervous system stimulant, may be of benefit [129].

Pruritus is a common complaint of patients with PBC. The cause of the pruritus is uncertain. It has been thought that pruritus is related to elevated bile acids, as cholestyramine, which

Table 6 Management of PBC.

Symptomatic	Therapy	Preventive	Therapy	Specific therapy	Therapy
Fatigue	None known	Fat-soluble vitamin deficiency	Supplements	Immunomodulators	Budesonide
Pruritus	Cholestyramine	Osteoporosis	Calcium	Choleretics	UDCA
	Rifampin		Vitamin D	Surgery	Liver transplantation
	Opioid antagonists		Bisphosphonates		
Sicca syndrome	Artificial tears		± HRT		
	Regular dental checks		? Vitamin K		

binds bile acid in the gut, often relieves this symptom. Cholestyramine is most effective when taken at the time of gallbladder emptying; thus, it is best given just before and just after breakfast, but 4 h from any other medication (to avoid their binding). It may cause abdominal bloating and constipation. Doses from 4–12 g/day are generally sufficient to control the pruritus. It should be used long term in those in whom it is effective to prevent ongoing pruritus (not to be taken only at the time of pruritus).

When cholestyramine fails, rifampin is a second-line therapeutic option, starting at 150 mg twice daily. For the 50% of patients in whom rifampin is effective, the benefit is felt within the first month of treatment [130]. Increasing the dose rarely helps further. As this drug is an enzyme inducer, care must be taken with regard to potential drug interactions. Patients taking rifampin need to be monitored closely as this drug may induce hepatitis, a haemolytic anaemia and impaired renal function. It stains the urine yellowish brown.

Pruritus is often worse in the winter, which may explain the observed seasonal variation in presentation. Although dry skin, not unusual in cold weather, may accentuate itching, it is also likely that the diminished amount of ultraviolet light leads to the worsening of this symptom. Treatment with very short bursts of ultraviolet light in the dermatologist's office (without sunblock) may be beneficial. The pruritus of PBC may also be precipitated by pregnancy. Exogenous hormone therapy such as the use of the oral contraceptive pill or hormone replacement therapy may also provoke pruritus. Not surprisingly, men with PBC complain less commonly of pruritus than women [12].

Others have suggested that circulating endogenous opioids, elevated in PBC, are the cause of pruritus [131] and may act centrally causing the sensation of pruritus. Indeed, the opioid antagonists naloxone and naltrexone have been used successfully to treat the pruritus of cholestasis [132,133]. Some patients develop 'withdrawal' symptoms typical of narcotic withdrawal and thus the introduction of this treatment should start at very low doses and build up slowly [134]. The chronic pain syndrome has been described with long-term use of opioid antagonists [135].

The dry eyes of the sicca syndrome may be relieved by artificial tears. The dry mouth is reduced by stimulants of salivary flow such as lemon juice or sour candy. Regular dental care to check for caries should be emphasized, and patients should be advised to take all medications in the upright position with plenty of fluid to avoid the development of drug-induced oesophageal ulcers.

Raynaud's syndrome is treated along conventional lines by avoiding immersion in cold water and the wearing of gloves. Although calcium channel blockers may help Raynaud's syndrome, they may make concurrent scleroderma of the oesophagus symptomatic by promoting reflux. Neuropathy and bone pain (from fractures or the more rare condition of periostitis) may be treated by analgesics, but non-steroidal anti-inflammatory drugs and aspirin should be avoided when oesophageal varices are present.

Preventive treatment

In the jaundiced patient, the associated steatorrhoea due to intestinal bile salt deficiency leads to malabsorption of vitamins A, D, E and K, and these should be supplied parenterally or in the water-soluble oral form if available.

Jaundiced patients with PBC may develop osteomalacia but, more importantly, all patients with PBC are at risk of osteoporosis, and their BMD should be regularly evaluated via DEXA rather than waiting for fractures to develop! Osteoporosis is difficult to treat, but calcium supplements and vitamin D (1500 mg/day and 400–1000 IU/day respectively) are recommended in all patients with PBC, who should also be encouraged to exercise regularly. Exposure to sunlight is also encouraged. Hormone replacement therapy (HRT) for postmenopausal patients taken either orally or using transdermal therapy may slightly worsen cholestasis [136] but probably prevents at least the postmenopausal component of osteoporosis [137]. Recent studies indicate that alendronate may be the most effective of the bisphosphonates for the treatment of osteoporosis associated with PBC [138]. A small study of vitamin K suggests that this too may delay osteoporosis [106].

If the patient has endoscopically proven large oesophageal varices, or has bled from them, non-selective beta-blockers such as propranolol or nadolol should be considered. However, if fatigue is a significant issue, endoscopic band ligation may be preferable.

Specific medical treatment

At present, no curative medical treatment can be recommended for PBC. Most reported trials have usually been too short, too small and poorly controlled. Statistically significant long-term benefits are difficult to establish in a disease with such a long survival and with the varied timing of liver transplant. Nevertheless, new therapeutic measures should continue to be evaluated in the context of large randomized controlled trials (RCTs). Three groups of drugs have been evaluated in the past. The immunomodulators would be expected to be most effective in the early stages of the disease, whereas the antifibrotics and anticholestatics may be helpful at all stages of disease in delaying progression to cirrhosis and liver failure. Fortunately, most individuals do have early disease when first given a diagnosis.

Immunomodulators

Azathioprine (Imuran) was of marginal benefit in improving survival [139] and occasionally led to serious side-effects. Prednisolone improves well-being and may relieve pruritus. Serum alkaline phosphatase, aminotransferases and procollagen III fall with this treatment. Liver histology also improves and in the first RCT of prednisolone, progression to cirrhosis was only seen in one of 12 patients in 3 years compared with four out of seven given placebo [140]. The observation that severe interface hepatitis in PBC is associated with faster progression to cirrhosis has prompted the suggestion that early corticosteroid therapy may

be appropriate in patients with this histological lesion. As the only trial employing prednisolone was associated with a significant reduction in BMD in the treated group, it has been suggested that budesonide may be a wiser steroid alternative. Pharmacokinetic data indicate that, when given to patients with established cirrhosis, adrenal suppression occurs because complete first-pass metabolism by the liver is lost in cirrhotics [141]. Two reports of small randomized studies of budesonide plus UDCA vs. UDCA monotherapy suggest that this combination therapy may be beneficial and safe in those patients with stage I and II PBC. One study was of budesonide 9 mg/day + UDCA 15 mg/day in stage I and II PBC [142], and a more recent 3-year RCT of 77 patients with early-stage PBC demonstrated a 20–25% reduction in inflammation and hepatic fibrosis in those who received budesonide (6 mg/day) and UDCA compared with a 70% increase in fibrosis in those on UDCA monotherapy [143]. This high rate of fibrosis progression in those on UDCA monotherapy is in stark contrast to the much larger studies of UDCA monotherapy discussed later in this chapter. One patient out of 37 who received budesonide developed glucocorticoid side-effects and was withdrawn.

Ciclosporin A reduces pruritus and fatigue, serum bilirubin and ALP, and hepatic histology improves, but it has no effect on survival [144]. The beneficial effects are achieved at the expense of complications, particularly impaired renal function and systemic hypertension. The use of ciclosporin in PBC has been abandoned because of the risks of administering a toxic drug over many years.

For the same reason, chlorambucil, shown in one small study to have a beneficial effect on liver chemistry in PBC, is not advocated; 25% of patients in this study needed to be withdrawn because of side-effects [145].

Methotrexate (MTX), given by mouth in a dose of 15 mg/week, has been reported to improve pruritus and fatigue and cause a fall in serum levels of ALP and bilirubin [146]. Liver biopsies showed a reduction in portal inflammation, but the Mayo prognostic score was unchanged. Subsequently, two RCTs have been conducted, one that employed low-dose MTX monotherapy [147] and the other that compared MTX plus UDCA with UDCA monotherapy [148], neither show a survival advantage.

Antifibrotics

Colchicine is an inexpensive, antifibrotic drug with few side-effects. Controlled trials showed that biochemical results and symptoms improved, but a long-term benefit was not shown [149]. Combination therapy (colchicine plus UDCA) appears to offer little more than UDCA monotherapy [150]; D-penicillamine, another antifibrotic, was also shown to be of no value in treating patients with PBC.

Choleretics

UDCA is a non-toxic, hydrophilic, choleretic bile acid, which may decrease the toxicity of retained bile acids in patients with cholestasis (*in vitro* studies indicate that it reduces bile acid-induced apoptosis of hepatocytes) [151]. It may stabilize hepatocyte membranes and does increase bile acid transport across the liver cell and canaliculus [152]. In PBC, UDCA modifies the bile acid pool so that it becomes the predominant bile acid. There have been many trials of therapy involving the use of UDCA (Table 6). The combined analysis of three placebo-controlled trials, all of which employed the same formulation of UDCA at a dose of 13–15 mg/kg/day, indicated that UDCA prolongs life by increasing the time to transplantation [153]. However, a meta-analysis of 15 studies reporting the effect of UDCA in varying doses, prescribed for periods that ranged from 6 months to 4 years, showed no survival benefit but did confirm that UDCA therapy was associated with a fall in serum bilirubin and a reduction in hepatic failure, namely ascites [154]. As UDCA is the current standard of care, no more randomized placebo-controlled trials can be performed [155].

The decision to treat the early, asymptomatic patient with UDCA is a difficult one, and a decision must be made in the individual patient, bearing in mind the cost and other comorbidities. However, a 5-year study of patients with predominantly early disease did show a significant reduction in the rate of disease progression on liver histology when treated with UDCA [156]; this was confirmed by Poupon *et al.* [157]. However, this beneficial effect of UDCA on liver histology was not observed in the Finnish study [143].

For successful treatment of PBC, it is likely that the therapy is best started early at the stage of acute bile duct inflammation. Even though AMA is a specific marker for this disease, not all those who test AMA positive are destined to develop PBC and, even if PBC is present, rate of progression of disease is highly variable. Further work is needed to identify reliable ways of predicting disease progression. In those patients who appear to have very early disease, it could be that they would benefit from immunosuppressive therapy given perhaps in addition to UDCA. However, much larger trials of combination therapy with UDCA and an immunosuppressive agent are needed to determine the ideal patient and timing for such an intervention. Once patients with PBC have an elevated bilirubin, progression to endstage liver disease is inevitable. In patients with a serum bilirubin > 35 mmol/L (2 mg/L), the 4-year transplantation-free survival is < 30% and for those with a bilirubin > 60 mmol/L (3.5 mg/L), it is < 10% [153]. There is no evidence that additional immunosuppressive therapy will help such patients and it may indeed be harmful.

Medical therapies to be considered

Cholesterol-lowering agents

There have been a number of pilot studies on the use of bezafibrate 400 mg/day in PBC. This drug, although best known for its lipid lowering effects, also induces the expression of MDR3, the canalicular transporter for phosphatidylcholine; therefore, it may act via promoting the formation of biliary

micelles. Treatment is associated with a fall in biliary enzymes and IgM. As a peroxisome proliferator-activated receptor (PPAR) activator, it may also reduce inflammation [158,159].

Simvastatin, another cholesterol lowering drug that inhibits HMG-CoA reductase, has been used successfully to treat hyperlipidaemia in patients with PBC who may also demonstrate a fall in ALP, GGT and IgM [160,161].

There are no randomized controlled data on the potential long-term benefit of these drugs in PBC.

Liver transplantation

PBC used to be one of the most common indications for liver transplantation in adults. Now, the proportion of subjects with this condition who undergo liver transplantation has decreased dramatically. This is related in part to a significant increase in the number of liver transplants performed for cirrhosis secondary to viral hepatitis. Despite the rising prevalence of PBC, a stable number of patients with this disease are referred for transplantation. This may suggest an improvement in the prognosis of PBC related either to earlier diagnosis or possibly to wide use of UDCA [162]. Indications for liver transplantation in PBC are comparable to indications in other chronic liver diseases and include endstage liver failure when anticipated survival is less than 1 year. The Mayo risk score (http://www.mayoclinic.org/gi-rst/mayomodel1.html) is useful to estimate the short-term (2-year) prognosis. The following symptoms suggest the necessity for liver transplant assessment: ascites, episodes of spontaneous bacterial peritonitis, recurrent episodes of variceal bleeding and/or encephalopathy not responding to appropriate treatment. The Mayo risk score remains a valid predictor of outcome when patients are treated with UDCA. The MELD (model for endstage liver disease) score, which includes bilirubin, creatinine and international normalized ratio (INR), has been found helpful in organ allocation for patients already on the transplant list. Serum bilirubin level is probably the most important single prognostic indicator in patients with PBC [163]. It has been shown convincingly that patients should be referred for liver transplant assessment once their bilirubin level reaches 100 μmol/L (5.9 mg/dL). If they are transplanted when serum bilirubin levels are around 170 μmol/L (10 mg/dL) or higher, the probability of survival after transplantation is greater than the probability of survival without transplantation [164].

Currently, the 5-year survival after liver transplantation for PBC ranges between 83% and 86%, indicating that PBC is one of the best indications for this procedure. Prior use of UDCA in PBC does not impair post-transplant outcome, despite patients being older [165].

Early mortality after surgery is caused mostly by multiorgan failure and sepsis [162]. Acute rejection occurs more commonly in patients with PBC than in those transplanted for other indications, but it has been postulated that acute rejection may in fact improve outcome as it may increase tolerance [166]. PBC may recur after liver transplantation in 17% of patients who manifest typical histological, serological and biochemical features of PBC [162]. This phenomenon is considered to be of little clinical significance, as only a very small proportion of patients with recurrent PBC post transplantation become symptomatic, and fewer still develop liver failure and require regrafting. Recurrence of PBC has been linked recently with tacrolimus- rather than ciclosporin-based immunosuppression.

Sometimes, it is appropriate to refer individuals with PBC for a liver transplant before they have evidence of liver failure because their quality of life as a result of uncontrollable pruritus is significantly impaired; less often patients are referred for liver transplant for severe fatigue – the effect of liver transplantation on fatigue is not well studied. Severe osteoporosis and primary liver cell cancer are two other reasons for referring a patient with PBC for a liver transplant even in the absence of liver failure.

Conclusions

There have been no significant breakthroughs in the treatment of PBC, and it remains an incurable condition. Ursodeoxycholic acid, as an anticholestatic agent, only delays the development of hepatic failure. Its early use in combination with an immunomodulating agent might give rise to more satisfactory results; early data need to be validated in larger trials. Hepatic transplantation gives excellent results in the well-chosen patient treated in a centre with a good proven track record [167].

References

1 Addison T, Gull W (1851) On a certain affection of the skin, vitiligoidea – α plana, β tuberosa. *Guy's Hosp Rep* 7, 265–276.

2 Hanot V (1892) *La cirrhosis hypertrophique avec ictere chronique*. Paris: Rueff et Cie.

3 MacMahon HE, Thannhauser SJ (1949) Xanthomatous biliary cirrhosis (a clinical syndrome). *Ann Intern Med* 30, 121.

4 Ahrens EH, Jr, Payne MA, Kunkle HG *et al.* (1950) Primary biliary cirrhosis. *Medicine* 29, 299–364.

5 Rubin E, Schaffner F, Popper H (1965) Primary biliary cirrhosis: chronic non-suppurative destructive cholangitis. *Am J Pathol* 46, 387–407.

6 Witt-Sullivan H, Heathcote J, Cauch K *et al.* (1990) The demography of primary biliary cirrhosis in Ontario, Canada. *Hepatology* 12, 98–105.

7 Howel D, Fischbacher CM, Bhopal RS *et al.* (2000) An exploratory population-based case–control study of primary biliary cirrhosis. *Hepatology* 31, 1055–1060.

8 Parkih-Patel A, Gold EB, Worman H *et al.* (2001) Risk factors for primary biliary cirrhosis in a cohort of patients from the United States. *Hepatology* 33, 16–21.

9 James OF, Bhopal R, Howel D *et al.* (1999) Primary biliary cirrhosis once rare, now common in the United Kingdom? *Hepatology* 30, 390–394.

10 Kim WR, Lindor KD, Locke GR *et al.* (2000) Epidemiology and natural history of primary biliary cirrhosis in a US community. *Gastroenterology* 119, 1631–1636.

11 Sood S, Gow PJ, Christie JM *et al.* (2004) Epidemiology of primary biliary cirrhosis in Victoria, Australia: high prevalence in migrant populations. *Gastroenterology* 127, 470–475.
12 Lucey MR, Neuberger JM, Williams R (1986) Primary biliary cirrhosis in men. *Gut* 27, 1373–1376.
13 Watson RG, Angus PW, Dewar M *et al.* (1995) Low prevalence of primary biliary cirrhosis in Victoria, Australia. *Gut* 36, 927–930.
14 Prince M, Chetwynd A, Newman W *et al.* (2002) Survival and symptom progression in a geographically based cohort of patients with primary biliary cirrhosis: follow-up for up to 28 years. *Gastroenterology* 123, 1044–1051.
15 Obha K, Omagari K, Kinoshita H *et al.* (2001) Primary biliary cirrhosis among atomic bomb survivors in Nagasaki, Japan. *J Clin Epidemiol* 54, 845–850.
16 Arbour L, Rupps R, Field L *et al.* (2005) Characteristics of primary biliary cirrhosis in British Columbia's First Nations population. *Can J Gastroenterol* 19, 305–310.
17 Douglas JG, Finlayson ND (1979) Are increased individual susceptibility and environmental factors both necessary for the development of primary biliary cirrhosis? *Br Med J* 2, 419–420.
18 Turchany JM, Uibo R, Kivik T *et al.* (1997) A study of antimitochondrial antibodies in a random population in Estonia. *Am J Gastroenterol* 92(1), 124–126.
19 Mattalia A, Quaranta S, Leung PS *et al.* (1998) Characterization of antimitochondrial antibodies in healthy adults. *Hepatology* 27(3), 656–661.
20 Shibata M, Onozuka Y, Morizane T *et al.* (2004) Prevalence of antimitochondrial antibody in Japanese corporate workers in Kanagawa. *J Gastroenterol* 39, 255–259.
21 Dahlan Y, Smith L, Simmonds D *et al.* (2003) Pediatric-onset primary biliary cirrhosis. *Gastroenterology* 125, 1476–1479.
22 Jones DEJ, Watt FE, Metcalf JV *et al.* (1999) Familiar primary biliary cirrhosis reassessed: a geographically-based population study. *J Hepatol* 30, 402–407.
23 Manns MP, Bremm A, Schneider PM *et al.* (1991) HLA DRW8 and complement C4 deficiency as risk factors in primary biliary cirrhosis. *Gastroenterology* 101, 1367–1373.
24 Bogdanos DP, Baum H, Vergani D (2003) Antimitochondrial and other autoantibodies. *Clin Liver Dis* 7, 759–777.
25 Mitchison HC, Bassendine MF, Hendrick A *et al.* (1986) Positive antimitochondrial antibody but normal alkaline phosphatase: is this primary biliary cirrhosis? *Hepatology* 6, 1279–1284.
26 Miyakawa H, Tanaka A, Kikuchi K *et al.* (2001) Detection of antimitochondrial autoantibodies in immunofluorescent AMA-negative patients with primary biliary cirrhosis using recombinant autoantigens. *Hepatology* 34, 243–248.
27 Kita H, Nalbandian G, Keeffe EB *et al.* (2003) Pathogenesis of primary biliary cirrhosis. *Clin Liver Dis* 7, 821–839.
28 Odin JA, Huebert RC, Casciola-Rosen L *et al.* (2001) Bcl-2-dependant oxidation of pyruvate dehydrogenase-E2, a primary biliary cirrhosis autoantigen, during apoptosis. *J Clin Invest* 108, 223–232.
29 Mato TK, Davis PA, Odin JA *et al.* (2004) Sidechain biology and the immunogenicity of PDC-E2, the major autoantigen of primary biliary cirrhosis. *Hepatology* 40, 1241–1248.
30 Mendel-Hartvig I, Nelson BD, Loof L *et al.* (1985) Primary biliary cirrhosis: further biochemical and immunological characterization of mitochondrial antigens. *Clin Exp Immunol* 62, 371–379.
31 Matsumura S, Van de WJ, Leung P *et al.* (2004) Caspase induction by IgA antimitochondrial antibody: IgA-mediated biliary injury in primary biliary cirrhosis. *Hepatology* 39, 1415–1422.
32 Macdonald P, Palmer J, Kirby JA *et al.* (2004) Apoptosis as a mechanism for cell surface expression of the autoantigen pyruvate dehydrogenase complex. *Clin Exp Immunol* 136, 559–567.
33 Selmi C, Balkwill DL, Invernizzi P *et al.* (2003) Patients with primary biliary cirrhosis react against a ubiquitous xenobiotic-metabolizing bacterium. *Hepatology* 38, 1250–1257.
34 Vergani D, Bogdanos DP, Baum H (2004) Unusual suspects in primary biliary cirrhosis. *Hepatology* 39, 38–41.
35 Feld JJ, Meddings J, Heathcote EJ (2006) Abnormal intestinal permeability in primary biliary cirrhosis. *Dig Dis Sci* 51, 1607–1613.
36 Abdulkarim AS, Petrovic LM, Kim WR *et al.* (2004) Primary biliary cirrhosis: an infectious disease caused by *Chlamydia pneumoniae*? *J Hepatol* 40, 380–384.
37 Kikuchi K, Lian ZX, Yang GX *et al.* (2005) Bacterial CpG induces hyper-IgM production in CD27(+) memory B cells in primary biliary cirrhosis. *Gastroenterology* 128, 304–312.
38 Xu L, Shen Z, Guo L *et al.* (2003) Does a betaretrovirus infection trigger primary biliary cirrhosis? *Proc Natl Acad Sci USA* 100, 8454–8459.
39 Xu L, Sakalian M, Shen Z *et al.* (2004) Cloning the human betaretrovirus proviral genome from patients with primary biliary cirrhosis. *Hepatology* 39, 151–156.
40 Selmi C, Ross SR, Ansari AA *et al.* (2004) Lack of immunological or molecular evidence for a role of mouse mammary tumor retrovirus in primary biliary cirrhosis. *Gastroenterology* 127, 493–501.
41 Mason AL, Farr GH, Xu L *et al.* (2004) Pilot studies of single and combination antiretroviral therapy in patients with primary biliary cirrhosis. *Am J Gastroenterol* 99, 2348–2355.
42 Neuberger J, Gunson B, Hubscher S *et al.* (2004) Immunosuppression affects the rate of recurrent primary biliary cirrhosis after liver transplantation. *Liver Transpl* 10, 488–491.
43 Inoue K, Sekiyama K, Yamada M *et al.* (2003) Combined interferon alpha2b and cyclosporin A in the treatment of chronic hepatitis C: controlled trial. *J Gastroenterol* 38(6), 567–572.
44 Leung PS, Quan C, Park O *et al.* (2003) Immunization with a xenobiotic 6-bromohexanoate bovine serum albumin conjugate induces antimitochondrial antibodies. *J Immunol* 170, 5326–5332.
45 Sasaki M, Ansari A, Pumford N *et al.* (2000) Comparative immunoreactivity of anti-trifluoroacetyl (TFA) antibody and anti-lipoic acid antibody in primary biliary cirrhosis: searching for a mimic. *J Autoimmun* 15, 51–60.
46 Kimura Y, Selmi C, Leung PS *et al.* (2005) Genetic polymorphisms influencing xenobiotic metabolism and transport in patients with primary biliary cirrhosis. *Hepatology* 41, 55–63.
47 Donaldson PT (2004) Genetics of liver disease: immunogenetics and disease pathogenesis. *Gut* 53, 599–608.
48 Brind AM, Bray GP, Portmann BC *et al.* (1995) Prevalence and pattern of familial disease in primary biliary cirrhosis. *Gut* 36, 615–617.
49 Jones DE, Donaldson PT (2003) Genetic factors in the pathogenesis of primary biliary cirrhosis. *Clin Liver Dis* 7, 841–864.
50 Selmi C, Mayo MJ, Bach N *et al.* (2004) Primary biliary cirrhosis in monozygotic and dizygotic twins: genetics, epigenetics and environment. *Gastroenterology* 127, 485–492.
51 Underhill JA, Donaldson PT, Bray G *et al.* (1992) Susceptibility to primary biliary cirrhosis is associated with the HLA-DR8-DQB1*0402 haplotype. *Hepatology* 16, 1404–1408.
52 Stone J, Wade JA, Cauch-Dudek K *et al.* (2002) Human leukocyte antigen class II associations in serum antimitochondrial antibodies

(AMA)-positive and AMA-negative primary biliary cirrhosis. *J Hepatol* 36, 8–13.

53 Maeda T, Onishi S, Saibara T *et al.* (1992) HLA DRw8 and primary biliary cirrhosis (letter). *Gastroenterology* 103(3):1118–1119.

54 Metcalf JV, Mitchison HC, Palmer JM *et al.* (1996) Natural history of early primary biliary cirrhosis. *Lancet* 348, 1399–1402.

55 Zein CO, Angulo P, Lindor KD (2003) When is liver biopsy needed in the diagnosis of primary biliary cirrhosis? *Clin Gastroenterol Hepatol* 1, 89–95.

56 Roll J, Boyer JL, Barry D *et al.* (1983) The prognostic importance of clinical and histological features in asymptomatic and symptomatic primary biliary cirrhosis. *N Engl J Med* 308, 1–7.

57 Corpechot C, Carrat F, Poupon R *et al.* (2002) Primary biliary cirrhosis: Incidence and predictive factors of cirrhosis development in ursodiol-treated patients. *Gastroenterology* 122, 652–658.

58 Kadokawa Y, Omagari K, Ohba K *et al.* (2005) Does the diagnosis of primary biliary cirrhosis or autoimmune cholangitis depend on the 'phase' of the disease? *Liver Int* 25, 317–324.

59 Michieletti P, Wanless IR, Katz A *et al.* (1994) Antimitochondrial antibody negative primary biliary cirrhosis: a distinct syndrome of autoimmune cholangitis. *Gut* 35, 260–265.

60 Cauch-Dudek K, Abbey S, Stewart DE *et al.* (1998) Fatigue in primary biliary cirrhosis. *Gut* 43, 705–710.

61 Goldblatt J, Taylor PJS, Lipman T *et al.* (2002) The true impact of fatigue in primary biliary cirrhosis: a population study. *Gastroenterology* 122, 1235–1241.

62 Forton DM, Patel N, Prince M *et al.* (2004) Fatigue and primary biliary cirrhosis: association of globus pallidus magnetisation transfer ratio measurements with fatigue severity and blood manganese levels. *Gut* 53, 587–592.

63 ter Borg PC, Fekkes D, Vrolijk JM *et al.* (2005) The relation between plasma tyrosine concentration and fatigue in primary biliary cirrhosis and primary sclerosing cholangitis. *BMC Gastroenterol* 5(1), 11.

64 Theal JJ, Toosi MN, Girlan L *et al.* (2005) A randomized, controlled crossover trial of ondansetron in patients with primary biliary cirrhosis and fatigue. *Hepatology* 41, 1305–1312.

65 Ng VL, Ryckman FC, Porta G *et al.* (2000) Long-term outcome after partial external biliary diversion for intractable pruritus in patients with intrahepatic cholestasis. *J Pediatr Gastroenterol Nutr* 30, 152–156.

66 Puri AS, Kumar N, Gondal R *et al.* (2001) Primary biliary cirrhosis: an Indian experience. *Ind J Gastroenterol* 20, 28–29.

67 Laurin JM, DeSotel CK, Jorgensen RA *et al.* (1994) The natural history of abdominal pain associated with primary biliary cirrhosis. *Am J Gastroenterol* 89, 1840–1843.

68 Nijhawan PK, Therneau TM, Dickson E *et al.* (1999) Incidence of cancer in primary biliary cirrhosis: the Mayo experience. *Hepatology* 29, 1396–1398.

69 Jones DEJ, Metcalf JV, Collier JD *et al.* (1997) Hepatocellular carcinoma in primary biliary cirrhosis and its impact on outcomes. *Hepatology* 26, 1138–1142.

70 Caballeria L, Pares A, Castells A *et al.* (2001) Hepatocellular carcinoma in primary biliary cirrhosis: similar incidence to that in hepatitis C virus-related cirrhosis. *Am J Gastroenterol* 96, 1160–1163.

71 Newton J, Francis R, Prince M *et al.* (2001) Osteoporosis in primary biliary cirrhosis revisited. *Gut* 49, 282–287.

72 Menon KVN, Angulo P, Weston S *et al.* (2001) Bone disease in primary biliary cirrhosis: independent indicators and rate of progression. *J Hepatol* 35, 316–323.

73 Guanabens N, Pares A, Ros I *et al.* (2005) Severity of cholestasis and advanced histological stage but not menopausal status are the major risk factors for osteoporosis in primary biliary cirrhosis. *J Hepatol* 42, 573–577.

74 Le Gans L, Grandpierre C, Chazouilleres O *et al.* (2002) Bone loss in primary biliary cirrhosis: absence of association with severity of liver disease. *Joint Bone Spine* 69, 195–200.

75 Watt FE, James OF, Jones DE (2004) Patterns of autoimmunity in primary biliary cirrhosis patients and their families: a population – based cohort study. *Q J Med* 97, 397–406.

76 Mang FW, Michieletti P, O'Rourke K *et al.* (1997) Primary biliary cirrhosis, sicca complex, and dysphagia. *Dysphagia* 12, 167–170.

77 Rai GS, Hamlyn AN, Dahl MG *et al.* (1977) Primary biliary cirrhosis, cutaneous capillaritis, and IgM-associated membranous glomerulonephritis. *Br Med J* 1, 817.

78 Pares A, Rimola A, Bruguera M *et al.* (1981) Renal tubular acidosis in primary biliary cirrhosis. *Gastroenterology* 80, 681–686.

79 Burroughs AK, Rosenstein IJ, Epstein O *et al.* (1984) Bacteriuria and primary biliary cirrhosis. *Gut* 25, 133–137.

80 Wolke AM, Schaffner F, Kapelman B *et al.* (1984) Malignancy in primary biliary cirrhosis. *Am J Med* 76, 1075.

81 Goudie BM, Burt AD, Boyle P *et al.* (1985) Breast cancer in women with primary biliary cirrhosis. *Br Med J* 291, 1597–1598.

82 Loof L, Adami HO, Sparen P *et al.* (1994) Cancer risk in primary biliary cirrhosis: a population-based study from Sweden. *Hepatology* 20, 101–104.

83 Chang PY, Lu SC, Su TC *et al.* (2004) Lipoprotein X reduces LDL atherogenicity in primary biliary cirrhosis by preventing LDL oxidation. *J Lipid Res* 45, 2116–2122.

84 Longo M, Crosignani A, Battezzati PM *et al.* (2002) Hyperlipidaemic state and cardiovascular risk in primary biliary cirrhosis. *Gut* 51, 265–269.

85 Doniach D, Walker G (1974) Mitochondrial antibodies (AMA). *Gut* 15, 664–648.

86 Van Norstrand DM, Malinchoc M, Lindor KD *et al.* (1997) Quantitative measurement of autoantibodies to recombinant mitochondrial antigens in patients with primary biliary cirrhosis: relationship of levels of autoantibodies to disease progression. *Hepatology* 25, 6–11.

87 Zuchner D, Sternsdorf T, Szostecki C *et al.* (1997) Prevalence, kinetics, and therapeutic modulation of autoantibodies against Sp100 and promyelocytic leukemia protein in a large cohort of patients with primary biliary cirrhosis. *Hepatology* 26, 1123–1130.

88 Muratori P, Muratori L, Ferrari R *et al.* (2003) Characterization and clinical impact of antinuclear antibodies in primary biliary cirrhosis. *Am J Gastroenterol* 98, 431–437.

89 Nukamura M, Shimizu-Yoshida Y, Takii Y *et al.* (2005) Antibody titer to gp210-C terminal peptide as a clinical parameter for monitoring primary biliary cirrhosis. *J Hepatol* 42, 386–392.

90 Nakanuma Y, Ohta G (1979) Histometric and serial section observations of the intrahepatic bile ducts in primary biliary cirrhosis. *Gastroenterology* 76, 1326–1332.

91 Goldstein NS, Soman A, Gordon SC (2001) Portal tract eosinophils and hepatocyte cytokeratin 7 immunoreactivity helps distinguish early-stage, mildly active primary biliary cirrhosis and autoimmune hepatitis. *Am J Clin Pathol* 116, 846–853.

92 Colina F, Pinedo F, Solis JA *et al.* (1992) Nodular regenerative hyperplasia of the liver in early histological stages of primary biliary cirrhosis. *Gastroenterology* 102, 1319–1324.

93 Scheuer P (1967) Primary biliary cirrhosis. *Proc Royal Soc Med* 60, 1257–1260.

94 Leuschner U (2003) Primary biliary cirrhosis – presentation and diagnosis. *Clin Liver Dis* 7, 741–758.

95 Bjornsson E, Boberg KM, Cullen S *et al.* (2002) Patients with small duct primary sclerosing cholangitis have a favourable long term prognosis. *Gut* 51, 731–735.

96 Ludwig J (1998) Idiopathic adulthood ductopenia: an update. *Mayo Clin Proc* 73(3), 285–291.

97 Keefe EB (1987) Sarcoidosis and primary biliary cirrhosis. Literature review and illustrative case. *Am J Med* 83, 977–980.

98 Spiteri MA, Johnson M, Epstein O *et al.* (1990) Immunological features of lung lavage cells from patients with primary biliary cirrhosis may reflect those seen in pulmonary sarcoidosis. *Gut* 31, 208–212.

99 Moradpour D, Altorfer J, Flury R *et al.* (1999) Chlorpromazine-induced vanishing bile duct syndrome leading to biliary cirrhosis. *Hepatology* 20, 1437–1441.

100 Gravhold CH, Juul S, Naeraa RW *et al.* (1998) Morbidity in Turner syndrome. *J Clin Epidemiol* 51, 147–158.

101 Sokol L, Stueben ET, Jaikishen JP *et al.* (2002) Turner syndrome associated with acquired von Willebrand disease, primary biliary cirrhosis, and inflammatory bowel disease. *Am J Hematol* 70(3), 257–259.

102 Milkiewicz P, Heathcote J (2005) Primary biliary cirrhosis in a patient with Turner syndrome. *Can J Gastroenterol* 19(10), 631–633.

103 Czaja AJ, Muratori L, Carpenter HA *et al.* (2004) Diagnostic and therapeutic implications of bile duct injury in autoimmune hepatitis. *Liver Int* 24, 322–329.

104 Springer JE, Cole DEC, Rubin LA *et al.* (2000) Vitamin D-receptor genotypes as independent genetic predictors of decreased bone mineral density in primary biliary cirrhosis. *Gastroenterology* 118, 145–151.

105 Pares A, Guanabens N, Alvarez L *et al.* (2001) Collagen type Ialpha1 and vitamin D receptor gene polymorphism and bone mass in primary biliary cirrhosis. *Hepatology* 33, 554–560.

106 Nishiguchi S, Shimoi S, Kurooka H *et al.* (2001) Randomized pilot trial of vitamin K2 for bone loss in patients with primary biliary cirrhosis. *J Hepatol* 35, 543–545.

107 Eastell R, Dickson ER, Hodgson SF *et al.* (1991) Rates of vertebral bone loss before and after liver transplantation in women with primary biliary cirrhosis. *Hepatology* 14, 296–300.

108 Phillips JR, Angulo P, Petterson T *et al.* (2001) Fat-soluble vitamin levels in patients with primary biliary cirrhosis. *Am J Gastroenterol* 96, 2745–2750.

109 Kowdley KV, Emond MJ, Sadowski JA *et al.* (1997) Plasma vitamin K1 level is decreased in primary biliary cirrhosis. *Am J Gastroenterol* 92, 2059–2061.

110 El-Husseini R, Kaplan MM (2004) Reversal of portal hypertension in a patient with primary biliary cirrhosis: disappearance of esophageal varices and thrombocytopenia. *Am J Gastroenterol* 99, 1859–1860.

111 Gores GJ, Wiesner RH, Dickson ER *et al.* (1989) Prospective evaluation of esophageal varices in primary biliary cirrhosis: development, natural history, and influence on survival. *Gastroenterology* 96, 1552–1559.

112 Bressler B, Pinto R, El Ashry D *et al.* (2005) Which patients with primary biliary cirrhosis or primary sclerosing cholangitis should undergo endoscopic screening for oesophageal varices detection? *Gut* 54, 407–410.

113 Sherlock S (1959) Primary biliary cirrhosis (chronic intrahepatic obstructive jaundice). *Gastroenterology* 37, 574–586.

114 Prince MI, Chetwynd A, Craig WL *et al.* (2004) Asymptomatic primary biliary cirrhosis: clinical features, prognosis, and symptom progression in a large population based cohort. *Gut* 53, 865–870.

115 Nyberg A, Loof L (1989) Primary biliary cirrhosis: clinical features and outcomes, with special reference to asymptomatic disease. *Scand J Gastroenterol* 24, 57–64.

116 Balasubramaniam K, Grambsch PM, Wiesner RH *et al.* (1990) Diminished survival in asymptomatic primary biliary cirrhosis. A prospective study. *Gastroenterology* 98, 1567–1571.

117 Mitchison HC, Lucey MR, Kelly PJ *et al.* (1990) Symptom development and prognosis in primary biliary cirrhosis: a study in two centres. *Gastroenterology* 99, 778–784.

118 Springer J, Cauch-Dudek K, O'Rourke K *et al.* (1999) Asymptomatic primary biliary cirrhosis: a study of its natural history and prognosis. *Am J Gastroenterol* 94, 47.

119 Mahl T, Shockcor W, Boyer JL (1994) Primary biliary cirrhosis: survival of a large cohort of symptomatic and asymptomatic patients followed for 24 years. *J Hepatol* 20, 1709–1713.

120 Uddenfeldt P, Danielsson A (2000) Primary biliary cirrhosis: survival of a cohort followed for 10 years. *J Intern Med* 248, 292–298.

121 Kilmurry MR, Cauch-Dudek K, O'Rourke K *et al.* (1996) Is the Mayo model for predicting survival useful after the introduction of ursodeoxycholic acid treatment for primary biliary cirrhosis? *Hepatology* 23, 1148–1153.

122 Vleggaar FP, van Buuren HR, Zondervan PE *et al.* (2001) Jaundice in a non-cirrhotic primary biliary cirrhosis: the premature ductopenic variant. *Gut* 49, 276–281.

123 Donaldson P, Agarwal K, Craggs A *et al.* (2001) HLA and interleukin 1 gene polymorphisms in primary biliary cirrhosis: associations with disease progression and disease susceptibility. *Gut* 48, 397–402.

124 Corpechot C, Benlin P, Barbu V *et al.* (2001) Apolipoprotein E polymorphism, a marker of disease severity in primary biliary cirrhosis? *J Hepatol* 35, 324–328.

125 Neuberger JM, Gunson BK, Buckels JA *et al.* (1990) Referral of patients with primary biliary cirrhosis for liver transplantation. *Gut* 31, 1069–1072.

126 Poupon RE, Chretien Y, Chazouilleres O *et al.* (2004) Quality of life in patients with primary biliary cirrhosis. *Hepatology* 40, 489–494.

127 Prince MI, Mitchison HC, Ashely D *et al.* (2003) Oral antioxidant supplementation for fatigue association with primary biliary cirrhosis: results of a multicentre, randomized, placebo-controlled, cross-over trial. *Aliment Pharmacol Ther* 17, 137–143.

128 Ter Borg PCJ, van Os E, van den Broek WW *et al.* (2004) Fluvoxamine for fatigue in primary biliary cirrhosis and primary sclerosing cholangitis: a randomized controlled trial. *BMC Gastroenterology* 4, 13.

129 Orchard TJ, Temprosa M, Ratner R (2005) Modafinil for the treatment of fatigue in primary biliary cirrhosis. *Ann Intern Med* 143, 546–547.

130 Ghent CN, Carruthers SG (1988) Treatment of pruritus in primary biliary cirrhosis with rifampin. Results of a double-blind, crossover, randomized trial. *Gastroenterology* 94, 488–493.

131 Bergasa NV, Liau S, Homel P *et al.* (2002) Hepatic Met-enkephalin immunoreactivity is enhanced in primary biliary cirrhosis. *Liver* 22(2), 107–113.

132 Bergasa NV, Alling DW, Talbot TL *et al.* (1995) Effects of naloxone infusions in patients with the pruritus of cholestasis: a double-blind randomized controlled trial. *Ann Intern Med* 123, 161–167.

133 Wolfhagen FH, Sternieri E, Hop WC *et al.* (1997) Oral naltrexone treatment for cholestatic pruritus: a double blind, placebo controlled study. *Gastroenterology* 113, 1264–1269.

134 Jones EA, Neuberger J, Bergasa NV (2002) Opiate antagonist therapy for pruritus of cholestasis: the avoidance of opioid withdrawal-like reactions. *Q J Med* 95, 547–552.

135 McRae CA, Prince MI, Hudson M *et al.* (2003) Pain as a complication of use of opiate antagonists for symptom control in cholestasis. *Gastroenterology* 125, 591–596.

136 Boone RH, Cheung AM, Girlan LM *et al.* (2006) Osteoporosis in primary biliary cirrhosis: a randomized trial of the efficacy and feasibility of estrogen/progestin. *Dig Dis Sci* 51, 1103–1112.

137 Ormarsdottir S, Mallmin H, Naessen T *et al.* (2004) An open, randomized, controlled study of transdermal hormone replacement therapy on the rate of bone loss in primary biliary cirrhosis. *J Intern Med* 256, 63–69.

138 Guanabens N, Pares A, Ros I *et al.* (2003) Alendronate is more effective than etidronate for increasing bone mass in osteopenic patients with primary biliary cirrhosis. *Am J Gastroenterol* 98, 2268–2274.

139 Christensen E, Neuberger J, Crowe J *et al.* (1985) Beneficial effect of azathioprine and prediction of prognosis in primary biliary cirrhosis. Final result of an international trial. *Gastroenterology* 89, 1084–1091.

140 Mitchison HC, Palmer JM, Bassendine MF *et al.* (1992) A controlled trial of prednisolone treatment in primary biliary cirrhosis. Three-year results. *J Hepatol* 15(3), 336–344.

141 Hempfling W, Grunhage F, Dilger K *et al.* (2003) Pharmacokinetics and pharmacodynamic action of budesonide in early- and late-stage primary biliary cirrhosis. *Hepatology* 38, 196–202.

142 Leuschner M, Maier K-P, Schlichtin J *et al.* (1999) Oral budesonide and ursodeoxycholic acid for treatment of primary biliary cirrhosis: results of a prospective double-blind trial. *Gastroenterology* 117, 918–925.

143 Rautiainen H, Karkkainen P, Karvonen A-L *et al.* (2005) Budesonide combined with UDCA to improve liver histology in primary biliary cirrhosis: a three-year randomized trial. *Hepatology* 41, 747–752.

144 Lombard M, Portmann B, Neuberger J (1993) Cyclosporine A treatment in primary biliary cirrhosis: results of a long-term placebo controlled trial. *Gastroenterology* 104, 519–526.

145 Hoofnagle JH, Davis GL, Schafer DF *et al.* (1986) Randomized trial of chlorambucil for primary biliary cirrhosis. *Gastroenterology* 91, 1327–1334.

146 Kaplan MM, Knox TA (1991) Treatment of primary biliary cirrhosis with low-dose weekly methotrexate. *Gastroenterology* 101, 1332–1338.

147 Hendrickse MT, Rigney E, Giaffer MH *et al.* (1999) Low-dose methotrexate is ineffective in primary biliary cirrhosis: long-term results of a placebo-controlled trial. *Gastroenterology* 117, 400–407.

148 Combes B, Emerson SS, Flye NL *et al.* (2005) Methotrexate (MTX) plus ursodeoxycholic acid (UDCA) in the treatment of primary biliary cirrhosis. *Hepatology* 42, 1184–1193.

149 Zifroni A, Schaffner F (1991) Long term follow up of patients with primary biliary cirrhosis on colchicine therapy. *Hepatology* 14, 990–993.

150 Almasio PL, Floreani A, Chiaramonte M *et al.* (2001) Multicentre randomized placebo-controlled trial of ursodeoxycholic acid with or without colchicines in symptomatic primary biliary cirrhosis. *Aliment Pharmacol Ther* 14(12), 1645–1652.

151 Rodrigues CM, Fan G, Wong PY *et al.* (1998) Ursodeoxycholic acid may inhibit deoxycholic acid induced apoptosis by modulatory mitochondrial transmembrane potential and reactive oxygen species production. *Mol Med* 4, 165–178.

152 Jazrawi RP, de Caestecker JS, Goggin PM *et al.* (1994) Kinetics of hepatic bile acid handling in cholestatic liver disease: effect of ursodeoxycholic acid. *Gastroenterology* 106, 34–42.

153 Poupon RE, Lindor KD, Cauch-Dudek K *et al.* (1997) Combined analysis of randomized controlled trials of ursodeoxycholic acid in primary biliary cirrhosis. *Gastroenterology* 113, 884–890.

154 Gluud C, Christensen E (2002) Ursodeoxycholic acid for primary biliary cirrhosis (Cochrane Review). *Cochrane Database Syst Rev* (1), CD000551.

155 Heathcote EJ (2000) Management of primary biliary cirrhosis: the American association for the study of liver diseases practice guidelines. *Hepatology* 31, 1005–1013.

156 Pares A, Caballería L, Rodés J *et al.* (2000) Long-term effects of ursodeoxycholic acid in primary biliary cirrhosis: results of a double-blind controlled multicentric trial. *J Hepatol* 32, 561–566.

157 Poupon RE, Lindor KD, Pares A *et al.* (2003) Combined analysis of the effect of treatment with ursodeoxycholic acid on histological progression in primary biliary cirrhosis. *J Hepatol* 39, 12–16.

158 Nakai S, Masaki T, Kurokohchi K *et al.* (2000) Combination therapy of bezafibrate and ursodeoxycholic acid in primary biliary cirrhosis: a preliminary study. *Am J Gastroenterol* 95, 326–327.

159 Kanda T, Yokosuka O, Imazeki F *et al.* (2003) Bezafibrate treatment: a new medical approach for PBC patients? *J Gastroenterol* 38, 573–578.

160 Ritzel U, Leonhardt U, Nather M *et al.* (2002) Simvastatin in primary biliary cirrhosis: effect on serum lipids and distinct disease markers. *J Hepatol* 36, 454–458.

161 Puppo MD, Kienle MG, Crosignani A *et al.* (2001) Cholesterol metabolism in primary biliary cirrhosis during simvastatin and UDCA administration. *J Lipid Res* 42, 437–441.

162 Liermann Garcia RF, Evangelista GC, McMaster P *et al.* (2001) Transplantation for primary biliary cirrhosis: retrospective analysis of 400 patients in a single centre. *Hepatology* 33, 22–27.

163 Krzeski P, Zych W, Kraszewska E *et al.* (1999) Is serum bilirubin concentration the only valid prognostic marker in primary cirrhosis? *Hepatology* 30, 865–869.

164 Christensen E, Gunson B, Neuberger J (1999) Optimal timing of liver transplantation for patients with primary biliary cirrhosis: use of prognostic modeling. *J Hepatol* 30, 285–292.

165 Heathcote EJ, Stone J, Cauch-Dudek K *et al.* (1999) Effect of pre-transplantation ursodeoxycholic acid therapy on the outcome of liver transplantation in patients with primary biliary cirrhosis. *Liver Transpl Surg* 5, 269–274.

166 Neuberger J, Adams DH (1998) What is the significance of acute liver allograft rejection? *J Hepatol* 29, 143–150.

167 Tinmouth J, Tomlinson G, Heathcote J *et al.* (2002) Benefit of transplantation in primary biliary cirrhosis between 1985–1997. *Transplantation* 73, 226.

11.2 Autoimmune hepatitis

Diego Vergani and Giorgina Mieli-Vergani

Introduction/definition

Autoimmune hepatitis (AIH) is an inflammatory liver disease, affecting mainly females, characterized by elevated transaminase levels, positive organ- and non-organ-specific autoantibodies, elevated immunoglobulin G (IgG) and a histological picture of interface hepatitis. Immune reactions against host liver antigens are believed to be the major pathogenic mechanism. AIH responds to immunosuppressive treatment in most cases. The diagnosis should be made as soon as possible because symptomatic AIH, if left untreated, progresses to liver failure requiring transplantation. The development of a panel of marker autoantibodies has allowed the subdivision of AIH into distinct types that have clinical and prognostic peculiarities [1–6].

Historical background

Reports of a non-viral chronic hepatitis affecting children or young adults with a female preponderance and associated with high serum proteins date back to the 1930s and 1940s [7,8]. The full description of AIH, however, was given at the first meeting after World War II of the German Society for Digestive and Metabolic Disorders at Bad Kissingen in September 1950 [9]. The report was by the Swedish physician Jan Gösta Waldeström who described six patients, five of whom were female, with a 'hepatitis sui generis', characterized by a substantial elevation of gammaglobulins. While investigating the amenorrhoea of these patients through the administration of adenocorticotrophic hormone (ACTH), Waldeström noted that this intervention was followed by a striking subjective improvement and by a dramatic fall in the sedimentation rate. He went on to predict that these 'patients may benefit from ACTH treatment in the future'. Female preponderance, hyperimmunoglobulinaemia G and response to corticosteroids, key characteristics of AIH, were defined in this early report. In 1951, Henry George Kunkel confirmed Waldeström's observation [8] and noted that some patients had additional clinical features such as fever, arthralgia and arthritis. In 1955, Joske and King [10] from the Clinical Research Unit of the Walter and Eliza Hall Institute of Medical Research in Melbourne, Australia, reported the finding of lupus erythematosus (LE) cells in the blood of two patients with hypergammaglobulinaemic active chronic hepatitis. Interestingly, a year earlier, Leoni had reported the '*fenomeno LE*' in the ascites of a patient with cirrhosis [11]. In a landmark article, Mackay *et al.* [12] described five additional hypergammaglobulinaemic chronic hepatitis patients recruited in the same unit as the two reported earlier by Joske and King. Because of the presence of LE cells, they provisionally designated the liver disorder in these seven patients as 'lupoid hepatitis'. Ten years later, when it was apparent that 'lupoid hepatitis' was a different entity from systemic lupus erythematosus, a condition in which liver disease is rare, and that LE cells reflect the presence of antinuclear antibody (ANA), Mackay suggested the alternative name of 'autoimmune hepatitis' [13]. This term, however, was finally accepted only in the 1990s, after several different labels had been given to this condition over the years. In addition to seropositivity for ANA, reports from the early 1960s showed that antismooth muscle antibodies could also act as markers of what is known today as AIH type 1 (AIH-1) [7,8]. Thirty years after the first description of 'lupoid hepatitis', AIH type 2 (AIH-2), characterized by the presence in the serum of liver/kidney microsomal antibody type 1, was described [14].

Epidemiological features

The prevalence of AIH is unknown. Most of the information available was collected before the introduction of the International Autoimmune Hepatitis Group (IAIHG) scoring system [15,16] and, therefore, no standardized way of evaluating patients was used. Moreover, early studies did not exclude hepatitis C. A study in a Norwegian population reports a mean annual incidence of 1.9 cases of AIH per 100 000 and a point prevalence of 16.9 cases per 100 000 population [17]. The rates of AIH found in this study are about twice those found in studies of idiopathic chronic active hepatitis in Iceland and of AIH within patients with chronic active hepatitis in Sweden and England [18]. Other reported prevalences range from 1 per 200 000 in the US general population [19] to 20 per 100 000 in females over

14 years of age in Spain [20], although both figures are probably underestimates.

The prevalence of AIH-2, which affects mainly children and young adults, is unknown, also owing to the fact that the diagnosis is often overlooked. At the King's College Hospital tertiary paediatric hepatology referral centre, there has been a sevenfold increase in the incidence of AIH over the last decade. AIH represents approximately 10% of some 400 new referrals per year, two-thirds of the cases being AIH-1 and one-third AIH-2.

Diagnosis and clinical features

The diagnosis of AIH is based on the presence of positive autoantibodies, elevated transaminase and IgG levels, and interface hepatitis on liver biopsy. The last item is required to confirm the diagnosis and to evaluate the severity of liver damage. The levels of transaminases and IgG do not reflect the extent of the histological inflammatory activity, nor do they indicate the presence or absence of cirrhosis. Other hepatic disorders that may share some of the above features need to be considered in the differential diagnosis. These include viral hepatitides (in particular B and C), Wilson disease and drug-induced liver disease (minocycline, nitrofurantoin, isoniazid, propylthiouracil, diclofenac, pemoline, atovastatin and alpha-methyldopa). Female patients outnumber male patients 3:1. A family history of autoimmune diseases is present in some 40% of the patients. Associated autoimmune disorders are present at diagnosis or develop during follow-up in at least one-fifth of the patients and include thyroiditis, ulcerative colitis, insulin-dependent diabetes, vitiligo, nephrotic syndrome, hypoparathyroidism and Addison's disease, the last two being observed in particular in liver/kidney microsomal type 1 (LKM-1) antibody-positive patients or in patients with autoimmune polyendocrinopathy–candidiasis–ectodermal dystrophy (APECED), a monogenic disorder with a variable phenotype that includes AIH in about 20% of the cases. Typically, AIH responds to immunosuppressive treatment, which should be instituted as soon as the diagnosis is made. The onset of AIH is often ill-defined, and it frequently mimics acute hepatitis, particularly in young patients. Two main types of AIH are recognized, according to the presence of smooth muscle antibody (SMA) and/or ANA or LKM-1 antibody (Fig. 1). Major targets of SMA are the microfilaments of smooth muscle, whereas the molecular target of anti-LKM-1 is cytochrome P4502D6 (CYP2D6). The distinction between type 1 and type 2 AIH is particularly relevant in paediatrics, as anti-LKM-1-positive disease is quite rare, but not absent, in adults. In paediatrics, anti-LKM-1-positive AIH represents one-third of all cases and has a clinical course similar to ANA/SMA-positive AIH, although anti-LKM-1-positive children present at a younger age, more often with an acute onset, including fulminant hepatitis, and have associated IgA deficiency [21]. There are three main patterns of disease presentation: an acute onset, characterized by non-specific symptoms of malaise, nausea/vomiting, anorexia and abdominal pain, followed by jaundice, dark urine and pale stools; an insidious onset, with an illness characterized by progressive fatigue, relapsing jaundice, headache, anorexia and weight loss; and, finally, presentation with complications of portal hypertension, such as haematemesis from oesophageal varices, bleeding diathesis, chronic diarrhoea, weight loss and vomiting. The mode of presentation of AIH is therefore variable, and the disease should be suspected and excluded in all patients presenting with symptoms and signs of prolonged or severe liver disease. Some patients, however, are completely asymptomatic and are diagnosed after incidental discovery of abnormal liver function tests.

The criteria for the diagnosis of AIH have been defined and revised by the IAIHG. This diagnostic system, which includes positive and negative scores, was devised mainly for comparative and research purposes [15,16] (Table 1) because, in most instances, clinical, laboratory and histological features allow the diagnosis of AIH to be made without the need for the scoring system. In the IAIHG scoring system, differences between a definite and probable diagnosis of AIH relate mainly to the degree of serum gammaglobulin or IgG elevation, levels of ANA, SMA or anti-LKM-1 and exposures to alcohol, medications or

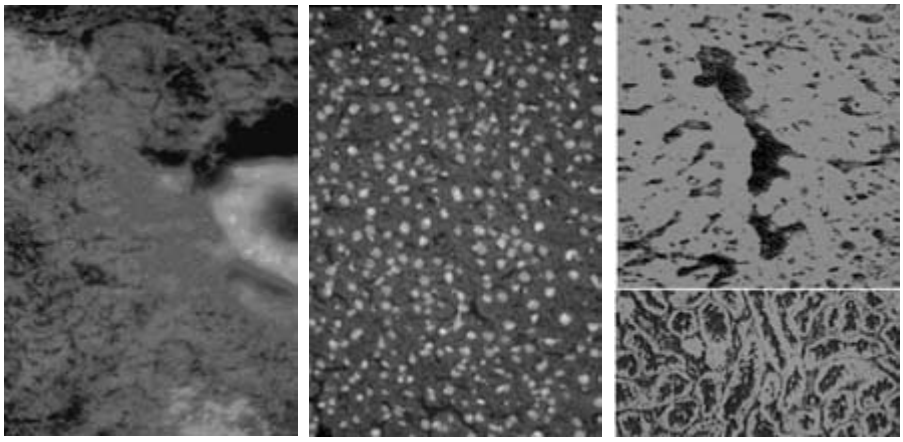

(a) (b) (c)

Fig. 1 Immunofluorescence pattern of smooth muscle (SMA), antinuclear (ANA) and anti-liver/kidney microsomal type 1 (LKM-1) autoantibodies on renal and liver rodent sections. SMA (a) stains the small artery and the glomeruli in the renal section, ANA (b) the nuclei in the liver section and LKM-1 (c) the cytoplasm of hepatocytes and proximal renal tubules.

infections that can cause liver injury. Cholestatic laboratory and histological changes carry a negative score. In rare cases, the presence of non-standard autoantibodies, such as those to asialoglycoprotein receptor (anti-ASGPR), liver-specific cytosol antigen type 1 (anti-LC1), soluble liver antigen/liver–pancreas (anti-SLA/LP) and perinuclear antineutrophil cytoplasmic antibodies (pANCA) (see below for all), supports a probable diagnosis in the absence of conventional autoantibodies. Response to steroids weights strongly towards the diagnosis of AIH and has been incorporated into the scoring system, because this condition typically enters remission during corticosteroid therapy and frequently relapses after drug withdrawal. A definite diagnosis before steroid treatment requires a score greater than 15, while a definite diagnosis after steroid treatment requires a score greater than 17 (Table 1). The diagnostic criteria for children are slightly different from those of adults. In view of the fact that autoantibodies are very rarely positive in healthy children, the presence of autoantibody titres as low as 1:20 for ANA and SMA and 1:10 for anti-LKM-1 is compatible with the diagnoses of type 1 and type 2 AIH respectively. Also, in adults, autoantibodies are present at times at low titre or even absent, the titre rising or becoming detectable during follow-up. Seronegative individuals, therefore, classified at presentation as having cryptogenic chronic hepatitis, may later be firmly diagnosed when conventional markers appear or when autoantibodies that are not generally available are tested.

Autoantibodies (see Table 2)

A key component of the criteria developed by the IAIHG [15,16,22] is detection by indirect immunofluorescence of autoantibodies to constituents of the nuclei (ANA), smooth muscle (SMA) and liver/kidney microsome type 1 (anti-LKM-1). Autoantibody detection not only assists in the diagnosis but also allows differentiation of AIH into type 1 and type 2. ANA and SMA, which characterize AIH-1, and anti-LKM-1, which defines AIH-2, are practically mutually exclusive; in those rare instances when they are present simultaneously, the clinical course is similar to that of AIH-2. Recognition and interpretation of the immunofluorescence patterns is not always straightforward. The operator dependency of the technique and the relative rarity of AIH explain the not infrequent occurrence of errors in reporting, particularly of less frequent specificities such as anti-LKM-1. Problems do exist between laboratory reporting and clinical interpretation of the results that are partly dependent on insufficient standardization of the tests, but also partly dependent on a degree of unfamiliarity of some clinicians with the disease spectrum of AIH. With regard to standardization, a lead has been taken by the IAIHG, which has established an internationally representative committee to define guidelines and develop procedures and reference standards for more reliable testing [22].

The basic technique for the routine testing of autoantibodies relevant to AIH is indirect immunofluorescence on a freshly

Table 1 IAIHG scoring system for the diagnosis of autoimmune hepatitis.

Parameter		Score
Principal parameters		
Sex	Female	+2
ALP:AST (or ALT) ratio	> 3	–2
	1.5–3	0
	< 1.5	+2
Serum globulins or IgG (times above normal)	> 2.0	+3
	1.5–2.0	+2
	1.0–1.5	+1
	< 1.0	0
ANA, SMA or anti-LKM-1 titres	>1:80	+3
	1:80	+2
	1:40	+1
	< 1:40	0
AMA	Positive	–4
Viral markers of active infection	Positive	–3
	Negative	+3
Hepatotoxic drug history	Yes	–4
	No	+1
Average alcohol	< 25 g/day	+2
	> 60 g/day	–2
Histological features	Interface hepatitis	+3
	Plasma cells	+1
	Rosettes	+1
	None of above	–5
	Biliary changes*	–3
	Atypical changes†	–3
Optional additional parameters		
Seropositivity for other defined autoantibodies	Anti-SLA/LP, actin, LC1, ASGPR, pANCA	+2
HLA	DR3 or DR4	+1
Response to therapy	Remission	+2
	Relapse	+3
Interpretation of aggregate scores		
Pretreatment		
Definite AIH		> 15
Probable AIH		10–15
Post treatment		
Definite AIH		> 17
Probable AIH		12–17

IAIHG, International Autoimmune Hepatitis Group; ALP, alkaline phosphatase; AST, aspartate aminotransferase; ALT, alanine aminotransferase; IgG, immunoglobulin G; ANA, antinuclear antibody; SMA, smooth muscle antibody; LKM-1, liver/kidney microsomal antibody type 1; AMA, antimitochondrial antibody; SLA/LP, soluble liver antigen/liver–pancreas; LC1, liver cytosol type 1; ASGPR, asialoglycoprotein receptor; pANCA, perinuclear antineutrophil cytoplasmic antibody; HLA, human leukocyte antigen; AIH, autoimmune hepatitis.
*Including granulomatous cholangitis, concentric periductal fibrosis, ductopenia, marginal bile duct proliferation with cholangiolitis.
†Any other prominent feature suggesting a different aetiology.
Modified from ref. 16.

Table 2 Methods, associations and reactants for autoantibodies in liver diseases.

Autoantibody[a]	Conventional method of detection†	Molecularly based assays[b]	Disease association	Molecular target(s)
ANA	IIF	NA	AIH-1; overlap syndromes	Multiple targets, particularly chromatin
SMA	IIF	NA	AIH-1; overlap syndromes	Microfilaments (actin?), intermediate filaments (vimentin, etc.)
Anti-LKM-1	IIF[c]	ELISA, IB, RIA	AIH-2; HCV infection (5%)	Cytochrome P4502D6
Anti-LC1	IIF, DID, CIE	ELISA, RIA	AIH-2	Formiminotransferase cyclodeaminase
SLA/LP	Inhibition ELISA	ELISA, IB, RIA	AIH-1; AIH-2 and AIH-negative for other reactivities	tRNP(Ser)Sec (see text)
Atypical pANCA (pANNA)	IIF	NA	AIH-1; sclerosing cholangitis	Unidentified antigen(s) at nuclear periphery
AMA	IIF	ELISA, IB, RIA	Primary biliary cirrhosis	E2 subunits of 2-oxoacid dehydrogenase complexes, particularly PDC-E2

[a]ANA, antinuclear antibody; SMA, antismooth muscle antibody; LKM-1, anti-liver/kidney microsomal antibody type 1; LC1, anti-liver cytosol type 1 antibody; SLA/LP, anti-soluble liver antigen/liver–pancreas antibody; pANCA, perinuclear antineutrophil cytoplasmic antibody; pANNA, perinuclear antineutrophil antibody; AMA, antimitochondrial antibody.
[b]IIF, indirect immunofluorescence (recommended cutoff titre for positivity is 1:40 except in children; see text); DID, double dimension immunodiffusion; CIE, counterimmunoelectrophoresis; ELISA, enzyme-linked immunosorbent assay; IB, immunoblot; RIA, radioimmunoprecipitation assay.
[c]Anti-LKM-1 and AMA both stain renal tubules and are frequently confused (see text).
NA, not available.

prepared rodent substrate that should include kidney, liver and stomach to allow the detection of ANA, SMA, anti-LKM-1 as well as anti-LC1, but also of antimitochondrial antibody (AMA), the serological hallmark of primary biliary cirrhosis (PBC). Positive sera should be titrated to extinction, while the pattern of nuclear staining for those who are ANA positive may be characterized further using HEp2 cells. Of particular importance is the plan of section and orientation of the kidney because both anti-LKM-1 and AMA stain renal tubules, but with different patterns distinguishable only in the presence of both proximal and distal tubules. Thus, AMA preferentially stains the distal tubules, which are smaller in size, whereas anti-LKM-1 characteristically stains the third portion of the proximal tubules. The sections of liver, kidney and stomach should be dried in air and used without further fixation. Commercially available sections are of variable quality because, to lengthen shelf-life, they are treated with fixatives (acetone, ethanol or methanol), which readily result in enhanced background staining that may hinder the recognition of diagnostic autoantibodies, especially when these are present at low titre.

As healthy adults may show reactivity at the conventional starting serum dilution of 1:10, the arbitrary dilution of 1:40 has been considered clinically significant by the IAIHG. In contrast, in healthy children, autoantibody reactivity is infrequent, so that titres of 1:20 for ANA and SMA and 1:10 for anti-LKM-1 are clinically relevant. Hence, the laboratory should report any level of positivity from 1:10, and the attending physician should interpret the result within the clinical context and the age of the patient.

Antinuclear antibody

ANA is readily detectable as a nuclear staining in kidney, stomach and liver. In the last organ in particular, the ANA pattern may be detected as homogeneous or coarsely or finely speckled. In most cases of AIH, but not all, the pattern is homogeneous. To obtain a much clearer and easier definition of the nuclear pattern, HEp2 cells that have prominent nuclei should be used. HEp2 cells, however, should not be used for screening purposes because nuclear reactivity to these cells is frequent at low serum dilution (1:40) in the normal adult population. For ANA, likely molecular targets include nuclear chromatin and histones, akin to lupus, but there are probably several others. The advent of new techniques using recombinant nuclear antigens and immunoassays will enable a better definition of ANA target antigens and an assessment of their specificity for diagnosis and their possible role in the pathogenesis of AIH-1.

Smooth muscle antibody

SMA is detected on kidney, stomach and liver, where it stains the walls of the arteries. In the stomach, it also stains the muscularis mucosa and the lamina propria. On the renal substrate, it is possible to visualize the V, G and T patterns; V refers to vessels, G to glomeruli and T to tubules [22]. The V pattern is also present in non-autoimmune inflammatory liver disease, in autoimmune diseases not affecting the liver and in viral infections, but the VG and VGT patterns are more specific for AIH. The VGT pattern corresponds to the so called 'F-actin' or microfilament (MF)

pattern observed using cultured fibroblasts as substrate. Neither the VGT nor the anti-MF patterns are, however, entirely specific for the diagnosis of AIH-1. Although the VGT-MF pattern has been suggested to result from a specific antibody uniquely found in AIH-1, it may just reflect high-titre SMA. The molecular target of the microfilament reactivity that is observed in AIH-1 remains to be identified. Although 'anti-actin' reactivity is strongly associated with AIH-1, some 20% of SMA-positive AIH-1 patients do not have the F-actin/VGT pattern. Therefore, the absence of anti-actin SMA does not exclude the diagnosis of AIH.

Anti-liver/kidney microsomal antibody

Anti-LKM-1 brightly stains the liver cell cytoplasm and the P3 portion of the renal tubules, but does not stain gastric parietal cells. Anti-LKM-1 is often confused with AMA, as both autoantibodies stain liver and kidney. Compared with LKM-1, AMA stains the liver more faintly and the renal tubules more diffusely with an accentuation of the small distal ones. In contrast to anti-LKM-1, AMA also stains the gastric parietal cells. In the context of AIH, there can be positivity for AMA in a small subset of patients (3–5%) in whom there are overlapping features with PBC. The identification of the molecular targets of anti-LKM-1, i.e. cytochrome P4502D6 (CYP2D6), and of AMA, i.e. enzymes of the 2-oxo-acid dehydrogenase complexes, has led to the establishment of immunoassays based on the use of the recombinant or purified antigens. Commercially available enzyme-linked immunosorbent assays (ELISAs) are accurate for the detection of anti-LKM-1, at least in the context of AIH-2, and reasonably accurate for the detection of AMA. Therefore, if a doubt remains after examination by immunofluorescence, this can be resolved by the use of molecularly based immunoassays.

Variant liver microsomal antibodies: anti-LM, anti-LKM-2 and -3

These antibodies are mostly directed against P450 cytochrome isoforms that are different from 2D6. Anti-LM antibodies stain only the liver cytoplasm, react with liver-specific cytochrome P4501A2 and occur in dihydralazine-induced hepatitis and in hepatitis associated with APECED. An anti-LKM-1-like pattern of immunofluorescence is given by autoantibodies to P4502A6 that occur in APECED and occasionally in hepatitis C. The term anti-LKM-2 was originally applied to LKM-1-like microsomal antibodies produced during hepatitis, induced by the no-longer marketed antihypertensive tienilic acid and directed against cytochrome P4502C9. Anti-LKM-3, which target members of the family 1 UDP glucuronosyltransferases (UGT), also gives an immunofluorescent pattern similar to anti-LKM-1, but mainly occurs in hepatitis D (delta).

Anti-liver cytosol type 1 (LC1)

This antibody was originally described either in association with anti-LKM-1 or in isolation, in both instances defining a clinical entity resembling AIH-2. Later, anti-LC1 was also found occasionally in association with the serological markers of AIH-1 and in patients with chronic hepatitis C virus infection. Anti-LC1 can be detected by indirect immunofluorescence using the standard tissue panel composed of rodent liver, kidney and stomach. It stains the cytoplasm of liver cells with relative sparing of the centrilobular area, but is usually obscured by the concurrent presence of anti-LKM-1. In the presence of anti-LKM-1, anti-LC1 can be detected by the use of liver cytosol in double-dimension immunodiffusion or counterimmunoelectrophoresis, and a positive reference serum. In Western blotting, anti-LC1 reacts with a 58 to 60-kDa protein when human liver cytosolic fraction is used as substrate. The molecular target has been identified as formiminotransferase cyclodeaminase (FTCD). The clinical relevance of anti-LC1 is currently being assessed using molecularly based immunoassays. The presence of anti-LC1 in isolation scores positively towards a diagnosis of AIH-2, allowing prompt initiation of treatment.

Anti-soluble liver antigen/liver–pancreas antigen (anti-SLA/LP)

Anti-SLA and anti-LP, previously described separately in AIH, target the same antigen and are therefore the same autoantibody. Anti-SLA was thought to identify a third type of AIH in which tests for conventional autoantibodies were negative. However, early reports predated the publication of the IAIHG recommendations and used a cutoff point for conventional autoantibody levels higher than that currently used for the diagnosis of AIH. Several patients considered to have AIH-3 were probably positive for conventional autoantibodies, and therefore had type 1 or 2 AIH. Screening of cDNA expression libraries using high-titre anti-SLA serum has allowed the identification of the molecular target antigen as UGA tRNA suppressor-associated antigenic protein (tRNP(Ser)Sec). Molecularly based diagnostic assays have become available, but their full evaluation is still under way. Although anti-SLA/LP is found occasionally in patients with AIH who are negative for ANA, SMA and anti-LKM-1, it is also frequently present in typical cases of AIH-1 and AIH-2, and also in AIH/sclerosing cholangitis overlap syndrome. Anti-SLA appears to be highly specific for the diagnosis of AIH. Its detection at the time of diagnosis identifies patients with more severe disease and worse outcome [23].

Antibodies to liver-specific lipoprotein complex and its components [4]

In the mid-1970s, it was reported that antibodies to the liver-specific lipoprotein (LSP) – a macromolecular complex present on the hepatocyte membrane and originally described by Meyer zum Büschenfelde and collaborators – are not only present in AIH but that their titre correlates with the biochemical and histological severity of the disease. A similar relationship to disease severity was later observed for the titres of an antibody to a well-characterized component of LSP, the asialoglycoprotein

receptor (ASGPR). More recently, antibodies to alcohol dehydrogenase (ADH), a second well-defined component of LSP, have been described in patients with AIH [24]. The measurement of these autoantibodies, however, is confined to research laboratories, in view of the difficulties in setting up and standardizing their detection assays.

Antineutrophil cytoplasmic antibodies (ANCA)

These autoantibodies are directed at cytoplasmic components of neutrophils and give either a perinuclear (pANCA) or a cytoplasmic (cANCA) pattern. cANCA mainly reacts with proteinase 3 and is found in Wegener's granulomatosis; pANCA reacts with myeloperoxidase and is frequently detected in microscopic polyangiitis. In AIH-1, akin to primary sclerosing cholangitis and inflammatory bowel disease, pANCA are frequently detected, but they are atypical as they reportedly react with peripheral nuclear membrane components (perinuclear antinuclear neutrophil antibodies; pANNA) [22]. In contrast to AIH-1, pANNA are virtually absent in AIH-2. Detection of atypical pANCA can act as an additional pointer towards the diagnosis of AIH, particularly in the absence of other autoantibodies [16].

Histology

Interface hepatitis (hepatitis at the portal–parenchymal interface) is characteristic of, but not exclusive to, AIH [25]. Other lesions typically present in AIH are periportal lymphocytic or lymphoplasmacytic infiltration, hepatocyte swelling and/or pycnotic necrosis (Plate 11.2.1a, facing p. 1268). Lymphocytes, plasma cells and histiocytes surround individual dying hepatocytes at the portal–parenchymal interface and in the lobule. Although plasma cells are usually abundant at the interface and throughout the lobule, their presence in low number does not preclude the diagnosis. In AIH presenting acutely or relapsing, panlobular hepatitis is often present, associated with bridging necrosis (Plate 11.2.1b, facing p. 1268) and, in the case of a fulminant presentation, with massive necrosis. Although sampling variation may occur in needle biopsy specimens, especially in the presence of cirrhosis, the severity of the histological appearance is usually of prognostic value. However, it is important to remember that even patients with cirrhosis at presentation respond well to immunosuppressive treatment. Rare histological manifestations of AIH include perivenular necrosis and multinucleated giant hepatocytes, which are, however, more commonly found in viral hepatitis and drug-induced liver disease.

Granulomatous cholangitis and changes such as granulomas, siderosis, heavy copper deposits and steatosis hinder the diagnosis of AIH. Inflammatory changes surrounding the bile ducts, which may be present in a small proportion of patients with AIH, suggest an overlap with sclerosing cholangitis, as reported more frequently in the paediatric setting [26].

Genetics

AIH is a 'complex trait' disease, i.e. a condition not inherited in a Mendelian autosomal dominant, autosomal recessive or sex-linked fashion. The mode of inheritance of a complex trait disorder is unknown and involves one or more genes, operating alone or in concert, to increase or reduce the risk of the trait, and interacting with environmental factors.

Susceptibility to AIH is imparted by genes within the histocompatibility lymphocyte antigen (HLA) region on the short arm of chromosome 6, especially those encoding DRB1 alleles. These class II major histocompatibility complex (MHC) molecules are involved in peptide antigen presentation to CD4 T cells, suggesting the involvement of MHC class II antigen presentation and T-cell activation in the pathogenesis of AIH.

In Europe and North America, susceptibility to AIH-1 is conferred by the possession of HLA DR3 (*DRB1*0301*) and DR4 (*DRB1*0401*), both heterodimers containing a lysine residue at position 71 of the DRB1 polypeptide and the hexameric amino acid sequence LLEQKR at positions 67–72 [27,28]. In Japan, Argentina and Mexico, susceptibility is linked to *DRB1*0405* and *DRB1*0404*, alleles encoding arginine rather than lysine at position 71, but sharing the motif LLEQ-R with *DRB1*0401* and *DRB1*0301* [29]. Thus, K or R at position 71 in the context of LLEQ-R may be critical for susceptibility to AIH, favouring the binding of autoantigenic peptides complementary to this hexameric sequence. However, an alternative model based on valine/glycine dimorphism at position 86 of the DR-beta polypeptide has been proposed, better representing the key HLA associations in patients from Argentina and Brazil [27,28]. In a study from Japan, patients with AIH-1 were found to have DRB1 alleles that encode histidine at position 13 [27,28]. There appear therefore to be at least three different models, suggesting that different genetic associations are present in different populations and that the peptides presented by HLA class II molecules to the T-cell receptors are different and may derive from different antigens. Thus, these HLA associations may be the molecular footprints of the prevailing environmental triggers that precipitate AIH-1 in different environments. In this context, it is of interest that, in South America, possession of the HLA *DRB1*1301* allele, which predisposes to paediatric AIH-1 in that population, is also associated with persistent infection with the endemic hepatitis A virus.

The lysine-71 and other models for AIH-1 cannot completely explain the disease as, for example, in European and North American patients, the presence of lysine-71 is associated with a severe, mainly juvenile, disease in those who are *DRB1*0301* positive, but with a mild, late-onset disease in those who are *DRB1*0401* positive. Other genes within and/or without the MHC are, therefore, likely to be involved in determining the phenotype. Possible candidates are the MHC-encoded complement and tumour necrosis factor (TNF)α genes, mapping to the class III MHC region, and the MHC class I chain-related A and B genes.

Susceptibility to AIH-2 is conferred by the possession of HLA DR7 (*DRB1*0307*) and DR3 (*DRB1*0301*), patients positive for *DRB1*0307* having a more aggressive disease and severe prognosis [30].

A form of AIH resembling AIH-2 affects some 20% of patients with APECED, a condition also known as autoimmune polyendocrine syndrome 1. APECED is a monogenic autosomal recessive disorder caused by homozygous mutations in the *AIRE1* gene and characterized by a variety of organ-specific autoimmune diseases, the most common of which are hypoparathyroidism and primary adrenocortical failure, accompanied by chronic mucocutaneous candidiasis [31,32]. The *AIRE1* gene sequence consists of 14 exons containing 45 different mutations, with a 13-bp deletion at nucleotide 964 in exon 8 accounting for more than 70% of APECED alleles in the UK [31]. The protein predicted to be encoded by *AIRE1* is a transcription factor. *AIRE1* is highly expressed in medullary epithelial cells and other stromal cells in the thymus involved in the clonal deletion of self-reactive T cells. Studies in a murine model indicate that the gene inhibits organ-specific autoimmunity by inducing thymic expression of peripheral antigens in the medulla, leading to central deletion of autoreactive T cells. Interestingly, APECED has a high level of variability in symptoms, especially between populations. As various gene mutations have the same effect on thymic transcription of ectopic genes in animal models, it is likely that the clinical variability across human populations relates to environmental or genetic modifiers. Of the various genetic modifiers, perhaps the most likely to synergize with *AIRE* mutations are polymorphisms in the HLA region. HLA molecules are not only highly variable and strongly associated with multiple autoimmune diseases, they are also able to affect thymic repertoire selection of autoreactive T-cell clones. Carriers of a single *AIRE* mutation do not develop APECED. However, although the inheritance pattern of APECED indicates a strictly recessive disorder, there are anecdotal data of mutations in a single copy of *AIRE* being associated with human autoimmunity of a less severe form than classically defined APECED [31,32]. The role of the *AIRE1* heterozygote state in the development of AIH remains to be established.

Animal models

Research on the pathogenesis of AIH has been hampered by the lack of animal models faithfully reproducing the human condition. Findings in animal models of AIH have been authoritatively reviewed by Jaeckel [33] and Peters [34].

As early as 1908, Jean-Noël Fiessinger, while studying the pathogenesis of cirrhosis for his doctorate thesis, described cirrhotic lesions in rabbits injected up to eight times intraperitoneally with nuclear extracts. However, when a liver antigen was injected in guinea pigs, no histological lesions were induced. Some 40 years later, Casals and Olitsky were able to induce liver cellular inflammation, focal necrosis and fibrosis by 10 consecutive intraperitoneal injections of allogeneic liver homogenate in mice. Although mild to moderate hepatic damage was achieved in these experiments, probably because of the allogeneic nature of the antigen used, more severe lesions were obtained by combining allogeneic liver antigen with complete Freund's adjuvant (CFA) (a mycobacterial extract emulsified in oil). The first researchers who attempted to characterize the nature of the liver antigens responsible for the formation of hepatic mononuclear cell infiltrates were Scheiffarth and collaborators. They induced liver cell necrosis and periportal infiltration, reminiscent of the histological changes seen in human chronic hepatitis, by multiple immunization of rabbits over a period of several months with allogeneic liver extracts in CFA, and showed that the cytosolic fraction of the liver homogenate was much more potent than the microsomal fraction, whereas the nuclear fraction was unable to induce pathological changes. Further studies aimed at defining the nature of the liver autoantigen in AIH were performed by Meyer zum Büschenfelde and collaborators, who identified two hepatocyte antigens, one located in the plasma membrane and the other in the cytosolic fraction, using autoantibody-containing sera from rabbits with experimental hepatitis, induced by repeated immunizations with xenogeneic (human) liver antigen over several months. The membrane-associated antigen, which was found to be a lipoprotein, was called liver-specific protein (LSP) and was later also identified in human liver. The fact that liver autoantibodies present in serum and on hepatocytes in this model did not correlate with histological liver damage and the previously reported inability to transfer the disease with antibodies questioned their pathogenic relevance, indirectly implying a role for cell-mediated immune damage. Subsequent *in vitro* studies in the rabbit model did find lymphocyte proliferative responses against liver antigen. *In vivo* evidence of cell-mediated liver damage was provided in a murine model in which experimental hepatitis could be induced through immunization with syngeneic liver antigen and adoptively transferred to naive mice with nylon wool-adherent lymphocytes (mainly T cells) [35]. Interestingly, this study showed that the susceptibility to liver damage was strain dependent, implying a genetic influence. The same group also reported that splenocytes from the animals with experimental hepatitis were able to suppress liver-specific and non-liver-specific immune responses [36]. The balance between effector and regulatory cells may explain the chronic relapsing course of AIH in humans. Kohda and collaborators went on to show that cytotoxic CD8+ T lymphocytes are central to the induction of the histological lesion. Neither the antigen nor the inflammatory cell infiltrate was characterized in these early studies of cellular immunity [33,34]. Other published murine models, aimed at breaking the immune homeostasis by overexpression of the proinflammatory cytokine interferon (IFN)γ, or by underexpression of the immunomodulatory cytokine tissue growth factor β-1, did obtain liver inflammatory histological lesions. A widely studied model of experimental hepatitis is that induced by concanavalin A. Although this model does not accurately

reflect the pathological entity of AIH in humans, it has provided evidence that liver damage mainly occurs within a type 1 T-helper cell (Th1) scenario, with the involvement of activated CD4+ T cells and release of the proinflammatory cytokines IFNγ and TNFα against a specific genetic background. Interleukin (IL)-4, a cytokine with mainly regulatory activity, is also required for the establishment of concanavalin A-induced hepatitis. This finding and those of Takeda and collaborators, who have shown that natural killer T cells, which secrete both IL-4 and IFNγ, are critical to the development of concanavalin A-induced hepatitis in C57/B6 mice, suggest that both adaptive and innate immunity are involved [33,34].

All the models described above, although informative regarding single steps leading to liver inflammation and damage, did not mimic the chronic relapsing course of human AIH. In fact, they demonstrate the difficulty in breaking tolerance towards liver antigens, and the involvement of regulatory mechanisms in maintaining it. The ideal model for AIH should have a well-defined initiating event followed by chronic inflammation leading to fibrosis. More recently, researchers have focused on animal models of AIH-2 because, in this condition, the autoantigens are well defined. The model produced by the group led by Alvarez [37] is based on immunizing C57BL/6 female mice three times every 2 weeks with a plasmid containing the antigenic region of human CYP2D6, the target of anti-LKM-1, and FTCD, the target of anti-LC-1, together with the murine end-terminal region of cytotoxic T-lymphocyte antigen 4 (CTLA-4). The latter was added to facilitate antigen uptake by antigen-presenting cells (APC). In a parallel set of experiments, a plasmid containing the DNA encoding IL-12, a Th1 skewing proinflammatory cytokine, was also used. When autoantigens and IL-12 were used to break tolerance, antigen-specific autoantibodies were produced, a relatively modest elevation in transaminase levels at 4 and 7 months was observed, and a portal and periportal inflammatory infiltrate composed of CD4 and CD8 T cells and, to a lesser extent, B cells was demonstrated 8–10 months after the third immunization. When the same immunization protocol was used in different mouse strains, either mild hepatitis or no inflammatory changes were observed, indicating the importance of a specific genetic background. Another model of AIH-2 uses CYP2D6 transgenic mice and aims at breaking tolerance with an adenovirus – CYP2D6 vector [38]. While focal hepatocyte necrosis was seen in both mice treated with the adenovirus – CYP2D6 vector and control mice treated with adenovirus alone, only the former developed chronic histological changes, including fibrosis, reminiscent of AIH. The hepatic lesion was associated with a specific immune response to an immunodominant region of CYP2D6, and a cytotoxic T-cell response to adenovirus – CYP2D6 vector-infected target cells. Although these two experimental approaches provide useful information on the possible pathogenic mechanisms leading to AIH-2, a model closely mimicking AIH in humans is still missing.

Pathogenic mechanisms

The liver is regarded as a lymphoid organ with unique immunological properties [39]. Because of its location and function, the liver is continuously exposed to a large antigenic load that includes pathogens, toxins, tumour cells, and dietary and self-antigens. The liver contains large numbers of phagocytic cells, APC and lymphocytes, and is a site for the production of cytokines, complement components and acute-phase proteins. The intrinsic lymphocyte population mainly resides in the portal tracts, but is also scattered throughout the parenchyma, consisting of cells of both the innate (natural killer T cells, natural killer cells and macrophages) and the adaptive (T and B cells) arms of the immune system. The blood entering the liver from the gut is rich in bacterial and dietary antigens that intermingle with lymphocytes. Immunoregulatory mechanisms are required to determine whether an antigen encounter will result in immunological unresponsiveness (tolerance) or reactivity. Liver autoimmunity implies loss of self-tolerance. Programmed cell death (apoptosis), which is responsible for the normal turnover of hepatocytes and the elimination of liver cells in inflammatory pathologies, is also relevant to the breakdown and/or maintenance of liver tolerance. First, death by apoptosis allows for non-inflammatory elimination of cell components in contrast to necrosis, which is proinflammatory and potentially autoantigenic. Second, apoptosis is a mechanism used by the immune system for the removal of autoreactive T and B lymphocytes.

Various mechanisms have been proposed to account for the onset of an autoimmune liver response, with no single initiating event being able to explain all instances of autoimmunity. However, two general conditions should prevail: self-reactive B and T lymphocytes must exist in the immunological repertoire, and autoantigens must be presented in conjunction with MHC class II molecules by APC.

Humoral autoimmunity

Titres of antibodies to LSP, a macromolecular complex present on the hepatocyte membrane, and to its well-characterized components ASGPR and ADH correlate with the biochemical and histological severity of AIH [40]. Immunofluorescence studies on monodispersed suspensions of liver cells obtained from patients with AIH show that these cells are coated with antibodies *in vivo*. A pathogenic role for these autoantibodies has been indicated by cytotoxicity assays, demonstrating that autoantibody-coated hepatocytes from patients with AIH are killed when incubated with autologous or allogeneic lymphocytes. The effector cell was identified as an Fc receptor-positive mononuclear cell [40].

In AIH-2, the target of the disease-defining antibody, anti-LKM-1, is CYP2D6, a member of the hepatic P450 cytochrome family. As CYP2D6 is expressed on the membrane of the hepatocytes and is readily accessible [41], anti-LKM-1 antibodies are

likely to play a pathogenic role. In AIH-2, anti-LKM-1 antibodies recognize linear regions of CYP2D6 in a hierarchical manner. The principal linear B-cell epitope, $CYP2D6_{193–212}$ is recognized by 93% of patients, $CYP2D6_{257–269}$ by 85%, $CYP2D6_{321–351}$ by 53%, and two additional minor epitopes, $CYP2D6_{373–389}$ and $CYP2D6_{410–429}$, are recognised by 7% and 13% respectively [42]. Intriguingly, anti-LKM-1 antibodies are also found in up to 10% of patients with hepatitis C virus (HCV) infection, in whom they appear to correlate with increased disease severity and adverse reactions to IFNα treatment. The major CYP2D6 epitope recognized by patients with AIH-2, $CYP2D6_{193–212}$, is also recognized by 50% of patients with anti-LKM-1-positive HCV infection. Interestingly, these patients have antibodies that cross-react with homologous regions of HCV (NS5B $HCV_{2985–2990}$) and CYP2D6 ($CYP2D6_{204–209}$), and also of cytomegalovirus (exon $CMV_{130–135}$) [42]. Cross-reactive mechanisms to explain the emergence of CYP2D6-specific autoimmunity have also been suggested for other sequences of CYP2D6 that share homologies with HCV and Herpes simplex virus (HSV), such as the sequence spanning amino acids 310–324 of E1 HCV and amino acids 156–170 of IE175 HSV1, which share homology with the CYP2D6 region comprising amino acids 254–271. As anti-LKM-1 antibodies cross-react with homologous regions of CYP2D6, HCV, HSV and CMV, a 'multihit' mechanism for the generation of these antibodies, and possibly of AIH-2, may be envisaged. In this model, multiple exposures to CMV or HSV, common viral pathogens, may establish permissive immunological conditions by priming a cross-reactive subset of T cells in a genetically predisposed host. Depending on the degree of immunological priming, the degree of genetic susceptibility (particularly at the HLA locus and coding regions for 'innate' components of immunity) and the antigenic dose of the infecting pathogens, a minority of individuals may progress to autoimmune disease. It is therefore conceivable that infection with an as yet unknown virus may be at the origin of the autoimmune attack in AIH, in agreement with the concept expressed by Rolf Zinkernagel that an autoimmune disease is a viral disease in which the virus is unknown [43].

Molecular mimicry

The central function of the adaptive immune system is to generate T and B lymphocytes that can specifically recognize a potentially infinite number of non-self-antigens without any prior information as to their structure. This is achieved by randomly generating a large number of T- and B-cell specificities (via their respective antigen receptors – the T-cell receptor and the antibody) that are then able to clonally expand and recruit effector mechanisms on recognition of their specific antigen. It is, however, becoming clear that even this system cannot cope with the extent of non-self-antigenic diversity and, in the past decade, convincing evidence for cross-reactivity as an inherent property of immune ontogeny has emerged [40]. This has been studied primarily in the context of T lymphocytes, where it is clear that altered peptide ligands (APLs) – peptides similar in structure to the peptide antigen which are initially encountered – are able to induce both stimulatory and inhibitory T-cell responses and, indeed, endogenous APLs operate in selecting the T-cell repertoire in the thymus. This implies that a single T cell, rather than responding to a single antigen specificity, is able to cross-reactively respond to a number of antigens, thus expanding the antigenic specificities of the immune system to a level that reflects the antigenic diversity of the external environment.

This inherent potential for cross-reactivity, while allowing efficient responses to a vast array of pathogens, also provides the immune system with the potential to cross-react with self, leading to autoimmunity. This concept has been termed 'molecular mimicry', in which immune responses to external pathogens become directed towards structurally similar self components. Molecular mimicry has been demonstrated to be a dominant mechanism in the pathogenesis of autoimmune disease both in experimental models and in the human setting at the level of both T and B cells [40].

Cellular autoimmunity

The histological picture of interface hepatitis, with its striking infiltrate of lymphocytes, plasma cells and macrophages, was the first to suggest an autoaggressive cellular immune attack in the pathogenesis of AIH. Whatever is the initial trigger, this massive recruitment of activated inflammatory cells is likely to cause damage. Immunohistochemical studies have identified a predominance of T lymphocytes mounting the alpha/beta T-cell receptor [44]. Among the T cells, a majority are positive for the CD4 helper/inducer phenotype, and a sizeable minority for the CD8 cytotoxic phenotype. Lymphocytes of non-T-cell lineage are fewer and include (in decreasing order of frequency) natural killer cells (CD16/CD56 positive), macrophages and B cells. The involvement of natural killer T cells is the focus of ongoing studies.

There are different possible pathways that an immune attack can follow to inflict damage on hepatocytes (Fig. 2), which are discussed below.

Impairment of T-regulatory cells

An impairment of immunoregulatory mechanisms, which would enable the autoimmune response to develop, has been reported repeatedly. Thus, in early studies, it was shown that patients with AIH have low levels of circulating T cells expressing the CD8 marker and impaired suppressor cell function, which segregates with the possession of the disease-predisposing HLA haplotype B8/DR3 and is correctable by therapeutic doses of corticosteroids [4]. Furthermore, patients with AIH have been reported to have a defect in a subpopulation of T cells controlling the immune response to liver-specific membrane

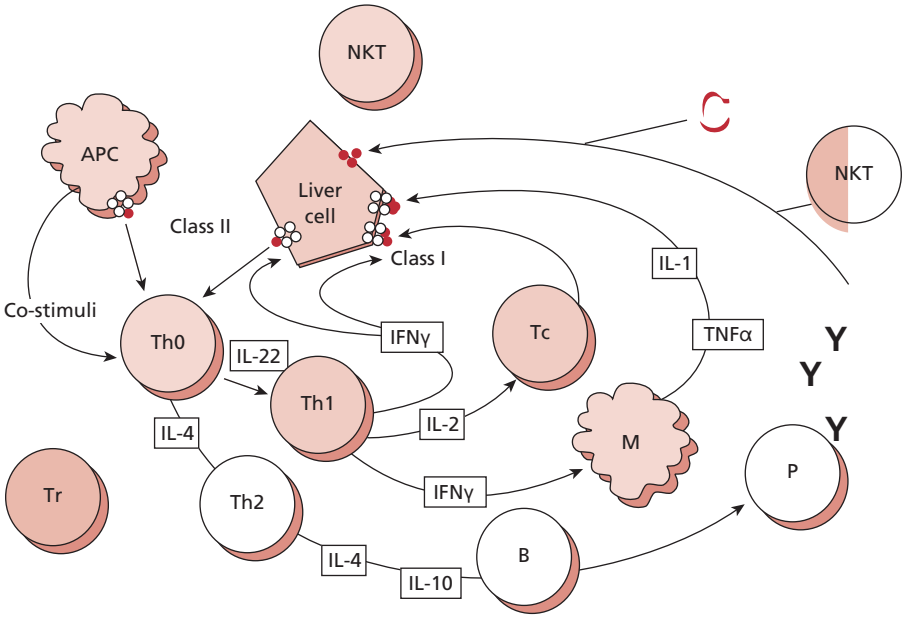

Fig. 2 Autoimmune attack to the liver cell. A specific autoantigenic peptide is presented to an uncommitted T-helper (Th0) lymphocyte within the HLA class II molecule of an antigen-presenting cell (APC). Th0 cells become activated and, according to the presence in the microenvironment of interleukin (IL)-12 or -4 and the nature of the antigen, differentiate into Th1 or Th2 and initiate a series of immune reactions determined by the cytokines they produce: Th2 secrete mainly IL-4 and IL-10 and direct autoantibody production by B lymphocytes; Th1 secrete IL-2 and interferon-gamma (IFNγ), which stimulate T-cytotoxic (Tc) lymphocytes, enhance expression of class I and induce expression of class II HLA molecules on hepatocytes and activate macrophages; activated macrophages release IL-1 and tumour necrosis factor alpha (TNFα). If regulatory T cells (Tr) do not oppose, a variety of effector mechanisms are triggered: liver cell destruction could derive from the action of Tc lymphocytes; cytokines released by Th1 and recruited macrophages; complement activation or engagement of Fc receptor-bearing cells such as natural killer (NK) lymphocytes by the autoantibody bound to the hepatocyte surface. The role of natural killer T cells is under investigation.

antigens. Recent experimental evidence confirms an impairment of the immunoregulatory function in AIH. Among recently defined T-cell subsets with potential immunosuppressive function, CD4+ T cells constitutively expressing the IL-2 receptor alpha chain (CD25) (T-regulatory cells; T-regs) have emerged as the dominant immunoregulatory lymphocytes. These cells, which represent 5–10% of the total population of peripheral CD4+ T cells in health, control the innate and the adaptive immune responses by preventing the proliferation and effector function of autoreactive T cells. Their mechanism of action mainly involves a direct contact with the target cells and, to a lesser extent, the release of immunoregulatory cytokines, such as IL-10 and tissue growth factor β-1. In addition to CD25, which is also present on T cells undergoing activation, T-regs express a number of additional markers such as the glucocorticoid-induced TNF receptor, CD62L, the cytotoxic T lymphocyte-associated protein-4 and the forkhead/winged helix transcription factor FOXP3, whose expression has been associated with the acquisition of regulatory properties. In patients with AIH, T-regs are defective in number compared with normal control subjects, and this numerical reduction relates to the stage of disease, being more evident at diagnosis than during drug-induced remission [45]. The percentage of T-regs correlates inversely with markers of disease severity, such as anti-SLA and anti-LKM-1 autoantibody titres, suggesting that a reduction in regulatory T cells favours the serological manifestations of autoimmune liver disease. If loss of immunoregulation is central to the pathogenesis of autoimmune liver disease, treatment should concentrate on restoring the ability of T-regs to expand, with consequent increase in their number and function. This is at least partially achieved by standard immunosuppression, as numbers of T-regs increase during remission.

CD4 autoreactive T cells

To trigger an autoimmune response, a peptide must be embraced by an HLA class II molecule and presented to uncommitted T-helper (Th0) cells by professional APC, with the co-stimulation of ligand–ligand (CD28 on Th0, CD80 on APC) interaction between the cells (Fig. 2). Once the autoimmune response has been initiated and in the absence of effective immunosuppressive treatment, tissue damage ensues and persists. Hepatocytes from patients with AIH, in contrast to normal hepatocytes, express HLA class II molecules [4]. Although lacking the antigen-processing machinery typical of APC, these hepatocytes may present peptides through a bystander mechanism. In the presence of impaired immunoregulation and inappropriate expression of HLA class II antigens on the hepatocytes, an autoantigenic peptide could be presented to the helper/inducer cells leading to their activation. Although no direct evidence exists as yet that an autoantigenic peptide is presented by hepatocytes and recognized by CD4 T-helper cells, activation of these cells has been documented in AIH [4]. Liver autoantigen-specific T-cell precursors are also found in normal subjects, but their frequency is at least 10-fold higher in AIH. This finding suggests that the pool of liver-autoreactive T cells undergoes a significant expansion in patients with AIH and may be involved in the initiation and perpetuation of the immune attack to the liver.

Given that T cells recognize antigens in a precise fashion, studies were conducted in the early 1990s at a single T-cell level in order to characterize antigen-specific T-cell recognition. T-cell clones generated from the peripheral blood were mainly CD4+ alpha/beta T cells, while a large proportion of liver-derived clones were either CD4–CD8– gamma/delta or CD8+ alpha/beta T cells. Both alpha/beta and gamma/delta T-cell clones proliferated in the presence of liver membrane antigens, alpha/beta being more reactive than gamma/delta clones. Some of the liver membrane-reactive clones also proliferated in the presence of LSP and/or ASGPR, responded in an HLA class II-restricted fashion and helped autologous B cells to produce immunoglobulins, and in particular autoantibodies to LSP and ASGPR [44].

T-cell ligands are best studied in AIH-2, as the target of anti-LKM-1 has been characterized as CYP2D6. CYP2D6$_{262–285}$-specific T-cell clones generated from liver tissue and peripheral blood express a Th1 CD4+ phenotype [46,47]. In contrast to the latter study that focused on a short antigenic sequence of CYP2D6, a systematic approach based on the construction of overlapping peptides covering the whole CYP2D6 molecule was recently adopted to define the specificity of *ex vivo* CYP2D6-reactive T cells in patients with AIH-2 [30]. This study has shown that T cells from patients positive for the predisposing HLA allele *DRB1*0701* recognize seven regions of CYP2D6 in a proliferation assay, four of which are also partially recognized by T cells of *DRB1*0701*-negative patients. While distinct peptides induce production of IFNγ, IL-4 or IL-10, peptides inducing IFNγ and proliferation overlap. There is also an overlap between sequences inducing T- and B-cell responses. The number of epitopes recognized and the quantity of cytokine produced by T cells are directly correlated to biochemical and histological markers of disease activity. These results indicate that the T-cell response to CYP2D6 in AIH-2 is polyclonal, involves multiple effector types targeting different epitopes and is associated with hepatocyte damage [30].

CD8 autoreactive T cells

In addition to the unfolding role of CYP2D6-specific CD4 T cells in AIH-2, there is growing evidence implicating an HLA class I-restricted CD8 response in the pathogenesis of autoimmune liver damage. In the early 1990s, CD8 T-cell clones specific for ASGPR were described in patients with AIH [44]. Studies currently in progress have identified CYP2D6-specific CD8 T cells capable of secreting IFNγ and of exerting cytotoxicity after recognition of CYP2D6 epitopic sequences in an HLA class I-restricted fashion.

Taken together, the data presented above suggest that a failure of immune homeostatic processes, normally keeping the response against self-antigens under control, is involved in the pathogenesis of AIH. The prime mechanism for tolerance breakdown remains to be elucidated. There is some experimental evidence that molecular mimicry mechanisms between viral and self-mimicking sequences may be involved, and such mechanisms are the focus of ongoing studies.

Treatment and outcome

Three small controlled clinical trials in the early 1970s have provided the basis for the current immunosuppressive regimens, collectively suggesting that treatment with prednisolone improves liver function tests, ameliorates symptoms and prolongs survival [48,49]. Although azathioprine was not able to induce remission when used on its own, it did allow the maintenance of remission in association with a significantly reduced dose of steroids. The suggestion in these reports that steroids should be given for the shortest possible time to control symptoms and then withdrawn has been rapidly superseded. In the 1980s and 1990s, a number of studies addressed two important questions: whether immunosuppression could safely be withdrawn after obtaining remission and whether steroid-free maintenance could be achieved [48,49]. It was shown that the great majority of cases relapse rapidly upon immunosuppression withdrawal, but that steroid-free maintenance could be achieved with azathioprine alone provided that its dose is increased to 2 mg/kg/day.

There is no doubt that immunosuppressive treatment is beneficial in patients with severe symptomatic disease, and it should be started as soon as possible, without waiting for 6 months as suggested in early studies. Most patients, including those with cirrhosis [49], will achieve remission on 30 mg of prednisolone daily for 1 month, after which azathioprine can be introduced at 1 mg/kg/day and the dose of prednisolone reduced to 5–15 mg/day to maintain the aminotransferase activity within the normal range. Although some authors define remission as transaminase levels up to twice the upper limit of normal, a better outcome has been reported when normal transaminase levels are attained and maintained [50]. If the patient develops steroid side-effects, the dose of azathioprine can be increased to 2 mg/kg/day and a complete withdrawal of steroids considered. The optimal duration of treatment is unknown. It is prudent not to attempt withdrawal of immunosuppression within 2 years of diagnosis. During withdrawal attempts, it is essential to monitor the liver function tests closely as relapse may be severe and even fatal. Patients who have successfully stopped immunosuppression should be followed up long term, as relapse may occur even 10 years later.

A question frequently asked is whether treatment can be continued safely during pregnancy. Although the experience is limited, there do not appear to be adverse events for mother and baby [51]. In particular, no teratogenic effects have been described with azathioprine in humans, although for women concerned about its use, treatment with steroids alone can be considered.

It is now clear that there are patients with a milder form of the disease who may be asymptomatic or paucisymptomatic and who are detected incidentally, during routine checkups. For

these patients, the approach to treatment is less clear. The benefit of therapy is undefined, and it may be so low that the risk of corticosteroid side-effects is unjustified. This is particularly relevant to postmenopausal women and elderly patients.

The most common side-effect of steroid treatment is cushingoid changes, which affect most patients after prolonged treatment. Less common but severe side-effects include osteoporosis, vertebral collapse, diabetes, cataract, hypertension and psychosis. Only 13% of treated patients develop complications that necessitate dose reduction or premature drug withdrawal, the most common reasons for treatment withdrawal being cosmetic changes or obesity, osteopenia with vertebral collapse and brittle diabetes [49].

Side-effects of azathioprine are uncommon, affecting less than 10% of patients, and include cholestatic hepatitis, veno-occlusive disease, pancreatitis, nausea and vomiting, rash and bone marrow suppression. Usually, these complications subside upon drug withdrawal [49]. A theoretical long-term complication of continuous immunosuppressive therapy is the development of malignancies. The risk of extrahepatic cancer in AIH has been reported to be 1.4-fold higher than that of an age- and sex-matched normal population [52]. Akin to other chronic liver diseases, the risk of primary hepatocellular cancer is related mainly to the presence of cirrhosis and is generally reported to be uncommon.

When the standard treatment fails, other drugs that have been tried include ciclosporin, ursodeoxycholic acid, budesonide and mycophenolate mofetil. Although encouraging results are described, these reports are anecdotal.

Liver transplantation is the ultimate treatment for most patients who present with fulminant hepatic failure and those who reach endstage chronic liver disease. Transplantation in AIH has an excellent prognosis, with a 5-year patient and graft survival between 80% and 90%. Before transplantation is considered, however, it is important to remember that even patients presenting with decompensated cirrhosis can respond to immunosuppressive treatment and avoid surgery for a long time [49]. AIH may recur after transplant (see below).

Treatment in children

Treatment of AIH in children is similar to that in adults [3]. The starting dose of prednisolone is usually 2 mg/kg/day (maximum 60 mg/day), which should be gradually but rapidly decreased over a period of 4–8 weeks in parallel with normalization of transaminase levels. The patient is then maintained on the minimal dose able to sustain normal transaminase levels, usually 2.5–5 mg/day. If progressive normalization of the liver function tests is not obtained or too high a dose of prednisolone is required to maintain normal transaminases, azathioprine is added at a starting dose of 0.5 mg/kg/day, which, in the absence of signs of toxicity, is increased up to a maximum of 2 mg/kg/day until biochemical control is achieved. Although an 80% decrease in initial transaminase levels is obtained within 6 weeks of starting treatment in most patients, complete normalization of liver function may take several months. Relapse while on treatment occurs in some 40% of patients, requiring a temporary increase in the steroid dose, especially if steroids are administered on an alternate-day schedule, often instituted in the belief that it has a less negative effect on the child's growth. It has been suggested that small daily doses should be used because they are more effective in maintaining disease control and minimize the need for high-dose steroid pulses during relapses, with attendant, more severe, side-effects [3]. In the King's experience, after 5 years of daily treatment, 56% of patients maintained the baseline centile for height or went up across a centile line, while only 6% dropped across two centile lines.

Cessation of treatment can be considered if a liver biopsy shows minimal or no inflammatory changes after 1 year of normal liver function tests, but should not be attempted during puberty, when relapses are more common. Successful long-term cessation of treatment is achieved in about 20% of children with AIH-1, but is very rare in those with AIH-2. Remission has been reported in a paediatric series of AIH using ciclosporin A alone for 6 months followed by combined low-dose prednisone and azathioprine for 1 month, after which ciclosporin A was stopped and the other two drugs were continued [53]. This therapeutic approach, however, does not appear to offer any real advantage over the standard corticosteroid/azathioprine treatment, apart from a decrease in early steroid side-effects. On the other hand, it is more expensive and potentially nephrotoxic.

Children with AIH/sclerosing cholangitis overlap syndrome respond to the same immunosuppressive treatment of typical AIH [26]. Ursodeoxycholic acid, which is used in adult primary sclerosing cholangitis, is often added empirically at a dose of 20–30 mg/kg/day.

The quality of life for both adult and paediatric patients, even for those with severe AIH at presentation, is excellent on low doses of azathioprine and prednisolone, or azathioprine alone. Most patients are asymptomatic with normal liver function tests and have a good prognosis.

Recurrence of AIH after transplant

Recurrence of AIH after liver transplant has been shown in several studies [54,55]. The diagnosis is based on the reappearance of clinical symptoms and signs, histological features of periportal hepatitis, and elevation of transaminases, circulating autoantibodies and elevated IgG, associated with response to steroids and azathioprine. Possession of the HLA DR3 allele appears to confer predisposition to disease recurrence, as it does to the original AIH, although this has not been universally confirmed. Recurrence has been noted in both adult and paediatric series and, although the rate of this complication increases with the post-transplant interval, it may appear as early as 1 month post surgery. Most transplant recipients with recurrent AIH respond to an increase in the dose of corticosteroids and azathioprine but, in a few, recurrence can lead to graft failure

and to the need for retransplantation. Caution should be taken in weaning immunosuppression in patients who undergo transplantation for AIH as discontinuation of corticosteroid therapy may increase the risk of recurrent disease.

De novo AIH after transplant

Tissue autoantibodies after liver transplantation, in particular ANA and SMA, are also common in patients transplanted for non-autoimmune liver disease [54]. Anti-LKM-1 is the third most frequently reported antibody, but its fluorescence pattern is at times atypical, preferentially staining the renal tubules and sparing the liver. The described prevalence of postliver transplant autoantibodies is variable, probably reflecting different techniques used for their detection, the cutoff point above which the autoantibodies are considered positive, the time after transplant at which they are tested, the nature of the clinical condition leading to transplantation and the presence or absence of post-transplant complications. In the late 1990s, it was observed that AIH can arise *de novo* after liver transplantation in patients who had not been transplanted for autoimmune liver disease [56]. After the original report in children, *de novo* AIH after liver transplant has been confirmed by several studies in both adult and paediatric patients [55]. Importantly, treatment with prednisolone and azathioprine, using the same schedule as for classical AIH, is also effective in *de novo* AIH leading to excellent graft and patient survival. It is of interest that these patients do not respond satisfactorily to standard antirejection treatment, making it essential to reach an early diagnosis to avoid graft loss.

Recurrence of AIH after transplant can be readily explained. The recipient's immune system is sensitized to species-specific antigens and has a pool of memory cells, which are restimulated and re-expanded when the target antigens, 'autoantigens', are presented to the recipient's immune system by either the recipient's APC repopulating the grafted liver or by the donor's APC sharing histocompatibility antigens with the recipient. In contrast, akin to autoimmune liver disease outside transplantation, the pathogenesis of post-transplant *de novo* AIH remains to be defined. There are several non-mutually exclusive explanations: in addition to release of autoantigens from damaged tissue, a possible mechanism is molecular mimicry, whereby exposure to viruses sharing amino acid sequences with autoantigens leads to cross-reactive immunity [54]. Viral infections, which are frequent post transplant, may also lead to autoimmunity through other mechanisms, including polyclonal stimulation, enhancement and induction of membrane expression of MHC class I and II antigens, and interference with immunoregulatory cells and/or with idiotype anti-idiotype network. Another possible mechanism is suggested by animal experiments showing that the use of calcineurin inhibitors predisposes to autoimmunity and autoimmune disease, possibly by interfering with the maturation of T lymphocytes or with the function of regulatory T cells, with consequent emergence and activation of autoaggressive T-cell clones. Lastly, it has been reported that an antibody directed to glutathione-*S*-transferase T1 is present in patients who develop *de novo* immune-mediated hepatitis [57]. As the gene encoding this protein is defective in a fifth of caucasoid subjects and the encoded enzyme is absent in some of the reported patients, it is possible to speculate that graft dysfunction results from recognition as foreign of glutathione-*S*-transferase T1 acquired with the graft.

Concluding remarks – future prospects

Before its recognition as a disorder associated with autoimmunity and therefore responsive to immunosuppression, AIH had a very poor prognosis. Today, prognosis is excellent, with symptom-free long-term survival in the majority of patients. Over the past five decades, several pathogenic aspects have been elucidated, including predisposing genetic factors and disease-specific humoral and cellular immune responses. Identification of the associated autoantibodies has led to the subdivision of AIH into two distinct types, with different age distribution and clinical course. Tasks for the future include a better understanding of its pathogenesis, possibly through the development of animal models faithfully reproducing the human disease, and the establishment of novel treatments aimed specifically at arresting liver autoaggression or, ideally, at reinstating tolerance to liver antigens.

References

1 Krawitt EL (2006) Autoimmune hepatitis. *N Engl J Med* 354(1), 54–66.
2 Manns MP, Vogel A (2006) Autoimmune hepatitis, from mechanisms to therapy. *Hepatology* 43(S1), S132–144.
3 Mieli-Vergani G, Vergani D (2002) Autoimmune hepatitis in children. *Clin Liver Dis* 6(3), 623–634.
4 Vergani D, Mieli-Vergani G (2003) Autoimmune hepatitis. *Autoimmun Rev* 2(5), 241–247.
5 Vergani D, Mieli-Vergani G (2004) Autoimmune hepatitis. *Minerva Gastroenterol Dietol* 50(2), 113–123.
6 Vergani D, Mieli-Vergani G (2004) Autoimmune hepatitis and sclerosing cholangitis. *Autoimmunity* 37(4), 329–332.
7 zum Buschenfelde KH (2003) Autoimmune hepatitis: 'Hepatitis sui generis'. *J Hepatol* 38(2), 130–135.
8 Reuben A (2003) A sheep in wolf's clothing. *Hepatology* 38(6), 1596–1601.
9 Waldeström J (1950) Leber, Blutproteine und Nahrungseiweiss. *Dtsch Z Verdau Staffwechselkr* 15, 113–119.
10 Joske RA, King WE (1955) The LE-cell phenomenon in active chronic viral hepatitis. *Lancet* 269(6888), 477–480.
11 Leoni A (1954) [The specificity of LE phenomenon.] *Minerva Med* 45(30), 1022–1027.
12 Mackay IR, Taft LI, Cowling DC (1956) Lupoid hepatitis. *Lancet* 271(6957), 1323–1326.
13 Mackay IR, Weiden S, Hasker J (1965) Autoimmune hepatitis. *Ann NY Acad Sci* 124(2), 767–780.
14 Homberg JC, Abuaf N, Bernard O *et al.* (1987) Chronic active hepatitis associated with antiliver/kidney microsome antibody type 1: a second type of 'autoimmune' hepatitis. *Hepatology* 7(6), 1333–1449.

15 Johnson PJ, McFarlane IG (1993) Meeting report: International Autoimmune Hepatitis Group. *Hepatology* 18(4), 998–1005.
16 Alvarez F, Berg PA, Bianchi FB *et al.* (1999) International Autoimmune Hepatitis Group Report: review of criteria for diagnosis of autoimmune hepatitis. *J Hepatol* 31(5), 929–938.
17 Boberg KM, Aadland E, Jahnsen J *et al.* (1998) Incidence and prevalence of primary biliary cirrhosis, primary sclerosing cholangitis, and autoimmune hepatitis in a Norwegian population. *Scand J Gastroenterol* 33(1), 99–103.
18 Feld JJ, Dinh H, Arenovich T *et al.* (2005) Autoimmune hepatitis: effect of symptoms and cirrhosis on natural history and outcome. *Hepatology* 42(1), 53–62.
19 Manns MP, Luttig B, Obermayer-Straub P (1998) Autoimmune hepatitis. In: Rose NR, Mackay IR (eds) *The Autoimmune Diseases*, 3rd edn. Burlington, MA: Academic Press, pp. 511–525.
20 Primo J, Merino C, Fernandez J *et al.* (2004) [Incidence and prevalence of autoimmune hepatitis in the area of the Hospital de Sagunto (Spain)]. *Gastroenterol Hepatol* 27(4), 239–243.
21 Gregorio GV, Portmann B, Reid F *et al.* (1997) Autoimmune hepatitis in childhood: a 20-year experience. *Hepatology* 25(3), 541–547.
22 Vergani D, Alvarez F, Bianchi FB *et al.* (2004) Liver autoimmune serology: a consensus statement from the committee for autoimmune serology of the International Autoimmune Hepatitis Group. *J Hepatol* 41(4), 677–683.
23 Ma Y, Okamoto M, Thomas MG *et al.* (2002) Antibodies to conformational epitopes of soluble liver antigen define a severe form of autoimmune liver disease. *Hepatology* 35(3), 658–664.
24 Ma Y, Gaken J, McFarlane BM *et al.* (1997) Alcohol dehydrogenase: a target of humoral autoimmune response in liver disease. *Gastroenterology* 112(2), 483–492.
25 Czaja AJ, Carpenter HA (2001) Autoimmune hepatitis In: Macsween RNM, Burt AD, Portmann BC (eds) *Pathology of the Liver*, 4th edn. London: Churchill Livingstone, pp. 415–434.
26 Gregorio GV, Portmann B, Karani J *et al.* (2001) Autoimmune hepatitis/sclerosing cholangitis overlap syndrome in childhood: a 16-year prospective study. *Hepatology* 33(3), 544–553.
27 Donaldson PT (2002) Genetics in autoimmune hepatitis. *Semin Liver Dis* 22(4), 353–364.
28 Donaldson PT (2004) Genetics of autoimmune and viral liver diseases; understanding the issues. *J Hepatol* 41(2), 327–332.
29 Czaja AJ, Donaldson PT (2000) Genetic susceptibilities for immune expression and liver cell injury in autoimmune hepatitis. *Immunol Rev* 174, 250–259.
30 Ma Y, Bogdanos DP, Hussain MJ *et al.* (2006) Polyclonal T-cell responses to cytochrome P450IID6 are associated with disease activity in autoimmune hepatitis type-2. *Gastroenterology* in press.
31 Simmonds MJ, Gough SC (2004) Genetic insights into disease mechanisms of autoimmunity. *Br Med Bull* 71, 93–113.
32 Liston A, Lesage S, Gray DH *et al.* (2005) Genetic lesions in T-cell tolerance and thresholds for autoimmunity. *Immunol Rev* 204, 87–101.
33 Jaeckel E (2002) Animal models of autoimmune hepatitis. *Semin Liver Dis* 22(4), 325–338.
34 Peters MG (2002) Animal models of autoimmune liver disease. *Immunol Cell Biol* 80(1), 113–116.
35 Lohse AW, Meyer zum Buschenfelde KH (1993) Remission of experimental autoimmune hepatitis is associated with antigen-specific and non-specific immunosuppression. *Clin Exp Immunol* 94(1), 163–167.
36 Lohse AW, Kogel M, Meyer zum Buschenfelde KH (1995) Evidence for spontaneous immunosuppression in autoimmune hepatitis. *Hepatology* 22(2), 381–388.
37 Lapierre P, Djilali-Saiah I, Vitozzi S *et al.* (2004) A murine model of type 2 autoimmune hepatitis: xenoimmunization with human antigens. *Hepatology* 39(4), 1066–1074.
38 Christen U, Rhode A, Johnson E *et al.* (2004) Development of an animal model for autoimmune hepatitis: breaking of self-tolerance in the CYP2D6 humanized mouse by viral infection. *Hepatology* 162A.
39 Mackay IR (2002) Hepatoimmunology: a perspective. *Immunol Cell Biol* 80(1), 36–44.
40 Vergani D, Choudhuri K, Bogdanos DP *et al.* (2002) Pathogenesis of autoimmune hepatitis. *Clin Liver Dis* 6(3), 727–737.
41 Muratori L, Parola M, Ripalti A *et al.* (2000) Liver/kidney microsomal antibody type 1 targets CYP2D6 on hepatocyte plasma membrane. *Gut* 46(4), 553–561.
42 Kerkar N, Choudhuri K, Ma Y *et al.* (2003) Cytochrome P4502D6(193–212): a new immunodominant epitope and target of virus/self cross-reactivity in liver kidney microsomal autoantibody type 1-positive liver disease. *J Immunol* 170(3), 1481–1489.
43 Aichele P, Bachmann MF, Hengartner H *et al.* (1996) Immunopathology or organ-specific autoimmunity as a consequence of virus infection. *Immunol Rev* 152, 21–45.
44 Wen L, Ma Y, Bogdanos DP *et al.* (2001) Pediatric autoimmune liver diseases: the molecular basis of humoral and cellular immunity. *Curr Mol Med* 1(3), 379–389.
45 Longhi MS, Ma Y, Bogdanos DP *et al.* (2004) Impairment of CD4(+)CD25(+) regulatory T-cells in autoimmune liver disease. *J Hepatol* 41(1), 31–37.
46 Lohr H, Manns M, Kyriatsoulis A *et al.* (1991) Clonal analysis of liver-infiltrating T cells in patients with LKM-1 antibody-positive autoimmune chronic active hepatitis. *Clin Exp Immunol* 84(2), 297–302.
47 Lohr HF, Schlaak JF, Lohse AW *et al.* (1996) Autoreactive CD4+ LKM-specific and anticlonotypic T-cell responses in LKM-1 antibody-positive autoimmune hepatitis. *Hepatology* 24(6), 1416–1421.
48 Johnson PJ (1997) Treatment of autoimmune hepatitis. *Gut* 41(1), 3–4.
49 Czaja AJ, Freese DK (2002) Diagnosis and treatment of autoimmune hepatitis. *Hepatology* 36(2), 479–497.
50 Seela S, Sheela H, Boyer JL (2005) Autoimmune hepatitis type 1: safety and efficacy of prolonged medical therapy. *Liver Int* 25(4), 734–739.
51 Heneghan MA, Norris SM, O'Grady JG *et al.* (2001) Management and outcome of pregnancy in autoimmune hepatitis. *Gut* 48(1), 97–102.
52 Wang KK, Czaja AJ, Beaver SJ *et al.* (1989) Extrahepatic malignancy following long-term immunosuppressive therapy of severe hepatitis B surface antigen-negative chronic active hepatitis. *Hepatology* 10(1), 39–43.
53 Alvarez F, Ciocca M, Canero-Velasco C *et al.* (1999) Short-term cyclosporine induces a remission of autoimmune hepatitis in children. *J Hepatol* 30(2), 222–227.
54 Vergani D, Mieli-Vergani G (2002) Autoimmunity after liver transplantation. *Hepatology* 36(2), 271–276.
55 Mieli-Vergani G, Vergani D (2004) De novo autoimmune hepatitis after liver transplantation. *J Hepatol* 40(1), 3–7.
56 Kerkar N, Hadzic N, Davies ET *et al.* (1998) De-novo autoimmune hepatitis after liver transplantation. *Lancet* 351(9100), 409–413.
57 Aguilera I, Sousa JM, Gavilan F *et al.* (2004) Glutathione S-transferase T1 mismatch constitutes a risk factor for de novo immune hepatitis after liver transplantation. *Liver Transpl* 10(9), 1166–1172.

11.3 Sclerosing cholangitis

Konstantinos N. Lazaridis and Nicholas F. LaRusso

Introduction – definitions

Sclerosing cholangitis may be primary or secondary to choledocholithiasis, congenital abnormalities of the bile ducts, infection, drugs, chemicals or iatrogenic trauma of bile ducts including postoperative strictures (Table 1). This chapter will focus entirely on the primary variety. The term 'primary' is used to indicate that this form of sclerosing cholangitis has an unknown aetiology. The term 'sclerosing' indicates induration of the biliary tree as a result of deposition of connective tissue, while 'cholangitis' describes the inflammation of the bile ducts. Although a strong association exists between primary sclerosing cholangitis (PSC) and inflammatory bowel disease (IBD), there is no evidence that the former is caused by the latter.

PSC is a disease that is characterized by chronic cholestasis due to diffuse inflammation and fibrosis of the biliary system. It is a progressive and often fatal illness. The pathological process leads to narrowing and obliteration of bile ducts and ultimately to biliary cirrhosis. PSC can be further defined in terms of involvement of the biliary system and findings on cholangiography. Global PSC involves the bile ducts both inside (i.e. intrahepatic) and outside (i.e. extrahepatic) the liver. Large duct PSC involves principally the extrahepatic ducts and those parts of the intrahepatic biliary ductal system that can be visualized cholangiographically. Small duct PSC involves only the intrahepatic ducts at the microscopic level and is characterized by findings on liver biopsy; however, in this condition, cholangiography shows ducts of normal appearance. Small duct PSC accounts for ~ 5% of patients with PSC.

Table 1 Causes of secondary sclerosing cholangitis.

Choledocholithiasis (in the absence of PSC)
Biliary trauma/ischaemia
Chemicals/drugs (i.e. 5-fluorouracil)
AIDS-associated cholangiopathy
Congenital bile duct abnormalities (i.e. Caroli's disease)
Idiopathic adulthood ductopenia

Epidemiology and natural history

PSC was once considered a rare disease. In fact, before 1980, fewer than 100 cases were reported in the English language literature. Following the introduction of endoscopic retrograde cholangiopancreatography (ERCP) in clinical practice (mid-1970s), PSC was recognized earlier, usually in the asymptomatic stage. To this end, studies reported increased frequency of diagnosis of PSC. However, these observations did not represent a true increase in the disease incidence but, more likely they did reflect the increased clinical awareness and availability of diagnostic procedures such as ERCP or magnetic resonance cholangiopancreatography (MRCP).

In the USA, the age-adjusted estimated incidence of PSC is 0.9 per 100 000 persons, whereas the calculated prevalence is 13.6 per 100 000 individuals [1]. PSC is predominantly a disease of young men. Approximately 70% of patients are male, and the average age at the time of diagnosis is 40 years [1]. The reason for this sex and age distribution is not apparent. Moreover, there appear to be no major differences between male and female PSC patients with regard to frequency of associated IBD or complications of cirrhosis.

The clinical course of PSC is variable but, generally, there is slow advance to portal hypertension and, eventually, premature death from liver failure or adenocarcinoma of the bile ducts (i.e. cholangiocarcinoma) [2]. PSC is associated in more than 70% of cases with IBD, commonly CUC [3]. Recent data from a retrospective study suggest that secondary sclerosing cholangitis has a worse prognosis than PSC [4].

Pathophysiology

At present, the cause of PSC is unknown. A plausible hypothesis proposes that the pathogenesis of PSC depends on the interplay of acquired toxic or infectious agents with certain inherited factors. Several observations are consistent with an important role for genetic factors. First, familial PSC cases have been reported [5]. Second, a recent report indicated increased prevalence of PSC in first-degree relatives of affected patients [6]. These authors calculated an almost 100-fold increased risk of

developing PSC in families with an affected member, supporting the familial contribution to disease pathogenesis. In addition, case–control studies have demonstrated genetic predisposition to PSC development. For example, the frequency of human leukocyte antigen (HLA)-B8 was reported to be significantly higher in patients with PSC (60%) compared with control subjects (25%) [7]. Another study revealed an association of PSC with the HLA-A1, -B8, -DR3 haplotype [8]. In the past 5 years, genetic polymorphisms in the tumour necrosis factor (TNF)α receptor [9], stromelysin (i.e. matrix metalloproteinase 3) [10], MICA (i.e. major histocompatibility complex class I-related MIC gene family) gene [11] and CCR5-delta 32 mutation [12] have been associated with susceptibility to PSC.

In addition to inherited factors, potential acquired exposures including toxins, infectious agents or altered immunity are postulated to contribute to PSC pathogenesis. Although elevated hepatic copper levels were initially thought to be potentially important in the development of the disease, the accumulation of copper in liver was found to be a nearly universal finding of chronic cholestasis and not specific for PSC. Moreover, negative results from a controlled trial with D-penicillamine (copper-chelating agent) make it unlikely that increased hepatic copper levels are pathogenetically important (see below) [13].

Limited evidence is available concerning the possible role of infectious agents in the aetiopathogenesis of PSC. Viruses have been proposed to cause PSC, but the data were never conclusive. Studies have excluded hepatitis B or C viruses as a causative agent. Cytomegalovirus may cause damage to intrahepatic bile ducts, but the histological picture appears to differ from that seen in PSC. Another hypothesis postulated portal bacteraemia, particularly in patients with associated IBD, as a cause of PSC [14]. However, this scenario seems an unlikely aetiology because: first, approximately 20% of patients have PSC without evidence of IBD; second, no striking differences are present in liver biopsy specimens from patients with PSC, with and without IBD; and third, portal phlebitis is mild and uncommon in liver biopsy specimens from patients with PSC [15].

Evidence supports an immunological basis for developing PSC including the presence of circulating immune complexes, decreased clearance of immune complexes, elevated serum IgM levels and increased complement metabolism. Moreover, the cells involved in the destruction of bile ducts in PSC have been shown to be T lymphocytes, and abnormalities in peripheral blood lymphocyte subpopulations have also been demonstrated [16]. These studies support the fact that the immune system is related to the development and/or the perpetuation of PSC, although a pathogenetic causation is not established and the exact mechanism(s) are still not understood.

Clinical features and diagnosis

Symptoms and signs

PSC usually begins insidiously; therefore, it is difficult to determine the time of disease onset with accuracy. The gradual onset of progressive fatigue and pruritus followed by jaundice is the most frequent symptom complex leading to the diagnosis of PSC. This complex is present in about two-thirds of patients. Clinical evidence of bacterial cholangitis, such as recurrent abdominal pain in the right upper quadrant, fever and jaundice, is uncommon unless biliary strictures, choledocholithiasis or cholancarcinoma are present.

Although some patients with PSC may have a normal physical examination, up to 75% of affected individuals usually have hepatomegaly, jaundice or splenomegaly. Hyperpigmentation and xanthelasma may also be seen, but these findings occur less often compared with primary biliary cirrhosis (PBC).

Associated diseases

A variety of diseases are proposed to be associated with PSC (Table 2). Thorpe *et al.* first described the strong correlation of PSC with IBD [17]. Early studies suggested a 25–30% prevalence of IBD in patients with PSC; however, later studies reported this fraction to be as high as 75–85%. Among the two types of IBD, CUC is more common in PSC. Although many patients have symptoms of intestinal disease before developing symptoms of PSC, the latter has been reported to occur before the intestinal disease becomes clinically apparent. Patients with coexisting PSC and IBD are clinically, biochemically, radiologically and histologically comparable to PSC patients without IBD. Of interest, patients with PSC and CUC have a higher risk of colonic dysplasia and colon cancer than those with CUC alone [18]. This may be related to a very long preclinical stage of IBD in patients with PSC. A small percentage of patients with PSC present with an overlap syndrome of PSC along with autoimmune hepatitis [19]. Several other diseases in addition to CUC and autoimmune hepatitis are also proposed to be associated with PSC (Table 2). Radiographical evidence of chronic pancreatitis by ERCP has been seen in ~ 10% of patients with PSC. However, clinical evidence of chronic pancreatitis is much less common. Finally, there have been case reports regarding the concurrence of rare diseases in patients with PSC, such as

Table 2 Diseases associated with PSC.

Chronic ulcerative colitis
Crohn's disease
Autoimmune hepatitis
Chronic pancreatitis
Sicca syndrome
Eosinophilia
Thyroiditis
Coeliac disease
Autoimmune haemolytic anaemia
Sarcoidosis
Glomerulonephritis
Retroperitoneal fibrosis
Mediastinal fibrosis
Systemic sclerosis

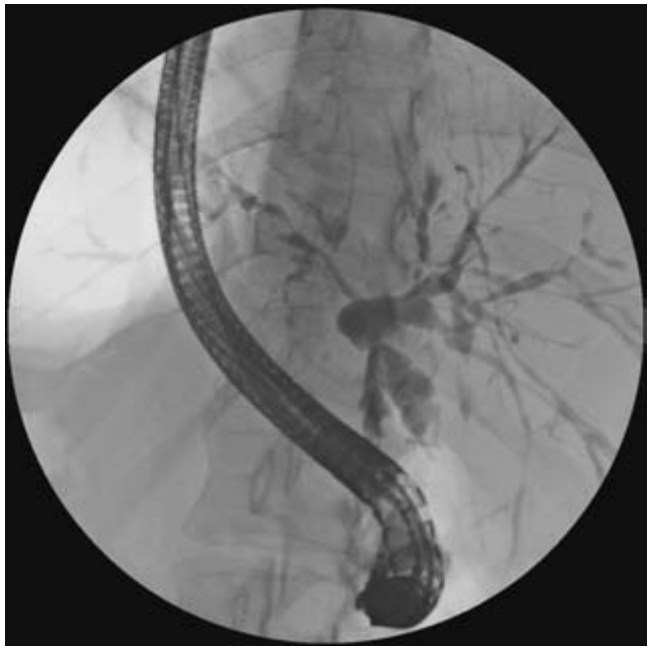

Fig. 1 Characteristic ERCP findings of PSC include multifocal stricturing and dilatation of intra- and extrahepatic bile ducts.

retroperitoneal and mediastinal fibrosis, histiocytosis X and pseudotumour of the orbit.

Diagnostic criteria

The diagnosis of PSC is based on a combination of clinical, biochemical, radiological and liver histology criteria. The major biochemical abnormality in serum is an elevated level of alkaline phosphatase. The main radiological anomaly and disease criterion is cholangiographic demonstration of diffusely distributed multifocal strictures of the bile ducts (Fig. 1). The strictures are characterized by irregularity of both intrahepatic and extrahepatic ducts. Histological findings of the liver are often categorized as shown in Table 3. In general, if a specific cause can be identified for the underlying sclerosing cholangitis (Table 1), the disease cannot be confidently classified as primary. For instance, PSC should not be diagnosed if the patient has had previous bile duct surgery (other than simple cholecystectomy) or documented choledocholithiasis, or if there is congenital disease of the biliary tract. In addition, PSC cannot be diagnosed confidently in a patient with biopsy-proven adenocarcinoma of the bile duct unless the carcinoma is a complication of PSC.

Investigations and other diagnostic considerations

Laboratory tests

Virtually all patients with PSC have biochemical cholestasis. The serum alkaline phosphatase is usually abnormal, although it may fluctuate occasionally within the normal range. Several patients have a mild increase in the levels of serum aspartate aminotransferase and alanine aminotransferase. Perhaps 50% of patients with PSC have a modest increase in serum total bilirubin at the time of initial diagnosis. However, in an individual patient, the serum bilirubin can fluctuate markedly over time. Hepatic copper levels are elevated in approximately 90% of patients, while urine levels are increased in up to two-thirds; both these tests are increased to levels seen in patients with PBC and Wilson's disease [20]. Nevertheless, serum copper and ceruloplasmin levels are usually increased in patients with PSC, but are low in those with Wilson's disease. Other non-specific laboratory abnormalities noted in patients with PSC include increased levels of serum IgM (~ 40% of patients) and eosinophilia of a mild degree. Antimitochondrial antibodies (AMA) are rare; however, antineutrophil cytoplasmic antibodies and anticardiolipin antibodies have been identified in ~ 80% and ~ 60% of patients respectively [21].

Table 3 PSC staging.

Portal stage (stage 1)	Portal oedema, inflammation, ductal proliferation; abnormalities do not extend beyond the limiting plate
Periportal stage (stage 2)	Periportal fibrosis, inflammation with or without ductular proliferation; piecemeal necrosis may be present
Septal stage (stage 3)	Septal fibrosis or bridging necrosis can be identified
Cirrhotic stage (stage 4)	Biliary cirrhosis

Cholangiographic features

Cholangiographic abnormalities may be seen in the intrahepatic and extrahepatic biliary ductal system. Usually, the abnormalities include diffusely distributed strictures that are short and annular with intervening segments of apparently normal or slightly dilated ducts producing the characteristic beaded appearance (Fig. 1). Short band-like strictures and diverticulum-like outpouchings are also found in ~ 25% of patients.

Although focal dilatation of bile ducts is often seen between strictures, diffuse non-segmental dilatation is unusual. In ~ 50% of PSC patients, coarse or fine irregularities are present which, when severe, produce a characteristic shaggy appearance. Cholangiographic abnormalities of the cystic duct and gallbladder are also seen in a smaller number of patients. Recently, MRCP is emerging as a new method of evaluating patients with PSC. Indeed, the diagnostic accuracy of MRCP is comparable to that of ERCP and less costly compared with the latter [22]. In one study, MRCP was better than ERCP in the evaluation of peripheral bile ducts for strictures [23].

Hepatic histology

Almost every patient with PSC has histological abnormalities in liver biopsy. The characteristic features range from bile duct proliferation in the early stages to periductal fibrosis and inflammation, ductal obliteration and loss of bile ducts as the disease progresses (Table 3). The disease usually begins with enlargement of portal tracts characterized by oedema, deposition of connective tissue and proliferation of interlobular bile ducts. Inflammatory infiltrates are not usually prominent. Histologically, this is stage 1 disease. With disease progression, extensions of connective tissue grow into the periportal parenchyma, again with only mild cellular inflammation (stage 2 disease). If the disease process results in the formation of fibrous septa, the disease is categorized histologically as stage 3. Ultimately, biliary cirrhosis develops (stage 4 disease). The pathognomonic histological changes (i.e. 'onion skin lesions') can be found in wedge liver excisions and only occasionally in hepatic needle biopsy specimens. These lesions are characterized by fibrous obliterative cholangitis, leading to the replacement of ductal segments by solid cords of connective tissue. In many instances of advanced PSC, complete loss of intrahepatic bile ducts may be observed.

From a histological viewpoint, the differential diagnosis of the abnormalities seen in PSC liver biopsy specimens includes: (i) PBC; (ii) prolonged extrahepatic biliary obstruction; and (iii) idiopathic adulthood ductopenia [24]. PBC has several histological features that overlap with those of PSC, including periportal cholestasis, copper deposition and granulomas. However, 'florid duct lesions' are not seen in PSC and are almost pathognomonic of PBC. In contrast, fibrous obliterative cholangitis, a hallmark of PSC, has not been observed in PBC.

Differential diagnosis

The diagnosis of PSC is usually straightforward, assuming that the clinician is aware of the disease and thus considers it in the differential diagnosis of conditions causing chronic cholestasis. PSC should be the major working diagnosis in a young male with IBD who develops chronic cholestasis. In a middle-aged woman with evidence of chronic cholestasis, PBC should be excluded. Although considerable overlap exists in the clinical, biochemical and hepatic histological features between PSC and PBC, it is not difficult to differentiate these diseases with confidence. The most useful diagnostic test in distinguishing these two clinical entities is cholangiographic visualization of the bile ducts. Although the intrahepatic bile ducts are radiographically abnormal in essentially all cases of large duct PSC, and rarely in patients with PBC, the extrahepatic ducts are always normal in the latter and eventually become anomalous in most patients with PSC. Therefore, in a patient suspected of having large duct PSC, a cholangiogram is all that is necessary for diagnosis. A liver biopsy may also be appropriate to provide confirmatory diagnostic information, accurate histological classification and prognosis. Nevertheless, in a patient with chronic cholestasis, if the cholangiogram is normal, liver biopsy is required to evaluate for small duct PSC.

Other conditions that need to be considered in the differential diagnosis include secondary sclerosing cholangitis, 'overlap syndrome' and idiopathic adulthood ductopenia. Secondary sclerosing cholangitis should be the diagnosis when biochemical cholestasis and radiological changes can be attributed confidently to an identifiable cause (Table 1). An 'overlap syndrome' has been described between autoimmune hepatitis and PSC [19]. These patients fulfil the criteria for autoimmune hepatitis and concurrently have cholangiographic changes typical of PSC. To this extent, patients with both autoimmune hepatitis and IBD should have a cholangiogram to exclude PSC. Idiopathic adulthood ductopenia is a very rare disease characterized by unexplained absence of interlobular bile ducts and cholestasis [24]. Patients with this disorder can be distinguished from patients with PSC because they have an essentially normal cholangiogram and no history of IBD.

Complications

Complications can be separated into two general categories: those common to any form of chronic liver disease and those to PSC.

In the first category, complications include portal hypertension, ascites, portosystemic encephalopathy, steatorrhoea, deficiencies in fat-soluble vitamins, liver failure and metabolic bone disease. One or more of such problems probably occurs in over 75% of patients with PSC.

Complications of the second category include recurrent biliary strictures and/or stones, gallbladder disease and adenocarcinoma of the bile duct. Dominant biliary stricture(s) occur in approximately one-third of patients with PSC during the course of the disease. The affected patients present with jaundice, pruritus and, at times, bacterial cholangitis. ERCP is required to evaluate the stricture(s) (i.e. location, extent, exclusion of cholangiocarcinoma) and perform biliary dilatation along with stenting. Nevertheless, it remains uncertain whether dominant biliary strictures alone are the cause of cholestasis in PSC patients [25].

Stones in the bile ducts may also complicate PSC. However, the diagnosis of choledocholithiasis in a patient with PSC can be difficult, because symptoms of bacterial cholangitis can occur in the absence of biliary stone disease. ERCP should be considered in the patient with PSC who has clinical and laboratory evidence of choledocholithiasis in order to identify and remove the bile duct stones.

Nearly one-third of PSC patients will have undergone cholecystectomy at some time during their illness. Nevertheless, only about 20% of such patients will actually have gallstones. These gallstones are often asymptomatic, and the original indication for surgery is often obscure jaundice rather than biliary colic. Indeed, abdominal ultrasound screening of patients with PSC

and intact gallbladders demonstrates that ~ 30% of subjects have gallstones. Recent evidence draws special attention to PSC patients with incidental gallbladder polyps seen during ultrasonography. Indeed, the presence of detectable gallbladder polyps by imaging is an indication for cholecystectomy because the chance of these polyps being malignant is substantial [26].

PSC predisposes to the development of carcinoma of the bile duct (i.e. cholangiocarcinoma). It is estimated that 8–15% of patients develop clinically detectable cholangiocarcinoma [27]. This percentage is even higher for PSC patients at autopsy. Patients whose disease is complicated by superimposed cholangiocarcinoma usually have liver cirrhosis, portal hypertension and longstanding IBD. In patients with PSC, cholangiocarcinoma usually involves the extrahepatic bile ducts. Patients with PSC and cholangiocarcinoma have poor survival rates, because many have local spread of the malignant disease at the time of diagnosis. Cholangiocarcinoma is difficult to detect because its growth pattern and clinical presentation are similar to those of PSC. The prognosis of cholangiocarcinoma remains poor, in part because of the low sensitivity and specificity of standard biliary cytology and biopsies [27]. CA19-9 is a serum tumour marker that has been used for diagnosis of cholangiocarcinoma in patients with PSC. Studies have reported a serum CA19-9 level > 100 U/mL to be ~ 80% specific and sensitive for cholangiocarcinoma [28,29]. Recently, the introduction of biliary fluorescence *in situ* hybridization (FISH) and digitized imaging analysis (DIA) have been shown to improve cholangiocarcinoma detection [30,31].

In some PSC patients, an incapacitating complication is recurrent episodes of bacteraemia, secondary to bacterial bloodstream seeding from a chronically infected biliary tract. Such episodes occur in PSC patients with or without IBD, may lead to the formation of hepatic abscesses and are unpredictable with regard to frequency and severity.

Therapy

General guidelines

Management of PSC is a challenge to the clinician, given the array of symptoms and complications that can develop and the absence of an effective specific therapy for the underlying disease. In the asymptomatic patient with mild liver test abnormalities and early-stage disease on liver biopsy, no specific therapy is available and, thus, observation is reasonable with annual follow-up. In such a case, medical therapy might be considered in the context of a randomized controlled trial. If a decision is made to treat symptoms or complications, the goals of therapy should be clearly identified.

Therapy for symptoms/complications

Pruritus and fat-soluble vitamin deficiencies are frequent problems in patients with PSC. When complications of liver cirrhosis develop, such as portal hypertension, portosystemic encephalopathy and variceal bleeding, appropriate intervention with conventional approaches to manage these problems is recommended but will not be reviewed here. However, complications specific for PSC, including dominant biliary stricture(s), bacterial cholangitis and cholangiocarcinoma, are discussed below.

Patients who develop dominant biliary stricture(s) present with rapid increases in serum bilirubin levels, recurrent episodes of bacterial cholangitis and aggravation of pruritus. Balloon dilatation of dominant biliary stricture(s) may be beneficial to relieve jaundice and bacterial cholangitis but does not affect the natural history of the underlying disease. Biliary obstruction is undoubtedly a cause of hepatic fibrosis; however, there have been no comparable studies of patients with PSC to test the results of balloon dilatation in terms of the development of fibrosis. Nonetheless, dilatation of biliary strictures in the symptomatic patient is required, particularly for patients with non-cirrhotic PSC. Depending upon their location, a percutaneous transhepatic versus endoscopic approach to the bile ducts along with temporary biliary stenting placement is recommended. Patients with recurrent episodes of bacterial cholangitis without dominant bile duct stricture(s) should be treated with broad-spectrum antibiotics (i.e. ciprofloxacin) as needed. Prophylactic antibiotics are favoured by some for PSC patients with frequent episodes of bacterial cholangitis, but the efficacy of this approach has not been firmly established.

The management of suspected or detected cholangiocarcinoma superimposed on PSC is complicated. If the cholangiocarcinoma is localized, liver transplantation in selected liver transplant centres should be considered [32,33].

Therapy for PSC

At present, there is no specific or effective treatment for the underlying hepatobiliary disease in patients with PSC. This reflects, in part, our lack of knowledge about the pathogenesis of this malady. Therapeutic approaches for the underlying hepatobiliary disease can be classified as medical and surgical.

Medical approaches

Medical therapies for the direct treatment of PSC have included the use of cupriuretic, immunosuppressive, antifibrogenic and choleretic agents. To date, no medical therapy has been shown to induce complete clinical, biochemical, radiological and histological remission in PSC.

The finding of elevated hepatic copper levels in PSC, and early reports showing apparent biochemical improvement induced by D-penicillamine (a copper-chelating agent), led to a randomized, prospective, double-blind trial. Although a predictable decrease in levels of hepatic copper was achieved in patients taking penicillamine, there was no beneficial effect on disease progression or on overall survival [13]. Moreover, the development of major side-effects led to the permanent discontinuation

of penicillamine in 21% of the patients taking the drug. A variety of pilot uncontrolled studies on small numbers of patients have assessed the effect of immunosuppressive agents, including prednisone, azathioprine and ciclosporin, and have found no apparent beneficial effect on the disease. The use of antifibrogenic agents, specifically colchicine, was not favourable either.

Considerable interest has been directed towards the potential benefit of ursodeoxycholic acid (UDCA) in the treatment of chronic cholestatic liver diseases. Several small uncontrolled trials suggested that this agent is beneficial in PSC. However, a randomized, double-blind controlled study of UDCA (13–15 mg/kg body weight/day) did not reveal any benefit in the treatment group [34]. Despite these findings, two small pilot studies reported a significant effect of high-dose UCDA (25–30 mg/kg body weight/day) on liver biochemistries, liver fibrosis and the PSC risk score in the treatment group compared with control group [35,36]. To this end, a multicentre randomized, placebo-controlled trial of high-dose UDCA is under way in the USA. UDCA may also have a protective effect on colonic dysplasia or cancer in patients with PSC and CUC [37]. Nevertheless, prospective studies are needed to address these issues.

Surgical approaches

Three surgical procedures have been used to treat or ameliorate the natural history of PSC, namely biliary tract reconstructive procedures, proctocolectomy in a patient with PSC and CUC and orthotopic liver transplantation (OLT).

Biliary reconstructive surgery

Some surgeons have encouraged an aggressive surgical approach in the treatment of PSC itself, using a variety of imaginative procedures for internal or external biliary drainage [38,39]. However, no controlled trials have been performed. Such procedures might provide transient and symptomatic benefit in the occasional patient with jaundice and pruritus secondary to a dominant stricture of the common bile or common hepatic ducts. However, it seems unlikely that these procedures will alter the natural history of PSC because, in most if not all cases, the disease involves the entire biliary ductal system, including the intrahepatic ducts. Moreover, many possible candidates already have liver cirrhosis at the time of operation, and this will not be improved by biliary drainage alone. It is reasonable to consider biliary tract reconstructive procedures in the same category as balloon dilatation, that is, as a palliative procedure to alleviate symptoms but one that is unlikely to affect the natural history of the disease. Finally, it is important to point out that biliary tract reconstructive procedures may make subsequent liver transplantation more difficult because of the fibrosis and scar tissue that often develops in the right upper quadrant.

Proctocolectomy

In the past it has been suggested that proctocolectomy in a patient with PSC and CUC may have a favourable effect on the hepatobiliary disease. This was an important consideration, not only because beneficial treatment for PSC was needed, but also because a proctocolectomy in a patient with PSC and CUC may be associated with considerable morbidity. For example, proctocolectomy with a conventional or continent ileostomy results in the development of varices around the stoma in at least 25% of patients with PSC [40]. In nearly 50% of these patients, major and often life-threatening bleeding occurs from varices. To this end, a study of patients with concurrent PSC and CUC demonstrated that proctocolectomy did not affect the onset of new complications, serial changes in biochemical tests, histological progression on liver biopsy and survival [41]. Thus, proctocolectomy was deemed not beneficial to PSC in patients with CUC. Indications for proctocolectomy in PSC patients should be guided only by the status and complications of colitis. When proctocolectomy is recommended, an ileal pouch-anal anastomosis (IPAA) is the procedure of choice because there is no evidence of this operation causing anastomotic or perineal bleeding [40] and the risk of postoperative pouchitis is less compared with Brook iseostomy [42].

Orthotopic liver transplantation (OLT)

OLT is the definitive therapeutic option for patients with PSC. The survival rate of patients with PSC following OLT is comparable to that of patients with other forms of non-infectious non-malignant chronic liver disease. The current 5-year survival rate is ~ 80%. Nonetheless, special problems are encountered in patients with PSC who undergo liver transplantation. First, primary duct-to-duct anastomosis is always difficult and often impossible, because of disease affecting the common bile duct. Therefore, the donor's bile duct is usually anastomosed to a limb of the recipient's jejunum. Such an anastomosis may create a greater number of postoperative problems than a direct duct-to-duct anastomosis. Second patients with PSC may have undergone previous abdominal surgical procedures (i.e. proctocolectomy or cholecystectomy), which may challenge technical aspects of liver transplantation. Third, not surprisingly, the risk of colon cancer in patients with CUC who undergo OLT for PSC actually increases following transplantation, probably because of chronic immunosuppression [43]. To this end, annual screening by colonoscopy is recommended following OLT for PSC. Finally, it is important to emphasize that PSC may recur after successful OLT [44].

Conclusion

PSC is an idiopathic, chronic cholestatic liver disease. The disorder is characterized by gradual fibrotic obliteration of bile ducts leading to biliary cirrhosis in many. Management of the primary disease and complications is challenging and requires a team approach. At present, liver transplantation is the definitive treatment, although disease recurrence in the allograph is not uncommon. More basic and clinical research studies are needed to shed light on the pathogenesis of this elusive liver disease. Emphasis should also be given to improving the early detection

of dreaded PSC complications such as cholangiocarcinoma and colon cancer.

References

1 Bambha K, Kim WR, Talwalkar J *et al.* (2003) Incidence, clinical spectrum, and outcomes of primary sclerosing cholangitis in a United States community. *Gastroenterology* 125, 1364–1369.

2 Kim WR, Therneau TM, Wiesner RH *et al.* (2000) A revised natural history model for primary sclerosing cholangitis. *Mayo Clin Proc* 75, 688–694.

3 MacFaul GR, Chapman RW (2005) Sclerosing cholangitis. *Curr Opin Gastroenterol* 21, 348–353.

4 Gossard AA, Angulo P, Lindor KD (2005) Secondary sclerosing cholangitis: a comparison to primary sclerosing cholangitis. *Am J Gastroenterol* 100, 1330–1333.

5 Quigley EMM, LaRusso NF, Ludwig J *et al.* (1983) Familial occurrence of primary sclerosing cholangitis and ulcerative colitis. *Gastroenterology* 85, 1160–1165.

6 Bergquist A, Lindberg G, Saarinen S *et al.* (2005) Increased prevalence of primary sclerosing cholangitis among first-degree relatives. *J Hepatol* 42, 252–256.

7 Chapman RW, Varghese Z, Gaul R *et al.* (1983) Association of primary sclerosing cholangitis with HLA-B8. *Gut* 24, 38–41.

8 Donaldson PT, Doherty DG, Hayllar KM *et al.* (1991) Susceptibility to autoimmune chronic active hepatitis: human leukocyte antigens DR4 and A1-B8-DR3 are independent risk factors. *Hepatology* 13, 701–706.

9 Mitchell SA, Grove J, Spurkland A *et al.* (2001) Association of the tumour necrosis factor alpha –308 but not the interleukin 10 –627 promoter polymorphism with genetic susceptibility to primary sclerosing cholangitis. *Gut* 49, 288–294.

10 Satsangi J, Chapman RW, Haldar N *et al.* (2001) A functional polymorphism of the stromelysin gene (MMP-3) influences susceptibility to primary sclerosing cholangitis. *Gastroenterology* 121, 124–130.

11 Norris S, Kondeatis E, Collins R *et al.* (2001) Mapping MHC-encoded susceptibility and resistance in primary sclerosing cholangitis: the role of MICA polymorphism. *Gastroenterology* 120, 1475–1482.

12 Eri R, Jonsson JR, Pandeya N *et al.* (2004) CCR5-Delta32 mutation is strongly associated with primary sclerosing cholangitis. *Genes Immun* 5, 444–450.

13 LaRusso NF, Wiesner RH, Ludwig J *et al.* (1988) Prospective trial of penicillamine in primary sclerosing cholangitis. *Gastroenterology* 95, 1036–1042.

14 Palmer KR, Duerden BJ, Holdworth CD (1980) Bacteriological and endotoxin studies in cases of ulcerative colitis submitted to surgery. *Gut* 21, 851–854.

15 Ludwig J, Barham SS, LaRusso NF *et al.* (1981) Morphologic features of chronic hepatitis associated with primary sclerosing cholangitis or chronic ulcerative colitis. *Hepatology* 1, 632–640.

16 Panasiuk A, Prokopowicz D, Zak J *et al.* (2004) Lymphocyte subpopulations in peripheral blood in primary sclerosing cholangitis. *Hepatogastroenterology* 51, 1289–1291.

17 Thorpe MEC, Scheuer PJ, Sherlock S (1967) Primary sclerosing cholangitis, the biliary tree, and ulcerative colitis. *Gut* 8, 435–448.

18 Ahnen DJ (1996) Controlled clinical trials: the controls are the key. *Gastroenterology* 110, 628–630.

19 Gohlke F, Lohse AW, Dienes HP *et al.* (1996) Evidence for an overlap syndrome of autoimmune hepatitis and primary sclerosing cholangitis. *J Hepatol* 24, 699–705.

20 LaRusso NF, Wiesner RH, Ludwig J *et al.* (1984) Primary sclerosing cholangitis. *N Engl J Med* 310, 899–903.

21 Angulo P, Peter JB, Gershwin ME *et al.* (2000) Serum autoantibodies in patients with primary sclerosing cholangitis. *J Hepatol* 32, 182–187.

22 Talwalkar JA, Angulo P, Johnson CD *et al.* (2004) Cost-minimization analysis of MRC versus ERCP for the diagnosis of primary sclerosing cholangitis. *Hepatology* 40, 39–45.

23 Vitellas KM, El-Dieb A, Vaswani KK *et al.* (2002) MR cholangiopancreatography in patients with primary sclerosing cholangitis: interobserver variability and comparison with endoscopic retrograde cholangiopancreatography. *Am J Roentgenol* 179, 399–407.

24 Ludwig J, Wiesner RH, LaRusso NF (1988) Idiopathic adulthood ductopenia: a cause of chronic cholestatic liver disease and biliary cirrhosis. *J Hepatol* 7, 193–199.

25 Bjornsson E, Lindqvist-Ottosson J, Asztely M *et al.* (2004) Dominant strictures in patients with primary sclerosing cholangitis. *Am J Gastroenterol* 99, 502–508.

26 Buckels DC, Lindor KD, LaRusso NF *et al.* (2002) In primary sclerosing cholangitis, gallbladder polyps are frequently malignant. *Am J Gastroenterol* 97, 1138–1142.

27 Lazaridis KN, Gores GJ (2005) Cholangiocarcinoma. *Gastroenterology* 128, 1655–1667.

28 Nichols JC, Gores GJ, LaRusso NF *et al.* (1993) Diagnostic role of serum CA 19-9 for cholangiocarcinoma in patients with primary sclerosing cholangitis. *Mayo Clin Proc* 68, 874–879.

29 Chalasani N, Baluyut A, Ismail A *et al.* (2000) Cholangiocarcinoma in patients with primary sclerosing cholangitis: a multicenter case-control study. *Hepatology* 31, 7–11.

30 Kipp BR, Stadheim LM, Halling SA *et al.* (2004) A comparison of routine cytology and fluorescence in situ hybridization for the detection of malignant bile duct strictures. *Am J Gastroenterol* 99, 1675–1681.

31 Baron TH, Harewood GC, Rumalla A *et al.* (2004) A prospective comparison of digital image analysis and routine cytology for the identification of malignancy in biliary tract strictures. *Clin Gastroenterol Hepatol* 2, 214–219.

32 Heimbach JK, Haddock MG, Alberts SR *et al.* (2004) Transplantation for hilar cholangiocarcinoma. *Liver Transpl* 10, S65–68.

33 Sudan D, DeRoover A, Chinnakotla S *et al.* (2002) Radiochemotherapy and transplantation allow long-term survival for nonresectable hilar cholangiocarcinoma. *Am J Transplant* 2, 774–779.

34 Lindor KD (1997) Ursodiol for primary sclerosing cholangitis. Mayo Primary Sclerosing Cholangitis-Ursodeoxycholic Acid Study Group. *N Engl J Med* 336, 691–695.

35 Mitchell SA, Bansi DS, Hunt N *et al.* (2001) A preliminary trial of high-dose ursodeoxycholic acid in primary sclerosing cholangitis. *Gastroenterology* 121, 900–907.

36 Harnois DM, Angulo P, Jorgensen RA *et al.* (2001) High-dose ursodeoxycholic acid as a therapy for patients with primary sclerosing cholangitis. *Am J Gastroenterol* 96, 1558–1562.

37 Tung BY, Emond MJ, Haggitt RC *et al.* (2001) Ursodiol use is associated with lower prevalence of colonic neoplasia in patients with ulcerative colitis and primary sclerosing cholangitis. *Ann Intern Med* 134, 89–95.

38 Pitt HA, Thompson HH, Tompkins RK *et al.* (1982) Primary sclerosing cholangitis: results of an aggressive surgical approach. *Ann Surg* 196, 259–266.

39 Cameron JL, Pitt HA, Zinner MJ *et al.* (1988) Resection of hepatic duct bifurcation and transhepatic stenting for sclerosing cholangitis. *Ann Surg* 207, 614–620.

40 Kartheuser AH, Dozois RR, LaRusso NF *et al.* (1996) Comparison of surgical treatment of ulcerative colitis associated with primary sclerosing cholangitis: ileal pouch-anal anastomosis versus Brooke ileostomy. *Mayo Clin Proc* 71, 748–756.

41 Cangemi JR, Wiesner RH, Beaver SJ *et al.* (1989) Effect of proctocolectomy for chronic ulcerative colitis on the natural history of primary sclerosing cholangitis. *Gastroenterology* 96, 790–794.

42 Penna C, Dozois R, Tremaine W *et al.* (1996) Pouchitis after ileal pouch-anal anastomosis for ulcerative colitis occurs with increased frequency in patients with associated primary sclerosing cholangitis. *Gut* 38, 234–239.

43 Loftus EV, Jr, Aguilar HI, Sandborn WJ *et al.* (1998) Risk of colorectal neoplasia in patients with primary sclerosing cholangitis and ulcerative colitis following orthotopic liver transplantation. *Hepatology* 27, 685–690.

44 Graziadei IW, Wiesner RH, Marotta PJ *et al.* (1999) Long-term results of patients undergoing liver transplantation for primary sclerosing cholangitis. *Hepatology* 30, 1121–1127.

11.4 Vanishing bile duct syndrome

Frank Grünhage and Tilman Sauerbruch

Introduction

The term vanishing bile duct syndrome comprises heterogeneous disorders that are characterized by loss of bile ducts leading to the histological finding of ductopenia and, clinically, to the sequelae of acute and/or chronic cholestasis. Some of these patients present with endstage liver disease, making it difficult to dissect the underlying pathophysiological mechanism. Often, therapy is symptomatic rather than causal. Hepatotoxic offending drugs must always be considered and stopped, and immunological disorders must be treated appropriately and in a timely manner.

Definition and epidemiology

The vanishing bile duct syndrome is a clinical and pathological entity with heterogeneous aetiology. It comprises a number of acute and chronic cholestatic liver diseases caused by an altered architecture of the biliary tree, histologically apparent as ductopenia. Probably because of the heterogeneity of the syndrome, no exact data on its overall prevalence exist. However, we know that 10–20% of all adult patients and up to 80% of children referred for liver transplantation suffer from any one kind of cholestatic liver disease which fulfils the definition of vanishing bile duct syndrome. The incidence of the most common causes of vanishing bile duct syndrome varies from 1:10 000 live births in biliary atresia to 6:100 000 in PSC patients [1].

Anatomy and function of the biliary tree

The biliary tree is a three-dimensional network of interconnected ducts. Primary bile is secreted into the canal of Hering. The first structure entirely lined by cholangiocytes is the interlobular ductule followed by the intraportal ductule, each less than 15 μm in diameter. The bile then flows into the interlobular ducts (15–100 μm), which merge into the septal ducts (100–300 μm). In contrast to these small ducts, area ducts (300–400 μm), segmental ducts (400–800 μm) and hepatic ducts (> 800 μm) are called large bile ducts. Branches of the hepatic artery form a periductular plexus, which braids the entire biliary tree [2,3].

The concept of passive bile flow from the hepatocytes into the biliary tree has changed to the understanding that the primary bile is secreted by hepatocytes and modified along its way to the papilla of Vater.

The biliary epithelium actively takes part in absorptive and secretory processes. Whereas the plasticity (e.g. proliferation) of the biliary tree is confined to the cholangiocytes lining smaller bile ducts, secretory functions are predominantly properties of the cholangiocytes lining interlobular and major bile ducts. Factors that are modified by the biliary epithelium include bile flow, volume, pH, bicarbonate content and bile salt constitution [1–6]. The factors influencing bile secretion and content may be subdivided into nerve stimulation (parasympathetic), gastrointestinal hormones (e.g. secretin, glucagon, vasoactive intestinal peptide, bombesin), other peptides (endothelin-1) and a variety of other substances, including bile salts, glutathione and purinergic nucleotides [5,7].

Intracellular cyclic adenosine monophosphate (cAMP) levels are critical regulators of bile flow and pH. Prosecretory signals (e.g. secretin) increase cAMP levels by stimulation of the transmembrane adenyl cyclase. Increased cAMP levels induce a rise in protein kinase A activity, which in turn opens the cystic fibrosis transmembrane conductance regulator (CFTR), a cAMP-dependent Cl^- channel [8]. The increase in intraluminal chloride concentration drives the chloride/bicarbonate exchanger that exports HCO_3^- into the lumen, thereby alkalizing the bile. Rising intraluminal salt concentrations stimulate water efflux through water channels (aquaporins). On the other hand, secretion is inhibited at low cAMP concentrations, which can be mediated by gastrin and other substances [8].

Active uptake of substances from the bile is also influenced by transporters. The main components absorbed by the biliary epithelium are bile salts, glucose and glutathione. Reabsorbed bile acids may modify mucin and bicarbonate secretion of the cholangiocellular epithelium [6].

Both proliferation and apoptosis occur simultaneously during the development of the biliary tree [9–12]. In young patients,

disturbance of the balance between proliferation and apoptosis may cause vanishing bile duct syndromes. Apoptosis and proliferation are also part of normal cell turnover in adult life. However, at some point in the development of ductopenic liver disease, apoptosis overrides proliferation and hence leads to ductopenia [11,12]. Experimental models of cholestatic liver disease demonstrate that bile acids accumulating in chronic cholestasis (e.g. taurolithocholate) may influence proliferative activity via a phosphatidylinositol 3-kinase-dependent pathway [9,13]. On the other hand, certain bile acids, e.g. ursodeoxycholic acid (UDCA), can ameliorate this affect [14].

Pathophysiology

Owing to the large variety of vanishing bile duct syndromes, it is difficult to develop a comprehensive pathophysiological model. In the model proposed by Lazaridis *et al.* [15], cholangiopathies develop as a consequence of failure in cholangiocyte function (congenital or acquired), as a reaction of the cholangiocyte to acute or chronic liver damage or as a result of immune-mediated cell damage. Early changes in ductular appearance and function may be reversible, whereas persistent damage to the epithelium may lead to ductopenic liver disease with progressive fibrosis and endstage liver disease [15]. Table 1 summarizes the main syndromes associated with vanishing bile ducts.

Injuries

Typical injuries to the biliary tree include toxic cholangiocyte destruction, hypovascularization and inflammatory processes. The last may be caused by exogenous factors or autoimmunity.

Response to injuries

Our knowledge about the response mechanisms of cholangiocytes to injury largely depends on animal models. The biliary epithelium induces choleresis, inflammation and proliferation in response to injury [16,17]. In addition, the otherwise silent cholangiocyte begins to communicate with mesenchymal cells, hepatic stellate cells and fibroblasts, as well as immunologically active cells. In this situation, cholangiocytes are targets as well as active participants in the interchange of cytokines, chemokines and inflammatory factors, as well as growth factors [i.e. tumour necrosis factor (TNF)α, interleukins, human growth factor and many others]. Under the influence of these factors, cholangiocytes may change their phenotypical appearance and express surface antigens normally found during ontogenesis, or they turn on antiapoptotic genes (Bcl-2). The induction of proliferation can be recognized in liver specimens as 'ductular reaction' with proliferation of the smallest biliary structures. On the other hand, cholangiocytes may influence the composition of the extracellular matrix and proliferation of the fibroblasts – one reason for naming them 'pacemakers of portal fibrosis' [18].

Causes

Congenital errors

A number of inherited conditions may also share some characteristics of the vanishing bile duct syndrome. Cholestasis may be a feature of autosomal dominant and recessive polycystic kidney and liver disease. However, in most cases, cholestasis is due to cysts rather than true ductopenia. Congenital hepatic fibrosis may also present with cholestasis, but the disease is rare and cholestasis is most commonly caused by microhamartomas surrounded by a dense fibrous stroma. True ductopenia is more common in Alagille's syndrome and cystic fibrosis. Of note, inherited alpha-1-antitrypsin defects may also present as vanishing bile ducts and should be considered if cholestasis occurs [19,20].

Fibropolycystic liver disease

The term fibropolycystic liver disease itself encompasses a number of inherited lesions (Caroli's disease, autosominal dominant polycystic disease, biliary hamartomas, congenital hepatic fibrosis and choledochal cysts) that result from ductal plate malformations. Biliary ducts develop from the ductal plate as a consequence of remodelling processes. Disturbance of the remodelling process may lead to disrupted development of small interlobular ducts (congenital hepatic fibrosis, bile duct hamartomas), medium-sized intrahepatic ducts (autosomal dominant polycystic disease) and large intrahepatic ducts (Caroli's disease). Although ductopenic liver disease is not a primary feature of the different malformation syndromes, progressive loss of bile ducts may result from the complications of the malformations, e.g. recurrent liver abscesses, intrahepatic gallstones and recurrent cholangitis [1,18].

Cystic fibrosis

Cystic fibrosis is caused by an autosomal recessive inherited defect in the CFTR gene, resulting in a diminished chloride permeability of plasma membranes in secretory epithelial cells. Defective chloride transport leads to thick, tenacious secretions, which obstruct the ducts of all excretory glands. Airway obstruction is the main manifestation. The obstruction of bile canaliculi may lead to chronic cholestasis, recurrent infection and hence loss of the normal biliary architecture [21].

Alagille syndrome (AGS)

AGS is one of the major forms of progressive liver disease in childhood with severe morbidity and a mortality of 10–20%. The syndrome was described more than three decades ago as a genetic entity characterized by five major features: chronic cholestasis owing to paucity of interlobular bile ducts; posterior embryotoxin; peripheral pulmonary stenosis; butterfly-like vertebral arch defect; and peculiar facies. Complex congenital heart disease and hepatic disease with or without liver transplantation contribute significantly to mortality. Children with AGS usually

Table 1 Conditions with vanishing bile ducts, their epidemiology, clinical features and treatment options.

Disease	Epidemiology	Clinical features	Aetiology	Pathomechanism	Therapy
Autoimmune mediated					
PBC	0.2–3.1/100 000 per year 1% of all cirrhosis	Antimitochondrial antibodies with specificity for the inner lipoyl domain of pyruvate dehydrogenase complex subunit 2 Granulomatous cholangitis	Unknown, genetic predisposition and infection with unknown pathogen due to molecular mimicry proposed	Granulomatous cholangitis	UDCA 13–15 mg/kg p.o. OLT in ELD
PSC	1–6/100 000 per year	Association with inflammatory bowel disease in 70–80% Autoantibodies (atypical ANCA, ANA, rarely anticardiolipin)	Unknown, genetic predisposition with a complex trait, susceptibility associated with certain HLA haplotypes	Concentric obliterative fibrosis, strictures and bile duct dilatation, chronic infection	High-dose UDCA (20 mg/kg) may slow liver fibrosis OLT in ELD
Overlap syndromes	?	Share characteristics of AIH, PSC, PBC	Same as PBC/PSC	Same as PBC/PSC	Immunosuppression, UDCA may be beneficial OLT in ELD
Acute/chronic allograft rejection	Acute: 20–70% within weeks after OLT Chronic: 4–8%, months to years after OLT	Acute: hepatitis accompanied by jaundice, liver failure Chronic: predominantly cholestasis, chronic biliary cirrhosis	Tissue incompatibility	T cell-mediated cholangiocyte destruction, foam cell arteriopathy with ischaemic bile duct damage	Acute: corticosteroid bolus, T-cell antibodies, interleukin-2 antibodies Acute and chronic: change in immunosuppression Retransplantation
Graft-vs.-host disease	20–30% of BMT (acute) 30–50% (chronic)	Acute: 10–50 days after BMT, life-threatening condition with severe hepatitis Chronic: from 40 days after BMT, multiorgan involvement	Tissue incompatibility	Acute: direct damage of small-calibre biliary structures by donor lymphocytes Chronic: portal infiltration with lymphocytes with or without plasma cells or eosinophils; predominantly interlobular ducts	Immunosuppression, extracorporeal photochemotherapy (PUVA) and others
Miscellaneous					
Ischaemic	Unknown	Jaundice, pruritus, lack of autoimmune features	Progressive loss of bile ducts due to acute or chronic ischaemia	Obliteration of the hepatic artery post transplantation or after manipulation or as a result of arteriosclerosis Ischaemia in shock Ischaemia due to obliteration of branches of the hepatic artery due to GVHD, allograft rejection and vasculitis (rare)	Hepatic artery reconstruction, immunosuppression if appropriate UDCA may be beneficial Liver transplantation in irreversible cases (i.e. in VBS after shock)
Sarcoidosis	2–6% of patients with sarcoidosis develop hepatic involvement	Jaundice, progressive liver failure, presence of other symptoms of sarcoidosis	Unknown, autoimmune?	Granulomatous cholangitis	Immunosuppression, UDCA may relieve symptoms and may slow progression OLT in ELD

Table 1 (*cont'd*)

Disease	Epidemiology	Clinical features	Aetiology	Pathomechanism	Therapy
Drugs	15–20% of all adverse drug reactions	Slowly or rapidly progressive, may have features of autoimmune disease	Genetic predisposition in drug metabolism, triggering of autoimmune reactions	Direct toxicity Autoimmune reaction with lymphocyte infiltration and cytotoxic cell destruction	Discontinuation of suspected drugs Corticosteroids may be helpful Symptomatic relief of symptoms
Malignancies	Rare	Predominantly in Hodgkin and non-Hodgkin's lymphoma		Infiltration with lymphoma cells Paraneoplastic reactions due to hormone/cytokine secretion	Chemotherapy May be reversible
Congenital					
Alagille syndrome	1/70 000 live births	Bile duct paucity with cholestasis, extrahepatic manifestation with heart failure, stroke, pulmonary stenosis, hypercholesterolaemia	Genetic, mutation of the *Jagged-1* gene in up to 70% identifiable	Progressive loss of interlobular bile duct	OLT in ELD
Cystic fibrosis (CF)	2–30% of CF patients	Hepatic manifestation with progressive cholestasis, predominantly pulmonary manifestations	Genetic, mutation in chloride transporter	Obliteration of bile ducts due to tenacious secretions, chronic infections of biliary tree	Supportive therapy OLT in ELD
Alpha-1-antitrypsin deficiency	Progressive bile duct loss as a single feature is rare	Chronic cholestasis, may be aggravated by drugs	Mutation of alpha-1-antitrypsin	Retention of defective protein in hepatocytes, histology may mimic extrahepatic bile duct atresia	OLT in ESD
Fibropolycystic disease (Caroli's disease, congenital hepatic fibrosis, biliary hamartomas, autosomal dominant polycystic disease, choledochal cysts)	Rare	Recurrent cholangitis, bile duct cysts	Sometimes associated with mutations in PKHD1, PKD 1+2		Symptomatic OLT in ELD disease UDCA in Caroli's disease
Bile duct atresia	1/10 000 live births	Progressive cholestasis postpartum with conjugated hyperbilirubinaemia, intrahepatic involvement	Unknown, mostly sporadic	Dysontogenesis of extrahepatic bile ducts, intrahepatic loss of bile ducts may develop within months	Symptomatic OLT in ELD

AIH, autoimmune hepatitis; ANA, antinuclear antibodies; ANCA, antineutrophil cytoplasmic antibodies; BMT, bone marrow transplantation; CF, cystic fibrosis; ELD, endstage liver disease; GVHD, graft-vs.-host disease; OLT, orthotopic liver transplantation; PBC, primary biliary cirrhosis; PKD, polycystic kidney disease; PKHD1, autosomal recessive polycystic kidney disease (ARPKD) gene; PSC, primary sclerosing cholangitis; PUVA, psoralen plus ultraviolet light A; UDCA, ursodeoxycholic acid; VBS, vanishing bile duct syndrome.

show a progressive loss of the intrahepatic bile ducts over the first year of life and narrowing of the bile ducts outside the liver. Autosomal dominant inherited mutations in the *Jagged-1* gene can be identified in about 70% of AGS patients [22].

Ductopenia of the child

Extrahepatic biliary atresia is non-syndromic and usually without family history. Although aberration of the extrahepatic bile duct is the main feature of the disease, paucity of the intrahepatic bile ducts develops within 4–5 months in response to chronic cholestasis. Another form of biliary atresia predominantly affects the intrahepatic structures of the biliary tree and appears to be an intrinsic malformation of the intrahepatic biliary tree. It does not exactly fulfil the dynamic characteristic of the definition of the vanishing bile duct syndrome as it is an a priori developmental defect of the ductal plate [18,23].

Drugs

The list of drugs that can cause damage to the biliary epithelium is constantly growing. Drugs that are repeatedly reported to induce ductopenia are in common use (e.g. ampicillin, non-steroidal anti-inflammatory drugs, terbinafine, carbamazepin and others) (Fig. 1). However, considering the large numbers of patients treated with these drugs, the frequency of toxic damage and subsequent vanishing bile ducts is rare [24]. Little is known about the pathomechanism of cholangiocyte toxicity. What is known is that the capability to metabolize drugs is differentially distributed throughout the biliary tract. Principally, cholangiocytes are able to metabolize not only via phase I but also via phase II metabolic pathways, which renders them vulnerable to different types of drugs [25,26]. Recirculation of toxic drugs via the cholehepatic circulation may increase the toxicity of certain drugs [27].

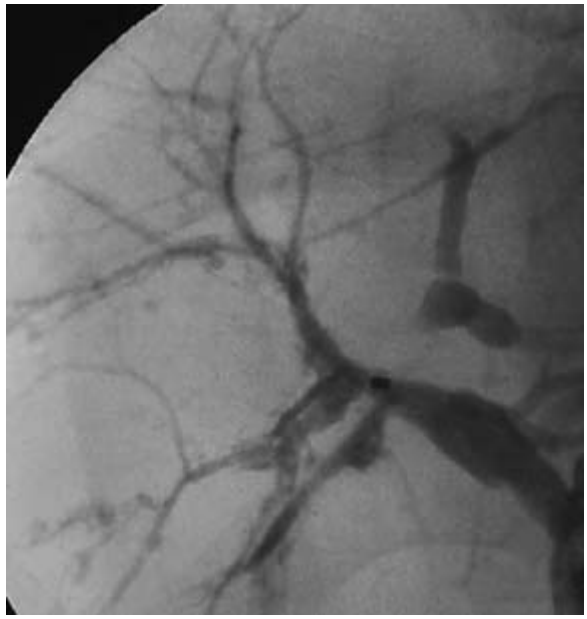

Fig. 1 Endoscopic retrograde cholangiogram of a patient after severe shock who developed diffuse microabscesses along the smaller branches of the biliary tree. Later on, chronic cholestatic liver disease consistent with vanishing bile duct syndrome developed, and the patient was referred for liver transplantation.

Ischaemia

In most cases, ischaemia of the biliary epithelium occurs after interventions. About 1–3% of all patients who underwent orthotopic liver transplantation suffered from stenosis or occlusion of the donor hepatic artery, resulting in an acute or chronic perfusion deficiency [1]. Other iatrogenic vanishing bile duct syndromes include hepatic artery catheterization with or without perfusion with chemotherapy. Of note, patients who suffered severe shock may also develop ischaemic ductopenia (Plate 11.4.1, facing p. 1268). Their overall prognosis seems to be poor, and they benefit from early listing for liver transplantation [28]. Obliterative arteriopathy may be present in allograft rejection and graft-vs.-host disease and represents another variant of ischaemic damage to the biliary epithelium with subsequent ductopenia.

Infections

Bacterial, viral and parasitic infections have been associated with ductopenic liver disease. Chronic ascending bacterial infections predominantly occur in chronic obstructive biliary disease or after surgical or endoscopic manipulation (biliodigestive anastomosis). Infectious bile duct destruction is also common in immunosuppression. In particular, cytomegalovirus (CMV)-induced bile duct loss in the transplanted liver has been extensively examined, but the pathogenetic role of the virus is still under debate [29–31]. Other viruses, such as Epstein–Barr virus (EBV) and hepatitis C virus (HCV), have also been associated with ductopenia after liver transplantation [32–35]. In acquired immune deficiency syndrome (AIDS), the most commonly isolated microorganism causing cholangiopathy with eventual ductopenic liver disease is *Cryptosporidium parvum* [36]. However, with effective antiviral therapy, cryptosporidiosis with progressive cholangitis is rarely seen.

Autoimmunity

Autoimmune liver diseases are frequent causes of ductopenia. Primary biliary cirrhosis (PBC) and primary sclerosing cholangitis (PSC) are the most common ones found in adults. PBC predominantly affects the small bile ducts with subsequent biliary fibrosis and eventual cirrhosis.

In contrast, PSC affects intrahepatic and extrahepatic bile ducts. Inflammation and obliterative fibrosis of the biliary tree are characteristics of the disease. As the major bile ducts are

more notable sites of injury, examination of liver specimens by a pathologist may not clarify a clinical situation definitively. Here, the clinical and laboratory findings as well as typical morphology in endoscopic retrograde cholangiopancreatography (ERCP) or magnetic resonance cholangiopancreatography (MRCP) will result in the correct diagnosis. In patients with a normal cholangiogram but histological features of fibrosing cholangitis, small duct PSC may be present. Patients with small duct PSC have better long-term survival than patients with predominantly large duct damage [41]. Overlap phenomena with characteristics of autoimmune hepatitis, PBS and PBC may also present as vanishing bile duct syndrome. Pathogenesis, clinical presentation and natural history, as well as discussion of the immunological background of these diseases, will be discussed in detail in Chapters 11.1 and 11.3.

Sarcoidosis is another cause of vanishing bile ducts which shares features of autoimmunity. A minority of patients (2–6%) may be affected [42].

Liver transplantation

Vanishing bile ducts after liver transplantation may be due to direct attack by host cells against the biliary structures (T cell-mediated cytotoxicity, cellular rejection) or obliteration of the blood supply of the biliary tree caused by vascular rejection. In acute rejection, mixed inflammatory cells infiltrate the liver parenchyme as well as bile ducts and blood vessels. This archetype of cellular rejection may be reversible under appropriate treatment. In contrast, severe acute rejections may cause irreversible loss of bile ducts with progressive cholestasis despite preservation of intact hepatocytes. Some patients develop ductopenia shortly after transplantation but, in the majority of patients, chronic rejection occurs within months or years after surgery with a peak incidence after 3 months [43]. Reversibility of vanishing bile duct syndrome in transplant rejection is possible, but may be confined to the early stages of graft rejection.

In addition, the recurrence of the primary disease (e.g. PSC, HCV) may lead to reoccurrence of the vanishing bile duct syndrome in the transplanted liver [44].

Others

Vanishing bile duct syndrome in malignancies

Infiltration of hepatic tissue and biliary structures by lymphatic tumour cells may also cause loss of biliary structures. Histology in these cases may be mistaken as an inflammatory process, but the monomorphic appearance of the tumour cells could indicate a malignancy. Vanishing bile duct syndrome may resolve once the tumour is controlled [45–47].

Vanishing bile duct syndrome in graft-vs.-host disease

Graft-vs.-host disease may present as acute hepatitis, but usually shows an indolent cholestatic disease [48,49]. Biliary structures are one of the main targets for acute and chronic graft-vs.-host reaction. Although reported predominantly after bone marrow transplantation, it also occurs after transplantation of grafts harbouring a large number of lymphatic cells (i.e. small bowel transplantation) [50].

Diagnosis

Symptoms and signs

Although considerably different in origin, the clinical presentation of all causes of vanishing bile ducts shares specific characteristics, especially in advanced disease. Jaundice and pruritus are almost always present. Fatigue and signs of portal hypertension are frequent. Hepatosplenomegaly may be present in the early stages. Later on, the liver can be small and hard, while splenomegaly persists. As the disease progresses, symptoms of chronic liver failure may appear. Frequently, ductopenic liver disease is just a bystander of a systemic disorder (e.g. cystic fibrosis). The clinical assessment should therefore always take into account symptoms and signs of the underlying conditions and must also include a thorough medical history with special emphasis on drug exposure.

Laboratory features

Laboratory findings in vanishing bile duct syndrome are unspecific. However, in the majority of patients, serum analysis shows elevated cholestasis parameters with or without elevated liver transaminases. Owing to the fact that the underlying conditions are so heterogeneous, it is not possible to give a general recommendation for a standard laboratory panel. Therefore, investigations should include appropriate parameters to characterize further the condition suspected according to the medical history (e.g. autoantibodies in autoimmune-mediated cholangiopathies or PSC). Laboratory results may reasonably be completed by selective diagnostic imaging (i.e. cholangiogram, ultrasound, arteriogram, etc.). Endoscopic retrograde cholangiography or magnetic resonance imaging of the biliary tree should be implemented early in the diagnostic work in order to identify macroscopic alterations of the biliary tree (e.g. in PSC).

Histology

To correctly diagnose the vanishing bile duct syndrome, the clinician largely depends on the histopathological findings. Conversely, for the interpretation of the biopsies, the pathologist needs detailed clinical information (e.g. age, presence of autoimmune markers, macromorphology of bile duct system).

Ideally, a minimum number of 20 portal tracts should be examined in the specimen. Ductopenic liver disease is apparent if more than 50% of hepatic artery branches lack an accompanying bile duct [19,20]. However, in most circumstances, only needle biopsy specimens are available, and only a few portal

tracts may be present in the sample. In this case, additional features secondary to ductopenia (e.g. periportal cholestasis, biliary piecemeal necrosis, copper retention, presence of Mallory bodies) will help the experienced pathologist to establish the diagnosis. In obstructive cholestasis, portal tract expansion, bile duct dilatation and early-stage fibrosis, as well as bile ductular proliferation and ductopenia of the larger bile ducts, may be present simultaneously. Some histopathological characteristics are of diagnostic value. Granulomatous cholangitis for instance helps to distinguish PBC from other ductopenic liver diseases. However, this finding is not specific as it also occurs in sarcoidosis. Furthermore, a variant of PBC with ductopenia but without evident bile duct destruction might complicate the diagnosis. Infiltration of the bile ducts with lymphocytes is unspecific and seen on many occasions, but the predominance of certain subpopulations of inflammatory cells is characteristic of certain situations (e.g. infiltration with eosinophils in cystic fibrosis and acute rejection). In chronic graft rejection, ductopenia may result from ischaemic bile duct destruction through obliterative arteriopathy or ineffective regeneration of the bile duct epithelium.

Bile duct loss secondary to obliterative arteriopathy, chronic infections of the biliary tract, inflammatory infiltration of biliary structures and neoplastic duct destruction are often obvious in histopathology. On the other hand, ductopenia in slow degenerative processes may be missed because of the absence of inflammatory infiltrates as a bystander lesion.

If alpha-1-antitrypsin deficiency is suspected, immune staining of the retained protein may be helpful. Of note, in early infancy, staining of the defective protein will not contrast against a background of other granules that are present at an early age. In this case, genetic investigation may be of greater value [19,20].

Sequelae of vanishing bile duct syndrome

In some patients, vanishing bile duct syndrome resolves completely once the triggering factor subsides. However, in most instances, presentation is late and bile duct destruction is already advanced. If the underlying process cannot be controlled, destruction of the bile ducts may proceed and eventually lead to liver fibrosis. In fact, the reactive cholangiocytes actively influence fibrogenesis [51]. Liver cirrhosis and liver failure are endstages of the vanishing bile duct syndrome.

Therapy

Therapy of the vanishing bile duct syndrome must always address the underlying condition. The immunologically mediated bile duct destruction – whether autoimmune or in graft-vs.-host disease – is targeted with immunosuppression. If infections of bile ducts are the cause, the causative agent should be isolated, if at all possible, and treated. In cases where anatomical problems support chronic infections (e.g. stenosis of bile ducts, biliodigestive anastomosis), surgical or endoscopic interventions are beneficial. Ischaemia due to stenosis after transplantation or arteriosclerosis should be treated surgically or by interventional radiology. Toxic drugs should be stopped. In genetically determined conditions (e.g. cystic fibrosis) or developmental malformation of the biliary tree (e.g. non-syndromic paucity of bile ducts), treatment often has only a supportive role in retarding manifestation of the disease. Control of symptoms includes treatment of pruritus. Here, UDCA may relieve the symptoms. UDCA is used clinically in a variety of vanishing bile duct manifestations, and anecdotal reports of improvements under UDCA are increasing. However, it is not approved for most applications. Putative mechanisms of action of UDCA are protection of cholangiocytes against cytotoxicity of hydrophobic bile acids, stimulation of hepatobiliary secretion and protection of hepatocytes against bile acid-induced apoptosis [52].

Other symptomatic therapies include cholestyramine to bind bile acids. Rifampicin and naltrexone may also have some effect on severe pruritus. A number of cases have been published in which albumin dialysis was beneficial in patients with severe pruritus [53–59]. Patients with late-stage ductopenic liver disease must be considered for liver transplantation.

Outlook

Understanding the normal function of the biliary epithelium and elucidating the pathophysiology of cholangiopathies may be the beginning of the development of new therapeutic concepts. As the dogma of irreversibility of cirrhosis has recently been eroded, new ways of influencing the potential in function and plasticity of the biliary epithelium may also help to augment or reverse the changes seen in the vanishing bile duct syndrome in future.

References

1 Strazzabosco M, Fabris L, Spirli C (2005) Pathophysiology of cholangiopathies. *J Clin Gastroenterol* 39(4 Suppl. 2), S90–102.
2 Saxena R, Theise N (2004) Canals of Hering: recent insights and current knowledge. *Semin Liver Dis* 24(1), 43–48.
3 Roskams TA, Theise ND, Balabaud C *et al.* (2004) Nomenclature of the finer branches of the biliary tree: canals, ductules, and ductular reactions in human livers. *Hepatology* 39(6), 1739–1745.
4 Kanno N, LeSage G, Glaser S *et al.* (2000) Functional heterogeneity of the intrahepatic biliary epithelium. *Hepatology* 31(3), 555–561.
5 Kanno N, LeSage G, Glaser S *et al.* (2001) Regulation of cholangiocyte bicarbonate secretion. *Am J Physiol Gastrointest Liver Physiol* 281(3), G612–625.
6 Kullak-Ublick GA, Stieger B, Meier PJ (2004) Enterohepatic bile salt transporters in normal physiology and liver disease. *Gastroenterology* 126(1), 322–342.
7 LeSage G, Glaser S, Alpini G (2000) Regulatory mechanisms of ductal bile secretion. *Dig Liver Dis* 32(7), 563–566.
8 Alvaro D, Mennone A, Boyer JL (1997) Role of kinases and phosphatases in the regulation of fluid secretion and Cl–/HCO3– exchange in cholangiocytes. *Am J Physiol* 273(2 Pt 1), G303–313.

9 Alpini G, Glaser SS, Ueno Y *et al.* (1999) Bile acid feeding induces cholangiocyte proliferation and secretion: evidence for bile acid-regulated ductal secretion. *Gastroenterology* 116(1), 179–186.

10 Alpini G, Ueno Y, Glaser SS *et al.* (2001) Bile acid feeding increased proliferative activity and apical bile acid transporter expression in both small and large rat cholangiocytes. *Hepatology* 34(5), 868–876.

11 Celli A, Que FG, Gores GJ *et al.* (1998) Glutathione depletion is associated with decreased Bcl-2 expression and increased apoptosis in cholangiocytes. *Am J Physiol* 275(4 Pt 1), G749–757.

12 Celli A, Que FG (1998) Dysregulation of apoptosis in the cholangiopathies and cholangiocarcinoma. *Semin Liver Dis* 18(2), 177–185.

13 Alpini G, Glaser SS, Ueno Y *et al.* (1998) Heterogeneity of the proliferative capacity of rat cholangiocytes after bile duct ligation. *Am J Physiol* 274(4 Pt 1), G767–775.

14 Alpini G, McGill JM, Larusso NF (2002) The pathobiology of biliary epithelia. *Hepatology* 35(5), 1256–1268.

15 Lazaridis KN, Strazzabosco M, Larusso NF (2004) The cholangiopathies: disorders of biliary epithelia. *Gastroenterology* 127(5), 1565–1577.

16 Reynoso-Paz S, Coppel RL, Ansari AA *et al.* (1999) Vanishing bile duct syndromes: considerations of the immunobiology of autoimmune biliary diseases. *Isr Med Assoc J* 1(1), 37–44.

17 Reynoso-Paz S, Coppel RL, Mackay IR *et al.* (1999) The immunobiology of bile and biliary epithelium. *Hepatology* 30(2), 351–357.

18 Desmet VJ (1998) Ludwig symposium on biliary disorders – part I. Pathogenesis of ductal plate abnormalities. *Mayo Clin Proc* 73(1), 80–89.

19 Li MK, Crawford JM (2004) The pathology of cholestasis. *Semin Liver Dis* 24(1), 21–42.

20 Desmet VJ, van Eyken P, Roskams T (1998) Histopathology of vanishing bile duct diseases. *Adv Clin Pathol* 2(2), 87–99.

21 Rowe SM, Miller S, Sorscher EJ (2005) Cystic fibrosis. *N Engl J Med* 352(19), 1992–2001.

22 Oda T, Elkahloun AG, Pike BL *et al.* (1997) Mutations in the human Jagged1 gene are responsible for Alagille syndrome. *Nature Genet* 16(3), 235–242.

23 Lykavieris P, Chardot C, Sokhn M *et al.* (2005) Outcome in adulthood of biliary atresia: a study of 63 patients who survived for over 20 years with their native liver. *Hepatology* 41(2), 366–371.

24 Velayudham LS, Farrell GC (2003) Drug-induced cholestasis. *Expert Opin Drug Safety* 2(3), 287–304.

25 Lakehal F, Wendum D, Barbu V *et al.* (1999) Phase I and phase II drug-metabolizing enzymes are expressed and heterogeneously distributed in the biliary epithelium. *Hepatology* 30(6), 1498–1506.

26 Marucci L, Alpini G, Glaser SS *et al.* (2003) Taurocholate feeding prevents CCl4-induced damage of large cholangiocytes through PI3-kinase-dependent mechanism. *Am J Physiol Gastrointest Liver Physiol* 284(2), G290–301.

27 Chitturi S, Farrell GC (2001) Drug-induced cholestasis. *Semin Gastrointest Dis* 12(2), 113–124.

28 Engler S, Elsing C, Flechtenmacher C *et al.* (2003) Progressive sclerosing cholangitis after septic shock: a new variant of vanishing bile duct disorders. *Gut* 52(5), 688–693.

29 Seehofer D, Rayes N, Tullius SG *et al.* (2002) CMV hepatitis after liver transplantation: incidence, clinical course, and long-term follow-up. *Liver Transpl* 8(12), 1138–1146.

30 Paya CV, Wiesner RH, Hermans PE *et al.* (1992) Lack of association between cytomegalovirus infection, HLA matching and the vanishing bile duct syndrome after liver transplantation. *Hepatology* 16(1), 66–70.

31 Lautenschlager I, Hockerstedt K, Jalanko H *et al.* (1997) Persistent cytomegalovirus in liver allografts with chronic rejection. *Hepatology* 25(1), 190–194.

32 Kikuchi K, Miyakawa H, Abe K *et al.* (2000) Vanishing bile duct syndrome associated with chronic EBV infection. *Dig Dis Sci* 45(1), 160–165.

33 Dousset B, Conti F, Houssin D *et al.* (1994) Acute vanishing bile duct syndrome after interferon therapy for recurrent HCV infection in liver-transplant recipients. *N Engl J Med* 330(16), 1160–1161.

34 Hoffmann RM, Gunther C, Diepolder HM *et al.* (1995) Hepatitis C virus infection as a possible risk factor for ductopenic rejection (vanishing bile duct syndrome) after liver transplantation. *Transpl Int* 8(5), 353–359.

35 Delladetsima JK, Makris F, Psichogiou M *et al.* (2001) Cholestatic syndrome with bile duct damage and loss in renal transplant recipients with HCV infection. *Liver* 21(2), 81–88.

36 Chen XM, Keithly JS, Paya CV *et al.* (2002) Cryptosporidiosis. *N Engl J Med* 346(22), 1723–1731.

37 Lee YM, Kaplan MM (1995) Primary sclerosing cholangitis. *N Engl J Med* 332(14), 924–933.

38 Fausa O, Schrumpf E, Elgjo K (1991) Relationship of inflammatory bowel disease and primary sclerosing cholangitis. *Semin Liver Dis* 11(1), 31–39.

39 Bambha K, Kim WR, Talwalkar J *et al.* (2003) Incidence, clinical spectrum, and outcomes of primary sclerosing cholangitis in a United States community. *Gastroenterology* 125(5), 1364–1369.

40 Escorsell A, Pares A, Rodes J *et al.* (1994) Epidemiology of primary sclerosing cholangitis in Spain. Spanish Association for the Study of the Liver. *J Hepatol* 21(5), 787–791.

41 Angulo P, Maor-Kendler Y, Lindor KD (2002) Small-duct primary sclerosing cholangitis: a long-term follow-up study. *Hepatology* 35(6), 1494–1500.

42 Kim WR, Ludwig J, Lindor KD (2000) Variant forms of cholestatic diseases involving small bile ducts in adults. *Am J Gastroenterol* 95(5), 1130–1138.

43 Neil DA, Hubscher SG (2002) Histologic and biochemical changes during the evolution of chronic rejection of liver allografts. *Hepatology* 35(3), 639–651.

44 Faust TW (2001) Recurrent primary biliary cirrhosis, primary sclerosing cholangitis, and autoimmune hepatitis after transplantation. *Liver Transpl* 7(11 Suppl. 1), S99–108.

45 Crosbie OM, Crown JP, Nolan NP *et al.* (1997) Resolution of paraneoplastic bile duct paucity following successful treatment of Hodgkin's disease. *Hepatology* 26(1), 5–8.

46 Hubscher SG, Lumley MA, Elias E (1993) Vanishing bile duct syndrome: a possible mechanism for intrahepatic cholestasis in Hodgkin's lymphoma. *Hepatology* 17(1), 70–77.

47 Liangpunsakul S, Kwo P, Koukoulis GK (2002) Hodgkin's disease presenting as cholestatic hepatitis with prominent ductal injury. *Eur J Gastroenterol Hepatol* 14(3), 323–327.

48 Strasser SI, Shulman HM, Flowers ME *et al.* (2000) Chronic graft-versus-host disease of the liver: presentation as an acute hepatitis. *Hepatology* 32(6), 1265–1271.

49 Stechschulte DJ, Jr, Fishback JL, Emami A *et al.* (1990) Secondary biliary cirrhosis as a consequence of graft-versus-host disease. *Gastroenterology* 98(1), 223–225.

50 Frezza EE, Tzakis A, Fung JJ *et al.* (1996) Small bowel transplantation: current progress and clinical application. *Hepatogastroenterology* 43(8), 363–376.

51 Strazzabosco M, Spirli C, Okolicsanyi L (2000) Pathophysiology of the intrahepatic biliary epithelium. *J Gastroenterol Hepatol* 15(3), 244–253.
52 Paumgartner G, Beuers U (2002) Ursodeoxycholic acid in cholestatic liver disease: mechanisms of action and therapeutic use revisited. *Hepatology* 36(3), 525–531.
53 Pares A, Caballeria L, Rodes J *et al.* (2000) Long-term effects of ursodeoxycholic acid in primary biliary cirrhosis: results of a double-blind controlled multicentric trial. UDCA-Cooperative Group from the Spanish Association for the Study of the Liver. *J Hepatol* 32(4), 561–566.
54 Burak KW, Pearson DC, Swain MG *et al.* (2000) Familial idiopathic adulthood ductopenia: a report of five cases in three generations. *J Hepatol* 32(1), 159–163.
55 Degott C, Zafrani ES, Callard P *et al.* (1999) Histopathological study of primary biliary cirrhosis and the effect of ursodeoxycholic acid treatment on histology progression. *Hepatology* 29(4), 1007–1012.
56 Oo YH, Neuberger J (2004) Options for treatment of primary biliary cirrhosis. *Drugs* 64(20), 2261–2271.
57 Bellmann R, Feistritzer C, Zoller H *et al.* (2004) Treatment of intractable pruritus in drug induced cholestasis with albumin dialysis: a report of two cases. *ASAIO J* 50(4), 387–391.
58 Bellmann R, Graziadei IW, Feistritzer C *et al.* (2004) Treatment of refractory cholestatic pruritus after liver transplantation with albumin dialysis. *Liver Transpl* 10(1), 107–114.
59 Agca E, Akcay A, Simsek H (2004) Ursodeoxycholic acid for terbinafine-induced toxic hepatitis. *Ann Pharmacother* 38(6), 1088–1089.

11.5 Overlap syndromes

Ulrich Beuers

Introduction

In hepatology, the term 'overlap syndrome' describes variant forms of autoimmune hepatitis (AIH) and autoimmune cholangiopathies. Hepatic overlap syndromes present with characteristics of AIH and primary biliary cirrhosis (PBC), primary sclerosing cholangitis (PSC) or autoimmune cholangitis [AIC; synonym antimitochondrial antibody (AMA)-negative PBC]. It remains unclear whether additional overlap between PBC and PSC exists. It is also a matter of discussion whether these overlap syndromes form distinct entities or are only variants of the major autoimmune hepatopathies [1–5].

Variant forms of AIH form a considerable fraction of autoimmune liver diseases [1]. Sequential syndromes characterized by transition from one to another autoimmune hepatopathy, e.g. from PBC to AIH [6,7] or from AIH to PSC [8,9], have also been reported. Diagnostic criteria for overlap syndromes have not been standardized so far, and misuse of the term 'overlap syndrome' is common in clinical practice. Thus, the term 'overlap syndrome' appears to be inadequate when characteristic features of an autoimmune hepatopathy are detected together with those of a second liver disease, e.g. chronic hepatitis C. This chapter summarizes current views [2–5] on hepatic overlap syndromes.

Characteristics of major autoimmune hepatopathies

A diagnosis of AIH, PBC or PSC always requires careful exclusion of other causes of liver damage, including alcohol, viral, drug- and toxin-induced, hereditary metabolic and non-alcoholic fatty liver disease, as outlined in detail in other chapters. The diagnosis of AIH, PBC and PSC is then based on a pattern of characteristic clinical, biochemical, histopathological and cholangiographic findings. None of these findings alone is diagnostic, and most criteria are of limited sensitivity and specificity for the diseases under discussion (Table 1).

Autoimmune hepatitis (AIH)

The International Autoimmune Hepatitis Group (IAIHG) provided a descriptive set of criteria for the diagnosis of AIH in routine clinical practice and established a scoring system for research purposes, which is also used increasingly, although not yet adequately validated, in clinical practice; it comprises characteristic clinical, biochemical and histological criteria of AIH [10]. These include gender distribution (female > male), the pattern of elevated serum liver tests (serum transaminases > serum alkaline phosphatase), elevated serum immunoglobulin (Ig)G or γ-globulins, the presence of antinuclear (ANA), anti-smooth muscle (ASMA) and type 1 antiliver/kidney microsomal (LKM1) serum autoantibodies, the absence of AMA and viral markers, lack of evidence for drug- or alcohol-induced liver disease, histological criteria such as interface hepatitis with piecemeal necrosis and lobular necroinflammatory changes, the presence of extrahepatic autoimmune diseases, other defined autoantibodies or histocompatibility leukocyte antigen (HLA) associations (B8, DR3, DR4) and a positive treatment response to corticosteroids [10]. The diagnostic value of antisoluble liver antigen (SLA) antibodies [11] and atypical perinuclear antineutrophil cytoplasmic (pANCA) antibodies [12] may be taken into consideration in a future version of the AIH scoring system.

Primary biliary cirrhosis (PBC)

Criteria for the diagnosis of PBC include: (i) a cholestatic serum enzyme pattern; (ii) elevated serum IgM; (iii) the presence of AMA detected by immunofluorescence (> 1:40) or PBC-specific AMA-M2 directed against the E2 subunit of the pyruvate dehydrogenase complex and detected by enzyme-linked immunosorbent assay (ELISA) or immunoblotting; and (iv) a 'florid bile duct lesion' of middle-sized intrahepatic bile ducts and bile duct paucity [13–15]. The cholestatic serum enzyme pattern, serum AMA and a compatible histology (Table 1) are regarded as mandatory for the diagnosis of PBC. A granulomatous cholangitis is not specific for PBC and is observed in

Table 1 Clinical, biochemical, histological and cholangiographic criteria of autoimmune liver diseases. 'Overlap syndromes' show characteristics of autoimmune hepatitis (AIH) and primary biliary cirrhosis (PBC), primary sclerosing cholangitis (PSC) or autoimmune cholangitis (AIC) (adapted from ref. 5).

	AIH	PBC	PSC	AIC
Female:male	4:1	9:1	1:2	9:1
Signs and symptoms	Fatigue, jaundice, arthropathy	Fatigue, pruritus	Fatigue, pruritus	Fatigue, pruritus
Predominant serum liver test elevation	ALT, AST	aP, γ-GT	aP, γ-GT	aP, γ-GT
Serum Ig elevation	IgG	IgM	IgG, IgM	IgM
Autoantibodies	ANA, ASMA, LKM1, SLA, pANCA	AMA, AMA-M2	pANCA	ANA, ASMA
HLA association	A3, B8, DR3, DR4	DR8	DR52	B8, DR3, DR4
Histology	Lymphocytic interface hepatitis (moderate/severe)	Florid bile duct lesion	Fibrosing bile duct lesion	Florid bile duct lesion
Diagnosis	AIH score > 15	AMA-M2, cholestatic serum enzyme pattern, compatible histology	Bile duct stenoses/dilatations (cholangiography), cholestatic serum enzyme pattern, inflammatory bowel disease, pANCA	Cholestatic serum enzyme pattern, AMA negative, ANA or ASMA positive, histology compatible with PBC
First-line medical therapy	Corticosteroids + azathioprine	UDCA	UDCA	UDCA

AIH, autoimmune hepatitis; AIC, autoimmune cholangitis; ALT, alanine aminotransferase; aP, alkaline phosphatase; AST, aspartate aminotransferase; AMA, antimitochondrial antibodies; ANA, antinuclear antibodies; ASMA, antismooth muscle antigen antibodies; γ-GT, γ-glutamyl transferase; LKM1, antiliver/kidney microsomal autoantibodies, type 1; pANCA, perinuclear antineutrophil cytoplasmic antibodies; PBC, primary biliary cirrhosis; PSC, primary sclerosing cholangitis; SLA, antisoluble liver antigen autoantibodies; UDCA, ursodeoxycholic acid.

less than one-third of biopsies from PBC patients [16,17]. PBC is frequently associated with other autoimmune disorders such as Sjögren's syndrome, Hashimoto thyroiditis and coeliac disease.

Primary sclerosing cholangitis (PSC)

Criteria for the diagnosis of PSC include: (i) a cholestatic serum enzyme pattern; (ii) typical cholangiographic findings of bile duct stenoses and dilatations without prior bile duct surgery or other underlying causes of secondary sclerosing cholangitis; (iii) histological findings compatible with PSC showing mild to moderate portal infiltration with mainly lymphocytes, but also neutrophils and eosinophils, and in small biopsy samples, only exceptionally the typical onion skin portal fibrosis around bile ductules; (iv) concomitant inflammatory bowel disease in 70–90% of patients (ulcerative colitis four- to fivefold more frequent than Crohn's colitis in PSC); and (v) the presence of atypical pANCA in more than 70% of patients [18] (Table 1). The cholestatic serum enzyme pattern, typical cholangiographic findings and a compatible histology are regarded as mandatory for the diagnosis of PSC. PSC is not regarded as a classical autoimmune disease because gender distribution (male > female) and lack of adequate response to corticosteroid treatment are not compatible with classical autoimmune disorders [14].

Autoimmune cholangitis (AIC)

AIC (synonym AMA-negative PBC) shares many features with PBC including the female preponderance, symptoms such as fatigue and pruritus, a cholestatic serum enzyme pattern, 'florid bile duct lesions', ductopenia and a slowly progressive course leading to fibrosis and cirrhosis of the liver [19]. Patients with AIC are, by definition, AMA negative and often present with serum ANA and/or ASMA (Table 1). In 1987, AIC was first reported as 'immunocholangitis' in three women who presented with signs and symptoms of PBC, but were AMA negative and ANA positive and responded to immunosuppressive therapy [20]. AIC was discussed as a variant of AIH [1,21], a hybrid of PBC and AIH [22], a result of sequential occurrence of PBC and AIH [6] or a heterogeneous jumble of rare cholangiopathies including atypical PBC, small duct PSC, idiopathic adulthood ductopenia and transitional stages of the classic diseases [23]. AIC and PBC were discussed as separate entities [24,25] or variants of one single disease, only differing in serum autoantibody pattern [3,26–30]. The latter view was supported by more recent studies: 22 of 30 patients with AIC (AMA-negative PBC) but 0 of 316 control subjects tested positive for a new AMA-M2 recombinant assay, which detected autoantibodies directed against human E2 members of the 2-oxoacid dehydrogenase

complex family [31]. In addition, immunohistochemical studies showed that PDC-E2 (E2 subunit of the mitochondrial pyruvate dehydrogenase complex) immunoreactivity was expressed on apical membranes of biliary epithelial cells not only in patients with PBC but also in seven of nine patients with AIC [32]. Similar autoimmune targeting directed towards PDC-E2 was observed in PBC and AIC when antibody expression was compared using phage display [33]. Autoantibodies to carbonic anhydrase [34] and antilactoferrin [35], which were first proposed as specific markers of AIC, were disclosed as non-specific [36,37]. In addition, treatment response to ursodeoxycholic acid (UDCA; 13–15 mg/kg daily) [38,39] and outcome of liver transplantation in endstage disease in AIC were similar to those in PBC [39]. Thus, a majority of AIC patients, when defined as AMA-negative PBC, apparently suffer from 'true' PBC.

Overlap syndromes (Fig. 1)

AIH–PBC overlap syndrome

PBC and AIH represent the major autoimmune hepatopathies with a prevalence of 33–40/100 000 [40,41] and 17/100 000 [42], respectively, in recent epidemiological studies from northern Europe and the United States. Female gender predominates in both AIH (80%) and PBC (90–95%). Pruritus is reported during the course of PBC by a majority of patients, whereas it is usually not observed in AIH. Serum liver tests typically show a hepatitic pattern in AIH and a cholestatic pattern with predominant elevation of alkaline phosphatase and γ-glutamyl transferase and only mild elevation of serum transaminases in PBC. Serum IgG is the predominant immunoglobulin elevated in AIH, whereas serum IgM is elevated in most patients with PBC.

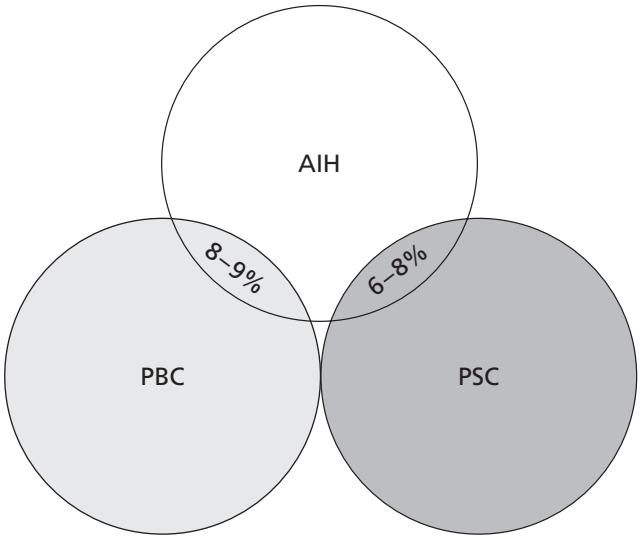

Fig. 1 Overlap syndromes of autoimmune hepatitis (AIH) and primary biliary cirrhosis (PBC) or primary sclerosing cholangitis (PSC) were reported at rates of nearly 10% in different studies [1,7,59,76]. Whether overlap between PBC and PSC exists remains elusive (adapted from ref. 5).

AIH–PBC overlap syndromes were first reported in the 1970s [43,44]. Two extended analyses provided evidence of AIH–PBC overlap in 8% of 199 patients with AIH ($n = 162$) or PBC ($n = 37$) [1] and in 9% of 130 patients with PBC [7]. A recent analysis of a smaller cohort of 82 consecutive patients with definite or probable AIH based on the revised AIH score of the IAIHG [10] still found overlap with PBC in 13% of patients [45].

The term 'overlap syndrome' was not used uniformly in these studies. In the French study, an AIH–PBC overlap syndrome was accepted when two or three criteria of PBC [(i) alkaline phosphatase > 2 × N or γ-glutamyl transferase > 5 × N; (ii) AMA positive; (iii) florid bile duct lesions] as well as AIH [(i) ALT > 5 × N; (ii) IgG > 2 × N or ASMA positive; (iii) portal and periportal lymphocytic inflammation and moderate or severe periportal lymphocytic piecemeal necrosis equal to interface hepatitis] were fulfilled [7]. Characteristic features of patients with AIH–PBC overlap syndrome include elevation of serum transaminases, markers of cholestasis and immunoglobulins M and G, the presence of AMA-M2 and ANA, ASMA or SLA and histological findings compatible with AIH, including moderate to severe interface hepatitis (Table 2).

A group of German patients with AIH–PBC overlap syndrome presented with typical features of PBC (AMA-M2; florid bile duct lesions), but a more hepatitic picture than PBC patients. As patients with AIH–PBC overlap syndrome showed a predominant HLA type B8, DR3 or DR4, similar to patients with AIH, and a good response to corticosteroid treatment, they were diagnosed with a hepatitic form of PBC [46].

A diagnostic score might help to differentiate PBC from PBC–AIH overlap syndrome and other autoimmune hepatocholangiopathies [47], but prospective evaluation is needed before the introduction of this score into the clinic.

Autoantibodies are generally believed to present a hallmark for the diagnosis of AIH, but up to 20% of patients with AIH present without ANA, ASMA or LKM1 [10]. ANA represent the least specific serum autoantibodies for the diagnosis of chronic liver diseases and are also found in up to 30% of elderly healthy control subjects, up to 10% of pregnant women and up to 30% of patients with malignancies [48]. ANA in the serum of patients with PBC are *not* a marker of AIH–PBC overlap syndrome, but are found at considerable rates in PBC patients without any further signs of AIH. In contrast, ANA with a specific immunofluorescence pattern of multiple nuclear dots directed against Sp100 (5–10 dots) or Coilin p80 (2–6 dots) are rather specific for AIH–PBC, although less sensitive for PBC [48]. In a small subgroup (3.9%) of 233 patients with PBC, the presence of SLA autoantibodies was a marker of AIH–PBC overlap syndrome, with a good response to immunosuppressive therapy [49].

At present, it remains unclear whether AIH–PBC overlap syndromes represent: (i) a 'hepatitic form of PBC' determined by the genetic susceptibility of the patient; (ii) the middle of a continuous spectrum of two autoimmune disorders, AIH and PBC, with florid bile duct lesions and bile duct paucity on

Table 2 Clinical, biochemical, histological and cholangiographic findings of 'overlap syndromes' (mandatory characteristics are marked*).

	AIH–PBC	AIH–PSC	AIH–AIC
Signs and symptoms	Fatigue, jaundice, arthralgia, pruritus	Fatigue, jaundice, pruritus	Fatigue, jaundice, pruritus
Predominant serum liver test elevation	ALT, AST, aP, γ-GT	ALT, AST, aP, γ-GT	ALT, AST, aP, γ-GT
Serum Ig elevation	IgG, IgM	IgG, IgM	IgG, IgM
Autoantibodies	(i) ANA, ASMA, SLA, pANCA (ii) AMA-M2*	ANA, ASMA, pANCA	ANA, ASMA, SLA, pANCA
Histology	(i) Lymphocytic interface hepatitis* (moderate/severe) (ii) Florid bile duct lesion*	(i) Lymphocytic interface hepatitis* (moderate/severe) (ii) Fibrosing bile duct lesion*	(i) Lymphocytic interface hepatitis* (moderate/severe) (ii) Florid bile duct lesion*
Additional features		Bile duct stenoses/dilatations* (cholangiography), inflammatory bowel disease	
First-line medical therapy	(i) UDCA (ii) Corticosteroids/azathioprine	(i) UDCA (ii) Corticosteroids/azathioprine	(i) UDCA (ii) Corticosteroids/azathioprine

AIH, autoimmune hepatitis; AIC, autoimmune cholangitis; ALT, alanine aminotransferase; aP, alkaline phosphatase; AST, aspartate aminotransferase; AMA, antimitochondrial antibodies; ANA, antinuclear antibodies; ASMA, antismooth muscle antigen antibodies; γ-GT, γ-glutamyl transferase; pANCA, perinuclear antineutrophil cytoplasmic antibodies; PBC, primary biliary cirrhosis; PSC, primary sclerosing cholangitis; SLA, antisoluble liver antigen autoantibodies; UDCA, ursodeoxycholic acid.

one hand, and lymphocytic piecemeal necrosis and lobular necroinflammatory changes on the other hand; or (iii) a coincidence of two autoimmune diseases, AIH and PBC, considering that autoimmune diseases are associated with one another in 5–10% of cases [4] and that both diseases may be observed sequentially in the same patient [6,7].

Therapy

The low prevalence of AIH–PBC overlap syndrome has made controlled therapeutic trials in these patients impossible so far. Thus, therapeutic recommendations rely on experience in the treatment of either AIH or PBC. The premise 'at least do not harm' [2] should be considered, and commencement with UDCA treatment (13–15 mg/kg/day) is recommended. If this therapy does not induce an adequate biochemical response, the addition of a glucocorticosteroid at tolerable doses (e.g. prednisolone, 10–15 mg/kg daily; budesonide, 6–9 mg/kg daily, in non-cirrhotic patients with AIH or PBC under evaluation in controlled trials) [2,50] is advisable. The role of other immunosuppressants, e.g. azathioprine (1–1.5 mg/kg daily), in the long-term management of patients with AIH–PBC overlap syndrome is unclear, but its successful use in AIH makes azathioprine an attractive alternative to corticosteroids for long-term immunosuppressive therapy [50]. For corticosteroid-resistant patients with AIH–PBC overlap syndrome, intermediate treatment with other immunosuppressants, such as ciclosporin A, has been considered [51]. Liver transplantation is regarded as the treatment of choice for endstage disease.

AIH–PSC overlap syndrome

AIH–PSC overlap syndromes have mainly been described in children, adolescents and young adults [52–59]. A literature review revealed an overlap between AIH and PSC, based on histological evaluation, in 6% of patients with AIH [1]. Use of the modified AIH score [10] led to the diagnosis of an overlap syndrome in 8% of 113 PSC patients [59] and 7% of 82 consecutive patients with definite or probable AIH [45]. In contrast, one retrospective analysis of 211 PSC patients disclosed only 1.4% of patients as fulfilling the criteria of an overlap syndrome [60]. This analysis differed in (i) patient age, (ii) the range of autoantibodies taken into consideration and (iii) the degree of completeness of analysed data from other studies.

Colleagues from the UK provided a meticulous prospective follow-up over up to 16 years of the largest case series of AIH–PSC overlap syndromes in children and adolescents [8]. A group of 55 children was studied who showed clinical, biochemical and histological signs of AIH. In 27 of the 55 children, cholangiographic findings were typical of sclerosing cholangitis, whereas other signs and symptoms were characteristic of AIH. Therefore, the term 'autoimmune sclerosing cholangitis' (ASC) was proposed for this AIH–PSC overlap syndrome. Patients with ASC more commonly suffered from inflammatory bowel disease and were more often positive for ANCA in serum than those with AIH. Serum transaminases tended to be higher in AIH, but serum alkaline phosphatase, although mostly elevated in PSC, was normal on several occasions in both diseases. Thus,

AIH and ASC may belong to the same disease process and may overlap with PSC.

Increasing awareness of the AIH–PSC overlap syndrome has led to the observation that AIH and PSC may be sequential in their occurrence, as first described in children [8]. More recently, similar observations have been reported in a small case series of six adults (mean age 31 years; four men; three with ulcerative colitis) who developed biochemical and cholangiographic features of PSC an average of 4.6 years after a diagnosis of AIH and became resistant to immunosuppressive therapy. Thus, in patients with AIH who become cholestatic and/or resistant to immunosuppression, PSC should be ruled out [9].

Therapy

UDCA is widely administered in PSC because of its beneficial effects on serum liver tests, histological features, prognostic surrogate markers and development of colonic dysplasia associated with accompanying ulcerative colitis, although the long-term efficacy of UDCA still remains unproven [61–64]. UDCA has been used in combination with immunosuppressive drugs in ASC, and the long-term course was reported as favourable [8]. Thus, UDCA in combination with an immunosuppressive regimen (azathioprine ± corticosteroid) may be an adequate medical treatment for most patients with ASC, although data from controlled trials are lacking. Liver transplantation should be considered in late-stage disease.

AIH–AIC overlap syndrome

Concomitant features of AIH and AIC have been reported. Histological specimens of 84 AMA-negative patients with 'definite' AIH (AIH score > 15) were studied for the presence of bile duct injury regarded as atypical of AIH [10]. Some 24% of patients showed features of bile duct injury, including destructive cholangitis and ductopenia, although they otherwise fulfilled all the criteria for the diagnosis of AIH [65]. Thus, the diagnosis of an AIH–AIC overlap syndrome cannot be based only on the presence of bile duct injury when other features are compatible with the diagnosis of AIH. An exception may be granulomatous portal lesions, which are described in PBC, AIC, drug-induced cholestasis, chronic hepatitis C, sarcoidosis and even PSC but not in AIH [17]. Features of an AIH–AIC overlap syndrome including hepatic and cholestatic biochemical changes, interface hepatitis and bile duct lesions with portal granulomata and bile duct proliferation have been described in an AMA-negative woman who responded to combined treatment with UDCA, prednisone and azathioprine [66].

Coexistence of liver diseases

Coexistence of PBC and PSC

Different from AIH–PBC and AIH–PSC overlap syndromes, evidence for an overlap of PBC and PSC is limited at best. Combined features of both PBC and PSC have been reported [67,68]. In one case, careful documentation and discussion of clinical, biochemical, histological and cholangiographic findings as well as follow-up clearly showed that features characteristic of PBC and PSC may be identified in a single patient [68]. However, the exceptional rarity of this scenario when compared with the frequency of AIH–PBC and AIH–PSC overlaps in patients with major autoimmune hepatobiliary diseases (6–10%, see above) may lead to the conclusion that pure coexistence of PBC and PSC, rather than an overlap syndrome, was documented in this single case.

Coexistence of AIH and chronic hepatitis C

The term 'overlap syndrome' for coexistence of AIH and chronic hepatitis C appears to be inappropriate. Autoantibodies are commonly detected in hepatitis C. In particular, ANA, ASMA and antithyroid antibodies, mainly at low titres, have been documented in up to 65% of patients with hepatitis C. LKM1 antibodies are the hallmark of AIH type 2. They are homogeneous, found at considerable titres and are directed against four small and linear epitopes on cytochrome P450 2D6 [69–71]. LKM1 antibodies were also observed in up to 7% of patients with chronic hepatitis C. Interestingly, hepatitis C virus (HCV)-associated LKM1 antibodies were found at lower titres, were more heterogeneous and directed against multiple epitopes [72].

In patients with AIH and hypergammaglobulinaemia, anti-HCV tests turned out to be false positive in many cases, with negative HCV RNA, as determined by recombinant immunoblot assay (RIBA) or polymerase chain reaction (PCR) [73–75]. Thus, it appears mandatory that anti-HCV-positive patients with signs of AIH are tested for the presence of HCV RNA by PCR before a diagnosis of hepatitis C can be made.

Therapy

When coexistence of AIH and chronic hepatitis C is assumed, treatment should be adapted to three groups of patients: (i) patients with true AIH and a false-positive anti-HCV test should be treated with immunosuppressive drugs; (ii) patients with true chronic hepatitis C and autoantibodies at low titres, but no other signs of AIH, should undergo antiviral treatment (e.g. pegylated interferon and ribavirin); and (iii) patients with true chronic hepatitis C and clear signs of AIH including young age, female gender, high autoantibody titres (ANA, SMA, LKM1) ≥ 1:320, hypergammaglobulinaemia and a history of extrahepatic autoimmune disorders should first be treated with an immunosuppressive regimen under careful control of clinical and biochemical features [50,75].

References

1 Czaja AJ (1996) The variant forms of autoimmune hepatitis. *Ann Intern Med* 125, 588–598.

2 Heathcote EJ (1999) Overlap syndromes. In: Bircher JBJ, McIntyre N,

Rizzetto M *et al.* (eds) *Oxford Textbook of Clinical Hepatology*, Vol. 2. Oxford: Oxford University Press, pp. 1135–1140.
3 Woodward J, Neuberger J (2001) Autoimmune overlap syndromes. *Hepatology* 33, 994–1002.
4 Poupon R (2003) Autoimmune overlapping syndromes. *Clin Liver Dis* 7, 865–878.
5 Beuers U (2005) Hepatic overlap syndromes. *J Hepatol* 42, S93–S99.
6 Colombato LA, Alvarez F, Cote J *et al.* (1994) Autoimmune cholangiopathy: the result of consecutive primary biliary cirrhosis and autoimmune hepatitis? *Gastroenterology* 107, 1839–1843.
7 Chazouilleres O, Wendum D, Serfaty L *et al.* (1998) Primary biliary cirrhosis–autoimmune hepatitis overlap syndrome: clinical features and response to therapy. *Hepatology* 28, 296–301.
8 Gregorio GV, Portmann B, Karani J *et al.* (2001) Autoimmune hepatitis/sclerosing cholangitis overlap syndrome in childhood: a 16-year prospective study. *Hepatology* 33, 544–553.
9 Abdo AA, Bain VG, Kichian K *et al.* (2002) Evolution of autoimmune hepatitis to primary sclerosing cholangitis: a sequential syndrome. *Hepatology* 36, 1393–1399.
10 Alvarez F, Berg PA, Bianchi FB *et al.* (1999) International Autoimmune Hepatitis Group Report: review of criteria for diagnosis of autoimmune hepatitis. *J Hepatol* 31, 929–938.
11 Kanzler S, Weidemann C, Gerken G *et al.* (1999) Clinical significance of autoantibodies to soluble liver antigen in autoimmune hepatitis. *J Hepatol* 31, 635–640.
12 Terjung B, Bogsch F, Klein R *et al.* (2004) Diagnostic accuracy of atypical p-ANCA in autoimmune hepatitis using ROC- and multivariate regression analysis. *Eur J Med Res* 9, 439–448.
13 Prince MI, Chetwynd A, Craig WL *et al.* (2004) Asymptomatic primary biliary cirrhosis: clinical features, prognosis, and symptom progression in a large population based cohort. *Gut* 53, 865–870.
14 Vierling JM (2004) Primary biliary cirrhosis and autoimmune cholangiopathy. *Clin Liver Dis* 8, 177–194.
15 Heathcote EJ (2000) Management of primary biliary cirrhosis. The American Association for the Study of Liver Diseases practice guidelines. *Hepatology* 31, 1005–1013.
16 Wiesner RH, LaRusso NF, Ludwig J *et al.* (1985) Comparison of the clinicopathologic features of primary sclerosing cholangitis and primary biliary cirrhosis. *Gastroenterology* 88, 108–114.
17 Ludwig J, Colina F, Poterucha JJ (1995) Granulomas in primary sclerosing cholangitis. *Liver* 15, 307–312.
18 Lee YM, Kaplan MM (1995) Primary sclerosing cholangitis. *N Engl J Med* 332, 924–933.
19 Heathcote J (1997) Autoimmune cholangitis. *Gut* 40, 440–442.
20 Brunner G, Klinge O (1987) [A chronic destructive non-suppurative cholangitis-like disease picture with antinuclear antibodies (immunocholangitis)]. *Dtsch Med Wochenschr* 112, 1454–1458.
21 Ben-Ari Z, Dhillon AP, Sherlock S (1993) Autoimmune cholangiopathy: part of the spectrum of autoimmune chronic active hepatitis. *Hepatology* 18, 10–15.
22 Sherlock S (1998) Ludwig Symposium on biliary disorders. Autoimmune cholangitis: a unique entity? *Mayo Clin Proc* 73, 184–190.
23 Czaja AJ, Carpenter HA, Santrach PJ *et al.* (2000) Autoimmune cholangitis within the spectrum of autoimmune liver disease. *Hepatology* 31, 1231–1238.
24 Michieletti P, Wanless IR, Katz A *et al.* (1994) Antimitochondrial antibody negative primary biliary cirrhosis: a distinct syndrome of autoimmune cholangitis. *Gut* 35, 260–265.
25 Taylor SL, Dean PJ, Riely CA (1994) Primary autoimmune cholangitis. An alternative to antimitochondrial antibody-negative primary biliary cirrhosis. *Am J Surg Pathol* 18, 91–99.
26 Goodman ZD, McNally PR, Davis DR *et al.* (1995) Autoimmune cholangitis: a variant of primary biliary cirrhosis. Clinicopathologic and serologic correlations in 200 cases. *Dig Dis Sci* 40, 1232–1242.
27 Omagari K, Ikuno N, Matsuo I *et al.* (1996) Autoimmune cholangitis syndrome with a bias towards primary biliary cirrhosis. *Pathology* 28, 255–258.
28 Invernizzi P, Crosignani A, Battezzati PM *et al.* (1997) Comparison of the clinical features and clinical course of antimitochondrial antibody-positive and -negative primary biliary cirrhosis. *Hepatology* 25, 1090–1095.
29 Kinoshita H, Omagari K, Whittingham S *et al.* (1999) Autoimmune cholangitis and primary biliary cirrhosis – an autoimmune enigma. *Liver* 19, 122–128.
30 Neuberger J, Thomson R (1999) PBC and AMA – what is the connection? *Hepatology* 29, 271–276.
31 Miyakawa H, Tanaka A, Kikuchi K *et al.* (2001) Detection of antimitochondrial autoantibodies in immunofluorescent AMA-negative patients with primary biliary cirrhosis using recombinant autoantigens. *Hepatology* 34, 243–248.
32 Tsuneyama K, Van De Water J, Van Thiel D *et al.* (1995) Abnormal expression of PDC-E2 on the apical surface of biliary epithelial cells in patients with antimitochondrial antibody-negative primary biliary cirrhosis. *Hepatology* 22, 1440–1446.
33 Ikuno N, Scealy M, Davies JM *et al.* (2001) A comparative study of antibody expressions in primary biliary cirrhosis and autoimmune cholangitis using phage display. *Hepatology* 34, 478–486.
34 Gordon SC, Quattrociocchi-Longe TM, Khan BA *et al.* (1995) Antibodies to carbonic anhydrase in patients with immune cholangiopathies. *Gastroenterology* 108, 1802–1809.
35 Ohana M, Okazaki K, Hajiro K *et al.* (1998) Antilactoferrin antibodies in autoimmune liver diseases. *Am J Gastroenterol* 93, 1334–1339.
36 Comay D, Cauch-Dudek K, Hemphill D *et al.* (2000) Are antibodies to carbonic anhydrase II specific for anti-mitochondrial antibody-negative primary biliary cirrhosis? *Dig Dis Sci* 45, 2018–2021.
37 Muratori L, Muratori P, Zauli D *et al.* (2001) Antilactoferrin antibodies in autoimmune liver disease. *Clin Exp Immunol* 124, 470–473.
38 Lacerda MA, Ludwig J, Dickson ER *et al.* (1995) Antimitochondrial antibody-negative primary biliary cirrhosis. *Am J Gastroenterol* 90, 247–249.
39 Kim WR, Poterucha JJ, Jorgensen RA *et al.* (1997) Does antimitochondrial antibody status affect response to treatment in patients with primary biliary cirrhosis? Outcomes of ursodeoxycholic acid therapy and liver transplantation. *Hepatology* 26, 22–26.
40 James OF, Bhopal R, Howel D *et al.* (1999) Primary biliary cirrhosis once rare, now common in the United Kingdom? *Hepatology* 30, 390–394.
41 Kim WR, Lindor KD, Locke GR, 3rd *et al.* (2000) Epidemiology and natural history of primary biliary cirrhosis in a US community. *Gastroenterology* 119, 1631–1636.
42 Boberg KM, Aadland E, Jahnsen J *et al.* (1998) Incidence and prevalence of primary biliary cirrhosis, primary sclerosing cholangitis, and autoimmune hepatitis in a Norwegian population. *Scand J Gastroenterol* 33, 99–103.
43 Geubel AP, Baggenstoss AH, Summerskill WH (1976) Responses to treatment can differentiate chronic active liver disease with cholangitic features from the primary biliary cirrhosis syndrome. *Gastroenterology* 71, 444–449.

44 Kloppel G, Seifert G, Lindner H *et al.* (1977) Histopathological features in mixed types of chronic aggressive hepatitis and primary biliary cirrhosis. Correlations of liver histology with mitochondrial antibodies of different specificity. *Virchows Arch A Pathol Anat Histol* 373, 143–160.

45 Gheorghe L, Iacob S, Gheorghe C *et al.* (2004) Frequency and predictive factors for overlap syndrome between autoimmune hepatitis and primary cholestatic liver disease. *Eur J Gastroenterol Hepatol* 16, 585–592.

46 Lohse AW, zum Buschenfelde KH, Franz B *et al.* (1999) Characterization of the overlap syndrome of primary biliary cirrhosis (PBC) and autoimmune hepatitis: evidence for it being a hepatitic form of PBC in genetically susceptible individuals. *Hepatology* 29, 1078–1084.

47 Yamamoto K, Terada R, Okamoto R *et al.* (2003) A scoring system for primary biliary cirrhosis and its application for variant forms of autoimmune liver disease. *J Gastroenterol* 38, 52–59.

48 Terjung B, Spengler, U (2005) Role of auto-antibodies for the diagnosis of chronic cholestatic liver diseases. *Clin Rev Allerg Immunol* 28, 117–132.

49 Kanzler S, Bozkurt S, Herkel J *et al.* (2001) [Presence of SLA/LP autoantibodies in patients with primary biliary cirrhosis as a marker for secondary autoimmune hepatitis (overlap syndrome)]. *Dtsch Med Wochenschr* 126, 450–456.

50 Leuschner U (2005) *Autoimmunkrankheiten der Leber und Overlapsyndrome*, 2nd edn. Bremen: UNI-MED Verlag AG.

51 Duclos-Vallee JC, Hadengue A, Ganne-Carrie N *et al.* (1995) Primary biliary cirrhosis–autoimmune hepatitis overlap syndrome. Corticoresistance and effective treatment by cyclosporine A. *Dig Dis Sci* 40, 1069–1073.

52 el-Shabrawi M, Wilkinson ML, Portmann B *et al.* (1987) Primary sclerosing cholangitis in childhood. *Gastroenterology* 92, 1226–1235.

53 Rabinovitz M, Demetris AJ, Bou-Abboud CF *et al.* (1992) Simultaneous occurrence of primary sclerosing cholangitis and autoimmune chronic active hepatitis in a patient with ulcerative colitis. *Dig Dis Sci* 37, 1606–1011.

54 Lawrence SP, Sherman KE, Lawson JM *et al.* (1994) A 39 year old man with chronic hepatitis. *Semin Liver Dis* 14, 97–105.

55 Debray D, Pariente D, Urvoas E *et al.* (1994) Sclerosing cholangitis in children. *J Pediatr* 124, 49–56.

56 Wilschanski M, Chait P, Wade JA *et al.* (1995) Primary sclerosing cholangitis in 32 children: clinical, laboratory, and radiographic features, with survival analysis. *Hepatology* 22, 1415–1422.

57 Gohlke F, Lohse AW, Dienes HP *et al.* (1996) Evidence for an overlap syndrome of autoimmune hepatitis and primary sclerosing cholangitis. *J Hepatol* 24, 699–705.

58 McNair AN, Moloney M, Portmann BC *et al.* (1998) Autoimmune hepatitis overlapping with primary sclerosing cholangitis in five cases. *Am J Gastroenterol* 93, 777–784.

59 van Buuren HR, van Hoogstraten HJE, Terkivatan T *et al.* (2000) High prevalence of autoimmune hepatitis among patients with primary sclerosing cholangitis. *J Hepatol* 33, 543–548.

60 Kaya M, Angulo P, Lindor KD (2000) Overlap of autoimmune hepatitis and primary sclerosing cholangitis: an evaluation of a modified scoring system. *J Hepatol* 33, 537–542.

61 Beuers U, Spengler U, Kruis W *et al.* (1992) Ursodeoxycholic acid for treatment of primary sclerosing cholangitis: a placebo-controlled trial. *Hepatology* 16, 707–714.

62 Stiehl A (1994) Ursodeoxycholic acid therapy in treatment of primary sclerosing cholangitis. *Scand J Gastroenterol Suppl* 204, 59–61.

63 Lindor KD (1997) Ursodiol for primary sclerosing cholangitis. Mayo Primary Sclerosing Cholangitis–Ursodeoxycholic Acid Study Group. *N Engl J Med* 336, 691–695.

64 Mitchell SA, Bansi DS, Hunt N *et al.* (2001) A preliminary trial of high-dose ursodeoxycholic acid in primary sclerosing cholangitis. *Gastroenterology* 121, 900–907.

65 Czaja AJ, Carpenter HA (2001) Autoimmune hepatitis with incidental histologic features of bile duct injury. *Hepatology* 34, 659–665.

66 Li CP, Tong MJ, Hwang SJ *et al.* (2000) Autoimmune cholangitis with features of autoimmune hepatitis: successful treatment with immunosuppressive agents and ursodeoxycholic acid. *J Gastroenterol Hepatol* 15, 95–98.

67 Rubel LR, Seeff LB, Patel V (1984) Primary biliary cirrhosis–primary sclerosing cholangitis overlap syndrome. *Arch Pathol Lab Med* 108, 360–361.

68 Burak KW, Urbanski SJ, Swain MG (2001) A case of coexisting primary biliary cirrhosis and primary sclerosing cholangitis: a new overlap of autoimmune liver diseases. *Dig Dis Sci* 46, 2043–2047.

69 Zanger UM, Hauri HP, Loeper J *et al.* (1988) Antibodies against human cytochrome P-450db1 in autoimmune hepatitis type II. *Proc Natl Acad Sci USA* 85, 8256–8260.

70 Manns MP, Johnson EF, Griffin KJ *et al.* (1989) Major antigen of liver kidney microsomal autoantibodies in idiopathic autoimmune hepatitis is cytochrome P450db1. *J Clin Invest* 83, 1066–1072.

71 Manns MP, Griffin KJ, Sullivan KF *et al.* (1991) LKM-1 autoantibodies recognize a short linear sequence in P450IID6, a cytochrome P-450 monooxygenase. *J Clin Invest* 88, 1370–1378.

72 Manns MP, Obermayer-Straub P (1997) Cytochromes P450 and uridine triphosphate-glucuronosyltransferases: model autoantigens to study drug-induced, virus-induced, and autoimmune liver disease. *Hepatology* 26, 1054–1066.

73 Lunel F, Abuaf N, Frangeul L *et al.* (1992) Liver/kidney microsome antibody type 1 and hepatitis C virus infection. *Hepatology* 16, 630–636.

74 Pawlotsky JM, Ben Yahia M, Andre C *et al.* (1994) Immunological disorders in C virus chronic active hepatitis: a prospective case–control study. *Hepatology* 19, 841–848.

75 Lunel F, Cacoub P (1999) Treatment of autoimmune and extrahepatic manifestations of hepatitis C virus infection. *J Hepatol* 31, 210–216.

76 Chazouilleres O (2000) Diagnosis of primary sclerosing cholangitis – autoimmune hepatitis overlap syndrome: to score or not to score? *J Hepatol* 33, 661–663.

12 Alcoholic liver disease

12.1 Epidemiological aspects of alcoholic liver disease

Juan Caballeria

The relationship between excessive alcohol consumption and the development of diseases, particularly hepatic lesions, has been recognized since early times, although these lesions had not been related to the direct toxic effect of alcohol until 50 years ago. Alcoholic hepatic cirrhosis is one of the most frequent liver diseases after those caused by the hepatitis virus and non-alcoholic steatohepatitis. Likewise, alcoholic hepatic cirrhosis is the second most common cause of liver transplantation in most healthcare centres. The prevalence and mortality of alcoholic cirrhosis are directly related to alcohol intake in a determined population [1,2]. This chapter will review the evolution of alcohol intake in different countries, the relationship between alcohol consumption and cirrhosis and other factors that may influence the toxic effect of alcohol on the liver.

Alcohol consumption

The consumption of alcohol rose progressively in most countries from the 1950s until the 1980s, with stabilization in alcohol intake or with even a slight increase being seen thereafter in many countries. According to the latest report by the World Health Organization, the consumption of alcohol in the adult population around the world in the last 5 years has stabilized at 5.1 L of pure alcohol per inhabitant per year, with 1.9 L corresponding to beer, 1.3 L to wine and 1.7 L to distilled beverages. These quantities obviously vary considerably according to the country and region analysed [3] (Table 1).

Countries in southern Europe such as France, Spain, Portugal and Italy are the greatest wine producers and, although the consumption of alcohol in these countries has declined, it remains high at around 12 L per inhabitant per year. A similar pattern may be observed in western European countries, where the decrease in alcohol intake is not as notable. However, the contrary may be seen in the northern European countries, and especially in eastern Europe, where the consumption of alcohol has risen, thereby reducing the differences among the different regions [4]. In the United States and Canada, the evolution of alcohol intake has been similar to that in Europe, with consumption being from 8.5 to 9 L per inhabitant and with a slight, albeit persistent, increasing trend [5].

Table 1 Estimated per capita alcohol consumption in representative countries from different worldwide regions in 2001 (population aged 15 years and older).

Country	Total (L/year)	Beer	Wine	Spirits
Argentina	8.55	2.30	5.63	0.42
Australia	9.19	5.20	2.98	1.49
Brazil	5.32	2.74	0.33	2.26
Canada	8.26	3.88	1.52	2.48
Chile	6.02	1.59	3.25	1.18
China	4.45	1.21	0.35	2.89
Czech Rep.	16.21	9.43	2.36	4.41
Denmark	11.93	6.02	4.57	1.34
Finland	10.43	4.89	2.94	2.61
France	13.54	2.20	8.38	2.96
Germany	12.89	7.26	3.38	2.24
Hungary	11.92	3.84	4.47	3.60
Ireland	14.45	9.24	2.05	3.07
Italy	9.14	1.68	6.99	0.47
Japan	7.38	2.20	1.15	4.02
Mexico	4.62	3.74	0.03	0.88
Netherlands	9.74	4.91	2.76	2.07
Poland	8.68	3.73	0.89	4.07
Portugal	12.49	3.66	7.16	1.67
Russia	10.58	1.82	1.12	7.64
Spain	12.25	4.38	5.07	2.80
Sweden	6.86	3.37	2.27	1.22
Thailand	8.47	1.31	0.04	7.13
UK	10.39	5.97	2.58	1.84
USA	8.51	4.76	1.15	2.44

Data from World Health Organization reports.

The most worrisome situation may be seen in the developing countries where an important increase in the consumption of alcohol, particularly of spirits, has been reported. This increase has been observed in all the Asian countries and, although it is

still markedly lower than that of western countries, it has doubled in only a relatively short period of time [6].

The preferences for the type of beverage consumed also vary from region to region, Beer consumption predominates in many European countries, wine is more often consumed in wine-producing countries, and spirits are more frequently consumed in northern Europe and in Asian countries. These preferences have changed in recent years, with the consumption of beer having risen considerably in Europe, while that of wine and spirits has remained stable. However, the consumption of wine has diminished in wine-producing countries and has increased in those that do not produce wine. As will be discussed later, the importance that the pattern of alcohol consumption has in the development of hepatic lesions is still not clear.

Alcohol consumption in a population, in general, is evaluated by taking into account the registry of production and alcohol sales. Therefore, consumption may be underestimated by not considering the illegal production of alcohol and the production of alcoholic beverages from the fermentation of different agricultural products. These aspects are important, especially in developing countries.

Furthermore, the average amount of alcohol consumed in a determined population should take into account other important aspects such as the percentage of people who drink regularly and the percentage of drinkers who consume a potentially dangerous amount of alcohol. In the United States, 67.3% of the adult population occasionally consume alcohol while 7.4% of the population (11% males and 4% females) fulfil the criteria of alcohol abuse or alcoholism. Likewise, 20% of the population consumes 80% of the alcohol [7]. Studies carried out in Spain have reported that 30% of the adult population is abstemious while 7.3% may be considered to be at risk of presenting an alcohol dependence syndrome or severe hepatic lesions [8].

Relationship between alcohol consumption and mortality from cirrhosis

Hepatic cirrhosis is one of the leading causes of death in all western countries with it having been estimated that approximately 150 000 people around the world die from cirrhosis every year. The real figure for the number of deaths by cirrhosis is probably greater as, in many cases, when this disease is compensated, it is not diagnosed. Alcohol is the primary cause of cirrhosis and is considered to be responsible for around 50% of the deaths from cirrhosis [9,10]. There is a clear parallel between alcohol intake in a determined population and the rate of death from cirrhosis, and these data are therefore considered to be an index of alcohol consumption in some countries (Fig. 1). Numerous epidemiological studies have demonstrated a relationship between the consumption of alcohol and death from cirrhosis, and studies performed in the United States during the time of prohibition and in France during the Second World War are considered classical.

From 1950 to 1973, the mortality from cirrhosis in the United States increased from 8.5 to 14.9 cases per 100 000 inhabitants in parallel with the increase in alcohol intake from 7.57 to 10.45 L per adult per year. A slow decline in both parameters has been observed since, with alcohol intake being 8.36 L per inhabitant per year and the mortality from cirrhosis being 7.9 cases per 100 000 inhabitants in 1993 (Fig. 2). In France, the mortality from cirrhosis decreased from 36 cases per 100 000 inhabitants in 1967 to 16 cases in 1992, coinciding with a 50% decrease in wine consumption.

One interesting fact is that, in these studies, there is no exact relationship between the time at which alcohol intake diminishes and when the mortality from cirrhosis decreases in a

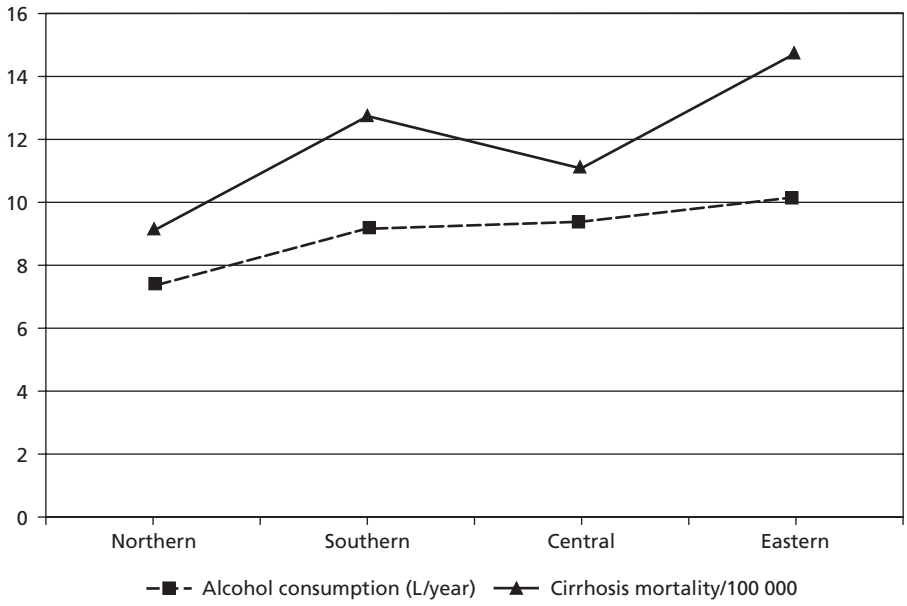

Fig. 1 Per capita total alcohol consumption and mortality from cirrhosis in different European regions, 2002 (WHO Regional Office for Europe Reports).

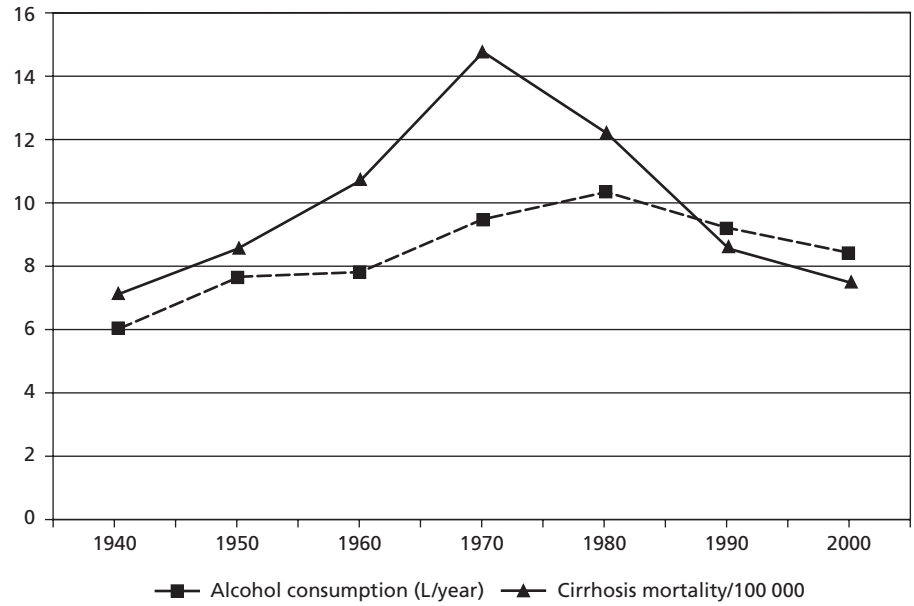

Fig. 2 Per capita total alcohol consumption and mortality from cirrhosis in the United States, 1940–2000 [2,3,5].

determined population. In the study cited from the United States, mortality from cirrhosis was at its highest in 1973, but alcohol consumption did not begin to fall until 1980. Several factors may explain this discordance [11]. First, the alcohol intake per inhabitant did not take into account the percentage of excessive drinkers, and the increase in alcohol consumption from one year to another may have been due to the increase in the total number of consumers, with the number of drinkers at risk of developing cirrhosis remaining constant. Secondly, changes in the treatment of alcohol dependence or cirrhosis and its complications may also influence mortality. Finally, a long period of excessive alcohol intake is required before the appearance of cirrhosis is observed and, thus, many years may go by before changes in the habits of alcohol consumption are reflected in the mortality from cirrhosis.

The close relationship between the variations in alcohol consumption and the mortality from cirrhosis has been demonstrated in two recent studies analysing the evolution of both parameters in Canada and in 14 European countries from 1950 to 1995 [12,13]. In the two studies, the curves of alcohol intake and mortality from cirrhosis followed a parallel course in both men and women. In the Canadian population, Ramstedt observed that an increase in alcohol consumption of 1 L per inhabitant per year was translated into an increase in mortality from cirrhosis of 17% in males and 13% in females, which is a 30% increase when only analysing the mortality from alcoholic cirrhosis. This increase in the rate of mortality from cirrhosis per litre of alcohol observed in Canada was greater than in the countries of southern (10%) and central (8%) Europe and lower than in countries of northern Europe (27%). Ramstedt suggested that, apart from the total amount of alcohol, the frequency of episodes of high consumption might raise the risk of cirrhosis. However, this aspect remains controversial.

Another aspect that could influence the mortality from cirrhosis is the type of alcoholic beverage consumed. In a study published in 1967 on alcohol consumption in the United States, Canada and the United Kingdom, Terris [14] suggested that the consumption of beer had little influence on mortality from cirrhosis and that the changes in the consumption of spirits were responsible for the variations in the mortality from cirrhosis. Similar results were obtained 30 years later, also analysing the variations in alcohol consumption and mortality from cirrhosis in several countries in which mainly beer is consumed. In their study, Kerr *et al.* [15] concluded that the consumption of spirits, more than that of beer or wine, was associated with mortality from cirrhosis. Finally, in a recent study, Roizen *et al.* [5] also observed that the curves of alcohol consumption and mortality from cirrhosis in the United States from 1949 to 1994 were more closely related to the curve of spirits consumption than the total curve of alcohol consumption or the curves of wine or beer intake (Fig. 3).

The relationship between alcohol consumption and the development of hepatic cirrhosis is also very evident in countries in which alcohol intake has become important in recent years, such as in Asian countries, especially Japan, Korea or Taiwan. In these countries, the consumption of alcohol per inhabitant per year was around 1 L 40 years ago and had risen to 7 L in 1980. This increase is even more important when only males or subjects with aldehyde dehydrogenase type 2 are considered. During this period of time, liver diseases of alcoholic aetiology have risen from 5.1% to 14.1% in Japan [16] and from 1.55% to 24% in Korea [17].

It is generally agreed that the development of cirrhosis is correlated with the magnitude and length of alcohol intake, although there are some discrepancies with regard to the dose of alcohol at which the risk of cirrhosis increases. In Germany, Lelbach [18] observed a clear relationship between the quantity

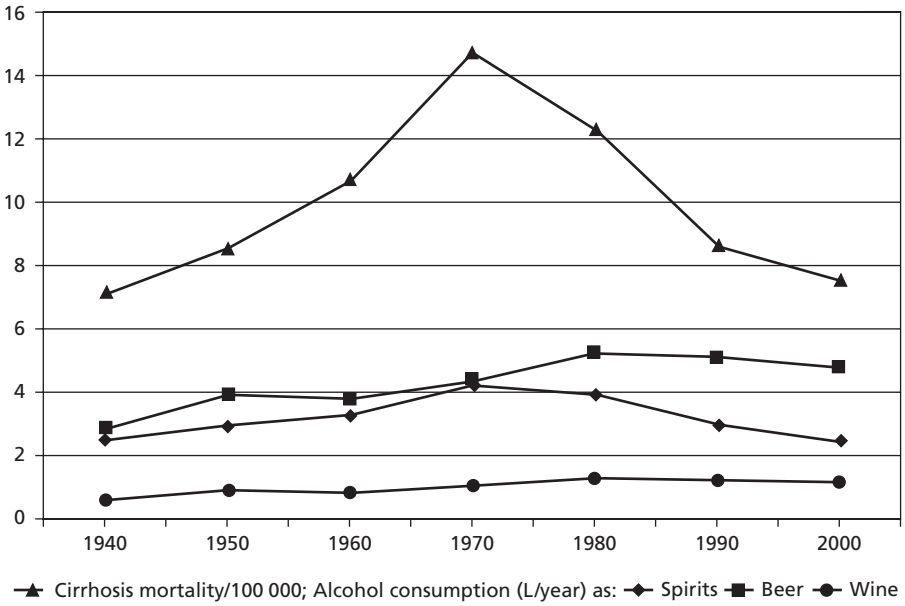

Fig. 3 Per capita alcohol consumption of distilled spirits, beer and wine, and mortality from cirrhosis in the United Sates, 1940–2000 [2,3,5].

and length of alcohol intake and the development and intensity of hepatic lesions. More recently, Anderson [19] analysed the results of four case–control studies demonstrating a relationship between the intensity of alcohol intake and the development of cirrhosis in all. There is evidence suggesting that the risk increases with the consumption of 60–80 g/day in males and 20 g/day in females, although according to the different studies, only between 6% and 41% of the subjects consuming these quantities developed cirrhosis. In the Dionysos study, only 13.5% of the subjects with an alcohol intake of > 120 g/day developed alcoholic liver disease. This study suggested that a minimum of 100 kg of alcohol over a lifetime is required to develop cirrhosis [10].

More recently, it has been suggested that above a relatively low, albeit not well-determined, level of alcohol consumption, the risk of developing cirrhosis is not influenced by the dose of alcohol consumed. Thus, alcohol could have a permissive and not dose-dependent role in the development of hepatic lesions. In a series of autopsies, a greater incidence of cirrhosis was observed with alcohol intake of > 80 g/day, but there was no relationship between alcohol consumption and the development of cirrhosis above this value [20]. In a prospective study carried out in Denmark, it was found that the mortality from alcoholic cirrhosis among alcoholics compared with the general population was 27-fold greater in males and 35-fold greater in women, but the risk of cirrhosis was not associated with the magnitude of consumption as no progressive increase in risk was observed above a consumption of 60 g/day [21].

Other factors that may influence mortality from alcoholic cirrhosis

Different studies have reported that only 15–30% of chronic alcoholics developed cirrhosis, suggesting that other factors may influence the development of this disease. Among these factors, the pattern of consumption, the type of beverage, lifestyle, gender, ethnicity and hepatitis virus infection, especially hepatitis C virus (HCV), have been mentioned.

As indicated previously, some studies have suggested that the pattern of alcohol intake or the type of beverage may influence the development of and mortality from cirrhosis. Therefore, important episodes of ingestion or the consumption of spirits preferentially may be more harmful than continued but moderate intake or the consumption of wine or beer [1,22]. It has also been suggested that individuals who drink daily have a greater risk of developing liver disease than weekend drinkers. However, all these aspects remain open to debate.

It has also been suggested that diet and lifestyle may influence the development of cirrhosis in alcoholics. Among the factors mentioned are the ingestion of pork products, smoking, socioeconomic levels and obesity [2]. Among these factors, the most frequently considered has possibly been obesity. Several studies have demonstrated that excess weight, defined by a body mass index of > 25 in males and > 27 in females, over at least 10 years is an independent risk factor for the development of alcoholic hepatitis and cirrhosis in subjects with excessive alcohol consumption [23,24]. Iturriaga *et al.* [25] also showed that overweight alcoholics had more frequent and more severe hepatic lesions. In contrast, the Dionysos study suggested that the development of cirrhosis in alcoholics was not dependent on weight and body mass index.

Women have a greater susceptibility to the harmful effects of alcohol and develop liver diseases that are equally as severe or more severe than those of males with a lower amount of daily alcohol intake and over a shorter period of time [26]. Thus, the amount of alcohol considered excessive in women is lower and, according to different authors, is between 20 and 60 g/day. Different factors have been proposed to explain the greater

susceptibility of women to developing hepatic lesions, including differences in the first-pass metabolism of alcohol and in the activity of enzymes related to its metabolism [27], greater blood and hepatic levels resulting from differences in the volume of distribution [28] and an effect related to estrogens [29].

There are marked differences in the incidence of and the mortality from cirrhosis among different ethnic groups. These differences are very evident in countries such as the United States where the mortality from cirrhosis is greater in Hispanic subjects followed by Afro-Americans, while the mortality from cirrhosis among Caucasians is lower [9]. Although there are no differences in the global consumption of alcohol among these populations, the number of excessive drinkers and the episodes of elevated alcohol consumption are greater in Hispanics and, to a lesser degree, in Afro-Americans [30]. However, it remains unclear whether these differences are due to genetic factors, differences in the pattern of consumption or in the type of beverage consumed or whether socioeconomic factors may play a role.

Excessive alcohol consumption and infection with HCV are the two main causes of chronic liver disease. On the other hand, both factors frequently coexist, and there is a great deal of evidence pointing to a synergic effect. The prevalence of HCV infection is greater in alcoholics than in the general population and is even greater in alcoholics with liver involvement [31]. Moreover, individuals with HCV infection and excessive alcohol intake have more severe liver lesions, a more rapid progression of the disease and more frequently develop cirrhosis and hepatocellular carcinoma [32,33]. Alcohol consumption also reduces the response to treatment with interferon. The mechanisms responsible for the interaction between alcohol abuse and HCV infection remain unknown. Neither is it known whether moderate alcohol intake also has a harmful effect on the evolution of chronic hepatitis by HCV. There is no clear evidence as to the influence of alcohol intake on infection by the hepatitis B virus.

Conclusions

Alcoholism currently continues to be a healthcare problem of first priority, and alcoholic hepatic cirrhosis is one of the leading causes of mortality in most countries. Despite a fall in both parameters in the last decades, there are worrisome data which foresee a stabilization or even an increase in mortality from cirrhosis. Among these factors, an increase in alcohol intake in developing countries, a greater consumption among youths and women, changes in drinking patterns, with an increase in episodes of sporadic and very high consumption of spirits, instead of regular consumption, and a predominance of wine and beer have to be considered. Likewise, the interaction between alcohol consumption and the rise in the prevalence of liver diseases such as chronic hepatitis C and non-alcoholic steatohepatitis foresee an increase in mortality from cirrhosis. All these aspects, as well as the identification of the populations at risk, should be the focus of future studies.

References

1 Mann RE, Smart RG, Govoni R (2003) The epidemiology of alcoholic liver disease. *Alcohol Res Health* 27, 209–219.

2 Mandayam S, Jamal M, Morgan TR (2004) Epidemiology of alcoholic liver disease. *Semin Liver Dis* 24, 217–232.

3 WHO (2004) *WHO Global Status Report on Alcohol*. Geneva: World Health Organization, Department of Mental Health and Substance Abuse.

4 Corrao G, Ferrari P, Zambon A *et al.* (1997) Trends of liver cirrhosis mortality in Europe, 1970–1989: age-period-cohort analysis and changing alcohol consumption. *Int J Epidemiol* 26, 100–109.

5 Roizen R, Kerr WC, Filmore KM (1999) Cirrhosis mortality and per capita consumption of distilled spirits, United States, 1949–94: trend analysis. *Br Med J* 319, 666–670.

6 Rehm J, Rehn N, Room R *et al.* (2003) The global distribution of average volume of alcohol consumption and patterns of drinking. *Eur Addict Res* 9, 147–156.

7 Kim WR, Brown RS Jr, Terrault NA *et al.* (2002) Burden of liver disease in the United States: summary of a workshop. *Hepatology* 36, 227–242.

8 Cherpitel CJ, Parés A, Rodés J (1991) Drinking patterns and problems: a comparison of emergency room population in the United States and Spain. *Drug Alcohol Depend* 28, 5–15.

9 Stinson FS, Grant BF, Dufour MC (2001) The critical dimension of ethnicity in liver cirrhosis mortality statistics. *Alcoholism Clin Exp Res* 25, 1181–1187.

10 Bellentani S, Saccoccio G, Costa G *et al.* (1997) Drinking habits as cofactor risk for alcohol induced liver damage. The Dionysos Study Group. *Gut* 41, 845–850.

11 Skog O-J (1988) Interpreting trends in alcohol consumption and alcohol related damage. *Alcohol Alcoholism* 23, 193–202.

12 Ramstedt M (2003) Alcohol consumption and liver cirrhosis mortality with and without mention of alcohol – the case of Canada. *Addiction* 98, 1267–1276.

13 Ramstedt M (2001) Per capita alcohol consumption and liver cirrhosis mortality in 14 European countries. *Addiction* 96 (Suppl 1), S19–S34.

14 Terris M (1967) Epidemiology of cirrhosis of the liver: national mortality data. *Am J Public Health* 56, 2076–2088.

15 Kerr WC, Fillmore KM, Marvy P (2000) Beverage-specific alcohol consumption and cirrhosis mortality in a group of English-speaking beer-drinking countries. *Addiction* 95, 339–346.

16 Hasumura Y, Takeuchi J (1991) Alcoholic liver disease in Japanese patients: a comparison with Caucasians. *J Gastroenterol Hepatol* 6, 520–526.

17 Park SC, Oh SI, Lee MS (1998) Korean status of alcoholics and alcohol-related health problems. *Alcohol Clin Exp Res* 22, 170S–172S.

18 Lelbach WK (1976) Epidemiology of alcoholic liver disease. *Prog Liver Dis* 5, 494–515.

19 Anderson P (1995) Alcohol and risk of physical harm. In: Holder HD, Edwards G (eds) *Alcohol and Public Policy: Evidence and Issues*. Oxford: Oxford University Press, pp. 82–113.

20 Savolainen VT, Liesto K, Mannikko A *et al.* (1993) Alcohol consumption and alcoholic liver disease: evidence of a threshold level of effects of alcohol. *Alcoholism Clin Exp Res* 17, 1112–1117.

21 Kamper-Jorgensen M, Gronbaek M, Tolstrup J *et al.* (2004) Alcohol and cirrhosis: dose–response or threshold effect? *J Hepatol* 41, 25–30.

22 Smart RG (1996) Behavioral and social consequences related to the consumption of different beverages types. *J Stud Alcohol* 57, 419–424.
23 Day CP (2000) Who gets alcoholic liver disease: nature or nurture? *J R Coll Phys Lond* 34, 557–562.
24 Naveau S, Giraud V, Borotto E *et al.* (1997) Excess weight risk factor for alcoholic liver disease. *Hepatology* 25, 108–111.
25 Iturriaga H, Bunout D, Hirsh S *et al.* (1988) Overweight as a risk factor for a predictive sign of histological liver damage in alcoholics. *Am J Clin Nutr* 47, 235–238.
26 Sato N, Lindros KO, Baraona E *et al.* (2001) Sex difference in alcohol-related organ injury. *Alcohol Clin Exp Res* 25, 40S–45S.
27 Frezza M, Di Padova C, Pozzato G *et al.* (1990) High blood alcohol levels in women. The role of decreased gastric alcohol dehydrogenase activity and first-pass metabolism. *N Engl J Med* 322, 95–99.
28 Marshall AW, Kingstone D, Boss M *et al.* (1983) Ethanol elimination in males and females: relationship to menstrual cycle and body composition. *Hepatology* 3, 701–706.
29 Yin M, Ikejima K, Wheeler MD *et al.* (2000) Estrogen is involved in early alcohol-induced liver injury in rat enteral feeding model. *Hepatology* 31, 117–123.
30 Caetano R, Kaskutas LA (1995) Changes in drinking patterns among whites, blacks and Hispanics, 1984–1992. *J Stud Alcohol* 56, 558–565.
31 Pares A, Barrera JM, Caballería J *et al.* (1990) Hepatitis C virus antibodies in chronic alcoholic patients: association with severity of liver injury. *Hepatology* 12, 1295–1299.
32 Jamal M, Morgan TR (2003) Liver disease in alcohol and hepatitis C. *Best Pract Res Clin Gastroenterol* 17, 649–662.
33 Bhattacharya R, Shuhart MC (2003) Hepatitis C and alcohol. Interactions, outcomes and implications. *J Clin Gastroenterol* 36, 242–252.

12.2 Ethanol metabolism and pathogenesis of alcoholic liver injury

Stephen F. Stewart and Chris P. Day

Introduction

In spite of intense research efforts there is still much debate about the main pathogenetic mechanisms through which ethanol causes liver injury. Several mechanisms have been proposed, and more than one is likely to be important (Table 1). These include the direct effect of ethanol metabolism on liver biochemistry, the release of cytokines as a result of portal endotoxinaemia and the liver-directed adaptive immune responses generated towards new antigens formed through these first two mechanisms. Before describing how these mechanisms may interact there is a brief description of the absorption, distribution, metabolism and elimination of alcohol. Alcohol metabolism will be discussed in terms of the fate of a unit of alcohol following ingestion. One unit is equivalent to 10 g or 12.5 mL of absolute alcohol, which is present in approximately half a pint (284 mL) of beer and one standard measure of wine (114 mL) or spirits (24 mL).

Absorption, distribution and excretion

After ingestion of one unit, peak blood alcohol concentration occurs after approximately 20 min and reaches between 10 and 15 mg/100 mL. The rate of rise and height of peak is a function of alcohol absorption and tissue distribution. Alcohol is absorbed from the gastrointestinal tract by simple diffusion [1] with 50–80% of absorption occurring in the duodenum and upper jejunum. The rate of absorption is delayed following a meal and increases in proportion to the alcohol concentration of the drink consumed.

Following absorption, the tissue distribution of alcohol is determined principally by blood flow and water content. The low lipid solubility of alcohol also explains why, following the ingestion of the same amount of alcohol per unit weight, an obese person attains a higher level of blood alcohol than a thin person, and a woman a higher level than a man [2]. Over 90% of circulating alcohol is oxidatively metabolized, primarily in the liver, and excreted as carbon dioxide and water. The remainder is eliminated unchanged in the urine (<1%) and breath (1–5%).

The rate of alcohol metabolism does not vary widely in the population, and above a concentration of 10 mg/100mL occurs at a constant rate of approximately 100 mg/kg body weight per hour – so-called 'zero-order' kinetics. A 70-kg man, therefore, eliminates one unit of alcohol in about 90 min. While there is therefore no rapid feedback mechanism to increase the rate of alcohol oxidation, heavy, repeated alcohol consumption can increase the rate of elimination by up to 100%.

Table 1 Main mechanisms through which ethanol may lead to liver injury.

Ethanol metabolism and oxidative stress
Endotoxin-mediated cytokine release
Immune-mediated

Alcohol metabolism

Site of alcohol oxidation

Alcohol metabolism is performed almost entirely by the liver, which contains several different high-affinity (low K_m) enzyme systems capable of oxidizing alcohol. The only other organ with potentially significant alcohol dehydrogenase (ADH) activity is the stomach, where the very high levels of alcohol following ingestion have led to the suggestion that there is a significant first-pass metabolism [3]. A study showing that gastritis results in a reduction in gastric ADH activity without affecting ethanol bioavailability casts doubt on the clinical role of this gastric first-pass effect [4].

Oxidation of alcohol to acetaldehyde

Alcohol oxidation in the liver takes place via three steps. First alcohol is oxidized, principally within the cytosol, to acetaldehyde. Then acetaldehyde is further oxidized to acetate, primarily within the mitochondria and, finally, acetate is released into the blood and oxidized to carbon dioxide and water in peripheral tissues. At least three enzyme systems with the capacity to

oxidize alcohol to acetaldehyde are present within the liver, although in normal individuals only the alcohol dehydrogenase enzymes are important.

The alcohol dehydrogenase (ADH) pathway

ADHs catalyse the oxidation of a variety of alcohols to aldehydes and ketones. This includes catalysing the oxidation of ethanol to acetaldehyde and transferring hydrogen to the cofactor nicotinamide adenine dinucleotide (NAD), which is converted to its reduced form NADH. The resulting increase in the ratio of NADH/NAD, which is further increased by acetaldehyde oxidation, is partly responsible for the metabolic imbalances that occur following alcohol ingestion and has been considered to play a major role in the initial pathogenesis of alcohol-induced fatty liver. The overall K_m of liver ADH activity is in the order of 1 mmol (4 mg/100 mL), which explains why alcohol follows zero-order kinetics at anything above very low blood levels.

The microsomal ethanol-oxidizing system (MEOS) pathway

In addition to ADH, alcohol is metabolized by the MEOS; an accessory pathway that principally involves a specific alcohol-inducible form of cytochrome P450 designated CYP2E1 [5]. The enzyme is located on the endoplasmic reticulum, is present in greater amounts in perivenular than periportal hepatocytes and requires oxygen and NADPH. The CYP2E1 protein has been purified and the human gene cloned, sequenced and localized to chromosome 10 [6]. The overall contribution of MEOS to alcohol oxidation *in vivo* is not yet fully clear. Its K_m for alcohol is in the order of 50–80 mg/100 mL, so it appears to play an important role at high blood alcohol levels or following chronic alcohol abuse, in view of its inducibility.

The catalase pathway

The third pathway for alcohol oxidation is catalysed by the enzyme catalase. This enzyme is located in the peroxisomes of most tissues and the pathway accounts for less than 2% of overall *in vivo* alcohol oxidation [7].

Oxidation of acetaldehyde to acetate

Over 90% of the acetaldehyde formed is further oxidized in the liver to acetate by aldehyde dehydrogenases (ALDHs). ALDH, like ADH, uses NAD as a cofactor and further increases the NADH/NAD ratio. Of the human ALDHs, ALDH2 is responsible for the majority of acetaldehyde oxidation [8]. The *ALDH2* gene exists in at least two allelic forms, *ALDH2*1* and *ALDH2*2* [9] with the gene product of the *ALDH2*2* allele having little or no catalytic activity [10]. This inactive form of ALDH2 is present in about 50% of Orientals but has not been found in Caucasian populations. Increased levels of acetaldehyde are thought to be the mechanism through which homozygotes for the *ALDH2*2* allele develop the 'flushing' reaction after alcohol. Interestingly, heterozygotes for the allele appear to develop advanced liver disease with lower levels of ethanol consumption [11], adding to the evidence that acetaldehyde is centrally involved in the pathogenesis of ALD. ALDH inhibitors such as disulfuram (Antabuse) have been used in the treatment of alcoholism to sensitize alcoholics to the unpleasant effects of alcohol intake secondary to high levels of acetaldehyde.

Alterations in alcohol metabolism following chronic consumption

Many studies have shown that chronic alcohol consumption increases the rate of alcohol elimination except in the presence of severe liver damage. This increase is due to induction of the MEOS and to adaptive changes in the ADH pathway. Increased ethanol metabolism coupled with a reduction in acetaldehyde metabolism [12] results in higher levels of acetaldehyde in both the blood and tissues of heavy drinkers [13,14]. This may have important implications for disease pathogenesis.

Alcohol metabolism and the pathogenesis of alcoholic liver disease (ALD)

There are several mechanisms through which ethanol metabolism may result in the generation of fatty liver (steatosis), oxidative stress/lipid peroxidation and acetaldehyde, all of which are thought to be important in disease pathogenesis.

The pathogenesis of fatty liver

The accumulation of triacylglycerol (TAG), synthesized via the sequential esterification of glycerol-3-phosphate within the liver, is an early and reversible effect of alcohol consumption in humans and animal models of ALD. It is the consequence of increased substrate supply – glycerol and free fatty acids (FFA) – increased esterification and decreased export of TAG from the liver [15]. The precise molecular mechanisms that lead to these three main effects have recently been elucidated.

The role of dietary fat

Rat models of ALD have shown that the rate of development of fatty liver is proportional to the fat content of the diet [16]. Alcohol intake also increases availability of FFA through the lipolysis of adipose tissue. The high concentrations of FFA further promote the synthesis of TAG by increasing the activity of the enzyme phosphatidate phosphohydrolase (PAP), which is the rate-limiting step for TAG synthesis, catalysing the dephosphorylation of phosphatidic acid to diacylglycerol [15,17].

Altered redox state

Both the ADH pathway and the MEOS pathway result in an increased NADH/NAD ratio, which has profound effects on the metabolism of carbohydrates and lipids. Gluconeogenesis is impaired and substrate flow through the citric acid cycle is

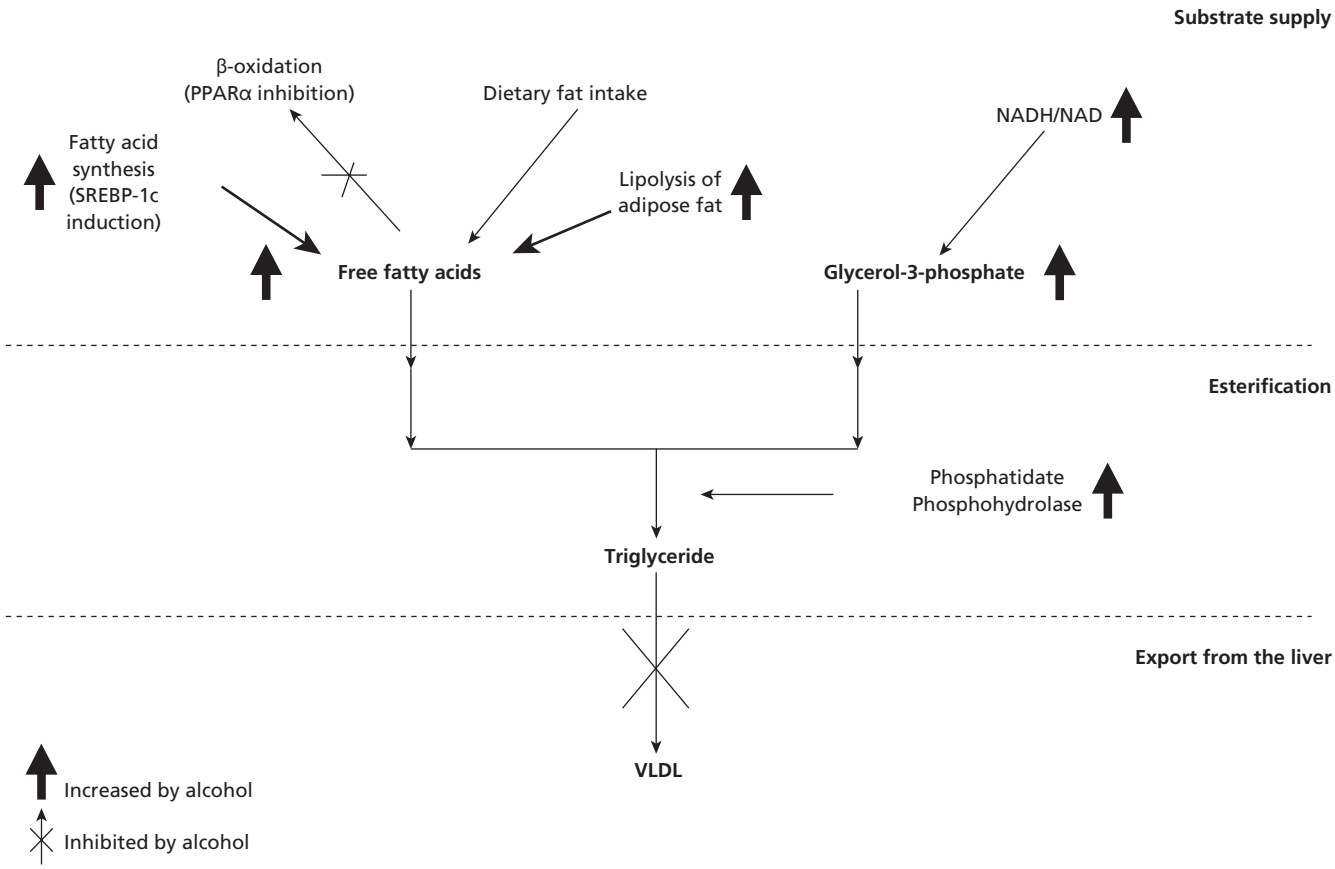

Fig. 1 The multiple mechanisms through which ethanol metabolism can lead to fatty liver. Ethanol causes fatty liver by increasing substrate supply, increasing fat esterification to triglyceride and reducing the export of very-low-density lipoprotein (VLDL) from the liver. PPARα, peroxisome proliferator-activated receptor α; SREBP-1c, sterol response element binding protein 1c.

diminished, with acetyl CoA diverted towards ketogenesis and fatty acid synthesis. In addition to increased fatty acid synthesis, the altered redox state also directly inhibits fatty acid oxidation, increasing substrate supply. The altered NADH/NAD ratio also increases the production of the other key component of TAG, glycerol-3-phosphate, again promoting TAG synthesis (Fig. 1).

The role of PPAR-α inhibition

Recent evidence suggests that ethanol also has an effect on fatty acid oxidation through the transcriptional factor peroxisome proliferator-activated receptor alpha (PPARα). This ligand-activated receptor/transcription factor is a critical component in the regulation of mitochondrial, microsomal and peroxisomal fatty acid oxidation systems in the liver [18]. Ethanol feeding results in a decrease in transcription and activity of many of these enzymes due to an inhibition of the transcriptional and DNA-binding activity of PPARα [19]. This effect was replicated with acetaldehyde, and inhibited by inhibiting ethanol metabolism, implicating acetaldehyde as the factor leading to PPARα inhibition [19]. Treatment with the PPARα agonists WY14,643 and clofibrate reversed the effects of ethanol feeding and the resulting abnormalities in hepatic lipid metabolism in rodent models [20,21], while alcohol-fed PPARα-null mice develop more steatosis, hepatocyte injury and fibrosis than their wild-type littermates [22]. The precise mechanism of acetaldehyde-induced PPARα inhibition is still unclear.

Mechanisms of altered triglyceride export

The ethanol-induced decrease in export of TAG from the liver appears to be primarily due to ethanol-induced downregulation of microsomal triglyceride transfer protein (MTP) [23]. MTP is the principal enzyme responsible for packaging TAG and apolipoprotein B (apoB) into VLDL (very-low-density lipoprotein) particles.

Role of tumour necrosis factor α in the pathogenesis of steatosis

The putative role of tumour necrosis factor α (TNFα) in the pathogenesis of necroinflammation in ALD is described in the section 'Endotoxin' below. Only recently, however, has this cytokine been linked to the development of hepatic steatosis. Interest in this area stemmed from a study showing that TNFα receptor 1 (TNFR1)-deficient mice developed considerably less

steatosis than their wild-type littermates when fed ethanol [24]. Recently, the mechanisms for this TNFα-induced steatosis have been better elucidated. They include the downregulation of MTP (discussed above), the increased expression of sterol response element binding protein 1c (SREBP-1c) [25], a transcription factor crucial in controlling *de novo* hepatic lipogenesis, and inhibition of adiponectin, an antisteatotic adipocytokine [26]. Because one of adiponectin's antisteatotic effects is via PPARα, the inhibition of adiponectin by TNFα provides a potential mechanism for ethanol's inhibition of PPARα activity discussed above.

Inhibition of the methionine cycle and endoplasmic reticular stress

Studies predominantly in micropigs have demonstrated that the inhibition of transmethylation reactions by ethanol is the major mechanism leading to the well-established abnormal methionine metabolism associated with ethanol consumption [27]. The principal enzyme inhibited by ethanol is methionine synthase (MS) [28], and a significant effect of this appears to be the development of hyperhomocysteinaemia.

Hyperhomocysteinaemia increases expression of the gene for SREBP-1c [29]. Previous studies have shown that ethanol induces SREBP-1c in rat hepatoma cell lines and mouse liver with a concomitant increase in the expression of lipogenic genes [30], and that this induction may be related to inhibition of adenosine monophosphate (AMP)-activated protein kinase (AMPK) [31]. Furthermore, feeding betaine, a methyl donor converting homocysteine to methionine, significantly inhibits the development of steatosis, implying that it is the inhibition of methylation and resulting hyperhomocysteinaemia that is responsible [32]. It has recently been shown that the effect of ethanol on the development of hyperhomocysteinaemia is independent of TNFα, and that these two mechanisms induce steatosis independently and in parallel [33].

The role of steatosis in the pathogenesis of advanced ALD

A growing body of evidence suggests that, rather than being an epiphenomenon of excessive alcohol intake, steatosis may play a direct role in progression to more advanced disease [34]. In several prospective studies of heavy drinkers, the severity and pattern of steatosis on index biopsy predicts the subsequent risk of fibrosis and cirrhosis [35,36]. These and other studies have led to steatosis being considered as the 'first hit', increasing the sensitivity of the liver to a variety of 'second hits', which could be gut-derived endotoxin, oxidative stress or immune mechanisms. In support, studies in animal models have shown that steatosis increases endotoxin-mediated necroinflammation [37] and the degree of lipid peroxidation in ethanol- and other drug-induced steatosis [38]. Furthermore, genetically obese mice with steatosis have altered proportions of intrahepatic lymphocyte subpopulations, raising questions whether steatosis itself may alter the intrahepatic immune milieu [39].

Table 2 Sources of oxidative stress in ALD.

Source	Main evidence
CYP2E1	Inhibition with diallyl sulphide reduces lipid peroxidation
Mitochondria	Gross ultrastructural changes in human and animal ALD
iNOS	Ethanol-fed iNOS–/– mice have reduced levels of lipid peroxidation
Kupffer cells	Inhibition with gadolinium chloride reduces lipid peroxidation

CYP2E1, cytochrome P4502E1; iNOS, inducible nitric oxide synthase.

Oxidative stress and lipid peroxidation

One of the most important consequences of cellular oxidative stress is the peroxidation of the polyunsaturated fatty acid (PUFA) constituents of membrane and lipoprotein lipids. This can lead directly to cell death [40] or to the release of reactive aldehydes with potent proinflammatory, profibrotic and proimmune properties [41]. An accumulating body of evidence now supports a role for oxidative stress and lipid peroxidation in the pathogenesis of ethanol-induced liver injury.

Sources of oxidative stress in ALD

Considerable controversy remains over the most important source of reactive oxygen species (ROS) in ALD but the most likely candidates are microsomal CYP2E1 (the only source of hydroxyethyl radicals [42,43]), the mitochondrial electron transport chain [44], inducible nitric oxide synthase and Kupffer cells (Table 2).

Depletion of antioxidant defences in ALD

Consumption of glutathione (GSH) during oxidative stress and inhibition of two enzymes – MS and methionine adenosyltransferase (MAT) – involved in the synthesis of its precursor, *S*-adenosylmethionine (SAMe), contribute to the decreased levels of hepatic SAMe and GSH observed in patients with ALD [45]. Depletion of mitochondrial GSH precedes and promotes the progression of alcoholic liver injury in animal models [46], with one mechanism of action being an increased sensitivity of hepatocytes to TNFα-induced cytotoxicity [47]. Heavy drinkers, including those with ALD, are deficient in the antioxidant trace element selenium [48], which is required for the activity of the antioxidant enzyme GSH peroxidase, the antioxidant vitamins A, C and E [49,50] and coenzyme Q [51]. Whether these deficiencies are a cause or an effect of ALD remains unclear, although the fact that antioxidant supplementation appears to be of no benefit in patients with ALD is perhaps more in favour of the latter explanation [52].

Manipulating oxidative stress in animal models influences disease severity

Diets that promote oxidative stress increase the severity of ALD in animal models. Rats fed diets high in corn oil [53], linoleic

acid [54] or fish oil [55] develop the most severe disease implying that polyunsaturated fats, which are much more vulnerable to attack from ROS, have a role in promoting liver injury. Dietary iron supplementation also leads to an increase in the concentration of the aldehyde endproducts of lipid peroxidation within the liver, exacerbates hepatocyte damage and promotes liver fibrogenesis [56]. Studies employing genetic manipulation to increase the degree of oxidative stress provide further support for its role as an important disease mechanism in ALD. Cytosolic superoxide dismutase (SOD-1) knockout mice develop more significant liver injury compared with wild-type littermates following ethanol feeding [57], while MAT knockout mice have reduced hepatic GSH levels and develop spontaneous steatohepatitis even without alcohol [58].

Further evidence supporting the role of oxidative stress in ALD comes from studies aimed at reducing its levels during ethanol feeding. Reduction of oxidative stress by supplementation with the GSH precursor and methyl donor SAMe reduced cell and mitochondrial injury in the baboon model of ALD [59] and led to the pilot study in humans discussed below. Inhibiting the pro-oxidant effect of iron with the oral chelator 1,2-dimethyl-3-hydroxypyrid-4-one reduced hepatic free iron (non-haem iron), lipid peroxidation and fat accumulation in chronically ethanol-fed rats [60], and inhibiting the induction of CYP2E1 with diallyl sulphide (DAS) and phenylethyl isothiocyanate (PIC) resulted in the production of fewer free radicals and endproducts of lipid peroxidation and ameliorated liver injury in the same model [61,62]. Amelioration of liver injury could also be achieved using an adenovirus to deliver the mitochondrial manganese-dependent superoxide dismutase-2 (SOD2) to rats fed ethanol [63], and mice deficient in NADPH oxidase have also been used to show the importance of this source of oxidants in the development of early alcohol-induced hepatitis [64].

Acetaldehyde

It has been known for some time that acetaldehyde can form Schiff bases with the valine, lysine and tyrosine residues on cellular proteins [65] resulting in both stable and unstable adduct formation. This may disrupt protein function and can result in the production of immunodominant antigenic determinants (discussed below) (Table 3).

More recently, a further and more complex role for acetaldehyde has been suggested. Hepatocytes are resistant to TNFα-induced cytotoxicity unless they have been previously exposed to ethanol [66]. As discussed above, selective depletion of mitochondrial GSH can induce this sensitization, and is postulated to be the mechanism through which it happens *in vivo*. When HepG2 cells are exposed to acetaldehyde, there is a selective reduction in mitochondrial GSH and increased sensitization to TNFα [47]. This has been shown to occur even when further metabolism of acetaldehyde is inhibited, and recent evidence suggests it is due to an inhibition of GSH transport into the mitochondria secondary to an increased proportion of cholesterol in the mitochondrial membrane and a resulting increase in viscosity [67]. It is postulated that acetaldehyde induces this increase in cholesterol through SREBP-1c upregulating the transcription of cholesterol-synthesizing enzymes. This effect on GSH transport will exacerbate the GSH depletion resulting from decreased SAMe synthesis and consumption during oxidative stress. In this way, the induction of SREBP-1c by TNFα and by acetaldehyde and hyperhomocysteinaemia can induce a vicious cycle resulting not only in steatosis, but also in sensitization to the cytotoxic effects of TNFα. This is particularly significant in view of the role of endotoxin in ALD, which acts predominantly as a stimulus to the release of TNFα from hepatic Kupffer cells.

Table 3 Mechanisms through which acetaldehyde may lead to liver injury.

Induction of steatosis through increasing the NADH/NAD ratio and inhibiting PPARα
Increasing sensitization to TNFα cytotoxicity by depleting mitochondrial glutathione
Forming Schiff bases with host proteins and affecting function and producing neoantigens

NAD, nicotinamide adenine dinucleotide; NADH, reduced NAD; PPARα, peroxisome proliferator-activated receptor α; TNFα, tumour necrosis factor α.

The innate immune system and the pathogenesis of ALD

A considerable body of evidence supports a role for the innate immune system activated by gut-derived endotoxin in the pathogenesis of ALD.

Endotoxin

Endotoxin, which refers collectively to the lipopolysaccharide (LPS) components of the cell wall of all Gram-negative bacteria, appears to play a central role in the development of ALD. Ethanol ingestion increases the translocation of endotoxin from the gut lumen [68] to the portal circulation where it is normally recognized by cells of the innate immune system – intrahepatic macrophages (Kupffer cells). Endotoxinaemia has been found in drinkers with varying degrees of liver disease [69], and in the ethanol-fed rat the level of plasma endotoxin correlated with the degree of liver injury [70]. When Kupffer cells encounter the LPS component of endotoxin in conjunction with lipopolysaccharide binding protein (LBP) [71], they respond by releasing cytokines and ROS. CD14 and the Toll-like receptor 4 (TLR4) are important signalling receptors [72], and current data suggest that LPS signalling occurs through activation clusters of these two receptors along with other membrane proteins. The importance of TLRs has been further highlighted recently by the

discovery that they control activation of adaptive immune responses as well as innate responses. This occurs through an interleukin 6 (IL-6) dependent pathway, resulting in suppression of CD4+CD25+ T-regulatory cells that normally specifically inhibit adaptive immune responses [73].

The role of endotoxin and Kupffer cells in the pathogenesis of ALD has been suggested largely by studies in the rodent model of continuous intragastric feeding developed by Tsukamoto *et al.* [74]. These animals develop lesions similar to human alcoholic hepatitis when fed a diet high in ethanol and fat. The eradication of Gram-negative faecal flora with antibiotics reduces endotoxin levels to those of controls not fed alcohol, and prevents liver injury [75]. Recent data reveal that this injury is also attenuated in CD14 and TLR4 knockout mice [76,77]. Alcohol can also affect Kupffer cell function directly. Rodents fed alcohol initially become more tolerant of endotoxin; however, with time, this response converts to one of sensitization [78]. An early suppressive effect of alcohol on Kupffer cell function and a later induction of CD14, both attributed to increased levels of endotoxin, may explain the time course of this response. Interestingly, when Kupffer cells are inactivated in the ethanol-fed rat model using gadolinium chloride, disease is ameliorated and the steatosis is diminished. This highlights the fact that these cells also have a role in the TAG accumulation, most likely through TNFα production, as discussed above.

Sinusoidal endothelial cells are also actively involved in the response to endotoxin. These cells constitutively express all the surface molecules necessary for antigen presentation, and may induce tolerance or immunity depending on the local microenvironment. This environment may be dictated by Kupffer cell release of immunomodulatory cytokines in response to varying doses of portal endotoxin, with high-dose endotoxin resulting in potentially harmful immunity, and low-dose endotoxin resulting in tolerance through the secretion of interleukin 10 (IL-10) [79].

The role of TNFα

Kupffer cells are the primary intrahepatic source of TNFα, a cytokine believed to be central to the pathogenesis of ALD. Peripheral blood mononuclear cells produce more basal and LPS-induced TNFα than controls [80], and plasma levels are higher in patients with more severe disease [81]. Furthermore, mice lacking TNFR1 develop less severe liver injury in the Tsukamoto–French model [24,33]. It has recently been shown that the mechanism of TNFα-induced cell death, necrosis or apoptosis, depends on the degree and site of GSH depletion [82]. Mitochondrial depletion leads to necrosis due to profound loss of mitochondrial function [47], whereas less severe, predominantly cytosolic depletion of GSH leads to apoptosis due to inhibition of the NFκB-induced transactivation of survival genes that normally follows binding of TNFα to its receptor. Recent studies showing a correlation between the degree of apoptosis and clinical indices of severity in patients with alcoholic hepatitis suggest that apoptosis plays an important role in this form of ALD [83,84].

Natural killer cells

A further, less well-understood, arm of the innate immune system that appears to be involved in the pathogenesis of ALD is the natural killer (NK) and natural killer T (NKT) cell population. These cells are abundant in the liver [85] and both populations have been reported to increase in the peripheral blood of heavy drinkers [86]. Recent evidence points to an increase in the number of NKT cells in the livers of mice after alcohol consumption, and augmenting their activation using a marine sphingolipid during ethanol feeding results in fatal hepatotoxicity [87]. The relevance of this to clinical liver disease is still unclear.

The adaptive immune system and the pathogenesis of ALD

Several clinical features imply that adaptive immune mechanisms may have a role in disease pathogenesis. Abstinent patients who return to drinking have a rapid and aggressive recurrence of their disease, which might imply an immunological anamnestic response. There is a partial response to immunosuppressive steroids in selected groups with severe disease [88]. It has been reported that patients receiving interferon therapy for hepatitis C, which can trigger autoimmune thyroid disease, can rapidly develop alcoholic hepatitis with no increase in their daily alcohol intake [89]. Patients with ALD also often display hypergammaglobulinaemia, and lymphocyte infiltration is a well-recognized histological feature of advanced disease [90]. These features have led researchers to look at how antigen-specific immune responses may lead to liver injury.

Humoral immune responses in ALD

Although nonspecific liver cell membrane antibodies have been implicated in ALD pathogenesis for some time [91,92], recent studies have focused on determining the antigen specificity of this humoral response.

Antibodies to acetaldehyde adducts

Adduction of acetaldehyde to host proteins can result in the formation of immunogenic epitopes [93]. Acetaldehyde-modified proteins have been found in the liver cytosol, membranes and mitochondria of rats chronically fed ethanol, and their decline over several weeks after ethanol withdrawal has been investigated [94]. They accumulate particularly in hepatocytes in the perivenular region, which is also the main area of distribution of the ethanol-metabolizing enzyme CYP2E1, the main site of lipid peroxidation and the first area to develop disease in ALD [95]. Interestingly, extracellular and not intracellular acetaldehyde-adduct staining correlates with fibrosis progression in humans

regardless of whether the patients abstained from alcohol or not [96].

Anti-acetaldehyde adduct (anti-AcA) antibodies have been found in the sera of heavy drinkers by several groups [96–98]; however, their relationship to the presence and severity of liver disease is controversial.

Antibodies to the other products of ethanol metabolism

Other targets for the humoral immune response in ALD include the hydroxyethyl radical (HER – a reactive intermediate formed by the action of CYP2E1 during ethanol metabolism [99]) and aldehydes generated as a result of prolonged oxidative stress, such as malondialdehyde (MDA) and 4-hydroxynonenal (4-HNE) [100]. Anti-HER antibodies have been found in significantly higher titre in patients with alcohol-induced cirrhosis than in non-alcohol-induced cirrhosis or normal controls [101]. The third, and final, antigen that has been studied in detail is a combination of acetaldehyde and malondialdehyde called malondialdehyde–acetaldehyde adducts (MAA). Antibodies to these hybrid conjugates have now been detected in sera from patients with alcohol-induced liver cirrhosis and alcoholic hepatitis but not in heavy drinkers with no liver disease or in healthy controls [102].

Autoantibodies

When ethanol is metabolized by CYP2E1, HER is produced [101], which can form immunogenic adducts with the cytochrome. It has now been demonstrated that a significant proportion of patients with ALD have antibodies reactive with the HER complexed with CYP2E1 [103]. Furthermore, both patients with ALD and rats fed ethanol have been shown to develop anti-CYP2E1-specific autoantibodies [104]. Interestingly, in humans with ALD, the presence of these autoantibodies is predicted by the presence of antibodies to HER suggesting a potential mechanism for tolerance breakdown [105].

Whether the humoral immune response is a cause or a consequence of liver disease remains an important question. Antibody-dependent cell cytotoxicity (ADCC) has been observed when sera from patients with ALD positive for anti-HER antibodies were cocultured with ethanol-treated rat hepatocytes and peripheral blood mononuclear cells from healthy controls [106]. Further studies are required to provide evidence for the role of this mechanism of disease *in vivo*.

Cellular immune responses in ALD

Both murine and human livers have significant numbers of T cells and some B cells, which recirculate from the peripheral pool; however, in contrast to peripheral blood, there are more CD8+ cells than CD4+ cells [85]. In addition, there are high frequencies of what appear to be resident liver lymphocytes that are found in very low frequencies in peripheral blood. These are NK cells, recognized by CD56 in humans and NK1.1 in mice, and NKT cells that express these cell surface proteins along with the T-cell receptor. In normal liver, these cell types are distributed throughout the parenchyma. In liver disease, this situation changes and, in alcoholic cirrhosis, expanded portal tracts contain large numbers of classical CD4+ and CD8+ lymphocytes [90]. No work has been done to determine the antigen-specificity of these intrahepatic lymphocyte populations; however, peripheral blood mononuclear cell responses to MDA have been detected in a significant proportion of patients [107]. Further work is required to determine whether antigen-specific cellular immune responses are an important part of disease progression in ALD.

Mechanisms of alcohol-induced fibrosis

In ALD, fibrosis starts in the perivenular area and progresses to bridging fibrosis and ultimately cirrhosis. As discussed, this early fibrosis occurs at the site of maximal alcohol-induced hepatocyte injury. The principal cell types involved in the activation of hepatic stellate cells (HSC) in ALD are Kupffer cells and hepatocytes. Kupffer cells are stimulated to release cytokines by endotoxin in ALD and, in turn, these cells can lead to the activation and proliferation of stellate cells through the production of transforming growth factor β (TGF-β), TNFα and ROS. During alcohol-induced injury, hepatocytes are rich sources of ROS, lipid peroxidation products and acetaldehyde, all of which have been shown to enhance collagen production by HSC [41,108,109]. CYP2E1 may be particularly important in this regard given its inducibility by alcohol and a high-fat diet and its perivenular distribution. HSC grown in the presence of hepatocyte cell lines that overexpress CYP2E1 increase their production of collagen, an effect that is prevented by antioxidants or a CYP2E1 inhibitor [110]. Hepatocyte apoptosis is a notable feature of alcoholic hepatitis [83], and apoptosing hepatocytes express Fas, which can promote stellate cell initiation through the TNF-related apoptosis-inducing ligand (TRAIL) [111]. Furthermore, apoptosing hepatocytes may also be ingested by Kupffer cells and HSC, which subsequently release TGF-β capable of activating HSC [112,113] (Table 4).

Mechanisms of hepatocellular cancer

Epidemiological studies reveal that alcohol plays a major contributory role in the development of hepatocellular cancer (HCC); however, the primary mechanisms through which this occurs are not clearly defined. Cirrhosis itself is a precancerous condition, and alcohol-related HCC without pre-existing cirrhosis is rare. Nevertheless, three features indicate that alcohol may be a cocarcinogen. The first is that heavy alcohol consumption is associated with several extrahepatic cancers. The second is that when the incidence of incidental HCCs in liver explants from patients with alcoholic cirrhosis is compared with that from other aetiologies, it lies between that of immune-mediated liver disease and viral hepatitis [114]. It appears, therefore, that

Table 4 The primary mechanisms thought to be involved in ethanol-induced hepatic fibrosis and hepatocellular carcinoma.

Fibrosis
Kupffer cell production of profibrotic cytokines
Kupffer cell production of profibrotic reactive oxygen species
Hepatocyte production of profibrotic reactive oxygen species
Hepatocyte production of acetaldehyde
Kupffer cell and hepatic stellate cell production of TGF-β after ingestion of apoptotic hepatocytes
Hepatocellular carcinoma
Lipid peroxidation and DNA mutagenesis
Activation of carcinogenic xenobiotics
Antiapoptotic effect of TNFα
DNA hypomethylation
Immunosuppression

the incidence of HCC is above that of the 'baseline' expected due to pure cirrhotic risk. The third is that there are several plausible mechanisms through which alcohol could promote carcinogenesis (Table 4). These include hypomethylation of oncogenes, aldehyde-induced DNA mutagenesis, the CYP2E1-mediated activation of xenobiotics, the antiapoptotic effect of TNFα, and immunosuppresion.

Susceptibility to alcoholic liver disease

Although the majority of heavy drinkers will develop some degree of steatosis (fatty liver), only around a third go on to develop alcoholic hepatitis and less progress to cirrhosis [115]. This leads to the obvious question – what factors determine whether or not a heavy drinker develops advanced ALD?

Dose of ethanol

Although the risk of ALD increases in proportion to the duration of intake, an initial study suggested that only 20% of consumers of more than 200 g of ethanol (around 20 standard 'drinks') per day developed cirrhosis after 13 years and less than 50% after 20 years [116]. Recent detailed studies have further examined the precise dose–response relationship between alcohol intake and risk of ALD, the gender effect and the risk threshold.

A large cohort study from Italy reported that the risk of developing ALD begins at 30 g/day of ethanol [115]. However, only 5.5% of the individuals drinking this much showed signs of liver disease. The risk increased according to daily dose, reaching 10% at 60 g per day. The study also reported that risk is higher among the over 50s if alcohol is drunk outside mealtimes or consumed in a variety of different beverages rather than one 'tipple of choice'. Interestingly, this study showed no gender effect. A further, even larger, study from Copenhagen [117] revealed a dose-dependent increase in risk, with women having a significant risk above 7–13 units per week, and men above 14–27 units per week. This group updated their data analysis recently by looking at type of alcohol consumed [118]. Their results suggest that the highest risk is seen in drinkers who do not include wine in their drinking repertoire. Furthermore, the relative risk of cirrhosis fell as the proportion of wine increased. This association between wine intake and ALD risk may be confounded by other factors associated with wine drinking such as a lower prevalence of obesity compared with beer and spirit drinkers.

Together, these studies reveal that no dose of alcohol confers a guarantee of developing cirrhosis regardless of the period it is consumed for, and that relatively low doses can cause problems.

Diet

The data from ethanol-fed rats linking a diet high in polyunsaturated fats with an increased risk of alcoholic liver injury, discussed above, are supplemented by an epidemiological study linking cirrhosis mortality with pork (high in linoleic acid) consumption and dietary intake of unsaturated fats [119]. A further case–control study has reported that the risk of cirrhosis is increased by diets high in fat and low in carbohydrate [120]. A more obvious role for diet in ALD risk has been suggested by two studies showing that obesity and associated hyperglycaemia increase the incidence of all stages of ALD in heavy drinkers [121,122]. Although these studies have provided evidence that dose, pattern and type of alcohol consumption and dietary (and presumably exercise-related) factors play a role in determining ALD risk, they have also demonstrated that 'endogenous' factors are likely to be equally, if not more, important.

Gender and risk of ALD

It has long been appreciated that women develop ALD at a lower intake of alcohol than men. The traditional explanation has been that women develop higher blood alcohol concentrations per unit of alcohol consumed due to their lower body mass index and because fat constitutes a higher percentage of their body mass than in men. More recent evidence suggests that estrogen increases gut permeability to endotoxin and upregulates endotoxin receptors on Kupffer cells leading to an increased production of TNF in response to endotoxin [123].

Non-gender-linked genetic factors and risk of ALD

Evidence for the importance of genetic factors comes from a study showing that concordance rates for alcoholic cirrhosis are three times higher in monozygotic than in dizygotic twin pairs [124]. This is not entirely explained by the difference in concordance rates for alcoholism *per se*. In addition, the death rate from ALD is subject to wide interethnic variation that is not entirely explained by variations in the prevalence of alcohol abuse [125,126]. Hispanics appear to be at particularly high risk, for example. Difficulties in performing family linkage studies in ALD have resulted in almost all of the relevant information thus far coming from classical case–control, candidate gene, allele

association studies. Accordingly, these studies are subject to all the common pitfalls of this type of study design and must be interpreted with caution [127]. Given that the most likely mechanisms of hepatocyte injury in excessive drinkers are related to fat accumulation, oxidative stress, endotoxin-mediated release of proinflammatory cytokines and immunological damage, the majority of studies reported thus far have focused on genes encoding proteins involved in these various pathways.

Genes influencing the severity of steatosis

Factors determining the severity of steatosis may play a key role in determining the risk of cirrhosis [34]. These could include genetic factors determining the degree of obesity or functional polymorphisms of genes encoding enzymes involved in hepatic lipid metabolism. There is a preliminary report that a 'low activity' promoter polymorphism in the gene encoding microsomal triglyceride transfer protein (MTP), the principal protein responsible for the export of fat from the liver, is associated with an increased risk of advanced ALD [128].

Genes influencing oxidative stress and risk of ALD

The principal classes of genes that influence the oxidant load in heavy drinkers are those encoding metabolic or antioxidant enzymes. Polymorphisms have been identified in two of the seven genes encoding alcohol dehydrogenases (*ADH2* and *ADH3*), in the promoter region of the *CYP2E1* gene and in the coding region of the gene encoding the mitochondrial form of aldehyde dehydrogenase (ALDH2). The genes encoding ADH2 and ALDH2 undoubtedly play a role in determining the risk of alcoholism and, to a lesser extent, ALD in Oriental populations [129–131]. Previously reported associations with *ADH3* probably reflect linkage disequilibrium with *ADH2* [132]. In Caucasians, results from studies reported to date support a role for the *ADH2* polymorphism in determining the risk of alcoholism but not ALD [133]. Several studies have looked for an association between the c2 promoter (*Rsa*I) polymorphism of the *CYP2E1* gene and ALD with no consistent results emerging in any population, although one study did report that the cumulative lifetime alcohol intake of patients with ALD heterozygous for the c2 (more transcriptionally active) allele was almost half that of patients with ALD homozygous for the c1, wild-type, allele [134].

Manganese-dependent SOD2 is the most important mitochondrial antioxidant enzyme, and a polymorphism altering its mitochondrial targeting sequence has been associated with ALD in a small French study [135], although not confirmed in a larger study from the UK [136]. This and other polymorphisms affecting the function of antioxidant defence systems are clearly worth further study.

Endotoxin receptor and cytokine genes and risk of ALD

With regard to endotoxin receptors, a study from Finland has recently reported an association between possession of the TT CD14 genotype, which results in increased levels of soluble and membrane CD14 [137] and advanced ALD [77]. This has not been observed in a larger study in northeast England [138]. This latter study also showed no association between ALD and possession of the $Asp_{299}Gly$ polymorphism in the *TLR4* gene, previously reported to be linked to hyporesponsiveness to LPS [139].

With respect to polymorphisms in the cytokine genes, the first such association was reported between alcoholic hepatitis and a polymorphism at position –238 in the TNFα promoter region [140]. The functional significance of this polymorphism is, however, unclear. An association with ALD has also been reported for a promoter polymorphism in interleukin-10 (IL-10). This immunoregulatory cytokine inhibits antigen presentation and the activation of classical CD4+ and CD8+ T cells and is antifibrotic. A variant C→A substitution at position –627 in the IL-10 promoter has been associated with decreased reporter gene transcription and decreased IL-10 secretion by peripheral blood monocytes. The association of the A allele with advanced ALD [141] is consistent with low IL-10 favouring inflammatory and immune-mediated mechanisms of disease as well as hepatic stellate cell collagen production.

Immune response genes and risk of ALD

In view of the immunoregulatory functions of IL-10, the association between ALD and a low-activity promoter polymorphism in IL-10 may be considered as evidence that immune mechanisms are involved in the pathogenesis of ALD. Further evidence supporting this comes from the association of an A→G polymorphism in cytotoxic T lymphocyte antigen 4 (CTLA-4) with advanced ALD. CTLA-4 is a T-cell surface molecule that suppresses immune responses by competing with CD28 on the surface of CD4+ T-helper (Th) cells for the antigen-presenting cell co-stimulatory molecule B7 or, indirectly, by activating T regulatory cells that act to inhibit CD4+ Th cell function [142]. Furthermore, the mutation has recently been associated with autoimmune liver diseases, insulin-dependent diabetes and autoimmune thyroid disease. Although the A→G exon 1 polymorphism has been associated with the titre of anti-CYP2E1 antibodies in one study [105] and with ALD in another [143], it has yet to be confirmed as an ALD susceptibility allele in large studies examining the full CTLA-4 gene haplotype.

References

1 Berggren S, Goldberg L (1940) The absorption of ethyl alcohol from the gastrointestinal tract as a diffusion process. *Acta Physiol Scand* 1, 246–270.

2 Marshall AW, Kingstone D, Boss M, Morgan MY (1983) Ethanol elimination in males and females: relationship to menstrual cycle and body composition. *Hepatology* 3, 701–706.

3 Caballeria J, Baraona E, Lieber CS (1987) The contribution of the stomach to ethanol oxidation in the rat. *Life Sci* 41, 1021–1027.

4 Brown AS, Fiatarone JR, Wood P *et al.* (1995) The effect of gastritis on human gastric alcohol dehydrogenase activity and ethanol metabolism. *Aliment Pharmacol Ther* 9, 57–61.

5 Lieber CS, DeCarli LM (1968) Ethanol oxidation by hepatic microsomes: adaptive increase after ethanol feeding. *Science* 162, 917–918.

6 Umeno M, McBride OW, Yang CS *et al.* (1988) Human ethanol-inducible P450IIE1: complete gene sequence, promoter characterization, chromosome mapping, and cDNA-directed expression. *Biochemistry* 27, 9006–9013.

7 Boveris A, Oshino N, Chance B (1972) The cellular production of hydrogen peroxide. *Biochem J* 128, 617–630.

8 Smith M (1986) Genetics of human alcohol and aldehyde dehydrogenases. *Adv Hum Genet* 15, 249–290.

9 Goedde HW, Agarwal DP (1987) Polymorphism of aldehyde dehydrogenase and alcohol sensitivity. *Enzyme* 37, 29–44.

10 Crabb DW, Edenberg HJ, Bosron WF, Li TK (1989) Genotypes for aldehyde dehydrogenase deficiency and alcohol sensitivity. The inactive ALDH2(2) allele is dominant. *J Clin Invest* 83, 314–316.

11 Enomoto N, Takase S, Takada N, Takada A (1991) Alcoholic liver disease in heterozygotes of mutant and normal aldehyde dehydrogenase-2 genes. *Hepatology* 13, 1071–1075.

12 Nuutinen H, Lindros KO, Salaspuro M (1983) Determinants of blood acetaldehyde level during ethanol oxidation in chronic alcoholics. *Alcohol Clin Exp Res* 7, 163–168.

13 Korsten MA, Matsuzaki S, Feinman L, Lieber CS (1975) High blood acetaldehyde levels after ethanol administration. Difference between alcoholic and nonalcoholic subjects. *N Engl J Med* 292, 386–389.

14 Lindros KO, Stowell A, Pikkarainen P, Salaspuro M (1980) Elevated blood acetaldehyde in alcoholics with accelerated ethanol elimination. *Pharmacol Biochem Behav* 13 (Suppl. 1), 119–124.

15 Day CP, Yeaman SJ (1992) Physical evidence for the presence of two forms of phosphatidate phosphohydrolase in rat liver. *Biochim Biophys Acta* 1127, 87–94.

16 Nanji AA, Tsukamoto H, French SW (1989) Relationship between fatty liver and subsequent development of necrosis, inflammation and fibrosis in experimental alcoholic liver disease. *Exp Mol Pathol* 51, 141–148.

17 Elabbadi N, Day CP, Gamouh A *et al.* (2005) Relationship between the inhibition of phosphatidic acid phosphohydrolase-1 by oleate and oleoyl-CoA ester and its apparent translocation. *Biochimie* 87, 437–443.

18 Aoyama T, Peters JM, Iritani N *et al.* (1998) Altered constitutive expression of fatty acid-metabolizing enzymes in mice lacking the peroxisome proliferator-activated receptor alpha (PPARalpha). *J Biol Chem* 273, 5678–5684.

19 Galli A, Pinaire J, Fischer M *et al.* (2001) The transcriptional and DNA binding activity of peroxisome proliferator-activated receptor alpha is inhibited by ethanol metabolism. A novel mechanism for the development of ethanol-induced fatty liver. *J Biol Chem* 276, 68–75.

20 Fischer M, You M, Matsumoto M, Crabb DW (2003) Peroxisome proliferator-activated receptor alpha (PPARalpha) agonist treatment reverses PPARalpha dysfunction and abnormalities in hepatic lipid metabolism in ethanol-fed mice. *J Biol Chem* 278, 27997–28004.

21 Nanji AA, Dannenberg AJ, Jokelainen K, Bass NM (2004) Alcoholic liver injury in the rat is associated with reduced expression of peroxisome proliferator-alpha (PPARalpha)-regulated genes and is ameliorated by PPARalpha activation. *J Pharmacol Exp Ther* 310, 417–424.

22 Nakajima T, Kamijo Y, Tanaka N *et al.* (2004) Peroxisome proliferator-activated receptor alpha protects against alcohol-induced liver damage [see comment]. *Hepatology* 40, 972–980.

23 Sugimoto T, Yamashita S, Ishigami M *et al.* (2002) Decreased microsomal triglyceride transfer protein activity contributes to initiation of alcoholic liver steatosis in rats. *J Hepatol* 36, 157–162.

24 Yin M, Wheeler MD, Kono H *et al.* (1999) Essential role of tumor necrosis factor alpha in alcohol-induced liver injury in mice. *Gastroenterology* 117, 942–952.

25 Ueki K, Kondo T, Tseng YH, Kahn CR (2004) Central role of suppressors of cytokine signaling proteins in hepatic steatosis, insulin resistance, and the metabolic syndrome in the mouse. *Proc Natl Acad Sci USA* 101, 10422–10427.

26 Xu A, Wang Y, Keshaw H *et al.* (2003) The fat-derived hormone adiponectin alleviates alcoholic and nonalcoholic fatty liver diseases in mice. *J Clin Invest* 112, 91–100.

27 Villanueva JA, Halsted CH (2004) Hepatic transmethylation reactions in micropigs with alcoholic liver disease. *Hepatology* 39, 1303–1310.

28 Kenyon SH, Nicolaou A, Gibbons WA (1998) The effect of ethanol and its metabolites upon methionine synthase activity *in vitro*. *Alcohol* 15, 305–309.

29 Outinen PA, Sood SK, Pfeifer SI *et al.* (1999) Homocysteine-induced endoplasmic reticulum stress and growth arrest leads to specific changes in gene expression in human vascular endothelial cells. *Blood* 94, 959–967.

30 You M, Fischer M, Deeg MA, Crabb DW (2002) Ethanol induces fatty acid synthesis pathways by activation of sterol regulatory element-binding protein (SREBP). *J Biol Chem* 277, 29342–29347.

31 You M, Matsumoto M, Pacold CM *et al.* (2004) The role of AMP-activated protein kinase in the action of ethanol in the liver. *Gastroenterology* 127, 1798–1808.

32 Ji C, Kaplowitz N (2003) Betaine decreases hyperhomocysteinemia, endoplasmic reticulum stress, and liver injury in alcohol-fed mice. *Gastroenterology* 124, 1488–1499.

33 Ji C, Deng Q, Kaplowitz N (2004) Role of TNF-alpha in ethanol-induced hyperhomocysteinemia and murine alcoholic liver injury. *Hepatology* 40, 442–451.

34 Day CP, James OF (1998) Hepatic steatosis: innocent bystander or guilty party? *Hepatology* 27, 1463–1466.

35 Sorensen TI, Orholm M, Bentsen KD *et al.* (1984) Prospective evaluation of alcohol abuse and alcoholic liver injury in men as predictors of development of cirrhosis. *Lancet* ii, 41–44.

36 Teli MR, Day CP, Burt AD *et al.* (1995) Determinants of progression to cirrhosis or fibrosis in pure alcoholic fatty liver [comment]. *Lancet* 346, 987–990.

37 Yang SQ, Lin HZ, Lane MD *et al.* (1997) Obesity increases sensitivity to endotoxin liver injury: implications for the pathogenesis of steatohepatitis. *Proc Natl Acad Sci USA* 94, 2557–2562.

38 Letteron P, Fromenty B, Terris B et al. (1996) Acute and chronic hepatic steatosis lead to *in vivo* lipid peroxidation in mice. *J Hepatol* 24, 200–208.

39 Guebre-Xabier M, Yang S, Lin HZ *et al.* (2000) Altered hepatic lymphocyte subpopulations in obesity-related murine fatty livers: potential mechanism for sensitization to liver damage. *Hepatology* 31, 633–640.

40 Halliwell B (1994) Free radicals, antioxidants, and human disease: curiosity, cause, or consequence? [see comments] *Lancet* 344, 721–724.

41 Parola M, Robino G (2001) Oxidative stress-related molecules and liver fibrosis. *J Hepatol* 35, 297–306.

42 Ekstrom G, Ingelman-Sundberg M (1989) Rat liver microsomal NADPH-supported oxidase activity and lipid peroxidation dependent on ethanol-inducible cytochrome P-450 (P-450IIE1). *Biochem Pharmacol* 38, 1313–1319.

43 Albano E, Tomasi A, Goria-Gatti L, Dianzani MU (1988) Spin trapping of free radical species produced during the microsomal metabolism of ethanol. *Chem-Biol Interact* 65, 223–234.

44 Slater TF, Sawyer BC, Strauli UD (1964) Changes in liver nucleotide concentrations in experimental liver injury. 2. Acute ethanol poisoning. *Biochem J* 93, 267–270.

45 Paredes SR, Kozicki PA, Fukuda H *et al.* 1987) *S*-adenosyl-L-methionine: its effect on aminolevulinate dehydratase and glutathione in acute ethanol intoxication. *Alcohol* 4, 81–85.

46 Hirano T, Kaplowitz N, Tsukamoto H *et al.* (1992) Hepatic mitochondrial glutathione depletion and progression of experimental alcoholic liver disease in rats. *Hepatology* 16, 1423–1427.

47 Colell A, Garcia-Ruiz C, Miranda M *et al.* (1998) Selective glutathione depletion of mitochondria by ethanol sensitizes hepatocytes to tumor necrosis factor. *Gastroenterology* 115, 1541–1551.

48 Dworkin B, Rosenthal WS, Jankowski RH *et al.* (1985) Low blood selenium levels in alcoholics with and without advanced liver disease. Correlations with clinical and nutritional status. *Dig Dis Sci* 30, 838–844.

49 Thurnham DI, Davies JA, Crump BJ *et al.* (1986) The use of different lipids to express serum tocopherol: lipid ratios for the measurement of vitamin E status. *Ann Clin Biochem* 23, 514–520.

50 Leo MA, Lieber CS (1982) Hepatic vitamin A depletion in alcoholic liver injury. *N Engl J Med* 307, 597–601.

51 Bianchi GP, Fiorella PL, Bargossi AM *et al.* (1994) Reduced ubiquinone plasma levels in patients with liver cirrhosis and in chronic alcoholics. *Liver* 14, 138–140.

52 Stewart SF, Prince M, Bassendine MF *et al.* (2002) A trial of antioxidant therapy alone or with corticosteroids in acute alcoholic hepatitis. *J Hepatol* 36 (Suppl. 1), 16.

53 Nanji AA, Mendenhall CL, French SW (1989) Beef fat prevents alcoholic liver disease in the rat. *Alcohol Clin Exp Res* 13, 15–19.

54 Nanji AA, French SW (1989) Dietary linoleic acid is required for development of experimentally induced alcoholic liver injury. *Life Sci* 44, 223–227.

55 Nanji AA, Zhao S, Sadrzadeh SM *et al.* (1994) Markedly enhanced cytochrome P450 2E1 induction and lipid peroxidation is associated with severe liver injury in fish oil-ethanol-fed rats. *Alcohol Clin Exp Res* 18, 1280–1285.

56 Tsukamoto H, Horne W, Kamimura S *et al.* (1995) Experimental liver cirrhosis induced by alcohol and iron. *J Clin Invest* 96, 620–630.

57 Kessova IG, Ho YS, Thung S, Cederbaum AI (2003) Alcohol-induced liver injury in mice lacking Cu, Zn-superoxide dismutase. *Hepatology* 38, 1136–1145.

58 Lu SC, Alvarez L, Huang ZZ *et al.* (2001) Methionine adenosyltransferase 1A knockout mice are predisposed to liver injury and exhibit increased expression of genes involved in proliferation. *Proc Natl Acad Sci USA* 98, 5560–5565.

59 Lieber CS (2002) S-Adenosyl-L-methionine and alcoholic liver disease in animal models: implications for early intervention in human beings. *Alcohol* 27, 173–177.

60 Sadrzadeh SM, Nanji AA, Price PL (1994) The oral iron chelator, 1,2-dimethyl-3-hydroxypyrid-4-one, reduces hepatic-free iron, lipid peroxidation and fat accumulation in chronically ethanol-fed rats. *J Pharmacol Exp Ther* 269, 632–636.

61 Albano E, Clot P, Morimoto M *et al.* (1996) Role of cytochrome P4502E1-dependent formation of hydroxyethyl free radical in the development of liver damage in rats intragastrically fed with ethanol. *Hepatology* 23, 155–163.

62 Morimoto M, Hagbjork AL, Nanji AA *et al.* (1993) Role of cytochrome P4502E1 in alcoholic liver disease pathogenesis. *Alcohol* 10, 459–464.

63 Wheeler MD, Nakagami M, Bradford BU *et al.* (2001) Overexpression of manganese superoxide dismutase prevents alcohol-induced liver injury in the rat. *J Biol Chem* 276, 36664–36672.

64 Kono H, Rusyn I, Yin M *et al.* (2000) NADPH oxidase-derived free radicals are key oxidants in alcohol-induced liver disease. *J Clin Invest* 106, 867–872.

65 Stevens VJ, Fantl WJ, Newman CB *et al.* (1981) Acetaldehyde adducts with hemoglobin. *J Clin Invest* 67, 361–369.

66 Pastorino JG, Hoek JB (2000) Ethanol potentiates tumor necrosis factor-alpha cytotoxicity in hepatoma cells and primary rat hepatocytes by promoting induction of the mitochondrial permeability transition. *Hepatology* 31, 1141–1152.

67 Lluis JM, Colell A, Garcia-Ruiz C *et al.* (2003) Acetaldehyde impairs mitochondrial glutathione transport in HepG2 cells through endoplasmic reticulum stress. *Gastroenterology* 124, 708–724.

68 Nolan JP (1989) Intestinal endotoxins as mediators of hepatic injury – an idea whose time has come again. *Hepatology* 10, 887–891.

69 Fukui H, Brauner B, Bode JC, Bode C (1991) Plasma endotoxin concentrations in patients with alcoholic and non-alcoholic liver disease: reevaluation with an improved chromogenic assay. *J Hepatol* 12, 162–169.

70 Nanji AA, Khettry U, Sadrzadeh SM, Yamanaka T (1993) Severity of liver injury in experimental alcoholic liver disease. Correlation with plasma endotoxin, prostaglandin E2, leukotriene B4, and thromboxane B2. *Am J Pathol* 142, 367–373.

71 Schumann RR, Leong SR, Flaggs GW *et al.* (1990) Structure and function of lipopolysaccharide-binding protein. *Science* 249, 1429–1431.

72 Poltorak A, He X, Smirnova I *et al.* (1998) Defective LPS signalling in C3H/HeJ and C57BL/10ScCr mice: mutations in Tlr4 gene. *Science* 282, 2085–2088.

73 Pasare C, Medzhitov R (2003) Toll pathway-dependent blockade of CD4+CD25+ T cell-mediated suppression by dendritic cells [comment]. *Science* 299, 1033–1036.

74 Tsukamoto H, Reidelberger RD, French SW, Largman C (1984) Long-term cannulation model for blood sampling and intragastric infusion in the rat. *Am J Physiol* 247, R595–599.

75 Adachi Y, Moore LE, Bradford BU *et al.* (1995) Antibiotics prevent liver injury in rats following long-term exposure to ethanol. *Gastroenterology* 108, 218–224.

76 Uesugi T, Froh M, Arteel GE *et al.* (2001) Toll-like receptor 4 is involved in the mechanism of early alcohol-induced liver injury in mice. *Hepatology* 34, 101–108.

77 Jarvelainen HA, Orpana A, Perola M *et al.* (2001) Promoter polymorphism of the CD14 endotoxin receptor gene as a risk factor for alcoholic liver disease [see comment]. *Hepatology* 33, 1148–1153.

78 Enomoto N, Ikejima K, Bradford B *et al.* (1998) Alcohol causes both tolerance and sensitization of rat Kupffer cells via mechanisms dependent on endotoxin. *Gastroenterology* 115, 443–451.

79 Knolle PA, Gerken G (2000) Local control of the immune response in the liver. *Immunol Rev* 174, 21–34.

80 McClain CJ, Cohen DA (1989) Increased tumor necrosis factor production by monocytes in alcoholic hepatitis. *Hepatology* 9, 349–351.

81 Bird G, Sheron N, Goka AK *et al.* (1990) Increased plasma tumour necrosis factor in severe alcoholic hepatitis. *Ann Intern Med* 112, 917–920.

82 Matsumaru K, Ji C, Kaplowitz N (2003) Mechanisms for sensitization to TNF-induced apoptosis by acute glutathione depletion in murine hepatocytes. *Hepatology* 37, 1425–1434.

83 Natori S, Rust C, Stadheim LM *et al.* (2001) Hepatocyte apoptosis is a pathologic feature of human alcoholic hepatitis. *J Hepatol* 34, 248–253.

84 Day CP (2001) Apoptosis in alcoholic hepatitis: a novel therapeutic target? [letter; comment]. *J Hepatol* 34, 330–333.

85 Crispe IN, Mehal WZ (1996) Strange brew. T cells in the liver. *Immunol Today* 17, 522–525.

86 Laso FJ, Madruga JI, Giron JA *et al.* (1997) Decreased natural killer cytotoxic activity in chronic alcoholism is associated with alcohol liver disease but not active ethanol consumption. *Hepatology* 25, 1096–1100.

87 Minagawa M, Deng Q, Liu ZX *et al.* (2004) Activated natural killer T cells induce liver injury by Fas and tumor necrosis factor-alpha during alcohol consumption. *Gastroenterology* 126, 1387–1399.

88 Mathurin P, Duchatelle V, Ramond MJ *et al.* (1996) Survival and prognostic factors in patients with severe alcoholic hepatitis treated with prednisolone. *Gastroenterology* 110, 1847–1853.

89 Zylberberg H, Fontaine H, Thepot V *et al.* (1999) Triggering of acute alcoholic hepatitis by alpha-interferon therapy. *J Hepatol* 30, 722–725.

90 Chedid A, Mendenhall CL, Moritz TE *et al.* (1993) Cell-mediated hepatic injury in alcoholic liver disease. Veterans Affairs Cooperative Study Group 275. *Gastroenterology* 105, 254–266.

91 Burt AD, Anthony RS, Hislop WS *et al.* (1982) Liver membrane antibodies in alcoholic liver disease: 1. prevalence and immunoglobulin class. *Gut* 23, 221–225.

92 Trevisan A, Cavigli R, Meliconi R *et al.* (1983) Detection of immunoglobulins G and A on the cell membrane of hepatocytes from patients with alcoholic liver disease. *J Clin Pathol* 36, 530–534.

93 Israel Y, Hurwitz E, Niemela O, Arnon R (1986) Monoclonal and polyclonal antibodies against acetaldehyde-containing epitopes in acetaldehyde-protein adducts. *Proc Natl Acad Sci USA* 83, 7923–7927.

94 Nicholls RM, Fowles LF, Worrall S *et al.* (1994) Distribution and turnover of acetaldehyde-modified proteins in liver and blood of ethanol-fed rats. *Alcohol Alcoholism* 29, 149–157.

95 Niemela O, Juvonen T, Parkkila S (1991) Immunohistochemical demonstration of acetaldehyde-modified epitopes in human liver after alcohol consumption. *J Clin Invest* 87, 1367–1374.

96 Holstege A, Bedossa P, Poynard T *et al.* (1994) Acetaldehyde-modified epitopes in liver biopsy specimens of alcoholic and non-alcoholic patients: localization and association with progression of liver fibrosis. *Hepatology* 19, 367–374.

97 Worrall S, De Jersey J, Shanley BC, Wilce PA (1990) Antibodies against acetaldehyde-modified epitopes: presence in alcoholic, non-alcoholic liver disease and control subjects. *Alcohol Alcoholism* 25, 509–517.

98 Niemela O, Klajner F, Orrego H *et al.* (1987) Antibodies against acetaldehyde-modified protein epitopes in human alcoholics. *Hepatology* 7, 1210–1214.

99 Albano E, Tomasi A, Persson JO *et al.* (1991) Role of ethanol-inducible cytochrome P450 (P450IIE1) in catalysing the free radical activation of aliphatic alcohols. *Biochem Pharmacol* 41, 1895–1902.

100 Mottaran E, Stewart SF, Rolla R *et al.* (2002) Lipid peroxidation contributes to immune reactions associated with alcoholic liver disease. *Free Radical Bio Med* 32, 38–45.

101 Clot P, Bellomo G, Tabone M *et al.* (1995) Detection of antibodies against proteins modified by hydroxyethyl free radicals in patients with alcoholic cirrhosis. *Gastroenterology* 108, 201–207.

102 Rolla R, Vay D, Mottaran E *et al.* (2000) Detection of circulating antibodies against malondialdehyde-acetaldehyde adducts in patients with alcohol-induced liver disease. *Hepatology* 31, 878–884.

103 Clot P, Albano E, Eliasson E *et al.* (1996) Cytochrome P4502E1 hydroxyethyl radical adducts as the major antigen in autoantibody formation among alcoholics. *Gastroenterology* 111, 206–216.

104 Lytton SD, Helander A, Zhang-Gouillon ZQ *et al.* (1999) Autoantibodies against cytochromes P-4502E1 and P-4503A in alcoholics. *Mol Pharmacol* 55, 223–233.

105 Vidali M, Stewart SF, Rolla R *et al.* (2003) Genetic and epigenetic factors in autoimmune reactions toward cytochrome P4502E1 in alcoholic liver disease. *Hepatology* 37, 410–419.

106 Clot P, Parola M, Bellomo G *et al.* (1997) Plasma membrane hydroxyethyl radical adducts cause antibody-dependent cytotoxicity in rat hepatocytes exposed to alcohol [see comments]. *Gastroenterology* 113, 265–276.

107 Stewart SF, Vidali M, Day CP *et al.* (2004) Oxidative stress as a trigger for cellular immune responses in patients with alcoholic liver disease. *Hepatology* 39, 197–203.

108 Holt K, Bennett M, Chojkier M (1984) Acetaldehyde stimulates collagen and noncollagen protein production by human fibroblasts. *Hepatology* 4, 843–848.

109 Ma X, Svegliati-Baroni G, Poniachik J *et al.* (1997) Collagen synthesis by liver stellate cells is released from its normal feedback regulation by acetaldehyde-induced modification of the carboxyl-terminal propeptide of procollagen. *Alcohol Clin Exp Res* 21, 1204–1211.

110 Nieto N, Friedman SL, Cederbaum AI (2002) Cytochrome P450 2E1-derived reactive oxygen species mediate paracrine stimulation of collagen I protein synthesis by hepatic stellate cells. *J Biol Chem* 277, 9853–9864.

111 Canbay A, Higuchi H, Bronk SF *et al.* (2002) Fas enhances fibrogenesis in the bile duct ligated mouse: a link between apoptosis and fibrosis. *Gastroenterology* 123, 1323–1330.

112 Canbay A, Taimr P, Torok N *et al.* (2003) Apoptotic body engulfment by a human stellate cell line is profibrogenic. *Lab Invest* 83, 655–663.

113 Fadok VA, Bratton DL, Konowal A *et al.* (1998) Macrophages that have ingested apoptotic cells *in vitro* inhibit proinflammatory cytokine production through autocrine/paracrine mechanisms involving TGF-beta, PGE2, and PAF. *J Clin Invest* 101, 890–898.

114 Nair S, Mason A, Eason J *et al.* (2002) Is obesity an independent risk factor for hepatocellular carcinoma in cirrhosis? *Hepatology* 36, 150–155 [erratum appears in *Hepatology* (2002) 36, 774].

115 Bellentani S, Saccoccio G, Costa G *et al.*(1997) Drinking habits as cofactors of risk for alcohol induced liver damage. The Dionysos Study Group [see comments]. *Gut* 41, 845–850.

116 Lelbach WK (1975) Cirrhosis in the alcoholic and its relation to the volume of alcohol abuse. *Ann NY Acad Sci* 252, 85–105.

117 Becker U, Deis A, Sorensen TI *et al.* (1996) Prediction of risk of liver disease by alcohol intake, sex, and age: a prospective population study. *Hepatology* 23, 1025–1029.

118 Becker U, Gronbaek M, Johansen D, Sorensen TI (2002) Lower risk for alcohol-induced cirrhosis in wine drinkers [see comment]. *Hepatology* 35, 868–875.

119 Nanji AA, French SW (1985) Relationship between pork consumption and cirrhosis. *Lancet* i, 681–683.

120 Rotily M, Durbec JP, Berthezene P, Sarles H (1990) Diet and alcohol in liver cirrhosis: a case-control study. *Eur J Clin Nutr* 44, 595–603.
121 Naveau S, Giraud V, Borotto E et al. (1997) Excess weight risk factor for alcoholic liver disease. *Hepatology* 25, 108–111.
122 Raynard B, Balian A, Fallik D *et al.* (2002) Risk factors of fibrosis in alcohol-induced liver disease. *Hepatology* 35, 635–638.
123 Enomoto N, Takei Y, Kitamura T *et al.* (2002) Estriol enhances lipopolysaccharide-induced increases in nitric oxide production by Kupffer cells via mechanisms dependent on endotoxin. *Alcohol Clin Exp Res* 26 (8 Suppl.), 66S–69S.
124 Hrubec Z, Omenn GS (1981) Evidence of genetic predisposition to alcoholic cirrhosis and psychosis: twin concordances for alcoholism and its biological end points by zygosity among male veterans. *Alcohol Clin Exp Res* 5, 207–215.
125 Stinson FS, Grant BF, Dufour MC (2001) The critical dimension of ethnicity in liver cirrhosis mortality statistics. *Alcohol Clin Exp Res* 25, 1181–1187.
126 Caetano R, Clark CL (1998) Trends in alcohol-related problems among whites, blacks, and Hispanics: 1984–1995. *Alcohol Clin Exp Res* 22, 534–538.
127 Daly A, Day CP (2001) Candidate gene case-control association studies: advantages and pitfalls. *Br J Clin Pharmacol* 52, 489–499.
128 Day CP, Leathart JB, Daly AK (2002) Genetic evidence that fatty liver is involved in the pathogenesis of advanced alcoholic liver disease. *Hepatology* 36 (Suppl. 1), 16.
129 Chao YC, Young TH, Tang HS, Hsu CT (1997) Alcoholism and alcoholic organ damage and genetic polymorphisms of alcohol metabolizing enzymes in Chinese patients. *Hepatology* 25, 112–117.
130 Chao YC, Wang LS, Hsieh TY *et al.* (2000) Chinese alcoholic patients with esophageal cancer are genetically different from alcoholics with acute pancreatitis and liver cirrhosis. *Am J Gastroenterol* 95, 2958–2964.
131 Tanaka F, Shiratori Y, Yokosuka O *et al.* (1996) High incidence of ADH2*1/ALDH2*1 genes among Japanese alcohol dependents and patients with alcoholic liver disease. *Hepatology* 23, 234–239.
132 Osier M, Pakstis AJ, Kidd JR *et al.* (1999) Linkage disequilibrium at the ADH2 and ADH3 loci and risk of alcoholism. *Am J Hum Genet* 64, 1147–1157.
133 Borras E, Coutelle C, Rosell A *et al.* (2000) Genetic polymorphism of alcohol dehydrogenase in Europeans: the ADH2*2 allele decreases the risk for alcoholism and is associated with ADH3*1. *Hepatology* 31, 984–989.
134 Grove J, Brown AS, Daly AK *et al.* (1998) The RsaI polymorphism of CYP2E1 and susceptibility to alcoholic liver disease in Caucasians: effect on age of presentation and dependence on alcohol dehydrogenase genotype. *Pharmacogenetics* 8, 335–342.
135 Degoul F, Sutton A, Mansouri A *et al.* (2001) Homozygosity for alanine in the mitochondrial targeting sequence of superoxide dismutase and risk for severe alcoholic liver disease. *Gastroenterology* 120, 1468–1474.
136 Stewart SF, Leathart JB, Chen Y *et al.* (2002) Valine-alanine manganese superoxide dismutase polymorphism is not associated with alcohol-induced oxidative stress or liver fibrosis. *Hepatology* 36, 1355–1360.
137 Baldini M, Lohman IC, Halonen M *et al.* (1999) A polymorphism* in the 5′ flanking region of the CD14 gene is associated with circulating soluble CD14 levels and with total serum immunoglobulin E. *Am J Respir Cell Mol Biol* 20, 976–983.
138 Leathart JB, Day CP, Daly AK (2001) No association between functional SNPs in the endotoxin receptors CD14 and TLR4 and alcoholic liver disease (ALD): is endotoxin important in the pathogenesis of ALD in humans? *Hepatology* 34, 459A.
139 Arbour NC, Lorenz E, Schutte BC *et al.* (2000) TLR4 mutations are associated with endotoxin hyporesponsiveness in humans. *Nat Genet* 25, 187–191.
140 Grove J, Daly AK, Bassendine MF, Day CP (1997) Association of a tumor necrosis factor promoter polymorphism with susceptibility to alcoholic steatohepatitis. *Hepatology* 26, 143–146.
141 Grove J, Daly AK, Bassendine MF *et al.* (2000) Interleukin 10 promoter region polymorphisms and susceptibility to advanced alcoholic liver disease [see comment]. *Gut* 46, 540–545.
142 Waterhouse P, Marengere LE, Mittrucker HW, Mak TW (1996) CTLA-4, a negative regulator of T-lymphocyte activation. *Immunol Rev* 153, 183–207.
143 Valenti L, De Feo T, Fracanzani AL *et al.* (2004) Cytotoxic T-lymphocyte antigen-4 A49G polymorphism is associated with susceptibility to and severity of alcoholic liver disease in Italian patients. *Alcohol Alcoholism* 39, 276–280.

12.3 Pathology of alcoholic liver disease

Elie Serge Zafrani

Introduction

Alcoholic liver disease is characterized by a wide spectrum of pathological changes ranging from steatosis to steatohepatitis, cirrhosis and even hepatocellular carcinoma [1]. Lesions show individual variation and overlap, and may be found in different combinations on pathological material.

Some particular histological patterns of alcoholic liver disease as well as the relationship and the differential diagnosis with other conditions will be emphasized, and the role of liver biopsy in patients' management will also be addressed.

Alcoholic fatty liver

Hepatocellular steatosis is the most common histological lesion in patients with chronic alcoholism [2,3]. It usually predominates around terminal hepatic veins, but may be observed in all lobular zones and can be diffuse, especially in severely involved livers [1]. Steatosis, which may appear within 2 days of alcohol ingestion [4], can disappear from the hepatocytes within 2–4 weeks of abstinence [3]. Two morphological types of steatosis are observed: macrovesicular steatosis, which is the most prevalent, and microvesicular steatosis, which is usually associated with the macrovesicular form and rarely predominates.

Macrovesicular steatosis

Hepatocellular steatosis consists of large intracytoplasmic lipid vacuoles displacing the nucleus to the cell periphery (Fig. 1). When they exist, necroinflammatory changes are minimal at this stage of alcoholic liver disease. Rupture of hepatocytes distended by large vacuoles of fat may lead to lipogranulomas consisting of small intralobular aggregates mainly made of macrophages and lymphocytes surrounding a lipid vacuole; neutrophils, epithelioid and multinucleated cells are rare. Mild pericellular fibrosis may be seen in association with lipogranulomas, but its prognostic significance with special reference to progressive fibrosis is not determined.

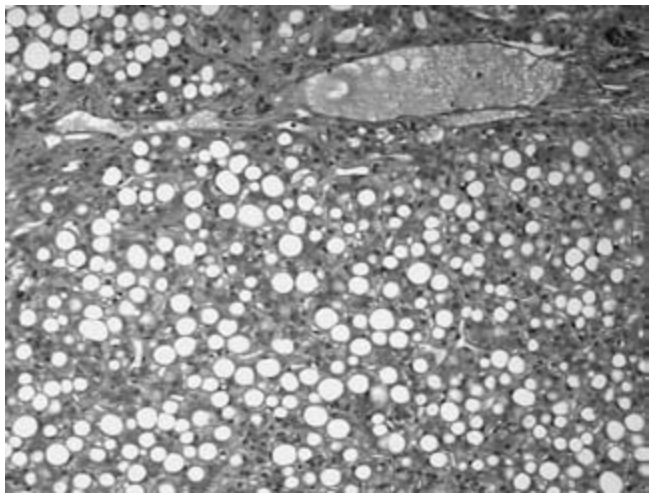

Fig. 1 Hepatocellular macrovesicular steatosis comprises large intracytoplasmic lipid vacuoles displacing the nucleus to the cell periphery; the lipid vacuoles appear empty because of tissue processing for paraffin embedding.

Steatosis may be responsible for anicteric cholestasis, and the clinical manifestations range from asymptomatic hepatomegaly to, very rarely, liver failure [3].

Microvesicular steatosis (alcoholic foamy degeneration)

A very rare variant of acute alcoholic liver injury is histologically characterized by predominant hepatocellular microvesicular steatosis, which consists of small intracytoplasmic lipid droplets leaving the nucleus at the center of the hepatocytes (Fig. 2). It has been described in less than 5% of patients with a history of chronic alcoholism, and may clinically mimic biliary obstruction [5,6]. Jaundice and hepatomegaly are usually present, and there is marked elevation of serum aminotransferases, alkaline phosphatase and γ-glutamyl-transpeptidase activities, as well as of the bilirubin level. Leucocytosis is absent. Liver biopsy shows normal lobular architecture with microvesicular steatosis giving

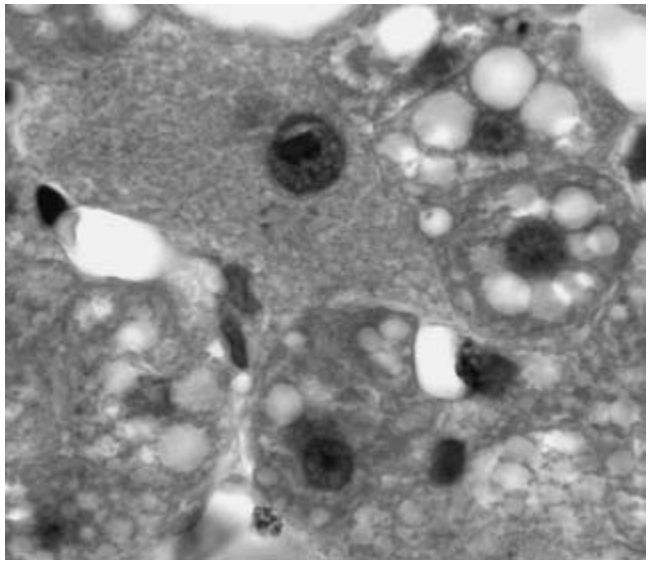

Fig. 2 Microvesicular steatosis consists of small intracytoplasmic lipid vacuoles leaving the nucleus at the centre of the hepatocytes. An induced hepatocyte is also seen at the top of the field.

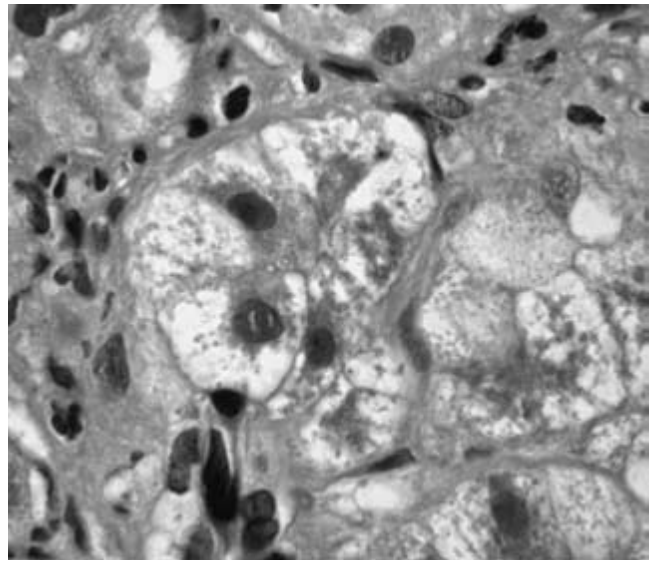

Fig. 3 Ballooned hepatocytes have a swollen and clarified cytoplasm, with an arachnoid appearance.

the swollen hepatocytes a foamy appearance. Microvesicular steatosis predominates around terminal hepatic veins, coexists with macrovesicular fatty change of various degrees, and may be associated with canalicular bile pigment accumulation; there is neither inflammatory infiltration nor Mallory body formation, but giant mitochondria and minimal perisinusoidal fibrosis can be seen. Recovery is rapid after alcohol withdrawal [5].

Prognosis of alcoholic fatty liver

Alcoholic fatty liver without evidence of necroinflammatory changes or fibrosis is generally assumed to have a very low risk of progression to cirrhosis. However, a study of alcoholic patients with steatosis on initial biopsy, without perivenular or pericellular fibrosis or any feature of alcoholic hepatitis, and who were followed up for a median of 10.5 years, showed that nine of 88 developed cirrhosis (eight of the nine having continued to drink alcohol) and a further seven developed fibrosis; mixed macrovesicular and microvesicular pattern of steatosis was an independent histological predictor of progression [7].

Alcoholic hepatitis (steatohepatitis)

Alcoholic hepatitis occurs in approximately 20% of chronic alcoholic patients and is associated with an increased risk of progression to cirrhosis [8]. It is an ill-defined syndrome with clinical presentation varying from absence of symptoms to pseudoangiocholitis or to hepatic failure [1,8]. Histological lesions of the liver are not always well correlated with clinical findings and produce a wide spectrum of changes, ranging from minimal damage to a marked necroinflammatory process [1].

Morphological abnormalities predominate around terminal hepatic veins. The main features of alcoholic hepatitis are:

- hepatocyte injury, with ballooning, apoptosis and, frequently, but not necessarily, Mallory bodies or steatosis;
- inflammatory infiltration essentially consisting of neutrophils;
- pericellular fibrosis.

Other histological lesions include giant mitochondria, induced and oncocytic hepatocytes, occlusive lesions of the terminal hepatic veins, bile pigment accumulation, cholangitis and cholangiolar proliferation.

Hepatocellular lesions

Ballooned hepatocytes are characterized by swelling of their cytoplasm, which is clarified and finely granular, with an arachnoid appearance (Fig. 3). This change is attributed to cytoskeletal dysfunction leading to impaired protein secretion and fluid retention [1].

Apoptosis (i.e. acidophilic bodies) mediated by death receptors is another feature of alcoholic hepatitis [9]. Increased apoptosis (Fig. 4) correlates with active NFκB expression and disease severity, and potentially constitutes a target for therapeutic intervention [9].

Mallory bodies are intracytoplasmic eosinophilic inclusions most often seen in ballooned hepatocytes (Fig. 5). Their morphological appearance varies from small irregular aggregates to perinuclear ribbons. They have a filamentous structure on electron microscopy and are composed of covalently cross-linked cytokeratins, essentially cytokeratin 8, as well as non-cytokeratin components such as ubiquitin, heat-shock proteins and M_M 120–1, SMI 31 and MPM-2 reactive antigens [10]. Hepatocellular expression of many of these proteins is triggered by

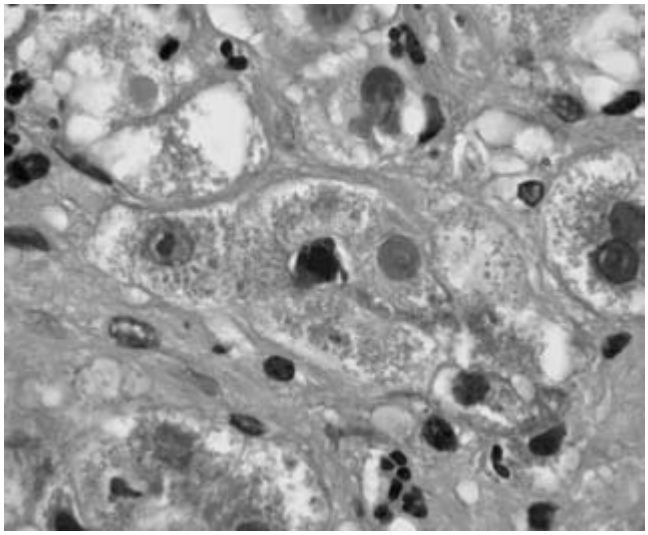

Fig. 4 An apoptotic hepatocyte is surrounded by several neutrophils.

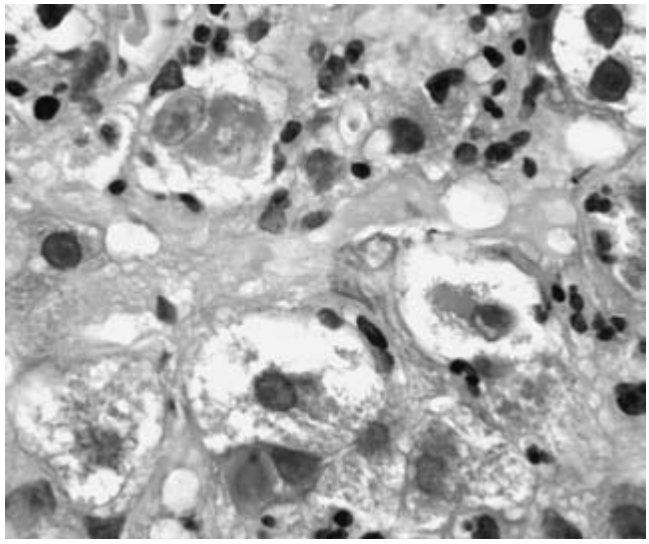

Fig. 5 Mallory bodies are irregular intracytoplasmic inclusions that are most often observed in ballooned hepatocytes. Inflammatory cells, including lymphocytes and neutrophils, can be noted near hepatocytes containing Mallory bodies.

the intracellular accumulation of proteins altered by a variety of stresses, including those produced by reactive oxygen species [10]. This expression also implies that proteasome degradation of misfolded proteins is impaired, probably by oxidative stress, as experimentally suggested in rats after alcohol administration [11,12]. Abnormal proteins thus accumulate in the cytoplasm of the hepatocytes and form Mallory bodies [10]. These inclusions are characteristic, though not pathognomonic, of alcoholic liver disease. They are observed in nonalcoholic fatty liver disease [13], in chronic cholestasis, as well as in various other disorders (e.g. Wilson's disease, Indian childhood cirrhosis) [1]. They may disappear from the hepatocytes within 6 weeks to 8 months of

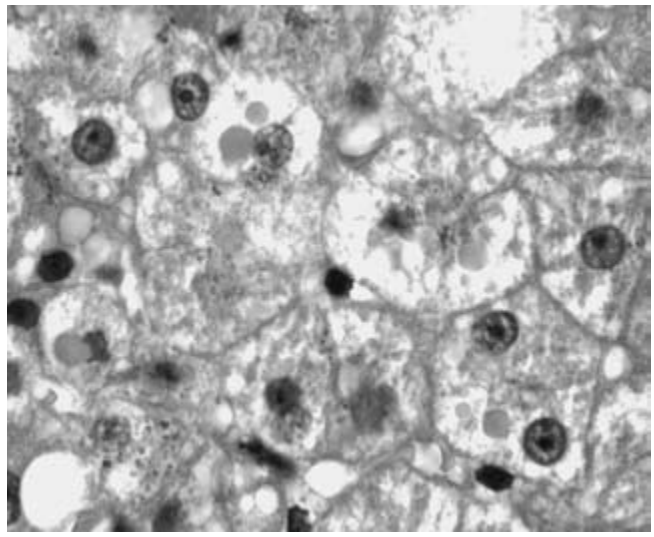

Fig. 6 Round inclusions corresponding to giant mitochondria can be seen in the cytoplasm of the hepatocytes.

alcohol withdrawal [3]. In alcoholic hepatitis, neutrophils are often seen intimately surrounding hepatocytes containing Mallory bodies.

Steatosis is most often observed in alcoholic hepatitis, but is not necessary for the histological diagnosis. Its presence and degree of severity depend on the existence or not of a history of recent alcohol intake.

Giant mitochondria form round or needlelike intracytoplasmic eosinophilic inclusions (Fig. 6), which are not stained with periodic acid–Schiff. They are seen in a minority of cases, at any stage of alcohol-induced liver disease [14]. Ultrastructurally, mitochondria are enlarged and distorted, with loss of cristae; they sometimes contain crystalline inclusions in their matrix [14]. Such changes are probably the morphological counterpart of the mitochondrial dysfunction, which is implicated in hepatocyte apoptosis and necrosis, and which may contribute to progression of the disease [15]. Hepatocytes are occasionally *oncocytic*, with a uniform eosinophilic cytoplasm, due to the presence of numerous mitochondria [1].

Induced hepatocytes are cells in which smooth endoplasmic reticulum is hyperplastic, giving a uniform appearance to the cytoplasm (Fig. 2). Cells resemble ground-glass hepatocytes of hepatitis B infection, but are not stained with modified orcein or anti-HBs (hepatitis B surface antigen) antibody [1,3]. Proliferation of smooth endoplasmic reticulum is an adaptative response corresponding to ethanol induction of CYP2E1 that increases acetaldehyde formation [16].

Inflammatory infiltration

The inflammatory reaction is predominantly composed of neutrophils located in the portal areas, in the sinusoids and, characteristically, around damaged hepatocytes, especially those

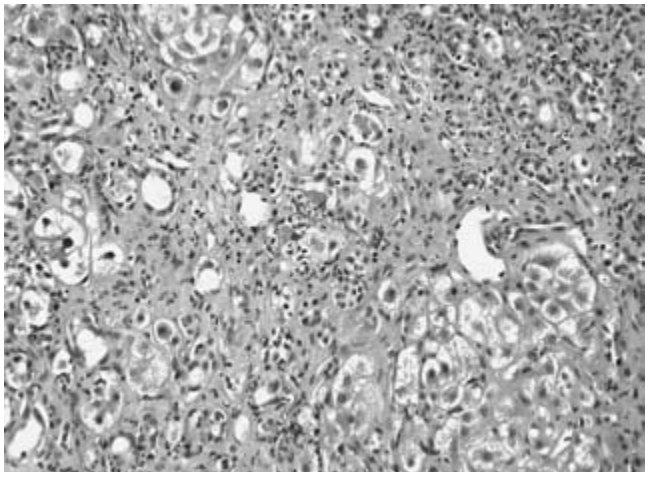

Fig. 7 The inflammatory infiltration is polymorphous, with numerous neutrophils.

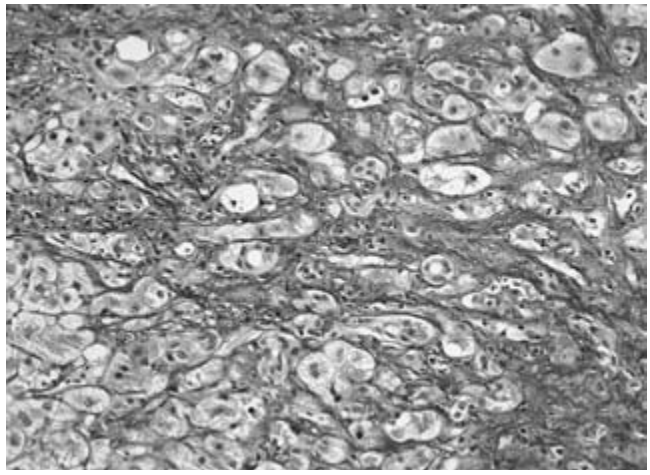

Fig. 8 Pericellular fibrosis producing a lattice-like pattern.

containing Mallory bodies (Fig. 7). Lymphocytes and macrophages are also present and Kupffer cells are enlarged. Numerous cytokines, chemokines and adhesion molecules play a major role in the recruitment of these inflammatory cells [17,18].

Sometimes, inflammatory infiltration is predominantly lymphocytic in alcoholic liver disease. Indeed, it has been shown in a series of 200 patients without serological markers of B and C viral hepatitis or evidence of autoimmune hepatitis that 40% of them had essentially lymphocytic inflammation and that such inflammatory infiltration was significantly associated with the portal and septal fibrosis index, after adjustment for age [19]. Such a high prevalence might be an overestimate and should be confirmed by other studies.

Pericellular fibrosis

Extracellular matrix proteins, including interstitial collagens and fibronectin, accumulate in a perisinusoidal distribution and surround individual hepatocytes or groups of hepatocytes. This pericellular fibrosis produces a lattice-like pattern (Fig. 8) and predominates in areas surrounding terminal hepatic veins.

Centrolobular pericellular fibrosis, frequently associated with fibrous thickening of terminal hepatic veins, is an early feature of alcoholic hepatitis. It is usually considered to be the result of necrosis and inflammation, which could thus be responsible for fibrosis progression towards cirrhosis. However, it has been shown that fibrosis with possible development of cirrhosis may occur in the absence of necroinflammatory changes [16,20]. This suggests that alcohol may directly affect stellate cells of the liver, activating them into collagen-producing myofibroblasts [16].

Other changes in alcoholic hepatitis

Occlusive venous lesions of three types have been recognized in patients with alcoholic liver disease [21]. Lymphocytic phlebitis,

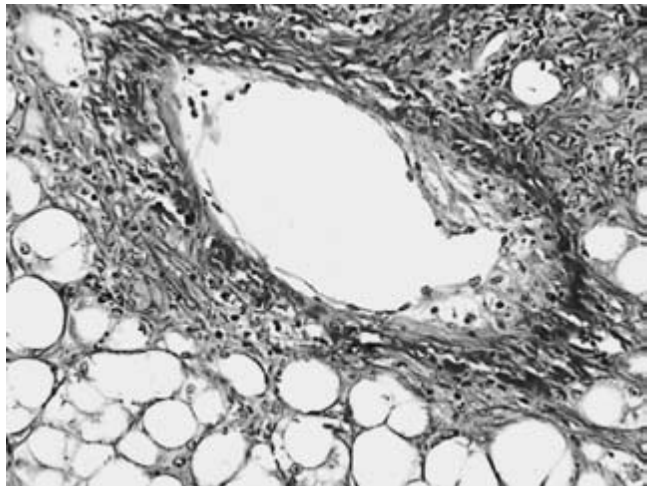

Fig. 9 Partial veno-occlusive lesion of a terminal hepatic vein, with eccentric lumen narrowing and mild intimal fibrous thickening containing inflammatory cells.

consisting of chronic inflammatory infiltration of terminal hepatic vein walls, was noted in 16.7% of 200 patients with non-cirrhotic alcoholic hepatitis and in 4.3% of patients with cirrhosis; perivenous scarring with gradual obliteration of the lumen of terminal hepatic veins was found to some degree in all patients with alcoholic hepatitis or cirrhosis; veno-occlusive lesions of terminal hepatic veins (Fig. 9) and occasionally of portal veins, with intimal proliferation, fibrosis and lumen narrowing, were observed in half of the patients with non-cirrhotic alcoholic hepatitis [21]. Such venous lesions could explain many cases of non-cirrhotic portal hypertension [21]. They are frequently seen in so-called sclerosing hyaline necrosis, a severe form of alcoholic hepatitis with extensive perivenous hepatocellular necrosis [22]. The relationship between the degree of veno-occlusive

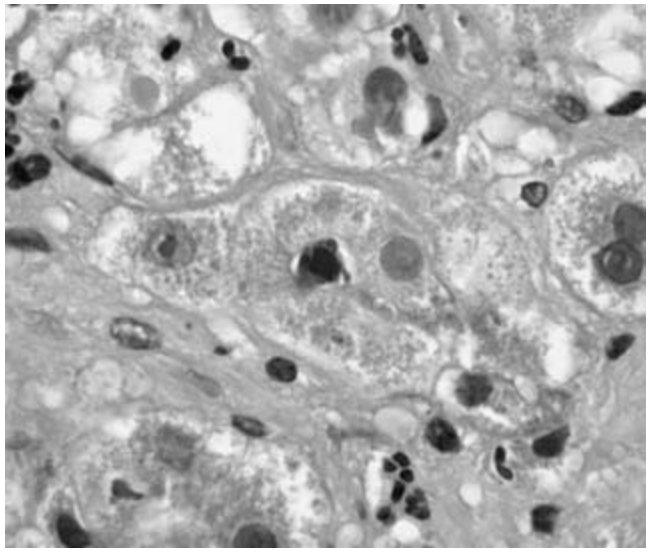

Fig. 10 Bile pigment accumulation is observed in a dilated canaliculus.

lesions and the severity of alcoholic hepatitis has more recently been confirmed [23].

Bile pigment accumulation within canaliculi (Fig. 10) and cholangiolar lumens may be striking in severe forms of alcoholic hepatitis. It is sometimes associated with neutrophilic *cholangitis*, thus mimicking biliary tract obstruction [24].

Cholangiolar proliferation usually accompanies portal and periportal fibrosis. Cholangiolar proliferation probably corresponds to an increase in the number of hepatic progenitor cells in reaction to the combination of oxidative stress and inhibition of hepatocellular replication secondary to alcohol exposure, as experimentally demonstrated in mice [25]. It has recently been demonstrated in patients with chronic viral hepatitis C that hepatic progenitor cell expansion was related to portal and periportal fibrosis and promoted by steatosis [26]. Such a potential role of steatosis in cholangiolar proliferation and fibrosis remains to be investigated in alcoholic liver disease.

Histological spectrum of alcoholic hepatitis

The intensity and the combination of the above described histological lesions vary considerably from case to case. Three histological patterns (i.e. minimal alcoholic hepatitis, moderately active alcoholic hepatitis, and markedly active alcoholic hepatitis) can be distinguished on the basis of the intensity of necroinflammatory activity and extension of fibrosis.

In *minimal alcoholic hepatitis*, necroinflammatory activity is mild. There are occasional ballooned or apoptotic hepatocytes, possibly a few Mallory bodies and a few neutrophils. The lesions are focal and tend to predominate in centrolobular areas in which perisinusoidal and venular fibrosis is minimal.

In *moderately active alcoholic hepatitis*, necroinflammatory activity is moderate, with more hepatocellular lesions and inflammatory infiltration. Perisinusoidal fibrosis is more extensive in centrolobular areas, is associated with portal and periportal fibrosis, and may form occasional central-to-central or central-to-portal fibrous bridges.

In *markedly active alcoholic hepatitis*, necroinflammatory activity is marked and perisinusoidal fibrosis surrounding individual hepatocytes or small groups of hepatocytes is extensive with formation of numerous fibrous bridges. Cholangiolar proliferation is usual and accumulation of bile may be striking. Terminal hepatic vein lesions and sclerosing hyaline necrosis are more prevalent in this severe type of alcoholic hepatitis. Hepatocellular regenerative activity is mild, particularly if alcohol intake is continued.

The histological features that may indicate a risk of progresssion to cirrhosis are the following:

- degree of perisinusoidal and terminal hepatic vein fibrosis, and extent of fibrous bridges with architectural distortion;
- severity of hepatocyte apoptosis and diffuse parenchymal disease;
- widespread obliteration of terminal hepatic veins;
- presence of numerous Mallory bodies [1,3].

Alcoholic cirrhosis

When liver injury progresses, the development of fibrous bridges leads to cirrhosis, defined as a diffuse process characterized by fibrosis and conversion of normal liver architecture into structurally abnormal nodules [27].

Alcoholic cirrhosis usually is *micronodular*, with hepatocellular nodules 3 mm or less in diameter (Fig. 11). Regenerative activity in the hepatocellular nodules, recognized by the presence of liver cell plates more than one cell thick, may be very mild because of the presumed inhibitory effect of alcohol on hepatic regeneration. Hepatic vein branches are difficult to

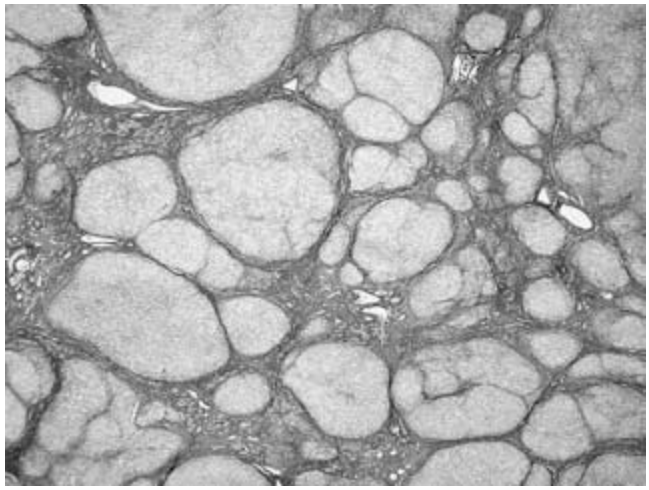

Fig. 11 Micronodular cirrhosis is characterized by hepatocellular nodules measuring 3 mm or less in diameter.

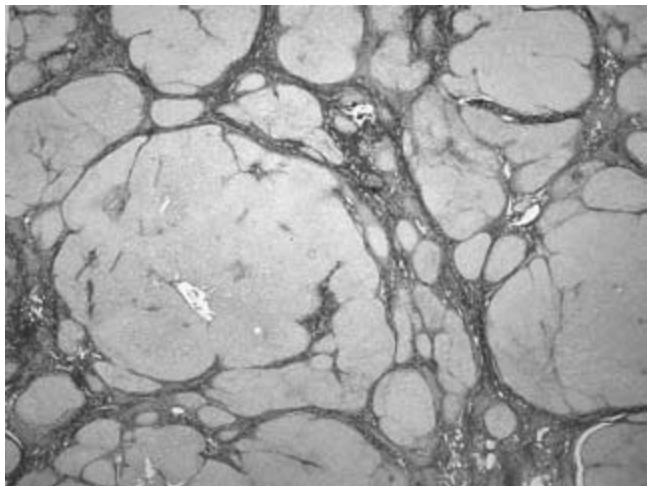

Fig. 12 Macronodular cirrhosis with hepatocellular hyperplastic nodules larger than those of micronodular cirrhosis.

identify within fibrosis. However, the presence of numerous newly formed small vessels within the fibrous bands might be explained by the action of several growth factors (e.g. vascular endothelial growth factor, inducible nitric oxide synthase) produced in reaction to local hypoxia secondary to alcohol consumption and involved in angiogenesis [28].

If alcohol intoxication ceases, proliferative activity of the hepatocytes increases and cirrhosis may become *macronodular* (Fig. 12) with possible development of large hyperplastic nodules [29]. The regenerative nodules vary greatly in size, some of them reaching several centimetres in diameter. They contain portal tracts and terminal hepatic veins that are abnormally related to each other. A *mixed micronodular and macronodular* pattern of cirrhosis is frequently noted.

Steatosis and alcoholic hepatitis may be superimposed on liver cirrhosis, thus indicating persistence of alcohol abuse. The grading of the activity of cirrhosis depends on the degree of necroinflammatory lesions. Major changes in portal flow are observed in cirrhosis with severe alcoholic hepatitis. Such changes, as well as steatosis involving less than 20% of the hepatocytes, have recently been shown to be independently associated with poor survival [30].

Impairment of bile secretion in cirrhosis could explain the minimal accumulation of copper-associated protein, stained by modified orcein, and of copper, stained by rhodanine, which is noted in occasional hepatocytes along fibrous bands [31].

Round intracytoplasmic eosinophilic periodic acid–Schiff diastase-positive globules of alpha-1-antitrypsin may be seen in the hepatocytes at the periphery of cirrhotic nodules: this accumulation has been considered the consequence of an abnormal excretion of the protein [32], but the possibility that hereditary alpha-1-antitrypsin deficiency might potentiate other liver diseases including alcoholic liver disease has also been raised [33].

It is traditional to state that cirrhosis is an irreversible process, even when alcohol is stopped. This dogma is now being debated because it has been suggested that fibrosis, and even cirrhosis, could regress, for instance in hepatitis C virus-infected patients under antiviral treatment [34]. If this is true for alcoholic cirrhosis, it is probably a rare event and one should be very cautious before asserting that cirrhosis has regressed, because micronodular cirrhosis can become macronodular after alcohol withdrawal and a needle biopsy may then fail to detect cirrhosis. The histological diagnosis of macronodular cirrhosis may indeed be difficult on the basis of a needle biopsy, and replacement of biopsy by non-invasive methods (e.g. blood markers, liver stiffness) has been proposed [35,36].

Hepatocellular carcinoma

Hepatocellular carcinoma arises in 5–15% of patients with alcoholic cirrhosis, usually when cirrhosis is macronodular [37]. There is no definite evidence that alcohol is a direct carcinogen, but it may enhance activation of various chemical procarcinogens by inducing microsomal CYP2E1 and it could act as a cocarcinogen for hepatitis B or hepatitis C virus [3,38].

The presence of small-cell or large-cell hepatocellular dysplasia in cirrhotic nodules must be clearly indicated in pathological reports. Indeed, small-cell hepatocellular dysplasia, particularly within macronodules, may be the precursor lesion to hepatocellular carcinoma. In a study of 34 radiologically detected hepatocellular nodules diagnosed by needle biopsy and followed up for more than 6 months, nuclear crowding, clear-cell change, small-cell dysplasia and fatty change indicated a high risk for evolution to hepatocellular carcinoma; the first two features were independent prognostic factors for malignant transformation [39]. Large-cell hepatocellular dysplasia is generally not thought to be a direct precursor of hepatocellular carcinoma, but it could be associated with an increased risk of tumour occurrence [40].

Alcoholic liver disease and other conditions

Alcoholic liver disease and non-alcoholic fatty liver disease

The spectrum of pathological lesions observed in non-alcoholic fatty liver disease is hardly distinguishable from that of alcoholic liver disease [13]. Differences between the two conditions are essentially based on clinical and biochemical arguments. Patients with alcoholic steatohepatitis are usually sicker, have higher serum bilirubin levels and an aspartate aminotransferase to alanine aminotransferase ratio greater than one; histologically, necroinflammatory activity and fibrosis are more severe, Mallory bodies more numerous, and the prevalence of cirrhosis is higher [41].

Table 1 Conditions associated with non-alcoholic fatty liver disease and responsible for histological lesions mimicking alcoholic liver disease.

Insulin resistance
Obesity
Diabetes
Disorders of lipid metabolism
Hypertriglyceridaemia
Abetalipoproteinaemia
Hypobetalipoproteinaemia
Lipodystrophy
Weber–Christian syndrome
Severe weight loss
Jejunoileal or gastric bypass
Starvation
Total parenteral nutrition
Iatrogenic agents
Drugs: amiodarone, tamoxifen, diltiazem
Toxic exposure: industrial solvents

Non-alcoholic fatty liver disease essentially represents the hepatic component of the metabolic syndrome, characterized by obesity, hyperinsulinaemia, peripheral insulin resistance, diabetes, hypertriglyceridaemia and hypertension [42]. Other conditions (Table 1) associated with non-alcoholic fatty liver disease are abnormalities of lipid metabolism, nutritional disorders (i.e. severe weight loss, jejunoileal or gastric bypass, starvation, total parenteral nutrition) and liver diseases induced by some drugs (e.g. amiodarone, tamoxifen, antiretroviral nucleoside analogues) and environmental factors (e.g. industrial solvents) [13]. It is of interest that many of these conditions have in common with alcoholic liver disease either abnormal fat metabolism or mitochondrial dysfunction [13]. Because non-alcoholic fatty liver disease does not occur in every patient with one of the above-mentioned disorders, it is reasonable to postulate that this liver disease results from the conjunction or the potentiation of the deleterious effects of several of these factors; alcohol could be an additional one.

Chronic hepatitis

It was mentioned above that predominantly lymphocytic portal and periportal inflammation and interface hepatitis could be observed in alcoholic liver disease, all other causes of chronic hepatitis (e.g. viral infections, drugs, autoimmunity) being excluded on strict clinical and biological criteria [19]. The prevalence of such features is not clearly determined.

However, it is noteworthy that steatosis and fibrosis are two of the histological hallmarks of chronic viral hepatitis C [43]. Steatosis is probably due to a direct cytopathic effect of genotype 3 hepatitis C virus, whereas associated metabolic factors explain the lesion in non-genotype 3 strains [44]. Alcohol can also interfere with chronic viral hepatitis, and it is known, for instance, that alcohol consumption, even in a moderate amount, aggravates necroinflammatory activity and fibrosis in patients with chronic hepatitis C [45].

Iron overload

Stainable iron deposits are often seen in both hepatocytes and Kupffer cells in patients with alcoholic liver disease, particularly when cirrhosis is established. Iron overload has been attributed to iron content of alcoholic beverages, increased intestinal absorption, hepatocellular necrosis, haemolytic episodes, or portocaval shunting [1,3]. It is usually mild or moderate, randomly distributed within the hepatic lobule, and can be explained by alcohol-induced upregulation of transferrin receptor expression in hepatocytes [46]. When iron overload is marked and predominates in periportal hepatocytes, an association with genetic haemochromatosis should be considered [1,3]. Heavy alcohol intake accentuates the clinical expression of haemochromatosis [47] and, conversely, iron overload seems to potentiate alcohol-induced liver injury [48]. A reasonable hypothesis would be that iron and alcohol act as cofactors in enhancing oxidative stress, stellate cell activation and fibrogenesis [47].

Role of liver biopsy in the management of patients with alcoholic liver disease

Liver biopsy is important in the clinical management of alcoholic patients. It is helpful to confirm or refute the diagnosis of alcoholic liver disease and possibly to reveal coexisting pathological conditions. It is useful to suggest the diagnosis in patients who deny alcohol abuse and in whom no other cause of liver disease is found. It may also be indicated in cirrhotic alcoholic patients in whom liver transplantation is proposed, in order to preclude histological lesions suggesting ongoing alcoholic hepatitis.

Because the prognosis of alcoholic liver disease partly depends on the severity of pathological findings, grading and staging the lesions observed on liver biopsy is necessary. There is no recognized system correlating histological features with long-term prognosis. Nonetheless, it might be proposed, as is done in other liver diseases (e.g. chronic viral hepatitis, non-alcoholic fatty liver disease), that grading of necroinflammatory activity and staging of fibrosis with description of architectural remodelling should be mentioned in the pathological report.

Finally, liver biopsy has an increasing role in evaluating survival and prognostic factors in patients with severe alcoholic liver disease treated by various agents such as corticosteroids, pentoxifylline, antibodies against tumour necrosis factor-α, or interleukin 10 [8].

References

1 Anon (1981) Alcoholic liver disease: morphological manifestations. Review by an international group. *Lancet* i, 707–711.

2 Edmondson HA, Peters RL, Frankel HH, Borowsky S (1967) The early stage of liver injury in the alcoholic. *Medicine (Baltimore)* 46, 119–129.

3 Hall P (2002) Alcoholic liver disease. In: MacSween RN, Burt AD, Portmann BC *et al.* (eds) *Pathology of the Liver.* London: Churchill Livingstone, pp. 273–311.

4 Rubin E, Lieber CS (1968) Alcohol-induced hepatic injury in non-alcoholic volunteers. *N Engl J Med* 278, 869–876.

5 Uchida T, Kao H, Quispe-Sjogren M, Peters RL (1983) Alcoholic foamy degeneration – a pattern of acute alcoholic injury of the liver. *Gastroenterology* 84, 683–692.

6 Suri S, Mitros FA, Ahluwalia JP (2003) Alcoholic foamy degeneration and a markedly elevated GGT: a case report and literature review. *Dig Dis Sci* 48, 1142–1146.

7 Teli MR, Day CP, Burt AD *et al.* (1995) Determinants of progression to cirrhosis or fibrosis in pure alcoholic fatty liver. *Lancet* 346, 987–990.

8 Mathurin P, Dharancy S, Malapel M *et al.* (2004) Hépatite alcoolique: données physiopathologiques et perspectives thérapeutiques. *Gastroenterol Clin Biol* 28 (5 Suppl.), D103–111.

9 Ribeiro PS, Cortez-Pinto H, Sola S *et al.* (2004) Hepatocyte apoptosis, expression of death receptors, and activation of NF-kappaB in the liver of nonalcoholic and alcoholic steatohepatitis patients. *Am J Gastroenterol* 99, 1708–1717.

10 Denk H, Stumptner C, Zatloukal K (2000) Mallory bodies revisited. *J Hepatol* 32, 689–702.

11 Fataccioli V, Andraud E, Gentil M *et al.* (1999) Effects of chronic ethanol administration on rat liver proteasome activities: relationship with oxidative stress. *Hepatology* 29, 14–20.

12 Bardag-Gorce F, Vu J, Nan L *et al.* (2004) Proteasome inhibition induces cytokeratin accumulation *in vivo*. *Exp Mol Pathol* 76, 83–89.

13 Zafrani ES (2004) Non-alcoholic fatty liver disease: an emerging pathological spectrum. *Virchows Arch* 444, 3–12.

14 Chedid A, Mendenhall CL, Tosch T *et al.* (1986) Significance of megamitochondria in alcoholic liver disease. *Gastroenterology* 90, 1858–1864.

15 Hoek JB, Cahill A, Pastorino JG (2002) Alcohol and mitochondria: a dysfunctional relationship. *Gastroenterology* 122, 2049–2063.

16 Lieber CS (1995) Medical disorders of alcoholism. *N Engl J Med* 333, 1058–1065.

17 Tilg H, Diehl AM (2000) Cytokines in alcoholic and nonalcoholic steatohepatitis. *N Engl J Med* 343, 1467–1476.

18 Purohit V, Russo D (2002) Cellular and molecular mechanisms of alcoholic hepatitis: introduction and summary of the symposium. *Alcohol* 27, 3–6.

19 Colombat M, Charlotte F, Ratziu V, Poynard T (2002) Portal lymphocytic infiltrate in alcoholic liver disease. *Hum Pathol* 33, 1170–1174.

20 Worner TM, Lieber CS (1985) Perivenular fibrosis as precursor lesion of cirrhosis. *JAMA* 254, 627–630.

21 Goodman ZD, Ishak KG (1982) Occlusive venous lesions in alcoholic liver disease. A study of 200 cases. *Gastroenterology* 83, 786–796.

22 Edmondson HA, Peters RL, Reynolds TB, Kuzma OT (1963) Sclerosing hyaline necrosis of the liver in the chronic alcoholic. A recognizable clinical syndrome. *Ann Intern Med* 59, 646–673.

23 Kishi M, Maeyama S, Iwaba A *et al.* (2000) Hepatic veno-occlusive lesions and other histopathological changes of the liver in severe alcoholic hepatitis – a comparative clinicohistopathological study of autopsy cases. *Alcohol Clin Exp Res* 24 (4 Suppl.), 74S–80S.

24 Afshani P, Littenberg GD, Wollman J, Kaplowitz N (1978) Significance of microscopic cholangitis in alcoholic liver disease. *Gastroenterology* 75, 1045–1050.

25 Roskams T, Yang SQ, Koteish A *et al.* (2003) Oxidative stress and oval cell accumulation in mice and humans with alcoholic and nonalcoholic fatty liver disease. *Am J Pathol* 163, 1301–1311.

26 Clouston AD, Powell EE, Walsh MJ *et al.* (2005) Fibrosis correlates with a ductular reaction in hepatitis C: roles of impaired replication, progenitor cells and steatosis. *Hepatology* 41, 809–818.

27 Anthony PP, Ishak KG, Nayak NC *et al.* (1978) The morphology of cirrhosis. Recommendations on definition, nomenclature, and classification by a working group sponsored by the World Health Organization. *J Clin Pathol* 31, 395–414.

28 Medina J, Arroyo AG, Sanchez-Madrid F *et al.* (2004) Angiogenesis in chronic inflammatory liver disease. *Hepatology* 39, 1185–1195.

29 Gluud C, Christoffersen P, Eriksen J *et al.* (1987) Influence of ethanol on development of hyperplastic nodules in alcoholic men with micronodular cirrhosis. *Gastroenterology* 93, 256–260.

30 Duvoux C, Radier C, Roudot-Thoraval F *et al.* (2004) Low-grade steatosis and major changes in portal flow as new prognostic factors in steroid-treated alcoholic hepatitis. *Hepatology* 40, 1370–1378.

31 Guigui B, Mavier P, Lescs MC *et al.* (1988) Copper and copper-binding protein in liver tumors. *Cancer* 61, 1155–1158.

32 Pariente EA, Degott C, Martin JP *et al.* (1981) Hepatocytic PAS-positive diastase-resistance inclusions in the absence of alpha-1-antitrypsin deficiency: high prevalence in alcoholic cirrhosis. *Am J Clin Pathol* 76, 299–302.

33 Graziadei IW, Joseph JJ, Wiesner RH *et al.* (1998) Increased risk of chronic liver failure in adults with heterozygous alpha-1-antitrypsin deficiency. *Hepatology* 28, 1058–1063.

34 Poynard T, McHutchison J, Manns M *et al.* (2002) Impact of pegylated interferon alfa-2b and ribavirin on liver fibrosis in patients with chronic hepatitis C. *Gastroenterology* 122, 1303–1313.

35 Trinchet JC, Grando-Lemaire V (2004) Diagnostic de cirrhose. *Gastroenterol Clin Biol* 28 (5 Suppl.), D121–128.

36 Ziol M, Handra-Luca A, Kettaneh A *et al.* (2004) Noninvasive assessment of liver fibrosis by measurement of stiffness in patients with chronic hepatitis C. *Hepatology* 41, 48–54.

37 Lee FI (1966) Cirrhosis and hepatoma in alcoholics. *Gut* 7, 77–85.

38 Bréchot C, Nalpas B, Couroucé AM *et al.* (1982) Evidence that hepatitis B virus has a role in liver-cell carcinoma in alcoholic liver disease. *N Engl J Med* 306, 1384–1387.

39 Terasaki S, Kaneko S, Kobayashi K *et al.* (1998) Histological features predicting malignant transformation of nonmalignant hepatocellular nodules: a prospective study. *Gastroenterology* 115, 1216–1222.

40 Lee RG, Tsamandas AC, Demetris AJ (1997) Large cell change (liver cell dysplasia) and hepatocellular carcinoma in cirrhosis: matched case-control study, pathological analysis, and pathogenetic hypothesis. *Hepatology* 26, 1415–1422.

41 Sanyal AJ (2002) AGA technical review on nonalcoholic fatty liver disease. *Gastroenterology* 123, 1705–1725.

42 Marchesini G, Bugianesi E, Forlani G *et al.* (2003) Nonalcoholic fatty liver, steatohepatitis, and the metabolic syndrome. *Hepatology* 37, 917–923.

43 Scheuer PJ, Ashrafzadeh P, Sherlock S *et al.* (1992) The pathology of hepatitis C. *Hepatology* 15, 567–571.

44 Castéra L, Chouteau P, Hézode C *et al.* (2005) Hepatitis C virus-induced hepatocellular steatosis. *Am J Gastroenterol* 100, 711–715.

45 Hézode C, Lonjon I, Roudot-Thoraval F *et al.* (2003) Impact of moderate alcohol consumption on histological activity and fibrosis in patients with chronic hepatitis C, and specific influence of steatosis: a prospective study. *Aliment Pharmacol Ther* 17, 1031–1037.

46 Suzuki Y, Saito H, Suzuki M *et al.* (2002) Up-regulation of transferrin receptor expression in hepatocytes by habitual alcohol drinking is implicated in hepatic iron overload in alcoholic liver disease. *Alcohol Clin Exp Res* 26(8 Suppl.), 26S–31S.

47 Fletcher LM, Powell LW (2003) Hemochromatosis and alcoholic liver disease. *Alcohol* 30, 131–136.

48 Raynard B, Balian A, Fallik D *et al.* (2002) Risk factors of fibrosis in alcohol-induced liver disease. *Hepatology* 35, 635–638.

12.4 Alcoholic liver disease: natural history, diagnosis, clinical features, evaluation, prognosis and management

Laurent Spahr and Antoine Hadengue

Introduction

In alcoholic liver disease (ALD), perhaps the oldest field in hepatology, profound changes have occurred since the last edition of this textbook. Besides classical descriptions of ALD, which will be reviewed briefly, this chapter will expand a little more on recent concepts.

First, although a 'unified theory' of steatohepatitis has not been reached, recent progress in non-alcoholic steatohepatitis (NASH) obviously has some relevance when considering the natural history of ALD [1]. The classical concept is that alcohol can cause liver steatosis, which may subside within weeks of abstinence. Steatosis, in turn, may be complicated by alcoholic steatohepatitis (ASH), and eventually cause progressive fibrosis. Alcohol used to stand as the principal aetiology of steatohepatitis, the others often being referred to as causing 'pseudo-alcoholic hepatitis' [2]. The rapid emergence of new concepts in NASH in the 1990s revolutionized our view of all aspects of steatohepatitis, including ALD. For the sake of clarity, the definition of NASH had to rule out significant alcohol consumption, arbitrarily set at 20 g/day [3]. However, it has become obvious that ASH and NASH share a number of risk factors, mechanisms and elementary histological lesions [4,5]. Per capita alcohol consumption correlates with cirrhosis-related mortality rate (see Chapter 12.1). It is difficult, however, to set a toxicity threshold for the development of serious alcoholic liver injury [6]. Thus, in addition to net alcohol intake, sex, body mass index, insulin resistance, iron load and oxidant status also contribute to the risk of ALD in a given individual and have to be evaluated for their contribution to steatohepatitis in subjects who drink alcohol.

Secondly, advances in the medical therapy of ASH have been slow, probably because of the multifactorial, multifaceted nature of the disease, difficult access to histology to confirm the diagnosis and the relative scarcity of randomized trials. However, things have changed, largely as a result of access to transvenous liver biopsy to rule out confounding diagnoses and of the systematic use of severity criteria. Data derived from recent trials and meta-analyses no longer allow sceptical therapeutic abstention in severe cases of confirmed ASH. And, here again, many concepts derived from what has been learned recently in NASH probably have some relevance in the management of patients with ALD.

Thirdly, the role of liver transplantation, now a stable, efficient tool in most endstage liver diseases, is still debated in many centres when it comes to providing liver grafts to patients with ALD. While issues of efficacy, in a disease often cured by abstinence alone, and justice of distribution of scarce resources, in a so-called self-inflicted disease, have been discussed eagerly, data gathered in most centres and registries now provide a stable basis to delineate the use of liver transplantation in ALD [7].

Although elementary histological lesions do not correlate clearly with the clinical manifestations of ALD, we will attempt to single out the features of alcoholic steatosis, ASH and alcoholic cirrhosis, seen as paradigms. In real life, most patients coming to the attention of a hepatologist usually present with different degrees (or grades) of each of three groups of lesions. Each of the three 'dimensions' of ALD, namely fat accumulation, inflammation and fibrosis, best delineated by liver biopsy, should be taken into account in the patient's management.

The natural history of alcoholic liver disease

Patients with ALD represent a very heterogeneous population. Clinical presentation ranges from asymptomatic alcoholic steatosis to decompensated cirrhosis, with or without ASH. We have chosen to describe alcoholic steatosis, ASH and cirrhosis as separate entities. In fact, these three main groups of alcohol-induced liver lesions usually coexist in the same individual.

The spectrum of ALD may be characterized in a static, cross-sectional manner according to the proportion of patients with each lesion or combination of lesions at liver pathology (Fig. 1). For obvious reasons, liver biopsy is not available in large population-based studies. Thus, the true prevalence of alcohol-

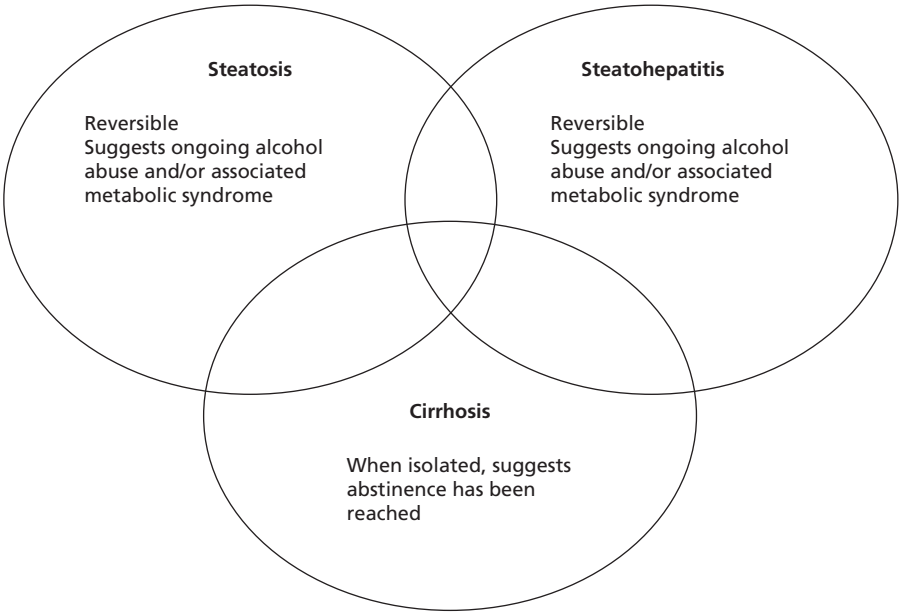

Fig. 1 The spectrum of ALD. Note that patients with steatohepatitis, by definition, have steatosis.

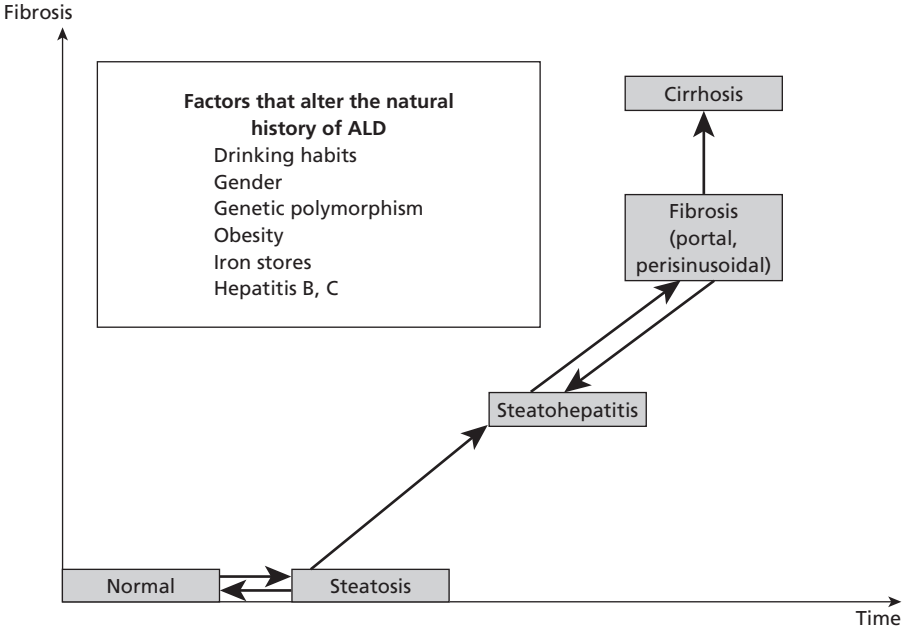

Fig. 2 A dynamic view of the natural history of ALD and factors associated with its progression over time (for details, see text).

induced liver lesions in subjects who drink alcohol is unknown. Similarly, the results of transversal studies are expected to vary according to the population examined (see Chapter 12.1). For example, cirrhosis was present in 37% of alcoholic patients hospitalized in a French hepatogastroenterology department [8], but in only 8% in a German general hospital [9]. In one recent study of 256 heavy drinkers (i.e. > 80 g/day) admitted to an internal medicine ward in Spain for non-liver-related diseases, some degree of ALD was present on liver biopsy in all cases, steatosis in 45%, ASH in 34%, ASH with superimposed cirrhosis in 10% and isolated cirrhosis in another 10% [10].

The spectrum of histological lesions induced by alcohol may be seen as a dynamic process (Fig. 2). Alcoholic steatosis may be the earliest histological lesion associated with alcohol abuse and may completely disappear within weeks of abstinence. ASH, which probably develops in only a minority of excessive drinkers with steatosis, is a fibrogenic process and may eventually induce cirrhosis [11]. Although ASH is recognized as being reversible within weeks of alcohol cessation, some degree of fibrosis usually persists. In wine-producing countries and patients with regular, daily alcohol consumption, cirrhosis is already present in the majority of cases at the time of diagnosis of ASH. Patients

with ASH but without cirrhosis, more frequently binge drinkers, are at substantial risk of developing cirrhosis over time [12]. Alcoholic cirrhosis is considered as the final stage of alcohol-induced liver injury. It has been considered as an irreversible process with regard to the amount of fibrous tissue that typically surrounds the sinusoids, but recent data suggest that, in some cases, fibrosis may undergo regression with resorption of septa [13]. As already mentioned, cirrhosis is often associated with ASH, to the point that steatohepatitis is one of the most frequent causes of decompensation in patients with alcoholic cirrhosis.

Factors that influence the natural history of alcoholic liver disease

The incidence of cirrhosis correlates with overall alcohol consumption, but does not increase linearly with mean alcohol consumption [14,15]. However, additional factors contribute to the risk of chronic liver disease, and only 15–20% of heavy alcohol consumers will develop cirrhosis over time [11] (see also Chapters 12.1 and 12.2).

Gender

At any given level of alcohol intake [15,16], women seem to be more susceptible than men to advanced ALD. Both the course of the disease and the prognosis seem to be worse in women [15,17]. This may be related to gut permeability changes and cytokine production in relation to sex hormones [15,18], and probably not to low levels of alcohol-metabolizing enzymes [19].

Ethnicity and genetic factors

In a population of regular drinkers from the United States, after adjustment for body mass index and viral hepatitis, Mexicans [odds ratio (OR) 9.1] and African Americans (OR 3.1) were more likely to have a twofold increase in liver transaminases compared with white non-Hispanic Americans [20]. It has been proposed that polymorphisms in alcohol-metabolizing genes [21], inflammatory regulator genes [22] and genes involved in drinking behaviour [23] may influence the predisposition to develop ALD.

Polymorphisms in alcohol metabolism

Some alleles of the inducible *CYP2E1* gene may result in increased activity and reactive oxygen species (ROS) production. Studies linking CYP2E1 polymorphism to ALD among excessive drinkers were significant in Japanese [24], but negative in Chinese [25] and Caucasian [21] populations. Genetic dimorphism in superoxide dismutase, key to detoxifying ROS, was reported to be associated with ALD in only one of two recent studies [26,27].

Polymorphism in inflammatory response

The TNF G→A allele at position –238 in the promoter region of tumour necrosis factor (TNF)α, a key mediator in ASH (see below), is associated with increased TNFα levels and was observed more frequently in British patients with ASH compared with healthy volunteers [22]. This was not confirmed in Spanish alcoholics [28] (the majority of whom had no liver biopsy). Polymorphism in CD14 genes involved in endotoxin signalling has been explored in Finnish drinkers [29]. The prevalence of the T allele, which increases CD14 expression, was associated with ASH (OR 2.48) and cirrhosis (OR 3.45), but not with steatosis.

Genetic polymorphism in interleukin (IL)-10, an anti-inflammatory cytokine, was more frequent in English patients with advanced ALD compared with healthy subjects (50% vs. 33%, $P < 0.01$) [30]. Similar findings were reported in a Spanish population [28].

Taken together, several distinct lines of evidence suggest that polymorphism in either proinflammatory or anti-inflammatory cytokine genes may result in exaggerated susceptibility to ALD. This evidence, however, cannot be applied today in routine clinical practice.

Drinking behaviour

The pattern of alcohol consumption, which may also be influenced by genetic polymorphisms, also plays a role in ALD. For example, alcohol dependence is associated with genetic polymorphisms in the GABA receptor [31] and neuropeptide Y [32], both molecules being involved in anxiety-related behaviour and control of alcohol consumption.

In the Dionysos study from northern Italy, consuming alcohol outside meals, as well as drinking more than one type of alcoholic beverage, was associated with an increased risk of cirrhosis [14]. Binge drinking mostly affects young adult males in northern and central Europe [33], and results in a higher incidence of death [34] and a more than fivefold risk of developing ASH [10]. Whether the type of alcohol consumed (wine, beer or spirits) might affect the risk of developing cirrhosis has been studied in Denmark [6]. For each level of pure alcohol consumption, a higher proportion of wine was associated with a lower risk of cirrhosis, with a relative risk of 0.3 when more than 50% of all alcohol was consumed as wine [6]. Concerns have been raised that hepatitis C virus (HCV) was not evaluated in this study and that wine consumption may also be a marker for drinking during meals and eating more fruit and vegetables [35].

The role of iron, viral hepatitis and obesity will be reviewed in the section on 'Interaction between alcohol and other liver diseases' below.

Alcoholic steatosis

Macrovesicular steatosis

Macrovesicular steatosis is characterized by the presence of one or more fat droplets that displace the nucleus at the periphery of the hepatocyte. Typically centrolobular, it may in severe cases extend to the entire lobule. Macrovesicular steatosis is thought to be the initial lesion associated with alcohol abuse. It is

observed at ultrasonography in more than 90% of patients with alcohol intake > 30 g/day [14], and at histology in all individuals who reported a median consumption of 63 drinks per week [36]. It should be kept in mind that ultrasonography can miss macrovesicular steatosis and is operator dependent. In addition, steatosis is not specific to alcohol abuse and may obviously be observed in other situations such as obesity, diabetes, chronic hepatitis C, starvation and drug abuse [37]. In a cross-sectional study from northern Italy [38], the prevalence of steatosis was 46% in individuals drinking more than 30 g of alcohol per day, 76% in obese non-drinking persons and 94% in obese individuals consuming more than 30 g of alcohol daily.

Pathogenesis

The intracytoplasmic accumulation of triglycerides seen as steatosis droplets may result from increased fatty acid synthesis and fat mobilization or defective fat export or breakdown in the liver (see Chapter 12.2). Lipid trafficking is altered by alcohol together with mitochondrial fatty acid metabolism [39].

Clinical manifestations and diagnosis

Alcoholic macrovesicular steatosis (unlike microvesicular steatosis) is usually asymptomatic. In a minority of cases, epigastric pain and/or right upper quadrant discomfort may be present. Hepatomegaly resulting from fat accumulation can be spectacular and may subside within weeks following alcohol abstinence.

Laboratory values

Biological abnormalities associated with steatosis should be distinguished from the laboratory markers used to detect alcoholism (see Chapters 5.2 and 12.5). For example, mean corpuscular volume of red blood cells and carbohydrate-deficient transferrin are influenced by heavy drinking [40] and are not considered as reliable indicators of steatosis.

Gamma-glutamyltransferase (γ-GT) is frequently elevated during regular alcohol abuse [41] and may be abnormal in the presence of hepatocellular damage. However, γ-GT is not liver specific, may be abnormal in obesity, correlates modestly with alcohol consumption and is not always elevated in alcohol drinkers [42]. The induction of serum γ-GT by chronic alcohol intake may be subject to genetic polymorphism [43]. Recent data suggested that high γ-GT levels may be a marker of oxidative stress [44] and associated with more rapid progression of liver disease [43].

Serum transaminases are not inducible by alcohol consumption. Thus, they may be regarded as sensitive indicators of liver cell injury in excessive drinkers. In these patients, transaminase levels can be normal or modestly elevated, less than 5 to 10 times the upper limit of normal (ULN) [37,45]. In 319 patients with biopsy-proven alcoholic steatosis, the mean aspartate aminotransferase (AST) increase was 3 ULN, but AST remained normal in 14% of the patients [46]. In addition, the coexistence of metabolic abnormalities in patients with ALD may influence transaminase levels [47]. In one study of subjects consuming more than 30 g of alcohol per day, obesity increased twofold the risk of elevated alanine aminotransferase (ALT) levels [38].

In the absence of cirrhosis, an AST level greater than the ALT level has been considered suggestive of an alcoholic aetiology [37]. An increased AST/ALT ratio may also be associated with NASH or denutrition, or cirrhosis, whatever its cause. For example, an AST/ALT ratio > 1 was observed in 92% of patients with ALD, but also in 70% of patients with viral cirrhosis [48].

Imaging studies

Imaging by ultrasonography (US), computerized tomography (CT) and magnetic resonance imaging (MRI) can demonstrate the presence of fat in the liver. US can detect liver steatosis with a 60–94% [49] sensitivity and is limited to the detection of macrovesicular steatosis [50]. Thirty-three per cent or more fat on liver biopsy is considered as an optimal threshold for the detection of steatosis on US [51]. US is relatively specific (88–95% [49]), but a 'bright' hyperechoic liver has also been described in other clinical situations, such as cystic fibrosis or schistosomiasis [52,53].

On CT (without intravenous contrast), the steatotic liver demonstrates a reduced density. The liver/spleen density ratio correlates inversely with the degree of fat infiltration at histology [54]. Similar to US, CT had a sensitivity and specificity of 93% or 100% in detecting hepatic steatosis of 33% or more [51] in a small group of patients with non-alcoholic fatty liver disease.

MRI may offer a better correlation with the presence of fat in the liver. In a study of 38 patients who had MRI performed within 2 weeks of a liver biopsy, a positive correlation was observed with both macrovesicular ($r = 0.92$) and microvesicular ($r = 0.6$) fat [55].

The natural history of steatosis

Alcoholic steatosis, similar to non-alcoholic steatosis, was considered a benign condition. In fact, steatosis should be seen as the first step to steatohepatitis, and may be a surrogate marker for increased mortality from both liver-related and non-liver-related causes. Dam-Larsen *et al.* [36] recently followed 417 patients with alcoholic or non-alcoholic fatty liver at biopsy. The risk of developing cirrhosis was 22% over 12 years in drinkers (> 30 g/day in men, 20 g/day in women) with steatosis, and mortality increased with the degree of steatosis. In contrast, in non-drinkers, the incidence of cirrhosis was 0.6% over 19.9 years, and survival was not related to the degree of steatosis.

Treatment

Alcoholic steatosis is reversible within weeks of discontinuation of alcohol consumption [11,16], meaning that specific medical therapy is not usually needed. Nevertheless, a 3-month course of metadoxine (a combination of pyridoxine and pyrrolidone described as improving intracellular alcoholic oxidative changes) was associated with a more rapid normalization of liver function tests and echographic alterations compared with placebo in patients with alcoholic steatosis [56].

When steatosis (as evidenced by US) and abnormal transaminases persists despite abstinence, the question of associated non-alcoholic fatty liver disease should be raised [47].

Microvesicular steatosis

Definition and natural history

On haematoxylin/eosin-stained material, microvesicular steatosis consists of small fat droplets evenly distributed throughout the cytoplasm and leaving the nucleus in its central position. Microvesicular steatosis, also named foamy degeneration, can be missed on standard staining and may require specific oil red-O lipid staining [57]. When induced by alcohol, microvesicular steatosis often predominates in the centrolobular area [58]. Associated lesions may include hepatocyte swelling, cholestasis and macrovesicular fat [57]. Because the microvesicular component may disappear within days of abstinence from alcohol, microvesicular fat is often featured on liver biopsies performed early, i.e. less than 5 days after cessation of alcohol intoxication [59], but may be missed thereafter. Acute, often symptomatic, microvesicular steatosis usually subsides within days. However, the presence of microvesicular steatosis on liver biopsy (or a mixed pattern with macrovesicular steatosis) probably identifies a subgroup of patients at risk of rapid fibrosis progression [38].

Pathogenesis

Microvesicular steatosis due to alcohol as well as other causes (Chapter 2.3.4) results from impaired mitochondrial function thought to be involved in the development of steatohepatitis [60,61].

Clinical presentation

When massive, often triggered by acute alcohol intoxication, microvesicular steatosis may present as an acute liver disease with abdominal pain, jaundice or hepatic encephalopathy. Typically, high levels of transaminases (up to 15 times the normal value) may be seen at hospital admission and subside together with clinical symptoms within days of alcohol abstinence [57,59]. Hyperbilirubinaemia may correspond to haemolysis and last longer [57]. Other serious clinical manifestations have been described including hypoglycaemia, metabolic acidosis, altered level of consciousness and sudden death [62]. We believe that the syndrome described by Zieve in 1958 [63] (abdominal pain, jaundice, hyperlipidaemia and haemolysis) may in fact correspond to microvesicular steatosis and haemolysis following heavy alcohol intake.

Alcoholic steatohepatitis

ASH occurs in only a minority of patients who report heavy alcohol intake. In the study by Barrio *et al.* [10] already mentioned, ASH was present in only a third of heavy drinkers. Above a threshold of 80–150 g of alcohol per day, ASH does not seem to correlate with alcohol intake, but appears to be more frequent in irregular, for example weekend, drinkers [10].

Definition and pathology

Steatohepatitis is defined by the coexistence of three histological criteria, namely ballooning degeneration of hepatocytes, steatosis (macro- and/or microvesicular) and lobular inflammation with mononuclear cells and polynuclear neutrophils [64] (see Chapter 12.3). Other lesions that may be present and suggestive, but should not be regarded as necessary for diagnosis, include Mallory's hyaline bodies, megamitochondria, perisinudoidal fibrosis and granular iron staining in hepatocytes or sinusoidal lining cells [3]. These lesions predominate in the perivenular region. Whether ASH and NASH can be distinguished on the basis of histology has been a matter of debate [65]. It has been suggested recently that steatosis was more extensive in NASH compared with ASH, as a result of obesity and hyperlipidaemia [66]. In our experience, marked cholestasis with bile plugs and neoductular proliferation is frequent in severe ASH, but unusual in NASH. In contrast, large glycogenic nuclei and gross hepatocyte ballooning contrasting with minimal inflammation are often seen in NASH (Laura Rubbia-Brandt, personal communication).

Pathogenesis

The pathogenesis of ASH is reviewed in Chapter 12.2. Oxidative stress, elevated endotoxin levels, stimulation of the expression and release of inflammatory mediators such as TNFα, apoptosis and immune reactions are particularly relevant for clinicians. Oxidative stress results from both overproduction of free radicals due to alcohol metabolism and poor hepatic reserve of antioxidants [67], which may be linked to the poor nutritional status of chronic alcoholics. Endotoxinaemia is facilitated by the effect of alcohol on gut permeability [68] and may trigger oxidative stress and the production of proinflammatory cytokines by Kupffer cells. These cytokines, mainly TNFα, IL-1, IL-6 and IL-8, mediate many aspects of ASH [69]. IL-8 facilitates the neutrophilic infiltration of the liver lobule, a feature that characterizes alcoholic ASH [70]. Inflammation is associated with stellate cell activation and fibrogenesis.

Clinical features

Patients with ASH may come to medical attention at the time of liver-related complications such as jaundice, ascites, variceal bleeding or hepatic encephalopathy. A minority of patients may present with frank abdominal pain, fever, nausea or vomiting. Clinical presentation may be limited to non-specific complaints such as fatigue, anorexia or vague abdominal discomfort. However, ASH may be asymptomatic and may be diagnosed at the time of hospitalization for alcohol withdrawal syndrome [10].

At clinical examination, it is usually difficult to sort out signs of decompensated cirrhosis from the features suggestive of ASH itself, which may indeed be the cause of decompensation. ASH may cause a rapid increase in portal pressure, with a bounding pulse and tachycardia, in line with systemic arterial vasodilation

and hyperkinetism. Spider angiomas and palmar erythema are often numerous and prominent, suggesting liver failure and angiogenesis. An audible bruit over the liver may be present, corresponding to intense vasodilation of the hepatic artery. The liver may be enlarged and tender. However, owing to the underlying cirrhosis, a dysmorphic liver or even liver atrophy is often present. Although fever, sometimes as high as 39°C, may be associated with ASH, infection should be sought systematically. Spontaneous bacterial peritonitis, urinary tract infection and pneumonia are among the most frequent causes of infection in patients with ASH. Cholangitis and biliary obstruction may be particularly difficult to exclude in patients with jaundice and fever. Other complications of portal hypertension, including ascites, variceal bleeding and hepatic encephalopathy, may be present. Additional features such as peripheral polyneuropathy, skeletal muscle wasting, Dupuytren's contracture, poor nutritional status at physical examination and lipodystrophy [71] may suggest alcohol as the aetiology (see Table 1).

Overall, it is important to realize that the performance of an experienced clinician is relatively poor in the diagnosis of ASH. It is often overdiagnosed when other causes, including gastrointestinal bleeding or infection, are responsible for the decompensation of cirrhosis. It is often underdiagnosed when asymptomatic. For example, when patients with a clinical diagnosis of severe ASH were included in a large randomized multicentre trial [72], diagnosis was confirmed at histology, obtained by transvenous liver biopsy, in only 85% of the cases, meaning that 15% of the patients could have been treated improperly if liver biopsy had not been available.

Laboratory values

Transaminases are usually moderately elevated, typically by less than five times ULN in patients with ASH. Higher values may suggest associated conditions, including prominent microvesicular steatosis, bile stone migration, drug-induced or other liver disease. Normal transaminase values do not rule out a diagnosis of ASH. The AST is often greater than the ALT level. However, as stated above, an AST/ALT ratio > 1 may be observed in the course of advanced liver disease whatever the cause.

Total bilirubin is elevated in the vast majority of severe forms of ASH. Conjugated bilirubin usually represents more than 50% of total bilirubin, reflecting preserved glucuronoconjugation. When more than 50% of total bilirubin is unconjugated, haemolysis should be suspected, typically related to acanthocytosis [73]. In keeping with the prognostic value of both bilirubin and creatinine plasma values, altered renal function may contribute to high total bilirubin levels.

γ-GT is of little diagnostic use in ASH. Alkaline phosphatase is usually mildly elevated. Whenever its value exceeds two to three times ULN, particular attention should be paid to the

Table 1 Extrahepatic manifestations of alcohol abuse.

Complication	Features
Nervous system	
Korsakoff's syndrome	Retrograde/anterograde amnesia
Alcohol withdrawal syndrome	Agitation, tremor, hyperadrenergic signs
Wernicke's encephalopathy	Confusion, ataxia, ophthalmoplegia
Peripheral neuropathy	Pain, cramps, decreased sensitivity
Alcoholic dementia	Progressive loss of cerebral functions
Hepatic encephalopathy	Altered consciousness, personality changes
Heart	
Atrial fibrillation	Palpitations
Arterial hypertension	May coexist with alcohol withdrawal syndrome
Dilated cardiomyopathy	Signs of cardiac insufficiency
Gastrointestinal	
Acute and chronic pancreatitis	Abdominal pain, diabetes, chronic diarrhoea
Gastritis, oesophagitis	Heartburn, haematemesis
Parotid gland enlargement	
Cancer (aerodigestive region, liver)	Dysphagia, weight loss
Skin, skeletal muscle, bone, adipose tissue	
Spider angioma	
Dupuytren's contracture	
Alcoholic myopathy	Muscle tenderness, wasting
Aseptic hip necrosis	Localized pain, walking disability
Alcoholic lipodystrophy	Aberrant body fat redistribution
Haematopoietic system	
Thrombocytopenia	Bleeding diathesis (may be transient due to alcohol myelotoxicity)

possibility of biliary obstruction, drug-induced liver lesions or granulomatosis.

A high white blood cell (WBC) count is a classical feature in ASH [40]. A leukaemoid reaction, with WBC counts as high as 40–50 g/L is not exceptional and can be misleading [74]. However, WBC counts may be normal or low, particularly when cirrhosis is present [75].

Prolonged prothrombin time is the most accessible marker of liver failure in ASH. In patients with poor nutritional status and/or prolonged jaundice, gross vitamin K deficiency should be ruled out before using prothrombin as a criteria for clinical decisions. Factor V measurement, when it can be reliably obtained, probably helps in this regard, although its use has not been validated in studies on ASH.

Low serum albumin in ASH may be due to low synthetic liver function, but changes in distribution as well as inflammation can alter serum concentration [76].

Iron studies are expected to be grossly abnormal at the time of ASH because of hepatocyte necrosis and inflammation. Thus, the iron status should be evaluated on liver biopsy or investigated later in time.

Proinflammatory cytokines, dominated by TNFα [69,77], but also including IL-6 [78,79], IL-8 [70], IL-18 [80] and intercellular adhesion molecule (ICAM)-1 [75], are high in the serum of patients with ASH. Although these markers are not used in routine clinical practice, they convey prognostic information. Cytokines may explain some of the clinical symptoms, such as anorexia, muscle wasting or fever [69]. Cytokines may trigger apoptosis [81,82] and promote neutrophilic adhesion [75].

Imaging and haemodynamic studies

Abdominal imaging (US, CT or MRI), although not useful for the diagnosis of ASH, will be performed to exclude liver tumours, biliary tract disease, splanchnic vein thrombosis or intra-abdominal infectious processes. Features suggestive of hepatic steatosis and portal hypertension may be present.

Pseudotumoral nodules can be found incidentally in patients with ASH [83]. It may prove difficult to distinguish a regenerative nodule with increased arterial flow with prominent angiogenesis [84] from hepatocellular carcinoma [85]. In addition, α-fetoprotein plasma values can be found to be elevated during the course of ASH, in relation to intense regenerative processes. Further characterization of the nodule(s) usually has to be delayed until liver function has improved.

Usually measured at the time of a transvenous liver biopsy, the hepatic venous pressure gradient (HVPG) is elevated in ASH, indicative of sinusoidal portal hypertension. The HVPG may decrease within weeks when liver function improves. Similarly, reverse hepatofugal portal blood flow can be observed in patients hospitalized with ASH and cirrhosis [86], and can be corrected after a few weeks.

Monoclonal chimeric anti-TNFα antibody administration has been associated with an early (40% at 24 h) and sustained reduction in HVPG in patients with severe ASH [87], suggesting that TNFα contributes to portal hypertension in ASH.

Clinical diagnosis of ASH and the role of liver biopsy

When a severe form of ASH is suspected (severity is defined in the section on prognosis), a confirmatory liver biopsy should be performed. It has to be pointed out that decompensated alcoholic cirrhosis is a clinical feature of ASH. In most patients with severe ASH, because of low prothrombin, low platelets or large-volume ascites, the liver biopsy should be performed transvenously. According to data from French [72] and Swiss [88] tertiary centres, a clinical diagnosis of ASH is confirmed at histology in 85% and 83% of cases respectively. The diagnosis of ASH can be ascertained when the histological criteria defined above are present together with a history of recent excessive alcohol intake.

When alcohol abuse is denied, the differential diagnosis of steatohepatitis, including NASH, should be considered (see Chapter 13.2). Looking for extrahepatic manifestations of alcohol abuse (see Table 1) may be helpful. It is still debated whether liver biopsy is of any use in distinguishing ASH from NASH (see the section on Pathogenesis above).

In non-severe forms of ASH, liver biopsy can be used to provide prognostic information on the risk of developing cirrhosis [38] and to evaluate the participation of factors such as iron overload [89], hepatitis C [90,91] or other associated causes of liver disease.

Prognosis

Short-term mortality in patients with ASH not treated by steroids is usually assessed by the score introduced by Maddrey *et al.* in 1978 [92] that combines serum bilirubin and prothrombin time and is usually referred to as Maddrey's discriminant function (DF). Maddrey's DF = bilirubin (mg/mL or μmol/L/17) + 4.6 times (patient prothrombin time–control prothrombin time). When Maddrey's DF is ≥ 32, a 50% mortality rate is expected at 2 months [93,94]. Although it is used routinely in clinical practice, some concerns have been raised regarding the conversion of prothrombin in the formula [95]. First, prothrombin time is poorly standardized across laboratories due to variations in thromboplastin used. One might suggest using the international normalized ratio (INR) instead of the prothrombin time in the formula, although this would need prospective validation. Secondly, the prognostic value of Maddrey's DF has not been re-evaluated for more than 20 years. Thirdly, in patients with a DF below 32, the risk of death still approaches 15% [88,93], suggesting a need for better 'discrimination'. The model for endstage liver disease (MELD), which combines INR, bilirubin and serum creatinine (a variable that carries independent information to predict short-term mortality [93]), was evaluated recently in two retrospective studies of patients with ASH not treated with steroids [96,97]. MELD score measured at admission [97] or during follow-up [96] was

comparable or even superior to Maddrey's DF in predicting short-term mortality. Using a cutoff value of 21 for MELD and 37 for Maddrey's DF, 90-day mortality was predicted by MELD with a sensitivity and specificity of 75%, and by the DF with a sensitivity of 88% and a specificity of 65%, making the c-statistic similar between the two scores [97]. Prospective validation of these data is awaited.

In patients with severe ASH (DF ≥ 32) treated with steroids, Mathurin *et al.* [98] used the bilirubin level at 7 days of therapy as a single criterion to predict 6-month survival. Early change in bilirubin level (ECBL) defined as bilirubin at day 7 lower than bilirubin at day 1, observed in 73% of patients, predicted an 83% 6-month survival rate, compared with 23% in patients without ECBL.

In the majority of patients with non-severe ASH (DF ≤ 32) who become abstinent from alcohol, improvement in both clinical and biological parameters is progressive over a number of months. The 1-year mortality rate in a group of 217 patients with cirrhosis was 26.5% and 7% in those with or without ASH respectively [99]. In another study of 122 alcoholic patients with cirrhosis followed over a 5-year period, persistent alcohol intake was an independent predictor of mortality, together with age and the Child–Pugh score [100].

Additional prognostic information can be derived from the measurement at hospital admission of plasma TNFα [101] or, better, the soluble form of the receptor 1 of TNFα [88], in line with the pathogenic role of TNFα in ASH. Some markers that may be used to assess short-term prognosis in ASH are listed in Table 2.

Treatment

The management of patients with ASH includes durable abstinence from alcohol and the treatment of associated liver-related complications including malnutrition. Specific therapies are aimed at controlling the inflammatory process, oxidative stress, hypermetabolism and fibrogenesis and allowing liver regeneration.

Corticosteroids downregulate the transcriptional factor NFκB [102], and decrease the expression of proinflammatory cytokines and the activation status of polymorphonuclear neutrophils [103]. The many studies on steroids in ASH in the last 30 years have generated conflicting data. Most studies included patients without a liver biopsy, probably mixing true severe ASH with cases of endstage cirrhosis, in whom steroids can trigger infection and be deleterious. Other studies included patients with non-severe forms of ASH, in whom no clear benefit could be expected. The recent meta-analysis of the individual data from all 215 patients with a severe form of ASH from three randomized controlled trials showed that a 4-week course of prednisone was associated with an increase in 1-month survival (65.1 ± 4.8% vs. 84.6 ± 3.4%, $P = 0.001$) [93]. Obviously, spontaneous bacterial peritonitis and nosocomial and opportunistic infections are the main drawbacks of steroids [104]. Appropriate investigations and cultures, including ascitic fluid analysis, should be performed before starting therapy and whenever appropriate thereafter. Although the efficacy of steroids is still disputed by some, most centres use steroids in biopsy-proven severe ASH as the standard of care.

Malnutrition is frequent in patients with ASH. Poor nutritional status increases the risk of infection, correlates with the degree of liver failure and influences the outcome [105,106]. A small randomized study did not show any survival benefit of a high caloric diet associated with the anabolic steroid oxandrolone compared with placebo [107]. More recently, Cabré *et al.* [108] reported similar 1-year mortality rates in a group of 71 patients with ASH randomized to either enteral feeding (2000 kcal/day) or prednisone 40 mg daily for 28 days, with early deaths being more frequent in the tube feeding group and infections more frequent in the steroid-treated group. The combination therapy with steroids and enteral feeding is promising but should be tested in a randomized controlled trial.

Anti-TNFα agents have been tested in patients with ASH. The first pilot trial included 20 patients who received either standard steroid therapy plus infliximab (an anti-TNFα monoclonal antibody), 5 mg/kg body weight as a single infusion, or placebo [78]. The drug was well tolerated and associated with an early decrease in IL-6 and IL-8, an improved Maddrey's score at day 28, but no changes in histology or short-term survival. Two other pilot studies [79,87] confirmed the beneficial effects of infliximab on biological parameters. However, a recent French multicentre randomized controlled study [109] reported higher mortality in infliximab-treated patients, related to a high frequency of infection (15 vs. 5 episodes). In this trial, 36 patients

Table 2 Some markers of short-term prognosis in alcoholic steatohepatitis.

Marker	Comments [refs]
Hepatic encephalopathy	≥ 50% 3-month mortality in early studies [92,259,260]
Maddrey discriminant function (DF)	≥ 35% 2-month mortality when DF ≥ 32 (untreated patients) [72,94]
MELD score	50% 3-month mortality when > 25 (retrospective study, untreated patients) [97]
Soluble TNFα receptor 1	If > 4835 pg/mL at admission, independent predictor of 3-month mortality [88]
Early biological response to bilirubin (EBR)	Bilirubin at day 7 lower than value at day 0 of steroid therapy predicts 83% survival at 6 months (vs. 23% in those without EBR) [98]

with severe ASH received methylprednisolone 32 mg daily and either infliximab 10 mg/kg at weeks 0, 2 and 4 or placebo. Conceivably, this very high dose of infliximab (six times that of pilot studies) contributed to infections and blunted the liver's ability to regenerate. Etanercept, a soluble receptor that binds to circulating TNFα, brought no evident clinical benefit in a small pilot study [110].

Pentoxyfilline, a phosphodiesterase inhibitor with anti-TNFα activity, has been tested in a randomized, double-blind controlled trial at a dose of 1200 mg daily for 4 weeks vs. placebo in 101 patients diagnosed with ASH on clinical and biological grounds [111]. The mortality rate was decreased by 40%, mainly because of reduced incidence of renal failure. Surprisingly, however, the evolution of the Maddrey's score during the study period was similar in the placebo and the treated group. Clinical benefit from pentoxyfilline in patients with severe ASH who did not reach an early biological response on steroids [98] was not confirmed in a recent trial [112].

In one study [113], albumin dialysis induced a sustained and significant (more than 20%) reduction in HVPG independent of systemic haemodynamic changes.

Other therapies for ASH, including supplemental amino acid infusion [114], promoters of hepatic regeneration [115–117], the metabolic 'regulator' propylthiouracil [118], colchicine [119,120], agents aimed at preventing alcoholic liver fibrosis [121] and hepatoprotective agents [122,123] failed to show a clinical benefit.

Alcoholic cirrhosis

Pathogenesis

Alcoholic cirrhosis develops in a minority of alcohol abusers. The factors thought to be associated with an increased risk of cirrhosis are reviewed in the section on factors influencing the natural history of the disease in this chapter. It is widely accepted that cirrhosis results from repeated bouts of ASH that may, or may not be, clinically apparent [11].

Definition and natural history

Alcoholic cirrhosis is typically micronodular, with small regenerative nodules surrounded by fibrous bands (see Chapter 12.3). All the histological features classically thought to be characteristic of alcoholic cirrhosis may in fact be observed in other conditions. First, both the micronodular aspect of the liver and the perisinusoidal distribution of fibrosis are features of steatohepatitis, either alcoholic or non-alcoholic. Secondly, steatosis may suggest persistent alcohol consumption, but can also be observed in cirrhosis of viral origin and in NASH. Thirdly, mild iron deposition in both Kupffer cells and hepatocytes is commonly observed in advanced cirrhosis whatever the cause [124,125]. Finally, over time and particularly when patients stop drinking [126], a transition from a micro- to a macronodular cirrhosis may be observed [13,127].

It has long been accepted that cirrhosis is a non-reversible condition. This classical view may be reconsidered in view of recent data. Thorough examination of nine explants from patients with alcoholic cirrhosis but prolonged abstinence showed significant resorption of both fibrous septa and perisinusoidal fibrosis [13].

Clinical presentation

Although often overlooked, physical examination may be of great value. For example, the presence of a firm liver with a thin lower edge in the epigastric region is a reliable sign of advanced fibrosis or cirrhosis. In a cohort of 138 patients undergoing liver biopsy, 25% of whom had ALD, the palpation of a firm liver in the epigastrium had a sensitivity of 86% and a specificity of 67% for the diagnosis of cirrhosis [128].

When compensated, alcoholic cirrhosis may be completely asymptomatic. Only in the decompensated phase may patients present with asthenia, weight loss, ascites, variceal bleeding, jaundice, hepatic encephalopathy or hepatocellular carcinoma (HCC).

The clinical aspects of cirrhosis in general are reviewed in Chapter 6.3. When present, extrahepatic manifestations of alcohol abuse, listed in Table 1, may point to alcohol as the cause of cirrhosis. Dupuytren's contracture is more frequently observed in alcoholics compared with non-alcoholics (30% vs. 6%) [129]. Parotid gland enlargement in alcoholics is associated with a decreased saliva flow rate as well as structural alterations of the glands [130]. Florid spider angiomas and gynaecomastia, both associated with high estrogen levels, may be suggestive of an alcoholic aetiology of cirrhosis.

Malnutrition in alcoholic cirrhosis

A large proportion of patients with ALD are malnourished [131]. Alcohol may provide up to 50% of daily calorie intake in these patients, but protein and/or vitamin spontaneous intake may be extremely low. Malnutrition, in turn, has deleterious immune consequences, blunts the absorption of nutriments [132], decreases muscle strength [133] and may contribute to poor survival. However, whether malnutrition, best assessed by anthropometric measures [134], is an independent predictor of mortality or a surrogate marker of liver failure remains a controversial issue. In a study of 212 hospitalized patients with cirrhosis, 121 of alcoholic aetiology, moderate to severe malnutrition was reported in 54% of patients and was an independent predictor of 2-year survival [134]. Low calorie intake (< 30 kcal/kg body weight) and protein malnutrition have been associated with an increased risk of septic complications and hospital mortality [135]. Malnutrition, especially when associated with refractory ascites, predicts poor survival and complications following surgery [136].

The pathogenesis of protein caloric malnutrition in alcoholic cirrhosis is multifactorial (see Chapter 23.2). Insufficient calorie intake due to the presence of ascites [135], increased protein

catabolism [136], unjustified protein restriction diet in encephalopathy, poor palatability of the low-sodium diet and increased cytokine production in ASH all contribute to malnutrition in these patients. In addition, hyperinsulinaemia is frequent in cirrhosis and may contribute to a preference for a carbohydrate-rich diet, which in turn induces early satiety [137]. Leptin levels are elevated in the early stages of ALD and cirrhosis [138,139]. However, at later stages, low leptin concentrations may be associated with denutrition and low fat mass [138].

Zinc deficiency is common during the course of alcoholic cirrhosis [140], due to a combination of malnutrition, decreased intestinal absorption and increased urinary excretion [141,142]. In animal studies, zinc deficiency alters zinc-dependent alcohol dehydrogenase activity [142]. This results in an increase in CYP2E1 alcohol metabolism, together with excessive oxidative stress. Thus, it has been postulated that zinc supplementation, associated with beneficial effects in animals [142], could improve liver function in patients with ALD. In 16 patients with alcoholic cirrhosis, administration of zinc sulphate 0.6 g daily, but not placebo, was associated with a decrease in serum bilirubin and in the prothrombin time [143]. However, no effects could be seen on microsomal function, as assessed by antipyrine clearance [144]. In our practice, patients with low zinc plasma levels are considered for zinc supplementation.

Laboratory values

No single biological test is specific for alcoholic cirrhosis. Elevation in transaminases above five times normal levels is unusual during the course of alcoholic cirrhosis *per se* and should prompt the search for an additional cause, including microvesicular steatosis, drug-induced toxicity or biliary tract disease. Again, an AST/ALT ratio > 1 may be seen in advanced liver disease whatever the cause, and this has poor specificity for alcoholic cirrhosis. Particular attention should be paid to laboratory values that typically improve with abstinence, such as high γ-GT (half-life 2–3 weeks), hypertriglyceridaemia, hyperuricaemia and others. Hypergammaglobulinaemia is a common feature of cirrhosis. High serum IgA levels, which are associated with IgA deposits in liver sinusoids, are thought to be a feature of ALD (for a review, see reference [145]). High IgA reverses after liver transplantation [146].

Macrocytic anaemia in alcoholic cirrhosis may result both from cirrhosis *per se* and from alcohol intoxication (for more details, see Chapter 6.3 and reference [147]). Similarly, low platelet count may be due to cirrhosis, a direct myelotoxic effect of alcohol or both. In this situation, thrombocytopenia may reverse within days of abstinence.

Direct measurement of alcohol in blood or urine remains a useful, incontestable method for determining recent alcohol consumption. Carbohydrate-deficient transferrin (half-life 15 days) has been claimed to be as sensitive as γ-GT but more specific. However, false-positive results can be observed in patients with all causes of advanced liver disease, related to altered transferrin metabolism. Sequential γ-GT measurements with direct measurement of alcohol is often used in outpatient liver clinics.

Imaging and haemodynamic studies

Standard evaluation of alcoholic cirrhosis includes abdominal US and Doppler studies of the portal and hepatic veins, as well as portal systemic collaterals (see Chapter 5.5). In a group of 493 patients with cirrhosis, the prevalence of a patent paraumbilical vein was higher in alcoholic cirrhosis (OR = 3.88; 95% CI 1.34–8.55) compared with cirrhosis of viral origin [148]. CT and MRI scans may be used to characterize focal lesions.

Haemodynamic studies are usually performed at the time of transjugular liver biopsy. The measurement of the HVPG is a reliable indicator of portal pressure in alcoholic liver disease [149]. The HVPG has an independent predictive value in patients with recent variceal bleeding [150]. The HVPG, which may evolve over time, is higher at the time of variceal bleeding [151] and may peak at the time of ASH and subside thereafter.

Both ethanol *per se* and alcohol-induced liver injury may influence hepatic haemodynamics. In 16 patients with alcoholic cirrhosis, oral administration of an alcoholic drink (0.5 g/kg ethanol) was associated with an increase in HVPG and azygous blood flow [152]. The HVPG correlates with the histological features of ASH [153]. In patients with ALD, HVPG changes over 10 months were independent predictors of bleeding and survival [154].

Diagnosis

Patients may present at either a compensated or a decompensated stage. The diagnosis of compensated cirrhosis may be difficult, because alcohol abuse may be denied, and physical findings and laboratory evidence for ALD may be subtle or absent (see section on 'Clinical presentation').

Liver biopsy (see Chapters 5.5 and 12.3) remains a gold standard for the diagnosis of cirrhosis. Liver biopsy should be obtained whenever a definite diagnosis of cirrhosis can influence patient management. In addition, liver biopsy may help to exclude other causes of liver disease, such as iron overload, metabolic disorders, drug-induced lesions or biliary tract alterations.

Alcoholic liver disease is a diffuse disease, and thus it is assumed that a random sample reflects damage to the organ as a whole. The interobserver variation for the assessment of liver biopsies in ALD demonstrates a good concordance for alcoholic cirrhosis ($\kappa = 0.75$) [155]. However, liver biopsy may be difficult to interpret if the specimen is fragmented, small in size or when micronodular alcoholic cirrhosis has evolved into macronodules [127].

Prognosis

Beyond the prognostic scores commonly used in cirrhosis in general (Child–Pugh score, MELD and others, reviewed in Chapter 6.3), the single most important factor that predicts progression or improvement of liver function in patients with

alcoholic liver disease is abstinence. Bell *et al.* [156] studied 100 patients with alcoholic cirrhosis for a 15-year period and reported a cumulative mortality of 49% at 12 months. Alcohol consumption of less than 10 g daily and an age below 58 years were associated with increased survival [156].

In patients with alcoholic cirrhosis who stop drinking, liver function usually improves over a few weeks or months. In those who fail to improve, alcohol relapse, persistent NASH or associated causes of liver disease should be considered. Prognostic factors in alcoholic cirrhosis are listed in Table 2.

Treatment

Standard care for patients with alcoholic cirrhosis includes abstinence reinforcement, treating malnutrition, preventing variceal bleeding and screening for HCC. The treatment of complications in decompensated patients and the role of liver transplantation are discussed in Sections 7 and 25.

In addition, we will discuss the disputed benefit from antioxidant and antifibrotic agents.

Abstinence from alcohol

Abstinence is a challenge in patients with alcohol dependence. Hepatologists should be aware that 50–70% of patients return to drinking within a year after an initial period of abstinence [157,158] (see Chapter 12.5). After abstinence has been achieved, alcohol relapses should be considered whenever decompensation and/or variceal bleeding occurs.

Management options for such patients include psychological support (also termed brief intervention) and pharmacotherapy. A 10-min brief intervention focused on dependence, somatic risk and potential for behavioural changes has proven efficacy [159]. Pharmacological agents aimed at supporting abstinence should, when possible, be initiated after cirrhosis has been recompensated. Both acamprosate and naltrexone improve abstinence rates [160], are well tolerated and are effective as adjuvant therapies for alcohol dependence [157]. Most hepatologists prefer to avoid disulfiram, which has been associated with severe hepatitis [161].

Nutrition

Simple dietary supplementation has been tested in several randomized trials involving a limited number of patients. The results showed no measurable effect [162], improvement in biological parameters [163,164] or clinically significant improvements [165,166]. Continuous enteral supplementation improved the markers of nutritional status in patients with cirrhosis and midarm circumference below the 25th percentile awaiting liver transplantation. However, owing to the limited power of the study (40 patients per arm), the effect on survival did not reach statistical significance ($P = 0.075$) [167]. Based on these results, we believe that nutritional support should be considered in patients with alcoholic cirrhosis and malnutrition as assessed by anthropometry [134,143]. Oral and enteral feeding should be preferred. Practically, patients with compensated cirrhosis should receive 25–30 kcal/kg/day + 1 g protein/kg/day. In cases of associated malnutrition, the nutritional intake should be increased to 35 kcal/kg/day + 1.5 g protein/kg/day [136]. On account of the increased risk of inhalation pneumonia, enteral feeding may prove difficult in patients with fluctuating hepatic encephalopathy.

Perspectives in antioxidant and antifibrotic therapy

Because oxidative stress and fibrogenesis are key players in the development of alcoholic cirrhosis, antioxidants (silymarin, *S*-adenosylmethionine, vitamin E) and antifibrotics (colchicine and polyenylphosphatidylcholine) have been tested with the aim of attenuating liver injury and improving long-term prognosis.

In a randomized, double-blind, multicentre trial involving 200 patients with alcoholic cirrhosis, silymarin at a dose of 450 mg daily was not associated with a better 2-year survival rate compared with placebo [168]. Similarly, the effect of daily supplementation with vitamin E 500 mg for 1 year in 33 outpatients with cirrhosis was not different from placebo [169].

The rationale for administering *S*-adenosylmethionine, a precursor of glutathione, is to enhance the antioxidant capacity of hepatocytes. In a randomized, double-blind, controlled trial, 123 patients with cirrhosis received either *S*-adenosylmethionine (1200 mg daily) or placebo for 2 years with no benefit in overall survival [170]. Subgroup analysis suggested some benefit in Child A and B patients, which should be tested in future studies.

As polyenylphosphatidylcholine has the ability to decrease stellate cell activation and cytochrome P450 activity, a huge randomized, double-blind, placebo-controlled trial was initiated in patients with ALD (but without cirrhosis) [121]. After 2 years of treatment, no effect on fibrosis was demonstrated on repeat liver biopsy.

Colchicine, an inhibitor of collagen synthesis, had been associated with improved survival compared with placebo (median survival 11 vs. 3.5 years) in a study of 100 patients with cirrhosis treated for an average of 4.7 years [171]. However, analysis of liver-related mortality did not confirm the beneficial effect of colchicine. These negative results have been confirmed recently in a large cohort [172].

Non-invasive markers of fibrosis in alcoholic liver disease

Fibrosis is essential to the development of complications from ALD. Liver biopsy is the reference method for assessing the stage of fibrosis as well as the activity of the liver disease. However, its use is limited by the risk associated with the procedure, interobserver variability and the sampling error when the specimen is less than 20 mm in length [173]. In a study of more than 68 000 percutaneous liver biopsies, 0.5% morbidity and 0.01% mortality [174] were reported.

The ideal marker of fibrosis should measure the stage of fibrosis and the degree of extracellular matrix remodelling, be specific to the liver without being influenced by extrahepatic changes, and be cheap and easy to perform repeatedly. In real life, most markers are influenced by age, postprandial state [175], renal function, extrahepatic inflammatory disorders [176] and active alcohol intoxication [176,177], and wide overlapping of values is observed, especially for the intermediate stages of fibrosis. Thus, no single marker may be used to determine the fibrosis stage with sufficient accuracy. The interpretation must take into account the clinical context.

Imaging studies

Doppler ultrasonography performs well in the diagnosis of advanced hepatic fibrosis or cirrhosis. When combining the spleen size and portal vein velocity, the diagnostic accuracy was 84% in a group of 243 patients [178]. This performance was improved to 89% when analysing hepatic vein spectrum of flow [179]. However, the operator-dependent character of the technique as well as the poor performance for intermediate stages of hepatic fibrosis have limited its use. Preliminary data on diffusion-weighted MRI suggested that it may potentially be useful for the evaluation of fibrosis stage [180].

Transient elastography is a novel non-invasive tool for measuring liver stiffness, based on the analysis of shear wave velocity transmitted to the liver by a transducer. The faster the shear wave, the harder the liver tissue. A positive correlation was reported between liver stiffness and fibrosis stages in patients with hepatitis C [181]. In a group of 380 individuals followed in an outpatient clinic for alcoholism, transient elastography was well accepted and had a high positive predictive value (97%) for the diagnosis of cirrhosis using a cutoff value of 13 kPa [182]. The performance of the technique may be limited by the presence of ascites or obesity.

Serum markers of fibrosis

The values of these biological tests become abnormal only in advanced stages of fibrosis or in cirrhosis. Thus, their use in the assessment of intermediate stages of fibrosis appears to be limited.

The AST/ALT ratio has been shown to be an independent predictor of fibrosis in NASH [183] and in chronic hepatitis C [184], but is a poor predictor of cirrhosis in alcoholics (diagnostic accuracy 65%) [185].

A low platelet count is a good indicator of portal hypertension, irrespective of the cause of liver injury. However, the diagnostic accuracy for the presence of compensated alcoholic cirrhosis is lower compared with the prothrombin time (56% vs. 85%).

The prothrombin index showed a statistically significant correlation with the fibrosis score ($r = 0.7$) in 193 patients with chronic liver diseases [186]. A value below 80% was predictive of severe fibrosis or cirrhosis [185], while a prothrombin index of 100% excluded this diagnosis.

Markers involved in the synthesis or remodelling of liver matrix include hyaluronic acid [187] and others [188–190] that will not be discussed here. Severe fibrosis on liver biopsies from 146 heavy drinkers was predicted with a similar diagnostic accuracy using serum hyaluronic acid (91.1%) or prothrombin index (89.7%) [191]. In 87 patients with different stages of alcoholic liver disease, Stickel *et al.* [192] showed that serum hyaluronic acid levels paralleled the severity of fibrosis. Using a cutoff value of 55.5 μg/L, the sensitivity and specificity of serum hyaluronic acid for the detection of mild fibrosis were 83% and 69% respectively. With a cutoff of 250 μg/L, the sensitivity for detecting cirrhosis was 100%. Thus, the greatest clinical utility of this marker may be its ability to exclude the presence of extensive fibrosis or cirrhosis when the serum hyaluronate value is below 60 μg/L.

Scores of fibrosis

Algorithms that combine serum markers to predict fibrosis have been generated by many centres and applied to different populations of patients with ALD. Tests originally designed to predict the METAVIR stage in chronic hepatitis C [193] have not been validated in ALD. Poynard *et al.* [194] reported that the PGA index (a combination of prothrombin time, gamma-glutamyltranspeptidase and apolipoprotein AI) could exclude or confirm the presence of cirrhosis in a group of 291 alcoholic patients with 100% and 86% accuracy respectively. The 'Fibrometer', combining α2-macroglobulin, platelets, prothrombin index, AST, hyaluronic acid, urea and age to determine the presence of clinically significant fibrosis, defined as F2–F4 according to METAVIR and area of fibrosis assessed on liver biopsy [195], had better sensitivity (91.8% vs. 80.5%), specificity (92.6% vs. 84.1%) and diagnostic accuracy (92 vs. 82.1%) for alcoholic ($n = 95$) than for viral-induced liver disease ($n = 383$). Obviously, none of these scores performed well enough to single out the intermediate stages of fibrosis.

Any new fibrosis score, either based on serum markers alone or combined with elastography, should overcome the limitations of the score due to the analytical variability among laboratories and be confirmed independently on a separate cohort of patients with ALD.

Interaction between alcohol and other liver diseases

Iron

Independent from hereditary haemochromatosis, chronic liver disease may lead to iron accumulation in the liver [196]. In patients with endstage ALD, increased deposition of iron may also be seen in other organs [197]. On histochemical staining, iron accumulation is usually restricted to hepatocytes and

Kupffer cells. The putative mechanisms of iron overload in alcoholic cirrhosis may include increased intestinal iron absorption in relation to spur cell haemolytic anaemia [198], increased transferrin receptor expression in hepatocytes [199] in regular drinkers and altered hepcidin expression in relation to chronic inflammation or hypoxia [200,201].

Both alcohol and iron are thought to increase oxidative stress during the course of steatohepatitis. Oxidative stress, in turn, may activate hepatic stellate cells, accelerate fibrogenesis [89] and participate in the production of proinflammatory cytokines. Thus, we believe that excess iron may be a significant cofactor in steatohepatitis in general, including ASH. Consistent with this view, stainable iron on liver biopsies was a strong predictor of mortality in 71 patients with alcoholic cirrhosis followed-up for 57 months [125]. Although iron depletion has been associated with improvement in liver function tests in non-alcoholic fatty liver disease (NAFLD) [202], no study has addressed the question of the possible beneficial effects of iron depletion in patients with ALD.

In hereditary haemochromatosis, alcohol abuse increases the prevalence of cirrhosis [203,204]. Patients homozygous for the C282Y mutation with excess (> 60 g/day) alcohol intake had a high risk of cirrhosis (relative risk of 9) and were diagnosed with cirrhosis at a younger age (46 vs. 54 years) than non- or mild drinkers [204]. Because heterozygosity for *HFE* (both C282Y and H63D) is not associated with an increased risk of advanced ALD [205], genetic testing is not routinely performed in patients with ALD. However, evaluation of iron status is clinically relevant. As interpretation of serum iron and ferritin is hampered in the acute phase of ASH or decompensated cirrhosis, clinicians often rely on imaging studies and/or liver biopsy.

Hepatitis B

Does chronic exposure to alcohol render the liver more susceptible to viral infections? Among 137 chronic alcoholic patients in Denmark, antibody to hepatitis B surface (HBs) antigen (Ag) or hepatitis B core (HBc) Ag, or both, was more frequently observed than in an age-matched population (26% vs. 4%) [206]. HBsAg was detected in 2% and anti-HBs with or without anti-HBc in 19% of 285 alcoholic patients from the UK [207]. In this study, hepatitis B virus (HBV) markers were related to former residence in a country with a high prevalence of hepatitis B and a history of blood transfusions or injections, but not to social status or marital state.

It has been suggested that prior HBV infection, whether occult or overt, might increase the risk of HCC in ALD. In northern Italy [208], both hepatitis B and C markers were twice as prevalent in patients with HCC and > 60 g of alcohol consumption compared with control subjects. In patients with HBsAg and chronic alcohol intake for more than 10 years, the age at diagnosis of HCC was 10 years younger than in those patients without a history of alcohol consumption [209]. In a recent prospective study of Japanese patients with alcoholic cirrhosis but negative for HBsAg, the presence of HBcAb (HBV core antibody) was associated with an increased risk of HCC (15% vs. 3% at 5 years) [210]. Integrated and episomal HBV DNA has been detected in the tumours of several patients with HCC who were negative for all HBV and HCV serum markers [211,212]. Taken together, these results do not support a major role for HBV in the development of cirrhosis in alcoholics. However, a role for HBV in the development of HCC in patients with alcoholic cirrhosis is highly probable.

Hepatitis C

Anti-HCV antibodies are found in 8–43% of patients with ALD [90,213]. Risk factors are probably similar in alcoholics and non-alcoholics [214], but are also possibly related to low socioeconomic status. Whether alcohol increases HCV RNA levels is debated [215,216]. Alcohol may contribute to HCV quasispecies pressure selection as well as host immunity [90]. Both hepatitis C and alcohol cause hepatic oxidative stress [217]. Thus, alcohol consumption has been recognized as a major risk factor, together with older age and male gender [91,218], for progression to cirrhosis in patients with chronic hepatitis C. An increased risk of compensated or decompensated cirrhosis has been reported in HCV-positive patients who consumed alcohol in excess (women > 40 g daily; men > 60 g daily) for more than 5 years [91]. Alcohol consumption may reduce the virological sustained response rate under interferon [219]. Finally, the risk of HCC is increased approximately twofold in patients with chronic hepatitis C and alcohol intake > 60 g daily [208]. Overall, patients infected with hepatitis C should be strongly encouraged to avoid alcohol to limit both the progression to cirrhosis and the development of HCC.

Non-alcoholic fatty liver disease

Steatohepatitis, whether alcoholic or non-alcoholic associated with the metabolic syndrome, is characterized by the association of steatosis, hepatocellular ballooning and necrosis, and inflammatory infiltration with polymorphonuclear cells. Both diseases can hardly be distinguished on histological features [220] (see Section 13). Pathogenic mechanisms at large are common to both ASH and NASH [5]. A recent study [221] has identified the production by adipose tissue of TNFα, a key inflammatory mediator involved in the pathophysiology of ALD (see also reference [1] for review). Insulin resistance, which is closely associated with NASH [222,223], has not been directly investigated in ASH. Although it may also be secondary to the associated cirrhosis and liver failure [224], insulin resistance, in our clinical experience, is also featured in ASH. Indeed, metabolic factors contributed to elevated ALT levels and insulin resistance in a large cohort of patients with chronic liver diseases dominated by ALD [47]. Thus, alcohol consumption may be one of the few elements that discriminate alcoholic from non-alcoholic steatohepatitis. The cutoff level above which the liver

disease is accepted as alcohol related is debatable, and the 20 g/day [220] threshold can only be seen as a compromise. Consistent with this view, being overweight (body mass index > 25 in women, > 27 in men) increases the risk of fibrosis in excessive drinkers [225]. In addition to obesity, older age, diabetes and increased iron stores (assessed using Perl's staining on liver biopsy) also predict fibrosis in patients with excessive alcohol consumption [17].

Realizing that the risk factors, mechanisms and histology of ASH and NASH are largely similar has clinical implications. To this day, no prospective study has addressed the benefit of correcting metabolic cofactors in ASH. Because of the weight of the above circumstantial evidence, we believe that patients with ALD should benefit from reducing body weight, progressive clinical exercise and depletion of iron stores. Implementation of these measures may be difficult and has to be delayed in the setting of ASH and poor liver function. Because of the lack of clinical studies in ASH, as well as potential liver toxic effects [226], pharmacological studies in NASH, including antidiabetic agents [227], cannot be transposed to ASH.

Alpha-antitrypsin deficiency

Homozygous PiZZ alpha-1-antitrypsin deficiency, an autosomal recessive endoplasmic reticulum storage disease (see Chapter 16.3), may be associated with chronic hepatitis, especially in the paediatric population. Cirrhosis, portal hypertension and HCC seem to be influenced by age. In a Swedish cohort of 246 PiZZ homozygous patients, cirrhosis was observed in 2% of individuals aged 20–50 years, but in 19% of those older than 50 years [228]. More recently, a case–control study confirmed that the risk of cirrhosis was higher in PiZZ patients over 50 years, but failed to show a role for alcoholism or viral hepatitis in the development of cirrhosis [229].

The assumption that PiMZ heterozygotes usually do not develop liver disease unless there is some other additional factor (such as alcohol or viral hepatitis) is supported by some but not all studies. In patients referred for liver transplantation, the heterozygous PiMZ phenotype was four times more frequent in patients with chronic viral hepatitis or alcoholic cirrhosis than in those with autoimmune liver diseases [230]. In another study [231], the PiMZ phenotype was more frequent in cryptogenic cirrhosis, a condition known to be associated with NASH [232], compared with cirrhosis of other causes. Thus, the hypothesis that PiMZ heterozygosity may potentiate both alcoholic and non-alcoholic steatohepatitis [231] and precipitates endstage liver disease of other causes is still debated.

Drug-induced hepatitis

Drug-induced steatohepatitis

Amiodarone-induced steatohepatitis, originally reported as 'pseudoalcoholic' hepatitis [233], has been reported in approximately 1% of patients receiving long-term amiodarone therapy [2]. On haematoxylin/eosin staining, histological liver lesions are similar in ASH and in amiodarone-associated steatohepatitis. Phospholipidosis after amiodarone exposure [2] reflects accumulation of the drug and is not directly related to the development of steatohepatitis. Thus, special caution is recommended with amiodarone therapy in patients with ALD. The same holds true for other drugs such as nifedipine, diltiazem and tamoxifen, more recently reported to induce steatohepatitis [2].

Methotrexate

Methotrexate can induce steatohepatitis and fibrosis [234,235] that correlates with the cumulative dose of the drug. The role of alcohol as a cofactor in methotrexate-associated fibrogenesis has been questioned. In an early series [235], the evolution of liver histology was studied retrospectively among 69 patients with psoriasis under methotrexate followed for a mean of 6.5 years. Three patients, all heavy drinkers, developed advanced fibrosis. More recent data [234] suggested that the risk of methotrexate-induced fibrosis was negligible in non-drinkers with a cumulative dose of less than 5 g of methotrexate. We believe that liver biopsy before initiating methotrexate therapy should be restricted to excess drinkers, patients with the metabolic syndrome or those with abnormal liver function tests.

Paracetamol

The cytochrome CYP2E1 oxidizes alcohol and also converts paracetamol into a toxic metabolite that may be scavenged by the antioxidant glutathione. When toxic metabolite production exceeds the reserve of cellular glutathione, liver injury may ensue.

Excess drinkers, when in poor nutritional condition and because of alcohol-induced CYP2E1 induction, are thought to be vulnerable to paracetamol toxicity. In fact, whether therapeutic doses of paracetamol may induce hepatitis in alcoholics remains a controversial issue, as no prospective controlled study has been conducted so far. Numerous case reports are often imprecise regarding alcohol consumption, exact dose of paracetamol and timing of alcohol intake. This information may be crucial, as alcohol may also compete with paracetamol for CYP2E1 degradation and the production of toxic metabolites [236]. Marginal increases in such toxic metabolites have been measured in alcoholics given paracetamol [237–240]. Before more precise or prospective information becomes available, paracetamol dosage should be kept below 4 g/day in excess drinkers. Even at this dose, paracetamol toxicity should be suspected in patients with an increase in transaminases and *N*-acetylcysteine therapy considered.

Alcoholic liver disease and surgery

Excessive alcohol consumption is frequent in patients who undergo a surgical procedure. In head and neck surgery and traumas, the prevalence of alcohol misuse approaches 50% [241], and alcohol consumption that exceeds 60 g/day has been associated with an increased risk of complications after surgery [242,243]. Compared with patients who do not consume

alcohol, alcohol misusers have an increased risk of alcohol withdrawal syndrome (see Chapter 12.5), infection, haemorrhage, cardiorespiratory failure and liver failure [244].

The hepatologist's task is to predict the risk of liver decompensation, according to what he believes the liver lesions may be. Liver biopsy may contribute to delineating these lesions, may be warranted before major surgery or when ASH is suspected, and may predict reversibility. The efficacy of alcohol abstinence prior to surgery should be emphasized at this stage. In 42 alcoholic patients scheduled for elective colorectal surgery, abstinence from alcohol for 1 month was associated with fewer postoperative complications compared with patients who continued to drink (31% vs. 74%, $P = 0.02$) [245].

Alcoholic steatosis

Alcoholic steatosis is not usually considered a contraindication to surgery. This general rule does not hold true for liver resection, where steatosis is associated with an increased mortality [246]. Similarly, in cases of microvesicular steatosis (see section on Microvesicular steatosis above), surgery should be considered with caution.

Alcoholic steatohepatitis

Whenever possible, surgery should be delayed in patients with ASH [247]. This recommendation comes from mortality rates exceeding 50% in patients with ASH who underwent liver surgery [248] or portosystemic shunt procedures in the 1970s [249]. Although these data are ancient and limited to open abdominal surgery, most hepatologists tend to avoid all types of surgery in patients with histologically proven ASH. Again, as little as 1 month of alcohol abstinence is demonstrated to limit postoperative morbidity in alcoholics [245].

Alcoholic cirrhosis

Surgery in patients with cirrhosis is discussed in Chapter 6.3. For example, patients with alcoholic cirrhosis have an 11-fold higher risk of postoperative mortality after open cholecystectomy [250]. In addition, alcoholic cirrhosis may be asymptomatic and present with normal liver function tests, especially when abstinence has been reached. Specific to alcoholic cirrhosis is the potential for reversibility after abstinence of both hepatic and extrahepatic complications of alcohol. In addition, malnutrition may be pronounced in alcoholics, affects the outcome of surgery and should be corrected.

Cancer screening in patients with alcoholic liver disease

Extrahepatic cancer

Independent of the presence of cirrhosis, alcohol increases the risk of both hepatic and extrahepatic cancer. In a large cohort study from Denmark, patients with alcoholic steatosis (but not cirrhosis) had 1.7 times more cancers than the general population [251]. Both HCC and other cancers were reported. A meta-analysis [252] confirmed an increased risk for squamous cell carcinoma of the aerodigestive tract. In our unit, screening patients with ALD for head and neck cancers has become a standard of care, especially in smokers [253] and after orthotopic liver transplantation (OLT) [254].

Hepatocellular carcinoma

Although HCC typically develops in a cirrhotic liver, a small proportion of HCC may arise in the absence of cirrhosis. In a retrospective surgical study, 84 out of 203 patients resected for HCC were non-cirrhotic, with 40% of them reporting chronic alcoholism as the only risk factor [255]. In this and other studies, HCC arising in a non-cirrhotic liver is often associated with some degree of portal and/or perisinusoidal fibrosis. The dose–effect relationship between alcohol consumption and HCC was investigated in a large case–control study from northern Italy [208], in which the incidence of HCC increased linearly with alcohol consumption. Consistent with the unified steatohepatitis concept, obesity is an independent predictor for HCC at the time of OLT for alcoholic cirrhosis (OR 3.2; 95% CI 1.5–6.6) but not viral-associated cirrhosis [256]. Despite this increased risk, the incidence of HCC in ALD remains well under 1%. Therefore, no screening policy is warranted in patients with ALD but without cirrhosis.

In patients with alcoholic cirrhosis, the yearly incidence of HCC is estimated to be 1–4% [257]. Hepatitis B or C coinfections, obesity, advanced age and male sex increase this risk. In a large Italian cross-sectional study, the prevalence of HCC in alcoholic cirrhosis was 10.1%, almost identical to the 10.3% incidence in HCV-related cirrhosis [258]. Patients with cirrhosis who stop drinking remain at risk of HCC for 10 years of abstinence [208].

References

1 Diehl AM (2004) Obesity and alcoholic liver disease. *Alcohol* 34, 81–87.
2 Chitturi S, Farrell GC (2001) Etiopathogenesis of nonalcoholic steatohepatitis. *Semin Liver Dis* 21, 27–41.
3 Neuschwander-Tetri BA, Caldwell SH (2003) Nonalcoholic steatohepatitis: summary of an AASLD Single Topic Conference. *Hepatology* 37, 1202–1219.
4 Ishii H (2004) Common pathogenic mechanisms in ASH and NASH. *Hepatol Res* 28, 18–20.
5 Diehl AM (2001) Nonalcoholic fatty liver disease: implications for alcoholic liver disease pathogenesis. *Alcohol Clin Exp Res* 25, 8S–14S.
6 Becker U, Gronbaek M, Johansen D *et al.* (2002) Lower risk for alcohol-induced cirrhosis in wine drinkers. *Hepatology* 35, 868–875.
7 Mathurin P (2005) Is alcoholic hepatitis an indication for transplantation? Current management and outcomes. *Liver Transpl* 11, S21–24.
8 Naveau S, Borotto E, Giraud V *et al.* (1999) [Descriptive epidemiology of patients with alcoholic liver disease hospitalized in a hepato-gastroenterology service]. *Gastroenterol Clin Biol* 23, 544–551.

9 Gerke P, Hapke U, Rumpf HJ *et al.* (1997) Alcohol-related diseases in general hospital patients. *Alcohol Alcohol* 32, 179–184.

10 Barrio E, Tome S, Rodriguez I *et al.* (2004) Liver disease in heavy drinkers with and without alcohol withdrawal syndrome. *Alcohol Clin Exp Res* 28, 131–136.

11 Diehl AM (1997) Alcoholic liver disease: natural history. *Liver Transpl Surg* 3, 206–211.

12 Alexander JF, Lischner MW, Galambos JT (1971) Natural history of alcoholic hepatitis. II. The long-term prognosis. *Am J Gastroenterol* 56, 515–525.

13 Wanless IR, Nakashima E, Sherman M (2000) Regression of human cirrhosis. Morphologic features and the genesis of incomplete septal cirrhosis. *Arch Pathol Lab Med* 124, 1599–1607.

14 Bellentani S, Saccoccio G, Costa G *et al.* (1997) Drinking habits as cofactors of risk for alcohol induced liver damage. The Dionysos Study Group. *Gut* 41, 845–850.

15 Becker U, Deis A, Sorensen TI *et al.* (1996) Prediction of risk of liver disease by alcohol intake, sex, and age: a prospective population study. *Hepatology* 23, 1025–1029.

16 Mandayam S, Jamal MM, Morgan TR (2004) Epidemiology of alcoholic liver disease. *Semin Liver Dis* 24, 217–232.

17 Raynard B, Balian A, Fallik D *et al.* (2002) Risk factors of fibrosis in alcohol-induced liver disease. *Hepatology* 35, 635–638.

18 Sato N, Lindros KO, Baraona E *et al.* (2001) Sex difference in alcohol-related organ injury. *Alcohol Clin Exp Res* 25, 40S–45S.

19 Frezza M, Buda A, Terpin MM *et al.* (1997) Gastrectomy, lack of gastric first pass metabolism of ethanol and alcoholic liver disease. Results of a multicentre study. *Ital J Gastroenterol Hepatol* 29, 243–248.

20 Stewart SH (2002) Racial and ethnic differences in alcohol-associated aspartate aminotransferase and gamma-glutamyltransferase elevation. *Arch Intern Med* 162, 2236–2239.

21 Wong NA, Rae F, Simpson KJ *et al.* (2000) Genetic polymorphisms of cytochrome p4502E1 and susceptibility to alcoholic liver disease and hepatocellular carcinoma in a white population: a study and literature review, including meta-analysis. *Mol Pathol* 53, 88–93.

22 Grove J, Daly AK, Bassendine MF *et al.* (1997) Association of a tumor necrosis factor promoter polymorphism with susceptibility to alcoholic steatohepatitis. *Hepatology* 26, 143–146.

23 Whitfield JB, Zhu G, Madden PA *et al.* (2004) The genetics of alcohol intake and of alcohol dependence. *Alcohol Clin Exp Res* 28, 1153–1160.

24 Tanaka F, Shiratori Y, Yokosuka O *et al.* (1997) Polymorphism of alcohol-metabolizing genes affects drinking behavior and alcoholic liver disease in Japanese men. *Alcohol Clin Exp Res* 21, 596–601.

25 Chao YC, Young TH, Tang HS *et al.* (1997) Alcoholism and alcoholic organ damage and genetic polymorphisms of alcohol metabolizing enzymes in Chinese patients. *Hepatology* 25, 112–117.

26 Nahon P, Sutton A, Pessayre D *et al.* (2005) Genetic dimorphism in superoxide dismutase and susceptibility to alcoholic cirrhosis, hepatocellular carcinoma, and death. *Clin Gastroenterol Hepatol* 3, 292–298.

27 Stewart SF, Leathart JB, Chen Y *et al.* (2002) Valine-alanine manganese superoxide dismutase polymorphism is not associated with alcohol-induced oxidative stress or liver fibrosis. *Hepatology* 36, 1355–1360.

28 Ladero JM, Fernandez-Arquero M, Tudela JI *et al.* (2002) Single nucleotide polymorphisms and microsatellite alleles of tumor necrosis factor alpha and interleukin-10 genes and the risk of advanced chronic alcoholic liver disease. *Liver* 22, 245–251.

29 Jarvelainen HA, Orpana A, Perola M *et al.* (2001) Promoter polymorphism of the CD14 endotoxin receptor gene as a risk factor for alcoholic liver disease. *Hepatology* 33, 1148–1153.

30 Grove J, Daly AK, Bassendine MF *et al.* (2000) Interleukin 10 promoter region polymorphisms and susceptibility to advanced alcoholic liver disease. *Gut* 46, 540–545.

31 Edenberg HJ, Dick DM, Xuei X *et al.* (2004) Variations in GABRA2, encoding the alpha 2 subunit of the GABA(A) receptor, are associated with alcohol dependence and with brain oscillations. *Am J Hum Genet* 74, 705–714.

32 Mottagui-Tabar S, Prince JA, Wahlestedt C *et al.* (2005) A novel single nucleotide polymorphism of the neuropeptide Y (NPY) gene associated with alcohol dependence. *Alcohol Clin Exp Res* 29, 702–707.

33 Kuntsche E, Rehm J, Gmel G (2004) Characteristics of binge drinkers in Europe. *Soc Sci Med* 59, 113–127.

34 Tolstrup JS, Jensen MK, Tjonneland A *et al.* (2004) Drinking pattern and mortality in middle-aged men and women. *Addiction* 99, 323–330.

35 Everhart JE (2003) In vino veritas? *J Hepatol* 38, 245–246.

36 Dam-Larsen S, Franzmann MB, Christoffersen P *et al.* (2005) Histological characteristics and prognosis in patients with fatty liver. *Scand J Gastroenterol* 40, 460–467.

37 Menon KV, Gores GJ, Shah VH (2001) Pathogenesis, diagnosis, and treatment of alcoholic liver disease. *Mayo Clin Proc* 76, 1021–1029.

38 Teli MR, Day CP, Burt AD *et al.* (1995) Determinants of progression to cirrhosis or fibrosis in pure alcoholic fatty liver. *Lancet* 346, 987–990.

39 Lieber CS (2004) Alcoholic fatty liver: its pathogenesis and mechanism of progression to inflammation and fibrosis. *Alcohol* 34, 9–19.

40 Levitsky J, Mailliard ME (2004) Diagnosis and therapy of alcoholic liver disease. *Semin Liver Dis* 24, 233–247.

41 Conigrave KM, Davies P, Haber P *et al.* (2003) Traditional markers of excessive alcohol use. *Addiction* 98(Suppl. 2), 31–43.

42 Sillanaukee P, Massot N, Jousilahti P *et al.* (2000) Dose response of laboratory markers to alcohol consumption in a general population. *Am J Epidemiol* 152, 747–751.

43 Matsuda Y, Tsuchishima M, Ueshima Y *et al.* (1993) The relationship between the development of alcoholic liver and pancreatic diseases and the induction of gamma glutamyl transferase. *Alcohol Alcohol* 1B(Suppl.), 27–33.

44 Sakuta H, Suzuki T, Yasuda H *et al.* (2005) Gamma-glutamyl transferase and metabolic risk factors for cardiovascular disease. *Intern Med* 44, 538–541.

45 McCullough AJ, O'Connor JF (1998) Alcoholic liver disease: proposed recommendations for the American College of Gastroenterology. *Am J Gastroenterol* 93, 2022–2036.

46 Naveau S, Montembault S, Balian A *et al.* (1999) [Biological diagnosis of the type of liver disease in alcoholic patients with abnormal liver function tests]. *Gastroenterol Clin Biol* 23, 1215–1224.

47 Ioannou GN, Weiss NS, Boyko EJ *et al.* (2005) Contribution of metabolic factors to alanine aminotransferase activity in persons with other causes of liver disease. *Gastroenterology* 128, 627–635.

48 Cohen JA, Kaplan MM (1979) The SGOT/SGPT ratio – an indicator of alcoholic liver disease. *Dig Dis Sci* 24, 835–838.

49 Joy D, Thava VR, Scott BB (2003) Diagnosis of fatty liver disease: is biopsy necessary? *Eur J Gastroenterol Hepatol* 15, 539–543.

50 Limanond P, Raman SS, Lassman C *et al.* (2004) Macrovesicular hepatic steatosis in living related liver donors: correlation between CT and histologic findings. *Radiology* 230, 276–280.

51 Saadeh S, Younossi ZM, Remer EM *et al.* (2002) The utility of radiological imaging in nonalcoholic fatty liver disease. *Gastroenterology* 123, 745–750.

52 Quillin SP, Siegel MJ, Rothbaum R (1993) Hepatobiliary sonography in cystic fibrosis. *Pediatr Radiol* 23, 533–535.

53 N'Gbesso RD, Attia A, Mahassadi A *et al.* (1998) [Hepatocellular carcinoma (HCC) observed in Abidjan: aspects and role of ultrasonography]. *J Radiol* 79, 409–414.

54 Longo R, Ricci C, Masutti F *et al.* (1993) Fatty infiltration of the liver. Quantification by 1H localized magnetic resonance spectroscopy and comparison with computed tomography. *Invest Radiol* 28, 297–302.

55 Fishbein M, Castro F, Cheruku S *et al.* (2005) Hepatic MRI for fat quantitation: its relationship to fat morphology, diagnosis, and ultrasound. *J Clin Gastroenterol* 39, 619–625.

56 Caballeria J, Pares A, Bru C *et al.* (1998) Metadoxine accelerates fatty liver recovery in alcoholic patients: results of a randomized double-blind, placebo-control trial. Spanish Group for the Study of Alcoholic Fatty Liver. *J Hepatol* 28, 54–60.

57 Uchida T, Kao H, Quispe-Sjogren M *et al.* (1983) Alcoholic foamy degeneration – a pattern of acute alcoholic injury of the liver. *Gastroenterology* 84, 683–692.

58 Montull S, Pares A, Bruguera M *et al.* (1989) Alcoholic foamy degeneration in Spain. Prevalence and clinico-pathological features. *Liver* 9, 79–85.

59 Flejou JF, Degott C, Kharsa G *et al.* (1987) [Alcoholic foamy steatosis: study of 3 cases]. *Gastroenterol Clin Biol* 11, 165–168.

60 Fromenty B, Grimbert S, Mansouri A *et al.* (1995) Hepatic mitochondrial DNA deletion in alcoholics: association with microvesicular steatosis. *Gastroenterology* 108, 193–200.

61 Fromenty B, Pessayre D (1997) Impaired mitochondrial function in microvesicular steatosis. Effects of drugs, ethanol, hormones and cytokines. *J Hepatol* 26(Suppl. 2), 43–53.

62 Yuzuriha T, Okudaira M, Tominaga I *et al.* (1997) Alcohol-related sudden death with hepatic fatty metamorphosis: a comprehensive clinicopathological inquiry into its pathogenesis. *Alcohol Alcohol* 32, 745–752.

63 Zieve L (1958) Jaundice, hyperlipemia and hemolytic anemia: a heretofore unrecognized syndrome associated with alcoholic fatty liver and cirrhosis. *Ann Intern Med* 48, 471–496.

64 Anon (1981) Alcoholic liver disease: morphological manifestations. Review by an international group. *Lancet* 1, 707–711.

65 Brunt EM (2003) Pathologic spectrum of fatty liver. *AASLD Postgraduate Course*, 65–74.

66 Kojima H, Sakurai S, Uemura M *et al.* (2005) Difference and similarity between non-alcoholic steatohepatitis and alcoholic liver disease. *Alcohol Clin Exp Res* 29, 259S–263S.

67 Meagher EA, Barry OP, Burke A *et al.* (1999) Alcohol-induced generation of lipid peroxidation products in humans. *J Clin Invest* 104, 805–813.

68 Parlesak A, Schafer C, Schutz T *et al.* (2000) Increased intestinal permeability to macromolecules and endotoxemia in patients with chronic alcohol abuse in different stages of alcohol-induced liver disease. *J Hepatol* 32, 742–747.

69 McClain CJ, Barve S, Deaciuc I *et al.* (1999) Cytokines in alcoholic liver disease. *Semin Liver Dis* 19, 205–219.

70 Sheron N, Bird G, Koskinas J *et al.* (1993) Circulating and tissue levels of the neutrophil chemotaxin interleukin-8 are elevated in severe acute alcoholic hepatitis, and tissue levels correlate with neutrophil infiltration. *Hepatology* 18, 41–46.

71 Addolorato G, Capristo E, Caputo F *et al.* (1999) Nutritional status and body fluid distribution in chronic alcoholics compared with controls. *Alcohol Clin Exp Res* 23, 1232–1237.

72 Ramond MJ, Poynard T, Rueff B *et al.* (1992) A randomized trial of prednisolone in patients with severe alcoholic hepatitis. *N Engl J Med* 326, 507–512.

73 Parmahamsa M, Reddy KR, Varadacharyulu N (2004) Changes in composition and properties of erythrocyte membrane in chronic alcoholics. *Alcohol Alcohol* 39, 110–112.

74 Morales A, Hashimoto L, Mokhtee D (2006) Alcoholic hepatitis with leukemoid reaction after surgery. *J Gastrointest Surg* 10, 83–85.

75 Spahr L, Rubbia-Brandt L, Pugin J *et al.* (2001) Rapid changes in alcoholic hepatitis histology under steroids: correlation with soluble intercellular adhesion molecule-1 in hepatic venous blood. *J Hepatol* 35, 582–589.

76 Giannini EG, Testa R, Savarino V (2005) Liver enzyme alteration: a guide for clinicians. *Can Med Assoc J* 172, 367–379.

77 Naveau S, Emilie D, Balian A *et al.* (1998) Plasma levels of soluble tumor necrosis factor receptors p55 and p75 in patients with alcoholic liver disease of increasing severity. *J Hepatol* 28, 778–784.

78 Spahr L, Rubbia-Brandt L, Frossard JL *et al.* (2002) Combination of steroids with infliximab or placebo in severe alcoholic hepatitis: a randomized controlled pilot study. *J Hepatol* 37, 448–455.

79 Tilg H, Jalan R, Kaser A *et al.* (2003) Anti-tumor necrosis factor-alpha monoclonal antibody therapy in severe alcoholic hepatitis. *J Hepatol* 38, 419–425.

80 Spahr L, Garcia I, Bresson-Hadni S *et al.* (2004) Circulating concentrations of interleukin-18, interleukin-18 binding protein, and gamma interferon in patients with alcoholic hepatitis. *Liver Int* 24, 582–587.

81 Neuman MG, Brenner DA, Rehermann B *et al.* (2001) Mechanisms of alcoholic liver disease: cytokines. *Alcohol Clin Exp Res* 25, 251S–253S.

82 Ziol M, Tepper M, Lohez M *et al.* (2001) Clinical and biological relevance of hepatocyte apoptosis in alcoholic hepatitis. *J Hepatol* 34, 254–260.

83 Colli A, Massironi S, Faccioli P *et al.* (2005) 'Pseudotumoral' hepatic areas in acute alcoholic hepatitis: a computed tomography and histological study. *Am J Gastroenterol* 100, 831–836.

84 Han SH, Rice S, Cohen SM *et al.* (2002) Duplex Doppler ultrasound of the hepatic artery in patients with acute alcoholic hepatitis. *J Clin Gastroenterol* 34, 573–577.

85 Kim SR, Maekawa Y, Imoto S *et al.* (2004) Hypervascular liver nodules in heavy drinkers of alcohol. *Alcohol Clin Exp Res* 28, 174S–180S.

86 Duvoux C, Radier C, Roudot-Thoraval F *et al.* (2004) Low-grade steatosis and major changes in portal flow as new prognostic factors in steroid-treated alcoholic hepatitis. *Hepatology* 40, 1370–1378.

87 Mookerjee RP, Sen S, Davies NA *et al.* (2003) Tumour necrosis factor alpha is an important mediator of portal and systemic haemodynamic derangements in alcoholic hepatitis. *Gut* 52, 1182–1187.

88 Spahr L, Giostra E, Frossard JL *et al.* (2004) Soluble TNF-R1, but not tumor necrosis factor alpha, predicts the 3-month mortality in patients with alcoholic hepatitis. *J Hepatol* 41, 229–234.

89 Rouault TA (2003) Hepatic iron overload in alcoholic liver disease: why does it occur and what is its role in pathogenesis? *Alcohol* 30, 103–106.

90 Safdar K, Schiff ER (2004) Alcohol and hepatitis C. *Semin Liver Dis* 24, 305–315.

91 Wiley TE, McCarthy M, Breidi L *et al.* (1998) Impact of alcohol on

the histological and clinical progression of hepatitis C infection. *Hepatology* 28, 805–809.

92 Maddrey WC, Boitnott JK, Bedine MS *et al.* (1978) Corticosteroid therapy of alcoholic hepatitis. *Gastroenterology* 75, 193–199.

93 Mathurin P, Mendenhall CL, Carithers RL, Jr *et al.* (2002) Corticosteroids improve short-term survival in patients with severe alcoholic hepatitis (AH): individual data analysis of the last three randomized placebo controlled double blind trials of corticosteroids in severe AH. *J Hepatol* 36, 480–487.

94 Carithers RL, Jr, Herlong HF, Diehl AM *et al.* (1989) Methylprednisolone therapy in patients with severe alcoholic hepatitis. A randomized multicenter trial. *Ann Intern Med* 110, 685–690.

95 Dunn W, Jamil LH, Brown LS *et al.* (2005) MELD accurately predicts mortality in patients with alcoholic hepatitis. *Hepatology* 41, 353–358.

96 Srikureja W, Kyulo NL, Runyon BA *et al.* (2005) MELD score is a better prognostic model than Child–Turcotte–Pugh score or Discriminant Function score in patients with alcoholic hepatitis. *J Hepatol* 42, 700–706.

97 Dunn W, Jamil LH, Brown LS *et al.* (2005) MELD accurately predicts mortality in patients with alcoholic hepatitis. *Hepatology* 41, 353–358.

98 Mathurin P, Abdelnour M, Ramond MJ *et al.* (2003) Early change in bilirubin levels is an important prognostic factor in severe alcoholic hepatitis treated with prednisolone. *Hepatology* 38, 1363–1369.

99 Orrego H, Blake JE, Blendis LM *et al.* (1987) Prognosis of alcoholic cirrhosis in the presence and absence of alcoholic hepatitis. *Gastroenterology* 92, 208–214.

100 Pessione F, Ramond MJ, Peters L *et al.* (2003) Five-year survival predictive factors in patients with excessive alcohol intake and cirrhosis. Effect of alcoholic hepatitis, smoking and abstinence. *Liver Int* 23, 45–53.

101 Bird GL, Sheron N, Goka AK *et al.* (1990) Increased plasma tumor necrosis factor in severe alcoholic hepatitis. *Ann Intern Med* 112, 917–920.

102 Thiele GM, Freeman TL, Klassen LW (2004) Immunologic mechanisms of alcoholic liver injury. *Semin Liver Dis* 24, 273–287.

103 Taieb J, Mathurin P, Elbim C *et al.* (2000) Blood neutrophil functions and cytokine release in severe alcoholic hepatitis: effect of corticosteroids. *J Hepatol* 32, 579–586.

104 Ichai P, Azoulay D, Feray C *et al.* (2002) [*Pneumocystis carinii* and cytomegalovirus pneumonia after corticosteroid therapy in acute severe alcoholic hepatitis: 2 case reports]. *Gastroenterol Clin Biol* 26, 532–534.

105 Mendenhall CL, Tosch T, Weesner RE *et al.* (1986) VA cooperative study on alcoholic hepatitis. II: Prognostic significance of protein-calorie malnutrition. *Am J Clin Nutr* 43, 213–218.

106 Mendenhall CL, Moritz TE, Roselle GA *et al.* (1995) Protein energy malnutrition in severe alcoholic hepatitis: diagnosis and response to treatment. The VA Cooperative Study Group #275. *J Parenter Enteral Nutr* 19, 258–265.

107 Mendenhall CL, Moritz TE, Roselle GA *et al.* (1993) A study of oral nutritional support with oxandrolone in malnourished patients with alcoholic hepatitis: results of a Department of Veterans Affairs cooperative study. *Hepatology* 17, 564–576.

108 Cabré E, Rodriguez-Iglesias P, Caballeria J *et al.* (2000) Short- and long-term outcome of severe alcohol-induced hepatitis treated with steroids or enteral nutrition: a multicenter randomized trial. *Hepatology* 32, 36–42.

109 Naveau S, Chollet-Martin S, Dharancy S *et al.* (2004) A double-blind randomized controlled trial of infliximab associated with prednisolone in acute alcoholic hepatitis. *Hepatology* 39, 1390–1397.

110 Menon KV, Stadheim L, Kamath PS *et al.* (2004) A pilot study of the safety and tolerability of etanercept in patients with alcoholic hepatitis. *Am J Gastroenterol* 99, 255–260.

111 Akriviadis E, Botla R, Briggs W *et al.* (2000) Pentoxifylline improves short-term survival in severe acute alcoholic hepatitis: a double-blind, placebo-controlled trial. *Gastroenterology* 119, 1637–1648.

112 Louvet A, Diaz E, Texier F *et al.* (2005) Evaluation of pentoxifylline in patients with severe alcoholic hepatitis non responders to corticosteroids: a pilot controlled study. *Hepatology* 42, 493A.

113 Sen S, Mookerjee RP, Cheshire LM *et al.* (2005) Albumin dialysis reduces portal pressure acutely in patients with severe alcoholic hepatitis. *J Hepatol* 43, 142–148.

114 Mezey E, Caballeria J, Mitchell MC *et al.* (1991) Effect of parenteral amino acid supplementation on short-term and long-term outcomes in severe alcoholic hepatitis: a randomized controlled trial. *Hepatology* 14, 1090–1096.

115 Trinchet JC, Balkau B, Poupon RE *et al.* (1992) Treatment of severe alcoholic hepatitis by infusion of insulin and glucagon: a multicenter sequential trial. *Hepatology* 15, 76–81.

116 Bird G, Lau JY, Koskinas J *et al.* (1991) Insulin and glucagon infusion in acute alcoholic hepatitis: a prospective randomized controlled trial. *Hepatology* 14, 1097–1101.

117 Baker AL, Jaspan JB, Haines NW *et al.* (1981) A randomized clinical trial of insulin and glucagon infusion for treatment of alcoholic hepatitis: progress report in 50 patients. *Gastroenterology* 80, 1410–1414.

118 Halle P, Pare P, Kaptein E *et al.* (1982) Double-blind, controlled trial of propylthiouracil in patients with severe acute alcoholic hepatitis. *Gastroenterology* 82, 925–931.

119 Trinchet JC, Beaugrand M, Callard P *et al.* (1989) Treatment of alcoholic hepatitis with colchicine. Results of a randomized double blind trial. *Gastroenterol Clin Biol* 13, 551–555.

120 Akriviadis EA, Steindel H, Pinto PC *et al.* (1990) Failure of colchicine to improve short-term survival in patients with alcoholic hepatitis. *Gastroenterology* 99, 811–818.

121 Lieber CS, Weiss DG, Groszmann R *et al.* (2003) Veterans Affairs Cooperative Study of polyenylphosphatidylcholine in alcoholic liver disease. *Alcohol Clin Exp Res* 27, 1765–1772.

122 Trinchet JC, Coste T, Levy VG *et al.* (1989) [Treatment of alcoholic hepatitis with silymarin. A double-blind comparative study in 116 patients]. *Gastroenterol Clin Biol* 13, 120–124.

123 Bird GL, Prach AT, McMahon AD *et al.* (1998) Randomised controlled double-blind trial of the calcium channel antagonist amlodipine in the treatment of acute alcoholic hepatitis. *J Hepatol* 28, 194–198.

124 Alla V, Bonkovsky HL (2005) Iron in nonhemochromatotic liver disorders. *Semin Liver Dis* 25, 461–472.

125 Ganne-Carrie N, Christidis C, Chastang C *et al.* (2000) Liver iron is predictive of death in alcoholic cirrhosis: a multivariate study of 229 consecutive patients with alcoholic and/or hepatitis C virus cirrhosis: a prospective follow up study. *Gut* 46, 277–282.

126 Gluud C, Christoffersen P, Eriksen J *et al.* (1987) Influence of ethanol on development of hyperplastic nodules in alcoholic men with micronodular cirrhosis. *Gastroenterology* 93, 256–260.

127 Fauerholdt L, Schlichting P, Christensen E *et al.* (1983) Conversion of micronodular cirrhosis into macronodular cirrhosis. *Hepatology* 3, 928–931.

128 McCormick PA, Nolan N (2004) Palpable epigastric liver as a physical sign of cirrhosis: a prospective study. *Eur J Gastroenterol Hepatol* 16, 1331–1334.

129 Attali P, Ink O, Pelletier G *et al.* (1987) Dupuytren's contracture, alcohol consumption, and chronic liver disease. *Arch Intern Med* 147, 1065–1067.

130 Dutta SK, Dukehart M, Narang A *et al.* (1989) Functional and structural changes in parotid glands of alcoholic cirrhotic patients. *Gastroenterology* 96, 510–518.

131 Caregaro L, Alberino F, Amodio P *et al.* (1996) Malnutrition in alcoholic and virus-related cirrhosis. *Am J Clin Nutr* 63, 602–609.

132 Stickel F, Hoehn B, Schuppan D *et al.* (2003) Review article: nutritional therapy in alcoholic liver disease. *Aliment Pharmacol Ther* 18, 357–373.

133 Andersen H, Borre M, Jakobsen J *et al.* (1998) Decreased muscle strength in patients with alcoholic liver cirrhosis in relation to nutritional status, alcohol abstinence, liver function, and neuropathy. *Hepatology* 27, 1200–1206.

134 Alberino F, Gatta A, Amodio P *et al.* (2001) Nutrition and survival in patients with liver cirrhosis. *Nutrition* 17, 445–450.

135 Campillo B, Richardet JP, Scherman E *et al.* (2003) Evaluation of nutritional practice in hospitalized cirrhotic patients: results of a prospective study. *Nutrition* 19, 515–521.

136 Lochs H, Plauth M (1999) Liver cirrhosis: rationale and modalities for nutritional support – the European Society of Parenteral and Enteral Nutrition consensus and beyond. *Curr Opin Clin Nutr Metab Care* 2, 345–349.

137 Richardson RA, Davidson HI, Hinds A *et al.* (1999) Influence of the metabolic sequelae of liver cirrhosis on nutritional intake. *Am J Clin Nutr* 69, 331–337.

138 Comlekci A, Akpinar H, Yesil S *et al.* (2003) Serum leptin levels in patients with liver cirrhosis and chronic viral hepatitis. *Scand J Gastroenterol* 38, 779–786.

139 Campillo B, Sherman E, Richardet JP *et al.* (2001) Serum leptin levels in alcoholic liver cirrhosis: relationship with gender, nutritional status, liver function and energy metabolism. *Eur J Clin Nutr* 55, 980–988.

140 McClain CJ, Antonow DR, Cohen DA *et al.* (1986) Zinc metabolism in alcoholic liver disease. *Alcohol Clin Exp Res* 10, 582–589.

141 Bergheim I, Parlesak A, Dierks C *et al.* (2003) Nutritional deficiencies in German middle-class male alcohol consumers: relation to dietary intake and severity of liver disease. *Eur J Clin Nutr* 57, 431–438.

142 Kang YJ, Zhou Z (2005) Zinc prevention and treatment of alcoholic liver disease. *Mol Aspects Med* 26, 391–404.

143 Weismann K, Christensen E, Dreyer V (1979) Zinc supplementation in alcoholic cirrhosis. A double-blind clinical trial. *Acta Med Scand* 205, 361–366.

144 Gronbaek K, Friis H, Feldman M *et al.* (1996) Lack of effect of zinc supplementation on antipyrine clearance in alcoholic liver disease. *Eur J Clin Pharmacol* 49, 397–399.

145 van de Wiel A, Schuurman HJ, Kater L (1987) Alcoholic liver disease: an IgA-associated disorder. *Scand J Gastroenterol* 22, 1025–1030.

146 Gonzalez-Quintela A, Lopez-Ben S, Perez LF *et al.* (2003) Time-course changes of serum immunoglobulins (IgA, IgG, IgM) after liver transplantation for alcoholic cirrhosis. *Transpl Immunol* 11, 73–77.

147 Latvala J, Parkkila S, Niemela O (2004) Excess alcohol consumption is common in patients with cytopenia: studies in blood and bone marrow cells. *Alcohol Clin Exp Res* 28, 619–624.

148 Chen CH, Wang JH, Lu SN *et al.* (2002) Comparison of prevalence for paraumbilical vein patency in patients with viral and alcoholic liver cirrhosis. *Am J Gastroenterol* 97, 2415–2418.

149 Huet PM, Pomier-Layrargues G (2004) The hepatic venous pressure gradient: 'remixed and revisited'. *Hepatology* 39, 295–298.

150 Patch D, Armonis A, Sabin C *et al.* (1999) Single portal pressure measurement predicts survival in cirrhotic patients with recent bleeding. *Gut* 44, 264–269.

151 Pomier-Layrargues G, Villeneuve JP, Willems B *et al.* (1987) Systemic and hepatic hemodynamics after variceal hemorrhage: effects of propranolol and placebo. *Gastroenterology* 93, 1218–1224.

152 Luca A, Garcia-Pagan JC, Bosch J *et al.* (1997) Effects of ethanol consumption on hepatic hemodynamics in patients with alcoholic cirrhosis. *Gastroenterology* 112, 1284–1289.

153 Poynard T, Degott C, Munoz C *et al.* (1987) Relationship between degree of portal hypertension and liver histologic lesions in patients with alcoholic cirrhosis. Effect of acute alcoholic hepatitis on portal hypertension. *Dig Dis Sci* 32, 337–343.

154 Vorobioff J, Groszmann RJ, Picabea E *et al.* (1996) Prognostic value of hepatic venous pressure gradient measurements in alcoholic cirrhosis: a 10-year prospective study. *Gastroenterology* 111, 701–709.

155 Bedossa P, Poynard T, Naveau S *et al.* (1988) Observer variation in assessment of liver biopsies of alcoholic patients. *Alcohol Clin Exp Res* 12, 173–178.

156 Bell H, Jahnsen J, Kittang E *et al.* (2004) Long-term prognosis of patients with alcoholic liver cirrhosis: a 15-year follow-up study of 100 Norwegian patients admitted to one unit. *Scand J Gastroenterol* 39, 858–863.

157 Bouza C, Angeles M, Munoz A *et al.* (2004) Efficacy and safety of naltrexone and acamprosate in the treatment of alcohol dependence: a systematic review. *Addiction* 99, 811–828.

158 Mann K, Lehert P, Morgan MY (2004) The efficacy of acamprosate in the maintenance of abstinence in alcohol-dependent individuals: results of a meta-analysis. *Alcohol Clin Exp Res* 28, 51–63.

159 Moyer A, Finney JW, Swearingen CE *et al.* (2002) Brief interventions for alcohol problems: a meta-analytic review of controlled investigations in treatment-seeking and non-treatment-seeking populations. *Addiction* 97, 279–292.

160 Garbutt JC, West SL, Carey TS *et al.* (1999) Pharmacological treatment of alcohol dependence: a review of the evidence. *JAMA* 281, 1318–1325.

161 Forns X, Caballeria J, Bruguera M *et al.* (1994) Disulfiram-induced hepatitis. Report of four cases and review of the literature. *J Hepatol* 21, 853–857.

162 Bunout D, Aicardi V, Hirsch S *et al.* (1989) Nutritional support in hospitalized patients with alcoholic liver disease. *Eur J Clin Nutr* 43, 615–621.

163 Marchesini G, Dioguardi FS, Bianchi GP *et al.* (1990) Long-term oral branched-chain amino acid treatment in chronic hepatic encephalopathy. A randomized double-blind casein-controlled trial. The Italian Multicenter Study Group. *J Hepatol* 11, 92–101.

164 Kearns PJ, Young H, Garcia G *et al.* (1992) Accelerated improvement of alcoholic liver disease with enteral nutrition. *Gastroenterology* 102, 200–205.

165 Cabre E, Gonzalez-Huix F, Abad-Lacruz A *et al.* (1990) Effect of total enteral nutrition on the short-term outcome of severely malnourished cirrhotics. A randomized controlled trial. *Gastroenterology* 98, 715–720.

166 Hirsch S, Bunout D, de la Maza P *et al.* (1993) Controlled trial on nutrition supplementation in outpatients with symptomatic alcoholic cirrhosis. *J Parenter Enteral Nutr* 17, 119–124.

167 Le Cornu KA, McKiernan FJ, Kapadia SA *et al.* (2000) A prospective randomized study of preoperative nutritional supplementation in patients awaiting elective orthotopic liver transplantation. *Transplantation* 69, 1364–1369.

168 Pares A, Planas R, Torres M *et al.* (1998) Effects of silymarin in alcoholic patients with cirrhosis of the liver: results of a controlled, double-blind, randomized and multicenter trial. *J Hepatol* 28, 615–621.

169 de la Maza MP, Petermann M, Bunout D *et al.* (1995) Effects of long-term vitamin E supplementation in alcoholic cirrhotics. *J Am Coll Nutr* 14, 192–196.

170 Mato JM, Camara J, Fernandez de Paz J *et al.* (1999) S-adenosylmethionine in alcoholic liver cirrhosis: a randomized, placebo-controlled, double-blind, multicenter clinical trial. *J Hepatol* 30, 1081–1089.

171 Kershenobich D, Vargas F, Garcia-Tsao G *et al.* (1988) Colchicine in the treatment of cirrhosis of the liver. *N Engl J Med* 318, 1709–1713.

172 Morgan TR, Weiss DG, Nemchausky B *et al.* (2005) Colchicine treatment of alcoholic cirrhosis: a randomized, placebo-controlled clinical trial of patient survival. *Gastroenterology* 128, 882–890.

173 Bedossa P, Dargere D, Paradis V (2003) Sampling variability of liver fibrosis in chronic hepatitis C. *Hepatology* 38, 1449–1457.

174 Piccinino F, Sagnelli E, Pasquale G *et al.* (1986) Complications following percutaneous liver biopsy. A multicentre retrospective study on 68,276 biopsies. *J Hepatol* 2, 165–173.

175 Idobe Y, Murawaki Y, Ikuta Y *et al.* (1998) Post-prandial serum hyaluronan concentration in patients with chronic liver disease. *Intern Med* 37, 568–575.

176 Pares A, Deulofeu R, Gimenez A *et al.* (1996) Serum hyaluronate reflects hepatic fibrogenesis in alcoholic liver disease and is useful as a marker of fibrosis. *Hepatology* 24, 1399–1403.

177 Tsutsumi M, Urashima S, Takase S *et al.* (1997) Characteristics of serum hyaluronate concentrations in patients with alcoholic liver disease. *Alcohol Clin Exp Res* 21, 1716–1721.

178 Aube C, Oberti F, Korali N *et al.* (1999) Ultrasonographic diagnosis of hepatic fibrosis or cirrhosis. *J Hepatol* 30, 472–478.

179 Aube C, Winkfield B, Oberti F *et al.* (2004) New Doppler ultrasound signs improve the non-invasive diagnosis of cirrhosis or severe liver fibrosis. *Eur J Gastroenterol Hepatol* 16, 743–751.

180 Koinuma M, Ohashi I, Hanafusa K *et al.* (2005) Apparent diffusion coefficient measurements with diffusion-weighted magnetic resonance imaging for evaluation of hepatic fibrosis. *J Magn Reson Imaging* 22, 80–85.

181 Ziol M, Handra-Luca A, Kettaneh A *et al.* (2005) Noninvasive assessment of liver fibrosis by measurement of stiffness in patients with chronic hepatitis C. *Hepatology* 41, 48–54.

182 Melin P, Dacon A, Gauchet A *et al.* (2005) Cirrhosis screening in alcoholism consultation using Fibroscan. *Hepatology* 42, 492A.

183 Angulo P, Keach JC, Batts KP *et al.* (1999) Independent predictors of liver fibrosis in patients with nonalcoholic steatohepatitis. *Hepatology* 30, 1356–1362.

184 Pohl A, Behling C, Oliver D *et al.* (2001) Serum aminotransferase levels and platelet counts as predictors of degree of fibrosis in chronic hepatitis C virus infection. *Am J Gastroenterol* 96, 3142–3146.

185 Oberti F, Valsesia E, Pilette C *et al.* (1997) Noninvasive diagnosis of hepatic fibrosis or cirrhosis. *Gastroenterology* 113, 1609–1616.

186 Croquet V, Vuillemin E, Ternisien C *et al.* (2002) Prothrombin index is an indirect marker of severe liver fibrosis. *Eur J Gastroenterol Hepatol* 14, 1133–1141.

187 Plevris JN, Haydon GH, Simpson KJ *et al.* (2000) Serum hyaluronan – a non-invasive test for diagnosing liver cirrhosis. *Eur J Gastroenterol Hepatol* 12, 1121–1127.

188 Stickel F, Urbaschek R, Schuppan D *et al.* (2001) Serum collagen type VI and XIV and hyaluronic acid as early indicators for altered connective tissue turnover in alcoholic liver disease. *Dig Dis Sci* 46, 2025–2032.

189 Nojgaard C, Johansen JS, Christensen E *et al.* (2003) Serum levels of YKL-40 and PIIINP as prognostic markers in patients with alcoholic liver disease. *J Hepatol* 39, 179–186.

190 Li J, Rosman AS, Leo MA *et al.* (1994) Tissue inhibitor of metalloproteinase is increased in the serum of precirrhotic and cirrhotic alcoholic patients and can serve as a marker of fibrosis. *Hepatology* 19, 1418–1423.

191 Tran A, Hastier P, Barjoan EM *et al.* (2000) Non invasive prediction of severe fibrosis in patients with alcoholic liver disease. *Gastroenterol Clin Biol* 24, 626–630.

192 Stickel F, Poeschl G, Schuppan D *et al.* (2003) Serum hyaluronate correlates with histological progression in alcoholic liver disease. *Eur J Gastroenterol Hepatol* 15, 945–950.

193 Imbert-Bismut F, Ratziu V, Pieroni L *et al.* (2001) Biochemical markers of liver fibrosis in patients with hepatitis C virus infection: a prospective study. *Lancet* 357, 1069–1075.

194 Poynard T, Aubert A, Bedossa P *et al.* (1991) A simple biological index for detection of alcoholic liver disease in drinkers. *Gastroenterology* 100, 1397–1402.

195 Cales P, Oberti F, Michalak S *et al.* (2005) A novel panel of blood markers to assess the degree of liver fibrosis. *Hepatology* 42, 1373–1381.

196 Cotler SJ, Bronner MP, Press RD *et al.* (1998) End-stage liver disease without hemochromatosis associated with elevated hepatic iron index. *J Hepatol* 29, 257–262.

197 Eng SC, Taylor SL, Reyes V *et al.* (2005) Hepatic iron overload in alcoholic end-stage liver disease is associated with iron deposition in other organs in the absence of HFE-1 hemochromatosis. *Liver Int* 25, 513–517.

198 Pascoe A, Kerlin P, Steadman C *et al.* (1999) Spur cell anaemia and hepatic iron stores in patients with alcoholic liver disease undergoing orthotopic liver transplantation. *Gut* 45, 301–305.

199 Suzuki Y, Saito H, Suzuki M *et al.* (2002) Up-regulation of transferrin receptor expression in hepatocytes by habitual alcohol drinking is implicated in hepatic iron overload in alcoholic liver disease. *Alcohol Clin Exp Res* 26, 26S–31S.

200 Detivaud L, Nemeth E, Boudjema K *et al.* (2005) Hepcidin levels in humans are correlated with hepatic iron stores, hemoglobin levels, and hepatic function. *Blood* 106, 746–748.

201 Ganz T, Nemeth E (2006) Iron imports. IV. Hepcidin and regulation of body iron metabolism. *Am J Physiol Gastrointest Liver Physiol* 290, G199–203.

202 Facchini FS, Hua NW, Stoohs RA (2002) Effect of iron depletion in carbohydrate-intolerant patients with clinical evidence of non-alcoholic fatty liver disease. *Gastroenterology* 122, 931–939.

203 Scotet V, Merour MC, Mercier AY *et al.* (2003) Hereditary hemochromatosis: effect of excessive alcohol consumption on disease expression in patients homozygous for the C282Y mutation. *Am J Epidemiol* 158, 129–134.

204 Fletcher LM, Dixon JL, Purdie DM *et al.* (2002) Excess alcohol greatly increases the prevalence of cirrhosis in hereditary hemochromatosis. *Gastroenterology* 122, 281–289.

205 Grove J, Daly AK, Burt AD *et al.* (1998) Heterozygotes for HFE mutations have no increased risk of advanced alcoholic liver disease. *Gut* 43, 262–266.

206 Gluud C, Aldershvile J, Henriksen J *et al.* (1982) Hepatitis B and A virus antibodies in alcoholic steatosis and cirrhosis. *J Clin Pathol* 35, 693–697.

207 Saunders JB, Wodak AD, Morgan-Capner P *et al.* (1983) Importance of markers of hepatitis B virus in alcoholic liver disease. *Br Med J (Clin Res Ed)* 286, 1851–1854.

208 Donato F, Tagger A, Gelatti U *et al.* (2002) Alcohol and hepatocellular carcinoma: the effect of lifetime intake and hepatitis virus infections in men and women. *Am J Epidemiol* 155, 323–331.

209 Ohnishi K, Iida S, Iwama S *et al.* (1982) The effect of chronic habitual alcohol intake on the development of liver cirrhosis and hepatocellular carcinoma: relation to hepatitis B surface antigen carriage. *Cancer* 49, 672–677.

210 Uetake S, Yamauchi M, Itoh S *et al.* (2003) Analysis of risk factors for hepatocellular carcinoma in patients with HBs antigen- and anti-HCV antibody-negative alcoholic cirrhosis: clinical significance of prior hepatitis B virus infection. *Alcohol Clin Exp Res* 27, 47S–51S.

211 Brechot C, Nalpas B, Courouce AM *et al.* (1982) Evidence that hepatitis B virus has a role in liver-cell carcinoma in alcoholic liver disease. *N Engl J Med* 306, 1384–1387.

212 Yotsuyanagi H, Hashidume K, Suzuki M *et al.* (2004) Role of hepatitis B virus in hepatocarcinogenesis in alcoholics. *Alcohol Clin Exp Res* 28, 181S–185S.

213 Pares A, Barrera JM, Caballeria J *et al.* (1990) Hepatitis C virus antibodies in chronic alcoholic patients: association with severity of liver injury. *Hepatology* 12, 1295–1299.

214 Caldwell SH, Jeffers LJ, Ditomaso A *et al.* (1991) Antibody to hepatitis C is common among patients with alcoholic liver disease with and without risk factors. *Am J Gastroenterol* 86, 1219–1223.

215 Pessione F, Degos F, Marcellin P *et al.* (1998) Effect of alcohol consumption on serum hepatitis C virus RNA and histological lesions in chronic hepatitis C. *Hepatology* 27, 1717–1722.

216 Anand BS, Thornby J (2005) Alcohol has no effect on hepatitis C virus replication: a meta-analysis. *Gut* 54, 1468–1472.

217 Wheeler M (2005) Ethanol and HCV-induced cytotoxicity: the perfect storm. *Gastroenterology* 128, 232–234.

218 Poynard T, Ratziu V, Charlotte F *et al.* (2001) Rates and risk factors of liver fibrosis progression in patients with chronic hepatitis c. *J Hepatol* 34, 730–739.

219 Loguercio C, Di Pierro M, Di Marino MP *et al.* (2000) Drinking habits of subjects with hepatitis C virus-related chronic liver disease: prevalence and effect on clinical, virological and pathological aspects. *Alcohol Alcohol* 35, 296–301.

220 Brunt EM, Ramrakhiani S, Cordes BG *et al.* (2003) Concurrence of histologic features of steatohepatitis with other forms of chronic liver disease. *Mod Pathol* 16, 49–56.

221 Fain JN, Bahouth SW, Madan AK (2004) TNFalpha release by the nonfat cells of human adipose tissue. *Int J Obes Relat Metab Disord* 28, 616–622.

222 Willy Haukeland J, Konopski Z, Linnestad P *et al.* (2005) Abnormal glucose tolerance is a predictor of steatohepatitis and fibrosis in patients with non-alcoholic fatty liver disease. *Scand J Gastroenterol* 40, 1469–1477.

223 Larter CZ, Farrell GC (2006) Insulin resistance, adiponectin, cytokines in NASH: which is the best target to treat? *J Hepatol* 44, 253–261.

224 Imano E, Kanda T, Nakatani Y *et al.* (1999) Impaired splanchnic and peripheral glucose uptake in liver cirrhosis. *J Hepatol* 31, 469–473.

225 Naveau S, Giraud V, Borotto E *et al.* (1997) Excess weight risk factor for alcoholic liver disease. *Hepatology* 25, 108–111.

226 Menon KVN, Angulo P, Lindor KD (2001) Severe cholestatic hepatitis from troglitazone in a patient with nonalcoholic steatohepatitis and diabetes mellitus. *Am J Gastroenterol* 96, 1631–1634.

227 Neuschwander-Tetri BA, Brunt EM, Wehmeier KR *et al.* (2003) Improved nonalcoholic steatohepatitis after 48 weeks of treatment with the PPAR-gamma ligand rosiglitazone. *Hepatology* 38, 1008–1017.

228 Larsson C (1978) Natural history and life expectancy in severe alpha1-antitrypsin deficiency, Pi Z. *Acta Med Scand* 204, 345–351.

229 Elzouki AN, Eriksson S (1996) Risk of hepatobiliary disease in adults with severe alpha 1-antitrypsin deficiency (PiZZ): is chronic viral hepatitis B or C an additional risk factor for cirrhosis and hepatocellular carcinoma? *Eur J Gastroenterol Hepatol* 8, 989–994.

230 Eigenbrodt ML, McCashland TM, Dy RM *et al.* (1997) Heterozygous alpha 1-antitrypsin phenotypes in patients with end stage liver disease. *Am J Gastroenterol* 92, 602–607.

231 Graziadei IW, Joseph JJ, Wiesner RH *et al.* (1998) Increased risk of chronic liver failure in adults with heterozygous alpha1-antitrypsin deficiency. *Hepatology* 28, 1058–1063.

232 Bugianesi E, Leone N, Vanni E *et al.* (2002) Expanding the natural history of nonalcoholic steatohepatitis: from cryptogenic cirrhosis to hepatocellular carcinoma. *Gastroenterology* 123, 134–140.

233 Lewis JH, Ranard RC, Caruso A *et al.* (1989) Amiodarone hepatotoxicity: prevalence and clinicopathologic correlations among 104 patients. *Hepatology* 9, 679–685.

234 Aithal GP, Haugk B, Das S *et al.* (2004) Monitoring methotrexate-induced hepatic fibrosis in patients with psoriasis: are serial liver biopsies justified? *Aliment Pharmacol Ther* 19, 391–399.

235 Zachariae H, Kragballe K, Sogaard H (1980) Methotrexate induced liver cirrhosis. Studies including serial liver biopsies during continued treatment. *Br J Dermatol* 102, 407–412.

236 Prescott LF (2000) Paracetamol, alcohol and the liver. *Br J Clin Pharmacol* 49, 291–301.

237 Kaplowitz N (2004) Acetaminophen hepatoxicity: what do we know, what don't we know, and what do we do next? *Hepatology* 40, 23–26.

238 Lauterburg BH, Velez ME (1988) Glutathione deficiency in alcoholics: risk factor for paracetamol hepatotoxicity. *Gut* 29, 1153–1157.

239 Villeneuve JP, Raymond G, Bruneau J *et al.* (1983) [Pharmacokinetics and metabolism of acetaminophen in normal, alcoholic and cirrhotic subjects]. *Gastroenterol Clin Biol* 7, 898–902.

240 Prescott LF, Critchley JA (1983) Drug interactions affecting analgesic toxicity. *Am J Med* 75, 113–116.

241 Spies C, Tonnesen H, Andreasson S *et al.* (2001) Perioperative morbidity and mortality in chronic alcoholic patients. *Alcohol Clin Exp Res* 25, 164S–170S.

242 Jurkovich GJ, Rivara FP, Gurney JG *et al.* (1993) The effect of acute alcohol intoxication and chronic alcohol abuse on outcome from trauma. *JAMA* 270, 51–56.

243 Felding C, Jensen LM, Tonnesen H (1992) Influence of alcohol intake on postoperative morbidity after hysterectomy. *Am J Obstet Gynecol* 166, 667–670.

244 Spies CD, Rommelspacher H (1999) Alcohol withdrawal in the surgical patient: prevention and treatment. *Anesth Analg* 88, 946–954.

245 Tonnesen H, Rosenberg J, Nielsen HJ *et al.* (1999) Effect of preoperative abstinence on poor postoperative outcome in alcohol misusers: randomised controlled trial. *Br Med J* 318, 1311–1316.

246 Behrns KE, Tsiotos GG, DeSouza NF *et al.* (1998) Hepatic steatosis as a potential risk factor for major hepatic resection. *J Gastrointest Surg* 2, 292–298.

247 Friedman LS (1999) The risk of surgery in patients with liver disease. *Hepatology* 29, 1617–1623.
248 Greenwood SM, Leffler CT, Minkowitz S (1972) The increased mortality rate of open liver biopsy in alcoholic hepatitis. *Surg Gynecol Obstet* 134, 600–604.
249 Mikkelsen WP, Kern WH (1974) The influence of acute hyaline necrosis on survival after emergency and elective portacaval shunt. *Major Probl Clin Surg* 14, 233–242.
250 Thulstrup AM, Sorensen HT, Vilstrup H (2001) Mortality after open cholecystectomy in patients with cirrhosis of the liver: a population-based study in Denmark. *Eur J Surg* 167, 679–683.
251 Sorensen HT, Mellemkjaer L, Jepsen P *et al.* (2003) Risk of cancer in patients hospitalized with fatty liver: a Danish cohort study. *J Clin Gastroenterol* 36, 356–359.
252 Bagnardi V, Blangiardo M, La Vecchia C *et al.* (2001) A meta-analysis of alcohol drinking and cancer risk. *Br J Cancer* 85, 1700–1705.
253 Cayuela A, Vioque J, Bolumar F (1991) Oesophageal cancer mortality: relationship with alcohol intake and cigarette smoking in Spain. *J Epidemiol Community Health* 45, 273–276.
254 Duvoux C, Delacroix I, Richardet JP *et al.* (1999) Increased incidence of oropharyngeal squamous cell carcinomas after liver transplantation for alcoholic cirrhosis. *Transplantation* 67, 418–421.
255 Dupont-Bierre E, Compagnon P, Raoul JL *et al.* (2005) Resection of hepatocellular carcinoma in noncirrhotic liver: analysis of risk factors for survival. *J Am Coll Surg* 201, 663–670.
256 Nair S, Mason A, Eason J *et al.* (2002) Is obesity an independent risk factor for hepatocellular carcinoma in cirrhosis? *Hepatology* 36, 150–155.
257 Llovet JM, Burroughs A, Bruix J (2003) Hepatocellular carcinoma. *Lancet* 362, 1907–1917.
258 De Bac C, Stroffolini T, Gaeta GB *et al.* (1994) Pathogenic factors in cirrhosis with and without hepatocellular carcinoma: a multicenter Italian study. *Hepatology* 20, 1225–1230.
259 Lesesne HR, Bozymski EM, Fallon HJ (1978) Treatment of alcoholic hepatitis with encephalopathy. Comparison of prednisolone with caloric supplements. *Gastroenterology* 74, 169–173.
260 Depew W, Boyer T, Omata M *et al.* (1980) Double-blind controlled trial of prednisolone therapy in patients with severe acute alcoholic hepatitis and spontaneous encephalopathy. *Gastroenterology* 78, 524–529.

12.5 Management of the alcoholic patient, including alcoholism and extrahepatic manifestations

Georges-Philippe Pageaux and Pascal Perney

Obviously, alcoholic liver disease (ALD) occurs in a context of alcoholism. Therefore, besides management of liver disease and its complications, many other treatment issues arise in patients with ALD. Within global management are included specific measures for alcohol withdrawal and continued abstinence, and the management of extrahepatic alcohol injury.

Alcohol withdrawal and continued abstinence

Benefits of drinking control in the management of ALD

ALD prognosis is strikingly related to abstinence. Abstinence alone allows alcoholic fatty liver to regress [1]. Sobriety decreases mortality in patients with alcoholic hepatitis and cirrhosis, with or without portal hypertension [2]. In cirrhotic patients with an excessive alcohol intake, multivariate analyses have demonstrated that persistent alcohol intake is associated with a significant increase in mortality [3]. Although alcohol provides 7.1 kcal/g, malnutrition is a frequent accompaniment of chronic alcoholism, and is always present to various degrees when ALD develops. Malnutrition enhances liver damage and increases mortality in patients with alcoholic liver disease [4]. Alcohol withdrawal allows for restoration of a good nutritional status, which has a beneficial effect on liver function [5]. Alcohol withdrawal decreases morbid and mortality independently from liver injury [6] and, thus, decreases health costs [7]. Therefore, abstinence from alcohol should be considered as a starting point in the management of ALD. However, as chronic alcoholism is a complex bio–psycho–social disease, alcohol withdrawal should be followed by reinforcement and rehabilitation phases.

Abstinence or controlled drinking

Addiction specialists tend to consider that control of drinking behaviour is a more realistic goal than complete abstinence. However, the impact of structured protocols designed to limit alcohol intake on liver injury has not been evaluated. In fact, complete abstinence is proposed to most patients with ALD, either because they are alcohol-dependent or because they have severe ALD.

Alcohol dependence has been defined as a maladaptative pattern of alcohol use, leading to clinically significant impairment [8]. Diagnosis of dependence is based on the presence of three or more of the following nine features occurring at any time in a 12-month period (*Diagnostic and Statistical Manual of Mental Disorders* (*DSM*) *IV*):

1 Tolerance, as defined by either of the following:

a A need for markedly increased amounts of the substance to achieve intoxication or desired effect.

b Markedly diminished effect with continued use of the same amount of the substance.

2 Withdrawal, as manifested by either of the following:

a The characteristic withdrawal syndrome for the substance

b The same (or a closely related) substance is taken to relieve or avoid withdrawal symptoms.

3 The substance is often taken in larger amounts or over a longer period than was intended (loss of control).

4 There is a persistent desire or unsuccessful efforts to cut down or control substance use (loss of control).

5 A great deal of time is spent in activities necessary to obtain the substance, use the substance or recover from its effects (preoccupation).

6 Important social, occupational or recreational activities are given up or reduced because of substance use (continuation despite adverse consequences).

7 The substance use is continued despite knowledge of having a persistent or recurrent physical or psychological problem that is likely to have been caused or exacerbated by the substance (adverse consequences).

Alcohol dependence should be recognized early in the management of patients with ALD, because heavy drinkers who will develop the most severe forms of the disease require total abstinence – although this may prove difficult to obtain.

According to the World Health Organization (WHO), moderate alcohol consumption corresponds to three or fewer standard glasses of alcoholic beverage containing 10–12 g of ethanol for a

man, and two or fewer for a woman. This consumption can be proposed as a realistic aim only to patients who are not alcohol dependent and who have a mild form of ALD. These levels of consumption have been shown to decrease global mortality or mortality from heart disease, not from cirrhosis. Actually, alcohol consumption increases mortality from cirrhosis proportionally to the amount ingested, a significant effect being discernible at a level as low as one to two standard glasses per day [9]. As discussed in Chapters 12.2 and 12.4 the risk of developing severe ALD depends on many factors unrelated to the level of alcohol consumption, including age, body mass index, female gender, liver iron overload and blood glucose levels [10]. At present, therefore, it is impossible to establish a standard limit below which an individual patient with mild ALD would not be at risk of developing cirrhosis.

The patient should be given all information in a clear and objective manner. A therapeutic programme should be discussed, considering not only ALD control but also quality of life improvement. Positive goals are more efficient motivation than a list of do-nots. Once the patient agrees with the therapeutic programme, weaning off alcohol can be undertaken.

Alcohol withdrawal

This step in management aims to relieve discomfort, to prevent withdrawal-related complications, and to prepare for rehabilitation. At present, there is no indication that progressive withdrawal is superior to abrupt withdrawal. Alcohol withdrawal syndrome occurs in heavy drinkers with physical dependence. The early phase components of the syndrome include neurovegetative hyperactivity (sweating, tachycardia), tremor, nausea or vomiting, insomnia, anxiety and generalized agitation. Without administration of a specific treatment, delirium tremens and seizures may occur. Careful differential diagnosis must be made with subdural haematoma, hypoglycaemia and, in cirrhotic patients, with hepatic encephalopathy.

Benzodiazepines stand as a reference among the numerous agents assessed for prevention of alcohol withdrawal syndrome. Chlordiazepoxide, diazepam, oxazepam and lorazepam are the most commonly used benzodiazepines [11–13]. A meta-analysis has shown that benzodiazepines significantly reduce withdrawal syndrome severity, incidence of delirium, and risk of seizures. Diazepam and chlordiazepoxide, having long half-lives, are the agents of choice to prevent delirium tremens and seizures. However, their plasma half-lives increase in patients with significant liver dysfunction. Furthermore, the proportion of free drug may increase in the presence of hypoalbuminaemia, causing hepatic encephalopathy [14]. Therefore, in patients with significant liver dysfunction, benzodiazepines with short half-lives (oxazepam or lorazepam) are preferred. Benzodiazepines are usually given at high doses for the first 3 days, and then tapered off over the next 4 days according to the patient's condition. In patients with severe agitation, neuroleptics (e.g. tiapride) can be carefully used in association with benzodiazepines [15].

Thiamine should always be administered concurrently although it is without effect on alcohol withdrawal. Thiamine deficiency results from poor diet and reduced intestinal absorption. Nutritional rehabilitation and/or intravenous (i.v.) glucose infusion during the withdrawal phase may exhaust thiamine stores, causing Wernicke–Korsakoff syndrome. Optimal dose and duration of thiamine administration have not been established. A dose of 500–1000 mg/day for 10–15 days can be recommended. Oral or intravenous fluids amounting to 2–3 L/day should be provided. In patients with ascites, fluid intake might be kept to 1 L/day.

Alcohol withdrawal can be performed in institutional or ambulatory settings. An institutional seetting is indicated in patients with severe ALD or other organic disorders requiring specific management, and in patients with psychiatric symptoms, signs of physical dependence, previous alcohol withdrawal syndrome, or after failure of a well-designed ambulatory rehabilitation. By contrast, ambulatory withdrawal is preferred for patients with no physical dependence, and a good social and familial environment. Studies comparing inpatient and outpatient management have generally failed to show significant differences in effectiveness [16,17].

Maintaining long-term abstinence

Successful management of the alcohol withdrawal phase enables subsequent efforts at rehabilitation. However, 40–70% of patients return to drinking within the year following the initial treatment. Rehabilitation management includes a variety of treatments, often combined. Cognitive and behavioural therapies, group therapy, family treatment and pharmacological approaches have been proposed. The cornerstone of rehabilitation therapies appears to be the involvement of the physician in charge of somatic disease. Special attention should be paid to the management of associated addictions.

Cognitive-behavioural treatments (CBTs) for maintaining abstinence

These are based on the hypothesis that cognitive and behavioural coping skills have a central role in alcohol disease. Deficits in the ability to cope with life stress in general and alcohol cues in particular serve to maintain excessive drinking [18]. All CBTs involve, first, recognition of emotions and circumstances that may favour alcohol consumption and, second, behavioural methods for promoting behavioural changes. Several behavioural methods have proved effective in alcohol-dependent patients [19,20].

The alcoholic patient may have conditioned reactions to stimuli (so-called cues) associated with substance use. These reactions increase the probability of drinking, through still poorly understood mechanisms [21,22]. Exposure to these cues, with the aim of modifying the patient's reactions, delays relapse to heavy drinking and decreases total alcohol consumption [23]. This effect persists over time [24]. A derived method aiming for

moderation in drinking could train nondependent drinkers to stop drinking after two to three drinks [25].

With community reinforcement methods, patients have (i) to determine the advantages and drawbacks they get from alcoholic behaviour and from abstinence; (ii) to identify the situations leading to alcohol consumption and be able to recognize positive attitudes towards alcohol in these risk situations; and (iii) to undertake changes in their lifestyle in order to increase the satisfaction found in activities done without alcohol, be they professional or personal. The patient's spouse can participate by encouraging the patient's efforts, even helping self-management with disulfiram. This type of global treatment has shown its efficacy, particularly in the long term [26,27].

Alcohol dependence is regarded as a maladaptive way of coping with problems or meeting needs. Coping skills training is aimed at improving patients' cognitive and behaviourial skills to change their drinking behaviour [28,29]. Skills training addresses coping deficits, reduces factors that may inhibit coping, and provides adequate practice so that skills will be readily available whenever needed.

With behavioural marital therapy, the alcohol user and his or her partner are simultaneously treated in order to facilitate communication and positive reinforcement within the couple. Long-term decrease in the frequency of alcoholic relapse as well as improved family-unit functioning have been demonstrated [30,31].

Self-help groups are nonprofessional, peer-operated organizations devoted to helping individuals having addiction-related, and particularly alcohol-related, problems [32]. Alcoholics Anonymous (AA) emphasizes accepting addiction as a disease that can be arrested but never eliminated. AA employs a 12-step approach to recovery. These steps aim to understand the characteristics of alcoholism and its consequences for the patients' and their families' lives (lack of power towards alcohol and damage caused to others). Many other self-help groups exist, with different approaches. All generally regard alcoholism as a chronic health problem that needs long-term treatment, just as does diabetes or high blood pressure [33]. Self-help groups are best viewed as a form of continuing care rather than as a substitute for acute treatment services [34]. Physicians' conviction in advising patients to participate in self-help groups appears crucial. The 12-step AA therapy has beeen shown to be as efficient as other forms of CBT and motivational enhancement therapy after a 12-month period, with continued long-term positive results (MATCH project). Some types of self-help treatment may carry a spiritual aspect that appeals less to atheist and agnostic patients, who would therefore be less motivated to initiate and follow through in AA attendance [35]. It is likely that other types of self-help groups achieve similar positive results with similar patients.

Pharmacological agents for maintaining abstinence

There are two types of agents specifically given to encourage abstinence: those with an antabuse effect that make absorption of alcohol impossible and those that diminish craving for alcohol. In clinical trials, endpoints consist of cumulative abstinence duration, continuous abstinence, time to first relapse, or percentage of abstinent patients.

Among agents with an antabuse effect, disulfiram provokes the most violent reactions and has been the best studied. It inhibits acetaldehyde dehydrogenase, the enzyme metabolizing acetaldehyde (the toxic metabolite of alcohol) into acetate (a nontoxic metabolite). In a patient treated with disulfiram, alcohol consumption is followed by increased blood levels of acetaldehyde, which results in flushes, dizziness, headache, vomiting, hypotension, tachycardia and palpitation.

When 128 alcoholic men were randomly assigned to unblinded administration of 250 mg of disulfiram, a pharmacologically inactive dose of disulfiram (1 mg), or no disulfiram, 21% of patients receiving regular doses of disulfiram and 25% of those who received the pharmacologically inactive dose remained abstinent versus only 12% in the control group, a nonsignificant difference [36]. These results suggest that fear of the disulfiram–ethanol reaction is the basis of the therapeutic effect. After 1 year of treatment, among patients who drank, those with the full doses of disulfiram reported significantly fewer drinking days. When 126 patients were randomized to receive 200 mg/day of disulfiram or 100 mg/day of vitamin C for 6 months, total alcohol consumption was reduced by 2572 units in the disulfiram group compared with 1448 units in the vitamin C group [37]. Serum γ-glutamyltransferase (γ-GT) fell in the disulfiram group and rose in the vitamin C group. Two-thirds of the disulfiram-treated patients wished to continue the treatment at the end of the study. As treatment relies on the patient's willingness and obedience [36], a 'supervised administration' of disulfiram by clinical staff or family members has been proposed to improve efficacy [38]. A review of 24 outcome studies of oral disulfiram confirmed the efficacy of this agent [39]. However, the use of disulfiram appears to be relatively limited, which may be related to a fear of its untoward effects. Disulfiram should not be considered a primary treatment [40], and should be proposed only to motivated patients with no suicidal ideas, with supervised ingestion.

Nausea, dyspepsia and drowsiness may occur with disulfiram apart from alcohol ingestion. These untoward effects disappear rapidly, spontaneously or when the drug is taken in the evening. Complaints of a metallic taste in the mouth depends on dose. Hepatitis accounts for up to 34% of the untoward effects [41], and the hepatitis-related mortality rate is estimated at 1 per 25 000 patients treated per year. Hepatotoxicity generally occurs after the second month of treatment so that liver function tests should be obtained before treatment, at 2-week intervals for 2 months and every 3 months thereafter [42]. Disulfiram is contraindicated in patients with markedly increased serum transaminases, or severe hepatic dysfunction, but not in patients with well-compensated cirrhosis. Likewise, disulfiram is contraindicated in patients with underlying cardiovascular disease – myocardial infarction, arrhythmia, hypotension and congestive

heart failure have been reported in such patients on disulfiram. Disulfiram is also contraindicated for pregnant women. The recommended dose of disulfiram is 250 mg/day initially. In patients who do not experience a disulfiram–ethanol reaction, dosage must be increased to 500 mg/day as a single morning dose [40].

Dependence on alcohol is accompanied by alterations in several neurotransmitter systems: gamma-aminobutyric acid (GABA), glutamate, dopamine, serotonin, adenosine, norepinephrine (noradrenaline), cannabinoids and opioids [43,44]. Acamprosate stimulates GABAergic transmission, and interacts with *N*-methyl-D-aspartate (NMDA) receptors and calcium channels. It is supposed to decrease central nervous system hyperexcitability induced by alcohol withdrawal [45]. A meta-analysis has shown that acamprosate administration significantly increases the proportion of abstinent patients, as well as the cumulative number of abstinent days (doubled in most studies) [46]. A pooled analysis of 1485 alcohol-dependent patients confirmed acamprosate is a useful agent for all patients with alcohol dependence [47]. A significant decrease in serum γ-GT values occurs during the period of treatment [48–51]. Administering acamprosate from the beginning of the alcohol withdrawal period appears to provide a neuroprotector effect [51].

Acamprosate is well tolerated. Side effects include diarrhoea, headaches and itching. No serious side effect has yet been reported. The recommended dose is 1.3 g/day (four tablets: two in the morning, one at lunchtime and one in the evening) for subjects weighing less than 60 kg, and 2 g/day (two tablets three times a day) for others. Recommended duration of treatment is 1 year.

Naltrexone is a purely antagonistic opioid whose effect on the consumption of alcohol was initially shown in animals [52,53]. Naltrexone blocks the release of dopamine and diminishes the craving for alcohol. Clinical trials have given contrasting results. In some trials, 3-month treatment with naltrexone was found to be superior to placebo in terms of abstinence rates, number of drinking days, relapse, severity of alcohol-related problems or craving [54–58]. However, these effects were more apparent in a 'per protocol' than an 'intention-to-treat' analysis. At the end of a 14-week lead-on period without treatment, the naltrexone group did no better than the placebo group [58]. Interestingly, after a standard treatment of naltrexone for 12 weeks, patients were only taking this drug when craving for alcohol, and this appeared to be effective in maintaining the reduction in heavy drinking [59]. No benefit of naltrexone over placebo could be shown in other large trials testing a 3-month or shorter duration [60–62]. Naltrexone seemed to reduce the relapse rate to heavy drinking, but not the other measures of alcohol consumption [63]. A large double-blind trial was recently reported on three groups of patients: 12-month naltrexone 50 mg daily; 3-month naltrexone followed by 9-month placebo; and 12-month placebo. At the end of the 1-year study, there were no differences among the three groups in the proportion of drinking days or the number of drinks per drinking day [64]. A recent meta-analysis of randomized controlled trials showed that 3-month treatment with naltrexone did not decrease the long-term risk of returning to drinking [65]. Thus, the results of this meta-analysis suggest that short-term (3 months) naltrexone administration may be insufficient, and that longer administration could improve drug efficacy [65]. A high-dose long-acting intramuscular formulation of naltrexone resulted in a 25% decrease in the event rate of heavy drinking days [66]. However, evidence for the long-term efficacy of this new formulation is still lacking [67]. The currently recommended oral dose of naltrexone is 50 mg daily for 3 months, although this duration might be too short. Naltrexone is well tolerated. The most common side effects are nausea and headache. Evening administration might improve acceptability.

A review including all reported double-blind, placebo-controlled trials of acamprosate and naltrexone concluded that both agents are useful. Nevertheless, there appear to be more consistent treatment effects and better tolerability with acamprosate than with naltrexone [67].

Combination of all three pharmacological agents – disulfiram, naltrexone and acamprosate – is attractive because they act through different mechanisms, but few studies of their combined use are available. In a trial including 110 patients, cumulative abstinence was 14% of the 360-day study period on placebo, 28% on acamprosate, 31% on disulfiram, and 55% on disulfiram plus acamprosate [68]. From a review of acamprosate plus naltrexone combination, it was concluded that combination was superior to acamprosate alone [69]. Of note, a synergistic effect of the combined treatment persisted for 12 weeks off therapy. Thus, this association could be of particular benefit to dependent patients who responded poorly to monotherapy.

Supportive psychotherapy achieved higher abstinence rates when associated with naltrexone [54], but not with acamprosate [70].

Whether there could be specific indications for each type of pharmacological treatment has been little studied. By comparing the rate of abstinence obtained with acamprosate and naltrexone according to characteristics of alcohol disease, it was suggested that acamprosate was mainly effective in patients with low baseline somatic distress, whereas naltrexone was more effective in patients with most severe baseline depression [71].

Prevention of alcoholic liver disease

Prevention can be targeted to subjects who have a harmful consumption. Ideally such preventive measures should take place early in a patient's drinking history and be instituted by a family practitioner. So-called brief interventions correspond to a combination of quantifying the consumption and informing the patient; explaining alcohol-associated risks; showing the benefit of reducing consumption; explaining the methods available for reducing consumption; reinforcing the patient's motivation; proposing realistic aims; and proposing a second consultation.

The efficacy of brief intervention has been shown by several meta-analyses [72,73]. However, the 1-year beneficial effect tends to decrease with time [73]. Brief intervention should thus be repeated. Moreover, short-term treatment is efficient mainly in patients who are not alcohol dependent and whose main aim is controlled consumption rather than total abstinence. Therefore, brief intervention is well suited to patients without ALD or with mild ALD, not for patients with cirrhosis.

Other addictive habits

Alcoholism is commonly associated with other addictive habits, whose consequences on the liver can be harmful, and which require simultaneous control. In fact, the addictive pattern is usually similar with all substances in an individual patient. The patient frequently goes from one product to another, sometimes consuming several products at the same time. Intravenous injection of drugs should obviously be proscribed, because of the risk of viral infections. Information about the recreational drug ecstasy is of importance as this product is generally considered 'safe' whereas it is potentially hepatotoxic [74,75]. Whether ecstasy toxicity on the liver is enhanced by alcohol is not known.

There is a close epidemiological link between alcohol drinking and tobacco smoking. In patients with chronic hepatitis C virus infection, smoking is associated with increased fibrosis progression [76]. Smoking is associated with an increased risk of cirrhosis in chronic alcohol consumers [3,77,78]. The risk of death due to hepatocellular carcinoma is related to the amount of tobacco smoking in the general population [79] and in the population of cirrhotic patients [80]. Furthermore, a synergistic effect between alcohol drinking and tobacco smoking has been suggested [76,80,81]. Recent studies have shown an increased death rate between 5 and 7 years after liver transplantation in the group of cirrhotic alcoholics [82]. This increased risk is related to resumption of alcohol and tobacco consumption. These data emphasize the need for specific treatment of tobacco addiction in patients suffering from ALD.

The proportion of people having ever used cannabis may be up to 30% in some western population groups [83]. The impact of cannabis consumption on ALD is not known. However, there is some concern about liver toxicity as cannabis is an independent predictor of a rapid fibrosis progression rate in patients with chronic hepatitis C [84].

In alcoholic patients, a high body mass index (BMI) is a risk factor for fibrosis progression [10]. Alcohol abstinence frequently increases the appetite for high sugar intake. High sugar intake can in turn increase the risk for intolerance to carbohydrates, and thus fibrosis progression. Therefore, adequate counselling about diet should also be provided to the alcoholic patient.

In summary, in patients with ALD, control of alcohol intake is better achieved through complete abstinence. Alcohol withdrawal is an important step that has been well clarified. For long-term control of alcohol consumption, CBT is an indispensable part of the management. Three pharmacological agents have a proven efficacy, acamprosate being the best validated of them. Other addictive behaviour should be treated simultaneously as all may induce progression of liver disease in alcoholic patients.

Management of alcoholism in the context of liver transplantation

Optimal timing for liver transplantation (LT) in alcoholic patients should be based on a balance between outcome with non-transplant management alone – including alcohol withdrawal – and outcome with transplantation and maintained abstinence [85].

Prior to transplantation

Numerous clinical guidelines have been proposed about indications for referral and assessment for LT, including ALD. A consensus conference held in 1993 stated that the indications for LT in alcoholic cirrhotic patients were limited to 'patients whose liver disease remains serious despite alcohol withdrawal, without any consensus on the ideal period of abstinence, 3 to 6 months or more' [86]. Most programmes require 6 months of abstinence before transplantation. Virtually all programmes consider active alcohol use as a contraindication to LT, and 62% would remove a relapsing patient from the transplant list permanently or for at least 6 months [87]. Indeed, most studies found that the length of abstinence before transplantation was the main predictor of subsequent behaviour. However, there are studies where the duration of pretransplant abstinence was poorly predictive for resumption of alcoholism [88–92]. Moreover, the 6-month delay might not be predictive for survival [93]. Furthermore, this arbitrary time limit would be detrimental to many patients with limited life expectancy [94]. However, this 6-month delay allows for an improvement in hepatic function following alcohol withdrawal, to a point where LT may no longer be indicated. In our experience, denial of alcoholism as a cause for liver disease is associated with a high rate of post-transplantation relapse.

The 6-month rule leads to an almost complete exclusion of patients with acute alcoholic hepatitis from access to LT [95]. However, early identification of patients with alcoholic hepatitis at risk of death within 6 months of abstinence has become feasible based on various criteria: absence of early change in bilirubin levels under corticosteroid therapy [96]; severe alcoholic hepatitis complicated by renal failure [97]; and absence of clinical improvement after 3 months' abstinence [98]. In a retrospective cohort study of 73 patients with alcoholic hepatitis, the MELD (Model for End-stage Liver Disease) score was found to be the only independent predictor of 90-day mortality: a score of 21 had a sensitivity of 75% and a specificity of 75% [99].

There are few data on the benefit of transplantation in patients with acute alcoholic hepatitis. In a study of nine liver transplant recipients in whom severe alcoholic hepatitis was retrospectively diagnosed, the long-term survival rate was

similar to that of patients transplanted for alcoholic cirrhosis [100]. In another retrospective study, the presence of alcoholic hepatitis in the explanted liver was associated with increased alcoholic relapse and progressive alcohol-related liver injury [101]. In alcoholic liver transplant recipients with and without alcoholic hepatitis, other studies found that survival [95,102] and alcoholic relapse rates [95] were similar. Several issues remain to be addressed regarding the role of liver transplantation in the management of severe acute alcoholic hepatitis, including optimal timing, level of priority and risk of alcoholic relapse.

After Starzl *et al.* reported that survival of patients with alcoholic cirrhosis was similar to that of patients with cirrhosis attributable to other causes [103], increasing numbers of patients with alcoholic cirrhosis have been referred for transplantation. In 1997, a US conference on liver transplantation in alcoholic patients recommended that only candidates belonging to Child–Pugh (CP) class B be placed on the waiting list [104]. However, recent data suggest that transplantation should be restricted to CP class C patients. Indeed, 1-year survival is 50–85% in class C patients compared with 75–95% in class B patients [105]. In a study using matched and simulated controls, a significant suvival benefit was shown only among class C patients, not among class B patients [106]. In a French randomized trial including 120 class B patients comparing transplantation with standard treatment, 2-year survival was no better in liver transplant recipients [107]. Moreover, transplantation was associated with a higher occurrence of extrahepatic malignant tumour.

Recently, the MELD score has been adopted by the United Network for Organ Allocation (UNOS) to determine priority among patients awaiting liver transplantation in the USA [108]. MELD predicts liver disease severity on the basis of serum creatinine, serum total bilirubin and international normalized ratio (INR). In a study cohort of 3437 liver transplant candidates, of whom 27.6% were alcoholic paitients, the waiting list mortality increased directly in proportion to the listing MELD score [109]. Patients having a MELD score < 9 experienced a 1.9% 3-month mortality rate, whereas patients having a MELD score ≥ 40 had a mortality rate of 71.3%. Using the c-statistic with 3-month mortality as the endpoint, the area under the receiver operating characteristic (ROC) curve for the MELD score was 0.83 compared with 0.76 for the Child–Pugh classification. Based on these data, transplantation might be considered in any alcoholic patient with cirrhosis and a MELD score greater than 13.

After liver transplantation

The main issue is the likelihood of relapse and its influence on outcome. Most studies have shown that mortality after transplantation for alcoholic cirrhosis does not differ from that for nonalcoholic liver disease after adjustment for liver disease severity [88,89,94,110–117]. However, patients with ALD have, on average, higher CP scores than nonalcoholic patients [118]. Rejection-related graft failure is less frequent among patients transplanted for ALD, perhaps reflecting diminished immunological function in this group of recipients [119]. Although recurrence of disease was rarely considered a reason for graft failure among recipients with ALD, by 4 years, 5% of patients treated for ALD have lost their liver graft because of alcohol-related complications [120]. Overall, taking into account patient and graft survival, rejection rate and infection rate, ALD appears to be a good indication for LT.

Maintenance of abstinence represents a central therapeutic goal for alcoholic patients after LT. Although relapse is defined as lack of abstinence, relapse to drinking is not the same as relapse to alcoholism itself [121]. A variety of terms have been used to describe post-transplantation drinking behaviour, including recidivism, treatment failure, relapse, pathological drinking, abstinence and sobriety. The absence of a common nomenclature makes these studies difficult to analyse and compare. Relapse rates reported in the literature range from 11.5% to 49%. Using a drastic definition of relapse – the report of any alcohol use after LT – we observed a high risk of relapse post-transplant at year 1 (27%) and year 3 (32%) [117]. However, at a mean follow-up of 54 months after LT, the rate of heavy drinking was 21% [122].

In addition to abstinence duration pretransplant, the main predictive factors for alcoholic relapse thus far identified include associated psychiatric problems before LT [123,124], social conditions [92,116,125], associated drug addiction [115] and young age [115,126]. However, results have often been inconsistent, which can be explained by several factors.

- First, regarding the level of risk and prognostic factors for relapse, alcoholic transplant recipients constitute a heterogeneous population, including alcohol-dependent patients, alcohol abusers and patients with associated psychiatric disorders [90,127,128]. Moreover, pretransplant assessment is based on clinical history taking into account previous drinking behaviour, attempts at therapy and rehabilitation, family and social life [129]. However, at this pretransplant stage, patients' assertions are unreliable, often because of hepatic encephalopathy [125].
- Second, the assessment of alcohol relapse after LT has varied from the report of any alcohol use after LT, to ALD recurrence (i.e. alcohol consumption and histological features of ALD on liver biopsy) [130].
- Third, methods for detecting relapse have varied from patient's self-report, or reports from family members, friends, or employers, to results of breath alcohol tests to confirm abstinence or detect the lack of abstinence. Patients' or families' reports were collected using diverse means that may influence their validity. In a British study, the rate of relapse rose from 30% to 95% when drinking behaviour and psychiatric outcome were assessed by an independent investigator who did not

belong to the transplant team [131]. When alcohol relapse after LT was examined by measuring alcohol in urine, 7% of patients admitted alcohol use, whereas alcohol in urine was detected in 18% [128]. Therefore the true relapse rate could be higher than self-reported. Carbohydrate-deficient transferrin (CDT) monitoring could be useful because a prospective study disclosed a sensitivity of 92% and a specificity of 98% for the detection of relapse [132].

• Fourth, extended follow-up periods are required to define ultimate relapse rates because the frequency of relapse appears to increase with duration of follow-up [113,128].

An important issue is to what extent alcohol relapse after LT matters. From the patient's and society's point of view, the most important outcome might be being alive and active 5 years after LT, rejection free, with low doses of toxic immunosuppressive drugs, rather than being completely abstinent. In our experience, analysis of biopsy specimens in long-term survivors after transplantation for alcoholic cirrhosis showed no difference between abstinent and user patients, except for one patient with acute alcoholic hepatitis [129]. In that study, neither fibrosis nor cirrhosis were observed although duration of follow-up was longer than the reported delay for recurrence of cirrhosis [133]. However, alcohol use may impact on extrahepatic health status [89]. Furthermore, return to alcohol consumption after LT has been associated with a rapid development of histological liver injury [90]. Actually, the consequences of alcohol relapse after LT may have greater impact on organ donation at a society level, than on the relapsing patient.

In conclusion, in terms of outcome after LT for ALD, survival endpoints are much better improved than endpoints related to drinking. Abstinence after transplantation should remain the goal, although resumption of drinking following transplantation does not necessarily mean a poor liver graft or patient outcome. Indeed, it is still impossible to predict *a priori* who will slip and who will relapse when an alcoholic begins drinking [121]. [Note that slip is different from relapse: a slip is the consumption of a limited amount of alcohol, followed by immediate procedures to re-establish abstinence.] After LT, most patients have recovered from their severe liver disease, but some need continuous management of their alcoholic disease. Lastly, the good results obtained with LT for ALD should be publicized to the general population in order to prevent stigmatization of the alcoholic patient and its possible consequences for liver graft donation.

Management of extrahepatic complications (Tables 1 and 2)

This very broad field will not be discussed in detail. Rather, it will focus on (i) the management of selected conditions that are of major concern in the context of LT for ALD, and (ii) manifestations of alcohol abuse that could be erroneously interpreted as being related to alcoholic cirrhosis.

Table 1 Extrahepatic manifestations of alcoholism (clinical).

Gastrointestinal tract
Oesophageal motor dysfunction
Acute and chronic gastritis
Delayed gastric emptying
Changes in motor activity of small intestine
Malabsorption
Changes in colonic motility
Acute and chronic pancreatitis
Nervous system
Wernicke's encephalopathy
Korsakoff syndrome
Alcoholic cerebellar degeneration
Central pontine myelinolysis
Marchiafava–Bignani syndrome
Alcoholic dementia
Alcoholic polyneuropathy
Acute and chronic myopathy
Cardiomyopathy
Renal disease: Berger's disease
Osteoporosis
Endocrinological consequences
Hypogonadism
Hyperestrogenism
Pseudo-Cushing syndrome
Skin manifestations
Telangiectasias
Plethoric facies
Oral changes
Porphyria cutanea tarda
Dupuytren's contracture
Madelung's disease
Exacerbation of skin diseases
Cancers
Oesophagus
Mouth
Larynx
Skin

Table 2 Extrahepatic manifestations of alcoholism (laboratory).

Haematological complications
Direct effect on erythropoiesis
Folate deficiency
Impairment of iron metabolism
Abnormal red cell membranes
Impairment of adherence and haemotaxis of leukocytes
Impairment of macrophage function
Impairment of lymphocyte function
Abnormal platelet function
Hyperuricaemia
Hypoglycaemia
Ketoacidosis

Conditions relevant to LT for ALD

Alcohol consumption is a well-known risk factor for pancreatitis [134]. In the setting of liver transplantation, attention should be paid to possible sequelae of previous pancreatic disease: abscess, splanchnic vein thromboses, adhesions, all of which could make the surgical transplant procedure more difficult. Moreover, the occurrence of pancreatic adenocarcinoma may be increased in alcoholic patients, although it correlates better with cigarette smoking than with alcohol consumption [135]. The exclusion of pancreatic carcinoma in a patient with chronic alcoholic pancreatitis may be difficult. Thus, high-quality imaging procedures are needed for the pretransplant evaluation.

Wernicke's encephalopathy and Korsakoff syndrome are nutritional disorders caused by thiamine deficiency. Chronic alcohol consumption can result in thiamine deficiency by causing inadequate nutritional thiamine intake, decreased absorption of thiamine from the gastrointestinal tract, and impaired thiamine utilization in the cells. Mental confusion, the main characteristic of these diseases, can be difficult to distinguish from chronic hepatic encephalopathy. Treatment consists of parenteral thiamine. In the majority of patients with Korsakoff syndrome, complete recovery is unlikely [136]. This condition represents a contraindication for LT.

Alcoholism is also responsible for dose-related injury to the peripheral nervous system. Direct cumulative neurotoxicity from alcohol, and nutritional and vitamin deficiencies, as well as cirrhosis *per se*, all contribute to this peripheral neuropathy [137]. Resolution of alcoholic neuropathy following LT has been reported [138]. Thus, this condition should not be considered a contraindication to LT. However, it must be emphasized that all calcineurin inhibitors used after transplantation induce a dose-related peripheral neurotoxicity that can worsen pretransplant alcoholic neuropathy.

Chronic alcohol consumption can lead to progressive cardiac dysfunction, resulting in congestive cardiomyopathy. Alcoholic cardiomyopathy is characterized by an increase in myocardial mass, dilation of the ventricles, and wall thinning. Changes in ventricular function may depend on the stage: the asymptomatic stage is associated with diastolic dysfunction, whereas systolic dysfunction is a common finding in symptomatic patients, leading to heart failure in the latter stages [139]. Moreover, cirrhosis *per se* is associated with impaired cardiac contractility, so-called cirrhotic cardiomyopathy [140]. The emergence of LT as an effective treatment for alcoholic cirrhosis has led to the recognition that previously subclinical cardiomyopathy and congestive heart failure account for significant mortality and morbidity after this procedure. Coronary heart disease that is associated with excessive alcohol consumption needs to be extensively examined in the setting of transplantation [141].

Numerous clinical and experimental studies have demonstrated that excessive alcohol consumption has deleterious effects on the kidney [142]. A variety of tubular defects have been described in these patients. They may be reversible with abstinence. By contrast, IgA nephropathy occurring in alcoholic patients is reponsible for irreversible glomerular lesions. These data suggest that alcoholic cirrhosis itself and the attendant abnormalities in renal function may predispose the liver transplant patient to permanent renal damage when treated with calcineurin inhibitors [143].

The progression of ALD to decompensated cirrhosis has profound effects on hepatic metabolism and, ultimately, on body composition and weight. This results in profound nutritional changes that include weight loss and evidence for protein caloric malnutrition [144]. Moreover, malnutrition is an additional factor superimposed on functional and structural muscle damage induced by chronic ethanol consumption. Poor preoperative nutritional status is associated with a longer stay in the intensive care unit and increased likelihood of post-transplant infections (see Chapter 23.2).

There is a clear association of heavy alcohol consumption with cancers of the mouth, larynx, pharynx, lung and oesophagus [145]. Moreover, alcoholics are also often heavy smokers. It is crucial to rule out any neoplastic disease or preneoplastic conditions during the pretransplant evaluation, because alcoholic cirrhotic patients have a higher incidence of malignancies after LT, especially oropharyngeal carcinomas [146].

Non-hepatic signs of alcohol abuse

Beside the skin abnormalities reported in association with advanced liver disease, namely spider naevi, palmar erythema and nail changes, alcohol consumption and abuse can have a variety of cutaneous manifestations [147]. Vascular changes from long-term alcohol abuse range from pinpoint telangiectasias to ecchymoses. Urticarial reactions have been reported to occur quickly after alcohol intake. Pruritus, local and generalized urticaria, as well as angioedema may be seen [148]. Alcohol consumption is a risk factor for certain types of mucocutaneous cancer, notably squamous cell carcinoma of the oral cavity and aggressive basal cell carcinoma [149]. Various changes are seen in the oral cavity of alcoholic patients, none of which are specific to alcohol abuse. Oral hygiene may be poor. Patients may demonstrate a black hairy tongue, which is due to hyperplasia of the filiform papillae. Alternatively, an atrophic tongue has been described, which may represent glossitis due to vitamin B deficiency. Other oral cavity findings include leucoplakia, chronic gingival inflammation, and chronic swelling of the parotid glands [147].

Porphyria cutanea tarda is the most common type of porphyria, and alcohol is the single most important aetiological factor causing sporadic porphyria cutanea tarda, with up to 90% of patients having a history of alcohol abuse [150]. Alcoholic patients have been found to have an increased prevalence of Dupuytren's contracture, which is a fibroproliferative disorder of the palmar aponeurosis [151]. Madelung's disease, or benign symmetric lipomatosis, is characterized by deforming fatty deposits located symmetrically around the neck and shoulder

girdle. Alcoholic patients are at greatest risk for this disease [152]. At least, alcohol abuse has been recognized as an exacerbating factor for certain skin disorders: psoriasis, rosacea, discoid eczema and seborrhoeic dermatitis.

Many endocrine changes are seen in the patient with chronic alcoholism. It is sometimes difficult to discriminate between the direct effect of ethanol on endocrine function and the endocrine consequences of advanced liver disease. Specifically, signs of hypogonadism and hyperestrogenism are seen in male patients with alcoholism. Hypogonadism is manifested by loss of libido and potency, testicular atrophy and reduced fertility. There is a direct inhibitory effect of alcohol on testicular testosterone production. Alcoholics exhibit an increase of luteinizing hormone (LH) and follicle-stimulating hormone (FSH), a decrease of testosterone levels, and a reduced count and motility of spermatozoa [153]. These abnormalities are reversed after ethanol withdrawal [154]. Hyperestrogenism is manifested by gynaecomastia, loss of body hair and change of pubic hair to a female distribution. It results from an increased secretion of estrone and estradiol. Hyperestrogenism without liver disease is unusual in alcoholic male patients [155]. Alcoholic female patients may demonstrate breast atrophy or menstrual abnormalities [155]. There is a probable association between alcohol consumption and breast cancer incidence [156]. A pseudo-Cushing syndrome may be observed in alcoholic patients, due to increased plasma cortisol resulting from chronic alcohol consumption [147]. A direct effect of alcohol on the adrenal cortex is involved.

Haematological manifestations are observed in alcoholics with or without liver disease. Independently of liver status, most alcoholics have enlarged erythrocytes, impairment of leucocyte functions, and thrombocytopenia. There are no significant changes in coagulation without advanced liver disease. Macrocytosis usually disappears after alcohol withdrawal. Several mechanisms are involved: simple macrocytosis is a consequence of a direct toxic effect of alcohol on erythroblasts or megaloblastic anaemia with folate deficiency [157]. Neutropenia, impairment of neutrophil adherence and chemotaxis, and impairment of macrophage and lymphocyte functions are observed in alcoholics and may explain in part the increased rate of infections [158]. Thrombocytopenia usually disappears after alcohol withdrawal. It seems to be due to a direct effect of alcohol on thrombocytopoiesis. Platelet function is also altered by alcohol [159]. Thus, alcoholic patients have prolonged bleeding times.

References

1 Teli MR, Day CP, Burt AD *et al.* (1995) Determinants of progression to cirrhosis or fibrosis in pure alcoholic fatty liver. *Lancet* 346, 987–990.

2 Borowsky SA, Strome S, Lott E (1981) Continued heavy drinking and survival in alcoholic cirrhotics. *Gastroenterology* 80, 1405–1409.

3 Pessione F, Ramond MJ, Peters L *et al.* (2003) Five-year survival predictive factors in patients with excessive alcohol intake and cirrhosis. Effect of alcoholic hepatitis, smoking and abstinence. *Liver Int* 23, 45–53.

4 Schenker S, Halff GA (1993) Nutritional therapy in alcoholic liver disease. *Semin Liver Dis* 13, 196–209.

5 Cabré E, Rodriguez-Iglesias P, Caballeria J *et al.* (2000) Short- and long-term outcome of severe alcohol-induced hepatitis treated with steroids or enteral nutrition: a multicenter randomized trial. *Hepatology* 32, 36–42.

6 Swift RM (1999) Drug therapy for alcohol dependence. *N Engl J Med* 340, 1482–1490.

7 Holder HD, Cisler RA, Longabaugh R (2000) Alcoholism treatment and medical care costs from Project MATCH. *Addiction* 95, 999–1013

8 Kranzler HR (1997) Treatment of alcohol dependence. *Liver Transpl Surg* 3, 311–321.

9 Thun MJ, Peto R, Lopez AD *et al.* (1997) Alcohol consumption and mortality among middle-aged and elderly U.S. adults. *N Engl J Med* 337, 1705–1714.

10 Raynard B, Balian A, Fallik D *et al.* (2002) Risk factors of fibrosis in alcohol-induced liver disease. *Hepatology* 35, 635–638.

11 Mayo-Smith F (1997) Pharmacological management of alcohol withdrawal. A meta-analysis and evidence-based practice guideline. American Society of Addiction Medicine Working Group on Pharmacological Management of Alcohol Withdrawal. *JAMA* 278, 144–151.

12 Williams D, McBride AJ (1998) The drug treatment of alcohol withdrawal symptoms: a systematic review. *Alcohol Alcoholism* 33, 103–115.

13 Kosten TR, O'Connor PG (2003) Management of drug and alcohol withdrawal. *N Engl J Med* 348, 1786–1795.

14 Perney P, Butterworth RF, Mousseau DD *et al.* (1998) Plasma and CSF benzodiazepine receptor ligand concentrations in cirrhotic patients with hepatic encephalopathy: relationship to severity of encephalopathy and to pharmaceutical benzodiazepine intake. *Metab Brain Dis* 13, 201–210.

15 Peters DH, Faulds D (1994) Tiapride. A review of its pharmacology and therapeutic potential in the management of alcohol dependence syndrome. *Drugs* 47, 1010–1032.

16 Berg B, Dublin WR (1990) Why 28 days? An alternative approach to alcoholism treatment. *Hosp Community Psychiatry* 41, 1175–1178.

17 Klijnsma MP, Cameron ML, Burns TP, McGuigan SM (1995) Outpatient alcohol detoxification outcome after 2 months. *Alcohol* 30, 669–673.

18 Morgenstern J, Longabaugh R (2000) Cognitive-behavorial treatment for alcohol dependence: a review of evidence for its hypothesized mechanisms of action. *Addiction* 95, 1475–1490.

19 Holder H, Longabaugh R, Miller WR *et al.* (1991) The cost effectiveness of treatment for alcoholism: a first approximation. *J Stud Alcohol* 52, 517–540.

20 Finney JW, Monahan SC (1996) The cost-effectiveness of treatment for alcoholism: a second approximation. *J Stud Alcohol* 57, 229–243.

21 Cooney NL, Litt MD, Morse PA *et al.* (1997) Alcohol cue reactivity, negative-mood reactivity, and relapse in treated alcoholic men. *J Abnorm Psychol* 106, 243–250.

22 Litt MD, Cooney NL, Kadden RM *et al.* (1990) Reactivity to alcohol cues and induced moods in alcoholics. *Addict Behav* 15, 137–146.

23 Drummond DC, Glautier S (1994) A controlled trial of cue exposure treatment in alcohol dependence. *J Consult Clin Psychol* 62, 809–817.

24 Monti PM, Rohsenow DJ, Rubonis AV *et al.* (1993) Alcohol cue reactivity: effects of detoxification and extended exposure. *J Stud Alcohol* 54, 235–245.

25 Sitharthan T, Sitharthan G, Hough MJ *et al.* (1997) Cue exposure in moderation drinking: a comparison with cognitive-behavior therapy. *J Consult Clin Psychol* 65, 878–882.

26 Azrin NH, Sisson RW, Meyers R *et al.* (1982) Alcoholism treatment by disulfiram and community reinforcement therapy. *J Behav Ther Exp Psychiatry* 13, 105–112.

27 Smith JE, Meyers RJ, Delaney HD (1998) The community reinforcement approach with homeless alcohol-dependent individuals. *J Consult Clin Psychol* 66, 541–548.

28 Kadden RM (2001) Behavioral and cognitive-behavioral treatments for alcoholism: research opportunities. *Addict Behav* 26, 489–507.

29 Longabaugh R, Morgenstern J (1999) Cognitive-behavioral coping-skills therapy for alcohol dependence. Current status and future directions. *Alcohol Res Health* 23, 78–85.

30 O'Farrell TJ, Choquette KA, Cutter HS (1998) Couples relapse prevention sessions after behavioral marital therapy for male alcoholics: outcomes during the three years after starting treatment. *J Stud Alcohol* 59, 357–370.

31 McCrady BS, Stout R, Noel N *et al.* (1991) Effectiveness of three types of spouse-involved behavioral alcoholism treatment. *Br J Addict* 86, 1415–1424.

32 Humphreys K, Wing S, McCarty D *et al.* (2004) Self-help organizations for alcohol and drug problems: toward evidence-based practice and policy. *J Subst Abuse Treat* 26, 151–158.

33 McLellan AT, Lewis DC, O'Brien CP *et al.* (2000) Drug dependence, a chronic medical illness: implications for treatment, insurance, and outcomes evaluation. *JAMA* 284, 1689–1695.

34 Humphreys K, Moos R (2001) Can encouraging substance abuse patients to participate in self-help groups reduce demand for health care? A quasi-experimental study. *Alcohol Clin Exp Res* 25, 711–716.

35 Tonigan JS, Miller WR, Schermer C (2002) Atheists, agnostics and Alcoholics Anonymous. *J Stud Alcohol* 5, 534–541.

36 Fuller RK, Roth HP (1979) Disulfiram for the treatment of alcoholism. An evaluation in 128 men. *Ann Intern Med* 90, 901–904.

37 Chick J, Gough K, Falkowski W *et al.* (1992) Disulfiram treatment of alcoholism. *Br J Psychiatry* 161, 84–89.

38 Brewer C (1992) Controlled trials of Antabuse in alcoholism: the importance of supervision and adequate dosage. *Acta Psychiatr Scand Suppl* 369, 51–58.

39 Hughes JC, Cook CC (1997) The efficacy of disulfiram: a review of outcome studies. *Addiction* 92, 381–395.

40 Fuller RK, Gordis E (2004) Does disulfiram have a role in alcoholism treatment today? *Addiction* 99, 21–24.

41 Poulsen H, Loft S, Andersen JR, Andersen M (1992) Disulfiram therapy – adverse drug reactions and interactions. *Acta Psychiatr Scand* 369, 59–65.

42 Wright C, Vafier JA, Lake CR (1988) Disulfiram-induced fulminating hepatitis: guidelines for liver-panel monitoring. *J Clin Psychiatry* 49, 430–434.

43 Enoch MA (2003) Pharmacogenomics of alcohol response and addiction. *Am J Pharmacogenomics* 3, 217–232.

44 Kenna GA, McGeary JE, Swift RM (2004) Pharmacotherapy, pharmacogenomics, and the future of alcohol dependence treatment, part 1. *Am J Health-Syst Pharm* 61, 2272–2279.

45 Littleton JM (1995) Acamprosate in alcohol dependence: how does it work? *Addiction* 90, 1179–1188.

46 Bouza C, Magro A, Munoz A, Amate JM (2004) Efficacy and safety of naltrexone and acamprosate in the treatment of alcohol dependence: a systematic review. *Addiction* 99, 811–828.

47 Verheul R, Lehert P, Geerlings PJ *et al.* (2005) Predictors of acamprosate efficacy: results from a pooled analysis of seven European trials including 1485 alcohol-dependent patients. *Psychopharmacology* 178, 167–173.

48 Lhuintre JP, Moore N, Tran G *et al.* (1990) Acamprosate appears to decrease alcohol intake in weaned alcoholics. *Alcohol Alcoholism* 25, 613–622.

49 Paille FM, Guelfi JD, Perkins AC *et al.* (1995) Double-blind randomized multicenter trial of acamprosate in maintaining abstinence from alcohol. *Alcohol* 30, 239–247.

50 Sass H, Soyka M, Mann K, Zieglgansberger W (1996) Relapse prevention by acamprosate. Results from a placebo-controlled study on alcohol dependence. *Arch Gen Psychiat* 53, 673–680.

51 Gual A, Lehert P (2001) Acamprosate during and after acute alcohol withdrawal: a double-blind placebo-controlled study in Spain. *Alcohol Alcoholism* 36, 413–418.

52 Kotlinska J, Langwinski R (1987) Does the blockade of opioid receptors influence the development of ethanol dependence? *Alcohol Alcoholism* 22, 117–119.

53 Myers RD, Borg S, Mossberg R (1986) Antagonism by naltrexone of voluntary alcohol selection in the chronically drinking macaque monkey. *Alcohol* 3, 383–388.

54 O'Malley SS, Jaffe AJ, Chang G *et al.* (1992) Naltrexone and coping skills therapy for alcohol dependence. A controlled study. *Arch Gen Psychiat* 49, 881–887.

55 Volpicelli JR, Alterman AI, Hayashida M, O'Brien CP (1992) Naltrexone in the treatment of alcohol dependence. *Arch Gen Psychiat* 49, 876–880.

56 Anton RF, Moak DH, Waid LR *et al.* (1999) Naltrexone and cognitive behavioral therapy for the treatment of outpatient alcoholics: results of a placebo-controlled trial. *Am J Psychiat* 156, 1758–1764.

57 Chick J, Anton R, Checinski K *et al.* (2000) A multicenter, randomized, double-blind, placebo-controlled trial of naltrexone in the treatment of alcohol dependence or abuse. *Alcohol* 35, 587–593.

58 Anton RF, Moak DH, Latham PK *et al.* (2001) Posttreatment results of combining naltrexone with cognitive-behavior therapy for the treatment of alcoholism. *J Clin Psychopharmacol* 21, 72–77.

59 Heinala P, Alho H, Kiianmaa K *et al.* (2001) Targeted use of naltrexone without prior detoxification in the treatment of alcohol dependence: a factorial double-blind, placebo-controlled trial. *J Clin Psychopharmacol* 21, 287–292.

60 Hersh D, Van Kirk JR, Kranzler HR (1998) Naltrexone treatment of comorbid alcohol and cocaine use disorders. *Psychopharmacology* 139, 44–52.

61 Knox PC, Donovan DM (1999) Using naltrexone in inpatient alcoholism treatment. *J Psychoactive Drugs* 31, 373–388.

62 Kranzler HR, Modesto-Lowe V, Van Kirk J (2000) Naltrexone vs. nefazodone for treatment of alcohol dependence. A placebo-controlled trial. *Neuropsychopharmacology* 22, 493–503.

63 Guardia J, Caso C, Arias F *et al.* (2002) A double-blind, placebo-controlled study of naltrexone in the treatment of alcohol-dependence disorder: results from a multicenter clinical trial. *Alcohol Clin Exp Res* 26, 1381–1387.

64 Krystal JH, Cramer JA, Krol WF *et al.* (2001) Veterans Affairs Naltrexone Cooperative Study 425 Group. Naltrexone in the treatment of alcohol dependence. *N Engl J Med* 345, 1734–1739.

65 Srisurapanont M, Jarusuraisin N (2005) Naltrexone for the treatment of alcoholism: a meta-analysis of randomized controlled trials. *Int J Neuropsychopharmacol* 8, 267–280.
66 Garbutt JC, Kranzler HR, O'Malley SS *et al.* (2005) Efficacy and tolerability of long-acting injectable naltrexone for alcohol dependence: a randomized controlled trial. *JAMA* 293, 1617–1625.
67 Mason BJ (2003) Acamprosate and naltrexone treatment for alcohol dependence: an evidence-based risk-benefits assessment. *Eur Neuropsychopharmacol* 13, 469–475.
68 Besson J, Aeby F, Kasas A *et al.* (1998) Combined efficacy of acamprosate and disulfiram in the treatment of alcoholism: a controlled study. *Alcohol Clin Exp Res* 22, 573–579.
69 Kiefer F, Wiedemann K (2004) Combined therapy: what does acamprosate and naltrexone combination tell us? *Alcohol Alcoholism* 39, 542–547.
70 De Wildt WA, Schippers GM, Van Der Brink W *et al.* (2002) Does psychosocial treatment enhance the efficacy of acamprosate in patients with alcohol problems? *Alcohol* 37, 375–382.
71 Kiefer F, Helwig H, Tarnaske T *et al.* (2005) Pharmacological relapse prevention of alcoholism: clinical predictors of outcome. *Eur Addict Res* 11, 83–91.
72 Wilk AI, Jensen NM, Havighurst TC (1997) Meta-analysis of randomised control trials addressing brief interventions in heavy alcohol drinkers. *J Gen Intern Med* 12, 274–283.
73 Moyer A, Finney JW, Swearingen CE, Vergun P (2002) Brief intervention for alcohol problems: a meta-analytic review of controlled investigations in treatment-seeking and non-treatment-seeking populations. *Addiction* 97, 279–292.
74 Jones AL, Simpson KJ (1999) Review article: mechanisms and management of hepatotoxicity in ecstasy (MDMA) and amphetamine intoxications. *Aliment Pharmacol Ther* 13, 129–133.
75 Garbino J, Henry JA, Mentha G (2001) Ecstasy ingestion and fulminant hepatic failure: liver transplantation to be considered as a last therapeutic option. *Vet Hum Toxicol* 43, 99–102.
76 Pessione F, Ramond MJ, Njapoum C *et al.* (2001) Cigarette smoking and hepatic lesions in patients with chronic hepatitis C. *Hepatology* 34, 121–125.
77 Klatsky AL, Armstrong MA (1992) Alcohol, smoking, coffee, and cirrhosis. *Am J Epidemiol* 136, 1248–1257.
78 Corrao G, Lepore AR, Torchio P *et al.* (1994) The effect of drinking coffee and smoking cigarettes on the risk of cirrhosis associated with alcohol consumption. A case-control study. Provincial Group for the Study of Chronic Liver Disease. *Eur J Epidemiol* 10, 657–664.
79 Chen ZM, Liu BQ, Boreham J *et al.* (2003) Smoking and liver cancer in China: case-control comparison of 36 000 liver cancer death vs. 17 000 cirrhosis deaths. *Int J Cancer* 107, 106–112.
80 Marrero JA, Fontana RJ, Fu S *et al.* (2005) Alcohol, tobacco and obesity are synergistic risk factors for hepatocellular carcinoma. *J Hepatol* 42, 218–224.
81 Kuper H, Tzonou A, Kaklamani E *et al.* (2000) Tobacco smoking, alcohol consumption and their interaction in the causation of hepatocellular carcinoma. *Int J Cancer* 85, 498–502.
82 Bellamy CO, DiMartini AM, Ruppert K *et al.* (2001) Liver transplantation for alcoholic cirrhosis: long-term follow-up and impact of disease recurrence. *Transplantation* 72, 619–626.
83 Smart RG, Ogborne AC (2000) Drug use and drinking among students in 36 countries. *Addict Behav* 25, 455–460.
84 Hezode C, Roudot-Thoraval F, Nguyen S *et al.* (2005) Daily cannabis smoking as a risk factor for progression of fibrosis in chronic hepatitis C. *Hepatology* 42, 63–71.
85 Tome S, Lucey MR (2004) Current management of alcoholic liver disease. *Aliment Pharmacol Ther* 19, 707–714.
86 Anon (1994) Consensus Conference on Indications of Liver Transplantation, 22–23 June, 1993. *Hepatology* 20 (Suppl.), 63S–68S.
87 Everson G, Bharadhwaj G, House R *et al.* (1997) Long-term follow-up of patients with alcoholic liver disease who underwent hepatic transplantation. *Liver Transpl Surg* 3, 263–274.
88 Gerhardt TC, Goldstein RM, Urschel HC *et al.* (1996) Alcohol use following liver transplantation for alcoholic cirrhosis. *Transplantation* 62, 1060–1063.
89 Lucey MR, Carr K, Beresford TP *et al.* (1997) Alcohol use after liver transplantation in alcoholics: a clinical cohort follow-up study. *Hepatology* 25, 1223–1227.
90 Tang H, Boulton R, Gunson B *et al.* (1998) Patterns of alcohol consumption after liver transplantation. *Gut* 43, 340–345.
91 Atterbury CE (1986) The alcoholic in the lifeboat. Should drinkers be candidates for liver transplantation? *J Clin Gastroenterol* 8, 1–4.
92 Tringali RA, Trzepacz PT, DiMartini A, Dew MA (1996) Assessment and follow-up of alcohol-dependent liver transplantation patients. A clinical cohort. *Gen Hosp Psychiatry* 18 (Suppl. 6), 70S–77S.
93 DiMartini A, Jain A, Irish W *et al.* (1998) Outcome of liver transplantation in critically ill patients with alcoholic cirrhosis. *Transplantation* 66, 298–302.
94 Kumar S, Stauber RE, Gavaler JS *et al.* (1990) Orthotopic liver transplantation for alcoholic liver disease. *Hepatology* 11, 159–164.
95 Tome S, Martinez-Rey C, Gonzalez-Quintela A *et al.* (2002) Influence of superimposed alcoholic hepatitis on the outcome of liver transplantation for end-stage alcoholic liver disease. *J Hepatol* 36, 793–798.
96 Mathurin P, Abdelnour M, Ramond MJ *et al.* (2003) Early change in bilirubin levels is an important prognostic factor in severe alcoholic hepatitis treated with prednisolone. *Hepatology* 38, 1363–1369.
97 Mutimer DJ, Burra P, Neuberger JM *et al.* (1993) Managing severe alcoholic hepatitis complicated by renal failure. *Q J Med* 10, 649–656.
98 Veldt BJ, Laine F, Guillygomarc'h A *et al.* (2002) Indication of liver transplantation in severe alcoholic liver cirrhosis: quantitative evaluation and optimal timing. *J Hepatol* 36, 93–98.
99 Dunn W, Jamil LH, Brown LS *et al.* (2005) MELD accurately predicts mortality in patients with alcoholic hepatitis. *Hepatology* 41, 353–358.
100 Shakil AO, Pinna A, Demetris J *et al.* (1997) Survival and quality of life after liver transplantation for acute alcoholic hepatitis. *Liver Transpl* 3, 240–244.
101 Conjeevaram HS, Hart J, Lissoos TW *et al.* (1999) Rapidly progressive liver injury and fatal alcoholic hepatitis occurring after liver transplantation in alcoholic patients. *Transplantation* 67, 1562–1568.
102 Bonet H, Manez R, Kramer D *et al.* (1993) Liver transplantation for alcoholic liver disease: survival of patients transplanted with alcoholic hepatitis plus cirrhosis as compared with those with cirrhosis alone. *Alcohol Clin Exp Res* 17, 1102–1106.
103 Starzl TE, Van Thier D, Tzakis AG, *et al.* (1988) Orthotopic liver transplantation for alcoholic cirrhosis. *JAMA* 260, 2542–2544.
104 Hoofnagle JH, Kresina T, Fuller RK *et al.* (1997) Liver transplantation for alcoholic liver disease: executive statement and recommendations. Summary of a National Institutes of Health workshop held December 6–7, 1996, Bethesda, Maryland. *Liver Transpl Surg* 3, 347–350.

105 Propst A, Propst T, Zangerl G *et al.* (1995) Prognosis and life expectancy in chronic liver disease. *Dig Dis Sci* 40, 1805–1815.

106 Poynard T, Naveau S, Doffoel M *et al.* (1999) Evaluation of efficacy of liver transplantation in alcoholic cirrhosis using matched and simulated controls: 5-year survival. Multi-centre group. *J Hepatol* 30, 1130–1137.

107 Miguet JP, Vanlemmens C, Milan C *et al.* (2003) Impact of liver transplantation on survival in Pugh B alcoholic cirrhotic patients: a multicenter randomized trial. *Hepatology* 38(Suppl. 1), A424.

108 Burra P, Lucey MR (2005) Liver transplantation in alcoholic patients. *Transplant Int* 18, 491–498.

109 Wiesner R, Edwards E, Freeman R *et al.* (2003) Model for End-Stage Liver Disease (MELD) and allocation of donor livers. *Gastroenterology* 124, 91–96.

110 Osorio RW, Ascher NL, Avery M *et al.* (1994) Predicting recidivism after orthotopic liver transplantation for alcoholic liver disease. *Hepatology* 20, 105–110.

111 Bird GL, O'Grady JG, Harvey FA *et al.* (1990) Liver transplantation in patients with alcoholic cirrhosis: selection criteria and rates of survival and relapse. *Br Med J* 301, 15–17.

112 Knechtle SJ, Fleming MF, Barry KL *et al.* (1992) Liver transplantation for alcoholic liver disease. *Surgery* 112, 694–701.

113 Berlakovich GA, Steininger R, Herbst F *et al.* (1994) Efficacy of liver transplantation for alcoholic cirrhosis with respect to recidivism and compliance. *Transplantation* 58, 560–565.

114 Raakow R, Langrehr JM, Lohmann R *et al.* (1995) Is orthotopic liver transplantation for end-stage alcoholic cirrhosis justified? *Transplant Proc* 27, 1241–1242.

115 Foster PF, Fabrega F, Karademir S *et al.* (1997) Prediction of abstinence from ethanol in alcoholic recipients following liver transplantation. *Hepatology* 25, 1469–1477.

116 Gish RG, Lee AH, Keeffe EB *et al.* (1993) Liver transplantation for patients with alcoholism and end-stage liver disease. *Am J Gastroenterol* 88, 1337–1342.

117 Pageaux GP, Michel J, Costes V *et al.* (1999) Alcoholic cirrhosis is a good indication for liver transplantation, even for cases of recidivism. *Gut* 45, 421–426.

118 Wiesner RH, Lombardero M, Lake JR *et al.* (1997) Liver transplantation for end-stage alcoholic liver disease: an assessment of outcomes. *Liver Transpl Surg* 3, 231–239.

119 Belle SH, Beringer KC, Detre KM (1997) Liver transplantation for alcoholic liver disease in the United States: 1988 to 1995. *Liver Transpl Surg* 3, 212–219.

120 Neuberger J, James O (1999) Guidelines for selection of patients for liver transplantation in the era of donor-organ shortage. *Lancet* 354, 1636–1639.

121 Fuller RK (1997) Definition and diagnosis of relapse to drinking. *Liver Transpl Surg* 3, 258–262.

122 Pageaux GP, Bismuth M, Perney P *et al.* (2003) Alcohol relapse after liver transplantation for alcoholic liver disease: does it matter? *J Hepatol* 38, 629–634.

123 Beresford TP (1997) Predictive factors for alcoholic relapse in the selection of alcohol-dependent persons for hepatic transplant. *Liver Transpl Surg* 3, 280–291.

124 Keeffe EB (1996) Assessment of the alcoholic patient for liver transplantation: comorbidity, outcome, and recidivism. *Liver Transplant* 2, 12–20.

125 Röggla H, Röggla G, Mühlbacher F (1996) Psychiatric prognostic factors in patients with alcohol-related end-stage liver disease before liver transplantation. *Wien Klin Wochensch* 108, 272–275.

126 Newton SE (1999) Recidivism and return to work posttransplant. Recipients with substance abuse histories. *J Subst Abuse Treat* 17, 103–108.

127 Tripp LE, Clemons JR, Goldstein RR *et al.* (1996) Drinking patterns in liver transplant recipients. *Psychosomatics* 37, 249–253.

128 Fabrega E, Crespo J, Casafont F *et al.* (1998) Alcoholic recidivism after liver transplantation for alcoholic cirrhosis. *J Clin Gastroenterol* 26, 204–206.

129 Lucey MR (1997) Issues in selection for and outcome of liver transplantation in patients with alcoholic liver disease. *Liver Transplant* 3, 227–230.

130 Lee RG (1997) Recurrence of alcoholic liver disease after liver transplantation. *Liver Transpl Surg* 3, 292–295.

131 Howard L, Fahy T, Wong P *et al.* (1994) Psychiatric outcome in alcoholic liver transplant patients. *Q J Med* 87, 731–736.

132 Berlakovich GA, Windhager T, Freundorfer E *et al.* (1999) Carbohydrate deficient transferrin for detection of alcohol relapse after orthotopic liver transplantation for alcoholic cirrhosis. *Transplantation* 67, 1231–1235.

133 Bernard PH, Le Bail B, Carles J *et al.* (1996) Liver retransplantation for alcoholic cirrhosis recurring within a 21-month period. *Transpl Int* 9, 524–525.

134 Hanck C, Whitcomb DC (2004) Alcoholic pancreatitis. *Gastroenterol Clin North Am* 33, 751–765.

135 Maisonneuve P, Lowenfels AB, Mullhaupt B *et al.* (2005) Cigarette smoking accelerates progression of alcoholic chronic pancreatitis. *Gut* 54, 510–514.

136 Butters N (1985) Alcoholic Korsakoff's syndrome: some unresolved issues concerning etiology, neuropathology, and cognitive deficits. *J Clin Exp Neuropsychol* 7, 181–210.

137 Chaudhry Y, Corse AM, O'Brian R *et al.* (1999) Autonomic and peripheral (sensorimotor) neuropathy in chronic liver disease: a clinical and electrophysiologic study. *Hepatology* 29, 1698–1703.

138 Gane E, Bergman R, Hutchinson D (2004) Resolution of alcoholic neuropathy following liver transplantation. *Liver Transplant* 10, 1545–1548.

139 Piano MR (2002) Alcoholic cardiomyopathy: incidence, clinical characteristics, and pathophysiology. *Chest* 121, 1638–1650.

140 Liu H, Lee SS (1999) Cardiopulmonary dysfunction in cirrhosis. *J Gastroenterol Hepatol* 14, 600–608.

141 Lucas DL, Brown RA, Wassef M *et al.* (2005) Alcohol and the cardiovascular system research challenges and opportunities. *J Am Coll Cardiol* 45, 1916–1924.

142 Cecchin E, De Marchi S (1996) Alcohol misuse and renal damage. *Addict Biol* 1, 7–17.

143 Ojo AO, Held PJ, Port FK *et al.* (2003) Chronic renal failure after transplantation of a nonrenal organ. *N Engl J Med* 349, 931–940.

144 Halsted CH (2004) Nutrition and alcoholic liver disease. *Semin Liver Dis* 24, 289–304.

145 Castellsague X, Quintana MJ, Martinez MC *et al.* (2004) The role of type of tobacco and type of alcoholic beverage in oral carcinogenesis. *Int J Cancer* 108, 741–749.

146 Duvoux C, Delacroix I, Richardet JP *et al.* (1999) Increased incidence of oropharyngeal squamous cell carcinomas after liver transplantation for alcoholic cirrhosis. *Transplantation* 67, 418–421.

147 Smith KE, Fenske NA (2000) Cutaneous manifestations of alcohol abuse. *J Am Acad Dermatol* 43, 1–16.

148 Sticherling M, Brasch J, Bruning H *et al.* (1995) Urticarial and anaphylactoid reactions following ethanol intake. *Br J Dermatol* 132, 464–467.

149 Kune GA, Bannerman S, Field B *et al.* (1992) Diet, alcohol, smoking, serum beta-carotene, and vitamin A in male nonmelanocytic skin cancer patients and controls. *Nutr Cancer* 18, 237–244.

150 McColl KE, Moore MR, Thompson GG *et al.* (1981) Abnormal haem biosynthesis in chronic alcoholics. *Eur J Clin Invest* 11, 461–468.

151 Attali P, Ink O, Pelletier G *et al.* (1987) Dupuytren's contracture, alcohol consumption, and chronic liver disease. *Arch Intern Med* 147, 1065–1067.

152 Smith PD, Stadelmann WK, Wassermann RJ *et al.* (1998) Benign symmetric lipomatosis (Madelung's disease). *Ann Plast Surg* 41, 671–673.

153 Villalta J, Ballesca JL, Nicolas JM *et al.* (1997) Testicular function in asymptomatic chronic alcoholics: relation to ethanol intake. *Alcohol Clin Exp Res* 21, 128–133.

154 Castilla-Garcia A, Santolaria-Fernandez FJ, Gonzalez-Reimers CE *et al.* (1987) Alcohol-induced hypogonadism: reversal after ethanol withdrawal. *Drug Alcohol Depend* 20, 255–260.

155 Morgan MY (1982) Alcohol and the endocrine system. *Br Med Bull* 38, 35–42.

156 Smith-Warner SA, Spiegelman D, Yaun SS *et al.* (1998) Alcohol and breast cancer in women: a pooled analysis of cohort studies. *JAMA* 279, 535–540.

157 Wu A, Chanarin I, Levi AJ (1974) Macrocytosis of chronic alcoholism. *Lancet* 1(7842), 829–831.

158 Rantala A, Lehtonen OP, Niinikoski J (1997) Alcohol abuse: a risk factor for surgical wound infections? *Am J Infect Control* 25, 381–386.

159 Lindenbaum J (1987) Hematologic complications of alcohol abuse. *Semin Liver Dis* 7, 169–181.

13 Hepatic non-alcoholic steatosis

13 Non-alcoholic fatty liver and non-alcoholic steatohepatitis

Geoffrey C. Farrell

Summary

Metabolic disorders are strongly associated with, and likely to cause, fatty liver diseases; they can also alter the progression of hepatitis C and alcoholic liver disease. In the absence of toxic or infective disorders, steatosis associated with metabolic disorders is referred to as non-alcoholic fatty liver disease (NAFLD). NAFLD covers a wide spectrum of liver pathology – from steatosis alone, through the necroinflammatory disorder of non-alcoholic steatohepatitis (NASH) to cirrhosis and liver cancer. Pathogenic concepts about NAFLD/NASH must account for the strong links with overnutrition and underactivity, insulin resistance (IR) and genetic factors. These interact to greatly expand hepatic lipid storage and cause hepatocellular injury with inflammatory recruitment by lipotoxicity, oxidative stress and/or release of cytokines and other proinflammatory mediators. While details of the disordered hepatic turnover of fatty acids that gives rise to steatosis are currently under investigation, it has become clear that steatosis, once present, can cause hepatic IR. Most probably for this reason, NAFLD/NASH is closely related to the burgeoning pandemic of visceral adiposity, obesity, type 2 diabetes mellitus (T2DM) and metabolic syndrome. The prevalence of NAFLD has been estimated to be 17–33% in some countries; NASH may be present in about one-third of such cases (prevalence ~ 5%), while 20–25% of NASH cases could progress to cirrhosis. Personal risk factors for NAFLD/NASH reflect its relationship to metabolic disorders, and provide insight into prevention, treatment and prognosis. NAFLD/NASH is often detected in asymptomatic persons and, when symptoms occur (particularly fatigue), they are usually non-specific. NAFLD is an important diagnosis to consider in anyone with abnormal liver tests (whether or not another possible cause is present), liver enlargement or an echogenic ('bright') liver ultrasonogram (USG). This chapter will provide a practical approach to diagnosis, including the role of anthropometrics, metabolic tests, hepatic imaging and liver biopsy. Natural history will be discussed, as well as early intervention, the importance of lifestyle modification as a public health measure and evidence about the effects of weight reduction and pharmacological therapies. Some special issues that will be touched on briefly include secondary causes of steatohepatitis, NASH in children, hepatocellular carcinoma, liver transplantation and interactive pathogenesis of metabolic factors in hepatitis C and alcoholic liver disease.

Definitions and pathology

Associations between obesity, T2DM and fatty liver (steatosis) have long been recognized, as has the high prevalence of cirrhosis in diabetes. Cases of fatty liver disease that resembled alcoholic steatohepatitis (ASH) but occurred in non-drinkers were described at least 25 years ago [1,2], when the term non-alcoholic steatohepatitis (NASH) was coined by Ludwig. In the last few years, the more embracing term NAFLD has been introduced to cover the full spectrum of metabolic fatty liver disorders [3–8]. The author's preference is to use the overlapping abbreviation NAFLD/NASH when pathological characterization is unclear and such uncharacterized cases seem clinically important [e.g. those with raised serum aminotransferase (AT) levels]. The terms steatosis, NASH and cirrhosis will be confined to cases defined by liver pathology. Other causes of steatohepatitis, sometimes referred to as secondary NASH, are best linked semantically to the known aetiology, for example 'drug-induced steatohepatitis' (Table 1).

Earlier classifications attempted to differentiate benign steatosis, with or without minor liver inflammation, from lesions shown to be harbingers of poor clinical outcomes; the latter included ballooning degeneration of hepatocytes, Mallory bodies and fibrosis [10–14]. A move to reach consensus at pathological classification has come from the Pathology Committee of the NASH Clinical Research Network of the US National Institutes of Health (NIH). They proposed a scoring system comprising 14 histological features [11]. Among these, four components – steatosis, lobular inflammation, hepatocellular ballooning (a marker of injury) and fibrosis – proved easier to semi-quantify, and were also more robust and reproducible than 10 others [11]. Although substantial sampling error can occur with needle biopsy of NAFLD [15], inter-rater variability

Table 1 Some specific causes of steatohepatitis (secondary NASH).

Alcohol (alcoholic hepatitis)
Drugs (drug-induced steatohepatitis, e.g. tamoxifen, amiodarone, methotrexate)
Copper toxicity (Wilson's disease, Indian childhood cirrhosis)
Jejunoileal bypass
Other causes of rapid, profound weight loss (massive intestinal resection, cachexia, bulimia, starvation)
Hypernutrition in adults (parenteral nutrition, intravenous glucose)
Abetalipoproteinaemia
Jejunal diverticulosis (contaminated bowel syndrome)
Familial and acquired lipodystrophies[a,b]
Polycystic ovary syndrome[a]

[a]Cause insulin resistance.
[b]Corrected by leptin therapy [9].

between expert pathologists in the NASH Clinical Research Network Pathology Committee was highest for fibrosis (kappa score 0.84) and steatosis (0.79) and lower for injury (0.56) and lobular inflammation (0.45). On the basis of the unweighted sum of scores for steatosis, lobular inflammation and hepatocellular ballooning, a new NAFLD activity score (NAS) was constructed. NAS can be used to classify cases into 'NASH', 'borderline' and 'not NASH'; however, agreement on diagnostic category was only moderate at 0.61. Other aspects of the pathology of NASH [11–14,16], such as Mallory bodies and portal vs. pericellular fibrosis, are not considered in this new system because they are difficult to quantify or lack reproducibility between observers [11,14,15]. However, Gramlich and colleagues [16] have emphasized the relationships between ballooning degeneration and/or Mallory bodies and the presence of perisinusoidal and perivenular fibrosis (Table 2).

Aside from pathology and excluding other causes of fatty liver disease (see Diagnosis), a key definitional issue is the threshold of alcohol consumption that allows reliable distinction between 'ASH' and 'NASH'. Authors have differed on this, from requiring total abstinence to allowing up to 20–40 g ethanol/day [2,17–19]; the latter approaches the threshold of alcohol intake that is associated with an increased risk of cirrhosis in women [20]. It now seems highly unlikely that regular small amounts of alcohol intake (one or two standard drinks or 10–20 g ethanol/day) worsen liver disease in hepatitis C [21], and likewise NAFLD, but the latter is harder to prove. Lifetime total alcohol intake may be more important [22]. Importantly, this level of regular alcohol intake lowers cardiovascular risk and improves insulin sensitivity in persons with T2DM – persons with metabolic syndrome would therefore benefit from these changes [6]. With these considerations in mind, the US NIH collaborative clinical network on NAFLD/NASH has agreed on the allowable level of alcohol intake for NAFLD to be two standard drinks a day (140 g ethanol/week) for men and one standard drink a day (70 g ethanol/week) for women; similar levels were adopted by the first book published on NAFLD/NASH [8,13,17].

General importance and epidemiology

As summarized in Table 3, NAFLD/NASH is important for several reasons. The most obvious is the high prevalence in many populations – North and South America, much of Asia and the western Pacific (including Australia), the Middle East and Europe. NASH has been referred to as a disease of the 'west', but altered socioeconomic circumstances and the related changes in food intake, food choices and levels of physical activity may each play a role; together, these are referred to in this chapter as 'lifestyle'. As discussed below, NASH is a hepatic manifestation of the metabolic syndrome (or IR syndrome), and so the link between high prevalence of NAFLD and obesity, T2DM and cardiovascular disease probably represents shared pathogenic factors.

While NAFLD is now the leading cause of referral to hepatology clinics in most regions (possible exceptions are alcoholic liver disease in some urban subpopulations and hepatitis B in some Asian-Pacific populations), accurate estimates of its incidence, prevalence and natural history are lacking [17]. The major difficulty with epidemiological studies of NAFLD and NASH is case definition; available data are based on tests that lack sensitivity and specificity, particularly unexplained AT elevations and abnormal hepatic USG. Conversely, studies based

Table 2 Some categories of non-alcoholic fatty liver disease (NAFLD).

Category	Pathology	Clinicopathological correlations and outcomes
Type 1	Simple steatosis	Non-progressive (several studies)
Type 2	Steatosis plus lobular inflammation	Probably benign (should not be regarded as NASH)
Type 3	Steatosis, ballooning degeneration, lobular inflammation	NASH without fibrosis – possibly good prognosis (few studies)
Type 4	Steatosis, ballooning degeneration (and Mallory bodies), lobular inflammation, fibrosis	NASH with fibrosis – may progress to cirrhosis and liver failure (several studies)

Modified from Matteoni *et al*. [10]. Note that recent studies have de-emphasized the importance of Mallory bodies and further emphasize the importance of hepatic fibrosis [11,14].

Table 3 Some reasons why NAFLD/NASH is important.

High prevalence in urbanized communities throughout the world
Commonest cause of abnormal liver tests; 17–33% of population may have NAFLD
More common than alcoholic liver disease and chronic hepatitis C among referrals to liver clinics and physicians' offices
A cause of cirrhosis that may be 'cryptogenic' and lead to endstage liver disease
Liver failure is the commonest cause of death in patients with cirrhosis due to NASH
In type 2 diabetes (T2DM), the increase in standardized mortality for liver disease exceeds that for vascular disease
NASH recurs after liver transplantation
Steatosis predisposes to primary graft non-function after liver transplantation
Metabolic determinants influence the pathogenesis of hepatitis C and alcoholic liver disease
T2DM and possibly steatosis may accelerate hepatocarcinogenesis

on histologically documented liver clinic cohorts are likely to be influenced by referral bias. It is therefore unclear whether the proportion of NAFLD cases associated with NASH or cirrhosis is ~ 20–25% (as reported from biopsy studies) or less than this (by analogy with hepatitis C, in which there are differences in the spectrum of liver pathology between patients in liver clinics and those in the community). Similar considerations apply to the natural history and clinical outcomes, discussed below.

Some data bearing on the prevalence of NAFLD/NASH are summarized in Table 4. Based on the third National Health and Nutritional Examination Survey (NHANES III), which determined AT levels and excluded known causes of liver disease, the likely prevalence of NAFLD in North America and similar regions is between 3% and 23% [5,17]. Population surveys using hepatic USG indicate a similar prevalence (~ 22%), from 16% in lean to 76% in obese individuals [23–25] (Table 4), but a recent study using proton magnetic resonance spectrometry found ~ 30% of the population to have increased hepatic triglyceride content [26]. An extrapolation of data from liver biopsy or autopsy studies is that 20–25% of such individuals, or 4–5% of the population, may have NASH and fibrosis or cirrhosis. Twenty-year-old autopsy studies found the frequency of steatosis among those who died suddenly (motor vehicle accident, plane crash) was 16–24%, and NASH was present in 2.1–2.4% [28,29]. Likewise, steatosis is found in 20% of liver donors with normal AT [31,32]. More than 60% of men and 45% of women in Australia and the USA are overweight, about one-third of whom are obese; autopsy and biopsy studies show that ~ 20% of obese subjects have NASH [30,33–37]. Thus, despite uncertainties about the precise prevalence of NAFLD and the proportion of community cases that are progressive [17], it is clear that NASH is now an important cause of cirrhosis in the community. Further, commensurate with the rapid increase in the prevalence of obesity and T2DM in North America and around the world, it is highly likely that NAFLD/NASH prevalence has increased appreciably in the decade since NHANES III was conducted. Coupled with the increasing frequency with which NASH is diagnosed in childhood [38–40], NASH is likely to contribute substantially to the burden of chronic liver disease in the coming decades.

Table 4 Some data that bear on the prevalence of NAFLD and NASH[a].

Type of study	Prevalence NAFLD (%)
General population studies	
Ultrasound [25–25]	~ 22
Bellanti *et al.* [24]	
Lean	16
Obese	76
PMRS Browning *et al.* [26]	24–45[b]
Liver enzymes (AT level)	
Patt *et al.* [27]	14–21
NHANES III [5,17]	3–23
Liver histology on selected groups	
Liver biopsy	
Seven studies – see McCullough [17]	15–84
Autopsy – random deaths	
Hilden *et al.* [28]	24
Ground [29]	16 (NASH = 2.1)
Hospitalized deaths	
Wanless and Lentz [30]	
Lean	3
Obese	19
Surgical patients	
Adult living liver donors [31,32]	20
Bariatric surgery [17,33–37]	56–86

NHANES III, Third (US) National Health and Nutritional Examination Survey.
PMRS, proton magnetic resonance spectrometry.
[a]Modified from McCullough [17].
[b]Depending on ethnicity and gender, as follows: 45% Hispanic, 33% white, 24% black; 42% white males, 24% white females.

Clinical features

Risk factors

These are summarized in Table 5. Obesity, T2DM and hypertriglyceridaemia are the best known [24–26,41–48]. There has been controversy about 'NASH in lean men' [41]. Earlier impressions that NAFLD/NASH was a female-predominant condition have now been dispelled [26,41–48], but there is no doubt that the prevalence and severity of NAFLD/NASH increase with age. The strongest association of NASH is with central (or visceral) rather than overall obesity [42,46–48]. Thus, many individuals labelled as 'non-obese' NAFLD [on the basis of body mass index(BMI)] have central obesity, and central obesity has strong correlations with IR and is a key feature of

Table 5 'Risk factors' and metabolic associations of NASH.

Type 2 diabetes mellitus
Family history of type 2 diabetes
Ethnicity (see Table 4)
Gender: male > female for prevalence of NAFLD (see [26])
Insulin resistance, with or without glucose intolerance
Central obesity (waist:hip ≥ 0.85 in women, ≥ 0.90 in men; waist > 85 cm in women, > 97 cm in men[a])
Obesity (BMI ≥ 30 kg/m^2 in Caucasians, ≥ 27 kg/m^2 in Asians)
Hypertriglyceridaemia
Other features of metabolic (insulin resistance) syndrome, e.g. hypertension (see [42,44,49] and Table 6)
Rapid and massive weight loss in overweight subjects

BMI, body mass index.
[a]Values vary between countries – 90 cm for women and 102 cm for men is often used in the USA; Asian criteria are > 80 cm for women and > 90 cm for men.

the metabolic syndrome [42,49]. This has implications for clinical assessment and management, as well as for understanding pathogenesis. There are undoubted genetic factors that predispose to NAFLD/NASH; for example, kindreds with more than one family member affected have been reported [50]. Further, a family history of T2DM in one or more first-degree relatives was found in two-thirds of NASH cases [42], while the prevalence of steatosis is higher in Hispanics than in white or black people [26].

The association of NASH with increasing age may be partly related to the increased prevalence of IR in older people, irrespective of body mass [51]. In addition, chronic liver disease appears to progress more rapidly to cirrhosis and its complications after the age of 50 years [52]. Thus, most patients with portal hypertension, hepatic decompensation or hepatocellular carcinoma (HCC) attributable to NASH are in the sixth to eighth decades of life. On the other hand, there is concern about the increasing frequency with which NAFLD is being diagnosed in childhood, occasionally with established fibrosis [38–40]. While most of the risk factors for NAFLD are readily explained in terms of the likely causal metabolic factors, an exception is rapid weight loss, which appears to have precipitated the diagnosis of NASH in some reports [53,54]. While the explanation for this is unclear (impaired glutathione synthesis is one possibility), it has implications for optimal rates of weight reduction during therapy (see later).

In addition to those factors associated with an increased prevalence of NAFLD, a subset of factors has been linked to disease severity. These are collated in Table 6. Some are likely to reflect the presence of established cirrhosis rather than reasons for its development. The most powerful determinants of disease severity appear to be T2DM, evidence of metabolic syndrome (e.g. arterial hypertension), obesity and age (Table 6). Employing these determinants and associates of disease severity, investigators have started to construct predictive scores to identify individuals with the most significant or least severe forms of NAFLD (Table 6); the hope is that these scores can be used to avoid (or select for) liver biopsy (see Diagnosis).

Presentation and clinical assessment

Common modes of presentation include:

1 detection of abnormal liver (function) tests (LFT) during routine screening;

2 abnormal hepatic USG performed for another purpose, e.g. suspicion of gallstones;

3 detection of hepatomegaly during physical examination of the abdomen (liver tests may be normal [26,58]).

Most patients have few if any symptoms at the time of diagnosis and, when present, symptoms are usually non-specific. Some fatigue is very common; it may be profound in physically inactive, overweight or obese individuals with NAFLD, but there is no apparent relationship with disease severity. The basis

Table 6 'Predictors' (risk factors and laboratory test associations) for fibrotic severity in NASH.

Indices	BARD [55]	BARG [56]	BAAT [57]	HAIR [33]	Angulo *et al.* (2007)[a]
BMI	Yes	Yes	Yes	–	Yes
Age	Yes	–	Yes	–	Yes
AST:ALT	Yes	Yes	–	–	Yes
ALT (any elevation)	–	–	Yes	Yes	–
Albumin	–	–	–	–	Yes
Platelets	–	–	–	–	Yes
Diabetes	Yes	–	–	–	(yes)[b]
$HgbA_{1c}$ (or hyperglycaemia)	–	Yes	–	–	Yes
Insulin resistance index	–	–	–	Yes	–
Triglycerides	–	–	Yes	–	–
Hypertension	–	–	–	Yes	–

ALT, alanine aminotransferase; AST, aspartate aminotransferase; $HgbA_{1c}$, haemoglobin A_{1c}.
[a]*Hepatology* (2007) in press.
[b]Fasting blood glucose level.

Table 7 Components of 'lifestyle change' in diabetes intervention studies[a].

Attempt modest weight reduction by modulating energy intake and the other measures listed below
Reduce total fat intake to < 30% energy intake
Replace saturated with unsaturated fats
Replace fat with complex carbohydrates containing at least 15 g fibre/day
Diet rich in fruit and vegetables
Minimum of 140 min exercise/week – fast walking as standard
Use of case manager to advise, encourage, monitor progress

[a]From refs 123,124.

for metabolic complications can be revealed by a well-taken personal and lifestyle history – events such as marriage, unemployment, change to a more sedentary lifestyle or a recent vacation may be linked to recent weight gain and/or gain in abdominal girth ('has your underwear or belt size changed recently?'). This history forms the basis for later discussions on lifestyle intervention as the first measure to correct the metabolic perturbations that cause NAFLD/NASH (Table 7).

Among other symptoms, abdominal discomfort is relatively common, but pain or substantial liver tenderness is rare. In cases with cirrhosis, the patient may complain of symptoms indicative of gastrointestinal bleeding (from portal hypertension), muscle weakness, ascites, jaundice or hepatic encephalopathy.

Diagnosis and investigations

Practical clinical diagnosis, anthropometrics

Other causes of liver disease need to be excluded, particularly alcohol (see earlier defined 'safe limits'), but also drugs and other secondary causes of steatohepatitis (Table 1). Apart from excluding common conditions such as hepatitis B or C, and rarer metabolic, toxic or autoimmune disorders, it is important to appreciate when NAFLD is the most likely cause of AT elevation in a person with another possible cause of liver disease [59]. Contemporary examples include raised alanine aminotransferase (ALT) in patients with non-replicative chronic hepatitis B virus (HBV) infection (HBV DNA not detectable) or after sustained antiviral response to peginterferon/ribavirin in chronic hepatitis C (when rapid weight gain is common), and patients with metabolic syndrome induced by corticosteroid therapy for autoimmune hepatitis or as immunosuppressive therapy after liver transplantation. In such cases, management should include attempts to correct the metabolic imbalance but, sometimes, hepatic imaging and even liver biopsy is required to clarify whether NAFLD/NASH rather than the underlying liver disease is the basis for these changes.

Practical clinical diagnosis can be made on the presence of risk factors, physical examination (usually normal, apart from minor rubbery hepatomegaly) and exclusion of other disorders. In addition to seeking signs of portal hypertension (e.g. splenomegaly) or cirrhosis (hard liver edge, spider naevi, muscle wasting, ascites, encephalopathy), physical examination should include simple anthropometric measurements. These are BMI [body weight (in kg) divided by height (in m^2)] and determination of abdominal girth (waist circumference with patient standing, halfway between lower ribcage and iliac crest, or waist to hip ratio – see Table 5 for normal values).

Liver and metabolic tests

Liver tests usually show minor non-specific abnormalities. ALT and gamma-glutamyl transpeptidase values are raised in most cases, but may be normal at the time of diagnosis despite the presence of histologically significant disease [26,58]. More significant abnormalities, such as a fall in serum albumin, rise in aspartate aminotransferase (AST):ALT ratio and lowered platelet count, are associated with cirrhosis (Table 6).

Metabolic tests should include fasting serum lipids (triglyceride, cholesterol) and lipoprotein levels (high-density lipoprotein cholesterol, low-density lipoprotein cholesterol), fasting blood glucose and a test of insulin sensitivity. For the last, a dynamic test is preferred, such as a shortened 75-g glucose tolerance test with fasting and 2-h serum insulin levels. Earlier studies used static measurements of fasting serum insulin and glucose to calculate IR by the homeostatic model assessment (HOMA) method [42–44], but a limitation is that results should be referenced to an appropriate local control population. Further, HOMA is unreliable in the presence of established diabetes when serum insulin levels start to decline, and in older patients [60]. It is of interest that most cases of NASH at diagnosis appear to be associated with high serum insulin levels [42–44,61]. Further, serum C-peptide levels are also raised [42], reflecting increased pancreatic secretion of insulin.

Tests of inflammation and iron studies

While NASH is an inflammatory disorder, serum markers of inflammation that reliably discriminate NASH from bland steatosis have not yet been defined. In particular, an earlier suggestion that highly specific C-reactive protein may be valuable in this respect has not been confirmed [62,63]. Likewise, while studies of cytokines and adipokines are of pathogenic interest in NASH [53,64–67], these do not yet have diagnostic utility. One commonly performed test that probably reflects hepatic inflammation is serum ferritin; values are elevated in ~ 60% of patients with NASH, but do not usually indicate an increase in hepatic iron stores because serum transferrin saturation or stainable iron in liver biopsy is not increased [18,19,68–70]. The finding of raised serum ferritin often gives rise to an erroneous assumption of iron storage disorder. However, while the role of iron in exacerbating NAFLD has been much debated [18,68–70], the weight of evidence is now against this, despite the fact that some studies have shown a weak association with mutations (C282Y) in the common haemochromatosis gene, *HFE* [19,70].

Hepatic imaging

Hepatic imaging provides supportive evidence of steatosis by showing increased echogenicity ('bright' scan) with USG or increased radiolucency with computerized tomography (CT). In the presence of moderate–severe steatosis (more than 33% hepatocytes show stainable fat), the sensitivity of both tests approximates 75–80% [71]. Ultrasound is cheaper than CT and magnetic resonance imaging (MRI), but it is also more operator dependent and less specific; hepatic fibrosis or cirrhosis may give rise to similar appearances. No imaging modality can distinguish NASH from the benign end of the NAFLD spectrum. Likewise, detection of cirrhosis is likely to have low sensitivity, but evidence should be sought for portal hypertension (portal vein dilatation, retroperitoneal varices, splenomegaly), which would indicate this. Body compositional studies, such as with dual-energy X-ray absorptiometry (DEXA), as used routinely to determine bone density, can reliably estimate the proportion of body weight as fat as well as its distribution (visceral vs. subcutaneous) [48], while proton magnetic resonance spectroscopy can also be used to estimate hepatic triglyceride content [26]. In the future, it is possible that this may be applied to monitor the effectiveness of measures to counter central obesity and reverse hepatic steatosis.

Liver biopsy

Liver biopsy is the only way to confirm the presence or absence of NASH in a person with features of NAFLD, and histology remains the only criterion for fibrotic severity [13]. The issue is whether liver biopsy is indicated [15,72], given that it is unlikely to change management other than to reinforce the need for weight reduction or other lifestyle changes. While this matter has not been resolved, several paradigms have been developed that allow identification of a high proportion of cases with no or minimal fibrosis with a high level of diagnostic accuracy; these are summarized in Table 6. If validated for local experience, application of these 'predictive indices' could avoid the need for biopsy in many cases. Their application makes the reasonable assumption that it is not important to know that someone has steatosis attributable to NAFLD without fibrosis, except to appreciate the need to correct those risk factors for metabolic disease that can be assessed by other means (see Prevention and management).

At the other end of the spectrum, it can be argued that the presence of 'warning signs' of cirrhosis is a stronger indication for liver biopsy in order to document with higher certainty the cause of liver disease – occasionally, an unsuspected alternative cause of liver disease may be present [13]. For cases that do not clearly fall into either end of the pathological spectrum of NAFLD, opinion is divided between those who believe that knowledge of fibrotic severity of NASH is important for prognosis, if not as an indication for choice of treatment modalities (discussed later), and others who reason that, while there is not yet specific treatment for NASH, liver biopsy with its inconvenience, risks and expense is not justified. The author's approach is summarized in Figure 1; it incorporates an initial attempt to normalize AT elevations by 'lifestyle intervention' (Table 7), followed by biopsy in informed patients in whom this is not achieved, and especially if there is reason to suspect relatively

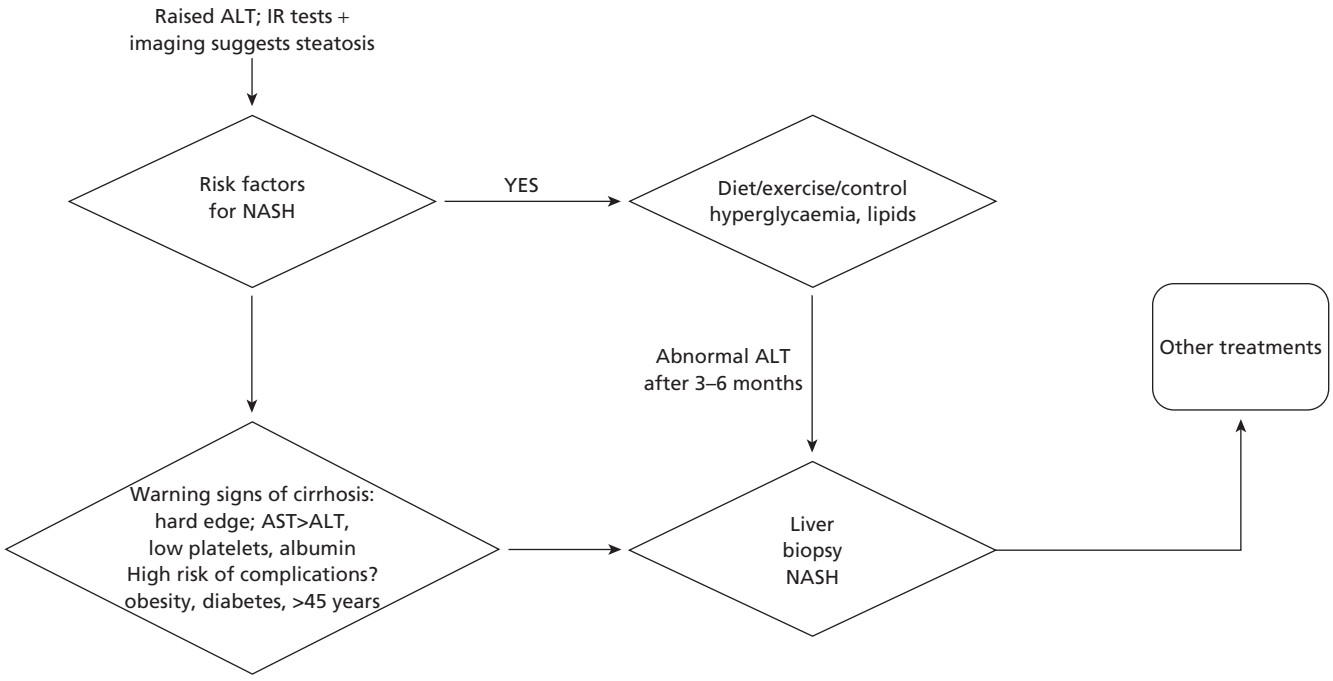

Fig. 1 An algorithm for considering whether and when to biopsy someone with abnormal liver tests considered likely to result from NAFLD.

severe disease or the diagnosis is not clear. However, a limitation of this approach is that many patients with NAFLD have normal ALT levels [26], even though histologically significant liver disease may be present [58].

Natural history and clinical outcome

Steatosis with or without minor inflammation appears to be non-progressive in most individuals (Table 2) [3–7,17]. However, initial assessment of NASH as benign is no longer supported by evidence [10,17,56,73–76]. Studies with progressive liver biopsy have shown histological progression of fibrosis in 32%, albeit regression in 18% [56]. Possible sampling error makes it difficult to be confident about rates of fibrotic progression [15], and larger and longer studies are required to determine these rates and the factors that influence them.

Long-term (more than 5 years) follow-up data on clinical outcomes are now available from several studies [10,17,56,73–76]. The estimated rate of cirrhosis development is 20% and of liver-related death is 12% over 10 years [17,74,76]. It is therefore apparent that patients with cirrhosis or advanced-stage fibrosis from NASH are at risk of developing complications of liver disease within the next 7 years – the projected rate is ~ 30%. In one study [76], this risk was very similar to that for chronic hepatitis C with cirrhosis and/or non-response to antiviral therapy.

Because most patients with cirrhosis due to NASH have T2DM and/or obesity and metabolic syndrome, a related issue is whether morbidity and mortality from liver disease is important compared with the other major health risks for such individuals (cardiovascular disease, stroke, cancer). In the Verona diabetes study [77], the age-adjusted mortality rate was high for cirrhosis, second only to cancer, and outstripped that for cardiovascular disease. It is therefore reasonable to assume that the age-adjusted mortality of patients with significant (fibrotic) NAFLD/NASH is increased because of liver disease, albeit that the absolute risk of someone with NAFLD developing major liver complications remains relatively low. While more definitive long-term studies are needed, the implications for individual patients with NAFLD/NASH is that they should consider interventions that could interrupt the progressive course of liver disease, as well as offering the other health benefits of correcting IR. Rare cases of NASH appear to have terminated in subacute liver failure [75], particularly after prolonged fasting or repeated cycles of rapid weight gain followed by precipitant weight loss [54]. The possibility that NASH may predispose to hepatocellular carcinoma is discussed later.

Pathogenesis of NAFLD/NASH

Metabolic studies in humans and animals show an almost inextricable intertwining of visceral adiposity (central obesity), steatosis and hepatic IR [23,24,26,33–35,42–48,53,60,65,66, 78–82]. Genetic factors may be important, as indicated by the strong family history of T2DM in first-degree relatives [42], the occurrence of NAFLD in multiple family members [50] and the apparent proclivity of some ethnic groups to NAFLD and metabolic syndrome [26]. Recent attention has focused on mitochondrial defects in the face of environmental factors [51,78,83,84]. Community studies of NAFLD that lack histological definition have all found strong associations with obesity, central obesity [23–26,45–48], T2DM, hyperlipidaemia and other features of the metabolic (or IR) syndrome. It remains unclear whether all such patients have hepatic IR secondary to steatosis, or whether the steatosis occurs as a response to peripheral IR and the resulting high serum insulin levels in the presence of fasting hyperglycaemia and hyperlipidaemia. The sequence of events in which steatosis comes before hepatic IR has been demonstrated with short-term high-fat feeding in rats [60,81,82,85] and in liver-specific lipoprotein lipase transgenic mice [80].

On the other hand, the near universal association of histologically defined NASH with IR, and usually with two or more features of the metabolic syndrome, is consistent with an aetiopathogenic role for IR in this disorder. The recurrence of NASH after liver transplantation (see later section) is also consistent with NASH arising secondary to a disordered metabolic milieu, rather than as a primary disorder within the liver. There is mounting evidence that NASH may actually be the hepatic manifestation of the metabolic syndrome; thus, two large studies have found that > 85% of patients with NASH have the IR or metabolic syndrome [42,44,49]. Further, Dixon and colleagues [33] and others (see Table 6) found that the more features of metabolic syndrome that are present, the higher the probability of steatohepatitis in a patient with NAFLD.

A key issue in NASH pathogenesis is how hepatic IR could give rise to hepatocellular injury and hepatic inflammation as well as the more readily explicable (or preceding) steatosis. It now seems that this could be attributable to the combined effects of severe IR and relative failure of humoral and cell signalling mediators that combat the effects of hepatic IR on lipid turnover by the liver, and particularly on mitochondrial β-oxidation of fatty acids and triglyceride secretion as very low-density lipoprotein (VLDL). Some (but not all) studies have characterized low serum levels of adiponectin as a factor distinguishing NASH from less severe forms of NAFLD [65,66]. Adiponectin is an adipocytokine that facilitates transport of fatty acids into mitochondria for β-oxidation and suppresses hepatic fatty acid synthesis, thereby countering the effects of high serum insulin levels and IR. Interestingly, serum levels of adiponectin fall before the onset of other complications of the metabolic syndrome, such as T2DM and cardiovascular disease. Experimental studies have shown that adiponectin can reverse steatohepatitis [86,87].

In animal models of metabolic steatohepatitis, there is increasing evidence that hepatocytes undergo adipogenesis, a phenotypical change similar to the maturation of adipocytes. Adipogenic transformation is under the regulatory control of

transcription factors such as peroxisome proliferator-activated receptor-gamma (PPARγ), liver X receptor (LXR) and sterol regulatory binding protein (SREBP)-1c [82]. It is possible that cell injury occurs when the capacity of hepatocytes with adipogenic characteristics to store fat safely is overwhelmed by continued uptake, local synthesis or impaired egress of fatty acids; these fatty acids then become toxic to the cell in a pathobiological process termed lipotoxicity. Lipotoxicity can cause cell death by the direct effects of lipid mediators on apoptosis. Alternatively, liberation of oxidized lipids and their peroxidation products (chemotactic aldehydes and organic acids) might be instrumental in recruiting and perpetuating the inflammatory response that characterizes NASH.

An older concept of NASH pathogenesis was that it is a two-tiered process [88]. Based on the reproducible observation that the fatty liver is predisposed to forms of injury that involve oxidant stress, it was conceptualized that steatosis provided the setting (or 'first hit') for NASH, but a second, injury- or inflammation-producing process (or 'second hit') was needed for development of necroinflammatory change and, ultimately, fibrogenesis. The 'two-hit' model of NASH pathogenesis was proposed in response to the experimental observations that:

1 endotoxin causes focal cytolysis and inflammation with exaggerated release of tumour necrosis factor-alpha (TNF) in rodent models of steatosis [64,67]; and

2 the livers of patients with NASH [89,90], as well as animal models of metabolic steatohepatitis, overexpress CYP2E1 [91,92], a microsomal fatty acid oxidase that generates reactive oxygen species (ROS). Irrespective of T2DM which, like alcohol, induces hepatic CYP2E1 expression, all patients with NASH have increased CYP2E1 activity *in vivo* [89,90].

Oxidative stress, TNF, and other cytokines and chemokines are all present in NASH [4,6,7,53,64,67], but the ways in which they initiate or perpetuate steatohepatitis and associated hepatic fibrosis and chronic liver disease remain uncertain. Recent data indicate that TNF may not be essential [93,94], and that oxidative stress may recruit inflammation via activation of the proinflammatory transcription factor, nuclear factor-kappa B (NFκB) [94]. Further, other factors that could mediate, amplify or reflect the operation of pathogenic processes include mitochondrial injury [83,84], stellate cell activation [95] and microvascular injury [61,96]. It seems likely that many of these processes reflect interactions between host genes and the environment in complex, interactive pathogenic networks rather than a simple two-hit process. For example, feeding obese (fa/fa) rats a high-fat diet was sufficient to cause oxidative stress associated with steatohepatitis and periportal fibrosis [85]. Further, while the importance of individual molecules or processes (adiponectin, oxidative stress, TNF) could have implications for the design of therapies to interrupt the progression of steatosis to fibrosing steatohepatitis, the results of interventions that reverse steatosis (discussed later) clearly indicate that stopping disease pathogenesis 'at source' is sufficient to obliterate all consequences of NAFLD on the liver.

Special contexts of NAFLD

Children

While epidemiologic studies of NAFLD in childhood are lacking, an increasing number of cases are being recognized from North America and Australia [38–40]. Some cases of advanced fibrotic NASH have been described in children, indicating the need to counter obesity and inactivity in children in order to prevent metabolic liver disease as well as T2DM. It has been suggested that there are subtle differences in the histological pattern of NAFLD in children compared with adults. In particular, a reproducible finding has been of portal and periportal fibrosis with less conspicuous lobular inflammatory change [13,38,39]. Recently, the pattern of periportal fibrosis with steatosis in the absence of other features of NASH has been described in adults [14]. Further studies are required to understand how common this is and whether there are any implications for natural history and clinical outcomes. Among the few studies of NASH treatment in children, vitamin E appeared to have some protective efficacy (Table 8) [97], but further studies are needed.

Liver transplantation

NASH is not a common indication for liver transplantation [98]. This may be partly attributable to the older age distribution of patients with hepatic decompensation due to NASH cirrhosis, and also because of the high prevalence of comorbidity (diabetes, vascular disease) related to the metabolic syndrome. It now seems possible that many cases of 'cryptogenic cirrhosis' are actually the endstage of NAFLD/NASH [57,99–101]. With the associated risk factors of T2DM, obesity, older age and cardiovascular disease, the risk of postoperative complications after liver transplantation and immunosuppression is high. Recurrence of NASH in the grafted liver is also a relatively frequent complication [98].

Hepatocellular carcinoma

Cases of hepatocellular carcinoma (HCC) have been described in patients with NASH; most, but not all, had HCC at initial diagnosis rather than during long-term follow-up [57,102,103]. In one small study, there were no cases of HCC at follow-up of patients with cirrhosis attributable to NASH [76], a striking contrast with the relatively high incidence (1–5% per annum) seen with hepatitis C-related cirrhosis. However, diabetes appears to be an independent risk factor for HCC irrespective of the presence of hepatitis B, hepatitis C or other liver disease [104,105]. A French study noted a relatively high incidence of HCC in obese patients with cirrhosis [57], but other known aetiological factors (previous HBV, alcohol) could have played an interactive role. Others have suggested that steatosis could increase the risk of HCC associated with other aetiologies [101,102]. In practical

Table 8 Drugs used to treat NASH.

Class of drug; agents [refs]	Type of study	Effects	Comments/adverse effect
Insulin-sensitizing			
Metformin [135]	Open label	Improved AT	Short-term studies (4–6 months), no histology
Pioglitazone (PPARγ agonist) [134]	Open label	Improved AT and liver histology	*n* = 18; loss of steatohepatitis; weight gain average 4%
Pioglitazone + vitamin E [136]	Randomized (open label)	Improved AT and liver histology	*n* = 21; both groups improved, but greater histological improvement in combination group
Rosiglitazone (PPARγ agonist) [133]	Open label	Improved AT and liver histology	*n* = 30; 10% withdrew, weight gain in 67%, median 7.3% of body weight; relapse post treatment
Antioxidant			
Vitamin E [97]	Open label	Improved AT	Children, *n* = 11, treated 4–10 months; no histology
Vitamin E [137]	Open label	Improved AT	*n* = 22; no histology
Vitamins E + C [138]	RCT vs. placebo	Improved histology	*n* = 45, but only nine biopsied post treatment; AT changes not mentioned
Betaine [139]	RCT vs. placebo	Improved AT	*n* = 191; no histology
Betaine [140]	Open label	Improved AT	*n* = 8; improved histology
Other hepatoprotectant			
Ursodeoxycholic acid [141]	RCT vs. placebo	AT improved in both groups (no difference)	*n* = 100; no difference between groups; no histology

AT, aminotransferase; RCT, randomized controlled trial.

terms, it does not seem as though patients with NASH have the same high risk of HCC as those with chronic hepatitis B or C, haemochromatosis or alcoholic cirrhosis. Screening for HCC should therefore only be considered in relation to other health issues and determinants of survival in such individuals.

Role of metabolic determinants in other liver diseases

Steatosis is present in 40–50% of liver biopsies from patients with hepatitis C [106–112]; other features of NASH (pericellular fibrosis, neutrophils) are found much less commonly [112]. While HCV genotype 3 is itself responsible for steatosis [108,113], and concomitant alcohol toxicity can play a role [109], most patients with steatosis and HCV genotype 1 infections have IR [108–113]. There is increasing evidence that HCV itself mediates these effects by interfering with insulin receptor signalling or through other effects, such as mitochondrial toxicity [114,115]. Thus, the incidence of T2DM is increased ~ 11-fold in patients with longstanding chronic HCV infection after having accounted for all other risk factors (family history, obesity, etc.) [116]. In addition to the role of HCV in worsening IR and causing steatosis, obesity, steatosis and IR have all been associated with fibrotic severity in chronic hepatitis C [106,112], while obesity [117], steatosis [113,118] and IR [119] are negative predictors of antiviral treatment response (see also Chapter 9.1.3.v). As for NASH, a programme of gradual weight reduction in association with increased physical activity can improve liver histology in hepatitis C [120,121]. Hence, the aetiopathogenic interactions between NASH and hepatitis C have management implications for people with hepatitis C; appropriate lifestyle adjustments (Table 7) have the potential to reduce the severity of liver disease and improve responsiveness to interferon-based antiviral therapy [112].

One epidemiological study has noted that obesity is a risk factor for severity of alcoholic liver disease [122]. If substantiated by further studies, this also has implications for optimal management.

Prevention and management of patients with NAFLD/NASH

Public health measures

As for obesity, T2DM, cardiovascular disease and several cancers, public health measures are indicated to reverse overnutrition and underactivity, the factors that lead to central obesity, IR and NAFLD/NASH. The efficacy and cost-effectiveness of such measures, as well as details about the special roles of physical activity, energy intake and food composition (glycaemic index, dietary fibre, lipid content, type of lipids, micronutrients) have not been clarified. However, it may be reasonable to apply similar principles of diabetes prevention/early intervention to NASH prevention [123,124], and to suppose that 'heart healthy' would also confer similar 'liver healthy' characteristics. Likewise, the logistics need to be worked out for professional advice and

supportive programmes of 'lifestyle intervention' (Table 7), how to pay for them and the roles of primary care physicians, specialist physicians, dieticians, personal trainers or case managers. Obesity prevention now seems likely to become the next major 'public health battleground' after the anti-smoking campaigns; the benefits in reducing long-term health costs are likely to be very substantial.

Early intervention

Available evidence, incomplete though it is, favours early intervention by increasing physical activity and dietary or other anti-obesity measures. The author applies the principles of reversing IR that have been adopted in very large T2DM intervention studies (Table 7) [123,124]. The emphasis needs to be on slow and modest reduction in body mass, not exceeding 1 kg (2 lbs)/week. This should be coupled with increasing physical activity (which may have beneficial effects on IR without weight loss) and with an emphasis on reducing abdominal girth rather than dramatically lowering body weight. What is ultimately required is the maintenance of beneficial changes as a lifelong commitment to better health. While patients with NAFLD can have raised AT without NASH, or NASH without raised AT, it seems pragmatic to use normalization of AT levels to indicate satisfactory improvement in liver disease after implementation of these lifestyle measures. Alternatively, USG could be used in a patient known to have normal ALT levels.

Effects of weight reduction

There is an extensive literature to document the beneficial effects of slow weight loss on AT levels in patients with likely or proven NAFLD [121–126]; this has been reviewed elsewhere [127]. Precipitant and profound weight loss (> 1 kg/week) has been associated with increased liver test abnormalities and worsening of hepatic fibrosis, or liver failure in some cases, particularly during repeated cycles of rapid weight gain and weight loss [54,75]. Thus, 'crash dieting' or other approaches to weight reduction equivalent to fasting must be avoided in persons with suspected NAFLD. Conversely, there is now increasing evidence that modest and sustained weight reduction, particularly in association with exercise, is associated not only with AT improvement and reduction in hepatic steatosis but also with resolution of steatohepatitis and reversal of hepatic fibrosis [121,126,128,129]. The concept that reversal of hepatic steatosis can 'unwind' NASH receives strong support experimentally from studies with the potent peroxisome proliferator-activated receptor-alpha (PPARα) agonist, Wy-14,643, in mice fed a methionine- and choline-deficient diet [130]; the PPARα agonist reversed all elements of fibrosing steatohepatitis in this model within 12 days. Just as impressively, in humans with morbid obesity subjected to bariatric surgery (gastric banding) to effect gradual and sustained weight reduction, follow-up biopsies performed 1–2 years later showed impressive resolution of NASH in most cases, including reduction in the severity of hepatic fibrosis [128,129].

In the absence of definitive controlled trials, it seems reasonable to conclude that attempts to treat obesity are important first-line therapy in patients with NASH. Specific measures, such as lipase inhibitors or safe forms of bariatric surgery, should be considered, especially in the morbidly obese (BMI > 35 kg/m^2). In most cases (those with established cirrhosis and evidence of impaired hepatocellular function may be exceptions), successful treatment, even with only modest weight loss (2–10 kg), may arrest or reverse fibrotic progression in NASH.

There has been considerable interest in pharmacological therapy of NASH [127]. Further, the paradigm established with PPARα agonists in mice indicates the possible utility of agents that alter hepatic lipid storage and turnover [130]. There is little published experience of PPARα agonists used for NAFLD/NASH in humans. In one preliminary study, clofibrate appeared to modify ALT levels [131], whereas another observation study found that bezafibrate corrected NAFLD in women taking tamoxifen [132]. There are species differences between humans and rodents concerning the relative importance of PPARα and PPARγ in the liver, and there has been considerable interest in the use of PPARγ agonists, such as the thiazolidinediones ('glitazones'), against NASH. In preliminary studies, troglitazone (now withdrawn because of hepatotoxicity), rosiglitazone and pioglitazone all improved AT levels (Table 8). Further, small controlled or open studies have demonstrated that the last two agents substantially improve liver histology after 1 year of therapy [133,134]. In addition to beneficial effects on IR, steatosis, necroinflammatory change and fibrosis were all substantially improved.

PPARγ agonists probably act principally on adipocytes to facilitate their differentiation and enhance their storage capacity for triglycerides, thereby effectively 'siphoning fat' out of the liver into subcutaneous deposits. As a result, weight gain is an unwanted effect; this occurred in at least two-thirds of patients in the rosiglitazone and pioglitazone NASH treatment trials [133,134]. Together with a relatively high frequency of other adverse effects and the high cost of these agents, this unwanted effect is likely to countermand the routine use of glitazones in patients with NAFLD/NASH. An exception might be for those with T2DM, in whom the additional beneficial effects of improved serum lipid and glycaemic control may warrant prescription of a glitazone.

Among other agents studied for efficacy in NASH (Table 8), a randomized controlled trial has now shown that ursodeoxycholic acid is ineffective [141], but vitamin E has shown some promise, particularly in combination with other agents [97,136–138]. Further trials are continuing. In conclusion, there is not as yet any accepted drug treatment of NASH; thus, application of any pharmacological therapy should be regarded as experimental and best conducted within the constraints of a randomized, controlled clinical trial. At present, the 'gold standard' for treatment of NAFLD/NASH is weight reduction,

preferably achieved by improving diet and levels of physical activity.

References

1 Adler M, Schaffner F (1979) Fatty liver hepatitis and cirrhosis in obese patients. *Am J Med* 67, 811–816.

2 Ludwig J, Viaggiano TR, McGill DB *et al.* (1980) Nonalcoholic steatohepatitis: Mayo Clinic experience with an hitherto unnamed disease. *Mayo Clin Proc* 55, 434–438.

3 James OFW, Day CP (1998) Nonalcoholic steatohepatitis (NASH): a disease of emerging identity and importance. *J Hepatol* 29, 495–501.

4 Angulo P (2002) Nonalcoholic fatty liver disease. *N Engl J Med* 16, 1221–1231.

5 Clark JM, Brancati FL, Diehl AM (2002) Nonalcoholic fatty liver disease. *Gastroenterology* 122, 1649–1657.

6 Farrell GC (2003) Okuda Lecture. Non-alcoholic steatohepatitis: what is it, and why is it important in the Asia-Pacific region. *J Gastroenterol Hepatol* 18, 124–138.

7 Neuschwander-Tetri BA, Caldwell SH (2003) Nonalcoholic steatohepatitis: summary of an AASLD single topic conference. *Hepatology* 37, 1202–1219.

8 Farrell GC, George J, Hall P de la M *et al.* (eds) (2005) *Fatty Liver Disease. NASH and Related Disorders*. Malden, MA: Blackwell Publishing, pp. 1–319.

9 Javor ED, Ghany MG, Cochran EK *et al.* (2005) Leptin reverses non-alcoholic steatohepatitis in patients with severe lipodystrophy. *Hepatology* 41, 753–760.

10 Matteoni CA, Younossi ZM, Gramlich T *et al.* (1999) Nonalcoholic fatty liver disease: a spectrum of clinical and pathological severity. *Gastroenterology* 116, 1413–1419.

11 Kleiner DE, Brunt EM, Van Natta M *et al.* (2005) Design and validation of a histological scoring system for non-alcoholic fatty liver disease. *Hepatology* 41, 1313–1321.

12 Brunt EM, Janney CG, Di Bisceglie AM *et al.* (1999) Nonalcoholic steatohepatitis: a proposal for grading and staging the histological lesions. *Am J Gastroenterol* 94, 2467–2474.

13 Hall P de la M, Kirsch R (2005) Pathology of steatosis, NASH and related conditions. In: Farrell GC, George J, Hall P de la M *et al.* (eds) *Fatty Liver Disease. NASH and Related Disorders*. Malden, MA: Blackwell Publishing, pp. 13–22.

14 Mendler MH, Kanel G, Govindarajan S (2005) Proposal for a histological scoring and grading system for non-alcoholic fatty liver disease. *Liver Int* 25, 294–304.

15 Ratziu V, Charlotte F, Heurtier A *et al.* (2005) Sampling variability of liver biopsy in nonalcoholic fatty liver disease. *Gastroenterology* 128, 1898–1906.

16 Gramlich T, Kleiner DE, McCullough AJ *et al.* (2004) Pathologic features associated with fibrosis in nonalcoholic fatty liver disease. *Hum Pathol* 35, 196–199.

17 McCullough AJ (2005) The epidemiology and risk factors of NASH. In: Farrell GC, George J, Hall P de la M *et al.* (eds) *Fatty Liver Disease. NASH and Related Disorders*. Malden, MA: Blackwell Publishing, pp. 23–37.

18 George DK, Goldwurm S, MacDonald GA *et al.* (1998) Increased hepatic iron concentration in non-alcoholic steatohepatitis is associated with increased fibrosis. *Gastroenterology* 114, 311–318.

19 Bonkovsky HL, Jawhid Q, Tortorelli K *et al.* (1999) Non-alcoholic steatohepatitis and iron: increased prevalence of mutations of the HFE gene in non-alcoholic steatohepatitis. *J Hepatol* 31, 421–429.

20 Norton R, Batey R, Dwyer T *et al.* (1987) Alcohol consumption and the risk of alcohol related cirrhosis in women. *Br Med J* 295, 80–82.

21 National Institutes of Health Consensus Development Conference Statement (2002) Management of Hepatitis C: 2002. *Hepatology* 36(Suppl. 1), S3–S21.

22 Hayashi PH, Harrison SA, Torgerson S *et al.* (2004) Cognitive lifetime drinking history in nonalcoholic fatty liver disease: some cases may be alcohol related. *Am J Gastroenterol* 99, 76–81.

23 Nomura H, Kashiwagi S, Hayashi J *et al.* (1988) Prevalence of fatty liver in a general population of Okinawa, Japan. *Jpn J Med* 27, 142–149.

24 Bellanti S, Saccoccio G, Masatti F *et al.* (2000) Prevalence of and risk factors for hepatic steatosis in Northern Italy. *Ann Intern Med* 132, 112–117.

25 Hasan I, Gani RA, Machmud R *et al.* (2002) Prevalence and risk factors for nonalcoholic fatty liver in Indonesia. *J Gastroenterol Hepatol* 17(Suppl), A154.

26 Browning JD, Szczepaniak LS, Dobbins R *et al.* (2004) Prevalence of hepatic steatosis in an urban population in the United States: impact of ethnicity. *Hepatology* 40, 1387–1395.

27 Patt CH, Yoo HY, Dibadji K *et al.* (2003) Prevalence of transaminase abnormalities in asymptomatic healthy subjects. *Dig Dis Sci* 48, 797–801.

28 Hilden M, Christoffersen P, Juhl E *et al.* (1977) Liver histology in a 'normal' population: examination of 503 consecutive fatal traffic casualties. *Scand J Gastroenterol* 12, 593–599.

29 Ground KE (1982) Liver biopsy in review. *Aviat Space Environ Med* 53, 14–18.

30 Wanless IR, Lentz JS (1990) Fatty liver hepatitis (steatohepatitis) and obesity: an autopsy study with analysis of risk factors. *Hepatology* 12, 1106–1110.

31 Marcos A, Fisher RA, Jam JM *et al.* (2000) Selection and outcome of living donors for adult right lobe. *Transplantation* 69, 2410–2415.

32 Hwang S, Lee SG, Jang SJ *et al.* (2004) The effect of donor weight reduction on hepatic steatosis for living donor liver transplantation. *Liver Transpl* 10, 721–727.

33 Dixon JB, Bhathal PS, O'Brien PE (2001) Nonalcoholic fatty liver disease: predictors of nonalcoholic steatohepatitis and liver fibrosis in the severely obese. *Gastroenterology* 121, 91–100.

34 Marceau P, Biron S, Hould FS *et al.* (1999) Liver pathology and the metabolic syndrome X in severe obesity. *J Clin Endocrinol Metab* 84, 1513–1517.

35 DelGaudio A, Boschi L, DelGaudio GA *et al.* (2001) Liver damage in obese persons. *Obes Surg* 11, 254–257.

36 Lucyckx FA, Desaive C, Tiry A *et al.* (1998) Liver abnormalities in severely obese subjects: effect of drastic weight loss after gastroplasty. *Int J Obes* 22, 222–226.

37 Silverman EM, Sapala JA, Appelman HD (1995) Regression of hepatic steatosis in morbidly obese persons after gastric bypass. *Am J Clin Pathol* 104, 23–31.

38 Roberts EA (2002) Steatohepatitis in children. *Best Pract Res Clin Gastroenterol* 16, 749–765.

39 Lavine JE, Schwimmer JB (2005) NAFLD/NASH in children. In: Farrell GC, George J, Hall P de la M *et al.* (eds) *Fatty Liver Disease. NASH and Related Disorders*. Malden, MA: Blackwell Publishing, pp. 229–240.

40 Manton ND, Lipsett J, Moore DJ *et al.* (2000) Non-alcoholic steatohepatitis in children and adolescents. *Med J Aust* 173, 476–479.

41 Bacon BR, Farahvash MJ, Janney CG *et al.* (1994) Nonalcoholic steatohepatitis: an expanded clinical entity. *Gastroenterology* 107, 1103–1109.

42 Chitturi S, Abeygunasekera S, Farrell GC *et al.* (2002) NASH and insulin resistance: insulin hypersecretion and specific association with the insulin resistance syndrome. *Hepatology* 35, 373–378.

43 Pagano G, Pacini G, Musso G *et al.* (2002) Nonalcoholic steatohepatitis, insulin resistance and metabolic syndrome: further evidence for an etiologic association. *Hepatology* 35, 367–372.

44 Marchesini G, Bugianesi E, Forlani G *et al.* (2003) Nonalcoholic fatty liver, steatohepatitis, and the metabolic syndrome. *Hepatology* 37, 917–923.

45 Angelico F, Del Ben M, Conti R *et al.* (2003) Non-alcoholic fatty liver syndrome: a hepatic consequence of common metabolic diseases. *J Gastroenterol Hepatol* 18, 1115–1117.

46 Kral JG, Schaffner F, Pierson RN Jr *et al.* (1993) Body fat topography as an independent predictor of fatty liver. *Metabolism* 42, 548–551.

47 Omagari KH, Kadokawa Y, Masuda J *et al.* (2002) Fatty liver in non-alcoholic non-overweight Japanese adults: incidence and clinical characteristics. *J Gastroenterol Hepatol* 17, 1089–1105.

48 Park SH, Jeon WK, Kim SH *et al.* (2006) Prevalence and risk factors of non-alcoholic fatty liver disease among Korean adults. *J Gastroenterol Hepatol* 21, 138–141.

49 Expert Panel on Detection, Evaluation, and Treatment of High Blood Cholesterol in Adults (2001) Executive Summary of the Third Report of the National Cholesterol Education Program (NCEP) Expert Panel on Detection, Evaluation and Treatment of High Blood Cholesterol in Adults (Adult Treatment Panel III). *JAMA* 285, 2486–2497.

50 Struben VMD, Hespenheide EE, Caldwell SH (2000) Nonalcoholic steatohepatitis and cryptogenic cirrhosis within kindreds. *Am J Med* 108, 9–13.

51 Petersen KF, Befroy D, Dufour S *et al.* (2003) Mitochondrial dysfunction in the elderly: possible role in insulin resistance. *Science* 300, 1140–1142.

52 Poynard T, Ratziu V, Benhamou Y *et al.* (2000) Fibrosis in patients with chronic hepatitis C: detection and significance. *Semin Liver Dis* 20, 47–55.

53 Chitturi S, Farrell GC (2001) Etiopathogenesis of nonalcoholic steatohepatitis. *Semin Liver Dis* 21, 27–41.

54 Capron J-P, Delamarre J, Dupas J-L *et al.* (1982) Fasting in obesity: another cause of liver injury with alcoholic hyaline? *Dig Dis Sci* 27, 265–268.

55 Angulo P, Keach JC, Batts KP *et al.* (1999) Independent predictors of liver fibrosis in patients with nonalcoholic steatohepatitis. *Hepatology* 30, 1356–1362.

56 Harrison SA, Torgerson S, Hayashi PH (2003) The natural history of nonalcoholic fatty liver disease: a clinical histopathological study. *Am J Gastroenterol* 98, 2042–2047.

57 Ratziu V, Bonhay L, Di Martino V *et al.* (2002) Survival, liver failure, and hepatocellular carcinoma in obesity-related cryptogenic cirrhosis. *Hepatology* 35, 1485–1493.

58 Mofrad P, Contos MJ, Haque M *et al.* (2003) Clinical and histologic spectrum of nonalcoholic fatty liver disease associated with normal ALT values. *Hepatology* 37, 1286–1292.

59 Ioannou GN, Weiss NS, Boyko EJ *et al.* (2005) Contribution of metabolic factors to alanine aminotransferase activity in persons with other causes of liver disease. *Gastroenterology* 128, 627–635.

60 Samuel VT, Shulman G (2005) Insulin resistance in NAFLD: potential mechanisms and therapies. In: Farrell GC, George J, Hall P de la M *et al.* (eds) *Fatty Liver Disease. NASH and Related Disorders*. Malden, MA: Blackwell Publishing, pp. 38–54.

61 Wanless IR, Shiota K (2004) The pathogenesis of nonalcoholic steatohepatitis and other fatty liver diseases: a four-step model including the role of lipid release and hepatic venular obstruction in the progression to cirrhosis. *Semin Liver Dis* 24, 99–106.

62 Park SH, Kim BI, Yun JW *et al.* (2004) Insulin resistance and C-reactive protein as independent risk factors for non-alcoholic fatty liver disease in non-obese Asian men. *J Gastroenterol Hepatol* 19, 694–698.

63 Hui J, Farrell GC, Kench JG *et al.* (2004) High sensitivity CRP protein values do not reliably predict the severity of histological change in NAFLD (letter). *Hepatology* 39, 1458–1459.

64 Tilg H, Diehl AM (2000) Cytokines in alcoholic and non-alcoholic steatohepatitis. *N Engl J Med* 343, 1467–1476.

65 Hui J, Hodge A, Farrell GC *et al.* (2004) Beyond insulin resistance in NASH: TNF-alpha or adiponectin? *Hepatology* 40, 19–22.

66 Bugianesi E, Pagotto U, Manini R *et al.* (2005) Plasma adiponectin in nonalcoholic fatty liver is related to hepatic insulin resistance and hepatic fat content, not to disease severity. *J Clin Endocrinol Metab* 90, 3498–3504.

67 Diehl AM, Li ZP, Lin HZ *et al.* (2005) Cytokines and the pathogenesis of non-alcoholic steatohepatitis. *Gut* 54, 303–306.

68 Bugianesi E, Manzini P, D'Antico S *et al.* (2004) Relative contribution of iron burden, HFE mutations, and insulin resistance to fibrosis in non-alcoholic fatty liver. *Hepatology* 39, 179–187.

69 Younossi ZM, Gramlich T, Bacon BR *et al.* (1999) Hepatic iron and nonalcoholic fatty liver disease. *Hepatology* 30, 847–850.

70 Chitturi C, Weltman M, Farrell GC *et al.* (2002) HFE mutations, hepatic iron, and fibrosis: ethnic-specific associations of NASH with C282Y but not with fibrotic severity. *Hepatology* 36, 142–148.

71 Saadeh S, Younossi ZM, Remer EM *et al.* (2002) The utility of radiological imaging in nonalcoholic fatty liver disease. *Gastroenterology* 123, 745–750.

72 Friedman LS (2004) Controversies in liver biopsy: who, where, when, how, why? *Curr Gastroenterol Rep* 6, 30–36.

73 Powell EE, Cooksley WGE, Hanson R *et al.* (1990) The natural history of nonalcoholic steatohepatitis: a follow-up study of forty-two patients for up to 21 years. *Hepatology* 11, 74–80.

74 Falck-Ytter Y, Younossi ZM, Marchesini G *et al.* (2001) Clinical features and natural history of nonalcoholic steatosis syndromes. *Semin Liver Dis* 21, 17–26.

75 Caldwell SH, Hespenheide EE (2002) Subacute liver failure in obese women. *Am J Gastroenterol* 97, 2058–2062.

76 Hui JM, Kench JG, Chitturi S *et al.* (2003) Long-term outcomes of cirrhosis in non-alcoholic steatohepatitis compared to hepatitis C. *Hepatology* 38, 873–881.

77 Brun E, Nelson RG, Bennett PH *et al.* (2000) Diabetes duration and cause-specific mortality in the Verona Diabetes Study. *Diabetes Care* 23, 1119–1123.

78 Lowell BB, Shulman GG (2005) Mitochondrial dysfunction and type 2 diabetes. *Science* 307, 384–387.

79 Samuel VT, Liu Z-X, Qu X *et al.* (2004) Mechanism of hepatic insulin resistance in non-alcoholic fatty liver disease. *J Biol Chem* 279, 32345–32353.

80 Kim JK, Fillmore JJ, Chen Y *et al.* (2001) Tissue-specific overexpression of lipoprotein lipase causes tissue-specific insulin resistance. *Proc Natl Acad Sci USA* 98, 7522–7527.

81 Kraegen EW, Clark PW, Jenkins AB *et al.* (1991) Development of muscle insulin resistance after liver insulin resistance in high-fat-fed rats. *Diabetes* 40, 1397–1403.

82 Browning JD, Horton JD (2004) Molecular mediators of hepatic steatosis and liver injury. *J Clin Invest* 114, 147–152.

83 Sanyal AJ, Campbell-Sargent C, Mirshahi F *et al.* (2001) Nonalcoholic steatohepatitis: association of insulin resistance and mitochondrial abnormalities. *Gastroenterology* 120, 1183–1192.

84 Caldwell SH, Swerdlow RH, Khan EM *et al.* (1999) Mitochondrial abnormalities in nonalcoholic steatohepatitis. *J Hepatol* 31, 430–434.

85 Carmiel-Haggai M, Cederbaum AI, Nieto N (2005) A high-fat diet leads to the progression of non-alcoholic fatty liver disease in obese rats. *FASEB J* 19, 136–138.

86 Masaki T, Chiba S, Tatsukawa H *et al.* (2004) Adiponectin protects LPS-induced liver injury through modulation of TNF-alpha in KK-Ay obese mice. *Hepatology* 40, 19–22.

87 Xu A, Wang Y, Keshaw H *et al.* (2003) The fat-derived hormone adiponectin alleviates alcoholic and nonalcoholic fatty liver diseases in mice. *J Clin Invest* 112, 91–100.

88 Day C, James O (1998) Steatohepatitis: a tale of two 'hits'? *Gastroenterology* 114, 842–845.

89 Weltman MD, Farrell GC, Ingelman-Sundberg M *et al.* (1998) Hepatic cytochrome P4502E1 is increased in patients with non-alcoholic steatohepatitis. *Hepatology* 27, 128–133.

90 Chalasani N, Gorski C, Asghar MS *et al.* (2003) Hepatic cytochrome P450 2E1 activity in nondiabetic patients with nonalcoholic steatohepatitis. *Hepatology* 37, 544–550.

91 Leclercq IA, Farrell GC, Field J *et al.* (2000) Cyp2e1 and Cyp4a as microsomal catalysts of lipid peroxides in murine non-alcoholic steatohepatitis. *J Clin Invest* 105, 1067–1075.

92 Robertson G, Leclercq I, Farrell GC (2001) Nonalcoholic steatosis and steatohepatitis. II. Cytochrome P450 enzymes and oxidative stress. *Am J Physiol Gastrointest Liver Physiol* 281, G1135–1139.

93 Deng Q-G, She H, Cheng J *et al.* (2005)Steatohepatitis induced by intragastric overfeeding in mice. *Hepatology* 42, 905–914.

94 de la Pena A, Leclercq I, Field J *et al.* (2005) NF-κB activation, rather than TNF, mediates hepatic inflammation in a murine dietary model of steatohepatitis. *Gastroenterology* 129, 1663–1674.

95 George J, Pera N, Phung N *et al.* (2003) Lipid peroxidation, stellate cell activation and hepatic fibrogenesis in a rat model of chronic steatohepatitis. *J Hepatol* 39, 756–764.

96 McCuskey R, Ito Y, Robertson GR *et al.* (2004) Hepatic microvascular dysfunction during evolution of dietary steatohepatitis in mice. *Hepatology* 40, 386–393.

97 Lavine JE (2000) Vitamin E treatment of non-alcoholic steatohepatitis in children: a pilot study. *J Pediatr* 136, 734–738.

98 Burke A, Lucey MR (2005) NAFLD, NASH and orthotopic liver transplantation. In: Farrell GC, George J, Hall P de la M *et al.* (eds) *Fatty Liver Disease. NASH and Related Disorders*. Malden, MA: Blackwell Publishing, pp. 208–217.

99 Caldwell SH, Oelsner DH, Iezzoni JC *et al.* (1999) Cryptogenic cirrhosis: clinical characterization and risk factors for underlying disease. *Hepatology* 29, 664–669.

100 Poonawala A, Nair SP, Thuluvath PJ (2000) Prevalence of obesity and diabetes in patients with cryptogenic cirrhosis: a case study. *Hepatology* 32, 689–692.

101 Bugianesi E, Leone N, Vanni E *et al.* (2002) Expanding the natural history of nonalcoholic steatohepatitis: from cryptogenic cirrhosis to hepatocellular carcinoma. *Gastroenterology* 123, 134–140.

102 Marrero JA, Fontana RJ, Su GL *et al.* (2002) NAFLD may be a common underlying liver disease in patients with hepatocellular carcinoma in the United States. *Hepatology* 36, 1349–1354.

103 Shimada M, Hashimoto E, Taniai M *et al.* (2002) Hepatocellular carcinoma in patients with non-alcoholic steatohepatitis. *J Hepatol* 37, 154–160.

104 El-Serag HB, Tran T, Everhart JE (2004) Diabetes increases the risk of chronic liver disease and hepatocellular carcinoma. *Gastroenterology* 126, 460–468.

105 Davila J, Morgan RO, Shaib Y *et al.* (2005) Diabetes increases the risk of hepatocellular carcinoma in the United States: a population based case control study. *Gut* 54, 533–539.

106 Hourigan LF, Macdonald GA, Purdie D *et al.* (1999) Fibrosis in chronic hepatitis C correlates with body mass index and steatosis. *Hepatology* 29, 1215–1219.

107 Hwang SJ, Luo JC, Chu CW *et al.* (2001) Hepatic steatosis in chronic hepatitis C virus infection: prevalence and clinical correlation. *J Gastroenterol Hepatol* 16, 190–195.

108 Hui JM, Kench J, Farrell GC *et al.* (2002) Genotype-specific mechanisms for hepatic steatosis in chronic hepatitis C infection. *J Gastroenterol Hepatol* 17, 873–881.

109 Monto A, Alonzo J, Watson JJ *et al.* (2002) Steatosis in hepatitis C: relative contributions of obesity, diabetes mellitus and alcohol. *Hepatology* 36, 729–736.

110 Kumar D, Farrell GC, Fung C *et al.* (2002) Hepatitis C virus genotype 3 is cytopathic to hepatocytes: reversal of hepatic steatosis after sustained therapeutic response. *Hepatology* 36, 1266–1272.

111 Hui J, Sud A, Farrell GC *et al.* (2003) Insulin resistance is associated with chronic hepatitis C virus infection fibrosis progression. *Gastroenterology* 125, 1695–1704.

112 Powell EE, Jonsson JR, Clouston AD (2005) Steatosis: co-factor in other liver diseases. *Hepatology* 42, 5–13.

113 Poynard T, Ratziu V, McHutchison J *et al.* (2003) Effect of treatment with peginterferon or interferon alfa-2b and ribavirin on steatosis in patients infected with hepatitis C. *Hepatology* 38, 75–85.

114 Kawaguchi T, Yoshida T, Harada M *et al.* (2004) Hepatitis C virus down-regulates insulin receptor substrates 1 and 2 through up-regulation of suppressor of cytokine signaling 3. *Am J Pathol* 165, 1499–1508.

115 Shintani Y, Fujie H, Miyoshi H *et al.* (2004) Hepatitis C virus infection and diabetes: direct involvement of the virus in the development of insulin resistance. *Gastroenterology* 126, 840–848.

116 Mehta SH, Brancati FL, Strathdee SA *et al* (2003) Hepatitis C virus infection and incident type 2 diabetes. *Hepatology* 38, 50–56.

117 Bressler BL, Guindi M, Tomlinson G *et al.* (2003) High body mass index is an independent risk factor for nonresponse to antiviral treatment in chronic hepatitis C. *Hepatology* 38, 639–644.

118 Patton HM, Patel K, Behling C *et al.* (2004) The impact of steatosis on disease progression and early and sustained treatment response in chronic hepatitis C patients. *J Hepatol* 40, 484–490.

119 D'Souza R, Sabin CA, Foster GR (2005) Insulin resistance plays a significant role in liver fibrosis in chronic hepatitis C and in the response to antiviral therapy. *Am J Gastroenterol* 100, 1509–1515.

120 Hickman IJ, Clouston AD, MacDonald GA *et al.* (2002) Effect of weight reduction on liver histology and biochemistry in patients with chronic hepatitis C. *Gut* 51, 89–94.

121 Hickman IJ, Jonsson JR, Prins JB *et al.* (2004) Modest weight loss and physical activity in overweight patients with chronic liver disease results in sustained improvements in alanine aminotransferase, fasting insulin and quality of life. *J Hepatol* 53, 413–419.

122 Naveau S, Giraud V, Borotto E *et al.* (1997) Excess weight risk factor for alcoholic liver disease. *Hepatology* 25, 108–111.

123 Tuomilehto J, Lindstrom J, Eriksson JG *et al.* (2001) Prevention of type 2 diabetes mellitus by changes in lifestyle among subjects with impaired glucose tolerance. *N Engl J Med* 344, 1343–1350.

124 Diabetes Prevention Program Research Group (2002) Reduction in the incidence of type 2 diabetes with lifestyle intervention or metformin. *N Engl J Med* 346, 393–403.

125 Palmer M, Schaffner F (1990) Effect of weight reduction on hepatic abnormalities in overweight patients. *Gastroenterology* 99, 1408–1413.

126 Ueno T, Sugawara H, Sujaku K *et al.* (1997) Therapeutic effects of restricted diet and exercise in obese patients with fatty liver. *J Hepatol* 27, 103–107.

127 Angulo P (2005) Management of NASH: current and future perspectives on treatment. In: Farrell GC, George J, Hall P de la M *et al.* (eds) *Fatty Liver Disease. NASH and Related Disorders*. Malden, MA: Blackwell Publishing, pp. 194–207.

128 Dixon JB, Bhathal PS, Hughs NR *et al.* (2004) Nonalcoholic fatty liver disease: improvement in liver histological analysis with weight loss. *Hepatology* 39, 1647–1654.

129 Kral JG, Thung SN, Biron S *et al.* (2004) Effects of surgical treatment of the metabolic syndrome on liver fibrosis and cirrhosis. *Surgery* 135, 48–58.

130 Ip E, Farrell G, Hall P *et al.* (2004) Administration of the potent PPARα agonist, Wy14,643, reverses nutritional fibrosis and steatohepatitis in mice. *Hepatology* 39, 1286–1296.

131 Laurin J, Lindor KD, Crippin JS *et al.* (2004) Ursodeoxycholic acid or clofibrate in the treatment of non-alcohol-induced steatohepatitis: a pilot study. *Hepatology* 23, 1464–1467.

132 Saibara T, Onishi S, Ogawa Y *et al.* (1999) Bezafibrate for tamoxifen-induced non-alcoholic steatohepatitis. *Lancet* 353, 1802.

133 Neuschwander-Tetri BA, Brunt EM, Wehmeier KR *et al.* (2003) Improved non-alcoholic steatohepatitis after 48 weeks of treatment with the PPAR-gamma ligand rosiglitazone. *Hepatology* 38, 1008–1017.

134 Pomrat K, Lutchman G, Uwaifo GI *et al.* (2004) A pilot study of pioglitazone treatment for non-alcoholic steatohepatitis. *Hepatology* 39, 188–196.

135 Marchesini G, Brizi M, Bianchi G *et al.* (2001) Metformin in non-alcoholic steatohepatitis. *Lancet* 358, 893–894.

136 Sanyal AJ, Mofrad PS, Contos MJ *et al.* (2004) A pilot study of vitamin E versus vitamin E and pioglitazone for the treatment of non-alcoholic steatohepatitis. *Clin Gastroenterol Hepatol* 2, 1107–1115.

137 Hasegawa T, Yoneda M, Nakamura K *et al.* (2001) Plasma transforming growth factor-β1 level and efficacy of α-tocopherol in patients with non-alcoholic steatohepatitis: a pilot study. *Aliment Pharmacol Ther* 15, 1667–1672.

138 Harrison SA, Togerson S, Hayashi P *et al.* (2003) Vitamin E and vitamin C treatment improves fibrosis in patients with non-alcoholic steatohepatitis. *Am J Gastroenterol* 98, 2485–2490.

139 Miglio F, Rovati LC, Santoro A *et al.* (2000) Efficacy and safety of oral betaine glucuronate in non-alcoholic steatohepatitis. *Arzneimittelforschung* 50, 722–727.

140 Abdelmalek M, Angulo P, Jorgensen RA *et al.* (2001) Betaine, a promising new agent for patients with non-alcoholic steatohepatitis: results of a pilot study. *Am J Gastroenterol* 96, 2711–2717.

141 Lindor KD, Kowdley KV, Heathcote EJ *et al.* (2004) Ursodeoxycholic acid for treatment of non-alcoholic steatohepatitis: results of a randomized trial. *Hepatology* 39, 770–778.

14 Toxic liver injury

14.1 Drug-induced liver injury

Dominique Pessayre and Dominique Larrey

Introduction

Drug-induced liver injury is a major challenge for the pharmaceutical industry because it is a frequent cause of drug recall and, for physicians, who can cure their patients by establishing the diagnosis and withdrawing the drug, whereas failure to recognize the liver disease and/or its drug aetiology may lead either to the worsening of the acute liver lesions or to the progressive development of chronic liver disease. Drug-induced clinical hepatitis is not uncommon. Its estimated incidence rate is 14 per 100 000 inhabitants per year [1], and drug-induced injury may be a frequent cause of hepatitis in elderly subjects receiving many drugs [2]. Early recognition of hepatic drug reactions is therefore a major concern for physicians.

Acquiring some knowledge of drug-induced liver lesions may seem a formidable task, however. More than a thousand drugs may be hepatotoxic [3], and this list is ever increasing as new molecules are released on the market. Furthermore, drugs may damage the liver through different mechanisms, and hepatic drug reactions may mimic almost any kind of liver disease [4]. Clearly, the human mind cannot memorize all these data, nor can they be fitted into the frame of a single chapter. It is necessary, however, to have some direct knowledge of the several types of drug-induced liver lesions, the main mechanisms of hepatotoxicity and the main drugs producing such effects. This chapter is an attempt to summarize this basic knowledge. Readers may find more exhaustive descriptions of the type of hepatitis produced by each individual drug in books that are entirely devoted to this topic [3–6]. The present chapter does not include environmental toxins, physical agents and herbal remedies, which are considered in Chapters 14.2, 14.3 and 14.4 respectively.

General considerations

Marketing of hepatotoxic drugs

Each year, several drugs are marketed that are hepatotoxic. In some instances, the hepatotoxic risk was already known at the time of marketing, but this risk is accepted knowingly, because the drug is highly effective against a serious disease, and there are no better or safer treatments.

However, in most instances, the hepatotoxic risk was initially thought to be absent or minimal, but is then recognized after the drug has been marketed. Animal trials may have shown no hepatic lesion, or they may have disclosed lesions at very high doses that were thought to be meaningless for the much lower doses employed in humans. Studies in cultured human hepatocytes may have concluded that there was no toxicity at clinically relevant concentrations, although hepatitis eventually occurs in humans as a result of immune reactions or idiosyncratic toxicity in a few metabolically susceptible patients. However, the main reason for the steady release of hepatotoxic drugs is that clinical trials are extremely expensive, thus limiting the size of the population that can be exposed to the drug in clinical trials to a few thousand patients. In general, drug-induced hepatocellular liver injury tends to cause a relatively high incidence of liver test abnormalities (e.g. 1–5/100), but infrequent cases of jaundice (1/1000 or less) and exceptional cases of deaths from liver failure (1/10 000 or less). Although clinical trials can easily disclose patients with slightly impaired liver function tests, these mild biological effects do not necessarily predict severe hepatotoxicity. For example, unfractionated heparins very frequently cause transaminitis, but exceptionally trigger clinical hepatitis.

Much more predictive are cases of cytolytic hepatitis that are severe enough to cause clinical jaundice. As shown by the late Hyman Zimmerman, the fatality rate in such patients may be around 10% [4]. However, if the frequency of severe hepatitis is low (e.g. 1/10 000 or 1/100 000), it can go undetected in clinical trials limited to a few thousand patients. Conversely, however, if clinical trials have disclosed many patients with both an increase in alanine aminotransferase (ALT) to more than 10 times the upper limit of normal (ULN) and a concomitant increase in bilirubin to more than 3.5 times the ULN, while no such cases – or only a few such cases – occur in the comparator group, then it can be safely concluded that the drug can cause severe liver injury in some patients. Should the drug be approved (due to a nevertheless favourable risk/benefit ratio), fatalities from liver injury

are expected to occur with a frequency of about 1/10th the frequency of patients exhibiting these severe liver test abnormalities.

Additional factors may also contribute to the inefficiency of clinical trials in the detection of hepatotoxicity. Some drugs may be intended for short use (e.g. antibiotics), and clinical trials may be devised accordingly. However, when the drug is released on the market, some patients take it for much longer periods. This leaves more time for immunization to occur, for example, and cases of immunoallergic hepatitis may then appear. Release of the drug on the market may also expose patients who had been excluded, or included in small numbers, during the clinical trials, but who subsequently turn out to display particular susceptibility (e.g. very young children for valproate hepatotoxicity; elderly subjects for benoxaprofen hepatotoxicity; patients with renal insufficiency for several drugs eliminated by the kidney).

It therefore seems inescapable that hepatotoxic molecules will continue to be marketed each year. Progress in pharmacovigilance should ensure that their hepatotoxic potential can then be recognized quickly. The responsibility of physicians in reporting all adverse events encountered with newly marketed drugs should be emphasized.

Frequency of adverse drug reactions among recipients

Once a drug is recognized as being hepatotoxic, it is important to try to know the frequency of this adverse effect. This can be determined accurately when the drug produces relatively frequent (e.g. 1/100 or 1/1000) clinical manifestations. Large cohort studies can then gather a sufficient number of clinical cases to estimate this frequency reliably. However, for drugs that produce clinical hepatotoxicity in 1/10 000 recipients or less, cohort studies would require a staggering number of patients and are therefore rarely conducted.

Theoretically, one should be able to estimate this frequency from the number of prescriptions and the spontaneous reports of adverse drug reactions. Although this reporting is supposed to be mandatory in several countries, there are many reasons why it tends to be neglected. In addition to the time spent in gathering the data and filling out the form, this report may lead to subsequent harassment by request(s) for more information made by the national drug agency, the drug company or both. Furthermore, there are plenty of convenient excuses to soothe one's guilt for not doing so: 'the hepatotoxicity of the drug is already known'; 'its responsibility in the present case is far from certain'; 'this is a minor adverse reaction'; 'I shall report it later, once I have ascertained that there is sustained normalization of liver function tests'. Although none of these excuses should be considered as valid, it is clear that frequencies estimated from the spontaneous reporting of adverse events by physicians represent underestimates of the real frequencies. A French population-based study in non-hospitalized patients has suggested that the number of hepatic adverse drug reactions may be 16 times greater than that reported to the French regulatory authorities [1]. Even in hospitalized patients, 13 times more patients had drug-induced liver injury than was reported to the French pharmacovigilance agency [7].

Prevalence of adverse drug reactions among various causes of liver disease

One would like also to know what is the proportion of patients with drug-induced hepatic injury among all patients affected with liver disease at a given time. Surveys conducted among patients admitted to liver units have given proportions ranging from 2% to 5% of cases of jaundice and about 10% of cases of hepatitis [2]. Similarly, in a study performed in patients hospitalized in the diverse medical departments of a large French hospital, drug-induced liver injury accounted for about 9% of patients with ALT > 2 ULN and/or alkaline phosphatase > 1.5 ULN [7]. However, data in hospitalized patients may give a biased view because only patients with difficult management problems may be referred to the hospital. General practitioners are now well trained in suspecting adverse hepatic reactions and quickly withdraw potentially hepatotoxic drugs. Patients improve without ever seeing hepatologists or without being referred to the hospital.

An estimate is possible, however, in cases that are necessarily sent to the hospital, such as cases of fulminant hepatitis. In a large survey of causes of fulminant hepatitis in France, 10–15% of cases were probably drug induced [8]. A much higher proportion (about 50%) is observed in England or the United States, due to the popularity of paracetamol as a means of attempting suicide in these countries [9]. In the USA, 40% of cases of acute liver failure are due to paracetamol, and approximately 12% to diverse other drugs [9].

Sex, age, infections, comorbidity and other susceptibility factors

A female predominance of drug-induced hepatitis is observed with several drugs (e.g. alpha-methyldopa, halothane or nitrofurantoin). This is not an obligatory rule, however. Instead, chronic liver injury due to azathioprine seems to occur mostly in men. Overall, the risk of developing 'toxic hepatitis' was similar in Danish men and women. In a French population-based study, the incidence rates of adverse hepatic reactions were similar in males and females until age 49 years, but then became twice as high in women as in men after this age [1].

The number of cases of drug-induced hepatitis per million person–years increases progressively with age, rising from a few cases during the first and second decades of life to about 45 cases during the eighth decade. Most of this increase is probably due to the progressive increase in drug consumption with age. However, at least with several dugs, the incidence of hepatitis in treated subjects also increases during old age. For example, the risks of halothane- and isoniazid-induced hepatitis increase several fold in patients over 40 years of age [5]. Not only the

frequency, but also the severity of drug-induced hepatitis can increase during old age. A notorious example is the anti-inflammatory drug, benoxaprofen, which caused several deaths in very old subjects.

In contrast, hepatic drug reactions tend to be uncommon in children. For example, halothane or erythromycin rarely cause hepatitis in children [5]. Notable exceptions, however, include the hepatotoxicity of some drugs that interfere with mitochondrial function. Whereas valproate rarely causes severe liver injury after 20 years of age, it frequently causes liver injury in children less than 3 years old, and should be avoided at this young age [5]. Whereas aspirin rarely causes severe liver injury in adults, it can occasionally trigger Reye syndrome after a viral infection in children [5].

Mild viral infections have been shown to increase the hepatotoxicity of several drugs. Although lethal overdoses of aspirin cause severe microvesicular steatosis in children, therapeutic doses do not, unless aspirin is administered during viral infections. In tuberculous patients treated with isoniazid, rifampin and/or pyrazinamide, the risk of drug-induced hepatitis was increased fivefold in patients infected with the hepatitis C virus (HCV), fourfold in patients with the human immunodeficiency virus (HIV) and 14-fold in patients coinfected with both viruses. In another study, the risk of antituberculous drug-induced hepatitis was increased threefold in hepatitis B virus (HBV) surface antigen carriers. Azathioprine-induced liver injury seemed to be increased by concomitant infections with HCV, HBV or cytomegalovirus. In HIV-infected patients receiving highly active antiretroviral therapy (HAART), the risk of developing severe hepatotoxicity was increased several fold by HCV or HBV coinfections. Finally, the hepatotoxicity of paracetamol is increased in patients with infectious mononucleosis, measles or acute hepatitis A or B. Although the mechanism of this increased toxicity is unknown, it has been suggested that the subliminal stimulation of death receptors by cytokines liberated during mild viral infections may aggravate the hepatotoxicity of drugs transformed into glutathione-depleting reactive metabolites and/or may cause additive mitochondrial toxicity with drugs that impair mitochondrial function [10].

Conceivably, the same mechanisms could be involved in the increased susceptibility of patients with inflammatory rheumatic diseases to some drugs. Salicylate-induced liver injury is more frequent in children with the juvenile form of rheumatoid arthritis and in patients with systemic lupus erythematosus [5]. Likewise, the risk of sulphasalazine-induced hepatitis may be higher in patients with rheumatoid arthritis [5].

Renal insufficiency may increase the risk of hepatotoxicity when the parent compound itself is the toxic species and this toxic compound is eliminated by the kidney. A well-known example is tetracycline. Fatal cases of microvesicular steatosis occurred more frequently in women with renal insufficiency [4].

Obesity- and/or diabetes-mediated steatohepatitis impairs mitochondrial function [11] and may sensitize patients to the hepatotoxic effects of drugs that impair mitochondrial function. Methotrexate, which targets mitochondrial DNA and mitochondrial function, can cause hepatic steatosis and fibrosis in humans [5]. The hepatotoxicity of methotrexate is enhanced by several other causes of mitochondrial dysfunction, including alcohol abuse, diabetes and obesity. Likewise, tamoxifen-associated steatohepatitis occurs mainly in obese women.

In contrast, there is no evidence that cirrhosis can increase the incidence of drug-induced hepatitis. Instead, cirrhosis decreases drug metabolism by cytochrome P-450 [12], which might decrease the formation of toxic or immunogenic metabolites. However, although cirrhosis may not increase the incidence of drug-induced hepatitis, it can obviously affect its clinical outcome. Whereas the acute destruction of 25% of hepatocytes may be well tolerated in a subject with an initially normal liver, the same destruction may trigger decompensation and death in a cirrhotic patient with already compromised liver function.

Genetic factors also play a major role in individual susceptibility to drug-induced liver injury. These genetic factors differ with the mechanisms of liver injury, and will be considered in subsequent sections.

Diversity of drug-induced liver diseases

Drugs may produce diverse liver lesions (Table 1) corresponding to different mechanisms of hepatotoxicity (Table 2).

Duration of the liver injury required to produce these lesions

The time interval between the onset of the treatment and the recognition of the liver disease corresponds to the sum of two periods: an initial period during which the drug is well tolerated and a second period of incipient, and then variably progressing, liver injury. Unless liver tests have been monitored, we do not know the actual duration of the liver injury that has led to a given liver lesion. A corollary is that terms such as 'subacute' or 'chronic' hepatitis, for example, should be understood as meaning the presence of histological lesions classified as such, rather than meaning any precise time definition.

Albeit hypothetical, Table 3 gives some tentative estimates of the probable duration of the liver injury required to produce various hepatocellular liver lesions.

Multiplicity of hepatotoxic drugs

Any list of hepatotoxic drugs represents a soon outdated snapshot, as new drugs are constantly released on the market, and many of those that cause frequent liver injury are either recalled or fall into disrepute. Furthermore, space limitation does not allow tabulation of the thousands of drugs that may cause liver injury [3]. The reader is referred to a constantly updated website maintained by Dr M. Biour: http://www.e-drugnews.com/index.cfm.

Table 1 Diversity and proposed classification of drug-induced liver disease.

Classification	Main lesions
Acute hepatitis	
Cytolytic hepatitis	Lobular hepatocyte necrosis + lobular and portal inflammation
Cholestatic hepatitis	Cholestasis + portal inflammation
Cholestatic hepatitis with cholangiolitis and cholangitis	Cholestasis + portal inflammation + acute lesions of intrahepatic bile ducts
Mixed hepatitis	Necrosis + cholestasis + lobular and portal inflammation
Granulomatous hepatitis[a]	Hepatic granulomas inflammation
Bland cholestasis	Cholestasis without other liver lesions
Lipid storage liver disease	
Macrovacuolar steatosis	Single large vacuole of fat
Microvesicular steatosis	Multiple small lipid vesicles
Phospholipidosis	Enlarged lysosomes with myelinic figures
Steatohepatitis	Steatosis, necrosis, inflammatory infiltrate, Mallory bodies, fibrosis
Stellate cell lipidosis	Hyperplasia of vitamin A-laden stellate cells ± perisinusoidal fibrosis
Subacute hepatitis, chronic hepatitis and cirrhosis	
Subacute hepatitis	Acute hepatitis with bridging necrosis + fibrosis
Chronic hepatitis	Periportal necrosis + portal inflammation + portal fibrosis
Cirrhosis	Disorganized architecture + extensive fibrosis + regenerative nodules
Prolonged cholestasis	
Vanishing bile duct syndrome	Rarefaction of intrahepatic bile ducts
Sclerosing cholangitis	Strictures on large bile ducts
Vascular and related lesions	
Portal veins	Thrombosis
Hepatic artery	Intimal hyperplasia or angiitis
Sinusoidal dilation	Dilation of sinusoids
Peliosis	Haphazardly distributed blood-filled cavities
Veno-occlusive disease	Non-thrombotic obstruction of centrolobular veins
Budd–Chiari syndrome	Thrombosis of large subhepatic veins
Periportal fibrosis	Portal fibrosis without cirrhosis
Nodular regenerative hyperplasia	Nodules without fibrosis
Tumours	
Hepatocellular adenoma	Benign tumour without central fibrous scar
Focal nodular hyperplasia	Benign tumour with central fibrous scar
Hepatocellular carcinoma	Malignant tumour derived from parenchymal cells
Angiosarcoma	Malignant tumour derived from endothelial cells

[a]The term should be restricted to cases in which granulomas are the outstanding liver lesion.

Diagnosis of drug-induced liver injury

Diagnosis of drug-induced liver injury can be obvious in some cases, but is often difficult. A useful rule is to consider systematically the possibility of an adverse drug reaction when faced with almost any kind of liver disease.

The first step in the diagnosis relies on establishing the list of medications. This may be time consuming in elderly patients who may have faltering memories and often suffer from several ailments, for which they consult various specialists. As each specialist often prescribes several drugs, elderly patients may end up with a dozen drugs that are frequently changed. Insistent questioning, and a look at the medical prescriptions, may disclose treatments that were not mentioned initially. In all patients, specific enquiries should be made of treatments that may not be considered as drugs by the patient (herbal remedies, over-the-counter analgesics, oral contraceptives), and of compounds that tend to be forgotten or concealed because of the patient's uneasiness in admitting their use or abuse (hypnotics, antidepressants, neuroleptics, anabolics, ecstasy, cocaine, morphinic drugs).

Once the list of ingested drugs has been established, the chronology of each treatment should be compared with that of

Table 2 Main mechanisms of diverse liver lesions.

Liver lesion	Main mechanism	Examples
Acute cytolytic hepatitis	Metabolite-mediated toxicity	Paracetamol
	Metabolite-mediated immunoallergy	Halothane, sulphonamides
	Metabolite-mediated autoimmunity	Dihydralazine, tienilic acid
	Impaired mitochondrial energy production	Tacrine (?)
Acute cholestatic/mixed hepatitis	Metabolite-mediated immunoallergy (?)	Macrolides, phenothazines
Acute bland cholestasis	Interference with bile secretion	Estrogens
Macrovacuolar steatosis	Decreased lipid secretion and other mechanisms	Methotrexate
Microvesicular steatosis	Impaired fatty acid β-oxidation	Tetracycline, valproate
Phospholipidosis	Inhibition of lysosomal phospholipases	Amiodarone
Steatohepatitis	Oxidative stress, increased cytokines	Amiodarone, tamoxifen
Subacute and chronic hepatitis	Prolonged immune reaction (?)	Iproniazid, methyldopa
Vanishing bile duct syndrome	Autoimmune (?) destruction of small bile ducts	Ajmaline, chlorpromazine
Sclerosing cholangitis	Toxicity to, or ischaemia of, large bile ducts	Formaldehyde, floxuridine
Perisinusoidal fibrosis	Hyperplasia and activation of stellate cells	Methotrexate, vitamin A
Vascular lesions	Endothelial injury (?)	Chemotherapeutic agents
Adenomas	Growth-promoting effects (?)	Oral contraceptives
Carcinomas	Growth-promoting and genotoxic effects (?)	Anabolic steroids, estrogens

Table 3 Probable duration of liver injury before the appearance of some liver lesions.

Initial lesion	Days or weeks	Weeks or months	Months or years
Necrosis	Acute hepatitis	Subacute or chronic hepatitis	Cirrhosis
Cholestasis	Acute cholestatic hepatitis		Prolonged cholestasis
Steatosis	Acute steatosis	Chronic steatosis	Steatohepatitis

the liver disease. As a general rule, the drugs that have been introduced during the last few months in the patient's treatment should be most suspected. Nevertheless, several pitfalls must be avoided.

1 The first would be to incriminate drugs that have been prescribed recently but for symptoms that actually heralded an incipient liver injury.

2 The second would be to neglect drugs that have been taken for many months without adverse effects. In an individual patient, even acute liver lesions can still occur under such circumstances.

3 The third pitfall would be to exclude all drugs that have been withdrawn before the onset of the liver injury. With some drugs, for example iproniazid or the amoxicillin/clavulanic acid combination, jaundice may not occur until a fortnight after interruption of the treatment. Similarly, drugs that are retained for a long time in the liver (amiodarone, perhexiline, vitamin A) may continue to damage the liver and may lead to chronic liver lesions several months after their administration has been interrupted.

4 A last pitfall would be to exclude recently marketed drugs because they are not known to be hepatotoxic. Instead, newly marketed drugs should always be suspected of being potentially hepatotoxic, because recognition of their hepatotoxic potential (if any) often requires several years of widespread utilization.

The second step in the diagnosis relies on the gathering of information that may either strengthen the case for an iatrogenic reaction (previous adverse effects with the drug or with structurally related analogues and/or the presence of immunoallergic manifestations, such as rash) or may instead favour another diagnosis (alcohol intake, blood transfusions, intravenous drug abuse, arrhythmia, cardiac failure, biliary colic).

The third step in the diagnosis relies on a comparison of the patient's disease with the type of liver disease produced by the potentially hepatotoxic drugs ingested by the patient. Indeed, the pattern of hepatotoxicity often differs with different drugs, with considerable differences in frequencies, times of onset, types of liver disease, associated extrahepatic features and outcome. Close concordance between the patient's presentation and the typical picture of hepatitis triggered by a given drug is added evidence of its possible involvement.

Once a drug or several drugs are suspected, they should usually be withdrawn immediately. As a general rule, they are not unique and therefore are not strictly necessary. In the rare instance when these treatments are really needed, alternative drugs are often available. If possible, drugs with a different

chemical structure and a different mechanism of action must be preferred, as cross-sensitivity can occur between closely related molecules (e.g. diverse erythromycin derivatives or diverse phenothiazines).

At the same time, investigations are started to rule out other diagnoses (viral serologies and, in cholestatic cases, ultrasonography) or strengthen the case for drug-induced liver injury. A differential white count may show eosinophilia. Non-specific autoantibodies (antinuclear, antismooth muscle), at relatively low titres that regress after interruption of the treatment, may strengthen a diagnosis of drug-induced acute or chronic hepatitis. In contrast, high titres persisting long after drug withdrawal suggest idiopathic autoimmune hepatitis. Specific serological markers are available with only a few drugs: antitrifluoracetylated proteins in halothane hepatitis; antimitochondrial type 6 (anti-M_6) autoantibody in iproniazid hepatitis; antiliver/kidney microsome type 2 (anti-LKM2) autoantibody in tienilic acid hepatitis; antiliver microsomes autoantibody in dihydralazine hepatitis [13,14]. Lymphocyte proliferation assays performed in the presence of an inhibitor of prostaglandin synthesis (because prostaglandins inhibit immune reactions) and using either the parent compound itself or the patient's sera (to include metabolites) have been reported to be frequently positive in immunoallergic drug-induced hepatitis [15,16].

A liver biopsy can be dispensed with in most cases of acute liver injury. Withdrawal of the offending drug will quickly cure these patients. In very difficult or severe cases, however, a liver biopsy is justified and may, at times, be very helpful for the diagnosis (e.g. centrolobular necrosis in paracetamol- or halothane-induced hepatitis; eosinophilic infiltration of the liver or the presence of hepatic granulomas in several cases of drug-induced allergic hepatitis; destructive bile duct lesions in some cases of cholestatic hepatitis; microvesicular steatosis with valproic acid). Suspected chronic liver lesions (chronic hepatitis, cirrhosis, many vascular lesions) usually require a liver biopsy, as this is the only way of establishing the diagnosis.

The last step in the diagnosis is based on the outcome of the liver disease. In most cases of 'cytolytic' ('hepatocellular') liver injury, serum transaminases start to improve within the first weeks following the interruption of treatment. However, in some severe forms of cytolytic liver injury, liver tests may initially continue to deteriorate for a few weeks, finally to improve later. In cholestatic reactions, the improvement may take more time, and a 50% reduction in alkaline phosphatase or bilirubin within 6 months is still suggestive of drug-mediated cholestasis. The improvement in the liver disease after drug removal may permit a probable diagnosis.

Although readministration of the suspected drug would afford a certain diagnosis, this is usually unethical. Rechallenge is particularly dangerous when the initial drug reaction was already severe, and when an immunoallergic mechanism is likely [5]. Fatal hepatic necrosis has occurred in patients rechallenged with halothane or sulphonamides [5]. However, there are a few circumstances in which a rechallenge may be proposed to the patient. When several drugs have been withdrawn but only one is reasonably suspected, readministration of these other, non-suspected drugs may be less unethical and may permit a definite diagnosis. This is important because an uncertain diagnosis may entice the patient into taking the offending drug again. Even a suspected drug may sometimes be reintroduced in therapeutically difficult cases. For example, when the likely mechanism is dose-related direct toxicity, and the drug is extremely important for the treatment of a severe disease, reintroduction of the drug at a lower dose (or in the absence of microsomal enzyme inducers) may be attempted with frequent liver test monitoring.

Differential diagnoses may include essentially all other causes of liver diseases, as drugs may produce the whole spectrum of liver pathology. However, these differential diagnoses are more restricted (and will be considered below) in the context of each particular drug-induced liver lesion.

Acute hepatitis

Liver lesions and terminology

Acute hepatitis is by far the most common drug-induced liver lesion. The gold standard for the classification of drug-induced hepatitis is liver histology. In all cases of acute hepatitis, there is at least some degree of inflammation, without fibrosis. Inflammation consists mostly of mononuclear cells, but may also include neutrophils or eosinophils and sometimes granulomas ('granulomatous' hepatitis). Inflammation is present at least in the portal tracts and often in the lobule also.

This inflammation may be associated with necrosis (or apoptosis) of the hepatocytes ('cytolytic' hepatitis), with cholestasis ('cholestatic' hepatitis) or with both necrosis and cholestasis ('mixed' hepatitis). In some forms of cholestatic hepatitis, there are lesions of bile ductules and interlobular bile ducts ('cholangiolitis' and 'cholangitis').

Because a liver biopsy is rarely necessary for the diagnosis, and therefore is rarely performed, it is useful nevertheless to be able to classify these cases from the maximal increase in serum ALT, a marker of hepatocyte damage or 'cytolysis', and that of alkaline phosphatase (AP), a marker of cholestasis, and from the ratio of ALT/AP, each activity being expressed in multiples of the ULN (N) [17]:

1 The liver injury is termed 'cholestatic' if only AP is increased (> 2N) or, when both ALT and AP are increased, if the ALT/AP ratio is 2 or less.

2 The liver injury is designated as 'mixed' when both ALT and AP are increased and the ALT/AP ratio is between 2 and 5.

3 The liver injury is classified as 'hepatocellular' if only ALT is increased (> 2N) or, when both activities are increased, if the ALT/AP ratio is 5 or more [17]. In this case, however, one cannot equate this 'hepatocellular' injury with 'cytolytic' hepatitis because many other lesions (e.g. microvesicular steatosis, Budd–Chiari syndrome, veno-occlusive disease, low cardiac output, etc.) may also give such a liver test profile.

Mechanisms of drug-induced acute hepatitis

Different mechanisms can cause drug-induced hepatitis.

Toxicity related to the therapeutic effect

In some instances, the therapeutic effect of the drug itself may be involved in hepatotoxicity. For example, the inhibitors of hydroxymethylglutaric coenzyme A reductase inhibit the synthesis of mevalonate. Because mevalonate is a precursor in the synthesis of cholesterol, these drugs are useful in the treatment of hypercholesterolaemic patients. However, mevalonate is also a precursor of other important isoprenoid derivatives, including ubiquinone and haem (two fundamental components of the mitochondrial respiratory chain), and others that serve in the isoprenylation of regulatory proteins (e.g. some low-molecular-weight G proteins) or structural proteins (e.g. nuclear lamins). Inhibition of isoprenoid biosynthesis seemed to be the mechanism for lovastatin-induced apoptosis in an *in vitro* system.

Impairment of mitochondrial energy production

In other instances, cytolytic hepatitis may be due to drug-induced impairment of mitochondrial energy production [18]. Normally, the transfer of electrons in the mitochondrial respiratory chain is coupled with the extrusion of protons from the mitochondrial matrix into the mitochondrial intermembrane space, thus creating a large electrochemical gradient across the inner membrane. When energy is needed, protons re-enter the matrix through ATP synthase, and the energy that is liberated by this re-entry is harnessed in the synthesis of ATP from ADP.

Drugs can impair mitochondrial energy formation through diverse mechanisms:

- A first mechanism is the uncoupling of mitochondrial respiration from ATP generation. Several non-steroidal anti-inflammatory drugs (NSAIDs) have a carboxylic group. In the uncharged acidic form (R-COOH), these carboxylic compounds can cross the lipid bilayer of the inner mitochondrial membrane, and can then release H^+ in the more alkaline matrix, thus forming the anionic form ($RCOO^-$). This negatively charged anionic form is then electrophoretically pulled by the membrane potential back into the intermembrane space. Inside the acidic intermembrane space, the uncharged acid form (COOH) is synthesized again, ready for another cycle of proton translocation. The protonophoric effect of acidic NSAIDs decreases the membrane potential and ATP formation, and can also trigger mitochondrial permeability transition and cell death [19,20].
- Some drugs, such as nilutamide or buprenorphine, may instead inhibit the transfer of electrons in the respiratory chain, thus decreasing the initial extrusion of protons [21,22]. This decreases the re-entry of protons into the matrix through ATP synthase, and therefore decreases ATP generation [21,22].
- Other drugs, such as tacrine, intercalate between hepatic mitochondrial DNA bases and impair mitochondrial DNA synthesis [23]. This causes a progressive depletion of hepatic mitochondrial DNA, which is required for the synthesis of some of the respiratory chain polypeptides [23].
- Finally, some drugs, such as betulinic acid or lonidamide, can directly trigger mitochondrial permeability transition and apoptosis [24,25].

Metabolic activation

By far the most frequent mechanism of drug-induced hepatitis is the formation of reactive metabolites, a process that is usually referred to as 'metabolic activation'. Indeed, many drugs that cause hepatitis are transformed by cytochrome P-450 (and/or, sometimes, other enzymes) into reactive, potentially hepatotoxic metabolites (Table 4).

The formation and hepatotoxicity of these reactive metabolites can be viewed as the untoward consequence of two xenophobic systems: the cytochrome P-450 system, which has

Table 4 Drugs transformed into reactive metabolites and causing cytolytic, mixed or cholestatic hepatitis.

Abacavir	Isaxonine
Amineptine	Isoflurane
Amitriptyline	Isoniazid
Amodiaquine	Ketoconazole
Benoxaprofen	Ketoprofen
Buprenorphine	Lomustine
Carbamazepine	Methimazole
Carmustine	Methoxsalen
Chloramphenicol	Metronidazole
Chloroform	α-Methyldopa
Chlorpromazine	Naproxen
Clozapine	Nefazodone
Cocaine	Nilutamide
Coumarin	Nitrofurantoin
Cyclophosphamide	Paracetamol
Cyproterone	Phenylbutazone
Dantrolene	Phenytoin
Dapsone	Procainamide
Diclofenac	Propoxyphene
Diflunisal	Propylthiouracil
Dihydralazine	Sulphamethoxazole
Disulfiram	Sulphonamides
Efavirens	Taurine
Enflurane	Tamoxifen
Erythromycin	Terbinafine
Felbamate	Tianeptine
Flutamide	Tienilic acid
Fluroxene	Ticlopidine
Germander	Tolbutamide
Halothane	Tolcapone
Hydralazine	Troleandomycin
Imipramine	Trichloroethylene
Indomethacin	Troglitazone
Iproniazid	Valproic acid

evolved in animals to eliminate small, alien molecules ('xenobiotics'), and the immune system, which has evolved to eliminate foreign microorganisms [26,27]. The formation of reactive metabolites by cytochrome P-450 may lead to direct toxicity, whereas the combination of cytochrome P-450 and the immune system may lead to the immune destruction of hepatocytes [26,27].

The cytochrome P-450 system

For a billion years, animals have been subjected to relentless biological warfare mounted by the plants that they ingested, as these plants have progressively developed new toxins [28]. Many of these plant toxins were liposoluble and could not be excreted as such in urine or bile. Clearly, animals that could develop systems able to transform these liposoluble xenobiotics into water-soluble metabolites, which could be excreted in urine or bile, benefited from an important survival advantage. This evolutionary pressure probably accounted for the development of a wide array of cytochrome P-450s able to metabolize xenobiotics in animals [28]. By duplication of an ancestral cytochrome P-450 gene, divergent evolution of these two genes and so forth, surviving animals have been endowed with a whole panoply of cytochrome P-450s able to metabolize and eliminate essentially all liposoluble xenobiotics in the environment, as well as most drugs used at present (Fig. 1).

These various cytochrome P-450s share the same oxidizing centre (the haem moiety) and a similar general architecture, but differ in their protein moieties (Fig. 1). Each cytochrome P-450 metabolizes partially overlapping, but largely different, sets of xenobiotics (Fig. 1).

Cytochrome P-450 is first reduced by NADPH-cytochrome P-450 reductase and may then bind molecular oxygen as a sixth ligand of the reduced haem iron (Fig. 1). After the introduction of a second electron, the oxygen molecule is split into its two atoms. One atom usually inserts into the substrate, while the other atom reacts with protons to form water. Cytochrome P-450 mediates an initial functionalization (e.g. a hydroxylation) of the substrate ('phase I' of drug metabolism). This creates a 'handle' onto which a polar molecule may then be added by conjugating enzymes ('phase II' of drug metabolism), so that the resulting hydrosoluble conjugate (e.g. sulpho-conjugate, glucuronide) can now be excreted in urine or bile (Fig. 2).

The cytochrome P-450s that metabolize xenobiotics are located in many organs but are particularly abundant in the liver. This disposition is probably not fortuitous. Indeed, the liver has the advantage of being both voluminous and richly vascularized and, more importantly, of draining the blood coming from the intestine. Therefore, after the intestine (which also contains some cytochrome P-450s), the liver can metabolize ingested xenobiotics even before they reach the systemic circulation. A further refinement of the system is that the endothelial cells of the hepatic sinusoids are perforated by fenestrae. Liposoluble xenobiotics circulate in the plasma thanks to their binding to plasma proteins. The sinusoidal fenestrae allow

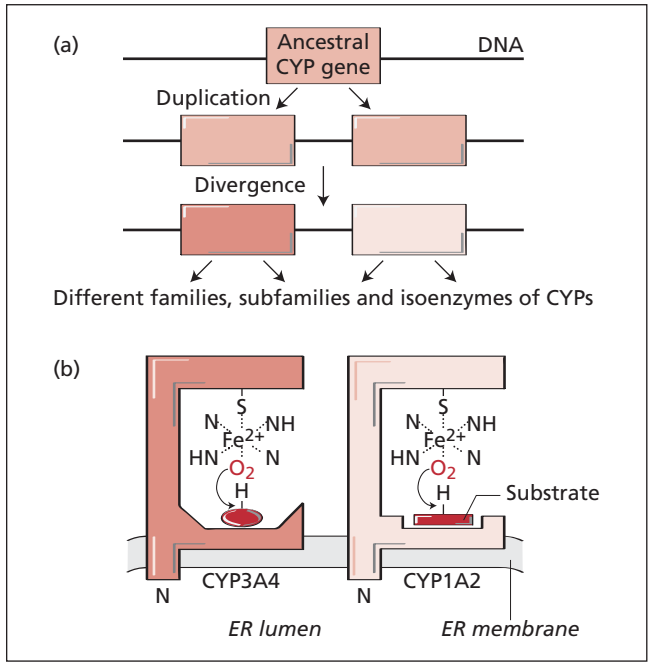

Fig. 1 Origin, structure and function of cytochrome P-450s (CYPs). (a) Gene duplications and divergences have given rise to different families, subfamilies and isoenzymes of CYPs. (b) CYPs are composed of a protein and a molecule of haem. The protein is anchored by its N-terminal part to the endoplasmic reticulum (ER) membrane. The diverse CYP proteins accommodate different series of substrates. The haem iron is coordinately bound to the four nitrogens of haem, and also to the sulphur atom of a deprotonated cysteine of the CYP protein. After being reduced to the ferrous state, the haem iron binds oxygen as a sixth coordination ligand. Upon further reduction of CYP, the oxygen molecule is split into its two atoms. One atom inserts into the substrate, while the other atom reacts with protons to form water.

proteins (and the xenobiotics they carry) to come into direct contact with the hepatocytes. This facilitates the removal of these xenobiotics, enabling the liver to totally metabolize some xenobiotics in a single pass through the hepatic sinusoid.

Formation of reactive metabolites

The development of the hepatic P-450 system as a means of eliminating xenobiotics had a major drawback. Although several xenobiotics are transformed by cytochrome P-450s into stable metabolites, many others are oxidized into unstable, chemically reactive intermediates (Fig. 2) [29]. These molecular 'bombs' can attack hepatic constituents (DNA, unsaturated lipids, proteins, glutathione) and can lead to either cancer or liver cell demise through direct toxicity or immune reactions.

Reactive metabolites are mainly formed through cytochrome P-450-mediated oxidative reactions. However, cytochrome P-450 in its reduced form (ferrous iron) may also catalyse the reductive dehalogenation of several haloalkanes (such as carbon tetrachloride or halothane) to the corresponding free radicals. Furthermore, NADPH-cytochrome P-450 reductase may reduce quinones into semiquinone radicals, and may reduce

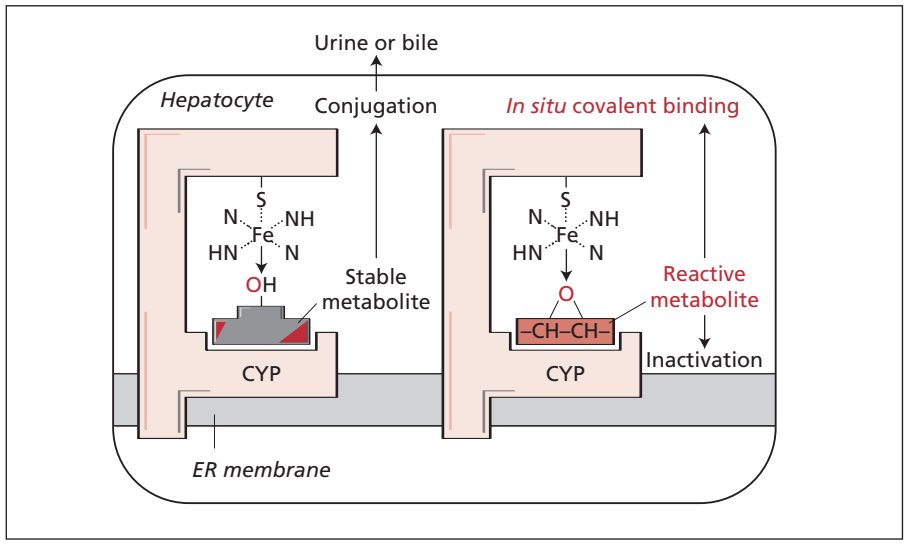

Fig. 2 Formation of stable or reactive metabolites by cytochrome P-450. Depending on the chemical structure of the parent drug, its oxidation by cytochrome P-450 (CYP) can generate stable metabolite(s) or reactive, electrophilic metabolite(s). Stable metabolites are often conjugated and then eliminated into urine or bile. Although electrophilic metabolites can be partly inactivated, they partly react with, and covalently bind to, hepatic glutathione, proteins and sometimes DNA.

nitroarenes into nitro anion radicals. These drug radicals may in turn reduce molecular oxygen to the superoxide anion radical ($O_2^{\cdot-}$), leading to other reactive oxygen species (H_2O_2, ·OH).

Therefore, the cytochrome P-450 system, albeit remarkably adapted to the elimination of an infinite array of liposoluble xenobiotics, nevertheless had the serious inconvenience of forming potentially toxic metabolites. Clearly, this system would not have been viable without the concomitant development of a variety of protective mechanisms.

Suicidal inactivation of cytochrome P-450. A first protective mechanism, which is automatically included in the system, is the inactivation of cytochrome P-450 by some reactive intermediates. Indeed, a reactive intermediate that has just been formed inside the hydrophobic active site of cytochrome P-450 may directly attack cytochrome P-450 itself and destroy it. This may occur in several ways. Some intermediates (e.g. the nitrosoalkane metabolites of macrolides) may form stable, inactive complexes with the iron(II) of cytochrome P-450. Other metabolites may covalently bind to an aminoacyl residue of the active site of P-450, or to a nitrogen of the haem molecule. Free radicals may form an unstable adduct with a vinyl group of haem that then covalently binds to the cytochrome P-450 protein. Whatever its molecular mechanism, this 'suicidal' inactivation prevents the further formation of the reactive intermediate.

Glutathione conjugation and other protective mechanisms. The tripeptide glutathione (L-γ-glutamyl-L-cysteinyl-glycine) is synthesized by the successive action of γ-glutamylcysteine synthase and glutathione synthetase. The first enzyme functions at less than the maximal rate because of feedback inhibition by glutathione. Thus, when the consumption of glutathione increases, and its hepatic concentration tends to decrease, the liver can markedly increase the synthesis of glutathione. Although hepatic glutathione is continuously secreted in both the hepatic sinusoid (serving as a precursor of cysteine for other organs) and bile, its active synthesis normally maintains a 10-mmol concentration of glutathione within hepatocytes (with distinct cytosolic, mitochondrial and nuclear pools). Glutathione exerts several protective functions within hepatocytes. One of these functions is to serve as a molecular sink for electrophilic metabolites. Indeed, electrophilic metabolites react spontaneously with the SH group of glutathione, preventing the alkylation of more critical hepatic constituents. This spontaneous reaction is greatly accelerated by several cytosolic and microsomal glutathione *S*-transferases. The resulting glutathione conjugates are then excreted in bile by a canicular multispecific organic anion transporter (cMOAT), which is now usually referred to as MRP2 (multidrug resistance-associated protein 2).

Several other enzymes may catalyse the rearrangement of reactive metabolites into stable metabolites. For example, microsomal, cytosolic and nuclear epoxide hydrolases speed up the hydration of reactive epoxides into diols. Superoxide dismutase, catalase, glutathione peroxidase and glutathione reductase act in concert to decrease the toxicity that could result from the formation of the superoxide anion by free radicals arising from the metabolism of xenobiotics. Vitamin E, vitamin C, glutathione and glutathione peroxidases limit the initiation and propagation of lipid peroxidation. Multiple DNA repair systems allow for the reparation of damaged DNA before a round of DNA replication can lead to somatic mutations.

Thanks to these protective mechanisms, recourse to the cytochrome P-450 system as a means of eliminating xenobiotics became tolerable, inasmuch as both the formation of reactive metabolites and their reaction with hepatic constituents could be partly limited. Only massive doses of these foreign substances and/or the extensive metabolism of a particular xenobiotic may then lead to direct toxicity.

In situ *reaction of reactive metabolites*

Some reactive metabolites (e.g. acetaldehyde or acyl-glucuronides) react slowly with tissue components and, therefore, can leave their site of formation and react elsewhere. Most reactive metabolites, however, are so highly unstable that they react *in situ* in the very organ that forms them [30]. The abundance of cytochrome P-450s in the liver, and the *in situ* reaction of reactive metabolites, explain the major role of these metabolites in drug-induced hepatitis. The centrolobular location of most cytochrome P-450s accounts for the frequently pericentral zonation of these lesions [26].

Molecular and cellular lesions leading to direct toxicity

Drugs transformed into free radicals can cause lipid peroxidation [31]. The first step in this process is the formation of lipid radicals. Either the addition of a reactive drug radical (R·) on the carbon of an unsaturated lipid or the abstraction by this radical of an hydrogen atom leads to a lipid radical (lipid·). This radical quickly adds molecular oxygen to form a peroxyl radical (lipid-OO·). This peroxyl radical may react with another lipid molecule ($lipid_2$-H) to form a hydroperoxide and a new lipid radical: $Lipid_1\text{-}OO\cdot + Lipid_2\text{-}H \rightarrow Lipid_1\text{-}OOH + Lipid_2\cdot$. Lipid peroxidation may thus extend from one lipid to the other, or along the same lipid chain. Eventually, unsaturated lipids are oxidized and cut into small fragments (alkanes, malondialdehyde, alkenals). The last two compounds are themselves reactive and bind covalently to proteins.

A second type of molecular lesion is observed mainly with electrophilic metabolites. These metabolites react with, and covalently bind to, several nucleophilic groups of proteins (e.g. the SH group of a cysteine residue or the ε-NH_2 group of a lysine residue), on which they remain attached by a covalent bond. These electrophilic metabolites also react with the SH group of glutathione, and this is an important protective mechanism, which prevents reaction with more critical cellular targets. However, when large amounts of the reactive metabolite are formed, the extensive formation of glutathione conjugates then exceeds the capacity of the liver to increase the synthesis of glutathione. The resulting depletion of glutathione, together with the direct covalent binding to protein thiols and/or the direct oxidation of protein thiols, all tend to decrease protein thiols (Fig. 3). Depletion of protein thiols has severe toxicological consequences (Fig. 3) [26,32].

1 A first consequence is the formation of disulphur bonds between different molecules of actin, forming inactive actin aggregates [33]. This destroys the microfilamentous network that is located beneath the plasma membrane and normally maintains the shape of this membrane through its attachment to integral plasma membrane proteins. Destruction of this network allows the formation of fragile plasma membrane blebs.

2 A second consequence of the oxidation of protein thiols is to decrease the activity of plasma membrane calcium ATPases, whose role is constantly to extrude calcium from the hepatocytes [34]. The resulting increase in cellular Ca^{2+} activates calcium-dependent transglutaminases (which form a cross-linked protein scaffold), calcium-dependent calpains (which further damage the cytoskeleton) and calcium-dependent endonucleases (which can cut nuclear DNA between nucleosomes) (Fig. 3) [35].

3 A last consequence of the oxidation of protein thiols is to cause mitochondrial permeability transition (Fig. 3) [36]. There exists, at contact sites between the outer and inner mitochondrial membranes, a multiprotein structure called the mitochondrial permeability transition pore [37]. This pore is normally closed, but may open after diverse stimuli, including the formation of disulphide bonds as a consequence of the depletion/oxidation of glutathione, the induction of proapoptotic proteins by the increased p53 resulting from DNA damage, the release of arachidonic acid by calcium-activated phospholipase A2 and, finally, the entry of calcium into the mitochondria due to the increased cytosolic concentration of calcium after the extensive formation of reactive metabolites [35,37]. Closure or opening of the mitochondrial permeability transition pore modulates cell survival or death [37]. While pore closure allows for continued cell life, pore opening triggers cell death through two main effects:

i A first effect is to allow the influx of protons from the intermembrane space into the mitochondrial matrix, thus dissipating the mitochondrial membrane potential and preventing ATP formation by the affected mitochondrion [38]. If the pore opens quickly in all mitochondria, major ATP depletion prevents apoptosis (an energy-requiring process) and instead causes necrosis [39].

ii A second consequence of pore opening, resulting from the osmolality of matrix proteins, is to cause the entry of water into the mitochondrial matrix. This causes matrix swelling and rupture of the circular outer membrane [38,40]. Outer membrane rupture releases proapoptotic substances (such as cytochrome *c*) from the mitochondrial intermembrane space into the cytosol, where cytochrome *c* activates caspases. If the pore only opens in some mitochondria, then unaffected organelles continue to generate ATP (thus preventing necrosis), while pore opening in other mitochondria releases proapoptotic substances, which activate caspases, to cause apoptosis [38,40].

Thus, the direct toxicity of reactive metabolites can cause necrosis, apoptosis or both types of liver lesions in different conditions. For example, the direct toxicity of the reactive metabolites of germander mainly triggered hepatocyte necrosis *in vivo* [41] but mainly caused apoptosis in isolated rat hepatocytes [35]. Apoptosis, or 'programmed cell death', is a complex physiological process responsible for the 'natural' cell death that occurs in embryogenesis, tissue atrophy, senescent cells, thymus selection and cell-mediated cytotoxicity. Typically, apoptosis is characterized by the activation of calcium-dependent transglutaminases leading to the formation of a cross-linked protein scaffold, by the activation of calcium-dependent and/or caspase-dependent endonucleases leading to internucleosomal DNA fragmentation and by typical ultrastructural changes including condensation of the cytoplasm, rim-like or crescent-like

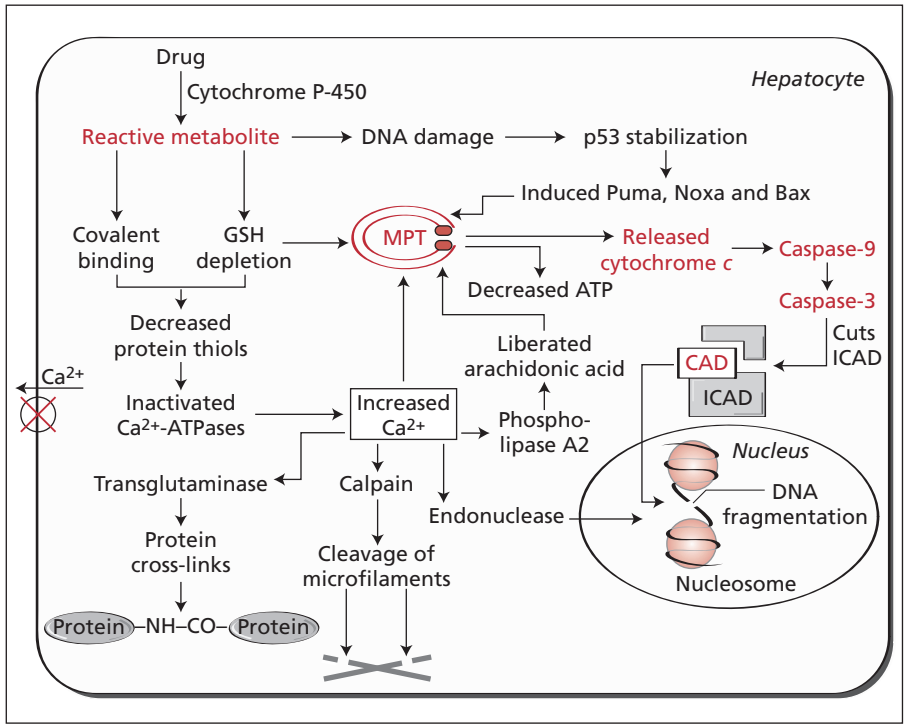

Fig. 3 Direct toxicity of reactive electrophilic metabolites. The extensive formation of reactive metabolites can deplete hepatic glutathione (GSH) and protein thiols, and can inactivate Ca^{2+}-ATPases. The increased cell calcium activates diverse calcium-dependent enzymes and triggers mitochondrial permeability transition (MPT). Mitochondria release cytochrome *c*, which activates caspases in the cytosol. Caspase-3 cuts ICAD (inhibitor of CAD), thus allowing CAD (caspase-activated deoxyribonuclease) to enter the nucleus and cut DNA between nucleosomes.

condensation of chromatin beneath the nuclear membrane and the formation of large cellular blebs that initially contain ultrastructurally unaltered cellular organelles [42]. This is followed by segmentation of both the cytoplasm and the nucleus, with the formation of apoptotic bodies.

Genetic and acquired factors involved in the direct toxicity of reactive metabolites

The direct toxicity of reactive metabolites concerns drugs for which the formation of the reactive metabolite is low enough to ensure the absence of hepatitis in most recipients (therefore allowing the marketing of the drug), but still high enough to lead to toxicity in metabolically susceptible subjects. Both genetic and acquired factors may explain the susceptibility of these few patients.

Genes may influence both the formation and the inactivation of reactive metabolites. The cytochrome P-450 isoenzymes are under genetic control, and the hepatic level of a given isoenzyme is considerably different in different people. While some reactive metabolites are formed by several cytochromes P-450s [43], other reactive metabolites are mainly formed by a particular isoenzyme [44]. A subject with a high genetic expression of this cytochrome P-450 might be at increased risk of developing hepatitis. In contrast, a deficiency of some cytochrome P-450 isoenzymes is observed in the poor metabolizer phenotypes of several polymorphisms of drug oxidation [45,46]. Such poor metabolizers should be protected against the toxicity of reactive metabolites that are normally formed by this deficient isoenzyme [47].

Genetic factors can also modify the inactivation of reactive metabolites. However, the effects of a deficiency in glutathione synthase vary with the experimental model. In an artificial model, the lymphocytes of subjects with a partial deficit in glutathione synthetase were more susceptible to the *in vitro* toxicity of paracetamol. However, the *in vivo* hepatotoxicity of paracetamol is critically dependent on the extent of hepatic glutathione depletion [10]. Even mild differences in the degree of glutathione depletion can dramatically modify the extent of paracetamol-induced liver cell necrosis [10]. A deficit in glutathione transferase is expected to attenuate the consumption of glutathione by the reactive paracetamol metabolite. Indeed, mice lacking glutathione transferase Pi exhibited a lesser decrease in hepatic glutathione and were markedly protected against the *in vivo* hepatotoxicity of paracetamol [48].

Physiological, nutritional or therapeutic modifications of drug metabolism may also explain the susceptibility of some subjects:

1 Pregnancy, for example, may decrease the capacity of the liver to resynthesize glutathione and markedly increases the hepatotoxicity of paracetamol in mice [49]. It is not known whether similar effects also occur in women.

2 Fasting, or protein denutrition, decreases hepatic glutathione content, and dramatically increases the hepatotoxicity of paracetamol in rats [50]. In humans, hepatitis has been observed after high therapeutic doses of paracetamol in a few subjects with malnutrition.

3 Microsomal enzyme induction by drugs administered concurrently may increase the formation of the reactive metabolite,

and the susceptibility to hepatitis. Thus, rifampicin, a microsomal enzyme inducer, apparently increases the hepatotoxicity of isoniazid [51]. Drugs used for premedication and general anaesthesia may induce microsomal enzymes [52], and may aggravate isoniazid hepatotoxicity [51]. Likewise, the recent introduction of microsomal enzyme inducers may have triggered fulminant hepatitis in three patients receiving prolonged treatment with iproclozide [53]. Chronic ethanol ingestion increases cytochrome P-450 2E1, which activates paracetamol. This aggravates the hepatotoxicity of therapeutic doses of paracetamol in humans [54]. Ethanol also tends to decrease hepatic glutathione concentration, an effect that may also contribute to increased paracetamol toxicity. Indeed, inducers and fasting had additive effects on the hepatotoxicity of paracetamol in rats [55].

Clinical features of hepatitis due to direct toxicity

Hepatitis caused by direct toxicity is not associated with hypersensitivity manifestations, and an inadvertent rechallenge does not lead to a prompter recurrence. The liver injury may have a relatively high frequency, consistent with direct toxicity. As explained above, it may be favoured by either genetic or acquired metabolic factors. It is important, however, to realize that metabolic factors will also influence immunologically mediated hepatitis, as discussed further on.

For many drugs, the formation of reactive metabolites may be so low that, even in metabolically susceptible subjects, this formation may at most cause mild transaminitis, but no major cell demise. Such drugs will not produce toxic liver cell necrosis. They may nevertheless produce severe hepatitis in a few subjects by interacting with the second xenophobic system of animals, namely the immune system.

The immune system

The necessity of fighting back against bacterial, fungal or viral infections has led to the development of the macrophagic and immune systems in animals. The latter is based on the acquisition, during evolution, of major histocompatibility complex molecules that can each present different sets of peptides on the cell surface, and on the development in each individual, by somatic mutation, of a whole panoply of helper T lymphocytes able to recognize among these peptides those that are foreign [56]. The ability of viruses to directly transfect neighbouring cells has required that one of the effector strategies of the immune system should be the immunological destruction of the infected cells.

The superposition of the cytochrome P-450 and the immune system created an additional problem for animals. Indeed, the covalent binding of a reactive metabolite to proteins modifies the self of the individual. In some subjects, this modification may 'mislead' the immune system into mounting an immune attack against hepatocytes [26]. This immune attack may be directed either against the modified self or against the unmodified self.

Immune attack directed against the modified self

The best studied example of immunoallergic hepatitis is the severe form of halothane hepatitis. Halothane is oxidized by cytochrome P-450 into a reactive acyl chloride (CF_3COCl) that reacts with the ε-NH_2 group of the lysine residues of proteins to form trifluoroacetylated proteins (CF_3CO-lysine proteins) [57]. In the serum of patients with severe halothane hepatitis, one finds antibodies that are directed against the parts of hepatic proteins that are modified by the covalent attachment of the trifluoroacetyl group [58,59].

After exposure to halothane, trifluoroacetylated proteins are found on the surface of hepatocytes [60]. Similarly, after exposure to isaxonine (another drug transformed into reactive metabolites and causing immunoallergic hepatitis), there are alkylated proteins on the plasma membrane [61]. These alkylated plasma membrane proteins can serve as antigenic targets for the antibodies directed against alkylated hepatic proteins. Indeed, the incubation of hepatocytes from rabbits exposed to halothane (leading to the trifluoroacetylation of plasma membrane proteins) with sera from patients with halothane hepatitis (containing antibodies against trifluroacetylated proteins) that had been previously adsorbed to untreated rabbit hepatocytes (thereby removing any antibody against normal rabbit hepatic proteins), followed by the addition of peripheral blood mononuclear cells from normal subjects, led to the immune destruction of the halothane-treated hepatocytes [59]. A similar antibody-dependent, cell-mediated cytotoxicity was reported with the sera of patients with hepatitis due to α-methyldopa [62], tienilic acid [63] or clometacin [64].

Immune attack directed against the self: anti-cytochrome P-450 autoantibodies

With a few drugs, the immune attack is directed, in part, against normal, unmodified epitopes of proteins. Thus, iproniazid can give rise to antimitochondrial autoantibodies called 'anti-M6', which are directed against monoamine oxidase B on the outer membrane of mitochondria [14]. Other autoantigens are the cytochrome P-450s [13]. Thus, tienilic acid-induced hepatitis is associated with a particular antiliver/kidney microsome autoantibody called the 'anti-LKM2' autoantibody [65]. This antibody is specifically directed against human cytochrome P-450 2C9, which transforms tienilic acid into a reactive metabolite that covalently binds to the cytochrome P-450 2C9 protein [65]. Similarly, dihydralazine hepatitis is associated with antiliver microsome ('anti-LM') autoantibodies directed against cytochrome P-450 1A2 [66]. This cytochrome P-450 isoenzyme oxidizes dihydralazine into reactive radicals, which covalently bind to the cytochrome P-450 1A2 protein [67]. These diverse antibodies exhibit a high affinity for the non-alkylated cytochrome P-450s of untreated subjects, and are therefore autoantibodies. Cases of drug-induced hepatitis associated with these anti-cytochrome P-450 autoantibodies have been classified

as 'autoimmune' hepatitis, although the relationship between the autoantibodies and the destruction of hepatocytes remains speculative, as discussed further on.

Presence of cytochrome P-450 on the plasma membrane. Cytochrome P-450 is synthesized on polyribosomes attached to the endoplasmic reticulum membrane, and is cotranslationally inserted in this membrane, where it remains anchored by at least one transmembrane fragment (Fig. 1). There is an extensive flow of vesicles going from the endoplasmic reticulum to the Golgi apparatus, and from there to the plasma membrane, thanks to molecular motors that draw these vesicles along microtubules. Neosynthesized cytochrome P-450 partly follows this vesicular route to reach the plasma membrane in rats [68,69].

When various anti-cytochrome P-450 autoantibodies were added to uncut, non-permeabilized and fixed rat or human hepatocytes (thus, under conditions precluding the entry of the antibody into the cells), immunofluorescent and immunoperoxidase labelling of the plasma membrane was obtained, showing that these autoantibodies recognized cytochrome P-450 epitopes expressed on the surface of hepatocytes [70,71]. It is thus possible that these autoantibodies may participate, to some extent, in the immunological destruction of hepatocytes, although cytotoxic T lymphocytes probably play a more important role [27].

Mixed immune reactions

Thus, the presence of the modified self may trigger an immune attack directed against either the modified self or the unmodified self. It is therefore not surprising that a single drug can concomitantly give rise to both types of immune reactions. For example, in patients with halothane-induced hepatitis, there are anti-adduct antibodies directed against trifluoroacetylated proteins [58], and there are also autoantibodies directed against native cytochrome P-450 2E1 (CYP2E1) [72,73]. Likewise, the sera of patients with tienilic acid-induced hepatitis contain not only anti-cytochrome P-450 2C (CYP2C) autoantibodies [65], but also anti-adduct antibodies recognizing the tienilic acid moiety of CYP2C–tienilic acid adducts [74]. Like native CYP2C, tienilic acid–CYP2C adducts are transported by vesicular flow to the external surface of the hepatocyte plasma membrane [74].

Because the immune reaction is often directed both against neoantigens and against the self, the distinction between drug-induced 'autoimmune' hepatitis (reaction against the self) and drug-induced 'immunoallergic' hepatitis (reaction against the modified self) seems to be largely academic.

Possible mechanism for the appearance of antibodies and autoantibodies

The mechanism leading to the appearance of (auto)antibodies remains unknown. However, from present knowledge of the immune system, the following mechanism may be proposed (Fig. 4) [27]. Some B lymphocytes are autoreactive, but normally remain quiescent in the absence of stimulation by helper T cells. Let us consider an autoreactive B cell expressing a membrane immunoglobulin on its surface that recognizes a normal, unalkylated epitope of a hepatic protein. After the death of a hepatocyte, this autoreactive B cell may capture a molecule of this hepatic protein (Fig. 4). After internalization and processing of the protein into peptides, the autoreactive B cell will be able to present peptides derived from the hepatic protein on its major histocompatibility complex class II molecules (Fig. 3). Normally, the hepatic protein is not alkylated, and the B lymphocyte only presents normal peptides. As there are no helper T cells that will recognize these normal peptides, the autoreactive B cell remains quiescent. However, if the subject has taken a drug whose reactive metabolite covalently binds to the hepatic protein, some segments of the hepatic protein may be modified by the presence of the covalently bound metabolite. After processing the hepatic protein into small peptides, the B lymphocyte may therefore present both normal peptides and also peptides modified by the covalent binding of the metabolite. Some T-helper cells may be able to recognize this 'modified self' (Fig. 4). This recognition will lead to bidirectional signalling, involving both the T cell, which is activated to proliferate, and the B cell, which undergoes clonal expansion and maturation [27]. The B cell will eventually secrete an autoantibody with the same specificity as the initial membrane immunoglobulin, that is an autoantibody directed against the hepatic protein (Fig. 3). This hypothetical mechanism may explain how the modification of a cytochrome P-450 by covalent binding ('modified self') may lead to immunization against the self with the appearance of autoantibodies [27].

The same mechanism may also result in the formation of antibodies recognizing metabolite-altered neoantigens (Fig. 4). Indeed, if the membrane immunoglobulin of a quiescent B cell is instead able to recognize the metabolite moiety of metabolite–protein adducts, this particular B cell will likewise internalize the hepatic protein, present alkylated peptides and be stimulated by helper T cells (Fig. 4). It will evolve into plasmocytes that will secrete the antibody into the plasma, thus explaining the appearance of antibodies directed against metabolite–protein adducts (Fig. 4).

Respective roles of the humoral and cellular immune responses

Using sensitive techniques, a mild humoral response has been detected in many patients receiving a drug but without liver test abnormalities. Indeed, antidiclofenac–protein adduct antibodies were found in 60% of patients treated with diclofenac but without liver test abnormalities [75]. Similarly, anti-cytochrome P-450 2E1 autoantibodies were found in all of 106 paediatric anaesthetists occupationally exposed to halothane, although only one of these anaesthetists exhibited liver disease (of unknown

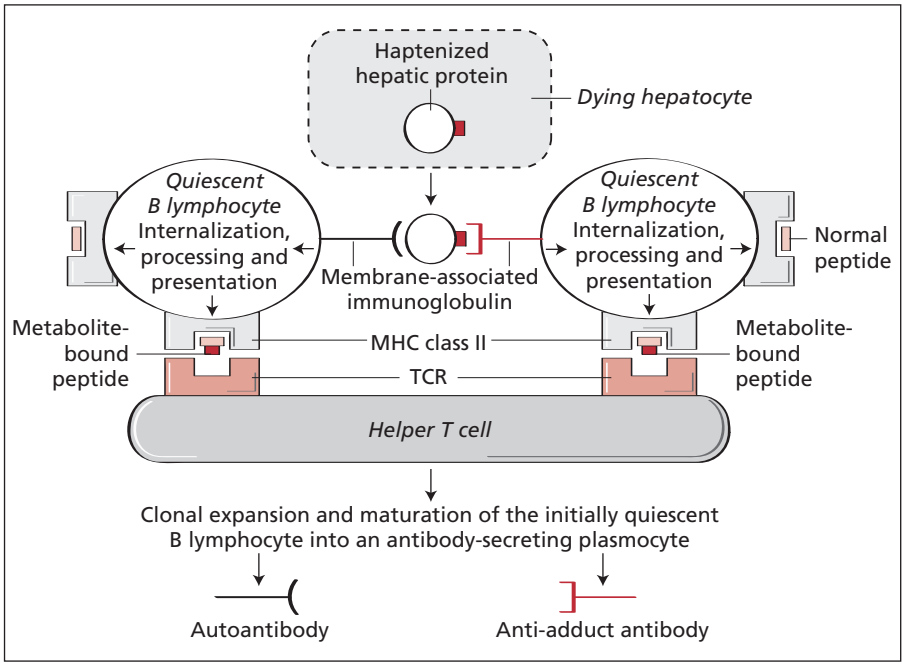

Fig. 4 Possible mechanism for humoral immune responses triggered by reactive metabolites. The covalent binding of reactive metabolites generates haptenized hepatic proteins. After the death of a hepatocyte, a haptenized hepatic protein may be taken up by a quiescent B lymphocyte expressing a membrane immunoglobulin against the normal protein, or by another quiescent B lymphocyte with a membrane immunoglobulin against the metabolite–protein adduct. Internalization of the protein and its processing into peptides can lead to the presentation of both normal peptides and haptenized peptides on the major histocompatibility complex (MHC) class II molecules of the B cell. Unlike normal peptides, metabolite-bound peptides differ from the self, and can be recognized by the T-cell receptor (TCR) of helper T cells. The help provided by helper T cells leads to the clonal expansion of B cells and their maturation into plasmocytes, which now secrete the immunoglobulin into the plasma.

cause) [76]. These data indicate, first, that a mild, infrapathological humoral immune response occurs much more frequently than initially anticipated and, second, that the humoral immune response may only play a limited role, if any, in clinical hepatitis.

In contrast, the lymphocyte proliferation test was reported to be frequently positive in patients with drug-induced liver injury, but constantly negative in patients taking the same drugs as these patients, but without liver injury [16]. It therefore seems likely that a cellular immune response involving cytotoxic T lymphocytes plays the major role in the immune destruction of hepatocytes.

Cytotoxic T lymphocytes

How T lymphocytes are stimulated in drug-induced hepatitis is not fully known, although Figure 5 shows a possible mechanism. In order to stimulate CD4+ helper T lymphocytes, immunogenic peptides must first be presented on the cell surface by major histocompatibility complex class II molecules [56]. Major histocompatibility complex class II molecules are not normally expressed by hepatocytes [77], but are expressed by Kupffer cells, sinusoidal endothelial cells and B lymphocytes. It is therefore tempting to speculate on the following mechanism [26]. During the turnover of hepatocytes, and particularly if this normally slow turnover is accelerated by mild, direct toxicity of the metabolite, proteins from dying hepatocytes may be phagocytosed by antigen-presenting cells, such as macrophages (Fig. 5). Inside these cells, the protein is degraded into small peptides, some of which are then presented on the cell surface by major histocompatibility complex class II molecules (Fig. 5).

If a subject has taken a drug leading to the 'alkylation' of hepatic proteins (i.e. the covalent binding of a reactive metabolite to these proteins), degradation of these alkylated proteins will form not only normal peptides, but also alkylated peptides (Fig. 5).

Normal peptides are not recognized by helper T lymphocytes, because autoreactive T lymphocytes are normally deleted. In contrast, alkylated peptides are different from the self of the individual. In the enormous pool of different helper T cells, some of them may be able to recognize these modified structures on the surface of the antigen-presenting cell (Fig. 5).

This recognition may stimulate the helper T lymphocyte, which will provide local help (through the release of cytokines) to effector immune cells that are also present because they have been able to recognize modified structures on hepatocytes. Effector cells that might be locally present are cytotoxic CD8+ T lymphocytes (Fig. 5). Indeed, hepatocytes express major histocompatibility complex class I molecules on their surface, and this expression is further increased as soon as the inflammatory reaction develops [77]. These major histocompatibility complex class I molecules may present alkylated peptides that might serve as molecular anchors for the attachment of CD8+ cytotoxic T lymphocytes (Fig. 4). Local help provided by the neighbouring helper T cells may then lead to the clonal expansion of these cytotoxic T lymphocytes.

Cytotoxic T lymphocytes kill their targets by expressing Fas ligand and tumour necrosis factor-α (TNFα) on their surface and by releasing granzyme B (Fig. 6) [37]. All three substances cut the proapoptotic protein Bid. Truncated Bid causes a conformational change in Bax, which translocates to mitochondria

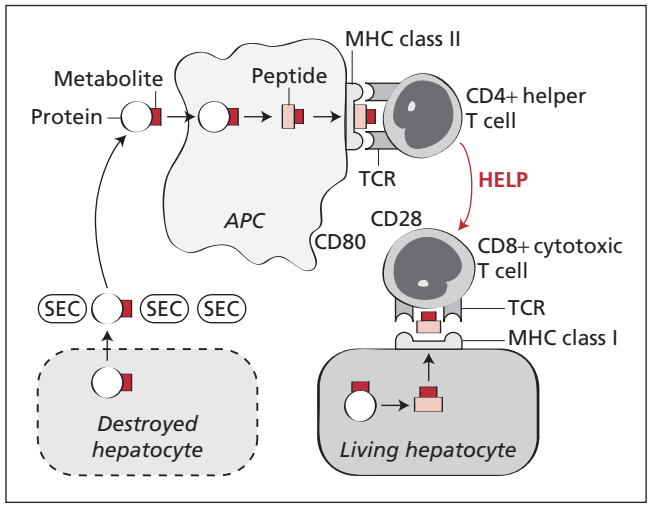

Fig. 5 Possible mechanism for cell-mediated immune responses triggered by reactive metabolites. The death of one hepatocyte may lead to the extrusion of a haptenized hepatic protein through the fenestrae of sinusoidal endothelial cells (SECs). The uptake of this haptenized protein by an antigen-presenting cell (APC), such as a Kupffer cell, may lead to the presentation of a haptenized peptide on a major histocompatibility (MHC) class II molecule of the APC, and the recognition of this modified peptide by the T-cell receptor (TCR) of a helper T cell. The latter may then provide help to a cytotoxic T lymphocyte recognizing haptenized peptides presented on the MHC class I molecules of hepatocytes.

and associates with mitochondrial Bak. Bax and Bak cause permeabilization of mitochondrial membranes. Cytochrome *c* is released from the mitochondrial intermembrane space into the cytosol, where cytochrome *c* activates caspases to trigger apoptosis [37].

Discrete direct toxicity as a permissive factor for severe immune hepatitis

Suggested mechanisms for immunization (Figs 4 and 5) presuppose the release of alkylated hepatic proteins (modified self) and their uptake by antigen-presenting cells (APCs). If this is correct, any mild toxic effect of the metabolite (leading to the release of alkylated hepatic proteins) should greatly increase the presentation of modified peptides by APCs. Furthermore, the inflammation caused by direct toxicity may switch the immune response from tolerization (a frequent outcome in the liver) towards immunization. For these two reasons, it appears extremely likely that any direct toxicity should increase the likelihood of immunization. Indeed, many drugs (including halothane) that produce immunoallergic hepatitis in a few patients also lead to a mild increase in serum transaminase activity in a much larger proportion of recipients. The view might be held, therefore, that discrete direct toxicity may be a permissive (but not sufficient) factor for immunization to develop. This might account, in part, for the role of genetic, metabolic factors in the frequency of immune hepatitis.

Genetic factors influencing drug-induced immune hepatitis

Although all subjects probably form the reactive metabolite to some extent, only a few develop immunoallergic and/or autoimmune hepatitis. At least two types of genetic factors may explain the particular susceptibility of these few subjects.

1 A first type of genetic factor may affect hepatic drug metabolism. As explained above, the modification of self as a result of the covalent binding of the reactive metabolites may be the initial stimulus leading to immunization. If some subjects are deficient in a metabolic pathway that normally diverts the drug away from the formation of reactive metabolites or that normally inactivates this reactive metabolite, these deficient subjects may undergo extensive alkylation of their hepatic proteins. Perhaps more importantly, defects in protective mechanisms might allow the threshold to be crossed between a total lack of direct toxicity and a discrete form of direct toxicity that will lead to the release of alkylated hepatic proteins and their uptake by APCs.

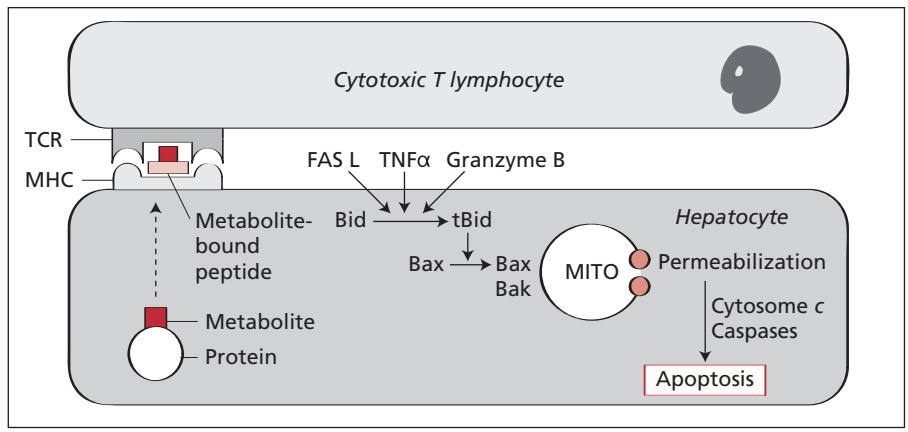

Fig. 6 Destruction of target cells by cytotoxic T lymphocytes. Covalent binding to hepatic proteins may lead to the presentation of metabolite-bound peptides on major histocompatibility (MHC) class I molecules on the surface of hepatocytes. These modified peptides may be recognized by the T-cell receptor (TCR) of cytotoxic T lymphocytes, which kill target cells by expressing Fas ligand (Fas L) and tumour necrosis factor-α (TNFα) and by releasing granzyme B at contact sites. All three substances indirectly or directly trigger Bid truncation. Truncated Bid (tBid) causes a conformational change in Bax, which translocates to the mitochondria and associates with Bak, to trigger mitochondrial membrane permeabilization, cytochrome *c* release, caspase activation and hepatocyte apoptosis.

i In rapid acetylators, dihydralazine [67] and sulphonamides[78] are detoxified by acetylation. In slow acetylators, however, this protective pathway is deficient, and a greater proportion of the dose is now transformed by cytochrome P-450s into reactive metabolites, leading to a higher incidence of immune hepatic reactions [67,78].

ii Using a lymphocyte cytotoxicity assay, it has been suggested that some inherited deficit(s) in the inactivation of the reactive metabolites may favour immune hepatitis due to sulphonamides [78], anticonvulsants [79], halothane [80] and amineptine [81]. Lymphocytes are very poor in cytochrome P-450, so that the reactive metabolite has to be formed by an artificial extracellular system (drug + murine liver microsomes + NADPH). Being standardized, this system produces a constant amount of reactive metabolite. Human lymphocytes are exposed to this metabolite-generating system. Although poor in cytochrome P-450, lymphocytes contain all the protective systems (such as epoxide hydrolase, glutathione, glutathione *S*-transferases, glutathione peroxidase and vitamin E). If the lymphocytes of some subjects are deficient in some of these protective mechanisms, they will not detoxify the metabolite as well, and will suffer increased lethality. The deficiency, being genetic, should be observed not only in subjects with drug-induced hepatitis, but also in some of their family members. With this technique, it has been reported that immunoallergic hepatitis due to sulphonamides, phenytoin, halothane and amineptine may occur selectively in subjects with a genetic deficiency in a protective mechanism [78–81]. However, as the deficit has never been delineated, one may wonder whether the test does indeed reflect deficits in inactivating mechanisms (as it is supposed to do), or instead reflects the inherited ability of lymphocytes to present alkylated peptides and undergo activation-triggered apoptosis.

2 Indeed, a second type of genetic factor that may modify the susceptibility of subjects to developing immune reactions is the polymorphism of major histocompatibility complex molecules. Major histocompatibility complex molecules, also termed human leukocyte antigen (HLA) molecules in humans, are extremely polymorphic. Each HLA molecule presents different, largely non-overlapping sets of peptides [56]. Having one or another HLA molecule may favour or not favour the presentation of an alkylated immunogenic peptide. Indeed, drug-induced hepatitis seemed to occur more frequently in subjects with a particular HLA molecule: HLA A11 in hepatitis due to halothane, tricyclic antidepressants or diclofenac; HLA DR6 in hepatitis caused by chlorpromazine or nitrofurantoin; or HLA B8 in clometacin hepatitis [82]. Likewise, cholestatic hepatitis due to the amoxicillin–clavulanic acid combination mostly occurs in patients with the extended DRB1*1501–DRB5*0101–DQB1*0602 HLA haplotype [83,84]. Yet another example is the cholestatic hepatitis due to tiopronin, which is highly linked to HLA A33, B44 and DR6.

Clinical characteristics of immunoallergic and autoimmune hepatitis

Whereas a mild, infraclinical humoral immune response may be frequent, clinical hepatitis due to immune mechanisms has a very low frequency. As in the case of hepatitis due to direct toxicity, the frequency of immune-mediated hepatitis may be influenced by either genetic or acquired metabolic factors, such as defects in protective mechanisms (see preceding section) or microsomal enzyme induction.

Immunoallergic hepatitis can be associated with hypersensitivity manifestations, such as fever, rash and blood eosinophilia, and/or with a marked inflammatory cell infiltrate in the liver with, sometimes, eosinophils and/or hepatic granulomas. However, these features are not constant. Their absence in an individual patient does not rule out an immunoallergic mechanism in this patient. In some cases (halothane, tienilic acid, clometacin, α-methyldopa, diclofenac), the patients' sera have been shown to contain antibodies directed against hepatic neoantigens. A lymphocyte proliferation assay (performed in the presence of indomethacin to prevent prostaglandin formation) was reported to be positive in 56% of 95 patients with drug-induced liver injury, but constantly negative in 106 healthy control subjects and also negative in 35 patients treated with the same drugs as the patients, but without hepatitis [16]. Immunoallergic hepatitis recurs promptly after an inadvertent drug rechallenge, sometimes after a single tablet.

Cases of 'autoimmune' drug-induced hepatitis have related characteristics. However, hypersensitivity manifestations might be less frequent, and chronic liver lesions more common, in autoimmune hepatitis than in immunoallergic hepatitis [26]. Autoantibodies against hepatic proteins are present. Although corticosteroids have seemed helpful in a few individual cases, their efficacy remains unproven. First, no controlled trial has been reported. Second, the mere interruption of the treatment suppresses the initial stimulus for immunization (i.e. the modification of self due to the covalent binding of the reactive metabolite). Withdrawing the treatment is associated with both a progressive decrease in autoantibody titres and the patient's recovery.

Overview of the role of the cytochrome P-450 and immune systems

Animals are fundamentally xenophobic. They have evolved two systems to eliminate the xenobiotics contained in the plants that they ingest (the hepatic cytochrome P-450 system) and the microorganisms that attack them (the immune system).

The strategy used by the first system relies on a whole array of cytochrome P-450s able to metabolize and thereby eliminate liposoluble xenobiotics (and drugs). Although this system has the inconvenience of forming reactive metabolites, their adverse consequences are largely prevented by a host of protective mechanisms. Only huge amounts of the xenobiotic, the extensive metabolism of a particular xenobiotic or genetic or acquired susceptibility factors will lead to direct toxicity and either apoptosis or necrosis. Investigational molecules that would lead to extensive alkylation of hepatic constituents, and constant hepatitis at therapeutic doses, are not marketed. Drugs are released

for human use only when the alkylation of hepatic constituents remains below the threshold for liver cell demise, at least in most recipients. In a few metabolically susceptible patients, however, this threshold may be exceeded with some drugs, producing severe hepatitis resulting from direct toxicity.

Most marketed drugs, however, may never reach the threshold for massive liver cell demise, although the threshold for mild toxicity may be reached in a few metabolically susceptible subjects. In most of these subjects, this will just produce a mild, asymptomatic increase in ALT activity. In a minority of these few subjects, however, the release of hepatic neoantigens may interfere with the immune system.

The immune system has evolved to recognize and destroy microorganisms and/or cells that harbour them. The system is based on the presentation of peptides on the cell surface and the recognition of those that are foreign by lymphocytes. A reactive metabolite that has been formed by cytochrome P-450 and has covalently bound to hepatic proteins may be considered as 'foreign'. The immune system may then apply its programme for the immunological destruction of the 'infected' cells, leading to drug-induced immunoallergic or autoimmune hepatitis. These immune reactions may represent the main cause of drug-induced hepatitis. They may lead to cytolytic, cholestatic or mixed hepatitis.

Different forms of acute hepatitis

Acute cytolytic hepatitis

Elevated serum transaminase activity is the main hallmark of acute 'cytolytic' hepatitis, reflecting the release of intracellular enzymes from dying hepatocytes. Other features depend on the severity of the disease. Indeed, with increasing degrees of liver cell necrosis, four patterns can be distinguished, each being characterized by the addition of new symptoms beyond those already present in milder forms:

1 'transaminitis' (isolated increases in ALT activity, without any clinical sign);
2 'anicteric hepatitis' (nausea, vomiting, abdominal pain, fever, anorexia or asthenia, but without jaundice);
3 'icteric hepatitis' (with jaundice, but without encephalopathy);
4 'fulminant hepatitis' (with hepatic encephalopathy). When, at the same time, the factor V level becomes less than 20% of normal, the spontaneous prognosis is usually very poor, and liver transplantation must be considered. This possibility of severe liver damage is the main concern in this type of drug-induced liver disease.

Fortunately, these various forms of cytolytic hepatitis do not have the same frequency. As a general rule, asymptomatic increases in ALT activity may be 10 times more frequent than icteric cases, which may themselves be 10 times more frequent than fulminant ones. However, the proportion of fulminant cases may be higher with some drugs (e.g. alpidem or iproniazid).

The clinical features that distinguish cases due to direct toxicity from those involving immune reactions have been described above in the section dealing with toxic or allergic mechanisms of acute hepatitis.

A liver biopsy is rarely performed in obvious or mild forms, but may be useful in difficult, severe cases. The main liver lesion is hepatocellular necrosis. With some drugs, such as halothane [5] or paracetamol [85], necrosis is characteristically centrolobular. With other agents, such as α-methyldopa [86], however, liver cell necrosis may have a more diffuse pattern, resembling that of viral hepatitis. In some cases, macrovacuolar steatosis may also be present. As in all cases of hepatitis, there is at least some degree of inflammation. While the inflammatory reaction may be mild to moderate in hepatitis due to direct toxicity, it may be extensive in cases due to immune reactions. In the latter case, hepatic eosinophils and, sometimes, granulomas may be present.

The differential diagnosis of acute drug-induced hepatitis mainly concerns viral hepatitis. The presence of positive IgM antibodies against the hepatitis A virus (HAV), the hepatitis B core (HBc) antigen or against the cytomegalovirus (CMV) or the Epstein–Barr virus (EBV) indicates an acute viral hepatitis. Because these acute viral infections are limited in time, it is unlikely that a patient may suffer at the same time from an acute drug-induced hepatitis. Therefore, the presence of these IgM antibodies usually suggests that hepatitis is due to HAV, HBV, CMV or EBV. Hepatitis E should also be considered in patients returning from a trip to Asia or Africa.

The differential diagnosis can be more difficult in patients with chronic viral infections, who are not immune to developing drug-induced liver injury during the very long period of persisting viral presence. The presence of a positive hepatitis B surface antigen (HBsAg) but negative IgM anti-HBc antibody indicates either chronic hepatitis B or a carrier state of the HBsAg, and clearly does not exclude an added episode of drug-induced hepatitis. Likewise, in a patient with chronic hepatitis C and mildly abnormal liver tests at baseline, the sudden deterioration in liver tests after the introduction of a new treatment and their improvement after cessation of this treatment indicate drug-induced liver injury rather than a flare of viral hepatitis.

Another important (and often difficult) differential diagnosis is the liver ischaemia and centrolobular liver cell necrosis that may result from a transient decrease in cardiac output and hepatic vascular flow. The episode of shock may have been transient and unrecorded. The diagnosis should be suspected in elderly patients with cardiac arrhythmias or cardiac failure, particularly when the liver failure is associated with azotaemia. Careful questioning about a possible episode of arrhythmias and/or shock, and results of the electrocardiogram (ECG), cardiac ultrasonography and haemodynamic investigations may suggest the diagnosis, which can be confirmed by a transvenous liver biopsy. Rapid improvement in liver and kidney function once the cardiac output is restored is often striking, and represents a further argument for this diagnosis.

Finally, the passage of a bile duct stone into the intestine may cause an acute rise in serum transaminase activity during the

transient episode of acute bile duct obstruction. The possible occurrence of similar episode(s) in the past, the acute onset of biliary colic, sometimes with fever and an increased neutrophil count, and the presence of gallbladder stones on ultrasonography may suggest the diagnosis. Although dilation of the common bile duct on ultrasonography would confirm the diagnosis, the choledochus may no longer be dilated after the stone has passed into the duodenum.

Acute cholestatic hepatitis

Cholestasis is defined as the failure of bile to reach the duodenum [87]. In cholestatic hepatitis, the dysfunction is located at the level of the bile canaliculus (canalicular cholestasis) and/or small bile ducts (see next section).

Cholestasis often predominates in the centrolobular area (zone three of the acinus). Histologically, the hepatocytes contain brownish bile granules in their cytoplasm, while canaliculi are often dilated and also contain brown bile pigment material. In cholestatic hepatitis, there must be some degree of portal inflammation (hence the term hepatitis), and liver necrosis should be either absent or very mild. Should inflammation be absent, the condition should be classified, instead, as 'pure (bland) cholestasis'. Should liver necrosis be more prominent, the liver injury should be referred to as 'mixed hepatitis'.

The full-blown clinical picture of cholestasis consists of jaundice and pruritus, with pale stools and dark urine. In mild forms, however, jaundice and even pruritus are lacking, and only the biochemical abnormalities are present. A first biochemical consequence of cholestasis is an increased plasma concentration of bile constituents such as conjugated bilirubin and bile acids. There is also increased synthesis and transfer into the blood of canalicular membrane enzymes, such as alkaline phosphatase and γ-glutamyltransferase [87]. In addition, there may be some leakage of cellular enzymes, such as aminotransferases, whose activity may be slightly increased in the serum. Ultrasonography and radiology show a normal biliary tree in this intrahepatic form of cholestasis.

Hypersensitivity manifestations such as fever, rash or blood eosinophilia are often present, consistent with an immune mechanism for this drug-induced disease. Indeed, several drugs producing cholestatic hepatitis are known to be transformed into reactive metabolites (Table 4) that probably lead to immunization. Which antigens may be involved in these cholestatic cases remain totally unknown, however. Abdominal pain and a tender liver may also occur in drug-induced cholestatic hepatitis, and this may confuse the diagnosis.

Indeed, the main differential diagnosis of drug-induced cholestatic hepatitis is jaundice due to biliary obstruction. In the past, several patients who presented with abdominal pain and fever, followed by jaundice and pruritus, have been operated upon with an erroneous clinical diagnosis of choledocholithiasis. Nowadays, however, the recourse to ultrasonography in all cases of cholestasis makes this distinction much easier and avoids unnecessary surgical exploration. Endoscopic ultrasonography and/or magnetic resonance cholangiography may also be useful in difficult cases.

A second differential diagnosis is with the rare, but possible, cholestatic forms of viral hepatitis, particularly hepatitis A. Viral hepatitis is detected by the viral serologies. Alcoholic hepatitis may also present as cholestasis in some rare cases. Questioning of the patient and his/her family, clinical stigmata of alcoholism, an increased mean corpuscular volume, a predominance of aspartate aminotransferase (AST) over ALT elevation and a markedly enlarged liver will suggest the diagnosis, confirmed by a liver biopsy.

Acute cholestatic hepatitis with cholangiolitis and cholangitis

After having been secreted by the hepatocytes into the bile canaliculus (a space between two adjacent hepatocytes), and after having flowed through this canalicular network towards the periphery of the lobule, bile then enters the bile ductules (or cholangioles), which are lined by flat epithelial cells. Bile is then collected by the portal (interlobular) bile ducts lined by columnar ductal cells [87].

Some cases of cholestatic (or mixed) hepatitis are associated with acute lesions of bile ducts and ductules. It is probable that, in the past, these lesions have been neglected in many short reports of cholestatic hepatitis. These bile duct lesions should be explicitly mentioned in case reports, because they may contribute to the pathogenesis of some cholestatic episodes and may help to explain the subsequent development of the vanishing bile duct syndrome in a few patients.

'Cholangiolitis' refers to inflammation of the ductules and is characterized by ductular proliferation, with oedema and infiltration by polymorphonuclear leukocytes in and around the ductules [87]. 'Cholangitis' refers to oedema and acute inflammatory changes in and around the portal bile ducts [87]. Cholangitis is the prominent lesion and is generally associated with cholangiolitis. In some cases, the lesions are marked. The bile ducts are dilated, and the epithelial cells are swollen or necrotic. The inflammatory infiltrate is usually polymorphic and contains lymphocytes, neutrophils and, sometimes, eosinophils [87].

The mechanism for acute cholangiolitis and cholangitis is unknown. However, the presence of eosinophils in the inflammatory infiltrate and the association with granulomas in several patients, as well as the frequent association with hypersensitivity manifestations, all suggest an immune mechanism [87].

The outcome of drug-induced cholangitis is generally good, with recovery occurring rapidly after discontinuation of the causative drug. However, in a few patients, cholestatic hepatitis may be followed by prolonged cholestasis due to the vanishing bile duct syndrome, as discussed further on.

Acute cholangiolitis and cholangitis have been observed mainly after the administration of ajmaline, the amoxicillin–clavulanic acid combination, flucloxacillin, chlorpromazine,

Table 5 Main drugs causing acute intrahepatic duct lesions.[a]

Ajmaline	Etretinate	Gold salts
Amitriptyline	Glibenclamide	Hydralazine
Amoxicillin–clavulanic acid	Chlorothiazide	Interleukin-2
Ampicillin	Chlorpromazine	Methahexamide
Allopurinol	Chlorpropamide	Methytestosterone
Azathioprine	Clometacin	D-Penicillamine
Barbiturates	Dantrolene	Propoxyphene (dextropropoxyphene)
Candesartan cilexetil	Diazepam	Sulindac
Carbamazepine	Difetarsone	Troleandomycin
Cefoperazone		

[a]Adapted from Larrey D, Michel H (1993) Drug-induced biliary tract pathology. *Gastroenterol Clin Biol* 17, H59–65.

carbamazepine and propoxyphene (dextropropoxyphene) [87]. Occasional instances have occurred with other drugs (Table 5).

Mixed hepatitis

Mixed hepatitis is characterized by the presence of both cholestasis and mild hepatocellular liver injury in the same patient. When necrosis is extensive, such cases should be classified as cytolytic hepatitis, even when there is some associated cholestasis. Accordingly, clinical and biochemical signs of mixed hepatitis are variable combinations of those of cholestatic hepatitis and mild hepatocellular damage.

Granulomatous hepatitis

Small rounded foci of epithelioid cells and round cells with, at times, multinucleated giant cells are present in the liver [88]. These drug-induced hepatic granulomas are always non-caseous. They may be surrounded by eosinophils. Granulomas may be located in the portal tract, the lobule or both.

The term granulomatous hepatitis should be reserved for cases in which hepatic granulomas are the main liver lesion, as in some cases of hepatitis due to allopurinol, carbamazepine, hydralazine, penicillin, phenylbutazone, quinidine or sulphonamides. When hepatic granulomas are just an epiphenomenon in the context of severe liver cell necrosis, as in some cases of hepatitis due to halothane or α-methyldopa, these cases must be classified as cytolytic hepatitis (with hepatic granulomas). Similarly, when granulomas accompany both liver cell necrosis and cholestasis, as in some cases of hepatitis due to allopurinol, phenylbutazone, quinidine or sulphonamides, the liver disease should be classified as mixed hepatitis (with hepatic granulomas).

Pure granulomatous hepatitis may be silent or sometimes announced by general symptoms, pruritus, mild icterus and an enlarged liver. Serum alkaline phosphatase activity may be increased. Drugs causing hepatic granulomas are listed in Table 6 [88].

Table 6 Main drugs causing hepatic granulomas.[a]

Allopurinol	Enflurane	Penicillamine
Amiodarone	Estroprogestatives	Perhexiline
Amoxicillin–clavulanic acid	Feprazone	Phenazone
Aprindine	Flucloxacillin	Phenindione
Aspirin	Fluconazole	Phenprocoumon
Azathioprine	Flumequine	Phenylbutazone
Bacillus Calmette–Guérin	Glibenclamide	Phenytoin
Carbamazepine	Glyuride	Piroxicam
Carbimazole	Gold salts	Prajmaline
Carbutamide	Halothane	Procainamide
Cephalexin	Hydralazine	Procarbazine
Chlorpromazine	Isoniazid	Quinidine
Chloroquine	Ketoconazole	Quinine
Chlorpropamide	Lovastatin	Ranitidine
Clindamycin	Mesalazine	Saridon
Clofibrate	Methimazole	Sulphadiazine
Co-trimoxazole	Methotrexate	Sulphadimethoxine
Cromoglycic acid	Methyldopa	Sulphadoxine
Cyclofenil	Minocycline	Sulphamethoxazole
Dapsone	Naproxen	Sulphanilamide
Diazepam	Nitrofurantoin	Sulphathiazole
Diclofenac	Nomifensine	Sulphasalazine
Dicloxacillin	Ofloxacin	Tacrine
Difebarbamate	Oxacillin	Ticlopidine
Diflunisal	Oxyphenbutazone	Tocainide
Diltiazem	Papaverine	Tolbutamide
Disopyramide	Penicillin	Troglitazone

[a]Adapted from Vial T, Descotes J (1993) Drug-induced granulomatous hepatitis. *Gastroenterol Clin Biol* 17, H44–48, and from the 'Hepatox' compilation of Michel Biour (www.e-drugnews.com/index.cfm).

Outcome of acute drug-induced hepatitis

Outcome of cytolytic hepatitis

If not already dying (or transplanted) because of fulminant hepatitis, patients with drug-induced cytolytic liver injury usually recover quickly after withdrawal of the offending drug. In severe cases, however, it is not unusual for serum transminases to continue to rise for 1 or 2 weeks before deceleration finally occurs. Furthermore, some patients with hepatitis due to iproniazid or tienilic acid have continued to worsen despite discontinuation of the treatment. With these two drugs, there are specific autoantibodies directed against normal cell constituents [14,65].

Conceivably, removal of the initiating drug may not stop such autoimmunity immediately.

When the administration of the offending drug is continued, the outcome is variable:

- In some patients, particularly those with only mild liver test abnormalities, a progressive return to normal values can occur despite continued drug administration, indicating adaptive changes.
- However, in other patients, cytolytic hepatitis worsens instead, possibly leading to fulminant or subfulminant hepatitis.
- Finally, the cytolytic liver injury may not worsen in severity, but may persist for a prolonged period of time, thus possibly leading to the development of chronic liver disease, as discussed further on.

Outcome of granulomatous, mixed or cholestatic hepatitis

Hepatitis usually has a good prognosis. In a few cases of cholestatic hepatitis, however, cholestasis may persist for several years after discontinuation of the offending drug (see 'Prolonged cholestasis' below).

Drugs causing acute hepatitis

Many drugs may cause acute hepatitis, but only the most commonly involved drugs (either because they are frequently hepatotoxic or because they are widely used) are discussed individually below.

Acebutol

Six cases of hepatitis possibly due to this β-adrenergic receptor antagonist had been reported to the United States Food and Drug Administration in 1988. Hepatitis exhibited a hepatocellular or mixed pattern, and was usually associated with fever. Two patients were rechallenged, with recurrence within 2 days, suggesting an immune mechanism.

Acitretin

This aromatic retinoid is the non-esterified analogue (and a metabolite) of etretinate. Like etretinate, it is teratogenic. Pregnancy must be avoided during and long after its administration, owing to its prolonged retention in the body. As with etretinate, monitoring of liver function tests is advised. Acitretin may increase ALT activity in 17% of recipients, and a few cases of clinical hepatitis have been observed [5].

Ajmaline

Jaundice has occurred after 8–16 days of treatment with this antiarrhythmic agent [89]. Chills, fever and abdominal pain often preceded icterus, simulating obstructive jaundice [89]. Eosinophilia was frequent, and the presumed mechanism was immunoallergy. Although jaundice usually subsided within 3 months after cessation of treatment, prolonged cholestasis due to rarefaction of bile ducts occurred in some patients, as discussed in a subsequent section. The drug has been abandoned in many countries.

Alpidem

Alpidem has been recalled because of its hepatotoxic potential. Although cytolytic hepatitis was not frequent, it often had a severe, subfulminant course leading to liver transplantation or death. This peripheral benzodiazepine ligand may favour mitochondrial permeability transition [90].

Allopurinol

Allopurinol can occasionally cause liver injury, particularly in those receiving diuretics or those with compromised renal function [91]. Hepatitis mostly occurs during the first month of treatment. The liver injury is predominantly hepatocellular. Fulminant hepatitis is possible. Hepatic granulomas are observed in about 50% of cases. These granulomas, and the frequent occurrence of fever, rash and eosinophilia (both peripheral and hepatic), suggest an allergic mechanism.

Amineptine

This tricyclic antidepressant caused 80% of the cases of hepatitis due to tricyclic antidepressants in France, and is no longer marketed. Amineptine produced two types of liver injury: the most frequent type was mixed or cholestatic hepatitis. The disease was sometimes associated with fever and blood eosinophilia, and promptly recurred after a rechallenge, suggesting an immune mechanism. Amineptine is activated into a reactive metabolite, which is efficiently detoxified by glutathione and does not lead to direct toxicity. Presumably, the metabolite caused immunoallergic hepatitis in some subjects.

In a few patients receiving amineptine, the liver lesion has been that of microvesicular steatosis. This may be due to inhibition of mitochondrial β-oxidation by the heptanoic side-chain of amineptine, as discussed further on.

Amitriptyline

Like other tricyclic antidepressants, amitriptyline may be transformed into a chemically reactive metabolite. It causes mixed hepatitis, usually with a marked necrotic component [92]. Hypersensitivity manifestations are seen in some patients [92].

Amodiaquine

This antimalarial drug can cause hepatocellular jaundice and fulminant hepatitis [93]. It is not clear whether hepatitis is due to direct toxicity, immunoallergy or possibly both (in different patients). Amodiaquine undergoes auto-oxidation into a reactive quinoneimine.

Amoxicillin–clavulanic acid

Although the risk of developing significant hepatic injury may be less than 1 in 100 000 patients treated with the amoxicillin–clavulanic acid combination, this is a frequent cause of

cholestatic hepatitis, because of the large number of prescriptions. Cholestatic hepatitis affects mainly elderly males [94] and/or subjects with a particular HLA haplotype [83,84]. Prolonged treatment for 10 days or more is a predisposing factor, and symptoms can appear 1–4 weeks after treatment has been stopped [94]. Some patients have eosinophilia and/or low titres of antismooth muscle, antinuclear or antimitochondrial antibodies [94]. Acute cholangiolitis is frequent [95].

Because the readministration of amoxicillin alone has been well tolerated, it is thought that the drug combination (probably the clavulanic moiety) is responsible [5]. In performing such rechallenges, however, one must be aware that amoxicillin given alone also has the potential to produce cholestasis, including the vanishing bile duct syndrome.

Aspirin

Hepatitis resulting from aspirin occurs after one to several weeks of treatment, and is due to the dose-related toxicity of salicylate [96]. Salicylate levels higher than 25 mg/dL frequently lead to hepatic injury, while levels lower than 15 mg/dL rarely do [96]. Hepatic injury is often silent, or at least anicteric; liver histology shows ballooning and focal necrosis. However, a few severe cases, with hepatic encephalopathy, have been described [96].

Utilization of aspirin during viral infections favours the secondary development of Reye syndrome in children (see 'Steatosis') [97].

Azathioprine

During its thiolysis to 6-mercaptopurine, azathioprine depletes hepatic glutathione, and it causes mitochondrial permeability transition, ATP depletion and necrosis in cultured rat hepatocytes [98]. Azathioprine can cause cholestatic jaundice. Seven renal transplant recipients developed jaundice 33–88 months after starting azathioprine, together with low doses of glucocorticoids [99]. Centrolobular cholestasis was associated with fatty liver in five of these seven patients, and with sinusoidal dilation in three. Clinical and laboratory manifestations disappeared within 1 month of stopping azathioprine. Reintroduction of azathioprine in three patients led to recurrence within 1 month [99]. The drug also produces a variety of vascular lesions, and might also trigger cancer, as discussed further on.

Benoxaprofen

This NSAID had to be withdrawn because of its hepatotoxic and nephrotoxic potential, mainly in elderly females [4]. Hepatitis was mixed. Benoxaprofen may be transformed into a reactive metabolite.

Benzarone and benzbromarone

These two structurally related drugs impair mitochondrial function [100]. Benzarone can cause cytolytic hepatitis, chronic active hepatitis and cirrhosis [101]. Benzbromarone can also cause hepatocellular liver injury.

Bromfenac

This NSAID was removed from the market because of its potential to cause severe cytolytic hepatitis.

Captopril

In one review, 14 cases of jaundice were reported after the administration of captopril, an angiotensin-converting enzyme inhibitor. Fever, rash, and eosinophilia were common. Nine cases were classified as cholestatic, four as mixed, and one as hepatocellular. Another report cites nine cases of hepatocellular injury, including two deaths.

Carbamazepine

This anticonvulsant drug may produce hepatitis within the first 6 weeks of treatment. Hepatitis is mixed, and there may be acute cholangitis. The possible occurrence of fever, rash, eosinophilia, pancytopenia, agranulocytosis, thrombocytopenia, lymphadenopathy and hepatic granulomas, as well as the prompt recurrence upon rechallenge, all suggest an allergic mechanism. Carbamazepine is transformed into the stable 10,11-epoxide, but also into several other (probably unstable) epoxides.

Carbimazole

This antithyroid drug is metabolized into methimazole and produces mixed, mostly cholestatic, hepatitis, sometimes with bile duct damage. The liver injury occurs within the first 6 weeks of treatment. It may be associated with fever and blood eosinophilia, and may recur immediately upon rechallenge.

Chlordiazepoxide

Hepatitis occurs within the first 6 weeks of treatment with chlordiazepoxide. This benzodiazepine mainly causes cholestatic jaundice, although a few cases of mixed or even cytolytic hepatitis have also occurred.

Chlorpromazine

Chlorpromazine was one of the first drugs known to cause cholestatic hepatitis [4]. Jaundice and pruritus usually occur within the first 5 weeks of therapy [4]. Serum alkaline phosphatase values are markedly elevated (more than three- or fourfold) in 50–70% of cases, whereas aminotransferases are moderately increased. Serum cholesterol is frequently augmented.

Prodromal signs, with fever or influenza-like symptoms, nausea or vomiting, and abdominal pain occur in 70–80% of cases. The syndrome may mimic extrahepatic obstruction, and a number of patients have been subjected to laparotomy [102]. However, signs of hypersensitivity (fever, eosinophilia) occur in up to 70% of patients, and a skin rash is reported in 3–5%. Antinuclear antibodies are found in 40% of cases [4]. Ultrasonography shows a normal biliary tree. The typical histological picture includes cholestasis with relatively little hepatocellular injury and a marked portal inflammatory infiltrate [102]. Eosinophils are seen in 25–50% of cases.

Cholangiolitis occurs in approximately 25% of cases, with infiltration of cholangioles with neutrophils and eosinophils [102].

Approximately one-third of patients recover within 4 weeks after cessation of treatment, and another third in 4–8 weeks. The remainder may have a more prolonged course, and prolonged cholestasis and even biliary cirrhosis may ensue, as discussed further on. Treatment is symptomatic. Corticosteroids do not influence the course.

Chlorpromazine may form reactive metabolites, and this might lead to metabolite-mediated immunoallergic hepatitis. Cross-sensitivity between chlorpromazine and several other phenothiazines has been observed [102].

Chlorpropamide

Chlorpropamide is rarely used nowadays because this long-acting hypoglycaemic agent sometimes causes severe and prolonged hypoglycaemia. It has been responsible in the past for several cases of mixed (mainly cholestatic) hepatitis, presumably due to immunoallergy [5].

Cimetidine

Asymptomatic increases in serum transaminase activity have been observed in a few patients on cimetidine, and a few cases of mixed hepatitis have been published. Hypersensitivity manifestations (fever, rash) and a prompt recurrence on rechallenge may suggest an allergic mechanism, at least in some patients.

Ciprofloxacin

Ciprofloxacin administration can cause cholestatic hepatitis, sometimes with ductopenia. It may also cause cytolytic hepatitis, which can be severe. Ciprofloxacin may poison mitochondrial topoisomerase II and cause double-stranded mitochondrial DNA breaks and mitochondrial DNA depletion *in vitro* [103]. Ciprofloxacin may also cause permeabilization of lysosomes, thus triggering conformational changes in Bax and Bak, mitochondrial permeability transition and apoptosis [104].

Clofibrate and other fibrates

Mild and often transient increases in serum ALT levels, usually without any clinical manifestations, can occur in patients on clofibrate. In some patients, the serum transaminase elevation may be part of a myalgia syndrome (with elevated serum creatine kinase). Clofibrate causes hepatomegaly and peroxisomal proliferation in rodents. Hepatomegaly might also occur in humans but without peroxisomal proliferation. Clofibrate administration also increases the saturation of bile and the incidence of gallstones.

The same types of effects may be observed with bezafibrate, fenofibrate and gemfibrozil. Although several cases of chronic liver injury and cirrhosis have been ascribed to the administration of fenofibrate and ciprofibrate, a difficulty is that the prescription of these drugs in patients with dyslipidaemia and/or the metabolic syndrome makes it difficult to distinguish between drug-induced and steatohepatitis-related chronic liver disease.

Clometacin

This analgesic was a frequent cause of cytolytic hepatitis in France, particularly in elderly females [105]. Clometacin also caused chronic hepatitis and cirrhosis [105]. Occurrence of fever, rash, eosinophilia, thrombocytopenia, interstitial nephritis, antismooth muscle and antidouble-stranded DNA autoantibodies, and the frequency of the HLA B8 antigen in affected patients, all suggested an allergic mechanism [105]. The drug is no longer used in France.

Clozapine

This neuroleptic has transformed the life of some schizophrenic patients, and is maintained despite its propensity to produce agranulocytosis and the need for frequent monitoring of the haemogram. Clozapine also increases ALT activity in 4–30% and can cause severe cytolytic hepatitis [106]. Clozapine is transformed into a reactive metabolite by hepatic cytochrome P-450 [107].

Cocaine

In 1991, it was estimated that 22 million Americans had used cocaine at least once, and that 5 million used it regularly. Fifteen per cent of hospitalized, non-parenteral cocaine users presented with mild elevations in liver enzymes. Acute cocaine intoxication may also lead to a severe syndrome that typically associates hyperpyrexia, hypotension, disseminated intravascular coagulation, acute renal failure, rhabdomyolysis and severe hepatic dysfunction. In these patients, massive increases in ALT activity occur within the first 48 h after admission, and liver lesions consist of both pericentral coagulative necrosis and periportal microvesicular steatosis. Although both hypotension and hyperthermia may participate in the pathogenesis of these lesions, a direct toxicity of cocaine has been demonstrated in several *in vitro* studies [108]. Cocaine is transformed by cytochrome P-450 into norcocaine, which is further oxidized to *N*-hydroxynorcocaine, norcocaine nitroxide and norcocaine nitrosonium ion. These metabolites may cause an oxidative stress and lipid peroxidation in hepatocytes [108]. In animals, toxicity is enhanced by cytochrome P-450 inducers, such as phenobarbital or ethanol, and is prevented by cytochrome P-450 inhibitors [108]. Extensive formation of reactive oxygen species may trigger mitochondrial permeability transition, caspase activation and apoptosis in cocaine-treated rat hepatocytes.

Co-trimoxazole (trimethoprim and sulphamethoxazole)

This frequently used antibacterial drug combination can cause an immunoallergic, cytolytic hepatitis, sometimes associated with pancreatitis. In one case, phospholipidosis was also present.

Cyproterone acetate

This synthetic steroid, which is used in oral contraceptives and antiandrogen formulations, may produce minor abnormalities in liver function tests. However, in several elderly patients treated for either prostatic or breast cancers, it has instead produced fulminant hepatitis without clinical or biochemical manifestations of hypersensitivity. The drug might also cause hepatocellular carcinomas.

Dantrolene

Prolonged administration of dantrolene increased serum transaminase activity in 1–8% of recipients, and produced jaundice in 0.6% [109]. The injury was mainly cytolytic, with a pattern of acute, subacute or chronic hepatitis and a fatality rate of 28% [109]. Hypersensitivity manifestations were uncommon.

Dapsone

This antileprosy drug is also used in dermatis herpetiformis and in the treatment of *Pneumocystis carinii* infections in patients with the acquired immunodeficiency syndrome (AIDS). Like other sulphonamides, the drug may be detoxified by acetylation of its NH_2 groups. As there are two such groups in dapsone, however, both the parent compound and monoacetyldapsone can be oxidized by cytochrome P-450 to hydroxylamine derivatives that can cause methaemoglobinaemia. Hyperbilirubinaemia due to haemolysis may occur. Dapsone may also cause cholestatic or hepatocellular jaundice, which may be part of the 'sulphone syndrome' consisting of fever, malaise, hepatic necrosis, exfoliative dermatitis, lymphadenopathy, methaemoglobinaemia and haemolytic anaemia [110].

Diclofenac

Diclofenac is among the most widely used anti-inflammatory drugs worldwide. Owing to this enormous use, several hundreds of cases of hepatitis have been observed, although the frequency of hepatitis does not appear to be particularly high [111]. Hepatitis due to diclofenac can sometimes be mixed or cholestatic, but is most usually hepatocellular, with a few cases of fulminant hepatitis [111]. Hypersensitivity manifestations have been observed in a few patients, but are relatively uncommon. Being an acidic compound, diclofenac uncouples mitochondrial respiration, which can favour mitochondrial permeability transition [20]. Diclofenac is also transformed by cytochrome P-450 into several reactive metabolites, and its administration elicits antidiclofenac–protein adduct antibodies [75]. It is suspected that various combinations of direct toxicity and immune reactions may trigger diclofenac-induced hepatitis in different patients.

Dihydralazine

Dihydralazine hepatitis occurs a few weeks to several months after the onset of treatment with this antihypertensive drug [112]. Slow acetylators are at increased risk of developing hepatitis [67]. Hepatitis is hepatocellular. It may be associated, in a few cases, with fever or blood eosinophilia, and may recur quickly after an inadvertent drug rechallenge. Dihydralazine-induced hepatitis is associated with antimicrosomal antibodies directed against the cytochrome P-450 1A2 isoenzyme, which transforms dihydralazine into reactive radicals [66,67]. Antismooth muscle, antimitochondrial and antimicrosomal autoantibodies have also been observed.

Disulfiram

Use of this drug in alcoholics has long delayed recognition of its hepatotoxicity. However, disulfiram-induced liver injury has also occurred in non-alcoholic patients and, furthermore, the role of disulfiram has been proven by rechallenge in alcoholic patients [3]. Disulfiram is widely used in some countries and was the fourth leading cause of drug-induced liver injury in Denmark. Disulfiram has caused abnormal liver biochemistry in 25% of recipients during the first weeks of treatment [3], suggesting some direct toxicity. However, clinically relevant liver cell necrosis occurs in only a few subjects. The onset is usually within the first 2 months of treatment, but may be more delayed. Disulfiram hepatitis is usually hepatocellular, and more than 15 cases of fulminant hepatitis have been reported [114]. There is a mixed cell infiltrate, usually including eosinophils. Although extrahepatic hypersensitivity manifestations are usually absent, this eosinophilic infiltrate, and the prompt and exaggerated response after rechallenge, may suggest an immune mechanism, at least in some patients.

In mitochondria, the disulphide bridge of disulfiram is split by two reduced glutathione (GSH) molecules, thus forming GSSG, which in turn consumes NAD(P)H during its secondary reduction [113]. The oxidation of NAD(P)H and GSH may favour mitochondrial permeability transition, which triggers cell death [113]. Disulfiram also covalently binds to proteins. As in many other examples, some mild direct toxicity may favour immunization, which may trigger severe immunoallergic hepatitis in a few patients.

'Ecstasy' (3,4-methylenedioxymethamphetamine)

This illicit, synthetic amphetamine derivative, known as 'ecstasy', is increasingly used as a recreational drug. *In vitro*, ecstasy can release mitochondrial cytochrome *c* and can trigger caspase-3 activation, DNA fragmentation and apoptosis in cultured rat liver cells. Its recreational use in humans, combined with vigorous exercise at all-night dance sessions, can produce a syndrome reminiscent of that caused by cocaine intoxication, with hyperthermia, hypotension, disseminated intravascular coagulation, rhabdomyolysis, acute renal failure, acute hepatic failure and death. Ecstasy-induced liver injury can also present independently, a few days to 4 weeks after ingestion of the drug, as mixed hepatitis in young patients. Ecstasy use should be specifically sought in all young patients with 'unexplained' jaundice.

Enalapril

Like captopril, this angiotensin-converting enzyme inhibitor

infrequently produces mixed hepatitis. One reversible icteric case was initially associated with ductopenia.

Enflurane

Hepatitis caused by this volatile anaesthetic closely resembles halothane hepatitis [115]. Like halothane, enflurane is transformed into reactive acyl halide metabolites that can lead to immunoallergic hepatitis.

Erythromycins

Not only erythromycin estolate [116], but also erythromycin ethylsuccinate, erythromycin propionate, clarithromycin and roxithromycin, may all cause hepatitis. Hepatitis occurs mainly during the first 2 weeks of treatment. The condition is frequently associated with abdominal pains (80%), fever (60%) and eosinophilia (45–80%) [117]. Hepatitis is usually cholestatic or mixed, and usually has a good prognosis [118]. However, fulminant hepatitis is possible, particularly after the administration of clarithromycin.

The liver injury often recurs within 24–48 h after rechallenge with the same erythromycin derivative [117]. It may or may not recur after the administration of another erythromycin derivative [117]. The erythromycins are demethylated and oxidized by cytochrome P-450 into nitrosoalkane metabolites in rats and humans. These unstable, electrophilic intermediates may react with the SH group of glutathione or cysteine, and may bind covalently to proteins. This might lead to immunization in some patients [119]. The antigenic targets remain unknown, however.

Etretinate

Like acitretin, this aromatic retinoid is used in the treatment of psoriasis. Like acitretin, it is teratogenic, and pregnancy must be avoided during, and long after, its administration (its half-life is 120 days). It is also hepatotoxic, and liver function tests must be monitored [3]. The drug produces liver function test abnormalities in up to 10–25% of subjects and has been responsible for several cases of severe liver cell necrosis. Fever may be present in some cases, and the inflammatory infiltrate of portal tracts may contain eosinophils. Positive rechallenges to small doses of etretinate have been observed. Owing to the drug's long half-life, features of hepatitis can appear and/or the patient's condition may deteriorate after discontinuation of treatment, with the possible development of chronic hepatitis and cirrhosis. Corticosteroids have seemed helpful in some of these deteriorating cases.

Felbamate

This antiepileptic drug, which is transformed into reactive metabolites, causes rather frequent cytolytic hepatitis in addition to severe aplastic anaemia [120]. Its use is restricted to patients whose seizures are not prevented by safer antiepileptic drugs.

Fipexide

This cognition activator is proposed in asthenia and memory disorders. The drug has produced fulminant hepatitis in three patients.

Flucloxacillin

The hepatotoxicity of flucloxacillin is reminiscent of that of the amoxicillin–clavulanic acid combination. Flucloxacillin is a frequent cause of cholestatic hepatitis, not because of a high frequency of this adverse effect, but because of the wide use of this antibiotic in some countries. Older patients and those receiving the drug for longer than 2 weeks are at increased risk. In a series of 11 cases, symptoms mainly appeared within 10–30 days after starting the drug [121]. Four of these patients had cholangitis or cholangiolitis [121]. Although the outcome of flucloxacillin-induced hepatitis is usually favourable, prolonged cholestasis due to the vanishing bile duct syndrome can occur in a few patients. In hepatocytes, flucloxacillin may be transformed by cytochrome P-450 3A into a metabolite toxic to bile duct cells [122]. A hypothetical mechanism for hepatitis could be that this metabolite may be eliminated into bile and may then covalently bind to the proteins of bile duct cells, to trigger both direct toxicity and immune reactions.

Flutamide

This nitroaromatic antiandrogen is used in the treatment of prostate cancer. It is transformed by cytochrome P-450 into reactive metabolites [43], and can cause cytolytic hepatitis, including a few cases of fulminant hepatitis.

Glafenine

This analgesic has produced hepatocellular jaundice in a few patients [3]. This adverse effect and other allergic manifestations have led to its recall.

Gold salts

Intrahepatic cholestasis is a rare complication of gold salt therapy [123,124]. Jaundice occurs within 5 weeks of the first administration of the various gold salts used in therapy [123]. It may mimic extrahepatic obstruction, and several patients have had surgery [123]. However, hepatitis may be associated with proteinuria, rash and eosinophilia, and ultrasonography shows a normal biliary tree. Cholestasis is predominantly centrolobular. Its recovery may take several months. One case associated with cholangitis and later followed by ductopenia and prolonged cholestasis has been reported. Although gold salts mainly cause cholestatic hepatitis, cases of mixed or cytolytic acute hepatitis and chronic hepatitis have also been reported.

Haloperidol

Although mild increases in alkaline phosphatase activity may occur in 70% of users, symptomatic cases have been infrequent. Fever, jaundice and sometimes blood eosinophilia appeared within 5 weeks of starting the treatment [4]. The disease is mainly cholestatic, although mild necrosis is often associated, and one case of mainly cytolytic hepatitis has been reported.

Halothane

Halothane accounted for 25% of the cases of drug-induced hepatitis reported to the Danish committee on adverse drug reactions between 1978 and 1987. Halothane is transformed by cytochrome P-450 via both an oxidative and a reductive pathway. Both pathways lead to reactive metabolites. The reductive pathway produces a reactive radical ($CF_3 \cdot CHCl$) which, under special conditions (usually microsomal enzyme induction plus hypoxia), may lead to direct hepatotoxicity in animals. Conceivably, this toxic mechanism may also explain the silent increase in transaminase activity seen in a number of human recipients.

The oxidative pathway forms a reactive acyl chloride (CF_3COCl), which binds covalently to hepatic proteins, including plasma membrane proteins. These trifluoroacetylated proteins can lead to immunization and to the severe form of hepatitis seen in exceptional subjects.

This severe form of hepatitis has all the characteristics of an allergic phenomenon [5]:

1 It is extremely uncommon (1/10 000) after a first anaesthesia and occurs within 2 weeks of this first procedure.

2 Jaundice is more frequent (7/10 000) after a repeated exposure and occurs sooner. The mean interval between exposure and onset of jaundice is 12 days after a first exposure, 7 days after a second and 5 days after a third exposure [5].

3 Jaundice is frequently associated with fever (75%) and eosinophilia (40%).

4 Sera from patients with severe halothane hepatitis contain antibodies against trifluoroacetylated plasma membrane proteins [58].

Halothane hepatitis is hepatocellular in type, and may lead to fulminant hepatitis requiring transplantation. Prevention may be obtained by using isoflurane (which may cause hepatitis, but less frequently) or by avoiding repeated exposure to halothane, particularly at short intervals [125]. These precautions are not always adhered to, and halothane hepatitis is still a problem in some countries, including France.

Hydralazine

Hydralazine forms reactive free radicals. This antihypertensive drug may cause hepatocellular jaundice [126]. Fever, rash, eosinophilia and, at times, hepatic granulomas may be seen in some patients.

Imipramine

Administration of imipramine may cause jaundice, usually within the first 2 months of treatment. Hypersensitivity manifestations (fever, rash, eosinophilia) are seen in some patients. Hepatitis is usually mixed, although either the cholestatic or the necrotic component may predominate in some patients [4]. Prolonged cholestasis and progressive hepatic fibrosis have been reported following imipramine therapy. Imipramine is transformed into a reactive metabolite, possibly leading to immunoallergic hepatitis.

Iprindole

This antidepressant may cause mixed (mostly cholestatic) liver injury within the first 3 weeks of treatment.

Iproniazid

Although withdrawn from clinical use in the USA, iproniazid is still used in some countries, including France. The drug may lead to cytolytic jaundice, which occurs mainly during the first 3 months of treatment [127]. Interestingly, hepatitis may start 4 weeks after the discontinuance of iproniazid [127]. Although interruption of the treatment led to recovery in 80% of affected patients, in the remainder, however, the disease continued to progress, eventually leading to death [127]. Iproniazid hepatitis is usually associated with a particular antimitochondrial autoantibody, the anti-M_6 autoantibody [128]. Iproniazid is transformed by cytochrome P-450 into the reactive isopropyl radical, which binds covalently to hepatic proteins. Iproniazid is also activated into reactive metabolites by the mitochondrial monoamine oxidase (MAO), and this may account for the development of the anti-M_6 autoantibodies, which are directed against MAO B [14]. Whether these autoantibodies have a pathogenic role remains to be determined. However, an autoimmune component might explain the possible progression of the disease despite discontinuance of the treatment [129].

Isoniazid given alone or in combination with rifampicin

Isoniazid given alone increases serum transaminase activity in 10% of patients, and causes clinical hepatitis in 1% [130]. The peak incidence of hepatitis occurs during the second month of therapy [130]. Hepatitis is cytolytic, most usually without hypersensitivity manifestations.

Isoniazid is transformed into a reactive metabolite toxic to the liver. Isoniazid is first acetylated into acetylisoniazid, which is hydrolysed into acetylhydrazine. Acetylhydrazine may be either acetylated again, into the non-toxic diacetylhydrazine, or transformed by cytochrome P-450 into the reactive acetyl radical that binds covalently to hepatic proteins.

The acetylation of isoniazid (and several other drugs) is under genetic control. About 40% of Caucasians and black Africans, but 90% of Japanese, are rapid acetylators of isoniazid. The acetylator phenotype influences both the acetylation of isoniazid and that of acetylhydrazine. Thus, rapid acetylators form acetylhydrazine at a faster rate but, at the same time, detoxify it to diacetylhydrazine at a faster rate. This complex situation may explain why divergent findings have been obtained regarding the influence of the acetylator phenotype on the hepatotoxicity of isoniazid. The hepatotoxicity risk has been variously reported to be higher in rapid acetylators, similar whatever the phenotype or higher in slow acetylators. The hepatotoxicity of antituberculous therapy is increased in old age and in patients infected with the HCV, HBV or HIV viruses.

Rifampicin (rifampin) given alone is not, or is seldom, hepatotoxic, and it mainly produces cholestatic liver injury. However,

in patients receiving both rifampicin and isoniazid, the incidence of cytolytic hepatitis is higher than with isoniazid alone, reaching 5–8%, and hepatitis occurs sooner, mainly during the first month of treatment. Fulminant isoniazid–rifampicin hepatitis develops even earlier, after about 1 week of treatment [51]. Hepatitis due to the combined administration of isoniazid and rifampicin is not associated with hypersensitivity manifestations and may be due to direct toxicity [51]. It has been suggested that rifampicin, a microsomal enzyme inducer, might increase the formation of the reactive isoniazid metabolite, and might thereby potentiate the hepatotoxicity of isoniazid in humans [51].

We believe that liver function tests should be monitored in patients receiving these antituberculous drugs, including during the first days of treatment, then every week during the first month and every month thereafter. Isoniazid should be withdrawn, temporarily or definitively, if ALT activities exceed three times the ULN.

Ketoconazole

The antifungal imidazole derivative, ketoconazole, produces silent elevations in serum transaminase activity in 6% of recipients, and may lead to symptomatic hepatic injury in one in 10 000 or 15 000 recipients [131]. Monitoring of liver function tests is recommended. Hepatitis is more frequent in females (ratio 2:1), and occurs after 1.5–26 weeks of treatment. Hepatitis is usually hepatocellular, with some cases of fulminant hepatitis. However, mixed or cholestatic hepatitis can also occur [131]. Hypersensitivity manifestations are usually absent, suggesting a toxic, idiosyncratic mechanism. The average length of time required for laboratory values to return to normal after cessation of treatment was 7 weeks. In several cases, however, liver test abnormalities have continued to deteriorate, and jaundice has become more pronounced during the first 1–2 weeks after the drug was withdrawn, and the final recovery has been long delayed.

Ketoconazole inhibits bromosulphthalein transport in the isolated perfused rat liver and decreases the uptake of bile acids by isolated rat hepatocytes. Ketoconazole is transformed into *N*-deacetyl-ketoconazole, which may be activated by flavin-containing monooxygenases, first into *N*-deacetyl-*N*-hydoxyketoconazole and then into diverse reactive metabolites. In rats, ketoconazole administration decreases hepatic glutathione, causes covalent binding to rat liver proteins and increases ALT activity.

Hepatitis can also occur after the administration of fluconazole, itraconazole or voriconazole.

Labetalol

Eleven cases of hepatitis due to this adrenergic receptor antagonist have been reviewed, nine of which occurred in women, with two fatalities [132]. Hepatic necrosis was present in the five cases with a histopathological assessment [132]. Features of hypersensitivity were infrequent.

Leflunomide

This immunosuppressant drug, which has antiproliferative activity, is used in the treatment of rheumatoid arthritis [133]. Leflunomide causes moderate to severe cytolytic liver injury in 9% of treated patients. Several fatal cases have been observed. Monitoring of liver function tests is recommended [133].

Methimazole (thiamazole)

Cases of hepatitis caused by this antithyroid drug have had mainly cholestatic features, but both a predominantly hepatocellular pattern or a granulomatous form can also occur. Rash, eosinophilia, leucopenia or agranulocytosis may be associated. Methimazole is transformed into a chemically reactive metabolite, and it causes centrolobular necrosis in mice with depleted hepatic glutathione stores.

Methyldopa

Administration of methyldopa may increase ALT activity in up to 6% of recipients. Clinical hepatitis is much less common. It predominates in females (70%). Hepatitis occurs mainly during the first 4 weeks of treatment, but a later onset (several years) is possible [86]. Hepatitis is usually hepatocellular, rarely mixed or cholestatic. In one-third of patients, hepatitis is heralded by fever, but eosinophilia is uncommon. The direct Coombs' test may be positive, and there may be antinuclear or antismooth muscle autoantibodies [86]. Readministration may lead to prompt recurrence, but there are exceptions.

Methyldopa is transformed into chemically reactive metabolites. It is possible that these metabolites may lead to either direct toxicity or allergic hepatitis in different patients. Indeed, 50% of sera from patients with α-methyldopa hepatitis contained antibodies against methyldopa-altered rabbit hepatocytes; these sera became cytotoxic in the presence of normal human mononuclear cells [62].

Minocycline

Unlike other tetracyclines, which can cause steatosis but rarely trigger hepatitis, minocycline can cause a severe form of immunoallergic hepatitis, with frequent eosinophilia and sometimes exfoliative dermatitis, within the first 6 weeks of treatment [134]. After prolonged administration for 1 or 2 years, minocycline can also cause an autoimmune form of hepatitis with autoantibodies (mostly antinuclear antibodies, and sometimes perinuclear antineutrophilic cytoplasmic antibodies) [134]. Autoimmune hepatitis can be associated with polyarthralgias/polyarthritis and lupus erythematosus. These various symptoms improve after the withdrawal of minocycline. Other minocycline-induced immune manifestations include serum sickness and vasculitis and an infectious mononucleosis-like syndrome, with lymphadenopathy, splenomegaly and atypical lymphocytes. Minocycline has been shown to decrease apoptosis in many models, including Fas-mediated hepatic apoptosis [135]. It would be interesting to see whether minocy-

cline also decreases the Fas-mediated destruction of activated lymphocytes, which might explain these various autoimmune manifestations.

Nefazodone

This antidepressant drug seems to have a high potential for triggering cytolytic, sometimes fulminant hepatitis, and it is no longer used in Canada.

Nicotinic acid (niacin)

This lipid-lowering agent causes minor and transient elevations in serum ALT, sometimes associated with decreased synthesis of clotting factors. Several cases of clinically overt acute hepatitis and some cases of mixed or cholestatic hepatitis have also been reported. With the crystalline form, hepatitis usually occurs after weeks or months of treatment with daily doses of 3 g or more. With time-release preparations, hepatitis may occur both sooner and after lower daily doses.

Nifedipine

Compared with the widespread use of this dihydropyridine calcium channel blocker, relatively few cases of drug-induced hepatitis have been reported. Hepatitis is mainly hepatocellular, rarely mixed [3]. Fever and blood eosinophilia are frequent, and there is rapid recurrence on rechallenge, suggesting an immunoallergic mechanism.

Nilutamide

Nilutamide is an antiandrogenic drug, which is used in prostate cancer. It can cause cytolytic hepatitis, including fulminant hepatitis. This nitroaromatic drug undergoes redox cycling, thus forming reactive oxygen species and causing oxidative stress. Nilutamide also impairs mitochondrial respiration and ATP formation [21].

Nimesulide

The NSAID, nimesulide, has caused cholestatic or cytolytic liver injury, including fulminant hepatitis [136]. However, the drug is widely used, and the hepatotoxic risk does not seem to be much higher with nimesulide than with some other NSAIDs [137]. Furthermore, the gastrotoxic risk, which is by far the main risk with these drugs, may be lower with nimesulide than with some other non-selective cyclooxygenase (COX) inhibitors. Although nimesulide inhibits both cyclooxygenase-1 (COX-1) and COX-2, it is much more active on COX-2 than on COX-1, which might explain its relatively good gastric tolerance.

Nitrofurantoin

Jaundice resulting from this urinary tract antiseptic affects mainly middle-aged or elderly females, which may reflect both high use in this group and higher susceptibility. Acute hepatitis occurs mainly during the first 5 weeks of treatment, and is associated with fever (60%), rash (30%) and blood eosinophilia (70%); it is mixed in type [3]. Nitrofurantoin may also lead to chronic hepatitis. Nitrofurantoin is transformed into reactive metabolites that might lead to immunoallergic hepatitis.

Paracetamol (acetaminophen)

Paracetamol is used extensively worldwide because of its good analgesic properties, its mild antipyretic effect and its availability without prescription. Paracetamol is detoxified by conjugation of its hydroxyl group with sulphate or glucuronic acid. Although a small fraction of the paracetamol dose is transformed by cytochrome P-450s 1A2, 2E1 and 3A4 into *N*-acetyl-*p*-benzoquinoneimine, the formation of this reactive metabolite remains limited after therapeutic doses and, furthermore, the metabolite is efficiently detoxified by conjugation with glutathione. Accordingly, paracetamol, taken at recommended doses (0.5–3 g/day), is usually a safe analgesic. However, taken at higher doses, paracetamol can produce hepatitis. At these higher doses, more reactive metabolite is formed. Furthermore, conjugating pathways may become partly saturated, so that a higher fraction of the dose then undergoes metabolic activation by cytochrome P-450. Finally, the extensive formation of the reactive quinoneimine depletes hepatic glutathione stores. Once this has occurred, the quinoneimine depletes protein thiols, increases cellular calcium, damages mitochondria, increases peroxynitrite formation, activates c-Jun N-terminal kinase and causes mitochondrial permeability transition and liver cell necrosis.

In humans, the hepatotoxicity of paracetamol can occur in three circumstances.

1 A frequent circumstance is the intentional ingestion of large overdoses of paracetamol in a manipulative or suicidal attempt [85]. Paracetamol ingestion is one of the most popular ways of attempting to take one's life in the United Kingdom or the United States. Fortunately, even before the use of antidotal treatments, most patients did not absorb enough to cause severe liver injury, and less than 1% died [85]. With the notable exception of alcoholics (discussed later on), death is unlikely unless 20 g or more of paracetamol have been ingested [85]. Because the ingested dose can be wrongly estimated and because vomiting (or the gastric lavage, which is often made within the first 4 h) may have decreased the amount actually absorbed, it is useful to measure paracetamol plasma levels, starting 4 h after the ingestion, as earlier measurements may be misleading due to still incomplete absorption. Those patients whose plasma paracetamol concentrations are above a line joining points of 150 mg/L at 4 h and 30 mg/L at 12 h after ingestion (on a semi-logarithmic plot) are at risk of developing severe liver damage and must be treated with *N*-acetylcysteine. Because alcoholic patients and those with eating disorders are more susceptible, a lower 'treatment line', joining plots of 100 mg/L at 4 h to 15 mg/L at 15 h, is recommended in these patients. Both the intravenous [85] and the oral [138] routes of administration of *N*-acetylcysteine have been shown to be remarkably effective when started during the first 12 h, but also, to some extent, up to 24 h after the ingestion of paracetamol [85]. Even at the time of overt liver failure,

N-acetylcysteine administration may still afford some benefit and is now recommended [139]. When administered early, *N*-acetylcysteine liberates cysteine, allowing resynthesis of hepatic glutathione, and thus preventing liver injury. Later, it might accelerate the recovery of protein thiols and improve the outcome of the liver disease. A few patients, however, really intend to die, take large overdoses of paracetamol and conceal this ingestion until it is too late for *N*-acetylcysteine to be effective (although this antidote is attempted nevertheless) [85]. After a period of possible vomiting during the first 12 h, the patient may be essentially symptom free until the second or third day, when anorexia, nausea, vomiting and malaise may herald the onset of the liver disease, followed by dark urine and jaundice. Serum ALT levels are extremely high. Hypoglycaemia is relatively frequent and should be prevented by infusions of glucose. The haemogram may be normal or may show hyperleucocytosis and thrombocytopenia. Metabolic acidosis with hyperlactataemia is relatively common. Hypophosphataemia with phosphaturia, oliguria, anuria and high creatinine levels may be due to associated acute tubular necrosis. Associated myocardial injury may lead to cardiac arrhythmia and left ventricular failure. If hepatic encephalopathy develops (in the absence of sedatives) and/or the factor V level drops below 20% of normal, expert advice should be sought and emergency liver transplantation should be considered.

2 A second circumstance leading to paracetamol-induced hepatitis is the ingestion of excessive therapeutic doses (4–10 g/day) by patients who are rendered susceptible by factors that either increase the formation of the reactive metabolite and/or decrease its inactivation by glutathione. Indeed, paracetamol-induced hepatitis (and renal failure) have been observed in chronic alcoholics, who display high levels of cytochrome P-450 2E1 and low hepatic glutathione stores [54]. Isoniazid administration also induces cytochrome P-450 2E1, and cases of severe paracetamol-induced hepatotoxicity have been observed in this setting. High therapeutic doses of paracetamol may also be hepatotoxic in patients with anorexia nervosa or starvation, which may decrease hepatic glutathione stores. The hepatotoxicity of therapeutic doses of paracetamol may also be increased in patients with infectious mononucleosis, measles or acute hepatitis A or B, and it has been suggested that the subliminal stimulation of death receptors by the cytokines formed during viral infections may aggravate the hepatotoxicity of paracetamol [10]. Finally, pregnancy has been shown to aggravate paracetamol hepatotoxicity in mice [49], but there is limited clinical evidence for a similar effect in women. However, in one woman, the combination of fatty liver of pregnancy and paracetamol-induced liver toxicity led to liver failure and postpartum transplantation.

3 Finally, in some very rare instances, paracetamol can also cause immune-mediated liver injury after the administration of normal daily doses. Indeed, paracetamol has been reported to be the cause of one case of cholestatic hepatitis associated with rash and eosinophilia, one case of cholestatic liver reaction and one case of granulomatous hepatitis, two cases of hepatitis with a marked recurrence of ALT elevation 1 day after rechallenge with 500 mg of paracetamol and one case of chronic liver injury that promptly recurred after resuming the intake of 3 g of paracetamol daily.

Pemoline

Pemoline is a central nervous system stimulant that is used in children with attention deficit disorders. It has caused several cases of severe, cytolytic hepatitis, sometimes associated with antinuclear autoantibodies. In some patients, a very slow improvement after interruption of the treatment has suggested an autoimmune mechanism; prompt recurrence after rechallenge has been observed in a few cases.

Penicillamine

Several cases of cholestatic jaundice have been recorded in patients taking penicillamine [4]. Jaundice appears after 3–5 weeks of treatment. Some cases have been associated with fever and rash, suggesting hypersensitivity.

Phenindione

This anticoagulant may produce mixed hepatitis, usually associated with a general hypersensitivity syndrome consisting of fever, rash, eosinophilia, lymphocytosis, renal injury and, at times, thrombocytopenia [5]. The drug has been largely abandoned in favour of the coumarin derivatives.

Phenprocoumon

Unlike other coumarin derivatives, which are rarely hepatotoxic, phenprocoumon may increase ALT activity in 37% of recipients. The drug is widely used in Germany and Switzerland, and can cause clinical hepatitis after 2–6 months of treatment. The type of injury is mainly hepatocellular, but cholestasis has also been observed. In one case, cross-sensitivity seemed to exist with acenocoumarol. A recent report included three cases of (sub)acute liver failure, leading to two transplantations and one death [140].

Phenylbutazone

Therapeutic doses may lead to hepatitis, usually occurring during the first weeks of treatment. Phenylbutazone-induced hepatitis may be classified as mixed. However, the hepatocellular component predominates in most patients, while a few have a mainly cholestatic pattern instead. Hepatitis is frequently associated with fever and/or rash, sometimes with eosinophilia and hepatic granulomas [141]. Intoxication with overdoses of phenylbutazone may produce a toxic type of hepatitis in the following days [141]. Phenylbutazone is transformed by prostaglandin H synthase into a reactive free radical.

Phenytoin

Administration of phenytoin, a microsomal enzyme inducer, commonly increases serum γ-glutamyltransferase activity, and

may lead to minor increases in serum ALT and alkaline phosphatase activity in some recipients. Clinical hepatitis is much less common [5]. It occurs within the first 6 weeks of therapy, and is usually associated with fever, rash, lymphadenopathy, lymphocytosis (sometimes with atypical lymphocytes) and eosinophilia, suggesting an allergic mechanism. The pattern may resemble infectious mononucleosis. An autoantibody against a 53-kDa microsomal protein has been reported. Hep-atitis is predominantly hepatocellular, but sometimes mixed. Granulomas may be present.

Phenytoin is transformed into a reactive 3,4-epoxide. It has been suggested (but not proven) that subjects with a deficiency in a protective mechanism (perhaps in epoxide hydrolase) might be uniquely susceptible [79]. For as yet unknown reasons, black people appear to be particularly susceptible.

Pirprofen

Prolonged administration of this NSAID (more than 2 months) has led to hepatocellular liver injury [142] and even fulminant hepatitis [143]. Hypersensitivity manifestations were absent, suggesting an idiosyncratic, toxic mechanism. In some patients with pirprofen-induced jaundice, microvesicular steatosis accompanied liver cell necrosis (see 'Microvesicular steatosis'). The drug has been recalled.

Propoxyphene (dextropropoxyphene)

This analgesic has increased γ-glutamyltransferase activity in 14% of recipients in one study. The drug may also cause symptomatic hepatic injury. Hepatitis is mixed (mainly cholestatic), sometimes with cholangitis. The disease is probably due to hypersensitivity. Fever, rash and blood eosinophilia were present in some cases, and rechallenges have led to relapses within 4 days. Propoxyphene is transformed into a reactive nitroso derivative and depletes hepatic glutathione in mice.

Propylthiouracil

Unlike other antithyroid drugs, which produce either cholestatic or mixed hepatitis, propylthiouracil can produce cytolytic, sometimes fatal, hepatitis. The reaction is uncommon, however. Propylthiouracil is transformed into a chemically reactive metabolite.

Pyrazinamide

Pyrazinamide may produce hepatocellular jaundice, particularly when the drug is continued in excess of the 2 months of treatment that are normally recommended [144]. Serum transaminases should be monitored [144]. The hepatotoxicity of pyrazinamide is not associated with hypersensitivity manifestations and is probably due to direct toxicity. Its molecular mechanism remains unknown, however.

A 2-month regimen of rifampicin and pyrazinamide is no longer recommended for the treatment of patients with latent tuberculosis infection, because the risk of hepatitis is threefold higher than with the standard 6-month treatment with isoniazid alone.

Combined treatments with rifampicin, isoniazid and pyrazinamide can lead to fulminant and subfulminant hepatitis [144]. Patients with a time interval greater than 15 days between the onset of treatment and the onset of fulminant or subfulminant hepatitis frequently exhibited a poor spontaneous prognosis. In contrast, when fulminant hepatitis occurred earlier, patients exhibited a good spontaneous prognosis [144]. This was reminiscent of the good prognosis of fulminant cases seen within the first 2 weeks of treatments with isoniazid and rifampicin without pyrazinamide. It has been hypothesized that the late-onset cases (with a poor prognosis) were actually due to pyrazinamide, whereas those occurring early (and with a good prognosis) were actually due to the isoniazid–rifampicin combination [144].

Quinidine

Initiation of treatment with this antiarrhythmic agent may produce fever and a mixed type of hepatitis (usually anicteric) 6–12 days later. Hepatic granulomas are frequent [145]. Readministration leads to prompt recurrence of fever and elevated transaminase levels. These features suggest an allergic mechanism.

Ranitidine

Clinical hepatitis due to ranitidine is probably most uncommon. Hepatitis has occurred 2–45 days after the onset of treatment. Hepatitis is mixed. In some cases, the presence of fever, chills, blood eosinophilia and the prompt recurrence on rechallenge have suggested an allergic mechanism.

Sulindac

Hepatitis due to sulindac occurs mainly in women, usually within 6 weeks of the initiation of treatment [146]. Fever is frequent (70%), but eosinophilia is uncommon. Hepatitis is mixed, but predominantly cholestatic. Binucleated hepatocytes may be present. Leucopenia, lymphopenia or thrombocytopenia may be associated. Rechallenge leads to recurrence within a few days. These features suggest an allergic mechanism. However, another effect contributing to the cholestatic effect of sulindac may be the inhibition of the bile salt export pump (Bsep).

Suloctidil

Suloctidil has caused several cases of cytolytic hepatitis, including severe cases, as well as cases of chronic hepatitis and cirrhosis.

Sulphonamides

Sulphonamides may be detoxified by *N*-acetylation or may be transformed by cytochrome P-450 into the hydroxylamine and then a highly reactive nitroso metabolite, which covalently modifies proteins. Administration of sulphonamides may lead to hepatitis, usually within the first month of therapy [147]. Hepatitis may be heralded by fever and rash. Hepatitis is usually mixed in type, but either the hepatocellular or the cholestatic

component may predominate in other patients. Hepatic granulomas may be present. Readministration leads to prompt recurrence. The mechanism is most probably allergic.

Only subjects who are slow acetylators appear to be affected [78]. As discussed above, the enhanced toxicity of reactive sulphonamide metabolites towards the patients' lymphocytes has suggested that these patients may have an additional defect in some protective mechanism [78]. However, this defect has never been characterized, and other interpretations are possible (see section on 'Mechanisms of acute hepatitis').

Patients with the immunodeficiency syndrome frequently receive the trimethoprim–sulphamethoxazole combination for the treatment of *Pneumocystis carinii* infections. These patients appear to be particularly susceptible to sulphonamide reactions, possibly because of impaired drug acetylation, which might be due to metabolic dysfunction rather than genetic deficiency.

Tacrine

This reversible cholinesterase inhibitor has been used in the symptomatic treatment of Alzheimer's disease. Careful monitoring of serum ALT levels and tolerance-dependent, stepwise escalation of the doses are recommended, because the drug increases ALT activity in approximately 50% of recipients [148]. In most patients, the rise in ALT occurs abruptly, usually at about 6 weeks of treatment [148]. Most affected subjects have mild ALT increases, without clinical manifestations. This extremely high incidence of liver dysfunction suggests direct toxicity rather than immunoallergy.

The weak base tacrine is taken up by mitochondria, where it may cycle back and forth across the mitochondrial inner membrane, uncoupling respiration and wasting energy without ATP production [149]. First-pass metabolism in the liver may spare other organs, explaining why the liver is selectively injured [149]. Tacrine also intercalates between DNA bases; it poisons topoisomerases and decreases the synthesis of mitochondrial DNA in mice [23]. This leads to a progressive depletion of mitochondrial DNA, eventually followed by the death of a few hepatocytes by necrosis or apoptosis in mice [23].

Although tacrine-induced liver injury remains mild in most patients, 2% of recipients develop ALT values greater than 20 times the ULN, and a few liver biopsies have shown liver cell necrosis [148]. Fever and rash are infrequent, but eosinophilia is present in 35% of those with ALT more than 20 times the ULN. Tacrine is transformed by cytochrome P-450 1A2 into reactive metabolites (Table 4). Through the immunization of some subjects, these metabolites might be involved in this uncommon, severe form of hepatitis.

Terbinafine

This newly developed antifungal drug has produced several cases of mixed hepatitis.

Ticlopidine

This antiplatelet agent is used for the prevention of arterial thrombosis. Ticlopidine can cause neutropenia and other blood dyscrasias, and has caused many cases of liver injury. Although ticlopidine mainly causes cholestatic hepatitis, it can occasionally trigger cytolytic, mixed or granulomatous hepatitis, and also prolonged cholestasis. An immune reaction may be involved. Ticlopidine is transformed into a reactive metabolite.

Tienilic acid (ticrynafen)

This drug has been withdrawn from clinical use because of its marked hepatotoxic potential [150]. Hepatitis usually occurred after 1–3 months of treatment [150]. The main liver lesion was liver cell necrosis. Prompt recurrence following rechallenge suggested an immune mechanism. Tienilic acid hepatitis was associated with an antimicrosomal autoantibody (the anti-LKM2 autoantibody) directed against cytochrome P-450 2C9, the isoenzyme that transforms the drug into a reactive metabolite [65].

Tolazamide and tolbutamide

These hypoglycaemic sulphonylureas have produced instances of mixed hepatitis [3,4]. They share this adverse effect with several other analogues, including acetohexamide, carbutamide, chlorpropamide, glibenclamide, glipizide and metahexamide [3,4].

Tolcapone

This catechol O-methyl transferase inhibitor is still used in patients with severe Parkinson's disease, because its therapeutic benefit in patients who are not, or are no longer, improved by other drugs seems to outweigh the risk of cytolytic, sometimes fulminant, hepatitis [151]. The mechanism of hepatitis is unknown. Although tolcapone uncouples mitochondrial respiration when incubated in the absence of albumin, this effect may not occur in the presence of albumin, which binds most of the drug in the plasma. The amine and acetylamine metabolites of tolcapone may undergo metabolic activation to reactive species.

Troglitazone, rosiglitazone and pioglitazone

Troglitazone, a peroxisome proliferator-associated receptor-γ (PPARγ) agonist, was removed from the market after more than 40 cases of acute liver failure had been reported to the United States Food and Drug Administration [152]. Serum aminotransferases could continue to rise for many days or weeks after stopping treatment, and the final resolution of liver injury could take weeks or months [152]. Although troglitazone also caused mixed hepatitis in some patients, it mostly triggered hepatocellular liver injury, which was sometimes severe enough to cause jaundice, death or transplantation [153].

Despite extensive efforts, the mechanism for the hepatotoxicity of troglitazone is not clear. One effect of troglitazone is to inhibit the canalicular bile salt export pump (Bsep) [154]. This inhibition may contribute to cholestasis in patients with mixed hepatitis, but cannot account for the severe, life-threatening,

hepatocellular injury observed in other patients. Troglitazone also triggers c-Jun N-terminal protein kinase activation, Bid truncation, mitochondrial permeability transition, mitochondrial potential collapse, mitochondrial cytochrome *c* release, reactive oxygen species formation and apoptosis in hepatic cell lines [155,156]. Finally, troglitazone undergoes metabolic activation on both its α-tocopherol moiety and its thiazolidinedione moiety [157]. Hypothetically, mitochondrial effects and/or the direct toxicity of reactive metabolites may kill a few hepatocytes, thus permitting the immunization of some patients against hepatic proteins modified by the covalent binding of reactive metabolites. A positive lymphocyte stimulation test or the presence of hepatic eosinophils or granulomas have been observed in some patients, suggesting an immunoallergic mechanism at least in these patients [158].

The thiazolidinedione moiety of troglitazone is also present in rosiglitazone and pioglitazone, although the α-tocopherol moiety is absent in these newer PPARγ agonists. Rosiglitazone and pioglitazone can also trigger hepatocellular liver injury, albeit less frequently than troglitazone.

Trovafloxacin

Trovafloxacin has caused cytolytic hepatitis more frequently than other fluoroquinolone antibiotics. The mechanism may include mitochondrial effects.

Troleandomycin

Administration of this antibiotic for 2 weeks or longer produced silent hepatic dysfunction in 50% of recipients and jaundice in 4% [159]. While this frequent liver dysfunction was probably due to direct toxicity, it remains unclear whether clinical hepatitis was due to direct toxicity or immunoallergy.

Troleandomycin is transformed by cytochrome P-450 into an unstable metabolite [119]. This nitroso derivative may react with the SH group of glutathione and cysteine [119]. Its covalent binding to hepatic proteins might lead to hepatitis [119].

Zafirlukast

Zafirlukast is a an oral leukotriene receptor antagonist, which has been approved for the treatment of chronic asthma in some countries. After an initial report of three severe cases of zafirlukast-associated hepatitis [160], 14 cases of liver failure had been reported worldwide by May 2004.

Pure hepatocellular cholestasis

In this uncommon entity, cholestasis is due to a specific interference of the drug with bile secretion, without hepatitis. Cholestasis is the only liver lesion, without inflammation or necrosis. In the typical case, there is jaundice and pruritus, but either one or both may be absent in milder cases. Typically, alkaline phosphatase and γ-glutamyltransferase activities are increased, with normal or slightly increased ALT values. The biliary tree is morphologically normal.

Estrogens and oral contraceptives

Estrogens interfere with bile secretion in experimental animals and man. Several mechanisms may be involved, although their respective roles need to be clarified:

1 Prolonged administration of estrogens increases the permeability of the paracellular pathway, possibly leading to the back diffusion of materials from bile canaliculi to blood [161].

2 Prolonged administration of estrogens also increases the activity of lecithin cholesterol acyltransferase, leading to the accumulation of cholesterol esters in plasma membranes, which may decrease membrane fluidity and inhibit Na^+,K^+-ATPase activity [162].

3 Estrogen administration also downregulates the expression of the mRNAs and proteins of the two sinusoidal bile acid transporters, namely Na-taurocholate-cotransporting polypepide (Ntcp) and organic anion-transporting polypeptide 1 (Oatp1) [163].

4 Finally, estrogens are quickly transformed into D-ring glucuronides that exhibit an immediate and extremely potent cholestatic effect [164]. These D-ring glucuronides may be secreted by the canalicular multidrug resistance protein 2 (Mrp2) transporter into the bile canaliculus, where they may transinhibit the bile salt export pump (Bsep) [165], and they may also cause a rapid endocytic internalization of both Bsep and Mrp2 [166,167].

Clinically, cholestasis has occurred in women taking the high-dosage oral contraceptives that were used in the past. Even at that time, the overt disease was extremely uncommon. Its prevalence was estimated to be approximately 1:10 000 in Europe or North America and 1:4000 in Chile or Scandinavia [168]. All drugs containing estrogens have been incriminated, especially the 17-ethinyl-substituted derivatives. Clinically overt cholestasis developed predominantly in women with an exaggerated genetic susceptibility to the normal cholestatic effects of estrogens [168]. This was suggested by the higher prevalence of cholestasis in some ethnic groups (Chile and Scandinavia) and by the familial clustering of both intrahepatic cholestasis of pregnancy (ICP) and cholestasis resulting from oral contraceptives. An association with benign recurrent intrahepatic cholestasis (BRIC) is also suggested. These conditions may be due to inborn defects in diverse transporters (see Chapter 16.10). In addition, the administration of estrogens may aggravate acquired cholestatic diseases, such as primary biliary cirrhosis.

Oral contraceptive-mediated cholestasis occurred usually within the first six cycles, and most commonly during the first or second [168]. Malaise, anorexia, nausea, vomiting and weight loss were frequent, but pruritus could be the only sign. Dark urine and jaundice followed after a few days. There was no fever, rash or abdominal pain. Jaundice was usually mild, and serum bilirubin rarely exceeded 170 μmol/L. Serum alkaline phosphatase was increased in only one-third of patients, while serum transaminase activity was moderately elevated in about two-thirds of patients [168]. When available, the liver histology showed bile pigment material in the canaliculi and within

hepatocytes, with little or no hepatocellular damage or inflammation. Bile ducts were normal. Electron microscopy showed mitochondrial alterations and dilated bile canaliculi exhibiting bile pigment deposits and distorted microvilli. Clinical and biochemical signs usually resolved 1–3 months after cessation of oral contraceptives, without chronic sequelae. However, worsening for up to 3 months with prolonged cholestasis and recovery after 6 months has been reported. Recurrence was frequent, if the drug was resumed.

This adverse effect is no longer seen nowadays, because of the lower estrogen content of present-day oral contraceptives. Nevertheless, drug interactions can still trigger the syndrome. An epidemic of bland cholestasis has been observed in women taking troleandomycin while receiving oral contraceptives [169]. A troleandomycin metabolite forms an inactive complex with cytochrome P-450 3A, and decreases the oxidation of estradiol to catechol estrogens [170]. It has been suggested that the decreased oxidative metabolism of estrogens might increase their conjugation into cholestatic D-ring glucuronides [170].

Anabolic–androgenic steroids

Anabolic–androgenic steroids with a C-17 alkyl substituent also interfere with bile secretion in experimental animals [171]. Several mechanisms have been proposed [171]. Anabolic–androgenic steroids may inhibit Na^+,K^+-ATPase [171]. This effect might reduce bile acid uptake, which utilizes the Na^+ gradient generated by Na^+,K^+-ATPase for the cotransport of bile acids. Anabolic–androgenic steroids also act at the canalicular level, producing a selective interference with the excretion of conjugated bilirubin into the canaliculi [171]. Finally, these agents may injure the pericanalicular microfilamentous network. This injury may impair the contractions of bile canaliculi and contribute to cholestasis.

Cholestasis resulting from anabolic–androgenic steroids has been extensively reviewed by Ishak and Zimmerman [171]. The anabolic steroids that can cause jaundice have an alkyl group in the C-17 position [171]. These include methyltestosterone, norethandrolone, oxymetholone, metenolone, metandienone, danazol and stanozolol [87]. Testosterone and 19-nortestosterone, which are not alkylated in the C-17 position, have led to rare instances of hyperbilirubinaemia, but hardly ever to jaundice [171].

Only a small minority of subjects receiving therapeutic doses of anabolic steroids become jaundiced, although the majority develop hepatic dysfunction [171]. Jaundice typically does not develop until the drug has been taken for at least 1 month, and often several months. Surprisingly, pruritus is uncommon, occurring in about 10% of subjects only. Approximately one-third of patients have normal alkaline phosphatase values, and 50% have values slightly above normal [171]. Liver biopsy shows bilirubin casts in canaliculi and bile staining of the hepatocytes, mainly in centrolobular areas. Electron microscopy shows dilated canaliculi, with blunting and loss of microvilli.

Subsidence of jaundice may require weeks or months. With a few exceptions (see the section on 'Prolonged cholestasis'), complete recovery occurs.

Ciclosporin A

Ciclosporin administration decreases bile flow in rats, particularly the bile salt-dependent fraction. Ciclosporin A inhibits both the sinusoidal uptake and the canalicular secretion of bile acids [172]. Ciclosporin A inhibits the canalicular bile salt export pump (Bsep) [165], and it may also cause Bsep internalization. Possibly because of cholestasis, ciclosporin A administration also decreases the expression of the mRNA for the canalicular, multidrug resistance protein 2 (Mrp2), and it decreases the biliary secretion of bromosulphophthalein and bilirubin in rats [173].

In humans who receive ciclosporin for conditions other than liver transplantation, the drug clearly interferes, in a dose-related manner, with the hepatic clearance of bile salts, bilirubin and bromosulphophthalein [173]. In most patients, however, these effects lead at most to mild increases in serum bilirubin and/or bile salts, with absent or mild increases in serum alkaline phosphatase and/or ALT activity [173]. These biochemical abnormalities occur 2 weeks to 3 months after the onset of the treatment [173]. They usually regress upon reduction of the dose [173].

With the widespread use of ciclosporin after organ transplantation, some cases of cholestasis have been reported. The small number of reported cases and the large number of recipients suggest that the incidence of marked cholestasis is low. However, another consequence of the effects of ciclosporin on bile secretion is to increase the incidence of bile stones.

Bosentan, glibenclamide and rifampicin (rifampin)

Bosentan, an endothelin receptor antagonist, inhibits Bsep and can cause dose-dependent increases in alkaline phosphatase activity and serum bile acids in humans [174]. Glibenclamide and rifampicin also inhibit Bsep and can cause cholestasis [165].

Lipid storage liver diseases

Lipid storage liver diseases are characterized by the deposition of either triglycerides ('steatosis') or both triglycerides and phospholipids ('steatosis and phospholipidosis') within hepatocytes (Table 7). Depending on the size and number of lipid droplets in a hepatocyte, steatosis can be further subdivided into 'macrovacuolar' and 'microvesicular' steatosis, although there are frequent associations and transitions between these two forms. Chronic steatosis may, in some patients, trigger several other alcohol-like liver lesions, described under the term of 'steatohepatitis'. This steatohepatitis can occur with or without associated phospholipidosis. Finally, hyperplastic stellate cells

Table 7 Lipid storage liver disease and main causative drugs.

Macrovacuolar steatosis
Alcohol
Glucocorticoids
Methotrexate
Microvesicular steatosis
Alcohol
Amineptine
Amiodarone
Asparaginase
Aspirin
Dideoxynucleosides (NRTIs[a])
Ethanol
Fialuridine
Glucocorticoids
Ibuprofen
Ketoprofen
Tetracyclines
Tianeptine
Perhexiline
Pirprofen
Valproate
Steatosis or steatohepatitis associated with phospholipidosis
Amiodarone
Diethylaminoethoxyhexestrol
Perhexiline
Steatohepatitis without phospholipidosis
Alcohol
Didanosine
Diethylstilbestrol
Diltiazem
Glucocorticoids
Hexestrol
Methotrexate
Nifedipine
Tamoxifen
Stellate cell lipidosis and perisinusoidal fibrosis
Vitamin A

[a]Nucleoside reverse transcriptase inhibitors.

laden with fat and vitamin A are observed after prolonged administration of excessive doses of vitamin A, and this stellate cell lipidosis may lead to perisinusoidal liver fibrosis.

Macrovacuolar and microvesicular steatosis

Macrovacuolar steatosis

The hepatocytes displaying macrovacular steatosis contain a single, large droplet of fat, which displaces the nucleus to the periphery of the cell. In the absence of other liver lesions, macrovacuolar steatosis by itself is a relatively benign condition, at least in the short term. There may be slight increases in ALT and/or γ-glutamyltransferase activities, without clinical manifestations. The liver may or may not be slightly enlarged on clinical examination, and it is usually hyper-reflective on ultrasonography.

Macrovacuolar steatosis may result from a combination of different mechanisms. These may include an increased mobilization of fat from adipose tissue, an increased hepatic synthesis of fat, a moderate decrease in fat oxidation in the liver (if this effect is major, it will instead produce microvesicular steatosis) and an impaired egress of lipids out of the liver [4]. Triglycerides leave the liver in the form of lipoproteins. Decreased output of triglycerides may result from a specific biochemical lesion, as with methotrexate, which impairs protein synthesis. It may also occur as a consequence of structural lesions to the endoplasmic reticulum, Golgi and plasma membrane. This may explain why macrovacuolar steatosis may be associated, at times, with hepatitis produced by many drugs (such as allopurinol, halothane, isoniazid and α-methyldopa) [4].

Microvesicular steatosis

In this condition, hepatocytes are occupied by numerous, small lipid vesicles that leave the nucleus in the centre of the cell and give the hepatocytes a 'foamy', 'spongiocytic' appearance [175]. When discrete, this lesion may be missed by a non-specialized pathologist. However, an oil Red O stain clearly shows the small reddish lipid vesicles that fill out the hepatocytes. Microvesicular steatosis affecting some hepatocytes may be associated with macrovacuolar steatosis in other hepatocytes. Patients exhibiting both lesions should be classified as cases of microvesicular steatosis (with associated macrovacuolar steatosis).

Whatever its aetiology (genetic defects, drugs or other causes), microvesicular steatosis is constantly related to a severe impairment in the mitochondrial β-oxidation of fatty acids [175]:

- Indeed, microvesicular steatosis occurs in several genetic defects affecting transporters or enzymes involved in the mitochondrial β-oxidation of fatty acids [176]. Microvesicular steatosis also occurs in the mitochondrial cytopathies, which are due to inborn defects in the respiratory chain [177]; these defects impair the mitochondrial reoxidation of NADH into NAD^+, which is required for the mitochondrial β-oxidation of fatty acids [178]. Other possible causes of microvesicular steatosis are genetic defects in urea cycle enzymes; these defects increase the levels of ammonium, which may impair fatty acid oxidation [179].
- The impairment in β-oxidation may also be acquired. Reye syndrome is the result of an acquired mitochondrial insult, possibly caused by the adverse effects of nitric oxide or cytokines (or viruses?) on mitochondrial function [175]. Pregnancy and/or female sex hormones cause ultrastructural and functional lesions in mitochondria [180,181]. Together with other genetic or acquired factors, these hormonal effects may contribute to the development of acute fatty liver of pregnancy in some women.
- Similarly, all drugs known to produce microvesicular steatosis impair the mitochondrial β-oxidation of fatty acids [182].

Because non-esterified fatty acids are poorly oxidized by mitochondria (due to the inhibition of β-oxidation), they instead undergo increased esterification into triglycerides, which represent the main form of lipids that are accumulated in these conditions [182]. Nevertheless, there is a residual increase in non-esterified fatty acids [182]. It has been suggested that these amphiphilic compounds may form an emulsifying rim around a core of neutral triglycerides [182]. Emulsification might explain the deposition of microvesicular fat in this condition. Yet another reason for the microvesicular pattern of fat deposition may be that the sudden onset or sudden aggravation of the impairment of fat oxidation may leave no time for the progressive coalescence of tiny lipid vesicles into large vacuoles [18]. Indeed, whereas the acute impairment of β-oxidation usually causes microvesicular steatosis, chronic impairments of β-oxidation often give rise to diverse combinations of macrovacuolar and microvesicular steatosis.

Another pathway removing fat from the liver is hepatic very-low-density lipoprotein (VLDL) secretion [183]. In the lumen of the endoplasmic reticulum and the Golgi apparatus, microsomal triglyceride transfer protein (MTP) lipidates apolipoprotein B into triglyceride-rich VLDL, which follows vesicular flow to the plasma membrane to be secreted [183]. Several steatogenic drugs have been shown to inhibit not only mitochondrial β-oxidation, but also MTP activity and hepatic VLDL secretion (Fig. 7) [183]. This added effect on lipoprotein secretion may prevent an adaptive increase in hepatic VLDL, which might otherwise compensate for the decreased oxidation of fat in the liver.

Depending on the causative drug, liver cell necrosis may be absent, as with tetracycline, or it may be present, as with valproic acid, which inhibits not only fatty acid oxidation but also mitochondrial ATP formation from pyruvate. However, even in the absence of liver cell necrosis, extensive microvesicular steatosis is, by itself, a serious condition. Although serum transaminase and bilirubin levels are only moderately increased, the prothrombin time may be prolonged. Development of haemorrhagic episodes, attacks of syncope, hypotension and shock may mark the seriousness of the entity, and may be followed by profound lethargy and coma [4]. Hypoglycaemia may occur. Azotaemia and pancreatitis may be associated, contributing to the poor overall prognosis [4].

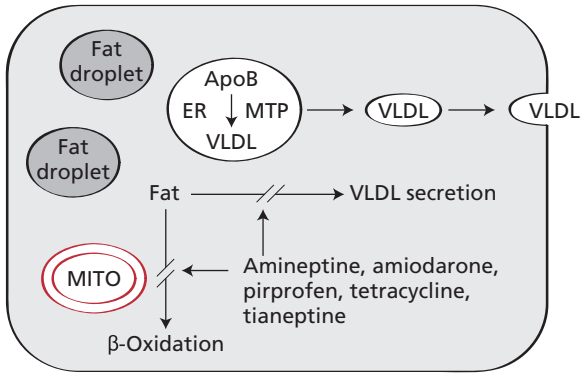

Fig. 7 Dual mechanisms for the microvesicular steatosis induced by several drugs. In the lumen of the endoplasmic reticulum (ER) and Golgi apparatus, microsomal triglyceride transfer protein (MTP) lipidates apolipoprotein B (apoB) into triglyceride-rich very-low-density lipoproteins (VLDL), which follow vesicular flow to the plasma membrane to be secreted. Several drugs cause hepatic steatosis by two effects. They inhibit the mitochondrial β-oxidation of fatty acids, and they also inhibit MTP activity and hepatic VLDL secretion.

Thus, microvesicular steatosis is the morphological hallmark of a serious metabolic condition. This severity could be related to a severe energy crisis under fasting conditions [182]:

- Normally, the oxidation of fat becomes the predominant source of energy in fasting conditions. However, impairment of the β-oxidation of fatty acids deprives the cell of this most important source of energy.
- Not only is lipid oxidation unavailable as a source of energy during fasting, but the recourse to glucose as an alternative fuel is also compromised. Normally, the acetyl-coenzyme A (CoA) formed by β-oxidation is an important allosteric activator of pyruvate carboxylase, a rate-limiting step in gluconeogenesis from lactate and pyruvate [182]. Furthermore, fatty acyl-CoAs inhibit glucose-6-phosphatase, which catalyses the terminal reaction of gluconeogenesis. When β-oxidation is impaired, the decreased levels of acetyl-CoA may reduce pyruvate carboxylase, while the increased levels of acyl-CoAs may impair glucose-6-phosphatase activity. These effects limit the recourse to glucose formation and subsequent oxidation as an alternative source of energy in extrahepatic organs.
- Furthermore, the accumulation of non-esterified fatty acids and their dicarboxylic acid derivatives uncouples oxidative phosphorylation [182]. Thus, not only are fuels less oxidized (fats) or less available (carbohydrates), but their oxidation is also wasted, producing heat instead of ATP.

Phospholipidosis

Hepatic phospholipidosis is characterized by the accumulation of phospholipids within liver cell lysosomes [184,185]. In humans, hepatic phospholipidosis has mainly been observed with three antianginal drugs, namely 4,4´-diethylaminoethoxyhexestrol [186,187], perhexiline maleate [188] and amiodarone [189]. These drugs are cationic amphiphilic compounds with a lipophilic moiety and an amine function that can become protonated (and thus positively charged) [184,185]. The uncharged, lipophilic drug easily crosses the lysosomal membrane. Inside the lysosome, the pH is acidic owing to the presence, on the lysosomal membrane, of H^+-ATPases that accumulate H^+ within the lysosome. Because of this acidic intralysosomal milieu, the unprotonated drug molecule is protonated within lysosomes. The protonated form is more hydrosoluble and is less able to cross back through the lysosomal

membrane, leading to its accumulation at high concentrations within lysosomes.

Lysosomes are the waste disposal system of the cell. During the process of autophagy (for example during fasting), evaginations of the hepatic endoplasmic reticulum membrane engulf and then isolate, in a double-membrane structure, whole parts of the cytoplasm (including cytosol, endoplasmic reticulum fragments and mitochondria). These eventually end up in lysosomes for final digestion. The phospholipids of these internal membrane structures are normally degraded by intralysosomal phospholipases.

The problem is that the protonated form of amiodarone, perhexiline or diethylaminoethoxyhexestrol forms non-covalent but tight complexes with phospholipids. Indeed, the lipophilic moiety of the protonated drug molecule may form hydrophobic bonds with the fatty acid moieties of phospholipids, while the protonated (positively charged) amine group may undergo electrostatic interaction with the negatively charged phosphate group of phospholipids [184,185]. These tight interactions hamper the action of intralysosomal phospholipases [184,185]. Phospholipids are not degraded, and they progressively accumulate, together with the bound drug molecules, within lysosomes. The accumulation of the drug–phospholipid complexes generates enormous lysosomes filled with pseudomyelinic figures.

The accumulation of phospholipids can be detected by histochemistry [188], but confirmation of the diagnosis requires electron microscopy. On ultrastructural examination, lysosomes are both abundant and increased in size, and they contain lamellar, reticular or pseudomyelinic figures. Phospholipidosis may affect not only the liver but also many other organs such as skin, myocardium, lungs and blood cells [184,185].

Phospholipidosis is extremely frequent, perhaps constant, after the administration of these drugs [190]. However, it may have no clinical consequence, or limited consequences, as phospholipidosis occurs in many patients who have no clinical symptoms and have no, or minor, biochemical disturbances [190].

After withdrawal of the causative drug, phospholipidosis regresses slowly because of the very slow dissociation of the drug–phospholipid complexes. Consequently, the drug may still be detectable in plasma many months after discontinuation of treatment [191]. This protracted retention influences the outcome of the second possible liver lesion, namely steatohepatitis.

Steatohepatitis (alcohol-like lesions) and phospholipidosis

In a few patients receiving these drugs (amiodarone, perhexiline, diethylaminoethoxyhexestrol) for several months or years, a more severe form of liver disease, termed 'alcohol-like liver lesions' or 'steatohepatitis', may develop. The incidence of these lesions is related to the duration of treatment and thus the cumulative dose. Generally, the disease develops insidiously and may be revealed by hepatomegaly or a moderate increase in serum ALT activity. In severe forms, jaundice, ascites and encephalopathy may be observed. Histological lesions are similar to those observed in alcoholic liver disease and may include microvesicular and macrovacuolar steatosis, Mallory bodies, a mixed inflammatory cell infiltrate (containing neutrophils), fibrosis and even cirrhosis. Despite the discontinuation of therapy, the disease may worsen, and fatal cirrhosis may occur [192]. This secondary aggravation may be related to the protracted persistence of the drug in its lysosomal deposits.

The induction of steatosis and, possibly, the other lesions that characterize the steatohepatitis syndrome may be related to the ability of these drugs to interfere with mitochondrial function [175]. Let us recall that the mitochondrion has two membranes, and that the transfer of electrons through complexes I, III and IV of the respiratory chain (located on the mitochondrial inner membrane) results in the translocation of protons from the matrix into the intermembranous compartment [175]. This creates an important electrochemical gradient across the mitochondrial inner membrane. The potential energy of this gradient is utilized secondarily to generate ATP. When protons re-enter the matrix via the F_0 moiety of ATP synthase (complex V), the energy released by this re-entry is harnessed in the synthesis of ATP by the F_1 portion of complex V. An analogy of this system would be the pumping up of water by a thermal engine (the respiratory chain) into a reservoir, followed by the harnessing of this energy by hydroelectric turbines (ATP synthase). Amiodarone [193,194], perhexiline [195] and diethylaminoethoxyhexestrol[196] produce similar effects on mitochondria, so that a common concept may be proposed [196]. The unprotonated form of these drugs is lipophilic and easily crosses the mitochondrial outer membrane. In the intermembranous space, owing to the abundance of protons, the drug molecule is protonated. The protonated molecule is positively charged, and is therefore 'pushed' inside the mitochondria by the high electrochemical potential existing across the mitochondrial inner membrane (with the outside being positively charged). In the relatively alkaline matrix, the protonated molecule dissociates into a proton and the uncharged parent compound (amiodarone, perhexiline or diethylaminoethoxyhexestrol). The re-entry of a proton into the mitochondrial matrix (bypassing ATP synthase) decreases the membrane potential and wastes energy, while the accumulation at high concentration of the lipophilic unprotonated molecule inside the mitochondria probably interferes with membranous phospholipids and polypeptides and inhibits both electron transfer through the respiratory chain and the β-oxidation of long-, medium- and short-chain fatty acids, thus explaining steatosis [193–196].

In addition to chronic steatosis, prolonged administration of these compounds may also cause necrosis, fibrosis, a neutrophil infiltrate and Mallory bodies. Similar steatohepatitic lesions may occur in obesity, diabetes, prolonged corticosteroid administration, jejunoileal bypass or Wilson's disease [182]. All these conditions are characterized by chronic steatosis. It seems, therefore, that chronic steatosis may somehow be involved in the possible development of these other liver lesions.

Steatosis, whether acute or chronic, leads to lipid peroxidation in mice [197]. With amiodarone, perhexiline and diethylaminoethoxyhexoestrol, lipid peroxidation is further increased as a result of the enhanced formation of reactive oxygen species resulting from the inhibition of the respiratory chain [196]. Chronic lipid peroxidation and an increase in several cytokines might account for the diverse liver lesions regrouped under the term of steatohepatitis [198]. In particular, TNFα and/or the Fas system may cause chronic hepatic apoptosis [199]. The uptake of apoptotic bodies by macrophages and Kupffer cells increases transforming growth factor-β (TGF-β) production by both cell types, and increases collagen production by stellate cells, thus leading to progressive liver fibrosis [200].

Steatohepatitis without phospholipidosis

Steatohepatitis without phospholipidosis has been described after the administration of alcohol, dideoxynucleoside analogues, diltiazem, glucocorticoids, hexestrol, methotrexate, nifedipine and tamoxifen.

Stellate cell lipidosis and perisinusoidal liver fibrosis

The hyperplasia and hypertrophy of stellate cells filled with vitamin A-laden lipid vacuoles can lead to perisinusoidal liver fibrosis after prolonged excessive intake of vitamin A, as discussed further on.

Drugs causing lipid storage liver diseases

Alcohol

Ethanol is probably the most widely used anxiolytic agent and is the most common cause of macrovacuolar steatosis due to exogenous agents. Macrovacuolar steatosis due to ethanol abuse may be related to increased mobilization of peripheral fat and a mild decrease in fat oxidation [201]. When the β-oxidation of fat is severely and suddenly impaired, microvesicular steatosis may develop instead [182]. Indeed, an uncommon form of alcohol-induced liver lesion is alcoholic foamy degeneration, a severe condition resembling Reye syndrome and characterized by massive accumulation of both microvesicular and macrovacuolar fat [182]. Such patients may present with jaundice and hepatomegaly, but no major hepatic failure. Nevertheless, lethargy, coma and death may occur a few hours or days after admission [182]. On electron microscopy, mitochondria display diverse abnormalities such as atrophy, disorganization of the matrix, loss of cristae or striking enlargement (megamitochondria) [182]. A milder form of microvesicular steatosis is less exceptional; patients have high serum transaminase activities compared with those with macrovacuolar steatosis and exhibit centrolobular foamy hepatocytes, but their short-term prognosis remains good [182].

Mitochondrial DNA (mtDNA) is 10–16 times more prone to oxidative damage than nuclear DNA, because of the attachment of mtDNA to the mitochondrial inner membrane (which is the main source of reactive oxygen species in the cell), the lack of protective histones in mtDNA and incomplete DNA repair processes in the mitochondria [202]. Oxidative damage to mtDNA produces single-strand breaks, which may favour slipped mispairing of repeated sequences during replication, thus leading to mtDNA deletions [202]. Oxidative damage to DNA may also cause the formation of 8-hydroxy-deoxyguanosine [202]. This modified base leads to misreading during replication, producing point mutations. Because mtDNA lacks introns, any oxidative damage is likely to involve a functionally important gene. However, as there are several hundreds of copies of the mitochondrial genome in a single cell, cells may accumulate a limited amount of various mtDNA mutations without initial detrimental effects. The mtDNA may thus serve as a molecular clock of the ageing process [202]. Accumulation of 8-hydroxy-deoxyguanosine, mtDNA deletions and mtDNA point mutations occur spontaneously in old age, resulting in a slow, progressive deterioration in mitochondrial function [202].

Ethanol consumption increases the generation of oxygen radicals in rat liver mitochondria [203]. Alcoholism might, therefore, accelerate the oxidative ageing of mtDNA, and this might in turn impair mitochondrial function and lead to microvesicular steatosis of the liver [204]. Indeed, various mtDNA deletions were found in most alcoholic patients with microvesicular steatosis, whereas deletions were uncommon in alcoholics with other liver lesions or in non-alcoholic patients of similar age [204,205].

The metabolism of ethanol to acetate leads to the reduction of NAD^+ into NADH. In subjects with a normal respiratory chain, NADH is, for the most part, reoxidized back to NAD^+, thus allowing continued activity of 3-hydroxyacyl-CoA dehydrogenase (an NAD^+-dependent enzyme involved in the third step in the mitochondrial β-oxidation process) [204]. Subjects with multiple mutations in the mtDNA genome might poorly reoxidize NADH in mitochondria [204]. This would lead to a considerable decrease in the NAD^+/NADH ratio after alcohol absorption, marked inhibition of mitochondrial β-oxidation and the development of alcoholic foamy degeneration. According to this view, alcoholic foamy degeneration would represent, at least in some patients, an acquired form of a mitochondrial cytopathy [204].

Amineptine

As explained in the section on acute hepatitis, this tricyclic antidepressant was a frequent cause of immunoallergic, mixed hepatitis, possibly due to the metabolic activation of its tricyclic moiety into reactive metabolites. Amineptine, however, is peculiar because of the presence of a heptanoic side-chain. This 7-carbon side-chain is metabolized *in vivo* by β-oxidation into the 5- and 3-carbon derivatives [206]. In the process, these unnatural fatty acid analogues reversibly inhibit the β-oxidation

of the medium- and short-chain fatty acids [206]. This may explain why microvesicular steatosis of the liver has been observed in a few patients receiving this antidepressant drug.

Amiodarone

Mild increases in serum aminotransferase activity have been reported in 15–55% of patients receiving this antiarrhythmic agent [207]. Amiodarone is a cationic amphiphilic drug that inhibits the lysosomal degradation of phospholipids, thus causing phospholipidosis, and also inhibits mitochondrial function [193,194], thus causing steatosis or steatohepatitis. Phospholipidosis appears to be almost constant [190], whereas overt liver disease with alcohol-like liver lesions is uncommon. Steatohepatitis occurs after several months or years of treatment and may continue to worsen after amiodarone withdrawal because of the persistence of this drug for many months in the liver [191]. Histological lesions induced by amiodarone tend to predominate in periportal areas, whereas those caused by alcohol are mainly located in centrolobular areas. Liver injury may be associated with other adverse effects of amiodarone, including thyroid dysfunction, pulmonary fibrosis, neuropathy, skin discoloration and corneal deposits. Amiodarone toxicity appears to be dose related, which may explain its higher incidence and earlier onset in North American countries, where daily doses have been higher than in Europe (400–600 mg vs. 200 mg). The morphological expression of phospholipidosis appears to correlate with the storage of amiodarone in liver tissue. Amiodarone accumulation may be assessed either by specific dosage in the liver or, non-invasively, by computed tomography scanning, thanks to the high iodine content of the drug [207].

L-Asparaginase

L-Asparaginase decreases the amino acid L-asparagine by hydrolysing it to L-aspartic acid and ammonia. Unlike normal cells, leukaemic cells cannot synthesize L-asparagine and are therefore selectively affected. *Escherichia coli* L-asparaginase also has glutaminase activity. It therefore depletes both asparagine and glutamine. As a consequence, protein synthesis decreases markedly. Decreased protein synthesis may explain the antineoplastic activity of this enzyme preparation, but it also causes a decrease in plasma albumin, clotting factors and plasma lipoproteins, and the development of fatty liver. Steatosis has been found in 50–90% of patients treated with this agent [4]. Serum transaminase and plasma bilirubin are increased. Blood levels of ammonia are also increased, at times strikingly. Associated adverse effects may include pancreatitis, central nervous system disturbances, hypersensitivity to this bacterial product and disseminated intravascular coagulopathy.

Aspirin and Reye syndrome

Reye syndrome is a severe form of microvesicular steatosis that occurs after viral infections (in particular influenza and varicella), most often, but not exclusively, in children. Cytokines impair mitochondrial function and may be responsible, in part, for the disease [182]. Some viruses may also directly impair mitochondrial function. However, these mitochondrial effects are, at best, very moderate in liver cells. The vast majority of viral infections are well tolerated. Other factors are thus probably required additively to impair mitochondrial function and trigger the syndrome in the infected subjects.

A first potentiating factor has been the intake of aspirin in febrile children. In the past, 93% of cases of Reye syndrome had occurred in children receiving aspirin, and the frequency of aspirin use was higher in those who subsequently developed this syndrome than in children with similar viral diseases not followed by Reye syndrome [97]. Aspirin is quickly hydrolysed into salicylic acid. This carboxylic metabolite is actively transformed by mitochondria (probably on their outer membrane) into the salicylyl-coenzyme A derivative. Extensive formation of this thioester sequesters extramitochondrial coenzyme A. The latter is no longer available for the activation of long-chain fatty acids, whose entry in mitochondria and subsequent β-oxidation is therefore decreased [208]. The drug-induced impairment in fatty acid oxidation (added to the effects of infection) probably helped to trigger the syndrome in children receiving aspirin for viral infections. Indeed, recommendations for the avoidance of aspirin in febrile children have led to a parallel decline in the use of aspirin and the incidence of Reye syndrome in the USA [209].

Nevertheless, a few cases of Reye syndrome are still being observed. A second factor that helps to trigger Reye syndrome is a previously latent defect in mitochondrial β-oxidation enzymes [210]. Now that the use of aspirin has been curtailed in febrile children, residual cases of Reye syndrome occur mainly in children with a previously latent genetic defect in β-oxidation [210]. The anorexia, vomiting and fever associated with the infectious disease, together with the fast imposed by some ill-advised mothers, may increase peripheral lipolysis. This may start a vicious circle by increasing the fatty acid burden of the liver. The liver may be unable to handle this increased load of fatty acids, because the inborn defect is further aggravated by the impairment in β-oxidation resulting from the infectious process.

Calcium hopantenate (pantoyl-γ-aminobutyrate)

This analogue of pantothenic acid may inhibit mitochondrial β-oxidation and has caused Reye-like syndromes in Japan.

Cocaine

As already mentioned, cocaine-induced liver lesions may combine both centrolobular necrosis and periportal microvesicular steatosis. Cocaine is transformed into reactive metabolites and triggers reactive oxygen species formation, mitochondrial permeability transition, caspase activation and apoptosis in rat hepatocytes [211].

Dideoxynucleosides (nucleoside reverse transcriptase inhibitors, NRTIs)

3′-Azido-2′,3′-dideoxythymidine (zidovudine, azidothymidine or AZT), 2′,3′-didehydro-3′-deoxythymidine (stavudine),

2′,3′-dideoxycytidine (zalcitabine, ddC), 2′,3′-dideoxyinosine (didanosine, ddI) and the unsaturated drug, abacavir, are all 2′,3′-dideoxynucleosides that are used in patients with HIV infection. The sugar analogue of these dideoxynucleosides possesses the normal 5′-hydroxyl group of deoxyribose. After activation to the triphosphate derivative, the analogue can thus be incorporated (in place of a natural nucleotide) into a growing chain of DNA. In contrast, the 3′-hydroxyl group of deoxyribose is absent in these sugar analogues. Once the nucleotide analogue has been added at the end of a growing chain of DNA, the DNA chain now lacks a 3′-hydroxyl end, and no other nucleotide can be incorporated, thus terminating DNA replication.

Therefore, the effects of these compounds depend on the ability of various polymerases to incorporate them into DNA. The HIV reverse transcriptase performs this incorporation, thus impairing the reverse transcription of the viral RNA into the HIV DNA [212]. The mammalian DNA polymerases that are involved in nuclear DNA replication poorly incorporate the dideoxynucleoside triphosphates into the growing chain of DNA. The replication of nuclear DNA is not impaired, allowing the utilization of these compounds as therapeutic agents [213].

The problem is that the mammalian DNA polymerase γ, which acts in mitochondria, can, like the viral reverse transcriptase, incorporate the dideoxynucleoside triphosphates into the growing chain of mtDNA [213]. This incorporation terminates mtDNA replication, unless the wrongly incorporated dideoxynucleoside analogue can eventually be removed by the proofreading 3′→5′-exonuclease activity of polymerase γ. The consequence therefore is markedly to slow down mtDNA replication. Unlike nuclear DNA, mtDNA keeps replicating in postmitotic tissues. When mtDNA replication is markedly impaired, a progressive loss of mtDNA can occur [214]. Furthermore, dideoxynucleoside analogues can increase reactive oxygen species formation, thus causing oxidative damage to mtDNA [215] and secondary mtDNA deletions [216]. Finally, the HIV infection itself can deplete mtDNA, at least in peripheral blood cells.

mtDNA depletion and/or mtDNA lesions can trigger the acquired equivalent of a mitochondrial cytopathy [217]. As in the inborn mitochondrial cytopathies, the clinical manifestations may be extremely polymorphic. Although each dideoxynucleoside analogue may more selectively affect certain organs rather than others, taken together, the 2′,3′-dideoxynucleoside analogues may lead to bone marrow suppression with anaemia, neutropenia and thrombocytopenia, pancreatitis, peripheral neuropathy, myopathy, pancreatitis, lactic acidosis and microvesicular steatosis of the liver [217].

Hepatic manifestations and lactic acidosis have been observed with all dideoxynucleosides, but seem to be particularly frequent with stavudine and high doses of didanosine [218]. The disease may be heralded by anorexia, vomiting, weight loss, abdominal pain, abdominal distension and tachycardia. Serum lactate can be moderately or severely increased; serum ALT and γ-glutamyltransferase are mildly increased, and the liver may be hyper-reflective on ultrasonography. The liver disease can be associated with facial and limb lipoatrophy due to mtDNA depletion in peripheral adipocytes, and with increased creatine kinase activity (due to myopathy) and/or elevated lipase (due to pancreatitis) [218]. After interruption of the NRTI treatment in symptomatic patients, mild lactataemia without acidosis frequently regresses. In contrast, a marked initial increase in serum lactate associated with a loss of bicarbonate and an acidic pH attest to the severity of the condition, which can be fatal despite the interruption of treatment.

Unlike other dideoxynucleoside analogues, abacavir has an unsaturated 2-cyclopentene-1-methanol moiety. The oxidation of its methanol group by alcohol dehydrogenase, followed by double bond migration, may form a reactive α,β-unsaturated aldehyde, which covalently binds to proteins. In addition to mild mitochondrial toxicity, abacavir can trigger immune reactions (mostly rash), particularly in patients with the HLA B57 molecule [219].

4,4′-Diethylaminoethoxyhexestrol

This coronary vasodilator has been recalled after being responsible for more than 100 cases of alcoholic-like liver disease associated with phospholipidosis in Japan, usually after treatments lasting 6 months or more [4]. Fatal cirrhosis has occurred in some patients [4]. 4,4′-Diethylaminoethoxyhexestrol is a cationic amphiphilic drug that impairs mitochondrial fatty acid β-oxidation, thus causing steatosis, and also partially impairs mitochondrial respiration, thus increasing mitochondrial reactive oxygen species formation and lipid peroxidation [196].

Fialuridine

Fialuridine (fluoroiodoarauracil, FIAU) has induced several cases of fatal microvesicular steatosis of the liver, leading to interruption of clinical trials [220]. A 3′-OH group is present in the sugar moiety of this analogue, so that the incorporation of one single molecule does not terminate mtDNA replication. However, the incorporation of several adjacent fialuridine nucleotides into mtDNA inhibits DNA polymerase γ and mtDNA replication [221].

Glucocorticoids

Glucocorticoids, particularly in large doses, lead to macrovacuolar steatosis of the liver [4]. The disease is clinically silent, although hepatomegaly may be present. Glucocorticoids may enhance the mobilization of lipids from adipocytes in high doses, and may inhibit protein synthesis [4]. Glucocorticoids also inhibit acyl-CoA dehydrogenases and the mitochondrial β-oxidation of fatty acids, and they trigger microvesicular steatosis of the liver in mice [222]. Prolonged treatments with high doses of glucocorticoids have led to steatohepatitis lesions in humans.

Ibuprofen

Like the other 2-arylpropionate derivatives, this NSAID is transformed into slightly reactive acyl-glucuronides that slowly covalently bind to hepatic proteins and might be responsible for the few cases of mixed hepatitis that may occur with these compounds. However, ibuprofen can also cause steatosis. Ibuprofen is a mixture of two enantiomers, both of which inhibit the β-oxidation of medium- and short-chain fatty acids [223].

Ketoprofen

Also a 2-arylpropionate derivative, this NSAID has produced a few instances of microvesicular steatosis.

Methotrexate

Methotrexate has been widely used for many years in patients with severe psoriasis, and is now also indicated in patients with severe rheumatoid arthritis. This potent inhibitor of dihydrofolate reductase impairs the metabolic transfer of 1-carbon units in a variety of biochemical reactions, leading to decreased DNA, RNA and protein synthesis. These effects may selectively target mitochondrial DNA. Methotrexate administration may cause hepatic steatosis, steatohepatitis, perisinusoidal fibrosis and cirrhosis [224,225].

The potential of methotrexate to induce liver lesions is mainly known from its use in the treatment of psoriasis. Excessive alcohol ingestion is relatively common in patients with severe psoriasis, and is the most important predisposing factor to methotrexate hepatotoxicity [5]. Obesity and diabetes mellitus, which also trigger hepatic fat accumulation, may also combine their effects with methotrexate to cause steatohepatitis [225]. Prolonged administration of methotrexate to psoriatic patients can induce fibrosis or cirrhosis [226]. The risk of developing such lesions increases with the time of exposure, being low for administrations shorter than 1 year but, in some studies, exceeding 12.5% and 25% after 2 and 5 years of treatment respectively. The incidence of liver injury also increases with the cumulative dose, particularly when it exceeds 2 or 4 g of methotrexate [226]. For the same cumulative dose, the incidence of liver injury was higher in the patients who had received methotrexate on a daily rather than on an intermittent schedule [226].

Fibrosis due to methotrexate (or diverse methotrexate/ethanol/obesity/diabetes combinations) is associated with macrovacuolar steatosis, mild portal inflammation, Kupffer cell proliferation and stellate cell hyperplasia. Electron microscopy shows fat deposition, abnormalities of lysosomes and mitochondria and hypertrophy of the smooth endoplasmic reticulum in hepatocytes as well as the deposition of collagen fibres in the space of Disse (perisinusoidal fibrosis) [5]. The disease develops insidiously. Although liver tests are usually slightly impaired, they have remained normal in some instances despite the presence of fibrosis or cirrhosis.

Prevention is based on avoiding the drug in mild forms of psoriasis or in patients with pre-existing liver lesions and those who cannot refrain from drinking alcohol [5]. Monitoring of liver tests every second month is advocated. Because liver tests may remain normal even in patients who develop fibrosis, serial liver biopsies at 2-yearly intervals, or after cumulative doses exceeding 2–4 g, have been recommended [5]. However, this recommendation is frequently overlooked in practice. An alternative may be to monitor procollagen III aminopeptide and only to perform biopsies in patients with elevated values. It will be interesting to see whether other non-invasive methods, such as the Fibroscan, may obviate the need for liver biopsies.

The hepatotoxicity of methotrexate in rheumatoid arthritis is less extensively documented. The general impression is that hepatotoxicity is less of a problem in rheumatoid arthritis than in psoriasis, perhaps because of lower frequency of ethanol abuse. However, fibrosis and cirrhosis can also develop, and monitoring of liver tests is also recommended [227]. Liver biopsies should be performed when liver test abnormalities persist or fluctuate over three consecutive years of treatment [227]. Whether a liver biopsy should also be performed in patients with normal liver tests but prolonged treatment remains unsettled.

A hepatocellular carcinoma has been observed in several patients treated with methotrexate.

Perhexiline maleate

An asymptomatic increase in serum aminotransferases occurs in 30% of patients treated with perhexiline maleate [230]. Clinical manifestations are much less frequent and are generally observed after several months or years of treatment. Liver lesions then associate features of alcohol-like hepatitis and phospholipidosis. Cirrhosis may occur [188], sometimes despite discontinuation of treatment [192]. Liver damage is frequently associated with weight loss, peripheral neuropathy and hypoglycaemia. Like steatohepatitis, these effects might be explained by the mitochondrial effects of this drug [195].

The toxicity of perhexiline maleate is mainly observed in subjects with a genetic impairment in drug oxidation capacity [231]. Perhexiline is oxidized by cytochrome P-450 2D6 [231]. This isoenzyme is deficient in the liver of 3–10% of Caucasians [232]. In deficient subjects, perhexiline oxidation is impaired, and the drug accumulates abnormally [231].

Pirprofen

This 2-arylpropionate NSAID had to be recalled because of its hepatotoxic potential. In some patients, microvesicular steatosis accompanied liver cell necrosis [143]. Like ibuprofen, this drug inhibits the mitochondrial β-oxidation of fatty acids and produces microvesicular steatosis of the liver in mice [233].

Tamoxifen

Tamoxifen is an antiestrogen, which is used in the treatment of advanced breast cancer. This cationic amphiphilic drug directly impairs mitochondrial function. Furthermore, it intercalates between DNA bases, inhibits mtDNA synthesis and depletes

mtDNA in mice [234]. Tamoxifen can cause steatohepatitis [235], particularly in overweight women [236]. Phospholipidosis does not seem to have been reported in human livers, although tamoxifen has been shown to impair lysosomal acidification and to cause intralysosomal storage of polar lipids after administration of high doses to animals.

Tetracycline derivatives

At currently administered oral doses, tetracycline may produce minor degrees of hepatic steatosis of no clinical concern in humans [4]. However, severe microvesicular steatosis has occurred in the past during the intravenous administration of tetracycline, usually in high doses [4]. Predisposing factors included impaired renal function, which decreased tetracycline elimination, and also pregnancy [4], which may slightly impair mitochondrial β-oxidation [180]. The syndrome usually appeared after 4–10 days of tetracycline infusion [4]. The disease resembled Reye syndrome. Renal failure and pancreatitis were frequently associated. Most of the reported cases have died, but milder cases may have gone unrecognized or unreported. Microvesicular steatosis has also been observed after intravenous administration of several other tetracycline derivatives [4].

Tetracycline itself and several tetracycline derivatives produce extensive microvesicular steatosis of the liver in experimental animals [228,229]. This is due to the dual effect of these antibiotics, which inhibit both the mitochondrial β-oxidation of fatty acids [228,229] and also the activity of microsomal triglyceride transfer protein and the hepatic secretion of VLDLs [183].

Tianeptine

This analogue of amineptine has a related tricyclic moiety and an identical heptanoic side-chain. Like amineptine, it is activated by cytochrome P-450 into reactive metabolites. Like amineptine, it is metabolized mainly by β-oxidation of its heptanoic side-chain, and it reversibly inhibits the mitochondrial β-oxidation of medium- and short-chain fatty acids. Unlike amineptine, however, tianeptine is used in much lower doses, and only one case of both hepatitis and microvesicular steatosis has been reported with this derivative.

Valproate

Administration of this anticonvulsant may produce silent increases in serum transaminase activity in 16–67% of recipients [237], and causes a hyper-reflective liver on ultrasonography in 60% of treated patients. Overt liver disease is much less common. It occurs mainly in young individuals (with the highest risk in children under 3 years of age) and is favoured by the concurrent administration of phenobarbital or phenytoin, two microsomal enzyme inducers [5]. Valproate toxicity may also be favoured by inborn defects impairing mitochondrial function, as discussed further on. The fully developed syndrome is usually marked by jaundice, sometimes with ascites, and haemorrhagic phenomena. The disease may result in coma, associated with azotaemia in 50% of cases [237]. Serum transaminase activity is moderately increased. The prothrombin time is prolonged. Serum ammonia levels are elevated. Hypoglycaemia may occur. Microvesicular steatosis is often associated with necrosis and, at times, with cirrhosis and cholestasis [237].

Valproic acid is a branched-chain fatty acid. Like natural fatty acids, it forms the acyl-coenzyme A derivative. Extensive formation of valproyl–coenzyme A inside the mitochondria depletes the intramitochondrial pool of coenzyme A [238]. The lack of coenzyme A decreases the oxidation of long-, medium- and short-chain fatty acids [238] and also blocks pyruvate dehydrogenase, which requires coenzyme A as a necessary cofactor, therefore inhibiting pyruvate-supported mitochondrial respiration. These various effects may explain why valproate administration can aggravate inborn β-oxidation defects and inborn mitochondrial cytopathies.

In addition to the sequestration of coenzyme A, another mechanism has been suggested. Cytochrome P-450s 2A6, 2B, 2C9 and 4A desaturate the ultimate and penultimate carbons of valproate, thus forming Δ_4-valproate. This metabolite is further metabolized in mitochondria, where its β-oxidation then produces the diene derivative: Δ_4,Δ_2-diene-valproyl-coenzyme A. This is an electrophilic metabolite that reacts with glutathione and might inactivate β-oxidation enzymes [239]. Although this inactivation remains to be demonstrated, this scheme would account for the increased hepatotoxicity of valproate during the concomitant administration of cytochrome P-450-inducing drugs.

Finally, like several other anionic uncouplers, valproic acid can potentiate calcium-induced mitochondrial permeability transition in isolated mitochondria [240]. These diverse effects of valproic acid may explain why this drug can cause not only steatosis, but also necrosis, fibrosis and cirrhosis.

Prevention of valproate hepatotoxicity relies mainly on the avoidance of this drug in children under 3 years of age or those taking other anticonvulsants [5]. These two precautions have led to a fourfold decline in the frequency of fatal liver injury [5]. Monthly monitoring of liver tests during the first 6 months of therapy is also recommended, but its efficacy remains unproven because there is a high incidence of liver enzyme elevations, which are often transient, and because severe hepatotoxicity may develop between the tests. Indications to stop the drug may include persisting ALT abnormalities (particularly if they exceed three times the ULN) and, certainly, any abnormality in coagulation factors, bilirubin or albumin or the appearance of lethargy, malaise, anorexia, nausea or vomiting [5].

Vitamin A (retinol, *all-trans*-retinol)

Hypervitaminosis A causes the hyperplasia and hypertrophy of stellate cells, which are filled with vitamin A-containing lipid vacuoles and compress the hepatic sinusoids [5]. Hypervitaminosis A can trigger perisinusoidal fibrosis [241–247] as a probable consequence of an increased synthesis of collagen by activated stellate cells. However, it is not clear

how this activation occurs. The supplementation of cultured hepatic stellate cells with *all-trans*-retinol or *all-trans*-retinoic acid instead prevents the morphological transition towards the collagen-secreting myofibroblastic phenotype. However, retinoids can trigger apoptosis in hepatic cell lines, and polar metabolites of retinol can trigger apoptosis in primary rat hepatocytes. The engulfment of apoptotic bodies has been shown to activate stellate cells into TGF-β-secreting, collagen-producing cells [200].

The adverse hepatic effects of vitamin A have occurred after a wide range of daily doses (20 000–1 200 000 units) and various lengths of treatment (7 weeks to 30 years) [243,245]. Usually, however, the disease becomes symptomatic after several years of treatment and a cumulative dose exceeding 100×10^6 units [245]. Skin disorders, in particular alopecia, are frequently observed [241]. There is moderate elevation in both serum transaminase activity and alkaline phosphatase activity [247]. Light and electron microscopy show stellate cell hyperplasia, with vitamin A accumulation in large vesicles [246]. The concentration of vitamin A is markedly increased in hepatic tissue. In contrast, its level in the serum is often normal [245].

Perisinusoidal fibrosis induced by hypervitaminosis A is frequently associated with sinusoidal dilation [246]. Portal and periportal fibrosis and even cirrhosis may develop if vitamin A administration is continued [244,245].

Withdrawal of vitamin A results in the reduction in ALT activity, but the increased alkaline phosphatase activity is much more persistent and, despite the withdrawal of the drug, cirrhotic lesions may develop as a result of the long persistence of vitamin A in the liver [247]. However, manifestations of portal hypertension may eventually improve after vitamin A withdrawal.

Subacute hepatitis, chronic hepatitis and postnecrotic cirrhosis

Prolonged destructive damage to hepatocytes, whatever its initial mechanism, may lead to subacute hepatitis, chronic hepatitis and cirrhosis. This is well demonstrated in experimental animals, which develop cirrhosis after repeated administration of many compounds that produce liver cell necrosis, such as carbon tetrachloride, dimethylnitrosamine or galactosamine [4]. In humans, prolonged drug-induced necrosis may also lead to subacute and chronic hepatitis, or even cirrhosis, in four different circumstances:

1 Most frequently, the liver lesion develops silently over a period of several months, but is only responsible for mild and non-specific symptoms such as asthenia. Therefore, the liver injury remains long unrecognized, and the treatment is continued. When the disease is eventually detected, chronic lesions are already present.

2 In some cases, acute hepatitis is diagnosed, but the causative drug is not recognized and its administration is continued, leading to chronic liver lesions.

3 In other patients, the causative drug has been withdrawn initially but has then been readministered (or ingested again by the patient) before complete recovery from the initial episode, leading to subacute hepatitis.

4 In a few cases, the process leading to the liver injury has continued despite the withdrawal of the offending drug. This has been observed with some drugs, such as tienilic acid, that trigger an autoimmune response directed against normal hepatocyte constituents [65].

Prolonged liver cell necrosis may lead to three main types of liver diseases, namely subacute hepatitis, chronic hepatitis and postnecrotic cirrhosis. Unless there has been a medical fault (continued administration despite awareness of the liver disease), the duration of the liver disease remains unknown. This precludes using any time-based definition for these drug-induced liver diseases. Therefore, terms such as drug-induced 'subacute hepatitis' or 'chronic hepatitis' are employed only to indicate the presence of particular liver lesions on liver biopsy at the time of diagnosis, without any time connotation.

Subacute hepatitis

Subacute hepatitis occurs mainly when the administration of the causative drug has been continued despite overt liver disease, or when it has been readministered before complete recovery from the initial acute episode. Clinical and biochemical manifestations persist, or even worsen, within a few weeks or a few months following the onset of jaundice. In some cases, ascites, encephalopathy, hypoalbuminaemia and hypoprothrombinaemia develop. Histologically, subacute hepatitis is characterized by the concomitant presence of lesions at three different stages of evolution:

- Acute lesions consist of the lobular necrosis and the lobular inflammation seen in acute hepatitis.
- Secondary lesions consist of 'bridging necrosis', a term describing bands of parenchymal collapse (due to necrosis and subsequent cell dropout) that link either two portal tracts together or a portal tract and a central vein.
- Late lesions are suggestive of a chronic process, with portal fibrosis and portal inflammation, with, in some cases, the presence of nodules of regeneration.

Chronic hepatitis

Generally, clinical symptoms are absent or non-specific over a long period, sometimes up to the time of the liver biopsy. In other cases, jaundice and manifestations of hepatic failure may arise suddenly or progressively. Serum aminotransferase activity is increased, whereas alkaline phosphatase activity is usually normal. Serum gammaglobulin level can be increased.

Drug-induced chronic hepatitis is histologically characterized by peripheral hepatocyte necrosis (piecemeal necrosis) and by portal inflammation and portal fibrosis, which may both extend into the peripheral parenchyma.

Postnecrotic cirrhosis

The clinical manifestations are extremely variable. Cirrhosis may be recognized fortuitously or may be revealed by jaundice, ascites, hepatic encephalopathy, hepatomegaly or complications of portal hypertension. Serum ALT activity is generally moderately increased. Hypoalbuminaemia and hypoprothrombinaemia are commonly observed.

Histologically, cirrhosis is characterized by a destruction of lobular architecture, extensive fibrosis and nodules of regeneration. These lesions may be associated with those of subacute hepatitis or chronic hepatitis.

Autoantibodies

Subacute hepatitis, chronic hepatitis and postnecrotic cirrhosis are frequently associated with autoantibodies. Some of these antibodies, such as the antinuclear or antismooth muscle antibodies, have no specificity and are observed with different drugs, in particular clometacin, methyldopa and papaverine [248].

In contrast, other autoantibodies appear to be more specifically associated with a particular drug-induced liver injury. The type 2 antiliver/kidney microsome antibodies (anti-LKM2) are observed in patients with liver injury caused by tienilic acid [65]. Antiliver microsome autoantibodies are found with dihydralazine [66]. The anti-M_6 antimitochondrial antibodies are found in patients with iproniazid-induced liver injury [128]. As opposed to the autoantibodies that are observed in idiopathic autoimmune hepatitis, these drug-induced autoantibodies slowly regress with time once the treatment is withdrawn.

Outcome of subacute hepatitis, chronic hepatitis and postnecrotic cirrhosis

These drug-induced liver lesions generally improve after withdrawal of the causative drug (with a few exceptions as mentioned above). Clinical manifestations disappear quickly, and serum aminotransferases decrease markedly within the first weeks, but further improvement may be slower. Similarly, autoantibodies tend to disappear progressively. Complete recovery may take several months and is not constant. Mild liver test abnormalities as well as fibrosis and inactive cirrhosis (without necrosis or inflammation) may persist as late sequelae.

Drugs causing subacute or chronic hepatitis and postnecrotic cirrhosis

Only the drugs that cause liver damage through prolonged hepatocyte necrosis are considered in this section and in Table 8. Drugs causing fibrosis or cirrhosis in the context of steatohepatitis (e.g. amiodarone and perhexiline) or stellate cell lipidosis (vitamin A) have been discussed above, while drugs causing cirrhosis as a consequence of chronic cholestasis (e.g. chlorpromazine, flucloxacillin) are considered in subsequent sections.

Table 8 Main drugs causing subacute hepatitis, chronic hepatitis, or cirrhosis as a result of prolonged hepatocyte necrosis.[a]

Acetohexamide	Halothane
Acitretin	Iproniazid
Amodiaquine	Isoniazid
Aspirin	Metahexamide
Atorvastatin	Methyldopa
Benzarone	Nicotinic acid
Busulfan	Nitrofurantoin
Chlorambucil	Oxyphenisatin
Ciprofibrate	Papaverine
Clometacin	Paracetamol
Cyanamide	Phenprocoumon
Cyproterone	Phenytoin
Dantrolene	Propylthiouracil
Diclofenac	Suloctidil
Ebrotidine	Tegafur
Etretinate	Tienilic acid
Fenofibrate	Trazodone
Frentizole	Troglitazone
Germander	Urethane
Glafenine	Valproate

[a]Drugs causing chronic liver injury or cirrhosis as a consequence of steatohepatitis, the vanishing bile duct syndrome or chronic vascular injury are not included in the table.

Amodiaquine

Subacute hepatitis has been observed in some patients who had continued to take the drug for more than 4 weeks after the first manifestations [93]. Recovery was very slow [93].

Clometacin

This analgesic has been a major cause of drug-induced chronic liver disease in France [249], but has now been recalled. Liver injury often developed silently, so that 30% of patients with clometacin-induced liver injury already had chronic liver disease when a liver biopsy was performed [249]. Chronic hepatitis was observed in 25% of these patients and cirrhosis in 5% [249]. Clometacin-induced liver injury was associated with hypersensitivity manifestations (fever, rash, blood eosinophilia) in 70% of patients. Serum autoantibodies were found in 66%; these were mainly antismooth muscle or antinuclear antibodies and, less frequently, antimitochondrial or anti-DNA antibodies [249]. Giant multinucleated hepatocytes have been observed in some patients [250].

Dantrolene

Several cases of chronic active hepatitis and cirrhosis have been observed after the administration of this myorelaxant for more than 2 years [109].

Diclofenac

Among 21 patients undergoing a liver biopsy for diclofenac-induced liver injury, six had chronic hepatitis [111].

Iproniazid

Fibrosis and cirrhosis may develop after the administration of this antidepressant [4]. Liver injury may worsen despite the discontinuation of the drug. Iproniazid liver injury appears to be specifically associated with the presence of anti-M_6 antimitochondrial autoantibodies [128].

Isoniazid

Although isoniazid induces mainly acute hepatitis, chronic hepatitis and cirrhosis can also occur [130].

Methyldopa

This antihypertensive compound was one of the most important causes of subacute hepatic necrosis [251], particularly in patients who continued to take the drug for several weeks after the onset of the first symptoms. Chronic active hepatitis or cirrhosis was also observed. Antismooth muscle and antinuclear antibodies were frequently present [248]. Liver damage was sometimes associated with haemolytic anaemia and a positive Coombs' direct antiglobulin test [86]. About 70% of patients with methyldopa-induced liver injury were female, which suggested some predisposition. With the availability of the new antihypertensive agents, the drug is much less used nowadays.

Nitrofurantoin

This anti-infectious agent has been responsible for many cases of chronic liver injury [252,253]. At the time of the liver biopsy, 33% of patients with hepatic injury exhibited lesions of chronic hepatitis or cirrhosis [253]. Most cases were in women. In addition to the more frequent use of urinary antiseptics in this gender, sex-related susceptibility was suggested. The duration of nitrofurantoin administration before the recognition of the disease exceeded 6 months in more than 85% of patients with chronic liver lesions [252,253]. Serum antinuclear and antismooth muscle antibodies were present in most patients. HLA DR2 and HLA DRw6 antigens were found more frequently in patients than in a control population, although statistical significance was not reached [253].

Oxyphenisatin

Prolonged administration of this laxative, usually for more than 6 months, has been a major cause of chronic hepatitis and cirrhosis in the past. This drug has been abandoned.

Papaverine

Chronic hepatitis or cirrhosis may develop in patients receiving long-term therapy. Antinuclear and antismooth muscle antibodies may be present.

Tienilic acid (ticrynafen)

Chronic active hepatitis and cirrhosis accounted for about 7% and 15%, respectively, of cases of liver damage caused by tienilic acid [150]. Hypersensitivity manifestations were frequently observed. As already mentioned, tienilic acid-induced liver injury was associated with specific antimicrosomal autoantibodies. These anti-LKM_2 autoantibodies were directed against the isoenzyme of cytochrome P-450 (the 2C9 isoenzyme) that transforms tienilic acid into a reactive metabolite [65]. The drug has been withdrawn.

Other drugs

Other drugs that have caused chronic active hepatitis and/or cirrhosis are listed in Table 8. Conceivably, most drugs responsible for acute hepatocellular injury might produce chronic liver damage under conditions leading to protracted liver cell necrosis.

Prolonged cholestasis

Drug-induced prolonged cholestasis may be divided into two different entities, depending on the size of the injured bile ducts [87]:

- A syndrome resembling primary biliary cirrhosis occurs in patients with protracted lesions of small interlobular bile ducts. These bile ducts disappear from the portal tracts, hence the term 'vanishing bile duct syndrome' [87].
- A syndrome resembling primary sclerosing cholangitis is due to sclerosing lesions of the extrahepatic or large intrahepatic bile ducts [87].

Vanishing bile duct syndrome

The characteristic portal tract lesion is the disappearance of interlobular bile ducts, with or without moderate polymorphous inflammatory infiltration and ductular proliferation. Cholestasis can be observed and, in severe cases, it can be associated with 'pseudoxanthomatous' degeneration or necrosis of periportal hepatocytes. A lobular inflammatory infiltration is mild or absent [4]. The lobular architecture is initially preserved, and portal fibrosis is usually moderate or absent [254]. However, secondary biliary cirrhosis can eventually develop in a few cases. The reversibility of cholestasis may depend upon the number of affected bile ducts [255].

Clinically, drug-induced prolonged cholestasis due to persisting lesions of small bile ducts has been defined as either the persistence of jaundice for more than 6 months or the persistence of high serum alkaline phosphatase and γ-glutamyltransferase activities for more than 1 year after the acute episode of drug-induced hepatitis and the withdrawal of the causative drug [87]. Three different clinical forms may be described, of increasing severity but decreasing frequency:

1 In the most frequent, but minor, form of the disease, the jaundice and pruritus that characterize the initial episode of acute cholestatic hepatitis rapidly disappear after interruption of treatment. However, high alkaline phosphatase and γ-glutamyltransferase activities persist for more than 1 year, and a liver biopsy shows partial rarefaction of the interlobular bile ducts. Liver tests keep improving, albeit very slowly, and they finally normalize after several years of follow-up.

2 In an uncommon, major, but eventually improving form, jaundice persists for more than 6 months despite interruption of treatment. Xanthomata and xanthelasmata can develop [256,257]. Hepatomegaly, splenomegaly and even symptoms related to malabsorption may appear. Serum alkaline phosphatase and γ-glutamyltransferase activities are very high, as are serum bilirubin, bile acids and cholesterol. Despite this impressive clinical presentation and the presence of histological features resembling severe primary biliary cirrhosis, patients nevertheless progressively improve. Jaundice eventually subsides, although this can take several years [257]. The high alkaline phosphatase and γ-glutamyltransferase activities then decrease very slowly, although, in one patient, abnormalities still persisted 14 years after onset of the liver disease.

3 Finally, in an exceptional, unrelenting form, jaundice persists unabated for many years, until secondary biliary cirrhosis develops, leading to death or liver transplantation.

The features of the initial episode of acute cholangitis are clearly consistent with an immunoallergic mechanism [87]. What is less clear is what prevents the restoration of normal bile ducts once the drug has been withdrawn. The rarefaction of bile ducts may increase progressively with time [258,259], long after the drug and its metabolites have been cleared from the body. This has led to the hypothesis of a drug-triggered, autoimmune attack against small bile ducts [87,255,258]. Persisting blood eosinophilia, circulating immune complexes or both [258] were observed in some cases. However, corticosteroid therapy has been attempted in a few patients without benefit [257]. Another possibility is that the few remaining bile ducts may be exposed to a very high flow rate of detersive bile acids, thus causing sustained toxicity to bile ducts. Administration of ursodeoxycholic acid may be worth trying, as this less detersive bile acid has been associated with clinical and biochemical improvement in some patients.

Drugs causing the vanishing bile duct syndrome

Chlorpromazine

Chlorpromazine has been involved in more than 30 cases of jaundice lasting for more than 1 year [4,102,254,256]. Prolonged cholestasis occurs in about 7% of patients with chlorpromazine-induced acute hepatitis [4]. Despite an impressive clinical and histological picture, prolonged cholestasis caused by this drug often finally improves, with eventual disappearance of jaundice, sometimes several years after the onset of the disease [4,254]. However, irreversible biliary cirrhosis leading to death can occur in some patients [4]. The main histological feature is the disappearance of interlobular bile ducts [4].

Ajmaline derivatives

Many cases of prolonged cholestasis have been ascribed to the ajmaline derivatives, and these drugs are no longer used [257,258]. Jaundice eventually subsided except in one patient in whom irreversible biliary cirrhosis developed [257].

Table 9 Drugs causing prolonged cholestasis resulting from lesions of small intrahepatic bile ducts.

Acepromethazine	Imipramine
Ajmaline	Methyltestosterone
Allopurinol	Norandrostenolone
Amitriptylline	Phenybutazone
Amoxicillin–clavulanic acid	Phenytoin
Barbiturate	Prochlorperazine
Carbamazepine	Ramipril
Carbutamide	Rosiglitazone
Chlorpromazine	Terbinafine
Cimetidine	Tenoxicam
Ciprofloxacin	Tetracycline
Cyamemazine	Thiabendazole
Cyproheptadine	Ticlopidine
Doxycycline	Tiopronin
Erythromycin + chlorpropamide	Tolbutamide
Fenofibrate	Trimethoprim–sulphamethoxazole
Flucloxacillin	Troleandomycin
Gold salts	Xenelamine
Haloperidol	

Flucloxacillin

This penicillinase-resistant penicillin is widely used in several countries and is a frequent cause of the vanishing bile duct syndrome [260,261]. Treatment with ursodeoxycholic acid may be beneficial.

Amoxacillin–clavulanic acid

Focal destructive cholangiopathy is found during acute cholestatic hepatitis due to the amoxicillin–clavulanic acid combination [262], and prolonged cholestasis associated with ductopenia can occur in a few patients [262].

Other drugs

Single cases or a few cases of prolonged cholestasis have been reported with several other drugs (Table 9).

Sclerosing cholangitis

In this condition, one or multiple segmental strictures affect the large intrahepatic and extrahepatic bile ducts. This lesion is seen either after administration of floxuridine infused in the hepatic artery or after the intracystic infusion of hypertonic saline or formaldehyde in hydatid cysts that communicate with intrahepatic bile ducts.

Floxuridine

Jaundice is a frequent complication of the infusion of floxuridine in the hepatic artery for the treatment of hepatic metastases from colorectal carcinoma [263,264]. Jaundice can be due to drug-induced acute hepatitis or to sclerosing cholangitis [264]. Sclerosing cholangitis may occur in 5–29% of patients receiving

this intra-arterial treatment. It usually develops several months (often 1 year) after starting this chemotherapy. It has been suggested that sclerosing cholangitis caused by floxuridine might be treated or prevented by intra-arterial dexamethasone.

Sclerosing cholangitis is characterized by multiple segmental strictures of varying lengths as shown by cholangiography. The strictures taper smoothly both proximally and distally. In contrast to those seen in primary sclerosing cholangitis, the strictures observed after floxuridine infusion occur almost exclusively in the region around the confluence of the left and right hepatic ducts and the proximal common bile duct. Because this region is selectively vascularized by the hepatic artery, it has been suggested that these strictures may be primarily due to arterial lesions that would then lead to the fibrosis of the ischaemic bile ducts [264]. Histological lesions resemble those found in primary sclerosing cholangitis [264].

The outcome of the sclerosing cholangitis caused by the intra-arterial infusion of floxuridine is variable. In some patients, bile duct strictures appear to be reversible. In most patients, however, they persist despite discontinuation of chemotherapy, and may require various types of biliary drainage. The condition may lead to death from progressive hepatic failure.

Other agents

Isolated cases of sclerosing cholangitis have also been observed after the intra-arterial infusion of 5-fluorouracil, given either alone or in association with intravenous streptozotocin or mitomycin. The lesion has also occurred after the administration of a doxorubicin–mitomycin association. Sclerosing cholangitis may also occur in the months following the intracystic injection of either 2% formaldehyde or hypertonic saline into hydatid cysts that happen to communicate with the biliary tree [265].

Vascular lesions

Drugs and chemicals can cause lesions at all levels of the hepatic vascular system (Table 10). Often, the same drug can cause several of these vascular lesions, suggesting some common mechanism, perhaps toxicity to endothelial cells [266,267].

Lesions of the portal vein and its branches

Thrombosis of the portal vein or its branches has been observed in a few women taking oral contraceptives or in patients receiving arsenical derivatives [267]. Four children suffered both portal vein thrombosis and veno-occlusive disease after intensive chemotherapy including busulfan.

Lesions of the hepatic artery and its branches

Arterial intimal hyperplasia of the hepatic artery can occur in women taking oral contraceptives. It is usually silent, but can occasionally lead to multifocal haemorrhagic necrosis or spontaneous rupture of the liver. Arterial intimal hyperplasia can be

Table 10 Drugs reported to cause vascular lesions of the liver.[a]

Thrombosis of the portal vein
Arsenical derivatives
Oral contraceptives
Intimal hyperplasia of the hepatic artery
Oral contraceptives
Necrotizing angiitis of the hepatic artery
Methamphetamine[b]
Sinusoidal dilation
Azathioprine
Chenodeoxycholic acid[b]
Oral contraceptives
Peliosis hepatis
Anabolic–androgenic steroids
Arsenical derivatives
Azathioprine
Corticosteroids[b]
Estrone sulphate[b]
Medroxyprogesterone[b]
Oral contraceptives[b]
Tamoxifen[b]
Thorium dioxide
Veno-occlusive disease
Azathioprine
Busulfan
Carmustine (BCNU)[b]
Cyclofenil[b]
Cyclophosphamide
Cysteamine[b]
Cytarabine
Dacarbazine
Doxorubicin (Adriamycin)[b]
Gemtuzumab ozogamicin
Indicine N-oxide[b]
6-Mercaptopurine
Mitomycin[b]
Progestins[b]
Pyrrolizidine alkaloids
Terbinafine[b]
6-Thioguanine
Urethane
Vincristine[b]
Vitamin E (intravenous)[b]
Budd–Chiari syndrome
Cyclosphosphamide[b]
Dacarbazine
Doxorubicin[b]
Oral contraceptives
Vincristine[b]

[a]Adapted from refs 266 and 267.
[b]Drugs for which a causal relationship with the vascular disorder remains to be confirmed.

associated with the obstruction of large and/or small hepatic veins [266].

Necrotizing angiitis of the hepatic artery has been observed in some subjects addicted to methamphetamine.

Sinusoidal dilation

This lesion is characterized by the dilation of hepatic sinusoids in the absence of any structural (e.g. Budd–Chiari) or haemodynamic (e.g. cardiac failure) restriction to the outflow of blood from the liver [266,267]. Although sinusoidal dilation is often asymptomatic, hepatomegaly, right upper quadrant abdominal pain, fever and a raised erythrocyte sedimentation rate can be occasional features [266,267]. Liver tests are normal or minimally disturbed.

The sinusoidal dilation due to oral contraceptives predominates in periportal areas [268] and can be associated with perisinusoidal fibrosis. Recovery occurs after withdrawal of the oral contraceptives, whereas their readministration may lead to relapse.

Sinusoidal dilation can also occur in patients receiving azathioprine and regresses after its withdrawal.

Peliosis hepatis

Peliosis hepatis is characterized by blood-filled cavities that are randomly distributed throughout the liver lobule. On electron microscopy, there are constant alterations in the endothelial lining cells. In the most severe forms, the endothelial lining is completely absent, and the blood cavities are bordered directly by the hepatocytes. In milder forms, sinusoidal endothelial cells can still be present, but only in places; the gaps between endothelial cells allow the entry of red blood cells into the space of Disse.

Most cases of peliosis hepatis are asymptomatic, and liver tests are either normal or minimally disturbed [266,267]. In some cases, however, the disease has been revealed by hepatomegaly, jaundice, portal hypertension, haemoperitoneum and even hepatic failure [266,267]. Longstanding peliosis may lead to either perisinusoidal fibrosis or nodular regenerative hyperplasia.

Numerous cases of peliosis hepatis have been ascribed to anabolic–androgenic steroids, in particular, but not exclusively, 17-α-alkylated steroids [171]. Mild sinusoidal dilation can be present concomitantly. Many cases remain asymptomatic.

Other compounds responsible for peliosis hepatis include azathioprine [269], 6-thioguanine [270], vinyl chloride and arsenical derivatives. Despite several reports of peliosis hepatis in users of oral contraceptives, this association might be fortuitous, considering the large number of women exposed and the low number of cases observed [268].

Obstruction of the small hepatic veins (veno-occlusive disease)

Veno-occlusive disease, also termed 'sinusoidal obstruction syndrome', is typically characterized by a non-thrombotic, concentric narrowing of the lumen of small centrolobular veins. Destruction of the vascular endothelium may lead to subintimal oedema and a loose subintimal network of reticulin fibres. Subsequent sclerosis of the vein wall may then produce the typical non-thrombotic narrowing of the vein lumen. An exception is the veno-occlusive disease mediated by dacarbazine, which can involve thrombosis. In other cases, the constrictive narrowing of the venous lumen blocks the outflow of blood from the hepatic sinusoids and thereby causes sinusoidal congestion and ischaemic necrosis of centrolobular hepatocytes. This is followed by centrolobular scarring in chronic forms.

Sinusoidal endothelial cells (SECs) have been documented as early targets in the monocrotaline-induced rat model [271]. Depletion of glutathione and depolymerization of actin microfilaments in SECs, together with the increased expression of matrix metalloproteinases by these cells, may allow the rounding up of SECs [271]. Gaps between SECs may allow blood cells to enter the space of Disse and to dissect away the endothelial lining, which may then obstruct the sinusoidal lumen, like a valve [271].

In humans, the clinical presentation of veno-occlusive disease may be either acute or chronic [272]. The acute form is characterized by the prompt onset of jaundice and painful hepatomegaly, together with ascites and weight gain due to fluid retention [272]. The diagnosis can be confirmed by histology after hepatic vein catheterization and a transjugular liver biopsy. Catheterization also documents the increase in the wedged-to-free hepatic venous pressure gradient. Although recovery is possible, this acute severe form of veno-occlusive disease can also lead to fatal hepatic failure [267]. In other patients, veno-occlusive disease develops insidiously, leading to extensive central fibrosis and cirrhosis [267].

The irradiation and/or chemotherapy (mostly busulfan and cyclophosphamide) that are used in the preparation for bone marrow transplantation (haematopoietic stem cell transplantation) are major causes of veno-occlusive disease [272]. This adverse effect may occur in 10–30% of transplanted patients. The risk of developing this complication is particularly high in patients with increased serum aminotransferase levels before the procedure, in patients undergoing intensive conditioning, in patients undergoing a single large dose of total body irradiation rather than fractionated irradiation doses and also in women receiving norethisterone for contraception [272]. The risk may also be increased in patients with a complete deficiency in glutathione *S*-transferase M1, which normally helps to detoxify both busulfan and a toxic metabolite of cyclophosphamide.

Veno-occlusive disease usually occurs from 1 week to 4 weeks after bone marrow transplantation. This early onset helps in the differential diagnosis from later complications, such as graft-vs.-host disease. The clinical course of veno-occlusive disease is frequently severe with a mortality rate of up to 50%. Veno-occlusive disease is the third leading cause of death in bone marrow-transplanted patients, with graft-vs.-host disease and infection as the two primary causes.

Veno-occlusive disease has also been ascribed to various immunosuppressive and antineoplastic agents in the absence of

irradiation. Causative drugs include gemtuzumab ozogamicin, urethane, vincristine, azathioprine, 6-mercaptopurine and 6-thioguanine (Table 10).

Defibrotide, a natural polydeoxyribonucleic acid that may have fibrinolytic and antithrombotic activity, seems to be promising in the treatment of veno-occlusive disease [272], and perhaps also in its prevention. The possible role of low-molecular-weight heparins in prevention also requires further investigation [272].

Obstruction of large hepatic veins (Budd–Chiari syndrome)

The Budd–Chiari syndrome is characterized by the obstruction of large hepatic veins [273]. This lesion results in hepatic congestion, followed by necrosis of the ischaemic centrolobular hepatocytes. The spigelian lobe, which is normally spared by the disease, undergoes compensatory hypertrophy. The severity of the syndrome varies with the site and the extent of thrombosis. The clinical presentation may be acute, with abdominal pain, hepatomegaly and ascites, or chronic, mimicking decompensated cirrhosis. In most cases, an ultrasound and Doppler imaging makes the diagnosis by showing the absence of flow in the thrombosed hepatic veins, as well as the presence of intrahepatic or subcapsular hepatic venous collaterals [273]. In difficult cases, the diagnosis may require magnetic resonance imaging and retrogade cannulation of the hepatic veins for venography and liver biopsy [273].

The risk of developing a Budd–Chiari syndrome was 2.4-fold higher in women using oral contraceptives [274]. Thrombosis has been ascribed to the estrogenic component, which may act mainly by exacerbating an underlying thrombogenic condition. Probably because of the lower estrogen content of current pills, this complication of oral contraceptives is rarely observed nowadays.

A Budd–Chiari syndrome has also occurred in patients receiving some antineoplastic agents. Dacarbazine has been responsible for several cases. The course of the disease was fatal in all cases, within a few days of the onset of the first manifestations. Other suspected agents include doxorubicin, vincristine and cyclophosphamide. The role of the last compounds is questionable, however, as they were administered concurrently with dacarbazine [267].

Treatment is mostly based on anticoagulation, which has markedly improved the prognosis [273]. In patients who do not improve, or who develop severe or recurrent complications, blood derivation techniques and eventually liver transplantation may be considered [273].

Lesions possibly related to vascular injury

Hepatoportal sclerosis

Hepatoportal sclerosis is characterized by portal and periportal fibrosis possibly caused by the obstruction of small portal venules, resulting in portal hypertension.

Hepatoportal sclerosis has been ascribed to various compounds, including vitamin A [241], azathioprine, methotrexate and arsenical derivatives. It is noteworthy that most of these compounds may also cause perisinusoidal fibrosis, a lesion that might be related to the activation of sinusoidal stellate cells.

Nodular hyperplasia of the liver

Nodular hyperplasia of the liver is characterized by small nodules made of hepatocytes; these nodules are randomly distributed throughout the liver, and are seen in the absence of any marked fibrosis [275]. The lesion has been ascribed hypothetically to some heterogeneity in liver vascularization [275]. Portal hypertension is its main manifestation. Nodular regenerative hyperplasia may be associated with peliosis hepatis [269] or sinusoidal dilation [267] and may, in some cases, appear as a late sequel of these lesions. Nodular hyperplasia has been observed after the administration of azathioprine, anabolic–androgenic steroids, oral contraceptives and corticosteroids [269,276].

Hepatic tumours

Initiation and promotion

Tumour development is thought to require both initiation and promotion steps. The initiation stage probably involves some initial damage to DNA [277]. DNA damage may be due to the drug itself when it is transformed into a reactive species, which produces modified DNA bases that lead to misreadings during DNA replication, or when it produces free radicals, including the hydroxyl radical, which can cause DNA breaks, followed by rearrangements [278]. The initial DNA damage may also result from other causes, including viral infections, the endogenous production of reactive oxygen radicals by mitochondria or the ingestion of environmental carcinogens, such as the aflatoxin contained in contaminated peanut products, the psoralens present in several comestible plants, the dimethylnitrosamine contained in beer or the benzopyrene and other carcinogens that are found in barbecued meat and tobacco smoke.

Because most DNA damage is repaired quickly, and because the cellular turnover of hepatocytes is normally slow, the chances are that these hepatic DNA lesions will be repaired before a round of cell division occurs. Furthermore, cells possess mechanisms to prevent the replication of damaged DNA. Indeed, DNA damage increases the cellular levels of p53. This cell cycle checkpoint protein transiently blocks the cell cycle, thus permitting the reparation of DNA lesions before the cell is allowed to proceed to the S phase of DNA replication. When the DNA damage is even more extensive, expression of wild-type p53 may also trigger apoptosis, thus destroying the damaged DNA together with the cell that harbours it. All these effects efficiently prevent the replication of damaged DNA.

However, all factors that will tend to stimulate cell division may lead to the replication of a molecule of DNA that has not yet

been repaired, leading to somatic mutations. Thus, 'promoting' events are mainly those that stimulate cell division [278]. This mitogenic response may be caused by hepatic regeneration after liver cell necrosis, by the direct growth effect of a promoting substance (for example a steroid hormone), by modifications in endogenous growth factors or by interruption of cell–cell communications [278].

Stepwise tumour development

Tumour development after exposure to chemicals is a long, stepwise process [277]. The initiated cells often exhibit changes in phenotype [277]. Transient elevation of serum α-fetoprotein, accompanied by the appearance of a new cell population with oval nuclei, the so-called 'oval cells', is often observed in the early stages of chemical hepatocarcinogenesis in the rat. Oval cells may be derived from a stem cell compartment that has the potential to differentiate into either hepatocytes or ductal epithelium. Oval cells have also been described in the regenerating nodules and the liver tissue surrounding the tumour in humans with hepatocellular carcinoma.

At first, the initiated cells may have no autonomy of growth unless promoting events are continuously applied [277]. However, further steps in proliferation produce increasingly abnormal progeny [277]. It is likely that there is stepwise acquisition of different mutations that eventually allow the cell totally to escape apoptosis and growth-controlling mechanisms. These diverse mutations may involve:

- the overexpression of receptors for growth stimuli, such as the hepatocyte growth factor receptor (c-*met* oncogene), the epidermal growth factor receptor (*neu* oncogene, c-*erbB*-2) or the insulin-like growth factor-1 receptor;
- mutations preventing the normal degradation of beta-catenin, which therefore translocates to the nucleus to stimulate the expression of c-Myc and cyclin D1;
- mutant *ras* proteins that have lost the ability to become inactivated and will thus stimulate growth autonomously, or multiplication of the alleles of the c-*myc* gene;
- a mutation in the gene encoding the cell cycle-blocking gene, *p*53, or various mutations affecting the components of the cyclin system;
- overexpression of telomerase, which avoids the shortening of telomeres after each mitosis;
- mutations in β2-microglubin that suppress the membrane expression of HLA class I molecules on the cell surface and thus enable the cell to escape immune surveillance;
- a variety of mutations involving cell–cell adhesion molecules (E-cadherin, CD44) that may allow the cell to metastasize.

Tumorigenicity of sex hormones

Together with genotoxic anticancer drugs, sex hormones are the chief suspects for drug-induced tumorigenicity in humans [277]. Accordingly, a vast body of literature has been devoted to the assessment of the experimental hepatotumorigenic effects of sex hormones [279]. It is now well established that sex hormones can have tumour-promoting effects. In animals initially exposed to a potent carcinogen such as *N*-nitroso-morpholine or diethylnitrosamine, the secondary administration of ethinylestradiol, mestranol and, in some reports, estradiol or testosterone has increased the incidence of hepatic carcinomas [279]. The promoting effects of androgens and estrogens are ascribed to the presence of androgen and estrogen receptors on hepatocytes and their stimulating effect on liver cell proliferation [171,279]. Progesterone can also induce liver cell proliferation in immature male rats.

Not only do sex hormones promote hepatic carcinomas initiated by experimental carcinogens, but they can also increase the prevalence of hepatic tumours when given alone [279]. Indeed, a somewhat higher prevalence of hepatic carcinomas has been observed in animals after administration of high doses of diethylstilbestrol, ethinylestradiol, norethisterone, norethinodrel and methyltestosterone [279]. These effects do not necessarily imply that sex hormones have initiating, genotoxic effects. Conceivably, they might act only by promoting the growth of cells initiated by spontaneous mutations, viruses or food carcinogens. Nevertheless, some sex hormones may also be genotoxic. Indeed, both stilbene estrogens and steroidal estrogens, whether natural or synthetic, form electrophilic metabolites, free radicals and oxygen radicals, all of which can damage DNA. Cyproterone acetate and also, to some extent, other progestins, such as chlormadinone acetate and megestrol, are also transformed into chemically reactive metabolites that covalently bind to DNA.

Drug-induced tumours

Drugs may cause either benign or malignant hepatic tumours (Table 11).

Hepatocellular adenoma

Hepatocellular adenoma is a benign tumour consisting of normal, tightly packed hepatocyte plates, often two to three cells thick, which are separated by compressed, slit-like sinusoids [277]. In contrast to the normal parenchyma, adenomas contain no portal tract or centrolobular vein [277]. Hepatic adenomas often express estrogen and progesterone receptors, and can also express androgen receptors. Nuclear accumulation of beta-catenin is observed in some adenomas, sometimes as a consequence of beta-catenin mutations.

Adenomas are frequently asymptomatic and are usually discovered incidentally by ultrasonography performed for unrelated complaints. However, large tumours may be revealed by right upper quadrant abdominal pain or, uncommonly, by intraperitoneal bleeding. Tumours greater than 2 cm are easily detected by ultrasound as hyper- or hypoechogenic nodules without specific features. Computerized tomography (CT) characteristically shows nodules of lower attenuation than

Table 11 Drugs reported to possibly cause, or affect the size or outcome of, hepatic tumours.[a]

Benign tumours
Hepatocellular adenoma
Anabolic–androgenic steroids
Clofibrate[b]
Clomiphene[b]
Oral contraceptives
Nodular focal hyperplasia
Anabolic–androgenic steroids[b]
Chorionic gonadotrophins[b]
Oral contraceptives[b] (may increase size and the risk of complications?)
Benign haemangioma
Oral contraceptives[b] (may increase size and the risk of complications?)
Malignant tumours
Hepatocellular carcinoma
Anabolic–androgenic steroids
Azathioprine
Cyclophosphamide
Cyproterone
Danazol
Doxorubicin
6-Mercaptopurine
Methotrexate[b]
Methyldopa[b]
Nitrofurantoin
Oral hypoglycaemic agents[b]
Oral contraceptives
Tamoxifen
Thorium dioxide
Vincristine
Other malignant tumours
Cholangiocarcinoma
Anabolic–androgenic steroids[b]
Methyldopa[b]
Oral contraceptives[b]
Thorium dioxide
Angiosarcoma
Anabolic–androgenic steroids
Arsenical derivatives
Oral contraceptives[b]
Phenelzine[b]
Thorium dioxide
Epithelioid haemangioendothelioma
Oral contraceptives[b]
Hepatoblastoma
Clomiphene[b]
Oral contraceptives[b]
Lymphomas
Immunosuppressive therapy (ciclosporin A, azathioprine and corticosteroids)

[a]Adapted from ref. 277.

[b]Compounds for which a causal relationship remains to be confirmed.

the surrounding normal parenchyma, with early contrast enhancement. Magnetic resonance imaging (MRI) provides similar features by showing a hypervascular, more or less homogeneous, tumour. When the diagnosis remains unclear after these investigations, a liver biopsy guided by ultrasound is sometimes performed. Hepatic resection is generally proposed, because large adenomas may be complicated by intratumoral or intraperitoneal bleeding, distinction from carcinoma can be difficult and adenomas can rarely degenerate into well-differentiated hepatic carcinomas.

At a time when high-dosage contraceptives were still being used, or had been used recently, it was shown that oral contraceptives markedly increased the risk of developing a hepatic adenoma [280–282]. The relative risk was practically unchanged during the first year of oral contraception, was slightly increased from 1 to 3 years, but was 116-fold the normal risk after 5 years of oral contraception and more than 500-fold after 7 years [281]. It was estimated that the annual incidence rate of hepatic adenomas was only 1 per million in females taking no oral contraceptive, but 34 per million in users of oral contraceptives [281]. However, these studies, which were performed in the 1970s, do not apply to the low-dosage pills used nowadays. There is little evidence for an increased risk of hepatic adenoma with the modern contraceptives. In the past, the discontinuation of oral contraceptives has occasionally been followed by a slow decrease in the tumour size and even complete regression. However, as indicated above, it is now felt that adenomas should be surgically removed, whenever possible.

The risk of developing a hepatic adenoma is also increased by prolonged administration of anabolic/androgenic steroids [283,284]. These drugs are used in Fanconi anaemia, or abused by body builders. Most cases have occurred with 17-α-alkylated steroids [283]. One case, however, has been attributed to testosterone enanthate, a non-17-α-alkylated steroid [284], and several cases have occurred with danazol. Decreases in tumour size have been observed after stopping the anabolic/androgenic drugs. However, adenomas caused by anabolic/androgenic steroids may also evolve into hepatocellular carcinomas [284], and resection is recommended whenever possible.

Isolated cases of adenoma have also been observed after the administration of clomiphene or norethisterone, a progestin.

Focal nodular hyperplasia

Focal nodular hyperplasia is a benign hepatic tumour (hamartoma) characterized by a central stellate scar surrounded by the liver cell nodule. The fibrous tissue septa contain blood vessels and bile ducts. Albeit uncommon, this tumour is now about 10 times more frequent than adenoma. In most cases, focal nodular hyperplasia is discovered fortuitously by ultrasonography performed for unrelated reasons. However, abdominal pain or the palpation of a liver mass may reveal the tumour. Ultrasound examination discloses a hypo-, iso- or hyperechogenic nodule. CT shows a slightly hypodense nodule, with a very hypodense

central zone corresponding to the artery feeding the tumour, and the fibrotic scar. CT may also show an early and massive enhancement of the nodule with a central hypodense area. However, this central scar, which is characteristic of focal nodular hyperplasia, is observed in only 50% of patients. MRI shows the central scar more easily, and is now the preferred, non-invasive method of ascertaining the diagnosis. Liver biopsy may be resorted to in difficult cases. In a few cases, the distinction from an adenoma or a well-differentiated hepatocellular carcinoma may not be possible.

A recent case–control study suggests that cigarette smoking might be an important risk factor for focal nodular hyperplasia of the liver. Varying views have been held regarding a possible association of focal nodular hyperplasia with oral contraceptives. It was first proposed that, although oral contraceptives may not promote the *de novo* formation of focal nodular hyperplasia [280], they may increase the size of the tumour and the risk of developing intratumorous or intraperitoneal haemorrhage. This has led some authors to propose the withdrawal of oral contraceptives in women with this tumour. It was then reported that neither the size nor the number of focal nodular hyperplasia lesions was influenced by oral contraceptive use, and that size changes during follow-up did not seem to correlate with changes in oral contraceptive use [285]. Finally, a recent case–control study again suggests an increased risk of focal nodular hyperplasia disclosure after oral contraceptive use for more than 3 years [286].

Even though focal nodular hyperplasia is associated with several genomic alterations detected by comparative genomic hybridization, these changes are less abundant than, and tend to be of a different type from, those found in hepatocellular adenomas and, in much greater numbers, in hepatocellular carcinomas. Focal nodular hyperplasia does not evolve into cancer, although both lesions can obviously occur coincidentally in different sites in the same liver. Furthermore, focal nodular hyperplasia exceptionally leads to intratumoral or intraperitoneal bleeding. Finally, when the hepatic imaging is typical of focal nodular hyperplasia, there is little risk that the tumour may actually be a hepatocarcinoma. Therefore, small and asymptomatic forms of focal nodular hyperplasia with typical imaging features can be left *in situ* and monitored by periodic ultrasound scans and α-fetoprotein measurements.

Benign haemangioma

Although this vascular tumour may not be induced by oral contraceptives, these drugs may have a role in the enlargement of a pre-existing haemangioma [287]. There seems to be a specific association of hepatic haemangiomas with focal nodular hyperplasia. One or two hepatic haemangiomas were present in 23% of 26 women with focal nodular hyperplasia, but in none of 26 women with a hepatocellular adenoma. Interestingly, all women with both haemangioma and hepatic nodular hyperplasia had been on oral contraceptives.

Hepatocellular carcinoma

This is a malignant tumour developed from hepatocytes. The tumour may be discovered fortuitously or revealed by cholestasis, abdominal pain, weight loss, asthenia or an enlarged liver.

A meta-analysis of six individual studies indicates an overall odds ratio of 2.5 in ever-users vs. never-users of oral contraceptives, with an even greater risk for those with the longest duration of use [288]. The risk of developing a hepatocellular carcinoma also appears to be increased by prolonged administration of anabolic–androgenic steroids [171]. A mean delay of 72 months between the beginning of the anabolic–androgenic steroid therapy and the discovery of the tumour has been reported [171].

The hepatocellular carcinomas that are associated with anabolic–androgenic steroids or oral contraceptives exhibit several features that distinguish them from the hepatocellular carcinomas complicating cirrhosis [171,283]. The cancer occurs in relatively young subjects (frequently less than 35 years old). There is no evidence of chronic liver disease or cirrhosis in the non-tumoral liver. The serum α-fetoprotein level is generally normal or moderately increased. Vascular extensions of the tumour and metastases are uncommon. Finally, the hepatocellular carcinomas induced by anabolic–androgenic steroids have sometimes receded after the discontinuation of these drugs [283].

Three cases of hepatocellular carcinoma have been reported in children receiving high doses of cyproterone acetate, a synthetic progestogen that suppresses gonadotrophin secretion and blocks male hormone receptors. A fourth case has been reported in an elderly male treated for prostate cancer. Tumorigenicity may be explained by the genotoxic and growth-promoting effects of this drug.

Hepatocellular carcinomas have also been reported after the administration of several immunosuppressive and/or anticancer drugs, such as azathioprine, cyclophosphamide, doxorubicin, 6-mercaptopurine, methotrexate and vincristine (Table 11). Finally, hepatocellular carcinomas have been reported after the administration of drugs known to cause chronic liver injury and cirrhosis, such as methyldopa, nitrofurantoin and tamoxifen (Table 11).

Cholangiocarcinoma

Cholangiocarcinoma is a malignant tumour made up of cells resembling biliary epithelial cells. The serum level of α-fetoprotein is usually normal, whereas that of the carcinoembryonic antigen is frequently increased. This tumour has been observed in subjects exposed to thorium dioxide [277]. It has occasionally been reported in patients on long-term anabolic–androgenic steroid therapy [171], in oral contraceptive users and also in a patient receiving methyldopa. However, the causal relationship between these treatments and the tumour remains to be confirmed.

Angiosarcoma

This is an uncommon, malignant tumour developed from the endothelial sinusoidal cells. This tumour may occur after exposure to several chemicals, in particular vinyl chloride and cupric sulphate, or after the administration of some drugs including arsenical derivatives and anabolic–androgenic steroids (Table 11) [287]. Interestingly, several of these compounds are also able to cause sinusoidal dilation, peliosis hepatis and perisinusoidal fibrosis [287]. This suggests some possible relationship between the mechanisms leading to these non-malignant diseases and the possible development of angiosarcoma [287]. Perhaps the common origin of these various lesions might be some initial toxic insult to sinusoidal endothelial cells [287].

Other malignant tumours

A hypothetical link between the occurrence of epithelioid haemangioendothelioma and the use of oral contraceptives has been suggested. A hepatoblastoma has been observed in two infants after maternal exposure to oral contraceptives or clomiphen [277], but this association may be fortuitous. Finally, the prolonged administration of immunosuppressive drugs increases the incidence of lymphomas, which can affect the liver (Table 11).

Outlook

Looking back over the last three decades, it appears that considerable progress has been made in the field of drug-induced liver injury. An astonishing variety of drug-induced liver lesions has been recognized, and a main mechanism has been proposed for most of them. It is clear, however, that our present understanding represents, at best, a much simplified overview of the reality. Because there are so many hepatotoxic drugs, only a few mechanistic aspects, if any, have been investigated for any single drug. The reasons behind the susceptibility of a few patients remain largely unknown, and the possibility of preventive measures has been little explored.

Few young hepatologists are devoting themselves to this field nowadays, and this seriously limits the chances of quicker progress. Hopefully, this trend may be reversed in the future. Recent advances in pharmacogenetics, molecular biology, immunology and cell biology offer renewed opportunities for new advances in this important field.

As drug-induced hepatotoxicity is relatively uncommon (when a single drug is concerned), large collaborative studies should be encouraged to better define the genetic background, acquired predisposing factors, frequency, early diagnosis, clinical characteristics and outcome of these iatrogenic diseases. Improved understanding of the hepatotoxicity of drugs may hopefully lead to the safer use of current molecules and the development of safer alternatives in the future.

References

1 Sgro C, Clinard F, Ouazir K *et al.* (2002) Incidence of drug-induced hepatic injuries: a French population-based study. *Hepatology* 36, 451–455.

2 Benhamou JP (1986) Drug-induced hepatitis. Clinical aspects. In: Fillastre JP (ed.) *Hepatotoxicity of Drugs*. Rouen: Presses Universitaires de Rouen, pp. 23–30.

3 Stricker BHC (1992) *Drug-Induced Hepatic Injury*, 2nd edn. Amsterdam: Elsevier.

4 Zimmerman HJ (1978) *Hepatotoxicity. The Adverse Effects of Drugs and Other Chemicals on the Liver*. New York: Appleton-Century-Crofts.

5 Farrell GC (1994) *Drug-induced Liver Injury*. New York: Churchill Livingstone.

6 Kaplowitz N, DeLeve LD (2003) *Drug-induced Liver Disease*. New York: Marcel Dekker.

7 Bagheri H, Michel F, Lapeyre-Mestre M *et al.* (2000) Detection and incidence of drug-induced liver injuries in hospital: a prospective analysis from laboratory signals. *Br J Clin Pharmacol* 50, 479–484.

8 Bernuau J, Rueff B, Benhamou JP (1986) Fulminant and subfulminant liver failure: definition and causes. *Semin Liver Dis* 6, 97–106.

9 Lee WM (2003) Acute liver failure in the United States. *Semin Liver Dis* 23, 217–226.

10 Tinel M, Berson A, Vadrot N *et al.* (2004) Subliminal Fas stimulation increases the hepatotoxicity of acetaminophen and bromobenzene in mice. *Hepatology* 39, 655–666.

11 Pessayre D, Fromenty B (2005) NASH: a mitochondrial disease. *J Hepatol* 42, 928–940.

12 Pessayre D, Lebrec D, Descatoire V *et al.* (1978) Mechanism for reduced drug clearance in patients with cirrhosis. *Gastroenterology* 74, 566–571.

13 Beaune P, Pessayre D, Dansette P *et al.* (1994) Autoantibodies against cytochromes P450: role in human diseases. *Adv Pharmacol* 30, 199–245.

14 Pons C, Dansette PM, Gregeois J *et al.* (1996) Human anti-mitochondrial autoantibodies appearing in iproniazid-induced immunoallergic hepatitis recognize human liver monoamine oxidase B. *Biochem Biophys Res Commun* 218, 118–124.

15 Maria VA, Pinto L, Victorino RM (1994) Lymphocyte reactivity to ex-vivo drug antigens in drug-induced hepatitis. *J Hepatol* 21, 151–158.

16 Maria VAJ, Victorino RMM (1997) Diagnostic value of specific T cell reactivity to drugs in 95 cases of drug induced liver injury. *Gut* 41, 534–540.

17 Benichou C (1990) Criteria for drug-induced hepatitis. Report of an international consensus meeting. *J Hepatol* 11, 272–276.

18 Pessayre D, Mansouri B, Fromenty B *et al.* (2002) Hepatotoxicity due to mitochondrial injury. In: Kaplowitz N, DeLeve L (eds) *Drug-induced Liver Disease.* New York: Marcel Dekker, pp. 55–84.

19 Mingatto FB, Rodrigues T, Pigoso AA *et al.* (2002) The critical role of mitochondrial energetic impairment in the toxicity of nimesulide to hepatocytes. *J Pharmacol Exp Therapeut* 303, 601–607.

20 Masubachi Y, Nakayama S, Horie T (2002) Role of mitochondrial permeability transition in diclofenac-induced hepatocyte injury in rats. *Hepatology* 35, 544–551.

21 Berson A, Schmets L, Fau D *et al.* (1994) Inhibition by nilutamide of the mitochondrial respiratory chain and ATP formation. Possible contribution to the adverse effects of this antiandrogen. *J Pharmacol Exp Therapeut* 270, 167–176.

22 Berson A, Fau D, Fornacciari R *et al.* (2001) Mechanism for experimental buprenorphine hepatotoxicity: major role of mitochondrial dysfunction versus metabolic activation. *J Hepatol* 34, 261–269.

23 Mansouri A, Haouzi D, Descatoire V *et al.* (2003) Tacrine inhibits topoisomerases and DNA synthesis to cause mitochondrial DNA depletion and apoptosis in mouse liver. *Hepatology* 38, 715–725.

24 Fulda S, Scaffidi C, Susin SA *et al.* (1998) Activation of mitochondria and release of mitochondrial apoptogenic factors by betulinic acid. *J Biol Chem* 273, 33942–33948.

25 Ravagnan L, Marzo I, Costantini P *et al.* (1999) Lonidamide triggers apoptosis via a direct, Bcl-2-inhibited effect on the mitochondrial permeability transition pore. *Oncogene* 18, 2537–2546.

26 Pessayre D (1995) Role of reactive metabolites in drug-induced hepatitis. *J Hepatol* 23 (Suppl. 1), 16–24.

27 Robin MA, Le Roy M, Descatoire V *et al.* (1997) Plasma membrane cytochromes P450 as neoantigens and autoimmune targets in drug-induced hepatitis. *J Hepatol* 26 (Suppl. 1), 23–30.

28 Gonzales FJ, Nebert DW (1990) Evolution of the cytochrome P-450 gene superfamily: animal–plant 'warfare', molecular drive and human genetic differences in drug oxidation. *Trends Genet* 6, 182–186.

29 Guengerich FP, Liebler DC (1985) Enzymatic activation of chemicals to toxic metabolites. *CRC Crit Rev Toxicol* 14, 259–307.

30 Breen K, Wandscheer JC, Peignoux M *et al.* (1982) *In situ* formation of the acetaminophen metabolite covalently bound in kidney and lung. Supportive evidence provided by total hepatectomy. *Biochem Pharmacol* 31, 115–116.

31 Esterbauer H, Schaur RJ, Zollner H (1991) Chemistry and biochemistry of 4-hydroxynonenal, malondialdehyde and related aldehydes. *Free Radical Biol Med* 11, 81–128.

32 Mitchell JR, Jollow DJ (1975) Metabolic activation of drugs to toxic substances. *Gastroenterology* 68, 392–410.

33 Mirabelli F, Salis A, Marinoni V *et al.* (1988) Menadione-induced bleb formation in hepatocytes is associated with the oxidation of thiol groups in actin. *Arch Biochem Biophys* 264, 261–269.

34 Bellomo G, Orrenius S (1985) Altered thiol and calcium homeostasis in oxidative hepatocellular injury. *Hepatology* 5, 876–882.

35 Fau D, Lekehal M, Farrell G *et al.* (1997) Diterpenoids from germander, a herbal medicine, induce apoptosis in isolated rat hepatocytes. *Gastroenterology* 113,1334–1346.

36 Fagian MM, Pereire-Da-Silva L, Martins IS *et al.* (1990) Membrane protein thiol cross-linking associated with the permeabilization of the inner membrane by Ca^{2+} plus prooxidants. *J Biol Chem* 32, 19955–19960.

37 Pessayre D, Haouzi D, Fau D *et al.* (1999) Withdrawal of life support, altruistic suicide, fratricidal killing and euthanasia by lymphocytes: different forms of drug-induced hepatic apoptosis. *J Hepatol* 31, 760–770.

38 Haouzi D, Lekehal M, Moreau A *et al.* (2000) Cytochrome P450-generated reactive metabolites cause mitochondrial permeability transition, caspase activation and apoptosis in rat hepatocytes. *Hepatology* 32, 303–311.

39 Leist M, Single B, Castoldi AF *et al.* (1997) Intracellular adenosine triphosphate (ATP) concentration: a switch in the decision between apoptosis and necrosis. *J Exp Med* 185, 1481–1486.

40 Feldmann G, Haouzi D, Moreau A *et al.* (2000) Opening of the mitochondrial permeability transition pore causes matrix expansion and outer membrane rupture in Fas-mediated hepatic apoptosis in mice. *Hepatology* 31, 674–683.

41 Loeper J, Descatoire V, Lettéron P *et al.* (1994) Hepatotoxicity of germander in mice. *Gastroenterology* 106, 464–472.

42 Arends MJ, Wyllie AH (1991) Apoptosis: mechanisms and roles in pathology. *Int Rev Exp Pathol* 32, 223–254.

43 Berson A, Wolf C, Chachaty C *et al.* (1993) Metabolic activation of the nitroaromatic antiandrogen flutamide by rat and human cytochromes P-450, including forms belonging to the 3A and 1A subfamilies. *J Pharmacol Exp Therapeut* 265, 3663–3672.

44 Larrey D, Tinel M, Letteron P *et al.* (1990) Metabolic activation of the new tricyclic antidepressant tianeptine by human liver cytochrome P-450. *Biochem Pharmacol* 40, 545–550.

45 Larrey D, Distlerath LM, Dannan GA *et al.* (1984) Purification and characterization of the rat liver microsomal cytochrome P-450 involved in the 4-hydroxylation of debrisoquine, a prototype for genetic variation in oxidative drug metabolism. *Biochemistry* 23, 2787–2795.

46 Jacqz E, Hall SD, Branch RA (1986) Genetically determined polymorphisms in drug oxidation. *Hepatology* 6, 1020–1032.

47 Larrey D, Tinel M, Amouyal G *et al.* (1989) Genetically determined oxidation polymorphism and drug hepatotoxicity. Study of 51 patients. *J Hepatol* 8, 158–164.

48 Henderson CJ, Wolf CR, Kitteringham N *et al.* (2000) Increased resistance to acetaminophen hepatotoxicity in mice lacking glutathione S-transferase Pi. *Proc Natl Acad Sci USA* 97, 12741–12745.

49 Larrey D, Letteron P, Foliot A *et al.* (1986) Effects of pregnancy on the toxicity and metabolism of acetaminophen in mice. *J Pharmacol Exp Therapeut* 237, 283–291.

50 Pessayre D, Dolder A, Artigou JY *et al.* (1979) Effect of fasting on metabolite-mediated hepatotoxicity in the rat. *Gastroenterology* 77, 264–271.

51 Pessayre D, Bentata C, Degott C *et al.* (1977) Isoniazid-rifampin fulminant hepatitis. A possible consequence of the enhancement of isoniazid hepatotoxicity by enzyme induction. *Gastroenterology* 72, 284–289.

52 Pessayre D, Allemand H, Benoist C *et al.* (1978) Effect of surgery under general anaesthesia on antipyrine clearance. *Br J Clin Pharmacol* 6, 505–513.

53 Pessayre D, de Saint-Louvent P, Degott C *et al.* (1978) Iproclozide fulminant hepatitis. Possible role of enzyme induction. *Gastroenterology* 75, 492–496.

54 Seef LB, Cuccherini BA, Zimmerman HJ *et al.* (1986) Acetaminophen hepatotoxicity in alcoholics. A therapeutic misadventure. *Ann Intern Med* 104, 399–404.

55 Pessayre D, Wandscheer C, Cobert B *et al.* (1980) Additive effects of inducers and fasting on acetaminophen hepatotoxicity. *Biochem Pharmacol* 29, 2219–2223.

56 Germain RN (1994) MHC-dependent antigen processing and peptide presentation: providing ligands for T lymphocyte activation. *Cell* 76, 287–299.

57 Gut J, Christen U, Huwyler J (1993) Mechanisms of halothane toxicity: novel insights. *Pharmacol Therapeut* 58, 133–155.

58 Kenna JG, Satoh H, Christ DD *et al.* (1988) Metabolic basis for a drug hypersensitivity: antibodies in sera from patients with halothane hepatitis recognize liver neoantigens that contain the trifluoroacetyl group derived from halothane. *J Pharmacol Exp Therapeut* 245, 1103–1119.

59 Vergani D, Mieli-Vergani G, Alberti A *et al.* (1980) Antibodies to the surface of halothane-altered rabbit hepatocytes in patients with severe halothane-associated hepatitis. *N Engl J Med* 303, 66–71.

60 Satoh H, Fukuda Y, Anderson DK *et al.* (1985) Immunological studies on the mechanism of halothane-induced hepatotoxicity: immunohistochemical evidence of trifluoroacetylated hepatocytes. *J Pharmacol Exp Therapeut* 233, 857–862.

61 Loeper J, Descatoire V, Amouyal G *et al.* (1989) Presence of covalently bound metabolites on rat hepatocyte plasma membrane proteins after administration of isaxonine, a drug leading to immunoallergic hepatitis in man. *Hepatology* 9, 675–678.

62 Neuberger J, Kenna JG, Aria KN *et al.* (1985) Antibody mediated hepatocyte injury in methyl-dopa induced hepatotoxicity. *Gut* 26, 1233–1239.

63 Neuberger J, Williams R (1989) Immune mechanisms in tienilic acid associated hepatotoxicity. *Gut* 30, 515–519.

64 Siprodhis L, Beaugrand M, Malledant Y *et al.* (1991) Use of adult human hepatocytes in primary culture for the study of clometacin-induced immunoallergic hepatitis. *Toxicity in Vitro* 5, 529–534.

65 Beaune P, Dansette PM, Mansuy D *et al.* (1987) Human anti-endoplasmic reticulum autoantibodies appearing in a drug-induced hepatitis are directed against a human liver cytochrome P-450 that hydroxylates the drug. *Proc Natl Acad Sci USA* 84, 551–555.

66 Bourdi M, Larrey D, Nataf J *et al.* (1990) Anti-liver endoplasmic reticulum autoantibodies are directed against human liver cytochrome P-450 IA2. A specific marker of dihydralazine-induced hepatitis. *J Clin Invest* 85, 1967–1973.

67 Bourdi M, Tinel M, Beaune P *et al.* (1994) Interactions of dihydralazine with cytochromes P4501A: a possible explanation for the appearance of anti-P4501A2 autoantibodies. *Mol Pharmacol* 45, 1287–1295.

68 Robin MA, Maratrat M, Le Roy M *et al.* (1995) Cytochrome P4502B follows a vesicular route to the plasma membrane in cultured rat hepatocytes. *Gastroenterology* 108, 1110–1123.

69 Robin MA, Descatoire V, Le Roy M *et al.* (2000) Vesicular transport of newly synthesized cytochromes P4501A to the outside of rat hepatocyte plasma membranes. *J Pharmacol Exp Therapeut* 294, 1063–1109.

70 Loeper J, Descatoire V, Maurice M *et al.* (1990) Presence of functional cytochrome P-450 on isolated rat hepatocyte plasma membrane. *Hepatology* 11, 850–858.

71 Loeper J, Descatoire V, Maurice M *et al.* (1993) Cytochrome P-450 on human hepatocyte plasma membrane. Recognition by several autoantibodies. *Gastroenterology* 104, 203–216.

72 Eliasson E, Kenna JG (1996) Cytochrome P4502E1 is a cell surface autoantigen in halothane hepatitis. *Mol Pharmacol* 50, 573–582.

73 Bourdi M, Chen W, Peter RM *et al.* (1996) Human cytochrome P4502E1 is a major autoantigen associated with halothane hepatitis. *Chem Res Toxicol* 9, 1159–1166.

74 Robin MA, Maratrat M, Le Roy M *et al.* (1996) Antigenic targets in tienilic acid hepatitis. Both cytochrome P450 2C11 and 2C11-tienilic acid adducts are transported to the plasma membrane of rat hepatocytes and recognized by human sera. *J Clin Invest* 98, 1471–1480.

75 Aithal GP, Ramsay L, Daly AK *et al.* (2004) Hepatic adducts, circulating antibodies, and cytokine polymorphisms in patients with diclofenac hepatotoxicity. *Hepatology* 39, 1430–1440.

76 Njoku DB, Greenberg RS, Bourdi M *et al.* (2002) Autoantibodies associated with volatile anesthetic hepatitis found in the sera of a large cohort of pediatric anesthesiologists. *Anesth Analg* 94, 243–249.

77 Volpes R, van den Oord JJ, Desmet VJ (1992) Can hepatocytes serve as activated immunomodulating cells in the immune response? *J Hepatol* 16, 228–240.

78 Shear NH, Spielberg SP, Grant DM *et al.* (1986) Differences in metabolism of sulfonamides predisposing to idiosyncratic toxicity. *Ann Intern Med* 105, 179–183.

79 Shear NH, Spielberg SP (1988) Anticonvulsant hypersensitivity syndrome. In vitro assessment of risk. *J Clin Invest* 82, 1826–1832.

80 Farrell G, Prendergast D, Murray M (1985) Halothane hepatitis. Detection of a constitutional susceptibility factor. *N Engl J Med* 313, 1310–1314.

81 Larrey D, Berson A, Habersetzner F *et al.* (1989) Genetic predisposition to drug hepatotoxicity. Role in hepatitis caused by amineptine, a tricyclic antidepressant. *Hepatology* 10, 168–173.

82 Berson A, Freneaux E, Larrey D *et al.* (1994) Possible role of HLA in hepatotoxicity. An exploratory study in 71 patients with drug-induced idiosyncratic hepatitis. *J Hepatol* 20, 336–342.

83 Hautekeete ML, Horsmans Y, Van Waeyenberge C *et al.* (1999) HLA association of amoxicillin-clavulanate-induced hepatitis. *Gastroenterology* 117, 1181–1186.

84 O'Donohue J, Oien KA, Donaldson P *et al.* (2000) Co-amoxiclav jaundice: clinical and histological features and HLA class II association. *Gut* 47, 717–720.

85 Prescott LF (1983) Paracetamol overdosage. Pharmacological considerations and clinical management. *Drugs* 25, 290–314.

86 Rodman JS, Deutsch DJ, Gutman SI (1976) Methyldopa hepatitis. A report of six cases and review of the literature. *Am J Med* 60, 941–948.

87 Larrey D, Erlinger S (1988) Drug-induced cholestasis. *Baillière's Clin Gastroenterol* 2, 423–452.

88 Ishak KG, Zimmerman HJ (1988) Drug-induced and toxic granulomatous hepatitis. In: Bircher J (ed.) *Baillière's Clinical Gastroenterology*. London: Baillière Tindall, pp. 463–480.

89 Pariente EA, Pessayre D, Bentata-Pessayre M *et al.* (1980) Hépatite à l'ajmaline. Description de 4 observations et revue de la littérature. *Gastroentérol Clin Biol* 4, 240–245.

90 Berson A, Descatoire V, Sutton A *et al.* (2001) Toxicity of alpidem, a peripheral benzodiazepine receptor ligand, but not zolpidem in rat hepatocytes. Role of mitochondrial permeability transition and metabolic activation. *J Pharmacol Exp Therapeut* 299, 793–800.

91 Al-kawas FH, Seeff LB, Berendson RA *et al.* (1981) Allopurinol hepatotoxicity. Report of two cases and review of the literature. *Ann Intern Med* 95, 588–590.

92 Danan G, Bernuau J, Moullot X *et al.* (1984) Amitriptyline-induced fulminant hepatitis. *Digestion* 30, 179–184.

93 Larrey D, Castot A, Pessayre D *et al.* (1986) Amodiaquine-induced hepatitis. A report of seven cases. *Ann Intern Med* 104, 801–803.

94 Larrey D, Vial T, Micaleff A *et al.* (1992) Hepatitis associated with amoxicillin–clavulanic acid combination. Report of 15 cases. *Gut* 33, 368–371.

95 Hautekeete ML, Brenard R, Horsmans Y *et al.* (1995) Liver injury related to amoxicillin–clavulanic acid: interlobular bile duct lesions and extrahepatic manifestations. *J Hepatol* 22, 71–77.

96 Zimmerman HJ (1981) Effects of aspirin and acetaminophen on the liver. *Arch Intern Med* 141, 333–342.

97 Waldman RJ, Hall WN, McGee H *et al.* (1982) Aspirin as a risk factor in Reye's syndrome. *JAMA* 247, 3089–3094.

98 Lee AU, Farrell GC (2001) Mechanism of azathioprine-induced injury to hepatocytes: roles of glutathione depletion and mitochondrial injury. *J Hepatol* 35, 756–764.

99 Loiseau D, Degos F, Degott C *et al.* (1987) Cholestasis after azathioprine administration in renal transplant recipients. *Clin Transpl* 1, 88–94.

100 Kaufmann P, Torok M, Hanni A *et al.* (2005) Mechanisms of benzarone and benzbromarone-induced hepatic toxicity. *Hepatology* 41, 925–935.

101 Hautekeete ML, Henrion J, Naegels S *et al.* (1995) Severe hepatotoxicity related to benzarone: a report of three cases with two fatalities. *Liver* 15, 25–29.

102 Ishak KG, Irey NS (1972) Hepatic injury associated with the phenothiazines. Clinico-pathologic and follow-up study of 36 patients. *Arch Pathol* 93, 283–304.

103 Lawrence JW, Claire DC, Weissig V *et al.* (1996) Delayed cytotoxicity and cleavage of mitochondrial DNA in ciprofloxacin-treated mammalian cells. *Mol Pharmacol* 50, 1178–1188.

104 Boya P, Andreau K, Poncet D *et al.* (2003) Lysosomal membrane permeabilization induces cell death in a mitochondrion-dependent fashion. *J Exp Med* 197, 1323–1334.

105 Islam S, Mekhloufi F, Paul JM *et al.* (1989) Characteristics of clometacin-induced hepatitis with special reference to the presence of anti-actin cable antibodies. *Autoimmunity* 2, 213–221.

106 Macfarlane B, Davies S, Mannan K *et al.* (1997) Fatal acute fulminant liver failure due to clozapine: a case report and review of clozapine-induced hepatotoxicity. *Gastroenterology* 112, 1707–1709.

107 Pirmohamed M, Williams D, Madden S *et al.* (1995) Metabolism and bioactivation of clozapine by human liver *in vitro*. *J Pharmacol Exp Therapeut* 272, 984–90.

108 Mallat A, Dhumeaux D (1991) Cocaine and the liver. *J Hepatol* 12, 275–278.

109 Utili R, Boitnott JK, Zimmerman HJ (1977) Dantrolene-associated hepatic injury. Incidence and character. *Gastroenterology* 72, 610–616.

110 Johnson DA, Cattau EL, Kuritsky JN *et al.* (1986) Liver involvement in the sulfone syndrome. *Arch Intern Med* 146, 875–877.

111 Banks AT, Zimmerman HJ, Ishak KG *et al.* (1995) Diclofenac-associated hepatotoxicity. Analysis of 180 cases reported to the food and drug administration as adverse reactions. *Hepatology* 22, 820–827.

112 Pariente EA, Pessayre D, Bernuau J *et al.* (1983) Dihydralazine hepatitis. Report of a case and review of the literature. *Digestion* 27, 47–52.

113 Balakirev MY, Zimmer G (2001) Mitochondrial injury by disulfiram: two different mechanisms of the mitochondrial permeability transition. *Chemico-Biol Interact*138, 299–311.

114 Forns X, Caballeria J, Bruguera M *et al.* (1994) Disulfiram-induced hepatitis. Report of four cases and review of the literature. *J Hepatol* 21, 853–857.

115 Lewis JH, Zimmerman HJ, Ishak KG *et al.* (1983) Enflurane hepatotoxicity. A clinico pathologic study of 24 cases. *Ann Intern Med* 98, 984–992.

116 Lunzer MR, Huang SN, Ward KM *et al.* (1975) Jaundice due to erythomycin estolate. *Gastroenterology* 68, 1284–1291.

117 Funck-Brentano C, Pessayre D, Benhamou JP (1983) Hépatites dues à divers dérivés de l'érythromycine. *Gastroentérol Clin Biol* 7, 362–369.

118 Zafrani ES, Ishak KG, Rudzki C (1979) Cholestatic and hepatocellular injury associated with erythromycin esters. Report of nine cases. *Am J Dig Dis* 24, 385–396.

119 Pessayre D, Larrey D, Funck-Brentano C *et al.* (1985) Drug interactions and hepatitis produced by some macrolide antibiotics. *J Antimicrob Chemother* 16, 181–194.

120 Pellock JM (1999) Felbamate in epilepsy therapy: evaluating the risks. *Therapy* 21, 225–239.

121 Oek GH, Stricker BH, Blok AP *et al.* (1994) Flucloxacillin-associated hepatic injury. *Liver* 14, 225–229.

122 Lakehal F, Dansette PM, Becquemont L *et al.* (2001) Indirect cytotoxicity of flucloxacillin toward human biliary epithelium via metabolite formation in hepatocytes. *Chem Res Toxicol* 14, 694–701.

123 Pessayre D, Feldmann G, Degott C *et al.* (1979) Gold-salt induced cholestasis. *Digestion* 19, 57–74.

124 Favreau M, Tannenbaum H, Lough J (1977) Hepatotoxicity associated with gold therapy. *Ann Intern Med* 87, 717–719.

125 Davis P, Holdsworth CD (1973) Jaundice after multiple halothane anaesthetics administered during the treatment of carcinoma of the uterus. *Gut* 14, 566–568.

126 Itoh S, Yamaba Y, Ichinoe A *et al.* (1980) Hydralazine-induced liver injury. *Dig Dis Sci* 25, 884–887.

127 Rosenblum LE, Korn RJ, Zimmerman HJ (1960) Hepatocellular jaundice as a complication of iproniazid therapy. *Arch Intern Med* 105, 583–593.

128 Homberg JC, Stelly M, Andreis I *et al.* (1982) A new antimitochondrial antibody (anti-M6) in iproniazid-induced hepatitis. *Clin Exp Immunol* 47, 93–103.

129 Danan G, Homberg JC, Bernuau J *et al.* (1983) Hépatite à l'iproniazide. Intérêt diagnostique d'un nouvel anticorps antimitochondrial, l'anti-M6. *Gastroentérol Clin Biol* 7, 529–532.

130 Black M, Mitchell JR, Zimmerman HJ *et al.* (1975) Isoniazid-associated hepatitis in 114 patients. *Gastroenterology* 69, 289–302.

131 Lewis JH, Zimmerman HJ, Benson G *et al.* (1984) Hepatic injury associated with ketoconazole therapy. Analysis of 33 cases. *Gastroenterology* 86, 503–513.

132 Clark JA, Zimmermann HJ, Tanner LA (1990) Labetalol hepatotoxicity. *Ann Intern Med* 113, 210–213.

133 van Roon EN, Jansen TL, Houtman NM *et al.* (2004) Leflunomide for the treatment of rheumatoid arthritis in clinical practise: incidence and severity of hepatotoxicity. *Drug Safety* 27, 345–352.

134 Lawrenson RA, Seaman HE, Sundstrom A *et al.* (2000) Liver damage associated with minocycline use in acne: a systematic review of the published literature and pharmacovigilance data. *Drug Safety* 23, 333–349.

135 Chu HC, Lin YL, Sytwu HK *et al.* (2005) Effects of minocycline on Fas-mediated fulminant hepatitis in mice. *Br J Pharmacol* 144, 275–282.

136 Van Steenbergen W, Peeters P, De Bondt J *et al.* (1998) Nimesulide-induced acute hepatitis: evidence from six cases. *J Hepatol* 29, 135–141.

137 Traversa G, Bianchi C, Da Cas R *et al.* (2003) Cohort study of hepatotoxicity associated with nimesulide and other non-steroidal anti-inflammatory drugs. *Br Med J* 327, 18–22.

138 Smilkstein MJ, Knapp GL, Fulig KW *et al.* (1988) Efficacy of oral *N*-acetylcysteine in the treatment of acetaminophen overdose. Analysis of the national multicenter study (1976 to 1985). *N Engl J Med* 319, 1557–1562.

139 Vale JA, Proudfoot AT (1995) Paracetamol (acetaminophen) poisoning. *Lancet* 346, 547–552.

140 Schimanski CC, Burg J, Mohler M *et al.* (2004) Phenprocoumon-induced liver disease ranges from mild acute hepatitis to (sub-)acute liver failure. *J Hepatol* 41, 67–74.

141 Benjamin SB, Ishak KG, Zimmerman HJ *et al.* (1981) Phenylbutazone liver injury: a clinical-pathologic survey of 23 cases and review of the literature. *Hepatology* 1, 255–263.

142 de Herder WW, Schröder P, Purnode A *et al.* (1987) Pirprofen-associated hepatic injury. *J Hepatol* 4, 127–132.

143 Danan G, Trunet P, Bernuau J *et al.* (1985) Pirprofen-induced fulminant hepatitis. *Gastroenterology* 89, 210–213.

144 Durand F, Bernuau J, Pessayre D *et al.* (1995) Deleterious influence of pyrazinamide on the outcome of patients with fulminant or subfulminant liver failure during antituberculous treatment including isoniazid. *Hepatology* 21, 929–932.

145 Koch MJ, Seeff LB, Crumley CE *et al.* (1976) Quinidine hepatotoxicity. A report of a case and review of the literature. *Gastroenterology* 70, 1136–1140.

146 Babany G, Pessayre D (1984) Hépatites dues aux nouveaux anti-inflammatoires non stéroïdiens. *Gastroentérol Clin Biol* 8, 523–529.

147 Dujovne CA, Char CH, Zimmerman HJ (1967) Sulfonamide hepatic injury. Review of the literature and report of a case due to sulfamethoxazole. *N Engl J Med* 277, 785–788.

148 Watkins PB, Zimmermann HJ, Knapp MJ *et al.* (1994) Hepatotoxic effects of tacrine administration in patients with Alzheimer's disease. *JAMA* 271, 992–998.

149 Berson A, Renault S, Lettéron P *et al.* (1996) Uncoupling of rat and human mitochondria: a possible explanation for tacrine-induced liver dysfunction. *Gastroenterology* 110, 1878–1890.

150 Zimmerman HJ, Lewis JH, Ishak KG *et al.* (1984) Ticrynafen associated hepatic injury: analysis of 340 cases. *Hepatology* 4, 315–323.

151 Assal F, Spahr L, Hadengue A *et al.* (1998) Tolcapone and fulminant hepatitis. *Lancet* 352, 958.

152 Watkins PB (2005) Insight into hepatotoxicity: the troglitazone experience. *Hepatology* 41, 229–230.

153 Murphy EJ, Davern DJ, Shakil AO *et al.* (2000) Troglitazone-induced fulminant hepatic failure. Acute Liver Failure Study Group. *Dig Dis Sci* 45, 549–553.

154 Funk C, Ponelle C, Scheuermann G *et al.* (2001) Cholestatic potential of troglitazone as a possible factor contributing to troglitazone-induced hepatotoxicity: *in vivo* and *in vitro* interaction at the canalicular bile salt export pump (Bsep) in the rat. *Mol Pharmacol* 59, 627–635.

155 Bae MA, Song BY (2003) Critical role of c-Jun N-terminal protein kinase activation in troglitazone-induced apoptosis of human HepG2 hepatoma cells. *Mol Pharmacol* 63, 401–408.

156 Shishido S, Koga H, Harada M *et al.* (2003) Hydrogen peroxide overproduction in megamitochondria of troglitazone-treated human hepatocytes. *Hepatology* 37, 136–147.

157 Kassahun K, Pearson PG, Tang W *et al.* (2001) Studies on the metabolism of troglitazone to reactive intermediates *in vitro* and *in vivo*. Evidence for novel pathways involving quinone methide formation and thiazolidinedione ring scission. *Chem Res Toxicol* 14, 62–70.

158 Kohlroser J, Mathai J, Reichheld J *et al.* (2000) Hepatotoxicity due to troglitazone: report of two cases and review of adverse events reported to the United States Food and Drug Administration. *Am J Gastroenterol* 95, 272–276.

159 Ticktin HE, Zimmermann HJ (1962) Hepatic dysfunction and jaundice in patients receiving triacetyloleandomycin. *N Engl J Med* 267, 964–968.

160 Reinus JF, Persky S, Burkiewicz JS *et al.* (2000) Severe liver injury after treatment with the leukotriene receptor antagonist zafirlukast. *Ann Intern Med* 133, 964–968.

161 Forker EL (1969) The effect of estrogen on bile formation in the rat. *J Clin Invest* 48, 654–663.

162 Simon FR, Gonzalez M, Sutherland E *et al.* (1980) Reversal of ethinyl estradiol-induced bile secretory failure with Triton WR-1339. *J Clin Invest* 65, 851–860.

163 Simon FR, Fortune J, Iwahashi M *et al.* (1996) Ethinyl estradiol cholestasis involves alterations in expression of liver sinusoidal transporters. *Am J Physiol (Gastrointest Liver Physiol)* 271, G1043–1052.

164 Vore M, Slikker W (1985) Steroid D-ring glucuronides: a new class of cholestatic agents. *Trends Pharmacol Sci* 6, 256–259.

165 Stieger B, Fattinger K, Madon J *et al.* (2000) Drug- and estrogen-induced cholestasis through inhibition of the hepatocellular bile salt export pump (Bsep) of rat liver. *Gastroenterology* 118, 422–430.

166 Crocenzi FA, Mottino AD, Cao J *et al.* (2003) Estradiol-17β-D-glucuronide induces endocytic internalization of Bsep in rats. *Am J Physiol (Gastrointest Liver Physiol)* 285, G449–459.

167 Mottino AD, Cao J, Veggi LM *et al.* (2002) Altered localization and activity of canalicular Mrp2 in estradiol-17β-D-glucuronide-induced cholestasis. *Hepatology* 35, 1409–1419.

168 Métreaux JM, Dhumeaux D, Berthelot P (1972) Oral contraceptives and the liver. *Gut* 7, 318–335.

169 Miguet JP, Vuitton D, Pessayre D *et al.* (1980) Jaundice from troleandomycin and oral contraceptives. *Ann Intern Med* 92, 434.

170 Fisher D, Labbe G, Berson A *et al.* (1990) Inhibition of rat liver estrogen 2/4-hydroxylase activity by troleandomycin. Comparison with erythromycin and roxithromycin. *J Pharmacol Exp Therapeut* 254, 1120–1127.

171 Ishak G, Zimmerman HJ (1987) Hepatotoxic effects of the anabolic/androgenic steroids. *Semin Liver Dis* 7, 230–236.

172 Böhme M, Müller M, Leier I *et al.* (1994) Cholestasis caused by inhibition of the adenosine triphosphate-dependent bile salt transport in rat liver. *Gastroenterology* 107, 255–265.

173 Cadranel JF, Babany G, Oppolon P *et al.* (1992) Pharmacocinétique et effets hépatiques de la cyclosporine A. *Gastroentérol Clin Biol* 16, 314–321.

174 Fattinger K, Funk C, Pantze M *et al.* (2001) The endothelin antagonist bosentan inhibits the canalicular bile salt export pump: a potential mechanism for hepatic adverse reactions. *Clin Pharmacol Therapeut* 69, 223–231.

175 Fromenty B, Pessayre D (1995) Inhibition of mitochondrial β-oxidation as a mechanism of hepatotoxicity. *Pharmacol Therapeut* 67, 101–154.

176 Vockley J (1994) The changing face of disorders of fatty acid oxidation. *Mayo Clin Proc* 69, 249–257.

177 Schon EA, Hirano M, DiMauro S (1994) Mitochondrial encephalomyopathies: clinical and molecular analysis. *J Bioenerg Biomembr* 26, 291–299.

178 Latipää PM, Kärki TT, Hiltunen JK *et al.* (1986) Regulation of palmitoylcarnitine oxidation in isolated rat liver mitochondria. Role of the redox state of NAD(H). *Biochim Biophys Acta* 875, 293–300.

179 Maddaiah VT (1985) Ammonium inhibition of fatty acid oxidation in rat liver mitochondria. A possible cause of fatty liver in Reye's syndrome and urea cycle defects. *Biochem Biophys Res Commun* 127, 565–570.

180 Grimbert S, Fromenty B, Fisch C *et al.* (1993) Decreased mitochondrial oxidation of fatty acids in pregnant mice: possible relevance to development of acute fatty liver of pregnancy. *Hepatology* 17, 628–637.

181 Grimbert S, Fisch C, Deschamps D *et al.* (1995) Effects of female sex hormones on liver mitochondria in non-pregnant female mice:

possible role in acute fatty liver of pregnancy. *Am J Physiol (Gastrointest Liver Physiol)* 268, G107–115.

182 Fromenty B, Pessayre D (1997) Impaired mitochondrial function in microvesicular steatosis. Effects of drugs, ethanol and some endogenous compounds. *J Hepatol* 26 (Suppl. 2), 43–53.

183 Lettéron P, Sutton A, Mansouri A *et al.* (2003) Inhibition of microsomal triglyceride transfer protein: Another mechanism for drug-induced steatosis in mice. *Hepatology* 38, 133–140.

184 Lüllman H, Lüllman-Rauch R, Wassermann O (1975) Drug-induced phospholipidoses. *CRC Crit Rev Toxicol* 4, 185–242.

185 Kodavanti UP, Mehendale HM (1990) Cationic amphiphilic drugs and phospholipid storage disorder. *Pharmacol Rev* 42, 327–354.

186 De La Inglesia FA, Feuer G, Takada A *et al.* (1974) Morphologic studies on secondary phospholipidosis in humans. *Lab Invest* 4, 539–549.

187 Shikata T, Kanetaka T, Endo Y *et al.* (1972) Drug-induced generalized phospholipidosis. *Acta Pathol Jap* 22, 517–531.

188 Pessayre D, Bichara M, Feldmann G *et al.* (1979) Perhexiline maleate-induced cirrhosis. *Gastroenterology* 76, 170–177.

189 Poucell S, Ireton J, Valenoia-Mayoral P *et al.* (1984) Amiodarone-associated phospholipidosis and fibrosis of the liver. Light, immunohistochemical, and electron microscopic studies. *Gastroenterology* 86, 926–936.

190 Guigui B, Perrot S, Berry JP *et al.* (1988) Amiodarone-induced hepatic phospholipidosis: a morphological alteration independent of pseudoalcoholic liver disease. *Hepatology* 8, 1063–1068.

191 Simon JB, Manley PN, Brien JF *et al.* (1984) Amiodarone hepatotoxicity simulating alcoholic liver disease. *N Engl J Med* 311, 167–172.

192 Beaugrand M, Chousterman M, Callard P *et al.* (1977) Hépatites au maléate de Perhexiline (Pexid) évoluant vers la cirrhose malgré l'arrêt du traitement (2 cas). *Gastroentérol Clin Biol* 1, 745–750.

193 Fromenty B, Fisch C, Berson A *et al.* (1990) Amiodarone inhibits the mitochondrial β-oxidation of fatty acids and produces microvesicular steatosis of the liver in mice. *J Pharmacol Exp Therapeut* 255, 1371–1376.

194 Fromenty B, Fisch C, Berson A *et al.* (1990) Dual effect of amiodarone on mitochondrial respiration. Initial protonophoric uncoupling effect followed by inhibition of the respiratory chain at the levels of complex I and complex II. *J Pharmacol Exp Therapeut* 255, 1377–1384.

195 Deschamps D, De Beco V, Fisch C *et al.* (1994) Inhibition by perhexiline of oxidative phosphorylation and the β-oxidation of fatty acids: possible role in pseudoalcoholic liver lesions. *Hepatology* 19, 948–961.

196 Berson A, de Beco V, Lettéron P *et al.* (1998) Steatohepatitis-inducing drugs cause mitochondrial dysfunction and lipid peroxidation in rat hepatocytes. *Gastroenterology* 114, 764–774.

197 Lettéron P, Fromenty B, Terris B *et al.* (1995) Acute and chronic hepatic lipid steatosis leads to *in vivo* lipid peroxidation in mice. *J Hepatol* 24, 200–208.

198 Pessayre D, Berson A, Fromenty B *et al.* (2001) Mitochondria in steatohepatitis. *Semin Liver Dis* 21, 57–69.

199 Feldstein AE, Canbay A, Angulo P *et al.* (2003) Hepatocyte apoptosis and Fas expression are prominent features of human nonalcoholic steatohepatitis. *Gastroenterology* 125, 437–443.

200 Canbay A, Taimr P, Torok N *et al.* (2003) Apoptotic body engulfment by a human stellate cell line is profibrogenic. *Lab Invest* 83, 655–663.

201 Lieber CS (1994) Alcohol and the liver: 1994 update. *Gastroenterology* 106, 1085–1105.

202 Shigenaga MK, Hagen TM, Ames BN (1994) Oxidative damage and mitochondrial decay in aging. *Proc Natl Acad Sci USA* 91, 1077–1078.

203 Kukielka E, Dicker E, Cederbaum AI (1994) Increased production of reactive oxygen species by rat liver mitochondria after chronic ethanol treatment. *Arch Biochem Biophys* 309, 377–386.

204 Fromenty B, Grimbert S, Mansouri A *et al.* (1995) Hepatic mitochondrial DNA deletion in alcoholics. Association with microvesicular steatosis. *Gastroenterology* 108, 193–200.

205 Mansouri A, Fromenty B, Berson A *et al.* (1997) Multiple hepatic mitochondrial DNA deletions suggest premature oxidative aging in alcoholics. *J Hepatol* 27, 96–102.

206 Le Dinh T, Freneaux E, Labbe G *et al.* (1988) Amineptine, a tricyclic antidepressant, inhibits the mitochondrial oxidation of fatty acids and produces microvesicular steatosis of the liver in mice. *J Pharmacol Exp Therapeut* 247, 745–750.

207 Adams PC, Bennett MK, Holt DW (1986) Hepatic effects of amiodarone. *Br J Clin Pract* 40, 81–92.

208 Deschamps D, Fisch C, Fromenty B *et al.* (1991) Inhibition by salicylic acid of the activation and thus oxidation of long-chain fatty acids. Possible role in the development of Reye's syndrome. *J Pharmacol Exp Therapeut* 259, 894–904.

209 Remington PL, Rowley D, McGee H *et al.* (1986) Decreasing trends in Reye syndrome and aspirin use in Michigan, 1979 to 1984. *Pediatrics* 77, 93–98.

210 Rowe PC, Valle D, Brusilow SW (1988) Inborn errors of metabolism in children referred with Reye's syndrome: a changing pattern. *JAMA* 260, 3167–3170.

211 Zaragoza A, Diez-Fernandez C, Alvarez AM *et al.* (2001) Mitochondrial involvement in cocaine-treated rat hepatocytes: effect of N-acetylcysteine and deferoxamine. *Br J Pharmacol* 132, 1063–1070.

212 Mitsuya H, Jarrett RF, Matsukura M *et al.* (1987) Long-term inhibition of human T-lymphotropic virus type III/lymphadenopathy-associated virus (human immunodeficiency virus) DNA synthesis and RNA expression in T cells protected by 2′,3′-dideoxynucleosides *in vitro*. *Proc Natl Acad Sci USA* 84, 2033–2037.

213 Simpson MV, Chin CD, Keilbaugh SA *et al.* (1989) Studies on the inhibition of mitochondrial DNA replication by 3′-azido-3′-deoxythymidine and other dideoxynucleoside analogs which inhibits HIV-1 replication. *Biochem Pharmacol* 38, 1033–1036.

214 Chariot P, Drogou I, de Lacroix-Szmania I *et al.* (1999) Zidovudine-induced mitochondrial disorder with massive liver steatosis, myopathy, lactic acidosis and mitochondrial DNA depletion. *J Hepatol* 30, 156–160.

215 Garcia de la Asuncion J, del Olmo ML, Sastre J *et al.* (1998) AZT treatment induces molecular and ultrastructural oxidative damage to muscle mitochondria. Prevention by antioxidant vitamins. *J Clin Invest* 102, 4–9.

216 Bartley PB, Westacott L, Boots RJ *et al.* (2001) Large hepatic mitochondrial DNA deletions associated with L-lactic acidosis and highly active antiretroviral therapy. *Acquir Immunodefic Syndrome* 15, 419–420.

217 Lewis W, Dalakas MC (1995) Mitochondrial toxicity of antiviral drugs. *Nature Med* 1, 417–422.

218 Spengler U, Lichterfeld M, Rockstoh JK (2002) Antiretroviral drug toxicity – a challenge for the hepatologist? *J Hepatol* 36, 283–294.

219 Hetherington S, McGuirk S, Powell G *et al.* (2000) Genetic variation in HLA-B region and hypersensitivity to abacavir. *Lancet* 359, 1121–1122.

220 McKenzie R, Fried MW, Sallie R *et al.* (1995) Hepatic failure and lactic acidosis due to fialuridine (FIAU), an investigational nucleoside analogue for chronic hepatitis B. *N Engl J Med* 333, 1099–1105.

221 Lewis W, Levine ES, Griniuviene B *et al.* (1996) Fialuridine and its metabolites inhibit DNA polymerase gamma at sites of multiple adjacent analog incorporation, decrease mtDNA abundance, and cause mitochondrial structural defects in cultured hepatoblasts. *Proc Natl Acad Sci USA* 93, 3592–3597.

222 Lettéron P, Brahimi-Bourouina N, Robin MA *et al.* (1997) Glucocorticoids inhibit mitochondrial matrix acyl-coenzyme A dehydrogenases and fatty acid β-oxidation. *Am J Physiol (Gastrointest Liver Physiol)* 272, G1141–1150.

223 Fréneaux E, Fromenty B, Berson A *et al.* (1990) Stereoselective and non-stereoselective effects of ibuprofen enantiomers on the mitochondrial β-oxidation of fatty acids. *J Pharmacol Exp Therapeut* 255, 529–535.

224 Dahl MGC, Gregory MM, Scheuer PJ (1971) Liver damage due to methotrexate in patients with psoriasis. *Br Med J* 1, 625–630.

225 Langman G, Hall PDLM, Todd G (2001) Role of non-alcoholic steatohepatitis in methotrexate-induced liver injury. *J Gastroenterol Hepatol* 16, 1395–1401.

226 Sznol M, Ohnuma T, Holland JF (1987) Hepatotoxicity of drugs used for hematologic neoplasia. *Semin Liver Dis* 7, 237–256.

227 Kremer JM, Lee RG, Tolman KG (1989) Liver histology in rheumatoid arthritis patients receiving long-term methotrexate therapy. A prospective study with baseline and sequential biopsy samples. *Arthritis Rheum* 32, 121–127.

228 Fréneaux E, Labbe G, Letteron P *et al.* (1988) Inhibition of the mitochondrial oxidation of fatty acids by tetracycline in mice and in man: possible role in microvesicular steatosis induced by this antibiotic. *Hepatology* 8, 1056–1062.

229 Labbe G, Fromenty B, Fréneaux E *et al.* (1991) Effects of various tetracycline derivatives on *in vitro* and *in vivo* β-oxidation of fatty acids, egress of triglycerides from the liver, accumulation of hepatic triglycerides, and mortality in mice. *Biochem Pharmacol* 41, 638–641.

230 Poupon R, Rosensztajn L, Prudhomme de Saint-Maur P *et al.* (1980) Perhexiline maleate-associated hepatic injury. Prevalence and characteristics. *Digestion* 20, 145–150.

231 Morgan MY, Reshef R, Shah RR *et al.* (1984) Impaired oxidation of debrisoquine in patients with perhexiline liver injury. *Gut* 10, 1057–1064.

232 Larrey D, Amouyal G, Tinel M *et al.* (1987) Polymorphism of dextrometorphan oxidation in a French population. *Br J Clin Pharmacol* 24, 676–679.

233 Genève J, Hayat-Bonon B, Labbe C *et al.* (1987) Inhibition of mitochondrial β-oxidation of fatty acids by pirprofen. Role in microvesicular steatosis due to this nonsteroidal anti-inflammatory drug. *J Pharmacol Exp Therapeut* 242, 1133–1137.

234 Larosche I, Lettéron P, Mansouri A *et al.* (2005) Tamoxifen inhibits mitochondrial function, topoisomerases and mitochondrial DNA synthesis and causes progressive depletion and steatosis in mouse liver. *J Hepatol* 42, 23–24.

235 Cortez Pinto H, Baptista A, Camilo MA *et al.* (1995) Tamoxifen-associated steatohepatitis – report of three cases. *J Hepatol* 23, 95–97.

236 Bruno S, Maisanneuve P, Castellana P *et al.* (2005) Incidence and risk factors for non-alcoholic steatohepatitis: prospective study of 5408 women enrolled in Italian tamoxifen chemoprevention trial. *Br Med J* 330, 932.

237 Zimmerman HJ, Ishak KG (1982) Valproate-induced hepatic injury. Analysis of 23 fatal cases. *Hepatology* 2, 591–597.

238 Kesterson JW, Granneman GR, Machinist JM (1984) The hepatotoxicity of valproic acid and its metabolites in rats. I. Toxicologic, biochemical and histopathological studies. *Hepatology* 4, 1143–1152.

239 Kassahun K, Farrell K, Abbott F (1991) Characterization of the glutathione and N-acetylcysteine conjugates of (E)-2-propyl-2,4-pentadienoic acid, a toxic metabolite of valproic acid, in rats and humans. *Drug Metab Dispos* 19, 525–535.

240 Trost LC, Lemasters JJ (1996) The mitochondrial permeability transition: a new pathophysiological mechanism for Reye's syndrome and toxic liver injury. *J Pharmacol Exp Therapeut* 278, 1000–1005.

241 Muenter MD, Perry HO, Ludwig J (1971) Chronic vitamin A intoxication in adults. Hepatic, neurologic, and dermatologic complications. *Am J Med* 50, 129–136.

242 Hruban Z, Russell RM, Boyer JL *et al.* (1974) Ultrastructural changes in livers of two patients with hypervitaminosis A. *Am J Pathol* 76, 451–461.

243 Minuk GY, Kelly JK, Hwang WS (1988) Vitamin A hepatotoxicity in multiple family members. *Hepatology* 8, 272–275.

244 Russell RM, Boyer IL, Bagheri SA *et al.* (1974) Hepatic injury from chronic hypervitaminosis A resulting in portal hypertension and ascites. *N Engl J Med* 291, 435–440.

245 Rosenbaum J, Amédée-Manesme O, Dhumeaux D (1985) Le foie et la vitamine A. *Gastroentérol Clin Biol* 9, 255–262.

246 Zafrani ES, Bemuau D, Feldmann G (1984) Peliosis-like ultrastructural changes of the hepatic sinusoids in human chronic hypervitaminosis A: report of three cases. *Hum Pathol* 15, 1166–1170.

247 Geubel AP, De Galocsy C, Alves N *et al.* (1991) Liver damage caused by therapeutic vitamin A administration: estimate of dose-related toxicity in 41 cases. *Gastroenterology* 100, 1701–1709.

248 Homberg JC, Abuaf N, Helmy-Khalil S *et al.* (1985) Drug-induced hepatitis associated with anticytoplasmic organelle autoantibodies. *Hepatology* 5, 722–727.

249 Furet Y, Breteau M (1984) Accidents hépatiques à la clométacine. *Thérapie* 39, 523–529.

250 Pessayre D, Degos F, Feldmann G *et al.* (1981) Chronic active hepatitis and giant multinucleated hepatocytes in adults treated with clometacin. *Digestion* 22, 66–72.

251 Maddrey WC, Boitnott JK (1977) Drug-induced chronic liver disease. *Gastroenterology* 72, 1348–1353.

252 Sharp JR, Ishak KG, Zimmerman HJ (1982) Chronic active hepatitis and severe hepatic necrosis associated with nitrofurantoin. *Ann Intern Med* 92, 1419.

253 Stricker BHC, Blok APR, Claas FH *et al.* (1988) Hepatic injury associated with the use of nitrofurans: a clinicopathological study of 52 reported cases. *Hepatology* 8, 599–606.

254 Read AE, Harrison CV, Sherlock S (1961) Chronic chlorpromazine jaundice. *Am J Med* 31, 249–258.

255 Manivel JC, Bloomer JR, Snover DC (1987) Progressive bile duct injury after thiabendazole administration. *Gastroenterology* 93, 245–249.

256 Walker CO, Combes B (1966) Biliary cirrhosis induced by chlorpromazine. *Gastroenterology* 51, 631–640.

257 Beerman B, Ericsson JLE, Hellström K *et al.* (1971) Transient cholestasis during treatment with ajmaline, and chronic xanthomatous cholestasis after administration of ajmaline, methyltestosterone and ethinylestradiol. *Acta Med Scand* 190, 241–250.

258 Larrey D, Pessayre D, Duhamel G *et al.* (1986) Prolonged cholestasis after ajmaline-induced acute hepatitis. *J Hepatol* 2, 81–87.

259 Degott C, Feldmann G, Larrey D *et al.* (1992) Drug-induced prolonged cholestasis: a histological semiquantitative study demonstrating progressive ductopenia. *Hepatology* 15, 244–251.

260 Olsson R, Wiholm BE, Sand C *et al.* (1992) Liver damage from flucloxaxillin, cloxacillin and dicloxacillin. *J Hepatol* 15, 154–161.

261 Davies MH, Harrison RF, Elias E *et al.* (1994) Antibiotic-associated acute vanishing bile duct syndrome: a pattern associated with severe, prolonged cholestasis. *J Hepatol* 20, 112–116.

262 Ryley NG, Fleming KA, Chapman RW (1995) Focal destructive cholangiopathy with amoxicillin/clavulanic acid (Augmentin). *J Hepatol* 23, 278–282.

263 Anderson SD, Holley HC, Berland LL *et al.* (1986) Causes of jaundice during hepatic artery infusion chemotherapy. *Radiology* 161, 439–442.

264 Bogniel C, Degott C, Rougier P *et al.* (1989) Etude anatomopathologique de la toxicité hépatique de la chimiothérapie intra-artérielle hépatique. *Gastroentérol Clin Biol* 13, 125–131.

265 Belghiti J, Benhamou JP, Houry H *et al.* (1986) Caustic sclerosing cholangitis. A complication of the surgical treatment of hydatid disease of the liver. *Arch Surg* 121, 1162–1165.

266 Zafrani ES, Pinaudeau Y, Dhumeaux D (1983) Drug-induced vascular lesions of the liver. *Arch Intern Med* 143, 495–502.

267 Valla D, Benhamou JP (1988) Drug-induced vascular and sinusoidal lesions of the liver. *Baillière's Clin Gastroenterol* 2, 481–500.

268 Valla D, Benhamou JP (1988) Liver diseases related to oral contraceptives. *Dig Dis Sci* 6, 76–86.

269 Degott C, Rueff B, Kreis H *et al.* (1978) Peliosis hepatis in recipients of renal transplants. *Gut* 19, 748–753.

270 Larrey D, Fréneaux E, Berson A *et al.* (1988) Peliosis hepatitis induced by 6-thioguanine administration. *Gut* 29, 1265–1269.

271 deLeve LD, Wang X, Tsai J *et al.* (2003) Sinusoidal obstruction syndrome (veno-occlusive disease) in the rat is prevented by matrix metalloproteinase inhibition. *Gastroenterology* 125, 882–890.

272 Coppel JA, Brown SA, Perry DJ (2003) Veno-occlusive disease: cytokines, genetics and haemostasis. *Blood Rev* 17, 63–70.

273 Janssen HL, Garcia-Pagan JC, Elias E *et al.* (2003) Budd–Chiari syndrome: a review by an expert panel. *J Hepatol* 38, 364–371.

274 Valla D, Le MG, Poynard T *et al.* (1986) Risk of hepatic vein thrombosis in relation to recent use of oral contraceptives. A case control study. *Gastroenterology* 90, 807–811.

275 Rougier P, Degott C, Rueff B *et al.* (1978) Nodular regenerative hyperplasia of the liver. Report of six cases and review of the literature. *Gastroenterology* 75, 169–172.

276 Stromeyer FW, Ishak KG (1981) Nodular transformation (nodular 'regenerative' hyperplasia) of the liver. A clinicopathological study of 30 cases. *Hum Pathol* 12, 60–71.

277 Anthony PP (1988) Liver tumours. *BaiIlière's Clin Gastroenterol* 2, 501–522.

278 Lutz WK, Maier P (1988) Genotoxic and epigenetic chemical carcinogenesis: one process, different mechanisms. *Trends Pharmacol Sci* 9, 322–326.

279 Metzler M, Degen GH (1987) Sex hormones and neoplasia: liver tumours in rodents. *Arch Toxicol* Suppl. 10, 251–263.

280 Klatskin G (1977) Hepatic tumors: possible relationship to use of oral contraceptives. *Gastroenterology* 73, 386–394.

281 Rooks JB, Ory HW, Ishak KG *et al.* (1979) Epidemiology of hepatocellular adenoma. The role of oral contraceptive use. *JAMA* 242, 645–668.

282 Edmonson HA, Henderson B, Benton B (1976) Liver cell adenoma associated with use of oral contraceptives. *N Engl J Med* 294, 470–472.

283 Ishak KG (1981) Hepatic lesions caused by anabolic and contraceptive steroids. *Semin Liver Dis* 1, 116–128.

284 Carrasco D, Prieto M, Pallardo L *et al.* (1985) Multiple hepatic adenomas after long-term therapy with testosterone enanthate. Review of the literature. *J Hepatol* 1, 573–578.

285 Mathieu D, Kobeiter H, Maison P *et al.* (2000) Oral contraceptive use and focal nodular hyperplasia of the liver. *Gastroenterology* 118, 560–564.

286 Scalori A, Tavani A, Gallus S *et al.* (2002) Oral contraceptives and the risk of focal nodular hyperplasia of the liver: a case control study. *Am J Obstet Gynecol* 186, 195–197.

287 Zafrani ES (1989) Update of vascular tumours of the liver. *J Hepatol* 8, 125–130.

288 Yu MC, Yuan JM (2004) Environmental factors and risk for hepatocellular carcinoma. *Gastroenterology* 127, S72–S78.

14.2 Toxic liver injury

Basuki Gunawan and Neil Kaplowitz

Introduction

Toxic liver injury caused by industrial and environmental agents not only poses a challenge to health professionals but also has a significant impact on economy, legislation and industry. Many epidemics involving liver injury caused by industrial and environmental agents have been reported [1–8], and some industrial agents have been discontinued from production or restricted partly because of hepatotoxicity, such as polychlorinated biphenyls (PCBs) or carbon tetrachloride (CCl_4). Diagnosing this type of liver injury can be challenging as a high index of suspicion and an understanding about the patient's occupation or knowledge about a specific natural toxin common in the patient's living area are required. It is, however, paramount to establish a diagnosis of industrial or environmental toxic liver injury to cease continued exposure and progressive irreparable damage and to initiate treatment, if possible, as well as to protect others in the environment.

Types of exposure: industrial and environmental toxins

Exposure to industrial toxins normally occurs in the workplace, through either accidents or exposure to agents that were not previously considered to be toxins. Moreover, industrial toxin exposure or intoxication can also occur with food contaminated with industrial toxins either from a factory or from the environment in the case of toxins that are hardly degradable, such as DDT or PCBs. Furthermore, exposure can occur from intentional intoxication in the case of suicides. Environmental toxin exposure can occur if a person unknowingly ingests a toxin, such as poisonous mushroom or food contaminated with environmental toxins.

Route of exposure can be through inhalation, ingestion and skin contact and absorption. Different routes of exposure may affect the liver differently, e.g. hepatotoxicity has been reported with ingestion of arsenic but not with inhalation [9]. Duration of exposure can also affect an agent's toxicity as a longer duration may lead to accumulation of the toxin, leading to more severe liver injury. Thus, low-level exposure to a specific toxin may not be harmful if it occurs during a short period of time, but may produce liver injury if exposure is chronic.

Types of hepatotoxicity

Liver injury can be predictable, which is normally dose dependent, reproducible in an animal model and presents after a short latency (hours to a few days), or unpredictable, which is not usually dose dependent or reproducible in animal models [10]. Unlike drug-induced hepatotoxicity, industrial and environmental toxins almost exclusively produce predictable liver injury. Certainly, some toxins do produce unpredictable liver injury, but this type of liver injury caused by industrial and environmental agents is not well reported or studied.

Pattern of liver injury

Industrial and environmental toxins can result in a variety of patterns of liver injury, from hepatocellular necrosis to non-cirrhotic portal fibrosis (Table 1). It may not be possible based on the pattern of liver injury alone to distinguish industrial and environmental toxins from other causes of liver injury as the clinicopathological presentation may mimic other causes. However, obtaining a thorough and complete history, especially occupational history and chemical exposure, is critical. Moreover, characterization of the pattern of liver injury may narrow the list of possible toxins and help to establish causality. Some industrial and environmental toxins have been reported to cause more than one pattern of liver injury, such as CCl_4 causing hepatocellular necrosis with or without steatosis and cirrhosis. However, others are associated with a typical liver injury, such as steatosis caused by hypoglycin or veno-occlusive disease caused by pyrrolizidine alkaloids.

Below are some typical industrial and environmental toxins with a short discussion of their clinicopathological presentations and possible mechanisms of injury.

Table 1 Types of liver injury.

Type of liver injury	Industrial or environmental agents	Main exposure
Hepatocellular necrosis	Carbon tetrachloride	In developed countries, it is only produced for experimental use; in developing countries, it is used in fire extinguishers and refrigerants
	Chloroform	Inhalation at workplace or ingestion of food or inhalation of air contaminated with it
	Dimethyl acetamide	Exposure at workplace, especially plastics and rubber industry
	Hydrochlorofluorocarbons	Exposure at workplace
	Poisonous mushrooms	Ingestion of specific mushrooms
	Tetrachloroethane	Ingestion of food or inhalation of air contaminated with it. Limited production as chemical intermediates
	Tetrachloroethylene	Inhalation at workplace, especially dry-cleaning industry
	Yellow phosphorus	Ingestion of rodenticides or fireworks
Steatosis	Carbon tetrachloride (normally found coexisting with hepatocellular necrosis)	In developed countries, it is only produced for experimental use; in developing countries, it is used in fire extinguishers and refrigerants
	Dimethylformamide	Inhalation or skin contact at workplace
	Hypoglycins	Ingestion of unripe ackee fruit
Cholestasis	Paraquat	Ingestion (either accidental or suicidal) or skin contact of herbicide
	Methylene dianiline	Exposed at workplace or ingestion of contaminated food
Cirrhosis	Carbon tetrachloride	Chronic exposure
	Polychlorinated biphenyls	Handling old electrical equipment or ingestion of contaminated food
	Pyrrolizidine alkaloids	Chronic exposure
Veno-occlusive liver disease	Pyrrolizidine alkaloids	Ingestion of contaminated food, herbal tea or herbal medicine
Non-cirrhotic portal fibrosis	Arsenic	Ingestion of contaminated food or medicine containing it
	Vinyl chloride	Inhalation at workplace, especially plastics industry
Hepatocellular carcinoma	Aflatoxin B1	Ingestion of contaminated food
Angiosarcoma	Arsenic	Ingestion of contaminated food or medicine containing it (long latency period)
	Vinyl chloride	Inhalation at workplace, especially plastics industry (long latency period)

Adapted and modified from ref. 11.

Hepatocellular necrosis

Carbon tetrachloride (CCl_4)

CCl_4 has been used in the past for a variety of reasons, including solvent, pesticide and medicinal. As a medicine, it was used as an anaesthetic and analgesic agent before being discontinued because of its toxicity. Nowadays, CCl_4 is mostly used as an experimental hepatotoxin, but it is still used in fire extinguishers and refrigerants in some countries. Because of the wide availability of CCl_4 in the past, its intoxication has been reported as a result of occupational exposure, suicidal ingestion or unintentional effect of medicines containing CCl_4 [12]. Most intoxication cases occurred through inhalation of CCl_4, but absorption also occurred through skin tissue. Shortly after inhalation, central nervous system effects predominate with symptoms such as dizziness, headache, confusion and coma. In addition, gastrointestinal symptoms, such as nausea, vomiting and diarrhoea, may occur. After 1–2 days, toxic hepatitis becomes noticeable, initially with tender hepatomegaly, jaundice and marked elevation of transaminases, then possibly followed by acute liver failure [12]. Renal failure usually accompanies the liver failure [12]. Histological liver injury (biopsies or autopsy) associated with acute CCl_4 intoxication is usually marked centrolobular necrosis and steatosis [13].

Unlike acute intoxication, chronic exposure to low concentrations of CCl_4 have been reported to cause fibrosis and cirrhosis [14], but data have been inconsistent about liver injury in workers exposed to CCl_4 for a long duration [15]. Similar histological findings have also been reported in animal research in which CCl_4 hepatotoxicity has been studied extensively and used as a model for many liver injury experiments. Acute exposure to high-dose CCl_4 results in centrolobular necrosis with or without steatosis, and repeated exposure results in fibrosis and cirrhosis [15].

Hepatotoxicity of CCl_4 occurs after its metabolism. CCl_4 is metabolized in endoplasmic reticulum and mitochondria

into a trichloromethyl free radical ($\cdot CCl_3$) [15]. This free radical subsequently reacts with oxygen to form a highly reactive trichloromethylperoxy free radical ($\cdot CCl_3O_2$), which initiates lipid peroxidation resulting in necrosis or steatosis [15–17]. This biotransformation is mediated primarily by CYP2E1, but evidence for CYP2B1/2 also exists [16,17]. As centrolobular hepatocytes have more CYP2E1, this area is primarily affected in CCl_4 toxicity. The free radical $\cdot CCl_3$ can also bind irreversibly to critical macromolecules, such as proteins, lipids and nucleic acids, resulting in cell impairment or death [15–17]. In fact, the free radicals can bind covalently to CYP2E1 leading to loss of CYP2E1 activity [15,16]. In addition, CCl_4 can inhibit endoplasmic reticulum or microsomal sequestration of calcium, probably as a result of damage caused by lipid peroxidation, which leads to increased calcium concentration within cells [15,17]. Increased cell calcium concentration may activate phospholipase A2, contribute to plasma membrane damage and recycle to mitochondria causing oxidative stress and promoting mitochondrial permeability transition [15,18]. Furthermore, tumour necrosis factor (TNF)α may also play a role. Initial cell damage activates macrophages, which then secrete TNFα, resulting in further inflammation and apoptosis [15,19]. Neutralization of TNFα or deletion of TNF receptor 1 (TNFR1) protects mice from CCl_4 [20]. Combination of these toxic effects ultimately produces substantial hepatotoxicity [17].

With regard to treatment of CCl_4 hepatotoxicity, hyperbaric oxygen has been reported to protect against CCl_4 hepatotoxicity in rats by inhibiting its metabolism [21,22]. However, the use of hyperbaric oxygen has not been studied extensively in humans. Therefore, management of CCl_4 hepatotoxicity in humans consists mainly of supportive treatment. If liver and kidney recover, complete recovery can be expected [12].

Chloroform

Chloroform is used as an organic solvent, refrigerant and propellant or to make other chemicals. In the past, it was used as an anaesthetic agent but was discontinued on account of its toxicity. Acute poisoning with high concentrations of chloroform is normally fatal as a result of respiratory paralysis or cardiac arrest. If a patient survives or is exposed to a lower concentration, liver injury may develop with liver enzyme abnormalities and prolonged prothrombin time and liver biopsy showing centrolobular necrosis [23]. Fulminant liver failure may also occur, as there have been reports of acute liver failure with delirium and coma in women during childbirth after exposure to chloroform in the past [24]. Toxic hepatitis has also been reported with chronic exposure, but data are limited [24].

The hepatotoxicity of chloroform is primarily due to its toxic metabolite. Chloroform is metabolized by cytochrome P-450 into toxic phosgene ($COCl_2$) before being converted into CO_2. This toxic intermediate binds covalently to lipids and proteins resulting in cell death [24]. However, there has been some evidence that lipid peroxidation also plays a role [16,24].

Hydrochlorofluorocarbons (HCFCs)

HCFCs are being used to replace chlorofluorocarbons (CFCs) as refrigerants, solvents and in air conditioning as they pose a smaller risk of ozone depletion. The chemical structure of HCFCs is similar to that of halothane, which is known to cause hepatitis in susceptible individuals [11]. A clinical picture of acute mixed hepatitis has been reported in workers who were accidentally exposed to HCFCs, and a liver biopsy from a worker who had the most severe hepatotoxicity demonstrated hepatocellular necrosis in zone 3 with bridging necrosis [25]. The hepatotoxicity of HCFCs has also been demonstrated in animal studies [11]. HCFCs' toxic mechanism is similar to that of halothane. They are both metabolized by two different pathways: (i) a reductive pathway leading to a free radical derivative that causes mild toxicity, which occurs frequently; and (ii) an oxidative pathway leading to acetylating metabolites that cause the appearance of neoantigens, which elicit severe immune-mediated toxicity, but only in rare cases involving susceptible individuals [26].

Poisonous mushrooms/*Amanita phalloides*

There are approximately 50 poisonous mushrooms of the *Amanita* species. Primarily, *Amanita phalloides* causes the majority of deadly poisoning [27,28]. *Amanita* species is a wild mushroom that can be found mostly in Europe but also in the USA, especially in the coastal Pacific north-west, northern California and the Blue Ridge Mountains of Pennsylvania, New Jersey and Ohio [27]. The symptoms of *Amanita phalloides* poisoning are characterized by three different phases [27]. Initially, there is a latency period which lasts 6–12 h after ingestion of the mushroom. In the first phase, which follows the latency period, patients present with gastrointestinal symptoms, such as vomiting, watery diarrhoea and abdominal pain. The second phase typically occurs in 1–2 days, with improvement of the gastrointestinal symptoms (which can therefore be misdiagnosed as viral gastroenteritis). However, in this phase, the liver is gradually and silently affected. Blood tests typically reveal a hepatitis-type picture with elevation of transaminases and bilirubin level and abnormal prothrombin time. In the final phase, patients present with hepatic encephalopathy and subsequently advance into liver failure. Liver biopsy demonstrates centrolobular necrosis with haemorrhage. It also reveals fatty degeneration and abnormal concentrations of lipid and carbohydrate in cell nuclei [27,29]. Besides the liver, the kidney is also affected, and renal failure typically accompanies liver failure. The mortality rate has been reported to be as high as 50% [30] but, once the late stage with hepatic encephalopathy has developed, the mortality rate is practically 100% without liver transplantation [28]. In patients without acute liver failure who recover, there are rare reports of persistent hepatitis [28,31].

The toxicity of *Amanita* species results from two toxins present in it, phalloidin and amanitin. Phalloidin causes the gastrointestinal symptoms seen in the first phase. However,

amanitin is more toxic and the reason for liver injury and failure. It is transported across the cell membrane by the same mechanisms as bile salts (accounting for targeting to liver and kidneys) and subsequently inhibits ribonucleic acid polymerase II [27]. This inhibition interferes with messenger RNA synthesis, thus preventing structural protein formation and eventually resulting in necrosis. Furthermore, it is possible that inhibition of RNA synthesis (survival gene expression) sensitizes to TNF cytotoxicity in these patients [32].

Treatment for *Amanita* species poisoning initially is to prevent further intestinal absorption, such as with activated charcoal administration. However, most patients present too late for this measure. Once the toxins are absorbed, clearance can be attempted using haemoperfusion [33] or forced diuresis [34]. However, their efficacy is not clear. Several agents have been studied as therapy, and penicillin G and silibinin are thought to be effective [27,28]. These agents are assumed to prevent uptake of toxin into hepatocytes. Finally, orthotopic liver transplantation may be required in patients with fulminant liver failure.

Steatosis

Hypoglycins

Hypoglycins can be found in ackee (*Blighia sapida*), which is a common fruit in West Africa, Jamaica and other countries in Latin America. Hypoglycin poisoning is also known as Jamaican vomiting sickness as it was first reported in Jamaica with ingestion of unripe ackee resulting in severe vomiting, hypoglycaemia and convulsions, followed by encephalopathy and coma [35,36]. Liver biopsy demonstrated massive liver steatosis with microvacuoles and macrovacuoles but no necrosis [3,35]. Death normally occurs within 2 days, and most fatal cases of hypoglycin poisoning occur in children, but adult cases have also been reported [35]. Early treatment with glucose has been effective in some, but not all, patients [37]. This clinicopathological presentation of hypoglycin poisoning resembles Reye syndrome, but it lacks one distinguishing feature, which is the presence of prodromal illness, such as viral infection [35]. Since the report from Jamaica, similar fatal poisonings have been reported in other countries, including Haiti and Burkina Faso [3,4]. In addition, a different clinical presentation with a chronic cholestatic picture has also been reported in an adult consuming ackee [38].

There are two types of hypoglycins found in ackee fruit, hypoglycin A, which is more toxic, and hypoglycin B [35]. Hypoglycin A and its major metabolite, methylenecyclopropylacetic acid, inactivates several flavoprotein acyl-CoA dehydrogenases, which then inhibit the oxidation of long-chain fatty acids leading to microvesicular steatosis [37]. Without long-chain fatty acid oxidation, gluconeogenesis is impaired resulting in severe hypoglycaemia. Hypoglycin A concentration is especially high in the unripe ackee fruit, which explains why poisoning occurs with eating unripe ackee fruit [39].

Cholestasis

Paraquat

Paraquat is a herbicide that is used worldwide mainly as a weedkiller and defoliant before crop harvesting. The mode of exposure is usually through ingestion, either by accident or due to attempted suicide, but intoxications through skin contact have also been reported [40]. Once ingested, it causes a burning sensation in the oropharyngeal area, nausea, vomiting, diarrhoea and abdominal pain. Respiratory distress and failure may occur. After 2–3 days, liver injury becomes obvious with jaundice and tender hepatomegaly. Liver tests become abnormal with a mixed hepatic–cholestatic picture, and liver biopsy reveals cholestasis, usually localized to the centrolobular zone. This histological change is usually associated with cholangiocellular injury involving the small and medium-sized bile ducts in the portal areas [40]. The mortality rate is high and is normally associated with severe pulmonary fibrosis at 2–4 weeks after ingestion [40,41].

The mechanisms of paraquat toxicity are thought to involve generation of superoxide anion and other toxic reactive oxygen species (redox cycling of paraquat), oxidation of nicotinamide adenine dinucleotide phosphate hydrogenase (NADPH), resulting in disruption of important biochemical processes that require NADPH, and lipid peroxidation [41–43].

Methylene dianiline (MDA)

Methylene dianiline is produced as an intermediate chemical in the synthesis of isocyanates and polyurethane polymers, and as an epoxy resin hardener. Therefore, many intoxication cases have occurred in industrial workers exposed to MDA; however, one study reported MDA intoxication involving the ingestion of bread made with flour contaminated with MDA, so-called Epping jaundice [44]. Typical presentation of MDA intoxication includes abdominal pain and jaundice accompanied by elevated serum alkaline phosphatase and transaminases [45,46]. Liver biopsy demonstrated intrahepatic cholestasis and necrosis [46,47]. Fortunately, the prognosis of MDA intoxication is good with complete recovery in most patients [44,46]. The mechanism of its hepatotoxicity is not known and has not been studied extensively.

Cirrhosis

Polychlorinated biphenyls (PCBs)

PCBs are a group of synthetic organic chemicals that have been used as coolants and lubricants in electrical equipment as they do not burn easily and hence make good insulators. However, PCBs have not been manufactured for more than two decades as they build up in the environment because of their resistance to biodegradation and can cause harmful health effects [48]. Owing to their stability, an individual can still be exposed to PCBs by handling old electrical equipment or eating contaminated food, especially fish [48]. PCB intoxication affects many

organs including the liver. Most of the knowledge about PCB hepatotoxicity came from two large studies in Asia involving ingestion of rice oil contaminated with PCBs, known as the Yusho and Yu-Cheng outbreaks (Japanese and Chinese terms for oil disease) [1,2]. Many victims of the outbreaks were reported to have elevated transaminases and γ-glutamyltransferase (GGT), as well as bilirubin. Follow-up studies from the cohort of victims found increased mortality from cirrhosis compared with the local populations [49,50]. In addition, abnormal liver enzymes have also been reported in workers exposed to PCBs and individuals consuming food contaminated with PCBs [48]. However, the data are not consistent, probably reflecting different levels of exposure to PCBs.

The toxic mechanism of PCBs is not well understood. However, it is known that PCBs are potent inducers of cytochrome P-450, which subsequently increases the metabolism of certain chemicals or drugs including PCBs themselves [12].

Veno-occlusive disease

Pyrrolizidine alkaloids

Pyrrolizidine alkaloids (PA) are plant toxins found on Boraginaceae (e.g. *Heliotropium* and *Symphytum* species), Asteraceae (e.g. *Senecio* species) and Leguminosae (e.g. *Crotalaria* species) plant families [51]. Intoxication usually occurred accidentally as epidemics resulting from consumption of crops contaminated with PA-containing plants [5,52] or consumption of herbal tea or herbal medicine containing PA [53,54].

The typical presentation of PA intoxication is sudden attacks of severe abdominal pain, vomiting, ascites, jaundice and hepatomegaly. Liver tests reveal elevated transaminases, hyperbilirubinaemia and prolonged prothrombin time [51,53,55]. There is a characteristic change in the affected liver with occlusion of the central veins and smaller branches of the hepatic vein in the absence of large hepatic vein lesions [51,55]. Consequently, these findings are associated with hepatic congestion and necrosis. This clinical presentation and histological change is referred to as veno-occlusive disease (VOD) of the liver. It is estimated that, after an acute outbreak, one-fifth of the patients die, one-half recover completely, and the remainder develop chronic liver disease [56]. PA intoxication can also present insidiously with progressive ascites and/or other signs of portal hypertension, and liver biopsy reveals fibrosis and inflammatory infiltration of the portal tract and eventually cirrhosis [51,52]. This type of presentation occurs with chronic ingestion of PA.

PA's parent compound is chemically unreactive but is metabolized into toxic pyrrolic metabolites by α-carbon oxidation (dehydrogenation), which is catalysed by cytochrome P-450 monooxygenases [55,56]. These toxic metabolites may bind covalently to sulphur-, nitrogen- and oxygen-containing groups on various macromolecules, including DNA and proteins, causing cross-linking within DNA and between DNA and nucleoproteins and subsequent damage to hepatocytes [56]. However, experiments have shown that sinusoidal endothelial cells are more susceptible to PA toxicity than hepatocytes [57]. PA caused sinusoidal endothelial cells to round up, and gaps formed between these cells allowing blood to enter into the space of Disse and dissect off the sinusoidal lining. The sloughed sinusoidal lining cells then embolize downstream and obstruct sinusoidal flow leading to VOD [57].

Non-cirrhotic portal fibrosis

Vinyl chloride

Vinyl chloride is mostly used in the plastics industry but has been used as a refrigerant or a propellant as well. It is a gas at room temperature; hence, most of the exposure occurs with inhalation and in the industrial setting. Industrial workers exposed to substantial amounts of vinyl chloride over a long period of time may develop hepatomegaly, but they initially have minimally abnormal or even normal liver enzymes [58,59]. Despite subtle initial presentation, a study revealed that, if peritoneoscopy was performed on exposed workers, 50% had granular changes in the liver surface and 86% had capsular fibrosis [59]. Furthermore, liver histology described in several studies revealed typical findings: portal tract and perisinusoidal fibrosis, hyperplasia of sinusoidal lining cells, sinusoidal dilatation and areas of hepatocyte degeneration [58–61]. Eventually, the symptoms and signs of non-cirrhotic portal hypertension ensue, such as gastrointestinal bleeding from oesophageal varices and splenomegaly [59]. In addition, an increased incidence of hepatic angiosarcoma has been observed in workers exposed to high levels of vinyl chloride [58,62]. The time period for development of angiosarcoma averaged 22 years after initial vinyl chloride exposure [62]. Prognosis is usually poor with death occurring within 1 year, and treatment is generally unsuccessful except perhaps for liver transplantation [62].

The mechanism of liver toxicity of vinyl chloride is due to its reactive metabolites. Vinyl chloride is metabolized by mixed function oxidases to 2-chloroethylene oxide and 2-chloroacetaldehyde, which then bind covalently to protein and DNA, resulting in cell death [58]. 2-Chloroethylene oxide also forms DNA adducts causing basepair substitution mutations and hence carcinogenesis [58].

Arsenic

Arsenic is ubiquitous, and liver damage from arsenic has been reported in patients who had chronic exposure to water or vegetables contaminated with arsenic [6–8]. Other cases include patients treated for psoriasis with Fowler's solution (potassium arsenite) that contained arsenic [63]. As with liver damage caused by vinyl chloride, initial presentation may include hepatomegaly [6,8] or bleeding from oesophageal varices and splenomegaly caused by non-cirrhotic portal hypertension [6,63]. Liver tests are usually normal [6,63], but cases with elevated alkaline phosphatase and hyperbilirubinaemia have

been documented [7]. Non-cirrhotic portal fibrosis was the predominant lesion in liver biopsies [6,8,63]. As with vinyl chloride, hepatic angiosarcoma has also been reported to be associated with chronic exposure [9].

Arsenic's toxic mechanism seems to involve the production of reactive oxygen species (ROS) and reactive nitrogen species (RNS) during its metabolism. The production of ROS and RNS causes oxidative stress in cells and leads to lipid peroxidation, protein oxidation, DNA damage and activation of signalling cascades associated with tumour promotion [64].

Hepatoma

Aflatoxin B1

Aflatoxin is a naturally occurring mycotoxin produced by two strains of mould, *Aspergillus flavus* and *Aspergillus parasiticus*. The moulds are widespread in nature, especially in tropical regions, where humidity and heat favour their growth. Therefore, aflatoxin can commonly be found in agricultural products such as peanuts and corns, and populations in Saharan Africa and east and south-east Asia are especially exposed to it. There are more than 10 types of aflatoxin, but aflatoxin B1 is considered to be the most prevalent and the most toxic [65].

Aflatoxin B1 has been reported to be associated with an increased incidence of hepatocellular carcinoma in many studies from many countries [66–68]. One of the largest studies originated from China, where 18 000 people in Shanghai were followed for 7 years, and subjects who had a positive urinary aflatoxin biomarker had a relative risk of 3.4 for developing hepatocellular carcinoma [66]. The relative risk is even higher, around 60, in subjects with positive hepatitis B surface antigen (HBsAg), whereas subjects with positive HbsAg but negative urinary aflatoxin biomarker had a relative risk of 7.3. These findings also suggest that there is a synergism between aflatoxin and hepatitis B virus infection in developing hepatocellular carcinoma.

The carcinogenicity of aflatoxin B1 has been associated with mutation of p53 tumour suppressor genes, especially G→T transition at codon 249, as this mutation was identified frequently in areas where there is a high incidence of hepatocellular carcinoma and high exposure to aflatoxin B1 [69–71]. *In vitro* experiments also support the association. Aguillar *et al.* [72] found that aflatoxin B1 induced G→T transition at codon 249 in HepG2 human hepatocarcinoma cells. The mechanism of aflatoxin B1 inducing this mutation is not clear. However, it may be due to its toxic metabolite, 8,9-exo-epoxide, which binds to DNA to form a number of adducts, as associations have been observed between levels of these adducts and the incidence of hepatocellular carcinoma [73].

Apart from the risk of developing hepatocellular carcinoma in the long term, acutely, ingestion of food contaminated with very high levels of aflatoxin B1 may result in poisoning (aflatoxicosis). Initial presentation includes vomiting, anorexia and jaundice followed by portal hypertension and/or liver failure. Liver biopsy reveals haemorrhagic necrosis, bile duct proliferation, periportal fibrosis and the presence of giant cells. The cases are mainly reported in developing countries and have caused high mortality [66,74,75].

Summary

Liver injury caused by industrial and environmental agents should be considered especially if no specific aetiology has been found or a patient reports working with or handling chemicals or ingesting unusual food. Establishing the diagnosis is important not only for treatment but also for prevention of further exposure. As many agents have a long latency period prior to developing liver injury or insidious initial clinical presentation, vigilance and searching for a potentially toxic agent is paramount.

References

1 Kuratsune M, Yoshimura T, Matzuzaka J *et al.* (1972) Epidmiologic study on Yusho, a poisoning caused by ingestion of rice oil contaminated with a commercial brand of polychlorinated biphenyls. *Environ Health Perspect* 1, 119–128.

2 Hsu ST, Ma CI, Hsu SK *et al.* (1985) Discovery and epidemiology of PCB poisoning in Taiwan: a four-year follow-up. *Environ Health Perspect* 59, 5–10.

3 Moya J (2001) Ackee (*Blighia sapida*) poisoning in the Northern Province, Haiti, 2001. *Epidemiol Bull* 22(2), 8–9.

4 Meda HA, Diallo B, Buchet JP *et al.* (1999) Epidemic of fatal encephalopathy in preschool children in Burkina Faso and consumption of unripe ackee (*Blighia sapida*) fruit. *Lancet* 353(9152), 536–540.

5 Mohabbat O, Younis MS, Merzad AA *et al.* (1976) An outbreak of hepatic veno-occlusive disease in North-Western Afghanistan. *Lancet* 2, 269–271.

6 Guha Mazumder DN, Chakraborty AK, Ghose A *et al.* (1988) Chronic arsenic toxicity from drinking tubewell water in rural West Bengal. *Bull World Health Organ* 66(4), 499–506.

7 Hernandez-Zavala A, Del Razo LM, Aguilar C *et al.* (1998) Alteration in bilirubin excretion in individuals chronically exposed to arsenic in Mexico. *Toxicol Lett* 99(2), 79–84.

8 Santra A, Das Gupta J, De BK *et al.* (1999) Hepatic manifestations in chronic arsenic toxicity. *Ind J Gastroenterol* 18(4), 152–155.

9 Agency for Toxic Substances and Disease Registry (ATSDR) (2000) *Toxicological Profile for Arsenic*. Atlanta, GA: US Department of Health and Human Services, Public Health Service.

10 Gunawan B, Kaplowitz N (2004) Clinical perspectives on xenobiotic-induced hepatotoxicity. *Drug Metab Rev* 36, 301–312.

11 Tolman KG (2003) Occupational and environmental hepatotoxicity. In: Kaplowitz N, DeLeve LD (eds) *Drug-induced Liver Disease*. New York: Marcel Dekker, pp. 725–738.

12 Pond SM (1982) Effects on the liver of chemicals encountered in the workplace. *West J Med* 137, 506–514.

13 Jennings RB (1955) Fatal fulminant acute carbon tetrachloride poisoning. *AMA Arch Pathol* 59, 269–284.

14 McDermott WV, Hardy HL (1963) Cirrhosis of the liver following chronic exposure to carbon tetrachloride. *J Occup Med* 5, 249–251.

15 Agency for Toxic Substances and Disease Registry (ATSDR) (2003) *Toxicological Profile for Carbon Tetrachloride*. Atlanta, GA: US Department of Health and Human Services, Public Health Service.

16 Plaa GL (2000) Chlorinated methanes and liver injury: highlights of the past 50 years. *Annu Rev Pharmacol Toxicol* 40, 42–65.
17 Weber LW, Boll M, Stampfl A (2003) Hepatotoxicity and mechanism of action of haloalkanes: carbon tetrachloride as a toxicological model. *Crit Rev Toxicol* 33, 105–136.
18 Glende EH, Recknagel RO (1992) Phospholipase A2 and cell injury in isolated rat hepatocytes exposed to bromotrichloromethane, chloroform, and 1–1 dichloroethylene as compared to effects of carbon tetrachloride. *Toxicol Appl Pharmacol* 113, 159–162.
19 Luster MI, Simeonova PP, Gallucci RM *et al.* (2000) The role of tumor necrosis factor α in chemical-induced hepatotoxicity. *Ann NY Acad Sci* 919, 214–220.
20 Kaplowitz N (2003) Mechanisms of cell death and relevance to drug hepatotoxicity. In: Kaplowitz N, DeLeve LD (eds) *Drug-induced Liver Disease*. New York: Marcel Dekker, pp. 85–95.
21 Burk RF, Reiter R, Lane JM (1986) Hyperbaric oxygen protection against carbon tetrachloride hepatotoxicity in the rat. Association with altered metabolism. *Gastroenterology* 90, 812–818.
22 Bernacchi A, Myers R, Trump BF *et al.* (1984) Protection of hepatocytes with hyperoxia against carbon tetrachloride-induced injury. *Toxicol Pathol* 12, 315–323.
23 Winslow SG, Gerstner HB (1978) Health aspects of chloroform – a review. *Drug Chem Toxicol* 1, 259–275.
24 Agency for Toxic Substances and Disease Registry (ATSDR) (1997) *Toxicological Profile for Chloroform*. Atlanta, GA: US Department of Health and Human Services, Public Health Service.
25 Hoet P, Graf ML, Bourdi M *et al.* (1997) Epidemic of liver disease caused by hydrochlorofluorocarbons used as ozone-sparing substitutes of chlorofluorocarbons. *Lancet* 350, 556–559.
26 White IN, De Matteis F (2001) The role of CYP forms in the metabolism and metabolic activation of HCFCs and other halocarbons. *Toxicol Lett* 124, 121–128.
27 Klein AS, Hart J, Brems JJ *et al.* (1989) Amanita poisoning: treatment and the role of liver transplantation. *Am J Med* 86(2), 187–193.
28 Broussard CN, Aggarwal A, Lacey SR *et al.* (1996) Mushroom poisoning – from diarrhea to liver transplantation. *Am J Gastroenterol* 11, 3195–3198.
29 Becker CE, Tong TG, Boerner U *et al.* (1976) Diagnosis and treatment of *Amanita phalloides*-type mushroom poisoning. *West J Med* 125, 100–109.
30 Parish RC, Doering PL (1986) Treatment of *Amanita* mushroom poisoning: a review. *Vet Hum Toxicol* 28(4), 318–322.
31 Fantozzi R, Ledda F, Caramelli L *et al.* (1986) Clinical findings and follow-up evaluation of an outbreak of mushroom poisoning – survey of *Amanita phalloides* poisoning. *Klin Wochenschr* 64, 38–43.
32 Leist M, Gantner F, Naumann H *et al.* (1997) Tumor necrosis factor-induced apoptosis during the poisoning of mice with hepatotoxins. *Gastroenterology* 112, 923–934.
33 Wauters JP, Rossel C, Farguet JJ (1978) *Amanita phalloides* poisoning treated by early charcoal hemoperfusion. *Br Med J* 11, 1465.
34 Vesconi S, Langer M, Iapichino G *et al.* (1985) Therapy of cytotoxic mushroom intoxication. *Crit Care Med* 13, 402–406.
35 Tanaka K, Kean EA, Johnson B (1976) Jamaica vomiting sickness. Biochemical investigation of two cases. *N Engl J Med* 295, 461–467.
36 Hill KR (1952) The vomiting sickness of Jamaica: a review. *West Ind Med J* 1, 243–264.
37 Sherrat HS, Turnbull DM (1999) Methylene blue and fatal encephalopathy from ackee fruit poisoning. *Lancet* 353, 1623–1624.
38 Larson J, Vender R, Camuto P (1994) Cholestatic jaundice due to ackee fruit poisoning, *Am J Gastroenterol* 89, 1577–1578.
39 Chase Jr, GW, Landen Jr, WO, Soliman AG (1990) Hypoglycin A content in the aril, seeds, and husks of ackee fruit at various stages of ripeness. *J Assoc Off Anal Chem* 73, 318–319.
40 Mullick FG, Ishak KG, Mahabir R *et al.* (1981) Hepatic injury associated with paraquat toxicity in humans. *Liver* 1(3), 209–221.
41 Bus JS, Aust SP, Gibson JE (1974) Superoxide and singlet-oxygen-catalyzed lipid peroxidation as a possible mechanism for paraquat (methylviologen) toxicity. *Biochem Biophys Res Commun* 58, 749–755.
42 Suntress ZE (2002) Role of antioxidant in paraquat toxicity. *Toxicology* 180, 65–77.
43 Smith LL (1987) Mechanism of paraquat toxicity in lung and its relevance to treatment. *Hum Toxicol* 6, 31–36.
44 Kopelman H (1968) Epping jaundice after two years. *Postgrad Med J* 44, 78–81.
45 Kopelman H, Robertson MH, Sanders PG *et al.* (1966) The Epping jaundice. *Br Med J* 1, 514–516.
46 Williams SV, Bryan JA, Burk JR *et al.* (1974) Toxic hepatitis and methylenedianiline. *N Engl J Med* 291, 1256.
47 Kopelman H, Scheuer PJ, Williams R (1966) The liver lesion of the Epping jaundice. *Quebec J Med* 35, 553–564.
48 Agency for Toxic Substances and Disease Registry (ATSDR) (2000) *Toxicological Profile for Polychlorinated Biphenyls (PCBs)*. Atlanta, GA: US Department of Health and Human Services, Public Health Service.
49 Hsieh SF, Yen YY, Lan SJ *et al.* (1996) A cohort study on mortality and exposure to polychlorinated biphenyls. *Arch Environ Health* 51(6), 417–424.
50 Yu ML, Guo YL, Hsu CC *et al.* (1997) Increased mortality from chronic liver disease and cirrhosis 13 years after the Taiwan 'yucheng' ('oil disease') incident. *Am J Ind Med* 31, 172–175.
51 Stewart MJ. Steenkamp V (2001) Pyrrolizidine poisoning: a neglected area in human toxicology. *Ther Drug Monit* 23(6), 698–708.
52 Selzer G, Parker R (1951) Senecio poisoning exhibiting as Chiari's syndrome: a report of twelve cases. *Am J Pathol* 27, 885–907.
53 Steenkamp V, Stewart MJ, Zuckerman M (2000) Clinical and analytical aspects of pyrrolizidine poisoning caused by South African traditional medicines. *Ther Drug Monit* 22(3), 302–306.
54 Weston CF, Cooper BT, Davies JD *et al.* (1987) Veno-occlusive disease of the liver secondary to the ingestion of comfrey. *Br Med J* 295, 183.
55 Pageaux GP, Larrey D (2003) Alternative medicine, vitamins, and natural hepatotoxins. In: Kaplowitz N, DeLeve LD (eds) *Drug-induced Liver Disease*. New York: Marcel Dekker, pp. 709–724.
56 Prakash AS, Pereira TN, Reilly PE *et al.* (1999) Pyrrolizidine alkaloids in human diet. *Mutat* Res 443(1–2), 53–67.
57 DeLeve LD, Shulman HM, McDonald GB (2002) Toxic injury to hepatic sinusoids: sinusoidal obstruction syndrome (venoocclusive disease). *Semin Liver Dis* 22, 27–41.
58 Agency for Toxic Substances and Disease Registry (ATSDR) (2004) *Toxicological Profile for Vinyl Chloride*. Atlanta, GA: US Department of Health and Human Services, Public Health Service.
59 Marsteller HJ, Lelbach WK, Muller R *et al.* (1975) Unusual splenomegalic liver disease as evidenced by peritoneoscopy and guided liver biopsy among polyvinyl chloride production workers. *Ann NY Acad Sci* 246, 95–134.
60 Gedigke P, Muller R, Bechtelsheimer H (1975) Morphology of liver damage among polyvinyl chloride production workers. A report on 51 cases. *Ann NY Acad Sci* 246, 278–285.

61 Popper H, Thomas LB (1975) Alterations of liver and spleen among workers exposed to vinyl chloride. *Ann NY Acad Sci* 246, 172–194.
62 Kielhorn J, Melber C, Wahnschaffe U *et al.* (2000) Vinyl chloride: still a cause for concern. *Environ Health Perspect* 108, 579–588.
63 Nevens F, Fevery J, Van Steenbergen W *et al.* (1990) Arsenic and non-cirrhotic portal hypertension. A report of eight cases. *J Hepatol* 11, 80–85.
64 Shi H, Shi X, Liu KJ (2004) Oxidative mechanism of arsenic toxicity and carcinogenesis. *Mol Cell Biochem* 255, 67–78.
65 Williams JH, Phillips TD, Jolly PE *et al.* (2004) Human aflatoxicosis in developing countries: a review of toxicology, exposure, potential health consequences, and interventions. *Am J Clin Nutr* 80, 1106–1122.
66 Qian GS, Ross RK, Yu MC *et al.* (1994) A follow-up study of urinary markers of aflatoxin exposure and liver cancer risk in Shanghai, People's Republic of China. *Cancer Epidemiol Biomarkers Prev* 3, 3–10.
67 Autrup JL, Schmidt J, Seremet T *et al.* (1991) Determination of exposure to aflatoxins among Danish workers in animal-feed production through the analysis of aflatoxin B1 adducts to serum albumin. *Scand J Work Environ Health* 17(6), 436–440.
68 Van Rensburg SJ, Cook-Mozaffari P, Van Schalkwyk DJ *et al.* (1985) Hepatocellular carcinoma and dietary aflatoxin in Mozambique and Transkei. *Br J Cancer* 51, 713–726.
69 Bressac B, Kew M, Wands J *et al.* (1991) Selective G to T mutations of p53 gene in hepatocellular carcinoma from southern Africa. *Nature* 350, 429–431.
70 Li D, Cao Y, He L *et al.* (1993) Aberrations of p53 gene in human hepatocellular carcinoma from China. *Carcinogenesis* 14, 169–173.
71 Jackson PE, Groopman JD (1999) Aflatoxin and liver cancer. *Baillieres Best Pract Res Clin Gastroenterol* 13(4), 545–555.
72 Aguillar F, Hussain SP, Cerruti P (1993) Aflatoxin B1 induces transversion of G→T in codon 249 of the p53 tumor suppressor gene in human hepatocytes. *Proc Natl Acad Sci USA*, 8586–8590.
73 Sharma RA, Farmer PB (2004) Biological relevance of adduct detection to the chemoprevention of cancer. *Clin Cancer Res* 10(15), 4901–4912.
74 Eisenberg HW (1970) Aspergillosis with aflatoxicosis. *N Engl J Med* 283(24), 1348.
75 Krishnamachari KA, Bhat RV, Nagarajan V *et al.* (1975) Hepatitis due to aflatoxicosis. An outbreak in Western India. *Lancet* 1, 1061–1063.

14.3 Hepatic injury due to physical agents

Bernhard H. Lauterburg and Haithem Chtioui

Besides trauma, which is the most common cause of physical injury to the liver (dealt with in Chapter 24.4), other physical forces, such as radiation and heat, can injure the liver with sometimes life-threatening consequences.

Radiation injury to the liver

Radiation injury to the liver parenchyma occurs secondary to total body irradiation, by inclusion of portions of the liver in radiotherapeutic treatment portals, for example in patients treated for upper abdominal malignant tumours or for breast carcinoma, and in patients undergoing targeted treatment of hepatic malignancies. The incidence of radiation-induced liver injury has decreased as radiotherapists have become more aware of the entity but, as a result of the increased use of three-dimensional radiotherapy in the treatment of liver tumours, total body radiation before bone marrow transplantation and whole abdominal radiation therapy for advanced gynaecological malignancies, patients with radiation injury to the liver may again be seen more often.

The risk of radiation-induced liver disease or radiation hepatitis depends on the dose of radiation and the irradiated volume of the liver [1,2]. Irradiation of the entire liver at normal fractionation below 30 Gy carries a low risk of radiation-induced liver disease. Following doses of more than 30 Gy to the entire liver, 5–10% of patients will develop radiation hepatitis within 3 weeks to 3 months following irradiation, and following doses in excess of 42 Gy, the risk of development of symptoms is approximately 50% [3]. However, doses higher than whole liver tolerance may be delivered without clinically significant toxicity, provided an adequate amount of normal liver parenchyma is spared [1,4]. With the advent of three-dimensional conformal radiotherapy, even higher doses can be applied to focal hepatic malignancies while sparing surrounding normal liver. Up to one-third of the liver can be radiated to a dose of 72.6 Gy and two-thirds up to 52.8 Gy without complications [5]. In addition to dose and volume, pre-existing liver disease is a risk factor. Thus, patients undergoing radiotherapy for hepatocellular carcinoma who are carriers of the hepatitis B virus or who have Child–Pugh B cirrhosis are more susceptible to radiation-induced liver disease [6]. Similar to surgical resection, the functional capacity of the non-irradiated volume of a cirrhotic liver is an important determinant of radiation tolerance [7].

Histopathologically, acute radiation hepatitis is characterized by centro- to panlobular sinusoidal congestion, leading to compression of adjacent liver cell plates. This is due to injury to the central and sublobular veins where focal deposits of fibrin and thickening of the vessel wall as well as obliteration of the lumen can be observed consistent with veno-occlusive disease. There is also an increase in perisinusoidal reticulin deposits, suggesting that the sinusoidal lining cells are as sensitive to radiation as the central veins. In the first weeks after stopping radiotherapy, hepatic stellate cells become activated in the vicinity of atrophic cords of hepatocytes in the irradiated and congested areas [8]. The lesions are usually reversible within 3–4 months but, in some instances, collagen deposition gradually increases, replacing the congestive and destroyed areas and leading to extensive fibrosis and parenchymal atrophy [9]. Nodular regeneration is uncommon, possibly because of a decreased regenerative capacity following irradiation.

Patients usually present with an asymptomatic increase in serum transaminases and an elevation of alkaline phosphatase that is often out of proportion to the increases seen in bilirubin. Unspecific increases in the activities of these enzymes are common in the clinical context where radiation injury to the liver occurs, and the differential diagnosis of abnormal liver tests tends to be extensive. Diagnostic criteria for radiation-induced liver injury are not standardized, but over grade 2 hepatic toxicity according to the common toxicity criteria of the National Cancer Institute, i.e. more than five times the upper limit of normal for transaminases, alkaline phosphatase and γ-glutamyltransferase or more than three times the upper limit of normal for bilirubin, may be considered clinically relevant acute radiation-induced liver disease. Depending on the irradiated volume of the liver and the extent of injury, the syndrome includes hepatomegaly and ascites.

Sonographically, the affected liver area has a hypoechogenic appearance, which is seen more readily in fatty livers. A typical

computerized tomographic (CT) feature of radiation hepatitis is a sharply bordered area of hypoattenuation of the liver corresponding to the shape of the radiotherapeutic treatment portal. Some of these areas exhibit a high attenuation with contrast CT [10]. By magnetic resonance imaging (MRI), T2-weighted images show hyperintensity in the area of hepatic radiation damage due to increased water content [11–14].

The majority of patients recover in 1–3 months, but a small percentage do progress to liver failure and death [15]. No controlled clinical trials addressing the treatment of radiation-induced liver injury are available. Case reports suggest a benefit of corticosteroids and anticoagulation. Experimentally, silymarin, melatonin and hepatocyte growth factor gene therapy appear to be effective.

Symptomatic veno-occlusive disease of the liver is an uncommon adverse effect of primary abdominal irradiation [16]. Patients may present with upper right quadrant pain, hepatomegaly, ascites and elevation of liver enzymes within 4 months following radiotherapy [17]. If conservative management with diuretics and possibly steroids fails, a transjugular intrahepatic portosystemic shunt has been used successfully for the treatment of intractable ascites due to hepatic veno-occlusive disease as a result of whole abdominopelvic radiotherapy [18].

Focal nodular hyperplasia of the liver may be a late complication of high doses of alkylating agents (e.g. busulfan or melphalan), veno-occlusive disease and liver radiotherapy, probably as a consequence of injury to the vascular endothelium and subsequent localized circulatory disturbances [19]. Many years after irradiation, biliary strictures have rarely occurred [20,21], and the development of cholangiocarcinoma has been described [22]. The strictures result from a progressive obliterative vasculitis with intimal arteriolar thickening, leading to epithelial atrophy, ulcerations and a dense inflammatory fibrosis replacing the muscular layer and inducing stenosis.

Exposure to alpha-particle radiation, as occurred in patients who received thorotrast, a colloidal suspension of thorium dioxide formerly used as a radiological contrast agent, and Russian nuclear weapons workers exposed to ingested plutonium, is associated with the formation of hepatic tumours. There is a significantly elevated risk of hepatocellular carcinoma, cholangiocarcinoma and haemangiosarcoma after thorotrast exposure, whereas haemangiosarcoma was the only liver tumour significantly associated with the lower alpha-particle doses experienced by the Russian workers [23]. The p53 tumour suppressor gene is a target for the carcinogenic action of alpha-particle radiation [24].

Heat stroke

Heat stroke is a potentially life-threatening systemic condition defined as a core body temperature >40.6°C. The acute-phase response to heat exposure is similar to the pathophysiological sequence of events in severe sepsis. Classic heat stroke, usually occurring in the very young or in elderly persons, and exertional heat stroke lead to the activation of cytokines, such as interleukin (IL)-1, IL-6 and tumour necrosis factor (TNF)α and, finally, heat shock proteins [25]. As expected in a systemic inflammatory response syndrome, every organ in the body can be injured. A metabolic encephalopathy is a frequent and early complication, and acute renal failure, hepatocellular injury, lactic acidosis, rhabdomyolysis, respiratory failure and intestinal infarction, among others, follow. Liver injury is asymptomatic in most cases of heat stroke and manifests itself as a transient elevation of transaminases that peaks at around the third day [26]. However, acute hepatic failure occurs in approximately 5%.

Hepatocytes are probably damaged by the hyperthermia itself. In addition, heat-induced peripheral vasodilatation results in a redistribution of blood away from the splanchnic area and may result in hepatic ischaemia. Disseminated intravascular coagulopathy (DIC) may also contribute to an impaired microcirculation and may be responsible for low fibrinogen and an elevated international normalized ratio (INR) in the early phase prior to hepatic failure. Histologically, there will be necrosis in acinar zones 3 and/or 2, and microvesicular fatty changes may be present [27].

Even extensive liver damage may recover with conservative management, i.e. cooling and supportive care [28]. The accepted prognostic criteria used to decide whether a patient in fulminant hepatic failure should be listed for transplantation may not be valid in the situation of heat stroke: impaired consciousness is a hallmark of heat stroke and may thus not represent a clinical sign of hepatic encephalopathy; the impairment of coagulation tests may be overestimated because of the endothelial injury and DIC associated with heat stroke. Several patients have been transplanted with poor outcome [29–31]. The high mortality in these patients is not surprising as the severity of multisystem organ failure at the time of transplantation is an important predictor of patient survival.

Local heating of the liver, as occurs during microwave coagulation therapy, which is one of the treatment modalities for patients with hepatocellular carcinoma, will result in focal necrosis of the liver. As complications of microwave interventions, portal vein thrombosis [32] and necrotic pseudotumours have been described [33].

Burns

Severe burns elicit a proinflammatory acute-phase response, which can persist for a prolonged period of time. Cytokines, such as IL-1, IL-6, IL-8 and IL-10, TNF and insulin-like growth factor (IGF) binding protein 1, have been reported to be elevated for over 1 month after thermal injury [34,35]. In addition, the marked hypermetabolic and catabolic state following burns increases peripheral lipolysis and free fatty acid concentrations in the circulation and leads to the development of fatty liver, which has been associated with immunodepression and increased mortality [34]. Experimentally, thermal injury is associated with

vasoconstriction of the hepatic artery. Postburn sepsis may amplify the impact on blood flow and may result in ischaemia/reperfusion injury, associated with a critical reduction in hepatic oxygen delivery and consumption [36]. Burned patients are exposed to a marked, longlasting oxidant/antioxidant imbalance, i.e. a systemic oxidant stress, in parallel to the severity of the injury [37].

In nearly all patients with major burns, the transaminases increase during the second week after injury [38]. There is no clear correlation between the overall increase in the transaminases and the extent of burned surface area. Complications of severe burns, such as arterial hypotension, shock, absorption of toxins from the injured area, drugs, malnutrition and sepsis, may subsequently contribute to liver injury.

Acute acalculous cholecystitis may be an occasional complication of severe burns [39]. It occurs in approximately 1% of burn victims. Predisposing factors are extensive burn area, multiple transfusions, bacteraemia, total parenteral nutrition, narcotic analgesics and positive pressure ventilation, i.e. very sick patients are prone to develop acalculous cholecystitis.

References

1 Austin-Seymour MM, Chen GT, Castro JR *et al.* (1986) Dose volume histogram analysis of liver radiation tolerance. *Int J Radiat Oncol Biol Phys* 12(1), 31–35.

2 Cromheecke M, Konings AW, Szabo BG *et al.* (2000) Liver tissue tolerance for irradiation: experimental and clinical investigations. *Hepatogastroenterology* 47(36), 1732–1740.

3 Dawson LA, Ten Haken RK, Lawrence TS (2001) Partial irradiation of the liver. *Semin Radiat Oncol* 11(3), 240–246.

4 Lawrence TS, Kessler ML, Robertson JM (1993) Conformal high-dose radiation plus intraarterial floxuridine for hepatic cancer. *Oncology (Williston Park)* 7(10), 51–57.

5 Robertson JM, Lawrence TS, Walker S *et al.* (1995) The treatment of colorectal liver metastases with conformal radiation therapy and regional chemotherapy. *Int J Radiat Oncol Biol Phys* 32(2), 445–450.

6 Cheng JC, Wu JK, Lee PC *et al.* (2004) Biologic susceptibility of hepatocellular carcinoma patients treated with radiotherapy to radiation-induced liver disease. *Int J Radiat Oncol Biol Phys* 60(5), 1502–1509.

7 Ohara K, Okumura T, Tsuji H *et al.* (1997) Radiation tolerance of cirrhotic livers in relation to the preserved functional capacity: analysis of patients with hepatocellular carcinoma treated by focused proton beam radiotherapy. *Int J Radiat Oncol Biol Phys* 38(2), 367–372.

8 Sempoux C, Horsmans Y, Geubel A *et al.* (1997) Severe radiation-induced liver disease following localized radiation therapy for biliopancreatic carcinoma: activation of hepatic stellate cells as an early event. *Hepatology* 26(1), 128–134.

9 Lewin K, Millis RR (1973) Human radiation hepatitis. *Arch Pathol* 96:21–26.

10 Ahmadi T, Itai Y, Onaya H *et al.* (1999) CT evaluation of hepatic injury following proton beam irradiation: appearance, enhancement, and 3D size reduction pattern. *J Comput Assist Tomogr* 23(5), 655–663.

11 Yankelevitz DF, Knapp PH, Henschke CI *et al.* (1992) MR appearance of radiation hepatitis. *Clin Imaging* 16(2), 89–92.

12 Unger EC, Lee JK, Weyman PJ (1987) CT and MR imaging of radiation hepatitis. *J Comput Assist Tomogr* 11(2), 264–268.

13 Yoshiokaa H, Itai Y, Saida Y *et al.* (2000) Superparamagnetic iron oxide-enhanced MR imaging for early and late radiation-induced hepatic injuries. *Magn Reson Imaging* 18(9), 1079–1088.

14 Mori H, Yoshioka H, Ahmadi T *et al.* (2000) Early radiation effects on the liver demonstrated on superparamagnetic iron oxide-enhanced T1-weighted MRI. *J Comput Assist Tomogr* 24(4), 648–651.

15 Lawrence TS, Robertson JM, Anscher MS *et al.* (1995) Hepatic toxicity resulting from cancer treatment. *Int J Radiat Oncol Biol Phys* 31(5), 1237–1248.

16 Reed GB, Jr, Cox AJ, Jr (1966) The human liver after radiation injury. A form of veno-occlusive disease. *Am J Pathol* 48(4), 597–611.

17 Bischof M, Zierhut D, Gutwein S *et al.* (2001) [Veno-occlusive liver disease after total infradiaphragmatic lymphoid irradiation. A rare complication]. *Strahlenther Onkol* 177(6), 296–301.

18 Shen-Gunther J, Walker JL, Johnson GA *et al.* (1996) Hepatic venoocclusive disease as a complication of whole abdominopelvic irradiation and treatment with the transjuglar intrahepatic portosystemic shunt: case report and literature review. *Gynecol Oncol* 61(2), 282–286.

19 Bouyn CI, Leclere J, Raimondo G *et al.* (2003) Hepatic focal nodular hyperplasia in children previously treated for a solid tumor. Incidence, risk factors, and outcome. *Cancer* 97(12), 3107–3113.

20 Geubel AP (1994) Radiation-induced bile duct injury: a vanishing cause of obstructive jaundice? *J Hepatol* 20(6), 687–688.

21 Di Fiore F, Savoye-Collet C, Savoye G *et al.* (2001) Magnetic resonance cholangiographic assessment of a delayed radiation-induced bile duct stricture. *Dig Liver Dis* 33(7), 584–586.

22 Cunningham JJ (1990) Cholangiocarcinoma occurring after childhood radiotherapy for Wilm's tumor. *Hepatogastroenterology* 37(4), 395–397.

23 Sharp GB (2002) The relationship between internally deposited alpha-particle radiation and subsite-specific liver cancer and liver cirrhosis: an analysis of published data. *J Radiat Res (Tokyo)* 43(4), 371–380.

24 Hollstein M, Bartsch H, Wesch H *et al.* (1997) p53 gene mutation analysis in tumors of patients exposed to alpha-particles. *Carcinogenesis* 18(3), 511–516.

25 Yeo TP (2004) Heat stroke: a comprehensive review. *AACN Clin Issues* 15(2), 280–293.

26 Hassanein T, Razack A, Gavaler JS *et al.* (1992) Heatstroke: its clinical and pathological presentation, with particular attention to the liver. *Am J Gastroenterol* 87(10), 1382–1389.

27 Rubel LR, Ishak KG (1983) The liver in fatal exertional heatstroke. *Liver* 3(4), 249–260.

28 Hadad E, Ben Ari Z, Heled Y *et al.* (2004) Liver transplantation in exertional heat stroke: a medical dilemma. *Intensive Care Med* 30(7), 1474–1478.

29 Saissy JM, Almanza L, Samuel D *et al.* (1996) [Liver transplantation after exertion-induced heat stroke associated with fulminant liver failure]. *Presse Med* 25(21), 977–979.

30 Berger J, Hart J, Millis M *et al.* (2000) Fulminant hepatic failure from heat stroke requiring liver transplantation. *J Clin Gastroenterol* 30(4), 429–431.

31 Hassanein T, Perper JA, Tepperman L *et al.* (1991) Liver failure occurring as a component of exertional heatstroke. *Gastroenterology* 100(5 Pt 1), 1442–1447.

32 Kojima Y, Suzuki S, Sakaguchi T *et al.* (2000) Portal vein thrombosis caused by microwave coagulation therapy for hepatocellular carcinoma: report of a case. *Surg Today* 30(9), 844–848.

33 Mikami Y, Shimizu M, Manabe T (1997) Tumorous necrotic nodule in the liver: unexpected effect of the microwave tissue coagulator. *J Clin Pathol* 50(8), 703–705.
34 Barret JP, Jeschke MG, Herndon DN (2001) Fatty infiltration of the liver in severely burned pediatric patients: autopsy findings and clinical implications. *J Trauma* 51(4), 736–739.
35 Jeschke MG, Barrow RE, Herndon DN (2004) Extended hypermetabolic response of the liver in severely burned pediatric patients. *Arch Surg* 139(6), 641–647.
36 Tadros T, Traber DL, Herndon DN (2000) Hepatic blood flow and oxygen consumption after burn and sepsis. *J Trauma* 49(1), 101–108.
37 Pintaudi AM, Tesoriere L, D'Arpa N *et al.* (2000) Oxidative stress after moderate to extensive burning in humans. *Free Radic Res* 33(2), 139–146.
38 Chiarelli A, Siliprandi L, Casadei A *et al.* (1987) Aminotransferase changes in burned patients. *Intensive Care Med* 13(3), 199–202.
39 Ross DC, Lee KC, Peters WJ *et al.* (1987) Acalculous cholecystitis in association with major burns. *Burns Incl Therm Inj* 13(6), 488–491.

14.4 Hepatic toxicity induced by herbal medicines

Felix Stickel and Detlef Schuppan

Introduction

Surveys from Europe and the US have demonstrated a sharp rise in the use of botanical drugs within the last few years, and up to 30–65% of patients with liver disease use herbal preparations [1–3].

The increasing popularity of herbal medicines is based on their perceived effectiveness in the treatment and prevention of disease, the belief that these treatments are 'natural' and therefore safe, a feeling of better control of the disease and its management, and a holistic philosophy behind complementary medicine that pays tribute to the patients' desire for wellness and quality of life, which standard healthcare seemingly fails to provide. Disappointment over conventional medicine because of lack of treatment success in many instances, unfavourable side-effects, lack of time with the doctor and insufficient empathy from healthcare providers also contribute to herbal medicine's appeal. Also, most countries do not impose prescription regulations upon herbal preparations and, therefore, access is unrestricted and cheap.

Regulatory issues and pharmacovigilance

Certain herbals have only recently been identified as a cause of acute and chronic hepatitis, cholestasis, drug-induced autoimmunity, vascular lesions and even hepatic failure and cirrhosis (Table 1). The frequency of adverse hepatic reactions to herbal medicine can only be estimated as the reporting of incidents of hepatotoxicity is voluntary and, for most preparations, the evidence relies on sporadic case reports. A recent retrospective case series revealed that, among 20 patients who underwent liver transplantation for fulminant hepatic failure, 35% were consumers of herbal supplements and thus constituted the largest subgroup of patients with liver failure within a period of 10 months in this single centre, exceeding cases attributable to paracetamol overdose or fulminant viral hepatitis [4].

In the US, herbal products are labelled dietary supplements and are not expected to meet the standards for drugs specified in the Federal Food, Drug, and Cosmetic Act. The only requirement is that these preparations follow the standards outlined in the Dietary Supplement and Health Education Act (DSHEA) issued in 1994, which allows marketing without prior approval of their efficacy and safety by the Food and Drug Administration (FDA). DSHEA allows manufacturers to claim that the product sold affects the body or its function, as long as there is no allegation that it prevents or treats certain diseases. Therefore, this simplified licensing practice does not guarantee efficacy and safety in the same strict way as with the approval of conventional medications and treatments.

In Germany, the Commission E as part of the Federal Institute for Drugs and Medicinal Devices (BfArM; Bundestinstitut für Arzneimittel und Medizinprodukte) issues approval for herbals on the basis of information contained in more than 300 monographs on herbs with detailed information on terminology, composition, side-effects, contraindications, interactions and mode of administration [5]. The Commission E also records voluntary reports on side-effects that occurred along with the intake of herbal preparations. Similarly, the European Commission has recently drafted a directive on the licensing of traditional herbal preparations, which allows premarketing assessment of the quality and safety of a drug, allowing pharmacovigilance and product revocations [6,7].

Mechanisms of hepatotoxicity

There is no uniform or predominant mechanism by which herbals cause liver damage. Theoretically, botanicals may damage the liver in just the same way as any other synthetic product (see Chapter 14.1). Acute hepatitis is the most frequently observed herbal drug-related liver lesion, and it occurs as a result of the toxicity of the either unprocessed herbal compound or its toxic metabolites. Another well-known mechanism leading to acute hepatitis is a metabolite-mediated immunoallergic reaction or drug-induced autoimmunity. With regard to the latter, granulomatous hepatitis may develop too. Likewise, acute cholestatic/mixed hepatitis or pure cholestasis has been described as a result of the intake of certain botanicals, which

Table 1 Herbs associated with acute and/or chronic liver damage.

Herbal	Application	Toxin	Toxic mechanism	Clinical presentation
Atractylis gummifera	Antiemetic, diuretic, chewing gum	Atractylosides	Inhibition of gluconeogenesis through interference with oxidative phosphorylation	Acute hepatitis, FHF
Callilepsis laureola (impila)	Traditional Zulu remedy	Atractylosides	Like *Atractylis gummifera*	Like *Atractylis gummifera*
Camphor	Rubefacient	Cyclic terpenes	Unknown	Necrolytic hepatitis
Cascara sagrada	Laxative	Anthracene glycosides	Cholestatic hepatitis through unknown mechanism	Cholestatic hepatitis
Chaparral	Antioxidant, liver and health tonic, snake bites	*Larrea tridentata* (nordihydroguaiaretic acid)	Inhibition of cyclooxygenase and several cytochrome P-450s	Cholestasis, cholangitis, chronic hepatitis, cirrhosis
Chinese herbal combinations				
Dai saiko-to (TJ-8)	Immunostimulation			Autoimmune hepatitis
Sho-saiko-to (TJ-9)	Chronic liver diseases	*Scutellaria*?	Unknown	Acute and chronic hepatitis
Paeonia spp.	Atopic dermatitis	Unknown	Unknown	Acute hepatitis, FHF
Greater celandine (*Chelidonium majus*)	Dyspepsia, irritable bowel syndrome	Unknown Chelidonin?	Unknown Idiosyncratic autoimmunity?	Chronic hepatitis, cholestatic hepatitis, fibrosis
Germander				
Teucrium chamaedrys	Weight reduction	Neoclerodane diterpenoids	Hepatocyte apoptosis	Acute and chronic hepatitis, fibrosis (subacute forms),
Teucrium polium	Anti-inflammatory	Unknown	Unknown	FHF (acute forms)
Isabgol	Laxative	Unknown	Unknown	Giant cell hepatitis
Jin Bu Huan	Sedative	*Lypocodium seratum*	Unknown	Acute and chronic cholestatic hepatitis, fibrosis
Kava	Anxiolytic, sleeping aid	Kava lactones (kavain, dihydrokavain)?	Idiosyncratic, dose-dependent toxicity?	Acute and chronic hepatitis, cholestasis, FHF
Ma-Huang	Weight reduction	Ephedrin	Immunoallergic?	Acute hepatitis, autoimmune hepatitis
Margosa oil	Health tonic	*Azadirachza indica*	Mitochondrial damage	Reye syndrome
Oil of cloves	Dental pain	Eugenol	Dose-dependent hepatotoxin	Hepatic necrosis
Pennyroyal oil	Abortifacient, pesticide	Menthofuran	Glutathione depletion through electrophilic metabolites	FHF
Pyrrolizidine alkaloids (PA) *Symphytum officinale* *Crotalaria* *Senecio longilobus* *Heliotropium*	Herbal tea, contamination of flour	Toxic pyrroles	Toxification of PA by cytochrome P-450 3A4	Veno-occlusive disease
Sassafras	Herbal tea	*Sassafras albidum*	Unknown	Hepatocarcinogenesis (animals)
Saw palmetto	Prostatism	*Serrenoa repens*	Unknown	Mild hepatitis
Shou-Wu-Pian	Multiple	*Polygonum multiflorum*?	Unknown	Acute hepatitis
Valerian	Sedative	*Valeriana officinalis*?	Unknown	Mild hepatitis

FHF, fulminant hepatic failure.

either induce immunoallergy or interfere with bile acid transporters. Chronic intake of subtoxic doses of certain herbals can lead to subacute or chronic hepatitis and even cirrhosis. Veno-occlusive disease (VOD) may occur as a rare but characteristic liver lesion following the intake of some herbals.

Risk factors for herbal hepatotoxicity are not well identified. However, a certain risk pattern has become evident, such as the observation that most affected individuals are females. This gender difference does not reflect a higher likelihood of women using these preparations, but rather their higher susceptibility towards herb-induced liver damage [1], as is observed for the majority of adverse hepatic reactions induced by synthetic drugs. Early clinical recognition of liver damage is important, especially as some patients even increase the dosage as symptoms of liver disease worsen. Most individuals who take herbals do not admit their intake, even on repeated questioning, either because they do not consider herbals as 'drugs' or because they fear not being taken seriously by their doctors for using herbals.

Furthermore, doctors who recommend herbals or patients who take them advocate the longstanding use of herbals in traditional medicine as proof of safety.

Another problem is that herbals are usually mixtures of several ingredients or plants harvested during different seasons and extracted through variable procedures, which makes the identification of both the pharmacologically active and the toxic compounds difficult. Also, contamination of herbals with microorganisms, fungal toxins such as aflatoxin, pesticides, heavy metals and synthetic drugs has been described [7].

Active components of herbals may interact with conventional drugs. For example, St John's Wort (*Hypericum perforatum*), which is promoted for the treatment of depression, interacts with numerous conventional drugs including ciclosporin, simvastatin, warfarin and digoxin because of its inducing properties on cytochrome P-450 3A4, 2C9 and the drug transporter MDR1 [8]. Several other herbals, such as *Salvia miltiorrhiza*, *Angelica sinensis* and *Papaya* (papain), can impair coagulation [5].

Botanicals associated with liver damage

Chinese herbs

In China, the use of herbals dates back as far as 2100 BC, with comprehensive records of Chinese medical theories dating back to 221 BC [9]. Most Chinese medicines are blends of four or five different herbs, of which one or two are the pharmacologically active 'King herbs'. The remaining constituents function as modifiers of toxicity, act synergistically with the King herb, improve the immune function or strengthen certain aspects of physical well-being. Hepatotoxicity has been described for both single herbs and herb combinations.

Jin Bu Huan (*Lypocodium serratum*), which has been widely used in the US for mild sedation, causes both acute and chronic hepatitis [10,11]. Final proof of causality is lacking, but liver histology showed focal necrosis and portal fibrosis without other possible explanations. In all published cases, elevated liver enzymes normalized after treatment discontinuation.

Ma-Huang (*Ephedra* sp.) is marketed in the USA to support weight loss therapies. A woman developed acute hepatitis together with elevated antinuclear antibodies and smooth muscle antibodies after only 3 weeks of intake of Ma-Huang, but liver abnormalities resolved after it was stopped [12]. Another report suggested that Ma-Huang hepatotoxicity is associated with compound heterozygosity for the haemochromatosis gene mutation, possibly through enhancing oxidative stress [13].

Along with studies that investigated the efficacy of Chinese herbal preparations in treating atopic dermatitis, several cases of acute hepatitis and even fulminant hepatic failure were reported [14,15]. The investigators failed to identify the causative agent, but all herbal combinations that led to liver abnormalities contained *Paeonia*. Whether *Paeonia* is the culprit needs clarification, as it is considered the 'King herb' for the treatment of atopic dermatitis [16].

Shou-Wu Pian, also termed He-Shou-Wu, is a remedy formulated from the roots and vines of *Polygonum multiflorum* and used as a treatment for dizziness, premature greying of hair, constipation and, interestingly, as a 'liver tonic'. Two case reports from Hong Kong and Australia identified Shou-Wu-Pian as the cause of acute hepatitis [17,18], which settled completely after cessation of its intake. Toxicity could relate to anthraquinones which are known constituents of *Polygonum multiflorum*. Anthraquinones are metabolized by gut bacteria to highly reactive anthrones in the colon that, when absorbed and transported to the liver, may cause hepatic damage [19].

Onshidou-Genbi-Kounou, a herbal marketed for weight loss, seemed to be the likely cause of a case of severe acute hepatitis in a woman who took this preparation for several months [20]. Serum levels of liver enzymes were massively elevated to > 9000 IU/L, and coagulopathy developed indicating liver failure. The patient recovered completely without intervention on cessation of drug intake. Onshidou-Genbi-Kounou combines several natural compounds (amachazuru, tea leaf, barbaloin, total saponin and polyphenols) and was found to contain *N*-nitroso-fenfluramine. Fenfluramine belongs to the group of amphetamines that are associated with valvular heart disease rather than with hepatotoxicity. So, it is believed that Onshidou-Genbi-Kounou contains unknown hepatotoxic compounds.

Two cases of poisoning with Chi R Yun (*Breynia officinalis*) were reported showing acute necrolytic hepatitis in a 43-year-old woman attempting suicide and a 51-year-old woman who aimed to treat her contact dermatitis [21]. The applied doses were markedly different and ingested with alcohol in the latter case. In daily Chinese medicine practice, *Breynia officinalis* is used as a therapy for venereal diseases, heart failure and conjunctivitis in combination with other traditional remedies. A detailed assessment of causality was not documented, so it remains speculative as to whether *Breynia officinalis* or some unknown adulterant was responsible for the observed adverse hepatic reaction.

Pyrrolizidine alkaloids

A dose-dependent hepatotoxicity of plants containing pyrrolizidine alkaloids is well established [22]. '*Senecio* disease' was first described in South Africa, followed by reports from Jamaica about children developing ascites, hepatomegaly and eventually cirrhosis after the ingestion of 'bush tea'. *Crotalaria* species in tea leaves were identified as the causative herbs. Later, a series of poisonings occurred in India and Afghanistan, where 'Gondli' cereal contaminated with *Heliotropium* alkaloids was responsible for numerous cases of VOD, the typical liver injury evoked by pyrrolizidine alkaloids. VOD from pyrrolizidine alkaloid intoxication was noticed in Arizona, such as in two infants exposed to herbal tea containing *Senecio longilobus* [23,24]. Similar events were also reported from Europe and elsewhere [25,26]. VOD is a non-thrombotic obliteration of the lumen of

terminal centrolobular hepatic veins resembling Budd–Chiari syndrome. The resulting venous outflow obstruction causes hepatic congestion and centrolobular necrosis, leading to either acute liver failure or liver fibrosis and cirrhosis [27].

Pyrrolizidine alkaloids extracted from *Heliotropium*, *Senecio*, *Symphytum* (comfrey) and *Crotalaria* exert a direct toxic effect related to biotransformation of pyrrolizidine alkaloids by cytochrome P-450s into pyrrole derivatives, which act as alkylating agents [22]. Toxicity of pyrrolizidine alkaloids can be increased by phenobarbital, a potent inducer of cytochrome P-450 3A4, 2B6 and several isoenzymes of the 2C family [28]. A standard treatment does not exist except for avoiding intake. In those with liver failure, liver transplantation may be the only effective therapy. The sale of comfrey is banned in Germany and Canada, while in the USA, companies have been advised to remove comfrey products for internal consumption from the market [29].

Germander

In 1986, germander (*Teucrium chamaedrys*) was approved as a drug for the supportive treatment of obesity and mild diarrhoea in France, although its active ingredients remained unknown [30]. Its large-scale use precipitated several reports to the French Pharmacovigilance Authorities in 1992 about germander-associated acute, chronic and even fulminant hepatitis [31]. The daily dosage ranged between 600 and 1600 mg/day, and hepatitis usually developed after 2 months of intake. Histologically, acute cytolytic hepatitis was found, and some patients with a chronic course of liver disease revealed patterns of chronic hepatitis with fibrosis and even cirrhosis. However, all patients recovered after the discontinuation of treatment except for those with cirrhosis, but relapsed under accidental re-exposure. Consequently, germander has been analysed thoroughly and found to contain saponins, glycosides, flavonoids and several furane-containing neoclerodane diterpenoids [32]. Animal experiments in mice demonstrated the formation of toxic metabolites from these diterpenoids by cytochrome P-450 3A. Their formation is enhanced by the induction of cytochrome P-450 3A and by glutathione depletion, and the toxified diterpenoids are potent inducers of hepatocyte apoptosis [33–35].

Lately, a case of fulminant hepatic failure after the ingestion of *Teucrium polium* has been described [36]. This plant is from the same genus as germander and has been used as an anti-inflammatory and antimicrobial drug as well as for the treatment of scars.

Greater celandine

Drugs containing greater celandine (*Chelidonium majus*) are frequently used in Europe for their alleged choleretic and antispasmodic properties, particularly in biliary disorders and irritable bowel syndrome. However, its therapeutic efficacy for these indications has never been tested in controlled trials [37]. Greater celandine contains at least 20 different alkaloids including berberine, coptisine, chelerythrine and chelidonine, the last of which serves to standardize the extract. Several reports demonstrated the potential hepatotoxicity of this herbal [38–41]. Nine out of 12 patients from a single centre [40,41] revealed cholestatic hepatitis together with low titres of autoantibodies, suggesting drug-induced autoimmunity after variable periods of ingestion. Importantly, patients had taken greater celandine preparations from different manufacturers, which strongly suggests that the plant extract has indeed been the cause of hepatotoxicity, although its mechanism remains unclear.

Kava

Kava (*Piper methysticum*, 'intoxicating pepper') has been used for centuries in Pacific island countries as a ceremonial beverage and for its psychotropic properties. In industrialized countries, kava-containing preparations were marketed for the treatment of anxiety disorders. Its sedative activity relates to kavapyrones, including kavain, dihydrokavain, methysticin and dihydromethysticin, which are γ-aminobutyric acid receptor agonists that inhibit activating neurons in the reticular formation and the limbic system [42]. The therapeutic potential to relieve stress and anxiety has been demonstrated in several controlled trials [43].

By 2003, eight cases of fulminant hepatic failure had been reported from Europe, two from the United States and one from Australia. A clinical diagnostic scale, developed and evaluated for the confirmation of drug-related liver damage, was applied to analyse seven of the eight published European cases and a further 29 so far unpublished cases [44,45]. Massive cytolytic or cholestatic hepatitis was noticed after highly variable doses and latency. Three patients died, two following an unsuccessful liver transplantation and one without. Individual doses and variable latency periods, as well as the absence of features of immune mechanisms, are suggestive of individual metabolic idiosyncrasy. This assumption is supported by Russmann and colleagues who have described a poor metabolizer phenotype of cytochrome P-450 2D6 in two individuals who experienced kava-induced hepatitis, pointing to a genetic predisposition for developing such liver damage [46].

The accumulating evidence of the potentially fatal adverse hepatic reactions along with the intake of kava preparations has led to the retraction of kava-containing pharmaceuticals in many western countries including the United States, Great Britain, Switzerland, Germany and Australia [47].

Interestingly, relevant liver damage has not been reported with traditional kava use [48]. A plausible explanation may be profound differences in the use of the kava plant parts: in traditional use, kava drinks are usually prepared from the underground parts or lower root stems, while commercial kava products were often extracted by ethanol or acetone from the aerial parts. The underground parts of the kava shrub contain large amounts of pharmacologically active kavalactones, such as

dihydromethysticin and desmethoxyangonin, while alkaloids, e.g. pipermethystin, are found mainly in leaves and stem peelings. Importantly, cell culture studies revealed that pipermethystin is a potent inducer of apoptosis [49].

Chaparral

Chaparral (*Larrea tridentata*) – commonly referred to as 'creosote bush' or 'greasewood' – grows in deserts and serves as a herbal remedy among native Americans to treat a variety of ailments such as common cold, bone and muscle pain and snake bites. Commercial plant extracts are sold for weight reduction and for their alleged anti-inflammatory and 'blood purifying' potential because of presumed antioxidant properties. Furthermore, chaparral is applied in alternative medicine regimens in the treatment of AIDS [50]. Since 1990, incidents of chaparral-related hepatotoxicity were reported to the FDA in the USA and reviewed. Thus, 13 out of 18 patients with chaparral-associated toxicity revealed liver damage, ranging from mild hepatitis to cirrhosis and fulminant liver failure [51]. The predominant pattern of liver damage was cholestatic hepatitis. A minority of patients presented with cirrhosis, and two patients required transplantation for fulminant hepatic failure. Some individuals were administered solely chaparral, while others took combinations with various other herbs. In all preparations, *Larrea tridentata* was found, while biochemical and microbial contamination could be excluded. A causal relationship was postulated because of a temporal correlation between intake of chaparral and the onset of liver disease, a consistent pattern of hepatic damage and through the observation that re-exposure to chaparral or an increased dose led to relapse or aggravation of clinical signs of liver disease. Chaparral toxicity is supposed to be due to nordihydroguaiaretic acid, which inhibits cyclooxygenase and cytochrome P-450 [52].

Atractylis gummifera and *Callilepsis laureola*

Atractylis gummifera is a known cause of toxic hepatitis in the Mediterranean. It is used as an antipyretic, emetic and diuretic. A bright fluid secreted from the plant is consumed as chewing gum [53]. The onset of hepatitis is usually acute and commences a few hours after ingestion with nausea, abdominal pain and headache. It is associated with a syndrome of neurovegetative symptoms, hepatorenal failure and pronounced hypoglycaemia. Death from fulminant hepatic failure is frequent. Consumption of *A. gummifera* is particularly dangerous during spring time when toxins are highly concentrated in roots or when the plant is confused with wild artichoke.

Numerous reports from South Africa provide clinical evidence of the potentially fatal nephro- and hepatotoxicity of *Callilepsis laureola* commonly named impila [54]. *C. laureola* is a traditional herbal remedy used among the Zulu people as a multipurpose treatment for stomach problems, impotence, infertility and to deter 'evil spirits'. Probably, the last is responsible for its continuing and widespread use, especially in children. Toxicity from *C. laureola* presents with a sudden onset, and mortality is staggeringly high, reaching up to 90% even in those patients that make it into hospital. Autopsy examinations consistently show centrolobular zonal necrosis of the liver, tubular renal necrosis and haemorrhages in lungs, skin and intestine. Paradoxically, impila is the Zulu word for 'health'. Despite its reputed toxicity, the underlying mechanism that causes liver damage is only partly understood. Animal studies in rats indicate that atractyloside and carboxy-atractyloside are potent inhibitors of oxidative phosphorylation and other mitochondrial functions leading to apoptosis [55]. Popat *et al.* have shown that impila extracts cause a concentration- and time-dependent loss of cell viability and mitochondrial glutathione (GSH) content in HepG2 cells [56]. The latter could be prevented by concomitant and post-treatment of HepG2 cells with *N*-acetylcysteine and *S*-adenosyl-L-methionine, precursors of GSH. In the same study, HepG2 cells were exposed to purified atractylosides without significant toxicity, suggesting that other components within the plant extracts are responsible for the observed liver damage.

Miscellaneous

Various other botanicals have been associated with toxic liver damage such as senna (*Cassia angustifolia*), which was identified as a cause of a relatively benign hepatitis in a woman taking approximately 10 times the recommended dose [57]. The causal relationship was confirmed through a positive rechallenge. Senna is biotransformed via intestinal bacteria to rhein anthrone, which shows structural similarities to the laxative anthrone. Likewise, anthraquinones, including rhein anthrone, contained in rhubarb have been suspected of causing liver injury [58]. Nadir *et al.* have described a man in whom short-term use of a commercial *Cascara sagrada* product caused cholestatic hepatitis with subsequent portal hypertension, prolonged prothrombin time and ascites [59]. *Cascara sagrada* also contains anthraquinone glycosides and is recognized as an effective laxative. Other frequent aetiologies were excluded, but the patient also took amitryptiline, cimetidine and baclofen at recommended doses. Further laboratory tests revealed elevated antinuclear and antismooth muscle antibodies at 1:640 and 1:40, respectively, and a liver biopsy showed an eosinophilic infiltrate suggesting drug-induced autoimmunity. Hepatotoxicity is a relatively unusual side-effect of *Cascara sagrada*, and it remains speculative which of its numerous constituents precipitated the liver damage.

Pennyroyal, also referred to as 'squawmint oil', is a herb containing leaves from either *Mentha pulegium* or *Hedeoma pulegoides*. It has long been applied as an abortifacient or pesticide against fleas. There are several reports on fulminant liver failure resulting from pennyroyal. Its primary constituents are pulegone and various other monoterpenes characteristically encountered in mint species [60]. However, pulegone is found

in greater concentrations in pennyroyal than in other mints. Hepatotoxicity appears to be caused by both pulegone producing oxidative stress and pulegone's primary metabolite menthofuran [61,62]. Direct depletion of GSH by the formation of electrophilic metabolites seems to be the crucial step in pulegone toxicity.

A combination of herbal ingredients, known as 'Prostata', was suspected to have caused cholestatic hepatitis in a man using this medication for the treatment of benign prostatic hyperplasia [63]. The assumed active ingredient is *Serrenoa serrulata*, which exerts estrogenic and antiandrogenic effects. Either hormone may be toxic to the liver under certain circumstances.

Ayurvedic herbal preparations such as Liv.52 have been studied for the treatment of chronic liver diseases either experimentally or clinically. Liv.52 contains *Capparis spinosa* (capers), *Cichorium intibus* (wild chicory), *Terminalia arjuna* (arjuna), *Solanum nigrum* (black nightshade), *Achillea millefolium* (yarrow) and others. Liv.52 was suggested to be useful for human alcohol-related liver cirrhosis by lowering acetaldehyde [64]. This initiated a European randomized controlled clinical trial in 188 patients with alcoholic liver cirrhosis [65]. While no effect of Liv.52 on survival was noticed in cirrhotics with Child class A and B disease increased liver-related mortality among those with Child class C led to premature termination of the study. Seven patients experienced acute hepatitis after the intake of LipoKinetix® (Syntrax, Cape Girardeau, MO, USA), which is sold as a dietary supplement in the US for augmenting weight loss [66]. All patients recovered after LipoKinetix® was stopped, but one female patient developed fulminant hepatic failure with stage 3 encephalopathy and was listed for liver transplantation, which fortunately was avoided as the patient recovered with intensive care. LipoKinetix® contains norephedrine hydrochloride, sodium usniate, diiodothyronine, yohimbine hydrochloride and caffeine, which was confirmed by analysing the used LipoKinetix® lots. None of the ingredients was previously associated with liver damage, and product contamination was excluded. For usnic acid, an uncoupling effect on oxidative phosphorylation in murine mitochondria has been described [67]. Both Liv.52 and LipoKinetix emphasize the potential hazards of poorly defined and incompletely tested herbal medications.

A 13-year-old child from France developed fulminant liver failure after taking Euphytose, a herbal mixture containing *Valeriana officinalis*, *Ballota nigra*, *Crataegus oxyacantha*, *Passiflora incarnata* and *Cola nitida*. Liver histology showed massive hepatocyte necrosis. All other possible explanations for liver failure were ruled out, and *Valeriana* was considered the most likely cause among these medicinal plants [68]. However, causality remains unproven.

Centella asiatica has been used in Ayurvedic medicine as a psychophysical regenerator and 'blood purifier' and to treat wounds and leprosy. At present, *Centella asiatica* has alleged benefit in the treatment of dementia, diabetic microangiopathy, skin defects and obesity [69]. Recently, three female patients who took this herbal for between 1 and 6 months to lose weight were diagnosed with severe hepatic injury, including granulomatous hepatitis and cirrhosis [70]. Unintentional re-exposure resulted in accelerated recurrence of hepatic lesions in two patients. Extracts of this herb contain pentacyclic triterpenic saponosides including asiaticoside, madecassoside and centellasaponins. The mechanism by which liver damage is precipitated is uncertain. Treatment with ursodeoxycholic acid at 10 mg/kg/day led to normalization of altered liver biochemistries in all three patients.

Noni juice (*Morinda citrifolia*) was the presumed cause of acute hepatitis in a 45-year-old man who drank a glass of this tropical fruit over several weeks for 'prophylactic reasons' [71]. Other possible aetiologies of acute hepatitis were ruled out, and liver tests rapidly returned to normal after the cessation of noni intake. Active components within noni extracts comprise flavonoids, glycosides, vitamins, anthraquinones and polyunsaturated fatty acids, but hepatotoxic components remained unidentified.

Diagnosis

The uncertainties of confirming causality in herbal drug-induced liver injury are well known. Often, the diagnosis can only be made based on clinical evidence. Therefore, numerical scores that account for clinical circumstances and findings were suggested for clinical routine use. Among the proposed systems, a scale developed by the Council for International Organizations of Medical Sciences (CIOMS) reveals the best discriminative power and allows satisfactory causality assessments (Table 2) [72].

Table 2 CIOMS score for causality assessment in drug-related liver injury.

Axis	Score
Chronologic criterion	
From drug intake until onset of event	+2 to +1
From drug withdrawal until onset of event	+1 to 0
Course of the reaction	–2 to +3
Risk factors	
Age	+1 to 0
Alcohol	+1 to 0
Concomitant drug therapy	–3 to 0
Exclusion of non-drug-related causes	–3 to +2
Bibliographic data	0 to +2
Rechallenge	–2 to +3

The CIOMS score is translated into categories of suspicion: definite or highly probable (score > 8), probable (score 6–8), possible (score 3–5), unlikely (1–2), excluded (< 1).

References

1 Kessler RC, Davis RB, Foster DF *et al.* (2001) Long-term trends in the use of complementary and alternative medical therapies in the United States. *Ann Intern Med* 135, 262–268.

2 Strader DB, Bacon BR, Lindsay KL *et al.* (2002) Use of complementary and alternative medicine in patients with liver disease. *Am J Gastroenterol* 97, 2391–2397.

3 Flora KD, Rosen HR, Brenner KG *et al.* (1996) The use of neuropathic remedies for chronic liver disease. *Am J Gastroenterol* 91, 2654–2655.

4 Estes JD, Stolpman D, Olyaei A *et al.* (2003) High prevalence of potentially hepatotoxic herbal supplement use in patients with fulminant hepatic failure. *Arch Surg* 138, 852–858.

5 Blumenthal M (ed.) (1998) *The Complete German Commission E Monographs – Therapeutic Guide to Herbal Medicines*. Austin, TX: American Botanical Council.

6 Anon (2002) *Licensing of Medicines: Policy on Herbal Medicines. Herbal Safety News*. London: Medicines Control Agency (http://www.mca.gov.uk/ourwork/licensingmeds/herbalsafety.htm).

7 De Smet PAGM (2002) Herbal remedies. *N Engl J Med* 347, 2046–2056.

8 Stedman C (2002) Herbal hepatotoxicity. *Semin Liver Dis* 22, 195–206.

9 Chen TSN, Chen PS (1998) Liver in traditional Chinese medicine. *J Gastroenterol Hepatol* 13, 437–442.

10 Woolf GM, Petrovic LM, Rojter SE *et al.* (1994) Acute hepatitis associated with the Chinese herbal product Jin Bu Huan. *Ann Intern Med* 10, 729–735.

11 Picciotto A, Campo N, Brizzolara R *et al.* (1998) Chronic hepatitis induced by Jin Bu Huan. *J Hepatol* 28, 165–167.

12 Nadir A, Agrawal S, King PD *et al.* (1996) Acute hepatitis associated with the use of a Chinese herbal product, Ma-Huang. *Am J Gastroenterol* 91, 1436–1438.

13 Bajaj J, Knox JF, Komorowski R *et al.* (2003) The irony of herbal hepatitis: Ma-Huang-induced hepatotoxicity associated with compound heterozygosity for hereditary hemochromatosis. *Dig Dis Sci* 48, 1925–1928.

14 Kane JA, Kane SP, Jain S *et al.* (1995) Hepatitis induced by traditional Chinese herbs; possible toxic components. *Gut* 36, 146–147.

15 Yoshida EM, McLean CA, Cheng ES *et al.* (1996) Chinese herbal medicine, fulminant hepatitis and liver transplantation. *Am J Gastroenterol* 12, 2647–2648.

16 Galloway JH, Marsh ID, Bittiner SB *et al.* (1991) Chinese herbs for eczema, the active compound? *Lancet* 337, 566.

17 But PP, Tomlinson B, Lee KL *et al.* (1996) Hepatitis related to the Chinese medicine Shou-wu-pian manufactured from *Polygonum multiflorum*. *Vet Hum Toxicol* 38, 280–282.

18 Park GJH, Mann SP, Ngu MC *et al.* (2001) Acute hepatitis induced by Shou-Wu-Pian, a herbal product derived from *Polygonum multiflorum*. *J Gastroenterol Hepatol* 16, 115–117.

19 Westendorf J (1993) Anthranoid derivatives – general discussion. In: De Smet, PAGM, Keller K, Hansel Chandler R (eds) *Adverse Effects of Herbal Drugs*. Berlin: Springer, pp. 105–118.

20 Kanda T, Yokosuko O, Okada O *et al.* (2003) Severe hepatotoxicity associated with Chinese diet product 'Onshidou-Genbi-Kounou'. *J Gastroenterol Hepatol* 18, 354–355.

21 Lin TJ, Tsai MS, Chiou MN *et al.* (2002) Hepatotoxicity caused by *Breynia officinalis*. *Vet Hum Toxicol* 44, 87–88.

22 Stickel F, Seitz HK (2000) The efficacy and safety of comfrey. *Pub Health Nutr* 3(4A), 501–508.

23 Stillman AE, Huxtable RJ, Fox D *et al.* (1977) Hepatic veno-occlusive disease due to pyrrolizidine (*Senecio*) poisoning in Arizona. *Gastroenterology* 73, 349–352.

24 Fox DW, Hart MC, Bergeson PS *et al.* (1978) Pyrrolizidine (*Senecio*) intoxication mimicking Reye's syndrome. *J Pediatr* 93, 980–982.

25 Weston CF, Cooper BT, Davis JD *et al.* (1987) Veno-occlusive disease of the liver secondary to ingestion of comfrey. *Br Med J* 295, 183.

26 Roulet M, Laurini R, Rivier L *et al.* (1988) Hepatic veno-occlusive disease in a newborn infant of a woman drinking herbal tea. *J Pediatr* 112, 433–436.

27 DeLeve LD, Shulman HM, McDonald GB *et al.* (2002) Toxic injury to hepatic sinusoids: sinusoidal obstruction syndrome (veno-occlusive disease). *Semin Liver Dis* 22, 27–42.

28 Mattocks AR (1986) *Chemistry and Toxicology of Pyrrolizidine Alkaloids*. London: Academic Press.

29 Willett KL, Roth RA, Walker L *et al.* (2004) Workshop overview: hepatotoxicity assessment for botanical dietary supplements. *Toxicol Sci* 79, 4–9.

30 Larrey D, Vial T, Pawels A *et al.* (1992) Hepatitis after germander (*Teucrium chamaedrys*) administration: another instance of herbal medicine hepatotoxicity. *Ann Intern Med* 117, 129–132.

31 Larrey D, Pageaux GP (1995) Hepatotoxicity of herbal remedies and mushrooms. *Semin Liver Dis* 15, 183–188.

32 Kouzi SA, McMurtry RJ, Nelson SD *et al.* (1994) Hepatotoxicity of germander (*Teucrium chamedrys* L.) and one of its constituent neoclerodane diterpenes, teucrin A in the mouse. *Chem Res Toxicol* 7, 850–856.

33 Loeper J, Descatoire V, Letteron P *et al.* (1994) Hepatotoxicity of germander in mice. *Gastroenterology* 106, 464–472.

34 Lekehal M, Pessayre D, Lerreau JM *et al.* (1996) Hepatotoxicity of the herbal medicine, germander. Metabolic activation of its furano diterpenoids by cytochrome P450 3A depletes cytoskeleton-associated protein thiols and forms plasma membrane blebs in rat hepatocytes. *Hepatology* 24, 212–218.

35 Fau D, Lekehal M, Farrell G *et al.* (1997) Diterpenoids from germander, an herbal medicine, induce apoptosis in isolated rat hepatocytes. *Gastroenterology* 113, 1334–1346.

36 Mattei A, Rucai P, Samuel D *et al.* (1995) Liver transplantation for severe acute liver failure after herbal medicine (*Teucrium polium*) administration. *J Hepatol* 22, 597.

37 Colombo ML, Bosisio E (1996) Pharmacological activities of *Chelidonium majus* L. (Papaveraceae). *Pharmacol Res* 33, 127–134.

38 Strahl S, Ehret V, Dahm HH *et al.* (1998) Necrotizing hepatitis after taking herbal medication extracts of kava or of common or lesser celandine (article in German). *Dtsch Med Wschr* 123, 1410–1414.

39 Greving I, Meister V, Monnerjahn C *et al.* (1998) *Chelidonium majus*: a rare reason for severe hepatotoxic reaction. *Pharmaepidemiol Drug Safety* 7, S66–69.

40 Benninger J, Schneider HT, Schuppan D *et al.* (1999) Acute hepatitis induced by greater celandine (*Chelidonium majus*). *Gastroenterology* 117, 1234–1237.

41 Stickel F, Poschl G, Seitz HK *et al.* (2003) Acute hepatitis induced by greater celandine. *Scand J Gastroenterol* 38, 565–568.

42 Davies LP, Drew CA, Duffield P *et al.* (1992) Kavapyrones and resin: studies on $GABA_A$, $GABA_B$ and benzodiazepine binding sites in rodent brain. *Pharmacol Toxicol* 71, 120–126.

43 Pittler MH, Ernst E (2000) Efficacy of kava extract for treating anxiety: systematic review and meta-analysis. *J Clin Psychopharmacol* 20, 84–89.

44 Aithal GP, Rawlins MD, Day CP *et al.* (2000) Clinical diagnostic scale: a useful tool in the evaluation of suspected hepatotoxic adverse drug reaction. *J Hepatol* 33, 949–952.

45 Stickel F, Baumuller HM, Seitz K *et al.* (2003) Hepatitis induced by kava-kava (*Piper methysticum rhizoma*). *J Hepatol* 39, 62–67.

46 Russmann S, Lauterburg BH, Helbling A *et al.* (2001) Kava hepatotoxicity. *Ann Intern Med* 135, 68–69.

47 Centers for Disease Control and Prevention (2003) Hepatic toxicity possibly associated with kava-containing products – United States, Germany, and Switzerland. *JAMA* 289, 36–37.

48 Currie BJ, Clough AR (2003) Kava hepatotoxicity with Western herbal products: does it occur with traditional kava use? *Med J Aust* 178, 421–422.

49 Nerurkar PV, Dragull K, Tang CS *et al.* (2004) In vitro toxicity of kava alkaloid, pipermethystine, in HepG2 cells compared to kavalactones. *Toxicol Sci* 79, 106–111.

50 Kassler WJ, Blanc P, Greenblatt R *et al.* (1991) The use of medicinal herbs by human immunodeficiency virus-infected patients. *Arch Intern Med* 151, 2281–2288.

51 Sheikh NM, Philen RM, Love LA *et al.* (1997) Chaparral-associated hepatotoxicity. *Arch Intern Med* 157, 913–919.

52 Agarwal R, Wang ZY, Bik DP *et al.* (1991) Nordihydroguaiaretic acid, an inhibitor of lipoxygenase, also inhibits cytochrome P-450-mediated monooxygenase activity in rat epidermal and hepatic microsomes. *Drug Metab Dispos* 19, 620–624.

53 Larrey D (1997) Hepatotoxicity of herbal remedies. *J Hepatol* 26, 47–54.

54 Popat A, Shear NH, Malkiewicz I *et al.* (2001). The toxicity of *Callilepsis laureola*, a South African traditional herbal medicine. *Clin Biochem* 34, 229–236.

55 Stewart MJ, Steenkamp V (2000) The biochemistry and toxicity of atractyloside: a review. *Ther Drug Monit* 22, 641–649.

56 Popat A, Shear NH, Malkiewicz I *et al.* (2002) Mechanism of Impila (*Callilepsis laureola*)-induced cytotoxicity in HepG2 cells. *Clin Biochem* 35, 57–64.

57 Beuers U, Spengler U, Pape GR *et al.* (1991) Hepatitis after chronic abuse of senna. *Lancet* 337, 372–373.

58 Popper H, Rubin E, Cardiol D *et al.* (1965) Drug-induced liver disease: a penalty for progress. *Arch Intern Med* 115, 128–136.

59 Nadir A, Reddy T, Van Thiel DH *et al.* (2000) *Cascara sagrada*-induced intrahepatic cholestasis causing portal hypertension: case report and review of herbal hepatotoxicity. *Am J Gastroenterol* 95, 3634–3637.

60 Anderson IB, Mullen WH, Meeker JE *et al.* (1996) Pennyroyal toxicity: measurement of toxic metabolite levels in two cases and review of the literature. *Ann Intern Med* 124, 726–734.

61 Thomassen D, Slattery JT, Nelson SD *et al.* (1990) Menthofuran-dependent and independent aspects of pulegone hepatotoxicity: roles of glutathione. *J Pharmacol Exp Ther* 253, 567–572.

62 Thomassen D, Knebel N, Slattery JT *et al.* (1992) Reactive intermediates in the oxidation of menthofuran by cytochromes P-450. *Chem Res Toxicol* 5, 123–130.

63 Hamid S, Rojter S, Vierling J *et al.* (1997) Protracted cholestatic hepatitis after the use of prostata. *Ann Intern Med* 127, 169.

64 Chauhan BL, Kulkarni RD (1991) Effect of LIV.52, a herbal preparation, on absorption and metabolism of ethanol in humans. *Eur J Clin Pharmacol* 40, 189–191.

65 Fleig WW, and a European multicenter study group (1997). The ayurvedic drug LIV.52 in patients with alcoholic cirrhosis. Results of a prospective, randomized, double-blind, placebo-controlled clinical trial (abstract). *J Hepatol* 26(Suppl. 1), 127.

66 Favreau JT, Ryu ML, Braunstein G *et al.* (2002) Severe hepatotoxicity associated with the dietary supplement LipoKinetix. *Ann Intern Med* 136, 590–595.

67 Abo-Khatwa AN, Al-Robai AA, Al-Jawhari DA *et al.* (1996) Lichen acids as uncouplers of oxidative phosphorylation of mouse-liver mitochondria. *Natural Toxins* 4, 96–102.

68 Bagheri H, Brue P, Lacroix I *et al.* (1998) Fulminant hepatic failure after herbal medicine ingestion in children. *Thérapie* 53, 77–83.

69 Brinkhaus B, Lindner M, Schuppan D *et al.* (2000) Chemical, pharmacological and clinical profile of the East Asian plant *Centella asiatica*. *Phytomedicine* 7, 427–448.

70 Jorge OA, Jorge AD (2005) Hepatotoxicity associated with the ingestion of *Centella asiatica*. *Rev Esp Enferm Dig* 97, 115–124.

71 Millonig G, Stadelmann S, Vogel W *et al.* (2005) Herbal hepatotoxicity: acute hepatitis caused by a Noni preparation (*Morinda citrifolia*). *Eur J Gastroenterol Hepatol* 17, 45–47.

72 Lucena MI, Camargo R, Andrade RJ *et al.* (2001) Comparison of two clinical scales for causality assessment in hepatotoxicity. *Hepatology* 33, 123–130.

15 Acute liver failure

15 Acute liver failure and related syndromes

François Durand and Jacques Bernuau

Acute liver failure defines a syndrome resulting from a rapid and massive impairment of liver functions in patients without previously known liver disease. The main causes of acute liver failure are currently represented by paracetamol overdose, viral hepatitis and idiosyncratic drug reactions. However, it is a frequent finding that two or more causative factors are associated, some of them being avoidable [1]. Nonetheless, as many as 20% of cases remain of unknown origin. Acute liver failure remains a life-threatening condition, with brain oedema representing the ultimate and most severe complication. Despite significant improvements in medical support during recent years, the prognosis of acute liver failure is still poor. The advent of emergency liver transplantation in the early 1980s has transformed the prognosis even though transplantation remains a demanding procedure [2].

Definitions

There is no consensus on the definitions of acute liver failure and related syndromes, particularly for the early stages preceding encephalopathy.

Originally, fulminant liver failure was defined as an acute liver disease complicated by encephalopathy within 8 weeks of the onset of symptoms [3]. This simple definition has several limitations. In particular, first manifestations are frequently difficult to identify in retrospect. Therefore, two sets of modifications, detailed in Table 1, have been proposed. Because no general agreement has been achieved yet, the core terms 'fulminant or subfulminant liver failure', on the one hand, and 'acute liver failure', on the other hand, continue to be used equally in the literature. It remains difficult not to qualify patients with massive liver cell damage and a profound decrease in coagulation factors as having some degree of 'liver insufficiency' even though they do not have clinical evidence of encephalopathy. This ambiguity has resulted in frequent and inappropriate use of the term 'acute liver failure' for patients without encephalopathy. Thus, it remains controversial whether the definition should include markers of poor liver function other than encephalopathy. Furthermore, the issue of which markers should then be included (e.g. coagulation factors) remains debated. A consensus is clearly needed for clinical practice.

In this chapter, a terminology based on 'early acute liver insufficiency' and 'acute liver failure' will be used. 'Early acute liver insufficiency' corresponds to a state characterized by a marked decrease in coagulation factors [prothrombin index below 50% of normal and/or international normalized ratio (INR) over 1.7] without encephalopathy. 'Acute liver failure' (acute liver failure, corresponding to the sum of either 'fulminant and subfulminant' cases or 'hyperacute, acute and subacute' cases) is characterized by the occurrence of encephalopathy. Patients with an underlying chronic liver disease but without previous manifestations are not excluded from these definitions.

The related syndrome of early acute liver insufficiency

As indicated above, the syndrome of 'early acute liver insufficiency' corresponds to the stages of marked deterioration of liver functions preceding the occurrence of encephalopathy. Apart from encephalopathy and brain oedema, almost all the manifestations observed during the acute liver failure syndrome (see below) can also be observed during the early acute liver insufficiency syndrome, even though these manifestations tend to be milder. By definition, coagulation factors are markedly decreased. Importantly, patients with early acute liver insufficiency have a marked propensity to develop extrahepatic complications, in particular acute renal insufficiency and bacterial infections, which may precipitate the course of the disease and hasten the occurrence of encephalopathy [1].

Manifestations of acute liver failure

The syndrome of acute liver failure includes manifestations directly related to liver cell damage and manifestations reflecting the indirect consequences of altered liver functions on other organs or systems.

Table 1 Proposed definitions for acute liver failure and related disorders.

	Bernuau *et al.* (1986) [99]	O'Grady *et al.* (1993) [20]
Definitions	*Severe liver failure*: any condition including an acute liver disease with coagulation factors below 50% of normal without clinical encephalopathy Fulminant or subfulminant liver failure: patients with the same coagulopathy and encephalopathy *Fulminant*: interval between jaundice and encephalopathy less than 2 weeks *Subfulminant*: interval between jaundice and encephalopathy from 2 weeks to 3 months	*Hyperacute liver failure*: patients who develop encephalopathy within 7 days of the appearance of jaundice *Acute liver failure*: patients who develop encephalopathy between 8 and 28 days after the appearance of jaundice *Subacute liver failure*: patients who develop encephalopathy between 5 and 12 weeks after the appearance of jaundice
Definitions including patients before the onset of encephalopathy	Yes	No
Coagulation is used as a marker of impaired liver function	Yes	No
Patients with previously asymptomatic chronic liver lesions enter the same definitions	Yes	Yes

Manifestations of liver cell damage

Jaundice is quite constant. However, serum bilirubin level is highly variable, depending on the mechanism of liver injury. Jaundice tends to be less intense (or even absent) in those with hyperacute liver failure compared with those with more slowly progressive diseases. In most cases, the inferior margin of the liver is undetectable at clinical examination, and the liver is not painful. Moderate ascites can be present, especially in patients with subacute diseases.

Serum aminotransferase level [alanine aminotransferase (ALT) and aspartate aminotransferase (AST)] is constantly and markedly increased. Values over 50 times normal are usually observed in patients with acute liver failure while values below 30 times normal are not uncommon in patients with subacute liver failure. Serum alkaline phosphatase and γ-glutamyl transpeptidase are normal or moderately raised. Again, coagulation factors are constantly decreased (see below).

Generally, liver imaging is of little help in the diagnosis. The liver can be decreased, normal or slightly increased in size, depending on the cause. Ultrasonography can help to detect subclinical ascites. Prominent signs of portal hypertension are absent. Some patients with subfulminant liver failure and a prolonged interval between jaundice and encephalopathy may present with large, tumour-like, regenerative nodules and irregular margins. These nodules may be hypervascular, thus mimicking malignant tumours. Hepatic venous pressure gradient usually exceeds 5 mmHg, reflecting moderate portal hypertension [4].

Metabolic encephalopathy and cerebral oedema

Metabolic encephalopathy

Encephalopathy is a non-specific manifestation of liver failure. In cirrhotic patients, encephalopathy can result from impaired liver functions, portosystemic shunts or a combination of both. During acute liver failure, conversely, the alteration in liver functions represents the sole mechanism for encephalopathy.

The most commonly used classification of encephalopathy includes four grades of increasing severity (grades 1 to 4) with manifestations ranging from asterixis to coma. These grades are detailed in Chapter 7.8. The Glasgow score can also be used for further staging in comatose patients. Electroencephalographic changes are present before the onset of clinical manifestations. None of them is specific.

As well as in cirrhotic patients, a number of factors other than liver insufficiency can induce or precipitate encephalopathy. The administration of sedative agents before referral remains a frequent finding in clinical practice. Other precipitating factors include sepsis, renal failure and hypoglycaemia.

Cerebral oedema and increased intracranial pressure

A feature particular to neurological changes during acute liver failure is the rapid development of brain oedema and intracranial hypertension when liver insufficiency persists or progresses. Brain oedema is a life-threatening complication which can be fatal within a few hours or days. In addition to altered consciousness, brain oedema is characterized by the occurrence of profuse sweating, fever, a progressive increase in heart rate, haemodynamic instability, bouts of arterial hypertension, hyperventilation, increased muscle tone and decerebrate posturing with pronation. The occurrence of pupil asymmetry or poorly responsive mydriasis indicates impending brainstem coning and/or irreversible brain anoxia. The incidence of generalized or partial seizures is about 25% [5]. Computerized tomography shows diffuse hypoattenuation of the brain, a loss of distinction between grey and white matter, swollen gyri and compressed or absent cisterns.

During the course of liver failure, there is a clear overlap between the manifestations related to metabolic encephalopathy and those related to brain oedema. While metabolic encephalopathy is fully reversible, brain oedema may cause irreversible damage. However, it is important to keep in mind that some patients with almost complete disappearance of brain electrical activity just before transplantation were shown to have full neurological recovery postoperatively.

Renal disorders

Renal disorders are a common finding. The usual features resemble those of functional renal insufficiency with oliguria and low urinary sodium concentration. As liver insufficiency worsens, renal dysfunction progresses in parallel, leading to anuria. Extrahepatic precipitating factors are frequently involved, including sepsis, hypotension, direct toxicity from paracetamol overdose, non-steroidal anti-inflammatory agents or the recent infusion of contrast media.

Cardiovascular disorders

Cardiovascular changes correspond to a hyperkinetic state with tachycardia, systemic vasodilatation and increased cardiac output. Arterial pressure is normal in the early stages but tends to decrease during more advanced stages. A normal heart rate in patients with grade 3–4 encephalopathy strongly suggests that encephalopathy has been precipitated by sedative agents and that the alteration in liver function is milder than suggested by the neurological status. Patients with brain oedema frequently develop a distributive shock resembling septic shock.

Pulmonary disorders

A progressive increase in respiratory rate is almost constant in patients with grade 3–4 encephalopathy. Hyperventilation is central in origin. Pulmonary oedema can develop in the absence of sepsis, overfilling and/or left ventricular failure. However, bacterial infections represent the main cause of pulmonary complications. Respiratory distress syndrome may result from bacterial pneumonia and/or pulmonary aspiration in comatose patients.

Coagulation disorders

By definition, coagulation factors are constantly decreased during acute liver failure because of reduced synthesis by the liver. However, an accelerated clearance of coagulation factors due to intravascular coagulation can also be associated.

Almost all patients with an altered level of consciousness have coagulation factors below 30% of normal and an INR above 2.5. There is a decrease in prothrombin index, a decrease in factor V and a prolongation of prothrombin time. Difficulties arise from the fact that these tests are not used uniformly in different countries. Prothrombin index and factor V are frequently used in Europe, while prothrombin time has been the reference in the UK. INR is increasingly used in the United States. This disparity makes the comparison between different populations difficult. In addition, the application of decision criteria based on a given coagulation marker may be difficult in countries where other markers are used. Nevertheless, in the very context of acute liver failure, these markers are strongly correlated one to the other (although not always linearly).

The decrease in coagulation factors is paralleled by a decreased level of coagulation inhibitors and regulating factors. The practical impact of the balance or imbalance between coagulation factors and inhibitors has not been clearly addressed.

Low platelet count is common during acute liver failure. Thrombopoietin, the primary regulator of platelet production, is mainly synthesized by the liver. Paradoxically, most patients with acute liver failure appear to have a normal or even elevated thrombopoietin level [6]. It was shown that the physiological inverse correlation between thrombopoietin and platelet count no longer exists during acute liver failure. The mechanisms of thrombopenia during acute liver failure are still unclear.

In clinical practice, although coagulation factors and platelets are simultaneously decreased, the incidence of spontaneous bleeding is low, unless invasive procedures are undertaken.

Acid–base balance and metabolic disorders

From the early stage of acute liver failure, hyperventilation results in respiratory alkalosis with low $P_a CO_2$. A normal or increased $P_a CO_2$ suggests respiratory depression secondary to sedative agents. Metabolic acidosis is a common finding at an advanced stage. Acidosis is especially frequent in cases of 'hyperacute' liver failure. For example, metabolic acidosis, elevated blood lactate, overt renal failure and distributive shock are common in patients with paracetamol overdose and severe encephalopathy.

Hypoglycaemia only occurs at the latest stage. Hyperammonaemia as well as an increased lactate level are common. Arterial lactate level is especially high in patients with paracetamol overdose and, whatever the cause of liver injury, in patients with multiple organ failure [7].

Bacterial and fungal infections

Severe infections are more frequent and appear at an earlier stage in patients with acute liver failure than in intensive care patients without liver failure. This observation suggests that profound alterations in liver functions, by themselves, impair defence mechanisms against infectious agents.

The overall incidence of bacterial infections was found to be as high as 80%. The main sites are the lungs (especially in patients under mechanical ventilation), urinary tract, ascites, catheters and blood. Gram-positive bacteria account for about 65% of early infections, the remaining 35% being represented by

Gram-negative bacteria [8]. Fever and hyperleucocytosis may be absent. Fungal infections are frequently disseminated. *Candida albicans* and, to a lesser extent, *Aspergillus fumigatus* are the most common agents. Interestingly, early infections were shown to precipitate encephalopathy [8].

Mechanisms

Acute liver failure: an imbalance between hepatocyte death and regeneration

Hepatocyte death can result from two distinct mechanisms, necrosis and apoptosis, which may coexist. Indeed, many factors responsible for apoptosis can also induce hepatocyte necrosis, in particular when mitochondrial injury is sufficient to exhaust the adenosine triphosphate (ATP) store [9]. The cellular content of glutathione, a protective antioxidant compound, is determinant for modulating the pathways of liver cell death. Complement also plays a key role in liver cell necrosis by the formation of a cytolytic membrane attack complex. A depletion of complement regulatory proteins, as observed during viral hepatitis, seems to favour the extent of hepatocyte necrosis [10].

Besides necrosis and apoptosis, microvesicular steatosis represents a particular lesion specifically associated with certain causes of acute liver failure. The reasons why the acute development of microvesicular steatosis can result in a massive impairment in liver functions remain unclear. Indeed, it is a paradox that microvesicular steatosis during chronic liver diseases, even if extensive, is a relatively benign condition. It can be speculated that the alteration in liver functions during 'acute' microvesicular steatosis results from a marked impairment in mitochondrial functions as well as other cell functions rather than the simple accumulation of lipid droplets within the hepatocytes. According to this view, steatosis might be better considered an accompanying than a causative disorder.

The potential for regeneration of the liver is considerable compared with other organs. The regeneration process occurs rapidly when liver cell death is extensive. This process is triggered by systemic as well as local factors. Hepatocyte growth factor (HGF), a cytokine with potent mitogenic effects, plays a pivotal role in the initiation of liver cell division. Other important factors include epidermal growth factor and transforming growth factor. It is noteworthy that sepsis inhibits hepatocyte regeneration [9]. Underlying fibrosis and advanced age are other factors limiting regeneration.

Overall, during the course of acute liver diseases, there is competition between liver cell death, on the one hand, and regeneration, on the other hand. Both mechanisms coexist. In most cases, liver cell damage stops and regeneration is rapid and efficient enough to prevent the occurrence of liver failure. In some patients, however, the extent of liver cell damage reaches the critical limit over which life-threatening complications appear. Again, in most cases, regeneration eventually outweighs liver cell damage, leading to rapid recovery. In only a minority, regeneration is insufficient and/or liver cell damage is too extensive, which leads to the occurrence of encephalopathy and brain oedema. However, it must be kept in mind that patients with impending brain oedema still have a potential for 'last minute' regeneration and complete recovery.

Encephalopathy and brain oedema

The precise mechanisms of hepatic encephalopathy are detailed in Chapter 7.8. Basically, the exposure of the brain to circulating neurotoxins is the predominant factor. Elevated blood ammonia level plays an important role. Hyperammonaemia results predominantly from decreased hepatic clearance. However, insufficient uptake by muscles and decreased elimination by the kidneys may also be implicated [11]. Other mediators including lactates and endogenous benzodiazepines are involved. In addition, brain glucose metabolism is altered.

Brain oedema is a characteristic feature of acute liver failure, although not absolutely specific. Indeed, some patients with cirrhosis and profound encephalopathy were also shown to have mild brain oedema. Conceptually, brain oedema arises from two mechanisms: an increase in total brain water content and an increase in cerebral blood flow. The increase in total brain water is mainly related to the swelling of astrocytes secondary to acute osmotic changes [12]. In healthy individuals, there is efficient hepatic uptake of ammonia leading to the synthesis of urea and glutamine. Liver failure results in decreased uptake by the liver and an increased peripheral load. The brain that lacks a complete urea cycle becomes an ammonia uptake organ. The metabolism of ammonia in the brain leads to the accumulation of glutamine within the astrocytes which, as a source of increased osmolarity, contributes to cell swelling. There are short- and long-term adaptive mechanisms for overcoming changes in astrocyte osmolarity. An increased exit of potassium from brain cells represents a short-term mechanism. The reduction in intracellular myoinositol represents a long-term adaptive mechanism. However, there is no evidence that the accumulation of intracellular myoinositol plays a significant role during acute liver failure [13]. Astrocytic glial fibrillary acid protein is the principal component of astrocytic intermediate filaments. Experimental models have shown that there is decreased expression of astrocytic glial fibrillary acid protein mRNA, and it seems likely that this mechanism contributes to astrocytic swelling.

An increased or inappropriate cerebral blood flow also contributes to intracranial hypertension. Under normal circumstances, adaptive mechanisms make sure that cerebral blood flow is maintained at a relatively constant level through significant changes in mean arterial pressure. Acute liver failure is characterized by a failure in cerebrovascular autoregulation [14]. Under such circumstances, a significant increase in cardiac output is associated with a proportional increase in cerebral blood flow, thus worsening intracranial hypertension.

Normal intracranial pressure ranges from 0 to 10 mmHg. In patients with brain oedema, these values may reach 70–

100 mmHg. Overall, intracranial hypertension compromises cerebral perfusion by reducing cerebral perfusion pressure, and predisposes to brain herniation.

Causes

Although the spectrum of potential causes is especially wide, acute liver failure remains a rare disorder, which is explained by a multifactorial aetiology. Indeed, several causes or cofactors are frequently associated. The different causes and the corresponding liver lesions are shown in Table 2.

Paracetamol (acetaminophen) overdose

Paracetamol overdose has become the predominant cause of acute liver failure in most western countries [15–17]. However, only a minority (less than 10%) of patients with paracetamol overdose eventually develop acute liver failure.

The hepatotoxicity of paracetamol is dose dependent. Liver cell damage is related to the generation of large amounts of the reactive metabolite *N*-acetyl-*p*-quinoneimine, overcoming the protective capacities of glutathione within liver cells. Acute liver failure is almost always observed in patients who ingested single

Table 2 Causes of acute liver failure and corresponding liver lesions.

Cause	Hepatocyte necrosis and/or apoptosis	Inflammatory infiltrates	Microvesicular steatosis
Paracetamol (acetaminophen) overdose	+	–	–
Hepatitis viruses			
Hepatitis A virus	+	+	–
Hepatitis B virus			
Acute HBV infection	+	+	–
Acute exacerbation of chronic HBV infection[a]	+	+	–
Hepatitis D virus	+	+	–
Hepatitis E virus	+	+	–
Other viruses			
Herpes simplex virus 1 and 2	+	–	–
Varicella-zoster virus	+	–	–
Epstein–Barr virus	+	–	–
Human herpes virus 6	+	±	–
Miscellaneous viruses			
Human parvovirus B19[b]	+	±	–
Haemorrhagic fever viruses	+	±	–
Amanita mushroom poisoning	+	–	–
Other toxins			
Industrial solvents	+	–	–
Herbal medicines	+	±	–
Illicit drugs			
Ecstasy	+	±	–
Cocaine	+	±	–
Intravenous buprenorphine	+	–	+
Drug-induced hepatitis	+	±	±
Hypoxic liver cell necrosis	+	–	–
Heat stroke	+	–	–
Wilson's disease[a]	+	–	±
Malignant infiltration of the liver	+	–	–
Autoimmune hepatitis[a]	+	+	–
Syncytial giant cell hepatitis	+	±	–
Acute fatty liver of pregnancy	±	–	+
HELLP syndrome	+	–	–
Reye syndrome	±	–	+
Obstruction of the hepatic veins[a]	+	–	–
Liver transplantation and liver surgery	+	±	–

HELLP, haemolysis, elevated liver function and low platelets.
[a]Underlying parenchymal fibrosis is frequently associated.
[b]The responsibility of this virus is highly uncertain.

doses superior to 15 g in an attempt at suicide. However, single doses of 6 g in adults as well as repeated daily doses of 2–6 g for a few days are sufficient to produce significant liver damage (or even acute liver failure) when predisposing factors are present [18]. Predisposing factors include starvation, poor nutritional status, alcoholism, concomitant ingestion of enzyme inducers and concomitant ingestion of isoniazid.

Paracetamol hepatotoxicity is characterized by a rapid increase in serum transaminases, starting approximately 24 h after ingestion with a peak 1–3 days later. Transaminase levels can exceed 100 times the upper limit of normal. The level of AST is generally superior to that of ALT. Jaundice is usually absent at presentation as bilirubin level peaks later than transaminases. Acute renal failure is almost constant in patients with grade 3–4 encephalopathy. Lactic acidosis and severe hypoglycaemia are frequent. Serum paracetamol can be undetectable in patients who have been referred recently after ingestion.

Almost all patients with grade 3–4 encephalopathy rapidly develop multiorgan failure (unless encephalopathy results from sedative drugs). It has been shown that some patients die less than 4 days after ingestion as a result of circulatory shock in the absence of overt brain oedema [19]. These patients tend to be older and have a lower arterial pH at admission than those with a more slowly progressive disease and who develop brain oedema. The benefit from emergency transplantation in this particular group is uncertain. Overall, it is estimated that survival rate without transplantation is about 35% [20].

The treatment is based on *N*-acetylcysteine. The administration of *N*-acetylcysteine allows the replenishment of glutathione stores, a key factor in protecting against the toxic effects of reactive metabolites. Intravenous administration should be preferred to the oral route as the latter frequently induces nausea and vomiting. The standard intravenous protocol consists of 150 mg/kg within 15 min, followed by 50 mg/kg over 4 h, followed by 100 mg/kg over 16 h. Additional infusions of 100 mg/kg/16–24 h can be administered during the following days, until there is a significant increase in coagulation factors (over 50% of normal). Self-limited urticaria, pruritus and flushing are frequent at the onset of treatment and should not lead to discontinuation. *N*-acetylcysteine is more effective when started very early after paracetamol ingestion. However, patients who are referred recently after ingestion should also be given this compound. Emergency liver transplantation is needed in a small proportion of patients. The criteria for deciding on transplantation are discussed below.

Hepatitis viruses

Hepatitis A virus (HAV)

It is estimated that acute liver failure only develops in 0.01–0.05% of patients with symptomatic hepatitis A. In western countries, most cases are observed in patients who have had a recent stay in developing countries (see Chapter 9.1.2). The course of the disease is more often acute than subacute. The diagnosis is based on the presence of anti-HAV IgM in the serum. There is no specific treatment. The prognosis is slightly better than that of hepatitis B virus (HBV)-related acute liver failure.

It has been suggested that patients with chronic hepatitis C virus (HCV) infection may be at higher risk of acute liver failure and fatal outcome in the case of superimposed acute hepatitis A [21]. These findings have led to proposals for systematic vaccination against HAV in patients with chronic hepatitis C not previously immune to HAV.

Acute infection with hepatitis B virus

HBV can be responsible for acute liver failure in two distinct ways: (i) recent HBV infection; and (ii) acute exacerbation (or reactivation) in chronic HBV carriers (see Chapter 9.1.2).

The risk of developing acute liver failure during the course of symptomatic acute hepatitis B is about 1%. In western countries, the incidence of HBV-related acute liver failure has decreased in parallel with vaccination programmes. Currently, fulminant hepatitis B occurs most often in injection drug users and sexual partners of HBV-infected individuals. The course is more often acute than subacute. The diagnosis is based on the presence of anti-HBV IgM in the serum. It is important to keep in mind that hepatitis B surface antigen (HBsAg) is undetectable in 15–20% of patients with acute liver failure because of accelerated clearance of this antigen [22]. Serum HBV DNA is usually undetectable or present at very low levels. Therefore, there is no justification for antiviral treatment. Almost all patients who recover eventually become immune to HBV and do not develop chronic hepatitis B.

Liver lesions result from the host's immune response against HBV-infected cells. According to this mechanism, acute liver failure may result from a particularly intense immune response against viral antigens. However, an especially rapid viral clearance, reflected by undetectable HBsAg, could be of better prognosis [22]. It has been suggested that patients infected by variant HBV strains with precore mutations could be more likely to develop acute liver failure [23]. However, the association between precore variants and the occurrence of acute liver failure has not been observed in all series [24]. There is no evidence that chronic HCV infection represents a risk factor for fulminant hepatitis B.

Acute reactivation of chronic HBV infection

Acute reactivation of chronic HBV infection usually occurs in patients with a recent history of immunosuppression [25]. However, it may occasionally develop in the absence of any identifiable precipitating factor.

Theoretically, the diagnosis relies on the evidence of a return to an HBV replicative state in HBV carriers who previously had undetectable or low replication rates. However, the presentation of acute reactivation can be indistinguishable from that of acute HBV infection. First, a past history of chronic HBV infection is frequently lacking. Secondly, anti-hepatitis B core (HBc) IgM are frequently present in the case of reactivation. Thirdly, even

in the absence of antiviral therapy, a rapid decline in serum HBV DNA is usual. Therefore, patients with grade 3–4 encephalopathy frequently present with very low or even undetectable HBV DNA. In such patients, fibrosis at liver biopsy is an argument for an underlying chronic disease, and thus for reactivation.

On very rare occasions, some patients who were immune to HBV can also develop abrupt reactivation after being subjected to profound immunosuppression, as a result of the persistence of viral particles in the liver. The same phenomenon explains why liver grafts from donors negative for HBsAg and positive for anti-HBc IgG are still infective when transplanted to immunosuppressed recipients.

It is generally accepted that urgent administration of lamivudine or adefovir is justified in patients with HBV reactivation. However, the efficacy of antiviral agents in this context has not been clearly documented. Patients with a very low viral replication rate at presentation are unlikely to benefit from antiviral therapy.

Hepatitis D (delta) virus

Hepatitis delta virus (HDV) can cause acute liver failure in two distinct ways: concomitant HBV and HDV infection or HDV superinfection in HBV chronic carriers. In western countries, HDV infection is essentially observed in intravenous drug users. Its incidence has become very low (see Chapter 9.1.2).

The presentation of concomitant HBV–HDV infection is comparable to that of HBV infection alone. The diagnosis is based on the presence of markers of both acute HBV and HDV infection (anti-HBc IgM and anti-HDV IgM). Serum HDV RNA is positive in only 10% of cases [26]. The mortality rate is comparable to that of HBV-related acute liver failure.

The presentation of HDV superinfection in chronic HBV carriers is more often subacute than acute [27]. The diagnosis is also based on the presence of anti-HDV IgM. Most patients, but not all, have undetectable serum HBV DNA. Mortality rates are higher than in patients with concomitant HBV–HDV infection. Patients who survive frequently develop rapidly progressive chronic HBV–HDV hepatitis.

Hepatitis C virus

It seems that HCV infection alone never results in acute liver failure, even in the case of profound immunosuppression. However, because of similar sources of infection, markers of HCV infection are found in a sizeable proportion of patients with acute liver failure resulting from HBV (see Chapter 9.1.2).

Hepatitis E virus

Hepatitis E predominates in south-eastern Asia, southern India and some areas in Africa. In India, hepatitis E virus (HEV) is responsible for about 75% of all cases of acute liver failure. In western countries, it is mostly, but not exclusively, observed in patients returning from endemic areas. The risk of acute liver failure seems to be especially high during the third trimester of pregnancy [28]. The manifestations are comparable to those of HAV-related acute liver failure. Serological markers (anti-HEV IgM and/or the appearance of anti-HEV IgG) are of uncertain diagnostic value. The diagnosis would be better based on the presence of HEV RNA in the serum or the stools (see Chapter 9.1.2).

Hepatitis G virus

Several studies have failed to demonstrate the role of this Flaviviridae as a cause of acute liver failure or even as a cofactor in patients with other causes.

Other viruses

Herpes simplex viruses 1 and 2

Herpes simplex viruses (HSV) have a high cytopathic potential. Liver cell damage is essentially due to the virus and not (or only modestly) to the immune response against infected cells. Herpes simplex-related acute liver failure generally develops in patients with immunosuppression [29]. However, it may occasionally occur in apparently healthy individuals. Some manifestations, although non-specific, are highly suggestive, including high-grade fever (39–41°C), leucopenia, an abrupt rise in serum transaminases over 100 times the upper limit of normal and a relatively low bilirubin level. Cutaneous or mucosal herpetic eruption is frequently absent. The progression of the disease is especially rapid with the occurrence, within a few hours or days, of a massive decrease in coagulation factors, encephalopathy and eventually multiorgan failure. Some patients may die from multiorgan failure without having prior evidence of encephalopathy. Importantly, patients with severe herpetic hepatitis never develop concomitant herpetic encephalitis.

Early diagnosis is crucial because some patients may recover when given early antiviral therapy, whereas a fatal outcome is usual in the absence of specific treatment. As a result, any patient with manifestations consistent with herpetic hepatitis (high-grade fever in particular) should be administered acyclovir in an emergency setting, before specific laboratory tests are available. Serological tests are of no value in this context. A definitive diagnosis is based on positive blood and/or liver tissue polymerase chain reaction (PCR) or culture. Liver histology is especially useful because liver lesions corresponding to patchy areas of liver cell necrosis with mild inflammatory infiltrates are quite specific. Unfortunately, not all patients recover with antiviral therapy, possibly because acyclovir is frequently started too late. Some patients have been successfully transplanted.

Other herpes viruses

Massive liver cell necrosis due to varicella-zoster virus is exceptional. It is mainly observed in immunosuppressed patients (see Chapter 9.1.2). Hepatitis is associated with epigastric pain and fever followed by a characteristic cutaneous eruption of umbilicated vesicles. Bilateral pulmonary infiltrates are frequent. The administration of acyclovir is recommended.

The cytopathic effects of cytomegalovirus (CMV) are modest compared with those of HSV. No observation of acute liver

failure with CMV as the only documented cause has been reported.

Extensive liver cell necrosis has been reported in more than 20% of patients with fatal Epstein–Barr virus (EBV)-related infectious mononucleosis. However, contributing factors for liver injury, haemophagocytic syndrome in particular, were associated [30]. Thus, it is uncertain whether EBV infection alone can lead to acute liver failure (see Chapter 9.1.2).

Human herpes virus 6 is a lymphotropic virus which has been considered as the primary cause of acute liver failure on very rare occasions [31].

Miscellaneous non-herpes viruses

Acute liver failure has occasionally been reported in association with adenovirus infection, sometimes occurring in immunosuppressed patients. High-grade fever and extensive pneumonia were present. The diagnosis relies on viral cultures or PCR from blood, liver parenchyma or other tissues.

Some patients with parvovirus B19-related aplastic anaemia also develop acute liver failure. In others without aplastic anaemia, parvovirus B19 has been identified in liver tissue [32]. However, it has been argued that the presence of the virus in liver tissue is not a demonstration of an ongoing infection.

Acute liver failure is a common feature in patients with severe viral haemorrhagic fever. The mortality rate is especially high. These infections are predominantly observed in Asia and Africa. Four distinct families of RNA viruses are involved (see Chapter 9.4). Flaviviridae include yellow fever and Dengue viruses. Bunyaviridae include Rift Valley fever virus and hantaviruses [33]. Arenaviridae are essentially represented by Lassa fever virus. Ribavirin is effective against this agent. Finally, Filoviridae include Marburg and Ebola viruses, both present in Africa.

Amanita mushroom poisoning

Amanita phalloides is a highly toxic white mushroom growing in many places in Europe and the United States. It contains two families of toxins, phalloidin and amatoxin, both heat stable and thus not altered by cooking. Amatoxin is present in other species including *Amanita verna* and *Lepiota*. Phalloidin causes severe gastrointestinal damage early after ingestion. Amatoxin causes liver cell necrosis through binding to RNA and inhibiting the production of mRNA. The ingestion of 50 g of mushroom is sufficient to cause fatal liver lesions [34].

The syndrome is characterized by the occurrence of abdominal pain, vomiting and profuse diarrhoea within 6–12 h after ingestion. At this early stage, fluid loss secondary to diarrhoea often results in hypovolaemia, prerenal failure and liver hypoxia (with an early rise in serum transaminases). The second phase, resulting from the hepatic toxicity of amatoxin, manifests 1–4 days after ingestion with a sudden increase (or re-elevation) in serum transaminases and a drop in coagulation factors. The association of acute renal failure and acute liver insufficiency results in severe metabolic acidosis. Encephalopathy may eventually occur within 4–8 days after ingestion. Some patients may die before the occurrence of encephalopathy as a result of multiorgan failure.

There is little evidence supporting the use of silibinin and penicillin G whose efficacy has not been clearly demonstrated. Extracorporeal detoxification systems have also been used, but it remains unclear whether they helped to improve survival.

The mortality rate is about 25%. It has been suggested recently that a prothrombin index less than 25% of normal and serum creatinine over 106 μmol/L were predictive of a poor outcome and, when present, should lead to the consideration of emergency transplantation [35].

Other toxins

Some industrial solvents and other toxins, such as carbon tetrachloride, 2-nitropropane, dimethyl formamide and chlorobenzene, can cause severe liver damage after occupational inhalation or accidental ingestion [36] (see Chapter 14.2). Herbal medicines (in particular Chinese herbal medicines) have also been responsible for occasional cases of acute liver failure, some of them requiring emergency transplantation. Germander (*Teucrium chamaedrys*) is the most clearly identified agent with a dose-dependent toxicity [37].

Among several illicit drugs, cocaine and ecstasy (3-4-methylene dioxy metamphetamine) represent potential causes of acute liver failure [38]. Severe hepatotoxicity has also been observed in drug-addicted patients using intravenous injections of buprenorphine, a substitution agent normally used orally [39].

Drug-induced hepatitis

Many drugs from different families can be responsible for acute liver failure (see Chapter 14.1). In developed countries, idiosyncratic drug reactions account for 5–15% of all causes of acute liver failure [40]. This proportion is lower (less than 5%) in developing countries.

The arguments suggesting that acute liver failure is related to drug hepatotoxicity are: (i) the recent introduction of a drug potentially responsible for acute liver cell damage (although the interval from initiation of therapy to first manifestations can occasionally exceed 3 months); (ii) immunoallergic manifestations (cutaneous rash, fever, hypereosinophilia); (iii) predominant centrolobular necrosis and/or massive microvesicular steatosis on liver histology; and (iv) the absence of any other cause. However, these criteria are neither constant nor specific. Furthermore, drug-induced hepatotoxicity can be a contributing factor in patients with other causes of liver injury.

Isoniazid, a widely used antituberculous agent, still remains one of the most frequent causes of drug-induced acute liver failure [40,41]. Manifestations occur in most cases within the first 2 weeks after initiation. Severe hepatotoxicity is favoured by high doses (over 5 mg/kg/day) and concomitant administration of rifampicin or any other enzyme inducer [42]. The prognosis

is generally good, provided the drug is rapidly discontinued. Pyrazinamide, another antituberculous agent, is also a potential cause of acute liver failure. In contrast to isoniazid, manifestations frequently occur more than 2 weeks after initiation and can include immunoallergic signs. The prognosis is worse than that of isoniazid-induced acute liver failure [42]. Rifampicin, as well as other antibiotics such as erythromycin and sulphonamides (trimethoprim–sulphamethoxazole), has rarely been involved in acute liver failure.

In the past, halothane, a volatile anaesthetic agent, has been a cause of acute liver failure with an especially high mortality rate (about 90%). Manifestations including fever and jaundice occurred 5–15 days after general anaesthesia. Halothane has since been almost abandoned. The hepatotoxicity of the currently used volatile anaesthetic agents (isoflurane and desflurane) is much more uncommon.

Propylthiouracil, an antithyroid agent, was found to be a significant cause of acute liver failure in the Unites States [43]. Manifestations of hypersensitivity may be present. Among anticonvulsive agents, phenytoin, lamotrigine, valproic acid and derivates can also cause acute liver failure [43]. Phenytoin and lamotrigine hepatotoxicity are frequently associated with hypersensitivity reactions, while valproic acid causes microvesicular steatosis. Acute liver failure has been reported in patients taking non-steroidal anti-inflammatory drugs, piroxicam being the main cause [44]. Nevirapine and efavirenz, two antiretroviral agents from the non-nucleoside reverse transcription inhibitors family, can cause acute liver failure with manifestations of hypersensitivity. Fialuridine and 2′-3′dideoxyinosine (ddI), two nucleoside analogues, can cause acute liver failure related to massive microvesicular steatosis [45].

Occasional observations of acute liver failure have been reported with many other drugs including amiodarone, linisopril, chlormezanone, hydroxychloroquine, ecarazine, flutamide, nilutamide and atorvastatin [46]. This list is not exhaustive (see Chapter 14.1).

Hypoxic liver cell necrosis

Hypoxic liver cell necrosis, commonly referred to as 'ischaemic hepatitis', is a frequent cause of severe hepatic injury and, paradoxically, often misdiagnosed. It may result from three distinct mechanisms: (i) decreased hepatic blood flow (both arterial and portal); (ii) major hypoxaemia; and (iii) venous congestion. It is a paradox that some patients with major circulatory disorders do not have obvious liver cell injury, while others with apparently minor (and sometimes asymptomatic) circulatory changes rapidly develop massive liver cell necrosis. It is likely that hypoxic liver cell necrosis only gives rise to clinical manifestations when at least two of the three above-cited mechanisms coexist (see Chapter 20.1).

Besides manifestations directly related to its cause, hypoxic liver cell necrosis is characterized by an abrupt rise in serum transaminases (AST being higher than ALT), an abrupt decrease in coagulation factors, normal or moderately increased serum bilirubin and a concomitant rise in serum creatinine.

A wide variety of circulatory and/or respiratory disorders may cause hypoxic liver cell necrosis, including septic shock, haemorrhagic shock, acute cardiomyopathy, arrhythmia, pericarditis, acute decompensation of chronic heart or lung disease, respiratory distress syndrome, obstructive sleep apnoea and severe crisis in sickle cell disease patients [47,48].

The treatment as well as the prognosis are essentially determined by the underlying disease. Unless there is an underlying chronic liver disease, the prognosis of liver insufficiency is good, provided the treatment of the cause is rapidly effective. It is highly uncommon that patients develop encephalopathy. Fatal outcome is rather related to circulatory failure and refractory shock.

Heat stroke

The mechanisms of hepatic injury during heat stroke are not clearly understood. They include direct thermal injury to the hepatocytes and liver cell hypoxia resulting from circulatory shock (see Chapters 3.2 and 14.2). The lesions are ischaemic-like with extensive centrolobular necrosis. In addition to hyperthermia (central temperature over 41°C), manifestations may include altered consciousness, seizures (status epilepticus is frequent), diarrhoea, hypovolaemia, arrhythmia, acute renal failure, metabolic acidosis, a major increase in serum transaminases and in creatine phosphokinase and features of disseminated intravascular coagulation. Occasional cases of successful transplantation have been reported [49]. However, patients listed for transplantation but who fully recovered with supportive care have also been reported [50]. The justification for and potential benefits from transplantation in this indication are unclear.

Wilson's disease

In children and young adults, the initial manifestations of Wilson's disease can mimic those of an acute liver failure syndrome, defining the so-called 'fulminant Wilson's disease' [51] (see Chapter 16.1). This rare presentation corresponds to the abrupt decompensation of an underlying and previously asymptomatic chronic liver disease (most patients have cirrhosis at this stage). Coombsnegative haemolytic anaemia, due to direct copper toxicity for red cells, is constant. Other arguments suggesting Wilson's disease include a moderate increase in serum transaminases, a major increase in serum bilirubin, low or undetectable serum ceruloplasmin (an inconstant finding) and increased urinary copper. Kayser–Fleischer ring is not constant but almost specific. Liver biopsy is useful by showing evidence of underlying fibrosis, liver cell necrosis and steatosis. In addition, biopsy sampling allows direct measurement of intrahepatic copper concentration, which is constantly increased.

In the absence of specific treatment, the outcome of fulminant Wilson's disease is almost always fatal unless emergency liver

transplantation is performed [52]. However, it has been shown that early administration of D-penicillamine, before the onset of encephalopathy, may rapidly reverse liver insufficiency in some patients, thus obviating the need for transplantation [51].

Malignant infiltration of the liver

Massive infiltration of the liver by various types of malignancies is an uncommon cause of acute liver failure. Possible mechanisms include ischaemic liver cell necrosis and haemophagocytic syndrome (see Chapter 18.3). Early recognition of this condition is of particular importance as it obviously represents a contraindication for transplantation, except in some patients with lymphoma.

Hodgkin's and non-Hodgkin's lymphoma, other types of leukaemias, breast cancer and melanoma are among the most frequently implicated malignancies [53,54]. The main arguments for a malignant infiltration include recent weight loss, liver enlargement, ascites and fever. However, the underlying malignancy can be difficult to identify. The liver can appear to be homogeneous on ultrasonography, which represents a possible pitfall. Liver biopsy and/or bone marrow aspirate are determinants for the diagnosis. The early institution of chemotherapy proved effective in some patients with leukaemia.

Autoimmune hepatitis

The initial presentation of autoimmune hepatitis can mimic that of acute hepatitis, including the progression to acute liver failure. This presentation is more frequent in females than in males. It can occur at any age, including over 60 years.

The diagnosis is based on the finding of high titres (usually over 1:100) of autoantibodies and/or marked hypergammaglobulinaemia (even if both criteria are inconstant) (see Chapter 11.2). Different patterns can be observed with elevated titres of anti-liver and -kidney microsome antibodies in some patients and high titres of antismooth muscle and/or antinuclear antibodies in others. Liver biopsy is useful showing prominent inflammatory infiltrates with mononuclear cells. In most but not all patients, there is some degree of fibrosis corresponding to the underlying chronic process.

Corticosteroids should be started. However, not all patients have a response to steroids at this stage. Therefore, emergency transplantation is frequently needed.

Syncytial–giant cell hepatitis (postinfantile giant cell hepatitis)

Syncytial–giant cell hepatitis refers to particular lesions with syncytial transformation of the hepatocytes, resulting in giant cells. It has been suggested that paramyxoviral infection could be the cause, with a subacute course and a poor prognosis [55]. Early post-transplantation recurrence has been reported [56]. However, the responsibility of paramyxovirus has never been clearly demonstrated. On the grounds that improvement can be observed with steroids, it is suspected that some patients have a particular form of autoimmune hepatitis. Overall, syncytial–giant cell hepatitis is a non-specific syndrome that can be observed in association with a variety of causes including viruses, drug reactions and autoimmunity.

Acute fatty liver of pregnancy

Acute fatty liver of pregnancy occurs during the second half of pregnancy (the third trimester in most cases). The mechanisms leading to microvesicular steatosis in this context are unknown (see Chapter 22.3). Polydipsia, polyuria followed by nausea, vomiting and abnormal liver tests are characteristic of this syndrome. Early diagnosis is crucial as the interruption of pregnancy prevents further deterioration and allows rapid recovery and infant survival. Acute liver failure is only observed when this disorder has been unrecognized and the termination of pregnancy has been delayed. In such cases, liver transplantation can be justified [57]. Severe liver injury and encephalopathy have become highly uncommon in recent years because of earlier recognition.

HELLP syndrome and pre-eclampsia

The association of haemolysis, elevated liver enzymes and low platelet count during the third trimester of pregnancy defines the HELLP syndrome [58]. The recent occurrence of epigastric pain is highly suggestive in this context, even if other manifestations of pre-eclampsia are absent. The main complication of HELLP syndrome does not consist of acute liver failure but rather intrahepatic and/or subcapsular haematoma. However, intra-abdominal rupture of liver haematoma can result in massive intraperitoneal bleeding and shock. In this context, haemorrhagic shock superimposed on liver microvascular changes characteristic of HELLP syndrome can occasionally result in acute liver failure. At this stage, multiorgan failure is almost constant. Termination of pregnancy is essential. Selective embolization of the hepatic artery has been used for treating intraperitoneal bleeding. Surgical haemostasis is not recommended as a first-line option because of an especially high mortality risk.

Reye syndrome

Reye syndrome is a rare disorder affecting children and occasionally young adults [59]. It is characterized by the occurrence of diffuse microvesicular steatosis following a benign viral infection and/or the ingestion of salicylates (see Chapters 14.1 and 16.9). It seems that brain oedema develops as an independent component of the disease rather than as the only consequence of liver failure. The precise mechanisms are unknown, and it remains uncertain whether Reye syndrome represents a specific disease entity. The prognosis is especially difficult to assess. Some

patients may fully recover, even if they have developed coma. Successful cases of emergency transplantations have been reported.

Obstruction of the hepatic veins

Rarely, acute liver failure may be the first manifestation of an obstructive disease of the hepatic veins, namely Budd–Chiari syndrome (see Chapter 17.3). However, this syndrome, even if first manifested by acute liver failure, must be considered as a chronic disease which has progressed over several months or years before the clinical onset. It is thought that acute liver failure results from an ultimate and abrupt extension of thrombosis to previously patent hepatic veins, compromising venous outflow and inducing massive liver cell necrosis.

Ascites and right upper quadrant pain are almost constant. Patients almost always have an underlying prothrombotic state. The findings of elevated haemoglobin concentration or elevated platelet count suggest that primary myeloproliferative disorder is the cause. Imaging techniques are of major importance in diagnosis. Apart from the presence of ascites and marked hypertrophy of the caudate lobe, ultrasonography shows evidence of obstruction of the hepatic veins.

Early diagnosis allows rescue therapies such as local fibrinolysis, vascular stents or transjugular intrahepatic portosystemic shunts (TIPS) in association with anticoagulation. In case of elevated haematocrit, emergency erythrocytapheresis must be considered. Patients with established encephalopathy are unlikely to improve with medical support. Emergency surgical shunting has been abandoned because of a high mortality rate. Emergency transplantation must be considered in some cases, even before the onset of encephalopathy.

Obstruction limited to small veins, as observed during veno-occlusive disease (now termed sinusoidal syndrome), can also result in subacute liver failure. The main causes are chemotherapy, radiation therapy and conditioning for bone marrow transplantation.

Liver surgery and transplantation

Improvements in surgical techniques have made it possible to perform extensive liver resections more frequently. In parallel, surgical resection has emerged as a cause of small-for-size remnant liver, sometimes resulting in postoperative acute liver failure (see Chapter 24.1). Besides the extent of resection, prolonged vascular clamping, underlying chronic parenchymal lesions and postoperative portal vein thrombosis are significant risk factors for postoperative liver failure.

In liver transplant recipients, the absence of recovery of adequate liver function within the first days after the procedure is termed primary non-function. Primary non-functions are likely to result from a number of cofactors including pre-harvesting alterations of the graft, prolonged cold ischaemia, technical difficulties resulting in prolonged warm ischaemia, outflow obstruction, hepatic artery thrombosis or even portal vein thrombosis. Hyperacute rejection has become a marginal cause of liver graft failure as a result of the efficacy of current immunosuppressive regimens. The use of partial grafts harvested in living donors further increases the risk of small-for-size syndrome and technical failures. In most cases, emergency retransplantation is the only option.

Acute liver failure of unknown origin

Despite in-depth investigations, a substantial proportion of patients with acute liver failure do not have any identifiable cause of acute liver injury [60]. Acute liver failure of unknown origin predominates in females and follows a subacute rather than an acute course. An undetermined proportion of such cases may correspond to occult autoimmune hepatitis. However, there is no evidence that the empirical use of steroids is effective. The prognosis is poor and emergency transplantation is usually required.

Overall course and prognosis of acute liver failure

The course and prognosis of acute liver failure depends on a number of factors including the extent and kinetics of liver cell damage, the regenerative capacity of the liver, associated comorbidities and, ultimately, therapeutic interventions and iatrogenic factors. The failure of other organs or systems plays an important role in governing outcome.

General prognosis

On the basis of relatively old series, before the advent of emergency transplantation, and more recent series coming from countries where transplantation is not routinely used, it can be estimated that recovery occurs in 20–40% of patients receiving conventional supportive care [22,61]. The results of uncontrolled studies investigating the impact of new therapeutic interventions on mortality should always be interpreted in the light of these 'reference' series.

Individual prognostic markers

Encephalopathy

Theoretically, encephalopathy should not be considered as a prognostic marker because, by definition, patients with acute liver failure do have encephalopathy. However, it is important to keep in mind that encephalopathy is one of the strongest predictors of outcome during acute liver diseases in general. For example, the risk of death in patients with acute liver disease who never develop encephalopathy is between 0% and 5%, whereas it may be as high as 80% in those with established encephalopathy. The maximal grade of encephalopathy also has a prognostic value [61]. Patients admitted with coma have an especially poor prognosis [17].

Cause and course of the disease

Independent of the degree of liver insufficiency, its cause has an important impact on the outcome. HAV- and HEV-related acute liver failure have a relatively good prognosis compared with that related to HBV. Paracetamol overdose also belongs to the group of diseases with a relatively good prognosis [7]. In contrast, the prognosis of acute liver failure of unknown origin is especially poor.

The interval between jaundice and encephalopathy also carries important prognostic information. The longer this interval is, the lower are the chances of recovery. In other words, the prognosis of subacute liver failure is poorer on average than that of hyperacute or acute liver failure. However, there is a clear interaction between the course and the cause of the disease.

Age

Advanced age has a deleterious impact on the outcome, particularly among the group of patients with rapidly progressive disease [61,62]. The influence of age has been demonstrated in paracetamol- and HBV-related acute liver failure, in particular. Survival is better in patients less than 40 years old [61].

Coagulation factors

Coagulation factor levels, along with encephalopathy, are determinant prognostic markers. Prothrombin time has been assessed in a number of surveys [62,63]. Factor V proved superior to prothrombin index in patients with HBV infection [22]. However, it was found to be less effective than prothrombin time in cases of paracetamol overdose [64]. INR is used increasingly and, in general, there is a close correlation between INR and prothrombin index. However, such a correlation has not been clearly documented for extreme values of coagulation. In addition, substantial differences in INR might be observed between different laboratories using different techniques (see Chapter 21.3). Therefore, further assessment of INR as a prognostic marker is needed.

Common laboratory variables other than coagulation

Importantly, serum transaminases have no predictive value in acute liver failure. In addition to coagulation, bilirubin and creatinine were found to be independent prognostic factors for acute liver failure in most series [7,63,65]. Arterial pH and arterial lactate concentration, either at admission or after fluid resuscitation, are additional prognostic indicators in cases of paracetamol overdose. Arterial lactates could also have a prognostic value for non-paracetamol causes [66]. Elevated leukocyte count and infection are associated with a poor prognosis [62,63]. Serum phosphorus was found to be inversely correlated with survival, with low concentration [below 0.8 mmol/L (2.5 mg/dL)] being a predictor of recovery [65]. Liver regeneration involves cell division and ATP synthesis using phosphate. Therefore, a decreased serum phosphorus concentration could be an indirect marker of regeneration and, thus, of recovery.

Other prognostic markers

Serum α-fetoprotein is an indirect marker of hepatocyte regeneration. It has been shown that a high α-fetoprotein level is significantly predictive of a favourable outcome in patients with severe paracetamol hepatotoxicity [67]. A threshold value of 3.9 μg/L on day 1 after peak ALT could identify survivors from non-survivors.

Liver cell necrosis results in the release of Gc protein, a member of the actin scavenger protein family mainly synthesized by the liver. It has been shown that the unbound serum Gc protein level could serve as a prognostic tool [68]. Gc protein is not routinely used.

Arterial ketone body ratio, namely the ratio of acetoacetate to β-hydroxybutyrate, is an indirect marker of hepatic energy reserve. An increase in arterial ketone body ratio over 0.6 within the first 24 h after admission correlates significantly with the outcome of patients with non-paracetamol causes [69]. The usefulness of this marker has not been validated by independent studies.

It has been suggested that less than 50% hepatocyte necrosis along with regenerative changes is predictive of a favourable outcome. However, it can be objected that liver histology can only be obtained via the transvenous route in patients with major coagulation changes and that those with less than 50% hepatocyte necrosis are highly unlikely to develop encephalopathy. Liver histology should rather be viewed as a means of clarifying the mechanisms and documenting underlying chronic liver lesions. The estimated volume of the liver on imaging techniques seems to be a more useful predictive variable [70]. Indeed, significant liver atrophy with a volume of less than 1000 mL seems to be a marker of prolonged liver injury and, consequently, of poor prognosis.

Prognostic scores

A scoring system comparable to the MELD score for chronic liver diseases still does not exist for acute liver failure. There are several sources of difficulty in this area. First, transplantation by itself represents an unavoidable bias for the interpretation of two determinant events: death and recovery in the absence of transplantation. Even if most patients listed for transplantation would have died if not transplanted, it can be objected that a minority would have recovered with medical support alone. It remains impossible to identify this subgroup after the fact. Secondly, prognostic scores for acute liver failure have a limited impact because, anyway, the prognosis is especially poor at this stage. Again, prognostic scores established at earlier stages, before the onset of encephalopathy, would be more informative. As indicated above, a number of individual markers were shown to have a prognostic value. Unfortunately, no large studies combining individual prognostic markers as listed above have been conducted yet.

Risk scores established outside the field of acute liver failure could be relevant in this setting. One study has suggested that the APACHE II score is highly effective for predicting outcome in

Table 3 Indications for in-hospital admission of a patient with evidence of acute liver disease and their justification.

Indication for admission	Justification
Prothrombin index below 50% of normal (≈ INR over 1.7)	Risk of further deterioration of liver function and subsequent complications
Persistent abdominal pain and/or ascites	Acute Budd–Chiari syndrome must be considered and, if confirmed, needs specific treatment
Permanent fever over 39°C	Herpetic hepatitis must be considered and antiviral treatment (acyclovir) should be started
Pregnancy	Acute fatty liver and HELLP syndrome must be considered and, if confirmed, expeditious termination of pregnancy is indicated
Paracetamol overdose or therapeutic administration of more than 3 g of paracetamol per day in patients with risk factors for toxicity	Need for early administration of *N*-acetylcysteine
Concomitant haemolytic anaemia in children or young adults	Wilson's disease must be considered and, if confirmed, needs specific therapy
Evidence or suspicion of hypoxic liver cell necrosis	Need for early and specific treatment of the causative disorder
Evidence or suspicion of autoimmune hepatitis	Need for administration of steroids
Evidence or suspicion of drug-induced hepatitis with jaundice	Increased risk of acute liver failure

patients with paracetamol-induced acute liver failure [71]. It has also been suggested that MELD score is relevant in patients with paracetamol and non-paracetamol acute liver failure [72]. This finding is not surprising as MELD score relies on three variables, namely bilirubin, creatinine and INR, which were also found to be independent predictors of outcome in these populations. However, the application of MELD score in such patients is questionable. In particular, MELD score does not take into account encephalopathy and other important variables such as blood lactates. In addition, it might underestimate the severity of the condition of patients with hyperacute liver failure and low bilirubin level. Overall, MELD score should be used with caution in patients with acute liver failure.

Prevention

Prevention of the cause

Vaccination against HBV is a simple and effective means of preventing HBV infection and, subsequently, HBV-related acute liver failure (see Chapter 9.1.3). The issue of a putative association between vaccination and the delayed occurrence of demyelinating neurological disorders has been raised. However, the potential risk of anti-HBV vaccination is much lower than that of HBV-related complications in non-vaccinated at-risk individuals [73]. Systematic vaccination against HAV in chronic HBV and/or HCV carriers can be recommended [74].

Drugs with dose-related hepatotoxicity, in particular paracetamol, should always be administered in the light of predisposing factors for toxicity and possible drug interactions. It is a rule that, in any patient presenting with severe acute liver injury, whatever the cause, all but absolutely essential drugs must be discontinued because they can be a source of deleterious interactions [1].

Prevention of liver failure and related complications in patients with established acute liver disease

Any patient with evidence of acute liver disease and prothrombin index below 50% of normal (INR above 1.7) should be oriented to a specialized unit. Otherwise, indications for in-hospital admission in patients with acute liver diseases are listed in Table 3.

In patients admitted at an early stage, several measures should be applied to prevent further deterioration and favour rapid liver regeneration. First, efforts should be made to avoid any factor, hepatotoxic agents in particular, which could cause additional liver cell damage. Secondly, attention should focus on the prevention of acute renal failure, which can be precipitated by nephrotoxic agents and hypovolaemia. Thirdly, sedative agents with a potential for precipitating encephalopathy should also be avoided.

Management

Objectives

The first objective in the management of patients with acute liver failure is to maintain an optimal condition for liver regeneration and recovery to occur. When it is impossible to achieve this goal and life-threatening complications are impending, the objectives are to take the decision for emergency transplantation with appropriate timing. Once patients are listed for transplantation, the objectives turn to the prevention of irreversible brain damage resulting from brain oedema and optimization for major surgery. It is important to keep in mind that, even after they have been listed for transplantation, some patients can eventually improve, be delisted and fully recover.

Specific treatment of the cause

A limited number of causes listed in Table 3 have to be considered systematically, even if rare, because they require specific therapy.

General management

Patients with acute liver failure should be placed in an intensive care unit, in close connection to a transplant centre. Patients with altered consciousness should undergo an electrocardiogram (ECG), and peripheral oxygen saturation and non-invasive arterial pressure monitoring. Haemodynamic instability and/or the need for frequent blood sampling justifies an arterial blood line with continuous pressure monitoring. The insertion of a gastric tube is recommended in order to reduce the risk of aspiration. Central venous catheters are frequently needed for supportive care. The subclavian route should be avoided because of the underlying coagulation disorders and the risk of haemothorax. The jugular route should be preferred to the femoral route because of a lower risk of infection.

Fluid administration is aimed at preventing hypovolaemia and subsequent reduction in renal perfusion. Mean arterial pressure should be maintained over 70 mmHg. Glucose (10%) should be administered in patients with hypoglycaemia. There is no evidence that intravenous nutritional support provides any benefit in this setting. Hypophosphoraemia is frequent and should be corrected by intravenous supplementation. Metabolic acidosis is frequent in patients with abrupt and massive liver cell necrosis. Intravenous alkali infusion is modestly and only transiently effective in this situation. Patients with severe acidosis should rather be placed on renal replacement therapy.

Because changes in neurological status are of major importance for assessing prognosis, sedatives should only be administered in patients with established grade 3–4 encephalopathy who need endotracheal intubation for airway protection. Adequate sedation is mandatory for intubation as excessive stimulation may further increase intracranial pressure. Propofol is frequently used for short-term sedation, but its administration should be monitored carefully in order to avoid significant hypotension. Benzodiazepines should be used if prolonged sedation is anticipated. High intrathoracic pressure resulting from high tidal volumes as well as elevated end-expiratory positive pressure should be avoided as they reduce cardiac output and compromise cerebral perfusion.

Owing to a high incidence of bacterial infections, in particular pneumonia, empirical antibiotics are recommended in patients under mechanical ventilation. Aminoglycosides must be avoided because of their nephrotoxicity. Beta-lactamins and quinolones are more adapted.

Gastric and/or duodenal ulcerations, although not very common, are a potential source of bleeding, which justifies antisecretory agents. There is no justification for prophylactic administration of fresh frozen plasma, unless invasive procedures other than the placement of central lines are needed. Indeed, haemorrhagic complications are uncommon, even in patients with a profound decrease in coagulation factors. More importantly, the administration of fresh frozen plasma makes it impossible to interpret coagulation factors as a prognostic marker. Some degree of intravascular coagulation is a frequent finding. However, controlled trials failed to demonstrate any benefit of antithrombin in improving survival [75]. Prostaglandin E1 has been tested because of its potential cytoprotective effects. Again, controlled trials failed to demonstrate any benefit from this agent.

It is worth noting that, whatever the cause, *N*-acetylcysteine could improve tissue oxygenation [76]. In addition, even if the main cause of liver cell damage is not paracetamol, the administration of *N*-acetylcysteine is recommended in patients who have recently ingested therapeutic doses of this agent.

Patients with marked hypotension not rapidly responding to fluid resuscitation should receive vasopressive agents. Cardiovascular monitoring with Swan–Ganz catheter or alternative monitoring techniques is highly recommended at this stage. Excessive vascular filling and/or unnecessary increase in cardiac output can precipitate intracranial hypertension. Therefore, haemodynamic parameters should be closely monitored to adapt the doses of vasopressive agents and, in parallel, fluid administration. Vasopressin and terlipressin should be avoided because they can worsen intracranial hypertension [77].

Acute renal failure is frequent and has a major influence on the outcome. Patients with acute renal failure are unlikely to improve with volume replacement alone, unless liver function improves rapidly. Therefore, they should be placed on renal replacement therapy. Intermittent dialysis, continuous haemodiafiltration or continuous high-flux haemofiltration can be used according to the experience in each centre. However, the haemodynamic tolerance of continuous replacement techniques has proved superior compared with intermittent dialysis in this setting.

Management of encephalopathy and intracranial hypertension

Invasive monitoring of intracranial hypertension

The optimal monitoring of intracranial hypertension remains a challenging and unresolved issue [78]. Theoretically, direct measurement of intracranial pressure via specific transducers is the reference. However, direct measurement has important limitations. Subdural transducers carry an unacceptable risk of intracranial bleeding related to coagulopathy [79]. Epidural devices, although safer than subdural devices in patients with coagulopathy, still carry a substantial risk of bleeding. Moreover, their accuracy is lower than that of subdural devices. Finally, even with the use of invasive monitoring, physicians are left with the observation of very high intracranial pressure values and very few means of lowering it. In addition, evidence that intracranial pressure monitoring improves survival is still

lacking. Therefore, many centres no longer use invasive monitoring for managing patients with acute liver failure. Nonetheless, if invasive devices are inserted, the goal is to maintain cerebral perfusion pressure over 50 mmHg and intracranial pressure below 20–30 mmHg. Again, it can be impossible to achieve this goal despite aggressive therapy.

Reverse jugular venous catheterization for measuring oxygen saturation in the jugular bulb and, in turn, estimating brain oxygen uptake is another method for monitoring neurological status [80]. This method has not been clearly validated and is not used routinely.

Non-invasive monitoring of neurological status

In addition to clinical evaluation, several methods have been proposed for monitoring neurological status. Conventional electroencephalography remains a useful tool for assessing brain activity in comatose patients and for detecting subclinical seizures. However, some patients with almost nil electroencephalographic activity have been transplanted and fully recovered. The usefulness of electroencephalography can be improved by using a continuous recording device.

Transcranial Doppler can be used for measuring cerebral blood flow velocity. Ultrasound has also been used for measuring the optic nerve sheath diameter which is grossly correlated to intracranial pressure [81]. However, intracranial pressure cannot be deduced directly from these techniques. Serial recording of sensory evoked potentials showed a correlation with survival [82]. This technique, which may help to detect high-risk patients, has not been developed further. Similarly, it has been impossible to determine a threshold value for separating patients with favourable or poor neurological outcome on the basis of circulating levels of neurospecific enolase [83].

Management

The following measures should be applied in order to reduce intracranial pressure in case of brain oedema. Again, adequate sedation is needed. The head and trunk should be elevated at 30°. Mild hyperventilation with hypocapnia is recommended. Arterial blood pressure should be monitored closely, and efforts should be made to prevent any episode of hypotension.

The first-line therapy for cerebral oedema consists of intravenous mannitol, an osmotic agent. Mannitol should be administered with bolus infusions of 0.5–1 g/kg, which can be repeated every 4 h if necessary. In patients with acute renal failure, mannitol is potentially dangerous as its impaired excretion may result in volume overload.

Hypernatraemia is a simple means of increasing extracellular osmolality. The administration of hypertonic sodium chloride in order to maintain serum sodium levels of 145–155 mmol/L proved effective in reducing intracranial pressure [84]. Hypernatraemia can be achieved with continuous infusions of 30% hypertonic saline at a rate of 5–20 mL/h. This simple method must be assessed further in patients with acute liver failure.

Several mechanisms explain why mild hypothermia (blood temperature between 32°C and 33°C) has beneficial effects on intracranial hypertension during acute liver failure [85]. First, hypothermia reduces arterial ammonia levels, brain generation of glutamine and astrocyte swelling. Secondly, hypothermia reduces cerebral hyperaemia and restores, at least in part, cerebral blood flow autoregulation. Thirdly, it reduces brain lactates and, in turn, the generation of reactive oxygen species within astrocytes. Uncontrolled studies have shown that mild hypothermia, obtained with the use of cooling blankets, helps to reduce intracranial pressure in patients with otherwise uncontrolled intracranial hypertension [86]. However, hypothermia could increase the risk of severe infections. As a result, further studies are needed before this technique can be adopted unequivocally.

On the grounds that subclinical seizures are frequent in patients with grade 3–4 encephalopathy and that continued seizure activity hastens the development of cerebral oedema, prophylactic phenytoin has been tested in controlled trials [5,87]. Although phenytoin significantly decreased the incidence of subclinical seizures, it did not prevent cerebral oedema, nor did it improve survival [5].

Barbiturates have been widely used in patients with refractory brain oedema. These agents may help to decrease intracranial pressure. However, they frequently induce hypotension which, in turn, may compromise cerebral perfusion. In addition, thiopental usually suppresses cerebral electrical activity, which makes it impossible to differentiate brain death from the effects of barbiturates on a clinical and electroencephalographical basis. Therefore, barbiturates should not be recommended as first-line therapy.

Extracorporeal liver assist devices

Extracorporeal liver assist devices are detailed in Chapter 25.8.2. On theoretical grounds, these devices have two principal goals. First, they may help to bridge high-risk patients to transplantation. A second and more putative goal is to help in stabilizing the patient's condition and controlling brain oedema until liver regeneration eventually occurs, allowing recovery without the need for transplantation. Techniques derived directly from renal replacement therapy proved ineffective, possibly because they are insufficient for removing protein-bound toxins accumulated during acute liver failure. Additionally, they do not replace liver cells' synthetic function.

Two distinct approaches have been developed in order to overcome these limitations. The first approach consists of the addition of albumin to the dialysate, which helps to remove some toxins with high affinity for proteins. The principal system developed up to now is named MARS® (for molecular adsorbents recirculating system). Until now, none of the studies conducted in acute liver failure patients has demonstrated a significant survival benefit. However, preliminary studies suggest that MARS® is superior to conventional techniques for

removing protein-bound toxins. The tolerance of MARS® was good in acute liver failure patients. In one controlled study, MARS® significantly improved the haemodynamic profile compared with conventional treatment [88]. A number of patients receiving MARS® therapy who recovered or were successfully bridged to transplantation have been reported. Unfortunately, these observations are not a demonstration of the efficacy of MARS® for improving survival. In addition, MARS® remains a complex and costly technique. Overall, an accumulating body of evidence suggests that albumin dialysis is potentially useful in unstable patients. The extended use of albumin dialysis should not be recommended in patients without encephalopathy.

The second, much more complex approach consists of using extracorporeal perfusion of hepatocyte cultures. These systems, frequently termed bioartificial liver assist devices, are also detailed in Chapter 25.8.2. Basically, two systems using either cryopreserved porcine [89] or human (hepatoblastoma) [90] cell lines have been developed. Both systems were shown to improve neurological status and could reduce waiting list mortality, providing more time for obtaining a graft. However, a controlled study failed to demonstrate a significant impact on survival, except in a subgroup with hyperacute liver failure [89]. Similarly, a systematic review of accumulated data coming from controlled and uncontrolled studies showed that artificial support systems do not clearly affect mortality [91]. There are also major safety concerns because of the possible transmission of porcine retroviruses. Devices based on human hepatoblastoma-derived cell lines carry a potential risk for the spread of malignant cells. None of the bioartificial liver assist devices is available for routine use.

Xenogenic extracorporeal liver perfusion, consisting of the perfusion of a whole animal liver with an extracorporeal blood circuit, has been used experimentally in a few patients [92]. Using this technique, some patients have been bridged to transplantation. However, the possible transmission of xenozoonosis is even more important than it is with bioartificial liver devices.

Proposed practical guidelines for the management of patients with acute liver failure are presented in Table 4.

Table 4 Proposed guidelines for the management of patients with acute liver failure and grade 3–4 encephalopathy.

Step 1: Patients with grade 3–4 encephalopathy, no clinical evidence of brain oedema, no renal insufficiency and no multiorgan failure
Listing for emergency liver transplantation if criteria fulfilled and no contraindications (see Table 6)
Insertion of a nasogastric tube
Endotracheal intubation and mechanical ventilation
Sedation with either propofol (1–5 mg/kg/h) or a combination of midazolam (5 mg/h) and fentanyl (1–5 μg/kg/h)
Insertion of an arterial line and careful haemodynamic monitoring
Systematic administration of antibiotics (beta-lactamins or quinolones)
Systematic administration of antisecretory agents
Adequate fluid administration for prevention of hypovolaemia (at least 2 L of 5% glucose/24 h plus 10% glucose in case of hypoglycaemia)
Prevention of hyponatraemia
Correction of hypophosphoraemia with intravenous phosphorus
Systematic intravenous administration of *N*-acetylcysteine (150 mg/kg/24 h)
No systematic use of fresh frozen plasma or other activated coagulation factors
Step 2: Patients with evidence of brain oedema and no renal insufficiency
Head and neck elevated at 30°
Intravenous mannitol (bolus infusions of 0.5–1 g/kg repeated at 4-h intervals if needed)
Controlled hypernatraemia (infusion of 5–20 mL/h 30% saline with a target serum sodium level of 145–155 mmol/L)[a]
Optimize mechanical ventilation
Induction of mild hypocapnia ($P_a$co$_2$ of 30–35 mmHg)
Avoidance of elevated intrathoracic pressure (maintain mean pressure below 25–30 mmHg)
Avoidance of positive end-expiratory pressure
Albumin dialysis is an option at this stage
Step 3: Patients with evidence of brain oedema, acute renal failure and/or multiorgan failure
Placement on renal replacement therapy (continuous should be preferred to intermittent dialysis)
Albumin dialysis is probably superior to conventional renal replacement therapy
Invasive haemodynamic monitoring is recommended for tailoring fluid administration and titrating vasopressive agents
Mean arterial pressure should be maintained over 70 mmHg
Step 4: Patients with refractory intracranial hypertension
Placement on albumin dialysis
Moderate hypothermia (32–33°C) using cooling blankets

[a]The possible interactions between mannitol and hypernatraemia have not been clearly documented.

Liver transplantation

Liver transplantation, although technically complex and demanding in the short and long term, remains the most effective option for patients who are unresponsive to other therapeutic interventions. In this group of patients, emergency transplantation allows 1-year survival rates of 60–80% compared with only 10–20% in the pretransplantation era.

Indications for transplantation and selection of candidates

Ideally, indications for emergency transplantation should represent an optimal compromise between listing patients at an early stage (when they have a significant chance of recovery without transplantation) or, in contrast, at the latest stages of the disease (when graft procurement may take too much time for the patient to survive until the procedure) (Table 5).

Two sets of criteria, namely Clichy and King's College criteria, are the most commonly used (Table 6). Both arise from studies performed before the generalization of emergency transplantation and both have limitations. The Clichy criteria were established in patients with fulminant hepatitis B. However, prognostic factors might be different for other causes, paracetamol in particular. The King's College criteria are different for paracetamol or non-paracetamol causes. However, prognostic markers may also differ within the heterogeneous non-paracetamol group. Both sets of criteria were aimed at predicting an 80–85% mortality rate with conventional supportive care. In the original reports, positive and negative predictive values were high, ranging from 84% to 98% [22,61]. The Clichy and King's College criteria have been tested in independent populations [70,71,93]. Almost all studies confirmed their high positive predictive values. However, negative predictive values were found to be lower than those reported in the original studies (about 50%). In addition, it was shown that the Clichy criteria are less efficient for paracetamol overdose, justifying the use of specific markers in this group. Besides the above-mentioned criteria, multiorgan failure and extremely poor neurological status should not be considered as a definitive contraindication as successful transplantations have been performed in such precarious patients.

Obviously, the Clichy and King's College criteria are not perfect, but they still represent a reliable basis for transplant decisions [94]. Unfortunately, a revision of these criteria would be especially difficult. Indeed, the generalization of transplantation in more recent study populations represents an unavoidable bias for reassessing prognostic factors.

Total deceased donor transplantation

This reference procedure consists of transplanting a whole deceased donor organ in orthotopic position. In western countries, prioritization makes it possible to obtain a compatible graft within 24–48 h in most cases. However, a sizeable risk of death on the waiting list still exists either because of an especially rapid deterioration or because no graft becomes available in due time. Waiting list mortality did not exceed 15–20% in recent series.

Preoperative management should focus on the need for achieving haemodynamic stability and preserving cerebral perfusion pressure throughout the procedure. The piggy-back technique is an efficient means of achieving haemodynamic stability in this setting as it preserves the native inferior vena cava, thus avoiding total inferior vena cava clamping [95].

In most series, survival rates of acute liver failure patients are about 10% lower than those of patients with chronic liver diseases (Table 7). The increased mortality that takes place during the early postoperative course is mainly due to a higher incidence of severe sepsis and multiorgan failure. Systematic prophylaxis with broad-spectrum antibiotics during the first postoperative days is strongly recommended. Preoperative

Table 5 Theoretical basis for the definition of criteria for emergency transplantation: respective advantages and limitations of early vs. late decision in the course of the disease.

Decision for transplantation and listing patients at an early stage	Decision for transplantation and listing patients at the latest stages
Advantages More time for obtaining a donor No incentive for accepting a marginal graft Lower risk of death on the waiting list Optimal condition for overcoming transplantation procedure and low operative risk	***Advantages*** Minimal risk of unnecessary transplantation in patients who, otherwise, would have recovered with medical support therapy only
Limitations Increased risk of unnecessary transplantation in patients who, otherwise, would have recovered with medical support only	***Limitations*** Less time for obtaining a donor Incentive for accepting an extended criteria graft Higher risk of death on the waiting list Poor condition at the time of transplantation procedure and high operative risk

Table 6 Proposed criteria for emergency liver transplantation in patients with acute liver failure.

The Clichy criteria [22]

Transplantation if:

- Encephalopathy with confusion and coma (grade 3 or 4) and
- Factor V < 20% of normal if under 30 years or
- Factor V < 30% of normal if over 30 years

The King's college criteria [61]

Paracetamol overdose

Transplantation if:

- Arterial pH < 7.3 after fluid resuscitation or
- Concurrent findings of
- Encephalopathy of grade 3 or above
- Creatinine > 300 μmol/L
- INR > 6.5

Non-paracetamol causes

Transplantation if:

- INR > 6.5 or
- Any three of
- Unfavourable cause (drug induced or unknown origin)
- Age < 10 or > 40 years
- Acute or subacute vs. hyperacute presentation
- Bilirubin > 300 μmol/L
- INR > 3.5

Proposed modifications of the King's College criteria for paracetamol overdose [7]

Strongly consider listing for transplantation if arterial lactate is above 3.5 mmol/L after early fluid resuscitation

Listing for transplantation if:

- Arterial pH is below 7.3 or arterial lactate is above 3 mmol/L after adequate fluid resuscitation
- Or concurrently: serum creatinine above 300 μmol/L, INR above 6.5 and encephalopathy grade 3 or more

predictors of poor outcome include acute renal failure, multiorgan failure, grade 3–4 encephalopathy (compared with grade 1–2) and the use of expanded criteria donors [96]. ABO-compatible grafts provide results identical to those of ABO-identical grafts. In contrast, ABO-incompatible grafts should be avoided in adults, when possible, because of an especially high rate of severe rejection and early graft failure. Full neurological recovery is observed in the large majority, although a small proportion of patients have irreversible brain damage after the procedure.

Auxiliary liver transplantation

Auxiliary liver transplantation consists of transplanting a partial graft and preserving part of the native liver with a potential for delayed regeneration. This technique is justified by the fact that, even in patients with acute liver failure and life-threatening brain oedema, liver regeneration can still occur. The first objective is to restore adequate liver function and reverse brain oedema. Therefore, a right graft, transplanted after right hepatectomy, is preferred to a left graft because of its larger volume. The limitations of auxiliary transplantation are represented by the complexity of the technique and an inconstant regeneration of the native liver. However, the potential for stopping immunosuppression, thus avoiding its long-term consequences, represents a major advantage. Initial studies conducted in poorly selected patients have shown that regeneration occurred in about 50% (Table 7) [97]. Patients with acute (or 'hyperacute') liver diseases are more likely to experience regeneration than those with subacute diseases. It must be noted that the results of auxiliary transplantation in terms of regeneration have improved in more recent series as a result of more appropriate selection of candidates [98]. Therefore, auxiliary transplantation might be strongly considered in patients below 50 years old, with hyperacute or acute liver failure and no multiorgan failure, provided a non-extended criteria graft is available.

Living donor liver transplantation

Living donor transplantation has been developed primarily in eastern countries where deceased donors are extremely scarce. This technique has expanded more recently in western countries. In the context of acute liver failure, living donor transplantation may occasionally be justified by an accelerated access to a graft. Indeed, it has proved logistically possible in specialized centres to perform complete medical assessment in a donor within less than 24 h. In almost all cases, a right lobe is necessary for obtaining sufficient graft volume in adult recipients. Besides the rapid access to a donor, living donor transplantation offers the opportunity to accelerate or, in contrast, delay the procedure according to the recipient's condition. Indeed, the status of

Table 7 Results of the different techniques of liver transplantation in patients with acute liver failure.

Authors/reference	Year	Patients	Waiting list mortality	Survival		Discontinuation of immunosuppression
				1-year	3-year	
Total deceased donor transplantation						
Devlin and Williams [100]	1996	44	–	70%	–	NA
Vickers *et al.* [101]	1988	26	58%	55%	–	NA
Iwatsuki *et al.* [102]	1989	42	–	59%	46%	NA
Gallinger *et al.* [103]	1989	21	14%	72%	–	NA
Emond *et al.* [104]	1989	17	6%	58%	–	NA
Bismuth *et al.* [96]	1995	139	16%	68%	62%	NA
Farmer *et al.* [105]	2003	204	–	72%	70%	NA
Washburn *et al.* [106]	1996	63	–	57%	55%	NA
Russo *et al.* [43]	2004	270	–	77%	–	NA
Auxiliary transplantation						
Chenard-Neu *et al.* [97]	1996	30	–	63%	–	68%[a]
Durand *et al.* [98][b]	2002	6	–	83%	–	100%[a]
Bismuth *et al.* [107]	1996	5	–	60%	–	66%[a]
Pereira *et al.* [108]	1997	7	–	57%	–	40%[a]
Sudan *et al.* [109]	1997	7	–	57%	57%	57%[a]
Living donor transplantation						
Uemoto *et al.* [110]	2000	34	–	56%	–	NA
Miwa *et al.* [111]	1999	14	–	90%	90%	NA

NA, not applicable.
[a]Percentage of the patients who survived transplantation.
[b]Patients with fulminant hepatitis B.

acute liver failure patients may change rapidly over time whether they tend to deteriorate or, in contrast, improve. In this very situation, the procedure can be delayed under careful evaluation if there is some evidence of improvement and if it is felt that the patient could recover. Living donor transplantation also has significant limitations, including technical complexity and potential pressures on the candidates for donation in a context of emergency.

Small series have been reported with excellent results (Table 7). However, prioritization in western countries means that most patients can receive a deceased donor graft in due time and that the need for living donation remains marginal.

References

1 Bernuau J (2004) Acute liver failure: avoidance of deleterious cofactors and early specific medical therapy for the liver are better than late intensive care for the brain. *J Hepatol* 41, 152–155.
2 Polson J, Lee WM (2005) AASLD position paper: the management of acute liver failure. *Hepatology* 41, 1179–1197.
3 Trey CDC (1970) The management of fulminant hepatic failure. *Prog Liver Dis* 3, 282–298.
4 Navasa M, Garcia-Pagan JC, Bosch J *et al.* (1992) Portal hypertension in acute liver failure. *Gut* 33, 965–968.
5 Bhatia V, Batra Y, Acharya SK (2004) Prophylactic phenytoin does not improve cerebral edema or survival in acute liver failure – a controlled clinical trial. *J Hepatol* 41, 89–96.
6 Schiodt FV, Balko J, Schilsky M *et al.* (2003) Thrombopoietin in acute liver failure. *Hepatology* 37, 558–561.
7 Bernal W, Donaldson N, Wyncoll D *et al.* (2002) Blood lactate as an early predictor of outcome in paracetamol-induced acute liver failure: a cohort study. *Lancet* 359, 558–563.
8 Vaquero J, Polson J, Chung C *et al.* (2003) Infection and the progression of hepatic encephalopathy in acute liver failure. *Gastroenterology* 125, 755–764.
9 Riordan SM, Williams R (2003) Mechanisms of hepatocyte injury, multiorgan failure, and prognostic criteria in acute liver failure. *Semin Liver Dis* 23, 203–215.
10 Pham BN, Mosnier JF, Durand F *et al.* (1995) Immunostaining for membrane attack complex of complement is related to cell necrosis in fulminant and acute hepatitis. *Gastroenterology* 108, 495–504.
11 Clemmesen JO, Kondrup J, Ott P (2000) Splanchnic and leg exchange of amino acids and ammonia in acute liver failure. *Gastroenterology* 118, 1131–1139.
12 Blei AT, Larsen FS (1999) Pathophysiology of cerebral edema in fulminant hepatic failure. *J Hepatol* 31, 771–776.
13 Butterworth RF (2003) Molecular neurobiology of acute liver failure. *Semin Liver Dis* 23, 251–258.
14 Larsen FS, Ejlersen E, Hansen BA *et al.* (1995) Functional loss of

cerebral blood flow autoregulation in patients with fulminant hepatic failure. *J Hepatol* 23, 212–217.
15 Lee WM (2004) Acetaminophen and the US Acute Liver Failure Study Group: lowering the risks of hepatic failure. *Hepatology* 40, 6–9.
16 Bernal W (2003) Changing patterns of causation and the use of transplantation in the United Kingdom. *Semin Liver Dis* 23, 227–337.
17 Ostapowicz G, Fontana RJ, Schiodt FV *et al.* (2002) Results of a prospective study of acute liver failure at 17 tertiary care centers in the United States. *Ann Intern Med* 137, 947–954.
18 Schiodt FV, Rochling FA, Casey DL *et al.* (1997) Acetaminophen toxicity in an urban county hospital. *N Engl J Med* 337, 1112–1117.
19 McCormick PA, Treanor D, McCormack G *et al.* (2003) Early death from paracetamol (acetaminophen) induced fulminant hepatic failure without cerebral oedema. *J Hepatol* 39, 547–551.
20 O'Grady JG, Schalm SW, Williams R (1993) Acute liver failure: redefining the syndromes. *Lancet* 342, 273–275.
21 Vento S, Garofano T, Renzini C *et al.* (1998) Fulminant hepatitis associated with hepatitis A virus superinfection in patients with chronic hepatitis C. *N Engl J Med* 338, 286–290.
22 Bernuau J, Goudeau A, Poynard T *et al.* (1986) Multivariate analysis of prognostic factors in fulminant hepatitis B. *Hepatology* 6, 648–651.
23 Sato S, Suzuki K, Akahane Y *et al.* (1995) Hepatitis B virus strains with mutations in the core promoter in patients with fulminant hepatitis. *Ann Intern Med* 122, 241–248.
24 Garfein RS, Bower WA, Loney CM *et al.* (2004) Factors associated with fulminant liver failure during an outbreak among injection drug users with acute hepatitis B. *Hepatology* 40, 865–873.
25 Lok AS, Liang RH, Chiu EK *et al.* (1991) Reactivation of hepatitis B virus replication in patients receiving cytotoxic therapy. Report of a prospective study. *Gastroenterology* 100, 182–188.
26 Mas A, Buti M, Esteban R *et al.* (1990) Hepatitis B virus and hepatitis D virus replication in HBsAg-positive fulminant hepatitis. *Hepatology* 11, 1062–1065.
27 Wu JC, Choo KB, Chen CM *et al.* (1995) Genotyping of hepatitis D virus by restriction-fragment length polymorphism and relation to outcome of hepatitis D. *Lancet* 346, 939–941.
28 Hamid SS, Jafri SM, Khan H *et al.* (1996) Fulminant hepatic failure in pregnant women: acute fatty liver or acute viral hepatitis? *J Hepatol* 25, 20–27.
29 Glorioso DV, Molloy PJ, Van Thiel DH *et al.* (1996) Successful empiric treatment of HSV hepatitis in pregnancy. Case report and review of the literature. *Dig Dis Sci* 41, 1273–1275.
30 Posthuma EF, Westendorp RG, van der Sluys Veer A *et al.* (1995) Fatal infectious mononucleosis: a severe complication in the treatment of Crohn's disease with azathioprine. *Gut* 36, 311–313.
31 Sobue R, Miyazaki H, Okamoto M *et al.* (1991) Fulminant hepatitis in primary human herpesvirus-6 infection. *N Engl J Med* 324, 1290.
32 Langnas AN, Markin RS, Cattral MS *et al.* (1995) Parvovirus B19 as a possible causative agent of fulminant liver failure and associated aplastic anemia. *Hepatology* 22, 1661–1665.
33 Elisaf M, Stefanaki S, Repanti M *et al.* (1993) Liver involvement in hemorrhagic fever with renal syndrome. *J Clin Gastroenterol* 17, 33–37.
34 Mas A (2005) Mushrooms, amatoxins and the liver. *J Hepatol* 42, 166–169.
35 Ganzert M, Felgenhauer N, Zilker T (2005) Indication of liver transplantation following amatoxin intoxication. *J Hepatol* 42, 202–209.
36 Babany G, Bernuau J, Cailleux A *et al.* (1991) Severe monochlorobenzene-induced liver cell necrosis. *Gastroenterology* 101, 1734–1736.
37 Larrey D, Vial T, Pauwels A *et al.* (1992) Hepatitis after germander (*Teucrium chamaedrys*) administration: another instance of herbal medicine hepatotoxicity. *Ann Intern Med* 117, 129–132.
38 Ellis AJ, Wendon JA, Portmann B *et al.* (1996) Acute liver damage and ecstasy ingestion. *Gut* 38, 454–458.
39 Berson A, Gervais A, Cazals D *et al.* (2001) Hepatitis after intravenous buprenorphine misuse in heroin addicts. *J Hepatol* 34, 346–350.
40 Lee WM (2003) Acute liver failure in the United States. *Semin Liver Dis* 23, 217–226.
41 Durand F, Jebrak G, Pessayre D *et al.* (1996) Hepatotoxicity of antitubercular treatments. Rationale for monitoring liver status. *Drug Safety* 15, 394–405.
42 Durand F, Bernuau J, Pessayre D *et al.* (1995) Deleterious influence of pyrazinamide on the outcome of patients with fulminant or subfulminant liver failure during antituberculous treatment including isoniazid. *Hepatology* 21, 929–932.
43 Russo MW, Galanko JA, Shrestha R *et al.* (2004) Liver transplantation for acute liver failure from drug induced liver injury in the United States. *Liver Transpl* 10, 1018–1023.
44 Paterson D, Kerlin P, Walker N *et al.* (1992) Piroxicam induced submassive necrosis of the liver. *Gut* 33, 1436–1438.
45 McKenzie R, Fried MW, Sallie R *et al.* (1995) Hepatic failure and lactic acidosis due to fialuridine (FIAU), an investigational nucleoside analogue for chronic hepatitis B. *N Engl J Med* 333, 1099–1105.
46 Durand F, Samuel D, Bernuau J *et al.* (1992) Fipexide-induced fulminant hepatitis. Report of three cases with emergency liver transplantation. *J Hepatol* 15, 144–146.
47 Mathurin P, Durand F, Ganne N *et al.* (1995) Ischemic hepatitis due to obstructive sleep apnea. *Gastroenterology* 109, 1682–1684.
48 Henrion J, Minette P, Colin L *et al.* (1999) Hypoxic hepatitis caused by acute exacerbation of chronic respiratory failure: a case-controlled, hemodynamic study of 17 consecutive cases. *Hepatology* 29, 427–433.
49 Saissy JM (1996) Liver transplantation in a case of fulminant liver failure after exertion. *Intens Care Med* 22, 831.
50 Hadad E, Ben-Ari Z, Heled Y *et al.* (2004) Liver transplantation in exertional heat stroke: a medical dilemma. *Intens Care Med* 30, 1474–1478.
51 Durand F, Bernuau J, Giostra E *et al.* (2001) Wilson's disease with severe hepatic insufficiency: beneficial effects of early administration of D-penicillamine. *Gut* 48, 849–852.
52 Stampfl DA, Munoz SJ, Moritz MJ *et al.* (1990) Heterotopic liver transplantation for fulminant Wilson's disease. *Gastroenterology* 99, 1834–1836.
53 Rowbotham D, Wendon J, Williams R (1998) Acute liver failure secondary to hepatic infiltration: a single centre experience of 18 cases. *Gut* 42, 576–580.
54 Te HS, Schiano TD, Kahaleh M *et al.* (1999) Fulminant hepatic failure secondary to malignant melanoma: case report and review of the literature. *Am J Gastroenterol* 94, 262–266.
55 Phillips MJ, Blendis LM, Poucell S *et al.* (1991) Syncytial giant-cell hepatitis. Sporadic hepatitis with distinctive pathological features, a severe clinical course, and paramyxoviral features. *N Engl J Med* 324, 455–460.
56 Durand F, Degott C, Sauvanet A *et al.* (1997) Subfulminant syncytial giant cell hepatitis: recurrence after liver transplantation treated with ribavirin. *J Hepatol* 26, 722–726.

57 Ockner SA, Brunt EM, Cohn SM *et al.* (1990) Fulminant hepatic failure caused by acute fatty liver of pregnancy treated by orthotopic liver transplantation. *Hepatology* 11, 59–64.

58 Sibai B, Dekker G, Kupferminc M (2005) Pre-eclampsia. *Lancet* 365, 785–799.

59 Casteels-Van Daele M, Wouters C, Van Geet C *et al.* (2002) Reye's syndrome revisited. Outdated concept of Reye's syndrome was used. *BMJ* 324, 546.

60 Mutimer D, Shaw J, Neuberger J *et al.* (1995) Failure to incriminate hepatitis B, hepatitis C, and hepatitis E viruses in the aetiology of fulminant non-A non-B hepatitis. *Gut* 36, 433–436.

61 O'Grady JG, Alexander GJ, Hayllar KM *et al.* (1989) Early indicators of prognosis in fulminant hepatic failure. *Gastroenterology* 97, 439–445.

62 Takahashi Y, Kumada H, Shimizu M *et al.* (1994) A multicenter study on the prognosis of fulminant viral hepatitis: early prediction for liver transplantation. *Hepatology* 19, 1065–1071.

63 Acharya SK, Dasarathy S, Kumer TL *et al.* (1996) Fulminant hepatitis in a tropical population: clinical course, cause, and early predictors of outcome. *Hepatology* 23, 1448–1455.

64 Izumi S, Langley PG, Wendon J *et al.* (1996) Coagulation factor V levels as a prognostic indicator in fulminant hepatic failure. *Hepatology* 23, 1507–1511.

65 Baquerizo A, Anselmo D, Shackleton C *et al.* (2003) Phosphorus as an early predictive factor in patients with acute liver failure. *Transplantation* 75, 2007–2014.

66 Dabos KJ, Newsome PN, Parkinson JA *et al.* (2004) Biochemical prognostic markers of outcome in non-paracetamol-induced fulminant hepatic failure. *Transplantation* 77, 200–205.

67 Schmidt LE, Dalhoff K (2005) Alpha-fetoprotein is a predictor of outcome in acetaminophen-induced liver injury. *Hepatology* 41, 26–31.

68 Schiodt FV, Rossaro L, Stravitz RT *et al.* (2005) Gc-globulin and prognosis in acute liver failure. *Liver Transpl* 11, 1223–1227.

69 Saibara T, Onishi S, Maeda T *et al.* (1992) Arterial blood ketone body ratio as a possible indicator for predicting fulminant hepatitis in patients with acute hepatitis. *Liver* 12, 392–396.

70 Shakil AO, Kramer D, Mazariegos GV *et al.* (2000) Acute liver failure: clinical features, outcome analysis, and applicability of prognostic criteria. *Liver Transpl* 6, 163–169.

71 Bailey B, Amre DK, Gaudreault P (2003) Fulminant hepatic failure secondary to acetaminophen poisoning: a systematic review and meta-analysis of prognostic criteria determining the need for liver transplantation. *Crit Care Med* 31, 299–305.

72 Wiesner RH (2004) MELD/PELD and the allocation of deceased donor livers for status 1 recipients with acute fulminant hepatic failure, primary nonfunction, hepatic artery thrombosis, and acute Wilson's disease. *Liver Transpl* 10, S17–22.

73 Poland GA, Jacobson RM (2004) Clinical practice: prevention of hepatitis B with the hepatitis B vaccine. *N Engl J Med* 351, 2832–2838.

74 Shim M, Khaykis I, Park J *et al.* (2005) Susceptibility to hepatitis A in patients with chronic liver disease due to hepatitis C virus infection: missed opportunities for vaccination. *Hepatology* 42, 688–695.

75 Langley PG, Hughes RD, Forbes A *et al.* (1993) Controlled trial of antithrombin III supplementation in fulminant hepatic failure. *J Hepatol* 17, 326–331.

76 Harrison PM, Wendon JA, Gimson AE *et al.* (1991) Improvement by acetylcysteine of hemodynamics and oxygen transport in fulminant hepatic failure. *N Engl J Med* 324, 1852–1857.

77 Shawcross DL, Davies NA, Mookerjee RP *et al.* (2004) Worsening of cerebral hyperemia by the administration of terlipressin in acute liver failure with severe encephalopathy. *Hepatology* 39, 471–475.

78 Blei AT (2005) Monitoring cerebral blood flow: a useful clinical tool in acute liver failure? *Liver Transpl* 11, 1320–1322.

79 Blei AT, Olafsson S, Webster S *et al.* (1993) Complications of intracranial pressure monitoring in fulminant hepatic failure. *Lancet* 341, 157–158.

80 White H, Baker A (2002) Continuous jugular venous oximetry in the neurointensive care unit – a brief review. *Can J Anaesth* 49, 623–629.

81 Helmke K, Burdelski M, Hansen HC (2000) Detection and monitoring of intracranial pressure dysregulation in liver failure by ultrasound. *Transplantation* 70, 392–395.

82 Madl C, Grimm G, Ferenci P *et al.* (1994) Serial recording of sensory evoked potentials: a noninvasive prognostic indicator in fulminant liver failure. *Hepatology* 20, 1487–1494.

83 Strauss GI, Christiansen M, Moller K *et al.* (2001) S-100b and neuron-specific enolase in patients with fulminant hepatic failure. *Liver Transpl* 7, 964–970.

84 Murphy N, Auzinger G, Bernel W *et al.* (2004) The effect of hypertonic sodium chloride on intracranial pressure in patients with acute liver failure. *Hepatology* 39, 464–470.

85 Vaquero J, Blei AT (2004) Cooling the patient with acute liver failure. *Gastroenterology* 127, 1626–1629.

86 Jalan R, Olde Damink SW, Deutz NE *et al.* (2004) Moderate hypothermia in patients with acute liver failure and uncontrolled intracranial hypertension. *Gastroenterology* 127, 1338–1346.

87 Ellis AJ, Wendon JA, Williams R (2000) Subclinical seizure activity and prophylactic phenytoin infusion in acute liver failure: a controlled clinical trial. *Hepatology* 32, 536–541.

88 Schmidt LE, Wang LP, Hansen BA *et al.* (2003) Systemic hemodynamic effects of treatment with the molecular adsorbents recirculating system in patients with hyperacute liver failure: a prospective controlled trial. *Liver Transpl* 9, 290–297.

89 Demetriou AA, Brown RS, Jr, Busuttil RW *et al.* (2004) Prospective, randomized, multicenter, controlled trial of a bioartificial liver in treating acute liver failure. *Ann Surg* 239, 660–667; discussion 667–670.

90 Ellis AJ, Hughes RD, Wendon JA *et al.* (1996) Pilot-controlled trial of the extracorporeal liver assist device in acute liver failure. *Hepatology* 24, 1446–1451.

91 Kjaergard LL, Liu J, Als-Nielsen B *et al.* (2003) Artificial and bioartificial support systems for acute and acute-on-chronic liver failure: a systematic review. *JAMA* 289, 217–222.

92 Chari RS, Collins BH, Magee JC *et al.* (1994) Brief report: treatment of hepatic failure with ex vivo pig-liver perfusion followed by liver transplantation. *N Engl J Med* 331, 234–237.

93 Pauwels A, Mostefa-Kara N, Florent C *et al.* (1993) Emergency liver transplantation for acute liver failure. Evaluation of London and Clichy criteria. *J Hepatol* 17, 124–127.

94 Blei AT (2005) Selection for acute liver failure: have we got it right? *Liver Transpl* 11, S30–34.

95 Belghiti J, Noun R, Sauvanet A *et al.* (1995) Transplantation for fulminant and subfulminant hepatic failure with preservation of portal and caval flow. *Br J Surg* 82, 986–989.

96 Bismuth H, Samuel D, Castaing D *et al.* (1995) Orthotopic liver transplantation in fulminant and subfulminant hepatitis. The Paul Brousse experience. *Ann Surg* 222, 109–119.

97 Chenard-Neu MP, Boudjema K, Bernuau J *et al.* (1996) Auxiliary liver transplantation: regeneration of the native liver and outcome in

30 patients with fulminant hepatic failure – a multicenter European study. *Hepatology* 23, 1119–1127.

98 Durand F, Belghiti J, Handra-Luca A *et al.* (2002) Auxiliary liver transplantation for fulminant hepatitis B: results from a series of six patients with special emphasis on regeneration and recurrence of hepatitis B. *Liver Transpl* 8, 701–707.

99 Bernuau J, Rueff B, Benhamou JP (1986) Fulminant and subfulminant liver failure: definitions and causes. *Semin Liver Dis* 6, 97–106.

100 Devlin J, Williams R (1996) Transplantation for fulminant hepatic failure: comparing tacrolimus versus cyclosporine for immunosuppression and the outcome in elective transplants. European FK506 Liver Study Group. *Transplantation* 62, 1251–1255.

101 Vickers C, Neuberger J, Buckels J *et al.* (1988) Transplantation of the liver in adults and children with fulminant hepatic failure. *J Hepatol* 7, 143–150.

102 Iwatsuki S, Stieber AC, Marsh JW *et al.* (1989) Liver transplantation for fulminant hepatic failure. *Transplant Proc* 21, 2431–2434.

103 Gallinger S, Greig PD, Levy G *et al.* (1989) Liver transplantation for acute and subacute fulminant hepatic failure. *Transplant Proc* 21, 2435–2438.

104 Emond JC, Aran PP, Whitington PF *et al.* (1989) Liver transplantation in the management of fulminant hepatic failure. *Gastroenterology* 96, 1583–1588.

105 Farmer DG, Anselmo DM, Ghobrial RM *et al.* (2003) Liver transplantation for fulminant hepatic failure: experience with more than 200 patients over a 17-year period. *Ann Surg* 237, 666–675; discussion 675–676.

106 Washburn WK, Bradley J, Cosimi AB *et al.* (1996) A regional experience with emergency liver transplantation. *Transplantation* 61, 235–239.

107 Bismuth H, Azoulay D, Samuel D *et al.* (1996) Auxiliary partial orthotopic liver transplantation for fulminant hepatitis. The Paul Brousse experience. *Ann Surg* 224, 712–724; discussion 724–726.

108 Pereira SP, McCarthy M, Ellis AJ *et al.* (1997) Auxiliary partial orthotopic liver transplantation for acute liver failure. *J Hepatol* 26, 1010–1017.

109 Sudan DL, Langnas AN, Shaw BW, Jr (1997) Long-term follow-up of auxiliary liver transplantation for fulminant hepatic failure. *Transplant Proc* 29, 485–486.

110 Uemoto S, Inomata Y, Sakurai T *et al.* (2000) Living donor liver transplantation for fulminant hepatic failure. *Transplantation* 70, 152–157.

111 Miwa S, Hashikura Y, Mita A *et al.* (1999) Living-related liver transplantation for patients with fulminant and subfulminant hepatic failure. *Hepatology* 30, 1521–1526.

16 Genetic and metabolic diseases

16.1 Wilson's disease

Michael Schilsky

Pathophysiology

Despite our limited knowledge of the intracellular trafficking of copper, it is clear that the absence or diminished function of ATP7B results in a decrease in biliary copper excretion, and the subsequent toxic hepatic accumulation of this metal in Wilson disease [1–3]. Excess copper is toxic to cells by the generation of free radicals, lipid peroxidation of membranes and DNA, inhibition of protein synthesis and alterations in the levels of cellular antioxidants [3,4]. Both hepatocellular necrosis and apoptosis may be triggered by copper-induced cell damage [5]. Along with chronic liver injury, there is the generation of fibrosis and eventual cirrhosis. Whether the injury is severe and acute or chronic, the functional status of the liver as a whole is determined by the balance between injury, cell death and the regenerative capacity of liver cells.

When hepatic storage capacity is exceeded, or following acute hepatocellular injury with the subsequent release of cellular copper into the circulation, the level of non-ceruloplasmin-bound copper is increased. The copper that is deposited in extrahepatic sites is thought to be derived from this pool of copper. The central nervous system, and in particular the brain, is the most critical site of copper accumulation. Copper-induced neuronal injury is responsible for the neurological and psychiatric manifestations of Wilson's disease and the characteristic pathological changes that may be seen in part by radiological imaging studies of the brain [4].

Clinical presentations

Liver disease

The range of liver disease includes asymptomatic biochemical dysfunction, chronic hepatitis, cirrhosis (compensated and decompensated) and liver failure. Clinically, improvement is seen by reduction of jaundice and diminution of ascites and oedema, if these were present. Fluid retention should be managed by sodium restriction and diuretics as necessary. Oesophageal or gastric varices warrant prophylactic treatment with beta-blockers. Biochemical markers of recovery from liver injury include improvement in synthetic function as well in clearance of bilirubin. With response to treatment, improvements include increasing levels of albumin, correction of international normalized ratio (INR) and reduction in bilirubin and transaminases. The timeframe for initial improvement in liver disease following treatment occurs over months. The most rapid changes occur during the first 6–12 months after the start of treatment [6]. Improvement may continue for the next 3–4 years at a slower rate, and probably over many years after with respect to regression of hepatic fibrosis once inflammation resulting from toxic copper is controlled. A recent report demonstrates regression of fibrosis with treatment of the underlying Wilson's disease [7].

Those with acute liver failure due to Wilson's disease now benefit from advances in intensive care management of all liver failure patients. One feature that differentiates them from other patients with acute liver failure is the marked excess of copper that is released by the acute hepatic necrosis. This copper contributes to further haemolysis and to renal tubular injury. Therefore, copper can be acutely removed from the circulation by several different means: exchange transfusion, plasmapheresis with plasma exchange, dialysis or haemofiltration against albumin or by the use of devices such as MARS (molecular absorbent recirculating system) that combine haemofiltration against albumin with anion exchange and charcoal filtration (see references in [8]). The use of chelating agents in the setting of acute liver failure is limited because of the possibility of drug hypersensitivity reaction, marrow suppression and the typical development of renal insufficiency. In future, the use of antioxidant therapy and caspase inhibitors may also have a role, as apoptosis is activated in Wilson's disease [5]. Other adjunctive measures such as lowering tissue iron content and the use of antioxidants could potentially reduce oxidative injury from copper.

Neurological disease

The goal for patients with neurological Wilson's disease is initial disease stabilization, then improvement. Neurological worsening

can occur in a minority of patients with treatment initiation due in part to the continued progression of disease in the central nervous system. Computerized tomography (CT) or magnetic resonance imaging (MRI) of the brain may give some clue to the extent of injury to specific brain areas; however, the findings are not sufficient to predict the entirety of the clinical picture, and clinical evaluation is important. Patients with significant Parkinsonian symptoms may benefit from a trial of dopaminergic stimulating agents, although success with these agents is mixed at best due to damage to pre- and postsynaptic neurons [9]. Tremors can be treated with benzodiazepines or medications such as mysoline. Muscle spasms and dystonia benefit from the use of benzodiazepines, short and longer acting, and other drugs such as baclofen as an antispasmodic agent. Localized dystonia can benefit from the use of botulinum toxin injections to reduce tone and spasm. Physical and occupational therapy can help to increase or maintain range of motion and relief from painful spasms. Dysphagia is typically a transfer dysphagia due to neuromuscular involvement, and speech and swallow evaluations by speech therapists can help to detect and treat this. Dietary adjustments can help to prevent aspiration; however, with very severe dysphagia with aspiration, percutaneous feeding gastrostomy is indicated. As for liver disease, improvement can occur over months and years.

Psychiatric disease

Psychiatric symptoms, varying from anxiety and depressive disorders to frank psychosis, must be addressed by treating physicians. Depression is by far the most common symptom experienced in patients with Wilson's disease [10]. Obvious severe depression and psychosis need pharmacotherapy directed at the associated symptoms. Serotonin uptake inhibitors may benefit those with depression, and can be used safely with appropriate monitoring for patients with liver disease. Other treatments directed at psychosis are not specific for Wilson's disease, but may be helpful for affected individuals. Their use must be directed by psychiatrists or psychopharmacologists in concert with the patient's medical doctor. Treatment of anxiety disorders with benzodiazepines can be helpful; however, in those with advanced liver disease, this class of medication could exacerbate underlying encephalopathy. An interesting and often underreported symptom of Wilson's disease is severe insomnia, and this must be sorted from depression or encephalopathy before treatment with sleeping aids. With treatment of the psychiatric symptoms in these individuals, it is important to remember that reassessment over time is necessary while the underlying disease is being treated. Close communication is therefore essential for treating health care professionals involved in their care.

Diagnosis

The age at which clinicians would consider a diagnosis of Wilson's disease has expanded from ages 5–45 years to include children less than 2 years of age and individuals in their seventh and eight decades of life [11,12]. Currently, Wilson's disease should be considered in individuals with liver disease, neurological or psychiatric disease and in family members of individuals in whom the diagnosis has been established. The diagnosis may be established by a series of clinical, biochemical and molecular tests (see below) that can be viewed in aggregate using a scoring system set forth at the last International Meeting on Wilson's Disease in Leipzig, Germany [13]. This scoring system helps to gauge the probability of diagnosis of this disorder; however, it is important to remember that this scoring system has yet to be prospectively evaluated. Studies are ongoing to determine whether advances in screening for Wilson's disease by biochemical testing for ceruloplasmin may be applied to larger populations [14]. If this is successful, a percentage of individuals with the disorder may be detected at a very early stage when they would be asymptomatic for the disease. However, as for all screening tests, it is likely that only a percentage of those affected will be identified. Therefore, suspicion for the diagnosis of Wilson's disease and the utilization of current methods for testing for this disorder will still be needed.

The initial strategies for evaluating a patient for Wilson's disease with hepatic or neuro/psychiatric manifestations involves testing for Kayser–Fleischer rings, for reductions in serum ceruloplasmin and for evidence of liver disease [8]. Other biochemical testing that may be applied involves analysis for 24-hour urine excretion of copper and liver biopsy for histology, histochemical screening for copper binding protein and quantitative analysis for copper. Brain imaging, MRI or CT may also provide evidence of Wilson's disease but are not diagnostic. Molecular studies provide direct evidence for the presence of Wilson's disease (see below), but are costly at the present time and are not always readily available. Even when molecular testing yields a diagnosis of Wilson's disease, the standard clinical and biochemical testing that includes estimates of liver function and copper balance provide useful information about the patient prior to treatment.

Biochemical tests

Ceruloplasmin is a circulating glycoprotein containing six copper atoms per molecule that is synthesized mainly in the liver. The ceruloplasmin peptide without copper, known as apoceruloplasmin, acquires its copper in the trans-Golgi prior to secretion from the hepatocytes [15]. ATP7B in the trans-Golgi receives cytosolic copper from HAH-1 and transports this copper across the Golgi membrane for incorporation into apoceruloplasmin. In Wilson's disease, where ATP7B is absent or its activity diminished, copper incorporation into ceruloplasmin is inhibited, and secretion of the apoprotein occurs with a shortened half-life compared with the protein with its full complement of copper [16]. This results in a reduced steady-state level of this protein in the circulation characteristic of most patients with Wilson's disease.

The liver biopsy may still play a role in the diagnosis of Wilson's disease; however, the cutoff values above which patients may be identified are probably lower than the prior accepted diagnostic level of 250 μg/g copper per dry weight liver [17]. While the levels of copper do not necessarily correspond to the degree of injury manifest in the liver, the typical pattern of injury is that of steatosis and fibrosis preceding cirrhosis. The steatosis is often microvesicular as well as macrovesicular, and corresponds with ultrastructural changes in the mitochondria [4]. These mitochondrial changes, dilated cristae and crystalline deposits, will disappear with time and be replaced by dense lysosomal inclusions. With treatment, the mitochondrial changes are reversible. Recent data show that the fibrosis present in many patients at the time of diagnosis can also improve with treatment [7]. In patients with fulminant liver failure, cirrhosis or advanced fibrosis may be present along with severe hepatocellular injury and cell dropout. Apoptosis is the predominant form of cell injury during this phase [5].

Urine copper excretion is also helpful as a diagnostic aid but, more importantly, provides a useful means for evaluating and monitoring treatment. In most symptomatic patients prior to treatment, the urine copper is elevated above 100 μg/day; however, this alone is not sufficient for a diagnosis given the elevations in urine copper that can occur in the face of active liver injury. The use of the penicillamine challenge remains standardized in paediatric patients [18], and limited data are available regarding its diagnostic value for adults.

Molecular genetics

Molecular genetics has greatly affected our understanding of Wilson's disease, and has more recently played a role in diagnostics. The *ATP7B* gene includes 21 exons and extends over 80 000 basepairs [19]. This initially made the *de novo* diagnosis of Wilson's disease by molecular means more challenging, except in unique populations where specific mutations were identified. In these populations, the unique mutation may be sought directly by amplification of the region by polymerase chain reaction and confirmed by sequencing. For instance, in the Slavic population in Europe, the most common mutation is the histidine to glutamate substitution at amino acid 1069 (H1069Q) [20]. In this population, this H1069Q is present in 37–63% of individuals. This mutation, and four others, account for 70% of all European mutations, suggesting that the strategy of screening for these first may be most efficient. In other populations, different mutations are more prevalent, suggesting that founder effects may have occurred in isolated groups. The H1069Q appears to be absent in Chinese patients, but R778L has been reported to represent 34–38% of mutations [21,22]. In a population from Saudi Arabia, the 4193delC mutation was present in multiple members of a single tribe [23]. Other relatively isolated populations in which unique mutations are found with higher frequency include Iceland and the island of Gran Canaria.

Early on, it was recognized that populations such as those in North America are very heterogeneous, and numerous mutations are present in the population [24]. The discovery that the regions flanking the gene were inherited along with *ATP7B* led to the use of haplotype analysis. This analysis is accomplished by determining patterns of DNA polymorphisms in the region around the *ATP7B* gene, which is useful for determining the status of siblings of an identified patient.

There are now more than 200 identified disease-specific mutations of the *ATP7B* gene that have been catalogued by investigators at the University of Edmonton in Alberta [19,25]. As the technology of DNA sequencing has continued to evolve, it is now possible to search directly for mutations of the *ATP7B* gene in any patient. Direct sequencing for mutation analysis, now commercially available from the Mayo Clinic Laboratories, may still miss some mutations outside the coding region of the *ATP7B* gene or that occur on other genes and still affect *ATP7B* transcription. These caveats aside, the ability to obtain sequence data *de novo* across the entire gene is very useful for patients in whom the diagnosis is difficult to establish by standard clinical and biochemical studies, and particularly useful in populations with mixed gene pools where the patient is most likely to be a compound heterozygote with two unique mutations of the *ATP7B* gene. With time and continued improvement in methodology, testing by DNA sequencing will become more cost-effective and more widely available.

The heterogeneity of the mutations of *ATP7B* and the relative rarity of Wilson's disease make it difficult for accurate genotype–phenotype correlations. As noted, the increased frequency of the H1069Q genotype in Europeans of Slavic heritage provided investigators with an opportunity to investigate whether this group differed from other mutations. In a meta-analysis study, homozygosity for H1069Q was associated with a slightly later onset of disease and with a neurological presentation of their disease [20]. Despite these data, there is still a great heterogeneity of disease presentation among siblings with the same mutations, as demonstrated in a recent case report on two siblings presenting with the disease in their eighth decade of life [11,12]. One of these individuals had cirrhosis with severe neurological degeneration, while the other had mild liver disease and minimal neurological symptoms.

Given the differences in disease presentation, it is clear that, for Wilson's disease, despite being monogenic with respect to requiring mutations or malfunction of *ATP7B*, other extragenic factors influence disease presentation. Patients with fulminant hepatic failure due to Wilson's disease are more commonly female [26] and, similarly, female LEC rats present earlier with more severe liver disease than male animals [27]. Other genes involved in antioxidant pathways, such as apolipoproteins, may also influence the expression of Wilson's disease [28]. More recently, polymorphisms of MURR1 were found to differ among those with earlier disease presentation compared with those with later onset disease [29]. The effect of many of these other genes influences the phenotypical presentation of Wilson's

disease, further confounding ATP7B genotype and phenotype correlations.

Therapy for Wilson's disease

The goal of treatment for symptomatic patients is to prevent disease progression and reverse copper-induced toxicity and, for asymptomatic patients, to prevent the development of active disease. For patients with fulminant hepatic failure due to Wilson's disease, the initial goal is disease stabilization while awaiting a donor organ for transplantation. Specific treatments for complications of liver and neuropsychiatric disease are discussed below.

The first systemic treatment for Wilson's disease was dimercaptopropanol or British anti-Lewisite, a compound that was delivered as an intramuscular injection in 1950 [30]. This therapy, initially utilized for patients identified as having Wilson's disease by their neurological disease, achieved miraculous improvements in some individuals who were previously considered doomed to suffer progressive deterioration and death. Dr John Walshe developed the first oral compound for treating Wilson's disease, D-penicillamine, and subsequently other compounds for those intolerant of this therapy [31,32]. With the advent of serological testing for liver function and the recognition that serum ceruloplasmin was abnormal in these patients [33], Wilson's disease could be diagnosed prior to the development of symptomatic disease. This led to the recommendation for earlier institution of lifelong medical therapy. We now recognize that successful treatment of Wilson's disease is also not limited to the treatment of the primary disorder of copper metabolism. It is important to remember that patients must be treated for their neurological or psychiatric symptoms, for complications of portal hypertension (ascites, encephalopathy, variceal bleeding) in addition to treatment of their Wilson's disease.

Treatment of Wilson's disease has not yet advanced to the point at which genotype identification of the mutations of the *ATP7B* gene alters our treatment choices for this disorder. Rather, the initial treatment choice remains, in part, determined by the phenotypical manifestations present in the individual patient, and the availability of the various treatment options in the patients' community. For those with fulminant hepatitis due to Wilson's disease or with intractable hepatic insufficiency, liver transplantation is necessary and is life-saving [26,34–36]. Patients with a range of liver disease, neurological or psychiatric disease or symptoms are managed medically in the following manner.

Patients with Wilson's disease may be considered as belonging to one of three groupings. There are those who are asymptomatic, those with active disease (severe hepatic inflammation or hepatic insufficiency) with or without symptoms or with neurological or psychiatric symptoms, and patients with previously active disease who are now asymptomatic or stable with respect to their disease as a result of prior treatment. Asymptomatic patients are most commonly those in whom the disease was found by family screening following identification of the proband.

For those patients with symptomatic illness due to Wilson's disease, first-line therapy is an oral chelating agent – either D-penicillamine or trientine. Chelating agents provide a more rapid elimination of copper compared with treatment with zinc, the latter functioning to block copper absorption. Initial studies of D-penicillamine demonstrated the efficacy of this compound in ameliorating and reversing the signs and symptoms of Wilson's disease [31]. While this medication is effective treatment for most, a minority experience adverse reactions that include drug hypersensitivity, marrow suppression and lupus-like syndromes with nephritis and nephrosis. Some experience neurological worsening on treatment. The actual frequency of occurrence of these and other side-effects of this medication are uncertain, but range from 10% to 50% of individuals [4,37]. The intolerance of D-penicillamine in some patients led to the development of another oral chelating agent, trientine dihydrochloride. Trientine is also an effective chelator of copper with a better safety profile than D-penicillamine [7,38]. While indicated for use in penicillamine-intolerant patients, initial reports following its introduction confirmed its effectiveness in treating patients unable to continue their D-penicillamine therapy [39]; other studies have confirmed the ability to use this as primary therapy for untreated patients [7,8,38].

Combination therapy for symptomatic Wilson's disease patients with a chelating agent and zinc, temporally spaced to prevent absorption of the zinc by the chelating agent, has been used empirically in the hope of providing an even more effective initial therapy [7]. However, there are no trials demonstrating that the use of combination therapy is more effective than a chelating agent used alone. Another adjunctive therapy for initial treatment is the use of antioxidant agents such as alpha-tocopherol. The basis for this is the report of reduced levels of vitamin E in patients with Wilson's disease, and its known antioxidant effect in animal models and *in vitro* [40]. While clinical trials are lacking, there is little downside to trial of limited quantities of this vitamin supplement along with standard therapy.

Tetrathiomolybdate (TM) remains a promising agent for those patients with initial neurological presentations [41]; however, it is not yet approved for use for Wilson's disease. Tetrathiomolybdate was first used by veterinarians for copper poisoning in animals, and was adapted for use in patients with symptomatic neurological disease due to Wilson's disease [42]. In a recent clinical trial that compared TM with trientine for first-line therapy for neurologically affected patients, there were no statistically significant differences between the study groups; however, there was a trend slightly favouring treatment with TM [43].

Patients who are asymptomatic or who became asymptomatic or stable with respect to their disease following treatment may be considered as similar groups with respect to treatment choices

and dosages for therapy. In these individuals, successful maintenance therapy can be achieved with a singe chelating agent or with zinc [8].

Zinc as a therapy for Wilson's disease was first developed by Schoewinck and reported by Hoogenrad *et al.* [see ref. 44] over 30 years ago, and was subsequently investigated by Brewer *et al.* [45–47]. Zinc acts to block copper absorption by enterocytes and yields a negative copper balance over time. Zinc does not directly compete with copper for uptake but, rather, zinc induces enterocyte synthesis of the endogenous chelator, metallothionein. This cysteine-rich peptide binds copper with a higher affinity than zinc. Copper that enters enterocytes binds to metallothionein and displaces zinc, and the copper–metallothionein complex remains within the enterocyte. When the enterocyte is shed into the intestinal lumen as part of its normal life cycle, faecal copper excretion increases. In this manner, zinc effects a negative copper balance in that copper absorption is reduced below cellular and secretory losses, thereby inducing a negative copper balance over time.

Restriction of dietary copper by reduced intake is recommended to all newly diagnosed patients. The major foods that contain higher copper contents include mushrooms, nuts, chocolate and organ meats such as liver. Information as to the content of copper in most foods may be found on the website of the US Department of Agriculture (http://www.usda.gov).

Liver transplant is life-saving for those patients with Wilson's disease with fulminant liver failure and for those with severe hepatic insufficiency not responding to medical therapy [8,26]. Whole organ transplantation and partial grafts, whether orthotopic or placed heterotopically, can successfully treat these patients. Most of the transplants for Wilson's disease in Europe and the United States are from deceased donors; however, there are reports of living donor surgery for Wilson's disease from Asia [48,49]. Transplantation of a heterozygous liver from a parent of a patient with Wilson's disease does not result in disease or excess copper accumulation in the recipient above that expected in carriers [50].

Following transplantation, the remaining excess non-hepatic stores of copper are mobilized and excreted, as witnessed by the gradual loss of Kayser–Fleischer rings and reduction in urinary copper excretion with time. Long-term survival of liver transplants for fulminant Wilson's disease is better than in patients transplanted for acute liver failure of other causes, typically 80–90% compared with 65% [51]. In the series from Spain, those with neurological disease had a poorer long-term survival of only 75% [52]. Only one report from Italy notes decreased long-term survival of the grafts in patients with Wilson's disease relative to other disorders [53].

Liver transplantation for patients with neurological Wilson's disease without severe liver disease remains controversial. There are reports of its success in some patients; however, given the donor liver shortage and the ability to stabilize and treat the disease with medical therapy, patients should be transplanted only as part of a carefully controlled trial. However, the advent of living donor liver transplant does change the ethical consideration for transplant, as a liver is not being used from the pool of organs available to other donors. Appropriate consideration of the possible outcomes and the risk to the donor must be weighed in any decision to perform transplantation using live donors.

Pregnancy

Medical treatment of Wilson's disease during pregnancy is essential. Successful term pregnancies with good outcomes have been reported for patients on D-penicillamine, trientine and zinc [46,54]. There have been reports of birth defects occurring with all these different treatments; however, it is not clear that their occurrence is any greater than that prevalent in the population at large. Nevertheless, as teratogenicity was reported for penicillamine in animal studies, it is reasonable to consider reducing the dosage of the chelating agents to the minimal necessary dosage to reduce fetal risk. Reduction of dosage also aids in wound healing for those patients with caesarean births or other surgical procedures during childbirth. Monitoring to ensure continued normal liver function during the course of the pregnancy should confirm adequate treatment. No dosage reduction is necessary for zinc therapy during pregnancy.

In those patients with portal hypertension, screening for varices should be done. For those found to have varices, non-selective beta-blockers should be administered with the permission of the obstetrician.

Biochemical parameters for monitoring treatment

Non-ceruloplasmin-bound copper

The non-ceruloplasmin-bound copper is a fraction that is typically ~10% of the total serum copper. We can estimate the amount of non-ceruloplasmin copper by simultaneously measuring serum ceruloplasmin and total serum copper. In an untreated patient with Wilson's disease, the percentage of non-ceruloplasmin copper rises to over 25–50% and may exceed 25 μg/dL. One biochemical measure of effective medical treatment is the lowering of the fraction of non-ceruloplasmin-bound copper to the normal range of 10–15 μg/dL. For patients on maintenance therapy, this lower target range should be maintained. When non-ceruloplasmin levels drop far below 10 μg, patients may experience further reduction in serum levels of ceruloplasmin and ferroxidase activity with resultant anaemia and, in some, the development of hepatic haemosiderosis [55]. In these individuals, dosages should be reduced. In those with non-adherence to their medical therapy, elevations of their non-ceruloplasmin copper should be detectable above normal levels, and abnormalities in liver function tests may appear along with the reappearance of Kayser–Fleischer rings.

Urinary copper excretion

Urinary copper excretion may be used to gauge the effectiveness of treatment for Wilson's disease. In symptomatic patients, basal (baseline or pretreatment) urinary copper is typically greater than 100 mg/dL per 24 h. Following initial treatment with chelating agents, 24-h urine copper excretion typically rises above 500 μg/24 h. With ongoing treatment, the urinary copper excretion falls, typically ranging between 250 and 500 μg/24 h [5,8]. For chronically treated patients, values less than 250 μg/24 h suggest either depletion of copper stores or non-adherence to therapy. The simultaneous estimation of non-ceruloplasmin copper by serum testing may help to distinguish between depletion and non-adherence, the former with values < 10 μg/dL while the latter are typically elevated above 25 μg/dL.

For patients on zinc therapy, the 24-h urinary copper excretion typically falls below 100 μg [44,45]. Once this range is achieved, values above 100 μg should suggest non-adherence. Again, non-adherence would also be suggested by elevations of non-ceruloplasmin copper in the serum. Another way to gauge adherence is to follow the 24-h urine zinc excretion. Values below 100–2000 μg/24 h suggest non-adherence to treatment. This can be confirmed by simultaneous measurement of zinc excretion or by examining serum for elevations in non-ceruloplasmin-bound copper.

For patients taking different forms of zinc salts, urinary zinc excretion is a way to gauge the absorption of the zinc. Following a change in the zinc salt, if urinary copper becomes elevated and zinc reduced, then either the formulation or the dosage of the zinc should be changed.

Liver function tests

The trend towards improvement in liver functions typically occurs during the first few months of treatment, and may continue slowly over the next years [6]. In some individuals, initiation of treatment may result in transient worsening of transaminases that usually settles back to the normal range with time. The development of abnormal transaminases in a previously stable patient should prompt a search for other infectious and metabolic causes of liver disease if there is no evidence for discontinuation of medical treatment. This may be one of the few reasons why a liver biopsy may be repeated in a patient with Wilson's disease. In some with very long-term treatment, there can even be the presence of a sideroblastic anaemia with resulting haemosiderosis due to reduced copper-dependent ferroxidase activity [55]. There is a very small minority of individuals who continue to have more than twofold elevations in transaminases despite adequate treatment based on parameters of copper metabolism, and no other identifiable cause for these abnormalities [56]. In these individuals, if a change in therapy for their Wilson's disease does not affect the abnormalities, and no other cause is evident, then continued maintenance treatment and follow-up is appropriate, along with reassurance to the patient that their overall hepatic function is stable.

One clinical parameter that can be followed in treated neurological patients is the dissipation of Kayser–Fleischer rings. While their disappearance may not completely parallel the initial clinical response, once they have dissipated, their reappearance suggests non-adherence to medical therapy.

Animal models of Wilson's disease

There are several rodent models of Wilson's disease that have lent insight into the pathogenesis and treatment of this disorder. The Long Evans Cinnamon (LEC) rat was first discovered as a model of spontaneous hepatitis and hepatocellular carcinoma, but was later found to have hepatic copper toxicosis [57]. Studies using these animals have been useful for demonstrating the trafficking of copper in hepatocytes, for studying the modes of copper-induced injury and rescue by treatment, for understanding the effects of sex and hormones on copper-induced liver injury and for studying the treatment of copper toxicosis by gene therapy and hepatocyte transplant therapy [58–60]. The defect in the toxic milk mouse model was shown to be in the mouse ATP7B protein [61]. This animal model was studied for the distribution of copper in the cells, and for the induction of metallothionein in the hepatocytes of these animals. The ATP7B knockout mouse behaves similarly to the toxic milk mouse, and studies show that they suffer hepatic copper accumulation and injury. In contrast to the human disease, none of the rodent models exhibits the same neurological effects that are seen in man. This is probably due to differences in the transport of copper by the blood–brain barrier. Another interesting model of copper toxicosis, the Bedlington terrier, was once thought to be a canine model of Wilson's disease. However, more recent studies suggest that this disorder in these dogs results from a defect in the MURR1 protein (also known as COMDI) that may be involved in intracellular copper transport [62].

Acknowledgements

I would like to acknowledge Dr Irmin Sternlieb for his valued mentorship and friendship, the Wilson's disease Association for their support of patients with Wilson's disease, and the many patients with Wilson's disease from whom I continue to learn.

References

1 Sternlieb I, van den Hamer CJA, Morell AG *et al.* (1973) Lysosomal defect of hepatic copper excretion in Wilson's disease (hepatolenticular degeneration). *Gastroenterology* 64, 99–105.

2 Gollan JL, Deller DT (1973) Studies on the nature and excretion of biliary copper in man. *Clin Sci* 44, 9.

3 Schilsky ML (1996) Wilson's disease – genetic basis of copper toxicity and natural history. In: Tavill AS, Bacon BR (eds) *Seminars in Liver Disease*, Vol. 16. New York: Thieme Medical Publishers, pp. 83–95.

4 Scheinberg IH, Sternlieb I (1984) Wilson's disease. In: Smith LH Jr (ed.) *Major Problems in Internal Medicine*, Vol. 23. Philadelphia, PA: W.B. Saunders pp. 25–35.
5 Strand S, Hofmann WJ, Grambihler A *et al.* (1998) Hepatic failure and liver cell damage in acute Wilson's disease involve CD95 (APO-1/Fas)-mediated apoptosis. *Nature Med* 4, 588–593.
6 Schilsky ML, Scheinberg IH, Sternlieb I (1991) Prognosis of Wilsonian chronic active hepatitis. *Gastroenterology* 100, 762–767.
7 Askari FK, Greenson J, Dick RD *et al.* (2003) Treatment of Wilson's disease with zinc. XVIII. Initial treatment of the hepatic decompensation presentation with trientine and zinc. *J Lab Clin Med* 142, 385–390.
8 Roberts EA, Schilsky ML (2003) A practice guideline on Wilson disease. *Hepatology* 37, 1475–1492.
9 Westermark K, Tedroff J, Thuomas KA *et al.* (1995) Neurological Wilson's disease studied with magnetic resonance imaging and with positron emission tomography using dopaminergic markers. *Mov Disord* 10, 596–603.
10 Portala K, Westermark K, von Knorring L *et al.* (2000) Psychopathology in treated Wilson's disease determined by means of CPRS expert and self-ratings. *Acta Psychiatr Scand* 101, 104–109.
11 Perri RE, Hahn SH, Ferber MJ *et al.* (2005) Wilson disease – keeping the bar for diagnosis raised. *Hepatology* 42, 974.
12 Ala A, Borjigin J, Rochwarger A *et al.* (2005) Wilson disease in septuagenarian siblings: raising the bar for diagnosis. *Hepatology* 41, 668–670.
13 Ferenci P, Caca K, Loudianos G *et al.* (2003) Diagnosis and phenotypic classification of Wilson disease. Consensus conference from the International Conference on Wilson disease, Leipzig, Germany. *Liver Int* 23, 139–142.
14 Hahn SH, Lee SY, Jang YJ *et al.* (2002) Pilot study of mass screening for Wilson's disease in Korea. *Mol Genet Metab* 76, 133–136.
15 Terada K, Kawarda Y, Muira N *et al.* (1995) Copper incorporation into ceruloplasmin in rat livers. *Biochim Biophys Acta* 1270, 58–62.
16 Holtzman NA, Gaumnitz BM (1970) Studies on the rate of release and turnover of ceruloplasmin and apoceruloplasmin in rat plasma. *J Biol Chem* 245, 2354–2358.
17 Ferenci P, Steindl-Munda P, Vogel W *et al.* (2005) Diagnostic value of quantitative hepatic copper determination in patients with Wilson disease. *Clin Gastroenterol Hepatol* 3, 811–818.
18 Martins da Costa C, Baldwin D, Portman B *et al.* (1992) Value of urinary copper excretion after penicillamine challenge in the diagnosis of Wilson's disease. *Hepatology* 15, 609–615.
19 His G, Cox DW (2004) A comparison of the mutation spectra of Menkes disease and Wilson disease. *Hum Genet* 114, 165–172.
20 Stapelbroek JM, Bollen CW, van Amstel JK *et al.* (2004) The H1069Q mutation in ATP7B is associated with late and neurologic presentation in Wilson disease: results of a meta-analysis. *J Hepatol* 41, 758–763.
21 Wu ZY, Wang N, Lin MT *et al.* (2001) Mutation analysis and the correlation between genotype and phenotype of Arg778Leu mutation in Chinese patients with Wilson disease. *Arch Neurol* 58, 971–976.
22 Gu YH, Kodama H, Du SL *et al.* (2003) Mutation spectrum and polymorphisms in ATP7B identified on direct sequencing of all exons in Chinese Han and Hui ethnic patients with Wilson's disease. *Clin Genet* 64, 479–484.
23 Al Jumah M, Majumdar R, Al Rajeh S *et al.* (2004) A clinical and genetic study of 56 Saudi Wilson disease patients: identification of Saudi-specific mutations. *Eur J Neurol* 11, 121–124.
24 Petrukhin K, Fischer SG, Pirastu M *et al.* (1993) Mapping, cloning and genetic characterization of the region containing the Wilson disease gene. *Nature Genet* 5, 338–343.
25 www.medicalgenetics.med.nalberta.ca/wilson/index.php.
26 Schilsky ML, Scheinberg ICH, Sternlieb I (1994) Hepatic transplantation for Wilson's disease: indication and outcome. *Hepatology* 19, 583–587.
27 Kasai N, Miyoshi I, Osanai T *et al.* (1992) Effects of sex hormones on fulminant hepatitis in LEC rats: a model of Wilson's disease. *Lab Anim Sci* 42, 363–368.
28 Schiefermeier M, Kollegger H, Madl C *et al.* (2000) The impact of apolipoprotein E genotypes on age and onset of symptoms and phenotype expression in Wilson's disease. *Brain* 123, 585–590.
29 Stuehler B, Reichert J, Stremmel W *et al.* (2004) Analysis of the human homologue of the canine copper toxicosis gene MURR1 in Wilson disease patients. *J Mol Med* 82, 629–634.
30 Vilensky JA, Robertson WM, Gilman S *et al.* (2002) Wilson's disease, and BAL (British antilewisite [2,3-dimercaptopropanol]). *Neurology* 59, 914–916 (archival footage from original films available from vilenski@ipfw.edu).
31 Walshe JM (1956) Penicillamine, a new oral therapy for Wilson's disease. *Am J Med* 21, 487–495.
32 Walshe JM (1982) Treatment of Wilson's disease with trientine (triethylene tetramine) dichloride. *Lancet* 1, 643–647.
33 Scheinberg IH, Gitlin D (1952) Deficiency of ceruloplasmin in patients with hepatolenticular degeneration (Wilson's disease). *Science* 116, 484–485.
34 Emre S, Atillasoy EO, Ozdemir S *et al.* (2001) Orthotopic liver transplantation for Wilson's disease: a single center experience. *Liver Transpl* 72, 1232–1236.
35 Schumacher G, Platz KP, Mueller AR *et al.* (1997) Liver transplantation: treatment of choice for hepatic and neurological manifestation of Wilson's disease. *Clin Transplant* 11(3), 217–224.
36 Robles R, Parrilla P, Sicilia J *et al.* (1999) Indications and results of liver transplants in Wilson's disease. *Transplant Proc* 31, 2453–2454
37 Brewer GJ, Terry CA, Aisen AM *et al.* (1987) Worsening of neurologic syndrome in patients with Wilson's disease with initial penicillamine therapy. *Arch Neurol* 44, 490–493.
38 Santos Silva EE, Sarles J, Buts JP *et al.* (1996) Successful medical treatment of severely decompensated Wilson's disease. *J Pediatr* 128, 285–287.
39 Scheinberg IH, Jaffe ME, Sternlieb I (1987) The use of trientine in preventing the effects of interrupting penicillamine therapy in Wilson's disease. *N Engl J Med* 317, 209–213.
40 Sokol RJ, McKim JM Jr, Devereaux MW (1996) Alpha-tocopherol ameliorates oxidant injury in isolated copper-overloaded rat hepatocytes. *Pediatr Res* 39, 259–263.
41 Brewer GJ, Hedera P, Kluin KJ *et al.* (2003) Treatment of Wilson's disease with ammonium tetrathiomolybdate: III. Initial therapy in a total of 55 neurologically affected patients and follow-up with zinc therapy. *Arch Neurol* 60, 379–385.
42 Walshe JM (1992) Thiomolybdates in the treatment of Wilson's disease. *Arch Neurol* 49, 132–133.
43 Brewer GJ, Askari F, Lorincz MT *et al.* (2006) Treatment of Wilson disease with ammonium tetrathiomolybdate. IV Comparison of tetrathiomolybdate and trientine in a double-blind study of treatment of the neurologic presentation of Wilson disease. *Arch Neurol* 63, 521–527.

44 Hoogenraad TU, Van den Hamer CJ, Koevoet R *et al.* (1978) Oral zinc in Wilson's disease. *Lancet* 2, 1262.

45 Brewer GJ, Dick RD, Johnson VD *et al.* (1998) Treatment of Wilson's disease with zinc. XV. Long-term follow-up studies. *J Lab Clin Med* 132, 264–278.

46 Brewer GJ, Dick RD, Johnson VD *et al.* (2001) Treatment of Wilson's disease with zinc. XVI: treatment during the pediatric years. *J Lab Clin Med* 137, 191–198.

47 Brewer GJ, Johnson VD, Dick RD *et al.* (2000) Treatment of Wilson's disease with zinc. XVII: treatment during pregnancy. *Hepatology* 31, 364–370.

48 Chen CL, Chen YS, Lui CC *et al.* (1997) Neurological improvement of Wilson's disease after liver transplantation. *Transplant Proc* 29, 497–498.

49 Wang XH, Zhang F, Li XC *et al.* (2004) Eighteen living related liver transplants for Wilson disease: a single-center. *Transpl Proc* 36, 2243–2245.

50 Komatsu H, Fujisawa T, Inui A *et al.* (2002) Hepatic copper concentration in children undergoing living related liver transplantation due to Wilsonian fulminant hepatic failure. *Clin Transplant* 16, 227–232.

51 Shakil AO, Dvorchik I, Fung JJ *et al.* (1997) Liver transplantation for acute liver failure: outcome analysis. *J Viral Hepat* 4(Suppl. 1), 107–110.

52 Robles R, Parrilla P, Sicilia J *et al.* (1999) Indications and results of liver transplants in Wilson's disease. *Transplant Proc* 31, 2453–2454.

53 Medici V, Mirante VG, Fassati LR *et al.*; Monotematica AISF 2000 OLT Study Group (2005) Liver transplantation for Wilson's disease: the burden of neurological and psychiatric disorders. *Liver Transpl* 11, 1056–1063.

54 Sternlieb I (2000) Wilson's disease and pregnancy. *Hepatology* 31, 531–532.

55 Condamine L, Hermine O, Alvin P *et al.* (1993) Acquired sideroblastic anaemia during treatment of Wilson's disease with triethylene tetramine dihydrochloride. *Br J Haematol* 83, 166–168.

56 Iorio R, D'Ambrosi M, Marcellini M *et al.* (2004) Persistence of elevated aminotransferases in Wilson's disease despite adequate therapy. *Hepatology* 39(4), 1173–1174.

57 Li Y, Togashi S, Sato T *et al.* (1991) Spontaneous hepatic copper accumulation in Long Evans Cinnamon rats with hereditary hepatitis. *J Clin Invest* 87, 1858–1861.

58 Irani AN, Malhi H, Slehria S *et al.* (2001) Correction of liver disease following transplantation of normal rat hepatocytes into Long-Evans Cinnamon rats modeling Wilson's disease. *Mol Ther* 3, 302–309.

59 Ha-Hao D, Merle U, Hofmann C *et al.* (2002) Chances and shortcomings of adenovirus-mediated ATP7B gene transfer in Wilson disease: proof of principle demonstrated in a pilot study with LEC rats. *Z Gastroenterol* 40, 209–216.

60 Terada K, Aiba N, Yang XL *et al.* (1999) Biliary excretion of copper in LEC rat after introduction of copper transporting P-type ATPase, ATP7B. *FEBS Lett* 448, 53–56.

61 La Fontaine S, Theophilos MB, Firth SD *et al.* (2001) Effect of the toxic milk mutation (tx) on the function and intracellular localization of Wnd, the murine homologue of the Wilson copper ATPase. *Hum Mol Genet* 10(4), 361–370.

16.2 Haemochromatosis

Antonello Pietrangelo

Definition and classification

The term haemochromatosis (HC) (synonymous for hereditary or idiopathic or primary haemochromatosis) today defines an autosomal recessive disorder of iron metabolism characterized by tissue iron overload, potentially leading to multiorgan disease, such as liver cirrhosis, endocrinopathy and cardiomyopathy, and associated with pathogenic mutations of at least four HC genes (i.e. *HFE*, *TFR2*, *HJV* and *HAMP*) [1]. The disorder is probably caused by a regulatory defect of iron homeostasis in the liver [1]. The distinguishing features of HC are reported in Table 1.

Historically, a clinical entity named 'diabète bronzé' [2] and 'cirrhose pigmentaire' [3] was first reported in the second half of the nineteenth century when the term 'haemochromatosis' was introduced to define the association of widespread tissue injury with massive tissue iron deposition [4]. Only after a century was the term associated with a hereditary disease [5], then linked to the major histocompatibility class (MHC) I complex A3, on the short arm of chromosome 6 [6,7]. In 1996, the most prevalent HC gene, *HFE*, was cloned [8]. However, once the *HFE* gene was identified, it immediately became clear that HFE mutations accounted for most but not all cases of HC [9]. Since then, unprecedented progress in the field of iron genetics has led to the identification of new genes involved in iron metabolism whose mutations are responsible for cases of *HFE*-negative HC. These genes are transferrin receptor-2 (*TfR2*), haemojuvelin (*HJV*) and hepcidin (*HAMP*). As these forms of non-HFE HC share clinical presentation and autosomal recessive trait with classic HFE HC pathogenic mechanisms, they should be considered different forms of the same clinicopathological syndrome, i.e. haemochromatosis [1]. This chapter will focus mainly on HC and briefly discuss other rarer hereditary iron overload states in humans (Table 2). A distinction should be made between iron overload disorders in which iron overload is secondary to specific diseases or acquired factors.

Table 1 Main features of haemochromatosis.

Autosomal recessive trait
Pathogenic mutations of one of the four HC genes: *HFE*, *TFR2*, *HJV*, *HAMP*
Early and progressive increase in circulatory iron (i.e. high transferrin saturation) that precedes iron accumulation in tissues (i.e. high serum ferritin)
Early and preferential iron deposition in parenchymal cells of the liver and other organs with potential for damage and disease
Unimpaired erythropoiesis and optimal response to phlebotomy
Inappropriate synthesis/activity of hepcidin

Table 2 Classification of disorders leading to systemic iron overload in humans.

Hereditary iron overload
Haemochromatosis (*HFE*, *TFR2*, *HJV* or *HAMP* related)
Ferroportin disease
Aceruloplasminaemia
A(hypo)transferrinaemia
H-ferritin-related hereditary iron overload[a]
Hereditary iron-loading anaemias (thalassaemia, hereditary sideroblastic anaemia, chronic haemolytic anaemia)[b]
Acquired iron overload
Dietary iron overload
Parental and transfusion iron overload
Long-term haemodialysis
Chronic liver disease
Hepatitis C
Alcoholic cirrhosis
Steatohepatitis
Porphyria cutanea tarda
Dysmetabolic iron overload syndrome
Miscellaneous
Iron overload in sub-Saharan Africa
Neonatal haemochromatosis

[a]A single pedigree has been described so far.
[b]While severe iron overload develops after multitransfusion regimens, parenchymal hepatic iron deposits are also appreciable at early stages probably due to increased iron absorption from inefficient erythropoiesis and to iron recycling from reticuloendothelial cells.

The haemochromatosis genes and proteins

HFE

HFE is a MHC I-like protein whose ancestral peptide-binding groove is too narrow to allow antigen presentation [10] and is incapable of binding iron [11]. Interaction between HFE and the transferrin receptor, TfR1, which mediates transferrin-bound iron uptake by most cells [11,12], has been fully documented, although its biological effects are still uncertain. However, it is unclear whether the interaction of HFE with TfR1 is key for the pathogenesis of HC [13,14].

The C282Y mutation, the most common pathogenic mutation of HFE, is associated with disruption of a disulphide bond in HFE that is critical for its binding to β2-microglobulin [15]. The latter interaction is necessary for the stabilization, (intracytoplasmic) transport and expression of HFE on the cell surface and endosomal membranes where HFE interacts with TfR1. The H63D mutation, a common HFE mutation whose pathogenic significance is still uncertain, does not impair HFE–TfR1 interaction. While the biological function of HFE is still unknown, recent studies indicate that it might be required for hepcidin synthesis in the hepatocytes (see section on Pathogenesis below).

Transferrin receptor 2 (*TFR2*)

In 1999, the gene for a second human transferrin receptor (*TFR2*) was cloned [16]. Unlike TfR1, the new receptor was found to be highly expressed in the liver, and it was not regulated by intracellular iron status [17]. TfR2 mediates the uptake of transferrin-bound iron by hepatocytes [16], possibly through the mechanism of receptor-mediated endocytosis similar to that described for TfR1, but its *in vitro* affinity for transferrin is 25- to 30-fold lower than that of TfR1 [18]. Yet, TfR2-mediated transferrin iron uptake may be of importance in hepatocytes, which express a small number of TfR1. *In vitro* studies with soluble recombinant forms of TFR2 and HFE have revealed no direct interaction between the two [18]. The biological role and function of TFR2 remain unknown, but recent studies suggest a role for TfR2 in hepcidin synthesis in the liver (see section on Pathogenesis below).

Haemojuvelin (HJV)

Haemojuvelin is transcribed from a gene of 4265 bp into a full-length transcript with five spliced isoforms [19]. The putative full-length protein is 426 amino acids long; the protein contains multiple protein motifs consistent with a function as a membrane-bound receptor or secreted polypeptide hormone. Analyses of haemojuvelin in human tissues detect substantial expression in adult and fetal liver, heart and skeletal muscle [19]. The function of haemojuvelin is presently unknown. However, hepcidin levels are depressed in individuals with *HJV* mutations [19], and a recent *in vitro* study suggested that HJV is a transcriptional regulator of hepcidin [20] (see section on Pathogenesis below).

Hepcidin (*HAMP*)

Hepcidin is an antimicrobial peptide produced by hepatocytes in response to inflammatory stimuli and iron [21–23]. Evidence from transgenic mouse models indicates that hepcidin is the principal downregulator of the absorption of iron in the small intestine, its transport across the placenta and its release from macrophages (reviewed in [24]). The absence of circulating hepcidin has been shown to produce the rare and severe juvenile haemochromatosis in humans [25]. While it was unclear how hepcidin modulated iron egress from cells until recently, its interaction with a main iron export protein, ferroportin (FPN), has been postulated recently, and a new model in which hepcidin downregulates iron exports by interacting with FPN and causing its degradation has been proposed [26]. Hepcidin, the iron hormone, is now seen as the central pathogenic factor in HC (see next section).

Pathogenesis

Historically, the intestine has been seen as the primary site of the defect in HC, and studies showing high expression of HFE in intestinal crypts reinforced this idea, leading to the development of a specific pathogenic model [1]. More recently, however, especially after the discovery of hepcidin and its involvement in iron homeostasis, attention has moved to the liver as the primary pathogenic site in HC.

The common feature of all forms of HC is the genetic predisposition for circulatory iron overload. This iron will eventually reach parenchymal cells of the liver, pancreas and heart, where it causes cytotoxicity and organ disease. The progressive expansion of the plasma iron pool in HC, which occurs at a much faster rate in the 'juvenile' forms of the disorder (HJV- and HAMP-related HC) compared with the late-onset forms (HFE- and TfR2-related HC), is the result of an increased transfer of iron to the blood compartment from enterocytes (i.e. increased intestinal absorption), and from reticuloendothelial macrophages [1]. The main regulator of iron efflux from enterocytes and macrophages in humans is hepcidin. In HFE-, TfR2- and HJV-related HC, hepatic expression or serum/urine levels of this peptide are inappropriately low [27–30]. Its expression in the liver is also significantly impaired in HFE, TfR2 and HJV knockout mice [31–34] and hepatic deposition of iron in HFE-KO animals can be prevented by hepcidin overexpression [35]. These findings suggest a unifying pathogenic model for all forms of HC [1], in which HFE, TfR2 and HJV are all independent but complementary regulators of hepcidin synthesis in the liver (Fig. 1).

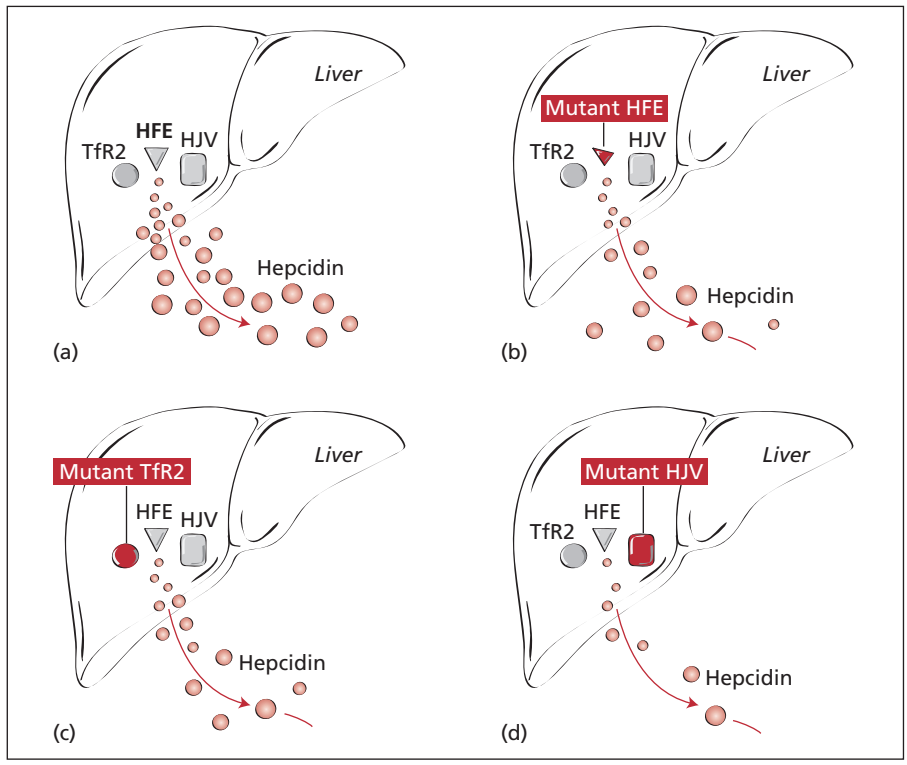

Fig. 1 A unifying pathogenic model for haemochromatosis. In this model, HFE, TfR2 and HJV are considered independent but complementary modulators of hepcidin synthesis in the liver. When all three proteins function correctly, an appropriate amount of hepcidin is produced by the liver (a): the peptide will then interact with ferroportin expressed on target cells (such as enterocytes, macrophages and hepatocytes) and dictate the extent of iron release from these cells (see text for details). Loss of *one* of the minor regulatory proteins such as HFE (b) or TfR2 (c) will result in lower hepcidin production and, consequently, uncontrolled release of iron from intestine and macrophages. This will be followed by tissue iron overload and organ damage (HFE- *or* TfR2-related HC). Loss of the *main* hepcidin regulator, HJV, will give rise to a more dramatic effect on iron trafficking leading to massive circulatory and tissue iron overload (*HJV*-related HC) (d). This picture will be similar to that produced by the complete loss of hepcidin (*HAMP*-related HC).

Genetics and epidemiology

HFE-related haemochromatosis (HFE HC) is the most common form of HC and also the most frequently inherited metabolic disorder found in white people. Genetic predisposition to this disease, i.e. C282Y homozygosity, is found in approximately 5/1000 individuals of northern European descent [36].

Organ disease is highly unlikely in simple C282Y heterozygotes [37,38], whereas 1–2% of compound C282Y/H63D heterozygotes seem to be predisposed to expression of the disease [39]. The clinical significance of other seemingly rarer forms of compound heterozygosity, e.g. monoallelic C282Y or H63D mutation with substitution of cysteine for serine at amino acid position 65 (S65C) or other rare changes on the second allele, is still being debated [1].

The frequency of TfR2 mutations is low and, so far, they have only been detected in a few pedigrees throughout the world. TfR2 mutations do not appear to be restricted to northern Europeans, as they have also been reported in other ethnic groups [40]. *TFR2* is relatively large, spanning 21 kilobases and including 18 exons, thus detection of new TFR2 mutations in single patients remains cumbersome. Analysis of TfR2 mutations should be considered especially in individuals with adult non-HFE haemochromatosis, particularly from families with high consanguinity.

The juvenile form of haemochromatosis is also rare. Most cases are due to mutations of *HJV* located on chromosome 1 [19]. In this original study, 12 families were found to be homozygous or compound heterozygous for six mutations in *HJV*. To date, 23 mutations have been identified in 43 HJV-related families. One common mutation, G320V, has been reported in all studies. It is present in half the families. However, a small proportion of patients carry mutations in *HAMP*, the gene encoding hepcidin [25].

Clinical aspects

HC should be regarded today as a unique syndromic entity with a polygenic nature and phenotypical continuum [1]. However, from a practical point of view, two basic HC phenotypes can be distinguished based primarily on age at symptom onset and phenotype severity: adult and juvenile. In the adult form, usually due to the C282Y HFE mutation and only in rare cases to TfR2 mutations, iron overload and disease progression are gradual and hepatic involvement predominates. Expressivity of the genetic defect may lead from simple biochemical abnormalities to mild symptoms and signs or overt organ disease. HFE HC should be suspected in middle-aged men presenting with cirrhosis of the liver, bronze skin, diabetes and other endocrine disorders (particularly hypogonadism) or joint inflammation and heart disease. However, this classical syndromic presentation is rare. Today, diagnosis is made at earlier stages as an effect of screening and enhanced case detection due to greater clinician awareness and a higher index of suspicion. The most common presenting symptoms are fatigue, malaise and arthralgia, while hepatomegaly is one of the earliest physical signs. Elevated

serum iron and moderately increased transaminase levels are common biochemical abnormalities. A diagnostic workup of patients with suspected haemochromatosis has been proposed recently [1]. Liver biopsy was widely used as a diagnostic tool before the era of *HFE* testing when an hepatic iron index above 1.9, i.e. hepatic iron divided by age, strongly suggested, in the absence of other obvious causes of iron overload, homozygote HC [1]. Today, liver biopsy has a mainly prognostic value in HFE HC: for instance, it should be considered in cases with serum ferritin above 1000 ng/mL because an underlying fibrosis cirrhosis may coexist, regardless of age or serum liver enzyme levels [41,42]. Liver biopsy still has a diagnostic value in non-*HFE* HC patients, in whom second-level genetic testing may not be available or may be inconclusive and qualitative (i.e. parenchymal and periportal iron distributions are typical of hereditary haemochromatosis as opposed to post-transfusion siderosis), and quantitative assessment of hepatic iron deposits, with calculation of the hepatic iron index, could therefore be diagnostic [1].

As specified above, while all patients referred for overt HFE-related HC carry the C282Y mutation on both HFE alleles, some C282Y homozygotes present no evidence of organ disease or biochemical abnormalities, although they should still be considered to be at increased risk. It is currently impossible to predict whether (and to what extent) these individuals will express the disease phenotype. In spite of seemingly contradictory findings in recent screening studies [43–46], we can conclude that, while the majority of C282Y homozygotes have laboratory evidence of plasma and tissue iron overload (i.e. high transferrin saturation and ferritin levels respectively), organ disease requiring medical treatment is much less common today [1].

Screening for haemochromatosis, particularly the HFE form, is a very attractive concept [47]. The disorder is highly prevalent and fatal if untreated; safe, effective and relatively low-cost treatment is available; the disease includes a long asymptomatic phase, and it can readily be detected by means of a simple and inexpensive laboratory test. Young adult males of northern European ancestry are the group at highest risk, and selective screening of this population based on measurement of transferrin saturation, with genetic testing for HFE mutations in those with confirmed levels exceeding 45%, should be no more difficult than large-scale general population screening for high cholesterol. In the case of HFE haemochromatosis, however, the anticipated benefits (in terms of early treatment and prolonged survival) have to be weighed against the potentially negative repercussions – psychological, social and legal – of positive diagnoses [48], especially those made in the absence of actual disease, i.e. based exclusively on genotype.

The juvenile form of HC is more severe and more rapidly progressive than the adult form, and cardiac and endocrine involvement is much more pronounced. Because of the higher rate of iron loading associated with this disorder (and possibly differential tissue sensitivities to this massive toxic insult), cardiomyopathy and endocrinopathy, including reduced glucose tolerance, appear earlier than they do in adult HC, and death before the age of 30 years is not uncommon [49,50]. The commonest symptom at presentation is hypogonadism, which may be present in all cases at the end of the second decade [49,50]. As mentioned, this form of HC is generally linked to mutations in *HJV* or, in fewer cases, *HAMP*. Intermediate phenotype may originate from inheritance of a heterozygote juvenile gene mutation (*HAMP* or HJV) in addition to a pathogenic mutation in HFE or TfR2 [1]: in this case, an earlier onset and more severe expression of adult-onset HC occurs. Interestingly, a juvenile form may also originate from combined mutations in HFE and TfR2, thus confirming the common polygenic basis of the disorder [51]. In general, it is important to recall that numerous host and environmental factors (e.g. dietary iron, alcohol-related or viral hepatitis) can modify the natural history of both forms of the disease, although the adult form is more susceptible to the effect of modifier factors [1].

Therapeutic phlebotomy is the safest, most effective and most economical approach to treatment for all forms of HC. One unit (400–500 mL) of blood (containing approximately 200–250 mg of iron) is removed weekly until serum ferritin is less than 20–50 μg/L and transferrin saturation drops below 30%. Maintenance therapy, which typically involves the removal of 2–4 units a year, can then be initiated, and it must be continued for the duration of the patient's life to keep transferrin saturation below 50% and ferritin levels below 50 μg/L. A more aggressive schedule can be adopted for juvenile cases. Phlebotomy has little effect if started after organ impairment has already developed: the hypogonadism, cirrhosis, destructive arthritis and insulin-dependent diabetes associated with HC are irreversible. Higher risk of liver cancer in HC is not avoided if treatment is initiated after cirrhosis is established [52].

Other hereditary iron overload disorders

Ferroportin disease (FD) (Table 2) is an autosomal dominant inherited disorder of iron metabolism that causes progressive iron retention, predominantly in reticuloendothelial cells of the spleen and liver, and is characterized by a steady increase in serum ferritin, inappropriately high compared with the extent of serum transferrin saturation, marginal anaemia and mild organ disease [53].

The disorder was described clinically in 1999 [54] and associated with the A77D mutation of ferroportin (FPN) in 2001 [55]. The disorder has been now reported in many countries and, at variance with the distribution of the *HFE* gene mutations that appear to be restricted to Caucasians of northern European ancestry, it appears to be spread worldwide in different ethnic groups [53].

FPN is the main iron export protein in mammals. It is expressed in several cell types that play critical roles in mammalian iron metabolism, including placental syncytiotrophoblasts, duodenal enterocytes, hepatocytes and reticuloendothelial

macrophages [56–58]. *In vitro*, FPN has been found to be the cellular receptor for hepcidin: in cultured cells stably expressing FPN, hepcidin administration causes FPN internalization and degradation [59]. This implies a decreased amount of surface FPN and reduced iron egress from cells such as enterocytes and macrophages, whenever circulating hepcidin levels are high, namely inflammation and iron overload. The opposite would occur when hepcidin is low, namely anaemia and hypoxia [24].

A current pathogenic model for FD is that loss-of-function mutations in FPN cause a mild but significant impairment of iron recycling, particularly by reticuloendothelial macrophages, which must normally process and release a large quantity of iron derived from the lysis of senescent erythrocytes [53]. As a consequence, iron retention by macrophages would lead to tissue iron accumulation (i.e. high serum ferritin) but decreased availability of iron for circulating transferrin (i.e. low transferrin saturation) and for bone marrow. At later stages, both iron retention in cells and activation of feedback mechanisms to increase intestinal absorption might contribute to more pronounced iron overload. This pathophysiological model is consistent with the finding that patients with the *SLC11A3* mutations in FPN have much larger reticuloendothelial iron stores than patients with HC. Although the patients are not anaemic in adulthood, indicating that adequate iron is available for normal erythropoiesis, they may show reduced tolerance to phlebotomy and become anaemic on therapy in spite of persistently elevated serum ferritin values [53]. It is possible that different mutations along the protein may differentially affect the function of FPN and indirectly lead to variability in clinical expressivity. In this context, recent *in vitro* studies [60–62] and so far one clinical report [63] suggest that a subgroup of patients with FD may carry gain-of-function mutations that might lead to enhanced iron release from enterocytes and macrophages and a phenotype similar to classic HC. FD should be suspected in all cases of isolated hyperferritinaemia in the absence of known secondary causes (such as infection, inflammation and malignancy) or unexplained anaemia with normal/high serum ferritin or familial hyperferritinaemia (see algorithm in reference [53]).

The phenotype of FD is strikingly similar to a distinct iron loading disorder, also termed Bantu siderosis, prevalent in Africa. This disease is particularly frequent among Africans who drink a traditional beer brewed in non-galvanized steel drums. Although the disorder was once attributed to dietary excess, it has later been suggested that an unidentified iron loading gene confers susceptibility to the disease [64,65]. One modifier gene could be FPN, as a common mutation in FPN seems to be highly prevalent in iron overload African subjects [66].

Aceruloplasminaemia, a rare autosomal recessive disorder, results from mutations in the ceruloplasmin (CP) gene [67,68]. CP has ferroxidase activity that is important in the release of iron from cells [69]. In the disease, iron accumulates in neural and glial cells of the brain (particularly the basal ganglia and dentate nucleus), hepatocytes, reticuloendothelial cells and pancreatic islet cells. Affected individuals present with progressive extrapyramidal signs, cerebellar ataxia, dementia, diabetes mellitus and hypochromic microcytic anaemia. In spite of severe iron overload, liver disease is mild. Aggressive chelation with deferroxamine associated with plasma and ceruloplasmin concentrate may be effective [70], while the tendency to anaemia may prevent the use of phlebotomy.

The main clinical feature of a(hypo)transferrinaemia, which dramatically impairs plasma iron transport and delivery to the bone marrow, is (not surprisingly) severe anaemia [71]. Tissue iron overload results from a compensatory increase in intestinal iron absorption. Mutation in the regulatory region of H ferritin causing tissue iron overload has also been described [72], but this single observation awaits validation by additional reports.

A final word will be given to the disorder often referred to as 'neonatal haemochromatosis', which is indeed characterized by massive hepatic iron loading and generally fatal perinatal liver failure [73]. Its hereditary nature is uncertain, although familial cases have been described [74], and it is also unclear whether the iron loading in these cases is a primary or a secondary event.

References

1 Pietrangelo A (2004) Hereditary hemochromatosis – a new look at an old disease. *N Engl J Med* 350, 2383–2397.

2 Trousseau A (1865) Glycosurie; diabete sucre. *Clin Med Hotel Paris* 2, 663–698.

3 Troisier M (1871) Diabète sucré. *Bull Soc Anat Paris* 44, 231–235.

4 von Recklinghausen FD (1889) Uber Haemochromatose. *Taggebl Versamm Dtsch Naturforsch Aerzte Heidelberg* 62, 324–325.

5 Sheldon JH (1935) *Hemochromatosis*. London: Oxford University Press.

6 Simon M, Pawlotsky Y, Bourel M *et al.* (1975) [Letter: Idiopathic hemochromatosis associated with HL-A 3 tissular antigen]. *Nouv Presse Med* 4, 1432.

7 Simon M, Le Mignon L, Fauchet R *et al.* (1987) A study of 609 HLA haplotypes marking for the hemochromatosis gene: (1) mapping of the gene near the HLA-A locus and characters required to define a heterozygous population and (2) hypothesis concerning the underlying cause of hemochromatosis-HLA association. *Am J Hum Genet* 41, 89–105.

8 Feder JN, Gnirke A, Thomas W *et al.* (1996) A novel MHC class I-like gene is mutated in patients with hereditary haemochromatosis. *Nature Genet* 13, 399–408.

9 Pietrangelo A (1998) Hemochromatosis 1998: is one gene enough? *J Hepatol* 29, 502–509.

10 Lebron JA, Bennett MJ, Vaughn DE *et al.* (1998) Crystal structure of the hemochromatosis protein HFE and characterization of its interaction with transferrin receptor. *Cell* 93, 111–123.

11 Feder JN, Penny DM, Irrinki A *et al.* (1998) The hemochromatosis gene product complexes with the transferrin receptor and lowers its affinity for ligand binding. *Proc Natl Acad Sci USA* 95, 1472–1477.

12 Gross CN, Irrinki A, Feder JN *et al.* (1998) Co-trafficking of HFE, a nonclassical major histocompatibility complex class I protein, with the transferrin receptor implies a role in intracellular iron regulation. *J Biol Chem* 273, 22068–22074.

13 Zhang AS, Davies PS, Carlson HL *et al.* (2003) Mechanisms of HFE-induced regulation of iron homeostasis: insights from the W81A HFE mutation. *Proc Natl Acad Sci USA* 100, 9500–9505.

14 Davies PS, Zhang AS, Anderson EL *et al.* (2003) Evidence for the interaction of the hereditary haemochromatosis protein, HFE, with the transferrin receptor in endocytic compartments. *Biochem J* 373, 145–153.

15 Waheed A, Parkkila S, Zhou XY *et al.* (1997) Hereditary hemochromatosis: Effects of C282Y and H63D mutations on association with beta[2]-microglobulin, intracellular processing, and cell surface expression of the HFE protein in COS-7 cells. *Proc Natl Acad Sci USA* 94, 12384–12389.

16 Kawabata H, Yang R, Hirama T *et al.* (1999) Molecular cloning of transferrin receptor 2. A new member of the transferrin receptor-like family. *J Biol Chem* 274, 20826–20832.

17 Kawabata H, Germain RS, Vuong PT *et al.* (2000) Transferrin receptor 2-alpha supports cell growth both in iron-chelated cultured cells and in vivo. *J Biol Chem* 275, 16618–16625.

18 West AP, Jr, Bennett MJ, Sellers VM *et al.* (2000) Comparison of the interactions of transferrin receptor and transferrin receptor 2 with transferrin and the hereditary hemochromatosis protein HFE. *J Biol Chem* 275, 38135–38138.

19 Papanikolaou G, Samuels ME, Ludwig EH *et al.* (2004) Mutations in HFE2 cause iron overload in chromosome 1q-linked juvenile hemochromatosis. *Nature Genet* 36, 77–82.

20 Lin L, Goldberg YP, Ganz T (2005) Competitive regulation of hepcidin mRNA by soluble and cell-associated hemojuvelin. *Blood* 106, 2884–2889.

21 Krause A, Neitz S, Magert HJ *et al.* (2000) LEAP-1, a novel highly disulfide-bonded human peptide, exhibits antimicrobial activity. *FEBS Lett* 480, 147–150.

22 Park CH, Valore EV, Waring AJ *et al.* (2001) Hepcidin, a urinary antimicrobial peptide synthesized in the liver. *J Biol Chem* 276, 7806–7810.

23 Pigeon C, Ilyin G, Courselaud B *et al.* (2001) A new mouse liver-specific gene, encoding a protein homologous to human antimicrobial peptide hepcidin, is overexpressed during iron overload. *J Biol Chem* 276, 7811–7819.

24 Ganz T (2005) Hepcidin – a regulator of intestinal iron absorption and iron recycling by macrophages. *Best Pract Res Clin Haematol* 18, 171–182.

25 Roetto A, Papanikolaou G, Politou M *et al.* (2003) Mutant antimicrobial peptide hepcidin is associated with severe juvenile hemochromatosis. *Nature Genet* 33, 21–22.

26 Nemeth E, Tuttle MS, Powelson J *et al.* (2004) Hepcidin regulates iron efflux by binding to ferroportin and inducing its internalization. *Science* 306, 2090–2093.

27 Bridle KR, Frazer DM, Wilkins SJ *et al.* (2003) Disrupted hepcidin regulation in HFE-associated haemochromatosis and the liver as a regulator of body iron homoeostasis. *Lancet* 361, 669–673.

28 Gehrke SG, Kulaksiz H, Herrmann T *et al.* (2003) Expression of hepcidin in hereditary hemochromatosis: evidence for a regulation in response to serum transferrin saturation and non-transferrin-bound iron. *Blood* 102, 371–376.

29 Nemeth E, Roetto A, Garozzo G *et al.* (2005) Hepcidin is decreased in TFR2-Hemochromatosis. *Blood* 105, 1803–1806.

30 Papanikolaou G, Tzilianos M, Christakis JI *et al.* (2005) Hepcidin in iron overload disorders. *Blood* 105, 4103–4105.

31 Muckenthaler M, Roy CN, Custodio AO *et al.* (2003) Regulatory defects in liver and intestine implicate abnormal hepcidin and Cybrd1 expression in mouse hemochromatosis. *Nature Genet* 34, 102–107.

32 Kawabata H, Fleming RE, Gui D *et al.* (2005) Expression of hepcidin is down-regulated in TfR2 mutant mice manifesting a phenotype of hereditary hemochromatosis. *Blood* 105, 376–381.

33 Niederkofler V, Salie R, Arber S (2005) Hemojuvelin is essential for dietary iron sensing, and its mutation leads to severe iron overload *J Clin Invest* 115, 2180–2186.

34 Huang FW, Pinkus JL, Pinkus GS *et al.* (2005) A mouse model of juvenile hemochromatosis. *J Clin Invest* 115, 2187–2191.

35 Nicolas G, Viatte L, Lou DQ *et al.* (2003) Constitutive hepcidin expression prevents iron overload in a mouse model of hemochromatosis. *Nature Genet* 34, 97–101.

36 Merryweatherclarke AT, Pointon JJ, Shearman JD *et al.* (1997) Global prevalence of putative haemochromatosis mutations. *J Med Genet* 34 (4), 275–278.

37 Powell LW, Summers KM, Board PG *et al.* (1990) Expression of hemochromatosis in homozygous subjects. Implications for early diagnosis and prevention. *Gastroenterology* 98, 1625–1632.

38 Bulaj ZJ, Griffen LM, Jorde LB *et al.* (1996) Clinical and biochemical abnormalities in people heterozygous for hemochromatosis. *N Engl J Med* 335, 1799–1805.

39 Rochette J, Pointon JJ, Fisher CA *et al.* (1999) Multicentric origin of hemochromatosis gene (HFE) mutations [published erratum appears in *Am J Hum Genet* 1999 May 64 (5), 1491]. *Am J Hum Genet* 64, 1056–1062.

40 Pietrangelo A (2004) Non-HFE hemochromatosis. *Hepatology* 39, 21–29.

41 Guyader D, Jacquelinet C, Moirand R *et al.* (1998) Noninvasive prediction of fibrosis in C282Y homozygous hemochromatosis. *Gastroenterology* 115, 929–936.

42 Morrison ED, Brandhagen DJ, Phatak PD *et al.* (2003) Serum ferritin level predicts advanced hepatic fibrosis among US patients with phenotypic hemochromatosis. *Ann Intern Med* 138, 627–633.

43 Asberg A, Hveem K, Thorstensen K *et al.* (2001) Screening for hemochromatosis: high prevalence and low morbidity in an unselected population of 65,238 persons. *Scand J Gastroenterol* 36, 1108–1115.

44 Olynyk JK, Cullen DJ, Aquilia S *et al.* (1999) A population-based study of the clinical expression of the hemochromatosis gene (see comments). *N Engl J Med* 341, 718–724.

45 Bulaj ZJ, Ajioka RS, Phillips JD *et al.* (2000) Disease-related conditions in relatives of patients with hemochromatosis. *N Engl J Med* 343, 1529–1535.

46 Beutler E, Felitti VJ, Koziol JA *et al.* (2002) Penetrance of 845G→A (C282Y) HFE hereditary haemochromatosis mutation in the USA. *Lancet* 359, 211–218.

47 Adams PC, Reboussin DM, Barton JC *et al.* (2005) Hemochromatosis and iron-overload screening in a racially diverse population. *N Engl J Med* 352, 1769–1778.

48 Anon (2000) EASL International Consensus Conference on Haemochromatosis – Part III. Jury document. *J Hepatol* 33, 496–504.

49 Rivard SR, Mura C, Simard H *et al.* (2000) Clinical and molecular aspects of juvenile hemochromatosis in Saguenay-Lac-Saint-Jean (Quebec, Canada). *Blood Cells Mol Dis* 26, 10–14.

50 De Gobbi M, Roetto A, Piperno A *et al.* (2002) Natural history of juvenile haemochromatosis. *Br J Haematol* 117, 973–979.

51 Pietrangelo A, Caleffi A, Henrion J *et al.* (2005) Juvenile hemochromatosis associated with pathogenic mutations of adult hemochromatosis genes. *Gastroenterology* 128, 470–479.

52 Tavill AS (2001) Diagnosis and management of hemochromatosis. *Hepatology*.33:1321–1328.
53 Pietrangelo A (2004) The ferroportin disease. *Blood Cells Mol Dis* 32, 131–138.
54 Pietrangelo A, Montosi G, Totaro A *et al.* (1999) Hereditary hemochromatosis in adults without pathogenic mutations in the hemochromatosis gene (see comments). *N Engl J Med* 341, 725–732.
55 Montosi G, Donovan A, Totaro A *et al.* (2001) Autosomal-dominant hemochromatosis is associated with a mutation in the ferroportin (SLC11A3) gene. *J Clin Invest* 108, 619–623.
56 Donovan A, Brownlie A, Zhou Y *et al.* (2000) Positional cloning of zebrafish ferroportin1 identifies a conserved vertebrate iron exporter. *Nature* 403, 776–781.
57 McKie AT, Marciani P, Rolfs A *et al.* (2000) A novel duodenal iron-regulated transporter, IREG1, implicated in the basolateral transfer of iron to the circulation. *Mol Cell* 5, 299–309.
58 Abboud S, Haile DJ (2000) A novel mammalian iron-regulated protein involved in intracellular iron metabolism. *J Biol Chem* 275, 19906–19912.
59 Nemeth E, Tuttle MS, Powelson J *et al.* (2004) Hepcidin regulates cellular iron efflux by binding to ferroportin and inducing its internalization. *Science* 306, 2090–2093.
60 Drakesmith H, Schimanski LM, Ormerod E *et al.* (2005) Resistance to hepcidin is conferred by hemochromatosis-associated mutations of ferroportin. *Blood* 106, 1092–1097.
61 Schimanski LM, Drakesmith H, Merryweather-Clarke AT *et al.* (2005) In vitro functional analysis of human ferroportin (FPN) and hemochromatosis-associated FPN mutations. *Blood* 105, 4096–4102.
62 De Domenico I, Ward DM, Nemeth E *et al.* (2005) The molecular basis of ferroportin-linked hemochromatosis. *Proc Natl Acad Sci USA* 102, 8955–8960.
63 Sham RL, Phatak PD, West C *et al.* (2005) Autosomal dominant hereditary hemochromatosis associated with a novel ferroportin mutation and unique clinical features. *Blood Cells Mol Dis* 34, 157–161.
64 Gordeuk V, Mukiibi J, Hasstedt SJ *et al.* (1992) Iron overload in Africa. Interaction between a gene and dietary iron content. *N Engl J Med* 326, 95–100.
65 Moyo VM, Mandishona E, Hasstedt SJ *et al.* (1998) Evidence of genetic transmission in African iron overload. *Blood* 91, 1076–1082.
66 Gordeuk VR, Caleffi A, Corradini E *et al.* (2003) Iron overload in Africans and African-Americans and a common mutation in the SCL40A1 (ferroportin 1) gene small star, filled. *Blood Cells Mol Dis* 31, 299–304.
67 Yoshida K, Furihata K, Takeda S *et al.* (1995) A mutation in the ceruloplasmin gene is associated with systemic hemosiderosis in humans. *Nature Genet* 9, 267–272.
68 Harris ZL, Takahashi Y, Miyajima H *et al.* (1995) Aceruloplasminemia: molecular characterization of this disorder of iron metabolism. *Proc Natl Acad Sci USA* 92, 2539–2543.
69 Goode CA, Dinh CT, Linder MC (1989) Mechanism of copper transport and delivery in mammals: review and recent findings. *Adv Exp Med Biol* 258, 131–144.
70 Miyajima H, Takahashi Y, Kamata T *et al.* (1997) Use of desferrioxamine in the treatment of aceruloplasminemia. *Ann Neurol* 41, 404–407.
71 Hayashi A, Wada Y, Suzuki T *et al.* (1993) Studies on familial hypotransferrinemia – unique clinical course and molecular pathology. *Am J Hum Genet* 53, 201–213.
72 Kato J, Fujikawa K, Kanda M *et al.* (2001) A mutation, in the iron-responsive element of H ferritin mRNA, causing autosomal dominant iron overload. *Am J Hum Genet* 69, 191–197.
73 Knisely AS, Mieli-Vergani G, Whitington PF (2003) Neonatal hemochromatosis. *Gastroenterol Clin North Am* 32, 877–889.
74 Cox TM, Halsall DJ (2002) Hemochromatosis – neonatal and young subjects. *Blood Cells Mol Dis* 29, 411–417.

16.3 Alpha-1-antitrypsin deficiency and related disorders

Jeffrey H. Teckman

Introduction

Alpha-1-antitrypsin (a1AT) is a glycoprotein primarily synthesized in the liver and secreted into the serum where its function is to prevent non-specific, neutrophil protease-induced host tissue damage [1,2]. Homozygosity for the autosomal codominant Z mutant allele of a1AT ('PIZZ' in WHO nomenclature) represents the classical form of a1AT deficiency [3]. The protein product of the mutant Z gene accumulates within hepatocytes rather than being efficiently secreted. The accumulated Z mutant protein may then attain an altered intracellular conformation in which many a1AT mutant Z molecules aggregate to form large polymers. PIZZ homozygous adults have a markedly increased risk of developing emphysema by a loss-of-function mechanism in which insufficient levels of circulating a1AT are available in the lung to inhibit connective tissue breakdown by neutrophil proteases. A subgroup of PIZZ homozygous children and adults may also develop liver disease and hepatocellular carcinoma via a separate mechanism in which the intracellular accumulation of a1AT mutant Z protein damages hepatocytes [4].

Genetics

Classical, PIZZ a1AT deficiency is caused by homozygosity for a point mutation at position 342 in the a1AT gene encoding the substitution of lysine for glutamate. The 12.2-kb gene is located on chromosome 14q and encodes a 55-kDa product of 95 amino acids [5]. PIZZ homozygotes are found at a frequency of 1 in 1500–3500 in North American and European populations [2,6]. Populations in, or derived from, Scandinavia, the British Isles, northern France and the South Tyrol region of Italy have the highest frequency of the mutant Z gene. A1AT deficiency is the most common genetic liver disease in children [7–9].

Pathophysiology

The key step in the pathophysiology of a1AT deficiency is retention of the newly synthesized mutant Z protein molecule within the endoplasmic reticulum (ER) of hepatocytes (Fig. 1) [10–13]. During biosynthesis, the nascent mutant Z polypeptide chain is appropriately assembled on the ribosome and translocated into the ER lumen. However, in the ER, the mutant Z protein molecule folds slowly and inefficiently into its final, secretion-competent conformation and may attain a variety of abnormal conformations, including a unique state in which multiple molecules aggregate to form large polymers [8,10,14]. A system of proteins within the ER, termed the 'quality control' apparatus, recognizes these mutant Z molecules as abnormal and directs them to a series of proteolytic systems rather than allowing progression down the secretory pathway [15,16–18]. The result of these processes is a significantly deficient, approximately 15% of normal, serum level of a1AT. Accumulation of the retained mutant Z protein molecules within hepatocytes appears to cause liver injury [1]. A small proportion of the retained molecules may remain in the polymerized conformation and accumulate as aggregates within dilated areas of ER. These accumulations may become so large that they are visible by light microscopy as eosinophilic hepatocellular inclusions by haematoxylin and eosin (H&E) or as the periodic acid–Schiff (PAS)-positive, diastase digestion-resistant globules classically described within hepatocytes in this disease (see below) [19].

The discovery of the polymerized conformation of a1AT mutant Z protein is critical in understanding the pathophysiology of this disease, although many of the mechanistic details are still being investigated [9,20]. The presence of the Z mutation in the a1AT molecule allows the protruding reactive site loop of one molecule to insert into a groove in the β-sheet of a neighbouring molecule. A conformational change then occurs, binding the molecules tightly together in the absence of covalent bonds. Long chains of a1AT mutant Z protein polymers are formed in this way, and physical–chemical studies suggest that this conformation is extremely stable and long-lived in biological systems. Mutagenesis studies of the a1AT mutant Z molecule show that most, but not all, mutations that disrupt the polymerized conformation also affect intracellular retention [10, 21,22]. Therefore, further investigation is proceeding into whether it is the actions of the cellular quality control apparatus, the effect of

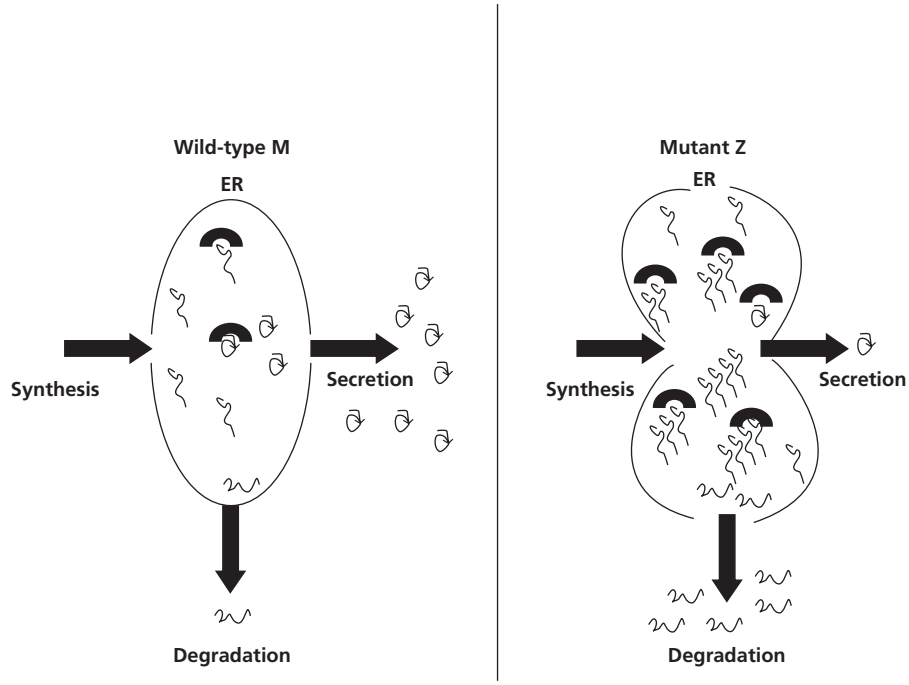

Fig. 1 Conceptual model of a1AT mutant Z protein ER retention in a1AT deficiency. During the biosynthesis of the normal, wild-type M, a1AT, the nascent polypeptide chain enters the ER lumen (shown as long wavy lines) and binds with chaperone proteins (dark semicircles), which assist in folding into the final, secretion-competent conformation (compact knot). Some molecules do not fold appropriately and are directed to proteolytic degradation pathways. However, during biosynthesis of the a1AT mutant Z, the nascent polypeptide in the ER lumen folds inefficiently and very few molecules achieve a secretion-competent conformation. Some of the molecules polymerize and some are directed to degradation pathways. The accumulation of the a1AT mutant Z molecules within the ER deforms the ER architecture leading to ER stress and triggering cell injury.

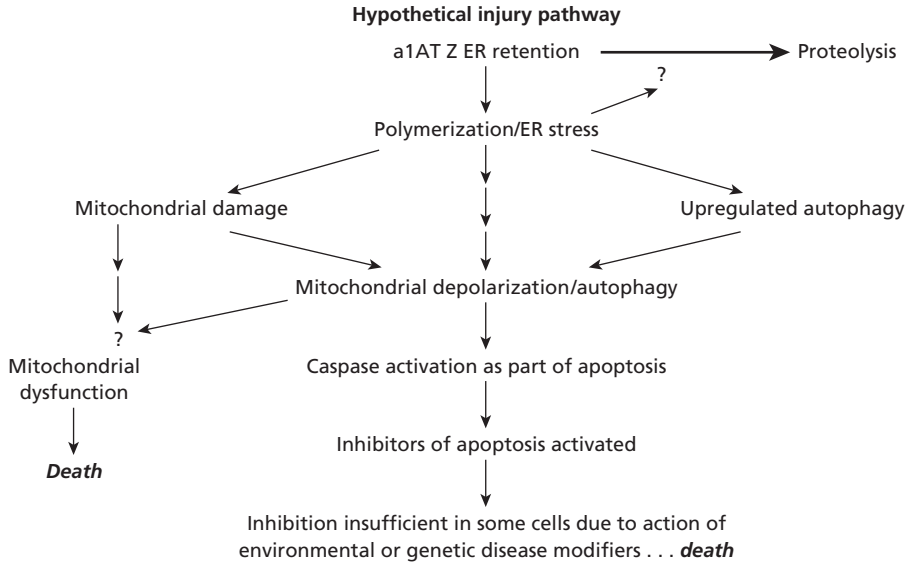

Fig. 2 Hypothetical hepatocellular injury pathway in PIZZ a1AT deficiency. The a1AT mutant Z protein is appropriately synthesized, but then retained in the ER of hepatocytes rather than being secreted. Quality control processes within the cells direct most of the mutant Z protein molecules into intracellular proteolysis pathways. However, some of the mutant Z protein molecules escape proteolysis and may attain a unique, polymerized conformation forming inclusions in the ER. This results in activation of a variety of cellular responses. Autophagy may be upregulated resulting in damage to mitochondria; mitochondria may be damaged directly or may be involved in activation of caspases and the intrinsic pathway of apoptosis. Hepatocellular death may result from mitochondrial dysfunction or from an uninhibited apoptotic cascade. Given the variable nature of clinical liver injury between individuals with the same genotype, and the usually slow disease progression, there are likely to be important environmental and genetic disease modifiers affecting the rate and magnitude of hepatocellular death.

the polymerized conformation or both that causes intracellular retention of the molecule within hepatocytes.

The mechanism(s) of hepatocellular injury resulting from a1AT mutant Z protein retention are also still being elucidated (Fig. 2). Studies suggest that multiple intracellular pathways are activated in response to the accumulation within the ER of the mutant protein [1,16–18,23–27]. This may include aspects of the ER stress responses and the autophagic response. Autophagy is a highly conserved cellular function in which targets destined for proteolytic degradation, including senescent organelles such as mitochondria, cytoplasmic debris and other molecules, are directed into a unique vacuolar degradation system during development, stress or nutrient deprivation. Autophagy may be one mechanism of cellular disposal of the accumulated a1AT mutant Z protein. Studies have suggested that stimulation of hepatocellular autophagy may lead to damage to mitochondria

as one mechanism for hepatocellular death in a1AT deficiency [26]. There is also evidence for a1AT mutant Z protein-specific damage to mitochondria that does not involve autophagy, and possible activation of apoptosis, which may also play a role in the hepatocellular injury in a1AT deficiency [23,26]. It is proposed that the chronic burden of hepatocellular death, from mitochondrial injury, apoptosis or other mechanisms, over time leads to organ injury and cirrhosis in this chronic, metabolic liver disease.

A series of studies have also examined the role of the proteasome, and other proteolytic systems, in explaining the considerable variability observed in the severity of liver disease between individual patients with a1AT deficiency. Some PIZZ individuals appear to be protected from liver disease because the quality control apparatus of the ER ensures relatively efficient degradation of the accumulated a1AT mutant Z protein [11,28]. However, in patients 'susceptible' to liver injury, subtle alterations in the quality control apparatus of the ER result in inefficient degradation of accumulated a1AT mutant Z protein, presumably a greater net burden in the ER and an increased potential for liver injury. Several genes and gene products critical to these processes have been identified within hepatocytes, which are related to a series of pathways known as the ER quality control and ER stress responses [12,15,18,29,30]. It has also been proposed that this extreme variability in clinical liver disease between individuals would indicate the existence of other important environmental (alcohol, viral infection) or genetic disease modifiers affecting many other parts of the pathophysiological cascade.

A variety of animal models have been developed to facilitate the study of the cellular pathophysiology of this disease *in vivo*. The most useful have been a series of mice strains transgenic for the human a1AT mutant Z gene, although in these cases the endogenous murine antiprotease genes have remained intact [7,13,19]. Several of these strains have been shown to be excellent models of human liver disease and recapitulate the intracellular accumulation of the mutant Z protein, the loop sheet protein polymerization, the histological features of the intracellular globules, increased autophagy and long-term hepatic dysplasia. However, there is still no generally accepted animal model of protease-deficient lung disease similar to a1AT deficiency. This is because mice have been found to have multiple antiprotease genes whose function overlaps that of human a1AT. Knocking out all these genes without inducing other significant changes in normal physiology has, to date, been an insurmountable technical hurdle.

Presentation and natural history

The presentation of patients with PIZZ a1AT deficiency can be highly varied, ranging from chronic liver disease to fulminant hepatic failure to adult emphysema [1,2]. In infancy, the typical presentation is one of neonatal cholestasis (also called the neonatal hepatitis syndrome) and may include the symptoms and signs of jaundice, abdominal distension, pruritis, poor feeding, poor weight gain, hepatomegaly and splenomegaly [31,32]. Laboratory evaluation may reveal elevated total and conjugated bilirubin, elevated serum aspartate aminotransferase (AST) and alanine aminotransferase (ALT), hypoalbuminaemia or coagulopathy due to vitamin K deficiency or to liver synthetic dysfunction. Liver biopsy findings may be highly variable in infants including giant cell transformation, lobular hepatitis, significant steatosis, fibrosis, hepatocellular necrosis, bile duct paucity or bile duct proliferation [1,5]. Globular, eosinophilic inclusions in some but not all hepatocytes under conventional H&E stain are usually seen, which represent dilated ER membranes engorged with polymerized a1AT mutant Z protein [19]. Staining with PAS followed by digestion with diastase, a technique that labels glycoproteins red, is used to highlight the red 'globules' ('PAS-positive') on a neutral blue background (see Plate 16.3.1, facing p. 1268). Examination of liver biopsies for PAS-positive globules should be done with caution as similar structures have been described in other liver diseases, the globules are not present in all hepatocytes or can be small and 'dust-like', and they are occasionally absent in very young infants. Although life-threatening liver disease can occur in the first few years of life, prospective, population-based studies indicate that 80% of PIZZ patients presenting with neonatal cholestasis are healthy and free of chronic disease by the age 18 years [33]. These data suggest that the overall risk of life-threatening liver disease in childhood may be as low as 3%, but that the risk of varying degrees of liver dysfunction in children may range from 15% to 60% [31]. There is no clear explanation for why an infant with a1AT-related hepatitis in the neonatal period would then experience a 'honeymoon period' of decreased or absent hepatic inflammation later in childhood. Some investigators have suggested that this represents a state of tolerance to the accumulated mutant protein, which might then be exploited as a potential treatment for individuals with severe disease. However, there are as yet no data to support this hypothesis.

In toddlers and older children, PIZZ a1AT deficiency may present as failure to thrive, possibly with poor feeding or hepatomegaly. Some children come to medical attention when asymptomatic hepatomegaly or splenomegaly is detected during routine medical checkups. Many children appear to be completely healthy, without evidence of liver injury, except for mild and usually clinically insignificant elevations in serum AST or ALT. Occasionally, children with previously unrecognized chronic liver disease and cirrhosis present with ascites, gastrointestinal bleeding or hepatic failure. However, many PIZZ children with cirrhosis may remain stable and grow and develop normally for a decade or more before beginning a process of decompensation [1,34–36].

There are few firm data on the incidence or the rate of progression of significant liver injury in PIZZ adults, although many authorities believe the development of life-threatening disease to be uncommon in the young and middle adult years [6,33,37]. Liver disease in adults may present as chronic hepatitis, with or without cirrhosis, and the risk of clinically significant disease may increase with advancing age [37]. The biochemical and

histopathological findings may be similar to those of adult alcoholic liver disease, which may lead to diagnostic confusion. There appears to be an increased risk of hepatocellular carcinoma in PIZZ adults, although the magnitude of the risk is unclear. Liver biopsy findings in older children and adults may include lobular inflammation, variable hepatocellular necrosis, fibrosis, cirrhosis, steatosis and PAS-positive, diastase-resistant globules in some, but not all, hepatocytes in nearly every patient [1]. Autopsy studies suggest that sometimes clinically inapparent, but histologically significant, liver injury and cirrhosis may be present in 30–40% of elderly PIZZ adults [37].

Children with PIZZ a1AT deficiency generally do not develop clinically detectable emphysema, although they may be at increased risk of childhood asthma [38]. Asthma or emphysema may develop during adulthood [39]. Smoking significantly increases the risk of progressive and irreversible lung disease, as do occupational lung exposures and environmental atmospheric pollutants, all of which are thought to increase the uninhibited proteolytic attack on lung connective tissue. Some studies suggest that exposure to secondhand smoke and environmental air pollutants in childhood is also a significant risk for the development of a1AT deficiency-associated adult emphysema [2].

Diagnosis

The gold standard for the diagnosis of a1AT deficiency is the phenotype (PI or PI type) of the a1AT protein present in a sample of the patient's serum as determined by isoelectric focusing gel electrophoresis [2]. If only the PI type Z band is present in the gel, it is then inferred that the patient is carrying two copies of the mutant Z a1AT gene. A normal patient with two copies of the wild-type M a1AT gene would only have the M band detected, and a heterozygote would have a combination of protein bands. The phenotype gel analysis is technically demanding and is therefore best performed in an experienced reference laboratory. As the presentations of a1AT deficiency are quite variable, sending serum to the reference laboratory for phenotype testing can be useful in a wide variety of clinical situations (Table 1) [1,2]. Measurement of the level of a1AT in peripheral blood can be used as a complementary test to compare the phenotype result against what would be an appropriate predicted level (Table 2) and to assist in the elucidation of unusual alleles whose protein products yield confusing phenotype results [40,41]. Some clinicians use the a1AT serum level as an introductory screening test, but then are reassured only by a result exactly within the normal PIMM reference range. This approach should be used with caution as a1AT is known to be an acute-phase reactant protein leading to modest increases in serum levels during periods of systemic inflammation even in deficient individuals. Liver biopsy is not required for the diagnosis of a1AT deficiency, although it is used in some cases to evaluate disease progression or to investigate the contribution of comorbid states. More recently, new commercial tests have become available based on polymerase chain reaction (PCR) analysis of genomic DNA obtained from blood leukocytes or buccal mucosa, although these tests usually only detect the most common S and Z mutant alleles. Prenatal diagnosis by amniocentesis or chorionic villus sampling can also be performed.

Table 1 Clinical presentation and indications for testing for a1AT deficiency.

Infant: Cholestatic jaundice
Child: Unexplained failure to thrive or poor feeding
Any age: Unexplained, asymptomatic hepatomegaly or elevated AST/ALT
Any age: Unexplained liver disease, cirrhosis or hepatocellular carcinoma
Adult: Severe asthma, any emphysema < 50 years old or at any age in a non-smoker

Table 2 a1AT phenotypes and corresponding typical a1AT serum levels.

Phenotype	Level (μM)[a]
PIMM	20–48
PIMZ	12–35
PISS	15–33
PISZ	8–19
PIZZ	2.5–7.0
Null–Null	0.0

[a]Convert micromolar to milligrams per decilitre by multiplying by a conversion factor of 5.2.

Neonatal screening has been performed in various locations as temporary, pilot studies, most notably in Sweden in the early 1970s [31]. The metabolic benefits of early, presymptomatic diagnosis are controversial, although the Swedish experience suggests that neonatal screening is very likely to reduce the rate of personal smoking and lung disease in adulthood [42,43]. However, concerns regarding employment, access to health care and the psychosocial consequences of asymptomatic screening limit testing in many countries [43,44]. Families of affected individuals should be offered testing in the context of appropriate education and genetic counselling. Targeted screening in populations of adults with chronic lung disease is common practice in many countries.

Management

There is no specific treatment for the liver disease associated with a1AT deficiency. Management focuses on preventing the complications of chronic liver disease, such as bleeding, ascites, pruritis, malnutrition, fat-soluble vitamin deficiency, infection, malignancy and growth disturbances, or attenuating the systemic repercussions if they do occur [1]. Many patients have normal health and can be monitored conservatively with infrequent visits to a physician knowledgeable in liver disease. Some experienced clinicians employ routine, but infrequent, screening imaging or biochemical monitoring of α-fetoprotein out of concern for the increased risk of hepatic carcinogenesis. However, some patients with significant degrees of liver injury, and even cirrhosis, often remain stable for many years with very little

intervention. If life-threatening liver disease does develop, then liver transplantation is commonly employed with excellent published success rates. All paediatric and adult patients with a1AT deficiency should be urgently cautioned against personal smoking, secondhand smoke and environmental lung exposures. Prospective studies indicate that the identification of a1AT-deficient patients as children dramatically reduces their incidence of smoking as adults and therefore decreases morbidity and mortality from lung disease [43,45]. Exogenous a1AT protein replacement is available as a treatment for the adult emphysema associated with a1AT deficiency; however, the efficacy of the therapy is controversial [2]. Exogenous a1AT replacement has no effect on the development of liver disease because liver injury is related to the accumulation of the a1AT mutant Z protein within hepatocytes, not a lack of circulating antiprotease activity. Experimental therapies including the use of so-called chemical chaperones, such as 4-phenylbutyrate, hepatocyte transplantation and gene therapy strategies are being investigated but have not yet been shown to be clinically useful [1,46,47].

Heterozygosity and other alleles

Individuals who are heterozygous for a1AT, carrying one normal M allele and one mutant Z allele ('PIMZ' or 'MZ') are generally considered to be asymptomatic and healthy. Data from referral centre studies suggest that some rare PIMZ adults may develop liver disease, including the development of PAS-positive globules in hepatocytes, although the possible genetic or environmental influences on the development of this injury remain controversial [2,48–50]. Limited but unselected population-based studies have so far failed to confirm this increased risk [34]. PIMZ children appear to be completely healthy and, even in adults, a PIMZ phenotype result is not readily accepted as the cause of otherwise unexplained liver disease.

Individuals have been described who are compound heterozygotes for the S and Z alleles of a1AT (PISZ) and who have developed liver disease identical to PIZZ patients, including PAS-positive, diastase-resistant globules. The S allele is also common in western European populations, especially on the Iberian peninsula. Physical–chemical studies have shown that the a1AT mutant S protein can heteropolymerize intracellularly when coexpressed with the mutant Z protein, which may explain the occurrence of liver injury in PISZ patients when liver disease is notably absent in PISS individuals [28,51]. However, the risk of liver disease in PISZ individuals is likely to be less than the risk in PIZZ individuals. PISZ individuals may also be at risk of adult emphysema. Over 100 other rare mutations in the a1AT gene have been described [2]. Some of these gene products yield a normal M result on the phenotype test but, when present in the heterozygous state with a Z allele, can accumulate within the liver and have been associated with liver disease [40,41]. Such patients are usually recognized by a profoundly low a1AT level in peripheral blood that is not in keeping with the phenotype result.

Related conditions

There are reports of liver diseases associated with the intracellular accumulation of other proteins. A familial fibrinogen storage disease associated with plasma deficiency and with autosomal dominant inheritance has been described in a few kindreds in Europe and Japan. The condition is associated with chronic liver disease varying from modest biochemical abnormalities to cirrhosis. Light microscopy reveals pale, faintly eosinophilic inclusions in the hepatocytes that are weakly PAS positive, representing dilated ER membranes similar to those of a1AT deficiency [52]. A similar, but less well-defined condition is plasma deficiency of α_1-antichymotrypsin [53]. α_1-Antichymotrypsin is a member of the serine protease inhibitor (serpin) family, which also includes a1AT. The neutrophil enzyme cathepsin G is the primary target of α_1-antichymotrypsin. A familial heterozygous deficiency of α_1-antichymotrypsin has been described associated with decreased plasma α_1-antichymotrypsin and liver disease of variable clinical severity. Hepatocytes may exhibit immunoreactive α_1-antichymotrypsin inclusions, although further details of the pathophysiology and genetics of this condition are still being investigated.

References

1 Perlmutter DH (2004) Alpha-1-antitrypsin deficiency: diagnosis and treatment. *Clin Liver Dis* 8 (4), 839–859, viii–ix.

2 American Thoracic Society/European Respiratory Society (2003) Statement: standards for the diagnosis and management of individuals with alpha-1 antitrypsin deficiency. *Am J Respir Crit Care Med* 168 (7), 818–900.

3 WHO (1997) Alpha 1-antitrypsin deficiency: memorandum from a WHO meeting. *Bull World Health Org* 75 (5), 397–415.

4 Eriksson S (1990) Discovery of alpha 1-antitrypsin deficiency. *Lung* 168 (Suppl.) 523–529.

5 Eriksson S (1999) Alpha 1-antitrypsin deficiency. *J Hepatol* 30 (Suppl. 1), 34–39.

6 Eriksson S (1996) A 30-year perspective on alpha 1-antitrypsin deficiency. *Chest* 110 (6 Suppl.), 237S–242S.

7 Perlmutter DH (1996) Alpha-1-antitrypsin deficiency: biochemistry and clinical manifestations. *Ann Med* 28 (5), 385–394.

8 Lomas DA, Evans DL, Finch JT *et al.* (1992) The mechanism of Z alpha 1-antitrypsin accumulation in the liver. *Nature* 357 (6379), 605–607.

9 Lomas DA, Parfrey H (2004) Alpha1-antitrypsin deficiency. 4: Molecular pathophysiology. *Thorax* 59 (6), 529–535.

10 Lomas DA, Mahadeva R (2002) Alpha1-antitrypsin polymerization and the serpinopathies: pathobiology and prospects for therapy. *J Clin Invest* 110 (11), 1585–1590.

11 Wu Y, Whitman I, Molmenti E *et al.* (1994) A lag in intracellular degradation of mutant alpha 1-antitrypsin correlates with the liver disease phenotype in homozygous PiZZ alpha 1-antitrypsin deficiency. *Proc Natl Acad Sci USA* 91 (19), 9014–9018.

12 Qu D, Teckman JH, Omura S *et al.* (1996) Degradation of a mutant secretory protein, alpha1-antitrypsin Z, in the endoplasmic reticulum requires proteasome activity. *J Biol Chem* 271 (37), 22791–22795.

13 Qu D, Teckman JH, Perlmutter DH (1997) Review: alpha 1-antitrypsin deficiency associated liver disease. *J Gastroenterol Hepatol* 12 (5), 404–416.

14 Dafforn TR, Mahadeva R, Elliot PR *et al.* (1999) A kinetic mechanism for the polymerization of alpha1-antitrypsin. *J Biol Chem* 274 (14), 9548–9555.

15 Cabral CM *et al.* (2000) 275 Processing by endoplasmic reticulum mannosidases partitions a secretion-impaired glycoprotein into distinct disposal pathways. *J Biol Chem* (32), 25015–25022.

16 Teckman JH, Burrows J, Hidvegi T *et al.* (2001) The proteasome participates in degradation of mutant alpha 1-antitrypsin Z in the endoplasmic reticulum of hepatoma-derived hepatocytes. *J Biol Chem* 276 (48), 44865–44872.

17 Teckman JH, Perlmutter DH (2000) Retention of mutant alpha(1)-antitrypsin Z in endoplasmic reticulum is associated with an autophagic response. *Am J Physiol Gastrointest Liver Physiol* 279 (5), G961–974.

18 Sifers RN (2003) Cell biology. Protein degradation unlocked. *Science* 299 (5611), 1330–1331.

19 An JK, Blomenkamp K, Lindblad D *et al.* (2005) Quantitative isolation of alphalAT mutant Z protein polymers from human and mouse livers and the effect of heat. *Hepatology* 41 (1), 160–167.

20 Perlmutter DH (2003) Alpha1-antitrypsin deficiency: liver disease associated with retention of a mutant secretory glycoprotein in the endoplasmic reticulum. *Methods Mol Biol* 232, 39–56.

21 Lomas DA, Evans DL, Stone SR *et al.* (1993) Effect of the Z mutation on the physical and inhibitory properties of alpha 1-antitrypsin. *Biochemistry* 32 (2), 500–508.

22 Lin L, Schmidt B, Teckman J *et al.* (2001) A naturally occurring non-polymerogenic mutant of alpha 1-antitrypsin characterized by prolonged retention in the endoplasmic reticulum. J Biol Chem 276 (36), 33893–33898.

23 Rudnick DA (2004) Analyses of hepatocellular proliferation in a mouse model of alpha-1-antitrypsin deficiency. *Hepatology* 39 (4), 1048–1055.

24 Wu Y (2003) Elucidation of the molecular logic by which misfolded alpha 1-antitrypsin is preferentially selected for degradation. *Proc Natl Acad Sci USA* 100 (14), 8229–8234.

25 Lawless MW (2004) Activation of endoplasmic reticulum-specific stress responses associated with the conformational disease Z alpha 1-antitrypsin deficiency. *J Immunol* 172 (9), 5722–5726.

26 Teckman JH, Blomenkamp K, Schmidt B *et al.* (2004) Mitochondrial autophagy and injury in the liver in alpha 1-antitrypsin deficiency. *Am J Physiol Gastrointest Liver Physiol* 286 (5), G851–862.

27 Teckman JH, An AK, Loethen S *et al.* (2002) Fasting in alpha1-antitrypsin deficient liver: constitutive [correction of consultative] activation of autophagy. *Am J Physiol Gastrointest Liver Physiol* 283 (5), G1156–1165.

28 Teckman JH, Perlmutter DH (1996) The endoplasmic reticulum degradation pathway for mutant secretory proteins alpha1-antitrypsin Z and S is distinct from that for an unassembled membrane protein. *J Biol Chem* 271 (22), 13215–13220.

29 Teckman JH, Gilmore R, Perlmutter DH (2000) Role of ubiquitin in proteasomal degradation of mutant alpha(1)-antitrypsin Z in the endoplasmic reticulum. *Am J Physiol Gastrointest Liver Physiol* 278 (1), G39–48.

30 Marcus NY, Perlmutter DH (2000) Glucosidase and mannosidase inhibitors mediate increased secretion of mutant alpha1 antitrypsin Z. *J Biol Chem* 275 (3), 1987–1992.

31 Sveger T (1976) Liver disease in alpha1-antitrypsin deficiency detected by screening of 200,000 infants. *N Engl J Med* 294 (24), 1316–1321.

32 Sveger T (1978) alpha 1-antitrypsin deficiency in early childhood. *Pediatrics* 62 (1), 22–25.

33 Sveger T, Eriksson S (1995) The liver in adolescents with alpha 1-antitrypsin deficiency. *Hepatology* 22 (2), 514–517.

34 Sveger T (1988) The natural history of liver disease in alpha 1-antitrypsin deficient children. *Acta Paediatr Scand* 77 (6), 847–851.

35 Mowat AP (1994) Alpha 1-antitrypsin deficiency (PiZZ): features of liver involvement in childhood. *Acta Paediatr Suppl* 393, 13–17.

36 Pittschieler K, Massi G (1988) Alpha 1 antitrypsin deficiency in two population groups in north Italy. *Padiatr Padol* 23 (4), 307–311.

37 Eriksson S (2001) Alpha-1-antitrypsin deficiency: natural course and therapeutic strategies. In: Boyer L, Blum HE, Maier K-P *et al.* (eds) *Falk Symposium 115: Liver Cirrhosis and its Development*. Dordrecht: Kluwer Academic Publishers, pp. 307–315.

38 Sveger T, Piitulainen E, Arborelius, M, Jr (1994) Lung function in adolescents with alpha 1-antitrypsin deficiency. *Acta Paediatr* 83 (11), 1170–1173.

39 Eden E *et al.* (2003) Asthma features in severe alpha1-antitrypsin deficiency: experience of the National Heart, Lung, and Blood Institute Registry. *Chest* 123 (3), 765–771.

40 Lomas DA, Finch JT, Seyama K *et al.* (1993) Alpha 1-antitrypsin Siiyama (Ser53→Phe). Further evidence for intracellular loop-sheet polymerization. *J Biol Chem* 268 (21), 15333–15335.

41 Lomas DA, Elliot PR, Sidhar SK *et al.* (1995) alpha 1-Antitrypsin Mmalton (Phe52-deleted) forms loop-sheet polymers in vivo. Evidence for the C sheet mechanism of polymerization. *J Biol Chem* 270 (28), 16864–16870.

42 Laurell CB, Sveger T (1975) Mass screening of newborn Swedish infants for alpha antitrypsin deficiency. *Am J Hum Genet* 27 (2), 213–217.

43 Sveger T, Thelin T, McNeil TF (1997) Young adults with alpha 1-antitrypsin deficiency identified neonatally: their health, knowledge about and adaptation to the high-risk condition. *Acta Paediatr* 86 (1), 37–40.

44 McNeil TF, Sveger T, Thelin T (1988) Psychosocial effects of screening for somatic risk: the Swedish alpha 1 antitrypsin experience. *Thorax* 43 (7), 505–507.

45 Piitulainen E, Sveger T (2002) Respiratory symptoms and lung function in young adults with severe alpha(1)-antitrypsin deficiency (PiZZ). *Thorax* 57 (8), 705–708.

46 Teckman JH (2004) Lack of effect of oral 4-phenylbutyrate on serum alpha-1-antitrypsin in patients with alpha-1-antitrypsin deficiency: a preliminary study. *J Pediatr Gastroenterol Nutr* 39 (1), 34–37.

47 Duan YY, Wu J, Zhu JL *et al.* (2004) Gene therapy for human alpha1-antitrypsin deficiency in an animal model using SV40-derived vectors. *Gastroenterology* 127 (4), 1222–1232.

48 Pittschieler K (1991) Liver disease and heterozygous alpha-1-antitrypsin deficiency. *Acta Paediatr Scand* 80 (3), 323–327.

49 Kaserbacher R, Propst T, Propst A *et al.* (1993) Association between heterozygous alpha 1-antitrypsin deficiency and genetic hemochromatosis. *Hepatology* 18 (3), 707–708.

50 Propst T, Propst A, Dietze O *et al.* (1992) High prevalence of viral infection in adults with homozygous and heterozygous alpha 1-antitrypsin deficiency and chronic liver disease. *Ann Intern Med* 117 (8), 641–645.

51 Mahadeva R, Chang WS, Dafforn TR *et al.* (1999) Heteropolymerization of S, I, and Z alpha1-antitrypsin and liver cirrhosis. *J Clin Invest* 103 (7), 999–1006.

52 Callea F, Brisigotti M, Fabbretti G *et al.* (1992) Hepatic endoplasmic reticulum storage diseases. *Liver* 12 (6), 357–362.

53 Lindmark BE, Eriksson SG (1985) Plasma alpha 1-antichymotrypsin in liver disease. *Clin Chim Acta* 152 (3), 261–269.

16.4 The liver in cystic fibrosis

Andrew P. Feranchak

Introduction

Cystic fibrosis is an autosomal recessive disease characterized by abnormal electrolyte transport in the epithelial cells of many organs. Affecting one in every 2400 live births in the United Kingdom, it is one of the most common genetic diseases in the Caucasian population [1]. The disease is due to a mutation in the gene for the cystic fibrosis transmembrane conductance regulator (CFTR), a membrane protein that functions as an anion channel in the epithelial cells of the airway, pancreas, intestine, biliary tract, sweat ducts and vas deferens.

In the past, the liver involvement in cystic fibrosis (CF) was eclipsed by the pulmonary manifestations of the disease, which led to early mortality in the majority of patients. While pulmonary complications still account for the greatest mortality, better treatments have led to an improved life expectancy, resulting in an increased recognition of hepatobiliary disease. In fact, hepatobiliary complications are now the second leading cause of death in CF. The identification of cystic fibrosis-associated liver disease (CFALD) continues to be difficult because, while it is progressive, the liver involvement is often asymptomatic until the appearance of endstage complications.

Role of CFTR in liver function

The gene for cystic fibrosis was discovered in 1989 by Riordan and colleagues [2]. Located on the long arm of chromosome 7, the gene contains 250 000 bp with 27 exons and encodes a polypeptide product of 1480 amino acids. The protein product of the CF gene belongs to a family of proteins known as adenosine triphosphate (ATP)-binding cassette (ABC) proteins, which all contain transmembrane sequences and hydrolyse ATP for activation. CFTR contains two domains, capable of spanning the membrane six times, separated by regulatory cytoplasmic domains consisting of two consensus nucleotide binding folds (NBF) with an intervening segment rich in phosphorylation sites assumed to be a regulatory domain. It is now well established that CFTR functions as a cAMP-dependent chloride channel in the apical membrane of secretory epithelia.

In the human liver, CFTR is located on the apical (luminal) membrane of bile duct epithelial cells known as cholangiocytes [3]. It is not expressed in hepatocytes or other cells of the liver. In cholangiocytes, CFTR appears to play an important role in bile formation through the regulated transport of Cl^-. While the factors regulating biliary secretion have not been fully elucidated, one accepted model involves the hormone secretin acting through receptors on the basolateral membrane to increase cAMP levels and CFTR activity [4]. Under normal conditions, cAMP-dependent protein kinase A (PKA) phosphorylates CFTR causing channel opening and efflux of Cl^- ions. Chloride efflux through CFTR is likely to function in parallel with Cl^-/HCO_3^- exchange to transport Cl^- and HCO_3^- into the lumen (Fig. 1). Alternatively, HCO_3^- may enter the lumen through a separate conductive pathway or through Cl^- channels including CFTR [5], although definitive studies in biliary epithelium are lacking. Water secretion into the bile duct lumen occurs through aquaporin proteins also located on the apical membrane of biliary duct cells. Thus, bile becomes more alkaline and more dilute as it traverses the bile duct.

Notably, most patients with CF do not develop clinically significant liver disease despite abnormal or absent biliary CFTR, suggesting that other secretory pathways are functional. In fact, several other anion channels in cholangiocytes have been identified, including Ca^{2+}-activated [6,7], volume-stimulated [8], G-protein/voltage-gated [9] and those linked to purinergic receptor stimulation [10,11] (Fig. 1). The functional significance of these alternative Cl^- channels, including regulation and contribution to biliary secretion, is largely unknown. Preliminary evidence suggests that these channels are regulated independently of CFTR. Additionally, in other secretory cells, the level of expression of Cl^- channels other than CFTR is an important determinant of organ-level disease in CF. In the CF mouse model, for example, increased Ca^{2+}-activated Cl^- channel expression in respiratory epithelium is associated with mild pulmonary disease [12]. Interestingly, in isolated cholangiocytes, the current density of the Ca^{2+}-activated Cl^- conductance is two- to fourfold greater than the cAMP-activated Cl^- conductance [13,14]. Additionally, recent evidence suggests that basolateral

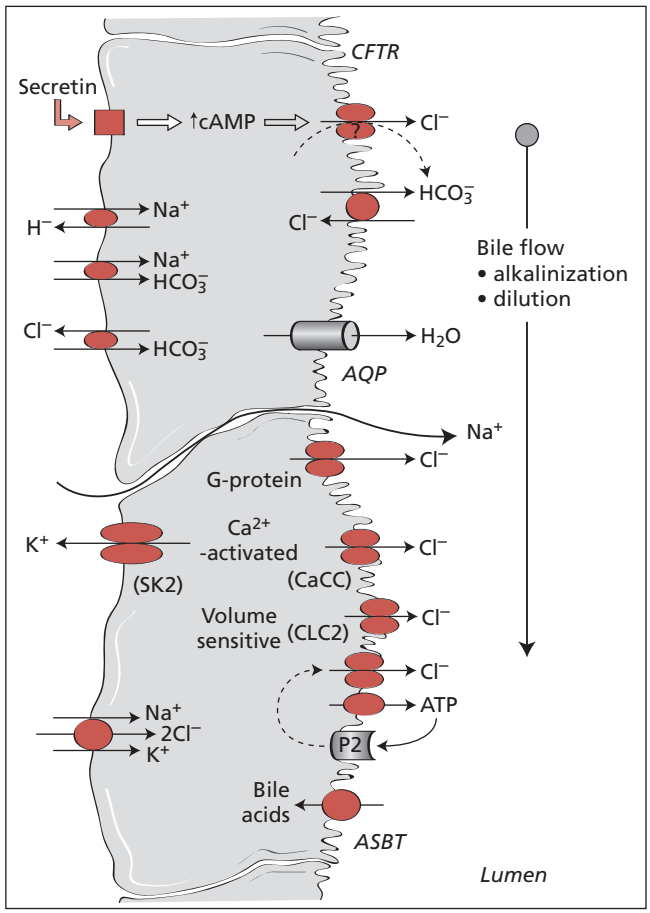

Fig. 1 Model of biliary epithelial secretion. Stimulation of basolateral receptors by secretin results in increases in cAMP and stimulation of Cl^- efflux through CFTR. The transmembrane Cl^- gradient drives Cl^-/HCO_3^- exchange. Alternatively, HCO_3^- efflux may be channel mediated. Water is transported via membrane aquaporin proteins (AQP). The increase in HCO_3^- and water secretion leads to alkalinization and dilution of bile. Other Cl^- channels, including volume-sensitive, G-protein and Ca^{2+}-activated, have been identified in cholangiocytes. Luminal factors, such as bile acids and ATP, are also regulators of secretion. ATP and other extracellular nucleotides stimulate secretion by binding to membrane P2 receptors, while bile acids are taken up by apical bile acid transporters (ASBT) and increase secretion possibly by stimulation of Ca^{2+}-activated Cl^- channels. A small conductance Ca^{2+}-activated K^+ channel (SK2) has been identified in the basolateral membrane and may work in parallel with apical Cl^- channels to hyperpolarize the membrane and provide the driving force for continued secretion. CFTR, cystic fibrosis transmembrane conductance regulator; AQP, aquaporin; P2, purinergic receptor; ASBT, apical sodium-dependent bile acid transporter; SK2, small conductance Ca^{2+}-activated potassium channel.

K^+ channels are important for normal secretion and work in parallel with apical Cl^- channels to provide the continued driving force for Cl^- efflux. Both human and rat bile duct epithelial cells express a small conductance Ca^{2+}-activated K^+ channel that appears to be an important regulator of secretion [14]. Consequently, these channels offer a potential site for regulation of secretion by cAMP-independent pathways and for pharmacological therapy of cystic fibrosis, and are therefore an exciting area of investigation.

In addition to hormones, such as secretin, acting on basolateral receptors, luminal factors, such as bile acids and ATP, also work as agonists to stimulate secretion. It has been shown that cholangiocytes take up bile acids from the lumen via an apical sodium-dependent bile acid transporter (ASBT) on the apical membrane [15]. In isolated cholangiocytes as well as intact biliary epithelial models, bile acids stimulate secretion, possibly through effects on Ca^{2+}-activated Cl^- channels [16,17]. Thus, luminal bile acids may have important regulatory effects on cholangiocyte secretion and bile flow. Other luminal factors shown to regulate cholangiocyte secretion include ATP and other nucleotides [10,18]. Both hepatocytes and cholangiocytes release ATP into bile where it is capable of binding to P2 receptors on the apical membrane of duct cells stimulating secretion [11,19,20]. It is interesting to note that this process takes place even in the absence of CFTR, suggesting that Cl^- secretion by purinergic receptor stimulation may be a therapeutic target to overcome the Cl^- secretory defect associated with CF [21]. The role of ATP and other nucleotides in the regulation of normal bile secretion as well as therapeutic agents in CF requires further study.

Pathogenesis

There are now over 1300 recognized mutations of the *CFTR* gene (CF Mutation Database, http://www.genet.sickkids.un.ca/cftr/). The various *CFTR* gene mutations are classified into five classes according to their effect on CFTR protein function (Fig. 2) [22]. Although specific gene mutations have been associated with the severity of pancreatic involvement, there is no

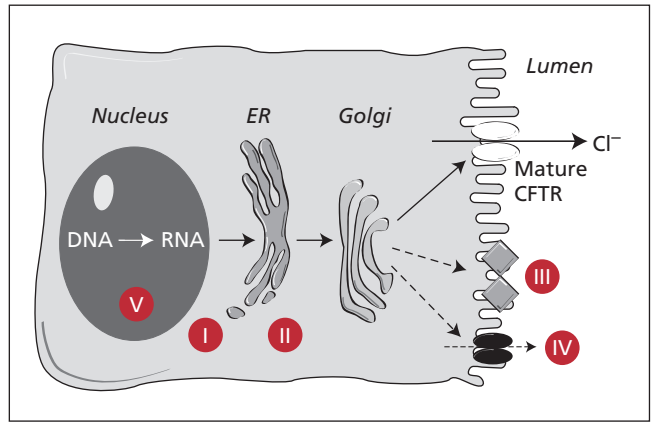

Fig. 2 Classes of CFTR mutations: (I) early stop codons resulting in no CFTR protein; (II) abnormal CFTR trafficking resulting in degradation in the endoplasmic reticulum; (III) mature CFTR protein is refractory to normal activation; (IV) CFTR activated normally, but with reduction in single-channel conductance; (V) splice site mutations resulting in decreased full-length mRNA and a decrease in functional CFTR at the apical membrane. ER, endoplasmic reticulum.

correlation between specific genotype and clinically detectable liver disease in patients with CF [23,24]. However, patients with liver disease usually have at least one severe mutation [25].

How a defective or absent CFTR protein in biliary epithelial cells leads to the manifestation of CFALD in a subset of patients is still unknown. One theory is that the thickened inspissated bile duct secretions lead to bile duct plugging and the subsequent manifestations of obstructive cholestatic liver disease. Ultimately, this can progress to fibrosis and cirrhosis. The thickened secretions may be a result of defective Cl^- or HCO_3^- transport, abnormal Na^+ reabsorption, altered mucin production or an abnormal bile acid pool. The bile duct plugging and/or cellular injury may result in the release of inflammatory mediators and the activation of stellate cells [26]. This in turn may lead to collagen deposition, progressive fibrosis and, ultimately, cirrhosis. There are many steps in this proposed model where modifier genes may play a role and, hence, this may explain some of the heterogeneity in the manifestation of CFALD.

Risk factors and modifiers

Male sex

A preponderance of male patients has been described in all age groups of patients with CF and liver disease. Given the reported survival advantage for males with CF [27], it is unclear whether male sex is indeed a risk factor or represents an over-representation in the study population.

HLA type

A possible immune contribution to the pathogenesis of hepatobiliary injury in CF is suggested by the finding of certain HLA type associations with the development of liver disease. In a multicentre study by Duthie *et al.* [28], DQ6 was found in 66% of patients with CFALD, but in only 33% of CF patients without liver disease, while DR15 and B7 were significant markers for liver disease with portal hypertension in males only. The role of modifiers of the immune response in relationship to the development of liver disease requires further exploration.

Meconium ileus

Several studies have suggested that a history of meconium ileus as an infant is a risk factor for the subsequent development of liver disease [29,30]. In recent studies, Colombo *et al.* [29] reported an approximate sixfold increase in the development of liver disease in those infants with a history of meconium ileus. However, other studies have failed to find such an association, and the majority of patients with CF and significant liver disease do not have a history of meconium ileus [31]. Zielenski *et al.* [32] have described a gene locus that modulates the severity of the gastrointestinal disease and the presence of meconium ileus in humans; however, a specific candidate gene and protein product have not been identified. Whether this locus is associated with a possible gene involved in the development of liver disease is only speculative. Other genes involved in liver and biliary tract disease, including other ion channels and transporters, will need to be examined for a possible role(s) in modifying disease expression.

Prevalence and manifestations

As there is no universally accepted definition of what constitutes CFALD, the true incidence and prevalence are unknown. However, several prospective studies have been conducted in different populations. A prospective study by Gaskin *et al.* found multilobular cirrhosis (defined by clinical, biochemical and imaging studies) in 13% of patients [33], while a study by Linblad *et al.* demonstrated abnormal biochemical markers suggestive of liver disease in approximately 25% of children, with 10% having significant fibrosis or cirrhosis on liver biopsy [34]. A more recent study by Colombo *et al.* followed 177 CF patients up to a median of 14 years and significant liver disease (defined as hepatomegaly, persistent elevation of at least two liver enzymes and abnormal ultrasound features of the liver) developed in ~ 27% of patients [25]. Liver disease may manifest in several distinct presentations, including neonatal cholestasis, hepatic steatosis, focal biliary cirrhosis and multilobular cirrhosis (Table 1).

Neonatal cholestasis

This may occur frequently in newborns with CF. Studies by Roy and colleagues described cholestasis or hepatomegaly in 35% of infants within the first month of life [35]. Additionally, autopsy data have revealed histological evidence of obstructive cholestasis in 38% of patients under 3 years of age with CF [36]. Several factors may contribute to prolonged cholestasis in the newborn including intestinal surgery, parental nutrition and sepsis. The natural history of cholestasis in the newborn is unclear. Conflicting reports exist, with some studies demonstrating an increased incidence of significant cirrhotic liver disease in infants with a history of neonatal cholestasis, while other studies do not demonstrate such an association [33].

Table 1 Liver and biliary complications of cystic fibrosis.

Condition	% Affected
Hepatomegaly	30
Hepatic steatosis	20–60
Neonatal cholestasis	2–38
Focal biliary cirrhosis	10–72
Multilobular cirrhosis	7–20
Cholelithiasis	1–10
Microgallbladder	20–30

Hepatic steatosis

This is characterized histologically by fat infiltration of hepatic parenchymal cells and clinically suggested by a large but soft liver upon palpation. Imaging studies, either ultrasound or computerized tomographic (CT) scan, reveal a liver with fat infiltration. The cause of hepatic steatosis is unknown; however, it has been suggested that steatosis may result from the effect of circulating cytokines on hepatic fatty acid oxidation. Hepatic steatosis has been associated with deficiencies in trace elements, essential fatty acids, diabetes and ethanol use. This lesion may resolve with correction of trace mineral, vitamin or fatty acid deficiencies and optimizing nutritional status. While this lesion is felt to be benign and non-progressive, the recent interest in non-alcoholic steatohepatitis (NASH) as a cause of cirrhosis in adults may lead to a reappraisal of this belief.

Focal biliary cirrhosis

This is characterized by focal areas of cholestasis with bile duct plugging and proliferation. The bile duct plugging by eosinophilic material is in fact considered a pathognomonic lesion in CF. The prevalence of focal biliary cirrhosis can only be established by autopsy data as the lesion is defined by histological criteria and the clinical manifestations may be silent. Focal biliary cirrhosis was identified in 10% of infants who died in the first 3 months of life, in 27% who died after the first year and in 72% of adults [36,37].

Multilobular cirrhosis

This is characterized histologically by extensive portal fibrosis, although often with intervening areas of preserved hepatic tissue. Upon examination, a hard and multilobulated liver suggests the diagnosis. Prospective studies have suggested prevalence rates between 7% and 17% [29,33,38]. It is interesting to note that the majority of patients identified with significant fibrosis in most series were under the age of 14 years. Multilobular cirrhosis rarely results in liver synthetic failure but rather manifests with complications related to portal hypertension. These complications, such as oesophageal varices, ascites, encephalopathy, fatigue, splenomegaly and coagulopathy, may lead to significant morbidity and mortality in these patients.

Biliary tract abnormalities

These are common in CF. A small (micro) or absent gallbladder is found in 20–30% of patients with CF [35]. How an abnormal or absent CFTR protein in biliary epithelium leads to this manifestation is unknown, but it suggests a role for CFTR in normal gallbladder development. Cholelithiasis occurs in 1–10% of patients with CF [38,39] and, being largely composed of calcium bilirubinate, these stones are resistant to dissolution therapy by bile acids.

Diagnosis

It is important to note that, at present, there are no established criteria for the diagnosis of CFALD. The diagnosis rests on a constellation of abnormal findings, including (i) biochemical analysis, (ii) liver examination and (iii) radiographic (ultrasound) studies. Presently, the two most common clinical scenarios to suggest the presence of CFALD are elevated liver enzymes upon routine screening and/or an abnormal liver on physical examination. Either of these findings should therefore prompt further evaluation.

The CF Foundation Hepatobiliary Disease Consensus Guidelines recommend that serum liver enzymes be obtained on a yearly basis [40]. These should include serum bilirubin, alkaline phosphatase, aspartate aminotransferase (AST) and alanine aminotransferase (ALT). If any of these values is greater than 1.5 times the upper limit of normal for age, it has been recommended that the test should be repeated at shorter intervals (3–6 months). Fluctuations in the values of these tests are quite common in CF. However, very high levels (greater than three times normal) or levels persistently elevated on two or more occasions should prompt further evaluation, including tests of liver synthetic function (prothrombin time, albumin, ammonia level). Other causes of liver enzyme elevation (such as medication, toxins, infection, gallstones, etc.) as well as other liver diseases such as biliary atresia, alpha-1-antitrypsin deficiency, autoimmune hepatitis, etc.) should be excluded.

A careful physical examination of the liver should be performed at every visit with special attention to the span, consistency and liver edge. Hepatomegaly is the most important finding to suggest liver involvement in CF and is found in ~ 30% of patients [29,33,34]. However, cor pulmonale or right heart failure may also lead to congestive hepatopathy and hepatomegaly and should always be considered in the patient with chronic lung or heart disease. Additionally, lung hyperexpansion may lead to downward displacement of the liver edge creating the false impression of hepatomegaly. A small and hard liver suggests cirrhosis. An abnormal physical examination should always prompt further evaluation.

Several recent studies suggest that ultrasound may be useful in establishing the diagnosis of CFALD as well as following the progression of disease. A prospective study by Lenaerts *et al.* [41] of 106 patients with CF demonstrated abnormal ultrasound findings in 18%, while a study by Williams *et al.* [42] revealed abnormal findings in 23% of patients undergoing yearly ultrasound examinations. The majority of abnormal findings consisted of a heterogeneous and/or a nodular parenchyma. Interestingly, in both studies, there was a disparity between ultrasound findings and serum liver enzyme levels, with many patients having normal enzyme levels at the time of abnormal ultrasound findings. While these studies suggest that abnormal ultrasound findings may aid in the diagnosis of CFALD, the true sensitivity and specificity of this test remains to be determined. Ultrasound is clearly beneficial in the individual patient to

exclude biliary tract abnormalities including gallstones, bile duct obstruction or stenosis.

The role of liver biopsy in the evaluation of CFALD is still controversial. Arguments *for* include the ability to define the predominant lesion as well as to exclude other causes of liver disease. Arguments *against* include the recognized risk of sampling error due to the heterogeneous distribution of liver lesions, the feeling that there is no need to make a rapid diagnosis as there is no definitive treatment that has been shown to alter outcome, and patients may be at higher risk of complications including pneumothorax (due to lung hyperexpansion) and bleeding (due to dilated hepatic veins in the face of cor pulmonale). Presently, there are no established recommendations regarding the role of liver biopsy in the diagnosis of CFALD.

Given the difficulty in the diagnosis of liver disease in CF, sensitive and specific serum markers to detect liver injury have been sought. Glutathione *S*-transferase B1 [43], high-molecular-mass alkaline phosphatase [44] and serum hyaluronic acid [45], markers of hepatic injury and inflammation, have been shown to be elevated in subsets of CF patients with liver disease, while collagen VI [46], collagen IV, tissue inhibitor of matrix metalloproteinase (TIMP-1) [47] and serum prolyl hydroxylase [48], markers of liver fibrosis, have been shown to be increased in a small number of CF patients with liver disease compared with those without. The use of these serum markers of liver injury, inflammation and fibrosis requires further study to determine their usefulness in screening programmes.

Treatment

The treatment of CFALD is largely supportive as no definitive therapy shown to alter outcome exists. Optimizing nutritional status, avoidance of liver toxic drugs and possibly UDCA therapy remain the cornerstones of the treatment regimen.

Nutrition

An important component of the management of liver disease in CF is optimizing the nutritional state. Overall energy intake requirements may exceed daily recommendations by 20–40%, because of the increased caloric expenditure from chronic lung disease and the increased oxygen consumption associated with cholestasis [49]. Intake of protein should not be restricted in children with CF unless decompensated hepatic failure with encephalopathy is present. To promote intestinal absorption of dietary lipid, infants with cholestasis may require formulas containing medium-chain triglyceride (MCT). Fat-soluble vitamin deficiency is common in CF patients, and monitoring of vitamin status is even more important in the presence of liver disease than in the patient with CF who has pancreatic insufficiency alone [50,51]. The importance of correcting nutritional parameters is demonstrated by the improvement in hepatic steatosis observed in some patients. In fact, in some patients with malnutrition, optimizing nutritional status, correcting trace element and mineral deficiencies and compliance with pancreatic enzyme replacement therapy are associated with resolution of the steatosis.

Ursodeoxycholic acid (UDCA)

While no therapy has yet been shown to alter the course of progression to cirrhosis in CF, UDCA has been shown to improve bile flow and biochemical parameters of liver injury. UDCA may have several mechanisms of action, including improving bile acid-dependent bile flow [52], enrichment of hydrophilic bile acids in the bile acid pool [53], ATP release and purinergic-stimulated increases in secretion [54], a cytoprotective effect [53], stimulation of biliary bicarbonate and Cl^- secretion [17] and immunomodulatory effects [55]. Interestingly, a recent study examining bile acid profiles in CF patients found a higher level of endogenous biliary UDCA in CF patients without liver disease compared with those with CFALD [56]. The authors suggest that the elevated UDCA in CF patients without liver disease may play a possible protective role.

Several trials of UDCA in paediatric patients with CF liver disease have shown significant improvement in biochemical markers of liver injury [57–59], although several studies suggest that higher doses (20 mg/kg/day) of UDCA may be necessary in the treatment of CFALD compared with other cholestatic liver disorders [60]. In addition to improvement in liver blood tests in CF liver disease, radionuclide hepatobiliary scintigraphy documented improved hepatobiliary excretory function after treatment with 15–20 mg/kg/day UDCA for 10–12 months [52], and a 10-year prospective study suggested that UDCA treatment might improve the ultrasound appearance of the liver [61]. In an uncontrolled study of 10 patients with CFALD, UDCA therapy for 2 years improved liver histology, with less inflammation and bile duct proliferation, in seven [62]. Lastly, improved nutritional status of patients with CFALD has been demonstrated after UDCA therapy. Long-term therapy with UDCA has been associated with increases in serum essential fatty acid, retinol and vitamin E levels [63,64]. Despite the improved biochemical, imaging studies and perhaps histological data, definitive data demonstrating that UDCA alters the natural course of liver disease in patients with CF are lacking. Nonetheless, the Cystic Fibrosis Foundation Hepatobiliary Disease Consensus Group recommended that it is 'prudent' to use UDCA in CF patients with evidence of liver disease [40]. Long-term studies demonstrating the effectiveness, optimum dosage and length of treatment are needed.

Endstage CFALD

It is unusual for CFALD to manifest as acute liver failure; rather, the endstages of the disease are manifested by the complications related to portal hypertension (gastrointestinal bleeding, hypersplenism, ascites). Surgical portosystemic shunt and transjugular

portosystemic shunt (TIPS) procedures may be indicated for the management of portal hypertension [65]. In a series by Debray *et al.* [66], elective surgical portosystemic shunt was performed successfully in patients without severe lung disease, allowing for prolonged survival. The efficacy of β-receptor antagonist therapy, as a prophylactic regimen to avoid variceal bleeding, has not been carefully evaluated in CF because of the possible effects of these agents on airway reactivity. Consideration should be given to liver transplantation in patients with life-threatening complications of portal hypertension. Special attention to pulmonary status, bacterial infection and colonization, and nutritional support is essential in these patients. Overall, patient and graft survival in CF appears to be similar to liver transplantation for other indications [67,68].

Acknowledgement

The studies in our laboratory are supported by the National Institute of Diabetes, Digestive and Kidney Diseases (NIDDK) of the National Institute of Health, and by the Cystic Fibrosis Foundation.

References

1 Dodge JA, Morison S, Lewis PA *et al.* (1997) Incidence, population, and survival of cystic fibrosis in the UK, 1968–95. UK Cystic Fibrosis Survey Management Committee. *Arch Dis Child* 77 (6), 493–496.
2 Riordan JR, Rommens JM, Kerem B-S *et al.* (1989) Identification of the cystic fibrosis gene: cloning and characterization of complementary DNA. *Science* 245, 1066–1073.
3 Cohn JA, Strong TA, Picciotto MA *et al.* (1993) Localization of CFTR in human bile duct epithelial cells. *Gastroenterology* 105, 1857–1864.
4 McGill JM, Basavappa S, Gettys TW *et al.* (1994) Secretin activates Cl- channels in bile duct epithelial cells through a cAMP-dependent mechanism. *Am J Physiol* 266 (4 Pt 1), G731–G736.
5 Kunzelmann K, Gerlach L, Frobe U *et al.* (1991) Bicarbonate permeability of epithelial chloride channels. *Pfluegers Arch* 417, 616–621.
6 Schlenker T, Fitz JG (1996) Calcium-activated chloride channels in a human biliary cell line: regulation by calcium/calmodulin-dependent protein kinase. *Am J Physiol* 271, G304–G310.
7 Fitz JG, Basavappa S, McGill J *et al.* (1993) Regulation of membrane chloride currents in rat bile duct epithelial cells. *J Clin Invest* 91, 319–328.
8 Roman RM, Wang Y, Fitz JG (1996) Regulation of cell volume in a human biliary cell line: Calcium-dependent activation of K+ and Cl– currents. *Am J Physiol* 271, G239–G248.
9 McGill J, Gettys TW, Basavappa S *et al.* (1993) GTP-binding proteins regulate high conductance anion channels in rat bile duct epithelial cells. *J Membr Biol* 133, 253–261.
10 Roman RM, Feranchak AP, Salter KD *et al.* (1999) Endogenous ATP regulates Cl^- secretion in cultured human and rat biliary epithelial cells. *Am J Physiol* 276, G1391–G400.
11 Feranchak AP, Roman RM, Doctor RB *et al.* (1999) The lipid products of phosphoinositide 3-kinase contribute to regulation of cholangiocyte ATP and chloride transport. *J Biol Chem* 274, 30979–30986.
12 Clarke LL, Grubb BR, Yankaskas J *et al.* (1994) Relationship of a non-cystic fibrosis transmembrane conductance regulator-mediated chloride conductance to organ-level disease in cftr(–/–) mice. *Proc Natl Acad Sci USA* 91, 479–483.
13 Fitz JG, Basavappa S, McGill J (1991) Ca2+- and cAMP-stimulated Cl– conductances in bile duct epithelial cells: a possible mechanism for ductular secretion. *Hepatology* 14, A416.
14 Feranchak AP, Doctor RB, Troetsch M *et al.* (2004) Calcium-dependent regulation of secretion in biliary epithelial cells: the role of apamin-sensitive SK channels. *Gastroenterology* 127 (3), 903–913.
15 Lazaridis KN, Pham L, Tietz P *et al.* (1997) Rat cholangiocytes absorb bile acids at their apical domain via the ileal sodium-dependent bile acid transporter. *J Clin Invest* 100 (11), 2714–2721.
16 Alpini G, Glaser S, Robertson W *et al.* (1997) Bile acids stimulate proliferative and secretory events in large but not small cholangiocytes. *Am J Physiol* 273 (2 Pt 1), G518–G529.
17 Shimokura GH, McGill J, Schlenker T *et al.* (1995) Ursodeoxycholate increases cytosolic calcium concentration and activates Cl– currents in a biliary cell line. *Gastroenterology* 109, 965–972.
18 Chari RS, Schutz SM, Haebig JA *et al.* (1996) Adenosine nucleotides in bile. *Am J Physiol* 270, G246–G252.
19 Feranchak AP, Fitz JG, Roman RM (2000) Volume-sensitive purinergic signaling in human hepatocytes. *J Hepatol* 33, 174–182.
20 Schlenker T, Romac JMJ, Sharara A *et al.* (1997) Regulation of biliary secretion through apical purinergic receptors in cultured rat cholangiocytes. *Am J Physiol* 273, G1108–G1117.
21 Taylor AL, Schwiebert LM, Smith JJ *et al.* (1999) Epithelial P2x purinergic receptor channel expression and function. *J Clin Invest* 104, 875–884.
22 Wilschanski M, Zielenski J, Markiewicz D *et al.* (1995) Correlation of sweat chloride concentration with classes of the cystic fibrosis transmembrane conductance regulator gene mutations. *J Pediatr* 127 (5), 705–710.
23 De Arce M, O'Brien S, Hegarty J *et al.* (1992) Deletion delta F508 and clinical expression of cystic fibrosis-related liver disease. *Clin Genet* 42 (5), 271–272.
24 Duthie A, Doherty DG, Williams C *et al.* (1992) Genotype analysis for delta F508, G551D and R553X mutations in children and young adults with cystic fibrosis with and without chronic liver disease. *Hepatology* 15 (4), 660–664.
25 Colombo C, Battezzati PM, Crosignani A *et al.* (2002) Liver disease in cystic fibrosis: a prospective study on incidence, risk factors, and outcome. *Hepatology* 36 (6), 1374–1382.
26 Lewindon PJ, Pereira TN, Hoskins AC *et al.* (2002) The role of hepatic stellate cells and transforming growth factor-beta (1) in cystic fibrosis liver disease. *Am J Pathol* 160 (5), 1705–1715.
27 Davis PB (1999) The gender gap in cystic fibrosis survival. *J Gend Specif Med* 2 (2), 47–51.
28 Duthie A, Doherty DG, Donaldson PT *et al.* (1995) The major histocompatibility complex influences the development of chronic liver disease in male children and young adults with cystic fibrosis. *J Hepatol* 23 (5), 532–537.
29 Colombo C, Apostolo MG, Ferrari M *et al.* (1994) Analysis of risk factors for the development of liver disease associated with cystic fibrosis. *J Pediatr* 124 (3), 393–399.
30 Maurage C, Lenaerts C, Weber A *et al.* (1989) Meconium ileus and its equivalent as a risk factor for the development of cirrhosis: an autopsy study in cystic fibrosis. *J Pediatr Gastroenterol Nutr* 9 (1), 17–20.
31 Lindblad A, Strandvik B, Hjelte L (1995) Incidence of liver disease in patients with cystic fibrosis and meconium ileus. *J Pediatr* 126 (1), 155–156.

32 Zielenski J, Corey M, Rozmahel R *et al.* (1999) Detection of a cystic fibrosis modifier locus for meconium ileus on human chromosome 19q13. *Nature Genet* 22 (2), 128–129.

33 Gaskin KJ, Waters DLM, Howman-Giles R *et al.* (1988) Liver disease and common bile duct stenosis in cystic fibrosis. *N Engl J Med* 318, 340–346.

34 Lindblad A, Glaumann H, Strandvik B (1999) Natural history of liver disease in cystic fibrosis. *Hepatology* 30 (5), 1151–1158.

35 Roy CC, Weber AM, Morin CL *et al.* (1982) Hepatobiliary disease in cystic fibrosis: a survey of current issues and concepts. *J Pediatr Gastroenterol Nutr* 1 (4), 469–478.

36 Oppenheimer EH, Esterly JR (1975) Hepatic changes in young infants with cystic fibrosis: possible relation to focal biliary cirrhosis. *J Pediatr* 86 (5), 683–689.

37 Vawter GF, Shwachman H (1979) Cystic fibrosis in adults: an autopsy study. *Pathol Annu* 14 (Pt 2), 357–382.

38 Feigelson J, Anagnostopoulos C, Poquet M *et al.* (1993) Liver cirrhosis in cystic fibrosis – therapeutic implications and long term follow up. *Arch Dis Child* 68 (5), 653–657.

39 Kovesi T, Corey M, Tsui L-C *et al.* (1992) The association between liver disease and mutations of the cystic fibrosis gene. *Pediatr Pulm* 8, 244.

40 Sokol RJ, Durie PR (1999) Recommendations for management of liver and biliary tract disease in cystic fibrosis. Cystic Fibrosis Foundation Hepatobiliary Disease Consensus Group. *J Pediatr Gastroenterol Nutr* 28 (Suppl. 1), S1–13.

41 Lenaerts C, Lapierre C, Patriquin H *et al.* (2003) Surveillance for cystic fibrosis-associated hepatobiliary disease: early ultrasound changes and predisposing factors. *J Pediatr* 143 (3), 343–350.

42 Williams SM, Goodman R, Thomson A *et al.* (2002) Ultrasound evaluation of liver disease in cystic fibrosis as part of an annual assessment clinic: a 9-year review. *Clin Radiol* 57 (5), 365–370.

43 Rattenbury JM, Taylor CJ, Heath PK *et al.* (1995) Serum glutathione S-transferase B1 activity as an index of liver function in cystic fibrosis. *J Clin Pathol* 48 (8), 771–774.

44 Schoenau E, Boeswald W, Wanner R *et al.* (1989) High-molecular-mass ('biliary') isoenzyme of alkaline phosphatase and the diagnosis of liver dysfunction in cystic fibrosis. *Clin Chem* 35 (9), 1888–1890.

45 Wyatt HA, Dhawan A, Cheeseman P *et al.* (2002) Serum hyaluronic acid concentrations are increased in cystic fibrosis patients with liver disease. *Arch Dis Child* 86 (3), (190–193.

46 Gerling B, Becker M, Staab D *et al.* (1997) Prediction of liver fibrosis according to serum collagen VI level in children with cystic fibrosis. *N Engl J Med* 336 (22), 1611–1612.

47 Pereira TN, Lewindon PJ, Smith JL *et al.* (2004) Serum markers of hepatic fibrogenesis in cystic fibrosis liver disease. *J Hepatol* 41 (4), 576–583.

48 Leonardi S, Giambusso F, Sciuto C *et al.* (1998) Are serum type III procollagen and prolyl hydroxylase useful as noninvasive markers of liver disease in patients with cystic fibrosis? *J Pediatr Gastroenterol Nutr* 27 (5), 603–605.

49 Pierro A, Koletzko B, Carnielli V *et al.* (1989) Resting energy expenditure is increased in infants and children with extrahepatic biliary atresia. *J Pediatr Surg* 24 (6), 534–538.

50 Feranchak AP, Sontag MK, Wagener JS *et al.* (1999) Prospective, long-term study of fat-soluble vitamin status in children with cystic fibrosis identified by newborn screen. *J Pediatr* 135 (5), 601–610.

51 Ramsey BW, Farrell PM, Pencharz P (1992) Nutritional assessment and management in cystic fibrosis: a consensus report. The Consensus Committee. *Am J Clin Nutr* 55 (1), 108–116.

52 Colombo C, Castellani MR, Balistreri WF *et al.* (1992) Scintigraphic documentation of an improvement in hepatobiliary excretory function after treatment with ursodeoxycholic acid in patients with cystic fibrosis and associated liver disease. *Hepatology* 15 (4), 677–684.

53 Heuman DM (1993) Hepatoprotective properties of ursodeoxycholic acid. *Gastroenterology* 104 (6), 1865–1870.

54 Nathanson MH, Burgstahler AD, Masyuk A *et al.* (2001) Stimulation of ATP secretion in the liver by therapeutic bile acids. *Biochem J* 358 (Pt 1), 1–5.

55 Calmus Y, Gane P, Rouger P *et al.* (1990) Hepatic expression of class I and class II major histocompatibility complex molecules in primary biliary cirrhosis: effect of ursodeoxycholic acid. *Hepatology* 11 (1), 12–15.

56 Smith JL, Lewindon PJ, Hoskins AC *et al.* (2004) Endogenous ursodeoxycholic acid and cholic acid in liver disease due to cystic fibrosis. *Hepatology* 39 (6), 1673–1682.

57 Colombo C, Battezzati PM, Podda M *et al.* (1996) Ursodeoxycholic acid for liver disease associated with cystic fibrosis: a double-blind multicenter trial. *Hepatology* 23, 1484–1490.

58 Cotting J, Lentze MJ, Reichen J (1990) Effects of ursodeoxycholic acid treatment on nutrition and liver function in patients with cystic fibrosis and longstanding cholestasis. *Gut* 31 (8), 918–921.

59 Galabert C, Montet JC, Lengrand D *et al.* (1992) Effects of ursodeoxycholic acid on liver function in patients with cystic fibrosis and chronic cholestasis. *J Pediatr* 121 (1), 138–141.

60 van de Meeberg PC, Houwen RH, Sinaasappel M *et al.* (1997) Low-dose versus high-dose ursodeoxycholic acid in cystic fibrosis-related cholestatic liver disease. Results of a randomized study with 1-year follow-up. *Scand J Gastroenterol* 32 (4), 369–373.

61 Nousia-Arvanitakis S, Fotoulaki M, Economou H *et al.* (2001) Long-term prospective study of the effect of ursodeoxycholic acid on cystic fibrosis-related liver disease. *J Clin Gastroenterol* 32 (4), 324–328.

62 Lindblad A, Glaumann H, Strandvik B (1998) A two-year prospective study of the effect of ursodeoxycholic acid on urinary bile acid excretion and liver morphology in cystic fibrosis-associated liver disease. *Hepatology* 27 (1), 166–174.

63 Lepage G, Paradis K, Lacaille F *et al.* (1997) Ursodeoxycholic acid improves the hepatic metabolism of essential fatty acids and retinol in children with cystic fibrosis. *J Pediatr* 130 (1), 52–58.

64 Thomas PS, Bellamy M, Geddes D (1995) Malabsorption of vitamin E in cystic fibrosis improved after ursodeoxycholic acid. *Lancet* 346 (8984), 1230–1231.

65 Schuster SR, Shwachman H, Toyama WM *et al.* (1977) The management of portal hypertension in cystic fibrosis. *J Pediatr Surg* 12 (2), 201–206.

66 Debray D, Lykavieris P, Gauthier F *et al.* (1999) Outcome of cystic fibrosis-associated liver cirrhosis: management of portal hypertension. *J Hepatol* 31 (1), 77–83.

67 Fridell JA, Bond GJ, Mazariegos GV *et al.* (2003) Liver transplantation in children with cystic fibrosis: a long-term longitudinal review of a single center's experience. *J Pediatr Surg* 38 (8), 1152–1156.

68 Molmenti EP, Squires RH, Nagata D *et al.* (2003) Liver transplantation for cholestasis associated with cystic fibrosis in the pediatric population. *Pediatr Transplant* 7 (2), 93–97.

16.5 Human hereditary porphyrias

Elisabeth Irene Minder and Xiaoye Schneider-Yin

Introduction

Porphyrias are inborn errors of porphyrin biosynthesis whose endproduct is haem (Fig. 1). Porphyrin synthesis takes place in all organs, particularly in bone marrow and the liver. Porphyrias are marked by acute abdominal colics and/or photosensitivity. Porphyrias characterized by acute crises are called acute (hepatic) porphyrias as opposed to the non-acute porphyrias that comprise hepatic as well as erythropoietic forms [1,2].

Acute porphyrias

The acute porphyric crisis

Acute porphyric crises are seen in the following four porphyrias, listed according to their prevalence: acute intermittent porphyria (AIP), porphyria variegata (PV), hereditary coproporphyria (HC) and aminolaevulinic acid (ALA) dehydratase deficiency (ALAD deficiency). Initial symptoms are abdominal pain,

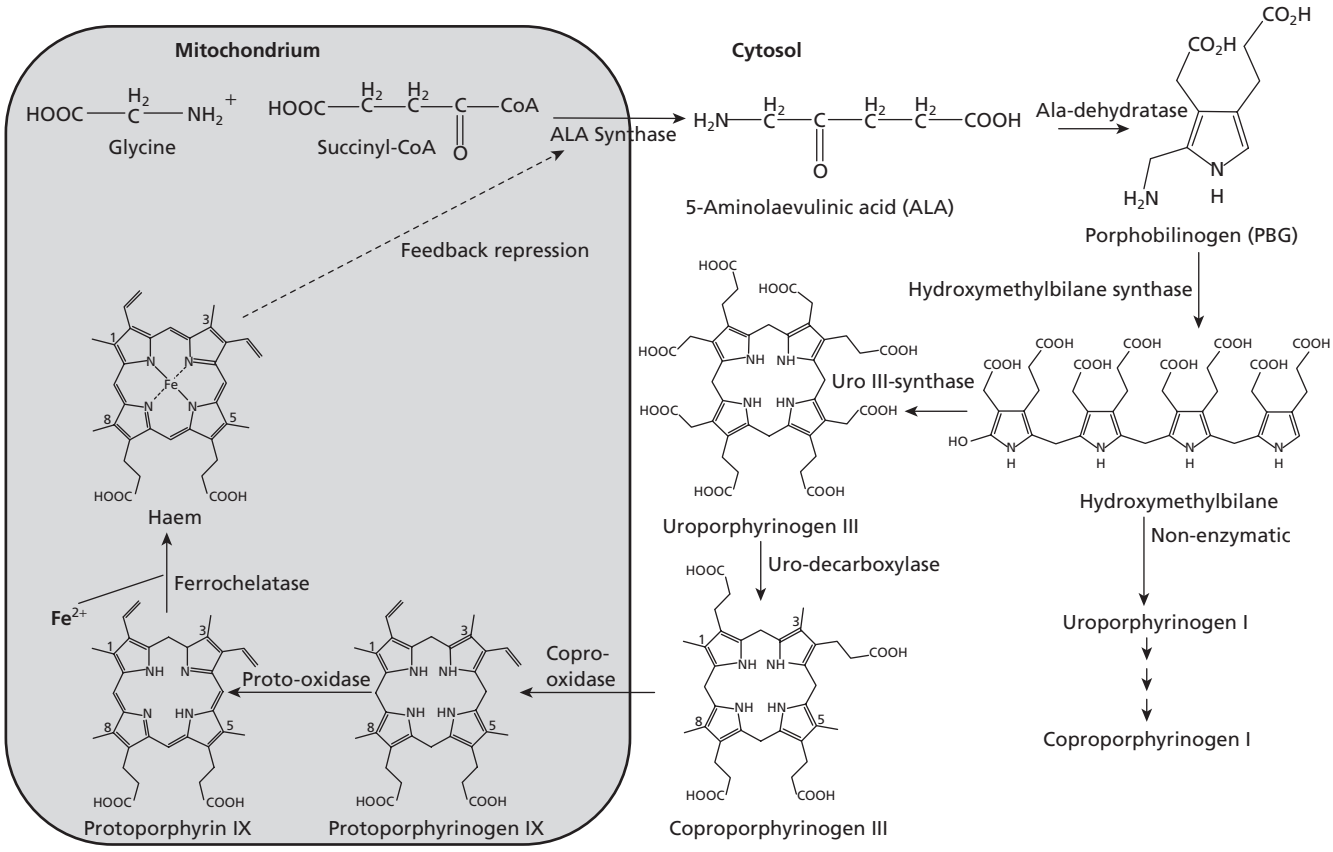

Fig. 1 Haem synthesis pathway.

crampy and diffuse belt-like in the midriff and upper abdomen, with nausea, vomiting and constipation, lasting more than half a day, often several days. Additionally, or in place of abdominal pain, some patients complain of back pain and pain in the proximal muscle groups of the extremities. No signs of peritoneal irritation are seen. Abdominal X-rays show minimal fluid levels, sometimes coprostasis. The patients suffer from insomnia and irritability that eventually precede the abdominal symptoms. On physical examination tachycardia and hypertension are found. Some patients mention a dark urine. But darkening of urine may become noticeable only after it has been standing awhile. A pronounced hyponatraemia is frequently seen, while urine is highly concentrated. In the Accident and Emergency Department, hyponatraemia might not be present initially but only develops later on [3]. Fever, leucocytosis and other signs of infection are rarely seen unless a secondary disorder is present that triggered the porphyria attack. In young women, such porphyria crises often start in the last week before menstruation and disappear on the second day of their menses. Prepubertal children are rarely affected. Abdominal pain can subside spontaneously, or – specifically after the intake of certain drugs – neuronal damage can progress to motor neuropathy, hyper-, dys- and hypaesthesia, epileptic seizures and loss of consciousness. In progressive motor neuropathy, tetraplegia with paralysis of respiratory muscles may develop, requiring artificial ventilation. These symptoms can be confused with those of Guillain–Barré syndrome, particularly as high protein levels in the cerebrospinal fluid (CSF) may be present [4]. Individual cases have been described in which quadriplegia developed within hours after seeming improvement of the abdominal symptoms [5]. The central nervous system can be involved (although infrequently) with magnetic resonance imaging (MRI) lesions similar to those in multiple sclerosis and limited to the white matter. Most probably, they are of vascular origin [6]. Epileptic seizures are seen in about 5% of cases [7,8]. Rarely, they are the first or only symptoms of acute porphyria [9]. In addition to the neurological damage, life-threatening cardiac arrhythmias may develop. Prognostically negative signs are low muscle strength, bulbar paralysis, impaired consciousness, hyponatraemia and mechanical ventilation [10].

Diagnosis of an acute porphyria is best established during the first days of an acute crisis by urinary ALA and porphobilinogen (PBG) (Table 1). Their levels are at least fivefold, more frequently 10- to 20-fold, above the upper limit of normal [1,2,11,12]. Their quantification in a spot urine instead of a 24-h urine speeds up the availability of results. Most qualitative emergency tests for porphobilinogen are suitable only to exclude a porphyria attack because of frequent false-positive results. All three frequent acute porphyrias (AIP, PV and HC) show increased levels of both ALA and PBG, while the rare ALAD deficiency and lead poisoning, which blocks several enzymes of porphyrin synthesis, leads to elevated ALA only. Urinary uroporphyrin and coproporphyrin (~ 90% isomer III) are strongly increased in the three frequent acute porphyrias. In rare ALAD deficiency and in lead poisoning, mainly coproporphyrin III is elevated.

Table 1 Synopsis of the relatively frequent porphyrias.

		ALAD deficiency	AIP	CEP	PCT	HC	PV	EPP
Clinical symptoms	Photosensitivity	None	None	Ulcers and mutilations	Blisters and fragility	Blisters and fragility	Blisters and fragility	Burning pain
	Abdominal pain	Present	Present	None	None	Present	Present	None
Urine	ALA	↑↑[a]	↑↑[a]	Normal	Normal–↑	↑↑[a]	↑↑[a]	Normal
	PBG	Normal[a]	↑↑[a]	Normal	Normal	↑↑[a]	↑↑[a]	Normal
	Uro	Normal[a]	↑↑	↑↑[a]	↑↑[a]	↑↑	↑↑	Normal
	Intermediaries	Normal[a]	↑	↑↑[a]	↑↑[a]	↑	↑	Normal
	Copro I	↑[a]	↑	↑↑[a]	Normal–↑	↑	↑	Normal
	Copro III	↑↑[a]	↑↑	↑[a]	Normal	↑↑	↑↑	Normal
Faeces	Copro I		Normal–(↑)		Normal	(↑)[a]	(↑)	Normal
	Copro III		Normal–(↑)		Normal	↑↑[a]	↑↑	Normal
	Copro III/I ratio		< 2		< 2	> 2[a]	> 2	< 2
	Proto		Normal–(↑)		Normal	Normal	↑↑	↑
Erythrocytes	Uro, Copro			↑↑[a]				Normal
	Proto			↑				↑↑[a]
Additional tests			HMBS activity ↓[a]	Isomer separation[a]	Isocoproporphyrin[a]		Plasma scan[a]	

[a]The diagnostic tests most significant for each porphyria.

ALAD, aminolaevulinate dehydratase; AIP, acute intermittent porphyria; CEP, congenital erythropoietic porphyria; PCT, porphyria cutanea tarda; HC, hereditary coproporphyria; PV, porphyria variegata; EPP, erythropoietic protoporphyria; Uro, uroporphyrin. Intermediaries: heptacarboxy-, hexacarboxy- and pentacarboxyporphyrins. Copro, coproporphyrin; Proto, protoporphyrin IX; HMBS, hydroxymethylbilane synthase.

Diagnosis of recurrent crises

As porphyria patients may excrete increased ALA, PBG and porphyrins in urine during asymptomatic periods, increased urinary levels of these metabolites do not prove an acute crisis *per se*. An increase in ALA and particularly PBG relative to a basal level in a latent phase may ensue. More reliable is the judgement of the patient as he or she knows 'his/her' porphyria symptoms and can distinguish them from non-porphyria-related symptoms. The objective symptoms, hypertension, tachycardia and hyponatraemia, support diagnosis. Porphyria patients may suffer from other intra-abdominal disorders, which must be excluded.

Treatment of an acute crisis

- All non-essential drugs should be stopped. Essential pharmaceuticals should be evaluated for safety. We recommend two databases, the Scandinavian list (http://www.drugs-porphyria.org/) and the South African list (http://web.uct.ac.za/depts/porphyria/common/common%20index.htm). In a life-threatening situation, any life-saving drug, irrespective of safety, must be applied. Patients with acute porphyria react only with several days' delay on an unsafe drug. Thus, there is sufficient time for treatment if a life-saving drug triggers or deteriorates a porphyria attack.
- Sufficient pain relief must be introduced, opiates (e.g. morphine) alone or combined with chlorpromazine (up to 75 mg intravenous per 24 h) or levomepromazine.
- Carbohydrate supply must be sufficient (200 g/day), either parenteral or by frequent peroral intake of sweetened drinks.
- In hospitalized patients, early treatment with haem is indicated [haem arginate (Normosang®) or panhaematin], particularly in constant vomiting [13]. Early treatment with haem is imperative when signs of motor neuropathy are present in order to forestall longlasting convalescence. Haem is administered at a dose of 3–5 mg/kg body weight in a short infusion once every 24 h for 4–5 days. Haem infusions may cause phlebitis. Mixing haem with 4% or 20% albumin solution improves compatibility. The vene should be rinsed with physiological saline. Patients who are often treated with haem need a Port-a-Cath.
- Haem treatment eliminates pain within 2–3 days [14]. When patients already suffer from established neurological impairment, reversal of symptoms is slower and requires months. After severe attacks, residual neurological impairment of the extremities often remains.

Prevention of porphyria crisis

Prophylactic measures include: avoiding unsafe drugs, including non-regulated substances; no fasting, regular intake of carbohydrates; no hormones or hormonal contraceptives; and no alcohol excesses.

We recommend testing the direct blood relatives [1,2,15], as 50% of them will be at risk. The advantage of diagnosing a latent carrier is to implement preventive measures and rapidly to start treatment in case of an attack.

Frequently recurrent and chronic porphyria crises

About 10% of symptomatic porphyria patients experience recurrent attacks or develop chronic symptoms [5]. In frequently recurrent attacks, we try to reduce the haem infusions to one or two doses per attack under adequate analgesia. All precipitating factors, including psychological stress situations, should be rigorously eliminated. Regular premenstrual attacks may be controlled by a minidose contraceptive [16]. The patient must be aware of possible deterioration requiring immediate discontinuation of the hormone therapy. Luteinizing hormone releasing hormone (LHRH) antagonists can be tried with low-dose percutaneous estrogens added after a few months to avoid late damage such as osteoporosis. If the patient does not respond or if the pain becomes chronic, one dose of haem per week can be tried to keep the patient free of pain. In patients whose symptoms no longer respond to haem, liver transplantation might be considered [17,18].

Inheritance mode and penetrance

AIP, PV and HC are autosomal dominant disorders with irregular penetrance, as only some of the heterozygous carriers are affected. Females are more often symptomatic than males. Overt disease is frequent in known AIP families [19–21]. Silent AIP mutation carriers are comparatively frequent within the normal population [22]. The familial clustering of overt disease suggests that other genetic factor(s) affect(s) the outbreak of AIP [23].

Pathogenesis

The acute porphyria crisis is triggered by increased demand for hepatic haem, e.g. by xenobiotics inducing the synthesis of haem containing cytochrome P-450. As a result, intracellular free haem concentration decreases to a level that no longer inhibits the initial and rate-limiting enzyme of haem synthesis, ALA synthase (ALAS). The partial deficiency of an intermediary enzyme, as in the case of acute porphyrias, impedes the process of ALA being metabolized to the physiological endproduct haem, which compounds the drug-induced haem deficiency and leads to a further derepression of ALAS.

All symptoms of a porphyria attack are due to neuronal damage [4]. Abdominal colics with constipation and subileus as well as tachycardia and hypertension are explained by damage to the autonomous nervous system. The motor neuropathy is characterized by axonal damage, demyelinization and chromatolysis of the motoneurons. Haem deficiency or ALA toxicity is considered as the most likely offending factor causing porphyric neuropathy. The hypothesis of haem deficiency is endorsed by a recently constructed knockout mouse model [24,25]. The hypothesis of ALA toxicity is based on clinical observations: ALA is increased in all forms of acute porphyria but in none of the non-acute porphyrias. It is also increased in tyrosinaemia and

lead intoxication, which are both characterized by symptoms similar to acute porphyrias. The hypothesis of ALA toxicity was recently enforced by a study in a rare homozygous AIP case [26]. Nonetheless, even prolonged application of high-dose ALA did not cause any harm to a volunteer.

Primary liver cell carcinoma

AIP, PV and HC carry a risk of primary liver cell carcinoma [27,28]. In women, the relative rate was 110, in men 19. Symptomatic as well as asymptomatic mutation carriers are afflicted. A prospective study in patients older than 55 years shows an incidence of ~ 10% in 10 years. Yearly imaging detected the early stages resulting in improved patient survival [29].

Acute intermittent porphyria (AIP; OMIM 176'000)

AIP is based on a 50% reduced activity of HMBS, the third enzyme in haem biosynthesis (Fig. 1). So far, more than 230 different mutations, mostly family specific, have been described [30]. Some studies postulate a dependence of penetrance rate on the genotype [12,19]. In several countries, one single mutation with high frequency indicated a 'founder effect' [20,31–34]. In one case the 'founder' was estimated to have lived 40 generations ago. Other repeatedly occurring mutations have been identified as 'mutation hotspots' [35].

AIP can be differentiated from other acute porphyrias by a decreased erythrocytic HMBS activity, with both sensitivity and specificity of 94% [20]. False low values might result from improper handling of samples. AIP patients can show false normal values in the acute stage [36] due to decreased lifespan of erythrocytes. If the mutation is in exon 1 of the *HMBS* gene, which affects only the hepatic enzyme, the erythrocytic HMBS activity will remain normal [37]. Faecal porphyrins are normal or only slightly elevated, and the ratio of coproporphyrin III to coproporphyrin I is < 2 in AIP but > 2 in PV and HC [1,36]. Investigation of the *HMBS* gene identifies the underlying mutation in 95% of the cases, providing the basis for family screening.

Porphyria variegata (PV; OMIM 176'200)

PV is characterized by a 50% reduced activity of protoporphyrinogen oxidase, the second last enzyme in haem synthesis (Fig. 1). Besides acute porphyria attacks, photosensitivity may be a symptom in PV (see the section on Photosensitivity below, also Plate 16.5.1, facing p. 1268). Twenty per cent of afflicted persons present with acute symptoms only, 58% with skin symptoms only and the rest with both [38].

In patients with only photosensitivity, PV can be differentiated only biochemically from other porphyrias (Table 1). Specific plasma fluorescence with an emission maximum at 626 nm [39] is of higher sensitivity than the faecal porphyrin analysis [40]. Molecular investigation of the protoporphyrinogen oxidase gene is required for family screening, as biochemical analyses are not sensitive enough to detect all latent mutation carriers. Over 100 mutations of protoporphyrinogen oxidase are published [30]. The long-known South African founder effect has been confirmed by a specific mutation (R59W) [41].

Hereditary coproporphyria (HC; OMIM 121'300)

The affected enzyme in HC is coproporphyrinogen oxidase, the third last enzyme in haem synthesis (Fig. 1). Patients suffering from HC can develop acute attacks, photosensitivity or both. HC seems to be the most benign of the three acute porphyrias. HC, like the other acute porphyrias, is diagnosed on the basis of greatly increased porphyrin precursors (ALA and PBG) during the acute attack.

Biochemically, it differs from the other porphyrias by elevated faecal coproporphyrin, a coproporphyrin III to I ratio of > 2 and a normal faecal protoporphyrin. An isolated increase in coproporphyrins in urine is rarely due to HC but, rather, a secondary interference in porphyrin synthesis, e.g. by alcohol, stress or enzyme-inducing drugs [42]. The identification of a mutation in the coproporphyrinogen oxidase gene enables the search for latent carriers among relatives. Thirty-seven mutations of the coproporphyrinogen oxidase gene are known [36]. HC penetrance might be modulated by a variable expression of the non-mutated allele [43].

Aminolaevulinic acid dehydratase deficiency (ALAD; OMIM 125'270)

This rare porphyria is caused by a homozygous, homo- or heteroallelic defect in the second enzyme of haem synthesis, ALA dehydratase [44] (Fig. 1) with a residual activity below 5%. Symptoms start mostly at birth or in early childhood. Because of the rarity of the disorder – so far only five cases have been published – its description is not comprehensive. ALAD deficiency patients can experience acute porphyria attacks that respond to haem. This form can be differentiated from the other acute porphyrias by the typical urinary porphyrin excretion pattern (see section on The acute porphyric crisis above). An identical urinary porphyrin pattern is seen in lead poisoning. Lead poisoning greatly reduces ALAD activity, which (in contrast to ALAD deficiency) can be reactivated by preincubation with an SH group reagent prior to activity assay [45]. Seven mutations of the *ALAD* gene have been described [30]. Counselling is recommended in affected families as the risk for disease among siblings is 25% and the course of the disorder is often severe with extensive neurological damage and early death.

Non-acute porphyrias

Photosensitivity

Photosensitivity caused by accumulated fluorescent porphyrins leads to skin damage which is limited to light-exposed areas.

Light-induced general symptoms such as headaches, nausea and weakness are not caused by porphyria. Daylight, especially sunlight, is the trigger. Artificial light does not induce symptoms, except for highly energy-rich sources such as operating lamps, which can cause severe damage in certain porphyria forms [46]. The damaging wavelength (in the visible range at 404 nm) is not filtered out by normal glass or UV-blocking sunscreens. Hence, they do not protect from skin damage.

Photosensitivity occurs in two forms. One is an acute, severely painful photodermatosis resulting from short light exposure (5–30 min) and lasting for several days. It is characteristic for erythropoietic protoporphyria (EPP), but also occurs in some cases of congenital erythropoietic porphyria (CEP). The other form is characterized by blisters of 1–2 cm diameter accompanied by a fragile skin (see Plate 16.5.1, facing p. 1268). The fluid-filled blisters appear hours or days after light exposure. They heal slowly and leave scars. It is typical of porphyria cutanea tarda (PCT), PV and HC. In the most severe porphyrias, CEP, hepatoerythropoietic porphyria (HEP) and the rare homozygous forms of PV and HC, blisters progress to chronic infected ulcers that lead to mutilated fingers, nose and ears.

Therapy of photosensitivity

Light exposure must be avoided. Protection is afforded in closed rooms, perhaps darkened when sun enters directly, light-impermeable clothing, covering the face and wearing gloves. In less severe sensitivity, light-reflecting sunscreen lotions and foil on windowpanes that absorbs in the critical range of 404 nm to mitigate the symptoms might be sufficient.

Betacarotene is given in EPP and eventually in homozygous porphyrias [47]. It produces a reddish-brown skin pigmentation, functions as a radical scavenger and thus minimizes the negative effects of fluorescent porphyrins. The dosage depends on the blood level, which should be at 600–800 μg/dL (11–15 μmol/L).

Porphyria cutanea tarda (PCT type 1, OMIM 176'090; PCT type 2, 176'100)

PCT is the most prevalent porphyria. The fourth enzyme in haem biosynthesis, uroporphyrinogen decarboxylase, is affected (Fig. 1). Overproduction of metabolic intermediaries occurs in the liver. PCT is seen in three forms. The most frequent is a sporadic form (type 1) with an enzyme defect limited to the liver. Type 2 is familial based on a heterozygous mutation of uroporphyrinogen decarboxylase with reduced enzyme activity in erythrocytes. Thirdly, a familial form is described with maintained enzyme activity in erythrocytes (type 3). In the familial form, 65 mutations have been described [30], while the sporadic form is considered to be acquired. The disorder starts mainly in the second half of life, in women after menopause [48], but childhood onset is possible. Triggering factors are liver damage, specifically haemosiderosis of the liver, alcohol excesses, chronic hepatitis C and, in women, estrogens. A strong association of PCT with heterozygous and homozygous HFE mutations has been described in several populations [49,50].

Characteristic symptoms are blisters and fragile skin, which are identical to those of other porphyrias. To differentiate PCT from PV, HC and late-onset forms of CEP, biochemical investigations of urine and faeces, eventually plasma scanning, are necessary. The most important laboratory findings are a typical urine porphyrin pattern and isocoproporphyrin in faeces [51]. Plasma scanning might show a peak at 620 nm but none at 626 nm. CEP, whose late-onset form can imitate PCT, shows a similar urinary pattern with prominent I isomers of all porphyrins.

Treatment of PCT

Triggering factors must be eliminated, particularly alcohol consumption and, in women, estrogens which (if indispensable) can be replaced by low-dose percutaneous administration that bypasses the first liver passage [52]. The affected skin areas have to be light protected. Excess liver iron, particularly in a case with homozygous HFE mutation, should be eliminated by phlebotomy until the clinical symptoms disappear or a slight iron anaemia occurs [53]. If bleeding is contraindicated, low-dose chloroquine therapy (2 × 125 mg/week) is recommended. Higher dose chloroquine therapies can provoke acute liver failure in PCT patients [54]. Both treatments require several months before clinical success. Recurrence of symptoms after years is possible and requires renewed therapy. PCT was positively influenced by interferon treatment in cases with hepatitis C as trigger, although patients with hepatitis C and PCT respond less to interferon than those without PCT [55].

Congenital erythropoietic porphyria (CEP; OMIM 263'700)

In contrast to the porphyrias mentioned above, CEP is recessively inherited. So far, only a few hundred patients are known. It is caused by a homozygous or compound heterozygous defect of uroporphyrinogen III synthase, the third enzyme in haem biosynthesis (Fig. 1). As the accumulated intermediate hydroxymethylbilane cyclizes non-enzymatically to form the physiologically no longer utilizable uroporphyrinogen I, this disorder is marked by excessive levels of porphyrin I isomers. As the next enzyme in the synthetic pathway – uroporphyrinogen decarboxylase – is not isomer specific, heptacarboxy-, hexacarboxy-, pentacarboxyporphyrin I, which are some of the intermediary products of uroporphyrinogen decarboxylase, as well as coproporphyrin I, one of the final products of the enzyme, accumulate. The excessive production of porphyrin intermediaries takes place primarily in the bone marrow.

CEP often manifests at birth or even prenatally. But late-onset forms [56] might be more common than previously thought as, in the 7-million Swiss population, four cases of molecular genetically confirmed CEP are known, of whom two patients showed symptoms only in adolescence (E. Minder, unpublished). Without determination of porphyrin isomers, these cases may be falsely diagnosed as PCT.

The early childhood symptomatic CEP runs a severe course. Haemolytic complications can occur prenatally. Postpartum,

these infants can show a haemolytic anaemia with icterus. Early diagnosis can be suspected as their porphyrin-rich urine colours the napkins red. Phototherapy ordered because of the neonatal icterus can lead to extensive and lethal skin burns [57]. Without complete protection from light, i.e. living exclusively in darkened rooms, extensive and chronic skin ulcers develop over the years that lead to severe mutilation. Different degrees of anaemia are seen that are caused by ineffective erythropoiesis and haemolysis. Survival rate in severe cases is limited, but bone marrow transplant can result in a complete cure [58]. Various symptomatic treatments have been described. Enteral absorption of the porphyrins by high-dose charcoal, successful elsewhere, was ineffective in one of our patients [59,60]. Inhibition of erythyropoiesis by transfusion (target level for haemoglobin > 12 g/100 mL) and simultaneous application of hydroxyurea is probably more effective [61].

Molecular genetic evaluation is of some prognostic value as a genotype–phenotype correlation has been described [62]. On the contrary, cases with highly divergent clinical pictures but identical molecular defects have been published [63].

Erythropoietic protoporphyria (EPP; OMIM 177'000)

The enzyme affected in EPP is ferrochelatase (FECH), which catalyses the last step in haem synthesis (Fig. 1). EPP is characterized by an extremely painful photodermatosis, similar to burn pain. If the patient does not withdraw from light, a severe attack develops with pale skin swelling, often accompanied by impairment of the general condition. These painful attacks last for days and can be alleviated to some extent with cold packs and/or painkillers. After severe attacks, sun sensitivity is increased for prolonged periods.

First manifestations usually occur in early childhood, only rarely after 8 years of age. In spring, the symptoms are aggravated because of the sun's increasing irradiance. Improvement is often noticed in pregnant females [64]. As a complication, acute liver failure develops in 2–5% of patients [65].

Diagnosis is based on increased erythrocytic free protoporphyrin, in our experience always exceeding 6 μmol/L (338 μg/100 mL) (reference < 0.2 μmol/L). Further, EPP patients present with a slight normo- to microcytic anaemia with low serum iron and ferritin, suggesting iron deficiency. Nevertheless, iron substitution tends to worsen the symptoms of EPP patients (E. Minder, unpublished) but may be of benefit in particular situations [66].

In EPP, a heterozygous mutation of FECH is present, while most of the mutation carriers are asymptomatic. EPP is usually addressed as autosomal dominant with irregular penetrance, but the term 'pseudorecessive' would be a better description. Siblings are at 25% risk of disease while the preceding and the following generation are mostly free of symptoms [67]. Further, FECH residual activity in asymptomatic mutation carriers is 50%, whereas in EPP patients, it is 30–40%. The molecular reason for this genetic constellation is a low expressed second allele in addition to the mutated FECH allele in EPP patients, while this second allele is normally expressed in asymptomatic mutation carriers [68,69]. As a basis for the lowered expression, a polymorphism localized in intron 3 was found (IVS3-48t→c), leading partially to aberrant mRNA splicing, a premature stop codon of the alternative splice products that are not translated into an active protein. This constellation occurs in 97% of non-consanguineous EPP patients. The remaining 3% are mostly recessive forms of homozygote or compound heterozygous mutations with comparatively high residual activity for at least one of the mutated alleles [70].

Therapy

Avoidance of painful attacks through protection from light exposure is essential. Intake of betacarotene or, alternatively, cysteine works only in some EPP patients. Light exposure training with initially minimal dosage might improve light tolerance, but it is rarely endured by patients with high erythrocytic protoporphyrin (> 30 μmol/L) in our experience.

Liver affections due to protoporphyria

EPP patients with a null allele mutation or with a recessive form are at increased risk of protoporphyrin-induced liver failure [71,72]. Exogenous liver-toxic factors eventually contribute to it [73], as not all patients with null allele mutations develop liver complications.

Bile salts can be tried to augment the biliary protoporphyrin secretion. Liver transplantation may be unavoidable, although this does not cure the metabolic disorder, and protoporphyrin-induced liver damage can recur in the transplant [74].

Rare homozygous forms and mixed forms of known heterozygous porphyrias

A few cases of homozygous variants of the above-mentioned heterozygous porphyrias have been described. Homozygous hetero- or homoallelic AIP manifests at birth or within the first two years of life [26] with psychomotor retardation and variable additional neurological symptoms. The diagnosis is based on elevated urinary ALA, PBG and porphyrins and a low residual erythrocytic HMBS activity. Three of six cases published died within the first decade of life.

Homozygous PV is marked by photosensitivity starting in the first two years of life and variable symptoms (mental retardation, convulsions, skeletal abnormalities, growth retardation and peripheral neuropathy) [75]. There is no correlation between genotype and severity of the non-cutaneous manifestations [76].

Homozygous HC occurs in two forms, harderoporphyria and homozygous HC [77,78]. Harderoporphyria seems to be caused by mutations in amino acids 401–404 of coproporphyrinogen oxidase. This localization apparently inhibits the second decarboxylation step in the conversion of coproporphyrinogen to

protoporphyrinogen, producing harderoporphyrin, which is excreted as tricarboxylated porphyrin in faeces. Harderoporphyria is characterized by neonatal haemolytic anaemia and partially by skin symptoms.

The hepatoerythropoietic porphyria is the homozygous form of familial PCT [79]. The clinical symptoms, its course and the variability are comparable to CEP.

Mixed forms are called 'dual porphyrias', in which PCT is combined with one of the acute porphyrias: PCT and AIP, PCT and PV, or PCT and HC. Dual porphyrias are suspected on the basis of porphyrin patterns that represent a mixture of the two forms involved. Confirmation of the diagnosis requires an enzymatic and/or a molecular genetic proof of the two porphyria forms.

References

1 Sandberg S, Elder GH (2004) Diagnosing acute porphyrias. *Clin Chem* 50, 803–805.

2 Anderson KE, Bloomer JR, Bonkovsky HL *et al.* (2005) Recommendations for the diagnosis and treatment of the acute porphyrias. *Ann Intern Med* 142, 439–450.

3 Liu YP, Lien WC, Fang CC (2005) ED presentation of acute porphyria. *Am J Emerg Med* 23, 164–167.

4 Albers JW, Fink JK (2004) Porphyric neuropathy. *Muscle Nerve* 30, 410–422.

5 Hift RJ, Meissner PN (2005) An analysis of 112 acute porphyric attacks in Cape Town, South Africa. Evidence that acute intermittent porphyria and variegate porphyria differ in susceptibility and severity. *Medicine* 84, 48–60.

6 Bylesjo I, Brekke OL, Prytz J *et al.* (2004) Brain magnetic resonance imaging white-matter lesions and cerebrospinal fluid findings in patients with acute intermittent porphyria. *Eur Neurol* 51, 1–5.

7 Bylesjö I, Forsgren L, Lithner F *et al.* (1996) Epidemiology and clinical characteristics of seizures in patients with acute intermittent porphyria. *Epilepsia* 37, 230–235.

8 Reynolds NC (1982) Seizure management and hepatic porphyrias. *Neurology* 32, 1409–1410.

9 Winkler AS, Peters TJ, Elwes RD (2005) Neuropsychiatric porphyria in patients with refractory epilepsy: report of three cases. *J Neurol Neurosurg Psychiatr* 76, 380–383.

10 Pischik E, Bulyanitsa A, Kazakov V *et al.* (2004) Clinical features predictive of a poor prognosis in acute porphyria. *J Neurol* 251, 1538–1541.

11 European Porphyria Initiative (2005) http://www.porphyria-europe.com/ (accessed June 2005).

12 von und zu Fraunberg M, Pischik E, Udd L *et al.* (2005) Clinical and biochemical characteristics and genotype-phenotype correlation in 143 Finnish and Russian patients with acute intermittent porphyria. *Medicine* 84, 35–47.

13 Mustajoki P, Nordmann Y (1993) Early administration of heme arginate for acute porphyric attacks. *Arch Intern Med* 153, 2004–2008.

14 Herrick AL, McColl KE, Moore MR *et al.* (1989) Controlled trial of haem arginate in acute hepatic porphyria. *Lancet* 1 (8650), 1295–1297.

15 Bonkovsky HL, Barnard GF (1998) Diagnosis of porphyric syndromes: a practical approach in the era of molecular biology. *Semin Liver Dis* 18, 57–66.

16 Gross U, Honcamp M, Daume E *et al.* (1995) Hormonal oral contraceptives, urinary porphyrin excretion and porphyrias. *Horm Metab Res* 27, 379–383.

17 Soonawalla ZF, Orug T, Badminton MN *et al.* (2004) Liver transplantation as a cure for acute intermittent porphyria. *Lancet* 363 (9410), 705–706.

18 Stojeba N, Meyer C, Jeanpierre C *et al.* (2004) Recovery from variegate porphyria by liver transplantation. *Liver Transpl* 10, 935–938.

19 Andersson C, Floderus Y, Wikberg A *et al.* (2000) The W198X and R173W mutations in the porphobilinogen deaminase gene in acute intermittent porphyria have higher clinical penetrance than R167W. *Scand J Clin Lab Invest* 60, 833–638.

20 Schuurmans MM, Schneider-Yin X, Rufenacht UB *et al.* (2001) Influence of age and gender on the clinical expression of acute intermittent porphyria based on molecular study of porphobilinogen deaminase gene among Swiss patients. *Mol Med* 7, 535–542.

21 De Siervi A, Rosetti MV, Parera VE *et al.* (1999) Acute intermittent porphyria: biochemical and clinical analysis in the Argentinean population. *Clin Chim Acta* 288, 63–71.

22 Nordmann Y, Puy H, Da Silva V *et al.* (1997) Acute intermittent porphyria: prevalence of mutations in the porphobilinogen deaminase gene in blood donors in France. *J Intern Med* 242, 213–217.

23 Grandchamp B (1998) Acute intermittent porphyria. *Semin Liver Dis* 18, 17–24.

24 Lindberg RLP, Porcher C, Grandchamp B *et al.* (1996) Porphobilinogen deaminase deficiency in mice causes a neuropathy resembling that of human hepatic porphyria. *Nature Genet* 12, 195–199.

25 Jover R, Hoffmann F, Scheffler-Koch V *et al.* (2000) Limited heme synthesis in porphobilinogen deaminase-deficient mice impairs transcriptional activation of specific cytochrome P450 genes by phenobarbital. *Eur J Biochem* 267, 7128–7137.

26 Solis C, Martinez-Bermejo A, Naidich T *et al.* (2004) Acute intermittent porphyria. Studies of the severe homozygous dominant disease provides insights into the neurologic attacks in acute porphyrias. *Arch Neurol* 61, 1764–1770.

27 Lithner F, Wetterberg L (1984) Hepatocellular carcinoma in patients with acute intermittent porphyria. *Acta Med Scand* 215, 271–274.

28 Andant C, Puy H, Bogard C *et al.* (2000) Hepatocellular carcinoma in patients with acute hepatic porphyria: frequency of occurrence and related factors. *J Hepatol* 32, 933–939.

29 Holmgren M, Andersson C (2005) Does screening for hepatocellular carcinoma benefit patients with acute intermittent porphyria? Abstract. Conference on Porphyrins and Porphyrias, Cape Town. http://www.porphyria-europe.com/02-for-healthcare/abstracts/abstractforms.asp/ (accessed June 2005).

30 Human Gene Mutation Database (2005) http://www.hmgd.cf.ac.uk/ (accessed June 2005).

31 Lee JS, Anvret M (1991) Identification of the most common mutation within the porphobilinogen deaminase gene in Swedish patients with acute intermittent porphyria. *Proc Natl Acad Sci USA* 88, 10912–10915.

32 De Siervi A, Rosetti MV, Parera VE *et al.* (1999) Identification and characterization of hydroxymethylbilane synthase mutations causing acute intermittent porphyria: evidence for an ancestral founder of the common G111R mutation. *Am J Med Genet* 86, 366–375.

33 Greene-Davis ST, Neumann PE, Mann OE *et al.* (1997) Detection of a R173W mutation in the porphobilinogen deaminase gene in the Nova Scotian 'foreign Protestant' population with acute intermittent porphyria: a founder effect. *Clin Biochem* 30, 607–612.

34 Schneider-Yin X, Hergersberg M, Goldgar D *et al.* (2002) Ancestral founder of mutation W283X in the porphobilinogen deaminase gene among acute intermittent porphyria patients. *Hum Hered* 54, 69–81.

35 Schneider-Yin X, Hergersberg M, Schuurmans MM *et al.* (2004) Mutation hotspots in the human porphobilinogen deaminase gene: recurrent mutations G111R and R173Q occurring at CpG motifs. *J Inherit Metab Dis 27*, 625–631.

36 Minder EI (1993) Coproporphyrin isomers in acute-intermittent porphyria. *Scand J Clin Lab Invest* 53, 87–90.

37 Grandchamp B, Picat C, Kauppinen R *et al.* (1989) Molecular analysis of acute intermittent porphyria in a Finnish family with normal erythrocyte porphobilinogen deaminase. *Eur J Clin Invest* 19, 415–418.

38 Whatley SD, Puy H, Morgan RR *et al.* (1999) Variegata porphyria in western Europe: identification of PPOX gene mutations in 104 families, extent of allelic heterogeneity, and absence of correlation between phenotype and type of mutation. *Am J Hum Genet* 65, 984–994.

39 Long C, Smyth SJ, Woolf J *et al.* (1993) Detection of latent variegate porphyria by fluorescence emission spectroscopy of plasma. *Br J Dermatol* 129, 9–13.

40 Hift RJ, Davidson BP, Van der Hoft C *et al.* (2004) Plasma fluorescence scanning and fecal porphyrin analysis for the diagnosis of variegate porphyria: precise determination of sensitivity and specificity with the detection of protoporphyrinogen oxidase mutations as a standard. *Clin Chem* 50, 915–923.

41 Meissner PN, Dailey TA, Hift RJ *et al.* (1996) A R59W mutation in human protoporphyrinogen oxidase results in decreased enzyme activity and is prevalent in South Africans with variegate porphyria. *Nature Genet* 13, 95–97.

42 McColl KE, Moore MR, Thompson GG *et al.* (1981) Abnormal haem biosynthesis in chronic alcoholics. *Eur J Clin Invest* 11, 461–468.

43 Gouya L, Puy H, Robreau AM *et al.* (2004) Modulation of penetrance by the wild-type allele in dominantly inherited erythropoietic protoporphyria and acute hepatic porphyrias. *Hum Genet* 114, 256–262.

44 Doss M, von Tiepermann R, Schneider J *et al.* (1979) New type of hepatic porphyria with porphobilinogen synthase defect and intermittent acute clinical manifestation. *Klin Wochenschr* 57, 1123–1127.

45 Granick JL, Sassa S, Granick S *et al.* (1973) Studies in lead poisoning. II. Correlation between the ratio of activated to inactivated delta-aminolevulinic acid dehydratase of whole blood and the blood lead level. *Biochem Med* 8, 149–159.

46 Meerman L, Verwer R, Slooff MJ *et al.* (1994) Perioperative measures during liver transplantation for erythropoietic protoporphyria. *Transplantation* 57, 155–158.

47 Mathews-Roth MM (1984) Treatment of erythropoietic protoporphyria with beta-carotene. *Photodermatology* 1, 318–321.

48 Nishioka E, Funasaka Y, Bito T *et al.* (2003) Porphyria cutanea tarda with postmenopausal exacerbation: the possible role of menstruation as natural phlebotomy. *J Am Acad Dermatol* 49, 547–550.

49 Kushner JP, Edwards CQ, Dadone MM *et al.* (1985) Heterozygosity for HLA-linked hemochromatosis as a likely cause of the hepatic siderosis associated with sporadic porphyria cutanea tarda. *Gastroenterology* 88, 1232–1238.

50 Roberts AG, Whatley SD, Nicklin S *et al.* (1997) The frequency of hemochromatosis-associated alleles is increased in British patients with sporadic porphyria cutanea tarda. *Hepatology* 25, 159–161.

51 Elder GH (1975) Differentiation of porphyria cutanea tarda symptomatica from other types of porphyria by measurement of isocoproporphyrin in faeces. *J Clin Pathol* 28, 601–607.

52 Bulaj ZJ, Franklin MR, Phillips JD *et al.* (2000) Transdermal estrogen replacement therapy in postmenopausal women previously treated for porphyria cutanea tarda. *J Lab Clin Med* 136, 482–488.

53 Stölzel U, Köstler E, Schuppan D *et al.* (2003) Hemochromatosis (HFE) gene mutations and response to chloroquine in porphyria cutanea tarda. *Arch Dermatol* 139, 309–313.

54 Goerz G, Krieg T, Eichenauer MG (1976) Accident in treatment of porphyria cutanea tarda by chloroquine (Resochin). *Arch Dermatol Res* 255, 169–176.

55 Fernandez I, Castello G, de Salamanca RE *et al.* (2003) Porphyria cutanea tarda as a predictor of poor response to interferon alfa therapy in chronic hepatitis C. *Scand J Gastroenterol* 38, 314–319.

56 Deybach JC, de Verneuil H, Phung N *et al.* (1981) Congenital erythropoietic porphyria (Gunther's disease): enzymatic studies on two cases of late onset. *J Lab Clin Med* 97, 551–558.

57 Tonz O, Vogt J, Filippini L *et al.* (1975) Severe light dermatosis following photo therapy in a newborn infant with congenital erythropoietic uroporphyria. *Helv Paediatr Acta* 30, 47–56.

58 Shaw PH, Mancini AJ, McConnell JP *et al.* (2001) Treatment of congenital erythropoietic porphyria in children by allogeneic stem cell transplantation: a case report and review of the literature. *Bone Marrow Transplant* 27, 101–105.

59 Pimstone NR, Gandhi SN, Mukerji SK (1987) Therapeutic efficacy of oral charcoal in congenital erythropoietic porphyria. *N Engl J Med* 316, 390–393.

60 Minder EI, Schneider-Yin X, Moll F (1994) Lack of effect of oral charcoal in congenital erythropoietic porphyria. *N Engl J Med* 330, 1092–1094.

61 Guarini L, Piomelli S (1994) Hydroxyurea in congenital erythropoietic porphyria. *N Engl J Med* 330, 1091–1092.

62 Warner CA, Yoo HW, Roberts AG *et al.* (1992) Congenital erythropoietic porphyria: identification and expression of exonic mutations in the uroporphyrinogen III synthase gene. *J Clin Invest* 89, 693–700.

63 Ged C, Megarbane H, Chouery E *et al.* (2004) Congenital erythropoietic porphyria: report of a novel mutation with absence of clinical manifestation in a homozygous mutant sibling. *J Invest Dermatol* 123, 589–591.

64 Bewley AP, Keefe M, White J (1998) Erythropoietic protoporphyria improving during pregnancy. *Br J Dermatol* 139, 145–147.

65 Bloomer JR, Phillips MJ, Davidson DL *et al.* (1975) Hepatic disease in erythropoietic protoporphyria. *Am J Med* 58, 869–882.

66 Gordeuk VR, Brittenham CM, Hawkins CW *et al.* (1986) Iron therapy for hepatic dysfunction in erythropoietic protoporphyria. *Ann Intern Med* 205, 27–31.

67 Went LN, Klasen EC (1984) Genetic aspects of erythropoietic protoporphyria. *Ann Hum Genet* 48, 105–117.

68 Gouya L, Deybach JC, Lamoril J *et al.* (1996) Modulation of the phenotype in dominant erythropoietic protoporphyria by a low expression of the normal ferrochelatase allele. *Am J Hum Genet* 58, 292–299.

69 Gouya L, Puy H, Robreau AM *et al.* (2002) The penetrance of dominant erythropoietic protoporphyria is modulated by expression of wildtype FECH. *Nature Genet* 30, 27–82 30.

70 Whatley SD, Mason NG, Khan M *et al.* (2004) Autosomal recessive erythropoietic protoporphyria in the United Kingdom: prevalence and relationship to liver disease. *J Med Genet* 41, e105.

71 Sarkany RP, Alexander GJ, Cox TM (1994) Recessive inheritance of erythropoietic protoporphyria with liver failure. *Lancet* 344, 958–959.

72 Minder EI, Gouya L, Schneider-Yin X *et al.* (2002) A genotype-phenotype correlation between null-allele mutations in the ferrochelatase

gene and liver complication in patients with erythropoietic protoporphyria. *Cell Mol Biol (Noisy-le-grand)* 48, 91–96.

73 Bonkovsky HL, Schned AR (1986) Fatal liver failure in protoporphyria. Synergism between ethanol excess and the genetic defect. *Gastroenterology* 90, 191–201.

74 Bloomer JR, Rank JM, Payne WD *et al.* (1996) Follow-up after liver transplantation for protoporphyric liver disease. *Liver Transpl Surg* 2 (4), 269–275.

75 Hift RJ, Meissner PN, Todd G *et al.* (1993) Homozygous variegate porphyria: an evolving clinical syndrome. *Postgrad Med J* 69, 781–786.

76 Roberts AG, Puy H, Dailey TA *et al.* (1998) Molecular characterization of homozygous variegate porphyria. *Hum Mol Genet* 7 (11), 1921–1925.

77 Nordmann Y, Grandchamp B, de Verneuil H *et al.* (1983) Harderoporphyria: a variant hereditary coproporphyria. *J Clin Invest* 72, 1139–1149.

78 Lamoril J, Puy H, Whatley SD *et al.* (2001) Characterization of mutations in the CPO gene in British patients demonstrates absence of genotype–phenotype correlation and identifies relationship between hereditary coproporphyria and harderoporphyria. *Am J Hum Genet* 68, 1130–1138.

79 de Verneuil H, Grandchamp B, Romeo P *et al.* (1986) Molecular analysis of uroporphyrinogen decarboxylase deficiency in a family with two cases of hepatoerythropoietic porphyria. *J Clin Invest* 77, 431–435.

16.6 Hyperbilirubinaemia

Peter L.M. Jansen

Introduction

Jaundice or icterus denotes a yellow discoloration of eyes and skin caused by the accumulation of bilirubin. To the old Greek, 'ikteros' was a yellow oriole (genus *Icterus*), and it was thought that, by gazing at this bird a jaundiced patient could transfer his yellow colour to the bird. Unfortunately, therapy of jaundice is not as simple as that. First of all, therapy very much depends on the diagnosis. Of all probabilities, an adult patient with jaundice has the greatest chance of having a bile duct obstructed by a stone or a tumour. In the second place comes liver disease with, as first possibility, acute viral hepatitis and drug-induced cholestasis. Decompensated liver cirrhosis, primary biliary cirrhosis, primary sclerosing cholangitis and genetic diseases are less frequent. Severe haemolysis can also cause jaundice but, in this case, the yellow tinge is usually lighter than the dark yellow colour of patients with liver disease. Neonatal jaundice and Gilbert syndrome are also frequent causes of jaundice. In the case of Gilbert syndrome, the jaundice is not severe and variable. In neonatal jaundice, haemolysis and in Gilbert syndrome, the jaundice is caused by unconjugated bilirubin; in the case of bile duct obstruction or liver disease, bilirubin is predominantly conjugated.

Bilirubin is the breakdown product of haem. It is a linear molecule that is formed by the oxidative opening of the α-methene bridge at the IX position of the haem tetrapyrrole ring structure. This is catalysed by the microsomal enzyme haem oxygenase. The immediate product of this reaction is biliverdin IXα, which is converted to bilirubin IXα by biliverdin reductase. With the opening of the ring structure, one molecule of iron and one molecule of carbon monoxide are released per molecule of biliverdin. Traditionally, bilirubin is regarded as a waste product formed in the spleen and the reticuloendothelial system. Recently, it has become clear that bilirubin may serve a useful biological function. As a reducing agent, bilirubin protects cells against oxidative stress [1]. Although most bilirubin is formed in the spleen, all tissues are able to produce bilirubin and, in these tissues, not just the endothelial cells and macrophages but also parenchymal cells produce low amounts of bilirubin. The enzymes responsible for biliverdin production are the haem oxygenases. There are two forms of haem oxygenase: the inducible endoplasmic reticulum (ER) enzyme haem oxygenase I (HO-1 or heat shock protein, HSP-32) and haem oxygenase II, an enzyme that is constitutively expressed in mitochondria of brain, testes, endothelium, liver, distal nephron and gut [2].

In the circulation, bilirubin is bound to albumin. Free unbound bilirubin is taken up in the liver across the basolateral or sinusoidal membrane. In human liver, this uptake is partly mediated by OATP-C, a member of the solute carrier family of membrane transport proteins [3]. Bilirubin, to some extent, may also be taken up by passive diffusion. In hepatocytes, bilirubin is bound to cytosolic binding proteins such as ligandin. Water-insoluble bilirubin is conjugated by microsomal UDP-glucuronosyltransferase UGT1A1 to the water-soluble monoglucuronide and diglucuronide [4]. These molecules are secreted into bile. This is mediated by the canalicular transport protein MRP2 [5], a member of the ATP-binding cassette (ABC) transport proteins. With bile, the bilirubin conjugates move to the lumen of the intestine where they are deconjugated and degraded by the intestinal microflora to a series of colourless urobilinogens and yellow urobilins, the urobilinoids. A fraction of these is reabsorbed to be resecreted into bile and urine. The remaining metabolites are excreted with the faeces.

Genetic and acquired causes of reduced secretion, conjugation, uptake or overproduction are underlying causes of hyperbilirubinaemia or jaundice. For practical purposes, it is important to realize that, on the basis of haemolysis, total serum bilirubin seldom rises above 100–150 μmol/L (6–9 mg/dL) [6]. Higher values indicate liver disease, bile duct obstruction or conjugation defects.

Clinical chemistry

Automated methods for the determination of unconjugated and conjugated bilirubin are still based on the traditional diazo reaction developed in the early 1950s. In this reaction, the diazonium salt of sulphanilic acid reacts directly with conjugated bilirubin to form dipyrrolic azopigments that can be measured

photometrically. Unconjugated bilirubin only reacts with the diazo reagent in the presence of a so-called reaction accelerator, alcohol or caffeine. This is the basis of the Hijmans van den Bergh reaction. 'Direct' bilirubin is a measure of conjugated bilirubin, and 'indirect' bilirubin is a measure of unconjugated bilirubin. Indirect bilirubin is the value obtained by subtracting 'direct' (without accelerator) from 'total' bilirubin (with accelerator). Although this is by far the most popular method of measuring bilirubin, it is not very accurate. Thus, although Gilbert syndrome is a form of unconjugated hyperbilirubinaemia, a low percentage of 'direct' bilirubin at moderately elevated levels of total bilirubin does not exclude Gilbert syndrome. Other methods have been developed that measure bilirubin and its various conjugates more accurately. High-performance liquid chromatography (HPLC) is both sensitive and specific. With this technique, one not only measures unconjugated bilirubin, the mono- and the diglucuronide, but also other sugar conjugates such as mono- and diglucoside conjugates, mixed glucuronide/glucoside conjugates and degradation products [7,8]. For daily practice, this technique is too difficult. As free unconjugated bilirubin is toxic to the brain, particularly in neonates, tests have been developed to measure this in serum. Some of these tests depend on the peroxidation of free unbound bilirubin. However, none of these tests is really satisfactory and they are seldom used. When dealing with bilirubin, it is important to realize that bilirubin is light sensitive. Upon standing in a lighted room, it is rapidly degraded.

Haemolysis in neonates can be assessed accurately by measuring carbon monoxide in respiratory air by gas chromatography or by measuring carboxyhaemoglobin in blood [9,10]. For monitoring bilirubin levels in neonates, transcutaneous bilirubinometry by reflectance spectrophotometry is useful as it obviates the need for frequent blood sampling [11].

Before radiological or endoscopic diagnosis of bile duct obstruction became popular, the clinician was dependent on laboratory tests. The complete absence of urinary urobilin in a jaundiced patient is an indication of total bile duct obstruction with complete interruption of the enterohepatic cycle. No bilirubin conjugates reach the intestine under these conditions and therefore no urobilin is produced. In haemolytic states, there is a more intense enterohepatic cycling with increased amounts of urobilin in the urine.

Is bilirubin toxic or beneficial?

In neonates, bilirubin is toxic to the brain. When the concentration of unconjugated bilirubin in plasma exceeds the binding capacity of albumin, or when bilirubin bound to albumin is replaced by drugs, free bilirubin can traverse the blood–brain barrier to accumulate in the basal nuclei. This will cause kernicterus, an irreversible condition characterized by severe mental and motor disability. The nature of bilirubin toxicity is incompletely understood. By perturbing the mitochondrial membrane, bilirubin may impair the mitochondrial redox potential and inhibit oxidative phosphorylation [12–14]. Bilirubin may also induce apoptosis [14,15]. Kernicterus is particularly feared in immature neonates with severe neonatal jaundice. However, it can also occur in adults. This is rare and has only been observed in patients with Crigler–Najjar syndrome [16]. There is no evidence for any toxicity of conjugated bilirubin.

Current evidence indicates that unconjugated bilirubin in low concentration may be beneficial. Bilirubin itself is rapidly oxidized and therefore is a powerful antioxidant [17]. Because of this capacity, it may protect cells against oxidative stress [18]. Oxidative stress has been recognized to play a role in a great number of inflammatory and metabolic diseases and in carcinogenesis. Proof for a possible beneficial role of bilirubin comes from epidemiological and experimental studies. Epidemiological data show an inverse relation between serum bilirubin levels and the incidence of cardiovascular disease (in men) and colorectal cancer; experimental data have provided evidence for a protective role of bilirubin in protection against ischaemic–reperfusion injury in heart and small bowel transplantation [19–24]. Bilirubin also appears to protect against oxidative stress-associated injury in inflammatory bowel disease [25]. These findings have led to attempts to decrease ischaemia–reperfusion injury and postmyocardial infarction tissue damage by the therapeutic delivery of the *haem oxygenase I* gene [26,27]. Induction of HO-1 in liver or kidney grafts before transplantation resulted in prolonged survival of recipient rats [28,29]. HO-1 constitutes a triple bonus: it converts and detoxifies pro-oxidant haem, and it produces antioxidant bilirubin and carbon monoxide, which has vasodilatory properties at low concentration.

Conjugation

UDP-glucuronosyltransferases (UGTs) in the ER of hepatocytes belong to a family of enzymes that catalyse the conjugation of endobiotics and drugs with glucuronic acid. The UGT superfamily belongs to group II biotransformation enzymes. Conjugation converts lipophilic agents into more hydrophilic compounds that are secreted via urine or bile. Conjugation also inactivates drugs and detoxifies toxins. The UGT superfamily consists of three enzyme families, UGT1, UGT2 and UGT8. *UGT1* is a complex gene on chromosome 2q37 with 13 different unique exons encoding the N-terminal domain of at least nine UGT1A enzyme proteins. The N-terminal domain confers substrate specificity to the enzyme. During transcription, these different exon 1s are spliced to exons 2–5, which encode a common carboxy-terminal domain. This domain contains the UDP-glucuronic acid binding site and a membrane-spanning domain. UGT1A1 is the bilirubin-conjugating enzyme [30]. This enzyme is also active towards 17α-ethinylestradiol, irinotecan, PhiP (a heterocyclic amine in the diet), paracetamol and other phenols [31,32]. Absence of UGT1A1 activity causes jaundice but does not lead to untoward sensitivity for paracetamol intoxication. This is due to the fact that at least three members of the UGT1

family are active towards paracetamol [33]. Although UGT1A1 has some activity in extrahepatic tissues, its main activity is in the liver. A variable expression of UGT1A1 was found in gastric mucosa and the small intestine [34,35]. Rat and dog kidneys, but not human kidneys, display some glucuronidation activity towards bilirubin [36].

Promoter polymorphisms have been shown to affect enzyme activity. The most prevalent of these is a TATAA box polymorphism. The *UGT1A1* promoter region contains a TATAA box that normally contains six TA repeats with $(TA)_6$TAA as general structure. A prolonged $(TA)_7$TAA box is associated with decreased enzyme activity [37,38]. *UGT1A1* genes with a $(TA)_8$TAA box or a $(TA)_5$TAA box encode fewer and more active enzymes respectively [39]. Patients with Gilbert syndrome are homozygous for the $(TA)_7$TAA allele. *UGT1A1* with the $(TA)_7$TAA promoter allele is called *UGT1A1*28*.

Regulation of UGT1A1

UGT1A1 expression is regulated by the nuclear hormone receptors PXR (pregnane X receptor) and CAR (constitutive androstane receptor) [40,41]. These transcription factors have a major role in protection against adverse side-effects of drugs. Upon exposure to appropriate ligands, they activate the expression of a number of cytochrome P-450 enzymes, UDP-glucuronosyltransferases and canalicular and basolateral ABC transporters. Rifampicin, ritonavir and clotrimazole are PXR ligands and potent stimulators of UGT1A1 expression in human hepatocytes. Phenobarbital and phenytoin are CAR ligands; they also stimulate UGT1A1 in human hepatocytes, but to a lesser extent.

Hepatic transport

Free unbound bilirubin is taken up from the circulation into hepatocytes (Fig. 1). Albumin does not enter these cells. In humans, the uptake of bilirubin is mainly mediated by OATP2 [3]. This protein is a member of the solute carrier (SLCs) family of proteins. They mediate uptake from blood to liver by facilitated diffusion. Electroneutrality is maintained by counter-transport of negatively charged ions.

In the liver, bilirubin is bound to a binding protein called ligandin. This protein has a double function; it is also a glutathione transferase [42]. How bilirubin is transported within hepatocytes is not clear. Bilirubin is conjugated in the ER. Circumstantial evidence indicates that, after conjugation, the reaction products are released at the inside of the ER channel. How the conjugates travel from the ER lumen to the canalicular membrane is unclear.

MRP2 (ABCC2) is an ATP-dependent transport protein that mediates the transport of bilirubin conjugates from hepatocyte to bile [43–45]. It is a multispecific organic anion transporter (hence its original name cMOAT) that transports a great number of organic anions. Unconjugated bilirubin is not a substrate for this transporter; bilirubin needs to be conjugated before it can be secreted into bile. The transporter accepts mono- and diconjugated bilirubin as substrate without preference. In the intestine, conjugated bilirubin is deconjugated by β-glucuronidase and is then converted to urobilinoids.

The nuclear hormone receptors PXR and CAR play important roles in the upregulation of MRP2 and MRP3 expression. Thus, these factors not only regulate bilirubin glucuronidation by upregulating *UGT1A1* expression, they also stimulate the efflux

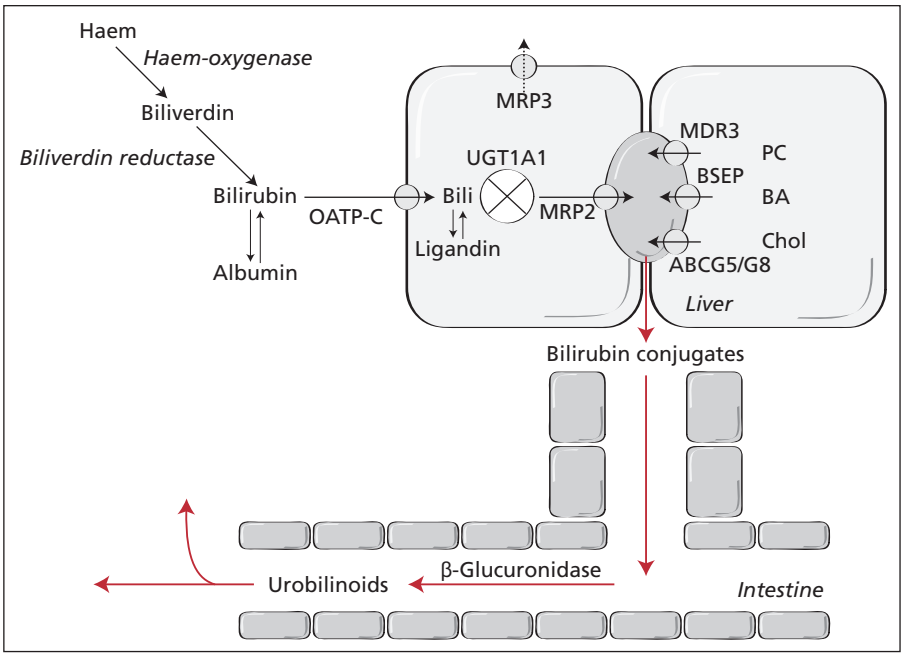

Fig. 1 Bilirubin metabolism in liver and intestine. PC, phosphatidylcholine; BA, bile acids; Chol, cholesterol.

of bilirubin conjugates across the canalicular membrane by MRP2 or, in the case of bile duct obstruction, by MRP3 across the basolateral membrane [40,41,46]. Mrp3 mRNA and protein expression in the livers and kidneys of Gunn rats and Mrp2-deficient EHBR rats and the livers of patients with Dubin–Johnson syndrome is enhanced [47–50]. These are models of unconjugated and conjugated hyperbilirubinaemia respectively. This suggests that unconjugated and conjugated bilirubin may induce the expression of Mrp3. However, direct evidence is lacking as infusion of unconjugated bilirubin in rats failed to induce Mrp3 protein expression despite an induced Mrp3 mRNA.

Physiological jaundice

Unconjugated hyperbilirubinaemia is a physiological phenomenon in the first days after birth. The cause of this physiological jaundice is a combination of increased breakdown of fetal haemoglobin and a not yet fully developed conjugation capacity. Excessive neonatal jaundice may occur in premature or immature babies. Treatment is by phototherapy and, when more severe, by exchange transfusion [51–53]. Indications for phototherapy and exchange transfusion depend on a combination of immaturity/prematurity, age and serum bilirubin values [53,54]. Under the influence of light, unconjugated 4Z,15Z bilirubin in the capillaries of the skin converts to water-soluble isomers that are mainly secreted via the bile. Lumirubin (4E,15Z-cyclobilirubin), the main isomer, is unstable and partially reverts back to 4Z,15Z bilirubin, which can be reabsorbed in the gut. Oral administration of bilirubin binding agents when combined with phototherapy makes phototherapy more effective [55]. This is of particular interest in genetic defects (see below) where phototherapy has to be administered chronically.

Prolonged neonatal jaundice during breast milk feeding is called breastfeeding jaundice and seems to be caused by an increased enterohepatic circulation of bilirubin. Bilirubin conjugates are secreted by the liver and hydrolysed by β-glucuronidase in the intestine. Unconjugated bilirubin is reabsorbed. Concurrent with this theory is the outcome of a recent trial in which it was shown that administration of the β-glucuronidase inhibitor L-aspartate ameliorated the jaundice [56].

Neonatal jaundice with very high serum bilirubin levels can occur in combination with glucose-6-phosphate dehydrogenase deficiency and Gilbert syndrome or a combination of the two [57].

Genetic defects

Crigler–Najjar syndrome is caused by an autosomal recessive deficiency of UGT1A1. A complete gene defect resulting from gene deletions, premature stop codons, splice site and single nucleotide mutations is the cause of Crigler–Najjar syndrome type 1. Single nucleotide mutations that leave the phenobarbital induction of the gene intact result in Crigler–Najjar syndrome type 2 [58].

The first manifestations of this disease are apparent in the postneonatal period. Jaundice persists after the expected episode of physiological neonatal jaundice. In the first year of life, there are no foolproof tests to differentiate Crigler–Najjar syndrome type 1 and type 2. In the first year, the phenobarbital response is often unconvincing. Immediate start of phototherapy or, when jaundice is severe, exchange transfusion is necessary to keep the serum bilirubin level within safe limits (< 340 μmol/L; < 20 mg/dL). Drugs that displace bilirubin from albumin should be avoided. Acidosis decreases the affinity of albumin for bilirubin and should therefore be corrected as soon as possible. MARS dialysis has the potential to decrease serum bilirubin levels, but its efficacy for this condition needs to be proven. Kernicterus is a severe and irreversible condition that can cause mental and motor disabilities. Phototherapy sessions of at least 12 h per day are necessary. During adolescence, phototherapy becomes less efficient and socially poorly acceptable. Sooner or later, patients with Crigler–Najjar syndrome type 1 need a liver transplant [59,60].

The diagnosis of Crigler–Najjar syndrome has to be considered when unconjugated hyperbilirubinaemia persists. The diagnosis is usually made on the clinical picture and the persistence of elevated unconjugated bilirubin serum levels. Analysis of collected bile may be helpful. In Crigler–Najjar syndrome type 1, there is an absolute absence of any conjugated bilirubin in bile, whereas in type 2, mono- and diconjugated bilirubin can easily be detected. The usual laboratory tests for detection of direct and indirect bilirubin are not suitable for bile analysis. The best current method implies HPLC analysis of the bilirubin conjugates after alkaline methanolysis or thin-layer chromatography of azopigments after reaction with the diazonium salt of ethylanthranilate [7,61]. Liver histology in these patients is entirely normal. Gene analysis may be indicated if there is a wish for future pregnancies in families with a child with Crigler–Najjar syndrome. If the mutation is established, prenatal diagnosis can be done and interruption of pregnancy can be considered.

The Gunn rat provides an animal model for this disease. Gunn rats have been the subject of extensive investigations on gene therapy and hepatocyte transplantation [62–64]. Hepatocyte transplantation has also been carried out in patients with Crigler–Najjar syndrome. Results have shown transient improvement of unconjugated hyperbilirubinaemia [65]. The results of gene therapy in Gunn rats are encouraging. Crigler–Najjar syndrome may one day be treated by gene therapy.

Gilbert syndrome affects about 6% of the population. The prevalence among men exceeds that among women. In western populations, the *UGT1A1* gene $TAA(TA)_7$ promoter defect (*UGT1A1*28* gene) is the dominant genetic cause of Gilbert syndrome [38,66]. The *UGT1A1*28* variant is present in about 12–16% of the population. Thus, the clinical manifestation of mild hyperbilirubinaemia (unconjugated bilirubin serum levels < 120 μmol/L; < 7 mg/dL) shows an incomplete penetrance. In

Japan, mutations affecting the structural part of the *UGT1A1* gene, in particular a G71R mutation, are prevalent and a frequent cause of Gilbert syndrome [67,68].

Patients with Gilbert syndrome have a normal lifespan and do not need any treatment. The diagnosis rests on a persistence of mild unconjugated hyperbilirubinaemia that increases upon fasting. A rise in serum bilirubin levels upon fasting or after intravenous administration of nicotinic acid is suggestive but not specific for this condition. Genetic analysis of TATAA box or structural gene defects can be done in special cases, as in unexpectedly high serum bilirubin levels in patients with haemolytic disease or patients with liver disease. As explained above, UGT1A1 is specific for bilirubin conjugation with irinotecan, 17β-estradiol and some antiretroviral drugs as exceptions. Irinotecan toxicity has been reported in patients with Gilbert syndrome [69,70]. Patients with Gilbert syndrome on antiretroviral therapy are at risk of developing hyperbilirubinaemia [71]. Among the normal population, there appears to be an inverse relation between serum bilirubin levels and the risk of colorectal cancer [22]. Therefore, the risk of colorectal cancer in Gilbert syndrome patients is likely to be decreased. Also, the risk of endometrial cancer in Gilbert syndrome patients has been reported to be decreased [72]. Epidemiological data indicate that men with coronary artery disease have lower serum bilirubin levels than their healthy counterparts [73]. However, there is no evidence that patients with Gilbert syndrome are at lower risk of developing coronary artery disease [74].

Whether decreased conjugation of bilirubin by itself explains the jaundice of people with Gilbert syndrome has always been debated among bilirubin experts. Decreased hepatic uptake or increased bilirubin production may contribute to the increased unconjugated bilirubin levels in these patients [10,75]. In newborns, combinations of haemolytic diseases such as glucose 6-phosphate deficiency or β-thalassaemia and Gilbert syndrome may lead to prolonged neonatal jaundice [76].

Dubin–Johnson syndrome is characterized by an elevated serum level of conjugated direct-reacting bilirubin. It is caused by mutations of the *MRP2/ABCC2* gene encoding MRP2, the canalicular transporter of conjugated bilirubin [77,78]. Patients with this syndrome have a normal life expectancy. No adverse drug reactions have been associated with this syndrome to date. A liver biopsy is helpful in establishing the diagnosis. On histological examination, a characteristic brownish lysosomal pigment is seen in an otherwise normal liver [79,80]. With appropriate antibodies, one can detect a lowered or absent expression of canalicular MRP2 and an increased basolateral expression of MRP3 [81]. The urine of these patients contains an increased proportion of coproporphyrin isomer I against the background of normal total coproporphyrin [82]. A plasma disappearance curve after injection of bromosulphthalein shows a characteristic second rise 45 min after injection of the dye [83]. Because of reported toxicity, this test is not recommended. Animal models include the TR^- rat, Corriedale sheep and golden lion tamarins [84,85,86].

Rotor syndrome is a very rare condition characterized by mild conjugated and unconjugated hyperbilirubinaemia. The pathogenetic mechanism is not well understood. Decreased hepatic storage of bilirubin has long been considered as the underlying cause, but a gene has not been identified so far [87,88].

Acquired hyperbilirubinaemia

Jaundice is commonly considered synonymous with acute viral hepatitis. However, it is clear that any liver disease can cause jaundice. Conjugated hyperbilirubinaemia signifies a dominant secretion defect. A mixed type of conjugated and unconjugated hyperbilirubinaemia is consistent with parenchymatous liver disease. Cytokine-mediated downregulation of MRP2 expression is considered as an important underlying mechanism for conjugated hyperbilirubinaemia in liver disease [89–91]. In most liver diseases, including simple bile duct obstruction, cytokine-mediated effects are seen, and it is not surprising therefore that some degree of conjugated hyperbilirubinaemia is seen in almost every liver disease.

Elevated levels of conjugated and unconjugated bilirubin are present in acute viral, toxic or autoimmune hepatitis. In liver cirrhosis, elevated serum bilirubin levels are a sign of decompensation and have a bad prognosis. The bilirubin level is an important determinant in the Child–Pugh score and is one of the components of the MELD score. Also, in primary biliary cirrhosis, serum bilirubin levels have prognostic value and are an important feature in most prognostic models. In general, once serum bilirubin levels start to rise in patients with primary biliary cirrhosis, liver transplantation needs to be considered.

References

1 Sedlak TW, Snyder SH (2004) Bilirubin benefits: cellular protection by a biliverdin reductase antioxidant cycle. *Pediatrics* 113 (6), 1776–1782.

2 Morse D, Choi AM (2005) Heme oxygenase-1: from bench to bedside. *Am J Respir Crit Care Med* 172 (6), 660–670.

3 Cui Y, Konig J, Leier I *et al.* (2001) Hepatic uptake of bilirubin and its conjugates by the human organic anion transporter SLC21A6. *J Biol Chem* 276 (13), 9626–9630.

4 Peters WH, Jansen PL (1986) Microsomal UDP-glucuronyltransferase-catalyzed bilirubin diglucuronide formation in human liver. *J Hepatol* 2 (2), 182–194.

5 Keppler D, Konig J (2000) Hepatic secretion of conjugated drugs and endogenous substances. *Semin Liver Dis* 20 (3), 265–272.

6 Berk PD, Martin JF, Blaschke TF *et al.* (1975) Unconjugated hyperbilirubinemia. Physiologic evaluation and experimental approaches to therapy. *Ann Intern Med* 82 (4), 552–570.

7 Blanckaert N, Kabra PM, Farina FA *et al.* (1980) Measurement of bilirubin and its monoconjugates and diconjugates in human serum by alkaline methanolysis and high-performance liquid chromatography. *J Lab Clin Med* 96 (2), 198–212.

8 Jansen PL, Cuypers HT, Peters WH (1984) Quantitation of bilirubin conjugates with high-performance liquid chromatography in patients with low total serum bilirubin levels. *Eur J Clin Invest* 14 (4), 295–300.

9 Kaplan M, Hammerman C (2005) Understanding severe hyperbilirubinemia and preventing kernicterus: adjuncts in the interpretation of neonatal serum bilirubin. *Clin Chim Acta* 356 (1–2), 9–21.

10 Kaplan M, Hammerman C, Rubaltelli FF *et al.* (2002) Hemolysis and bilirubin conjugation in association with UDP-glucuronosyltransferase 1A1 promoter polymorphism. *Hepatology* 35 (4), 905–911.

11 Nanjundaswamy S, Petrova A, Mehta R *et al.* (2005) Transcutaneous bilirubinometry in preterm infants receiving phototherapy. *Am J Perinatol* 22 (3), 127–131.

12 Mustafa MG, Cowger ML, King TE (1969) Effects of bilirubin on mitochondrial reactions. *J Biol Chem* 244 (23), 6403–6414.

13 Noir BA, Boveris A, Garaza Pereira AM *et al.* (1972) Bilirubin: a multi-site inhibitor of mitochondrial respiration. *FEBS Lett* 27 (2), 270–274.

14 Rodrigues CM, Sola S, Castro RE *et al.* (2002) Perturbation of membrane dynamics in nerve cells as an early event during bilirubin-induced apoptosis. *J Lipid Res* 43 (6), 885–894.

15 Hanko E, Hansen TW, Almaas R *et al.* (2005) Bilirubin induces apoptosis and necrosis in human NT2-N neurons. *Pediatr Res* 57 (2), 179–184.

16 Chalasani N, Chowdhury NR, Chowdhury JR *et al.* (1997) Kernicterus in an adult who is heterozygous for Crigler–Najjar syndrome and homozygous for Gilbert-type genetic defect. *Gastroenterology* 112 (6), 2099–2103.

17 Stocker R, Yamamoto Y, McDonagh AF *et al.* (1987) Bilirubin is an antioxidant of possible physiological importance. *Science* 235 (4792), 1043–1046.

18 Baranano DE, Rao M, Ferris CD *et al.* (2002) Biliverdin reductase: a major physiologic cytoprotectant. *Proc Natl Acad Sci USA* 99 (25), 16093–16098.

19 Djousse L, Levy D, Cupples LA *et al.* (2001) Total serum bilirubin and risk of cardiovascular disease in the Framingham offspring study. *Am J Cardiol* 87 (10), 1196–1200.

20 Madhavan M, Wattigney WA, Srinivasan SR *et al.* (1997) Serum bilirubin distribution and its relation to cardiovascular risk in children and young adults. *Atherosclerosis* 131 (1), 107–113.

21 Temme EH, Zhang J, Schouten EG *et al.* (2001) Serum bilirubin and 10-year mortality risk in a Belgian population. *Cancer Causes Control* 12 (10), 887–894.

22 Zucker SD, Horn PS, Sherman KE (2004) Serum bilirubin levels in the U.S. population: gender effect and inverse correlation with colorectal cancer. *Hepatology* 40 (4), 827–835.

23 Nakao A, Neto JS, Kanno S *et al.* (2005) Protection against ischemia/reperfusion injury in cardiac and renal transplantation with carbon monoxide, biliverdin and both. *Am J Transplant* 5 (2), 282–291.

24 Nakao A, Otterbein LE, Overhaus M *et al.* (2004) Biliverdin protects the functional integrity of a transplanted syngeneic small bowel. *Gastroenterology* 127 (2), 595–606.

25 Naito Y, Takagi T, Yoshikawa T (2004) Heme oxygenase-1: a new therapeutic target for inflammatory bowel disease. *Aliment Pharmacol Ther* 20 (Suppl. 1), 177–184.

26 Pachori AS, Melo LG, Hart ML *et al.* (2004) Hypoxia-regulated therapeutic gene as a preemptive treatment strategy against ischemia/reperfusion tissue injury. *Proc Natl Acad Sci USA* 101 (33), 12282–12287.

27 Tang YL, Tang Y, Zhang YC *et al.* (2004) Protection from ischemic heart injury by a vigilant heme oxygenase-1 plasmid system. *Hypertension* 43 (4), 746–751.

28 Redaelli CA, Tian YH, Schaffner T *et al.* (2002) Extended preservation of rat liver graft by induction of heme oxygenase-1. *Hepatology* 35 (5), 1082–1092.

29 Wagner M, Cadetg P, Ruf R *et al.* (2003) Heme oxygenase-1 attenuates ischemia/reperfusion-induced apoptosis and improves survival in rat renal allografts. *Kidney Int* 63 (4), 1564–1573.

30 Bosma PJ, Seppen J, Goldhoorn B *et al.* (1994) Bilirubin UDP-glucuronosyltransferase 1 is the only relevant bilirubin glucuronidating isoform in man. *J Biol Chem* 269 (27), 17960–17964.

31 Iyer L, King CD, Whitington PF *et al.* (1998) Genetic predisposition to the metabolism of irinotecan (CPT-11). Role of uridine diphosphate glucuronosyltransferase isoform 1A1 in the glucuronidation of its active metabolite (SN-38) in human liver microsomes. *J Clin Invest* 101 (4), 847–854.

32 Ebner T, Remmel RP, Burchell B (1993) Human bilirubin UDP-glucuronosyltransferase catalyzes the glucuronidation of ethinylestradiol. *Mol Pharmacol* 43 (4), 649–654.

33 Court MH, Duan SX, Von Moltke LL *et al.* (2001) Interindividual variability in acetaminophen glucuronidation by human liver microsomes: identification of relevant acetaminophen UDP-glucuronosyltransferase isoforms. *J Pharmacol Exp Ther* 299 (3), 998–1006.

34 Strassburg CP, Kneip S, Topp J *et al.* (2000) Polymorphic gene regulation and interindividual variation of UDP-glucuronosyltransferase activity in human small intestine. *J Biol Chem* 275 (46), 36164–36171.

35 Strassburg CP, Nguyen N, Manns MP *et al.* (1998) Polymorphic expression of the UDP-glucuronosyltransferase UGT1A gene locus in human gastric epithelium. *Mol Pharmacol* 54 (4), 647–654.

36 Soars MG, Riley RJ, Findlay KA *et al.* (2001) Evidence for significant differences in microsomal drug glucuronidation by canine and human liver and kidney. *Drug Metab Dispos* 29 (2), 121–126.

37 Bosma PJ, Chowdhury JR, Bakker C *et al.* (1995) The genetic basis of the reduced expression of bilirubin UDP-glucuronosyltransferase 1 in Gilbert's syndrome. *N Engl J Med* 333 (18), 1171–1175.

38 Monaghan G, Ryan M, Seddon R *et al.* (1996) Genetic variation in bilirubin UPD-glucuronosyltransferase gene promoter and Gilbert's syndrome. *Lancet* 347 (9001), 578–581.

39 Beutler E, Gelbart T, Demina A (1998) Racial variability in the UDP-glucuronosyltransferase 1 (UGT1A1) promoter: a balanced polymorphism for regulation of bilirubin metabolism? *Proc Natl Acad Sci USA* 95 (14), 8170–8174.

40 Zhou J, Zhang J, Xie W (2005) Xenobiotic nuclear receptor-mediated regulation of UDP-glucuronosyl-transferases. *Curr Drug Metab* 6 (4), 289–298.

41 Saini SP, Mu Y, Gong H *et al.* (2005) Dual role of orphan nuclear receptor pregnane X receptor in bilirubin detoxification in mice. *Hepatology* 41 (3), 497–505.

42 Kaplowitz N, Kuhlenkamp J, Clifton G (1975) Hepatic glutathione S-transferases: identification by gel filtration and in vitro inhibition by organic anions. *Proc Soc Exp Biol Med* 149 (1), 234–237.

43 Jansen PL, Peters WH, Lamers WH (1985) Hereditary chronic conjugated hyperbilirubinemia in mutant rats caused by defective hepatic anion transport. *Hepatology* 5 (4), 573–579.

44 Kartenbeck J, Leuschner U, Mayer R *et al.* (1996) Absence of the canalicular isoform of the MRP gene-encoded conjugate export pump from the hepatocytes in Dubin–Johnson syndrome. *Hepatology* 23 (5), 1061–1066.

45 Paulusma CC, Kool M, Bosma PJ *et al.* (1997) A mutation in the human canalicular multispecific organic anion transporter gene causes the Dubin–Johnson syndrome. *Hepatology* 25 (6), 1539–1542.

46 Wagner M, Halilbasic E, Marschall HU *et al.* (2005) CAR and PXR agonists stimulate hepatic bile acid and bilirubin detoxification and elimination pathways in mice. *Hepatology* 42 (2), 420–430.

47 Konig J, Rost D, Cui Y *et al.* (1999) Characterization of the human multidrug resistance protein isoform MRP3 localized to the basolateral hepatocyte membrane. *Hepatology* 29 (4), 1156–1163.

48 Ogawa K, Suzuki H, Hirohashi T *et al.* (2000) 278 Characterization of inducible nature of MRP3 in rat liver. *Am J Physiol Gastrointest Liver Physiol* (3), G438–G446.

49 Kuroda M, Kobayashi Y, Tanaka Y *et al.* (2004) Increased hepatic and renal expressions of multidrug resistance-associated protein 3 in Eisai hyperbilirubinuria rats. *J Gastroenterol Hepatol* 19 (2), 146–153.

50 Higuchi K, Kobayashi Y, Kuroda M *et al.* (2004) Modulation of organic anion transporting polypeptide 1 and multidrug resistance protein 3 expression in the liver and kidney of Gunn rats. *Hepatol Res* 29 (1), 60–66.

51 Gartner LM, Catz CS, Yaffe SJ (1994) Neonatal bilirubin workshop. *Pediatrics* 94 (4 Pt 1), 537–540.

52 Lee KS, Gartner LM (1983) Management of unconjugated hyperbilirubinemia in the newborn. *Semin Liver Dis* 3 (1), 52–64.

53 Alkalay AL, Simmons CF (2005) Hyperbilirubinemia guidelines in newborn infants. *Pediatrics* 115 (3), 824–825.

54 Anon (2004) Management of hyperbilirubinemia in the newborn infant 35 or more weeks of gestation. *Pediatrics* 114 (1), 297–316.

55 Van der Veere CN, Jansen PL, Sinaasappel M *et al.* (1997) Oral calcium phosphate: a new therapy for Crigler–Najjar disease? *Gastroenterology* 112 (2), 455–462.

56 Gourley GR, Li Z, Kreamer BL *et al.* (2005) A controlled, randomized, double-blind trial of prophylaxis against jaundice among breastfed newborns. *Pediatrics* 116 (2), 385–391.

57 Kaplan M, Hammerman C (2004) Glucose-6-phosphate dehydrogenase deficiency: a hidden risk for kernicterus. *Semin Perinatol* 28 (5), 356–364.

58 Seppen J, Bosma PJ, Goldhoorn BG *et al.* (1994) Discrimination between Crigler–Najjar type I and II by expression of mutant bilirubin uridine diphosphate-glucuronosyltransferase. *J Clin Invest* 94 (6), 2385–2391.

59 Van der Veere CN, Sinaasappel M, McDonagh AF *et al.* (1996) Current therapy for Crigler–Najjar syndrome type 1: report of a world registry. *Hepatology* 24 (2), 311–315.

60 Sokal EM, Silva ES, Hermans D *et al.* (1995) Orthotopic liver transplantation for Crigler–Najjar type I disease in six children. *Transplantation* 60 (10), 1095–1098.

61 Fevery J, Van DB, Michiels R *et al.* (1972) Bilirubin conjugates in bile of man and rat in the normal state and in liver disease. *J Clin Invest* 51 (9), 2482–2492.

62 Nguyen TH, Bellodi-Privato M, Aubert D *et al.* (2005) Therapeutic lentivirus-mediated neonatal in vivo gene therapy in hyperbilirubinemic Gunn rats. *Mol Ther* 12 (5), 852–859.

63 Toietta G, Mane VP, Norona WS *et al.* (2005) Lifelong elimination of hyperbilirubinemia in the Gunn rat with a single injection of helper-dependent adenoviral vector. *Proc Natl Acad Sci USA* 102 (11), 3930–3935.

64 Takahashi M, Deb NJ, Kawashita Y *et al.* (2003) A novel strategy for in vivo expansion of transplanted hepatocytes using preparative hepatic irradiation and FasL-induced hepatocellular apoptosis. *Gene Ther* 10 (4), 304–313.

65 Fox IJ, Chowdhury JR, Kaufman SS *et al.* (1998) Treatment of the Crigler–Najjar syndrome type I with hepatocyte transplantation. *N Engl J Med* 338 (20), 1422–1426.

66 Bosma PJ, Chowdhury JR, Bakker C *et al.* (1995) The genetic basis of the reduced expression of bilirubin UDP-glucuronosyltransferase 1 in Gilbert's syndrome. *N Engl J Med* 333 (18), 1171–1175.

67 Maruo Y, Sato H, Yamano T *et al.* (1998) Gilbert syndrome caused by a homozygous missense mutation (Tyr486Asp) of bilirubin UDP-glucuronosyltransferase gene. *J Pediatr* 132 (6), 1045–1047.

68 Koiwai O, Nishizawa M, Hasada K *et al.* (1995) Gilbert's syndrome is caused by a heterozygous missense mutation in the gene for bilirubin UDP-glucuronosyltransferase. *Hum Mol Genet* 4 (7), 1183–1186.

69 Wasserman E, Myara A, Lokiec F *et al.* (1997) Severe CPT-11 toxicity in patients with Gilbert's syndrome: two case reports. *Ann Oncol* 8 (10), 1049–1051.

70 Kitagawa C, Ando M, Ando Y *et al.* (2005) Genetic polymorphism in the phenobarbital-responsive enhancer module of the UDP-glucuronosyltransferase 1A1 gene and irinotecan toxicity. *Pharmacogenet Genomics* 15 (1), 35–41.

71 Rotger M, Taffe P, Bleiber G *et al.* (2005) Gilbert syndrome and the development of antiretroviral therapy-associated hyperbilirubinemia. *J Infect Dis* 192 (8), 1381–1386.

72 Duguay Y, McGrath M, Lepine J *et al.* (2004) The functional UGT1A1 promoter polymorphism decreases endometrial cancer risk. *Cancer Res* 64 (3), 1202–1207.

73 Kronenberg F, Coon H, Gutin A *et al.* (2002) A genome scan for loci influencing anti-atherogenic serum bilirubin levels. *Eur J Hum Genet* 10 (9), 539–546.

74 Breimer LH, Wannamethee G, Ebrahim S *et al.* (1995) Serum bilirubin and risk of ischemic heart disease in middle-aged British men. *Clin Chem* 41 (10), 1504–1508.

75 Persico M, Persico E, Bakker CT *et al.* (2001) Hepatic uptake of organic anions affects the plasma bilirubin level in subjects with Gilbert's syndrome mutations in UGT1A1. *Hepatology* 33 (3), 627–632.

76 Kaplan M, Renbaum P, Levy-Lahad E *et al.* (1997) Gilbert syndrome and glucose-6-phosphate dehydrogenase deficiency: a dose-dependent genetic interaction crucial to neonatal hyperbilirubinemia. *Proc Natl Acad Sci USA* 94 (22), 12128–12132.

77 Paulusma CC, Kool M, Bosma PJ *et al.* (1997) A mutation in the human canalicular multispecific organic anion transporter gene causes the Dubin–Johnson syndrome. *Hepatology* 25 (6), 1539–1542.

78 Kartenbeck J, Leuschner U, Mayer R *et al.* (1996) Absence of the canalicular isoform of the MRP gene-encoded conjugate export pump from the hepatocytes in Dubin–Johnson syndrome. *Hepatology* 23 (5), 1061–1066.

79 Arias IM, Blumberg W (1979) The pigment in Dubin–Johnson syndrome. *Gastroenterology* 77 (4 Pt 1), 820–821.

80 Kitamura T, Alroy J, Gatmaitan Z *et al.* (1992) Defective biliary excretion of epinephrine metabolites in mutant (TR–) rats: relation to the pathogenesis of black liver in the Dubin–Johnson syndrome and Corriedale sheep with an analogous excretory defect. *Hepatology* 15 (6), 1154–1159.

81 Konig J, Rost D, Cui Y *et al.* (1999) Characterization of the human multidrug resistance protein isoform MRP3 localized to the basolateral hepatocyte membrane. *Hepatology* 29 (4), 1156–1163.

82 Wolkoff AW, Cohen LE, Arias IM (1973) Inheritance of the Dubin–Johnson syndrome. *N Engl J Med* 288 (3), 113–117.

83 Rodes J, Zubizarreta A, Bruguera M (1972) Metabolism of the bromsulphthalein in Dubin–Johnson syndrome. Diagnostic value of the paradoxical increase in plasma levels at BSP. *Am J Dig Dis* 17 (6), 545–552.

84 Jansen PL, Peters WH, Lamers WH (1985) Hereditary chronic conjugated hyperbilirubinemia in mutant rats caused by defective hepatic anion transport. *Hepatology* 5 (4), 573–579.

85 Mia AS, Gronwall RR, Cornelius CE (1970) Unconjugated bilirubin transport in normal and mutant Corriedale sheep with Dubin–Johnson syndrome. *Proc Soc Exp Biol Med* 135 (1), 33–37.

86 Shulman F, Montali R, Bush M *et al*. (1993) Dubin–Johnson-like syndrome in Golden Lion Tamarins (*Leonthopitheous rosalia rosalia*). *Vet Pathol* 30, 491–498.

87 Wolkoff AW, Wolpert E, Pascasio FN *et al.* (1976) Rotor's syndrome. A distinct inheritable pathophysiologic entity. *Am J Med* 60 (2), 173–179.

88 Wolpert E, Pascasio FM, Wolkoff AW *et al.* (1977) Abnormal sulfobromophthalein metabolism in Rotor's syndrome and obligate heterozygotes. *N Engl J Med* 296 (19), 1099–1101.

89 Trauner M, Arrese M, Soroka CJ *et al.* (1997) The rat canalicular conjugate export pump (Mrp2) is down-regulated in intrahepatic and obstructive cholestasis. *Gastroenterology* 113 (1), 255–264.

90 Zollner G, Fickert P, Zenz R *et al.* (2001) Hepatobiliary transporter expression in percutaneous liver biopsies of patients with cholestatic liver diseases. *Hepatology* (3), 633–646.

91 Assenat E, Gerbal-Chaloin S, Larrey D *et al.* (2004) Interleukin 1beta inhibits CAR-induced expression of hepatic genes involved in drug and bilirubin clearance. *Hepatology* 40 (4), 951–960.

16.7 The liver in intracellular and extracellular lipidosis

Dominique P. Germain

Liver involvement is seen in several inherited lipidoses. In intracellular lipidosis, the pattern of liver disease reflects the cell type involved in the disease. Among lysosomal storage disorders, Gaucher disease and Niemann–Pick type A and B disease are primarily Kupffer cell lipidoses while cholesterol ester storage disease and Niemann–Pick type type C disease affect hepatocytes as well as Kupffer cells. There have been major breakthroughs in the delineation and treatment of Gaucher disease, which is considered as a paradigm for the modern management of genetic diseases. As patients with Gaucher disease may remain undetected during childhood and first present to the hepatologist because of an enlarged liver in adult life, this topic will be covered extensively in this chapter. In extracellular lipidosis, a primary genetic defect in the hepatocytes leads to abnormal intravascular trafficking of lipids, causing extrahepatic disease that can be associated with hepatic steatosis.

Lysosomal storage disorders

Gaucher disease

Gaucher disease (GD) is an inborn error of glycosphingolipid metabolism, inherited in an autosomal recessive manner and caused by deficiency in the lysosomal hydrolase acid β-glucosidase (glucocerebrosidase, EC 3.2.1.45) [1]. The deficiency in acid β-glucosidase leads to the widespread accumulation of abnormal mononuclear phagocytes (Gaucher cells) laden with the enzyme's main substrate, glucosylceramide (or glucocerebroside), which is derived from the degradation of membrane glycosphingolipids of effete cells. GD is one of the most frequent lysosomal storage disorders. In the non-Jewish population, the exact gene frequency is unknown. Some patients remain asymptomatic, and the disease is often missed and its prevalence therefore underestimated. Although GD is panethnic, it is the most frequent genetic disease in the Ashkenazi Jewish population, for which the epidemiological data, based on estimated gene frequencies, are more reliable, with one case per 850 live births. Three major phenotypes of GD are conventionally distinguished on the basis of the absence (type 1) or presence and severity (types 2 and 3) of primary central nervous system (CNS) lesions.

Type 1 GD

Type 1 GD (OMIM 230800) is by far the most frequent form. By definition, there is no impairment of the CNS through storage, and all neurological symptoms observed are secondary to the systemic complications of the disease. Type 1 GD is a multisystem storage disease, characterized by a great variability in the age of onset, clinical signs and course. Patients with type 1 GD may present in early childhood with major hepatosplenomegaly associated with anomalies of hepatic function, pancytopenia and crippling skeletal disease. The infants may die of the complications of their type 1 GD during the first or second year of life. In contrast, homozygotes for the p.N370S mutation may come to light in the ninth decade of life because of the incidental finding of splenomegaly. Whereas the median age of diagnosis for homozygotes for the p.N370S mutation is about 30 years, that for the compound heterozygotes is under 10 years. A few asymptomatic patients, although authentically deficient in glucocerebrosidase activity, are only diagnosed in the context of a familial or population study.

The visceral manifestations are explained by the distribution of Gaucher cells, consisting of macrophages filled with the accumulation of non-degraded substrates (insoluble glycolipids) and derived from phagocytosis of senescent red and white blood cells. Gaucher cells are responsible for hepatosplenomegaly and, sometimes, spleen and/or liver failure, bone marrow replacement, pancytopenia, lung infiltration, a hypermetabolic state and a skeletal disease of variable seriousness. Asthenia and fatigability are constant and seem independent of the existence of anaemia, but rather to reflect an abnormality of basal metabolism and cytokine secretion. The usual presentation is with non-tender splenomegaly, which is present in 90% of patients and is often associated with cytopenia. The degree of splenomegaly is highly variable and the absolute size of the spleen can vary from 300 g to over 10 kg, accounting for 15–25% of body weight (a normal spleen is about 0.2% of body weight), distending the entire abdomen. In the course of childhood

febrile exanthema, splenomegaly may rapidly progress, while rapid enlargement of the spleen in an adult patient should lead to suspicion of an associated disorder, for example haematological malignancy or immune thrombocytopenia. Acute pain of the left hypochondrial area may reflect subcapsular splenic infarcts. Splenic nodules may represent regions extramedullary haematopoietic, collections of Gaucher cells or resolving infarcts.

Hepatomegaly is present in 70% of cases of type 1 GD. Kupffer cells, which are specialized macrophages, are a site of constant glycosphingolipid accumulation on biopsy. Hepatocytes do not manifest overt glycolipid storage, presumably because there is substantial excretion of glycosylceramide in the bile and because the bulk of glycolipid turnover from effete cells is handled by mononuclear phagocytes. The sparing of the hepatocytes is in keeping with a low incidence of severe liver failure. Liver volumes range from 0.75 to 8 times the normal values (a normal liver is 2.5% of body weight) with a median of 1.75. Hepatic glycosylceramide levels are raised from 20- to 390-fold above normal, that is, 700 μg/g to 18 mg/g wet weight compared with normal levels of 30–45 μg/g [2]. Clinical reflection of the liver's pathological storage is, however, rare. Abnormalities of liver function tests, minor elevation of liver enzymes and an increase in one-stage prothrombin (Quick) time are reported in 50% of cases. The level of serum ferritin may be high although transferrin saturation is normal. Liver failure and cirrhosis with portal hypertension and ascites are rare, occurring in less than 10% of cases [3]. Portal hypertension can be accentuated by compression of the sinusoids by Gaucher cells. Death from variceal haemorrhage has been reported.

Thrombocytopenia is the most classic haematological abnormality, but remains moderate with a platelet count usually between 50 000 and 100 000/μL. In the disease, thrombocytopenia is frequently caused by splenic sequestration of platelets and responds to splenectomy. Later and/or in patients having undergone splenectomy, thrombocytopenia may be explained by the invasion of bone marrow by Gaucher cells. An acquired coagulopathy due to deficiency of factor XI is common but there is a high incidence of genetic deficiency of factor XI among the Ashkenazim. Macrocytic anaemia is classically moderate, but may occasionally be marked. Iron deficiency is also regularly reported. Bone marrow failure and myelofibrosis due to displacement of medullary precursors by Gaucher cells is fairly rare and most frequently observed in splenectomized patients.

Lymphoproliferative disorders appear more frequently in patients presenting with GD than in the overall population. Polyclonal hypergammaglobulinaemia, oligo- and monoclonal gammopathies and amyloidosis are observed with increased frequency. Malignant proliferations, in particular multiple myeloma, but also chronic lymphoid leukaemia, Hodgkin's disease and non-Hodgkinian lymphomas, have been reported, in particular among Ashkenazi Jews. It is not known whether enzyme treatment can prevent their emergence.

Skeletal involvement is frequent (75%) and constitutes the major complication in terms of morbidity and functional prognosis [4]. Bone lesions are eminently variable, ranging from osteopenia to marked destructive lesions. In addition to the chronic pain, severe acute painful episodes, known as bone crises, secondary to medullary infarction, occur in 20–40% of patients. The attacks are more frequent in childhood and adolescence. Aseptic necroses of the heads of the femurs and humeri and vertebral compression fractures are the most frequently observed destructive bone lesions. In type 1 GD, radiography shows a decrease in bone mass. The generalized osteopenia is complicated by pathological fractures. A disorder of bone remodelling, initially affecting the distal extremity of the femurs and proximal tibias (Erlenmeyer flask deformation), is the most characteristic abnormality, but only occurs in 30% of patients. Sacroiliac osteosclerosis and thinning of cortical bone are also conventionally described [4]. Dixon quantitative chemical shift imaging (Dixon QCSI) has recently been shown to be a useful clinical parameter to assess quantitatively the extent of skeletal involvement in type 1 GD [5].

Clinically frank pulmonary involvement is rare, but may occur due to several pathophysiological mechanisms. Potentially fatal respiratory insufficiency may be due to diffuse infiltration of Gaucher cells into the alveolar spaces, and perivascular, peribronchial and septal regions, the last of which may give rise to interstitial fibrosis. A restrictive syndrome, due to pulmonary compression consecutive to hepatosplenomegaly or kyphoscoliosis due to vertebral compression fractures, has also been documented. Right-to-left shunting as a complication of long-standing liver disease has been reported. Pulmonary hypertension is a well-documented complication of GD [6] and has been described in the presence of right-to-left shunting [7]. Progression to severe, life-threatening pulmonary hypertension occurs in the presence of additional genetic factors (non-p.N370S *GBA* mutation, positive family history) and epigenetic modifiers (i.e. asplenia), and splenectomy should be avoided. In high-risk patients, management requires optimal treatment of the underlying GD and the addition of vasodilators in the more severe cases [6].

By definition, there is no primary involvement of the central nervous system due to the storage process in type 1 GD. A few rare neurological manifestations have been reported, subsequent to secondary complications – in particular fatty emboli – in authentic type 1 GD. Signs of bone marrow or nerve root compression may also be observed following vertebral crush fractures due to osteonecrosis.

Other manifestations of type 1 Gaucher disease include yellow-brown cutaneous pigmentation and a 25% increase in the resting energy expenditure, which is associated with increased basal glucose production.

The course of GD varies widely, with some subjects remaining asymptomatic up to the age of 70 or 80 years, in contrast to the sometimes fatal progression in childhood. Several papers have been published that give information about the natural course of

the untreated disease. These studies show that the c.1226A→G homozygotes show minimal progression during adult life [8] while the clinical manifestations tend to be progressive in the majority of compound heterozygotes, children as well as adults [9]. The latter results emphasize the need for a regular follow-up to enable timely initiation of enzyme therapy. In any case, it is important to collect the clinical data acquired prior to treatment initiation and, in particular, age of onset, distribution and severity of visceral lesions and course of the bone lesions.

Type 2 GD

Type 2 Gaucher disease is the most severe form of the disease. It is characterized by the presence of early-onset, very rapidly progressing neurological signs. This variant is very rare, accounting for less than one case per 500 000 births. A congenital form, characterized by hydrops fetalis and/or severe cutaneous abnormalities, presenting as congenital ichthyosiform erythroderma [10], has been reported. The central nervous system involvement predominates in type 2 GD with supranuclear horizontal oculomotor paralysis, bulbar signs, progressive spasticity and choreoathetotic movements. Visceral involvement with hepatosplenomegaly is also the rule. Children with type 2 GD die during the first two years of life, in a context of psychomotor deterioration [11].

Type 3 GD

Type 3 Gaucher disease is rare, with less than one case per 100 000 births, and is characterized by the presence of a later-onset, more slowly progressing neurological syndrome than in type 2. Type 3 GD has sometimes been subdivided into three subtypes. Type 3A is the phenotype observed in the northern Swedish region of Norbotten [12], characterized by later onset in adolescence, and slowly progressive neurological impairment, but for which the course is very severe, with dementia and ataxia. Visceral involvement is moderate. Type 3B emerges in early childhood, with predominantly visceral manifestations that progress rapidly and result in death due to the complications of portal or pulmonary hypertension. The neurological involvement is essentially restricted to horizontal supranuclear gaze palsy. Type 3C is characterized by the existence of early-onset isolated oculomotor paralysis. Type 3C always seems to be associated with the presence of mutation c.1342G→C (D409H) for one of the alleles. Mitral and aortic cardiac valve involvement has been reported in homozygous cases of that mutation [13].

Diagnosis of GD

Enzymatic diagnosis is the reference method and is to be systematically used to confirm the diagnosis of GD. Acid β-glucosidase is present in the lysosomes of all tissues, except erythrocytes. Peripheral blood leukocytes thus normally have marked β-glucosidase activity. Enzymology enables definitive confirmation of the diagnosis, by evidencing the deficiency in acid β-glucosidase activity in leukocytes in cases of GD. However, the reference diagnostic method, enzymology, has several disadvantages, including the labile nature of enzymatic activity, which demands analysis of the blood sample within 48 hours. In addition, enzymatic assay of β-glucosidase activity is not a satisfactory method for screening heterozygotes. While the leukocytes from heterozygous subjects generally have decreased enzymatic activity, compared with normal values, there is considerable variability, which prevents a formal conclusion in the majority of cases. Lastly, enzymatic diagnosis is unable to differentiate the three types of GD.

Ancillary diagnostic markers exploit the increase in various enzyme activities in the plasma of patients presenting with GD, particularly tartrate-resistant acid phosphatase (isoenzyme 5B), the angiotensin-converting enzyme and chitotriosidase [14], whose levels decline following induction of enzymatic replacement therapy (ERT) and may therefore be of value in the laboratory follow-up of treatment. More recently, it has been reported that in plasma of symptomatic GD patients, the chemokine CCL18 is elevated, without overlap between patients' and control values. Plasma CCL18 concentrations decreased during therapy, and monitoring of plasma CCL18 levels proved to be very useful in the determination of therapeutic efficacy, especially in patients who are deficient in chitotriosidase activity [15].

Molecular diagnosis has the advantage of being qualitative, using stable DNA samples that can be shipped, and having a certain prognostic value. In Ashkenazi Jewish populations, a small number of mutations is involved and the genotype may be identified for a very high percentage of patients by the analysis of five recurrent alleles. A small residual risk of false negatives cannot, however, be excluded. In contrast, in the overall population, the existence of numerous rare alleles restricts diagnosis by DNA study to those families in which the genotype is known.

Biochemical prenatal diagnosis of GD by determination of acid β-glucosidase activity in chorionic villi at 10 weeks of pregnancy or in cultured amniotic cells at about 14 weeks of pregnancy is technically feasible. For ethical reasons, prenatal diagnosis is usually only suggested in cases of type 2 and type 3 GD. Of note, the presence of at least one p.N370S allele excludes primary CNS involvement. However, the possibility of intrafamilial phenotype variations complicates genetic counselling. Moreover, while genotype/phenotype correlations have been defined, they are not absolute and it is important to take into account the potential role of the environment, possible modifier genes and genetic background.

Molecular heterogeneity

Several studies have demonstrated the molecular heterogeneity of GD and over 200 mutations of the acid β-glucosidase gene have been described [16]. Among the mutations characterized in patients presenting with GD, only three have a high frequency. The mutations p.N370S, p.L444P and c.84insG account for 55%, 20% and 8%, respectively, of the alleles evidenced in GD. However, the frequency and distribution of the three mutations vary with the population studied. Investigation for the above three mutations in the Ashkenazi population enables

diagnosis of 93% of the alleles (p.N370S – 77%; p.L444P – 3%; c.84insG – 13%). However, the three mutations, p.N370S, p.L444P and c.84insG only account for 70% of all deleterious alleles in non-Jewish populations. Another group of mutations includes those known as 'private', that is, identified in a single or small number of families.

Management of GD

Due to the great variability of the GD phenotype, genetic counselling and appropriate medical management of patients are difficult. The clinical phenotype may vary from an asymptomatic course throughout life to cases of extreme severity. Numerous authors have stressed that there is no correlation between the residual β-glucosidase activity determined *in vitro* using an artificial substrate (4-methylumbelliferyl-glucopyranoside) and the clinical severity or type of GD. Mutation analysis is thus rational, because it is the main prognostic criterion and enables, to a certain degree, prediction of the type of disease and, in particular, whether or not neurological involvement will occur.

None of the patients in whom we evidenced the presence of at least one p.N370S allele presented with neurological involvement [17]. These data confirm those of many authors, who have found a strong correlation between the presence of at least one copy of the p.N370S allele and type 1 GD [18]. While heteroallelism for mutation p.N370S enables prediction of non-progression towards a neurological form of the disease, the associated visceral involvement remains eminently variable. Genotyping does not enable certain prediction of course, because, for a given genotype, there is a marked interfamilial variability in the clinical expression of the disease [19]. Only a few complementary findings may be outlined. Homozygosity for mutation c.1226A→G is classically associated with a low-severity phenotype, or even the absence of clinical manifestations. That genotype is encountered in most clinically asymptomatic cases, detected in the course of familial studies. Heteroallelism for allele p.L444P may be encountered in association with type 1, 2 or 3 GD. The influence of the second allele therefore appears essential to determining the emergence of neurological involvement. Several studies confirm the classically described association between neurological symptoms (GD type 2 or 3) and homozygosity for allele p.L444P.

The interfamilial and intrafamilial phenotype variations observed for a given genotype illustrate the imperfection in genotype–phenotype correlations [19], the importance of the genetic background and the value of identifying modifying genes or environmental factors that may possibly be implicated in genotype modulation [17]. It appears that genotyping, while it may yield an orientation, cannot consistently predict the associated prognosis.

GD is one of the rare genetic diseases that are amenable to specific treatment. Enzyme replacement therapy (ERT) [20], possibly associated with adjuvant treatments [21], is now central to modern management of GD [22,23]. The aim of ERT is to achieve reversal of the symptomatic clinical manifestations and prevent irreversible lesions of the various organs. The current indications include the presence of symptomatic bone disease, severe anaemia, a tendency to bleed due to thrombocytopenia whether or not associated with a coagulopathy, hepatic infiltration with disorders of liver function, and pulmonary involvement. The choice of the optimum date for treatment initiation in order to prevent irreversible damage is a key point. Over 3000 patients are receiving treatment worldwide, with a maximum follow-up of 13 years. The therapeutic results have been the subject of several analyses [22]. The response to ERT is generally excellent, although marked interindividual variability exists [24]. Persistent hypersplenism and multiple splenic infarctions, hepatic cirrhosis and pulmonary hypertension are all determinant factors for a poor response.

Patients generally respond well to ERT, irrespective of the degree of severity of the disease. Patients who are initially very severely affected respond as well as less severely affected cases [22]. The majority of patients report rapid resolution of asthenia and bone and abdominal pain. In patients presenting with hepatomegaly, the reduction in liver volume is, on average, 20% and 30% after 6 and 12 months respectively. In subjects presenting with major splenomegaly, a 50% reduction in spleen volume after 12 months may be expected. The alleviation of organomegaly is frequently particularly marked over the first 6 months of treatment and appears to be more marked in severely affected patients. However, in patients with advanced cirrhosis, intensive enzyme therapy, whatever the regimen, fails to ameliorate portal hypertension and the risk of life-threatening variceal haemorrhage. In anaemic patients, the haemoglobin level rises to 1.5 g/dL in 6 months and normalizes in 1 year [22]. Thrombocytopenia responds more slowly and 12 months of replacement therapy are necessary to achieve a twofold increase in platelet count. Patients initially presenting with severe thrombocytopenia (< 30 000 platelets/μL) respond only very slowly, particularly in the event of major splenomegaly. The haematological response is better in splenectomized patients [22]. The results of ERT on bone lesions require longer durations to become clinically appreciable. While bone pain gradually subsides over 3 months, contributing to the improvement in the patients' quality of life [25], a duration of 3 years may be necessary for objective documentation of alleviation of bone involvement, in particular in trabecular and cortical bone. The slow therapeutic response is perhaps better explained by pre-existing bone lesions, which should be concomitantly treated with adjuvants, such as bisphosphonates [21]. The optimum dosing regimen (dosage and dosing frequency) for the enzyme is still under discussion, given the high cost of the therapy, but also taking into account patients' quality of life. Dosage should be determined on an individual basis. The minimal effective dose for the non-skeletal manifestations of Gaucher disease can be achieved either by initiating enzyme replacement therapy with a high dose followed by a stepwise dose reduction or by starting treatment at the minimal dose. While the optimum dosing frequency remains controversial, the analysis of the various published

studies clearly shows that high dosages are not superior with respect to improving haematological and clinical parameters [26]. The therapeutic threshold for macrophage-targeted glucocerebrosidase appears to be 15 IU/kg body weight every 2 weeks. The response to enzyme therapy should be monitored by following symptoms, radiology and laboratory markers of Gaucher disease.

There are indications that enzyme therapy may also ameliorate some of the neurological features of subacute GD (type 3). ERT in GD type 2 has not been shown to alter the ultimate neurological outcome and its use in these patients is deemed inappropriate [27].

ERT is usually well tolerated. The main problem related to alglucerase injections is immediate hypersensitivity reactions. Antibodies of type IgG (subclasses 1 and 3) against alglucerase develop in 10–15% of patients treated, about 6 months after the initiation of treatment. Of those patients, 50% present with pruritus or urticaria on enzyme infusion, without it being necessary to discontinue treatment. Some patients develop neutralizing antibodies [28,29]. A small number of seronegative patients, not responding to ERT, for unknown reasons, have been reported. Recombinant glucocerebrosidase (imiglucerase) has comparable efficacy to alglucerase, with less adverse effects.

Splenectomy, formerly indicated for the treatment of severe anaemia and thrombocytopenia, has become much less widely indicated since the advent of ERT. The fact that pulmonary and bone involvement appears to progress more rapidly in splenectomized patients is another argument for rejecting splenectomy. The current indications for splenectomy are the rare cases in which splenomegaly seems to be the cause of a poor response to ERT.

The clinical manifestations of type 1 GD are due to substrate overload of monocyte/macrophage cells. Bone marrow transplant has therefore been suggested and some patients have received a bone marrow transplant successfully (including decreased organomegaly and improved general condition). However, several deaths after bone marrow transplant have also been reported. With the advent of safe and effective ERT, the indication of bone marrow transplant as the first-line treatment of type 1 GD now appears extremely limited.

Orthotopic liver transplantation has been claimed to cure Gaucher disease through microchimaerism between donor macrophages and lymphocytes in extrahepatic tissues of the recipient, where these donor-derived cells produce normal enzyme for uptake by deficient cells [30]. However, unlike other lysosomal enzymes, endogenous glucocerebrosidase does not undergo secretion–recapture and therefore, as expected, Gaucher disease progresses rapidly following transplantation if replacement enzyme is not infused [31]. Thus, the only indications for orthotopic liver transplantation in Gaucher disease are the rare patients with cirrhosis and hepatic decompensation.

Substrate reduction therapy has been examined as a means of reducing tissue GSL (glycosphingolipid) storage by limiting the amount of the precursor synthesized to a level that can be cleared by the affected enzyme with residual hydrolytic activity. There are two classes of GSL synthesis inhibitors: the PDMP (1-phenyl-2-decanoylamino-3-morpholino-propanol) and *N*-alkylated imino sugar analogues. These compounds act on ceramide-specific glucosyl transferase. Of these compounds, only NB-DNJ (miglustat) has been through clinical trials [32]. A multicentre phase I/II open-label study of miglustat to adult patients with GD type 1 was conducted on a total of 28 subjects. At 12 months there was a significant mean decrease in liver and spleen volume from baseline with corresponding modest increases in haemoglobin (0.26 g/dL) and platelets (8.3×10^9/L). These findings were associated with a significant decrease in plasma chitotriosidase activity (16.4%) [32]. A total of 18 patients continued to receive miglustat in an extended treatment protocol, and evaluation at 18 months revealed continued improvement and/or no signs of clinical GD deterioration. After 3 years of continuous miglustat treatment, mean reductions in liver and spleen volume were 17.5% and 29.6%, respectively, with a mean increase in platelet count of 22×10^9/L and an increase in haemoglobin concentration of 0.95 g/dL. Several adverse events prompted a study to evaluate the safety and efficacy of a lower drug dose (50 mg t.i.d.) [33]. A total of 18 patients were enrolled in an open-label 6-month study followed by an optional extended-use phase for an additional 6 months. The observed responses (5.9% and 4.5% reduction in liver and spleen volume, respectively, with a 4.6% decrease in chitotriosidase levels at 6 months) were less than those reported on 100 mg t.i.d. of miglustat [33]. The efficacy of miglustat for the neuronopathic forms of GD was not examined in the current clinical trials. The most common adverse reactions noted with the use of miglustat included weight loss, bloating, flatulence and diarrhoea. During the trial, 30% of patients on miglustat reported tremor or exacerbation of an existing tremor. In many cases, the tremor resolved between 1 and 3 months whilst on treatment. The European Agency for the Evaluation of Medicinal Products (EMAE) and the US Food and Drug Administration (FDA) granted marketing authorization for miglustat in 2002 and 2003 respectively. The role of substrate-reduction therapy for the treatment of type 1 GD has been reviewed by an independent international advisory council to the European Working Group on Gaucher Disease [27].

More recently, advances in molecular genetics have enabled exploration of other potential therapeutic options such as chaperone-mediated enhancement therapy [34].

The exogenous enzyme administered by infusion does not cross the blood–brain barrier and the neurological component does not respond to ERT. In particular, type 2 GD is not amenable to any current therapeutic resource [35]. The efficacy of ERT in type 3 GD is partial and controversial. While the visceral manifestations are conventionally alleviated, treatment does not arrest the emergence or progression of neurological deterioration. Because the neurological forms of GD do not respond to ERT, the pursuit of gene therapy studies remains justified [36–38].

Type A and B Niemann–Pick diseases

Niemann–Pick disease (NPD) is a lysosomal storage disease caused by the deficient activity of acid sphingomyelinase (ASM) and the accumulation of sphingomyelin within cells of the monocyte/macrophage system. Niemann–Pick disease types A and B are inherited as autosomal recessive traits and result from allelic mutations in the *ASM* gene. Niemann–Pick (NP) type A (NP-A), which is more frequent in the Ashkenazi Jewish population, is a fatal neurodegenerative disorder of infancy [39]. In contrast, NP type B (NP-B), which is panethnic, is a non-neuronopathic disease characterized by hepatosplenomegaly, hyperlipidaemia and pulmonary involvement, with most patients living into adulthood. Other features of NP-B may include liver dysfunction, cardiac disease, retinal stigmata and growth retardation. There is a wide spectrum of disease manifestations among NP-B patients, ranging from onset in childhood with massive hepatosplenomegaly with secondary hypersplenism, an atherogenic lipid profile, growth restriction, and later pulmonary involvement or liver failure to a milder, attenuated course during which symptoms appear to remain generally slight over a long period, with the late development of a restrictive ventilatory defect [40]. In NP-B, the evaluation of liver function reveals mild elevations of serum transaminase activities and bilirubin concentrations. Biopsy specimens show vacuolated, lipid-laden cells with or without fibrosis. In addition, several cases of severe liver disease have been reported in patients with NP-B, ranging from children with fatal hepatic failure to adults with cirrhosis and portal hypertension. These clinical descriptions, coupled with the findings on pathological examination of the liver, raise concerns about the ultimate contribution of liver dysfunction to the morbidity and mortality of NP-B patients. Serum transaminases are abnormal in most patients and tend not to change significantly over time. Diagnosis can be made in childhood or adulthood by finding hepatosplenomegaly or chronic interstitial pattern on chest radiographs. As in other lysosomal storage diseases, this marked phenotypic variability is influenced by genotype although other factors such as gender and age may also contribute to disease severity.

Niemann–Pick disease type C

Niemann–Pick disease type C (NP-C) is an autosomal recessive lipidosis with protean clinical manifestations. At the cellular level, the disorder is characterized by accumulation of unesterified cholesterol and glycolipids in the lysosomal/late endosomal system. Approximatively 95% of patients have mutations in the *NPC1* gene (mapped at 18q11), which encodes a large membrane glycoprotein primarily located in late endosomes [41]. The remainder have mutations in the *NPC2* gene (mapped at 14q24.3), which encodes a small soluble lysosomal protein with cholesterol-binding properties. The phenotypic presentation of NP-C is remarkably variable. Onset may occur at any age, but the 'classical' juvenile type commonly presents at preschool age with clumsiness (ataxial gait) and/or hepatosplenomegaly. Prominent manifestations include progressive dementia, cataplexy, dysarthria, dystonia, dysphagia and seizures, Vertical supranuclear gaze palsy is a hallmark of NP-C. The diagnosis should also be considered in patients with unexplained neonatal hepatitis, especially if splenomegaly is a persistent feature. Children showing symptoms before 1 year of age usually die before entering school, while those who present with symptoms at school age typically live into their teens. The rarer adult-onset form has a slowly progressive course. Psychotic manifestations associated with cerebellar syndrome, vertical supranuclear gaze palsy, and splenomegaly are very suggestive of NP-C disease, which can be reliably diagnosed on cultured skin fibroblasts by filipin staining [42]. Recent insights into the pathophysiology of NP-C raise the possibility of small molecule therapies to interdict pathways triggering apoptosis and related routes to cell death and dysfunction [43].

Wolman disease and cholesteryl ester storage disease

Wolman disease and cholesteryl ester storage disease (CESD) are rare allelic autosomal recessive inherited disorders of lipid metabolism caused by deficient activity of lysosomal acid lipase (LAL). The mature 378-amino-acid protein is encoded by the *LIPA* gene on chromosome 10q23.2-q23.3, which contains 10 exons over a 38-kb region. LAL is essential for the intralysosomal breakdown of cholesteryl esters and triglycerides in various lipoproteins that are taken up by receptor-mediated endocytosis. An inherited deficiency results in massive intralysosomal storage of the respective lipid substrates in most tissues of the body. As the enzyme is synthesized by all nucleated cells, lipid-laden cells are found in all organs, particularly in liver, spleen, adrenal, marrow, intestine and lymph nodes.

The deficiency of LAL in humans causes two different phenotypes: Wolman disease and cholesteryl ester storage disease (CESD). Wolman disease is an early-onset fulminant disorder of infancy with massive infiltration of the liver, spleen and other organs by macrophages filled with cholesteryl esters and triglycerides. Wolman disease leads to hydrops fetalis and congenital ascites as well as an abnormal neurological development, and is nearly always fatal before the age of 1 year. Affected infants show signs of lipid storage in most tissues, including hepatosplenomegaly, abdominal distension, vomiting, steatorrhoea, failure to thrive and adrenal calcifications. CESD is less severe and presents as a milder form associated with higher residual enzyme activity; it results in widespread lipid deposition and can induce symptoms at any age. CESD patients present in childhood with hepatomegaly and dyslipidaemia characterized by elevated total cholesterol and low-density lipoprotein cholesterol (LDL-C), with elevated triglycerides and depressed high-density lipoprotein cholesterol (HDL-C). Most patients are diagnosed by age 20 but CESD may not be detected until

adulthood. Lipid deposition is widespread, although hepatomegaly may be the only clinical abnormality. Hyperlipidaemia is common and premature atherosclerosis may be severe.

Hepatomegaly is a constant feature of Wolman disease and CESD. The architecture of the liver is occasionally preserved but more often is severely distorted. The liver in CESD has a remarkable orange appearance. Microscopic examination of CESD liver reveals many of the same abnormalities as in Wolman disease. The hepatocytes are hypertrophied and vacuolated. There are lipid droplets in hepatic parenchymal cells resembling those in ordinary fatty infiltration and enlargement of Kupffer cells by smaller vacuoles and by periodic acid–Schiff-positive granules. This is accompanied by variable amounts of septal fibrosis and there may be micronodular cirrhosis with oesophageal varices. Liver function tests, and other routine laboratory investigations, are usually normal.

The diagnosis is often made after a liver biopsy, as the sample has a characteristic orange appearance and there are typical abnormalities on light and electron microscopy. The cholesteryl ester content of the biopsy is very high. Samples should be taken for electron microscopy in all young patients who might have a metabolic cause for hepatomegaly. However, the liver biopsy is not necessary if the condition is suspected on clinical grounds as the diagnosis can be confirmed by demonstration of a reduced LAL activity in peripheral blood leukocytes or cultured skin fibroblasts and liver homogenates. Patients with either Wolman disease or CESD will have a drastically reduced activity. More recently, mutational screening of the human LAL gene (*LIPA*) has been used for diagnosis [44].

Lipoprotein disorders

Hypolipoproteinaemias

Abetalipoproteinaemia

Abetalipoproteinaemia is an autosomal recessive trait characterized by the absence of plasma apolipoprotein B-containing lipoproteins – chylomicrons, low-density lipoprotein (LDL) and very-low-density lipoprotein (VLDL). In contrast, apolipoprotein B and triglyceride accumulate in hepatocytes and enterocytes. Clinical features include abnormalities of red-cell morphology (acanthocytosis), which affect 50–100% of circulating erythrocytes. Abnormal red cells are not found in the marrow, suggesting that the membrane changes leading to malformations are acquired by contact with plasma. Red-cell survival is frequently shortened and hyperbilirubinaemia has been described. Like the erythrocytes, the platelet membranes show compositional changes. The prothrombin time is prolonged due to vitamin K deficiency. Malabsorption of fat is a central pathophysiological feature of abetalipoproteinaemia. It is frequently observed in neonates, with vomiting, diarrhoea and failure to thrive. The transport of tocopherol in blood is severely inhibited in abetalipoproteinaemia, leading to spinocerebellar ataxia together with peripheral neuropathy, and ceroid pigment myopathy. The most prominent ophthalmic abnormality is degenerative pigmentary retinopathy. The metabolic defect in abetalipoproteinaemia is due to mutations in the gene encoding microsomal triglyceride transfer protein, a factor critical to the intracellular lipidation of apolipoprotein B [45]. Despite the inability of the liver to secrete VLDL, abnormalities of liver function are uncommon in abetalipoproteinaemia. A few patients have abnormal serum levels of transaminases, and cirrhosis has been reported in three cases. However, two of these cases had been treated with medium-chain triglycerides.

Treatment involves reduction of dietary fat to prevent steatorrhoea and supplementation with tocopherol to prevent progression of the neuromuscular degenerative disease [46].

Familial hypobetalipoproteinaemia

Truncation-causing mutations in the *APOB* gene on chromosome 2 cause most cases of familial hypobetalipoproteinaemia (FHBL), a rare autosomal dominant disorder with a gene dosage effect characterized by marked hypocholesterolaemia. Naturally occurring gene mutations in affected families have been useful in identifying important domains of apoB. In the homozygous state, clinical manifestations are indistinguishable from those of abetalipoproteinaemia. A major difference is that hypolipidaemia is present in FHBL heterozygotes. Fatty liver and liver fibrosis have been reported in hypobetalipoproteinaemia [47].

Tangier disease

Mutations in the ATP-binding cassette transporter 1 (*ABCA1*) gene cause a severe high-density lipoprotein (HDL) deficiency syndrome called Tangier disease (TD), or familial analphalipoproteinaemia. The major clinical signs of TD include hyperplastic yellow-orange tonsils, relapsing neuropathy, splenomegaly, ocular abnormalities, cardiovascular disease and hepatomegaly (in about one-third of cases). Liver function tests are usually normal. Homozygotes have a virtual absence of plasma HDL and apolipoprotein (apo) A-I, hypocholesterolaemia and normal or elevated triglyceride levels. Heterozygotes have no clinical manifestations but half the normal levels of HDL cholesterol and apo A-I. TD is characterized by an accumulation of cholesteryl esters in reticuloendothelial cells of tissues including tonsils, thymus, lymph node, bone marrow, spleen, liver, cornea and intestinal mucosa. Many patients also have lipid deposits in neuronal Schwann cells. Tangier fibroblasts are characterized by defective lipid efflux. There is no specific treatment for Tangier disease.

Hyperlipoproteinaemia

Types 1, 4 and 5

Type 1 hyperlipidaemia is characterized by an accumulation of chylomicrons in plasma. Familial lipoprotein lipase deficiency is a rare autosomal recessive disorder characterized by absence of lipoprotein lipase (LPL) activity and a massive accumulation of chylomicrons in plasma. Patients suffer recurrent abdominal

pain due to acute pancreatitis triggered by massively elevated triglycerides in plasma, and eruptive cutaneous xanthomas. Hepatomegaly is very common in LPL deficiency. Familial LPL deficiency should be considered in anyone with the chylomicronaemia syndrome. With the recognition of the disease, the avoidance of unnecessary abdominal surgery and the maintenance of a low-fat diet, these patients can lead a fairly normal life. Familial apolipoprotein C II deficiency is a very rare autosomal recessive disorder in which apo C-II is absent, the clearance of chylomicrons from the blood is greatly impaired and triglycerides accumulate in plasma. The clinical manifestations are similar to those in primary LPL deficiency but it has been suggested that apo CII-deficient patients do not have hepatosplenomegaly as often [48].

Type 4 hyperlipidaemia is characterized by hypertriglyceridaemia with an increased concentration of VLDL. Most patients with this phenotype have an acquired abnormality, and the familial cases are rare. In the latter, the nature of the genetic abnormality is not known, neither is the mechanism of hypertriglyceridaemia, but some patients may have excess VLDL secretion and others impaired VLDL catabolism.

Type 5 hyperlipoproteinaemia is a highly diverse group of primary and secondary disorders with moderate to severe hypertriglyceridaemia and the presence in fasting plasma of large amounts of both chylomicrons and VLDL. Many individuals with monogenic familial hypertriglyceridaemia have moderate hypertriglyceridaemia with chylomicrons present in plasma after an overnight fast. Familial combined hyperlipidaemia is associated with large amounts of both chylomicrons and VLDL in fasting plasma. Each of the primary familial disorders with high plasma triglyceride and chylomicronaemia is rare. It has been demonstrated that the majority of patients with highly elevated plasma triglyceride levels have both a common familial form of hypertriglyceridaemia and a common secondary cause.

In each of these types of hyperlipoproteinaemia an enlarged and easily palpable liver is commonly found when there is severe hypertriglyceridaemia. The size of the organ decreases when plasma triglyceride falls in favour of a reversible accumulation of triglyceride within the liver, which contains lipid-laden macrophages (foam cells). The hepatocytes may also show vacuolation.

Familial hypercholesterolaemia

Familial hypercholesterolaemia (FH) is inherited as an autosomal dominant trait with a gene dosage effect, and is characterized clinically by an elevated concentration of LDL, the major cholesterol-transport protein in human plasma, and widespread accumulation of LDL-derived cholesterol in skin and tendons (xanthomas) and in arteries, resulting in severe coronary atherosclerosis. The primary defect in FH is a mutation in the gene encoding the receptor for LDL. The LDL receptor, which is located on the surfaces of cells in the liver and other organs, binds LDL with high affinity to mediate endocytosis and its delivery to lysosomes, where the ligand is degraded and its cholesterol released. When LDL receptors are deficient, the rate of removal of LDL from blood is markedly slowed, leading to elevation of LDL, which is in turn deposited in macrophages and other cell types, producing xanthomas and atheromas. More than 400 mutations in the gene encoding the LDL receptor have been reported to impair receptor function. The prevalence of heterozygotes is about 1 in 500, and that of homozygotes is estimated to be one in one million people. Heterozygotes have a mean twofold increase in plasma cholesterol from birth. Tendon xanthomas and coronary atherosclerosis develop after the mid-twenties. Both skin xanthomas and coronary heart disease begin in childhood. Patients frequently die from myocardial infarction before age 20.

In homozygous familial hypercholesterolaemia there is little or no response to dietary modification, bile-acid-binding resins, ileal bypass, or to hydroxymethylglutaryl-CoA (HMG-CoA) reductase inhibitors, which all act by inducing the normal LDL receptor gene. The main interest of FH for hepatologists lies in the surgical treatments that have been used in this life-threatening condition. Portocaval shunt surgery has the property to reduce plasma cholesterol by 25–50%. Studies suggested that diversion of portal blood away from the liver reduced total body cholesterol synthesis, LDL synthesis as well as bile-acid synthesis, through an unknown mechanism. Portocaval shunt surgery, although well tolerated, is not associated with sufficient reduction of cholesterol levels to be used as the sole therapy in familial hypercholesterolaemia homozygotes.

Liver transplantation has been proposed based on experimental data in animals showing that more than 70% of LDL receptors are in the liver. There are at least nine cases of patients with homozygous FH who have undergone liver transplantation. There was a dramatic reduction of LDL cholesterol to near-normal levels in all patients. Moreover, liver transplantation conferred responsiveness to HMG-CoA reductase inhibitors resulting in a further reduction of LDL levels and concomitant regression of xanthomatous deposits. However, the risk of the surgical procedure in patients with severe atherosclerosis together with the risks of long-term immunosuppression, have to be carefully considered [49].

References

1 Brady RO, Kanfer JN, Shapiro D (1965) Metabolism of glucocerebrosidase II. Evidence of an enzymatic deficiency in Gaucher's disease. *Biochem Biophys Res Commun* 18, 221–225.

2 Brady RO, Pentchev PG, Gal AE *et al.* (1974) Replacement therapy for inherited enzyme deficiency. Use of purified glucocerebrosidase in Gaucher's disease. *N Engl J Med* 291, 989–993.

3 Lachmann RH, Wight DG, Lomas DJ *et al.* (2000) Massive hepatic fibrosis in Gaucher's disease: clinico-pathological and radiological features. *Q J Med* 93, 237–244.

4 Wenstrup RJ, Roca-Espiau M *et al.*(2002) Skeletal aspects of Gaucher disease: a review. *Br J Radiol* 75 (Suppl. 1), A2–A12.

5 Maas M, Hollak CE, Akkerman EM *et al.* (2002) Quantification of skeletal involvement in adults with type I Gaucher's disease: fat

fraction measured by Dixon quantitative chemical shift imaging as a valid parameter. *Am J Roentgenol* 179, 961–965.

6 Mistry PK, Sirrs S, Chan A *et al.* (2002) Pulmonary hypertension in type 1 Gaucher's disease: genetic and epigenetic determinants of phenotype and response to therapy. *Mol Genet Metab* 77, 91–98.

7 Dawson A, Elias DJ, Rubenson D *et al.* (1996) Pulmonary hypertension developing after alglucerase therapy in two patients with type 1 Gaucher disease complicated by the hepatopulmonary syndrome. *Ann Intern Med* 125, 901–904.

8 Beutler E, Demina A, Laubscher K *et al.* (1995) The clinical course of treated and untreated Gaucher disease. A study of 45 patients. *Blood Cells Mol Dis* 21, 86–108.

9 Maaswinkel-Mooij P, Hollak C, van Eysden-Plaisier M *et al.* (2000) The natural course of Gaucher disease in The Netherlands: implications for monitoring of disease manifestations. *J Inherit Metab Dis* 23, 77–82.

10 Sidransky E, Sherer DM, Ginns EI (1992) Gaucher disease in the neonate: a distinct Gaucher phenotype is analogous to a mouse model created by targeted disruption of the glucocerebrosidase gene. *Pediatr Res* 32, 494–498.

11 Brady RO, Barton NW, Grabowski GA (1993) The role of neurogenetics in Gaucher disease. *Arch Neurol* 50, 1212–1224.

12 Erikson A (1986) Gaucher disease: Norrbottnian type 3. Neuropediatric and neurobiological aspects of clinical patterns and treatment. *Acta Paediatr Scand* 326, 1–42.

13 George R, McMahon J, Lytle B *et al.* (2001) Severe valvular and aortic arch calcification in a patient with Gaucher's disease homozygous for the D409H mutation. *Clin Genet* 59, 360–363.

14 Hollak CEM, van Weely S, van Oers MHJ, Aerts JMFG (1994) Marked elevation of plasma chitotriosidase activity. A novel hallmark of Gaucher disease. *J Clin Invest* 93, 1288–1292.

15 Boot RG, Verhoek M, De Fost M *et al.* (2004) Marked elevation of the chemokine CCL18/PARC in Gaucher disease: a novel surrogate marker for assessing therapeutic intervention. *Blood* 103, 33–39.

16 Grabowski GA (1997) Gaucher disease: gene frequencies and genotype/phenotype correlations. *Genet Test* 1, 5–12.

17 Germain DP, Puech JP, Caillaud C *et al.* (1998) Exhaustive screening of the acid beta-glucosidase gene, by fluorescence-assisted mismatch analysis using universal primers: mutation profile and genotype/phenotype correlations in Gaucher disease. *Am J Hum Genet* 63, 415–427.

18 NIH Technology Assessment Panel on Gaucher Disease (1996) Gaucher disease. Current issues in diagnosis and treatment. *JAMA* 275, 548–553.

19 Lachmann RH, Grant IR, Halsall D, Cox TM (2004) Twin pairs showing discordance of phenotype in adult Gaucher's disease. *Q J Med* 97, 199–204.

20 Barton NW, Brady RO, Dambrosia JM *et al.* (1991) Replacement therapy for inherited enzyme deficiency – macrophage-targeted glucocerebrosidase for Gaucher's disease. *N Engl J Med* 324, 1464–1470.

21 Wenstrup RJ, Bailey L, Grabowski GA *et al.* (2004) Gaucher disease: alendronate disodium improves bone mineral density in adults receiving enzyme therapy. *Blood* 104, 1253–1257.

22 Weinreb NJ, Charrow J, Andersson HC *et al.* (2002) Effectiveness of enzyme replacement therapy in 1028 patients with type 1 Gaucher disease after 2 to 5 years of treatment: a report from the Gaucher Registry. *Am J Med* 113, 112–119.

23 Grabowski GA, Hopkin RJ (2003) Enzyme therapy for lysosomal storage disease: principles, practice, and prospects. *Annu Rev Genomics Hum Genet* 4, 403–436.

24 Perel Y, Bioulac-Sage P, Chateil JF *et al.* (2002) Gaucher's disease and fatal hepatic fibrosis despite prolonged enzyme replacement therapy. *Pediatrics* 109, 1170–1173.

25 Damiano AM, Pastores GM, Ware JE Jr (1998) The health-related quality of life of adults with Gaucher's disease receiving enzyme replacement therapy: results from a retrospective study. *Qual Life Res* 7, 373–386.

26 Altarescu G, Schiffmann R, Parker CC *et al.* (2000) Comparative efficacy of dose regimens in enzyme replacement therapy of type I Gaucher disease. *Blood Cells Mol Dis* 26, 285–290.

27 Cox TM, Aerts JM, Andria G *et al.* (2003) The role of the iminosugar N-butyldeoxynojirimycin (miglustat) in the management of type I (non-neuronopathic) Gaucher disease: a position statement. *J Inherit Metab Dis* 26, 513–526.

28 Brady RO, Murray GJ, Oliver KL *et al.* (1997) Management of neutralizing antibody to Ceredase in a patient with type 3 Gaucher disease. *Pediatrics* 100, e11–e14.

29 Germain DP, Kaneski CR, Brady RO (2001) Mutation analysis of the acid beta-glucosidase gene in a patient with type 3 Gaucher disease and neutralizing antibody to alglucerase. *Mutat Res* 483, 89–94.

30 Starzl TE, Demetris AJ, Trucco M *et al.* (1993) Chimerism after liver transplantation for type IV glycogen storage disease and type 1 Gaucher's disease. *N Engl J Med* 328, 745–749.

31 Carlson DE, Busuttil RW, Giudici TA, Barranger JA (1990) Orthotopic liver transplantation in the treatment of complications of type 1 Gaucher disease. *Transplantation* 49, 1192–1194.

32 Cox T, Lachmann R, Hollak C *et al.* (2000) Novel oral treatment of Gaucher's disease with N-butyldeoxynojirimycin (OGT 918) to decrease substrate biosynthesis. *Lancet* 355, 1481–1485.

33 Heitner R, Elstein D, Aerts J *et al.* (2002) Low-dose N-butyldeoxynojirimycin (OGT 918) for type I Gaucher disease. *Blood Cells Mol Dis* 28, 127–133.

34 Sawkar AR, Adamski-Werner SL, Cheng WC *et al.* (2005) Gaucher disease-associated glucocerebrosidases show mutation-dependent chemical chaperoning profiles. *Chem Biol* 12, 1235–1244.

35 Vellodi A, Bembi B, de Villemeur TB *et al.* (2001) Management of neuronopathic Gaucher disease: a European consensus. *J Inherit Metab Dis* 24, 319–327.

36 Kohn DB (2001) Gene therapy for genetic haematological disorders and immunodeficiencies. *J Intern Med* 249, 379–390.

37 Kim EY, Hong YB, Lai Z *et al.* (2005) Long-term expression of the human glucocerebrosidase gene *in vivo* after transplantation of bone-marrow-derived cells transformed with a lentivirus vector. *J Gene Med* 7, 878–887.

38 Lee KO, Luu N, Kaneski CR *et al.* (2005) Improved intracellular delivery of glucocerebrosidase mediated by the HIV-1 TAT protein transduction domain. *Biochem Biophys Res Commun* 337, 701–707.

39 McGovern MM, Aron A, Brodie SE *et al.* (2006) Natural history of type A Niemann-Pick disease: possible endpoints for therapeutic trials. *Neurology* 66, 228–232.

40 Wasserstein MP, Desnick RJ, Schuchman EH *et al.* (2004) The natural history of type B Niemann-Pick disease: results from a 10-year longitudinal study. *Pediatrics* 114, e672–e677.

41 Pentchev PG (2004) Niemann-Pick C research from mouse to gene. *Biochim Biophys Acta* 1685, 3–7.

42 Vanier MT, Millat G (2003) Niemann-Pick disease type C. *Clin Genet* 64, 269–281.

43 Patterson MC, Platt F (2004) Therapy of Niemann-Pick disease, type C. *Biochim Biophys Acta* 1685, 77–82.
44 Assmann G, Seedorf U (2001) Acid lipase deficiency: Wolman disease and cholesteryl ester storage deficiency. In: Scriver CR, Sly WS, Barton Childs AL *et al*. (eds) *The Metabolic and Molecular Bases of Inherited Disease*. New York: McGraw Hill, pp. 3551–3572.
45 Wetterau JR, Aggerbeck LP, Bouma ME *et al.* (1992) Absence of microsomal triglyceride transfer protein in individuals with abetalipoproteinemia. *Science* 258, 999–1001.
46 Kane JP, Havel R (2001) Disorders of the biogenesis and secretion of lipoproteins containing the B apolipoproteins. In: Scriver CR, Sly WS, Barton Childs AL *et al*. (eds) *The Metabolic and Molecular Bases of Inherited Disease*. New York: McGraw Hill, pp. 2717–2752.
47 Schonfeld G (2003) Familial hypobetalipoproteinemia: a review. *J Lipid Res* 44, 878–883.
48 Brunzell JD, Deeb SS (2001) Familial lipoprotein lipase deficiency, apo C-II deficiency, and hepatic lipase deficiency. In: Scriver CR, Sly WS, Barton Childs AL *et al*. (eds) *The Metabolic and Molecular Bases of Inherited Disease*. New York: McGraw Hill, pp. 2789–2816.
49 Goldstein JL, Hobbs HH, Brown MS (2001) Familial hypercholesterolemia. In: Scriver CR, Sly WS, Barton Childs AL *et al*. (eds) *The Metabolic and Molecular Bases of Inherited Disease*. New York: McGraw Hill, pp. 2863–2913.

16.8 Glycogen storage diseases

Philippe Labrune

Glycogen storage diseases (GSDs) are rare inherited disorders of glycogen metabolism that may have various clinical manifestations, according to the most seriously affected tissues, even though liver and muscle, which have abundant quantities of glycogen, are the most frequently and seriously affected. Several types of GSDs have been described and identified, in accordance with the disease-causing enzymatic defects.

Glycogen metabolism and classification of GSDs [1]

Glycogen is the storage form of glucose in almost all animal cells. The main function of glycogen may vary in different tissues. In the liver, glucose is taken from the bloodstream after meals and stored as glycogen; conversely, when blood glucose levels are decreasing, glucose is released into the blood for supplying tissues that cannot produce glucose by themselves. In the skeletal muscle, glycogen is used as a fuel for short-term consumption by the cell in which it is stored.

The synthesis and breakdown of glycogen involve many enzymes. Hexokinases catalyse the first step of glucose metabolism, namely the transformation of glucose and adenosine triphosphate (ATP) into glucose 6-phosphate and ADP (Fig. 1); they are not regulated by insulin or glucagon. Glucokinase, also called hexokinase IV, is expressed in liver and pancreas β cells. Its activity is the same as that of hexokinases, but glucokinases have highly regulated activities. Glucose 6-phosphate is then converted into glucose 1-phosphate, which serves as a substrate to uridine diphosphoglucose (UDP-glucose) pyrophosphorylase. This enzyme provides the UDP-glucose needed by glycogen synthase. Glycogen synthase, the rate-limiting enzyme in glycogen synthesis, transfers glucose units from UDP-glucose to a glycogen primer; liver and muscle glycogen synthases are different gene products. Glycogen synthase activity is highly regulated, being stimulated by insulin and inhibited by glucagon and epinephrine. Glycogen synthase deficiency has sometimes been referred to as GSD type 0 and results from mutations within the gene coding liver glycogen synthase. Glycogen branching enzyme is less abundant in muscle than in liver. It transfers at least six α1–4 glucosyl units from the end of the chain of glycogen into an α1–6 position on the same or a close chain. Glycogen branching enzyme deficiency is referred to as GSD type 4.

Glycogen phosphorylase degrades the glycogen chains and stops four glucosyl units before an α1–6 branch point; then the transferase activity of debranching enzyme transfers three glucose to the end of another branch. Debranching enzyme can then hydrolyse the α1–6 branch point, using its amylo-1,6-glucosidase activity. Debranching enzyme has two independent activities occurring at different sites on the same polypeptide. Debranching enzyme deficiency is referred to as GSD type 3. The human debranching enzyme gene has been cloned: it is a large gene spanning 85 kb and containing 35 exons.

Glycogen phosphorylase cleaves glucose units from α1–4-linked chains of glycogen, liberating glucose 1-phosphate. Three different isozymes, encoded by three different genes, have been identified in humans (liver, muscle and brain). All three are activated by phosphorylation (induced by glucagon and epinephrine) and inhibited by dephosphorylation by protein phosphatase. Hepatic phosphorylase deficiency is referred to as GSD type 6, whereas muscle phosphorylase deficiency, whose clinical manifestations are entirely different, is referred to as GSD type 5 (McArdle disease).

Phosphorylase kinase is a protein kinase that is able to phosphorylate and thus to activate glycogen phosphorylase, resulting in glycogen breakdown. Phosphorylase kinase is itself activated by Ca^{2+} and by phosphorylation by cAMP-dependent protein kinase. Phosphorylase kinase is made of four different subunits: two (α and β) are regulatory subunits, one (γ) is the catalytic subunit and the δ subunit, regulated by Ca^{2+}, is the protein calmodulin. The four subunits are encoded by different genes. There are different forms of phosphorylase kinase deficiency, referred to as GSD type 9.

The glucose 6-phosphatase system catalyses the final step in both glycogenolysis and neoglucogenesis. It transforms glucose 6-phosphate into glucose and phosphate, thus producing important amounts of free glucose. Glucose 6-phosphatase activity is highly expressed in liver, kidney and pancreas β cells.

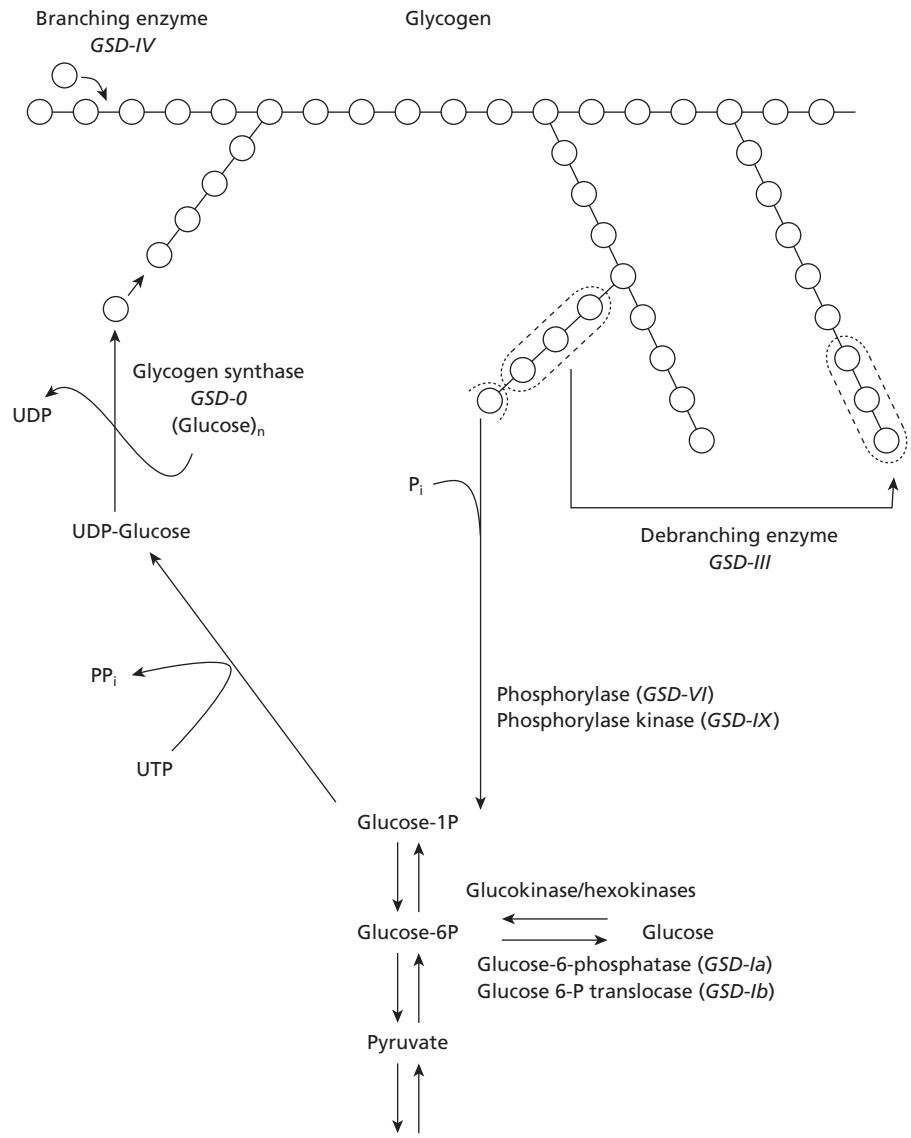

Fig. 1 Steps in glycogen metabolism.

It is active within the lumen of the endoplasmic reticulum, thus implying that its substrates and products must cross the endoplasmic reticulum membrane. The catalytic unit of glucose 6-phosphatase is the product of a single gene whose expression is reduced by insulin. The deficiency of this catalytic activity is referred to as GSD type 1a. The human gene has been cloned, spans 12.5 kb and consists of 5 exons.

In order to be hydrolysed, glucose 6-phosphate must be transported into the lumen of the endoplasmic reticulum. To date, the existence of a transporter 'T1' (glucose 6-phosphate translocase) has been confirmed by the cloning of a cDNA coding for a putative transporter, even though the transporter itself has not been purified. Mutations in this gene, which consists of nine exons, cause GSD type 1b. A phosphate transport protein has been purified, but neither its gene nor its cDNA has been cloned; thus, the existence of GSD type 1c (related to a deficiency in phosphate transporter) is still controversial.

GSD type 1

Clinical and biological manifestations

Type 1 GSD, often referred to as 'von Gierke disease', is due to the deficiency of glucose 6-phosphatase activity. Irrespective of the subtype, patients with GSD I usually present at 4–6 months of age with protruded abdomen (related to hepatomegaly), symptoms of acute metabolic derangement (hypoglycaemia often resulting in seizures, lactic acidosis), failure to thrive or growth retardation, muscular hypotonia and recurrent infections (especially in GSD Ib). In rare cases, fasting tolerance is subnormal and patients may be asymptomatic [2]. These children often have doll-like facies and thin extremities. Physical examination only reveals massive and soft hepatomegaly. Splenomegaly may be noted in type 1b, especially when granulocyte colony-stimulating factor (G-CSF) or

granulocyte–macrophage colony-stimulating factor (GM-CSF) injections are performed. Skin xanthomas may be present in infancy. In patients with GSD Ib, recurrent infections, oral and mucosal ulcerations may be noted, as well as symptoms suggesting inflammatory bowel disease. The biological hallmarks of GSD I are fast-induced (sometimes hardly 3 h) hypoglycaemia and lactic acidosis, hyperuricaemia, hypertriglyceridaemia and, less prominently, hypercholesterolaemia. Impaired platelet adhesion and aggregation are common, often resulting in easy bruising and epistaxis. Increased levels of numerous serum proteins are frequently observed, especially fibrinogen and C-reactive protein. Similarly, increased levels of haemostasis proteins with hepatic synthesis have been reported [3]. In type 1b, neutropenia and impaired neutrophil function are common.

Long-term outcome

To date, the complications observed in adults occur in patients whose disease has not been adequately treated, and it is hoped that, with correct treatment and follow-up, most of these complications can be prevented [2]. Growth is often impaired and puberty usually delayed (with delayed bone maturation). According to the results of a European study on GSD I, adult height might be reduced: median at –1.2 SD for type 1a, –2.6 SD for type 1b. Adult height was reached at a median age of 21 years in males and at a median age of 20 years in females. Osteopenia is frequent but rarely leads to complications such as multiple fractures. Polycystic ovaries are quite frequent on ultrasound examination in teenage girls. Mental development may be delayed in patients who had experienced hypoglycaemic coma (32% of low to borderline IQ), whereas it is normal in other patients [3]. Recently, cerebral lesions likely to be secondary to hypoglycaemic episodes have been reported on magnetic resonance imaging (MRI) in GSD I patients [4]. Complications resulting from hyperlipidaemia are not very frequent (pancreatitis) and, even though these patients should be predisposed to atherosclerosis, convincing data have been reported showing that GSD I is not associated with premature atherosclerosis [5]. Complications due to hyperuricaemia can be observed such as renal calcifications, kidney stones, gouty arthritis and tophi; they can be prevented by xanthine oxidase inhibitors. Complications related to bleeding tendency are frequent and must be prevented, especially when surgical procedures are considered.

Hepatocellular adenomas (HCAs) are present in most patients by the second or third decade of life, their prevalence increasing with age; their pathophysiological mechanisms are still unclear, but metabolic causes seem more likely than hormonal [6]. The main complications of HCAs are bleeding and malignant transformations into hepatocellular carcinoma (HCC). Even if HCC is a rare event, several cases have been reported, always following the previous detection of HCA [7]. The follow-up of patients with HCAs is difficult because neither α-fetoprotein not carcinoembryonic antigen is a reliable marker to detect the malignant transformation. The diagnosis of HCC relies primarily on radiological examinations. Aggressive interventional management of HCAs with rapid growth or poorly defined margins may be necessary to prevent the development of HCC [7].

Renal disease is also frequent, and the overall prevalences of proteinuria and microalbuminuria were 13% and 31%, respectively, in a series of 288 GSD I patients. Hypertension, renal stones and nephrocalcinosis may develop. Progressive glomerular disease may evolve to terminal renal failure, requiring dialysis and transplantation. Pulmonary hypertension has been reported in seven patients: its origin is unknown (an abnormal platelet metabolism of serotonin has been suggested), and its prognosis poor [8]. Some complications are specific to GSD Ib: recurrent infections and inflammatory bowel disease. Gastrointestinal symptoms may be noted in up to 75% of GSD Ib patients with chronic abdominal pains, diarrhoea, perianal fistula or abscess; these symptoms may be indistinguishable from idiopathic Crohn disease [2]. Contraception (which must be adapted to the metabolic abnormalities) and pregnancy raise specific problems in women with GSD I [9,10]: owing to frequent nausea at the beginning of pregnancy, regular feeding may be difficult, and there is a risk of severe lactic acidosis during labour. Three young GSD I women gave birth to three healthy children, and two young men had five healthy offspring [2].

Genetics

Both cDNAs encoding human liver glucose 6-phosphatase and glucose 6-phosphate translocase have been cloned, and mutations responsible for type 1a and type 1b GSD have been identified. In both cases, allelic heterogeneity is noted, and exhaustive reviews have been published [11]. Ethnic-specific mutations in the glucose 6-phosphatase gene have been reported: p.R83C and p.Q347X in Caucasians, p.R83C in Jews. Genotype–phenotype correlations are rare: homozygosity for the p.G188R mutation in the glucose 6-phosphatase gene seems to be associated with a GSD I non-a phenotype and homozygosity for the c.727G→T mutation may be associated with a milder phenotype but an increased risk of HCC. Similarly, two mutations, p.G339C and c.1211delCT, are prevalent in Caucasian patients with GDSD Ib. The mutational analyses provide, in almost all cases, a non-invasive way of diagnosing GSD, and the indications of liver needle biopsy have become very rare. However, as neutropenia and recurrent infections are not always present in GSD I non-a and neutrophil dysfunction may be present in some GSD Ia patients, analysis of both genes is recommended before considering a liver biopsy [11]. Molecular analyses are the only reliable way to perform prenatal diagnosis.

Treatment

The aim of the treatment is to achieve optimal metabolic control, thereby avoiding hypoglycaemia and suppressing decompensations as much as possible [12,13]. Different approaches may be

used: frequent daily meals, oral administration of uncooked cornstarch, nocturnal gastric drip feeding. Breastfeeding may be used as long as the targets are reached. Fructose and galactose intakes must be reduced. Glucose requirements decrease with age and are calculated from the theoretical glucose production rate. The target is to maintain a preprandial blood glucose concentration above 3.5–4.0 mmol/L, with a urine lactate/creatinine ratio under 0.06 mmol/mmol. When, in spite of adjusted dietary treatment, venous blood bicarbonate is under 20 mmol/L or blood base excess below –5 mmol/L, lactacidaemia must be corrected, using sodium bicarbonate 1–2 mmol/kg/day orally; recent work has shown that hypocitraturia occurs in GSD Ia patients and worsens with age, thus suggesting that alkalinization with citrate may be more appropriate in preventing urolithiasis and nephrocalcinosis. Allopurinol may be indicated when hyperuricaemia is above the high normal range for age and laboratory; marked hypertriglyceridaemia may also require medical treatment (fibrates, nicotinic acid). When persistent microalbuminuria is noted, an angiotensin-converting enzyme (ACE) inhibitor must be started to slow down any further deterioration in renal function, in analogy to diabetic nephropathy; additional blood pressure-lowering drugs should be started if, in spite of ACE inhibitors, blood pressure remains above the 95th percentile for age. Oral supplementations of vitamins and minerals may be necessary, and special attention is required regarding calcium (limited milk intake) and vitamins D and B1 (oral supplementation may be indicated in a few patients). In GSD Ib, G-CSF and GM-CSF have been used successfully to correct neutropenia; they are also useful in decreasing the severity of inflammatory bowel disease [14]. Finally, liver and renal transplantations are rarely indicated, and their indications must be discussed in specialized units [15,16]. It is noteworthy that liver transplantation does not correct neutropenia in GSD Ib patients. Guidelines for management of both types of GSD type 1 have been published recently [12,13]. Several studies are still in progress to evaluate the feasibility of gene replacement therapy.

GSD type 3

Owing to the deficiency of debranching enzyme, GSD type 3 is also called Cori or Forbes disease. Sometimes, it is referred to as limit dextrinosis. Most patients have both liver and muscle involvements (GSD 3a), but 15% of patients only have hepatic manifestations (GSD 3b). In infancy and childhood, it is sometimes difficult to distinguish between type 3 and type 1, as hepatomegaly, fast-induced hypoglycaemia and hypertriglyceridaemia are common to both types. However, hypoglycaemia is not associated with hyperlactacidaemia (lactic acid is consumed in neoglucogenesis); furthermore, lactic acid concentration increases after meals. In most patients, fasting tolerance is longer than in type 1, even though some patients only bear a 4-h fast. In most patients, hepatic symptoms improve with age and become less prominent after puberty, even though liver involvement may evolve to fibrosis then cirrhosis in a few cases [17]. HCAs are less frequent than in type 1 patients, and malignant transformation into HCC has not been reported; however, two patients with endstage cirrhosis developed HCC. Muscular involvement is, in most children, minimal, even though it may result in abnormal fatigability and muscular pains. Conversely, in adults, muscular involvement can become severe, with progressing weakness and wasting and, sometimes, orthopaedic complications (genu varum, scoliosis) [18]. Electromyography shows diffuse myopathy, and nerve conduction may be abnormal too. Cardiac dysfunction is rare, even though ventricular hypertrophy is frequent on ultrasound examination. Polycystic ovaries are frequent in women with GSD III, but their fertility appears to be normal.

The biological hallmarks of GSD type 3 are fast-induced hypoglycaemia without hyperlactacidaemia, hypertriglyceridaemia, elevation of liver transaminases and, in most cases, elevation of serum muscle enzymes (creatine kinase). Uric acid concentration is usually normal [17].

In most patients with both myopathy and liver symptoms, the enzyme defect is generalized, and the diagnosis may be ascertained by its identification in red blood cells or lymphocytes. In patients with type 3b GSD, the enzyme activity is deficient only in the liver, whereas it is normal in the muscle. These data are important as only patients with muscle debranching enzyme deficiency are at risk of developing progressive myopathy and/or cardiomyopathy.

Molecular studies are not routinely used to ascertain the diagnosis [19,20]. However, they may be useful in providing a non-invasive way of differentiating type 3a from type 3b: two mutations, p.R864X and p.R1228X, were detected in both 3a and 3b patients of Caucasian origin, whereas two others, namely c.17delAG and p.Q6X, appeared to be specific for type 3b. Molecular characterization has also shown ethnic-specific mutations such as c.4455delT in North African Jewish 3a patients.

The dietary treatment in type 3 is less strict than in type 1. Frequent meals, enriched in proteins and carbohydrates, cornstarch and nocturnal gastric drip feeding may be used efficiently; lactose and fructose restrictions are not necessary. There is no efficient way to slow the progression of myopathy. The fertility of women with GSD type 3 seems to be normal; cardiac function must be monitored regularly during pregnancy. The prenatal diagnosis of type 3 may be performed on chorionic villi, using enzymatic assay and/or DNA-based techniques when available (mutation analysis or linkage studies).

GSDs type 6: hepatic phosphorylase deficiency (HERS disease)

This is a benign disease. In early childhood, these patients have hepatomegaly and growth retardation; there is no muscle involvement. Hypoglycaemia and hyperlipidaemia are mild when they are present, whereas lactic acid and uric acid serum concentrations are normal. Growth retardation and hepatomegaly

usually improve during the second decade, and final height is normal. In most patients, there is no need for specific dietary treatments, whereas frequent meals and an enriched carbohydrate diet are useful when hypoglycaemia is noted.

The liver phosphorylase gene (*PGYL*) has been cloned, and mutations causing GSD type 6 have been identified in different ethnic groups [21].

GSDs type 9: phosphorylase kinase deficiencies

Phosphorylase kinase consists of four different subunits encoded by four different genes. This genetic complexity explains why a confusing numerical classification has long been used for this type of GSD. Several subtypes of GSD IX are individualized.

X-linked liver phosphorylase kinase deficiency (type 9a)

This is the most frequent form of GSD IX (about 75% of all cases). The main symptoms consist, in a young child aged 1–5 years, of growth retardation and protuberant abdomen due to hepatomegaly. Mild hypoglycaemia, hypertriglyceridaemia and hypercholesterolaemia are frequently noted. Growth retardation may be more pronounced in a few children, thus becoming a real concern. However, in almost all patients, these abnormalities progressively disappear with age, and most adults are asymptomatic. Mild symptoms in heterozygotic females have been described, as well as in asymptomatic males carrying the deficiency. In most cases, the diagnosis may be ascertained by enzymatic assay in red blood cells and leukocytes. The gene encoding the liver isoform of the phosphorylase kinase α subunit has been mapped to Xp22, and several types of disease-causing mutations have been identified and reported [22–24]. The treatment is symptomatic with frequent meals if necessary, but most patients do not need specific measures.

Autosomal liver and muscle phosphorylase kinase deficiency (type 9b)

Hepatomegaly and growth retardation are frequent in early childhood, sometimes associated with muscle hypotonia. The usual clinical course is similar to that of type 9a. This subtype of GSD IX is due to mutations in the β subunit of the phosphorylase kinase gene (*PHKB*).

Autosomal liver phosphorylase kinase deficiency (type 9c)

In this rare subtype of GSD IX, the enzymatic deficiency is restricted to the liver. Clinical manifestations are more severe than in other subtypes, and the evolution to liver cirrhosis is frequent. This phenotype is due to mutations [25] in the testis/liver isoform of the γ subunit of the gene (*PHKG2*).

Muscle-specific phosphorylase kinase deficiency (type 9d)

Only a few cases of this subtype with enzymatic deficiency restricted to muscle have been reported. The major symptoms were first noted in adolescents or adults and consisted of either cramps with myoglobinuria or progressive muscle weakness with atrophy, whereas there was neither hepatomegaly nor cardiomyopathy. Molecular results are very limited: a mutation has been identified in the *PHKA1* gene (muscle isoform of the a subunit) in one patient.

Phosphorylase kinase deficiency limited to heart

Sporadic cases, whose molecular characterization has not been identified, have been reported with cardiac failure leading to death in early infancy.

GSD type 4

GSD IV is rare, representing 0.3% of all GSD. It is due to a deficiency of the glycogen branching enzyme (GBE), leading to the accumulation of an abnormal glycogen with fewer branch points (polyglucosan) in tissues, which results in tissue damage. The deficiency of GBE affects mainly the liver, the brain, the heart and skeletal muscles, leading to variable clinical presentations in children or adults. Unlike the other GSDs, GSD IV is an extremely heterogeneous disorder, with variable clinical manifestations and different tissue involvement [26,27]. Fetal and paediatric forms are very rare: affected infants may present with hydrops fetalis, arthrogryposis or severe hypotonia. Neonatal forms are very rare and may mimic Werdnig–Hoffmann's disease [28]. Polyhydramnios and reduced fetal movements are often noted in the antenatal period. The classic form reported by Andersen in 1956 [29] is characterized by progressive cirrhosis, portal hypertension developing in the first 18 months of life, leading to hepatic failure between the ages of 3 and 5 years, unless liver transplantation is performed. Milder non-progressive hepatic forms have also been identified characterized by hepatosplenomegaly and mildly elevated serum transaminases levels.

Microscopic examination of affected tissues and enzymatic determination of GBE activity confirm the diagnosis of GSD IV. The human *GBE1* gene is mapped on chromosome 3p14, and molecular studies have shown that both hepatic and neuromuscular forms are caused by mutations in the same *GBE1* gene. There is no specific treatment for this type of GSD. Liver transplantation is the only possibility in children with hepatic failure [30].

Glycogen synthase deficiency (GSD type 0)

This enzyme deficiency does not result, strictly speaking, in a GSD, as it leads to a decrease in glycogen stores. In early infancy,

affected patients present in the morning with fatigue and drowsiness and sometimes hypoglycaemia-induced convulsions [31]. There is no hepatomegaly. Hyperglycaemia and hyperlactacidaemia may be noted after meals, whereas hypoglycaemia and hyperketonaemia develop during fasting. The ascertainment of the diagnosis usually requires liver needle biopsy for enzymatic assay. However, the identification of mutations within the liver glycogen synthase gene (located on chromosome 12p12.2) may provide a non-invasive way of making a definitive diagnosis [32]. The treatment involves frequent meals with night-time cornstarch intakes. The prognosis is very good.

Glycogenosis with renal Fanconi syndrome (Fanconi–Bickel syndrome)

This rare disease is characterized by proximal renal tubular dysfunction, accumulation of glycogen in kidneys and liver and impaired galactose and glucose metabolism [33–35]. Clinical manifestations begin during the first year of life, with rickets, failure to thrive and hepatomegaly. Laboratory data include glucosuria, bicarbonate wasting, phosphaturia, hyperaminoaciduria and hypophosphataemia with increased alkaline phosphatase levels. Radiological findings of rickets are noted on skeletal X-rays. This condition is due to defects in the facilitative glucose transporter 2 (GLUT2), the gene of which has been cloned [33]. The treatment is symptomatic.

References

1 Chen YT (2001) Glycogen storage diseases. In: Scriver CR, Beaudet AL, Sly WS *et al.* (eds) *The Metabolic and Molecular Bases of Inherited Disease*, 8th edn. New York: McGraw-Hill, pp. 1521–1551.

2 Rake JP, Visser G, Labrune P *et al.* (2002) Glycogen storage disease type I: diagnosis, management, clinical course and outcome. Results of the European Study on Glycogen Storage Disease Type I (ESGSD I). *Eur J Pediatr* 161, S20–S34.

3 Marfaing-Koka A, Wolf M, Boyer-Neumann C *et al.* (2003) Increased levels of hemostatic proteins are independent of inflammation in glycogen storage disease type Ia. *J Pediatr Gastroenterol Nutr* 37, 566–570.

4 Melis D, Parenti G, Della Casa R *et al.* (2004) Brain damage in glycogen storage disease type I. *J Pediatr* 144, 637–642.

5 Ubels FL, Rake JP, Slaets JPJ *et al.* (2002) Is glycogen storage disease type Ia associated with atherosclerosis? *Eur J Pediatr* 161, S62–S64.

6 Lee PJ (2002) Glycogen storage disease type I: pathophysiology of liver adenomas. *Eur J Pediatr* 161, S46–S49.

7 Franco LM, Krishnamurthy V, Bali D *et al.* (2005) Hepatocellular carcinoma in glycogen storage disease type Ia: a case series. *J Inherit Metab Dis* 28, 141–152.

8 Humbert M, Labrune P, Simonneau G (2002) Severe pulmonary hypertension in type I glycogen storage disease. *Eur J Pediatr* 161, S93–S96.

9 Mairovitz V, Labrune P, Fernandez H *et al.* (2002) Contraception and pregnancy in women affected by glycogen storage diseases. *Eur J Pediatr* 161, S97–S101.

10 Lewis R, Scrutton M, Lee P *et al.* (2005) Antenatal and intrapartum care of a pregnant woman with glycogen storage disease type Ia. *Eur J Obstet Gynecol Reprod Biol* 10, 111–112.

11 Matern D, Seydewitz HH, Bali D *et al.* (2002) Glycogen storage disease type I: diagnosis and phenotype/genotype correlation. *Eur J Pediatr* 161, S10–S19.

12 Rake JP, Visser G, Labrune P *et al.* (2002) Guidelines for management of glycogen storage disease type I. European Study on Glycogen Storage Disease Type I (ESGSD I). *Eur J Pediatr* 161, S112–S119.

13 Visser G, Rake JP, Labrune P *et al.* (2002) Consensus guidelines for management of glycogen storage disease type Ib. European Study on Glycogen Storage Disease Type I. *Eur J Pediatr* 161, S120–S123.

14 Visser G, Rake JP, Labrune P *et al.* (2002) Granulocyte colony-stimulating factor in glycogen storage disease type Ib. Results of the European Study on Glycogen storage Disease type I. *Eur J Pediatr* 161, S83–S87.

15 Labrune P (2002) Glycogen storage disease type I: indications for liver and/or kidney transplantation. *Eur J Pediatr* 161, S53–S55.

16 Lee P, Muiesan P, Heaton N (2004) Successful pregnancy after combined renal-hepatic transplantation in glycogen storage disease type Ia. *J Inherit Metab Dis* 27, 537–538.

17 Coleman R, Winter H, Wolf B *et al.* (1992) Glycogen storage disease type III (glycogen debranching enzyme deficiency): correlation of biochemical defects with myopathy and cardiomyopathy. *Ann Intern Med* 116, 896–900.

18 Coleman R, Winter H, Wolf B *et al.* (1992) Glycogen debranching enzyme deficiency: long-term study of serum enzyme activities and clinical features. *J Inherit Metab Dis* 15, 869–881.

19 Shen J, Bao Y, Liu HM *et al.* (1996) Mutations in exon 3 of the glycogen debranching enzyme gene are associated with glycogen storage disease type III that is differentially expressed in liver and muscle. *J Clin Invest* 98, 352–357.

20 Shen J, Liu HM, McConkie-Rosell A *et al.* (1998) Prenatal diagnosis and carrier detection for glycogen storage disease type III using polymorphic DNA markers. *Prenat Diagn* 18, 61–64.

21 Hendrickx J, Willems PJ (1996) Genetic deficiencies of the glycogen phosphorylase system. *Hum Genet* 97, 551–556.

22 Huijing F, Fernandes J (1969) X-chromosomal inheritance of liver glycogenosis with phosphorylase kinase deficiency. *Am J Hum Genet* 21, 275–284.

23 Hendrickx J, Dams E, Coucke P *et al.* (1996) X-linked liver glycogenosis type II (XLG II) is caused by mutations in PHKA2, the gene encoding the liver alpha subunit of phosphorylase kinase. *Hum Mol Genet* 5, 649–652.

24 van den Berg I, van Beurden E, Malingre H *et al.* (1995) X-linked liver phosphorylase kinase deficiency is associated with mutations in the human liver phosphorylase kinase alpha subunit. *Am J Hum Genet* 56, 381–387.

25 Maichele A, Burwinkel B, Maire I *et al.* (1996) Mutations in the testis/liver isoform of the phosphorylase kinase gamma subunit (PHKG2) cause autosomal liver glycogenosis in the gsd rat and in humans. *Nature Genet* 14, 337–340.

26 Moses SW, Parvari R (2002) The variable presentations of glycogen storage disease type IV: a review of clinical, enzymatic and molecular studies. *Curr Mol Med* 2, 177–188.

27 Bruno C, Van Diggelen OP, Cassandrini D *et al.* (2004) Clinical and genetic heterogeneity of branching enzyme deficiency (glycogenosis type IV). *Neurology* 63, 1053–1058.

28 Giuffre B, Parini R, Rizzuri T *et al.* (2004) Severe neonatal onset of glycogenosis type IV: clinical and laboratory findings leading to diagnosis in two siblings *J Inherit Metab Dis* 27, 609–619.
29 Andersen DH (1956) Familial cirrhosis of the liver with storage of abnormal glycogen. *Lab Invest* 5, 11–20.
30 Selby R, Starzl TE, Yunis E *et al.* (1991) Liver transplantation for type IV glycogen storage disease. *N Engl J Med* 324, 39–42.
31 Gitzelmann R, Spycher M, Feil G *et al.* (1996) Liver glycogen synthase deficiency: a rarely diagnosed entity. *Eur J Pediatr* 155, 561–567.
32 Orho M, Bosshard N, Buisl N *et al.* (1998) Mutations in the liver glycogen synthase gene in children with hypoglycemia due to glycogen storage disease type 0. *J Clin Invest* 102, 507–515.
33 Santer R, Schneppenheim R, Dombrowski A *et al.* (1997) Mutations in GLUT2, the gene for the liver-type glucose transporter, in patients with Fanconi–Bickel syndrome. *Nature Genet* 17, 324–326 [erratum in *Nature Genet* 1998 Mar 18 (3), 298].
34 Santer R, Schneppenheim R, Suter D *et al.* (1998) Fanconi–Bickel syndrome – the original patient and his natural history, historical steps leading to the primary defect, and a review of the literature. *Eur J Pediatr* 157, 783–797.
35 Santer R, Steinmann B, Schaub J (2002) Fanconi–Bickel syndrome – a congenital defect of facilitative glucose transport. *Curr Mol Med* 2, 213–227.

16.9 Mitochondriopathies

Pierre Rustin

Mitochondrial oxidative phosphorylation

Biochemical features

The mitochondrial oxidative phosphorylation (OXPHOS) ensures the conversion of the energy derived from mitochondrial substrate oxidation into adenosine triphosphate (ATP) (Fig. 1a). This process takes place on the inner membrane of the mitochondria thanks to the presence of five multisubunit complexes. These are further arranged into a compact superstructure termed the respirasome [1,2] consisting of more than 100 different polypeptides. A set of dehydrogenases, varying according to tissues, competes to transfer electrons to the quinone pool, electrons being further conveyed to molecular oxygen by the cytochrome segment of the respiratory chain. The electron transfer is accompanied by a concomitant proton extrusion, resulting in the generation of a membrane potential and a pH gradient across the mitochondrial inner membrane (Fig. 1a). The proton gradient drives the ATP synthesis from inorganic phosphate and adenosine diphosphate (ADP) by the ATP synthase. Intrinsic leak of protons through the proteophospholipid barrier constitutive of the inner membrane or a protein-catalysed proton transfer through uncoupling proteins, e.g. UCP, can interfere with the use of protons by the ATP synthase [3].

In vivo, however, sustained ATP production requires the involvement of much more mitochondrial components, i.e. a number of oxidizing enzymes located in the mitochondrial matrix, and of membranous carriers. On the other hand, the OXPHOS system intervenes in many more processes than ATP synthesis, such as the transport of anions and cations through the mitochondrial inner membrane. In addition, a number of the components of the respirasome, and of associated proteins, are engaged in alternative functions, e.g. apoptosis signalling in the case of cytochrome *c* [4], or of apoptosis-inducing factor (AIF) proteins [5]. Because only a few of the more than 100 proteins in the respiratory chain have a defined function in electron/proton transfer, it can be predicted that a number of the respirasome components either control or are involved in as yet undefined processes.

Finally, while the organization of the OXPHOS machinery is essentially found unchanged between mammal cells, its composition, particularly the dehydrogenase equipment, and therefore the activity of the respiratory chain, can differ significantly according to tissues. This presumably allows the mitochondria to cope with the different metabolic activities taking place in each cell/tissue. In this regard, the distinctive features of the liver mitochondria presumably echo the many functions of the liver.

Genetic trait

Mitochondria differ from the other organelles of human cells by being endowed with their own packed 16.5-kb DNA molecules [6]. These encode the entirety of the 24 mitochondrial tRNAs and the two subunits of the mitochondrial ribosomes, but only 13 of the more than 100 components of the respiratory chain. This leaves the nuclear genome in charge of the synthesis of the vast majority of the respiratory chain components, and of most components of the mitochondrial replicative and transcriptional machinery. Indeed, more than 1000 nuclear genes (about 1/40 in the nuclear genome) supposedly target their product to the mitochondrion (Fig. 1b). To this diversity in the genetic origin of the mitochondrial components corresponds the variety of the inheritance of genetic defects. Indeed, all known types of inheritance can be encountered in affected families, to which should be added a significant number of sporadic cases [7]. Genetic complexity also arises from the many interactions between the mitochondrial and the nuclear genomes necessary for the concerted expression of components of the OXPHOS machinery.

Liver mitochondria

Liver cells are actively involved in a number of processes, i.e. synthesis, storage, detoxification and immunological functions, and it may be predicted that mitochondria play a direct or indirect role in many of these. This is echoed by their high number

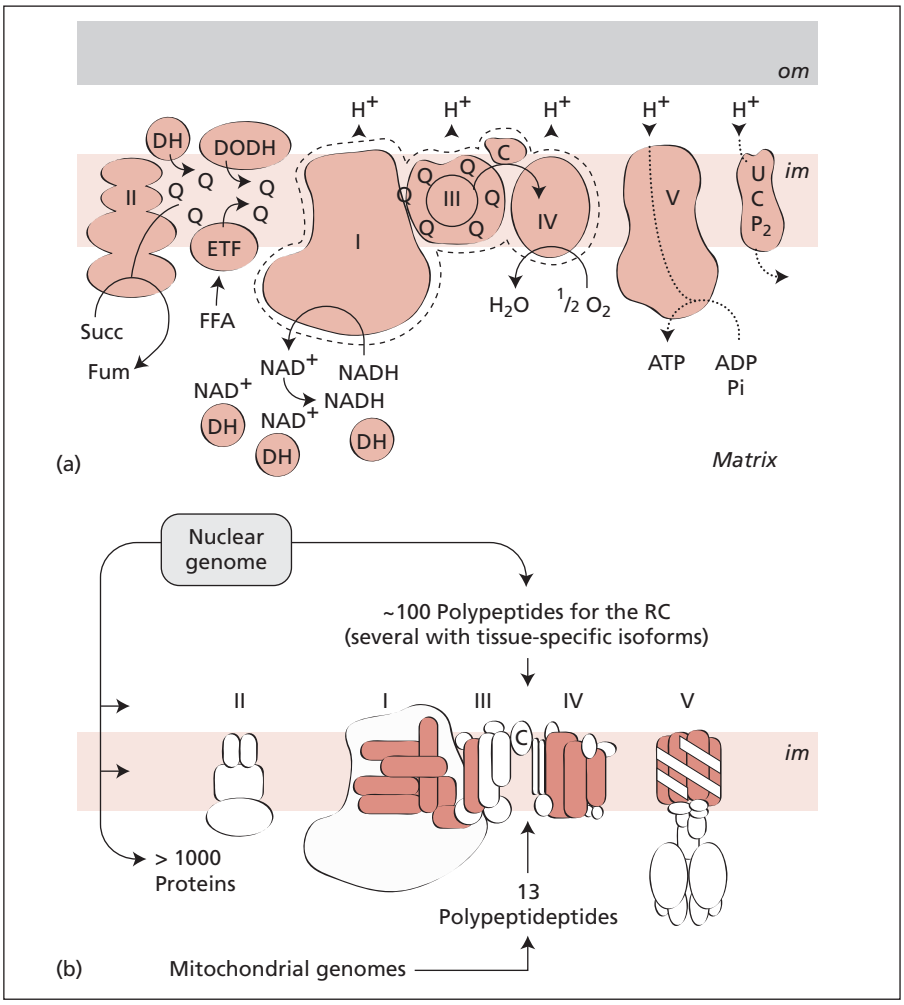

Fig. 1 The respiratory chain and its dual genetic origin. (a) The respiratory chain is organized as a respirasome (underlined with a discontinuous line) packing the different complexes together in order to increase the efficacy of electron transfer and to minimize the risk of deleterious redox reactions with oxygen. (b) The many components of the respiratory chain are mostly encoded by the nuclear genome, but a subset of essential ones is encoded by the mitochondrial genomes present in various quantities (from a few to several thousands) in each cell. In addition, the functioning of the respiratory chain requires the concerted expression of several thousand nuclear genes, thus explaining the genetic complexity of mitochondrial diseases. I–V, the various complexes of the respiratory chain; c, cytochrome c; DH, dehydrogenase; DODH, dihydroorotate dehydrogenase; ETF, electron transfer flavoprotein; FFA, free fatty acids, Fum, fumarate; im, inner membrane; om, outer membrane; Q, ubiquinone (coenzyme Q_{10}); Succ, succinate; UCP, uncoupling protein.

and their specific enzyme equipment. However, their actual *in vivo* function is much less characterized than their *in vitro* properties. Indeed, mitochondria-enriched fractions can be readily prepared from liver – a soft, easy to grind tissue – endowed with a large number of these organelles. Accordingly, these have been studied extensively, and rat liver mitochondria have been used widely to dissect the organization/function of the OXPHOS system.

A distinctive hallmark of human liver mitochondria resides in the high capacity of a number of dehydrogenases, e.g. succinate dehydrogenase, compared with the oxidizing capacity of the cytochrome segment of the respiratory chain [8]. As a result of such an unusual imbalance, reverse electron flow from complex II to complex I will be favoured [9]. Reverse electron flow has also been suggested to favour an uncoupled oxidation of fatty acids promoted by pyruvate and hydroxycitrate (Fig. 2) [10].

Inherited mitochondrial liver diseases

Two forms of hepatic failure resulting from genetic defects of OXPHOS have been recognized on the basis of clinical course and severity: a severe neonatal form (40%) and a delayed-onset form (60%) [11]. The neonatal form has an early onset (before 1 week), a rapidly fatal issue and frequently includes severe hypotonia, myoclonus epilepsy and psychomotor retardation [12]. The second form has a delayed onset (from 2 to 18 months), a milder clinical course, inconstant neurological involvement and an occasionally fatal outcome. Considering the severe prognosis and the expected recurrence risk (25%), children with unexplained myoclonus epilepsy in early infancy should be screened for OXPHOS enzyme deficiency in a needle biopsy of their liver.

Abnormal histology (steatosis, micro- and macronodular cirrhosis) and elevated plasma or cerebrospinal fluid (CSF) lactate are consistent features of the disease, regardless of the clinical subtype. With reference to extension of the disease, the brain is often the most severely affected organ, but other organs could occasionally be involved.

Mitochondrial DNA mutation

Liver complex IV (COX, cytochrome oxidase; Fig. 1a) deficiency has been ascribed to mutation in the *COX II* gene, a mitochondrial

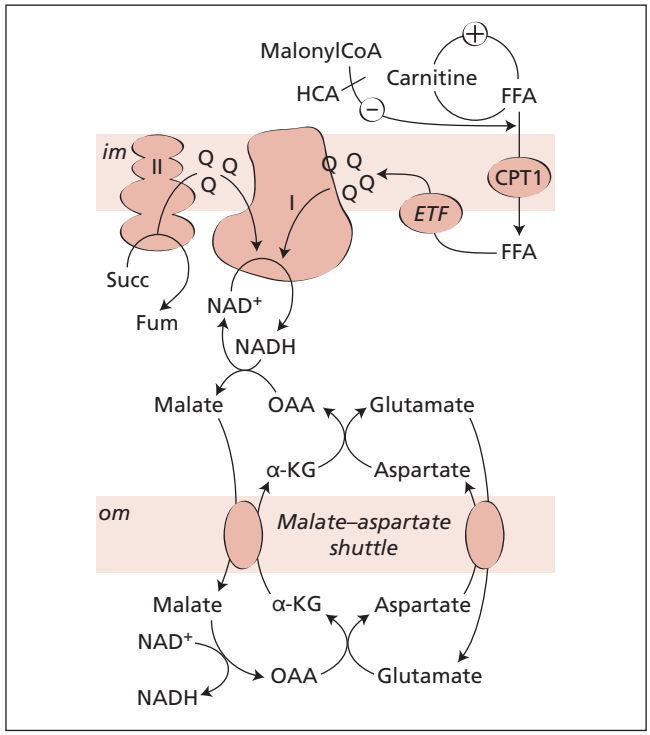

Fig. 2 The reverse electron flow in the respiratory chain. Under a subset of physiological circumstances, the conditions are met to favour a particular functioning of the respiratory chain, during which electrons can be conveyed from the reduced quinone pool to NAD^+, allowing for the formation of NADH, instead of being conveyed to oxygen. This results in low or no ATP formation, and the reducing power (accumulated as NADH) is possibly used for biogenesis processes. I–II, complex I and II of the respiratory chain respectively; CPT, carnitine palmitoyltransferase 1; DH, dehydrogenase; ETF, electron transfer flavoprotein; FFA, free fatty acids, Fum, fumarate; HCA, hydroxyacetate; im, inner membrane; α-KG, α-ketoglutarate; OAA, oxaloacetate; om, outer membrane; Q, ubiquinone (coenzyme Q_{10}); Succ, succinate.

(mt) gene encoding the COXII subunit [13]. Multiple deficiencies affecting respiratory chain complexes in children with liver involvement can result from primary point mutation in the tRNA lys of mtDNA or large single deletion of the mt genome [14]. Predictably, many more mutations of the mitochondrial DNA will be described in the future, resulting in an OXPHOS deficiency and liver disease, isolated or not. However, most of the multiple defects have been shown to result secondarily from mutation of nuclear genes.

Nuclear gene mutations

Deleterious mutations in a few genes encoding assembly factors, such as *BCS1L* and *SCO1*, have been shown to result in isolated respiratory chain complex deficiency, complex III and IV respectively [15,16]. In comparison, a significant proportion of the 'mtDNA depletion syndromes' associated with Alpers syndrome has been ascribed to compound heterozygous mutations in the *POLG1* gene encoding the mitochondrial gamma-polymerase [17]. Alpers syndrome is a liver disease with micronodular cirrhosis and typically involves refractory seizures, psychomotor regression and cortical blindness. Noticeably, a depletion in the mtDNA has also been shown possibly to result from mutation of the thymidine kinase gene (*TK2*) in children with myopathy, sparing the liver [18], and of the deoxyguanosine kinase gene (*DGUOK*) in children with hepato/cerebral syndrome, sparing skeletal muscle [19]. Both kinases control the balance of pools of mitochondrial nucleosides. The tissue specificity has been ascribed to the overlapping substrate specificity of the deoxycytidine kinase (*dCK*) that would account for the relative sparing of muscle in the case of deoxyguanosine kinase deficiency, while high *TK2* activity would render liver less susceptible to *TK2* impairment. Early onset in the postnatal period is observed in the case of *DGUOK* mutations with frequent elevated blood lactate, hypoglycaemia and hyperammonaemia, progressive liver failure often being fatal in the first months of life [20].

Drug hepatotoxicity

While an inherited defect of OXPHOS with liver involvement may represent as little as 1/100 000 children under 16 years, a much higher number of patients may suffer acquired mitochondrial hepatopathies caused by a number of mitochondrial poisons.

Valproate and liver mitochondria

The antiepileptic drug, valproate, has been shown to impair mitochondrial fatty acid beta-oxidation through CoA sequestering [21]. Rather than the parent drug, the metabolites derived from valproate have been suggested to mediate the impairment of beta-oxidation causing the microvesicular steatosis that characterizes valproate-associated liver injury. Liver cytochrome oxidase has also been shown to be targeted by the drug, which should therefore be proscribed in case of respiratory chain deficiency [22]. Finally, the drug potentially causes a broad mitochondrial oxidative stress with associated apoptosis and/or necrosis [21].

Alcohol and liver mitochondria

While enzymes capable of metabolizing ethanol are widely distributed in the organism, they are especially active in the liver and, to a lesser extent, in the stomach. In keeping with this, hepatotoxicity is a long-known consequence of excessive alcohol intake [23]. Hepatotoxicity has been ascribed to excessive reducing power, liberated as NADH, and to overactivity of cytochrome P-450 induced by ethanol. But, depending on hepatic iron, liver toxicity of ethanol also appears to be largely mediated by oxidative insult through reactive oxygen and nitrogen species, which readily takes place in the mitochondria. Excessive alcohol intake can therefore result in a severe decrease

in mitochondrial oxygen consumption rates and in cytochrome oxidase activity. The subsequent decrease in the mitochondrial reduced glutathione store has been shown to be sufficient to sensitize hepatocytes to tumour necrosis factor (TNF)α-mediated cell death [24]. The relative contribution of these, possibly additive, phenomena remains to be established.

Antiretrovirals and liver mitochondria

HAART (highly active antiretroviral therapy) has been responsible for a dramatic decrease in acquired immune deficiency syndrome (AIDS) mortality since 1996, and has changed the clinical profile of human immunodeficiency virus (HIV) infection from a subacute lethal to a chronic ambulatory disease. However, hepatotoxicity is a frequent adverse effect from HAART [25]. It is a cause of morbidity and mortality among treated patients and challenges the treatment of HIV infection. A number of antiretroviral drugs cause fatal hepatitis, but most often they result in asymptomatic transaminase elevation. A number of pathogenic mechanisms can concur with HAART-related liver dysfunction, including a direct toxicity of these drugs on mitochondria. Either depletion of mitochondrial DNA or targeting of various mitochondrial components, e.g. the adenylate carrier, by nucleoside analogues can result in acute hepatitis. Antiretroviral first-line therapy is rapidly moving towards more convenient and less toxic regimens. Various nucleoside reverse transcriptase inhibitor (NRTI) formulations are now available, and the risk of mitochondrial toxicity is lower with drugs such as 3TC, FTC and tenofovir. Similarly, atazanavir, a recently available protease inhibitor (PI), can be given and is less metabolically toxic than other PIs.

Diagnosis of OXPHOS deficiency

As the respiratory chain (RC) catalyses the divalent reduction of molecular oxygen to water with concomitant ATP production, a disorder of OXPHOS should result in: (i) an increase in reducing equivalents in both mitochondria and cytosol (e.g. elevated NADH/NAD ratio); (ii) a decrease in mitochondrial ATP formation; (iii) an increase in monovalent reduction of oxygen, resulting in superoxide formation; and (iv) the functional impairment of numerous metabolic pathways requiring RC function, e.g. the tricarboxylic acid cycle and betaoxidation. Therefore, an increase in ketone body (β-OH butyrate/acetoacetate) and lactate/pyruvate (L/P) molar ratios with secondary elevation of blood lactate might be found in the plasma of individuals affected with mitochondria-related liver disease [26]. This is particularly true in the postabsorptive period, when more NAD^+ is required for adequate oxidation of glycolytic substrates. Similarly, as a consequence of the functional impairment of the citric acid cycle, ketone body synthesis increases after meals as a result of the channelling of acetyl CoA towards ketogenesis. The elevation of total ketone bodies in a fed individual is paradoxical, as it should normally decrease after meals, because of insulin release (paradoxical hyperketonaemia). The current screening of OXPHOS deficiency should therefore include the determination of plasma lactate, pyruvate, ketone bodies and their molar ratios as indexes of oxidation/reduction status in cytoplasm and mitochondria respectively. These determinations should be made in fasted and 1-h-fed individuals and repeated over days. In order to avoid artifactual elevation of lactic acid, blood samples should be taken from a patient at rest through a heparinized venous catheter and immediately deproteinized by perchloric acid [27]. Samples can be either forwarded on ice for analysis or frozen immediately (–20°C or below). Blood glucose and non-esterified fatty acids should be monitored simultaneously.

The observation of a persistent hyperlactataemia (> 2.5 mM) with elevated L/P (> 20) and ketone body molar ratios is suggestive of an OXPHOS deficiency (particularly in the postabsorptive period) [26]. When basal screening tests are inconclusive, a glucose loading test (2 g/kg orally) can unmask latent hyperlactataemia and/or paradoxical hyperketonaemia [28]. The urinary excretion of Krebs cycle intermediates and/or 3-methyl-glutaconic aciduria has a good diagnostic value but is non-specific as it is frequently encountered in non-OXPHOS deficiency-related syndromes [29]. When the redox status in plasma is not altered, the determination of the redox status in the CSF can be performed. The amino acid chromatography shows indirect evidence of hyperlactataemia (i.e. elevated plasma alpha-alanine and proline) and occasionally hypermethioninaemia.

Diagnostic tests include polarographic and spectrophotometric studies, each providing an independent clue to diagnose RC deficiency.

Polarographic studies consist of the measurement of oxygen consumption by cells or mitochondria-enriched fractions using a Clark electrode in the presence of various substrates (malate + pyruvate, malate + glutamate, succinate, palmitate, etc.) [30]. In case of complex I deficiency, polarographic studies show impaired respiration with NADH-producing substrates, while respiration and phosphorylation are normal with FADH2-producing substrates (succinate). The opposite is observed in the case of complex II deficiency, whereas a block at the level of complexes III or IV impairs oxidation of both NADH- and FADH2-producing substrates. In complex V deficiency, there is an impaired oxidation with various substrates, but adding an uncoupling agent returns the oxidation rate to normal, suggesting that the limiting step involves phosphorylation rather than the RC. Polarographic studies may also detect PDH deficiency, citric acid cycle enzyme deficiency and defects in coenzymes, carriers and shuttles (including cytochrome *c*, ubiquinone, cations and adenylate carriers), as these conditions also impair the production of reducing equivalents in the mitochondrion. In these cases, however, independent enzyme activities are expected to be normal (see below).

The scaled-down procedures now available allow the rapid recovery of mitochondria-enriched fractions (400–500 μg of

proteins) from small skeletal muscle biopsies (100–200 mg obtained under local anaesthesia) and make polarographic studies feasible in infants and children. Measurement of oxygen consumption by intact or detergent-permeabilized circulating lymphocytes (isolated from 10 mL of blood on a Percoll cushion) and cultured cells (lymphoblastoid cell lines, skin fibroblasts) is also feasible and represents a non-invasive and easily reproducible diagnostic test. The only limitation of these techniques is the absolute requirement for fresh material: no polarographic studies are possible on frozen material.

Spectrophotometric studies consist of isolated or combined respiratory enzyme assays, using specific electron donors and acceptors. They do not require isolation of mitochondrial fractions and can be carried out on tissue homogenates. For this reason, the amount of material required for enzyme assays (1–20 mg) is very small and can easily be derived from needle biopsies of liver or from a pellet of lymphocytes or cultured skin fibroblasts. Samples can be frozen immediately and kept dry in liquid nitrogen (or at –80°C).

The question of what tissue should be investigated deserves particular attention. In principle, a relevant tissue is one that clinically expresses the disease. In the case of liver disease, a needle biopsy of the liver [11] is usually feasible. However, for obvious reasons, peripheral tissues should be tested extensively (including skeletal muscle, cultured skin fibroblasts, circulating lymphocytes). Whatever the affected organ, it is mandatory to take skin biopsies from patients for subsequent investigations on cultured fibroblasts (even post mortem).

It should be borne in mind, however, that the *in vitro* investigation of OXPHOS remains difficult and several pitfalls should be noted:

- Normal respiratory enzyme activities can be found in peripheral tissues that did not clinically express the disease. One might be dealing with a restricted hepatocerebral or pure hepatic disease, specific to a subset of organ(s), as observed in Friedreich's ataxia [31].
- Normal respiratory enzyme activity does not preclude mitochondrial dysfunction, even if the tissue tested clinically expresses the disease. One might be dealing with a kinetic mutant, tissue heterogeneity or cellular mosaicism (heteroplasmy). In this case, one should pay particular attention to histoenzymatic investigations, carry out extensive molecular genetic analyses, test other tissues and possibly repeat investigations.
- The apparent discrepancy between normal complex I, II and III activities and impaired combined complex I–III or II–III activities is indicative of a deficient quinone pool. Inborn errors of quinone synthesis remain largely unknown but are worthy of recognition, as these rare forms of RC deficiency respond to quinone administration *in vitro* and *in vivo* [32]. On the other hand, incorrect freezing may result in a rapid loss of quinone-dependent activities, probably due to peroxidation of membrane lipids [30]. Of note, tissue samples fixed for morphological studies are inadequate for respiratory enzyme assays.
- The scattering of control activities and the frequent accumulation of partially defective mitochondria in patient cells occasionally hamper the recognition of OXPHOS enzyme deficiencies, as normal values frequently overlap those found in the patients. It is helpful to express results as ratios, especially as normal oxidative phosphorylation requires balanced ratios of respiratory chain enzyme activities. Using activity ratios, patients whose absolute activities are in the low normal range can be unambiguously diagnosed as enzyme deficient [33]. Yet, this method of expressing results may fail to identify generalized defects.
- The phenotypical expression of respiratory enzyme deficiencies in cultured cells is unstable, and activities tend to return to normal values when cells are grown in a standard medium. Adding uridine (200 μM) and pyruvate (4 mM) to the culture medium prevents a counterselection of RC-deficient cells, thereby stabilizing the mutant phenotype (the availability of uridine, required for nucleic acid synthesis, is reduced by the secondary deficiency of the RC-dependent dihydroorotate dehydrogenase activity; Fig. 1a) [34].
- Discrepancies between control values may indicate faulty experimental conditions. Relative activities should be consistent when tested under non-rate-limiting conditions. For example, normal succinate-cytochrome *c* reductase (SCCR) activity should be twice as high as normal succinate-quinone DCPIP reductase (SQDR) activity (because one e- is required to reduce cytochrome *c* while two e- are required to reduce DCPIP).

Therapeutic management

As for most OXPHOS defects, therapy of those affecting the liver is essentially supportive, with adapted nutrition, surgical correction, treatment of seizures and correction of acidosis, allowing for quality of life improvement. Until recently, very few animal models of OXPHOS diseases were available allowing for drug testing, and none actually exists for mitochondria-associated liver disease so far. A number of drugs have been suggested possibly to rescue cell energetics, including creatine, thiamine, carnitine, riboflavin, coenzyme Q_{10} and various antioxidants. Nevertheless, contradictory results have been reported for most placebo-controlled, double-blind trials, which suggests that benefit might be restricted to only a few patients.

The delayed-onset form of liver disease deserves intensive efforts because, in several cases, spontaneous recovery or marked improvement after ursodeoxycholic acid therapy and liver transplantation has occurred. It is reasonable to limit liver transplantation to patients with severe hepatic failure but without neurological symptoms or evidence of extrahepatic involvement [35].

As in the case of HAART, low liver toxicity often resolves and does not necessarily justify interrupting the treatment. On the other hand, severe liver deficiency (severe icterus plus/minus encephalopathy, ascites) should lead to withdrawal of treatment [25]. After clinical features are resolved, attempts should be made to change to drugs showing less mitochondrial hepatotoxicity.

Of note, mitochondrial involvement is not necessarily the only aspect of drug toxicity, and other aspects (e.g. allergic reaction) should be taken care of.

References

1 Schagger H, de Coo R, Bauer MF *et al.* (2004) Significance of respirasomes for the assembly/stability of human respiratory chain complex I. *J Biol Chem* 279, 36349–36353.

2 Briere JJ, Chretien D, Benit P *et al.* (2004) Respiratory chain defects: what do we know for sure about their consequences in vivo? *Biochim Biophys Acta* 1659, 172–177.

3 Ricquier D (2005) Respiration uncoupling and metabolism in the control of energy expenditure. *Proc Nutr Soc* 64, 47–52.

4 Garrido C, Kroemer G (2004) Life's smile, death's grin: vital functions of apoptosis-executing proteins. *Curr Opin Cell Biol* 16, 639–646.

5 Vahsen N, Cande C, Briere JJ *et al.* (2004) AIF deficiency compromises oxidative phosphorylation. *EMBO J* 23, 4679–4689.

6 Larsson NG, Clayton DA (1995) Molecular genetic aspects of human mitochondrial disorders. *Annu Rev Genet* 29, 151–178.

7 Munnich A, Rustin P (2001) Clinical spectrum and diagnosis of mitochondrial disorders. *Am J Med Genet* 106, 4–17.

8 Chretien D, Rustin P, Bourgeron T *et al.* (1994) Reference charts for respiratory chain activities in human tissues. *Clin Chim Acta* 228, 53–70.

9 Rustin P, Munnich A, Rotig A (2002) Succinate dehydrogenase and human diseases: new insights into a well-known enzyme. *Eur J Hum Genet* 10, 289–291.

10 McCarty MF, Gustin JC (1999) Pyruvate and hydroxycitrate/carnitine may synergize to promote reverse electron transport in hepatocyte mitochondria, effectively 'uncoupling' the oxidation of fatty acids. *Med Hypotheses* 52, 407–416.

11 Cormier-Daire V, Chretien D, Rustin P *et al.* (1997) Neonatal and delayed-onset liver involvement in disorders of oxidative phosphorylation. *J Pediatr* 130, 817–822.

12 Bakker HD, Scholte HR, Dingemans KP *et al.* (1996) Depletion of mitochondrial deoxyribonucleic acid in a family with fatal neonatal liver disease. *J Pediatr* 128, 683–687.

13 Uusimaa J, Finnila S, Vainionpaa L *et al.* (2003) A mutation in mitochondrial DNA-encoded cytochrome c oxidase II gene in a child with Alpers-Huttenlocher-like disease. *Pediatrics* 111, e262–268.

14 Chinnery PF, DiMauro S (2005) Mitochondrial hepatopathies. *J Hepatol* 43, 207–209.

15 de Lonlay P, Valnot I, Barrientos A *et al.* (2001) A mutant mitochondrial respiratory chain assembly protein causes complex III deficiency in patients with tubulopathy, encephalopathy and liver failure. *Nature Genet* 29, 57–60.

16 Valnot I, Osmond S, Gigarel N *et al.* (2000) Mutations of the SCO1 gene in mitochondrial cytochrome c oxidase deficiency with neonatal-onset hepatic failure and encephalopathy. *Am J Hum Genet* 67, 1104–1109.

17 Naviaux RK, Nguyen KV (2004) POLG mutations associated with Alpers' syndrome and mitochondrial DNA depletion. *Ann Neurol* 55, 706–712.

18 Saada A, Shaag A, Mandel H *et al.* (2001) Mutant mitochondrial thymidine kinase in mitochondrial DNA depletion myopathy. *Nature Genet* 29, 342–344.

19 Mandel H, Szargel R, Labay V *et al.* (2001) The deoxyguanosine kinase gene is mutated in individuals with depleted hepatocerebral mitochondrial DNA. *Nature Genet* 29, 337–341.

20 Labarthe F, Dobbelaere D, Devisme L *et al.* (2005) Clinical, biochemical and morphological features of hepatocerebral syndrome with mitochondrial DNA depletion due to deoxyguanosine kinase deficiency. *J Hepatol* 43, 333–341.

21 Pessayre D, Mansouri A, Haouzi D *et al.* (1999) Hepatotoxicity due to mitochondrial dysfunction. *Cell Biol Toxicol* 15, 367–373.

22 Chabrol B, Mancini J, Chretien D *et al.* (1994) Valproate-induced hepatic failure in a case of cytochrome c oxidase deficiency. *Eur J Pediatr* 153, 133–135.

23 Mansouri A, Fromenty B, Berson A *et al.* (1997) Multiple hepatic mitochondrial DNA deletions suggest premature oxidative aging in alcoholic patients. *J Hepatol* 27, 96–102.

24 Fernandez-Checa JC (2003) Alcohol-induced liver disease: when fat and oxidative stress meet. *Ann Hepatol* 2, 69–75.

25 Nunez M, Soriano V (2005) Hepatotoxicity of antiretrovirals: incidence, mechanisms and management. *Drug Saf* 28, 53–66.

26 Munnich A, Rotig A, Chretien D *et al.* (1996) Clinical presentations and laboratory investigations in respiratory chain deficiency. *Eur J Pediatr* 155, 262–274.

27 Trijbels JM, Scholte HR, Ruitenbeek W *et al.* (1993) Problems with the biochemical diagnosis in mitochondrial (encephalo-)myopathies. *Eur J Pediatr* 152, 178–184.

28 Touati G, Rigal O, Lombes A *et al.* (1997) In vivo functional investigations of lactic acid in patients with respiratory chain disorders. *Arch Dis Child* 76, 16–21.

29 Gibson KM, Elpeleg ON, Jakobs C *et al.* (1993) Multiple syndromes of 3-methylglutaconic aciduria. *Pediatr Neurol* 9, 120–123.

30 Rustin P, Chretien D, Bourgeron T *et al.* (1994) Biochemical and molecular investigations in respiratory chain deficiencies. *Clin Chim Acta* 228, 35–51.

31 Rotig A, de Lonlay P, Chretien D *et al.* (1997) Aconitase and mitochondrial iron-sulphur protein deficiency in Friedreich ataxia. *Nature Genet* 17, 215–217.

32 Rotig A, Appelkvist EL, Geromel V *et al.* (2000) Quinone-responsive multiple respiratory-chain dysfunction due to widespread coenzyme Q10 deficiency. *Lancet* 356, 391–395.

33 Chretien D, Gallego J, Barrientos A *et al.* (1998) Biochemical parameters for the diagnosis of mitochondrial respiratory chain deficiency in humans, and their lack of age-related changes. *Biochem J* 329 (Pt 2), 249–254.

34 Bourgeron T, Chretien D, Rotig A *et al.* (1993) Fate and expression of the deleted mitochondrial DNA differ between human heteroplasmic skin fibroblast and Epstein–Barr virus-transformed lymphocyte cultures. *J Biol Chem* 268, 19369–19376.

35 Sokal EM, Sokol R, Cormier V *et al.* (1999) Liver transplantation in mitochondrial respiratory chain disorders. *Eur J Pediatr* 158 (Suppl. 2), S81–S84.

16.10 Genetic cholestatic diseases

Ronald P.J. Oude Elferink

Inherited forms of cholestasis can be divided into three classes: transport defects, metabolic defects and developmental defects. Various genetic defects in transport function have been identified. These all concern transport proteins in the canalicular membrane of the hepatocyte. Three types of progressive familial intrahepatic (PFI) cholestasis are now discerned, which are caused by mutations in a canalicular flippase (PFIC type 1), the canalicular transporter for bile salts (PFIC type 2) and the canalicular floppase for phospholipids (PFIC type 3). Metabolic defects involve genes encoding enzymes of bile salt synthesis and metabolism. Bile salts are the main driving force for bile formation; defects in biosynthesis of bile salts therefore cause cholestasis. Finally, in the case of developmental defects, genes are mutated that encode signalling pathways involved in the formation of bile ducts. A prime example of such a disorder is Alagille syndrome, which is caused by the improper formation of intrahepatic bile ducts.

By definition, inherited forms of cholestasis are characterized by increased serum bile salt levels. Increases in transaminases and especially γ-glutamyltransferase may differ significantly, however. Patients present with symptoms at a young age. The chronic cholestasis usually leads to progressive fibrosis and hepatitis. Depending on the severity of the cholestatic syndrome, there is loss of hepatic function in time and, in many of these syndromes, liver transplantation is eventually required.

Inherited canalicular transport defects

A group of very rare inherited forms of cholestasis has been defined in the last decade by linking genetic analysis to clinical phenotype (Fig. 1). These disorders are now referred to as progressive familial intrahepatic cholestasis (PFIC). Three subgroups of patients (PFIC type 1–3) can be defined on the basis of mutations in the genes for three relevant canalicular transporter genes [1]. The background of this somewhat confusing nomenclature is that the clinical phenotype was considered to be very similar for a long time. Upon genetic distinction of the three

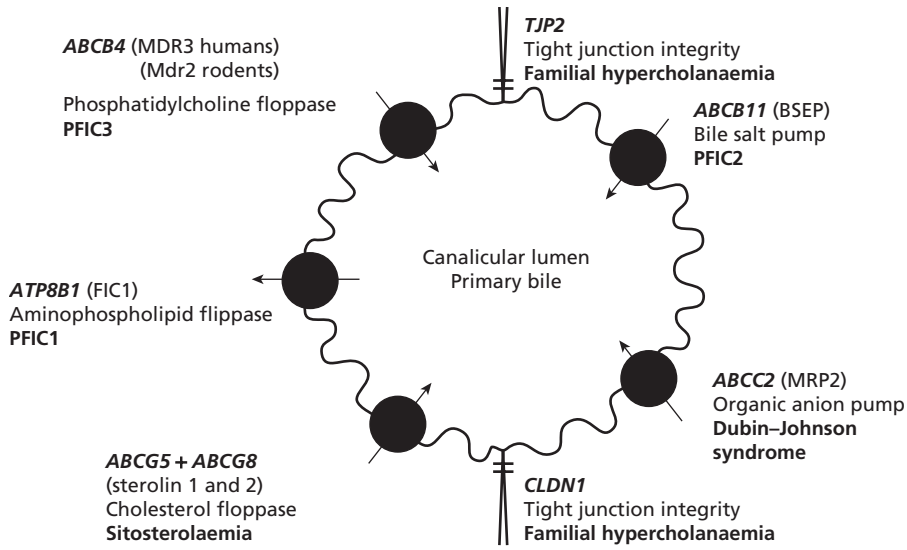

Fig. 1 Inherited diseases associated with mutations in genes encoding canalicular proteins. The figure gives the name of a canalicular transporter gene in bold and the trivial name of its gene product between brackets. The second line indicates its function and the third line indicates in bold the corresponding disease.

types of PFIC, subtle differences in the clinical presentation have become more evident.

PFIC type 1 and BRIC1

PFIC1 was formerly called Byler disease after the Amish family in which this disease was first described [2]. Patients usually present at a young age (neonatal period) with typical cholestatic symptoms; serum bile salt, bilirubin and transaminase levels are elevated but, in contrast to other paediatric cholestatic syndromes such as biliary atresia or Alagille syndrome, serum γ-glutamyltransferase (GGT) levels are low. Liver histology reveals fibrosis but no bile duct proliferation. The patients often develop endstage liver disease requiring liver transplantation. Electron microscopic analysis of liver tissue, if available, allows a differential diagnosis between PFIC1 and other forms of cholestasis with low serum GGT levels. In PFIC1 liver specimens, the canalicular lumen contains 'coarse granular bile' while, in biopsies from livers with other causes of cholestasis, the canalicular lumen contains amorphous bile [3]. The background to this morphological difference is presently unclear.

PFIC1 is the least well understood of the three forms of this disease. It is caused by mutations in the *ATP8B1* gene [4]. Importantly, mutations in this gene not only cause PFIC1 but also benign recurrent intrahepatic cholestasis (BRIC) type 1. BRIC1 is characterized by episodes of cholestasis, the onset and resolution of which are caused by unknown factors. During cholestatic periods, serum bile salt and bilirubin are increased, and patients characteristically suffer from pruritus. With the increasing number of genetically identified patients with either of the two clinical diagnoses, it has become clear that the two syndromes actually represent a continuum in which PFIC1 is the severe end of the spectrum and BRIC the milder form. Indeed, patients who were initially diagnosed as having BRIC may develop a continuous and progressive form of cholestasis that is indistinguishable from PFIC1 [5]. Missense mutations are more often associated with BRIC than with PFIC1, while the reverse is true for nonsense mutations and deletions [4]. This suggests that, in BRIC patients, residual ATP8B1 (FIC1) protein activity may be present, whereas the mutations in PFIC1 patients generally knock out the entire activity. Importantly, in addition to cholestasis, patients with PFIC1 may also suffer from extrahepatic symptoms, such as diarrhoea, pancreatitis, hearing problems and elevated sweat chloride concentrations (the last symptom being similar to that observed in patients with cystic fibrosis). Liver transplantation resolves the cholestatic phenotype, but extrahepatic symptoms such as diarrhoea and failure to thrive remain [6]. Like PFIC1 patients, BRIC patients may develop pancreatitis [7].

More than 15 years ago, Whitington *et al.* [8,9] performed chronic partial biliary diversion in low-GGT PFIC patients, which improved the clinical symptoms. Several centres have now adopted this strategy, and it turns out to be beneficial in both PFIC1 and PFIC2 (low-GGT PFIC) [10–12].

PFIC type 2 and BRIC2

PFIC2 is caused by mutations in the *ABCB11* gene, which encodes the main canalicular bile salt transporter ABCB11 (BSEP) [13]. Liver histology displays portal inflammation and giant cell hepatitis. Serum bile salt and transaminase activities are increased, but serum cholesterol and GGT are low. As mentioned above, PFIC2 can be distinguished from PFIC1 by electron microscopic analysis of liver biopsies, with amorphous bile in the canalicular lumen of PFIC2 liver tissue [3].

Importantly, it was reported recently that patients who are diagnosed with BRIC may have a mutation in the *ABCB11* gene rather than in the *ATP8B1* gene. Hence, two types of BRIC can now be discerned: BRIC1, caused by mutation in *ATP8B1*, and BRIC2, caused by mutations in *ABCB11*. The similarity between the two syndromes is the episodic cholestasis, but BRIC2 is often associated with gallstones, which is not the case with BRIC1. Conversely, BRIC1 patients may develop pancreatitis, and this is not observed in BRIC2 patients [14].

PFIC type 3

Patients with PFIC3 usually present at a few years of age and suffer from chronic and progressive cholestasis. Liver histology reveals fibrosis (progressing into cirrhosis) with portal inflammation and, in contrast to the other forms of PFIC, strong bile duct proliferation. As a consequence of the cirrhosis, the patients are prone to gastrointestinal bleeding. Another difference from the two other forms of PFIC is a characteristic high serum GGT activity. About 50% of the patients need a liver transplantation, while the other half may benefit from treatment with ursodeoxycholic acid (UDCA) [15]. This type of PFIC is caused by mutations in the *ABCB4* (*MDR3*) gene, which leads to defective biliary phospholipid secretion. Translocation of phosphatidylcholine from the inner leaflet of the canalicular membrane to the outer leaflet is mediated by ABCB4 and makes phospholipid available for extraction by bile salts [1,16]. This process is essential for protection of the canalicular membrane of hepatocytes as well as the apical membrane of cholangiocytes against the detergent action of bile salts. Biliary bile salt secretion is normal in these patients. The absence of biliary phospholipid excretion together with normal bile salt excretion causes damage to membranes [15,17].

More recently, it has become clear that mutations in the *ABCB4* gene that may reduce but not eliminate the activity of the protein can cause a variety of milder PFIC3 phenotypes. This also applies in the case of heterozygosity for mutations that eliminate transporter activity [18]. Mutations in the *ABCB4* gene have been detected in patients with symptoms of primary biliary cirrhosis (PBC) [19]. Such patients may be primarily if not exclusively found in the subgroup of PBC patients without antimitochondrial antibodies (AMA–), i.e. patients with symptoms of PBC that may not be caused by autoimmunity. Lucena

et al. [19] as well as Thompson *et al.* [20] reported on AMA-negative patients with mutations in the *ABCB4* gene, while Pauli-Magnus *et al.* [21] could not find *ABCB4* mutations in a group of PBC patients with antimitochondrial antibodies (AMA-positive). Furthermore, *ABCB4* mutations have been reported in patients with intrahepatic cholesterol gallstones (see below) [19,22].

Dubin–Johnson syndrome

Although the Dubin–Johnson syndrome is not strictly a cholestatic syndrome, it is characterized by one of the most prominent features of cholestasis, conjugated hyperbilirubinaemia. The Dubin–Johnson syndrome is caused by mutations in the *ABCC2* gene encoding MRP2, a canalicular ABC transporter that extrudes organic anions and neutral compounds. Diagnostically, these patients have a chronic conjugated hyperbilirubinaemia without elevated serum GGT or transaminases [1]. This rare syndrome is considered to be benign, although anecdotal reports of primary hepatocellular carcinoma have been published [1]. Although the best known substrate is conjugated bilirubin, MRP2 should be considered a drug transporter responsible for the elimination of endogenous and exogenous compounds. In many cases, this concerns products of phase I and phase II metabolism.

Canalicular lipid transport defects can cause gallstone formation

It is well established that supersaturation of bile with cholesterol, which occurs in a large proportion of humans, leads to the formation of cholesterol gallstones. Biliary cholesterol solubilization depends not only on the concentration of the sterol itself but also on the bile salt and phospholipid concentration [23]. Mixed micelles of bile salts and phospholipids solubilize cholesterol better than simple bile salt micelles. Hence, the rate of phospholipid excretion can be expected to be an important factor in the prevention of gallstone formation. In normal humans, biliary cholesterol saturation is already high. One might therefore also expect that partial defects in phospholipid secretion may cause cholesterol gallstone formation. This has, indeed, been shown. Individuals with mutations in the *ABCB4* gene are particularly prone to cholesterol gallstone formation. Gallstone formation was observed in several PFIC type 3 patients [15] and, conversely, mutations in *ABCB4* were observed in patients with intrahepatic gallstones [19,22]. Importantly, the latter group of patients was not diagnosed as PFIC patients. As these patients were adults with symptoms differing from PFIC type 3, it was hypothesized that this concerned a mild form of PFIC caused by mutations in *ABCB4* that leave residual activity of the transporter. Rosmorduc *et al.* [22] designated this low phospholipid-associated cholelithiasis (LPAC) syndrome.

More recently, it was reported that cholelithiasis is also frequently observed in patients with PFIC type 2 [24] and in patients with BRIC type 2 [14] who have mutations in the *ABCB11* gene. It remains to be determined by which mechanism the expression level of *ABCB11* determines susceptibility to gallstone formation.

Association between canalicular transport defects and cholestasis of pregnancy

Intrahepatic cholestasis of pregnancy (ICP) is a reversible form of cholestasis that may develop in the third trimester of pregnancy and usually resolves rapidly after delivery. The incidence of ICP lies between 10 and 100 cases per 10 000 pregnancies, but there is a strong ethnic background to this phenomenon. Notably, in the Chilean population, ICP develops in as many as 16% of pregnancies and, within the Araucanian Indian subpopulation, it is as high as 28% [25]. The main symptoms are pruritus and, to a lesser extent, jaundice. Serum bile salt levels are increased [26,27]. Increased incidence of fetal distress, premature birth and even stillbirth in association with ICP have been reported (see Chapter 22.3 for a clinical description of this syndrome). It is generally accepted that women who have suffered from ICP are also susceptible to the development of cholestasis upon the use of oral contraceptives.

Several reports have shown that women with mutations in the *ABCB4* gene can develop ICP [18,29–31]. In all cases, the reported mutations were shown not to occur in control populations. More recently, ICP has also been associated with mutations in the *ATP8B1* gene [32,33]. Indeed, ICP patients can be divided into a group with low serum GGT (about 70%) and a group with high serum GGT activity (about 30%) [34]. In most cases described, the cholestatic symptoms resolved upon delivery. Thus, the observed mutations do not cause transporter deficiencies that are strong enough to induce symptoms of PFIC. Most probably, mutations in ICP patients reduce transporter activity partly and only give rise to clinical symptoms during pregnancy. It can therefore be hypothesized that, during the third trimester of pregnancy, there is a generalized impairment of bile formation. Indeed, not only ABCB4 and ABCB11 function is compromised during pregnancy, but ABCC2 deficiency (Dubin–Johnson syndrome) may also be unmasked during pregnancy [35–37].

The mechanism of this phenomenon has not been completely revealed. It is thought that estrogens play an important role; it is known that estradiol glucuronide is excreted into bile and, indeed, treatment of rodents with estrogens induces cholestasis [38]. It remains to be demonstrated, however, whether this mechanism is also operative in pregnant women and whether sufficiently high concentrations of the estrogen glucuronides build up to cause intracanalicular inhibition of the bile salt transporter. Finally, it must be stressed that the present data suggest that the manifestations are caused by mutations in canalicular transporter genes only in a minority of ICP patients [39,40].

A defect in intracellular transport

Arthrogryposis–renal dysfunction–cholestasis (ARC) syndrome

ARC syndrome is an autosomal recessive multisystem disorder characterized by neurogenic arthrogryposis multiplex congenita, renal tubular dysfunction and neonatal cholestasis with bile duct hypoplasia and low γ-glutamyl-transpeptidase (gGT) activity. Platelet dysfunction is common. Affected infants do not thrive and usually die in the first year of life. Gissen *et al.* [41] demonstrated that these patients have mutations in VPS33B, which encodes a homologue of the class C yeast vacuolar protein sorting protein gene, *Vps33*, which is important in the targeting of intracellular vesicles to their proper target and their subsequent fusion with the target membrane.

Interestingly, a screen for genes causing hepatomegaly in zebrafish pointed to *Vps18* from the same gene family [42]. A mutation in this gene resulted in zebrafish with large, vesicle-filled hepatocytes, which was attributed to impaired endosomal–lysosomal trafficking. These mutants developed defects in the bile canaliculi and marked biliary paucity, suggesting that *Vps18* also functions to traffic vesicles to the canalicular membrane of hepatocytes.

Clinical features of ARC syndrome are thought to be caused by abnormal intracellular protein trafficking and defective membrane fusion mechanisms in the kidneys, liver, nervous system and platelets. How defective vesicular transport relates to these features is as yet unknown.

Bile salt synthetic defects (PFIC type 4)

Inherited defects in the bile salt synthetic pathway are responsible for about 2% of the cases of chronic cholestasis in infants. A review by Bove *et al.* [43] provides a detailed description of the different defects, their clinical pictures and the genes involved. Depending on the nature of the defect, these patients suffer from liver disease that ranges from mild to severe. Progression of liver disease is most rapid when the defect results in accumulation of toxic monohydroxy and unsaturated oxo-bile salts. Histological findings include intralobular cholestasis with giant cell transformation, prevalence of necrosis and portal inflammation and fibrosis that sometimes develops into cirrhosis. The larger interlobular bile ducts are usually spared. These findings, together with the slow progressive development of the disease, are very reminiscent of those in PFIC type 1 and 2. Similar to these two syndromes, γ-glutamyltransferase (GGT) activity in serum is low. For this reason, it has also been advocated to refer to this group of genetic defects as PFIC type 4. The resemblance of these syndromes makes a differential diagnosis important by analysis of aberrant bile salt metabolites in bile, blood and/or urine, which can be achieved by mass spectrometry. In several of the biosynthetic defects, successful therapy consists of oral administration of the primary bile salt cholate [43].

Defects have now been reported in several genes encoding enzymes involved in bile salt synthesis, including oxysterol 7α-hydroxylase, 3β-hydroxy-C27 steroid dehydrogenase, oxo-steroid 5β-reductase and mitochondrial C-27 hydroxylase (causing cerebrotendinous xanthomatosis, CTX). In addition, several peroxisomal disorders lead to defective bile salt synthesis because the shortening of the bile salt side-chain occurs in the peroxisomes [43].

Reports on the occurrence of pruritus as a symptom in patients with bile salt synthetic defects have been variable. Bove *et al.* [43] observed pruritus in patients with 3β-hydroxy-C27 steroid dehydrogenase/isomerase deficiency. On the other hand, Jacquemin *et al.* [44] described a group of five patients with the same defect, none of whom suffered from pruritus. The latter observation is interesting; it would confirm the hypothesis that cholestatic pruritus is primarily caused by high concentrations of circulating bile salts, because these patients are cholestatic but do not have any primary bile salts in the plasma.

It was shown that conjugation of bile salts with glycine or taurine is essential for their transport into bile. Within the group of Amish patients diagnosed for familial hypercholanaemia (see below), individuals were found who had a mutation in the *BAAT* gene, which encodes the enzyme bile acid coenzyme A:amino acid *N*-acyltransferase [45]. This enzyme catalyses the conjugation of bile salts with glycine and/or taurine. Patients with this mutation suffered from coagulopathy, pruritus and failure to thrive; they had elevated serum bile salt levels and all bile salts were unconjugated. Penetrance of the clinical phenotype was not complete.

Defects affecting the integrity of tight junctions in hepatocytes and cholangiocytes

Tight junctions are protein complexes that separate the apical and basolateral membranes of epithelial cells. The physical barrier of tight junctions is composed of polypeptide strands of claudins and occludins. In this way, epithelial cells form a barrier against the potentially hostile external environment. In the biliary tree, this barrier is of particular importance because bile is a highly toxic substance, as described above. Thus, the tight junctions in hepatocytes and cholangiocytes seal off the canalicular lumen and the lumen of the bile ducts in order to prevent leakage of bile into the parenchyma. The importance of efficient containment of bile within the biliary tree is underlined by the recent finding that defects in tight junctional functioning lead to cholestatic syndromes.

Familial hypercholanaemia

This syndrome was described in the Amish population and resembles a mild form of PFIC type 1 and 2. Serum bile acid concentration in affected individuals fluctuates (often very high, occasionally normal). Fat malabsorption, reflecting low intestinal bile acid levels, is manifested by failure to thrive, potentially

life-threatening vitamin K-dependent coagulopathy and rickets. Symptoms usually respond to treatment with UDCA [45]. Some of these patients were shown to have a mutation in the *TJP2* gene, which encodes the tight junctional protein 2 (TJP2). Through binding to claudin and occludin, TJP2 is presumed to affect tight junction structure and the open or closed state of hypothesized claudin pores. Indeed, an aberrant morphology of the tight junctions was observed in the liver of a patient with a mutation causing familial hypercholanaemia [45].

Neonatal sclerosing cholangitis with ichthyosis

Neonatal sclerosing cholangitis presents almost invariably with jaundice and acholic stools. Liver histology is indistinguishable from that of biliary atresia, but cholangiography demonstrates the patency of the bile ducts, with characteristic changes of sclerosing cholangitis [46]. A very rare specific combination of this syndrome with ichthyosis was reported recently [47]. It was subsequently demonstrated that the underlying cause was a mutation in the Claudin-1 (*CLDN1*) gene. The claudins are essential components of the tight junctional complex.

Lymphoedema–cholestasis (Aagenaes) syndrome

In lymphoedema–cholestasis syndrome (LCS or Aagenaes syndrome), severe neonatal cholestasis and evidence of hepatocellular injury accompany lymphoedema that mainly affects the lower extremities. Patients have hyperbilirubinaemia and high serum concentrations of bile salts. Liver histology displays giant-cell transformation of hepatocytes. Manifestations of liver disease lessen during early childhood and become episodic, as in BRIC. However, in a few patients, the course of cholestasis resembles that in PFIC, with cirrhosis and death in childhood; other patients develop cirrhosis as adults. The lymphoedema that is typical of this syndrome manifests either at birth or during childhood, and becomes chronic and severe, mainly affecting the lower extremities, but also the hands, scrotum and periorbital soft tissues. Later in life, lymphoedema can affect the small intestine and the thoracic soft tissue, with chylothorax. Lymph vessels in patients with LCS are hypoplastic. Most reported patients with LCS are from a small region of south-western Norway, but the syndrome has been diagnosed in other countries as well. Transmission of LCS is autosomal recessive in Norwegian patients, in whom a locus (*LCS1*) has been mapped to chromosome 15q [48].

Defects in the development of bile ducts

Alagille syndrome

Alagille syndrome is an autosomal dominant paediatric disorder that is characterized by developmental abnormalities in many organs including the liver, heart, kidney, face, eyes and vertebrae. The hallmark of liver pathology in Alagille syndrome is a postnatal age-related increase in the proportion of portal tracts that have no bile duct (bile duct paucity), without evidence of prominent bile duct damage. These children suffer from pruritus, growth impairment, hypercholesterolaemia and may develop cirrhosis requiring liver transplantation.

In the majority of cases, it could be shown that the disease is caused by mutations in the *JAG1* (or *JAGGED1*) gene [49]. JAG1 is a plasma membrane protein that functions as a ligand in the Notch pathway, an evolutionarily conserved, fundamental signalling pathway first studied in *Drosophila melanogaster*. The Notch signalling pathway is a complex developmental pathway that has been demonstrated to regulate cell fate determination. JAG1 is expressed widely throughout development and specifically during embryogenesis in structures that are destined to contribute to the cardiovascular system and the bile ducts [50]. It is currently thought that the absence of this signalling pathway causes a lack of branching and elongation of bile ducts during postnatal liver growth, leading to peripheral bile duct paucity and cholestasis.

References

1 Oude Elferink RP, Groen AK (2002) Genetic defects in hepatobiliary transport. *Biochim Biophys Acta* 1586, 129–145.

2 Clayton RJ, Iber FL, Ruebner BH *et al.* (1969) Byler disease. Fatal familial intrahepatic cholestasis in an Amish kindred. *Am J Dis Child* 117, 112–124.

3 Bull LN, Carlton VE, Stricker NL *et al.* (1997) Genetic and morphological findings in progressive familial intrahepatic cholestasis (Byler disease [PFIC-1] and Byler syndrome): evidence for heterogeneity. *Hepatology* 26, 155–164.

4 Klomp LW, Vargas JC, van Mil SW *et al.* (2004) Characterization of mutations in ATP8B1 associated with hereditary cholestasis. *Hepatology* 40, 27–38.

5 van Ooteghem NA, Klomp LW, Berge-Henegouwen GP *et al.* (2002) Benign recurrent intrahepatic cholestasis progressing to progressive familial intrahepatic cholestasis: low GGT cholestasis is a clinical continuum. *J Hepatol* 36, 439–443.

6 Lykavieris P, van MS, Cresteil D *et al.* (2003) Progressive familial intrahepatic cholestasis type 1 and extrahepatic features: no catch-up of stature growth, exacerbation of diarrhea, and appearance of liver steatosis after liver transplantation. *J Hepatol* 39, 447–452.

7 Bull LN, van Eijk MJ, Pawlikowska L *et al.* (1998) A gene encoding a P-type ATPase mutated in two forms of hereditary cholestasis. *Nature Genet* 18, 219–224.

8 Whitington PF, Freese DK, Alonso EM *et al.* (1994) Clinical and biochemical findings in progressive familial intrahepatic cholestasis. *J Pediatr Gastroenterol Nutr* 18, 134–141.

9 Whitington PF, Whitington GL (1988) Partial external diversion of bile for the treatment of intractable pruritus associated with intrahepatic cholestasis. *Gastroenterology* 95, 130–136.

10 Kalicinski PJ, Ismail H, Jankowska I *et al.* (2003) Surgical treatment of progressive familial intrahepatic cholestasis: comparison of partial external biliary diversion and ileal bypass. *Eur J Pediatr Surg* 13, 307–311.

11 Kurbegov AC, Setchell KD, Haas JE *et al.* (2003) Biliary diversion for

progressive familial intrahepatic cholestasis: improved liver morphology and bile acid profile. *Gastroenterology* 125, 1227–1234.

12 Melter M, Rodeck B, Kardorff R *et al.* (2000) Progressive familial intrahepatic cholestasis: partial biliary diversion normalizes serum lipids and improves growth in noncirrhotic patients. *Am J Gastroenterol* 95, 3522–3528.

13 Strautnieks SS, Bull LN, Knisely AS *et al.* (1998) A gene encoding a liver-specific ABC transporter is mutated in progressive familial intrahepatic cholestasis. *Nature Genet* 20, 233–238.

14 van Mil SW, van der Woerd WL, van der BG *et al.* (2004) Benign recurrent intrahepatic cholestasis type 2 is caused by mutations in ABCB11. *Gastroenterology* 127, 379–384.

15 Jacquemin E, de Vree JM, Cresteil D *et al.* (2001) The wide spectrum of multidrug resistance 3 deficiency: from neonatal cholestasis to cirrhosis of adulthood. *Gastroenterology* 120, 1448–1458.

16 Oude Elferink RP, Tytgat GN, Groen AK (1997) Hepatic canalicular membrane 1: the role of mdr2 P-glycoprotein in hepatobiliary lipid transport. *FASEB J* 11, 19–28.

17 de Vree JM, Jacquemin E, Sturm E *et al.* (1998) Mutations in the MDR3 gene cause progressive familial intrahepatic cholestasis. *Proc Natl Acad Sci USA* 95, 282–287.

18 Jacquemin E, Cresteil D, Manouvrier S *et al.* (1999) Heterozygous non-sense mutation of the MDR3 gene in familial intrahepatic cholestasis of pregnancy. *Lancet* 353, 210–211.

19 Lucena JF, Herrero JI, Quiroga J *et al.* (2003) A multidrug resistance 3 gene mutation causing cholelithiasis, cholestasis of pregnancy, and adulthood biliary cirrhosis. *Gastroenterology* 124, 1037–1042.

20 Thompson RJ, Strautnieks SS, Gerred S *et al.* (2001) Adult onset cholangiopathy (AMA-ve PBC) due to mutations in ABCB4. In: Oude Elferink RJ (ed.) *Best Practice and Research Clinical Gastroenterology*, 34th edn, p. 184.

21 Pauli-Magnus C, Kerb R, Fattinger K *et al.* (2004) BSEP and MDR3 haplotype structure in healthy Caucasians, primary biliary cirrhosis and primary sclerosing cholangitis. *Hepatology* 39, 779–791.

22 Rosmorduc O, Hermelin B, Boelle PY *et al.* (2003) ABCB4 gene mutation-associated cholelithiasis in adults. *Gastroenterology* 125, 452–459.

23 Carey MC, Small DM (1978) The physical chemistry of cholesterol solubility in bile. Relationship to gallstone formation and dissolution in man. *J Clin Invest* 61, 998–1026.

24 Bull L, Freimer N, Czubkowski P *et al.* (2002) Clinical and biochemical features of FIC1 (ATP8B1) and BSEP (ABCB11) disease. In: Oude Elferink RJ (ed.) *Best Practice and Research Clinical Gastroenterology*, 36th edn, p. 310A.

25 Reyes H, Gonzalez MC, Ribalta J *et al.* (1978) Prevalence of intrahepatic cholestasis of pregnancy in Chile. *Ann Intern Med* 88, 487–493.

26 Bacq Y, Myara A, Brechot MC *et al.* (1995) Serum conjugated bile acid profile during intrahepatic cholestasis of pregnancy. *J Hepatol* 22, 66–70.

27 Laatikainen T, Tulenheimo A (1984) Maternal serum bile acid levels and fetal distress in cholestasis of pregnancy. *Int J Gynaecol Obstet* 22, 91–94.

28 Paus TC, Schneider G, Van D *et al.* (2004) Diagnosis and therapy of intrahepatic cholestasis of pregnancy. *Z Gastroenterol* 42, 623–628.

29 Dixon PH, Weerasekera N, Linton KJ *et al.* (2000) Heterozygous MDR3 missense mutation associated with intrahepatic cholestasis of pregnancy: evidence for a defect in protein trafficking. *Hum Mol Genet* 9, 1209–1217.

30 Gendrot C, Bacq Y, Brechot MC *et al.* (2003) A second heterozygous MDR3 nonsense mutation associated with intrahepatic cholestasis of pregnancy. *J Med Genet* 40, e32.

31 Mullenbach R, Linton KJ, Wiltshire S *et al.* (2003) ABCB4 gene sequence variation in women with intrahepatic cholestasis of pregnancy. *J Med Genet* 40, e70.

32 Mullenbach R, Bennett A, Tetlow N *et al.* (2005) ATP8B1 mutations in British cases with intrahepatic cholestasis of pregnancy. *Gut* 54, 829–834.

33 Painter JN, Savander M, Ropponen A *et al.* (2005) Sequence variation in the ATP8B1 gene and intrahepatic cholestasis of pregnancy. *Eur J Hum Genet* 13, 435–439.

34 Milkiewicz P, Gallagher R, Chambers J *et al.* (2003) Obstetric cholestasis with elevated gamma glutamyl transpeptidase: incidence, presentation and treatment. *J Gastroenterol Hepatol* 18, 1283–1286.

35 Cohen L, Lewis C, Arias IM (1972) Pregnancy, oral contraceptives, and chronic familial jaundice with predominantly conjugated hyperbilirubinemia (Dubin–Johnson syndrome). *Gastroenterology* 62, 1182–1190.

36 Lindberg MC (1992) Hepatobiliary complications of oral contraceptives. *J Gen Intern Med* 7, 199–209.

37 Seligsohn U, Shani M (1977) The Dubin Johnson syndrome and pregnancy. *Acta Hepatogastroenterol (Stuttg)* 24, 167–169.

38 Vore M, Liu Y, Huang L (1997) Cholestatic properties and hepatic transport of steroid glucuronides. *Drug Metab Rev* 29, 183–203.

39 Savander M, Ropponen A, Avela K *et al.* (2003) Genetic evidence of heterogeneity in intrahepatic cholestasis of pregnancy. *Gut* 52, 1025–1029.

40 Pauli-Magnus C, Lang T, Meier Y *et al.* (2004) Sequence analysis of bile salt export pump (ABCB11) and multidrug resistance p-glycoprotein 3 (ABCB4, MDR3) in patients with intrahepatic cholestasis of pregnancy. *Pharmacogenetics* 14, 91–102.

41 Gissen P, Johnson CA, Morgan NV *et al.* (2004) Mutations in VPS33B, encoding a regulator of SNARE-dependent membrane fusion, cause arthrogryposis-renal dysfunction-cholestasis (ARC) syndrome. *Nature Genet* 36, 400–404.

42 Sadler KC, Amsterdam A, Soroka C *et al.* (2005) A genetic screen in zebrafish identifies the mutants Vps18, nf2 and foie gras as models of liver disease. *Development* 132, 3561–3572.

43 Bove KE, Heubi JE, Balistreri WF *et al.* (2004) Bile acid synthetic defects and liver disease: a comprehensive review. *Pediatr Dev Pathol* 7, 315–334.

44 Jacquemin E, Setchell KD, O'Connell NC *et al.* (1994) A new cause of progressive intrahepatic cholestasis: 3 beta-hydroxy-C27-steroid dehydrogenase/isomerase deficiency. *J Pediatr* 125, 379–384.

45 Carlton VE, Harris BZ, Puffenberger EG *et al.* (2003) Complex inheritance of familial hypercholanemia with associated mutations in TJP2 and BAAT. *Nature Genet* 34, 91–96.

46 Mieli-Vergani G, Vergani D (2001) Sclerosing cholangitis in the paediatric patient. *Best Pract Res Clin Gastroenterol* 15, 681–690.

47 Hadj-Rabia S, Baala L, Vabres P *et al.* (2004) Claudin-1 gene mutations in neonatal sclerosing cholangitis associated with ichthyosis: a tight junction disease. *Gastroenterology* 127, 1386–1390.

48 Bull LN, Roche E, Song EJ *et al.* (2000) Mapping of the locus for cholestasis–lymphedema syndrome (Aagenaes syndrome) to a 6.6-cM interval on chromosome 15q. *Am J Hum Genet* 67, 994–999.

49 Spinner NB, Colliton RP, Crosnier C *et al.* (2001) Jagged1 mutations in Alagille syndrome. *Hum Mutat* 17, 18–33.

50 Crosnier C, ttie-Bitach T, Encha-Razavi F *et al.* (2000) JAGGED1 gene expression during human embryogenesis elucidates the wide phenotypic spectrum of Alagille syndrome. *Hepatology* 32, 574–581.

17 Vascular diseases

17.1 Hepatic artery diseases

Peter C. Hayes

Introduction

The hepatic artery provides 35% of liver blood flow (800–1200 mL/min) and 50% of the oxygen supply [1]. The portal vein supplies 65% of the blood flow, and there is a relationship between hepatic arterial and portal venous flow known as reciprocity or the hepatic artery buffer response [2,3], which serves to maintain liver blood flow so that a decreased flow in one vessel leads to an increased flow in the other. There is evidence that this form of autoregulation may be mediated by adenosine acting as a dilator, accumulating locally after a reduction in blood flow [4]. The portal venous system acts primarily as a passive conduit for splenic and intestinal outflow of blood. The hepatic oxygen supply is not critical as the liver extracts only half of its normal oxygen supply. Liver arterial blood flow is maintained as long as the mean arterial pressure remains above 60–80 mmHg. Although the ultimate destination of the hepatic arterial and portal venous blood is the sinusoids, the intra- and extrahepatic biliary systems receive their blood supply preferentially from the hepatic artery.

Anatomy

The hepatic artery, in comparison with the portal vein, demonstrates considerable anatomical variation with only 55–65% of cases demonstrating the conventional pattern of the common hepatic artery originating from the coeliac axis [5]. In this most common arrangement, after the origin of the gastroduodenal artery, the hepatic artery enters the porta hepatis. It divides into the right, left and occasionally middle hepatic arteries. In 45% of subjects, the middle hepatic artery emerges from the left hepatic artery and is the main supply of the quadrate lobe, and sometimes the caudate lobe and gallbladder. The last, however, is more often supplied by the cystic artery branch of the right hepatic artery before it enters the right hepatic lobe. In 25% of cases, an accessory hepatic artery arises from the left gastric artery (which may replace the left hepatic artery or exist in addition to it); in 14%, an accessory right hepatic artery arises from the superior mesenteric artery and, in 8%, the right hepatic artery is replaced by an artery arising from the mesenteric artery. (There are other rarer anatomical variations.) These anatomical variations are obviously particularly important when it comes to hepatobiliary surgery, transplantation and interventional radiology.

Hepatic artery occlusion

Aetiology and natural history

Hepatic artery occlusion is uncommon and is usually diagnosed at autopsy. It may be caused by atheroma, thrombosis, emboli, tumour invasion, polycythaemia, polyarteritis nodosa, surgical trauma, blunt abdominal trauma or follow transcatheter therapeutic procedures. Occlusion does not necessarily lead to hepatic infarction because of collateral circulation and, in fact, ligation of the hepatic artery is widely used to control bleeding in liver injury and the treatment of liver tumours. The consequences of hepatic artery occlusion depend on the site, the duration over which occlusion takes place and the state of the portal circulation [6]. When occlusion of the hepatic artery occurs distal (on the liver side) to the branching of the gastroduodenal artery, development of collateral circulation does not take place. Thrombosis that occurs slowly is better tolerated than sudden occlusion. Occlusion of the hepatic artery and portal vein is almost invariably fatal. Non-occlusive hepatic infarction may occur during low cardiac output states and diabetic ketoacidosis. Embolization of branches of the hepatic artery with particulate material is generally well tolerated and used as a therapeutic approach in the treatment of hepatocellular carcinoma, and clinically significant hepatic infarction and abscess formation is rare.

Pathophysiology

Animal models of liver ischaemia–reperfusion have demonstrated that liver injury and hepatocellular necrosis and microvascular injury correlate with enhanced Kupffer cell activity and neutrophil activation and infiltration. These cells and

endothelial cells generate inflammatory mediators, which may lead to further liver injury [7]. Inhibition of Kupffer cells with gadolinum chloride or latex reduces liver injury and improves survival in animal models [8,9]. Certain agents, such as albumin, prostacyclin E1 and misoprostol, protect against ischaemia–reperfusion injury in experimental models. The systemic microvascular abnormalities and hypotension that accompany ischaemic liver injury may well be secondary to inflammatory mediators including platelet-activating factor [10].

Clinical features

As mentioned above, hepatic artery occlusion may be asymptomatic. However, if there is hepatic infarction, presenting features include right upper quadrant abdominal or back pain with tenderness and guarding and a variable tachycardia, hypotension and signs of liver insufficiency. Abnormalities in liver function are primarily elevation of serum aminotransferases as well as bilirubin and prolongation of the prothrombin time. Fever and elevated white blood cell count are common features. Acute liver failure with hepatic encephalopathy may occur. The treatment of this condition depends on the underlying cause, and acute liver failure should be managed as for other causes. Features of the underlying precipitating cause of hepatic artery occlusion may be present. The prognosis of hepatic artery occlusion with hepatic infarction is poor.

Investigations

The diagnosis will usually be suggested by Doppler ultrasound and confirmed by hepatic arteriography, computerized tomography (CT) or magnetic resonance (MR) angiography. CT and MRI scanning may be useful in determining the extent of the ischaemic injury.

Hepatic artery lesions following orthotopic liver transplantation

Hepatic artery lesions following orthotopic liver transplantation are relatively common and are potentially serious with a prevalence of 7–36% [11–13] (see Chapter 25.3). The main hepatic arterial lesions following transplantation are hepatic artery occlusion, stenosis and anastomotic aneurysms. Allograft hepatic artery thrombosis, which complicates approximately 2% of adult transplants and 5% of paediatric transplants, is a serious and life-threatening complication if it occurs soon after transplant. Clinical features, usually presenting between days 1 and 21 postoperatively, are variable but may be acute liver failure, delayed biliary leak or relapsing bacteraemia secondary to graft necrosis, bile duct necrosis or abscess formation. Biliary leaks or obstructive biliary complications should prompt investigation of the hepatic arterial supply. In patients in whom hepatic artery thrombosis is delayed and gradual, hepatic necrosis may not develop because of the development of collateral circulation. Some patients with occult hepatic artery thrombosis present with relapsing subacute sepsis. Hepatic artery stenosis may present with unexplained abnormalities in liver function tests. In patients in whom hepatic artery thrombosis is suspected, Doppler ultrasound examination of the hepatic artery is a useful screening test. Confirmation of the diagnosis requires either hepatic arteriography or CT angiography. Treatment of hepatic artery thrombosis occurring early after liver transplantation is retransplantation. Deferment in patients who appear to have well-preserved hepatic function not uncommonly leads to sepsis with abscess formation, which may well subsequently preclude retransplantation.

Risk factors for hepatic artery thrombosis may be surgical (the incidence has been falling in recent years), ABO incompatibility use of older donors and preoperative chemoembolization [14].

Hepatic artery aneurysms

Aneurysms of the hepatic artery can be divided into true, pseudo and mycotic variants. Hepatic artery aneurysms are the fourth most common abdominal aneurysms but are rare, occurring most often in middle-aged men. Visceral arterial aneurysms occur with increased frequency in patients with cirrhosis. Hepatic artery aneurysms may be intra- or extrahepatic, the latter being four times more frequent with the main hepatic artery being the most common site. The size is usually between 2 and 10 cm.

Aetiology and pathophysiology

Aetiology of hepatic arterial aneurysms may be arteriosclerosis, systemic infections, especially bacterial endocarditis, syphilis, tuberculosis and intra-abdominal sepsis, including cholecystitis, appendicitis and liver abscess, trauma, including liver biopsy and biliary surgery (Fig. 1), vasculitic disease, especially polyarteritis nodosa, a weakness in the arterial wall as in Marfan syndrome,

Fig. 1 Angiogram showing a pseudoaneurysm of hepatic artery following cholecystectomy.

Ehlers–Danlos syndrome, Osler–Weber–Rendu disease and fibromusculo-hyperplasia. Some occur in otherwise healthy people with no known cause. In polyarteritis nodosa, the liver is involved in 66% of cases, particularly multiple fusiform or sacular aneurysms associated with an irregular calibre of medium and small vessels. These aneurysms may thrombose and cause peripheral infarction or rupture and cause haemorrhage. Nodular regenerative hyperplasia may complicate this disorder. Hepatic arterial dissections are rare, but have been described in association with abdominal surgery, peritonitis, systemic hypertension, pre-existing arterial disease and trauma [15]. Mycotic pseudoaneurysm is a rare complication following liver transplantation [16].

Clinical features

Hepatic artery aneurysms are usually discovered in middle age with a male to female ratio of 4:1. Patients may remain asymptomatic for long periods of time. Abdominal pain is the first symptom in 75% of cases [17]. The pain may be severe when due to dissection or vague when due to compression, and is often misinterpreted as biliary or pancreatic pain. Rupture occurs in up to 80% of cases and produces an intraperitoneal haemorrhage with extrahepatic aneurysms or haemobilia associated with gastrointestinal bleeding and jaundice with intrahepatic aneurysms [18]. The triad of abdominal pain, jaundice and gastrointestinal haemorrhage is said to be suggestive of hepatic artery aneurysms, but only occurs in approximately 30% of cases. The mortality from hepatic artery aneurysm rupture is 80%. An uncommon presentation is with jaundice due to extrinsic compression of the biliary tree [19].

Diagnosis

Diagnosis is often missed as it is not considered. Abdominal radiography shows calcification in the aneurysm in less than 50% of cases, and therefore ultrasonography and/or CT is better [20]. Arteriography is the definitive diagnostic methodology, although MRI or CT is now used in the diagnosis of hepatic artery aneurysms (Fig. 2).

Treatment

The treatment of a ruptured aneurysm is emergency surgery or transcatheter embolization dictated by the circumstances. In asymptomatic patients, excision or obliteration of the aneurysm may be considered. An aneurysm in the common hepatic artery proximal to the gastroduodenal artery can be safely ligated, whereas in aneurysms distal to the gastroduodenal artery, ligation interrupts the collateral artery circulation and may produce liver ischaemia. Aneurysms in this area are treated with resection and reconstruction. Intrahepatic aneurysms may be treated by resection of the liver or by ligating the specific feeding vessel. Transcatheter embolization is nowadays the preferred alternative treatment because of its high efficacy and low morbidity [21]. Obliteration using coils [4,22] or percutaneous thrombin injection [5,23] has been suggested.

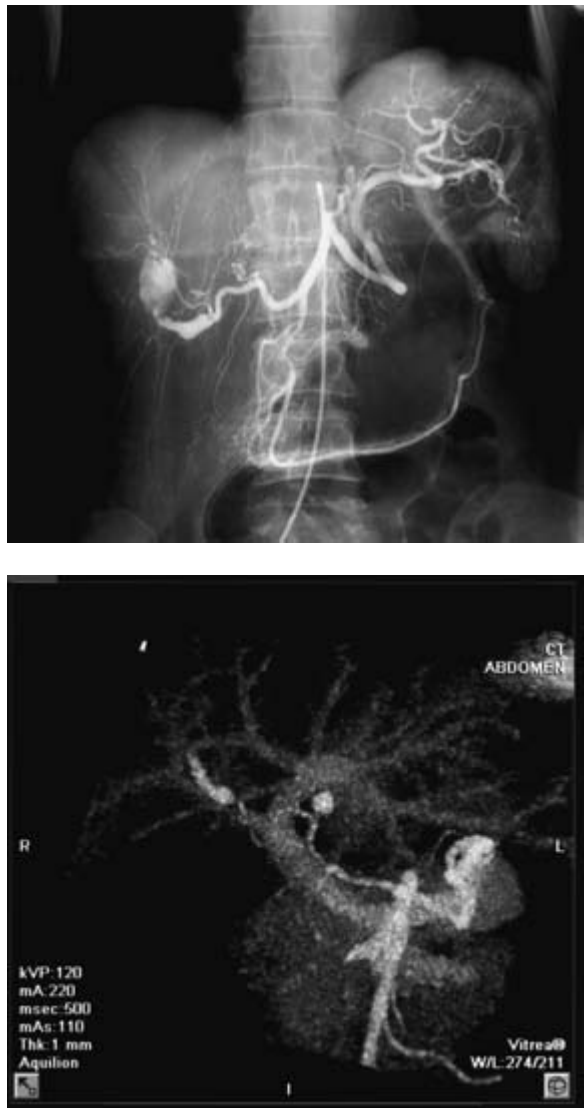

Fig. 2 (a) An angiogram of a hepatic artery aneurysm and (b) a computerized tomography angiogram showing bilateral hepatic artery aneurysms (embolised).

Hepatic arterioportal fistulae

An hepatic arterioportal fistula is a rare but potentially treatable cause of portal hypertension. Arterioportal fistulae occur secondary to trauma including liver biopsy or other diagnostic or therapeutic procedures, hepatocellular tumours or congenital disorders such as hereditary haemorrhagic telangiectasia. Fistulae between the extrahepatic hepatic artery and portal vein usually occur as a result of the rupture of an hepatic artery aneurysm or trauma.

Arterioportal fistulae may be asymptomatic or present with abdominal pain, intestinal ischaemia or portal hypertension with upper gastrointestinal bleeding, ascites or, unusually, congestive cardiac failure. Portal hypertension develops in approximately 40% of patients, particularly in those with a fistulae involving large vessels, and abdominal bruit are present in 80% of patients. Diagnostically, Doppler ultrasound may detect arterioportal fistulae, but a CT scan or angiography is required for accurate anatomical assessment. Treatment for arterioportal fistulae depends on their size and position and the presence of portal hypertension or other symptoms. For patients with small intrahepatic fistulae without portal hypertension, observation is appropriate as they may remain constant in size and even close spontaneously. By comparison, extrahepatic fistulae have a tendency to increase in size and should therefore be treated, even if asymptomatic, by either surgery or transcatheter embolization [24].

References

1 Tygstrup N, Winkler K, Mellemgaard K *et al.* (1962) Determination of the hepatic arterial flow and oxygen supply in man by clamping the hepatic artery during surgery. *J Clin Invest* 41, 447–454.

2 Richardson PD, Withrington PG (1981) Liver blood flow. I. Intrinsic and nervous control of liver blood flow. *Gastroenterology* 8, 159–173.

3 Lautt WW (1981) The role and control of the hepatic artery. In: Lautt WW (ed.) *Hepatic Circulation in Health and Disease*. New York: Raven Press, pp. 203–206.

4 Ezzat WR, Loutt WW (1987) Hepatic arterial pressure-flow autoregulation is adenosine mediated. *Am J Physiol* 252, H836–845.

5 Friedman AC (1987) *Radiology of the Liver, Biliary Tract, Pancreas and Spleen*. Baltimore: Williams and Williams.

6 Bechstein WO, Blumhardt G, Ringe B *et al.* (1987) Surgical complications in 200 consecutive liver transplants. *Transpl Proc* 19, 3830–3831.

7 Liu P, McGuire GM, Fisher MA *et al.* (1995) Activation of Kupffer cells and neutrophils for reactive oxygen formation is responsible for endotoxin-enhanced liver injury after hepatic ischaemia. *Shock* 3, 56–62.

8 Shiratori Y, Kiriyama H, Fukushi Y *et al.* (1994) Mediation of ischaemia and reperfusion-induced hepatic injury by Kupffer cells. *Dig Dis Sci* 39, 1265–1272.

9 Suzuki S, Toledo-Pereyra LH, Rodrigues F *et al.* (1994) Role of Kupffer cells in neutrophil activation and infiltration following hepatic ischaemia and reperfusion. *Circ Shock* 42, 204–209

10 Fukuoka T, Nakajima Y, Nakano H (1995) The platelet activating factor as a pivotal mediator of shock after liver ischaemia. *Surg Today* 25, 351–356.

11 Wozney P, Zajko AB, Bron KM *et al.* (1986) Vascular complications after liver transplantation, a 5 year experience. *Am J Roentgenol* 147, 657–663.

12 Tzakis AG, Gordon RD, Shaw BW (1985) Clinical presentation of hepatic artery thrombosis after liver transplantation in the cyclosporin era. *Transplantation* 40, 667–671.

13 Urbani L, Catalano G, Biancofiore G *et al.* (2003) Surgical complications after liver transplantation. *Minerva Chir* 58, 675–692.

14 Proposito D, Lornaz Segunda C, Garcia Garcia I *et al.* (2001) Assessment of risk factors in the incidence of hepatic artery thrombosis in a consecutive series of 687 liver transplants. *An Ital Chir* 72, 187–205.

15 Bushkin FL, MacGregor AM, Hawkins IF (1972) Hepatic artery dissections as a result of abdominal trauma. *Surg Gynaecol Obstet* 135, 721–726.

16 Houssin D, Ortega D, Richardson A *et al.* (1988) Mycotic aneurysm of the hepatic artery complicating human liver transplantation. *Transplantation* 46, 469–472.

17 Busuttil RW, Brin BJ (1980) The diagnosis and management of visceral artery aneurysms. *Surgery* 88, 619–624.

18 Chen MF, Chou FF, Wang CH *et al.* (1983) Hematobilia from ruptured hepatic artery aneurysm. Report of two cases. *Arch Surg* 118, 759–761.

19 Shultz S, Druy EM, Friedman AC (1985) Common hepatic artery aneurysm: pseudo-pseudocyst of the pancreas. *Am J Radiol* 144, 1287–1288.

20 Kibbler CC, Cohen DL, Cruickshank JK *et al.* (1985) Use of CAT scanning in the diagnosis and management of hepatic artery aneurysm. *Gut* 26, 752–756.

21 Kramann B, Daoyu H, Kubale R *et al.* (1995) Experiences with the endovascular embolization therapy of aneurysms of the splanchnic arteries – a report on 13 cases. *Rofo* 163 (5), 414–423.

22 Nosher JL, Trooskin SZ, Amorosa JK (1986) Occlusion of a hepatic arterial aneurysm with gianturco coils in a patient with Ehlers–Danlos syndrome. *Am J Surg* 152, 326–328.

23 Cope C, Zest R (1986) Coagulation of aneurysms by direct percutaneous thrombin injection. *Am J Radiol* 147, 383–387.

24 Uflacker R, Saadi J (1982) Transcatheter embolization of superior mesenteric arteriovenous fistula. *Am J Radiol* 139, 1212–1214.

17.2 Obstruction of the portal vein

Juan Carlos García-Pagán, Manuel Hernández-Guerra and Jaime Bosch

Thrombosis of the portal venous axis

The term portal vein thrombosis (PVT) refers to thrombosis developing in the trunk of the portal vein, from where it can extend to the right and the left intrahepatic branches. It can also extend to the splenic vein and the superior or the inferior mesenteric veins. Thrombosis of the portal venous system refers to thrombosis at any of the above sites [1].

Aetiology

Causes of PVT are summarized in Table 1.

General thrombophilic factors have been identified in approximately 60% and local factors in 40% of patients with PVT [2–4]. Several factors are frequently associated [5–8]. However, despite complete screening for these factors, up to 30% of PVT remains idiopathic.

Among the hypercoagulable states, primary myeloproliferative disorders are the leading cause [3,4,9,10]. Other much less common acquired disorders are the antiphospholipid syndrome and paroxysmal nocturnal haemoglobinuria. Inherited prothrombotic disorders such as protein S, protein C and antithrombin III deficiencies and, less frequently, factor V Leiden mutation, factor II gene mutation and methylenetetrahydrofolate

Table 1 Aetiological factors in portal vein thrombosis (excluding cancer and cirrhosis).

Causal factor	Recommended investigation
Acquired thrombophilic disorders	
Primary myeloproliferative disorders	Bone marrow biopsy, total red cell mass, erythropoietin level and assessment of endogenous erythroid colonies. JAK 2 determination
Antiphospholipid syndrome	Anticardiolipin (ELISA)
Paroxysmal nocturnal haemoglobinuria	Blood flow cytometry
Hyperhomocysteinaemia	Homocysteine serum levels
Inherited prothrombotic disorders	
Factor V Leiden mutation	Activated protein C resistance or assessment for mutation (G1691A)
Factor II prothrombin gene mutation	Molecular biology for G20210A polymorphism
Protein C deficiency	Ratio to factor II, V, VII or X and family studies
Protein S deficiency	
Antithrombin deficiency	
Local factors	
Focal inflammatory lesions (e.g. omphalitis, pancreatitis, diverticulitis, cholecystitis)	Clinical data and imaging techniques
Portal vein axis injury (e.g. splenectomy, cholecystectomy, colectomy)	
Other risk factors for thrombosis	
Pregnancy	Patient's history record
Contraceptives	

reductase gene mutation have also been identified [2–4]. Other prothrombotic systemic conditions associated with PVT are the use of oral contraceptives, pregnancy and inflammatory and malignancy states [2].

Interpretation of the results of antithrombin III, protein C and protein S deficiencies may be a challenge for physicians when liver deterioration is present [11]. In this situation, a ratio of protein C antigen, protein S antigen or antithrombin values to (factor II + factor X)/2 below 0.7 is highly suspicious of deficiency [3], which might be confirmed by investigation of first-degree relatives [4,7]. Half of the patients with PVT, in whom a predisposing factor cannot be identified, suffer from a primary myeloproliferative disorder (mostly polycythaemia vera) that cannot be detected by conventional criteria [9]. In these patients, spontaneous formation of erythroid colonies in culture is helpful in identifying myeloproliferative disorders [12,13]. The recent identification of molecular markers associated with the presence of myeloproliferative disorders, such as the Janus kinase 2 (JAK2) gene mutation, will probably change this scenario [14].

Local factors include local inflammatory/infectious lesions (pancreatitis, cholecystitis, cholangitis and appendicitis) [15], local injury to the portal venous axis (splenectomy, surgical portocaval shunting and other intra-abdominal surgical procedures) [16] and intra-abdominal malignant tumours (pancreatic and hepatocellular carcinoma) [17]. The presence of these factors does not exclude the presence of systemic risk factors [8]. A history of omphalitis or umbilical vein catheterization is frequently described in children with PVT [18,19].

Cirrhosis may be considered as a local factor promoting PVT. The prevalence of portal thrombosis in cirrhotic patients without associated hepatocellular carcinoma ranges between 0.5% and 26% [13,20,21]. The concomitant existence of thrombophilic factors in cirrhotic patients has been suggested to increase the risk of PVT [22,23]. Other factors that have been involved are endoscopic sclerotherapy, the use of vasoactive drugs and a past history of variceal bleeding [13,24].

Portal vein thrombosis after liver transplantation, although not frequent, may occur at the anastomotic site in the early postoperative period. Several risk factors have been identified, such as technical complications, a small diameter of the donor portal vein, a history of previous PVT and previous splenectomy [25].

Clinical presentation

At presentation, PVT may manifest as an acute process characterized by prominent abdominal pain and signs suggestive of intestinal venous ischaemia. However, the acute episode is more frequently asymptomatic or paucisymptomatic, and PVT is not diagnosed until the development of complications secondary to portal hypertension [8].

The acute thrombotic episode

Clinical manifestations

The presence and severity of symptoms in the acute episode are probably related to the velocity of development and the extent of venous thrombosis. Patients complain of abdominal pain and fever. More frequent is the presence of unspecific dyspeptic symptoms (nausea, postprandial fullness) and general malaise. In some cases, these manifestations overlap with those of the triggering factor, such as recent surgery or acute pancreatitis. When diagnosis and treatment are delayed or venous thrombosis affects the small mesenteric arches, features of intestinal ischaemia may appear with continuous abdominal pain and ileus. If the disease progresses, bowel infarction occurs. This should be suspected when there is haematochezia, rebound tenderness at abdominal examination, accumulation of abdominal fluid or when metabolic acidosis, renal or respiratory failure develop.

Diagnosis

The clinical suspicion (e.g. unexplained acute abdominal pain in a patient with a known thrombophilic factor) should prompt ultrasonography (US) of the portal venous system. The identification of solid echoes within the portal vein and the absence of flow when using US pulsed-Doppler equipment confirms the diagnosis [26]. Computerized tomography (CT) scanning and magnetic resonance angiography imaging (MRI) may provide additional information, especially regarding the extent of thrombosis. In the acute phase, invasive diagnostic techniques such as angiography have been almost abandoned.

Lack of significant periportal collaterals, presence of high luminal density on the thrombosed vessel in the CT scan [27,28] and no evidence of chronic portal hypertension (gastrointestinal bleeding, ascites, collateral portosystemic circulation or hypersplenism) are features that help to differentiate the recent thrombosis from the chronic form [8]. This is relevant as it implies important prognostic and therapeutic consequences.

Treatment

Although no randomized controlled trials (RCTs) have been performed, after the diagnosis of acute PVT, early initiation of anticoagulation is recommended. This is based on the clinical observation that spontaneous recanalization is extremely infrequent. However, over 50% of patients receiving early anticoagulation show successful recanalization [29,30]. The extent of the initial thrombosis within the portal venous system has been identified as a predictive factor for lack of recanalization [30]. In our experience, the presence of more than one prothrombotic factor is associated with a lower probability of recanalization (0% vs. 59% in patients with only one prothrombotic factor), and the rate of partial or complete recanalization decreases from 69% when anticoagulation is instituted within the first week after the start of symptoms to 25% when it is started during the second week [31]. These data, although needing to be

confirmed, reinforce the idea that the earlier the anticoagulation begins the better. Anticoagulation should be instituted even in the presence of severe underlying disorders.

In cases of recent thrombosis, local thrombolytic therapy through a catheter introduced in the portal vein either percutaneously or by the transjugular approach may be useful (if there are no contraindications) [32,33]. Insertion of transjugular intrahepatic portosystemic shunting (TIPS) to maintain a high-velocity flow in the portal vein has also been proposed [34,35]. However, there are no studies evaluating whether these invasive approaches offer advantages over early anticoagulation.

Surgical thrombectomy is not indicated because recurrence is the rule unless anticoagulation is administered simultaneously. Laparotomy is indicated when short bowel damage is suspected.

Recanalization may be expected to occur even 4–6 months after the beginning of anticoagulation. Therefore, it is recommended to keep patients on anticoagulation for at least 6 months [30]. There are no data to advise maintaining anticoagulation beyond 6 months. However, long-term anticoagulation seems rational in patients with an identified underlying prothrombotic disorder, recurrent episodes of thrombosis or familial history of vein thrombosis [8]. Subcutaneous low-molecular-weight heparin (LMWH) is at least as effective and safe as intravenous heparin [36]. LMWH has a more predictable dose–response relationship, which makes laboratory monitoring unnecessary and confers a lower risk of bleeding or allergic thrombocytopenia. In the outpatient setting, oral vitamin K antagonists targeting the international normalized ratio (INR) to a range of 2–3 is the preferable option.

Once diagnosed, the specific treatment for the underlying prothrombotic disorder should be adequately established.

Long-term prognosis

Hitherto, mortality was high (20–50%) with intestinal necrosis being the main cause of death even when surgery was carried out. The outcome has improved through early diagnosis, as a result of enhanced clinical awareness and improved diagnostic techniques, and probably also through the use of early anticoagulation [29,30] and antibiotics [37]. In our experience, 5-year survival was 85%, with complications related to the underlying disorder being the main cause of death [31].

Chronic portal vein thrombosis/portal cavernoma

Clinical manifestations

In many cases, the initial episode of PVT is asymptomatic, and PVT is diagnosed in a late phase either in the study of a portal hypertension-related complication (thrombocytopenia, splenomegaly, variceal bleeding) or incidentally during a diagnostic imaging test performed for other unrelated issues [8].

Tortuous collateral veins around/inside the thrombus, the so-called portal cavernoma, appear as soon as a few days after portal blood flow interruption. Portal hypertension-related complications are the main clinical manifestations of chronic PVT. Twenty-two per cent of the patients screened in the study by Condat *et al.* [30] had varices and 43% in our own series [31]. Gastro-oesophageal varices may develop as early as 1 month after the acute PVT episode. However, in those patients with a negative early endoscopy, varices might still develop during follow-up. This settles the rationale to recommend early screening for varices (2–3 months after the acute PVT diagnosis) and, if no varices are present, to repeat the screening in 9–12 months. The schedule for further follow-up screening endoscopies is unknown and should be investigated. The presence of ectopic varices is significantly more frequent than in patients with cirrhosis [38].

Variceal bleeding is more common in children than in adults, but it is still the most frequent manifestation in adults [39]. Bleeding-related mortality in patients with PVT is much lower than in cirrhotics [6,19,40,41].

Portal biliopathy is defined as abnormalities of the extrahepatic and intrahepatic bile ducts and gallbladder wall in patients with portal cavernoma [42]. It is attributed to ischaemic injury secondary to PVT, but more probably to biliary compression by periportal collaterals composing the cavernoma [43–45]. Obstructive biliary signs and symptoms have been identified by means of cholangiographic imaging techniques in more than 80% of patients after longstanding portal vein obstruction [43,45,46]. However, we have found radiological abnormalities of portal biliopathy as early as 1 year after acute PVT. Despite the high rate of biliary tract abnormalities (mainly stenosis, dilatation, angulation and bile duct irregularity), clinical consequences are infrequent [43], albeit increased serum alkaline phosphatase is common. Severe and life-threatening manifestations (cholecystitis, cholangitis, obstructive jaundice) may occur, although the real incidence is unknown.

Other symptoms, such as early satiety and abdominal discomfort and fullness, are related to massive splenomegaly [19,47,48]. Growth retardation is common in childhood [49].

Ascites has been considered a late-phase manifestation and always associated with gastrointestinal bleeding or infection. However, in our experience, the 2-year actuarial probability of developing ascites after acute PVT was 18%. Contrary to what has been suggested previously [50], these patients had preserved liver function. Ascites is usually easy to control with medical treatment [50,51].

Overt encephalopathy occurs rarely in patients with PVT without liver failure. However, patients with non-cirrhotic non-tumoral PVT develop subclinical neurological abnormalities compatible with minimal hepatic encephalopathy [52]. Whether these alterations have a clinical impact on the natural history of PVT needs further evaluation.

A low prothrombin ratio and mild increase in transaminases are common, and are usually associated with subtle histological findings and minor changes in liver morphology detected by

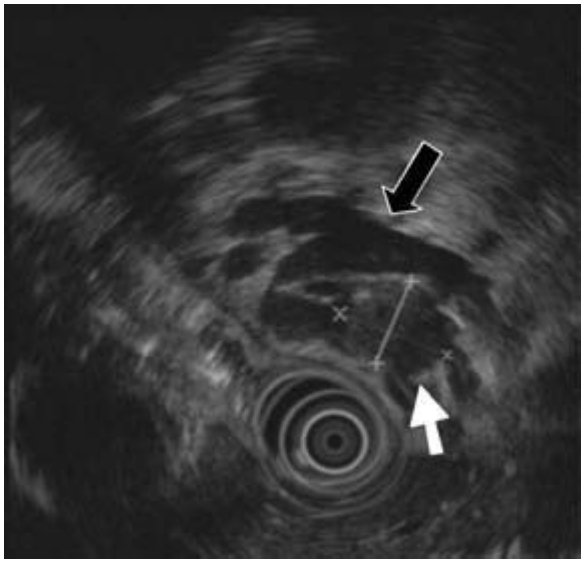

Fig. 1 Endoscopic ultrasound image showing the collaterals (black arrow) around the dilated choledocho (white arrow).

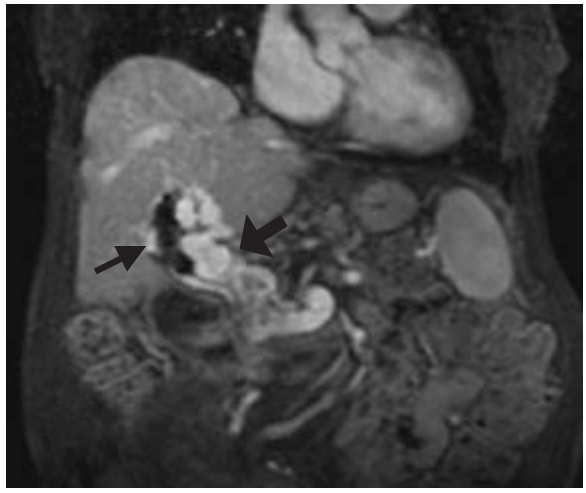

Fig. 2 MRI showing the collaterals (black arrow) compressing the bile duct (white arrow) that dilates upstream.

ultrasound. These findings are probably related to altered liver perfusion, despite the arterial compensatory vasodilation. The real impact of these abnormalities is unknown.

Diagnosis

The diagnosis is performed by imaging techniques. US, CT scan and MRI angiography demonstrating portosystemic collaterals and the presence of portal cavernoma are all extremely useful [27,53]. A liver biopsy will help to rule out a chronic liver disease associated with PVT in patients with altered liver biochemistry or appearance on US. Angiography is usually restricted to cases in which a shunt procedure is required. Endoscopic ultrasound [54] has also been used as an adjuvant to endoscopic retrograde cholangiopancreatography (ERCP) (Fig. 1) and magnetic resonance cholangiography to assess portal biliopathy (Fig. 2) [55]. Endoscopy reveals gastric varices in a much higher proportion of patients than in cirrhotic portal hypertension.

Treatment

Anticoagulation has been shown to prevent the progression and recurrence of thrombosis [41]. These beneficial effects were observed without increasing the risk or severity of gastrointestinal bleeding provided that adequate prophylactic measures to prevent variceal bleeding or rebleeding are adopted before starting anticoagulation [41]. Thus, although this should be decided on an individual basis, it is our policy to initiate long-term anticoagulation in all patients with an underlying prothrombotic disorder or a history of previous thrombosis in other territories.

The acute gastrointestinal bleeding episode should be managed as in cirrhotic patients [8]. It has been suggested that the use of vasoconstrictor agents may theoretically favour thrombus extension by reducing splanchnic blood flow. However, this has not been documented.

There is insufficient data on whether pharmacological or endoscopic therapy should be preferred for primary prophylaxis [8]. Endoscopic therapy has been shown to be effective in secondary prophylaxis [56,57]. Two studies performed in India have shown that variceal band ligation is superior to sclerotherapy, with earlier variceal eradication and lower recurrent variceal bleeding and complications [58,59]. The role of beta-blockers in comparison or associated with endoscopic therapy should be evaluated in prospective randomized studies [8].

Decompressive surgery should only be considered for patients with failure of endoscopic therapy. In all cases, the surgical procedure must be individualized. In our experience, however, 37% of patients with PVT also had thrombosis of the splenic and superior mesenteric vein and, therefore, are not suitable for conventional derivative surgery. Other procedures such as oesophageal transection or splenectomy and ligation of the varices are less useful because of the high frequency of late rebleeding due to reappearance of the varices. Novel shunting techniques, such as the splanchnic intrahepatic portal bypass, need to be validated [60]. TIPS and percutaneous stenting in the setting of chronic portal vein thrombosis are sometimes possible in adults and children [61,62].

Ursodeoxycholic acid (UDCA) has been proposed for the treatment of patients with symptomatic portal biliopathy, including those with abnormal cholestatic tests [45]. However, no clinical data support this recommendation. Choledocholithiasis might be present, complicating a bile duct stenosis. In that case, an ERCP with sphincterotomy is indicated [63]. When there is no evidence of common bile duct stones contributing to the symptoms, sphincterotomy might be useless [64]. In some severe cases, portosystemic shunt, aimed at decompressing the collaterals, or placement of a biliary stent may be considered.

Biliointestinal bypass should be avoided because it has high morbidity and mortality [45,65].

Long-term prognosis

Morbidity is mainly related to variceal bleeding, recurrent thrombosis, symptomatic portal biliopathy and hypersplenism [8]. Mortality among patients with PVT is low (5-year mortality of 5–10%) and is mainly related to associated diseases rather than to complications of portal hypertension [6].

Splenic vein thrombosis

The main causes of isolated splenic vein thrombosis are chronic pancreatitis and carcinoma of the pancreas [15,66]. Occasionally, splenic vein thrombosis has been described in relation to pancreatic pseudotumour, pancreatic pseudocyst, retroperitoneal abscess, renal neoplasms, perirenal abscess and segmental splenic vein resection during a benign pancreatic tumour (iatrogenic cause).

The physical examination reveals an enlarged spleen; biochemical analysis determinations are usually normal, while haematological parameters may show signs of hypersplenism [67]. The triad of gastric varices with splenomegaly and normal liver function is highly suspicious of isolated splenic vein thrombosis [67,68]. Usually, splenic vein obstruction is diagnosed after a bleeding episode related to gastric varices, which are common [15,68,69]. The diagnosis is established by ultrasound, CT scan and MRI. For those inconclusive diagnostic cases, the venous phase of splenic artery angiography is indicated [70]. In some cases, endoscopic ultrasonography may be helpful [71]. It is very unlikely that the use of splenoportography, transhepatic catheterization of the portal vein or peroperative measurements will be required [72,73].

As splenectomy eliminates venous collateral outflow, surgical treatment is clearly justified in patients presenting with variceal bleeding [74]. However, in patients without prior bleeding, a decision for splenectomy is questionable because of the risks and long-term care that will be needed afterwards. Splenic artery embolization is a second-line option for high operative risk patients or in whom intervention is contraindicated [75].

Congenital stenosis of the portal vein

It is important to consider this aetiology in children with prehepatic portal hypertension. The stenosis may be located at any point along the portal vein, but it is particularly common at the hepatic hilus or in the middle of its traject [19,39]. The mechanism of the stenosis is not fully understood, but is thought to be related to the circulatory changes that occur soon after birth.

As in other patients with prehepatic portal hypertension, the disease is usually diagnosed after the patient suffers gastrointestinal bleeding due to ruptured gastro-oesophageal varices. The physical examination may show splenomegaly and subcutaneous collateral vessels. Liver function parameters remain within the normal range, and ultrasound shows the patency of the portal vein, thus making a false diagnosis of intrahepatic portal hypertension. However, liver histology is normal, as is the measurement of hepatic venous pressures. Careful ultrasound examination of the portal vein and analysis of the venous phase of splanchnic angiography may reveal the stenosis, which can thereafter be confirmed by measuring the venous pressure along the portal vein and showing a pressure gradient just at the location of the stenosis. Some cases may be corrected by transluminal angioplasty; otherwise, these patients should be managed surgically.

Aneurysms of the portal vein

Abnormal, aneurysm-like dilatations of the portal vein are rare, representing 3% of all aneurysms of the venous system [76]. In some cases, they appear to be associated with portal hypertension [76,77]. However, there are reports suggesting that such dilatation may occur in subjects with normal portal pressure [78]. The most frequent location of these aneurysms is at the junction of the splenic and mesenteric veins, although there have been cases with other locations (even intrahepatic) [79]. The mechanism of the abnormal portal vein dilatation is not known, but there is evidence of both a congenital and an acquired origin [79–81]. Most portal venous system aneurysms are asymptomatic and are usually diagnosed by chance during Doppler ultrasound examination in a patient known, or suspected, to have portal hypertension. CT scanning and MRI are also useful in showing the enlarged diameter of the portal vein [76, 82]. Venous phase angiography confirms the diagnosis and may sometimes reveal aneurysms or congenital malformations in other locations, thus favouring the suggestion of a congenital origin.

Unlike arterial aneurysms, the risk of spontaneous rupture of an aneurysm of the portal vein seems to be minimal [83]. It is likely that rupture occurs only when there is portal hypertension in patients with very large aneurysms of the portal vein (i.e. > 50 mm in diameter) (Fig. 3). In these cases, portacaval shunts and aneurysmorrhaphy are the therapeutic options [84,85].

Several cases of portal hepatic venous shunt via an intrahepatic portal vein aneurysm, in patients with or without portal hypertension, have been described in the literature [86]. This situation is easily diagnosed by colour Doppler ultrasonography [87].

Extrinsic compression of the portal vein

Portal hypertension due to the stenosis of the portal vein induced by a mass or a process located in the vicinity of its traject is an unusual condition. However, as already discussed, the splenic vein may be compressed by benign or malignant disease of the pancreas.

Partial nodular transformation of the liver is an infrequent disease of unknown origin characterized by the appearance of large nodules (up to 8 cm) located in the hilar area of the liver

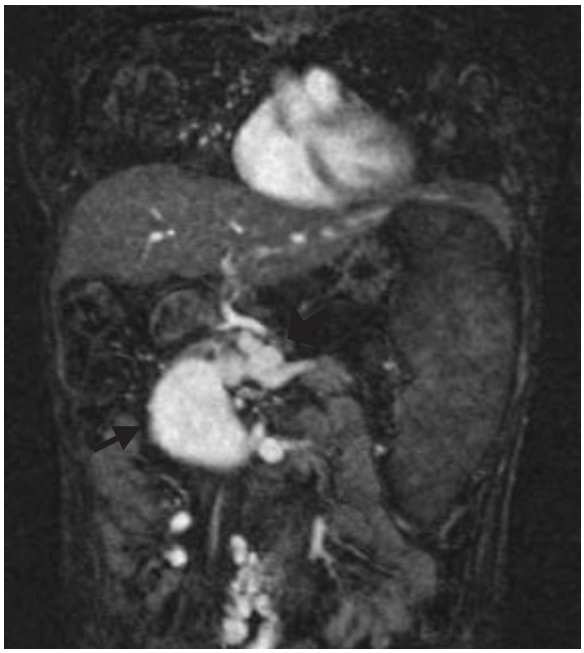

Fig. 3 Aneurysm of the portal vein axis (white arrow) associated with portal cavernoma (black arrow) and portal hypertension (enlarged spleen and collaterals).

[88]. Liver function tests are usually normal, and patients are diagnosed either after bleeding from oesophageal varices or during the diagnostic workup of an enlarged spleen. Pathological examination shows the hilar nodules, composed of normal hepatocytes with minimal fibrosis, while the surrounding liver has a normal appearance [88]. The nodules compress the portal vein, which shows a characteristic smooth narrowing at the hepatic hilum on portography.

Retroperitoneal fibrosis is a chronic inflammation of the cellular tissue of the lower lumbar area. This inflammatory process may constrict the vessels. There are several case reports of patients with portal hypertension secondary to the severe constriction of the portal vein due to retroperitoneal fibrosis [89].

Arteriovenous fistulae in the portal venous system

Portal pressure is the result of the relationship between portal blood flow and the vascular resistance offered to that flow [90]. It is possible, therefore, that portal hypertension could be related to a greatly increased blood flow, which cannot be counteracted by a large enough decrease in vascular resistance. This is in part the mechanism of increased portal pressure in patients with an arteriovenous fistula [91], in whom no evidence of liver disease can be demonstrated. However, it should be stressed that, in some patients, portal hypertension is not entirely corrected despite the surgical closure of the fistula [92], thus indicating that increased portal pressure was, at least in part, related to increased vascular resistance. It is unclear whether this develops as a long-term consequence of arterialization of the portal system.

Arteriovenous fistulae may be located intra- or extrahepatically. They may have a congenital origin, be associated with the Rendu–Osler–Weber syndrome (see Chapter 17.4) or be due to trauma [93]. Intrahepatic arterioportal fistulae may result from liver biopsy or other invasive procedures [94]. In other cases, the fistula is observed within a hepatocellular carcinoma [95]. In patients with cirrhosis, the development of an intrahepatic arteriovenous fistula may markedly aggravate portal hypertension. In rare cases, an aneurysm of the hepatic artery may rupture into the portal vein and give rise to a fistula and portal hypertension. About one-third of patients complain of abdominal pain and, in some of these, it is possible to hear an abdominal bruit. Treatment of these patients is based on percutaneous arterial embolization [96] or surgical ligation of the fistula.

References

1 Valla DC, Condat B (2000) Portal vein thrombosis in adults: pathophysiology, pathogenesis and management. *J Hepatol* 32(5), 865–871.

2 Denninger MH, Chait Y, Casadevall N *et al.* (2000) Cause of portal or hepatic venous thrombosis in adults: the role of multiple concurrent factors. *Hepatology* 31(3), 587–591.

3 Janssen HL, Meinardi JR, Vleggaar FP *et al.* (2000) Factor V Leiden mutation, prothrombin gene mutation, and deficiencies in coagulation inhibitors associated with Budd–Chiari syndrome and portal vein thrombosis: results of a case-control study. *Blood* 96(7), 2364–2368.

4 Bombeli T, Basic A, Fehr J (2002) Prevalence of hereditary thrombophilia in patients with thrombosis in different venous systems. *Am J Hematol* 70(2), 126–132.

5 Rosendaal FR (1999) Venous thrombosis: a multicausal disease. *Lancet* 353(9159), 1167–1173.

6 Janssen HL, Wijnhoud A, Haagsma EB *et al.* (2001) Extrahepatic portal vein thrombosis: aetiology and determinants of survival. *Gut* 49(5), 720–724.

7 Primignani M, Martinelli I, Bucciarelli P *et al.* (2005) Risk factors for thrombophilia in extrahepatic portal vein obstruction. *Hepatology* 41(3), 603–608.

8 de Franchis R (2005) Evolving consensus in portal hypertension. Report of the Baveno IV Consensus Workshop on methodology of diagnosis and therapy in portal hypertension. *J Hepatol* 43(1), 167–176.

9 Valla D, Casadevall N, Huisse MG *et al.* (1988) Etiology of portal vein thrombosis in adults. A prospective evaluation of primary myeloproliferative disorders. *Gastroenterology* 94(4), 1063–1069.

10 Denninger MH, Helley D, Valla D *et al.* (1997) Prospective evaluation of the prevalence of factor V Leiden mutation in portal or hepatic vein thrombosis. *Thromb Haemost* 78(4), 1297–1298.

11 Robson SC, Kahn D, Kruskal J *et al.* (1993) Disordered hemostasis in extrahepatic portal hypertension. *Hepatology* 18(4), 853–857.

12 De Stefano V, Teofili L, Leone G *et al.* (1997) Spontaneous erythroid colony formation as the clue to an underlying myeloproliferative disorder in patients with Budd-Chiari syndrome or portal vein thrombosis. *Semin Thromb Hemost* 23(5), 411–418.

13 Chait Y, Condat B, Cazals-Hatem D *et al.* (2005) Relevance of the criteria commonly used to diagnose myeloproliferative disorder in patients with splanchnic vein thrombosis. *Br J Haematol* 129(4), 553–560.

14 Kralovics R, Passamonti F, Buser AS *et al.* (2005) A gain-of-function mutation of JAK2 in myeloproliferative disorders. *N Engl J Med* 352(17), 1779–1790.

15 Bernades P, Baetz A, Levy P *et al.* (1992) Splenic and portal venous obstruction in chronic pancreatitis. A prospective longitudinal study of a medical-surgical series of 266 patients. *Dig Dis Sci* 37(3), 340–346.

16 Fujita F, Lyass S, Otsuka K *et al.* (2003) Portal vein thrombosis following splenectomy: identification of risk factors. *Am Surg* 69(11), 951–956.

17 Bick RL (1992) Coagulation abnormalities in malignancy: a review. *Semin Thromb Hemost* 18(4), 353–372.

18 Shaldon S, Sherlock S (1962) Obstruction to the extrahepatic portal system in childhood. *Lancet* 1, 63–68.

19 Webb LJ, Sherlock S (1979) The aetiology, presentation and natural history of extra-hepatic portal venous obstruction. *Q J Med* 48(192), 627–639.

20 Okuda K, Ohnishi K, Kimura K *et al.* (1985) Incidence of portal vein thrombosis in liver cirrhosis: an angiographic study in 708 patients. *Gastroenterology* 89(2), 279–286.

21 Nonami T, Yokoyama I, Iwatsuki S *et al.* (1992) The incidence of portal vein thrombosis at liver transplantation. *Hepatology* 16(5), 1195–1198.

22 Amitrano L, Brancaccio V, Guardascione MA *et al.* (2000) Inherited coagulation disorders in cirrhotic patients with portal vein thrombosis. *Hepatology* 31(2), 345–348.

23 Amitrano L, Guardascione MA, Brancaccio V *et al.* (2004) Risk factors and clinical presentation of portal vein thrombosis in patients with liver cirrhosis. *J Hepatol* 40(5), 736–741.

24 Stoltenberg PH, Goodale RL, Silvis SE (1987) Portal vein thrombosis following combined endoscopic variceal sclerosis and vasopressin therapy for bleeding varices. *Am J Gastroenterol* 82(12), 1297–1300.

25 Langnas AN, Marujo W, Stratta RJ *et al.* (1991) Vascular complications after orthotopic liver transplantation. *Am J Surg* 161(1), 76–82.

26 Van GD, Avni EF, Delcour C *et al.* (1985) Sonographic features of portal vein thrombosis. *Am J Roentgenol* 144(4), 749–752.

27 Mathieu D, Vasile N, Grenier P (1985) Portal thrombosis: dynamic CT features and course. *Radiology* 154(3), 737–741.

28 Mori H, Hayashi K, Uetani M *et al.* (1987) High-attenuation recent thrombus of the portal vein: CT demonstration and clinical significance. *Radiology* 163(2), 353–356.

29 Baril N, Wren S, Radin R *et al.* (1996) The role of anticoagulation in pylephlebitis. *Am J Surg* 172(5), 449–452.

30 Condat B, Pessione F, Helene DM *et al.* (2000) Recent portal or mesenteric venous thrombosis: increased recognition and frequent recanalization on anticoagulant therapy. *Hepatology* 32(3), 466–470.

31 Turnes J, Hernandez-Guerra M, Gonzalez M *et al.* (2005) Historia natural de la trombosis portal aguda no cirrótica no neoplasica. *Gastroenterol Hepato*l 28(1), A107.

32 Lopera JE, Correa G, Brazzini A *et al.* (2002) Percutaneous transhepatic treatment of symptomatic mesenteric venous thrombosis. *J Vasc Surg* 36(5), 1058–1061.

33 Aytekin C, Boyvat F, Kurt A *et al.* (2001) Catheter-directed thrombolysis with transjugular access in portal vein thrombosis secondary to pancreatitis. *Eur J Radiol* 39(2), 80–82.

34 Ganger DR, Klapman JB, McDonald V *et al.* (1999) Transjugular intrahepatic portosystemic shunt (TIPS) for Budd–Chiari syndrome or portal vein thrombosis: review of indications and problems. *Am J Gastroenterol* 94(3), 603–608.

35 Liatsos C, Vlachogiannakos J, Patch D *et al.* (2001) Successful recanalization of portal vein thrombosis before liver transplantation using transjugular intrahepatic portosystemic shunt. *Liver Transpl* 7(5), 453–460.

36 Dolovich LR, Ginsberg JS, Douketis JD *et al.* (2000) A meta-analysis comparing low-molecular-weight heparins with unfractionated heparin in the treatment of venous thromboembolism: examining some unanswered questions regarding location of treatment, product type, and dosing frequency. *Arch Intern Med* 160(2), 181–188.

37 Plemmons RM, Dooley DP, Longfield RN (1995) Septic thrombophlebitis of the portal vein (pylephlebitis): diagnosis and management in the modern era. *Clin Infect Dis* 21(5), 1114–1120.

38 Ganguly S, Sarin SK, Bhatia V *et al.* (1995) The prevalence and spectrum of colonic lesions in patients with cirrhotic and noncirrhotic portal hypertension. *Hepatology* 21(5), 1226–1231.

39 Alvarez F, Bernard O, Brunelle F *et al.* (1983) Portal obstruction in children. I. Clinical investigation and hemorrhage risk. *J Pediatr* 103(5), 696–702.

40 Merkel C, Bolognesi M, Bellon S *et al.* (1992) Long-term follow-up study of adult patients with non-cirrhotic obstruction of the portal system: comparison with cirrhotic patients. *J Hepatol* 15(3), 299–303.

41 Condat B, Pessione F, Hillaire S *et al.* (2001) Current outcome of portal vein thrombosis in adults: risk and benefit of anticoagulant therapy. *Gastroenterology* 120(2), 490–497.

42 Sarin SK, Agarwal SR (2002) Extrahepatic portal vein obstruction. *Semin Liver Dis* 22(1), 43–58.

43 Khuroo MS, Yattoo GN, Zargar SA *et al.* (1993) Biliary abnormalities associated with extrahepatic portal venous obstruction. *Hepatology* 17(5), 807–813.

44 Dhiman RK, Puri P, Chawla Y *et al.* (1999) Biliary changes in extrahepatic portal venous obstruction: compression by collaterals or ischemic? *Gastrointest Endosc* 50(5), 646–652.

45 Condat B, Vilgrain V, Asselah T *et al.* (2003) Portal cavernoma-associated cholangiopathy: a clinical and MR cholangiography coupled with MR portography imaging study. *Hepatology* 37(6), 1302–1308.

46 Malkan GH, Bhatia SJ, Bashir K *et al.* (1999) Cholangiopathy associated with portal hypertension: diagnostic evaluation and clinical implications. *Gastrointest Endosc* 49(3 Pt 1), 344–348.

47 Mitra SK, Kumar V, Datta DV *et al.* (1978) Extrahepatic portal hypertension: a review of 70 cases. *J Pediatr Surg* 13(1), 51–57.

48 Cohen J, Edelman RR, Chopra S (1992) Portal vein thrombosis: a review. *Am J Med* 92(2), 173–182.

49 Sarin SK, Bansal A, Sasan S *et al.* (1992) Portal-vein obstruction in children leads to growth retardation. *Hepatology* 15(2), 229–233.

50 Rangari M, Gupta R, Jain M *et al.* (2003) Hepatic dysfunction in patients with extrahepatic portal venous obstruction. *Liver Int* 23(6), 434–439.

51 Webb LJ, Sherlock S (1979) The aetiology, presentation and natural history of extra-hepatic portal venous obstruction. *Q J Med* 48(192), 627–639.

52 Minguez B, García-Pagán JC, Bosch J *et al.* (2006) Noncirrhotic portal vein thrombosis exhibits neuropsychological and MR changes consistent with minimal hepatic encephalopathy. *Hepatology* 43, 707–714.

53 Ueno N, Sasaki A, Tomiyama T *et al.* (1997) Color Doppler ultrasonography in the diagnosis of cavernous transformation of the portal vein. *J Clin Ultrasound* 25(5), 227–233.

54 Lai L, Brugge WR (2004) Endoscopic ultrasound is a sensitive and specific test to diagnose portal venous system thrombosis (PVST). *Am J Gastroenterol* 99(1), 40–44.

55 Umphress JL, Pecha RE, Urayama S (2004) Biliary stricture caused by portal biliopathy: diagnosis by EUS with Doppler US. *Gastrointest Endosc* 60(6), 1021–1024.

56 Sarin SK, Sachdev G, Nanda R (1986) Follow-up of patients after variceal eradication. A comparison of patients with cirrhosis, noncirrhotic portal fibrosis, and extrahepatic obstruction. *Ann Surg* 204(1), 78–82.

57 Chawla YK, Dilawari JB, Ramesh GN *et al.* (1990) Sclerotherapy in extrahepatic portal venous obstruction. *Gut* 31(2), 213–216.

58 Zargar SA, Javid G, Khan BA *et al.* (2002) Endoscopic ligation compared with sclerotherapy for bleeding esophageal varices in children with extrahepatic portal venous obstruction. *Hepatology* 36(3), 666–672.

59 Zargar SA, Javid G, Khan BA *et al.* (2005) Endoscopic ligation vs. sclerotherapy in adults with extrahepatic portal venous obstruction: a prospective randomized study. *Gastrointest Endosc* 61(1), 58–66.

60 de Ville de Goyet J, Alberti D, Clapuyt P *et al.* (1998) Direct bypassing of extrahepatic portal venous obstruction in children: a new technique for combined hepatic portal revascularization and treatment of extrahepatic portal hypertension. *J Pediatr Surg* 33(4), 597–601.

61 Radosevich PM, Ring EJ, LaBerge JM *et al.* (1993) Transjugular intrahepatic portosystemic shunts in patients with portal vein occlusion. *Radiology* 186(2), 523–527.

62 Cwikiel W, Keussen I, Larsson L *et al.* (2003) Interventional treatment of children with portal hypertension secondary to portal vein occlusion. *Eur J Pediatr Surg* 13(5), 312–318.

63 Bhatia V, Jain AK, Sarin SK (1995) Choledocholithiasis associated with portal biliopathy in patients with extrahepatic portal vein obstruction: management with endoscopic sphincterotomy. *Gastrointest Endosc* 42(2), 178–181.

64 Sezgin O, Oguz D, Altintas E *et al.* (2003) Endoscopic management of biliary obstruction caused by cavernous transformation of the portal vein. *Gastrointest Endosc* 58(4), 602–608.

65 Chaudhary A, Dhar P, Sarin SK *et al.* (1998) Bile duct obstruction due to portal biliopathy in extrahepatic portal hypertension: surgical management. *Br J Surg* 85(3), 326–329.

66 Koklu S, Yuksel O, Arhan M *et al.* (2005) Report of 24 left-sided portal hypertension cases: a single-center prospective cohort study. *Dig Dis Sci* 50(5), 976–982.

67 Han DC, Feliciano DV (1998) The clinical complexity of splenic vein thrombosis. *Am Surg* 64(6), 558–561.

68 Goldberg S, Katz S, Naidich J *et al.* (1984) Isolated gastric varices due to spontaneous splenic vein thrombosis. *Am J Gastroenterol* 79(4), 304–307.

69 Weber SM, Rikkers LF (2003) Splenic vein thrombosis and gastrointestinal bleeding in chronic pancreatitis. *World J Surg* 27(11), 1271–1274.

70 Muhletaler C, Gerlock AJ Jr, Goncharenko V *et al.* (1979) Gastric varices secondary to splenic vein occlusion: radiographic diagnosis and clinical significance. *Radiology* 132(3), 593–598.

71 Lewis JD, Faigel DO, Morris JB *et al.* (1998) Splenic vein thrombosis secondary to focal pancreatitis diagnosed by endoscopic ultrasonography. *J Clin Gastroenterol* 26(1), 54–56.

72 Vanwaeyenbergh J, Vierendeels T, Smekens L *et al.* (1989) Peroperative ultrasonography in the diagnosis of splenic vein thrombosis. *Hepatogastroenterology* 36(5), 376–378.

73 Keiding S, Solvig J, Gronbaek H *et al.* (2004) Combined liver vein and spleen pulp pressure measurements in patients with portal or splenic vein thrombosis. *Scand J Gastroenterol* 39(6), 594–599.

74 Sutton JP, Yarborough DY, Richards JT (1970) Isolated splenic vein occlusion. Review of literature and report of an additional case. *Arch Surg* 100(5), 623–626.

75 Owman T, Lunderquist A, Alwmark A *et al.* (1979) Embolization of the spleen for treatment of splenomegaly and hypersplenism in patients with portal hypertension. *Invest Radiol* 14(6), 457–464.

76 Lopez-Machado E, Mallorquin-Jimenez F, Medina-Benitez A *et al.* (1998) Aneurysms of the portal venous system: ultrasonography and CT findings. *Eur J Radiol* 26(2), 210–214.

77 Hermann RE, Shafer WH (1965) Aneurysm of the portal vein and portal hypertension: first reported case. *Ann Surg* 162(6), 1101–1104.

78 Ozbek SS, Killi MR, Pourbagher MA *et al.* (1999) Portal venous system aneurysms: report of five cases. *J Ultrasound Med* 18(6), 417–422.

79 Ohnishi K, Nakayama T, Saito M *et al.* (1984) Aneurysm of the intrahepatic branch of the portal vein. Report of two cases. *Gastroenterology* 86(1), 169–173.

80 Hagiwara H, Kasahara A, Kono M *et al.* (1991) Extrahepatic portal vein aneurysm associated with a tortuous portal vein. *Gastroenterology* 100(3), 818–821.

81 Gallagher DM, Leiman S, Hux CH (1993) In utero diagnosis of a portal vein aneurysm. *J Clin Ultrasound* 21(2), 147–151.

82 Atasoy KC, Fitoz S, Akyar G *et al.* (1998) Aneurysms of the portal venous system. Gray-scale and color Doppler ultrasonographic findings with CT and MRI correlation. *Clin Imaging* 22(6), 414–417.

83 Okur N, Inal M, Akgul E *et al.* (2003) Spontaneous rupture and thrombosis of an intrahepatic portal vein aneurysm. *Abdom Imaging* 28(5), 675–677.

84 Glazer S, Gaspar MR, Esposito V *et al.* (1992) Extrahepatic portal vein aneurysm: report of a case treated by thrombectomy and aneurysmorrhaphy. *Ann Vasc Surg* 6(4), 338–343.

85 Jin B, Sun Y, Li YQ *et al.* (2005) Extrahepatic portal vein aneurysm: two case reports of surgical intervention. *World J Gastroenterol* 11(14), 2206–2209.

86 Sakai T, Katoh T, Asada K *et al.* (1992) Portal hepatic venous shunt via an intrahepatic portal vein aneurysm. *Intern Med* 31(7), 899–903.

87 Tanaka S, Kitamura T, Fujita M *et al.* (1992) Intrahepatic venous and portal venous aneurysms examined by color Doppler flow imaging. *J Clin Ultrasound* 20(2), 89–98.

88 Nakanuma Y (1990) Nodular regenerative hyperplasia of the liver: retrospective survey in autopsy series. *J Clin Gastroenterol* 12(4), 460–465.

89 Hisatomi K, Ohya T, Asayama M *et al.* (2004) Hypoplasia of the right hepatic lobe associated with portal hypertension and idiopathic retroperitoneal fibrosis. *J Gastroenterol* 39(7), 685–691.

90 Hernandez-Guerra M, Garcia-Pagan JC, Bosch J (2005) Increased hepatic resistance: a new target in the pharmacologic therapy of portal hypertension. *J Clin Gastroenterol* 39(4 Suppl. 2), S131–S137.

91 von Hellens WI (1960) Arteriovenous fistula as the cause of portal hypertension. *Ann Chir Gynaecol Fenn* 49, 410–455.

92 Donovan AJ, Reynolds TB, Mikkelsen WP *et al.* (1969) Systemic-portal arteriovenous fistulas: pathological and hemodynamic observations in two patients. *Surgery* 66(3), 474–482.

93 Vauthey JN, Tomczak RJ, Helmberger T *et al.* (1997) The arterioportal fistula syndrome: clinicopathologic features, diagnosis, and therapy. *Gastroenterology* 113(4), 1390–1401.

94 Preger L (1967) Hepatic arteriovenous fistula after percutaneous liver biopsy. *Am J Roentgenol Radium Ther Nucl Med* 101(3), 619–620.

95 Nagasue N, Inokuchi K, Kobayashi M *et al.* (1977) Hepatoportal arteriovenous fistula in primary carcinoma of the liver. *Surg Gynecol Obstet* 145(4), 504–508.

96 Ricketts RR, Finck E, Yellin AE (1978) Management of major arteriovenous fistulas by arteriographic techniques. *Arch Surg* 113(10), 1153–1159.

17.3 Disorders of the hepatic veins and hepatic sinusoids

Dominique-Charles Valla

The main disorders of the hepatic venous system are represented by Budd–Chiari syndrome (BCS), which is considered here, and by fistulas, which are discussed in Chapter 17.4. Disorders of sinusoids frequently mimic the obstruction of the hepatic venous system. They include a variety of rare conditions, namely sinusoidal obstruction syndrome, sinusoidal dilatation, peliosis hepatis, sinusoidal fibrosis and infiltration of the sinusoids.

Budd–Chiari syndrome

Definitions

BCS is a heterogeneous disorder characterized by an obstacle to the hepatic venous outflow, be it at the level of the small hepatic veins, large hepatic veins or the suprahepatic portion of the inferior vena cava (IVC) [1]. BCS is further defined as primary when the obstructing process arises from the venous wall (phlebitis or fibrous thickening) or the venous lumen (thrombosis) [1]. BCS is considered secondary when the veins are compressed or invaded by a lesion arising outside these veins. Veno-occlusive disease is a misleading denomination that should be substituted by either 'sinusoidal obstruction syndrome' for toxic injury to sinusoidal endothelial cells or Budd–Chiari syndrome where appropriate.

Epidemiology

Surveys performed in the early 1990s in Japan [2] and France (unpublished data from the Observatoire National du Syndrome de Budd–Chiari) could identify only a few hundreds of cases over one or two decades. Current estimates of prevalence would be higher because of increased awareness and improved diagnostic methods. Moreover, in some places such as Nepal, a high prevalence has been recorded [3].

Causes

Primary BCS

A systematic investigation allows the identification of one or several thrombotic risk factors in about 90% of patients with primary BCS; and two or more of these factors in at least 25% [4–8]. Estimates of the frequencies or odds ratios for these risk factors in BCS patients are presented in Table 1.

Myeloproliferative diseases (MPD)

These represent the major cause of primary BCS [4,8,9]. In contrast, only 1–3% of MPD patients develop BCS [10,11]. Most affected patients are women of young age (30 years on average). It is poorly understood why some patients with MPD develop hepatic vein or IVC thrombosis. Association with other risk factors for thrombosis can be identified in about 70% of BCS patients with MPD [8]. At the time of presentation with BCS, MPD has not usually been recognized previously; moreover, in half the patients, peripheral blood cell counts at presentation are not suggestive of MPD [4,8,12,13]. These 'occult', 'latent' or 'atypical' forms can be explained in part by hypersplenism, iron deficiency and dilution into a marked increase in plasma volume, all factors related to portal hypertension [14]. Diagnosis has been made by showing clusters of dystrophic megakaryocytes at bone marrow biopsy [13] or by showing the formation of so-called 'spontaneous' or 'endogenous' colonies in cultures of erythroid progenitors on erythropoietin-poor media [4,12,14,15]. These two criteria are simultaneously present in over 85% of BCS patients with MPD [13]. In a patient with features of marked portal hypertension, platelet counts over 200 000/μL strongly suggest that a MPD is present [13]. The recent demonstration that the somatic mutation V617F in the *JAK2* gene is responsible for a majority of MPD will allow an easy diagnosis of MPD in BCS patients by direct molecular testing on peripheral blood cells [16]. However, it remains to be shown whether this mutation accounts for all BCS patients with MPD. Late transformation into leukaemia and the spent phase of MPD has been reported to occur at a frequency close to that in unselected MPD patients [13]. No specific information is available on the treatment of MPD complicated by BCS.

Paroxysmal nocturnal haemoglobinuria (PNH)

This accounts for 1–5% of cases of primary BCS. Conversely,

Table 1 Thrombotic risk factors in BCS patients.

Risk factor	Israel [4]	Netherlands [5,7]		India [7]		France [8]
	N positive/ *N* tested (%)	*N* positive/ *N* tested (%)	OR for BCS (95%CI)	*N* positive/ *N* tested (%)	OR for BCS (95%CI)	*N* positive/ *N* tested (%)
Myeloproliferative disorders	10/22 (45.4%)	NA	NA	NA	NA	31/61 (50.8%)
Occult	8/22 (36.4%)	NA	NA	NA	NA	15/61 (24.6%)
Classical	2/22 (9.0%)	12/43 (27.0%)	NA	NA	NA	16/61 (26.2%)
Antiphospholipid syndrome	5/22 (23.0%)	2/43 (4.6%)	NA	6/53 (11.3%)	NA	9/63 (14.3%)
Paroxysmal nocturnal haemoglobinuria	1/22 (4.4%)	0/43	NA	NA	NA	1/63 (1.6%)
Factor V Leiden mutation	6/22 (27.2%)	11/43 (25.6%)	11.3 (4.6–26.5)	14/53 (26.4%)	14.4 (11.9–35.7)	20/63 (31.7%)
Factor II mutation	NA	2/43 (4.7%)	2.1 (0.4–9.6)	0/53	–	3/47 (6.4%)
Protein C deficiency	7/22 (31.8%)	4/43 (9.3%)	6.8 (1.9–24.4)	7/53 (13.2%)	8.3 (2.1–10.9)	4/21 (19.0%)
Protein S deficiency	4/22 (18.2%)	0/43	–	3/53 (5.7%)	4.4 (2.2–20.6)	2/30 (6.6%)
Antithrombin deficiency	5/22 (22.7%)	0/43	–	2/53 (3.8%)	4.4 (2.1–10.9)	0/47
Plasminogen deficiency	NA	NA	–	NA	NA	1/21 (4.7%)
Recent pregnancy	NA	NA	–	2/17 (11.7%)	NA	3/47 (6.4%)
Recent oral contraceptive use	NA	12/20 (60%)	2.4 (0.9–6.2)	1/17 (5.9%)	NA	23/47 (48.9%)

CI, confidence interval; OR, odds ratio; NA, not available.

BCS has developed in up to 12% of patients with PNH [17]. In many cases, thrombosis is limited to the small hepatic veins and the patient is asymptomatic [18]. A diagnosis of PNH is made by showing decreased CD55- and CD59-positive blood cells using flow cytometry [4]. The mechanisms for hepatic vein or IVC thrombosis are not known. Treatment is not well established. The outcome is poor because of BCS and the other complications of blood disease. Resolution of BCS following bone marrow transplantation has been reported [19]. The risk of severe deterioration from superimposed sinusoidal obstruction syndrome due to conditioning should be considered strongly before making a decision for bone marrow transplantation. Liver transplantation has been performed successfully in anecdotal BCS patients with PNH, but recurrence has been observed [20].

Inherited thrombophilias

All known inherited thrombophilias have been implicated in BCS [4–8]. As a rule, they are cured by liver transplantation. Activated protein C resistance, generally related to factor V Leiden mutation, is found in about 25% of patients with BCS, whereas its prevalence is about 5% in the Caucasian population [5,8]. When present, it is usually associated with another thrombotic risk factor. Factor V Leiden mutation is particularly frequent in some subgroups of BCS patients: those with progressive IVC obstruction; those with acute BCS related to pregnancy; and among oral contraceptive users [8]. Diagnosis is ruled out by a normal test for activated protein C resistance. Confirmation is obtained by molecular biology. The G20210A mutation in the prothrombin gene is responsible for increased plasma levels of prothrombin and a moderate increase in the risk of venous thrombosis. It is found in about 5% of BCS patients, whereas the background prevalence in western countries is about 2% [5,8]. Diagnosis is made by molecular biology. Afibrinogenaemia may paradoxically predispose to thrombosis and has been implicated as a cause of BCS [21]. Increased plasma levels of factor VII, factor VIII or homocysteine are risk factors for thrombosis [22]. Plasma levels of these three substances are altered in patients with liver disease. Therefore, the significance of their plasma level in patients with BCS is unclear.

Antithrombin, protein C or protein S being produced by the liver, their plasma level is non-specifically decreased in many patients with BCS. Family studies are necessary to establish a low plasma level as a primary deficiency. Formulas taking into account the degree of liver insufficiency have yielded a prevalence estimate of about 25% for primary protein C deficiency in patients with BCS [5,8]. However, these formulas require further validation. These three inherited thrombophilias are cured with liver transplantation from an unaffected donor.

The antiphospholipid syndrome

The antiphospholipid syndrome associated with BCS has usually been of the primary type, i.e. the American Rheumatism Association criteria for the diagnosis of systemic lupus were not fulfilled [23,24]. Anticardiolipin antibodies have been reported in about 25% of primary BCS patients [4–9]. Anti-beta-2-glycoprotein-1 antibodies, lupus anticoagulant and association with other autoantibodies are more convincing evidence for the diagnosis of antiphospholipid syndrome than the mere presence of low-titre anticardiolipin antibodies.

Behcet's disease

This accounts for less than 5% of BCS patients in western countries [25]. In countries where the disease is prevalent, such as Turkey, the corresponding figure is close to 40% [26,27]. Conversely, the incidence of BCS in patients with Behcet's disease is 5–10%. Over 80% of affected patients have IVC

involvement with or without extension to the hepatic veins. The outcome of BCS patients with Behcet's disease seems to be particularly poor. Liver transplantation has been performed successfully in a few patients.

Idiopathic hypereosinophilic syndrome

This has been associated with a few cases of idiopathic BCS [28]. The endothelial toxicity of certain eosinophil constituents has been incriminated [29]. Eosinophilia associated with 5q deletion has also been reported [30].

Idiopathic granulomatous venulitis

Idiopathic granulomatous venulitis has been described [31–33]. The criteria for a diagnosis of sarcoidosis were fulfilled in some [31], but not all, cases. A good response to corticosteroid therapy has been recorded [32].

Coeliac disease and ulcerative colitis

Coeliac disease [34,35] and ulcerative colitis [36,37] have been reported in association with BCS. The mechanisms involved in coeliac disease are unknown. For ulcerative colitis, thrombosis has been attributed to the associated inflammatory syndrome, but reports of an association with an underlying myeloproliferative disorder cast doubts on this simple explanation [38].

Risk factors for primary BCS

The causal role of pregnancy is supported by a time relationship with the onset of acute, and generally severe, manifestations of BCS [8,39–41]. However, many pregnant patients have other thrombotic risk factors [9]. Similar to deep vein thrombosis at other sites, BCS related to pregnancy is strongly associated with factor V Leiden [8].

Drug-related BCS appears to be exceptional [42]. It is of note that, in drug- and plant-related sinusoidal obstruction syndrome, the obstructive process begins in the sinusoids and may affect central veins, but does not progress to involve the major hepatic veins [43]. A case of hepatic vein thrombosis attributed to a slimming drug preparation was reported recently [44].

A case–control study has established oral contraceptives as a risk factor for BCS [45]. However, this study was performed in the era of pills with high estrogen content. In a more recent study, the increased risk in oral contraceptive users fell short of statistical significance [5]. In both studies, oral contraceptive users generally had other risk factors for thrombosis. Therefore, the role of current oral contraceptives should be re-evaluated.

A case–control study performed in Nepal has shown that a poor standard of living was strongly associated with the development of BCS due to IVC obstruction, although the pathogenetic mechanisms remain unknown.

Secondary BCS

Compression by space-occupying lesions alone is unlikely to induce thrombosis, unless an underlying prothrombotic state is associated [9]. The prothrombotic state associated with inflammation is probably involved in BCS cases reported in association with amoebic and pyogenic liver abscess [46,47]. Cystic hydatid disease due to *Echinococcus granulosus* rarely produces overt BCS [47]. In contrast, alveolar hydatid disease due to *Echinococcus multilocularis* commonly invades the hepatic veins or IVC [48].

Following blunt abdominal trauma, hepatic veins or IVC can be compressed by an intrahepatic haematoma [49] or by a ruptured right hemidiaphragm allowing herniation of the liver within the thorax [50] and compression of the hepatic veins. Hepatic vein ligation during hepatic resection can be followed by hepatic decompensation when asymptomatic obstruction of the remaining veins is overlooked [51,52]. Following liver transplantation, misplacement of the graft resulting in a torsion of the hepatic veins or IVC, or stenosis of the hepatic venous anastomosis, can result in hepatic venous outflow block [53].

Secondary liver cancer is an uncommon cause of hepatic venous outflow block [54]. Compression by a thoracoabdominal aortic aneurysm has been reported [55]. In polycystic dominant kidney disease, compression of the hepatic veins by large or infected liver cysts is the cause of portal hypertension occasionally found in this disease [56]. Solitary simple cyst of the liver or focal nodular hyperplasia may compress one or several of the three major hepatic veins, albeit without giving rise to signs or symptoms. This occurs when the cyst or nodule is large and located in the upper central part of the liver.

BCS related to luminal invasion by a tumour is a specific complication of certain malignancies that progress inside the lumen of their venous outflow tract, towards the IVC, up to the point at which hepatic vein ostia are obstructed. These malignant tumours include Wilm's tumour [57] and renal cell carcinoma [58], hepatocellular carcinoma [59], adrenocortical carcinoma [60], leiomyosarcoma of the IVC [61] and hepatic angiosarcoma [62]. Right atrial myxoma can obstruct the IVC by a similar but retrograde mechanism [63]. The endoluminal tumour can usually be cleaved from the venous walls. This allows an urgent operation to be performed to relieve the obstruction. However, prognosis is dismal because lung metastasis is almost always present. Protracted remission or cure is likely only when an efficient systemic therapy is available.

Workup for causes

Whether or not there is evidence of an underlying disorder from clinical data and routine laboratory tests, a comprehensive investigation is recommended. Indeed, recognition of associated risk factors for thrombosis allows for better monitoring and earlier identification of subsequent complications of the underlying disease, and for counselling relatives with inherited thrombophilia [1]. A proposal for initial workup is presented in Table 2.

Pathology and pathogenesis of venous lesions

Fresh thrombi are not the most common finding in explanted livers. Rather, fibrous subendothelial thickening is found,

Table 2 Initial workup for causes of Budd–Chiari syndrome.

For local factors or tumours
Abdominal imaging (otherwise needed for BCS diagnosis)
For systemic diseases
Clinical history and examination
For myeloproliferative disorders and paroxysmal nocturnal haemoglobinuria
Complete blood cell counts, V617F JAK2 mutation. If negative, bone marrow biopsy. If negative, endogenous erythroid colony assays
Flow cytometry for CD55- and CD59-deficient cells
For antiphospholipid syndrome
Lupus anticoagulant, anticardiolipin antibodies, anti-beta2-glycoprotein-1 and antinuclear factors
For inherited coagulopathies
Activated protein C resistance (or factor V Leiden mutation) and factor II gene mutation; protein C, protein S and antithrombin plasma levels in patients without decreased clotting factor levels
For hyperhomocysteinaemia
Blood folate and vitamine B12 levels rather than serum homocysteine level or MTHFR polymorphism

involving various lengths of the hepatic veins or IVC, with or without superimposed thrombosis [54]. Short-length stenoses can even take the aspect of a membrane. These short-length stenoses or membranes are now considered to be sequelae of thrombosis. This view is based on several observations: a transformation of recent thrombi into short-length stenoses [64,65]; the persistence of a continuous media within the stenosed segment [66]; the similarly high prevalence of underlying thrombophilias in patients with and without short-length stenoses [67]; and adulthood presentation of most patients with short-length stenoses, dismissing a congenital malformation [66–68]. Short-length stenoses are found in about 25% of patients with hepatic vein obstruction and in over 60% of patients with IVC obstruction [66–68].

Compared with pure hepatic vein thrombosis, IVC thrombosis is the predominant form of BCS in the Far East; it runs a more indolent course and is more commonly complicated by hepatocellular carcinoma [68]. Thus, the recently proposed distinction of primary hepatic vein thrombosis ('true BCS') from primary IVC thrombosis ('obliterative hepatocavopathy') is well grounded for clinical and therapeutic purposes [68]. However, the causes are similar [6,7,15]. What remains to be elucidated is why the IVC is so frequently involved in the Far East and relatively spared in the west. It has been hypothesized that nutritional deficiencies could play a role in IVC obstruction observed in eastern countries, whereas widespread oral contraceptive use could explain the predominance of hepatic vein thrombosis in western countries.

The reason why, in the setting of a generalized thrombotic diathesis, thrombosis develops in the hepatic veins or the suprahepatic IVC is unknown. A local factor is found in less than 5% of cases [8,67]. A role for trauma induced to the hepatic veins or to the IVC by diaphragmatic motion of has been advanced [67].

Combining the available data obtained from clinical, imaging and pathological studies, it is clear that the usual scenario for primary BCS due to hepatic vein obstruction is that of a successive, random involvement of the three major hepatic veins. In contrast, the simultaneous, abrupt formation of a thrombus in all three major veins appears to be extremely rare.

Pathophysiology and histopathology of liver damage

Autopsy studies [47,54] and analyses in explanted liver at transplantation [69,70] have allowed a detailed description of the hepatic lesions at an advanced stage of the disease. Liver biopsy provides information on earlier stages of the disease [39,71–73], but with considerable sampling variation due to inhomogeneous distribution of the lesions [69,70].

The obstruction of a single main hepatic vein is clinically silent [54]. The obstruction of two or three main hepatic veins produces two types of haemodynamic changes: an increased sinusoidal blood pressure and a reduced sinusoidal blood flow. Raised sinusoidal pressure explains liver enlargement, pain and ascites through several mechanisms: (i) there is sinusoidal dilatation and congestion, predominating in the central area of the hepatic lobules where it is almost constant [74]; (ii) the filtration of interstitial fluid increases, which leads to its passage through the liver capsule when the capacity for lymph drainage is exceeded. Usually, the filtrated fluid has a high protein content because of the high permeability of the sinusoidal wall to proteins; (iii) portal pressure increases [75].

Changes in total hepatic blood flow have not been well characterized. Indirect evidence suggests that, in the areas with an impaired outflow, perfusion with portal blood decreases while perfusion with arterial blood increases [76,77]. These alterations are unevenly distributed within the liver. Ischaemic-type damage to the liver cells is found in about 70% of cases [54]. Reperfusion injury may participate in liver cell damage, which would explain why alanine aminotransferase (ALT) and aspartate aminotransferase (AST) levels rapidly return to normal in the majority of patients [78]. When hepatic veins and portal veins are simultaneously obstructed in the same region, confluent cell loss occurs in regions supplied by preterminal and larger portal tracts [69]. Liver dysfunction resulting from ischaemic liver cell necrosis rarely takes the form of fulminant hepatic failure. Within a few weeks after the onset of hepatic outflow obstruction, fibrosis develops. Fibrosis can either predominate in the centrolobular area (when there is pure hepatic vein obstruction) or also develop in the periportal area (when there is associated obstruction of the portal veins) [69,74]. Within a few months, regenerative changes take place, predominantly in the periportal area; they may lead to nodular regenerative hyperplasia [54,69,70,74]. Cirrhosis can eventually develop,

but it is found in only 10–20% of patients coming to transplantation [54,69,70].

Whereas there is evidence for increased sinusoidal pressure being a stable, permanent state, decreased hepatic perfusion appears to be inconstant. Indeed, centrolobular necrosis is lacking in 20–45% of patients [73,79]. Moreover, at the time of presentation, the ALT level is normal in over half the patients and transient as judged from the course of serum transaminases. Natural mechanisms able to compensate for decreased perfusion probably explain these findings. They include: (i) development of venous collateral channels bypassing the obstructed veins [80,81]; (ii) redistribution of portal flow from areas where outflow is impaired towards areas where outflow is preserved [76,77]; (iii) increased portal pressure; and (iv) increased arterial flow.

Superimposed thrombosis of the intrahepatic portal veins appears to be common at an advanced stage, which can be explained by the combination of stagnant flow and the underlying thrombophilic state. Obstruction of the extrahepatic portal vein is present in 10–20% of patients [79,82]. Severe obliteration of intrahepatic portal veins can be found in over half the cases of explanted liver at transplantation [69,70]. The areas where portal and hepatic veins are simultaneously obstructed may undergo infarction or parenchymal extinction (i.e. transformation into fibrotic areas devoid of parenchymal cells [69,70]. Depending on whether only hepatic veins or both hepatic veins and portal vein are obstructed, bridging fibrosis can be found in a venovenous and a portovenous or portoportal disposition respectively [69,70].

Because obstruction of the hepatic and portal vein branches is usually asynchronous, areas of atrophy may coexist with congestive or compensatory enlargement in other areas. In 80% of cases, the caudate lobe is hypertrophied, causing IVC stenosis [83,84]. Caudate lobe enlargement is explained by its veins draining directly into the IVC caudal to the ostia of the main hepatic veins; they are long preserved from the thrombotic process affecting the main hepatic veins. Preservation of this drainage allows for compensatory hypertrophy and also serves as an outflow for intrahepatic venous collaterals.

A frequent feature of longstanding BCS is the development of multiple large regenerative nodules, some of which resemble focal nodular hyperplasia [69,70,85,86]. These nodules can be viewed as a response to a focal loss of portal perfusion and hyperarterialization in areas with preserved hepatic venous outflow [69,70].

There are several reports of hepatocellular carcinoma developing in BCS patients [87–92]. However, there are few data to quantify the risk of malignancy. It is noteworthy that, in most of the reported cases, there was longstanding, asymptomatic occlusion of the IVC; the patients originated from Asia, Africa or Jamaica, and cirrhosis was documented in all of them. The growth of cancer seems to be much slower in patients with BCS than in patients with hepatitis B virus (HBV)-related chronic liver disease [89]. There is no evidence, at present, that hepatocellular carcinoma resulted from the transformation of benign regenerative macronodules [70,85].

Manifestations and course

Affected patients are 35 years of age on average, and most of them are females [79]. The cardinal features of BCS in various geographical areas are presented in Table 3.

Table 3 Main clinical and laboratory features of BCS patients according to the area.

Country **Predominant site of venous obstruction**	**India [39]** **Mostly IVC**	**Japan [2]** **Mostly IVC**	**France, Netherlands, USA [79]** **Mostly hepatic veins**
Number of patients	119	157	237
Ascites (%)	86	31	84
Abdominal pain (%)	57	23	NA
Hepatomegaly (%)	89	55	79
Dilated veins over body, trunk (%)	49	27	NA
Leg oedema (%)	41	32	NA
Jaundice (%)	18	6	NA
Platelet count ($\times 10^3$/μL)	NA	121 ± 64[a]	265 (10–896)[b]
ALT (× ULN)	NA	NA	1.0 (0.1–86)[b]
Serum bilirubin (μmol/L)	> 17 in 51%	27.4 ± 14.8[a]	28 (3–301)[b]
Serum albumin (g/L)	< 30 in 37%	NA	34 (17–57)[b]
Serum creatinine (μmol/L)	NA	NA	80 (35–469)[b]
Prothrombin	< 70% in 19%	NA	INR > 2.3 in 26%
Child–Pugh score	NA	NA	A 24%, B 54%, C 22%
Cirrhosis (%)	NA	NA	11

ALT, alanine aminotransferase; INR, international normalized ratio; NA, not available; ULN, upper limit of normal values.

[a]Mean ± SD.

[b]Median (range).

Presentation varies from a fulminant picture to an asymptomatic condition recognized fortuitously [80]. Several classifications into acute, subacute and chronic presentation have been proposed because prognosis and management would differ accordingly. Schematically, the acute presentation is characterized by a short illness, abdominal pain and fever, ascites, marked elevation in serum transaminase levels and markedly decreased coagulation factors, whereas the chronic presentation is characterized by indolent development of ascites, rare portal hypertensive bleeding, absent or mild jaundice, normal or mildly increased serum transaminase levels and moderately decreased plasma coagulation factors. The chronic presentation is more frequent than the acute presentation. Except for descriptive purposes, however, the utility of these classifications is still uncertain [1]. It is important to keep in mind that extensive parenchymal fibrosis, indicating a protracted course of the disease, is commonly found in patients presenting with an acute illness [39].

Presentation appears to depend on both the extent and the speed of the obstructive process [54]. Thus, obstruction of only one major hepatic vein usually develops without symptoms; slow obstruction of two or three major veins produces a chronic presentation or, when accompanied by extensive collaterals, no symptoms at all [80]; both rapid obstruction of at least two major veins and a fresh thrombus superimposing on a longstanding but partial obstruction give rise to an acute presentation.

Diagnosis

BCS should be suspected when ascites, liver enlargement and upper abdominal pain are present simultaneously, or when intractable ascites contrasts with moderate alteration in liver function tests, when liver disease occurs in a patient with known risk factors for thrombosis or when liver disease remains unexplained after other common or uncommon causes have been excluded.

The diagnosis of BCS is established by the demonstration of an obstructed hepatic venous outflow tract. X-ray venography remains a reference for the evaluation of the hepatic veins [93]. Three patterns of opacification are regarded as specific at retrograde catheterization: (i) spreading out from the catheter tip wedged into a blocked vein, a fine 'spider-web' network pattern without filling of venous radicals; (ii) when there is incomplete occlusion of the hepatic veins, a coarse network of collateral veins that arch outward from the catheter tip and then come together again near the site of entry of the hepatic vein into the IVC; and (iii) a patent vein upstream from a stricture. Diagnostic pitfalls include failure to cannulate the hepatic vein ostia and a distorted appearance of hepatic veins. These two features are encountered in patients with cirrhosis of other origin. Direct percutaneous venography can show a localized obstruction in the vicinity of the ostia when the hepatic veins cannot be entered using retrograde cannulation. Inferior venacavography allows for the demonstration of caval stenosis or occlusion. In many patients with pure hepatic vein thrombosis, the IVC appears to be narrowed at its intrahepatic portion in relation to the enlarged caudate lobe. An increased pressure gradient across the IVC stenosis, or the presence of a collateral cavacaval circulation, are better indications of the impact of intrahepatic stenosis on caval haemodynamics than the apparent degree of stenosis.

Sonography must combine colour Doppler imaging and pulse Doppler analysis of hepatic vein waveform. The following features can be considered specific for hepatic vein obstruction: (i) a large hepatic vein appearing void of flow signal, or with a reversed or turbulent flow; (ii) large intrahepatic or subcapsular collaterals with continuous flow connecting the hepatic veins or the diaphragmatic or intercostal veins; (iii) a spider-web appearance usually located in the vicinity of the hepatic vein ostia, together with the absence of a normal hepatic vein in the area; (iv) an absent or flat hepatic vein waveform without fluttering; (v) a hyperechoic cord replacing a normal vein [77,94].

Absence of visualization, or tortuosity of the hepatic veins at greyscale real-time sonography, albeit with flow signals at Doppler imaging, are common but not specific, also being observed in advanced cirrhosis of other origin. A distinctive feature, however, is the association with intrahepatic or subcapsular hepatic venous collaterals. This collateral circulation is the most sensitive feature for the diagnosis, being found in over 80% of cases [77,94].

Magnetic resonance imaging (MRI) with spin-echo and gradient-echo sequences, and intravenous gadolinium injection, allows visualization of obstructed hepatic veins and IVC, intrahepatic or subcapsular collaterals, as well as a spider-web network pattern [76,77]. MRI, however, is not as effective as sonography in demonstrating the intrahepatic collaterals. It does not allow an easy determination of the flow direction.

At computerized X-ray tomography, failure to visualize the hepatic veins suggests hepatic vein obstruction. However, there are problems of false-positive and indeterminate results in approximately 50% of cases [77].

Liver biopsy is not necessary to make a diagnosis of BCS when imaging has shown obstruction of hepatic veins or IVC. However, the rare form of BCS due to involvement of the small hepatic veins with patent large veins can be recognized only at liver biopsy [95]. The absence of congestion in the centrolobular area is a strong argument against the diagnosis of hepatic vein thrombosis. Serious consideration should be given to the risk of bleeding from the puncture site in these patients who are likely to receive early anticoagulation or, urgently, thrombolytic therapy.

Liver imaging can also show hypertrophy of the caudate lobe in about 80% of patients [84] or an altered parenchymal perfusion pattern following bolus intravenous contrast injection (early homogeneous central enhancement together with delayed patchy enhancement and prolonged retention of the contrast medium in the periphery of the liver) [77]. However, none of these features is sensitive nor specific for BCS, being observed in other conditions [96].

Colour Doppler imaging combined with pulsed Doppler in the first line and magnetic resonance in the second line can be recommended. The major advantages of ultrasound study, beyond sensitivity and specificity, are relatively low cost, wide availability, complete lack of harm and minimal technical difficulty. Limitations lie in the patient's body habitus, which may preclude complete sonographic evaluation, and in insufficient examiner expertise. MRI is a minimally invasive investigation with no harm from contrast injection to kidney function. Techniques can be standardized, and the results are not operator dependent.

In the minority of patients in whom uncertainty persists, the third line of investigation can be liver biopsy because it is expected to give information not only for a diagnosis of hepatic vein thrombosis but also for important differential diagnoses. When coagulation disorders preclude liver biopsy through the transcapsular approach, an attempt at retrograde cannulation of the hepatic veins for venography and liver biopsy using the transjugular route should be performed.

X-ray venography is no longer considered necessary for establishing the diagnosis [1]. In planning treatment, however, X-ray venography remains a gold standard, permitting a precise delineation of outflow obstruction, which is facilitated by prior non-invasive imaging.

Differential diagnosis

Clinical features of right-sided heart failure and constrictive pericarditis closely mimic those of BCS [97]. Moreover, there is evidence that cirrhosis, which develops in some patients with chronic heart failure, is actually related to superimposed hepatic vein thrombosis [98]. A finding of dilated hepatic veins and IVC at ultrasonography usually allows the diagnosis of cardiac disease. In difficult cases, catheterization of the heart and hepatic veins for haemodynamic studies may be required [99]. Characteristically, low atrial and free hepatic venous pressures and increased hepatic venous pressure gradient are found in BCS patients, whereas the opposite findings are found in patients with cardiac or pericardial disease.

Clinical presentation of chronic BCS is similar to that of cirrhosis of any origin. In cirrhotic patients, hepatic veins and hepatic IVC can have a markedly distorted appearance. The main clues to the diagnosis of BCS are a high protein content of ascitic fluid, the absence of usual causes for cirrhosis and the presence of hepatic vein or IVC collaterals at imaging [77].

Various disorders of hepatic sinusoids can present with clinical, histological and imaging features resembling those of BCS. These disorders are discussed at the end of this chapter.

Therapy

Treatment for the underlying condition

Treatment for the underlying condition is logical. This part of therapy is beyond the scope of this article. Preventing extension of thrombosis in the hepatic veins, in their collaterals and in the intrahepatic or extrahepatic portal venous system aims at preventing deterioration, and at keeping feasible all the therapeutic options that require a patent portal vein [1]. The evidence for the efficacy of anticoagulation therapy is circumstantial, including: (i) an improved outcome since the introduction of systematic anticoagulation, in non-transplant as well as in transplant patients [73,100–102]; (ii) reports of repermeation of thrombosed hepatic veins, and of thrombosed portal vein associated with thrombosed hepatic veins [103]; and (iii) the efficacy of therapy in patients with portal vein or other deep vein thrombosis [104]. The type and the duration of optimal anticoagulation therapy have not been established. In most centres, heparin followed by long-term administration of a vitamin K antagonist have been used, whatever the underlying thrombotic risk factor. Low-molecular-weight heparins are preferred to unfractionated heparins because of a lower risk of heparin-induced thrombocytopenia and easier administration and monitoring. Newer agents and alternative protocols require further evaluation [105].

Management of complications

Treatments recommended for portal hypertension and ascites in cirrhotic patients probably apply to BCS patients, albeit with some caution. Anticoagulant therapy increases the risk of bleeding from paracentesis. During active bleeding from oesophageal varices, the reduction in splanchnic blood flow induced by exogenous vasoconstrictors might theoretically precipitate portal venous thrombosis. Anticoagulation therapy may make endoscopic therapy for oesophageal varices difficult.

Liver decompression

Decompression aims at decreasing sinusoidal pressure by restoring the outflow of hepatic blood by either recanalizing the obstructed venous outflow or side-to-side portocaval shunting. Recanalization can be attempted using thrombolytic therapy for recent thrombosis, percutaneous angioplasty or surgery.

The benefit/risk ratio of thrombolysis is still unclear. From the limited experience reported thus far, *in situ* thrombolysis combined with angioplasty for a pre-existing stenosis appears to be superior to thrombolysis alone, whether systemic or *in situ* [102,106].

Percutaneous angioplasty, primarily or secondarily associated with stenting, has permitted the achievement of long-term patency rates in the order of 80–90% for both IVC and hepatic veins [102,107,108]. An immediate relief of manifestations has generally been reported. Rethrombosis and restenosis are amenable to *in situ* thrombolysis and reangioplasty respectively. Data on long-term effects are encouraging for IVC obstruction but still scarce for hepatic vein obstruction. Factors that should prompt primary stenting need to be clarified. Surgical angioplasty and the hepatoatrial anastomosis ('Senning's procedure') [109] have been abandoned with the development of percutaneous manoeuvres.

Side-to-side portocaval shunting aims to transform the portal vein into an outflow tract, with the expectation that deprivation

of portal inflow will be compensated by an increased arterial flow. When IVC is patent, porto- or mesocaval shunts have given better results than other surgical shunts [71,110–115]. Interposition of a venous or prosthetic graft is usually necessary. Reported in-hospital mortality averages 20%. Most surviving patients have no ascites and an improved liver function at 1 year of follow-up. Reversal of fibrosis has been reported [71,116]. Shunt dysfunction, occurring in about 30% of patients, can result from thrombosis, stenosis or caval compression by the caudate lobe [117]. The outcome of shunt dysfunction is poor. Shunt stenosis can be amenable to percutaneous angioplasty and stenting [118]. Haemodynamically significant compression of intrahepatic IVC can be corrected with the insertion of a stent before or after porto- or mesocaval shunting [114]. In patients with obliteration of the IVC at its terminal portion, or severe compression at its intrahepatic portion, when percutaneous manoeuvres are not possible, long prosthetic interposition grafts have been used to construct porto- or mesoatrial, cavoatrial with portoatrial or mesoinominate anastomoses [115,116]. Post-shunt encephalopathy seems to be rare [71]. The impact of surgical shunting on survival remains unclear. Two multivariate analyses failed to show a survival advantage in surgically shunted patients compared with patients receiving only medical treatment [73,119]; however, a benefit was suggested in a third one [79]. High operative mortality and late shunt dysfunction could cancel the long-term beneficial impact of maintained liver decompression.

Except when the terminal IVC is obliterated, transjugular intrahepatic portosystemic stent shunt (TIPS) appears to be technically successful in most cases [120–122]. The shunt can be constructed through the suprahepatic IVC when no hepatic vein stump is available [123,124]. Intrahepatic caval stenosis is bypassed by the TIPS. Insertion of a TIPS has been successful in patients with partial portal vein thrombosis. Secondary thrombosis or shunt dysfunction requiring revision occurs in about 70% of cases by 6 months [122,125]. Interestingly, TIPS dysfunction was not always associated with deterioration in the patient's condition [122]. However, another study found no survival difference in similarly severely ill patients treated with surgical shunt or TIPS [79]. TIPS insertion is more difficult and hazardous in BCS patients than in cirrhotic patients [121]. Intrahepatic haematomas have been reported [126,127]. Secondary stenosis of the terminal IVC has required stenting or liver transplantation [128].

Liver transplantation

Liver transplantation has been used as an alternative to, or after failure of, shunting [100,111,129–131]. The 10-year survival rate is about 75%, a result not different from that for other indications for transplantation. However, interpretation of these data requires further cohort studies including transplant and non-transplant patients, and survival analyses adjusted for baseline prognostic factors. The risk of recurrence is acceptably low when anticoagulant therapy is instituted early [130]. The apparently low risk of exacerbating malignant transformation of an underlying myeloproliferative disorder requires further assessment [130,131].

Management

In this area where evidence is scarce, there appear to be some areas of consensus [1,132]. First, treatment of the underlying condition and lifelong anticoagulation therapy should be initiated without delay. Second, in asymptomatic patients, interventional therapy should be considered only when a short-length stenosis is present and easily amenable to percutaneous therapy. In other patients, angioplasty should be considered first and then TIPS when angioplasty is not technically feasible or fails to improve the patient's condition. Liver transplantation should be considered only in patients with technical failure of the percutaneous procedures or lack of satisfactory clinical response. Indeed, there is evidence from recent retrospective studies that applying the above algorithm without consideration of the severity of the patient's condition or presentation is associated with a marked improvement in medium-term survival compared with other recent cohorts where patients were mainly treated with purely medical means, surgical shunting or transplantation [133].

The possible need for prompt transplantation should be kept in mind because deterioration in the patient's condition can be rapid. Stent placement should be in a position where it will not hamper subsequent transplantation if needed. Preservation of good renal function deserves attention so that optimal immune suppression regimens can be used early post-transplant. Patients are better managed at, or in close connection with, centres where all possible treatment options, including transplant, are readily available.

Finally, the problem patient is the one with associated portal vein thrombosis, who is generally in a poor condition and in whom derivative procedures and transplantation will be impossible or hazardous [82]. When portal vein thrombosis is recent, TIPS combined with thrombolysis may meet with some success [106,134].

Survival and prognosis

Data on the natural history of BCS are limited. In early studies where no therapy was administered, diagnosis was difficult *in vivo*. One-year mortality was estimated at about 60% [135]. Since these early days, however, non-invasive imaging now allows recognition of asymptomatic forms with an excellent spontaneous outcome in up to 20% of patients [80]. Furthermore, various forms of therapy have been implemented. Large cohorts of patients have showed an overall 5-year survival rate of 65–69% [73,79,119]. Figure 1 shows the overall survival curve in the largest cohort of western patients reported so far [79]. Roughly, there are two portions to the survival curve. The downward slope is steep during the first 2 years, which accounts for half of the mortality. Thereafter, the slope is less steep, but still

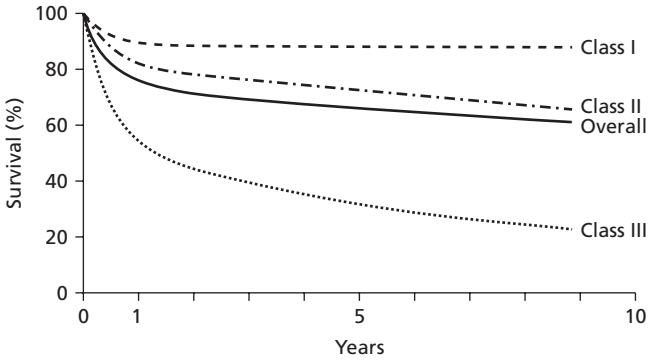

Fig. 1 Survival in a cohort of 237 western patients with Budd–Chiari syndrome (1987–2002). The curves refer to the survival in the whole cohort and in 3 subclasses of prognostic score. Class I accounts for a quarter of the patients, class II for half the patients, and class III for the remaining quarter. Adapted from data in ref. 79.

Table 4 Prognostic scores for Budd–Chiari syndrome.

Zeitoun *et al.* [73]	0.75 ascites score (1, 2 or 3)[a] + 0.28 Pugh score + 0.037 age (years) + 0.0036 creatinine (μmol/L)
Langlet *et al.* [119]	0.95 ascites score (1, 2 or 3)[a] + 0.35 Pugh score + 0.047 age (years) + 0. 0045 creatinine (μmol/L) + 2.2 acute-on-chronic form (0 or 1)[b] – 0.26
Murad *et al.* [79]	1.27 encephalopathy (0 or 1)[b] + 1.04 ascites (0 or 1)[b] + 0.72 prothrombin (INR) + 0.004 bilirubin (μmol/L)

INR, international normalized ratio.
[a]Ascites score: 1, absent without diuretics; 2, absent on diuretics; 3, refractory.
[b]0, absent; 1, present.

does not appear to plateau. The main causes of death in that cohort were liver failure and postoperative multiorgan failure.

Recent multivariate analyses have assessed the prognostic significance of disease characteristics at the time of diagnosis as well as treatment-related variables. Several prognostic scores have been derived (Table 4). Some limitations in these studies have to be kept in mind. First, the impact of causal factors on prognosis has not been adequately assessed due to a lack of systematic investigations. Some studies have suggested that patients with Behcet's disease [136] have a worse outcome than those with the other, more common causes of BCS. The excess mortality could be related to extrahepatic involvement. Second, the cohorts have been constituted over periods of 20 years or more, a lapse of time during which many aspects of management have evolved. These multivariate analyses brought significant information for therapy (discussed above) and prognosis. All studies have identified the Child–Pugh score or its components as the major prognostic variables. None of the four studies found liver biopsy data to be of independent prognostic value once adjustment for Child–Pugh score was performed. Many previous data suggest that portal vein thrombosis is a factor for poor outcome in BCS patients [69,70,82]. However, in multivariate analysis adjusting for the Child–Pugh score component, extrahepatic portal vein thrombosis had no independent prognostic value [79]. Further studies addressing this issue are needed. In the study that evaluated a clinicopathological classification, the acute-on-chronic form had an extremely poor outcome compared with the purely acute or purely chronic form. The independent value persisted after adjustment for other prognostic variables [119]. Most importantly, these studies have allowed a better appreciation of the extreme heterogeneity of BCS with regard to outcome. For example, in a large international multicentre cohort, based on data at diagnosis, a quarter of patients had a 15-year survival probability of about 90% and, at the other end of the spectrum, another quarter had a 5-year survival rate of only 49% (Fig. 1) [79]. The most recent studies indicate that an overall 5-year survival above 85% can be expected currently with minimal use of liver transplantation [133]. Thus, long-term survival might be more related to the severity of the underlying disease than to BCS that revealed this disease.

Disorders of hepatic sinusoids

Sinusoidal obstruction syndrome (SOS)

SOS is characterized by initial, acute damage to the endothelial cells. This is followed by their detachment and their embolization in the central area of the lobule where they cause a postsinusoidal outflow block [43]. Histologically, the subendothelial space of central and subendothelial veins is widened and occupied by diverse cellular debris. There is congestion and necrosis within the centrolobular area, followed by subendothelial deposition of fibrous tissue in central and sublobular veins and in sinusoids. Causes of SOS include exposure to certain toxic substances (i.e. pyrrolizidine alkaloids, azathioprine and various chemotherapeutic agents), hepatic irradiation or a combination of irradiation and chemotherapy (as used in myeloablative therapy). Myeloablative therapy for stem cell transplantation has become the major cause of SOS. Depending on the myeloablative conditioning regimen, the incidence varies from 0% to 50%, the prevalence being highest with regimens of cyclophosphamide and total body irradiation of more than 13.2 Gy. The following factors have been shown to increase the risk of SOS: chronic infection with hepatitis C virus, treatment with norethisterone, previous chemotherapy and irradiation to the abdomen. There is also interindividual variation in the risk in relation to drug metabolism.

The features of SOS mimic those of BCS. In the context of myeloablative therapy, the onset of the syndrome is heralded by fluid retention and tender hepatomegaly, beginning 10–20 days after the initiation of cyclophosphamide regimens and later after other myeloablative regimens [43]. Increased serum bilirubin follows, usually before the 30th day. Serum transaminases are increased. Clinical diagnosis requires that other possible causes

of liver disease are ruled out (particularly severe sepsis and hyperacute graft-vs.-host disease). When an association with other liver diseases is possible, transvenous liver biopsy coupled with hepatic venous pressure gradient measurement are useful. Severity varies from patient to patient, ranging from silent forms to fulminant hepatic failure. Some patients recover completely while others develop lethal forms, usually in association with multiorgan failure. In the context of myeloablative therapy, reported mortality rates have varied between 0% and 67% [43]. However, the highest figures may be a reflection of death with SOS in fragile patients rather than death from SOS. Actually, recovery from SOS may occur in up to 70% of cases. A poor prognosis is correlated with high serum transaminase levels, high hepatic venous pressure gradient, development of portal vein thrombosis, renal insufficiency and decreased oxygen saturation [43]. Besides alterations in the conditioning regimen in high-risk patients, there is no established way of preventing SOS related to myeloablative therapy. Likewise, no therapy has been established to be of clinically significant benefit once SOS has developed. Uncontrolled data have suggested the potential benefit of defibrotide, *N*-acetylcysteine and prostaglandin E1 [43].

Peliosis hepatis

Peliosis hepatis is characterized by blood-filled cavities of various sizes, bordered by hepatocellular plates and randomly distributed throughout the hepatic lobule [137]. The hepatocytes that border the peliotic cavities are often atrophic or compressed. Peliosis hepatis, sinusoidal dilatation, perisinusoidal fibrosis and nodular regenerative hyperplasia may coexist. The peliotic cavities consist of dilated sinusoids and the space of Disse. The pathogenesis is unknown. Indirect evidence suggests two mechanisms: obstruction at the junctions of sinusoids and central veins; and a primary lesion of the sinusoidal (mainly endothelial) cells. Peliosis hepatis is frequently associated with extrahepatic diseases (Table 5) [137]. Most of these associated diseases share the following features: (i) a chronic debilitating condition; (ii) frequently associated with severe infections; and (iii) commonly leading to the administration of androgenic–anabolic steroids. Several drugs and chemicals have been incriminated; however, rather than a direct toxic effect, these substances may only potentiate the action of as yet unidentified endogenous factors. In patients with acquired immunodeficiency syndrome (AIDS), an infectious form of peliosis hepatis has been characterized under the name of bacillary peliosis hepatis [138]. It is related to infection by *Bartonella henselae* and is cured by erythromycin.

Perisinusoidal fibrosis is a late sequela after resolution of the peliotic cavities, but can be demonstrated by electron microscopy in the early stages [139,140]. Perisinusoidal fibrosis could thus explain the intrahepatic block observed in peliosis hepatis. Mild lesions induce no sign or symptom whereas, in severe lesions, hepatomegaly, ascites, oesophageal varices or liver failure are present. Liver tests are usually mildly impaired.

Table 5 Associated conditions reported with peliosis hepatis or sinusoidal dilatation (in the absence of hepatic venous outflow or portal venous inflow impairment).

Drugs and chemicals
Androgenic anabolic steroids
Contraceptive steroids
Azathioprine
Corticosteroids
Arsenic
Thorium dioxide
Vinyl chloride
Toxic oil syndrome
Bacterial infections
Tuberculosis
Endocarditis
Pyelonephritis
Monoclonal gammopathies
Multiple myeloma
Waldenström macroglobulinaemia
Malignancies
Malignant tumours
Hodgkin's disease
Other conditions
Renal transplantation
Diabetes
Acquired immunodeficiency syndrome
Crohn's disease

A marked increase in serum alkaline phosphatase and γ-glutamyltransferase activities can occur. At laparoscopy, peliosis hepatis can be recognized as dark blebs on the surface of the liver. Macroscopic blood-filled cavities can be demonstrated by ultrasound, computerized tomography (CT) or MRI [141]. Liver biopsy is required to demonstrate the blood lakes. Death results from intraperitoneal bleeding, liver failure or a complication of the associated conditions, but not from portal hypertension. Symptomatic peliosis hepatis should be regarded as a feature of a bad prognosis, even though it is rarely the direct cause of death. There is no specific treatment.

Sinusoidal dilatation

By far the main cause of sinusoidal dilatation is represented by hepatic outflow impairment related to BCS or heart disease. Rarely, sinusoidal dilatation is present in the absence of outflow impairment. In the latter situation, the lesion of sinusoidal dilatation differs from peliosis hepatis in the following characteristics: (i) the ectatic sinusoids do not take the cystic appearance that is typical of peliosis hepatis; (ii) the dilatation is not randomly distributed but affects a distinct part (pericentral and midzonal or periportal) of the lobule; and (iii) the endothelial lining is preserved. However, the separation between the two

entities may be difficult to make morphologically and aetiologically. As in peliosis hepatis, sinusoidal dilatation has been reported alone or in association with nodular regenerative hyperplasia and perisinusoidal fibrosis. Sinusoidal dilatation unrelated to outflow impairment is associated with portal inflow impairment [142,143], with systemic inflammatory disorders [144,145] or with the administration of steroid analogues [42]. Thus, sinusoidal dilatation unassociated with disorders of hepatic or portal veins shares most of the causes of peliosis hepatis and nodular regenerative hyperplasia (Table 5) [142–144]. In recent series, the antiphospholipid syndrome was the commonest cause of sinusoidal dilatation unrelated to drugs or Crohn's disease [146]. In the past, oral contraceptives have been considered as a cause of sinusoidal dilatation. However, an underlying inflammatory condition was almost always associated. The pathogenesis remains unelucidated. Clinical features of sinusoidal dilatation may be absent or include right upper quadrant pain, fever and hepatomegaly. Ascites and oesophageal varices have been reported. The erythrocyte sedimentation rate and serum gammaglobulin are frequently raised. Liver function test results are moderately abnormal. Perisinusoidal fibrosis may persist as a late sequela. The diagnosis raises the same difficulties as that of peliosis hepatis. Diffuse, mottled alterations in hepatic perfusion can be seen at CT or MRI persisting through all phases of contrast injection. In the absence of hepatic venous outflow block or portal vein obstruction, this pattern is suggestive of sinusoidal dilatation. Still, a liver biopsy cannot be avoided to exclude malignant infiltration of the liver or obstruction limited to the small hepatic veins. The differential diagnosis of right upper quadrant pain with fever and mild or absent abnormalities of liver tests includes acute cholecystitis, perihepatitis, acute hepatic venous outflow block and right heart failure. Ultrasound plays a major role in this differential diagnosis. There is no specific treatment for this benign condition. The manifestations disappear with the resolution of the associated acute or chronic disease.

Sinusoidal fibrosis

Pure sinusoidal fibrosis predominating in the perivenous area is usually associated with venous scarring. The main causes are resolved steatohepatitis (alcoholic or non-alcoholic) and right-sided heart failure or constrictive pericarditis. Chronic intoxication with vitamin A is a prototype for pure sinusoidal fibrosis without zonal predominance. A distinctive feature is the hypertrophy of the lipid-laden stellate cells [147]. Chronic therapy with methotrexate has been related to sinusoidal fibrosis, although the distinction from coexistent alcoholic or metabolic liver disease is difficult [148]. Mastocytosis may produce an almost pure aspect of perisinusoidal fibrosis [149]. All causes of obliterative portal venopathy have been associated with pure sinusoidal fibrosis, which raises the issue of portal vein lesions having been missed in small biopsy specimens where pure sinusoidal fibrosis was found [142].

Infiltration of the sinusoids

The perisinusoidal space can be infiltrated by the deposition of various substances including immune globulin light chain (myeloma), various amyloid substances (AL type in myeloma, AA type in chronic inflammatory disorders) or immune globulin A (alcoholics). Liver enlargement and cholestatic liver tests are the main manifestations of these lesions. The sinusoidal lumen can be the site of fibrin deposition in conditions in which intravascular activation of coagulation occurs, such as pre-eclampsia, the haemolytic and uraemic syndrome and thrombotic thrombocytopenic purpura. Liver haematomas and intraperitoneal rupture may occur, albeit rarely. Upper abdominal pain occurring in the setting of the haemolysis, elevated liver function and low platelets (HELLP) syndrome heralds the development of intra- or extrahepatic bleeding. In sickle cell anaemia, falciformation within the sinusoids causes painful liver enlargement and abnormal liver enzymes. Diffuse infiltration of the sinusoids with abnormal cells may occur in patients with breast carcinoma or undifferentiated carcinoma [150], myeloproliferative disease, lymphomas and leukaemias [151], mastocytosis [149] and the haemophagocytic syndrome [152]. In rare instances, the disorders present with apparently pure liver involvement. Liver enlargement is constant. Ascites and acute liver failure are frequent. Prognosis is poor.

References

1 Janssen HL, Garcia-Pagan JC, Elias E *et al.* (2003) Budd–Chiari syndrome: a review by an expert panel. *J Hepatol* 38, 364–371.

2 Okuda H, Yamagata H, Obata H *et al.* (1995) Epidemiological and clinical features of Budd–Chiari syndrome in Japan. *J Hepatol* 22, 1–9.

3 Shrestha SM, Okuda K, Uchida T *et al.* (1996) Endemicity and clinical picture of liver disease due to obstruction of the hepatic portion of the inferior vena cava in Nepal. *J Gastroenterol Hepatol* 11, 170–179.

4 Hirshberg B, Shouval D, Fibach E *et al.* (2000) Flow cytometric analysis of autonomous growth of erythroid precursors in liquid culture detects occult polycythemia vera in the Budd–Chiari syndrome. *J Hepatol* 32, 574–578.

5 Janssen HL, Meinardi JR, Vleggaar FP *et al.* (2000) Factor V Leiden mutation, prothrombin gene mutation, and deficiencies in coagulation inhibitors associated with Budd–Chiari syndrome and portal vein thrombosis: results of a case–control study. *Blood* 96, 2364–2368.

6 Bhattacharyya M, Makharia G, Kannan M *et al.* (2004) Inherited prothrombotic defects in Budd–Chiari syndrome and portal vein thrombosis: a study from North India. *Am J Clin Pathol* 121, 844–847.

7 Mohanty D, Shetty S, Ghosh K *et al.* (2001) Hereditary thrombophilia as a cause of Budd–Chiari syndrome: a study from Western India. *Hepatology* 34, 666–670.

8 Deltenre P, Denninger MH, Hillaire S *et al.* (2001) Factor V Leiden related Budd–Chiari syndrome. *Gut* 48, 264–268.

9 Denninger MH, Chait Y, Casadevall N *et al.* (2000) Cause of portal or hepatic venous thrombosis in adults: the role of multiple concurrent factors. *Hepatology* 31, 587–591.

10 Anger BR, Seifried E, Scheppach J *et al.* (1989) Budd–Chiari syndrome and thrombosis of other abdominal vessels in the chronic myeloproliferative diseases. *Klin Wochenschr* 67, 818–825.

11 Wanless IR, Peterson P, Das A *et al.* (1990) Hepatic vascular disease and portal hypertension in polycythemia vera and agnogenic myeloid metaplasia: a clinicopathological study of 145 patients examined at autopsy. *Hepatology* 12, 1166–1174.

12 De Stefano V, Teofili L, Leone G *et al.* (1997) Spontaneous erythroid colony formation as the clue to an underlying myeloproliferative disorder in patients with Budd–Chiari syndrome or portal vein thrombosis. *Semin Thromb Hemost* 23, 411–418.

13 Chait Y, Condat B, Cazals-Hatem D *et al.* (2005) Relevance of the criteria commonly used to diagnose myeloproliferative disorder in patients with splanchnic vein thrombosis. *Br J Haematol* 129, 553–560.

14 Valla D, Casadevall N, Lacombe C *et al.* (1985) Primary myeloproliferative disorder and hepatic vein thrombosis. A prospective study of erythroid colony formation *in vitro* in 20 patients with Budd–Chiari syndrome. *Ann Intern Med* 103, 329–334.

15 Dayal S, Pati HP, Pande GK *et al.* (1997) Multilineage hemopoietic stem cell defects in Budd Chiari syndrome. *J Hepatol* 26, 293–297.

16 James C, Ugo V, Le Couedic JP *et al.* (2005) A unique clonal JAK2 mutation leading to constitutive signalling causes polycythaemia vera. *Nature* 434, 1144–1148.

17 Socie G, Mary JY, de Gramont A *et al.* (1996) Paroxysmal nocturnal haemoglobinuria: long-term follow-up and prognostic factors. French Society of Haematology. *Lancet* 348, 573–577.

18 Valla D, Dhumeaux D, Babany G *et al.* (1987) Hepatic vein thrombosis in paroxysmal nocturnal hemoglobinuria. A spectrum from asymptomatic occlusion of hepatic venules to fatal Budd–Chiari syndrome. *Gastroenterology* 93, 569–575.

19 Graham ML, Rosse WF, Halperin EC *et al.* (1996) Resolution of Budd–Chiari syndrome following bone marrow transplantation for paroxysmal nocturnal haemoglobinuria. *Br J Haematol* 92, 707–710.

20 Bahr MJ, Schubert J, Bleck JS *et al.* (2003) Recurrence of Budd–Chiari syndrome after liver transplantation in paroxysmal nocturnal hemoglobinuria. *Transpl Int* 16, 890–894.

21 Offenstadt G, Desaint B, Conard J *et al.* (1982) [Budd–Chiari syndrome with massive thrombosis of the subdiaphragmatic venous system and major fibrinopenia (author's transl.)]. *Nouv Presse Med* 11, 2139–2141.

22 Rosendaal FR (1999) Venous thrombosis: a multicausal disease. *Lancet* 353, 1167–1173.

23 Espinosa G, Font J, Garcia-Pagan JC *et al.* (2001) Budd–Chiari syndrome secondary to antiphospholipid syndrome: clinical and immunologic characteristics of 43 patients. *Medicine (Baltimore)* 80, 345–354.

24 Pelletier S, Landi B, Piette JC *et al.* (1994) Antiphospholipid syndrome as the second cause of non-tumorous Budd–Chiari syndrome. *J Hepatol* 21, 76–80.

25 Bismuth E, Hadengue A, Hammel P *et al.* (1990) Hepatic vein thrombosis in Behcet's disease. *Hepatology* 11, 969–974.

26 Bayraktar Y, Balkanci F, Bayraktar M *et al.* (1997) Budd–Chiari syndrome: a common complication of Behcet's disease. *Am J Gastroenterol* 92, 858–862.

27 Saatci I, Ozmen M, Balkanci F *et al.* (1993) Behcet's disease in the etiology of Budd–Chiari disease. *Angiology* 44, 392–398.

28 Walker M (1987) Idiopathic hypereosinophilia associated with hepatic vein thrombosis. *Arch Intern Med* 147, 2220–2221.

29 Elouaer-Blanc L, Zafrani ES, Farcet JP *et al.* (1985) Hepatic vein obstruction in idiopathic hypereosinophilic syndrome. *Arch Intern Med* 145, 751–753.

30 Zylberberg H, Valla D, Viguie F *et al.* (1996) Budd–Chiari syndrome associated with 5q deletion and hypereosinophilia. *J Clin Gastroenterol* 23, 66–68.

31 Russi EW, Bansky G, Pfaltz M *et al.* (1986) Budd–Chiari syndrome in sarcoidosis. *Am J Gastroenterol* 81, 71–75.

32 Young ID, Clark RN, Manley PN *et al.* (1988) Response to steroids in Budd–Chiari syndrome caused by idiopathic granulomatous venulitis. *Gastroenterology* 94, 503–507.

33 Saito T, Harada K, Nakanuma Y (2002) Granulomatous phlebitis of small hepatic vein. *J Gastroenterol Hepatol* 17, 1334–1339.

34 Martinez F, Berenguer M, Prieto M *et al.* (2004) Budd–Chiari syndrome caused by membranous obstruction of the inferior vena cava associated with coeliac disease. *Dig Liver Dis* 36, 157–162.

35 El Younsi S, Nassif T, Kuoch V *et al.* (2003) [Association of Budd–Chiari syndrome and celiac disease]. *Gastroenterol Clin Biol* 27, 236–237.

36 Junge U, Wienke J, Schuler A (2001) Acute Budd–Chiari syndrome, portal and splenic vein thrombosis in a patient with ulcerative colitis associated with antiphospholipid antibodies and protein C deficiency. *Z Gastroenterol* 39, 845–852.

37 Kraut J, Berman JH, Gunasekaran TS *et al.* (1997) Hepatic vein thrombosis (Budd–Chiari syndrome) in an adolescent with ulcerative colitis. *J Pediatr Gastroenterol Nutr* 25, 417–420.

38 Decaens T, Maitre S, Marfaing A *et al.* (2004) [Inflammatory bowel disease and latent thrombocythemia: a novel cause of hepatic vein thrombosis]. *Gastroenterol Clin Biol* 28, 394–397.

39 Dilawari JB, Bambery P, Chawla Y *et al.* (1994) Hepatic outflow obstruction (Budd–Chiari syndrome). Experience with 177 patients and a review of the literature. *Medicine (Baltimore)* 73, 21–36.

40 Khuroo MS, Datta DV (1980) Budd–Chiari syndrome following pregnancy. Report of 16 cases, with roentgenologic, hemodynamic and histologic studies of the hepatic outflow tract. *Am J Med* 68, 113–121.

41 Singh V, Sinha SK, Nain CK *et al.* (2000) Budd–Chiari syndrome: our experience of 71 patients. *J Gastroenterol Hepatol* 15, 550–554.

42 Valla D, Benhamou JP (1988) Drug-induced vascular and sinusoidal lesions of the liver: *Bailliere's Clin Gastroenterol* 2, 481–500.

43 DeLeve LD, Shulman HM, McDonald GB (2002) Toxic injury to hepatic sinusoids: sinusoidal obstruction syndrome (veno-occlusive disease). *Semin Liver Dis* 22, 27–42.

44 Coche JC, Horsmans Y, Greer Y *et al.* (1995) Budd–Chiari syndrome likely related to a slimming drug preparation. *J Hepatol* 23, 626–627.

45 Valla D, Le MG, Poynard T *et al.* (1986) Risk of hepatic vein thrombosis in relation to recent use of oral contraceptives. A case–control study. *Gastroenterology* 90, 807–811.

46 Gupta S, Blumgart LH, Hodgson HJ (1986) Budd–Chiari syndrome: long-term survival and factors affecting mortality. *Q J Med* 60, 781–791.

47 Aikat BK, Bhusnurmath SR, Chhuttani PN *et al.* (1978) Hepatic vein obstruction – a retrospective analysis of 72 autopsies and biopsies. *Ind J Med Res* 67, 128–144.

48 Fleiner-Hoffmann AF, Pfammatter T, Leu AJ *et al.* (1998) Alveolar echinococcosis of the liver: sequelae of chronic inferior vena cava obstructions in the hepatic segment. *Arch Intern Med* 158, 2503–2508.

49 Markert DJ, Shanmuganathan K, Mirvis SE *et al.* (1997) Budd–Chiari syndrome resulting from intrahepatic IVC compression secondary to blunt hepatic trauma. *Clin Radiol* 52, 384–387.

50 Fernandez-Gonzalez AL, Llorens R, Herreros JM *et al.* (1994) Blunt traumatic rupture of the right hemidiaphragm and Budd–Chiari syndrome. *Ann Thorac Surg* 58, 559–561.

51 Ambrosetti P, Widmann JJ, Robert J *et al.* (1992) [Acute Budd–Chiari's syndrome after surgical treatment of polycystic liver disease]. *Gastroenterol Clin Biol* 16, 894–896.

52 Benesch M, Urban C, Deutschmann H *et al.* (2002) Management of Budd–Chiari syndrome by hepatic vein stenting after extended right hepatectomy. *J Pediatr Surg* 37, 1640–1642.

53 Dousset B, Legmann P, Soubrane O *et al.* (1997) Protein-losing enteropathy secondary to hepatic venous outflow obstruction after liver transplantation. *J Hepatol* 27, 206–210.

54 Parker RGF (1959) Occlusion of the hepatic veins in man. *Medicine (Baltimore)* 38, 369–402.

55 Sigal E, Pogany A, Goldman IS (1984) Marked hepatic congestion caused by a thoracoabdominal aneurysm. *Gastroenterology* 87, 1367–1371.

56 Uddin W, Ramage JK, Portmann B *et al.* (1995) Hepatic venous outflow obstruction in patients with polycystic liver disease: pathogenesis and treatment. *Gut* 36, 142–145.

57 Schraut WH, Chilcote RR (1985) Metastatic Wilms' tumor causing acute hepatic-vein occlusion (Budd–Chiari syndrome). *Gastroenterology* 88, 576–579.

58 Ciancio G, Soloway M (2001) Renal cell carcinoma invading the hepatic veins. *Cancer* 92, 1836–1842.

59 Saisse J, Hardwigsen J, Castellani P *et al.* (2001) Budd–Chiari syndrome secondary to intracardiac extension of hepatocellular carcinoma. Two cases treated by radical resection. *Hepatogastroenterology* 48, 836–839.

60 Carbonnel F, Valla D, Menu Y *et al.* (1988) Acute Budd–Chiari syndrome as first manifestation of adrenocortical carcinoma. *J Clin Gastroenterol* 10, 441–444.

61 Gowda RM, Gowda MR, Mehta NJ *et al.* (2004) Right atrial extension of primary venous leiomyosarcoma: pulmonary embolism and Budd–Chiari syndrome at presentation – a case report. *Angiology* 55, 213–216.

62 Rademaker J, Widjaja A, Galanski M (2000) Hepatic hemangiosarcoma: imaging findings and differential diagnosis. *Eur Radiol* 10, 129–133.

63 Anagnostopoulos GK, Margantinis G, Kostopoulos P *et al.* (2004) Budd–Chiari syndrome and portal vein thrombosis due to right atrial myxoma. *Ann Thorac Surg* 78, 333–334.

64 Terabayashi H, Okuda K, Nomura F *et al.* (1986) Transformation of inferior vena caval thrombosis to membranous obstruction in a patient with the lupus anticoagulant. *Gastroenterology* 91, 219–224.

65 Sevenet F, Deramond H, Hadengue A *et al.* (1989) Membranous obstruction of the inferior vena cava associated with a myeloproliferative disorder: a clue to membrane formation? *Gastroenterology* 97, 1019–1021.

66 Kage M, Arakawa M, Kojiro M *et al.* (1992) Histopathology of membranous obstruction of the inferior vena cava in the Budd–Chiari syndrome. *Gastroenterology* 102, 2081–2090.

67 Valla D, Hadengue A, el Younsi M *et al.* (1997) Hepatic venous outflow block caused by short-length hepatic vein stenoses. *Hepatology* 25, 814–819.

68 Okuda K (2002) Inferior vena cava thrombosis at its hepatic portion (obliterative hepatocavopathy). *Semin Liver Dis* 22, 15–26.

69 Tanaka M, Wanless IR (1998) Pathology of the liver in Budd–Chiari syndrome: portal vein thrombosis and the histogenesis of veno-centric cirrhosis, veno-portal cirrhosis, and large regenerative nodules. *Hepatology* 27, 488–496.

70 Cazals-Hatem D, Vilgrain V, Genin P *et al.* (2003) Arterial and portal circulation and parenchymal changes in Budd–Chiari syndrome: a study in 17 explanted livers. *Hepatology* 37, 510–519.

71 Henderson JM, Warren WD, Millikan WJ *et al.* (1990) Surgical options, hematologic evaluation, and pathologic changes in Budd–Chiari syndrome. *Am J Surg* 159, 41–48; discussion 48–50.

72 Tang TJ, Batts KP, de Groen PC *et al.* (2001) The prognostic value of histology in the assessment of patients with Budd–Chiari syndrome. *J Hepatol* 35, 338–343.

73 Zeitoun G, Escolano S, Hadengue A *et al.* (1999) Outcome of Budd–Chiari syndrome: a multivariate analysis of factors related to survival including surgical portosystemic shunting. *Hepatology* 30, 84–89.

74 Akiyoshi H, Terada T (1999) Centrilobular and perisinusoidal fibrosis in experimental congestive liver in the rat. *J Hepatol* 30, 433–439.

75 Beattie C, Sitzmann JV, Cameron JL (1988) Mesoatrial shunt hemodynamics. *Surgery* 104, 1–9.

76 Menu Y, Sebag G, Vigrain V *et al.* (1990) Budd–Chiari syndrome: MR evaluation. *Diagn Interv Radiol* 2, 23–28.

77 Miller WJ, Federle MP, Straub WH *et al.* (1993) Budd–Chiari syndrome: imaging with pathologic correlation. *Abdom Imaging* 18, 329–335.

78 Gonzalez-Flecha B, Reides C, Cutrin JC *et al.* (1993) Oxidative stress produced by suprahepatic occlusion and reperfusion. *Hepatology* 18, 881–889.

79 Murad SD, Valla DC, de Groen PC *et al.* (2004) Determinants of survival and the effect of portosystemic shunting in patients with Budd–Chiari syndrome. *Hepatology* 39, 500–508.

80 Hadengue A, Poliquin M, Vilgrain V *et al.* (1994) The changing scene of hepatic vein thrombosis: recognition of asymptomatic cases. *Gastroenterology* 106, 1042–1047.

81 Cho KJ, Geisinger KR, Shields JJ *et al.* (1982) Collateral channels and histopathology in hepatic vein occlusion. *AJR Am J Roentgenol* 139, 703–709.

82 Mahmoud AEA, Helmy AS, Billingham S *et al.* (1997) Poor prognosis and limited therapeutic options in patients with Budd–Chiari syndrome and portal venous system thrombosis. *Eur J Gastroenterol Hepatol* 9, 485–489.

83 Gupta S, Barter S, Phillips GW *et al.* (1987) Comparison of ultrasonography, computed tomography and 99mTc liver scan in diagnosis of Budd–Chiari syndrome. *Gut* 28, 242–247.

84 Mathieu D, Kracht M, Zafrani E *et al.* (1990) Budd–Chiari syndrome. In: Ferrucci J, Matthieu D (eds) *Advances in Hepatobiliary Radiology*. St Louis: C.V. Mosby Co., pp. 3–28.

85 Vilgrain V, Lewin M, Vons C *et al.* (1999) Hepatic nodules in Budd–Chiari syndrome: imaging features. *Radiology* 210, 443–450.

86 Ibarrola C, Castellano VM, Colina F (2004) Focal hyperplastic hepatocellular nodules in hepatic venous outflow obstruction: a clinicopathological study of four patients and 24 nodules. *Histopathology* 44, 172–179.

87 Kage M (2004) Budd–Chiari syndrome and hepatocellular carcinoma. *J Gastroenterol* 39, 706–707.

88 Takamura M, Ichida T, Yokoyama J *et al.* (2004) Recurrence of hepatocellular carcinoma 102 months after successful eradication and removal of membranous obstruction of the inferior vena cava. *J Gastroenterol* 39, 681–684.

89 Shin SH, Chung YH, Suh DD *et al.* (2004) Characteristic clinical features of hepatocellular carcinoma associated with Budd–Chiari syndrome: evidence of different carcinogenic process from hepatitis B virus-associated hepatocellular carcinoma. *Eur J Gastroenterol Hepatol* 16, 319–324.

90 Jang JW, Yoon SK, Bae SH *et al.* (2003) Rapidly progressing Budd–Chiari syndrome complicated by hepatocellular carcinoma. *Kor J Intern Med* 18, 191–195.

91 Havlioglu N, Brunt EM, Bacon BR (2003) Budd–Chiari syndrome and hepatocellular carcinoma: a case report and review of the literature. *Am J Gastroenterol* 98, 201–204.

92 Matsui S, Ichida T, Watanabe M *et al.* (2000) Clinical features and etiology of hepatocellular carcinoma arising in patients with membranous obstruction of the inferior vena cava: in reference to hepatitis viral infection. *J Gastroenterol Hepatol* 15, 1205–1211.

93 Wilson MW, Ring EJ, LaBerge JM *et al.* (1996) Percutaneous transhepatic hepatic venography in the delineation and treatment of Budd–Chiari syndrome. *J Vasc Interv Radiol* 7, 133–138.

94 Ohta M, Hashizume M, Tomikawa M *et al.* (1994) Analysis of hepatic vein waveform by Doppler ultrasonography in 100 patients with portal hypertension. *Am J Gastroenterol* 89, 170–175.

95 Ludwig J, Hashimoto E, McGill D *et al.* (1990) Classification of hepatic venous outflow obstruction: ambiguous terminology of the Budd–Chiari syndrome. *Mayo Clin Proc* 65, 51–55.

96 Mathieu D, Vasile N, Grenier P (1985) Portal thrombosis: dynamic CT features and course. *Radiology* 154, 737–741.

97 Solano FX, Young E, Talamo TS *et al.* (1986) Constrictive pericarditis mimicking Budd–Chiari syndrome. *Am J Med* 80, 113–115.

98 Wanless I, Liu J, Butany J (1995) Role of thrombosis in the pathogenesis of congestive hepatic fibrosis (cardiac cirrhosis). *Hepatology* 21, 1232–1237.

99 Myers RP, Cerini R, Sayegh R *et al.* (2003) Cardiac hepatopathy: clinical, hemodynamic, and histologic characteristics and correlations. *Hepatology* 37, 393–400.

100 Halff G, Todo S, Tzakis AG *et al.* (1990) Liver transplantation for the Budd–Chiari syndrome. *Ann Surg* 211, 43–49.

101 Min AD, Atillasoy EO, Schwartz ME *et al.* (1997) Reassessing the role of medical therapy in the management of hepatic vein thrombosis. *Liver Transpl Surg* 3, 423–429.

102 Barrault C, Plessier A, Valla D *et al.* (2004) [Non surgical treatment of Budd–Chiari syndrome: a review]. *Gastroenterol Clin Biol* 28, 40–49.

103 Schmets L, Hagege H, Merlet C *et al.* (1993) [Porto-hepatic thrombosis, revealing paroxysmal nocturnal hemoglobinuria, followed by regression induced by heparin therapy]. *Gastroenterol Clin Biol* 17, 955–958.

104 Condat B, Pessione F, Hillaire S *et al.* (2001) Current outcome of portal vein thrombosis in adults: risk and benefit of anticoagulant therapy. *Gastroenterology* 120, 490–497.

105 D'Amico EA, Villaca PR, Gualandro SF *et al.* (2003) Successful use of Arixtra in a patient with paroxysmal nocturnal hemoglobinuria, Budd–Chiari syndrome and heparin-induced thrombocytopenia. *J Thromb Haemost* 1, 2452–2453.

106 Sharma S, Texeira A, Texeira P *et al.* (2004) Pharmacological thrombolysis in Budd Chiari syndrome: a single centre experience and review of the literature. *J Hepatol* 40, 172–180.

107 Fisher NC, McCafferty I, Dolapci M *et al.* (1999) Managing Budd–Chiari syndrome: a retrospective review of percutaneous hepatic vein angioplasty and surgical shunting. *Gut* 44, 568–574.

108 Xu PQ, Dang XW (2004) Treatment of membranous Budd–Chiari syndrome: analysis of 480 cases. *Hepatobiliary Pancreat Dis Int* 3, 73–76.

109 Vogt PR, Andersson LC, Jenni R *et al.* (1996) Dorsocranial liver resection and direct hepatoatrial anastomosis for hepatic venous outflow obstruction: long-term outcome and functional results. *Am J Gastroenterol* 91, 539–544.

110 Bismuth H, Sherlock DJ (1991) Portasystemic shunting versus liver transplantation for the Budd–Chiari syndrome. *Ann Surg* 214, 581–589.

111 Shaked A, Goldstein RM, Klintmalm GB *et al.* (1992) Portosystemic shunt versus orthotopic liver transplantation for the Budd–Chiari syndrome. *Surg Gynecol Obstet* 174, 453–459.

112 Mahmoud AEA, Mendoza AEA, Meshokhes AN *et al.* (1996) Clinical spectrum, investigations and treatment of Budd–Chiari syndrome. *Q J Med* 89, 37–43.

113 Ahn SS, Yellin A, Sheng FC *et al.* (1987) Selective surgical therapy of the Budd–Chiari syndrome provides superior survivor rates than conservative medical management. *J Vasc Surg* 5, 28–37.

114 Pisani-Ceretti A, Intra M, Prestipino F *et al.* (1998) Surgical and radiologic treatment of primary Budd–Chiari syndrome. *World J Surg* 22, 48–53; discussion 53–54.

115 Kohli V, Pande GK, Dev V *et al.* (1993) Management of hepatic venous outflow obstruction. *Lancet* 342, 718–722.

116 Orloff MJ, Daily PO, Orloff SL *et al.* (2000) A 27-year experience with surgical treatment of Budd–Chiari syndrome. *Ann Surg* 232, 340–352.

117 Panis Y, Belghiti J, Valla D *et al.* (1994) Portosystemic shunt in Budd–Chiari syndrome: long-term survival and factors affecting shunt patency in 25 patients in Western countries. *Surgery* 115, 276–281.

118 Pelage JP, Denys A, Valla D *et al.* (2003) Budd–Chiari syndrome due to prothrombotic disorder: mid-term patency and efficacy of endovascular stents. *Eur Radiol* 13, 286–293.

119 Langlet P, Escolano S, Valla D *et al.* (2003) Clinicopathological forms and prognostic index in Budd–Chiari syndrome. *J Hepatol* 39, 496–501.

120 Rossle M, Olschewski M, Siegerstetter V *et al.* (2004) The Budd–Chiari syndrome: outcome after treatment with the transjugular intrahepatic portosystemic shunt. *Surgery* 135, 394–403.

121 Mancuso A, Fung K, Mela M *et al.* (2003) TIPS for acute and chronic Budd–Chiari syndrome: a single-centre experience. *J Hepatol* 38, 751–754.

122 Perello A, Garcia-Pagan JC, Gilabert R *et al.* (2002) TIPS is a useful long-term derivative therapy for patients with Budd–Chiari syndrome uncontrolled by medical therapy. *Hepatology* 35, 132–139.

123 Soares GM, Murphy TP (1999) Transcaval TIPS: indications and anatomic considerations. *J Vasc Interv Radiol* 10, 1233–1238.

124 Gasparini D, Del Forno M, Sponza M *et al.* (2002) Transjugular intrahepatic portosystemic shunt by direct transcaval approach in patients with acute and hyperacute Budd–Chiari syndrome. *Eur J Gastroenterol Hepatol* 14, 567–571.

125 Cejna M, Peck-Radosavljevic M, Schoder M *et al.* (2002) Repeat interventions for maintenance of transjugular intrahepatic portosystemic shunt function in patients with Budd–Chiari syndrome. *J Vasc Interv Radiol* 13, 193–199.

126 Fickert P, Trauner M, Hausegger K *et al.* (2000) Intra-hepatic haematoma complicating transjugular intra-hepatic portosystemic shunt for Budd–Chiari syndrome associated with anti-phospholipid antibodies, aplastic anaemia and chronic hepatitis C. *Eur J Gastroenterol Hepatol* 12, 813–816.

127 Hasegawa S, Eisenberg LB, Semelka RC (1998) Active intrahepatic gadolinium extravasation following TIPS. *Magn Reson Imaging* 16, 851–853.

128 Turnes J, Garcia-Pagan JC, Gonzalez-Abraldes J *et al.* (2001) Stenosis of the suprahepatic inferior vena cava as a complication of transjugular intrahepatic portosystemic shunt in Budd–Chiari patients. *Liver Transpl* 7, 649–651.

129 Ringe B, Lang H, Oldhafer KJ *et al.* (1995) Which is the best surgery for Budd–Chiari syndrome: venous decompression or liver transplantation? A single-center experience with 50 patients. *Hepatology* 21, 1337–1344.

130 Srinivasan P, Rela M, Prachalias A *et al.* (2002) Liver transplantation for Budd–Chiari syndrome. *Transplantation* 73, 973–977.

131 Saigal S, Norris S, Srinivasan P *et al.* (2001) Successful outcome of orthotopic liver transplantation in patients with preexisting malignant states. *Liver Transpl* 7, 11–15.

132 Valla DC (2003) The diagnosis and management of the Budd–Chiari syndrome: consensus and controversies. *Hepatology* 38, 793–803.

133 Eapen CE, Velissaris D, Heydtmann M *et al.* (2005) Favourable medium term outcome following hepatic vein re-canalisation and/or TIPS for Budd Chiari syndrome. *Gut* 55, 878–884.

134 Opitz T, Buchwald AB, Lorf T *et al.* (2003) The transjugular intrahepatic portosystemic stent-shunt (TIPS) as rescue therapy for complete Budd–Chiari syndrome and portal vein thrombosis. *Z Gastroenterol* 41, 413–418.

135 Tavill AS, Wood EJ, Kreel L *et al.* (1975) The Budd–Chiari syndrome: correlation between hepatic scintigraphy and the clinical, radiological, and pathological findings in nineteen cases of hepatic venous outflow obstruction. *Gastroenterology* 68, 509–518.

136 Orloff LA, Orloff MJ (1999) Budd–Chiari syndrome caused by Behcet's disease: treatment by side-to-side portacaval shunt. *J Am Coll Surg* 188, 396–407.

137 Voinchet O, Degott C, Scoazec JY *et al.* (1988) Peliosis hepatis, nodular regenerative hyperplasia of the liver, and light-chain deposition in a patient with Waldenstrom's macroglobulinemia. *Gastroenterology* 95, 482–486.

138 Koehler JE, Sanchez MA, Garrido CS *et al.* (1997) Molecular epidemiology of bartonella infections in patients with bacillary angiomatosis-peliosis. *N Engl J Med* 337, 1876–1883.

139 Scoazec JY, Marche C, Girard PM *et al.* (1988) Peliosis hepatis and sinusoidal dilation during infection by the human immunodeficiency virus (HIV). An ultrastructural study. *Am J Pathol* 131, 38–47.

140 Zafrani ES, Cazier A, Baudelot AM *et al.* (1984) Ultrastructural lesions of the liver in human peliosis. A report of 12 cases. *Am J Pathol* 114, 349–359.

141 Gouya H, Vignaux O, Legmann P *et al.* (2001) Peliosis hepatis: triphasic helical CT and dynamic MRI findings. *Abdom Imaging* 26, 507–509.

142 Hillaire S, Bonte E, Denninger MH *et al.* (2002) Idiopathic non-cirrhotic intrahepatic portal hypertension in the West: a re-evaluation in 28 patients. *Gut* 51, 275–280.

143 Kakar S, Kamath PS, Burgart LJ (2004) Sinusoidal dilatation and congestion in liver biopsy: is it always due to venous outflow impairment? *Arch Pathol Lab Med* 128, 901–904.

144 Bruguera M, Aranguibel F, Ros E *et al.* (1978) Incidence and clinical significance of sinusoidal dilatation in liver biopsies. *Gastroenterology* 75, 474–478.

145 Bruguera M, Caballero T, Carreras E *et al.* (1987) Hepatic sinusoidal dilatation in Hodgkin's disease. *Liver* 7, 76–80.

146 Saadoun D, Cazals-Hatem D, Denninger MH *et al.* (2004) Association of idiopathic hepatic sinusoidal dilatation with the immunological features of the antiphospholipid syndrome. *Gut* 53, 1516–1519.

147 Geubel AP, De Galocsy C, Alves N *et al.* (1991) Liver damage caused by therapeutic vitamin A administration: estimate of dose-related toxicity in 41 cases. *Gastroenterology* 100, 1701–1709.

148 Whiting-O'Keefe QE, Fye KH, Sack KD (1991) Methotrexate and histologic hepatic abnormalities: a meta-analysis. *Am J Med* 90, 711–716.

149 Mican JM, Di Bisceglie AM, Fong TL *et al.* (1995) Hepatic involvement in mastocytosis: clinicopathologic correlations in 41 cases. *Hepatology* 22, 1163–1170.

150 Rowbotham D, Wendon J, Williams R (1998) Acute liver failure secondary to hepatic infiltration: a single centre experience of 18 cases. *Gut* 42, 576–580.

151 Dubois A, Dauzat M, Pignodel C *et al.* (1993) Portal hypertension in lymphoproliferative and myeloproliferative disorders: hemodynamic and histological correlations. *Hepatology* 17, 246–250.

152 de Kerguenec C, Hillaire S, Molinie V *et al.* (2001) Hepatic manifestations of hemophagocytic syndrome: a study of 30 cases. *Am J Gastroenterol* 96, 852–857.

17.4 Congenital vascular malformations

Guadalupe García-Tsao

Congenital vascular malformations of the liver result mostly in abnormal shunting of blood through the liver. Shunting may be so severe as to cause symptoms, but most patients are discovered incidentally while undergoing ultrasonography or other imaging studies for other reasons. Except for liver involvement by hereditary haemorrhagic telangiectasia (HHT), symptomatic anomalies are usually diagnosed in infants or children. Given the vascular anatomy of the liver, shunting can occur from the hepatic artery to the hepatic vein (arteriovenous shunt), from the hepatic artery to the portal vein (arterioportal shunt) and/or from the portal vein to the systemic circulation (portosystemic shunt). In liver involvement by HHT, the three types of shunt may coexist and, therefore, this entity will be considered separately.

Congenital arteriovenous malformations (AVM)

Although congenital hepatic vascular neoplasms, such as haemangioendothelioma, account for the great majority of hepatic arteriovenous shunting in infants [1], they cannot be considered AVMs [2,3] and are therefore not considered in this chapter. Congenital AVMs are usually discrete, localized in one lobe of the liver and, unlike AVMs associated with haemangiomas, they do not grow or regress [3]. The usual clinical presentation is that of high-output heart failure occurring in a neonate. Ultrasonographically, AVMs share features with haemangiomas, and magnetic resonance imaging (MRI) is the most useful tool to make the differential diagnosis. The condition is very rare and carries a mortality rate higher than that of haemangioendothelioma [1]. Treatment initially consists of the conservative management of heart failure. In patients who fail to respond to this therapy, embolization and surgical resection are preferred treatments.

Congenital arterioportal malformations (APM)

Congenital intrahepatic arterioportal shunts are a rare cause of portal hypertension. While most are isolated anomalies, they can be associated with hereditary HHT (see below), Ehlers–Danlos syndrome and biliary atresia [4]. Portal hypertension manifests itself within the first year of life with splenomegaly, hypersplenism and/or variceal haemorrhage. Hepatoportal sclerosis and fibrosis of the portal radicles subsequently develop, contributing further to an increased portal pressure. Therefore, these lesions should be treated as soon as they are diagnosed. Doppler ultrasound is the single most useful diagnostic method [3]. Most arterioportal shunts are resolved by embolization of the feeding artery with or without resection, although liver transplantation is a therapeutic option if embolization is unsuccessful.

Congenital portosystemic shunts (PSS)

These are very rare anomalies that occur in the absence of portal hypertension and result from developmental abnormalities of the portal venous system. Two types of congenital PSS have been described: extrahepatic and intrahepatic. Symptomatology, when present, is similar between the two types and is secondary to shunting of blood away from the liver. As galactose and ammonia are absorbed from the gut and extracted and metabolized by the liver, PSS can result in postprandial hypergalactosaemia and hyperammonaemia.

Extrahepatic congenital portosystemic shunt

In extrahepatic congenital PSS (Abernethy shunt), the intestinal and splenic venous drainage bypasses the liver and drains directly into the inferior vena cava (IVC), the left renal vein, the left hepatic vein, the iliac veins or the right atrium. Two types of extrahepatic PSS have been described: in type 1, there is congenital absence of the portal vein with total shunting of blood from the mesenteric and splenic veins into the systemic circulation, while, in type 2, the portal vein (or intrahepatic branches) is patent, but some of its flow is diverted into a systemic vein through an extrahepatic communication (partial shunt) [5]. Misclassification of extrahepatic PSS may occur because of lack of sensitivity of the radiological technique (i.e. intrahepatic

portal venous flow may be present but is beyond the resolution of the imaging technique used, and the patient is misclassified as PSS type 1). Despite this caveat, type 1 is female predominant, and diagnosis is established at a median age of 10 years (range 31 weeks of intrauterine life to 76 years), while type 2 has no gender predominance and its diagnosis is established at a median age of 18 months (range 28 weeks of intrauterine life to 69 years) [6]. Extrahepatic PSS, particularly type 1, is commonly associated with complex congenital heart abnormalities, biliary atresia, and skeletal and renal abnormalities. With the widespread use of ultrasound, extrahepatic PSS have been increasingly discovered in otherwise healthy patients [3]. Interestingly, extrahepatic PSS are frequently (up to 40% of cases) associated with hepatic tumours (including focal nodular hyperplasia, adenoma and hepatocellular carcinoma), and the development of at least some of these (e.g. focal nodular hyperplasia) may be related to an uneven liver vascular perfusion [6,7]. The clinical presentations of PSS vary widely. More often, shunts are detected incidentally in the radiological investigation of cardiac anomalies or liver dysfunction. Occasionally, shunts are detected as the cause of psychiatric disturbance or mental retardation secondary to chronic hyperammonaemia. Patients with symptomatic congenital PSS exhibit abnormalities in neuropsychological tests, magnetic resonance spectroscopy and response to oral glutamine challenge similar to those observed in patients with cirrhosis and minimal hepatic encephalopathy [8]. Overt encephalopathy is present in a minority (about 15%) of congenital PSS cases [6], usually in adults and an age-dependent decrease in the tolerance of the central nervous system to hyperammonaemia has been implicated [9], although more compelling data indicate that the presence of encephalopathy may be more dependent on the degree of shunting [10]. There are several cases of hepatopulmonary syndrome (characterized by hypoxaemia and intrapulmonary vascular dilatation) associated with congenital PSS [11]. Therefore, evidence indicates that portosystemic shunting is the main pathogenic factor in the development of both hepatic encephalopathy and the hepatopulmonary syndrome observed in cirrhotic patients with portal hypertension.

Treatment in symptomatic patients consists of surgical or laparoscopic ligation of the shunt or obliteration by interventional radiology using metallic coils. A key factor affecting the outcome after shunt occlusion is the patency (or lack of patency) of the portal vein and the consequent degree of increase in portal pressure after shunt ligation [6]. Preoperative evaluation of portal pressure and determination of the type of PSS by angiography is crucial. Ligation/occlusion of the PSS is an option when there is portal patency. Orthotopic liver transplantation (OLT) may be the only treatment option when there is an absent portal vein or with intractable encephalopathy [9].

Intrahepatic congenital portosystemic shunt

Congenital intrahepatic PSS are abnormal intrahepatic connections between a branch of the portal vein and the hepatic vein, including patent ductus venosus (PDV). Neonatal skin haemangiomas and liver haemangioma have been associated with intrahepatic PSS. Ductus venosus is a structure that, during fetal life, connects the umbilical vein and the IVC and closes shortly after birth [12]. PDV is the persistence of this embryonic portosystemic shunt, probably as a result of a poorly developed intrahepatic portal system. It is rare and is usually reported in the paediatric literature [13]. In adults, it is usually asymptomatic. As in extrahepatic PSS, encephalopathy is not a prominent clinical feature in intrahepatic PSS, and its development in children has been correlated to the degree of shunting or shunt ratio [14]. Parkinsonism has been described as evidence of encephalopathy in a patient with intrahepatic PSS [15]. Nephrolithiasis can also develop as a consequence of chronic hyperammonaemia. Interestingly, hypoxia resulting from pulmonary vasodilatation (hepatopulmonary syndrome) has also been described in PDV. PDV has been associated with partial nodular transformation of the liver, a rare condition in which nodules composed of hepatocytes replace portions of the parenchyma and whose pathogenesis would appear to be similar to that previously proposed for nodular regenerative hyperplasia, that is atrophy occurs in parenchyma with insufficient blood supply and nodules arise by hyperplasia in areas with adequate supply [16]. Doppler ultrasonography is most useful in the diagnosis of PDV and also in determining the shunt ratio (obtained by dividing the total flow volume in the shunt by that in the portal vein). Of note, spontaneous closure of the shunt may occur within the first 2 years of life, and thus close follow-up is warranted because most of them are asymptomatic. Treatment is restricted to symptomatic patients and should be initially conservative based on protein restriction plus lactulose. In non-responders to conservative treatment, PDV occlusion, either surgical or radiological, is an option, provided the intrahepatic portal system is patent. In cases of severely hypoplastic intra- and extrahepatic portal system, liver transplantation should be considered.

Liver involvement by HHT

HHT, or Rendu–Osler–Weber disease, is a genetic disease with an autosomal dominant inheritance pattern, characterized by widespread cutaneous, mucosal and visceral telangiectases that can involve lung, brain and/or liver. It has an estimated prevalence of 1–2 cases per 10 000. The telangiectasia is the characteristic lesion of HHT, arising from a dilated postcapillary venule that fuses with an arteriole, bypassing the capillary system [17].

Mutations in at least two different genes have been associated with HHT and have led to its subclassification into types 1 and 2. In HHT type 1, the mutation is in the gene encoding for endoglin (*ENG*) and, in HHT type 2, the gene encoding for activin receptor type 2-like kinase (*ALK-1* or *ACVRL1*) is mutated. These genes encode for transmembrane proteins that are components of the receptor complex for transforming growth factor (TGF)-β and are expressed predominantly in vascular

endothelium. Although the genotypical–phenotypical correlations are not yet fully defined, it appears that liver involvement by HHT is mostly associated with mutations in the *ALK1* gene (HHT-2), but rarely with *ENG* mutations [18–20]. A family of patients with a typical HHT phenotype has not been linked to either of these mutations, suggesting the participation of a third gene [21].

Liver involvement by HHT is characterized by diffuse vascular malformations throughout the liver that result in different types of shunting (arteriovenous, arterioportal, portosystemic). Three-dimensional analysis of the liver reveals focal sinusoidal ectasia, arteriovenous shunts through abnormal direct communications between arterioles and ectatic sinusoids and portovenous shunts due to frequent and large communications between portal veins and ectatic sinusoids.[22]. Although difficult to demonstrate angiographically, other histological studies have demonstrated anastomoses between portal vein and hepatic vein [23].

Epidemiology

The prevalence of hepatic involvement has been estimated to be between 8% and 31% in retrospective studies [24,25] but, in more recent large prospective studies in which Doppler ultrasound or multislice computerized tomography (CT) have been performed systematically in HHT families or in HHT-affected subjects, prevalence is 41% [26] and 74% [27] respectively. Patient selection and regional genotypical variation probably account for some of this variability. However, most of these patients are asymptomatic. Symptomatic liver involvement by HHT occurs in about 8% of the patients with HHT who have hepatic imaging abnormalities [26,27].

Clinical features

Unlike other congenital vascular malformations, symptoms appear around the age of 30 years. Symptoms of liver involvement by HHT are very diverse and have been broadly categorized into three distinct clinical patterns that may occur concurrently or successively and that may have spontaneous exacerbations and remissions [28]. The most common is that of high-output cardiac failure with shortness of breath, dyspnoea on exertion, ascites and oedema. It occurs predominantly in middle-aged females. In most of these patients, a hepatic artery to hepatic vein shunt is demonstrated radiologically. The next most common clinical type is portal hypertension, which presents most commonly with ascites, but also with varices and variceal haemorrhage. It occurs equally in males and females at a median age of around 60 years. An arterioportal shunt can be identified radiologically in the majority of patients, although, at least theoretically, portal hypertension could also result from nodular regenerative hyperplasia (see Associated conditions below). Biliary disease is characterized by biliary strictures/dilation and bile cysts presenting with abdominal pain and cholestasis with or without cholangitis (i.e. jaundice and fever). It has been reported only in women of a median age of 45 years. Although no predominant shunt is demonstrated radiologically, the biliary presentation probably results from shunting of blood away from the peribiliary plexus (arteriovenous or arterioportal shunting), leading to biliary ischaemia. In its extreme, biliary ischaemia can lead to bile duct necrosis and liver necrosis, a catastrophic event that has been termed 'hepatic disintegration' [29]. The patient presents with sudden right upper quadrant pain and development of cholangitis, sepsis and/or liver haemorrhage.

Other, less common presentations are hepatic encephalopathy due to portovenous shunting and abdominal angina due to mesenteric arterial 'steal' through pancreaticoduodenal arteries.

Biochemically, the most common abnormalities are elevations in alkaline phosphatase and gamma-glutamyltransferase which, as expected, are mostly observed in the biliary type, although they can also be seen in the other clinical presentations. Notably, liver synthetic function and platelet count are normal (even in the portal hypertension type) because these patients do not have cirrhosis and therefore they do not develop liver insufficiency [28].

Diagnosis

The diagnosis of liver involvement by HHT has to be made in the context of a symptomatic patient with clinical characteristics that suggest the presence of HHT, such as epistaxis, cutaneous or mucosal telangiectases, family history of HHT and a personal or family history of stroke or intracerebral haemorrhage (from pulmonary and cerebral AVMs respectively). Liver involvement is suspected by finding a thrill/bruit in the abdominal right upper quadrant. The definitive diagnosis of liver involvement is radiological, not necessarily by angiography. In expert hands, Doppler ultrasonography is very useful in establishing the diagnosis and in grading its severity [26]. The diameter of the common hepatic artery (> 7 mm) and intrahepatic hypervascularization have a high sensitivity and specificity in diagnosing HHT involvement of the liver [30]. However, multiphase CT is probably the most utilized non-invasive test for diagnosing HHT liver disease and for evaluation of the different shunts. All patients with symptomatic liver involvement have diffuse liver telangiectases that lead to a markedly heterogeneous hepatic enhancement pattern and a markedly dilated hepatic artery (Figs 1 and 2). The type of shunting can be determined in over two-thirds of patients by looking for early or differential enhancement of hepatic or portal veins during various phases of imaging [31] (Figs 3 and 4). Although arterioportal shunting is found significantly more frequently in patients with the portal hypertension type, there is no real correlation between CT findings and the type of symptoms [31]. Notably, biliary abnormalities (Fig. 5) are more prevalent on CTs of symptomatic patients (even in those without biliary symptoms) compared with series from asymptomatic patients, suggesting that the development of biliary abnormalities occurs later in the

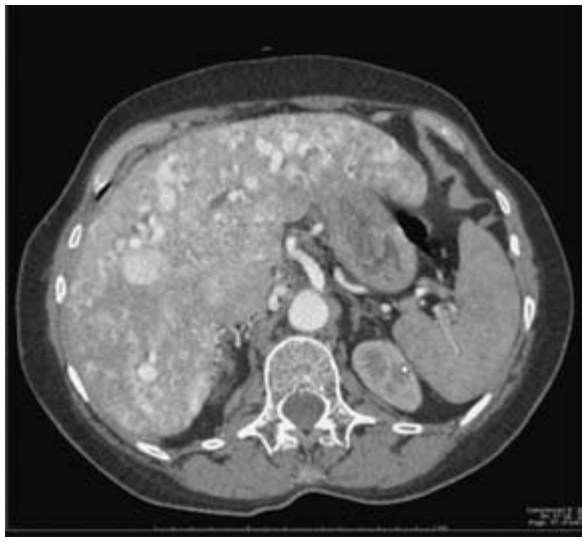

Fig. 1 Axial CT arterial phase image from a patient with hereditary haemorrhagic telangiectasia liver disease showing diffuse parenchymal heterogeneity and numerous intrahepatic telangiectases.

Fig. 3 Axial CT arterial phase image in a patient with hereditary haemorrhagic telangiectasia and high-output heart failure. There is marked dilatation of the common hepatic artery (arrow) and extensive parenchymal heterogeneity and vascularity. There is early filling of the right hepatic vein (arrowhead) consistent with an arteriovenous shunt.

Fig. 2 Axial CT arterial phase image in a patient with symptomatic hereditary haemorrhagic telangiectasia liver disease showing a markedly dilated common hepatic artery measuring 18 mm in diameter (arrow).

Fig. 4 Axial CT arterial phase image in a patient with symptomatic hereditary haemorrhagic telangiectasia liver disease. There is early filling of the right, middle and left hepatic veins (arrows) during the arterial phase of the study, consistent with an arteriovenous shunt.

disease process at a time when the degree of liver ischaemia is greater.

Screening of asymptomatic patients is a controversial issue and should be done in the context of research studies unless the presence of liver involvement is a decisive factor in establishing a diagnosis of 'definite' HHT [32].

The diagnosis of liver involvement by HHT is not histological, and liver biopsy should be avoided in patients with HHT given the high prevalence of vascular malformations that would increase procedure-related bleeding complications [32].

Associated conditions

Livers with HHT may show hepatocellular regenerative activity, either diffuse or partial, leading to nodular regenerative hyperplasia or focal nodular hyperplasia respectively.

Fig. 5 Axial CT images from a female with the biliary subtype of hereditary haemorrhagic telangiectasia liver disease. A left lobe cyst (arrow) can be observed, along with an enlarged hepatic artery.

Blood shunting leads to perfusion abnormalities in liver parenchyma that, in turn, lead to regenerative nodular hyperplasia [23]. The combination of histological hepatic nodules (nodular regenerative hyperplasia) and fibrosis (around abnormal vessels) together with portal hypertension may lead to a misdiagnosis of cirrhosis. However, this is not true cirrhosis (and has been called 'pseudocirrhosis') as it is not associated with liver insufficiency. Cases of true cirrhosis described in HHT may have been the result of multiple blood transfusions and the development of chronic viral hepatitis before the establishment of routine screening of blood donors for hepatitis markers.

It has been reported recently that the prevalence of focal nodular hyperplasia (FNH) in patients with HHT is 100-fold greater than in the general population, given the finding of five cases of FNH in 173 HHT-affected individuals (prevalence of 2.9%), four of whom had liver involvement [33].

Treatment

No treatment is currently recommended for patients with asymptomatic liver involvement by HHT. In patients with symptomatic liver involvement, management depends on the type of clinical presentation. High-output heart failure responds in the majority of cases to intensive medical therapy, including correction of arrhythmias. Of note, pregnant patients who develop high-output cardiac failure due to hepatic involvement of HHT should be treated medically and delivered as expeditiously as possible because of the known spontaneous regression of this condition postpartum.

Complications of portal hypertension (bleeding from gastro-oesophageal varices, ascites) should be treated as recommended in cirrhotic patients [34].

Abdominal pain from biliary ischaemia is treated with analgesics with the addition of systemic antibiotics when associated with cholangitis. This complication is potentially lethal, and patients who develop biliary necrosis have a very poor prognosis. Patients should not be subjected to invasive biliary imaging as this can precipitate cholangitis [28].

Transarterial embolization or ligation of the hepatic artery has been used in the therapy of high-output heart failure, but it is a palliative, temporizing and high-risk procedure that should be used only as a last resort in patients who are not candidates for liver transplantation [32]. In 24 patients who have undergone this procedure, 10 (42%) have experienced significant morbidity or death secondary to hepatobiliary necrosis [28,35]. Transarterial embolization or ligation of the hepatic artery is proscribed in patients with biliary symptoms/signs [32].

OLT has been proposed as the only definitive curative option for liver involvement in HHT. Most published accounts of liver transplantation for HHT are single case reports [36], with the largest series (six patients) being one from the French literature [37]. Liver transplantation in these patients is described as a difficult procedure on account of increased intraoperative bleeding, with a blood loss estimated at a median of 59 units in the French series. Other case reports have also reported a high intraoperative bleeding rate [38,39], and another case of unsuccessful liver transplantation due to fatal intraoperative haemorrhage has been described [28]. Nevertheless, survival in 27 reported cases is around 97% in variable follow-up periods. Therefore, liver transplantation is a reasonably successful option in this setting. Of note, 8 out of 27 liver transplants have been performed because of hepatobiliary necrosis secondary to hepatic artery embolization, strengthening the recommendation that this procedure should be avoided in these patients. Liver transplantation is indicated when the disease is symptomatic and progressive. Experience suggests that the natural history of this condition tends to be favourable in many patients treated medically [28]. Patients with high-output heart failure who are symptomatic despite maximal medical therapy should be transplanted [40]. Given the poor natural history of acute biliary necrosis, emergent liver transplant should be considered in patients with symptoms suggestive of acute hepatobiliary necrosis [32,38,41,42].

References

1 Boon LM, Burrows PE, Paltiel HJ *et al.* (1996) Hepatic vascular anomalies in infancy: a twenty-seven-year experience. *J Pediatr* 129, 346–354.

2 Prokurat A, Kluge P, Chrupek M *et al.* (2002) Hemangioma of the liver in children: proliferating vascular tumor or congenital vascular malformation? *Med Pediatr Oncol* 39, 524–529.

3 Gallego C, Miralles M, Marin C *et al.* (2004) Congenital hepatic shunts. *Radiographics* 24, 755–772.

4 Burrows PE, Dubois J, Kassarjian A (2001) Pediatric hepatic vascular anomalies. *Pediatr Radiol* 31, 533–545.
5 Morgan G, Superina R (1994) Congenital absence of the portal vein: two cases and a proposed classification system for portosystemic vascular anomalies. *J Pediatr Surg* 29, 1239–1241.
6 Murray CP, Yoo SJ, Babyn PS (2003) Congenital extrahepatic portosystemic shunts. *Pediatr Radiol* 33, 614–620.
7 Kim T, Murakami T, Sugihara E *et al.* (2004) Hepatic nodular lesions associated with abnormal development of the portal vein. *Am J Roentgenol* 183, 1333–1338.
8 Nakasaki H, Tanaka Y, Ohta M *et al.* (1989) Congenital absence of the portal vein. *Ann Surg* 210, 190–193.
9 Wojcicki M, Haagsma EB, Gouw AS *et al.* (2004) Orthotopic liver transplantation for portosystemic encephalopathy in an adult with congenital absence of the portal vein. *Liver Transpl* 10, 1203–1207.
10 Akahoshi T, Nishizaki T, Wakasugi K *et al.* (2000) Portal-systemic encephalopathy due to a congenital extrahepatic portosystemic shunt: three cases and literature review. *Hepatogastroenterology* 47, 1113–1116.
11 Cheung KM, Lee CY, Wong CT *et al.* (2005) Congenital absence of portal vein presenting as hepatopulmonary syndrome. *J Paediatr Child Health* 41, 72–75.
12 Rudolph AM (1983) Hepatic and ductus venosus blood flows during fetal life. *Hepatology* 3, 254–258.
13 Yoshimoto Y, Shimizu R, Saeki T *et al.* (2004) Patent ductus venosus in children: a case report and review of the literature. *J Pediatr Surg* 39, E1–E5.
14 Uchino T, Endo F, Ikeda S *et al.* (1996) Three brothers with progressive hepatic dysfunction and severe hepatic steatosis due to a patent ductus venosus. *Gastroenterology* 110, 1964–1968.
15 da Rocha AJ, Braga FT, da Silva CJ *et al.* (2004) Reversal of parkinsonism and portosystemic encephalopathy following embolization of a congenital intrahepatic venous shunt: brain MR imaging and 1H spectroscopic findings. *Am J Neuroradiol* 25, 1247–1250.
16 Wanless IR, Lentz JS, Roberts EA (1985) Partial nodular transformation of liver in an adult with persistent ductus venosus. Review with hypothesis on pathogenesis. *Arch Pathol Lab Med* 109, 427–432.
17 Guttmacher AE, Marchuk DA, White RI (1995) Hereditary hemorrhagic telangiectasia. *N Engl J Med* 333, 918–924.
18 Kuehl HK, Caselitz M, Hasenkamp S *et al.* (2005) Hepatic manifestation is associated with ALK1 in hereditary hemorrhagic telangiectasia: identification of five novel ALK1 and one novel ENG mutations. *Hum Mutat* 25, 320.
19 Argyriou L, Pfitzmann R, Wehner LE *et al.* (2005) ALK-1 mutations in liver transplanted patients with hereditary hemorrhagic telangiectasia. *Liver Transpl* 11, 1132–1135.
20 Letteboer TG, Mager HJ, Snijder RJ *et al.* (2006) Genotype–phenotype relationship in hereditary hemorrhagic telangiectasia. *J Med Genet* 43, 371–377.
21 Wallace GM, Shovlin CL (2000) A hereditary haemorrhagic telangiectasia family with pulmonary involvement is unlinked to the known HHT genes, endoglin and ALK-1. *Thorax* 55, 685–690.
22 Sawabe M, Arai T, Esaki Y *et al.* (2001) Three-dimensional organization of the hepatic microvasculature in hereditary hemorrhagic telangiectasia. *Arch Pathol Lab Med* 125, 1219–1223.
23 Wanless IR, Gryfe A (1986) Nodular transformation of the liver in hereditary hemorrhagic telangiectasia. *Arch Pathol Lab Med* 110, 331–335.
24 Plauchu H, DeChadarevian JP, Bideau A *et al.* (1989) Age-related clinical profile of hereditary hemorrhagic telangiectasia in an epidemiologically recruited population. *Am J Med Genet* 32, 291–297.
25 Reilly PJ, Nostrant TT (1984) Clinical manifestations of hereditary hemorrhagic telangiectasia. *Am J Gastroenterol* 79, 363–367.
26 Buscarini E, Danesino C, Olivieri C *et al.* (2004) Doppler ultrasonographic grading of hepatic vascular malformations in hereditary hemorrhagic telangiectasia – results of extensive screening. *Ultraschall Med* 25, 348–355.
27 Ianora AA, Memeo M, Sabba C *et al.* (2004) Hereditary hemorrhagic telangiectasia: multi-detector row helical CT assessment of hepatic involvement. *Radiology* 230, 250–259.
28 Garcia-Tsao G, Korzenik JR, Young L *et al.* (2000) Liver disease in patients with hereditary hemorrhagic telangiectasia. *N Engl J Med* 343, 931–936.
29 Blewitt RW, Brown CM, Wyatt JI (2003) The pathology of acute hepatic disintegration in hereditary haemorrhagic telangiectasia. *Histopathology* 42, 265–269.
30 Caselitz M, Bahr MJ, Bleck JS *et al.* (2003) Sonographic criteria for the diagnosis of hepatic involvement in hereditary hemorrhagic telangiectasia (HHT). *Hepatology* 37, 1139–1146.
31 Wu JS, Saluja S, Garcia-Tsao G *et al.* (2006) Liver involvement in hereditary hemorrhagic telangiectasia. Can multiphase CT determine the clinical subtype in symptomatic patients? *Am J Roentgenol* 187, W399–405.
32 Buscarini E, Plauchu H, Garcia-Tsao G *et al.* (2006) Liver involvement in hereditary hemorrhagic telangiectasia: consensus recommendations. *Liver Int* 26, 1040–1046.
33 Buscarini E, Danesino C, Plauchu H *et al.* (2004) High prevalence of hepatic focal nodular hyperplasia in subjects with hereditary hemorrhagic telangiectasia. *Ultrasound Med Biol* 30, 1089–1097.
34 Garcia-Tsao G (2001) Current management of the complications of cirrhosis and portal hypertension: varices and variceal hemorrhage, ascites and spontaneous bacterial peritonitis. *Gastroenterology* 120, 726–748.
35 Whiting JH, Jr, Korzenik JR, Miller FJ, Jr *et al.* (2000) Fatal outcome after embolotherapy for hepatic arteriovenous malformations of the liver in two patients with hereditary hemorrhagic telangiectasia. *J Vasc Interv Radiol* 11, 855–858.
36 Buscarini E, Danesino C, Olivieri C *et al.* (2005) Liver involvement in hereditary haemorrhagic telangiectasia or Rendu–Osler–Weber disease. *Dig Liver Dis* 37, 635–645.
37 Azoulay D, Precetti S, Emile JF *et al.* (2002) [Liver transplantation for intrahepatic Rendu–Osler–Weber's disease: the Paul Brousse hospital experience]. *Gastroenterol Clin Biol* 26, 828–834.
38 Boillot O, Bianco F, Viale J-P *et al.* (1999) Liver transplantation resolves the hyperdynamic circulation in hereditary hemorrhagic telangiectasia with hepatic involvement. *Gastroenterology* 116, 187–192.
39 Saxena R, Hytiroglou P, Atillasoy EO *et al.* (1998) Coexistence of hereditary hemorrhagic telangiectasia and fibropolycystic liver disease. *Am J Surg Pathol* 22, 368–372.
40 Thevenot T, Vanlemmens C, Di MV *et al.* (2005) Liver transplantation for cardiac failure in patients with hereditary hemorrhagic telangiectasia. *Liver Transpl* 11, 834–838.
41 Hillert C, Broering DC, Gundlach M *et al.* (2001) Hepatic involvement in hereditary hemorrhagic telangiectasia: an unusual indication for liver transplantation. *Liver Transpl* 7, 266–268.
42 Dominguez IB, Annet L, Waignein F *et al.* (2005) Extensive ischemic liver necrosis complicating hereditary hemorrhagic telangiectasia: a rare indication for liver transplantation. *Liver Int* 25, 677–679.

18 Tumours of the liver

18.1 Benign hepatic tumours

18.1.1 Liver haemangioma

Jean-Pierre Benhamou

Haemangioma is the most common benign tumour of the liver. At necropsy, the prevalence of liver haemangioma is 2–5%. The prevalence is not different in males and females. The size of liver haemangioma is greater in women than in men.

Pathology

The size of liver haemangioma varies from a few mm to 10–15 cm (giant haemangioma). Liver haemangioma may be single or multiple. Haemangioma may be located at the surface of the liver or inside the liver. On macroscopic examination, liver haemangioma has a soft spongy consistency and contains dark blood and occasionally thrombi. On microscopic examination, liver haemangioma are composed of large vascular channels lined by mature, flattened endothelial cells, enclosed in a loose fibroblastic stroma with various amounts of connective tissue.

In the majority of cases, liver haemangiomas are isolated. In a few cases, they are associated with focal nodular hyperplasia of the liver [1], extrahepatic haemangioma or Rendu–Osler–Weber disease [2].

Presentation and diagnosis

In most cases, liver haemangioma is asymptomatic and is recognized fortuitously by ultrasonography performed for symptoms that are either non specific or unrelated to haemangioma. In a few patients, liver haemangioma is recognized because of abdominal pain which is often due to associated irritable colon.

Clinical examination is normal in most cases, except in the few patients in whom a large haemangioma results in a palpable tumour. Liver tests are normal, except in patients in whom haemangioma is associated with an unrelated diffuse liver disease.

Diagnosis of liver haemagioma is based on ultrasonography: liver haemangioma appears as a well-defined hyperechoic area. If the liver is fatty, haemangioma may be as echoic as, or even less echoic, than the rest of the liver parenchyma. On a computed tomography (CT) scan without contrast, liver haemangioma appears as a hypodense area. On a CT scan after intravenous injection of a contrast bolus, there is an irregular, globular enhancement in the periphery of the lesion; this anomaly is very characteristic [3]; after several minutes, the area of enhancement increases towards the center of the lesion [4]. The most sensitive and specific procedure for diagnosing hepatic haemangioma is magnetic resonance imaging (MRI): it appears as a well-defined, very high-intensity area on T2 sequences [5]. In a few patients, haemangioma appears as an hypervascular area and/or is associated with an arterioportal shunt [6,7]. Arteriography is no longer used for the diagnosis of haemangioma. Likewise, scanning with $^{99}Tc^{m}$-labelled human red cells is no longer used for the diagnosis of haemangioma (labelled red cells accumulate within the haemangioma). The diagnosis of haemangioma is reinforced by the absence of changes of the lesion on a second series of imaging procedures (ultrasound or CT scan) six months later.

It is generally admitted that liver biopsy may be dangerous because of the risk of haemoperitoneum. However, liver biopsy has been performed in some patients without being complicated by intraperitoneal bleeding [8,9]. Because liver haemangioma is soft, the tumour is pushed by the liver biopsy needle and therefore, often no fragment of the tumour is collected.

Natural history and treatment

Usually, liver haemangioma does not increase in size with time. However, it has been reported that, during pregnancy or during estrogen therapy, the tumour may grow [10]. In a small number of patients, in the absence of pregnancy and oestrogen therapy, the tumour may increase in size [11,12].

Spontaneous rupture of liver haemangioma is very rare [13]. Large haemangiomas can be complicated by thrombosis, which results in a triad of symptoms consisting of fever, right upper quadrant abdominal pain, and normal white cell count [14,15].

Large haemangiomas can be complicated by thrombocytopenia, consumptive coagulopathy, and microangiopathic anaemia (Kasabach–Merritt syndrome) [16]. In the few cases with arterioportal shunt, heart failure can develop. Large haemangiomas can result in abdominal discomfort.

In most patients, liver haemangioma needs no treatment [17]. Complicated liver haemangioma must be treated by surgical resection [18] or enucleation [19,20]. Spontaneous rupture of liver haemangioma can be treated by transcatheter hepatic arterial embolization, which can be followed by surgical resection [21].

Neither oral contraceptives nor pregnancy are contraindicated in women with uncomplicated liver haemangioma.

Hepatic haemangiomatosis

Hepatic haemangiomatosis, i.e. haemangioma involving the liver entirely and diffusely, is very rare. It can be isolated or associated with extrahepatic haemangioma or with Rendu–Osler–Weber disease. A case has been reported in a patient receiving metoclopramide [22]. Heart failure [23], intraperitoneal bleeding [24] and Kasabach–Merritt syndrome are common.

References

1 Mathieu D, Aziza G, Vilgrain V *et al.* (1989) [Ultrasonographic and x-ray computed tomographic aspects of Mirizzi's syndrome] *Gastroenterol Clin Biol* 13, 905–909.
2 Buscarini E, Buscarini L, Danesino C *et al.* (1997) Hepatic vascular malformations in hereditary hemorrhagic telangiectasia: Doppler sonographic screening in a large family. *J Hepatol* 26, 111–118.
3 Quinn SF, Benjamin GG (1992) Hepatic cavernous hemangiomas: simple diagnostic sign with dynamic bolus CT. *Radiology* 182, 545–548.
4 Itai Y, Araki T, Yoshikawa K *et al.* (1980) Computed tomography of gallbladder carcinoma. *Radiology* 137, 713–780.
5 Itai Y, Ohtomo K, Furui S *et al.* (1985) Noninvasive diagnosis of small cavernous hemangioma of the liver: advantage of MRI. *Am J Roentgenol* 145, 1195–1199.
6 Ando K, Okita K, Fukumoto Y (1984) Curious manifestations in cavernous hemangioma of the liver. *J Clin Gastroenterol* 6, 365–368.
7 Shimada M, Matsumata T, Ikeda Y *et al.* (1994) Multiple hepatic hemangiomas with significant arterioportal venous shunting. *Cancer* 73, 1589–1594.
8 Cronan JJ, Dorfman GS, Grusmark J (1988) Cavernous hemangioma of the liver: role of percutaneous biopsy. *Radiology* 166, 135–138.
9 Tung GA, Cronan JJ (1993) Percutaneous needle biopsy of hepatic cavernous hemangioma. *J Clin Gastroenterol* 16, 117–122.
10 Reading NG, Forbes A, Nunnerley HB, Williams R (1988) Hepatic haemangioma: a critical review of diagnosis and management. *Q J Med* 67, 431–445.
11 Trastek VF, van Heerden JA, Sheedy PF *et al.* (1983) Cavernous hemangiomas of the liver: resect or observe? *Am J Surg* 145, 49–53.
12 Conter RL, Longmire WP (1988) Recurrent hepatic hemangiomas. Possible association with estrogen therapy. *Ann Surg* 207, 115–119.
13 Aiura K, Ohshima R, Matsumoto K, *et al.* (1996) Spontaneous rupture of liver hemangioma: risk factors for rupture. *J Hepatobiliary Pancreatic Surg* 3, 308–312.
14 Bornman PC, Terblanche J, Blumgart RL, *et al.* (1987) Giant hepatic hemangiomas: diagnostic and therapeutic dilemmas. *Surgery* 101, 445–449.
15 Paterson WP, Selucky M, Hynna-Liepert TT (1991) Effect of intraesophageal location and muscarinic blockade on balloon distension-induced chest pain. *Dig Dis Sci* 36, 282–288.
16 Watzke HH, Linkesch W, Hay U (1989) Giant hemangioma of the liver (Kasabach-Merritt syndrome): successful suppression of intravascular coagulation permitting surgical removal. *J Clin Gastroenterol* 11, 347–350.
17 Farges O, Daradkeh S, Bismuth H (1995) Cavernous hemangiomas of the liver: are there any indications for resection? *World J Surg* 19, 19–24.
18 Schwartz SI, Husser WC (1987) Cavernous hemangioma of the liver. A single institution report of 16 resections. *Ann Surg* 205, 456–465.
19 Alper A, Ariogul O, Emre A *et al.* (1988) Treatment of liver hemangiomas by enucleation. *Arch Surg* 123, 660–661.
20 Baer HU, Dennison AR, Mouton W, *et al.* (1992) Enucleation of giant hemangiomas of the liver. Technical and pathologic aspects of a neglected procedure. *Ann Surg* 216, 673–676.
21 Yamamoto T, Kawarada Y, Yano T, *et al.* (1991) Spontaneous rupture of hemangioma of the liver: treatment with transcatheter hepatic arterial embolization. *Am J Gastroenterol* 86, 1645–1649.
22 Fuerle GE (1990) Arteriovenous shunting and cholestasis in hepatic hemangiomatosis associated with metoclopramide. *Gastroenterology* 99, 252–262.
23 Vorse HB, Smith EI, Luckstead EF, Fraser Jr JJ (1983) Hepatic hemangiomatosis of infancy. *Am J Dis Child* 137, 672–673.
24 Painter (1961) Angiomatosis of liver causing fatal haemorrhage. *Br J Surg* 49, 8–10.

18.1.2 Benign hepatocellular tumours

Massimo Colombo and Riccardo Lencioni

Introduction

Benign hepatocellular tumours comprise both regenerative and neoplastic lesions for which a descriptive nomenclature was established by an International Panel of Experts sponsored by the World Congress of Gastroenterology 1994 (Table 1) [1]. This chapter focuses on focal nodular hyperplasia, hepatocellular adenoma and nodular regenerative hyperplasia because these are the most common and clinically relevant benign hepatocellular nodes that gained popularity following the widespread use of imaging techniques, which led to the recognition of an increased number of affected patients.

Focal nodular hyperplasia

Definition

Focal nodular hyperplasia (FNH) of the liver is a rare, completely benign lesion that presents in two broad categories defined by

Table 1 Classification of benign hepatocellular nodular lesions of the liver.

Regenerative lesions	Monoacinar regenerative nodule
	Diffuse nodular hyperplasia without fibrous septa (nodular regenerative hyperplasia)
	Diffuse nodular hyperplasia with fibrous septa or in cirrhosis
	Multiacinar regenerative nodule
	Lobar or segmental hyperplasia
	Focal nodular hyperplasia
Dysplastic or neoplastic lesions	Hepatocellular adenoma
	Dysplastic focus
	Dysplastic nodule

morphological characteristics: the solid type (70% of cases), characterized by a central scar, and the non-classical forms, including the telangiectatic, the mixed hyperplastic/adenomatous and multiple FNH syndrome [1–3].

Epidemiology

FNH is the second most common benign tumour of the liver. The estimated prevalence is 0.4–3% in unselected autopsy series [3,4] and 0.03% in a clinical series [5]. The tumour has a female:male ratio of between 2:1 and 26:1, and the average age at presentation is between the ages of 35 and 50 years. An increased prevalence of FNH has been reported in patients with vascular malformations [6].

Pathogenesis

FNH appears to be the result of a hyperplastic response of liver cells to hypoxia provided by arterial malformation and/or portal venous ischaemia [2]. Typical FNH is composed of reactive polyclonal liver cells, i.e. a common feature of regenerative processes, in contrast to the telangiectatic type of FNH, which displays a monoclonal molecular pattern closer to the neoplastic process of hepatocellular adenomas [7,8]. The role of oral contraceptives in FNH is disputed [9,10]. The telangiectatic type of FNH is increasingly being recognized in women on oral contraceptives.

Pathology

Most FNHs are solitary tumours, located in the right lobe. However, up to 20% of the patients may have two to five nodules and 3% as many as 15–30 nodular lesions from 1 mm to 19 cm (median 3 cm) in size [11]. Microscopically, classical FNH shows nodular hyperplastic parenchyma, and the nodules are completely or incompletely surrounded by fibrous septa. The histopathological hallmark of the solid type of FNH is the central scar containing malformed vessels of various calibre, mostly large and tortuous arteries showing intimal or muscular fibrohyperplasia, and proliferating bile ducts. A mild degree of macrovesicular steatosis is often present. Atypical forms of FNH lack either nodular architecture or malformed vessels.

Clinical features and natural history

FNH is usually an incidental finding, but a few patients may have symptoms as a palpable mass or hepatomegaly. Liver chemistry is usually unaltered (Table 2), and the serum tumour markers alpha-fetoprotein (AFP), Ca19.9 and carcinoembryonic antigen (CEA) are invariably negative. One peculiar type of FNH is the syndrome of multiple FNH, i.e. the presence of FNH, hepatic haemangiomas and disorders of the central nervous system such as meningioma, astrocytoma and arterial malformations. This syndrome has been described in association with the Klippel–Trenaunay–Weber syndrome, a non-hereditary congenital condition characterized by capillary malformations, hemihypertrophy and venous stasis [12].

FNH is a completely benign condition with the potential for changing in size in less than 10% of the patients who were followed for 9 years [10,13]. The risk of bleeding or neoplastic transformation of FNH seems remote [14]. In a series of 53 patients in Hanover, Germany, upper abdominal symptoms developed in 21 (40%) during an observation period of 3 years, and were severe in two cases (4%) [13].

Diagnostic workup

FNH is detected incidentally in 74% of cases [15]. Diagnostic confirmation of FNH relies solely on imaging findings, provided that typical features are shown in the proper clinical setting.

Table 2 Clinical findings leading to a diagnosis of FNH.

Clues to diagnosis of FNH	Weimann *et al.* (1997) [13] ($n = 150$)	Nguyen *et al.* (1999) [11] ($n = 130$)
Incidental	66 (44%)	46 (35%)
Abdominal pain	49 (37%)	75 (58%)
Palpable mass	3 (2%)	5 (4%)
Abnormal LFT	18 (12%)	17 (13%)

LFT, liver function tests.

Computerized tomography (CT) can be used to characterize lesions of medium to large size, but it has limitations in the diagnosis of small lesions. Magnetic resonance imaging (MRI) is the most accurate technique for diagnosing FNH through the use of liver-specific agents [16]. When clinical, biochemical or imaging data are not typical of FNH, histological diagnosis is mandatory [17]. In patients with atypical FNH on imaging, a scoring system is available to categorize lesions into definite FNH, possible FNH and negative for FNH [18].

Ultrasound and contrast ultrasound

FNH usually appears as a round mass that is slightly hypoechoic or slightly hyperechoic compared with liver parenchyma [19]. The central scar is rarely seen at baseline ultrasound, but it is easily visualized by colour or power Doppler ultrasound [20]. On contrast-enhanced ultrasound, FNH shows central vascular supply with centrifugal filling in the early arterial phase, followed by homogeneous enhancement in the late arterial phase [17].

Computerized tomography

FNH is usually isoattenuating or slightly hypoattenuating to surrounding liver at baseline CT scanning. The detection rate of the central scar, which appears as a hypoattenuating structure, is 35% for nodes smaller than 3 cm and 65% for those exceeding 3 cm [21]. FNH shows strong homogeneous enhancement during the arterial phase of the contrast-enhanced CT study, in contrast to the central scar, which is typically hypoattenuating during the arterial phase. In the portal venous and delayed phases, FNH becomes isoattenuating to the hepatic parenchyma. On delayed images, the central scar may become hyperattenuating because of contrast distribution within its fibrous stroma. CT features may enable correct characterization of FNH in 78% of cases [21].

Magnetic resonance imaging

MRI is the most accurate imaging method for the characterization of FNH (Fig. 1). FNH is usually slightly hypointense

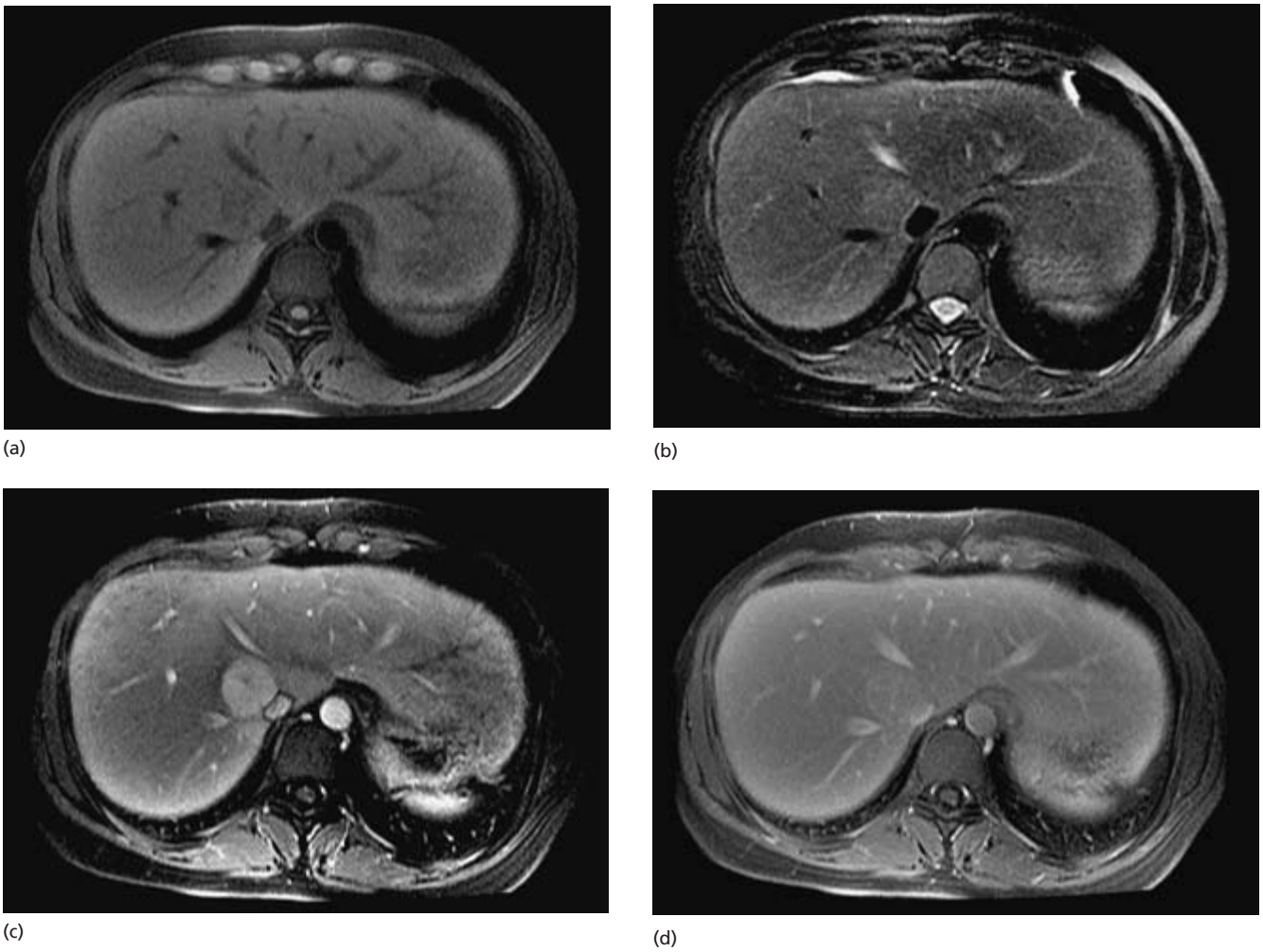

Fig. 1 Focal nodular hyperplasia. MR imaging. (a) On baseline T1-weighted image, the lesion – located in segment VIII – is slightly hypointense to the liver. (b) On baseline T2-weighted image, the lesion is slightly hyperintense to the surrounding parenchyma; hyperintense linear structures radiating from the centre to the periphery correspond to the central scar. (c) In the arterial phase of the gadolinium-enhanced dynamic MR study, a clearcut homogeneous enhancement sparing the central scar is observed. (d) In the delayed phase, the lesion becomes isointense to the liver, while the central scar is slightly hyperintense.

or isointense with respect to normal liver parenchyma on T1-weighted images and slightly hyperintense or isointense on T2-weighted images [22]. Owing to hypervascularization, the central stellate scar is hypointense on T1-weighted images and hyperintense on T2-weighted images. However, the diagnostic accuracy of baseline MRI is only 22% [23]. Following the administration of a gadolinium chelate, FNH shows strong, homogeneous enhancement in the arterial phase sparing the central scar, whereas it becomes isointense to liver parenchyma in the portal venous and delayed phases with a diagnostic accuracy of 95% [24]. The central scar escapes detection with gadolinium in 80% of FNHs smaller than 3 cm. With liver-specific MR contrast agents, the central scar, which does not take up the hepatocyte-targeted agent, becomes well delineated in up to 90% of cases [25]. By MRI with reticuloendothelial system (RES)-targeted agents, the central scar is usually well delineated on post-contrast images as it does not contain Kupffer cells [23].

^{99m}Tc sulphur colloid scintigraphy

On ^{99m}Tc sulphur colloid scintigraphy, up to 80% of FNHs show uptake owing to their Kupffer cell population, but the specificity is only 15%, independently of tumour size [26].

Treatment

Typical asymptomatic FNHs should be managed conservatively in association with oral contraceptive discontinuation, as these drugs could have a trophic effect on FNHs by increasing their size and creating vascular changes [15]. Haemorrhage, clinically important symptoms and uncertain diagnosis are indications for surgical resection. Treatment of FNH should be reserved for patients with a lesion that demonstrates growth on sequential imaging. In a series of 150 patients with FNH in Hanover, Germany, five (3%) underwent hepatic resection because of the onset of symptoms. However, recurrence or persistence of presenting symptoms following resection may exceed 20% [27].

Hepatocellular adenoma

Definition

Hepatocellular adenomas (HA) are rare, frequently capsulated nodular lesions of the liver characterized by proliferating liver cells. Liver adenomatosis refers to the presence of ≥ 10 adenomas in an otherwise normal liver [28].

Epidemiology

HA is a less common tumour than FNH, with an estimated HA:FNH ratio of 1:10 [15]. However, in a consecutive necropsy series, the prevalence of HA was 1% compared with 3% for FNH [4]. The lesions occur predominantly in women of reproductive age and women who used oral contraceptives for more than 9 years [14]. The incidence of HA appears to have increased in males, because the use of anabolic drugs has become widespread in sports [29].

Pathogenesis

Clonality studies showing a non-random pattern of X-chromosome inactivation indicate that HA is a tumoral proliferation [30]. Limited genetic alterations found in patients with HA, such as gain of chromosome 7p, 17q and 20q and deletions from exon 3 to exon 4 of the beta-catenin gene, further support this interpretation. One study described heterogeneous expression of the membrane glycoprotein cadherins as well [31]. Owing to the absence of genetic changes in the p53, axin and adenomatous polyposis colon genes, the pathogenic sequence adenoma–carcinoma is not postulated to operate in HA. Oral contraceptives may have a role in the evolution of HA, probably by causing vascular liver damage and intrahepatic vascular shunts [32].

Pathology

HA are soft, yellow lesions often with a highly vascularized surface and a capsule with focal areas of haemorrhage in the parenchyma. The histological features are sheets of hepatocytes two or more cells thick without cellular atypia (to differentiate them from adenocarcinoma), portal tracts (to differentiate them from liver cell regeneration) and biliary ductules and fibrosis (to differentiate them from FNH). There may be fatty infiltration at the periphery of small areas of liver cell proliferation (adenomatous hyperplasia) seen between large adenomas. Some degree of liver cell dysplasia may be present in adenomas, particularly in those with a pseudofollicular pattern. Foci of malignant transformation have been described that may escape detection in small specimens obtained with a thin-needle liver biopsy [33].

Clinical features and natural history

HA are usually solitary, but up to 30% of the patients may have multiple nodules. A few patients have liver adenomatosis. Compared with FNH, HA may present (50% of cases) with symptoms such as pain or abdominal mass, probably caused by intratumoral haemorrhage (Table 3) [27,33]. The diagnosis of liver adenomatosis is made as a result of such complications of adenomas as intraperitoneal bleeding, intratumoral haemorrhage or necrosis producing acute pain, on account of hepatomegaly with or without symptoms, or as an incidental finding. While the massive form of liver adenomatosis is rare and can be unilobular, most patients have multifocal liver adenomatosis spread in both lobes [35].

Regression of HA has been documented upon cessation of oral contraceptive use [32]. The potential of HA to increase in size in women taking oral contraceptives and to progress to cancer is uncertain. The risk of malignancy seems to be higher in patients with multiple adenomas than in those with solitary

Table 3 Clinical findings leading to a diagnosis of HA.

Clues to diagnosis of HA	Weimann *et al.* (1997) [13] (*n* = 44)	Herman *et al.* (2000) [34] (*n* = 10)	Terkivatan *et al.* (2001) [27] (*n* = 33)
Incidental	12 (27%)	2 (20%)	10 (30%)
Abdominal pain	19 (43%)	8 (80%)	10 (30%)
Elevated GGTP	3 (7%)	4 (40%)	0
Bleeding	6 (13%)	NA	12 (36%)

GGTP, gamma-glutamyltransferase; NA, not available.

lesions, but this is not universally accepted [36]. The well-established clinical concern of HA is bleeding, which involves approximately one-quarter of all patients [27]. HA has been associated with glycogen-storage disease, anabolic drug use and diabetes [35].

Diagnostic workup

Laboratory tests are not helpful during the diagnostic workup. However, negative tests for serum AFP and hepatitis B and C corroborate the exclusion of malignant disease. Percutaneous liver biopsy is of little value because of the possible lack of specific features in a small specimen, while the procedure carries the risk of needle-induced bleeding in hypervascular nodes. In liver adenomatosis, two- or three-fold increases in alkaline phosphatase or γ-glutamyltransferase levels have been described [35]. Diagnosis of liver adenomatosis is better obtained by exploration of the liver by laparoscopy or laparotomy, allowing the operator to obtain biopsy specimens of several different lesions without the risk of haemorrhage [35]. Radiological diagnosis of HA is very difficult, and the only finding that may suggest the diagnosis is the detection of intratumoral haemorrhage.

Ultrasound and contrast ultrasound

HA has variable sonographic appearances, ranging from slightly hypoechoic to isoechoic or hyperechoic. HA with necrotic or haemorrhagic changes appear as a complex mass with a large cystic component. Colour or power Doppler may show arterial vessels running along the border of the lesion in a 'basket' pattern [37]. At contrast-enhanced ultrasound, HA shows intense enhancement during the arterial phase, whereas it becomes isoechoic or slightly hyperechoic during the portal venous and equilibrium phases [38]. None of these features, unfortunately, is specific enough for the diagnosis.

Computerized tomography

At baseline CT, the presence of fat or intralesional haemorrhage suggests the diagnosis of HA. During dynamic contrast-enhanced CT scanning, non-complicated adenomas may enhance rapidly and appear homogeneously hyperdense compared with the surrounding liver. The enhancement is usually transient because of arteriovenous shunting within the lesion. Larger or complicated HAs may be highly heterogeneous because of cell necrosis or intralesional haemorrhage [39].

Magnetic resonance imaging

HA shows variable signal intensity at MRI (Fig. 2). Up to 77% of adenomas are hyperintense on T1-weighted images on account of intralesional fat or glycogen or because of recent haemorrhage, in contrast to low signal intensity areas related to cell necrosis [39]. HAs may appear homogeneously or heterogeneously hyperintense on T2-weighted images. Dynamic MRI shows early enhancement during the arterial phase, whereas it becomes isointense to the liver in the portal venous and delayed phases of imaging, thus mimicking other hypervascular tumours [40]. Tissue-specific MRI agents do not increase the diagnostic accuracy of MRI. HAs show positive enhancement upon administration of mangafodipir trisodium (MnDPDP) [41], whereas contrast uptake may not occur with gadobenate dimeglumine (Gd-BOPTA) [39].

Treatment

For patients on oral contraceptives with an incidentally discovered, less than 4-cm tumour, the best option would be treatment withdrawal and close monitoring with sequential ultrasound examinations of the abdomen. Patients with HA regression may escape or delay surgical treatment or locoregional ablation. In contrast, patients with larger, symptomatic HAs that are unresponsive to contraceptive withdrawal should be considered for surgical treatment. Tumour ablation should also be considered for patients who, for medical reasons, cannot stop oral contraceptives or for those who plan to become pregnant [42]. Treatment of patients with ruptured HA requires stabilization with selective arterial embolization prior to resection [27]. The management of liver adenomatosis is problematic. The unilobular, massive form can be treated with hepatic resection. For patients with multifocal liver adenomatosis, surgery of the largest or of complicated adenomas is an option. Patients with malignant transformation are candidates for liver transplantation.

Nodular regenerative hyperplasia

Definition

Nodular regenerative hyperplasia (NRH) of the liver is an acquired architectural disturbance in which nodules of proliferating hepatocytes develop with mild or no fibrosis. The lesion is commonly seen at the hepatic hilum or around large portal

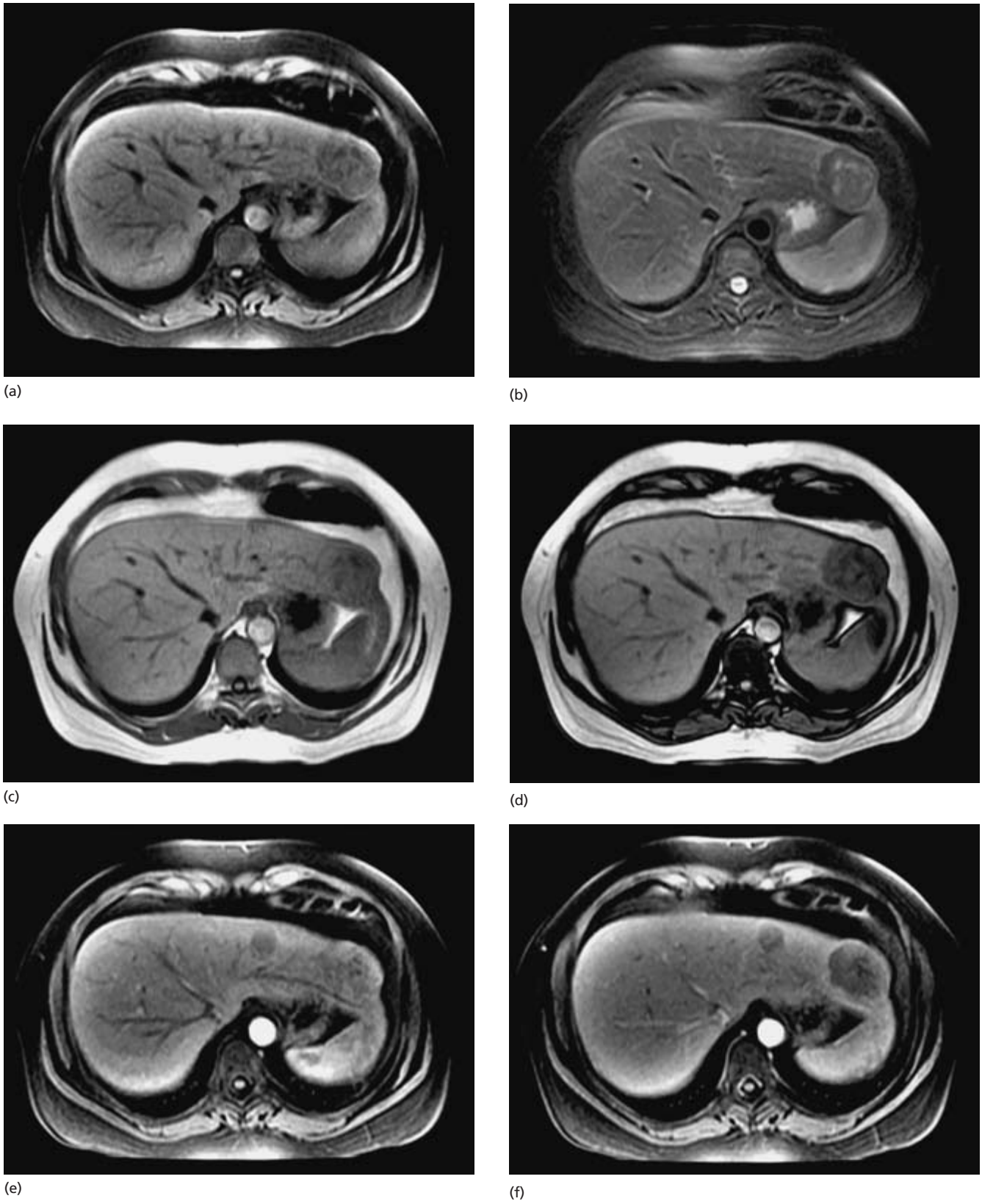

Fig. 2 Hepatocellular adenoma. MR imaging. (a) Baseline T1-weighted image shows large, heterogeneously hypointense mass in the left liver lobe. The lesion contains internal foci of low signal intensity corresponding to necrosis. (b) On baseline T2-weighted image, the lesion is hypointense to the surrounding parenchyma, while necrotic areas are hyperintense. Comparison of in-phase (c) and out-of-phase (d) T1-weighted MR images shows signal intensity decrease, due to fatty infiltration. (e) The lesion shows peripheral inhomogeneous enhancement in the arterial phase of the contrast-enhanced MR study. (f) In the portal venous phase, the lesion is hypointense to the liver. Pulsation artifact from the aorta is detected in contrast-enhanced images, mimicking a second focal lesion.

tracts and may be associated with features of portal hypertension and subclinical cholestasis [43].

Epidemiology

NRH is largely underdiagnosed clinically. Two autopsy series of approximately 3000 patients demonstrated NRH in approximately 2.5% of the patients, with a female:male ratio of approximately 1:1 to 2:1 [44,45]. NRH predominantly affects those older than 60 years and patients with portal hypertension or portal vein thrombosis [44]. However, the disease has also been reported in children as young as 7 months old as well as in young adults. NRH has frequently been reported in patients with autoimmune disease, organ transplants and haematological malignancies and in those undergoing 6-thioguanine therapy in inflammatory bowel disease (IBD) [45,46]. NRH has also been reported as a complication of longstanding coeliac disease in patients with poor dietary compliance [47].

Pathogenesis

The precise pathogenic mechanisms of NRH have not yet been established. NRH may be caused by obliteration or thrombosis of the portal vein system causing ischaemic atrophy in the central zones of the hepatic acinus and subsequent compensatory proliferation of liver cells from periportal areas, which form regenerative nodules [48]. This sequence of events is accounted for by several portal venous abnormalities such as venous thrombi and phlebosclerosis [44,45]. Some NRH cases might result from chronic, cytotoxic CD8+ T lymphocyte targeting of sinusoidal endothelial cells [49]. NRH could also be a generalized proliferative disorder of the liver with the potential to progress to hepatocellular carcinoma, as suggested by the frequent occurrence of liver cell dysplasia in NRH [50].

Pathology

NRH is part of a spectrum of architectural changes known as nodular transformation, i.e. regions of atrophy of liver tissue juxtaposed with normal or hyperplastic areas with a curved contour and no intervening fibrous septa. Diffuse nodular hyperplasia may also be associated with fibrous septa or be superimposed on a previously cirrhotic liver [1]. Macroscopically, the liver is normal in size and shows nodules of 1–10 mm in diameter that are centred on a larger portal tract. The nodes show liver cell plates that are one or two cells thick, whereas the sinusoids are narrow. In the intranodular regions, the cell plates are one cell thick, hepatocytes may be atrophic, and sinusoids are usually dilated.

Clinical features and natural history

NRH is often an incidental finding in patients presenting with features of hepatic disease or lymphoproliferative disorders. In a few patients, the condition may present with endstage liver disease. The typical presentation of symptomatic NRH is bleeding from oesophageal varices due to portal hypertension [44,51]. Hepatomegaly and splenomegaly occur in less than half of patients with NRH. Life-threatening bleeds and deaths are uncommon. In a few patients undergoing liver transplantation, liver failure was the presenting feature [52].

NRH tends to be an indolent condition. The few patients developing clinical decompensation will have a slow progression towards endstage liver disease. In a few patients receiving chemotherapy for associated myeloproliferative disease, NRH was exacerbated whereas in others, haemoperitoneum developed following rupture of a regenerative nodule [53]. Hepatic failure rarely occurs.

Diagnostic workup

Most patients with NRH have no specific signs or symptoms related to their hepatic disease. Liver function tests are normal in most patients. Alkaline phosphatase is elevated to more than 1.5 times the upper limit of normal in one-third of patients [45]. The histopathological diagnosis of NRH requires a large sample size of tissue, as NRH, incomplete cirrhosis and complete cirrhosis may occur in different regions of the same liver [45]. As portal pressure deterioration is a clue to the diagnosis of NRH, the procedure of transjugular liver biopsy allowing for both histopathological diagnosis and hepatic vein pressure measurement is an important diagnostic aid.

Imaging findings

At sonography, multiple isoechoic or hyperechoic nodules are seen, which may become hypoechoic or anechoic following intratumoral haemorrhage [54]. Colour or power Doppler ultrasound shows the presence of intratumoral vessels and sometimes the presence of a central feeding artery [54]. On baseline CT, the lesions are usually isodense to the liver. Subcapsular lesions may distort the surface of the liver. During the dynamic study, both hypervascular lesions and nodules with the same attenuation as the surrounding parenchyma are visible [55]. The lesions are frequently isointense to normal liver on T1- and T2-weighted images. However, some nodules may show high signal intensity on T1-weighted images, probably correlated to copper deposits. Hepatobiliary contrast agents reveal nodules hyperintense to the liver as they contain normal hepatocytes and altered bile ducts. Nodules rich in Kupffer cells take up iron oxide particles, thus showing a signal intensity decrease on T2-weighted images, like the normal parenchyma [56]. Although imaging findings of NRH are non-specific, the diffuse nature of the lesions, portal hypertension and the clinical history may help in diagnosis.

Treatment

NRH is a slowly evolving, asymptomatic condition, generally

requiring no treatment. However, a few patients may develop symptomatic portal hypertension presenting with variceal bleeding, which may be an indication for recurrent endoscopic therapy or portocaval shunt [32]. Three patients presenting with progressive liver failure from NRH underwent orthotopic liver transplantation and, in at least one of these patients, NRH has recurred after transplantation [52].

Conclusions

Benign hepatocellular tumours are indolent processes that are usually identified by imaging assays and rarely require treatment. In most cases, single or multiple imaging methods may accomplish acceptable diagnostic specificity, whereas liver biopsy or surgical resection is required only for lesions failing to fulfil specific diagnostic criteria by radiological imaging. Patients with FNH require follow-up with imaging assays whenever typical imaging of FNH is obtained with demonstration of a central scar by CT scan or MRI. Biopsy or resection is advocated in patients with expanding large masses or those presenting with atypical features. HAs are often advocated for surgical resection or ablation, because of concern regarding bleeding and progression to hepatocellular carcinoma. Biopsy is required to distinguish NRH from cirrhosis, which requires no treatment in the majority of the patients.

References

1 International Working Party (1995) Terminology of nodular hepatocellular lesions. *Hepatology* 22, 983–993.
2 Wanless IR, Mawdsley C, Adams R (1985) On the pathogenesis of focal nodular hyperplasia of the liver. *Hepatology* 5, 1194–1200.
3 Wanless IR, Albrecht S, Bilbao J *et al.* (1989) Multiple focal nodular hyperplasia of the liver associated with vascular malformations of various organs and neoplasia of the brain: a new syndrome. *Mod Pathol* 2, 456–462.
4 Karhunen PJ (1986) Benign hepatic tumours and tumour like conditions in men. *J Clin Pathol* 39, 183–188.
5 Buscarini L, Fornari F, Civardi G *et al.* (1993) Laparoscopy integrates ultrasound and ultrasound guided biopsy for diagnosis of benign liver tumors. *Acta Endosc* 23, 27–36.
6 Buscarini E, Danesino C, Plauchu H *et al.* (2004) High prevalence of hepatic focal nodular hyperplasia in subjects with hereditary hemorrhagic telangiectasia. *Ultrasound Med Biol* 30, 1089–1097.
7 Gaffey MJ, Iezzoni JC, Weiss LM (1996) Clonal analysis of focal nodular hyperplasia of the liver. *Am J Pathol* 4, 1089–1096.
8 Bioulac-Sage P, Rebouissou S, Da Cunha A *et al.* (2005) Clinical, morphologic, and molecular features defining so-called telangiectatic focal nodular hyperplasias of the liver. *Gastroenterology* 128, 1211–1218.
9 Scalori A, Tavani A, Gallus S *et al.* (2002) Oral contraceptives and the risk of focal nodular hyperplasia of the liver: a case–control study. *Am J Obstet Gynecol* 186, 195–197.
10 Mathieu D, Kobeiter H, Maison P *et al.* (2000) Oral contraceptive use and focal nodular hyperplasia of the liver. *Gastroenterology* 118, 560–564.
11 Nguyen BN, Flejou JF, Terris B *et al.* (1999) Focal nodular hyperplasia of the liver: a comprehensive pathologic study of 305 lesions and recognition of new histologic forms. *Am J Surg Pathol* 23, 1441–1454.
12 Haber M, Reuben A, Burrell M *et al.* (1995) Multiple focal nodular hyperplasia of the liver associated with hemihypertrophy and vascular malformations. *Gastroenterology* 108, 1256–1262.
13 Weimann A, Rìnge B, Klempnauer J *et al.* (1997) Benign liver tumors: differential diagnosis and indication for surgery. *World J Surg* 21, 983–990.
14 Sadowski DC, Lee SS, Wanless IR *et al.* (1995) Progressive type of focal nodular hyperplasia characterized by multiple tumors and recurrence. *Hepatology* 61, 210–214.
15 Cherqui D, Rahmouni A, Charlotte F *et al.* (1995) Management of focal nodular hyperplasia and hepatocellular adenoma in young women: a series of 41 patients with clinical, radiological, and pathological correlations. *Hepatology* 22, 1674–1681.
16 Lencioni R, Cioni D, Crocetti L *et al.* (2004) Magnetic resonance imaging of liver tumors. *J Hepatol* 40, 162–171.
17 Kim MJ, Lim HK, Kim SH *et al.* (2004) Evaluation of hepatic focal nodular hyperplasia with contrast-enhanced gray scale harmonic sonography: initial experience. *J Ultrasound Med* 23, 297–305.
18 Fabre A, Audet P, Vilgrain V *et al.* (2002) Histological scoring of liver biopsy in focal nodular hyperplasia with atypical presentation. *Hepatology* 35, 414–420.
19 Bioulac-Sage P, Balabaud C, Wanless IR (2001) Diagnosis of focal nodular hyperplasia not so easy. *Am J Surg Pathol* 25, 1322–1325.
20 Gaiani S, Piscaglia F, Serra C *et al.* (1999) Hemodynamics in focal nodular hyperplasia. *J Hepatol* 31, 576.
21 Brancatelli G, Federle MP, Grazioli L *et al.* (2001) Focal nodular hyperplasia: CT findings with emphasis on multiphasic helical CT in 78 patients. *Radiology* 219, 61–68.
22 Bartolozzi C, Cioni D, Donati F *et al.* (2001) Focal liver lesions: MR imaging–pathologic correlation. *Eur Radiol* 11, 1374–1388.
23 Ba-Ssalamah A, Schima W, Schmook MT *et al.* (2002) Atypical focal nodular hyperplasia of the liver: imaging features of nonspecific and liver-specific MR contrast agents. *Am J Roentgenol* 179, 1447–1456.
24 Grazioli L, Morana G, Federle MP *et al.* (2001) Focal nodular hyperplasia: morphologic and functional information from MR imaging with gadobenate dimeglumine. *Radiology* 221, 731–739.
25 Savellano DH, Kostler H, Baus S *et al.* (2004) Assessment of sequential enhancement patterns of focal nodular hyperplasia and hepatocellular carcinoma on mangafodipir trisodium enhanced MR imaging. *Invest Radiol* 39, 305–312.
26 Broglia L, Bezzi M, Massa R *et al.* (1998) Computerized tomography, magnetic resonance, and nuclear medicine in the non-invasive diagnosis of focal nodular hyperplasia of the liver. *Radiol Med* 96, 218–225.
27 Terkivatan T, de Wilt JH, de Man RA *et al.* (2001) Indications and long-term outcome of treatment for benign hepatic tumors: a critical appraisal. *Arch Surg* 136, 1033–1038.
28 Flejou JF, Barge J, Menu Y *et al.* (1985) Liver adenomatosis. An entity distinct from liver adenoma? *Gastroenterology* 89, 1132–1138.
29 Creagh TM, Rubin A, Evans DJ (1988) Hepatic tumours induced by anabolic steroids in an athlete. *J Clin Pathol* 41, 441–443.
30 Paradis V, Laurent A, Flejou JF *et al.* (1997) Evidence for the polyclonal nature of focal nodular hyperplasia of the liver by the study of X-chromosome inactivation. *Hepatology* 26, 891–895.
31 Kozyraki R, Scoazec JY, Flejou JF *et al.* (1996) Expression of cadherins and alpha-catenin in primary epithelial tumors of the liver. *Gastroenterology* 110, 1137–1149.

32 Trotter JF, Everson GT (2001) Benign focal lesions of the liver. *Clin Liver Dis* 5, 17–42.

33 Kerlin P, Davis GL, McGill DB *et al.* (1983) Hepatic adenoma and focal nodular hyperplasia: clinical, pathologic, and radiologic features. *Gastroenterology* 84, 994–1002.

34 Herman P, Pugliese V, Machado MA *et al.* (2000) Hepatic adenoma and focal nodular hyperplasia: differential diagnosis and treatment. *World J Surg* 24, 372–376.

35 Chiche L, Dao T, Salame E *et al.* (2000) Liver adenomatosis: reappraisal, diagnosis, and surgical management: eight new cases and review of the literature. *Ann Surg* 231, 74–81.

36 Foster JH, Berman MM (1994) The malignant transformation of liver cell adenomas. *Arch Surg* 129, 712–717.

37 Golli M, Van Nhieu JTV, Mathieu D *et al.* (1994) Hepatocellular adenoma: color Doppler US and pathologic correlation. *Radiology* 190, 741–744.

38 Nicolau C, Bru C (2004) Focal liver lesions: evaluation with contrast-enhanced ultrasonography. *Abdom Imaging* 29, 348–359.

39 Grazioli L, Federle MP, Brancatelli G *et al.* (2001) Hepatic adenomas: imaging and pathologic findings. *Radiographic* 21, 877–894.

40 Chung KY, Mayo-Smith WW, Saini S *et al.* (1995) Hepatocellular adenoma: MR imaging features with pathologic correlation. *Am J Roentgenol* 165, 303–308.

41 Coffin CM, Diche T, Mahfouz AE *et al.* (1999) Benign and malignant hepatocellular tumours: evaluation of tumoral enhancement after mangafodipir trisodium injection on MR imaging. *Eur Radiol* 9, 444–449.

42 Charny CK, Jarnagin WR, Schwartz LH *et al.* (2001) Management of 155 patients with benign liver tumours. *Br J Surg* 88, 808–813.

43 Hoso M, Terada T, Nakanuma Y (1996) Partial nodular transformation of liver developing around intrahepatic portal venous emboli of hepatocellular carcinoma. *Histopathology* 29, 580–582.

44 Nakanuma Y (1990) Nodular regenerative hyperplasia of the liver: retrospective survey in autopsy series. *J Clin Gastroenterol* 12, 46–50.

45 Wanless IR (1990) Micronodular transformation (nodular regenerative hyperplasia) of the liver: a report of 64 cases among 2500 autopsies and a new classification of benign hepatocellular nodules. *Hepatology* 11, 787–797.

46 Seiderer J, Zech CJ, Reinisch W *et al.* (2005) A multicenter assessment of liver toxicity by MRI and biopsy in IBD patient on 6-thioguanine. *J Hepatol* 43, 303–309.

47 Austin A, Campbell E, Lane P *et al.* (2004) Nodular regenerative hyperplasia of the liver and coeliac disease: potential role of IgA anticardiolipin antibody. *Gut* 53, 1032–1034.

48 McEntee MF, Wright KN, Wanless I *et al.* (1998) Non cirrhotic portal hypertension and nodular regenerative hyperplasia of the liver in dogs with mucopolysaccharidosis type I. *Hepatology* 28, 385–390.

49 Ziol M, Poirel H, Kountchou GN *et al.* (2004) Intrasinusoidal cytotoxic CD8+ T cells in nodular regenerative hyperplasia of the liver. *Hum Pathol* 35, 1241–1251.

50 Nzeako UC, Goodman ZD, Ishak KG (1996) Hepatocellular carcinoma and nodular regenerative hyperplasia: possible pathogenetic relationship. *Am J Gastroenterol* 91, 879–884.

51 Hillaire S, Bonte E, Denninger MH *et al.* (2002) Idiopathic non-cirrhotic intrahepatic portal hypertension in the West: a re-evaluation in 28 patients. *Gut* 51, 275–280.

52 Loinaz C, Colina F, Musella M *et al.* (1998) Orthotopic liver transplantation in 4 patients with portal hypertension and non-cirrhotic nodular liver. *Hepatogastroenterology* 45, 1787–1794.

53 Al-Mukhaizeem KA, Rosenberg A, Sherker AH (2004) Nodular regenerative hyperplasia of the liver: an under-recognized cause of portal hypertension in haematological disorders. *Am J Hepatol* 75, 225–230.

54 Patriarche C, Pelletier G, Attali P *et al.* (1988) Ultrasonography, angiography, computed tomography and magnetic resonance in nodular regenerative hyperplasia of the liver: report a pseudo-tumoral case. *Radiat Med* 6, 111–114.

55 Brancatelli G, Federle MP, Grazioli L *et al.* (2002) Large regenerative nodules in Budd–Chiari syndrome and other vascular disorders of the liver: CT and MR imaging findings with clinicopathologic correlation. *Am J Roentgenol* 178, 877–883.

56 Reimer P, Balzer T (2003) Ferucarbotran (Resovist): a new clinically approved RES-specific contrast agent for contrast-enhanced MRI of the liver: properties, clinical development, and applications. *Eur Radiol* 13, 1266–1276.

18.2 Malignant tumours

18.2.1 Primary liver cell carcinoma

Jordi Bruix, Alejandro Forner, María Varela, Carmen Ayuso and Josep María Llovet

Introduction

Hepatocellular carcinoma (HCC) was classically considered an infrequent cancer in the western world, mostly limited to sub-Saharan Africa and Asia. In addition, the diagnosis was usually made with the appearance of symptoms, habitually in the context of advanced disease, when treatment was not possible and prognosis very poor. Therefore, diagnosis of HCC in a cirrhotic patient was considered a terminal situation and elicited low interest in the scientific community. However, in the past few decades, the situation has changed dramatically. It is well known that the incidence of HCC has risen in the western world [1–3], and further increase is expected in the next two decades [4]. Nowadays, HCC is the leading cause of death in cirrhotic patients [5]. In addition, when diagnosis is achieved at an early stage, effective therapies that improve long-term survival can be applied [6]. This chapter will review the most relevant aspects regarding the epidemiology, pathogenesis, diagnosis and treatment of this neoplasm.

Epidemiology

Recent estimates indicate that primary liver cancer is now the fifth most common cancer in the world and the third cause of cancer-related mortality [1,2]. Nowadays, more than half a million cases are diagnosed every year on a worldwide basis, but there are significant geographical differences in incidence [7]. Eastern Asia and sub-Saharan Africa account for a majority of the cases, and the annual incidence rates there largely exceed 15 cases/100 000 habitants. Southern European countries show incidence rates between 5 and 15 cases/100 000 habitants, while lower incidence rates (below 5 cases/100 000 habitants) are described in northern Europe and America [3]. In the last decades, slight changes have been detected in some specific areas. In countries where hepatitis B virus (HBV) infection is the main risk factor, such as Taiwan, incidence rates have decreased as a result of the universal implementation of effective vaccination against HBV [8]. Conversely, increasing incidence rates have been reported in Australia, the United Kingdom [9], Canada [10] and the United States [4,11,12], probably reflecting the spread of hepatitis C virus (HCV) infection. In countries where the spread of HCV infection occurred earlier, such as Japan, the incidence may have reached a plateau [13].

Differences between races and ethnicities have also been described. However, it is likely that these race-related differences reflect the different exposure to risk factors and time of acquisition rather than genetic predisposition. Consequently, the difference in HCC incidence according to race may disappear in populations with mixed ethnicity but a homogeneous risk profile.

Males have a higher prevalence of HCC than females. The magnitude of the ratio varies widely between different countries; it exceeds 4:1 in some specific regions of France, Italy and Switzerland, and is lower than 2:1 in South America [2,3]. The male predominance may be due not only to specific genetic and hormonal profiles but also higher prevalence of known risk factors, such as viral infection, alcoholism and smoking.

The age at which HCC appears varies according to gender, geographical area and risk factors associated with cancer development. In most areas, the median age at which the cancer occurs is higher in females than in males [2,3]. In high-incidence areas, where HBV is the main aetiological agent, disease frequency peaks at 40 years, whereas in low-incidence areas, it peaks at about 75 years. [2,3].

The marked worldwide heterogeneity of HCC incidence is related to differences in the distribution of risk factors. HBV is widespread in Asia (with the exception of Japan) and sub-Saharan Africa. Frequently, it is acquired at birth or during childhood and is commonly associated with exposure to aflatoxin, a potent oncogenic agent that contaminates food stored in humid conditions in several Asian countries. It explains the

high incidence ratio and earlier appearance of HCC in these countries. On the other hand, the main risk factors in Japan, Europe and the United States are HCV infection and alcohol intake. The different spread of HCV in these areas explains why the peak incidence of HCC in Japan and southern Europe has been registered earlier there than in the United States [12,13].

Risk factors for HCC

Cirrhosis underlies HCC in almost 80% of affected individuals. Therefore, any agent leading to chronic liver damage and, ultimately, cirrhosis should be considered as a potential risk factor for HCC [14]. HBV, HCV and alcohol are the main causes of HCC because of their high prevalence rates. In addition, less prevalent conditions, such as hereditary haemochromatosis, primary biliary cirrhosis, non-alcoholic steatohepatitis, porphyria cutanea tarda (PCT) and Wilson's disease, have also been associated with HCC development [14].

Hepatitis B virus

Chronic HBV infection is by far the most important risk factor for HCC in humans and is the main cause of HCC in high-incidence areas, including China and Africa [15,16]. Several large cohort studies have shown that the incidence of HCC in HBV carriers is significantly increased [14]. Several factors affect the rate of HCC occurrence among patients with HBV chronic infection. Older age at diagnosis is an independent factor affecting progression to HCC, probably because it reflects a longer duration of cirrhosis [17]. The severity of the liver disease also determines the risk of HCC and appears to vary depending on geographical area. In studies performed in Europe, the overall HCC incidence was approximately 0.02 per 100 person–years in inactive carriers, 0.1 in patients affected with chronic hepatitis B without cirrhosis, and 2.2 in persons with compensated cirrhosis. However, in similar studies conducted in Asia, the overall HCC incidence was 0.2, 1 and 3.2 per 100 person–years respectively; the higher incidence of HCC in Asian patients may be due to earlier acquisition of the infection [14,17–21]. The role of specific genotypes or mutations is not well established [20,22,23]. It has been described how HBV DNA can be integrated into the host cellular genome, inducing genetic damage, and some HBV proteins can disrupt cellular functions and lead to neoplastic transformation [24,25]. The evidence for oncogenic properties of HBV in the absence of liver inflammation supports the importance of occult HBV in hepatitis B surface antigen (HBsAg)-negative patients, especially when no other risk factors have been found [26]. Consequently, the importance of HBV may be even higher than suggested by studies based on serological assessment of HBV infection.

Finally, the significant decrease in HCC incidence after the universal implementation of effective vaccination against HBV [8] is the final proof of the importance of HBV in the pathogenesis of this cancer.

Hepatitis C virus

Immediately after the discovery of this virus and the availability of a serological test, it became evident that chronic HCV infection was a major risk factor for HCC [27]. The prevalence of HCV in HCC cohorts varies according to the penetration of the agent in the population in each geographical area [3]. In a prospective study performed in Taiwan that included 12 000 men, a 20-fold increased risk of HCC in infected individuals was described [28]; similar results were obtained in a meta-analysis of 21 case–control studies [12]. As in HBV infection, the risk is clearly related to the degree of liver damage induced by the virus: The incidence of HCC in patients with chronic hepatitis is below 1%, and the risk increases sharply when cirrhosis is established [29,30]. With established cirrhosis, the annual incidence ranges between 3.7% and 7.1% [14]. The progression from acute infection to cirrhosis may take 20–30 years [31]. Therefore, the different spread of HCV worldwide explains the heterogeneic distribution of HCC in areas where HCV is the major risk factor [12,13].

Several risk co-factors for HCC development among patients with chronic HVC infection are known. Independent factors associated with progression to HCC are older age at diagnosis (> 55 years: two- to fourfold increased risk) and male sex (two- to threefold increased risk) [32]. Comorbid conditions are thought to increase the risk of HCC among patients with HCV-related cirrhosis. In a cohort study, cirrhotic patients (90% anti-HCV positive) with PCT had a twofold higher risk of HCC than patients without PCT [33]. Two meta-analyses clearly showed synergism between chronic HCV infection and overt or occult HBV infection [34,35]. Finally, patients with chronic HCV infection coinfected with human immunodeficiency virus (HIV) present a faster evolution to cirrhosis, and thus may develop HCC earlier than patients who are anti-HIV negative. In fact, liver failure and/or HCC are the major causes of death in these patients [36]. A synergy between HCV infection and alcohol intake has been shown in several case–control studies; the risk of HCC is augmented two- to fourfold among patients drinking more than 60–80 g of alcohol per day [37,38]. Finally, there is no evidence of an association between HCV genotype and the risk of HCC [14].

Alcohol

Alcohol is a known risk factor for HCC. Because testing for HCV infection was not available until the 1990s and a significant proportion of alcoholic cirrhotics are also infected with HCV, the assessment of the risk of HCC in alcoholics was doubtless overestimated in earlier studies [28]. The risk for HCC appears when alcohol intake exceeds 60 g/day and increases linearly with intake greater than 60 g/day [37,39,40]. A fivefold risk increase has been reported with alcohol consumption above 80 g/day for more than 10 years [39]; the risk is further increased upon development of cirrhosis, with a yearly incidence above 2% in

decompensated cirrhosis [40]. As mentioned previously, infection with HBV or HCV exerts a synergistic effect and further increases HCC risk.

Aflatoxin

Aflatoxin is a mycotoxin that contaminates food stored in humid conditions, which commonly occurs in undeveloped countries. It is a powerful and well-known oncogenic agent that induces specific damage in the p53 gene (G→T transversions at codon 249) [41]. A prospective population-based cohort study in Shanghai, detecting aflatoxin urine metabolites as a marker of exposure, linked aflatoxin intake to the development of HCC [42,43]. The areas of heavy aflatoxin contamination overlap with areas of high prevalence of HBV infection, and a synergistic effect is described. Aflatoxin exposure in association with HBV infection induces a 60-fold increase in risk, while aflatoxin alone increases the risk fourfold [42].

Non-alcoholic steatohepatitis (NASH), obesity and diabetes

Several case–control and cohort studies conducted in Europe and the USA have implicated diabetes and obesity as risk factors for HCC, especially when they are associated with chronic HBV/HCV infection or alcohol consumption [44–46]. Obesity and/or diabetes are likely to be important contributors to the increased HCC incidence seen in the USA. Data on the prevalence and incidence of HCC in NASH patients is still limited. Available information suggests that some patients with HCC in the setting of cryptogenic cirrhosis may indeed have suffered NASH [47–49], but the specific importance of NASH as a risk factor for HCC is currently unknown.

Iron and copper deposition

Patients diagnosed with hereditary haemochromatosis have a greatly increased risk of HCC; the 5-year HCC incidence in patients with cirrhosis due to hereditary haemochromatosis is reported to be 21% [50]. Iron deposition is responsible for oxidative damage and probably for cancer development. Wilson's disease is characterized by copper deposition and oxidative damage; however, a low incidence of HCC development has been reported in patients affected with cirrhosis due to Wilson's disease [51].

Autoimmune hepatitis

Development of HCC in autoimmune hepatitis is rare in the absence of chronic HCV or HBV infection. In a study from the USA, only 1 of 88 patients with cirrhosis secondary to autoimmune hepatitis developed HCC, establishing an incidence of 0.1 per 100 person–years.

Primary biliary cirrhosis

The risk of HCC appears almost exclusively in male patients with advanced stages of disease, with a reported incidence of 0.8 to 1.8 per 100 person-years and a cumulative 5-year incidence of 4% [52–54].

Alpha-1-antitrypsin deficiency

This condition is associated with cirrhosis and HCC, but most patients with HCC present evidence of either HCV or HBV infection. Therefore, associated viral infection may play a more important role in the development of HCC than the metabolic disorder itself [55].

Tobacco and coffee

Multiple chemical components of cigarette smoke are known hepatic carcinogens in animals. The role of smoking in promoting HCC development has been difficult to establish because of the frequent association with other risk factors, mainly alcohol consumption. Nevertheless, recent data suggest that smoking increases the risk of HCC [56–58]. On the contrary, a recent prospective study performed in Japan showed that coffee consumption reduces the risk [59], while soya consumption has no preventive capacity [60].

Hormonal compounds

The relationship between oral contraceptives and liver adenoma is well established. Oral contraceptives have also been linked with the development of HCC, but the link is less robust [61]. Several case report studies conducted in Europe and the USA, mostly in non-cirrhotic women, have shown an increased risk of HCC in oral contraceptive users [61]. Androgenic steroid treatments have also been linked with adenoma and HCC development [62], but strong supporting data are not available.

Cirrhosis

As mentioned previously, the development of cirrhosis, regardless of the specific damaging agent, constitutes a major risk factor for the appearance of HCC [14,63]. The risk varies according to aetiology [62,64] and, more importantly, the degree of liver functional impairment. There is a steady increase in incidence from early cirrhosis without portal hypertension to decompensated cirrhosis fitting into Child–Pugh class C [32,65]. A 5% prevalence of HCC has been reported in unscreened compensated cirrhosis, and this percentage increases to 15–20% when patients with variceal bleeding or bacterial peritonitis are taken into consideration [63].

Older age emerges in most studies as a significant predictor, but it is possibly only a surrogate marker of the duration of the disease. Male sex is also a marker of increased risk, and it may

reflect either the simultaneous oncogenic effect of coincidental agents (smoking, alcohol intake) or a higher oncogenicity related to androgens [14].

Another relevant factor in HCC development is the activity of the liver disease. Sustained HBV replication and higher HCV-related inflammation, as reflected by increased alanine aminotransferase levels, have been shown to correlate with a higher HCC incidence [66]. Increased proliferation, illustrated, for instance, by proliferating cell nuclear antigen (PCNA) [67] staining, has been correlated with an increased HCC risk. Several histological findings have been linked to HCC risk. Small-cell and large-cell dysplasias are frequently seen in cirrhotic livers with HCC, but their importance in HCC development is controversial [67–69].

Abnormal alpha-fetoprotein (AFP) concentration has consistently been associated with an increased risk of HCC [70]. One needs to take into account, however, that chronic hepatic inflammation and regeneration may induce transient increases in this tumour marker, a phenomenon that is well described in chronic HBV and HCV infection, even in the absence of cirrhosis.

Pathogenesis

Active inflammation with oxidative damage is a chief cause of genetic damage that may eventually lead to cancer. Active inflammation is present in both viral infection and the metabolic derangement that occurs in metal accumulation, alcohol consumption or NASH. The exact molecular events responsible for the development and progression of HCC are still not well known [71,72].

Malignant hepatocytes are the result of cumulative genetic mutations occurring in mature hepatocytes or stem cells. The step-by-step process is initiated through the generation of foci of dysplastic hepatocytes without an overtly malignant phenotype. While low-grade dysplastic nodules harbour a low malignant potential, the likelihood of evolving to HCC is significant in high-grade dysplastic foci. In fact, after a follow-up of 5 years, 30% of these nodules turn into HCC [73,74]. Dysplastic nodules and very early HCC maintain their hepatocytic differentiation and do not show an extensive network of newly formed vessels [75]. At this stage, the nodules usually measure less than 2 cm in diameter. However, they slowly increase in size and simultaneously undergo active neoangiogenesis, resulting in an enhanced blood supply derived from the hepatic artery [76,77]. At this point, the tumour has achieved an unequivocally malignant profile, its degree of differentiation is lost progressively, and the tumour develops the capacity to invade and disseminate that characterizes all neoplasms [76,77].

Active research is attempting to describe the specific genetic mutations that determine cancer progression. The most frequently affected chromosomes are 1, 4, 8, 16 and 17, but none of them is abnormal in more than 60% of cases [71]. Loss of heterozygosity at 1p (1p36–p34) and in M6F/IGF2R is frequently described in the early stages, together with telomere shortening [78]. Altered expression of genes such as SP70, glypican-3 or survivin has been proposed as an early marker of HCC. A specific mutation in p53 (G→T transversions at codon 249) is commonly seen in HCC secondary to aflatoxin exposure [41].

The molecular pathway leading to HCC development may differ according to the underlying risk factor. HBV-related HCC shows more intense genetic instability, with multiple chromosome alterations [79]. On the other hand, non-HBV-related HCC is less unstable genetically and more frequently presents mutations of the beta-catenin gene, leading to abnormal activation of the Wnt signalling pathway [80]. This typically results in the development of large, non-disseminated tumours, which have a better prognosis. Array studies have allowed the study of subsets of tumours grouped according to aetiology and/or stage, leading to the identification of a large number of genes linked to cell proliferation, inflammation, collagen deposition, angiogenesis and apoptosis [81–83]. Some studies have established a relationship between the expression of some genes and tumour progression (skp2, p16, p27, SOCS-1, PEG10) or dissemination and metastases [nm23-H1, osteopontin, ARHC (RhoC), KA-1, MMP14]. However, the biological meaning of these findings is not well established, and these data need to undergo extensive validation prior to becoming a reliable prognostic tool in clinical practice.

Pathology

The pathological characteristics of HCC are modified during its transition from early to advanced stage [76,77]. Malignant cells resemble normal hepatocytes in the initial stages but, in advanced stages, the differentiation of the cells is progressively lost. Conventionally, the differentiation degree is established following the Edmonson and Steiner criteria [84], which define grades I to IV according to the degree of nuclear irregularity, hyperchromatism and nuclear/cytoplasmic ratio. While grade I defines a well-differentiated cell undistinguishable from a benign hepatocyte according to its cell pattern, highly abnormal cells characterize grade IV. As early small HCC are usually well differentiated, the establishment of a definitive diagnosis through the analysis of biopsy material requires extensive expertise (Fig. 1).

Malignant cells usually have well-defined cell membranes and show a finely granular eosinophilic cytoplasm. Cells may accumulate bile and, at early stages, it is frequently possible to recognize fat deposition [85]. Mallory bodies and alpha-1-antitrypsin globules have been described in a minority of cases. Immunostaining can identify the presence of cytokeratins 7, 8, 18 and 19, carcinoembryonic antigen, AFP and several tumour markers, but most of them are not specific and do not allow a confident diagnosis of HCC [76,77].

Malignant hepatocytes usually grow in a trabecular pattern, in which cells accumulate in thin (microtrabecular) or thick (macrotrabecular) layers separated by sinusoids that may still

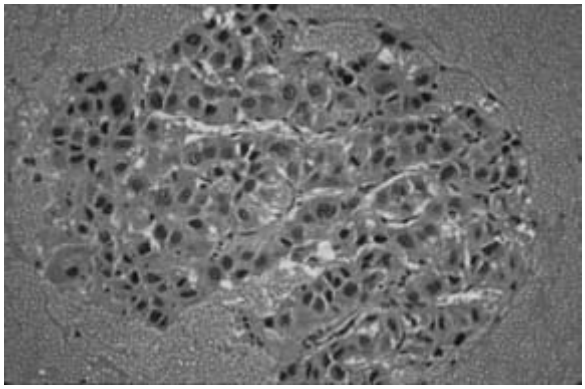

Fig. 1 Cellular sample obtained by fine needle biopsy. Microscopic examination shows a nest of malignant cells corresponding to a well-differentiated hepatocellular carcinoma.

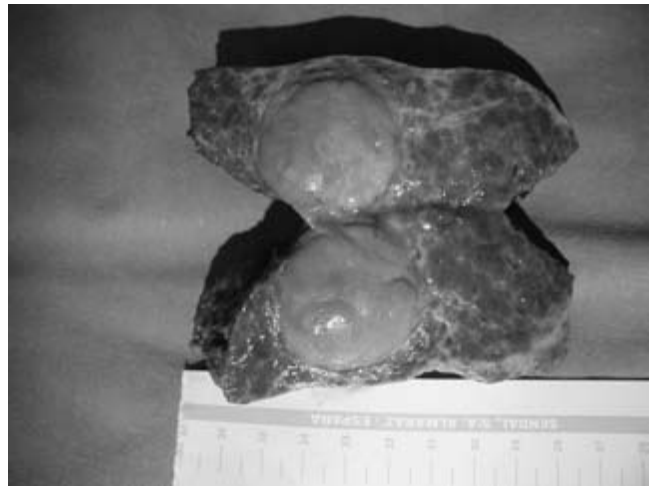

Fig. 2 Pathology examination of a resected tumour. The hepatocellular carcinoma corresponds to the so-called indistinctly nodular type. Margins are ill defined, there is no capsule formation, and detailed slicing did not identify microscopic vascular invasion.

Fig. 3 Segmentectomy for a small encapsulated hepatocellular carcinoma in a cirrhotic liver. The tumour measures less than 3 cm in size, is well defined, and no satellites or vascular invasion are seen macroscopically.

contain Kupffer and stellate cells. However, they may also exhibit a pseudoglandular or acinar pattern. Reticulin fibres are scarce, and the blood vessels are arranged in a capillary pattern. Less than 5% of HCC exhibit a mixed pattern that combines characteristics of both cholangiocarcinoma and hepatocarcinoma, probably reflecting the common embryonic origin of biliary cells and hepatocytes.

Traditionally, tumours can be described according to their gross macroscopic appearance as expansive, infiltrative or diffuse. The expansive type compresses the surrounding liver and frequently exhibits a reticulin pseudocapsule that partially or completely surrounds the tumour [76,77]. The infiltrative type has no distinct margins and invades the surrounding liver without the formation of a pseudocapsule. Finally, the diffuse type emerges as a multinodular entity that resembles cirrhotic nodules.

The most common appearance is a distinct nodule of varying size (Fig. 2) that progressively increases in size, loses its differentiation and is associated with the development of satellite foci in the surrounding area of the main tumour and invasion of the segmental portal pedicle. Thereafter, the tumour spreads, and several HCC nodules are detected in the liver. The incidence of portal vein invasion increases in parallel with the size of the tumour and the loss of differentiation [76], especially when all or most of the liver parenchyma is replaced by the tumour. Extrahepatic dissemination is frequent at late stages, commonly detected by lymph node involvement in the hepatic hilum and metastases to the adrenal glands, lungs and bones.

Vascular invasion is one of the most characteristic findings of this neoplasm. It is a sign of an advanced malignant phenotype and haematogenous spread, which may lead to recurrence after initially effective treatment and carries a dismal prognosis. The incidence of microscopic vascular invasion increases with tumour size, appearing in 20% of HCC < 2 cm in diameter, 30–60% of HCC between 2 and 5 cm, and 60–90% of larger nodules.

Small HCCs ≤ 2 cm are classified by Japanese pathologists into two major subtypes according to the growth pattern: distinctly nodular type and indistinctly (vaguely) nodular [86]. The distinct type has well-defined borders and is frequently encapsulated. Histologically, it is moderately differentiated, has arterial vascularization and, upon careful analysis, reveals satellites in 10% of cases and vascular invasion in up to 25%. The indistinct type has ill-defined margins (Fig. 3). Histologically, it is a well-differentiated tumour that maintains portal tracts, and vascular invasion and/or intrahepatic metastases are rarely seen. The distinct nodular type represents a more advanced tumour despite its small size. On the contrary, the indistinct type corresponds to the carcinoma *in situ* entity [87,88], and it is known by Japanese authors as early HCC. Many of the early HCCs diagnosed in Japan tend to be interpreted as high-grade dysplastic nodules (HGDN) in western countries.

Fibrolamellar carcinoma is a particular variant of HCC that has a distinctive pattern. In contrast to standard HCC, it usually appears in a normal liver and is more frequent in young women. It has not been linked to contraceptive usage or viral infection. It usually appears as a large, non-encapsulated mass with a firm consistency. It commonly has large areas of fibrous septae, and the tumour cells may form thick trabeculae. Malignant hepatocytes are large and polyhedral or round in shape. The cytoplasm is eosinophilic and shows marked granularity because of an increased number of mitochondria [77]. A slower growth rate and less capacity for dissemination have been reported, conferring a better prognosis than common HCC at early stages.

Clinical manifestations

As the majority of HCCs are associated with cirrhosis, most of the clinical findings will be indistinguishable from those observed in patients with cirrhosis without HCC. A variable proportion of cases will present with jaundice, ascites, encephalopathy or bleeding due to ruptured oesophageal varices. Cancer-related symptoms, such as abdominal pain or constitutional syndrome (weight loss, anorexia and malaise), are a reflection of advanced tumour stage, and are usually associated with a grim prognosis. A minor proportion of patients will be diagnosed as a result of either acute haemoperitoneum, which is the result of tumour rupture, or bone metastases.

The proportion of symptomatic patients depends on the population studied. Cohorts of cirrhotics entered into surveillance will reveal patients with early disease without cancer-related symptoms, and the main findings will be associated with the underlying cirrhosis [89]. In contrast, HCC patients who have no underlying liver disease will more frequently present with cancer symptoms, thus triggering the medical evaluation with eventual diagnosis. This is common among young patients with previously normal livers, in whom the diagnosis is made at advanced stages because of the presence of symptoms or, in some areas such as South Africa, where the growth of the tumour is faster and, despite regular screening, the diagnosis is made at advanced stage with cancer-related symptoms, great tumour burden and a dismal prognosis.

Biochemistry is also related to the underlying liver disease. Large tumours may induce increased alkaline phosphatase and γ-glutamyltransferase levels. Hypoglycaemia or hypercholesterolaemia have been reported in a minority of patients. The latter affects up to 30% of black Africans with HCC and is the result of excessive cholesterol production by tumour cells lacking the normal regulatory mechanisms.

Several paraneoplastic syndromes have been described in patients with HCC. The most common are diarrhoea and severe hypoglycaemia. Diarrhoea is secondary to the release of vasoactive substances by the tumour and is usually intermittent. However, in some cases, it can be intense and becomes the major symptom leading to diagnosis. Other manifestations include polymyositis, hypercalcaemia, thrombophlebitis, sexual changes and skin rashes.

Diagnosis and staging

Classically, most HCCs were diagnosed at an advanced stage, when cancer-related symptoms were already present and a large mass could easily be detected by physical examination. Diagnosis was confirmed by either an increased AFP level or pathological analysis of a mass biopsy obtained without image guidance. Nowadays, the development of ultrasonography (US), computerized tomography (CT) and magnetic resonance imaging (MRI) has allowed the diagnosis of HCC at an early subclinical stage during the routine evaluation of patients at risk for HCC. When HCC is diagnosed at an advanced stage in symptomatic patients, the prognosis is dismal. On the contrary, the diagnosis of HCC at an early stage allows for the application of potentially curative treatments. This is the reason why the practice of screening for HCC was established in high-risk patients. Despite worldwide acceptance of surveillance for HCC, until recently, there was no concrete evidence of its benefit [63]. At the present time, there is a single randomized controlled trial (RCT) of surveillance vs. no surveillance that has shown a survival benefit of biannual surveillance with AFP measurements and ultrasound [90]. This study was performed in China and recruited 18 816 patients with antecedent HBV infection. Even with poor compliance (adherence less than 60%), the HCC-related mortality was reduced by 37% in the surveillance arm.

The aim of screening is to diminish tumour-related mortality through the detection of HCC at an early stage when the application of effective treatment is still possible [63,89]. According to this endpoint, it is recommended that screening be limited to Child–Pugh A and B patients (Table 1) [91]. Child–Pugh C patients should be evaluated for liver transplantation because of liver insufficiency, and early diagnosis of HCC has no impact on survival.

It is still not known which screening interval and diagnostic tools are the most appropriate, on account of the heterogeneous behaviour of this tumour. In its last recommendations, the American Association for the Study of Liver Diseases (AASLD) proposed screening with abdominal ultrasound every 6 months [91].

When a nodule is detected on abdominal ultrasound during screening, recall procedures may be instituted. The specific manner in which they are employed, however, depends directly on the nodule size [63]. When a nodule is less than 1 cm, the likelihood of it being HCC is very low [76], especially if it does not show contrast uptake on dynamic imaging studies [92]. However, minute hepatic nodules detected by US may become malignant over time [93]. Thus, these nodules need to be followed every 3 months for 1–2 years in order to detect malignant transformation.

Lesions 1–2 cm in diameter in a cirrhotic liver have a high probability of being HCC. The AASLD has suggested that, in

Table 1 Patients in whom surveillance is recommended. Reproduced with permission from ref. 95.

Hepatitis B carriers
Asian males ≥ 40 years
Asian females ≥ 50 years
All cirrhotic hepatitis B carriers
Family history of HCC
Africans over age 20 years
For non-cirrhotic hepatitis B carriers not listed above, the risk of HCC varies depending on the severity of the underlying liver disease and current and past hepatic inflammatory activity. Patients with high HBV DNA concentrations and those with ongoing hepatic inflammatory activity remain at risk of HCC
Non-hepatitis B cirrhosis
Hepatitis C
Alcoholic cirrhosis
Genetic haemochromatosis
Primary biliary cirrhosis
Although the following groups have an increased risk of HCC, no recommendations for or against surveillance can be made because a lack of data precludes an assessment of whether surveillance would be beneficial
Alpha-1-antitrypsin deficiency
Non-alcoholic steatohepatitis
Autoimmune hepatitis

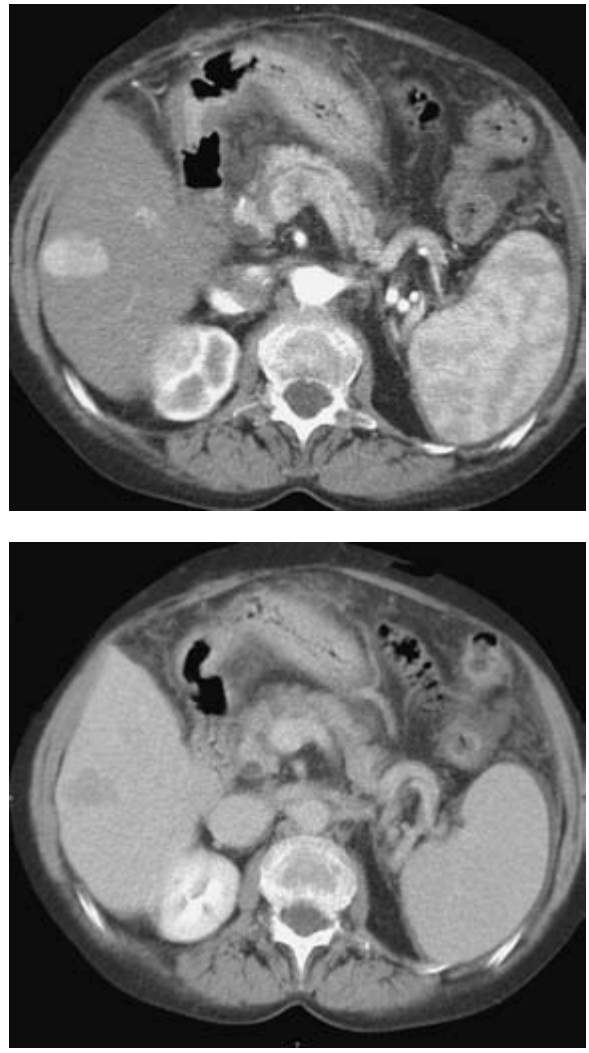

Fig. 4 Hepatic CT scan of a patient in whom ultrasound detected a nodule located in the right lobe. Dynamic CT scan shows that the tumour presents a marked contrast uptake in the arterial phase (a) and that the contrast is washed out in the delayed venous phase (b). These findings are highly specific for hepatocellular carcinoma if observed in a nodule in a cirrhotic liver, and no biopsy is requested to confirm the malignant nature of the mass. If the vascular pattern is not highly specific, a biopsy should be obtained to establish the diagnosis as both cholangiocarcinoma and metastases may appear as slightly hypervascular tumours.

nodules 1–2 cm in diameter, when the specific vascular pattern of HCC (arterial uptake of a contrast agent followed by washout in the delayed venous phase) is detected coincidentally in two dynamic imaging techniques, HCC diagnosis can be made confidently without histological confirmation [91]. When the vascular pattern is typical in only one technique or atypical in both of them, a biopsy is recommended. However, biopsy of nodules less than 2 cm is not always feasible. First, needle placement may be difficult, and one cannot be sure that the sample has come from the lesion. Also, it may be difficult to distinguish between dysplasia and well-differentiated HCC [75], and a negative biopsy report does not confidently exclude malignancy. Nevertheless, recognition of dysplasia within the nodules and arterial hypervascularization on dynamic imaging have been shown to be powerful predictors of malignant transformation during follow-up [73,74,93–95]. Therefore, if these lesions have a non-specific vascular profile and a negative biopsy, enhanced follow-up is advised.

Finally, in nodules > 2 cm in cirrhotic patients, if the lesion shows arterial hypervascularization and washout in the delayed venous phase, only a single imaging technique is necessary for diagnosis [91]. If the vascular pattern on dynamic imaging is not characteristic (Fig. 4) a biopsy is recommended. The diagnostic algorithm recommended by AASLD is summarized in Figure 5 [91].

The strategy upon the detection of an increased concentration of AFP is less conclusive. A minor increase in AFP may occur in patients with chronic liver disease as a result of inflammation flares [96]. However, a persistently elevated AFP on follow-up has been shown to be a strong indicator of an increased risk of HCC development [97]. Enhanced follow-up has been suggested in such cases. AFP determination should not be recommended as a tool for screening or early diagnosis because of its low sensitivity and specificity [70,91]. The use of other tumour markers such as des-gamma-carboxy-prothrombin [98], lectin-bound AFP [99] or glypican [100] has been proposed to improve the efficacy of AFP, but their use has still not demonstrated a benefit in the early diagnosis of HCC.

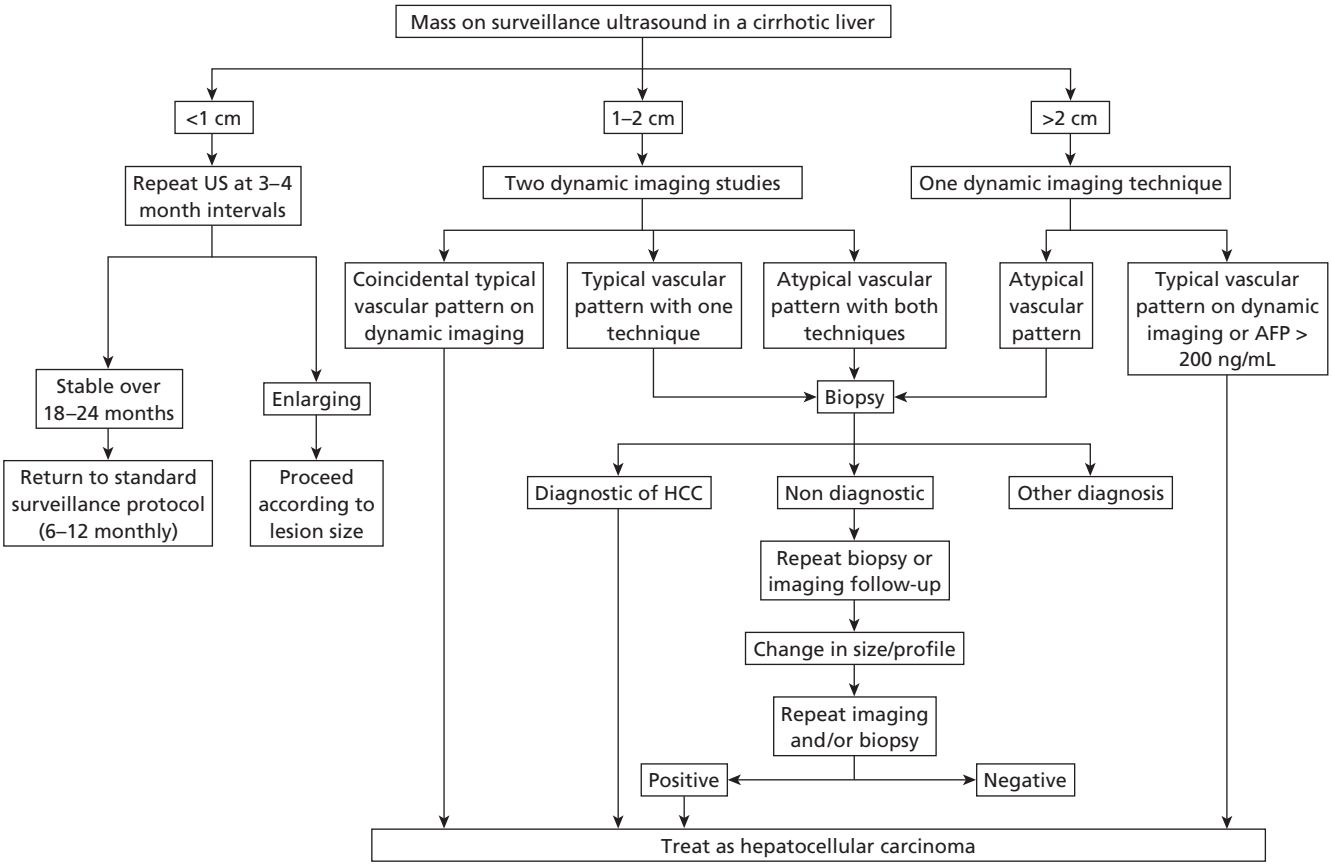

Fig. 5 Diagnostic algorithm suggested by AASLD practice guideline. Reproduced with permission from ref. 91. PEI/RFA, percutaneous ethanol injection/radiofrequency ablation.

After HCC detection and diagnosis, tumour stage and extension need to be evaluated. This should be done with state-of-the-art CT or MRI. CT and MRI are both equally effective in the detection of tumours > 2 cm, but MRI angiography is more effective for nodules < 2 cm. However, the characterization of minute nodules < 1 cm with MRI remains problematic [94]. Angiography has a minor role in diagnosis and staging, and lipiodol CT lacks adequate usefulness and its use is discouraged. Finally, extrahepatic spread should also be evaluated. Although lung metastases are exceptional in the early stages, a chest CT is recommended when radical treatments are being considered. Bone metastases are usually symptomatic and should be ruled out by bone scintigraphy.

Prognostic prediction

Prognostic prediction is necessary to determine the correct treatment and to give adequate information to patients and their relatives about the disease. In most neoplasms, the prognosis parallels tumour burden at the time of diagnosis. Owing to the fact that there is underlying cirrhosis in a majority of patients with HCC, the prognosis depends not only on tumour burden but also on the degree of liver functional impairment [6]. In addition, the choice of treatment not only affects the patient's outcome but also depends on liver functional status, as certain treatment choices may induce hepatic dysfunction.

Any proposal intending to stratify patients into different prognostic groups or to link treatment with staging should consider this complex interaction. Systems that only contemplate one element will be incapable of correctly predicting the outcome. This is the case with the TNM classification [101], which is widely used in most neoplasms and only takes into account tumour burden while ignoring liver function, or the Child–Pugh [102] or Model for Endstage Liver Disease (MELD) systems [103], which disregard tumour burden. These unidimensional systems are useful only in recognizing patients with very advanced disease and already reduced life expectancy.

The classification proposed by Okuda *et al.* [104] was widely used for many years but has been replaced more recently by other proposals. In the past few years, several multidimensional systems have been developed in the USA [105], Spain [106, 107], France [108], Germany [109], Austria [110], Hong Kong [111], Italy [112–114] and Japan [112,115,116] (Table 2). They stratify patients into separate groups and take into account a

Table 2 Strategies and systems to predict prognosis in patients with HCC.

Prognostic variables				
Author name	**Staging system**	**Liver function**	**Tumour stage**	**Health status**
AJCC [101]	TNM	No	TNM	No
Okuda *et al.* [104]	Okuda	Ascites, albumin and bilirubin	Tumour greater or less than 50% of cross-sectional area of liver	No
Llovet *et al.* [106]	BCLC	Child–Pugh	Tumour size, number of nodules and portal vein thrombosis	PS score
Chevret *et al.* [108]	GRETCH	Bilirubin, alkaline phosphatase	Portal vein thrombosis	Karnofsky index
Leung *et al.* [111]	CUPI index	Bilirubin, alkaline phosphatase and ascites	TNM	Symptoms
Omagari *et al.* [112]	SLiDe	Liver damage by LCSGJ, PIVKA	TNM	No
Villa *et al.* [113]	ER classification	Bilirubin	Estrogen receptor status	No
CLIP [114]	CLIP	Child–Pugh	Number of nodules, tumour greater or less than 50% area of liver and portal vein thrombosis	No
Kudo *et al.* [115]	JIS	Child–Pugh	TNM	No
Tateishi *et al.* [116]	Tokyo score	Albumin, bilirubin	Number of nodules, size of nodules	No

LCSGJ, Liver Cancer Study Group of Japan; PIVKA, proteins induced by vitamin K antagonism; PS, performance status; TNM, tumour node metastases.

combination of liver functional variables and tumour parameters. Of all of them, only the Barcelona Clinic Liver Cancer (BCLC) [117–119] and the Italian [120,121] systems have been externally validated. The BCLC system is the only one that links staging with treatment indication. It includes variables such as liver function, tumour burden and performance status and stratifies patients into five stages. Stage 0 describes tumours ≤ 2 cm that do not show vascular invasion or satellites, corresponding to the so-called very early HCC or carcinoma *in situ*. Stage A is composed of tumours diagnosed at an early stage when curative treatment (percutaneus ablation, liver transplantation or resection) is still possible. Patients have solitary tumours of < 5 cm or ≤ 3 nodules of < 3 cm and preserved liver function. As mentioned previously, these patients are eligible for curative treatments and may experience 5-year survival rates between 50% and 75%. Patients with tumours beyond stage A, namely large or multinodular tumours, who experience preserved liver function and the absence of cancer-related symptoms, belong to stage B (intermediate stage). These patients are candidates for transarterial chemoembolization (TACE) and can achieve 3-year survival rates of around 50%. Patients with cancer-related symptoms or vascular invasion or extrahepatic spread fit into stage C (advanced stage). For these patients, no treatment has shown survival benefit, and they are candidates for RCTs to test new therapies. Their survival at 3 years is < 10%. Finally, patients with severe cancer-related symptoms (performance status ≥ 3), severe liver dysfunction (Child–Pugh C) or tumour burden corresponding to class 3 of the Okuda staging system correspond to stage D (terminal stage). Their median survival is < 6 months and symptomatic treatment is recommended.

As expressed previously, the current prognostic estimation is derived from the assessment of tumour burden, liver function and cancer-related symptoms. In the near future, improvements in translational research will allow prognostic predictions to be based on the identification of genomic and proteomic markers associated with the activation of the mechanisms that induce cancer progression and dissemination.

Treatment

Several therapeutic options can be considered in patients with HCC, but only a few of them may result in long-term cure of the disease. These include surgical resection, percutaneous ablation and liver transplantation [6]. However, the feasibility of these treatments is restricted to patients diagnosed at an early stage, which is currently < 40% of the patients evaluated in referral units. Most patients are diagnosed at a more advanced stage, and the only treatment that has been shown to affect their survival is transarterial chemoembolization [122]. Moreover, its applicability is restricted to < 20% of these advanced cases. Consequently, approximately half of the patients are ineligible to receive effective therapy and, thus, might be considered to receive supportive care or participate in research investigations to evaluate new therapeutic strategies. Treatment indication requires a careful assessment of the tumour stage, liver function and general health. The staging and treatment algorithm followed by the BCLC group is shown in Figure 6 [6,106].

The tumour burden can be accurately evaluated by a combination of US and CT or MRI and should define the size of the tumour, the presence of satellites and the existence of

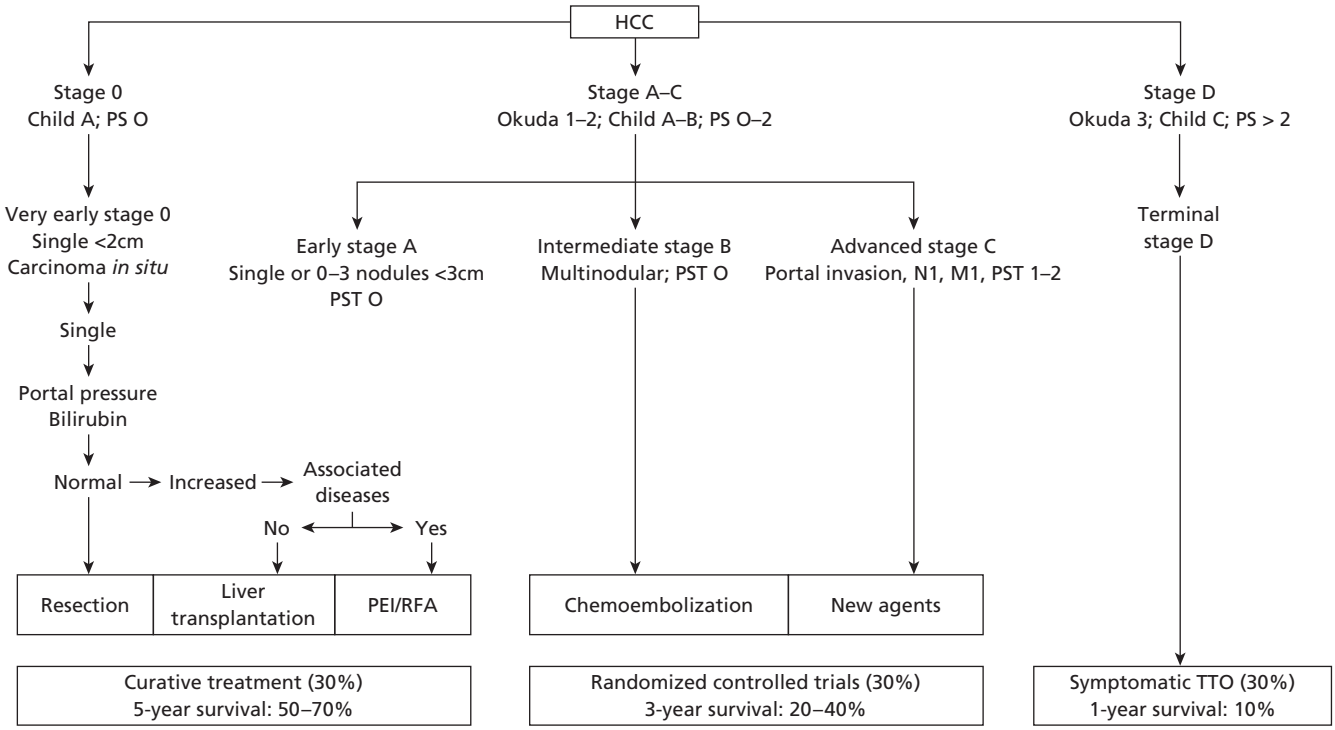

Fig. 6 Strategy for staging and treatment assignment in patients diagnosed with hepatocellular carcinoma according to the Barcelona Clinic Liver Cancer proposal. Reproduced with permission from ref. 106.

extrahepatic spread and/or vascular invasion, particularly of the portal vein. Liver functional assessment is another important aspect in the evaluation of patients with HCC. The majority of patients present with underlying cirrhosis, so a precise evaluation of liver function is obligatory. All treatments that have shown survival benefit, except liver transplantation, can cause decompensation in liver function; therefore, severe liver insufficiency may preclude surgery, percutaneous ablation and chemoembolization. Finally, the evaluation of the general condition of the patient should precede any therapeutic regimen. As in the majority of diseases, concomitant morbidities increase the risk of treatment-related complications and death. In addition, evaluation of cancer-related symptoms by performance status (PS) score or Karnofsky index is mandatory. A PS of 3–4 or Karnofsky index < 60 identifies patients with terminal disease that will not benefit from any oncological treatment, and they should receive palliative care.

Curative treatments

Surgical resection

For years, surgical resection was the only treatment available that showed a survival benefit. The development of liver transplantation and percutaneous ablation techniques initiated a debate about the current role of liver resection and whether or not surgery should still be the first therapeutic option. The lack of RCTs comparing liver resection, percutaneous ablation and liver transplantation in cirrhotic patients prevents any general recommendation, and the therapeutic algorithm depends on the resources available in each setting.

In patients with a normal non-cirrhotic liver, resection is considered the best option. These patients represent a minority of the HCC patients in western countries, while the proportion may reach 40% in some areas where HBV acquired during childhood is the main aetiological agent. In patients with decompensated cirrhosis, surgical resection is clearly precluded, and liver transplantation is the sole effective therapeutic option. Controversy exists, however, regarding patients with compensated cirrhosis.

Two decades ago, when resection was the sole alternative, the postoperative mortality could exceed 20%, and the 3-year survival rate was usually < 50%. More recently, more accurate tumour staging, refined functional evaluation of the underlying liver function and improvements in surgical techniques have dramatically decreased the postoperative morbidity and mortality and increased survival. In fact, the current standard is to have a perioperative mortality < 3%, a transfusion rate < 10% and a 5-year survival rate > 50% [6].

The success of surgical resection depends on correct evaluation of tumour stage and liver function. A precise preoperative estimate of tumour extension is mandatory. A presurgical workup (either CT scan or MRI) along with intraoperative

ultrasound (IOUS) is recommended to assess tumour stage, detect additional nodules and guide anatomical resection. Resection is restricted to patients with a solitary nodule. The upper limit of the size of this nodule is not well established. It is well known that the probability of vascular invasion and dissemination increases with size [76], but there are slow-growing tumours that reach a large size without evidence of invasion or satellite disease. Liver function is widely evaluated by the Child–Pugh classification [102], and patients in classes B and C are excluded. However, some Child–Pugh A patients will develop liver decompensation and early death after resection, so more in-depth evaluation is required. In Europe, bilirubin and portal pressure have been recognized as the best parameters for the selection of optimal surgical candidates [123]. Clinically relevant portal hypertension (PHT) is defined as the presence of oesophageal varices, splenomegaly with a platelet count of < 100 000/μL or a hepatic venous pressure gradient of ≥ 10 mmHg. Subjects without relevant PHT and normal bilirubin show the best outcome after surgical resection, with 5-year survival rates of up to 70% [123,124]. The main problem with surgical resection is the high recurrence rate, which may reach 70% at 5 years [123,125–130]. True recurrences (intrahepatic metastases) can be distinguished from *de novo* tumours. From genomic investigations, it has been determined that 60–70% of recurrences are intrahepatic metastases, whereas 30–40% are *de novo* tumours. True recurrences typically emerge within 2 years after resection and correspond to intrahepatic metastases undetected at the time of resection; they are usually associated with vascular invasion, a poor degree of histological differentiation and satellites [123,125,126]. Conversely, *de novo* tumours occur later, habitually > 2 years after resection [131–134], and their appearance is related to prior oncogenic events.

Several strategies have been tested to prevent recurrence [135,136]. Preoperative chemoembolization and adjuvant chemotherapy have shown no benefit and may even complicate the intervention. Promising results have been reported with adoptive immunotherapy with activated lymphocytes [137], internal radiation [138] and retinoid [139] or interferon administration [140]. However, all the data lack enough strength and, hence, large randomized studies should be conducted prior to introducing any of them into routine clinical practice.

As mentioned previously, recurrence is the drawback with surgical resection, and treatment of recurrence offers disappointing results. In the majority of cases, HCC recurrence is secondary to disease dissemination that occurred prior to resection and appears as multifocal disease, beyond the limits of curative treatment. As liver transplantation presents a low risk of recurrence when it is applied to patients at a similar stage to resected patients, some groups have proposed to enlist for liver transplantation the patients in whom analysis of the resected specimen reveals vascular invasion and/or additional satellites [141]. Late recurrences during follow-up are usually solitary *de novo* tumours, and the treatment strategy is the same as for primary HCC.

Liver transplantation

Liver transplantation offers the potential to both resect the entire potentially tumour-bearing liver and eliminate the underlying cirrhosis. In the beginning, the poor results obtained (recurrence rate of 32–54% and 5-year survival rate below 40%) brought into question the acceptability of liver transplantation as a treatment for HCC. The outcomes obtained were secondary to the initial acceptance of advanced tumours with macroscopic vascular invasion, lymph node involvement and extrahepatic spread [142,143]. However, patients transplanted because of endstage cirrhosis who incidentally had tumours at explant showed similar outcomes to patients with non-malignant disease [144]. This finding prompted the reconsideration of liver transplantation as a treatment for well-selected patients. Mazzaferro and colleagues demonstrated that patients with a single HCC ≤ 5 cm or up to three nodules each < 3 cm, the so-called Milan criteria, experienced a 70% 5-year survival rate and a recurrence rate below 15% [145]. These results were similar to those reported previously in the best series of surgical resection, although with a significantly lower rate of recurrence. As in surgical resection, recurrence is higher if histological analysis of the explant reveals vascular invasion and/or tumour satellites [146,147]. The appearance of these histologically adverse parameters is related to tumour size, so the expansion of current enlistment criteria, as proposed by some authors [148,149], is controversial. In addition, the excellent results reported by Mazzaferro *et al.* were achieved in the era of an average waiting time of less than 6 months. At the present time, the shortage of donors and the increasing number of candidates have led to an increase in the waiting times to more than 12 months, with dropout rates of 20% and decreased survival according to the intention-to-treat principle [123,150]. Because of the limited resource of donor organs, transplantation for HCC using deceased donors is acceptable only when the probability of living for 5 years after the procedure exceeds 50% [151].

There are three strategies to improve survival after liver transplantation according to the intention-to-treat principle. First, the pools of donors can be increased by the use of living donors, domino/split liver transplantation or high-risk donors. Living donor liver transplantation (LDLT) has become the most feasible alternative to cadaveric liver transplantation. It may be applied in 20% of candidates, and a cost-effectiveness study has shown benefit when the waiting time exceeds 7 months [152,153]. A large multicentre survey in Japan showed that survival in LDLT is comparable to cadaveric liver transplantation [154], and several groups have initiated live donation programmes with expanded criteria [155–157].

In spite of initial results supporting the use of LDLT in patients with HCC, there are several issues that should be clarified. It must be taken into account that the risk of death for the donors is around 0.7%, and a high rate of surgical complications, particularly biliary complications, have been reported. In addition, it has been suggested that HCV reinfection after LDLT is more aggressive than after cadaveric transplantation, with

faster progression to cirrhosis and liver failure [158]. Long-term results in large cohorts are urgently needed to clarify the real benefit of live donation programmes in patients with HCC.

Another strategy is the use of priority policies; understanding the importance of waiting times in the effectiveness of liver transplantation, UNOS has implemented the MELD system to offer priority to the sickest patients. Currently, patients with HCC meeting the Milan criteria and tumours ≥ 2 cm in diameter are prioritized by being given a pre-established number of MELD points [159,160]. Nevertheless, this system lacks proper validity. Several studies have shown that the MELD system is unable to predict the prognosis of HCC patients or their risk of exclusion while waiting for a cadaveric liver. Furthermore, the MELD points of patients waiting for a liver are not homogeneous between transplant programmes and, hence, whereas in some centres a given value of MELD points will give excessive priority to HCC patients, in others, HCC patients may be excluded if the non-HCC population exhibits a high MELD score.

A final strategy to reduce the dropout rate could be the application of adjuvant therapies while awaiting transplantation. The most frequently used treatments are resection, ablative therapies and chemoembolization [161–167]. The benefit of adjuvant therapies depends on the risks associated with each treatment and the expected length of waiting time, and randomized studies are clearly required to elucidate the real benefits of adjuvant therapies. A cost-effectiveness analysis using a Markov model suggested a survival improvement for neoadjuvant treatments when waiting times exceeded 6 months [168].

Percutaneous treatments

Percutaneous ablation has become an effective therapeutic option with curative capability that has grown rapidly during the last decades. Currently, it is the first-line treatment in patients with early HCC who are not eligible for surgical resection and for whom liver transplantation has been precluded [6]. Tumour ablation can be achieved by the injection of chemical substances, namely ethanol or acetic acid, or by modification of the tumour temperature by the insertion of different types of probes, as in the cases of radiofrequency, microwave, laser and cryotherapy ablation. All these techniques can be performed percutaneously, habitually with ultrasound guidance, or laparoscopically. Treatment response is assessed by dynamic CT at 1 month and is defined by the absence of contrast uptake as a sign of tumour necrosis [63]. The most widely used ablative therapies are percutaneous ethanol injection (PEI) and radiofrequency ablation (RFA).

PEI consists of the injection of absolute ethanol into lesions through fine needles. It is the best studied and most widely used ablative therapy. It is inexpensive and usually well tolerated with few side-effects. Ethanol injection can achieve complete tumour necrosis in 70–80% of single tumours ≤ 3 cm and obtains a 5-year survival rate in Child–Pugh A patients of 50% [169], which are similar results to those obtained with surgical resection [170]. The response is reduced to 50% in tumours of 3–5 cm [171]. Failures are due to the presence of intratumoral septa that prevent the spread of injected ethanol.

The suboptimal efficacy of PEI in larger tumours and the need for repeated ethanol injections has prompted the development of alternative techniques to ablate larger nodules in fewer sessions. RFA is the most widely used alternative to PEI. It produces thermal injury in living tissue via an alternating electric current in the radiofrequency range (460–500 kHz) delivered through single or multiple cooled-tip electrodes. Ablation can be performed percutaneously, laparoscopically or via laparotomy [172]. The advantage of RFA is that it achieves a complete response in significantly fewer sessions and delivers a better response rate in tumours > 3 cm [173]. The main drawbacks are the high cost of the equipment and the high rate and severity of adverse effects, with a reported mortality rate of 0.5% and complication rate of approximately 10% [174,175]. Another disadvantage is the lesser applicability compared with PEI; superficial tumours and tumours close to the hepatic hilum, gallbladder, bowel, heart or major blood vessels are not suitable for RFA.

In a recent RCT performed in Japan, 238 patients with early HCC were randomized to RFA vs. PEI. Four-year survival was significantly higher with RFA than with PEI (74% vs. 57%), with similar rates of adverse events [176]. These outcomes encourage the use of RFA, but additional studies performed in Europe or the USA are required to validate these results.

Similar to surgical resection, recurrence after successful percutaneous treatment is frequent, approximately 50% at 3 years and more than 70% at 5 years [171,177].

Palliative treatments

Several therapeutic modalities have been tested for patients with advanced stage HCC. However, only a few of them have been appropriately tested in prospective RCTs comparing active therapy versus the best supportive care. Most treatments have been evaluated in the context of phase II trials or RCTs in which two active interventions were compared. A meta-analysis of all the available studies showed that chemoembolization was the sole intervention that offered a survival benefit [122].

Transarterial chemoembolization (TACE)/embolization (TAE)

HCC obtains its blood supply almost exclusively through the hepatic artery. This fact provides the basis for the typical radiological features of HCC as well as the development of arterial obstruction as an effective therapy.

The procedure consists of hepatic artery catheterization and intra-arterial injection of a chemotherapeutic agent suspended in a carrier substance, usually lipiodol, which is selectively retained within the tumour. The dose of chemotherapy to be administered must be adjusted according to the patient's liver function. Chemotherapeutic agents should be distributed between both hepatic lobes: when the tumour affects only one lobe, it is

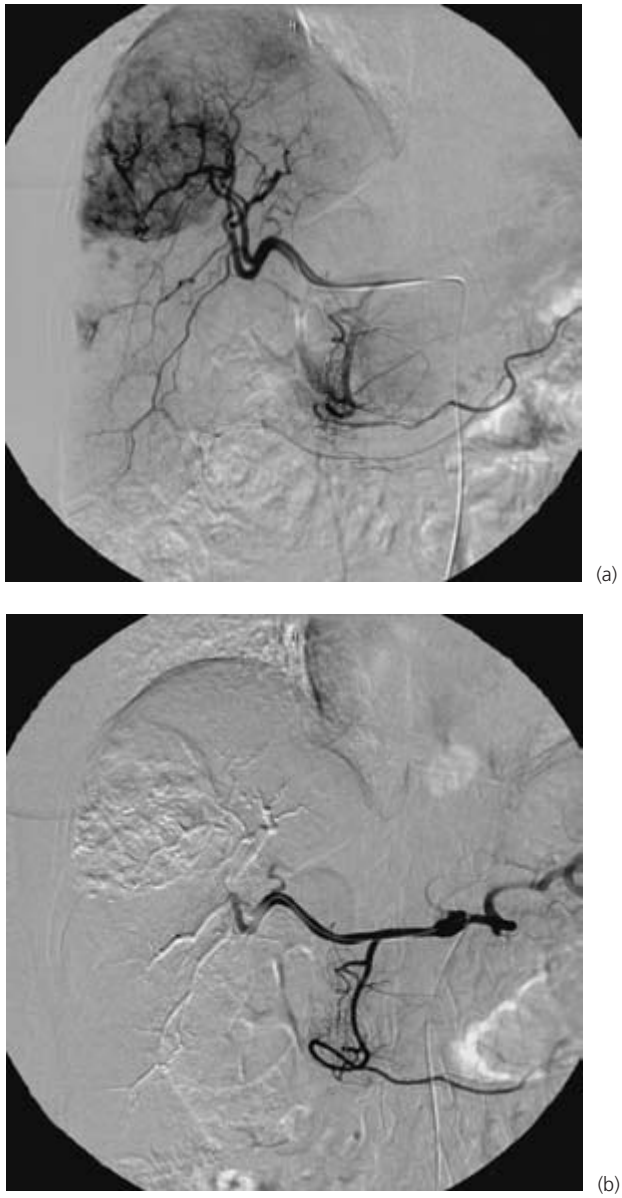

Fig. 7 An example of transarterial chemoembolization. (a) The typical arterial hypervascularization of HCC on arteriography. (b) The result after selective embolization of the feeding arteries.

common practice to inject 25% of the agent into the tumour-free lobe, with the idea that it will act on potentially undetected implants. Several chemotherapeutic agents have been used, cisplatin and doxorubicin being the most common [178,179], although none has been shown to be superior to any of the others [180]. Once the antineoplastic agent has been injected, hepatic artery blood flow is obstructed by intra-arterial injection of one of several agents: Gelfoam, polyvinyl alcohol, metallic coils, starch microspheres or even autologous blood clots (Fig. 7). The most widely used agent is gelatin sponge prepared as 0.5- to 1-mm cubes [180]. The procedure should be as selective as possible to limit the injury to the surrounding non-tumoral liver, and the cystic artery should be preserved to avoid necrosis of the gallbladder.

This procedure is not innocuous. Most patients experience the post-embolization syndrome, consisting of ileus, transient abdominal pain and fever. Prophylactic antibiotics are not used routinely because post-procedure fever is usually a sign of successful tumour necrosis. It is usually self-limited so, if fever persists, severe infectious complications such as cholecystitis or a hepatic abscess should be ruled out.

The side-effects of intra-arterial injection of chemotherapy are the same as for systemic administration: nausea, vomiting, renal impairment, bone marrow suppression and alopecia. Fasting is recommended for 24 h prior to the procedure, and intravenous hydration is mandatory to avoid renal impairment.

Extrahepatic spread has to be excluded before TACE/TAE. Contraindications to the procedure are the presence of decompensated cirrhosis and advanced liver disease (Child–Pugh class C), cancer-related symptoms, impaired clotting test results (platelet count < 50 000/μL or prothrombin activity < 50%) or renal failure. The presence of a hepatofugal blood flow, portosystemic shunt or portal thrombosis precludes the procedure, as they can prompt necrosis of the non-tumoral liver left without blood supply and produce liver failure and death.

The efficacy of arterial embolization in terms of inducing objective responses is clear. Objective responses registered by the identification of intratumoral necrosis and reduced tumour burden on dynamic CT scan or MRI are seen in 15–55% of patients, significantly higher than in untreated control subjects. These responses are associated with delayed tumour progression and vascular invasion [181,182].

The real impact of embolization on survival was unclear until the recent publication of two studies from Hong Kong [183] and Barcelona [182] and a meta-analysis [122] that demonstrated significant survival benefits of chemoembolization with respect to conservative treatment.

Some questions should be answered in the coming years. First, it should be determined which are the best chemotherapeutic drugs and embolization agents and how best to increase the intratumoral concentrations of the drug. Second, it remains to be seen whether repeat treatment should be undertaken according to a fixed schedule or upon disease progression after initial response. The last issue is whether there is a synergistic or additive effect between arterial embolization and intra-arterial chemotherapy and, consequently, whether chemoembolization is better than embolization.

Intra-arterial chemotherapy

Intra-arterial chemotherapy is based on the intra-arterial infusion of chemotherapeutic agents, routinely using lipiodol as a vehicle, with no occlusion of hepatic artery flow. It has been indicated in patients in whom portal thrombosis precludes hepatic artery embolization. Currently, there is scarce scientific evidence of survival benefit and, thus, its use is not recommended [184].

Internal radiation

The low radiation tolerability of the liver parenchyma and tumour radioresistance have limited the use of whole-liver external beam radiation therapy. Internal radiation, however, aims to selectively deliver high radiation doses to arterial-fed tumours, thereby sparing the normal liver parenchyma. Iodine-131 (^{131}I)-lipiodol was the first internal radiation agent to be applied. Its use was evaluated in several studies, with an objective tumour response in 40–52% of cases [185,186]. More recently, yttrium-90 microspheres, a pure beta emitter, were assessed in several studies, demonstrating promising results [187–189]. However, additional studies are needed to evaluate the actual benefit of internal radiation in unresectable HCC.

Systemic treatments

Several cytotoxic drugs have been tested in advanced HCC. A recent review and a meta-analysis have shown that HCC is usually chemoresistant, and cytotoxic drugs are habitually poorly tolerated and associated with high rates of severe adverse effects. Therefore, because of the absence of a clear improvement in survival and a high rate of severe side-effects, systemic chemotherapy should be discouraged in cirrhotic patients with advanced HCC, and the efficacy of new cytotoxic drugs should be evaluated only through phase II and III trials in selected patients.

Because of the presence of estrogen receptors in tumour cells, it has been theorized that antiestrogenic drugs such as tamoxifen could slow tumour growth and increase survival. Although initial studies reported a survival benefit in patients treated with tamoxifen [190], larger and more recent trials reported negative results [191–195], and three meta-analyses found no antitumoral effect and no survival benefit [196,197]. Tamoxifen must not be prescribed in patients with advanced HCC as an effective therapy.

Interferon alpha (IFN-α) has antiangiogenic and antiproliferative effects, and it has been tested in patients with advanced HCC. IFN treatment was poorly tolerated, and no survival benefit was found [198]. Consequently, its use cannot be recommended.

Finally, other treatments such as megestrol [199], octreotide [200,201] and antiandrogen derivatives [202,203] have shown no survival improvement, and their use is discouraged.

Future agents

Advances in our knowledge of the molecular pathogenesis of HCC responsible for tumour development and progression [72] have led to the evaluation of several new molecules that may act through some disrupted molecular pathways. A great number of new agents have been developed recently and are currently under evaluation. These include tyrosine kinase inhibitors, antiangiogenic agents against vascular endothelial growth factor (VEGF), inhibitors of epidermal growth factor (EGF) and telomerase pathway inhibitors, among others. The molecules that have shown promising results in phase I trials should be evaluated in large RCTs comparing the new agent vs. the best supportive care. One example is BAY 43-9006 (Sorafenib), a promising molecule that inhibits multiple pathways, mainly VEGF and Raf kinase. It has recently been tested in a phase I trial, showing a partial response in a patient with advanced HCC [204], and a multicentre, phase II–III trial with this agent is currently under way.

Prevention

When a cancer has well-defined risk factors, avoidance of these risk factors could promote a reduction in the incidence of and deaths associated with the disease. HCC arises, in the majority of the cases, as a result of an aetiological agent that has first caused liver disease. HCC is frequently associated with viral infection, and the propagation of both HBV and HCV can be effectively prevented. Universal HBV vaccination has successfully diminished the carrier rate in the countries where it was implemented, and it has been associated with a significant reduction in HCC incidence [8]. Therefore, HCC is a cancer that can be partially prevented by vaccination. Unfortunately, there is no effective vaccination for HCV, and prevention of its transmission is based on the improvement of hygiene standards. Because HCV is transmitted parenterally, control of blood transfusion and blood derivatives is mandatory. Also, objects that may be spoiled by contaminated blood, such as used needles, razors or body piercing equipment, should be avoided. Health campaigns should encourage a reduction in excessive alcohol consumption and promote a healthy lifestyle in order to control obesity, which is frequently associated with chronic liver disease classified as cryptogenic. In countries where aflatoxin exposure is a major cause of HCC, improvement in food-storage conditions may reduce aflatoxin contamination. Some drugs, such as oltipraz, which may help to metabolize aflatoxin, or chlorophyllin, which enhances aflatoxin elimination, have been tested in several trials; the real impact of these strategies and their cost-effectiveness are still unknown [205].

When the aetiological agent is already present or has induced liver damage, the tools for prevention and their efficacy are suboptimal. Current antiviral therapy against HBV may effectively inhibit viral replication and achieve an inactive HBV carrier state [206]. In America and Europe, the risk of HCC in the absence of cirrhosis is low. However, in Asia, where HBV is the main cause of HCC, the risk of tumour development may persist even in the absence of viral activity. When cirrhosis is already present, a reduction in HCC risk with antiviral therapy has not been proved [207]. Although promising preliminary results have been obtained with lamivudine [208], further studies are needed before recommending the use of antiviral therapy to prevent HBV-related HCC.

Treatment of hepatitis C with IFN-α and ribavirin can induce sustained clearance of HCV and, in the case of non-cirrhotic chronic liver disease, can prevent progression to cirrhosis and also reverse the liver injury. However, when cirrhosis is already established, the impact of treatment is less clear, and

the results of small prospective studies as well as larger retrospective analyses are discrepant [209]. Large RCTs attempting to clarify this matter including HCV cirrhosis are currently under way.

There are other health interventions that are associated with the prevention of HCC. The control of iron deposition in patients with hereditary haemochromatosis can prevent progression to cirrhosis and cancer [210]. Dietary antioxidants, specifically retinoids and selenium, may attenuate the deleterious effects of viral and chemical exposures that may lead to HCC development [61]. Glycyrrhizin has been prescribed widely in Japan as a therapy for viral hepatitis, and its long-term administration has been shown to slightly reduce both cirrhosis and HCC development in chronically infected HCV patients [211]. One case–control study suggests that coffee drinking is inversely associated with HCC regardless of its aetiology [212], but prospective studies are needed to validate these results. Finally, a subgroup analysis of a prospective randomized controlled study in women with viral cirrhosis receiving 45 mg/day vitamin K2 to prevent osteoporosis showed a significant reduction in HCC risk in patients receiving active treatment [213]. The small size of the study and the exceedingly high rates of HCC in untreated women, however, suggest a patient selection bias that prevents any robust conclusions.

Future prospects

Major progress in the diagnosis, staging and treatment of HCC has taken place over the last 20 years. The earlier diagnosis, better evaluation and staging of the disease and more structured treatment decision algorithms have led to significant improvements in the survival rate. Nevertheless, the fact remains that half the patients affected by HCC are diagnosed too late for any effective treatment to be applied.

In the next few years, major efforts should be made to implement and develop effective prevention strategies. In addition, improvements in screening tools to diagnose tumours when they have not yet acquired a fully overt malignant phenotype is mandatory. Finally, the efficacy of therapy should be further improved, in particular through the development of adjuvant agents and tumour-targeting biological mechanisms.

Elucidation of the molecular pathways that determine tumour development and dissemination will allow not only an earlier diagnosis and the development of new therapeutic agents, but also more accurate prediction of the evolutionary course of the disease and its response to treatment. Accomplishment of all these expectations will come from genomic and proteomic research, which is currently being conducted.

References

1 Parkin DM, Bray FI, Devesa SS (2001) Cancer burden in the year 2000. The global picture. *Eur J Cancer* 37 (Suppl. 8), S4–66.

2 Parkin DM, Ferlay J, Raymond L *et al.* (2002) *Cancer Incidence in Five Continents*. Lyon: IARC Scientific Publications.

3 Bosch FX, Ribes J, Diaz M *et al.* (2004) Primary liver cancer: worldwide incidence and trends. *Gastroenterology* 127 (5 Suppl. 1), S5–16.

4 El-Serag HB, Mason AC (1999) Rising incidence of hepatocellular carcinoma in the United States. *N Engl J Med* 340 (10), 745–750.

5 Benvegnu L, Gios M, Boccato S *et al.* (2004) Natural history of compensated viral cirrhosis: a prospective study on the incidence and hierarchy of major complications. *Gut* 53 (5), 744–749.

6 Llovet JM, Burroughs A, Bruix J (2003) Hepatocellular carcinoma. *Lancet* 362 (9399), 1907–1917.

7 Parkin DM, Bray F, Ferlay J *et al.* (2001) Estimating the world cancer burden: Globocan 2000. *Int J Cancer* 94 (2), 153–156.

8 Chang MH, Chen CJ, Lai MS *et al.* (1997) Universal hepatitis B vaccination in Taiwan and the incidence of hepatocellular carcinoma in children. Taiwan Childhood Hepatoma Study Group. *N Engl J Med* 336 (26), 1855–1859.

9 Khan SA, Taylor-Robinson SD, Toledano MB *et al.* (2002) Changing international trends in mortality rates for liver, biliary and pancreatic tumours. *J Hepatol* 37 (6), 806–813.

10 elSaadany S, Tepper M, Mao Y *et al.* (2002) An epidemiologic study of hepatocellular carcinoma in Canada. *Can J Publ Health* 93 (6), 443–446.

11 El-Serag HB, Mason AC (2000) Risk factors for the rising rates of primary liver cancer in the United States. *Arch Intern Med* 160 (21), 3227–3230.

12 El-Serag H (2004) Hepatocellular carcinoma: recent trends in the United States. *Gastroenterology* 127 (5 Suppl. 1), S27–S34.

13 Kiyosawa K, Umemura T, Ichijo T *et al.* (2004) Hepatocellular carcinoma: recent trends in Japan. *Gastroenterology* 127 (5 Suppl. 1), S17–26.

14 Fattovich G, Stroffolini T, Zagni I *et al.* (2004) Hepatocellular carcinoma in cirrhosis: incidence and risk factors. *Gastroenterology* 127 (5 Suppl. 1), S35–50.

15 Yeh FS, Yu MC, Mo CC *et al.* (1989) Hepatitis B virus, aflatoxins, and hepatocellular carcinoma in southern Guangxi, China. *Cancer Res* 49, 2506–2509.

16 Kew MC, Yu MC, Kedda MA *et al.* (1997) The relative roles of hepatitis B and C viruses in the etiology of hepatocellular carcinoma in southern African blacks. *Gastroenterology* 112, 184–187.

17 Fattovich G, Giustina G, Schalm SW *et al.* (1995) Occurrence of hepatocellular carcinoma and decompensation in western European patients with cirrhosis type B. The EUROHEP Study Group on Hepatitis B Virus and Cirrhosis. *Hepatology* 21 (1), 77–82.

18 Yang HI, Lu SN, Liaw YF *et al.* (2002) Hepatitis B e antigen and the risk of hepatocellular carcinoma. *N Engl J Med* 347 (3), 168–174.

19 Manno M, Camma C, Schepis F *et al.* (2004) Natural history of chronic HBV carriers in northern Italy: morbidity and mortality after 30 years. *Gastroenterology* 127 (3), 756–763.

20 Sanchez-Tapias JM, Costa J, Mas A *et al.* (2002) Influence of hepatitis B virus genotype on the long-term outcome of chronic hepatitis B in western patients. *Gastroenterology* 123 (6), 1848–1856.

21 Sherman M, Peltekian KM, Lee C (1995) Screening for hepatocellular carcinoma in chronic carriers of hepatitis B virus: incidence and prevalence of hepatocellular carcinoma in a North American urban population. *Hepatology* 22 (2), 432–438.

22 Kuang SY, Jackson PE, Wang JB *et al.* (2004) Specific mutations of hepatitis B virus in plasma predict liver cancer development. *Proc Natl Acad Sci USA* 101 (10), 3575–3580.

23 Kao JH, Chen PJ, Lai MY *et al.* (2003) Basal core promoter mutations of hepatitis B virus increase the risk of hepatocellular carcinoma in hepatitis B carriers. *Gastroenterology* 124 (2), 327–334.

24 Brechot C (2004) Pathogenesis of hepatitis B virus-related hepatocellular carcinoma: old and new paradigms. *Gastroenterology* 127 (5 Suppl. 1), S56–61.

25 Ferber MJ, Montoya DP, Yu C *et al.* (2003) Integrations of the hepatitis B virus (HBV) and human papillomavirus (HPV) into the human telomerase reverse transcriptase (hTERT) gene in liver and cervical cancers. *Oncogene* 22 (24), 3813–3820.

26 Pollicino T, Squadrito G, Cerenzia G *et al.* (2004) Hepatitis B virus maintains its pro-oncogenic properties in the case of occult HBV infection. *Gastroenterology* 126 (1), 102–110.

27 Bruix J, Barrera JM, Calvet X *et al.* (1989) Prevalence of antibodies to hepatitis C virus in Spanish patients with hepatocellular carcinoma and hepatic cirrhosis. *Lancet* 2 (8670), 1004–1006.

28 Sun CA, Wu DM, Lin CC *et al.* (2003) Incidence and cofactors of hepatitis C virus-related hepatocellular carcinoma: a prospective study of 12 008 men in Taiwan. *Am J Epidemiol* 157 (8), 674–682.

29 Yoshida H, Shiratori Y, Moriyama M *et al.* (1999) Interferon therapy reduces the risk for hepatocellular carcinoma: national surveillance program of cirrhotic and noncirrhotic patients with chronic hepatitis C in Japan. IHIT Study Group. Inhibition of Hepatocarcinogenesis by Interferon Therapy. *Ann Intern Med* 131 (3), 174–181.

30 Liang TJ, Heller T (2004) Pathogenesis of hepatitis C-associated hepatocellular carcinoma. *Gastroenterology* 127 (5 Suppl. 1), S62–71.

31 Lauer GM, Walker BD (2001) Hepatitis C virus infection. *N Engl J Med* 345 (1), 41–52.

32 Degos F, Christidis C, Ganne-Carrie N *et al.* (2000) Hepatitis C virus related cirrhosis: time to occurrence of hepatocellular carcinoma and death. *Gut* 47, 131–136.

33 Fracanzani AL, Taioli E, Sampietro M *et al.* (2001) Liver cancer risk is increased in patients with porphyria cutanea tarda in comparison to matched control patients with chronic liver disease. *J Hepatol* 35, 498–503.

34 Donato F, Boffetta P, Puoti M (1998) A meta-analysis of epidemiological studies on the combined effect of hepatitis B and C virus infections in causing hepatocellular carcinoma. *Int J Cancer* 75, 347–354.

35 Shi J, Zhu L, Liu S *et al.* (2005) A meta-analysis of case–control studies on the combined effect of hepatitis B and C virus infections in causing hepatocellular carcinoma in China. *Br J Cancer* 92, 607–612.

36 Puoti M, Bruno R, Soriano V *et al.* (2004) Hepatocellular carcinoma in HIV-infected patients: epidemiological features, clinical presentation and outcome. *AIDS* 18 (17), 2285–2293.

37 Donato D, Tagger A, Gelatti U *et al.* (2002) Alcohol and hepatocellular carcinoma: the effect of lifetime intake and hepatitis virus infections in men and women. *Am J Epidemiol* 155, 323–331.

38 Hassan M, Hwang L, Hatten C *et al.* (2002) Risk factors for hepatocellular carcinoma: synergism of alcohol with viral hepatitis and diabetes mellitus. *Hepatology* 36, 1206–1213.

39 Bagnardi V, Blangiardo M, La Vecchia C *et al.* (2001) Alcohol consumption and the risk of cancer: a meta-analysis. *Alcohol Res Health* 25 (4), 263–270.

40 Morgan TR, Mandayam S, Jamal MM (2004) Alcohol and hepatocellular carcinoma. *Gastroenterology* 127 (5 Suppl. 1), S87–96.

41 Ozturk M (1999) Genetic aspects of hepatocellular carcinogenesis. *Semin Liver Dis* 19 (3), 235–242.

42 Qian GS, Ross RK, Yu MC *et al.* (1994) A follow-up study of urinary markers of aflatoxin exposure and liver cancer risk in Shanghai, People's Republic of China. *Cancer Epidemiol Biomarkers Prev* 3 (1), 3–10.

43 Ross R, Yuan J, Yu M *et al.* (1992) Urinary aflatoxin biomarkers and risk of hepatocellular carcinoma. *Lancet* 339, 943–946.

44 Adami HO, Chow WH, Nyren O *et al.* (1996) Excess risk of primary liver cancer in patients with diabetes mellitus. *J Natl Cancer Inst* 88 (20), 1472–1477.

45 El-Serag HB, Richardson PA, Everhart JE (2001) The role of diabetes in hepatocellular carcinoma: a case–control study among United States Veterans. *Am J Gastroenterol* 96 (8), 2462–2467.

46 Calle EE, Rodriguez C, Walker-Thurmond K *et al.* (2003) Overweight, obesity, and mortality from cancer in a prospectively studied cohort of U.S. adults. *N Engl J Med* 348 (17), 1625–1638.

47 Ratziu V, Bonyhay L, Di Martino V *et al.* (2002) Survival, liver failure, and hepatocellular carcinoma in obesity-related cryptogenic cirrhosis. *Hepatology* 35 (6), 1485–1493.

48 Nair S, Mason A, Eason J *et al.* (2002) Is obesity an independent risk factor for hepatocellular carcinoma in cirrhosis? *Hepatology* 36 (1), 150–155.

49 Bugianesi E, Leone N, Vanni E *et al.* (2002) Expanding the natural history of nonalcoholic steatohepatitis: from cryptogenic cirrhosis to hepatocellular carcinoma. *Gastroenterology* 123 (1), 134–140.

50 Fracanzani A, Conte D, Fraquelli M *et al.* (2001) Increased cancer risk in a cohort of 230 patients with hereditary hemochromatosis in comparison to matched control patients with non-iron-related chronic liver disease. *Hepatology* 33, 647–651.

51 Walshe J, Waldenstrom E, Sams V *et al.* (2003) Abdominal malignancies in patients with Wilson's disease. *Q J Med* 96, 637–662.

52 Caballeria L, Pares A, Castells A *et al.* (2001) Hepatocellular carcinoma in primary biliary cirrhosis: similar incidence to that in hepatitis C virus-related cirrhosis. *Am J Gastroenterol* 96 (4), 1160–1163.

53 Shibuya A, Tanaka K, Miyakawa H *et al.* (2002) Hepatocellular carcinoma and survival in patients with primary biliary cirrhosis. *Hepatology* 35, 1172–1178.

54 Jones DEJ, Metcalf JV, Collier JD *et al.* (1997) Hepatocellular carcinoma in primary biliary cirrhosis and its impact on outcomes. *Hepatology* 26, 1138–1142.

55 Propst T, Propst A, Dietze O *et al.* (1994) Prevalence of hepatocellular carcinoma in alpha-1-antitrypsin deficiency. *J Hepatol* 21, 1006–1011.

56 Wang LY, You SL, Lu SN *et al.* (2003) Risk of hepatocellular carcinoma and habits of alcohol drinking, betel quid chewing and cigarette smoking: a cohort of 2416 HBsAg-seropositive and 9421 HBsAg-seronegative male residents in Taiwan. *Cancer Causes Control* 14 (3), 241–250.

57 Kuper H, Tzonou A, Kaklamani E *et al.* (2000) Tobacco smoking, alcohol consumption and their interaction in the causation of hepatocellular carcinoma. *Int J Cancer* 85 (4), 498–502.

58 Marrero JA, Fontana RJ, Fu S *et al.* (2005) Alcohol, tobacco and obesity are synergistic risk factors for hepatocellular carcinoma. *J Hepatol* 42 (2), 218–224.

59 Inoue M, Yoshimi I, Sobue T *et al.* (2005) Influence of coffee drinking on subsequent risk of hepatocellular carcinoma: a prospective study in Japan. *J Natl Cancer Inst* 97 (4), 293–300.

60 Sharp GB, Lagarde F, Mizuno T *et al.* (2005) Relationship of hepatocellular carcinoma to soya food consumption: a cohort-based, case–control study in Japan. *Int J Cancer* 115 (2), 290–295.

61 Yu MC, Yuan JM (2004) Environmental factors and risk for hepatocellular carcinoma. *Gastroenterology* 127, S72–78.

62 Fasani P, Sangiovanni A, De Fazio C *et al.* (1999) High prevalence of multinodular hepatocellular carcinoma in patients with cirrhosis attributable to multiple risk factors. *Hepatology* 29 (6), 1704–1707.

63 Bruix J, Sherman M, Llovet JM *et al.* (2001) Clinical management of hepatocellular carcinoma. Conclusions of the Barcelona 2000 EASL Conference. European Association for the Study of the Liver. *J Hepatol* 35 (3), 421–430.

64 Benvegnu L, Noventa F, Bernardinello E *et al.* (2001) Evidence for an association between the aetiology of cirrhosis and pattern of hepatocellular carcinoma development. *Gut* 48 (1), 110–115.

65 Velazquez RF, Rodriguez M, Navascues CA *et al.* (2003) Prospective analysis of risk factors for hepatocellular carcinoma in patients with liver cirrhosis. *Hepatology* 37 (3), 520–527.

66 Benvegnu L, Fattovich G, Noventa F *et al.* (1994) Concurrent hepatitis B and C virus infection and risk of hepatocellular carcinoma in cirrhosis. A prospective study. *Cancer* 74 (9), 2442–2448.

67 Donato MF, Arosio E, Del Ninno E *et al.* (2001) High rates of hepatocellular carcinoma in cirrhotic patients with high liver cell proliferative activity. *Hepatology* 34, 523–528.

68 Lee RG, Tsamandas AC, Demetris AJ (1997) Large cell change (liver cell dysplasia) and hepatocellular carcinoma in cirrhosis: matched case–control study, pathological analysis, and pathogenetic hypothesis. *Hepatology* 26, 1415–1422.

69 Kojiro M, Roskams T (2005) Early hepatocellular carcinoma and dysplastic nodules. *Semin Liver Dis* 25 (2), 133–142.

70 Sherman M (2001) Alphafetoprotein: an obituary. *J Hepatol* 34 (4), 603–605.

71 Buendia MA (2000) Genetics of hepatocellular carcinoma. *Semin Cancer Biol* 10 (3), 185–200.

72 Thorgeirsson SS, Grisham JW (2002) Molecular pathogenesis of human hepatocellular carcinoma. *Nature Genet* 31 (4), 339–346.

73 Borzio M, Fargion S, Borzio F *et al.* (2003) Impact of large regenerative, low grade and high grade dysplastic nodules in hepatocellular carcinoma development. *J Hepatol* 39, 208–214.

74 Seki S, Sakaguchi H, Kitada T *et al.* (2000) Outcomes of dysplastic nodules in human cirrhotic liver: a clinicopathological study. *Clin Cancer Res* 6 (9), 3469–3473.

75 Kojiro M (2004) Focus on dysplastic nodules and early hepatocellular carcinoma: an Eastern point of view. *Liver Transpl* 10 (2 Suppl. 1), S3–8.

76 Nakashima T, Kojiro M (1987) *Hepatocellular Carcinoma*. Tokyo: Springer Verlag.

77 Ishak KG, Goodman ZD, Stocker JT (2001) *Tumors of the Liver and Intrahepatic Bile Ducts*. Washington, DC: Armed Forces Institute of Pathology.

78 Lechel A, Manns MP, Rudolph KL (2004) Telomeres and telomerase: new targets for the treatment of liver cirrhosis and hepatocellular carcinoma. *J Hepatol* 41 (3), 491–497.

79 Laurent-Puig P, Legoix P, Bluteau O *et al.* (2001) Genetic alterations associated with hepatocellular carcinomas define distinct pathways of hepatocarcinogenesis. *Gastroenterology* 120 (7), 1763–1773.

80 Calvisi DF, Factor VM, Ladu S *et al.* (2004) Disruption of b-catenin pathway or genomic instability define two distinct categories of liver cancer in transgenic mice. *Gastroenterology* 126, 1374–1386.

81 Lee JS, Thorgeirsson SS (2004) Genome-scale profiling of gene expression in hepatocellular carcinoma: classification, survival prediction, and identification of therapeutic targets. *Gastroenterology* 127 (5 Suppl. 1), S51–55.

82 Smith MW, Yue ZN, Korth MJ *et al.* (2003) Hepatitis C virus and liver disease: global transcriptional profiling and identification of potential markers. *Hepatology* 38 (6), 1458–1467.

83 Ye Q, Qin LX, Forgues M *et al.* (2003) Predicting hepatitis B virus-positive metastatic hepatocellular carcinomas using gene expression profiling and supervised machine learning. *Nature Med* 9 (4), 416–423.

84 Edmonson H, Steiner PE (1954) Primary carcinoma of the liver: a study of 100 cases among 48 900 necropsies. *Cancer* 7, 462–503.

85 Kutami R, Nakashima Y, Nakashima O *et al.* (2000) Pathomorphologic study on the mechanism of fatty change in small hepatocellular carcinoma of humans. *J Hepatol* 33 (2), 282–289.

86 Nakashima Y, Nakashima O, Tanaka M *et al.* (2003) Portal vein invasion and intrahepatic micrometastasis in small hepatocellular carcinoma by gross type. *Hepatol Res* 26 (2), 142–147.

87 Sakamoto M, Hirohashi S (1998) Natural history and prognosis of adenomatous hyperplasia and early hepatocellular carcinoma: multi-institutional analysis of 53 nodules followed up for more than 6 months and 141 patients with single early hepatocellular carcinoma treated by surgical resection or percutaneous ethanol injection. *Jpn J Clin Oncol* 28 (10), 604–608.

88 Takayama T, Makuuchi M, Hirohashi S *et al.* (1998) Early hepatocellular carcinoma as an entity with a high rate of surgical cure. *Hepatology* 28 (5), 1241–1246.

89 Bolondi L, Sofia S, Siringo S *et al.* (2001) Surveillance programme of cirrhotic patients for early diagnosis and treatment of hepatocellular carcinoma: a cost effectiveness analysis. *Gut* 48 (2), 251–259.

90 Zhang BH, Yang BH, Tang ZY (2004) Randomized controlled trial of screening for hepatocellular carcinoma. *J Cancer Res Clin Oncol* 130 (7), 417–422.

91 Bruix J, Sherman M (2005) Management of hepatocellular carcinoma. *Hepatology* 42 (5), 1208–1236.

92 Iwasaki M, Furuse J, Yoshino M *et al.* (1998) Sonographic appearances of small hepatic nodules without tumor stain on contrast-enhanced computed tomography and angiography. *J Clin Ultrasound* 26 (6), 303–307.

93 Fracanzani AL, Burdick L, Borzio M *et al.* (2001) Contrast-enhanced doppler ultrasonography in the diagnosis of hepatocellular carcinoma and premalignant lesions in patients with cirrhosis. *Hepatology* 34 (6), 1109–1112.

94 Burrel M, Llovet JM, Ayuso C *et al.* (2003) MRI angiography is superior to helical CT for detection of HCC prior to liver transplantation: an explant correlation. *Hepatology* 38 (4), 1034–1042.

95 Gaiani S, Celli N, Piscaglia F *et al.* (2004) Usefulness of contrast-enhanced perfusional sonography in the assessment of hepatocellular carcinoma hypervascular at spiral computed tomography. *J Hepatol* 41 (3), 421–426.

96 Trevisani F, D'Intino PE, Morselli-Labate AM *et al.* (2001) Serum alpha-fetoprotein for diagnosis of hepatocellular carcinoma in patients with chronic liver disease: influence of HBsAg and anti-HCV status. *J Hepatol* 34 (4), 570–575.

97 Oka H, Tamori A, Kuroki T *et al.* (1994) Prospective study of alpha-fetoprotein in cirrhotic patients monitored for development of hepatocellular carcinoma. *Hepatology* 19 (1), 61–66.

98 Marrero JA, Su GL, Wei W *et al.* (2003) Des-gamma carboxyprothrombin can differentiate hepatocellular carcinoma from non-malignant chronic liver disease in American patients. *Hepatology* 37 (5), 1114–1121.

99 Kumada T, Nakano S, Takeda I *et al.* (1999) Clinical utility of *Lens culinaris* agglutinin-reactive alpha-fetoprotein in small hepatocellular carcinoma: special reference to imaging diagnosis. *J Hepatol* 30 (1), 125–130.

100 Capurro M, Wanless IR, Sherman M *et al.* (2003) Glypican-3: a novel serum and histochemical marker for hepatocellular carcinoma. *Gastroenterology* 125 (1), 89–97.

101 Greene FL, Page DL, Fleming ID *et al.* (2002) *Cancer Staging Handbook*. Chicago, IL: AJCC.

102 Pugh RN, Murray-Lyon IM, Dawson JL *et al.* (1973) Transection of the oesophagus for bleeding oesophageal varices. *Br J Surg* 60 (8), 646–649.

103 Forman LM, Lucey MR (2001) Predicting the prognosis of chronic liver disease: an evolution from child to MELD. Mayo End-stage Liver Disease. *Hepatology* 33 (2), 473–475.

104 Okuda K, Ohtsuki T, Obata H *et al.* (1985) Natural history of hepatocellular carcinoma and prognosis in relation to treatment. Study of 850 patients. *Cancer* 56 (4), 918–928.

105 Stuart KE, Anand AJ, Jenkins RL (1996) Hepatocellular carcinoma in the United States. Prognostic features, treatment outcome, and survival. *Cancer* 77 (11), 2217–2222.

106 Llovet JM, Bru C, Bruix J. (1999) Prognosis of hepatocellular carcinoma: the BCLC staging classification. *Semin Liver Dis* 19 (3), 329–338.

107 Llovet JM, Bustamante J, Castells A *et al.* (1999) Natural history of untreated nonsurgical hepatocellular carcinoma: rationale for the design and evaluation of therapeutic trials. *Hepatology* 29 (1), 62–67.

108 Chevret S, Trinchet JC, Mathieu D *et al.* (1999) A new prognostic classification for predicting survival in patients with hepatocellular carcinoma. Groupe d'Etude et de Traitement du Carcinome Hepatocellulaire. *J Hepatol* 31 (1), 133–141.

109 Caselitz M, Masche N, Flemming P *et al.* (2004) [Prognosis of hepatocellular carcinoma according to new staging classifications]. *Dtsch Med Wochenschr* 129 (33), 1725–1730.

110 Schoniger-Hekele M, Muller C, Kutilek M *et al.* (2001) Hepatocellular carcinoma in Central Europe: prognostic features and survival. *Gut* 48 (1), 103–109.

111 Leung TW, Tang AM, Zee B *et al.* (2002) Construction of the Chinese University Prognostic Index for hepatocellular carcinoma and comparison with the TNM staging system, the Okuda staging system, and the Cancer of the Liver Italian Program staging system: a study based on 926 patients. *Cancer* 94 (6), 1760–1769.

112 Omagari K, Honda S, Kadokawa Y *et al.* (2004) Preliminary analysis of a newly proposed prognostic scoring system (SLiDe score) for hepatocellular carcinoma. *J Gastroenterol Hepatol* 19 (7), 805–811.

113 Villa E, Moles A, Ferretti I *et al.* (2000) Natural history of inoperable hepatocellular carcinoma: estrogen receptors' status in the tumor is the strongest prognostic factor for survival. *Hepatology* 32 (2), 233–238.

114 CLIP (1998) A new prognostic system for hepatocellular carcinoma: a retrospective study of 435 patients: the Cancer of the Liver Italian Program (CLIP) investigators. *Hepatology* 28 (3), 751–755.

115 Kudo M, Chung H, Haji S *et al.* (2004) Validation of a new prognostic staging system for hepatocellular carcinoma: the JIS score compared with the CLIP score. *Hepatology* 40 (6), 1396–1405.

116 Tateishi R, Yoshida H, Shiina S *et al.* (2005) Proposal of a new prognostic model for hepatocellular carcinoma: an analysis of 403 patients. *Gut* 54 (3), 419–425.

117 Marrero JA, Fontana RJ, Barrat A *et al.* (2005) Prognosis of hepatocellular carcinoma: comparison of 7 staging systems in an American cohort. *Hepatology* 41 (4), 707–716.

118 Cillo U, Bassanello M, Vitale A *et al.* (2004) The critical issue of hepatocellular carcinoma prognostic classification: which is the best tool available? *J Hepatol* 40 (1), 124–131.

119 Grieco A, Pompili M, Caminiti G *et al.* (2005) Prognostic factors for survival in patients with early-intermediate hepatocellular carcinoma undergoing non-surgical therapy: comparison of Okuda, CLIP, and BCLC staging systems in a single Italian centre. *Gut* 54 (3), 411–418.

120 Ueno S, Tanabe G, Sako K *et al.* (2001) Discrimination value of the new western prognostic system (CLIP score) for hepatocellular carcinoma in 662 Japanese patients. Cancer of the Liver Italian Program. *Hepatology* 34 (3), 529–534.

121 Levy I, Sherman M (2002) Staging of hepatocellular carcinoma: assessment of the CLIP, Okuda, and Child–Pugh staging systems in a cohort of 257 patients in Toronto. *Gut* 50 (6), 881–885.

122 Llovet JM, Bruix J (2003) Systematic review of randomized trials for unresectable hepatocellular carcinoma: chemoembolization improves survival. *Hepatology* 37 (2), 429–442.

123 Llovet JM, Fuster J, Bruix J (1999) Intention-to-treat analysis of surgical treatment for early hepatocellular carcinoma: resection versus transplantation. *Hepatology* 30 (6), 1434–1440.

124 Song TJ, Ip EW, Fong Y (2004) Hepatocellular carcinoma: current surgical management. *Gastroenterology* 127, S248–260.

125 Poon RT, Fan ST, Lo CM *et al.* (2002) Long-term survival and pattern of recurrence after resection of small hepatocellular carcinoma in patients with preserved liver function: implications for a strategy of salvage transplantation. *Ann Surg* 235 (3), 373–382.

126 Imamura H, Matsuyama Y, Tanaka E *et al.* (2003) Risk factors contributing to early and late phase intrahepatic recurrence of hepatocellular carcinoma after hepatectomy. *J Hepatol* 38 (2), 200–207.

127 Belghiti J, Panis Y, Farges O *et al.* (1991) Intrahepatic recurrence after resection of hepatocellular carcinoma complicating cirrhosis. *Ann Surg* 214, 114–117.

128 Okada S, Shimada K, Yamamoto J *et al.* (1994) Predictive factors for postoperative recurrence of hepatocellular carcinoma. *Gastroenterology* 106, 1618–1624.

129 Adachi E, Maeda T, Matsumata T *et al.* (1995) Risk factors for intrahepatic recurrence in human small hepatocellular carcinoma. *Gastroenterology* 108, 768–775.

130 Kumada T, Nakano S, Takeda I *et al.* (1997) Patterns of recurrence after initial treatment in patients with small hepatocellular carcinoma. *Hepatology* 25, 87–92.

131 Iizuka N, Oka M, Yamada-Okabe H *et al.* (2003) Oligonucleotide microarray for prediction of early intrahepatic recurrence of hepatocellular carcinoma after curative resection. *Lancet* 361, 923–929.

132 Ng IO, Guan XY, Poon RT *et al.* (2003) Determination of the molecular relationship between multiple tumor nodules in hepatocellular carcinoma differentiates multicentric origin from intrahepatic metastasis. *J Pathol* 199 (3), 345–353.

133 Chen YJ, Yeh SH, Chen JT *et al.* (2000) Chromosomal changes and clonality relationship between primary and recurrent hepatocellular carcinoma. *Gastroenterology* 119, 431–440.

134 Finkelstein SD, Marsh W, Demetris AJ *et al.* (2003) Microdissection-based allelotyping discriminates de novo tumor from intrahepatic spread in hepatocellular carcinoma. *Hepatology* 37, 871–889.

135 Schwartz JD, Schwartz M, Mandeli J *et al.* (2002) Neoadjuvant and adjuvant therapy for resectable hepatocellular carcinoma: review of the randomised clinical trials. *Lancet Oncol* 3 (10), 593–603.

136 Colombo M, Donato MF (2005) Prevention of hepatocellular carcinoma. *Semin Liver Dis* 25 (2), 155–161.

137 Takayama T, Sekine T, Makuuchi M *et al.* (2000) Adoptive immunotherapy to lower postsurgical recurrence rates of hepatocellular carcinoma: a randomised trial. *Lancet* 356 (9232), 802–807.

138 Lau WY, Leung TW, Ho SK *et al.* (1999) Adjuvant intra-arterial iodine-131-labelled lipiodol for resectable hepatocellular carcinoma: a prospective randomised trial. *Lancet* 353 (9155), 797–801.

139 Muto Y, Moriwaki H, Ninomiya M *et al.* (1996) Prevention of second primary tumors by an acyclic retinoid, polyprenoic acid, in patients with hepatocellular carcinoma. Hepatoma Prevention Study Group. *N Engl J Med* 334 (24), 1561–1567.

140 Ikeda K, Arase Y, Saitoh S *et al.* (2000) Interferon beta prevents recurrence of hepatocellular carcinoma after complete resection or ablation of the primary tumor. A prospective randomized study of hepatitis C virus-related liver cancer. *Hepatology* 32 (2), 228–232.

141 Sala M, Fuster J, Llovet JM *et al.* (2004) High pathological risk of recurrence after surgical resection for hepatocellular carcinoma: an indication for salvage liver transplantation. *Liver Transpl* 10 (10), 1294–1300.

142 Ringe B, Pichlmayr R, Wittekind C *et al.* (1991) Surgical treatment of hepatocellular carcinoma: experience with liver resection and transplantation in 198 patients. *World J Surg* 15 (2), 270–285.

143 Iwatsuki S, Starzl TE, Sheahan DG *et al.* (1991) Hepatic resection versus transplantation for hepatocellular carcinoma. *Ann Surg* 214 (3), 221–228.

144 Iwatsuki S, Gordon RD, Shaw BW, Jr *et al.* (1985) Role of liver transplantation in cancer therapy. *Ann Surg* 202 (4), 401–407.

145 Mazzaferro V, Regalia E, Doci R *et al.* (1996) Liver transplantation for the treatment of small hepatocellular carcinomas in patients with cirrhosis. *N Engl J Med* 334 (11), 693–699.

146 Bismuth H, Majno PE, Adam R (1999) Liver transplantation for hepatocellular carcinoma. *Semin Liver Dis* 19 (3), 311–322.

147 Jonas S, Bechstein WO, Steinmuller T *et al.* (2001) Vascular invasion and histopathologic grading determine outcome after liver transplantation for hepatocellular carcinoma in cirrhosis. *Hepatology* 33 (5), 1080–1086.

148 Yao FY, Ferrell L, Bass NM *et al.* (2001) Liver transplantation for hepatocellular carcinoma: expansion of the tumor size limits does not adversely impact survival. *Hepatology* 33 (6), 1394–1403.

149 Marsh JW, Dvorchik I (2003) Liver organ allocation for hepatocellular carcinoma: are we sure? *Liver Transpl* 9 (7), 693–696.

150 Yao FY, Bass NM, Nikolai B *et al.* (2002) Liver transplantation for hepatocellular carcinoma: analysis of survival according to the intention-to-treat principle and dropout from the waiting list. *Liver Transpl* 8 (10), 873–883.

151 Bruix J, Llovet JM (2002) Prognostic prediction and treatment strategy in hepatocellular carcinoma. *Hepatology* 35 (3), 519–524.

152 Marcos A (2005) A right lobe living donor liver transplantation: a review. *Liver Transpl* 6, 3–20.

153 Sarasin FP, Majno PE, Llovet JM *et al.* (2001) Living donor liver transplantation for early hepatocellular carcinoma: a life-expectancy and cost-effectiveness perspective. *Hepatology* 33 (5), 1073–1079.

154 Todo S, Furukawa H (2004) Living donor liver transplantation for adult patients with hepatocellular carcinoma: experience in Japan. *Ann Surg* 240 (3), 451–459; discussion 459–461.

155 Kawasaki S (2002) Living-donor liver transplantation for hepatocellular carcinoma. *Hepatogastroenterology* 49 (43), 53–55.

156 Gondolesi GE, Roayaie S, Munoz L *et al.* (2004) Adult living donor liver transplantation for patients with hepatocellular carcinoma: extending UNOS priority criteria. *Ann Surg* 239 (2), 142–149.

157 Steinmuller T, Pascher A, Sauer I *et al.* (2002) Living-donation liver transplantation for hepatocellular carcinoma: time to drop the limitations? *Transplant Proc* 34 (6), 2263–2264.

158 Garcia-Retortillo M, Forns X, Llovet JM *et al.* (2004) Hepatitis C recurrence is more severe after living donor compared to cadaveric liver transplantation. *Hepatology* 40 (3), 699–707.

159 Schwartz M (2004) Liver transplantation for hepatocellular carcinoma. *Gastroenterology* 127 (5 Suppl 1), S268–276.

160 Freeman RB, Wiesner RH, Edwards E *et al.* (2004) Results of the first year of the new liver allocation plan. *Liver Transpl* 10 (1), 7–15.

161 Stone MJ, Klintmalm GB, Polter D *et al.* (1993) Neoadjuvant chemotherapy and liver transplantation for hepatocellular carcinoma: a pilot study in 20 patients. *Gastroenterology* 104 (1), 196–202.

162 Olthoff KM, Rosove MH, Shackleton CR *et al.* (1995) Adjuvant chemotherapy improves survival after liver transplantation for hepatocellular carcinoma. *Ann Surg* 221 (6), 734–741.

163 Oldhafer KJ, Chavan A, Fruhauf NR *et al.* (1998) Arterial chemoembolization before liver transplantation in patients with hepatocellular carcinoma: marked tumor necrosis, but no survival benefit? *J Hepatol* 29 (6), 953–959.

164 Majno PE, Adam R, Bismuth H *et al.* (1997) Influence of preoperative transarterial lipiodol chemoembolization on resection and transplantation for hepatocellular carcinoma in patients with cirrhosis. *Ann Surg* 226 (6), 688–701.

165 Graziadei IW, Sandmueller H, Waldenberger P *et al.* (2003) Chemoembolization followed by liver transplantation for hepatocellular carcinoma impedes tumor progression while on the waiting list and leads to excellent outcome. *Liver Transpl* 9 (6), 557–563.

166 Mazzaferro V, Battiston C, Perrone S *et al.* (2004) Radiofrequency ablation of small hepatocellular carcinoma in cirrhotic patients awaiting liver transplantation: a prospective study. *Ann Surg* 240 (5), 900–909.

167 Lu DS, Yu NC, Raman SS *et al.* (2005) Percutaneous radiofrequency ablation of hepatocellular carcinoma as a bridge to liver transplantation. *Hepatology* 41(5), 1130–1137.

168 Llovet JM, Mas X, Aponte JJ *et al.* (2002) Cost effectiveness of adjuvant therapy for hepatocellular carcinoma during the waiting list for liver transplantation. *Gut* 50 (1), 123–128.

169 Livraghi T, Giorgio A, Marin G *et al.* (1995) Hepatocellular carcinoma and cirrhosis in 746 patients: long-term results of percutaneous ethanol injection. *Radiology* 197 (1), 101–108.

170 Castells A, Bruix J, Bru C *et al.* (1993) Treatment of small hepatocellular carcinoma in cirrhotic patients: a cohort study comparing surgical resection and percutaneous ethanol injection. *Hepatology* 18 (5), 1121–1126.

171 Castellano L, Calandra M, Del Vecchio BC *et al.* (1997) Predictive factors of survival and intrahepatic recurrence of hepatocellular carcinoma in cirrhosis after percutaneous ethanol injection: analysis of 71 patients. *J Hepatol* 27 (5), 862–870.

172 Head HW, Dodd GD III (2004) Thermal ablation for hepatocellular carcinoma. *Gastroenterology* 127 (5 Suppl. 1), S167–178.

173 Lencioni RA, Allgaier HP, Cioni D *et al.* (2003) Small hepatocellular carcinoma in cirrhosis: randomized comparison of radio-frequency thermal ablation versus percutaneous ethanol injection. *Radiology* 228 (1), 235–240.

174 Lencioni R, Cioni D, Crocetti L *et al.* (2005) Early-stage hepatocellular carcinoma in patients with cirrhosis: long-term results of percutaneous image-guided radiofrequency ablation. *Radiology* 234 (3), 961–967.

175 Livraghi T, Solbiati L, Meloni MF *et al.* (2003) Treatment of focal liver tumors with percutaneous radio-frequency ablation: complications encountered in a multicenter study. *Radiology* 226 (2), 441–451.

176 Shiina S, Teratani T, Obi S *et al.* (2005) A randomized controlled trial of radiofrequency ablation with ethanol injection for small hepatocellular carcinoma. *Gastroenterology* 129 (1), 122–130.

177 Ishii H, Okada S, Nose H *et al.* (1996) Predictive factors for recurrence after percutaneous ethanol injection for solitary hepatocellular carcinoma. *Hepatogastroenterology* 43 (10), 938–943.

178 Kanematsu T, Furuta T, Takenaka K *et al.* (1989) A 5-year experience of lipiodolization: selective regional chemotherapy for 200 patients with hepatocellular carcinoma. *Hepatology* 10 (1), 98–102.

179 Sasaki Y, Imaoka S, Kasugai H *et al.* (1987) A new approach to chemoembolization therapy for hepatoma using ethiodized oil, cisplatin, and gelatin sponge. *Cancer* 60 (6), 1194–1203.

180 Bruix J, Sala M, Llovet JM (2004) Chemoembolization for hepatocellular carcinoma. *Gastroenterology* 127 (5 Suppl. 1), S179–188.

181 Groupe d'Etude et de Traitement du Carcinome Hepatocellulaire (1995) A comparison of lipiodol chemoembolization and conservative treatment for unresectable hepatocellular carcinoma. Groupe d'Etude et de Traitement du Carcinome Hepatocellulaire. *N Engl J Med* 332 (19), 1256–1261.

182 Llovet JM, Real MI, Montana X *et al.* (2002) Arterial embolisation or chemoembolisation versus symptomatic treatment in patients with unresectable hepatocellular carcinoma: a randomised controlled trial. *Lancet* 359 (9319), 1734–1739.

183 Lo CM, Ngan H, Tso WK *et al.* (2002) Randomized controlled trial of transarterial lipiodol chemoembolization for unresectable hepatocellular carcinoma. *Hepatology* 35 (5), 1164–1171.

184 Chung YH, Song IH, Song BC *et al.* (2000) Combined therapy consisting of intraarterial cisplatin infusion and systemic interferon-alpha for hepatocellular carcinoma patients with major portal vein thrombosis or distant metastasis. 88 (9), 1986–1991.

185 Raoul JI, Bretagne JF, Caucanas JP *et al.* (1992) Internal radiation therapy for hepatocellular carcinoma. Results of a French multicenter phase II trial of transarterial injection of iodine 131-labeled Lipiodol. *Cancer* 69 (2), 346–352.

186 Leung WT, Lau WY, Ho S *et al.* (1994) Selective internal radiation therapy with intra-arterial iodine-131-Lipiodol in inoperable hepatocellular carcinoma. *J Nucl Med* 35 (8), 1313–1318.

187 Cao X, He N, Sun J *et al.* (1999) Hepatic radioembolization with Yttrium-90 glass microspheres for treatment of primary liver cancer. 112 (5), 430–432.

188 Carr BI (2004) Hepatic arterial 90Yttrium glass microspheres (Therasphere) for unresectable hepatocellular carcinoma: interim safety and survival data on 65 patients. *Liver Transpl* 10 (2 Suppl. 1), S107–110.

189 Liu MD, Uaje MB, Al, Herman J *et al.* (2004) Use of Yttrium-90 TheraSphere for the treatment of unresectable hepatocellular carcinoma. *Am Surg* 70 (11), 947–953.

190 Martinez Cerezo FJ, Tomas A, Donoso L *et al.* (1994) Controlled trial of tamoxifen in patients with advanced hepatocellular carcinoma. *J Hepatol* 20 (6), 702–706.

191 Chow P, Kiat TC, Choo TB *et al.* (1998) Tamoxifen in hepatocellular carcinoma. *Lancet* 352 (9130), 819–820.

192 Castells A, Bruix J, Bru C *et al.* (1995) Treatment of hepatocellular carcinoma with tamoxifen: a double-blind placebo-controlled trial in 120 patients. *Gastroenterology* 109 (3), 917–922.

193 CLIP (1998) Tamoxifen in treatment of hepatocellular carcinoma: a randomised controlled trial. CLIP Group (Cancer of the Liver Italian Programme). *Lancet* 352 (9121), 17–20.

194 Liu CL, Fan ST, Ng IO *et al.* (2000) Treatment of advanced hepatocellular carcinoma with tamoxifen and the correlation with expression of hormone receptors: a prospective randomized study. *Am J Gastroenterol* 95 (1), 218–222.

195 Barbare JC, Bouche O, Bonnetain F *et al.* (2005) Randomized controlled trial of tamoxifen in advanced hepatocellular carcinoma. *J Clin Oncol* 23 (19), 4338–4346.

196 Nowak AK, Stockler MR, Chow PK *et al.* (2005) Use of tamoxifen in advanced-stage hepatocellular carcinoma. A systematic review. *Cancer* 103 (7), 1408–1414.

197 Riestra S, Rodriguez M, Delgado M *et al.* (1998) Tamoxifen does not improve survival of patients with advanced hepatocellular carcinoma. *J Clin Gastroenterol* 26 (3), 200–203.

198 Llovet JM, Sala M, Castells L *et al.* (2000) Randomized controlled trial of interferon treatment for advanced hepatocellular carcinoma. *Hepatology* 31 (1), 54–58.

199 Villa E, Ferretti I, Grottola A *et al.* (2001) Hormonal therapy with megestrol in inoperable hepatocellular carcinoma characterized by variant oestrogen receptors. *Br J Cancer* 84 (7), 881–885.

200 Yuen MF, Poon RT, Lai CL *et al.* (2002) A randomized placebo-controlled study of long-acting octreotide for the treatment of advanced hepatocellular carcinoma. *Hepatology* 36 (3), 687–691.

201 Allgaier HP, Becker G, Olschewski M *et al.* (2003) Octreotide treatment in patients with advanced hepatocellular carcinoma: first results of the randomized placebo-controlled double-blind Hector trial. *Hepatology* 38, 760A.

202 Grimaldi C, Bleiberg H, Gay F *et al.* (1998) Evaluation of antiandrogen therapy in unresectable hepatocellular carcinoma: results of a European Organization for Research and Treatment of Cancer multicentric double-blind trial. *J Clin Oncol* 16 (2), 411–417.

203 Groupe d'Etude et de Traitement du Carcinome Hepatocellulaire (2004) Randomized trial of leuprorelin and flutamide in male patients with hepatocellular carcinoma treated with tamoxifen. *Hepatology* 40 (6), 1361–1369.

204 Strumberg D, Richly H, Hilger RA *et al.* (2005) Phase I clinical and pharmacokinetic study of the novel Raf kinase and vascular endothelial growth factor receptor inhibitor BAY 43-9006 in patients with advanced refractory solid tumors. *J Clin Oncol* 23 (5), 965–972.

205 Kensler TW, Egner PA, Wang JB *et al.* (2004) Chemoprevention of hepatocellular carcinoma in aflatoxin endemic areas. *Gastroenterology* (5 Suppl. 1), S310–318.

206 EASL Jury (2003) EASL International Consensus Conference on Hepatitis B. 13–14 September, 2002: Geneva, Switzerland. Consensus statement. *J Hepatol* 38 (4), 533–540.

207 Lok AS (2004) Prevention of hepatitis B virus-related hepatocellular carcinoma. *Gastroenterology* 127 (5 Suppl. 1), S303–309.

208 Liaw YF, Sung JJ, Chow WC *et al.* (2004) Lamivudine for patients with chronic hepatitis B and advanced liver disease. *N Engl J Med* 351 (15), 1521–1531.

209 Heathcote EJ (2004) Prevention of hepatitis C virus-related hepatocellular carcinoma. *Gastroenterology* 127 (5 Suppl. 1), S294–302.

210 Kowdley KV (2004) Iron, hemochromatosis, and hepatocellular carcinoma. *Gastroenterology* 127, S79–86.

211 Arase Y, Ikeda K, Murashima N *et al.* (1997) The long term efficacy of glycyrrhizin in chronic hepatitis C patients. *Cancer* 79 (8), 1494–1500.

212 Gelatti U, Covolo L, Franceschini M *et al.* (2005) Coffee consumption reduces the risk of hepatocellular carcinoma independently of its aetiology: a case–control study. *J Hepatol* 42, 528–534.

213 Habu D, Shiomi S, Tamori A *et al.* (2004) Role of vitamin K2 in the development of hepatocellular carcinoma in women with viral cirrhosis of the liver. *JAMA* 292 (3), 358–361.

18.2.2 Malignant mesenchymal tumours of the liver

Miguel Bruguera and Juan Rodés

Primary mesenchymal tumours of the liver are much less common than tumours of epithelial origin. Angiosarcoma, epithelioid haemangioendothelioma and undifferentiated embryonal sarcoma are those most frequently observed. Others, such as rhabdomyosarcoma, fibrosarcoma, leiomyosarcoma and malignant fibrotic histiocytoma, are exceedingly rare.

In general, the aetiology of these tumours is unknown, although nowadays the cause of angiosarcoma is recognized in some patients. The clinical course depends on the type of tumour: very aggressive in angiosarcoma and relatively benign in haemangioendothelioma. Diagnosis is based on morphological examination of the tumour.

Several excellent reviews of this topic have been published [1–4]. The most outstanding clinical and morphological characteristics are described in this chapter.

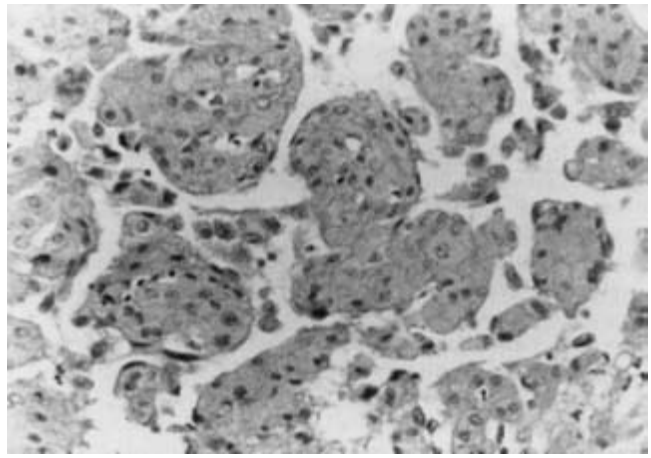

Fig. 1 Angiosarcoma. Large malignant endothelial cells cover thick hepatic cords and are present in the lumen of dilated sinusoids (H&E × 175).

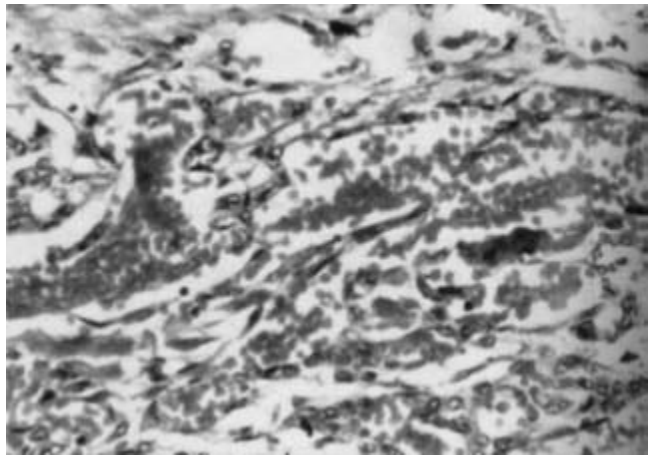

Fig. 2 Angiosarcoma. The hepatic structure has been replaced by vascular spaces lined by spindle-shaped cells (H&E × 245).

Angiosarcoma

Occurrence

Angiosarcoma, also termed haemangiosarcoma or malignant haemangioendothelioma, is the most frequent mesenchymal primary malignant tumour affecting the liver [3]. It accounts for 2% of all malignant tumours seen at autopsy, with an estimated 25 cases occurring annually in the United States [5] and one or two in Great Britain [6].

Angiosarcoma originates from the endothelial cells of the sinusoidal lining [7]. It generally appears in adults, although it has been recognized in some children, mostly in association with infantile haemangioendothelioma [8]. It has been reported to occur in patients with haemochromatosis [9] and with von Recklinghausen's disease [10].

Pathology

The tumour affects both lobes and appears as multiple nodules of varied size that have ill-defined borders, are greyish-white in colour and have haemorrhagic foci which occasionally produce a blood-filled cavity. The uninvolved liver is often normal.

The tumour cells are spindle-shaped or irregular in outline and have elongated and hyperchromatic nuclei with prominent nucleoli. Other cells are polyhedric or irregular with conspicuous cytoplasm and rounded nuclei (Fig. 1).

The tumour cells infiltrate sinusoids, hepatic and portal veins and, finally, substitute the hepatic parenchyma. Three histological patterns, which may coexist in the same patient, may be seen: (i) a sinusoidal pattern in which proliferating cells are within the sinusoids and induce sinusoidal dilatation and atrophy of hepatic plates (Fig. 1); (ii) a solid pattern characterized by a dense proliferation of sarcomatous cells, which replace large areas of hepatic parenchyma; and (iii) a cavernomatous pattern consisting of large vascular spaces surrounded by thick fibrotic cords lined by multilayered tumour cells (Fig. 2).

Staining of tumour cells with antibodies to the factor VIII-related antigen and *Ulex europaeus* I lectin is positive in most cases [11]. Extramedullary haematopoiesis is often present within the tumour.

In angiosarcomas associated with thorotrast, this material may be identified in the form of refractile granules of brown colour. Its nature is confirmed by autoradiography or by X-ray dispersive energy microanalysis [12,13].

Non-tumoral hepatic tissue is usually not cirrhotic, but may show several morphological changes, particularly in patients exposed to vinyl chloride, such as increased thickness of Glisson's capsule, portal and periportal fibrosis, deposition of collagen in

the space of Disse, proliferation and activation of sinusoidal cell lining, and hypertrophic hepatocytes with abnormal and double nuclei [14–16].

Clinical features

Angiosarcoma usually develops in the sixth and seventh decades of life, and is more frequent in males than in females (ratio 3:1). The clinical presentation is variable [4]. Two-thirds of patients have symptoms and signs mimicking chronic liver disease, such as malaise, anorexia, weight loss, right upper quadrant pain and ascites, often serohaematic. Occasionally, abdominal pain is intense and may be the first symptom. In approximately 15% of patients, the initial complaint is an acute spontaneous haemoperitoneum secondary to the rupture of a nodule on the surface of the liver. In other patients, clinical manifestations are related to the presence of pulmonary or skeletal metastases [17].

Physical examination reveals liver enlargement, which is often painful, or a palpable abdominal mass. Splenomegaly is greatly accentuated in patients with angiosarcoma associated with exposure to vinyl chloride monomer. At diagnosis, metastases are common. Hepatic bruits may be heard on auscultation, reflecting the arteriovenous shunting in these tumours [18].

There are no specific biochemical changes. Standard liver function tests are abnormal in more than two-thirds of cases. High serum alkaline phosphatase activity is the most frequent alteration. Microangiopathic haemolytic anaemia and thrombocytopenia secondary to blood cell damage by passing through the tumoral vascular channels may be observed [18]. Intravascular disseminated coagulation is detected very occasionally [19]. Plasma levels of α-fetoprotein are not elevated.

Imaging techniques show non-specific changes. Ultrasonography and computerized tomography (CT) scans reveal hepatic areas of dense heterogeneity, while hepatic arteriography shows a peripheral hypervascularity with an avascular central area. False-negative imaging with CT and ultrasound scans may occur when the tumour infiltrates hepatic sinusoids.

When the tumour is associated with previous thorotrast administration, storage of radio-opaque material in the liver, spleen and lymph nodes is seen on abdominal radiography [20].

Liver biopsy is required for histological diagnosis. Needle biopsy is hazardous because it may be complicated by uncontrollable bleeding [4].

Natural history

The prognosis of angiosarcoma is dismal. Most patients die within 6 months of diagnosis. The most frequent causes of death are hepatic failure and intra-abdominal bleeding. Fifty per cent of patients develop metastases before death [3]. Very few patients have limited tumour at the time of diagnosis to allow surgical resection.

Pathogenesis

In more than 70% of patients, the pathogenesis is unknown. In the remainder, the development of angiosarcoma has been found to be associated with the following agents: (i) exposure to thorotrast [21,22]; (ii) continuous exposure to arsenic in insecticides used by vineyard sprayers [23], following prolonged treatment for psoriasis with Fowler liquor (potassium arsenite) [24] or due to consumption of water contaminated with arsenic [25]; (iii) prolonged industrial exposure to vinyl chloride monomer [26–28]; and (iv) treatment with anabolic drugs [29].

Single cases of angiosarcoma have been reported in a patient with primary haemochromatosis [10], in patients treated with phenelzine (a monoaminocyclase inhibitor) [30], diethylstilbestrol [31] and urethane [32], and in association with von Recklinghausen's disease [33].

Thorotrast is a 20% colloidal solution of thorium dioxide that was used as a radiological contrast medium between 1930 and 1953. It accumulates in the reticuloendothelial system, particularly in the liver, emitting α-radiation for a long period. The biological half-life of thorotrast is 400 years. The time required for development of the tumour is between 12 and 40 years [34]. In addition to angiosarcoma, patients who received thorotrast may develop other malignant tumours, such as hepatocellular carcinoma and cholangiocarcinoma, which may present simultaneously [35].

Angiosarcoma has been reported in males working in contact with vinyl chloride monomer. This chemical is polymerized to polyvinyl chloride on autoclaving, and residual deposits were removed manually from the walls of the autoclaves. During this procedure, large amounts of trapped gaseous vinyl chloride monomer are released and, in the past, were inhaled by the cleaners. Although the frequency of angiosarcoma associated with vinyl chloride is diminishing because of technological changes and strict programmes applied to plastics factories [27], it is calculated that new cases will still appear in western Europe and in the United States in future years, as there is a latency period of 12–29 years between first exposure to the chemical and the development of angiosarcoma [36].

Treatment

Surgical removal of the tumour or liver transplantation are rarely possible as the tumours are large and multifocal at the time of diagnosis. Radiotherapy and chemotherapy are ineffective.

Epithelioid haemangioendothelioma

Occurrence

This tumour was described initially in the lungs and later identified in soft tissue and bone. In 1984, Ishak *et al.* [37] reported 32 patients with epithelioid haemangioendothelioma primarily affecting the liver. The tumour may be found at any

age and is more frequent among women. It has been reported particularly in Caucasian patients.

Pathology

On gross examination, it consists of multiple nodules of variable size (0.5–12 cm diameter), which at times form confluent masses, grey-white colour and firm consistency, distributed diffusely throughout the liver. The uninvolved liver is usually normal, although cases with cirrhosis have been recorded. Tumour calcification is not rare [38].

Histologically, it comprises two types of cells, epithelioid and dendritic, surrounded by a myxoid stroma, which becomes sclerotic and may occasionally be calcified [39]. Epithelioid cells are rounded, display abundant cytoplasm and have hyperchromatic nuclei with prominent nucleoli. They grow in cohesive groups on the periphery of the nodules infiltrating the sinusoids, producing atrophy and eventually disappearance of the hepatic plates. Dendritic cells are irregular in shape with interdigitating processes and are embedded singly in the central stromal matrix; many have cytoplasmic vacuoles that represent intracellular vascular lumina which may contain erythrocytes (Fig. 3). Recognition of these vacuoles facilitates diagnosis of the tumour [40].

Two features of epithelioid haemangioendothelioma are: (i) the tendency for invasion by blood vessels, portal vein branches and central veins; and (ii) a peripherally active growth, with the central part of the tumour becoming sclerotic.

Clinical features

The most common clinical manifestations of the tumour (in 45% of patients) are weakness, anorexia, pain in the right upper abdominal quadrant and loss of body weight. The clinical presentation occasionally mimics decompensated chronic liver disease, and patients present with ascites and gastrointestinal bleeding related to the intravascular growth of the tumour [41]. A single patient has presented with veno-occlusive liver disease [42]. In some 20% of patients, the tumour is discovered by chance as a consequence of ultrasound or CT examination at the workup for some unrelated problem.

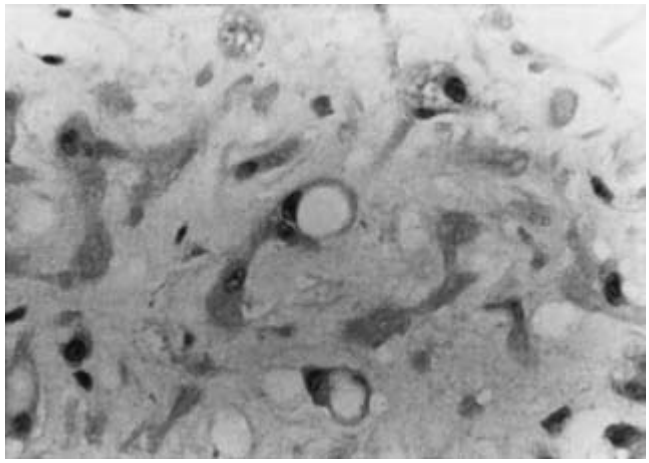

Fig. 3 Epithelioid haemangioendothelioma. Isolated epithelioid neoplastic cells are intermingled with spindle-shaped cells in a fibromyxoid stroma. Some cells contain large intracytoplasmic vacuoles (HE × 280).

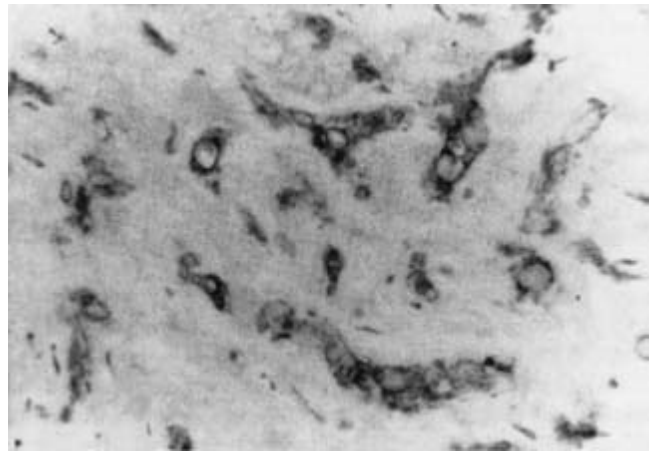

Fig. 4 Epithelioid haemangioendothelioma. Factor VIII-related antigen is present in the cytoplasm of the neoplastic cells (avidin–biotin–peroxidase technique × 245).

Physical examination reveals liver enlargement in all patients. Splenomegaly rarely develops. Liver function tests may be normal, except for an increased serum alkaline phosphatase activity. α-Fetoprotein is negative (Fig. 4).

Imaging methods allow recognition of the tumour, but do not permit its distinction from metastatic tumours. Abdominal ultrasound shows hypoechogenic nodules with a centre of variable echogenicity. CT scan reveals nodules of low density with an undefined periphery [43–45]. The finding of multiple peripheral hepatic lesions with capsular retraction on CT scans or magnetic resonance imaging (MRI) is suggestive of epithelioid haemangioendothelioma [46]. Abdominal plain films may reveal calcifications. On hepatic arteriography, the tumour appears as an avascular mass [47].

Natural history

The evolution of epithelioid haemangioendothelioma is unpredictable. In some patients, the clinical course is long and apparently benign, without affecting the general health status for many years, whereas in others, it is rapidly progressive with the development of hepatic failure causing death within a few months [48,49]. Twenty per cent of the patients reported by Ishak *et al.* [37] had died within 2 years of diagnosis, while another 20% had a survival rate of over 5 years. The presence of metastases at diagnosis of the tumour does not represent a worse prognosis compared with those patients without metastases [50]. About 40% of patients have metastases at diagnosis or during follow-up, although distinction between metastases and multicentric disease is not easy.

Pathogenesis

The pathogenesis is unknown. Some authors have suggested a relationship with oral contraceptives [50,51], but this has not been confirmed by others. In one patient, epithelioid haemangioendothelioma developed after exposure to vinyl chloride [52] and, in another, it was associated with primary biliary cirrhosis [53]. In general, the tumour does not arise in a setting of chronic liver disease.

Treatment

Surgical removal is not feasible as the tumour is multifocal and chemotherapy is not effective. Successful transplantation has been performed in several patients [50,54,55]. Such treatment could be performed even when metastases are present, as the survival expectancy of these patients may be prolonged [56]. However, it is possible that the survival rates are not influenced by hepatic transplantation as this tumour has a relatively good prognosis. Gelin *et al.* [52] have proposed liver transplantation only in patients with a rapidly progressive course. Tumour recurrence after liver transplantation has been reported.

Undifferentiated (embryonal) sarcoma

Undifferentiated sarcoma, also termed primary sarcoma, embryonal sarcoma, mesenchymal sarcoma, fibromyxosarcoma or malignant mesenchymoma, is a very uncommon tumour that appears in older children, aged between 6 and 10 years; more than 95% of cases develop in patients under 20 years of age. The sexes are equally affected [57].

Pathology

The tumour appears as a single, large, globular mass (10–20 cm in diameter), usually in the right lobe of the liver. It is soft or gelatinous and of variable colour. A thick fibrous pseudocapsule is usually present. Cystic areas containing blood and necrotic tissue may exist within the tumour.

Histologically, it is composed of fusiform or stellate cells, of ill-defined outline, with rounded or elongated nuclei, inconspicuous nucleoli and eosinophilic cytoplasm. Mitoses are abundant. The neoplastic cells are compactly or loosely arranged in a myxoid stroma that contains trapped bile ducts. Occasionally, this matrix has collagenous or reticulin fibres. The tumour is vascularized and usually contains extramedullary haematopoietic foci. Sarcomatous cells have no histological element of differentiation, rhabdomyoblast or fibroblast. Most tumours contain large cells with cytoplasmic globular inclusions positive for periodic acid–Schiff stain [58]. The nature of these inclusions is unknown but, in one case, they reacted with α-1-antitrypsin serum antibody [59].

Clinical features

The most frequent clinical manifestations are abdominal pain, the presence of a mass in the upper right abdominal quadrant, or both. Fever and weight loss may be present. In one patient, the invasion of the inferior vena cava and right atrium produced clinical manifestations of a cardiac tumour [60]. Tumour markers in the peripheral blood are not raised.

Ultrasonography demonstrates a large solid mass, isoechoic or hyperechoic relative to the surrounding liver parenchyma, with hypoechoic areas resulting from intratumoral necrosis [61]. CT scans show a hypodense mass with a dense peripheral ring corresponding to the pseudocapsule. Arteriography reveals an avascular mass.

Treatment

The prognosis for undifferentiated sarcoma is very poor, and most patients die within the first year after diagnosis as a result of liver failure [61]. Usually, the tumour cannot be removed surgically, but those patients in whom surgery was feasible have survived for several years. Promising results have been obtained using aggressive therapy combining radiotherapy, chemotherapy and ligation of the hepatic artery [58,62,63].

Fibrosarcoma

Fibrosarcoma is a very uncommon tumour; fewer than 25 cases have been reported. It develops in middle-aged or elderly adults, and is more frequent in males (85% of cases).

Pathology

Usually, it consists of a single, large, well-circumscribed, greyish-white, non-encapsulated mass. Histologically, it is composed of spindle cells with hyperchromatic and pleomorphic nuclei arranged in interlacing bundles. Mitoses are not prominent. Among the tumour cells, there is a high number of collagen fibres.

Clinical features and treatment

An abdominal mass and hepatic enlargement are the most common clinical features. Acute spontaneous haemoperitoneum may occur as a consequence of rupture of the tumour. Their association with recurrent hypoglycaemia has been documented. Survival of patients with hepatic fibrosarcoma is very short, although some have survived several years following surgical resection or radiotherapy.

Leiomyosarcoma

This is another very rare tumour. Gates *et al.* [64] have reviewed

a total of 54 cases in world literature. Cases have been observed in middle-aged and elderly people, with both sexes being equally affected. This tumour may be primarily hepatic [65], may arise in the ligamentum teres [66] or in the wall of the suprahepatic veins [67]. Some cases have been associated with cirrhosis [68,69].

Pathology

Leiomyosarcoma is a large, greyish-white, solitary, non-encapsulated mass formed by spindle cells with slightly eosinophilic cytoplasm, which display longitudinal striations. The nuclei are hyperchromatic and elongated with abundant mitoses. Vimentin reaction is often diffusely positive. Desmin and myosin are positive only in some cases.

Clinical features

The tumour presents as an abdominal mass, sometimes associated with pain in the right upper abdominal quadrant, weakness, anorexia and weight loss. A Budd–Chiari syndrome may develop secondary to hepatic vein obstruction. Hepatic arteriography detects an avascular lesion.

Treatment

Surgical removal, when possible, is indicated because it is followed by prolonged survival. When resection is not feasible because of a massive tumour, the patient survives only a few months [70,71]. The prognosis is worse in tumours that arise in the hepatic veins or in the ligamentum teres than in those that develop in the liver.

Malignant fibrous histiocytoma

The liver is very rarely the primary location for this tumour [72]. To date, only 21 cases have been reported [73]. It may appear as either a solitary mass or multiple nodules. Histologically, it is formed by fibrohistiocytic pleomorphic cells with numerous atypical mitoses disposed in a fascicular or storiform pattern, admixed with collagen bundles and with inflammatory cells, lymphocytes and plasma cells [74]. A moderate number of giant cells is common.

Neoplastic cells are positive for vimentin and negative for cytokeratin and desmin. Ultrastructural examination shows that tumour cells share features of fibroblasts and histiocytes.

Clinically, the tumour is revealed as a palpable abdominal mass. Laboratory studies are unremarkable. Metastatic malignant fibrous histiocytoma from soft tissue (retroperitoneum or extremities) must be considered in the differential diagnosis. Surgical removal is indicated [75], but the overall prognosis is dismal.

Embryonal rhabdomyosarcoma

This is an extrahepatic biliary tract tumour growing towards the liver. In general, it occurs in children (most patients are under 5 years of age; [76]), but it has been documented in adults [77].

Clinically, this tumour causes obstructive jaundice because of the intrahepatic location. Imaging techniques may reveal a hilar mass. Histologically, there is a proliferation of rounded, spindle- or strap-shaped cells, with numerous mitoses and cross-striations in the cytoplasm, set in a loose myxoid stroma. Immunohistochemistry demonstrates myoglobin, myosin and desmin in tumour cells.

Malignant rhabdoid tumour

This is an infantile tumour that usually arises in the kidneys. Three primarily hepatic cases with a very aggressive clinical course not responding to chemotherapy have been reported [78,79]. Tumour cells are polygonal with eccentric and vesicular nuclei, prominent nucleoli and eosinophilic globular inclusions in the cytoplasm. They react with antibodies to cytokeratins, epithelial antigen membranes and vimentin.

References

1 Ishak KG (1988) Malignant tumours of the liver. In: Okuda K, Ishak KG (eds) *Neoplasms of the Liver*. Berlin: Springer-Verlag, pp. 160–176.

2 Craig JR, Peters RL, Edmonson HA (1988) *Tumors of the Liver and Intrahepatic Bile Ducts*. Washington, DC: Armed Forces Institute of Pathology.

3 Zafrani ES (1989) Update on vascular tumors of the liver. *J Hepatol* 8, 125–130.

4 Locker GY, Doroshow JH, Zwelling LA *et al.* (1979) The clinical features of hepatic angiosarcoma: a report of four cases and review of English literature. *Medicine* 58, 48–64.

5 Falk H, Herbert J, Crowley S *et al.* (1981) Epidemiology of hepatic angiosarcoma in the United States: 1964–1974. *Environ Health Perspect* 41, 107–113.

6 Baxter PJ, Anthony PP, MacSween RNM *et al.* (1980) Angiosarcoma of the liver: annual occurrence and aetiology in Great Britain. *Br J Ind Med* 37, 213–221.

7 Fortwengler HP, Jones D, Espinosa E *et al.* (1981) Evidence for endothelial cell origin of vinyl chloride-induced hepatic angiosarcoma. *Gastroenterology* 80, 1415–1419.

8 Noronha R, Gonzalez-Crussi F (1984) Hepatic angiosarcoma in childhood. *Am J Surg Pathol* 8, 863–871.

9 Sussman EB, Nydick J, Gray GF (1974) Hemangioendothelial sarcoma of the liver and hemochromatosis. *Arch Pathol Lab Med* 97, 39–42.

10 Andreu V, Elizalde I, Mallafre C *et al.* (1997) Plexiform neurofibromatosis and angiosarcoma of the liver in von Recklinghausen disease. *Am J Gastroenterol* 92, 1229–1230.

11 Miettinen M, Holthofer H, Lehto VP *et al.* (1983) *Ulex europaeus* I lectin as a marker for tumors derived from endothelial cells. *Am J Clin Pathol* 79, 32–36.

12 Bowen JH, Woodward BH, Mossler JA *et al.* (1980) Energy dispersive X-ray detection of thorium dioxide. *Arch Pathol Lab Med* 104, 459–461.

13 Landas S, Turner JW, Moore KC *et al.* (1984) Demonstration of iron and thorium in autopsy tissues by X-ray microanalysis. *Arch Pathol Lab Med* 108, 231–233.

14 Delorme F, Mark L (1975) Angiosarcomas of the liver in workers having had prolonged contact with vinyl chloride: morphological description of the lesions. *Union Med Can* 104, 1836.

15 Thomas LB, Popper H, Berk PD *et al.* (1975) Vinyl-chloride-induced liver disease. From idiopathic portal hypertension (Banti's syndrome) to angiosarcomas. *N Engl J Med* 292, 17–22.

16 Tamburro CH, Makk L, Popper H (1984) Early hepatic histologic alterations among chemical (vinyl monomer) workers. *Hepatology* 4, 413–418.

17 Molina E, Hernandez A (2003) Clinical manifestations of primary hepatic angiosarcoma. *Dig Dis Sci* 48, 677–682.

18 Neshiwat LF, Friedland ML, Schorr-Lesnick B *et al.* (1992) Hepatic angiosarcoma. *Am J Med* 93, 219–222.

19 Truell JE, Peck SD, Reiquam CW (1973) Hemangiosarcoma of the liver complicated by disseminated intravascular coagulation. A case report. *Gastroenterology* 65, 936–942.

20 Levy DW, Rindsberg S, Friedman AC *et al.* (1986) Thorotrast-induced hepatosplenic neoplasia: CT identification. *Am J Roentgenol* 146, 997–1004.

21 Falk H, Caldwell GG, Ishak KG *et al.* (1981) Arsenic-related hepatic angiosarcoma. *Am J Ind Med* 2, 43–50.

22 Kojiro M, Nakashima T, Ito Y *et al.* (1985) Thorium dioxide-related angiosarcoma of the liver. Pathomorphologic study of 29 autopsy cases. *Arch Pathol Lab Med* 109, 853–857.

23 Roth F (1957) After effects of chronic arsenism in Moselle wine makers. *Dtsch Med Wochenschr* 82, 211–217.

24 Lander JJ, Stanley RJ, Sumner HW *et al.* (1975) Angiosarcoma of the liver associated with Fowler's solution (potassium arsenite). *Gastroenterology* 68, 1582–1586.

25 Rennke H, Prat G, Etcheverry R *et al.* (1971) [Malignant hemangioma of the liver and chronic arsenicism]. *Rev Med Child 99*, 664–668 [in Spanish].

26 Berk PD, Martin JF, Young RS *et al.* (1976) Vinyl chloride-associated liver disease. *Ann Intern Med* 84, 717–731.

27 Dannaher CL, Tamburro CH, Yam LT. (1981) Occupational carcinogenesis: the Louisville experience with vinyl chloride-associated hepatic angiosarcoma. *Am J Med* 70, 279–287.

28 Lee FI, Smith PM, Bennett D *et al.* (1996) Occupationally related angiosarcoma of the liver in the United Kingdom 1972–1994. *Gut* 39, 312–318.

29 Falk H, Thomas LB, Popper H *et al.* (1979) Hepatic angiosarcoma associated with androgenic-anabolic steroids. *Lancet* ii(8152), 1120–1123.

30 Daneshmend TK, Scott GL, Bradfield JW (1979) Angiosarcoma of liver associated with phenelzine. *Br Med J* 1(6179), 1679.

31 Hoch-Ligeti C (1978) Angiosarcoma of the liver associated with diethylstilbestrol. *JAMA* 240, 1510–1511.

32 Cadranel JF, Legendre C, Desaint B *et al.* (1993) Liver disease from surreptitious administration of urethane. *J Clin Gastroenterol* 17, 52–56.

33 Lederman SM, Martin EC, Laffey KT *et al.* (1987) Hepatic neurofibromatosis, malignant schwannoma, and angiosarcoma in von Recklinghausen's disease. *Gastroenterology* 92, 234–239.

34 Selinger M, Koff RS (1975) Thorotrast and the liver: a reminder. *Gastroenterology* 68, 799–803.

35 Kojiro M, Kawano Y, Kawasaki H *et al.* (1982) Thorotrast-induced hepatic angiosarcoma, and combined hepatocellular and cholangiocarcinoma in a single patient. *Cancer* 49, 2161–2164.

36 Forman D, Bennett B, Stafford J *et al.* (1985) Exposure to vinyl chloride and angiosarcoma of the liver: a report of the register of cases. *Br J Ind Med* 42, 750–753.

37 Ishak KG, Sesterhenn IA, Goodman ZD *et al.* (1984) Epithelioid hemangioendothelioma of the liver: a clinicopathological and follow-up study of 32 cases. *Hum Pathol* 15, 839–852.

38 den Bakker MA, den Bakker AJ, Beenen R *et al.* (1998) Subtotal liver calcification due to epithelioid hemangioendothelioma. *Pathol Res Pract* 194, 189–194; discussion p. 195.

39 Dietze O, Davies SE, Williams R *et al.* (1989) Malignant epithelioid haemangioendothelioma of the liver: a clinicopathological and histochemical study of 12 cases. *Histopathology* 15, 225–237.

40 Weiss SW, Ishak KG, Dail DH *et al.* (1986) Epithelioid hemangioendothelioma. *Diagn Histopathol* 3, 259–287.

41 Rojter S, Villamil FG, Petrovic LM *et al.* (1995) Malignant vascular tumors of the liver presenting as liver failure and portal hypertension. *Liver Transpl Surg* 1, 156–161.

42 Eckstein RP, Ravich RB (1986) Epithelioid hemangioendothelioma of the liver. Report of two cases histologically mimicking veno-occlusive disease. *Pathology* 18, 459–462.

43 Radin DR, Craig JR, Colletti PM *et al.* (1988) Hepatic epithelioid hemangioendothelioma. *Radiology* 169, 145–148.

44 Furui S, Itai Y, Ohtomo K *et al.* (1989) Hepatic epithelioid hemangioendothelioma: report of five cases. *Radiology* 171, 63–68.

45 Van Beers B, Roche A, Mathieu D *et al.* (1992) Epithelioid hemangioendothelioma of the liver: MR and CT findings. *J Comput Assist Tomogr* 16, 420–424.

46 Miller WJ, Dodd GD III, Federle MP *et al.* (1992) Epithelioid hemangioendothelioma of the liver: imaging findings with pathologic correlation. *Am J Roentgenol* 159, 53–57.

47 Clements D, Hubscher S, West R *et al.* (1986) Epithelioid haemangioendothelioma. A case report. *J Hepatol* 2, 441–449.

48 Scoazec JY, Lamy P, Degott C *et al.* (1988) Epithelioid hemangioendothelioma of the liver. Diagnostic features and role of liver transplantation. *Gastroenterology* 94, 1447–1453.

49 Terg R, Bruguera M, Campo E *et al.* (1988) Epithelioid hemangioendothelioma of the liver: report of two cases. *Liver* 8, 105–110.

50 Kelleher MB, Iwatsuki S, Sheahan DG (1989) Epithelioid hemangioendothelioma of liver. Clinicopathological correlation of 10 cases treated by orthotopic liver transplantation. *Am J Surg Pathol* 13, 999–1008.

51 Dean PJ, Haggitt RC, O'Hara CJ (1985) Malignant epithelioid hemangioendothelioma of the liver in young women. Relationship to oral contraceptive use. *Am J Surg Pathol* 9, 695–704.

52 Gelin M, Van de Stadt J, Rickaert F *et al.* (1989) Epithelioid hemangioendothelioma of the liver following contact with vinyl chloride. Recurrence after orthotopic liver transplantation. *J Hepatol* 8, 99–106.

53 Terada T, Nakanuma Y, Hoso M *et al.* (1989) Hepatic epithelioid hemangioendothelioma in primary biliary cirrhosis. *Gastroenterology* 97, 810–881.

54 Bancel B, Patricot LM, Caillon P *et al.* (1993) [Hepatic epithelioid hemangioendothelioma. A case with liver transplantation. Review of the literature.] *Ann Pathol* 13, 23–28.

55 Debernardi VW, Brunello F, Gubetta L *et al.* (1996) Epithelioid haemangioendothelioma of the liver: report of a case submitted to orthotopic liver transplantation. *Ital J Gastroenterol* 28, 28–30.
56 Marino IR, Todo S, Tzakis AG *et al.* (1988) Treatment of hepatic epithelioid hemangioendothelioma with liver transplantation. *Cancer* 62, 2079–2084.
57 Stocker JT, Ishak KG (1978) Undifferentiated embryonal sarcoma of the liver. *Cancer* 42, 336–348.
58 Walker (1992) *Cancer* 69, 52.
59 Abramowsky CR, Cebelin M, Choudhury A *et al.* (1980) Undifferentiated (embryonal) sarcoma of the liver with alpha-1-antitrypsin deposits: immunohistochemical and ultrastructural studies. *Cancer* 45, 3108–3113.
60 Gallivan MVE, Lack EE, Chun B *et al.* (1983) Undifferentiated (embryonal) sarcoma of the liver: Ultrastructure of a case presenting as a primary intracardiac tumor. *Pediatr Pathol* 1, 291–300.
61 Ros PR, Olmstead WW, Dachman AH *et al.* (1986) Undifferentiated (embryonal) sarcoma of the liver: radiologic–pathologic correlation. *Radiology* 161, 1410–1415.
62 Horowitz ME, Etcubanas E, Webber BL *et al.* (1987) Hepatic undifferentiated (embryonal) sarcoma and rhabdomyosarcoma in children. Results of therapy. *Cancer* 59, 396–402.
63 Lack EE, Schloo BL, Azumi N *et al.* (1991) Undifferentiated (embryonal) sarcoma of the liver. Clinical and pathologic study of 16 cases with emphasis on immunohistochemical features. *Am J Surg Pathol* 15, 1–6.
64 Gates LK Jr, Cameron AJ, Nagorney DM *et al.* (1995) Primary leiomyosarcoma of the liver mimicking liver abscess. *Am J Gastroenterol* 90, 649–652.
65 Fong JA, Ruebner BH (1974) Primary leiomyosarcoma of the liver. *Hum Pathol* 5, 115–119.
66 Tomaszewski MM, Kuenster JT, Hartman K (1986) Leiomyosarcoma of ligamentum teres of liver: case report. *Pediatr Pathol* 5, 147–156.
67 MacMahon HE, Ball HG III (1971) Leiomyosarcoma of hepatic vein and the Budd–Chiari syndrome. *Gastroenterology* 61, 239–243.
68 Ruiz Valverde MP, Vargas V, Tallada N *et al.* (1991) [Primary solid hepatic sarcoma. Diagnosis by cytological puncture] *Med Clin (Barc)* 97, 783–785 [in Spanish].
69 Tsuji M, Takenaka R, Kashihara T *et al.* (2000) Primary hepatic leiomyosarcoma in a patient with hepatitis C virus-related liver cirrhosis. *Pathol Int* 50, 41–47.
70 Masur H, Sussman EB, Molander DW (1975) Primary hepatic leiomyosarcoma: a report of two cases. *Gastroenterology* 69, 994–997.
71 Chen KT (1983) Hepatic leiomyosarcoma. *J Surg Oncol* 24, 325–328.
72 Katsuda S, Kawahara E, Matsui Y *et al.* (1988) Malignant fibrous histiocytoma of the liver: a case report and review of the literature. *Am J Gastroenterol* 83, 1278–1282.
73 Fujita S, Lauwers GY (1998) Primary hepatic malignant fibrous histiocytoma: report of a case and review of the literature. *Pathol Int* 48, 225–229.
74 Fukayama M, Koike M (1986) Malignant fibrous histiocytoma arising in the liver. *Arch Pathol Lab Med* 110, 203–206.
75 McGrady BJ, Mirakhur MM (1992) Recurrent malignant fibrous histiocytoma of the liver. *Histopathology* 21, 290–292.
76 Ruymann FB, Raney RB Jr, Crist WM *et al.* (1985) Rhabdomyosarcoma of the biliary tree in childhood. A report from the Intergroup Rhabdomyosarcoma Study. *Cancer* 56, 575–581.
77 Aldabagh SM, Shibata CS, Taxy JB (1986) Rhabdomyosarcoma of the common bile duct in an adult. *Arch Pathol Lab Med* 110, 547–550.
78 Gonzalez-Crussi F, Goldschmidt RA, Hsueh W *et al.* (1982) Infantile sarcoma with intracytoplasmic filamentous inclusions: distinctive tumor of possible histiocytic origin. *Cancer* 49, 2365–2375.
79 Parham DM, Peiper SC, Robicheaux G *et al.* (1988) Malignant rhabdoid tumor of the liver. Evidence for epithelial differentiation. *Arch Pathol Lab Med* 112, 61–64.

18.3 Metastatic tumours

18.3.1 Metastatic liver disease

Masamichi Kojiro and Antoni Castells

It is well known that the liver is one of the most common organs for metastases of malignant solid tumours. While some malignant tumours, such as renal cell carcinoma, rather infrequently metastasize to the liver, other malignancies, in particular cancers of the digestive system, breast and lung, are responsible for most hepatic metastases. Metastasis to the liver is mainly haematogenous via the portal vein system, but some tumours, such as carcinomas of the extrahepatic bile duct system, frequently metastasize to the liver via the lymphatic system.

Incidence

Although the incidence of primary liver cancers, principally hepatocellular carcinoma (HCC), is increasing greatly worldwide due to widespread hepatitis B virus and hepatitis C virus infections, metastatic liver cancers are still far more frequent. In the large series of 19 208 autopsies of malignant extrahepatic tumours at the LACUSC-MC and USC Liver Unit in the United States from 1918 to 1980, Craig *et al.* [1] described how metastatic liver cancers were 7299 times more common than primary malignant tumours, while primary liver cancers were only 405 times and metastatic liver tumours 18 times more common. Pickren *et al.* [2] also reported a far greater frequency of metastatic liver tumours (41 times) than primary hepatic tumours in the large autopsy series at Roswell Park Memorial Institute. Even in Asian countries, where the incidence of primary liver cancers is significantly higher than in western countries, metastatic liver cancers are more common than primary cancers, although the discrepancy in frequency is not as prominent as that seen in western countries. According to the annual registration of pathological autopsy cases in Japan in 2002, while metastatic liver cancers numbered 5504 (32.2%) among 17 085 malignant tumours, there were 2183 (12.7%) primary liver cancers (HCC and cholangiocarcinoma), meaning that the frequency of metastatic liver cancers was 2.5 times higher than that of primary liver cancers; however, the frequency of metastatic liver cancers is clinically much higher than that of autopsy series.

Regarding primary sites of metastases, lung, colon, pancreas, breast and stomach were the most common among 1151 autopsy cases of metastatic liver cancers in the United States [1]. Similar frequency but less common metastasis of breast cancer was also observed among 5504 autopsy cases of metastatic liver cancers in Japan in 2002 (Table 1). Thus, the proportion of metastatic and primary liver cancers and common primary sites is different geographically because of the different incidence of each tumour.

It is a matter of controversy that metastasis to cirrhotic livers is less common compared with non-cirrhotic livers. Lieber [3] reported the rarity of carcinoma metastasis to the liver and suggested that alterations in vascular relationships and fibrosis within the liver, attendant with the cirrhotic state, might represent an impediment to neoplastic emboli to the liver. Lisa *et al.* [4] also described the rarity of metastasis in cirrhotic liver and explained that it may be the result of the infrequent association of cirrhosis and extrahepatic metastasis. Gall [5] reported that

Table 1 Liver metastases in Japan[a] and the United States in autopsy cases.

Primary site	Cases	Liver metastasis	Incidence (%)	Incidence in United States (%)[b]
Pancreas	910	604	66.3	70
Extrahepatic bile duct system	201	124	61.7	78
Lung	2670	1008	37.7	42
Breast	326	123	37.7	53
Stomach	2021	629	31.1	44
Urinary bladder	359	105	29.2	38
Oesophagus	569	165	28.9	30
Colon	1510	364	24.1	56

[a]Annual registration of pathological autopsy cases in Japan in 2002.
[b]Cited in ref. 60.

the incidence of metastasis to the cirrhotic liver was 1% in autopsy series, but 10% in the general autopsy incidence of metastatic hepatic tumour. Melato *et al.* [6] studied the frequency of hepatic metastasis in 5241 consecutive autopsies performed in Italy and in 6511 autopsies in Japan in 1989, and also found a lower frequency of hepatic metastasis in cirrhotics in both countries. On the other hand, Fisher *et al.* [7] stressed a misconception about the rarity of hepatic metastasis in cirrhosis based on an analysis of 2865 consecutive autopsies in 1960. They found no statistical significance in the incidence of hepatic metastases from primary extrahepatic carcinoma of various sites in the cirrhotic patients. They described how a significant number of cirrhotics probably fail to achieve a sufficient span of life to develop extrahepatic carcinomas because the mean age at time of death of cirrhotics without extrahepatic carcinomas was significantly lower than that of cirrhotics with hepatic metastases. It is predicted that the incidence of metastases to cirrhotics may have changed in the past two decades on account of prolonged survival time due to the advancement of treatment for liver cirrhosis.

Biology of metastasis

Since the proposal of the 'seed and soil' hypothesis in cancer metastasis by Paget in 1889 [8], numerous studies on the mechanism of cancer metastasis have been reported. The development of metastasis may be seen clinically as a simple, mechanical event merely involving the release of neoplastic cells from the primary tumour and their subsequent seeding and growth into the new organ. However, the path between the appearance of the primary tumour and the recognition of a metastatic nest is a complex process. Now, it is well known that the development of metastasis takes sequential steps as follows: detachment and release of cancer cells to lymphatics and/or blood vessels; survival in the circulation; arrest in the vessel walls of organs; extravasation; progressive growth with angiogenesis; metastasis. These steps are regulated at a molecular level and involve the activation–inactivation of various genes [9–12], and only limited numbers of cancer cells reach the organ and form metastatic lesions.

When a malignant cell is to invade and disseminate, it must be able to detach from the neighbouring cells and basement membrane and migrate in the proper direction. In addition, the surrounding extracellular matrix has to be degraded to allow the cell to penetrate and reach a vascular or lymphatic vessel. The degradation of the surrounding extracellular matrix is tightly regulated by proteases, with most of the available knowledge involving serine proteases and matrix metalloproteinases (MMPs) [13]. The metalloproteinase family comprises seven members with known activity: intestinal collagenase, neutrophil collagenase, stromelysin-1, stromelysin-2, matrilysin, gelatinase A and gelatinase B. The timing and degree of activation of these different agents, which may have tissue specificity in terms of both expression and effects, determine the invasive potential of malignant cells. Furthermore, it must be taken into account that, until being released into a vessel, the invasive displacement of the cell requires the proteolytic or adhesive activity to be differentially expressed along the cell surface: the invading protrusion of the cell should exhibit proteolytic activity, while the remaining surface of the cell remains attached to the matrix by the expression of adhesion molecules [9]. Now, it has been clarified that MMPs have a broader role and affect more steps in the metastatic process than was reported previously [14,15].

Upon arriving at a vessel, the wall of the vessel is destroyed to permit the passage of the cell into the bloodstream. While being displaced by the blood flow, the neoplastic cell must survive the deleterious effects of turbulent flow and the action of the immune system. Thus, the risk of an organ suffering metastatic invasion is related not only to the organ blood flow, but also to the specific characteristics of the tissue favouring the growth of a metastatic colony of a given organ; this ability to host a metastatic nest is quantified by the so-called metastatic efficiency index. The seeding of the cell into a new organ requires cell attachment to the vessel wall, which is then perforated to allow the escape of the cell into the matrix. In addition, successful growth after leaving the vessel depends on the creation of a new vascular supply, with this new vascularization also being regulated by a complex angiogenic process, which has also occurred during the growth of the main tumour [9,10]. Molecular interactions between cancer cells and secondary organs including the liver can contribute to organ-specific metastasis [15]. Some molecular factors such as transforming growth factor (TGF)-α affect the ability of colon and other cancer cells to grow in the liver [16,17]. Müller *et al.* [18] reported that tumour cells expressing chemokine receptors metastasize specifically to the organs expressing matching chemokines.

It is rarely encountered that metastasis occurs years after successful treatment of malignant tumours such as thyroid cancer, breast cancer and melanoma with compete remission. Where are they hiding? What wakes them up? Recent experimental studies are providing some information on tumour dormancy. Holmgren *et al.* [19] studied dormant lung metastases under angiogenesis suppression in mice. They clarified that metastases remain dormant when tumour cell proliferation is balanced by an equivalent rate of cell death and suggested that angiogenesis inhibitors control metastatic growth by indirectly increasing apoptosis in tumour cells.

At any point during this sequential chain of molecular events, the cell may receive different signals or sense the presence of an adverse environment, and this can prompt the activation of apoptotic cell death, which is supposed to be the main factor in determining the non-viability of most of the cells released from the main tumour. The very active research in cancer development and progression will allow a complete understanding of the previously depicted process, and it is expected that, in the future, the prevention and treatment of metastasis will be based on the modulation of one or more of these steps.

Pathology of metastatic liver cancers

Although most metastatic liver cancers present multiple nodules of various size and are whitish grey in colour, they can be found as a solitary tumour or confluent mass as well. It was reported that metastases to the liver were found in 39% of cases in a series of 8455 autopsies of malignant tumours and only 6% of them were solitary [2]. The metastatic tumours locating close to the liver capsule tend to show 'umbilication', which is a central depression of the tumour surface caused by central necrosis due to insufficient blood supply, and 'umbilication' is regarded as the morphological characteristic of metastatic tumours in the liver (Fig. 1). In general, the development of arterial vascularity in metastatic liver tumours is poor in the central area of the tumours, and it frequently causes central necrosis or extensive necrosis of the tumour. Cancer invasion into the portal veins, which is common in HCC, is rather rare in hepatic metastases, even in massive metastases. In malignant solid tumours, such as malignant melanoma and angiosarcoma, the characteristic gross appearance is seen as a deep blackish tumour and haemorrhagic tumour respectively. Their metastatic tumours in the liver also present the same gross features as those of the primary tumour, and it is easy to specify the primary tumour on gross examination. Metastasis of breast carcinoma that was repeatedly treated with chemotherapy may represent the coarsely lobulated appearance known as 'hepar lobatum' seen in hepatic syphilis [20] (Fig. 2).

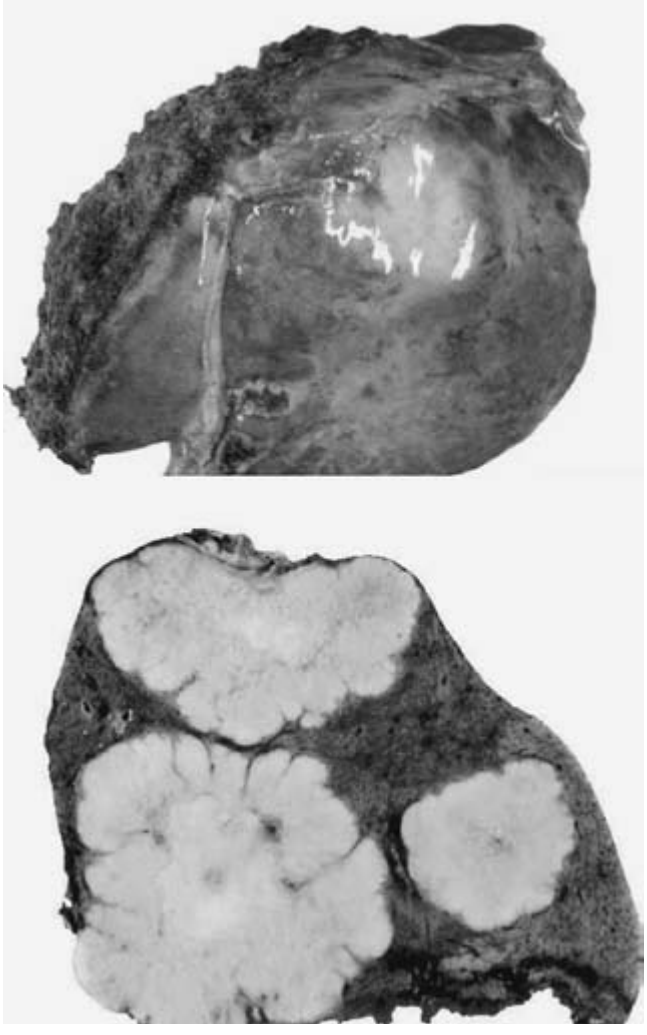

Fig. 1 Resected hepatic metastases of colon cancer. Central areas of the tumours are necrotic, and tumour beneath the liver capsule shows central depression 'umbilication'.

Fig. 2 Metastasis of breast carcinoma repeatedly treated with chemotherapy represents the coarsely lobulated appearance known as 'hepar lobatum' seen in hepatic syphilis.

On biopsy diagnosis of metastatic adenocarcinoma in the liver, in which the primary organ is clinically undefined, it is frequently difficult to specify the primary site. Moreover, it is also frequently difficult to distinguish metastatic adenocarcinoma from intrahepatic cholangiocarcinoma. Rullier *et al.* [21] reported that immunohistochemical analysis of cytokeratin (CK) 7 and 20 allows distinction between intrahepatic cholangiocarcinoma and metastases of colorectal adenocarcinoma. They described how cholangiocarcinoma is positive for CK7 and CK20 in 96% and 70% of cases, respectively, and the labelling index of CK7 is high, but is low or moderate for CK20. On the other hand, many metastatic colorectal adenocarcinomas (81%) are negative for CK7, but all are positive for CK20 with a high labelling index.

Clinical signs and laboratory tests

It is well known that metastases in the liver are silent clinically and biochemically, even in cases with widespread metastases, because of the vigorous compensatory ability of the liver. Accordingly, most patients with hepatic metastases are asymptomatic for a long period of time. The symptoms such as fatigue, weight loss, ascites, jaundice and pain, associated with large or

rapidly growing hepatic tumours, indicate a later sign of progressive liver failure and patient demise. Progressive obstructive jaundice may develop in association with occlusion of the common hepatic duct or with extensive hepatic replacement, and it has a rapidly fatal course.

Laboratory measurements of liver enzymes and tumoral markers have been examined as a method of detecting hepatic metastases and as prognostic determinants. Patients with minute or solitary liver metastases may show a normal biochemical profile. When the disease progresses, the liver function parameters disclose cholestasis due to the space occupied by the neoplastic masses. On the other hand, some investigators have correlated abnormal liver function tests, such as bilirubin, alkaline phosphatase and lactate dehydrogenase, with survival [22]. In a multivariate analysis, Lahr *et al.* [23] correlated hyperbilirubinaemia and elevated alkaline phosphatase with poor prognosis. Unfortunately, elevation of these parameters is non-specific, and no definitive association with survival has been established.

Several authors have found that most patients with colorectal hepatic metastases (from 73% to 90%) have elevated serum carcinoembryonic antigen (CEA) levels [24,25]. However, it is still controversial whether preoperative serum CEA levels are of prognostic value with regard to resectability [26]. Otherwise, CEA levels can be especially helpful when tracking patients after primary tumour resection and may be the first indication of potential recurrence of metastasis [24].

Diagnostic imaging

Ultrasonography (US)

US is an economical non-invasive imaging modality for screening liver metastases. US examination is highly dependent on equipment and sonographer expertise. The appearance of liver metastases on US may vary from discrete hypoechoic masses to mixed echo patterns. The introduction of intraoperative US has contributed to improving surgical hepatic resection [27,28]. This technique can identify liver tumours located deep in the liver parenchyma and can define the relationship to vascular structures. In a study summarizing the results of a combined series for prospective evaluation of intraoperative US compared with preoperative US, arteriography, computerized tomography (CT) and surgeon palpation, intraoperative US showed the best sensitivity (78%), specificity (100%) and diagnostic accuracy (84%) [27].

Computerized tomography

The development of multislice CT allows imaging with better spatial resolution of hepatic metastases. In addition, abdominal CT enhanced with specific contrast agents is the recommended procedure of choice in evaluating liver metastases [29] (Fig. 3). This technique is highly accurate in defining the total number and anatomical position of liver tumours. In addition, extrahepatic abdominal spread is also well evaluated and is fairly reproducible worldwide. However, recent studies have proposed a variant of CT, arteriographically enhanced CT, as the standard radiological investigation that best defines hepatic tumours preoperatively [30]. This sophisticated technique is highly sensitive in detecting lesions less than or equal to 2 cm in diameter [31]. CT arterial portography has a sensitivity of 94% in detecting liver metastases, compared with 70% by hepatic magnetic resonance imaging (MRI), with the former being significantly higher for lesions of less than 1 cm [31].

Magnetic resonance imaging

On MRI, metastases are seen as low signal areas on T1-weighted images and high signal areas on T2-weighted images [29]. MRI has a similar accuracy in the detection of liver metastases to dynamic CT [32]. None the less, MRI has significantly greater accuracy than dynamic CT in demonstrating vascular

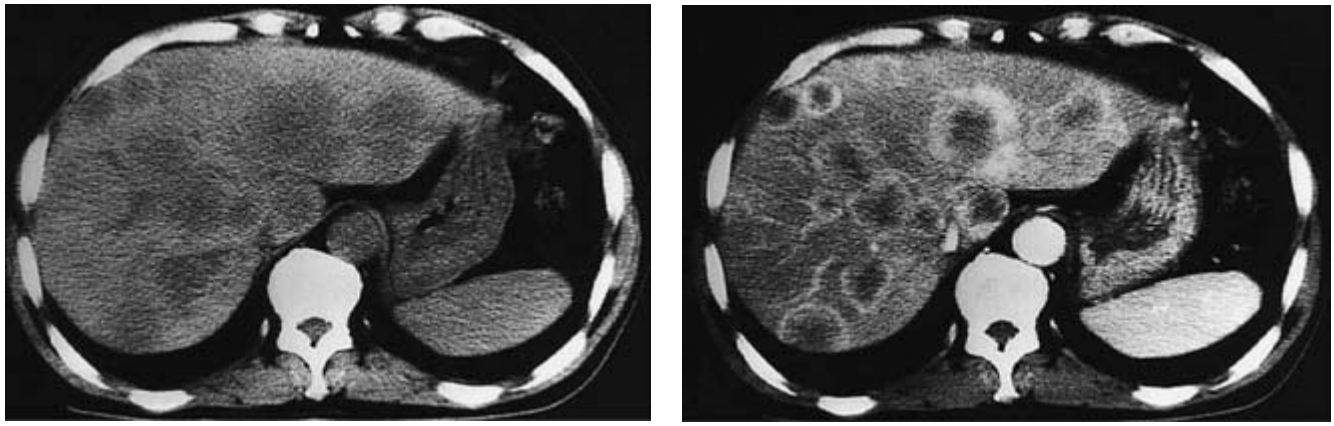

(a) (b)

Fig. 3 CT scan of widespread hepatic metastases of colon cancer. (a) Plain CT shows hypoattenuated vaguely nodular tumours. (b) On contrast CT, the tumours are clearly demonstrated with peripheral enhancement.

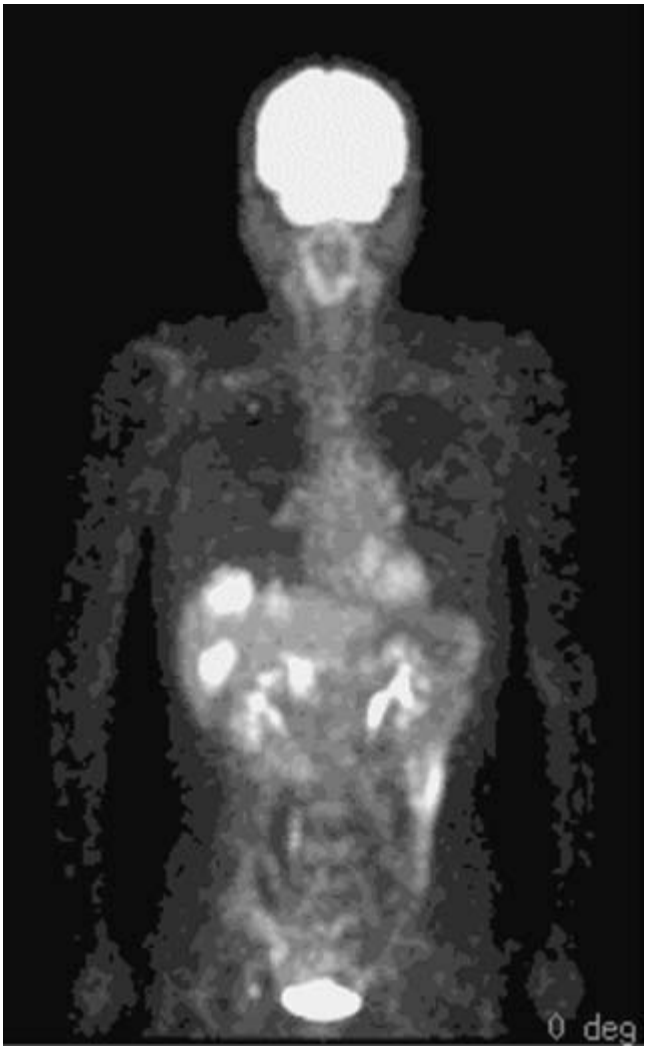

Fig. 4 PET imaging of metachronous hepatic metastases of colon cancer.

involvement [31]. Otherwise, CT allows for assessment of abdominal metastases in a slightly more precise way than MRI. Further studies are necessary to determine the definitive role of MRI in the imaging assessment of liver metastases.

Positron emission tomography (PET)

PET provides a non-invasive determination of tumorous lesions, and it is regarded as the most sensitive imaging modality for detecting cancerous lesions in the whole body including liver metastases at the present time (Fig. 4). PET has the ability to detect cancerous lesions by tracing increased accumulation of 2-[18F]fluoro-2-deoxy-D-glucose (FDG) according to the mechanism that cancers have increased glucose uptake. Zhuang *et al.* [33] compared 80 PET and CT scans with surgical pathology and clinical outcome and found a sensitivity of 100% by PET but 71.4% by CT. They stressed that PET is an excellent imaging modality for the detection and staging of liver metastases in patients with colorectal carcinomas. Similar results were also reported by Frohlich *et al.* [34] for liver metastases of pancreatic carcinomas. Furthermore, a combined PET and CT system in a single imaging setting provides optimal coregistration of image data and may provide a highly accurate demonstration of liver metastases.

Treatment

Surgical resection

Improvements in surgical technique and postoperative management have reduced operative mortality remarkably [35–38], and liver resection is the standard treatment for liver metastases without extrahepatic metastases. However, only limited numbers of patients are eligible for resection. Furthermore, complete resection is the only potentially curative treatment option for liver metastases with a 5-year survival rate of approximately 30–55% [39–42]. In addition, it is difficult to interpret the results of surgical resection because no uniform staging system is used and prospective controlled trials are lacking. The studies analysing the results of hepatic resection in patients with colorectal metastases in the liver have identified which factors determine their outcome. Among these, the parameters with a clear prognostic significance are the presence of extrahepatic disease, metastatic lymph nodes, positive margins and more than three or four lesions.

Radiofrequency ablation therapy (RFA)

In recent years, RFA has been used increasingly for the treatment of liver metastases [41–46] as well as primary liver cancers. Survival after surgical resection and RFA of solitary colorectal liver metastases is comparable, and RFA is less invasive and requires either an overnight stay or daycare facilities. RFA is also applied to patients with unresectable liver metastases in terms of downstaging, and increases in resectability and improvements in survival have been reported [41–44].

Systemic chemotherapy

In systemic chemotherapy for liver metastases, only a modest efficacy with fluoropyrimidines (5-fluorouracil, 5-fluorodeoxyuridine), nitrosoureas and mitomycin C is reported. Among these drugs, 5-fluorouracil (5-FU) is the most commonly used for liver metastases of colorectal carcinoma and has been administered as an oral agent, intravenously in bolus doses or by continuous intravenous infusion [47–50]. Selective infusion of chemotherapy agents into the hepatic arterial system has been reported to be more effective in the treatment of unresectable colorectal liver metastases [49–51]. Response rates using continuous hepatic arterial infusion of 5-fluorodeoxyuridine or 5-FU to treat hepatic metastases in unresectable colorectal cancer patients have ranged from 51% to 88%; these figures are

greater than those obtained when these drugs are administered systemically [51–54]. Recently, it has been suggested that alternating systemic chemotherapy and regional transcatheter arterial chemoembolization is an active and feasible regimen in patients with liver metastases of gastrointestinal malignancies [55].

Other treatments

In recent years, novel immunotherapies including monoclonal antibody therapy, biological modifier therapy, antiangiogenic therapy and gene therapy have been spotlighted, but most of them are still experimental. Although radiation therapy has been of modest benefit in the treatment of liver metastases, it has been used in combination with chemotherapy in most cases. In the majority of patients treated by liver transplantation for unresectable liver metastases, long-term results are poor because of early tumour recurrence. However, it has been reported that metastasis of neuroendocrine origin is eligible for liver transplantation because of its less aggressive nature [56–59].

References

1 Craig JR, Peters RL, Edmondson HA (1988) Tumors of the liver and intrahepatic bile ducts. In: Craig JR, Peters RL, Edmondson HA (eds) *Atlas of Tumor Pathology*, 2nd series, Fascicle 26, Washington, DC: Armed Forces Institute of Pathology, pp. 256–267.

2 Pickren JW, Tsukada Y, Lane WW (1982) Liver metastasis: analysis of autopsy data. In: Weiss L, Gilbert HA (eds) *Liver Metastasis*. Boston: Hall Medical Publishers, pp. 2–18.

3 Lieber MM (1957) Rare occurrence of metastatic carcinoma in cirrhotic liver. *Am J Med Sci* 233, 145–152.

4 Lisa JR, Solomon C, Gordon EJ (1942) Secondary carcinoma in cirrhosis of liver. *Am J Pathol* 18, 137–140.

5 Gall E (1960) Primary and metastatic carcinoma of the liver. Relationship to hepatic cirrhosis. *Arch Pathol* 70, 226–232.

6 Melato M, Laurino L, Mucli E *et al.* (1989) Relationship between cirrhosis, liver cancer, and hepatic metastases: an autopsy study. *Cancer* 64, 455–459.

7 Fisher E, Hellstrom HR, Fisher B (1960) Rarity of hepatic metastasis in cirrhosis – a misconception. *JAMA* 174, 366–369.

8 Paget S (1889) The distribution of secondary growths in cancer of the breast. *Lancet* 1, 571–573.

9 Kohn EC, Liotta LA (1995) Molecular insights into cancer invasion: strategies for prevention and intervention. *Cancer Res* 55, 1856–1862.

10 Chambers AF, Groom AC, MacDonald IC (2002) Dissemination and growth of cancer cells in metastatic sites. *Nature Rev* 2, 563–572.

11 O'Reilly MS, Holmgren L, Shing I *et al.* (1994) Angiostatin: a novel angiogenesis inhibitor that mediates the suppression of metastases by a Lewis lung carcinoma. *Cell* 79, 315–328.

12 Wyckoff JB, Jones JG, Gondeelis JS *et al.* (2000) A critical step in metastasis: in vivo analysis of intravasation at the primary tumor. *Cancer Res* 60, 2504–2511.

13 Stetler-Stevenson WG, Liotta LA, Kleiner DE (1993) Extracellular matrix 6: role of matrix metalloproteinases in tumor invasion and metastasis. *FASEB J* 7, 1434–1441.

14 Chambers AF, Matrisian LM (1997) Changing views of the role of matrix metalloproteineses in metastasis. *J Natl Cancer Inst* 89, 1260–1270.

15 Ogawa M, Ikeuchi K, Watanabe M *et al.* (2005) Expression of matrix metalloproteinase 7, laminin and type IV collagen-associated liver metastasis in human colorectal cancer: immunohistochemical approach. *Hepatogastroenterology* 52, 875–880.

16 Radinsky R (1995) Modulation of tumor cell gene expression and phenotype by the organ-specific metastatic environment. *Cancer Metast Rev* 14, 323–338.

17 Radinsky R (1995) Molecular mechanisms for organ-specific colon carcinoma metastasis. *Eur J Cancer* 31A, 1091–1095.

18 Müller A, Homy S, Soto H *et al.* (2001) Involvement of chemochine receptors in breast cancer metastasis. *Nature* 410, 50–56.

19 Holmgren L, O'Reilly MS, Folkman J (1995) Dormancy of micrometastases: balanced proliferation and apoptosis in the presence of angiogenesis suppression. *Nature Med* 1, 117–118.

20 Qizilbash A, Kontozoglou T, Sianos JM *et al.* (1987) Hepar lobatum associated with chemotherapy and metastatic breast cancer. *Arch Pathol Lab Med* 111, 58–61.

21 Rullier A, Le Bail B, Fawaz R *et al.* (2000) Cytokeratin 7 and 20 expression in cholangiocarcinomas varies along the biliary tract but still differs from that in colorectal carcinoma metastases. *Am J Surg Pathol* 24, 870–876.

22 Kemeny N, Braun DW, Jr (1983) Prognostic factors in advanced colorectal carcinoma. Importance of lactic dehydrogenises level, performance status, and white blood cell count. *Am J Med* 74, 786–794.

23 Lahr CJ, Soong SJ, Cloud G *et al.* (1983) A multifactorial analyses of prognostic factors in patients with liver metastases from colorectal carcinoma. *J Clin Oncol* 1, 720–726.

24 Wanebo JH, Stearna M, Schwarts MK (1978) Use of CEA as an indicator of early recurrence and as a guide to a selected second-look procedure in patients with colorectal cancer. *Ann Surg* 188, 481–493.

25 Hohenberger P, Schlag PM, Gerneth T *et al.* (1994) Pre- and postoperative carcinoembryonic antigen determinations in hepatic resection for colorectal metastases. Predictive value and implications for adjuvant treatment based on multivariate analysis. *Ann Surg* 219, 135–143.

26 Doci R, Gennari L, Bignami P *et al.* (1991) One hundred patients with hepatic metastases from colorectal cancer treated by resection: analysis of prognostic determinants. *Br J Surg* 78, 797–780.

27 Sheiner PA, Brower ST (1994) Treatment of metastatic cancer to the liver. *Semin Liver Dis* 14, 169–177.

28 Igawa S, Sakai K, Kinoshita H *et al.* (1985) Intraoperative sonography: clinical usefulness in liver surgery. *Radiology* 156, 473–478.

29 Bennett WF, Bova JG (1990) Review of hepatic imaging and a problem-oriented approach to liver masses. *Hepatology* 12, 761–775.

30 Sitzmann JV, Coleman J, Pitt HA *et al.* (1990) Preoperative assessment of malignant hepatic tumors. *Am J Surg* 159, 137–142.

31 Nelson RC, Chezmar JL, Sugarbaker PH *et al.* (1989) Hepatic tumors: comparison of CT during arterial portography, delayed CT, and MR imaging for preoperative evaluation. *Radiology* 172, 27–34.

32 Stark DD, Wittenberg J, Butch RJ *et al.* (1987) Hepatic metastases: randomized, controlled comparison of detection with MR imaging and CT. *Radiology* 165, 399–406.

33 Zhuang H, Sinha P, Pourdehnad M *et al.* (2000) The role of positron emission tomography with fluorine-18-deoxyglucose in identifying cancer metastases to liver. *Nucl Med Commun* 9, 793–798.

34 Frohlich A, Diederichs CG, Stalb L *et al.* (1999) Detection of liver metastases from pancreatic cancer using FDG PET. *J Nucl Med* 40, 250–255.

35 Steele G, Jr, Bleday R, Mayer RJ *et al.* (1991) A prospective evaluation of hepatic resection for colorectal carcinoma metastases to the liver: Gastrointestinal Tumour Study Group Protocol, 6584. *J Clin Oncol* 9, 1105–1112.
36 Makuuchi M, Hasegawa H, Yamazaki S (1985) Ultrasonically guided subsegmentectomy. *Surg Gynecol Obstet* 161, 346–350.
37 Butler J, Attiyeh FF, Daly JM (1986) Hepatic resection for metastases of the colon and rectum. *Surg Gynecol Obstet* 102, 109–113.
38 Iwatsuki S, Sheahan DG, Starzl TE (1989) The changing face of hepatic resection. *Curr Problems Surg* 26, 283–379.
39 Curley SA, Izzo F, Abdalla E *et al.* (2004) Surgical treatment of colorectal cancer metastasis. *Cancer Metast Rev* 23, 165–182.
40 Ruers T, Bleichrodt RP (2002) Treatment of liver metastases, an update on the possibility and results. *Eur J Cancer* 38, 1023–1033.
41 Oshowo A, Gilliamas A, Harrison E *et al.* (2003) Comparison of resection and radiofrequency ablation for treatment of solitary colorectal liver metastases. *Br J Surg* 90, 1240–1243.
42 Registry of Hepatic Metastases (1988) Resection of the liver for colorectal carcinoma metastases: a multi-institutional study of indications from resection. *Surgery* 103, 278–288.
43 Evard S, Becouarn Y, Fonck M *et al.* (2004) Surgical treatment of liver metastases by radiofrequency ablation, resection, or combination. *Eur J Surg* 39, 399–406.
44 Parlkh AA, Curley SA, Fornage BD *et al.* (2002) Radiofrequency ablation of hepatic metastases. *Semin Oncol* 29, 168–182.
45 Lau TN, Lo RH, Tan BS (2003) Colorectal hepatic metastases: role of radiofrequency ablation. *Ann Acad Med Sing* 32, 21–28.
46 Gazelle GS, McMahon PM, Beinfeld MT *et al.* (2004) Metastatic colorectal carcinoma: cost-effectiveness of percutaneous radiofrequency ablation versus that of hepatic resection. *Radiology* 233, 729–739.
47 Grage TB, Vassilopoulos PP, Shingleton WW *et al.* (1979) Results of a prospective randomized study of hepatic artery infusion with 5-fluorouracil vs intravenous 5-fluorouracil in patients with hepatic metastases from colorectal cancer. *Surgery* 86, 550–555.
48 Machover D, Goldschmidt E, Chollet P *et al.* (1986) Treatment of advanced colorectal and gastric adenocarcinoma with 5-fluorouracil and high-dose folinic acid. *J Clin Oncol* 4, 685–696.
49 Petrelli N, Douglass HO, Jr, Herrera L *et al.* (1989) The modulation of fluorouracil with leucovorin in metastatic colorectal carcinoma: a prospective randomized phase III trial. *J Clin Oncol* 7, 1419–1426.
50 Ardalan B, Chua L, Tian EM *et al.* (1991) A phase II study of weekly 24-hour infusion with high-dose fluorouracil with leucovorin in colorectal carcinoma. *J Clin Oncol* 9, 625–630.
51 Balch CM, Urist MM, McGregor ML (1983) Continuous regional chemotherapy for metastatic colorectal cancer using a totally implantable infusion pump. A feasibility study in 50 patients. *Am J Surg* 145, 285–290.
52 Reed ML, Vaitevicius VK, Al-Sarraf M *et al.* (1981) The practicality of chronic hepatic artery infusion therapy of primary and metastatic hepatic malignancies: ten-year results of 124 patients in a prospective protocol. *Cancer* 47, 402–409.
53 Niederhuber JE, Ensminger W, Gyves J *et al.* (1984) Regional chemotherapy of colorectal cancer metastatic to the liver. *Cancer* 53, 1336–1343.
54 Sugihara K (1995) Continuous hepatic arterial infusion of 5-fluouracil for unresectable colorectal liver metastases: phase II study. *Surgery* 117, 624–628.
55 Bavisotto LM, Patel NH, Althaus SJ *et al.* (1999) Hepatic transcatheter arterial chemoembolization alternating with systemic protracted continuous infusion of 5-fluouracil for gastrointestinal malignancies metastatic to liver: a phase II trial of the Puget Sound Oncology Consortium (PSOC 1104). *Clin Cancer Res* 5, 95–109.
56 Lang H, Schlitt HJ, Schmidt H *et al.* (1999) Total hepatectomy and liver transplantation for metastatic neuroendocrine tumors of the pancreas – a single center experience with ten patients. *Arch Surg* 384, 370–377.
57 Lang H, Oldhafer KJ, Weimann A *et al.* (1997) Liver transplantation for metastatic neuroendocrine tumors. *Ann Surg* 225, 347–354.
58 Fernandez JA, Robles R, Marin C *et al.* (2003) Role of liver transplantation in the management of metastatic neuroendocrine tumors. *Transplant Proc* 35, 1832–1833.
59 Florman S, Toure B, Kim L *et al.* (2004) Liver transplantation for neuroendocrine tumors. *J Gastrointest Surg* 8, 208–212.
60 Okuda K, Kojiro M, Okuda H (1997) Neoplasms of the liver. In: Schiff L, Schiff ER (eds) *Diseases of the Liver*, 7th edn. Philadelphia, PA: Lippincott Williams & Wilkins.

18.3.2 Carcinoid tumours

Humphrey J.F. Hodgson

Carcinoid tumours arise from endocrine cells of the gut, bronchus and other organs. They constitute one major subtype of neuroendocrine tumours, clinically distinct from other neuroendocrine tumours such as pancreatic insulinomas and vipomas or phaeochromocytomas. The distinguishing characteristics of the carcinoids are morphological, histochemical and biochemical – particularly the capacity to synthesize and secrete serotonin. Their clinical fascination stems from their potential to induce the striking systemic features of the carcinoid syndrome – predominantly diarrhoea and cutaneous flushing, sometimes with asthma or cardiac disease – if their secretory products reach the systemic circulation. Hepatic carcinoid tumours are usually secondary deposits from gastrointestinal primaries but, although these patients are suffering from metastatic disease, their prognosis is substantially better than for those with secondary adenocarcinomas in the liver.

Cell of origin

Carcinoids arise from enterochromaffin or enterochromaffin-like cells, one constituent of the diffuse neuroendocrine system scattered throughout the body [1]. These cells are characterized by the presence of neurosecretory granules and the biochemical pathways for amine precursor uptake and decarboxylation (APUD), and lie scattered in the gut lamina propria near the base of intestinal crypts (Kulchitsky cells) and in the submucosal layers of bronchi. 'Enterochromaffin' means they stain with potassium chromate. They are also 'argentaffin', taking up and spontaneously reducing silver salts. Other closely related cells may take up silver, but do not spontaneously reduce it ('argyrophilic' cells). These properties are variably present in

Table 1 Relative frequency of sites of carcinoid tumours reported in recent large surveys, incidence of regional and distal spread and comparative propensity to cause carcinoid syndrome.

Site	% of all carcinoids	% regional spread	% distal metastasis	Likelihood of carcinoid syndrome
Bronchus	10–20	15	5	+
Oesophagus	< 0.1	–	–	–
Stomach	2–5	10	15	+
Small intestine	18–28	35	28	++++
Duodenum	2–4			
Jejunum	1–3			
Ileum	10–16			
Unspecified	5–9			
Liver (primary)	0.2–0.4	–	–	++
Biliary	< 0.4	20	20	+
Pancreas	0.2	12	60	++
Colon (not appendix)	3–8	30	25	–
Appendix	35–50	20	5	–
Rectum	12–18	4	4	–
Ovary	1	4	25	+
Thymus	< 0.2	–	–	+

All figures are approximate and include reporting bias which will understate incidental tumours, particularly appendiceal and rectal.

carcinoid tumours in different sites, based on their embryological fore-, mid- or hindgut origin (Table 1). The main product released from the oval neurosecretory granules of the commonest clinically important carcinoid, in the midgut, is serotonin (5-hydroxytryptamine), while the enterochromaffin-like cells in the stomach are rich in histamine. However, many other substances have been identified in different carcinoid tumours – substance P, chromogranin A, kallikrein, neurokinin A, neuropeptide K, peptide YY, prostaglandins, insulin, somatostatin, glucagon, cholecystokinin, encephalins, gastrin, pancreatic polypeptide, adrenocorticotrophic hormone (ACTH), β-melanocyte-stimulating hormone (MSH), calcitonin, catecholamines and chorionic gonadotrophin [2]. Because the enterochromaffin cell population is heterogeneous, there are different histochemical reactions from carcinoid tumours in different sites, and tumours arising in different sites have varying potential to release active substances to induce the carcinoid syndrome.

Molecular analysis reveals that, in ~ 20% of cases of foregut carcinoids, the tumour tissue bears mutations affecting the same tumour suppressor gene that gives rise to the familial neuroendocrine cancer syndrome multiple endocrine neoplasia (MEN) type 1 [3].

Macroscopic characteristics

Primary carcinoids are most common in the appendix, followed by the rectum, small intestine, stomach and colon (Table 1) [4,5] The majority of appendiceal and rectal carcinoids are generally insignificant in size and clinically irrelevant. In the midgut, most tumours arise within 70 cm of the ileocaecal valve, and one-third are multiple. Gastric carcinoids may also be multiple, but a single antral tumour is more common. Bronchial carcinoids are usually solitary, arising in the main bronchi, although a minority are peripheral or multiple. Rare sites include ovary and testis, larynx, biliary ducts and gallbladder, pancreas, thymus, uterus, breast, kidney and skin.

Primary carcinoids are usually spherical, submucosal and yellow because of their high lipid content. In the gut, tumours rarely ulcerate but spread outwards. Carcinoids from all sites are potentially malignant, but there are marked differences in their metastatic potential depending on their site. If invasive, the tumour spreads locally throughout the muscularis mucosa to the serosa, involving lymphatics. A dense, fibrotic reaction may occur around the tumour and extend into the mesentery. Local nodal involvement, which may be massive, precedes hepatic involvement. Carcinoid tumours in the liver are usually multiple and secondary. The pattern of deposits is variable, either diffuse infiltration with multiple, small deposits or larger masses which may be 10 cm or more in diameter. Occasionally, apparently solitary secondaries occur, and also apparently primary hepatic carcinoids are occasionally reported [6].

Microscopic appearances

The tumours have no capsule, with uniform polygonal cells and a nucleus containing speckled chromatin and basal granules (Fig. 1). Cellular arrangements may be insular, trabecular, glandular, schirrhous or mixed or undifferentiated. A high mitotic rate is prognostically poor. Electron-dense granules are seen on electron microscopy (Fig. 2).

Classical histochemical stains (e.g. brown with potassium chromate, brownish black with silver nitrate) are being replaced by chromogranin A, neurone-specific enolase and synaptophysin

Fig. 1 A haematoxylin and eosin-stained section of an argentaffin (serotonin-producing) carcinoid tumour of the ileum. Uniform, polygonal cells with abundant cytoplasm are arranged in sheets and nests separated by fine, fibrovascular stroma (×150).

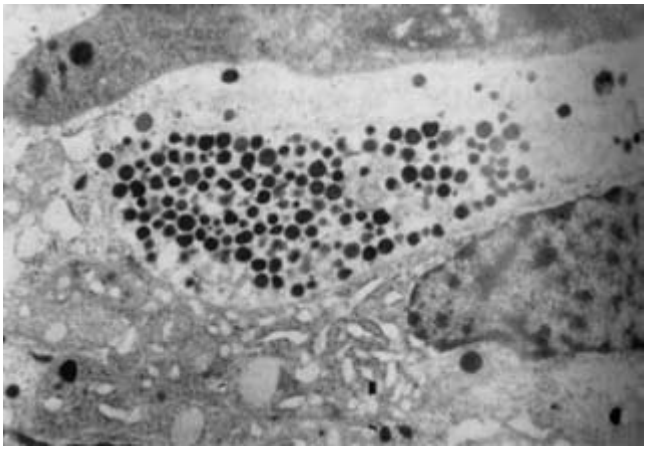

Fig. 2 An electron micrograph of an ileal carcinoid tumour showing abundant secretory granules that are typically electron-dense with an irregular shape (× 6000).

immunostaining. The cells generally express somatostatin receptors (types 2 and 5) [7].

Clinical features

Most primary carcinoids are asymptomatic. Autopsy series indicate an incidence of about 1% – mostly asymptomatic appendiceal tumours. The annual incidence of diagnosis in life is ~ 3 cases per 100 000 population, with the mean age being ~ 60 years, although presentation in the twenties is not uncommon, both sexes being affected [8]. Most cases are sporadic, although there is a fourfold elevation of risk in relatives. Occasionally, carcinoid tumours may appear as a feature of MEN 1 or neurofibromatosis type 1 [8]. Multiple gastric carcinoids have been reported in patients with pernicious anaemia, probably representing the trophic effect of gastrin on enterochromaffin-like cells, but those carcinoids appear to have minimal metastatic potential [9].

If primary carcinoids in the gut are clinically apparent, this normally reflects a mass effect with pain, obstruction or, more rarely, bleeding. With time, the associated desmoplastic reaction may cause obstruction. In the appendix, carcinoids may be found incidentally at surgery. Routine endoscopy often reveals rectal and gastric carcinoids. Bronchial lesions may appear as coincidental coin lesions, or with haemoptysis, cough, wheezing or segmental obstruction. Very occasionally, primary carcinoids present with features of the carcinoid syndrome in the absence of hepatic metastases.

Hepatic carcinoids may be found on survey of patients presenting with primary lesions, may present with local symptoms of hepatomegaly or pain or be found on investigation of one or more symptoms of the carcinoid syndrome. Local symptoms from hepatic carcinoids are relatively uncommon, except when spontaneous haemorrhage or tumour necrosis occurs. Occasionally, portal hypertension may follow pressure on the portal or hepatic veins. Thus, the presentation of hepatic carcinoid tumours in the absence of carcinoid syndrome differs little from those of other space-occupying lesions in the liver. However, as hepatic carcinoids are compatible with long survival, hepatomegaly may be huge. Local bruits, and occasionally hepatic rubs, are detectable. Presentation with the carcinoid syndrome is discussed below.

Laboratory investigations for hepatic carcinoid tumours

Non-functioning carcinoid tumours in the liver are diagnosed by imaging techniques followed by biopsy. Histological assessment of cell proliferation, by markers such as Ki-67, is important prognostically [10]. Most midgut-derived carcinoids have a low proliferative index, correlating with their often indolent growth and poor response to chemotherapy.

Of routine biochemical tests, serum alkaline phosphatase is often abnormal, but may confusingly be normal even in the presence of large tumour deposits. Jaundice is rare except in advanced disease. Chromogranin A is a sensitive but not very specific plasma marker, being elevated in other neuroendocrine tumours [11]. Screening for 5-hydroxyindoleacetic acid, the breakdown product of 5-hydroxytryptamine, in the urine is worthwhile, even if there are no symptoms suggestive of the carcinoid syndrome, as elevations may precede symptoms. Other tumour markers such as elevated circulating pancreatic polypeptide may also be detected with no obvious clinical correlate [12]. Some hepatic carcinoid deposits, particularly from hindgut primaries, are truly 'non-functioning', insofar as no secretory products can be detected in the circulation, and thus, even when huge, hindgut-derived tumours virtually never cause the carcinoid syndrome.

Fig. 3 CT scan (transverse section of abdomen at the level of liver) showing multiple deposits of carcinoid tumour.

Imaging techniques [13]

Hepatic ultrasonography should reveal carcinoid deposits of l cm or greater, of variable echogenicity, occasionally cystic, with sometimes both hyper- and hypoechoic lesions in the same patient. Computerized tomographic (CT) scanning of the liver should reveal lesions of 0.5 cm or more, usually of low but occasionally of high attenuation (Fig. 3). The carcinoid shows early transient hypervascularity on dynamic imaging but, subsequently, usually becomes isodense with surrounding liver. Magnetic resonance imaging (MRI) can sometimes detect tumours with greater clarity than CT and may be preferred for long-term follow-up. Carcinoid deposits are hypointense on T1-weighted and hyperintense on T2-weighted scans, and enhance intensely on early-phase gadolinium scans. At angiography, a variety of patterns may be seen – diffuse fine nodular, diffuse coarse nodular or single masses (Fig. 4). Most blush dramatically during the capillary phase. Angiography may also detect a primary site within the territory of the superior mesenteric artery.

Isotope studies using radioiodinated *m*-iodobenzyl guanidine [14] or labelled somatostatin analogues (Fig. 5) can also visualize tumours [15]. The latter technique is particularly effective for extrahepatic deposits. Positron emission tomographic (PET) scanning with labelled 5-hydroxytryptophan has also been developed [16].

Hepatic carcinoid tumours with carcinoid syndrome

The carcinoid syndrome occurs when the tumour produces bioactive substances that reach the systemic circulation in adequate amounts, resulting in the characteristic symptoms of flushing, diarrhoea and heart disease. With gastrointestinal carcinoids, in 95% of cases, the presence of the syndrome is associated with hepatic metastases from a midgut primary. Occasionally, primary tumours in the gut with extensive nodal involvement giving direct access to the systemic venous circulation cause the syndrome without liver metastases. Also, occasionally, primary ovarian and bronchial carcinoids can give symptoms directly [17,18], although in fact metastases in the liver are usually present when the syndrome occurs. The classical manifestations of the carcinoid syndrome may rarely be associated with neuroendocrine carcinomas such as medullary carcinoid of the thyroid and oat cell carcinoma of the lung [19]. Not all midgut carcinoids metastatic to the liver will produce the carcinoid syndrome and, in particular, hindgut carcinoids do not (Table 1).

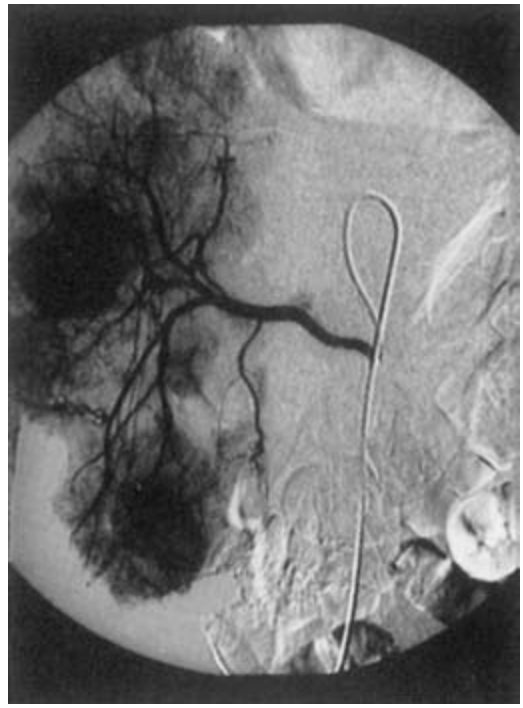

Fig. 4 Arterial phase of visceral arteriogram in a patient with carcinoid syndrome showing multiple, densely vascular deposits.

Clinical features

There is an annual incidence of about 1 case per million [5]. Both men and women are affected, the sixth decade being the most common time for presentation. The cardinal features are flushing, diarrhoea and heart disease, with differing symptoms in individuals reflecting the origin and mass of the tumours, length of history and qualitative and quantitative differences in the release of tumour products. Table 2 lists the presenting features in 63 patients.

Cutaneous manifestations

Ninety per cent of patients experience flushing attacks, mainly affecting the upper part of the body. The attacks are highly

Table 2 Presenting features in 63 patients with the carcinoid syndrome.

Feature	Number	%
Diarrhoea	14	22
Flushing	10	16
Diarrhoea and flushing	7	11
Hepatic enlargement	9	14
Bowel obstruction	5	8
Abdominal pain	7	10
Haemoptysis	2	3
Wheeze	1	1.5
Sweating	1	1.5
Palpitations	1	1.5
Geographical rash	1	1.5
Incidental during investigation for other cause	3	5
Incidental during laparotomy for other cause	2	3
Total	***63***	

variable, lasting minutes to hours, often with sweating, lacrimation, itching, facial and conjunctival oedema, palpitations, hypotension (more rarely hypertension) and diarrhoea. Some patients remain entirely unaware of dramatic flushes. The episodes may be spontaneous or precipitated by stress, alcohol, exertion or abdominal palpation. Gastric carcinoids producing predominantly histamine may cause a specific pattern of prolonged bright red geographical flushing of the face and neck [20]. The long-term effects on the skin include telangiectasia and sometimes rosacea of the face, morphoea-like thickening of the skin (carcinoid-associated scleroderma) and occasionally pellagra [21] (see below).

Gastrointestinal manifestations

Diarrhoea occurs in about 75% of cases. Although classically attributed to circulating hormone products and associated with proven hypermotility, borborygmi and a secretory state in the small intestine, abdominal symptoms and diarrhoea may often be due to other causes. These include subacute intestinal obstruction due to the primary tumour, previous intestinal resection, bile salt spillage, bacterial overgrowth, lymphatic obstruction and side-effects of somatostatin therapy. Abdominal pain may reflect intestinal obstruction, spontaneous necrosis of hepatic metastases or, rarely, gut ischaemia due to fibrotic narrowing of mesenteric vessels [22].

Cardiac manifestations

Some 40–50% of patients with malignant carcinoids and the syndrome develop heart disease. Unlike the flushing and diarrhoea that are immediate responses to released tumour products, the cardiac disease is due to a slowly developing fibrosis, usually involving the endocardium of the right side of the heart, leading progressively to right-sided failure, with tricuspid regurgitation and mixed pulmonary regurgitation and stenosis being the most common lesions [23].

Other manifestations

A similar fibrosis to that in the heart may occur in the intima of the great vessels, in the pleura and pericardium and retroperitoneally. Wheezing occurs in about 10% of patients, and late-onset asthma may occasionally be a presenting feature. Intrapulmonary shunting (as in the 'hepatopulmonary syndrome') has been reported [24]. Confusional states may occur as part of prolonged flushing episodes, particularly in patients with gastric or bronchial carcinoids; they may also be a feature of liver failure with advanced disease or part of the pellagra syndrome. A rare peripheral arthropathy has been reported [25].

Pathogenesis of carcinoid syndrome

The syndrome represents the long- and short-term results of release of substances from the tumour into the systemic circulation. Midgut carcinoids secrete large amounts of 5-HT (serotonin), which is responsible for many of the clinical features. 5-HT markedly increases gut motility and probably induces secretion in the small intestine. It may play a part in producing bronchoconstriction and seems to be involved in fibrotic reactions that occur in the heart and elsewhere. The metabolic pathway is shown in Figure 6, which also demonstrates how nicotinic acid (niacin) deficiency can occur in the carcinoid syndrome, as dietary nicotinic acid becomes sidetracked for the synthesis of 5-HT.

Foregut tumours lack the decarboxylase enzyme and may thus secrete 5-hydroxytryptophan, not 5-HT. Other tissues, however, usually metabolize sufficient 5-hydroxytryptophan to 5-HT and allow a diagnostic amount of 5-hydroxyindoleacetic acid to appear in the urine. The monoamine oxidase normally present in the liver is responsible for the fact that serotonin solely draining into the splanchnic circulation is not associated with systemic symptoms.

Primary gastric carcinoids often produce predominantly histamine. This seems to be associated with the distinctive flush. Carcinoids contain kallikrein, an enzyme that converts plasma kininogen to vasoactive lysylbradykinin, and thence bradykinin,

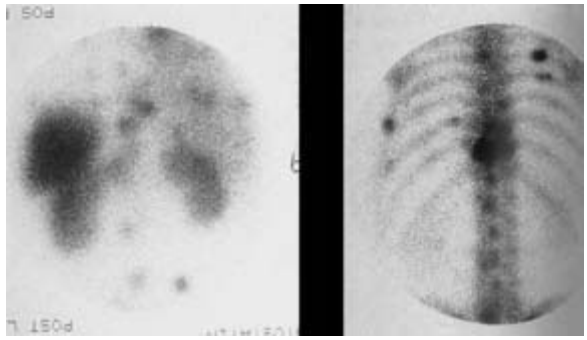

Fig. 5 Labelled octreotide scan (left) demonstrating uptake of octreotide into hepatic and bony metastases in a patient with carcinoid. The conventional bone scan (right) is also positive.

and probably plays some part in initiating flushing. Tachykinins have also been identified as potential mediators of flushing. Prostaglandins E, F and other unidentified prostaglandins have been extracted from carcinoid tumours. However, the response to inhibitors of prostaglandin synthesis suggests that they are unlikely to be major mediators of flushing and diarrhoea. Although gastrointestinal peptides of many kinds can be identified in carcinoid tumours, when symptoms of diarrhoea have been induced in patients with carcinoid syndrome, no changes in plasma concentrations of insulin, gastrin, pancreatic polypeptide, vasoactive intestinal polypeptide, gastric inhibitory polypeptide, somatostatin or neurotensin have been found [26].

Diagnosis of carcinoid syndrome

Once the suspicion has been raised, making the diagnosis of carcinoid is not difficult. Measurement of plasma chromogranin A, a product of the chromaffin granules, is now the most convenient test, being very sensitive (> 90%) for carcinoids in the liver, although other neuroendocrine tumours are also positive. Very high levels are associated with a poor prognosis. Measurement of urinary 5-hydroxyindoleacetic acid quantitatively in a 24-h sample is more specific though less sensitive. Levels of more than 30 mg (90 mmol)/24 h are usually diagnostic. Mild elevations may, however, be seen in the blind-loop syndrome, Whipple's disease and coeliac disease. False-positive results can occur if patients are eating large amounts of food containing 5-HT (bananas, pineapples and walnuts) or taking reserpine, acetanilide, methysergide or cough medicines containing glyceryl guaiacolate. As already mentioned, foregut carcinoids may not be associated with elevated excretion of 5-hydroxyindoleacetic acid. Circulating concentrations of substance P are elevated and, in some cases, human chorionic gonadotrophin may be elevated.

Prognosis

Both primary carcinoid tumours and metastases may grow slowly. Trivial symptoms of occasional mild flushing or diarrhoea may persist for some years with no treatment. The survival may be relatively long with some patients surviving over 30 years. Five-year survival for midgut carcinoids after diagnosis is 50–77% [10]. There is, however, an increased risk of also having another tumour, which may worsen prognosis [5].

Treatment of carcinoid tumours

The management of primary carcinoid tumours presenting without the syndrome is surgical, at least for disease that is not too advanced locally [27].

The optimal policy for apparently solitary hepatic secondaries amenable to local hepatic resection is probably also surgery, both to prevent local symptoms and to slow progression. Usually, complete surgical resection is not possible. Choice between conservative treatment, palliative surgery, chemotherapy or other debulking approaches may be difficult: these procedures reduce tumour mass, but it is not clear that this prolongs survival. Recent trends, however, show an increasing tendency to debulk liver carcinoid deposits surgically. The presence or absence of the carcinoid syndrome is obviously of major importance. However, for some patients with these slowly progressive neoplasms, medical therapy aimed at controlling the synthesis, release or peripheral effects of active substances from the tumour may provide extremely effective palliation and induce a greater improvement in the quality of life than is obtained with debulking.

Treatment of carcinoid syndrome

Factors known to precipitate carcinoid attacks such as alcohol, provocative foods or marked physical activity may be avoided. Sufficient nicotinamide should be included in the diet to prevent the development of pellagra. Codeine phosphate or lopramide may control diarrhoea, and potassium supplements may be necessary. In the presence of an ileal resection, cholestyramine may prevent bile salt-induced colonic secretion. Asthmatic attacks should be treated with aminophylline or salbutamol. Prognosis is poor after heart failure has developed, but patients with heart involvement should be formally assessed to consider the potential for valve surgery.

Specific pharmacological therapy

The receptors of 5-HT have been subdivided into 5-HT_1, 5-HT_2 and 5-HT_3 receptors, present in different parts of the body in smooth muscle and neural tissue. Many drugs have been used to modify the acute attacks of flushing and diarrhoea by inhibition or blocking of the synthesis of tumour products, but most have become obsolete following the introduction of somatostatin therapy.

Cyproheptadine

This 5-HT_2 receptor antagonist is predominantly used in the treatment of diarrhoea. In addition, it possesses weak anticholinergic activity and is a histamine H_1 blocker and a central depressant. It is one of the mainstays of medical therapy for mild symptoms in the carcinoid syndrome. The usual dose is 4 mg four times daily.

Methysergide

This 5-HT_1 and 5-HT_2 receptor antagonist, at doses of 3–8 mg/day, reduces diarrhoea but has no significant effect upon flushing. Numerous side-effects include nausea, heartburn, abdominal pain and vomiting, and even diarrhoea and central effects including unsteadiness, drowsiness, confusion and psychosis have been reported. Its major drawback is the occurrence

of retroperitoneal fibrosis after as little as 3 months of therapy. Carcinoids themselves may induce retroperitoneal fibrosis, and so the use of this drug is severely limited.

Ondansetron

This 5-HT_3 antagonist may be helpful in reducing stool frequency [28].

Histamine antagonists

Combination therapy with the H_1 antagonist diphenhydramine (50 mg four times daily) and the H_2 antagonist cimetidine (300 mg four times daily) may reduce the flushing and hypotension associated with gastric carcinoids.

Corticosteroids

Prednisolone in doses of 20 mg/day is said to reduce the facial oedema, diarrhoea and hyperdynamic state associated with bronchial carcinoids. It has little or no effect on symptoms associated with a gastrointestinal carcinoid.

Somatostatin

Intravenous infusion of short-acting somatostatin was shown to abolish flushing caused by gastric or ileal carcinoids. Long-acting analogues of somatostatin (e.g. octreotide) relieved diarrhoea, flushing and other symptoms in 75–80% of patients. Patients who do not respond tend to have low expression of tumour somatostatin receptors. With an initial dose of 50 μg three times daily, control is usually established for a few months, but escalating doses are required over time. Eventually, troublesome steatorrhoea due to inhibition of pancreatic enzyme release may limit its usefulness. The drug frequently induces the appearance of small cholesterol gallstones and may precipitate hypothyroidism. Its mode of action is a combination of a reduction in output of 5-HT and other substances and peripheral inhibition of end-organ activity. In a small proportion of patients, an action in reducing tumour mass is reported, but this is generally temporary. Longer acting depot preparations, administered every 2–4 weeks, have made this therapy more practicable, although it remains costly.

Debulking

Surgery

For the treatment of hepatic metastases, surgery has been advocated to reduce tumour mass, in particular if there are associated local symptoms, and also as a means of reducing the release of 5-HT and other substances. Partial hepatectomy, shelling out of metastases, ligation of the hepatic artery and extensive surgical devascularization of the liver except for the main hepatic artery,

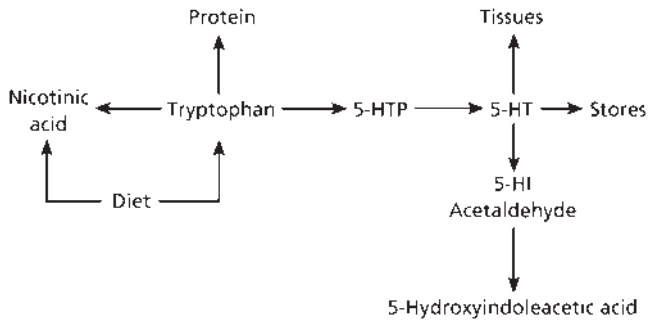

Fig. 6 Pathway of serotonin metabolism. 5-HTP, 5-hydroxytryptophan; 5-HI, 5-hydroxyindole.

followed by intermittent occlusion of that artery via a percutaneous sling, have all been advocated. Liver transplantation can be performed but, in general, the identification of extrahepatic tumour dissemination prevents this, and there is some evidence that, after transplantation, development of extrahepatic metastases may accelerate [29].

Surgery is potentially hazardous, as a result of rapid alterations in blood pressure, bronchial constriction, hyperapnoea, vomiting, diarrhoea and hyperglycaemia [30]. Such patients should initially be blocked pharmacologically to prevent the action of released 5-HT, using a regimen based on somatostatin, with a potential role for aprotinin as a modifier of the effect of kinins, and high-dose corticosteroids. Precipitators of flushing attacks should be avoided in anaesthesia, and nerve blockers, acetylcholine and morphine should all be used with care. Hypotensive episodes should be treated with transfusion and angiotensin (not catecholamines). Hydralazine has been recommended for hypertension.

Hepatic artery embolization

Arterial embolization reduces the blood flow to both tumour deposits and normal liver cells [31,32]. The latter survive because of their simultaneous blood supply from the portal circulation. Destruction of hepatic deposits may release large amounts of bioactive substances from the tumours causing severe symptoms, so blocking agents are used before and after the procedure. Infusion of somatostatin (100 μg/h) is the mainstay, maintained for 24–48 h after the procedure, sometimes supplemented by aprotinin infusions and methyl prednisolone. Prophylactic antibiotics are generally advocated, and maintenance of hydration is important. The procedure involves selective cannulation of the coeliac axis and hepatic artery, and requires the portal blood supply to the liver to be intact. A variety of absorbable or non-absorbable embolic materials can be used. Usually, successful embolization is followed by fever, a leucocytosis and hepatic pain, with a marked rise in serum hepatic enzymes.

The results of this procedure are variable, depending on the selection of patients. It has some effect in reducing the local

symptoms of the tumour, but is most effective in control of distressing symptoms due to release of active substances. In a majority of patients, flushing and abdominal pain can be abolished, with improvement in diarrhoea and a significant reduction in urinary excretion of 5-hydroxyindoleacetic acid. Clinical remissions last from 1 to 18 months, and re-embolization can be performed with further remissions. Whether long-term survival is affected by embolization is not yet clear. Chemoembolization combining transcatheter embolization with local chemotherapy (iodized oil plus deoxorubicin) has also been advocated, but evidence of enhanced effectiveness is only anecdotal.

Other debulking approaches

Radiofrequency ablation [33] – which can be administered percutaneously, at laparoscopy or at laparotomy – and cryotherapy [34] have been used as sole or adjunctive means of reducing tumour bulk. They are particularly suitable for deposits 3–4 cm in diameter, and these approaches can be repeated.

Radiotherapy

The best established place for conventional radiotherapy is in symptomatic relief from skin and bone metastases. In well-selected cases, local disease stabilization and local symptomatic relief are probably achievable in 50% of cases [35].

Chemotherapy

A variety of studies have suggested that single agents, or drug combinations, may produce a reduction in the size of liver metastases [36]. The most generally used regimen has been a combination of streptozotocin and 5-fluorouracil, which produces partial response in ~ 30% of patients treated, but with considerable toxicity. In the midgut carcinoids that give rise to the carcinoid syndrome, chemotherapy is rarely effective, reflecting the low rate of cell turnover in these tumours.

Interferon-alpha

Partial remission was observed in 47% of a group of patients treated with daily interferon, with remissions lasting for up to 3 years. The treatment may be symptomatically successful after long-acting somatostatin (octreotide) has failed. Combined use of interferon and somatostatin reduced excretion of 5-hydroxyindoleacetic acid in 72% of cases in one series, although it is unclear whether this is better than either drug used alone [36]. The side-effects of interferon are predominantly transient malaise at the initiation of treatment, mild pancytopenia and depression, but these frequently lead to a significant lowering of quality of life.

Targeted isotope therapy

Radioactive *m*-iodobenzyl guanidine injected intravenously will localize in carcinoid deposits, but has not been widely adopted [37]. There is more enthusiasm for the use of isotopically labelled somatostatin, which in a variety of forms will localize radioactivity to sites of somatostatin uptake. Over 80% of patients with carcinoid syndrome will accumulate somatostatin in secondary deposits, and the therapy will reduce hormone excretion in over half of patients, with apparent reduction of tumour bulk in about 25% [38,39]. All targeted isotope therapy is complex, reflecting the necessity for protection of other individuals and the environment from the radioactivity, involving short-term isolation and other protective measures.

Choosing the right therapy

In patients with hepatic metastases from carcinoid tumours without systemic symptoms, surgery is indicated for readily resectable tumours, in particular if the primary tumour is also resectable. Such a policy should prolong life. If the tumour is not readily resectable, and the patient is asymptomatic, many physicians will hesitate to recommend chemotherapy or radiotherapy, but may reserve such relatively ineffective but potentially distressing therapies until symptoms occur.

For patients with carcinoid syndrome, the indications for surgery are as above. For patients with mild symptoms, no active treatment for the syndrome may be required other than avoidance of precipitating factors. As symptoms become more severe, a reasonable approach is to use cyproheptadine and codeine phosphate to control diarrhoea and, subsequently, most patients will respond to a long-acting somatostatin analogue. The options for debulking, whether surgically or by ablation, transcatheter embolization or targeted isotope therapy, should always be considered early as part of the long-term approach to such patients. Decisions on which to pursue, and whether any individual patient should undergo them, will reflect the individual anatomical characteristics and site of tumour deposits, the age and frailty of the patient, the symptomatology and the extent to which symptoms are controllable medically. Reflecting the heterogeneity of the carcinoid syndrome in tumour site, tumour characteristics and symptomatology, there is a major lack of comparative clinical trials to guide the selection of optimal therapy.

References

1 Langley K (1994) The neuroendocrine concept today. *Ann NY Acad Sci* 733, 1–17.

2 Lips CJ, Lentjes EG, Hoppener JW (2003) The spectrum of carcinoid tumours and carcinoid syndromes. *Ann Clin Biochem* 40 (Pt 6), 612–627.

3 Leotlela PD, Jauch A, Holtgreve-Grez H *et al.* (2003) Genetics of neuroendocrine and carcinoid tumours. *Endocr Relat Cancer* 10 (4), 437–450.

4 Soga J (2003) Carcinoids and their variant endocrinomas. An analysis of 11 842 reported cases. *J Exp Clin Cancer Res* 22 (4), 517–530.

5 Modlin IM, Lye KD, Kidd M (2003) A 5-decade analysis of 13 715 carcinoid tumors. *Cancer* 97 (4), 934–959.

6 Iwao M, Nakamuta M, Enjoji M *et al.* (2001) Primary hepatic carcinoid tumor: case report and review of 53 cases. *Med Sci Monit* 7 (4), 746–750.

7 de Herder WW, Hofland LJ, van der Lely AJ *et al.* (2003) Somatostatin receptors in gastroentero-pancreatic neuroendocrine tumours. *Endocr Relat Cancer* 10 (4), 451–458.

8 Griffiths DF, Williams GT, Williams ED (1987) Duodenal carcinoid tumours, phaeochromocytoma and neurofibromatosis: islet cell tumour, phaeochromocytoma and the von Hippel–Lindau complex: two distinctive neuroendocrine syndromes. *Q J Med* 64 (245), 769–782.

9 Modlin IM, Kidd M, Latich I *et al.* (2005) Current status of gastrointestinal carcinoids. *Gastroenterology* 128 (6), 1717–1751.

10 Rorstad O (2005) Prognostic indicators for carcinoid neuroendocrine tumours of the gastrointestinal tract. *J Surg Oncol* 89, 151–160.

11 Eriksson B, Oberg K, Stridsberg M (2000) Tumor markers in neuroendocrine tumors. *Digestion* 62 (Suppl 1), 33–38.

12 Ardill JE, Erikkson B (2003) The importance of the measurement of circulating markers in patients with neuroendocrine tumours of the pancreas and gut. *Endocr Relat Cancer* 10 (4), 459–462.

13 Kaltsas G, Rockall A, Papadogias D *et al.* (2004) Recent advances in radiological and radionuclide imaging and therapy of neuroendocrine tumours. *Eur J Endocrinol* 151 (1), 15–27.

14 Shapiro B, Sisson JC, Shulkin BL *et al.* (1995) The current status of meta-iodobenzylguanidine and related agents for the diagnosis of neuro-endocrine tumors. *Q J Nucl Med* 39 (4 Suppl 1), 3–8.

15 Warner RR, O'dorisio TM (2002) Radiolabeled peptides in diagnosis and tumor imaging: clinical overview. *Semin Nucl Med* 32 (2), 79–83.

16 Sundin A, Eriksson B, Bergstrom M *et al.* (2004) PET in the diagnosis of neuroendocrine tumors. *Ann NY Acad Sci* 1014, 246–257.

17 De la Torre J, Garcia A, Castellvi J *et al.* (2004) Primary ovarian trabecular carcinoid tumour: a case report with an immunohistochemical study and a review of the literature. *Arch Gynecol Obstet* 270 (4), 274–277.

18 Hage R, de la Riviere AB, Seldenrijk CA *et al.* (2003) Update in pulmonary carcinoid tumors: a review article. *Ann Surg Oncol* 10 (6), 697–704.

19 Barakat MT, Meeran K, Bloom SR (2004) Neuroendocrine tumours. *Endocr Relat Cancer* 11 (1), 1–18.

20 Modlin IM, Tang LH (1999) Cell and tumour biology of the gastric enterochromaffin-like cell. *Ital J Gastroenterol Hepatol* 31 (Suppl 2), S117–130.

21 Bell HK, Poston GJ, Vora J *et al.* (2005) Cutaneous manifestations of the malignant carcinoid syndrome. *Br J Dermatol* 152 (1), 71–75.

22 Hansen MB, Dresner LS, Wait RB (1998) Profile of neurohumoral agents on mesenteric and intestinal blood flow in health and disease. *Physiol Res* 47 (5), 307–327.

23 Fox DJ, Khattar RS (2004) Carcinoid heart disease: presentation, diagnosis, and management. *Heart* 90 (10), 1224–1228.

24 Lee DF, Lepler LS (1999) Severe intrapulmonary shunting associated with metastatic carcinoid. *Chest* 115 (4), 1203–1207.

25 Plonk JW, Feldman JM (1974) Carcinoid arthropathy. *Arch Intern Med* 134 (4), 651–654.

26 Calhoun K, Toth-Fejel S, Cheek J *et al.* (2003) Serum peptide profiles in patients with carcinoid tumors. *Am J Surg* 186 (1), 28–31.

27 Sutton R, Doran HE, Williams EM *et al.* (2003) Surgery for midgut carcinoid. *Endocr Relat Cancer* 10 (4), 469–481.

28 Wymenga AN, de Vries EG, Leijsma MK *et al.* (1998) Effects of ondansetron on gastrointestinal symptoms in carcinoid syndrome. *Eur J Cancer* 34 (8), 1293–1294.

29 Le Treut YP, Delpero JR, Dousset B *et al.* (1997) Results of liver transplantation in the treatment of metastatic neuroendocrine tumors. A 31-case French multicentric report. *Ann Surg* 225 (4), 355–364.

30 Kinney MA, Warner ME, Nagorney DM *et al.* (2001) Perianaesthetic risks and outcomes of abdominal surgery for metastatic carcinoid tumours. *Br J Anaesth* 87 (3), 447–452.

31 Ahlman H, Nilsson O, Olausson M (2004) Interventional treatment of the carcinoid syndrome. *Neuroendocrinology* 80 (Suppl 1), 67–73.

32 Norton JA, Kerlan RK (2003) Hepatic artery embolization for treatment of patients with metastatic carcinoid tumors: a commentary. *Cancer J* 9 (4), 241–243.

33 Henn AR, Levine EA, McNulty W *et al.* (2003) Percutaneous radiofrequency ablation of hepatic metastases for symptomatic relief of neuroendocrine syndromes. *AJR Am J Roentgenol* 181 (4), 1005–1010.

34 O'Toole D, Maire F, Ruszniewski P (2003) Ablative therapies for liver metastases of digestive endocrine tumours. *Endocr Relat Cancer* 10 (4), 463–468.

35 Warren WH, Gould VE (1990) Long-term follow-up of classical bronchial carcinoid tumors. Clinicopathologic observations. *Scand J Thorac Cardiovasc Surg* 24 (2), 125–130.

36 Oberg K (2001) Chemotherapy and biotherapy in the treatment of neuroendocrine tumours. *Ann Oncol* 12 (Suppl 2), S111–114.

37 Safford SD, Coleman RE, Gockerman JP *et al.* (2004) Iodine-131 metaiodobenzylguanidine treatment for metastatic carcinoid. Results in 98 patients. *Cancer* 101 (9), 1987–1993.

38 Tomassetti P, Migliori M, Campana D *et al.* (2003) The role of somatostatin analogs in the management of carcinoid tumors. *J Endocrinol Invest* 26 (8 Suppl), 79–81.

39 Leong WL, Pasieka JL (2002) Regression of metastatic carcinoid tumors with octreotide therapy: two case reports and a review of the literature. *J Surg Oncol* 79 (3), 180–187.

19 Biliary tract diseases

19.1 Intrahepatic cholestasis

Olivier Chazouillères and Chantal Housset

Definition

Cholestasis has long been defined as a decrease in bile flow. Normal bile flow being closely linked to the biliary secretion of bile acids, most clinical, biochemical and histological manifestations of cholestasis are related to the accumulation of bile acids in the liver, in extrahepatic tissues and in the plasma. Therefore, cholestasis is more accurately defined as a defect in bile acid transport from the liver to the intestine. Broadly speaking, cholestasis may be classified as intrahepatic or extrahepatic. Intrahepatic cholestasis refers to all situations in which the impairment of bile secretion occurs primarily within the liver. Intrahepatic cholestasis itself may result from hepatocellular functional defects or from obstructive lesions of the intrahepatic biliary tract distal from bile canaliculi. Even though intrahepatic bile ducts comprise both small and large ducts, in clinical practice, affections of large bile ducts (i.e. those visible at macroscopic imaging) are excluded from the definition of intrahepatic cholestasis because these affections, like those of extrahepatic bile ducts, raise distinct diagnostic and therapeutic issues. In addition, because hepatocellular bile secretion may be impaired in severe liver injury, whatever its cause, the term 'cholestatic' is restricted to conditions with predominant cholestatic features, excluding global hepatocellular dysfunction. Progress over the past 10 years in the knowledge of hepatic transport has led to a better understanding of cholestatic mechanisms.

Mechanisms of intrahepatic cholestasis

Because the transport of bile constituents, and primarily that of bile salts across the canalicular membrane of hepatocytes, is the rate-limiting step in bile formation, disturbance in the expression and/or function of canalicular transporters is recognized as a fundamental mechanism of hepatocellular intrahepatic cholestasis (Fig. 1) [1]. This has been demonstrated in hereditary human cholestatic disorders and in rodent models of these disorders. Thus, benign and progressive forms of familial intrahepatic cholestasis of type 2 are caused by defects in the *ABCB11* gene, which encodes the canalicular bile salt export pump (BSEP), while Bsep knockout mice also develop intrahepatic cholestasis. Patients with multidrug resistance 3 P-glycoprotein (MDR3)/*ABCB4* gene mutations and Mdr2(MDR3 murine homologue)/*Abcb4* knockout mice develop cholangitis as a result of toxic, phospholipid-deficient bile.

In acquired forms of intrahepatic cholestasis, primary events are often multifactorial and difficult to distinguish from secondary events. However, a number of mechanisms that may cause and/or contribute to cholestasis have been identified in rodent models of acquired cholestasis. While bile duct ligation is the most common model of extrahepatic cholestasis, models of intrahepatic cholestasis include those induced by endotoxin, drugs, estrogen or lithocholate feeding. Various drugs are thought to cause cholestasis through inhibition of BSEP function in a competitive manner [2], 17β-estradiol glucuronide indirectly *trans*-inhibits Bsep after secretion into the bile canaliculus by multidrug resistance-associated protein 2 (Mrp2). Another mechanism of drug-induced cholestatic injury is illustrated by the effect of bosentan on Mrp2-mediated canalicular bile formation [3]. It was shown that bosentan stimulates and significantly increases Mrp2-dependent bilirubin excretion and bile salt-independent bile flow, while biliary lipid secretion was profoundly inhibited and uncoupled from bile salt secretion. Inhibition of biliary lipid secretion was not observed in Mrp2-deficient TR^- rats, suggesting that translocation of organic anions across the canalicular membrane is a prerequisite for the occurrence of the uncoupling effect. Thus, Mrp2-induced choleresis might dilute bile salts in the bile canaliculi below the concentration required for the extrusion of phosphatidylcholine and cholesterol. Consequently, decreased biliary phospholipid secretion does not necessarily mean a defect in the canalicular phospholipid flippase MDR3, but could also be explained by a physicochemical disequilibrium in bile composition. Drugs and/or their metabolites may also cause bile duct damage. For example, it was shown that a metabolite of flucloxacillin, produced in hepatocytes, was selectively toxic for biliary epithelial cells [4].

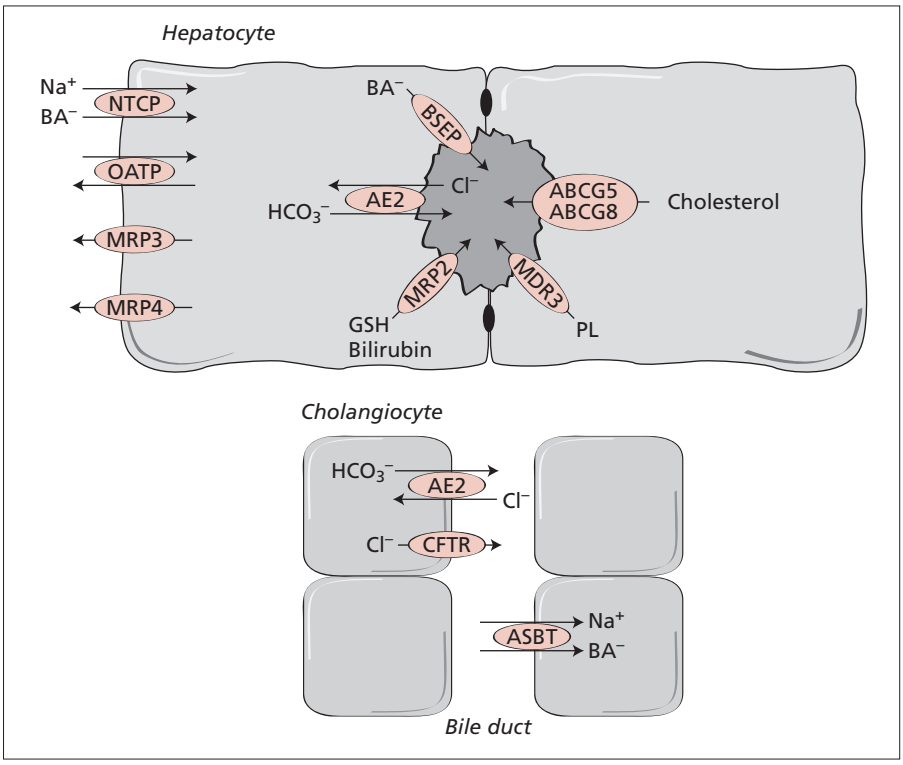

Fig. 1 Major hepatobiliary transporters. NTCP(*SLC10A1*), Na^+-taurocholate-cotransporting polypeptide; OATP(*SLC21A*), organic anion-transporting polypeptide; BSEP(*ABCB11*), bile salt export pump; MDR3(*ABCB4*), multidrug resistance 3 P-glycoprotein; MRP2(*ABCC2*), multidrug resistance-associated protein 2; MRP3(*ABCC3*), multidrug resistance-associated protein 3; MRP4(*ABCC4*), multidrug resistance-associated protein 4; AE2(*SLC4A2*), anion exchanger isoform 2; CFTR(*ABCC7*), cystic fibrosis transmembrane conductance regulator; ASBT(*SLC10A2*), apical sodium-dependent bile salt transporter. BA, bile acid; GSH, glutathione; PL, phospholipids.

In addition to alterations in transporters, cytoskeleton changes and disruption of cell junctions may contribute to intrahepatic cholestasis. Tight junctions create the paracellular barrier required to maintain the electrochemical gradient used for epithelial transport. When the barrier fails, the gradient dissipates, and this can lead to cholestasis. Many compounds that can cause cholestasis in clinical situations [e.g. the phalloidin toxin, lithocholate, chlorpromazine, carmiustin-1,3-bis(1-chloroethyl)-1-nitrosurea] have been shown to increase the biliary clearance of paracellular markers in experimental animals [5]. Alterations in hepatocyte tight junctions have been documented by the immunolabelling of tight junction proteins including 7H6, which correlate closely with paracellular permeability, in both bile duct ligation- and ethinyl estradiol-induced cholestasis, although with different lobular distributions [6]. Tight junction impairment occurs predominantly in periportal hepatocytes after bile duct ligation, but more diffusely throughout the lobule after ethinyl estradiol treatment [6]. Functional tests in these two models have shown that junctional permeability was paralleled by the degree of cholestasis [7]. In rat models of colitis, cholestasis has been attributed to the altered structure and function of hepatocyte tight junctions, which could itself result from increased levels of endotoxin in the portal blood [8,9]. In human disease, substantial alterations in the tight junction proteins have been shown to occur predominantly in bile ducts in primary biliary cirrhosis, but in hepatocytes in primary sclerosing cholangitis, suggesting increased paracellular permeability along different paracellular routes for bile regurgitation in these diseases [10]. Along these lines, bile regurgitation from leaky bile ducts has been proposed as a cause of sclerosing cholangitis in Mdr2 knockout mice [11].

Endotoxin in animal models causes a decrease in bile acid-dependent and -independent bile flow associated with a decrease in the expression of Na^+-taurocholate-cotransporting polypeptide (Ntcp), a decrease in Na,K-ATPase in hepatocytes and with abnormal expression localization of Bsep and Mrp2 [12,13]. The downregulation of Ntcp is reproduced by the proinflammatory cytokines tumour necrosis factor (TNF)α and interleukin (IL)-1β [14]. Proinflammatory cytokines also act on ductular secretion by modifying transporter activities and the epithelial barrier function. They decrease cystic fibrosis transmembrane conductance regulator (CFTR) and anion exchanger isoform 2 (AE2) activity and increase tight junction permeability in bile ducts [15]. An impairment in ductal secretion could result from a CFTR defect and lead to cholestatic injury, a mechanism proposed to explain cystic fibrosis liver disease. However, it remains to be determined if ductal cholestasis may be purely functional or if a certain cholangio-obstructive/destructive component is necessary to cause cholestasis.

Finally, because intestinal absorption is a critical step in the enterohepatic circulation of bile salts, alterations in the intestinal uptake of bile salts could cause, or at least contribute to, cholestasis, as suggested in the familial intrahepatic cholestasis of type 1 [16].

Adaptive response to cholestasis

The liver can rapidly respond to bile acid accumulation through

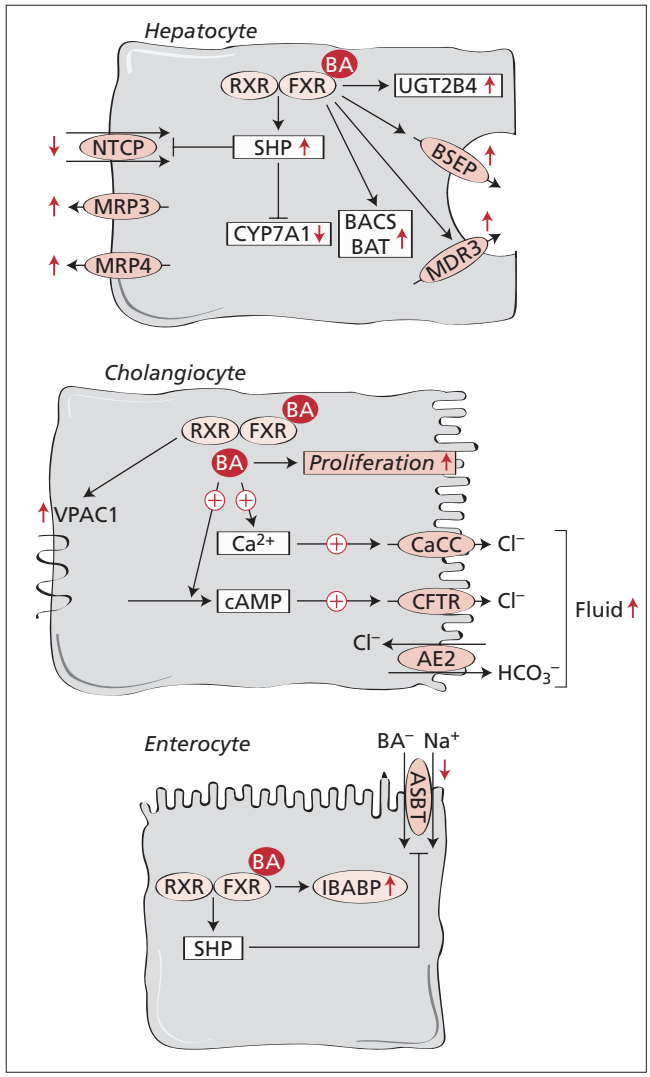

Fig. 2 Adaptive response to cholestasis. In hepatocytes, bile acids (BA) bind to the farnesoid X receptor (FXR), which, upon heterodimerization with retinoid X receptor α (RXRα), activates gene transcriptions of the bile salt export pump (BSEP), of the multidrug resistance 3 P-glycoprotein (MDR3), of the bile acid-CoA synthetase (BACS) and the bile acid-CoA:amino acid N-acetyltransferase (BAT), enzymes involved in the conjugation of bile acids to taurine and glycine, of the uridine 5′ diphosphate-glucuronosyltransferase 2B4 (UGT2B4) and of the short heterodimer partner (SHP). SHP represses gene transcription of cytochrome P-450 7A1 (*CYP7A1*), the cholesterol-7α-hydroxylase enzyme and of Na^+-taurocholate-cotransporting polypeptide (NTCP). Multidrug resistance-associated protein 3 (MRP3) and multidrug resistance-associated protein 4 (MRP4) are induced by an FXR-independent mechanism in these cells. In cholangiocytes, activated FXR stimulates gene transcription of the vasoactive intestinal polypeptide receptor-1 (VPAC1). Bile acids also stimulate proliferation and fluid secretion through the stimulation of calcium-dependent chloride channels (CaCC) and the potentiation of the cAMP-dependent chloride channel, cystic fibrosis transmembrane conductance regulator (CFTR), which are coupled with the anion exchanger-2 (AE2). In enterocytes, activated FXR stimulates gene transcription of the ileal bile acid-binding protein (IBABP), necessary for the apical to basal transport of bile acids within these cells, and of SHP, which represses gene transcription of the apical sodium-dependent bile salt transporter (ASBT). Thus, the entry of bile acids in enterocytes is decreased, while their exit is facilitated.

transcriptional gene regulation. The farnesoid X receptor (FXR, *NR1H4*), a nuclear receptor for bile salts, plays a key role in this response [17,18]. Among bile acids, the major activators of FXR are chenodeoxycholate (the most potent), deoxycholate and lithocholate. Upon heterodimerization with the retinoid X receptor alpha (RXRα), FXR either positively or negatively regulates the transcription of genes involved in different aspects of bile salt synthesis and transport in hepatocytes and in enterocytes [18–20] (Fig. 2). Negative transcriptional regulation is mediated by the short heterodimer partner (SHP), a gene repressor induced by FXR [20]. Thus, in response to elevated bile salt levels, FXR is activated, which subsequently stimulates SHP. SHP in its turn downregulates the gene encoding cholesterol-7α-hydroxylase (*CYP7A1*), the key enzyme in bile acid synthesis [21]. Other enzymes that conjugate bile acids to taurine and glycine are induced by FXR [22]. The uridine 5′ disphosphate-glucuronosyltransferase 2B4 (UGT2B4), which forms glucuronide conjugates of bile acids, is also upregulated through FXR [23]. Therefore, high bile acid levels lead, through FXR-mediated mechanisms, to inhibition of their own *de novo* synthesis and to the production of hydrophilic derivatives. FXR induces a downregulation in bile acid uptake systems, i.e. the basolateral NTCP (*SLC10A1*) in hepatocytes and the apical bile salt transporter (ASBT, *SLC10A2*) in enterocytes, which are both mediated by SHP [20,24]. In contrast, FXR transactivates the expression of BSEP [19]. Therefore, in cholestatic conditions, FXR-mediated regulation prevents further accumulation of bile acids in hepatocytes. FXR regulates the phospholipid export pump MDR3 [25]. Other nuclear receptors such as the xenobiotic receptor pregnane X receptor (PXR/SXR, *NR1I2*) and vitamin D receptor (VDR, *NR1I1*) are also activated by hydrophobic toxic bile salts such as lithocholate. The protection provided by FXR and PXR against bile acid toxicity has been demonstrated in FXR–/– and PXR–/– mice fed with cholate and lithocholate respectively [26,27]. Another xenobiotic receptor, constitutive androstane receptor (CAR, *NR1I3*), is activated by bilirubin [1].

Accordingly, in different animal models of cholestasis, in particular in the bile duct ligation model, a marked decrease in Ntcp mRNA levels contrasts with little or no significant change in the mRNA levels of Bsep and of Mrp2 [28]. The implication of FXR in this regulation has been demonstrated in FXR knockout mice. Bile acid feeding, which causes Ntcp downregulation and Bsep upregulation in wild-type mice, has no such effects in FXR knockout mice [26]. In wild-type mice and in rats, bile acid feeding causes an upregulation in the expression of Mdr2, leading to an increase in the canalicular secretion of phospholipids [1,29,30]. Bile salts also exert a posttranscriptional regulation on transporters. Taurocholate, via the activation of phosphatidyl-inositol 3-kinase (PI3K), increases the amount of Bsep, Mdr2 and Mrp2 at the canalicular membrane through vesicular exocytosis [31,32]. The alternative bile acid export pumps Mrp3 and Mrp4, which are expressed in the basolateral membrane of hepatocytes, are also induced through an FXR-independent mechanism [33]. Other adaptive transporter changes include an

induction of alternative efflux pumps (Mrp2, Mrp4) together with a downregulation of Asbt in the kidney.

Another response that is almost constant in all cholestatic disorders with the exception of familial intrahepatic cholestasis of types 1 and 2 is bile duct proliferation. It has been demonstrated in bile duct-ligated and α-naphthylisothiocyanate (ANIT)-fed rats that cholangiocytes of the ductular reaction are functionally similar to cholangiocytes of a normal liver and that newly formed bile ducts form a well-organized network connected with the pre-existing biliary tree [34,35]. It has been proposed that the ductular reaction may create an alternative draining route for bile secretion when native bile ducts are injured. This possibility has recently received support from a model of ischaemia-induced cholestasis, in which all biochemical signs of cholestasis completely disappeared while bile duct hyperplasia was maximal [36]. Because cholangiocytes are able to transport bile acids via ASBT, the ductular reaction may provide a cholehepatic shunt pathway for bile acids. The cholehepatic shunt could subserve a defence mechanism and prevent prolonged exposure of the biliary tract to bile acids. In addition, bile acids increase the secretory capacity of cholangiocytes by transcriptional regulation of cyclic adenosine monophosphate (cAMP)-coupled receptors, including FXR-mediated upregulation of the vasoactive intestinal polypeptide (VIP) receptor [37,38], and by stimulating the activity of cAMP-dependent and -independent chloride channels [39,40] (Fig. 2). These effects could contribute to increase ductal secretion, together with bile duct proliferation, which may be viewed as an attempt to restore normal bile secretion.

Pathology of cholestasis [41,42]

In morphological terms, cholestasis is the presence of visible bile in tissue sections. It is also known as bilirubinostasis because the main component seen by light microscopy is bilirubin. However, in contrast to extrahepatic biliary obstruction, chronic intrahepatic cholestasis may evolve over years without morphological cholestasis. As a consequence, liver biopsy is performed not to confirm the diagnosis of cholestasis but to obtain a diagnosis of the cause, to exclude potential aetiologies and to assess the consequences of cholestasis, especially in terms of fibrosis. Regarding the cause, the pathologist's chief goal in evaluating the cholestatic liver is no longer, at least in adults, to distinguish large bile duct obstruction from other causes ('surgical' cholestasis vs. 'medical' cholestasis) because of tremendous improvements in imaging techniques of the liver and biliary tree, but to distinguish diseases involving small bile ducts from those in which cholestasis is purely hepatocellular in origin. It should be kept in mind that hepatocellular changes exhibit considerable overlap among these two types of cholestasis; it is only after finding additional changes in portal tracts that a bile duct disease can be inferred. In all instances, it is essential to examine the biopsy in a systematic manner with special attention to bile ducts.

Pathological features of cholestasis

The main hepatocellular feature is brown pigmentation from retained bilirubin (bilirubinostasis). Pigmentation includes accumulation of bilirubin in hepatocytes (hepatocellular cholestasis), inspissated bile in swollen canaliculi (canalicular cholestasis) and, during cholestasis of long duration, bile regurgitation into the sinusoidal space with phagocytosis by Kupffer cells (Kupffer cell cholestasis) [43]. These features occur predominantly in the perivenular region as well as the associated changes in hepatocytes undergoing toxic degeneration that appear enlarged with a flocculent cytoplasm (feathery degeneration). In contrast, the cytological alterations described as cholate stasis because they are thought to be caused by the detergent action of retained bile acids occur in periportal areas: i.e. hepatocytes undergo 'ballooning degeneration' and may contain Mallory bodies and copper. In addition to cholate stasis, the so-called biliary piecemeal necrosis is observed in some severe cases of cholestasis and comprises hepatocyte necrosis or apoptosis, inflammation, fibroplasia and ductular proliferation in variable combinations [41]. The term 'ductular reaction' is now preferred to 'ductular proliferation' because it implies a reaction of ductular phenotype possibly, but not necessarily, of ductular origin (progenitor cells or biliary metaplasia of hepatocytes) [44]. Neutrophils may predominate in the inflammatory infiltrate and surround bile ductules (neutrophilic cholangiolitis). Ductular proliferation is virtually always associated with neutrophils, so that the presence of these cells is not in itself evidence of bile duct obstruction or bacterial infection [45]. Proliferating cholangioles are found at the margins of portal tracts and should not be confused with bile ducts; changes in the cholangioles do not have the same significance as identical changes in bile ducts. Indeed, only acute cholangitis, which is characterized by the presence of neutrophils in or around the acinar bile duct, is highly suggestive of large bile duct obstruction. Lastly, chronic cholestasis, especially in children, may give rise to liver cell rosettes consisting of dilated bile canaliculi surrounded by more than two hepatocytes in a pseudotubular arrangement. In common with chronic extrahepatic biliary obstruction, progressive fibrosis at the limiting plate produces gradual enlargement of the portal areas followed by portal–portal fibrous bridging and, eventually, the development of cirrhosis. However, until very advanced, the process spares the basic acinar architecture with terminal hepatic venules and portal tracts maintaining an almost normal anatomical relationship.

Pathological features of bile duct disease

Once cholestasis is suspected, the portal tracts should be examined carefully with special attention to the presence of a ductular reaction and the integrity of interlobular bile ducts (or their paucity). Inflammatory changes in portal tracts (or at their margin) are usually absent in 'hepatocellular cholestasis' except

when biliary piecemeal necrosis (described in the preceding section) occurs or during sustained sepsis. In this latter condition, a massive dilatation of bile ductules may be observed and has been described as cholangitis lenta. The mechanism is thought to be general shutdown not only of the hepatocellular bile secretion but also of the ability of the ductules to conduct bile [46]. Besides these two unusual conditions, a marked ductular reaction, eventually associated with portal tract oedema, is indicative of 'obstructive' cholestasis but does not in itself distinguish between the many causes of bile duct diseases. Ductopenia is a major pathological feature of bile duct disease but is lacking specificity, as it represents the endstage of a number of bile duct destructive diseases. Ductopenia is classically defined by the loss of interlobular bile ducts from more than half the portal tracts [47], which show prominent hepatic arterioles without accompanying bile ducts. Less strict criteria have also been proposed [48]. It is essential that the liver specimen has an adequate number of portal tracts (at least 10) for a diagnosis of ductopenia to be made accurately [49]. Immunohistochemical staining for bile duct cytokeratins (cytokeratins 7 or 19) may be helpful.

In contrast, identification of distinctive bile duct lesions is highly informative about causes. The two main characteristic bile duct lesions are the non-suppurative destructive cholangitis and the fibrous obliterative cholangitis. It should be emphasized that early lesions of bile ducts are usually heterogeneous within the liver and segmental within the duct system. As a consequence, cholangitis may vary greatly in degree from one portal tract to another or even be absent in small biopsy samples, and serial sections are useful. Causes of the different types of cholangitis are indicated in Table 1. *Non-suppurative destructive cholangitis* is characterized by a mononuclear inflammatory infiltrate surrounding and penetrating the bile duct epithelium with associated epithelial damage and/or destruction of the basement membrane. Biliary epithelial damage consists of loss of the normal epithelial columnar shape, nuclear enlargement or pyknosis and cytoplasmic eosinophilia or vacuolization. In addition to lymphocytes, eosinophils or even some neutrophils may be present, but the lymphocytes appear to be the primary effectors of injury, and this destructive cholangitis is described as lymphocytic. In some cases, the bile ducts are surrounded by epithelioid granulomas, and the term granulomatous destructive cholangitis is used. The non-suppurative destructive lymphocytic cholangitis (florid duct lesion) is highly suggestive but not pathognomonic of primary biliary cirrhosis (PBC) (Table 1). The granulomatous destructive cholangitis may be observed in PBC, sarcoidosis and drug-induced cholangitis. The histological changes designated as non-destructive cholangitis (mononuclear cells infiltrating the bile duct epithelium but not obviously damaging epithelium or destroying the bile duct basement membrane) are less informative about causes. *Fibrous obliterative cholangitis* is characterized by an 'onion skin' type of periductal fibrosis with degeneration and atrophy of the epithelial lining and possible replacement of the bile duct by fibrous cords [41]. The 'onion skin' lesion is a typical feature of sclerosing cholangitis, either primary or secondary, but is also occasionally present in hepatic sarcoidosis [50] (Table 1). However, in patients with primary sclerosing cholangitis (PSC), this nearly diagnostic lesion is rarely present in biopsy specimens, and it is more common to find only a paucity of normal bile ducts and non-specific fibrosis and inflammation in the portal triads. PSC typically involves less inflammation than PBC.

Unusual cholangitis includes malignant cholangitis and neutrophilic cholangitis. Malignant cholangitis is characterized by specific cells penetrating the bile duct epithelium. In patients with Hodgkin's lymphoma, progressive cholestasis may also relate to ductopenia without evidence of malignant infiltration [51]. Neutrophilic cholangitis, with or without the involvement of large bile ducts, is associated with neutrophilic dermatosis and, especially, generalized pustular psoriasis [52].

Table 1 Typical biliary lesions and their main causes (graft setting excluded).

1 Non-suppurative destructive cholangitis	Primary biliary cirrhosis Primary sclerosing cholangitis Autoimmune hepatitis Drug-induced cholangitis Chronic hepatitis C, B Sarcoidosis
2 Fibrous obliterative cholangitis	Primary sclerosing cholangitis Secondary sclerosing cholangitis Sarcoidosis
3 Other cholangitis (unusual)	Malignant cholangitis: Lymphoma (Hodgkin's or non-Hodgkin's) Systemic mastocytosis Langerhans cell histiocytosis Neutrophilic cholangitis: neutrophilic dermatosis
4 Ductal plate malformations (congenital hepatic fibrosis)	

Lastly, abnormal bile duct-like structures associated with fibrosis are observed in ductal plate malformations and especially in congenital hepatic fibrosis [53].

Other pathological features

It must be kept in mind that raised serum alkaline phosphatase activity may be the main presenting feature of numerous other liver diseases. These diseases do not fit the criteria of 'true' chronic cholestatic diseases, i.e. potential progression towards cirrhosis or hepatocellular insufficiency due to cholestasis itself, but raise similar diagnostic issues. In this setting, histopathological evaluation may either be diagnostic by revealing storage disease or diffuse infiltrative disorders [amyloidosis and its variants, metastatic cancer (breast, melanoma), lymphoma] or provide helpful information to guide patient management by showing particular features including hepatic granulomas (without cholangitis), nodular regenerative hyperplasia, peliosis and sinusoidal dilatation (eventually associated with haemophagocytic histiocytosis). The pathogenesis of cholestasis in these conditions is often unclear. The mechanisms proposed include occult bile duct compression or ductular reaction and aberrant release of cytokines with resultant impairment of bile formation.

Clinical features of cholestasis

The clinical features of the cholestatic syndrome result from: (i) accumulation of substances in the liver, blood and other tissues that are normally excreted in bile, including bile acids, bilirubin and biliary lipids (primary features); and (ii) malabsorption of fat and fat-soluble vitamins A, D, E and K as a result of inadequate postprandial bile acid concentrations in the upper small intestine (secondary features).

Primary features

Jaundice is far from being a constant feature of cholestasis, and typically follows the onset of symptoms such as pruritus and raised serum alkaline phosphatase by weeks or even years, as often occurs in patients with primary biliary cirrhosis.

Pruritus is a major, but not invariable, feature of cholestasis. It is generally intermittent, occurring mainly in the evening and at night. If severe, it may result in significant sleep deprivation, depression and even suicide. The pruritus of cholestasis has commonly been assumed to result from the accumulation of unidentified pruritogenic agents normally excreted in bile. A causative role for bile acids has been postulated for decades, but direct evidence is lacking. Application of bile acids to skin blisters causes pruritus (but at higher concentrations than those found in cholestastic patients with pruritus). When considering bile acids as the pruritogens in cholestasis, the lack of correlation between pruritus severity and total levels of bile acids in serum, skin or interstitial fluid has to be considered and explained [54]. Indeed, increased plasma levels of bile acids are not associated with pruritus in all patients; the pruritus is intermittent despite the absence of apparent changes in serum bile acids; and, in liver failure, when serum bile acids peak, the pruritus of cholestasis tends to cease. In addition, the bile acid-binding agent cholestyramine often relieves the pruritus of cholestasis, but it may also relieve the pruritus of uraemia and polycythaemia rubra vera, in which serum bile acids are not elevated, and relief of pruritus by several other agents does not correlate with lowering of serum bile acids. However, an indirect role of bile acids is not excluded, and it has been proposed that pruritus might result from an unidentified component of the liver that is released by the detergent action of retained bile acids [55]. Work by Bergasa and Jones [56] and Jones and Bergasa [57] has suggested that increased endogenous opiate activity contributes to the pruritus of cholestasis by a central mechanism. Supporting observations in both humans and animals include: (i) several opiate agonists cause pruritus, which can be reversed by naloxone; (ii) opiate 'tone', serum enkephalin levels and liver enkephalin mRNA are increased in cholestasis; and (iii) opiate antagonists improve the pruritus of cholestasis in double-blind studies. As pruritus is a nociceptive stimulus, systems mediating nociception such as the serotonin and the endogenous cannabinoid systems might also play a role.

Fatigue is common in chronic cholestasis and especially in PBC. It diminishes quality of life and interferes with many aspects of daily living [58]. The pathogenesis is unclear, but fatigue might be centrally mediated and not peripheral in origin. The mechanisms proposed for this centrally mediated fatigue include abnormal neuroendocrine function and altered serotonergic neurotransmission [59].

Cholesterol deposits in the periorbital skin folds (xanthelasmas) and in tendon sheaths, bony prominences and peripheral nerves (xanthomas) are the result of chronic hyperlipidaemia and are only observed in prolonged and severe cholestasis. However, there is no evidence that cholestasis predisposes to atheroma or coronary artery disease.

Secondary features of cholestasis (observed only in cases of prolonged and severe cholestasis)

Fat-soluble vitamin malabsorption (vitamins A, D, E and K)

Steatorrhoea may occur in the advanced stages of chronic cholestatic liver disease and is due primarily to an inability to digest dietary lipids as a result of impaired intestinal bile acid delivery and inadequate micelle formation. Low serum levels of vitamin A are commonly found, but are rarely associated with impairment of dark adaptation. Neurological impairment secondary to vitamin E deficiency (hyporeflexia and later ataxia, loss of vibration and position sensation, peripheral neuropathy and quadriplegia) is much more common in children than in adults with chronic cholestasis. Malabsorption of vitamin D may occur but does not seem to play a major role in the pathogenesis

of metabolic bone disease associated with cholestasis. Malabsorption of vitamin K results in prolongation of the prothrombin time, but serious haemorrhage is very uncommon.

Bone disease (osteopenia)

The major bone disease in chronic cholestasis is osteoporosis, whereas osteomalacia is rarely seen [60]. The pathogenesis of the osteoporosis remains poorly understood. Both decreased osteoblastic activity and increased osteoclastic activity contribute to the development of osteoporosis [61]. A direct effect of cholestasis on bone formation has been suggested by experiments in which serum from patients with cholestasis inhibited the proliferation of cultured osteoblasts. The serum inhibitor seems to be bilirubin because the effect was simulated by bilirubin but not by bile acids and was blocked by removal of bilirubin from serum by photobleaching [62]. Other likely contributing factors to the osteoporosis include malabsorption of calcium, steroid treatment of the underlying liver disease, immobility, generalized failure of protein synthesis and malnutrition.

Biochemical features of cholestasis

Biochemical tests of cholestasis reflect: (i) hepatocellular or cholangiocellular cell damage induced by bile salts; (ii) functional consequences of altered bile secretion.

Tests of cell damage consist of elevated serum concentrations of the liver enzymes alkaline phosphatase, γ-glutamyltransferase (γ-GT) and 5′-nucleotidase. Alkaline phosphatase isoenzymes catalyse the hydrolysis of phosphate esters at alkaline pH. These enzymes are synthesized in a variety of tissues, i.e. liver, bone, intestine, kidney and placenta. Their enzymatic activity would result in the detoxification of endotoxins [63]. In the liver, alkaline phosphatase enzymatic activity has been detected in the sinusoidal and canalicular plasma membrane and in the cytosol of hepatocytes. The serum levels of alkaline phosphatase vary with age and gender. They increase during the second and third trimesters of pregnancy. In cholestatic conditions, an increase in alkaline phosphatase synthesis in the liver occurs via a posttranscriptional mechanism in response to bile salts, and would account for elevated serum levels. The delay required for synthesis explains the fact that, in acute biliary obstruction, the serum levels of alkaline phosphatase may be normal whereas those of transaminases are increased. Alkaline phosphatase elevation is also missing in up to 3% of cases in sclerosing cholangitis [64].

γ-GT catalyses the transfer of the γ-glutamyl group from peptides such as glutathione onto other amino acids, and thus allows γ-glutamyl recycling [65]. The most common dosage method of γ-GT is based on the formation of a chromogen (*p*-nitroaniline) from the substrate γ-L-glutamyl-*p*-nitroanilide. γ-GT is expressed in different tissues. In the liver, the enzyme is localized all along the biliary tree, from hepatocytes to the common bile duct, although at highest levels in the bile ducts. The serum level of γ-GT varies with age and gender. It is the most sensitive biochemical test of cholestasis. In cholestatic liver diseases, there is a very good correlation between γ-GT and alkaline phosphatase serum levels. Cholestatic diseases with normal γ-GT are very rare. They include the benign and progressive forms of intrahepatic cholestasis of types 1 and 2 and the early stages of cystic fibrosis liver disease. The close link between γ-GT serum levels and bile duct injury is supported by the fact that, in progressive familial intrahepatic cholestasis (PFIC1 and PFIC2), normal or nearly normal γ-GT serum levels are accompanied by little or no bile duct proliferation, which is also a unique feature among cholestatic diseases. Because the BSEP defect (in PFIC2) prevents bile salt efflux out of hepatocytes, and for reasons that are unclear in the ATP8B1 defect (PFIC1), the biliary concentrations of bile acids are abnormally low in both conditions. Consequently, bile ducts are not the target of bile salt-induced injury. In the early stages of cystic fibrosis liver disease, focal biliary lesions have been described and may account for normal γ-GT serum levels. When isolated, γ-GT serum elevation has little specificity for cholestasis and may also result from enzymatic induction in response to alcohol or drug intake.

5′-Nucleotidase catalyses the hydrolysis of nucleotides between phosphate group(s) and the atom of carbon no. 5 in the pentose. This enzyme is probably involved in the metabolism of nucleic acids in many tissues. The circulating enzyme is of hepatic origin and, in the liver, the enzyme is localized in hepatocytes, predominantly within their sinusoidal and canalicular membrane. The rise in its serum concentration in cholestasis is attributed to the detergent effect of bile acids on the hepatocellular plasma membrane. In liver disorders, there is a good correlation between the serum concentrations of 5′-nucleotidase and alkaline phosphatase. This test is of particular value in children and pregnant women.

Functional tests of altered bile secretion include bilirubinaemia and serum levels of bile acids and lipids. Bilirubin is the endproduct of haem degradation. As opposed to mono- or diglucuronide conjugates of bilirubin, unconjugated bilirubin is water insoluble and in circulation is bound to albumin. The most common dosage method of bilirubin is based on a reaction with diazonium. This method provides a direct measurement of conjugated bilirubin (or direct bilirubin), and total bilirubin is measured in the presence of an activator such as methanol. This method tends to overestimate bilirubin conjugates, which do not normally exceed 4–5% of total serum bilirubin (i.e. 1 μmol/L), which may be misleading in situations of moderate unconjugate type hyperbilirubinaemia such as in Gilbert syndrome. Total bilirubinaemia is normally < 17 μmol/L. Hyperbilirubinaemia predominantly of unconjugate type may result from polymorphism or mutations in the *ugt1* gene which encodes the uridine–phosphate–glucuronosyltransferase bili-UGT1. The polymorphism is associated with Gilbert syndrome (frequent and benign) while other mutations cause Crigler–Najjar syndrome (rare and severe with a high risk of neonatal neurotoxicity). In cholestasis, hyperbilirubinaemia is predominantly of conjugate type and does not exceed 500 μmol/L with the

exception of haemolysis or renal insufficiency. Bilirubinaemia is a cholestatic test of low sensitivity. It has a strong prognostic value in chronic cholestatic diseases, in particular in PBC and PSC. Hyperbilirubinaemia of predominantly conjugate type may also result from a genetic defect in the canalicular transporter MRP2/*ABCC2* in the Dubin–Johnson syndrome. The serum concentration of bile acids is a more sensitive test of cholestasis than bilirubinaemia. This is explained by the fact that the biliary output of bile acids is 100-fold higher than that of bilirubin. It is a cholestatic test frequently used in children [66] and pregnant women [67]. The dosage of total bile acids shows similar sensitivity compared with the dosage of individual bile acids. The major interest in dosing individual bile acids is to verify that ursodeoxycholic acid (UDCA) has become the major bile acid in PBC patients under UDCA treatment. Cholestasis causes hypercholesterolaemia, which is, at least partly, the result of increased cholesterol synthesis. Cholestasis is also responsible for the emergence of an abnormal lipoprotein called lipoprotein X, a 40- to 100-nm vesicle with an aqueous lumen containing phospholipids and cholesterol. The plasma concentration of this lipoprotein is correlated with the activity of MDR3/Mdr2. It is absent in Mdr2 knockout mice. The increase in prothrombin time caused by cholestasis is accompanied by a decrease in vitamin K-dependent coagulation factors (factors II, VII, IX, X) without a defect in factor V.

Specific intrahepatic disorders

As nearly all cholestatic disorders listed in Tables 2 and 3 have been described separately in other sections, only features of the main disorders will be reviewed briefly. Full discussion of paediatric cholestasis is beyond the scope of this section, and the focus will be on some particular diseases in non-transplanted adults.

Primary biliary cirrhosis [68]

PBC is a presumed autoimmune disease of the liver, which predominantly affects middle-aged women. Most cases are diagnosed when asymptomatic. The diagnosis is based on a biochemical cholestatic pattern, the presence of serum antimitochondrial antibodies (AMA) (≥ 1/40 titre) and compatible or diagnostic pathological features. The diagnosis is classically considered as definite when these three criteria are present and probable in the presence of two criteria in patients with otherwise unexplained disease. The major hallmark of PBC is the presence of AMA (90–95% of cases), the specificity of which for PBC is greater than 95%. The usual and simplest test is immunofluorescence, but immunoblotting tests and enzyme-linked immunosorbent assay (ELISA) using recombined or purified antigens have been shown to be more sensitive for AMA detection. Less frequent 'PBC-specific' antibodies are antibodies against the nuclear pore protein gp210 and antibodies against p62, a nuclear pore glycoprotein. Liver biopsy is useful to confirm the diagnosis and to determine the prognosis. Although the diagnosis of PBC may seem straightforward, subsets of patients must be individualized in terms of diagnostic criteria or management. These variant forms include AMA-negative PBC (also named autoimmune cholangitis by some authors) [69], PBC–autoimmune hepatitis overlap syndrome [70] and premature ductopenic PBC [71].

Table 2 Causes of intrahepatic cholestasis in adulthood.

Non-obstructive
Bacterial infection: endotoxaemia, sepsis
Cholestatic variety of viral, alcoholic hepatitis or NASH
Toxic: drug, parenteral nutrition
Paraneoplastic syndrome: e.g. Hodgkin's disease
Inherited disease: Wilson's disease, familial cholestatic syndromes (including BRIC)
Pregnancy: intrahepatic cholestasis of pregnancy
Infiltrative disorders: malignant (haematological diseases and metastatic cancer), amyloidosis, granulomatosis, storage diseases
Ductal plate malformation
Nodular regenerative hyperplasia
Chronic vascular diseases of the liver (congestive hepatopathy, Budd–Chiari syndrome, veno-occlusive disease)
Cirrhosis (any cause)
Small bile duct diseases
Primary conditions
Primary biliary cirrhosis (with or without AMA)
Primary sclerosing cholangitis
Idiopathic adulthood ductopenia
Conditions with specific aetiology
Drug-induced cholestasis
Secondary sclerosing cholangitis
Rejection of transplant liver
Inherited disorders: MDR3/*ABCB4* deficiency, erythropoietic protoporphyria
Part of systemic conditions
Sarcoidosis
Cystic fibrosis
Graft-vs.-host disease
Cholestasis associated with malignancy

Mixed mechanisms of cholestasis including bile duct damage may be involved in some diseases such as sarcoidosis, drug toxicity and lymphoma. PFIC3, although the primary defect is located at the hepatocyte level, is viewed as a biliary disease because of the secretion of a 'toxic bile' inducing bile duct damage.
NASH, non-alcoholic steatohepatitis; BRIC, benign recurrent intrahepatic cholestasis; AMA, antimitochondrial antibodies.

Sclerosing cholangitis [72]

Sclerosing cholangitis (SC) is a chronic cholestatic liver disease characterized by fibrosing inflammation of the intrahepatic and/or the extrahepatic biliary tree. Within the intrahepatic biliary tree, large and/or small bile ducts may be involved. In the

Table 3 Causes of intrahepatic cholestasis in infancy and childhood.

Metabolic disease
With biliary tract compromise: α-1-antitrypsin storage disease, cystic fibrosis
Without biliary tract compromise: galactosaemia, tyrosinaemia, fatty acid oxidation defects, lipid and glycogen storage disorders, peroxisomal disorders
Specific defects in biliary function
Disorders of bile acid biosynthesis and conjugation
Disorders of canalicular secretion (PFIC)
Paucity of bile ducts
Syndromic: Alagille syndrome (Jagged 1 defect)
Non-syndromic
Ductal plate malformation
Infections: bacterial, viral
Toxic: total parenteral nutrition, drugs
Idiopathic neonatal hepatitis
Cirrhosis (any cause)

PFIC, progressive familial intrahepatic cholestasis.

Table 4 Causes of secondary sclerosing cholangitis.

Prolonged biliary obstruction[a]
Gallstones
Stricture of the common bile duct (postoperative, miscellaneous)
Chronic bacterial cholangitis (without obstruction)
Biliary enterostomy
Sphincterotomy
Severe immune deficiencies[b]
Secondary: AIDS
Primary: X-linked agammaglobulinaemia, hyperIgM syndrome
Ischaemia
Proven
Liver transplantation (with or without arterial occlusion)
Transarterial chemoembolization
Vascular trauma
Hereditary haemorrhagic telangiectasia, polyarteritis nodosa
Radiation therapy
Probable
Thrombotic disorders: paroxysmal nocturnal haemoglobinuria, sickle cell disease, antiphospholipid syndrome (systemic lupus erythematosus)
Vasculitis: giant cell arteritis, Behçet's disease, Kawasaki's disease
Turner syndrome
Toxic cholangitis
Intraductal formaldehyde or hypertonic saline (Echinococcal cyst removal)
Intra-arterial floxuridine
Septic shock
Haematological diseases[c]
Langerhans cell histiocytosis
Systemic mastocytosis
Hypereosinophilic syndrome
Angioimmunoblastic lymphadenopathy

[a]Major role of recurrent bacterial cholangitis.
[b]Often but not constantly associated with opportunistic infections (cytomegalovirus, *Cryptosporidium parvum*, etc.).
[c]Specific involvement of the biliary tree, at least in part.

usual form (large duct SC), the diagnosis is based on characteristic cholangiographic changes in combination with a cholestatic biochemical profile, liver histology findings and the presence of extrahepatic diseases, especially inflammatory bowel diseases (IBD). Typical cholangiographic findings include multifocal strictures and dilatations. These biliary changes may be missed by ultrasonography, and biliary tree visualization is a key step in the diagnosis. This has traditionally been performed using endoscopic retrograde cholangiopancreatography (ERCP) but, more recently, non-invasive magnetic resonance cholangiopancreatography (MRCP) has proved to be a valuable tool. Liver biopsy in this condition is more useful for staging purposes than for diagnosis itself. Because the disease is focal in the early stages, the typical onion skin fibrosis is seen in only a minority of patients, and false negatives are not exceptional (5–10%). A subgroup of patients with typical histological changes but without cholangiographic abnormalities has been defined, and the term 'small duct' SC has been adopted [73]. Other causes of small duct diseases have to be carefully ruled out before making this diagnosis. PSC refers to an idiopathic disorder that can occur independently or in association with other diseases or syndromes, most commonly IBD (the prevalence of which varies with geography). The mean age at diagnosis of PSC is 40 years, and men are affected about twice as often as women. PSC is classically assumed to be one disease, when it is more likely to be a group of diseases with different aetiologies that share clinical similarities. The term secondary sclerosing cholangitis specifically refers to SC that results from a known pathogenesis or injury (Table 4). It should be noted that biliary tract calculi may be found in patients with PSC and do not exclude a diagnosis of PSC. There are also several categories of SC that fall between the convenient bookends of primary and secondary varieties of SC, resulting in various classifications. This is especially the case with SC thought to be of ischaemic origin. For example, bile duct alterations resembling small duct SC are common in Turner syndrome (known to be associated with vascular malformations) and are probably related to ischaemia occurring in the liver microcirculation [74]. As a consequence, this SC can be classified either as PSC associated with Turner syndrome or as SC secondary to Turner syndrome. It should be emphasized that strict definition of intrahepatic cholestasis (see Introduction) excludes intrahepatic large duct SC. Isolated small duct SC is mainly of the primary variety, although some convincing cases of ischaemic cause have been reported [75]. Interestingly, the clinical course of small duct PSC appears to be relatively benign with only a minority of patients progressing

to develop classical PSC and no reports of cholangiocarcinoma. Another important variant form of PSC is PSC–autoimmune hepatitis overlap syndrome, which is frequent in children and young adults.

Drug-induced cholestasis [76–78]

Drugs may cause cholestasis through either impairment of bile secretion by the hepatocyte with (cholestatic hepatitis) or without (pure cholestasis) hepatocellular damage, or bile duct injury involving the ductules (cholangiolitis) or the interlobular ducts (cholangitis). Rarely, drugs can cause obstruction of large bile ducts by inducing cholelithiasis or by producing SC. Factors appearing to influence the susceptibility of developing drug-induced cholestasis include age, gender, genetic determinants, comorbidities and nutritional status. Criteria for drug-induced hepatotoxicity have been generated that take into consideration the time from drug intake to clinical presentation and the clinical response to drug withdrawal [79]. In the case of cholestatic reactions, the time to onset of liver injury is required to be within 30 days of drug intake, but it should be noted that exceptions (up to 8 weeks) have been reported in cases of cholestatic hepatitis attributable to flucloxacillin or amoxicillin–clavulanate [80]. There are no unambiguous hallmarks that can be used to diagnose drug reactions from other patterns of liver histology. However, liver biopsy can be useful when there is doubt as to the diagnosis, and it can provide features of prognostic significance. Indeed, although most patients have an uncomplicated course once the offending agent is promptly withdrawn, the severity of bile duct injury appears to be predictive of chronic cholestasis after cholestatic hepatitis [81], and hepatic fibrosis present in baseline biopsy indicates a higher possibility of developing chronic liver disease [82]. The clinical presentation is dependent on the mechanism of cholestasis, and some major clinicopathological syndromes have been recognized (Table 5).

Cholestasis without hepatitis (pure/bland cholestasis)

Clinical features most often begin 2–3 months after starting therapy. The major symptom is pruritus. Liver histology shows cholestasis, with no portal tract, biliary or parenchymal changes. Recovery usually occurs within days to weeks of stopping causative agents.

Cholestasis with hepatitis

This is the most common form of drug-induced liver injury. Liver histology shows cholestasis, portal tract inflammation, sometimes with bile duct injury, and lobular necroinflammation. Clinical features appear 1–6 weeks after commencing treatment. Patients may present with fever, upper abdominal pain and jaundice. Pruritus is usually less severe than in 'bland' cholestasis. Resolution occurs within 4–8 weeks in the majority of cases but, depending on the individual drug, chronicity may also occur.

Cholestasis with bile duct injury

Bile duct injury is the main histological finding. The clinical features often resemble cholestatic hepatitis. In some cases, the syndrome resembles bacterial cholangitis, with high fever, rigors, abdominal pain, jaundice and tender hepatomegaly. Usually, the acute symptoms resolve in a few days or weeks. Sometimes, prolonged cholestasis (> 6 months) with progression to the vanishing bile duct syndrome (VBDS) may occur even after withdrawal of the causative agent.

Vanishing bile duct syndrome

The clinical and laboratory picture resembles PBC but AMA are absent. At least 30 drugs have been implicated, but the prototype is chlorpromazine. In general, the outcome is good, with a partial or total resolution of the clinical and biochemical symptoms despite the persistence of ductopenia. However, cases of secondary biliary cirrhosis have been described, eventually resulting in death or liver transplantation.

Table 5 Clinicopathological syndromes of drug-induced cholestasis (adapted from ref. 78).

Type of cholestasis	Clinical picture	Examples
Acute		
Cholestasis without hepatitis (pure/bland cholestasis)	Cholestasis (itch, dark urine, jaundice)	Estrogens, tamoxifen, anabolic steroids, danazol
Cholestasis with hepatitis (cholestatic hepatitis, mixed hepatocellular/cholestatic injury)	Cholestasis (described above) May resemble acute cholangitis with fever and abdominal pain	Chlorpromazine, macrolides, oxypenicillins, amoxycillin–clavulanate, NSAIDs
Cholestasis with bile duct injury (cholangiolytic, ductular)	Similar to cholestatic hepatitis May resemble bacterial cholangitis with high fever, rigors and abdominal pain	Dextropropoxyphene, flucloxacillin, paraquat
Chronic		
Vanishing bile duct syndrome (VBDS)	Pruritus, fatigue, resembles PBC (but AMA-negative)	Chlorpromazine, flucloxacillin, carbamazepine
Sclerosing cholangitis-like	Cholestasis, large bile duct strictures, resembles PSC	Intra-arterial floxuridine, scolicidal agents

AMA, antimitochordrial antibodies; NSAIDs, non-steroidal anti-inflammatory drugs; PBC, primary biliary cholangitis; PSC, primary sclerosing cholangitis.

Sclerosing cholangitis-like

Strictures affecting large bile ducts have been ascribed to intra-arterial administration of the chemotherapy agent floxuridine and to intrabiliary instillation of scolicidal agents.

Drug-induced lithiasis

Ceftriaxone and dipyridamole have been reported to precipitate in bile and induce sludge or stone formation in the gallbladder or in the common bile duct. Other drugs, such as clofibrate, may cause increased secretion of cholesterol.

MDR3 (*ABCB4*) deficiency

The *ABCB4* gene, human homologue of Mdr2, encodes the MDR3 glycoprotein, a canalicular phospholipid translocator involved in biliary phosphatidylcholine (PC) excretion (Fig. 1). Phospholipids are the major carrier and solvent of cholesterol, and they exert a protective effect against bile salt-induced biliary mucosa injury. Defects in MDR3 function determine the production of bile with a low content of PC, increased lithogenicity and high detergent power, which causes damage to biliary epithelial cells. Indeed, mutations in the *ABCB4* gene are strongly associated with progressive intrahepatic cholestasis type 3 (PFIC3) and with the recently described low phospholipid-associated cholelithiasis syndrome (LPAC) [83]. Heterozygous mutations have also been reported in some patients with a history of intrahepatic cholestasis of pregnancy with raised serum γ-GT [84] or in adults with idiopathic cholestasis [85]. As a consequence, *ABCB4* deficiency should be suspected not only in children or young people with high γ-GT cholestasis, but also in middle-aged or older patients with chronic idiopathic cholestasis. In addition, the concept of 'toxic bile' as a result of hereditary and/or acquired *ABCB4* defects might apply to specific, yet to be defined, subgroups of patients with SC.

Hereditary haemorrhagic telangiectasia [86]

Rendu–Osler–Weber disease is an autosomal dominant disease characterized by angioplastic lesions (telangiectases and arteriovenous malformations) that affect many organs, including the skin, lungs, gastrointestinal tract, brain and liver. Patients may present with a biochemical cholestatic pattern related to either nodular regenerative hyperplasia or biliary disease characterized by bile duct abnormalities resembling Caroli syndrome or SC. These changes are thought to result from ischaemia induced by arteriovenous shunts either at the level of ascini (the adjacent parenchyma with an intact blood supply undergoing compensatory hyperplasia) or at the level of the peribiliary plexus causing injury of extrahepatic or intrahepatic bile ducts with the subsequent development of biliary strictures or cysts containing bile. In cases similar to Caroli's disease, it has also been hypothesized that abnormalities in vascular formation at the ductal plate could arrest the normal development of the bile duct system.

Erythropoietic protoporphyria (EPP) [87]

EPP is a metabolic disorder in which protoporphyrin accumulates within the liver because of inherited deficient ferrochelatase activity. The principal extrahepatic manifestation is photosensitivity. The biochemical hallmark is an increased level of protoporphyrin in red blood cells and faeces. Accumulation of protoporphyrin causes liver damage, eventually leading to hepatic failure. Liver biopsy demonstrates pigment deposits not only in hepatocytes and Kupffer cells, but also in cholangiocytes, canaliculi and interlobular bile ducts. This is the reason why EPP is considered to be a cause of small bile duct disease.

Inflammatory hepatocellular cholestasis

The common denominator of this entity is inhibition of transporter expression and function by proinflammatory cytokines, including TNFα, IL-1 and IL-6. The most striking examples are cholestasis associated with sepsis and paraneoplastic cholestatic syndromes in patients with renal cell carcinoma (Stauffer syndrome) or other malignancies including Hodgkin's disease that are known to secrete cytokines. Proinflammatory cytokines are also likely to play a role in other cholestatic conditions such as alcoholic hepatitis, granulomatosis, parenteral nutrition-associated cholestasis and the cholestatic variants of viral hepatitis. Thus, these cytokines appear to be the final common mediators of cholestasis associated with a variety of inflammatory diseases.

Cholestasis associated with sepsis [88]

Endotoxins and lipopolysaccharides (LPS) (contained within the wall of Gram-negative bacteria) are potent inducers of proinflammatory cytokine production. Sepsis-associated cholestasis has to be considered as part of the differential diagnosis of jaundice in the hospitalized or critically ill patient. The principal sign is the development of a disproportionate elevation in serum bilirubin in comparison with serum alkaline phosphatase and aminotransferase levels [89]. Although Gram-negative bacteria are the predominant causative agents, jaundice has been reported in association with a number of bacteria, including Gram-positives, such as *Staphylococcus aureus*. Liver biopsy is rarely necessary to establish the diagnosis of sepsis-related jaundice. If performed, the most prominent finding is intrahepatic cholestasis eventually associated with Kupffer cell hyperplasia, portal mononuclear cell infiltrates, focal hepatocyte dropout and steatosis. A major dilatation of bile ductules has been described in patients at great risk of death.

Haemophagocytic syndrome [90]

Hepatic manifestations of this syndrome are also thought to be related to cytokine effects on liver function. Haemophagocytic syndrome is characterized by the combination of proliferation of benign macrophages exhibiting phagocytosis of blood cells in haematopoietic organs with fever, splenomegaly, cytopenia and

hypertriglyceridaemia. It occurs in severe viral infections or in various conditions of immune deficiencies including lymphoma. The biochemical profile is a moderate increase in serum transaminases associated with marked cholestasis. Liver biopsy is a useful diagnostic tool in this setting by showing sinusoidal dilatation associated with haemophagocytic histiocytosis (even in case of non-specific bone marrow biopsy findings) and, eventually, specific lesions of the associated disease. The outcome is poor, and the main prognostic factors are early recognition and therapy of the underlying disorder.

Hepatic sarcoidosis [50]

Sarcoidosis is a systemic disease of uncertain aetiology that is characterized by the presence of granulomas in multiple organs. Hepatic involvement in sarcoidosis may cause cholestasis by different mechanisms. Liver biopsy is diagnostic and may show a wide array of histological features. Non-caseating epithelioid granulomas are constant and are most often located in the portal/periportal region. In addition to the granulomas, bile duct lesions similar to PBC (destructive cholangitis) or periductal fibrosis reminiscent of PSC (fibrous obliterative cholangitis) may be found as well as vascular changes consisting of sinusoidal dilatation and nodular regenerative hyperplasia. Lastly, association of sarcoidosis with PBC (AMA positive) and PSC has been reported.

Hodgkin's disease

Various causes of cholestasis have been described. Cholestasis may be directly related to the tumour cells by malignant infiltration of the liver or by involvement of the extrahepatic bile ducts or lymph nodes in the porta hepatis. In some cases, the mechanism is indirect, and cholestasis seems to be caused by the effects of cytokines released from extrahepatic lymphoma cells and may resolve with response to systemic therapy. Progressive loss of small intrahepatic bile ducts represents a particular form of this paraneoplastic syndrome [51].

Approach to the diagnosis of intrahepatic cholestasis in adults

Patient history and physical examination may provide important clues regarding the aetiology of cholestasis and are always major steps in the diagnostic process. Diagnostic hypotheses in the severely ill patient (infections, haemophagocytic syndrome, malignant infiltration of the liver, etc.) are quite different from those in the ambulatory care setting (PBC, PSC). In addition, some causes are unique to special populations and may require specific investigations that are not relevant in other populations. For example, the causes of intrahepatic cholestasis after liver transplantation may be categorized by time of occurrence and include ischaemia/reperfusion injury, small-for-size graft, bacterial infection, acute or chronic rejection, cytomegalovirus infection, intrahepatic biliary strictures with or without hepatic artery thrombosis, drug hepatotoxicity and recurrent disease [91]; in human immunodeficiency virus (HIV)-infected patients, the main causes are drug hepatotoxicity, opportunistic infections, neoplasms and HIV cholangiopathy [92]. Nevertheless, whatever the presentation and the setting, investigations should first exclude extrahepatic biliary obstruction and then attempt to establish the cause of the intrahepatic cholestasis. The choice of biliary imaging procedure is determined by the clinical presentation, local expertise and availability. However, abdominal ultrasonography is usually preferred to exclude dilated intrahepatic ducts and mass lesions because it is rather sensitive and specific, non-invasive, portable (of major interest in the evaluation of the critically ill patient) and relatively inexpensive. Its disadvantages are that its findings are operator dependent, and it may be difficult to interpret in some patients. Lastly, abnormalities of bile ducts such as are observed in SC may be missed.

Once diagnosis of intrahepatic cholestasis is made, liver biopsy should be considered in cases of severe and recent cholestasis if features of the patient's illness are not highly suggestive of a precise aetiology (keeping in mind that viral hepatitis and alcoholic hepatitis may occasionally present with profound cholestasis) and if a definite diagnosis seems to be of key importance (for example, malignant liver infiltration). In patients with chronic cholestasis, an intermediate step before liver biopsy is AMA testing because the diagnosis of PBC, which is the major cause of small duct biliary diseases [93], can be made with confidence in a patient with high-titre AMA (≥ 1/40), and a cholestatic biochemical profile in the absence of an alternative explanation [68]. If AMA testing is negative, a liver biopsy should be performed and is likely to yield useful information (Fig. 3). As already emphasized, particular attention to the condition of bile ducts is critical in the histological evaluation. From a practical standpoint, it is useful to classify biopsy findings under the broad categories of: (i) disorders involving bile ducts (Table 1); (ii) disorders not involving bile ducts, including a variety of storage or infiltrative liver diseases, hepatic granulomas (without cholangitis), nodular regenerative hyperplasia, peliosis, sinusoidal dilatation and cirrhosis (Table 2); and (iii) cholestasis with only minimal histological abnormalities as observed in the following conditions: benign recurrent cholestasis, estrogen or anabolic steroid therapy, sepsis, total parenteral nutrition and paraneoplastic phenomenon. It should be kept in mind that lack of bile duct lesions does not rule out biliary disease because of the high degree of sampling variability seen in liver biopsy specimens from patients with small bile duct disease. If diagnosis remains elusive despite liver biopsy findings, MRCP should be performed to visualize the biliary tree with a superior accuracy than conventional ultrasound or computerized tomography (CT). Cholangiographic changes may then be diagnostic of SC. In a clinical setting suggestive of PSC (patient with IBD) or if a non-invasive approach is favoured, MRCP may be performed before liver biopsy. However, it has been shown that, in patients with unexplained cholestasis, cholangiographic abnormalities are extremely rare in the absence of biliary lesions on liver biopsy, suggesting that, from a diagnostic performance perspective,

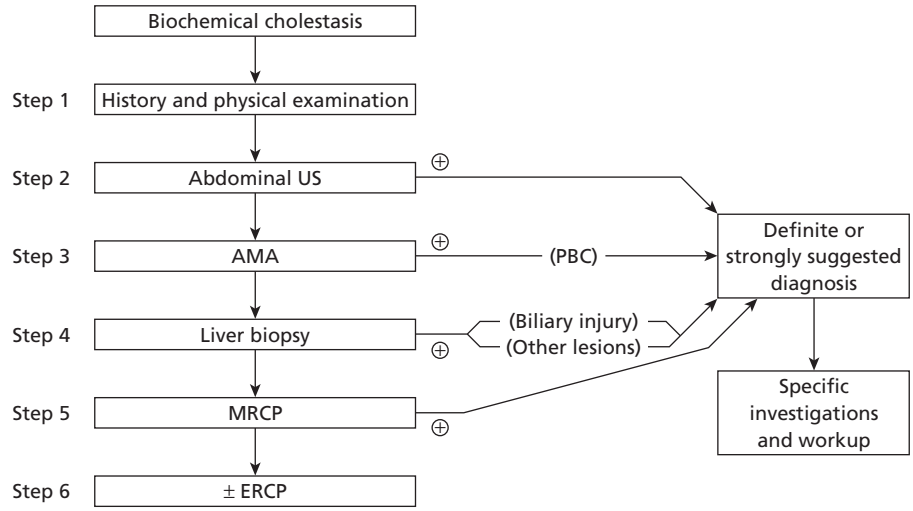

Fig. 3 Diagnostic approach to adult patients with chronic cholestasis (see text for comments). US, ultrasound; AMA, antimitochondrial antibodies; MRCP, magnetic resonance cholangiopancreatography; ERCP, endoscopic retrograde cholangiopancreatography.

liver biopsy should be performed first [94]. When there is persistent uncertainty regarding the cause, diagnostic ERCP, because of its potential morbidity, is indicated only if SC is suspected.

Medical management of intrahepatic cholestasis

In intrahepatic cholestasis secondary to an identified cause, the optimal treatment is directed towards the underlying aetiology (for example, inflammatory or drug-induced cholestasis, rejection, etc.), emphasizing the importance of making a correct diagnosis. When a specific treatment is not available, therapy acting on cholestasis itself via stimulation of defective transporter expression and function should be considered. Presently, UDCA is the only drug widely used in this setting. Future therapies are likely to target ligand-activated nuclear receptors known to regulate the transport and metabolism of biliary constituents.

Ursodeoxycholic acid

UDCA was initially isolated from bear bile, which has been used in Chinese traditional medicine for the treatment of liver diseases. UDCA is a dihydroxylated bile acid with higher hydrophilicity than most endogenous bile acids. It is the epimer 7β of chenodeoxycholic acid. In humans, it represents less than 3% of endogenous bile acids, the majority of which consists of cholic acid (35%), chenodeoxycholic acid (35%) and deoxycholic acid (25%). After oral administration, UDCA is absorbed by passive non-ionic diffusion mainly in the small intestine. Its absorption rate is affected by the availability of endogenous bile acids in the intestinal lumen, which is high during meals and low under cholestatic conditions. After uptake into the liver, UDCA is conjugated and secreted into bile. UDCA conjugates are reabsorbed mainly from the distal ileum where they compete with endogenous bile acids for active transport, undergoing an effective enterohepatic circulation. Non-absorbed UDCA and UDCA conjugates enter the colon and, after bacterial deamidation of conjugates, are mostly converted to lithocholic acid by bacterial enzymes and eliminated in the faeces. Only small amounts of the poorly soluble lithocholic acid are reabsorbed via the colonic mucosa, sulphated in the liver, secreted into bile and excreted in the faeces.

UDCA is administrated in two to four divided doses with food. At a chronic dose of 13–15 mg/kg/day, UDCA constitutes 30–50% of serum and biliary bile acids. Optimal doses may vary according to disease (see below). Importantly, in patients with pruritus and/or jaundice, UDCA should be initiated at a low dosage (200–250 mg/day), and the dosage should be increased with regular monitoring of serum bilirubin levels (and ideally of serum bile acid concentrations). An increase in bilirubinaemia may require the discontinuation of UDCA [95].

Putative mechanisms of action of UDCA (see Fig. 4)
When administered at a dose of 10–15 mg/kg/day in patients with cholestatic diseases, UDCA inhibits the intestinal reabsorption of endogenous bile acids. While the size of the endogenous bile acid pool shows little variation, UDCA becomes the predominant bile acid in bile and serum. UDCA has been shown to stimulate the canalicular secretion of bile acids in animal models [96] and in patients with biliary diseases [97]. In mice, UDCA feeding causes an upregulation in the expression of Bsep and Mrp2 without changing Ntcp expression [98], and also induces the expression of Mrp3 and Mrp4 involved in alternative excretory pathways [99]. There is evidence to indicate that some of the transcriptional effects of UDCA could be mediated by PXR, but not FXR. Tauroursodeoxycholate (TUDC) increases the canalicular secretion of taurocholate via PI3K-dependent/Ras/MAP kinase activation and translocation of BSEP within the canalicular membrane [96,100]. UDCA also stimulates the translocation of Mrp2 within the canalicular membrane through

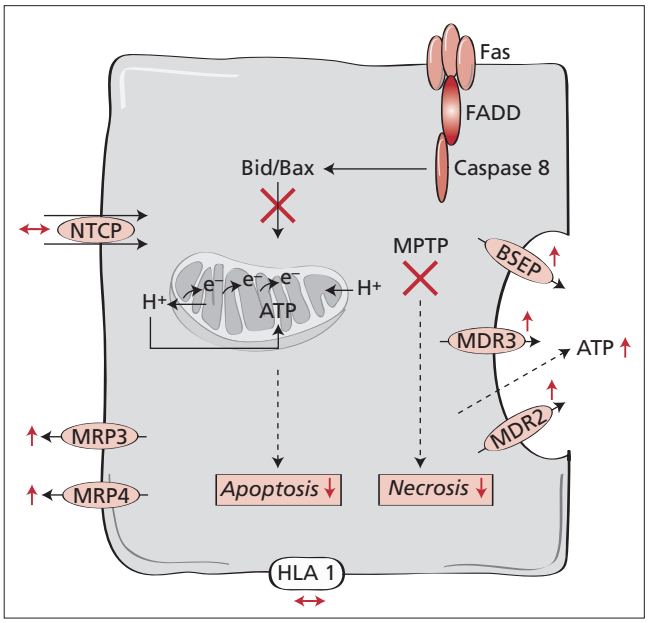

Fig. 4 Mechanisms of action of ursodeoxycholic acid (UDCA) in hepatocytes. UDCA causes upregulation in the expression of BSEP, MDR3 and MRP2, without changing NTCP expression, and also induces MRP3 and MRP4 expression. UDCA stimulates the secretion of ATP, which may subsequently stimulate cholangiocyte secretion. UDCA inhibits the effects of endogenous bile acids on the proapoptotic proteins Bid and Bax and on the opening of the mitochondrial permeability transition pore (MPTP), thus preventing both apoptosis and necrosis. UDCA also counteracts the effect of endogenous bile acids on the induction of HLA class I molecules.

the exocytosis of intracytoplasmic vesicles [101]. This regulatory effect is mediated by an increase in the intracellular concentrations of calcium and by the activation of protein kinase C (PKC)α, and counteracts the effect of a very hydrophobic bile acid lithocholic acid, which inhibits the vesicular transport and recruitment of canalicular proteins through the PKC isoform ε. A 3-week treatment with UDCA in human subjects causes an increase in BSEP and MDR3 protein levels without a change in the mRNA levels [102]. UDCA is also able to stimulate the secretion of adenosine triphosphate (ATP) by hepatocytes, leading to increased concentrations of ATP in bile [103]. ATP present in bile stimulates ductal secretion through $P2Y_2$ purinergic receptors expressed on the apical membrane of cholangiocytes. According to the cholehepatic shunt theory, UDCA, being unconjugated when first secreted by hepatocytes, is protonated and then reabsorbed in bile ducts, leading to the generation of bicarbonate in bile. Patients with PBC display a downregulation in the expression of the anion exchanger AE2, which mediates bicarbonate secretion in both hepatocytes and cholangiocytes. In patients under UDCA treatment, expression of this exchanger is restored together with normalization of biliary bicarbonate secretion [104]. It was shown that, in gallbladder epithelial cells, TUDC compared with an endogenous bile acid, taurochenodeoxycholic acid (TCDC), triggers mucin secretion to a lesser extent [39], while stimulating hydroelectrolytic secretion to similar extent. It may be anticipated that, through these effects, UDCA decreases the ratio of mucin/fluid content in bile and thus augments bile fluidity.

UDCA provides protection for hepatocytes against both necrosis and apoptosis caused by endogenous bile acids. Bile acids may induce necrosis through the disruption of plasma membranes. It has been shown that the affinity of bile acid tauroconjugates for membrane phospholipids increases with their hydrophobicity in the following order: TUDC < taurocholate << taurochenodeoxycholate ≤ taurodeoxycholate. At high concentrations, exceeding the critical micellar concentration (≥ 2 mmol/L), the adsorption of taurodeoxycholate to phospholipids is markedly diminished in the presence of TUDC [105]. Hepatocellular necrosis may also result from altered mitochondrial permeability through direct interaction of bile acids with the mitochondrial membrane or through the opening of the permeability transition pore when a large number of mitochondria are damaged. The resulting defect in ATP causes cell necrosis. The increase in mitochondrial membrane permeability induced by glycodeoxycholate in hepatocytes is inhibited by UDCA [106]. Bile acids at submicellar concentrations may cause mitochondrial translocation of Bid and Bax (proapoptotic proteins of the bcl2 family) and elicit the mitochondrial release of cytochrome *c*, which activates the caspase cascade leading to apoptosis. In hepatocytes, UDCA inhibits the activation of the proteins Bid/Bax and the release of cytochrome *c* induced by either glycochenodeoxycholate or glycodeoxycholate [107]. UDCA also prevents apoptosis through the inhibition of cytochrome *c* release in cholangiocytes [108] (Fig. 5). Also, whereas in patients with cholestatic diseases, abnormal expression of human leukocyte antigen (HLA) class I molecules probably contributes to the destruction of hepatocytes by cytotoxic T lymphocytes, UDCA counteracts the induction of these molecules by endogenous bile acids on hepatocytes [109]. In summary, the major potential therapeutic properties of UDCA include: (i) an increase in canalicular bile secretion through the upregulation and recruitment of canalicular transporters; (ii) an increase in ductal secretion possibly through the restoration of AE2 expression, cholehepatic shunt and ATP release; (iii) an inhibition of necrosis and apoptosis in both hepatocytes and cholangiocytes; and (iv) immunomodulation. The overall result is the improvement in, or at least the preservation of, bile secretory functions together with a decrease in cell toxicity.

Therapeutic uses and efficacy of UDCA in cholestatic liver diseases

UDCA has been administered to patients with a large variety of cholestatic disorders. The drug is very well tolerated [95]. Indications can be classified under the broad categories of proven efficacy, justifiable administration and questionable efficacy [101,110,111].

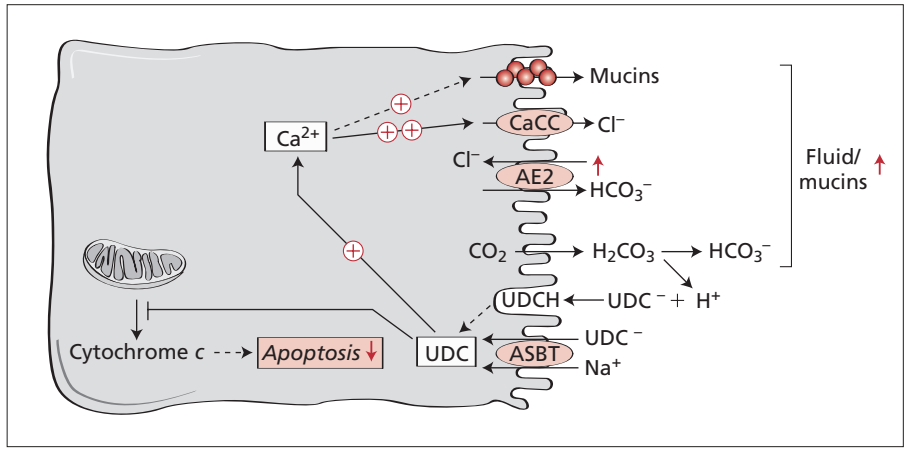

Fig. 5 Mechanisms of action of ursodeoxycholic acid (UDCA) in cholangiocytes. Cholangiocytes may reabsorb unconjugated UDCA after protonation, which generates bicarbonate, and conjugated UDCA through the apical sodium-dependent bile salt transporter (ASBT). UDCA restores the expression of the anion exchanger-2 (AE2) in these cells. Via calcium-dependent pathways, UDCA stimulates chloride secretion by the calcium-dependent chloride channel (CaCC) and, to a lesser extent, mucin secretion, which should lead to increased bile fluidity. UDCA also prevents cholangiocyte apoptosis through the inhibition of cytochrome c release in these cells.

Proven efficacy

Primary biliary cirrhosis Randomized, double-blind, placebo-controlled trials have shown that UDCA at doses of 13–15 mg/kg/day improves serum liver tests including bilirubin, the major prognostic marker in PBC, and liver histology. Most importantly, combined analysis of data from three large trials showed a significant prolongation of transplant-free survival after 4 years of UDCA treatment [112]. To date, UDCA is the only drug approved by the US Food and Drug Administration for the treatment of PBC.

Intrahepatic cholestasis of pregnancy (ICP) Although only limited data are available, two randomized trials have shown improvement in pruritus and liver tests [113,114]. Importantly, babies were delivered closer to term than those in the non-UDCA groups, and no side-effects have been reported in children or women. Therefore, UDCA may be considered to be a safe treatment for ICP in the third trimester at a dose of 8–16 mg/kg/day.

Low phospholipid-associated cholelithiasis syndrome UDCA is a well-established therapy for small cholesterol gallstones, and descriptive studies have shown that UDCA has a dramatic efficacy on the recurrence of symptoms in patients with LPAC syndrome [83]. Thus, UDCA is recommended in this setting at a dose of 8–10 mg/kg/day.

Justifiable administration

Primary sclerosing cholangitis UDCA, 12–15 mg/kg/day, improves liver tests (including bilirubin, which is an important prognostic marker), but the largest published placebo-controlled trial failed to demonstrate improvement in transplant-free survival [115]. However, two preliminary studies have suggested that higher doses (20–30 mg/kg/day) may have a positive effect on histological stage, cholangiographic appearance and projected survival [116,117]. In addition, UDCA use is associated with a lower prevalence of colonic neoplasia in patients with ulcerative colitis and PSC [118]. Thus, administration of UDCA seems to be justified, although prolongation of survival has not been proven, and the optimal dose remains to be determined. The effect of high doses is currently being evaluated in a large multicentre study.

Liver disease in cystic fibrosis (CF) In a randomized, placebo-controlled trial for 1 year, UDCA improved biochemical cholestasis, nutritional status and general condition [119]. Histological improvement has been reported as well. However, its effect on survival has yet to be proven. A high dosage (20 mg/kg/day) appears to induce a better response than a lower dosage (10 mg/kg/day), possibly because of impaired intestinal absorption.

Progressive familial intrahepatic cholestasis Patients with PFIC have been treated with 20–30 mg/kg/day UDCA for periods of 2–4 years [120]. Improvement in liver tests was associated with weight gain in about two-thirds of the patients. It has been suggested that response could be related to the residual activity of altered transporters.

Chronic graft-vs.-host disease A randomized trial showed that prophylactic administration of UDCA (600–900 mg/day) in patients undergoing bone marrow transplantation decreased the incidence of hepatic complications [121].

Miscellaneous cholestatic disorders (drug- and parenteral nutrition-induced cholestasis, bile duct paucity, etc.) A beneficial effect of UDCA has been suggested in small case series [110]. Because of the rarity of these disorders, randomized, controlled trials are unlikely to be performed.

Questionable efficacy

Among the authentic cholestatic diseases, benign recurrent intrahepatic cholestasis is the only disorder for which experience with UDCA is highly controversial (but limited) [110].

UDCA has also been used in various other liver diseases [alcoholic hepatitis, non-alcoholic steatohepatitis (NASH), chronic hepatitis C, etc.]. As cholestasis is not the primary and dominant feature of these diseases, UDCA efficacy in this setting will not be discussed here.

Medical treatment of symptoms of chronic cholestasis

Pruritus

Antihistamines are helpful only as sedatives to combat the insomnia associated with pruritus. The non-absorbable anion exchange resin, cholestyramine, is the first-line medication that most physicians use. Cholestyramine may be successful within a few days in patients who can tolerate the unpleasant side-effects of bad taste, bloating and constipation. The recommended dose of 4–16 g/day orally is most effective in patients with an intact gallbladder when taken before and after breakfast to allow maximal bile acid binding. As this drug not only binds bile acids but also oral medications, notably UDCA, thyroxin, digoxin and contraceptive pills, 4 h should lapse between the taking of cholestyramine and any other medication. Rifampicin is the second-line therapy. Most patients respond within 1 week. The starting dose is 150 mg twice a day, but higher doses are occasionally needed [122]. Rifampicin induces drug-metabolizing enzymes, and caution is required when prescribing other drugs. Side-effects include unconjugated hyperbilirubinaemia, dark staining urine and, on occasion, hepatitis, thrombocytopenia and renal tubular damage. The mechanism of its antipruritic effect is unknown. Interestingly, rifampicin has also been shown to improve the biochemical pattern of patients with PBC [123]. A complementary stimulation of hepatobiliary transport and detoxification systems by rifampicin and UDCA has been demonstrated in humans, suggesting that a combination of both agents may be beneficial in the treatment of cholestatic liver diseases [102]. In resistant cases, opioid antagonists can be considered. Intravenous infusion of naloxone has shown a clear benefit in a double-blind study [124]. In other trials, oral antagonists, such as nalmefene (60–120 mg/day) [125] and naltrexone (50 mg/day) [126] were successful. A narcotic 'withdrawal' syndrome was reported in some patients. Longer and larger trials are needed to evaluate their safety.

Steatorrhoea and fat-soluble deficiency

The steatorrhoea can usually be corrected by dietary medium-chain triglyceride supplementation (up to 40 g/day) and a decrease in neutral fat intake. In patients who do not respond, the possibility of pancreatic dysfunction and jejunal villus atrophy should be considered, because pancreatic enzyme replacement or withdrawal of gluten may then be of benefit. Serum vitamin A and D levels and prothrombin time should be monitored, and vitamins A, D and K replaced as necessary. Deficiency of vitamin E is very rare in adults. Replacement may be done orally or parenterally depending on the severity of depletion, jaundice and steatorrhoea. When deficiency is encountered, 25 000–50 000 IU of oral vitamin D given once or twice a week and 25 000–50 000 IU of oral vitamin A given two or three times a week are usually sufficient to achieve normal levels. Vitamin K deficiency is corrected by parenteral administration (10 mg), and patients can be maintained on oral water-soluble vitamin K (5 mg/day).

Bone disease

To prevent osteoporosis, regular exercise, moderate sunlight exposure and a daily oral intake of 1.5 g of elemental calcium should be encouraged. In postmenopausal patients, hormone replacement therapy can be considered [68]. If osteoporosis is evident, therapy with a biphosphonate is advised (for more details, see Chapter 11.1 on PBC).

Fatigue

No known treatment exists for this debilitating symptom of cholestasis. In a recent placebo-controlled, crossover trial, ondansetron did not confer clinically significant fatigue reduction [127].

Future therapeutic developments

Norursodeoxycholic acid (norUDCA)

The C[23] homologue of UDCA is a powerful choleretic molecule. NorUDCA undergoes cholehepatic shunting and induces a bicarbonate-rich hypercholeresis in humans [128]. It has been shown that norUDCA was superior to UDCA in the treatment of SC in Mdr2 knockout mice. This effect has been attributed to a higher induction of detoxifying enzymes and biliary transporters [129]. The next step will be to determine the safety and efficacy of norUDCA in therapeutic trials of human cholangiopathies.

Nuclear receptors as potential therapeutic targets

Nuclear receptors known to regulate the transport and metabolism of biliary constituents have been proposed as potential therapeutic targets [1]. FXR, the hepatic expression of which is decreased in cholestatic diseases, has raised great interest [130]. Thus, it has been shown that an FXR pharmacological agonist provided hepatoprotection in two rat models of intra- and extrahepatic cholestasis (i.e. ANIT feeding and bile duct ligation) [28]. In addition, FXR agonists have shown antifibrotic properties [131]. Drugs that have long been used empirically in the treatment of cholestatic manifestations, in particular pruritus, are the ligands of other nuclear receptors, i.e. rifampicin, a PXR ligand, and phenobarbital, a CAR ligand. Both PXR and CAR ligands induce bile acid detoxification/hydroxylation and sulphation, and both are able to regulate bilirubin conjugation and excretion. In addition, PXR agonists repress bile acid synthesis via CYP7A1, and CAR also induces the expression of Mrp4 [1]. Peroxisome proliferator receptor-α (PPARα) agonists such as fibrates stimulate the expression of Mdr2 and

vitamin D via its nuclear receptor, that of Mrp3 [132]. It is proposed in the future to combine agents that have independent, but complementary, effects such as rifampicin and UDCA [102].

References

1 Trauner M, Wagner M, Fickert P *et al.* (2005) Molecular regulation of hepatobiliary transport systems: clinical implications for understanding and treating cholestasis. *J Clin Gastroenterol* 39, S111–124.

2 Pauli-Magnus C, Meier PJ (2005) Hepatocellular transporters and cholestasis. *J Clin Gastroenterol* 39, S103–110.

3 Fouassier L, Kinnman N, Lefevre G *et al.* (2002) Contribution of mrp2 in alterations of canalicular bile formation by the endothelin antagonist bosentan. *J Hepatol* 37, 184–191.

4 Lakehal F, Dansette PM, Becquemont L *et al.* (2001) Indirect cytotoxicity of flucloxacillin toward human biliary epithelium via metabolite formation in hepatocytes. *Chem Res Toxicol* 14, 694–701.

5 Anderson JM (1996) Leaky junctions and cholestasis: a tight correlation. *Gastroenterology* 110, 1662–1665.

6 Kawaguchi T, Sakisaka S, Sata M *et al.* (1999) Different lobular distributions of altered hepatocyte tight junctions in rat models of intrahepatic and extrahepatic cholestasis. *Hepatology* 29, 205–216.

7 Rahner C, Stieger B, Landmann L (1996) Structure–function correlation of tight junctional impairment after intrahepatic and extrahepatic cholestasis in rat liver. *Gastroenterology* 110, 1564–1578.

8 Kawaguchi T, Sakisaka S, Mitsuyama K *et al.* (2000) Cholestasis with altered structure and function of hepatocyte tight junction and decreased expression of canalicular multispecific organic anion transporter in a rat model of colitis. *Hepatology* 31, 1285–1295.

9 Lora L, Mazzon E, Martines D *et al.* (1997) Hepatocyte tight-junctional permeability is increased in rat experimental colitis. *Gastroenterology* 113, 1347–1354.

10 Sakisaka S, Kawaguchi T, Taniguchi E *et al.* (2001) Alterations in tight junctions differ between primary biliary cirrhosis and primary sclerosing cholangitis. *Hepatology* 33, 1460–1468.

11 Fickert P, Fuchsbichler A, Wagner M *et al.* (2004) Regurgitation of bile acids from leaky bile ducts causes sclerosing cholangitis in Mdr2 (Abcb4) knockout mice. *Gastroenterology* 127, 261–274.

12 Bolder U, Ton-Nu HT, Schteingart CD *et al.* (1997) Hepatocyte transport of bile acids and organic anions in endotoxemic rats: impaired uptake and secretion. *Gastroenterology* 112, 214–225.

13 Trauner M, Arrese M, Soroka CJ *et al.* (1997) The rat canalicular conjugate export pump (Mrp2) is down-regulated in intrahepatic and obstructive cholestasis. *Gastroenterology* 113, 255–264.

14 Green RM, Beier D, Gollan JL (1996) Regulation of hepatocyte bile salt transporters by endotoxin and inflammatory cytokines in rodents. *Gastroenterology* 111, 193–198.

15 Spirli C, Nathanson MH, Fiorotto R *et al.* (2001) Proinflammatory cytokines inhibit secretion in rat bile duct epithelium. *Gastroenterology* 121, 156–169.

16 Chen F, Ananthanarayanan M, Emre S *et al.* (2004) Progressive familial intrahepatic cholestasis, type 1, is associated with decreased farnesoid X receptor activity. *Gastroenterology* 126, 756–764.

17 Makishima M, Okamoto AY, Repa JJ *et al.* (1999) Identification of a nuclear receptor for bile acids. *Science* 284, 1362–1365.

18 Parks DJ, Blanchard SG, Bledsoe RK *et al.* (1999) Bile acids: natural ligands for an orphan nuclear receptor. *Science* 284, 1365–1368.

19 Ananthanarayanan M, Balasubramanian N, Makishima M *et al.* (2001) Human bile salt export pump promoter is transactivated by the farnesoid X receptor/bile acid receptor. *J Biol Chem* 276, 28857–28865.

20 Denson LA, Sturm E, Echevarria W *et al.* (2001) The orphan nuclear receptor, shp, mediates bile acid-induced inhibition of the rat bile acid transporter, ntcp. *Gastroenterology* 121, 140–147.

21 Chiang JY, Kimmel R, Weinberger C *et al.* (2000) Farnesoid X receptor responds to bile acids and represses cholesterol 7alpha-hydroxylase gene (CYP7A1) transcription. *J Biol Chem* 275, 10918–10924.

22 Pircher PC, Kitto JL, Petrowski ML *et al.* (2003) Farnesoid X receptor regulates bile acid-amino acid conjugation. *J Biol Chem* 278, 27703–27711.

23 Barbier O, Torra IP, Sirvent A *et al.* (2003) FXR induces the UGT2B4 enzyme in hepatocytes: a potential mechanism of negative feedback control of FXR activity. *Gastroenterology* 124, 1926–1940.

24 Neimark E, Chen F, Li X *et al.* (2004) Bile acid-induced negative feedback regulation of the human ileal bile acid transporter. *Hepatology* 40, 149–156.

25 Huang L, Zhao A, Lew JL *et al.* (2003) Farnesoid X receptor activates transcription of the phospholipid pump MDR3. *J Biol Chem* 278, 51085–51090.

26 Sinal CJ, Tohkin M, Miyata M *et al.* (2000) Targeted disruption of the nuclear receptor FXR/BAR impairs bile acid and lipid homeostasis. *Cell* 102, 731–744.

27 Staudinger JL, Goodwin B, Jones SA *et al.* (2001) The nuclear receptor PXR is a lithocholic acid sensor that protects against liver toxicity. *Proc Natl Acad Sci USA* 98, 3369–3374.

28 Liu Y, Binz J, Numerick MJ *et al.* (2003) Hepatoprotection by the farnesoid X receptor agonist GW4064 in rat models of intra- and extrahepatic cholestasis. *J Clin Invest* 112, 1678–1687.

29 Frijters CM, Ottenhoff R, van Wijland MJ *et al.* (1997) Regulation of mdr2 P-glycoprotein expression by bile salts. *Biochem J* 321(Pt 2), 389–395.

30 Gupta S, Todd Stravitz R, Pandak WM *et al.* (2000) Regulation of multidrug resistance 2 P-glycoprotein expression by bile salts in rats and in primary cultures of rat hepatocytes. *Hepatology* 32, 341–347.

31 Folli F, Alvaro D, Gigliozzi A *et al.* (1997) Regulation of endocytic–transcytotic pathways and bile secretion by phosphatidylinositol 3-kinase in rats. *Gastroenterology* 113, 954–965.

32 Misra S, Ujhazy P, Gatmaitan Z *et al.* (1998) The role of phosphoinositide 3-kinase in taurocholate-induced trafficking of ATP-dependent canalicular transporters in rat liver. *J Biol Chem* 273, 26638–26644.

33 Wagner M, Fickert P, Zollner G *et al.* (2003) Role of farnesoid X receptor in determining hepatic ABC transporter expression and liver injury in bile duct-ligated mice. *Gastroenterology* 125, 825–838.

34 Alpini G, Lenzi R, Sarkozi L *et al.* (1988) Biliary physiology in rats with bile ductular cell hyperplasia. Evidence for a secretory function of proliferated bile ductules. *J Clin Invest* 81, 569–578.

35 Masyuk TV, Ritman EL, LaRusso NF (2001) Quantitative assessment of the rat intrahepatic biliary system by three-dimensional reconstruction. *Am J Pathol* 158, 2079–2088.

36 Beaussier M, Wendum D, Fouassier L *et al.* (2005) Adaptative bile duct proliferative response in experimental bile duct ischemia. *J Hepatol* 42, 257–265.

37 Alpini G, Glaser SS, Ueno Y *et al.* (1999) Bile acid feeding induces cholangiocyte proliferation and secretion: evidence for bile acid-regulated ductal secretion. *Gastroenterology* 116, 179–186.

38 Chignard N, Mergey M, Barbu V *et al.* (2005) VPAC1 expression is regulated by FXR agonists in the human gallbladder epithelium. *Hepatology* 42, 549–557.

39 Chignard N, Mergey M, Veissiere D *et al.* (2001) Bile acid transport and regulating functions in the human biliary epithelium. *Hepatology* 33, 496–503.

40 Chignard N, Mergey M, Veissiere D *et al.* (2003) Bile salts potentiate adenylyl cyclase activity and cAMP-regulated secretion in human gallbladder epithelium. *Am J Physiol Gastrointest Liver Physiol* 284, G205–212.

41 Portmann BC, MacSween RNM (1994) Diseases of the intrahepatic bile ducts. In: MacSween RNM, Anthony PP, Scheuer PJ *et al.* (eds) *Pathology of the Liver*. Edinburgh: Churchill Livingstone, pp. 477–512.

42 Scheuer PJ, Lefkowitch JH (2000) Assessment and differential diagnosis of pathological features. In: Saunders WB (ed) *Liver Biopsy Interpretation*. London: Harcourt Publishers Ltd, pp. 51–65.

43 Desmet VJ (1986) Current problems in diagnosis of biliary disease and cholestasis. *Semin Liver Dis* 6, 233–245.

44 Roskams TA, Theise ND, Balabaud C *et al.* (2004) Nomenclature of the finer branches of the biliary tree: canals, ductules, and ductular reactions in human livers. *Hepatology* 39, 1739–1745.

45 Lefkowitch JH (2004) Histological assessment of cholestasis. *Clin Liver Dis* 8, 27–40, v.

46 Li MK, Crawford JM (2004) The pathology of cholestasis. *Semin Liver Dis* 24, 21–42.

47 Ludwig J, Wiesner RH, LaRusso NF (1988) Idiopathic adulthood ductopenia. A cause of chronic cholestatic liver disease and biliary cirrhosis. *J Hepatol* 7, 193–199.

48 Moreno A, Carreno V, Cano A *et al.* (1997) Idiopathic biliary ductopenia in adults without symptoms of liver disease. *N Engl J Med* 336, 835–838.

49 Demetris A, Adams D, Bellamy C *et al.* (2000) Update of the International Banff Schema for Liver Allograft Rejection: working recommendations for the histopathologic staging and reporting of chronic rejection. An International Panel. *Hepatology* 31, 792–799.

50 Devaney K, Goodman ZD, Epstein MS *et al.* (1993) Hepatic sarcoidosis. Clinicopathologic features in 100 patients. *Am J Surg Pathol* 17, 1272–1280.

51 Hubscher SG, Lumley MA, Elias E (1993) Vanishing bile duct syndrome: a possible mechanism for intrahepatic cholestasis in Hodgkin's lymphoma. *Hepatology* 17, 70–77.

52 Viguier B (2004) Functional adaptations in the craniofacial morphology of Malagasy primates: shape variations associated with gummivory in the family Cheirogaleidae. *Ann Anat* 186, 495–501.

53 Desmet VJ (1992) Congenital diseases of intrahepatic bile ducts: variations on the theme 'ductal plate malformation'. *Hepatology* 16, 1069–1083.

54 Ghent CN, Bloomer JR, Klatskin G (1977) Elevations in skin tissue levels of bile acids in human cholestasis: relation to serum levels and to pruritus. *Gastroenterology* 73, 1125–1130.

55 Ghent CN (1987) Pruritus of cholestasis is related to effects of bile salts on the liver, not the skin. *Am J Gastroenterol* 82, 117–118.

56 Bergasa NV, Jones EA (1995) The pruritus of cholestasis: potential pathogenic and therapeutic implications of opioids. *Gastroenterology* 108, 1582–1588.

57 Jones EA, Bergasa NV (1990) The pruritus of cholestasis: from bile acids to opiate agonists. *Hepatology* 11, 884–887.

58 Poupon RE, Chretien Y, Chazouilleres O *et al.* (2004) Quality of life in patients with primary biliary cirrhosis. *Hepatology* 40, 489–494.

59 Swain MG, Maric M (1997) Improvement in cholestasis-associated fatigue with a serotonin receptor agonist using a novel rat model of fatigue assessment. *Hepatology* 25, 291–294.

60 Hay JE (1995) Bone disease in cholestatic liver disease. *Gastroenterology* 108, 276–283.

61 Guichelaar MM, Malinchoc M, Sibonga J *et al.* (2002) Bone metabolism in advanced cholestatic liver disease: analysis by bone histomorphometry. *Hepatology* 36, 895–903.

62 Janes CH, Dickson ER, Okazaki R *et al.* (1995) Role of hyperbilirubinemia in the impairment of osteoblast proliferation associated with cholestatic jaundice. *J Clin Invest* 95, 2581–2586.

63 Xu Q, Lu Z, Zhang X (2002) A novel role of alkaline phosphatase in protection from immunological liver injury in mice. *Liver* 22, 8–14.

64 Cooper JF, Brand EJ (1988) Symptomatic sclerosing cholangitis in patients with a normal alkaline phosphatase: two case reports and a review of the literature. *Am J Gastroenterol* 83, 308–311.

65 Whitfield JB (2001) Gamma glutamyl transferase. *Crit Rev Clin Lab Sci* 38, 263–355.

66 Jansen PL, Muller M, Sturm E (2001) Genes and cholestasis. *Hepatology* 34, 1067–1074.

67 Walker IA, Nelson-Piercy C, Williamson C (2002) Role of bile acid measurement in pregnancy. *Ann Clin Biochem* 39, 105–113.

68 Heathcote EJ (2000) Management of primary biliary cirrhosis. The American Association for the Study of Liver Diseases practice guidelines. *Hepatology* 31, 1005–1013.

69 Heathcote J (1997) Autoimmune cholangitis. *Gut* 40, 440–442.

70 Chazouilleres O, Wendum D, Serfaty L *et al.* (1998) Primary biliary cirrhosis–autoimmune hepatitis overlap syndrome: clinical features and response to therapy. *Hepatology* 28, 296–301.

71 Vleggaar FP, van Buuren HR, Zondervan PE *et al.* (2001) Jaundice in non-cirrhotic primary biliary cirrhosis: the premature ductopenic variant. *Gut* 49, 276–281.

72 Lee YM, Kaplan MM (1995) Primary sclerosing cholangitis. *N Engl J Med* 332, 924–933.

73 Wee A, Ludwig J (1985) Pericholangitis in chronic ulcerative colitis: primary sclerosing cholangitis of the small bile ducts? *Ann Intern Med* 102, 581–587.

74 Roulot D, Degott C, Chazouilleres O *et al.* (2004) Vascular involvement of the liver in Turner's syndrome. *Hepatology* 39, 239–247.

75 Bognel C, Degott C, Rougier P *et al.* (1989) [Anatomo-pathologic study of hepatic toxicity in intra-arterial hepatic chemotherapy]. *Gastroenterol Clin Biol* 13, 125–131.

76 Biour M, Ben Salem C, Chazouilleres O *et al.* (2004) [Drug-induced liver injury: fourteenth updated edition of the bibliographic database of liver injuries and related drugs]. *Gastroenterol Clin Biol* 28, 720–759.

77 Levy C, Lindor KD (2003) Drug-induced cholestasis. *Clin Liver Dis* 7, 311–330.

78 Velayudham LS, Farrell GC (2003) Drug-induced cholestasis. *Expert Opin Drug Saf* 2, 287–304.

79 Benichou C (1990) Criteria of drug-induced liver disorders. Report of an international consensus meeting. *J Hepatol* 11, 272–276.

80 Ryley NG, Fleming KA, Chapman RW (1995) Focal destructive cholangiopathy associated with amoxycillin/clavulanic acid (Augmentin). *J Hepatol* 23, 278–282.

81 Degott C, Feldmann G, Larrey D *et al.* (1992) Drug-induced prolonged cholestasis in adults: a histological semiquantitative study demonstrating progressive ductopenia. *Hepatology* 15, 244–251.

82 Aithal PG, Day CP (1999) The natural history of histologically proved drug induced liver disease. *Gut* 44, 731–735.

83 Rosmorduc O, Hermelin B, Poupon R (2001) MDR3 gene defect in adults with symptomatic intrahepatic and gallbladder cholesterol cholelithiasis. *Gastroenterology* 120, 1459–1467.

84 Dixon PH, Weerasekera N, Linton KJ *et al.* (2000) Heterozygous MDR3 missense mutation associated with intrahepatic cholestasis of pregnancy: evidence for a defect in protein trafficking. *Hum Mol Genet* 9, 1209–1217.

85 Lucena JF, Herrero JI, Quiroga J *et al.* (2003) A multidrug resistance 3 gene mutation causing cholelithiasis, cholestasis of pregnancy, and adulthood biliary cirrhosis. *Gastroenterology* 124, 1037–1042.

86 Garcia-Tsao G, Korzenik JR, Young L *et al.* (2000) Liver disease in patients with hereditary hemorrhagic telangiectasia. *N Engl J Med* 343, 931–936.

87 Bloomer JR, Phillips MJ, Davidson DL *et al.* (1975) Hepatic disease in erythropoietic protoporphyria. *Am J Med* 58, 869–882.

88 Moseley RH (2004) Sepsis and cholestasis. *Clin Liver Dis* 8, 83–94.

89 Sikuler E, Guetta V, Keynan A *et al.* (1989) Abnormalities in bilirubin and liver enzyme levels in adult patients with bacteremia. A prospective study. *Arch Intern Med* 149, 2246–2248.

90 de Kerguenec C, Hillaire S, Molinie V *et al.* (2001) Hepatic manifestations of hemophagocytic syndrome: a study of 30 cases. *Am J Gastroenterol* 96, 852–857.

91 Ben-Ari Z, Pappo O, Mor E (2003) Intrahepatic cholestasis after liver transplantation. *Liver Transpl* 9, 1005–1018.

92 Te HS (2004) Cholestasis in HIV-infected patients. *Clin Liver Dis* 8, 213–228, viii–ix.

93 Ludwig J (1998) Idiopathic adulthood ductopenia: an update. *Mayo Clin Proc* 73, 285–291.

94 Sapey T, Turlin B, Canva-Delcambre V *et al.* (1999) [Importance of liver puncture biopsy and endoscopic retrograde cholangiography in patients with chronic anicteric unexplained cholestasis. A retrospective study in 79 patients]. *Gastroenterol Clin Biol* 23, 178–185.

95 Hempfling W, Dilger K, Beuers U (2003) Systematic review: ursodeoxycholic acid – adverse effects and drug interactions. *Aliment Pharmacol Ther* 18, 963–972.

96 Schliess F, Kurz AK, vom Dahl S *et al.* (1997) Mitogen-activated protein kinases mediate the stimulation of bile acid secretion by tauroursodeoxycholate in rat liver. *Gastroenterology* 113, 1306–1314.

97 Jazrawi RP, de Caestecker JS, Goggin PM *et al.* (1994) Kinetics of hepatic bile acid handling in cholestatic liver disease: effect of ursodeoxycholic acid. *Gastroenterology* 106, 134–142.

98 Fickert P, Zollner G, Fuchsbichler A *et al.* (2001) Effects of ursodeoxycholic and cholic acid feeding on hepatocellular transporter expression in mouse liver. *Gastroenterology* 121, 170–183.

99 Zollner G, Fickert P, Fuchsbichler A *et al.* (2003) Role of nuclear bile acid receptor, FXR, in adaptive ABC transporter regulation by cholic and ursodeoxycholic acid in mouse liver, kidney and intestine. *J Hepatol* 39, 480–488.

100 Kurz AK, Block C, Graf D *et al.* (2000) Phosphoinositide 3-kinase-dependent Ras activation by tauroursodesoxycholate in rat liver. *Biochem J* 350(Pt 1), 207–213.

101 Beuers U, Boyer JL, Paumgartner G (1998) Ursodeoxycholic acid in cholestasis: potential mechanisms of action and therapeutic applications. *Hepatology* 28, 1449–1453.

102 Marschall HU, Wagner M, Zollner G *et al.* (2005) Complementary stimulation of hepatobiliary transport and detoxification systems by rifampicin and ursodeoxycholic acid in humans. *Gastroenterology* 129, 476–485.

103 Nathanson MH, Burgstahler AD, Masyuk A *et al.* (2001) Stimulation of ATP secretion in the liver by therapeutic bile acids. *Biochem J* 358, 1–5.

104 Prieto J, Garcia N, Marti-Climent JM *et al.* (1999) Assessment of biliary bicarbonate secretion in humans by positron emission tomography. *Gastroenterology* 117, 167–172.

105 Heuman DM, Bajaj RS, Lin Q (1996) Adsorption of mixtures of bile salt taurine conjugates to lecithin-cholesterol membranes: implications for bile salt toxicity and cytoprotection. *J Lipid Res* 37, 562–573.

106 Botla R, Spivey JR, Aguilar H *et al.* (1995) Ursodeoxycholate (UDCA) inhibits the mitochondrial membrane permeability transition induced by glycochenodeoxycholate: a mechanism of UDCA cytoprotection. *J Pharmacol Exp Ther* 272, 930–938.

107 Rodrigues CM, Fan G, Ma X *et al.* (1998) A novel role for ursodeoxycholic acid in inhibiting apoptosis by modulating mitochondrial membrane perturbation. *J Clin Invest* 101, 2790–2799.

108 Que FG, Phan VA, Phan VH *et al.* (1999) GUDC inhibits cytochrome c release from human cholangiocyte mitochondria. *J Surg Res* 83, 100–105.

109 Hillaire S, Boucher E, Calmus Y *et al.* (1994) Effects of bile acids and cholestasis on major histocompatibility complex class I in human and rat hepatocytes. *Gastroenterology* 107, 781–788.

110 Lazaridis KN, Gores GJ, Lindor KD (2001) Ursodeoxycholic acid 'mechanisms of action and clinical use in hepatobiliary disorders'. *J Hepatol* 35, 134–146.

111 Paumgartner G, Beuers U (2002) Ursodeoxycholic acid in cholestatic liver disease: mechanisms of action and therapeutic use revisited. *Hepatology* 36, 525–531.

112 Poupon RE, Lindor KD, Cauch-Dudek K *et al.* (1997) Combined analysis of randomized controlled trials of ursodeoxycholic acid in primary biliary cirrhosis. *Gastroenterology* 113, 884–890.

113 Kondrackiene J, Beuers U, Kupcinskas L (2005) Efficacy and safety of ursodeoxycholic acid versus cholestyramine in intrahepatic cholestasis of pregnancy. *Gastroenterology* 129, 894–901.

114 Palma J, Reyes H, Ribalta J *et al.* (1997) Ursodeoxycholic acid in the treatment of cholestasis of pregnancy: a randomized, double-blind study controlled with placebo. *J Hepatol* 27, 1022–1028.

115 Lindor KD (1997) Ursodiol for primary sclerosing cholangitis. Mayo Primary Sclerosing Cholangitis–Ursodeoxycholic Acid Study Group. *N Engl J Med* 336, 691–695.

116 Harnois DM, Angulo P, Jorgensen RA *et al.* (2001) High-dose ursodeoxycholic acid as a therapy for patients with primary sclerosing cholangitis. *Am J Gastroenterol* 96, 1558–1562.

117 Mitchell SA, Bansi DS, Hunt N *et al.* (2001) Preliminary trial of high-dose ursodeoxycholic acid in primary sclerosing cholangitis. *Gastroenterology* 121, 900–907.

118 Tung BY, Emond MJ, Haggitt RC *et al.* (2001) Ursodiol use is associated with lower prevalence of colonic neoplasia in patients with ulcerative colitis and primary sclerosing cholangitis. *Ann Intern Med* 134, 89–95.

119 Colombo C, Battezzati PM, Podda M *et al.* (1996) Ursodeoxycholic acid for liver disease associated with cystic fibrosis: a double-blind multicenter trial. The Italian Group for the Study of Ursodeoxycholic Acid in Cystic Fibrosis. *Hepatology* 23, 1484–1490.

120 Jacquemin E, Hermans D, Myara A *et al.* (1997) Ursodeoxycholic acid therapy in pediatric patients with progressive familial intrahepatic cholestasis. *Hepatology* 25, 519–523.

121 Essell JH, Schroeder MT, Harman GS *et al.* (1998) Ursodiol prophylaxis against hepatic complications of allogeneic bone marrow

transplantation. A randomized, double-blind, placebo-controlled trial. *Ann Intern Med* 128, 975–981.

122 Ghent CN, Carruthers SG (1988) Treatment of pruritus in primary biliary cirrhosis with rifampin. Results of a double-blind, crossover, randomized trial. *Gastroenterology* 94, 488–493.

123 Bachs L, Pares A, Elena M *et al.* (1992) Effects of long-term rifampicin administration in primary biliary cirrhosis. *Gastroenterology* 102, 2077–2080.

124 Bergasa NV, Alling DW, Talbot TL *et al.* (1995) Effects of naloxone infusions in patients with the pruritus of cholestasis. A double-blind, randomized, controlled trial. *Ann Intern Med* 123, 161–167.

125 Bergasa NV, Schmitt JM, Talbot TL *et al.* (1998) Open-label trial of oral nalmefene therapy for the pruritus of cholestasis. *Hepatology* 27, 679–684.

126 Wolfhagen FH, Sternieri E, Hop WC *et al.* (1997) Oral naltrexone treatment for cholestatic pruritus: a double-blind, placebo-controlled study. *Gastroenterology* 113, 1264–1269.

127 Theal JJ, Toosi MN, Girlan L *et al.* (2005) A randomized, controlled crossover trial of ondansetron in patients with primary biliary cirrhosis and fatigue. *Hepatology* 41, 1305–1312.

128 Hofmann AF, Zakko SF, Lira M *et al.* (2005) Novel biotransformation and physiological properties of norursodeoxycholic acid in humans. *Hepatology* 42, 1391–1398.

129 Fickert P, Wagner M, Marschall HU *et al.* (2006) 24-norUrsodeoxycholic acid is superior to ursodeoxycholic acid in the treatment of sclerosing cholangitis in Mdr2 (Abcb4) knockout mice. *Gastroenterology* 130, 465–481.

130 Demeilliers C, Jacquemin E, Barbu V *et al.* (2006) Altered hepatobiliary gene expressions in PFIC1: ATP8B1 gene defect is associated with CFTR down-regulation. *Hepatology* 43, 1125–1134.

131 Fiorucci S, Antonelli E, Rizzo G *et al.* (2004) The nuclear receptor SHP mediates inhibition of hepatic stellate cells by FXR and protects against liver fibrosis. *Gastroenterology* 127, 1497–1512.

132 McCarthy TC, Li X, Sinal CJ (2005) Vitamin D receptor-dependent regulation of colon multidrug resistance-associated protein 3 gene expression by bile acids. *J Biol Chem* 280, 23232–23242.

19.2 Extrahepatic biliary obstruction: systemic effects, diagnosis and management

Michelle C. Gallagher and James S. Dooley

Definition

This chapter describes the hepatic and extrahepatic consequences of obstructive jaundice as well as the workup and general management of biliary obstruction. For present purposes, extrahepatic biliary obstruction is anatomical obstruction to the common bile duct, common hepatic duct and major intrahepatic bile ducts. Causes include calculi, malignant and benign tumours, and benign strictures including primary sclerosing cholangitis.

The aim is to encourage all those involved in the care of patients with obstructive jaundice to use optimal management based on available experimental and clinical data, and to develop new approaches to reduce postoperative and postprocedural complications based on knowledge of the underlying abnormalities present.

Pathophysiology of obstructive jaundice

Obstruction to bile flow increases biliary pressure with dilatation of the biliary tree. Bile passes into the circulation by several routes. Accumulation of bile constituents results in hepatocellular damage. The degree of rise in biliary pressure depends upon the secretory capacity of the hepatocytes and ductular cells, and the distensibility of the biliary tract. It is difficult to study directly.

Entry of bile into circulation

With biliary obstruction, some bile reaches the circulation via the lymphatics. In the rat, lymph flow from the liver increases after bile duct ligation and approaches the normal bile flow of 0.5–1.0 mL/h [1]. Paracellular flow, between hepatocytes, is another potential route. There is also passage of bile across the hepatocyte in intracellular vacuoles [2]. Only a small rise in biliary pressure is necessary for regurgitation of bile into the circulation [3].

Hepatocellular damage

Bile duct obstruction results in numerous changes in hepatic structure and function. Collagen content is increased. Glycogen content is reduced. Hepatocellular nitric oxide production is increased [4]. Mitochondrial changes include loss of cristae and internal structure. Rough endoplasmic reticulum is reduced [5]. The mitochondrial concentration of antioxidants (glutathione, ubiquinones) decreases whereas products of lipid peroxidation increase, changes that correlate with mitochondrial electron transport chain dysfunction [6]. Mitochondrial fatty acid oxidation is also disturbed [7]. Vesicle transport to the canaliculus is inhibited and the integrity of tight junctions impaired [8]. Interestingly, neither the trafficking of newly synthesized albumin and transferrin from endoplasmic reticulum to basolateral membrane and serum nor receptor-mediated endocytosis at the basolateral membrane is affected [8].

The cause of the hepatocellular injury is likely to be multifactorial. Apoptosis as well as necrosis are involved [9]. At high concentrations, retained bile salts have detergent properties and are cytotoxic *in vitro*. These cause plasma and intracellular membrane damage. Reactive oxygen species are generated [10]. The toxicity increases with increasing relative hydrophobicity. This depends on the number of hydroxyl groups, the addition of which makes bile salts more hydrophilic (less hydrophobic). Thus, in general, monohydroxy bile salts such as lithocholate are more toxic than dihydroxy bile salts such as chenodeoxycholate or deoxycholate, which in turn are more toxic than trihydroxy bile acids such as cholate. Experimentally, the hydroxylation capacity of the liver is decreased 3 days after bile duct obstruction, which may result in higher levels of more toxic bile salts [11].

At lower concentrations, bile acids cause cell death by switching on apoptosis by several mechanisms including oligomerization of the Fas death receptor [9] and through mitochondrial-controlled pathways [12]. Thus, two distinct methods of cell death are triggered by elevated concentrations of (particularly the hydrophobic) bile acids – necrosis at higher and apoptosis at lower concentrations [13].

Copper, normally excreted in bile, is retained in cholestasis. High copper levels in the liver in Wilson's disease are associated with mitochondrial lipid peroxidation [14] and defective oxidative phosphorylation [15]. However, the copper that accumulates in chronic cholestatic liver diseases does not seem to have the same mitochondrial effects [15].

Whatever the mechanism, mitochondrial respiratory enzyme activity and ketogenesis are impaired and take several weeks to recover after relief of obstruction [16]. Antipyrine elimination is also impaired. Antipyrine, a minor analgesic, depends almost entirely on oxidation in the liver for its elimination, which thus gives an indication of hepatic damage. In patients with obstructive jaundice, its half-life is considerably prolonged compared with control patients (28.4 h compared with 10.4 h) [17]. Postoperative mortality is greater in those patients with an antipyrine half-life of > 20 h. The half-life improves with percutaneous biliary drainage. The hepatic mitochondrial response to oral glucose (redox tolerance test) is impaired in patients with obstructive jaundice and relates to survival [18].

Hepatic transport processes appear to remain intact. After relief of bile duct obstruction, bile acid transport into bile begins virtually immediately, and the serum non-sulphated bile acid concentration rapidly falls to normal [19]. Bilirubin excretion has a lower T_{max}, and it is uncertain whether transport is impaired. In general, after the relief of obstruction, serum bilirubin concentrations fall with a half-life of approximately 7 days [20]. Persistent hyperbilirubinaemia is seen when there is cholangitis, partial obstruction to drainage or when there are hepatic metastases.

During prolonged obstruction, serum albumin falls even in the absence of sepsis. Experimentally, this relates initially to increased capillary permeability and the lack of a compensatory increase in albumin synthesis; later, there is an increased plasma volume and decreased albumin synthesis [21]. The prothrombin time lengthens, but this is primarily due to malabsorption of vitamin K, correcting rapidly after parenteral administration of vitamin K.

Systemic effects

General

The clinically apparent systemic effects of extrahepatic biliary obstruction are fatigue, jaundice and itching. Cardiovascular effects are usually subclinical, but become important after surgical and non-surgical intervention. Clinical risks include renal failure, sepsis, delayed wound healing and gastrointestinal bleeding. The cause of these is likely to be multifactorial. Bilirubin, bile acids, lipids and endotoxin have been implicated. Cytokines, prostaglandins and nitric oxide may play a role. Plasma membrane and receptor characteristics are altered.

Bilirubin can be toxic to tissues. The kernicterus of the newborn, resulting from unconjugated hyperbilirubinaemia, is well known. High concentrations of unconjugated bilirubin have been shown to uncouple oxidative phosphorylation by brain mitochondria [22]. Whether such toxic effects have any relevance in the conjugated hyperbilirubinaemia of cholestasis is unknown, although ultrastructural studies showed mitochondrial and plasma membrane abnormalities in the presence of unbound conjugated bilirubin [23].

The hepatocellular effects of bile acids have already been mentioned. Bile acids are detergents and in excess would be expected to interfere with cellular function systemically. Many studies have shown this, including dysfunction of isolated cardiac mitochondria [24]. Bile acids have a negative inotropic effect on isolated ventricular myocytes [25]. At high concentrations, they alter cell-mediated immune mechanisms.

Plasma free cholesterol, phospholipids and triglycerides are elevated in obstructive jaundice, and there are changes in lipoproteins and particles, which depend in part on whether lecithin cholesterol acyltransferase (LCAT) activity falls (see Chapter 19.1) [26]. A change in cell membrane composition follows [27], and there are changes in membrane fluidity and function [28]. There is inhibition of frusemide-sensitive sodium transport [29], and receptor-mediated uptake of ligands may also be altered [30]. However, there is also modulation of hepatic adenosine triphosphate-binding cassette (ABC) transporters in the lipid membrane, which may have a cytoprotective effect [31].

Systemic endotoxaemia occurs in some patients with obstructive jaundice and experimentally has many effects (see below), such as those on kidney function and coagulation.

Fatigue

This is a common complaint in those with prolonged cholestasis, as well as those with chronic hepatocellular disease. The mechanism is not well understood, but a central neurotransmitter alteration seems likely. In experimental cholestasis, behavioural changes, which may be equivalent to clinical fatigue, have been found in association with impaired corticotrophin-releasing hormone responses, abnormal serotonergic neurotransmission and increased brain sensitivity to interleukin (IL)-1β [32–34]. In patients with primary biliary cirrhosis, it has been suggested that abnormal manganese homeostasis in the central nervous system is associated with the development of fatigue, but the mechanism has not been identified [35].

Itching

This may be the predominant symptom in obstructive jaundice. It disappears within a few days of biliary decompression. In the past, bile salts were suggested as the cause of itching, but most of the evidence was circumstantial. Although cholestyramine relieves itching in patients with cholestasis, it binds many compounds other than bile salts and also relieves the itching of uraemia [36] in which bile salts are not implicated. These data,

together with studies of the bile salt concentration and pattern in blister fluid [37], suggest that bile salts are not the cause of itching in cholestasis. Antihistamines are sometimes prescribed for cholestatic itching, but evidence for a role of mast cells in the generation of this symptom is lacking [38].

The focus has moved towards mechanisms that may produce itching by a central neurotransmitter effect. Animal studies and therapeutic trials suggest that an endogenous opioid peptide may be responsible [39]. In experimental cholestasis, endogenous opioids accumulate, and the animals are in a state of analgesia, reversible by naloxone. The perception of itching in cholestatic patients is less during naloxone treatment [40] and may be improved by bright light therapy [41]. Serotonin may also have a central role, although a randomized controlled trial of 5 days of ondansetron, a 5-hydroxytryptamine type 3 receptor antagonist, for cholestatic itching showed no benefit [42]. However, these new concepts and data hold promise for effective alternative therapies for patients with chronic liver disease and severe itching resistant to cholestyramine.

Cardiovascular effects [43] (see also Chapter 21.1)

The peripheral vascular resistance is reduced in both humans and animals with obstructive jaundice [44]. Blood pressure is usually normal, but there is an exaggerated hypotensive response to volume depletion. The capacity for vasoconstriction is impaired, as shown by the greater fall in blood pressure after venesection in jaundiced dogs compared with normal control animals [45]. There is also a reduced responsiveness of skeletal muscle vasculature to noradrenaline *in vitro* [46]. This is associated with an enhanced pressor response in renal and cerebral vessels. There is evidence for a functional defect in the expression of α1-adrenoreceptors [47]. Studies on cardiac papillary muscles and the mesenteric vascular bed suggest that increased nitric oxide production and endogenous opioids contribute to these changes [48,49].

Cardiac changes include bradycardia, an increase in the PR–QT interval on electrocardiography and the depletion of myocardial cell glycogen [50]. At the cellular level, there is mitochondrial swelling and a decrease in glycogen content in rat atria exposed to bile acids. Bile acids have a negative chronotropic effect at concentrations found in human serum in bile duct obstruction. They also have a concentration-dependent negative inotropic action on rat papillary muscle and isolated ventricular myocytes [25].

Although reports on the changes in cardiac output in obstructive jaundice are conflicting, data suggest that there is a jaundice-induced cardiac myopathy. Thus, there is a depressed response to isoproterenol in dogs after ligation of the common bile duct [51]. Left ventricular function is impaired [52]. Susceptibility to hypotension in obstructive jaundice has been attributed to a blunting of the myocardial contractile response to sympathomimetic stimulation.

These changes in both cardiac function and peripheral vascular resistance provide the basis for prerenal renal failure under hypovolaemic conditions in patients with obstructive jaundice.

Renal changes

Renal failure (acute tubular necrosis) is the classic complication of obstructive jaundice after surgery or an invasive procedure [53] Approximately 60–75% of such patients have a fall in glomerular filtration rate (GFR) after surgery. The overall incidence of acute renal failure is 8%.

The mechanism is multifactorial. The changes in cardiovascular responses described above – reduced peripheral vasoconstriction under hypovolaemic circumstances with increased renal vasoconstriction, even in the apparently healthy patient or animal – will play a part. Other possible contributing factors are bile acids, bilirubin, endotoxin and oxidant stress [54]. The role of the endothelium and the interplay between vasoconstrictors, in particular endothelin 1, and vasodilators such as nitric oxide and prostaglandins appear to be central to the development of renal dysfunction.

Overall, the data on GFR and renal blood flow in obstructive jaundice are conflicting [43]. However, there is a shift in renal blood flow away from the outer cortex to the deep cortex and medulla. This may be related to the exaggerated response of the renal vasculature to α-adrenergic stimulation. However, the synthesis of endothelin 1 by renal papillary tissue is increased in obstructive jaundice [55]. This would lead to renal arterial vasoconstriction and reduced GFR. The latter can be reversed by bosentan, an endothelin 1 antagonist [55]. However, the GFR may be preserved by other mechanisms including a compensatory vasodilation mediated by nitric oxide and prostaglandins. Increased nitric oxide overproduction in cholestasis has been inferred [49,56], and its role in the arterial hypotension of cirrhosis is more widely studied [56] (see Section 6). Prostaglandins E_2 and I_2 are increased in obstructive jaundice [58]. There is enhanced synthesis of renal glomerular thromboxane A_2, which suppresses GFR and predisposes to renal failure [59]. Treatment with receptor antagonists restores GFR [54,59].

Bile components, bile acids and conjugated bilirubin seem to potentiate ischaemic injury, rather than being directly toxic themselves [60,61]. Histological changes are seen in the kidney during obstructive jaundice. There are pigmented granules in the glomeruli and changes in the epithelial and endothelial cells and the basement membrane [62]. These changes may reduce GFR. Finally, there are data to suggest that hypercholesterolaemia [63] and endotoxaemia (see below) may be involved.

Whatever the mechanism, the combination of an impaired systemic vasoconstrictor response to hypotension and an increased renal vascular response to adrenergic stimuli favours the development of renal hypoperfusion when there is dehydration or haemorrhage. Interestingly, there is evidence for renal tubular cell damage, based on greatly increased urinary

N-acetylglucosaminidase excretion in patients with obstructive jaundice before any intervention, despite normal blood urea and creatinine levels [64].

Apart from the effects of obstructive jaundice on cardiac and renovascular responses, and the direct effects of biliary components and endotoxin on the kidney, there are also changes in total body water, sodium and potassium. Bile acids reduce sodium and water absorption from the proximal tubule [65] and increase urine flow, fractional sodium excretion and potassium excretion [66,67], without changing inulin or *p*-aminohippurate (PAH) clearance. The mechanism may be a non-specific detergent effect of bile acids, or it may depend upon changes in cyclooxygenase (prostaglandin E_2) [68]. Indomethacin abolishes the natriuresis. Other data have shown that sulphated bile acids (elevated in cholestasis) impair Na^+/H^+ antiporter function [69].

These findings provide the basis for changes in experimental models. Body water compartments change following ligation of the common bile duct [70]. There is a significant decrease in water intake (60%), creatinine clearance, total body water (15%), extracellular water (24%) and plasma volume (15%), which persists for at least 12 days following duct ligation. In patients with cholangiocarcinoma and jaundice, urinary sodium excretion increases [71], and there is an inability to retain sodium. These changes will increase the risk of hypotension and renal failure associated with obstructive jaundice, and are the opposite of those seen with chronic hepatocellular disease and cirrhosis.

An additional iatrogenic factor that is potentially nephrotoxic is the use of aminoglycosides. A prospective study of renal failure in patients with obstructive jaundice found that 32% of patients treated with gentamicin developed nephrotoxicity compared with 11% of those treated with other antibiotics or no antibiotic [72]. The most significant predictor of gentamicin toxicity was serum bilirubin level. Although a control trial of antibiotic treatment of acute cholangitis with and without tobramycin did not show increased renal damage in those treated with the aminoglycoside [73], the renal toxicity of gentamicin is increased in experimental studies of obstructive jaundice [74].

Endotoxaemia

In some patients with obstructive jaundice, endotoxaemia is present before surgery. This correlates with reduced pre- and postoperative creatinine clearance [75]. Postoperative systemic endotoxaemia can be detected in 50% or more of patients with jaundice [53] and relates to outcome [76]. In these patients, endotoxaemia is caused by increased intestinal absorption of endotoxin together with reduced clearance by reticuloendothelial cells, particularly in the liver.

In obstructive jaundice, there is an increased passage of bacteria across the intestinal mucosa [77]. There is also increased intestinal absorption of endotoxin, probably because of the decrease in luminal bile salts [78]. Oral administration of bile salts reduces endotoxaemia in animal studies [79] and prevents renal dysfunction in patients with obstructive jaundice [80].

Biliary microorganisms are another source of systemic endotoxin. During percutaneous manipulation of the obstructed biliary tree, both the presence of infected bile and the serum bilirubin concentration before the procedure predict the development of endotoxaemia [81].

Clearance of endotoxin from the circulation depends upon the liver (Kupffer cells) and the reticuloendothelial system elsewhere. In both obstructive jaundice and liver disease *per se*, Kupffer cell clearance capacity is impaired [82]. The important role of the liver in removing endotoxin is shown by the greater degree of endotoxaemia in patients with cirrhosis undergoing a portal systemic shunt than in patients with jaundice having surgery to relieve obstruction [83].

Circulating endotoxin has many effects. Interaction with macrophages produces reactive oxygen molecules, bioactive lipids and cytokines (e.g. IL-1 and -6 and tumour necrosis factor). Endotoxin stimulates the production of vasoactive compounds including nitric oxide, prostaglandins, thromboxanes, leukotrienes and platelet activation factor. Systemic effects include fever, metabolic acidosis, disseminated intravascular coagulation, haemodynamic instability, reduced cellular immunity, renal failure and gastrointestinal haemorrhage. Excretion of bilirubin and taurocholate into bile is decreased by endotoxin [84].

Opinions vary as to the importance of endotoxin in the pathogenesis of renal failure in obstructive jaundice [43,53]. Administration of polymyxin B, a non-absorbable antibiotic active against endotoxin-producing bacteria, did not produce clinical benefit [85]. On the other hand, experimental infusion of endotoxin into the renal artery reduces renal blood flow [86] and GFR in animal studies. Electron microscopy shows abnormalities including endothelial swelling [87], and endotoxin can cause intracapillary thrombosis [88]. Endotoxin appears to have a role, but this interlinks with so many other molecular changes, making a clear mechanism difficult to define [89,90].

Gastrointestinal changes

Haemorrhagic gastritis has been reported to occur in approximately 7% of patients (fatal in half) [91]. However, these data predate the availability of proton pump inhibitors. The mechanism is not clear, but the role of noradrenaline and prostaglandin E_2 and the reduced mucosal blood flow have been studied in rat gastric mucosa [92]. Stress produced greater falls in gastric wall blood flow and in mucosal noradrenaline and prostaglandin E_2 content in animals with obstructive jaundice. In addition, the degree of gastric damage (predominantly erosions) was greater. Administration of oral prostaglandin E_2 prevented the fall in mucosal blood flow after stress.

There are pancreatic changes in rats after 1 day of bile duct ligation, including an increase in volume, weight, protein content and amylase (both basal and after secretin stimulation) [93].

Bicarbonate secretion does not change. Microscopically, there is an increase in acinar cell number, size and number of zymogen granules, with dilatation of cisternae in the Golgi apparatus. The authors postulated that hyperbilirubinaemia and inhibition of normal mitochondrial function might inhibit granule discharge from the acinar cell.

Nutrition

Experimentally, there is anorexia, weight loss and decreased nitrogen balance initially [94]. Later, the appetite returns and nitrogen balance becomes normal. Anorexia is a frequent symptom in patients with biliary obstruction. Decreased food intake has been shown to correlate with elevated cholecystokinin levels and serum bilirubin, with symptoms improving following successful biliary drainage [95]. Hypoalbuminaemia in obstructive jaundice is related to decreased hepatic synthesis and increased capillary permeability. It correlates poorly with other changes in nutritional status such as weight loss and nitrogen balance. The plasma amino acid pattern in obstructive jaundice is essentially unchanged from normal. There are mild increases in levels of methionine, phenylalanine, aspartic acid and glutamine, but these are minimal compared with the major increases seen in acute hepatitis [96]. Total hepatic amino acid uptake is unaltered in experimental bile duct obstruction, but peripheral uptake by skeletal muscle is decreased [97]. Muscle protein is reduced.

Wound healing

Wound healing after surgery for obstructive jaundice is impaired [98]. Some studies designed to test wound strength in jaundiced animals have demonstrated wound weakness [99]. Other studies did not confirm this [100], but there are data showing that neovascularity [101], polyhydroxylase activity [102] and collagen production [100] are all reduced in experimental wounds in the presence of obstructive jaundice. Moreover, fibroblast proliferation in tissue culture is reduced when bilirubin is added [103].

The available data strongly suggest that, in the presence of obstructive jaundice, there is impaired wound healing. Analysis of various features in clinical studies have implicated poor nutritional status and malignancy rather than simply hyperbilirubinaemia *per se* in the pathogenesis of this problem [98].

Lipid metabolism [26]

The absence of bile acids in the intestinal lumen impairs the absorption of fat because of the lack of micelle formation. In addition, plasma free cholesterol, phospholipids and triglycerides increase, and there are changes in lipoproteins [26]. Low-density lipoprotein has an abnormal composition and, if plasma LCAT activity is low, lipoprotein X appears. Very-low-density lipoprotein has an altered lipid content and lipoprotein pattern. Changes in high-density lipoprotein are controversial, but the normal pattern changes, especially in patients with a high serum bilirubin [104]. The reason for the changes in plasma lipids is complex. At least four factors have been implicated, including regurgitation of biliary cholesterol into the circulation, increased hepatic synthesis of cholesterol, reduced plasma LCAT activity and, finally, regurgitation of biliary lecithin, which produces a shift of cholesterol from pre-existing tissue cholesterol into the plasma. As a result of the changes in lipoprotein particle composition seen in chronic liver disease, there are rapid alterations in membrane composition [28,105] that are likely to affect receptor function [30,106]. Similar changes in membrane function would be expected to occur in obstructive jaundice. Normal lipids and lipoproteins also appear to have a role in protecting against the effects of endotoxin. The normalization of the cholestatic pattern of lipids and lipoproteins after relief of biliary obstruction parallels a fall in the systemic and cellular sensitivity to endotoxin [107].

Bone disease [108]

In short-term obstructive jaundice, bone disease is not a clinical problem and has not been studied. With prolonged cholestasis, bone disease – so-called hepatic osteodystrophy – occurs as it does in chronic hepatocellular disease (see Chapter 21.9).

In prolonged cholestasis, bone pain and fractures occur. Although malabsorption of vitamin D will occur, depending on the degree of steatorrhoea, and osteomalacia is therefore a risk, the bone disease that occurs more frequently in patients with primary biliary cirrhosis and primary sclerosing cholangitis is osteoporosis. Bone mineral density is reduced in patients with advanced primary biliary cirrhosis and primary sclerosing cholangitis, particularly with more severe disease [109,110]. The pathogenesis is complex. It has been suggested that reduced bone formation occurs in patients with precirrhosis, and increased resorption in those with advanced disease. Immobility, poor nutrition and a reduced muscle mass probably play a role, as well as changes in vitamin D, calcitonin, parathyroid hormone, growth hormone and sex steroids. Plasma from patients with jaundice inhibits osteoblast proliferation [111]. Unconjugated bilirubin, but not bile salts, has an inhibitory effect.

Resistance to infection [112]

Infection frequently causes morbidity and mortality after surgery for obstructive jaundice. Postoperative septic complications are related not only to biliary bacteria but also to defective host defence mechanisms. After 2 weeks of biliary obstruction, there is a decreased phagocytic capacity, which correlates inversely with bilirubin levels (but not aminotransferase or bile salt concentration) [113] and endotoxin and anticore glycolipid concentration [82]. Changes in plasma membranes, in particular the phospholipid fatty acid profile [114], may affect cell function.

Experimentally administered bacteria are cleared slowly [115,116]. This appears to be the result of reduced Kupffer cell function, as the number of Kupffer cells increases [117]. Other cellular responses, such as phagocytosis and cytokine production by extrahepatic phagocytes and polymorphonuclear cells, are impaired [118,119], as is neutrophil adhesion [120]. Although some functions of polymorphonuclear cells are enhanced [121], this is probably due to a proinflammatory state related to cytokines and/or endotoxaemia. The function of Kupffer cells is restored by a short period of internal bile drainage [122].

Specific cell-mediated (T cell) immunity is impaired [123,124] and is related to the duration of jaundice. There is prolonged allograft survival in hosts with obstructive jaundice [125]. B-cell function does not seem to be impaired [126]. Studies suggest that impaired cellular immunity is related to endotoxin [119] as well as other factors [127], although endoscopic biliary drainage did not reverse T-lymphocyte dysfunction in a group of patients with malignant biliary obstruction [128].

Unconjugated bilirubin impairs many aspects of the host antibacterial defence mechanisms *in vitro*, for example phagocytosis [129], movement of neutrophils in response to chemotactic agents [130] and lymphocyte responses to mitogens [131].

Anergy is well documented in jaundiced patients with biliary obstruction, but there is no difference between malignant and benign obstruction [132]. A greater incidence of postoperative septic complications was found in the patients with anergy.

Circulating tumour necrosis factor (TNF), IL-6 and C-reactive protein are increased in bile duct obstruction, particularly due to malignant disease [133,134]. It is immunoreactive rather than biologically active TNF, because of the presence of soluble TNF receptors (TNFr), which are shed or released from the cell membrane. TNFr are thought to play a role in the regulation of the effects of TNF and correlate with postoperative mortality [135]. Experimental administration of TNFα reduces bile flow and basal bile salt excretion [136]. After endoscopic biliary drainage, there is transitory improvement in cytokine levels, but they may still remain high 1 week later, relating to positive bile culture [134].

Finally, many studies have shown increased translocation of viable enteric bacteria across the mucosal barrier to lymph nodes and other tissues in obstructive jaundice [137,138]. This is related to lack of intraluminal bile [139] and endotoxaemia [140]. It may be inhibited by activating mucosal macrophages with liposomal muramyl tripeptide phosphatidylethanolamine [141]. The clinical significance of bacterial translocation is uncertain. However, the absence of bile from the intestine is associated with a reduced mucous blanket over duodenal cells and an increase in coliform microorganisms [142].

Coagulation

Although the administration of vitamin K rapidly corrects the prolonged prothrombin time in patients with obstructive jaundice, blood coagulation does not necessarily then return to normal. Bleeding sometimes still appears greater than expected at surgery, although the cause is not established. Data have shown that there is a low-grade disseminated intravascular coagulation (DIC) in some patients [143], and serum fibrin degradation products are often increased. Procoagulant production by mononuclear phagocytes is enhanced [144], and fibrin degradation products may be increased in the serum. There is also inhibition of fibrinolysis [145,146] which, in combination with DIC, may result in fibrin thrombosis and subsequent tissue damage. It seems likely that DIC is caused by the presence of increased circulating levels of endotoxin and activated coagulation enzymes.

Platelet function may be impaired. *In vitro* platelet aggregation in response to adenosine diphosphate and collagen is decreased following bile duct ligation, and this could be related to elevated bile acid concentrations or an as yet uncharacterized plasma inhibitor [147].

Clinical features of biliary obstruction

History

Features in the presenting history cannot be taken as specific for a particular cause. Thus, fever, jaundice and right upper quadrant pain, although suggestive of cholangitis caused by a stone in the common duct, may occur with cholestatic hepatitis resulting from a drug [148]. In general, however, certain features linked with jaundice are associated with a particular cause.

Fever

Fever usually indicates choledocholithiasis. When common duct stones are present, bacteria are usually present in bile. Duct obstruction raises biliary pressure, and infected bile enters the circulation with systemic signs of sepsis. Bile from patients with a malignant bile duct obstruction is usually sterile, so that fever is rare in these cases. This generalization is not true for patients who have had diagnostic or therapeutic cholangiography. Thus, in patients who have been treated with an endoscopic or surgical stent, bacteria adhere to the stent, bile is colonized, and stent blockage results in systemic sepsis ('cholangitis').

Pain

Pain should suggest calculus rather than malignant obstruction, the latter classically producing painless jaundice. However, there may be a preceding history of pain in some patients with carcinoma of the pancreas, bile duct or ampulla.

Itching

Itching may occur with any cause of biliary obstruction, but tends to be more frequent with malignant obstruction or intrahepatic cholestasis. It is unusual for there to be itching in calculus obstruction, perhaps because obstruction is rarely complete and may not be sufficiently prolonged to cause retention of the

pruritic agent. Relief of obstruction is followed by loss of itching in a few days.

Weight loss

Weight loss occurs more often with malignant obstruction, although benign causes resulting in prolonged steatorrhoea will do the same.

Previous cholecystectomy

Previous cholecystectomy clearly arouses suspicion of a retained common duct stone. If surgery is recent and followed by abnormal drainage of bile through the wound or drain, a traumatic bile duct injury should be suspected.

Drugs

A complete list of previous medication is mandatory. Many drugs, and occasionally herbal remedies, are capable of mimicking obstructive jaundice.

Ethnic origin

Any patient with jaundice and fever from the Far East may have recurrent pyogenic cholangitis.

Inflammatory bowel disease

A history of inflammatory bowel disease should raise the possibility of primary sclerosing cholangitis as a cause of jaundice and itching. Up to 5% of patients with ulcerative colitis may be affected by primary sclerosing cholangitis, with the lifetime risk of malignancy in this group estimated at between 5% and 15% [149,150].

Previous malignancy

Previous malignancy, especially colonic, may indicate jaundice due to hepatic metastases or bile duct obstruction from lymph node involvement. In patients with a known primary malignancy, the clinical pattern of biliary obstruction will mimic primary hepatobiliary malignancy, but differentiation on history and imaging is usually straightforward. Oncological management of these patients after biliary decompression will be influenced by the site of the known primary tumour.

Examination

Jaundice, scratch marks and loss of body mass are clearly non-specific findings. Signs of chronic liver disease (spider naevi, palmar erythema) denote longstanding intrahepatic cholestasis (primary sclerosing cholangitis, primary biliary cirrhosis) rather than obstruction to the major bile ducts, although these signs may be seen in the now rare patient with secondary biliary cirrhosis.

The liver is usually palpable in patients with bile duct obstruction. This sign is again non-specific unless nodules are palpable because of tumour. Splenomegaly denotes hepatic rather than major bile duct disease, except in the case of splenic vein block due to carcinoma of the pancreas. A palpable gallbladder suggests malignant obstruction to the distal common bile duct (Courvoisier's law), but is only present in approximately half of such patients. A tender gallbladder (Murphy's sign) suggests cholecystitis.

Laboratory investigations

Full blood count, urea, electrolytes, serum creatinine, prothrombin time and liver function tests should be done. There may be leucocytosis in cholangitis. It is essential to check the levels of urea, electrolytes and serum creatinine. Impaired renal function is a complication of obstructive jaundice. Hyponatraemia and hypokalaemia are often found. The prothrombin time may be prolonged due to malabsorption of vitamin K. Liver tests characteristically show raised bilirubin (total and conjugated), alkaline phosphatase and γ-glutamyltransferase. When there is acute obstruction of the bile duct, the levels of aspartate and alanine aminotransferases may be very high [151], even reaching 50 times normal for a short time and causing confusion as to the cause of jaundice. There are changes in lipids, in particular lipoprotein X, but these are not of diagnostic value.

To assess liver function in more detail, tests such as galactose elimination are helpful, but are used at present only as research tools.

Liver function tests are not specific to any one diagnosis but are used in combination with clinical data (history and examination) to choose the next step in the diagnostic workup. Imaging provides a further step along the route and, in some cases, the definitive diagnosis.

Imaging (see also Chapter 5.6)

The workup for cholestatic jaundice uses non-invasive techniques first; ultrasonography (US), computerized tomography (CT), magnetic resonance imaging (MRI) and magnetic resonance cholangiopancreatography (MRCP). These techniques will be followed by invasive endoscopic or percutaneous cholangiography, where indicated. The choice between CT and MRI will depend in part upon local expertise and the availability of imaging techniques.

Non-invasive techniques

These are to show whether the bile ducts are dilated, thus differentiating between 'surgical' and 'medical' jaundice. US is the technique of choice and demonstrates duct dilatation in 95% of patients with bile duct obstruction. In the small number of false-negative cases, either there is failure on the part of the radiologist or radiographer, or there is truly no duct dilatation, as may occur in calculus disease of the common duct. US and CT show the level of obstruction in about two-thirds of patients, and can define the cause in only around one-third. They should not therefore be used as diagnostic tests, but as a guide to the next step in the workup, that is cholangiography or liver biopsy (Fig. 1).

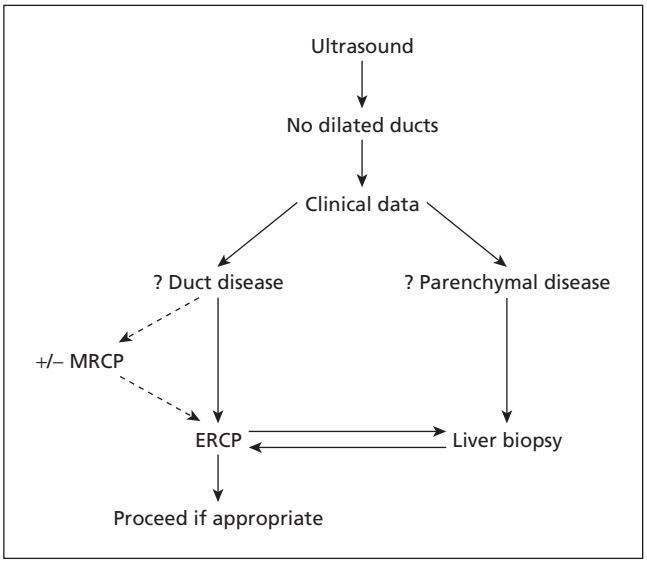

Fig. 1 Imaging of cholestasis: non-dilated ducts. ERCP, endoscopic retrograde cholangiopancreatography; MRCP, magnetic resonance cholangiopancreatography.

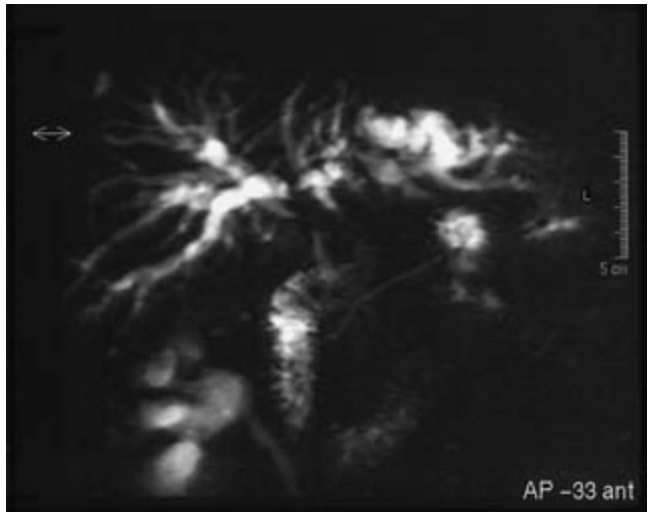

(a)

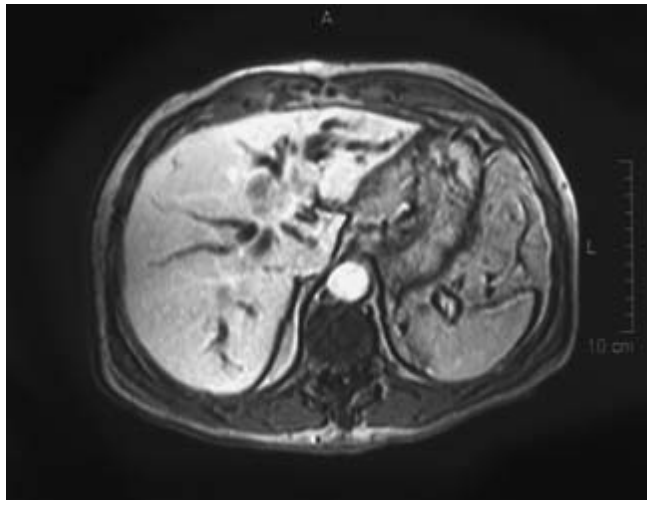

(b)

Fig. 2 (a) MRCP in patient with cholestatic jaundice and an ultrasound showing hilar obstruction. The right and left intrahepatic ducts are obstructed and do not communicate. (b) Cross-sectional MRI in the same patient. The hilar mass is seen between the right and left intrahepatic ducts.

US is usually readily available and should be performed. However, even if the US is normal, if the clinical history is strongly suggestive of a common bile duct stone, endoscopic retrograde cholangiopancreatography (ERCP) or MRCP is the next step as stones can be missed on US and therapeutic biliary intervention may be required. US is still valuable, however, to show whether there are stones in the gallbladder. This may influence subsequent management.

Although cross-sectional MRI adds little to CT, MRI scans can be used to give two- or three-dimensional images of both biliary and pancreatic systems. Such MRCP does not need any contrast material, biliary and pancreatic systems being visible because of the water content of bile and pancreatic juice. MRCP is highly accurate in the diagnosis of bile duct obstruction and its cause and is gaining increasing importance in the management of biliary diseases. The sensitivity and specificity of good-quality MRCP approaches those of ERCP [152,153] and, as such, it has been argued that MRCP should replace ERCP as a diagnostic test. In centres with expertise in such non-invasive imaging, ERCP is evolving into a predominantly therapeutic procedure predominantly for stent insertion, stone extraction and obtaining tissue for cytology. MRCP may be particularly useful in certain circumstances, including patients who are poor candidates for ERCP due to comorbid illness, staging of cholangiocarcinoma and imaging the inaccessible biliary system (failed ERCP, Billroth II anatomy). Cholangiocarcinoma should be suspected when imaging demonstrates intrahepatic duct dilatation without dilatation of the common bile duct. In these cases, MRI/MRCP is indicated to provide information on liver and biliary anatomy and the local extent of tumour, including the extent of duct involvement [154] (Fig. 2). In most cases, good-quality MRCP with MRI is sufficient to assess resectability, without the potential hazards of ERCP or percutaneous transhepatic cholangioscopy (PTC).

To visualize the biliary system, CT cholangiography (CTC) by an equivalent reconstructive process is also possible but, for best results, intravenous contrast material needs to be given. This limits the technique to patients with normal or near normal liver function. CTC has been shown to be highly effective for the detection of duct calculi in patients with normal bilirubin [155]. Intravenous cholangiography (IVC) has been superseded by

non-invasive techniques including CT and MRCP, because of the poor diagnostic accuracy of IVC and the associated morbidity.

Additional diagnostic information may be obtained using endoscopic ultrasound (EUS), which should be regarded as complementary to other imaging modalities. In the context of extrahepatic biliary obstruction, EUS may be particularly useful in evaluating pancreatic and periampullary neoplasms, including assessment of vascular invasion [156,157]. EUS is at least as sensitive as ERCP in detecting stones and strictures, and can be used to guide fine-needle aspiration or biopsy for tissue diagnosis [158,159].

The major application of radioisotopic imaging with an iminodiacetic acid derivative (IDA) is in the diagnosis of acute cholecystitis. It can also differentiate between the obstructed and normal biliary system, but US is more appropriate. However, biliary scintigraphy is valuable in demonstrating bile leaks after cholecystectomy or liver transplantation, and after hepatic trauma or liver biopsy [160,161]. Scintigraphy is also useful in differentiating bile duct obstruction from intrahepatic cholestasis even in deeply jaundiced patients if a third-generation agent such as bromotrimethyl or iododiethyl iminodiacetic acid is used.

Invasive techniques

Percutaneous transhepatic cholangiography (PTC) and ERCP provide direct cholangiography. PTC, the older procedure, first described in the 1930s [162], was radically modified in the 1970s with the introduction of the fine gauge, Chiba or skinny needle in Japan [163]. This allowed bile ducts of any size to be punctured using a 22-, 23- or even 25-gauge needle. Success rates approach 100%, and an accurate diagnosis can be made in 95% of cases. The risk of bile leakage is reduced with the fine-needle technique, and the overall complication rate is less than 5% (bleeding, peritonitis and sepsis).

ERCP was first described in the early 1970s. The success rate is between 80% and 90% depending on the experience of the endoscopist. Certain features make the procedure more difficult, including previous Billroth II gastrectomy, a periampullary diverticulum, papillary stenosis or tumour. Complications occur in 2–5% of examinations (sepsis, pancreatitis, perforation or bleeding) [164].

PTC and ERCP should be regarded as complementary. Both can be successful in demonstrating the biliary system in most patients and may be used to decompress the biliary system when obstructed. The endoscopic techniques carry a lower complication rate [165]. If dilated ducts are shown by US, MRCP or CT, the next step is to plan future management depending upon the clinical status of the patient (age, other medical diseases) and probable diagnosis. Liaison between physician, surgeon and radiologist as necessary is wise at this stage.

Imaging strategy (Fig. 3)

If the history and/or US scan is suggestive of common bile duct stones, the next step is ERCP. If the clinical data are less secure, MRCP is very useful in visualizing the biliary system non-invasively, before committing to ERCP. This is particularly so in elderly patients. If the first ERCP is unsuccessful, it is usually repeated, with a needle knife cut if necessary. A combined procedure (PTC and placement of a catheter or wire across the ampulla followed by ERCP) may be required to achieve clearance of the bile duct.

In cases in which non-calculus biliary obstruction is suspected on US, the management will be determined by the suspected diagnosis and the results of additional imaging. Patients with suspected carcinoma will require a multidisciplinary approach involving endoscopist, surgeon, radiologist and oncologist.

If the site of bile duct obstruction is distal, the sequence of subsequent investigations often depends on local availability. CT and/or MRI will be needed to define the periampullary region and pancreas. EUS may be requested. In jaundiced patients, few centres can offer surgical resection (if not ruled out by scanning) so rapidly that increasing cholestasis is not an issue. ERCP with stent insertion is therefore done almost universally. This will also allow cytology or biopsy to be done. If ERCP fails, then the decision is made whether to repeat ERCP (success is sometimes possible at a second session) or to refer for PTC after appropriate discussion with the radiologist. If imaging shows a potentially resectable pancreatic mass, and there are no metastases, then laparoscopy is usually done to rule out peritoneal deposits not seen on scanning.

In cases in which the level of obstruction on US is at the hilum, the next step should be MRCP/MRI to delineate the anatomy and assess the local extent of disease. If the patient is septic, percutaneous drainage may be necessary at an early stage before definitive decisions have been made on the clinical and imaging data. In the uncomplicated jaundiced patient, ERCP with stent insertion should not be rushed into for diagnostic or therapeutic reasons. The fit patient may be made septic by ERCP, and the clinical management made more complex than it might have been.

If scanning shows an inoperable cholangiocarcinoma with bilobar obstruction, ERCP may still be done, but many prefer PTC with drainage as the placement of stents by this route is usually more accurate [166]. Both lobes may be drained.

Most stents inserted to relieve biliary obstruction are initially plastic. Metallic stents (endoscopic or radiological) should not be inserted unless a tumour has been staged as inoperable. They are also generally reserved for patients with an estimated survival of 6 months or more. It should be remembered that mesh metal stents are not free of the risk of blockage with tissue exudate or tumour ingrowth. Patients then need a further intervention to treat sepsis and recurrent jaundice.

If non-invasive imaging does not show dilated bile ducts, the next procedure will depend upon the clinical picture. If intrahepatic cholestasis is probable, for example a drug reaction, then liver biopsy is the next step. MRCP may provide additional diagnostic information and, in some circumstances, ERCP may be clinically indicated, for example for suspected common bile duct stone. Some patients will need both biliary imaging and liver biopsy.

Fig. 3 Management algorithm for dilated bile ducts: (a) suspected stones; (b) suspected malignant bile duct stricture.

Management of the patient with obstructive jaundice

Fluid balance

The patient with obstructive jaundice must be kept well hydrated because of the increased susceptibility to acute renal failure (tubular necrosis). Fluid balance charts are essential to monitor input and output. Skin turgor is observed; urea, electrolytes and serum creatinine are monitored daily if necessary. Before a procedure such as US, CT or cholangiography, when eating and drinking is forbidden, the jaundiced patient should have parenteral fluid replacement to avoid dehydration. Normal saline (0.9% NaCl) is given to all but the elderly patient with cardiac disease, in whom heart failure is a concern.

Prophylactic measures against renal failure

Good hydration, as pointed out above, is central to the avoidance of renal problems. A randomized controlled trial examined the effects of the administration of intravenous fluids prior to endoscopic drainage. Although the use of intravenous fluids was associated with plasma volume expansion, increased diuresis and improved creatinine clearance, these changes were transient, and the authors concluded that it is critical to produce satisfactory biliary drainage to reduce the likelihood of significant renal dysfunction [167]. Other measures have been studied and some appear valuable. Pre- and perioperative intravenous mannitol, as an osmotic diuretic, was advocated in the past [168]. However, hydration with parenteral normal saline is essential in parallel to avoid dehydration caused by the diuretic response to mannitol. The value of mannitol has been challenged by a controlled study that showed no beneficial effect on postoperative renal failure in patients with obstructive jaundice [169]. Hydration and effective biliary decompression appear to be the most important measures to prevent renal failure.

Endotoxaemia is implicated in many of the complications seen in association with obstructive jaundice, and is thought to occur because of increased absorption of endotoxin from the intestine and reduced clearance of endotoxin by the reticuloendothelial cells in the liver. Many experimental and clinical studies have attempted to identify measures that might reduce endotoxaemia and thus the development of (in particular) renal dysfunction.

Bile acids have antiendotoxaemic effects. Experimentally, the absorption of endotoxin from the intestine is increased when there is no bile present [78], and absorption is prevented when oral bile acids are given [170]. Clinical studies show the same effect of oral sodium deoxycholate in patients with obstructive jaundice with protection of renal function [171]. Chenodeoxycholic acid is less effective. A randomized controlled trial has shown a beneficial effect of preoperative sodium deoxycholate in preventing postoperative renal dysfunction, but only in those patients with normal preoperative renal function [172]. In a study of ursodeoxycholic acid (UDCA), portal venous endotoxaemia was reduced, but systemic endotoxaemia was not, and there did not appear to be any protection of renal function [173]. It seems likely that this difference is due to the lower antiendotoxic effect of UDCA than of sodium deoxycholate. Thus, the antiendotoxic activity of bile salts has been shown to be related to their known detergent activities; deoxycholate and its conjugates are the most effective both *in vitro* and *in vivo* [174].

Lactulose, a synthetic disaccharide, also has an antiendotoxin effect and, when given orally, reduces systemic endotoxaemia [175]. This agent was initially evaluated in hepatocellular diseases and cirrhosis. Experimental studies in rats given lactulose orally have shown that it reduces endotoxin-related mortality and, in patients with obstructive jaundice, portal and systemic endotoxaemia was prevented, as well as renal dysfunction [176]. The same randomized controlled trial mentioned above [172] showed that oral lactulose given preoperatively has the same protective effect on postoperative renal function as does sodium deoxycholate.

Polymyxin B and bowel preparations with antibiotics might be expected to reduce endotoxaemia, but have not been found to produce any benefit in patients with obstructive jaundice [85].

Despite the positive benefit shown with preoperative bile acids and lactulose, these are not routinely used clinically. Careful preoperative hydration remains the most important measure to reduce the risk of renal dysfunction/failure. Dopamine adds no protection [177].

Correction of coagulopathy

In some patients with obstructive jaundice, the prothrombin time is prolonged. Vitamin K given intravenously at a dose of 10 mg should be prescribed and continued for 3 days – an empirical duration. In the majority of patients, the prothrombin time returns to normal rapidly, sometimes overnight. If it does not, then underlying parenchymal liver disease or metastases should be suspected.

Prevention of infectious complications

Bacteria may be present in the obstructed bile duct without clinical symptoms or signs. Radiological, endoscopic and surgical procedures may produce systemic sepsis in such cases, with resulting Gram-negative septicaemia, abscess formation and wound infection. Premedication with a single dose of antibiotic reduces the risk of postsurgical sepsis [178]. It is necessary to continue the antibiotic until biliary drainage is completely unobstructed [179]. Suitable antibiotics for such prophylaxis include ciprofloxacin, cefotaxime or piperacillin. Ciprofloxacin has the advantage of oral use. The choice should depend upon knowledge of the sensitivity of microorganisms in the hospital, which will change with the use of selected antibiotics [180]. Both the American Society of Gastrointestinal Endoscopy and the British Society of Gastroenterology recommend antibiotic

prophylaxis for ERCP [181,182]. It should be emphasized that successful biliary decompression is central to avoiding post-procedural sepsis.

Itching

Itching due to bile duct obstruction from a stricture or stone usually disappears within a few days of biliary decompression, whether surgical, endoscopic or percutaneous. Before drainage, cholestyramine and antihistamines are generally ineffective.

Preoperative non-surgical biliary drainage

Early reports of preoperative percutaneous transhepatic external bile drainage suggested that it was beneficial, reducing post-operative mortality and morbidity after surgery for the relief of malignant bile duct obstruction [183]. However, subsequent randomized controlled trials showed no reduction in postoperative mortality [184–186]. Thus, despite the theoretical benefit of a lower serum bilirubin concentration at the time of surgery, the complications associated with percutaneous drainage removed any advantage [187]. Preoperative endoscopic drainage, although a safer approach than percutaneous drainage, showed no benefit on postoperative morbidity or mortality in a randomized controlled trial [188].

Because of the risks of surgery in the patient with cholangitis, endoscopic biliary drainage is indicated [189]. If obstruction is caused by a gallstone, then endoscopic sphincterotomy and stone removal, or drainage by nasobiliary tube, is necessary. If endoscopic access is not possible, percutaneous transhepatic bile drainage can be performed, and may be valuable. The problem of this approach, however, is the risk of bile reflux into the circulation because of vascular–biliary fistulas frequently caused by percutaneous transhepatic catheterization [190].

Prediction of risk

Several studies have analysed factors that may predict increased mortality and morbidity after surgery for obstructive jaundice. In a small study including 52 patients with malignant biliary obstruction, three factors were identified with independent significance in predicting mortality – cholangitis, significant weight loss and operative or postoperative blood transfusion [191]. In a previous study of 373 patients with obstructive jaundice [192], three independent risk factors were identified that were associated with a significantly increased risk of postoperative mortality. These were an initial haematocrit of 30% or less, an initial plasma bilirubin of > 200 μmol/L (normally < 17 μmol/L) and a diagnosis of malignant rather than benign obstruction. Patients with two or three of these risk factors had a 30% risk of dying postoperatively. Despite correction of the low haematocrit by transfusion, this remained a risk factor. Clearly, the underlying cause of obstruction – malignant or benign – cannot be influenced by such therapy. Finally, although the serum bilirubin can be lowered by preoperative percutaneous biliary drainage, as reviewed above, this procedure has not been found to be beneficial.

References

1 Bloom D, Daniel PM, Pratt OE *et al.* (1978) Lymphatic drainage from the liver in biliary obstruction. *J Physiol* 281, 8P.

2 Raper SE, Barker ME, Jones AL *et al.* (1989) Anatomic correlates of bacterial cholangiovenous reflux. *Surgery* 105, 352–359.

3 Huang T, Bass JA, Williams RD (1969) The significance of biliary pressure in cholangitis. *Arch Surg* 98, 629–632.

4 Tu W, Kitade H, Satoi S *et al.* (2002) Increased nitric oxide production in hepatocytes is involved in liver dysfunction following obstructive jaundice. *J Surg Res* 106, 31–36.

5 Muriel P, Suarez OR, Gonzalez P *et al.* (1994) Protective effect of S-adenosyl-L-methionine on liver damage induced by biliary obstruction in rats: a histological, ultrastructural and biochemical approach. *J Hepatol* 21, 95–102.

6 Krahenbuhl S, Talos C, Lauterburg BH *et al.* (1995) Reduced antioxidative capacity in liver mitochondria from bile duct ligated rats. *Hepatology* 22, 607–612.

7 Krahenbuhl S, Talos C, Reichen J (1994) Mechanisms of impaired hepatic fatty acid metabolism in rats with long-term bile duct ligation. *Hepatology* 19, 1272–1281.

8 Stieger B, Meier PJ, Landmann L (1994) Effect of obstructive cholestasis on membrane traffic and domain-specific expression of plasma membrane proteins in rat liver parenchymal cells. *Hepatology* 20, 201–212.

9 Guicciardi ME, Gores GJ (2005) Cholestatic hepatocellular injury: what do we know and how should we proceed. *J Hepatol* 42, 297–300.

10 Sokol RJ, Dahl R, Devereaux MW *et al.* (2005) Human hepatic mitochondria generate reactive oxygen species and undergo the permeability transition in response to hydrophobic bile acids. *J Pediatr Gastroenterol Nutr* 41, 235–243.

11 Vitale GC, Siow Y, Baker PR *et al.* (1992) Reversible bile acid changes in bile duct obstruction and its potential for hepatocellular injury. *J Hepatol* 14, 151–156.

12 Schoemaker MH, Gommans WM, Conde de la Rosa L *et al.* (2003) Resistance of rat hepatocytes against bile acid-induced apoptosis in cholestatic liver injury is due to nuclear factor-kappa B activation. *J Hepatol* 39, 153–161.

13 Rolo AP, Palmeira CM, Holy JM *et al.* (2004) Role of mitochondrial dysfunction in combined bile acid-induced cytotoxicity: the switch between apoptosis and necrosis. *Toxicol Sci* 79, 196–204.

14 Sokol RJ, Twedt D, McKim JM, Jr *et al.* (1994) Oxidant injury to hepatic mitochondria in patient's with Wilson's disease and Bedlington terriers with copper toxicosis. *Gastroenterology* 107, 1788–1798.

15 Gu M, Cooper JM, Butler P *et al.* (2000) Oxidative-phosphorylation defects in liver of patients with Wilson's disease. *Lancet* 356, 469–474.

16 Koyama K, Takagi Y, Ito K *et al.* (1981) Experimental and clinical studies on the effect of biliary drainage in obstructive jaundice. *Am J Surg* 142, 293–299.

17 McPherson GA, Benjamin IS, Boobis AR *et al.* (1982) Antipyrine elimination as a dynamic test of hepatic functional integrity in obstructive jaundice. *Gut* 23, 734–738.

18 Tsubono T, Tsukada K, Hatakeyama K (1995) Hepatic functional reserve in patients with obstructive jaundice: an assessment by the redox tolerance test. *Am J Surg* 169, 300–303.

19 Dooley JS, Bartholomew C, Summerfield JA *et al.* (1984) The biliary excretion of sulphated and non-sulphated bile acids and bilirubin in patients with external bile drainage. *Clin Sci* 67, 61–68.

20 Little JM, Robotin M (1986) Serum bilirubin after surgery for obstructive jaundice. *Aust NZ J Surg* 56, 35–37.

21 Krahenbuhl S, Marti U, Grant I *et al.* (1995) Characterization of mechanisms causing hypoalbuminemia in rats with long-term bile duct ligation. *J Hepatol* 23, 79–86.

22 Ostrow JD, Pascolo L, Shapiro SM *et al.* (2003) New concepts in bilirubin encephalopathy. *Eur J Clin Invest* 33, 988–997.

23 Gollan JL, Billing BH, Huang SN (1976) Ultrastructural changes in the isolated rat kidney induced by conjugated bilirubin and bile acids. *Br J Exp Pathol* 57, 571–581.

24 Ferreira M, Coxito PM, Sardao VA *et al.* (2005) Bile acids are toxic for isolated cardiac mitochondria: a possible cause for hepatic-derived cardiomyopathies? *Cardiovasc Toxicol* 5, 63–73.

25 Binah O, Rubinstein I, Bomzon A *et al.* (1987) Effects of bile acids on ventricular muscle contraction and electrophysiological properties: studies in rat papillary muscle and isolated ventricular myocytes. *Arch Pharmacol* 335, 160–165.

26 Harry DS, McIntyre N (1992) Plasma lipoproteins and the liver. In: Millward-Sadler GH, Wright R, Arthur MJP (eds) *Liver and Biliary Disease*, 3rd edn. London: W.B. Saunders, pp. 61–78.

27 Owen JS, Bruckdorfer KR, Day RC *et al.* (1982) Decreased erythrocyte membrane fluidity and altered lipid composition in human liver disease. *J Lipid Res* 23, 124–132.

28 Owen JS (1990) Extrahepatic cell lipid abnormalities and cellular dysfunction in liver disease. *Drugs* 40 (Suppl. 3), 73–83.

29 Jackson PA, Morgan DB (1982) The relation between membrane cholesterol and phospholipids and sodium efflux in erythrocytes from healthy subjects and patients with chronic cholestasis. *Clin Sci* 62, 101–107.

30 North P, Fleischer S (1983) Alteration of synaptic membrane cholesterol/phospholipid ratio using a lipid transfer protein. Effect on gamma-aminobutyric acid uptake. *J Biol Chem* 258, 1242–1253.

31 Hyogo H, Tazuma S, Nishioka T *et al.* (2001) Phospholipid alterations in hepatocyte membranes and transporter protein changes in cholestatic rat model. *Dig Dis Sci* 46, 2089–2097.

32 Swain MG, Maric M (1995) Defective corticotrophin-releasing hormone mediated neuroendocrine and behavioural responses in cholestatic rats: implications for cholestatic liver disease-related sickness behaviors. *Hepatology* 22, 1560–1564.

33 Burak KW, Le T, Swain MG (2002) Increased sensitivity to the locomotor-activating effects of corticotrophin-releasing hormone in cholestatic rats. *Gastroenterology* 122, 681–688.

34 Swain MG, Le T (1998) Chronic cholestasis in rats induces anhedonia and a loss of social interest. *Hepatology* 28, 6–10.

35 Forton DM, Patel N, Prince M *et al.* (2004) Fatigue and primary biliary cirrhosis: association of globus pallidus magnetisation transfer ratio measurements with fatigue severity and blood manganese levels. *Gut* 53, 475–477.

36 Silverberg DS, Iaina A, Reisin E *et al.* (1977) Cholestyramine in uraemic pruritus. *Br Med J* 1, 752–753.

37 Bartholomew TC, Summerfield JA, Billing BH *et al.* (1982) Bile acid profiles of human serum and skin interstitial fluid and their relationship to the pruritus studied by gas chromatography-mass spectrometry. *Clin Sci* 63, 65–73.

38 O'Keeffe C, Baird AW, Nolan N *et al.* (2004) Cholestatic pruritus – the role of cutaneous mast cells and nerves. *Aliment Pharmacol Ther* 19, 1293–1300.

39 Bergasa NV (2005) The pruritus of cholestasis. *J Hepatol* 43, 1078–1088.

40 Bergasa NV, Alling DW, Talbot TL *et al.* (1995) Effect of naloxone infusions in patients with the pruritus of cholestasis. A double-blind, randomized, controlled trial. *Ann Intern Med* 123, 161–167.

41 Bergasa NV, Link MJ, Keogh M *et al.* (2001) Pilot study of bright-light therapy reflected towards the eyes for the pruritus of chronic liver disease. *Am J Gastroenterol* 96, 1563–1570.

42 O'Donoghue JW, Pereira SP, Ashdown AC *et al.* (2005) A controlled trial of ondansetron in the pruritus of cholestasis. *Aliment Pharmacol Ther* 21, 1041–1045.

43 Green J, Better OS (1995) Systemic hypotension and renal failure in obstructive jaundice – mechanistic and therapeutic aspects. *J Am Soc Nephrol* 5, 853–871.

44 Sharsha SM, Better OS, Chaimovitz C *et al.* (1976) Haemodynamic studies in dogs with bile duct ligations. *Clin Sci* 50, 533–537.

45 Williams RD, Elliott DW, Zollinger RM (1960) The effect of hypotension in obstructive jaundice. *Arch Surg* 81, 334–340.

46 Bomzon L, Wilton PB, McCalden TA (1978) Impaired skeletal muscle vasomotor response to infused noradrenaline in baboons with obstructive jaundice. *Clin Sci* 55, 109–112.

47 Jacob G, Said O, Finberg J *et al.* (1993) Peripheral vascular neuroeffector mechanisms in experimental cholestasis. *Am J Physiol* 265, G579–586.

48 Ebrahimi F, Tavakoli S, Hajrasouliha AR *et al.* (2005) Contribution of endogenous opioids and nitric oxide to papillary muscle contractile impairment in cholestatic rats. *Eur J Pharmacol* 523, 93–100.

49 Borhani AA, Houshmand G, Samini M *et al.* (2005) Alpha2-adrenoceptor subsensitivity in mesenteric vascular bed of cholestatic rats: the role of nitric oxide and endogenous opioids. *Eur J Pharmacol* 514, 183–189.

50 Tajuddin M, Tariq M, Bilgrami NL *et al.* (1980) Biochemical and pathological changes in the heart following bile duct ligation. *Adv Myocardiol* 2, 209–212.

51 Binah O, Bomzon A, Blendis LM *et al.* (1985) Obstructive jaundice blunts myocardial contractile response to isoprenaline in the dog: a clue to the susceptibility of jaundice patients to shock? *Clin Sci* 69, 647–653.

52 Green J, Beyar R, Sideman S *et al.* (1986) The 'jaundiced heart', a possible explanation for post-operative shock in obstructive jaundice. *Surgery* 100, 14–20.

53 Fogarty BJ, Parks RW, Rowlands BJ *et al.* (1995) Renal dysfunction in obstructive jaundice. *Br J Surg* 82, 877–884.

54 Holt S, Marley R, Fernando B *et al.* (1999) Acute cholestasis-induced renal failure: effects of antioxidants and ligands for the thromboxane A2 receptor. *Kidney Int* 55, 271–277.

55 Kramer HJ, Schwarting K, Backer A *et al.* (1997) Renal endothelin system in obstructive jaundice: its role in impaired renal function of bile-duct ligated rats. *Clin Sci (Lond)* 92, 579–585.

56 Utkan ZN, Utkan T, Sarioglu Y *et al.* (2000) Effects of experimental obstructive jaundice on contractile responses of dog isolated blood vessels: role of endothelium and duration of bile duct ligation. *Clin Exp Pharmacol Physiol* 27, 339–344.

57 Claria J, Jimenez W, Ros J *et al.* (1992) Pathogenesis of arterial hypotension in cirrhotic rats with ascites: role of endogenous nitric oxide. *Hepatology* 15, 343–349.

58 Zambraski EJ, Dunn MJ (1984) Importance of renal prostaglandins in control of renal function after chronic ligation of the common bile duct in dogs. *J Lab Clin Med* 103, 549–559.

59 Kramer HJ, Schwarting K, Backer A (1995) Impaired renal function in obstructive jaundice: enhanced glomerular thromboxane synthesis and effects of thromboxane receptor blockade in bile duct-ligated rats. *Clin Sci (Lond)* 88, 39–45.

60 Baum M, Stirling GA, Dawson JL (1969) Further study into obstructive jaundice and ischaemic renal damage. *Br Med J (Clin Res)* 2, 229–231.

61 Aoyagi T, Lowenstein LM (1968) The effect of bile salts and renal ischaemic on renal function. *J Lab Clin Med* 71, 686–692.

62 Allison MEM, Moss NG, Fraser MM *et al.* (1978) Renal function in chronic obstructive jaundice: a micropuncture study in rats. *Clin Sci* 54, 649–659.

63 Bloom D, McCalden TA, Rosendorff C (1975) The effects of hypercholesterolaemic plasma on vascular sensitivity to noradrenaline. *Br J Pharmacol* 54, 421–427.

64 Dooley JS, Hamilton-Miller JMT, Boss M *et al.* (1983) Tubular cell damage and impaired renal clearance of mezlocillin in patients with obstructive jaundice. *Hepatology* 3, 853A.

65 Better OS, Guckian V, Giebisch G *et al.* (1987) The effect of sodium taurocholate on proximal tubular reabsorption in the rat kidney. *Clin Sci (Lond)* 72, 139–141.

66 Alon U, Berant M, Mordechovitz D *et al.* (1982) The effect of intrarenal infusion of bile on kidney function in the dog. *Clin Sci (Lond)* 62, 431–433.

67 Finestone H, Fechner C, Levy M (1984) Effects of bile and bile salt infusions on renal function in dogs. *Can J Physiol Pharmacol* 62, 762–768.

68 Alon U, Daviddai G, Harpaz S *et al.* (1988) Role of renal prostaglandins in bile-induced diuresis in the dog. *Miner Electrolyte Metab* 14, 338–342.

69 Sellinger M, Haag K, Burckhardt G *et al.* (1990) Sulfated bile acids inhibit Na(+)-H+ antiport in human kidney brush-border membrane vesicles. *Am J Physiol* 258, F986–991.

70 Martinez-Rodenas F, Oms LM, Carulla X *et al.* (1989) Measurement of body water compartments after ligation of the common bile duct in the rabbit. *Br J Surg* 76, 461–464.

71 Sitprija V, Kashemsant U, Sriratanaban A *et al.* (1990) Renal function in obstructive jaundice in man: cholangiocarcinoma model. *Kidney Int* 38, 948–955.

72 Lucena MI, Andrade RJ, Cabello MR *et al.* (1995) Aminoglycoside-associated nephrotoxicity in extrahepatic obstructive jaundice. *J Hepatol* 22, 189–196.

73 Thompson JE, Pitt HA, Doty JE *et al.* (1990) Broad spectrum penicillin as an adequate therapy for acute cholangitis. *SGO* 171, 275–282.

74 Vakil N, Abu-Alfa A, Mujais SK (1989) Gentamicin nephrotoxicity in extrahepatic cholestasis: modulation by dietary calcium. *Hepatology* 9, 518–524.

75 Thompson JN, Cohen J, Moore RH *et al.* (1988) Endotoxemia in obstructive jaundice. Observations on cause and clinical significance. *Am J Surg* 155, 314–321.

76 Ingoldby CJ, McPherson GA, Blumgart LH (1984) Endotoxemia in human obstructive jaundice. Effect of polymyxin B. *Am J Surg* 147, 766–771.

77 Clements WD, Parks R, Erwin P *et al.* (1996) Role of the gut in the pathophysiology of extrahepatic biliary obstruction. *Gut* 39, 587–593.

78 Kocsar LT, Bertok L, Varteresz V (1969) Effect of bile acids on the intestinal absorption of endotoxin in rats. *J Bacteriol* 100, 220–223.

79 Van Bossuyt H, Desmaretz C, Gaeta GB *et al.* (1990) The role of bile acids in the development of endotoxaemia during obstructive jaundice in the rat. *J Hepatol* 10, 274–279.

80 Cahill CJ (1983) Prevention of postoperative renal failure in patients with obstructive jaundice – the role of bile salts. *Br J Surg* 70, 590–595.

81 Lumsden AB, Henderson JM, Alspaugh J (1989) Endotoxemia during percutaneous manipulation of the obstructed biliary tree. *Am J Surg* 158, 21–24.

82 Clements WD, Halliday MI, McCaigue MD *et al.* (1993) Effects of extrahepatic obstructive jaundice on Kupffer cell clearance capacity. *Arch Surg* 128, 200–204.

83 Lumsden AB, Henderson JM, Kutner MH (1988) Endotoxin levels measured by a chromogenic assay in portal, hepatic and peripheral venous blood in patients with cirrhosis. *Hepatology* 8, 232–235.

84 Roelofsen H, van der Veere CN, Ottenhoff R *et al.* (1994) Decreased bilirubin transport in the perfused liver of endotoxemic rats. *Gastroenterology* 107, 1075–1084.

85 Ingoldby CJ, McPherson GA, Blumgart LH (1984) Endotoxaemia in human obstructive jaundice. Effect of polymyxin B. *Am J Surg* 147, 766–771.

86 Cavanagh D, Rao PS, Sutton DM *et al.* (1970) Pathophysiology of endotoxin shock in the primate. *Am J Obstet Gynecol* 108, 705–722.

87 Kikeri D, Pennell JP, Hwang KH *et al.* (1986) Endotoxemic acute renal failure in awake rats. *Am J Physiol* 250, F1098–1106.

88 Colucci M, Paramo JA, Collen D (1985) Generation in plasma of a fast-acting inhibitor of plasminogen activator in response to endotoxin stimulation. *J Clin Invest* 75, 818–824.

89 Inan M, Sayek I, Tel BC *et al.* (1997) Role of endotoxin and nitric oxide in the pathogenesis of renal failure in obstructive jaundice. *Br J Surg* 84, 943–947.

90 Jolobe OMP (1998) Role of endotoxin and nitric oxide in the pathogenesis of renal failure in obstructive jaundice. *Br J Surg* 85, 1747.

91 Dixon JM, Armstrong CP, Duffy SW *et al.* (1984) Upper gastrointestinal bleeding. A significant complication after surgery for relief of obstructive jaundice. *Ann Surg* 199, 271–275.

92 Urakawa T, Nagahata Y, Nakamoto M *et al.* (1987) An approach to the mechanism of acute ulceration in obstructive jaundice. *Scand J Gastroenterol* 22, 634–640.

93 Yoshida M, Koga A (1988) Alterations with time of secretion and ultrastructure of the exocrine pancreas in rats with an obstructed biliary system. *Br J Exp Pathol* 69, 441–448.

94 Gouma DJ, Roughneen PT, Kumar S *et al.* (1986) Changes in nutritional status associated with obstructive jaundice and biliary drainage in rats. *Am J Clin Nutr* 44, 362–369.

95 Padillo FJ, Andicoberry B, Naranjo A *et al.* (2001) Anorexia and the effect of internal biliary drainage on food intake in patients with obstructive jaundice. *J Am Coll Surg* 192, 584–590.

96 Freund H, James JH, Brenner W *et al.* (1980) Plasma amino acid analysis in the differential diagnosis of jaundice. *Am J Surg* 139, 142–148.

97 Starnes HF, Jr, Conti PS, Warren RS *et al.* (1987) Altered peripheral amino acid uptake in obstructive jaundice. *J Surg Res* 42, 383–393.

98 Armstrong CP, Dixon JM, Duffy SW *et al.* (1984) Wound healing in obstructive jaundice. *Br J Surg* 71, 267–270.

99 Arnaud J-P, Humbert W, Eloy M-R *et al.* (1981) Effect of obstructive jaundice on wound healing. An experimental study in rats. *Am J Surg* 141, 593–596.

100 Greaney MG, VanNoort R, Smythe A *et al.* (1979) Does obstructive jaundice adversely affect wound healing? *Br J Surg* 66, 478–481.

101 Bayer I, Ellis H (1976) Jaundice and wound healing: an experimental study. *Br J Surg* 63, 392–396.

102 Than T (1976) Skin prolyl hydroxylase and tensiometry in jaundice. PhD Thesis, University of Glasgow.

103 Ellis H, Heddle R (1977) Does the peritoneum need to be closed at laparotomy? *Br J Surg* 64, 733–736.

104 Clifton PM, Barter PJ, Malkinon AM (1982) High density lipoprotein particle size distribution in subjects with obstructive jaundice. *J Lipid Res* 23, 121–125.

105 Owen JS, Brown DJC, Harry DS *et al.* (1985) Erythrocyte echinocytosis in liver disease. Role of abnormal plasma high density lipoproteins. *J Clin Invest* 76, 2275–2285.

106 Heron DS, Shinitzky M, Hershkowitz M *et al.* (1980) Lipid fluidity markedly modulates the binding of serotonin to mouse brain membranes. *Proc Natl Acad Sci USA* 77, 7463–7467.

107 Kimmings N, Sewnath ME, Mairuhu WM *et al.* (2001) The abnormal lipid spectrum in malignant obstructive jaundice in relation to endotoxin sensitivity and the result of preoperative biliary drainage. *Surgery* 129, 282–291.

108 Hay JE (1998) Osteoporosis. *Clin Liver Dis* 2, 407–419.

109 Guanabens N, Pares A, Ros I *et al.* (2005) Severity of cholestasis and advanced histological stage but not menopausal status are the major risk factors for osteoporosis in primary biliary cirrhosis. *J Hepatol* 42, 573–577.

110 Hay JE, Lindor KD, Wiesner RH *et al.* (1991) The metabolic bone disease of primary sclerosing cholangitis. *Hepatology* 14, 257–261.

111 Janes CH, Dickson ER, Okazaki R *et al.* (1995) Role of hyperbilirubinaemia in the impairment of osteoblast proliferation associated with cholestatic jaundice. *J Clin Invest* 95, 2581–2586.

112 Kimmings AN, van Deventer SJH, Obertop H *et al.* (1995) Inflammatory and immunological effects of obstructive jaundice: pathogenesis and treatment. *J Am Coll Surg* 181, 567–581.

113 Pain JA (1987) Reticulo-endothelial function in obstructive jaundice. *Br J Surg* 74, 1091–1094.

114 Scriven MW, Horrobin DF, Puntis MC (1994) Study of plasma and red cell phospholipids fatty acids in extrahepatic cholestatic jaundice. *Gut* 35, 987–990.

115 Ding JW, Andersson R, Stenram U *et al.* (1992) Effect of biliary decompression on reticuloendothelial function in jaundiced rats. *Br J Surg* 79, 648–652.

116 Scott-Conner CE, Grogan JB, Scher KS *et al.* (1989) Impaired clearance of *Escherichia coli* bacteremia in early biliary obstruction. *Am J Surg* 157, 210–214.

117 Collier DS, Pain JA, Wight DG *et al.* (1986) The Kupffer cell in experimental extrahepatic cholestasis in the rat – a light microscopy, immunohistochemical and electron microscopy study. *J Pathol* 150, 187–194.

118 Roughneen PT, Drath DB, Kulkarni AD *et al.* (1987) Impaired nonspecific cellular immunity in experimental cholestasis. *Ann Surg* 206, 578–582.

119 Greve JW, Gouma DJ, Soeters PB *et al.* (1990) Suppression of cellular immunity in obstructive jaundice is caused by endotoxins: a study with germ-free rats. *Gastroenterology* 98, 478–485.

120 Swain MG, Tjandra K, Kanwar S *et al.* (1995) Neutrophil adhesion is impaired in rat model of cholestasis. *Gastroenterology* 109, 923–932.

121 Levy R, Schlaeffer F, Keynan A *et al.* (1993) Increased neutrophil function induced by bile duct ligation in a rat model. *Hepatology* 17, 908–914.

122 Clements WD, McCaigue M, Erwin P *et al.* (1996) Biliary decompression promotes Kupffer cell recovery in obstructive jaundice. *Gut* 38, 925–931.

123 Roughneen PT, Gouma DJ, Kulkarni AD *et al.* (1986) Impaired specific cell-mediated immunity in experimental biliary obstruction and its reversibility by internal biliary drainage. *J Surg Res* 41, 113–125.

124 Feduccia TD, Scott-Conner CE, Grogan JB (1988) Profound suppression of lymphocyte function in early biliary obstruction. *Am J Med Sci* 296, 39–44.

125 Beaudoin JG, Rabbat AG (1969) Effect of biliary obstruction on skin allograft survival in mice. *Transplantation* 7, 576–577.

126 Roughneen PT, Kulkarni AD, Gouma DJ *et al.* (1986) Suppression of host-versus-graft response in experimental biliary obstruction. *Transplantation* 42, 687–689.

127 Thompson RL, Ranjbar S, Rowlands BJ (1993) T-lymphocyte transformation in experimental obstructive jaundice: the role of serum-suppressive factors. *World J Surg* 17, 783–785.

128 Fan ST, Lo CM, Lai EC *et al.* (1994) T lymphocyte function in patients with malignant biliary obstruction. *J Gastroenterol Hepatol* 9, 391–395.

129 Thong YH, Ferrante A, Ness D (1977) Neutrophil phagocytic and bactericidal dysfunction induced by bilirubin. *Aust Paediatr J* 13, 287–289.

130 Thong YH, Ferrante A (1977) Adverse effect of bilirubin on the chemotactic responsiveness of human neutrophils. *IRCS J Med Sci* 5, 483.

131 Rola-Pleszcynski M, Hensen SA, Vincent MM *et al.* (1975) Inhibitory effects of bilirubin on cellular responses in man. *J Pediatr* 86, 690–696.

132 Cainzos M, Patel J, Puente JL (1988) Anergy in jaundiced patients. *Br J Surg* 75, 147–149.

133 Bemelmans MH, Gouma DJ, Greve JW *et al.* (1992) Cytokines tumour necrosis factor and interleukin-6 in experimental biliary obstruction in mice. *Hepatology* 15, 1132–1136.

134 Padrillo FJ, Muntane J, Muntero JL *et al.* (2002) Effect of internal biliary drainage on plasma levels with obstructive jaundice. *World J Surg* 26, 1328–1332.

135 Bemelmans MH, Greve JW, Gouma DJ *et al.* (1996) Increased concentrations of tumour necrosis factor (TNF) and soluble TNF receptors in biliary obstruction in mice: soluble TNF receptors as prognostic factors for mortality. *Gut* 38, 447–453.

136 Whiting JF, Green RM, Rosenbluth AB *et al.* (1995) Tumour necrosis factor-alpha decreases hepatocyte bile salt uptake and mediates endotoxin-induced cholestasis. *Hepatology* 22, 1273–1278.

137 Deitch EA, Sittig K, Li M *et al.* (1990) Obstructive jaundice promotes bacterial translocation from the gut. *Am J Surg* 159, 79–84.

138 Ding JW, Andersson R, Soltesz V *et al.* (1994) Obstructive jaundice impairs reticuloendothelial function and promotes bacterial translocation in the rat. *J Surg Res* 57, 238–245.

139 Slocum MM, Sittig KM, Specian RD *et al.* (1992) Absence of intestinal bile promotes bacterial translocation. *Am Surg* 58, 305–310.

140 Deitch EA, Ma L, Ma WJ *et al.* (1989) Inhibition of endotoxin-induced bacterial translocation in mice. *J Clin Invest* 84, 36–42.

141 Ding JW, Andersson R, Soltesz VL *et al.* (1994) Inhibition of bacterial translocation in obstructive jaundice by muramyl tripeptide phosphatidylethanolamine in the rat. *J Hepatol* 20, 720–728.

142 Kalambaheti T, Cooper GN, Jackson GD (1994) Role of bile in non-specific defence mechanisms of the gut. *Gut* 35, 1047–1052.

143 Hunt DR, Allison ME, Prentice CR *et al.* (1982) Endotoxemia, disturbance of coagulation, and obstructive jaundice. *Am J Surg* 144, 325–329.

144 Semeraro N, Montemurro P, Chetta G *et al.* (1989) Increased procoagulant activity of peripheral blood monocytes in human and experimental obstructive jaundice. *Gastroenterology* 96, 892–898.

145 Jedrychowski A, Hillenbrand P, Ajdukiewicz AB *et al.* (1973) Fibrinolysis in cholestatic jaundice. *Br Med J* i, 640–642.

146 Wardle EN (1974) Fibrinogen in liver disease. *Arch Surg* 109, 741–746.

147 Bowen DJ, Clemmons RM, Meyer DJ *et al.* (1988) Platelet functional changes secondary to hepatocholestasis and elevation of serum bile acids. *Thromb Res* 52, 649–654.

148 Nissan A, Spira RM, Seror D *et al.* (1996) Captopril-associated 'pseudocholangitis'. A case report and review of the literature. *Arch Surg* 131, 670–671.

149 Taylor-Robinson SD, Toledano MB, Arora S *et al.* (2001) Increase in mortality rates from intrahepatic cholangiocarcinoma in England and Wales 1968–1998. *Gut* 48, 816–820.

150 Boberg KM, Bergquist A, Mitchell S *et al.* (2002) Cholangiocarcinoma in primary sclerosing cholangitis: risk factors and clinical presentation. *Scand J Gastroenterol* 37, 1205–1211.

151 Fortson WC, Tedesco FJ, Starnes EC *et al.* (1985) Marked elevation of serum transaminase activity associated with extrahepatic biliary tract disease. *J Clin Gastroenterol* 7, 502–505.

152 Romagnuolo J, Bardou M, Rahme E *et al.* (2003) Magnetic resonance cholangiopancreatography: a meta-analysis of test performance in suspected biliary disease. *Ann Intern Med* 139, 547–557.

153 Vaishali MD, Agarwal AK, Upadhyaya DN *et al.* (2004) Magnetic resonance cholangiopancreatography in obstructive jaundice. *J Clin Gastroenterol* 38, 887–890.

154 Zidi SH, Prat F, Le Guen O *et al.* (2000) Performance characteristics of magnetic resonance cholangiography in the staging of malignant hilar stricture. *Gut* 46, 103–106.

155 Gibson RN, Vincent JM, Speer T *et al.* (2005) Accuracy of computed tomographic intravenous cholangiography (CT-IVC) with iotroxate in the detection of choledocholithiasis. *Eur Radiol* 15, 1634–1642.

156 Shoup M, Hodul P, Aranha GV *et al.* (2000) Defining a role for endoscopic ultrasound in staging periampullary tumors. *Am J Surg* 179, 453–456.

157 Yusuf TE, Bhutani MS (2004) Role of endoscopic ultrasonography in diseases of the extrahepatic biliary system. *J Gastroenterol Hepatol* 19, 243–250.

158 Rosch T, Hofrichter K, Frimberger E *et al.* (2004) ERCP or EUS for tissue diagnosis of biliary strictures? A prospective comparative study. *Gastrointest Endosc* 60, 390–396.

159 Lee JH, Salem R, Aslanian H *et al.* (2004) Endoscopic ultrasound and fine-needle aspiration of unexplained bile duct strictures. *Am J Gastroenterol* 99, 1069–1073.

160 Kurzawinski TR, Selves L, Farouk M *et al.* (1997) Prospective study of hepatobiliary scintigraphy and endoscopic cholangiography for the detection of early biliary complications after orthotopic liver transplantation. *Br J Surg* 84, 620–623.

161 Tripathi M, Chandrashekar N, Kumar R *et al.* (2004) Hepatobiliary scintigraphy: an effective tool in the management of bile leak following laparoscopic cholecystectomy. *Clin Imaging* 28, 40–43.

162 Huang P, Do-Xuan-Hop (1937) La ponction transhepatique des canaux bilaires. *Bull Soc Med Chir Indochine* 62, 1090–1100.

163 Okuda K, Tanikawa K, Emura T *et al.* (1974) Non surgical percutaneous transhepatic cholangiography: diagnostic significance in medical problems of the liver. *Am J Dig Dis* 19, 21–36.

164 Cotton PB (2005) ERCP overview – a 30 year experience. In: Cotton P, Leung J (eds) *Advanced Digestive Endoscopy: ERCP.* Oxford: Blackwell Publishing Ltd, pp. 1–8.

165 Speer AG, Cotton PB, Russell RC *et al.* (1987) Randomised trial of endoscopic versus percutaneous stent insertion in malignant obstructive jaundice. *Lancet* 2, 57–62.

166 Khan SA, Davidson BR, Goldin R *et al.* (2002) Guidelines for the diagnosis and treatment of cholangiocarcinoma: consensus document. *Gut* 51 (Suppl. 6), 1–9.

167 Padillo FJ, Briceno J, Cruz A *et al.* (2005) Randomized clinical trial of the effects of intravenous fluid administration on hormonal and renal dysfunction in patients with obstructive jaundice undergoing endoscopic drainage. *Br J Surg* 92, 39–43.

168 Dawson JL (1965) Post-operative renal function in obstructive jaundice: effect of a mannitol diuresis. *Br Med J* i, 82–86.

169 Gubern JM, Sancho JJ, Simo J *et al.* (1988) A randomized trial on the effect of mannitol on postoperative renal function in patients with obstructive jaundice. *Surgery* 1–3, 39–44.

170 Bailey ME (1976) Endotoxin, bile salts and renal function in obstructive jaundice. *Br J Surg* 63, 774–778.

171 Cahill CJ, Pain JA, Bailey ME (1987) Bile salts, endotoxin and renal function in obstructive jaundice. *Surg Gynecol Obstet* 165, 519–522.

172 Pain JA, Cahill CJ, Gilbert JM *et al.* (1991) Prevention of postoperative renal dysfunction in patients with obstructive jaundice: a multicentre study of bile salts and lactulose. *Br J Surg* 78, 467–469.

173 Thompson JN, Cohen J, Blenkharn JI *et al.* (1986) A randomised clinical trial of oral ursodeoxycholic acid in obstructive jaundice. *Br J Surg* 73, 634–636.

174 Pain JA, Bailey ME (1988) Prevention of endotoxaemia in obstructive jaundice – a comparative study of bile salts. *Hepato-Biliary Pancreatic Surg* 1, 21–27.

175 Liehr H, Englisch G, Rasenack U (1980) Lactulose – a drug with antiendotoxin effect. *Hepatogastroenterology* 27, 356–360.

176 Pain JA, Bailey ME (1986) Experimental and clinical study of lactulose in obstructive jaundice. *Br J Surg* 73, 775–778.

177 Parks RW, Diamond T, McCrory DC *et al.* (1994) Prospective study of postoperative renal function in obstructive jaundice and the effect of perioperative dopamine. *Br J Surg* 81, 437–439.

178 Van den Hazel SJ, Speelman P, Dankert J *et al.* (1996) Piperacillin to prevent cholangitis after endoscopic retrograde cholangiopancreatography. *Ann Intern Med* 125, 442–447.

179 Byl B, Deviere J, Strachan MJ *et al.* (1995) Antibiotics prophylaxis for infectious complications after therapeutic endoscopic retrograde cholangiopancreatography: a randomised, double-blind, placebo-controlled study. *Clin Infect Dis* 20, 1236–1240.

180 Subhani JM, Kibbler C, Dooley JS (1999) Review article: antibiotic prophylaxis for endoscopic retrograde cholangiopancreatography (ERCP). *Aliment Pharmacol Ther* 13, 103–116.

181 ASGE (2003) Guidelines for antibiotic prophylaxis for GI endoscopy. *Gastrointest Endosc* 58, 475–482.

182 Mani V, Cartwright K, Dooley J *et al*. (1997) Antibiotic prophylaxis in gastrointestinal endoscopy: a report by a Working Party for the British Society of Gastroenterology Endoscopy Committee. *Endoscopy* 29, 114–120.

183 Nakayama T, Ikeda A, Okuda K (1978) Percutaneous transhepatic drainage of the biliary tract: technique and results in 104 patients. *Gastroenterology* 74, 554–559.

184 Hatfield AR, Tobias R, Terblanche J *et al*. (1982) Preoperative external biliary drainage in obstructive jaundice. A prospective controlled trial. *Lancet* 2, 896–899.

185 McPherson GA, Benjamin IS, Hodgson HJ *et al*. (1984) Pre-operative percutaneous transhepatic biliary drainage: the results of a controlled trial. *Br J Surg* 71, 371–375.

186 Pitt HA, Gomes AS, Lois JF *et al*. (1985) Does preoperative percutaneous biliary drainage reduce operative risk or increase hospital costs? *Ann Surg* 201, 545–553.

187 Sewnath ME, Karsten TM, Prins MH *et al*. (2002) A meta-analysis on the efficacy of preoperative biliary drainage for tumors causing obstructive jaundice. *Ann Surg* 236, 17–27.

188 Lai EC, Mok FP, Fan ST *et al*. (1994) Preoperative endoscopic drainage for malignant obstructive jaundice. *Br J Surg* 81, 1195–1198.

189 Lai EC, Mok FP, Tan ES *et al*. (1992) Endoscopic biliary drainage for severe acute cholangitis. *N Engl J Med* 326, 1582–1586.

190 Hoevels J, Nilsson U (1980) Intrahepatic vascular lesions following nonsurgical percutaneous transhepatic bile duct intubation. *Gastrointest Radiol* 5, 127–135.

191 Kama NA, Coskun T, Yuksek YN *et al*. (1999) Factors affecting post-operative mortality in malignant biliary tract obstruction. *Hepatogastroenterology* 46, 103–107.

192 Dixon JM, Armstrong CP, Duffy SW *et al*. (1983) Factors affecting morbidity and mortality after surgery for obstructive jaundice: a review of 373 patients. *Gut* 24, 845–852.

19.3 Gallstone disease

Frank Lammert, Franz-Ludwig Dumoulin and Tilman Sauerbruch

Gallstones represent a serious burden for our healthcare systems: 10–20% of Europeans and Americans carry gallbladder stones [1,2], and the prevalence of gallstone disease seems to be rising as a result of longer life expectancy. Many gallstones are silent, but symptoms and severe complications ensue in around 25% of cases, necessitating surgical removal of the gallbladder, usually by laparoscopic cholecystectomy. Each year, an estimated 700 000 cholecystectomies are performed in the US and 170 000 in Germany [3,4]. Cholelithiasis incurs annual medical expenses of $6.5 billion in the US and is the second most expensive digestive disease, currently exceeded only by gastro-oesophageal reflux disease [5].

Pathogenesis

Molecular mechanisms of bile formation

Bile formation enables the removal of excess cholesterol, either directly or after catabolism to bile salts, and it is a key function of the liver. Bile is an aqueous solution of lipids, with bile salts (67% of solutes by weight), phospholipids (22%) and cholesterol (4%) representing the three main lipid species [6]. Hepatocytes express specific adenosine triphosphate (ATP)-dependent transport proteins – known as ABC transporters – for each of these three lipids at the canalicular membrane domain [7]. The ABCB11 transporter is the bile salt export pump, ABCB4 is the transporter for the major biliary phospholipid phosphatidylcholine (lecithin) (Table 1), and ABCG5/ABCG8 form obligate heterodimers for biliary cholesterol secretion (Figure 1) [7].

On biliary secretion, phosphatidylcholine and cholesterol form metastable unilamellar vesicles, which are converted into mixed micelles during their passage through the biliary tree (Fig. 1) [6,8]. These micelles solubilize hydrophobic molecules such as cholesterol. The composition of hepatic bile is further modified by the bicarbonate- and chloride-rich secretion of cholangiocytes, which is associated with a net influx of water into bile through aquaporin channels. An important chloride channel in cholangiocytes is the cystic fibrosis transmembrane conductance regulator (CFTR), the gene for which is mutated in cystic fibrosis (Table 1).

Cholesterol gallbladder stones

Gallstones are classified as cholesterol and pigment stones (Table 2, Fig. 2). More than 80% of gallstones consist mainly of cholesterol crystals and are formed within the gallbladder [8]. Three key mechanisms contribute to the formation of cholesterol gallbladder stones: cholesterol supersaturation of bile, gallbladder hypomotility and destabilization of bile by kinetic protein factors. Cholesterol is virtually insoluble in water, and its solubility in bile depends on the detergent properties of bile salts and phospholipids [9]. Cholesterol-supersaturated bile contains more cholesterol than can be solubilized by mixed micelles at

Table 1 Potential single gene defects associated with gallstone formation.

Gene	Protein/function	Potential mechanism
ABCB4	Hepatocanalicular phosphatidylcholine (lecithin) flippase	Biliary phospholipid secretion ↓
ABCB11	Hepatocanalicular bile salt export pump	Biliary bile salt secretion ↓
APOB	Apolipoprotein B	Hepatic VLDL synthesis ↓
CCKAR	CCK-A receptor	Gallbladder hypomotility
CFTR	Cystic fibrosis transmembrane regulator (chloride channel)	Bile pH ↓, biliary bilirubin secretion ↑, faecal bile salt excretion ↑
CPY7A1	Cholesterol 7α-hydroxylase (rate-limiting enzyme of bile salt synthesis)	Bile salt synthesis ↓

CCK, cholecystokinin; VLDL, very-low-density lipoprotein.

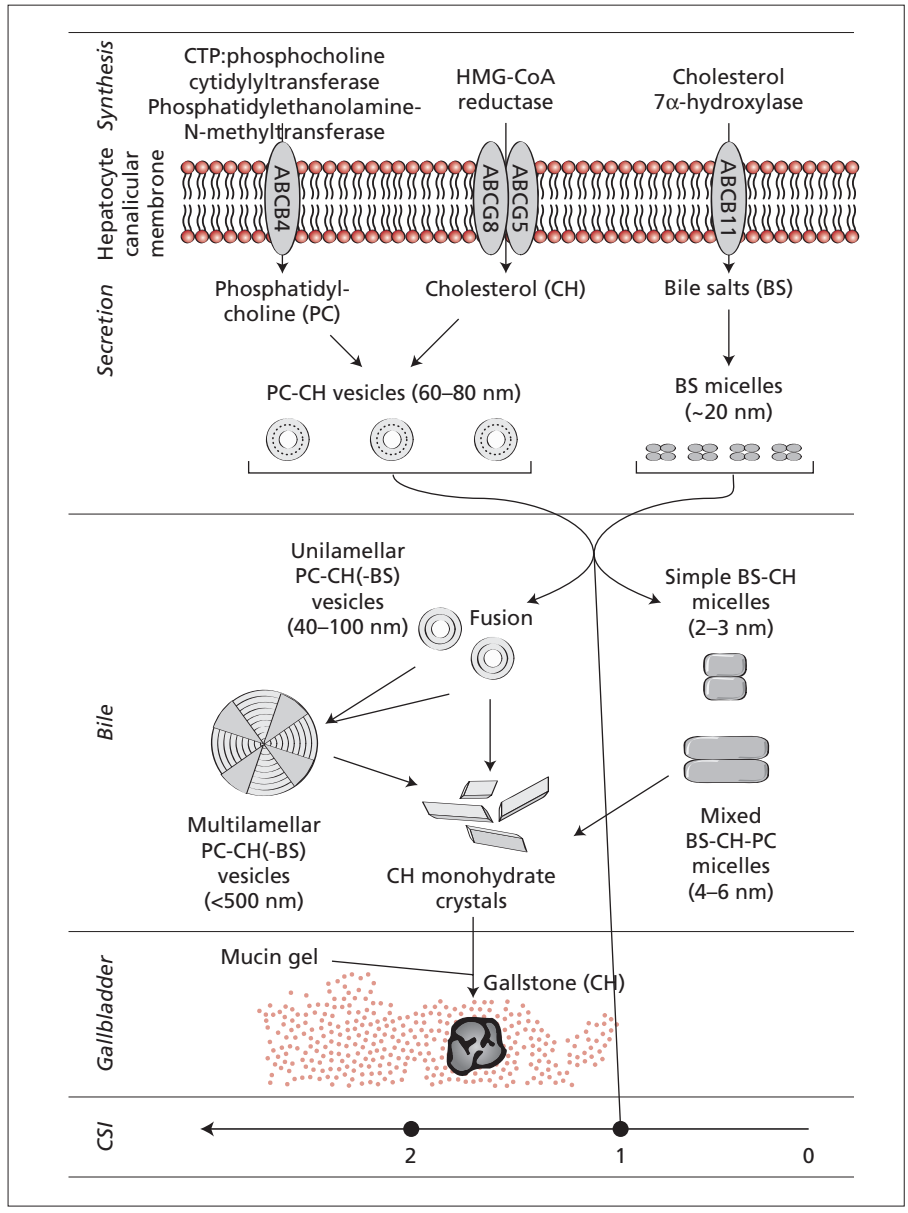

Fig. 1 Pathogenesis of cholesterol gallstone formation. Schematic diagram of rate-limiting enzymes for synthesis and hepatocanalicular transport proteins of hepatobiliary lipids, cholesterol carriers in bile and cholesterol saturation index (CSI). The biliary lipids phosphatidylcholine, cholesterol and bile acids) are secreted into bile by ATP-dependent transport proteins (ABC transporters). The cholesterol transporter is a heterodimer (ABCG5/G8). On biliary secretion, phosphatidylcholine and cholesterol form metastable unilamellar vesicles and bile salts form simple micelles. These lipid aggregates are converted into mixed micelles during their passage through the biliary tract into the gallbladder. If bile contains more cholesterol than can be solubilized by mixed micelles, it is supersaturated with cholesterol, and cholesterol-rich multilamellar vesicles form, fuse and nucleate solid cholesterol crystals. Thus, conditions that increase the ratio of cholesterol to bile salts and phospholipids favour gallstone formation. Cholesterol supersaturation is indicated by a CS > 1. The gallbladder secretes mucous glycoproteins, which form the matrix for precipitation of crystal aggregates and gallstones.

Table 2 Classification of gallstones.

Type	Localization	Prevalence (%)	Composition	Colour	CT
Pure cholesterol stone	Gallbladder	75	Cholesterol monohydrate	Yellow	Iso- or hypodense compared with bile
Black pigment stone	Gallbladder	5	Polymerized calcium bilirubinate	Black	Mainly hyperdense
Brown pigment stone	Bile ducts	20	Calcium salts of long-chain fatty acids (palmitate, stearate) + cholesterol	Brown	Partly hyperdense

CT, computerized tomography.

equilibrium [cholesterol saturation index (CSI) > 1)] (Fig. 1). The CSI is defined as the ratio of the actual biliary cholesterol concentration and the maximal concentration that would be soluble at phase equilibrium in model bile with equal lipid composition [10]. Cholesterol-supersaturated bile contains multilamellar vesicles (liquid crystals), whose fusion and aggregation precede the formation of solid cholesterol crystals (Fig. 1). As illustrated in the classic triangular phase diagram [9,10],

(a)



(b)



(c)

Fig. 2 Gallstones. (a) Pure cholesterol gallbladder stone. (b) Black pigment gallbladder stone. (c) Endoscopically extracted mixed bile duct stone with typical cholesterol core, which nucleated in the gallbladder and served as a nidus for the brown pigment layer.

solid crystals occur in bile at high relative bile salt and low phospholipid concentrations, and at cholesterol:phospholipid ratios > 1.

An excess of biliary cholesterol in relation to bile salts and phospholipids can result from hypersecretion of cholesterol, or from hyposecretion of bile salts or phospholipids (Table 3). Cholesterol hypersecretion, which is the most common cause of supersaturation [8], might be caused by increased hepatic uptake or synthesis of cholesterol, decreased hepatic synthesis of bile salts or decreased hepatic synthesis of cholesteryl esters for incorporation in very-low-density lipoproteins (VLDL). In non-obese individuals who form cholesterol-rich gallbladder stones, gallstones were associated with a small bile salt pool cycling at a normal frequency within the enterohepatic circulation [11]. Furthermore, it has been suggested that slow intestinal transit increases bacterial degradation of primary to secondary bile salts in the colon [12]. Bile then contains a greater proportion of deoxycholate conjugates, which, in turn, increases biliary cholesterol secretion and saturation, thereby enhancing gallstone formation [13].

In humans, most cholesterol present in gallstones is of dietary origin, consistent with the observation that hepatic biosynthesis contributes less than 20% to biliary cholesterol [14]. The hepatic uptake of cholesterol is mediated by the scavenger receptor B-I for high-density lipoproteins (HDL), which contribute most of the biliary cholesterol under physiological conditions, the apolipoprotein (Apo) B/E receptor for low-density lipoproteins (LDL) and the LDL receptor-related protein for chylomicron remnants, which carry exogenous cholesterol from the intestine to the liver. The inverse correlation between serum HDL levels and gallstones suggests that cholesterol cholelithiasis is associated with an induced reverse cholesterol transport and hepatic catabolism of HDL (Table 3) [14]. The rate-limiting enzymes of hepatic cholesterol and bile salt synthesis are 3-hydroxy-3-methylglutaryl-coenzyme A (HMG-CoA) reductase and cholesterol 7α-hydroxylase (CYP7A1) respectively (Table 1, Fig. 1). These enzymes are regulated by the sterol regulatory element-binding protein (SREBP) and nuclear receptor (NR) signalling pathways. Studies in knockout and transgenic mice have demonstrated that many of the genes involved in hepatic cholesterol metabolism affect cholesterol gallstone formation *in vivo* [15–18] but, with few exceptions, variants of these genes have yet to be investigated in patients with gallstones.

Stasis of bile in the gallbladder favours stone formation, as indicated by stone formation during pregnancy, rapid weight loss or total parenteral nutrition (Table 3). Gallbladder emptying in response to either a test meal or a cholecystokinetic stimulus, such as intravenous cholecystokinin (CCK), or intraduodenal fat or amino acids is impaired in many patients with gallstones [8]. Both the fasting and the residual postprandial gallbladder volumes are greater in most patients with cholesterol gallbladder stones than in control subjects. Gallbladder hypomotility is probably due to absorption of cholesterol from supersaturated

Table 3 Causes and risk factors for gallstone formation and potential mechanisms.

Cholesterol gallbladder stones	
General factors	
Age	Biliary cholesterol secretion ↑
	Biliary bile salt secretion ↓
Gender	Higher gallstone prevalence related to parity and estrogens
Pregnancy/estrogens	Hepatic cholesterol uptake and synthesis ↑
	Cholesterol 7α-hydroxylase activity ↓
	Biliary cholate and dexoxycholate pool ↑
	Gallbladder hypomotility ⇒ biliary sludge
Nutritional/metabolic factors	
High-caloric low-fibre diet	Biliary cholesterol secretion ↑
	Intestinal transit time ↑ ⇒ bacterial bile salt catabolism ↑ ⇒ biliary deoxycholate pool ↑
High-carbohydrate diet, dietary glycaemic load	Hepatic cholesterol synthesis ↑
	Bile salt malabsorption
	Insulin resistance
Obesity	Cholesterol synthesis ↑ ⇒ biliary cholesterol secretion ↑
Rapid weight loss/surgery for obesity	Hepatic cholesterol uptake ↑
	Bile salt synthesis ↓
	Mucin secretion ↑ ⇒ nucleation
	Low-fat diet ⇒ gallbladder hypomotility
Hypertriglyceridaemia/low HDL cholesterol	Biliary cholesterol secretion ↑
Disease associations	
Pancreatic insufficiency	CCK production ↓ ⇒ gallbladder hypomotility
Spinal cord injury	Gallbladder hypomotility (neuronal)
Black pigment gallbladder stones	
Crohn disease with severe ileal manifestation or ileal resection	Intestinal bilirubin absorption ↑
	Vitamin B12 malabsorption
Total parenteral nutrition	Gallbladder hypomotility
	Enterohepatic cycling of bilirubin ↑
Vitamin B12 or folic acid deficiency	Ineffective erythropoiesis
Chronic haemolysis (e.g. liver cirrhosis, malaria sickle cell disease, thalassaemia, spherocytosis)	Bilirubin load ↑
Liver cirrhosis	Bile salt synthesis ↓
	Bile salt malabsorption ⇒ intestinal bilirubin absorption ↑
	Gallbladder hypomotility
	Chronic haemolysis
Cystic fibrosis	Enterohepatic cycling of bilirubin ↑
	Bile pH ↓ ⇒ biliary β-glucuronidase activity ↑
	Formation of thick mucus layer
Brown pigment bile duct stones	
Cholangitis	Deconjugation of bilirubin by bacterial enzymes
Anatomic abnormalities	
Biliary stricture	Ascending cholangitis
Duodenal diverticulum	Ascending cholangitis
Drugs	
Estrogens	Biliary cholesterol secretion ↑
Octreotide	Large intestinal transit time ↑ ⇒ deoxycholate pool ↑ ⇒ biliary cholesterol secretion ↑
	CCK release ↓ ⇒ gallbladder hypomotility
Clofibrate	Biliary cholesterol secretion ↑
Ceftriaxone	Biliary secretion of drug ⇒ precipitation

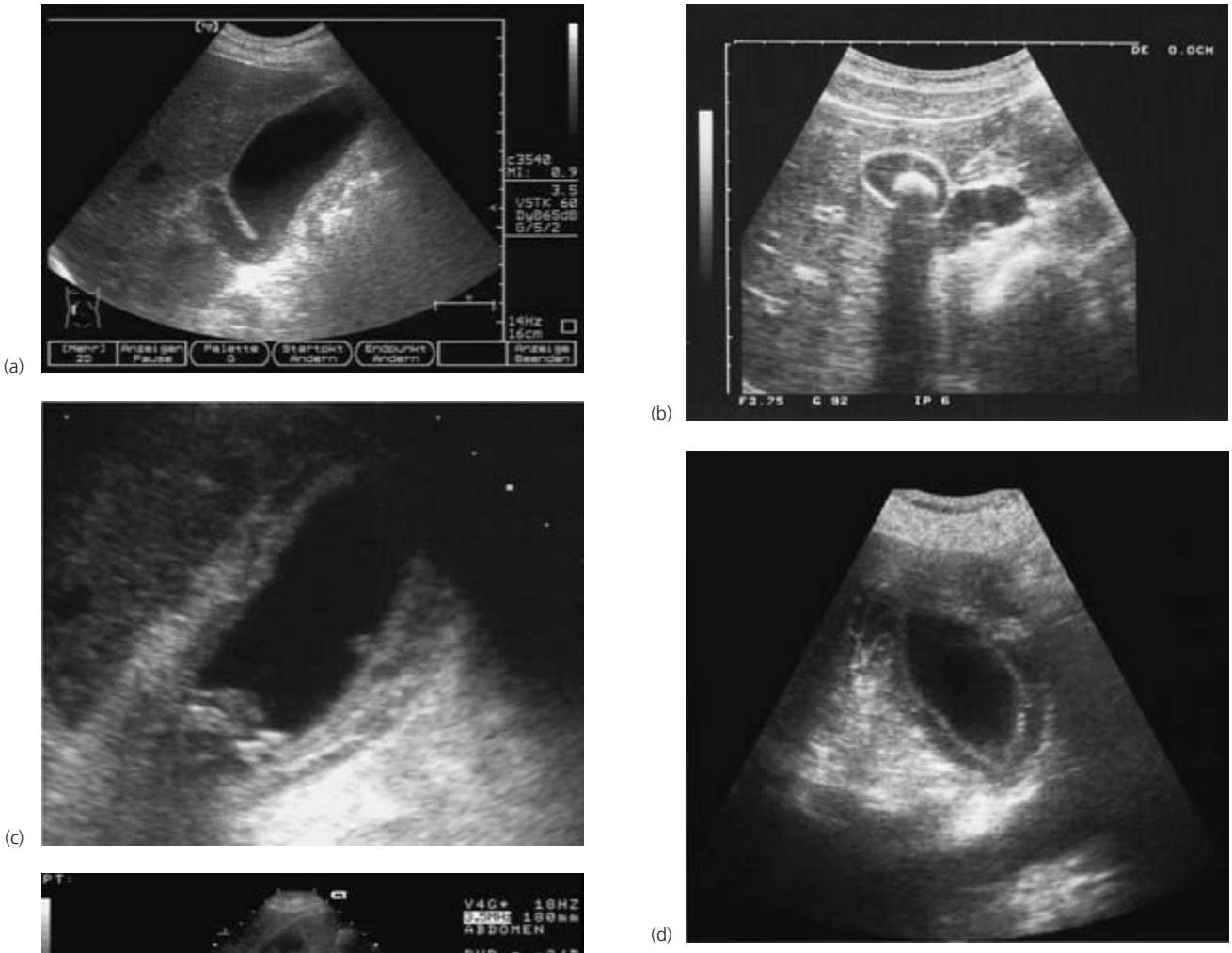

Fig. 3 Ultrasound appearance of biliary sludge, gallbladder stones and cholecystitis. (a) Biliary sludge. Sludge is defined as a mixture of particulate matter and bile that occurs when solutes in bile precipitate. Sludge is detected on ultrasound as low-amplitude echoes without acoustic shadowing, which layer in the most dependent part of the gallbladder and shift with positioning. (b) Solitary stone. The hyperechoic stone generates a characteristic dorsal acoustic shadowing. (c) Acute calculous cholecystitis. Thickening and stratification of the gallbladder wall and pericholecystic fluid collection indicate acute cholecystitis. (d) Acalculous cholecystitis diagnosed during mechanical ventilation for severe pneumonia. (e) Emphysematous cholecystitis. The hyperechoic reflexes represent gas bubbles in the gallbladder. Note the hypoechoic thickening of the gallbladder wall and the pericholecystic fluid collection. The diagnosis of acalculous cholecystitis was confirmed after open cholecystectomy.

bile by the gallbladder wall. Excess cholesterol in smooth muscle cells might stiffen sarcolemmal membranes and decouple the G protein-mediated signal transduction that usually ensues when CCK-A binds to its receptor, thereby paralysing gallbladder contractile function [18].

Nucleation and growth of cholesterol crystals in model biles *in vitro* are modulated by promoter and inhibitor proteins, which interact with vesicles and solid crystals respectively [19,20]. However, only gallbladder mucin – the main component of biliary sludge (Fig. 3a) – has been shown to promote stone formation *in vivo* (Fig. 1) [21]. Mucin is a mixture of sparingly soluble high-molecular-weight mucous glycoproteins that are secreted by biliary epithelial cells. In animals, aspirin and other non-steroidal anti-inflammatory drugs (NSAID) prevent the increase in biliary mucous glycoprotein induced by a lithogenic diet and stone formation [22], but the effects of aspirin or NSAID on bile composition in humans are controversial, and there is scant evidence that chronic aspirin/NSAID

ingestion affects the incidence of gallstones. Emerging experimental evidence indicates that enterohepatic bacteria and bacterial biofilms promote cholesterol crystallization, as well as the formation of sludge and gallstones [23].

Black pigment gallbladder stones

A small proportion of gallbladder stones are black pigment stones. These consist predominantly of polymerized calcium bilirubinate, which precipitates if the ion product of calcium and unconjugated bilirubin exceeds its solubility product and polymerizes slowly in biliary sludge.

Haemolytic anaemias or ineffective erythropoiesis are the most conspicuous sources of excess unconjugated bilirubin (Table 3). Another pathway involves ileal disease or resection that cause spillage of bile salts into the colon, which promotes solubilization and absorption of unconjugated bilirubin and results in increased enterohepatic cycling and biliary secretion of bilirubin [24,25].

The most common cause of gallstones containing calcium salts is a calcium carbonate saturation index > 1. The major underlying abnormality is a high pH in gallbladder bile, as calcium carbonate solubility changes dramatically when the pH of gallbladder bile increases slightly, such as in the setting of decreased ion secretion by the gallbladder mucosa [26].

Brown pigment bile duct stones

Brown pigment stones are mostly formed within the bile ducts as a consequence of bacterial infection and hydrolysis of glucuronic acid from bilirubin by bacterial β-glucuronidase. This results in decreased solubility of deconjugated bilirubin, ultimately leading to the formation of stones consisting of calcium salts of unconjugated bilirubin, deconjugated bile salts and varying amounts of cholesterol and saturated long-chain fatty acids. Many bile duct stones are mixed stones (cholesterol stones originating from the gallbladder with a pigment shell) (Fig. 2c).

Intrahepatic brown pigment stones are related to infestation with the parasites *Clonorchis sinensis* and *Ascaris lumbricoides* [27]. In western countries, intrahepatic gallstones tend to be associated with periampullary diverticula [28], Caroli syndrome, strictures, tumours and other ductal abnormalities causing biliary stasis and infection (Table 3). Bacteria are found in the bile in almost all patients with intrahepatic stones.

Calculous cholecystitis

Over 90% of patients with calculous cholecystitis (Fig. 3c) have an obstruction of the cystic duct by the impaction of sludge (Fig. 3a) or a gallstone in the gallbladder neck. The increased intraluminal pressure together with lithogenic bile triggers an inflammatory reaction within the gallbladder wall. In up to 50% of cases, a secondary bacterial infection (most commonly by *Escherichia coli*, *Klebsiella* and Enterococci) is observed [29].

Acalculous cholecystitis

Acalculous cholecystitis (Fig. 3d) develops in the absence of gallstones as a result of ischaemia and gallbladder stasis [30]. Acalculous cholecystitis is predominantly seen with an incidence of up to 3% in critically ill patients (multiple trauma, burns, sepsis, shock, mechanical ventilation, major surgery) or in patients with vascular disorders or interventions (atherosclerosis, vasculitis, embolization of hepatic tumours), but may also result from primary microbial infection of the gallbladder, both in immunocompetent (e.g. typhoid fever, leptospirosis, *Campylobacter jejuni*, *Listeria monocytogenes*) and in immunocompromised patients (e.g. *Salmonella enteritidis*, candida, cryptosporidium, cytomegalovirus) [29]. A particularly virulent form known as emphysematous cholecystitis is rare; it results from infection with gas-forming organisms (Fig. 3e).

Epidemiology

Gallstone prevalence ranges from 10% to 20% in the western world with considerable variation between different ethnic groups [1,2]. Gallstones are more frequent with increasing age and in young women. As determined by cross-sectional ultrasound surveys [1,31], prevalence rates of gallbladder stones show remarkable geographical variations. Gallbladder stones are common in most European countries, as well as in North and South America, but the prevalence is low in Asia and Africa. Environmental factors are likely to contribute to these marked differences. Data from several large epidemiological studies in the US, Europe, China and Japan implicate chronic overnutrition with refined carbohydrates and triglycerides as well as depletion of dietary fibre as environmental triggers for cholesterol gallstone formation (Table 3) [14]. Gallstone disease phenotypes are likely to result from the complex interaction of genetic factors, high-carbohydrate, high-fat and low-fibre diets [32] and other not fully defined environmental factors including low physical activity (Table 3) [2,33]. This hypothesis is supported by the profound increases in cholesterol gallstone prevalence rates in Native Americans, postwar European countries and current urban centres in East Asia, all of which were associated with the introduction of high-caloric 'westernized' diets [14,32].

However, a cholesterol-rich diet significantly induces lithogenic bile only in gallstone carriers but not in stone-free control subjects [34], indicating that intestinal cholesterol absorption [35] and/or biliary cholesterol secretion are in part genetically determined. Such genetic factors are probably contributing to the extraordinarily high prevalence of gallstones in American Indian populations in both North and South America. A recent ultrasound survey in 13 American Indian tribes [36] found cumulative stone prevalence rates of 64% in American Indian women and 30% in men, even though their total caloric intake is comparable to that of white Americans. The Pima Indians of Arizona have the highest recorded prevalence

rate for gallstones [37]. Pima women develop supersaturated bile around the age of puberty; by the age of 25–30 years, most have borne several children and up to 80% have developed gallstones. It has been speculated that the wide distribution of genes conferring gallstone susceptibility in American Indians might be related to 'thrifty' genes that conferred survival advantages when Palaeo-Indians migrated to the Americas during the last Great Ice Age [50 000–10 000 years ago) [38]. This speculation is driven by the epidemiological associations of gallstones with obesity and type 2 diabetes mellitus, both of which might be caused by 'thrifty' genes [14,38]. The main pathophysiological link appears to be biliary hypersecretion of cholesterol owing to persistently increased cholesterol synthesis in obese and hyperinsulinaemic patients (Table 3) [1].

In the Third National Health and Nutrition Examination Survey [39], the highest age-standardized gallstone prevalence was seen in Mexican American women (27%), followed by white (17%) and African American women (14%). These differences can be attributed to the American Indian heritage of Mexican–Americans. This 'admixture hypothesis' is supported by a genetic study from Chile [40], which assessed the degree of admixture by mitochondrial DNA (mtDNA) in Mapuche Indians, Easter Island Maoris and Hispanics. The prevalence of gallstone disease was highest (35%) in Mapuches, who migrated from North America (100% American Indian mtDNA), intermediate (27%) in Hispanics (88% American Indian mtDNA) and still 21% in Maoris, who originate from Polynesia (0% American Indian mtDNA) and in whom obesity appears to be a major environmental factor causing gallstones.

Genetics

Twin studies

A large study in Swedish twins provided strong evidence for a role of genetic factors in gallstone pathogenesis [41]. The Swedish Twin Registry was linked with the inpatient discharge and causes of death registries for symptomatic gallstone disease and gallstone surgery-related diagnoses in 43 141 twin pairs born between 1900 and 1958. Concordance rates were significantly higher in monozygotic compared with dizygotic twins for both genders. Genetic factors accounted for 25% [95% confidence interval (CI) 9–40%], shared environmental effects (e.g. diet in childhood) for 13% (CI 1–25%) and individual environmental effects for 62% (CI 56–68%) of the phenotypical variation among twins, as estimated by structural equation modelling [41].

To investigate biliary lipid compositions in twins, 35 male pairs were randomly selected from the Finnish Twin Cohort [42]. Serum levels of methylsterols, which reflect hepatic cholesterol synthesis, and biliary concentrations of deoxycholate showed significant correlations in monozygotic but not dizygotic twins. These findings are consistent with the concept that genetic factors determine biliary lipid secretion.

Family and linkage studies

Ultrasound surveys have documented that gallstones are two to four times more common in first-degree relatives of gallstone patients compared with age-matched stone-free control subjects [14]. Duggirala *et al.* [43] employed variance component analysis in Mexican–American families to assess the genetic determinants of symptomatic gallbladder disease. Heritability for gallbladder disease was high (26–77%) and comparable to the heritability of type 2 diabetes mellitus and obesity [43,44]. In the recent follow-up study [44], a genome-wide scan for gallstone susceptibility loci in 715 individuals, employing genetic markers at an average distance of 10 cM, detected significant genetic linkage (LOD scores 3.4–3.7] for symptomatic cholelithiasis on human chromosome 1p [44]. Another variance component analysis in 358 families in Wisconsin, each of which contained at least two obese siblings, determined that the heritability of symptomatic gallstones is 29 ± 14% [45], which is similar to the figure obtained in the Swedish twin study [41].

Monogenic cholelithiasis

Despite accumulating evidence that gallstone formation is genetically determined in humans, direct confirmation of the role of individual genes in human gallstone disease is sparse. In small groups of patients with gallstones, monogenic predisposition has been ascribed to mutations in the genes that encode the ABC transporters for phosphatidylcholine (*ABCB4*) or bile salts (*ABCB11*), cholesterol 7α-hydroxylase (*CYP7A1*), the CCK-A receptor (*CCKAR*) and the cystic fibrosis gene (*CFTR*) (Table 1).

The first evidence that a single gene defect causes gallstone formation in a defined subgroup – young patients with a recurring form of cholelithiasis – was provided by Rosmorduc *et al.* [46]. The group performed a mutation search in the *ABCB4* gene in patients with cholesterol gallbladder stones and intrahepatic sludge or microlithiasis, recurrence of biliary symptoms after cholecystectomy, positive family history and mild chronic cholestasis and/or intrahepatic cholestasis of pregnancy; point mutations were identified in 18 out of 32 patients (56%) [46]. These findings are clinically relevant, as asymptomatic carriers might benefit from prevention with ursodeoxycholic acid (UDCA) [46]. The pathophysiological basis of the ABCB4 deficiency syndrome is consistent with the spontaneous occurrence of cholecystolithiasis in *Abcb4* knockout mice [47].

Homozygous *ABCB4* mutations that lead to complete absence of the phospholipid transporter and virtually no secretion of phospholipids into bile result in progressive familial intrahepatic cholestasis (PFIC) type 3 and early liver cirrhosis in childhood. PFIC type 2 is caused by mutations in the bile salt export pump gene *ABCB11*. A subgroup of patients with benign recurrent intrahepatic cholestasis (BRIC), who display intermittent attacks of cholestasis without progression to liver cirrhosis,

have *ABCB11* mutations [48]. The majority of *ABCB11*-affected BRIC patients (65%) develop gallstones [48].

Pullinger *et al.* [49] proposed an association between another single gene defect and gallstone formation. Gallstone patients with homozygous deficiency of cholesterol 7α-hydroxylase (*CYPA1*) display hypertriglyceridaemia and hypercholesterolaemia, but faecal bile salt excretion is markedly deficient [49]. Recently, a Chinese association study [50] demonstrated that a common single nucleotide polymorphism (SNP) within the *CYP7A1* promoter is associated with increased LDL cholesterol levels and gallstones. Furthermore, similar to *ABCB4* and *ABCB11* deficiency, the relevance of *CYP7A1* for gallstone pathogenesis has been demonstrated in *CYP7A1* transgenic mice, which are resistant to stone induction by a high-fat/high-cholesterol diet [51].

In contrast to CYP7A1 deficiency, familial hypobetalipoproteinaemia due to mutations in the *APOB* gene might also be associated with cholesterol gallstone formation, which could result from increased cholesterol secretion as a compensatory mechanism to eliminate cholesterol not incorporated into ApoB-containing VLDL [52]. Of note, significant associations between a common polymorphism in exon 26 and cholesterol gallstone prevalence, as well as increased total cholesterol, LDL cholesterol and ApoB concentrations in serum, have been detected in two Chinese studies [50,53]. However, the lipid profile is not typical of cholesterol stone patients [14], and the association could not be detected in a Finnish population [54] and a study from India [55].

Altered CCK-AR structure has been associated with gallstone formation in isolated cases of gallstones [56,57]. Although further screening did not detect mutations in the coding region of the *CCKAR* gene in patients with gallstones [58,59], the link between *CCKAR* and gallstones is supported by *Cckar* knockout mice [18,59]. These mice display profound gallbladder hypomotility and prolonged small intestinal transit times [18], resulting in increased cholesterol absorption.

Single gene mutations causing haemolytic anaemias (hereditary spherocytosis, *ANK1*, *EPB42*, *SPTA1*, *SPTB*, *SLC4A1*; sickle cell disease, *HBB*; thalassaemia major and intermedia, *HBB*; and erythrocyte enzyme deficiencies, *AK1*, *G6PD*, *GPI*, *GSR*, *PGK1*, *PKLR*, *TPI1*) and thus increased biliary bilirubin concentrations are well documented (for gene abbreviations, see OMIM database at http://www.ncbi.nlm.nih.gov/entrez). In addition to these gene defects, in which black pigment stones are to be expected, there are also genes that predispose to increased enterohepatic cycling of bilirubin, another cause of pigment stone formation [25]. Such a gene defect that is associated with pigment stone formation is cystic fibrosis. Gallstone prevalence in cystic fibrosis is 10–30% compared with < 5% in age-matched control subjects, but biliary cholesterol saturation does not differ between patients with and without gallstones [25]. Experimental findings in mice with mutations in the *CFTR* gene indicate that enterohepatic cycling, as well as biliary secretion and deconjugation of bilirubin, is increased in cystic fibrosis.

Polygenic cholelithiasis

In humans, the identification of lithogenic genes is hampered by the multifactorial pathogenesis of gallstones, so cross-breeding experiments in inbred mouse strains that differ in genetic susceptibility to cholesterol gallstone formation have been used to identify the genetic factors that contribute to gallstone formation. The mouse model is based on a lithogenic diet that contains 15% fat, 1% cholesterol and 0.5% cholic acid, which promotes intestinal absorption and biliary secretion of cholesterol [14,16,60]. Using quantitative trait locus (QTL) analysis [14,16,60] and *in silico* association mapping [61], more than 20 murine gene loci for gallstone susceptibility (*Lith* genes) and several candidate genes (ABC transporters, NRs, mucins) have been identified (for updates, see http://pga.jax.org/qtl).

However, detailed analyses of human *LITH* genes have yet to be performed. Only *APOE* polymorphisms have been extensively investigated in human gallstone disease. ApoE is the high-affinity ligand for the hepatic LDL receptor and the LDL receptor-related protein. There are three common codominant *APOE* alleles (*ε2*, *ε3* and *ε4*), and the six resulting ApoE isoforms (E2/E2, E3/E3, E4/E4, E2/E3, E2/E4, E3/E4) can be distinguished by isoelectric focusing. These isoforms cause differences in receptor binding affinities and clearance rates of circulating lipoproteins. The presence of the *ε4* allele has been associated with conditions such as coronary heart disease and Alzheimer's disease, and Bertomeu *et al.* [62] showed that the *ε4* allele is also associated with cholelithiasis. The ApoE2 isoform, in contrast, was found less frequently in women with gallstones than in control subjects [63]. In line with these findings, *Apoe* knockout mice show a markedly lower frequency of gallstones than wild-type controls upon challenge with a high-cholesterol diet [64]. The association between gallstones and *APOE* could be due to increased hepatic cholesterol uptake via chylomicrons in patients carrying the isoform ApoE4; alternatively, biliary ApoE might have a role in the destabilization of bile [1,62]. However, recent studies failed to confirm the association between gallstones and ApoE isoforms (reviewed in [1]). Different ethnicities with lower gallstone prevalence rates and the inclusion of younger control probands might explain the discrepancies, as the *ε4* allele frequency is low in Asian populations and decreases with age. Of note, other studies showed a higher *ε4* allele frequency in patients with cholesterol stones than in patients with pigment stones [65], and a higher stone recurrence rate within 7 years after extracorporeal shock wave lithotripsy (ESWL) in *ε4* carriers (73% vs. 50%) [66]. Screening for carriers of common ApoE variants cannot be recommended on the basis of the current association studies and does not guide therapy.

Clinical presentation

Cholecystolithiasis

Cholecystolithiasis is asymptomatic in 60–80% of patients

Table 4 Clinical presentation of cholelithiasis.

Asymptomatic cholecystolithiasis
60–80% of gallstone carriers
Frequency of symptoms
1–6%/year in asymptomatic gallstone carriers
6–69%/year in symptomatic gallstone patients
Frequency of complications
0.1–0.3%/year in asymptomatic gallstone carriers
1–3%/year in symptomatic gallstone patients

[67,68]. Stones within the gallbladder may cause biliary pain; they may lead to acute cholecystitis and empyema or cause cystic duct obstruction. Biliary colic due to intermittent obstruction of the cystic duct by a gallstone is defined as a steady localized pain in the mid-epigastrium or the right upper abdomen, which may radiate to the right shoulder tip or the right scapular region, because of shared sensory innervation; it typically lasts longer than 15 min and may be accompanied by nausea and/or vomiting.

In prospective studies of asymptomatic stone carriers, biliary pain developed at a rate of 2–6% per year during the first 5 years; afterwards, the frequency of symptoms was 1–3% per year (Table 4). The overall incidence was 15–26% at 10 years [67,69–71]. Complications (cholecystitis, biliary obstruction, ascending cholangitis, pancreatitis) develop in 1–4% of asymptomatic stone carriers during 4–20 years of follow-up, resulting in a low complication rate of 0.1–0.3% per year (Table 4) [68–70].

Once an episode of biliary pain has occurred, the risk of repeated attacks or symptoms ranges from 6% to 69% (Table 4), most of which occur in the first year and are preceded by episodes of biliary pain [68,72]. Abdominal discomfort following fatty meals may have a similar predictive value [73]. Characteristic biliary pain is an indicator of an elevated risk of biliary complications. More than 90% of patients with complications have experienced biliary colic before. The incidence of complications in these symptomatic patients is 1–3%, which represents a 10-fold higher risk compared with asymptomatic stone carriers (Table 4) [68,70,74]. The risk of developing additional complications after the first complication is 10% in the first 4 weeks and 30–50% within 1 year. After 5 years without symptoms, the risks of biliary colic or complications are as low as those of asymptomatic stone carriers [68].

Patients with gallbladder hypomotility and obese patients develop symptoms and complications more often (Table 3) [68,75,76]. The risk of acute cholecystitis is higher in patients with solitary stones, whereas the risk of acute pancreatitis is higher in patients with small multiple stones and preserved gallbladder motility [77].

Acute cholecystitis

Cholecystitis typically causes a worsening biliary pain lasting longer than 5 hours. It is located in the right upper quadrant and accompanied by signs of inflammation such as fever, chills, or – in severe cases – signs of sepsis. There may be mild jaundice if the inflammatory process extends to the common bile duct and impairs bile flow. On examination, physical signs of right-sided peritoneal irritation with varying degrees of tenderness, and pain to palpation in the right upper quadrant (Murphy sign) may be present and have a sensitivity and specificity of 65% and 87% respectively [73].

Chronic cholecystitis

The symptoms and signs of chronic cholecystitis can be vague and non-specific. Typically, they include right upper quadrant abdominal pain or discomfort, often following a heavy meal. Other much less specific symptoms include feelings of bloating, distension and excessive flatulence. Clinical signs are usually absent, although occasionally there may be some tenderness in the right upper quadrant, and a palpable gallbladder may be found, if a stone blocks the cystic duct.

Chronic cholecystitis and cholecystolithiasis *per se* are associated with an increased risk of gallbladder cancer. Most patients with gallbladder cancer are older than 60 years, and 70–90% of patients have concurrent gallstones. However, as the absolute incidence of gallbladder cancer is low, the small risk does not justify prophylactic cholecystectomy in general [78].

Choledocholithiasis

About 10–25% of patients with gallbladder stones have associated choledocholithiasis at cholecystectomy [79]. Vice versa, 95% of patients with bile duct stones have concurrent gallbladder stones. Bile duct stones can exist in the common duct for months or years without symptoms and without any abnormality in liver function tests even when the bile duct is completely obstructed and markedly dilated. Their presence may only become obvious if they obstruct the bile duct and cause pain, jaundice, abnormal liver function tests or cholangitis. The natural history of choledocholithiasis is not well defined. Although complications are more common and more severe compared with symptomatic cholecystolithiasis [80], it has been assumed that 50% of the stones remain asymptomatic [81], but this rate could be even be higher than 50% [82]. Longstanding choledocholithiasis may lead to secondary biliary cirrhosis and bile duct carcinoma.

Other complications of gallstone disease associated with inflammatory changes are rare: thus, a stone impacted in the cystic duct may produce intermittent obstruction of the common bile duct (Mirizzi syndrome), and gallstones can erode the gallbladder wall resulting in a biliary fistula with or without subsequent duodenal obstruction (Bouveret syndrome) or gallstone ileus [83].

Intrahepatic gallstones

Intrahepatic gallstones are defined as stones found in any of the bile ducts proximal to the junction of the left and right hepatic

ducts [84]. Intrahepatic gallstones are common in the Far East, where they constitute up to 50% of all cases of cholelithiasis.

Patients with intrahepatic stones experience few symptoms if bile flow is not disturbed and if there is no biliary infection. The most common initial symptom is pain in the right upper quadrant or upper abdomen, followed by jaundice and fever. Lethargy, nausea and vomiting may also occur.

Diagnostic methods

Cholecystolithiasis and choledocholithiasis

Physical examination during an episode of biliary pain may reveal right upper quadrant tenderness, but it is usually normal between the attacks. Blood chemistry will be normal in the majority of patients, but may show increases in serum bilirubin, alkaline phosphatase and γ-glutamyltransferase in the case of biliary obstruction. There is usually a modest elevation in serum aminotransferases but, in some patients with acute obstruction, the aminotransferase levels can be very high (> 1000 U/L). Indeed, biliary obstruction due to gallstones is a relatively common cause of a marked elevation in aminotransferase levels in general clinical practice. This may lead to an erroneous diagnosis of viral hepatitis – a diagnostic error, particularly when cholangitis is present, as it delays antibiotic therapy and drainage of the bile duct. In cholangitis, signs of inflammation (fever, leucocytosis) may be seen, and blood cultures may become positive.

Transabdominal ultrasound examination (Table 5, Fig. 3) is the most common and accurate method of detecting gallbladder stones, having a sensitivity of 97% and a specificity of 95% [85]. Ultrasound can also be employed to determine gallbladder volume and assess gallbladder motility [77], using the formula for the volume of an ellipsoid [volume (mL) = 0.52 × sagittal × transversal × longitudinal diameter (cm)]. If the gallbladder of a fasted patient contracts normally, the volume should decrease by at least 60% 30 min after a standardized liquid meal. Common bile duct stones may be visualized by ultrasound but, in the majority of patients, only indirect evidence, such as the presence of dilated bile ducts together with gallbladder stones, can be obtained [86].

Table 5 Diagnostic methods for gallstones.

Cholelithiasis/cholecystitis
Routine blood tests including blood cultures
Transabdominal ultrasound
Computerized tomography
Bile duct stones/cholangitis
Routine blood tests including blood cultures
Transabdominal ultrasound
ERC (PTC) in patients with high suspicion of bile duct stones
MRC in patients with low suspicion of bile duct stones or inaccessibility of bile ducts
Endoscopic ultrasound
Computerized tomography

Both endoscopic retrograde cholangiography (ERC) and endoscopic ultrasound have the highest sensitivity and specificity (> 90%) for the detection of bile duct stones [87,88]. ERC is the preferred diagnostic method in patients with a high suspicion for choledocholithiasis (Figs 4 and 5a), as it allows subsequent therapeutic intervention. Magnetic resonance cholangiography (MRC) has a sensitivity and specificity of 90–95% for the detection of common bile duct stones > 5mm (Fig. 5b) [89] and is well suited for ruling out bile duct stones in patients with intermediate clinical suspicion (Fig. 4). Computerized tomography (CT) has its role in the workup of abdominal pain or acute abdomen (Fig. 4). Finally, intraoperative cholangiography might be performed in patients who undergo cholecystectomy, but this approach is probably inadequate as less than 4% of patients harbour unidentified stones [90]. When intrahepatic gallstones

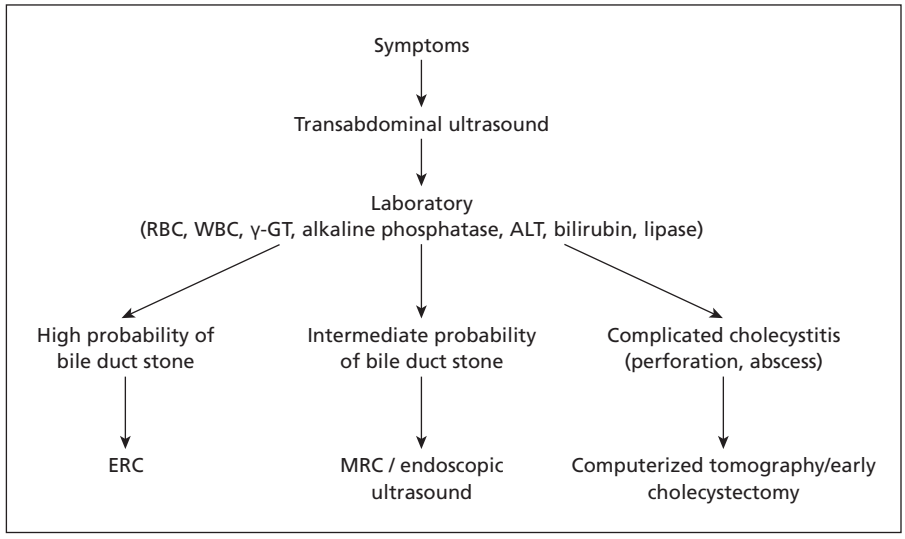

Fig. 4 Diagnostic algorithm for patients with suspected biliary colic. ALT, alanine aminotransferase; γ-GT, γ-glutamyltransferase; RBC, red blood cell; WBC, white blood cell.

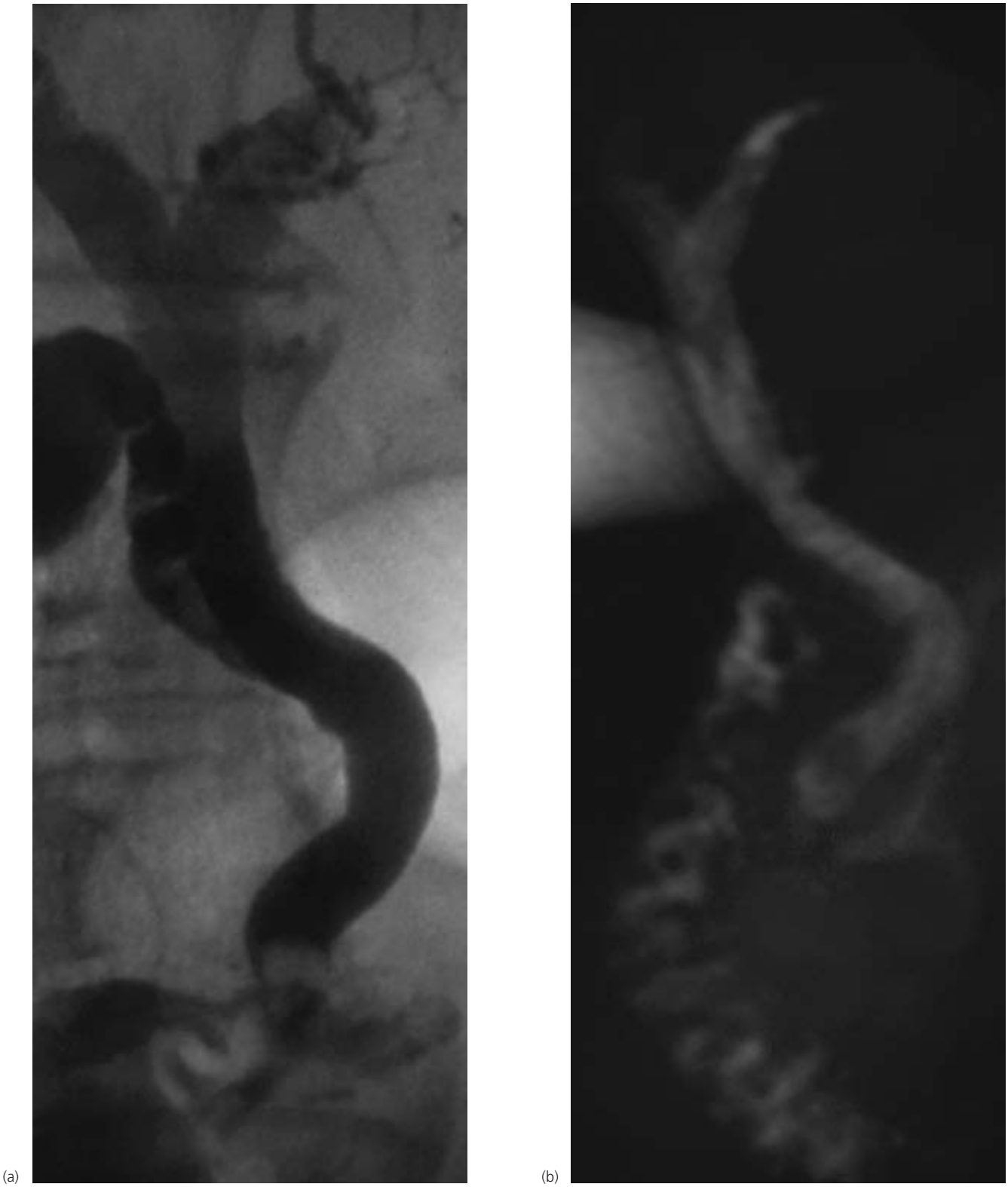

Fig. 5 Endoscopic retrograde cholangiography (ERC) and magnetic resonance cholangiography (MRC) of a common bile duct stone. The intraductal stone can be clearly visualized by both ERC (a) and MRC (b).

are suspected, the best diagnostic techniques are ultrasound, MRC and percutaneous transhepatic cholangiography (PTC), which gives a diagnosis in 97%, compared with 87% with ERC and 81% with CT [91,92].

Cholecystitis

Blood chemistry will show signs of inflammation and possibly of cholestasis; aerobe and anaerobe blood cultures may become positive [30]. Transabdominal ultrasound (Fig. 3c) is a very useful diagnostic tool for acute cholecystitis [73,93]. Typical findings are gallbladder distension, halo sign of subserosal oedema and thickening of the gallbladder wall (> 4 mm), which, however, may also be present in patients with ascites or hypalbuminaemia. It may be possible in an acutely inflamed gallbladder to elicit an 'ultrasound Murphy sign', where marked tenderness is provoked by pressure with the probe over the inflamed organ; this sign has a sensitivity > 90% and a specificity > 80%. Emphysematous cholecystitis may present with gas bubbles (Fig. 3e). However, in critically ill patients, ultrasound is less reliable, and CT scans might be required in patients with a high suspicion of cholecystitis [94,95].

Differential diagnosis

Cholecystolithiasis and choledocholithiasis

Gallbladder stones have to be discriminated from cholesterolosis ('cholesterol polyps'). In this benign condition, triglycerides and cholesterol esters are incorporated in macrophages in the gallbladder wall and, if these project into the lumen, they produce the macroscopic change known as a 'strawberry gallbladder' [96]. Typically, cholesterol polyps cannot be shifted by positioning during transabdominal ultrasound examination.

The differential diagnosis of recurrent abdominal pain comprises a large number of possible diseases (Table 6). In addition to the biliary tract, abdominal pain may originate from the chest, stomach, small intestine, colon, pancreas, kidneys, uterus or ovaries. Moreover, ischaemia, neurogenic (e.g. *Herpes zoster*) or musculosketetal pain should be considered. Jaundice and pain suggest choledocholithiasis, while painless jaundice favours liver disease or malignant biliary obstruction.

Cholecystitis and cholangitis

The major differentials of cholecystitis or cholangitis include acute problems arising above the diaphragm (from the heart, lungs or pleura) or within the abdomen as a result of acute pancreatitis, perforated peptic ulcer, acute appendicitis, pyelonephritis or stones in the right kidney (Table 6).

Diagnosis of acalculous cholecystitis in critically ill patients is notoriously difficult, and thus a high grade of suspicion of cholecystitis as a possible focus in patients with sepsis of unknown cause is required [94].

Table 6 Differential diagnosis of epigastric pain.

Symptomatic cholecystolithiasis/acute cholecystitis
Choledocholithiasis/acute cholangitis
Acute/chronic pancreatitis
Kidney stone/acute pyelonephritis
Peptic ulcer disease
Acute appendicitis
Hepatic abscess
Acute myocardial infarction
Basal pneumonia with pleuritis

As the symptoms of chronic cholecystitis are vague and variable, differential diagnosis in these patients includes diseases of practically all abdominal and thoracic organs, as well as problems arising from the spine.

Primary prevention of gallbladder stones

Primary prevention strategies are summarized in Table 7 [1]. For specific conditions that are associated with an increased gallstone risk, such as rapid weight loss or total parenteral nutrition, gallstone formation can be prevented by UDCA (at least 500 mg/day) [97] or early enteral nutrition respectively. Administration of CCK (50 ng/kg/day i.v.) [98] or motilin agonists such as erythromycin or clarithromycin (500–600 mg) might also have protective effects in the latter setting [99].

Therapeutic strategies

Asymptomatic cholecystolithiasis

Asymptomatic cholecystolithiasis is not an indication for cholecystectomy, as the risk of complications from surgery outweighs the advantage of preventing possible complications from asymptomatic gallbladder stones including gallbladder cancer. Expectant management is also the best strategy for kidney and/or pancreas transplant recipients [100], whereas a recent decision analysis [101] indicated that prophylactic posttransplantation cholecystectomy might be preferred for cardiac transplant patients, in particular for diabetic patients [102]. There are some additional situations that require discussion of prophylactic cholecystectomy in patients with asymptomatic gallbladder stones.

The prevention of gallbladder cancer may be an indication for cholecystectomy in asymptomatic patients with gallbladder stones > 3 cm (up to 10-fold increased risk for gallbladder cancer), in those with polyps > 10 mm (cancer risk 3–6% in patients > 60 years) or patients with a calcified gallbladder (cancer risk up to 20%) [103–108].

Table 7 Prevention of cholesterol gallstone disease.[a]

Intervention	Evidence grade[b]	Potential mechanisms
Physical activity (> 10 metabolic equivalent h/week; 2–3 h jogging or cycling reduce the risk by 20–40%)	1	Colonic transit time ↓ ⇒ intestinal bile salt dehydroxylation ↓ Gallbladder motility ↑
Slow weight reduction in obesity (< 1 kg/week; risk reduction from 28% to 8% during weight loss of > 25% in 4 weeks)	1	Biliary cholesterol secretion ↓
Ursodeoxycholic acid during rapid weight loss (600 mg/day reduces the risk from 28% to 3% during weight loss of > 25% in 4 months)	1	Biliary cholesterol secretion ↓ Formation of liquid crystals increases cholesterol solubility in gallbladder bile Intestinal cholesterol absorption ↓
CCK-octapeptide (50 ng/kg/day i.v.) during total parenteral nutrition	2	Gallbladder motility ↑
Supplementation of low-caloric diet with long-chain triglycerides (15–25 g/day)	2	Gallbladder motility ↑

[a]Adapted from ref. 1.
[b]Evidence was graded according to the US Preventive Services Task Force ratings.

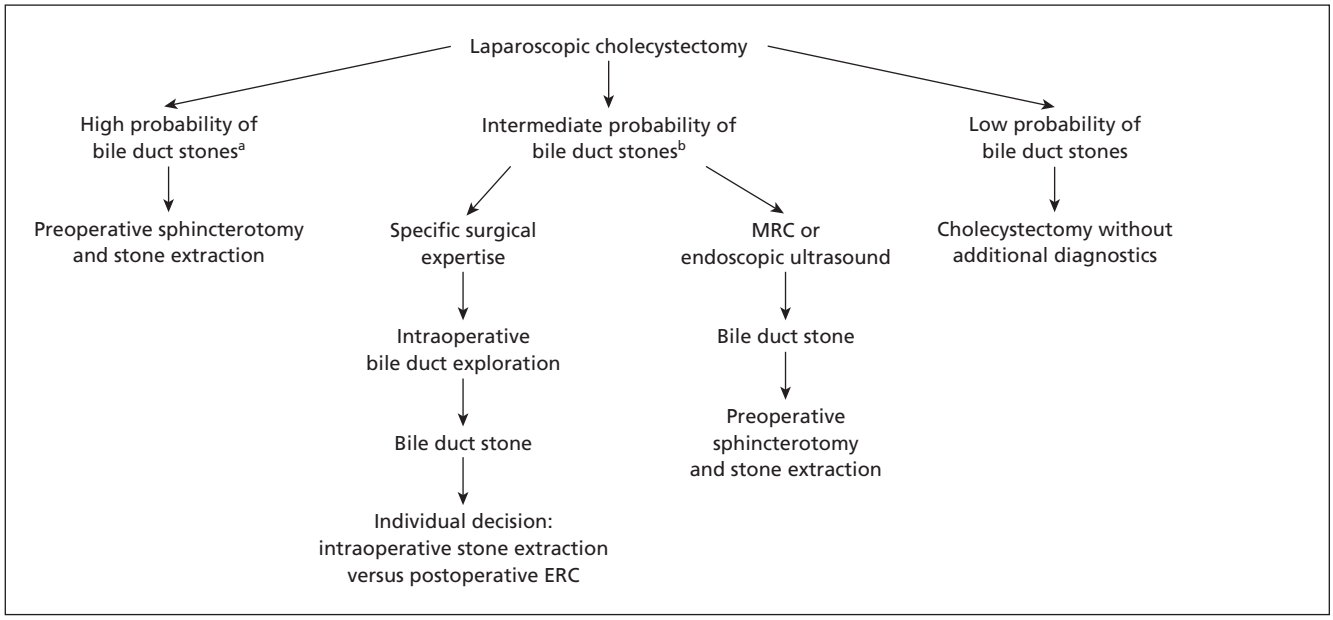

Fig. 6 Therapy of symptomatic gallbladder and bile duct stones.
[a]Criteria for high probability of concurrent bile duct stones: major: hyperbilirubinaemia, bile duct dilatation (ultrasound); minor: elderly, multiple small gallbladder stones, pancreatitis.
[b]Criteria for intermediate probability of concurrent bile duct stones: moderately elevated or decreasing serum lipase activities without concurrent hyperbilirubinaemia, moderately elevated γ-glutamyltransferase or alkaline phosphatase without bile duct dilatation.

Symptomatic cholecystolithiasis

Emergency treatment of biliary colic is accomplished with spasmolytics (e.g. N-butyl-scopolamin 40 mg i.v.) and NSAIDs (e.g. metamizol 1 g i.v., diclofenac 50 mg p.o.) [109].

Cholecystectomy

Preferably by the laparoscopic approach (see Fig. 6), this should be performed to avoid the high rate of recurrence and the 1–3% annual risk of complications from gallstone disease [68,70,72,74]. With laparoscopic cholecystectomy, the incidence

of postoperative pain and complications, such as chest and wound infections, is lower than following open surgery. Moreover, most patients undergoing laparoscopic cholecystectomy spend less time in hospital and have a shorter period of convalescence, and patient satisfaction following the laparoscopic approach to cholecystectomy is good mainly because they are left with fewer and less visible scars. The results of recent surveys show that the prevalence of bile duct injury is not increased after laparoscopic cholecystectomy compared with the open abdominal approach [110]; bile duct injuries occur in 0.25–0.56% of cholecystectomies. Bile duct injuries comprise small biliary leaks closing spontaneously, biliary strictures, which may be managed by endoscopic stent insertion, and large leaks or complete biliary obstruction usually requiring surgical revision. Mortality rates following cholecystectomy range from less than 0.1% in clinical studies [111] to 0.7% (as documented for all cholecystectomies performed in Germany in 2004) [4].

Oral litholysis

More than 20 years ago, several studies investigated non-surgical treatment options for symptomatic gallbladder stones. Based on the physical–chemical principles of cholesterol gallstone formation [6,9], small (< 5 mm) non-calcified cholesterol stones (Table 1) can be successfully dissolved with oral administration of UDCA (10–15 mg/kg/day) [112,113]. UDCA, which comprises < 10% of the physiological bile salt pool, decreases biliary cholesterol secretion, increases the solubility of cholesterol by the formation of liquid crystals and reduces intestinal cholesterol absorption [1,112]. Alternatively, chenodeoxycholic acid, which causes more side-effects [114], or the combination of both bile salts have been used for oral litholysis [113].

As stone diameter decreases on average by only 0.7 mm/month [115], oral litholysis takes several months. For ideal patients, stone clearance rates of 70–80% were reported [113,116]. Significant side-effects were not observed with UDCA, except for transient diarrhoea in 10% of patients. However, follow-up studies demonstrated that stones recur in 10% of patients, and recurrence rates exceed 50% after 5 years [117–119].

Extracorporeal shock wave lithotripsy (ESWL)

ESWL for gallstones was pioneered in the 1980s at the University of Munich [120,121]. The aim of ESWL was to fragment larger stones, so that spontaneous stone clearance or oral litholysis is possible [120]. The original machine used an underwater spark-gap generator; the sudden evaporation of water caused shock waves, which were focused on to the target stones with a semi-ellipsoid reflector. The newer machines, which require no anaesthesia or analgesia, operate on the basis of an array of piezoelectric crystals, electrohydraulic lithotripters or an electromagnetically activated metal membrane [122,123].

The rate of complete fragment clearance 9–12 months after ESWL is 76–85% [124–126]. The best results are obtained for patients with a well-contracting gallbladder [127] and stones < 2 cm with CT attenuation values < 84 HU [126,128]. However, up to 36% of patients experience biliary pain, and the recurrence rate is as high as 31–60% after 5 years and 80% after 10 years [66,124–126,129,130]; complications of ESWL include acute pancreatitis (2%) and transient cholestasis (1%) [124].

Owing to the advantages of laparoscopic cholecystectomy, non-surgical approaches have lost their impact on therapy. Only in a very few selected patients with infrequent and mild gallstone-related symptoms and small non-calcified stones who do not wish to undergo an operation is an attempt with UDCA justified.

Choledocholithiasis

Choledocholithiasis is an indication for treatment, probably also in asymptomatic stone carriers, as complications are more severe than in cholecystolithiasis. The treatment algorithms depend on stone localization, the presence of complications (acute cholangitis, biliary pancreatitis) and history of previous cholecystectomy. In the last case, patients undergo endoscopic stone extraction after sphincterotomy.

In the majority of patients, cholecysto- and choledocholithiasis coexist and three different options are available: (i) strict surgical treatment with (laparoscopic) cholecystectomy and bile duct exploration [131–133]; (ii) strict therapeutic splitting with endoscopic removal of bile duct stones followed by (laparoscopic) cholecystectomy, which is the standard of care for most patients with acute cholangitis and biliary pancreatitis; or (iii) flexible splitting, e.g. intraoperative or postoperative splitting [134,135].

While the combined surgical approach has the advantage of subjecting the patient to just one procedure, laparoscopic duct exploration is technically demanding and time consuming. On the other hand, sphincterotomy and endoscopic bile duct clearance with standard equipment (Dormia basket and balloon) are successful in over 90% of patients. The complication rate of sphincterotomy ranges from 4% to 20% and was 16% in prospective studies [136]. The major complications are pancreatitis (1–2%), bleeding (2–3%) and duodenal perforation. Mortality rates up to 1% have been reported [136–138]. In a study of 540 patients who underwent ERC in our department, complications occurred in 7% of the procedures, and the mortality rate was 0.2% [139].

Treatment options for difficult stones include mechanical lithotripsy (Fig. 7), laser lithotripsy, electrohydraulic lithotripsy and ESWL (Fig. 8). Factors that predict failure of mechanical lithotripsy are not absolute stone diameter but stone impaction in the bile duct [140] and stone size in relation to bile duct diameter. All transpapillary approaches can also be performed via a percutaneous access with similar success rates. We employ ESWL to fragment very large bile duct stones [141]. For ESWL, a nasobiliary catheter is inserted for localization of the stones and control of fragmentation (Fig. 8). The question of which method should be used depends on local expertise. ESWL might be somewhat less efficient than laser lithotripsy or electrohydraulic

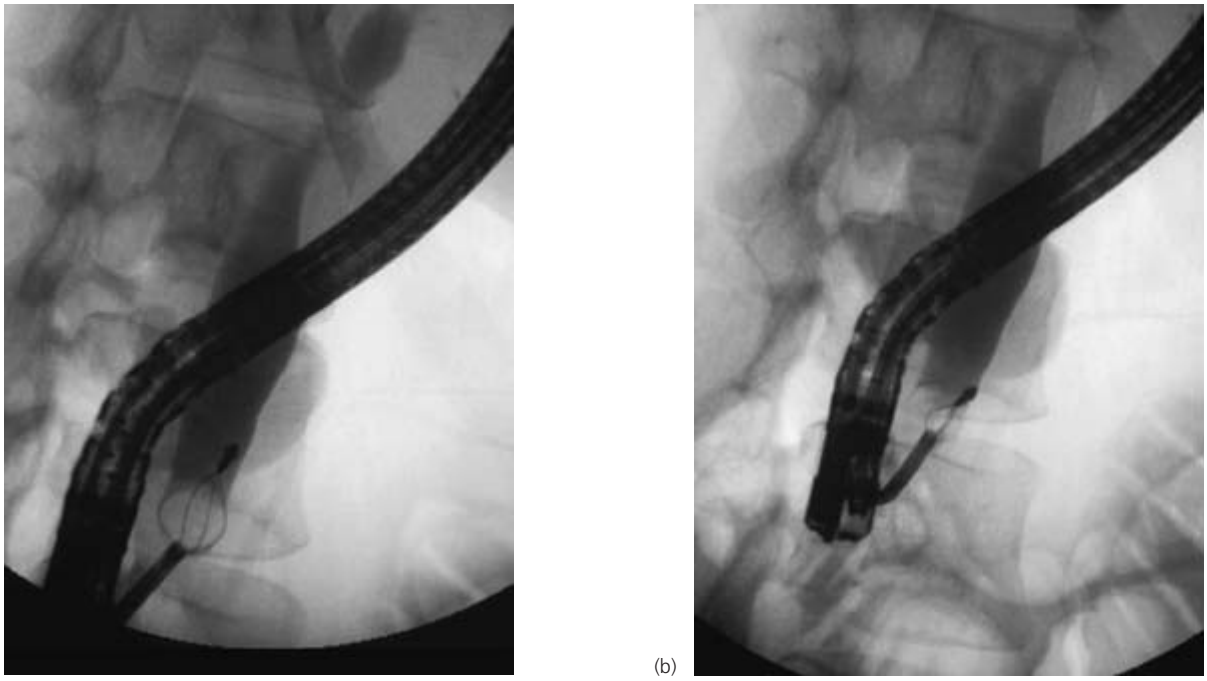

(a) (b)

Fig. 7 Mechanical lithotripsy of a stone in the common bile duct during ERC. (a) The stone is detected in the dilated common bile duct; lithotripter *in situ*. (b) Fragmented stone after lithotripsy; clearance of the common bile duct.

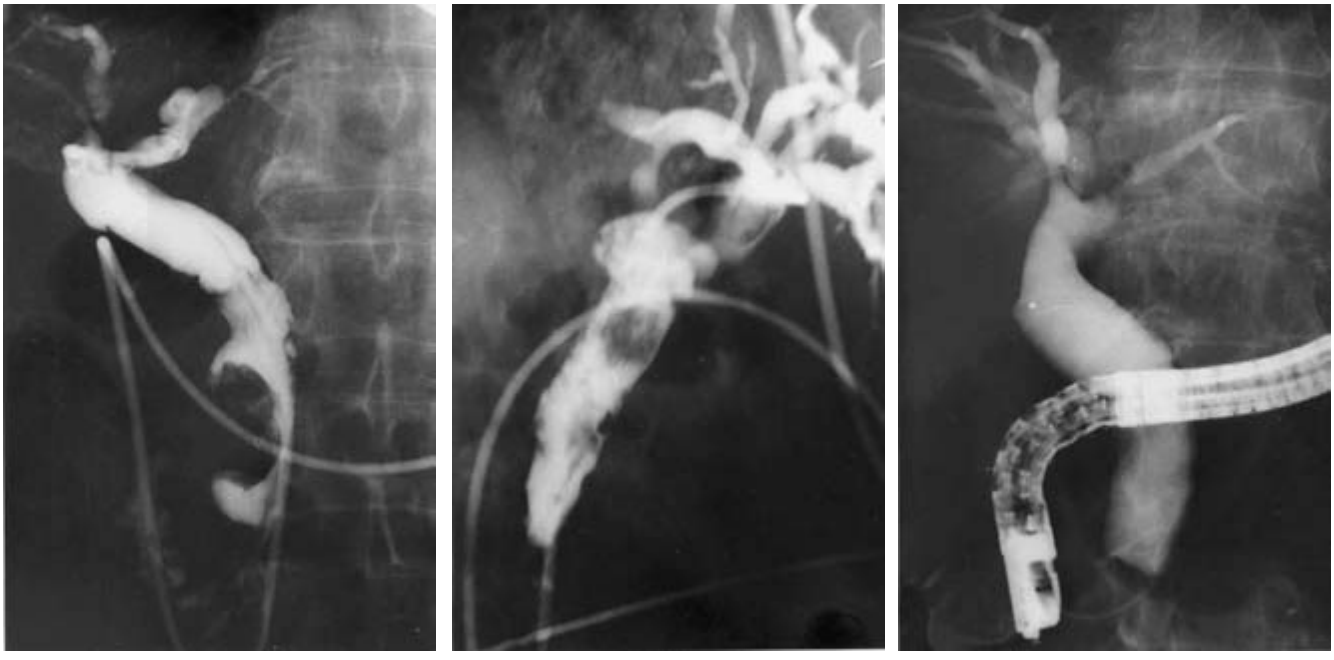

(a) (b) (c)

Fig. 8 Efficacy of extracorporeal shock wave lithotripsy (ESWL). (a) Multiple filling defects due to common bile duct stones. (b) A nasobiliary drainage is inserted to facilitate visualization of stones for planned ESWL. (c) Complete duct clearance after two ESWL treatments and subsequent ERC with extraction of stone fragments by Dormia basket and balloon.

lithotripsy [142] but, on the other hand, it is technically less demanding and might be associated with lower complication rates.

Alternatively, surgical bile duct exploration remains an option, in particular for large impacted stones in patients with an indication of cholecystectomy. It is to be determined whether simultaneous laparoscopic cholecystectomy and intraoperative ERC offers advantages [143]. Under certain circumstances (e.g. in elderly patients unfit for surgery with large bile duct stones), laparoscopic cholecystectomy and endoscopic sphincterotomy with stenting are accepted alternatives [144]. However, as some of these patients develop cholangitis, endoscopic duct clearance should be the preferred strategy [145].

After endoscopic treatment of choledocholithiasis, a wait-and-see policy in combined choledocholithiasis and asymptomatic cholecystolithiasis cannot be recommended, as the risk of cholecystitis, jaundice or other complications exceeds 15% [146,147]. Similarly, all patients with cystic duct obstruction should undergo cholecystectomy, whereas this is not indicated for patients without gallbladder stones and patent cystic duct.

In spite of successful endoscopic sphincterotomy and stone extraction, 10–15% of patients develop recurrent symptomatic bile duct stones within 10 years. This is favoured by impaired bile flow and recurrent episodes of cholangitis. Most of the patients with recurrent choledocholithiasis can be treated easily endoscopically. Patients with early recurrence of stones (≤ 5 years), dilated bile duct (≥ 15 mm) and periampullary diverticulum are most susceptible to stone recurrence even after removal of the stones [148], but retreatment is safe and feasible.

There is no evidence-based medical prophylaxis for bile duct stone formation. Antibiotics did not have beneficial effects in controlled studies. UDCA induces choleresis and showed a slight reduction in recurrence rates of bile duct stones in a small cohort with short follow-up [149].

Intrahepatic gallstones

The management of intrahepatic gallstones is very difficult, and patients should be referred to a specialized hepatobiliary unit. Treatment is directed primarily at the removal of stones and the relief of biliary obstruction, which may be contributing to the formation of stones. There is, as yet, no satisfactory method for dissolving intrahepatic pigment stones *in vivo*, and it can be very difficult to remove these stones by the endoscopic route.

For localized disease, hepatic lobectomy may offer a chance of cure. Success is reported with cholangioscopy, either through a sinus tract established after percutaneous biliary drainage or postoperatively via a T-tube or T-tube tract. Several techniques (such as drills and forceps) can be employed to remove stones or to crush them before removal of the fragments. Direct surgical approaches are also used, including lithotomy via an extended choledochotomy and scooping or evacuation of stones, which is followed by sphincteroplasty or choledochoenterostomy.

Table 8 Complications of cholelithiasis and their management.

Acute cholecystitis
Emergency therapy with fasting, fluids, analgesics and antibiotics
Early (laparoscopic) cholecystectomy within 72 h (laparoscopic or open), otherwise laparoscopic cholecystectomy after 6 weeks
Percutaneous or transpapillary drainage in critically ill patients
Gallbladder perforation
Cholecystectomy (open)
Broad antibiotics
Chronic cholecystitis/calcified gallbladder
Cholecystectomy
Acute cholangitis
Endoscopic (or percutaneous) biliary drainage
Antibiotics
Biliary pancreatitis
Early endoscopic sphincterotomy in patients with obstructive jaundice or severe biliary pancreatitis
Supportive therapy including prophylactic antibiotics in severe pancreatitis
Mirizzi syndrome
Cholecystectomy (open)
Occasionally patients unfit for surgery might be treated endoscopically with sphincterotomy/lithotripsy
Cholecystoenteric fistula/gallstone ileus
Surgical treatment only if ileus or other symptoms
Gallbladder or bile duct carcinoma
Surgery
Endoscopic drainage
Consider photodynamic therapy

Complications and their management

Cholecystitis

Complications of gallstones and their management are summarized in Table 8. The single most frequent complication of gallstone disease is cholecystitis. Acute cholecystitis may become gangrenous (2–30%) or lead to gallbladder perforation (10%) with a mortality rate of 30%, biliary fistula, gallstone ileus or biliary sepsis [29]. Early diagnosis of local complications by ultrasound and/or CT is important (Fig. 6).

Medical treatment

Emergency treatment consists of fasting, fluid resuscitation, spasmolytics and analgesia preferably with NSAID, as these drugs can reverse inflammation of the gallbladder wall [109]. In addition, intravenous antibiotic therapy covering Gram-negative enteric microorganisms (e.g. broad-spectrum acyl-ureido-penicillins, third-generation cephalosporins or chinolones) should be started.

Surgery

Most patients respond to initial conservative medical treatment within the first days. However, up to 20% develop signs of advanced cholecystitis (fever > 38°C, serum bilirubin > 10 mg/dL) and need emergency surgery to avoid complications [29]. The timing of surgery in the remaining 60–80% of patients has been under debate. Recent meta-analyses indicate that early laparoscopic surgery (within 72 h of the onset of symptoms) is preferred, as it does not carry a higher risk of mortality and morbidity, and total hospital stay and costs can be reduced significantly compared with patients undergoing elective cholecystectomy [150,151]. The overall complication rates range from 3% to 15%, with bile duct injuries between 0.7% and 1.3%, which is comparable to complication rates of open cholecystectomy in these patients [152–154].

Percutaneous cholecystostomy

Percutaneous (ultrasound or CT-guided) drainage of the gallbladder is an alternative temporary treatment in patients with acalculous cholecystitis or empyema unfit for surgery [155]. The possibility of a bedside procedure renders this technique a treatment option in critically ill patients, but no prospective studies have been performed.

Cholangitis

Ascending cholangitis is usually due to bile duct obstruction with subsequent infection by Gram-negative enteric bacteria or enterococci. It is a potentially life-threatening complication presenting with fever, chills and often post-hepatic jaundice. If choledocholithiasis is complicated by ascending cholangitis, emergency treatment with fluid resuscitation, parenteral antibiotics and decompression of the bile ducts, preferably by endoscopic means such as stone extraction or nasobiliary drainage, is necessary. A simultaneous sphincterotomy is not mandatory if sufficient biliary drainage is established by stent placement or nasobiliary drain [156], both of which are equally effective [157]. If untreated, long-term complications of cholangitis include stricture formation, intrahepatic stone formation and secondary biliary cirrhosis.

Biliary pancreatitis

Passage of gallstones through the lower end of the common bile duct is an important cause of acute pancreatitis and is assumed to result from transient gallstone blockage of the common channel [158]. Small gallstones are associated with an increased risk of acute pancreatitis [159]. It has also been suggested that biliary sludge, identified by ultrasound (Fig. 3a) or by analysis of bile samples (obtained at ERC or by duodenal intubation and injection of CCK), may cause pancreatitis in patients without gallstones who have no other obvious cause of pancreatitis [160].

The clinical picture of gallstone pancreatitis is similar to that of other forms of pancreatitis. However, within the first 48 h of the attack, abnormalities of liver tests (serum bilirubin, aminotransferases and alkaline phosphatase) and of serum lipase are more pronounced with gallstone pancreatitis.

Although early release of the obstruction is likely to be beneficial for the further clinical course of biliary pancreatitis, emergency ERC with sphincterotomy is not necessary in all patients, as the stone may have passed spontaneously and the inflammatory cascade is not interrupted by sphincterotomy. An excellent summary of the controlled studies on this issue [161] indicated that urgent ERC ± sphincterotomy is mandatory for patients with bile duct obstruction (jaundice) and/or cholangitis [162,163]. In these patients, sphincterotomy treats cholangitis, which represents a severe complication, causing sepsis in 10% of patients [79]. Recent meta-analyses [164] suggest that sphincterotomy might reduce the complications of biliary pancreatitis in general, albeit the effects are non-significant in predicted mild disease and for reduction of mortality in general [165].

With gallbladder *in situ*, cholecystectomy should be performed early (within the same hospital stay) in patients with mild pancreatitis. This minimizes the frequency of subsequent attacks, although they may still occur because of missed stones or the formation of new stones [166]. However, to reduce the risk of sepsis and complications of cholecystectomy, surgery should be delayed in patients with moderate to severe acute pancreatitis who demonstrate peripancreatic fluid collections or pseudocysts until these resolve or persist beyond 6 weeks [167]. Endoscopic sphincterotomy without cholecystectomy could be an acceptable option to prevent recurrence in patients who are not candidates for surgery [168].

Mirizzi syndrome

In rare cases, a stone impacted in the cystic duct or neck of the gallbladder (or in a cystic duct remnant) causes a localized obstruction of the common hepatic duct, thought to be due to direct pressure and/or secondary inflammatory changes around the duct. This constitutes the Mirizzi syndrome, which deserves attention because it may cause diagnostic confusion. The obstruction of the common hepatic duct can cause right upper quadrant pain, nausea and vomiting, recurrent cholangitis and jaundice. A cholecysto-choledochal fistula may form between the common hepatic duct and the cystic duct or the gallbladder [169].

Ultrasound might show dilated ducts above and normal-sized ducts below the block, and may reveal the stone in the neck of the gallbladder or cystic duct. On ERC, the characteristic appearance is of a broad extrinsic impression on the lateral aspect of the common hepatic duct, with dilated ducts above and a normal duct diameter below the narrowing; the cystic duct and gallbladder do not usually fill with contrast (Fig. 9).

In most patients, surgical treatment is required, with laparoscopic procedures carrying a potential risk of complications. ERC with sphincterotomy, cholangioscopy, laser lithotripsy and

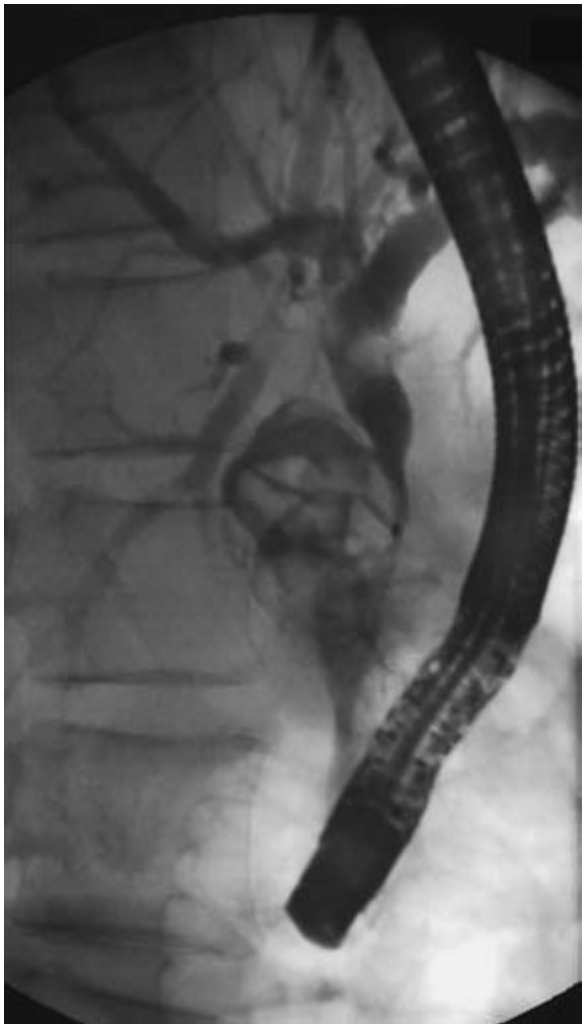

Fig. 9 Endoscopic retrograde cholangiography (ERC) appearance of Mirizzi syndrome. Note the eccentric stenosis of the common hepatic duct in close vicinity to the cystic duct and the presence of multiple stones in both the gallbladder and the bile ducts. The patient underwent open cholecystectomy, and a large defect in the wall of the common hepatic duct was diagnosed intraoperatively.

stone extraction may be helpful, particularly for poor surgical candidates.

Biliary fistulae

Biliary fistulae are thought to result from longstanding impacted stones [170]. The most common are those between the gallbladder and intestine, and those connecting two parts of the biliary tract. The most prevalent type of biliary enteric fistula (77%) is cholecystoduodenal, and the next most common is cholecystocolic (15%) [170]. Most patients with biliary enteric fistulae have symptoms similar to those of chronic cholecystitis or recurrent biliary infection, but there can also be long asymptomatic periods [170]. Patients may also suffer from 'bile salt diarrhoea' if there is a cholecystocolic fistula.

A fistula should be suspected if air is found in the biliary tree and, in a consecutive gastrografin swallow, contrast may be seen to pass into the gallbladder or bile ducts. The standard approach to management of biliary fistulae in patients without accompanying gallstone ileus is primary repair of the fistula with cholecystectomy.

Gallstone ileus

Although gallstone ileus is a relatively uncommon cause of intestinal obstruction (2–3%), it is responsible for up to 20% of cases of intestinal obstruction in those over 65 years of age. Gallstones impact most commonly in the last 50 cm of the terminal ileum (60% of patients with ileus); they obstruct the mid-ileum in 25%, the jejunum in 10% and the duodenum in up to 10% of patients [170,171]. Gallstone ileus is almost invariably due to the earlier development of a biliary enteric fistula, most commonly cholecystoduodenal.

Symptoms may be moderate or intermittent, and the diagnosis is to be suspected if – in addition to the features of intestinal obstruction – there is air in the biliary tree [172]. In the management of intestinal obstruction due to a gallstone, relief of the obstruction is the first concern after correction of dehydration and proper preoperative preparation. The stone is removed through an enterotomy and/or intestinal resection; in most patients, correction of the biliary fistula is performed later. It is necessary to repair the fistula, as ileus recurs in 2–13% of patients and there is a high incidence of cholangitis. The average mortality due to gallstone ileus has been reported to range from 5% to 20%.

Prognosis

Prognosis with treatment

The prognosis of cholecystolithiasis and calculous cholecystitis is good. The overall mortality rate after surgical treatment is 0.1–0.7%. However, after cholecystectomy, up to 10% of patients complain of recurrent or persistent pain, which is referred to as 'post-cholecystectomy syndrome'. In some cases, this may represent continuation of preoperative non-gallstone pain that was misattributed to coincidental gallstones. In cases in which the symptoms are genuine, they might be due to abnormally high tone of the sphincter of Oddi, although this is very difficult to elicit, e.g. by sphincter of Oddi manometry, morphine–prostigmine provocation test (Nardi test) or magnetic resonance pancreaticography with secretion stimulation [173]. Acalculous cholecystitis in critically ill patients carries a poor prognosis, and the mortality may be higher than 50%.

Prognosis without treatment

Acute cholecystitis resolves spontaneously in half of patients within 7–10 days. However, the rate of gangrenous cholecystitis

with gallbladder perforation may be as high as 10%. If cholecystitis is treated without cholecystectomy, the recurrence rate is 60% in 6 years. Ascending bacterial cholangitis has a marked mortality rate if unrecognized or left untreated.

References

1 Lammert F, Sauerbruch T (2005) Mechanisms of disease: the genetic epidemiology of gallbladder stones. *Nature Clin Pract Gastroenterol Hepatol* 2, 423–433.

2 Völzke H, Baumeister SE, Alte D *et al.* (2005) Independent risk factors for gallstone formation in a region with high cholelithiasis prevalence. *Digestion* 71, 97–105.

3 Liver Disease Subcommittee of the Digestive Diseases Interagency Coordinating Committee (2005) Gallbladder and biliary disease. In: National Institutes of Health (ed.) *Action Plan for Liver Disease Research*. Bethesda, MD: NIH, pp. 145–150.

4 Anon (2005) Cholezystektomie. In: BQS Bundesgeschäftsstelle Qualitätssicherung (ed.) *Qualität sichtbar machen. BQS-Qualitätsreport 2004*. Düsseldorf: BQS, pp. 22–34.

5 Sandler RS, Everhart JE, Donowitz M *et al.* (2002) The burden of selected digestive diseases in the United States. *Gastroenterology* 122, 1500–1511.

6 Carey MC, LaMont JT (1992) Cholesterol gallstone formation. 1. Physical-chemistry of bile and biliary lipid secretion. *Prog Liver Dis* 10, 136–163.

7 Small DM (2003) Role of ABC transporters in secretion of cholesterol from liver into bile. *Proc Natl Acad Sci USA* 100, 4–6.

8 Paumgartner G, Sauerbruch T (1991) Gallstones: pathogenesis. *Lancet* 338, 1117–1121.

9 Admirand WH, Small DM (1968) The physicochemical basis of cholesterol gallstone formation in man. *J Clin Invest* 47, 1045–1052.

10 Carey MC (1978) Critical tables for calculating the cholesterol saturation of native bile. *J Lipid Res* 19, 945–955.

11 Vlahcevic ZR, Bell CC, Buhac I *et al.* (1970) Diminished bile acid pool size in patients with gallstones. *Gastroenterology* 59, 165–173.

12 Thomas LA, Veysey MJ, Bathgate T *et al.* (2000) Mechanism for the transit-induced increase in colonic deoxycholic acid formation in cholesterol cholelithiosis. *Gastroenterology* 119, 806–815.

13 Berr F, Kullak-Ublick GA, Paumgartner G *et al.* (1986) 7α-hydroxylating bacteria enhance deoxycholic acid input and cholesterol saturation of bile in patients with gallstones. *Gastroenterology* 111, 1611–1620.

14 Paigen B, Carey MC (2002) Gallstones. In: King RA, Rotter JF, Motulsky AG (eds) *The Genetic Basis of Common Diseases*. London: Oxford University Press, pp. 298–335.

15 Buhman KK, Accad M, Novak S *et al.* (2000) Resistance to diet-induced hypercholesterolemia and gallstone formation in ACAT2-deficient mice. *Nature Med* 6, 1341–1347.

16 Lammert F, Carey MC, Paigen B (2001) Chromosomal organization of candidate genes involved in cholesterol gallstone formation: a murine gallstone map. *Gastroenterology* 120, 221–238.

17 Moschetta A, Bookout AL, Mangelsdorf DJ (2004) Prevention of cholesterol gallstone diseases by FXR agonists in a mouse model. *Nature Med* 10, 1352–1358.

18 Wang DQ, Schmitz F, Kopin AS *et al.* (2004) Targeted disruption of the murine cholecystokinin-1 receptor promotes intestinal cholesterol absorption and susceptibility to cholesterol cholelithiasis. *J Clin Invest* 114, 521–528.

19 Holzbach RT, Busch N (1991) Nucleation and growth of cholesterol crystals. Kinetic determinants in supersaturated native bile. *Gastroenterol Clin North Am* 20, 67–84.

20 Jirsa M, Groen AK (2001) Role of biliary proteins and non-protein factors in kinetics of cholesterol crystallization and gallstone growth. *Front Biosci* 6, e154–167.

21 Ko CW, Sekijima JH, Lee SP (1999) Biliary sludge. *Ann Intern Med* 130, 301–311.

22 Lee SP, Carey MC, LaMont JT (1981) Aspirin prevention of cholesterol gallstone formation in prairie dogs. *Science* 211, 1429–1431.

23 Maurer KJ, Ihrig MM, Rodgers AB *et al.* (2005) Identification of cholelithogenic enterohepatic *Helicobacter* species and their role in murine cholesterol gallstone formation. *Gastroenterology* 128, 1023–1033.

24 Brink MA, Slors JF, Keulemans YC *et al.* (1999) Enterohepatic cycling of bilirubin: a putative mechanism for pigment gallstone formation in ileal Crohn's disease. *Gastroenterology* 116, 1420–1427.

25 Vitek L, Carey MC (2003) Enterohepatic cycling of bilirubin as a cause of 'black' pigment gallstones in adult life. *Eur J Clin Invest* 33, 799–810.

26 Shiffman ML, Sugerman HJ, Moore EW (1990) Human gallbladder mucosal function. Effect of concentration and acidification of bile on cholesterol and calcium solubility. *Gastroenterology* 99, 1452–1459.

27 Huang MH, Chen CH, Yen CM *et al.* (2005) Relation of hepatolithiasis to helminthic infestation. *J Gastroenterol Hepatol* 20, 141–146.

28 Tham TC, Kelly M (2004) Association of periampullary duodenal diverticula with bile duct stones and with technical success of endoscopic retrograde cholangiopancreatography. *Endoscopy* 36, 1050–1053.

29 Indar AA, Beckingham IJ (2002) Acute cholecystitis. *Br Med J* 325, 639–643.

30 Barie PS, Eachempati SR (2003) Acute acalculous cholecystitis. *Curr Gastroenterol Rep* 5, 302–309.

31 Kratzer W, Mason RA, Kachele V (1999) Prevalence of gallstones in sonographic surveys worldwide. *J Clin Ultrasound* 27, 1–7.

32 Tsai CJ, Leitzmann MF, Willett WC *et al.* (2005) Glycemic load, glycemic index, and carbohydrate intake in relation to risk of cholecystectomy in women. *Gastroenterology* 129, 105–112.

33 Leitzmann MF, Rimm EB, Willett WC *et al.* (1999) Recreational physical activity and the risk of cholecystectomy in women. *N Engl J Med* 341, 777–784.

34 Kern F (1994) Effects of dietary cholesterol on cholesterol and bile acid homeostasis in patients with cholesterol gallstones. *J Clin Invest* 93, 1186–1194.

35 Lammert F, Wang DQ (2005) New insights into the genetic regulation of intestinal cholesterol absorption. *Gastroenterology* 129, 718–734.

36 Everhart JE, Yeh F, Lee ET *et al.* (2002) Prevalence of gallbladder disease in American Indian populations: findings from the Strong Heart Study. *Hepatology* 35, 1507–1512.

37 Sampliner RE, Bennett PH, Comess LJ *et al.* (1970) Gallbladder disease in Pima Indians. Demonstration of high prevalence and early onset by cholecystography. *N Engl J Med* 283, 1358–1364.

38 Carey MC, Paigen B (2002) Epidemiology of the American Indians' burden and its likely genetic origins. *Hepatology* 36, 781–791.

39 Everhart JE, Khare M, Hill M *et al.* (1999) Prevalence and ethnic differences in gallbladder disease in the Unites States. *Gastroenterology* 117, 632–639.

40 Miquel JF, Covarrubias C, Villaroel L *et al.* (1998) Genetic epidemiology of cholesterol cholelithiasis among Chilean Hispanics, Amerindians, and Maoris. *Gastroenterology* 115, 937–946.

41 Katsika D, Grjibovski A, Einarsson C *et al.* (2005) Genetic and environmental influences on symptomatic gallstone disease: a Swedish study of 43 141 twin pairs. *Hepatology* 41, 1138–1143.

42 Kesäniemi YA, Koskenvuo M, Vuoristo M *et al.* (1989) Biliary lipid composition in monozygotic and dizygotic pairs of twins. *Gut* 30, 1750–1756.

43 Duggirala R, Mitchell BD, Blangero J *et al.* (1999) Genetic determinants of variation in gallbladder disease in the Mexican-American population. *Genet Epidemiol* 16, 191–204.

44 Puppala S, Dodd GD, Fowler S *et al.* (2006) A genomewide search finds major susceptibility loci for gallbladder disease on chromosome 1 in Mexican Americans. *Am J Hum Genet* 78, 377–392.

45 Nakeeb A, Comuzzie AG, Martin L *et al.* (2002) Gallstones: genetics versus environment. *Ann Surg* 235, 842–849.

46 Rosmorduc O, Hermelin B, Boelle PY *et al.* (2003) *ABCB4* gene mutation-associated cholelithiasis in adults. *Gastroenterology* 125, 452–459.

47 Lammert F, Wang DQ, Hillebrandt S *et al.* (2004) Spontaneous cholecysto- and hepatolithiasis in *Mdr2*$^{-/-}$ mice: a model for low phospholipid-associated cholelithiasis. *Hepatology* 39, 117–128.

48 Van Mil SW, van der Woerd WL, van der Brugge G *et al.* (2004) Benign recurrent intrahepatic cholestasis type 2 is caused by mutations in ABCB11. *Gastroenterology* 127, 379–384.

49 Pullinger CR, Eng C, Salen G *et al.* (2002) Human cholesterol 7α-hydroxylase (*CYP7A1*) deficiency has a hypercholesterolemic phenotype. *J Clin Invest* 110, 109–117.

50 Jiang ZY, Han TQ, Suo GJ *et al.* (2004) Polymorphisms at cholesterol 7alpha-hydroxylase, apolipoproteins B and E and low density lipoprotein receptor genes in patients with gallbladder stone disease. *World J Gastroenterol* 10, 1508–1512.

51 Miyake JH, Duong-Polk XT, Taylor JM *et al.* (2002) Transgenic expression of cholesterol 7α-hydroxylase prevents atherosclerosis in C57BL/6J mice. *Arterioscler Thromb Vasc Biol* 22, 121–126.

52 Lancellotti S, Zaffanello M, Di Leo E *et al.* (2005) Pediatric gallstone disease in familial hypobetalipoproteinemia. *J Hepatol* 43, 188–191.

53 Han T, Jiang Z, Suo G *et al.* (2000) Apolipoprotein B-100 gene XbaI polymorphism and cholesterol gallstone disease. *Clin Genet* 57, 304–308.

54 Juvonen T, Savolainen MJ, Kairaluoma MI *et al.* (1995) Polymorphisms at the *apoB*, *apoA-I*, and cholesteryl ester transfer protein gene loci in patients with gallbladder disease. *J Lipid Res* 36, 804–812.

55 Singh MK, Pandey UB, Ghoshal UC *et al.* (2004) Apolipoprotein B-100 XbaI gene polymorphism in gallbladder cancer. *Hum Genet* 114, 280–283.

56 Miller LJ, Holicky EL, Ulrich CD *et al.* (1995) Abnormal processing of the human cholecystokinin receptor gene in association with gallstones and obesity. *Gastroenterology* 109, 1375–1380.

57 Schneider H, Sanger P, Hanisch E (1997) In vitro effects of cholecystokinin fragments on human gallbladders. Evidence for an altered CCK-receptor structure in a subgroup of patients with gallstones. *J Hepatol* 26, 1063–1068.

58 Nardone G, Ferber IA, Miller LJ (1995) The integrity of the cholecystokinin receptor gene in gallbladder disease and obesity. *Hepatology* 22, 1751–1753.

59 Miyasaka K, Takata Y, Funakoshi A (2002) Association of cholecystokinin A receptor gene polymorphism with cholelithiasis and the molecular mechanisms of this polymorphism. *J Gastroenterol* 37, S102–S106.

60 Wittenburg H, Lyons MA, Li R *et al.* (2003) FXR and ABCG5/ABCG8 as determinants of cholesterol gallstone formation from quantitative trait locus mapping in mice. *Gastroenterology* 125, 868–881.

61 Pletcher MT, McClurg P, Batalov S *et al.* (2004) Use of a dense single nucleotide polymorphism map for in silico mapping in the mouse. *PLoS Biol* 2, e393.

62 Bertomeu A, Ros E, Zambon D *et al.* (1996) Apolipoprotein E polymorphism and gallstones. *Gastroenterology* 111, 1603–1610.

63 Niemi M, Kervinen K, Rantala A *et al.* (1999) The role of apolipoprotein E and glucose intolerance in gallstone disease in middle aged subjects. *Gut* 44, 557–562.

64 Amigo L, Quinones V, Mardones P *et al.* (2000) Impaired biliary cholesterol secretion and decreased gallstone formation in apolipoprotein E-deficient mice fed a high-cholesterol diet. *Gastroenterology* 118, 772–779.

65 Van Erpecum KJ, Portincasa P, Dohlu MH *et al.* (2003) Biliary pronucleating proteins and apolipoprotein E in cholesterol and pigment stone patients. *J Hepatol* 39, 7–11.

66 Venneman NG, van Berge-Henegouwen GP, Portincasa P *et al.* (2001) Absence of apolipoprotein E4 genotype, good gallbladder motility and presence of solitary stones delay rather than prevent gallstone recurrence after extracorporeal shock wave lithotripsy. *J Hepatol* 35, 10–16.

67 Gracie WA, Ransohoff DF (1982) The natural history of silent gallstones: the innocent gallstone is not a myth. *N Engl J Med* 307, 798–800.

68 Friedman GD, Raviola CA, Fireman B (1989) Prognosis of gallstones with mild or no symptoms: 25 years of follow-up in a health maintenance organization. *J Clin Epidemiol* 42, 127–136.

69 Ransohoff DF, Gracie WA, Wolfenson LB *et al.* (1983) Prophylactic cholecystectomy or expectant management for silent gallstones. A decision analysis to assess survival. *Ann Intern Med* 99, 199–204.

70 Attili AF, De Santis A, Capri R *et al.* (1995) The natural history of gallstones: the GREPCO experience. The GREPCO Group. *Hepatology* 21, 655–660.

71 Festi D, Sottili S, Colecchia A *et al.* (1999) Clinical manifestations of gallstone disease: evidence from the multicenter Italian study on cholelithiasis (MICOL). *Hepatology* 30, 839–846.

72 Thistle JL, Cleary PA, Lachin JM *et al.* (1984) The natural history of cholelithiasis: the National Cooperative Gallstone Study. *Ann Intern Med* 101, 171–175.

73 Trowbridge RL, Rutkowski NK, Shojania KG (2003) Does this patient have acute cholecystitis? *JAMA* 289, 80–86.

74 Ransohoff DF, Gracie WA (1990) Management of patients with symptomatic gallstones: a quantitative analysis. *Am J Med* 88, 154–160.

75 Jørgensen T (1989) Gall stones in a Danish population. Relation to weight, physical activity, smoking, coffee consumption, and diabetes mellitus. *Gut* 30, 528–534.

76 Heaton KW, Braddon FE, Mountford RA *et al.* (1991) Symptomatic and silent gall stones in the community. *Gut* 32, 316–320.

77 Venneman NG, Renooij W, Rehfeld JF *et al.* (2005) Small gallstones, preserved gallbladder motility, and fast crystallization are associated with pancreatitis. *Hepatology* 41, 738–746.

78 Maringhini A, Moreau JA, Melton LJ *et al.* (1987) Gallstones, gallbladder cancer, and other gastrointestinal malignancies. An epidemiological study in Rochester, Minnesota. *Ann Intern Med* 107, 30–35.

79 Sherman S, Hawes RH, Lehman GA (1990) Management of bile duct stones. *Semin Liver Dis* 10, 205–221.

80 Ko CW, Lee SP (2002) Epidemiology and natural history of common bile duct stones and prediction of disease. *Gastrointest Endosc* 56, S165–S169.

81 Johnson AG, Hosking SW (1987) Appraisal of the management of bile duct stones. *Br J Surg* 74, 555–560.

82 Caddy GR, Kirby J, Kirk SJ *et al.* (2005) Natural history of asymptomatic bile duct stones at time of cholecystectomy. *Ulster Med J* 74, 108–112.

83 Abou-Saif A, Al-Kawas FH (2002) Complications of gallstone disease: Mirizzi syndrome, cholecystocholedochal fistula, and gallstone ileus. *Am J Gastroenterol* 97, 249–254.

84 Nakayama F (1982) Intrahepatic calculi: a special problem in East Asia. *World J Surg* 6, 802–804.

85 Shea JA, Berlin JA, Escarce JJ *et al.* (1994) Revised estimates of diagnostic test sensitivity and specificity in suspected biliary tract disease. *Arch Intern Med* 154, 2573–2581.

86 Gandolfi L, Torresan F, Solmi L *et al.* (2003) The role of ultrasound in biliary and pancreatic diseases. *Eur J Ultrasound* 16, 141–159.

87 Buscarini E, Tansini P, Vallisa D *et al.* (2003) EUS for suspected choledocholithiasis: do benefits outweigh costs? A prospective, controlled study. *Gastrointest Endosc* 57, 510–518.

88 Kondo S, Isayama H, Akahane M *et al.* (2005) Detection of common bile duct stones: comparison between endoscopic ultrasonography, magnetic resonance cholangiography, and helical-computed-tomographic cholangiography. *Eur J Radiol* 54, 271–275.

89 Romagnuolo J, Bardou M, Rahme E *et al.* (2003) Magnetic resonance cholangiopancreatography: a meta-analysis of test performance in suspected biliary disease. *Ann Intern Med* 139, 547–557.

90 Metcalfe MS, Ong T, Bruening MH *et al.* (2004) Is laparoscopic intraoperative cholangiogram a matter of routine? *Am J Surg* 187, 475–481.

91 Nakayama F (1988) Intrahepatic stones. In: Blumgart LH (ed.) *Surgery of the Liver and Biliary Tract*. Edinburgh: Churchill Livingstone, pp. 639–645.

92 Shoda J, Tanaka N, Osuga T (2003) Hepatolithiasis – epidemiology and pathogenesis update. *Front Biosci* 8, e398–e409.

93 Kalimi R, Gecelter GR, Caplin D *et al.* (2001) Diagnosis of acute cholecystitis: sensitivity of sonography, cholescintigraphy, and combined sonography-cholescintigraphy. *J Am Coll Surg* 193, 609–613.

94 Ko CW, Lee SP (2003) Gastrointestinal disorders of the critically ill. Biliary sludge and cholecystitis. *Best Pract Res Clin Gastroenterol* 17, 383–396.

95 Singh AK, Sagar P (2005) Gangrenous cholecystitis: prediction with CT imaging. *Abdom Imaging* 30, 318–321.

96 Berk RN, van der Vegt JH, Lichtenstein JE (1983) The hyperplastic cholecystoses: cholesterolosis and adenomyomatosis. *Radiology* 146, 593–601.

97 Broomfield PH, Chopra R, Sheinbaum RC *et al.* (1988) Effects of ursodeoxycholic acid and aspirin on the formation of lithogenic bile and gallstones during loss of weight. *N Engl J Med* 319, 1567–1572.

98 Sitzmann JV, Pitt HA, Steinborn PA *et al.* (1990) Cholecystokinin prevents parenteral nutrition induced biliary sludge in humans. *Surg Gynecol Obstet* 170, 25–31.

99 Portincasa P, Altomare DF, Moschetta A *et al.* (2000) The effect of acute oral erythromycin on gallbladder motility and on upper gastrointestinal symptoms in gastrectomized patients with and without gallstones: a randomized, placebo-controlled ultrasonographic study. *Am J Gastroenterol* 95, 3444–3451.

100 Jackson T, Treleaven D, Arlen D *et al.* (2005) Management of asymptomatic cholelithiasis for patients awaiting renal transplantation. *Am J Surg* 175, 320–321.

101 Kao LS, Flowers C, Flum DR (2005) Prophylactic cholecystectomy in transplant patients: a decision analysis. *J Gastrointest Surg* 9, 965–972.

102 Englesbe MJ, Dubay DA, Wu AH *et al.* (2005) Gallbladder disease in cardiac transplant patients: a survey study. *Arch Surg* 140, 399–404.

103 Diehl AK (1983) Gallstone size and the risk of gallbladder cancer. *JAMA* 250, 2323–2326.

104 Lowenfels AB, Lindstrom CG, Conway MJ *et al.* (1985) Gallstones and risk of gallbladder cancer. *J Natl Cancer Inst* 75, 77–80.

105 Lowenfels AB, Walker AM, Althaus DP *et al.* (1989) Gallstone growth, size, and risk of gallbladder cancer: an interracial study. *Int J Epidemiol* 18, 50–54.

106 Koga A, Watanabe H, Fukiyama T *et al.* (1988) Diagnosis and operative indications for polypoid lesions of the gallbladder. *Arch Surg* 123, 26–29.

107 Okamoto M, Okamoto H, Kitahara F *et al.* (1999) Ultrasonographic evidence of association of polyps and stones with gallbladder cancer. *Am J Gastroenterol* 94, 446–450.

108 Ashur H, Siegal B, Oland Y *et al.* (1978) Calcified gallbladder (porcelain gallbladder). *Arch Surg* 113, 594–596.

109 Akriviadis EA, Hatzigavriel M, Kapnias D *et al.* (1997) Treatment of biliary colic with diclofenac: a randomized, double-blind, placebo-controlled study. *Gastroenterology* 113, 225–231.

110 Keus F, de Jong JA, Gooszen HG *et al.* (2006) Laparoscopic versus open cholecystectomy for patients with symptomatic cholecystolithiasis. *Cochrane Database Syst Rev* CD006231.

111 Velanovich V, Morton JM, McDonald M *et al.* (2006) Analysis of the SAGES outcomes initiative cholecystectomy registry. *Surg Endosc* 20, 43–50.

112 Nakagawa S, Makino I, Ishizaki T *et al.* (1977) Dissolution of cholesterol gallstones by ursodeoxycholic acid. *Lancet* 2, 367–369.

113 Podda M, Zuin M, Battezzati PM *et al.* (1989) Efficacy and safety of a combination of chenodeoxycholic acid and ursodeoxycholic acid for gallstone dissolution: a comparison with ursodeoxycholic acid alone. *Gastroenterology* 96, 222–229.

114 Schoenfield LJ, Lachin JM (1981) Chenodiol (chenodeoxycholic acid) for dissolution of gallstones: the National Cooperative Gallstone Study. A controlled trial of efficacy and safety. *Ann Intern Med* 95, 257–282.

115 Senior JR, Johnson MF, DeTurck DM *et al.* (1990) In vivo kinetics of radiolucent gallstone dissolution by oral dihydroxy bile acids. *Gastroenterology* 99, 243–251.

116 Jazrawi RP, Pigozzi MG, Galatola G *et al.* (1992) Optimum bile acid treatment for rapid gall stone dissolution. *Gut* 33, 381–386.

117 O'Donnell LD, Heaton KW (1988) Recurrence and re-recurrence of gall stones after medical dissolution: a longterm follow up. *Gut* 29, 655–658.

118 Villanova N, Bazzoli F, Taroni F *et al.* (1989) Gallstone recurrence after successful oral bile acid treatment. A 12-year follow-up study and evaluation of long-term postdissolution treatment. *Gastroenterology* 97, 726–731.

119 Hood KA, Gleeson D, Ruppin DC *et al.* (1993) Gall stone recurrence and its prevention: the British/Belgian Gall Stone Study Group's post-dissolution trial. *Gut* 34, 1277–1288.

120 Sauerbruch T, Delius M, Paumgartner G *et al.* (1986) Fragmentation of gallstones by extracorporeal shock waves. *N Engl J Med* 314, 818–822.

121 Sackmann M, Delius M, Sauerbruch T *et al.* (1988) Shock-wave lithotripsy of gallbladder stones. The first 175 patients. *N Engl J Med* 318, 393–397.

122 Schneider HT, Hummel T, Janowitz P *et al.* (1992) Pain in extracorporeal shock-wave lithotripsy: a comparison of different lithotripters in volunteers. *Gastroenterology* 102, 640–646.

123 Benninger J, Schneider HT, Hahn EG *et al.* (1993) A clinical comparison of an electrohydraulic and a piezoelectric lithotripter in gallstone therapy. *Am J Gastroenterol* 88, 58–63.

124 Sackmann M, Pauletzki J, Sauerbruch T *et al.* (1991) The Munich Gallbladder Lithotripsy Study. Results of the first 5 years with 711 patients. *Ann Intern Med* 114, 290–296.

125 Sauter G, Kullak-Ublick GA, Schumacher R *et al.* (1997) Safety and efficacy of repeated shockwave lithotripsy of gallstones with and without adjuvant bile acid therapy. *Gastroenterology* 112, 1603–1609.

126 Rabenstein T, Radespiel-Troger M, Hopfner L *et al.* (2005) Ten years experience with piezoelectric extracorporeal shockwave lithotripsy of gallbladder stones. *Eur J Gastroenterol Hepatol* 17, 629–639.

127 Pauletzki J, Sailer C, Klüppelberg U *et al.* (1994) Gallbladder emptying determines early gallstone clearance after shock-wave lithotripsy. *Gastroenterology* 107, 1496–1502.

128 Pereira SP, Veysey MJ, Kennedy C *et al.* (1997) Gallstone dissolution with oral bile acid therapy. Importance of pretreatment CT scanning and reasons for nonresponse. *Dig Dis Sci* 42, 1775–1782.

129 Sackmann M, Niller H, Klüppelberg U *et al.* (1994) Gallstone recurrence after shock-wave therapy. *Gastroenterology* 106, 225–230.

130 Portincasa P, van Erpecum KJ, van De Meeberg PC *et al.* (1996) Apolipoprotein E4 genotype and gallbladder motility influence speed of gallstone clearance and risk of recurrence after extracorporeal shock-wave lithotripsy. *Hepatology* 24, 580–587.

131 Fielding GA (2002) The case for laparoscopic common bile duct exploration. *J Hepatobil Pancreat Surg* 9, 723–728.

132 Sgourakis G, Karaliotas K (2002) Laparoscopic common bile duct exploration and cholecystectomy versus endoscopic stone extraction and laparoscopic cholecystectomy for choledocholithiasis. A prospective randomized study. *Minerva Chir* 57, 467–474.

133 Paganini AM, Guerrieri M, Sarnari J *et al.* (2005) Long-term results after laparoscopic transverse choledochotomy for common bile duct stones. *Surg Endosc* 19, 705–709.

134 Binmoeller KF, Schafer TW (2001) Endoscopic management of bile duct stones. *J Clin Gastroenterol* 32, 106–118.

135 Nathanson LK, O'Rourke NA, Martin IJ *et al.* (2005) Postoperative ERCP versus laparoscopic choledochotomy for clearance of selected bile duct calculi: a randomized trial. *Ann Surg* 242, 188–192.

136 Christensen M, Motzen P, Schulze S *et al.* (2004) Complications of ERCP: a prospective study. *Gastrointest Endosc* 60, 721–731.

137 Cotton PB, Geenen JE, Sherman S *et al.* (1998) Endoscopic sphincterotomy for stones by experts is safe, even in younger patients with normal ducts. *Ann Surg* 227, 201–204.

138 Carr-Locke DL (2002) Therapeutic role of ERCP in the management of suspected common bile duct stones. *Gastrointest Endosc* 56, S170–S174.

139 Sauerbruch T, Scheurlen C, Neubrand M (2001) Non-surgical treatment of bile duct stones. In: Acalovschi M, Paumgartner G (eds) *Hepatobiliary Diseases: Cholestasis and Gallstones*. Dordrecht: Kluwer Academic Publishers, pp. 153–159.

140 Garg PK, Tandon RK, Ahuja V *et al.* (2004) Predictors of unsuccessful mechanical lithotripsy and endoscopic clearance of large bile duct stones. *Gastrointest Endosc* 59, 601–605.

141 Sauerbruch T, Stern M (1989) Fragmentation of bile duct stones by extracorporeal shock waves. A new approach to biliary calculi after failure of routine endoscopic measures. *Gastroenterology* 96, 146–152.

142 Jakobs R, Adamek HE, Maier M *et al.* (1997) Fluoroscopically guided laser lithotripsy versus extracorporeal shock wave lithotripsy for retained bile duct stones: a prospective randomized study. *Gut* 40, 678–682.

143 Enochsson L, Lindberg B, Swahn F *et al.* (2004) Intraoperative endoscopic retrograde cholangiopancreatography (ERCP) to remove common bile duct stones during routine laparoscopic cholecystectomy does not prolong hospitalization: a 2-year experience. *Surg Endosc* 18, 367–371.

144 Katsinelos P, Galanis I, Pilpilidis I *et al.* (2003) The effect of indwelling endoprosthesis on stone size or fragmentation after long-term treatment with biliary stenting for large stones. *Surg Endosc* 17, 1552–1555.

145 Chopra KB, Peters RA, O'Toole PA *et al.* (1996) Randomised study of endoscopic biliary endoprosthesis versus duct clearance for bile duct stones in high-risk patients. *Lancet* 348, 791–793.

146 Boerma D, Rauws EA, Keulemans YC *et al.* (2002) Wait-and-see policy or laparoscopic cholecystectomy after endoscopic sphincterotomy for bile-duct stones: a randomised trial. *Lancet* 360, 761–765.

147 Lau JY, Leow CK, Fung TM *et al.* (2006) Cholecystectomy or gallbladder in situ after endoscopic sphincterotomy and bile duct stone removal in Chinese patients. *Gastroenterology* 130, 96–103.

148 Sugiyama M, Suzuki Y, Abe N *et al.* (2004) Endoscopic retreatment of recurrent choledocholithiasis after sphincterotomy. *Gut* 53, 1856–1859.

149 Swobodnik W, Janowitz P, Kratzer W *et al.* (1990) Preventing the recurrence of common bile duct calculi following endoscopic papillotomy with ursodeoxycholic acid. *Z Gastroenterol* 28, 621–625.

150 Papi C, Catarci M, D'Ambrosio L *et al.* (2004) Timing of cholecystectomy for acute calculous cholecystitis: a meta-analysis. *Am J Gastroenterol* 99, 147–155.

151 Shikata S, Noguchi Y, Fukui T (2005) Early versus delayed cholecystectomy for acute cholecystitis: a meta-analysis of randomized controlled trials. *Surg Today* 35, 553–560.

152 Madan AK, Aliabadi-Wahle S, Tesi D *et al.* (2002) How early is early laparoscopic treatment of acute cholecystitis? *Am J Surg* 183, 232–236.

153 Liu TH, Consorti ET, Mercer DW (2002) Laparoscopic cholecystectomy for acute cholecystitis: technical considerations and outcome. *Semin Laparosc Surg* 9, 24–31.

154 Kitano S, Matsumoto T, Aramaki M *et al.* (2002) Laparoscopic cholecystectomy for acute cholecystitis. *J Hepatobiliary Pancreat Surg* 9, 534–537.

155 Byrne MF, Suhocki P, Mitchell RM *et al.* (2003) Percutaneous cholecystostomy in patients with acute cholecystitis: experience of 45 patients at a US referral center. *J Am Coll Surg* 197, 206–211.

156 Hui CK, Lai KC, Yuen MF *et al.* (2003) Does the addition of endoscopic sphincterotomy to stent insertion improve drainage of the bile duct in acute suppurative cholangitis? *Gastrointest Endosc* 58, 500–504.

157 Sharma BC, Kumar R, Agarwal N *et al.* (2005) Endoscopic biliary drainage by nasobiliary drain or by stent placement in patients with acute cholangitis. *Endoscopy* 37, 439–443.

158 Acosta JM, Ledesma CL (1974) Gallstone migration as a cause of acute pancreatitis. *N Engl J Med* 290, 484–487.

159 Venneman NG, Buskens E, Besselink MG *et al*. (2005) Small gallstones are associated with increased risk of acute pancreatitis: potential benefits of prophylactic cholecystectomy? *Am J Gastroenterol* 100, 2540–2550.

160 Lee SP, Nicholls JF, Park HZ (1992) Biliary sludge as a cause of acute pancreatitis. *N Engl J Med* 326, 589–593.

161 Law CH, McKay D, Tandan VR (2004) Gallstone disease. In: McDonald JW, Burroughs AK, Feagan BG (eds) *Evidence-based Gastroenterology and Child Health*. Oxford: Blackwell Publishing, pp. 311–320.

162 Neoptolemos JP, Carr-Locke DL, London NJ *et al*. (1988) Controlled trial of urgent endoscopic retrograde cholangiopancreatography and endoscopic sphincterotomy versus conservative treatment for acute pancreatitis due to gallstones. *Lancet* 2, 979–983.

163 Fölsch UR, Nitsche R, Ludtke R *et al*. (1997) Early ERCP and papillotomy compared with conservative treatment for acute biliary pancreatitis. The German Study Group on Acute Biliary Pancreatitis. *N Engl J Med* 336, 237–242.

164 Sharma VK, Howden CW (1999) Metaanalysis of randomized controlled trials of endoscopic retrograde cholangiography and endoscopic sphincterotomy for the treatment of acute biliary pancreatitis. *Am J Gastroenterol* 94, 3211–3214.

165 Ayub K, Imada R, Slavin J (2004) Endoscopic retrograde cholangiopancreatography in gallstone-associated acute pancreatitis. *Cochrane Database Syst Rev* CD003630.

166 Kelly TR, Swaney PE (1982) Gallstone pancreatitis: the second time around. *Surgery* 92, 571–575.

167 Nealon WH, Bawduniak J, Walser EM (2004) Appropriate timing of cholecystectomy in patients who present with moderate to severe gallstone-associated acute pancreatitis with peripancreatic fluid collections. *Ann Surg* 239, 741–749.

168 Hernandez V, Pascual I, Almela P *et al*. (2004) Recurrence of acute gallstone pancreatitis and relationship with cholecystectomy or endoscopic sphincterotomy. *Am J Gastroenterol* 99, 2417–2423.

169 Cornud F, Grenier P, Belghiti J *et al*. (1981) Mirizzi syndrome and biliobiliary fistulas: roentgenologic appearance. *Gastrointest Radiol* 6, 265–268.

170 Glenn F, Reed C, Grafe WR (1981) Biliary enteric fistula. *Surg Gynecol Obstet* 153, 527–531.

171 Kasahara Y, Umemura H, Shiraha S *et al*. (1980) Gallstone ileus. Review of 112 patients in the Japanese literature. *Am J Surg* 140, 437–440.

172 Van Hillo M, van der Vliet JA, Wiggers T *et al*. (1987) Gallstone obstruction of the intestine: an analysis of ten patients and a review of the literature. *Surgery* 101, 273–276.

173 Frulloni L, Cavallini G (2001) Acute recurrent pancreatitis and dysfunction of the sphincter of Oddi: comparison between invasive and non-invasive techniques. *J Pancreas* 2, 406–413.

19.4 Cholangitis and biliary tract infections

Ulrich Beuers

The term cholangitis summarizes a spectrum of inflammatory diseases of the biliary tree, both infectious and non-infectious. This chapter focuses on different forms of infectious cholangitis. Non-infectious forms such as primary sclerosing cholangitis (Chapter 11.3) and autoimmune cholangiopathies including chronic destructive non-suppurative cholangitis (primary biliary cirrhosis; Chapter 11.1), autoimmune cholangitis, overlap syndromes of these with autoimmune hepatitis (Chapter 11.5), and congenital ductal cystic abnormalities including Caroli syndrome, choledochal and foregut cyst (Chapter 8.2) are discussed elsewhere.

Bacterial cholangitis

Acute bacterial cholangitis is a severe, potentially life-threatening disease that is characterized by the clinical symptoms summarized as 'Charcot's triad': jaundice, spiking fever (with chills) and right upper quadrant (RUQ) abdominal pain [1]. Mortality from acute bacterial cholangitis has fallen from 100% at the beginning of the last century [2] to < 10% at its end [3] as a result of enormous advances in diagnostic and therapeutic measures.

Pathogenesis

Development of acute cholangitis requires two pathogenetic factors in immunocompetent individuals: (i) the presence of microorganisms in bile and (ii) bile duct obstruction by calculi, benign strictures or a malignant disease, leading to increased intraductal pressure [1]. Bacteria in a normal bile duct with low pressure (8–12 cmH_2O) do not cause clinical cholangitis, as can be observed after routine endoscopic retrograde cholangiography when cholangitis is only observed in a very low percentage of patients [4], although bacterial contamination of the biliary tree can barely be avoided. Experimental studies indicate that transfer of bacteria from bile to blood mainly via a transcellular route requires an elevation of biliary pressure to at least 15–20 cmH_2O [5].

Microorganisms in bile

Bile is usually sterile [6–8]. Anatomical barriers protect bile from being invaded by bacteria both via the haematogenous route by hepatocellular and cholangiocellular gap junctions and via the enteric route by a well-functioning sphincter of Oddi, constant bile flow and the bacteriostatic/bacteriocidal action of bile acids and immunoglobulins, particularly IgA in bile [9]. Risk factors for invasion of bacteria into the biliary tree (bacterobilia) include common bile duct (CBD) stones, benign and, to a markedly lesser degree, malignant biliary strictures, endoscopic sphincterotomy (EST) and biliary endoprosthesis. Obstructive jaundice, recent clinical infections, age > 70 years, diabetes and previous biliary interventions may further enhance the risk of bacterobilia (reviewed in [9]). In the early phase of acute cholangitis, bacteria are detected in at least 75% of bile cultures and often in blood cultures taken during rise in temperature. Mixed infections of bile are found in 30–80% of bacterial cholangitis [10] and in > 80% of cases with severe acute suppurative cholangitis [11]. The most commonly detected bacteria are Gram-negative *Escherichia coli* (44–58%) and *Klebsiella* spp. (14–34%) as well as *Enterococcus* spp. (0–53%) [9,10,12]. *Enterobacter* spp. (5–13%), *Citrobacter* spp. (0–6%), *Proteus* spp. (3–10%) and anaerobes such as *Bacteroides* spp. (1–18%) or *Clostridium* spp. (4–16%) may be found in a minority of cases. After biliary endoscopic or surgical interventions, a mixed flora of the above-mentioned Gram-negative bacteria together with anaerobes or *Pseudomonas* spp. can be expected [13]. Insertion of biliary stents is universally associated with bacterobilia, and stent occlusion frequently leads to bacterial cholangitis. It is generally assumed, but not proven, that bacteria invade the biliary tree under pathological conditions via the duodenum. The pattern of bacteria found in bile mirrors the predominant bacteria isolated from the upper gastrointestinal tract [14].

Bile duct obstruction

The most frequent cause of bacterial cholangitis is choledocholithiasis (see Chapter 19.3). In about 10–15% of patients with cholecystolithiasis, gallbladder stones pass into the CBD,

and this rate may rise to 25% in the elderly. Thus, all patients with symptomatic cholecystolithiasis should be screened for the presence of CBD stones [15]. CBD stones remain undetected in 1–5% of patients after cholecystectomy for symptomatic cholelithiasis. Bile duct stones deriving from the gallbladder are most commonly cholesterol stones. In contrast, those developing in the biliary tree after cholecystectomy, during chronic recurrent cholangitis, during parasitic infections of the biliary tree, due to congenital anatomical anomalies such as Caroli syndrome or due to secondary stricturing, sclerosis and dilatation of the bile ducts are mainly pigment stones. Choledocholithiasis leads to bacterial cholangitis in about 10% of patients, whereas malignant strictures of the biliary tree only exceptionally induce bacterial cholangitis as long as interventions have not been performed.

Diagnosis

The diagnosis of bacterial cholangitis is based on clinical, biochemical and imaging studies. Charcot's triad is observed less frequently today than 25 years ago [16]: while fever is observed in 90% of patients with bacterial cholangitis, jaundice is observed in two out of three patients, and RUQ abdominal pain only in less than half the patients [17]. However, severe cases with sepsis and shock who fulfil Reynold's pentad (Charcot's triad + confusion + hypotension) are still found in 5% of the mostly elderly patients with acute bacterial cholangitis. In addition to clinical symptoms, laboratory tests may be helpful: leucocytosis (> 10 g/L) is common (70%), but leucopenia may be found in the most severe cases [17]. C-reactive protein is elevated at least 10- to 20-fold in many cases. Hyperbilirubinaemia > 2 mg/dL (> 34 μmol/L) in 80% and a two- to fivefold increase in alkaline phosphatase in up to 75% of patients may be indicators of bacterial cholangitis, whereas serum transaminases are markedly elevated only in a minority of patients [17]. Blood cultures are positive in 60% of cases, whereas bile cultures, which are not routinely recommended before the start of antibiotic treatment, may even be positive in 75–100%.

Choledocholithiasis represents the most frequent cause of bacterial cholangitis as outlined above (see Chapter 19.2). A meta-analysis of 22 studies including more than 9000 patients with symptomatic cholecystolithiasis analysed 10 clinical, biochemical and ultrasound findings for the prediction of choledocholithiasis [18]. The positive likelihood ratio (LR+: sensitivity/1–specificity) indicating choledocholithiasis was highest for Charcot's triad (18.3) followed by suspicion of bile duct stones on ultrasound (13.6), jaundice (10.1), a dilated CBD > 6–7 mm (6.9), hyperbilirubinaemia (4.8), elevated alkaline phosphatase (2.6), pancreatitis (2.1), cholecystitis (1.6) and elevated amylase (1.5). None of the criteria alone reached a sufficient sensitivity for the detection of bile duct stones, although 7 out of 10 criteria reached a specificity above 90% [18].

Abdominal ultrasound has a sensitivity of up to 50% in detecting bile duct stones. A CBD > 6 mm enhances its sensitivity to 75% in non-cholecystectomized patients [19]. Conventional abdominal computerized tomography (CT) has a sensitivity similar to ultrasound, but requires more sophisticated technical equipment and is associated with considerable exposure to irradiation. Conventional CT, therefore, has no place in routine clinical practice for the detection of choledocholithiasis. In contrast, endoscopic ultrasound (EUS) has a high sensitivity (95–100%) and specificity (97–98%) for the detection of extrahepatic bile duct stones and has become the diagnostic procedure of choice in centres with highly skilled endoscopists. Magnetic resonance cholangiography (MRC) and helical computerized tomographic cholangiography (HCT-C) have developed recently into highly sensitive and specific (> 85–100%) techniques for the detection of bile duct stones or other causes of biliary obstruction [20–23]. MRC is not invasive and not accompanied by exposure to irradiation. Thus, MRC may be helpful in the diagnostic workup of a patient with bacterial cholangitis in centres equipped with up-to-date technology. The accuracy of HCT-C for detection of choledocholithiasis appears to be comparable to MRC, but HCT-C is associated with exposure to irradiation and a risk of adverse reactions to the contrast agent administered intravenously [20].

Endoscopic retrograde cholangiography (ERCP) remains the gold standard for concomitant detection and treatment of choledocholithiasis [24]. In experienced hands, a sensitivity of 90–100% and a specificity > 90% for the detection of bile duct stones are reached. Although accompanied by complications such as pancreatitis, cholangitis or bleeding after EST, this procedure combines high diagnostic accuracy with the option of efficient bile drainage after obstruction by stones or strictures. Adequate drainage can be achieved by extraction of stones, dilatation of strictures and biliary decompression via stenting or temporary nasobiliary drainage [24].

Treatment

Therapeutic measures are directed against the key pathogenetic factors of cholangitis, microorganisms in bile and obstruction of bile flow. Thus, adequate antibiotic treatment and decompression and drainage of the biliary tree are equally warranted [25].

Antibiotic treatment (see Table 1)

The antibiotic is chosen empirically according to: (i) the most common pathogens expected to cause cholangitis (see above); (ii) biliary enrichment and activity of the antibiotic; and (iii) the likelihood of resistance of pathogens in the clinical environment [10]. Ureidopenicillins such as mezlocillin and piperacillin cover Gram-negative bacteria as well as *Enterococcus* spp. more efficiently than aminopenicillins, are effectively secreted into bile not only in health, but also in patients with cholangitis, and may reach biliary levels higher than the mean inhibitory concentration for common biliary pathogens [26]. In addition,

Table 1 Antibiotics recommended for treatment of acute bacterial cholangitis.

Drug	Gram-neg.	*Enterococcus* spp.	*Pseudomonas* spp.	Anaerobes	Dose i.v.[a]	Oral
Amoxicillin + clavulanic acid	+	±		±	3 × 2.2 g	+
Ampicillin + sulbactam	+	±		±	3 × 3 g	+
Mezlocillin[b]	+	+		±	3 × 5 g	
Mezlocillin + combactam	+	+		+	M: 3 × 5 g; C: 3 × 1 g	
Piperacillin[b]	+	+	+	±	3 × 4 g	
Piperacillin + tazobactam	+	+	+	+	3 × 4.5 g	
Ceftazidim (group 3b ceph.)	+		+		3 × 2 g	
Cefotaxim (group 3a ceph.)	+				3 × 2 g	
Cefuroxim (group 2 ceph.)	+				4 × 1.5 g	
Ciprofloxacin (group 2 fluo.)[b]	+	±	+		3 × 0.4 g	+
Moxifloxacin (group 4 fluo.)	+	+	+	+	1 × 0.4 g	+
Imipenem/meropenem	+	+	+	+	3 × 1 g	
Metronidazole				+	3 × 0.5 g	+

Adequate coverage of Gram-negative enterobacteriaceae (*E. coli*, *Klebsiella* spp., *Enterobacter* spp., *Citrobacter* spp. and *Proteus* spp.), *Enterococcus* spp. and, in the case of previous endoscopic/surgical interventions at the biliary tree, *Pseudomonas* spp. appears to be crucial in the empirical selection of antibiotic treatment for bacterial cholangitis [10]. Thus, aminopenicillins + beta-lactamase inhibitors, ureidopenicillins (+ beta-lactamase inhibitors), group 2 or 3 cephalosporins (+ metronidazole) or group 2 fluoroquinolones (+ metronidazole) appear to be useful as first-line treatment considering the spectrum of bacteria covered, potential side-effects and costs. Aminoglycosides (e.g. gentamicin, tobramycin, gernebcin; cave: oto-, nephrotoxicity, aggravated in cholestasis), active against Gram-negative bacteria and *Pseudomonas* spp., and vancomycin, active against *Enterococcus* spp., are inadequately excreted into bile. Group 4 fluoroquinolones and carbapenemes should be reserved for severe cases unresponsive to other treatment options.

[a]Dose: a high daily dose for adults with normal kidney and liver function is provided (adaptation to the individual case needed).

[b]Increasing rates of resistance against ureidopenicillins (monotherapy) and ciprofloxacin have been observed recently in some areas for *E. coli* and other Gram-negative bacteria.

effective biliary bactericidia has been shown *in vivo* [27]. The addition of a beta-lactamase inhibitor broadens the spectrum of amino- and ureidopenicillins and diminishes bacterial resistance. Most recently, increasing resistance rates of Gram-negative bacteria, including *E. coli*, against ureidopenicillins have made the use of a combination of ureidopenicillins with beta-lactamase inhibitors mandatory in some areas. Cephalosporins (groups 2 and 3) also cover Gram-negative bacteria and are adequately excreted into bile, but are less effective against *Enterococcus* spp. and *Pseudomonas aeruginosa* [10]. Ciprofloxacin is excreted into bile effectively, can be administered orally and covers Gram-negative bacteria and *Pseudomonas aeruginosa* [10], although increasing resistance rates have been reported recently. The new generation fluoroquinolone (group 4), moxifloxacin, is also effectively secreted into bile not only in health, but also in obstructive cholangitis, reaching biliary concentrations sufficiently above the minimal inhibitory concentrations for most of the expected bacteria including *Enterococcus* spp. and anaerobes [28]. Imipenem/meropenem represent potent parenteral antibiotics that cover the whole spectrum of bacteria causing ascending cholangitis including Gram-negative strains, *Pseudomonas aeruginosa*, *Enterococcus* spp. and anaerobes [10]. They should, however, be reserved for the most severe, life-threatening infections when other regimens have failed (Table 1). Short-term duration (3 days) of antibiotic treatment appears to be sufficient when adequate drainage is achieved and fever is abating [29].

Decompression of bile ducts

Severe bacterial cholangitis requires immediate mechanical decompression of the biliary tree. A prospective analysis of a cohort of patients with clinical signs of acute cholangitis revealed that a heart rate > 100/min, serum albumin < 30 g/L, serum bilirubin > 50 μmol/L (≥ 3 mg/dL) and/or a prothrombin time > 14 s (normal ≤ 13.2 s) each indicated the need for an emergency intervention, which had to be performed in 40% of those who fulfilled at least one criterion on admission, but in only 1.5% of those who did not [30]. ERCP is the therapeutic procedure of choice which allows, after EST [24,31,32] [or endoscopic balloon dilatation (EBD) of the papilla in patients with coagulopathy and small calculi [33] [34] [35]], extraction of calculi, stenting of stenoses or biliary drainage via a nasobiliary tube [36]. Stenting has been shown to be equivalent to nasobiliary drainage in the acute management of severe obstructive cholangitis [37]. Pregnancy [38] or advanced age [39] are not contraindications for ERCP. Only when ERCP cannot be performed for technical reasons (e.g. after Billroth II and other gastrointestinal surgery, or tumour growth impairing endoscopic access to the biliary tree), should the percutaneous transhepatic route be chosen to achieve biliary decompression.

Table 2 Recommendations for antibiotic prophylaxis prior to surgical, transcutaneous (PTC/PTBD) or endoscopic (ERCP) interventions at the biliary tree.

Intervention	Rate of infectious complications	Recommended antibiotic regimen	Reference
Biliary tract surgery	Wound infection15% (range 3–47%)	beta-lactam antibacterial (e.g. cefuroxime, ceftriaxone, cefotaxime, piperacillin) or fluoroquinolone 1 h before surgery	[40] [10]
PTC/PTBD	Cholangitis ≤ 30%	beta-lactam antibacterial (cephalosporin or ureidopenicillin ± beta-lactamase inhibitor) or fluoroquinolone	[41,42]
ERCP i) no biliary obstruction ii) biliary obstruction expected and/or unrelieved iii) sclerosing cholangitis iv) immunodeficiency (e.g. post liver transplant, HIV)	Cholangitis 1–2%	 i) none ii) beta-lactam antibacterial (cephalosporin or ureidopenicillin ± beta-lactamase inhibitor) or fluoroquinolone, until obstruction relieved (see Table 1) iii and iv) ciprofloxacin 750 mg p.o.2 h before and 6 h after ERCP or beta-lactam antibacterial i.v. (optimal dose and length of treatment unknown)	[49] [44] [10] [9]

Controlled trials have been published for antibiotic prophylaxis prior to surgical and endoscopic, but not transcutaneous, interventions.

Prophylaxis

The risk of infectious complications after surgical, percutaneous or endoscopic interventions at the biliary tree is known (see Table 2).

Wound infections after biliary tract surgery

After biliary tract surgery, the rate of wound infections was reported to be 15% (range 3–47%), as documented in a meta-analysis encompassing 42 randomized controlled trials with 4125 patients [40]. Risk factors included an age > 60 years, CBD stones, previous biliary tract interventions, jaundice, morbid obesity and diabetes mellitus. Antibiotic prophylaxis with beta-lactam antibacterials (e.g. cefuroxime, ceftriaxone, cefotaxime, piperacillin) was shown to effectively diminish the rate of wound infections in these cohorts by 9%. A single dose before surgery was as effective as multiple doses. Fluoroquinolones have more recently been shown to be as effective as common beta-lactam antibacterials [10].

Cholangitis after percutaneous transhepatic cholangiography (PTC)/biliary drainage (PTBD)

After PTC, the effect of antibiotic prophylaxis has not been studied in trials comparable to those after surgery or ERCP. However, the frequency of cholangitis, which reaches up to 30% after PTBD [41,42], may justify regular use of antibiotic prophylaxis until appropriate clinical trials are available. A protocol such as the one mentioned below for patients at risk of post-ERCP cholangitis may be considered.

Cholangitis after endoscopic retrograde cholangiography

After ERCP, cholangitic sepsis was observed in 1.4% of 10 881 patients studied for post-ERCP complications in 10 large cohorts [9] and in 2% of a large unselected population of 10 000 patients assembled by postal questionnaires [4]. Mortality of post-ERCP cholangitis reached 10% [4] to 16% in severe cases [43], but was only 2.9% in a series of prospective, placebo-controlled trials on the use of antibiotic prophylaxis, in which 6.5% of 539 placebo-treated patients developed cholangitis [9].

Risk factors for septicaemia following endoscopic biliary stenting were incomplete drainage, prior cholangitis, elevated white blood cell count, bile duct strictures and number of ERCs in 347 patients with obstructive cholestasis studied prospectively [44]. Incomplete drainage alone predicted 91% of cases with subsequent septicaemia.

These data suggest that antibiotic prophylaxis before/after ERCP should be restricted to: (i) patients with unrelieved biliary obstructions – antibiotic treatment should be continued in these patients until complete biliary drainage is achieved; (ii) patients with (primary) sclerosing cholangitis as they are at particular risk of at least focal incomplete biliary drainage and chronic bacterobilia after ERCP; and (iii) immunocompromised individuals at high risk of infectious complications [e.g. post liver transplant; human immunodeficiency virus (HIV)] (see Table 2). A regimen of ciprofloxacin, 750 mg p.o. 2 h before ERCP (or directly afterwards when the diagnosis is just made) and 6 h after ERCP, has been proposed [9] and can be recommended as first-line antibiotic prophylaxis in these patients, as it appropriately considers activity against the bacterial spectrum expected, adequate biliary drug enrichment even in cholestasis, drug tolerability and costs [9]. No valid data exist regarding the optimal duration of prophylactic treatment after endoscopic interventions.

Recurrent cholangitis after biliodigestive anastomosis

Patients who are at risk of recurrent cholangitis independently of surgical, percutaneous or endoscopic interventions at the biliary tree, such as those with recurrent ascending cholangitis

after biliodigestive anastomosis, may need long-term antibiotic prophylaxis to avoid the development of biliary fibrosis/cirrhosis. As an alternative to oral fluoroquinolones, cotrimoxazole (trimethoprim/sulphamethoxazole) has been proposed for long-term use in these patients at risk [10].

Recurrent pyogenic cholangitis

Recurrent pyogenic cholangitis (RPC; synonyms: oriental cholangiohepatitis, hepatolithiasis) is characterized by intrahepatic pigment gallstone formation, biliary strictures and dilatations mainly of the intrahepatic bile ducts, and recurrent episodes of febrile bacterial cholangitis [45,46]. RPC is mostly restricted to Southeast Asian countries and emigrants from this part of the world. RPC is mainly found in rural areas and areas with a low socioeconomic status. Patients present with first symptoms at the age of 20–40 years, but may also become symptomatic at a more advanced age. Overall mortality was 10.3% in one long-term study of 427 patients undergoing surgical or non-surgical transcutaneous treatment [47].

Pathogenesis

The aetiology of RPC remains unknown. Parasitic infections [48] and malnutrition [49] have been suggested to be responsible for the development of RPC. More recently, congenital anomalies of the biliary tree and immunological anomalies have also become a matter for discussion [45,46].

Parasitic infections

The similarity in the geographical distribution of RPC and parasites of the biliary system such as *Clonorchis sinensis*, *Opisthorchis viverrini* and *Opisthorchis felineus* in Asia and *Ascaris lumbricoides* outside Asia is obvious. Nevertheless, RPC is found in certain areas in Asia that are virtually free of *Clonorchis* infection, and *Clonorchis* infection is mainly found in males, whereas RPC affects both genders equally. Past or present parasite infection has been disclosed in up to 45% of patients with RPC [48]. Also, analysis of pigment stones in RPC revealed the presence of parasite debris. *Clonorchis* infection may lead to severe damage to the bile ducts, particularly the left-sided ducts, which are also mainly involved in RPC [50]. Thus, epithelial damage and biliary obstruction by parasitic infestation have been assumed to be the initiating insult leading to RPC.

Malnutrition

The poor nutritional status of many RPC patients has led to the assumption that malnutrition may play a pathogenetic role in RPC [50]. Recurrent bacterial gastroenteritis of the malnourished with invasion of bacteria into the portal vein and bacterial transition into bile was discussed as one pathogenetic mechanism. Low-protein nutrition with consecutive deficiency of biliary glucaro-1:4-lactone, an inhibitor of bacterial β-glucuronidase, and enhanced bacterial deconjugation of bilirubin glucuronides with subsequent calcium bilirubinate precipitation as a nidus for pigment gallstone formation and biliary obstruction were discussed as alternative pathogenetic mechanisms [46]. A decline in the incidence of RPC both in Asia and in Asians immigrating to western countries supports a role for malnutrition and biliary parasitic infections in RPC.

Diagnosis

Clinical symptoms are those of acute bacterial cholangitis and include Charcot's triad with jaundice, spiking fever and RUQ abdominal pain. Hepatomegaly is a frequent finding, and the gallbladder may be enlarged. Leucocytosis and a cholestatic serum enzyme pattern indicate obstructive cholangitis. Blood and bile cultures reveal a pattern of bacteria almost identical to that found in acute bacterial cholangitis (*E. coli*, *Klebsiella* spp., *Proteus* spp. and rarely anaerobes). Mixed infections are also commonly observed. Cholangiography preferably via the endoscopic route (ERCP) reveals dilatation of extra- and large intrahepatic bile ducts, biliary strictures at the papilla and at intrahepatic sites and typical involvement specifically of the lateral part of the left hepatic duct. Bile ducts are filled with debris and small stones in up to 100% of patients. Differentiation of RPC from sclerosing cholangitis or congenital cystic duct abnormalities may be difficult in some cases.

The high incidence of parasitoses in patients with RPC, e.g. *Clonorchis* infection, should stimulate examination of stool or biliary debris for ova.

Complications of RPC include Gram-negative septicaemia and septic shock, empyema of the gallbladder, rupture or fistulization of an obstructed intrahepatic bile duct into neighbouring structures, haemobilia, portal vein thrombosis, abscesses in liver, lungs and brain, biliary cirrhosis, acute pancreatitis and cholangiocarcinoma mainly in the left atrophic lobe (in 3% of a cohort of 427 patients followed for 4–10 years [47]).

Treatment

Acute cholangitis in RPC is managed as outlined above for bacterial cholangitis [45]. The majority of patients will respond to fluid substitution, broad-spectrum antibiotics (see Table 1) and endoscopic (if not available, percutaneous or surgical) measures including removal of biliary stones and debris, dilatation of stenoses, stenting or nasobiliary or transcutaneous biliary drainage [45,46]. Emergency surgery of acute cholecystitis or bile duct perforation is needed infrequently.

Long-term management of RPC is more difficult [45,46] as complete removal of extra- and intrahepatic stones and debris as well as adequate treatment of strictures by endoscopic or transcutaneous measures will be successful only in a subgroup of RPC patients, leaving the majority at high risk of recurrent attacks of cholangitis and sepsis [51]. Also, surgical stone removal is complete in only a minority of cases, as documented

in a recent series of only 55 successfully treated out of 245 RPC patients who underwent surgical choledocholithotomy. Complete postoperative stone removal via the T-tube, however, was then achieved in 88% of those patients [52]. Thus, many RPC patients, particularly those with remaining stones in the intrahepatic ducts and RPC restricted to the left hepatic ducts, are candidates for elective surgical treatment [53]. In isolated left hepatic RPC, left hepatic lobectomy has been shown to prevent recurrent stone disease in a larger percentage than left lateral segmentectomy [54,55]. In RPC patients with recurrent stone disease, end-to-side (rather than side-to-side) Roux-en-Y choledochojejunostomy with a lateral limb that was brought out as a cutaneous stoma has recently been proposed as a potential surgical approach [56] when endoscopic measures alone are ineffective. Laparoscopic segmentectomy and laparoscopic choledochoduodenostomy have recently been described as safe, feasible and effective surgical treatments for patients with RPC [57,58].

AIDS-related cholangitis

Cholestasis and liver injury are a common feature in HIV-infected patients, of which acquired immunodeficient syndrome (AIDS)-related cholangitis (synonym: HIV cholangiopathy) represents only one of a considerable number of different causes. Elevation of serum biochemical markers of cholestasis such as alkaline phosphatase and γ-glutamyltransferase levels has been reported in up to 55% of patients [59]. These alterations can be explained in part by concomitant infections with hepatitis B or C or alcohol abuse. Also, drugs represent a major cause of liver damage in HIV-infected patients and may cause relevant liver injury in up to 10% of patients under highly active antiretroviral therapy (HAART) with nucleoside and non-nucleoside reverse transcriptase inhibitors or protease inhibitors [60]. Antimicrobial agents such as the macrolides clarithromycin and azithromycin for the prophylaxis of respiratory infections and *Mycobacterium avium* complex (MAC) disease, trimethoprim–sulphamethoxazole for the prophylaxis and treatment of *Pneumocystis carinii* pneumonia, antifungal agents such as ketoconazole, itraconazole, and, to a lesser extent, fluconazole for the treatment of oesophageal candidiasis and systemic mycoses, and antituberculosis agents such as isoniazid, rifampin and pyrazinamide are associated with considerable rates of hepatotoxicity.

Systemic infections with involvement of the hepatobiliary system accompanying HIV disease include bacillary angiomatosis caused by *Rochalimaea henselae* and *R. quintana*, mycobacterial infections including MAC and *Mycobacterium tuberculosis*, as well as fungal infections with *Cryptococcus neoformans*, *Coccidioides imitis*, *Sporothrix schenckii* or histoplasmosis.

Beside these numerous causes of hepatobiliary injury in HIV disease, a specific type of cholangitis, first reported in 1986 [61], has been described mainly in the advanced stages of HIV infection, which resembles primary sclerosing cholangitis and has been named HIV cholangiopathy.

Pathogenesis

The cause of HIV cholangiopathy is unclear, but is most probably infectious. No single causative agent has been identified so far. In biopsy specimens, cytomegalovirus, *Cryptosporidium*, microsporidia and MAC have all been isolated, albeit at variable rates from occasional up to 75% [59].

Diagnosis

Clinical signs and symptoms include epigastric or RUQ abdominal pain (73–90%) and fever (50–65%), whereas jaundice and pruritus are uncommon. Alkaline phosphatase is markedly [mean five- to sevenfold upper limit of normal (ULN)] elevated in almost all patients, and serum transaminases are only mildly elevated. Abdominal ultrasound and CT scan are of limited diagnostic help. ERCP or MRC disclose the typical features of bile duct damage, and four patterns of HIV cholangiopathy have been described [62]: (i) sclerosing cholangitis and papillary stenosis (50%); (ii) papillary stenosis alone (15%); (iii) intrahepatic sclerosing cholangitis (20%); and (iv) extrahepatic bile duct strictures with or without intrahepatic sclerosing cholangitis (15%). Liver histology reveals features of cholangitis with portal oedema, neutrophilic infiltrations, bile ductular proliferation and cholestasis.

Treatment

Treatment of HIV cholangiopathy [59,63] includes EST in symptomatic patients with papillary stenosis, which may cause relief of RUQ pain, but does not regularly affect biochemical abnormalities [64,65]. Medical treatment with ursodeoxycholic acid improves cholestasis, but the long-term effects are unknown. In contrast, treatment of opportunistic pathogens does not seem to have an effect on HIV cholangiopathy. In studies in the 1990s, survival of patients suffering from HIV cholangiopathy was poor [64,65], mainly due to progression of the underlying HIV disease, indicating that HIV cholangiopathy is a late manifestation of HIV infection. Improvement in prognosis, most probably due to HAART, has been shown recently [66].

Parasitic cholangitis

Biliary parasites are responsible for cholangitic features at considerable rates in different areas of the world. The nematode *Ascaris lumbricoides*, the trematodes ('liver flukes') *Clonorchis sinensis*, *Fasciola hepatica*, *Opisthorchis viverrini* and *Opisthorchis felineus*, and the cestodes *Echinococcus granulosus* and *Echinococcus multilocularis* are the most common biliary parasites.

Pathogenesis

Bile duct damage with cholangiocyte necrosis, cholangitis, strictures, focal bile duct dilatations and biliary fibrosis is supposed to be caused both by the parasites themselves and by additional bacterial superinfection [67]. Parasite-induced damage and inflammation may be induced by chemical irritation of biliary endothelia by parasitic secretion and parasite eggs, mechanical bile duct obstruction and initiation of pigment stone formation. In addition, parasite-induced bacterial contamination together with mechanical obstruction may be responsible for episodes of acute cholangitis.

Subgroups: diagnosis and treatment (Table 3)

Nematode cholangitis (see Chapter 10.4.3)

The nematode *Ascaris lumbricoides* may cause cholangitis worldwide, but is reported as a major cause of cholangitis and biliary pain mainly in (often young) patients from tropical and subtropical areas [68], e.g. India or South America. Nematode eggs are mostly ingested with contaminated vegetables via the oral route. Cholangitis is usually induced by migration of L5 larvae or young adult worms into the biliary tree where they may cause – in conjunction with comigrating intestinal bacteria – suppurative cholangitis, biliary obstruction, abscesses, cholangiectases, sometimes papillary hyperplasia, gallstone formation and biliary fibrosis, and even cirrhosis. The diagnosis of *Ascaris lumbricoides* cholangitis is made by blood eosinophilia and stool examination (low specificity), ultrasound, CT and ERCP. The treatment includes antibiotics for bacterial superinfection, antispasmotics for pain relief and anthelminthic drugs (mebendazole 100 mg b.i.d. for 3 days; albendazole 400 mg daily for 3 days; pyrantel 10 mg/kg body weight once). Worms can then be removed via the endoscopic route.

Trematode ('liver fluke') cholangitis

The digenetic trematodes *Clonorchis sinensis*, *Opisthorchis felineus* and *Opisthorchis viverrini* are found mainly in Asia and in Asian immigrants to other parts of the world [69]. They undergo a biphasic life cycle in an intermediate host (a freshwater snail and subsequently freshwater fish) and a definitive host, a mammal. Trematode eggs are passed in the faeces of the definitive host, and develop to ciliated microcidia in fresh water, which are ingested by or penetrate into snails and multiply into tailed cercariae. Cercariae are taken up by or penetrate freshwater fish. Humans and other mammals develop liver fluke cholangitis after ingestion of raw infected fish. After infection, patients are often asymptomatic, but may develop recurrent cholangitis, secondary gallstone disease and fibrosing bile duct alterations. Long-term biliary infection is a serious risk factor for the development of cholangiocarcinoma [70]. The diagnosis is made by detection of ova in the stool or in bile. Praziquantel, 25 mg/kg body weight t.i.d. for 1 day, is the treatment of choice. Alternatively, albendazole 400 mg b.i.d. for 7 days can be administered.

Fasciola hepatica [71] is found worldwide. Definitive hosts are mainly cattle and sheep, but humans may also be infected after ingestion of contaminated watercress or other waterplants. Signs and symptoms of cholangitis together with blood eosinophilia develop in the early migratory phase of infection. Later, eosinophilic infiltrates, liver abscesses and fibrosing cholangitis are observed. The diagnosis is made by detection of ova in stool or bile, fasciola antigen in stool and a serological test. Triclabendazole, 10 mg/kg body weight after a meal on one or two subsequent days, is the preferred treatment.

Cestode cholangitis (see Chapter 10.4.2)

Infections with the cestodes *Echinococcus granulosus* and *Echinococcus multilocularis* are discussed in detail elsewhere. For treatment, see also Table 3.

Table 3 Parasitic cholangitis.

	Parasite	Source of infection (distribution)	Anthelminthic medical treatment options
Nematodes	*Ascaris lumbricoides*	Vegetables (worldwide, but mainly Asia and South America)	Mebendazole (100 mg b.i.d., 3 days) Albendazole (400 mg daily, 3 days) Pyrantel (10 mg/kg body weight once)
Trematodes	i) *Clonorchis sinensis* i) *Opisthorchis felineus* i) *Opisthorchis viverrini* ii) *Fasciola hepatica*	i) Raw freshwater fish (Asia and Eastern Europe) ii) Watercress and other waterplants	i) Praziquantel (25 mg/kg body weight, t.i.d., 1 day) i) Albendazole (400 mg b.i.d., 7 days) ii) Triclabendazole (10 mg/kg body weight once, 1 or 2 days)
Cestodes	*Echinococcus granulosus* *Echinococcus multilocularis*	Vegetables or wild fruits contaminated with fox (or dog) faeces (worldwide)	Albendazole (12–15 mg/kg body weight daily in two doses, for adults 400 mg b.i.d., 3 months) Mebendazole (50–60 mg/kg body weight daily in three doses during meals, 3–12 months)

References

1 Dooley JS (1999) Cholangitis and biliary tract infections. In: Bircher H, Benhamou, JP, McIntyre N *et al.* (eds) *Oxford Textbook of Clinical Hepatology*. Oxford: Oxford University Press, pp. 1649–1656.

2 Rogers L (1903) Biliary abscesses of the liver: with operation. *Br Med J* 2, 706–707.

3 Lee JG (1998) Role of endoscopic therapy in cholangitis. *Am J Gastroenterol* 93, 2016–2018.

4 Bilbao MK, Dotter CT, Lee TG *et al.* (1976) Complications of endoscopic retrograde cholangiopancreatography (ERCP). A study of 10,000 cases. *Gastroenterology* 70, 314–320.

5 Huang T, Bass JA, Williams RD (1969) The significance of biliary pressure in cholangitis. *Arch Surg* 98, 629–632.

6 Csendes A, Fernandez M, Uribe P (1975) Bacteriology of the gallbladder bile in normal subjects. *Am J Surg* 129, 629–631.

7 Nielsen ML, Justesen T (1976) Anaerobic and aerobic bacteriological studies in biliary tract disease. *Scand J Gastroenterol* 11, 437–446.

8 Hatfield AR, Leung T, Ahmet Z *et al.* (1982) The microbiology of direct bile sampling at the time of endoscopic retrograde cholangiopancreatography. *J Infect* 4, 119–125.

9 Subhani JM, Kibbler C, Dooley JS (1999) Review article: antibiotic prophylaxis for endoscopic retrograde cholangiopancreatography (ERCP). *Aliment Pharmacol Ther* 13, 103–116.

10 Westphal JF, Brogard JM (1999) Biliary tract infections: a guide to drug treatment. *Drugs* 57, 81–91.

11 Shimada K, Noro T, Inamatsu T *et al.* (1981) Bacteriology of acute obstructive suppurative cholangitis of the aged. *J Clin Microbiol* 14, 522–526.

12 Leung JW, Ling TK, Chan RC *et al.* (1994) Antibiotics, biliary sepsis, and bile duct stones. *Gastrointest Endosc* 40, 716–721.

13 Pitt HA, Postier RG, Cameron JL (1982) Biliary bacteria: significance and alterations after antibiotic therapy. *Arch Surg* 117, 445–449.

14 Bapat RD, Supe AN, Patwardhan A *et al.* (1996) Biliary sepsis: an ascending infection. *Ind J Gastroenterol* 15, 126–128.

15 EAES Consensus (1998) Diagnosis and treatment of common bile duct stones (CBDS). Results of a consensus development conference. Scientific Committee of the European Association for Endoscopic Surgery (EAES). *Surg Endosc* 12, 856–864.

16 Boey JH, Way LW (1980) Acute cholangitis. *Ann Surg* 191, 264–270.

17 Keaveny AP (2000) Infections of the bile ducts. In: Afdhal NH (ed.) *Gallbladder and Biliary Tract Diseases*. New York: Marcel Dekker, pp. 823–842.

18 Abboud PA, Malet PF, Berlin JA *et al.* (1996) Predictors of common bile duct stones prior to cholecystectomy: a meta-analysis. *Gastrointest Endosc* 44, 450–455.

19 Majeed AW, Ross B, Johnson AG *et al.* (1999) Common duct diameter as an independent predictor of choledocholithiasis: is it useful? *Clin Radiol* 54, 170–172.

20 Kondo S, Isayama H, Akahane M *et al.* (2005) Detection of common bile duct stones: comparison between endoscopic ultrasonography, magnetic resonance cholangiography, and helical-computed-tomographic cholangiography. *Eur J Radiol* 54, 271–275.

21 Varghese JC, Liddell RP, Farrell MA *et al.* (2000) Diagnostic accuracy of magnetic resonance cholangiopancreatography and ultrasound compared with direct cholangiography in the detection of choledocholithiasis. *Clin Radiol* 55, 25–35.

22 de Ledinghen V, Lecesne R, Raymond JM *et al.* (1999) Diagnosis of choledocholithiasis: EUS or magnetic resonance cholangiography? A prospective controlled study. *Gastrointest Endosc* 49, 26–31.

23 Fulcher AS, Turner MA, Capps GW *et al.* (1998) Half-Fourier RARE MR cholangiopancreatography: experience in 300 subjects. *Radiology* 207, 21–32.

24 Classen M, Tytgat GNJ, Lightdale CJ (2002) *Gastroenterological Endoscopy*. Stuttgart: Thieme.

25 Lum DF, Leung JW (2001) Bacterial cholangitis. *Curr Treat Options Gastroenterol* 4, 139–146.

26 Dooley JS, Hamilton-Miller JM, Brumfitt W *et al.* (1984) Antibiotics in the treatment of biliary infection. *Gut* 25, 988–998.

27 Wacha H, Helm EB (1982) Efficacy of antibiotics in bacteriobilia. *J Antimicrob Chemother* 9(Suppl. A), 131–137.

28 Schwab D, Grauer M, Hahn EG *et al.* (2005) Biliary secretion of moxifloxacin in obstructive cholangitis and the non-obstructed biliary tract. *Aliment Pharmacol Ther* 22, 417–422.

29 van Lent AU, Bartelsman JF, Tytgat GN *et al.* (2002) Duration of antibiotic therapy for cholangitis after successful endoscopic drainage of the biliary tract. *Gastrointest Endosc* 55, 518–522.

30 Hui CK, Lai KC, Yuen MF *et al.* (2001) Acute cholangitis – predictive factors for emergency ERCP. *Aliment Pharmacol Ther* 15, 1633–1637.

31 Classen M, Demling L (1974) [Endoscopic sphincterotomy of the papilla of Vater and extraction of stones from the choledochal duct (author's transl.)]. *Dtsch Med Wochenschr* 99, 496–497.

32 Kawai K, Akasaka Y, Murakami K *et al.* (1974) Endoscopic sphincterotomy of the ampulla of Vater. *Gastrointest Endosc* 20, 148–151.

33 Staritz M, Poralla T, Dormeyer HH *et al.* (1985) Endoscopic removal of common bile duct stones through the intact papilla after medical sphincter dilation. *Gastroenterology* 88, 1807–1811.

34 Bergman JJ, Rauws EA, Fockens P *et al.* (1997) Randomised trial of endoscopic balloon dilation versus endoscopic sphincterotomy for removal of bileduct stones. *Lancet* 349, 1124–1129.

35 Baron TH, Harewood GC (2004) Endoscopic balloon dilation of the biliary sphincter compared to endoscopic biliary sphincterotomy for removal of common bile duct stones during ERCP: a metaanalysis of randomized, controlled trials. *Am J Gastroenterol* 99, 1455–1460.

36 Lai EC, Mok FP, Tan ES *et al.* (1992) Endoscopic biliary drainage for severe acute cholangitis. *N Engl J Med* 326, 1582–1586.

37 Sharma BC, Kumar R, Agarwal N *et al.* (2005) Endoscopic biliary drainage by nasobiliary drain or by stent placement in patients with acute cholangitis. *Endoscopy* 37, 439–443.

38 Kahaleh M, Hartwell GD, Arseneau KO *et al.* (2004) Safety and efficacy of ERCP in pregnancy. *Gastrointest Endosc* 60, 287–292.

39 Hui CK, Liu CL, Lai KC *et al.* (2004) Outcome of emergency ERCP for acute cholangitis in patients 90 years of age and older. *Aliment Pharmacol Ther* 19, 1153–1158.

40 Meijer WS, Schmitz PI, Jeekel J (1990) Meta-analysis of randomized, controlled clinical trials of antibiotic prophylaxis in biliary tract surgery. *Br J Surg* 77, 283–290.

41 Rosch T, Triptrap A, Born P *et al.* (2003) Bacteriobilia in percutaneous transhepatic biliary drainage: occurrence over time and clinical sequelae. A prospective observational study. *Scand J Gastroenterol* 38, 1162–1168.

42 Nomura T, Shirai Y, Hatakeyama K (1999) Bacteribilia and cholangitis after percutaneous transhepatic biliary drainage for malignant biliary obstruction. *Dig Dis Sci* 44, 542–546.

43 Benchimol D, Bernard JL, Mouroux J *et al.* (1992) Infectious complications of endoscopic retrograde cholangio-pancreatography managed in a surgical unit. *Int Surg* 77, 270–273.

44 Motte S, Deviere J, Dumonceau JM *et al.* (1991) Risk factors for septicemia following endoscopic biliary stenting. *Gastroenterology* 101, 1374–1381.

45 Jeyarajah DR (2004) Recurrent pyogenic cholangitis. *Curr Treat Options Gastroenterol* 7, 91–98.

46 Mahadevan U, Bass NM (2002) Sclerosing cholangitis and recurrent pyogenic cholangitis. In: Feldman M, Friedman LS, Sleisenger MH (eds) *Sleisenger & Fordtran's Gastrointestinal and Liver Disease*. Philadelphia: Saunders, pp. 1131–1152.

47 Jan YY, Chen MF, Wang CS *et al.* (1996) Surgical treatment of hepatolithiasis: long-term results. *Surgery* 120, 509–514.

48 Carmona RH, Crass RA, Lim RC Jr *et al.* (1984) Oriental cholangitis. *Am J Surg* 148, 117–124.

49 Chou ST, Chan CW (1980) Recurrent pyogenic cholangitis: a necropsy study. *Pathology* 12, 415–428.

50 Lim JH (1990) Radiologic findings of clonorchiasis. *AJR Am J Roentgenol* 155, 1001–1018.

51 Tanaka M, Ikeda S, Ogawa Y *et al.* (1996) Divergent effects of endoscopic sphincterotomy on the long-term outcome of hepatolithiasis. *Gastrointest Endosc* 43, 33–37.

52 Cheng YF, Lee TY, Sheen-Chen SM *et al.* (2000) Treatment of complicated hepatolithiasis with intrahepatic biliary stricture by ductal dilatation and stenting: long-term results. *World J Surg* 24, 712–716.

53 Stain SC, Incarbone R, Guthrie CR *et al.* (1995) Surgical treatment of recurrent pyogenic cholangitis. *Arch Surg* 130, 527–532; discussion 532–533.

54 Sun WB, Han BL, Cai JX (2000) The surgical treatment of isolated left-sided hepatolithiasis: a 22-year experience. *Surgery* 127, 493–497.

55 Leow CK, Lau WY (1998) Re: Biliary access procedure in the management of oriental cholangiohepatitis. *Am Surg* 64, 99.

56 Gott PE, Tieva MH, Barcia PJ *et al.* (1996) Biliary access procedure in the management of oriental cholangiohepatitis. *Am Surg* 62, 930–934.

57 Tang CN, Tai CK, Siu WT *et al.* (2005) Laparoscopic treatment of recurrent pyogenic cholangitis. *J Hepatobiliary Pancreat Surg* 12, 243–248.

58 Tang CN, Tai CK, Ha JP *et al.* (2005) Laparoscopy versus open left lateral segmentectomy for recurrent pyogenic cholangitis. *Surg Endosc* 19, 1232–1236.

59 Te HS (2004) Cholestasis in HIV-infected patients. *Clin Liver Dis* 8, 213–228, viii–ix.

60 Spengler U, Lichterfeld M, Rockstroh JK (2002) Antiretroviral drug toxicity – a challenge for the hepatologist? *J Hepatol* 36, 283–294.

61 Margulis SJ, Honig CL, Soave R *et al.* (1986) Biliary tract obstruction in the acquired immunodeficiency syndrome. *Ann Intern Med* 105, 207–210.

62 Cello JP (1992) Human immunodeficiency virus-associated biliary tract disease. *Semin Liver Dis* 12, 213–218.

63 Yusuf TE, Baron TH (2004) AIDS cholangiopathy. *Curr Treat Options Gastroenterol* 7, 111–117.

64 Cello JP, Chan MF (1995) Long-term follow-up of endoscopic retrograde cholangiopancreatography sphincterotomy for patients with acquired immune deficiency syndrome papillary stenosis. *Am J Med* 99, 600–603.

65 Bouche H, Housset C, Dumont JL *et al.* (1993) AIDS-related cholangitis: diagnostic features and course in 15 patients. *J Hepatol* 17, 34–39.

66 Ko WF, Cello JP, Rogers SJ *et al.* (2003) Prognostic factors for the survival of patients with AIDS cholangiopathy. *Am J Gastroenterol* 98, 2176–2181.

67 Carpenter HA (1998) Bacterial and parasitic cholangitis. *Mayo Clin Proc* 73, 473–478.

68 Sandouk F, Haffar S, Zada MM *et al.* (1997) Pancreatic-biliary ascariasis: experience of 300 cases. *Am J Gastroenterol* 92, 2264–2267.

69 Harinasuta T, Pungpak S, Keystone JS (1993) Trematode infections. Opisthorchiasis, clonorchiasis, fascioliasis, and paragonimiasis. *Infect Dis Clin North Am* 7, 699–716.

70 Watanapa P, Watanapa WB (2002) Liver fluke-associated cholangiocarcinoma. *Br J Surg* 89, 962–970.

71 Dobrucali A, Yigitbasi R, Erzin Y *et al.* (2004) Fasciola hepatica infestation as a very rare cause of extrahepatic cholestasis. *World J Gastroenterol* 10, 3076–3077.

19.5 Haemobilia

Antonio Lacy and Nader K. Francis

Haemobilia is defined as a haemorrhage into the biliary tree. It has been termed 'haemo-bilia' [1] from the Greek term *haima* (blood) and the Latin *bilis* (bile), compared with the reverse condition, bilaemia, which refers to bile entering the bloodstream.

Background and history

The history of haemobilia has been repeatedly discovered to be forgotten, probably due to the obscure nature of the condition, which was first recorded in 1654 by Francis Glisson, the Regius Professor of Physic at Cambridge from 1636 to 1637. In his first detailed description of the anatomy of the liver [1,2], he described the possibility of haemorrhage through the biliary tract in a fatal case of penetrating abdominal trauma sustained by a young man in a sword duel. The patient died 1 week following his injury.

Francis Glisson's finding sank into oblivion for a whole century, prior to Morgagni's epistle (1765), the founder of clinical pathology noticing that a combination of liver abscesses and sharp gallstones could lead to bleeding through the biliary ducts [3].

Antoine Portal reported the first documented case of making the diagnosis of haemobilia before the death of a patient, which was confirmed after autopsy, in 1777 [4]. In his early treatise, Portal drew attention to the difficulty of identifying the source of bleeding in haemobilia. In the USA, the first case of haemobilia was described by Jackson in 1834, who gave a clinical and pathological description of hepatic artery aneurysm, bursting into the biliary ducts [5]. In 1871, the German surgeon Quincke described the three cardinal features of the condition, namely gastrointestinal haemorrhage, biliary colic and jaundice [6].

The recent history of haemobilia, however, starts with Sandblom in 1948, when he first used the word haemobilia in his paper on haemorrhage into the biliary tree following trauma [1]. More recently, and with the advent of more sophisticated imaging and interventional radiological techniques, including percutaneous hepatic procedures and angiography, this has culminated not only in an increased frequency of diagnosis of haemobilia but also in the potential for its successful management.

Aetiology of haemobilia

The causes of haemobilia include iatrogenic and accidental trauma, gallstones, vascular malformations and tumours (Table 1).

Table 1 Causes of haemobilia from 222 cases, published by Green *et al.* [9].

	No. of cases (%)
Trauma	
Blunt	10 (5)
Penetrating	2 (1)
Iatrogenic	
Liver biopsy	30 (13)
Percutaneous transhepatic cholangiography	10 (4)
Percutaneous biliary drainage	43 (19)
Instrumentation	23 (10)
Cholecystectomy	29 (13)
Other surgery	4 (2)
Other procedures	9 (4)
Malignancy	
Cholangiocarcinoma	6 (3)
Hepatocellular carcinoma	6 (3)
Metastasis	2 (1)
Inflammation	
Gallstone disease	11 (5)
Acalculous cholecystitis	2 (1)
Ascariasis	1 (1)
Polyarteritis nodosa	2 (1)
Cholangitis	11 (5)
Vascular	
Coagulopathy	4 (2)
Vascular malformations	16 (7)
Other	
Pancreatic pseudocyst	1 (1)

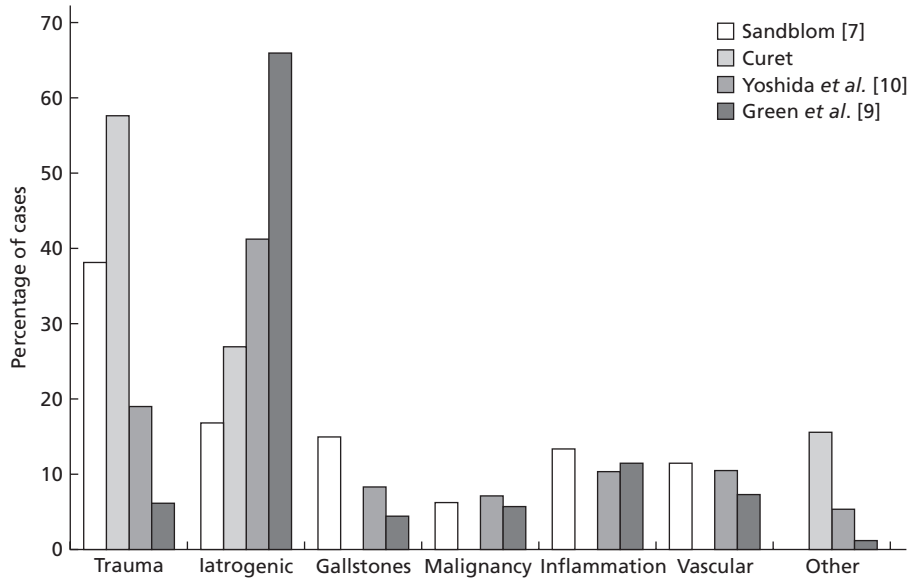

Fig. 1 Change in the trend of causes of haemobilia from 1972 until 2001.

Earlier studies by Sandblom [7] and Goodnight and Blaisdell [8] reported that trauma accounted for 50% of all cases of haemobilia, with a ratio of iatrogenic to accidental trauma of 1:2 [7,8].

However, with the increasing use of diagnostic and therapeutic liver procedures, there has been a complete shift in the pattern of the aetiology of haemobilia over the past three decades [9] (Fig. 1). Nowadays, iatrogenic haemobilia is the most commonly reported cause, accounting for 38–60% of cases, while accidental trauma only accounts for 20% [9].

Iatrogenic liver trauma

Diagnostic liver procedures

These represent 38% of all causes of haemobilia [9]. However, the incidence of developing haemobilia following each diagnostic liver procedure appears to lie between 0.06 and 1% [10–12]. Nevertheless, within the context of such intervention, there are patients at greater risk, such as those with ascites (which prevents tamponade of the puncture site by the abdominal wall), coagulopathy (even when corrected for the procedure), cirrhosis (small livers allow other intra-abdominal structures to be hit), vascular liver pathology (such as haemangioma) and liver transplant (the liver may be hypervascular and may lie in an abnormal position) [13].

There are other factors that determine the complication rate following percutaneous liver biopsy, which was first reported by Cox in 1967 [14], such as the expertise of the physician and the type and the calibre of the needle. It has been shown that making more needle passes (three or more) increases the incidence of complications following liver biopsy [15]. Also, Piccinino *et al.* reported a complication rate of 3.5/1000 for the Tru-cut biopsy needle compared with 1/1000 for the Menghini needle [12].

Hence, attempts have been made to reduce the incidence of complications by using an ultrafine needle and ultrasonographically guided biopsy or using alternative techniques, such as laparoscopic biopsy, transjugular biopsy [16] and biopsy with tract embolization [17]. Although the overall complication rate has been reduced by these techniques, there is no reduction in the incidence of haemobilia. This is, perhaps, not surprising as haemobilia arises as a result of the accidental laceration of a hepatic artery, which is unlikely to be avoided by the above methods with the possible exception of tract embolization.

Percutaneous transhepatic biliary drainage

These procedures carry a high risk of haemobilia (2–10%), compared with diagnostic-only procedures [18,19], because of the use of larger needles and the pre-existing bile stasis. Hoevels and Nilsson [20] demonstrated that the incidence of vascular injury during biliary drainage catheter placement is very high, occurring in up to one-third of patients.

The incidence of haemobilia following percutaneous transhepatic cholangiography (PTC) alone is up to 4%, although this may be reduced by using fine-needle cholangiography [21].

Stenting of biliary strictures

This is associated with haemobilia in up to 10% of procedures [22,23]. Lithotripsy, whether endoscopic or extracorporeal, is also associated with an incidence of haemobilia of up to 10% [24–26]. However, the reported incidence of haemobilia does not necessarily rise when lithotripsy is combined with stenting for hepatolithiasis [27].

In general, there are two types of bleeding that may be encountered with percutaneous transhepatic biliary intervention. Minor venous haemobilia, which is usually due to disposition of the catheter into the adjacent portal vasculature,

is usually minor bleeding and self-limited with catheter readjustment. On the other hand, an arterial haemobilia is a major complication with a reported incidence of about 2%, and this can be devastating, as exsanguinations can occur if the bleeding is not recognized and treated immediately [28].

Accidental liver trauma

Although accidental liver trauma is the second commonest cause of haemobilia, and one would expect increasing incidence of haemobilia with the trend towards conservative management of liver trauma, haemobilia is only encountered in less than 3% of all liver injuries [29,30].

Blunt liver trauma usually due to a road traffic accident can cause an early and a late presentation of haemobilia. First, shearing of arteries, veins and bile ducts without capsular rupture may result in an acute presentation of haemobilia. Those who present with capsular rupture usually present with significant haemodynamic compromise, which often requires emergency surgical intervention to stop the intraperitoneal bleeding, and haemobilia is rare on these occasions.

The mechanism of late presentation of haemobilia following a blunt liver trauma is more complicated. The parenchymal liver injury (or central liver rupture) predisposes to bile stasis within a haematoma, and the combination of liver contusions and lacerations in the presence of static bile do not allow the liver to heal. Also, bile has been shown to inhibit fibrin formation and granulation in liver wounds [31]. Healing may be further impaired by expanding pools of necrotic tissue within the liver parenchyma, which may eventually erode into hepatic blood vessels, allowing fistula formation between them and the bile ducts, which results in haemobilia. Alternatively, the haematoma inside the cavity gradually increases with continual oozing of blood and bile, which delays coagulation. Finally, after days, weeks or even months, the pressure in the cavity will suddenly force the clot down the biliary tract, into the intestine, followed by a gush of blood and bile.

Penetrating trauma, particularly following percutaneous instrumentation of the liver, is less likely to cause cavitation, but may still lacerate blood vessels and bile ducts, predisposing to immediate fistula formation and acute presentation of haemobilia. However, damage to a hepatic artery may result in a pseudoaneurysm, which may expand until it erodes into the biliary tree, again resulting in a fistula. On the other hand, the damaged artery may form a true aneurysm and rupture much later. In the last two scenarios, the presentation of haemobilia is delayed, sometimes by several months.

Another factor that plays a role in developing haemobilia following liver trauma is the type of surgical intervention for liver injury. The highest incidence has been reported following liver packing, less with ligation of hepatic artery and least with resection [32]. Deep mattress sutures may also increase the risk of haemobilia, as they may contribute to cavity formation and necrosis.

Table 2 Causes of hepatic artery aneurysm.

Causes of hepatic artery aneurysm
Common causes
Atherosclerosis
Surgical trauma
Hepatobiliary surgery
Percutaneous transhepatic procedures
Accidental trauma (blunt and penetrating)
Rare causes
Obstructive Inflammation
Gallstones and calcular cholecystitis
Parasitic infestations (ascariasis–clonorchiosis)
Non-obstructive biliary inflammation (reflux cholangitis)
Causes of cystic artery pseudoaneurysm (rare)
Post cholecystectomy
Cholecystitis
Cholelithiasis

Hepatic/cystic artery aneurysm

Hepatic artery aneurysms account for about 10% of all causes of haemobilia [33]. Causes of hepatic artery aneurysm are summarized in Table 2 and include trauma (either accidental or iatrogenic, following percutaneous transhepatic procedures or postoperative after hepatobiliary surgery) or atherosclerosis [34]. Inflammatory causes, which are less common, are biliary obstruction by impacted stones in the bile ducts, which erode the mucosal lining of the duct system involving the arterial wall, or parasites (in the Far East), such as ascariasis–clonorchiosis, which have the tendency to invade the bile ducts and induce bleeding. Rarely, hepatic artery aneurysm can be caused by non-obstructive chronic cholangitis following endoscopic sphincterotomy, resulting in biliary reflux and causing longlasting intrahepatic bilomas, which erode the arterial wall and lead to pseudoaneurysm formation [35].

Cystic artery pseudoaneurysm, on the other hand, is an extremely rare disease, and only 18 cases have been reported in the literature [36,37]. It is usually associated with acute cholecystitis or cholelithiasis, and is rarely due to acute pancreatitis.

The difference between a true aneurysm and a pseudoaneurysm is that the latter does not have all the arterial wall layers. Instead, fibrotic material and adjacent structures form the sac of the aneurysm, which is usually caused by chronic inflammation.

Despite the high incidence of cholecystitis, the rarity of pseudoaneurysms of the cystic artery may reflect early thrombosis of the cystic artery as a response to adjacent inflammation. Nevertheless, in rare situations, a saccular aneurysm of the cystic artery can be formed after repeated episodes of cholecystitis, and may communicate with the wall of the gallbladder, which contains areas of focal necrosis [38].

Other causes of haemobilia

Hepatobiliary surgery

Biliary surgery, especially exploration of the biliary tree, may also cause haemorrhage as the intrahepatic ducts are in close proximity to the hepatic arteries [39]. Damage to the hepatic artery may be caused by a suture needle, diathermy or clip. A pseudoaneurysm develops around the damaged part of the hepatic artery prior to the onset of haemobilia, which can be delayed up to several weeks after the primary surgery.

Concern has been raised regarding the incidence of hepatic artery aneurysm following laparoscopic cholecystectomy during the past decade [40]. The mechanism of injury to the right hepatic artery is thought to be due to either direct trauma or diathermy damage on surgical clips, which is more likely to occur in the presence of abnormal anatomy.

Although hepatic artery pseudoaneurysm can cause significant haemorrhage and even mortality from uncontrolled haemobilia, reported in two cases [9,40], haemobilia is extremely rare following laparoscopic cholecystectomy nowadays.

Nevertheless, minor haemobilia may be encountered during intraoperative cholangiogram, causing a filling defect, which can be misinterpreted as stones in the common bile ducts, leading unnecessarily to exploration of the bile duct [39].

Liver biopsy is the major risk of haemobilia in liver transplant patients [13,42,43]. In this situation, management decisions are more difficult as the transplanted liver relies on the dual blood supply from the portal vein and hepatic arteries, and embolic occlusion of a major hepatic artery in a transplanted liver may result in hepatic necrosis, ischaemic cholangitis [44] or biliary stricture formation [45]. Hence, superselective arterial occlusion is necessary in this situation.

Also, haemobilia has been reported following hepaticojejunostomy [46], choledochoduodenostomy and hepatic lobectomy [47]. A T-tube eroding into a hepatic artery has also been recorded, although it may be that the injury was sustained at the time at which the T-tube was sited [39].

Hepatobiliary malignancy

Malignant neoplasms of the liver, bile ducts, gallbladder and pancreas occasionally present with haemobilia [48,49]. However, overall, they represent only 6–7% of all causes of haemobilia [9], Bleeding occurs when the tumour invades the ductal system (which more often presents with obstructive jaundice). The rate of blood loss is rarely rapid, but it can be chronic, causing anaemia.

Vascular anomalies

As mentioned above, primary vascular anomalies may present with haemobilia, especially hepatic artery aneurysm; angiodysplasia, arteriovenous malformation and haemangioma are less common causes of significant haemobilia. Vasculitis has been reported to cause significant haemobilia, and may be associated with other connective tissue diseases [50].

Coagulation disorders

Haemobilia can result from coagulopathy, with or without minimal trauma [51,52]. Correction of the diathesis prior to any hepatobiliary intervention is necessary to minimize the risks of haemobilia. The most common bleeding disorders that can lead to haemobilia are:

1 coagulopathy from anticoagulation therapy with international normalized ratio (INR) > 1.5;
2 thrombocytopenia (platelets less than 60 000/μL);
3 patients with renal failure (platelets and clotting factor disorders leading to prolonged bleeding time);
4 haemophilia.

Haemobilia in immune-compromised patients

Prasad *et al.* [53] reported a case of haemobilia caused by cytomegalovirus cholangiopathy in an immune-suppressed patient resulting from long-term steroid therapy for hyperoesinophilic syndrome. The virus caused deep ulcerations in the biliary tract, confirmed by an endoscopic retrograde cholangiopancreatography (ERCP), which also showed blood clots emerging from the major papilla, explaining the haematemesis.

Haemobilia and pancreatitis

Acute pancreatitis is a rare complication of haemobilia, which was first described by Dean and Falconer in 1912 [54]. However, the first case report was by Redman and Joseph in 1975 [55]. There are few reported cases of acute pancreatitis and haemobilia following percutaneous liver needle biopsy [56–58]. A large volume of haemobilia can cause pancreatitis due to obstruction by blood clots, which is analogous to gallstone pancreatitis.

On the other hand, haemorrhage of the pancreas can rarely lead to haemobilia [7]. This usually develops as a consequence of chronic pancreatitis causing pseudoaneurysm of the splenic artery, which then ruptures into the pancreatic duct, often through a pseudocyst [59]. Blood from the pancreatic duct (i.e. haemosuccus pancreaticus) will mix with the bile in 70% of cases in which the contents of the duct of Wirsung and the common bile duct enter the duodenum through a common channel.

Pathophysiology and fate of haemobilia

Bleeding into the biliary ducts may originate in the liver parenchyma, or in the intrahepatic or extrahepatic biliary system, including the gallbladder or the pancreas, although the latter is a rare cause. The course of haemobilia is influenced by the magnitude and the source of the bleeding into the biliary system. Most haemorrhage of consequence is of arterial origin, while venous bleeding is usually minor; however, it can be substantial if the portal pressure is raised.

Yoshida *et al.* [10] have found that 50% of bleeding into the biliary tree is intrahepatic and the other 50% is mostly from the extrahepatic bile ducts or gallbladder, and rarely from the pancreas. Risk factors for the delayed onset of haemobilia

Table 3 The differences between mixed and pure clots within the biliary system.

	Mixed clots	Pure clots
Origin	Profuse haemorrhage	Minor haemobilia
Character	Soft and friable	Solid and tenacious
Fate	Easy to remove and lyse	Difficult to both remove and lyse

include bile stasis, hepatic necrosis and the formation of a slowly expanding pseudoaneurysm.

Profuse haemorrhage into the biliary system produces mixed clots of blood and bile, whereas minor haemobilia usually causes a clot of pure blood [59]. This is due to the fact that minor haemorrhage flows immiscibly to the lowest level of the ducts, where it forms a cast of blood within the lumen. There are noticeable differences between pure and mixed blood clots within the biliary system (Table 3). First, the mixed clots usually have a mushy consistency and dissolve rapidly through the fibrinolytic action of the bile, whereas pure clots are solid and tenacious. Also, the mixed ones have a tendency to adhere to the epithelial lining of the bile duct.

When the blood clots are subjected to the flowing bile, they usually dissolve through the fibrinolytic effect of bile. However, in certain circumstances, the blood clots may escape this lytic process if they are diverted through a T-tube or when the bile duct is completely occluded by the clot. In the latter situation, the bile drainage will cease completely, and these clots will often have to be removed in order to relieve the obstructive jaundice. Decompression of the bile ducts leads to resolution of the jaundice and, in some cases, cessation of bleeding as well. Eventually, the clot may act as a nidus for the formation of pigment stones.

Following an interventional diagnostic liver puncture, a blood clot in the biliary system causes a filling defect, which mimics a biliary stone. However, there are certain features that can distinguish a clot from a stone. Calculi are generally ovoid in shape and sometimes multilobular, but rarely round. Clots are generally casts of the lumen where they are produced, i.e. cylindrical in the common bile duct, or they may show the impression of the sphincter if they are formed at the pancreatic duct. Clots within the ampulla are rounded with one flat surface [59].

Complications of haemobilia

Apart from bleeding with its consequences, there are other complications of haemobilia, which are uncommon and include pancreatitis [60], cholecystitis [61] and cholangitis [62]. These are secondary to the haemobilia and must be differentiated from primary pancreatitis, haemorrhagic cholecystitis and cholangitis causing haemobilia.

Pancreatitis secondary to haemobilia has a good prognosis once the haemorrhage has been controlled, and it may be successfully managed conservatively [60]. Cholangitis following haemobilia may be severe and, although it is rarely reported, carries a high mortality rate even when treated aggressively with antibiotics and biliary drainage. Cholecystitis may occur early due to the presence of haematoma in the gallbladder or later following the formation of pigment stones. In early cases, immediate cholecystectomy and T-tube drainage of the common bile duct is recommended both to allow biliary decompression and to wash out any remaining clots.

Clinical presentation

The classic presentation of haemobilia, which was described by Quincke in 1871, involving a triad of upper abdominal pain, upper gastrointestinal haemorrhage and jaundice, is only present in up to 22% of cases (Fig. 2). Atypical presentations may involve upper abdominal pain with gastrointestinal bleeding only or cholangitis, with high fever and rigors.

In major haemobilia, the rate of bleeding is immediately life-threatening. In minor haemobilia, although the blood loss is clinically significant, the patient is haemodynamically stable. If bleeding is brisk, it may present with lower gastrointestinal haemorrhage as well. Slow blood loss leads to chronic anaemia, which is an uncommon presentation, although it is of interest that faecal occult blood testing was once used as a diagnostic test in cases of biliary colic due to gallstones [7].

Bleeding following percutaneous transhepatic biliary intervention may present with venous or arterial haemobilia. Venous haemobilia is characterized by intermittent passage of dark blood in the biliary drainage bag or by repetitive bouts of melaena with internal drainage. Usually, the blood loss is not significant enough to cause a haemodynamic compromise. The biliary drainage

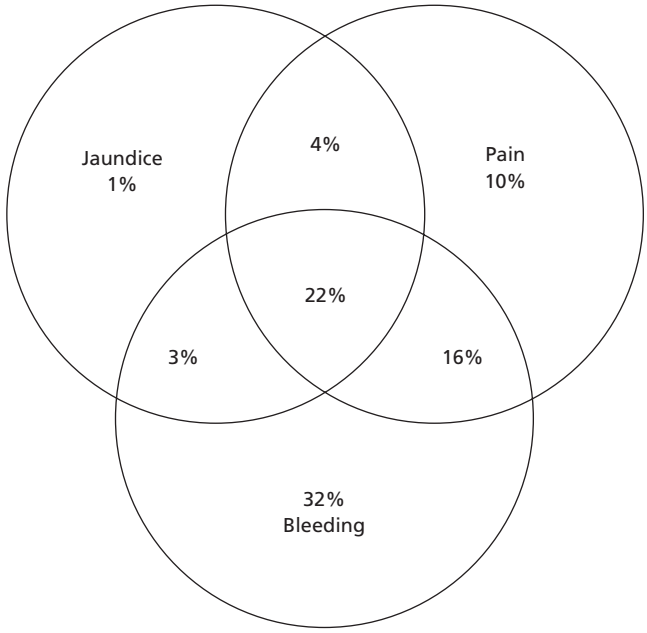

Fig. 2 Presenting symptoms of haemobilia from a review of the literature by Green *et al.* [9].

catheter needs to be evaluated immediately and changed, with the proximal side hole repositioned.

On the other hand, arterial haemobilia may present just after tube placement, with rapid accumulation of blood in the external biliary drainage bag. If the biliary drainage catheter is internalized (the bag is removed and the tube capped after insertion of an internal stenting device), the patient may instead present with gastrointestinal bleeding, usually in the form of melaena. If the bleeding is severe enough, this may present with haematemesis and/or rectal bleeding.

In the trauma scenario, the haemorrhage may be of rapid onset following the injury or may be delayed by weeks. Occasionally, it may be recurrent, with a prodrome of epigastric discomfort that is relieved at the onset of upper gastrointestinal haemorrhage.

Investigations

Investigation of a suspected case of haemobilia depends on the presentation and suspected aetiology. It must be remembered that haemobilia often presents days to months after the initial injury or intervention, and one should be aware of this syndrome in order to make an early diagnosis and undertake prompt management.

When haemobilia is suspected, the following diagnostic procedures should be undertaken in turn [59].

Upper gastrointestinal endoscopy

This should be carried out by an experienced endoscopist aiming to reach the papilla of Vater as direct observation of flowing blood (or blood clot) from the ampulla is not uncommon in haemobilia. It may be combined with ERCP, which sometimes reveals (and drains) clots in the biliary ducts.

Many patients with minor haemobilia can be managed adequately on the basis of endoscopic and cholangiographic findings. However, as little as 12% of these endoscopies may be diagnostic [10], and further investigation may be required. The choice of subsequent investigation depends on the history, leading cause and the level of suspicion. For trauma cases, it seems reasonable to perform computerized tomography (CT), followed by angiography, which is now recognized as the definitive investigation.

Angiography

Selective angiography of the hepatic artery is now the gold standard for identifying, and often dealing with, the source of bleeding in haemobilia. Angiography was first used to demonstrate gastrointestinal bleeding in 1960 [63] and can be expected to detect a vascular abnormality in over 90% of cases of significant haemobilia [3]. As well as detecting active bleeding from an arteriobiliary fistula, an arterioportal fistula and a true or pseudoaneurysm may be seen.

However, there are certain technical difficulties that may arise with anomalous origins of the hepatic artery or when there has been previous surgery; in some cases, the angiogram may appear normal, particularly if the study is performed when there is no active bleeding [64].

Computerized tomography (CT)

Many patients presenting with haemobilia will have CT performed at some point, particularly those with blunt trauma to the abdomen. The possible findings of CT in suspected haemobilia patients are summarized in Table 4.

Active bleeding, either arterial or venous, may be seen at the time of the investigation. This indicates ongoing life-threatening haemorrhage that requires prompt angiographic or surgical control. Large liver haematoma and the formation of pseudoaneurysms of the hepatic artery can also be detected by CT (Fig. 3). Evidence of active or recent bleeding into the biliary tree and gallbladder may be identified by pooling of contrast medium, intraluminal clots and biliary dilatation [65].

Table 4 CT findings in patients with suspected haemobilia.

Trauma
Active bleeding in liver haematoma
Active bleeding into the biliary tree and the gallbladder
Liver haematoma
Biloma
Pseudoaneurysm of the hepatic artery
Intraluminal biliary clots
Biliary obstruction and dilatation
'Periportal tracking'
Non-trauma
Liver sepsis
Liver cavitation
Aneurysm and pseudoaneurysm of the hepatic artery

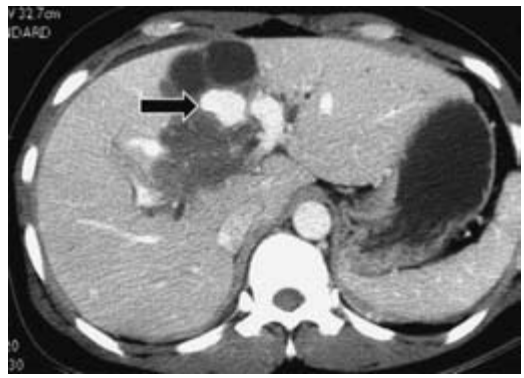

Fig. 3 Contrast-enhanced CT scan obtained 14 days after liver trauma shows a newly developed, well-circumscribed pseudoaneurysm (arrow) within the hepatic haematoma [68].

It is worth knowing that CT grading of liver injury alone is not a good predictor of the development of subsequent haemobilia [66]. However, follow-up CT of trauma patients can be useful for monitoring the progress in these lesions. 'Periportal tracking' can be detected, which is an area of low attenuation around segmental portal veins representing more subtle liver injury associated with an increased risk of developing haemobilia [67].

In non-trauma situations, CT scan can also be useful in identifying various risk factors for developing haemobilia including cavitating lesions, with or without sepsis, and pseudoaneurysm of the hepatic artery.

Ultrasonography (US) of liver

Although liver US for suspected cases of haemobilia can be useful, it may be misleading. Immediately following a bleed into the biliary tract, there may be diffuse but high echogenicity similar to that of the liver itself, so that the bile ducts may not be seen at all. During the first 24–48 h after the formation of the clot, a soft tissue mass may fill part of the duct with dilatation of the proximal duct. The clot then contracts, forming a tubular configuration conforming to the wall of the duct, and the residual lumen may be mistaken for the true lumen. However, the evolution of diffuse hyper-reflectivity to less reflective masses strongly supports the diagnosis of haemobilia [69].

Aneurysm and pseudoaneurysm of the hepatic arteries may be noted as well-circumscribed anechoic masses; although they are not necessarily pulsatile, Doppler ultrasonography may show flow within them, differentiating them from biloma or cyst. Fresh blood clots within the gallbladder are highly echogenic. They appear as non-shadowing, non-mobile masses, and the changes of acute cholecystitis may be seen.

Cholangiography

Cholangiography is useful if there is already percutaneous access or when combined with gastroscopy as ERCP is performed. The possible findings of cholangiography in cases of haemobilia are summarized in Table 5.

Scintigraphy

Although the role of scintigraphic studies in investigating haemobilia is controversial, it seems to be of value when other investigations have not identified the bleeding source.

Table 5 Cholangiographic findings in haemobilia.

Blood refluxing down the papilla of Vater
Filling defects in the biliary tree, which can mimic calculi
Indentation of the bile duct, caused by aneurysm or biloma
Parasitic infection of the biliary tree, causing haemobilia

Although bleeding rates as low as 0.1 mL/h may be detected, the liver provides a large pool of radioisotope that obscures visualization of extravasation into the bile ducts. ^{99m}Tc-labelled sulphur colloid has a low background activity and is rapidly cleared by the reticuloendothelial system. However, this clearance results in high levels of isotope-masking pathology in the bile ducts.

^{99m}Tc-labelled red blood cell scans can provide direct evidence of bleeding into the bile ducts and indirect evidence by demonstrating localized 'hotspots' where isotope has been obstructed by clot in the intrahepatic bile ducts. Haemorrhage into the gallbladder may also be seen.

Treatment of haemobilia

The main goal of treatment of haemobilia is to stop the bleeding and relieve the obstruction by biliary decompression. The mechanisms to achieve these aims depend on the aetiology and the severity of the bleeding.

Iatrogenic haemobilia following liver biopsy or biliary drainage

When haemobilia is suspected following liver biopsy and the patient is stable, it is important to establish if there is an associated liver haematoma [59]. If there is no haematoma, most haemorrhages will cease spontaneously. However, in cases of haematoma formation or significant bleeding that compromises the haemodynamic status, resuscitation is necessary prior to considering angiography and embolization.

The treatment of minor haemobilia following percutaneous biliary intervention begins with assessment of catheter position. In many cases, haemobilia presents as minimal blood in the draining tubing, and the patient is haemodynamically stable. This often stops either spontaneously or when the drain is removed, and no further investigation or treatment is required.

However, if the bleeding persists, consider migration of the side holes of the catheter outside of the biliary tree, which can result in bloody drainage. This can usually be corrected by repositioning of the catheter. Fistulous communication of the biliary tree with a portal or hepatic vein branch can result in haemobilia, which can also be managed by upsizing the drainage catheter with resultant tamponade of the bleeding site.

In cases of major haemobilia, affecting the haemodynamic status, or failing conservative approaches in the aforementioned situations, an aggressive resuscitation is required to stabilize the patient prior to considering a transarterial angiogram and embolization (TAE). The surgical option is only required when angiographic embolization fails.

Haemobilia following accidental liver trauma

Full description of the management of patients with liver trauma is beyond the scope of this chapter, but the main outlines

Fig. 4 Traumatic pseudoaneurysm (arrow) is seen to arise from the left hepatic artery on a coeliac arteriogram [68].

for managing suspected traumatic haemobilia are summarized below.

There are two different categories of liver trauma patients. In those with liver capsular tear and intraperitoneal haemorrhage, who are usually haemodynamically unstable, haemobilia is rare as the blood flows more readily into the lower pressure peritoneal cavity than down the biliary tract. Immediate resuscitation and laparotomy is mandatory in order to control the bleeding and save the patient's life.

Traumatic haemobilia is found more often in patients with an intact liver capsule, but with a central liver rupture, causing less acute and more obscure symptoms. Haemobilia may present early or, more often, late. Regardless of the onset of haemobilia, managing these patients usually requires resuscitation and consideration of angiogram and embolization as the initial treatment in controlling haemobilia and rendering the patient stable in preparation for elective and definitive surgery.

Circumstantial haemobilia (that detected by CT or US scan a long time after the trauma) requires close monitoring and, if pseudoaneurysm of the hepatic artery is found, it should be treated by TAE to avoid the risk of rupture.

Transarterial angiogram and embolization

This was first reported in 1976 by Walter *et al.* [70], when they successfully embolized a hepatic artery to control bleeding. With recent improvements in selective catheters, this has now become the first line of intervention to stop bleeding for most causes of haemobilia. The indications for TAE are:

1 major haemobilia requiring blood transfusion;
2 prolonged or recurrent bleeding despite correction of coagulopathy;
3 minor haemobilia causing anaemia;
4 CT (or US) indicates vascular injury;
5 elective embolization of aneurysms and pseudoaneurysms because of the likelihood of rupture.

Technique of selective TAE

Selective TAE involves catheterization of a hepatic artery followed by embolic occlusion by autologous blood, balloon, microcoils, cyanoacrylate or Gelfoam. The success rate of TAE has been shown to be between 80% and 100% [10,71–74]. Causes of failure are technical or due to the extensive collateral hepatic and bile duct blood vessels.

The portal vein should be patent prior to attempting arterial embolization, and hepatic sepsis is a relative contraindication for TAE. Antibiotic prophylaxis is recommended if hepatic haematoma is present. Transient rise in liver enzymes may follow TAE, but they usually return to normal after 6 weeks.

The mortality and morbidity rates are reported to be lower than those after surgery [75]. Death secondary to hepatic ischaemia following TAE has been reported [76] but, nowadays, it has been used successfully even in some liver transplant patients in whom the portal flow has proved adequate. However, TAE must be recognized as a high-risk procedure in such patients [77].

Surgical treatment of haemobilia

One cannot stress enough the fact that TAE must still be considered as a first line of treatment for haemobilia even if laparotomy is required for other pathology. However, there are certain situations when surgical intervention is required, such as:

1 cholecystitis;
2 failed drainage of the biliary tree;
3 failed drainage of liver sepsis;
4 failed TAE.

Surgery for bleeding involves ligation of the bleeding vessel or excision or repair of the aneurysm. When this cannot be identified, non-selective ligation of the right or left hepatic artery may be performed. If there is concern that the blood supply to the liver will be compromised, arterial reconstruction is indicated, bypassing the affected section of blood vessel using venous autograft or splenohepatic anastomosis. If haemorrhage from collateral vessels continues even after ligation of the common hepatic artery, resection of the affected liver segment may be necessary.

Further surgical options are dependent on whether the site of bleeding is intrahepatic or extrahepatic. If intrahepatic, such as following severe trauma or for tumour, partial hepatectomy may be necessary. Haemorrhage from the gallbladder and haemorrhagic cholecystitis require urgent cholecystectomy, as does cholecystitis following haemobilia.

In cases of liver trauma, TAE should be sought first in order to control the bleeding, and further management of delayed or persistent haemobilia can be arranged at a later stage when the patient's condition allows extensive surgery, as simple packing or drainage is not usually sufficient. Careful exploration of cavities, precise haemostasis and suture or drainage of any damaged biliary ducts are required. If all of these fail, more radical procedures will be necessary including liver resection.

(a) (b)

Fig. 5 Selective right hepatic arteriogram demonstrating a pseudoaneurysm (arrow; a) that was successfully obliterated with the use of an embolization coil (b).

Mortality from haemobilia

In 1972, Sandblom reported a 27% mortality rate following haemobilia [7]. Since then, there has been a constant reduction in the mortality rate and, by 1987. it reached 12% [10]. More recently, there were only five cases of reported death from 222 cases of haemobilia [9]. The reasons for this marked reduction in mortality are an increased incidence of reporting minor haemobilia, with excellent outcome, and improvement in the techniques of management of significant haemobilia, especially TAE.

Summary

The most common causes of haemobilia are iatrogenic and accidental trauma. Classically, haemobilia presents with abdominal pain, upper gastrointestinal bleeding and jaundice; however, a high level of suspicion is required in atypical cases. Fortunately, haemobilia usually causes complications in only a small number of patients. However, urgent investigation of patients who are suspected of having significant haemobilia, using endoscopy and angiography, is required to confirm the diagnosis.

Angiography should be undertaken with a view to TAE, which is the first choice of therapy with a high success rate. If other conditions require operation, surgery remains an alternative, but TAE must still be considered as a means of minimizing the extent of the surgery required. Biliary decompression and restoration of bile flow past clots may also be necessary, and this may be all that is required in cases of minor haemobilia. With the change in aetiology and the advent of new diagnostic and therapeutic techniques, the mortality rate associated with haemobilia is low.

References

1 Sandblom P (1948) Hemorrhage into the biliary tract following trauma: 'traumatic hemobilia'. *Surgery* 24, 571–586.
2 Glisson F (1654) *Anatomia Hepatis.* London: O. Pullein.
3 Morgagni S (1765) Liber III, Epist. XXXVII, 82.
4 Portal A (1780) Sur quelues maladies du foie qu'on attribute a d'autres organs. *Hist Acad R Sci* 1777, 601.
5 Jackson JBS (1834) Aneurysm of the hepatic artery bursting into the hepatic duct. *Med Mag Boston* 3, 115.
6 Quincke H (1871) Ein Fall von Aneurysma der Leberarterie. *Klin Wochenschr* 8, 349–351.
7 Sandblom P (1972) *Hemobilia (Biliary Tract Hemorrhage). History, Pathology, Diagnosis, Treatment.* Springfield, IL: Charles C Thomas.
8 Goodnight JE Jr, Blaisdell FW (1981) Hemobilia. *Surg Clin North Am* 61, 973–979.
9 Green MHA, Duell RM, Johnson CD *et al.* (2001) Haemobilia. *Br J Surg* 88, 773–786.
10 Yoshida J, Donahue PE, Nyhus LM (1987) Hemobilia: review of recent experience with a worldwide problem. *Am J Gastroenterol* 82, 448–453.
11 Pongchairerks P (1993) Ultrasound-guided liver biopsy: accuracy, safety and sonographic findings. *J Med Assoc Thai* 76, 597–600.
12 Piccinino F, Sagnelli E, Pasquale G *et al.* (1986) Complications following percutaneous liver biopsy. A multicentre retrospective study on 68 276 biopsies. *J Hepatol* 2, 165–173.
13 Jabbour N, Reyes J, Zajko A *et al.* (1995) Arterioportal fistula following liver biopsy. Three cases occurring in liver transplant recipients. *Dig Dis Sci* 40, 1041–1044.
14 Cox EF (1967) Haemobilia following percutaneous needle biopsy of the liver. *Arch Surg* 95, 198–201.
15 Maharaj B, Bhoora IG (1992) Complications associated with percutaneous needle biopsy of the liver when one, two or three specimens are taken. *Postgrad Med J* 68, 964–967.
16 Gorriz E, Reyes R, Lobrano MB *et al.* (1996) Transjugular liver biopsy: a review of 77 biopsies using a spring-propelled cutting needle (biopsy gun). *Cardiovasc Intervent Radiol* 19, 442–445.
17 Smith TP, McDermott VG, Ayoub DM *et al.* (1996) Percutaneous transhepatic liver biopsy with tract embolization. *Radiology* 198, 769–774.
18 Gazzaniga GM, Faggioni A, Bondanza G *et al.* (1990) Percutaneous transhepatic biliary drainage – twelve years' experience. *Hepatogastroenterology* 37, 517–523.
19 Nilsson U, Evander A, Ihse I *et al.* (1983) Percutaneous transhepatic cholangiography and drainage. Risks and complications. *Acta Radiol Diagn (Stockh)* 24, 433–439.

20 Hoevels J, Nilsson U (1980) Intrahepatic vascular lesions following nonsurgical percutaneous transhepatic bile duct intubation. *Gastrointest Radiol* 5, 127–135.
21 Harbin WP, Mueller PR, Ferrucci JT Jr (1980) Transhepatic cholangiography: complications and use patterns of the fine-needle technique: a multi-institutional survey. *Radiology* 135, 15–22.
22 Kaskarelis IS, Minardos IA, Abatzis PP *et al.* (1996) Percutaneous metallic self-expandable endoprostheses in biliary obstruction caused by metastatic cancer. *Hepatogastroenterology* 43, 785–791.
23 Stoker J, Lameris JS, van Blankenstein M (1993) Percutaneous metallic self-expandable endoprostheses in malignant hilar biliary obstruction. *Gastrointest Endosc* 39, 43–49.
24 Lomanto D, Fiocca F, Nardovino M *et al.* (1996) ESWL experience in the therapy of difficult bile duct stones. *Dig Dis Sci* 41, 2397–2403.
25 Kusano T, Masato F, Isa T *et al.* (1999) Percutaneous transhepatic cholangioscopic lithotripsy and change of biliary manometry patterns. *Hepatogastroenterology* 46, 2153–2158.
26 Moody FG, Amerson JR, Berci G *et al.* (1989) Lithotripsy for bile duct stones. *Am J Surg* 158, 241–247.
27 Sheen-Chen SM, Cheng YF, Chou FF *et al.* (1995) Ductal dilatation and stenting make routine hepatectomy unnecessary for left hepatolithiasis with intrahepatic biliary stricture. *Surgery* 117, 32–36.
28 Winick AB, Waybill PN, Venbrux AC (2001) Complications of percutaneous transhepatic biliary interventions. *Tech Vasc Interv Radiol* 4(3), 200–206.
29 Merrell SW, Schneider PD (1991) Hemobilia – evolution of current diagnosis and treatment. *West J Med* 155, 621–625.
30 Croce MA, Fabian TC, Spiers JP *et al.* (1994) Traumatic hepatic artery pseudoaneurysm with hemobilia. *Am J Surg* 168, 235–238.
31 Sandblom P, Saegesser F, Mirkovitch V (1984) Hepatic haemobilia: haemorrhage from the intrahepatic biliary tree, a review. *World J Surg* 8, 41.
32 Krige JEL, Bornman PC, Terblanche J (1997) Liver trauma in 446 patients. *S Afr J Surg* 35, 10–15.
33 Harlaftis NN, Akin JT (1977) Haemobilia from ruptured hepatic artery aneurysm. Report of a case and review of the literature. *Am J Surg* 133, 229–232.
34 Stauffer JT, Weinman MD, Bynum TE (1989) Haemobilia in a patient with multiple hepatic artery aneurysms, a case report and review of the literature. *Am J Gastroenterol* 84, 59–62.
35 Liu TT, Hou MC, Lin HC *et al.* (2003) Life threatening haemobilia caused by hepatic artery pseudoaneurysm: a rare complication of chronic cholangitis. *World J Gastroenterol* 9, 2883–2884.
36 England RE, March PJ, Ashleigh R *et al.* (1998) Case report: pseudoaneurysm of the cystic artery: a rare cause of haemobilia. *Clin Radiol* 53, 72–75.
37 Delgadillo X, Berney T, Didier D *et al.* (1999) Successful treatment of pseudoaneurysm of the cystic artery with microcoil embolisation. *J Vasc Interv Radiol* 10, 789–792.
38 Barba CA, Bret PM, Hinchey EJ (1994) Pseudoaneurysm of the cystic artery: a rare cause of haemobilia. *Can J Surg* 37(1), 64–66.
39 Sandblom P (1986) Iatrogenic hemobilia. *Am J Surg* 151, 754–758.
40 Stewart BT, Abraham RJ, Thomson KR *et al.* (1995) Post-cholecystectomy haemobilia: enjoying a renaissance in the laparoscopic era? *Aust NZ J Surg* 65, 185–188.
41 Nicholson T, Travis S, Ettles D *et al.* (1999) Hepatic artery angiography and embolization for hemobilia following laparoscopic cholecystectomy. *Cardiovasc Intervent Radiol* 22, 20–24.
42 Figueras J, Soubrane O, Pariente D *et al.* (1994) Fatal hemobilia after liver graft biopsy in a transplanted child. *Gastroenterol Clin Biol* 18, 786–788.
43 Sherman S, Jamidar P, Shaked A *et al.* (1995) Biliary tract complications after orthotopic liver transplantation. Endoscopic approach to diagnosis and therapy. *Transplantation* 60, 467–470.
44 Pitre J, Dousset B, Massault PP *et al.* (1997) Multiple intrahepatic stones caused by hemobilia in liver transplant recipients. *Surgery* 121, 352–354.
45 Zajko AB, Chablani V, Bron KM *et al.* (1990) Hemobilia complicating transhepatic catheter drainage in liver transplant recipients: management with selective embolization. *Cardiovasc Intervent Radiol* 13, 285–288.
46 Todo S, Kishkawa T, Toyoda K *et al.* (1983) Management of massive hemobilia with angiographic embolization. *Jpn J Surg* 13, 348–353.
47 Taylor SA, Dawson JL (1978) The treatment of haemobilia. *Br J Surg* 65, 252–253.
48 Vagianos C, Karavias D, Dragotis C *et al.* (1993) Obstructive jaundice due to intracholedochal blood clot: an unusual early presentation of primary hepatic carcinoma. *Br J Clin Pract* 47, 222–223.
49 Spieth ME, Hou CC, Ewing PD *et al.* (1995) Hemobilia presenting as intermittent gastrointestinal hemorrhage with sincalide confirmation. A case report. *Clin Nucl Med* 20, 391–394.
50 Yazici Z, Savci G, Parlak M *et al.* (1997) Polyarteritis nodosa presenting with hemobilia and intestinal hemorrhage. *Eur Radiol* 7, 1059–1061.
51 Elte P, van Aken WG, Agenant DMA *et al.* (1980) Haemobilia after liver biopsy. Early detection in a patient with mild haemophilia A. *Arch Intern Med* 140, 839.
52 Sharma P, McDonald GB, Banaji M (1982) The risks of bleeding after percutaneous liver biopsy: relation to platelet count. *J Clin Gastroenterol* 4, 451–453.
53 Prasad GA, Abraham SC, Baron TH *et al.* (2005) Case report: haemobilia caused by cytomegalovirus cholangiopathy. *Am J Gastroenterol* 100, 2592–2595.
54 Dean C, Falconer AW (1912) Aneurysm of the hepatic artery. *Edinburgh Med J* 48, 124–131.
55 Redman HC, Joseph RR (1975) Haemobilia and pancreatitis as complication of percutaneous transhepatic cholangiography. *Am J Dig Dis* 20, 691–698.
56 de Ribot X, Casellas F, Papo M *et al.* (1995) Haemobilia causing acute pancreatitis after percutaneous liver biopsy. *J Clin Gastroenterol* 21, 171–172.
57 Kim HJ, Shin JH, Lee YY *et al.* (1999) Haemobilia causing acute biliary pancreatitis after percutaneous liver biopsy. *Endoscopy* 31, S1b–9.
58 Machicao VI, Lukens FJ, Lange SM *et al.* (2002) Arterioportal fistula causing acute pancreatitis and haemobilia after liver biopsy. *J Clin Gastroenterol* 34, 481–484.
59 Sandblom P (1994) In: Blumgart LH (ed.) *Surgery of the Liver and Biliary Tract*, 2nd edn. Philadelphia, PA: WB Saunders, pp. 1259–1274.
60 Van Os EC, Petersen BT (1996) Pancreatitis secondary to percutaneous liver biopsy-associated hemobilia. *Am J Gastroenterol* 91, 577–580.
61 Cacho G, Abreu L, Calleja JL *et al.* (1996) Arterioportal fistula and hemobilia with associated acute cholecystitis: a complication of percutaneous liver biopsy. *Hepatogastroenterology* 43, 1020–1023.
62 Worobetz LJ, Passi RB, Sullivan SN (1983) Hemobilia after percutaneous liver biopsy: role of endoscopic retrograde cholangiopancreatography and sphincterotomy. *Am J Gastroenterol* 78, 182–184.

63 Shapiro MJ (1994) The role of the radiologist in the management of gastrointestinal bleeding. *Gastroenterol Clin North Am* 23, 123–181.
64 Willner IR, El-Sakr R, Werkman RF *et al.* (1998) A fistula from the portal vein to the bile duct: an unusual complication of transjugular intrahepatic portosystemic shunt. *Am J Gastroenterol* 93, 1952–1955.
65 Samuels RS, Shriver M, Patel NH (1996) Hemobilia after a gunshot injury to the liver. *Am J Roentgenol* 166, 1304.
66 Meredith JW, Young JS, Bowling J *et al.* (1994) Nonoperative management of blunt hepatic trauma: the exception or the rule? *J Trauma* 36, 529–534; discussion 534–535.
67 Yokota J, Sugimoto T (1994) Clinical significance of periportal tracking on computed tomographic scan in patients with blunt liver trauma. *Am J Surg* 168, 247–250.
68 Yoon W, Jeong YY, Kim JK *et al.* (2005) CT in blunt liver trauma. *RadioGraphics* 25, 87–104.
69 Marchal G, Fevery J, Snowball S *et al.* (1985) The sonographic aspects of haemobilia. Clinical and experimental study. *Eur J Radiol* 5, 211–215.
70 Walter JF, Paaso BT, Cannon WB (1976) Successful transcatheter embolic control of massive hematobilia secondary to liver biopsy. *Am J Roentgenol* 127, 847–849.
71 L'Hermine C, Ernst O, Delemazure O *et al.* (1996) Arterial complications of percutaneous transhepatic biliary drainage. *Cardiovasc Intervent Radiol* 19, 160–164.
72 Horak D, Guseinov E, Adamyan A *et al.* (1996) Poly (2-hydroxyethyl methacrylate) particles for management of hemorrhage of complicated origin: treatment of hemobilia. *J Biomed Mater Res* 33, 193–197.
73 Dousset B, Sauvanet A, Bardou M *et al.* (1997) Selective surgical indications for iatrogenic hemobilia. *Surgery* 121, 37–41.
74 Nicholson T, Travis S, Ettles D *et al.* (1999) Hepatic artery angiography and embolization for hemobilia following laparoscopic cholecystectomy. *Cardiovasc Intervent Radiol* 22, 20–24.
75 Lygidakis NJ, Okazaki M, Damtsios G (1991) Iatrogenic hemobilia: how to approach it. *Hepatogastroenterology* 38, 454–457.
76 Vaughan R, Rosch J, Keller FS *et al.* (1984) Treatment of hemobilia by transcatheter vascular occlusion. *Eur J Radiol* 4, 183–189.
77 Croutch KL, Gordon RL, Ring EJ *et al.* (1996) Superselective arterial embolization in the liver transplant recipient: a safe treatment for hemobilia caused by percutaneous transhepatic biliary drainage. *Liver Transpl Surg* 2, 118–123.

19.6 Biliary dyskinesia

C. Ritchie Chalmers and Giles J. Toogood

Introduction

The term biliary dyskinesia is used to refer to a range of biliary tract functional disorders, essentially those of the gallbladder and sphincter of Oddi (SO). Dysfunction of the gallbladder or the SO can be characterized by similar patterns of biliary or pancreatic-type symptoms and pain in the absence of macroscopic organic or structural disease as identified by laboratory, ultrasonographic and magnetic resonance imaging (MRI) examination. However, it is often diagnostically difficult to differentiate purely functional problems from subtle or microscopic organic or structural disease, and so the alternative label of biliary dysfunction may be a more accurate, all-encompassing term for these conditions. The diagnosis, evaluation and treatment of biliary dysfunction are not therefore without controversy. Estimates of the prevalence of biliary dysfunction have been made at 2.4% by population studies [1], although higher levels have been recorded by ultrasound screening studies, suggesting a frequency of acalculous biliary-type pain of 7.6% in men [2] and 20.7% in women [3]. However, ultrasonography has a false-negative rate of approximately 2–5%, so these figures may be artificially slightly elevated [4].

Biliary dysfunction can be broadly divided into dysfunction of the gallbladder and dysfunction of the SO, subdivided into biliary and pancreatic-types. The typical biliary symptoms in dysfunctional biliary disease were defined by the 1999 Rome II Committee on Functional Gastrointestinal Disorders [5] as: episodes of severe, steady pain located in the epigastrium or right upper quadrant associated with symptom episodes lasting 30 min or more with pain-free intervals; symptoms occurring on one or more occasions in the last 12 months; steady pain interrupting daily activities or requiring consultation with a physician; no evidence of structural abnormalities to explain the diagnosis; evidence of abnormal gallbladder functioning with regard to emptying. Pain may also be associated with nausea and vomiting, radiation to the back or right scapula region, onset after meals or during the night. These biliary symptoms are a feature of both gallbladder and SO dysfunction (Table 1).

Table 1 The Rome II criteria for biliary-type symptoms in biliary dysfunction [5].

Episodes of severe, steady pain located in the epigastrium or right upper quadrant associated with:	
A	symptom episodes lasting 30 min or more with pain-free intervals
B	symptoms occurring on one or more occasions in the last 12 months
C	steady pain interrupting daily activities or requiring consultation with a physician
D	no evidence of structural abnormalities to explain the diagnosis
E	evidence of abnormal gallbladder functioning with regard to emptying

These criteria are due to be updated by the Rome III committee in 2006.

Gallbladder dysfunction

Normal gallbladder physiology

The gallbladder and bile ducts comprise a low-pressure system regulating the bile flow from hepatocytes to the duodenum. The secretory pressure of the hepatocytes, the tone of the gallbladder and ducts and the resistance of the SO are responsible for the maintenance of normal pressures of approximately 5–10 mmHg above duodenal pressure [6]. The gallbladder acts as a reservoir, storing and concentrating bile to absorb increases in pressure from the biliary tree. In the fasting state, 90% of the free-flowing hepatic bile is channelled into the gallbladder for storage by tonic contraction of the SO, which raises the choledochal pressure and diverts bile flow through the cystic duct. Higher choledochal pressures also stimulate a choledocho–cholecysto neurological inhibitory reflex causing gallbladder relaxation to accommodate the increase in bile volume [7].

The gallbladder exhibits two types of muscular contraction. Non-propulsive contractions cause small-volume partial emptying and refilling of the gallbladder during the interdigestive period, and this is thought to be important for the intracholecystic mixing of bile, maintaining the relatively insoluble constituents such as cholesterol and bilirubin in solution and preventing the formation of microcalculi. This process, with the expulsion of

up to 25% of gallbladder residual volume, occurs approximately every 100 min under neurohumoral control by the enteric hormone motilin acting via the vagus nerve [8]. It is temporally coordinated with the phases of the migrating motor complex (MMC) of the small intestine, with contractions causing bile emptying into the duodenum predominantly throughout late phase II [9]. Phase III of the MMC is believed to have a housekeeping role, and the release of bile into the duodenum prior to this stage may prevent bacterial overgrowth. Additionally, the entry of bile into the distal duodenum is thought to contribute to the regulation of the cyclical nature of the MMC of the gastrointestinal tract itself [10].

The second type of muscular contraction in the gallbladder is propulsive. Propulsive contractions are responsible for fractional gallbladder emptying of 75% of residual volume during the digestive phase. Gallbladder emptying is initiated by cephalic and local gastroduodenal neurological reflexes and maintained by circulating levels of the enteric hormone, cholecystokinin (CCK), released from the duodenum in response to its exposure to luminal gastric acid, fats and amino acids [7]. Cholinergic input from the vagus nerve is thought to increase the sensitivity of the gallbladder to CCK [11] and to send afferent sensory impulses in a feedback loop to modulate its contraction.

CCK acts on specific smooth muscle receptors (CCK-A) in the gallbladder causing a slow and steady contraction of the muscular wall. This generates an intracholecystic pressure that is only slightly higher than the resting choledochal pressure, resulting in a steady delivery of bile down a pressure gradient through the relaxed SO and the ampulla of Vater into the duodenum. The resistance of the cystic duct itself, generated by the mucosal valves of Heister, may also play a role in regulating the flow of bile between the gallbladder and the common bile duct. Increased resistance in the cystic duct has been demonstrated after exposure to intravenous morphine, and it is known to have a dense neurological supply, although full understanding of its physiological role is still lacking.

Pathophysiology and disorders of gallbladder motility

Gallbladder dysfunction has been predominantly ascribed to delayed or abnormal gallbladder emptying. It may, however, be associated with mild structural or organic pathologies that are difficult to identify on routine preoperative workup, such as structural narrowing of the cystic duct, gallbladder muscle hypertrophy, impairment of gallbladder filling, hyperalgesia or chronic inflammation. The female hormones estrogen and progesterone have been associated with alterations in cholesterol metabolism and the reduction in gallbladder and SO motility, and this is likely to explain the female preponderance of these diseases [12]. Transient changes in gallbladder motility may also result from disruption to normal physiology by autonomic neurological disorders, drugs (e.g. anticholinergics, opiates, calcium channel blockers [13]), metabolic disorders (e.g. diabetes [14], obesity [15]) and normal physiological conditions (e.g. pregnancy [16]).

Disorders of gallbladder motility result in gallbladder stasis with resulting sludge and microcalculi, contributing to inflammation or gallstone formation. Acutely, this is demonstrated in patients with critical illness maintained on long-term total parenteral nutrition in whom a decrease in gallbladder motility leads to increasing sludge formation, cystic duct obstruction and acute acalculous cholecystitis [17]. Gallbladder dysfunction causing stasis is thought to contribute to chronic cholelithiasis in up to 70% of patients with symptomatic disease [18] and is confined to cases where bile is supersaturated with cholesterol. Excess cholesterol becomes incorporated into the plasma membrane of the smooth muscle cells in the gallbladder wall [19] affecting muscular contractility, and this has been demonstrated by impaired contractility after provocation tests with cholecystokinin-octapeptide (CCK-OP) [20]. Interestingly, the function of the gallbladder muscle, as demonstrated by normal reaction to CCK-OP, does not appear to be impaired in patients with pigment stones, which are smaller and less often implicated in the development of cholecystitis. Muscle cells of the gallbladder wall of patients with cholesterol stones do not respond normally to receptor-dependent agonists, G-protein activators and second messengers [21]. The inflammatory process, acute or chronic, also contributes to dyskinesia of the muscular gallbladder wall mediated by endothelins and prostaglandins [17,22], and biliary stasis may cause chemical damage and subsequent inflammation of the gallbladder mucosal and muscular layers.

The process of gallbladder dyskinesia may itself give rise to symptomatology and pain in acalculous patients. The mechanism of pain may be due to gallbladder spasm, excessive contraction, gallbladder distension (either due to obstruction by viscous bile or intermittent high residual volumes) or incoordination between the gallbladder and the cystic duct or SO [5]. Synonyms for gallbladder dysfunction include gallbladder hypersensitivity, gallbladder spasm, cystic duct syndrome and biliary dyskinesia (Table 2).

Clinical presentation of gallbladder dysfunction

Chronic gallbladder dysfunction presents in a similar manner to symptomatic cholelithiasis. Patients are usually female, aged between 20 and 50 years, presenting with a history of recurrent biliary type pain as defined by the Rome II criteria. In gallbladder dysfunction, abdominal examination may reveal right upper quadrant tenderness, and there may be localized guarding, but this condition is not associated with signs of peritonism. There is no evidence of pyrexia or leucocytosis, and hepatic transaminases, alkaline phosphatase, bilirubin and serum albumin are normal.

Investigation of gallbladder dysfunction

Ultrasonography

Typical biliary pain is usually initially investigated for underlying cholelithiasis and alternative pathologies by abdominal

Table 2 The pathophysiology of gallbladder and sphincter of Oddi motility disorders. Biliary dysfunction or dyskinesia may result from a structural or functional abnormality. The relationship between inflammation and gallbladder dysfunction is complex. Abnormal gallbladder motility may be caused by chronic inflammation (due to cholelithiasis or microlithiasis) and, conversely, biliary stasis secondary to abnormal motility may result in microlithiasis and chronic cholecystitis.

	Structural	Functional
Gallbladder	Cholelithiasis Narrowed cystic duct Gallbladder muscle hypertrophy	Inflammation Hormonal flux Pregnancy Autonomic neurological disease Drugs Anti-cholinergics Opiates Calcium-channel blockers Metabolic disease Diabetes Obesity Parenteral nutrition Critical illness
Sphincter of Oddi	Fibrotic stenosis Trauma (passage of stone or post-endoscopic sphincterotomy) results in inflammation, healing and fibrotic stricture Smooth muscle hypertrophy	Sphincter irritability Associated with irritable bowel and other functional disorders Autonomic neurological disease Drugs Anti-cholinergics Opiates Calcium-channel blockers Metabolic disease Diabetes Obesity

ultrasonography. Negative ultrasonography of the upper abdomen may be a consequence of several clinical scenarios. Alternative pathology of the gastrointestinal tract and pancreas should be excluded. There is a false-negative rate of calculus identification by ultrasonography of approximately 2% [4], and sensitivity is particularly poor for the identification of sludge or calculi smaller than 3–5 mm in the gallbladder and also for stones in the common bile duct (CBD). The sensitivity of ultrasonography for cholelithiasis is often not improved by repeating the investigation [23]. Endoscopic ultrasonography is capable of detecting microlithiasis of less than 3 mm and may be helpful, although this is not in routine use [24] and, during cholecystectomy, intraoperative CBD ultrasound [25] or cholangiogram [26] have proved to be sensitive in the detection of choledocholithiasis. Symptoms may be due to the passage of a stone into the CBD or through the biliary tree and into the duodenum. Alternatively, symptoms may be due to dysfunctional disease, either of the gallbladder itself or of the SO. In some cases, SO dysfunction is subsequently unmasked by cholecystectomy, and the diagnosis of SO dysfunction in the presence of a functioning gallbladder is controversial.

Historically, a pain provocation test was performed, essentially attempting to duplicate symptoms by stimulation of the gallbladder using intravenous CCK, but these tests have been abandoned due to low sensitivity and the limited production of useful clinical information. It is recommended that, in the absence of cholelithiasis on ultrasonography in patients with normal liver function tests, clinicians should proceed to exclude alternative causes of pain via upper gastrointestinal endoscopy and undertake further assessment of gallbladder function by non-invasive cholescintigraphy.

Cholescintigraphy

Cholescintigraphy is performed using ^{99m}Tc-radiolabelled hepatoiminodiacetic acid (HIDA). This compound is excreted by the liver into the bile and can be traced by quantification of changes in radioactivity over different regions of the biliary tree using a gamma camera and computer analysis. Initially, the accumulation of ^{99m}HIDA in the gallbladder is assessed, followed by the administration of CCK-OP (20 ng/kg infused slowly intravenously over 30 min) to stimulate gallbladder emptying and provide a measurement of gallbladder ejection fraction (GBEF). GBEF can be calculated as a percentage of gallbladder volume or as a percentage of radioactive counts [27,28]. A normal gallbladder will empty more than 50% of its volume in response to CCK-OP stimulation and, therefore, a GBEF of less than 40% is considered to indicate gallbladder dysfunction [5].

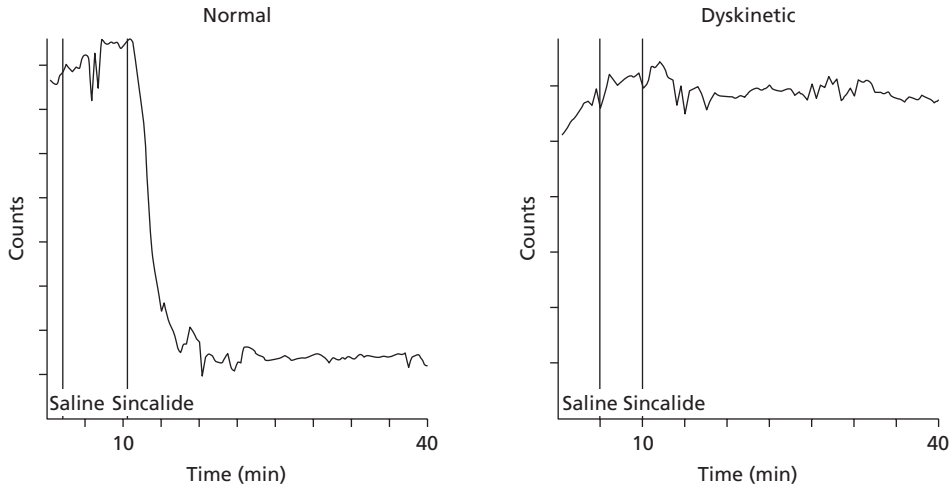

Fig. 1 Response curves generated by quantification of ^{99m}HIDA levels in the gallbladder. Quantification of ^{99m}HIDA levels in the gallbladder after stimulation with CCK-OP is used to calculate the GBEF, with significant abnormality in response resulting in a GBEF < 40%.

There are also a number of other conditions that are associated with a low GBEF and that present without biliary-type pain including pregnancy, diabetes, obesity, cirrhosis and idiopathic slow transit constipation. Various drugs may lower GBEF (atropine, morphine, octreotide, nifedipine and progesterone), and reduced GBEF may be associated with a generalized dyskinetic syndrome of the entire gastrointestinal tract involving the stomach, duodenum and biliary tree (Fig 1; see also Plate 19.6.1, facing p. 1268).

MRI and magnetic resonance cholangiopancreatography

If the GBEF is considered to be normal or the patient has deranged liver function tests, cross-sectional MRI of the liver and magnetic resonance cholangiopancreatography (MRCP) should be considered in order to identify alternative hepatobiliary pathology. MRCP has been developed fairly recently, and there are an increasing number of studies showing excellent identification of biliary tract dilatation and choledocholithiasis, in which MRCP performs comparably with endoscopic retrograde cholangiopancreatography (ERCP) [29,30]. MRCP may also aid in the exclusion of alternative pathology such as bile duct strictures (benign and malignant), choledochal cyst and Caroli syndrome. In addition, MRCP is non-invasive and avoids exposure to radiation and the complication rate inherent in ERCP. However, its limitations include contraindications to MRI, artefact associated with metal clips in a surgical field and the inability to offer therapeutic intervention as part of the same procedure. ERCP should not be used for diagnosis but be reserved for patients requiring manometric assessment of the SO during investigation of suspected dysfunction post cholecystectomy.

Treatment of gallbladder dysfunction

The initial management of an acute episode of gallbladder dysfunction is directed at the relief of discomfort, using an appropriate analgesic and conservative management. If there is no obvious cause of impaired gallbladder emptying, and the GBEF is less than 40%, then cholecystectomy is considered to be appropriate [5]. This is not, however, without controversy.

Evidence demonstrating clinical improvement after cholecystectomy in patients with gallbladder dysfunction is taken from a number of studies in the literature with widely variable methodology. The use of a variety of doses and administration regimes of CCK-OP in order to determine GBEF makes comparison between these studies difficult to interpret, and different definitions of abnormal GBEF vary between 35% and 65% [31]. The regime and GBEF value outlined above are taken from the Rome II criteria and combine a mid-range dose of CCK-OP with an administration time of 30 min, providing similarity with the normal physiological release of CCK after a fatty meal.

In the authors' experience, patients with suboptimal GBEF and no other identifiable cause of their pain who have undergone cholecystectomy subsequently demonstrate histopathological evidence of chronic cholecystitis in more than 95% of cases. Conversely, there is a limited amount of evidence indicating that patients presenting with typical biliary pain in the absence of demonstrable cholelithiasis but with a suboptimal GBEF may improve with conservative management [32].

Some centres have reported demonstrable improvement in symptoms after cholecystectomy in up to 55% of patients with typical biliary pain who have a normal GBEF at cholescintigraphy,

but these studies invariably involve low numbers of patients. Surgeons may have a low threshold for performing laparoscopic cholecystectomy under these circumstances, as these patients may demonstrate histopathological changes consistent with chronic cholecystitis [33]. Cholecystectomy under these circumstances remains controversial, but most centres will not proceed with investigations into SO function unless the patient has previously undergone cholecystectomy. The investigation and management of gallbladder dysfunction are summarized in Figure 2.

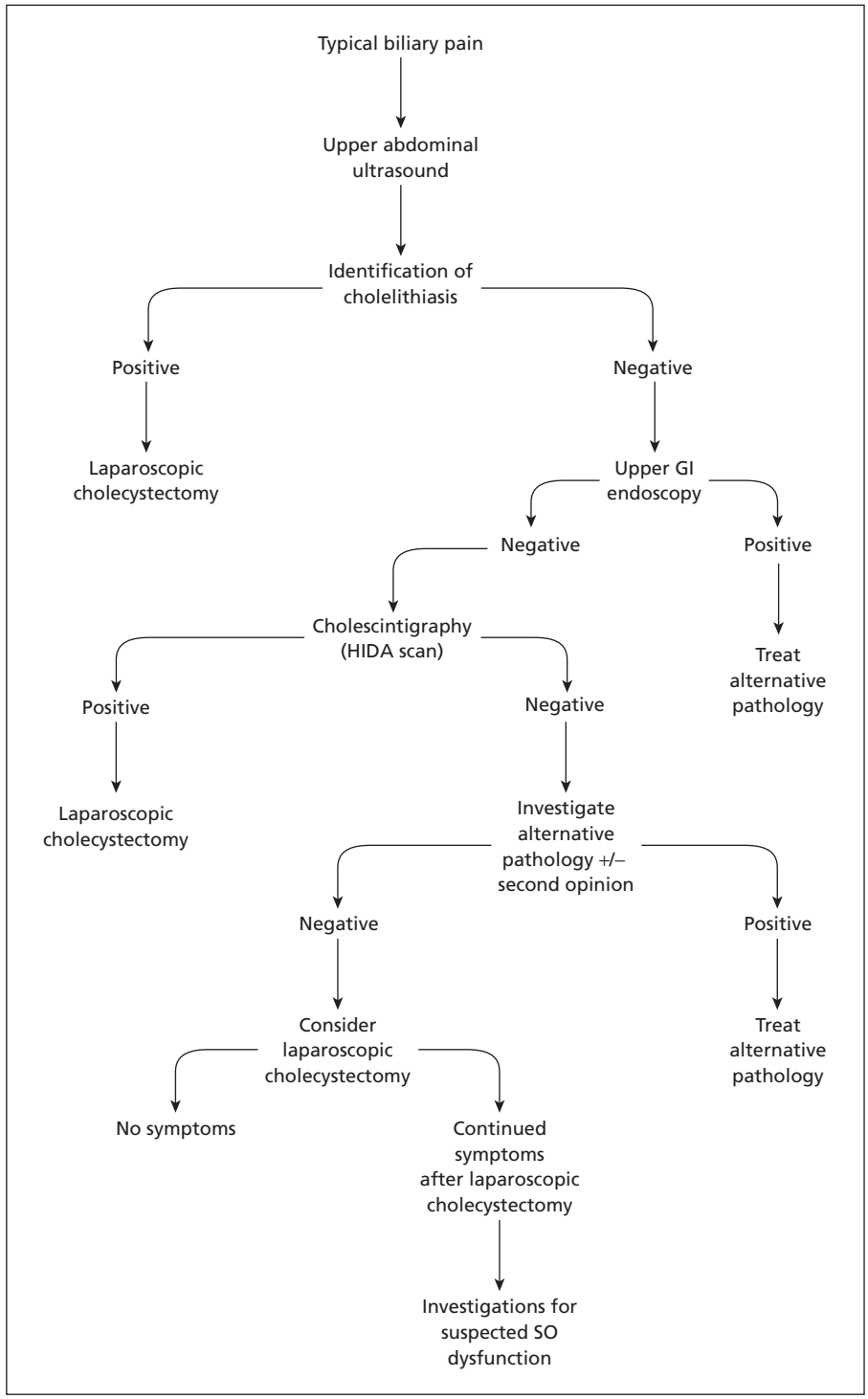

Fig. 2 The investigation and management of gallbladder dysfunction. The absence of cholelithiasis on investigation of typical biliary pain by ultrasound should prompt investigation into alternative upper gastrointestinal pathology by endoscopy. Cholescintigraphy is then performed to assess gallbladder ejection fraction (GBEF). The efficacy of laparoscopic cholecystectomy for patients with low GBEF has been demonstrated by a number of studies, although patients with a relatively normal GBEF may also benefit from cholecystectomy. Diagnosis of sphincter of Oddi dysfunction (SOD) in the presence of an intact gallbladder is controversial. GI, gastrointestinal.

Sphincter of Oddi dysfunction (SO syndrome or SOD)

Normal anatomy and physiology of the SO

The SO is an anatomically distinct neuromuscular structure lying at the junction between the CBD, the pancreatic duct and the duodenum. It is approximately 1 cm in length and traverses the duodenal wall, ending in the lumen of the duodenum as the ampulla of Vater. It is regarded as forming three groups of muscle fibres encircling the distal portion of the bile duct: the sphincter choledochus; the distal portion of the pancreatic duct, the sphincter pancreaticus; and a common sphincter proximal to the ampulla. The SO is anatomically distinct from but functionally linked to the biliary unit of the CBD, pancreatic duct and duodenum. It controls the pressure gradients within the biliary tree, and changes in the resistance of the SO to the flow of bile and pancreatic juice act to modulate the efflux into the duodenum. The SO also protects the biliary tree from reflux of duodenal contents (Fig. 3).

The SO is believed to comprise two separate regions, proximal and distal, although opinion is divided as to whether these regions are capable of independent action and differential response to similar neurohumoral stimuli [34]. In the interdigestive phase, the SO exhibits resting basal pressure due to spontaneous contractile activity, regulated by interstitial cells of Cajal (ICC) with cyclical depolarization and repolarization (slow waves) similar to those regulating the spontaneous activity of the small intestine [34]. This pacemaker activity is thought to be located in the proximal region of the SO and drives a predominantly antegrade peristalsis towards the duodenum. Additional active contractions display a cyclical motility, closely coordinated with phase II and III of the MMC of the stomach and duodenum [9]. The timing of these additional contractions allows bile flow into the duodenum prior to phase III, known to be important in duodenal housekeeping, and protects the biliary tree from the increased pressure generated by subsequent contraction of the duodenum. This coordination of activity between the duodenum and the SO is referred to as the SO–duodenal reflex.

The SO is extensively innervated receiving both external and internal signals [35]. External innervation is passed via preganglionic parasympathetic fibres in the vagus nerves and postganglionic fibres from the coeliac ganglion. Intrinsic innervation occurs via the ganglia of the enteric nervous system. There is extensive neural coordination between the SO and the stomach, gallbladder [36], bile ducts [37] and duodenum [38]. Additionally, intrasphincteric reflexes may exist between the different regions of the SO.

In the digestive phase, exposure of the SO to circulating CCK stimulates non-adrenergic, non-cholinergic inhibitory neurones to release vasoactive intestinal peptide [39] and nitric oxide [40]. This results in inhibition of the phasic contractions of the smooth muscle cells, allowing a fall in basal pressure, and synchronizes SO relaxation with gallbladder contraction to allow the release of large volumes of bile into the duodenum.

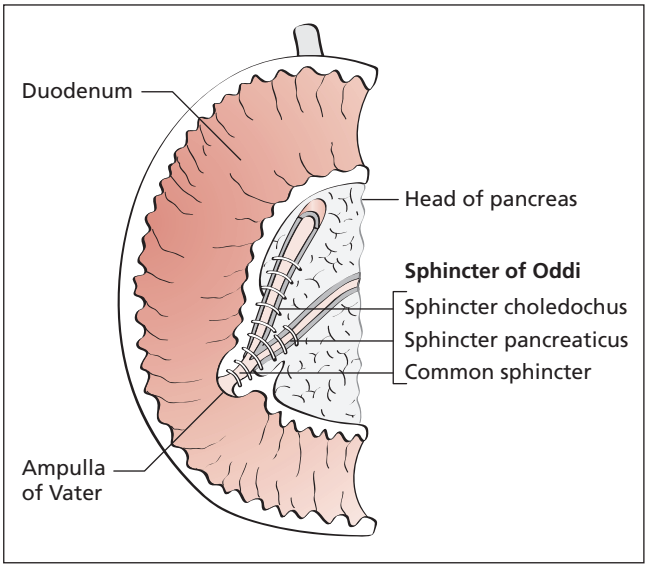

Fig. 3 The anatomy of the sphincter of Oddi. Muscular fibres of the sphincter of Oddi (SO) encircle the distal portion of the common bile duct (CBD) as the sphincter choledochus, the pancreatic duct as the sphincter pancreaticus and form a common sphincter proximal to the ampulla of Vater. The ampulla of Vater refers to the papilla visible in the third part of the duodenum.

Pathophysiology and disorders of SO motility

The SO comprises regions individually encircling both the CBD and the pancreatic duct. SOD may occur in either or both regions and therefore presents with features of either biliary obstruction or pancreatic inflammation, with elevation of pancreatic enzymes and pancreatitis. SOD may be associated with a number of other gastrointestinal disorders that are believed to have a functional basis, such as irritable bowel syndrome and duodenal hyperalgesia. Synonyms for SOD include biliary spasm, biliary dyskinesia, ampullary stenosis, papillitis, oddities, biliary dys-synergia and post-cholecystectomy syndrome.

Mechanistically, dysfunction of the SO causes increased resistance to the passage of bile and pancreatic juice into the duodenum, resulting in raised choledochal pressure. This backpressure on the biliary tree is thought to be the primary mechanism of pain, causing distension, spasm and inflammation [5]. Recurrent pancreatitis may result from the retention of pancreatic exocrine secretions by pressure obstruction or structural obstruction caused by inflammation of the pancreatic duct [41]. The effects of acute alcohol consumption on the function of the SO also remain to be fully elucidated [42].

There appear to be two subtypes of SOD: SO dyskinesia, a pure motor disorder, and SO stenosis of part or the whole of the sphincter, which may result from previous trauma due to the passage of a stone or inflammation associated with episodes of pancreatitis [43], resulting in fibrosis or smooth muscle hypertrophy. Rarely, stenosis may reoccur after previous endoscopic sphincterotomy [44]. It is often difficult to distinguish between dyskinesia and stenosis and, therefore, the term SOD is commonly applied to both. Additionally, there is a group of patients who experience typical biliary pain with no objective evidence of delayed biliary drainage, and these patients may be suffering from visceral hyperalgesia of either the SO itself or the duodenum [45].

Manometry provides a truly objective quantification of SO function and can differentiate between SO stenosis and true dyskinesia. The identification of these separate conditions allows appropriate targeting of therapy. SO stenosis manifests as a persistently elevated basal pressure of more than 40 mmHg (normal range 3–35 mmHg). Stenosis may affect the sphincter choledochus, the sphincter pancreaticus or both sphincters. SO dyskinesia includes a number of patterns of dysfunctional contraction that may be identified manometrically. Sphincter irritability and spasm may manifest in one of two patterns. Rapid phasic contractions, referred to as 'tachy Oddia' and typically at a rate of > 6/min, are separate from the contractile activity associated with the MMC and may coincide with the experience of characteristic pain. Intermittent episodes of basal elevated pressure (> 35 mmHg) with an interspersed normal baseline may also be indicative of sphincter irritability. Excessive retrograde peristalsis (> 50% of contractions) is sometimes observed but has low specificity for SOD. Paradoxical responses to CCK-OP, consisting of increases in basal pressure or stimulation of SO contraction, may also be observed and are thought to represent absence of or damage to inhibitory neurones.

Motility disorders of the SO causing biliary-type symptoms most commonly present in patients post cholecystectomy. The presence and identification of SOD in patients with an intact gallbladder is controversial, although some studies have identified SOD in approximately 10% of patients returning with post-cholecystectomy pain and in 0.9% of patients before cholecystectomy [46]. It is thought that removal of the gallbladder, which acts as a reservoir to minimize pressure changes within the biliary tree, may precipitate symptoms from a dysfunctional SO. Disruption to the SO CCK response occurs after cholecystectomy [47] because of the removal of inhibitory neural links between the gallbladder and the SO resulting in increased SO tone. Additionally, these patients have a documented history of previous cholelithiasis, and several studies indicate a relationship between the presence of gallstones and increased SO resistance, where SOD may play a role as either the primary or the secondary pathology. Gallstones are frequently associated with increased SO tone [48], and higher SO resistance may contribute to gallbladder stasis, resulting in the development of cholelithiasis. Alternatively, the repeated passage of stones down the CBD and into the duodenum may cause SO trauma with resulting inflammation, fibrosis, stricture and subsequent dysfunction. It is currently unclear as to whether microlithiasis plays a role in the pathogenesis of SOD. Rarely, microlithiasis may form *de novo* in the bile ducts after cholecystectomy, and this gravel or sludge can cause both biliary colic and obstruction resulting in acute pancreatitis [49,50]. However, the largest studies so far have not demonstrated a correlation between microlithiasis and increased SO resistance at manometry [51].

Biliary-type SOD

Clinical presentation of biliary-type SOD

Patients are commonly female, between the ages of 20 and 50 years and may present 2–10 (average 4–5) years post cholecystectomy. They present with biliary symptomatology as defined by the Rome II criteria and may describe two types of pain. First, severe episodic pain that presents with a similar pattern to that produced by gallbladder dysfunction and occurs episodically every few weeks or months. In most cases, patients describe a recurrence of the pain that they suffered due to gallstone disease. Additionally, these patients may also describe a more constant discomfort that occurs daily and on to which the episodic pain is superimposed. In some cases, the recurrence of pain may have a definite antecedent history of opiate use, either as a commercial formulation or as a premedication for an unrelated procedure.

On examination during an acute episode, the patient is usually agitated and writhing to seek relief from the pain. Abdominal examination may reveal mild tenderness in the right upper quadrant but no signs of peritonism. There is no associated pyrexia or leucocytosis. Some patients may exhibit transient biliary obstruction, with elevated bilirubin, alkaline phosphatase and transaminases.

Classification of biliary-type SOD

The Milwaukee classification

The Milwaukee classification [43] was introduced two decades ago to guide diagnosis and treatment on the basis of clinical findings. This classification applies clinical, laboratory and ERCP findings to define three groups of SOD with differing prognosis after intervention by sphincterotomy (Table 3).

The predictability of true SOD using the Milwaukee classification is: category I 65–95%; category II 50–63%; and category III 12–28%. There remains controversy over the classification of patients with only slight increases in serum liver tests as to preferential inclusion in category II or III, but there is some evidence that these patients may correspond best to category II and should be managed similarly [52].

Classification using manometry

SO dysfunction may also be classified on the basis on manometric findings on investigation of the SO. This is a reproducible, more

Table 3 The Milwaukee classification.

Criteria	
A	Typical biliary-type pain
B	Abnormal liver function (elevation of AST ± ALP twofold) documented on two or more occasions
C	Delayed drainage of contrast medium at ERCP (> 45 min)
D	Dilated CBD with a corrected diameter ≥ 12 mm at ERCP
Category	
I	Patients exhibiting all four criteria (A–D)
II	Patients exhibiting A criteria plus one or more of B, C or D
III	Patients exhibiting A criteria only

AST, aspartate aminotransferase; ALP, alkaline phosphatase; CBD, common bile duct; ERCP, endoscopic retrograde cholangiopancreatography.

reliable form of patient assessment dividing patients into groups based on normal SO function, SO stenosis (persistent baseline pressure > 40 mmHg) and SO dyskinesia [53] (intermittent elevation of the baseline to pressure > 35 mmHg at a frequency of > 6 episodes per minute; > 50% retrograde peristalsis; paradoxical contraction in response to CCK). These categories are more accurate than the Milwaukee classification in predicting outcome after intervention [54,55].

Investigation of biliary-type SOD

Investigation should begin with a repeat measurement of liver function tests and upper abdominal ultrasonography to exclude alternative pathologies and intrahepatic or choledocholithiasis.

The morphine provocation (or Nardi) test

The original application of the morphine provocation test [56] referred to patients presenting with idiopathic recurrent pancreatitis and attempted to identify patients with SOD on the basis of the reproducibility of symptoms after the administration of morphine, to which the SO is known to be sensitive. Although patients with a positive morphine provocation test have been shown to have a greater incidence of sphincter stenosis on subsequent manometry [57], a positive morphine provocation result is not predictive of outcome after sphincterotomy [55] and is thus considered to provide only limited clinical information. The Nardi test tends to be used for screening in specialist centres before proceeding to manometry. Patients receive an injection of morphine and neostigmine and then venous samples are taken at 30-min intervals. Levels of amylase, lipase, aspartate aminotransferase and alanine aminotransferase are measured and are considered to be positive if greater than four times baseline values.

^{99m}HIDA cholescintigraphy

The CCK-OP-stimulated flow of ^{99m}HIDA across the SO may be used as a non-invasive screening investigation of SO function. Impaired drainage is likely to represent a raised SO resistance to bile flow. This use of cholescintigraphy is compromised by a degree of intraindividual variation that impairs reproducibility. Variability in the study regimes used for CCK-OP stimulation have led to contradictory reports in the literature as to the sensitivity of this technique compared with the gold standard investigation, SO manometry [58,59]. However, the non-invasive nature of this test avoids the morbidity associated with alternative invasive forms of diagnosis, and it is a useful screening test before proceeding to definitive diagnosis by manometry.

Cholangiopancreatography

Patients presenting with biliary-type pain with suspected SOD should undergo MRCP or ERCP to visualize the biliary and pancreatic ducts and in an attempt to identify alternative causes for their symptoms. Additionally, identification of duct dilatation and recording of the drainage time of contrast from the bile duct allow categorization using the Milwaukee classification. It has been shown that duct dilatation is not an inevitable consequence of previous cholecystectomy and is more likely to represent a relative SO stenosis [6]. Manometry may be performed in conjunction with ERCP, and endoscopic sphincterotomy provides a treatment option. Postprocedure, standard ERCP may be complicated by pancreatitis or duodenal perforation, and the rate of such complications for standard ERCP is reported as being up to 3% [30].

Manometry

The gold standard investigation for SOD is triple lumen manometry [6]. Manometry catheters are made of Teflon or polyethylene, and the diameter measures between 1.5 and 1.7 mm, a size shown to minimize SO spasm on insertion. They have three side-holes spanning 5 mm of the recording tip. Each lumen is connected to a capillary perfusion system and pressure force transducer. The manometer may be introduced to the SO endoscopically via duodenoscope (Fig. 4) in a manner similar to ERCP, intraoperatively via the cystic duct or postoperatively via a T-tube. In each case, the concomitant use of pharmacological substances known to affect biliary motility, such as anticholinergics and opiates, should be avoided. Diazepam (10–30 mg) may be used for sedation during endoscopy. The effects of general anaesthesia on biliary motility are unknown and may complicate the interpretation of readings obtained intraoperatively. The injection of a small volume of radio-opaque contrast is used to determine optimal manometer positioning across the SO. Baseline recordings from the sphincter are made for 5 min, followed by response to a bolus injection of CCK-OP (20 ng/kg) and a further period of baseline activity. In general, recordings can be made for up to 15 min before the patient fails to tolerate the endoscope.

Complications of manometry include mild to moderate pancreatitis in 10–20% of patients, most commonly in the group under investigation for recurrent idiopathic pancreatitis. Recently, measurements of intrabiliary pressures have been shown to correlate grossly with manometric readings from the

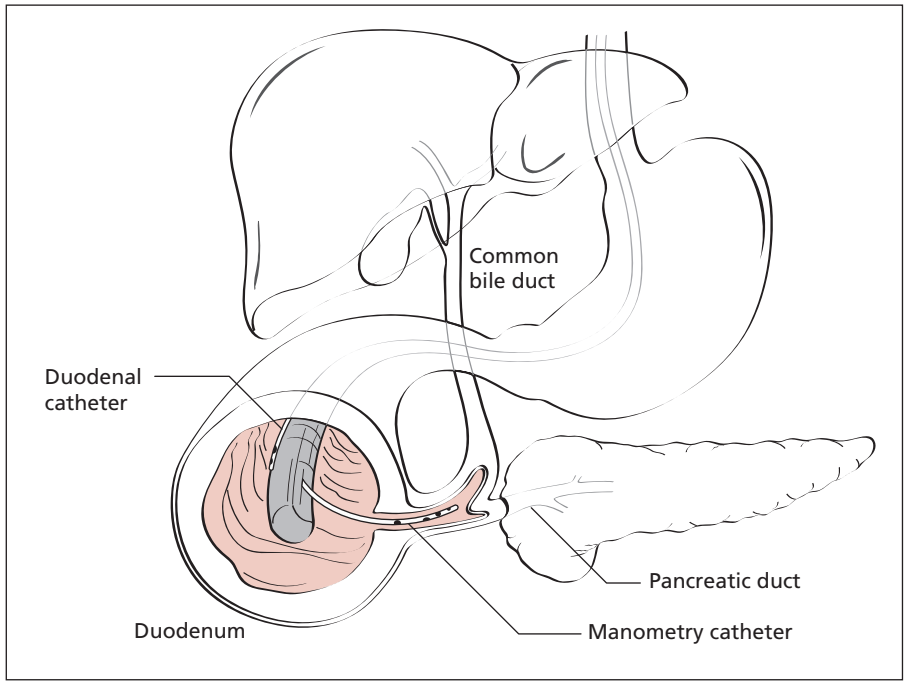

Fig. 4 Insertion of the manometry catheter into the sphincter of Oddi via duodenoscope. A duodenoscope is used to insert a manometry catheter through the ampulla of vater and into the sphincter of Oddi (SO). The manometry catheter is used to record pressures from the three regions of the SO – the sphincter choledochus, the sphincter pancreaticus and the common sphincter proximal to the ampulla. The resting basal pressure and patterns of contractile activity can be measured. Abnormalities in resting pressure or patterns of contractile activity correspond to different types of SO dysfunction.

SO and, should this be corroborated by other studies, this may provide an alternative diagnostic modality without the inherent risks of manometry.

Treatment of biliary-type SOD

The initial management of an acute episode of SOD is directed at the relief of discomfort, using an appropriate analgesic. Pethidine is more appropriate than morphine, which may provoke additional SO spasm or sensitivity [61]. Hyoscine-N-butylbromide (Buscopan) may also be useful in the relief of spasm.

As a general rule, it has been recommended that invasive investigations should not be performed on patients with infrequent episodes who do not manifest elevated liver function tests [5]. Patients corresponding to Milwaukee category I can be identified clinically and have been shown to manifest excellent outcomes after endoscopic sphincterotomy without the requirement for assessment by manometry [5]. More than 90% of category I patients report long-term relief of symptoms after division of the biliary sphincter. Manometry should be performed in patients corresponding to the Milwaukee II category, and studies have shown that sphincterotomy provides long-term relief in category II patients with elevated basal pressures indicative of SO stenosis [62]. Sphincterotomy has no proven benefit in patients suffering from SO dyskinesia, and a trial of an alternative therapy such as temporary relaxation of the sphincter with botulinum toxin or pharmacotherapy with smooth muscle relaxants such as calcium channel antagonists (e.g. nifedipine), nitrates or hyoscine-N-butylbromide may be attempted [13,62].

Manometry is essential in type 3 patients prior to surgical intervention, but should not otherwise be performed in this group. A subgroup of patients in category III may be demonstrated to have increased basal pressures on manometry but, despite endoscopic division of the sphincter, these patients fail to demonstrate persistent relief of their symptoms. Some authors have suggested that patients in category III may benefit from a trial of analgesic agents, such as low-dose tricyclic antidepressants (TCA), that have been proven to be useful in other functional gastrointestinal disorders.

Endoscopic therapy of SOD tends to occur in centres with skilled endoscopists. The complications of endoscopic sphincterotomy for SOD are well recognized. Pancreatitis rates of up to 20% have been reported as well as 1–2% mortality. Recurrent stenosis is another significant complication and has been reported in up to 25–33% of patients [60].

Surgical management of biliary-type SOD should probably be reserved for patients who have failed to improve despite endoscopic sphincterotomy. Surgical options include open transduodenal sphincteroplasty or hepaticojejunostomy. During transduodenal sphincteroplasty, a catheter is passed through an incision in the CBD (choledochotomy) and into the duodenum allowing visualization of the ampulla of Vater through a larger transduodenal incision. The ampulla and SO are divided as a bile duct sphincteroplasty, bringing the narrow opening of the pancreatic duct into view. A lacrimal probe is inserted into the pancreatic duct, and the pancreatic sphincter is divided in a similar manner to the biliary sphincter, with division of the intervening septal tissue. A large series of patients managed with transduodenal sphincteroplasty has been reported recently, and

careful patient selection remains essential in achieving good results [65]. Although not reported to the same degree, hepaticojejunostomy, with division of the CBD and anastomosis to a Roux loop of small bowel, provides a valid alternative by effectively bypassing the SO.

Pancreatic-type SOD

Clinical presentation of pancreatic-type SOD

Dysfunction of the pancreatic portion of the SO may present as a subgroup of patients who have been diagnosed with idiopathic recurrent pancreatitis in the absence of the traditional aetiological factors (e.g. cholelithiasis and alcohol). Pain is described as epigastric in nature, radiating to the back and partially relieved by bending forwards. In the same manner as the Milwaukee classification of biliary-type SOD, patients with pancreatic-type SOD may present with a spectrum of symptomatology. This ranges from classical pancreatitis with associated elevated serum amylase to pancreatic-type pain in the absence of objective clinical findings [63].

Investigation of pancreatic-type SOD

Patients presenting with suspected pancreatic-type SOD should undergo MRCP to assess potential underlying structural abnormality. If no structural abnormality is demonstrated on MRCP, investigation should proceed to manometry of both biliary and pancreatic sphincters by ERCP. Evidence of concurrent biliary-type SOD in these patients should prompt endoscopic sphincterotomy. Manometric evidence of dysfunction of the pancreatic sphincter is found in 39–90% of patients with suspected pancreatic-type dysfunction and predominantly represents an increase in resting SO basal pressure.

Treatment of pancreatic-type SOD

Confirmed pancreatic-type SOD requires division of the pancreatic sphincter. In the short term, some clinicians consider placing a pancreatic stent to assess response before surgery. However, this must be tempered by the complication rate of pancreatitis during stent placement [64]. Definitive treatment is performed by operative sphincteroplasty and pancreatic septoplasty as described above. Surgery should only be undertaken in carefully selected patients, as there is an improvement rate of 70–80% and a high complication rate of 30%, predominantly due to pancreatitis and wound infection [65,66].

Post-cholecystectomy pain

Post-cholecystectomy syndrome refers to continuing or recurrent pain post cholecystectomy. It may result from a number of causes, not all of which arise from the biliary tract. The differential diagnosis includes alternative upper gastrointestinal pathologies (stomach, duodenum, colon), postoperative basal lung atelectasis, nerve entrapment at the incision or musculoskeletal causes, predominantly of the ribs. These alternative causes of pain should be excluded before investigation of the biliary tree.

Biliary symptoms post cholecystectomy may result from retained or *de novo* stones in the hepatic ducts or CBD, microlithiasis causing transient obstruction and CBD damage or strictures as well as SOD. For this reason, the term 'post-cholecystectomy syndrome' is not clinically descriptive and should not be used as a substitute for an accurate diagnosis.

References

1 Barbara L, Sama C, Morselli Labate AM *et al.* (1987) A population study on the prevalence of gallstone disease: the Sirmione Study. *Hepatology* 7(5), 913–917.

2 GREPCO (1988) The epidemiology of gallstone disease in Rome, Italy. Part I. Prevalence data in men. The Rome Group for Epidemiology and Prevention of Cholelithiasis (GREPCO). *Hepatology* 8(4), 904–906.

3 GREPCO (1984) Prevalence of gallstone disease in an Italian adult female population. Rome Group for the Epidemiology and Prevention of Cholelithiasis (GREPCO). *Am J Epidemiol* 119(5), 796–805.

4 Chintapalli KN, Ghiatas AA, Chopra S *et al.* (1999) Sonographic findings in cases of missed gallstones. *J Clin Ultrasound* 27(3), 117–121.

5 Corazziari E, Shaffer EA, Hogan WJ *et al.* (1999) Functional disorders of the biliary tract and pancreas. *Gut* 45(Suppl. 2), II48–54.

6 Toouli J (1993) *Surgery of the Biliary Tract*, 1st edn. Edinburgh: Churchill Livingstone.

7 Behar J (1999) Clinical aspects of gallbladder motor function and dysfunction. *Curr Gastroenterol Rep* 1(2), 91–94.

8 Stolk MF, van Erpecum KJ, Smout AJ *et al.* (1993) Motor cycles with phase III in antrum are associated with high motilin levels and prolonged gallbladder emptying. *Am J Physiol* 264(4 Pt 1), G596–600.

9 Yokohata K, Tanaka M (2000) Cyclic motility of the sphincter of Oddi. *J Hepatobiliary Pancreat Surg* 7(2), 178–182.

10 Hellstrom PM, Nillson I, Svenberg T (1995) Role of bile in regulation of gut motility. *J Intern Med* 237(4), 395–402.

11 Takahashi T, May D, Owyang C (1991) Cholinergic dependence of gallbladder response to cholecystokinin in the guinea pig *in vivo*. *Am J Physiol* 261(4 Pt 1), G565–569.

12 Tierney S, Qian Z, Burrow C *et al.* (1994) Estrogen inhibits sphincter of Oddi motility. *J Surg Res* 57(1), 69–73.

13 Craig A, Toouli J (2002) Sphincter of Oddi dysfunction: is there a role for medical therapy? *Curr Gastroenterology Rep* 4(2), 172.

14 Gaur C, Mathur A, Agarwal A *et al.* (2000) Diabetic autonomic neuropathy causing gall bladder dysfunction. *J Assoc Phys India* 48(6), 603–605.

15 Fraquelli M, Pagliarulo M, Colucci A *et al.* (2003) Gallbladder motility in obesity, diabetes mellitus and coeliac disease. *Dig Liver Dis* 35(Suppl. 3), S12–16.

16 Everson G (1992) Gastrointestinal motility in pregnancy. *Gastroenterol Clin North Am* 21(4), 751–776.

17 Pozo MJ, Camello P, Mawe GM (2004) Chemical mediators of gallbladder dysmotility. *Curr Med Chem* 11(13), 1801–1812.

18 Behar J, Lee KY, Thompson WR *et al.* (1989) Gallbladder contraction in patients with pigment and cholesterol stones. *Gastroenterology* 97(6), 1479–1484.

19 Chen Q, Amaral J, Biancani P (1999) Excess membrane cholesterol alters human gallbladder muscle contractility and membrane fluidity. *Gastroenterology* 116(3), 678–685.

20 Pomeranz IS, Schaffer E (1985) Abnormal gallbladder emptying in a subgroup of patients with gallstones. *Gastroenterology* 88(3), 787–791.

21 Amaral J, Xiao ZL, Chen Q *et al.* (2001) Gallbladder muscle dysfunction in patients with chronic acalculous disease. *Gastroenterology* 120(2), 506–511.

22 Woods CM, Mawe GM, Shaffer EA *et al.* (2003) Effects of bioactive agents on biliary motor function. *Curr Gastroenterol Rep* 5(2), 154–159.

23 Birch PD, Cook JV, Fletcher CJ *et al.* (1989) Are multiple examinations of the gall-bladder helpful? *Clin Radiol* 40(3), 262–263.

24 Amouyal P, Palazzo L, Amouyal G *et al.* (1989) Endosonography: promising method for diagnosis of extrahepatic cholestasis. *Lancet* 2(8673), 1195–1198.

25 Orda R, Sayfan J, Strauss S *et al.* (1994) Intra-operative ultrasonography as a routine screening procedure in biliary surgery. *Hepatogastroenterology* 41(1), 61–64.

26 Ludwig K, Bernhardt J, Lorenz D (2002) Value and consequences of routine intraoperative cholangiography during cholecystectomy. *Surg Laparosc Endosc Percutan Tech* 12(3), 154–159.

27 Krishnamurthy GT, Brown PH (2002) Comparison of fatty meal and intravenous cholecystokinin infusion for gallbladder ejection fraction. *J Nucl Med* 43(12), 1603–1610.

28 Fink-Bennett D, DeRidder P, Kolozsi WZ *et al.* (1991) Cholecystokinin cholescintigraphy: detection of abnormal gallbladder motor function in patients with chronic acalculous gallbladder disease. *J Nucl Med* 32(9), 1695–1699.

29 Terhaar OA, Abbas S, Thornton FJ, Duke D *et al.* (2005) Imaging patients with 'post-cholecystectomy syndrome': an algorithmic approach. *Clin Radiol* 60(1), 78–84.

30 Kaltenthaler E, Vergel YB, Chilcott J *et al.* (2004) A systematic review and economic evaluation of magnetic resonance cholangiopancreatography compared with diagnostic endoscopic retrograde cholangiopancreatography. *Health Technol Assess* 8(10), iii, 1–89.

31 Rastogi A, Slivka A, Moser AJ *et al.* (2005) Controversies concerning pathophysiology and management of acalculous biliary-type abdominal pain. *Dig Dis Sci* 50(8), 1391–1401.

32 Mishkind MT, Pruitt RF, Bambini DA *et al.* (1997) Effectiveness of cholecystokinin-stimulated cholescintigraphy in the diagnosis and treatment of acalculous gallbladder disease. *Am Surg* 63(9), 769–774.

33 Yap L, Wycherley A, Morphett AD *et al.* (1991) Acalculous biliary pain: cholecystectomy alleviates symptoms in patients with abnormal cholescintigraphy. *Gastroenterology* 101(3), 786–793.

34 Woods CM, Mawe G, Toouli J *et al.* (2005) The sphincter of Oddi: understanding its control and function. *Neurogastroenterol Motil* 17(Suppl. 1), 31–40.

35 Toouli J, Baker RA (1991) Innervation of the sphincter of Oddi: physiology and considerations of pharmacological intervention in biliary dyskinesia. *Pharmacol Ther* 49(3), 269–281.

36 Thune A, Saccone GT, Scicchitano JP *et al.* (1991) Distension of the gall bladder inhibits sphincter of Oddi motility in humans. *Gut* 32(6), 690–693.

37 Thune A, Thornell E, Svanvik J (1986) Reflex regulation of flow resistance in the feline sphincter of Oddi by hydrostatic pressure in the biliary tract. *Gastroenterology* 91(6), 1364–1369.

38 Saccone GT, Baker RA, Toouli J (1994) Intramural neural pathways between the duodenum and sphincter of Oddi in the Australian brush-tailed possum *in vivo*. *J Physiol* 481(Pt 2), 447–456.

39 Wiley JW, O'Dorisio TM, Owyang C (1988) Vasoactive intestinal polypeptide mediates cholecystokinin-induced relaxation of the sphincter of Oddi. *J Clin Invest* 81(6), 1920–1924.

40 Pauletzki JG, Sharkey KA, Davison JS *et al.* (1993) Involvement of L-arginine-nitric oxide pathways in neural relaxation of the sphincter of Oddi. *Eur J Pharmacol* 232(2–3), 263–270.

41 Fazel A, Geenen JE, MoezArdalan K *et al.* (2005) Intrapancreatic ductal pressure in sphincter of Oddi dysfunction. *Pancreas* 30(4), 359–362.

42 Tierney S, Quian Z, Lipsett PA *et al.* (1998) Ethanol inhibits sphincter of Oddi motility. *J Gastrointest Surg* 2(4), 356–362.

43 Hogan WJ, Geewan J (1988) Biliary dyskinesia. *Endoscopy* 20(Suppl. 1), 179–183.

44 Rosch W, Riemann J, Lux G, Lindner HG (1981) Long-term follow-up after endoscopic sphincterotomy. *Endoscopy* 13(4), 152–153.

45 Desautels SG, Slivka A, Hutson WR *et al.* (1999) Postcholecystectomy pain syndrome: pathophysiology of abdominal pain in sphincter of Oddi type III. *Gastroenterology* 116(4), 900–905.

46 Piccinni GMA, Testini A, Bonomo M *et al.* (2004) Diagnosing and treating sphincter of Oddi dysfunction: a critical literature review and reevaluation. *J Clin Gastroenterol* 38(4), 350–359.

47 Luman W, Williams A, Pryde A, Smith GD *et al.* (1997) Influence of cholecystectomy on sphincter of Oddi motility. *Gut* 41(3), 371–374.

48 Cicala M, Habib FI, Fiocca F *et al.* (2001) Increased sphincter of Oddi basal pressure in patients affected by gall stone disease: a role for biliary stasis and colicky pain? *Gut* 48(3), 414–417.

49 Saraswat VA, Sharma BC, Agarwal DK *et al.* (2004) Biliary microlithiasis in patients with idiopathic acute pancreatitis and unexplained biliary pain: response to therapy. *J Gastroenterol Hepatol* 19(10), 1206–1211.

50 Rhee JY, Elta GH (2003) The relationship of bile duct crystals to sphincter of Oddi dysfunction. *Curr Gastroenterol Rep* 5(2), 160–163.

51 Quallich LG, Stern M, Rich M, Chey WD *et al.* (2002) Bile duct crystals do not contribute to sphincter of Oddi dysfunction. *Gastrointest Endosc* 55(2), 163–166.

52 Silverman WB, Slivka A, Rabinovitz M, Wilson J (2001) Hybrid classification of sphincter of Oddi dysfunction based on simplified Milwaukee criteria: effect of marginal serum liver and pancreas test elevations. *Dig Dis Sci* 46(2), 278–281.

53 Toouli J, Roberts-Thomson I, Dent J, Lee J (1985) Manometric disorders in patients with suspected sphincter of Oddi dysfunction. *Gastroenterology* 88(5 Pt 1), 1243–1250.

54 Geenen JE, Hogan W, Dodds WJ, Toouli J *et al.* (1989) The efficacy of endoscopic sphincterotomy after cholecystectomy in patients with sphincter-of-Oddi dysfunction. *N Engl J Med* 320(2), 82–87.

55 Toouli J, Roberts-Thomson IC, Kellow J *et al.* (2000) Manometry based randomised trial of endoscopic sphincterotomy for sphincter of Oddi dysfunction. *Gut* 46(1), 98–102.

56 Nardi GL, Acosta JM (1966) Papillitis as a cause of pancreatitis and abdominal pain: role of evocative test, operative pancreatography and histologic evaluation. *Ann Surg* 164(4), 611–621.

57 Roberts-Thomson IC, Toouli J (1985) Abnormal responses to morphine-neostigmine in patients with undefined biliary type pain. *Gut* 26(12), 1367–1372.

58 Toouli J (2005) Biliary scintigraphy versus sphincter of Oddi manometry in patients with post-cholecystectomy pain: is it time to disregard the scan? *Curr Gastroenterol Rep* 7(2), 154–159.

59 Madacsy L, Middelfart HV, Matzen P *et al.* (2000) Quantitative hepatobiliary scintigraphy and endoscopic sphincter of Oddi manometry in patients with suspected sphincter of Oddi dysfunction: assessment of flow-pressure relationship in the biliary tract. *Eur J Gastroenterol Hepatol* 12(7), 777–786.

60 Freeman ML (2003) Understanding risk factors and avoiding complications with endoscopic retrograde cholangiopancreatography. *Curr Gastroenterol Rep* 5(2), 145–153.

61 Thune A, Baker RA, Saccone GT *et al.* (1990) Differing effects of pethidine and morphine on human sphincter of Oddi motility. *Br J Surg* 77(9), 992–995.

62 Craig AG, Toouli J (2001) Sphincterotomy for biliary sphincter of Oddi dysfunction. *Cochrane Database Syst Rev* 3, CD001509.

63 Petersen B (2004) Sphincter of Oddi dysfunction, part 2: Evidence-based review of the presentations, with 'objective' pancreatic findings (types I and II) and of presumptive type III. *Gastrointest Endosc* 59(6), 670–687.

64 Sheehan SJ, Lee J, Wells CK, Topazian M (2005) Serum amylase, pancreatic stents, and pancreatitis after sphincter of Oddi manometry. *Gastrointest Endosc* 62(2), 260–265.

65 Madura JA, Madura JA Jn, Sherman S, Lehman GA (2005) Surgical sphincteroplasty in 446 patients. *Arch Surg* 140(5), 504–511.

66 Tzovaras G, Rowlands B (2002) Transduodenal sphincteroplasty and transampullary septectomy for sphincter of Oddi dysfunction. *Ann R Coll Surg Engl* 1, 14–19.

19.7 Benign biliary tumours

Miguel Bruguera

Bile duct adenoma

Bile duct adenoma, also termed cholangioadenoma and benign cholangioma in earlier literature, is a tumour-like lesion, small in size (1–22 mm in diameter), usually solitary and subcapsular in location, found incidentally at laparotomy or autopsy in adults older than 40 years of age [1].

Macroscopically, it is a firm, grey-white, well-circumscribed, uncapsulated nodule. Histologically, bile duct adenomas are formed by a compact proliferation of narrow duct-like structures containing mucin, but no bile, with tubular or tortuous appearance. They are included in a fibrous stroma containing inflammatory cells, typically lymphocytes, which allows their differentiation from von Meyenburg complexes formed by dilated bile ducts containing bile and included in a mature connective stroma. Bile duct adenomas may be confounded macroscopically with metastatic carcinoma but, histologically, they may be distinguished by the absence of nuclear hyperchromatism, mitotic activity and vascular invasion. During their evolution, the inflammatory component surrounding the bile ducts decreases and the fibrous stroma increases, giving the aspect of a subcapsular scar [2].

The pathogenesis of bile duct adenoma is obscure, but it has been suggested that it may be considered as a peribiliary gland hamartoma because the cells of the tumour have the phenotype of normal peribiliary glands [3]. Unlike von Meyenburg complexes, malignant transformation has not been documented.

It is an asymptomatic lesion almost always discovered incidentally as a subcapsular nodule either during a laparotomy or during explant or postmortem examination [4].

Biliary papillomatosis

Biliary papillomatosis is an extremely uncommon condition, characterized by multiple polypoid masses growing in the intra- or extrahepatic biliary tract [5]. Fewer than 50 cases had been reported up to 1995, most being in middle-aged or elderly people, with a slightly higher incidence in men.

It presents clinically with recurrent bouts of obstructive jaundice, which may be complicated by bacterial cholangitis. Patients die within a few years of diagnosis as a result of recurrent cholangitis, liver failure or malignant transformation [6].

Histologically, this tumour is a papillary adenoma composed of mucus-secreting columnar epithelial cells supported by a delicate, branching, fibrovascular core [7].

Hepatic lobectomy may be useful for the rare patients in whom biliary papilloma is restricted to one hepatic lobe [8]. When the common bile duct is affected, curettage and drainage may temporarily relieve bile obstruction. Hepatic transplantation should be considered in these patients [9].

Biliary hamartoma (microhamartoma, von Meyenburg complex)

Biliary hamartoma represents a developmental malformation consisting of an anomalous collection of small bile ducts surrounded by abundant fibrous stroma; it falls into the spectrum of fibropolycystic diseases of the liver resulting from ductal plate malformation [10].

Occurrence

It is usually an incidental finding of laparotomy (0.6% of cases; [11]), autopsy (0.7% of cases; [12]) or needle liver biopsies.

Pathology

On gross examination, biliary hamartomas appear as small grey-white nodules (less than 0.5 cm in diameter). They may be single, but they are more often multiple. Microscopically, they consist of small, irregular bile ducts, sometimes dilated with a branching configuration, lined by cuboidal or flattened epithelial cells that are embedded in a hyalinous fibrous stroma. Some bile ducts contain proteinaceous or bile-stained secretions. Microhamartomas develop at the border of hepatic parenchyma and the portal tracts.

Biliary hamartoma should be differentiated from well-differentiated cholangiocarcinoma and from bile duct adenoma.

Clinical features

Microhamartomas are asymptomatic. A slight elevation in γ-glutamyltransferase activity is seen in cases with multiple lesions [13]. They may be found associated with other polycystic diseases of the liver, congenital hepatic fibrosis, Caroli syndrome or adult polycystic liver disease.

On ultrasound examination, these lesions can mimic metastatic disease because they are seen as multiple anechoic, hypoechoic or hyperechoic nodules, uniformly or non-uniformly distributed throughout the liver [14]. On computerized tomography (CT) scans, biliary hamartomas are hypodense without evidence of contrast enhancement [15]. On magnetic resonance imaging (MRI), they are slightly hypodense with respect to liver on T1-weighted images and hyperintense on T2-weighted images [16]. Guided biopsy of the liver with a large-gauge needle is needed whenever hamartomas must be distinguished from metastases, as imaging methods cannot differentiate between these conditions. However, multiple bile duct hamartomas should be suspected when multiple small nodules are found on ultrasound examination in a patient with otherwise good health and normal liver tests.

Four patients have been reported in whom malignant transformation from a microhamartoma to a cholangiocarcinoma was thought to occur [17–19].

References

1 Allaire GS, Rabin L, Ishak KG *et al.* (1988) Bile duct adenoma. A study of 152 cases. *Am J Surg Pathol* 12, 708–715.

2 Govindarajan S, Peters RL (1984) The bile duct adenoma. A lesion distinct from Meyenburg complex. *Arch Path Lab Med* 108, 922–924.

3 Bathal PS, Hughes NR, Goodman ZD (1996) The so called bile duct adenoma is a peribiliary gland hamartoma. *Am J Surg Pathol* 20, 858–864.

4 Brunt EM (2001) Benign tumors of the liver. *Clin Liver Dis* 5, 1–16.

5 Veloso FT, Ribeiro AT, Teixeira AA *et al.* (1983) Biliary papillomatosis: report of a case with 5-year follow-up. *Am J Gastroenterol* 78, 645–648.

6 Colombari R, Tsui WMS (1995) Biliary tumours of the liver. *Semin Liver Dis* 15, 402–413.

7 Padfield CJ, Ansell ID, Furness PN (1988) Mucinous biliary papillomatosis: a tumour in need of wider recognition. *Histopathology* 13, 687–694.

8 Gouma DJ, Mutum SS, Benjamin IS *et al.* (1984) Intrahepatic biliary papillomatosis. *Br J Surg* 71, 72–74.

9 Rambaud S, Nores JM, Meeus F *et al.* (1989) Malignant papillomatosis of the bile ducts: a new indication for liver transplantation? *Am J Gastroenterol* 4, 448–449.

10 Summerfield JA, Nagafuchi Y, Sherlock S *et al.* (1986) Hepatobiliary fibropolycystic diseases. A clinical and histological review of 51 patients. *J Hepatol* 2, 141–156.

11 Thommesen N (1978) Biliary hamartomas (von Meyenburg complexes) in liver needle biopsies. *Acta Pathol Microbiol Scand A* 86, 93–99.

12 Chung EB (1970) Multiple bile-duct hamartomas. *Cancer* 26, 287–296

13 Saló J, Bru C, Vilella A *et al.* (1992) Bile-duct hamartomas presenting as multiple focal lesions on hepatic ultrasonography. *Am J Gastroenterol* 87, 221–223.

14 Tan A, Shen JF, Hecht AH (1989) Sonogram of multiple bile duct hamartomas. *J Clin Ultrasound* 17, 667–669.

15 Lev-Toaff AS, Bach AM, Wechsler RJ *et al.* (1995) The radiologic and pathologic spectrum of biliary hamartomas. *AJR Am J Roentgenol* 165, 309–313.

16 Slone HW, Bennett WF, Bova JG (1993) MR findings of multiple biliary hamartomas *AJR Am J Roentgenol* 161, 581.

17 Honda N, Cobb C, Lechago J (1986) Bile duct carcinoma associated with multiple von Meyenburg complexes in the liver. *Hum Pathol* 17, 1287–1290.

18 Dekker A, Ten Kate FJ, Terpstra OT (1989) Cholangiocarcinoma associated with multiple bile-duct hamartomas of the liver. *Dig Dis Sci* 34, 952–958.

19 Burns CD, Kuhns JG, Wieman TJ (1990) Cholangiocarcinoma in association with multiple biliary microhamartomas. *Arch Pathol Lab Med* 114, 1287–1289.

19.8 Gallbladder carcinoma

Thomas A. Aloia, Christopher H. Crane and Jean-Nicolas Vauthey

Epidemiology and risk factors

Owing to its well-described association with chronic cholesterol cholelithiasis, the worldwide distribution of gallbladder cancer is heterogeneous (Fig. 1). In Europe, the highest rates are seen in Poland, the Czech Republic and Slovakia. In South America, the highest rates are seen in certain populations of Indians located in Chile, Bolivia and Mexico. In the United States, gallbladder carcinoma is the sixth most common carcinoma of the gastrointestinal tract, and it will account for approximately 80% of the estimated 7480 cases of biliary tract cancer diagnosed in 2005 [1]. As in other countries, in the US, there is a higher incidence of gallbladder cancer in Alaska and New Mexico, mirroring the incidence of cholelithiasis in ethnic groups that inhabit these regions. In the US, however, the incidence and mortality rates of gallbladder cancer have been decreasing since 1970, at least in part as a result of increasing numbers of cholecystectomies performed annually for benign gallbladder disease [2].

The association between cholesterol cholelithiasis and gallbladder carcinoma is based on multiple lines of evidence. The mechanism by which lithogenic bile leads to gallbladder cancer is believed to be mediated by chronic inflammation of the gallbladder mucosa. This inflammatory state induces epithelial hyperplasia, which provides a rich environment for the development of mutations, ultimately leading to carcinoma formation [3,4]. Other pathological conditions associated with gallbladder

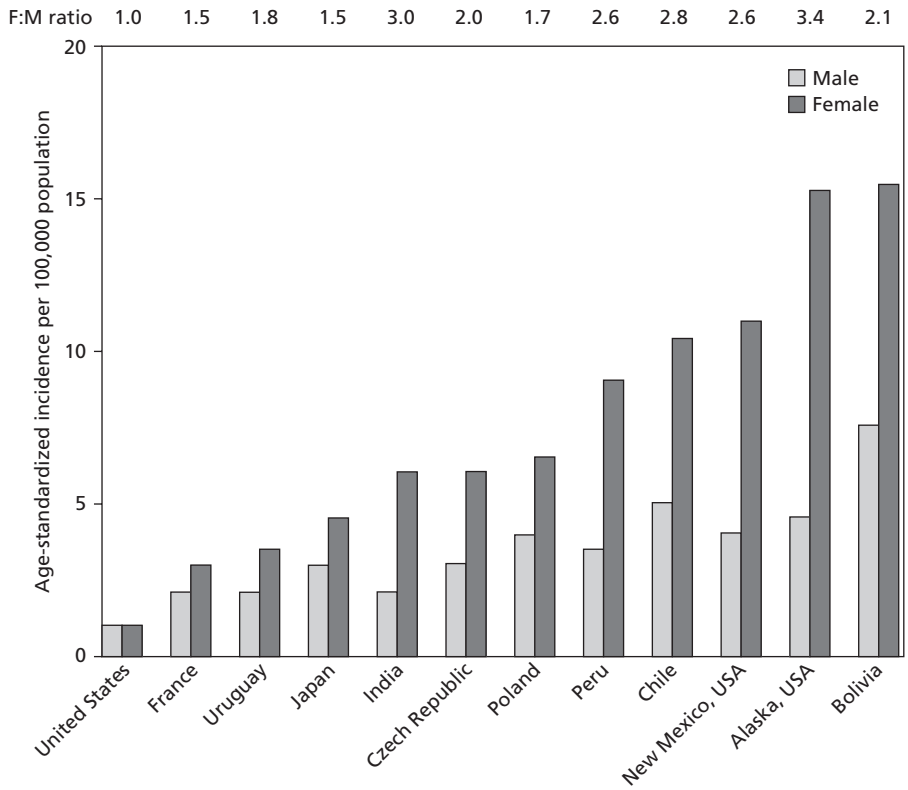

Fig. 1 Age-standardized incidence of gallbladder carcinoma per 100 000 inhabitants in selected countries by gender distribution. Female and male ratios of incidence are shown. Higher ratios are seen in countries showing higher levels of incidence. Data from Alaska are based on a small number of cases (reproduced with permission from ref. 8).

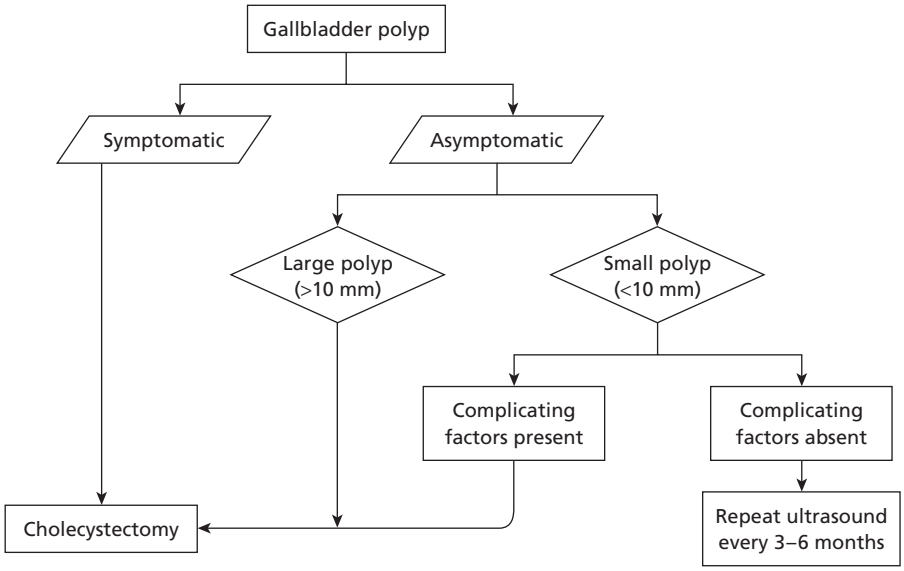

Fig. 2 Strategies for the management of gallbladder polyps. 'Complicating factors' include age greater than 50 years and cholelithiasis (adapted with permission from ref. 7).

carcinoma include cholecystoenteric fistula, aberrant pancreaticobiliary duct junction (APBDJ), the presence of Mirizzi syndrome, exposure to chemical carcinogens and typhoid infection.

Although the majority of gallbladder cancers arise from dysplastic lesions, gallbladder carcinomas can arise from gallbladder adenomas, particularly in polypoid lesions of the gallbladder (PLG) larger than 10 mm [5,6]. Other risk factors for the development of gallbladder adenocarcinoma include solitary PLG, symptomatic PLG, concurrent gallstones and patient age greater than 50 years. An assessment for the presence of these factors then allows for the proper selection of patients with PLG who would be most likely to benefit from cholecystectomy (Fig. 2) [7].

Genetic alterations in gallbladder cancer

Although a detailed analysis of the molecular oncogenesis of gallbladder cancer is outside the scope of this chapter, no discussion of the topic would be complete without a summary of the major genetic alternations seen in this disease. The current understanding of the timing and impact of each of these mutations on gallbladder cancer carcinogenesis is presented in Figure 3. For a more detailed review, we suggest that the reader begin with the reference from Wistuba and Gazdar in *Nature Reviews* [8].

p53

The *p53* gene, located on chromosome 17p, produces a 53-kDa nuclear phosphoprotein that mediates apoptotic pathways. Loss of normal function of this gene results in inappropriate survival of genetically damaged cells. Genetic alterations in the *p53* gene are some of the most common abnormalities identified in human malignancies, and gallbladder cancer is no exception. Several immunohistochemical and genetic mutation analyses have identified *p53* abnormalities in 35–92% of gallbladder cancer specimens. In over two-thirds of these studies, more than 50% of cases showed evidence of *p53* mutations. In addition, several studies have identified *p53* mutations in adjacent areas of dysplastic epithelium (0–32%) and adjacent areas of carcinoma *in situ* (45–86%), leading to the conclusion that, for many gallbladder cancers, *p53* mutations are early events that encourage progression along the pathway of dysplasia to carcinoma *in situ* to adenocarcinoma. Although *p53* mutations are common in gallbladder premalignant and malignant lesions, the presence of *p53* mutations has not been correlated with prognosis or with recurrence.

K-ras

The K-*ras* gene produces a 21-kDa inner membrane-bound protein that normally mediates growth signal transduction. Mutations, which have been identified most commonly in codons 12, 13 and 61, lead to a state of unopposed growth stimulation within the cell. Although chronic cholelithiasis-associated gallbladder carcinomas rarely demonstrate K-*ras* mutations, the subset of gallbladder carcinomas seen in Japan in association with APBDJ frequently demonstrate K-*ras* mutations. Between 50% and 83% of APBDJ-associated cases harbour mutations in codons 12 and 13 of the K-*ras* gene. When present in the absence of APBDJ, it appears that K-*ras* mutations are a late event in carcinogenesis, with a higher prevalence of mutations in cases of less well-differentiated tumours. In contrast, both phenotypically normal mucosa and dysplastic lesions from patients with APBDJ can contain K-*ras* mutations, suggesting a unique pathogenic mechanism in these patients.

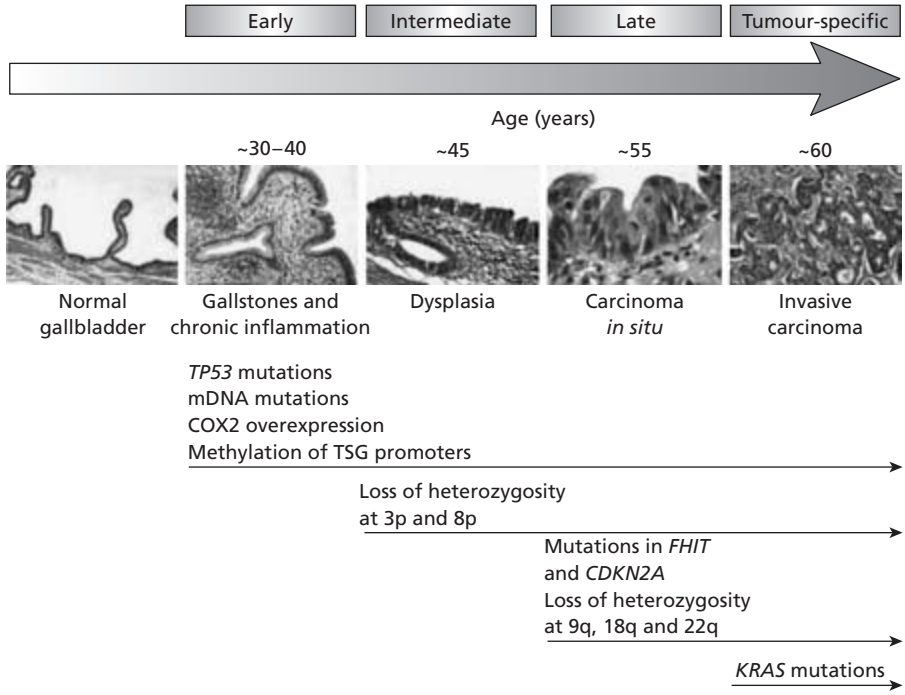

Fig. 3 Sequential histopathological and molecular changes in the pathogenesis of gallbladder carcinoma associated with gallstones and inflammation. The median age at diagnosis of each histopathological change is shown. These histological changes are accompanied by progressive molecular abnormalities, which commence in the histologically normal-appearing epithelium that is present in chronic cholecystitis (reproduced with permission from ref. 8).

Clinical presentation and diagnosis

Gallbladder carcinoma affects women three times more often than men, and its incidence increases steadily with age, with a steep rise beyond the age of 60 years. The symptoms of gallbladder cancer are typically those of benign gallbladder disease. Common symptoms include right upper quadrant abdominal pain, nausea and fatty food intolerance. A careful history frequently identifies symptoms consistent with cholelithiasis-associated gallbladder inflammation that have been present for many years. With more advanced cases, symptoms can include jaundice, anorexia and weight loss. Physical findings may include right upper quadrant tenderness, a palpable mass and ascites. Laboratory studies are typically unremarkable unless the patient has developed obstructive jaundice. Unfortunately, none of the commonly utilized gastrointestinal tumour markers, including carcinoembryonic antigen and CA19-9, reliably detect early-stage disease.

Given the non-specific presentation of patients with gallbladder carcinoma, the disease is difficult to diagnose preoperatively. If a gallbladder cancer is suspected preoperatively, usually as a result of an abnormally thickened gallbladder wall or the presence of a gallbladder mass on ultrasound, then further investigation with contrast-enhanced computerized tomography scan or magnetic resonance imaging is warranted (Fig. 4). These imaging modalities are critical in the determination of resectability, providing information about the local extent of disease, including portal vascular invasion, as well as the presence of lymphadenopathy and liver metastases. Preoperative percutaneous fine-needle aspiration is helpful to confirm the diagnosis of gallbladder carcinoma, to determine the extent of the planned surgical resection and to determine indications for associated treatments, including portal vein embolization and preoperative chemoradiation.

Fig. 4 A 66-year-old woman with cholelithiasis and a contrast-enhanced mass arising from the gallbladder wall (arrow). In the absence of other signs of cholecystitis (diffusely thickened gallbladder wall or pericholecystic fluid), the diagnosis of gallbladder carcinoma should be made preoperatively. In this patient, a preoperative percutaneous fine-needle aspiration biopsy of the mass confirmed adenocarcinoma.

Treatment of gallbladder cancer

Prognosis and staging

Patients diagnosed with gallbladder cancer typically present in one of three ways: (i) an incidental finding in the gallbladder

specimen removed at cholecystectomy for suspected benign disease; (ii) a diagnostic finding of a suspected or confirmed lesion that appears to be resectable after preoperative studies; (iii) advanced, unresectable disease. Irrespective of presenting scenario, the current management of patients with gallbladder carcinoma is determined by the stage of disease at presentation, with surgical resection as the only curative option.

Unfortunately, only 10–30% of patients present with surgically resectable disease. For this subset, the extent of surgery is largely dictated by the T stage of the tumour, which also predicts the likelihood of lymph node metastases (N stage) and peritoneal and distant dissemination (M stage). Historically, patients with tumours localized to the gallbladder wall (T1–2) could expect a 32% 5-year survival, while only 10% of those with more advanced primary lesions (T3–4) are likely to be alive 5 years after diagnosis. Recent surgical series, however, indicate modest improvements in survival following resection.

In its sixth edition, the American Joint Committee on Cancer (AJCC) revised the TNM staging system for gallbladder carcinoma (Table 1) [9]. The most significant change in the staging system is that there is no longer a distinction between T3 and T4 tumours based on the depth of liver invasion. Tumours that perforate the serosa (visceral peritoneum) and/or directly invade the liver and/or one other adjacent organ or structure, such as the stomach, duodenum, colon, pancreas, omentum or extrahepatic bile ducts, are classified as T3. In contrast, tumours classified as T4 include those that invade the main portal vein or the hepatic artery or those that invade multiple extrahepatic organs or structures.

Table 1 Definition of TNM.

Primary tumour (T)			
TX	Primary tumour cannot be assessed		
T0	No evidence of primary tumour		
Tis	Carcinoma *in situ*		
T1	Tumour invades lamina propria or muscle layer		
T1a	Tumour invades lamina propria		
T1b	Tumour invades muscle layer		
T2	Tumour invades perimuscular connective tissue; no extension beyond serosa or into liver		
T3	Tumour perforates the serosa (visceral peritoneum) and/or directly invades the liver and/or one other adjacent organ or structure, such as the stomach, duodenum, colon or pancreas, omentum or extrahepatic bile ducts		
T4	Tumour invades main portal vein or hepatic artery or invades multiple extrahepatic organs or structures		
Regional lymph nodes (N)			
NX	Regional lymph nodes cannot be assessed		
N0	No regional lymph node metastasis		
N1	Regional lymph node metastasis		
Distant metastasis (M)			
MX	Distant metastasis cannot be assessed		
M0	No distant metastasis		
M1	Distant metastasis		
Stage grouping			
Stage 0	Tis	N0	M0
Stage IA	T1	N0	M0
Stage IB	T2	N0	M0
Stage IIA	T3	N0	M0
Stage IIB	T1	N1	M0
	T2	N1	M0
	T3	N1	M0
Stage III	T4	Any N	M0
Stage IV	Any T	Any N	M1

Surgical therapy

Complete surgical resection offers the only chance for cure of gallbladder cancer. For patients with gallbladder carcinoma *in situ* (Tis) or invasive carcinoma limited to the mucosa (T1a), most surgeons agree that simple cholecystectomy is adequate treatment provided that the cystic duct margin is negative. The incidence of lymph node metastases in patients with T1a tumours is only 2.5% [10]. Therefore, an extended resection to include the regional lymph nodes, with its attendant increased morbidity and mortality, is not justified for the small potential survival benefit. Given a 15% incidence of nodal metastases with T1b (invasive of muscle) tumours, extended resection seems to be justified in these cases, although the data are conflicting.

As T2 (invasive of perimuscular connective tissue) tumours are associated with a 56% incidence of regional lymph node metastases [10], an extended cholecystectomy with regional lymphadenectomy is warranted. In addition, as a routine cholecystectomy employs a subserosal plane of dissection on the liver surface that may result in a positive margin, an extended cholecystectomy including at least a wedge resection of the gallbladder fossa of the liver (segments IVb and V) leads to improved long-term outcome. Radical second operations for T2 tumours incidentally found at cholecystectomy are also associated with improved 5-year survival rates of 61–75% [11,12].

The consensus opinion about the role of surgery in the treatment of locally advanced gallbladder cancer is far less nihilistic today than it was just a decade ago. Most recently, investigators have reported 5-year survival rates from 21% to 44% for patients with T3 and T4 tumours after radical resection [11,13,14]. For patients with locally advanced disease, the extent of hepatic resection is determined by the degree to which the tumour invades the gallbladder fossa of the liver and the degree to which it involves the right portal triad. Large tumours may require a formal right hepatectomy or an extended right hepatectomy (trisectionectomy) in order to achieve a negative margin and thus the best chance for long-term survival. As precise preoperative or intraoperative diagnosis of hepatoduodenal ligament invasion is difficult, if not impossible, some surgeons feel that consideration should be given to routine resection of the extrahepatic bile duct and lymph nodes in order to achieve a

Table 2 Survival following resection for gallbladder carcinoma.

Study	Patients (*n*)	Morbidity (%)	Mortality (%)	Survival (%)		
				1 year	3 years	5 years
Donohue *et al.* [13]	40	13	5	–	–	33
Ogura *et al.* [10]	984	23	5	87	66	51
Shirai *et al.* [25]	40	–	0	–	–	65
Ouchi *et al.* [26]	25	–	0	95	70	61
Chijiiwa *et al.* [27]	17	–	–	–	–	53
Bartlett *et al.* [28]	23	26	0	81	66	58
Fong *et al.* [11]	37	29	4	–	–	38
Kondo *et al.* [14]	80	45	15	55	30	24
Ito *et al.* [29]	18	–	–	73	–	31

margin-negative (R0) resection. Most surgeons, however, resect the extrahepatic bile duct only if there is evidence of gross tumour invasion or positive cystic duct margins. Lastly, in patients with locally advanced disease, some long-term survivors have been reported following radical resections to include *en bloc* resection of grossly involved neighbouring structures such as the pancreas and portal vein as well as extensive lymphadenectomies to include the peripancreatic and para-aortic lymph nodes, but such extensive resections are associated with high rates of perioperative morbidity (~ 50%) and mortality (~ 20%).

The most significant prognostic factor in gallbladder cancer is lymph node involvement. Although several studies from Japan have reported long-term survival after resection of node-positive gallbladder cancers, western studies consistently report a dismal outcome for these patients. Accordingly, most surgeons in the United States consider a patient with positive peripancreatic, periportal or coeliac nodes (formerly known as N2 nodes) to be unresectable. Other poor prognostic factors include histologies other than papillary adenocarcinoma and vascular invasion.

Table 2 summarizes the outcomes of several series of patients undergoing attempted curative resection of gallbladder carcinoma. Although the studies are heterogeneous with respect to the types of patients included and the extent of resection performed, all the reports confirm that long-term survival is possible after extended resection in selected patients with gallbladder carcinoma.

Palliative therapy

Patients with locally advanced, unresectable gallbladder carcinoma may present with symptoms of jaundice, pain and bowel obstruction. These patients have a life expectancy in the order of months, especially in the setting of liver and/or peritoneal dissemination. As such, one should choose a mode of palliation that combines the most durable relief of symptoms with the least morbidity possible. Biliary drainage is best achieved by endoscopic or percutaneous means, as palliative surgical biliary bypass is associated with a high complication rate. For patients with gallbladder cancer-associated intestinal obstruction, intestinal bypass may provide symptomatic relief, although there are reports of excellent palliation of malignant duodenal obstruction by the endoscopic placement of expandable metal stents.

Adjuvant therapy

Gallbladder cancer is a relatively rare malignancy and, as such, there are few centres that have treated a sufficient number of patients to make meaningful conclusions about the natural history and optimal treatment approach to these tumours. Although collective experience indicates that a R0 resection is the most effective treatment and the only hope for long-term survival, the role for adjuvant therapy is less clearly defined. Given the rarity of the disease, there have been few randomized adjuvant therapy trials, each enrolling small numbers of patients and, consequently, there is no consensus as to the optimal adjuvant therapy regimen. In addition, no sufficiently accurate serological tumour marker exists to assist with detection of recurrence or assessment of treatment response.

In order to develop a rational, effective strategy for adjuvant therapy, one must understand the patterns of failure of gallbladder carcinoma after surgical resection. In a recent retrospective review of the patterns of initial disease recurrence after potentially curative surgical resection, Jarnagin *et al.* [15] followed 80 patients with gallbladder carcinoma and compared them with 76 patients with hilar cholangiocarcinoma (CCA). The median time to disease recurrence was shorter for patients with gallbladder cancer (11.5 months) compared with patients with hilar CCA (20.3 months). The site of initial disease recurrence was locoregional in only 15% of patients with gallbladder cancer compared with 59% of patients with hilar CCA. In contrast, 85% of patients with gallbladder cancer had a distant (+/– locoregional) site as their initial site of failure compared with 41% of patients with hilar CCA. This study provides insight into the clinical behaviour of these malignancies and suggests that, in the case of gallbladder cancer, improvements in survival are most likely to be achieved with more effective systemic

therapies as opposed to locoregional adjuvant treatment such as radiation therapy.

Radiation therapy

There are very few reports consisting of small series of non-randomized patients that suggest a survival benefit for adjuvant radiation therapy after surgical resection of gallbladder carcinoma. In one of the largest single-institution series of adjuvant external beam radiation therapy (EBRT) by Houry *et al.* [16], 20 patients were treated postoperatively with EBRT and seven received concomitant 5-fluorouracil (5-FU)-based chemotherapy. The authors concluded that adjuvant EBRT was associated with improved survival in palliative but not curative surgical resections. Hanna and Rider [17] reported on 51 patients with gallbladder carcinoma from the Princess Margaret Hospital, 35 of whom underwent a potentially curative surgical resection and EBRT. There was a survival advantage for those patients who received adjuvant EBRT in addition to surgery compared with those who had surgery alone. Recently, Kresl *et al.* [18] published their retrospective analysis of adjuvant EBRT with concurrent 5-FU after curative surgical resection in 21 patients with gallbladder cancer treated at the Mayo Clinic from 1985 to 1997. Patients with a R0 resection followed by adjuvant EBRT plus 5-FU had a favourable 5-year survival rate of 64%. However, similar to the findings reported in other hepatobiliary centres, 67% of the patients suffered distant failure, emphasizing the need for more effective adjuvant chemotherapy for this disease.

Intraoperative radiation therapy (IORT) has been advocated as a means of delivering high-dose, small-field therapy directly to the tumour bed without the dose limitations associated with EBRT. Todoroki *et al.* [19] have reported the most substantial experience with IORT in 85 patients with AJCC stage IV gallbladder cancer who underwent aggressive surgical resection with or without IORT at a mean dose of 21 Gy. Forty-seven patients in total received some form of radiation therapy (EBRT and/or IORT). The local control rate was significantly higher after adjuvant radiotherapy (59%) than after resection alone (36%). Moreover, the 5-year survival rate was significantly higher after adjuvant radiotherapy (9%) than after resection alone (3%), with the most pronounced improvement in 5-year survival rate (17%) in patients with only microscopic residual disease (R1 resection).

The role of radiation therapy for the palliation of symptoms such as jaundice, pain and pruritus in patients with unresectable disease is difficult to ascertain, as published studies consist of small numbers of patients with the significant confounding variable that most patients also underwent a biliary drainage procedure.

Chemotherapy

Most published studies concerning the role of chemotherapy in patients with locally advanced or metastatic gallbladder carcinoma are limited by the small numbers of patients and by the inclusion of patients with biliary tract cancers. Unfortunately, no single chemotherapeutic agent or combination of agents has been identified to be effective in the treatment of this disease (Table 3). Although overall response rates range as high as 64%, complete responses are rare, and median overall survival rates range from only 20 weeks to 15 months.

Fluorouracil (5-FU), administered either alone or in combination, is the most extensively studied chemotherapeutic agent for this disease. 5-FU administered in combination with doxorubicin and mitomycin C (FAM) or in combination with cisplatin and epirubicin (CEF) has yielded response rates of 8% and 33% respectively [20]. Better response rates have been documented in patients treated with combinations of 5-FU with hydroxyurea (30%) [21] or interferon α-2b (34%) [22].

Other chemotherapeutic agents have exhibited variable success in the treatment of advanced gallbladder cancer (Table 3). While cisplatin, mitomycin C, paclitaxel and CPT-11 have produced response rates of 10% or less as single agents, several case reports have shown that gemcitabine is active in the treatment of patients with gallbladder carcinoma, particularly when used in combination with other agents. Based on these studies, it appears that gemcitabine is an important component of the systemic therapy of gallbladder carcinoma, but additional studies of gemcitabine in combination with other agents are warranted, as the survival benefit with existing regimens is modest at best.

Hepatic arterial infusion chemotherapy has been studied in a few patients with locally unresectable gallbladder cancer. Partial response rates of up to 60% have been reported, but the median duration of response was only 3 months, and all patients developed progressive disease [23,24]. The median overall survival rates of 12–14 months in these studies are comparable with that achieved with intravenous chemotherapy, providing little impetus to recommend this more complicated mode of drug delivery.

Conclusions

Gallbladder carcinoma is a relatively rare gastrointestinal malignancy strongly associated with chronic cholesterol cholelithiasis. Most commonly, local inflammation of the gallbladder mucosa leads to several known, and probably many as yet unknown, genetic mutations, which initiate a cascade of phenotypical changes from dysplasia to adenocarcinoma.

The disease typically presents at an advanced stage and is rapidly fatal. Less commonly, the disease is diagnosed or incidentally discovered at an early stage. In this group, complete surgical resection offers the only chance of cure. T1 tumours, which have a low incidence of nodal metastases, are sufficiently treated with simple cholecystectomy. Radical resection is indicated for early-stage (T2) tumours and can result in long-term survival, even in patients with locally advanced (T3 or T4) tumours. Radical re-resection should be offered to patients with localized disease who are incidentally discovered to have gallbladder carcinoma at the time of cholecystectomy.

Table 3 Systemic chemotherapy for advanced gallbladder carcinoma.

Study (phase)	Agent(s)	No. of patients	Response rate	Median overall survival
Falkson *et al.* [30]	5-FU +/– streptozocin or methyl-CCNU	53	9% (PR 5; CR 0)	–
Taal *et al.* (II) [31]	MMC	30[a] (13 GBCa)	10% (PR 3; CR 0)	–
Okada *et al.* (II) [32]	Cisplatin	13[a] (6 GBCa)	8% (PR 1; CR 0)	–
Jones *et al.* (II) [33]	Paclitaxel	15[a] (4 GBCa)	0%	NA
Gebbia *et al.* (II) [21]	5-FU/LV/hydroxyurea	70[a] (30 GBCa)	30%* (PR 9; CR 0)	8 months
Patt *et al.* (II) [22]	5-FU/IFNα-2b	35[a] (10 GBCa)	34% (PR 12; CR 0)	12 months
Sanz-Altamira *et al.* (II) [34]	CPT-11	25[a] (10 GBCa)	8% (PR 2; CR 0)	10 months
Alberts *et al.* (II) [35]	CPT-11	36[a]	8% (PR 2; CR 1)	–
Kuhn *et al.* [36]	Gemcitabine/docetaxel	43[a] (26 GBCa)	9% (PR 4; CR 0)	12 months
Malik *et al.* (II) [37]	Gemcitabine/cisplatin	11	64% (PR 6; CR 1)	42 weeks
Kim *et al.* (II) [38]	Cisplatin/xeloda	42[a] (19 GBCa)	32%* (PR 5; CR 1)	9.1 months
Malik and Aziz [39]	5-FU/folinic acid	30	7% (PR 2; CR 0)	14.8 months
Doval *et al.* (II) [40]	Gemcitabine/cisplatin	30	36% (PR 7; CR 4)	20 weeks
Ishii *et al.* [20]	Cisplatin/epirubicin/5-FU	21	33% (PR 7; CR 0)	–
	5-FU/doxorubicin/MMC	25	8% (PR 2; CR 0)	–
Knox *et al.* [41]	Gemcitabine/5-FU	27[a] (7 GBCa)	71%* (PR 5; CR 0)	5.3 months
Patt *et al.* [42]	Xeloda	63[a] (8 GBCa)	50%* (PR 2; CR 2)	9.9 months
Alberts *et al.* (II) [43]	Gemcitabine/5-FU/leucovorin	42[a] (14 GBCa)	21%* (PR 3; CR 0)	9.7 months

[a]These studies include patients with both extrahepatic biliary tract carcinoma as well as patients with gallbladder carcinoma (GBCa). The response rates are for all the patients included in the study unless indicated by an asterisk, in which case the response rate is for the subset of patients with GBCa.
5-FU, 5-fluorouracil; MMC, mitomycin C; LV, leucovorin; IFN, interferon; PR, partial response; CR, complete response; NA, not applicable.

Despite reports showing improvement in survival following complete surgical resection, there is a high incidence of recurrence, particularly distant recurrence, emphasizing the need for effective adjuvant therapies and prevention strategies. Given the rarity of this cancer, prospective, multi-institutional studies investigating novel agents and multimodality treatment schema will be necessary to accrue sufficient numbers of patients to make meaningful progress in the treatment of this disease.

References

1 Jemal A, Murray T, Ward E *et al.* (2005) Cancer statistics, 2005. *CA Cancer J Clin* 55, 10–30.
2 Fraumeni JF Jr, Devesa SS, McLaughlin JK *et al.* (1996) Biliary tract cancer. In: Schottenfeld D, Fraumeni JF, Jr (eds) *Cancer Epidemiology and Prevention.* New York: Oxford University Press, pp. 794–803.
3 Tazuma S, Kajiyama G (2001) Carcinogenesis of malignant lesions of the gall bladder. The impact of chronic inflammation and gallstones. *Langenbecks Arch Surg* 386 (3), 224–229.
4 Balkwill F, Mantovani A (2001) Inflammation and cancer: back to Virchow? *Lancet* 357, 539–545.
5 Moriguchi H, Tazawa J, Hayashi Y *et al.* (1996) Natural history of polypoid lesions in the gall bladder. *Gut* 39 (96), 860–862.
6 Csendes A, Burgos AM, Csendes P *et al.* (2001) Late follow-up of polypoid lesions of the gallbladder smaller than 10 mm. *Ann Surg* 234 (5), 657–660.
7 Boulton RA, Adams DH (1997) Gallbladder polyps: when to wait and when to act. *Lancet* 349 (9055), 817.
8 Wistuba II, Gazdar AF (2004) Gallbladder cancer: lessons from a rare tumour. *Nature Rev Cancer* 4 (9), 695–706.
9 (2002) Gallbladder (Carcinoid tumors and sarcomas are not included). In: Greene FL, Page DL, Fleming ID *et al.* (eds) *American Joint Committee on Cancer Staging Manual*, 6th edn. New York: Springer-Verlag, pp. 131–144.
10 Ogura Y, Mizumoto R, Isaji S *et al.* (1991) Radical operations for carcinoma of the gallbladder: present status in Japan. *World J Surg* 15 (3), 337–343.
11 Fong Y, Jarnagin W, Blumgart LH (2000) Gallbladder cancer: comparison of patients presenting initially for definitive operation with those presenting after prior noncurative intervention. *Ann Surg* 232 (4), 557–569.
12 Suzuki S, Yokoi Y, Kurachi K *et al.* (2004) Appraisal of surgical treatment for pT2 gallbladder carcinomas. *World J Surg* 28 (2), 160–165.
13 Donohue JH, Nagorney DM, Grant CS *et al.* (1990) Carcinoma of the gallbladder: does radical resection improve outcome? *Arch Surg* 125 (2), 237–241.
14 Kondo S, Nimura Y, Hayakawa N *et al.* (2002) Extensive surgery for carcinoma of the gallbladder. *Br J Surg* 89 (2), 179–184.
15 Jarnagin WR, Ruo L, Little SA *et al.* (2003) Patterns of initial disease recurrence after resection of gallbladder carcinoma and hilar cholangiocarcinoma: implications for adjuvant therapeutic strategies. *Cancer* 98 (8), 1689–1700.
16 Houry S, Schlienger M, Huguier M *et al.* (1989) Gallbladder carcinoma: role of radiation therapy. *Br J Surg* 76 (5), 448–450.
17 Hanna SS, Rider WD (1978) Carcinoma of the gallbladder or extrahepatic bile ducts: the role of radiotherapy. *Can Med Assoc J* 118 (1), 59–61.
18 Kresl JJ, Schild SE, Henning GT *et al.* (2002) Adjuvant external beam radiation therapy with concurrent chemotherapy in the management of gallbladder carcinoma. *Int J Radiat Oncol Biol Phys* 52 (1), 167–175.

19 Todoroki T, Iwasaki Y, Orii K *et al.* (1991) Resection combined with intraoperative radiation therapy (IORT) for stage IV (TNM) gallbladder carcinoma. *World J Surg* 15 (3), 357–366.

20 Ishii H, Furuse J, Yonemoto N *et al.* (2004) Chemotherapy in the treatment of advanced gallbladder cancer. *Oncology* 66 (2), 138–142.

21 Gebbia V, Majello E, Testa A *et al.* (1996) Treatment of advanced adenocarcinomas of the exocrine pancreas and the gallbladder with 5-fluorouracil, high dose levofolinic acid and oral hydroxyurea on a weekly schedule: results of a multicenter study of the Southern Italy Oncology Group (GOIM). *Cancer* 78 (6), 1300–1307.

22 Patt YZ, Jones DV, Jr, Hoque A *et al.* (1996) Phase II trial of intravenous fluorouracil and subcutaneous interferon alfa-2b for biliary tract cancer. *J Clin Oncol* 14 (8), 2311–2315.

23 Smith GW, Bukowski RM, Hewlett JS *et al.* (1984) Hepatic artery infusion of 5-fluorouracil and mitomycin C in cholangiocarcinoma and gallbladder carcinoma. *Cancer* 54 (8), 1513–1516.

24 Makela JT, Kairaluoma MI (1993) Superselective intra-arterial chemotherapy with mitomycin for gallbladder cancer. *Br J Surg* 80 (7), 912–915.

25 Shirai Y, Yoshida K, Tsukada K *et al.* (1992) Radical surgery for gallbladder carcinoma: long-term results. *Ann Surg* 216 (5), 565–568.

26 Ouchi K, Suzuki M, Saijo S *et al.* (1993) Do recent advances in diagnosis and operative management improve the outcome of gallbladder carcinoma? *Surgery* 113 (3), 324–329.

27 Chijiiwa K, Tanaka M (1994) Carcinoma of the gallbladder: an appraisal of surgical resection. *Surgery* 115 (6), 751–756.

28 Bartlett DL, Fong Y, Fortner JG *et al.* (1996) Long-term results after resection for gallbladder cancer: implications for staging and management. *Ann Surg* 224 (5), 639–646.

29 Ito H, Matros E, Brooks DC *et al.* (2004) Treatment outcomes associated with surgery for gallbladder cancer: a 20-year experience. *J Gastrointest Surg* 8 (2), 183–190.

30 Falkson G, MacIntyre JM, Moertel CG (1984) Eastern Cooperative Oncology Group experience with chemotherapy for inoperable gallbladder and bile duct cancer. *Cancer* 54 (6), 965–969.

31 Taal BG, Audisio RA, Bleiberg H *et al.* (1993) Phase II trial of mitomycin C (MMC) in advanced gallbladder and biliary tree carcinoma: an EORTC Gastrointestinal Tract Cancer Cooperative Group Study. *Ann Oncol* 4 (7), 607–609.

32 Okada S, Ishii H, Nose H *et al.* (1994) A phase II study of cisplatin in patients with biliary tract carcinoma. *Oncology* 51 (6), 515–517.

33 Jones DV, Jr, Lozano R, Hoque A *et al.* (1996) Phase II study of paclitaxel therapy for unresectable biliary tree carcinomas. *J Clin Oncol* 14 (8), 2306–2310.

34 Sanz-Altamira PM, O'Reilly E, Stuart KE *et al.* (2001) A phase II trial of irinotecan (CPT-11) for unresectable biliary tree carcinoma. *Ann Oncol* 12 (4), 501–504.

35 Alberts SR, Fishkin PA, Burgart LJ *et al.* (2002) CPT-11 for bile-duct and gallbladder carcinoma: a phase II North Central Cancer Treatment Group (NCCTG) study. *Int J Gastrointest Cancer* 32 (2–3), 107–114.

36 Kuhn R, Hribaschek A, Eichelmann K *et al.* (2002) Outpatient therapy with gemcitabine and docetaxel for gallbladder, biliary, and cholangiocarcinomas. *Invest New Drugs* 20 (3), 351–356.

37 Malik IA, Aziz Z, Zaidi SH *et al.* (2003) Gemcitabine and cisplatin is a highly effective combination chemotherapy in patients with advanced cancer of the gallbladder. *Am J Clin Oncol* 26 (2), 174–177.

38 Kim TW, Chang HM, Kang HJ *et al.* (2003) Phase II study of capecitabine plus cisplatin as first-line chemotherapy in advanced biliary cancer. *Ann Oncol* 14 (7), 1115–1120.

39 Malik IA, Aziz Z (2003) Prospective evaluation of efficacy and toxicity of 5-fu and folinic acid (Mayo Clinic regimen) in patients with advanced cancer of the gallbladder. *Am J Clin Oncol* 26 (2), 124–126.

40 Doval DC, Sekhon JS, Gupta SK *et al.* (2004) A phase II study of gemcitabine and cisplatin in chemotherapy-naive, unresectable gall bladder cancer. *Br J Cancer* 90 (8), 1516–1520.

41 Knox JJ, Hedley D, Oza A *et al.* (2004) Gemcitabine concurrent with continuous infusional 5-fluorouracil in advanced biliary cancers: a review of the Princess Margaret Hospital experience. *Ann Oncol* 15 (5), 770–774.

42 Patt YZ, Hassan MM, Aguayo A *et al.* (2004) Oral capecitabine for the treatment of hepatocellular carcinoma, cholangiocarcinoma, and gallbladder carcinoma. *Cancer* 101 (3), 578–586.

43 Alberts SR, Al-Khatib H, Mahoney MR *et al.* (2005) Gemcitabine, 5-fluorouracil, and leucovorin in advanced biliary tract and gallbladder carcinoma: a North Central Cancer Treatment Group phase II trial. *Cancer* 103 (1), 111–118.

19.9 Cholangiocarcinoma

Steven M. Strasberg and William G. Hawkins

Introduction

Cholangiocarcinoma is an uncommon epithelial malignancy of the biliary tract. Cholangiocarcinomas may arise at any level of the biliary tree. They are subdivided into intrahepatic cholangiocarcinomas and extrahepatic cholangiocarcinomas; the latter are subdivided into hilar or upper duct tumours and lower duct tumours. Intrahepatic cholangiocarcinomas usually present as liver masses, and extrahepatic cholangiocarcinomas tend to obstruct bile ducts and present with jaundice. Sporadic cholangiocarcinomas are relatively uncommon, but the incidence increases significantly in certain inflammatory and infectious conditions. Surgical resection is the most effective treatment and is currently the only option that provides a chance for cure, but the majority of patients are not eligible for surgical resection. The most commonly utilized classification and staging systems reflect the importance that anatomical location plays in the management of this disease. Information on cholangiocarcinoma is derived almost entirely from small case series gathered over many years and therefore tends to be descriptive. Level 1 data are largely non-existent. Consequently, claims for the best modalities for clinical investigation or treatment must be interpreted cautiously.

Incidence and natural history

Cholangiocarcinoma is an uncommon malignancy of older persons. It may arise anywhere along the course of the biliary tree and is often classified and enumerated with tumours of the liver, gallbladder or pancreas, making the true incidence of cholangiocarcinoma difficult to determine [1,2]. In the United States, the incidence is estimated to be 0.85 per 100 000 population or approximately 5000 new cases per year [3,4]. This represents approximately 2% of all reported cancers [5]. Even excluding gallbladder cancer, biliary tumours are more frequently extrahepatic than intrahepatic [4,6,7]. Rates of intrahepatic cholangiocarcinoma appear to be increasing in some developed countries, while those for extrahepatic cholangiocarcinomas are decreasing [8–11]. Intrahepatic cholangiocarcinoma has previously been confused with other malignancies, and some experts believe that the increase in incidence of intrahepatic cholangiocarcinoma may be partially explained by the wider availability of percutaneous methods of diagnosis [12,13]. Sporadic cholangiocarcinoma is a disease affecting older people with the majority of patients presenting after 65 years of age. The peak incidence is in the eighth decade of life [3]. The age of onset can be considerably younger in patients with predisposing conditions or in areas endemic to certain parasitic infections [3]. Cholangiocarcinoma is 1.5 times more common in males than females [3]. Asians are affected twice as often as whites or blacks [3].

Most biliary cancers are rapidly fatal with a median survival of 6–12 months from diagnosis until death. There is growing evidence that modern techniques to relieve obstruction and treat cholangitis have improved the short-term outcomes for patients with cholangiocarcinoma, but not overall survival. For example, in patients with intrahepatic cholangiocarcinoma, the 1-year relative survival increased from 16.4% in the period from 1975 to 1979 to 27.6% in the period from 1995 to 1999, but the 5-year survival rate remains unchanged and below 5% [11]. Death is often related to infectious complications secondary to biliary obstruction and is rarely a result of tumour burden. In fact, a number of authors have found that bile duct tumours are relatively slow growing [14–16], especially compared with tumours of the gallbladder or pancreas. Although nodal, peritoneal and haematogenous metastases have been described, local disease is the most common finding at presentation. Haematogenous metastases are uncommon, and nodal disease is present in about one-third of cases in series of resected patients [6,7,15]. Extended survival depends almost entirely on complete surgical resection. Survival has traditionally been considered to be worse for lesions at the confluence and better for lesions at the ampulla, but this probably reflects relatively later presentation and more complex operative management as opposed to a difference in biology. Location within the biliary tree may have little impact on survival provided that complete resection can be achieved [7].

Epidemiology and aetiology

The aetiology of cholangiocarcinoma is not clearly understood, but recent advances in genetic and proteomic assays promise to shed light on the molecular basis of the disease in the near future. Chronic inflammation appears to play an important role in initiation and promulgation of molecular change. Inflammation is the one unifying factor present in conditions that are associated with an increased incidence of cholangiocarcinoma. Chronic inflammation has been associated with several malignancies of the gastrointestinal tract, including pancreatic cancer, gastric cancer and colon cancer, lending further credibility to this assertion [17–20]. The conditions that confer an increased risk of developing cholangiocarcinoma can be divided into two broad categories. The first are those conditions which confer a high incidence in a localized area. Examples of this category include parasitic infections of the biliary tree and intrahepatic stones. The second category confers a lower risk over the larger global community. This group includes autoimmune disorders such as primary sclerosing cholangitis (PSC) and ulcerative colitis, as well as congenital cystic disorders of the biliary tree. Thorotrast, although best known for causing angiosarcomas of the liver, has also been associated with an increased risk of cholangiocarcinoma [21]. Fortunately, thorotrast-related cholangiocarcinomas are now very uncommon and mainly of historical interest. Several other chemicals, including radon, nitrosamines, dioxin and asbestos, may be associated with an increased risk of cholangiocarcinoma, but the data remain fairly speculative.

Endemic infections

Liver fluke infestations with *Opisthorchis* species (Thailand) and *Clonorchis* species (China) are common in countries where raw fish is consumed with frequency [22,23]. In these countries, raw fish is more frequently consumed by men, partially explaining the higher incidence of cholangiocarcinoma in men [24]. The larval stage of flukes, as consumed in raw fish, establishes a chronic infection and inflammation in the biliary tree. The risk of cancer has been associated with the degree of infestation as measured by the stool egg count [22,25–27]. In areas where these parasites are endemic, the incidence of cholangiocarcinoma is as high as 87 per 100 000 [28]. There is some evidence that nitrosamines may be the carcinogens involved. Infestation has been associated with increased nitrosamine levels in body fluids, and treatment with praziquantel restores levels to normal [24,29–31]. Liver fluke infestation is also associated with increased intrahepatic choledocholithiasis, and this condition is itself thought to be an independent risk factor [32–34].

Oriental cholangiohepatitis is a recurrent pyogenic infection prevalent in areas of south-east Asia and Japan. Pathologically, the intra- and extrahepatic ducts are dilated and contain soft pigmented stones and pus. There are inflammatory changes including proliferation, periportal inflammation and segmental stenosis. The pathogenesis is unknown, but associations with liver flukes and nutritional deficiency have been suggested. One theory is that the flukes act as foreign bodies causing stasis around which organisms are protected from the natural antibacterial mechanisms in bile. These organisms, such as *Escherichia coli*, secrete β-glucuronidase, which deconjugates bilirubin and renders it much less soluble. Consequently, bilirubin precipitation and brown stone formation ensues. These soft brown stones contain bilirubin but are largely made up of bacterial cell bodies, as evidenced by their high content of calcium palmitate. Intrahepatic ducts are intermittently obstructed by stones and ultimately become secondarily infected with bacterial organisms of gastrointestinal origin. These infections are potentially life threatening in their own right and may also lead to stricture formation. Once strictures occur, the cycle of ensuing bile stasis is established, and the disease process may continue even after stone removal [32]. It is estimated that about 10% of such patients will go on to develop cancer [34].

Autoimmune diseases

PSC is an autoimmune disease characterized by periductal inflammation, as seen on histological sections, and multifocal strictures of both intrahepatic and extrahepatic bile ducts, as demonstrated by cholangiography [35–37]. The majority of PSC patients (70–80%) have associated ulcerative colitis, but the converse is not true. Approximately 10% of patients with ulcerative colitis have PSC. The incidence of cholangiocarcinoma remains elevated in patients with PSC even when medical or surgical management appears to control the inflammatory process. In other words, treatment of ulcerative colitis by colectomy does not offer protection from development of cholangiocarcinoma in patients with PSC [38,39]. Cholangiocarcinoma is commonly reported to occur in about 10% of patients with PSC [35–37], but the lifetime incidence may be considerably higher. In one Swedish study of 305 patients followed for a median of 5 years, 8% developed cholangiocarcinoma [35]. The incidence of incidentally identified cholangiocarcinomas in explants of patients with PSC undergoing an orthotopic liver transplant was reported to be between 8% and 36%, while the incidence in autopsy specimens was reported to be as high as 40% [36–40]. Patients with underlying PSC and cholangiocarcinoma who undergo resection are at a higher risk for remnant liver failure and for developing a second cholangiocarcinoma. In appropriately selected patients, liver transplant with or without neoadjuvant therapy is a better option [41,42].

Choledochal cysts and anatomical anomalies

The risk of development of cholangiocarcinoma in congenital biliary cysts may also be related to inflammation [43–46]. Many patients with choledochal cysts have an anomalous pancreatobiliary junction (APBJ). In such patients, the confluence of the pancreatic duct and bile duct occurs at a greater distance from the ampulla than usual, thereby lengthening the common

channel. This predisposes to reflux of pancreatic secretions into the biliary ducts [43–45]. Presumably, the pancreatic enzymes become activated by bile and an inflammatory response follows. Stasis in the ducts might also lead to bacterial contamination and additional inflammation. In patients who have early surgical intervention for choledochal cysts, the risk of cholangiocarcinoma is greatly reduced. The incidence of cholangiocarcinoma in untreated biliary cysts is not well established. Congenital choledochal cysts themselves are rare, with estimates ranging between 1 in 13 000 and 1 in 2 000 000 live births [47]. Most of these are diagnosed and treated in childhood, but about 20% go undiagnosed until adulthood. The majority of cancers present in adults. As the condition is uncommon and case series are usually small, precise figures for the risk of development of cancer in patients with choledochal cysts are lacking; reported rates in untreated cysts range from 10% to 30% [47–49]. There is some evidence that the incidence of cholangiocarcinoma increases dramatically in patients not treated until after the age of 20 years or in patients treated with cyst drainage as opposed to cyst resection [44,45].

Additional evidence that anatomical anomalies that result in reflux and inflammation may play a role in cholangiocarcinoma is seen in patients who undergo operative sphincteroplasty. Seven per cent of patients developed a cholangiocarcinoma in a series of 119 patients who had previously received a transduodenal sphincteroplasty for benign disease and who were followed for up to 22 years [50]. Presumably, bacterial contamination and inflammation may result from surgical sphincteroplasty. There is currently no evidence to suggest that endoscopic sphincterotomy carries the same degree of risk.

Pathology

Pathology and histological classification

Multiple classification systems have been used to describe the gross and histological appearances of intrahepatic and extrahepatic cholangiocarcinomas. The most widely used classifications are that of Weinbren and Mutum, who described the histological features of three subtypes of cholangiocarcinomas, nodular, sclerosing and papillary [51], and that of Klatskin, who described three major macroscopic subtypes of hilar cholangiocarcinomas: a small hard nodule, a segmental stenosis and a papillary growth [14]. The radiological appearance of these lesions has been variably described. Recently, the Liver Cancer Study Group of Japan has proposed a new macroscopic classification for intrahepatic cholangiocarcinomas pairing the radiographical description with the gross appearance in three subtypes: mass-forming, periductal-infiltrating and intraductal-growing [52,53]. The Japanese have further subdivided extrahepatic cholangiocarcinomas into additional macroscopic types [53]. While the additional classification to the extrahepatic system adds precision, it is somewhat difficult to apply when discussing older literature. For the purposes of this chapter,

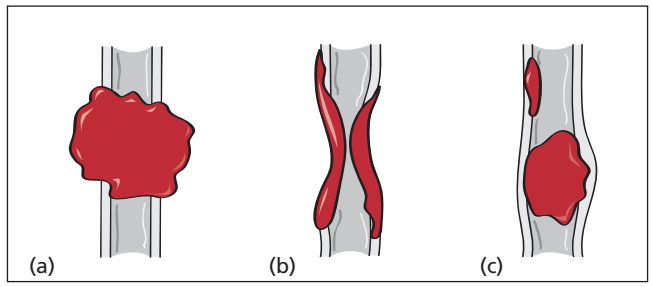

Fig. 1 The morphological classification of intrahepatic and extrahepatic cholangiocarcinomas. Sketches depict (a) mass-forming (MF), (b) periductal-infiltrating (PI) and (c) intraductal-growing (IG) subtypes of cholangiocarcinoma. Cholangiocarcinoma may constrict (b) or expand (c) the duct. Skip lesions (c) are also demonstrated.

we have adopted the terms mass-forming (MF), periductal-infiltrating (PI) and intraductal growth (IG) to describe cholangiocarcinomas at all levels of the biliary tree (Fig. 1). These generally correspond to the terms nodular, sclerosing and papillary in the earlier literature. In specific areas, we will refer to additional subtypes when they are clinically relevant. It is important to note that combined types are more common than a single variant. Thus, any tumour may have a component that infiltrates along the duct or a component that projects into or away from the lumen of the bile duct.

In all three subtypes, the cancer originates in the biliary epithelium. Cancers do not develop in frequencies proportional to the surface area of this epithelial layer. The exact proportion arising in any location is hard to ascertain with precision because reports are greatly influenced by referral patterns. Hilar cholangiocarcinomas have been estimated to account for between 40% and 60% of all cholangiocarcinomas [6,7,54]. Intrahepatic cholangiocarcinomas account for approximately 10% of cases with distal tumours making up the difference [6,52]. Approximately 10% of patients with cholangiocarcinoma have multifocal disease [16].

Adenocarcinomas account for more than 90% of all cholangiocarcinomas. Variants of adenocarcinoma of the bile duct include pleomorphic, giant cell, adenosquamous, oat cell and colloid carcinoma. The microscopic extent of these cancers frequently extends for long distances beyond the palpable tumour. In a series of 29 cases, the mean distance of microscopic invasion beyond the gross margin was 16.8 mm towards the liver and 6.5 mm towards the duodenum [55]. The histological diagnosis of malignant bile duct tumours may be difficult at times. Cancers of the upper duct are more frequently well differentiated, whereas tumours of the lower duct are more frequently poorly differentiated. Well-differentiated cancers with little invasion are difficult to differentiate from inflammatory pseudotumour [58] (see below) or PSC [56–58]. Often, perineural invasion, a prominent feature of cholangiocarcinoma that is not present in PSC or other benign lesions, is the single most useful

feature in sorting out the true nature of the disease [51,59]. In series of upper duct lesions, benign inflammation accounted for 13–15% of resections [58,60]. Poorly differentiated tumours of the lower duct may be difficult to distinguish from pancreatic or duodenal cancers [53]. Biliary tumours of the lower duct, although often poorly differentiated, tend to present early. Therefore, lower duct biliary tumours are less likely to have spread to surrounding lymph nodes or to have metastasized distantly than pancreatic cancers, portending a more favourable prognosis following a pancreaticoduodenectomy [61].

Mass-forming (MF) cholangiocarcinoma

MF tumours are less common than the PI type and more common than the IG type [6,37]. On gross examination, they are commonly larger then PI or IG tumours [52,53]. MF tumours are the most common intrahepatic variant and have frequently been classified as nodular grossly and histologically. They are characterized by a nodular mass that projects into the lumen of the duct and out into the surrounding tissues (Fig. 1a). The tumour is firm and whitish grey on account of the large amount of fibrous stroma (see Plate 19.9.1, facing p. 1268). The margin is often well circumscribed but may be lobulated. Multicentricity is more common for this subtype and may be the result of the propensity of the tumour to invade adjacent branches of the portal vein. Multicentricity may also be due to the fact that the MF growth pattern results in late onset of symptoms and thus provides more time for tumour growth compared with the IG or PI subtypes. Central necrosis is a common feature when the tumours are large [52,53]. Bile ducts peripheral to the mass may or may not be dilated. Regional lymph node metastases are more common with large tumour masses and are therefore more common with this subtype [62]. Enlarged metastatic lymph nodes are most commonly located in the porta hepatis. In tumours arising in the left lateral section, it is not uncommon to encounter nodes in the gastrohepatic ligament.

Periductal-infiltrating (PI) cholangiocarcinoma

In contrast to MF tumours, PI cholangiocarcinomas grow along the bile duct and are commonly described as elongated, branch-like or spiculated (see Plate 19.9.1, facing p. 1268) [53]. They penetrate the bile duct wall, growing both in the wall and along the exterior of it for extended distances [55] (Fig. 1b). Irregular narrowing or obliteration of the involved bile duct commonly occurs, and the proximal biliary tree is almost universally dilated. PI tumours are the most common variant and are the predominant subtype found at the biliary confluence [16]. PI lesions are frequently described as sclerosing and fibrotic on histological examination [53] (see Plate 19.9.1, facing p. 1268). The overlying epithelium may appear atypical or may be absent. PI tumours are characterized by annular thickening with diffuse infiltration and fibrosis of the periductal tissues. PI lesions may be poorly differentiated and may show signet ring cells (see Plate 19.9.1, facing p. 1268). In pure PI tumours, there is no mass, and differentiation from benign disease is occasionally difficult [58].

Intraductal-growing (IG) cholangiocarcinoma

IG tumours account for approximately 10% of all cholangiocarcinomas [63]. IG tumours grow into the lumen. Although they originate in the wall, they do not usually penetrate it, and the outer margin of the bile duct remains intact (Fig. 1c). IG tumours may be polypoid, sessile or can be elongated sheets of tumour spreading along the bile duct lumen, or skip lesions. These tumours can grow to several centimetres in size and may expand rather than constrict the bile duct, in sharp contrast to the sclerotic process seen in PI tumours. The majority of IG tumours are of the papillary subtype comprised of numerous frond-like infoldings of proliferated columnar epithelial cells [52] (see Plate 19.9.1, facing p. 1268). Atypical epithelium is easily identified in this variant and may be classified as well differentiated, meaning that much of the normal epithelial architecture is preserved. These may arise from a stalk or may be broader based, spreading superficially along the surface. Biliary obstruction may result from a large tumour blocking the duct, from an excessive amount of mucin or pieces of tumour that have broken off and embolized lower levels of the biliary tree. In some instances, these tumour emboli have even obstructed the common channel, leading to pancreatitis. There is a variant of this subtype that is very similar to intraductal papillary mucinous tumour (IPMT) of the pancreas, in which mucinous secretions are the predominant feature [53]. Patients with IG tumours usually have a better outcome than those with other subtypes [37,63], in part because they tend to present at an earlier stage [63]. Patients with the papillary subtype fare better than patients with the nodular sclerosing subtypes (MF, PI) even when compared stage for stage. This suggests that at least some of the observed difference in patient outcome is derived from the more favourable biological behaviour of the well-differentiated papillary subtype [63].

Molecular genetics

That cancer results from the accumulation of multiple genetic abnormalities in a single cell is now a widely accepted theory in a wide array of tumour types [64]. This multistep process of carcinogenesis involves multiple genes with mutations often occurring in a predictable sequence over a variable period of time [64]. There has been an exponential growth in the number of publications that focus on the basic derangements that allow for the initiation, promulgation and progression of cancer [65]. Research in more common malignancies such as colon and pancreatic adenocarcinomas have often led the way for discoveries in more uncommon tumours such as cholangiocarcinoma [65]. These incremental improvements in our understanding have

been ushered in by advances in genetic and proteomic assays over the past two decades. Important mutations include genes that control the cell cycle leading to unregulated growth, as well as those that allow cells to evade signals for cell death by avoiding apoptosis. A less well-characterized but contemporary topic is alterations that allow cancerous cells to evade the immune system [66,67].

The molecular derangements in cholangiocarcinomas appear to be similar to those for other gastrointestinal cancers and commonly include mutations in the *ras*, *myc*, *p53* and *erbB2* oncogenes. The role that inflammation plays in initiation and promulgation of these molecular changes is a topic of intense investigation. Cholangiocarcinomas are very similar to pancreatic cancer in the types of mutations present and in the implication of inflammation, suggesting that the biliary and pancreatic epithelium may share exposure to common carcinogens or react similarly as they are of similar embryological origin. Prior to the development of invasive cholangiocarcinoma, it is possible to detect evidence of some derangements in the premalignant epithelium and occasionally in the bile. For example, patients with PSC and biliary maljunction have been shown to have mutations in *p53*, *INK4a* and k-*ras* [68,68–72].

Growth factors and growth factor receptors, including the epidermal growth factor (EGF) receptor and platelet-derived growth factor, are elevated and lead to dysregulated cell proliferation in patients with cholangiocarcinoma. The *erbB2* oncogene (also called the HER2 *neu* oncogene) encodes a cell surface protein that interacts with several distinct cellular receptors, including the receptor for EGF [73]. Overexpression of *erbB2* has been identified in tumours of the breast, ovary, stomach, pancreas, lung and prostate. Several authors have reported expression of *erbB2* in cholangiocarcinoma [74–77]. A wide range of expression has been described with the more recent reports suggesting that approximately 70% of cholangiocarcinomas overexpress *erbB2* [74,76]. The *ras* family of oncogenes transduce proliferative signals from the cell surface to the cell interior [68,78–80]. One member of this family, k-*ras*, has been shown to be mutated in multiple gastrointestinal and non-gastrointestinal adenocarcinomas, including a significant fraction of colon, pancreatic and lung carcinomas [72,79,81–84]. Point mutations involving k-*ras* may occur in more than half of all cholangiocarcinomas [71,77,80,83].

Multiple other genes, including the *myc* gene and *p53* gene, have been studied in bile duct tumours [85–89]. These genes encode proteins that reside in the cell nucleus and control transcription of growth regulatory genes. Mutation of the *myc* gene appears to be an almost universal feature of cholangiocarcinomas, whereas *p53* mutation has been identified in 50–60% of cholangiocarcinomas.

Classification and staging

Multiple staging and classification systems have been proposed and each has merits and disadvantages.

Anatomical classification

Most authorities in this area now classify cholangiocarcinoma into three types depending upon anatomical location. These are intrahepatic cholangiocarcinomas, hilar cholangiocarcinomas and lower duct cholangiocarcinomas. These are treated as distinct clinical entities linked by the cell of origin and aetiological factors. Synonyms for hilar cholangiocarcinoma are upper duct extrahepatic cholangiocarcinomas and Klatskin tumours. Synonyms for lower duct cholangiocarcinomas are intrapancreatic bile duct tumours (or cholangiocarcinomas) and distal bile duct tumours (or cholangiocarcinomas). The latter is a confusing term not having anything to do with the correct meaning of distal.

In each location, the tumours are further subdivided into their gross appearance as described above, i.e. mass-forming, periductal-infiltrating or intraductal-growing.

Intrahepatic cholangiocarcinomas arise from small ducts or ductules and usually present as an intrahepatic mass. Patients with intrahepatic tumours rarely present with jaundice. Hilar cholangiocarcinomas arise in the larger bile ducts at or near the confluence of the left and right hepatic ducts, and the presentation is variable but more frequently includes jaundice. Lower duct tumours commonly arise within the intrapancreatic portion of the bile duct. The differential diagnosis is pancreatic cancer, ampullary cancer, biliary stones and stricture (often pancreatitis). These patients nearly always present with painless jaundice and frequently present at an earlier stage, resulting in a better long-term prognosis than intrahepatic or hilar tumours.

Subclassification of intrahepatic tumours

The *American Joint Committee on Cancer* (*AJCC*) *Staging Manual* (sixth edition) considers intrahepatic biliary tumours in the same schema as primary liver tumours reflecting the differential diagnosis and treatment (Table 1) [90]. One advantage of the AJCC staging system is its universal recognition. Tumours are stratified based on the concept of tumour, regional nodes and metastasis (TNM). In the current system, the most important prognostic factors, such as tumour number and vascular invasion, are incorporated into the T stage. As such, T stage is the dominant prognostic factor. While T stage adequately stratifies patients in a way that is helpful for surgical planning, the system does have shortcomings. For example, multiple liver nodules, which more frequently represent metastases as opposed to multifocal disease, are incorporated into the T stage as opposed to the M stage. Another disadvantage of the current AJCC system is the predominant role that hepatocellular carcinoma (HCC) plays in influencing this system. Prognosis and course for cholangiocarcinoma may be different from that for HCC but is not accurately predicted by this model. For this reason, Okabayashi *et al.* [91] have proposed a separate staging system for MF intrahepatic cholangiocarcinomas.

Table 1 Staging of liver (including hepatic ducts).

Primary tumour (T)

TX	Primary tumour cannot be assessed
T0	No evidence of primary tumour
Tis	Carcinoma *in situ*
T1	Solitary tumour without vascular invasion
T2	Solitary tumour with vascular invasion or multiple tumours none more than 5 cm
T3	Multiple tumours more than 5 cm or tumour involving a major branch of the portal or hepatic vein(s)
T4	Tumour(s) with direct invasion of the adjacent organs other than the gallbladder or with perforation of visceral peritoneum

Regional lymph nodes (N)

NX	Distant lymph nodes cannot be assessed
N0	No regional lymph node metastasis
N1	Regional lymph node metastasis

Distant metastasis (M)

MX	Distant metastasis cannot be assessed
M0	No distant metastasis
M1	Distant metastasis

Stage grouping

I	T1	N0	M0
II	T2	N0	M0
IIIA	T3	N0	M0
IIIB	T4	N0	M0
IIIC	Any T	N1	M0
IV	Any T	Any N	M1

Subclassification of hilar and extrahepatic cholangiocarcinomas

Several methods have been proposed to classify hilar tumours. One of the most resilient has been the modified Bismuth–Corlette system, which classifies patients based on the extent of involvement of the biliary tree (Fig. 2) [92]. While this classification strategy is simple and facilitates communication between physicians, it fails to include other major factors contributing to the determination of operability, such as vascular involvement and atrophy. This has become of greater importance in recent years as the scope of the operation has expanded to include major liver resection and, occasionally, vascular resection and reconstruction [93,94]. In order to aid surgeons in determining operability in the modern era, Burke *et al.* [15] proposed a revised staging system for hilar cholangiocarcinomas. In their system, unilateral and contralateral biliary and vascular involvement are used to determine resectability. Certain aspects of their proposal have been incorporated into the new AJCC staging system for extrahepatic cholangiocarcinomas (Table 2).

Table 2 Staging of extrahepatic bile duct cancer.

Primary tumour (T)

TX	Primary tumour cannot be assessed
T0	No evidence of primary tumour
Tis	Carcinoma *in situ*
T1	Tumour confined to the bile duct histologically
T2	Tumour invades beyond the wall of the bile duct
T3	Tumour invades the liver, gallbladder, pancreas and/or ipsilateral branches of the portal vein (right or left) or hepatic artery (right or left)
T4	Tumour invades any of the following: main portal vein or its branches bilaterally, common hepatic artery or other adjacent structures, such as the colon, stomach, duodenum or abdominal wall

Regional lymph nodes (N)

NX	Distant lymph nodes cannot be assessed
N0	No regional lymph node metastasis
N1	Regional lymph node metastasis

Distant metastasis (M)

MX	Distant metastasis cannot be assessed
M0	No distant metastasis
M1	Distant metastasis

Stage grouping

0	Tis	N0	M0
IA	T1	N0	M0
IB	T2	N0	M0
IIA	T3	N0	M0
IIB	T1	N1	M0
	T2	N1	M0
	T3	N1	M0
III	T4	Any N	M0
IV	Any T	Any N	M1

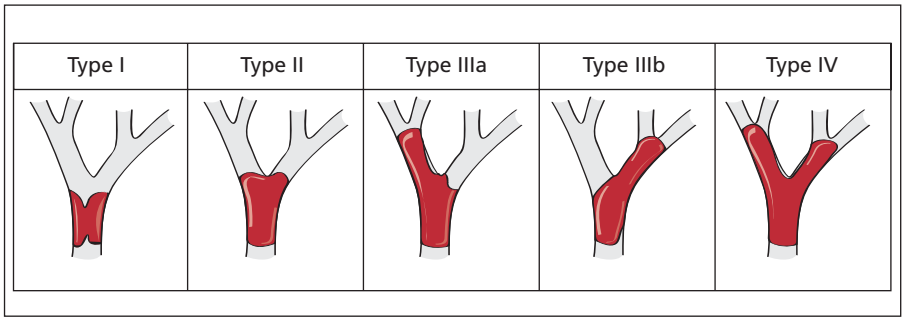

Fig. 2 The Bismuth–Corlette classification of hilar cholangiocarcinomas. Type 1 remains below the confluence of the right and left ducts while type 2 involves the confluence. Type 3 extends to the secondary radicals on one side while type 4 involves the secondary radicals on both sides.

For instance, in the current AJCC schema, depth of tumour invasion and involvement of the major blood vessels are incorporated into the T stage. Although the T4 stage usually indicates unresectable local disease, we have seen the occasional patient with an AJCC T4 stage tumour who is resectable for an attempt at cure. In the current AJCC system, lower duct tumours are grouped together with hilar tumours, and a specific point is made to separate these from pancreatic tumours and ampullary tumours because of the difference in outcomes [90]. In practice, separating lower duct adenocarcinomas of biliary origin from those of pancreatic origin or duodenal origin can be quite difficult.

Clinical presentation

Extrahepatic cholangiocarcinomas, whether in the lower duct or in the hilum, present with painless jaundice or jaundice with mild pain in more than 90% of cases. Severe pain suggestive of biliary colic is uncommon. Jaundice is of the obstructive type and is associated with the constellation of dark urine, clay-coloured stools and often pruritus. Non-specific gastrointestinal symptoms such as anorexia and nausea as well as mild weight loss and fatigue are not unusual. Cholangitis with fever and chills as well as jaundice may occur, but this is unusual prior to instrumentation of the bile ducts. Rarely, the first manifestation of disease is pancreatitis, which is initiated by pancreatic duct obstruction by tumour emboli that have travelled down the bile duct. In later stages of the disease, weight loss and inanition may appear. Sometimes, the first sign of disease is an abnormality in blood chemistry or an unexpected finding on imaging for another indication in an otherwise healthy individual. It is not uncommon for newly diagnosed patients to have recently had a cholecystectomy, presumably because it was believed that gallstones were the source of symptoms, or mild abnormalities in liver function tests.

Intrahepatic cholangiocarcinomas usually present consequent to detection of a mass or abdominal fullness by the patient or as upper abdominal discomfort or pain. Sometimes, the initial presentation is that of weight loss and inanition. Jaundice may occur as a result of compression of hilar structures by centrally placed tumours, secondary to tumour embolizing into major bile ducts or due to compromise of overall liver function in end-stage disease. Occasionally, the tumour is detected by imaging done for investigation of an unrelated problem.

Diagnosis and surgical staging

As noted previously, the macroscopic appearance of cholangiocarcinomas has recently been reclassified into three types, mass-forming (MF), periductal-infiltrating (PI) and intraductal growth (IG). These correspond generally to the older terms of nodular, sclerosing and papillary. Growth types may coexist. The growth type determines the imaging pattern of the tumour.

Hilar cholangiocarcinoma

Rationale for diagnosis and preoperative surgical staging

Diagnosis

The surgical treatment of hilar cholangiocarcinoma is presently dependent on reaching a clinical diagnosis. Routine preoperative pathological diagnosis would be desirable if it were readily achievable, but currently that is not the case. The rationale for proceeding on the basis of a clinical diagnosis only results from the moderately low sensitivity of tests for providing a preoperative pathological diagnosis and the need for timely treatment of patients who have a high likelihood of malignancy. The clinical diagnosis of hilar cholangiocarcinoma is made in the large majority of patients by the demonstration of a focal obstruction of the bile ducts at the hilum in a patient presenting with jaundice. This is usually sufficient diagnostically to proceed to resection.

Preoperative surgical staging

Surgical staging of a hilar cholangiocarcinoma is subservient to the goals of surgical resection. These are to remove all gross and microscopic tumour, while preserving adequate liver function. To achieve these goals, there must be no evidence of tumour spread outside the confines of the resection, such as lymph node metastases outside the resection zone, peritoneal metastases or extra-abdominal metastases. The upper extent of the tumour must be limited to the extent that a clear resection margin on the bile ducts can be obtained without the need to remove so much liver tissue that the risk of postoperative liver failure becomes prohibitive. This will be discussed further under surgical planning and preparation. If vascular invasion is present, it must be located on the side of a planned resection. Invasion of the main portal or proper hepatic arteries is a relative contraindication. If atrophy has affected one hemiliver, it must be on the side chosen for resection (Fig. 3). If there is local invasion of the tumour into the liver, it must be limited to the extent that clear resection margins can be obtained during the planned resection. Tumour nodules within the liver distant from the hilum are considered to be a contraindication. These criteria are modified when the resection is part of an orthotopic liver transplant. Table 3 lists the eight staging questions that are asked when evaluating a hilar cholangiocarcinoma.

Diagnostic and staging tests

A large number of diagnostic and staging tests are available. Imaging technology changes continually; thus, valid comparison of efficacy among tests is difficult and the clinical relevance of results is often temporary.

Serum and bile markers

The remarks in this section on serum and bile markers pertain to cholangiocarcinoma at all levels of the biliary tree. When the

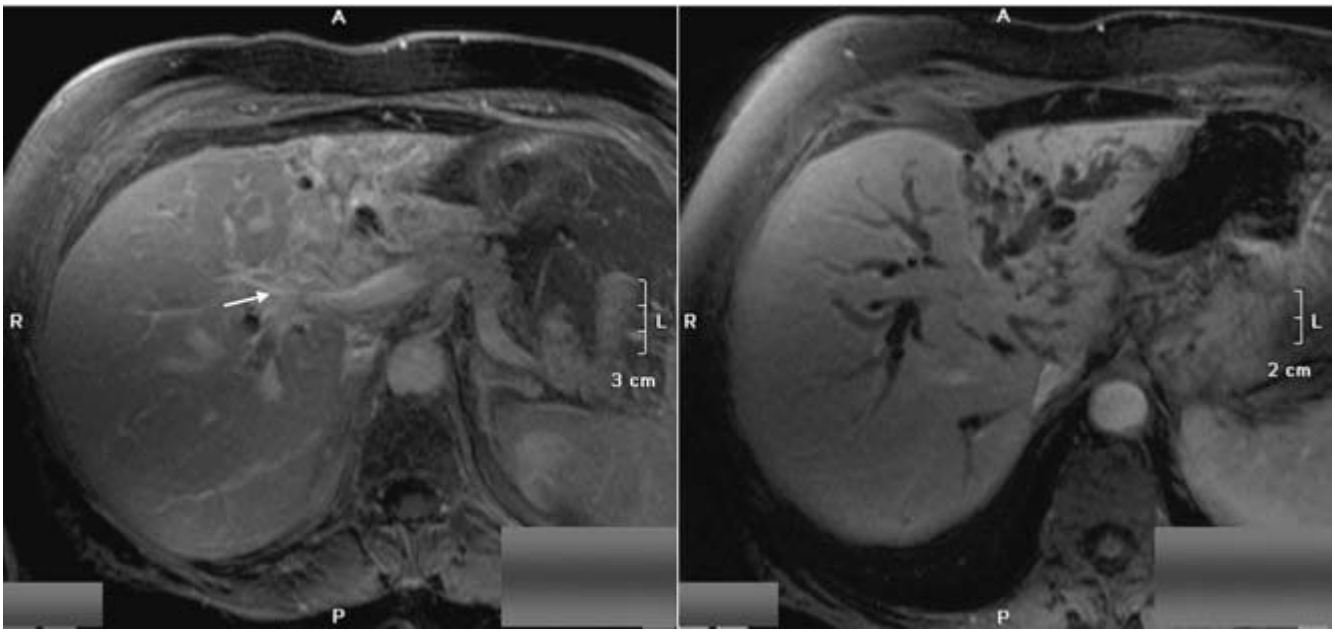

Fig. 3 Images from magnetic resonance imaging of patient with hilar cholangiocarcinoma. Left, 3-D gradient echo post-contrast maximum intensity projection (MIP) image demonstrating narrowing of right portal vein (arrow) by infiltrating hilar mass. Right, 3-D gradient echo post-contrast minimum intensity projection (MinIP) image demonstrating bile duct dilation throughout liver with atrophy of left liver and hypertrophy of right liver. Note 'crowding' of ducts of left liver. Because the right portal vein was involved with the tumor and the left liver was atrophic, the patient was not operable.

Table 3 Surgical staging questions for cholangiocarcinoma.

1	What is the macroscopic extent of the tumour along the bile ducts?
2	What is the relationship of the tumour to blood vessels?
3	What is the extent of hepatic atrophy?
4	What is the extent of local hepatic invasion by the tumour?
5	What is the extent of lymph node involvement?
6	Are there distant intrahepatic metastases?
7	Are there peritoneal metastases?
8	Are there extra-abdominal metastases?

obstruction is complete, as it usually is at the time of presentation of hilar and lower duct tumours, the bilirubin rises over several weeks to a level of about 30 mg/dL. The direct reacting fraction accounts for more than 50% of the total bilirubin. Marked elevation of serum alkaline phosphatase and γ-glutamyltransferase levels and mild elevation of transaminase levels are also usual. In intrahepatic cholangiocarcinoma, bile drainage from the unaffected side is usually unimpaired, and bilirubin levels are usually normal, but alkaline phosphatase levels are often elevated.

CA19-9 is the most commonly used tumour marker for diagnosis of cholangiocarcinoma. In a large study of 322 patients with biliary cancer, the sensitivity and specificity of CA19-9 were 78% and 83%, respectively, at the cutoff value of 37 U/mL in patients without cholangitis or cholestasis [95]. In patients with cholangitis or cholestasis, the sensitivity and specificity of CA19-9 were 74% and 42%, respectively, whereas the specificity reached 87% at 300 U/mL [95]. As many patients with cholangiocarcinoma have cholestasis or cholangitis, CA19-9 is most useful when the levels are quite elevated. In cholangitis, the level may be extremely high [96]; therefore, it is advisable to obtain blood for measurement of CA19-9 in the jaundiced patient prior to instrumentation of the ducts. CA19-9 is not specific for cholangiocarcinoma and may be elevated in pancreatic cancer and in intestinal and gynaecological malignancies. In patients with PSC, the specificity of CA19-9 is low if the cutoff value of 37 U/mL is used [97]. A cutoff value of 100 U/mL seems to provide the most satisfactory balance between sensitivity and specificity in PSC [98].

Serum carcinoembryonic antigen (CEA) levels may also be mildly elevated in cholangiocarcinoma and have been used by Ramage *et al.* [99] to increase diagnostic accuracy for cholangiocarcinoma in PSC by combining CEA with CA19-9 levels to form an index, although others have found the index to be less useful [100]. CA125 has a low sensitivity for detection of cholangiocarcinoma, but a high specificity as it is rarely elevated in inflammatory conditions [101].

CA19-9 and CEA in bile Attempts have been made to improve diagnostic sensitivity and specificity for the detection of cholangiocarcinoma by measurement of these markers in bile, but the results have been disappointing [98].

Endoscopic retrograde cholangiopancreatography (ERCP) and percutaneous transhepatic cholangioscopy (PTC)

ERCP and PTC are considered together as they both involve direct intubation of the bile ducts and the injection of contrast into potentially obstructed ducts. With both tests, ducts that have been injected with contrast must remain intubated because of the risk of infection. Often, ERCP is chosen as the first investigation when a patient presents with obstructive jaundice. In the case of hilar cholangiocarcinoma, the unfortunate result may be insertion of bilateral stents, including a stent into the hemiliver to be resected. This is undesirable because the goal in the preoperative period is to encourage hypertrophy of the hemiliver to be retained and atrophy of the hemiliver to be resected (see Preoperative preparation). Insertion of bilateral stents works against this purpose. Also, if the malignant stricture is tight, ERCP may only show the lower limit of the stricture. In the past, this problem has been approached by supplementing the ERCP findings with PTC, although PTC is uncommonly used for this particular purpose today. Beginning the investigation of the jaundiced patient with axial imaging such as computerized tomography (CT) or magnetic resonance imaging (MRI) rather than ERCP has distinct advantages. If a hilar cholangiocarcinoma is present, it will be suspected by the presence of intrahepatic bile duct dilation in the absence of extrahepatic ductal dilation. Atrophy of a hemiliver or section may also be seen. It is at this point that the patient is best evaluated by a multidisciplinary team with expertise in this disease and a decision regarding which side of the biliary tree to decompress (if any) can be taken. Whether to use stents or not in hilar cholangiocarcinoma is debatable but, if a stent is inserted, only the side to be retained should be intubated. The side to be surgically removed should be intubated only if there is evidence of cholangitis on that side or if that side is inadvertently injected with contrast. Another disadvantage of early intubation of the biliary tree is that it interferes with staging by MRI [102]. Even if the patient is not a surgical candidate, intubation of both sides of the liver by ERCP is disadvantageous because it commits the patient to bilateral rather than unilateral stenting (see Palliation).

One advantage of endoluminal techniques is that biopsies may be obtained by brushings, fine-needle aspiration or forceps biopsy. However, the individual sensitivity of these test is less than 50% and only 65% when combined [103,104]. Attempts to improve the results of routine cytology include digital image analysis (DIA), which uses aneuploidy as a marker for malignancy, and fluorescence *in situ* hybridization (FISH). DIA was found to increase sensitivity from 18% to 40% but lower specificity from 98% to 77% in 100 patients [105]. The FISH assay uses a mixture of fluorescently labelled probes to centromeres of chromosomes to identify cells with chromosomal abnormalities [106]. In 100 patients, the sensitivity for the detection of malignancy in bile duct brushing specimens was 15% and 34% for routine cytology and FISH, respectively, and the specificity was 91% and 98% [106].

Percutaneous intubation of the bile ducts has been used to obtain biopsy material and to determine the upper extent of the lesion in the bile ducts [107,108]. Cholangioscopy may be useful in determining whether a focal biliary stricture is benign or malignant [109,110]. Of particular interest is whether cholangioscopy might be able to determine reliably whether a focal stricture is benign and thus avoid unnecessary surgery or reduce the extent of surgical resection. However, as benign focal hilar strictures are uncommon and the case series are small, good data on this point are lacking. MRI and cholangioscopic findings were found to be highly correlated with respect to determining the upper extent of the lesion, a finding which indicates that cholangioscopy may no longer be required for this purpose [111]. Cholangioscopy may be of most value when the upper limit of the lesion is indefinite on MRI and the tumour is mucin producing. In this case, percutaneous cholangiography is hampered by the thick mucin. With cholangioscopy, the mucin may be aspirated and the upper limit of the tumour defined [112].

Magnetic resonance imaging

MRI has been increasingly favoured for the diagnosis and staging of hilar tumours as this one study can provide a clinical diagnosis as well as the answer to many of the local staging questions, namely questions 1–6 in Table 3. In terms of bile duct involvement, MRI cholangiography has the same sensitivity (80%) and specificity (100%) as ERCP for the detection of malignancy [113]. Furthermore, MRI is far superior to ERCP in detecting the upper extent of the lesion, for the reasons noted above.

On MRI, an MF hilar lesion appears as a nodule 1–2 cm in diameter (Fig. 4). The tumour is usually hypointense on T1-weighted images but hyperintense on T2-weighted images. In the PI type, the tumour appears as a concentric, sometimes irregular, thickening with gradual or abrupt transition to normal duct (Fig. 5). The periductal tissue may appear to be invaded, and lymph node metastases are frequently seen [52]. The IG type is seen as an intraductal enhancing mass confined to the lumen of the bile duct. It may have a rounded or bullet shape or appear as a cast of the duct. Usually, the bile duct wall can be visualized where it passes around the mass, i.e. as the tumour does not penetrate the duct, the outer bile duct margin is intact [52]. Portions of the tumour may break off and be seen in the lower ducts [114]. There may be multiple tumours along different segments of the bile ducts.

In all three morphological types, obstruction of the bile duct is usually present so that the bile ducts peripheral to the tumour are dilated (Figs 3 and 5), although they usually display normal wall thickness. When atrophy has been induced in a hemiliver or hepatic section, the dilated bile ducts will make up much of the residual volume of the affected part, giving the appearance of 'crowding' of the ducts (Fig. 3). Sometimes, MRI cholangiography may not give the fine detail required for surgical staging. This is especially true when the tumour appears to encroach on sectional ducts on the side to be retained. Direct cholangiography by PTC remains superior to MRI when this level of detail is needed [102]. MRI also accurately depicts the extent of liver invasion and secondary tumours in the liver.

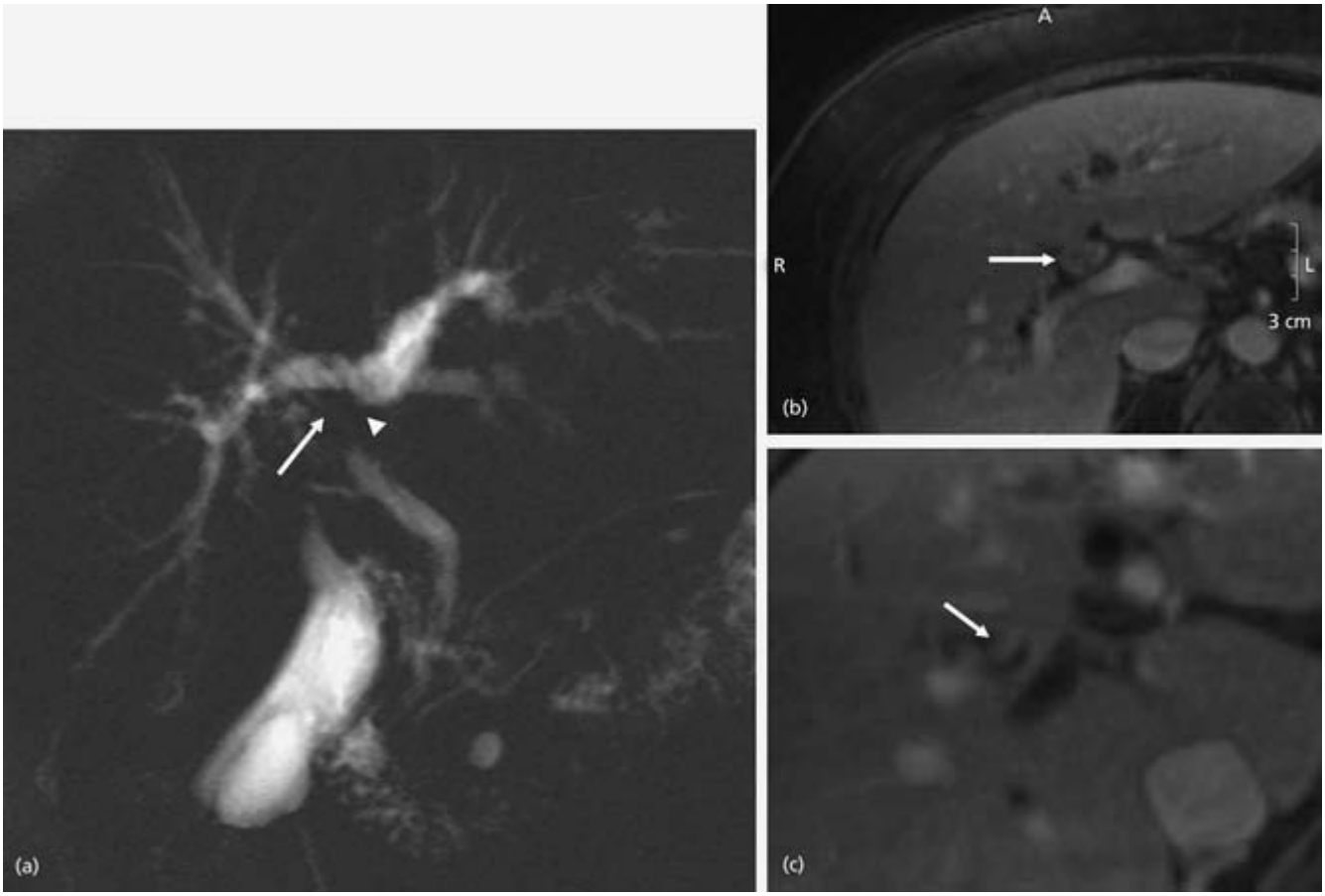

Fig. 4 Magnetic resonance imaging of hilar cholangiocarcinoma. (a) Magnetic resonance cholangiopancreatography image showing dilated intrahepatic biliary system. Note the common anomaly of a right posterior sectional duct which joins the left hepatic duct. The cholangiocarcinoma involves the confluence of the right anterior sectional duct (arrow), the left hepatic duct (arrowhead) and the top of the common hepatic duct. 3-D gradient echo post-contrast images (b,c) demonstrate the cholangiocarcinoma as a 1.0 cm mass (arrow) adjacent to the thickened duct (b). (c) A segment of the right anterior hepatic duct with wall thickening from cholangiocarcinoma (arrow). This patient had a bile duct resection with right hepatectomy and caudate lobectomy.

Computerized tomography

The typical PI cholangiocarcinoma is seen on the portal or delayed phases as an enhancing thickened bile duct and the MF type as a hypoattenuating mass. While usual spiral CT images have not been able to stage hilar cholangiocarcinomas with the detail provided by MRI, the newer multidetector row CT scanners provide high-quality images of the biliary tree and blood vessels after administration of intravenous contrast agents. These images provide the same information as MRI images [102]. A disadvantage of the agents used in CT is that they are nephrotoxic, unlike MRI contrast agents, a feature that may be of importance, particularly in elderly patients. Thin-section CT accurately predicted the upper extent of PG-type hilar tumours in 65% of cases in one study [115].

Ultrasonography

Sonography may detect all three types of hilar cholangiocarcinoma and is generally more sensitive in the hilum than at lower levels of the biliary tree, where intestinal gas is more likely to interfere with visibility. It can often display the extent of the tumour in the biliary tree. Flow Doppler sonography is particularly useful for defining vascular invasion. The disadvantages of sonography is that it is more operator dependent than axial imaging techniques and its images are somewhat more difficult for the surgeon to use as a guide in the operating room.

Angiography

Contrast angiography obtained by intubation of mesenteric vessels has been replaced by the less invasive methods of MR angiography or CT angiography.

Positron emission tomography (PET)

The role of 2-[18F]fluoro-2-deoxy-D-glucose (FDG)-PET in the diagnosis and staging of cholangiocarcinoma is incompletely investigated. At present, it is not a standard part of preoperative investigation. FDG-PET detected cholangiocarcinoma with high sensitivity and specificity in one study that included patients with advanced disease [116] and in another more recent study

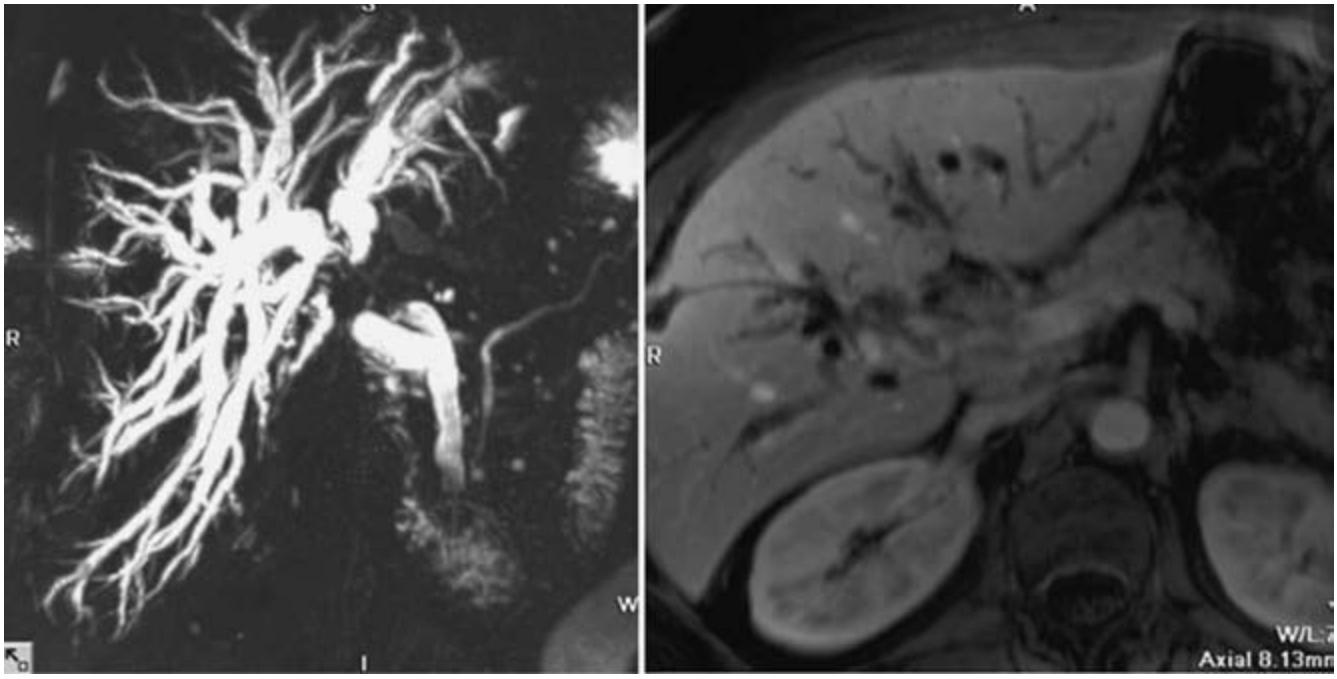

(a) (b)

Fig. 5 3-D magnetic resonance cholangiopancreatography image (a) demonstrating intrahepatic biliary ductal dilation and narrowing of the common hepatic duct from cholangiocarcinoma. 3-D gradient echo post-contrast image (b) demonstrates a portion of the mass lesion adjacent to the portal vein in the porta hepatis. Note the external biliary drainage catheter.

of 22 patients [117]. In another study, it did not differentiate effectively between inflammatory conditions and cholangiocarcinoma, nor was it positive in patients in whom the carcinoma was of the relatively acellular mucinous type [118]. However, 20% of patients were diagnosed with metastatic disease based on the FDG-PET scan [118]. Larger studies are required to define the frequency with which FDG-PET is able to detect metastases. Should a detection rate of 20% be confirmed, then it would be a valuable study considering the magnitude of the surgical procedure that would be avoided.

Endoscopic ultrasound (EUS)

EUS biopsies may have a higher sensitivity than endoluminal biopsy techniques. In one study in 44 patients whose imaging was suspicious for hilar cholangiocarcinoma, adequate material was almost always obtained. Accuracy, sensitivity and specificity were 91%, 89% and 100%, respectively, although 4 out of 12 patients with 'benign results' actually had malignancy [119]. EUS biopsy has the advantage over ERCP that bacteria are not introduced into obstructed bile ducts. However, unlike EUS biopsy of pancreatic lesions, the peritoneal cavity is traversed when hilar masses are biopsied, raising the possibility of tumour seeding [119].

Laparoscopy

Staging laparoscopy is performed after standard imaging is completed with the purpose of avoiding unnecessary laparotomy by detection of metastatic lesions missed by standard imaging techniques. Lesions as small as 1 mm, which are far below the detection limit of radiological imaging, may be detected on the peritoneum or liver surface [120,121]. Laparoscopy is performed either as a separate procedure or under the same general anaesthetic as the surgical resection. Sensitivity for T1 lesions is low, but that for T2/T3 lesions is over 30% [120]. Its use is now generally limited to situations in which unresectability is strongly suspected.

Current selection of diagnostic and staging tests for patients with suspected hilar cholangiocarcinoma

Our current approach to the diagnostic workup and staging of a patient with obstructive jaundice is to start with a thin-cut, three-phase CT scan of the abdomen as carcinoma of the pancreas is the commonest cause of this presentation, and a 'pancreas protocol' CT scan often provides complete clinical diagnosis and staging. When the pattern of bile duct dilation shows that the biliary obstruction is at the hilum, the CT is followed by MRI with MR angiography and MR cholangiopancreatography. Percutaneous cholangiography is used when MRI does not provide adequate imaging of the upper extent of the tumour on the side of the liver to be retained, and this provides preoperative decompression of the side to be retained without entering the other hemiliver. Brushings may be obtained at PTC. CA19-9 is measured. CT examination of the chest is performed.

This approach provides adequate answers to the questions in Table 3. In resectable patients, no further staging is used. We do not currently use FDG-PET or staging laparoscopy.

In actual practice, many patients who are referred have one or bilateral ERCP stents in place. In them, it is already known that a hilar lesion is present. Abdominal MRI and CT of the chest complete the investigation. Occasionally, the side to be retained has not been cannulated by ERCP, and PTC is still needed to define the upper limit of the tumour.

When staging indicates that the tumour is unresectable due to the extent of disease in the bile ducts, vascular invasion, atrophy or a combination of these, tissue diagnosis is obtained by ERCP with brushings and forceps biopsy, by EUS and, occasionally, by CT or ultrasound-guided percutaneous biopsies. If bulky lymph node disease is present, EUS biopsy is done as we currently consider such patients not to be surgical candidates if metastatic cancer is present in grossly enlarged nodes.

Lower duct cholangiocarcinomas

Rationale for diagnosis and surgical staging

These tumours are located in the part of the bile duct that lies in the head of the pancreas or at the level of the first part of the duodenum. They are one of the members of the tetrad of 'periampullary tumours', which commonly present with obstructive jaundice. The group also includes cancers of the ampulla of Vater, duodenum and pancreas, the last being by far the commonest of the four. Presumably all three subtypes of cholangiocarcinoma can occur in this region but, as the MF type would be very difficult to differentiate from pancreas cancer and as the IG type is very uncommon, it is the cicatrizing PI type that is usually recognized.

Diagnosis

In the patient presenting with jaundice, axial imaging may or may not demonstrate a pancreatic mass. If mass is present, the diagnosis is taken to be other than cholangiocarcinoma, either a malignancy of the head of the pancreas or focal pancreatitis, although, as already stated, some of these may actually be MF cholangiocarcinoma. When no mass is present, then cholangiocarcinoma is a possibility.

Surgical staging

The staging questions to be answered are 5–8 in Table 3. When the tumours are at the upper border of their range at the level of the duodenum, involvement of the portal vein and hepatic artery is possible. The extent of the tumour in the bile duct is rarely a staging question as the treatment is a Whipple procedure in which the entire common bile duct is removed along with the gallbladder and cystic duct.

Diagnostic and staging tests

If the initial diagnostic test for painless jaundice is a CT scan, as we recommend, then the findings will be those of obstruction of the bile duct in the intrapancreatic portion with no mass. Dilation of the bile ducts may terminate anywhere from the upper border of the pancreas to the duodenum depending on the extent of the tumour. MRI or ERCP are currently both good choices as the second test under these conditions, and there are no evidence-based data to select between them. The former test is less invasive but also less informative. ERCP provides an endoscopic view of the duodenum that allows identification and biopsy of ampullary and duodenal tumours, which may block the bile duct and produce jaundice without being seen as a mass on CT scan, and MRI is less informative in this regard. ERCP may provide a tissue diagnosis and decompress the bile duct when that is desirable. On the other hand, ERCP requires the placement of a stent into the obstructed duct, and complications such as pancreatitis and haemorrhage have occurred. Both tests will confirm the presence of a bile duct stricture and display its form, although direct cholangiography is still somewhat superior. The MRI characteristics are those for a PI as described under hilar cholangiocarcinoma.

Focal strictures, especially those with shoulders, suggest malignancy. Long tapering strictures limited to the intrapancreatic portion of the bile duct suggest chronic pancreatitis. Concomitant narrowing of the pancreatic duct in the head of the pancreas (double duct sign) suggests the presence of a small pancreatic cancer, not visible on CT scan. Longer or multiple pancreatic strictures suggest chronic pancreatitis. A single focal bile duct stricture in the absence of pancreatic duct abnormalities is the hallmark of cancer of the lower bile duct. Infiltrating cancers of the bile duct may cause more than one stricture along the bile duct but, when more than one stricture is present, other diagnoses such as PSC should be considered. Patients with the classical double duct sign or single focal shouldered bile duct strictures are likely to have small pancreatic or bile duct tumours. Further diagnostic support is usually not needed prior to laparotomy, although it is reassuring when the CA19-9 is over 100 U.

When doubt persists after ERCP or MRI, EUS is often quite useful. EUS may identify a small mass not seen on CT scan and biopsies may be obtained. Occasionally, enlarged lymph nodes are seen by EUS, and these may also be biopsied. However, negative EUS biopsies in patients who present with painless jaundice do not exclude malignancy and, for such a patient with an identifiable mass on EUS, pancreatoduodenectomy is recommended, even in the presence of negative EUS-guided biopsy. If a non-operative approach is followed, short-term follow-up at 4–6 weeks with repeat imaging and biopsy is mandatory. If findings persist, then laparotomy is advisable. At laparotomy, detection of a mass by palpation or intraoperative ultrasound is reasonable evidence of malignancy, and a pancreatoduodenectomy should be performed. In the absence of a mass and where clinical or imaging results suggest a benign aetiology for the stricture, ultrasound-guided core biopsies of the bile duct stricture may be helpful in avoiding pancreatoduodenectomy.

Our current preoperative evaluation consists of CT scan followed by ERCP and then EUS if needed. In the unresectable patient, pathological diagnosis is obtained by ERCP, EUS or biopsy of a metastasis such as an intrahepatic tumour.

Intrahepatic cholangiocarcinoma

Rationale for diagnosis and surgical staging

Diagnosis

Clinical diagnosis of the common MF type is dependent on the presence of a liver mass that resembles a metastasis on axial imaging, such as MRI or CT scan, in a patient without a history of liver disease or evidence of an extrahepatic primary. The presence of an elevated serum CA19-9 level is helpful. To rule out primary tumours in the intestine, upper and lower endoscopy is usually performed. FDG-PET scan and mammography are other imaging tests that have been used to search for an extrahepatic primary. The pathological diagnosis may be made by needle biopsy, but this is required only when diagnostic doubt exists.

Surgical staging

The aim again is subservient to the surgical goals of removal of gross and microscopic tumour, while preserving adequate liver function. The questions to be answered are similar to those for cholangiocarcinoma, although the vessels in question are the intrahepatic arteries and veins including the hepatic veins. Atrophy is less of an issue as it is almost always on the side to be resected, as is the case for the extent of bile duct involvement in the PI and IG types.

Diagnostic and staging tests

Magnetic resonance imaging

The MF type usually appears as an unencapsulated tumour, hypointense on T1-weighted images and hyperintense on T2-weighted images, although the pattern varies depending on the presence of fibrosis, necrosis and mucin in the tumour [114,122]. Hypointensity on T2-weighted images may be seen especially in larger tumours. In these cases, differentiation from the central scar of focal nodular hyperplesia (FNH) is usually possible by the use of gadobenate dimeglumine (Gd BOPTA) [123]. With dynamic imaging, peripheral enhancement with progressive filling towards the centre of the lesion is common. Satellite lesions are frequent as is capsular retraction [114]. The PI type appears as a thickened branching spiculated duct with dilation of the ducts peripheral to the tumour, i.e., much like the PI type of hilar tumour but displaced beyond the sectional ducts. In later stages, the surrounding liver may appear to be invaded. The IG type is seen as an intraductal enhancing mass with dilation of ducts peripheral to the mass. The intrahepatic variant otherwise has the characteristics of the hilar type described above and, indeed, this tumour may exist at any and all levels of the biliary tree.

Fig. 6 Computerized tomography scan of a large mass-forming intrahepatic cholangiocarcinoma of the right hemiliver. Note peripheral enhancement and capsular retraction (white arrow). A portal lymph node is enlarged (black arrow). An incidental liver cyst is present (asterisk) adjacent to the mass lesion. This patient had a right hepatectomy.

Computerized tomography

The typical appearance of the MF lesion is of a large hypoattenuating irregular mass, minimally enhancing at the periphery, sometimes with calcifications and often with capsular retraction, satellite lesions and enlarged malignant-appearing periportal nodes (Fig. 6) [114].

Sonography

MF tumours are usually hypoechoic, but may be isoechoic or hypoechoic and homogeneous or heterogeneous [114]. There are no features that differentiate them from metastatic disease, although peripheral ductal dilation is more common in cholangiocarcinoma [114].

ERCP

ERCP may be helpful in the PI and IG types when the diagnosis is unclear or after MRI when the extent of the tumour in the ducts is incompletely elucidated.

Current preoperative evaluation of patients with intrahepatic cholangiocarcinoma

Most tumours are MF type, and patients often arrive with a sonogram or a CT scan showing a liver mass. We currently use three-phase CT of abdomen, pelvis and chest as the first test when an MF intrahepatic cholangiocarcinoma is suspected This is usually adequate to define the extent of the tumour in the liver and its relation to intrahepatic vessels. Primary tumours in the abdomen or chest may sometimes be detected when the liver

lesion is actually a metastasis. CA19-9 is measured. FDG-PET scan and upper and lower endoscopy are done; in women, a mammogram is obtained. Percutaneous biopsy is not routinely performed preoperatively, but is done when there is diagnostic doubt in the asymptomatic patient or when the patient is unresectable. When the intrahepatic cholangiocarcinoma is of the PI or IG type, MRI with MPRC is done and occasionally ERCP with biopsies.

Differential diagnosis

Hilar and lower duct cholangiocarcinomas

Primary sclerosing cholangitis

PSC may be mistaken for cholangiocarcinoma at the time of presentation. However, the more common issue is how to detect new-onset cholangiocarcinoma in a patient with established PSC. The periductal infiltrating type of cholangiocarcinoma may produce skip lesions suggestive of the multiple strictures seen in PSC. In the former case, the lesions are usually confined to one part of the ductal system, whereas in the latter, they are usually found diffusely in the biliary tree. New-onset cholangiocarcinoma in PSC may be heralded by a change in clinical condition, such as onset of jaundice or an increase in the level of CA19-9 to over 100 IU [124]. Imaging may detect a mass, and brush or forceps biopsy may provide a histological diagnosis.

Eosinophilic cholangitis and lymphoplasmocytic cholangitis

The former is a rare inflammatory entity thought to be of allergic origin as eosinophils are seen abundantly in the inflamed tissues. It is thought to be part of the spectrum of eosinophilic gastrointestinal (GI) inflammation, which may affect other parts of the GI tract including the stomach and pancreas. The strictures may be long and multiple and therefore mimic PSC. Patients respond very well to systemic steroid administration. This is both a treatment and a diagnostic test. Lymphoplasmocytic cholangitis has the characteristics of an autoimmune disease and more commonly affects the pancreas [125]. Features of this disease overlap with PSC [126,127].

Benign inflammatory tumours

This inflammatory process of unknown aetiology was first described by Stamatakis *et al.* (128) and has several synonyms including 'hepatic inflammatory pseudotumour' [128], 'benign fibrosing disease' [60] and 'malignant masquerade at the hilum' [129]. The masses consist of chronic inflammatory cells and fibrosis. Benign inflammatory tumours appear to occur most frequently in extrahepatic upper ducts, but also occur intrahepatically [130] and, less commonly, in lower ducts.

Benign inflammatory tumours mimic malignant biliary obstructions at the hilum, causing jaundice. In one series, the median age of presentation was about 50 years, i.e. about 10 years younger than the typical patient with cholangiocarcinoma [131]. Inflammatory tumours cannot be differentiated from localized malignant strictures on the basis of presentation or liver function tests. CA19-9 serum levels are normal or slightly elevated [131] unless cholangitis is present. However, about 20% of patients with malignant strictures also have normal CA19-9 serum levels. A mass at the hilum is commonly present on axial imaging, but vascular invasion/encasement has not been described with this process [60,129]. Consequently, investigations are much better at determining that a cholangiocarcinoma is present by detection of high CA19-9 levels or vascular invasion than in differentiating between benign inflammatory tumours and cholangiocarcinoma when these features are absent.

This inflammation has been reported to account for 13–24% of hilar tumours [58,60,131,132]. Currently, they are treated as cholangiocarcinomas and resected. When the diagnosis is suspected, direct biopsy of the lesion at surgery may make the diagnosis, allowing the surgeon to limit the resection to the bile ducts only [131]. Failure to appreciate the possibility of this diagnosis may lead to inappropriate therapies such as long-term stenting or hepatic resection.

Cholelithiasis and choledocholithiasis

Choledocholithiasis may be mistaken for cholangiocarcinoma. In the so-called Mirizzi syndrome, a stone impacted in the neck of an inflamed gallbladder compresses the common duct, producing jaundice and often fever and pain [133]. Radiologically, the stricture is usually located in the mid duct and is smooth, long and bows the duct convexly to the left. The impacted gallstone can often be seen adjacent to the site of the stricture. These observations may be made by MRI or a combination of direct cholangiography and ultrasonography. The right hepatic duct may also be independently narrowed by this process.

A gallstone(s) impacted in the lower end of the bile duct may appear as a stricture on cholangiography when dye is able to pass only along one side of the stone. This type of impaction may be associated with an inflammatory mass, heightening the suggestion of tumour. Detection of the stone by MRI or intraoperative ultrasound or palpation will lead to the correct diagnosis. Multiple small gallstones in the bile duct may be confused with the IG type of cholangiocarcinoma. Differentiation is provided by the fact that tumours enhance on contrast CT and that stones tend to be smooth and faceted on cholangiography.

Adenoma of the bile duct

This benign tumour of the bile duct is rare, but may easily be confused with a focal IG tumour (papillary cholangiocarcinoma). In fact, adenomas may degenerate into papillary cholangiocarcinoma as do adenomas in other sites [134]. These tumours characteristically present with jaundice or pain. They may be polypoid and moveable within the duct. If an adenoma is suspected, a local bile duct resection is the treatment of choice.

Carcinoma of the gallbladder

The commonest cause of a malignant bile duct stricture in the midportion of the common duct is not cholangiocarcinoma but compression or invasion by gallbladder cancer. Patients may present with painless or relatively painless jaundice as in cholangiocarcinoma. The diagnosis may be suspected by the detection of gallstones in the gallbladder as well as gallbladder wall thickening, sometimes eccentric in type, along with the midbile-duct stricture. Invasion of the tumour into the liver under the gallbladder may also raise suspicion of a gallbladder cancer rather than cholangiocarcinoma. Once a gallbladder cancer has invaded and occluded the bile duct, the prognosis is very poor [135].

Neuroendocrine cancer of the bile duct

This is a rare slow-growing tumour that may present with jaundice [136]. A small mass is often present that enhances on the arterial phase. Local resection of the tumour and the bile duct is usually adequate treatment.

Granular cell tumours

These tumours, which are probably of Schwann cell origin, are extremely rare in the biliary tree. Biliary obstruction may be caused by a tumour in the common duct or hepatic duct confluence [137]. Treatment consists of surgical excision. Prognosis is favourable.

Sarcoma of the bile duct

These are extremely rare tumours, usually embryonal rhabdomyosarcomas [138] or leiomyosarcomas, which can present with jaundice and a mass.

Lymph nodes

Lymph nodes in the porta hepatis, which become enlarged as a result of either malignancy or inflammation, may compress the bile duct causing jaundice

Periampullary processes causing biliary obstruction

Lower duct cholangiocarcinomas cause obstruction within the portion of the bile duct that lies within the head of the pancreas. Therefore, other malignancies causing obstruction, such as pancreatic head cancers and cancers of the ampulla of Vater and duodenum, lie within the differential diagnosis of lower duct cholangiocarcinoma. The last two are usually easily separated from cholangiocarcinoma. A CT scan may show the intraduodenal process, and upper endoscopy will confirm the diagnosis. Often it is difficult to differentiate a small pancreatic cancer obstructing the bile duct from a lower duct cholangiocarcinoma, but the differentiation is of little clinical importance as pancreaticoduodenectomy is the treatment for both. Indeed, as cholangiocarcinoma may be mass forming, it may even be difficult for pathologists to be completely confident about the origin of the tumour. Chronic pancreatitis, either focal or diffuse, may also cause bile duct obstruction and should be considered in the differential diagnosis, although usually the differentiation is between cancer of the pancreas and chronic pancreatitis.

Intrahepatic cholangiocarcinoma

The differential diagnosis is that from other mass-forming lesions in the case of the MF type of cholangiocarcinoma, and from PSC and intraductal stones for the PI and IG types respectively. In the case of the last two, the considerations are the same as for extrahepatic tumours discussed above.

Hepatocellular carcinoma

Unlike intrahepatic cholangiocarcinoma, HCC usually arises in the cirrhotic liver. The imaging characteristics are usually distinct from those of intrahepatic cholangiocarcinoma. Alpha-fetoprotein (AFP) is not usually elevated in cholangiocarcinoma, and CA19-9 is usually normal in HCC.

Secondary tumours

Secondary tumours are difficult to differentiate as they occur in otherwise normal livers, as do cholangiocarcinomas. Their clinical presentation and imaging characteristics also mimic MF cholangiocarcinomas. A high suspicion of secondary tumour should be maintained when there is a history of a prior malignancy. Some malignancies, such as breast and renal primaries, may present with secondary tumours a decade or more after eradication of the primary. Biopsy may be helpful in the case of unusual hepatic secondaries such as those from sarcoma, but most secondary tumours are adenocarcinomas. Special stains may be of help in differentiating among adenocarcinomas. The diagnosis requires exclusion of other primaries by thorough physical examination, upper and lower gastrointestinal endoscopies, CT scan of the abdomen, chest radiography and mammography. FDG-PET scan may be helpful.

Angiosarcoma

A rare tumour of endothelial origin associated with prior exposure to vinyl chloride, arsenicals or thorotrast (in the past). There is a male predominance. The tumours are rapidly growing, present at a late stage and are rarely resectable, although this should be attempted if possible.

Epithelioid haemangioendothelioma (EHE)

EHE is a rare tumour of young adults that arises from endothelial cells, as evidenced by antibodies to endothelial markers such as factor VIII antigen. It usually arises in normal livers and is usually multifocal. MRI may be useful in making the diagnosis [139], but biopsy is usually required and, even then, it may be difficult to differentiate from other tumours because of the fibrotic stroma. Some 20% of patients have metastatic disease at the time of diagnosis. Resection is rarely possible and the role of liver transplantation is uncertain.

Primary hepatic lymphoma

Very rarely, this tumour presents as a single mass and can be confused with MF cholangiocarcinoma. If no other disease exists, local resection may be considered along with chemotherapy.

Preoperative preparation

Jaundiced patients require vitamin K. Resective procedures for cholangiocarcinomas are major procedures and, therefore, patients should have good functional status especially if they are elderly. There is no evidence that patients with lower duct cholangiocarcinomas benefit from preoperative decompression. In fact, the evidence is to the contrary [140]. Unlike cancers of the lower bile duct, hilar cancers of the upper bile duct usually require major liver resection. Consequently, it is reasoned that the chance of postoperative liver failure may be lessened by preoperative decompression, especially decompression of the side to be retained. Decompression has the dual purpose of allowing that side to recover function and actually to hypertrophy. On the other hand, stents may introduce bacteria and cause cholangitis. As noted above, selective percutaneous decompression is an accepted strategy in Japan and multiple stents are often inserted [141]. A reasonable strategy is to proceed to surgery in younger patients (age less than 70 years) without serious comorbidities who have been jaundiced for less than 4 weeks, whose serum bilirubin is less than 10 mg/dL and whose future remnant liver will be > 40% of total liver mass. Also, such patients should not have had biliary instrumentation, which always contaminates the obstructed biliary tract. For the remainder, we routinely decompress the side of the liver to be retained and wait until the serum bilirubin falls to 3 mg/dL. When the size of the future remnant liver is 'small', portal vein embolization of the side to be resected can be used to cause hypertrophy of the future remnant liver. What is defined as small under the conditions of a hilar cholangiocarcinoma is in a state of flux. Currently, we use embolization when the size of the future remnant liver is less than 40% with the aim of bringing it over 50%. It should be noted that this is much larger than is required when a liver resection is performed in a normal liver for a diagnosis not associated with obstruction of the future remnant liver, such as liver resection for colorectal metastases or indeed for an MF cholangiocarcinoma. In those cases, a future remnant liver of 25% is often adequate.

Treatment

Hilar cholangiocarcinoma

The goals of surgical resection are to remove the tumour with negative resection margins and to perform a portal and coeliac node dissection. In order to achieve this, hemihepatectomy with resection of the caudate lobe as well as the suprapancreatic extrahepatic bile duct and the portal and coeliac lymph nodes is required. Resection of the caudate lobe is needed because, when the tumour is Bismuth 2 or greater, the orifices of the caudate ducts may be involved with tumour. Hemihepatectomy is required when the tumour involves the sectional ducts (Bismuth 3) on one side of the liver or the artery or portal vein to one side of the liver. Theoretically, resection of a Bismuth 2 tumour could be accomplished by resection of bile ducts with the caudate lobe but, in practice, negative margins are much more likely to be accomplished by a hemihepatectomy with resection of the caudate lobe [63,142,143]. Therefore, surgical practice has evolved in the past 20 years to the point at which there is a consensus that virtually all hilar cholangiocarcinomas should be resected by hemihepatectomy and caudate resection. Low-lying Bismuth 1 tumours, in which a negative upper margin can be obtained on the common hepatic duct, i.e. below the level of the orifices of the caudate ducts, may be resected without removing liver tissue, but these instances are uncommon.

A detailed description of the operative technique is beyond the purpose of a textbook on hepatology. Briefly, the main steps in the operation are as follows. A thorough laparotomy is performed to detect liver and peritoneal metastases or lymph node metastases outside the resection zone. Bulky lymph node metastases in the coeliac area are considered to be a contraindication to resection by most hepatopancreatobiliary (HPB) surgeons as cure is very unlikely. However, today, bulky node disease is usually diagnosed by imaging and biopsy in the preoperative staging period. Next, the bile duct is divided where it enters the pancreas, and a frozen section is obtained to confirm a negative margin. The coeliac nodes are mobilized towards the porta hepatis so that they are included in the specimen. With anterior traction of the divided bile duct, the common duct and gallbladder are dissected up and away from the portal vein and proper hepatic artery, leaving the latter structures bare, i.e. all portal nodes and soft tissue are taken with the specimen. In a low-lying Bismuth 1 tumour, the bile duct is divided a second time at or just below the confluence of the right and left ducts, and the specimen is removed and the upper duct margin sent for frozen section. In most cases, one hemiliver will have been selected for resection. Therefore, at this point, the hepatic artery and portal vein to the side to be resected are divided. When the right liver is to be resected, the right hepatic artery, which normally crosses the common hepatic duct left-to-right, is divided to the left side of the bile duct after display of the left hepatic artery. Next, the bile duct on the side to be retained is divided as close to the confluence of the sectional ducts on that side as possible. On the left side, this is almost at the level of the umbilical fissure, 3–4 cm from the confluence of the right and left bile ducts as the course of the left hepatic duct is usually long. On the right side, the point of division of the right duct will usually be 1–2 cm from the confluence of the right and left ducts as the right hepatic duct is usually short. The liver is then mobilized taking the caudate veins and the right or left hepatic vein, and the liver is divided close to the midplane. The specimen is sent for frozen section of the upper bile duct margin.

Unfortunately, cholangiocarcinomas have a well-known propensity to spread microscopically for long distances along the bile duct [144]. A positive resection margin occurs in 20–40% of cases even when liver resection has been done [63,142,143,145]. The resection margin may be extended by dividing through the termination of the sectional ducts, but there is a limit to how far this can be carried. Mobilizing the portal vein in the umbilical fissure aids this manoeuvre on the left as the bile ducts to the left lateral section pass behind this vein [146]. The operation can also be extended by taking the left medial section with the right liver (right trisectionectomy) or the right anterior section with the left liver (left trisectionectomy). The operation may also be extended by vascular resections. Involvement of the portal vein may require replacement of the anterior wall of this structure or circumferential resection with anastomosis of the main portal vein to the left portal vein or, less commonly, the right portal vein with or without an interposition graft. It has been proposed to remove the anterior wall of the portal vein as a routine in order to obtain a higher rate of negative margins [143]. This recommendation lacks supporting randomized data and is not routinely followed. Arterial reconstruction of the proper hepatic artery is less commonly performed. Pancreatoduodenectomy is performed in up to 15% of cases in some series in order to obtain negative lower margins or to remove potentially malignant nodes. Reconstruction of the biliary tract is by a Roux-en-Y hepaticojejunostomy. The Roux limb is made at least 60 cm in length to avoid reflux of intestinal contents into the biliary tree.

Results of surgical treatment from selected recent case series are given in Table 4. The important trends are as follows. Portal vein embolization [147] is becoming more common as a preoperative preparation [148]. Some 15–50% of patients are found to be unresectable at surgery [63,142,148] but, in recent years, the figure has been decreasing towards the lower limit of this range [63,149]. More procedures include a major hepatic resection [63,142,145,147–150] because the chance of achieving an R0 resection is substantially higher when a major resection is performed [63,142,145,147–150] (Table 4). Mortality rates are falling. While mortality rates for series often spanning 10–15 years are still relatively high, i.e. > 5%, these rates are not reflective of the most recent 5-year results. In these series, mortality rates are usually less than 5% [63,147–150]. Morbidity rates are still high, reflecting the magnitude of the procedure. R0 resection is necessary for cure; almost no patients who have had R1 resection survive 5 years without recurrence. Even with R0 resection, the overall 5-year survival is only 20–35% [63,142,145,147–150]. Factors affecting survival include R0 resection [63,148], *en bloc* hepatectomy [63], absence of tumour in lymph nodes [145,148], tumour grade [63] and tumour type with IG type (papillary) having better survival than other types [63]. The need to perform a vascular resection is associated with a poorer outcome in some series [93,145,149]. The value of pancreatoduodenectomy is unclear at this time. Most patients requiring this addition to the procedure have had a relatively short survival.

Lower duct tumours

The rationale and extent of the procedure is the same as that used for pancreatic carcinoma. The procedure has reached very low mortality rates at tertiary care centres specializing in HPB surgery [151]. Often, the tissue of origin of the tumour, i.e. whether pancreatic, ampullary or bile duct in origin, is uncertain until after the specimen is examined pathologically and, even then, doubt can remain. The main complication of this procedure is a fistula from the pancreatic–jejunal anastomosis, which occurs in 5–10% of patients [151]. Biliary fistulas occur in about 2% of patients. Patients rarely die from these complications today because of improvements in diagnostic and interventional radiology, intensive care and treatment of infection [151].

Table 4 Recent results of surgical resection of hilar cholangiocarcinoma in series with more than 75 patients.

Author [reference] (year of publication)	Years of treatment	No. of patients resected	% Major resections (3Sg or more)	% R0 resection (with/without major resection)	Morbidity (%)	Mortality (%)	5-year overall survival (%)
Jarnagin *et al.* [63] (2005)	1991–2003	106	82	78 (83/47)	62	8	29[a]
Nagino *et al.* [150] (2005)[b]	1999–2003	100	100	NA	67	3	NA
Kawasaki *et al.* [148] (2003)	1990–2001	79	87	68	14	1	33[a]
Lee *et al.* [142] (2000)	1989–1997	128	88	71 (77/23)	48	6	22[a]
Gerhards *et al.* [149] (2000)	1983–1998	112	29	NA	65	18	NA
Miyazaki *et al.* [145] (1999)	1981–1999	93	70	80 (80/80)	38	10	26
Neuhaus *et al.* [143] (1999)	1988–1998	80[c]	82	70 (61/29)	59[d]	8	22[d]

[a]Calculated. Postoperative deaths not included.
[b]Includes 19 patients with gallbladder cancer.
[c]Excludes patients who underwent total liver resection and transplantation.
[d]Includes 15 patients who underwent transplantation.

Resection of part of the stomach is no longer required for lower duct cholangiocarcinoma, although there is little or no difference in short-term outcome or quality of life between the pylorus-preserving and standard types of pancreaticoduodenectomy [152]. Many patients require pancreatic enzyme replacement after this procedure, but few become diabetic.

Five-year overall survival in recent case series varies from 16% to 37% [153–155], and results have not improved in the last decade. Overall, the results of pancreatoduodenectomy for lower bile duct cancer are much the same as those for adenocarcinoma of the pancreas and unlike those for ampullary and duodenal cancers, which have a much better prognosis.

Intrahepatic cholangiocarcinomas

The principles of treatment are as for other malignant intrahepatic hepatic lesions. The tumour must be resected with a margin of normal tissue to obtain microscopically free resection margins (a 1-cm tumour-free resection margin is the goal), yet leave enough normally functioning liver tissue behind for the patient to have adequate liver function in the postoperative period. The size of the resection may vary from a single segment or less to resection of three of the four hepatic sections. The role of resection of extrahepatic lymph nodes is unclear, but it is being done with increasing frequency [156]. Lymph node positivity is common in tumours over 4.5 cm in size, but rare in patients with smaller tumours, and lymphadenectomy might reasonably be limited to large tumours [157].

Four recent series of patients with MF intrahepatic cholangiocarcinoma treated by surgical resection in 60, 35, 52 and 104 patients reported 5-year survival rates of 29%, 33%, 34% and 10% respectively [91,158–160]. Multivariate analyses of prognostic risk factors identified symptomatic patient [91], positive surgical margin [159], multiple tumours [91,156], vascular invasion [91,159], lymph node metastases [91,159] and high microvessel counts indicative of angiogenesis [156] as predictors of poor outcome. Mucin (MUC)4 expression in carcinoma tissues is also associated with poor outcome in MF intrahepatic cholangiocarcinoma [161]. Fewer data are available for the less common IG and PI types of intrahepatic cholangiocarcinoma. The IG type has the best prognosis [162,163].

Liver transplantation

Liver transplantation has been performed for intrahepatic and upper duct cholangiocarcinoma, but the results have been disappointing until recently. In one series published in 1993 [164], only 3 of 14 patients (21%) lived more than 28 months after the procedure. Even in a more recent series, in which transplantation was performed in patients with cholangiocarcinoma in the setting of PSC, the 5-year survival was only 35% [165]. While these are not poor results for a visceral cancer, they must be evaluated with the knowledge that many patients with endstage chronic liver disease are dying while on a waiting list for liver transplantation, and the comparative survival rate in this group of patients would be expected to be about 90%. However, two American centres have reported better results for hilar cholangiocarcinoma. The Mayo Clinic group reported on 56 patients who entered a trial of liver transplantation for unresectable cholangiocarcinoma or cholangiocarcinoma in the setting of PSC. The patients were staged by EUS and also by staging laparotomy. All patients received neoadjuvant chemoradiation. Approximately half the patients were transplanted, with a 5-year actuarial survival of 82% in transplanted patients [41]. The other group using a similar approach achieved a 5-year survival rate of 50% [166].

Adjuvant chemotherapy or radiotherapy

One randomized controlled trial of adjuvant therapy using mitomycin C and 5-fluorouracil vs. surgery alone enrolled 139 patients with cholangiocarcinoma at various levels [146]. There was no survival benefit, although there was benefit in a group of patients with gallbladder cancer treated with the same regimen [146]. External beam radiotherapy was associated with improved postoperative survival in patients with hilar cholangiocarcinoma in one non-randomized trial [167]. However, patients in the control group were treated at an earlier time period or tended to be in poor general condition. In an earlier study in which groups of patients with hilar cholangiocarcinoma were more comparable, external beam radiation did not result in improved survival [36]. Intraluminal brachytherapy does not extend survival and is associated with an increased incidence of complications [167]. Recurrence of cholangiocarcinoma is often local, suggesting that adjuvant chemotherapy and/or radiation would be beneficial but, currently, there is no evidence to support its use outside clinical trials.

Palliation

The purpose of palliation is to relieve jaundice and pruritus and to extend life. Jaundice and pruritus are treated by stenting, usually by endoscopic or percutaneous means or, less commonly, by surgery. Several randomized trials of surgical bypass vs. endoscopic intubation for lower duct tumours have been published [168–171]. The three earlier trials favoured endoscopic stenting [168,170,171]. Two of these trials were quite small and, in the third [168], the surgical procedures were performed by registrars; surgical complication rates were unusually high by current standards. The reintervention rate was high in the stent group. There was no difference in survival. In a more recent trial of patients found to be unresectable by staging laparoscopy, surgical bypass was favoured over stenting with the surgical group achieving a longer survival [169]. The current surgical consensus is that a surgical bypass should be performed by an experienced HPB surgeon in younger patients without distant metastases or obvious peritoneal disease. When unresectability is determined at laparotomy, a double bypass is performed to

decompress the biliary tree and bypass the duodenum, which may become obstructed. Surgical decompression of hilar tumours may also be accomplished by bypass to the segment 3 duct, the so-called Bismuth–Corlette procedure [92]. This provides decompression of the left liver. It is usually only done when a patient is found to be unresectable at the time of exploration.

Decompression with stents may be achieved by endoscopic or percutaneous means, with the former favoured because it is less invasive. Metal stents are generally used because of improved stent patency rates. In the hilum, plastic stents also have the theoretical disadvantage that their solid walls may block smaller side-branches. For lesions below the bifurcation, a single stent will decompress the entire liver. Bilateral stents or forked stents have been used to decompress tumours obstructing the confluence. However, it seems that a unilateral stent is often just as effective provided that it is placed selectively, based upon a preprocedure MRCP, on the side of the liver that will result in decompression of the most functional liver [172]. It is essential that the side of the liver not to be stented is not cannulated as that often results in cholangitis on that side, and this is associated with much poorer results [172]. Should inadvertent cannulation of the side of the liver occur on the side that was not intended to be decompressed, then it is best to employ bilateral stents in order to avoid cholangitis. Intraluminal brachytherapy has not improved results and, as reported in the adjuvant setting, is associated with more complications [167]. Photodynamic therapy, in which an intravenously administered photosensitizer, which preferentially localizes to cancer cells, is activated by an endoscopic light source, is a promising palliative therapy. In one randomized trial, survival and quality of life were improved [173] with this technique.

References

1 Liu CL, Fan ST, Lo CM *et al.* (2003) Hepatic resection for combined hepatocellular and cholangiocarcinoma. *Arch Surg* 138 (1), 86–90.

2 Jarnagin WR, Weber S, Tickoo SK *et al.* (2002) Combined hepatocellular and cholangiocarcinoma: demographic, clinical, and prognostic factors. *Cancer* 94 (7), 2040–2046.

3 Shaib Y, El Serag HB (2004) The epidemiology of cholangiocarcinoma (review with 46 refs). *Semin Liver Dis* 24 (2), 115–125.

4 Jemal A, Murray T, Ward E *et al.* (2005) Cancer statistics, 2005. *CA Cancer J Clin* 55 (1), 10–30.

5 Kuwayti K, Baggenstoss AH, Stauffer MH *et al.* (1957) Carcinoma of the major intrahepatic and the extrahepatic bile ducts exclusive of the papilla of Vater. *Surg Gynecol Obstet* 104 (3), 357–366.

6 Nakeeb A, Pitt HA, Sohn TA *et al.* (1996) Cholangiocarcinoma. A spectrum of intrahepatic, perihilar, and distal tumors. *Ann Surg* 224 (4), 463–473; discussion 473–475.

7 Nagorney DM, Donohue JH, Farnell MB *et al.* (1993) Outcomes after curative resections of cholangiocarcinoma. *Arch Surg* 128 (8), 871–877.

8 Patel T (2001) Increasing incidence and mortality of primary intrahepatic cholangiocarcinoma in the United States. *Hepatology* 33 (6), 1353–1357.

9 Taylor-Robinson SD, Foster GR, Arora S *et al.* (1997) Increase in primary liver cancer in the UK, 1979–94 (see comment). *Lancet* 350 (9085), 1142–1143.

10 Taylor-Robinson SD, Toledano MB, Arora S *et al.* (2001) Increase in mortality rates from intrahepatic cholangiocarcinoma in England and Wales 1968–1998 (see comment). [Erratum appears in *Gut* (2001) Aug; 49 (2), 315]. *Gut* 48 (6), 816–820.

11 Shaib YH, Davila JA, McGlynn K *et al.* (2004) Rising incidence of intrahepatic cholangiocarcinoma in the United States: a true increase? (see comment). *J Hepatol* 40 (3), 472–477.

12 Wood R, Brewster DH, Fraser LA *et al.* (2003) Do increases in mortality from intrahepatic cholangiocarcinoma reflect a genuine increase in risk? Insights from cancer registry data in Scotland. *Eur J Cancer* 39 (14), 2087–2092.

13 Sharp GB, Cologne JB, Fukuhara T *et al.* (2001) Temporal changes in liver cancer incidence rates in Japan: accounting for death certificate inaccuracies and improving diagnostic techniques. *Int J Cancer* 93 (5), 751–758.

14 Klatskin G (1965) Adenocarcinoma of the hepatic duct at its bifurcation within the porta hepatis. an unusual tumor with distinctive clinical and pathological features. *Am J Med* 38, 241–256.

15 Burke EC, Jarnagin WR, Hochwald SN *et al.* (1998) Hilar cholangiocarcinoma: patterns of spread, the importance of hepatic resection for curative operation, and a presurgical clinical staging system (review with 22 refs). *Ann Surg* 228 (3), 385–394.

16 Jarnagin WR, Fong Y, DeMatteo RP *et al.* (2001) Staging, resectability, and outcome in 225 patients with hilar cholangiocarcinoma. *Ann Surg* 234 (4), 507–517; discussion 517–519.

17 Jura N, Archer H, Bar-Sagi D (2005) Chronic pancreatitis, pancreatic adenocarcinoma and the black box in-between (review with 39 refs). *Cell Res* 15 (1), 72–77.

18 Farrow B, Evers BM (2002) Inflammation and the development of pancreatic cancer (review with 170 refs). *Surg Oncol* 10 (4), 153–169.

19 Murthy S, Winkler JD (2002) Inflammation and oncogenesis. *Inflamm Res* 51 (2), 76.

20 Correa P (2003) Bacterial infections as a cause of cancer (review with 28 refs). *J Natl Cancer Inst* 95 (7), E3.

21 Lipshutz GS, Brennan TV, Warren RS (2002) Thorotrast-induced liver neoplasia: a collective review (review with 47 refs). *J Am Coll Surg* 195 (5), 713–718.

22 Itoh M, Pairojkul C, Thamawit W *et al.* (1994) Association of antibodies to *Opisthorchis viverrini* with hepatobiliary disease in northeastern Thailand. *Am J Trop Med Hyg* 51 (4), 424–429.

23 Sithithaworn P, Haswell-Elkins MR, Mairiang P *et al.* (1994) Parasite-associated morbidity: liver fluke infection and bile duct cancer in northeast Thailand. *Int J Parasitol* 24 (6), 833–843.

24 Haswell-Elkins MR, Mairiang E, Mairiang P *et al.* (1994) Cross-sectional study of *Opisthorchis viverrini* infection and cholangiocarcinoma in communities within a high-risk area in northeast Thailand. *Int J Cancer* 59 (4), 505–509.

25 Elkins DB, Haswell-Elkins MR, Mairiang E *et al.* (1990) A high frequency of hepatobiliary disease and suspected cholangiocarcinoma associated with heavy Opisthorchis viverrini infection in a small community in north-east Thailand. *Trans R Soc Trop Med Hyg* 84 (5), 715–719.

26 Mairiang E, Elkins DB, Mairiang P *et al.* (1992) Relationship between intensity of *Opisthorchis viverrini* infection and hepatobiliary disease detected by ultrasonography. *J Gastroenterol Hepatol* 7 (1), 17–21.

27 Vatanasapt V, Martin N, Sriplung H *et al.* (1995) Cancer incidence in Thailand, 1988–1991. *Cancer Epidemiol Biomarkers Prev* 4 (5), 475–483.

28 Watanapa P (1996) Cholangiocarcinoma in patients with opisthorchiasis. *Br J Surg* 83 (8), 1062–1064.

29 Haswell-Elkins MR, Satarug S, Tsuda M *et al.* (1994) Liver fluke infection and cholangiocarcinoma: model of endogenous nitric oxide and extragastric nitrosation in human carcinogenesis. *Mutat Res* 305 (2), 241–252.

30 Satarug S, Haswell-Elkins MR, Sithithaworn P *et al.* (1998) Relationships between the synthesis of N-nitrosodimethylamine and immune responses to chronic infection with the carcinogenic parasite, *Opisthorchis viverrini*, in men. *Carcinogenesis* 19 (3), 485–491.

31 Ohshima H, Bandaletova TY, Brouet I *et al.* (1994) Increased nitrosamine and nitrate biosynthesis mediated by nitric oxide synthase induced in hamsters infected with liver fluke (*Opisthorchis viverrini*). *Carcinogenesis* 15 (2), 271–275.

32 Jan YY, Chen MF, Wang CS *et al.* (1996) Surgical treatment of hepatolithiasis: long-term results. *Surgery* 120 (3), 509–514.

33 Chu KM, Lo CM, Liu CL *et al.* (1997) Malignancy associated with hepatolithiasis. *Hepatogastroenterology* 44 (14), 352–357.

34 Kubo S, Kinoshita H, Hirohashi K *et al.* (1995) Hepatolithiasis associated with cholangiocarcinoma. *World J Surg* 19 (4), 637–641.

35 Broome U, Olsson R, Loof L *et al.* (1996) Natural history and prognostic factors in 305 Swedish patients with primary sclerosing cholangitis. *Gut* 38 (4), 610–615.

36 Pitt HA, Nakeeb A, Abrams RA *et al.* (1995) Perihilar cholangiocarcinoma. Postoperative radiotherapy does not improve survival. *Ann Surg* 221 (6), 788–797; discussion 797–798.

37 Pitt HA, Dooley WC, Yeo CJ *et al.* (1995) Malignancies of the biliary tree (review with 238 refs). *Curr Problems Surgery* 32 (1), 1–90.

38 Goss JA, Shackleton CR, Farmer DG *et al.* (1997) Orthotopic liver transplantation for primary sclerosing cholangitis. A 12-year single center experience. *Ann Surg* 225 (5), 472–481; discussion 481–483.

39 Knechtle SJ, D'Alessandro AM, Harms BA *et al.* (1995) Relationships between sclerosing cholangitis, inflammatory bowel disease, and cancer in patients undergoing liver transplantation (review with 18 refs). *Surgery* 118 (4), 615–619; discussion 619–620.

40 Katoh H, Shinbo T, Otagiri H *et al.* (1988) [Character of a human cholangiocarcinoma CHGS, serially transplanted to nude mice]. *Hum Cell* 1 (1), 101–105.

41 Heimbach JK, Gores GJ, Haddock MG *et al.* (2004) Liver transplantation for unresectable perihilar cholangiocarcinoma. *Semin Liver Dis* 24 (2), 201–207.

42 Sudan D, DeRoover A, Chinnakotla S *et al.* (2002) Radiochemotherapy and transplantation allow long-term survival for nonresectable hilar cholangiocarcinoma. *Am J Transplant* 2 (8), 774–779.

43 Tanaka K, Ikoma A, Hamada N *et al.* (1998) Biliary tract cancer accompanied by anomalous junction of pancreaticobiliary ductal system in adults. *Am J Surg* 175 (3), 218–220.

44 Lipsett PA, Pitt HA (2003) Surgical treatment of choledochal cysts. *J Hepatobiliary Pancreat Surg* 10 (5), 352–359.

45 Lipsett PA, Pitt HA, Colombani PM *et al.* (1994) Choledochal cyst disease. A changing pattern of presentation. *Ann Surg* 220 (5), 644–652.

46 Jeng KS, Ohta I, Yang FS *et al.* (1994) Coexisting sharp ductal angulation with intrahepatic biliary strictures in right hepatolithiasis. *Arch Surg* 129 (10), 1097–1102.

47 Soreide K, Korner H, Havnen J *et al.* (2004) Bile duct cysts in adults (review with 99 refs). *Br J Surg* 91 (12), 1538–1548.

48 Stain SC, Guthrie CR, Yellin AE *et al.* (1995) Choledochal cyst in the adult. *Ann Surg* 222 (2), 128–133.

49 Liu CL, Fan ST, Lo CM *et al.* (2002) Choledochal cysts in adults. *Arch Surg* 137 (4), 465–468.

50 Hakamada K, Sasaki M, Endoh M *et al.* (1997) Late development of bile duct cancer after sphincteroplasty: a ten- to twenty-two-year follow-up study. *Surgery* 121 (5), 488–492.

51 Weinbren K, Mutum SS (1983) Pathological aspects of cholangiocarcinoma. *J Pathol* 139 (2), 217–238.

52 Lim JH (2003) Cholangiocarcinoma: morphologic classification according to growth pattern and imaging findings (review with 40 refs). *AJR Am J Roentgenol* 181 (3), 819–827.

53 Lim JH, Park CK (2004) Pathology of cholangiocarcinoma (review with 33 refs). *Abdominal Imaging* 29 (5), 540–547.

54 D'Angelica MI, Jarnagin WR, Blumgart LH (2004) Resectable hilar cholangiocarcinoma: surgical treatment and long-term outcome (review with 40 refs). *Surgery Today* 34 (11), 885–890.

55 Shimada H, Niimoto S, Matsuba A *et al.* (1988) The infiltration of bile duct carcinoma along the bile duct wall. *Int Surg* 73 (2), 87–90.

56 Ahrendt SA, Pitt HA, Nakeeb A *et al.* (1999) Diagnosis and management of cholangiocarcinoma in primary sclerosing cholangitis. *J Gastrointest Surg* 3 (4), 357–367; discussion 367–368.

57 Burak K, Angulo P, Pasha TM *et al.* (2004) Incidence and risk factors for cholangiocarcinoma in primary sclerosing cholangitis. *Am J Gastroenterol* 99 (3), 523–526.

58 Gerhards MF, Vos P, van Gulik TM *et al.* (2001) Incidence of benign lesions in patients resected for suspicious hilar obstruction. *Br J Surg* 88 (1), 48–51.

59 Ruby SG (2000) Protocol for the examination of specimens from patients with hepatocellular carcinoma and cholangiocarcinoma, including intrahepatic bile ducts. Cancer Committee of the College of American Pathologists. *Arch Pathol Lab Med* 124 (1), 41–45.

60 Verbeek PC, van Leeuwen DJ, de Wit LT *et al.* (1992) Benign fibrosing disease at the hepatic confluence mimicking Klatskin tumors. *Surgery* 112 (5), 866–871.

61 Fong Y, Blumgart LH, Lin E *et al.* (1996) Outcome of treatment for distal bile duct cancer. *Br J Surg* 83 (12), 1712–1715.

62 Okami J, Dohno K, Sakon M *et al.* (2000) Genetic detection for micrometastasis in lymph node of biliary tract carcinoma. *Clin Cancer Res* 6 (6), 2326–2332.

63 Jarnagin WR, Bowne W, Klimstra DS *et al.* (2005) Papillary phenotype confers improved survival after resection of hilar cholangiocarcinoma. *Ann Surg* 241 (5), 703–712; discussion 712–714.

64 Vogelstein B, Kinzler KW (1993) The multistep nature of cancer. *Trends Genet* 9 (4), 138–141.

65 Roberts SK, Ludwig J, Larusso NF (1997) The pathobiology of biliary epithelia. *Gastroenterology* 112 (1), 269–279.

66 Dunn GP, Bruce AT, Ikeda H *et al.* (2002) Cancer immunoediting: from immunosurveillance to tumor escape. *Nature Immunol* 3 (11), 991–998.

67 Dunn GP, Old LJ, Schreiber RD (2004) The immunobiology of cancer immunosurveillance and immunoediting. *Immunity* 21 (2), 137–148.

68 Kubicka S, Kuhnel F, Flemming P *et al.* (2001) K-ras mutations in the bile of patients with primary sclerosing cholangitis. *Gut* 48 (3), 403–408.

69 Rizzi PM, Ryder SD, Portmann B *et al.* (1996) p53 protein overexpression in cholangiocarcinoma arising in primary sclerosing cholangitis. *Gut* 38 (2), 265–268.
70 Taniai M, Higuchi H, Burgart LJ *et al.* (2002) p16INK4a promoter mutations are frequent in primary sclerosing cholangitis (PSC) and PSC-associated cholangiocarcinoma. *Gastroenterology* 123 (4), 1090–1098.
71 Matsubara T, Sakurai Y, Zhi LZ *et al.* (2002) K-ras and p53 gene mutations in noncancerous biliary lesions of patients with pancreaticobiliary maljunction. *J Hepatobiliary Pancreat Surg* 9 (3), 312–321.
72 Matsubara T, Sakurai Y, Sasayama Y *et al.* (1996) K-ras point mutations in cancerous and noncancerous biliary epithelium in patients with pancreaticobiliary maljunction. *Cancer* 77(8 Suppl), 1752–1757.
73 Lofts FJ, Gullick WJ (1992) c-erbB2 amplification and overexpression in human tumors. *Cancer Treat Res* 61, 161–179.
74 Brunt EM, Swanson PE (1992) Immunoreactivity for c-erbB-2 oncopeptide in benign and malignant diseases of the liver. *Am J Clin Pathol* 97 (5 Suppl 1), S53–S61.
75 Collier JD, Guo K, Mathew J *et al.* (1992) c-erbB-2 oncogene expression in hepatocellular carcinoma and cholangiocarcinoma. *J Hepatol* 14 (2–3), 377–380.
76 Voravud N, Foster CS, Gilbertson JA *et al.* (1989) Oncogene expression in cholangiocarcinoma and in normal hepatic development. *Hum Pathol* 20 (12), 1163–1168.
77 Su WC, Shiesh SC, Liu HS *et al.* (2001) Expression of oncogene products HER2/Neu and Ras and fibrosis-related growth factors bFGF, TGF-beta, and PDGF in bile from biliary malignancies and inflammatory disorders. *Dig Dis Sci* 46 (7), 1387–1392.
78 Ohashi K, Nakajima Y, Kanehiro H *et al.* (1995) Ki-ras mutations and p53 protein expressions in intrahepatic cholangiocarcinomas: relation to gross tumor morphology. *Gastroenterology* 109 (5), 1612–1617.
79 Rodenhuis S (1992) ras and human tumors. *Semin Cancer Biol* 3 (4), 241–247.
80 Tannapfel A, Benicke M, Katalinic A *et al.* (2000) Frequency of p16(INK4A) alterations and K-ras mutations in intrahepatic cholangiocarcinoma of the liver. *Gut* 47 (5), 721–727.
81 Nonomura A, Ohta G, Nakanuma Y *et al.* (1988) Simultaneous detection of epidermal growth factor receptor (EGF-R), epidermal growth factor (EGF) and ras p21 in cholangiocarcinoma by an immunocytochemical method. *Liver* 8 (3), 157–166.
82 Nonomura A, Mizukami Y, Matsubara F *et al.* (1989) Human chorionic gonadotropin and alpha-fetoprotein in cholangiocarcinoma in relation to the expression of ras p21: an immunohistochemical study. *Liver* 9 (4), 205–215.
83 Caldas C, Hahn SA, Hruban RH *et al.* (1994) Detection of K-ras mutations in the stool of patients with pancreatic adenocarcinoma and pancreatic ductal hyperplasia. *Cancer Res* 54 (13), 3568–3573.
84 Khanna M, Park P, Zirvi M *et al.* (1999) Multiplex PCR/LDR for detection of K-ras mutations in primary colon tumors. *Oncogene* 18 (1), 27–38.
85 Lemaitre JM, Buckle RS, Mechali M (1996) c-Myc in the control of cell proliferation and embryonic development. *Adv Cancer Res* 70, 95–144.
86 Bergan A, Gladhaug IP, Schjolberg A *et al.* (2000) p53 accumulation confers prognostic information in resectable adenocarcinomas with ductal but not with intestinal differentiation in the pancreatic head. *Int J Oncol* 17 (5), 921–926.
87 Diamantis I, Karamitopoulou E, Perentes E *et al.* (1995) p53 protein immunoreactivity in extrahepatic bile duct and gallbladder cancer: correlation with tumor grade and survival. *Hepatology* 22 (3), 774–779.
88 Lee YC, Song SY, Chung JB *et al.* (1996) p53 protein expression in extrahepatic bile duct cancer. *Yonsei Med J* 37 (2), 112–117.
89 Tannapfel A, Weinans L, Geissler F *et al.* (2000) Mutations of p53 tumor suppressor gene, apoptosis, and proliferation in intrahepatic cholangiocellular carcinoma of the liver. *Dig Dis Sci* 45 (2), 317–324.
90 American Joint Committee on Cancer (2002) *AJCC Cancer Staging Manual*, 6th edn. New York: Springer-Verlag.
91 Okabayashi T, Yamamoto J, Kosuge T *et al.* (2001) A new staging system for mass-forming intrahepatic cholangiocarcinoma: analysis of preoperative and postoperative variables. *Cancer* 92 (9), 2374–2383.
92 Bismuth H, Corlette MB (1975) Intrahepatic cholangioenteric anastomosis in carcinoma of the hilus of the liver. *Surg Gynecol Obstet* 140 (2), 170–178.
93 Hawkins WG, DeMatteo RP, Cohen MS *et al.* (2005) Caudate hepatectomy for cancer: a single institution experience with 150 patients. *J Am Coll Surg* 200 (3), 345–352.
94 Pawlik TM, Poon RT, Abdalla EK *et al.* (2005) Hepatectomy for hepatocellular carcinoma with major portal or hepatic vein invasion: results of a multicenter study. *Surgery* 137 (4), 403–410.
95 Kim HJ, Kim MH, Myung SJ *et al.* (1999) A new strategy for the application of CA19-9 in the differentiation of pancreaticobiliary cancer: analysis using a receiver operating characteristic curve. *Am J Gastroenterol* 94 (7), 1941–1946.
96 Albert MB, Steinberg WM, Henry JP (1988) Elevated serum levels of tumor marker CA19-9 in acute cholangitis. *Dig Dis Sci* 33 (10), 1223–1225.
97 Hultcrantz R, Olsson R, Danielsson A *et al.* (1999) A 3-year prospective study on serum tumor markers used for detecting cholangiocarcinoma in patients with primary sclerosing cholangitis. *J Hepatol* 30 (4), 669–673.
98 Nehls O, Gregor M, Klump B (2004) Serum and bile markers for cholangiocarcinoma (review with 137 refs). *Semin Liver Dis* 24 (2), 139–154.
99 Ramage JK, Donaghy A, Farrant JM *et al.* (1995) Serum tumor markers for the diagnosis of cholangiocarcinoma in primary sclerosing cholangitis. *Gastroenterology* 108 (3), 865–869.
100 Bjornsson E, Kilander A, Olsson R (1919) CA19-9 and CEA are unreliable markers for cholangiocarcinoma in patients with primary sclerosing cholangitis. *Liver* (6), 501–508.
101 Ker CG, Chen JS, Lee KT *et al.* (1991) Assessment of serum and bile levels of CA19-9 and CA125 in cholangitis and bile duct carcinoma. *J Gastroenterol Hepatol* 6 (5), 505–508.
102 Takehara Y (2004) Preoperative assessment of extrahepatic cholangiocarcinoma with imaging (review with 21 refs). *Abdominal Imaging* 29 (5), 572–580.
103 Foutch PG (1996) Endobiliary cytotechniques for cancer diagnosis (review with 36 refs). *Endoscopy* 28 (8), 712–717.
104 Ponchon T, Gagnon P, Berger F *et al.* (1995) Value of endobiliary brush cytology and biopsies for the diagnosis of malignant bile duct stenosis: results of a prospective study. *Gastrointest Endosc* 42 (6), 565–572.
105 Baron TH, Harewood GC, Rumalla A *et al.* (2004) A prospective comparison of digital image analysis and routine cytology for the

identification of malignancy in biliary tract strictures (see comment). *Clin Gastroenterol Hepatol* 2 (3), 214–221.

106 Kipp BR, Stadheim LM, Halling SA *et al.* (2004) A comparison of routine cytology and fluorescence in situ hybridization for the detection of malignant bile duct strictures (see comment). *Am J Gastroenterol* 99 (9), 1675–1681.

107 Nimura Y (1993) Staging of biliary carcinoma: cholangiography and cholangioscopy. *Endoscopy* 25 (1), 76–80.

108 Tamada K, Kurihara K, Tomiyama T *et al.* (1999) How many biopsies should be performed during percutaneous transhepatic cholangioscopy to diagnose biliary tract cancer? (see comment). *Gastrointest Endosc* 50 (5), 653–658.

109 Maier M, Kohler B, Benz C *et al.* (1995) [Percutaneous transhepatic cholangioscopy (PTCS) – an important supplement in diagnosis and therapy of biliary tract diseases (indications, technique and results)]. [German]. *Z Gastroenterol* 33 (8), 435–439.

110 Seo DW, Kim MH, Lee SK *et al.* (1999) Usefulness of cholangioscopy in patients with focal stricture of the intrahepatic duct unrelated to intrahepatic stones. *Gastrointest Endosc* 49 (2), 204–209.

111 Lee SS, Kim MH, Lee SK *et al.* (2002) MR cholangiography versus cholangioscopy for evaluation of longitudinal extension of hilar cholangiocarcinoma. *Gastrointest Endosc* 56 (1), 25–32.

112 Sakamoto E, Hayakawa N, Kamiya J *et al.* (1999) Treatment strategy for mucin-producing intrahepatic cholangiocarcinoma: value of percutaneous transhepatic biliary drainage and cholangioscopy. *World J Surg* 23 (10), 1038–1043; discussion 1043–1044.

113 Adamek HE, Albert J, Weitz M *et al.* (1998) A prospective evaluation of magnetic resonance cholangiopancreatography in patients with suspected bile duct obstruction (see comment). *Gut* 43 (5), 680–683.

114 Choi BI, Lee JM, Han JK (2004) Imaging of intrahepatic and hilar cholangiocarcinoma (review with 41 refs). *Abdominal Imaging* 29 (5), 548–557.

115 Han JK, Choi BI, Kim TK *et al.* (1997) Hilar cholangiocarcinoma: thin-section spiral CT findings with cholangiographic correlation. *Radiographics* 17 (6), 1475–1485.

116 Kluge R, Schmidt F, Caca K *et al.* (2001) Positron emission tomography with [(18)F]fluoro-2-deoxy-D-glucose for diagnosis and staging of bile duct cancer. *Hepatology* 33 (5), 1029–1035.

117 Reinhardt MJ, Strunk H, Gerhardt T *et al.* (2005) Detection of Klatskin's tumor in extrahepatic bile duct strictures using delayed 18F-FDG PET/CT: preliminary results for 22 patient studies. *J Nucl Med* 46 (7), 1158–1163.

118 Fritscher-Ravens A, Bohuslavizki KH, Broering DC *et al.* (2001) FDG PET in the diagnosis of hilar cholangiocarcinoma. *Nucl Med Commun* 22 (12), 1277–1285.

119 Fritscher-Ravens A, Broering DC, Sriram PV *et al.* (2000) EUS-guided fine-needle aspiration cytodiagnosis of hilar cholangiocarcinoma: a case series. *Gastrointest Endosc* 52 (4), 534–540.

120 Weber SM, DeMatteo RP, Fong Y *et al.* (2002) Staging laparoscopy in patients with extrahepatic biliary carcinoma. Analysis of 100 patients. *Ann Surg* 235 (3), 392–399.

121 Vollmer CM, Drebin JA, Middleton WD *et al.* (2002) Utility of staging laparoscopy in subsets of peripancreatic and biliary malignancies (see comment). *Ann Surg* 235 (1), 1–7.

122 Manfredi R, Barbaro B, Masselli G *et al.* (2004) Magnetic resonance imaging of cholangiocarcinoma (review with 40 refs). *Semin Liver Dis* 24 (2), 155–164.

123 Grazioli L, Morana G, Federle MP *et al.* (2001) Focal nodular hyperplasia: morphologic and functional information from MR imaging with gadobenate dimeglumine. *Radiology* 221 (3), 731–739.

124 Nichols JC, Gores GJ, Larusso NF *et al.* (1993) Diagnostic role of serum CA19-9 for cholangiocarcinoma in patients with primary sclerosing cholangitis. *Mayo Clinic Proc* 68 (9), 874–879.

125 Weber SM, Cubukcu-Dimopulo O, Palesty JA *et al.* (2003) Lymphoplasmacytic sclerosing pancreatitis: inflammatory mimic of pancreatic carcinoma. *J Gastrointest Surg* 7 (1), 129–137; discussion 137–139.

126 Abraham SC, Cruz-Correa M, Argani P *et al.* (2003) Lymphoplasmacytic chronic cholecystitis and biliary tract disease in patients with lymphoplasmacytic sclerosing pancreatitis. *Am J Surg Pathol* 27 (4), 441–451.

127 Kawaguchi K, Koike M, Tsuruta K *et al.* (1991) Lymphoplasmacytic sclerosing pancreatitis with cholangitis: a variant of primary sclerosing cholangitis extensively involving pancreas. *Hum Pathol* 22 (4), 387–395.

128 Stamatakis JD, Howard ER, Williams R (1979) Benign inflammatory tumour of the common bile duct. *Br J Surg* 66 (4), 257–258.

129 Hadjis NS, Collier NA, Blumgart LH (1985) Malignant masquerade at the hilum of the liver. *Br J Surg* 72 (8), 659–661.

130 Schmid A, Janig D, Bohuszlavizki A *et al.* (1996) Inflammatory pseudotumor of the liver presenting as incidentaloma: report of a case and review of the literature (review with 9 refs). *Hepato-Gastroenterology* 43 (10), 1009–1014.

131 Koea J, Holden A, Chau K *et al.* (2004) Differential diagnosis of stenosing lesions at the hepatic hilus. *World J Surg* 28 (5), 466–470.

132 Wetter LA, Ring EJ, Pellegrini CA *et al.* (1991) Differential diagnosis of sclerosing cholangiocarcinomas of the common hepatic duct (Klatskin tumors). *Am J Surg* 161 (1), 57–62; discussion 62–63.

133 Chan CY, Liau KH, Ho CK *et al.* (2003) Mirizzi syndrome: a diagnostic and operative challenge. *Surgeon J R Coll Surg Edin Ireland* 1 (5), 273–278.

134 Hasebe T, Sakamoto M, Mukai K *et al.* (1995) Cholangiocarcinoma arising in bile duct adenoma with focal area of bile duct hamartoma. *Virchows Arch* 426 (2), 209–213.

135 Hawkins WG, DeMatteo RP, Jarnagin WR *et al.* (2004) Jaundice predicts advanced disease and early mortality in patients with gallbladder cancer. *Ann Surg Oncol* 11 (3), 310–315.

136 Hubert C, Sempoux C, Berquin A *et al.* (2005) Bile duct carcinoid tumors: an uncommon disease but with a good prognosis? (review with 57 refs). *Hepato-Gastroenterology* 52 (64), 1042–1047.

137 te Boekhorst DS, Gerhards MF, van Gulik TM *et al.* (2000) Granular cell tumor at the hepatic duct confluence mimicking Klatskin tumor. A report of two cases and a review of the literature (review with 19 refs). *Dig Surg* 17 (3), 299–303.

138 Aggarwal K, Pahuja S, Chadha R (2004) Botryoid rhabdomyosarcoma of common bile duct. *Ind J Pediatr* 71 (4), 363–364.

139 Van Beers B, Roche A, Mathieu D *et al.* (1992) Epithelioid hemangioendothelioma of the liver: MR and CT findings. *J Comput Assist Tomogr* 16 (3), 420–424.

140 Povoski SP, Karpeh MS, Jr, Conlon KC *et al.* (1999) Preoperative biliary drainage: impact on intraoperative bile cultures and infectious morbidity and mortality after pancreaticoduodenectomy (see comment). *J Gastrointest Surg* 3 (5), 496–505.

141 Kamiya S, Nagino M, Kanazawa H *et al.* (2004) The value of bile replacement during external biliary drainage: an analysis of intestinal permeability, integrity, and microflora. *Ann Surg* 239 (4), 510–517.

142 Lee SG, Lee YJ, Park KM *et al.* (2000) One hundred and eleven liver resections for hilar bile duct cancer. *J Hepato-Biliary-Pancreatic Surg* 7 (2), 135–141.

143 Neuhaus P, Jonas S, Bechstein WO *et al.* (1999) Extended resections for hilar cholangiocarcinoma. *Ann Surg* 230 (6), 808–818; discussion 819.
144 Yamaguchi K, Chijiiwa K, Saiki S *et al.* (1997) Carcinoma of the extrahepatic bile duct: mode of spread and its prognostic implications. *Hepato-Gastroenterology* 44 (17), 1256–1261.
145 Miyazaki M, Ito H, Nakagawa K *et al.* (1999) Parenchyma-preserving hepatectomy in the surgical treatment of hilar cholangiocarcinoma. *J Am Coll Surg* 189 (6), 575–583.
146 Takada T, Amano H, Yasuda H *et al.* (2002) Is postoperative adjuvant chemotherapy useful for gallbladder carcinoma? A phase III multicenter prospective randomized controlled trial in patients with resected pancreaticobiliary carcinoma (see comment). *Cancer* 95 (8), 1685–1695.
147 Makuuchi M, Thai BL, Takayasu K *et al.* (1990) Preoperative portal embolization to increase safety of major hepatectomy for hilar bile duct carcinoma: a preliminary report. *Surgery* 107 (5), 521–527.
148 Kawasaki S, Imamura H, Kobayashi A *et al.* (2003) Results of surgical resection for patients with hilar bile duct cancer: application of extended hepatectomy after biliary drainage and hemihepatic portal vein embolization. *Ann Surg* 238 (1), 84–92.
149 Gerhards MF, van Gulik TM, de Wit LT *et al.* (2000) Evaluation of morbidity and mortality after resection for hilar cholangiocarcinoma – a single center experience. *Surgery* 127 (4), 395–404.
150 Nagino M, Kamiya J, Arai T *et al.* (2005) One hundred consecutive hepatobiliary resections for biliary hilar malignancy: preoperative blood donation, blood loss, transfusion, and outcome. *Surgery* 137 (2), 148–155.
151 Strasberg SM, Drebin JA, Soper NJ (1997) Evolution and current status of the Whipple procedure: an update for gastroenterologists (review with 75 refs). *Gastroenterology* 113 (3), 983–994.
152 Seiler CA, Wagner M, Bachmann T *et al.* (2005) Randomized clinical trial of pylorus-preserving duodenopancreatectomy versus classical Whipple resection – long term results. *Br J Surg* 92 (5), 547–556.
153 Lygidakis NJ, Jain S, Sacchi M *et al.* (2005) Reappraisal of a method of reconstruction after pancreatoduodenectomy. *Hepato-Gastroenterology* 52 (64), 1077–1082.
154 Yeo CJ, Cameron JL, Lillemoe KD *et al.* (2002) Pancreaticoduodenectomy with or without distal gastrectomy and extended retroperitoneal lymphadenectomy for periampullary adenocarcinoma, part 2: randomized controlled trial evaluating survival, morbidity, and mortality. *Ann Surg* 236 (3), 355–366; discussion 366–368.
155 Yoshida T, Matsumoto T, Sasaki A *et al.* (2002) Prognostic factors after pancreatoduodenectomy with extended lymphadenectomy for distal bile duct cancer. *Arch Surg* 137 (1), 69–73.
156 Shirabe K, Shimada M, Tsujita E *et al.* (2004) Prognostic factors in node-negative intrahepatic cholangiocarcinoma with special reference to angiogenesis. *Am J Surg* 187 (4), 538–542.
157 Sasaki A, Kawano K, Aramaki M *et al.* (2004) Correlation between tumor size and mode of spread in mass-forming intrahepatic cholangiocarcinoma. *Hepato-Gastroenterology* 51 (55), 224–228.
158 Uenishi T, Hirohashi K, Kubo S *et al.* (2001) Clinicopathological factors predicting outcome after resection of mass-forming intrahepatic cholangiocarcinoma. *Br J Surg* 88 (7), 969–974.
159 Inoue K, Makuuchi M, Takayama T *et al.* (2000) Long-term survival and prognostic factors in the surgical treatment of mass-forming type cholangiocarcinoma. *Surgery* 127 (5), 498–505.
160 Fu XH, Tang ZH, Zong M *et al.* (2004) Clinicopathologic features, diagnosis and surgical treatment of intrahepatic cholangiocarcinoma in 104 patients. *Hepatobil Pancreatic Dis Int* 3 (2), 279–283.
161 Shibahara H, Tamada S, Higashi M *et al.* (2004) MUC4 is a novel prognostic factor of intrahepatic cholangiocarcinoma-mass forming type. *Hepatology* 39 (1), 220–229.
162 Tajima Y, Kuroki T, Fukuda K *et al.* (2004) An intraductal papillary component is associated with prolonged survival after hepatic resection for intrahepatic cholangiocarcinoma. *Br J Surg* 91 (1), 99–104.
163 Yeh CN, Jan YY, Yeh TS *et al.* (2004) Hepatic resection of the intraductal papillary type of peripheral cholangiocarcinoma. *Ann Surg Oncol* 11 (6), 606–611.
164 Goldstein RM, Stone M, Tillery GW *et al.* (1993) Is liver transplantation indicated for cholangiocarcinoma? *Am J Surg* 166 (6), 768–771; discussion 771–772.
165 Brandsaeter B, Isoniemi H, Broome U *et al.* (2004) Liver transplantation for primary sclerosing cholangitis: predictors and consequences of hepatobiliary malignancy (see comment). *J Hepatol* 40 (5), 815–822.
166 Sudan D, DeRoover A, Chinnakotla S *et al.* (2002) Radiochemotherapy and transplantation allow long-term survival for nonresectable hilar cholangiocarcinoma. *Am J Transplant* 2 (8), 774–779.
167 Gerhards MF, van Gulik TM, Gonzalez GD *et al.* (2003) Results of postoperative radiotherapy for resectable hilar cholangiocarcinoma. *World J Surg* 27 (2), 173–179.
168 Smith AC, Dowsett JF, Russell RC *et al.* (1994) Randomised trial of endoscopic stenting versus surgical bypass in malignant low bile duct obstruction. *Lancet* 344 (8938), 1655–1660.
169 Nieveen van Dijkum EJ, Romijn MG, Terwee CB *et al.* (2003) Laparoscopic staging and subsequent palliation in patients with peripancreatic carcinoma. *Ann Surg* 237 (1), 66–73.
170 Andersen JR, Sorensen SM, Kruse A *et al.* (1989) Randomised trial of endoscopic endoprosthesis versus operative bypass in malignant obstructive jaundice. *Gut* 30 (8), 1132–1135.
171 Shepherd HA, Royle G, Ross AP *et al.* (1988) Endoscopic biliary endoprosthesis in the palliation of malignant obstruction of the distal common bile duct: a randomized trial. *Br J Surg* 75 (12), 1166–1168.
172 De Palma GD, Galloro G, Siciliano S *et al.* (2001) Unilateral versus bilateral endoscopic hepatic duct drainage in patients with malignant hilar biliary obstruction: results of a prospective, randomized, and controlled study (see comment). *Gastrointest Endosc* 53 (6), 547–553.
173 Ortner ME, Caca K, Berr F *et al.* (2003) Successful photodynamic therapy for nonresectable cholangiocarcinoma: a randomized prospective study (see comment). *Gastroenterology* 125 (5), 1355–1363.

20 The liver in diseases of other systems

20.1 The liver in cardiovascular disease

Susan Tiukinhoy-Laing, Andres T. Blei and Mihai Gheorghiade

Involvement of the liver occurs in several cardiac diseases. It can be the result of acute cardiac problems [1], such as myocardial infarction or shock, or be the manifestation of chronic disease [2], such as heart failure, constrictive pericarditis and pulmonary arterial hypertension. In some situations, the manifestations of cardiac disease are subtle, and the liver abnormalities dominate the clinical picture. Hepatic complications may also arise after cardiac surgery. Medications used for the treatment of cardiac disease can induce specific abnormalities.

Acute cardiac events

Ischaemic hepatitis

A major consequence of a sudden decrease in cardiac output is the development of hepatic ischaemia. The terms 'ischaemic hepatitis' or 'shock liver' have been used to describe this entity [3]. Others have argued for a more physiological definition by using the term 'hypoxic' hepatitis [4]. Even the term 'hepatitis' can be questioned, as inflammatory features are seldom seen on liver histology. Nonetheless, the term has gained wide acceptance as the laboratory features (very high aminotransferases) can mimic those of other causes of acute hepatitis.

A proposed definition of ischaemic hepatitis is based on three criteria: an underlying acute cardiac and/or circulatory failure; a massive increase in serum aminotransferases that is rapidly reversible; and the exclusion of other causes of acute liver injury [5–7]. Centrolobular hepatic necrosis is the pathological hallmark, but a liver biopsy is seldom required for diagnosis when a classic clinical picture is seen. The clinical presentation may vary from an asymptomatic elevation of aminotransferases [8] to a presentation of fulminant liver failure [9,10]. A low cardiac output state may be the sole, unsuspected finding in patients with a 'hepatitis'-like presentation, characterized by constitutional symptoms and marked elevation of aminotransferases [11]. Regarding the presentation with fulminant liver failure, underlying heart disease is usually present. In six patients with underlying chronic heart failure, an episode of acute cardiac decompensation resulted in massive liver cell necrosis. Hepatic encephalopathy and jaundice became apparent 1–3 days after the episode of circulatory failure, even when the haemodynamic picture had normalized [9]. On other occasions, the diagnosis of a heart condition is more elusive. A recent experience from the same liver group highlights a series of 14 patients admitted to an intensive care liver unit in whom hypoxic hepatitis was not suspected as a cause of acute liver failure [10]. Milder forms of encephalopathy have also been reported [12]. Hypoglycaemia may occur with severe liver injury, but hyperglycaemia is most often demonstrated [7]. Regardless of the clinical manifestations, ischaemic hepatitis carries a poor prognosis, with mortalities of 30–50% reflecting the severity of the underlying cardiac/circulatory problem [13,14].

The incidence of ischaemic hepatitis is low. In an analysis of 18 000 hospital admissions, 29 subjects carried the diagnosis of ischaemic hepatitis [13]. However, the problem will be more evident in specialized units. A prospective evaluation during 1 year in high-risk patients in a coronary care unit indicated a prevalence of 2.6% of ischaemic hepatitis [4]. A group of 91 subjects with low cardiac output was divided according to the presence or absence of ischaemic hepatitis. The incidence of shock was not different between the two groups, but central venous pressure was raised to a much higher extent in patients with ischaemic hepatitis [4].

Pathogenesis

Systemic hypotension and/or shock due to traumatic injury will seldom result in the type of hepatic injury seen in ischaemic hepatitis [7]. Ischaemic liver injury occurs in the clinical setting, repeatedly observed in several series, of a combination of 'forward' failure, resulting in hepatic hypoperfusion, and 'backward' failure, as a result of high central filling pressures with subsequent hepatic congestion. Under normal conditions [15,16], the hepatic artery maintains hepatic oxygenation when the portal venous oxygen content varies with physiological events such as the postprandial state. Under conditions of 'forward' failure, a reduction in total hepatic blood flow can be demonstrated [17], possibly aggravated by mesenteric arterial vasoconstriction (the result of activation of compensatory

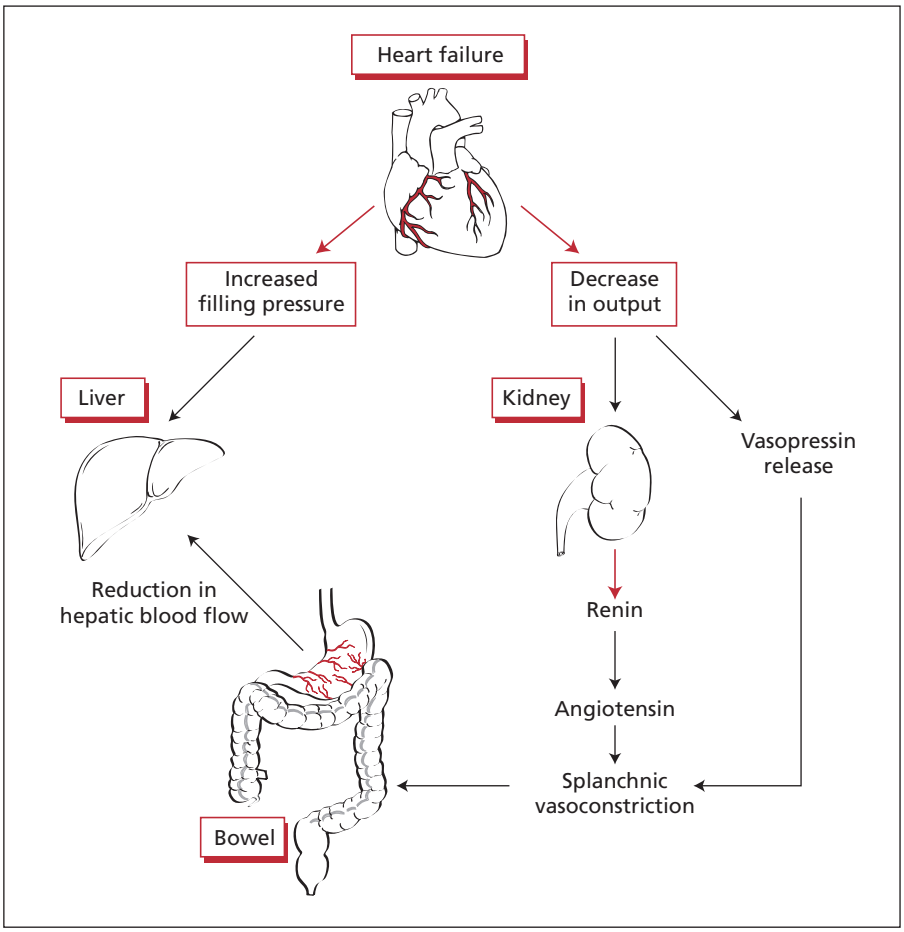

Fig. 1 The consequences of heart failure on the liver arise from both 'forward' and 'backward' mechanisms. A decrease in output will not only result in a reduction in splanchnic blood flow, but the neurohumoral response (release of vasopressin, angiotensin) potentiates the reduction in hepatic blood flow. The increased filling pressures in the right heart result in prolongation of circulation times in the liver and aggravate hepatic oxygenation.

release of angiotensin and vasopressin [18]). A decrease in haemoglobin and/or arterial oxygen content may potentiate the reduction in oxygen delivery to the liver, as noted by the development of 'hypoxic' hepatitis in patients with respiratory failure [19]. In all these situations, the additional effect of passive congestion of the liver will result in a reduction in sinusoidal blood flow, resulting in less oxygen delivery to zone 3 of the hepatic acinus. Such events underlie the pathogenesis of centrolobular necrosis [20] (Fig. 1 and Plate 20.1.1, facing p. 1268).

The generation of reactive oxygen species in the setting of hypoxia is well described [21], the deleterious effects of which may be augmented in the setting of ischaemia–reperfusion that characterizes the recovery from the acute insult [22]. Serum markers of oxidative stress were elevated in patients with ischaemic hepatitis to a greater extent than in patients with circulatory shock without hepatic injury [23].

Pathology

Liver biopsies indicate that centrolobular congestion *per se* is not associated with the clinical picture of ischaemic hepatitis; centrolobular necrosis is the pathological hallmark, even though the two findings are correlated [20,24]. Midzonal necrosis can be a distinct pattern of injury, sometimes associated with, but present even in the absence of, centrolobular necrosis [25]. In more severe cases, damaged endothelia, rupture of sinusoids and extravasation of red cells in zone 3 can be demonstrated. Infiltration with polymorphonuclear leukocytes can be seen, but this is not a universal finding. Review of autopsy findings indicates a clear association between ischaemic hepatitis and renal and adrenal ischaemic injury [24]. The reverse is not necessarily the case; the kidneys are affected more commonly than the liver by the combination of pathogenic events depicted in Figure 1.

Laboratory findings

Both aspartate aminotransferase (AST) and alanine aminotransferase (ALT) rise to similar levels; lactate dehydrogenase (LDH) can be conspicuously increased, more than in subjects with viral hepatitis. The time course of the change in aminotransferase levels is important for the differential diagnosis, as values return towards normal by the sixth day, in contrast to persistent elevations seen in viral or drug-induced hepatitis. Mild hyperbilirubinaemia can be demonstrated; mean values showed doubling of the upper limit of normal in a series of 34 patients [8]. Alkaline phosphatase is seldom more than twice normal, and the prothrombin time will vary according to the extent of the injury.

Parameters of renal function can also be deranged, reflecting similar pathogenic mechanisms.

Acute myocardial infarction

The repercussions of an acute myocardial infarction will depend on the size of the infarct and the underlying heart condition. Still, abnormal hepatic chemistries can be seen in patients with uncomplicated myocardial infarction. In a series of 17 patients, without hypotension or congestive heart failure, retention of bromosulphophthalein, a dye eliminated in the liver, was increased threefold [26]. However, this may reflect alterations in hepatic blood flow rather than true alterations in hepatocellular function. A state of haemodynamic congestion may develop abruptly, with higher left ventricular end-diastolic pressure and right-sided filling pressures. The AST level can increase as a result of myocardial injury, with values averaging 200 IU/mL; ALT and the LDH5 isoenzyme are unchanged for the most part. Unconjugated bilirubin can be elevated, normalizing by day 5. The source of the latter rise most probably reflects alterations in bilirubin uptake.

Complicated myocardial infarctions, including acute mitral regurgitation, ventricular septal defect and rupture of chordae tendinae, resulting in a combination of severe heart failure and a low output state, can lead to ischaemic hepatitis [27], as discussed in the previous section. Streptokinase, used as a thrombolytic agent, may rarely result in jaundice [28].

Liver injury has been reported after cardiopulmonary resuscitation, including the development of traumatic liver tears [29], resulting in haemoperitoneum [30]. Autopsy studies show 3% of livers exhibiting lacerations following external cardiac massage [24]. This may occur more often in children as a result of their relative size.

Postsurgical liver dysfunction

Postoperative jaundice can occur as a result of multiple factors (see Chapter 2.4.3). In the case of cardiac surgery, specific factors have been postulated, including the degree of heart failure, the age of the subject and the bypass time. In an analysis of over 3000 cases of different types of cardiac surgery, hepatic dysfunction occurred in 3.2% of cases, defined as a serum bilirubin of > 3 mg% [31]. Decreased perioperative hepatic blood flow and an increased bilirubin load were associated with liver dysfunction. Patients exhibiting liver problems required more prolonged mechanical ventilation, had a longer stay in the intensive care unit and had a higher mortality rate.

More specifically, in the case of cardiopulmonary bypass surgery, a prospective evaluation noted postoperative jaundice in 20% of subjects [31]. Jaundice was detectable by day 2 and was not associated with hypotension, hypoxia or hypothermia. It occurred more frequently with multiple valve replacement, long bypass time and high transfusion requirements, but also occurred after uncomplicated surgery. Haemolysis was not a major factor, and a defect in the hepatic excretion of bilirubin was suggested. 'Shock' liver was not seen in those subjects who came to autopsy.

However, in another prospective series of 154 patients, the preoperative severity of right heart failure as well as hypotension or hypoxaemia during the procedure was associated with postoperative jaundice [32]. Measurements of hepatic blood flow using the galactose clearance technique, before and during cardiopulmonary bypass, showed an average reduction of 19% [33]. The development of postoperative jaundice after cardiac surgery is multifactorial [34].

Children and cardiac surgery

Cardiac surgery in children can be associated with postoperative liver failure [35]. Special consideration arises from the experience with the Fontan procedure. Used for unique congenital defects such as tricuspid atresia and single ventricle, it rests on the premise that blood can flow through the lungs without the assistance of a pumping right ventricle; essentially, the vena cava (or the right atrium) is connected directly to the pulmonary arteries.

Almost two-thirds of patients who undergo this procedure exhibit abnormalities of liver chemistries [36]. The most common biochemical abnormality was a prolongation of the prothrombin time. Hepatic cirrhosis has been described [37], even progressing to the development of hepatic adenomas and hepatomas. Increased hepatic venous pressures underlie the pathogenesis of hepatic complications after this procedure, as shown by direct pressure measurements as well as a compatible histology revealing fibrous septa bridging hepatic veins.

Viral hepatitis

Postoperative acquisition of non-A, non-B hepatitis, a common problem after transfusion for cardiopulmonary bypass surgery [38], has been virtually eliminated since the discovery of hepatitis C. Both hepatitis B and C can be transmitted by cardiothoracic surgeons [39].

Chronic cardiac events

Congestive heart failure

Coronary artery disease and arterial hypertension are the current leading causes of heart failure. Multiple organs are affected in decompensated heart failure (Fig. 1). The term congestive hepatopathy, in contrast to ischaemic hepatitis [40], has been coined to reflect the importance of passive hepatic venous congestion in the clinical and pathological manifestations.

Clinical manifestations

In a series published more than 50 years ago, hepatomegaly was observed in more than 90% of patients with both acute and chronic congestive heart failure [4]. The liver edge is smooth and firm. A positive hepatojugular reflex can be elicited after hepatic

compression. While splenomegaly was seen in 20% of subjects with chronic congestive heart failure [42], its presence should raise the possibility of more advanced liver disease with portal hypertension. The incidence of right upper quadrant pain is variable, more often seen with acute congestion as a result of stretching of the liver capsule. Nausea and vomiting can be prominent [42].

Ascites was diagnosed clinically in approximately one-third of patients with congestive heart failure [42]. Protein concentration was > 2.5 g/dL in 13 subjects studied systematically (of 43), who all exhibited a serum–ascites albumin gradient of > 1.1 g/dL. Ascitic fluid LDH and red blood cell count were higher than in a group of patients with ascites as a result of cirrhosis. Of note, in a group of 262 patients with ascites, cardiac ascites represented only 5% of the entire cohort [43]. Peripheral oedema and pleural effusion may be present as part of the signs of congestive heart failure.

Cardiac cirrhosis may occur with longstanding hepatic congestion. Encephalopathy may develop [44], and ascites may be prominent. The course of the liver disease is dependent on the evolution of the heart condition. Abnormalities of liver chemistries predict mortality in chronic heart failure. Outcomes were examined in 552 patients with heart failure at initial evaluation and followed for a maximum of 13 years [45]. Multivariate analysis of laboratory variables indicated elevations in AST and bilirubin adversely affecting outcome. The relative risk of death for an increase of one unit of AST (U/L) was 1.011 and for bilirubin (μmol/L) was 1.035.

Laboratory tests

Jaundice is unusual, occurring in 5–15% of patients [46,47]. The latter series included patients with very high values, up to 22 mg/dL, suggestive of additional injury. Mild elevations in serum bilirubin, of up to 3 mg%, may be seen in up to 80% of individuals [46,48]. Indirect hyperbilirubinaemia predominates, and its presence reflects alterations in hepatic blood flow and bilirubin uptake. When seen within the context of a differential diagnosis of a high bilirubin, 8 of 661 patients (1.2%) with heart failure had jaundice as their presenting symptom [49].

Only mild elevations in alkaline phosphatase are noted, without correlation with changes in serum bilirubin or aminotransferases. Very prominent hepatomegaly may be associated with a further increase in alkaline phosphatase values [46], probably as a result of an impairment in canalicular bile flow. In this series of 175 patients, aminotransferases were elevated in 50% of subjects with acute congestion, but in only 5% of individuals with chronic heart disease. Values were mostly between 40 and 80 IU/mL; marked elevations in aminotransferases suggest the presence of ischaemic hepatitis (see above). An increased LDH may also be present in 20–60% of individuals.

A prolongation in prothrombin time can be seen in up to 80% of individuals [46] and, if poorly responsive to the administration of vitamin K, the presence of hepatocellular dysfunction is likely. Caution should be exercised with the administration of warfarin in these circumstances. The prolonged prothrombin time improves with the resolution of cardiac failure. Albumin levels may be decreased in 30–50% of subjects, with most values between 2.5 and 2.9 g/dL. Mild elevation in total globulins can also be detected in 50% of patients, with lack of resolution after correction of the cardiac failure.

A detailed examination of liver chemistries according to cardiac haemodynamics was performed in 133 patients [48]. Patients were divided according to their cardiac index (CI). Patients with CI ≥ 1.5 L/min/m^2 had minimal elevations in alkaline phosphatase and reduction in albumin, whereas gamma-glutamyltransferase (γ-GT) and bilirubin were slightly increased in the group with a CI between 1.5 and 2.0 L/min/m^2. Only in subjects with a CI < 1.5 L/min/m^2 were changes more conspicuous, with 27–80% showing some or multiple abnormalities: mean AST 65 IU/mL, ALT 77 IU/mL and bilirubin 29 μmol/L (1.7 mg/dL). Liver chemistry abnormalities were weakly correlated with the actual value of CI and right atrial pressure; the combination of reduced forward flow and increase backward congestion was thought to explain the laboratory abnormalities.

Pathology

Traditional macroscopic descriptions of the liver with passive congestion describe a 'nutmeg' appearance upon sectioning, the reflection of passive congestion. A large autopsy series of 103 patients (in whom preterminal hypotension was excluded) noted the predominance of congestion with variable necrosis in 75–100% of cases, somewhat lower prevalence of hepatic fibrosis (also termed cardiac sclerosis; 33–88%) and even lower prevalence of necrosis with an inflammatory reaction (18–33%) [20]. Canalicular cholestasis was seen in only 12% of specimens. Nodular regenerative hyperplasia was found occasionally. Full-blown cirrhosis was seen in only one individual. Hepatic findings were similar in atherosclerotic, valvular heart and hypertensive heart disease as well as in the presence of cardiomyopathy.

Pathogenesis

Passive congestion results in haemodynamic changes in the liver, characterized by sinusoidal dilatation and a decreased sinusoidal transit time. As a result, hepatic oxygen extraction will increase, and oxygen availability in zone 3 will be reduced [16]. However, overt hepatocyte necrosis is unusual, with atrophy of hepatic cords in the centrolobular area being a prominent finding.

Movement of plasmatic fluid into the space of Disse, representing the interstitial fluid compartment, occurs as a result of the increase in venous pressure. Ascites develops when drainage of the space of Disse through the lymphatic system is overwhelmed and fluid moves towards the hepatic capsule [43]. This change explains the high protein content of the ascitic fluid seen in this condition. While absolute sinusoidal pressure may increase, a collateral portal–systemic circulation does not develop and oesophageal varices are absent. The transmission of the high right ventricular pressure to a similar extent into both the

hepatic vein and the inferior vena cava precludes the movement of blood from the portal venous system to the azygos/vena cava system.

A detailed histological examination of autopsied liver in 25 cases with congestive heart failure provides novel insights into the development of hepatic fibrosis [50]. The traditional observation has been the increase in hepatic collagen in the centrolobular areas. Parenchymal fibrous septa connect the affected centrolobular areas. But, in this study, the distribution within the liver was noted to be highly variable. More importantly, intimal fibrosis and obstruction of small and medium hepatic veins were seen in such livers, with a morphology suggestive of organized thrombosis. A venular lesion had been described for some years [51]. The authors took this observation one step further and hypothesized that such thromboses originate in sinusoids and propagate to the hepatic veins, resulting ultimately in the development of parenchymal extinction and fibrosis.

Treatment

The liver condition improves if the congestive heart failure comes under control. Cardioversion-induced fulminant ischaemic hepatitis may reflect the reduction in cardiac output that can occur after the restoration of sinus rhythm [52]. If cirrhosis is present, afterload reduction may increase splanchnic blood flow, a measure that could result in a further increase in hepatic sinusoidal pressure and aggravation of ascites.

The pharmacokinetics of drugs used in the treatment of cardiac disease may be affected by the concomitant liver involvement [53]. Hepatic elimination of lidocaine is dependent on hepatic blood flow, and dosage adjustments may be required [54]. Caution should be exercised with other drugs that undergo preferential hepatic clearance (propranolol, nitrates). The use of calcium channel blockers has been associated with increased mortality in the setting of hepatic ischaemia [55]. Several types of hepatic injury, most of them due to idiosyncratic reactions, may occur with drugs used for cardiovascular disease (Table 1 and Chapter 14.1). Of these, amiodarone is noticeable for being associated with both acute [56] and chronic [57] liver injury. The former may reflect the intravenous administration of the drug [56].

Table 1 Hepatic toxicity associated with the use of drugs for cardiac conditions.

Liver condition	Drug
Acute hepatitis	Acebutolol, aprindine, benzarone, captopril, diltiazem, enalapril, hydralazine, labetalol, linisopril, methyldopa, metoprolol, nifedipine, quinidine, verapamil
Chronic hepatitis/cirrhosis	Benzarone, labetalol, methyldopa
Cholestasis, cholestatic hepatitis	Atenolol, captopril, disopyramide, enalapril, hydralazine, methyldopa, prajmaline, procainamide, propafenone, warfarin
Granulomatous hepatitis	Diltiazem, hydralazine, perhexiline, procainamide, quinidine, quinine
Phospholipidosis	Amiodarone
Non-alcoholic steatohepatitis	Amiodarone, perhexiline

Constrictive pericarditis

The presence of prominent ascites with scant findings suggestive of a cardiac condition can lead to a misdiagnosis of primary liver disease. Constrictive pericarditis is seen in patients with a history of infections (mainly tuberculosis), uraemia, connective tissue disease (systemic lupus erythematosus) and post trauma, including cardiac surgery. A careful history may provide useful diagnostic clues [58].

Confusion with established liver disease arises from the presence of varying degrees of hepatomegaly. Other physical findings can be more subtle and are better described in specialized textbooks. A pulse of small volume with a reduction in arterial pressure during inspiration may be present. A prominent 'y' descent may be seen in a jugular waveform, and a pericardial 'knock' may be heard. A hepatic pulsation may be detected when an open communication exists between the right atrium and the hepatic veins [59] (i.e. if the constricted pericardium does not impinge on the right atrium/inferior vena cava connection site).

Ascitic fluid protein can be markedly elevated, with a high serum–ascites albumin gradient [43]. Chylous ascites may also be present [60]. Cardiac imaging and cardiac catheterization can reach a definitive diagnosis, the latter also allowing measurements of hepatic venous pressure gradients and, hence, the exclusion of parenchymal liver disease and/or hepatic vein obstruction as a cause of the ascites [61].

Patients were studied 1–25 years after surgical correction of constrictive pericarditis, mainly due to tuberculosis. Bromosulphophthalein retention at 45 min was abnormal in all 29 subjects studied [62]. The authors postulated a detrimental effect on the liver as a result of passive congestion that is still present after correction of the underlying cause.

Other cardiac diseases

Ischaemic cardiomyopathy may present with hepatic failure as its initial manifestation in the absence of symptoms suggestive of congestive heart failure. Alcoholic cardiomyopathy is a frequent cause of dilated cardiomyopathy, and its presence may aggravate the course of alcohol-induced liver injury [63].

Patients with mitral valve disease in New York Heart Association (NYHA) functional class II–III and a normal bilirubin concentration showed a normal uptake of radiolabelled bilirubin [64]. However, they also showed a delayed elimination of conjugated bilirubin, which the authors related to a decrease

in hepatic blood flow, as the abnormality was inversely related to the CI. Similar changes were not seen in patients with aortic valvular disease.

References

1 Gheorghiade M, Zannad F, Sopko G *et al.* (2005) Acute heart failure syndromes: current state and framework for future research. *Circulation* 112, 3958–3968.

2 Felker GM, Adams KF Jr, Konstam MA *et al.* (2003) The problem of decompensated heart failure: nomenclature, classification, and risk stratification. *Am Heart J* 145, S18–S25.

3 Giallourakis CC, Rosenberg PM, Friedman LS (2002) The liver in heart failure. *Clin Liver Dis* 6, 947–967.

4 Henrion J, Schapira M, Luwaert R *et al.* (2003) Hypoxic hepatitis: clinical and hemodynamic study in 142 consecutive cases. *Medicine* 82, 392–406.

5 Bynum TE, Boitnott JK, Maddrey WC (1979) Ischemic hepatitis. *Dig Dis Sci* 24, 129–135.

6 Gitlin N, Serio KM (1992) Ischemic hepatitis: widening horizons. *Am J Gastroenterol* 87, 831–836.

7 Seeto RK, Fenn B, Rockey DC (2000) Ischemic hepatitis: clinical presentation and pathogenesis. *Am J Med* 109, 109–113.

8 Fuchs S, Bogomolski-Yahalom V, Paltiel O *et al.* (1998) Ischemic hepatitis: clinical and laboratory observations of 34 patients. *J Clin Gastroenterol* 26, 183–186.

9 Nouel O, Henrion J, Bernuau J *et al.* (1980) Fulminant hepatic failure due to transient circulatory failure in patients with chronic heart disease. *Dig Dis Sci* 25, 49–52.

10 Denis C, Kerguennec C, Bernuau J *et al.* (2004) Acute hypoxic hepatitis ('liver shock'): still frequently overlooked cardiological diagnosis. *Eur J Heart Fail* 6, 561–565.

11 Cohen JA, Kaplan MM (1978) Left-sided heart failure presenting as hepatitis. *Gastroenterology* 74, 583–587.

12 Henrion J, Descamps O, Luwaert R *et al.* (1994) Hypoxic hepatitis in patients with cardiac failure: incidence in a coronary care unit and measurement of hepatic blood flow. *J Hepatol* 21, 696–703.

13 Hickman PE, Potter JM (1990) Mortality associated with ischaemic hepatitis. *Aust NZ J Med* 20, 32–34.

14 Naschitz JE, Slobodin G, Lewis RJ *et al.* (2000) Heart diseases affecting the liver and liver diseases affecting the heart. *Am Heart J* 140, 111–120.

15 Bradley SE (1963) The circulation and the liver. *Gastroenterology* 44, 403–409.

16 Lautt WW, Greenway CV (1987) Conceptual review of the hepatic vascular bed. *Hepatology* 7, 952–963.

17 Myers JD, Hickam JB (1948) An estimation of the hepatic blood flow and splanchnic oxygen consumption in heart failure. *J Clin Invest* 27, 620–627.

18 Bailey RW, Brengman ML, Fuh KC *et al.* (2000) Hemodynamic pathogenesis of ischemic hepatic injury following cardiogenic shock/resuscitation. *Shock* 14, 451–459.

19 Henrion J, Minette P, Colin L *et al.* (1999) Hypoxic hepatitis caused by acute exacerbation of chronic respiratory failure: a case-controlled, hemodynamic study of 17 consecutive cases. *Hepatology* 29, 427–433.

20 Lefkowitch JH, Mendez L (1986) Morphologic features of hepatic injury in cardiac disease and shock. *J Hepatol* 2, 313–327.

21 Chandel NS, Maltepe E, Goldwasser E *et al.* (1998) Mitochondrial reactive oxygen species trigger hypoxia-induced transcription. *Proc Natl Acad Sci USA* 95, 11715–11720.

22 Henrion J (2000) Ischemia/reperfusion injury of the liver: pathophysiologic hypotheses and potential relevance to human hypoxic hepatitis. *Acta Gastroenterol Belg* 63, 336–347.

23 Biasi F, Chiarpotto E, Lanfrance G *et al.* (1994) Oxidative stress in the development of human ischemic hepatitis during circulatory shock. *Free Radic Biol Med* 17, 225–233.

24 Arcidi JM Jr, Moore GW, Hutchins GM (1981) Hepatic morphology in cardiac dysfunction. *Am J Pathol* 104, 159–166.

25 de la Monte SM, Arcidi JM, Moore GW *et al.* (1984) Midzonal necrosis as a pattern of hepatocellular injury after shock. *Gastroenterology* 86, 627–631.

26 Das G, Nussbaum HE, Leff WA (1974) Hepatic function in acute myocardial infarction. *JAMA* 230, 1558–1560.

27 Szawarski P, Sensky PR, Doshi M *et al.* (2004) Fulminant liver failure: an indicator of silent myocardial rupture. *Postgrad Med J* 80, 553–554.

28 Gomez Guindal JA, Roldan Rabadan I, Perea Egido J *et al.* (1999) Ictericia inducida por estreptocinasa [Streptokinase-induced jaundice]. *Rev Esp Cardiol* 52, 1025–1027.

29 Pezzi A, Pasetti G, Lombardi F *et al.* (1999) Liver rupture after cardiopulmonary resuscitation (CPR) and thrombolysis. *Intens Care Med* 25, 1032.

30 Ziegenfuss MD, Mullany DV (2004) Traumatic liver injury complicating cardio-pulmonary resuscitation. The value of a major intensive care facility: a report of two cases. *Crit Care Resusc* 6, 102–104.

31 Collins JD, Bassendine MF, Ferner R *et al.* (1983) Incidence and prognostic importance of jaundice after cardiopulmonary bypass surgery. *Lancet* 1, 1119–1123.

32 Chu CM, Chang CH, Liaw YF *et al.* (1984) Jaundice after open heart surgery: a prospective study. *Thorax* 39, 52–56.

33 Hampton WW, Townsend MC, Schirmer WJ *et al.* (1989) Effective hepatic blood flow during cardiopulmonary bypass. *Arch Surg* 124, 458–459.

34 Michalopoulos A, Alivizatos P, Geroulanos S (1997) Hepatic dysfunction following cardiac surgery: determinants and consequences. *Hepatogastroenterology* 44, 779–783.

35 Jenkins JG, Lynn AM, Wood AE *et al.* (1982) Acute hepatic failure following cardiac operation in children. *J Thorac Cardiovasc Surg* 84, 865–871.

36 Narkewicz MR, Sondheimer HM, Ziegler JW *et al.* (2003) Hepatic dysfunction following the Fontan procedure. *J Pediatr Gastroenterol Nutr* 36, 352–357.

37 Ghaferi AA, Hutchins GM (2005) Progression of liver pathology in patients undergoing the Fontan procedure: chronic passive congestion, cardiac cirrhosis, hepatic adenoma, and hepatocellular carcinoma. *J Thorac Cardiovasc Surg* 129, 1348–1352.

38 Arenson DM, Lewis JH, Zimmerman HJ (1984) Post-transfusion hepatitis after cardiac surgery. *Br Med J (Clin Res Ed)* 288, 403–404.

39 Esteban JI, Gomez J, Martell M *et al.* (1996) Transmission of hepatitis C virus by a cardiac surgeon. *N Engl J Med* 334, 555–560.

40 Henrion J, Schapira M, Heller FR (1996) Ischemic hepatitis: the need for precise criteria. *J Clin Gastroenterol* 23, 305–306.

41 White TJ, Leevy CM, Brusca AM *et al.* (1955) The liver in congestive heart failure. *Am Heart J* 49, 250–257.

42 Dunn GD, Hayes P, Breen KJ *et al.* (1973) The liver in congestive heart failure: a review. *Am J Med Sci* 265, 174–189.

43 Runyon BA (1988) Cardiac ascites: a characterization. *J Clin Gastroenterol* 10, 410–412.

44 Moussavian SN, Dincsoy HP, Goodman S *et al.* (1982) Severe hyperbilirubinemia and coma in chronic congestive heart failure. *Dig Dis Sci* 27, 175–180.
45 Batin P, Wickens M, McEntegart D *et al.* (1995) The importance of abnormalities of liver function tests in predicting mortality in chronic heart failure. *Eur Heart J* 16, 1613–1618.
46 Richman SM, Delman AJ, Grob D (1961) Alterations in indices of liver function in congestive heart failure with particular reference to serum enzymes. *Am J Med* 30, 211–225.
47 Sherlock S (1951) The liver in heart failure: relation of anatomical, functional, and circulatory changes. *Br Heart J* 13, 273–293.
48 Kubo SH, Walter BA, John DH *et al.* (1987) Liver function abnormalities in chronic heart failure: Influence of systemic hemodynamics. *Arch Intern Med* 147, 1227–1230.
49 van Lingen R, Warshow U, Dalton HR *et al.* (2005) Jaundice as a presentation of heart failure. *J R Soc Med* 98, 357–359.
50 Wanless IR, Liu JJ, Butany J (1995) Role of thrombosis in the pathogenesis of congestive hepatic fibrosis (cardiac cirrhosis). *Hepatology* 21, 1232–1237.
51 Kanel GC, Ucci AA, Kaplan MM *et al.* (1980) Distinctive perivenular hepatic lesion associated with heart failure. *Am J Clin Pathol* 73, 235–239.
52 Moriel M, Morali G, Rosenmann E *et al.* (2001) Cardioversion-induced fulminant ischaemic hepatitis. *Eur J Gastroenterol Hepatol* 13, 1481–1483.
53 Sokol SI, Cheng A, Frishman WH *et al.* (2000) Cardiovascular drug therapy in patients with hepatic diseases and patients with congestive heart failure. *J Clin Pharmacol* 40, 11–30.
54 Lalka D, Griffith RK, Cronenberger CL (1993) The hepatic first-pass metabolism of problematic drugs. *J Clin Pharmacol* 33, 657–669.
55 Potter JM, Hickman PE (1992) Cardiodepressant drugs and the high mortality rate associated with ischemic hepatitis. *Crit Care Med* 20, 474–478.
56 Bravo AE, Drewe J, Schlienger RG *et al.* (2005) Hepatotoxicity during rapid intravenous loading with amiodarone: description of three cases and review of the literature. *Crit Care Med* 33, 128–134.
57 Lewis JH, Ranard RC, Caruso A *et al.* (1989) Amiodarone hepatotoxicity: prevalence and clinicopathologic correlations among 104 patients. *Hepatology* 9, 679–685.
58 Myers RB, Spodick DH (1999) Constrictive pericarditis: clinical and pathophysiologic characteristics. *Am Heart J* 138, 219–232.
59 Calleja HB, Rosenow OF, Clark TE (1961) Pulsations of the liver in heart disease. *Am J Med* 30, 202–210.
60 England RW, Grathwohl KW, Powell GE (2002) Constrictive pericarditis presenting as chylous ascites. *J Clin Gastroenterol* 35, 104–105.
61 Fred HL (1999) Curable conspicuous ascites: the forgotten four. *Hosp Pract (Minn.)* 34, 98–100.
62 Cohen CD, Kirsch RE, Saunders SJ *et al.* (1981) Hepatic sequelae of congestive cardiac failure: evidence for a liver lesion in patients in whom cardiac function had been restored to normal. *S Afr Med J* 59, 213–216.
63 Estruch R, Fernandez-Sola J, Sacanella E *et al.* (1995) Relationship between cardiomyopathy and liver disease in chronic alcoholism. *Hepatology* 22, 532–538.
64 Bohmer T, Kjekshus E, Nitter-Hauge S (1994) Studies on the elimination of bilirubin pre-operatively in patients with mitral valve disease. *Eur Heart J* 15, 10–16.

20.2 The liver in lung diseases

Andres T. Blei and Jacob I. Sznajder

Involvement of the liver in pulmonary diseases is not a frequent finding. Some diseases can affect both liver and lung, such as cystic fibrosis (see Chapter 16.4), sarcoidosis (see Chapter 20.12) and alpha-1-antitrypsin deficiency (see Chapter 16.3). The main impact of lung disease on liver function is the result of hypoxaemia. Even in lung conditions that arise from liver disease, such as the hepatopulmonary syndrome (see Chapter 7.7), the prominent hypoxaemia affects the course of liver failure. A brief discussion of the pathophysiological consequences of hypoxia is in order.

Hypoxia

At sea level, the fraction of inspired oxygen is 0.21, which results in an alveolar oxygen partial pressure of ~ 150 mmHg, an arterial Po_2 of ~ 100 mmHg (equivalent to 16% oxygen concentration) and a venous Po_2 of ~ 40 mmHg (5–6% oxygen). However, during many pathophysiological conditions, severe alveolar hypoxia may develop. For example, during the ascent to high altitude, a decrease in alveolar oxygen tension occurs as the result of a lower barometric pressure. Severe alveolar hypoxia during either ascent to high altitudes or in patients with pulmonary oedema and/or acute respiratory distress syndrome can be attributed to hypoxic pulmonary vasoconstriction, increased vascular permeability and inhibition of fluid reabsorption from the alveolar spaces [1–3].

Mitochondria as an oxygen sensor

As cells are exposed to decreasing concentrations of oxygen, there is a time-dependent increase in the generation of mitochondrial reactive oxygen species (ROS), which peaks at ~ 150 min of exposure and then returns to basal levels [4,5]. Furthermore, hypoxic induction of mitochondrial ROS has been shown to be required for a variety of cell responses to hypoxia, including gene transcription and oxidative modification of DNA, factors that result in pulmonary artery vasoconstriction [6,7] (Fig. 1).

Maintenance of oxygen homeostasis is required for the survival of higher organisms. Mammalian cells detect decreases in oxygen concentration to activate a variety of responses that help cells to adapt to low oxygen levels (hypoxia). The transcription

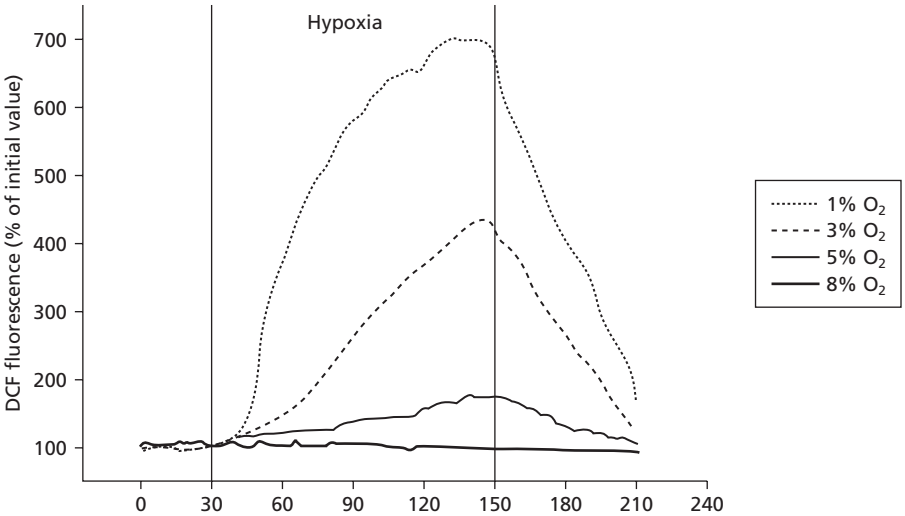

Fig. 1 Time course of reactive oxygen species production in cells exposed to hypoxia. Reproduced with permission from Chandel NS, Maltepe E, Goldwasser E *et al.* (1998) Mitochondrial reactive oxygen species trigger hypoxia-induced transcription. *Proc Natl Acad Sci USA* 95(20), 11715–11720.

factor, hypoxia inducible factor (HIF), has a crucial role in oxygen homeostasis by integrating the decrease in oxygen levels to increase hypoxic gene expression. How cells sense the decrease in oxygen levels to elicit an increase in HIF-dependent stabilization has been described recently in elegant studies [8–10].

In the lung, epithelial hypoxia results in the increased production of ROS, which activate protein kinase C (PKC), which in turn phosphorylates serine residues of the Na^+–K^+ATPase N-terminus, causing its endocytosis from the plasma membrane into intracellular compartments with the resultant inhibition of the Na^+ pump function [11]. A similar role for ROS in the induction of hypoxia-induced inhibition of Na^+–K^+ATPase has been shown recently in trout hepatocytes [12]. More prolonged hypoxia results in ubiquitination and degradation of the Na^+–K^+ATPase [13].

In the liver, several pathophysiological processes are affected by hypoxia. Inhibition of the release of hepatocyte growth factor and decreased expression of its receptor, c-Met, may contribute to the failure of liver regeneration in the liver with experimental cirrhosis [14]. The hypoxia-induced release of angiogenic factors, such as vascular endothelial growth factor (VEGF), may contribute to angiogenesis after biliary cirrhosis in the rat [15]. Similar findings have been reported in rats with dimethylnitrosamine-induced cirrhosis [16].

Hypoxia-induced angiogenesis may be important for the development and progression of hepatic fibrosis as well as hepatocarcinogenesis. Experimental studies indicate that hepatocellular hypoxia and angiogenesis evolve in parallel to hepatic fibrogenesis after liver injury, implying a direct contribution of hypoxia to liver fibrosis [16]. In stellate cells, hypoxia prevents the prolyl-hydroxylase-mediated ubiquitination and degradation of HIF-1α, which allows the latter molecule to signal and increase VEGF production [17]. Such upregulation of HIF-1α and subsequent VEGF production may be important in tumour progression after chemoembolization for hepatocellular carcinoma [18].

Liver function in chronic pulmonary disease

The repercussion of chronic pulmonary disease on liver function will depend on the interplay between the degree of arterial hypoxaemia, hypercapnia and the height of the right atrial pressure; the nature of left ventricular function (with possible 'forward failure') also needs to be considered. While the role of these different variables can be dissected in the experimental setting, they are more difficult to separate in human disease.

One study demonstrated higher liver chemistries (bilirubin, aminotransferases, γ-glutamyltransferase and alkaline phosphatase) in patients with chronic pulmonary disease [19]; such abnormalities were found when the $Pa\mathrm{o}_2$ fell below values of 60 mmHg. Such a view is supported by findings in severe asthma, especially during status asthmaticus; elevated aminotransferases were related to the severity of the episode [20,21]. However, in chronic bronchitis, no abnormalities in liver chemistries were seen in patients with values of $Pa\mathrm{o}_2$ between 44 and 83 mmHg [22]. The authors suggested that heart failure is required to express liver chemistry abnormalities in the setting of chronic pulmonary disease.

A recent study has shed further light on this controversy [23]. In a prospective evaluation of 142 episodes of hypoxic injury to the liver, 17 were related to an acute exacerbation of chronic respiratory failure without left ventricular cardiac failure. Liver chemistries of 'hypoxic hepatitis' were conspicuous, with a peak aspartate aminotransferase (AST) of 3115 IU/L and alanine aminotransferase (ALT) of 2115 IU/L; bilirubin was only slightly elevated (2.3 mg%), but prothrombin activity was impaired (35%). Results were compared with patients with hypoxic injury in the setting of congestive heart failure (positive control) and with subjects with respiratory failure without hepatic injury (negative control). Arterial hypoxaemia was more severe in the study group, with a mean $Pa\mathrm{o}_2$ of 34 mmHg (vs. 70 mmHg and 45.5 mmHg in the other two groups) with good left ventricular function. However, an elevated central venous pressure was also seen in the study group, suggesting that the liver is injured as a result of the combined effects of low oxygen delivery and passive congestion.

The liver in obstructive sleep apnoea

In obstructive sleep apnoea, nocturnal arterial oxygen desaturation can result in hypoxaemia. It is more commonly seen in patients with obesity and features of the metabolic syndrome, and has been postulated to accelerate the atherogenic process by initiating oxidative stress [24]. The liver may be affected by similar pathways. After a report of a well-described obese patient with hypoxic hepatitis [25], studies in two additional patients showed liver injury with normal right and left ventricular function [26]. Echoing the controversy depicted in the previous paragraph, the authors suggested a pathogenic role for severe arterial hypoxaemia in the absence of cardiac and circulatory failure.

In a series of 40 obese patients with obstructive sleep apnoea, elevated aminotransferases were seen in 35% of patients [27]. However, liver biopsies were not obtained, and elevated aminotransferases may reflect the presence of underlying non-alcoholic fatty liver disease (NAFLD) in the obese. Continuous positive airway pressure (CPAP) was administered for up to 6 months, with a significant reduction in aminotransferases at 1 and 6 months. High serum leptin levels, which may contribute to hepatic injury in obese patients, were reduced by CPAP administration.

Could obstructive sleep apnoea result in chronic liver injury? A prospective series from France suggests that severe sleep apnoea is a risk factor for more severe manifestations of NAFLD [28]. In 163 patients who were not consuming alcohol, severe sleep apnoea was seen in 27% of the cohort. In a multivariate analysis, a high body mass index (BMI) and severe sleep apnoea

were associated with high aminotransferases. Patients with severe apnoea had evidence of more insulin resistance as well as higher scores of steatosis, necrosis and fibrosis on liver biopsy, independent from the BMI. Some biopsies also exhibited lobular hepatitis, suggesting direct liver effects from hypoxia.

Other metabolic consequences of hypoxia have been noted in the obese liver: nocturnal hypoxaemia was correlated with activation of CYP2E1 in non-diabetic patients with biopsy-proven non-alcoholic steatohepatitis [29].

Pneumonia

Chapter 10.1 discusses the liver involvement in bacterial infections. The association of pneumonia with abnormal liver chemistries has been recognized for a long time [30]. The pattern of liver chemistries may provide clues to the type of infectious pneumonia. Lobar pneumonia may be associated with elevations in bilirubin; aminotransferases predominate in Legionnaire's disease, psittacosis and *Mycoplasma pneumoniae* infection, while alkaline phosphatase is prominent in Q fever. Cytomegalovirus pneumonia can result in jaundice and elevation of alkaline phosphatase and aminotransferases [31].

In pneumococcal pneumonia, jaundice occurs in 3–25% of cases, even after the advent of antibiotic therapy [32]. Liver chemistry abnormalities, which are reversible, are even more frequent in the presence of bacteraemia [33]. A group of 28 patients with lobar pneumonia and jaundice were compared with 70 subjects with similar lobar pneumonia but who were not icteric [34]. Jaundice was associated with the male sex, showed a higher prevalence with right lower lobe consolidation, and patients exhibited right upper quadrant tenderness. Jaundice developed between the 3rd and 6th days of illness, but was not associated with a poorer outcome. Surprisingly, haemolysis was found in the jaundiced cohort, as a result of glucose-6-phosphate deficiency [35]. Liver biopsies showed evidence of cholestasis [36]. Microsomal function appeared to be impaired, as assessed by antipyrine clearance [37]; this may be important at the time of choosing the appropriate antibiotic therapy.

Legionnaire's disease arises from infection with *Legionella pneumophila*. In the initial reports in the late 1970s, increases in aminotransferases and alkaline phosphatase were reported in almost 50% of affected individuals [38]. The prevalence appeared to be lower in subsequent series [39], although jaundice was reported in 11/30 subjects with severe community-acquired legionella pneumonia [40]. In the latter series, use of rifampicin was associated with the development of jaundice, a known effect of the drug. Liver biopsy findings included both portal and lobular alterations: chronic portal inflammation, the presence of polymorphonuclear leukocytes in the lobule, Kupffer cell hyperplasia and centrolobular congestion [41,42]. These findings are not specific, and the procedure is seldom indicated.

Reports of Legionnaire's disease in allograft recipients have included liver transplant recipients, a finding that highlights a permissive role for immunosuppression in the development of infection. In one hospital outbreak, this required renovation of the surgery unit's hot water system [43]. The infection in such patients can be severe, including the development of cavitary pneumonia [44].

The liver in granulomatous disorders that can affect the lung

See sarcoidosis (Chapter 20.12), tuberculosis (Chapter 10.1) and histoplasmosis (Chapter 10.2).

Histiocytosis

While this term encompasses a wide range of entities [45], we will focus on Langerhans cell histiocytosis (LCH). This entity has undergone changes in nomenclature, relegating terms such as histiocytosis X, eosinophilic granuloma (a localized disease in bone and lung), Letterer–Siwe and Hand–Schuller Christian disease (systemic disorders). The characteristic feature is the pathological accumulation of the Langerhans cell, a bone marrow-derived dendritic cell that expresses the Cd1a glycoprotein and plays an important role in the presentation of foreign antigen [46]. The cell contains a unique intracytoplasmic inclusion, the Birbeck granule, which allows its histological recognition. In LCH, there is a clonal expansion of this cellular element [47].

This entity is mainly, but not exclusively, seen in the paediatric population. A retrospective review of 348 cases showed a median age at diagnosis of 30 months [48]. One-third had isolated unifocal or bifocal bone involvement, 19% had multifocal bone involvement, 39% soft tissue involvement without organ dysfunction and 11% had organ dysfunction. The disease spectrum is wide, including the involvement of bones, lung, liver, thymus, spleen and bone marrow. Otitis media, diabetes insipidus and prominent lymphadenopathy can be present. Lung manifestations can be severe, although a unique entity, pulmonary Langerhans cell histiocytosis [49], refers to an uncommon disorder of young adult smokers.

A series of 182 patients noted 36 children (20%) who presented with liver involvement, as defined by palpable hepatomegaly or abnormal liver chemistries [50]. Cholestasis was seen in 12; unique ultrasound findings included periportal hyperechogenicity or a hypoechoic periportal halo. Biopsy and cholangiographic findings indicated the presence of sclerosing cholangitis in 11/12 subjects. Otherwise, liver biopsies may not show evidence of LCH, with a wide range of changes, including bile duct proliferation, variable fibrosis with histiocytic infiltrates and cirrhosis [51].

The presence of sclerosing cholangitis, even in the absence of demonstrable histological involvement with LCH, was noted in small series in the 1980s [52,53], in which evolution towards liver failure was noted. Such biliary lesions were also seen in adults [54]. Both paediatric [50,55] and adult [56] liver transplantation

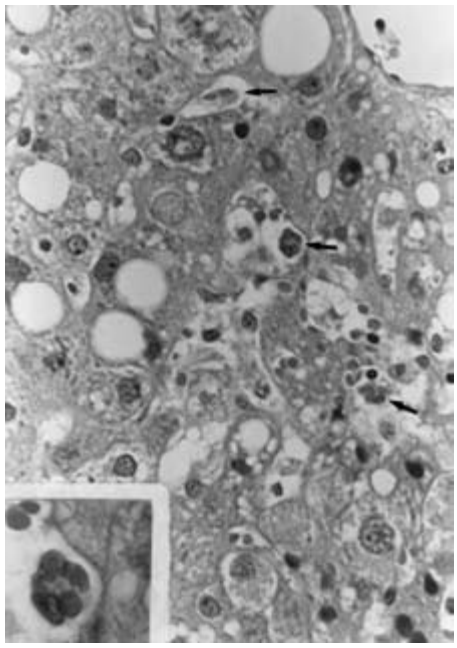

Fig. 2 Liver biopsy (× 400). Sinusoidal spaces are dilated and filled with numerous histiocytes showing active erythrophagocytosis (arrow). Inset (× 1000). Phagocytosis of erythrocytes by normal-appearing macrophages. Reproduced with permission from ref. 56.

has been performed, with reports of clinical improvement and control of the underlying disease. The decision to perform a liver transplant is made simpler if the patient does not respond to current chemotherapeutic approaches.

A proliferation of cytologically benign histiocytes can be seen in the haemophagocytic syndrome, usually in bone marrow, spleen or lymph nodes, associated with fever, splenomegaly and pancytopenia. Hepatic involvement has been reported, with abnormal liver chemistries and jaundice [57]; liver failure may ensue. Liver biopsy characteristically shows sinusoidal dilatation with haemophagocytic histiocytes (Fig. 2). The syndrome can be associated with underlying conditions of altered immunity, infection and neoplasia (such as leukaemia and lymphoma). It has also been reported after liver transplantation [57].

Liver involvement in carcinoma of the lung

Small cell carcinoma of the lung can exhibit overt liver involvement in approximately 30% of cases [58]. Liver involvement may range from mild to moderate elevations in liver chemistries [59] to presentation of the disease as massive infiltration of the liver with fulminant hepatic failure [60,61]. Icteric presentations may be seen with a large metastatic volume, a poor prognostic sign, resulting in death within 8 months; however, in a series of 12 patients, three had obstruction of the biliary tree by pancreatic metastases with a better outcome [62].

In non-small cell lung cancer, non-invasive staging can now be carried out with a wide range of modalities. However, a review of the published literature indicates a high negative predictive value for clinical assessment in the ascertainment of hepatic metastases (physical examination and laboratory tests) [63]. Thus, while positron emission tomography (PET) scanning has the best sensitivity and specificity for the detection of mediastinal involvement, the need to include additional imaging for liver involvement depends on the clinical setting [64].

References

1 Stenmark KR, Bouchey D, Nemenoff R *et al.* (2000) Hypoxia-induced pulmonary vascular remodeling: contribution of the adventitial fibroblasts. *Physiol Res* 49, 503–517.

2 Das M, Bouchey DM, Moore MJ *et al.* (2001) Hypoxia-induced proliferative response of vascular adventitial fibroblasts is dependent on G protein-mediated activation of mitogen-activated protein kinases. *J Biol Chem* 276, 15631–15640.

3 Jain M, Sznajder JI (2005) Effects of hypoxia on the alveolar epithelium. *Proc Am Thorac Soc* 2(3), 202–205.

4 Chandel NS, Maltepe E, Goldwasser E *et al.* (1998) Mitochondrial reactive oxygen species trigger hypoxia-induced transcription. *Proc Natl Acad Sci USA* 95, 11715–11720.

5 Wood JG, Johnson JS, Mattioli LF *et al.* (2000) Systemic hypoxia increases leukocyte emigration and vascular permeability in conscious rats. *J Appl Physiol* 89, 1561–1568.

6 Waypa GB, Chandel NS, Schumacker PT (2001) Model for hypoxic pulmonary vasoconstriction involving mitochondrial oxygen sensing. *Circ Res* 88, 1259–1266.

7 Chandel NS, McClintock DS, Feliciano CE *et al.* (2000) Reactive oxygen species generated at mitochondrial complex III stabilize hypoxia-inducible factor-1alpha during hypoxia: a mechanism of O_2 sensing. *J Biol Chem* 275, 25130–25138.

8 Mansfield KD, Guzy RD, Pan Y *et al.* (2005) Mitochondrial dysfunction resulting from loss of cytochrome c impairs cellular oxygen sensing and hypoxic HIF-alpha activation. *Cell Metab* 1(6), 393–399.

9 Brunelle JK, Bell EL, Quesada NM *et al.* (2005) Oxygen sensing requires mitochondrial ROS but not oxidative phosphorylation. *Cell Metab* 1(6), 409–414.

10 Guzy RD, Hoyos B, Robin E *et al.* (2005) Mitochondrial complex III is required for hypoxia-induced ROS production and cellular oxygen sensing. *Cell Metab* 1(6), 401–408.

11 Dada L, Chandel N, Pedemonte C *et al.* (2003) Hypoxia-induced endocytosis of Na,K-ATPase in alveolar epithelial cells is mediated by mitochondrial reactive oxygen species and PKC-zeta. *J Clin Invest* 111, 1057–1064.

12 Bogdanova A, Grenacher B, Nikinmaa M *et al.* (2005) Hypoxia responses of Na+/K+ ATPase in trout hepatocytes. *J Exp Biol* 208, 1793–1801.

13 Comellas AP, Dada LA, Lecuona E *et al.* (2006) Hypoxia-mediated degradation of Na,K-ATPase via mitochondrial reactive oxygen species and the ubiquitin-conjugating system. *Circ Res* 98, 1314–1322.

14 Corpechot C, Barbu V, Wendum D *et al.* (2002) Hepatocyte growth factor and c met inhibition by hepatic cell hypoxia: a potential mechanism for liver regeneration failure in experimental cirrhosis. *Am J Pathol* 160, 613–620.

15 Rosmorduc O, Wendum D, Corpechot C *et al.* (1999) Hepatocellular hypoxia-induced vascular endothelial growth factor expression and angiogenesis in experimental biliary cirrhosis. *Am J Pathol* 155, 1056–1073.

16 Corpechot C, Barbu V, Wendum D *et al.* (2002) Hypoxia-induced VEGF and collagen I expressions are associated with angiogenesis and fibrogenesis in experimental cirrhosis. *Hepatology* 35(5), 1010–1021.

17 Wang YQ, Luk JM, Ikeda K *et al.* (2004) Regulatory role of vHL/HIF-1alpha in hypoxia-induced VEGF production in hepatic stellate cells. *Biochem Biophys Res Commun* 317(2), 358–362.

18 Yang ZF, Poon RT, To J *et al.* (2004) The potential role of hypoxia inducible factor 1alpha in tumor progression after hypoxia and chemotherapy in hepatocellular carcinoma. *Cancer Res* 64(15), 5496–5503.

19 Subirats Bayego E, Cavalle Obiols F, Vila Subirana T *et al.* (1982) [Changes in liver function in acute episodes during chronic respiratory insufficiency: clinical and biological study] [article in Spanish]. *Rev Clin Esp* 166(3–4), 137–140.

20 Colldahl H (1960) A study of serum enzymes in patients suffering from periods of respiratory insufficiency, especially asthma and emphysema. *Acta Med Scand* 166, 399–400.

21 Thomas AJ, Rees HA, Saunders RA (1965) Liver function in pulmonary heart disease. *Br Heart J* 27, 791–796.

22 Whelan G, Pierce AK, Schenker S *et al.* (1969) Hepatic function in patients with hypoxia due to chronic pulmonary disease. *Aust Ann Med* 18, 243–247.

23 Henrion J, Minette P, Colin L *et al.* (1999) Hypoxic hepatitis caused by acute exacerbation of chronic respiratory failure: a case-controlled, hemodynamic study of 17 consecutive cases. *Hepatology* 29, 427–433.

24 Lavie L (2003) Obstructive sleep apnoea syndrome – an oxidative stress disorder. *Sleep Med Rev* 7(1), 35–51.

25 Mathurin P, Durand F, Ganne N *et al.* (1995) Ischemic hepatitis due to obstructive sleep apnea. *Gastroenterology* 109(5), 1682–1684.

26 Henrion J, Colin L, Schapira M *et al.* (1997) Hypoxic hepatitis caused by severe hypoxemia from obstructive sleep apnea. *J Clin Gastroenterol* 24, 245–249.

27 Chin K, Nakamura T, Takahashi K *et al.* (2003) Effects of obstructive sleep apnea syndrome on serum aminotransferase levels in obese patients. *Am J Med* 114, 370–376.

28 Tanné F, Gagnadoux F, Chazouillères O *et al.* (2005) Chronic liver injury during obstructive sleep apnea. *Hepatology* 41, 1290–1296.

29 Chalasani NM, Gorski JC, Asghar MS *et al.* (2003) Hepatic cytochrome P450 2E1 activity in nondiabetic patients with non-alcoholic steatohepatitis. *Hepatology* 37(3), 544–550.

30 Zimmerman HJ, Thomas LJ (1950) The liver in pneumococcal pneumonia: observations in 94 cases on liver function and jaundice in pneumonia. *J Lab Clin Med* 35(4), 556–567.

31 Amory JK, Rosen H, Sukut C *et al.* (2006) A jaundiced eye. *N Engl J Med* 354, 1516–1521.

32 Radford AJ, Rhodes FA (1967) The association of jaundice with lobar pneumonia in the territory of Papua and New Guinea. *Med J Aust* 2(15), 678–681.

33 Murphy TF, Fine BC (1984) Bacteremic pneumococcal pneumonia in the elderly. *Am J Med Sci* 288(3), 114–118.

34 Tugwell P, Williams AO (1977) Jaundice associated with lobar pneumonia. A clinical, laboratory and histological study. *Q J Med* 46(181), 97–118.

35 Tugwell P (1973) Glucose-6-phosphate-dehydrogenase deficiency in Nigerians with jaundice associated with lobar pneumonia. *Lancet* 1(7810), 968–969.

36 Williams AO, Tugwell P, Edington GM (1976) Glucose-6-phosphate dehydrogenase deficiency and lobar pneumonia. Fine structure of the liver. *Arch Pathol Lab Med* 100(1), 25–31.

37 Sonne J, Dossing M, Loft S *et al.* (1985) Antipyrine clearance in pneumonia. *Clin Pharmacol Ther* 37(6), 701–704.

38 Kirby BD, Snyder KM, Meyer RD *et al.* (1978) Legionnaires' disease: clinical features of 24 cases. *Ann Intern Med* 89(3), 297–309.

39 Woodhead MA, MacFarlane JT (1986) Legionnaires' disease: a review of 79 community acquired cases in Nottingham. *Thorax* 41(8), 635–640.

40 Hubbard RB, Mathur RM, MacFarlane JT (1993) Severe community-acquired legionella pneumonia: treatment, complications and outcome. *Q J Med* 86(5), 327–332.

41 Winn WC Jr, Myerowitz RL (1981) The pathology of the Legionella pneumonias. A review of 74 cases and the literature. *Hum Pathol* 12(5), 401–422.

42 Weisenburger DD, Helms CM, Renner ED (1981) Sporadic Legionnaires' disease. A pathological study of 23 fatal cases. *Arch Pathol Lab Med* 105(3), 130–137.

43 Prodinger WM, Bonatti H, Allerberger F *et al.* (1994) Legionella pneumonia in transplant recipients: a cluster of cases of eight years' duration. *J Hosp Infect* 26(3), 191–202.

44 Fraser TG, Zembower TR, Lynch P *et al.* (2004) Cavity Legionella pneumonia in a liver transplant recipient. *Transpl Infect Dis* 6(2), 58–62.

45 Cline MJ (1994) Histiocytes and histiocytosis. *Blood* 84(9), 2840–2853.

46 Chu T, Jaffe R (1994) The normal Langerhans cell and the LCH cell. *Br J Cancer Suppl* 23, S4–10.

47 Willman CL, Busque L, Griffith BB *et al.* (1994) Langerhans'-cell histiocytosis (histiocytosis X) – a clonal proliferative disease. *N Engl J Med* 331(3), 154–160.

48 The French Langerhans' Cell Histiocytosis Study Group (1996) A multicentre retrospective survey of Langerhans' cell histiocytosis: 348 cases observed between (1983 and 1993). *Arch Dis Child* 75(1), 17–24.

49 Sundar KM, Gosselin MV, Chung HL *et al.* (2003) Pulmonary Langerhans cell histiocytosis: emerging concepts in pathobiology, radiology, and clinical evolution of disease. *Chest* 123(5), 1673–1683.

50 Braier J, Ciocca M, Latella A *et al.* (2002) Cholestasis, sclerosing cholangitis, and liver transplantation in Langerhans cell histiocytosis. *Med Pediatr Oncol* 38, 178–182.

51 Heyn RM, Hamoudi A, Newton WA Jr (1990) Pretreatment liver biopsy in 20 children with histiocytosis X: a clinicopathological correlation. *Med Pediatr Oncol* 18(2), 110–118.

52 Leblane A, Hadchouel M, Jehan P *et al.* (1981) Obstructive jaundice in children with histiocytosis X. *Gastroenterology* 80(1), 134–139.

53 Thompson HH, Pitt HA, Lewin JK *et al.* (1984) Sclerosing cholangitis and histiocytosis X. *Gut* 25(5), 526–530.

54 Kaplan KJ, Goodman ZD, Ishak KG (1999) Liver involvement in Langerhans' cell histiocytosis: a study of nine cases. *Mod Pathol* 12(4), 370–378.

55 Zandi P, Panis Y, Debray D *et al.* (1995) Pediatric liver transplantation for Langerhans' cell histiocytosis. *Hepatology* 21(1), 129–133.

56 Griffiths W, Davies S, Gibbs P *et al.* (2006) Liver transplantation in an adult sclerosing cholangitis due to Langerhans' cell histiocytosis. *J Hepatol* 44, 829–831.

57 de Kerguenec C, Hillaire S, Molinié V *et al.* (2001) Hepatic manifestations of hemophagocytic syndrome: a study of 30 cases. *Am J Gastroenterol* 96(3), 852–857.

58 Ihde DC, Makuch RW, Carney DN *et al.* (1981) Prognostic implications of stage of disease and sites of metastases in patients with small cell carcinoma of the lung treated with intensive combination chemotherapy. *Am Rev Respir Dis* 123(5), 500–507.

59 Schreve RH, Terpstra OT, Ausema L *et al.* (1984) Detection of liver metastases. A prospective study comparing liver enzymes, scintigraphy, ultrasonography and computed tomography. *Br J Surg* 71(12), 947–949.

60 McGuire BM, Cherwitz DL, Rabe KM *et al.* (1997) Small-cell carcinoma of the lung manifesting as acute hepatic failure. *Mayo Clin Proc* 72(2), 133–139.

61 Athanasakis E, Mouloudi E, Prinianakis G *et al.* (2003) Metastatic liver disease and fulminant hepatic failure: presentation of a case and review of the literature. *Eur J Gastroenterol Hepatol* 15(11), 1235–1240.

62 Johnson DH, Hainsworth JD, Greco FA (1985) Extrahepatic biliary obstruction caused by small-cell lung cancer. *Ann Intern Med* 102(4), 487–490.

63 Toloza EM, Harpole L, McCrory DC (2003) Noninvasive staging of non-small cell lung cancer: a review of the current evidence. *Chest* 123, 137S–146S.

64 Pope RJ, Hansell DM (2003) Extra-thoracic staging of lung cancer. *Eur J Radiol* 45(1), 31–38.

20.3 The effect of gastrointestinal diseases on the liver and biliary tract

Roger W. Chapman and Peter W. Angus

The hepatobiliary system and the alimentary tract are closely linked embryologically, physiologically, biochemically and anatomically, with all mesenteric venous drainage ascending via the portal vein into the liver. It is not surprising, therefore, that the liver is especially vulnerable to the development of complications from many different gastrointestinal diseases, particularly inflammatory bowel disease and malabsorption syndromes.

Hepatobiliary complications of inflammatory bowel diseases

The first association between colonic ulceration and liver disease was made in 1873 by Thomas, who described a young man who died of a 'much enlarged, fatty liver in the presence of ulceration of the colon' [1]. The association was confirmed by Lister in 1899, who reported a patient with ulcerative colitis and secondary diffuse hepatitis [2]. Over the next 100 years, it has become well established that there is a close relationship between inflammatory bowel disease and various hepatobiliary disorders. These disorders are listed in Table 1.

In the last 30 years, a different concept of hepatobiliary disorder in inflammatory bowel disease has emerged. It is now apparent that the major hepatobiliary diseases seen in association with both ulcerative colitis and Crohn's disease, namely primary sclerosing cholangitis (PSC), cirrhosis, cholangiocarcinoma and most cases of autoimmune hepatitis, represent different aspects of the same spectrum of hepatobiliary disease.

Table 1 Hepatobiliary disorders associated with inflammatory bowel disease.

	Associated with	
	Ulcerative colitis	**Crohn's disease**
Primary sclerosing cholangitis (PSC)		
Large duct PSC	+	+
Small duct PSC ('pericholangitis')	+	+
Cirrhosis	+	+
Hepatoma	+	+
Cholangiocarcinoma	+	+
Miscellaneous disorders		
Fatty liver	+	+
Granulomas		+
Amyloidosis		+
Hepatic abscess		+
Gallstones		+
Autoimmune hepatitis	+	
Primary biliary cirrhosis	(+)	
Budd–Chiari syndrome	(+)	(+)

+, definite association; (+), possible association.

Prevalence of liver disease

The prevalence of liver disease in patients with ulcerative colitis and Crohn's disease has varied widely in different series. The discrepancy between the series may be largely due to differences in the number of patients included with severe, active or extensive inflammatory bowel disease, and also in the method used to investigate liver dysfunction.

Abnormal liver function tests are found in over half of patients with inflammatory bowel disease requiring surgery and are due to a number of factors such as malnutrition, sepsis, total parenteral nutrition and blood transfusions with the subsequent risk of viral infection. However, significant liver disease is much less common. The true prevalence of hepatobiliary abnormality is difficult to determine, as it would involve obtaining liver histology and cholangiography from an unselected group of patients with inflammatory bowel disease. Most series, therefore, have relied upon detecting persistent abnormalities on serum biochemical testing before proceeding to hepatic biopsy or endoscopic retrograde cholangiography. Technological advances such as magnetic resonance cholangiography and spectroscopy will allow more accurate assessments of the prevalence of liver abnormality to be made in the future.

In an early study from Oxford, 5–6% of 300 unselected adult patients with ulcerative colitis had significant histological

Table 2 Prevalence of primary sclerosing cholangitis in patients with ulcerative colitis.

Country of origin	No. of patients with ulcerative colitis	Percentage with primary sclerosing cholangitis
Oxford, UK [3]	681	2.9
Oslo, Norway [5]	336	5
Stockholm, Sweden [6]	1500	3.7 (5.5 in total colitis)

abnormalities on hepatic histology compared with 10% of 100 unselected patients with Crohn's disease; none of these patients underwent cholangiography [3,4]. A group of 336 Norwegian patients with ulcerative colitis and persistently abnormal liver function tests were investigated using cholangiography [5]. This study found that more than 14% of patients had some form of hepatobiliary disease and 5% of all patients had PSC, although most were asymptomatic (Table 2).

Similar results were obtained in 1500 Swedish patients with ulcerative colitis [6]. In this thorough study, endoscopic cholangiography was obtained in 65 out of 72 patients with elevated values of serum alkaline phosphatase. PSC was diagnosed in 3.7% of the ulcerative colitis group. The prevalence was 5.5% in patients with extensive colitis and only 0.5% in patients with distal disease [6]. This figure may be an underestimate, as a study from the Mayo Clinic has shown that standard liver function tests may be normal despite the presence of PSC on cholangiography [7].

PSC is also associated with Crohn's disease, but has only been reported in patients with extensive colonic involvement. One study from Norway has suggested that PSC is as common in patients with colonic Crohn's disease as it is in ulcerative colitis [8]. Although studies to date have suggested a prevalence of 1.3–13% of PSC among Crohn's patients, some of the patients with PSC were diagnosed as Crohn's disease solely on the basis of rectal sparing, which is observed in 25% of patients with PSC and ulcerative colitis [8,9]. It is likely, therefore, that the prevalence of Crohn's disease may have been overestimated in PSC patients.

The prevalence of hepatobiliary abnormalities with normal liver function tests in patients with ulcerative colitis has been investigated in a study from Sweden [10]. Liver biopsies were assessed from 74 patients with ulcerative colitis and normal liver function tests. A total of 50% had a completely normal liver biopsy. The biopsies of three patients with total colitis displayed concentric periductular fibrosis, and the rest showed minimal portal inflammation or fatty infiltration. The patients were then followed for a mean of 18 years. None of the three patients with concentric fibrosis developed abnormal liver function tests, although cholangiography was not performed. Two other patients developed liver disease, cirrhosis in one and autoimmune chronic hepatitis and cholangiocarcinoma in the other.

In summary, approximately 5% of adult patients with inflammatory bowel disease will have significant hepatobiliary disease. Although the number of patients with hepatobiliary abnormality is approximately the same for ulcerative colitis and Crohn's disease, severe significant liver disease is more commonly seen in patients with ulcerative colitis and, when it occurs in Crohn's disease, it is usually associated with extensive colonic involvement.

Primary sclerosing cholangitis

PSC is a chronic cholestatic liver disease characterized by an obliterative inflammatory fibrosis that usually involves the whole biliary tree (Fig. 1), although the changes may sometimes be localized to either the extra- or intrahepatic bile ducts and the degree of involvement varies from patient to patient. The true prevalence of PSC associated with inflammatory bowel disease is unknown. As stated previously, there is an estimated 2.4–7.5% prevalence of PSC in patients with ulcerative colitis. The prevalence of PSC in the United States has been estimated to be 2–7 cases per 100 000 population, based on a prevalence of ulcerative

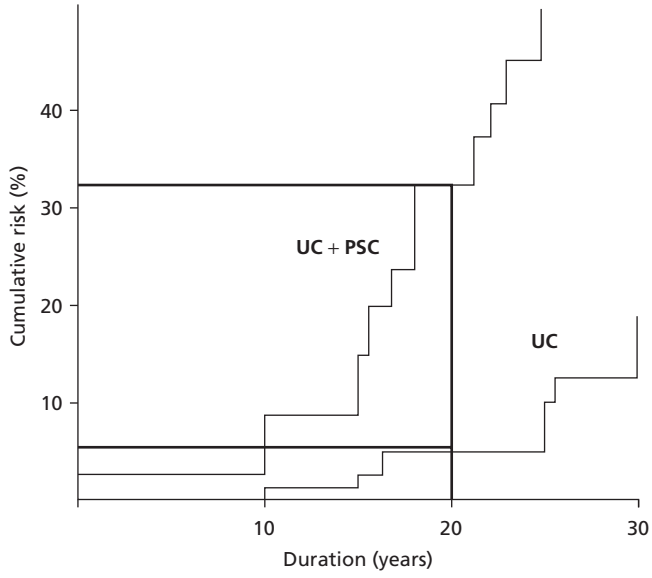

Fig. 1 The cumulative risk of developing colonic or biliary dysplasia in 40 patients with primary sclerosing cholangitis (PSC) and ulcerative colitis (UC), compared with 80 matched controls with UC alone. (From ref. 27, with permission.)

Table 3 Prevalence of inflammatory bowel disease (IBD) in patients with primary sclerosing cholangitis (PSC).

Institution (country of origin)	No. of patients with (PSC)	Percentage with IBD
Royal Free Hospital (UK) [10]	29	72
Mayo Clinic (USA) [9]	50	70
Huddinge (Sweden)	305	72
King's College London (UK – children)	13	77
Okolicsanyi (Italy) [14]	82	54
Escorsell (Spain) [13]	43	47

colitis of 40–225 cases per 100 000. This estimate has been confirmed by the results from Olsson *et al.* [6], who noted the prevalence of ulcerative colitis and PSC to be 171 and 6.3 cases per 100 000 population respectively. The most recent data from Norway found a prevalence of 8.5 cases of PSC per 100 000 population [12]. These results, however, probably underestimate the actual prevalence of PSC, as the disease can occur in patients with normal serum levels of alkaline phosphatase, and 20–30% of patients with PSC have no associated inflammatory bowel disease. PSC is more common than previously suspected and may have a frequency similar to that of primary biliary cirrhosis.

The relationship of primary sclerosing cholangitis with inflammatory bowel disease

Association with ulcerative colitis

Approximately 70% of northern European patients with PSC have coexisting ulcerative colitis, and PSC is the most common form of chronic liver disease found in ulcerative colitis [9,12] (Table 3). Studies from southern Europe, however, have found that only 36–44% of patients with PSC have underlying ulcerative colitis, although not all patients in these studies underwent total colonoscopy and colonic biopsies [13,14]. Data from Japan suggest that the relationship is even weaker with only 20% of PSC patients having a diagnosis of ulcerative colitis [15].

Interestingly, patients with ulcerative colitis and PSC have a male predominance, with a male:female ratio of 2:1, which is in contrast to the slight female predominance of ulcerative colitis in isolation [16,17].

Smoking

Cigarette smoking has been recognized as a protective factor against the development of ulcerative colitis. Three studies have suggested that cigarette smoking may also additionally protect against the development of PSC. Moreover, this protective effect was more marked in patients with PSC than in those with ulcerative colitis and was seen in patients with and without inflammatory bowel disease (IBD) [18–20]. The mechanism of protection in both disorders remains unknown.

Onset

Although the symptoms of ulcerative colitis usually develop before those of sclerosing cholangitis, in some patients, the onset of PSC may precede the symptoms of colitis by up to 4 years. Although large-scale studies have not been performed, there is some evidence that the prevalence of liver abnormality may be higher in children than in adults with colitis. Abnormal liver function tests were detected in 60% of 34 children with ulcerative colitis; abnormalities were most commonly seen in total colitis. Cholangiography was only performed in two patients, one of whom had sclerosing cholangitis [21].

Outcome

The outcome of the hepatobiliary disease is completely unrelated to the activity, severity or clinical course of the colitis. This is borne out by the fact that colectomy makes no difference to the clinical progression or to the mortality of patients with PSC. Indeed, liver disease may develop some years after a total colectomy has been performed [22]. Patients with combined ulcerative colitis and PSC may have a worse prognosis from liver disease than patients with PSC alone [17]. Involvement of the extrahepatic bile ducts alone is more frequently seen in patients who do not have IBD [17].

Comparison of IBD in patients with and without PSC

In a recent study, the clinical and endoscopic features of IBD were compared in IBD patients with and without PSC. Rectal sparing and backwash ileitis were more common in the PSC group (52% and 51% respectively) than in control subjects (6% and 7.5% respectively) with IBD alone [23].

Many studies from different parts of the world have reviewed the clinical features of patients with ulcerative colitis and PSC. The findings from all studies have been remarkably consistent. Paradoxically, the colitis is usually total but symptomatically mild, often with no rectal bleeding, and is often characterized by prolonged remissions [16,24,25].

In a Swedish study of 76 patients with PSC, 11 had no symptoms or past history of IBD. Nine of these patients underwent

Table 4 Clinical, endoscopic and histological findings that characterize PSC-IBD.

Male predominance
Quiescent colitis
Pancolitis
Rectal sparing
Backwash ileitis
Pouchitis
Colorectal dysplasia/carcinoma
Different extracolonic manifestations

total colonoscopy and multiple biopsies. Seven had endoscopic and/or histological evidence of IBD [24]. Indeed, two out of nine patients already had dysplasia. Given that rectal sparing is a common feature, all newly diagnosed PSC patients should undergo total colonoscopy as fibreoptic sigmoidoscopy is insufficient to accurately diagnose IBD. This characteristic clinical phenotype has led to the suggestion that IBD associated with PSC represents a clinically distinct form of IBD called PSC-IBD [23] (Table 4).

Biliary and colorectal cancer in ulcerative colitis and PSC

The association between ulcerative colitis and colorectal carcinoma has been recognized since the 1920s [26]. In 1995, Broome *et al.* [27] suggested that there was an increased risk of colorectal neoplasia in patients with concomitant PSC. This hypothesis has been extensively tested since then with conflicting data sets published in recent years. Most experts currently agree that PSC is an independent risk factor for developing colorectal carcinoma [28]. The possible mechanisms for the increased susceptibility to neoplasia are not clear, but genetic predisposition, alterations in the bile salt pool due to cholestasis and folate deficiency are all possibilities [29]. Recent studies have suggested that ursodeoxycholic acid therapy may reduce the risk of developing colorectal cancer [30,31]. Annual colonoscopy is recommended in patients with ulcerative colitis and PSC.

Two recent studies have shown that PSC patients consistently develop a more proximal colorectal carcinoma than patients with ulcerative colitis alone [32,33]. This observation may be explained by the higher exposure of the right side of the colon to the carcinogenic properties of the secondary bile acids produced in cholestasis, although this hypothesis remains unproven. The increased risk of carcinoma of the bile ducts including gallbladder carcinoma in patients with ulcerative colitis is also well established and appears now to occur almost exclusively in the context of pre-existing PSC. Furthermore, one study has suggested that cholangiocarcinoma develops significantly more often in patients with colonic dysplasia or carcinoma, thus suggesting that these patients may constitute a high-risk subgroup requiring increased colonic and biliary surveillance [34]. However, further prospective studies are needed to confirm these findings.

Liver transplantation in PSC patients with ulcerative colitis

Orthotopic liver transplantation (OLT) is the only effective treatment for PSC. The presence of IBD does not affect the outcome, but is associated with a higher rate of severe acute graft rejection [35,36]. Surprisingly, there is some evidence that the clinical course of IBD worsens post-transplant, despite the immunosuppression given to protect the graft from rejection. In different series, there is a highly variable course of IBD after liver transplantation. In a study by Maclean *et al.* [35], one-third improved, one-third remained stable and one-third worsened. A series published by the Royal Free Hospital found an increase in the clinical activity of the associated colitis in 8 out of 16 patients transplanted for PSC [36]. Similar data have been published from Birmingham with 9 out of 26 (35%) patients noticing a worsening of their symptoms of IBD [33]. In contrast, Gavaler *et al.* [37] and Shaked *et al.* [38] found no worsening of IBD symptoms post-transplant in 23 and 24 patients respectively. These conflicting data may be explained, in part, by the differences in immunosuppressive regimens used post-transplantation. The Royal Free and Birmingham centres usually withdraw steroids early and maintain immunosuppression with ciclosporin or tacrolimus with or without azathioprine. The Gavaler and Shaked reports are from units where steroids are used as maintenance immunosuppression. However, other factors such as the presence of cytomegalovirus, cessation of smoking and variable use of 5-aminosalicylate (5ASA) after transplantation may also be important.

Recent reports suggest that PSC recurs in 30% of patients post-transplantation after 5 years and that recurrence is commonest in male patients with ulcerative colitis with an intact colon [39,40].

The risk of colon cancer in PSC patients increases after transplantation, occurring most commonly in the early postoperative period, and is probably associated with high-level immunosuppression accelerating the growth of malignant cells. Colonoscopy with extensive mucosal biopsies is therefore recommended prior to transplantation and annually thereafter in this particularly high-risk group [41–44].

Pouchitis

Patients with ulcerative colitis treated by colectomy with an ileal reservoir (pouch) are sometimes affected by a non-specific inflammation of the pouch (pouchitis). This complication is much more common in patients with PSC and ulcerative colitis (64% of patients affected) than in those with ulcerative colitis alone (32% of patients affected) [45], and is the major complication of this operation. The risk of pouchitis is not related to the severity of the liver disease [45]. Prior to the development of pouch operations, the Brooke ileostomy was the most com-

monly performed operation for ulcerative colitis. In patients with coexistent PSC, however, peristomal varices occur in approximately 25% of cases, and bleeding from these varices can be difficult to manage [21,46]. Although the intra- and postoperative complication rate and mortality are comparable in the two operations, pouchitis tends to present a less difficult management problem than recurrent peristomal variceal bleeds and, therefore, ileal pouch–anal anastomosis is usually the operation of choice in these patients.

Association with Crohn's disease

PSC is associated with Crohn's disease, although most authorities suggest that the prevalence is lower than for ulcerative colitis, and the prevalence of bile duct carcinoma is lower in Crohn's disease [8–10]. The explanation for these apparent differences in prevalence between the two inflammatory bowel diseases is unclear, but may be related to the less frequent occurrence of total colonic involvement in patients with Crohn's disease. As discussed earlier, one study from Norway has suggested that PSC is as common in patients with colonic Crohn's disease as it is in ulcerative colitis [8]. Although studies to date have suggested a prevalence of 1.3–13% of PSC among Crohn's patients, some of the patients with PSC were diagnosed as Crohn's disease solely on the basis of rectal sparing, which is observed in 25% of patients with PSC and ulcerative colitis [8–10]. This may also explain why typical perianal disease and colonic stricturing are said to be rarely seen in Crohn's patients with PSC. It is likely, therefore, that the prevalence of Crohn's disease may have been overestimated in PSC patients.

Small duct PSC: 'pericholangitis'

Pericholangitis is a histological diagnostic term that has been used to describe inflammatory reactions in the portal zones of the liver, which are characterized by periductal inflammation and fibrosis. For many years, the term 'pericholangitis' has been synonymous with involvement of the liver in IBD [47,48]. Some patients with pericholangitis were reported to progress to cirrhosis of the liver and cholangiocarcinoma [49]. However, it has become clear that the majority of patients with histological pericholangitis and persistently abnormal liver function tests will have cholangiographic appearances diagnostic of PSC at endoscopic retrograde cholangiography [50,51]. A minority of patients with ulcerative colitis will have persistently abnormal liver function tests, together with histological appearances such as concentric fibrosis, but have normal bile ducts at cholangiography. The term 'small duct PSC' has been proposed to replace the term 'pericholangitis' in this group of patients, as the evidence suggests that these conditions are all part of the same disease spectrum. Wee and Ludwig [52] have described two patients who progressed from small duct PSC to develop extrahepatic biliary involvement diagnostic of sclerosing cholangitis.

A number of other portal tract lesions, such as chronic periportal inflammation and/or increased cellularity of portal tracts, have also been described as 'pericholangitis' in patients with ulcerative colitis [53].

In view of the confusing use of the term pericholangitis, which has been applied to a heterogeneous mixture of hepatobiliary disorders by different authors, it has been proposed that the term and concept of pericholangitis should be abandoned [54]. Three recent studies from different units have shown that the prognosis of small duct PSC is far better than that of large duct disease with a higher proportion of Crohn's (50%) and only approximately 25% of patients progressing to large duct disease [54,55]. Importantly, no patients developed cholangiocarcinoma.

Autoimmune hepatitis

Autoimmune hepatitis has been reported to occur in association with ulcerative colitis [56]. However, interface hepatitis (piecemeal necrosis) on liver histology can accompany the classic bile duct changes of PSC on cholangiography [12], and it seems likely that the majority of patients with autoimmune hepatitis and IBD will have either large or small duct PSC. The diagnosis of autoimmune hepatitis should not be made in patients with IBD unless cholangiography is normal. The diagnostic difficulties are compounded by the presence of circulating serum autoantibodies, such as antinuclear antibodies, smooth muscle antibodies, antineutrophil cytoplasmic antibodies, and elevated serum immunoglobulins in some patients with PSC [57]. Moreover, both autoimmune hepatitis and PSC are associated with an increased prevalence of the tissue antigens human leukocyte antigen (HLA) B8 and HLA DR3 [31], and overlap syndromes exist [58]. It is unclear from current evidence whether the prevalence of autoimmune hepatitis without underlying sclerosing cholangitis is increased in patients with IBD.

Cirrhosis

The incidence of cirrhosis associated with IBD has varied between 1% and 5% in different series [59–62]. Most patients in these reports are classified as having biliary cirrhosis and, as patients with sclerosing cholangitis can present with portal hypertension and established cirrhosis with no preceding symptoms, it seems likely that the majority of these patients will have underlying endstage PSC. However, not all patients with cirrhosis and IBD will have PSC, and it is possible that some cases may be due to chronic hepatitis C infection [63] associated with previous blood transfusions. Patients with cirrhosis may present with the typical symptoms of liver failure including jaundice, ascites and variceal haemorrhage. Although the variceal bleeding usually occurs from veins in the oesophagus, patients with concomitant IBD who have undergone total proctocolectomy may bleed from peristomal varices some 6–13 years after formation of the ileostomy stoma [21].

Cholangiocarcinoma

Cholangiocarcinoma in ulcerative colitis usually occurs in the context of pre-existing PSC and is therefore associated with longstanding total colitis. A large study from the Cleveland Clinic has reported a prevalence rate of 0.5% [64]. The prevalence of cholangiocarcinoma in patients with PSC and IBD ranges from 7% to 13% [65]. Bile duct carcinoma has been reported in association with Crohn's disease, but it occurs much more rarely [66,67].

The clinical presentation of bile duct cancer is usually that of a progressive cholestatic jaundice. Diagnosis of cholangiocarcinoma in the context of PSC can be extremely difficult. Cholangiography usually reveals a particularly narrow bile duct stricture. Brush cytology obtained endoscopically may be useful in confirming malignancy but suffers from low sensitivity. Computerized tomography (CT) scanning showing intrahepatic bile duct dilatation is suggestive but not diagnostic of malignant change. Positron emission tomography (PET) scanning has been used with some success in the early diagnosis of small cholangiocarcinomas and may become a useful tool in differentiating benign and malignant strictures [68], although a recent study has not been confirmatory [69].

The tumour usually pursues a progressive course, and the prognosis is very poor, with a median survival of 9 months [70]. Liver transplantation for isolated cholangiocarcinoma occurring in PSC, as discussed previously, has been disappointing with rapid recurrence of tumour [71].

There has been considerable interest in developing a laboratory test to detect early cholangiocarcinoma in patients with PSC. A combination of the serum tumour markers carcinoembryonic antigen (CEA) and CA19-9 was thought to be promising but appears to lack specificity and sensitivity in detecting small tumours [72]. There is currently no evidence that CA19-9 identifies patients at an early stage with localized cholangiocarcinoma or biliary dysplasia who would benefit from surgery [73].

New techniques are currently being evaluated for the detection and characterization of biliary dysplasia. If vulnerable dysplastic tissue can be reliably identified on liver biopsy specimens, liver transplantation should be possible to prevent the subsequent development of neoplastic change. Unfortunately, the current cytobrush specimen usually taken from suspicious areas at endoscopic retrograde cholangiopancreatography (ERCP) is usually inadequate for definitive diagnosis of dysplasia and much less so for distinguishing which subjects with dysplasia are most likely to progress quickly. Serial collection of material from the suspicious area and genetic analysis may in the future allow the likelihood of progression to cholangiocarcinoma to be predicted [74].

Hepatocellular carcinoma

Two case reports have described the development of fibrolamellar hepatocellular cancer in male patients with ulcerative colitis and PSC. Neither patient was cirrhotic [75,76]. In the single patient who received a transplant, the tumour recurred in the donor liver [76]. In common with most causes of chronic liver disease, patients with PSC and established cirrhosis have an increased risk of developing primary liver cell cancer [77].

Fatty change

Fatty liver or steatosis is the most common type of hepatobiliary lesion found in patients who have IBD. It has been recorded as occurring in 45% of patients with ulcerative colitis who undergo colectomy [78] and in 40% of patients with Crohn's disease who undergo similar surgery [79]. The presence of fatty liver is related to the general state of health of these patients and the severity of the underlying colitis rather than any other specific factor. In an unselected Italian series, of 583 consecutive patients with IBD studied by ultrasonography, fatty liver was found in 35.5% and 39.5% of patients with ulcerative colitis and Crohn's disease respectively [80].

The pathogenesis of fatty liver in IBD is unknown. It is probably multifactorial, secondary to causes such as poor nutrition, drugs, bacterial and chemical toxins, and unsuspected alcohol abuse. The steatosis is usually of the macrovesicular type, and all types of distribution, including diffuse, periportal and centrolobular, have been described in patients with IBD.

There are no symptoms associated with fatty liver, although, on abdominal examination, hepatomegaly may be detected. Treatment of the underlying bowel disorder and improvement in the general health of the patient will normally result in a resolution of the fatty change. There is no evidence that the lesion progresses to chronic liver disease. In view of improvements in the management of IBD, the incidence of fatty change has probably fallen.

Gallstones

Patients with Crohn's disease of the small bowel have an increased incidence of gallstones. The reported incidence in patients with Crohn's ileitis, ileal resection or intestinal bypass ranges from 13% to 34% [81–84]. However, the incidence of gallstones in patients with ulcerative colitis and those with Crohn's disease confined to the colon is approximately 5% and does not differ from that of the general population. Total colectomy with ileoanal anastomosis does not predispose to the formation of cholesterol gallstones [85]. The increased rate of formation of gallstones in patients with inflammation or absence of the terminal ileum is due to a reduction in bile salt absorption, leading to depletion of the bile salt pool. As a result, the concentration of biliary bile salts falls, and there is a relative increase in the concentration of biliary cholesterol. Thus, bile may become supersaturated with cholesterol, which in turn increases cholesterol precipitation in the gallbladder and predisposes to the formation of cholesterol gallstones. There may be additional factors predisposing to gallstones in these patients.

One study has demonstrated impaired gallbladder contractibility, most marked in patients who have undergone bowel resection or who have both large and small bowel disease [86].

Amyloidosis

Hepatic amyloidosis is a rare complication, occurring in less than 1% of patients with IBD; it is much more commonly associated with Crohn's disease than ulcerative colitis. The development of amyloid can occur in association with Crohn's disease involving either the small or the large bowel.

The amyloid deposition in the liver is found in the media of portal blood vessels and in the sinusoidal wall, and eventually leads to atrophy and disappearance of hepatocytes. In addition to IBD, most patients who develop amyloidosis have either extraintestinal foci of suppuration or arthropathy. In addition, most Crohn's disease patients who develop amyloid have chronically active disease. Aggressive anti-inflammatory treatment of the intestinal lesions probably reduces the chance of developing systemic amyloid. More effective recent treatment probably accounts for the reduced prevalence of amyloid. Although regression of amyloidosis has been reported after colectomy in the majority of patients, the prognosis is poor [87].

Granulomas

Granulomas are occasionally seen in the liver biopsy specimens of patients with Crohn's disease, some of whom may show a moderate elevation in serum alkaline phosphatase [88]. The granulomas can be present in portal tracts as well as in the parenchyma. The presence of hepatic granulomas in patients with Crohn's disease often reflects granulomas in the bowel [88]. There have been a few isolated reports of hepatic granulomas occurring in association with ulcerative colitis, but the relationship remains unproven. Granulomas are found in 3–4% of liver biopsies from patients with PSC [89].

Liver abscess

Intra-abdominal abscess is a frequent complication of Crohn's disease. However, the development of hepatic abscess in association with IBD is very uncommon. The abscesses are often multiple and are associated with a high mortality [90]. Streptococci, especially *Streptococcus milleri*, are the most frequent organisms isolated from the abscesses [91].

Primary biliary cirrhosis

A total of 18 patients have been described with concomitant ulcerative colitis and primary biliary cirrhosis [92]. In 13 out of the 18 patients, the IBD occurred first. The prevalence of primary biliary cirrhosis in ulcerative colitis appears to be 30 times higher than in the general population, and there may be a true immunological link between the two diseases [92].

Budd–Chiari syndrome

At least five patients with active ulcerative colitis have now been reported who have developed hepatic vein thrombosis and the clinical symptoms and signs of Budd–Chiari syndrome. Four of the five had no known risk factors for venous thrombosis [93–94]. The most recent patient reported was found to have positive anticardiolipin antibodies [95]. There has also been one report of Budd–Chiari syndrome in association with Crohn's disease [96].

Drug-induced hepatitis

There have been a few case reports of drug-induced hepatitis in patients with IBD with mesalazine, sulphasalazine and azathioprine all having been implicated [97–101]. In practical terms, however, drug toxicity is a rare cause of hepatic injury in the context of IBD.

The effect of malabsorption syndromes on the hepatobiliary system

There are a large number of hepatobiliary abnormalities that may occur in patients with various malabsorptive disorders (Table 5). The hepatobiliary abnormalities are subdivided into those that are closely associated with the primary disease process and those in which the liver dysfunction is due to the secondary

Table 5 Prevalence of liver test abnormalities in patients with coeliac disease.

Series	Coeliac patients tested (*n*)	Abnormal liver biochemistry, *n* (%)	Elevated transaminases[a]	Response to treatment, *n* (%)
Hagander *et al.* [104]	53/75	29 (39)	Yes	19 (100)
Jacobsen *et al.* [106]	132	62 (47)	Yes (isolated elevated ALP in 14)	24–32 (75)
Bodé and Gudmand-Høyer [110]	50	? (19) [sic]	Yes	–
Bardella *et al.* [107]	158	67 (42)	Yes	60/67 (95)
Novacek *et al.* [108]	178	72 (40)	Yes	64/72 (89)
Mugica *et al.* [119]	20	8 (40)	Yes	–

[a]In all cases, alanine aminotransferase (ALT) > aspartate aminotransferase (AST). ALP, alkaline phosphatase.

nutritional consequences of malabsorption rather than the primary gut disease itself. This section will concentrate mainly on those liver abnormalities associated with primary gut disease. The effects of malnutrition on the liver have been described in Chapter 20.4.

Coeliac disease and the liver

Unlike IBD, the relationship between coeliac disease and liver disease has not been extensively studied [102]. The association was first reported by Pollock in 1977 [103]: two out of five coeliac patients had chronic hepatitis, one of whom had cirrhosis and hepatoma. Subsequent studies of the incidence and exact nature of chronic liver disorders that occur in association with coeliac disease have been few. However, all the reports have documented frequent abnormalities in liver biochemical tests in coeliac patients, particularly elevated transaminases (Table 5).

In a Swedish study, Hagander *et al.* [104] examined the case records of 74 consecutive adult patients with coeliac disease. Abnormalities of liver function tests were found in 39% of the 74 patients and histological evidence of liver injury in 16%. Liver biopsies were obtained in 13 patients; seven of these were found to have cirrhosis and/or chronic active hepatitis and five were described as having 'reactive hepatitis'. Three of the patients with cirrhosis subsequently died of the effects of chronic liver disease [100]. In 19 of the 29 patients with elevated serum enzymes, several of the levels were measured before and after the institution of a gluten-free diet. A significant reduction was observed in many patients after gluten withdrawal.

In another early Scandinavian study from Lindberg *et al.* [105], elevated aminotransferase levels were noted not only in children with coeliac disease, but also in children with allergies to cow's milk and other proteins. It was suggested that the development of hepatic dysfunction in this context was related to the severity of the mucosal lesion rather than the specific disease entity. In a study of 132 patients with coeliac disease, 47% had elevated liver function tests [105]. Liver biopsies were performed in 37 patients and findings were normal in five; nonspecific changes were described in 25 patients and chronic active hepatitis was demonstrated in five patients [105]. It is unclear from published data whether the incidence of chronic active hepatitis is truly increased in patients with coeliac disease, although both disorders are associated with the HLA B8, DR3 haplotype.

Coeliac patients with liver test abnormalities have similar clinical features to other coeliac patients. An Italian study of 158 consecutive adult coeliac patients compared the 67 (42%) with elevated transaminases with those with normal tests at presentation (58%) [106]. The two groups were indistinguishable on anthropomorphic, epidemiological and histological criteria [106].

Improvement in the biochemical abnormalities after the introduction of a gluten-free diet may take up to 1 year. Seventy-two patients with elevated transaminases were followed with sequential biochemical tests; 17 were still abnormal at 3 months, 13 at 6 months and 8 at 12 months [107]. This study is supported by a further report of 72 out of 178 consecutive adult coeliac patients with elevated transaminases [107]. Only eight patients had abnormal transaminases at 1 year, and an alternative diagnosis was established in all [107].

While the above and other studies have established that untreated coeliac disease is associated with elevated liver transaminases [108–110] (Table 5), it remains controversial whether coeliac disease leads to chronic liver disease and liver failure [99]. However, there is a clear association between coeliac disease and autoimmune cholestatic liver disease. The first report of primary biliary disease (primary biliary cirrhosis) associated with coeliac disease in 1978 [111] has led to a number of confirmatory studies from various European countries [112–114].

In 1988, three patients were reported with coexisting coeliac disease and PSC; two of the patients were suffering from ulcerative colitis [115] and were confirmed in other studies [116]. In a recent population-based study, 4732 coeliac patients were compared with 23 620 age- and sex-matched control subjects [117]; there was a higher prevalence of both primary biliary cirrhosis and PSC compared with the general population. However, in view of the relatively low prevalence rates (0.17% and 0.04% respectively), it was concluded that routine screening for autoimmune cholestatic liver diseases was not justified in a coeliac population [117].

In the converse situation, patients with chronic liver disease appear to have a higher prevalence of coeliac disease than expected compared with a general population [118,119]. The prevalence was increased 15-fold in a Swedish population of chronic liver disease patients [120] and 4–10 times in a Finnish report [121]. Moreover, there is a suggestion from the Finnish study that untreated or non-compliant coeliac disease may worsen the clinical course of patients with chronic liver disease [121].

Gallbladder contractility is sluggish in untreated coeliac disease [122], probably as a result of impaired release of cholecystokinin from the diseased small intestine [123]. However, there is no evidence to suggest an increased incidence of gallstones in coeliac disease.

Tropical sprue and hepatic dysfunction

Very few studies of liver function have been reported in patients with tropical sprue. In one study, liver function tests and liver biopsies were performed in eight patients with mild to severe tropical sprue [124]. Only minimal abnormalities in liver function were noted, and no significant changes were found on hepatic histology.

Whipple's disease and the liver

The liver is involved in most patients with Whipple's disease [125]. The characteristic macrophages positive for periodic

acid–Schiff staining are usually seen on liver biopsy, and are most frequently observed in the Kupffer cells [125].

Cystic fibrosis (see also Chapter 16.4)

Approximately 7–10% of patients with cystic fibrosis develop a biliary cirrhosis, often preceded by cholestasis and fatty liver [126]. There is an increased prevalence among male patients bearing the haplotype B7, DR15, DQ6 [126]. A prior history of meconium ileus is also associated with liver disease in later life [127]. Strictures of the distal common bile duct are common [128], but these stenoses probably do not contribute to the development of significant liver disease. In a cholangiographic study of 104 adult patients with cystic fibrosis, those with significant liver disease had biliary changes confined to the intrahepatic biliary tree [129].

Although it is unpredictable, cirrhosis may develop between 4 and 15 years of age, and some patients suffer from bleeding oesophageal varices secondary to portal hypertension [130].

Treatment with high-dose ursodeoxycholic acid (18–22 mg/kg/day [131]) has been shown to improve liver function tests, but it has no effect on nutritional status in malnourished patients [132]. Longer term studies are needed to assess the effects of ursodeoxycholic acid on the prognosis of the liver disease.

Hepatobiliary disease after surgical bypass operations for obesity

A number of surgical procedures have been tried for the treatment of morbid obesity. From the mid-1950s to the mid-1970s, the jejunoileal bypass operation was widely performed. In this procedure, the proximal jejunum is anastomosed to the terminal 10 cm of distal ileum. The subsequent profound malabsorption produces significant weight loss in the majority of patients. However, in view of serious hepatic side-effects, the operation has largely been abandoned and replaced by gastric procedures that have few or no serious liver complications.

The cause of hepatic damage following jejunoileal bypass is unknown. A number of possible mechanisms have been advanced including: (i) bacterial overgrowth of the isolated intestinal segment leading to production of hepatotoxins; (ii) malnutrition caused by the malabsorption; and (iii) miscellaneous causes such as concurrent viral infections or toxicity due to anaesthetic agents. There is no convincing evidence in favour of any of these theories.

The majority of patients undergoing jejunoileal bypass will develop mild elevations in serum transaminases, although the enzymes usually return to normal after stabilization of body weight. However, approximately 5% of patients who have undergone jejunoileal bypass will develop significant liver injury [133]. The symptoms of liver dysfunction are non-specific and include malaise, anorexia, nausea and vomiting.

There is often a disparity between serum biochemical tests and the severity of hepatic injury judged histologically [134], although patients with severe liver damage usually have hypoalbuminaemia, coagulopathy and elevated aminotransferase and bilirubin levels. The presence of an elevated serum bilirubin at 3 months following a bypass procedure is associated with a poor prognosis; indeed, a level of 50 mmol/L or more carries a mortality rate of 50–75% [135].

Most obese patients will have a fatty liver before surgery, although there is no correlation between the amount of fat present in the liver biopsy and the degree of obesity. The severity of fatty liver is increased by jejunoileal bypass surgery. Some patients develop more severe liver injury with evidence of periductular fibrosis, portal inflammation and bile duct proliferation. Occasionally, a non-alcoholic steatohepatitis (NASH)-type histological picture similar to alcoholic hepatitis may develop, with infiltration of neutrophil polymorphs, Mallory body formation and hepatic necrosis. The presence of pericentral fibrosis often precedes the development of cirrhosis [136]. These various types of hepatic injury are sometimes seen in obese patients who have not undergone bypass surgery, particularly in the presence of diabetes mellitus and in patients who have undergone massive small bowel resection with short bowel syndrome [137].

Significant liver damage usually occurs within 3–12 months after intestinal bypass [138]. Initial treatment is usually carried out by means of hyperalimentation [139], but reanastomosis may be required if no improvement is seen. The response of the hepatic damage to reanastomosis is unclear [140].

References

1 Thomas CH (1873) Ulceration of the colon with a much enlarged fatty liver. *Trans Pathol Soc Philadelphia* 4, 87–88.

2 Lister JD [1988] A specimen of diffuse ulcerative colitis with secondary diffuse hepatitis. *Trans Pathol Soc London* 50, 130–135.

3 Perret AD, Higgins G, Johnston HH *et al.* (1971) The liver in ulcerative colitis. *Q Med* 40, 211–238.

4 Perret AD, Higgins G, Johnston HH *et al.* (1971) The liver in Crohn's disease. *Q Med* 40, 187–209.

5 Schrumpf E, Fausa O, Kolmannskog F *et al.* (1982) Sclerosing cholangitis in ulcerative colitis. A follow-up study. *Scand Gastroenterol* 17, 33–39.

6 Olsson R, Danielson A, Jarnerot G *et al.* (1991) Prevalence of primary sclerosing cholangitis in patients with ulcerative colitis. *Gastroenterology* 100, 1319–1323.

7 Balasubramaniam K, Wiesner RH, LaRusso NF (1988) Primary sclerosing cholangitis with normal serum levels of alkaline phosphatase. *Gastroenterology* 95, 1395–1398.

8 Rasmussen HH, Fallingborg JF, Mortensen PB *et al.* (1997) Hepatobiliary dysfunction and primary sclerosing cholangitis in patients with Crohn's disease. *Scand J Gastroenterol* 32, 604–610.

9 Wiesner RH, LaRusso NF (1980) Clinicopathologic features of the syndrome of primary sclerosing cholangitis. *Gastroenterology* 79, 200–206.

10 Broome V, Glaumann H, Hultcrantz R (1990) Liver histology and follow-up of 68 patients with ulcerative colitis and normal liver function tests. *Gut* 31, 468–472.

11 Boberg KM, Aadland E, Jahnsen J *et al.* (1998) Incidence and prevalence of primary biliary cirrhosis, primary sclerosing cholangitis

and autoimmune hepatitis in a Norwegian population. *Scand J Gastroenterol* 33, 99–103.

12 Chapman RW, Arborgh BA, Rhodes JM *et al.* (1980) Primary sclerosing cholangitis – a review of its clinical features, cholangiography and hepatic histology. *Gut* 21, 870–877.

13 Escorsell A, Pares A, Rodes J *et al.* (1994) Epidemiology of primary sclerosing cholangitis in Spain. *J Hepatol* 21, 787–791.

14 Okolicsanyi L, Fabris L, Viaggi S *et al.* (1996) Primary Italian multicentre study. The Italian PSC Study Group. *Eur J Gastroenterol Hepatol* 8(7), 685–691.

15 Takikawa H (1999) Recent status of primary sclerosing cholangitis in Japan. *J Hepat Bil Panc Surg* 6(4), 352–355.

16 Lundgrist K, Broome U (1997) Differences in colonic disease activity in patients with primary sclerosing cholangitis. *Dis Colon Rectum* 40, 1–6.

17 Rabinovitz M, Gavalier JS, Schade RR *et al.* (1991) Does primary sclerosing cholangitis occurring in association with inflammatory bowel disease differ from that occurring in the absence of inflammatory bowel disease. *Hepatology* 11, 7–11.

18 Loftus EV Jr, Sandborn WJ, Tremaine WJ *et al.* (1996) Primary sclerosing cholangitis is associated with non-smoking: a case–control study. *Gastroenterology* 110, 1496–1502.

19 Van Erpecium KJ, Smits SJ, Van-de-Meeberg PC *et al.* (1996) Risk of primary sclerosing cholangitis is associated with non-smoking behaviour. *Gastroenterology* 110, 1503–1506.

20 Mitchell SA, Thyssen M, Orchard TR *et al.* (2002) Cigarette smoking, appendicectomy and tonsillectomy as risk factors for the development of primary sclerosing cholangitis. *Gut* 51, 567–573.

21 Nemeth A, Ejderhamn J, Glaumann H *et al.* (1990) Liver damage in juvenile inflammatory bowel disease. *Liver* 10, 239–248.

22 Wiesner RH, La Russo NF, Dozois RR *et al.* (1986) Peristomal varices after proctocolectomy in patients with primary sclerosing cholangitis. *Gastroenterology* 90, 316–322.

23 Loftus EV Jr, Harewood GC, Loftus CG *et al.* (2005) PSC-IBD, a unique form of inflammatory bowel disease associated with primary sclerosing cholangitis. *Gut* 54, 91–96.

24 Broome U, Lofberg R, Lundqvist K *et al.* (1995) Subclinical time span of inflammatory bowel disease in patients with primary sclerosing cholangitis. *Dis Colon Rectum* 38, 1301–1305.

25 Moayyeri A, Daryani NE, Bahrami H *et al.* (2005) Clinical course of ulcerative colitis in patients with and without primary sclerosing cholangitis. *J Gastroenterol Hepatol* 20, 366–370.

26 Bargen JA (1928) Chronic ulcerative colitis associated with malignant change. *Arch Surg* 17, 561–576.

27 Broome U, Lofberg R, Veress B *et al.* (1995) Primary sclerosing cholangitis: evidence for increased neoplastic potential. *Hepatology* 22, 1404–1408.

28 Jayaram H, Satsangi J, Chapman RWG (2001) Increased colorectal neoplasia in chronic ulcerative colitis complicated by primary sclerosing cholangitis: fact or fiction? *Gut* 48, 430–434, 900–907.

29 Broome U, Bergquist A (2006) Primary sclerosing cholangitis, inflammatory bowel disease and colon cancer. *Semin Liver Dis* 26, 31–41.

30 Tung BY, Emond MJ, Haggitt RC *et al.* (2001) Ursodiol use is associated with lower prevalence of colonic neoplasia in patients with ulcerative colitis and primary sclerosing cholangitis. *Ann Intern Med* 134, 89–95.

31 Pardi DS, Loftus EV Jr, Kremers WK *et al.* (2003) Ursodeoxycholic acid is a chemoprotective agent in patients with ulcerative colitis and primary sclerosing cholangitis. *Gastroenterology* 124, 889–893.

32 Marchesa P, Lashner BA, Lavery IC *et al.* (1997) The risk of cancer and dysplasia among ulcerative colitis patients with primary sclerosing cholangitis. *Am J Gastroenterol* 92, 1285–1288.

33 Shetty K, Rybicki L, Bzezinski A *et al.* (1999) The risk for cancer or dysplasia in ulcerative colitis patients with primary sclerosing cholangitis. *Am J Gastroenterol* 94, 1643–1649.

34 Broomé U, Chapman RW (1997) Ulcerative colitis: sclerosing cholangitis today, cancer tomorrow? *Gut* 41, 571–572.

35 Maclean AR, Lilly L, Cohen Z *et al.* (2003) Outcome of patients undergoing liver transplantation for primary sclerosing cholangitis. *Dis Colon Rectum* 46, 1124–1128.

36 Papatheodoridis GV, Hamilton M, Rolles K *et al.* (1998) Liver transplantation and inflammatory bowel disease. *J Hepatol* 28, 1070–1076.

37 Gavaler JS, Delemos B, Belle SH *et al.* (1991) Ulcerative colitis disease activity as subjectively assessed by patient-completed questionnaires following orthotopic liver transplantation for sclerosing cholangitis. *Dig Dis Sci* 36, 321–338.

38 Shaked A, Colonna JO, Goldstein L *et al.* (1992) The inter-relation between sclerosing cholangitis and ulcerative colitis in patients undergoing liver transplantation. *Ann Surg* 215, 598–603.

39 Haagsma EB, Van Den Berg AP *et al.* (2003) Inflammatory bowel disease after liver transplantation: the effect of different immunosuppressive regimens. *Aliment Pharmacol Ther* 18, 33–44.

40 Dvorchik I, Subotin M, Demetris AJ *et al.* (2002) Effect of liver transplantation on inflammatory bowel disease in patients with primary sclerosing cholangitis. *Hepatology* 35, 380–384.

41 Gow PJ, Chapman RW (2000) Liver transplantation for primary sclerosing cholangitis. *Liver* 20, 97–103.

42 Narumi S, Roberts JP, Emond JC *et al.* (1995) Liver transplantation for sclerosing cholangitis. *Hepatology* 22, 451–457.

43 Vera A, Moledina S, Gunson B *et al.* (2002) Risk factors for recurrence of primary sclerosing cholangitis after liver allograft. *Lancet* 360, 43–44.

44 Vera A, Gunson BK, Ussatof V *et al.* (2003) Colorectal cancer in patients with inflammatory bowel disease after liver transplantation. *Transplantation* 75, 1983–1988.

45 Penna C, Duzois R, Tremaine W *et al.* (1996) Pouchitis after ileal pouch – anal anastomosis for ulcerative colitis occurs with increased frequency in patients with associated primary sclerosing cholangitis. *Gut* 38, 234–239.

46 Pemberton JH (2000) *The role of proctocolectomy in patients with primary sclerosing cholangitis and inflammatory bowel disease. Primary sclerosing cholangitis: controversies and consensus.* Clinical Research Single Topic Conference. Alexandria, VA: AASLD.

47 Mistilis SP (1965) Pericholangitis and ulcerative colitis: pathology, aetiology and pathogenesis. *Ann Intern Med* 63, 1–16.

48 Mistilis SP, Skyring AP, Goulston SJM (1965) Pericholangitis and ulcerative colitis: II clinical aspects. *Ann Intern Med* 63, 17–26.

49 Boden RE, Rankin JG, Goulston SJ *et al.* (1959) The liver in ulcerative colitis: the significance of raised serum alkaline phosphatase levels. *Lancet* 2, 245–248.

50 Blackstone MO, Nemchausky BA (1978) Cholangiographic abnormalities in ulcerative colitis associated pericholangitis which resemble sclerosing cholangitis. *Dig Dis Sci* 23, 579–585.

51 Shepherd HA, Selby WS, Chapman RW *et al.* (1983) Ulcerative colitis and liver dysfunction. *Q Med* 52, 503–513.

52 Wee A, Ludwig J (1985) Pericholangitis in chronic ulcerative colitis: primary sclerosing cholangitis of the small ducts? *Ann Intern Med* 102, 581–587.

53 Desmet VJ, Gebass K (1987) Liver lesions in inflammatory bowel disorders. *Pathology* 151, 247–255.

54 Bjornsson E, Boberg KM, Cullen S *et al.* (2002) Patients with small duct primary sclerosing cholangitis have a favourable long term prognosis. *Gut* 51, 731–735.

55 Chapman RW (2002) Small duct primary sclerosing cholangitis. *J Hepatol* 36, 692–694.

56 Olsson R, Hulten L (1975) Concurrence of ulcerative colitis and chronic active hepatitis. Clinical courses and results of colectomy. *Scand J Gastroenterol* 10, 331–335.

57 Hashimoto E, Lindor KD, Homburger HA *et al.* (1993) Immunohistochemical characterization of hepatic lymphocytes in primary biliary cirrhosis in comparison with primary sclerosing cholangitis and autoimmune hepatitis. *Mayo Clin Proc* 68(11), 1049–1055.

58 Gotike F, Lohse AW, Dienes HP *et al.* (1996) Evidence for an overlap syndrome of autoimmune hepatitis and primary sclerosing cholangitis. *J Hepatol* 24, 699–705.

59 Tumen HJ, Moaghan JF, Jobb E (1947) Hepatic cirrhosis as a complication of chronic ulcerative colitis. *Ann Intern Med* 26, 542–553.

60 Holdsworth CD, Hall EW, Dawson AM (1965) Ulcerative colitis in chronic liver disease. *Q Med* 34, 211–226.

61 Lupinetti M, Mehigan D, Cameron JL (1980) Hepato-biliary complications of ulcerative colitis. *Am Surg* 139, 113–117.

62 Schrumpf E, Elgjo K, Fausa O *et al.* (1980) Sclerosing cholangitis in ulcerative colitis. *Scand Gastroenterol* 15, 689–697.

63 Broome U, Glaumann H, Hellers G *et al.* (1994) Liver disease in ulcerative colitis: an epidemiological and follow-up study in the county of Stockholm. *Gut* 35, 84–89.

64 Mir-Madjlessi SH, Farmer RG, Sivak MV (1987) Bile duct carcinoma in patients with ulcerative colitis. *Dig Dis Sci* 32, 145–154.

65 Lazaridis KN, Gores GJ (2006) Primary sclerosing cholangitis and cholangiocarcinoma. *Semin Liver Dis* 26, 42–49.

66 Berman MD, Falchuk KR, Trey C (1980) Carcinoma of the biliary tree complicating Crohn's disease. *Dig Dis Sci* 25, 795–797.

67 Choi PM, Nugent FW, Zelig MP *et al.* (1994) Cholangiocarcinoma and Crohn's disease. *Dig Dis Sci* 39, 667–670.

68 Keiding S, Hansen SB, Rasmussen HH *et al.* (1998) Detection of cholangiocarcinoma in primary sclerosing cholangitis by positron emission tomography. *Hepatology* 28, 700–706.

69 Fevery J, Buchel O, Nevens F *et al.* (2005) Positron emission tomography is not a reliable method for the diagnosis of early cholangiocarcinoma in patients with primary sclerosing cholangitis. *J Hepatol* 43, 358–360.

70 Rosen CB, Nagorney DM, Wiesner RH *et al.* (1991) Cholangiocarcinoma complicating primary sclerosing cholangitis. *Ann Surg* 213, 21–25.

71 Stieber AL, Marino IR, Iwatsuki S *et al.* (1989) Cholangiocarcinoma in sclerosing cholangitis: the role of liver transplantation. *Int Surg* 74, 1–3.

72 Ramage JK, Donaghy A, Farrant JM *et al.* (1995) Serum tumour markers for the diagnosis of cholangiocarcinoma in primary sclerosing cholangitis. *Gastroenterology* 108, 865–869.

73 Levy C, Lymp J, Angulo P *et al.* (2005) The value of serum CA19-9 in predicting cholangiocarcinomas in patients with primary sclerosing cholangitis. *Dig Dis Sci* 50, 1734–1740.

74 Harrison PM (1999) Prevention of bile duct cancer in primary sclerosing cholangitis. *Ann Oncol* 10, 208–211.

75 Klompmaker IJ, DeBruign KM, Gouw AS *et al.* (1988) Recurrence of hepatocellular carcinoma after liver transplantation. *Br Med J* 296, 1445.

76 Snook JA, Kelly P, Chapman RW *et al.* (1989) Fibrolamellar hepatocellular carcinoma complicating ulcerative colitis with primary sclerosing cholangitis. *Gut* 30, 243–245.

77 Harnois DM, Goves GJ, Ludwig J *et al.* (1997) Are patients with cirrhotic stage primary sclerosing cholangitis at risk for development of hepatocellular cancer? *J Hepatol* 27, 512–516.

78 Eade MN (1970) Liver disease in ulcerative colitis. I: analysis of operative liver biopsy in 138 consecutive patients having colectomy. *Ann Intern Med* 72, 457–487.

79 Eade MN, Cooke WT, Brooke BN *et al.* (1970) Liver disease in Crohn's colitis. A study of 21 consecutive patients having colectomy. *Ann Intern Med* 74, 518–528.

80 Bargigia S, Maconi G, Elli M *et al.* (2003) Sonographic prevalence of liver steatosis and biliary tract stones in patients with inflammatory bowel disease: study of 511 patients at a single centre. *J Clin Gastroenterol* 36, 417–420.

81 Cohen S, Kaplan M, Glottlieb L *et al.* (1971) Liver disease and gallstones in regional enteritis. *Gastroenterology* 60, 243–245.

82 Kratzer W, Haenle MM, Mason RA *et al.* (2005) Prevalence of cholelithiasis in patients with chronic inflammatory bowel disease. *World J Gastroenterol* 11, 6170–6175.

83 Baker EJ, Merritt CRB, Sullivan MA *et al.* (1974) Gallstones in inflammatory bowel disease. *Am Dig Dis* 19, 109–112.

84 Kangas E, Lehmusto P, Matikainen M (1990) Gallstones in Crohn's disease. *Hepatogastroenterology* 37, 83–83.

85 Galatola G, Fracchia M, Gazrawi RP (1995) Effect of colectomy with ileal and anal anastomosis on the biliary lipids. *Eur J Clin Invest* 25, 534–538.

86 Murray FE, McNicholas M, Stack W *et al.* (1993) Impaired fatty meal stimulated gall bladder contractivity in patients with Crohn's disease. *Clin Sci* 83, 689–693.

87 Fausa O, Nygaard K, Elgjo K (1977) Amyloidosis and Crohn's disease. *Scand J Gastroenterol* 12, 657–662.

88 Mayer HL, Hughes RW, Jarrett HF *et al.* (1967) Granulomatous hepatitis associated with regional enteritis. *Gastroenterology* 53, 301–305.

89 Ludwig J, Colina F, Poterucha JJ (1995) Granulomas in primary sclerosing cholangitis. *Liver* 15, 307–312.

90 Greenstein AJ, Schar DB, Lowenthal D *et al.* (1955) Pyogenic liver abscess in Crohn's disease. *Q J Med* 56, 505–518.

91 Mir-Madjlessi SH, McHenry MC, Farmer RG (1986) Liver abscess in Crohn's disease. *Gastroenterology* 91, 987–993.

92 Xiao WB, Liu JL (2003) Primary biliary cirrhosis and ulcerative colitis: a case report and review of the literature. *World J Gastroenterol* 9, 878–880.

93 Brinson RR, Curtis WD, Schuman BM *et al.* (1988) Recovery from hepatic vein thrombosis (Budd–Chiari syndrome) complicating ulcerative colitis. *Dig Dis Sci* 33, 1615–1620.

94 Chesner IM, Muller S, Newman J (1986) Ulcerative colitis complicated by Budd–Chiari syndrome. *Gut* 27, 1096–1100.

95 Kraut K, Berman JH, Gunasekaran TS *et al.* (1997) Hepatic vein thrombosis (Budd–Chiari syndrome) in an adolescent with ulcerative colitis. *J Pediatr Gastroenterol Nutr* 25(4), 417–420.

96 Praderio L, Dagna L, Longhi P *et al.* (2000) Budd–Chiari syndrome in a patient with ulcerative colitis: association with anticardiolipin antibodies. *J Clin Gastroenterol* 30(2), 203–204.

97 Maccini DM, Berg JC, Bell GA (1989) Budd–Chiari and Crohn's disease. An unreported association. *Dig Dis Sci* 34(12), 1615–1620.

98 Braun M, Fraser GM, Kunin M *et al.* (1999) Mesalazine-induced granulomatous hepatitis. *Am J Gastroenterol* 94(7), 1973–1974.
99 Delentre P, Berson A, Marcellin P *et al.* (1999) Mesalazine (5-aminosalicylic acid) induced chronic hepatitis. *Gut* 44(6), 886–888.
100 Besnard M, Debray D, Durand P *et al.* (1998) Sulfasalazine-induced fulminant hepatitis in pediatric Crohn's disease: report of two cases. *J Pediatr Gastroenterol Nutr* 26(1), 119–120.
101 Romagnuolo J, Sadowski DC, Lalor E *et al.* (1998) Cholestatic hepatocellular injury with azathioprine: a case report and review of the mechanisms of hepatotoxicity. *Can J Gastroenterol* 12(7), 479–483.
102 Duggan JP, Duggan AE (2005) The liver in coeliac disease. *Aliment Pharmacol Ther* 21, 515–520.
103 Pollock DJ (1977) The liver in coeliac disease. *Histopathology* 1, 421–430.
104 Hagander B, Berg NO, Brandt L *et al.* (1977) Hepatic injury in adult coeliac disease. *Lancet* 2, 270–272.
105 Lindberg J, Ahren C, Iwarson S (1979) Intestinal villous atrophy in chronic active hepatitis. *Scand J Gastroenterol* 14, 1015–1018.
106 Jacobsen MB, Fausa O, Elgjo K *et al.* (1990) Hepatic lesion in adult coeliac disease. *Scand J Gastroenterol* 25, 656–662.
107 Bardella MT, Fraquelli M, Quatrini M *et al.* (1995) Prevalence of hypertransaminasaemia in adult coeliac patients and effect of gluten-free diet. *Hepatology* 22, 833–836.
108 Novacek G, Miehsler W, Wrba F *et al.* (1999) Prevalence and clinical importance of hypertransaminasaemia in coeliac disease. *Eur J Gastroenterol Hepatol* 11, 283–288.
109 Vajro P, Fontanella A, Mayer M *et al.* (1993) Elevated serum aminotransferase activity as an early manifestation of gluten-sensitive enteropathy. *J Paediatr* 122, 416–419.
110 Bodé S, Gudmand-Høyer E (1996) Symptoms and haematological features in consecutive adult coeliac patients. *Scand J Gastroenterol* 31, 54.
111 Logan RF, Ferguson A, Finlayson ND *et al.* (1978) Primary biliary cirrhosis and coeliac disease: an association? *Lancet* 1, 230–238.
112 Sørensen HT, Thulstrup AM, Blomqvist P *et al.* (1999) Risk of primary biliary cirrhosis in patients with coeliac disease: Danish and Swedish cohort data. *Gut* 44, 736–738.
113 Habior A, Lewartowska A, Orlowska J *et al.* (2003) Association of coeliac disease with primary biliary cirrhosis in Poland. *Eur J Gastroenterol Hepatol* 15, 159–164.
114 Kingham JG, Parker DR (1998) The association between primary biliary cirrhosis and coeliac disease: a study of relative prevalences. *Gut* 42, 120–122.
115 Hay JE, Wiesner RH, Shorter RG *et al.* (1988) Primary sclerosing cholangitis and celiac disease. A novel association. *Ann Intern Med* 109, 713–717.
116 Volta U, Rodrigo L, Granito A *et al.* (2002) Coeliac disease in autoimmune cholestatic liver disorders. *Am J Gastroenterol* 97, 2609–2613.
117 Lawson A, West JA, Aithall GP *et al.* (2005) Autoimmune cholestatic liver disease in people with coeliac disease: a population-based study of their association. *Aliment Pharmacol Ther* 21, 401–405.
118 Volta U, De Franceschi L, Molinaro N *et al.* (1998) Frequency and significance of anti-gliadin and anti-endomysial antibodies in autoimmune hepatitis. *Dig Dis Sci* 43, 2190–2195.
119 Mugica F, Aranzadi MJ, Recasens M *et al.* (2000) Adult coeliac disease and hypertransaminasaemia. *Rev Esp Inferm Dig* 92, 78–85.
120 Lindgren S, Sjoberg K, Eriksson S (1994) Unsuspected coeliac disease in chronic cryptogenic liver disease. *Scand J Gastroenterol* 29, 661–664.
121 Kaukinen K, Halme L, Farkkila M *et al.* (2002) Coeliac disease in patients with severe liver disease: gluten-free diet may reverse hepatic failure. *Gastroenterology* 122, 881–888.
122 Low Beer TS, Harvey RF, Davies ER *et al.* (1975) Abnormalities of serum cholecystokinin and gall bladder emptying in coeliac disease. *N Engl J Med* 292, 961–963.
123 Maton PN, Selden AC, Fitzpatrick ML *et al.* (1985) Defective gall bladder emptying and cholecystokinin release in coeliac disease: reversal by gluten free diet. *Gastroenterology* 88, 391–396.
124 Floch MK, Thomassen RW, Guerra R *et al.* (1963) The structural and functional status of the liver in tropical sprue. *Am Dig Dis* 8, 344–349.
125 Haubrich WE, Watson JHL, Sieracki JC (1960) Unique morphological features of Whipple's disease. A study by light and electron microscopy. *Gastroenterology* 39, 454–468.
126 Upton AC (1952) Histochemical investigations of the mesenchymal lesions in Whipple's disease. *Am Clin Pathol* 22, 755–764.
127 Fiegelson J, Anagnostopoulos C, Poquet M *et al.* (1993) Liver cirrhosis in cystic fibrosis: therapeutic implications and long term follow-up. *Arch Dis Child* 68, 653–657.
128 Duthie A, Doherty DG, Donaldson PT *et al.* (1995) A major histocompatibility complex influences the development of chronic liver disease in male children and young adults with cystic fibrosis. *J Hepatol* 23, 532–537.
129 Colobo C, Apostolo MG, Ferarri M *et al.* (1994) Analysis of risk factors for the development of liver disease associated with cystic fibrosis. *J Pediatr* 124, 393–399.
130 Gaskin KJ, Walters DLM, Howman-Giles R *et al.* (1988) Liver disease and common bile duct stenosis in cystic fibrosis. *N Engl J Med* 318, 340–344.
131 O'Brien S, Keogan M, Casey M *et al.* (1992) Biliary complications of cystic fibrosis. *Gut* 33, 387–391.
132 Psacharopoulos HT, Howard ER, Portmann B *et al.* (1981) Hepatic complications of cystic fibrosis. *Lancet* 2, 78–80.
133 Merli M, Bertasi S, Servi R *et al.* (1994) The effect of a medium dose of ursodeoxycholic acid with or without tuartine supplementation on the nutritional status of patients with cystic fibrosis. A randomised placebo controlled cross over trial. *J Pediatr Gastroenterol Nutr* 19, 198–203.
134 Buchwald H, Lober PH, Varco RL (1974) Liver biopsy findings in seventy-seven consecutive patients undergoing jejuno ileal bypass for morbid obesity. *Am Surg* 127, 48–52.
135 Solhang JH, Gluck H (1976) Morphological and functional changes of the liver following small intestinal bypass for obesity. *Scand J Gastroenterol* 11, 793–800.
136 Marubbio AT, Rucker RD, Schneider PK *et al.* (1979) The liver in morbid obesity and following bypass surgery for obesity. *Surg Clin North Am* 59, 1079–1093.
137 Peura DA, Stromeyer FW, Hohnson LF (1980) Liver injury with alcoholic hyaline after intestinal resection. *Gastroenterology* 79, 128–130.
138 Spin FP, Weisman RE (1975) Death from hepatic failure after jejuno ileal anastomosis. *Am Surg* 130, 88–91.
139 Heimbeuger SL, Steiger E, Lo Gerfo P *et al.* (1975) Reversal of severe fatty hepatic infiltration after intestinal bypass for morbid obesity by calorie free amino acid infusion. *Am Surg* 129, 229–235.
140 Geiss DM, Chields S, Watts JD (1976) Reversibility of hepatic failure following jejunoileal bypass. *Arch Surg* 3, 1362–1365.

20.4 Total parenteral nutrition-related liver disease

Sean W.P. Koppe and Alan L. Buchman

Introduction

In the late 1960s, long-term parenteral nutrition was introduced and, within a few years, severe cholestasis with progressive hepatic failure was described in an infant who had been receiving total parenteral nutrition (TPN) for 2.5 months [1,2]. The hepatobiliary complications of TPN are now well recognized, and significant advances have been made in understanding their pathogenesis. Hepatic abnormalities generally manifest in one of two patterns – steatosis or cholestasis – although quite often overlap is observed. Multiple pathogenic mechanisms have been put forward to explain these abnormalities including nutrient excess, nutrient deficiency and bacterial overgrowth. Biliary complications of TPN include calculous and acalculous cholecystitis, and gallbladder hypocontractility resulting in biliary stasis is thought to be the cause. While TPN is often used as a temporary means of supplying adequate nutrition, a small number of patients find themselves dependent on parenteral nutrition, and advanced liver disease can be a feared long-term sequela, which may require liver or liver–intestinal transplantation in a minority of patients.

Prevalence of TPN-associated liver injury

Elevations in aminotransferase levels of 1.5- to threefold can commonly occur during the initial 1–3 weeks of TPN, and these generally resolve within days to weeks [3,4]. The serum bilirubin concentration is rarely elevated during this period in adults, but is much more commonly elevated in preterm infants. Total serum bilirubin concentration may begin to increase in some adults after 10 weeks or more of TPN [5]. Increases in the serum alkaline phosphatase concentration may be observed as well, although this abnormality may be related in part to the metabolic bone disease that occurs in patients who receive long-term TPN [6].

While early and transient abnormalities in liver chemistries are well recognized, the more important concern is whether long-term TPN is associated with chronic and potentially irreversible liver disease. Multiple case reports and case series have suggested that patients with intestinal failure who required TPN were at increased risk for the development of chronic liver disease and hepatic failure in the absence of other readily identifiable causes [7–11].

In one study of 90 patients on long-term TPN, chronic cholestasis occurred in 55% of patients who received TPN for at least 2 years, 64% at 4 years and 72% at 6 years of TPN [12]. The prevalence of complicated liver disease was 26% at 2 years, 39% at 4 years, 50% at 6 years and 53% at 8 years [12]. Another study reporting on 42 patients on TPN for > 1 year showed that 15% of patients developed endstage liver disease (ESLD) after widely varying times on TPN (range 1–20 years) [13]. Increased duration of TPN (9.2 years vs. 6.3 years) suggested an increased risk of ESLD; however, this did not reach statistical significance. Elevation of bilirubin did portend a poor prognosis, with death occurring at an average of 10.8 months from the time of elevation. Several studies suggest that individuals with the least residual intestine appear to be at greatest risk for the eventual development of hepatic failure and death [9,10,12].

The prevalence of TPN-associated liver disease is much greater in infants, particularly in those born prematurely. Sondheimer *et al.* [14] reported that approximately 65% of infants developed cholestasis, with 13% developing hepatic failure after only 6 weeks of TPN. Other centres have reported a prevalence ranging from 15% to 85%. Development of TPN-associated liver disease is associated with the degree of prematurity, underlying disease, frequency of infections and antibiotic use, number of surgeries, as well as the number of blood transfusions [15].

Histological patterns of liver injury

Macrovesicular steatosis is demonstrated soon after initiating TPN in a majority of adult patients. The distribution of steatosis is periportal initially, but can progress to become centrolobular

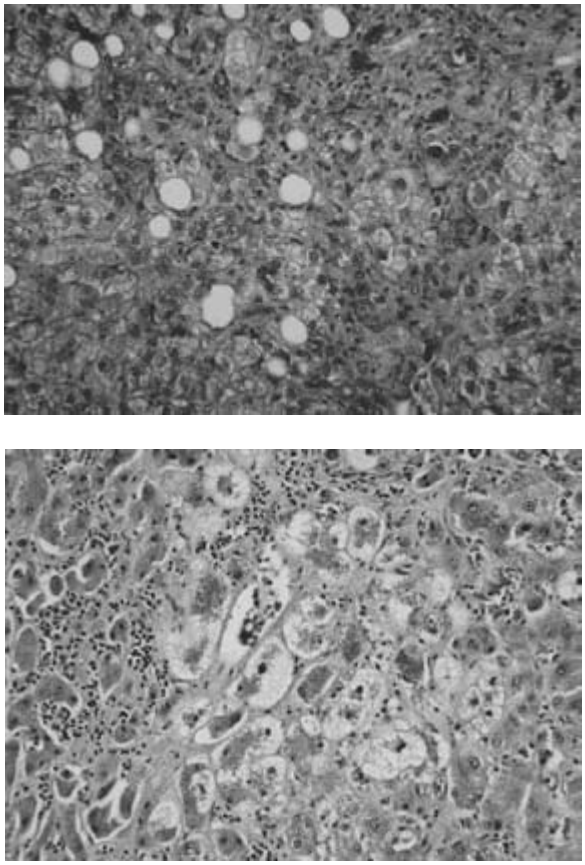

Fig. 1 Histological specimens from patients on TPN demonstrating (a) steatosis and cholestasis and (b) steatohepatitis, cholestasis and balloon degeneration of hepatocytes. (H&E, original magnification × 180) (courtesy of S. Rao, Northwestern University School of Medicine).

or panlobular over an extended period, often accompanied by cholestasis [16,17] (Fig. 1). Microvesicular steatosis and, rarely, phospholipidosis can also occur in patients on long-term TPN [12,18].

Cholestatic changes predominate in infants placed on TPN. Centrolobular cholestasis is an early finding, often with bile duct proliferation and non-specific periportal inflammation. Steatosis can also be found, although less often than in the adult population. Expansion of portal tracts and development of portal fibrosis can ensue over time with increased risk of cirrhosis with longer duration of TPN use.

While TPN appears to be consistently shown to induce characteristic histopathological abnormalities, nearly all studies do not have a control group with similar comorbidities, which makes it difficult to separate TPN-induced abnormalities from abnormalities induced by the patients' underlying medical illness that necessitates TPN. One study attempted to have a matched control group and suggested that TPN itself did not appear to be a risk factor for histological abnormalities but, rather, the patients' pre-existing liver disease and medical comorbidities were the aetiology of any abnormalities [19].

Pathophysiology

Nutrient deficiencies

Choline

Choline is a product of the hepatic trans-sulphuration pathway and is low in > 90% of patients who require long-term TPN [20]. Deficiency of choline in rodents results in hepatic steatosis because of impaired very-low-density lipopolysaccharide (VLDL) synthesis resulting in hepatic triglyceride accumulation [21]. Studies in humans have found an inverse relationship between hepatic aminotransferase abnormalities and plasma free choline concentration, and intravenous choline supplementation to patients on TPN results in impressive reversal of steatosis and improvement in liver chemistries [22–24] (Fig. 2). Methionine, a sulphur amino acid that is the substrate for choline synthesis, is also metabolized to cysteine and other metabolites via the hepatic trans-sulphuration pathway; however, supply via the portal

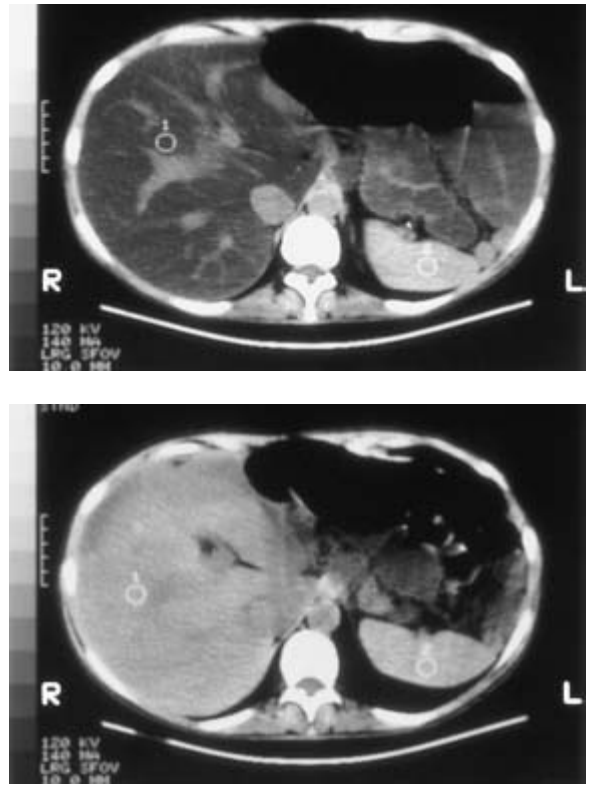

Fig. 2 Choline supplementation results in improvement in hepatic steatosis. Computerized tomography (CT) scan results from one sample patient with marked steatosis on pretreatment CT (a). After 2 weeks of intravenous choline supplementation (b), the steatosis improved and the liver was nearly isodense relative to the spleen (reproduced with permission from ref. 23).

circulation appears to be required for its metabolism. One study showed that, when methionine was infused intravenously in normal volunteers, cysteine was nearly undetectable in blood as opposed to when methionine had been consumed in the diet or administrated via a nasogastric tube [25]. It is likely that the plasma free choline concentration is low in patients who receive TPN because the methionine supplied intravenously via the TPN solution is not metabolized to choline to any significant extent, which results in choline becoming an essential nutrient [26]. Although choline is ubiquitous in the diet, patients requiring TPN for malabsorption are often unable to absorb an adequate amount of choline and, while lipid emulsions contain some choline, it is not sufficient to prevent choline deficiency [20,22,27].

Although choline deficiency appears to be necessary for the development of TPN-associated hepatic steatosis, it is not clear whether choline deficiency alone is sufficient to result in the eventual development of advanced liver disease. It is possible that a 'second hit' triggers progression to fibrosing steatohepatitis. Choline-deficient rats treated with endotoxin (LPS) exhibit substantially increased serum hepatic aminotransferase concentrations and steatohepatitis on liver histology compared with choline-sufficient rats treated with LPS, who demonstrate only minor increases in liver tests and no histological changes [28].

Carnitine

Carnitine is essential for the transport of long-chain fatty acids across the inner mitochondrial membrane for oxidation, and hepatic steatosis develops in congenital and acquired carnitine deficiency [29]. Plasma total and free carnitine concentrations are decreased in patients who receive long-term TPN because carnitine is not present in the TPN solution [30,31]. However, carnitine concentrations are only decreased to approximately 50% of normal with TPN vs. 10% of normal in true carnitine deficiency [29–31]. The lack of complete carnitine deficiency is presumably related to some ability to process the precursors (methionine and lysine) into carnitine despite their supply via the intravenous route. Significantly, no correlation between plasma carnitine concentration and hepatic aminotransferase abnormalities has been observed, and carnitine supplementation improves neither hepatic aminotransferase abnormalities nor hepatic steatosis in patients requiring long-term TPN [32,33].

Taurine

Taurine is an amino acid supplied in neonatal TPN, although not routinely in adults. At one point, it had been widely believed that taurine supplementation was responsible for the decreased incidence observed of neonatal TPN-associated liver disease [34,35]. Recent data have shown that taurine supplementation does not lead to a lower incidence of cholestasis, and it is more likely that overall improvements in neonatal critical care, including treatment of sepsis, hypoxia, hypotension and early enteral feeding, contributed to the previously observed decline in the incidence of TPN-associated liver disease in the neonatal population [36–39].

Vitamin E and selenium

It has been suggested that vitamin E deficiency may play a role in the development of TPN-associated liver disease via increased lipid peroxidation. However, vitamin E deficiency in patients who require TPN is very rare, especially in patients who routinely receive lipid emulsion [40,41]. Selenium, a cofactor of glutathione peroxidase, may be deficient in patients with cirrhosis, but there is no evidence that selenium deficiency plays a role in the development of TPN-associated liver disease [42].

Nutrient excess

Carbohydrate excess

Overfeeding patients with carbohydrate may be associated with the development of hepatic steatosis and/or cholestasis. Infusion of > 50 kcal/kg/day as dextrose results in an increased portal insulin:glucagon ratio and the development of hepatic steatosis [43,44]. Mitochondrial carnitine acyltransferase, the rate-limiting factor in fatty acid oxidation, is inhibited by the increased insulin concentration [45]. Increased hepatic acetyl-coenzyme A (CoA) concentration and induction of acetyl-CoA carboxylase can occur with excessive carbohydrate infusion, which in turn stimulates fatty acid synthesis [46]. Cycling TPN to an overnight infusion is associated with a decreased risk of hepatic dysfunction, probably related to the intermittent nature of the increase in portal insulin concentration [47].

Lipid excess

Excess administration of lipids has also been shown to contribute to TPN-induced hepatotoxicity. In one study, 10 out of 18 patients administered lipids at a rate of 3 g/kg/day developed TPN-induced cholestasis whereas only 1 out of 17 patients developed cholestasis at a dose of 1 g/kg/day [49]. Other studies have shown similar results with lipid infusions > 1 g/kg/day, and TPN infusions should routinely maintain lipid infusions at or less than 1 g/kg/day [12,48] (Fig. 3).

Manganese, aluminium and copper

Manganese (Mn) is contained in TPN both as a contaminant and as an additive, and several case reports describe increased serum Mn concentrations in patients with TPN-associated cholestasis [50–53]. Nearly all Mn excretion is via the biliary tract, however, and it is likely that Mn retention occurs because of cholestasis rather than as a primary cause of cholestasis [54]. Another metal, aluminium (Al), has been associated with the development of cholestasis in rodent TPN models [55,56]. Current TPN formulations have little Al contamination, and Al contamination is < 2% of pre-1985 levels [57]. Although the copper contained in the multitrace metal formulation used in TPN does not lead to hepatotoxicity, it is biliary excreted and

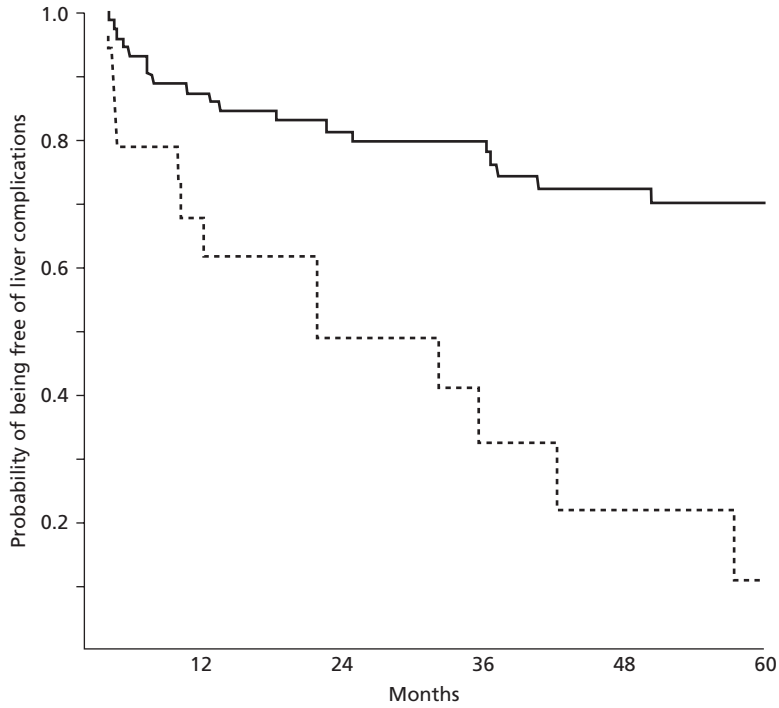

Patients at risk, *n*						
Lipids < 1 g/kg/day	10	8	8	4	2	1
Lipids ≥ 1 g/kg/day	59	52	52	41	32	28

Fig. 3 Parenteral lipid intake of 1 g/kg/day or more (dashed line) significantly increased the risk of complicated TPN-related liver disease compared with intake of less than 1 g/kg/day (solid line) ($P < 0.001$) (reproduced with permission from ref. 12).

should be removed from the TPN solutions in patients with significant cholestasis to prevent potential copper toxicity [58].

Phytosterols

One hypothesis for the role of lipid emulsion in the pathogenesis of TPN-associated liver disease involves the role of plant sterols (phytosterols) [59]. These are present in lipid emulsion, and blood concentrations are correspondingly increased in patients who receive TPN with lipid emulsion [60]. They have been primarily implicated as a cause of cholestatic liver disease; however, as biliary secretion is the primary means of excretion of phytosterols, their accumulation may be secondary to the cholestatic liver disease induced by TPN itself and not the primary cause. Additionally, patients with hereditary sitosterolaemia, a rare genetic disorder resulting in significant accumulation of phytosterols, do not have any increased risk of developing cholestatic liver disease. This suggests that increased phytosterols in patients on TPN is not the primary cause of liver dysfunction.

Bacterial overgrowth

Similar to other forms of liver disease, bacterial overgrowth with portal endotoxaemia has been hypothesized to play a role in TPN-associated liver disease. A small retrospective human study suggested that metronidazole prevented elevation of liver function tests in patients on TPN for 30 days [61]. Another study revealed a hepatoprotective effect of metronidazole in patients placed on TPN during acute exacerbation of Crohn's disease [62]. One additional study found a decrease in transaminase levels but no change in bilirubin levels in neonates on TPN and co-administered metronidazole for 2–3 weeks [63]. The results from these small uncontrolled human studies as well as animal studies suggest the possibility of some benefit from reducing the gut flora; however, it is likely that any short-term gain derived from antibiotic usage would be offset by the development of resistant organisms or deleterious side-effects from their chronic use (i.e. neuropathy from metronidazole).

Biliary complications of TPN

Biliary complications of TPN include both acalculous and calculous cholecystitis. The former was first described in 1972, and results from diminished gallbladder contractility secondary to decreased meal-stimulated cholecystokinin (CCK) release [64,65]. Although the exact pathogenesis of the development of acalculous cholecystitis in TPN patients is unknown, bile stasis and increased bile lithogenicity are clearly contributing factors [66,67]. Acalculous cholecystitis has been reported in ~4% of patients in one study on TPN for at least 3 months [78].

TPN-associated cholelithiasis was first described in 1980 in preterm infants who had received 30–60 days of TPN [68]. It was later reported by Pitt *et al.* [69] that upwards of 40% of children who required home TPN, and even 25% of those who

had never undergone ileal resection or had Crohn's disease, developed gallstones. Messing *et al.* [70] found that sludge developed in 50% of patients who had received TPN for 4–6 weeks in the absence of any oral intake, and 100% of patients had developed sludge by 6 weeks of TPN use. The sludge resolved in all patients within 4 weeks of oral refeeding. The major factor in the development of biliary sludge is biliary stasis, resulting from incomplete CCK-stimulated gallbladder contraction [71–73]. Surprisingly, it is not cholesterol gallstones that are produced, but predominantly calcium bilirubinate gallstones, which is related to an increase in biliary calcium bilirubinate concentrations during TPN [72,74,75]. Several studies have shown that bile lithogenicity does not increase on TPN [71,76,77]. In one study, after maintenance on TPN for at least 3 months, calculous cholecystitis was reported in ~19% of patients [78].

Prevention of hepatobiliary disease

The first step in avoiding TPN-induced liver disease is to minimize the time that patients rely on parenteral nutrition. Most patients on chronic TPN have short gut, and aggressive management by a gastroenterologist with particular expertise in this area can allow for weaning of TPN in some of these cases. For those who must remain on TPN, care must be taken accurately to estimate their nutritional requirements. The Harris–Benedict equation is used to calculate caloric needs in conjunction with various 'correction factors' to account for the patient's medical condition. Lipid infusions should be kept below 1 g/kg/day, and TPN should be cycled overnight. TPN formulations have been modified over the years to minimize any micronutrient excess and deficiencies.

Correction of choline deficiency by the routine addition of choline to TPN solutions is an area of active investigation. The results of early studies examining this possibility seem promising, and larger studies carried out over longer durations are warranted. While short-term studies suggest possible benefit, long-term antibiotic administration to diminish any bacterial overgrowth is complicated by issues of resistance and drug toxicity, and thus is not recommended. Ursodiol has been used in several small studies and appears to result in improvement in most liver biochemical profiles [79–83]. The studies generally involve small numbers with variable doses of ursodiol and also lack any demonstration of histological improvement. Nevertheless, it may ultimately have a role, particularly in the paediatric population, where cholestasis is the predominant way in which TPN-associated hepatobiliary disease manifests itself.

The easiest method of preventing either acalculous or calculous cholecystitis is to encourage oral food intake. Periodic oral intake is necessary, even if there is relatively minimal caloric intake, as continuous enteral feeding via a nasoenteric tube fails to stimulate CCK release [84]. Prophylactic cholecystectomy has been recommended by some, but this is generally not necessary as virtually all patients with intestinal failure can be encouraged to have some oral intake. One investigational approach to the stimulation of gallbladder contraction has included CCK injections, although this approach is expensive, has not been universally successful and may be associated with nausea and abdominal discomfort [70,85,86]. Rapid bolus intravenous amino acid infusion has also been shown to stimulate gallbladder contraction, although the effect is lost when the infusion lasts more than 2 h, as is the case with normal TPN/amino acid infusion [87–89].

Indications for liver and liver–intestinal transplant in patients with TPN-related liver disease

Besides hepatic complications, long-term TPN administration can be associated with central venous complications, specifically thrombosis and infection. At present, the indications for small intestine transplant are: (i) frequent central line-related sepsis; (ii) thrombosis of major central venous channels; (iii) frequent severe dehydration; and (iv) impending or overt liver failure [90]. While frequent line-related sepsis is presently an indication, this remains controversial as most often line infections are preventable when patients and caregivers practise good sterile protocols when handling their central lines. Of the indications for small bowel transplant, the last is the only one for which a combined liver–small intestine transplant is necessary. Previously, patients waiting for a liver–small intestine transplant were dependent on their listing status on the liver transplant list. This led to an exceptionally high mortality rate in patients on the waiting list relative to those waiting for just livers alone [91]. UNOS (United Network for Organ Sharing) policy now dictates that patients waiting for a combined liver–small intestine transplant be transplanted according to their status on the small intestine waiting list provided that there is no other local or regional status 1 liver patient waiting for a liver [92]. In the paediatric population, combined liver–small intestine transplants outnumber intestine alone (306 vs. 223 of all transplants worldwide between 1985 and 2003) [93]. In the adult population, isolated small intestine transplants are more common than combined liver–small intestine transplants (210 vs. 80 of all transplants worldwide between 1985 and 2003) [93]. In rare circumstances, infants who appear certain to transition from TPN to enteral feedings in the near future may develop endstage liver disease necessitating transplantation before this transition occurs. In this unique situation, isolated liver transplant may be sufficient so long as complete transition to enteral feedings occurs [94]. Hepatic abnormalities and early fibrosis appear to be potentially reversible if isolated small intestine transplant can occur before cirrhosis occurs [95]. Most instances in which liver disease develops will require a combined liver–small intestine transplantation. In the past, survival for combined liver–intestine transplant was worse than for intestine alone, largely because of the ability to remove the graft in the intestine-only group should there be any life-threatening graft or immunosuppression-related complication. As the number of

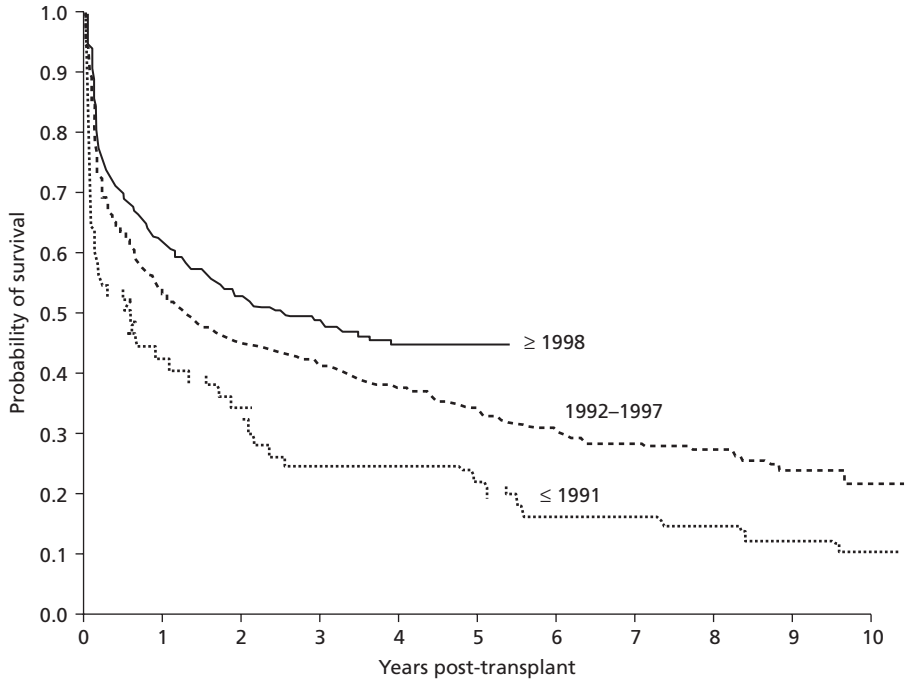

Fig. 4 Graft survival rates after intestine transplantation have significantly improved over time with increasing experience ($P < 0.001$) (reproduced with permission from ref. 93).

intestine and liver–intestine transplants performed has increased in recent years, the experience with immunosuppressive regimens has also increased, and this has translated into improved outcomes overall and less discrepancy in outcomes between liver–intestine and intestine transplants (Fig. 4). Since 1998, 1-year survival for combined liver–intestine transplants is comparable to intestine alone (59%/60% graft/patient survival for liver–intestine vs. 65%/77% graft/patient survival for intestine alone) [93].

References

1 Dudrick SJ, Wilmore DW, Vars HM *et al.* (1968) Long-term total parenteral nutrition with growth, development, and positive nitrogen balance. *Surgery* 64, 134–142.

2 Penden VH, Witzleben CL, Skelton MA (1971) Total parenteral nutrition. *J Pediatr* 78, 180–181.

3 Grant JP, Cox CE, Kleinman LM *et al.* (1977) Serum hepatic enzyme and bilirubin elevations during parenteral nutrition. *Surg Gynecol Obstet* 145, 573–580.

4 Lindor K, Fleming C, Abrams A *et al.* (1979) Liver function values in adults receiving total parenteral nutrition. *JAMA* 241, 2398–2400.

5 Clarke PJ, Ball MJ, Kettlewell MGW (1991) Liver function tests in patients receiving parenteral nutrition. *J Parenteral Enteral Nutr* 15, 54–59.

6 Buchman AL, Moukarzel A (2000) Metabolic bone disease associated with total parenteral nutrition. *Clin Nutr* 19, 217–231.

7 Rabeneck L, Freeman H, Owen D (1984) Death due to TPN-related liver failure (abstract). *Gastroenterology* 86, 1215.

8 Bowyer BA, Fleming CR, Ludwig J *et al.* (1985) Does long-term home parenteral nutrition in adult patients cause chronic liver disease? *J Parenteral Enteral Nutr* 9, 11–17.

9 Stanko RT, Nathan G, Mendelow H *et al.* (1987) Development of hepatic cholestasis and fibrosis in patients with massive loss of intestine supported by prolonged parenteral nutrition. *Gastroenterology* 92, 197–202.

10 Ito Y, Shils ME (1991) Liver dysfunction associated with long-term total parenteral nutrition in patients with massive bowel resection. *J Parenteral Enteral Nutr* 15(3), 271–276.

11 Craig RM, Neumann T, Jeejeebhoy KN *et al.* (1980) Severe hepatocellular reaction resembling alcoholic cirrhosis after massive small bowel resection and prolonged total parenteral nutrition. *Gastroenterology* 79, 131–137.

12 Cavicchi M, Beau P, Crenn P *et al.* (2000) Prevalence of liver disease and contributing factors in patients receiving home parenteral nutrition for permanent intestinal failure. *Ann Intern Med* 132, 525–532.

13 Chan S, McCowen KC, Bistrian BR *et al.* (1999) Incidence, prognosis, and etiology of end-stage liver disease in patients receiving home total parenteral nutrition. *Surgery* 126, 28–34.

14 Sondheimer JM, Asturias E, Cadnapaphornchai M (1998) Infection and cholestasis in neonates with intestinal resection and long-term parenteral nutrition. *J Pediatr Gastroenterol Nutr* 27, 131–137.

15 Drongowski RA, Coran AG (1989) An analysis of the factors contributing to the development of total parenteral nutrition-induced cholestasis. *J Parenteral Enteral Nutr* 13, 586–589.

16 Jacobson S, Ericcson JLE, Obel AL (1971) Histopathological and ultrastructural changes in the human liver during complete intravenous nutrition for seven months. *Acta Chir Scand* 173, 335.

17 MacFadyen BV, Dudrick SJ, Baquero G *et al.* (1979) Clinical and biological changes in liver function during intravenous hyperalimentation. *J Parenteral Enteral Nutr* 3, 438.

18 Degott C, Messing B, Moreau D *et al.* (1988) Liver phospholipidosis induced by parenteral nutrition: histologic, histochemical, and ultrastructural investigations. *Gastroenterology* 95, 183–191.

19 Wolfe BM, Walker BK, Shaul DB *et al.* (1988) Effect of total parenteral nutrition on hepatic histology. *Arch Surg* 123(9), 1084–1090.

20 Buchman AL, Moukarzel AA, Jenden DJ *et al.* (1993) Low plasma free choline is prevalent in patients receiving long term parenteral nutrition and is associated with hepatic aminotransferase abnormalities. *Clin Nutr* 12, 33–37.

21 Yao ZM, Vance DE (1990) Reduction in VLDL, but not HDL, in plasma of rats deficient in choline. *Biochem Cell Biol* 68, 552–558.

22 Buchman AL, Dubin M, Jenden D *et al.* (1992) Lecithin supplementation causes a decrease in hepatic steatosis in patients receiving long term parenteral nutrition. *Gastroenterology* 102, 1363–1370.

23 Buchman AL, Dubin M, Moukarzel A *et al.* (1995) Choline deficiency: a cause of hepatic steatosis associated with parenteral nutrition that can be reversed with an intravenous choline chloride supplementation. *Hepatology* 22, 1399–1403.

24 Buchman AL, Sohel M, Dubin M *et al.* (2001) Choline deficiency causes reversible hepatic abnormalities in patients during parenteral nutrition: proof of a human choline requirement; a placebo-controlled trial. *J Parenteral Enteral Nutr* 25, 260–268.

25 Steginck LD, Besten LD (1972) Synthesis of cysteine from methionine in normal adult subjects: effect of route of alimentation. *Science* 178, 514–516.

26 Chawla RK, Berry CJ, Kutner MH *et al.* (1985) Plasma concentrations of transsulfuration pathway products during nasoenteral and intravenous hyperalimentation of malnourished patients. *Am J Clin Nutr* 42, 577–584.

27 Sheard NF, Tayek JA, Bistrian BR *et al.* (1986) Plasma choline concentration in humans fed parenterally. *Am J Clin Nutr* 43, 219–224.

28 Eastin CE, McClain CJ, Lee EY *et al.* (1997) Choline deficiency augments and antibody to tumor necrosis factor-α attenuates endotoxin-induced hepatic injury. *Alcohol Clin Exp Res* 21, 1037–1041.

29 Karpati G, Carpenter S, Engel AG *et al.* (1975) The syndrome of systemic carnitine deficiency: clinical, morphologic, biochemical and pathologic features. *Neurology* 25, 16–24.

30 Dahlstrom KA, Ament ME, Moukarzel A *et al.* (1990) Low blood and plasma carnitine levels in children receiving long-term parenteral nutrition. *J Pediatr Gastroenterol Nutr* 11, 375–379.

31 Moukarzel AA, Dahlstrom KA, Buchman AL *et al.* (1992) Carnitine status of children receiving long-term total parenteral nutrition: a longitudinal prospective study. *J Pediatr* 120, 759–762.

32 Bowyer BA, Fleming CR, Listrup D *et al.* (1986) Plasma carnitine levels in patients receiving home parenteral nutrition. *Am J Clin Nutr* 43, 85–91.

33 Bowyer BA, Miles JM, Haymond MW *et al.* (1988) L-carnitine therapy in home parenteral nutrition patients with abnormal liver tests and low plasma carnitine concentration. *Gastroenterology* 94, 434–438.

34 Okamoto E, Rassin DK, Zucker CL *et al.* (1984) Role of taurine in feeding the low-birth-weight infant. *J Pediatr* 104, 936–940.

35 Desai TK, Reddy J, Kinzie JL *et al.* (1993) Taurine supplementation and cholestasis during bone marrow transplantation. *Gastroenterology* 104, A616.

36 Cooke RJ, Whitington PF, Kelts D (1984) Effects of taurine supplementation on hepatic function during short-term parenteral nutrition in the premature infant. *J Pediatr Gastroenterol* 3, 234–238.

37 Heubi JE, Wiechmann DA, Creutzinger V *et al.* (2002) Tauro-ursodeoxycholic acid (TUDCA) in the prevention of total parenteral nutrition-associated liver disease. *J Pediatr* 141, 237–242.

38 Snyder J, Love K, Bratton B *et al.* (2003) TPN cholestasis in neonates: results of a randomized, double-blind study of amino acid composition (abstract). *Gastroenterology* 124, A30.

39 Balistreri WF, Bucuvalas JC, Farrell MK *et al.* (1992) Total parenteral nutrition-associated cholestasis: factors responsible for the decreasing incidence. In: Lentze M, Reichen J (eds) *Falk Symposium 63, Pediatric Cholestasis. Novel Approaches to Treatment*. London: Kluwer Academic Publishers.

40 Pironi L, Ruggeri E, Zolezzi C *et al.* (1998) Lipid peroxidation and antioxidant status in adults receiving lipid-based home parenteral nutrition. *Am J Clin Nutr* 68, 888–893.

41 Jeppesen PB, Hoy CE, Mortensen PB (2000) Deficiencies of essential fatty acids, vitamin A and E and change in plasma lipoproteins in patients with reduced fat absorption or intestinal failure. *Eur J Clin Nutr* 54, 632–642.

42 Burk RF, Early DS, Hill KE (1998) Plasma selenium in patients with cirrhosis. *Hepatology* 27, 794–798.

43 Lowry SF, Brennan MF (1979) Abnormal liver function during parenteral nutrition: relation to infusion excess. *J Surg Res* 26, 300.

44 Meguid MM, Akahoshi MP, Jeffers S *et al.* (1984) Amelioration of metabolic complications of conventional parenteral nutrition. *Arch Surg* 119, 1294–1298.

45 Kaminski DL, Adams A, Jellinek M (1980) The effect of hyperalimentation on hepatic lipid content and lipogenic enzyme activity in rats and man. *Surgery* 88, 93–100.

46 Meguid MM, Chen TY, Yang ZJ *et al.* (1991) Effects of continuous graded total parenteral nutrition on feeding indexes and metabolic concomitants in rats. *Am J Physiol* 260, E126–E140.

47 Maini B, Blackburn GL, Bistrian BM *et al.* (1976) Cyclic hyperalimentation: an optimal technique for preservation of visceral protein. *J Surg Res* 20, 515–525.

48 Salvian AJ, Allardyce DB (1980) Impaired bilirubin secretion during total parenteral nutrition. *J Surg Res* 28, 547–555.

49 Allardyce DB (1982) Cholestasis caused by lipid emulsions. *Surg Gynecol Obstet* 154, 641–647.

50 Buchman AL, Neely M, Grossie VB Jr *et al.* (2001) Organ heavy-metal accumulation during parenteral nutrition is associated with pathologic abnormalities in rats. *Nutrition* 17, 600–606.

51 Ejima A, Imaamura T, Nakamura S *et al.* (1992) Manganese intoxication during parenteral nutrition (letter). *Lancet* 339, 426.

52 Taylor S, Manara AR (1994) Manganese toxicity in a patients with cholestasis receiving total parenteral nutrition (letter). *Anaesthesia* 49, 1013.

53 Azaz A, Thomas A, Miller V *et al.* (1995) Manganese in long-term paediatric parenteral nutrition (letter). *Arch Dis Child* 73, 89.

54 Messing B, Bories C, Kunstlinger F *et al.* (1983) Does total parenteral nutrition induce gallbladder sludge formation and lithiasis? *Gastroenterology* 84, 1012–1019.

55 Klein GL, Sedman AB, Heyman MB *et al.* (1987) Hepatic abnormalities associated with aluminum loading in piglets. *J Parenteral Enteral Nutr* 11, 293–297.

56 Klein GL, Heyman MB, Lee TC *et al.* (1988) Aluminum associated hepatobiliary dysfunction in rats: relationships to dosage and duration of exposure. *Pediatr Res* 23, 275–278.

57 Klein GL (1991) The aluminum content of parenteral solutions: current status. *Nutr Rev* 49, 74–79.

58 Buchman AL, Neely M, Grossie VB Jr *et al.* (2001) Organ heavy-metal accumulation during parenteral nutrition is associated with pathologic abnormalities in rats. *Nutrition* 17, 600–606.

59 Iyer KR, Spitz L, Clayton P (1998) BAPS prize lecture: New insight into mechanisms of parenteral nutrition-associated cholestasis: role of plant sterols. British Association of Paediatric Surgeons. *J Pediatr Surg* 33, 6.

60 Clayton PT, Bowron A, Mills KA *et al.* (1993) Phytosterolemia in children with parenteral nutrition-associated cholestatic liver disease. *Gastroenterology* 105, 1806–1813.

61 Lambert JR, Thomas SM (1985) Metronidazole prevention of serum liver enzyme abnormalities during total parenteral nutrition. *J Parenteral Enteral Nutr* 9, 501–503.

62 Capron JP, Herve MA, Gineston JL *et al.* (1983) Metronidazole in prevention of cholestasis associated with total parenteral nutrition. *Lancet* 26, 446–447.

63 Kubota A, Okada A, Imura K *et al.* (1990) The effect of metronidazole on TPN-associated liver dysfunction in neonates. *J Pediatr Surg* 25(6), 618–621.

64 Anderson DL (1972) Acalculous cholecystitis – a possible complication of parenteral hyperalimentation. Report of a case. *Med Ann DC* 41, 448.

65 Gullick HD (1960) Roentgenologic study of gallbladder following non-biliary tract surgery. *Ann Surg* 151, 403.

66 Flati G, Flati D, Jonsson PE *et al.* (1984) Role of cholesterol and calcium bilirubinate crystals in acute postoperative acalculous cholecystitis. *Ital J Surg Sci* 14, 333.

67 Deitch EA, Engel JM (1984) Acute acalculous cholecystitis. *Am J Surg* 142, 472.

68 Whitington PF, Black DD (1980) Cholelithiasis in premature infants treated with parenteral nutrition and furosemide. *J Pediatr* 97, 647.

69 Pitt HA, King W, Mann LL *et al.* (1983) Increased risk of cholelithiasis with prolonged parenteral nutrition. *Am J Surg* 145, 106.

70 Messing B, Bories C, Kunstlinger F *et al.* (1983) Does total parenteral nutrition induce gallbladder sludge formation and lithiasis? *Gastroenterology* 84, 1012.

71 Doty JE, Pitt HA, Porter-Fink V *et al.* (1984) The effect of intravenous fat and total parenteral nutrition on biliary physiology. *J Parenteral Enteral Nutr* 8, 263.

72 Lee SP, Maher K, Nicholls JF (1988) Origin and fate of biliary sludge. *Gastroenterology* 94, 170.

73 Cano N, Cicero F, Ranieri F *et al.* (1986) Ultrasonographic study of gallbladder motility during total parenteral nutrition. *Gastroenterology* 91, 313.

74 Allen B, Bernhoft R, Blanckaert N *et al.* (1981) Sludge is calcium bilirubinate associated with bile stasis. *Am J Surg* 141, 51.

75 Pitt HA, Berquist WE, Mann LL *et al.* (1983) Parenteral nutrition induces calcium bilirubinate gallstones. *Gastroenterology* 84, 1274.

76 Doty JE, Pitt HA, Porter-Fink V *et al.* (1985) Cholecystokinin prophylaxis of parenteral nutrition-induced gallbladder disease. *Ann Surg* 201, 76.

77 Messing B, Aprahamian M, Rautureau M *et al.* (1984) Gallstone formation during total parenteral nutrition: a prospective study in man. *Gastroenterology* 86, 1183.

78 Roslyn JJ, Pitt HA, Mann LL *et al.* (1983) Gallbladder disease in patients on long-term parenteral nutrition. *Gastroenterology* 84(1), 148–154.

79 Lindor KD, Burnes J (1991) Ursodeoxycholic acid for the treatment of home parenteral nutrition-associated cholestasis. *Gastroenterology* 101, 250–253.

80 Beau P, Labat-Labourdette J, Ingrand P *et al.* (1994) Is ursodeoxycholic acid an effective therapy for total parenteral nutrition-related liver disease. *J Hepatol* 20, 240–244.

81 Cocjin J, Vanderhal A, Sehgal S *et al.* (1993) Ursodeoxycholic acid therapy for total parenteral nutrition-associated cholestasis. *Gastroenterology* 104, A615.

82 Spagnuolo MI, Iorio R, Vegnente A *et al.* (1996) Ursodeoxycholic acid for treatment of cholestasis in children on long-term total parenteral nutrition: a pilot study. *Gastroenterology* 111, 716–719.

83 Levine A, Maayan A, Shamir R *et al.* (1999) Parenteral nutrition-associated cholestasis in preterm neonates: evaluation of ursodeoxycholic acid treatment. *J Pediatr Endocrin Metab* 12, 549–553.

84 Mashako MNK, Cezard JP, Boige N *et al.* (1991) The effect of artificial feeding on cholestasis, gallbladder sludge and lithiasis in infants: correlation with plasma cholecystokinin levels. *Clin Nutr* 10, 320.

85 Sitzman JV, Pitt HA, Steinborn PA *et al.* (1990) Cholecystokinin prevents parenteral nutrition induced biliary sludge in humans. *Surg Gynecol Obstet* 170, 25.

86 Apelgren KN, Willard DA, Vargish T (1988) TPN alters gallbladder responsivity to cholecystokinin. *J Parenteral Enteral Nutr* 12S, 115.

87 De Boer SY, Masclee AAM, Lam WF *et al.* (1994) Effect of intravenous glucose on intravenous amino acid-induced gallbladder contraction and CCK secretion. *Dig Dis Sci* 39, 268.

88 Zoli G, Ballinger A, Healy J *et al.* (1993) Promotion of gallbladder emptying by intravenous amino acids. *Lancet* 341, 1240.

89 Kalfarentzos F, Vagenas C, Michail A *et al.* (1991) Gallbladder contraction after administration of intravenous amino acids and long-chain triacylglycerols in humans. *Nutrition* 7, 347.

90 Medicare Coverage Policy Decisions, Intestinal and Multivisceral Transplantation, CAG-00036, October 4, 2000.

91 Fryer J, Pellar S, Ormand D *et al.* (2003) Mortality in candidates waiting for combined liver-intestine transplants exceeds that for other candidates waiting for liver transplants. *Liver Transpl* 9(7), 748–753.

92 UNOS Policy (3.11 – Organ Distribution: Intestinal Organ Allocation; rev. 11/04): http://www.unos.org/policiesandbylaws/policies.asp?resources=true.

93 Grant D, Abu-Elmagd K, Reyes J *et al.* (2005) 2003 report of the intestine transplant registry: a new era has dawned. *Ann Surg* 241(4), 607–613.

94 Horslen SP, Kaufman SS, Sudan DL *et al.* (2000) Isolated liver transplantation in infants with total parenteral nutrition-associated end-stage liver disease. *Transplant Proc* 32(6), 1241.

95 Sudan DL, Kaufman SS, Shaw BW Jr *et al.* (2000) Isolated intestinal transplantation for intestinal failure. *Am J Gastroenterol* 95(6), 1506–1515.

20.5 The effect of skin diseases on the liver

Daniel Glass and Malcolm Rustin

Introduction

This chapter briefly describes those skin disorders that also have an impact on liver function. The hepatotoxic effects of many treatments used in skin diseases are outlined.

Inflammatory skin diseases

Psoriasis

Psoriasis is a chronic inflammatory skin condition affecting 2% of the world's population. The prevalence varies from 4.6% of Caucasians in the USA to 0.4% within certain African and Asian groups [1]. The characteristic lesion is a red, thickened, scaly plaque typically affecting the scalp, extensor surfaces of the elbows and knees, lower back and genitals. The frequency of nail involvement ranges from 10% to 79% of patients in different studies [2,3]. Up to 39% of patients with severe psoriasis have an associated psoriatic arthritis but, overall, approximately 7% of patients have psoriatic arthritis with the skin disease preceding the joint disease by an average of 10 years in 85% of patients.

Family studies have revealed that, if one parent is affected by psoriasis, 16% of offspring are affected and, if both parents are affected, then 37% of children will have the disease [4].

Psoriasis is thought to have a polygenic mode of inheritance, and large numbers of chromosomal loci have been proposed to confer susceptibility to the disease [5]. Positive data have only been replicated in a few of these cases, for example the *PSORS1* locus on chromosome 6p21.3. This locus, found in a region that codes for human leukocyte antigens (HLA), is thought to be the major susceptibility locus, responsible for 30–50% of the genetic contribution to the disease [6].

Excessive alcohol may exacerbate psoriasis [7]. One study showed alcohol misuse in psoriasis patients to be as high as 38% [8]. However, the effect of stress needs to be considered as psoriasis may be precipitated by stress, and the disease is associated with anxiety and poor self-esteem [9]. Increased alcohol consumption is a recognized response to stress and, therefore, there is debate as to whether alcohol misuse is a cause or a consequence of psoriasis. There is also evidence that alcohol can provoke psoriasis and that abstinence is associated with remission of the disease [10].

Alcohol is a cause of excess mortality of patients with psoriasis. A total of 5500 patients admitted because of their psoriasis were followed up for 22 years; 1918 deaths were observed compared with 1211 expected from population averages, and mortality was high for all causes of death directly related to alcohol [11].

Recent data suggests that psoriasis is an independent risk factor for myocardial infarction. In a recent prospective cohort study which recruited over 130 000 psoriasis patients and 550 000 controls, young male patients with severe psoriasis had an adjusted relative risk of 3.10 (95% CI 1.98–4.86) for myocardial infarction [see ref. 121]. Systemic risk factors include obesity, hypertension, dyslipidaemia and diabetes. There is evidence that chronic inflammation may be causative.

Generalized pustular psoriasis is a rare form of psoriasis in which large areas of erythema are associated with numerous pustules and lakes of pus. It can be provoked by withdrawal of corticosteroid therapy, infections and hypocalcaemia. Some 90% of these patients have at least one abnormal liver parameter, with 50% being reported to have pronounced abnormalities: jaundice (18%), γ-glutamyltransferase level higher than five times the normal value (45%), alkaline phosphatase higher than twice the normal value (32%) and/or aminotransferases higher than three times the normal value (32%). These abnormalities returned to normal at the time of remission of the pustular psoriasis, suggesting that these severe liver abnormalities could be associated with severe cutaneous disease. Neutrophilic cholangitis was observed on liver biopsy [12]. Psoriasis may become erythrodermic, and this has been associated with raised bilirubin levels or hypoalbuminaemia as a result of oligaemia, sepsis and general toxicity [13].

Reactive systemic amyloidosis can occur as a sequitur of many chronic inflammatory diseases, and this has been reported in generalized psoriasis, chronic pustular psoriasis and psoriatic arthropathy [14]. Many drugs used in the treatment of psoriasis are hepatotoxic, and this will be discussed later in the chapter.

Lichen planus

Lichen planus is a self-limiting papular eruption that is

characterized by intensely pruritic violaceous papules. Oral involvement is characterized by lace-like patterning and ulceration and may be found in up to 65% of patients [15].

Lichen planus is considered to be a T cell-mediated disease targeting basal keratinocytes that express altered self-antigens on their surface. It has been proposed that cytotoxic T cells recognize an unknown antigen on lesional keratinocytes [16]. A tentative genetic predisposition has been suggested by familial cases of lichen planus and a significant association with both HLA 3 and HLA 5 [17], although others have found no such linkage.

A cutaneous eruption similar to lichen planus may occur after ingestion of drugs or contact with certain chemicals [18]. The list of drugs that can induce lichenoid drug reactions include gold, penicillamine, antimalarials, β-blockers, angiotensin-converting enzyme (ACE) inhibitors and thiazide diuretics.

Histology of lesional skin is identical whether the disease is idiopathic or due to a drug eruption. Patients with lichen planus seem to be more likely to develop liver disease including chronic active hepatitis. Raised levels of liver enzymes have been found in 7–52% of patients [19], and a link between erosive oral lichen planus and cirrhosis has been reported [20]. Extensive literature has been published on the epidemiological association between hepatitis C virus infection and lichen planus; this will be discussed in Chapter 21.6.

Primary biliary cirrhosis has been associated with lichen planus. It was initially described in patients with primary biliary cirrhosis receiving treatment with penicillamine, which is known to cause a lichenoid drug reaction [21]. However, lichen planus was subsequently reported in patients with primary biliary cirrhosis unrelated to therapy [22], although this association was recognized to occur rarely, with one large study identifying 7 out of 268 patients with primary biliary cirrhosis (2.6%) having lichen planus [23]. Concurrent oral lichen planus and primary sclerosing cholangitis has been described [24].

The association of lichen planus with chronic active hepatitis and primary biliary sclerosis has also been described as unusual and possibly coincidental [25].

Sarcoidosis

Cutaneous involvement in sarcoidosis can present in 17–30% of patients with the non-specific erythema nodosum [26] or as specific skin lesions manifesting as orange-brown granulomatous papules, nodules that may coalesce into plaques and possibly infiltration of scars. There are a large number of other manifestations of cutaneous sarcoidosis including hypopigmentation, ulceration, palmoplantar, ungual types and vasculitic eruptions. Lupus pernio is a bluish-red shiny eruption that occurs most frequently on the nose, cheeks and ears. Annular lesions are seen in up to 18% of Caucasian patients with cutaneous sarcoidosis [27]. The coexistence of erythema nodosum and bilateral hilar lymphadenopathy is associated with a good prognosis. Up to a third of patients with sarcoid have skin lesions that may be the only manifestation of the disease. Sarcoidosis of the liver is discussed fully in Chapter 20.12.

Autoimmune disorders

Systemic lupus erythematosus

Systemic lupus erythematosus (SLE) is a multisystem autoimmune disorder in which 80% of patients have involvement of the skin: butterfly rash, alopecia, photosensitivity, vasculitis, urticaria, lupus pernio and Raynaud's phenomenon.

Liver abnormalities are found in 56% of patients with active SLE [28]. Most of these abnormalities are mild and subside as the activity of the SLE decreases. The cause of raised liver enzymes in patients with SLE is usually attributed to hepatotoxic drugs, viral hepatitis and fatty liver. However, an autoimmune hepatitis has been described in patients with SLE, and there is controversy as to whether this is a primary liver disease or a hepatic manifestation of SLE [29].

Wegener's granulomatosis

This is a triad of small vessel vasculitis, necrotizing granulomatous inflammation of the respiratory tract and glomerulonephritis. Some 40% of patients with Wegener's granulomatosis (WG) have involvement of the skin. The commonest lesions are papules, nodules, vasculitis and pyoderma gangrenosum-like lesions. The detection of antineutrophil cytoplasmic antibody directed against proteinase-3 is highly specific for WG. Combination treatment with corticosteroids and cytotoxic drugs or antitumour necrosis factor antibodies is indicated, but hepatocellular carcinoma has been described following the use of cyclophosphamide [30]. Hepatotoxicity from methotrexate is described later in this chapter. Incomplete septal cirrhosis is part of the spectrum of hepatoportal sclerosis, which is associated with collagen vascular disorders and has been reported in patients with WG [31].

Polyarteritis nodosa

There is continuing debate as to whether cutaneous polyarteritis nodosa (C-PAN) is a localized form of PAN or simply an early manifestation of systemic PAN. C-PAN is usually a benign skin disease (vasculitis of small and medium-sized arteries, nodules, ulceration and livedo reticularis) with a relapsing course, but it may present with constitutional symptoms and mild nerve and muscle involvement [32]. Cutaneous lesions are described in 25–60% of patients with systemic PAN [33]. Hepatic arteritis demonstrating the PAN type of arteritis has been described in patients with PAN and other collagen disorders [34]. PAN has also been linked to hepatic haematomas, multiple hepatic artery aneurysms and may cause acute pancreatitis. Systemic PAN remains a life-threatening disease necessitating long-term treatment with corticosteroids with or without immunosuppressive drugs such as azathioprine and methotrexate.

Infectious diseases

Lyme disease

Lyme disease (LD) is caused by the spirochaete *Borrelia burgdorferi*, and patients are infected by a tick bite, the most common vector being the *Ixodes* tick. Some 90% of patients develop localized LD, erythema chronicum migrans, at the site of inoculation usually 7–10 days after the bite. Typically, an expanding erythematous circular eruption with central clearing advances at a rate of several centimetres a week. It may be associated with lymphadenopathy. Disseminated LD may present with multiple lesions of erythema migrans and late LD with acrodermatitis chronica atrophicans.

Mild elevation in liver function tests has been reported in 40% of patients with LD, and this is even more likely in patients with early disseminated LD. Gamma-glutamyltransferase and alanine transaminase were most commonly raised, and these normalized within 3 weeks of antibiotic treatment [35]. Occasionally, hepatic disorders have been reported as the presenting complaint in patients with LD as either febrile jaundice or a cholestatic pattern on liver function tests [36].

Bartonella

Bartonella are Gram-negative bacilli that can invade mammalian cells, and the clinical manifestations depend on the immune status of the host. *Bartonella henselae* is a common infection of cats causing an asymptomatic bacteraemia but, in immunocompetent humans, it can cause cat-scratch disease (CSD). CSD is a benign, self-limiting infection characterized by a papule, vesicle or pustule appearing 1–8 weeks after a cat scratch or contact with a cat. Uncommonly, fever, urticaria or erythema nodosum may occur. Patients often have regional lymphadenopathy, and this can rarely be generalized. Hepatosplenic localization of CSD has been reported in both adults and children, with liver biopsy showing granulomatous inflammation [37,38].

Bacillary angiomatosis is a systemic infection caused by *B. henselae* and *B. quintana*, occurring in immunocompromised individuals, almost exclusively human immunodeficiency virus (HIV)-infected patients. The characteristic lesion is a cutaneous vascular tumour often mistaken for Kaposi's sarcoma (KS). The purple/red/skin-coloured papulonodular lesions may number from one to over a thousand. Systemic infection commonly involves the liver (peliosis hepatitis) and/or the spleen (parenchymal bacillary peliosis). Hepatosplenomegaly, liver abscesses, necrotizing splenitis and necrotizing granulomata may occur.

Tumours

Kaposi's sarcoma

KS is a multisystem vascular neoplasm that is now considered to be caused by human herpes virus 8 (HHV-8). HHV-8 DNA has been found in all forms of KS, and the viral genome has been shown to encode for several proto-oncogenes that have the potential for malignant transformation, although there is still debate as to whether KS is a true or reactive neoplasm. KS is 20 000 times more common in HIV-infected individuals and about 300 times more common in people who are immunosuppressed for other reasons.

The violaceous skin lesions often begin as macules evolving into papules, plaques and nodules. Lesions typically begin in traumatized skin particularly at acral sites and are often associated with lymphoedema of the lower limbs. Visceral KS has been described in all organs except the brain. Almost 85% of patients who had died from AIDS had liver changes at post mortem, the commonest being KS [39]. Fatal KS has also been reported in previously HHV-8-seronegative patients who were recipients of a liver transplant from an HHV-8-seropositive donor [40].

Mastocytosis

Mastocytosis represents a clonal proliferation of mast cell haematopoietic progenitors caused by gain-of-function mutations in the c-kit gene. Patients with the cutaneous form may or may not have systemic involvement and can demonstrate spontaneous regression. Systemic mastocytosis is a persistent disease ranging from being asymptomatic to a highly aggressive and rapidly devastating mast cell leukaemia.

The commonest type of cutaneous mastocytosis is urticaria pigmentosa characterized by multiple reddish-brown macules, papules or nodules. Lesions may urticate spontaneously or after rubbing (Darier's sign). In children, cutaneous mastocytosis can present as a solitary mastocytoma or as a diffuse (erythrodermic) cutaneous mastocytosis in which there is diffuse infiltration of the entire skin, resulting in blistering with intense pruritus. Depending on the mast cell load, patients may also develop flushing, abdominal pain, diarrhoea and hypotension.

The liver is frequently involved in mastocytosis ranging from hepatomegaly (48%) and splenomegaly (41%) to severe liver disease with ascites, which is rare and carries a poor prognosis. Cholangitis has also been described [41]. The most common liver function test abnormality is an elevated serum alkaline phosphatase but amino transaminases and γ-glutamyltransferase may also be raised [42]. Analysis of liver biopsies performed on 25 patients showed that systemic mastocytosis is commonly associated with hepatic mast cell hyperplasia, fibrosis and, less commonly, nodular regenerative hyperplasia, portal venopathy and/or veno-occlusive disease. Other studies have noted similar findings, with hepatic mast cell infiltration as a frequent finding [43].

Histiocytoses

The histiocytoses represent a heterogeneous group of diseases characterized by the accumulation of reactive or neoplastic

histiocytes in various tissues. Three histiocytes are important in the skin: the Langerhans cell, the mononuclear cell or macrophage and the dermal dendrocyte. Historically, histiocytoses were categorised by many different names, but they are now classified as class I histiocytoses involving the Langerhans cell (LCH), class IIa histiocytoses involving the dermal dendrocyte lineage, class IIb involving cells other than Langerhans cells and dermal dendrocytes and class III representing malignancies of the monocyte/macrophage series of cells [44].

Cutaneous findings in LCH include a seborrhoeic dermatitis-like eruption in which flexural lesions may ulcerate, and some lesions may become xanthomatous. Many organs including liver, lung, lymph and bone can become infiltrated by LCH clonal cells that affect organ function [45]. In a large series of 124 patients, 50% had liver disease manifested by hepatomegaly, ascites and cholestatic jaundice due to fibrotic obstruction of the biliary tree [46]. Within the class IIb histiocytoses, there is a subset of patients with necrobiotic xanthogranuloma. These patients have papules or nodules with a yellow, xanthomatous hue. The lesions, commonly found periorbitally, can ulcerate. Hepatosplenomegaly is a common finding. The majority have an associated paraprotein, usually an IgG κ or λ, and many have a raised erythrocyte sedimentation rate (ESR) and are hypocomplementaemic. Treatment is generally directed against the associated paraproteinaemia with alkylating agents such as melphelan or with combinations of vinblastine, etoposide, prednisolone, mercaptopurine and methotrexate or with oral psoralen and long-wave ultraviolet light (PUVA) phototherapy or radiotherapy for cutaneous disease.

Kawasaki disease

Kawasaki disease is an acute febrile vasculitis with a peak incidence at the age of 1–2 years; 80% of cases occur in children aged less than 4 years. It is characterized by a widespread erythematous exanthem, dry, red and cracked lips, conjunctival injection, cervical lymphadenopathy and a red tongue with prominent papillae ('strawberry tongue'). The rash becomes localized on the hands and feet, which become oedematous and then desquamate. Associated cardiac involvement with the development of myocarditis, pericarditis and coronary artery aneurysms is not uncommon and must be excluded [47]. The aetiology of Kawasaki disease is not known, but bacteria or bacterial superantigens have been implicated following the isolation of toxin-producing staphylococcal or streptococcal strains from patients with the disorder [48].

Abdominal pain and jaundice have been described as the presenting complaint in Kawasaki disease [49]. Ten to fifteen per cent of children with Kawasaki disease develop upper abdominal pain during their illness [50]. In one series, hepatomegaly was noted in 15%, and a non-specific increase in serum aminotransferases was found in 31% of cases [51]. There is also a known association with hydrops of the gallbladder, although its pathogenesis remains unclear [52]. Three patients with Kawasaki disease have been reported to have had histological evidence of intrahepatic cholangitis and necrosis of the intrahepatic bile duct epithelium [53]. Intrahepatic cholangitis in a child who had persistent hepatomegaly has also been reported [54]. Vasculitis, portal inflammation, fatty degeneration and severe hepatic congestion have all been reported at autopsy and could contribute towards hepatic dysfunction [55].

Neurofibromatosis type 1

Neurofibromatosis type 1 (NF1) or von Recklinghausen's disease is the most common neurocutaneous disorder, occurring in 1 in 2500 to 7800 persons [56]. It has an autosomal dominant mode of inheritance, but 50% of affected individuals have NF1 as a result of a new NF1 gene mutation. The gene for this disease has been localized to chromosome 17q11.2 [57].

Cutaneous features include café-au-lait spots, which may be present at birth or develop during infancy, axillary freckling, which is pathognomonic of neurofibromatosis, and cutaneous neurofibromas, which are soft flesh-coloured papules and nodules. Other presentations include subcutaneous neurofibromas involving nerves, nodular plexiform neurofibromas in the subcutis involving dorsal nerve roots, and diffuse plexiform neurofibromas, which may involve all layers of skin and penetrate deeply into muscle, bone and viscera. There are occasional reports of plexiform neurofibromas involving the liver, which may be extensive, as in the case of a 5-year-old boy who presented with a neurofibroma involving the retroperitoneum, mesentery and liver [58], and that of a 15-year-old girl in whom infiltration had occurred into the porta hepatis and intrahepatic portal branches of the liver, leading to hepatomegaly and right upper quadrant tenderness [59]. Extrahepatic biliary obstruction leading to obstructive jaundice has also been reported [60].

Gastrointestinal stromal tumours are found both sporadically and in association with neurofibromatosis. Liver metastases have been reported [61].

One per cent of neurofibromatosis patients develop phaeochromocytomas; these tumours can be situated in the liver themselves, but adrenal phaeochromocytomas are also documented as causing marked abnormalities in liver function including cholestasis. This effect, due to tumour production of interleukin (IL)-6 and IL-1β, resolves spontaneously following tumour resection [62,63].

Neurofibromatosis type 2

Skin manifestations in NF2 are not as common as in type 1 disease, and liver involvement is extremely rare. The human neurofibromatosis 2 gene encodes for a tumour suppressor protein called schwannomin, a member of a family of proteins thought to link cytoskeletal elements to cell membrane contents. Schwannomin seems not to be present in the liver, possibly explaining the infrequency of liver involvement [64].

Drugs

Retinoids

The synthetic retinoid acitretin has an established role in the treatment of psoriasis, disorders of keratinization such as Darier's disease, severe types of ichthyosis and pityriasis rubra pilaris. Isotretinoin is the retinoid used in the treatment of acne. Retinoids are teratogenic, and pregnancy is contraindicated for 2 years following cessation of acitretin and for 1 month after isotretinoin. The main side-effects are dryness of the skin and mucous membranes causing cheilitis and conjunctivitis. Side-effects of the retinoids are similar but, because isotretinoin is rarely prescribed for periods longer than 1 year, subsequent focus will be on acitretin.

In 525 patients taking acitretin in clinical trials, 66% had increases in triglycerides > 20 mg/dL and 33% had a doubling in total cholesterol. Baseline lipid measurements are recommended followed by regular testing until the effect on lipids is established [65]. Hyperlipidaemia should be managed by reducing the dose of acitretin, dietary measures and lipid-lowering drugs. Lipid levels usually normalize after stopping acitretin.

One-third of patients taking acitretin have transient and reversible rises in aspartate aminotransferase (AST), alanine aminotransferase (ALT) or lactate dehydrogenase (LDH) [65]. Acute hepatitis progressing to chronic liver disease is rare [66]. Liver biopsies carried out in a series of patients on etretinate for 2 years showed no consistent abnormalities [67]. Baseline liver function tests are measured before acitretin or isotretinoin and intermittently thereafter; routine liver biopsy is not recommended. Alcoholics, diabetics and patients on other hepatotoxic medication will require closer monitoring.

Methotrexate

Methotrexate has been a treatment for psoriasis since the 1950s. The mode of action has been attributed to inhibition of DNA synthesis and cell division of keratinocytes by competitive inhibition of the enzyme dihydrofolate reductase, but effects on T cells may be more important [68]. Use of methotrexate is limited by risks of myelosuppression, pulmonary fibrosis and hepatotoxicity. Methotrexate use was linked to 164 fatalities reported over 35 years to the Committee on the Safety of Medicines [69]. While myelosuppression was the most common cause of mortality, eight deaths were attributed to liver complications.

Methotrexate-induced hepatotoxicity ranges from mild hepatitis to fibrosis, cirrhosis and, rarely, fulminant hepatic failure. Progression to cirrhosis in psoriatics receiving methotrexate varies greatly in different publications from 25% to more recent estimates of 0–4% [70]. Histological findings commence with increased collagen in the space of Disse, progressing to fibrosis and, eventually, micronodular cirrhosis. Fatty infiltration is not uncommon, although hepatocellular damage is not usually a feature.

Increased risk of liver damage on methotrexate is linked to a high cumulative dosage, alcohol consumption in excess of 10 units per week, diabetes, obesity and older age [71]. Patients with psoriasis who are treated with methotrexate seem to be more susceptible to liver damage than those with rheumatoid arthritis. This is attributed to patients with rheumatoid arthritis taking more oral corticosteroids and having less associated alcohol consumption and obesity.

Monitoring of patients on methotrexate is of vital importance and, if patients are selected beforehand and reviewed regularly, then methotrexate has been shown to be a relatively safe therapy [72]. Conventional serum tests of liver function are relatively insensitive and non-specific, and may not accurately reflect the degree of liver injury. Liver histology is still the most accurate way of assessing methotrexate toxicity, but debate exists as to how often liver biopsy should be performed. The American Academy of Dermatology guidelines suggest a liver biopsy after a cumulative dose of 1.5 g of methotrexate and thereafter at 1- to 1.5-g intervals. However, needle biopsy samples only a minute proportion (1/50 000 of the total liver size), and sampling error is estimated at 30%. The risk of significant morbidity following liver biopsy is 2% and risk of mortality is 1:10 000 [73].

A non-invasive method of assessing hepatic fibrosis would be preferable, and measurement of procollagen III aminopeptide (PIIINP), which is produced during the synthesis of collagen type 3 and appears to correlate with the amount of ongoing liver fibrosis, has been advocated as a useful marker in psoriasis patients on methotrexate. A recent audit over 24 months in four UK centres compared two groups of patients, one in which recommended biopsy guidelines were adhered to and the other in which liver biopsy was only undertaken if there was high pre-treatment PIIINP, or persistently raised PIIINP on methotrexate (measured four times a year). There was a sevenfold reduction in the need for liver biopsies in the PIIINP group. Abnormalities in the liver biopsy sufficient to alter management were found in 6% of patients using the recommended biopsy guidelines but in 20% of the group biopsied if patients had abnormal PIIINP levels [74].

Another recent study examined the ability of PIIINP measurements to identify those patients on methotrexate with hepatic fibrosis. Forty-six liver biopsies from 34 patients were compared with PIIINP levels taken within 12 months of the biopsy. A consistent increase in PIIINP level was seen across each grade of fibrosis. No biopsy showed fibrosis if all PIIINP levels were normal, but 50% of liver biopsies without fibrosis had at least one abnormal PIIINP assay [75].

PIIINP is a sensitive but not a specific marker and can be raised in arthritis, scleroderma, hyperthyroidism and during physiological growth in childhood. Larger studies will have to be undertaken before definitive recommendations to substitute regular PIIINP assays for routine liver biopsies can be made.

Azathioprine

Azathioprine is a 6-mercaptopurine derivative immunosuppressive agent frequently used in dermatological practice, often in combination with systemic steroids, as a steroid-sparing agent. Skin diseases for which azathioprine is an established treatment include the bullous disorders pemphigus and pemphigoid, atopic eczema (particularly of the photosensitive type), actinic reticuloid, systemic lupus erythematosus and dermatomyositis [76]. Cholestasis and elevation of liver enzymes are seen only occasionally during therapy and are usually reversible on withdrawal of the drug. Very rarely, azathioprine induces a hypersensitivity reaction, which may include cholestatic jaundice, portal fibrosis, hepatocellular necrosis, fever and shock [77].

Thiopurine methyl transferase (TPMT) is an enzyme involved in the metabolism of azathioprine and other thiopurines. Allelic polymorphisms in the TPMT gene predict the activity of the enzyme, such that 1 in 10 of the population are heterozygous and have approximately 50% of normal activity, whereas 1 in 300 are completely deficient. Patients with no TPMT activity have grossly elevated levels of thiopurine drugs and can develop potentially fatal myelosuppression and hepatotoxicity [78]. Some studies found that heterozygous patients did not necessarily have more toxicity from azathioprine and, hence, focused on inosine triphosphate pyrophosphatase (ITPase). Lack of ITPase can cause toxic levels of 6-thio-ITP, which is a metabolite of azathioprine. Polymorphism in the ITPase gene predicts intolerance to azathioprine, although as yet it is not measured routinely in clinical practice [79].

Ciclosporin

Ciclosporin is a treatment for a variety of disorders including psoriasis, atopic eczema, pyoderma gangrenosum, Behçet's disease, epidermolysis bullosa acquisita, lichen planus, pemphigus and bullous pemphigoid. The standard dose is between 3 and 5 mg/kg/day given in two divided doses. It is usually well tolerated. Monitoring of renal function and blood pressure is mandatory because long-term use of this drug in transplant recipients has been found to cause an irreversible reduction in the glomerular filtration rate associated with characteristic renal histopathological changes [80]. Ciclosporin is metabolized predominantly by the hepatic cytochrome P-450 enzyme system with only 6% excreted unaltered in the urine. Caution is therefore necessary when ciclosporin is given to patients with pre-existing liver disease, as the risk of further damage is potentiated and increased blood levels may be expected [81].

Ciclosporin may cause a rise in serum bilirubin, alkaline phosphatase and aminotransferases. Hyperbilirubinaemia is the most common alteration in liver function noted and occurs in up to 50% of patients. These changes are usually asymptomatic and return to normal on dosage reduction. Their significance is unclear. It has been suggested that oxidative stress may cause hepatotoxicity associated with ciclosporin, and recent animal studies have suggested a protective effect of several antioxidants when given with ciclosporin [82]. In addition, preliminary data suggest that concomitant use of the recently introduced biologics with ciclosporin may lead to a lower incidence of hepatic and renal impairment [83].

Tumour necrosis factor alpha immunomodulators

Tumour necrosis factor alpha (TNFα) has a pathogenic role in rheumatoid arthritis, Crohn's disease, psoriasis, psoriatic arthritis, atopic dermatitis and ankylosing spondylitis. In these diseases, TNFα blockade with either infliximab or etanercept has been shown to be of benefit. A range of skin diseases have been treated successfully with anti-TNFα therapy including Behçet's disease [84], granuloma annulare [85], hidradenitis suppurativa, panniculitis, pyoderma gangrenosum, SAPHO (synovitis, acne, pustulosis, hyperostosis and osteitis) syndrome, sarcoidosis, subcorneal pustular dermatosis, Sweet syndrome, toxic epidermal necrolysis and Wegener's granulomatosis [86]. TNFα antibodies have been used in patients with chronic hepatitis C with no significant changes in liver enzymes, [87], but there have been anecdotal reports of severe hepatic reactions including jaundice, hepatitis, cholestasis, fulminant hepatitis and acute liver failure in patients receiving infliximab [88].

Fumaric acid esters

Fumaric acid esters (FAEs) have been shown to be an effective treatment for severe psoriasis and are now considered to be the first-line systemic therapy in Germany. FAEs have also provided benefit in disseminated granuloma annulare, annular elastolytic giant cell granuloma, sarcoidosis, necrobiosis lipoidica and granulomatous cheilitis [89]. Three-quarters of patients report some mild side-effects, which generally do not interfere with treatment. A quarter of patients had moderate liver enzyme elevation that resolved on stopping therapy [90].

Psoralens

Psoralens are photosensitizers that cross-link with DNA in the presence of ultraviolet light. This reaction is utilized when psoralens are given in combination with PUVA for conditions such as psoriasis, cutaneous T-cell lymphoma and vitiligo [91]. PUVA has been rarely associated with hepatitis [92] and is known to induce liver microsomal enzymes [93].

Leflunomide

Leflunomide, a new oral immunomodulatory agent, is effective for the treatment of rheumatoid arthritis. Its mechanism of

action in suppressing inflammation is based on its inhibition of dihydro-orotate dehydrogenase, a key enzyme in the *de novo* synthesis of pyrimidine-containing ribonucleotides. Leflunomide has also been used in the treatment of psoriasis, psoriatic arthritis, Felty syndrome, vasculitis, Sjögren syndrome, Wegener's granulomatosis and bullous pemphigoid [94,95]. In a recent study of 101 patients taking leflunomide for rheumatoid arthritis, 8.9% of patients had moderate or severe elevation of liver enzymes; most occurred within the first 6 months of therapy and resolved during continued follow-up [96]. Although none of these patients showed clinical signs of hepatotoxicity, there are other reports of patients on leflunomide presenting with acute hepatitis [97].

Dapsone

Dapsone is an antibacterial sulphonamide that was originally used in the treatment of leprosy. More recently, it has been used as a treatment for several other skin conditions: immunobullous disorders (mainly dermatitis herpetiformis), pyoderma gangrenosum, vasculitis, Henoch Schönlein purpura, Sweet syndrome and Behçet's disease. Patients on dapsone frequently develop haematological side-effects such as haemolysis and methaemoglobinaemia. Hepatitis has also been reported, both alone and as part of the 'dapsone hypersensitivity syndrome', which occurs in between 0.2% and 0.5% of patients [98]. It begins with a rash and eosinophilia and, if dapsone is not stopped immediately, patients can develop an exfoliative dermatitis, hepatitis, hypoalbuminaemia, psychosis and death. Both hepatocellular and cholestatic liver damage have also been described. Patients with cholestasis may run a more benign course. Cholangitis has also been described as part of the dapsone syndrome [99]. Severe cases respond well to corticosteroid therapy.

Terbinafine

Terbinafine is now considered to be the first-line treatment of dermatophyte infections of the nails and may be an option for ringworm infections when oral therapy is appropriate. The frequency of adverse effects is about 10%, with gastrointestinal symptoms being most common (nausea, diarrhoea, abdominal pain and dyspepsia). A postmarketing surveillance study of 25 884 patients showed a 0.2% incidence of hepatic enzyme increases and, although hepatobiliary toxicity with terbinafine is uncommon (1/45 000), cholestasis, liver failure and hepatorenal syndrome have been described [100]. The pathophysiology of liver reactions to terbinafine is unclear, possibly being idiosyncratic or via a reactive metabolite [101].

Itraconazole

Itraconazole is a broad-spectrum triazole antimycotic used for topical treatment failures or as a first-line treatment for ringworm fungal infections, pityriasis versicolor and onychomycosis. Apart from skin diseases, itraconazole is also licensed for aspergillosis, systemic candidiasis, cryptococcosis and histoplasmosis. The frequency of liver impairment in patients on itraconazole ranges from 31.5% of 9228 patients in a recent meta-analysis [102] to 0.003% of prescriptions in a UK study of 54 803 patients [103]. There is a lack of standard definitions of hepatotoxicity across these studies, which may explain the wide range described. Severe hepatotoxicity has been described and, recently, a patient has been reported who developed liver failure requiring transplantation following itraconazole treatment for onychomycosis [104]. There is, however, a recommendation that liver function tests are required if treatment exceeds 1 month.

Griseofulvin

Griseofulvin has been used for over 40 years in dermatophyte infections with infrequent side-effects. However, the length of treatment may result in poor compliance, and the newer faster-acting agents (itraconazole and terbinafine) are often the preferred option for onychomycosis. Griseofulvin is still used regularly for tinea capitis in children. Hepatic side-effects are rare, but reports include intrahepatic cholestasis [105], exacerbation of acute intermittent porphyria [106] and drug-induced lupus erythematosus.

Minocycline

Minocycline is an antibiotic that is regularly used in the treatment of acne. Although generally safe, 6% of patients taking minocycline have been reported to develop hepatotoxicity. Two different clinical scenarios of liver involvement are described: autoimmune hepatitis associated with lupus-like symptoms occurring after a median duration of exposure to minocycline of 365 days in females and 730 days in males or a hypersensitivity reaction associated with eosinophilia and exfoliative dermatitis occurring within 35 days of therapy [107].

Flucloxacillin

Flucloxacillin is a semi-synthetic penicillinase-resistant penicillin primarily used to treat cutaneous staphylococcal infections. Flucloxacillin is a well-recognized cause of drug-induced cholestatic hepatitis, often associated with prolonged cholestasis and the vanishing bile duct syndrome [108]; occasional fatal hepatic injury has also been reported [109]. A recent study of 283 097 first-time users of flucloxacillin showed that 8.5/100 000 developed cholestasis within 45 days of starting treatment, and a further 1.8/100 000 were affected within 90 days of starting treatment. In the UK, flucloxacillin remains the most common antistaphylococcal antibiotic prescribed, although in the USA, following reports of cholestasis, dicloxacillin is increasingly used as an alternative [110].

Spironolactone

The aldosterone antagonist diuretic spironolactone is used in the treatment of hirsutism and in hyperandrogenetic conditions such as polycystic ovary syndrome as a consequence of its weak antiandrogenetic properties. Hepatic toxicity is extremely rare with only a few reported cases [111]. Although spironolactone has been shown to cause tumours, including liver tumours, in rats when used at doses 25–100 times higher than those used in humans [112], no reported cases of spironolactone-related tumours have been reported in humans.

Cyproterone acetate

Women suffering from acne or hirsutism, often secondary to the polycystic ovary syndrome, may be treated with the antiandrogen cyproterone acetate (CPA) in combination with ethinylestradiol. The oral contraceptive preparation Dianette contains a small dose of CPA (2 mg daily) and 35 μg of ethinylestradiol; it is not recommended solely for contraception, but should be used in women who have androgen-dependent skin conditions. CPA is contraindicated in patients with pre-existing liver disease. A report of 105 prostate cancer patients taking high daily doses (150 mg) of CPA showed hepatotoxicity in 9.5%, which resolved in 90% after stopping the CPA [113]. A recent case–control study of Dianette use suggested no increase in hepatotoxicity compared with the general population, which implies that this is a dose-dependent effect [114].

Several reports point towards a rare link between prolonged use of high-dose CPA and the development of hepatocellular carcinoma. This is most frequently reported when CPA is used in higher doses, often for prostate carcinoma, but a healthy female with no other risk factors has developed hepatocellular carcinoma after 14 years of taking Dianette [115]. Progestogens are classified by the International Agency for Research on Cancer (IARC) as possibly carcinogenic to humans. It is suggested that this results from the genotoxicity of CPA. A reactive metabolite of CPA is produced in the liver, which forms DNA adducts eliciting DNA repair in hepatocytes, in both rats and humans [116].

Danazol

Danazol, an inhibitor of pituitary gonadotropin with weak androgenic effects, is currently used in the treatment of endometriosis, hereditary angio-oedema, systemic lupus erythematosus and idiopathic thrombocytopenic purpura. Its hepatological side-effects have been well documented. These include reversible elevations in serum aminotransferases, cholestatic hepatitis [117], hepatic peliosis, hepatocellular adenomas and, rarely, hepatocellular carcinoma [118]. Danazol can induce aminolaevulinic acid (ALA) synthetase activity and, hence, may precipitate porphyria.

Stanozolol

Stanozolol is similar in structure to danazol and is used in chronic venous disease, Raynaud's disease, hereditary angio-oedema, urticaria, cryofibrinogenaemia and for the vascular manifestations of Behçet's disease because of its fibrinolytic effect. Like danazol, slight elevation in liver enzymes may be seen and porphyria precipitated [119]. Very rarely, stanozolol may induce hepatic tumours and peliosis hepatitis with prolonged treatment [120].

References

1 Christophers E (2001) Psoriasis: epidemiology and clinical spectrum. *Clin Exp Dermatol* 26, 314–320.
2 Calvert HI, Smith MA, Wells RS (1963) Psoriasis and the nails. *Br J Dermatol* 75, 415–418.
3 de Jong EMGJ, Seegers BAMPA, Gulnick MK *et al.* (1996) Psoriasis of the nails associated with disability in a large number of patients: results of a recent interview with 1728 patients. *Dermatology* 193, 300–303.
4 Swanbeck G, Inerot A, Martinsson T *et al.* (1997) Genetic counselling in psoriasis: empirical data on psoriasis among first-degree relatives of 3095 psoriatic probands. *Br J Dermatol* 137(6) 939–942.
5 Giardina E, Sinibaldi C, Novelli G (2004) The psoriasis genetics as a model of complex disease. *Curr Drug Targets Inflamm Allergy* 3, 129–136.
6 Trembath RC, Lee Clough R, Rosbotham JL *et al.* (1997) Identification of a major susceptibility locus on chromosome 6p and evidence for further disease loci revealed by a two stage genome wide search in psoriasis. *Hum Mol Gen* 6(5), 813–820.
7 Poikolainen K, Reunala T, Karvonen J *et al.* (1990) Alcohol intake: a risk factor for psoriasis in young and middle aged men? *Br Med J* 300, 780–783.
8 Higgins EM, du Vivier AW (1992) Alcohol and the skin. *Alcohol Alcohol* 27, 595–602.
9 Ramsay B, O'Reagan M (1988) A survey of the social and psychological effects of psoriasis. *Br J Dermatol* 118, 195–201.
10 Vincenti GE, Blunden SM (1987) Psoriasis and alcohol abuse. *J R Army Med Corps* 133, 77–78.
11 Poikolainen K, Karvonen J, Pukkala E (1999) Excess mortality related to alcohol and smoking among hospital-treated patients with psoriasis. *Arch Dermatol* 135(12), 1541–1542.
12 Viguier M, Allez M, Zagdanski AM *et al.* (2004) High frequency of cholestasis in generalized pustular psoriasis: evidence for neutrophilic involvement of the biliary tract. *Hepatology* 40(2), 452–458.
13 Warren DJ, Winney RJ, Beveridge GW (1974) Oligaemia, renal failure, and jaundice associated with acute pustular psoriasis. *Br Med J* 2(916), 406–408.
14 Bergis M, Dega H, Planquois V (2003) Amyloidosis complicating psoriatic arthritis [in French]. *Ann Dermatol Venereol* 130 (11), 1039–1042.
15 Strauss RA, Fattore L, Soltani K (1989) The association of mucocutaneous lichen planus and chronic liver disease. *Oral Surg* 68, 406–410.
16 Sugerman PB, Savage NW, Walsh LJ *et al.* (2002) The pathogenesis of oral lichen planus. *Crit Rev Oral Biol Med* 13, 350–365.
17 Lowe NJ, Cudworth AG, Woodrow JC (1976) HL-A antigens in lichen planus. *Br J Dermatol* 95, 169–171.

18 Halevy S, Shai A (1993) Lichenoid drug eruptions. *J Am Acad Dermatol* 29, 249–255.

19 Korkij W, Chuang TY, Soltani K (1984) Liver abnormalities in patients with lichen planus. A retrospective case-control study. *J Am Acad Dermatol* 11, 609–615.

20 Ayala F, Balato N, Tranfaglia A *et al.* (1986) Oral erosive lichen planus and chronic liver disease. *J Am Acad Dermatol* 14, 139–140.

21 Seehafer JR, Rogers RS III, Fleming CR *et al.* (1981) Lichen planus-like lesions caused by penicillamine in primary biliary cirrhosis. *Arch Dermatol* 117, 140–142.

22 Graham-Brown (1981) *Lancet*, ii:1046

23 Powell FC, Rogers RS III, Dickson ER (1983) Primary biliary cirrhosis and lichen planus. *J Am Acad Dermatol* 9, 540–545.

24 Tong DC, Ferguson MM (2002) Concurrent oral lichen planus and primary sclerosing cholangitis. *Br J Dermatol* 147, 356–358.

25 Epstein O (1984) Lichen planus and liver disease. *Br J Dermatol* 111, 473–475.

26 James DG, Siltzbach TE (1976) A world wide review of sarcoidosis. *Ann NY Acad Sci* 278, 321–334.

27 Veien NK, Stahl D, Brodthagen H (1987) Cutaneous sarcoidosis in Caucasians. *J Am Acad Dermatol.* 16. 534–540.

28 Kushimoto K, Ngasawa K, Ueda A *et al.* (1989) Liver abnormalities and liver membrane autoantibodies in systemic lupus erythematosus. *Ann Rheum Dis* 48(11), 946–952A.

29 Tojo J, Ohira H, Abe K *et al.* (2004) Autoimmune hepatitis accompanied by SLE. *Intern Med* 43(3) 258–262.

30 Okano A, Matsusue R, Takkuwa H *et al.* (2003) Hepatocellular carcinoma associated with long term cyclophosphamide therapy for Wegener's granulomatosis *Intern Med* 42(5), 406–409.

31 Zen Y, Sunagozaka H, Tsuneyyama K (2002) Incomplete septal cirrhosis associated with Wegener's granulomatosis. *Liver* 22(5), 388–393.

32 Bauza A, Espana A, Idoate M (2002) Cutaneous polyarteritis nodosa. *Br J Dermatol* 146, 694–699.

33 Bonsib SM (2001) Polyarteritis nodosa. *Semin Diagn Pathol* 18, 14–23.

34 Matsumoto T, Kobayashi S, Shimizu H *et al.* (2000) The liver in collagen diseases. *Liver* 20(5), 366–373.

35 Horowitz HW, Dworkin B, Forseter G *et al.* (1996) Liver dysfunction in early Lyme disease. *Hepatology* 23(6), 1412–1417.

36 Dadamessi I, Brazier F, Smail A *et al.* (2001) Hepatic disorders related to Lyme disease. *Gastroenterol Clin Biol* 25(2), 193–196.

37 Le Tallec V, Abugueguen P, Pichard E *et al.* (2003) Hepatic localization of cat scratch disease in immuno competent adults. *Gastroenterol Clin Biol* 27(2), 225–229.

38 Ventura A, Massei F, Not T *et al.* (1999) Systemic *Bartonella henselae* infection with hepatosplenic involvement. *J Pediatr Gastroenterol Nutr* 29(1), 52–56.

39 Schneiderman DJ, Arenson DM, Cello JP *et al.* (1987) *Hepatology* 7(5), 925–930.

40 Marcelin AG, Roque-Afonso AM, Hurtova M *et al.* (2004) Fatal disseminated Kaposi's sarcoma following human herpes virus 8 primary infections in liver-transplant recipients. *Liver Transpl* 10(2), 295–300.

41 Marbello L, Anghilieri M, Nosari A *et al.* (2004) Aggressive systemic mastocytosis mimicking sclerosing cholangitis. *Haematologica* 89(9) 35.

42 Mican JM, Di Bisceglie AM, Fong TL *et al.* (1995) Hepatic involvement in mastocytosis. *Hepatology* 22(4 Pt 1), 1163–1170.

43 Yam LT, Chan CH, Li CY (1986) Hepatic involvement in systemic mast cell disease. *Am J Med* 80, 819–826.

44 Chu AC (2005) Histiocytoses. In: Burns A, Breathnach S, Cox N (eds) *Textbook of Dermatology*. Oxford: Blackwell, pp. 52.1–52.33.

45 Nagai S, Kusumoto M, Yakushiji S (2004) A case of pulmonary Langerhans' cell histiocytosis with liver involvement. *Nihon Kokyuki Gakkai Zasshi* 42(10), 924–927.

46 Rivera-Luna R, Rueda-Fanco F, Lanche-Guevara NT *et al.* (1988) Langerhans cell histiocytosis: clinical experience with 124 patients. *Pediatr Dermatol* 5, 145–150.

47 Gersony WM (1991) Diagnosis and management of Kawasaki disease. *JAMA* 265, 2699–2703.

48 Leung DY, Meissner HC, Fulton DR (1993) Toxic shock syndrome toxin-secreting Staphylococcus aureus in Kawasaki syndrome. *Lancet* 342(8884), 1385–1388.

49 Granel B, Serratrice J, Ene N *et al.* (2004) Painful jaundice revealing Kawasaki disease in a young man. *J Gastroenterol Hepatol* 19(6), 713–715.

50 Melish ME, Hicks RV, Reddy V (1982) Kawasaki syndrome: an update. *Hosp Pract (Hosp Ed)* 17, 99–106.

51 Burns JC, Mason WH, Glode MP *et al.* (1991) Clinical and epidemiologic characteristics of patients referred for evaluation of possible Kawasaki disease. United States Multicenter Kawasaki Disease Study Group. *J Pediatr* 118, 680–686.

52 Mofenson HC, Greensher J, Molavi M (1980) Gallbladder hydrops: complication of Kawasaki disease. *N Y State J Med* 80, 249–251.

53 Bader-Meunier B, Hadchouel M, Fabre M *et al.* (1992) Intrahepatic bile duct damage in children with Kawasaki disease. *J Pediatr* 120, 750–752.

54 Edwards KM, Glick AD, Greene HL (1985) Intrahepatic cholangitis associated with mucocutaneous lymph node syndrome. *J Pediatr Gastroent Nutr* 4, 140–142.

55 Ohshio G, Furukawa F, Fujiwara H *et al.* (1985) Hepatomegaly and splenomegaly in Kawasaki disease. *Pediatr Pathol* 4, 257–264.

56 Zvulunov A, Esterly N (1995) Neurocutaneous syndromes associated with pigmentary skin lesions. *J Am Acad Dermatol* 32, 915–935.

57 Schmidt MA, Michels VV, Dewald GW (1987) Cases of neurofibromatosis with rearrangements of chromosome-17 involving band 17q11.2. *Am J Med Genet* 28, 771–777.

58 Fenton LZ, Foreman N, Wyatt-Ashmead J (2001) Diffuse, retroperitoneal mesenteric and intrahepatic periportal plexiform neurofibroma in a 5-year-old boy. *Pediatr Radiol* 31(9), 637–639.

59 Kakitsubata Y, Kakitsubata S, Sonoda T *et al.* (1994) Neurofibromatosis type 1 involving the liver: ultrasound and CT manifestations. *Pediatr Radiol* 24, 66–67.

60 Meyer GW, Griffiths WJ, Welsh J *et al.* (1982) Hepatobiliary involvement in von Recklinghausen's disease. *Ann Int Med* 97, 722–723.

61 Diment J, Tamborini E, Casali P *et al.* (2005) Carney triad: case report and molecular analysis of gastric tumor. *Hum Pathol* 36(1), 112–116.

62 Kang JM, Lee WJ, Kim WB *et al.* (2005) Systemic inflammatory syndrome and hepatic inflammatory cell infiltration caused by an interleukin-6 producing pheochromocytoma. *Endocr J* 52(2), 193–198.

63 Chung CH, Wang CH, Tzen CY *et al.* (2005) Intrahepatic cholestasis as a paraneoplastic syndrome associated with pheochromocytoma. *J Endocrinol Invest* 28(2), 175–179.

64 Huynh DP, Tran TM, Nechiporuk T *et al.* (1996) Expression of neurofibromatosis 2 transcript and gene product during mouse fetal development. *Cell Growth Differ* 7(11), 1551–1561.

65 Katz HI, Waalen J, Leach EE (1999) Acitretin in psoriasis. *J Am Acad Dermatol* 41(3 Pt 2), S7–S12.

66 Van Ditzhuijsen TJ, van Haelst UJ, van Dooren-Greebe RJ *et al.* (1990) Severe hepatotoxic reaction with progression to cirrhosis after use of a novel retinoid (acitretin). *J Hepatol* 11, 185–188.

67 Roenigk HH, Callen JP, Guzzo CA *et al.* (1999) Effects of acitretin on the liver. *J Am Acad* 41(4), 584–588.

68 Yamasaki E, Soma Y, Kawa Y *et al.* (2003) Methotrexate inhibits proliferation and regulation of the expression of intercellular adhesion molecule-1 and vascular adhesion molecule-1 by cultured human umbilical vein endothelial cells. *Br J Dermatol* 149, 30–38.

69 MacDonald A, Burden AD (2005) Noninvasive monitoring for methotrexate hepatotoxicity. *Br J Dermatol* 152, 405–408.

70 Saporito FC, Menter MA (2004) Methotrexate and psoriasis in the era of the new biologic agents. *J Am Acad Dermatol* 50, 301–309.

71 Whiting-O'Keefe QE, Fye KH, Sack KD (1991) Methotrexate and histologic hepatic abnormalities: a meta-analysis. *Am J Med* 90, 711–716.

72 Van Dooren-Greebe RJ, Kuijpers AL, Mulder J *et al.* (1994) Methotrexate revisited: effects of long-term treatment in psoriasis. *Br J Dermatol* 130, 204–210.

73 Campbell MS, Reddy KR (2004) Review article: the evolving role of liver biopsy. *Aliment Pharmacol Ther* 20, 249–259.

74 Chalmers RJG, Kirby B, Smith A *et al.* (2005) Replacement of routine liver biopsy by procollagen III aminopeptide for monitoring patients with psoriasis receiving long term methotrexate: a multicentre audit and health economic analysis. *Br J Dermatol* 152, 443–449.

75 Maurice PDL, Maddox AJ, Green CA *et al.* (2005) Monitoring patients on methotrexate. *Br J Dermatol* 152, 451–458.

76 Anstey A (1995) Azathioprine in dermatology: a review in the light of advances in understanding methylation pharmacogenetics. *J R Soc Med* 88, 155P–160P.

77 Saway PA, Heck LW, Bonner JR *et al.* (1988) Azathioprine hypersensitivity. Case report and review of the literature. *Am J Med* 84, 960–964.

78 Sanderson J, Ansari A, Marinaki T *et al.* (2004) Thiopurine methyltransferase: should it be measured before commencing thiopurine drug therapy? *Ann Clin Biochem* 41(Pt 4), 260–262.

79 Marinaki AM, Ansari A, Duley JA *et al.* (2004) Adverse drug reactions to azathioprine therapy are associated with polymorphism in the gene encoding inosine triphosphate pyrophosphatase (ITPase). *Pharmacogenetics* 14(3), 181–187.

80 Mihatsch MJ, Thiel G, Ryffel B (1988) Morphologic diagnosis of cyclosporine nephrotoxicity *Semin Diagn Pathol* 5, 104–121.

81 Wadhwa NK, Schroeder TJ, Pesce AJ *et al.* (1987) Cyclosporine drug interactions: a review. *Ther Drug Monit* 9, 399–406.

82 Rezzani R, Buffoli B, Rodella L *et al.* (2005) Protective role of melatonin in cyclosporine A-induced oxidative stress in rat liver. *Int Immunopharmacol* 5(9), 1397–1405.

83 Stebbins WG, Lebwohl MG (2004) Biologics in combination with nonbiologics: efficacy and safety. *Dermatol Ther* 217(5), 432–440.

84 Leiba M, Ehrenfeld M (2005) Behcet's disease: current therapeutic perspectives. *Curr Treat Options Cardiovasc Med* 7(2), 139–148.

85 Hertl MS, Haendle I, Schuler G *et al.* (2005) Rapid improvement of recalcitrant disseminated granuloma annulare upon treatment with the tumour necrosis factor-alpha inhibitor, infliximab. *Br J Dermatol* 152(3), 552–555.

86 Gupta AK, Skinner AR (2004) A review of the use of infliximab to manage cutaneous dermatoses. *J Cutan Med Surg* 8(2), 77–89.

87 Peterson JR, Hsu FC, Simkin PA *et al.* (2003) Effect of tumour necrosis factor alpha antagonists on serum transaminases and viraemia in patients with rheumatoid arthritis and chronic hepatitis C infection. *Ann Rheum Dis* 11, 1078–1082.

88 Michel M, Duvoux C, Hezode C *et al.* (2003) Fulminant hepatitis after infliximab in a patient with hepatitis B virus treated for an adult onset still's disease. *J Rheumatol* 30(7), 1624–1625.

89 Breuer K, Gutzmer R, Volker B *et al.* (2005) Therapy of noninfectious granulomatous skin diseases with fumaric acid esters. *Br J Dermatol* 152(6), 1290–1295.

90 Hoefnagel JJ, Thio HB, Willemze R *et al.* (2004) Long-term safety aspects of systemic therapy with fumaric acid esters in severe psoriasis. *Br J Dermatol* 149(2), 363–369.

91 British Photodermatology Group guidelines for PUVA (1994) *Br J Dermatol* 130, 246–255.

92 Bjellerup M, Bruze M, Krook G *et al.* (1981) Toxic hepatitis after PUVA. *J Am Acad Dermatol* 4, 481.

93 Bickers DR, Mukhtar H, Molica SJ Jr *et al.* (1982) The effect of psoralens on hepatic and cutaneous drug metabolizing enzymes and cytochrome P-450. *J Invest Dermatol* 79, 201–205.

94 Sanders S, Harisdangul V (2002) Leflunomide for the treatment of rheumatoid arthritis and autoimmunity. *Am J Med Sci* 323(4), 190–193.

95 Kaltwasser JP, Nash P, Gladman D *et al.* (2004) Efficacy and safety of leflunomide in the treatment of psoriatic arthritis and psoriasis: a multinational, double-blind, randomized, placebo-controlled clinical trial. *Arthritis Rheum* 50(6), 1939–1950.

96 van Roon EN, Jansen TL, Houtman NM *et al.* (2004) Leflunomide for the treatment of rheumatoid arthritis in clinical practice: incidence and severity of hepatotoxicity. *Drug Saf* 27(5), 345–352.

97 Sevilla-Mantilla C, Ortega L, Agundez JA *et al.* (2004) Leflunomide-induced acute hepatitis. *Dig Liver Dis* 36(1), 82–84.

98 Puri AS, Gupta R, Ghoshal UC *et al.* (1995) Hepatic injury in sulfone syndrome: hepatitis or cholestasis? *Ind J Gastroenterol* 14, 20.

99 Itha S, Kumar A, Dhingra S (2003) Dapsone induced cholangitis as a part of dapsone syndrome: a case report. *BMC Gastroenterol* 3(1), 21.

100 Chambers WM, Millar A, Jain S *et al.* (2001) Terbinafine-induced hepatic dysfunction. *Eur J Gastroenterol Hepatol* 13(9), 1115–1118.

101 Iverson SL, Uetrecht JP (2001) Identification of a reactive metabolite of terbinafine: insights into terbinafine-induced hepatotoxicity. *Chem Res Toxicol* 14(2), 175–181.

102 Girois SB, Chapuis F, Decullier E *et al.* (2005) Adverse effects of antifungal therapies in invasive fungal infections: review and meta-analysis. *Eur J Clin Microbiol Infect Dis* 24(2), 119–130.

103 Bradbury BD, Jick SS (2002) Itraconazole and fluconazole and certain rare, serious adverse events. *Pharmacotherapy* 22(6), 697–700.

104 Srebrnik A, Levtov S, Ben-Ami R *et al.* (2005) Liver failure and transplantation after itraconazole treatment for toenail onychomycosis. *J Eur Acad Dermatol Venereol* 19(2), 205–207.

105 Chiprut RO, Viteri A, Jamroz C *et al.* (1976) Intrahepatic cholestasis after griseofulvin administration. *Gastroenterology* 70, 1141–1143.

106 Redeker AG, Sterling RE, Bronow RS (1964) Effect of griseofluvin in acute intermittent porphyria. *JAMA* 188, 466–468.

107 Lawrenson RA, Seaman HE, Sundstrom A (2000) Liver damage associated with minocycline use in acne: a systematic review of the published literature and pharmacovigilance data. *Drug Saf* 23(4), 333–349.

108 Farrell GC (1997) Drug-induced hepatic injury. *J Gastroenterol Hepatol* 12(9–10), S242–50.

109 Dobson JL, Angus PW, Jones R (2005) Flucloxacillin-induced aplastic anaemia and liver failure. *Transpl Int* 18(4), 487–489.
110 Russmann S, Kaye JA, Jick SS (2005) Risk of cholestatic liver disease associated with flucloxacillin and flucloxacillin prescribing habits in the UK: cohort study using data from the UK General Practice Research Database. *Br J Clin Pharmacol* 60(1), 76–82.
111 Thai KE, Sinclair RD (2001) Spironolactone-induced hepatitis. *Australas J Dermatol* 42(3), 180–182.
112 Brest AN (1986) Spironolactone in the treatment of hypertension: a review. *Clin Ther* 8, 586–585.
113 Lin AD, Chen KK, Lin AT (2003) Antiandrogen-associated hepatotoxicity in the management of advanced prostate cancer. *J Chin Med Assoc* 66(12), 735–740.
114 Seaman HE, de Vries CS, Farmer RD (2003) The risk of liver disorders in women prescribed cyproterone acetate in combination with ethinyloestradiol (Dianette): a nested case-control study using the GPRD. *Pharmacoepidemiol Drug Saf* 12(7), 541–550.
115 Rudiger T, Beckmann J, Queisser W (1995) Hepatocellular carcinoma after treatment with cyproterone acetate combined with ethinyloestradiol. *Lancet* 345(8947), 452–453.
116 Brambilla G, Martelli A (2002) Are some progestins genotoxic liver carcinogens? *Mutat Res* 512(2–3), 155–163.
117 Qaseem T, Jafri W, Khurshid M *et al.* (1992) Cholestatic jaundice associated with danazol therapy. *Postgrad Med J*, 68, 984–985.
118 Confavreux C, Sève P, Broussolle C (2003) Danazol-induced hepatocellular carcinoma. *Q J Med* 96, 317.
119 Helfman T, Falanga V (1995) Stanozolol as a novel therapeutic agent in dermatology. *J Am Acad Dermatol* 33, 254–258.
120 Soe KL, Soe M, Gluud C (1992) Liver pathology associated with the use of anabolic androgenic steroids. *Liver* 12, 73–79.
121 Gelfand JM, Neimann AL, Shin DB *et al.* (2006) Risk of myocardial infarction in patients with psoriasis. *JAMA* 296(14), 1735–1741.

20.6 The liver in urogenital diseases

Mónica Guevara, Vicente Arroyo and Juan Rodés

This chapter includes hepatic disturbances observed in some urogenital diseases, such as hypernephroma and prostatic carcinoma, as well as those associated with haemodialysis and renal transplantation.

The nephrogenic hepatic dysfunction syndrome

This syndrome was first described by Stauffer *et al.* in 1961 [1] in five patients with hypernephroma without hepatic metastases. These patients had abnormal standard liver function tests and hepatomegaly, which completely disappeared upon removal of the tumour. This syndrome has also been observed in patients with renal sarcoma and xanthogranulomatous pyelonephritis. Strict confirmation of this syndrome requires the following criteria: (i) return to normal of liver function tests after nephrectomy and (ii) absence of hepatic metastases at autopsy. The incidence of this syndrome is unknown. The clinical picture is characterized by the presence of hepatomegaly, fever, weight loss, anaemia, high alkaline phosphatase, prolonged prothrombin time and impaired excretion of sulphobromophthalein. In some patients, thombocytosis may be observed, probably as a paraneoplastic manifestation. No relationship has been found between the development of this syndrome and the histological characteristics of the renal cancer.

Liver biopsy shows only minimal changes, including steatosis, spotty necrosis, moderate lymphocyte infiltration in the portal tracts and haemosiderosis. There is no relationship between the hepatic morphological lesions and the degree of alteration in liver function tests. The pathogenesis of nephrogenic hepatic dysfunction is unknown. It has been suggested that it may be due to the presence of undetected micrometastases in the liver, with disappearance after nephrectomy, as reported for lung metastases. This, however, is unlikely as liver metastases were not detected at necropsy in some cases. An alternative hypothesis is that this syndrome is due to a 'hepatotoxic hormone' produced by the tumour itself [2].

Recognition of this syndrome is clinically important for two reasons: (i) renal cancer should be considered in the diagnosis of any patient with fever, hepatomegaly, abnormal standard liver function tests and normal or only minimally altered hepatic histology; and (ii) patients with kidney tumours and abnormal standard liver function tests do not necessarily have hepatic metastases [3].

Haemodialysis and the liver

Patients treated with haemodialysis frequently present abnormal standard liver function tests. Approximately 30% of haemodialysis patients show mild elevation of transaminases [4]. Hepatitis B, D and C viruses are the main cause of liver disease in such patients. Other aetiological factors include drugs, iron overload from repeated blood transfusions, cytomegalovirus, Epstein–Barr virus, bacterial infections or foreign bodies. Finally, some liver and renal diseases have a common aetiology such as amyloidosis, diabetes or vasculitis.

Hepatitis B

With the extensive use of haemodialysis in the 1960s, it became apparent that viral hepatitis was a major problem associated with this therapy [5,6]. In 1972, it was found that patients submitted to chronic haemodialysis were at great risk of acquiring hepatitis B virus (HBV) infection [7]. Subsequently, several studies confirmed the high incidence of HBV infection in haemodialysis units; at least one serological HBV marker was positive in about 40% of the patients, and chronic hepatitis B surface (HBs) antigenaemia was found in 10–15% [8]. The prevalence of serological markers in patients dialysed at home is lower (5–6%), suggesting that transmission of HBV from other patients or hospital personnel may be important in the spread of HBV infection in haemodialysis units. Most HBs antigen (HBsAg) carriers are discovered before entering the haemodialysis programme. However, between 5% and 10% of patients become HBsAg positive after starting haemodialysis in spite of preventive measures [9,10] (Table 1). Many sources, including transfusions [11], needles [12] and dialysis machinery [13], have been implicated in the spread of HBV infection. In 1977, the

Table 1 Prevalence and seroconversion rates of HBV infection in patients on dialysis (by country).

Country	Unadjusted prevalence (%)	Adjusted prevalence[a] % (95% CI)	Unadjusted seroconversion/ 100 patient–years (%)	Adjusted[a] seroconversion/ 100 patient–years % (95% CI)
France	5	3.7 (2.9–4.7)	0.9	1.0 (0.4–3.1)
Germany	5.2	4.6 (3.6–5.8)	1.1	1.8 (0.6–4.9)
Italy	6.6	4.3 (3.4–5.4)	0.5	0.5 (0.1–0.1)
Japan	3.3	2.1 (1.6–2.6)	1.2	1.0 (0.4–2.8)
Spain	3.1	2.1 (1.6–2.7)	0.7	0.7 (0.2–2.1)
United Kingdom	0.0	0.0	0.4	0.5 (0.1–2.3)
United States	2.8	2.4 (2.1–2.7)	0.4	0.4 (0.2–0.6)

[a]Adjusted for the average of each of the following patient characteristics: age, gender, race, time on endstage renal disease (ESRD) and alcohol or drug abuse in the past 12 months (reproduced with permission from ref. 10). CI, confidence interval.

Centers for Disease Control and Prevention (CDC), which has been conducting surveillance of viral hepatitis in dialysis centres since 1969, issued recommendations to reduce the spread of HBV within haemodialysis units. These guidelines included segregation of HBsAg-positive patients by room, dialysis machine and staff, as well as routine serological screening for HBsAg and anti-HBs. Implementation of these recommendations reduced the incidence of HbsAg seropositivity in dialysis units in the USA from 3% (1976) to 0.5% (1983) for patients and from 2.6% to 0.5% for staff [14]. In subsequent years, the prevalence of HBV infection and its incidence among haemodialysis patients and staff in the USA and Europe has continued to decline. The main factors that contributed to this declination were the screening of blood donors for HbsAg (1972) and anti-hepatis B core (HBc) antibodies (1987), and the introduction of erythropoietin (1986), which led to a diminished need for blood transfusions. Vaccination of dialysis patients against HBV began in 1982; despite its undeniable role, the major decline in the incidence of HBV infection was between 1976 and 1980. Currently, active HBV vaccination is recommended for all patients with endstage renal disease (ESRD). However, non-response or incomplete response to standard HBV vaccines is more frequent in these patients [15]. Thus, general precautions for the prevention of viral transmission are still mandatory [16].

Despite all these preventive methods, HBV infection among haemodialysis patients continues to be reported in developed countries [10,17].

In the Asia–Pacific region, HBV remains a major problem. In this region, the prevalence of HBV infection in haemodialysis patients reflects that in the local population (8–20%) [18].

The illness resulting from HBV infection in the dialysis patient is usually asymptomatic (shown only by elevated transaminases and the appearance of HBsAg in the blood), whereas relatives or staff members display a more severe course [19]. In fact, in a multicentre study (27 countries) carried out in Europe [20], 16 of the 778 staff members in dialysis units who contracted hepatitis died as a consequence of acute hepatic failure. This different outcome between dialysed patients and staff members may be due to immunodeficiency occurring in renal patients compared with the normal immune response of their healthy counterparts. Dialysis patients who develop acute HBV infection have about a 60% chance of becoming chronic HBsAg carriers [21]. Interestingly, only 5% of dialysis-related cases of acute hepatitis B subsequently develop persistent elevation of aminotransferases due to chronic hepatitis. A study using monoclonal HBs antibody suggested that the prevalence of HBsAg in haemodialysis patients might be higher [22]. It has been shown that active viral replication in these patients promotes histological progression [23]. The high risk of chronicity as well as progression of liver disease in haemodialysis patients has been attributed to depressed cell-mediated immunity [24].

Liver disease in chronic HBsAg carriers receiving haemodialysis is characteristically asymptomatic. Initially, the histology of the liver is also mild with moderate inflammatory infiltration and liver cell necrosis. However, the course of the disease may be progressive, leading to more severe forms such as chronic hepatitis and cirrhosis. This explains the high incidence of HBV with advanced chronic liver disease found in patients treated with haemodialysis for many years [25,26].

A recent multicentre survey [27] demonstrated that the risk of liver cancer is significantly higher in ESRD patients treated by dialysis compared with the general population. This is probably related to the high prevalence of hepatitis C virus (HCV) coinfection in this group of patients. No difference in survival has been found between HBsAg-positive and HBsAg-negative patients on dialysis in North America. Despite cirrhosis not being a frequent complication in these patients in the developed world, its presence significantly increases mortality in these patients. The period for developing HBV-related complications is probably higher than the mean life expectancy of many dialysis patients. Therefore, HBsAg-positive patients on dialysis are likely to die with the infection rather than from it [17]. The aim of antiviral therapy of HBsAg-positive renal transplant candidates should be prevention of cirrhosis before and after transplant. The efficacy of interferon is poor in dialysis patients; moreover, recommended doses for HBV infection are poorly tolerated by patients on dialysis. This frequency of side-effects may be attributed to various mechanisms, such as an altered

pharmacokinetic profile of interferon in chronic uraemia or increased interferon synthesis at the end of each dialysis session [28]. Lamivudine is a major advance in the treatment of HBV infection before and after renal transplantation. No controlled trials for the treatment of HBV with either lamivudine or interferon in dialysis patients are currently available. Indications for treatment should be similar to those for immunocompetent patients. Finally, adefovir was effective in the treatment of HBV-induced fibrosing cholestatic hepatitis, despite the presence of renal impairment and lamivudine resistance. However, it is just one case that has been reported. Therefore, because of poor results and the side-effects of interferon, nucleosides appear to be superior to interferon in these patients [16,18,29].

Hepatitis D

Hepatitis D virus infection is not a major problem in haemodialysis. Several reports have indicated the absence of hepatitis D virus infection in HBV-infected haemodialysed patients [30]. However, hepatitis D virus infection should be considered in these patients when there is rapidly deteriorating liver disease.

Hepatitis C

HCV infection is very common among haemodialysed patients. This chronic viral infection can result in significant morbidity and mortality [31]. Viral hepatitis was suspected to be prevalent in patients with ESRD maintained on dialysis nearly three decades ago. Development of serological testing for HBV confirmed the high incidence among patients and staff in this population [32]. As mentioned above, HBV infection dramatically decreased with the mandatory measures initiated by the CDC. However, many cases of liver disease in endstage renal failure were unexplained and were named non-A, non-B hepatitis. Later on, with the discovery of HCV, it could be proved that this virus was frequent in patients with ESRD on haemodialysis in the absence of the usual parenteral risk factors [32]. An average of 10–20% of chronic haemodialysis patients in the USA have serological evidence of chronic HCV infection. Effective screening of blood products and the routine use of erythropoietin to manage anaemia in patients with ESRD virtually eliminated HCV transmission by blood a decade ago. However, the prevalence of the disease varies widely from centre to centre [31,33].

The diagnosis of chronic HCV infection can be difficult in patients with chronic renal failure. Most of these patients have normal serum transaminase values. As a consequence, diagnosis of HCV infection requires sensitive and specific methods [34–38]. The introduction of third-generation anti-HCV assays has improved the accuracy of diagnostic testing in this population. HCV viral load is frequently low in haemodialysis patients with HCV infection, although polymerase chain reaction (PCR) and branched DNA assays are positive in these patients and are useful in the detection of seroconversion [37,39].

HCV infection is a persistent public health concern in haemodialysis patients. Haemodialysis patients are vulnerable to HCV infection because of the risk of exposure to HCV associated with the dialysis procedure. Patients with HCV infection often have minimal clinical manifestations of the disease. However, HCV in patients with ESRD has been associated with greater morbidity and mortality. Moreover, these patients develop more complications after receiving renal transplantation [40].

Despite control measures established to prevent bloodborne virus transmission in the ESRD population, HCV persists within haemodialysis units. Differences in community behaviour and application of different protocols to control infection among haemodialysis units may be responsible for this result. A recent study has evaluated the prevalence and the incidence of HCV in 308 dialysis units in Europe, Japan and the USA. The prevalence of HCV in haemodialysis units varies from 2.6% to 22.9% (Table 2). Increased prevalence of HCV infection was associated with longer time on dialysis, male gender, black race, diabetes, HBV infection, prior renal transplant and alcohol or drug abuse in the previous 12 months. Seroconversion occurred in 56% of the haemodialysis units and was related to longer time on dialysis, human immunodeficiency virus (HIV), HBV infection and recurrent cellulitis or gangrene. A better trained staff was

Table 2 Prevalence and seroconversion rate of HCV infection in patients on dialysis (by country).

Country	Unadjusted prevalence (%)	Adjusted prevalence[a] % (95% CI)	Unadjusted seroconversion/ 100 patient–years (%)	Adjusted[a] seroconversion/ 100 patient–years % (95% CI)
France	14.7	10.4 (9.7–11.2)	1.9	2 (1.4–2.8)
Germany	3.9	3.8 (3.3–4.4)	1.7	1.7 (1.2–2.5)
Italy	22.2	20.5 (19.4–21.7)	3.6	3.9 (2.9–5.2)
Japan	19.9	14.8 (14.0–15.6)	3.1	3.0 (2.3–3.9)
Spain	22.2	22.9 (21.7–24.1)	3.0	3.5 (2.5–4.8)
United Kingdom	2.7	2.6 (2.1–3.2)	1.1	1.2 (0.7–2.0)
United States	14.4	14.0 (13.6–14.5)	3.1	2.5 (2.1–2.9)

[a]Adjusted for age, gender, race, time on dialysis, previous transplantation, alcohol use, HCV and drug abuse in the past 12 months (reproduced with permission from ref. 40).

associated with lower HCV prevalence [40]. HCV infection is less common in patients on continuous peritoneal dialysis. The reasons for these differences have not yet been fully evaluated [41].

The clinical features of acute HCV infection among haemodialysis patients are similar to those of acute HBV infection. In most patients, the illness is either asymptomatic or associated with mild symptoms. Furthermore, in a study conducted in chronic HCV infection by Pol *et al.* [38], only 31% of the patients with HCV RNA in the blood had abnormal liver tests. However, the clinical consequences of HCV infection in haemodialysis patients are more severe than was initially considered. In three studies, liver biopsy demonstrated that the incidence of chronic hepatitis, cirrhosis and even hepatocellular carcinoma is relatively high. Therefore, liver biopsy is the most accurate way of assessing the severity of liver injury in these patients [42–44].

Despite the high prevalence of HCV infection in the haemodialysis population, the role of antiviral therapy in dialysis patients with HCV is still a matter of debate. Two meta-analyses have evaluated the efficacy of interferon as monotherapy in the haemodialysis population [45,46]. The first included 14 clinical trials including two controlled trials [45]. The mean sustained virological response (SVR) was 37%. The frequency of side-effects requiring interruption of interferon was high (approximately 50%). In conclusion, the tolerance of interferon was poor in a HCV dialysis population, although one-third of patients achieved a SVR. The second analysed 11 studies and reached similar conclusions [46]. Currently, it is not clear which patients with HCV infection on dialysis should be treated with interferon. It seems rational to offer treatment with interferon to those patients with long expected survival. However, it should be done after careful evaluation of the potential benefits and risks of treatment [33].

A few studies with a small number of patients have evaluated the effect of interferon plus ribavirin in these groups of patients. Bruchfeld and coworkers identified three requirements for using ribavirin in infected HCV patients on dialysis. First, a marked reduction in the dose of ribavirin, second, close monitoring of plasma ribavirin concentration and, finally, an increase in the erythropoietin dose to compensate for the ribavirin-associated haemolytic anaemia [47]. Further and expanded studies are needed to determine the role of ribavirin plus interferon in the treatment of HCV patients on dialysis.

There is little existing information on using pegylated interferon-α2a in the HCV haemodialysis population. A recent study included 10 patients with HCV infection on haemodialysis [48]. They had to reduce the dose of Peg-interferon in only two cases. Even if side-effects occurred in most of the patients (flu-like syndrome, thrombocytopenia or leucopenia), they did not discontinue treatment. A virological response was achieved in 87% of the cases. However, the SVR remains to be analysed. Therefore, longer studies are needed to assess the effect of pegylated interferon in this population.

Other hepatic lesions

Other hepatic lesions that occasionally affect haemodialysis patients include spontaneous liver haematoma, haemorrhagic cholecystitis, diffuse hepatic calcification, hepatic infarction, liver deposition of silicone, haemosiderosis and haemochromatosis.

Spontaneous haemorrhagic complications of haemodialysis are diverse and have occasionally been observed in the liver and in the gallbladder. Although hepatic haematoma has been reported in a few patients, an incidence of 1.5% has been published among haemodialysis patients with manifestations of spontaneous bleeding [49]. The clinical picture of hepatic haematoma is characterized by upper quadrant pain, tenderness on palpation of the liver, fever, a decrease in haematocrit and an increase in alkaline phosphatase levels. Radioisotope scanning, ultrasonography or computerized tomography (CT) scan provide supportive evidence of this complication. Management is dependent on the extent and location of liver injury. Central haematomas can simply be evacuated, whereas haematomas causing subcapsular tear and bleeding may require partial hepatectomy. Haemorrhagic cholecystitis [50] is usually associated with right-sided abdominal pain, fever, nausea, vomiting and leucocytosis. Radionuclide scanning is useful for confirming this diagnosis. The treatment is cholecystectomy.

Recently, hepatic infarction was reported as developing in a patient with systemic lupus erythematosus and chronic renal failure treated with haemodialysis [51]. This complication is very uncommon as haemodialysis patients have a decreased tendency for vascular thrombosis. However, this may not be true in the presence of circulating antiphospholipid antibodies as occurs in patients with systemic lupus erythematosus.

Particles of silicone have been observed in the livers of patients treated with haemodialysis [52,53]. The hepatic lesion is characterized by the presence of granulomas associated with varying degrees of inflammation and fibrosis (Fig. 1). The

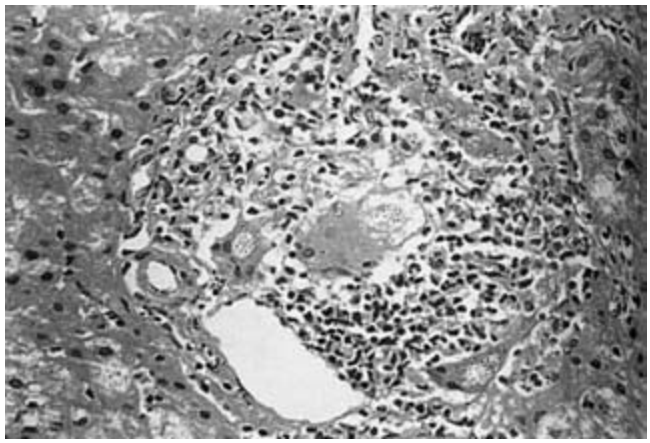

Fig. 1 Silicone deposit in the liver. Granules of a brilliant material are seen within several multinucleated cells in a portal tract. This material was refractile, but not refringent under polarized light (H and E × 180).

incidence of this lesion in haemodialysis patients is about 50%. Most of these patients are asymptomatic, although fever and malaise may occur in some patients. It has been suggested that hepatic silicone deposition could be a cause of chronic hepatic dysfunction in haemodialysis patients [4].

Renal transplant and the liver

Hepatic dysfunction, recognized by increased levels of transaminases, is frequently seen in renal transplant patients. In the 1970s, the reported incidence varied from 7% to 67% [54–57]. In most patients, chronic liver disease is due to hepatitis virus infection, particularly HBV and HCV [30,58]. Other hepatic lesions have been described resulting from renal transplantation *per se* or as a consequence of immunosuppression therapy, for example peliosis hepatis [59], idiopathic portal hypertension [60], hepatic veno-occlusive disease [61], nodular regenerative hyperplasia and cholestasis [62].

Hepatitis B

Renal transplantation and associated therapeutic immunosuppression affect the outcome of infected HBV patients [63–65]. Prospective studies using sequential liver biopsy have demonstrated that HBV infection in renal transplant recipients usually leads to a severe form of chronic liver disease. Pol *et al.* [66] showed histological worsening of the liver during the post-transplant period in 80% of HBV-infected patients. Such patients may develop chronic hepatitis, cirrhosis and even hepatocellular carcinoma [27]. It was found that HBV renal transplant patients had a lower post-transplant survival than patients not infected with HBV [67], although others have reported different results [66,68], indicating that the survival of renal transplanted patients with HBV infection was similar to that of patients negative for HBV.

Taken together, the above studies showed that reactivated HBV infection is common after kidney transplantation, severe liver disease often occurs in kidney recipients who are HBsAg positive, and diminished survival due to chronic hepatitis B is frequently observed [69].

On the other hand, vaccination to prevent the infection in patients with ESRD induces a weak or absent response [10,15]. For several years, interferon was the only therapeutic option for this group of patients. However, there are well-documented cases of acute allograft rejection precipitated by interferon, making this drug unsuitable after renal transplantation. Interferon therapy may also cause deterioration of graft function by other mechanisms, such as direct nephrotoxicity, induction of acute interstitial nephritis and induction of cytokines [17].

Over the past few years, with the appearance of lamivudine, a big change has occurred for HBV patients with ESRD. The efficacy and safety of lamivudine monotherapy in renal transplantation recipients with chronic HBV infection has been evaluated by a recent meta-analysis including 14 clinical trials. The results of this meta-analysis reveal that lamivudine induced a clearance of HBV DNA of 91% and of HBeAg of 27%. Moreover, it was associated with normalization of alanine aminotransferase (ALT) in 81% and the appearance of lamivudine resistance in 18% of the cases. In conclusion, lamivudine is well tolerated, and lamivudine resistance occurred with prolonged therapy [71].

Gane and Pilmore [18] have recently suggested an algorithm for management of HBsAg-positive renal transplant candidates. This algorithm suggests that all these patients should undergo liver biopsy before listing. Patients without chronic hepatitis can be listed for transplant. Liver function tests should be closely monitored after transplantation and acute dysfunction investigated with liver biopsy and HBV DNA analysis. Post-transplant HBV reactivation should be treated with lamivudine. Alternatively, HBV reactivation can be prevented by universal lamivudine prophylaxis in all HBsAg-positive candidates from the time of transplant. Lamivudine should start before transplant in HBV-positive renal transplant candidates who have HBV DNA $> 10^5$copies/mL and active liver disease despite haemodialysis.

In conclusion, HBV infection remains a concern in patients with ESRD, although its transmission in haemodialysis units has dramatically decreased over the last 30 years. Finally, the appearance of lamivudine has improved the survival of patients with HBV infection and ESRD.

Hepatitis D

Hepatitis D virus infection is an infrequent clinical condition in renal transplant recipients. Kharsa *et al.* [72] reported three cases of fulminant hepatitis among 300 renal transplant recipients. In two of these three cases, direct staining of liver tissue identified hepatitis D virus, indicating that this virus should be considered as a cause of fulminant hepatitis in renal transplant recipients.

Hepatitis C

HCV infection in dialysis patients is usually asymptomatic with an apparently indolent course. In the majority of patients, chronic hepatitis C is present before transplantation. However, some patients acquire HCV during the perioperative period from infected donor organs [31]. However, liver disease is recognized as an important cause of morbidity and mortality in renal transplant recipients, with a prevalence varying from 4% to 38%. Liver failure has been reported to be the cause of death in 8–28% of long-term survivors after renal transplant, chronic HCV infection being the major cause of liver disease among renal transplant recipients [33].

The transmission of HCV by solid organ transplantation has been shown unequivocally. However, the transmission depends on various factors, such as prevalence of HCV viraemia among donors, viral HCV load, differences in organ preservation and other unrecognized causes. A widely shared opinion is

that HCV-positive kidneys should not be transplanted into HCV-negative recipients because of the high rate of HCV infection [32]. Several studies have compared the outcome of HCV-positive renal transplant recipients with that of HCV-negative renal transplant recipients. Most of the studies conclude that HCV-positive patients show a worse survival than HCV-negative patients. It appears that therapeutic immunosuppression following renal transplant may accelerate the course of HCV infection, leading to hepatocellular failure [32]. A similar concern exists with regard to graft survival in renal transplantation recipients with HCV infection, with recent studies showing reduced graft survival [18,32]. Up to now, few trials have evaluated the effect of interferon after renal transplantation in patients with HCV infection. These studies report that interferon is poorly tolerated in patients with renal transplantation and has frequently had to be withdrawn. Interferon induced renal failure in approximately 30% of patients, rejection being the most frequent cause of renal failure in this group of patients. Thus, the overall consensus is that interferon is best avoided in renal transplant recipients [32,73–75]. It has been suggested that interferon may increase the risk of acute rejection; however, this issue is still under discussion [76]. Nevertheless, nowadays, it is not known whether interferon is useful in the treatment of these patients. In a preliminary report, Koenig *et al.* [77] found that interferon was as effective as in non-uraemic patients, although more side-effects were detected.

At present, HCV infection is not considered an absolute contraindication for renal transplantation. However, before considering renal transplantation, HCV-infected patients should be tested for HCV RNA and submitted to liver biopsy in order to detect advanced liver disease at an early stage. Patients with mild or moderate chronic hepatitis should be considered for renal transplantation while patients with more advanced liver disease should remain on haemodialysis, or should be considered for kidney–liver transplantation [41].

Other hepatic lesions

One hepatic lesion that is undoubtedly related to renal transplantation is peliosis hepatis, as it is not observed in haemodialysed patients or in liver biopsies performed on the day of transplantation. This lesion consists of sinusoidal dilatation and blood-filled spaces, without endothelial lining, located predominantly in centrolobular areas. The development of this lesion has been related to immunosuppression therapy, particularly azathioprine [78]. The estimated prevalence of peliosis hepatis in renal transplant patients is 2–4% [79], and it is more frequent in males than in females. The clinical manifestations of peliosis hepatis in renal transplant patients are variable. In some cases, it is clinically latent, whereas in others, it may produce hepatomegaly, portal hypertension, oesophageal varices and ascites. Renal graft rejection is relatively common in patients with peliosis hepatis. The prognosis of this lesion depends on the degree of portal hypertension. In some renal transplant recipients, it has been shown that peliosis hepatis causes severe fibrosing liver lesions. The course of vascular hepatic disease is not modified by azathioprine withdrawal [80].

Idiopathic portal hypertension causing ascites, oesophageal varices and gastrointestinal bleeding has been described in renal transplant patients treated with azathioprine. In all these cases, perisinusoidal fibrosis was demonstrated by electron microscopy. This lesion may be the cause of portal hypertension, through a partial obstruction of hepatic sinusoids [81]. A fatal case of partial obstruction due to nodular regenerative hyperplasia of the liver was reported following renal transplantation [62,82,82].

Approximately 5% of renal transplant patients develop acute cholestasis secondary to azathioprine therapy, which resolves slowly after drug withdrawal. Fatal hepatic veno-occlusive disease has also been reported in a renal transplant patient receiving azathioprine [61].

Prostatic carcinoma and the liver

In addition to hepatic metastases, which are uncommon, patients with prostatic carcinoma may present with obstructive jaundice due to infiltration of the subhepatic tissues around the common bile duct [83] or as a consequence of a lesion resembling sclerosing cholangitis [84]. This biliary obstruction may improve or disappear with orchidectomy and with the administration of diethylstilbestrol.

In about 30–50% of treated patients with prostatic cancer, diethylstilbestrol may produce a slight increase in transaminases within 2 weeks of starting treatment. With treatment withdrawal, values usually return to normal. This study also showed that 20% of patients presented a moderate increase in serum bilirubin, which returned to basal values 1 month later. As several of these patients may have liver function test alterations before treatment with estrogen, the dosage of diethylstilbestrol should be adjusted according to liver function. In the 1970s, cyproterone acetate was introduced in the treatment of prostatic carcinoma. Cyproterone acetate has been used in men not only to treat prostatic cancer but also in the treatment of hypersexuality and sexual deviation, and in women for the treatment of severe acne and hirsutism. It has been shown that about 15–20% of patients may develop a transient and slight increase in transaminases after 6 weeks or even several months of therapy [85,86]. However, liver function in these patients became normal 4–9 weeks after treatment. Nonetheless, in other patients, hepatitis was very severe [85,87–89]. The mechanism responsible for this hepatotoxicity is under discussion. However, most researchers recommend that hepatic function should be assessed 2 and 4 weeks after initiating therapy and every 2 months thereafter [86].

It has been reported that patients receiving cyproterone acetate have developed hepatocellular carcinoma [86,90,91]. All were treated with high doses of cyproterone acetate. These tumours were observed in prostate carcinoma patients, during

puberty in women with Turner syndrome and in a woman receiving cyproterone acetate in combination with an oral contraceptive for more than 10 years. The mechanism by which cyproterone acetate intake may cause hepatocellular carcinoma is, at present, not well understood. However, experimental studies have shown that cyproterone acetate induces DNA adduct formation and DNA repair activities in rat hepatocytes. In addition, these DNA adducts may accumulate in liver cells facilitating the development of hepatocellular carcinoma [86,92–94].

Bladder cancer and the liver

Patients with superficial bladder cancer are usually treated with intravesical bacillus Calmette–Guérin (BCG). BCG is commonly given in three clinical settings: (i) prophylaxis in tumour-free patients; (ii) treatment of residual tumour in patients with papillary transitional cell carcinoma other than carcinoma *in situ*; and (iii) treatment of patients with carcinoma *in situ*. Long-term studies of BCG therapy have reported favourable responses in 50–89% of patients, and it is considered that this treatment probably exerts its antitumoral effect through immune mechanisms or as a consequence of an inflammatory reaction induced by the intravesical instillation of BCG [12]. Complications of this therapy include local side-effects such as haematuria, cystitis, granulomatous prostatitis, bladder contractures and renal abscess. Systemic side-effects such as granulomatous hepatitis, pneumonitis, azotaemia and pancytopenia have also been described [86,95]. The systemic side-effects are believed to be the result of either a hypersensitivity reaction to BCG or clinical illness caused by BCG mycobacteria [96]. Liver biopsies show intrahepatic granulomas without mycobacteria in most patients. Recently, a patient with mycobacteraemia and granulomatous hepatitis occurring after the initial intravesical instillation of BCG has been reported [97]. Treatment of systemic BCG infection in acutely ill patients with isoniazid, rifampicin and ethambutol is recommended [95]. Granulomatous hepatitis should be considered as an important side-effect of intravesical instillation of BCG for bladder cancer, and its presence should be taken into account in any patient with persistent fever and abnormal liver function tests after BCG instillation.

References

1 Stauffer JM, Granville GE, Law SW (1961) Recurrent hypoglycemia and retroperitoneal fibrosarcoma. *N Engl J Med* 265, 979–982.

2 Hanash KA, Utz DC, Ludwig J *et al.* (1971) Syndrome of reversible hepatic dysfunction associated with hypernephroma: an experimental study. *Invest Urol* 8(4), 399–404.

3 Strickland RC, Schenker S (1977) The nephrogenic hepatic dysfunction syndrome: a review. *Am J Dig Dis* 22(1), 49–55.

4 Parfrey PS, Paradinas FJ, O'Driscoll JB *et al.* (1983) Chronic liver disease in haemodialysis patients. *Proc Eur Dial Transplant Assoc* 19, 153–158.

5 Eastwood JB, Curtis JR, Wing AJ *et al.* (1968) Hepatitis in a maintenance hemodialysis unit. *Ann Intern Med* 69(1), 59–66.

6 Friedman EA, Thomson GE (1966) Hepatitis complicating chronic haemodialysis. *Lancet* 2(7465), 675–678.

7 Marmion BP, Tonkin RW (1972) Control of hepatitis in dialysis units. *Br Med Bull* 28(2), 169–179.

8 Ware AJ, Gorder NL, Gurian LE *et al.* (1983) Value of screening for markers of hepatitis in dialysis units. *Hepatology* 3(4), 513–518.

9 Hawe BJ, Goldsmith HJ, Jones PO (1971) Dialysis-associated hepatitis: prevention and control. *Br Med J* 1(5748), 540–543.

10 Burdick RA, Bragg-Gresham JL, Woods JD *et al.* (2003) Patterns of hepatitis B prevalence and seroconversion in hemodialysis units from three continents: the DOPPS. *Kidney Int* 63(6), 2222–2229.

11 Jones EA, Clain D, Clink HM *et al.* (1967) Hepatic coma due to acute hepatic necrosis treated by exchange blood-transfusion. *Lancet* 2(7508), 169–172.

12 Snydman DR, Bryan JA, Macon EJ *et al.* (1976) Hemodialysis-associated hepatitis: report of an epidemic with further evidence on mechanisms of transmission. *Am J Epidemiol* 104(5), 563–570.

13 Pattison CP, Maynard JE, Berquist KR *et al.* (1973) Serological and epidemiological studies of hepatitis B in haemodialysis units. *Lancet* 2(7822), 172–174.

14 Alter MJ, Favero MS, Maynard JE (1986) Impact of infection control strategies on the incidence of dialysis-associated hepatitis in the United States. *J Infect Dis* 153(6), 1149–1151.

15 Fabrizi F, Martin P, Dixit V *et al.* (2004) Meta-analysis: the effect of age on immunological response to hepatitis B vaccine in end-stage renal disease. *Aliment Pharmacol Ther* 20(10), 1053–1062.

16 Tillmann HL, Wedemeyer H, Manns MP (2003) Treatment of hepatitis B in special patient groups: hemodialysis, heart and renal transplant, fulminant hepatitis, hepatitis B virus reactivation. *J Hepatol* 39(Suppl. 1), S206–S211.

17 Fabrizi F, Bunnapradist S, Martin P (2004) HBV infection in patients with end-stage renal disease. *Semin Liver Dis* 24(Suppl. 1), 63–70.

18 Gane E, Pilmore H (2002) Management of chronic viral hepatitis before and after renal transplantation. *Transplantation* 74(4), 427–437.

19 London WT, Di Figlia M, Sutnick A *et al.* (1969) An epidemic of hepatitis in a chronic-hemodialysis unit. Australia antigen and differences in host response. *N Engl J Med* 281(11), 571–578.

20 Jacobs C, Brunner FP, Chantler C *et al.* (1977) Combined report on regular dialysis and transplantation in Europe, VII, 1976. *Proc Eur Dial Transplant Assoc* 14, 3–69.

21 London WT, Drew JS, Lustbader ED *et al.* (1977) Host responses to hepatitis B infection in patients in a chronic hemodialysis unit. *Kidney Int* 12(1), 51–58.

22 Fujita YK, Kamata K, Kameda H *et al.* (1986) Detection of hepatitis B virus infection in hepatitis B surface antigen-negative hemodialysis patients by monoclonal radioimmunoassays. *Gastroenterology* 91(6), 1357–1363.

23 Harnett JD, Parfrey PS, Kennedy M *et al.* (1988) The long-term outcome of hepatitis B infection in hemodialysis patients. *Am J Kidney Dis* 11(3), 210–213.

24 Lee BW, Yap HK, Tan M *et al.* (1991) Cell-mediated immunity in patients on hemodialysis: relationship with hepatitis B carrier status. *Am J Nephrol* 11(2), 98–101.

25 Degott C, Degos F, Jungers P *et al.* (1983) Relationship between liver histopathological changes and HBsAg in 111 patients treated by long-term hemodialysis. *Liver* 3(6), 377–384.

26 Franceschini N, Goncalves LF, Prompt CA *et al.* (1994) Fine needle aspirative biopsy of the liver in HBsAG-positive patients with end-stage renal failure. *Ren Fail* 16(4), 491–499.

27 Maisonneuve P, Agodoa L, Gellert R *et al.* (1999) Cancer in patients on dialysis for end-stage renal disease: an international collaborative study. *Lancet* 354(9173), 93–99.

28 Fabrizi F, Lunghi G, Martin P (2002) Recent advances in the management of hepatitis C in the dialysis population. *Int J Artif Organs* 25(6), 503–511.

29 Fontana RJ (2003) Renal transplantation in HBsAg+ patients: is lamivudine your 'final answer'? *J Clin Gastroenterol* 37(1), 9–11.

30 Martin P, Friedman LS (1995) Chronic viral hepatitis and the management of chronic renal failure. *Kidney Int* 47(5), 1231–1241.

31 Carithers RL Jr (1999) Hepatitis C and renal failure. *Am J Med* 107(6B), 90S–94S.

32 Fabrizi F, Poordad FF, Martin P (2002) Hepatitis C infection and the patient with end-stage renal disease. *Hepatology* 36(1), 3–10.

33 Poordad FF, Fabrizi F, Martin P (2004) Hepatitis C infection associated with renal disease and chronic renal failure. *Semin Liver Dis* 24(Suppl. 2), 69–77.

34 Bukh J, Wantzin P, Krogsgaard K *et al.* (1993) High prevalence of hepatitis C virus (HCV) RNA in dialysis patients: failure of commercially available antibody tests to identify a significant number of patients with HCV infection. Copenhagen Dialysis HCV Study Group. *J Infect Dis* 168(6), 1343–1348.

35 Chan TM, Lok AS, Cheng IK *et al.* (1993) Prevalence of hepatitis C virus infection in hemodialysis patients: a longitudinal study comparing the results of RNA and antibody assays. *Hepatology* 17(1), 5–8.

36 Fabrizi F, Lunghi G, Guarnori I *et al.* (1995) Virological characteristics of hepatitis C virus infection in chronic hemodialysis patients: a cross-sectional study. *Clin Nephrol* 44(1), 49–55.

37 Fabrizi F, Martin P, Dixit V *et al.* (1998) Quantitative assessment of HCV load in chronic hemodialysis patients: a cross-sectional survey. *Nephron* 80(4), 428–433.

38 Pol S, Romeo R, Zins B *et al.* (1993) Hepatitis C virus RNA in anti-HCV positive hemodialyzed patients: significance and therapeutic implications. *Kidney Int* 44(5), 1097–1100.

39 Fabrizi F, Martin P, Dixit V *et al.* (1998) Acquisition of hepatitis C virus in hemodialysis patients: a prospective study by branched DNA signal amplification assay. *Am J Kidney Dis* 31(4), 647–654.

40 Fissell RB, Bragg-Gresham JL, Woods JD *et al.* (2004) Patterns of hepatitis C prevalence and seroconversion in hemodialysis units from three continents: the DOPPS. *Kidney Int* 65(6), 2335–2342.

41 Davis CL, Gretch DR, Carithers RL (1994) Hepatitis C virus in renal disease. *Curr Opin Nephrol Hypertens* 3(2), 164–173.

42 Caramelo C, Ortiz A, Aguilera B *et al.* (1993) Liver disease patterns in hemodialysis patients with antibodies to hepatitis C virus. *Am J Kidney Dis* 22(6), 822–828.

43 Gilli P, Soffritti S, De PV *et al.* (1995) Prevention of hepatitis C virus in dialysis units. *Nephron* 70(3), 301–306.

44 Rao KV, Anderson WR, Kasiske BL *et al.* (1993) Value of liver biopsy in the evaluation and management of chronic liver disease in renal transplant recipients. *Am J Med* 94(3), 241–250.

45 Fabrizi F, Martin P, Dixit V *et al.* (2004) Meta-analysis: effect of hepatitis C virus infection on mortality in dialysis. *Aliment Pharmacol Ther* 20(11–12), 1271–1277.

46 Russo MW, Goldsweig CD, Jacobson IM *et al.* (2003) Interferon monotherapy for dialysis patients with chronic hepatitis C: an analysis of the literature on efficacy and safety. *Am J Gastroenterol* 98(7), 1610–1615.

47 Bruchfeld A, Wilczek H, Elinder CG (2004) Hepatitis C infection, time in renal-replacement therapy, and outcome after kidney transplantation. *Transplantation* 78(5), 745–750.

48 Sporea I, Sirli R, Golea O *et al.* (2004) Peg-interferon alfa 2a (40kDa) in patients on chronic haemodialysis with chronic C hepatitis. Preliminary results. *Rom J Gastroenterol* 13(2), 99–102.

49 Borra S, Kleinfeld M (1980) Subcapsular liver hematomas in a patient on chronic hemodialysis. *Ann Intern Med* 93(4), 574–575.

50 McFadden DW, Smith GW (1987) Hemodialysis-associated hemorrhagic cholecystitis. *Am J Gastroenterol* 82(10), 1081–1083.

51 Kaplan B, Cooper J, Lager D *et al.* (1995) Hepatic infarction in a hemodialysis patient with systemic lupus erythematosus. *Am J Kidney Dis* 26(5), 785–787.

52 Leong AS, Disney AP, Gove DW (1981) Silicone particles and haemodialysis. *Lancet* 2(8239), 210.

53 Leong AS, Disney AP, Gove DW (1982) Spallation and migration of silicone from blood-pump tubing in patients on hemodialysis. *N Engl J Med* 306(3), 135–140.

54 Ware AJ, Luby JP, Hollinger B *et al.* (1979) Etiology of liver disease in renal-transplant patients. *Ann Intern Med* 91(3), 364–371.

55 Berne TV, Butler J, Silberman H (1979) Hepatic dysfunction in renal transplant recipients: a serious problem. *Transplant Proc* 11(2), 1282–1283.

56 Aronoff A, Gault MH, Huang SN *et al.* (1973) Hepatitis with Australia antigenemia following renal transplantation. *Can Med Assoc J* 108(1), 43–50.

57 Allison MC, Mowat A, McCruden EA *et al.* (1992) The spectrum of chronic liver disease in renal transplant recipients. *Q J Med* 83(301), 355–367.

58 Goffin E, Pirson Y, van Ypersele DS (1995) Implications of chronic hepatitis B or hepatitis C infection for renal transplant candidates. *Nephrol Dial Transplant* 10(Suppl. 6), 88–92.

59 Degott C, Rueff B, Kreis H *et al.* (1978) Peliosis hepatis in recipients of renal transplants. *Gut* 19(8), 748–753.

60 Nataf C, Feldmann G, Lebrec D *et al.* (1979) Idiopathic portal hypertension (perisinusoidal fibrosis) after renal transplantation. *Gut* 20(6), 531–537.

61 Marubbio AT, Danielson B (1975) Hepatic veno-occlusive disease in a renal transplant patient receiving azathioprine. *Gastroenterology* 69(3), 739–743.

62 Bredfeldt JE, Havey AL (1981) Nodular regenerative hyperplasia of the liver following renal transplantation. *Dig Dis Sci* 26(3), 271–274.

63 Cohen GA, Goffinet JA, Donabedian RK *et al.* (1976) Observations on decreased serum glutamic oxalacetic transaminase (SGOT) activity in azotemic patients. *Ann Intern Med* 84(3), 275–280.

64 Parfrey PS, Farge D, Forbes RD *et al.* (1985) Chronic hepatitis in end-stage renal disease: comparison of HBsAg-negative and HBsAg-positive patients. *Kidney Int* 28(6), 959–967.

65 Parfrey PS, Forbes RD, Hutchinson TA *et al.* (1985) The impact of renal transplantation on the course of hepatitis B liver disease. *Transplantation* 39(6), 610–615.

66 Pol S, Debure A, Degott C *et al.* (1990) Chronic hepatitis in kidney allograft recipients. *Lancet* 335(8694), 878–880.

67 Pirson Y, Alexandre GP, Ypersele C (1977) Long-term effect of hbs antigenemia on patient survival after renal transplantation. *N Engl J Med* 296(4), 194–196.

68 Rivolta E, De Vecchi A, Tarantino A *et al.* (1987) Prognostic significance of hepatitis B surface antigenemia in cadaveric renal transplant patients. *Transplant Proc* 19(1 Pt 3), 2153–2154.
69 Perrillo RP (2002) Hepatitis B and renal transplantation: securing the sword of Damocles. *Hepatology* 36(5), 1041–1045.
70 Ramos EL, Kasiske BL, Alexander SR *et al.* (1994) The evaluation of candidates for renal transplantation. The current practice of US transplant centers. *Transplantation* 57(4), 490–497.
71 Fabrizi F, Dulai G, Dixit V *et al.* (2004) Lamivudine for the treatment of hepatitis B virus-related liver disease after renal transplantation: meta-analysis of clinical trials. *Transplantation* 77(6), 859–864.
72 Kharsa G, Degott C, Degos F *et al.* (1987) Fulminant hepatitis in renal transplant recipients. The role of the delta agent. *Transplantation* 44(2), 221–223.
73 Rostaing L, Modesto A, Baron E *et al.* (1996) [Acute renal insufficiency in renal transplants treated with interferon-alpha for chronic hepatitis C]. *Nephrologie* 17(4), 247–254.
74 Ozgur O, Boyacioglu S, Telatar H *et al.* (1995) Recombinant alpha-interferon in renal allograft recipients with chronic hepatitis C. *Nephrol Dial Transplant* 10(11), 2104–2106.
75 Therret E, Pol S, Legendre C *et al.* (1994) Low-dose recombinant leukocyte interferon-alpha treatment of hepatitis C viral infection in renal transplant recipients. A pilot study. *Transplantation* 58(5), 625–628.
76 Pol S (1995) Hepatitis C virus infection in hemodialyzed patients and kidney allograft recipients. *Adv Nephrol Necker Hosp* 24, 315–330.
77 Koenig P, Vogel W, Umlauft F *et al.* (1994) Interferon treatment for chronic hepatitis C virus infection in uremic patients. *Kidney Int* 45(5), 1507–1509.
78 Izumi S, Nishiuchi M, Kameda Y *et al.* (1994) Laparoscopic study of peliosis hepatis and nodular transformation of the liver before and after renal transplantation: natural history and aetiology in follow-up cases. *J Hepatol* 20(1), 129–137.
79 Degott C, Rueff B, Kreis H *et al.* (1978) Peliosis hepatis in recipients of renal transplants. *Gut* 19(8), 748–753.
80 Cavalcanti R, Pol S, Carnot F *et al.* (1994) Impact and evolution of peliosis hepatis in renal transplant recipients. *Transplantation* 58(3), 315–316.
81 Yoshimura N, Oka T, Ohmori Y *et al.* (1994) Idiopathic portal hypertension in renal transplant recipients: report of two cases. *Surg Today* 24(12), 1111–1114.
82 Gane E, Portmann B, Saxena R *et al.* (1994) Nodular regenerative hyperplasia of the liver graft after liver transplantation. *Hepatology* 20(1 Pt 1), 88–94.
83 Chen MC, Mullane MR (1990) Metastatic prostatic carcinoma presenting as cholangiocarcinoma ('Klatskin tumor'). *Ann Intern Med* 112(11), 881.
84 Taylor J, Lindor K (1993) Metastatic prostate cancer simulating sclerosing cholangitis. *J Clin Gastroenterol* 16(2), 143–145.
85 Crombie C, Raghavan D, Page J *et al.* (1987) Phase II study of megestrol acetate for metastatic carcinoma of the prostate. *Br J Urol* 59(5), 443–436.
86 Roila F, Crino L, Carloni G *et al.* (1993) Cyproterone acetate: hepatotoxicity and prostatic cancer treatment. *Ann Oncol* 4(8), 701.
87 Meijers WH, Willemse PH, Sleijfer DT *et al.* (1986) Hepatocellular damage by cyproterone acetate. *Eur J Cancer Clin Oncol* 22(9), 1121–1122.
88 Levesque H, Trivalle C, Manchon ND *et al.* (1989) Fulminant hepatitis due to cyproterone acetate. *Lancet* 1(8631), 215–216.
89 Dourakis SP, Alexopoulou AA, Hadziyannis SJ (1994) Fulminant hepatitis after flutamide treatment. *J Hepatol* 20(3), 350–353.
90 Watanabe S, Yamasaki S, Tanae A *et al.* (1994) Three cases of hepatocellular carcinoma among cyproterone users. Ad hoc Committee on Androcur Users. *Lancet* 344(8936), 1567–1568.
91 Kattan J, Durand M, Droz JP *et al.* (1994) Phase I study of retelliptine dihydrochloride (SR 95325 B) using a single two-hour intravenous infusion schedule. *Am J Clin Oncol* 17(3), 242–245.
92 Werner S, Topinka J, Wolff T *et al.* (1995) Accumulation and persistence of DNA adducts of the synthetic steroid cyproterone acetate in rat liver. *Carcinogenesis* 16(10), 2369–2372.
93 Martelli A, Mattioli F, Fazio S *et al.* (1995) DNA repair synthesis and DNA fragmentation in primary cultures of human and rat hepatocytes exposed to cyproterone acetate. *Carcinogenesis* 16(6), 1265–1269.
94 Topinka J, Andrae U, Schwarz LR *et al.* (1993) Cyproterone acetate generates DNA adducts in rat liver and in primary rat hepatocyte cultures. *Carcinogenesis* 14(3), 423–427.
95 Lamm DL (1992) Long-term results of intravesical therapy for superficial bladder cancer. *Urol Clin North Am* 19(3), 573–580.
96 Lage JM, Bauer WC, Kelley DR *et al.* (1986) Histological parameters and pitfalls in the interpretation of bladder biopsies in bacillus Calmette-Guerin treatment of superficial bladder cancer. *J Urol* 135(5), 916–919.
97 Proctor DD, Chopra S, Rubenstein SC *et al.* (1993) Mycobacteremia and granulomatous hepatitis following initial intravesical bacillus Calmette-Guerin instillation for bladder carcinoma. *Am J Gastroenterol* 88(7), 1112–1125.

20.7 The effect of haematological and lymphatic diseases on the liver

Miguel Bruguera and Rosa Miquel

Liver abnormalities are frequently seen in patients with haematological diseases. The changes are due to liver involvement by the haematological disorder, the measures employed for its treatment or a concurrent and independent disease. Occasionally, clinical evidence of liver disease is the first manifestation of a primary haematological condition. This chapter summarizes the hepatic abnormalities found in the different haematological diseases. Hepatic complications related to bone marrow transplantation are described in Chapter 11.4.

Hodgkin's disease

Frequency

Hepatic involvement in Hodgkin's disease is regarded as evidence of stage IV disease. Thus, it has a wide variation depending on the duration of the disease [1]. The prevalence ranges from 5% to 14% in liver biopsies obtained at the time of diagnosis of Hodgkin's disease, increases to 30% during the course of disease and becomes as high as 60% in autopsy series.

Liver infiltration is more common in the aggressive histological subtypes of Hodgkin's disease – the lymphocyte-depleted and the mixed cellularity varieties. The lymphocyte-predominant type has the lowest incidence [2]. Splenic and medullary involvement correlates closely with the risk of hepatic involvement, and is associated with hepatomegaly, malaise and fever. When multiple nodules are found in the spleen, the likelihood of hepatic infiltration is high [3]. There is a single instance reported of liver infiltration in the absence of splenic Hodgkin's disease [4].

Histology

Hepatic infiltration in Hodgkin's disease occurs multifocally in the portal tracts. Sometimes, large infiltrates coalesce forming large tumour nodules. The diagnosis of liver involvement requires the finding of Reed–Sternberg cells, admixed with lymphocytes, eosinophils, plasma cells and atypical histiocytes. Histiocytes can form non-necrotizing granulomas, which may contain Reed–Sternberg cells or atypical mononuclear neoplastic cells (Fig. 1) [2]. The finding of atypical histiocytes even without Reed–Sternberg cells is highly suggestive of hepatic involvement by Hodgkin's disease. If typical cytological features of Hodgkin's disease are not present, deeper histological sections and immunostaining should be performed to find characteristic CD30- and CD15-positive neoplastic cells.



Fig. 1 Hodgkin's disease. Nodular infiltrate in the parenchyma composed of atypical histiocytes, eosinophils and lymphocytes (HE × 60).

Epithelioid granulomas, either in the hepatic lobules or in the portal tracts, may be seen in 10% of liver biopsies [5]. They often occur in patients without involvement of the liver by Hodgkin's disease [6].

Non-specific inflammatory infiltrates of portal tracts are seen in a high proportion of cases [7]. They should not be mistaken for liver involvement by Hodgkin's disease. Sinusoidal dilatation is present in many patients with systemic (B) symptoms [8] and reverses when disease activity is abolished by chemotherapy. Peliosis hepatis has been documented in one patient [9].

Clinical features

Patients with liver involvement often remain asymptomatic.

An enlarged liver is a common finding, but does not necessarily indicate hepatic infiltration.

Jaundice is rare as an initial manifestation but relatively frequent in the late stages [10], resulting from extensive liver infiltration by tumour [11] or extrahepatic biliary obstruction produced by hilar adenopathies [12]. A few patients exhibit a syndrome of idiopathic intrahepatic cholestasis, for which none of the known causes of jaundice can be implicated [13,14]. A paraneoplastic hormonal effect unrelated to the bulk of tumour has been suggested as a cause of jaundice. In some patients with cholestasis, a vanishing bile duct syndrome (ductopenia) unassociated with tumour infiltration is found in the liver biopsy [15]. Cholestasis may remit with chemotherapy. In a few patients presenting with jaundice associated with fever and severe hepatic failure (acute cholestasis of Hodgkin's disease), liver biopsy demonstrates tumoral infiltration in the liver with loss of bile ducts in portal tracts [16–19]. The development of Hodgkin's disease several years after the diagnosis of primary sclerosing cholangitis has been reported [20]. Exceptionally, Hodgkin's disease may present as fulminant hepatic failure as a paraneoplastic manifestation of the disease [21].

Liver function tests are of little value in diagnosing liver involvement. Increased serum alkaline phosphatase activity is found in many patients with hepatic infiltration, but may also be associated with non-specific histological changes, such as granulomas or sinusoidal dilatation [6]. An isolated elevation of serum alkaline phosphatase activity may represent a minor form of the syndrome of idiopathic cholestasis of Hodgkin's disease [22].

Non-Hodgkin's lymphomas

Frequency

Liver involvement in non-Hodgkin's lymphoma is more common than in Hodgkin's disease. Liver biopsies obtained at diagnosis of lymphoma show hepatic infiltration in about 15% of the cases. Around 100 cases have been reported in which the liver was the only tissue affected by the lymphoma [23–29]. Primary lymphomas of the liver account for 0.4% of all extranodal lymphomas. Some 21% of these patients had an infection due to hepatitis virus [30]. Criteria for diagnosis of primary lymphoma are: (i) absence of lymphadenopathy or splenomegaly; (ii) normal abdominal and thoracic computerized tomographic (CT) scans; and (iii) normal bone marrow and blood counts [31].

Histology

Hepatic infiltration is more common in low-grade B-cell lymphomas (small cell) than in high-grade (diffuse large B-cell, T-cell histiocytic) lymphomas [2], but primary lymphomas of the liver more frequently belong to the large B-cell type. The hepatic infiltration consists of a well-circumscribed nodular and monomorphic infiltration of portal tracts by packed malignant cells, which may infiltrate the sinusoids when the disease evolves to a leukaemic phase. Large tumour nodules effacing the hepatic architecture may be observed [32,33].

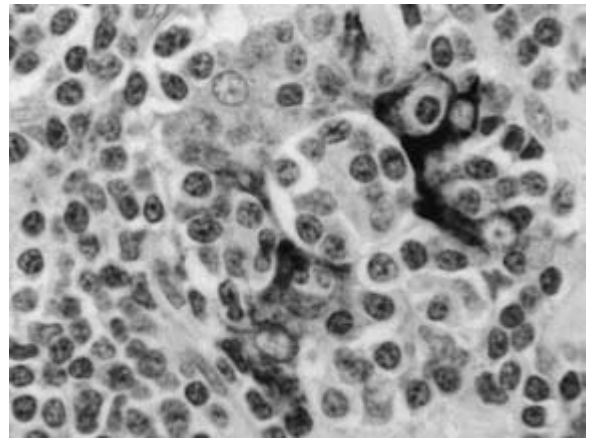

Fig. 2 Primary hepatic marginal zone B-cell lymphoma. Immunostaining with cytokeratin 7 highlights the lymphoepithelial lesion of the portal bile duct.

Immunohistochemistry may help to characterize the lymphoid infiltrates present in liver biopsies [34,35]. The demonstration of monoclonality supports the diagnosis of lymphoma.

To date, fewer than 20 cases of primary hepatic marginal zone B-cell lymphomas of MALT type (mucosa-associated lymphoid tissue) have been described [36,37]. An underlying liver disease, such as viral or autoimmune hepatitis or primary biliary cirrhosis, has been found in some of them, suggesting the role of chronic antigenic stimulation in their pathogenesis. These tumours are characterized by a dense portal infiltrate and are CD20 positive, with the presence of lymphoid follicles and germinal centres and lymphoepithelial lesions of the bile ducts (Fig. 2). One case had a stable remission after rituximab administration [37].

Epithelioid granulomas are found in up to 10% of liver biopsies from patients with non-Hodgkin's lymphoma [38]; they do not indicate that the liver is affected by the lymphoma.

Clinical features

Hepatic infiltration with non-Hodgkin's lymphoma is usually silent. Mild to moderate elevations in serum alkaline phosphatase may be present. Jaundice is uncommon and, when it occurs, is more likely to be due to extrahepatic obstruction at the liver hilum than to hepatic infiltration [39]. Exceptionally, jaundice with liver failure is the first clinical manifestation of lymphoma. The diagnosis should be suspected if there is liver enlargement and lactic acidosis. Neither feature is seen when acute liver failure is due to viral or toxic agents. Diagnosis must be confirmed histologically before starting chemotherapy; liver transplantation should be avoided [40–43]. Untreated patients follow a rapid course to death. Liver tissue examination reveals massive tumoral infiltration of sinusoids and replacement of

hepatic cords by malignant cells. Lymphomas presenting as severe hepatic failure are of various histological types, such as Burkitt type and small- or large-cell lymphoma [44]. Cases previously reported as malignant histiocytosis would probably now be classified as large-cell lymphomas [45]. Healthy carriers of hepatitis B virus with non-Hodgkin's lymphoma have experienced severe reactivation of hepatitis B followed by liver failure and death after the withdrawal of chemotherapy [46,47]. Lamivudine before starting chemotherapy or treatment with rituximab prevents hepatitis B reactivation [48–50].

Primary lymphoma usually affects middle-aged people and presents with abdominal pain and B symptoms (fever, weight loss and night sweats), but without ascites or jaundice. There is a consistent increase in serum alkaline phosphatase activity and a less constant increase in serum aminotransferases. Ultrasound and CT scans are not specific, and may be confused with hepatocellular carcinoma or metastases. The lesions are hypo- or hyperechoic on sonography, and of low density on CT scans. Diagnosis of lymphoma can only be achieved by liver biopsy.

One primary lymphoma of the extrahepatic bile duct has been documented [51].

Peripheral hepatosplenic gamma/delta T-cell lymphoma

Hepatosplenic gamma/delta T-cell lymphoma (TCL) is a rare, aggressive subset of non-cutaneous, peripheral TCL that presents with hepatosplenomegaly without lymphadenopathy, and medullary involvement causing cytopenia [52–55]. Liver function tests were only slightly modified. One patient presented with jaundice mimicking acute hepatitis [56].

Diagnosis is based on the histology of the liver, which is characterized by sinusoidal infiltration by atypical lymphoid cells. Neoplastic cells express the γ/δ cell receptor, suggesting that their origin is a small population of normal liver T cells expressing the γ/δ receptor. Tumour cells express CD3+ and are CD4– CD8– [57]. In the spleen, infiltration by these cells is diffuse and predominates in the sinuses. Cytogenetic analysis shows an isochromosome 7q [58].

Chronic lymphoid leukaemia

Patients with chronic lymphoid leukaemia often have mild to moderate liver enlargement. Functional impairment of the liver is a late manifestation [59]. Extensive lymphocytic infiltration is seen in portal tracts, sometimes associated with periportal fibrosis that may lead to portal hypertension [60]. Nodular regenerative hyperplasia of the liver has been reported [61].

Hairy cell leukaemia

Hairy cell leukaemia is an indolent lymphoproliferative disorder characterized by the proliferation of mononuclear cells, which harbour atypical hair-like cytoplasmic projections, in peripheral blood, bone marrow, spleen, liver and, rarely, lymph nodes. The liver is always infiltrated by leukaemic cells, which invade both portal tracts and sinusoids [62]. They may be identified by the halo-like clear cytoplasm around rounded or indented nuclei, and by the demonstration of a tartrate-resistant acid phosphatase activity [63]. The finding of intra-acinar cavities lined by leukaemic cells and filled by red cells is very characteristic of hairy cell leukaemia [64].

Liver enlargement is found in less than 40% of patients, and serum biochemical abnormalities are rarely seen [62].

Monoclonal gammopathies

In multiple myeloma, hepatomegaly is found in 15–40% of cases. It is usually mild to moderate and sometimes accompanied by splenomegaly; other manifestations of liver involvement are uncommon [65,66]. Jaundice is rarely seen. Two histological patterns of hepatic infiltration can be observed: (i) diffuse sinusoidal and portal tract infiltration; and (ii) large nodules simulating metastatic carcinoma. Amyloid deposition is exceedingly uncommon. There is one report of primary extramedullary plasmocytoma of the liver, which presented as a painful liver with a single nodule in segment VII; it was successfully treated by surgical resection [67].

Various liver lesions have been described in patients with Waldenstrom's macroglobulinaemia: infiltration of malignant cells into portal tracts giving rise to portal hypertension [68], massive blastic infiltration revealed by hepatic failure [69], amyloidosis, light-chain deposits [70], peliosis hepatis [71] and nodular regenerative hyperplasia [72].

Acute leukaemia

Hepatic involvement in acute leukaemia is usually mild and silent at the time the disease is diagnosed. Infiltration by leukaemic cells is localized in portal tracts in acute lymphoblastic leukaemia, and in portal tracts and sinusoids in acute myeloblastic leukaemia. A slight elevation in serum alkaline phosphatase activity and a mild to moderate liver enlargement may be noted.

Post-transfusion chronic viral hepatitis, drug-induced hepatotoxicity or bacterial and fungal infections affecting the liver may occur in patients with leukaemia. Exceptionally, massive infiltration of the liver by leukaemic cells has presented as fulminant liver failure [73]. Transfusion iron overload is a relatively common sequela of successful management of acute leukaemia in adults, for which routine evaluation should be performed and for which therapeutic phlebotomy should be used as treatment [74].

Focal hepatic candidiasis is being recognized with increasing frequency in patients with acute leukaemia [75,76]. Clinically, it presents as a well-tolerated and prolonged fever, unresponsive to broad-spectrum antibiotics, when the neutropenia following chemotherapy is returning to normal. There is hepatomegaly,

abdominal pain and minimal liver impairment, other than a raised serum alkaline phosphatase activity. The finding of 'bull's eye' lesions on ultrasound examination is characteristic [77]. At laparoscopy, white nodules, 0.5–2 cm in diameter, displaying a nipple-like prominence can be seen on the liver surface [78]. Liver biopsy, guided by ultrasound or peritoneoscopy, reveals yeasts and pseudohyphae of *Candida* spp. within a granulomatous reaction. Prolonged treatment with amphotericin B is required, often in association with other antifungal drugs. Patients with hepatic candidiasis have been treated with cytosine arabinoside, which often induces extensive lesions in the mucosa of the gastrointestinal tract, favouring local invasion by *Candida* spp.

Chronic myeloproliferative disorders

Myeloid metaplasia

Liver involvement in primary myelofibrosis, also termed agnogenic myeloid metaplasia, is common and due to any of the following mechanisms, individually or in combination: extramedullary haematopoiesis, increased hepatic blood flow, haemosiderosis secondary to either blood transfusions or ineffective erythropoiesis, and post-transfusion chronic viral hepatitis.

Histology

Hepatic extramedullary haematopoiesis is found in 90–100% of patients with myeloid metaplasia [79]. Because of this high frequency, its demonstration is often used to confirm the diagnosis of primary myelofibrosis. However, care should be taken when patients with agnogenic myeloid metaplasia are submitted to liver biopsy because of the risk of bleeding related to platelet dysfunction. A transjugular approach [80] or a 'plugged' percutaneous liver biopsy [81] should be considered.

In the early stages, extramedullary haematopoiesis is confined to the sinusoids, whereas portal tract involvement is a feature of more advanced disease [82]. The three haemopoietic cell lines are usually represented, but the most commonly observed are megakaryocytes, which are often dysplastic (Fig. 3). Sinusoidal dilatation is found in half the cases, and it is probably related to the obstruction of blood flow by sinusoidal foci of haematopoietic cells. An increase in the reticulin network is present in 30–40% of cases. It has been attributed to some factor released by dysplastic megakaryocytes that induces transformation of Ito cells into fibroblasts [83]. Haemosiderin deposition in hepatocytes and Kupffer cells is always present.

Clinical features

Liver enlargement is found in nearly all patients. The size of the liver correlates with the stage of the disease, and increases following splenectomy [84]. Such an increase is usually gradual over several years, but is rapidly progressive in some patients. In some of the latter, fatal hepatic failure of obscure origin has

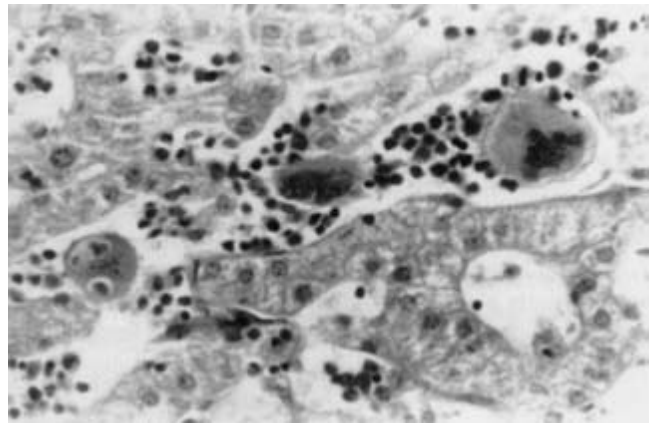

Fig. 3 Marked sinusoidal infiltration by haemopoietic cells in idiopathic myelofibrosis. Note the presence of bizarre megakaryocytes (HE × 375).

been reported after splenectomy [85,86]. Palpable splenomegaly is also a common finding; its absence makes the diagnosis of agnogenic myeloid metaplasia unlikely.

Ascites and oesophageal varices develop in about 7% of patients. Portal hypertension is caused by an increased intrahepatic vascular resistance related to sinusoidal fibrosis, and to infiltration by haemopoietic cells [87,88]. Nodular regenerative hyperplasia related to an obstruction of intrahepatic portal vein branches is another well-recognized cause of portal hypertension [89].

Abnormal liver function tests can be detected in 40–60% of patients [82]. High serum alkaline phosphatase activity is the most common abnormality and seems to reflect the severity of sinusoidal dilatation rather than the grade of hepatic myeloid metaplasia.

Polycythaemia vera

Liver involvement is uncommon in polycythaemia vera. Patients in whom the disorder evolves into myelofibrosis develop myeloid metaplasia. Other patients may present with an acute or chronic Budd–Chiari syndrome. Polycythaemia vera is found in over 40% of patients with Budd–Chiari syndrome, although this proportion may be even higher as a latent myeloproliferative disorder is demonstrated in many patients with idiopathic Budd–Chiari syndrome by *in vitro* erythroid colony formation in the absence of erythropoietin [90].

Chronic myeloid leukaemia

At presentation, 50% of patients display mild to moderate hepatomegaly, without altered liver function tests [91]. Portal and sinusoidal infiltration by a mixed population of mature and immature myeloid cells is usually seen. In blastic phases of the disease, liver enlargement increases due to the sinusoidal infiltration by immature cells. Serum alkaline phosphatase activity also increases.

A single patient has been reported in whom the initial manifestation of blast crisis was acute hepatic failure due to massive infiltration of the liver by leukaemic cells [92].

Myelodysplasias

Myelodysplasias are a group of chronic haematological disorders characterized by variable degrees of cytopenia in the presence of quantitatively normal or rich bone marrow, dyshaemopoietic features and frequent evolution to acute leukaemia. Hepatic involvement can occur through two mechanisms. In patients with sideroblastic anaemia or refractory anaemia, the liver often shows iron deposition due to both frequent transfusions and increased iron absorption as a result of decreased iron utilization by bone marrow. Infiltrative hepatomegaly is observed in patients with refractory anaemia with excess of blasts or with chronic myelomonocytic leukaemia.

Haemolytic anaemias

Sickle-cell disease

Sickle-cell disease is an inherited disorder of haemoglobin producing chronic haemolytic anaemia with recurrent acute haemolytic crisis. The liver is commonly involved as a result of viral hepatitis transmitted by blood transfusion, iron overload, jaundice due to biliary tract obstruction by gallstones, cardiac dysfunction due to secondary haemochromatosis or a clinical disorder unique in sickle-cell disease, termed 'hepatic crisis' [93]. The last presents with upper right abdominal quadrant pain, fever, jaundice, leucocytosis and a variable elevation in hepatic serum enzymes, mimicking acute cholecystitis. With general supportive care, clinical improvement is seen within several days but, occasionally, the disease follows a fulminant course to death. Some young patients exhibit extreme hyperbilirubinaemia, not associated with pain or fever. Jaundice resolves over several weeks without permanent sequelae.

Histologically, the liver consistently shows intrasinusoidal obliteration by sickled red blood cells and Kupffer cell erythrophagocytosis, which may result in impairment of intrahepatic blood flow. Other histological changes that may be detected are iron deposition, which is often massive, chronic hepatitis and cirrhosis [94].

Cholelithiasis is frequently observed in patients with sickle-cell disease (40–80%). Gallstones are related to haemolysis and may cause cholecystitis and bile duct obstruction.

Thalassaemia

In patients with thalassaemia, major chronic liver disease is due to haemochromatosis related to ineffective erythropoiesis and/or post-transfusion viral hepatitis B or C [95]. Massive iron deposition is found in the liver and other organs. Heart failure due to haemochromatosis is the main cause of death in these patients [96]. It has been suggested that repeated blood transfusions protect against the development of serious hepatic disease.

Paroxysmal nocturnal haemoglobinuria

Paroxysmal nocturnal haemoglobinuria is a chronic haemolytic anaemia related to an acquired defect in the membrane of red cells that renders them especially sensitive to the lytic action of complement when blood pH falls. Besides haemolysis, the disease is associated with a high tendency to develop venous thrombosis. Budd–Chiari syndrome and portal vein thrombosis are consequences of the disease [97,98]. Up to 10% of cases of Budd–Chiari syndrome may be related to paroxysmal nocturnal haemoglobinuria [99].

One patient with paroxysmal nocturnal haemoglobinuria presented with abdominal pain and anicteric cholestasis. Endoscopic retrograde cholangiopancreatography showed a radiological pattern of sclerosing cholangitis, which was interpreted as ischaemic cholangiopathy [100].

Other haematological diseases

Haemophilia

Chronic viral hepatitis is common in haemophiliac patients who received clotting factor concentrates before the availability of virus-inactivated factors in the mid-1980s. Up to 90% of patients have serological markers of past or ongoing hepatitis B virus infection; 50–70% are anti-hepatitis C virus positive, and 25% of hepatitis B carriers have hepatitis D-virus superinfection [101–104]. Nearly 70% of patients have altered liver function tests; in most, chronic active hepatitis or cirrhosis related to chronic viral infection is found on liver biopsy [105]. The risk of hepatitis is higher in patients treated on a regular basis than in those treated according to need, and higher in those who started treatment at an earlier age [106].

Needle liver biopsy is a hazardous procedure in these patients, even under the cover of clotting factor concentrates, and should be avoided [107]; however, it has been carried out without problems by some authors [108,109].

Exclusion of blood donors infected by hepatitis B and C virus, as well as the introduction of effective viral inactivation procedures such as pasteurization of factor VIII concentrates, has reduced the risk of hepatitis [110,111].

The efficacy and tolerability of antiviral treatment in haemophiliacs do not differ from other patients with chronic hepatitis [112].

Aplastic anaemia (see Chapter 21.3)

Aplastic anaemia is a rare complication of viral hepatitis. In up to 10% of patients, the development of aplastic anaemia follows a recent episode of hepatitis, which is rarely due to hepatitis B

virus [113] or to hepatitis C virus [114], but is more often due to a still unidentified non-A, non-B, non-C virus [115,116]. The role of parvovirus B19 is being investigated, particularly in those patients who have developed aplastic anaemia following liver transplantation [117,118]. When it is due to HBV, the administration of lamivudine may be life saving [119]. A direct injury of stem cells has been postulated for the pathogenesis of this complication. Bone marrow transplantation yields similar efficacy in patients with hepatitis-related aplastic anaemia and in those with anaemia of unknown aetiology.

Anabolic steroids given for long periods of time as treatment for aplastic anaemia can induce peliosis hepatis [120] and hepatocellular adenoma [121].

Remission of aplastic anaemia associated with HBV infection was obtained with lamivudine therapy [122]. One patient was successfully treated with antilymphocyte globulin [123].

Mastocytosis

Subclinical hepatic involvement is frequent in systemic mastocytosis. Hepatosplenomegaly is common and due to infiltration by mast cells. Identification of mast cells in paraffin-embedded sections stained with haematoxylin and eosin is difficult. Histochemical staining with Giemsa and immunostaining with mast cell tryptase is useful for recognizing these cells. CD117 (ckit) can also help [124]. Tissue eosinophilia is often seen [125]. Portal hypertension attributed to mast cell infiltration and sinusoidal fibrosis has been reported occasionally [126,127]. Mast cell infiltration of the bile duct walls may cause a cholangiopathy radiographically similar to primary sclerosing cholangitis [128]. Mastocytosis was revealed by liver involvement, liver failure and jaundice, in two patients [129].

Essential mixed cryoglobulinaemia

Essential mixed cryoglobulinaemia is a condition clinically characterized by purpura, arthralgias and glomerulonephritis, associated with circulating mixed (IgM–IgG) cryoprecipitable globulins. Earlier reports suggested an association of this syndrome with hepatitis B virus infection [130.131], but this could not be confirmed in other studies [132].

Stronger support for an association between essential mixed cryoglobulinaemia and hepatitis C virus infection has been gained from recent studies [133–137], based on a high prevalence of anti-hepatitis C virus antibodies and hepatitis C virus RNA in the serum cryoprecipitates of patients with essential mixed cryoglobulinaemia. Cryoglobulinaemia is found in about one-third of patients with chronic hepatitis C, but the proportion of patients with clinical expression of essential mixed cryoglobulinaemia is much lower [138]. The mechanisms by which hepatitis C virus infection allows cryoprecipitable immune complexes to deposit in vascular tissue causing tissue injury remain to be determined. Interferon transiently improves the biochemical and clinical manifestations of essential mixed cryoglobulinaemia in parallel with its effect on virological markers of hepatitis C virus [139].

References

1 Givler RL, Brunk SF, Hass CA *et al.* (1971) Problems of interpretation of liver biopsy in Hodgkin's disease. *Cancer* 28, 1335–1342.
2 Jaffe ES (1987) Malignant lymphomas: pathology of hepatic involvement. *Semin Liver Dis* 7, 257–268.
3 Colby TV, Hoppe RT, Warnke RA (1982) Hodgkin's disease: a clinicopathologic study of 659 cases. *Cancer* 49, 1848–1858.
4 Fialk MA, Jarowski CI, Coleman M *et al.* (1979) Hepatic Hodgkin's disease without involvement of the spleen. *Cancer* 43, 1146–1147.
5 Kadin (1974) *N Engl J Med* 27, 1277.
6 Belliveau RE, Wiernik PH, Abt AB (1974) Liver enzymes and pathology in Hodgkin's disease. *Cancer* 34, 300–305.
7 Leslie KO, Colby TV (1984) Hepatic parenchymal lymphoid aggregates in Hodgkin's disease. *Hum Pathol* 15, 808–809.
8 Bruguera M, Caballero T, Carreras E *et al.* (1987) Hepatic sinusoidal dilatation in Hodgkin's disease. *Liver* 7, 76–80.
9 Bhaskar KV, Joshi K, Banerjee CK *et al.* (1990) Peliosis hepatis in Hodgkin's disease: an infrequent association. *Am J Gastroenterol* 85, 628–629.
10 Birrer MJ, Young RC (1987) Differential diagnosis of jaundice in lymphoma patients. *Semin Liver Dis* 7, 269–277.
11 Levitan R, Diamond HD, Craver LF (1961) Jaundice in Hodgkin's disease. *Am J Med* 30, 99–111.
12 Perera DR, Greene ML, Fenster LF (1974) Cholestasis associated with extrabiliary Hodgkin's disease. Report of three cases and review of four others. *Gastroenterology* 67, 680–685.
13 Piken EP, Abraham GE, Hepner GW (1979) Investigation of a patient with Hodgkin's disease and cholestasis. *Gastroenterology* 77, 145–147.
14 Lieberman DA (1986) Intrahepatic cholestasis due to Hodgkin's disease. An elusive diagnosis. *J Clin Gastroenterol* 8, 304–307.
15 Ripoll C, Carretero L, Sabin P *et al.* (2002) Idiopathic cholestasis associated with progressive ductopenia in two patients with Hodgkin's disease. *Gastroenterol Hepatol* 25, 313–315 (in Spanish).
16 Trewby PN, Portmann B, Brinkley DM *et al.* (1979) Liver disease as presenting manifestation of Hodgkin's disease. *Q J Med* 48, 137–150.
17 Lefkowitch JH, Falkow S, Whitlock RT (1985) Hepatic Hodgkin's disease simulating cholestatic hepatitis with liver failure. *Arch Pathol Lab Med* 109, 424–426.
18 Hubscher SG, Lumley MA, Elias E (1993) Vanishing bile duct syndrome: a possible mechanism for intrahepatic cholestasis in Hodgkin's lymphoma. *Hepatology* 17, 70–77.
19 Cervantes F, Briones J, Bruguera M *et al.* (1996) Hodgkin's disease presenting as a cholestatic febrile illness: incidence and main characteristics in a series of 421 patients. *Ann Hematol* 72, 357–360.
20 Man KM, Drejet A, Keeffe EB *et al.* (1993) Primary sclerosing cholangitis and Hodgkin's disease. *Hepatology* 18, 1127–1131.
21 Dourakis SP, Tzemanakis E, Deutsch M *et al.* (1999) Fulminant hepatic failure as a presenting paraneoplastic manifestation of Hodgkin's disease. *Eur J Gastroenterol Hepatol* 11, 1055–1058.
22 Carreras E, Rozman C, Rodes J *et al.* (1987) Functional cholestasis associated with Hodgkin's disease. *Med Clin (Barc)* 89, 43–49 (in Spanish).
23 Strayer DS, Reppun TS, Levin M *et al.* (1980) Primary lymphoma of the liver. *Gastroenterology* 78, 1571–1576.

24 Osborne BM, Butler JJ, Guarda LA (1985) Primary lymphoma of the liver. Ten cases and a review of the literature. *Cancer* 56, 2902–2910.

25 DeMent SH, Mann RB, Staal SP *et al.* (1987) Primary lymphomas of the liver. Report of six cases and review of the literature. *Am J Clin Pathol* 88, 255–263.

26 Anthony PP, Sarsfield P, Clarke T (1990) Primary lymphoma of the liver: clinical and pathological features of 10 patients. *J Clin Pathol* 43, 1007–1013.

27 Scoazec JY, Degott C, Brousse N *et al.* (1991) Non-Hodgkin's lymphoma presenting as a primary tumor of the liver: presentation, diagnosis and outcome in eight patients. *Hepatology* 13, 870–875.

28 Ohsawa M, Aozasa K, Horiuchi K *et al.* (1992) Malignant lymphoma of the liver. Report of five cases and review of the literature. *Dig Dis Sci* 37, 1105–1109.

29 Santos ES, Raez LE, Salvatierra J *et al.* (2003) Primary hepatic non-Hodgkin's lymphomas: case report and review of the literature. *Am J Gastroenterol* 98, 2789–2793.

30 Bronowicki JP, Bineau C, Feugier P *et al.* (2003) Primary lymphoma of the liver: clinical-pathological features and relationship with HCV infection in French patients. *Hepatology* 37, 781–787.

31 Caccamo D, Pervez NK, Marchevsky A (1986) Primary lymphoma of the liver in the acquired immunodeficiency syndrome. *Arch Pathol Lab Med* 110, 553–555.

32 Lotz MJ, Thomas LB, Johnson BC (1976) Pathological staging of 100 consecutive patients with non-Hodgkin's lymphomas. *Cancer* 37, 266–270.

33 Kim H, Dorfman RF, Rosenberg SA (1976) Pathology of malignant lymphomas of the liver: application in staging. *Progr Liver Dis* 5, 683–694.

34 Verdi CJ, Grogan TM, Protell R *et al.* (1986) Liver biopsy immunotyping to characterize lymphoid malignancies. *Hepatology* 6, 6–13.

35 Voigt JJ, Vinel JP, Caveriviere P *et al.* (1989) Immunochemical diagnosis of hepatic localizations in malignant lymphoid hematologic diseases. Study of 80 cases. *Gastroenterol Clin Biol* 13, 343–352 (in French).

36 Maes M, Depardieu C, Dargent JL *et al.* (1997) Primary low-grade B-cell lymphoma of MALT-type occurring in the liver: a study of two cases. *J Hepatol* 27, 922–927.

37 Gockel HR, Heidemann J, Lugering A *et al.* (2005) Stable remission after administration of rituximab in a patient with primary hepatic marginal zone B-cell lymphoma. *Eur J Haematol* 74, 445–447.

38 Braylan RC, Long JC, Jaffe ES *et al.* (1977) Malignant lymphoma obscured by concomitant extensive epithelioid granulomas: report of three cases with similar clinicopathologic features. *Cancer* 39, 1146–1155.

39 Boddie AW, Eisenberg BL, Mullins JD *et al.* (1980) The diagnosis and treatment of obstructive jaundice secondary to malignant lymphoma: a problem in multidisciplinary management. *J Surg Oncol* 14, 111–123.

40 Saló J, Nomdedeu B, Bruguera M (1993) Acute liver failure due to non-Hodgkin's lymphoma. *Am J Gastroenterol* 88, 774–776.

41 Zafrani ES, Leclercq B, Vernant JP *et al.* (1983) Massive blastic infiltration of the liver: a cause of fulminant hepatic failure. *Hepatology* 3, 428–432.

42 Gargot (1994) *Eur J Gastroenterol Hepatol* 6, 843.

43 Woolf GM, Petrovic LM, Rojter SE *et al.* (1994) Acute liver failure due to lymphoma. A diagnostic concern when considering liver transplantation. *Dig Dis Sci* 6, 1351–1358.

44 Thompson DR, Faust TW, Stone MJ *et al.* (2001) Hepatic failure as the presenting manifestation of malignant lymphoma. *Clin Lymphoma* 2, 123–128.

45 Colby TV, LaBrecque DR (1982) Lymphoreticular malignancy presenting as fulminant hepatic disease. *Gastroenterology* 82, 339–345.

46 Pariente EA, Goudeau A, Dubois F *et al.* (1988) Fulminant hepatitis due to reactivation of chronic hepatitis B virus infection after allogeneic bone marrow transplantation. *Dig Dis Sci* 33, 1185–1191.

47 Pinto PC, Hu E, Bernstein-Singer M *et al.* (1990) Acute hepatic injury after the withdrawal of immunosuppressive chemotherapy in patients with hepatitis B. *Cancer* 65, 878–884.

48 Idilman R, Arat M, Soydan E *et al.* (2004) Lamivudine prophylaxis for prevention of chemotherapy-induced hepatitis B virus reactivation in hepatitis B virus carriers with malignancies. *J Viral Hepat* 11, 141–147.

49 Tsutsumi Y, Kawamura T, Saitoh S *et al.* (2004) Hepatitis B virus reactivation in a case of non-Hodgkin's lymphoma treated with chemotherapy and rituximab: necessity of prophylaxis for hepatitis B virus reactivation in rituximab therapy. *Leuk Lymphoma* 45, 627–629.

50 Yeo W, Chan PK, Ho WM *et al.* (2004) Lamivudine for the prevention of hepatitis B virus reactivation in hepatitis B s-antigen seropositive cancer patients undergoing cytotoxic chemotherapy. *J Clin Oncol* 22, 927–934.

51 Nguyen GK (1982) Primary extranodal non-Hodgkin's lymphoma of the extrahepatic bile ducts. Report of a case. *Cancer* 50, 2218–2222.

52 Gaulard P, Zafrani ES, Mavier P *et al.* (1986) Peripheral T-cell lymphoma presenting as predominant liver disease: a report of three cases. *Hepatology* 6, 864–868.

53 Falini B, Pileri S, De Solas I *et al.* (1990) Peripheral T-cell lymphoma associated with hemophagocytic syndrome. *Blood* 75, 434–444.

54 Farcet JP, Gaulard P, Marolleau JP *et al.* (1990) Hepatosplenic T-cell lymphoma: sinusal/sinusoidal localization of malignant cells expressing the T-cell receptor gamma delta. *Blood* 75, 2213–2219.

55 Gaulard P, Bourquelot P, Kanavaros P *et al.* (1990) Expression of the alpha/beta and gamma/delta T-cell receptors in 57 cases of peripheral T-cell lymphomas. Identification of a subset of gamma/delta T-cell lymphomas. *Am J Pathol* 137, 617–628.

56 King PD, Diaz-Arias AA, Birkby WF *et al.* (1994) Reactive hemophagocytic syndrome simulating acute hepatitis. A case due to hepatic peripheral T-cell lymphoma. *J Clin Gastroenterol* 19, 234–237.

57 Salhany KE, Feldman M, Kahn MJ *et al.* (1997) Hepatosplenic gammadelta T-cell lymphoma: ultrastructural, immunophenotypic, and functional evidence for cytotoxic T lymphocyte differentiation. *Hum Pathol* 28, 674–685.

58 François A, Lesesve JF, Stamatoullas A *et al.* (1997) Hepatosplenic gamma/delta T-cell lymphoma: a report of two cases in immunocompromised patients, associated with isochromosome 7q. *Am J Surg Pathol* 21, 781–790.

59 Sweet DL, Golomb HM, Ultmann JE (1987) The clinical features of chronic lymphocytic leukaemia. *Clin Haematol* 6, 185–202.

60 Schwartz JB, Shamsuddin AM (1981) The effects of leukemic infiltrates in various organs in chronic lymphocytic leukemia. *Hum Pathol* 12, 432–440.

61 Rozman (1988) *Medicina Clin* 92, 26.

62 Yam LT, Janckila AJ, Chan CM (1983) Hepatic involvement in hairy cell leukaemia. *Cancer* 51, 1487–1504.

63 Grouls V, Stiens R (1984) Hepatic involvement in hairy cell leukemia: diagnosis by tartrate-resistant acid phosphatase enzyme

histochemistry on formalin fixed and paraffin-embedded liver biopsy specimens. *Pathol Res Pract* 178, 332–334.

64 Roquet ML, Zafrani ES, Farcet JP (1985) Histopathological lesions of the liver in hairy cell leukemia: a report of 14 cases. *Hepatology* 5, 496–500.

65 Thomas FB, Clausen KP, Greenberger NJ (1973) Liver disease in multiple myeloma. *Arch Intern Med* 132, 195–202.

66 Perez-Soler R, Esteban R, Allende E *et al.* (1985) Liver involvement in multiple myeloma. *Am J Hematol* 20, 25–29.

67 Weichhold W, Labouyrie E, Merlio JP *et al.* (1995) Primary extramedullary plasmacytoma of the liver. A case report. *Am J Surg Pathol* 19, 1197–1202.

68 Brooks AP (1976) Portal hypertension in Waldenstrom's macroglobulinaemia. *Br Med J* 1(6011), 689–690.

69 Beau P, Touchard G, Lessard M *et al.* (1984) Massive sarcomatous infiltration of the liver disclosed by jaundice and hepatocellular failure in Waldenstrom's disease. *Gastroenterol Clin Biol* 8, 57–61 (in French).

70 Rodrigo Saez L, Riera Velasco JR, Rodriguez Garcia M *et al.* (1987) Intrahepatic cholestasis associated with light-chain deposition disease. *Rev Esp Enferm Apar Dig* 71, 55–56 (in Spanish).

71 Voinchet O, Degott C, Scoazec JY *et al.* (1988) Peliosis hepatis, nodular regenerative hyperplasia of the liver, and light-chain deposition in a patient with Waldenstrom's macroglobulinemia. *Gastroenterology* 95, 482–486.

72 Wanless IR, Solt LC, Kortan P *et al.* (1981) Nodular regenerative hyperplasia of the liver associated with macroglobulinemia. A clue to the pathogenesis. *Am J Med* 70, 1203–1209.

73 Zafrani ES, Leclercq B, Vernant JP *et al.* (1983) Massive blastic infiltration of the liver: a cause of fulminant hepatic failure. *Hepatology* 3, 428–432.

74 Barton JC, Bertoli LF (2000) Transfusion iron overload in adults with acute leukemia: manifestations and therapy. *Am J Med Sci* 319, 73–78.

75 Haron E, Feld R, Tuffnell P *et al.* (1987) Hepatic candidiasis: an increasing problem in immunocompromised patients. *Am J Med* 83, 7–26.

76 Thaler M, Pastakia B, Shawker TH *et al.* (1988) Hepatic candidiasis in cancer patients: the evolving picture of the syndrome. *Ann Intern Med* 108, 88–100.

77 von Eiff M, Essink M, Roos N *et al.* (1990) Hepatosplenic candidiasis, a late manifestation of Candida septicaemia in neutropenic patients with haematologic malignancies. *Blut* 60, 242–248.

78 Bladé J, Lopez-Guillermo A, Rozman C *et al.* (1992) Chronic systemic candidiasis in acute leukemia. *Ann Hematol* 64, 240–244.

79 Ligumski M, Polliack A, Benbassat J (1978) Nature and incidence of liver involvement in agnogenic myeloid metaplasia. *Scand J Haematol* 21, 81–93.

80 Lebrec D (1996) Various approaches to obtaining liver tissue—choosing the biopsy technique. *J Hepatol* 25 (Suppl 1), 20–24.

81 Sawyerr AM, McCormick PA, Tennyson GS *et al.* (1993) A comparison of transjugular and plugged-percutaneous liver biopsy in patients with impaired coagulation. *J Hepatol* 17, 81–85.

82 Pereira A, Bruguera M, Cervantes F *et al.* (1988) Liver involvement at diagnosis or primary myelofibrosis: a clinicopathological study of twenty-two cases. *Eur J Haematol* 40, 355–361.

83 Roux D, Merlio JP, Quinton A *et al.* (1987) Agnogenic myeloid metaplasia, portal hypertension, and sinusoidal abnormalities. *Gastroenterology* 92, 1067–1072.

84 Towell BL, Levine SP (1987) Massive hepatomegaly following splenectomy for myeloid metaplasia. Case report and review of the literature. *Am J Med* 82, 371–375.

85 Perez-Villa F, Font J, Feliu E *et al.* (1988) Severe post-splenectomy hepatic insufficiency in a patient with agnogenic myeloid metaplasia. *Med Clin (Barc)* 91, 108–110 (in Spanish).

86 Lopez-Guillermo A, Cervantes F, Bruguera M *et al.* (1991) Liver dysfunction following splenectomy in idiopathic myelofibrosis: a study of 10 patients. *Acta Haematol* 85, 184–188.

87 Dubois A, Dauzat M, Pignodel C *et al.* (1993) Portal hypertension in lymphoproliferative and myeloproliferative disorders: hemodynamic and histological correlations. *Hepatology* 17, 246–250.

88 Alvarez-Larran A, Abraldes JG, Cervantes F *et al.* (2005) Portal hypertension secondary to myelofibrosis: a study of three cases. *Am J Gastroenterol* 100, 2355–2358.

89 Wanless IR, Peterson P, Das A *et al.* (1990) Hepatic vascular disease and portal hypertension in polycythemia vera and agnogenic myeloid metaplasia: a clinicopathological study of 145 patients examined at autopsy. *Hepatology* 12, 1166–1174.

90 Valla D, Casadevall N, Lacombe C *et al* (1985) Primary myeloproliferative disorders and hepatic vein thrombosis A prospective study of erythroid colony formation in vitro in 20 patients with Budd–Chiari syndrome *Ann Intern Med* 103, 329–334.

91 Cervantes F, Rozman C (1982) A multivariate analysis of prognostic factors in chronic myeloid leukemia. *Blood* 60, 1298–1304.

92 Ondreyco SM, Kjeldsberg CR, Fineman RM *et al.* (1981) Monoblastic transformation in chronic myelogenous leukemia: presentation with massive hepatic involvement. *Cancer* 48, 957–963.

93 Omata M, Johnson CS, Tong MS *et al.* (1986) Pathological spectrum of liver diseases of sickle cell disease. *Dig Dis Sci* 31, 247–256.

94 Bauer TMN, Moore GW, Hutchins GFM (1980) The liver in sickle cell disease. A clinicopathologic study of 70 patients. *Am J Med* 69, 833–837.

95 Pastore G, Tannoia N, Angarano G *et al.* (1983) Chronic viral hepatitis in thalassemic liver disease. A long-term study in patients with acute hepatitis with nontransfusion-dependent thalassemia minor. *Vox Sang* 44, 14–24.

96 Barry M, Flynn DM, Letsky EA *et al.* (1974) Long-term chelation therapy in thalassaemia major: effect on liver iron concentration, liver histology, and clinical progress. *Br Med J* 2 (5909), 16–20.

97 Grossman JA, McDermott WV Jr (1974) Paroxysmal nocturnal hemoglobinuria associated with hepatic and portal venous thrombosis. *Am J Surg* 127, 733–736.

98 Leibowitz AI, Hartmann RC (1981) The Budd-Chiari syndrome and paroxysmal nocturnal haemoglobinuria. *Br J Haematol* 48, 1–6.

99 Sobrino J, Llach J, Perez Ayuso R *et al.* (1987) Budd-Chiari syndrome as an early complication of paroxysmal nocturnal hemoglobinuria. Apropos of a case. *Med Clin (Barc)* 88, 773–775 (in Spanish).

100 Le Thi Huong D, Valla D, Franco D *et al.* (1995) Cholangitis associated with paroxysmal nocturnal hemoglobinuria: another instance of ischemic cholangiopathy? *Gastroenterology* 109, 1338–1343.

101 Rizzetto M, Morello C, Mannucci PM *et al.* (1982) Delta infection and liver disease in hemophilic carriers of hepatitis B surface antigen. *J Infect Dis* 145, 18–22.

102 Brettler DB, Alter HJ, Dienstag JL *et al.* (1990) Prevalence of hepatitis C virus antibody in a cohort of hemophilia patients. *Blood* 76, 254–256.

103 Rumi MG, Colombo M, Gringeri A *et al.* (1990) High prevalence of antibody to hepatitis C virus in multitransfused hemophiliacs with normal transaminase levels. *Ann Intern Med* 112, 379–380.

104 Franchini M (2004) Hepatitis C in haemophiliacs. *Thromb Haemost* 92, 1259–1268.

105 Hay CR, Preston FE, Triger DR *et al.* (1985) Progressive liver disease in haemophilia: an understated problem? *Lancet* 1(8444), 1495–1498.

106 Colombo M, Rumi MG (1984) Liver disease and pathology in hemophilia. *Scand J Haematol Suppl* 44, 341–348.

107 Aledort (1995) *Blood* 66, 67.

108 Mannucci PM, Ronchi G, Rota L *et al.* (1978) A clinicopathological study of liver disease in haemophiliacs. *J Clin Pathol* 31, 779–783.

109 Preston FE, Triger DR, Underwood JC *et al.* (1978) Percutaneous liver biopsy and chronic liver disease in haemophiliacs. *Lancet* 2 (8090), 592.

110 Mannucci PM, Schimpf K, Brettler DB *et al.* (1990) Low risk for hepatitis C in hemophiliacs given a high-purity, pasteurized factor VIII concentrate. International Study Group. *Ann Intern Med* 113, 27–32.

111 Schwartz RS, Abildgaard CF, Aledort LM *et al.* (1990) Human recombinant DNA-derived antihemophilic factor (factor VIII) in the treatment of hemophilia A. recombinant Factor VIII Study Group. *N Engl J Med* 323, 1800–1805.

112 Husa P, Roznovsky L, Smejkal P *et al.* (2005) Efficacy and safety of chronic hepatitis C treatment in hemophilic patients. *Hepatogastroenterol* 52, 1541–1544.

113 Casciato DA, Klein CA, Kaplowitz N *et al.* (1978) Aplastic anemia associated with type B viral hepatitis. *Arch Intern Med* 138, 1557–1558.

114 Gruber A, Grillner L, Norder H *et al.* (1993) Severe aplastic anemia associated with seronegative community-acquired hepatitis C virus infection. *Ann Hematol* 66, 157–159.

115 Pol S, Driss F, Devergie A *et al.* (1990) Is hepatitis C virus involved in hepatitis-associated aplastic anemia? *Ann Intern Med* 113, 435–437.

116 Hibbs JR, Frickhofen N, Rosenfeld SJ *et al.* (1992) Aplastic anemia and viral hepatitis. Non-A, Non-B, Non-C? *JAMA* 267, 2051–2054.

117 Langnas AN, Markin RS, Cattral MS *et al.* (1995) Parvovirus B19 as a possible causative agent of fulminant liver failure and associated aplastic anemia. *Hepatology* 22, 1661–1665.

118 Wong S, Young NS, Brown KE (2003) Prevalence of parvovirus B19 in liver tissue: no association with fulminant hepatitis or hepatitis-associated aplastic anemia. *J Infect Dis* 187, 1581–1586.

119 Bozkaya H, Yurdaydin C, Toruner M *et al.* (2002) Remission of severe aplastic anemia associated with hepatitis B virus infection after viral clearance: potential role of lamivudine. *Dig Dis Sci* 47, 1782–1785.

120 Bagheri SA, Boyer JL (1974) Peliosis hepatis associated with androgenic-anabolic steroid therapy. A severe form of hepatic injury. *Ann Intern Med* 81, 610–618.

121 Hernandez-Nieto L, Bruguera M, Bombi J *et al.* (1977) Benign liver-cell adenoma associated with long-term administration of an androgenic-anabolic steroid (methandienone). *Cancer* 40, 1761–1764.

122 Bozkaya H, Yurdaydin C, Toruner M *et al.* (2002) Remission of severe aplastic anemia associated with hepatitis B virus infection after viral clearance: potential role of lamivudine. *Dig Dis Sci* 47, 1782–1785.

123 Bhattacharyya M, Oakervee H, Dalley C *et al.* (2005) Hepatitis-associated aplastic anaemia treated successfully with antilymphocyte globulin. *Clin Lab Haematol* 27, 331–333.

124 Natkunam Y, Rouse RV (2000) Utility of paraffin section immunohistochemistry for C-KIT (CD117) in the differential diagnosis of systemic mast cell disease involving the bone marrow. *Am J Surg Pathol* 24, 81–91.

125 Yam LT, Yam CF, Li CY (1980) Eosinophilia in systemic mastocytosis. *Am J Clin Pathol* 73, 48–54.

126 Ghandur-Mnaymneh L, Gould E (1985) Systemic mastocytosis with portal hypertension. Autopsy findings and ultrastructural study of the liver. *Arch Pathol Lab Med* 109, 76–78.

127 Narayanan MN, Liu Yin JA, Azzawi S *et al.* (1989) Portal hypertension and ascites in systemic mastocytosis. *Postgrad Med J* 65, 394–396.

128 Baron TH, Koehler RE, Rodgers WH *et al.*(1995) Mast cell cholangiopathy: another cause of sclerosing cholangitis. *Gastroenterology* 109, 1677–1681.

129 Wendum D, Prevot S, Poujol-Robert A *et al.* (2004) Liver involvement revealing systemic mastocytosis: report of two cases. *Gastr Clin Biol* 28, 80–83 (in French).

130 McIntosh RM, Koss MN, Gocke KJ (1976) The nature and incidence of cryoproteins in hepatitis B antigen (HbsAg) positive patients. *Q J Med* 45, 23–38.

131 Levo Y, Gorevic PD, Kassab HJ *et al.* (1977) Association between hepatitis B virus and essential mixed cryoglobulinemia. *N Engl J Med* 296, 1501–1504.

132 Popp (1990) *Ann Int Med* 92, 379.

133 Ferri C, Greco F, Longombardo G *et al.* (1991) Antibodies to hepatitis C virus in patients with mixed cryoglobulinemia. *Arthritis Rheum* 34, 1606–1610.

134 Agnello V, Chung RT, Kaplan LM (1992) A role for hepatitis C virus infection in type II cryoglobulinemia. *N Engl J Med* 327, 1490–1495.

135 Misiani R, Bellavita P, Fenili D *et al.* (1992) Hepatitis C virus infection in patients with essential mixed cryoglobulinemia. *Ann Intern Med* 117, 573–577.

136 Marcellin P, Descamps V, Martinot-Peignoux M *et al.* (1993) Cryoglobulinemia with vasculitis associated with hepatitis C virus infection. *Gastroenterology* 104, 272–277.

137 Lunel F, Musset L, Cacoub P *et al.* (1994) Cryoglobulinemia in chronic liver diseases: role of hepatitis C virus and liver damage. *Gastroenterology* 106, 1291–1300.

138 Pawlotsky JM, Ben Yahia M, Andre C *et al.* (1994) Immunological disorders in C virus chronic active hepatitis: a prospective case-control study. *Hepatology* 19, 841–848.

139 Misiani R, Bellavita P, Fenili D *et al.* (1994) Interferon alfa-2a therapy in cryoglobulinemia associated with hepatitis C virus. *N Engl J Med* 330, 751–756.

20.8 The liver in graft-vs.-host disease

Enric Carreras, Carmen Martínez and Miguel Bruguera

Introduction

Graft-vs.-host disease (GVHD) is not a disease *per se*. It is the consequence of a physiological inflammatory response of donor immunocompetent cells when introduced in a foreign environment. This undesired response can be observed after any transplantation of organs and tissues containing immunocompetent cells [1].

Allogeneic haematopoietic stem cell transplantation (HSCT) is a clinical situation with a high risk of developing GVHD, which is the major complication in HSCT. With the haematopoietic transplant, large quantities of donor lymphocytes are introduced into a severely immunodepressed foreign host with an increased expression of adhesion molecules, cytokines and cell surface recognition molecules. Additionally, after engraftment, haematopoietic stem cells perpetuate the production of a population of lymphocytes that can continue recognizing host tissues as foreign [2–4].

Timing, incidence, clinical manifestations and severity of GVHD after HSCT are extremely variable depending on several patient-, donor- and transplant-related factors (Table 1). We use the term acute GVHD (aGVHD) to describe a distinctive syndrome of dermatitis, hepatitis and enteritis. Usually, these manifestations appear soon after HSCT (within the first 100 days). The term chronic GVHD (cGVHD) describes a more polymorphic syndrome resembling an autoimmune disease that classically develops after day 100 [4]. Nowadays, despite this classical description, we know that it is not exceptional for

Table 1 Risk factors for acute and chronic graft-vs.-host disease after HSCT.

Risk factor	Factors associated with higher risk of GVHD
Acute graft-vs.-host disease	
Donor/recipient HLA match	Antigen mismatch > allelic mismatch > full match
Type of donor	Unrelated > other relatives > sibling > twin
Donor sensitization	Female with previous pregnancies or transfused donors
Donor/recipient sex match	Female to male > other combinations
Conditioning regimen	Myeloablative > RIC
Source of progenitors	Peripheral blood[a] > bone marrow > cord blood
T cells of the inoculum	Unmanipulated inoculum > TCD
GvHD prophylaxis	No prophylaxis > CsA or MTX > CsA + MTX > TCD
Protective environment	Non-LAF > LAF (only in severe aplastic anaemia)
GI decontamination	None > selective > total
Chronic graft-vs.-host disease	
Donor/recipient HLA match	Antigen mismatch > allelic mismatch > match
Acute GvHD	Present > absent
Patient age	Older > younger
Source of progenitors	Peripheral blood > bone marrow > cord blood
Donor lymphocyte infusion	Administered > not administered
CMV serology	Positive > negative

[a]Only in some studies.
TCD, T-cell depletion; CsA, ciclosporin A; MTX, methotrexate; LAF, laminar air flow; GI, gastrointestinal; RIC, reduced intensity conditioning; HLA, human leukocyte antigen; CMV, cytomegalovirus.

aGVHD to appear after day 100 and for cGVHD to appear before this date. The use of T lymphocyte-depleted (TCD) grafts, reduced-intensity conditioning regimens (RIC) and donor lymphocyte infusions (DLI) for treating mixed chimaeras and relapses after HSCT are the main causes of this change [5–8].

Acute graft-vs.-host disease

Pathogenesis [2,3]

The earliest phase of aGVHD starts before the donor cells are infused into the recipient. The chemoradiotherapy used as a conditioning regimen to eradicate the population of abnormal cells causing the disease and to immunosuppress the recipient to overcome graft rejection damages and activates host tissues. Activated host cells secrete proinflammatory cytokines such as tumour necrosis factor alpha (TNFα) and interleukin-1 (IL-1), among others. These inflammatory cytokines increase the expression of adhesion molecules, co-stimulatory molecules and major histocompatibility complex antigens. This increased expression is critical for the activation of host dendritic cells (DCs) and other host antigen-presenting-cells (APCs), necessary for the initiation of primary and secondary immune responses. This process explains why patients receiving intensive conditioning have a higher incidence of aGVHD than those treated with a RIC [6,7]. Similarly, if the infusion of donor cells is delayed until the resolution of tissue injury, the risk of aGVHD is lower [9].

The second phase of aGVHD consists of donor T-cell interaction with APCs and their consequent activation, proliferation and differentiation. APCs can be activated by TNFα and IL-1 but also by microbial products [as lipopolysaccharide (LPS), peptidoglycans and other components of bacteria], which enter into the systemic circulation from the damaged intestinal mucosa and necrotic cells damaged during conditioning [10]. Alloantigen presentation induces activation of individual T cells [mainly T-helper 1 (Th1) subset] and the production of a second step on the cytokine cascade. The main Th1 cytokines (IL-2 and interferon-γ) seem to play a major role in further T-cell activation, induction of cytotoxic T lymphocytes (CTLs) and natural killer cells (NK), and priming donor and residual host monocytes and macrophages to produce more TNFα and IL-1. That is the reason why ciclosporin and tacrolimus, inhibitors of IL-2 production, and monoclonal antibodies against IL-2 receptor are effective agents for GVHD prophylaxis and treatment [11,12].

The third phase, or target tissue destruction phase, is less well known but seems to be mediated by cellular effectors such as CTLs and NK cells, and local injury of inflammatory effectors such as TNFα, IL-1 and nitric oxide. These effector cells lyse target cells through two mechanisms: the Fas/Fas ligand (mostly used by CD4+ CTLs) and the perforin/granzyme (mostly used by CD8+ CTLs) pathways [13,14]. TNFα and IL-2 can also be produced, in addition to the previously mentioned sources, by monocytes and macrophages stimulated by microbial products from intestinal mucosa or skin damaged by the conditioning regimen [9]. In this phase, TNFα recruits effector T cells, neutrophils and monocytes in the target organs and produces direct tissue damage by inducing apoptosis and necrosis. The role of TNFα in aGVHD pathogenesis is suggested by the increased levels observed in patients with aGVHD and by its inhibition after the infusion of anti-TNFα monoclonal antibodies [15,16]. Despite an evident participation in this third phase of aGVHD development, the exact role of IL-2 and nitric oxide is not well understood. Similarly, the exact role for donor CD4+ CD25+ T cells (regulatory T cells) is not well known, but there is evidence that the balance between these cells and CD4+ C25– T cells determines the outcome of aGVHD [17].

An intriguing aspect of aGVHD is why this reaction is limited to gut, liver and skin when other organs are also susceptible to allogeneic cellular injury. A possible explanation could be that all of them share an extensive exposure to the previously mentioned endotoxin and other microbial products that can trigger and amplify local inflammation. As first barriers to infection, these organs have large populations of professional APCs such as DCs that may enhance graft-vs.-host reaction [3]. The impact of APCs in hepatic recruitment of alloreactive donor CD8+ T cells and subsequent development of aGVHD has been demonstrated recently in animal models [18]. These models suggest that macrophage inflammatory protein-1 induces migration of CCR5-expressing CD8+ T cells into portal areas [19]. The analysis of gene expression of the liver after experimental HSCT also shows an increased expression of genes associated with the attraction and activation of T cells induced by TNFγ early after transplantation [20]. Finally, during hepatic GVHD, Fas expression on bile duct epithelial cells is upregulated, and the administration of an anti-Fas ligand significantly blocks the hepatic damage in murine models, indicating that Fas ligand-mediated cytotoxicity plays a central role in hepatic GVHD [21,22].

Clinical aspects

The incidence of aGVHD ranges from 5% to 80% depending on the presence or absence of the variables mentioned in Table 1 [4]. In patients receiving a myeloablative HSCT with conventional GVHD prophylaxis, aGVHD usually starts after day 15, simultaneously with haematopoietic engraftment. Hepatic aGVHD usually follows manifestations of dermal and/or intestinal GVHD. Despite that, nowadays, it is not infrequent to observe liver or intestinal abnormalities as first (or unique) manifestations of aGVHD [4,23].

The most usual and characteristic clinical manifestation of dermal aGVHD is a cutaneous maculopapular exanthema. Lesions may be pruritic or painful and red to violaceous in colour, and usually involve palms and soles. In severe forms, skin lesions can include generalized erythroderma and epidermal necrosis. Gastrointestinal manifestations of distal small bowel and colon include profuse diarrhoea, intestinal bleeding, crampy abdominal pain and ileus. In its proximal or enteric

Table 2 Staging and grading of acute graft-vs.-host disease.

Target organ	Stage	Clinical characteristics
Skin	+	Maculopapular rash < 25% body surface
	++	Maculopapular rash 25–50% body surface
	+++	Generalized erythroderma
	++++	Generalized erythroderma with desquamation and bullae
Liver	+	Bilirubin 2–3 mg/dL
	++	Bilirubin 3.1–6 mg/dL
	+++	Bilirubin 6.1–15 mg/dL
	++++	Bilirubin > 15 mg/dL
Gut	+	Diarrhoea 500–1000 mL/day or persistent nausea
	++	Diarrhoea 1000–1500 mL/day
	+++	Diarrhoea > 1500 mL/day
	++++	Abdominal pain with or without intestinal ileus

Overall grade	Stage skin		Stage liver		Stage gut	FI
Grade 0	0		0		0	0
Grade I	+ to ++	and	0	and	0	0
Grade II[a]	+ to +++	and	+	and/or	+	+
	+++			or	+ gastric biopsy	
Grade III	++ to +++	and	++ to +++	and/or	++ to +++	++
Grade IV	++ to ++++	and	++ to ++++	and/or	++ to ++++	+++

[a]Generalized erythroderma and proximal gastrointestinal GVHD are also considered grade II GVHD.
FI, functional impairment.

form, gut GVHD is characterized by anorexia and dyspepsia. Hepatic GVHD is characterized by a gradual rise in serum bilirubin and alkaline phosphatase (AP) levels up to 20 times the upper normal level and aminotransferases up to 10 times the normal levels, but usually the rise in serum bilirubin greatly exceeds serum enzyme levels [23]. Clinical data of hepatocellular failure are unusual. The most characteristic system for staging and grading aGVHD is shown in Table 2.

Cholestasis after HSCT can be attributable to many causes (Table 3), and its differential diagnosis could be complex due to the difficulty in obtaining liver samples in the early phase after HSCT (see later). Occasionally, the presentation of hepatic aGVHD can simulate an acute hepatitis. This has been observed mainly after DLI or after discontinuing immunosuppression [24,25].

Table 3 Causes of cholestasis after HSCT.

Drug toxicity (methotrexate, ciclosporin, tacrolimus)
Sepsis (cholangitis lenta)
Veno-occlusive disease (sinusoidal obstruction syndrome)
Acute graft-vs.-host disease
Parenteral nutrition
Biliary sludge syndrome
Bacterial, fungal and viral infections of the liver
Cholecystitis
Nodular regenerative hyperplasia
Chronic graft-vs.-host disease
Extrahepatic biliary obstruction

Pathological findings

In the liver, aGVHD is characterized by portal hepatitis, non-suppurative destructive cholangitis, cholestasis and endotheliitis. In both experimental and clinical settings, histopathological and ultrastructural studies demonstrate that the small interlobular and marginal bile ducts at the periphery of the portal spaces are the preferential targets of the alloimmune reaction [26]. Characteristic liver biopsy findings of aGVHD include lymphocytic infiltration of small bile ducts with nuclear pleomorphism and epithelial cell dropout. Owing to the immunosuppression of these patients, the inflammatory infiltration can be minimal. Parenchymal changes are usually minimal and less specific for GVHD, but include scattered acidophilic bodies, lobular disarray and centrolobular cholestasis (Fig. 1). If liver biopsy is performed during the first 2 weeks after aGVHD development, the biopsy may be non-diagnostic. In cases of hepatic aGVHD with a hepatitic onset, the predominant histology is one of lobular inflammation, but there are usually abnormalities in small bile ducts characteristic of aGVHD [24,27]. Recently, an extended histological analysis showed that a high level of lobular inflammation and a low level of hepatocyte ballooning were independently favourable prognostic factors for transplant-related mortality, indicating that liver biopsy can be useful not

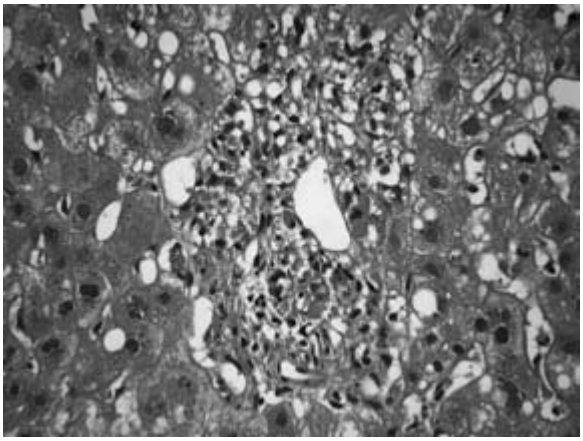

Fig. 1 Acute graft-vs.-host disease. A portal tract shows oedema and a mild inflammatory infiltrate composed of lymphocytes and eosinophils. The interlobular bile duct has a very small lumen because of the vacuolization of the cytoplasm of cholangiocytes.

only to exclude other causes of liver injury, but also to predict clinical outcome [28].

Treatment

Treatment of aGVHD of the liver usually involves the addition of methylprednisolone (2 mg/kg/day) to the prophylactic immunosuppressive regimen already given [4]. A large retrospective analysis from the Seattle group showed that only 30% of patients with liver disease had resolution of liver abnormalities after the first-line treatment and that, in more than 30% of cases, the response could not be evaluated due to another concomitant liver disease [29]. The second-line treatment only improved or resolved an additional 25% of patients; the remaining progress to cGVHD [30]. More than 50% of patients without evidence of aGVHD will eventually develop *de novo* cGVHD, which may be seen as early as 40–50 days after HSCT [4,23].

Chronic graft-vs.-host disease

Pathogenesis [3,23,31]

Chronic GVHD is considered to be an autoimmune disease because of its similarities to various autoimmune disorders. In animal models of cGVHD, T cells are considered autoreactive because they recognize common class II molecule determinants rather than polymorphic major or minor histocompatibility antigens. In these models, T cells produce unusual patterns of cytokines, such as IL-4 or interferon-γ in the absence of IL-2. These cytokines may stimulate collagen production by fibroblasts [3]. In both experimental and clinical studies of cGVHD, thymic atrophy, lymphocyte depletion and loss of epithelial secretory function are observed. The autoreactive cells of cGVHD are associated with an impaired capacity of the thymus to delete autoreactive T cells and induce tolerance. This thymic damage may be a consequence of the direct toxicity of the conditioning regimen or the thymic injury caused by aGVHD [32].

Clinical aspects

The incidence of cGVHD ranges from 30% in human leukocyte antigen (HLA)-identical sibling transplants to 80% in one-antigen mismatch unrelated transplants [4]. In addition to HLA, prior aGVHD, patient age and the use of peripheral blood stem cells for transplantation are the most important factors related to an increased risk of cGVHD (Table 1) [33,34,35].

Onset of cGVHD can occur as early as 40–50 days after transplantation, but the median time for its appearance after an HLA-identical sibling HSCT is around day 150, usually while tapering or stopping immunosuppression. Chronic GVHD beyond the first year is exceptional (< 5%) unless a DLI has been carried out [4,31,36].

Chronic GVHD can be classified according to the type of onset, staging and mortality risk. The majority of patients with cGVHD have had prior aGVHD. In these cases, cGVHD can evolve directly from aGVHD (progressive; 20–30%) or reappear after a period of clinical resolution (quiescent; 30–40%). Patients can develop cGVHD with no history of prior aGVHD (*de novo*; 30–40%) [31]. For cGVHD staging, the most commonly used system is the limited/extensive classification. This classification, based on clinical and histological criteria, has been revised recently to clarify some ambiguities in the original classification (Table 4). Usually, patients with limited cGVHD do not require systemic treatment, whereas those with extensive disease do [31]. Finally, several scales have been developed to evaluate the mortality risk of patients with cGVHD. The Hopkins model, validated with patients from the Nebraska, Seattle and Minnesota teams, stratifies patients according to the presence or absence of extensive skin involvement, thrombocytopenia ($< 100 \times 10^9$ cells/L) and a progressive clinical onset [37].

Chronic GVHD can affect several organs with skin and liver being the most frequently observed. Skin involvement can be focal or generalized in the form of erythema, maculopapular rash, lichen planus-like lesions, scleroderma, hyperkeratosis and desquamation, patchy hypo- and hyperpigmentation, alopecia and nail loss, among others. Liver involvement is manifested by a cholestasis resembling primary biliary cirrhosis. Other anatomical areas that can also be affected by cGVHD are exocrine glands (ocular, oral and vaginal sicca syndrome), squamous epithelium (affecting the mouth, oesophagus and genital tract), neuromuscular system (myasthenia gravis, polymyositis) and lungs (obliterative bronchiolitis) [4,23].

Liver involvement is present in 80% of patients with cGVHD and frequently follows aGVHD [23]. The most characteristic manifestation is a slowly progressive cholestasis with an increase in serum AP, γ-glutamyltransferase and bilirubin. Serum aminotransferase levels may also be slightly elevated. Evolution to cirrhosis seems to be exceptional if a viral infection does not

Table 4 Original and revised classification of chronic graft-vs.-host disease.

Original Seattle classification	Revised classification
Limited chronic GVHD	
Localized skin involvement	Oral abnormalities consistent with cGVHD[a]
Hepatic dysfunction due to GVHD	Mild liver test abnormalities[a,b]
	< Six papulosquamous plaques, macular–papular or liquenoid rash involving < 20% BSA, dyspigmentation involving < 20% BSA; or erythema involving < 50% BSA[a]
	Ocular sicca (Schirmer's test < 5 mm with no more than minimal ocular symptoms)[a]
	Vaginal or vulvar abnormalities[a]
Extensive chronic GVHD	
Any documented manifestation of cGVHD beyond limited cGVHD, including:	
Karnofsky or Lansky clinical score < 60%	
≥ 15% weight loss	
recurrent infections not due to other causes, with biopsy documentation of cGVHD in any organ	

BSA, body surface area.
[a]With a positive skin or lip biopsy and no other manifestations of cGVHD.
[b]Alkaline phosphatase ≤ twice the upper limit of normal, aspartate aminotransferase or alanine aminotransferase ≤ three times the upper limit of normality and total bilirubin ≤ 1.6.

coexist [38]. Recently, a hepatitic variant of cGVHD has been described. It usually appears in patients without or with minimal immunosuppression, or after receiving DLI, who present an acute hepatitis with aminotransferase levels of more than 2000 UI [23,24,27]. In these cases, a liver biopsy is essential to make a correct diagnosis.

Pathological findings

Histological features of cGVHD of the liver include lymphocytic infiltration of portal tracts, degeneration and destruction of small bile ducts, periportal fibrosis, cholestasis, piecemeal necrosis and hepatocyte degeneration (Fig. 2) [23,26]. In its hepatitic form, a panlobular hepatitis is seen histologically. As some of these features can also be observed in chronic hepatitis C virus (HCV) infection, histological differential diagnosis may be difficult [39]. In longstanding cGVHD of the liver, the only histological abnormality can be a vanishing bile duct syndrome [40].

Fig. 2 Chronic graft-vs.-host disease. A small portal tract with fibrosis but without inflammation, lacking a bile duct.

Treatment

Treatment of extensive forms of cGVHD requires immunosuppressive treatment (corticosteroids, antithymocyte globulin, azathioprine, ciclosporin, thalidomide, mofetil mycophenolate) associated with an active antimicrobial prophylaxis [31]. Ursodeoxycholic acid, in conjunction with standard immunosuppression, may be useful in treating hepatic cGVHD [41]. It has been suggested that ursodiol reduces class I HLA expression, a target for CD8+ T cells, on hepatocytes [42]. In some cases of severe cGVHD, liver transplantation has been performed successfully [43].

Clinical approach to the patient with cholestasis after HSCT

The differential diagnosis between the possible aetiologies causing cholestasis after HSCT (Table 3) can be extremely difficult. The presence or absence of some clinical, laboratory or imaging data can be useful when carefully evaluated (Table 5). Despite that, in most cases, the definitive diagnosis can only be established after a liver biopsy is performed. Liver biopsy is not usually required when hepatic abnormalities consistent with GVHD are associated with skin or intestinal involvement confirmed by

Table 5 Differential diagnosis of a cholestasis appearing after HSCT.

Aspect evaluated	Finding	Consider
Day of onset	Before day +5[a]	Drug toxicity
		Severe VOD
	From +5 to engraftment	Mild–moderate VOD[b]
		Sepsis
		Haemolysis
	After engraftment (days +15 to +50)	Acute GVHD[b]
		Fungal/viral infection
		TPN/biliary sludge
	Between days +60 and +100	Acute GVHD
		Fungal/viral infection
		Early chronic GVHD
	After day +100	Chronic GVHD
		Fungal/viral infection
		Nodular regenerative hyperplasia
		Extrahepatic biliary obstruction
Clinical manifestations	Weight gain, oedemas, ascites, painful hepatomegaly	VOD
	Fever during neutropenia	Sepsis
	Prolonged TPN	Sludge
	Skin rash, non-infectious diarrhoea	Acute GVHD
	Persistent fever despite antibiotics and neutropenia recovery	Fungal/viral infection
	Skin lesions, sicca syndrome	Chronic GVHD
Laboratory findings	Increased PAI-1	VOD
	↑ Bilirubin, normal AP	CsA toxicity
	↑↑↑ Bilirubin, ↑ AP	Cholestasis of sepsis
	Normal bilirubin, ↑ AP	Hepatosplenic candidiasis
	Cholestasis + ↑ ALT/AST	Viral hepatitis
		Hepatitic form of GVHD
	Positive blood cultures	Sepsis
		Hepatosplenic candidiasis
	CMV antigenaemia +	CMV infection
Imaging tests	Ascites, gallbladder wall thickening, reverse portal flow	VOD
	Nodules	Hepatosplenic candidiasis, nodular regenerative hyperplasia, other infectious or tumoral causes
Hemodynamic studies	HVPG > 15 mmHg	Severe VOD
	HVPG > 10 mmHg	VOD[b]
		Chronic liver disease
	HVPG < 10 mmHg	Other than VOD

[a]Considering day O as the day of HSCT.
[b]Occasionally VOD and aGVHD can coexist [45].
ALT, alanine aminotransferase; AST, aspartate aminotransferase; AP, alkaline phosphatase; VOD, veno-occlusive disease; CsA, ciclosporin A; CMV, cytomegalovirus; HVPG, hepatic venous pressure gradient; TPN, total parenteral nutrition.

biopsy. In the remaining cases, especially if an aggressive therapeutic approach is planned for its treatment, liver biopsy will be necessary. Percutaneous or laparoscopic needle biopsies have a high risk of bleeding during the thrombocytopenic phase after HSCT [44]. In these cases, a transvenous liver biopsy through the jugular vein can be obtained successfully despite very low platelet counts [45]. This approach, when performed by an adequately trained hepatic haemodynamist, permits one to measure the hepatic venous pressure gradient (a useful datum for differential diagnosis) and to obtain adequate liver samples [45,46]. However, samples obtained by this method, in spite of being excellent for veno-occlusive disease diagnosis, frequently have a low number of portal tracts, making the diagnosis of GVHD difficult [45]. Additionally, the sensitivity and specificity of liver biopsy in GVHD diagnosis may also be considered. Liver biopsy is not a sensitive procedure in the early phases (showing a mild lobular hepatitis), and bile duct abnormalities are not specific to this complication [39].

The most relevant entities to include in differential diagnosis are as follows.

Veno-occlusive disease of the liver (VOD)

This complication, also labelled sinusoidal obstruction syndrome because of its pathogenesis, is one of the most common causes of hepatic dysfunction after HSCT. It usually appears early after conditioning (within the first 21 days), but some cases have been reported after day +30 in patients receiving an association of alkylating agents as a conditioning regimen [47]. Classically, the diagnosis of VOD is accepted when jaundice, painful hepatomegaly and unexplained weight gain associated or not with ascites appear soon after HSCT [48]. In cases of VOD that appear after day +14, the differential diagnosis with aGVHD can be difficult, especially as both pathologies may coexist [45]. The presence of fluid retention, ascites or oedemas and the absence of data for aGVHD in other target organs are very useful in ruling out a GVHD diagnosis.

Drug toxicity

Several drugs commonly used for HSCT can produce cholestasis. The most frequent are ciclosporin, tacrolimus, methotrexate, estrogens, erythromycin and other macrolides, some antifungal agents (azoles) and total parenteral nutrition. Their differential diagnosis with other causes of cholestasis may be difficult. The detection of increased bilirubin levels with normal AP levels as well as high levels of parent drug and/or their metabolites can be useful for suspecting ciclosporin or tacrolimus toxicity. In the remaining cases, the diagnosis may be established by exclusion or by means of a liver biopsy.

Cholangitis of sepsis

Its most frequent presentation is a sudden elevation in serum bilirubin disproportionate to elevation of AP in a febrile patient with clinical evidence of sepsis. Apparently, the cause of cholestasis in these patients is a marked impairment of basolateral bile salt transporters and canalicular organic anion transporters mediated by endotoxins [23]. The diagnosis should be based on clinical data as liver biopsies only show a minimal and non-specific intrahepatic cholestasis [49].

Fungal infections

Usually, invasive fungal infections produce systemic clinical manifestations in addition to fever that permit one to establish a correct diagnosis. Only *Candida* spp. can reach the liver by traversing the intestinal mucosa, producing fungal abscesses in the liver. This diagnosis can be suspected in a patient with persistent fever and increasing AP levels during the phase of neutrophil recovery. However, the systematic use of prophylactic fluconazole in HSCT has dramatically reduced the incidence of this complication. Blood cultures, panfungal polymerase chain reaction, magnetic resonance, computerized tomography and ultrasonography can be useful in achieving the correct diagnosis [50,51].

Viral infections

They do not usually represent a problem in differential diagnosis with GVHD because of the characteristic increase in serum aminotransferase levels. Despite that, it is always necessary to remember that some GVHD can have a hepatitic form. These cases are usually seen after DLI or when stopping immunosuppression. In this situation, only serological and molecular viral analysis and the liver biopsy allow for a correct diagnosis [23,24,27]. To differentiate cGVHD from chronic viral hepatitis can be difficult because bile duct damage may be seen in both cases [39].

Nodular regenerative hyperplasia

Nodular transformation of the liver is probably a consequence of intrahepatic vascular damage related to cytoreductive therapy. This complication has been described in many clinical situations other than HSCT. As these nodules produce portal hypertension, their clinical manifestations are similar to those observed in VOD but develop after day +100. Pathology is characterized by nodules of regeneration not encircled by fibrosis, limited by hepatocellular plates separated by dilated sinusoids. Differential diagnosis with cGVHD should be based on clinical manifestations and histological features [23,52]. Owing to their limited size, transvenous liver biopsies are not usually useful in establishing this diagnosis [45].

Total parenteral nutrition (TPN)/biliary sludge

TPN can cause mild increases in AP, bilirubin and transaminases that usually reverse promptly when TPN is stopped. Histological abnormalities include steatosis, steatohepatitis and cholestasis. When these aetiologies are suspected, stopping, reducing or changing the composition or timing of administration should be considered [23,53]. Additionally, TPN can contribute to biliary sludge and gallstone development.

Biliary sludge is extremely common in HSCT (100% of cases at autopsy) and can easily be demonstrated by ultrasound. Although it is usually asymptomatic, it has occasionally been related to abnormal liver enzymes and acute acalculous cholecystitis and pancreatitis after HSCT [23,54,55].

References

1 Ferrara JL, Deeg HJ (1991) Graft-versus-host disease. *N Engl J Med* 7, 667–674.

2 Ferrara JL, Cooke KR, Teshima T (2003) The pathophysiology of acute graft-versus-host disease. *Int J Hematol* 78, 181–187.

3 Ferrara JLM, Antin JH (1999) The pathophysiology of graft-versus-host. In: Thomas ED, Blume KG, Forman SJ (eds) *Hematopoietic Cell Transplantation*, 2nd edn. Cambridge, MA: Blackwell Science, pp. 305–315.

4 Sullivan KM (1999) Graft-versus-host disease. In: Thomas ED, Blume KG, Forman SJ (eds) *Hematopoietic Cell Transplantation*, 2nd edn. Cambridge, MA: Blackwell Science, pp. 515–536.

5 Urbano-Ispizua A, Brunet S, Solano C *et al.* (2001) Allogeneic transplantation of CD34+-selected cells from peripheral blood in patients with myeloid malignancies in early phase: a case control comparison with unmodified peripheral blood transplantation. *Bone Marrow Transplant* 28, 349–354.

6 Lowsky R, Takahashi T, Liu YP *et al.* (2005) Protective conditioning for acute graft-versus-host disease. *N Engl J Med* 353, 1321–1331.

7 Pérez-Simón JA, Díez-Campelo M, Martino R *et al.* (2005) Influence of the intensity of the conditioning regimen on the characteristics of acute and chronic graft-versus-host disease after allogeneic transplantation. *Br J Haematol* 130, 394–403.

8 Ma SY, Au WY, Lie AK *et al.* (2004) Liver graft-versus-host disease after donor lymphocyte infusion for relapses of hematologic malignancies post allogeneic hematopoietic stem cell transplantation. *Bone Marrow Transplant* 34, 57–61.

9 Johnson BD, Truitt RL (1995) Delayed infusion of immunocompetent donor cells after bone marrow transplantation breaks graft-host tolerance allows for persistent antileukemic reactivity without severe graft-versus-host disease. *Blood* 85, 3302–3312.

10 Hill GR, Ferrara JL (2000) The primacy of the gastrointestinal tract as a target organ of acute graft-versus-host disease: rationale for the use of cytokine shields in allogeneic bone marrow transplantation. *Blood* 95, 2754–2759.

11 Bierer BE, Hollander G, Fruman D *et al.* (1993) Cyclosporin A and FK506: molecular mechanisms of immunosuppression and probes for transplantation biology. *Curr Opin Immunol* 5, 763–773.

12 Belanger C, Esperou-Bourdeau H, Bordigoni P *et al.* (1993) Use of an anti-interleukin-2 receptor monoclonal antibody for GVHD prophylaxis in unrelated donor BMT. *Bone Marrow Transplant* 11, 293–297.

13 Kagi D, Vignaux F, Ledermann B *et al.* (1994) Fas and perforin pathways as major mechanisms of T cell-mediated cytotoxicity. *Science* 265, 528–530.

14 Graubert TA, DiPersio JF, Russell JH *et al.* (1997) Perforin/granzyme-dependent and independent mechanisms are both important for the development of graft-versus-host disease after murine bone marrow transplantation. *J Clin Invest* 100, 904–911.

15 Schmaltz C, Alpdogan O, Muriglan SJ *et al.* (2003) Donor T cell-derived TNF is required for graft-versus-host disease and graft-versus-tumor activity after bone marrow transplantation. *Blood* 101, 2440–2445.

16 Cooke KR, Hill GR, Gerbitz A *et al.* (2000) Tumor necrosis factor-alpha neutralization reduces lung injury after experimental allogeneic bone marrow transplantation. *Transplantation* 70, 272–279.

17 Johnson BD, Konkol MC, Truitt RL (2002) CD25+ immunoregulatory T-cells of donor origin suppress alloreactivity after BMT. *Biol Blood Marrow Transplant* 8, 525–535.

18 Zhang Y, Shlomchik WD, Joe G *et al.* (2002) APCs in the liver and spleen recruit activated allogeneic CD8+ T cells to elicit hepatic graft-versus-host disease. *J Immunol* 169, 7111–7118.

19 Murai M, Yoneyama H, Harada A. *et al.* (1999) Active participation of CCR5(+)CD8(+) T lymphocytes in the pathogenesis of liver injury in graft-versus-host disease. *J Clin Invest* 104, 49–57.

20 Ichiba T, Teshima T, Kuick R *et al.* (2003) Early changes in gene expression profiles of hepatic GVHD uncovered by oligonucleotide microarrays. *Blood* 102, 763–771.

21 Ueno Y, Ishii M, Yahagi K *et al.* (2000) Fas-mediated cholangiopathy in the murine model of graft versus host disease. *Hepatology* 4, 966–974.

22 Hattori K, Hirano T, Miyajima H *et al.* (1998) Differential effects of anti-Fas ligand and anti-tumor necrosis factor alpha antibodies on acute graft-versus-host disease pathologies. *Blood* 91, 4051–4055.

23 Strasser SI, McDonald GB (2003) Hepatobiliary complications of hematopoietic cell transplantation. In: Shiff ER, Sorrell MF, Maddrey WC (eds) *Schiff's Diseases of the Liver*, 9th edn. Philadelphia, PA: Lippincott, pp. 1635–1663.

24 Akpek G, Boitnott JK, Lee LA *et al.* (2002) Hepatitic variant of graft-versus-host disease after donor lymphocyte infusion. *Blood* 100, 3903–3907.

25 Fujii N, Takenaka K, Shinagawa K *et al.* (2001) Hepatic graft-versus-host disease presenting as an acute hepatitis after allogeneic peripheral blood stem cell transplantation. *Bone Marrow Transplant* 27, 1007–1010.

26 Sale GE, Shulman HM, Hackman RC (1999) Pathology of hematopoietic cell transplantation. In: Thomas ED, Blume KG, Forman SJ (eds) *Hematopoietic Cell Transplantation*, 2nd edn. Cambridge, MA: Blackwell Science, pp. 248–263.

27 Strasser SI, Shulman HM, Flowers ME *et al.* (2000) Chronic graft-versus-host disease of the liver: presentation as an acute hepatitis. *Hepatology* 32, 1265–1271.

28 Duarte RF, Delgado J, Shaw BE *et al.* (2005) Histologic features of the liver biopsy predict the clinical outcome for patients with graft-versus-host disease of the liver. *Biol Blood Marrow Transplant* 10, 805–813.

29 Martin PJ, Schoch G, Fisher L *et al.* (1990) A retrospective analysis of therapy for acute graft-versus-host disease: initial treatment. *Blood* 76, 1464–1472.

30 Martin PJ, Schoch G, Fisher L *et al.* (1991) A retrospective analysis of therapy for acute graft-versus-host disease: secondary treatment. *Blood* 77, 1821–1828.

31 Lee SJ, Vogelsang G, Flowers ME (2003) Chronic graft-versus-host disease. *Biol Blood Marrow Transplant* 9, 215–233.

32 Komanduri KV (2002) Thymic function and allogeneic T-cell responses in stem-cell transplantation. *Cytotherapy* 4, 333–342.

33 Atkinson K, Horowitz MM, Gale RP *et al.* (1990) Risk factors for chronic graft-versus-host disease after HLA-identical sibling bone marrow transplantation. *Blood* 75, 2459–2464.

34 Ochs LA, Miller WJ, Filipovich AH *et al.* (1994) Predictive factors for chronic graft-versus-host disease after histocompatible sibling donor bone marrow transplantation. *Bone Marrow Transplant* 13, 455–460.

35 Akpek G, Zahurak ML, Piantadosi S *et al.* (2001) Development of a prognostic model for grading chronic graft-versus-host disease. *Blood* 97, 1219–1226.

36 Loughran TP Jr, Sullivan K, Morton T *et al.* (1990) Value of day 100 screening studies for predicting the development of chronic graft-versus-host disease after allogeneic bone marrow transplantation. *Blood* 76, 228–234.

37 Akpek G, Lee SJ, Flowers ME *et al.* (2003). Performance of a new clinical grading system for chronic graft-versus-host disease: a multicenter study. *Blood* 102, 802–809.

38 Strasser SI, Sullivan KM, Myerson D *et al.* (1999) Cirrhosis of the liver in long-term marrow transplant survivors. *Blood* 93, 3259–3266.

39 Shulman HM, Sharma P, Amos D *et al.* (1988) A coded histologic study of hepatic graft-versus-host disease after human bone marrow transplantation. *Hepatology* 8, 463–470.
40 Yeh KH, Hsieh HC, Tang JL *et al.* (1994) Severe isolated acute hepatic graft-versus-host disease with vanishing bile duct syndrome. *Bone Marrow Transplant* 14, 319–321.
41 Erlinger S (1992) Chronic graft-vs.-host disease of the liver: another indication of ursodeoxycholic acid? *Hepatology* 16, 1305–1307.
42 Fried RH, Murakami CS, Fisher LD *et al.* (1992) Ursodeoxycholic acid treatment of refractory chronic graft-versus-host disease of the liver. *Ann Intern Med* 116, 624–629.
43 Barshes NR, Myers GD, Lee D *et al.* (2005) Liver transplantation for severe hepatic graft-versus-host disease: an analysis of aggregate survival data. *Liver Transpl* 11, 525–531.
44 Sharma P, McDonald GB, Banaji M (1982) The risk of bleeding after percutaneous liver biopsy: relation to platelet count. *J Clin Gastroenterol* 4, 451–453.
45 Carreras E, Grañena A, Navasa M *et al.* (1993) Transjugular liver biopsy in BMT. *Bone Marrow Transplant* 11, 21–26.
46 Shulman HM, Gooley T, Dudley MD *et al.* (1995) Utility of transvenous liver biopsies and wedged hepatic venous pressure measurements in sixty marrow transplant recipients. *Transplantation* 59, 1015–1022.
47 Lee JL, Gooley T, Bensinger W *et al.* (1999) Veno-occlusive disease of the liver after busulfan, melphalan, and thiotepa conditioning therapy: incidence, risk factors, and outcome. *Biol Blood Marrow Transplant* 5, 306–315.
48 Carreras E (2000) Veno-occlusive disease of the liver after hemopoietic cell transplantation. *Eur J Haematol* 64, 281–291.
49 Moseley RH (2004) Sepsis and cholestasis. *Clin Liver Dis* 8, 83–94.
50 Hebart H, Loffler J, Reitze H *et al.* (2000) Prospective screening by a panfungal polymerase chain reaction assay in patients at risk for fungal infections: implications for the management of febrile neutropenia. *Br J Haematol* 111, 635–640.
51 Anttila VJ, Lamminen AE, Bondestam S *et al.* (1996), Magnetic resonance imaging is superior to computed tomography and ultrasonography in imaging infectious liver foci in acute leukaemia. *Eur J Haematol* 56(1–2), 82–87.
52 Snover DC, Weisdorf S, Bloomer J *et al.* (1989) Nodular regenerative hyperplasia of the liver following bone marrow transplantation. *Hepatology* 9, 443–448.
53 Sandhu IS, Jarvis C, Everson GT (1999) Total parenteral nutrition and cholestasis. *Clin Liver Dis* 3, 489–508.
54 Jacobson AF, Teefey SA, Lee SP *et al.* (1993) Frequent occurrence of new hepatobiliary abnormalities after bone marrow transplantation: results of a prospective study using scintigraphy and sonography. *Am J Gastroenterol* 88, 1044–1049.
55 Ko CW, Murakami C, Sekijima JH *et al.* (1996) Chemical composition of gallbladder sludge in patients after marrow transplantation. *Am J Gastroenterol* 91, 1207–1210.

20.9 The effect of endocrine diseases on liver function

Anthony J. DeSantis and Andres T. Blei

Introduction

Many disorders of the endocrine system are associated with liver abnormalities. The indolent nature of many endocrinological diseases coupled with the propensity of these diseases to present with protean symptoms often leads to thorough laboratory evaluations in search of a diagnosis. Often, abnormalities in liver function tests are identified, leading to an inaccurate conclusion of hepatic disease and a delay in the identification of the endocrine abnormality.

The common association between abnormalities in liver chemistries and obesity, diabetes and disorders of lipid metabolism reflects the seminal role of the liver in energy metabolism. One of the criteria for severe thyrotoxicosis, or 'thyroid storm', is elevation of serum aminotransferases; a deficiency of glucocorticoid secretion may rarely be associated with this pattern as well.

Treatments used to manage the panoply of endocrine diseases may lead to liver injury or dysfunction. Sulphonylurea agents and peroxisome proliferator-activated receptor (PPAR)γ agonists used in the treatment of type 2 diabetes mellitus (DM), thionamides utilized in hyperthyroidism and ketoconazole in the treatment of hypercortisolism have all been associated with liver inflammation and injury. Octreotide and other longer acting somatostatin analogues used in the treatment of endocrine tumours are associated with a high risk of cholelithiasis. Synthetic oral androgen and estrogen compounds can be associated with cholestasis and the development of benign and malignant tumours of the liver.

Not surprisingly, many diseases can affect both the hepatic and the endocrine systems. Infectious disorders such as tuberculosis, syphilis, human immunodeficiency virus (HIV) and fungal disease; granulomatous disorders such as sarcoidosis, Langerhans cell histiocytosis and eosinophilic granulomatosis; infiltrative diseases such as haemochromatosis, amyloidosis and Wilson's disease; and haematological disorders such as lymphoma may present with abnormalities in both hepatic and endocrine function. The reader is referred to Chapter 21.2 for further insight into normal endocrine physiology.

Diabetes mellitus

DM affects 21 million individuals in the United States and has a prevalence of 151 million worldwide [1,2]. The vast majority of these individuals have type 2 DM (approximately 85%). It is estimated that twice this number of subjects have impaired glucose regulation and are at risk for the development of overt DM. Type 1 DM is an autoimmune disorder characterized by pancreatic islet cell destruction and loss of endogenous insulin formation and secretion. Individuals with type 1 DM have a complete dependence on exogenous insulin and a propensity to develop diabetic ketoacidosis if insufficient amounts of insulin are administered. Type 2 DM is a disorder of insulin resistance at peripheral tissues and relative insulin deficiency. Insulin resistance at the level of the adipocytes leads to increased lipolysis and the generation of free fatty acids in the plasma, which may subsequently lead to more insulin resistance. Insulin resistance at the level of the skeletal muscle can cause a reduction in glucose uptake and, at the liver, an increase in glycogenolysis, both leading to hyperglycaemia.

The role of the liver in glucose metabolism

The liver is integral to normal glucose regulation. In the fasting state, basal glucose output from the liver equals glucose utilization by peripheral tissues such as the brain and muscle. Hepatic glucose is generated from the breakdown of liver glycogen stores (glycogenolysis) or newly manufactured from other substrates (gluconeogenesis). Conversely, in the postprandial state, endogenous insulin promotes uptake of glucose into peripheral tissues and inhibits hepatic glucose output. The liver is also able to generate glucose in response to hypoglycaemia via stimulation by counter-regulatory epinephrine (adrenaline) and glucagon.

The metabolic fate of a carbohydrate load presented to the liver via the portal vein is dependent on a complex orchestration of hormones and neuronal stimuli. Approximately 30–40% of the glucose entering the portal vein will be taken up by the liver and converted to glycogen stores. The major hormones involved

in glucose metabolism by the liver are insulin and glucagon, with contributory effects from epinephrine and efferent stimuli from the vagal nerve. Insulin and glucagon promote opposing effects on carbohydrate metabolism. Insulin stimulates hepatic glucose uptake and increases glycogen formation through the activation of glycogen synthase. Conversely, glucagon reduces net hepatic glucose uptake and inhibits glycogen synthase and glycogen storage. Epinephrine will increase the maximal rate of both glycolysis and gluconeogenesis, thus increasing net hepatic glucose production.

Glucose in the portal vein is detected by afferent sensors of the hepatic branches of the vagal nerve sending signals to the hypothalamus. This results in modulation of the efferent firing rate of the pancreatic and hepatic branches of the vagal nerve, resulting in increased insulin secretion by the pancreas and increased glucose uptake and glycogen storage by the liver.

Insulin is primarily metabolized in the liver with an approximate 50% first-pass clearance rate.

Diabetes mellitus and liver function

DM is associated with a spectrum of liver disease ranging from innocuous elevations in liver chemistries to acute liver injury, non-alcoholic steatohepatitis, hepatocellular carcinoma and cirrhosis. Much of the association between liver injury and type 1 and type 2 DM can be attributed to the effects of these disorders on lipid and carbohydrate metabolism and the significant role that the liver plays in this process.

Abnormalities in liver function tests

An elevation in liver chemistries above the normal reference range is common in individuals with DM, occurring in 10–20% of patients. Often, a cholestatic picture is seen. In a combined series, totalling 646 individuals with both type 1 and type 2 DM, elevations in γ-glutamyltransferase (GGT), alkaline phosphatase, alanine aminotransferase (ALT) and aspartate aminotransferase (AST) were seen in 16.5%, 9%, 11% and 6% respectively [3–5]. Abnormalities in liver function tests were more commonly seen in individuals with type 2 DM than in those with type 1 DM. However, liver chemistry abnormalities are commonly seen with diabetic ketoacidosis. In type 2 DM, no correlation was observed between the liver abnormality and the duration of DM and level of glycaemic control [5]. Often, the liver test abnormalities were fleeting. After 6 months of observation, 50% of individuals had a return to normal of a previously elevated ALT value. The laboratory abnormalities correlated poorly with liver histology. The aforementioned increased prevalence of abnormal liver chemistries in individuals with type 2 DM compared with those with type 1 DM may reflect the increased prevalence of non-alcoholic fatty liver disease (NAFLD) seen among individuals with type 2 DM (see below). Lifestyle modifications leading to weight reduction are associated with an improvement in insulin resistance and normalization of liver test abnormalities [6].

Glycogen-induced hepatomegaly

Excess glycogen deposition leading to hepatomegaly was described as one of the manifestations of Mauriac syndrome. This disorder, caused by severe insulin deficiency with intermittent administration of high doses of insulin, is characterized by stunted growth, truncal obesity, hyperlipidaemia and delayed puberty [7]. With the advent of improved insulin administration, the Mauriac syndrome is infrequent; however, overinsulinization has also been associated with excess liver glycogen storage and hepatomegaly [8]. Histologically, the hepatocytes are enlarged and engorged with glycogen deposition throughout the cytoplasm and nucleus. Hepatomegaly is not associated with pain and, most often, liver function tests are normal. Liver size improves with adjustments in insulin administration [8].

Non-alcoholic fatty liver disease and diabetes mellitus

NAFLD is discussed in more detail in Chapter 13. The following discussion will briefly detail the role of DM in this disorder.

Hepatic steatosis, a benign, fatty infiltration of hepatocytes, is common in diabetes. The frequency in type 1 DM is estimated at 4–17% [9], and is seen with increased frequency in type 2 DM, ranging from 21% to 78% in various series and as high as 100% in those with type 2 DM and obesity.

A number of patients with diabetes and hepatic steatosis progress to hepatic steatohepatitis, fatty infiltration of hepatocytes with accompanying inflammation. Steatosis may progress to hepatic necrosis and fibrosis, which can lead to cirrhosis and endstage liver disease as well as an increased incidence of hepatocellular carcinoma. Approximately 50% of diabetic individuals with suspected fatty liver disease have steatohepatitis and 19% have cirrhosis on biopsy [10–12].

The mechanisms responsible for NAFLD are incompletely understood; it is currently the most prevalent liver disease in the United States [13]. Insulin resistance is central to our views of the pathogenesis of NAFLD [14]. In addition, type 2 DM is associated with an elevation in circulating free fatty acids. Increased lipolysis as a consequence of insulin resistance can overwhelm the mitochondrial β-oxidation system, resulting in an increase in circulating free fatty acids and resultant accumulation in the liver. Fatty acids induce inflammatory cytokines which lead to the generation of free radicals, cell injury and apoptosis [15].

Histologically, steatohepatitis may resemble alcoholic hepatitis with Mallory's hyaline deposition evident in the hepatocytes, together with periportal or perisinusoidal fibrosis. In advanced forms, bridging fibrosis occurs with variable degrees of hepatocellular necrosis. There is no classic clinical picture of steatohepatitis. The diagnosis is suspected in diabetic individuals with abnormalities in liver function tests that fit the clinical profile of older age, central obesity and no alcohol abuse. Often, generalized malaise or fullness in the right upper quadrant is reported; rarely, hepatomegaly is appreciated.

Elevated aminotransferases are the most common abnormal pattern on liver function testing. Mild ALT elevations are more commonly seen than AST increases. Serum alkaline phosphatase and GGT levels are less commonly abnormal. In one series of biopsy-proven steatohepatitis, the severity of illness indicators included a ratio of AST to ALT greater than 1, older age, obesity and diabetes mellitus [16].

Imaging studies may contribute to the diagnosis of hepatic steatosis. Ultrasound images show a diffuse increase in liver echogenicity with 'phantom tumour' appearance of spared areas of fat infiltration. Retrospective studies indicate that ultrasound has a sensitivity of 89% and specificity of 93% for the detection of steatosis [17]. However, prospective studies indicate a cut-off of 33% steatosis for the diagnostic accuracy of ultrasound [18]. Magnetic resonance imaging (MRI) can improve the quantification of the degree of fatty infiltration [19], but only liver biopsy can determine the extent of liver damage and provide a prognosis based on disease severity.

Hepatic steatosis for the majority of patients will remain a benign disorder. However, a progression of the disease from hepatic steatosis to steatohepatitis to cirrhosis and, ultimately, hepatocellular carcinoma is well described. The factors contributing to progressive liver failure are unknown, and prognosis worsens with the progression to each stage of disease. Although the prevalence of NAFLD may be no higher in those with diabetes than in weight-matched control subjects without diabetes, the presence of diabetes may portend disease progression and a worse prognosis. In one study of morbidly obese subjects undergoing gastric bypass, the frequency of steatohepatitis and cirrhosis was 48% and 9.7%, respectively, in subjects with type 2 DM, compared with 33% and 2.2% in those without diabetes [12]. Whether diabetes promotes worsening liver disease or is a consequence of an inflammatory response associated with liver damage remains unknown. Longitudinal studies have described disease-specific mortality as being as high as 36% [20].

The mainstay of treatment for NAFLD remains weight loss. Weight reduction will improve insulin resistance and reverse the pathological processes leading to hepatic fat infiltration [21–23]. However, a transient worsening of hepatic inflammation and cirrhosis may accompany rapid weight loss [21,24,25]. A recommended loss of 1.0–1.5 kg/week has been suggested; however, the ideal rate of weight loss is not known [21].

Multiple pharmacological agents have been used to treat NAFLD. Treatment with gemfibrizole [26], vitamin E [27], betaine [28], ursodeoxycholic acid [29,30], pioglitazone [31–34], rosiglitazone [35], atorvastatin [36,37] and metformin [38,39] has been associated with improvement in elevated liver enzymes. Readers are referred to Chapter 13 for a more detailed analysis of such results.

Insulin-sensitizing and cholesterol-lowering drugs are logical therapeutic choices for non-alcoholic steatohepatitis given the role of insulin resistance and hyperlipidaemia in its pathophysiology. Pioglitazone use has been associated with histological improvement in non-alcoholic steatohepatitis with varying durations of use [32,34]. Rosiglitazone was associated with the improvement in metabolic parameters of insulin resistance and a reduction in hepatic fat content, inflammation and fibrosis after 24 weeks of use [35]. Atorvastatin therapy was associated with improved liver histology among individuals with non-alcoholic steatohepatitis.

In individuals with type 1 DM and endstage renal disease on continuous ambulatory peritoneal dialysis and treated with intraperitoneal insulin, hepatic subcapsular steatosis has been described. It is believed to be caused by the combination of high concentrations of insulin and glucose in proximity to the liver.

Viral hepatitis

Epidemiological studies have shown an increased risk of viral hepatitis among individuals with DM. In Beirut, diabetes was associated with a twofold increase in hepatitis B viral antibody positivity [40]. Likewise, an increased prevalence of hepatitis C is seen among individuals with DM compared with the general population [41,42].

Many reasons have been postulated for this increased risk. Diabetes does not adversely affect clearance of hepatitis B or C virus. However, individuals with diabetes are more exposed to viral contact with increased hospital admissions and more frequent need for needlesticks [40]. The increased prevalence of hepatitis C virus among individuals with diabetes is confounded by the increasing evidence to support a causative association of the virus with the development of diabetes [43–45] (see Chapter 21.2).

Cirrhosis

Cirrhosis is a common cause of death among individuals with diabetes. The standardized mortality ratio for cirrhosis ranks higher than cardiovascular disease for those with diabetes compared with the non-diabetic population [46]. The ratio increases for those with more severe type 2 DM, as defined by the need for insulin therapy.

The association between diabetes and cirrhosis is strong [13]; however, a causative link is indirect. The leading cause of cryptogenic cirrhosis is steatohepatitis, with DM being the leading cause of the latter. As discussed previously, the presence of diabetes is a risk factor for the progression of steatosis to steatohepatitis and cirrhosis [12]. The association is further confounded by the increased prevalence of glucose intolerance and frank diabetes among those with cirrhosis [47].

Hepatocellular carcinoma

Multiple population studies have noted the association between type 2 DM and hepatocellular carcinoma. Initially, this was described in a small cohort of Scottish individuals with

hepatocellular carcinoma having an incidence of diabetes four times the rate of the general population [48]. Larger reviews of cancer registries in Denmark and Sweden have corroborated the converse association, reporting a fourfold higher incidence of diabetes among those with hepatocellular carcinoma [49,50]. Other epidemiological studies have confirmed these findings [51,52]. Still, this association requires consideration of the confounding fact that cirrhosis *per se*, a preneoplastic condition, may result in diabetes.

Insulin has anabolic and mitogenic properties mediated through its binding to the insulin receptor. It has been postulated that higher insulin levels, such as those seen in insulin-resistant states, may lead to greater cell proliferation and an increased risk of mutation leading to malignancy [53,54].

Cholelithiasis

Diabetes does impart a small increased risk of gallstone development [55–57]. The risk is higher in those with type 2 DM compared with type 1 diabetics [58]. Prior studies estimated the relative risk at two- to threefold; however, with adjustment for obesity and hypertriglyceridaemia, the relative risk decreases to 1.6 [59].

Stone composition is predominantly of the cholesterol type and does not seem to differ between the diabetic and non-diabetic populations [60]. Treatment of diabetes may affect the lipid concentration of bile. Insulin therapy in a cohort of Pima Indians was associated with qualitative changes in bile acid composition that led to protection against stone formation [61]. Evidence supports gallbladder hypocontractility and a decreased gallbladder ejection fraction as possible aetiological factors [62,63]. The reason for cholecystoparesis was presumed to be peripheral neuropathy. However, the risk of gallstone formation is independent of diabetes severity, glycaemic control or the presence of neuropathic complications [62].

Prior to improvements in surgical technique and perioperative medical management, diabetes was associated with worse surgical outcome following gallbladder resection. More recent operative series reveal no increase in morbidity or mortality following cholecystectomy among those with diabetes [64]. Nonetheless, prophylactic cholecystectomy for asymptomatic gallstones imparts no measurable benefit when modelled in a decision analysis [65].

Effect of pharmacological therapy for diabetes on the liver

Insulin is a life-saving necessity for individuals with type 1 DM. Multiple medication options are available for the treatment of type 2 DM; these include sulphonylureas, metformin, thiazolidinediones, meglitinides, alpha-glucosidase inhibitors and insulin. Undue concern over the effects of liver injury on drug metabolism and of the potential for therapy to induce worsening liver function may compromise glycaemic control. In general, in patients experiencing acute or worsening liver failure, metformin should be avoided because of the increased risk of lactic acidosis. Likewise, thiazolidinediones should be used with caution in individuals with ascites and peripheral oedema because of the potential for these agents to cause fluid retention. Most experts recommend initial therapy with a sulphonylurea agent with prompt institution of insulin to achieve glycaemic control. Insulin sensitizers, metformin and thiazolidinediones, should be the treatment of choice for individuals with hepatic steatosis and normal liver function.

Of the treatment options outlined, only the sulphonylurea compounds, α-glucosidase inhibitors and the thiazolidinediones have been associated with hepatotoxicity. The incidence of acute liver injury is rare, reported as 1 in 10 000 person–years of treatment for diabetes in a recent cohort study [66]. Specifically, the hazard ratio for liver failure was 2.41 for individuals receiving insulin therapy and 1.42 and 1.37 for those receiving sulphonylureas and metformin respectively. This information must be considered in the appropriate context. The associated use of these medications and liver injury may not reflect a direct toxic effect of the drug on hepatocytes but the association between liver damage from any cause and an increase in insulin resistance mentioned previously.

The thiazolidinedione drugs deserve more discussion. This class of agents activates the PPARγ receptor and leads to insulin sensitization at peripheral target tissues. As mentioned previously, their effect on lipid metabolism and their ability to reduce insulin resistance make them an intriguing treatment option for NAFLD. Troglitazone, pioglitazone and rosiglitazone have been approved for use by the Food and Drug Administration (FDA) for the treatment of type 2 DM. Troglitazone has since been withdrawn because of the relatively high incidence of liver failure associated with its use. The mechanism by which the drug induces liver injury is controversial [67]. Both rosiglitazone and pioglitazone have been associated with mild aminotransferase elevation, most commonly ALT. Because of this, the FDA has recommended frequent monitoring of liver enzymes with the use of these agents, a guideline that has since been repealed given the experiential safety of these drugs.

Sixty-eight cases of hepatitis or acute liver injury among individuals prescribed rosiglitazone have been reported to the FDA, whereas pioglitazone has been associated with 37 cases [68]. Many of these reports are confounded by concomitant illness (fatty liver) or medication use (statins).

Disorders of lipid metabolism and obesity

The effects of disorders of lipid metabolism and obesity on the liver are those related to fatty infiltration of hepatocytes as discussed previously in the section on non-alcoholic fatty liver disease; these will be covered in detail in Chapters 2.3.2 and 13.

Thyroid disorders

Thyroid physiology

The thyroid gland produces and secretes two iodine-containing hormones, thyroxine (T4) and triiodothyronine (T3), under the direct stimulation of thyroid-stimulating hormone (TSH), a glycopeptide secreted by thyrotrope cells in the anterior pituitary. TSH secretion is regulated by two mechanisms. Thyrotropin-secreting hormone (TRH), a hypothalamic peptide, stimulates TSH secretion, while T4 and T3 directly inhibit it. The thyroid gland is the sole producer of T4; the majority of T3 (80%) in the circulation is derived from deiodination of T4 at peripheral sites, predominantly the liver and kidney. T3 is the metabolically active form of the hormone; binding of T3 to its receptor activates the protean biological effects of thyroid hormone. Approximately 85 μg of T4 is secreted by the thyroid gland daily, and 20–30 μg of T3 is produced daily. T4 and T3 circulate in serum in both free and protein-bound forms. The free pool is the biologically active component and is extremely small, accounting for 0.03% of the total circulating T4 and 0.3% of the circulating T3. The majority is avidly bound to plasma proteins produced by the liver. Thyroxine-binding globulin (TBG) accounts for 75% of thyroid hormone binding, while transthyretin and albumin account for 15% and 10% of T4 binding respectively. The commonly used thyroid hormone assays measure either the total (free and protein-bound) or the free hormone compartments. Conditions that alter the levels of binding proteins will affect total thyroid hormone assay results. However, free hormone assays will remain undisturbed. The liver is also a primary site of thyroid hormone metabolism and clearance. The terms hyperthyroidism and hypothyroidism refer to states of excess or diminished thyroid hormone levels respectively. Given the important relationship between the liver and thyroid, it is not surprising that many disorders affect both systems.

Hyperthyroidism

Hyperthyroidism affects nearly every organ system with multiple clinical signs and symptoms. Hyperthyroidism will affect liver metabolism, and irregularities in liver enzymes are not uncommon. With improved diagnosis and treatment of hyperthyroidism, severe liver injury is rare. In one series, 76% of hyperthyroid patients had at least one liver enzyme abnormality. The most common clinical scenario was one of self-limited mild abnormalities that improved with regulation of thyroid excess [69]. In a minority of patients, centrolobar necrosis with perivenular fibrosis can progress to acute liver failure [70]. Usually, this occurs in the presence of accompanying thyrotoxic cardiac arrhythmias and decompensation. The degree of hepatic injury was postulated to be reflected by serum isocitrate dehydrogenase levels; this enzyme has been described as a marker for the grading of liver damage [71]. The appearance of hyperthyroidism in a patient with previously diagnosed liver injury can lead to significant hepatic decompensation [72].

Mechanistically, liver injury is due to an increase in liver oxygen demand without an associated increase in hepatic blood flow. Histologically, hepatocellular necrosis can be seen in centrolobular areas, with a pancellular inflammatory infiltrate [73]. On electron microscopy, hyperplasia of the smooth endoplasmic reticulum, a decrease in cytoplasmic granules and an increase in mitochondria has been described [74].

The laboratory pattern most frequently seen among individuals with hyperthyroidism is an elevation in serum alkaline phosphatase with an estimated prevalence of 64% [75]. A significant proportion of this enzyme is generated from bone. The more specific serum indicators of cholestasis are less frequently abnormal; GGT and bilirubin elevations are seen in 17% and 5% respectively [75]. The histological pattern is similar to that described for hepatitis with associated centrolobular intrahepatitic cholestasis. Jaundice is rare and, when seen, is often a hallmark of concomitant liver injury or cardiac decompensation.

Thyrotoxicosis is associated with a generalized increase in metabolic processes and produces an overall catabolic state. This is accompanied by an increase in hepatic gluconeogenesis and glycogenolysis as well as protein and lipid breakdown [76]. Both hepatic cholesterol production and clearance is increased. However, clearance rates predominate, leading to a reduction in serum lipid concentrations. An alteration in serum proteins generated by the liver may be seen. Typically, serum albumin and TBG levels are normal, and sex hormone-binding globulin is increased in hyperthyroidism.

Thyroid storm

The clinical significance of excessive thyroid hormone depends on the degree of thyroid hormone overproduction and the underlying health of the patient. In its most aggressive form, thyroid storm, hyperthyroidism consists of a constellation of signs and symptoms of metabolic compromise associated with high mortality. The most frequent clinical manifestations of thyroid storm are fever, confusion and evidence of endorgan failure. Often tachycardia exists (heart rate > 140 beats/min) with associated pyrexia leading to cardiac arrhythmias and compromise. Gastrointestinal and hepatic manifestations are common; abdominal pain, nausea, diarrhoea, emesis and hepatic dysfunction are frequently seen. The presence of jaundice in the right clinical scenario (tachycardia, body temperature > 38.5°C and elevated T4 and T3) is associated with a high specificity for thyroid storm. Accompanying rhabdomyolysis and renal failure may contribute to elevations in serum AST, ALT and indirect bilirubin.

Thyroid storm is usually the result of a rapid increase in serum thyroid hormone. Often, this is due to increased hormone production and release or decreased hormone clearance secondary to accompanying illness. The stress of concurrent sepsis or organ failure may lead to a rise in serum catecholamines and an exacerbation of thyroid hormone effect.

Treatment of thyroid storm is similar to treatment of other forms of hyperthyroidism with a critical component being the identification and treatment of the associated illness.

The effect of drugs used in the treatment of hyperthyroidism on the liver

Select therapy for hyperthyroidism may affect liver function. The thionamides, propylthiouracil (PTU), methimazole and carbimazole inhibit the major steps in thyroid hormone production and are the first line of medical therapy for hyperthyroidism. The true incidence of liver enzyme abnormalities associated with PTU use is unknown, and is difficult to separate from the liver abnormalities seen with hyperthyroidism described previously. However, increased serum levels of AST and ALT are reported to occur in 30% of such patients [77]. The rise in aminotransferases appears to be dose related and peaks in the initial weeks of therapy. Elevations improve over time with decreasing doses of PTU, and enzymes diminish to normal with attainment of euthyroidism in the vast majority of patients. Rarely (incidence < 0.5%), fulminant hepatic failure with histological evidence of hepatic necrosis has been reported. Approximately 30 cases of confirmed PTU-associated toxicity have been reported, with mortality from liver failure seen in eight patients [77]. The aetiology is unknown; however, some studies suggest an immune reaction to the drug via lymphocyte sensitization [78]. Most often, liver injury was reported in the initial months after PTU initiation. An increased female preponderance was seen with a female to male ratio of 8:1. Liver injury often responded to drug discontinuation, but progressed in a minority despite such discontinuation. Survival from liver failure did not correlate with age, dose or duration of PTU use; however, it correlated positively with the use of ^{131}I radiotherapy for thyrotoxicosis [77]. Liver function testing prior to drug initiation did not predict the development of PTU-associated hepatotoxicity. Treatment consists of discontinuation of PTU, administering alternative therapy for thyrotoxicosis, general supportive care of liver injury and early recognition of the need for transplantation.

Liver abnormalities are less common with methimazole and carbimazole use and most often present as a cholestatic pattern [79]. Elevations in alkaline phosphatase, bilirubin and GGT predominate. This is usually seen within the first weeks of therapy and may persist despite drug discontinuation. Liver biopsy reveals intrahepatic cholestasis.

Hypothyroidism

Nondescript symptoms such as fatigue and weight gain are common clinical manifestations of both hypothyroidism and declining liver function. In the most severe form of hypothyroidism, myxoedema coma, an accompanying diminished sensorium and myxoedema ascites [80] may make clinical differentiation from liver failure even more difficult.

A modest increase in serum AST and ALT (usually more than three times the upper limit of normal) may be seen in untreated individuals with hypothyroidism, reported with a frequency of 84% and 60% respectively [72]. The muscle isoenzyme predominates with associated elevation in serum creatinine phosphokinase and aldolase levels in the majority of patients. Increased release of these enzymes from muscle injury and decreased clearance by the liver contribute to increased serum levels. Serum alkaline phosphatase, bilirubin and GGT levels usually remain normal, and aminotransferase elevations diminish with appropriate thyroid hormone replacement.

Hypothyroidism can affect bile acid synthesis and bilirubin metabolism. Experimentally induced hypothyroidism in the rat resulted in a 50% decrease in bile salt flow secretion and enhanced hepatic bilirubin UDP-glucuronosyltransferase activity with subsequent increases in serum conjugated bilirubin levels [81]. In humans, cholestasis and jaundice have rarely been reported in association with hypothyroidism. A persistence of neonatal jaundice may suggest congenital hypothyroidism [82]. Hypothyroidism is associated with elevated serum cholesterol, decreased biliary flow and reduced gallbladder contractility, a triumvirate of circumstances leading to an increased incidence of cholelithiasis. In a case–control Swedish cohort, treatment for hypothyroidism was associated with a twofold risk of choledocholithiasis, probably as a result of improved gallbladder contractility [83].

A unique clinical finding in severe hypothyroidism is myxoedema ascites. The peritoneal fluid is exudative in nature with significantly elevated protein content. Confounding data as to the aetiology of the ascites exist. One hypothesis is that severe hypothyroidism leads to right-sided heart failure and hepatic congestion, supported by findings of central congestive fibrosis on liver biopsy in some patients [84]. Another case report documented normal right heart pressures in a patient with myxoedema ascites. The authors concluded the serous exudates were a result of increased vascular permeability leading to fluid collections in serosal cavities throughout the body [85]. Nevertheless, the fluid collections resolve with appropriate thyroid hormone replacement, and liver injury is reversed with no residual damage [86].

Adrenal disease and the liver

Adrenal physiology

The adrenal cortex is responsible for the production and secretion of glucocorticoids, mineralocorticoids and adrenal androgens. Cortisol is the primary glucocorticoid secreted and is intricately involved in caloric metabolism. Cortisol promotes gluconeogenesis and glycogenolysis and lipid and protein catabolism. Production of cortisol is directly influenced by adrenocorticotropic hormone (ACTH) binding to the ACTH receptor in the zona fasciculata of the adrenal cortex. ACTH is produced by corticotroph cells in the anterior pituitary and is under the positive stimulus of corticotrophin-releasing

hormone (CRH) produced by the hypothalamus. In a classic endocrine feedback loop, cortisol negatively inhibits CRH and ACTH secretion to maintain steady-state levels. Serum cortisol circulates in a predominantly protein-bound form, carried by cortisol-binding globulin and albumin, both produced in the liver. The free steroid component is the biologically active compound. States of excessive serum cortisol are known collectively as Cushing syndrome. Hypercortisolism can be the result of overproduction of cortisol by the adrenals, or excessive ACTH production by pituitary corticotroph adenomas or ectopic ACTH-secreting tumours. Cortisol deficiency may be the result of adrenal damage (primary adrenal failure or Addison's disease), or pituitary (secondary adrenal insufficiency) or hypothalamic (tertiary adrenal insufficiency) injury. Aldosterone is the primary mineralocorticoid produced by the zona glomerulosa cells of the adrenal cortex. It is responsible for maintaining plasma volume and cation homeostasis. It is primarily under the control of the renin–angiotensin system and is secreted in response to renal sensors of low perfusion pressure. Aldosterone production is independent of the hypothalamic–pituitary–adrenal axis and therefore only becomes deficient in disorders of primary adrenal injury.

The effects of adrenal insufficiency on the liver

Elevations in liver aminotransferases have been reported in individuals with adrenal insufficiency [87,88]. Although some patients have varying degrees of liver pathology on biopsy [87], suggesting a hepatic origin, others have reported normal liver histology [88]. It is believed, in the latter cases, that the excess serum ALT and AST is primarily the skeletal muscle isoform. Regardless of the tissue of origin, the abnormalities resolve with appropriate hormone replacement. The reported delay in bromosulphthalein elimination in patients with adrenal insufficiency is believed to be secondary to hypovolaemia associated with the disorder and a subsequent decrease in hepatic perfusion [89].

The effects of Cushing syndrome on the liver

Hypercortisolism causes a metabolic syndrome phenotype with insulin resistance, truncal obesity, hypertriglyceridaemia and overt diabetes. Therefore, it is not surprising that these individuals are at risk for the development of non-alcoholic steatohepatitis. The development of fatty liver infiltration may be accompanied by an elevation in serum GGT in as many as 50% of individuals with Cushing syndrome [90]. Aminotransferase levels are usually normal but may rarely be elevated. Steatohepatitis may be diffuse or isolated in nature. The true prevalence of non-alcoholic steatohepatitis among individuals with hypercortisolism is debated, with reported rates ranging from 20% to 50% [90,91]. A similar process may be seen with the administration of supraphysiological doses of exogenous steroids. Fat emboli to the pulmonary and systemic vascular beds have been described in patients with Cushing's disease. This usually occurs during rapid resolution of the hypercortisolaemic state and can be fatal [92].

Ketoconazole inhibits a number of the enzymes that catalyse the conversion of cholesterol to cortisol and is therefore utilized in the medical management of patients with Cushing syndrome. The drug has been infrequently associated with severe liver injury [92]. The more common liver assay abnormalities are consistent with hepatocyte injury with ALT and AST elevations. A mixed hepatocellular and cholestatic picture has also been described with accompanying elevations in alkaline phosphatase values. Liver necrosis and failure has been reported. Jaundice and liver enzyme abnormalities are usually seen in the first 10 days of therapy initiation. Transient elevations in serum aminotransferases and alkaline phosphatase levels have been described during the initial days of ketoconazole therapy in a significant minority of individuals [93]. Most often, the abnormalities are transient; however, they should be monitored for progression of worsening liver function. Liver chemistries return to normal within months after drug cessation in the majority of individuals. Monitoring of liver tests has been suggested at baseline, within the first weeks of therapy and monthly thereafter during ketoconazole use [92].

Sex hormones and the liver

Sex hormone physiology (see Chapter 21.2)

The gonads are bifunctional organs, serving as the site of sex steroid production, primarily testosterone in the testis and estrogen in the ovaries, and gamete formation. The hypothalamic–pituitary–gonadal axis regulates these functions via a series of hormones and neurotransmitters in a closed loop feedback mechanism. The hypothalamus regulates the release of gonadotropin-releasing hormone (GnRH). GnRH is released in predetermined pulses into the portal circulation to stimulate pituitary gonadotropin synthesis and release. The GnRH pulse frequency determines the amount and relative ratio of luteinizing hormone (LH) and follicle-stimulating hormone (FSH) released into the systemic circulation. GnRH synthesis and release is regulated by extrahypothalamic central nervous system signals, systemic sex steroids and systemic peptide hormones such as prolactin, inhibin, leptin and activin. Testosterone and estradiol exert inhibitory effects on GnRH synthesis and release.

LH and FSH are glycoproteins secreted by the gonadotropin cells of the anterior pituitary gland in a pulsatile fashion in response to a GnRH stimulus. The hormones consist of two polypeptide subunits, an α- and a β-subunit, with the α-subunit identical in both hormones and the β-subunit imparting specificity. LH binding to surface receptors on Leydig cells in the testes promotes testosterone production. LH binding to cell receptors in the ovary promotes estrogen, progesterone and androgen production for follicular maturation, ovulation and

maintenance of the corpus luteum. FSH binding to Sertoli cell receptors in the testes stimulates the production of multiple proteins including inhibin and activin. In conjunction with high local testosterone levels produced by the Leydig cells, FSH promotes spermatogenesis and inhibits germ cell apoptosis. In the ovary, FSH binding to its receptor on granulosa cells in the primordial follicle similarly promotes the synthesis of multiple proteins including inhibin and activin to promote follicular cell duplication and maturation. Gonadotropin synthesis is stimulated by pulsatile GnRH secretion, as mentioned previously. Negative inhibition by sex hormones and their metabolites occurs at the pituitary level. Inhibin inhibits the pituitary secretion of FSH while activin promotes its synthesis. Circulating estrogen levels affect gonadotropin hormone release in a complex fashion. In general, estrogen inhibits both FSH and, to a lesser extent, LH secretion from the gonadotrophs. However, at high circulating levels, estrogen exerts a positive stimulus for LH secretion, manifest in mid-menstrual cycle as an LH surge to promote ovulation.

Testosterone is produced in the Leydig cells via a series of enzymatic steps under the stimulation of LH. Approximately 4–8 mg is produced daily in men to achieve serum levels ranging from 3 to 12 μg/L. The testes also directly secrete 5α-dihydrotestosterone (5DHT), a more potent androgen. The majority of 5DHT production comes from peripheral conversion of testosterone via the action of 5α-reductase enzyme predominantly in the prostate gland, but also in other peripheral tissues. The serum levels of 5DHT are approximately 1/10th those of serum testosterone. About 40 mg of estradiol is produced in the adult male daily. The majority (75%) is the result of peripheral conversion of testosterone to estradiol by the aromatase enzyme; the rest is directly secreted by the testes. Peripheral aromatization occurs predominantly in skin, muscle and fat. The majority of circulating testosterone is bound to sex hormone-binding globulin (SHBG) or albumin; the minority (2–3%) is in the free, unbound form. Both the free and albumin-bound forms are available for cell entry, thus known as the bioavailable portion. Many factors affect SHBG and albumin secretion including liver injury. Estrogens and thyroid hormone promote SHBG production, whereas androgens and obesity (via the effects of insulin) diminish it. Obviously, SHBG and albumin levels will influence the percentage of testosterone circulating in the free form. Testosterone that is not aromatized to estradiol or converted to 5DHT is metabolized to the inactive metabolites etiocholanolone or androsterone in the liver. The liver is capable of degrading approximately 50% of the testosterone reaching the splanchnic circulation in men and 100% in women.

Serum estrogen levels in adult women vary depending on the stage of the menstrual cycle. Levels are low during the early follicular phase (60–100 ng/L) and higher (200–700 ng/L) during the late luteal phase of the cycle. Estrogen is primarily formed by peripheral conversion of androstendione. In the premenopausal female, androstendione production is equally performed by the ovary and adrenal; after the menopause, ovarian production disappears and the adrenals become the main source of the steroid. Testosterone levels in women are 5% of those seen in males. The ovaries secrete testosterone directly, but the majority comes from peripheral conversion of androstendione (ovarian androgen) and dehydroandrostendione (adrenal androgen). Estrogen circulates in the free and protein-bound forms, with the primary protein carriers SHBG and albumin, similar to testosterone. Unlike testosterone, estrogen is less tightly bound to these carriers; therefore, fluctuations in serum SHBG and albumin concentrations do not have as great an impact on tissue bioavailability.

The effects of sex steroids on the liver

The effects of sex steroids on the liver can range from innocuous alterations in liver enzymes to the development of cirrhosis and acute liver failure. Another well-documented association exists between sex steroids and the development of both benign and malignant hepatic tumours. There is increasing evidence that the liver displays sexual dimorphism with stark differences in liver pathophysiology between genders.

Anabolic steroids

The use of androgens for the treatment of haematological disorders and cachexia has decreased with the development of more specific and efficacious therapies for these conditions. However, the misuse of anabolic androgens among competitive and non-competitive athletes has increased to alarming numbers over the last decade [94]. The prevalence of toxic effects following the use of anabolic steroids is unknown due to under-reporting of use. However, the use of anabolic androgens has increasingly been associated with adverse outcomes including liver injury.

Oral androgens have been associated with hepatotoxicity and cholestatic jaundice, particularly the C17 alkylated formulations [95]. Although mild hepatic enzyme abnormalities are seen in the majority of individuals taking oral androgens, severe injury is rare. Jaundice is usually accompanied by symptoms of anorexia, nausea, emesis and abdominal fullness, and occurs within the first few months of initiation of oral androgen therapy. Cholestasis will usually regress within months following discontinuation of androgens, although it has rarely been associated with progression to cirrhosis [95].

Peliosis hepatis is a rare disorder consisting of blood-filled spaces of various sizes within the liver parenchyma. The disorder is associated with chronic inflammatory illnesses such as tuberculosis and acquired immunodeficiency syndrome (AIDS). It has also been well described in patients treated with anabolic androgens for refractory anaemia and malignancy-induced anorexia [96]. Reports of the development of peliosis hepatis have been described in athletes abusing anabolic steroids, although this association seems to be rare [97]. The condition may be mild and asymptomatic; however, it has been associated with hepatorenal syndrome, severe parenchymal haemorrhage and hepatic failure [96]. Lesions display characteristic findings

on ultrasound, computerized tomography (CT) and angiographic evaluation of the liver. The aetiology of the disorder is unknown, but a greater association with the use of C17 alkylated androgens is seen. Severity of lesions is associated with the dose, but not the duration, of therapy. Spontaneous regression of lesions has been documented [98].

Androgens are associated with the development of hepatic adenomas and hepatocellular carcinoma. Hepatic adenomas are uncommon benign neoplasms most prevalent in women on oral contraceptives (see below). Although benign, adenomas can lead to serious consequences (see Chapter 18.1.2). Hepatic adenomas are highly vascular tumours and have been reported to be associated with severe haemorrhage [99]. Often, tumours can become large, leading to obstruction of liver parenchyma, portal vasculature and biliary flow causing jaundice [100]. Differentiation of hepatic adenomas from hepatocellular carcinoma requires biopsy with overlapping radiological features between the two tumour types [101]. The probability of hepatic adenoma transformation into a malignant tumour is unknown and controversial, however most experts recommend close monitoring [101]. Mutations in β-catenin may indicate an increased risk of neoplastic transformation [102].

Males are at increased risk for the development of hepatocellular carcinoma (HCC) [103] and have a higher mortality associated with HCC compared with females. Some researchers postulate that androgens influence the development and severity of HCC. Androgen receptors are present in normal liver tissue, and their expression and activation are increased in the tumour tissue of individuals with HCC [104]. The presence of androgen receptors in HCC has been associated with an increased risk of tumour recurrence and reduced survival following hepatic resection [104]. Five-year survival for androgen receptor-negative individuals was reported at 55%, while the rate for androgen receptor-positive individuals was 0%.

HCC as a consequence of androgen therapy was first reported in an individual receiving therapy for Fanconi's anaemia, an autosomal recessive disorder associated with aplastic anaemia [105]. Initially, it was believed that the risk of HCC in these patients was secondary to a chromosomal mutation predisposing them to malignancy. However, soon, cases of androgen-associated HCC in individuals without Fanconi's anaemia were reported. One retrospective review of the literature reported 21 cases of androgen-associated HCC among individuals with Fanconi's anaemia and 49 cases among individuals without a diagnosis of Fanconi's anaemia [106]. Men were at greater risk for the development of HCC. The dose of androgen did not correlate with HCC risk, nor did the route of administration (oral vs. parenteral); however, the specific androgen utilized did. Individuals administered either oxymethalone or methyltestosterone had a statistically significantly greater risk of HCC development compared with individuals treated with danazole therapy [106]. To date, no association between hepatic adenoma or hepatocellular carcinoma has been described with the use of transdermal testosterone preparations.

Estrogens

Oral contraceptives and estrogen replacement are commonly prescribed therapies. These compounds are known to exert a number of metabolic effects on the liver. Estrogen therapy will affect hepatic protein synthesis and release. The best studied of these is TBG. Estrogen therapy will increase serum TBG via a reduction in hepatic clearance of the protein [107]. The result is an increase in total thyroxine and triiodothyronine serum values; however, free thyroid hormone levels are unchanged. Similar effects have been described in other proteins synthesized by the liver.

During therapy with an oral contraceptive agent, increases in serum aminotransferase concentrations may be seen in 5–20% of women. Abnormalities are more commonly associated with the C17 alkylated compounds, are mild and resolve with discontinuation of contraception. Liver irregularities that do not resolve warrant further investigation. Cholestasis is a known complication of these agents. Estrogens can decrease bile flow and secretion of bile acids, leading to a propensity for gallstone development. The Nurses Health Study, an epidemiological study of 96 211 women, detailed the effects of these compounds on cholelithiasis and cholecystitis [108]. When compared with women who never used oral contraception, current short-term users had an age-adjusted relative risk for cholecystitis of 1.6. The risk remained the same after 10 or more years of use but declined with discontinuation of oral contraception. However, the relative risk of cholecystitis remained higher among those women who had ever used contraception compared with those who had not (relative risk 1.2). The Heart and Estrogen/progestin Replacement Study (HERS) reported an increase in need for biliary surgery of approximately 45% among users of hormonal replacement therapy compared with non-users [109]. In a Canadian study of 800 000 women, estrogen users were significantly more likely to have undergone cholecystectomy [110].

The overall rate of thromboembolic events associated with the use of estrogen and progesterone compounds is low. However, the risk increases with increasing age, smoking and a history of thrombosis or disorders leading to thrombosis [111]. Hepatic vein occlusion and the Budd–Chiari syndrome have been reported among users of oral contraceptives [112] (see Chapter 17.3).

Hepatic adenomas are relatively rare, benign tumours; the incidence of these lesions increases with estrogen use and duration of therapy [113,114]. Risk is increased after 5 years of oral contraceptive therapy [114]. The lesions are usually asymptomatic and most commonly found incidentally on imaging studies. However, due to the vascular quality of these lesions, patients are at risk of intraperitoneal haemorrhage. Spontaneous regression of tumours has been described with cessation of contraceptive therapy [114,115]. The association between oral contraceptive use and HCC is controversial. Some studies report a small increased risk with their use [116], while others contradict this premise [117]. Risk may be gender and race specific or depend on co-infection with hepatitis B or C virus [116,117].

Sexual dimorphism of liver function

Gender differences in liver function and response to stimuli exist in many species. The differentiation of fetal organs in response to hormonal stimuli, a process termed imprinting, may result in a male or female pattern of organ function. Although more pronounced in certain animal species, sexual dimorphism may have clinical implications in humans. Gender differences in the metabolism of certain drugs and hormones as a result of variations in enzymatic activity have been described. With regard to alcohol, women display much greater toxicity from alcohol than men [118] and may exhibit a different incidence of fatty liver, cirrhosis and hepatocellular carcinoma [119]. Differences in hepatic lipid clearance have been well described. The complete clinical impact of this phenomenon still awaits further investigation.

The growth hormone (GH)–insulin-like growth factor (IGF) system

Physiology

GH is a 191-amino-acid polypeptide secreted by the somatotroph cells of the anterior pituitary. GH secretion and release is primarily modulated by three peptide hormones: growth hormone-releasing hormone (GHRH), ghrelin and somatostatin. GHRH and ghrelin have potent stimulatory effects on GH release, while somatostatin exhibits inhibitory effects. Although all three hormones are synthesized and secreted by the hypothalamus, somatostatin and ghrelin are distributed throughout neural and gastrointestinal tissue.

GH does demonstrate some direct effects on tissue; however, the majority of its effects are mediated through another set of hormones known as insulin-like growth factors (IGFs). The IGFs exhibit biological growth properties on various tissues throughout the body, and their production, primarily in the liver, is under the direct control of GH. Two predominant IGFs exist. IGF-1 is a 70-amino-acid peptide with homology to proinsulin. IGF-2 shares significant homology with IGF-1, but the two proteins have specific receptors underlining their unique biological effects. The hormones are carried in serum by a variety of insulin-like growth hormone-binding proteins manufactured in the liver. In addition to stimulation of growth throughout the body, both hormones negatively inhibit the secretion of GH from the anterior pituitary and GHRH from the hypothalamus.

The effects of alterations in the GH–IGF-1 axis on the liver

Acromegaly

Acromegaly is a disorder characterized by excessive GH secretion, usually from a benign tumour of the anterior pituitary somatotroph cells. The condition is associated with soft tissue and organ growth and insulin resistance. Although hypertrophy and growth of many organs is well described, hepatomegaly is a relatively rare phenomenon in acromegaly and warrants further evaluation [120].

Alkaline phosphatase elevations may be seen in patients with acromegaly, but they most commonly originate from the bone isozyme reflecting the high degree of bone turnover in this disorder. GH and IGF-1 alter the transcription of a number of liver-specific genes. Galactose elimination and the ability to excrete bromosulphthalein are increased in patients with acromegaly, presumably because of an upregulation of the enzymes involved in these processes [121].

Surgical excision of the GH-producing tumour is the first line of therapy for acromegaly. However, surgical cure rates vary depending on surgical expertise and tumour size and are estimated at 50–90%. Often, radiation or medical therapy is necessary following surgery in order to normalize serum IGF-1 levels and reduce morbidity and mortality. Somatostatin analogue therapy, both short-acting preparations such as octreotide and longer-acting analogues, is used as initial therapy for patients failing surgery or unable to tolerate surgery. These agents have been associated with the development of cholelithiasis. Asymptomatic echogenic gallbladder lesions, including both sludge and gallstones, develop in about 25% of patients treated with these medications [122]. Gallbladder injury usually occurs within 2 years of therapy. The prevalence of cholelithiasis during octreotide therapy may vary geographically, suggesting a dietary or environmental predisposition to injury [123,124]. Somatostatin analogues have been shown to reduce gallbladder contractility and biliary excretion either through direct influence on somatostatin receptor activity or indirectly via somatostatin inhibition of cholecystokinin, secretin, motilin, gastrin or vasoactive intestinal peptide [125,126]. The GH receptor antagonist, pegvisomant, directly inhibits peripheral GH binding to the GH receptor. It is recommended for use in patients with acromegaly requiring medical therapy recalcitrant to somatostatin analogues. Pegvisomant has been associated with alterations in liver enzymes. In the initial clinical trial to evaluate the efficacy of pegvisomant, a 10-fold increase in AST and ALT was reported in two patients (1.2% of population) [127]. Subsequently, surveillance studies in Europe have reported a prevalence of 11–13% in the development of aminotransferase elevations greater than three times the upper limit of normal during therapy [128,129]. These studies are confounded by prior therapy with somatostatin analogues and evidence of concomitant hepatitis C infection and gallstones in some patients. Aminotranferase elevations returned to normal with cessation of therapy and did not result in permanent liver injury.

GH deficiency

Growth hormone deficiency is caused by congenital defects in childhood or is the result of pituitary injury from tumour, surgery or radiation. Occasionally, isolated GH deficiency is seen in adulthood. GH deficiency of any cause is associated with

a decrease in lean body mass and hyperlipidaemia [130]. Cross-sectional studies in Japan have documented an increased incidence of abnormalities in liver function tests among individuals with GH deficiency. One series reported a statistically significant increase in serum AST, ALT and GGT among individuals with GH deficiency compared with GH-sufficient matched control subjects [131]. In the second, liver dysfunction, defined as an increase in serum AST, ALT or GGT greater than twice the upper limit of normal, was reported in 12% of GH-deficient patients, twice the rate seen in matched control subjects [132]. The aetiology of the liver injury was not elucidated; however, individuals with liver dysfunction had a higher incidence of obesity, diabetes and/or hyperlipidaemia, suggesting that fatty infiltration of the liver plays a causative role.

References

1 Number of Americans with diabetes continues to increase (press release). Atlanta, GA: Center for Disease Control and Prevention; October 26, 2005. Available at www.cdc.gov/ad/oc/media/pressrel/fs051026.htm.

2 Wild S, Roglic G, Green A *et al.* (2004) Global prevalence of diabetes: estimates for the year 2000 and projections for 2030. *Diabetes Care* 27, 1047–1053.

3 Foster KJ, Griffith AH, Dewbury K *et al.* (1980) Liver disease in patients with diabetes mellitus. *Postgrad Med J* 56, 767–772.

4 Salmela PI, Sotaniemi EA, Niemi M *et al.* (1984) Liver function tests in diabetic patients. *Diabetes Care* 3, 248–254.

5 Orrell JM, Neithercut WD, Henderson J *et al.* (1990) Raised liver associated enzyme activity and post-prandial bile acid concentrations in sera from treated diabetic outpatients. *Diabetes Res Clin Pract* 10, 51–57.

6 Eriksson S, Eriksson KF, Bondesson L (1986) Nonalcoholic steatohepatitis in obesity: a reversible condition. *Acta Med Scand* 220, 83–88.

7 Najjar S, Ayash MA (1974) The Mauriac syndrome. *Clin Pediatr* 13, 723–725.

8 Rosenbloom A, Giordano B (1977) Chronic overtreatment of insulin in children and adolescents. *Am J Dis Child* 131, 881–885.

9 Marks J, Skyler J (1999) The liver and the endocrine system. In: Schiff ER, Sorrell MF, Maddrey WC (eds) *Schiff's Diseases of the Liver*, 8th edn. Philadelphia: Lippincott-Raven Publishers.

10 Silverman J, Pories W, Caro J (1989) Liver pathology in diabetes mellitus and morbid obesity. Clinical, pathological, and biochemical considerations. *Pathol Annu* 24, 275–302.

11 Silverman JF, O'Brien KF, Long S *et al.* (1990) Liver pathology in morbidly obese patients with and without diabetes. *Am J Gastroenterol* 85, 1349–1355.

12 Marchesini G, Brizi M, Morselli-Labate AM *et al.* (2000) Association of nonalcoholic fatty liver disease with insulin resistance. *Am J Med* 109, 171.

13 Bugianesi E, McCullough AJ, Marchesini G (2005) Insulin resistance: a metabolic pathway to chronic liver disease. *Hepatology* 42, 987–1000.

14 Caldwell S, Oelsner D, Iezzoni J *et al.* (1999) Cryptogenic cirrhosis: clinical characterization and risk factors for underlying disease. *Hepatology* 29, 664–669.

15 Angulo P (2002) Non-alcoholic fatty liver disease. *N Engl J Med* 346, 1221–1231.

16 Angulo P, Keach J, Batts K *et al.* (1999) Independent predictors of liver fibrosis in patients with nonalcoholic fatty liver disease. *Hepatology* 30, 1356–1362.

17 Joseph A, Saverymuttu S, al-Sam S *et al.* (1991) Comparison of liver histology with ultrasonography in assessing diffuse, parenchymal liver disease. *Clin Radiol* 43, 26–31.

18 Saadeh S, Younossi ZM, Remer EM *et al.* (2002) The utility of radiological imaging in nonalcoholic fatty liver disease. *Gastroenterology* 123, 745–750.

19 Longo R, Polleseelo P, Ricci C *et al.* (1995) Proton MR spectroscopy in quantitative *in vivo* determination of fat content in human liver steatosis. *J Magn Reson Imaging* 5, 281–285.

20 Matteoni, C, Younossi Z, Gramlich T *et al.* (1999) Nonalcoholic fatty liver disease: a spectrum of clinical and pathological severity. *Gastroenterology* 116, 1413–1419.

21 Andersen T, Gluud C, Franzmann M *et al.* (1991) Hepatic effects of dietary weight loss in morbidly obese subjects. *J Hepatol* 12, 224–229.

22 Luyckx FH, Desaive C, Thiry A *et al.* (1998) Liver abnormalities in severely obese subjects: effect of drastic weight loss after gastroplasty. *Int J Obes Relat Metab Disord* 22, 222–226.

23 Palmer M, Schaffner F (1990) Effect of weight reduction on hepatic abnormalities in overweight patients. *Gastroenterology* 99, 1408–1413.

24 Rozental B, Biava C, Spencer H *et al.* (1967) Liver morphology and function tests in obesity and during total starvation. *Am J Dig Dis* 12, 198–208.

25 Drenick E, Simmons F, Murphy J (1970) Effect on hepatic morphology of treatment of obesity by fasting, reducing diets, and small-bowel bypass. *N Engl J Med* 282, 829–834.

26 Basaranoglu M, Acbay O, Sonsuz A (1999) A controlled trial of gemfibrizole in the treatment of patients with non-alcoholic steatohepatitis (letter). *J Hepatol* 31, 384.

27 Lavine J (2000) Vitamin E treatment of non-alcoholic steatohepatitis in children: a pilot study. *J Pediatr* 136, 734–738.

28 Abdelmalek A, Angulo P, Jorgensen R *et al.* (2001) Betaine, a promising new agent for patients with nonalcoholic steatohepatitis: results of a pilot study. *Am J Gastroenterol* 96, 2711–2717.

29 Laurin J, Lindor KD, Crippin JS *et al.* (1996) Ursodeoxycholic acid or clofibrate in the treatment of non alcohol-induced steatohepatitis: a pilot study. *Hepatology* 23, 1464–1467.

30 Lindor KD, Kowdley KV, Heathcote EJ *et al.* (2004) Ursodeoxycholic acid for treatment of nonalcoholic steatohepatitis: results of a randomized trial. *Hepatology* 39, 770–778.

31 Bajaj M, Suraamornkul S, Pratipanawatr T *et al.* (2003) Pioglitazone reduces hepatic fat content and augments splanchnic glucose uptake in patients with type 2 diabetes. *Diabetes* 52, 1364–1370.

32 Freedman R, Uwaifo G, Lutchman G *et al.* (2003) Changes in insulin sensitivity and improvements in liver histology in patients with nonalcoholic steatohepatitis (NASH) treated with pioglitazone (PIO) (abstract). *Diabetes* 52(Suppl. 1), 76A.

33 Acosta R, Molina E, O'Brien C *et al.* (2001) The use of pioglitazone in nonalcoholic steatohepatitis (abstract). *Gastroenterology* 120(Suppl. 1), A546.

34 Sanyal AJ, Mofrad PS, Contos MJ *et al.* (2004) A pilot study of vitamin E versus vitamin E and pioglitazone for the treatment of nonalcoholic steatohepatitis. *Clin Gastroenterol Hepatol* 2, 1107–1115.

35 Neuschwander-Tetri B, Brunt E, Wehmeier K *et al.* (2003) Interim results of a pilot study demonstrating the early effects of the PPAR-gamma ligand rosiglitazone on insulin sensitivity, aminotransferases, hepatic steatosis, and body weight in patients with non-alcoholic steatohepatitis. *J Hepatol* 38, 434–440.
36 Horlander J, Kwo P, Cummings O (2001) Atorvastatin for the treatment of NASH (abstract). *Gastroenterology* 120(Suppl.), A544.
37 Kiyici M, Gulten M, Gurel S *et al.* (2003) Ursodeoxycholic acid and atorvastatin in the treatment of nonalcoholic steatohepatitis. *Can J Gastroenterol* 17, 713–718.
38 Nair S, Diehl A, Perille R (2002) Metformin in non-alcoholic steatohepatitis: efficacy and safety: a preliminary report (abstract). *Gastroenterology* 122(4 Suppl.), Abstract 4.
39 Marchesisni G, Brizi M, Bianchi G *et al.* (2001) Metformin in non-alcoholic steatohepatitis (letter). *Lancet* 358, 893–894.
40 Khuri K, Shamma AM, Abourizk N (1985) Hepatitis B virus markers in diabetes mellitus. *Diabetes Care* 8, 250–253.
41 Gray H, Wreghitt, T Stratton I *et al.* (1995) High prevalence of hepatitis C infection in Afro-Caribbean patients with Type 2 diabetes and abnormal liver function tests. *Diabet Med* 12, 244–249.
42 Simo R, Hernandez C, Genesca J *et al.* (1996) High prevalence of hepatitis C virus infection in diabetic patients. *Diabetes Care* 19, 998–1000.
43 Lonardo A, Adinolfi L, Loria P *et al.* (2004) Steatosis and hepatitis C virus: mechanisms and significance for hepatic and extra-hepatic disease. *Gastroenterology* 126, 586–597.
44 Mason A, Lau J, Hoang N *et al.* (1999) Association of diabetes mellitus and chronic hepatitis C virus infection. *Hepatology* 29, 328–333.
45 Allison M, Wreghitt T, Palmer C *et al.* (1994) Evidence for a link between hepatitis C virus infection and diabetes mellitus in a cirrhotic population. *J Hepatol* 21, 1135–1139.
46 de Marco R, Locatelli F, Zoppini G *et al.* (1999) Cause-specific mortality in type 2 diabetes. The Verona Diabetes Study. *Diabetes Care* 5, 756–761.
47 Kingston M, Ali M, Atiyeh M *et al.* (1984) Diabetes mellitus in chronic active hepatitis and cirrhosis. *Gastroenterology* 87, 688–694.
48 Lawson D, Gray J, McKillop C *et al.* (1986) Diabetes mellitus and primary hepatocellular carcinoma. *Q J Med* 61, 945–955.
49 Adami H, Chow W, Nyren O *et al.* (1996) Excess of risk of primary liver cancer in patients with diabetes mellitus. *J Natl Cancer Inst* 88, 1472–1477.
50 Wideroff L, Gridley G, Mellemkjaer L *et al.* (1997) Cancer incidence in a population based cohort of patients hospitalized with diabetes mellitus in Denmark. *J Natl Cancer Inst* 89, 1360–1365.
51 Fujino Y, Mizoue T, Tokui N *et al.* (2001) Prospective study of diabetes mellitus and liver cancer in Japan. *Diabetes Metab Res Rev* 17, 374–379.
52 El-Serag H, Tran T, Everhart J (2004) Diabetes increases the risk of chronic liver disease and hepatocellular carcinoma. *Gastroenterology* 126, 460–468.
53 Ito T, Sasaki Y, Wands J (1996) Overexpression of human insulin receptor substrate 1 induces cellular transformation with activation of mitogen-activated protein kinases. *Mol Cell Biol* 16, 943–951.
54 Tanaka S, Wands J (1996) Insulin receptor 1 substrate over expression in human hepatocellular carcinoma cells prevents transforming growth factor beta 1-induced apoptosis. *Cancer Res* 56, 3391–3394.
55 Lieber M (1952) The incidence of gallstones and their correlation with other diseases. *Ann Surg* 135, 394–405.
56 DeSantis A, Attila A, Ginanni Corradini S *et al.* (1997) Gallstones and diabetes: a case–control study in a free living population sample. *Hepatology* 25, 787–790.
57 Attili A, Capocaccia R, Carulli N *et al.* (1997) Factors associated with gallstone disease in the MICOL experience. Multicenter Italian Study of Epidemiology of Cholelithiasis. *Hepatology* 26, 809–818.
58 Chapman B, Wilso I, Frampton C *et al.* (2000) Prevalence of gallbladder disease in diabetes mellitus. *Dig Dis Sci* 45, 2002–2006.
59 Haffner S, Diehl A, Mitchell B *et al.* (1990) Increased prevalence of clinical gallbladder disease in subjects with non-insulin diabetes mellitus. *Am J Epidemiol* 132, 327–335.
60 Haber G, Heaton K (1979) Lipid composition of bile in diabetics and obesity-matched controls. *Gut* 20, 518–522.
61 Sturdevant RA, Pearce ML, Dayton S (1973) Increased prevalence of cholelithiasis in men ingesting a serum-cholesterol-lowering diet. *N Engl J Med* 288, 24–27.
62 Stone B, Gavaler J, Belle S *et al.* (1988) Impairment of gallbladder emptying in diabetes mellitus. *Gastroenterology* 95, 170–176.
63 Pazzi P, Scaliarini R, Gamberini S *et al.* (2000) Review article: gallbladder motor function in diabetes mellitus. *Aliment Pharmacol Ther* 14(Suppl. 2), 62–65.
64 Sandler R, Maule W, Baltus M (1986) Factors associated with post-operative complications in diabetics after biliary tract surgery. *Gastroenterology* 91, 157–162.
65 Freidman L, Roberts M, Brett A *et al.* (1988) Management of asymptomatic gallstones in the diabetic patient. A decision analysis. *Ann Intern Med* 109, 913–919.
66 Chan K, Truman A, Gurwitz J *et al.* (2003) A cohort study of the incidence of serious acute liver injury in diabetic patients treated with hypoglycemic agents. *Arch Intern Med* 163, 728–734.
67 Chojkier M (2005) Troglitazone and liver injury: in search of answers. *Hepatology* 41, 229–230.
68 Zawadski J, Green L, Graham B (2002) Troglitazone-associated 15 month post-marketing hepatotoxicity. FDA Science Forum. Accessed at www.cfsan.fda.gov/~frf/forum02/a187ab4.htm.
69 Beckett G, Kellett H, Gow S *et al.* (1985) Raised plasma glutathione S-transferase values in hyperthyroidism and in hypothyroid patients receiving thyroxine replacement: evidence for hepatic damage. *Br Med J* 291(6493), 427–431.
70 Sola J, Pardo-Mindan F, Zozaya J *et al.* (1991) Liver changes in patients with hyperthyroidism. *Liver* 11, 193–199.
71 Chung Y, Jung S, Song B *et al.* (2001) Plasma isocitrate dehydrogenase as a marker of centrilobular hepatic necrosis in patients with hyperthyroidism. *J Clin Gastroenterol* 33, 118–122.
72 Fong T, McHutchison J, Reynolds T (1992) Hyperthyroidism and hepatic dysfunction. *J Clin Gastroenterol* 14, 240–224.
73 Malik R, Hodgson H (2002) The relationship between the thyroid gland and the liver. *Q J Med* 95, 559–569.
74 Klion FM, Segal R, Schaffner F (1971) The effect of altered thyroid function on the ultrastructure of the human liver. *Am J Med* 50, 317–324.
75 Doran G (1978) Serum enzyme disturbances in thyrotoxicosis and myxedema. *J R Soc Med* 71, 189–194.
76 Sandler MP, Robinson RP, Rabin D *et al.* (1983) The effect of thyroid hormones on gluconeogenesis and forearm metabolism in man. *J Clin Endocrinol Metab* 56, 479–485.
77 Williams K, Nayak S, Becker D *et al.* (1997) Fifty years of experience with propylthiouracil-associated hepatotoxicity: what have we learned? *J Clin Endocrinol Metab* 82, 1727–1733.

78 Seidman D, Livini E, Ilie B *et al.* (1986) Propylthiouracil-induced cholestatic jaundice. *Clin Toxicol* 24, 353–360.

79 Ayensa C, Diazde Otazu R, Cia JM (1986) Carbimazole-induced cholestatic hepatitis. *Arch Intern Med* 146, 1455.

80 Thobe N, Pilger P, Jones M (2000) Primary hypothyroidism masquerading as hepatic encephalopathy: case report and review of the literature. *Postgrad Med J* 76, 424–426.

81 Van Steenbergen W, Fevery J, De Vos R *et al.* (1989) Effects of hypothyroidism and hyperthyroidism on the hepatic transport of bilirubin mono- and diconjugates in the Wistar rat. *Hepatology* 2, 314–321.

82 Labrune P, Myara A, Huguet P *et al.* (1992) Bilirubin uridine diphosphate glucuronosyltransferase hepatic activity in jaundice associated with congenital hypothyroidism. *J Pediatr Gastroenterol Nutr* 1, 79–82.

83 Inkinen J, Sand J, Nordback I (2000) Association between common bile duct stones and treated hypothyroidism. *Hepatogastroenterology* 47, 919–921.

84 Klein I, Levey G (1984) Unusual manifestations of hypothyroidism. *Arch Intern Med* 144, 123–128.

85 Baker A, Kaplan M, Wolfe H (1972) Central congestive fibrosis of the liver in myxedema ascites. *Ann Intern Med* 77, 927–929.

86 Huang M, Liaw Y (1995) Clinical associations between thyroid and liver diseases. *J Gastroenterol Hepatol* 10, 344–350.

87 Olsson RG, Lindgren A, Zettergren L (1990) Liver involvement in Addison's disease. *Am J Gastroenterol* 85, 435–438.

88 Boulton R, Hamilton MI, Dhillon AP *et al.* (1995) Subclinical Addison's disease: a cause of persistent abnormalities in transaminase values. *Gastroenterology* 109, 1324–1327.

89 McIntyre N, Mulligan R, Carson E (1973) BSP Tm and S: a critical re-evaluation. In: Paumgartner G, Preisig R (eds) *The Liver: Quantitative Aspects of Structure and Function*. Basel: Karger, pp. 417–427.

90 Sato T, Tajiri J, Shimada T *et al.* (1984) Abnormal blood chemistry data in Cushing's syndrome: comparison with those for fatty liver. *Endocrinol Jpn* 31, 705–710.

91 Jones JP Jr, Engleman EP, Najarian JS (1965) Systemic fat embolism after renal homotransplantation and treatment with corticosteroids. *N Engl J Med* 273, 1453–1458.

92 Lake-Bakaar G, Scheuer PJ, Sherlock S (1987) Hepatic reactions associated with ketoconazole in the United Kingdom. *Br Med J* 294, 419–422.

93 McCance DR, Hadden DR, Kennedy L *et al.* (1987) Clinical experience with ketoconazole as a therapy for patients with Cushing's syndrome. *Clin Endocrinol* 27, 593–599.

94 Caitlin D (1995) Anabolic steroids. In: DeGroot L (ed.) *Endocrinology*. Philadelphia: Saunders, pp. 2362–2376.

95 Ishak KG, Zimmerman HJ (1987) Hepatotoxic effects of the anabolic/androgenic steroids. *Semin Liver Dis* 7, 230–236.

96 Bagheri SA, Boyer JL (1974) Peliosis hepatis associated with androgenic-anabolic steroid therapy. A severe form of hepatic injury. *Ann Intern Med* 81, 610–618.

97 Cabasso A (1994) Peliosis hepatis in a young adult bodybuilder. *Med Sci Sports Exerc* 26, 2–4.

98 Socas L, Zumbado M, Perez-Luzardo O *et al.* (2005) Hepatocellular adenomas associated with anabolic androgenic steroid abuse in bodybuilders: a report of two cases and a review of the literature. *Br J Sports Med* 39, e27.

99 Hernandez-Nieto L, Bruguera M, Bombi J *et al.* (1977) Benign liver-cell adenoma associated with long-term administration of an androgenic-anabolic steroid (methandienone). *Cancer* 40, 1761–1764.

100 Nakao A, Sakagami K, Nakata Y *et al.* (2000) Multiple hepatic adenomas caused by long-term administration of androgenic steroids for aplastic anemia in association with familial adenomatous polyposis. *J Gastroenterol* 35, 557–562.

101 Grazioli L, Federle MP, Brancatelli G *et al.* (2001) Hepatic adenomas: imaging and pathologic findings. *Radiographics* 4, 877–892.

102 Monga M (2006) Hepatic adenomas: presumed innocent until proven to be beta-catenin mutated. *Hepatology* 43, 401–404.

103 El-Serag HB (2004) Hepatocellular carcinoma: recent trends in the United States. *Gastroenterology* 127(5 Suppl. 1), S27–34.

104 Nagasue N, Yu L, Yukaya H *et al.* (1995) Androgen and oestrogen receptors in hepatocellular carcinoma and surrounding liver parenchyma: impact on intrahepatic recurrence after hepatic resection. *Br J Surg* 82, 542–547.

105 Recant L, Lacy P (1965) Fanconi's anemia and hepatic cirrhosis. *Am J Med* 39, 464–475.

106 Velazquez I, Alter BP (2004) Androgens and liver tumors: Fanconi's anemia and non-Fanconi's conditions. *Am J Hematol* 77, 257–267.

107 Ain KB, Mori Y, Refetoff S (1987) Reduced clearance rate of thyroxine-binding globulin (TBG) with increased sialylation: a mechanism for estrogen-induced elevation of serum TBG concentration. *J Clin Endocrinol Metab* 65, 689–696.

108 Grodstein F, Colditz GA, Hunter DJ *et al.* (1994) A prospective study of symptomatic gallstones in women: relation with oral contraceptives and other risk factors. *Obstet Gynecol* 84, 207–214.

109 Hulley S, Furberg C, Barrett-Connor E *et al.*; HERS Research Group (2002) Noncardiovascular disease outcomes during 6.8 years of hormone therapy: Heart and Estrogen/progestin Replacement Study follow-up (HERS II). *JAMA* 288, 58–66.

110 Mamdani MM, Tu K, van Walraven C *et al.* (2000) Postmenopausal estrogen replacement therapy and increased rates of cholecystectomy and appendectomy. *Can Med Assoc J* 162, 1421–1424.

111 Nelson HD, Humphrey LL, Nygren P *et al.* (2002) Postmenopausal hormone replacement therapy: scientific review. *JAMA* 288, 872–881.

112 Valla D, Le MG, Poynard T *et al.* (1986) Risk of hepatic vein thrombosis in relation to recent use of oral contraceptives. A case–control study. *Gastroenterology* 90, 807–811.

113 Baum JK, Bookstein JJ, Holtz F *et al.* (1973) Possible association between benign hepatomas and oral contraceptives. *Lancet* 2, 926–929.

114 Steinbrecher UP, Lisbona R, Huang SN *et al.* (1981) Complete regression of hepatocellular adenoma after withdrawal of oral contraceptives. *Dig Dis Sci* 26, 1045–1050.

115 Buhler H, Pirovino M, Akobiantz A *et al.* (1982) Regression of liver cell adenoma. A follow-up study of three consecutive patients after discontinuation of oral contraceptive use. *Gastroenterology* 82, 775–782.

116 Prentice RL (1991) Epidemiologic data on exogenous hormones and hepatocellular carcinoma and selected other cancers. *Prev Med* 20, 38–46.

117 Yu MW, Chang HC, Chang SC *et al.* (2003) Role of reproductive factors in hepatocellular carcinoma: impact on hepatitis B- and C-related risk. *Hepatology* 38, 1393–1400.

118 Sato N, Lindros KO, Baraona E *et al.* (2001) Sex difference in alcohol-related organ injury. *Alcohol Clin Exp Res* 25(5 Suppl. ISBRA), 40S–45S.

119 Shimizu I (2003) Impact of oestrogens on the progression of liver disease. *Liver Int* 23, 63–69.

120 Ezzat S (1992) Hepatobiliary and gastrointestinal manifestations of acromegaly. *Dig Dis* 10, 173–180.

121 Avagnina P, Martini M, Terzolo M *et al.* (1996) Assessment of functional liver mass and plasma flow in acromegaly before and after long-term treatment with octreotide. *Metabolism* 45, 109–113.

122 Melmed S, Casanueva FF, Cavagnini F *et al.*; Acromegaly Treatment Consensus Workshop Participants (2002) Guidelines for acromegaly management. *J Clin Endocrinol Metab* 87, 4054–4058.

123 Shi YF, Zhu XF, Harris AG *et al.* (1993) Prospective study of the long-term effects of somatostatin analog (octreotide) on gallbladder function and gallstone formation in Chinese acromegalic patients. *J Clin Endocrinol Metab* 76, 32–37.

124 Ayuk J, Stewart SE, Stewart PM *et al.* (2002) Long-term safety and efficacy of depot long-acting somatostatin analogs for the treatment of acromegaly. *J Clin Endocrinol Metab* 87, 4142–4146.

125 Zhu XF, Harris AG, Yang MF *et al.* (1994) Effect of octreotide on dynamic excretion of bile in Chinese acromegalic patients assessed by [99mTc]EHIDA hepatobiliary scan. *Dig Dis Sci* 39, 284–288.

126 van Liessum PA, Hopman WP, Pieters GF *et al.* (1989) Postprandial gallbladder motility during long term treatment with the long-acting somatostatin analog SMS 201–995 in acromegaly. *J Clin Endocrinol Metab* 69, 557–562.

127 Trainer PJ, Drake WM, Katznelson L *et al.* (2000) Treatment of acromegaly with the growth hormone-receptor antagonist pegvisomant. *N Engl J Med* 342, 1171–1177.

128 Colao A, Pivonello R, Auriemma RS *et al.* (2006) Efficacy of 12-month treatment with the GH receptor antagonist pegvisomant in patients with acromegaly resistant to long-term, high-dose somatostatin analog treatment: effect on IGF-I levels, tumor mass, hypertension and glucose tolerance. *Eur J Endocrinol* 154, 467–477.

129 Biering H, Saller B, Bauditz J *et al.*; German pegvisomant investigators (2006) Elevated transaminases during medical treatment of acromegaly: a review of the German pegvisomant surveillance experience and a report of a patient with histologically proven chronic mild active hepatitis. *Eur J Endocrinol* 154, 213–220.

130 Salomon F, Cuneo RC, Hesp R *et al.* (1989) The effects of treatment with recombinant human growth hormone on body composition and metabolism in adults with growth hormone deficiency. *N Engl J Med* 321, 1797–1803

131 Kaji H, Sakurai T, Iguchi G *et al.* (2002) Adult growth hormone deficiency in Japan: results of investigation by questionnaire. *Endocr J* 49, 597–604.

132 Irie M, Itoh Y, Miyashita Y *et al.* (2004) Complications in adults with growth hormone deficiency – a survey study in Japan. *Endocr J* 51, 479–485.

20.10 Musculoskeletal diseases and the liver

N. Guañabens, J. van den Bogaerde and H.L.C. Beynon

Introduction

Hepatic manifestations of rheumatic diseases are highly heterogeneous in terms of their clinical, biochemical and histological profile. In fact, a variety of rheumatic diseases affect the liver in addition to the drugs used in the pharmacological interventions in musculoskeletal diseases. It is a challenge for physicians involved in rheumatic and liver diseases, and a better understanding of the immunogenetics and pathogenesis might lead to more rational and successful management.

Connective tissue diseases may cause abnormalities of liver function tests as well as a variety of histological changes. The severity of the underlying connective tissue disease influences the course of the liver disease, and immunosuppressive treatment can affect liver chemistries. Generally, the symptoms of the connective tissue disease dominate the clinical presentation, and liver involvement rarely causes diagnostic or therapeutic problems. Frequently, however, deranged liver function tests, in conjunction with evidence of other organ involvement, may pose major diagnostic and therapeutic challenges to the practising clinician.

This chapter will focus on liver involvement in a variety of rheumatic diseases, including systemic lupus erythematosus, antiphospholipid antibody syndrome, rheumatoid arthritis, Felty syndrome, Sjögren syndrome, scleroderma and vasculitis. The aim is to provide a resource for the hepatologist in the management of patients with rheumatic diseases in clinical practice.

Connective tissue diseases

Systemic lupus erythematosus

Systemic lupus erythematosus (SLE) is a disease with a complex set of immunological abnormalities that appear to involve multiple mechanisms of dysregulation characterized by a wide range of autoantibodies directed against both intra- and extracellular antigens [1,2]. Anti-double-stranded (ds)DNA antibodies are characteristic of SLE. It is often held up as the paradigm of a disease mediated by the deposition of immune complexes.

The revised American College of Rheumatology classification criteria are widely used in clinical practice, as they encompass the heterogeneous manifestations of the disease [3]. In 1997, changes were recommended regarding the immunological disorder of these classification criteria, including the antiphospholipid component. The presence of four or more of the criteria, not necessarily at the same time, is sufficient to make the diagnosis of SLE. The criteria are: malar (butterfly) rash; discoid rash; photosensitivity; oral ulcers; non-erosive arthritis; serositis (pleuritis or pericarditis); renal involvement with proteinuria or cellular casts; haematological involvement (haemolytic anaemia or leucopenia or lymphopenia); central nervous system involvement (psychosis or epilepsy); immunological disorder [anti-DNA or anti-smooth muscle (Sm) or LE cells or antiphospholipid antibodies]; and positive antinuclear antibody. Abnormalities of liver function are not included in the classification criteria of SLE, and the liver is not a major target organ for damage in this disorder [4].

SLE occurs 10 times more commonly in women than in men, and the overall prevalence in women is approximately 100 per 100 000 individuals. There are approximately 3 million women and 300 000 men affected worldwide [2]. The aetiopathogenesis of this disease is complex, and it probably represents a combination of genetic and environmental factors [5,6]. Target tissue damage is caused primarily by pathogenic autoantibodies and immune complexes [2]. The trigger for the formation of immune complexes is the breakdown of tolerance to autoantigens, possibly as a result of microbial and viral antigenic mimicry or an abnormality of idiotypic networks [7].

Clinically significant hepatic disease is uncommon in SLE [8]. Hepatomegaly occurs in 12–55% of patients, depending on the series [9,10,11]. Liver enzyme elevations, usually aminotransferases, are found in 23–50% of patients with SLE at some point [10,12]. These abnormalities have been associated with active disease and the administration of non-steroidal anti-inflammatory drugs (NSAIDs), especially salicylates. Liver enzyme abnormalities return to normal when the lupus is under control and the drugs are stopped. Alkaline phosphatase is usually not elevated in patients with lupus, although 31% of patients in some

historical series showed elevated serum alkaline phosphatase values [4]. In clinical practice, haemolysis as a result of the disease may cause an increase in unconjugated bilirubin, and myositis may result in an elevation in serum alanine and aspartate aminotransferases. Abnormal enzyme values may be related to microthrombi in the livers of patients with antiphospholipid antibody syndrome [13].

Fatty change is the most common histological finding [14], and steroid use has been implicated in patients with steatosis, but this condition has been found in patients with lupus who were not using these drugs [15]. Centrolobular necrosis and progressive fibrosis [14], as well as liver granulomas, have been described in patients with lupus [14,16]. Liver vasculitis is very rare but has been reported [17], as have hepatic rupture, hepatic infarction, giant cell hepatitis, inflammation of the portal tracts and hepatic amyloidosis [10,15,18,19].

Lupoid hepatitis is a synonym for autoimmune hepatitis, and is a separate entity from the hepatic features of SLE when taking into account the clinical findings and pathological changes. In contrast, serological criteria alone may lead to diagnostic confusion as both have features of an autoimmune disorder, such as the presence of antinuclear, anti-Sm or anticardiolipin antibodies [4].

An association has been reported between primary biliary cirrhosis (PBC) and a multisystem disease consistent with SLE. Whether this is a chance coexistence or a direct relationship between both diseases remains to be elucidated [12,20,21]. Also, Budd–Chiari syndrome has rarely been described in patients with SLE and lupus anticoagulant [22] as well as sclerosing cholangitis [23].

NSAIDs are commonly used in patients with SLE and sometimes cause liver damage. Immunosuppressive therapy may result in infections, both systemic and hepatic, and there is also an increased risk of malignancy, which may involve the liver. The incidence of non-Hodgkin's lymphoma is fourfold higher in patients with lupus than in the general population [24]. It is noteworthy that this study demonstrated that patients with lupus were at lower risk of malignancy than patients with rheumatoid arthritis or systemic sclerosis.

The antiphospholipid antibody syndrome

The antiphospholipid antibody syndrome is characterized by a range of autoantibodies that bind to negatively charged phospholipids (phosphatidylserine and phosphatidylcholine). This syndrome presents clinically with recurrent thromboembolic disease or multiple miscarriages.

Antiphospholipid antibody syndrome can occur as an isolated disorder, known as primary antiphospholipid antibody syndrome, or it can be associated with another rheumatic disease and known as secondary antiphospholipid antibody syndrome [25]. Thus, it may be found in diverse conditions such as SLE, Sjögren syndrome [26,27], scleroderma, vasculitis and dermatomyositis. Drugs such as phenytoin, hydralazine, chlorpromazine and quinidine are responsible for approximately 1/10th of patients with antiphospholipid antibodies, but not for the syndrome.

Other manifestations of the antiphospholipid antibody syndrome include: (i) pulmonary hypertension; (ii) multiple sclerosis-like syndrome, non-focal neurological symptoms and chorea; (iii) thrombocytopenia and haemolytic anaemia; (iv) livedo reticularis, digital gangrene and skin ulcers; (v) cardiac valve disease; (vi) renal failure; and (vii) catastrophic vascular occlusion syndrome [25].

In clinical practice, there are two commonly performed tests that detect antibodies against negatively charged phospholipids. These are the lupus anticoagulant test and the cardiolipin antibody test. A false-positive Venereal Disease Research Laboratory (VDRL) test does not fulfil the laboratory criterion. Although thrombotic complications dominate the clinical presentation, the partial thromboplastin time is characteristically increased. One group of antiphospholipid antibodies binds to β_2-glycoprotein 1, and the presence of these antibodies may predict a worse clinical outcome, particularly in pregnant patients [28–30].

A variety of hepatic abnormalities may be seen in association with antiphospholipid antibody syndrome. Budd–Chiari syndrome associated with hepatic vein occlusion has been reported [22,31,32]. Thus, antiphospholipid antibody syndrome should be excluded in any patient who presents with unexplained hepatic vascular thromboses [4]. In addition, inferior vena cava obstruction [33] has been reported in patients with antiphospholipid antibodies. Published reports have indicated that nodular regenerative hyperplasia of the liver associated with SLE is usually related to anticardiolipin antibodies and/or lupus anticoagulant [34]. Therefore, Abraham *et al.* [8] pointed out that the diagnosis of nodular regenerative hyperplasia should be considered and liver specimens obtained in patients with antiphospholipid antibodies who develop persistently altered liver function tests or signs and symptoms of portal hypertension.

Rheumatoid arthritis

Rheumatoid arthritis is the most common inflammatory disease of synovial joints, affecting from 0.5% to 1% of the general population worldwide. It is a true multisystem disease, but joint involvement is usually the predominant feature [35]. Although the aetiology is unknown, it is considered to be a disease of multifactorial origin, including a genetic predisposition, and is characterized by immune-driven chronic inflammation. Both T cell-dependent and -independent processes might contribute to disease initiation and perpetuation, with differences in disease pathogenesis at various stages of the process.

Rheumatoid arthritis is a clinical diagnosis. The 1987 American Rheumatism Association revised criteria for the classification of rheumatoid arthritis are widely used to establish the diagnosis [36]. The presence of four or more of the following criteria is sufficient to make the diagnosis: (i) morning stiffness (lasting longer than 1 h, for more than 6 weeks); (ii) arthritis of

three or more areas (objective swelling for more than 6 weeks); (iii) arthritis of hand joints; (iv) symmetrical arthritis; (v) rheumatoid nodules; (vi) serum rheumatoid factor (the laboratory method must diagnose this factor in less than 5% of control subjects); and (vii) radiographic changes (anteroposterior wrist and hand radiographs).

Hepatic involvement is not generally recognized as a significant extra-articular feature of rheumatoid arthritis. However, abnormalities in liver function tests are often seen in patients with rheumatoid arthritis, and as many as one-half of patients with rheumatoid arthritis may have raised alkaline phosphatase levels [37–39]. Some authors have proposed that alkaline phosphatase and γ-glutamyltransferase elevations in patients with rheumatoid arthritis correlate with levels of acute-phase proteins and the erythrocyte sedimentation rate [40]. Accordingly, with control of disease activity, the test abnormalities return to normal. In addition, the effects of NSAIDs in the liver function tests must be differentiated from those induced by disease activity [41]. Enzyme elevations in patients with rheumatoid arthritis are not associated with consistent histological changes in the liver, and the clinical significance of these abnormalities is not clear. Furthermore, the source of alkaline phosphatase, bone vs. liver, is somewhat controversial [4].

Liver biopsy findings in rheumatoid arthritis are non-specific. Liver biopsies were performed on 117 unselected patients with rheumatoid arthritis, many of whom had normal liver function tests. Abnormal hepatic histology was found in 65%, with steatosis present in 22% [42]. Occasionally, up to 3% of patients with rheumatoid arthritis have hepatic fibrosis before the initiation of methotrexate therapy. Patients may have mild inflammatory changes, mainly involving the portal tracts, with occasional fat-containing hepatocytes, and scattered foci of liver cell necrosis.

Synovial fluid of patients with rheumatoid arthritis was shown to produce interleukin (IL)-1 and -6 in sufficient quantities to induce serum amyloid A production by hepatic cells [43]. Rheumatoid arthritis is a well-recognized cause of secondary amyloidosis [44,45], in which liver involvement is well described.

Juvenile rheumatoid arthritis

Juvenile rheumatoid arthritis is the most frequent chronic arthritis of children at or below the age of 16 years. Females are more commonly affected than males. Systemic onset of juvenile chronic rheumatoid arthritis is called Still's disease and is characterized by high fever, hepatosplenomegaly, polyserositis, coagulopathy, lymphadenopathy and rash. This subset of patients with juvenile rheumatoid arthritis may be associated with liver enlargement and aminotransferase elevation [46]. A true hepatitis, not related to NSAIDs, may occur. In patients with hepatic involvement, periportal mononuclear cell infiltration, Kupffer cell hyperplasia and steatosis are seen. The hepatomegaly and liver cell dysfunction regress during remission of the systemic disease. Focal hepatic lesions have also been seen in patients with juvenile rheumatoid arthritis [47], as well as a macrophage activation syndrome associated with hepatosplenomegaly and bone marrow infiltration [48]. Adult-onset Still's disease may also be associated with hepatomegaly and abnormal aminotransferase elevation [49].

Treatment of young patients with NSAIDs may also cause liver dysfunction, although children may be more resistant to aspirin-induced hepatotoxicity than adults [50]. The use of methotrexate in children with juvenile rheumatoid arthritis, at doses of 10–15 mg/week, has been shown to be at least as safe as in adults and may become the treatment of choice in children with this disease [51].

Felty syndrome

Felty syndrome is characterized by the triad of rheumatoid arthritis, leucopenia and splenomegaly. Severe joint disease and extra-articular features may be seen [52]. Mild hepatomegaly is common in Felty syndrome, and elevations in alkaline phosphatase and aminotransferases may occur. An association between Felty syndrome, nodular regenerative hyperplasia and portal hypertension has been described [53]. Nodular regenerative hyperplasia is a diffuse hepatic regenerative process that differs from cirrhosis by not having fibrous septa [54]. Conditions such as partial nodular transformation, focal nodular hyperplasia and hepatocellular adenomatosis (usually seen in young women taking oral contraceptives) must be differentiated from nodular regenerative hyperplasia [55,56]. In one study, 12 out of 18 patients with Felty syndrome had abnormal liver findings, five with nodular regenerative hyperplasia and seven with portal fibrosis or abnormal lobular architecture [57]. One-third of these had portal hypertension, which caused bleeding in a significant number. Only seven out of the 12 with abnormal histology had abnormal biochemistry, suggesting that, in patients with Felty syndrome, portal hypertension and oesophageal varices should be excluded even if liver function tests are normal.

Mixed connective tissue disease

Mixed connective tissue disease is characterized by the overlap of the clinical features of SLE, scleroderma, dermatomyositis and polymyositis. High titres of anti-U1 RNP (ribonucleoprotein of extractable nuclear antigen) antibodies are invariably found. Raynaud's phenomenon, swollen fingers, synovitis, myositis and acrosclerosis are the clinical features included in the diagnostic criteria.

Hepatomegaly has been described in up to 15% of patients, but serious liver disturbance is rare. In one study, only four out of 61 patients with mixed connective tissue disease had evidence of liver disease [58]. Chronic active hepatitis and cirrhosis were documented in one patient, steatosis in another, and

the remaining two patients had liver congestion secondary to pulmonary hypertension. The presence of autoimmune hepatitis in patients with mixed connective tissue disease should be suspected if anti-Sm antibodies are found, and occasional association with Budd–Chiari syndrome has been documented [59].

Sjögren syndrome

Sjögren syndrome is a chronic autoimmune disease of unknown aetiology, which is characterized by lymphocytic infiltration and destruction of epithelial exocrine glands [1]. Objective demonstration of dry eyes (Schirmer's test), dry mouth (parotid flow rate) and lymphocytic salivary gland infiltrate is required to make the diagnosis, in addition to abnormal autoantibodies. Both antinuclear and rheumatoid factor (IgM anti-IgG) antibodies may be present in titres exceeding 1:320. The most specific antibodies are anti-SS A (Ro) and anti-SS B (La), but these are also seen in SLE. The accepted nomenclature for this syndrome is as follows: primary Sjögren syndrome is best defined as dry eyes and dry mouth secondary to autoimmune dysfunction of the exocrine glands; secondary Sjögren syndrome is defined as the first definition in association with another autoimmune connective tissue disorder. It is found in association with rheumatoid arthritis (20%) and SLE (30%), as well as scleroderma, among others.

The following are clinical features of Sjögren syndrome: (i) xerostomia, keratoconjuctivitis sicca, parotid gland enlargement; (ii) nasal and upper airway dryness, xerotrachea, pulmonary infiltrate; (iii) arthralgias, arthritis, Raynaud's phenomenon; (iv) lymphadenopathy, splenomegaly; (v) renal tubular acidosis, interstitial nephritis; and (vi) hepatitis, myositis, neuropathy, vasculitis and B-cell lymphoma.

Hepatomegaly has been documented in 25% of patients, and alkaline phosphatase and aminotransferase levels may also be elevated in patients with Sjögren syndrome. Antimitochondrial antibodies are found in approximately 10% of patients [60,61]. Positive titres for antimitochondrial antibodies are usually accompanied by histopathological abnormalities consistent with PBC. Thus, in the largest series to date, 300 patients with primary Sjögren syndrome were investigated for liver disease. Seven per cent of patients showed evidence of liver disease, which was either subclinical (2%) or asymptomatic (5%) with raised liver enzymes. In 6.6% of patients, antimitochondrial antibodies were detected, and the liver biopsy analysis showed features consistent with stage I PBC [4,8,62].

The prevalence of antibodies to hepatitis C virus (HCV) in patients with primary Sjögren syndrome has been found to be between 13% and 19%, with histopathological evidence of chronic hepatitis in those who underwent a liver biopsy [4,8,63,64].

Sjögren syndrome is common in patients with chronic liver disease and may accompany chronic active hepatitis (35%) or cryptogenic cirrhosis (24%) [66], sclerosing cholangitis, mixed connective tissue disease or PBC [62,65–68].

Scleroderma

Systemic sclerosis (scleroderma) is a multisystem connective tissue disease of unknown origin, which is more common in women than in men [69]. It is characterized pathologically by the overproduction of connective tissue and collagen. Patients may present with widespread vascular damage and microvascular obliteration. Among its classifications, the most frequent subgroups, based on clinical and prognostic differences, are diffuse scleroderma and limited scleroderma or CREST syndrome (subcutaneous calcinosis, Raynaud's phenomenon, oesophageal dysmotility, sclerodactyly, telangiectases).

Clinically, there is a disease spectrum ranging from limited systemic sclerosis, with skin thickening of the face, arms below the elbow and legs below the knee, to diffuse systemic sclerosis with widespread skin thickening. Anticentromere antibodies are found in 50–96% of patients with limited systemic sclerosis, and in less than 10% of individuals with diffuse scleroderma. Between 20% and 40% of patients with systemic sclerosis and diffuse scleroderma have serum antibodies reactive with Scl-70 (anti-topoisomerase 1) [69,70]. Although the aetiology is unknown and the pathogenesis remains uncertain, there is evidence that vascular and endothelial cell activation play an important role in fibroblast activation [71].

The liver disease that is usually associated with scleroderma is PBC. This association has been well documented [72–74]. Thus, in several reviews of patients with PBC, a subset of patients with systemic sclerosis and particularly CREST syndrome has been reported [75,76]. Only 3–4% of patients with systemic sclerosis also have PBC, and systemic sclerosis usually precedes the latter. The presence of antimitochondrial antibodies in patients with systemic sclerosis should alert the clinician to the possibility of PBC. Hepatic fibrosis may also occur, but it is uncommon in patients with systemic sclerosis [77].

Eosinophilic fasciitis

Eosinophilic fasciitis is an uncommon disease that may be confused with scleroderma. Symmetrical swelling and induration of the distal parts of the limbs occurs; the hands, feet and trunk are involved less frequently, and eosinophilia is found in 90% of cases. Antinuclear antibodies and thyroiditis are sometimes associated, and patients with granulomatous or a reactive hepatitis have rarely been described [78–80].

Dermatomyositis/polymyositis

Liver involvement is rarely found in patients with poly/dermatomyositis. Muscle involvement may result in enzyme elevations, which can mistakenly be attributed to the liver. Chronic active hepatitis, biliary cirrhosis, peliosis hepatitis and Wilson's disease have been described in these patients

[82–84]. Primary or metastatic liver disease may result in dermatomyositis [84,85].

Vasculitis and liver disease

Systemic vasculitis may be defined as an inflammatory disorder of the blood vessels, which usually results in necrosis of the vessel wall with subsequent vascular occlusion. There are a group of diseases such as Wegener's granulomatosis and polyarteritis nodosa, in which vasculitis appears to represent the primary pathology. Even when vasculitis has been associated with a specific infection such as hepatitis B virus, the clinical features and pathology may be diverse, ranging from polyarteritis nodosa to localized vasculitic lesions affecting the skin and kidneys. Among the reports of systemic vasculitis, the liver has been found to be more or less commonly involved in polyarteritis nodosa, giant cell arteritis and Behçet's disease. In addition, other vasculitis may involve a variety of organs, and abnormal liver function tests have occasionally been described in all types of primary vasculitic syndromes [86–88].

Polyarteritis nodosa is a systemic, non-granulomatous vasculitis, affecting medium-sized and small arteries. Hepatitis B virus infection is found in 10–20% of patients. Liver involvement is common; cirrhosis, acute and chronic hepatitis, hepatic infarction and hepatic arteriole involvement have been documented [89,90]. Rupture of intra- or extrahepatic arterial aneurysms may occur. Hepatomegaly may be seen in 20% of patients, but bilirubin and liver enzyme elevations are documented in approximately 10%. Acute cholecystitis may be the presenting manifestation of polyarteritis nodosa [91]. Patients with hepatitis B-associated polyarteritis nodosa may deteriorate during treatment with immunosuppressive agents such as steroids and cyclophosphamide. In these patients, initial brief steroid therapy may be used to control the serious complications of polyarteritis nodosa, followed by plasma exchange and antiviral therapy (interferon or vidarabine) [92].

Polymyalgia rheumatica is relatively common with a reported prevalence of 500 per 100 000 population over 50 years old [93]. The disease has the following characteristics [94]: (i) patients are usually more than 50 years old; (ii) pain or stiffness of shoulder, hip or neck; (iii) sedimentation rate of more than 40 mm/h; (iv) rapid response to relatively low steroid dose (15 mg/day); and (v) exclusion of other connective tissue or primary muscle diseases.

Giant cell arteritis is a vasculitic disease, predominantly affecting branches of the carotid artery, in particular the temporal artery. Peripheral arteries may be involved in 10% of patients [95]. The prevalence of biopsy-proven giant cell arteritis has been reported to be 223 per 100 000 population aged 50 years or older [96]. Headache, temporal artery tenderness of tortuosity and jaw claudication are common and specific findings. Constitutional symptoms are present in one-half of patients, and optical and neurological symptoms may occur in one-third [97].

Polymyalgia rheumatica and giant cell arteritis are often associated [98]. Patients with giant cell arteritis have polymyalgic symptoms in approximately 30–50% of cases. The prevalence of giant cell arteritis in patients with polymyalgia rheumatica is lower, and probably occurs in 10–15% of unselected patients [93].

The incidence of mild liver test abnormalities in patients with polymyalgia rheumatica or giant cell arteritis is 40–60% [99]. Alkaline phosphatase or aminotransferase levels may be elevated in approximately 50% of patients [100], and enzyme levels may return to normal when the disease is treated with steroids. Liver biopsy is usually non-specific, but steatosis, hepatic granulomas and portal tract inflammation have been seen [101]. Cholestatic liver disease [102,103], arteritis of hepatic arterioles and arterioli as well as granulomatous hepatitis have been documented in patients with giant cell arteritis [104]. The correlation between abnormal liver histology and biochemical tests is poor.

Behçet's disease is a systemic vasculitis, which occurs predominantly in young men. The aetiology of this disease is unknown. The diagnosis is confirmed by the presence of recurrent oral ulceration with two out of the following four other criteria: recurrent genital ulceration, typical eye lesions (uveitis or iridocyclitis), typical skin lesions (erythema nodosum, skin ulcers) or a positive pathergy test. Other systems such as the lungs, gastrointestinal tract, joints and veins may be involved. A necrotizing vasculitis involving arteries, arterioles and veins is found [105]. Thrombosis is initiated by inflammation of veins, and Behçet's disease may be a more important cause of venous occlusion than SLE [105]. The liver is rarely involved except in the development of hepatic vein and vena caval thrombosis, as well as Budd–Chiari syndrome [106–108].

References

1 Beynon HL, Athanassiou P, Davies KA (1995) Role of the endothelium in systemic lupus erythematosus and Sjögren's syndrome. In: Savage COS, Pearson JD (eds) *Immunological Aspects of the Vascular Endothelium*. Cambridge: Cambridge University Press, pp. 124–152.

2 Edworthy SM (2005) Clinical manifestations of systemic lupus erythematosus. In: Harris ED, Budd RC, Firestein GS *et al.* (eds) *Kelley's Textbook of Rheumatology*, 7th edn. Philadelphia: Elsevier Saunders, pp. 1201–1224.

3 Tan EM, Cohen AS, Fries JF *et al.* (1982) The 1982 revised criteria for the classification of systemic lupus erythematosus. *Arthritis Rheum* 25, 1271–1277.

4 Youssef WI, Tavill AS (2002) Connective tissue diseases and the liver. *J Clin Gastroenterol* 35, 345–349.

5 Walport MJ, Black CM, Batchelor JR (1982) The immunogenetics of SLE. *Clin Rheum Dis* 8, 3–21.

6 Kahaleh MB (1992) The role of vascular endothelium in fibroblast activation and tissue fibrosis, particularly in scleroderma (systemic sclerosis) and pachydermoperiostosis (primary hypertrophic osteoarthropathy). *Clin Exp Rheumatol* 10 (Suppl. 7), 51–56.

7 Walport MJ (1993) Systemic lupus erythematosus. In: Lachman PJ,

Peters DK, Rosen FS *et al.* (eds) *Clinical Aspects of Immunology*, 5th edn. Boston: Blackwell Scientific Publishers, pp. 1161–1204.
8 Abraham S, Begum S, Isenberg D (2004) Hepatic manifestations of autoimmune rheumatic diseases. *Ann Rheum Dis* 63, 123–129.
9 Cairns A, McMahon RF (1996) Giant cell hepatitis associated with systemic lupus erythematosus. *J Clin Pathol* 49, 183–184.
10 Van-Hoek B (1996) The spectrum of liver disease in systemic lupus. erythematosus. *Neth J Med* 48, 244–253.
11 Rothfield NF (1977) Systemic lupus erythematosus. In: Katz WA (ed.) *Rheumatic Diseases: Diagnosis and Management*. Philadelphia: JB Lippincott, p. 765.
12 Miller MH, Urowitz MB, Gladman DD *et al.* (1984) The liver in systemic lupus erythematosus. *Q J Med* 53, 401–409.
13 Inam S, Sidki K, al-Marshedy AR *et al.* (1991) Addison's disease, hypertension, renal and hepatic microthrombosis in 'primary' antiphospholipid syndrome. *Postgrad Med J* 67, 385–388.
14 Runyon BA, Labrecque DR, Anuras S (1980) The spectrum of liver disease in systemic lupus erythematosus. *Am J Med* 69, 187–194.
15 Atsumi T, Sagawa A, Jodo S *et al.* (1995) Severe hepatic involvement without inflammatory changes in systemic lupus erythematosus, report of two cases and review of the literature. *Lupus* 4, 225–228.
16 Estes D, Christian CL (1971) The natural history of systemic lupus erythematosus by prospective. analysis. *Medicine* 50, 85–95.
17 Dubois EL, Tuffanelli DL (1964) Clinical manifestations of SLE. Computer analysis of 520 cases. *JAMA* 190, 104–111.
18 Dohmen K, Ohtsuka S, Nakamura H *et al.* (1994) Post-infantile giant cell hepatitis in an elderly female patient with systemic lupus erythematosus. *J Gastroenterol* 29, 362–368.
19 Garcia-Tobaruela A, Gil A, Lavilla P *et al.* (1995) Hepatic amyloidosis associated with systemic lupus erythematosus. *Lupus* 4, 75–77.
20 Nachbar F, Korting HC, Hoffmann RM *et al.* (1984) Unusual coexistence of systemic lupus erythematosus and primary biliary cirrhosis. *Lupus* 188, 313–7.
21 Iliffe GD, Naidoo S, Hunter T (1982) Primary biliary cirrhosis associated with features of systemic lupus erythematosus. *Dig Dis Sci* 27, 274–278.
22 Asherson RA, Thompson RP, MacLachlan N *et al.* (1989) Budd Chiari syndrome, visceral arterial occlusions, recurrent fetal loss and the 'lupus anticoagulant' insystemic lupus erythematosus. *J Rheumatol* 16, 219–24.
23 Alberti-Flor JJ, Jeffers L, Schiff ER (1984) Primary sclerosing cholangitis occurring in a patient with systemic lupus erythematosus and diabetes mellitus. *Am J Gastroenterol* 79, 889–891.
24 Abu-Shakra M, Gladman DD, Urowitz MB *et al.* (1996) Malignancy in systemic lupus erythematosus. *Arthritis Rheum* 39, 1050–1054.
25 Font J, Khamashta MA (2004) Síndrome antifosfolipídico. In: Farreras P, Rozman C, Cardellach F (eds) *Medicina Interna*, 15th edn. Madrid: Elsevier, pp. 1107–1109.
26 Asherson RA, Hackett D, Gharavi AE *et al.* (1986) Pulmonary hypertension in systemic lupus erythematosus, a report of three cases. *J Rheumatol* 13, 416–420.
27 Bowles CA (1990) Vasculopathy associated with the antiphospholipid. antibody syndrome. *Rheum Dis Clin North Am* 16, 471–489.
28 Harris EN, Pierangeli S (1990) What is the 'true' antigen for antiphospholipid antibodies? *Lancet* 336, 1505.
29 Katano K, Aoki A, Sasa H *et al.* (1996) Beta 2-glycoprotein I-dependent anticardiolipin antibodies as a predictor of adverse pregnancy outcomes in healthy pregnant women. *Hum Reprod* 11, 509–512.
30 Tsutsumi A, Matsuura E, Ichikawa K *et al.* (1996) Antibodies to beta-2 glycoprotein 1 and clinical manifestations in patients with systemic lupus erythematosus. *Arthritis Rheum* 39, 1466–1474.
31 Mackworth-Young CG, Melia WM, Harris EN *et al.* (1986) The Budd-Chiari syndrome. Possible pathogenetic role of anti-phospholipid antibodies. *J Hepatol* 3, 83–6.
32 Van Steenbergen W, Beyls J, Vermylen J *et al.* (1986) 'Lupus' anticoagulant and thrombosis of the hepatic veins (Budd-Chiari syndrome). Report of three patients and review of the literature. *J Hepatol* 3, 87–94.
33 Terabayashi H, Okuda K, Nomura F *et al.* (1986) Transformation of inferior vena caval thrombosis to membranous obstruction in a patient with the lupus anticoagulant. *Gastroenterology* 91, 219–224.
34 Morla RM, Ramos-Casals M, Garcia-Carrasco M *et al.* (1999) Nodular regenerative hyperplasia of the liver and antiphospholipid antibodies, report of two cases and review of the literature. *Lupus* 8, 160–163.
35 Wolheim FA (1993) Rheumatoid arthritis, the clinical picture. In: Maddison PJ, Isenberg DA, Woo P *et al.* (eds) *Oxford Textbook of Rheumatology*. Oxford: Oxford Medical Publications, pp. 639–666.
36 Arnett FC, Edworthy SM, Bloch DA *et al.* (1988) The American Rheumatism Association 1987 revised criteria for the classification of rheumatoid arthritis. *Arthritis Rheum* 31, 315–324.
37 Cockel R, Kendall MJ, Becker JF *et al.* (1971) Serum biochemical values in rheumatoid disease. *Ann Rheum Dis* 30, 166–170.
38 Webb J, Whaley K, MacSween RN *et al.* (1975) Liver disease in rheumatoid arthritis and Sjogren's syndrome. Prospective study using biochemical and serological markers of hepatic dysfunction. *Ann Rheum Dis* 34, 70–81.
39 Mills PR, Sturrock RD (1982) Clinical associations between arthritis and liver disease. *Ann Rheum Dis* 41, 295–307.
40 Lowe JR, Pickup ME, Dixon JS *et al.* (1978) Gamma glutamyl transpeptidase levels in arthritis, a correlation with clinical and laboratory indices of disease activity. *Ann Rheum Dis* 37, 428–431.
41 Matteson EL, Cohen MD, Conn DL (1994) Rheumatoid arthritis. Clinical features – systemic involvement. In: Klippel JH, Dieppe PA (eds) *Rheumatology*. London: Mosby, pp. 3(5.1–8).
42 Rau R, Pfenninger K, Boni A (1975) Proceedings, Liver function tests and liver biopsies in patients with rheumatoid arthritis. *Ann Rheum Dis* 34, 198–199.
43 McNiff PA, Stewart C, Sullivan J *et al.* (1995) Synovial fluid from rheumatoid arthritis patients contains sufficient levels of IL-1 beta and IL-6 to promote production of serum amyloid A by Hep3B cells. *Cytokine* 7, 209–219.
44 Pai S, Helin H, Isomaki H (1993) Frequency of amyloidosis in Estonian patients with rheumatoid arthritis. *Scand J Rheumatol* 22, 248–249.
45 al-Janadi M, al-Wabel A, Raziuddin S (1994) Soluble CD23 and interleukin-4 levels in autoimmune chronic active hepatitis and systemic lupus erythematosus. *Clin Immunol Immunopathol* 71, 33–37.
46 Schaller J (1971) The liver and arthritis. *J Pediatr* 79, 139–141.
47 Agarwal RK, O'Neil KM, Bedi D (1994) Focal radiolucent hepatic lesions in a patient with juvenile rheumatoid arthritis. *J Rheumatol* 21, 580–581.
48 Stephan JL, Zeller J, Hubert P *et al.* (1993) Macrophage activation syndrome and rheumatic disease in childhood, a report of four new cases. *Clin Exp Rheumatol* 11, 451–456.
49 Larson EB (1984) Adult Still's disease. Evolution of a clinical syndrome and diagnosis, treatment, and follow-up of 17 patients. *Medicine* 63, 82–91.

50 Fry SW, Seeff LB (1995) Hepatotoxicity of analgesics and anti-inflammatory agents. *Gastroenterol Clin North Am* 24, 875–905.

51 Giannini EH, Cassidy JT (1993) Methotrexate in juvenile rheumatoid arthritis. Do the benefits outweigh the risks? *Drug Safety* 9, 325–339.

52 Sienknecht CW, Urowitz MB, Pruzanski W *et al.* (1977) Felty's syndrome. Clinical and serological analysis of 34 cases. *Ann Rheum Dis* 36, 500–507.

53 Blendis LM, Lovell D, Barnes CG *et al.* (1978) Oesophageal variceal bleeding in Felty's syndrome associated with nodular regenerative hyperplasia. *Ann Rheum Dis* 37, 183–186.

54 Dachman AH, Ros PR, Goodman ZD *et al.* (1987) Nodular regenerative hyperplasia of the liver, clinical and radiologic observations. *Am J Roentgenol* 148, 717–722.

55 Sherlock S, Feldman CA, Moran B *et al.* (1966) Partial nodular transformation of the liver with portal hypertension. *Am J Med* 40, 195–203.

56 Evans JE, Dick R, Sherlock S (1980) Focal nodular hyperplasia of the liver. *Br J Surg* 67, 175–177.

57 Thorne C, Urowitz MB, Wanless I *et al.* (1982) Liver disease in Felty's syndrome. *Am J Med* 73, 35–40.

58 Marshall JB, Ravendhran N, Sharp GC (1983) Liver disease in mixed connective tissue disease. *Arch Intern Med* 143, 1817–1818.

59 Cosnes J, Robert A, Levy VG *et al.* (1980) Budd-Chiari syndrome in a patient with mixed connective-tissue disease. *Dig Dis Sci* 25, 467–469.

60 Whaley K, Webb J, McAvoy BA *et al.* (1973) Sjogren's syndrome. 2. Clinical associations and immunological phenomena. *Q J Med* 42, 513–548.

61 Webb J, Whaley K, MacSween RN *et al.* (1975) Liver disease in rheumatoid arthritis and Sjogren's syndrome. Prospective study using biochemical and serological markers of hepatic dysfunction. *Ann Rheum Dis* 34, 70–81.

62 Skopouli FN, Barbatis C, Moutsopoulos HM (1994) Liver involvement in primary Sjogren's syndrome. *Br J Rheumatol* 33, 745–748.

63 Garcia-Carrasco M, Ramos M, Cervera R *et al.* (1997) Hepatitis C virus infection in 'primary' Sjogren's syndrome, prevalence and clinical significance in a series of 90 patients. *Ann Rheum Dis* 56, 173–175.

64 Esteban JI, Esteban R, Viladomiu L *et al.* (1989) Hepatitis C virus antibodies among risk groups in Spain. *Lancet* 2, 294–297.

65 Golding PL, Smith M, Williams R (1973) Multisystem involvement in chronic liver disease. Studies on the incidence and pathogenesis. *Am J Med* 55, 772–782.

66 Montefusco PP, Geiss AC, Bronzo RL *et al.* (1984) Sclerosing cholangitis, chronic pancreatitis, and Sjogren's syndrome, a syndrome complex. *Am J Surg* 147, 822–826.

67 Rutan G, Martinez AJ, Fieshko JT *et al.* (1986) Primary biliary cirrhosis, Sjogren's syndrome, and transverse myelitis. *Gastroenterology* 90, 206–210.

68 Wada T, Motoo Y, Ohmizo R *et al.* (1991) Association of mixed connective tissue disease, Sjogren's syndrome and autoimmune hepatitis, report of a case. *Jpn J Med* 30, 278–280.

69 Tamaki T, Mori S, Takehara K (1991) Epidemiological study of patients with systemic sclerosis in Tokyo. *Arch Dermatol Res* 283, 366–371.

70 Isenberg DA, Black C (1995) ABC of rheumatology. Raynaud's phenomenon, scleroderma, and overlap syndromes. *Br Med J* 310, 795–798.

71 Denton CP, Bickerstaff MC, Shiwen X *et al.* (1995) Serial circulating adhesion molecule levels reflect disease severity in systemic sclerosis. *Br J Rheumatol* 34, 1048–1054.

72 Murray-Lyon IM, Thompson RP, Ansell ID *et al.* (1970) Scleroderma and primary biliary cirrhosis. *Br Med J* 3, 258–259.

73 Reynolds TB, Denison EK, Frankl HD *et al.* (1971) Primary biliary cirrhosis with scleroderma, Raynaud's phenomenon and telangiectasia. New syndrome. *Am J Med* 50, 302–312.

74 O'Brien ST, Eddy WM, Krawitt EL (1972) Primary biliary cirrhosis associated with scleroderma. *Gastroenterology* 62, 118–121.

75 Clarke AK, Galbraith RM, Hamilton EB *et al.* (1978) Rheumatic disorders in primary biliary cirrhosis. *Ann Rheum Dis* 37, 42–47.

76 Powell FC, Schroeter AL, Dickson ER (1987) Primary biliary cirrhosis and the CREST syndrome, a report of 22 cases. *Q J Med* 62, 75–82.

77 Gruschwitz MS, Steffan C, Albrecht HP *et al.* (1994) [Initial visceral involvement with diffuse systemic scleroderma] *Hautarzt* 45, 787–791.

78 Jacobs MB (1985) Eosinophilic fasciitis, reactive hepatitis, and splenomegaly. *Arch Intern Med* 145, 162–163.

79 Loeliger AE, van den Brink HR, Derksen RH *et al.* (1991) Eosinophilic fasciitis presenting with a reactive hepatitis. *Clin Rheumatol* 10, 440–444.

80 Siberry GK, Cohen BA, Johnson B (1994) Cutaneous polyarteritis nodosa. Reports of two cases in children and review of the literature. *Arch Dermatol* 130, 884–889.

81 Buonanno G, Cione G, Perrone Donnorso R (1969) [Nosographic and pathogenic considerations on a case of association of dermatomyositis and chronic autoimmune hepatitis] *Policlinico [Med]* 76, 117–129.

82 Lorcerie B, Grobost O, Lalu-Fraisse A *et al.* (1990) [Peliosis hepatis in dermatomyositis treated with azathioprine and corticoids] *Rev Med Interne* 11, 25–28.

83 el Alaoui-Faris M, Benabdeljalil M, Slassi I *et al.* (1994) [Dermatomyositis and Wilson disease] *Rev Neurol (Paris)* 150, 391–392.

84 Allan RN, Dykes PW, Harris OD *et al.* (1972) Dermatomyositis associated with hepatic secondaries from carcinoma of the colon. *Gastroenterology* 62, 1227–1231.

85 Leaute-Labreze C, Perel Y, Taieb A (1995) Childhood dermatomyositis associated with hepatocarcinoma. *N Engl J Med* 333, 1083.

86 Camilleri M, Pusey CD, Chadwick VS *et al.* (1983) Gastrointestinal manifestations of systemic vasculitis. *Q J Med* 52, 141–149.

87 Gambari PF, Ostuni PA, Lazzarin P *et al.* (1989) Eosinophilic granuloma and necrotizing vasculitis (Churg-Strauss syndrome?) involving a parotid gland, lymph nodes, liver and spleen. *Scand J Rheumatol* 18, 171–175.

88 Yoshimoto T, Kagotani K, Hirao F *et al.* (1989) [Wegener's granulomatosis in a woman with asymptomatic primary biliary cirrhosis]. *Nihon Kyobu Shikkan Gakkai Zasshi* 27, 1545–1550.

89 Duffy J, Lidsky MD, Sharp JT *et al.* (1976) Polyarthritis, polyarteritis and hepatitis B. *Medicine* 55, 19–37.

90 Cowan RE, Mallinson CN, Thomas GE (1977) Polyarteritis nodosa of the liver, a report of two cases. *Postgrad Med J* 53, 89–93.

91 LiVolsi VA, Perzin KH, Porter M (1973) Polyarteritis nodosa of the gallbladder, presenting as acute cholecystitis. *Gastroenterology* 65, 115–123.

92 Guillevin L, Lhote F, Gherardi R (1997) The spectrum and treatment of virus-associated vasculitides. *Curr Opin Rheumatol* 9, 31–36.

93 Chuang TY, Hunder GG, Ilstrup DM *et al.* (1982) Polymyalgia rheumatica, a 10-year epidemiologic and clinical study. *Ann Intern Med* 97, 672–680.

94 Cohen MD, Ginsburg WW (1990) Polymyalgia rheumatica. *Rheum Dis Clin North Am* 16, 325–339.

95 Klein RG, Hunder GG, Stanson AW *et al.* (1975) Large artery involvement in giant cell (temporal) arteritis. *Ann Intern Med* 83, 806–812.
96 Machado EB, Michet CJ, Ballard DJ *et al.* (1988) Trends in incidence and clinical presentation of temporal arteritis in Olmsted County, Minnesota, 1950–1985. *Arthritis Rheum* 31, 745–749.
97 Hunder GG (1990) Giant cell (temporal) arteritis. *Rheum Dis Clin North Am* 16, 399–409. Review.
98 Bruckle W, Schattenkirchner M (1989) [Joint involvement in polymyalgia rheumatica/temporal arteritis]. *Z Rheumatol* 48, 19–25.
99 Wadman B, Werner I (1972) Observations on temporal arteritis. *Acta Med Scand* 192, 377–383.
100 Hall GH, Hargreaves T (1972) Giant-cell arteritis and raised serum-alkaline-phosphatase levels. *Lancet* 2, 48.
101 Long R, James O (1974) Polymyalgia rheumatica and liver disease. *Lancet* 1(7847), 77–79.
102 Ilan Y, Ben-Chetrit E (1993) Liver involvement in giant cell arteritis. *Clin Rheumatol* 12, 219–222.
103 Achar KN, Ashfield RP (1995) Gross cholestatic dysfunction in giant cell arteritis. *Postgrad Med J* 71, 59–60.
104 de Bayser L, Roblot P, Ramassamy A *et al.* (1993) Hepatic fibrin-ring granulomas in giant cell arteritis. *Gastroenterology* 105, 272–273.
105 O'Duffy JD (1990) Vasculitis in Behcet's disease. *Rheum Dis Clin North Am* 16, 423–431.
106 Kansu E, Ozer FL, Akalin E *et al.* (1972) Behcet's syndrome with obstruction of the venae cavae. A report of seven cases. *Q J Med* 41, 151–168.
107 Bismuth E, Hadengue A, Hammel P *et al.* (1990) Hepatic vein thrombosis in Behçet's disease. *Hepatology* 11, 969–974.
108 Bayraktar Y, Ozaslan E, Van Thiel DH (2000) Gastrointestinal manifestations of Behcet's disease. *J Clin Gastroenterol* 30, 144–154.

20.11 Amyloidosis

Philip N. Hawkins

Introduction

Amyloidosis is a clinical disorder caused by extracellular deposition of insoluble abnormal fibrils, derived from aggregation of misfolded normally soluble protein. About 20 different unrelated proteins are known to form amyloid fibrils *in vivo*, which share a pathognomonic ultrastructure. Systemic amyloidosis, in which amyloid deposits are present in the viscera, blood vessel walls and connective tissues, is usually fatal and is the cause of about 1/1000 deaths in developed countries. There are also various localized forms of amyloidosis in which the deposits are confined to specific foci or to a particular organ or tissue. These may be clinically silent or trivial, or they may be associated with serious disease, such as haemorrhage in local respiratory or urogenital tract AL amyloidosis. (Amyloidosis nomenclature comprises the letter A to designate amyloid, followed by an abbreviation of the name of the fibril protein.) In addition, there are important diseases associated with local amyloid deposition in which the pathogenetic role of the amyloid remains unclear, notably including Alzheimer's disease, the prion disorders and type 2 diabetes mellitus.

In addition to the fibrils, amyloid deposits always contain the normal plasma protein serum amyloid P component (SAP), because it binds specifically to an as yet uncharacterized ligand expressed by all amyloid fibrils. Radiolabelled SAP has been developed as a specific, quantitative tracer for imaging of amyloid deposits scintigraphically [1]. Treatment of amyloidosis comprises measures to support impaired organ function, including dialysis and transplantation, along with vigorous efforts to control underlying conditions responsible for the production of fibril precursors. Serial SAP scintigraphy has demonstrated that reduction in the supply of amyloid fibril precursor proteins leads to regression of amyloid deposits and clinical benefit in many cases.

Pathogenesis of amyloidosis

Amyloidogenesis involves substantial refolding of the native structures of the various amyloid precursor proteins, which enables them to autoaggregate in a highly ordered manner to form fibrils with a characteristic β-sheet structure [2]. Amyloid fibrils may contain the intact amyloidogenic protein or be composed of cleavage fragments. Wild-type transthyretin (TTR) is inherently amyloidogenic and, even at normal concentrations, it forms amyloid fibrils in almost all individuals over 80 years, sometimes causing senile systemic amyloidosis. The other amyloidogenic wild-type proteins, serum amyloid A protein (SAA) and β_2-microglobulin (β_2M), form amyloid only when they have been present at grossly supraphysiological concentration for very prolonged periods. Aberrant proteins with enhanced amyloidogenicity can be acquired, as with the monoclonal immunoglobulin light chains responsible for AL amyloidosis, or inherited as in familial amyloidosis. There is always a lag period, often of many years, between the first appearance of a potentially amyloidogenic protein and the deposition of clinically significant amyloid, but accumulation of amyloid can nevertheless occur very rapidly once the process has begun, probably reflecting a seeding phenomenon. Amyloidosis is exceptionally rare in children and even young adults, and increasing age may thus favour amyloid deposition, although the underlying mechanisms are not known.

All amyloid deposits contain abundant heparan sulphate and dermatan sulphate proteoglycans and glycosaminoglycan chains, some of which are tightly bound to the fibrils and may contribute to amyloid fibrillogenesis as well as stabilization of the fibril structure [3]. All amyloid deposits also contain amyloid P component, which is identical to and derived from the normal circulating plasma protein SAP. SAP undergoes avid ($K_d \sim 1$ μmol/L), specific, calcium-dependent, reversible binding to amyloid fibrils of all types, leading to its remarkable specific concentration in amyloid deposits. SAP binds to both glycosaminoglycans and protein ligands specifically present on all types of amyloid fibril, and may also promote the formation of and/or stabilize the fibrils. Other plasma proteins, such as apolipoprotein E, are sometimes detectable in amyloid deposits, but none with the universality and abundance of SAP.

The mechanisms by which amyloid deposits damage tissues and compromise organ function are incompletely understood.

Massive deposits, which may amount to kilograms, are structurally disruptive and incompatible with normal function, as are strategically located small deposits, for example in the glomeruli or nerves. However, the relationship between the quantity of amyloid and organ dysfunction differs greatly between individuals, and there is a strong impression that the rate of new amyloid deposition is at least as important a determinant of progressive organ failure as the amyloid load itself. *In vitro* studies have suggested that certain isolated amyloid fibrils have cytotoxic properties.

Major unanswered questions concern the tissue distribution and time of appearance of amyloid deposits as well as their variable clinical consequences. Although many features of the various forms of amyloidosis overlap, the clinical phenotype associated with a particular fibril type can be enormously variable, even between family members with identical amyloidogenic mutations. There are clearly major genetic or environmental factors that influence amyloidogenesis *in vivo*, other than simply the presence of an adequate supply of an amyloidogenic protein.

Clinical amyloidosis

Localized amyloidosis

The commonest form of local amyloidosis is caused by foci of otherwise benign monoclonal B cells or plasma cells producing monoclonal immunoglobulin light chains (L) that are deposited as AL amyloid, most frequently in the respiratory tract, urogenital tract or skin. Local amyloid composed of β-protein within the walls of cerebral blood vessels can be responsible for Congophilic amyloid angiopathy causing cerebral haemorrhage and stroke. Peptide hormones forming amyloid deposits in benign or malignant tumours of endocrine tissue, and microscopic senile amyloid deposits, composed of various different proteins in the arterial wall, the heart, the seminal vesicles and the prostate, are incidental histological findings with little evidence that the amyloid causes disease.

Acquired systemic amyloidosis

Acquired systemic amyloidosis is the cause of death in about 1 in 1000 of the British population, and is probably much underdiagnosed in the elderly population in which it probably occurs most frequently. Systemic AL amyloidosis is the most serious and commonly diagnosed form, outnumbering referrals of AA amyloidosis to the UK National Amyloidosis Centre by fourfold. Although less serious, dialysis related β_2-microglobulin amyloidosis causes much suffering in about one million patients receiving long-term renal replacement therapy worldwide. Senile systemic amyloidosis, which predominantly involves the heart and is often referred to as senile cardiac amyloidosis, occurs in about one-quarter of individuals over the age of 80 years, a sector of the population that is ever increasing.

Systemic AA amyloidosis

Formerly known as secondary amyloidosis, this is a complication of chronic infections and inflammatory conditions characterized by a sustained acute phase response in which there is persistently increased production of serum amyloid A protein (SAA). SAA is an apolipoprotein of high-density lipoprotein particles, produced predominantly in the liver, and is, together with C-reactive protein, the most dynamic acute phase protein. SAA concentration rises from less than 5 mg/L in healthy subjects to as much as 2000 mg/L at the peak of a severe acute phase response. In rheumatoid arthritis, juvenile rheumatoid arthritis, other inflammatory arthritides, Crohn's disease and familial Mediterranean fever and the various hereditary periodic fever syndromes, the SAA concentration can remain at tens or hundreds of mg/L for months and years unless the inflammatory activity remits or is suppressed by therapy. Up to around 5% of individuals with sustained high SAA values may eventually develop AA amyloidosis. In hereditary periodic fever syndromes, the genetic bases of which are increasingly being elucidated, the incidence of AA amyloidosis can be much higher. A small number of patients with AA amyloidosis have no clinically overt inflammatory disease, although some are carriers of inherited fever syndrome genes.

AA amyloid involves the viscera but may be widely distributed without causing clinical symptoms. More than 95% of patients present with non-selective proteinuria or renal failure. Kidney size is usually normal, but may be enlarged or, in advanced cases, reduced. Endstage chronic renal failure is the cause of death in 40–60% of cases, but acute renal failure may be precipitated by hypotension and/or salt and water depletion following surgery, excessive use of diuretics or intercurrent infection. The second most common presentation is with organ enlargement, such as hepatosplenomegaly or occasionally thyroid goitre, with or without overt renal abnormality, but in any case amyloid deposits are almost always widespread at the time of presentation. Clinically significant involvement of the heart is rare, as is liver failure, but gastrointestinal dysfunction including bleeding is common in advanced disease.

The median duration of inflammatory disorders associated with AA amyloidosis is 17 years, but latency can be as short as just 1 year. The prognosis is closely related to the degree of renal dysfunction and the effectiveness of anti-inflammatory treatment, although the availability of haemodialysis and renal transplantation prevents early death from uraemia *per se*.

Systemic AL amyloidosis

Previously known as primary amyloidosis, this is the most common form of clinical amyloid disease in developed countries. AL fibrils are derived from monoclonal immunoglobulin light chains and consist of the whole or part of the variable (VL) domain. Almost any B-cell dyscrasia, including myeloma, lymphomas and macroglobulinaemia, may be complicated by AL amyloidosis, but over 80% of cases are associated with subtle and otherwise 'benign' monoclonal gammopathies.

Histologically, amyloid deposition occurs in up to 15% of patients with myeloma, but usually in clinically insignificant amounts, and about 2% of patients with 'benign' monoclonal gammopathy develop clinical amyloidosis. A monoclonal paraprotein or free light chain can be detected in serum or urine by conventional electrophoresis and immunofixation in only about 80–90% patients with AL amyloidosis, but high-sensitivity serum free light chain assays can confirm a monoclonal gammopathy in most remaining cases. Until recently, it has been practice to diagnose apparently 'primary' cases of amyloidosis, with no previous predisposing inflammatory condition or family history of amyloidosis, as AL type by exclusion. However, it has lately been recognized that hereditary amyloidosis is often poorly penetrant and can have a late onset, so that there may be no family history [4]. The coincident occurrence of a monoclonal gammopathy may then be gravely misleading, and it is essential to exclude all known amyloidogenic mutations (see below) when immunohistochemical or biochemical identification of the amyloid fibril protein has not given positive results.

AL amyloid occurs equally in men and women, usually over the age of 50 years but as early as the third decade. The clinical manifestations are protean, as virtually any tissue other than the brain may be directly involved [5]. Uraemia, heart failure or other effects of the amyloid usually cause death within 1–2 years of diagnosis, unless the underlying B-cell clone is suppressed. The heart is affected pathologically in up to 90% of AL patients, in 30% of whom restrictive cardiomyopathy is the presenting feature. Renal AL amyloid has the same manifestations as renal AA amyloid, but the prognosis is worse. Gut involvement may cause motility disturbances (often secondary to autonomic neuropathy), malabsorption, perforation, haemorrhage or obstruction. Macroglossia occurs rarely but is almost pathognomonic. Hyposplenism sometimes occurs in both AA and AL amyloidosis. Painful sensory polyneuropathy with early loss of pain and temperature sensation followed later by motor deficits is seen in 10–20% of cases and carpal tunnel syndrome in 20%. Autonomic neuropathy leading to orthostatic hypotension, impotence and gastrointestinal disturbances may occur alone or together with the peripheral neuropathy, and has a very poor prognosis. Skin involvement takes the form of papules, nodules and plaques usually on the face and upper trunk, and involvement of dermal blood vessels results in purpura occurring either spontaneously or after minimal trauma, and is quite common. Articular amyloid is rare, but the symptoms may mimic an inflammatory polyarthritis. Infiltration of the glenohumeral joint and surrounding soft tissues occasionally produces the characteristic 'shoulder pad' sign. A rare but serious manifestation of AL amyloid is an acquired bleeding diathesis that may be associated with deficiency of factor X and sometimes also factor IX; this does not occur in AA amyloidosis, but vascular deposits in all types of systemic amyloidosis may cause serious bleeding in the absence of a clotting factor deficiency.

Dialysis-associated amyloidosis (Aβ_2M)

This is a complication of long-term dialysis for endstage renal failure. β_2-Microglobulin (β_2M) is cleared and catabolized only by the kidney and is very poorly cleared by peritoneal or haemodialysis. In endstage renal failure, its circulating concentration rises from 1–2 mg/L to around 50–70 mg/L. After 7–10 years on dialysis, Aβ_2M amyloid is deposited, usually presenting with painful and disabling deposition in and around bones and joints. This is an intractable complication of long-term dialysis, and is effectively treated only by renal transplantation. However the incidence of Aβ_2M is apparently now falling, possibly as a result of the use of new dialysis membranes, cleaner dialysis fluids and higher flux dialysis.

Senile transthyretin amyloidosis (ATTR)

Over the age of 80 years, wild-type TTR amyloid deposits in the heart, kidneys and respiratory tract are an almost universal incidental finding at autopsy, but some elderly patients with more extensive TTR amyloid deposits in the heart develop restrictive cardiomyopathy. This syndrome, often known as senile cardiac amyloidosis, is untreatable other than by heart transplantation in rare younger patients. Occasionally, genetic variants of TTR present in a similar manner, notably including TTR Ile122 in black Africans (see next section).

Hereditary systemic amyloidosis

This disorder is rare but can sometimes be treated very effectively, and its study has provided invaluable information on amyloid fibrillogenesis and pathogenetic mechanisms, leading to the development of new potentially therapeutic drugs for amyloidosis. The most common cause of hereditary amyloidosis is mutation in the gene for TTR, which affects around 10 000 individuals worldwide. The other amyloid fibril proteins that cause hereditary amyloidosis are apolipoprotein AI (apoAI) and apoAII, fibrinogen A α-chain, gelsolin and lysozyme in systemic amyloidosis, cystatin C in the Icelandic form of hereditary cerebral haemorrhage with amyloidosis and β-protein in the Dutch form of this disease. Over 80 mutations, most of which are amyloidogenic, are known in TTR, and new amyloidogenic mutations in the other proteins listed continue to be discovered.

Severe and ultimately fatal peripheral and/or autonomic neuropathy are major features of hereditary TTR amyloidosis (familial amyloidotic polyneuropathy, FAP), but fatal cardiac and subtle but significant renal involvement are also common. ApoAI amyloidosis sometimes causes neuropathy, but this is not a feature of the other hereditary types, which typically involve the viscera. Age of onset, distribution of amyloid deposits and clinical presentation can vary widely both within and between families, even with the same mutation. All the amyloidogenic mutations are dominant, but they are variably penetrant and there may be no family history. AL amyloidosis is sometimes diagnosed by exclusion because rigorous positive immunohistochemical identification of AL-type fibrils is not possible in some

cases and, without the use of the new sensitive and reliable test for free immunoglobulin light chains in serum, the amyloid deposits may be the only sign of monoclonal gammopathy. There is thus scope for misdiagnosis of hereditary amyloidosis as AL type and the inappropriate use of dangerous cytotoxic regimens aimed at ablation of clonal B-cell disease. It is thus absolutely mandatory that the amyloid fibril type is positively identified in all systemic amyloidosis patients and/or that there is comprehensive testing for all known amyloidogenic mutations.

Familial amyloidotic polyneuropathy

FAP is caused by point mutations in the gene for the plasma protein TTR and is an autosomal dominant syndrome with variable penetrance. Symptoms typically present between the third and seventh decades. The disease is characterized by progressive and disabling peripheral and autonomic neuropathy and varying degrees of visceral amyloid involvement. Severe cardiac amyloidosis is common. Deposits within the vitreous of the eye occur in a proportion of cases and are very characteristic, but renal, thyroid, spleen and adrenal deposits are usually asymptomatic. There are well-recognized foci in Portugal, Japan and Sweden, but FAP has been reported in most ethnic groups throughout the world. There is considerable phenotypical variation in the age of onset, rate of progression, involvement of different systems and disease penetrance generally, although the pattern may be quite consistent within families. More than 80 variant forms of TTR are associated with FAP, the most frequent of which is Met30. TTR Ala60 is the most frequent cause of FAP in the British population, and usually presents after age 50 years, often with predominant cardiac amyloidosis.

Hereditary lysozyme amyloidosis

Hereditary non-neuropathic systemic amyloidosis has been described in association with four lysozyme variants, His67, Thr56, Ile57 and Arg64. Most patients present in middle age with proteinuria, very slowly progressive renal impairment and sometimes hepatosplenomegaly with or without purpuric rashes. Virtually all patients have substantial gastrointestinal amyloid deposits and, although these are often asymptomatic, they are important as gastrointestinal haemorrhage or perforation is a frequent cause of death.

Hereditary apolipoprotein AI amyloidosis

About a dozen amyloidogenic variants are known, which variably present with massive abdominal visceral amyloid involvement, predominant cardiomyopathy, hoarseness or a FAP-like syndrome. The majority of patients eventually develop renal failure but, despite extensive hepatic amyloid deposition, liver function usually remains well preserved. Normal wild-type apoAI amyloid is itself weakly amyloidogenic, and is the precursor of small amyloid deposits that occur quite frequently in aortic atherosclerotic plaques.

Hereditary fibrinogen A alpha chain amyloidosis

Fibrinogen A alpha chain was first isolated from amyloid fibrils in 1993. Four amyloidogenic mutations have been described in eight unrelated kindreds. These include Leu554 and two frameshifting deletion mutations. However, much the commonest variant is Val526, which is now known to have low penetrance in most families. Indeed, 5% of patients referred to the UK National Amyloidosis Centre with a diagnosis of acquired AL amyloidosis have been shown on further investigation to have hereditary fibrinogen A alpha chain Val526 amyloidosis. Most patients present in middle age with proteinuria or hypertension and progress to endstage renal failure over 4–10 years. Amyloid deposition is seen in the kidneys, spleen and sometimes the liver, but is usually asymptomatic in the last two sites. Renal grafts frequently fail within 7 years because of recurrent amyloidosis.

The liver in systemic amyloidosis

Amyloid can be deposited in the liver in most forms of systemic amyloidosis, and widespread vascular deposits are almost universal [6]. The liver is also the source of many variant proteins that cause hereditary amyloidosis. Liver function tests can remain normal in the face of very substantial parenchymal deposits, and even sometimes with giant amyloid hepatomegaly. In our extensive experience of SAP scintigraphy in over 2000 patients with systemic amyloidosis, hepatic involvement has been demonstrated in about one-fifth of patients with AA amyloidosis and about one-half of those with the AL type. It is extremely common in hereditary apoAI and lysozyme types and has been associated with spontaneous liver rupture in several patients with the lysozyme His67 variant. Derangements in liver function tests usually begin with elevations in serum alkaline phosphatase and gamma-glutamyltransferase, followed by variable and often modest elevations in alanine and aspartate aminotransferases. Elevation of serum bilirubin occurs very late, and overt jaundice is a marker of impending liver failure. Liver biopsy is associated with some degree of haemorrhage in up to 5% of cases, and hepatic amyloidosis is always associated with major deposits in other organs even if these are clinically silent. Fortunately, endstage hepatic failure due to amyloidosis is exceptionally rare, and it is virtually restricted to a small proportion of patients with systemic AL type. The role of liver transplantation is described below.

Diagnosis of amyloidosis

Until recently, amyloidosis was an exclusively histological diagnosis, and green birefringence of deposits stained with Congo red when viewed in cross-polarized light remains the gold standard. Immunohistochemical staining of amyloid-containing tissue is the simplest method for identifying the amyloid fibril type. However, biopsies provide small samples that cannot provide information on the extent, localization, progression or

regression of amyloid deposits, aspects in which histology is complemented by whole-body radiolabelled SAP scintigraphy.

Histochemical diagnosis of amyloid

Amyloid may be an incidental finding on biopsy of the kidneys, liver, heart, bowel, peripheral nerve, lymph node, skin, thyroid or bone marrow. When amyloidosis is suspected clinically, biopsy of rectum or subcutaneous fat is the least invasive method. Amyloid is present in these sites in more than 90% of cases of systemic AA or AL amyloidosis. Alternatively, a clinically affected tissue may be biopsied directly. Many cotton dyes, fluorochromes and metachromatic stains have been used, but Congo red staining is the pathognomonic histochemical test for amyloidosis. The stain is unstable and must be freshly prepared every 2 months or less. Section thickness of 5–10 μm and inclusion in every staining run of a positive control tissue containing modest amounts of amyloid are critical.

Immunohistochemistry

Although many amyloid fibril proteins can be identified immunohistochemically, demonstration of amyloidogenic proteins in tissue does not, on its own, establish the presence of amyloid. Congo red staining and green birefringence are always required. Commercially available antibodies to SAA and β_2M generally yield definitive results, but AL deposits are stainable with standard antisera to κ or λ light chains in only about half of fixed biopsies. Immunohistochemical staining of amyloid may require pretreatment of sections with formic acid or alkaline guanidine or deglycosylation.

Electron microscopy

Transmission electron microscopy reveals the typical fibrillar ultrastructure of tissue amyloid deposits, but fibrils cannot always be convincingly identified and electron microscopy alone is not sufficient to confirm the diagnosis of amyloidosis. Isolated purified amyloid fibrils can be imaged by negatively stained electron microscopy as straight, non-branching fibrils of indeterminate length and about 10 nm in diameter.

Non-histological investigations

Two-dimensional echocardiography showing small, concentrically hypertrophied ventricles, generally impaired contraction, dilated atria, homogeneously echogenic valves and increased echodensity of ventricular walls is virtually diagnostic of cardiac amyloidosis. However, clinically significant restrictive diastolic impairment may be difficult to detect even by comprehensive Doppler and other functional studies. Imaging after injection of isotope-labelled, calcium-seeking tracers has poor sensitivity and specificity and is of no routine clinical value. Recent studies of cardiac magnetic resonance imaging seem promising.

In cases of known or suspected hereditary amyloidosis, the gene defect must be characterized, but it remains essential to corroborate DNA findings by confirming one way or another that the respective protein is indeed the main constituent of the amyloid.

A high-sensitivity, latex-enhanced serum immunoassay (the Freelite immunoassay) has been developed lately that can quantify circulating free immunoglobulin light chains with remarkable sensitivity of < 5 mg/L. This compares with typical detection limits of 150–500 mg/L by immunofixation and 500–2000 mg/L by electrophoresis. In a series of 262 patients undergoing assessment at the UK National Amyloidosis Centre, a monoclonal immunoglobulin could not be detected at presentation by electrophoresis or immunofixation, in either serum or urine, in 21% of cases. In a further 26% of cases, monoclonal light chains could only be detected qualitatively by immunofixation. In contrast, monoclonal free immunoglobulin light chains were quantified using the serum free light chain immunoassay in 98% of patients. This assay has a major application in monitoring the response to chemotherapy of the clonal disease in patients with AL amyloidosis, enabling such treatment to be given on a much more rational basis than previously.

SAP scintigraphy

SAP is a highly conserved, invariant plasma glycoprotein of the pentraxin family that becomes specifically and highly concentrated in amyloid deposits of all types as a result of its calcium-dependent binding to amyloid fibrils. Following intravenous injection, radiolabelled SAP distributes between the circulating and the amyloid-bound SAP pools in proportion to their size and can then be imaged and quantified [7]. This safe non-invasive method uniquely provides invaluable information on the diagnosis, distribution and extent of amyloid deposits throughout the body, and serial scans monitor progress and response to therapy. Serial SAP scans have unequivocally demonstrated that amyloid deposits of all types can regress when the supply of the respective amyloid fibril precursor protein is sufficiently reduced. This technique is not available commercially, but is used routinely in the UK National Amyloidosis Centre.

Management of amyloidosis

Localized amyloid masses can only be treated surgically. The twin aims of management in systemic amyloidosis are reduction in the supply of amyloid fibril precursor proteins so that amyloid deposition ceases and regression of existing deposits may occur, and scrupulous general care, including dialysis and organ transplantation if necessary, to keep patients alive long enough for this to take effect. The prognosis of systemic amyloidosis remains poor for many patients, especially those with the AL type, in whom the diagnosis is often made late when they already have substantial visceral and/or neural involvement, but recent advances have greatly extended median survival. Awareness of

the compromised functional reserve of amyloidotic organs and extreme care to protect renal function are critically important. Outcomes are much better in centres with specialist expertise.

Rational management has been greatly improved by the recent availability of routine assays for circulating SAA in AA and immunoglobulin free light chains in AL amyloidosis. Treatment of the underlying inflammatory disorder in AA amyloidosis, to reduce SAA values ideally to normal, dramatically improves survival [8]. The new biological agents that neutralize tumour necrosis factor (TNF) and IL-1 potently suppress the acute phase response in many patients with rheumatoid arthritis, seronegative spondyloarthropathies, Crohn's disease and some hereditary periodic fever syndromes. Treatment with colchicine prevents AA amyloidosis in familial Mediterranean fever [9]. Excision of solitary Castleman's disease masses that produce IL-6 can be very effective when this condition is complicated by AA amyloidosis.

Suppression of the B cells producing amyloidogenic monoclonal immunoglobulin light chains through chemotherapy is associated with arrest of amyloid deposition, regression of deposits, preservation of organ function and enhanced survival in many patients with systemic AL amyloidosis. Availability of the robust, sensitive, Freelite immunoassay for immunoglobulin free light chains in serum has been one of the most important advances in the management of AL amyloidosis [10,11]. The AL fibril precursor protein can now be monitored prospectively and chemotherapy tailored accordingly. Sustained reduction in the serum concentration of free monoclonal light chains reduces amyloid deposition, and suppression by 50% or more is associated with enhanced survival. Unfortunately, many patients with AL amyloidosis tolerate chemotherapy poorly, and a proportion of plasma cell clones are refractory to high-dose therapy. Oral melphalan and prednisolone are tolerated better than more aggressive treatment, but responses are few and very delayed. Intermediate-dose infusional chemotherapy regimes, such as vincristin, adriamycin and dexamethasone, or melphalan and dexamethasone, can induce swifter responses. High-dose chemotherapy with peripheral stem cell rescue has recently been used quite widely, but treatment-related mortality is extremely high at 15–25% in this setting, especially outside specialist amyloidosis centres [12]. Other current approaches include thalidomide alone or in combination chemotherapy, rituximab in patients with CD20-positive clones, and new agents including the proteasome inhibitor bortezomib. The satisfactory response to less intense chemotherapy indicates that high-dose regimes are excessive in some cases, but there is currently no way to identify which individuals will tolerate and respond best to which treatment. The key point is to sufficiently suppress production of the amyloidogenic free light chain without unacceptable toxicity, and this requires careful individual monitoring.

At present, apart from transplantation to replace failed organs and liver transplantation to remove the source of amyloidogenic proteins of hepatic origin, only symptomatic treatment is available for hereditary systemic amyloidosis. The liver is the source of plasma TTR, and over 700 liver transplants have been performed for treatment of hereditary TTR amyloidosis since this 'surgical gene therapy' approach was introduced in 1991 [13]. In younger patients carrying the common Met30 amyloidogenic mutation, the outcome is generally good, with arrest of neuropathy, but paradoxical acceleration of TTR amyloid deposition following liver transplantation may occur in the heart and certain other sites in some patients; this unexpected phenomenon has been best documented in older patients with non-Met30 variants. A few combined heart and liver transplants have been performed.

The livers of patients with hereditary TTR amyloidosis contain only microscopic amyloid deposits in the blood vessels and interstitial tissues, and retain normal liver function. A large number of domino liver transplants have therefore been conducted in recipients with various terminal liver diseases for whom normal livers were not available. This has certainly prolonged their lives, but the first such recipient has now developed symptomatic systemic TTR amyloidosis 8 years after transplantation [14].

Combined liver and kidney transplantation was dramatically effective in patients with hereditary fibrinogen amyloidosis [15] who had received two consecutive renal transplants and then developed amyloidotic liver failure; several more AFib patients have now received liver and kidney transplants. These operations have demonstrated that the liver is the sole site of synthesis of plasma fibrinogen, but the appropriate roles of liver vs. renal and/or combined liver plus kidney transplantation in the management of this disease have yet to be determined. Patients with apoAI amyloidosis can develop kidney, liver and cardiac amyloidosis, and several organ transplants have been performed, so far with excellent results. In one apoAI amyloidosis patient, aged 44 years, who underwent combined heart and kidney transplantation for endstage failure 12 years ago, there are minor amyloid deposits in the transplanted heart and kidney but no organ dysfunction despite no intervention to reduce the production of the amyloidogenic protein. In contrast, in a patient with lysozyme amyloidosis and a marked familial phenotype of hepatic amyloidosis leading to hepatic rupture, liver transplantation was eventually followed by fatal reaccumulation of liver amyloid. Liver transplantation has also been performed in a very small number of patients with hepatic failure due to systemic AL amyloidosis, most of whom have fared badly.

Elucidation of aspects of the molecular pathogenesis of amyloid and amyloidosis has generated a variety of novel approaches to therapy. We have developed a drug that targets SAP with the goal of eliminating SAP from amyloid deposits, in the hope that this may reduce amyloid deposition and/or accelerate amyloid clearance [16]. Preliminary open-label studies are in progress in patients with systemic amyloidosis to optimize dosing and SAP depletion. Neurochem, Inc. have just completed a double-blind, controlled clinical trial in AA amyloidosis of Fibrillex, a small-molecule glycosaminoglycan analogue aimed at blocking the proamyloidogenic interaction between SAA and

glycosaminoglycans [17]. Promising early findings have been released, and detailed analysis of outcomes is awaited. Small-molecule ligands that stabilize the native tetrameric structure of TTR and prevent its fibrillogenesis are being actively investigated for prophylaxis and therapy in TTR amyloidosis. Other strategies include stabilizing native structures of other amyloidogenic proteins and preventing and reversing fibrillogenesis, as well as disrupting established deposits, using antibodies, synthetic peptides and small-molecule drugs. Some of these potential new therapies may enter clinical trials within the next few years and offer exciting prospects for improvements in treatment.

Acknowledgements

The work of the Centre for Amyloidosis and Acute Phase Proteins is supported by Medical Research Council Programme Grant G79/00051, a grant from the Wolfson Foundation and NHS R&D funds. The National Health Service National Amyloidosis Centre is funded entirely by the UK Department of Health.

References

1 Hawkins PN (2002) Serum amyloid P component scintigraphy for diagnosis and monitoring amyloidosis. *Curr Opin Nephrol Hypertens* 11, 649–655.

2 Sunde M, Serpell LC, Bartlam M *et al.* (1997) Common core structure of amyloid fibrils by synchrotron X-ray diffraction. *J Mol Biol* 273, 729–739.

3 Kisilevsky R, Fraser P (1996) Proteoglycans and amyloid fibrillogenesis. *Ciba Found Symp* 199, 58–67.

4 Lachmann HJ, Booth DR, Booth SE *et al.* (2002) Misdiagnosis of hereditary amyloidosis as AL (primary) amyloidosis. *N Engl J Med* 346, 1786–1791.

5 Kyle RA, Gertz MA (1995) Primary systemic amyloidosis: clinical and laboratory features in 474 cases. *Semin Hematol* 32, 45–59.

6 Lovat LB, Persey MR, Madhoo S *et al.* (1998) The liver in systemic amyloidosis: insights from ^{123}I serum amyloid P component scintigraphy in 484 patients. *Gut* 42, 727–734.

7 Hawkins PN, Lavender JP, Pepys MB (1990) Evaluation of systemic amyloidosis by scintigraphy with ^{123}I-labeled serum amyloid P component. *N Engl J Med* 323, 508–513.

8 Gillmore JD, Lovat LB, Persey MR *et al.* (2001) Amyloid load and clinical outcome in AA amyloidosis in relation to circulating concentration of serum amyloid A protein. *Lancet* 358, 24–29.

9 Zemer D, Pras M, Sohar E *et al.* (1986) Colchicine in the prevention and treatment of amyloidosis of familial Mediterranean fever. *N Engl J Med* 314, 1001–1005.

10 Lachmann HJ, Gallimore R, Gillmore JD *et al.* (2003) Outcome in systemic AL amyloidosis in relation to changes in concentration of circulating free immunoglobulin light chains following chemotherapy. *Br J Haematol* 122, 78–84.

11 Bradwell AR, Carr-Smith HD, Mead GP *et al.* (2001) Highly sensitive, automated immunoassay for immunoglobulin free light chains in serum and urine. *Clin Chem* 47, 673–680.

12 Comenzo RL, Gertz MA (2002) Autologous stem cell transplantation for primary systemic amyloidosis. *Blood* 99, 4276–4282.

13 Herlenius G, Wilczek HE, Larsson M *et al.* (2004) Ten years of international experience with liver transplantation for familial amyloidotic polyneuropathy: results from the Familial Amyloidotic Polyneuropathy World Transplant Registry. *Transplantation* 77, 64–71.

14 Stangou AJ, Heaton ND, Hawkins PN (2005) Transmission of systemic transthyretin amyloidosis by means of domino liver transplantation. *N Engl J Med* 352, 2356.

15 Gillmore JD, Booth DR, Rela M *et al.* (2000) Curative hepatorenal transplantation in systemic amyloidosis caused by the Glu526Val fibrinogen α-chain variant in an English family. *Q J Med* 93, 269–275.

16 Pepys MB, Herbert J, Hutchinson WL *et al.* (2002) Targeted pharmacological depletion of serum amyloid P component for treatment of human amyloidosis. *Nature* 417, 254–259.

17 Kisilevsky R, Lemieux LJ, Fraser PE *et al.* (1995) Arresting amyloidosis *in vivo* using small molecule anionic sulphonates or sulphates: implications for Alzheimer's disease. *Nature Med* 1, 143–148.

20.12 Hepatic granulomas

Laura M. Kulik and Andres T. Blei

Granulomas are focal accumulations of macrophages that have undergone transformation into epithelioid cells. A wide range of aetiologies can result in the presence of hepatic granulomas, discovery of which on liver biopsy prompts a series of investigations to ascertain the diagnosis. They may be present solely in the liver or be part of a systemic illness with hepatic repercussions.

The inciting agent responsible for the formation of hepatic granuloma is dependent upon the nature and geographic location of the population in whom such lesions are identified. In most cases, this is a foreign agent, and thus granulomas can be viewed teleologically as a means of containing the influence of a potentially harmful invader. Not surprisingly, the lung and liver are the most common organs affected by granulomatous disease, reflecting their exposure to agents in the inhaled air or acquired via the gastrointestinal tract.

Classification of hepatic granulomas

Three approaches are simultaneously applied to the classification of hepatic granulomas [1].

Hepatic histology

Four main types of granulomas are identified.

Non-caseating granulomas are the most common (Fig. 1a)

These are composed of epithelioid cells and lymphocytes, generally located in the periphery of the acinus. Fusion of epithelioid cells can lead to the formation of giant cells. Unique pathological features within the granuloma can provide diagnostic clues. Sarcoidosis may present asteroid bodies [2], composed of non-collagenous filaments and myelinoid membranes. Schaumann bodies are large concentric inclusions composed of calcium and iron, also seen in sarcoidosis [3]. Non-caseating granulomas can also be seen in primary biliary cirrhosis, drug-related lesions and infectious aetiologies.

Caseating granulomas (Fig. 1b)

Here, the centre of the granulomas contains an eosinophilic necrotic material; they are mainly observed in patients infected with *Mycobacterium tuberculosis*.

Fibrin-ring granulomas (Fig. 1c)

These exhibit a central vacuolated space surrounded by a ring of fibrin and epithelioid cells. They are characteristically seen in Q fever.

Lipogranulomas (Fig. 1d)

These are lipid vacuoles surrounded by lymphocytes and macrophages. While present in patients with fatty livers, they may reflect the effects of ingestion of mineral oil or food products. In the experimental animal, strain differences exist in the formation of these lesions after feeding different hydrocarbons; those with a lower melting point were more likely to induce lipogranulomas [4].

Aetiological category

Five categories can be identified [1].

Immunological

In two large series from the UK, this group was the most represented, including sarcoidosis and primary biliary cirrhosis [5,6]. Other aetiologies in this group include giant cell arteritis, Wegener's granulomatosis, chronic granulomatous disease, idiopathic hypogammaglobulinaemia and allergic granulomatosis.

Infectious

The frequency of this type will vary according to geographical location. The long list of aetiologies includes viral agents [hepatitis C, cytomegalovirus (CMV), Epstein–Barr virus (EBV)], mycobacterial agents [tuberculosis, *Mycobacterium avium-intracellulare* in patients with acquired immune deficiency syndrome (AIDS), leprosy, bacillus Calmette–Guérin], bacteria (brucellosis, typhoid fever, Whipple's disease, tularaemia,

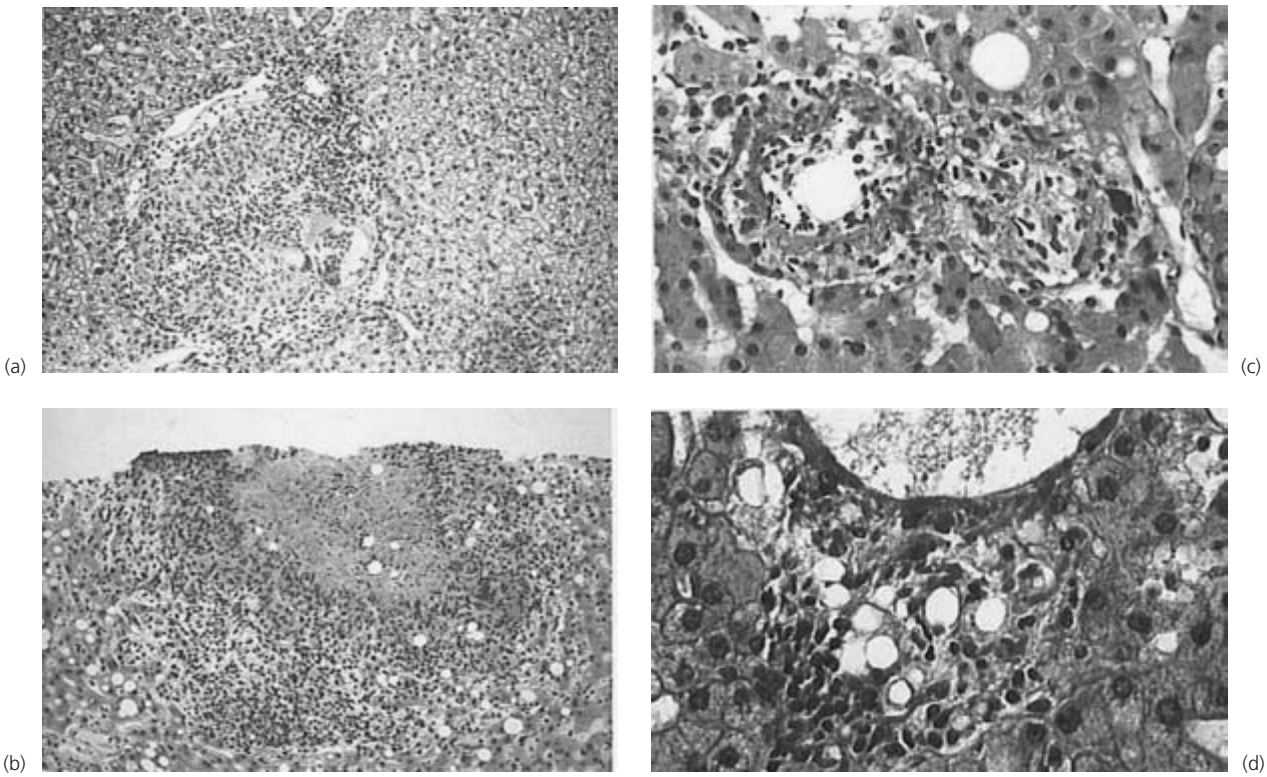

Fig. 1 Different histological types of granulomas. (a) Photomicrograph of an epithelioid granuloma with giant cells (lower right) in a case of sarcoidosis. (b) Caseating granuloma in a patient with tuberculosis. Note the central eosinophilic material. (c) A case of fibrin-ring granuloma in Q fever. A central vacuole is surrounded by a fibrin ring. (d) Lipogranuloma near a central vein in a patient who ingested mineral oil. Reproduced from Klatskin G, Conn HO (1993) *Histopathology of the Liver*. Oxford: Oxford University Press, with permission from the authors and publishers.

yersiniosis, cat-scratch disease), fungi (histoplasmosis, blastomycosis, coccidiomycosis, candidiasis), rickettsia (Q fever), protozoa (leishmaniasis, toxoplasmosis, syphilis) and metazoa (schistosomiasis, fasciolasis and viscerale larva migrans).

Medications

Probable and possible associations with a medicinal agent were found in almost a third of cases in a series from the American South [7]. Among implicated agents are the penicillins, diphenylhydantoin and allopurinol. The diagnosis still requires exclusion of other categories [8].

Neoplastic

The presence of hepatic granulomas without direct liver involvement has been noted in patients with Hodgkin's disease [9] and in hypernephroma [10].

Foreign body

These are related to occupational activities, such as exposure to beryllium. Surgical procedures may result in reactions to talc or suture material. Thorotrast, an α-emitting radionuclide (discontinued as a tool for hepatic scintigraphy), resulted in a range of hepatic lesions, including tumours and granulomas.

Primary liver disease vs. a systemic condition

Hepatic granulomas are commonly seen in primary biliary cirrhosis [5,6], a condition in which other histological features are prominent. Granulomas may also be seen in other primary liver conditions, including autoimmune hepatitis and primary sclerosing cholangitis and, as noted recently, in patients with hepatitis C viral infection [11]. A pathogenic relation to the underlying liver disease is clearer in cases of primary biliary cirrhosis (small bile duct damage) than in the other aetiologies mentioned, where conditions such as sarcoidosis and tuberculosis need to be excluded.

Pathogenesis

The process of granuloma formation has been described as occurring in four phases (Fig. 2). T cells contribute to the different phases of the process [12].

Initiation

This is triggered by the inflammatory/infectious agent. Persistent stimulation attracts macrophages; these cells

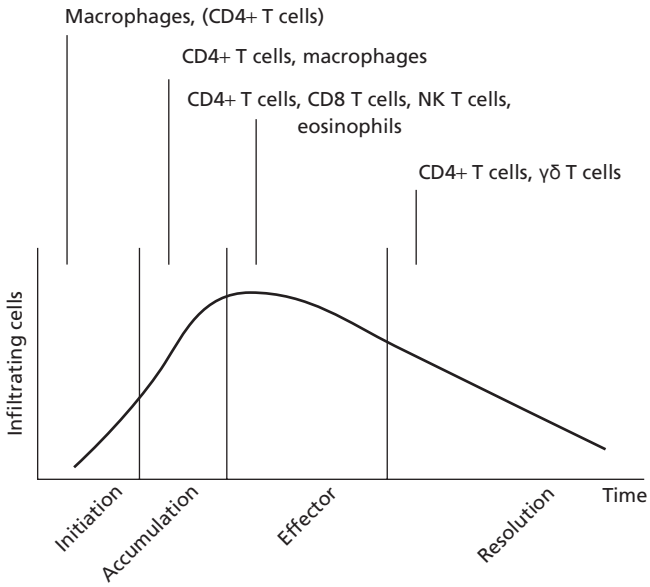

Fig. 2 Phases of granuloma formation. The text above each phase indicates the major cellular populations that are recruited during that phase. Reproduced from ref. 12 with permission from the authors and publishers. NK, natural killer.

phagocytose (in the case of foreign bodies) or endocytose (via receptor-mediated recognition of the infectious material) the putative agent. After internal degradation of the material, peptide fragments are complexed with class II major histocompatibility complex molecules and transported to the cell surface, where their display can be analysed by CD4+ cells.

Accumulation of CD4+ T cells

This play a key role in the recruitment of effector cells, including more T cells and macrophages. Multiple mechanisms participate in the accumulation of such cells, including the release of chemokines and cytokines via a complex regulatory network that dictates the profiles of local chemokine expression [13]. The amplification of the immune response is further enhanced by the expression of other cytokines, including tumour necrosis factor (TNF) and osteopontin (reviewed in [12]). Several clinical situations highlight the importance of such T cells in the control of infections, as noted by the disorganized appearance of granulomas in patients with human immunodeficiency virus (HIV) infection, decreasing CD4 counts and infection with intracellular pathogens (*Mycobacterium avium-intracellulare*, *Histoplasma capsulatum*) [14].

Effector phase

Other cells are now involved, including non-specific T cells, eosinophils and B cells, an interaction well described in mycobacterial infections [15]. The nature of the inciting agent may result in the release of cytokines related to T-helper 1 (Th1) cells [such as interferon (IFN)-γ in the case of mycobacterial infections] or T-helper 2 (Th2) cells [as is the case of interleukin (IL)-4, -5 and -13 related to schistosomal egg antigens] [16]. Sarcoidosis is characterized by the expression of IFN-γ, suggesting that it is a dominant Th1 disorder (reviewed in [17]). This may explain the appearance of sarcoidosis after the administration of a Th1 promoter, such as IFN-α [18].

Fibrosis

Fibrosis in granulomas can be viewed as part of the wound healing process. At times, however, the fibrotic response will aggravate the clinical picture, as seen in the pulmonary or hepatic complications of sarcoidosis or in the development of portal hypertension with schistosomiasis. Cytokines have been implicated in the development of fibrosis. Transforming growth factor (TGF)-β, which in the liver participates in the transdifferentiation of hepatic stellate cells into myofibroblasts [19], has been found in fibrotic granulomas of human sarcoidosis and tuberculosis [20]. Cross-talk of TGF-β with other cytokines, such as IL-13 [21], may amplify the fibrogenic response.

Specific diseases

Immunological diseases

Sarcoidosis

Several series have identified sarcoidosis as a leading cause of hepatic granuloma [5,6,22]. Sarcoidosis is a systemic disease characterized by non-caseating granulomas of unclear aetiology. The liver is the third most commonly affected organ, preceded by lung and lymphatic involvement [23]. The diagnosis of sarcoidosis requires identification of non-caseating granulomas in at least two different organs and exclusion of other causes for the lesion.

Hepatic granulomas can be identified in liver biopsy specimens in 80–95% of patients with this condition, making liver biopsy an important diagnostic tool [24]. While granulomas may be found throughout the liver lobule, a characteristic appearance is a cauliflower cluster-like presence within portal tracts or in the periportal zone. The histological appearance of the granuloma is dependent upon the degree of maturation. With ageing, a fibrous rim may surround the granuloma and, with healing, may lead to the formation of fibrous nodules. Caseation is not a feature, although central fibrinoid necrosis may be present. Damage to the bile ducts may mimic the pathological findings in primary biliary cirrhosis [24–26].

The clinical consequences of hepatic sarcoidosis are variable. However, the majority of patients are asymptomatic. An elevated alkaline phosphatase, a classic feature of 'space-occupying lesions', is not an invariable feature; in a series of 100 patients, it was elevated in over one-third [22]. Aminotransferases are mildly increased. An elevated angiotensin-converting enzyme

activity supports the diagnosis, but elevations are not exclusive to sarcoidosis [27].

There are two distinct clinical syndromes associated with hepatic sarcoidosis.

Cholestasis

Small bile duct lesions are common in sarcoidosis, including a florid duct lesion (mimicking primary biliary cirrhosis), a pattern of periductal fibrosis (mimicking primary sclerosing cholangitis) and a decrease in the number of bile ducts (ductopenia, mimicking the vanishing bile duct syndrome) [22]. In the last series, an acute cholangitis picture mimicking mechanical obstruction was seen in 12% of cases.

Chronic intrahepatic cholestasis may present with jaundice, hypercholesterolaemia, pruritus and hepatosplenomegaly. This presentation has been reported in young African American males and may evolve into a picture of micronodular biliary-type cirrhosis [25]. A negative antimitochondrial antibody test supports the diagnosis of sarcoidosis. The destruction of bile ducts has been explained by the presence of granulomas in the portal tracts, with accompanying fibrosis to account for ductopenia. Extrahepatic involvement of the biliary tree is possible, via sarcoidosis of either the hilar lymph nodes or the common bile duct itself [28]. However, direct involvement of the bile ducts by sarcoidosis may be possible. Laboratory responses to ursodeoxycholic acid [29,30] or corticosteroids [31], with a reduction in values of alkaline phosphatase and an improvement in symptoms, do not appear to prevent the progression to cirrhosis. Liver transplantation has been performed in such cases [32].

Portal hypertension

A review of the literature on sarcoidosis and portal hypertension reveals 47 reported cases [33], although the exact prevalence is unknown. Several mechanisms may be in play. These include an increased presinusoidal resistance to portal venous flow as a result of inflammation in the portal tracts and/or obliteration of the small portal venules by granulomas [24]. An alternative explanation lies in the development of granulomatous phlebitis and thrombosis of the portal/hepatic veins. Examination of the whole liver at explant or autopsy in four patients with sarcoidosis exhibiting fibrosis/cirrhosis or diffuse nodular hyperplasia noted such vascular changes [34]. Chronic cholestasis leading to cirrhosis may also result in clinical manifestations of portal hypertension. Granulomatous disease in the hepatic veins may lead to a Budd–Chiari-like appearance [35]; thrombosis of the major hepatic veins is not a clinical feature.

Variceal bleeding may occur, including the development of haemorrhage as a presenting symptom of the disease [33]. The use of corticosteroids has no demonstrable benefit for this complication. It has been noted that most reports of extensive fibrosis or cirrhosis developing significant portal hypertension were published before the identification of the hepatitis C virus [36].

As noted already, current therapies for hepatic sarcoidosis offer limited relief for the clinical problems of the disease. Corticosteroids may alleviate the acute inflammatory reaction and decrease fever, constitutional symptoms and even the jaundice associated with the acute cholangitis-like presentation. The role of ursodeoxycholic acid appears to be quite limited. Newer approaches to therapy have arisen from an understanding of the basic mechanisms responsible for the disease [17]. Immunosuppressive drugs, such as methotrexate and azathioprine, may be steroid sparing in subjects with continued inflammatory activity. However, toxic hepatic reactions to methotrexate occurred in more than 10% of patients treated with the drug for more than 2 years [37]. Another line of potential new therapies comes from studies of genetic variation. These indicate a role of genetic polymorphisms of different genes in both the appearance and the progression of the disease (reviewed in [38]), including that of TNF. The effectiveness of anti-TNF agents, such as pentoxyphylline, thalidomide and infliximab, is under investigation. Yet another line of enquiry focuses on the first step in the pathogenic process: inhibition of antigen presentation by antimalarial drugs [17]. Regression of hepatic granulomas was reported with the use of chloroquine [39].

Sarcoidosis necessitating liver transplantation is a rare event. Reports of post-transplant outcomes are therefore limited. A recent case–control study found no statistical difference in the rates of acute cellular rejection, chronic rejection or *de novo* autoimmune hepatitis in those transplanted for sarcoidosis compared with transplants for other aetiologies of liver disease [40]. Recurrent hepatic sarcoidosis after liver transplant has been documented in four cases, including one with severe hypercalcaemia [41]. Exacerbation of pulmonary sarcoidosis after liver transplantation has also been documented despite maintenance immunosuppression with calcineurin inhibitors; the patient responded to corticosteroid therapy [42]. While calcineurin inhibitors may decrease the Th1 response, a factor that could decrease the inflammatory response in granulomas, a controlled trial of ciclosporin in pulmonary sarcoidosis did not show a steroid-sparing effect [43].

Idiopathic hepatic granulomas

Patients with hepatic granulomas, but without an identifiable underlying aetiology after a full diagnostic workup, are said to have an 'idiopathic' cause. In a tertiary referral centre, half of 86 cases revealed idiopathic hepatic granulomas confined to the liver [44]. The majority of these patients were middle-aged females with a predominantly cholestatic profile and an overall benign clinical course.

A subset of patients may present with systemic symptoms, including fever, weight loss and arthralgias. It is unclear whether these patients represent a distinct clinical entity or a variant of sarcoidosis. Fever of unknown origin may be the clinical presentation [45]. In 23 patients presenting with fever of unknown origin and exhibiting hepatic granulomas in western Canada, three had Q fever, two mycobacterial disease and one

histoplasmosis; no aetiology was established in the rest after almost 4 years of follow-up. In 7 of the 17 patients with no known aetiology, the fever resolved spontaneously [46].

Treatment, as shown in this series [46], is based on immunosuppression, either a short- or a long-term course of corticosteroids, according to the nature of the therapeutic response and the recurrence of symptoms with tapering of the medication. A series of six febrile patients who did not respond to corticosteroid therapy were treated with low-dose oral pulse methotrexate (15 mg/week). A positive clinical response was seen within 3 months in all subjects, and hepatic granulomas were not seen in subsequent liver biopsies [47].

Infectious diseases

The reader is referred to other sections of the textbook that deal with repercussions of infectious diseases on the liver (see Sections 9 and 10). Thus, the focus in this chapter is to highlight those features that surround the diagnosis of hepatic granulomas.

Tuberculosis

The diagnosis of tuberculosis can be difficult in biopsies of hepatic granulomas. The lesions do not exhibit a preferential location within the lobule, and caseation is seen in only a minority of cases in the west, although the presence of caseation may be higher in other areas, such as South Africa [48]. Caseation can also be seen in fungal granulomas and even in patients with Hodgkin's disease [49].

In a series of 96 patients presenting with tuberculosis and features of liver disease, hepatic granulomas were seen in 96% of cases [50]. Acid-fast bacilli were demonstrated in the granulomas in 9% of cases. Chest radiographs were normal in 25% of cases. Other forms of presentation of hepatic tuberculosis include nodules (tuberculoma), abscesses and involvement of hilar nodes. Miliary tuberculosis can be cryptic, with hepatic granulomas as a sole manifestation [51].

The detection of *M. tuberculosis* among patients with hepatic granulomas was reported using a polymerase chain reaction (PCR) assay [52]. It was positive in 88% of cases vs. a 12% diagnostic accuracy for conventional methods. PCR assays were used to confirm the tuberculous aetiology of hepatic nodules suspected to be malignant [53]. The detection of mycobacterial DNA in clinical samples by PCR offers the promise of a rapid diagnosis of infection; a recent review points at technical pitfalls including DNA contamination and the presence of inhibitors of the reaction [54].

Brucellosis

This can be an important cause of granulomas in countries that face endemic infections, such as Spain [55]. In this series, 50% of subjects showed epithelioid granulomas, which can present with high aminotransferases [56]. There may be differences in the development of granulomas according to the different subtypes, with controversy surrounding the incidence of granulomas with *Brucella melitensis* [57,58]. Coalescence of lesions can result in the formation of a brucelloma, a mass that can be visible with hepatic imaging techniques [59]. Diagnosis is based on serology and blood cultures.

Granulomas in patients with HIV infection

Patients with HIV and low CD4 counts are susceptible to a wide range of infections that may result in hepatic granulomas. Several publications, totalling 92 patients, have documented the presence of hepatic granulomas in 75% of patients with AIDS who underwent a liver biopsy [60–63]. Mycobacterial infections are the most common aetiology. Unique histological features of the granulomas include a paucity of lymphocytes and pale macrophages with striated cytoplasm, indicating the presence of abundant, packed *Mycobacterium avium-intracellulare*. Other aetiologies for granulomas have been reported, including cat-scratch disease [64] and leishmaniasis [65]. Lymphomas and drug reactions are also aetiological factors; on occasions, no explanation is found for the hepatic granulomas [66].

Schistosomiasis

Infection with *Schistosoma mansoni* and *S. japonicum* is a major health problem in endemic areas [67]. The adult worms shed their eggs into the mesenteric venules and the intestinal lumen, and a granulomatous reaction develops around the egg in the occluded portal venule. The development of granulomas in schistosomiasis is modulated by several factors [68]. For example, the different response of various mouse strains indicates a genetic background. The induction of a Th2 response is characteristic of schistosomal infection, and secretion of TGF-β and IL-13 by such T cells is critical in the development of 'pipestem' fibrosis. Different egg antigens may modulate the granulomatous response [69].

Portal hypertension with variceal haemorrhage is a common clinical presentation. Egypt is a country with a high prevalence of schistosomiasis as well as hepatitis C, the latter the result of an epidemic arising from efforts to eradicate the parasite [70]. Patients with both conditions have more severe liver injury, with progression to cirrhosis.

Other infectious aetiologies

Q fever

This is a rickettsial disease, caused by *Coxiella burnetti* and acquired after contact with cows, goats and sheep. The characteristic 'doughnut-like' granuloma has a central fat vacuole surrounded by a fibrinoid ring, and was seen in 14/17 cases with the infection (Fig. 1c) [71]. Other infectious and non-infectious conditions may also cause this histological appearance (CMV, hepatitis A, EBV, leishmaniasis, toxoplasmosis, staphylococcal epidermidis, Hodgkin's disease, allopurinol toxicity) [72,73]. Diagnosis is based on serology.

Whipple's disease

This is caused by *Tropheryma whipplei*. Non-caseating granulomas containing periodic acid–Schiff (PAS) diastase-positive material can be found in both the gastrointestinal tract and the liver [74]. DNA testing may allow a rapid diagnosis.

Other

There is a long list of infectious agents that can present occasionally with hepatic granulomas (reviewed in [36]). It is rare that the liver be the sole organ affected by the condition. Special stains of the hepatic granuloma may assist in the identification of the infectious agent. These include the Gram stain (*Brucella*), Ziehl–Neelsen stain (acid-fast bacilli), Grocott–Gomori methenamine–silver stain (fungi), PAS stain (*M. avium*, Whipple's), Warthin–Starry silver stain (syphilis, cat-scratch disease) and immunostaining (CMV).

Granulomas in lymphoma

Granulomas may herald the diagnosis of Hodgkin's lymphoma, even in the absence of clinical findings of the tumour [75,76]. They are found in approximately 10% of staging liver biopsies [77]. Their presence is not indicative of liver infiltration but may represent a paraneoplastic phenomenon in response to an altered immunity.

The presence of hepatic granulomas was reported to be a good prognostic sign in Hodgkin's lymphoma [9]; a subsequent report with a longer follow-up did not confirm this positive trend [78].

Hepatic granulomas may also be observed in non-Hodgkin's lymphoma [76,79].

Primary liver/gastrointestinal conditions associated with granulomas

Viral hepatitis

The incidence of hepatic granulomas associated with hepatitis C is increasingly recognized. In a series of 53 patients who underwent liver transplantation in Paris, 10% of the livers showed granulomas, diffusely distributed within the liver [11]. Tests for tuberculosis and brucellosis were negative, and no subsequent infectious disease occurred after transplantation. The pathogenic role of the virus, although suspected, was not confirmed.

A more detailed relation between hepatic granulomas, sarcoidosis and hepatitis C was provided in a multicentre experience in Spain [18]. In a series of 68 patients, 18 treatment-naive subjects presented mainly with pulmonary and cutaneous sarcoidosis. In 50 patients, sarcoidosis appeared within 6 months of starting therapy with IFN-α alone or in combination with ribavarin, again with predominant cutaneous and pulmonary involvement. The evolution of the disease in these patients was satisfactory in the majority, although 21/50 subjects required corticosteroid therapy. Patients with pre-existing sarcoidosis had a more chronic, less favourable course.

Table 1 Characteristics of primary biliary cirrhosis (PBC) and sarcoidosis.

Characteristic	PBC	Sarcoidosis
Gender prevalence	Female	Male
AMA test	95% positive	–
IgM level	Increased	Normal
Hepatic granulomas	+	+++
Extrahepatic granulomas	–	++
Bile duct destruction	+++	+
ERCP	Normal	Normal

Reproduced from ref. 81, with permission.
AMA, antimitochondrial antibodies; ERCP, endoscopic retrograde cholangiopancreatography; IgM, immunoglobulin M; +, weakly positive; ++, positive; +++, strongly positive.

Fibrin-ring hepatic granulomas have been reported in hepatitis A infection [80].

Primary biliary cirrhosis

Clinical, histological and biochemical features are helpful in the differentiation between primary biliary cirrhosis (PBC) and sarcoidosis (Table 1) [81]. Granulomas are reported in approximately 25% of patients with PBC and are located adjacent to the interlobular bile ducts undergoing immunological destruction [82]. They are seen more often at earlier stages of the disease and confer a better prognosis [83].

The presence of such granulomas has fuelled the search for an infectious aetiology for PBC. Various infectious agents have been hypothesized to be acting as molecular mimics to the E2 structural component of the inner mitochondrial membrane responsible for the characteristic antimitochondrial antibody seen in PBC [84]. Candidate agents have included *Escherichia coli*, *Mycobacterium gordonae*, *Propionibacterium acnes* and betaretrovirus. There are a few reports of concomitant sarcoidosis in patients with PBC [85,86].

Other

Granulomas were seen in 7% of liver explants in patients who underwent transplantation with primary sclerosing cholangitis (PSC); a control group of livers transplanted for PBC showed a similar prevalence of granulomas [87]. In 13% of cases of PSC, there was a granulomatous epithelioid response to extravasated bile, sometimes with a foreign body reaction. The granulomas in PSC, in contrast to PBC, were seen in all phases of the disease and were not a feature of bile duct destruction.

Hepatic granulomas may also be seen in patients with inflammatory bowel disease, predominantly Crohn's disease [88]. Colectomy may result in the resolution of the granulomas. Medications used in the treatment of inflammatory bowel disease, such as sulphasalazine, may result in the development of hepatic granulomas [89].

A diagnostic approach to hepatic granulomas

Two practical approaches have been proposed to narrow the differential diagnosis of hepatic granulomas. An international group of liver pathologists proposed a four-point approach [90].

1 See the cause of the granuloma (like a schistosomal egg).
2 Know the cause (medical history).
3 Suspect the cause: a combination of clinical and pathological elements.
4 Cause is unknown. Still be certain that tuberculosis is not present.

Experienced hepatologists also proposed a five-point rule [36], which in fact complements the former.

1 Obtain complementary investigation of the biopsy (e.g. special stains).
2 Obtain exhaustive drug history, exposure to toxic chemicals.
3 Evaluate the nature of extrahepatic signs and symptoms.
4 Serological tests and blood cultures, as appropriate.
5 Re-evaluate in 3 months.

References

1 Lefkowitch JH (1999) Hepatic granulomas. *J Hepatol* 30, 40–45.
2 Kirkpatrick CJ, Curry A, Bisset DL (1988) Light-and electron-microscopic studies on multinucleated giant cells in sarcoid granuloma: new aspects of asteroid and Schaumann bodies. *Ultrastruct Pathol* 12, 581–597.
3 Uehlinger E (1964) The sarcoid tissue reaction. The origin and significance of inclusion bodies. Differential diagnosis with particular delineation from tuberculosis. *Acta Med Scand Suppl* 425, 7–13.
4 Fleming KA, Zimmerman H, Shubik P (1998) Granulomas in the livers of humans and Fischer rats associated with the ingestion of mineral hydrocarbons: a comparison. *Regul Toxicol Pharmacol* 27, 75–81.
5 McCluggage WG, Sloan JM (1994) Hepatic granulomas in Northern Ireland: a thirteen year review. *Histopathology* 25, 219–228.
6 Gaya DR, Thorburn D, Oien KA *et al.* (2003) Hepatic granulomas: a 10 year single centre experience. *J Clin Pathol* 56, 850–853.
7 McMaster KR 3rd, Hennigar GR (1981) Drug-induced granulomatous hepatitis. *Lab Invest* 44, 61–73.
8 Ishak KG, Zimmerman HJ (1988) Drug-induced and toxic granulomatous hepatitis. *Baillieres Clin Gastroenterol* 2, 463–480.
9 Sacks EL, Donaldson SS, Gordon J *et al.* (1978) Epithelioid granulomas associated with Hodgkin's disease: clinical correlation in 55 previously untreated patients. *Cancer* 41, 562–567.
10 Strickland RC, Schenker S (1977) The nephrogenic hepatic dysfunction syndrome: a review. *Am J Dig Dis* 22, 49–55.
11 Emile JF, Sebagh M, Feray C *et al.* (1993) The presence of epithelioid granulomas in hepatitis C virus-related cirrhosis. *Hum Pathol* 24, 1095–1097.
12 Co DO, Hogan LH, Kim SI *et al.* (2004) T cell contributions to the different phases of granuloma formation. *Immunol Lett* 92, 135–142.
13 Chiu BC, Freeman CM, Stolberg VR *et al.* (2003) Cytokine–chemokine networks in experimental mycobacterial and schistosomal pulmonary granulomas formation. *Am J Respir Cell Mol Biol* 29, 106–116.
14 Horsburgh CR Jr (1999) The pathophysiology of disseminated *Mycobacterium avium* complex disease in AIDS. *J Infect Dis* 179, S461–S465.
15 Co DO, Hogan LH, Kim SI *et al.* (2004) Mycobacterial granulomas: keys to a long-lasting host-pathogen relationship. *Clin Immunol* 113, 130–136.
16 Chensue SW, Warmington K, Ruth J *et al.* (1994) Cytokine responses during mycobacterial and schistosomal antigen-induced pulmonary granulomas formation. Production of Th1 and Th2 cytokines and relative contribution of tumor necrosis factor. *Am J Pathol* 145, 1105–1113.
17 Moller DR (2003) Treatment of sarcoidosis – from a basic science point of view. *J Int Med* 253, 31–40.
18 Ramos-Casals M, Mana J, Nardi N *et al.*; HISPAMEC Study Group (2005) Sarcoidosis in patients with chronic hepatitis C virus infection: analysis of 68 cases. *Medicine (Baltimore)* 84, 69–80.
19 Gressner AM, Weiskirchen R, Breitkopf K *et al.* (2002) Roles of TGF-beta in hepatic fibrosis. *Front Biosci* 7, d793–d807.
20 Marshall BG, Wangoo A, Cook HT *et al.* (1996) Increased inflammatory cytokines and new collagen formation in cutaneous tuberculosis and sarcoidosis. *Thorax* 51, 1253–1261.
21 Wynn TA (2004) Fibrotic disease and the T(H)1/T(H)2 paradigm. *Nature Rev Immunol* 4, 583–594.
22 Devaney K, Goodman ZD, Epstein MS *et al.* (1993) Hepatic sarcoidosis. Clinicopathologic features in 100 patients. *Am J Surg Pathol* 17, 1272–1280.
23 Newman LS, Rose CS, Maier LA (1997) Sarcoidosis. *N Engl J Med* 336, 1224–1234.
24 Ishak KG (1998) Sarcoidosis of the liver and bile ducts. *Mayo Clin Proc* 73, 467–472.
25 Rudzki C, Ishak KG, Zimmerman HJ (1975) Chronic intrahepatic cholestasis of sarcoidosis. *Am J Med* 59, 373–387.
26 Kim WR, Ludwig J, Lindor KD (2000) Variant forms of cholestatic diseases involving small bile ducts in adults. *Am J Gastroenterol* 95, 1130–1138.
27 Lieberman J (1989) Enzymes in sarcoidosis. Angiotensin-converting-enzyme (ACE). *Clin Lab Med* 9, 745–755.
28 Rezeig MA, Fashir BM (1997) Biliary tract obstruction due to sarcoidosis: a case report. *Am J Gastroenterol* 92, 527–528.
29 Baratta L, Cascino A, Delfino M *et al.* (2000) Ursodeoxycholic acid treatment in abdominal sarcoidosis. *Dig Dis Sci* 45, 1559–1562.
30 Alenezi B, Lamoureux E, Alpert L *et al.* (2005) Effect of ursodeoxycholic acid on granulomas liver disease due to sarcoidosis. *Dig Dis Sci* 50, 196–200.
31 Murphy JR, Sjogren MH, Kikendall JW *et al.* (1990) Small bile duct abnormalities in sarcoidosis. *J Clin Gastroenterol* 12, 555–561.
32 Casavilla FA, Gordon R, Wright HI *et al.* (1993) Clinical course after liver transplantation in patients with sarcoidosis. *Ann Intern Med* 118, 865–866.
33 Valla D, Pessengueiro-Miranda H, Degott C *et al.* (1987) Hepatic sarcoidosis with portal hypertension. A report of seven cases with a review of the literature. *Q J Med* 63, 531–544.
34 Moreno-Merlo F, Wanless IR, Shimamatsu K *et al.* (1997) The role of granulomatous phlebitis and the thrombosis in the pathogenesis of cirrhosis and portal hypertension in sarcoidosis. *Hepatology* 26, 554–560.
35 Nakanuma Y, Ohta G, Doishita K *et al.* (1980) Granulomatous liver disease in the small hepatic and portal veins. *Arch Pathol Lab Med* 104, 456–458.

36 Valla DC, Benhamou JP (2000) Hepatic granulomas and hepatic sarcoidosis. *Clin Liver Dis* 4, 269–285.

37 Baughman RP, Koehler A, Bejarano PA *et al.* (2003) Role of liver function tests in detecting methotrexate-induced liver damage in sarcoidosis. *Arch Intern Med* 163, 615–620.

38 Baughman RP, Lower EE, du Bois RM (2003) Sarcoidosis. *Lancet* 361, 1111–1118.

39 Galwanker S, Vyas M, Desai D *et al.* (1999) Hepatic sarcoidosis responding to chloroquine as steroid-sparing drug. *Ind J Gastroenterol* 18, 177–178.

40 Lipson EJ, Fiel MI, Florman SS *et al.* (2005) Patient and graft outcomes following liver transplantation for sarcoidosis. *Clin Transplant* 19, 487–491.

41 Cengiz C, Rodriguez-Davalos M, deBoccardo G *et al.* (2005) Recurrent hepatic sarcoidosis post-liver transplantation manifesting with severe hypercalcemia: a case report and review of the literature. *Liver Transpl* 11, 1611–1614.

42 Shibolet O, Kalish Y, Wolf D *et al.* (2002) Exacerbation of pulmonary sarcoidosis alter liver transplantation. *J Clin Gastroenterol* 35, 356–358.

43 Wyser CP, van Schalkwyk EM, Alheit B *et al.* (1997) Treatment of progressive pulmonary sarcoidosis with cyclosporin A. A randomized controlled trial. *Am J Respir Crit Care Med* 156, 1371–1376.

44 Sartin JS, Walker RC (1991) Granulomatous hepatitis: a retrospective review of 88 cases at the Mayo Clinic. *Mayo Clin Proc* 66, 914–918.

45 Simon HB, Wolff SM (1973) Granulomatous hepatitis and prolonged fever of unknown origin: a study of 13 patients. *Medicine (Baltimore)* 52, 1–21.

46 Zoutman DE, Ralph ED, Frei JV (1991) Granulomatous hepatitis and fever of unknown origin. An 11-year experience of 23 cases with three years' follow-up. *J Clin Gastroenterol* 13, 69–75.

47 Knox TA, Kaplan MM, Gelfand JA *et al.* (1995) Methotrexate treatment of idiopathic granulomatous hepatitis. *Ann Intern Med* 122, 592–595.

48 Maharaj B, Leary WP, Pudifin DJ (1987) A prospective study of hepatic tuberculosis in 41 black patients. *Q J Med* 63, 517–522.

49 Johnson LN, Iseri O, Knodell RG (1990) Caseating hepatic granulomas in Hodgkin's lymphoma. *Gastroenterology* 99, 1837–1840.

50 Essop AR, Posen JA, Hodkinson JH *et al.* (1984) Tuberculosis hepatitis: a clinical review of 96 cases. *Q J Med* 53, 465–477.

51 Yu YL, Chow WH, Humphries MJ *et al.* (1986) Cryptic miliary tuberculosis. *Q J Med* 59, 421–428.

52 Alcantara-Payawal DE, Matsumura M, Shiratori Y *et al.* (1997) Direct detection of *Mycobacterium tuberculosis* using polymerase chain reaction assay among patients with hepatic granuloma. *J Hepatol* 27, 620–627.

53 Huang WT, Wang CC, Chen WJ *et al.* (2003) The nodular form of hepatic tuberculosis: a review with five additional new cases. *J Clin Pathol* 56, 835–839.

54 Garg SK, Tiwari RP, Tiwari D *et al.* (2003) Diagnosis of tuberculosis: available technologies, limitations, and possibilities. *J Clin Lab Anal* 17, 155–163.

55 Cervantes F, Bruguera M, Carbonell J *et al.* (1982) Liver disease in brucellosis. A clinical and pathological study of 40 cases. *Postgrad Med J* 58, 346–350.

56 Vilaseca J, Guardia J, Cuxart A *et al.* (1978) [Granulomas hepatitis: aetiological study of 107 cases (author's transl.)]. *Nouv Presse Med* 7, 3323–3325.

57 Young EJ (1979) *Brucella melitensis* hepatitis: the absence of granulomas. *Ann Intern Med* 91, 414–415.

58 Jordans HG, DeBruin KD (1980) Granulomas in *Brucella melitensis* infection. *Ann Intern Med* 92, 264–265.

59 Ruiz Carazo E, Munoz Parra F, Jimenez Villares MP *et al.* (2005) Hepatosplenic brucelloma: clinical presentation and imaging features in six cases. *Abdom Imaging* 30, 291–296.

60 Orenstein MS, Tavitian A, Yonk B *et al.* (1985) Granulomatous involvement of the liver in patients with AIDS. *Gut* 26, 1220–1225.

61 Gordon SC, Reddy KR, Gould EE *et al.* (1986) The spectrum of liver disease in the acquired immunodeficiency syndrome. *J Hepatol* 2, 475–484.

62 Kahn SA, Saltzman BR, Klein RS *et al.* (1986) Hepatic disorders in the acquired immune deficiency syndrome: a clinical and pathological study. *Am J Gastroenterol* 81, 1145–1148.

63 Cappell MS, Schwartz MS, Biempica L (1990) Clinical utility of liver biopsy in patients with serum antibodies to the human immunodeficiency virus. *Am J Med* 88, 123–130.

64 Delahoussaye PM, Osborne BM (1990) Cat-scratch disease presenting as abdominal visceral granulomas. *J Infect Dis* 161, 71–78.

65 Canalias J, Falco J, Martin J *et al.* (1997) Macronodular hepatic granulomas due to visceral leishmaniasis in an AIDS patient: imaging findings. *J Comput Assist Tomogr* 21, 677–679.

66 Kennedy M, O'Reilly M, Bergin CJ *et al.* (1998) Liver biopsy pathology in human immunodeficiency virus infection. *Eur J Gastroenterol Hepatol* 10, 255–258.

67 McKerrow JH, Sun E (1994) Hepatic schistosomiasis. *Prog Liver Dis* 12, 121–135.

68 Stadecker MJ (1999) The development of granulomas in schistosomiasis: genetic backgrounds, regulatory pathways, and specific egg antigen responses that influence the magnitude of disease. *Microbes Infect* 1, 505–510.

69 Asahi H, Stadecker MJ (2003) Analysis of egg antigen inducing hepatic lesions in schistosomiasis infection. *Parasitol Int* 52, 361–367.

70 Strickland GT (2006) Liver disease in Egypt: hepatitis C superseded schistosomiasis as a result of iatrogenic and biological factors. *Hepatology* 43, 915–922.

71 Pelligrin M, Delsol G, Auvergnat JC *et al.* (1980) Granulomatous hepatitis in Q fever. *Hum Pathol* 11, 51–57.

72 Marzuela M, Moreno A, Yebra M *et al.* (1991) Hepatic fibrin-ring granulomas: a clinicopathologic study of 23 patients. *Hum Pathol* 22, 607–613.

73 Font J, Bruguera M, Perez-Villa F *et al.* (1987) Hepatic fibrin-ring granulomas caused by *Staphylococcus epidermidis* generalized infection. *Gastroenterology* 93, 1449–1451.

74 Saint-Marc Girardin MF, Zafrani ES, Chaumette MT *et al.* (1984) Hepatic granulomas in Whipple's disease. *Gastroenterology* 86, 753–756.

75 Kadin ME, Donaldson SS, Dorfman RF (1970) Isolated granulomas in Hodgkin's disease. *N Engl J Med* 283, 859–861.

76 Aderka D, Kraus M, Avidor I *et al.* (1984) Hodgkin's and non-Hodgkin's lymphomas masquerading as 'idiopathic' liver granulomas. *Am J Gastroenterol* 79, 642–644.

77 Sans M, Andreu V, Bordas JM *et al.* (1998) Usefulness of laparoscopy with liver biopsy in the assessment of liver involvement at diagnosis of Hodgkin's and non-Hodgkin's lymphomas. *Gastrointest Endosc* 47, 391–395.

78 Abrams J, Pearl P, Moody M *et al.* (1988) Epithelioid granulomas revisited: long-term follow-up in Hodgkin's disease. *Am J Clin Oncol* 11, 456–460.

79 Saito K, Nakanuma Y, Ogawa S *et al.* (1991) Extensive hepatic granulomas associated with peripheral T-cell lymphoma. *Am J Gastroenterol* 86, 1243–1246.
80 Ponz E, Garcia-Pagan JC, Bruguera M *et al.* (1991) Hepatic fibrin-ring granulomas in a patient with hepatitis A. *Gastroenterology* 100, 268–270.
81 Layden TJ, Kulik L (2002) Hepatic manifestations of pulmonary diseases. *Clin Liver Dis* 6, 969–979.
82 Nakanuma Y, Ohta G (1983) Quantitation of hepatitis granulomas and epithelioid cells in primary biliary cirrhosis. *Hepatology* 3, 423–427.
83 Lee RG, Epstein O, Jauregui H *et al.* (1981) Granulomas in primary biliary cirrhosis: a prognostic feature. *Gastroenterology* 81, 983–986.
84 Leung PS, Coppel RL, Gershwin ME (2005) Etiology of primary biliary cirrhosis: the search for the culprit. *Semin Liver Dis* 25, 327–336.
85 Leff JA, Ready JB, Repetto C *et al.* (1990) Coexistence of primary biliary cirrhosis and sarcoidosis. *West J Med* 153, 439–441.
86 Harrington AC, Fitzpatrick JE (1992) Cutaneous sarcoidal granulomas in a patient with primary biliary cirrhosis. *Cutis* 49, 271–274.
87 Ludwig J, Colina F, Poterucha JJ (1995) Granulomas in primary sclerosing cholangitis. *Liver* 15, 307–312.
88 Dew MJ, Thompson H, Allan RN (1979) The spectrum of hepatic dysfunction in inflammatory bowel disease. *Q J Med* 48, 113–135.
89 Callen JP, Soderstrom RM (1978) Granulomas hepatitis associated with salicylazosulfapyridine therapy. *South Med J* 71, 1159–1160.
90 Denk H, Scheuer PJ, Baptista A *et al.* (1994) Guidelines for the diagnosis and interpretation of hepatic granulomas. *Histopathology* 25, 209–218.

21 The impact of liver disease on other systems

21.1 The effect of liver disease on the cardiovascular system

Jens H. Henriksen and Søren Møller

Introduction

In addition to obvious signs of portal hypertension and liver dysfunction, patients with chronic liver disease often present clinically with signs of circulatory dysfunction [1].

The systemic circulation in advanced liver disease is hyperdynamic with increased heart rate and cardiac output and low arterial blood pressure [2,3]. Impaired cardiac performance with prolonged Q-T_C interval and dyssynchronous electrical and mechanical function is common in patients with cirrhosis [4].

A number of neurohumoral homoeostatic systems, such as the renin–angiotensin–aldosterone system (RAAS), the sympathetic nervous system (SNS) and the hypothalamic/neuropituitary release of vasopressin, are activated in the majority of patients with advanced chronic liver disease, especially in cirrhosis [5–7]. Over the last decade, intensive research has revealed that nitric oxide (NO), other vasodilators and the endothelin (ET) systems are implicated in the haemodynamic derangement [3,6,8].

The retention of fluid and the formation of ascites are closely linked to the derangement in systemic cardiovascular haemodynamics, and it is evident that the abnormal distribution of the blood volume and flow is important for the kidney dysfunction and sodium–water retention found in advanced liver disease [2,7].

The objective of this chapter is to outline some basic elements of the circulatory changes in chronic liver disease with focus on cardiac and vascular dysfunction and neurohumoral control of haemodynamics and distribution of blood volume. Special attention is paid to biodynamics and bioactive substances that may affect vasodilatation/vasoconstriction and neuroendocrine compensation of the severe systemic circulatory dysfunction in chronic liver disease, most characteristically found in cirrhosis.

Cardiac dysfunction

Cardiac output (CO) is increased in cirrhosis as a compensatory response to the systemic (especially splanchnic) vasodilatation and the presence of portal-systemic and arteriovenous shunts [1,2,4,9]. At first glance, cardiac function may appear normal at rest but, under physical or pharmacological strain, cardiac contractility becomes impaired [4,8,10,11], a condition termed 'cirrhotic cardiomyopathy'.

Systolic dysfunction

Most patients with cirrhosis have a myocardial mass within the normal range. A few have increased left ventricular mass with left eccentric and, especially, septal hypertrophy. Some have a normal left ventricular end-diastolic volume; others have increased end-diastolic and end-systolic volumes and an enlarged left atrium [4,11,12]. With respect to the right heart, reduced, normal and increased atrial and ventricular volumes have been reported [13]. Most often, the right ventricular pressure, pulmonary artery pressure and pulmonary capillary wedged pressure are in the upper normal limit, but within the normal range during rest. Physical and pharmacological strain may affect the cardiac pressures. Thus, after exercise, the left ventricular end-diastolic pressure increases, whereas the cardiac stroke index and left ventricular ejection fraction fall, which indicates an abnormal ventricular response to an increase in ventricular filling pressure [4]. Aerobic exercise capacity and maximum heart rate are reduced due to skeletal muscle waste, autonomic dysfunction, reduced oxygen transfer, etc.

The circulation is mainly hyperdynamic in the supine patient, becoming normal when the position changes to upright [14,15]. Some studies in postural changes suggest that an increased preload may contribute to the increased CO in the supine position [14]; other studies suggest a mechanism similar to that of exercise [15]. Left ventricular ejection fraction is often normal at rest, but a reduced ejection fraction after standing indicates impaired myocardial response to the erect posture [16]. The reduced cardiac performance is probably caused by a combination of blunted heart rate response, reduced myocardial contractility and wasting of skeletal muscle with impaired extraction of and demand for peripheral oxygen.

Head-out water immersion increases the CO and central and arterial blood volume [7]. Insertion of a transjugular intrahepatic portosystemic shunt (TIPS) increases the CO, as well as the

cardiac pressures, whereas infusion of packed red blood cells may not change these variables. After orthotopic liver transplantation (OLT), CO increases initially, but later becomes normal together with the arterial blood pressure and systemic vascular resistance [17]. These changes may be attributed primarily to normalization of the liver function and portal pressure. On the other hand, liver transplantation is often associated with a high incidence of cardiovascular complications, which is a major cause of mortality after transplantation [18]. Identification of patients at risk of developing cardiac failure in the post-transplantation period is important, but difficult.

Diastolic dysfunction

Patchy fibrosis, oedema and increased heart weight may increase the stiffness of the myocardial wall and lead to impaired left ventricular filling and diastolic dysfunction. Expanded blood volume may increase the cardiac preload and thus contribute to overloading and impaired cardiac contractility [11]. Dextran infusion in experimental and human cirrhosis shows limited cardiac preload reserve with a decreased ability to modulate cardiac performance under various loading conditions. Different ventricular diastolic filling supports the presence of a subclinical myocardial disease with a diastolic dysfunction, reflected on an echocardiograph as a decreased E/A ratio (peak diastolic flow velocity relative to peak atrial systolic flow velocity).

Conductance abnormalities and electromechanical coupling

The fluidity of the cardiomyocyte membrane and the function of its ion channels are impaired in cirrhosis. Ward *et al.* [19] have described a decrease in K^+ currents in the ventricular myocytes of cirrhotic rats, which prolongs the Q-T interval. A prolonged Q-T interval is often found in chronic liver disease, potentially leading to ventricular arrhythmias and sudden cardiac death [4,12,17]. Bernardi *et al.* [20] have reported a prolonged Q-T interval, which is significantly related to the severity of the liver disease, plasma noradrenaline and survival. Changes in the Q-T interval seem to revert with improved liver function, for instance after OLT [17]. Results from our group indicate that the frequency-adjusted Q-T_C becomes partly normalized after oral β-blocker treatment [21]. The prolonged Q-T interval in cirrhosis should be considered as an element in the cirrhotic cardiomyopathy and may be of potential use in identifying patients at risk [10,12]. Pathophysiological and clinical research is needed to assess the prognostic and therapeutic significance of prolonged Q-T_C in chronic liver disease.

Coupling between the heart and the arterial system

The coupling between the cardiac contractions and the arterial system is of major importance to the amount of work performed by the left ventricular myocardium, and thereby to the strain on the heart [22]. The ascending aorta and aortic arc are the most compliant systemic arteries in the body. The ability to contain the entire stroke volume without excessive deflection in the arterial systolic pressure profile is essential, especially in patients with a large CO and stroke volume. On the other hand, too compliant a central arterial system will not be able to deliver blood promptly to the different parts of the body, but may delay the flow to important areas of the vascular bed. Thus, the heart and central arterial tree work together in an essential coordination of the oscillating blood flow. This is especially necessary when vascular beds with highly different haemodynamic resistances are connected to the central arterial system, as in chronic liver disease (see later).

Consequences of changed preload and afterload

The work of the heart is reduced in the resting cirrhotic patient owing to a reduced afterload, but is increased by the increased preload and CO, and cardiac failure may become manifest under strain [23,24]. The left ventricular ejection fraction may be reduced in patients with ascites, especially after paracentesis, as part of a postparacentesis syndrome [11]. Normalization of the low overall systemic vascular resistance with infusion of vasoconstrictors produces a rise in left atrial and left ventricular filling pressures without changing the CO. Hence, attempts to normalize or increase the reduced cardiac afterload may unmask a latent ventricular failure, which appears to be resistant to inotropic drugs. Moreover, the expanded blood volume in advanced cirrhosis may increase cardiac preload and overload the heart with impaired cardiac contractility as the outcome [25]. The potential effects of changes in preload in patients with cirrhosis are illustrated in Figure 1.

Cirrhotic cardiomyopathy

The experimental data advocating the existence of cirrhotic cardiomyopathy derive from research by Lee *et al.* in chronic bile duct-ligated rats [10,12,26]. Moreover, animals with portal vein ligation display abnormalities in the coupling between excitation and contraction of the myocytes, and extrahepatic portal hypertension with or without liver dysfunction in patients may lead to cardiac dysfunction [27]. Alcohol is well known to be toxic to myocytes, and will contribute to cardiac dysfunction [28].

The morphological basis for cirrhotic cardiomyopathy is cardiac hypertrophy, patchy fibrosis, subendothelial oedema and increased myocardial weight [4] (see Fig. 2). Determinants of diastolic dysfunction include delayed early diastolic transmitral filling and increased stiffness of the myocardium. Studies of ventricular diastolic filling support the presence of diastolic dysfunction, which, in ascitic patients, improves after paracentesis and worsens after TIPS. In addition, peptides that reflect

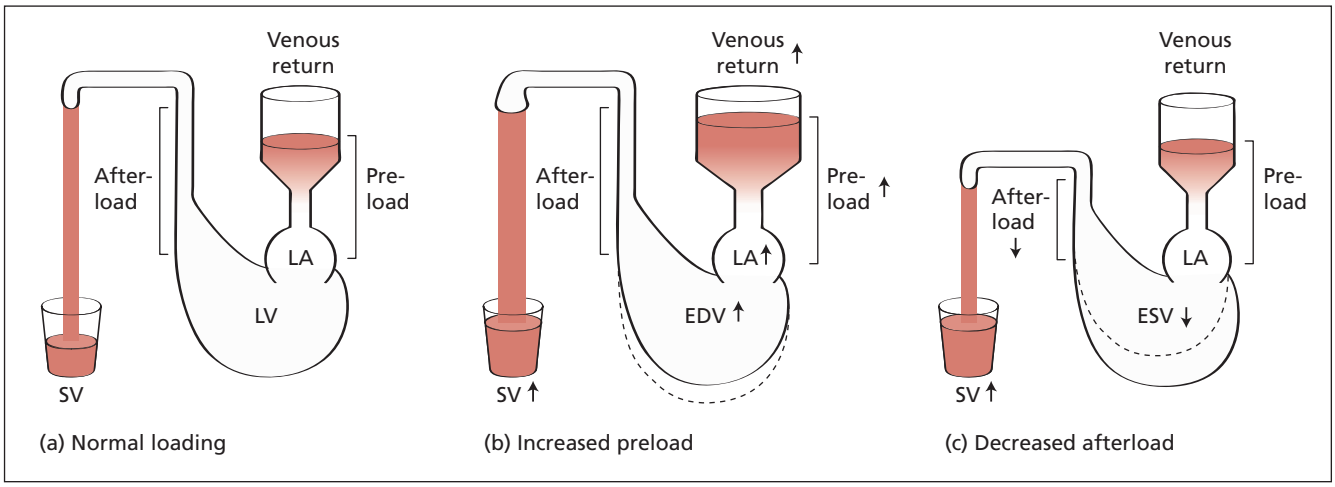

Fig. 1 Simplified illustration of the effects on circulation of increased and decreased afterload. (a) Normal loading. (b) Increased preload. Increased venous return leads to increased left atrial (LA) and end-diastolic volumes (EDV) and increased stroke volume (SV) and cardiac output. (c) Decreased afterload. Reduced systemic resistance leads to reduced end-systolic volume (ESV) and increased stroke volume and cardiac output. The circulation in cirrhosis with a hyperdynamic circulation and increased sympathetic nervous activity may be a combination of (b) and (c).

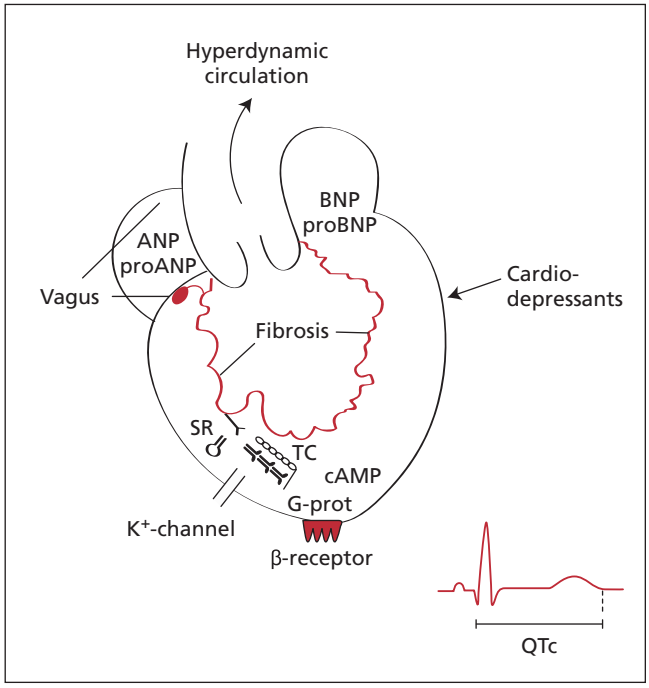

Fig. 2 Potential pathophysiological mechanisms involved in the development of cirrhotic cardiomyopathy. ANP, atrial natriuretic peptide; BNP, brain natriuretic peptide; cAMP, cyclic adenosine monophosphate; proANP, N-terminal propeptide of atrial natriuretic peptide; proBNP, N-terminal propeptide of brain natriuretic peptide; Q-T_c, Q-T interval from start of Q wave to end of T wave (frequency adjusted); SR, sarcoplasmatic reticulum; TC, cardiac troponin C; G-PROT, signal protein of G type (postreceptor defects).

ventricular dysfunction [brain natriuretic peptide (BNP) and proBNP] are increased in a substantial number of patients with cirrhosis [29]. Cirrhotic patients seldom have signs of central overfilling, as their central blood volume is either normal or reduced (see later). Thus, increased concentrations of proBNP and BNP are not caused by central volume overloading. However, patients with a decreased central blood volume may have locally expanded subcompartments, such as the left ventricle [13]. Abnormal distribution of the circulating medium may thus contribute to mask overt cardiac failure in patients with cirrhosis.

Patients with cirrhosis have a latent systolic and a diastolic dysfunction with reduced work capacity [8,11,23]. In some patients, failure becomes manifest if the heart is challenged. The type of cardiac insufficiency in cirrhosis may best be characterized as a high-output failure with reduced responsiveness. It is likely that the systolic cardiac dysfunction in cirrhosis contributes to the generally low degree of physical activity reported in several patients. Thus, after OLT, both physical activity and cardiac function seem to improve [17,18]. Diastolic dysfunction may be a significant factor in the development of heart failure and may precede systolic dysfunction in patients with cirrhosis. Moreover, cardiac dysfunction probably plays a role in the pathogenesis of sodium–fluid retention in cirrhosis (see Chapter 7.5).

The vascular system

Background of vascular hyporeactivity

The pathogenesis of hyporeactivity of the vascular system in chronic liver disease is still under debate. Experimental and clinical observations favour the presence of surplus circulating

vasodilators, either escaping hepatic degradation or bypassing the liver through portal-systemic shunting [3,8,30]. Combined with a resistance to pressor substances, this leads to vasodilatation with reduced splanchnic vascular resistance and abnormal distribution of the circulating blood volume [31–34]. Vasodilatation and activation of counter-regulatory mechanisms are closely related to the general circulatory dysfunction with impaired reaction to circulatory challenges, such as pressor stimuli, changes in body position and exercise [5,35]. Patients with cirrhosis are resistant to the pressor effect of noradrenaline, angiotensin II and vasopressin, and there is a shift in the pressor concentration giving 50% effect, as well as a reduction in the maximum effect of the vasopressor [6,36,37]. This may be a result of a change in receptor affinity, a decrease in the number of receptors and several postreceptor defects (Fig. 3). In recent years, research on vascular hyporeactivity has also focused on vasodilators such as NO, glucagon, calcitonin gene-related peptide (CGRP), tumour necrosis factor alpha (TNFα) and adrenomedullin [8,30,38].

The overall vascular resistance is decreased in patients with cirrhosis. However, a closer look at the individual organs and tissues shows areas of hypoperfusion, normal perfusion and hyperperfusion, which demonstrate vascular beds with a high haemodynamic resistance (the kidneys), normal resistance (the brain) and low resistance (the splanchnic system). Studies of regional perfusion have shown that the circulatory abnormalities can be characterized as a universal dyscirculatory, hyperkinetic and hyporeactive syndrome [3].

The hepatic and splanchnic circulation

The level of portal pressure is determined by the hepatic vascular resistance and portal inflow. The raised hepatic vascular resistance includes both structural and functional components. Among the former are steatosis, fibrosis and regenerative nodules. Dynamic components are cells with contractile properties, such as hepatic stellate cells, myofibroblasts and smooth muscle cells. Portal venous inflow is mainly determined by the degree of splanchnic vasodilatation. In healthy subjects, the hepatic blood flow equals the splanchnic blood flow, but patients with portal hypertension have a substantial portosystemic collateral circulation and an increased mesenteric inflow of up to several litres per

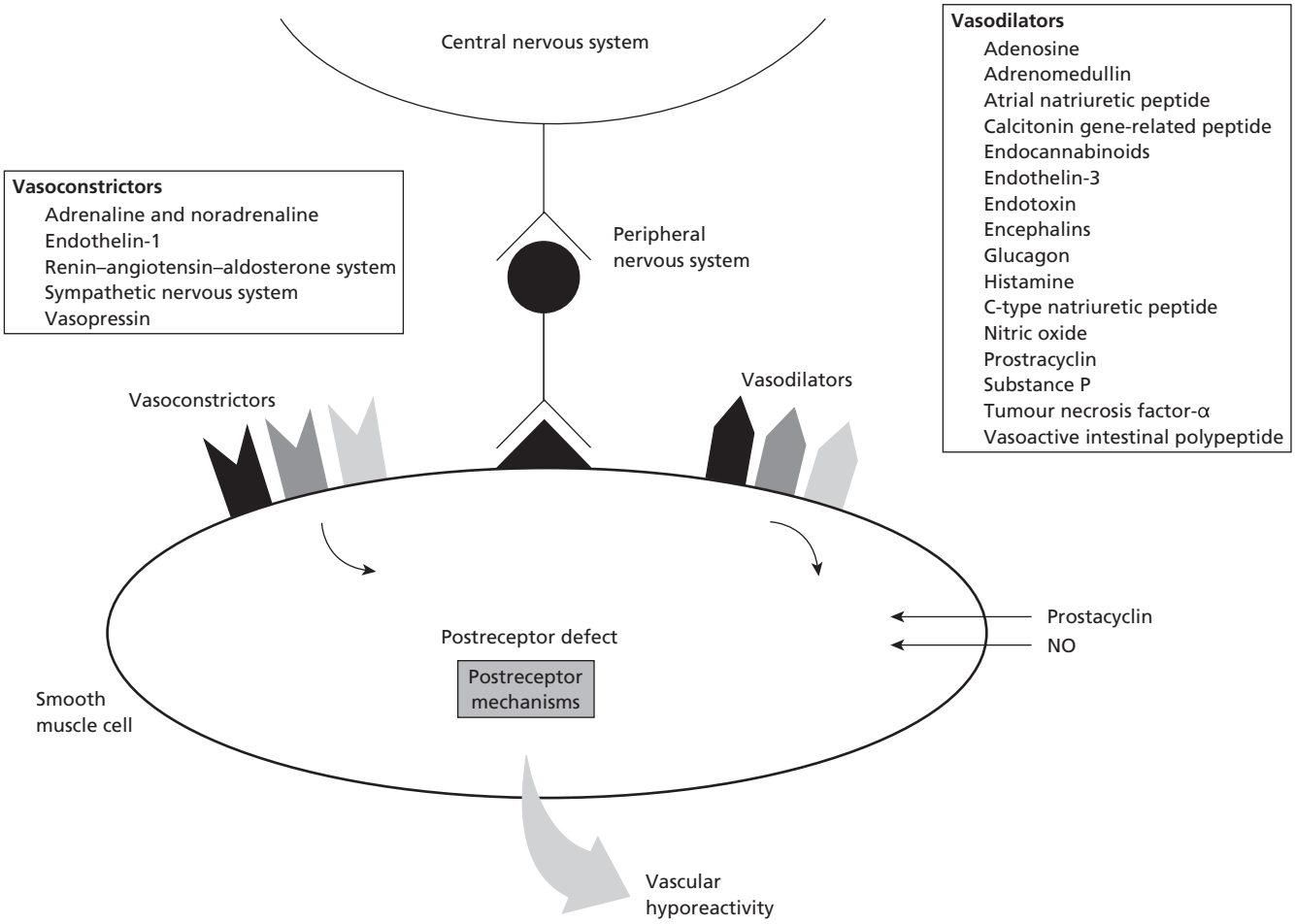

Fig. 3 Potential pathophysiological components involved in the development of vascular hyporeactivity.

minute. Thus, a large part of the increased cardiac output is returned through portosystemic collaterals. Collateral blood flow through the azygos vein is especially important, as the azygos vein drains oesophageal varices, and an increased flow here is associated with an increased risk of variceal bleeding. In addition, there may be portopulmonary collaterals and mesenteric arteriolar dilations.

A defective sinusoidal endothelial NO synthase (eNOS)-derived production of NO may be present in cirrhosis [8]. Other endogenous vasoactive substances in the increased hepatic sinusoidal resistance are ET-1, AII, catecholamines and leukotrienes. The haemodynamic imbalance with a predominantly sinusoidal constriction is a major target for treatment (see Section 7).

The renal circulation

Renal hypoperfusion in chronic liver disease and its role in sodium–water retention are considered elsewhere (see Chapter 7.1). However, some features of systemic haemodynamic alterations are important and necessary for the low renal blood flow and renal dysfunction [7]. Decreased mean arterial blood pressure and increased renal venous hydrostatic pressure, especially in patients with ascites, will reduce the effective renal perfusion pressure [36]. Activation of the RAAS contributes to the decreased renal perfusion, but it may also have more complex regulatory effects within the kidney [5]. Vasopressin does not change the renal perfusion substantially. Noradrenaline, adrenaline and ET-1 are powerful renal vasoconstrictors and important elements in the renal hypoperfusion, the right-sided shift of autoregulation profile and sodium–water retention in advanced cirrhosis [36]. Local vasodilators, such as the prostaglandins, are most probably operative in order to compensate, at least in part, for the progressive renal vasoconstriction seen in advanced cirrhosis.

Normalization of the low arterial blood pressure by infusion of noradrenaline [6], midrodine, AII or vasopressin increases renal perfusion and sodium excretion in some patients. Another problem is the abnormal distribution of the circulating medium with effective hypovolaemia [39] (see later). Accordingly, a combination of prolonged administration of ornipressin or terlipressin and albumin infusion may reverse the renal hypoperfusion and dysfunction [40]. A serious problem with intensive diuretic treatment and effective treatment of portal hypertension is the adverse effects on the systemic haemodynamics, as deranged systemic haemodynamics will reduce the renal function [36]. Treatment with α-adrenergic blocking agents and, potentially, ET-1 blockers may reverse the renal vasoconstriction, but their effect on arterial blood pressure may overrule beneficial local effects on the kidneys [7].

The cerebral circulation

Only a few studies have addressed cerebral perfusion in chronic liver disease. Cerebral perfusion seems to be normal in patients without encephalopathy, reduced in patients with early encephalopathy, but may be both reduced and increased in patients with cerebral oedema and hepatic coma [41]. In patients with fulminant hepatic failure, autoregulation is absent and, therefore, cerebral blood flow changes with the level of the arterial blood pressure. Autoregulation of the cerebral blood flow is generally preserved in patients with cirrhosis, but it may be impaired in advanced disease. In some patients, however, regional cerebral blood flow may be impaired, and the abnormalities may reverse after OLT. Acute changes in cerebral blood flow have also been reported in relation to the insertion of TIPS. Regulation of the cerebral circulation in patients with cirrhosis is complex and should be made the topic of future research.

The peripheral circulation

The cutaneous and muscular blood flow may be increased in patients with cirrhosis [3,8]. Palmar erythema, spider naevi and potatory face were early recognized as clinical signs of cutaneous hyperperfusion. These types of circulatory abnormalities illustrate capillary hyperperfusion and the presence of arteriovenous fistulae. Muscle blood flow may be increased, normal or reduced in patients with cirrhosis. Evaluation of limb blood flow (brachial artery, femoral artery) by colour and spectral Doppler has failed to disclose a definite hyperdynamic perfusion of the limbs [42]. Moreover, estimates of skin blood flow by nuclear medicine techniques have shown normal capillary skin blood flow, and Doppler measurements of the forearm blood flow are also normal. Venous occlusion plethysmography of the arm and thigh (a method that measures a combination of cutaneous and muscle blood flow) has given identical baseline values in patients and healthy control subjects. The cutaneous and muscle circulations in cirrhosis are still important topics for new research, as recent studies of overall flow suggest that peripheral blood flow in cirrhosis may be reduced rather than increased.

At present, it can be concluded that the CO is increased in patients with cirrhosis and that systemic vascular beds are hyperperfused, normoperfused and hypoperfused, but the exact distribution of the increased CO to the various organs, tissues and types of vessels remains to be clarified. The blood flow pattern will probably change as the disease advances through the preportal hypertensive preascitic, portal hypertensive preascitic and portal hypertensive ascitic stages to the full-blown hepatorenal syndrome.

The pulmonary circulation

Pulmonary vascular resistance is generally decreased in cirrhosis [43,44]. Analysis of the pulmonary circulation in relation to lung function may be obscured by the result of heavy smoking, which is commonly seen in patients with alcoholic liver disease. Thus, there may be considerable elements of chronic obstructive lung disease in addition to hepatic dysfunction, and areas with a high perfusion rate in relation to alveolar ventilation are

often present. Regular pulmonary arteriovenous shunts and portopulmonary shunts have also been described [44].

The hepatopulmonary syndrome consists of a reduced transfer factor, a low ventilation/perfusion ratio or pulmonary shunts, low arterial oxygen saturation and pulmonary hyperdynamics [45]. Increased pulmonary vascular endothelial NOS, NO-dependent pulmonary vasodilatation and an increased expression of ET receptors have been found in experimental models, and clinical studies show increased NO in the exhaled air of cirrhotic patients. The hepatopulmonary syndrome has been reversed by successful OLT and, recently, by the insertion of TIPS [46].

It may thus be concluded that a hyperkinetic condition with reduced pulmonary vascular resistance is most often present in cirrhotic patients but, when these patients do develop chronic obstructive lung disease, pulmonary hypertension with increased pulmonary vascular resistance may follow, as in other patients with chronic pulmonary dysfunction.

Arterial compliance

Systemic arterial compliance (i.e. an increase in intra-arterial volume relative to an increase in transmural arterial blood pressure) is raised in patients with decompensated cirrhosis [47,48] (Fig. 4). The altered static and dynamic characteristics of the wall of large arteries are closely associated with the circulatory and homoeostatic derangement [47–49]. The changes in arterial mechanics are reversible, at least in part. Arterial compliance is an important determinant of the coupling between the heart and the arterial system and of the dynamics of intravascular volume relocation [22]. An element in the elevated arterial compliance in advanced cirrhosis is the reduced arterial blood volume and blood pressure [48]. The increased arterial compliance is directly related to the severity of the liver disease and to the circulating vasodilator, CGRP, but inversely related to circulating adrenaline, and is not related to indicators of potent vasoconstrictor systems (SNS and ET-1) [49]. Other operative elements in the abnormal arterial compliance are blood volume abnormalities, hypoxia and abnormalities in the C-type natriuretic peptide (CNP), but not arterial natriuretic peptide. Arterial compliance is not affected by β-adrenergic blockade, whereas terlipressin almost normalizes it [37].

The arteriolar tone adjusts the level of the blood pressure and may thereby influence large artery compliance. Arterial compliance depends on the properties of arterial intrinsic elastic structures and smooth muscle, whereas arteriolar tone should result more from the balance between vasoconstrictors and vasodilators. Recent data suggest that the hyperdynamic circulation is mainly caused by circulatory alterations in the splanchnic area [50]. Thus, arteriolar vasodilatation would be a more localized event, whereas the elevation in arterial compliance may be more 'systemic' [48]. Arterial compliance may therefore be an integral variable for vascular responsiveness, together with the systemic vascular resistance. Changed dynamic and static

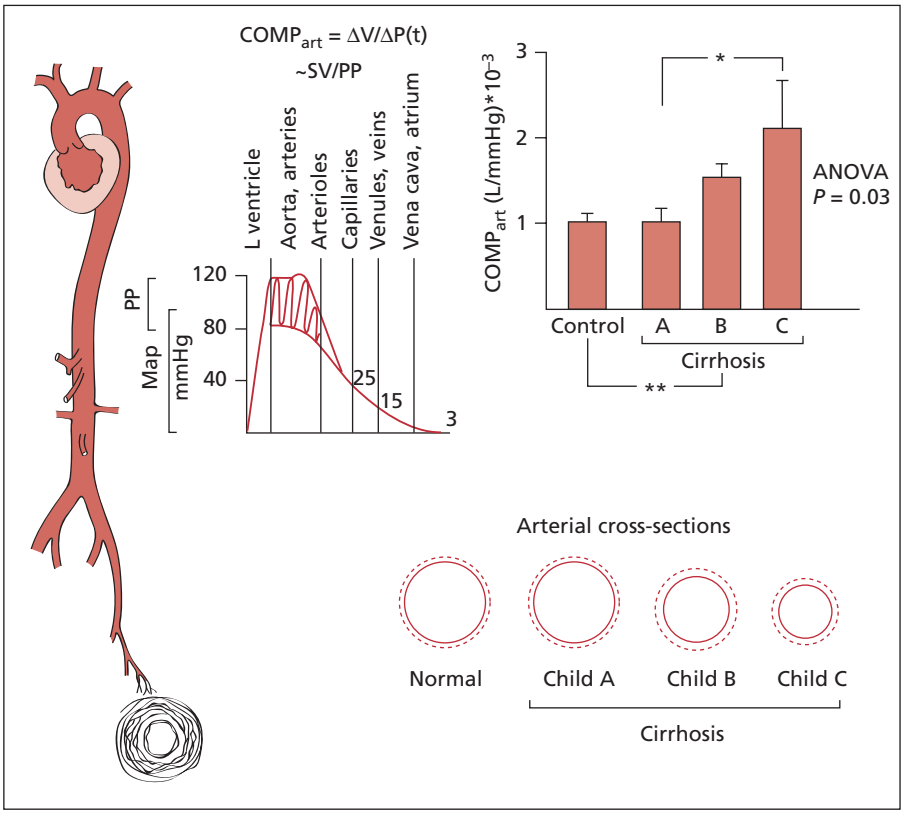

Fig. 4 Illustration of arterial compliance ($COMP_{art}$) in healthy subjects and patients with varying severity of cirrhosis. Arterial compliance is a fundamental property of large arteries. By definition, $COMP_{art}$ is a change in arterial blood volume relative to a change in transmural pressure [ΔV/ΔP(t)]. An index of $COMP_{art}$ is stroke volume relative to pulse pressure (SV/PP), where PP equals systolic minus diastolic arterial blood pressure. $COMP_{art}$ is shown for patients with cirrhosis, stratified in Child classes (A, B, C) and control subjects. Substantial changes with high arterial compliance are present in patients with advanced cirrhosis as an element of their circulatory dysfunction and reduced effective arterial blood volume $*P < 0.05$; $**P < 0.01$.

function of the arterial tree may contribute to the abnormal reactions of volume and baroreceptors, and have implications for the abnormal circulatory regulation and, potentially, for therapy with vasoactive drugs. These aspects are, however, a topic for further research.

In conclusion, arterial compliance is elevated in advanced cirrhosis. Besides a relation to age, body size, sex and the level of arterial blood pressure, arterial compliance is directly related to the severity of cirrhosis and the hyperdynamic circulatory derangement.

Dysregulation of vascular adaptation

The level of arterial blood pressure depends on the CO and the systemic vascular resistance. CO is primarily determined by venous return, heart rate and myocardial contractility. The systemic vascular resistance is determined by blood viscosity and the tone of the smooth muscle cells in the small arteries and arterioles, which are governed by complex local and central neurohumoral factors [8]. The arterial blood pressure has a circadian rhythm, but is kept within its usual range by an arterial negative feedback baroreceptor reflex and other regulatory systems [51]. A shifted and flat blood pressure–heart rate relation in patients with cirrhosis suggests that the regulation is abnormal (see later).

Arteriolar vasodilatation may lead to the activation of SNS and RAAS, increased non-osmotic release of vasopressin and probably release of endothelins [2,3,8]. These systems may counter-regulate the cirrhotic vasodilatation and keep the otherwise very low arterial blood pressure almost within the normal range. Several studies have shown a relation between the degree of arterial hypotension in cirrhosis and the severity of hepatic dysfunction, signs of decompensation and survival [9,52]. An abnormal diurnal variation in arterial blood pressure and the immense activation of neurohumoral systems probably contribute to the abnormal regulation and distribution of the circulating medium and to sodium–fluid retention [51].

Volume distribution

Blood volume distribution

Patients with cirrhosis have increased blood and plasma volumes [2,31]. The distribution of the blood in the various vascular beds is abnormal and relates to the severity of the disease [33]. Dynamic, as well as static, techniques have shown that the central and arterial blood volume (mainly thoracic) is most often decreased, whereas the non-central (especially the splanchnic) blood volume is increased in patients with cirrhosis [31,34,53] (Fig. 5). The effective arterial blood volume is decreased with

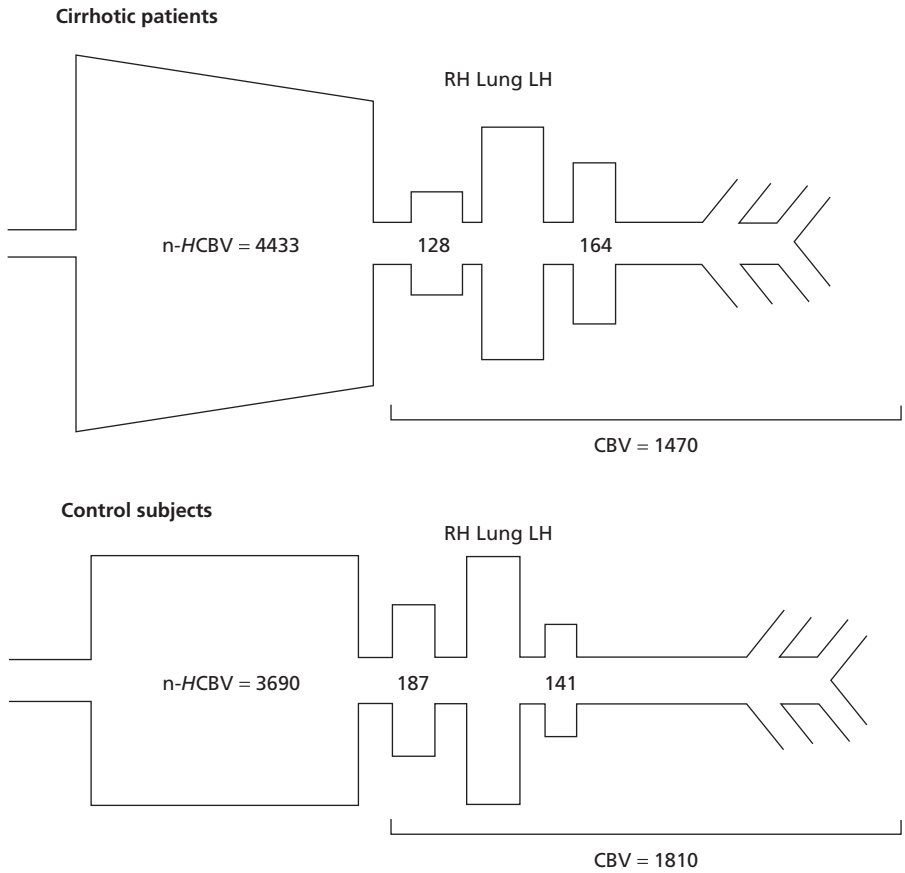

Fig. 5 Schematic presentation of the differences in central (CBV), non-central (n-CBV) and heart blood volumes in patients with cirrhosis and in control subjects. RH, average right heart volume (i.e. the sum of the mean right ventricular volume and the mean right atrial volume); LH, average left heart volume (i.e. the sum of the mean left ventricular volume and the mean left atrial volume). Note the increased n-CBV and the decreased CBV and right heart volume in cirrhosis. All volumes are expressed in mL.

regard to the systemic circulatory derangement. Moreover, the central circulation time (i.e. central blood volume relative to CO) is substantially reduced and has a significant relation with poorer survival in advanced cirrhosis [52,54].

Volume expansion

During volume expansion, most cirrhotic patients respond with a further reduction in systemic vascular resistance rather than a rise in arterial blood pressure [33,55]. Volume expansion by relocation of the circulating medium, like isothermic head-out water immersion, in principle provides the same volume changes (central relocation) as in healthy subjects [7]. However, especially in decompensated cirrhosis, there may be a further fall in the arterial blood pressure, owing to unloading of baroreceptors, and renal salt–water excretion is prolonged and incomplete.

The infusion of oncotic material (albumin) in patients with cirrhosis initially gives a fluid shift from the interstitial space into the plasma volume with an expansion in the latter [55]. Albumin infusion is important in the prevention of postparacentesis circulating dysfunction and the circulatory dysfunction of functional renal failure in chronic liver disease [38] (see Chapters 7.5 and 7.6).

When considering volume expansion in terms of the severity of the disease, certain differences become clear [33]. Irrespective of severity, volume expansion produces an increase in the stroke volume and CO. In early cirrhosis, there is a proportional expansion in the central and non-central parts of the blood volume, whereas in late cirrhosis, expansion is mainly confined to the non-central part, with a proportionally smaller increase in CO, probably because of cardiac dysfunction (cirrhotic cardiomyopathy) and abnormal vascular compliance [33,55].

Volume and flow adaptation

Autonomic dysfunction

Evidence of autonomic defects in patients with chronic liver disease has emerged from various studies on haemodynamic responses to standard cardiovascular reflex tests, such as the Valsalva ratio, heart rate variability and isometric exercise [16,24,56,57]. A high prevalence of autonomic dysfunction is seen in cirrhosis with associations to liver dysfunction and survival [57]. The autonomic dysfunction may be temporary, as a consequence of liver dysfunction, and may reverse after OLT. Abnormal activity in the SNS, as well as vagal impairment, is important for sodium–fluid retention. Blood pressure responses to orthostasis are impaired, probably because of a blunted baroreflex function [15,16]. Correction of autonomic dysfunction by captopril indicates that vagal dysfunction is partly caused by neuromodulation by AII [58]. Canrenone, an aldosterone antagonist, may normalize cardiac responses to postural changes in compensated cirrhotic patients, which suggests that overactivity of RAAS plays a role [59].

The pathophysiological basis for the autonomic dysfunction is unknown, but could be found within the central nervous system, although damage to the peripheral nerves or changes in neurotransmission, in terms of postreceptor defects, may also be important. At present, a multifactorial aetiology of autonomic dysfunction in chronic liver disease seems most likely.

Homoeostasis of the arterial blood pressure

Potent vasodilators such as NO, CGRP, histamine, bradykinin and serotonin have been implicated in the regulation of blood pressure in chronic liver disease [8]. A significant inverse relation of the potent vasodilator adrenomedullin to arterial blood pressure and ET suggests that these two vasoactive systems play a role in blood pressure regulation in cirrhosis. NOS blockade raises arterial blood pressure in cirrhotic rats. Inhibition of the endocannabinoid CB1 receptor raises arterial blood pressure in experimental cirrhosis, and anandamide from the monocytes of cirrhotic rats may contribute to the arterial hypotension observed [30,60]. However, the significance of blood pressure dysregulation in human cirrhosis awaits further studies.

The circulatory outcome of the decreased systemic vascular resistance in cirrhosis is an increase in heart rate and CO and an expanded plasma volume with effective hypovolaemia [6,34,61]. The arterial blood pressure is kept in the low normal range, depending on the state of the disease, as a circulatory compromise between vasodilating and counter-regulatory vasoconstricting forces affecting both vascular resistance and compliance.

The arterial blood pressure possesses a circadian variation. Twenty-four-hour determinations in cirrhotic patients show that the systolic, diastolic and mean arterial blood pressures are substantially reduced during the day, whereas the values at night are unexpectedly normal [51]. In cirrhosis, the drop from daytime to nighttime and the rise from nighttime to daytime show lower values than those in control subjects. It is known from several diseases, such as uraemia and different types of heart failure, that the circulation of patients classified as 'non-dippers' is abnormally regulated. The combination of normal blood pressure and increased heart rate at night suggests abnormal regulation of the circulation in cirrhosis. Prolonged rest in the supine position (as during sleep) may lessen the abnormal distribution of the blood volume and improve the ability to maintain a normal 'sleeping' arterial blood pressure, but only at the cost of an increased heart rate and CO. The upright position further aggravates central hypovolaemia, and normal arterial blood pressure cannot be maintained, even when the heart rate and CO are increased [14–16]. The negative correlation of the arterial blood pressure with the Child score during the day and at night confirms that the haemodynamic derangement is related to the severity of the liver disease [52].

The low arterial blood pressure, the abnormal distribution of the circulating medium and the diurnal variation in arterial blood pressure, and the marked activation of neurohumoral

systems contribute to the abnormal homoeostatic regulation in patients with cirrhosis.

Homoeostasis of blood volumes

In cirrhosis, there is a progressive increase in vasopressor and sodium–water-retaining systems from normal values to slightly increased values in preportal hypertensive preascitic patients to highly increased values in ascitic patients and patients with the hepatorenal syndrome [6,8,33,50]. However, mechanisms and timeframes may differ from one patient to another and in accordance with the aetiology of the cirrhosis. This is still an important topic for future research.

The increased CO and plasma volume in cirrhosis should be considered secondary to the activation of neurohumoral mechanisms consequent on arterial vasodilatation, low arterial blood pressure and reduced central and arterial blood volume [8]. However, a non-volume-dependent activation of the SNS through hepatic reflexes, owing to portal hypertension, may occur. This has been documented in animal experiments, and there are indications of such a reflex in man [62]. Although the relative importance of non-volume-dependent sympathetic activation and volume/arterial pressure-dependent activation of SNS and other neurohumoral systems has not been finally settled, the latter is probably by far the most important.

Concluding remarks and clinical consequences

The cardiovascular dysfunction in chronic liver disease is roughly related to the degree of portal hypertension and liver failure and is more pronounced in patients with fluid retention than in those without. The hyperdynamic circulation in cirrhosis is part of a multiorgan failure and may significantly affect the patient's prognosis. Splanchnic vasodilation in relation to portal hypertension is responsible for the increased CO and abnormal distribution of blood volume, with a reduced 'effective arterial blood volume' and activation of baroreceptor and volume receptor reflexes as the outcome. The enhanced vasodilation and counter-regulatory overactivity of vasoconstrictor systems play a major role in the development of the multiorgan failure in cirrhosis with impaired function and perfusion of kidneys, lungs, brain, skin and muscles. The cardiac function in cirrhosis is disturbed, with an increase in the CO, heart rate and stroke volume. Cardiac function is often impaired, owing to the presence of cirrhotic cardiomyopathy. The cirrhotic heart is both hyperdynamic and dysfunctional, and strain may unmask latent heart failure.

Although major questions still remain to be solved, the circulatory and neuroendocrine derangements play important roles in the clinical aggravation, renal disorders with sodium–water retention, hepatopulmonary dysfunction and circulatory reactivity. This aspect is important to take into account in the clinical handling of the patient and the assessment of the prognosis. At the moment, OLT is the only ultimate treatment, but studies of specific neuroendocrine agonists and antagonists show promising results, and these agents have a potential as future pharmacotherapy in the circulatory derangement, especially in cirrhosis.

Acknowledgement

The authors thank Ms Georgina Narvaez for skilful assistance with the manuscript.

References

1 Møller S, Bendtsen F, Henriksen JH (2001) Splanchnic and systemic haemodynamic derangement in decompensated cirrhosis. *Can J Gastroenterol* 15, 94–106.
2 Schrier RW, Arroyo V, Bernardi M *et al.* (1988) Peripheral artery vasodilatation hypothesis: a proposal for the initiation of renal sodium and water retention in cirrhosis. *Hepatology* 5, 1151–1157.
3 Groszmann RJ (1994) Vasodilatation and hyperdynamic circulatory state in chronic liver disease. In: Bosch J, Groszmann RJ (eds) *Portal Hypertension. Pathophysiology and Treatment*. Oxford: Blackwell, pp. 17–26.
4 Møller S, Henriksen JH (2002) Cirrhotic cardiomyopathy: a pathophysiological review of circulatory dysfunction in liver disease. *Heart* 87, 9–15.
5 Henriksen JH, Møller S, Ring-Larsen H *et al.* (1998) The sympathetic nervous system in liver disease. *J Hepatol* 29, 328–341.
6 Schrier RW, Niederberger M, Weigert A *et al.* (1994) Peripheral arterial vasodilatation: determinant of functional spectrum of cirrhosis. *Semin Liver Dis* 14, 14–22.
7 Epstein M (1996) Renal sodium handling in liver disease. In: Epstein M (ed.) *The Kidney in Liver Disease*. Philadelphia: Hanley and Belfus, pp. 1–31.
8 Møller S, Henriksen JH (1999) The systemic circulation in cirrhosis. In: Arroyo V, Gines P, Rodes J *et al.* (eds) *Ascites and Renal Dysfunction in Liver Disease*. Malden: Blackwell, pp. 307–329.
9 Llach J, Ginés P, Arroyo V *et al.* (1988) Prognostic value of arterial pressure, endogenous vasoactive systems, and renal function in cirrhotic patients admitted to the hospital for the treatment of ascites. *Gastroenterology* 94, 482–487.
10 Liu HQ, Lee SS (1999) Cardiopulmonary dysfunction in cirrhoses. *J Gastroenterol Hepatol* 14, 600–608.
11 Pozzi M, Carugo S, Boari G *et al.* (1997) Evidence of functional and structural cardiac abnormalities in cirrhotic patients with and without ascites. *Hepatology* 26, 1131–1137.
12 Ma, Z, Lee SS (1996) Cirrhotic cardiomyopathy: getting to the heart of the matter. *Hepatology* 24, 451–459.
13 Møller S, Søndergaard L, Møgelvang J *et al.* (1995) Decreased right heart blood volume determined by magnetic resonance imaging: evidence of central underfilling in cirrhosis. *Hepatology* 22, 472–478.
14 Bernardi M, Fornale L, Dimarco C *et al.* (1995) Hyperdynamic circulation of advanced cirrhosis: a re-appraisal based on posture-induced changes in haemodynamics. *J Hepatol* 22, 309–318.
15 Møller S, Nørgaard A, Henriksen JH *et al.* (2004) Effects of tilting on central haemodynamics and homeostatic mechanisms in cirrhosis. *Hepatology* 40, 811–819.

16 Laffi G, Lagi A, Cipriani M *et al.* (1996) Impaired cardiovascular autonomic response to passive tilting in cirrhosis with ascites. *Hepatology* 24, 1063–1067.

17 Torregrosa M, Aguade S, Dos L *et al.* (2005) Cardiac alterations in cirrhosis: reversibility after liver transplantation. *J Hepatol* 42, 68–74.

18 Myers RP, Lee SS (2000) Cirrhotic cardiomyopathy and liver transplantation. *Liver Transpl* 6(Suppl.), S44–S52.

19 Ward CA, Ma Z, Lee SS (1997) Potassium currents in atrial and ventricular myocytes from a rat model of cirrhosis. *Am J Physiol* 273, G537–544.

20 Bernardi M, Calandra S, Colantoni A *et al.* (1998) Q-T interval prolongation in cirrhosis: prevalence, relationship with severity, and etiology of the disease and possible pathogenetic factors. *Hepatology* 27, 28–34.

21 Henriksen JH, Bendtsen F, Hansen EF *et al.* (2004) Acute non-selective beta-adrenergic blockade reduces prolonged frequency adjusted Q-T ($Q\text{-}T_C$) in patients with cirrhosis. *J Hepatol* 40, 239–246.

22 Rowell LB (1993) *Reflex Control during Orthostasis. Human Cardiovascular Control.* Oxford: Oxford University Press, pp. 37–80.

23 Grose RD, Nolan J, Dillon JF *et al.* (1995) Exercise-induced left ventricular dysfunction in alcoholic liver cirrhosis. *J Hepatol* 22, 326–332.

24 Epstein SK, Ciubotaru RL, Zilberberg MD *et al.* (1998) Analysis of impaired exercise capacity in patients with cirrhosis. *Dig Dis Sci* 43, 1701–1707.

25 Huonker M, Schumacher YO, Ochs A *et al.* (1999) Cardiac function and haemodynamics in alcoholic cirrhosis and effects of the transjugular intrahepatic portosystemic stent shunt. *Gut* 44, 743–748.

26 Ma Z, Miyamoto A, Lee SS (1996) Role of altered beta-adrenoceptor signal transduction in the pathogenesis of cirrhotic cardiomyopathy in rats. *Gastroenterology* 110, 1191–1198.

27 Zavecz JH, Bueno O, Maloney RE *et al.* (2000) Cardiac excitation–contraction coupling in the portal hypertensive rat. *Am J Physiol Gastrointest Liver Physiol* 79, G28–39.

28 Harcombe AA, Ramsay L, Kenna JG *et al.* (1995) Circulating antibodies to cardiac protein-acetaldehyde adducts in alcoholic heart muscle disease. *Clin Sci (Colch)* 88, 263–268.

29 Henriksen JH, Gotze JP, Fuglsang S *et al.* (2003) Increased circulating pro-brain natriuretic peptide (proBNP) and brain natriuretic peptide (BNP) in patients with cirrhosis: relation to cardiovascular dysfunction and severity disease. *Gut* 52, 1511–1517.

30 Fernández-Varo G, Ros J, Morales-Ruiz M *et al.* (2003) Nitric oxide synthase 3-dependent vascular remodelling and circulatory dysfunction in cirrhosis. *Am J Pathol* 162, 1985–1993.

31 Henriksen JH, Bendtsen F, Sørensen TIA *et al.* (1989) Reduced central blood volume in cirrhosis. *Gastroenterology* 97, 1506–1513.

32 Colombato LA, Albillos A, Groszmann RJ (1996) The role of central blood volume in the development of sodium retention in portal hypertensive rats. *Gastroenterology* 110, 193–198.

33 Møller S, Bendtsen F, Henriksen JH (1995) Effects of volume expansion on systemic haemodynamics and central and arterial blood volume in cirrhosis. *Gastroenterology* 109, 1917–1925.

34 Møller S, Henriksen JH, Bendtsen F (2003) Central and noncentral blood volumes in cirrhosis: relationship to anthropometrics and gender. *Am J Physiol Gastrointest Liver Physiol* 284, G970–G979.

35 Di Bona GF, Kopp U (1997) Neural control of renal function. *Physiol Rev* 77, 75–197.

36 Henriksen JH, Ring-Larsen H (1993) Renal effects of drugs used in the treatment of portal hypertension. *Hepatology* 18, 688–695.

37 Møller S, Hansen EF, Becker U *et al.* (2000) Central and systemic haemodynamic effects of terlipressin in portal hypertensive patients. *Liver* 20, 51–59.

38 Møller S, Henriksen JH (2005) The systemic circulation in cirrhosis. In: Gines P, Arroyo V, Schrier RW *et al.* (eds) *Ascites and Renal Dysfunction in Liver Disease.* Malden: Blackwell Scientific, pp. 139–155.

39 Møller S, Bendtsen F, Henriksen JH (2005) Pathophysiological basis of pharmacotherapy in the hepatorenal syndrome. *Scand J Gastroenterol* 40, 491–500.

40 Gines P, Guevara M, Arroyo V *et al.* (2003) Hepatorenal syndrome. *Lancet* 362, 1819–1827.

41 Larsen FS, Olsen KS, Ejlersen E *et al.* (1995) Cerebral blood flow autoregulation and transcranial Doppler sonography in patients with cirrhosis. *Hepatology* 22, 730–736.

42 Luca A, Garcia-Pagan JC, Feu F *et al.* (1995) Noninvasive measurement of femoral blood flow and portal pressure response to propranolol in patients with cirrhosis. *Hepatology* 21, 83–88.

43 Fallon MB, Abrams GA (2000) Pulmonary dysfunction in chronic liver disease. *Hepatology* 32, 859–865.

44 Krowka MJ (1997) Hepatopulmonary syndrome versus portopulmonary hypertension: distinctions and dilemmas. *Hepatology* 25, 1282–1284.

45 Rodriguez-Roisin R, Krowka MJ, Herve P *et al.* (2004) Pulmonary–hepatic vascular disorders (PHD). *Eur Respir J* 24, 861–880.

46 Martinez GP, Barbera JA, Visa J *et al.* (2001) Hepatopulmonary syndrome in candidates for liver transplantation. *J Hepatol* 34, 651–657.

47 Henriksen JH, Møller S, Schifter S *et al.* (1999) Increased arterial compliance in decompensated cirrhosis. *J Hepatol* 31, 712–718.

48 Henriksen JH, Fuglsang S, Bendtsen F *et al.* (2001) Arterial compliance in patients with cirrhosis. *Am J Physiol Gastrointest Liver Physiol* 280, G584–G594.

49 Henriksen JH, Møller S, Schifter S *et al.* (2001) High arterial compliance in cirrhosis is related to low adrenaline and elevated circulating calcitonin gene related peptide but not to activated vasoconstrictor systems. *Gut* 49, 112–118.

50 Ruiz-Del-Arbol L, Monescillo A, Arocena C *et al.* (2005) Circulatory function and hepatorenal syndrome in cirrhosis. *Hepatology* 42, 439–447.

51 Møller S, Wiinberg N, Henriksen JH (1995) Noninvasive 24-hour ambulatory arterial blood pressure monitoring in cirrhosis. *Hepatology* 22, 88–85.

52 Møller S, Bendtsen F, Christensen E *et al.* (1994) Prognostic variables in patients with cirrhosis and oesophageal varices without prior bleeding. *J Hepatol* 21, 940–946.

53 Kiszka-Kanowitz M, Henriksen JH, Møller S *et al.* (2001) Blood volume distribution in patients with cirrhosis: aspects of the dual-head gamma-camera technique. *J Hepatol* 35, 605–612.

54 Albrecht T, Blomley MJK, Cosgrove DO *et al.* (1999) Non-invasive diagnosis of hepatic cirrhosis by transit-time analysis of an ultrasound contrast agent. *Lancet* 353, 1579–1583.

55 Henriksen JH, Kiszka-Kanowitz M, Bendtsen F *et al.* (2002) Review article: volume expansion in patients with cirrhosis. *Aliment Pharmacol Ther* 16, 12–23.

56 MacGilchrist AJ, Reid JL (1990) Impairment of autonomic reflexes in cirrhosis. *Am J Gastroenterol* 85, 288–292.

57 Hendrickse MT, Thuluvath PJ, Triger DR (1992) Natural history of autonomic neuropathy in chronic liver disease. *Lancet* 339, 1462–1464.

58 Dillon JF, Nolan J, Thomas H *et al.* (1997) The correction of autonomic dysfunction in cirrhosis by captopril. *J Hepatol* 26, 331–335.
59 Villa GL, Barletta G, Romanelli RG *et al.* (2002) Cardiovascular effects of canrenone in patients with preascitic cirrhosis. *Hepatology* 35, 1441–1448.
60 Ros J, Claria J, To-Figueras J *et al.* (2002) Endogenous cannabinoids: a new system involved in the homeostasis of arterial pressure in experimental cirrhosis in the rat. *Gastroenterology* 122, 85–93.
61 Møller S, Becker U, Schifter S *et al.* (1996) Effect of oxygen inhalation on systemic, central, and splanchnic haemodynamics in cirrhosis. *J Hepatol* 25, 316–328.
62 Jalan R, Hayes PC (2000) Sodium handling in patients with well compensated cirrhosis is dependent on the severity of liver disease and portal pressure. *Gut* 46, 527–533.

21.2 The effect of liver disease on the endocrine system

Yolanta T. Kruszynska and Pierre M. Bouloux

Introduction

The liver is involved in the metabolism of many steroid and peptide hormones. It synthesizes plasma hormone binding proteins whose levels influence plasma hormone levels and their tissue distribution. It is a major target tissue for many hormones, and it produces hormones (for example insulin-like growth factor-1, IGF-1) that influence the synthesis and secretion of hormones by other endocrine glands. It is therefore not surprising that the metabolic disturbance of liver disease may cause abnormalities of neuroendocrine function and circulating hormone levels. Moreover, some liver disorders, particularly those with an autoimmune basis, may be associated with endocrine disorders (for example autoimmune thyroid disease).

Abnormalities of circulating hormone levels may be due to impaired hepatic metabolism of a hormone, to a compensatory increase in hormone production because of tissue resistance to its action, to abnormalities of plasma hormone binding proteins, or to effects of liver disease or its treatment on hormone secretion. The hepatologist needs to be aware of the effect of liver disease on the endocrine system and plasma hormone levels to enable him or her to interpret the results of endocrine tests correctly. In addition, it is important to recognize that certain endocrine presentations, such as hypogonadism or glucose intolerance, may be due to liver disease and may be the presenting complaint.

Glucose intolerance and diabetes in liver disease

The liver plays a key role in glucose and insulin metabolism. In the postabsorptive and fasted states it releases glucose (derived from glycogen or gluconeogenesis) into the circulation for use by other tissues. After meals it switches from net glucose production to net glucose uptake, and stores glucose (taken up from plasma or synthesized by gluconeogenesis) as glycogen. It thus helps to limit the rise in plasma glucose levels after carbohydrate ingestion while ensuring a supply of glucose to extrahepatic tissues in the postabsorptive and fasted states. The liver is also the major site of insulin metabolism; about 60% of the insulin secreted into the portal vein is removed by the liver on first pass [1]. It is thus not surprising that abnormalities of glucose and insulin metabolism are found in patients with liver disease. The role of the liver in carbohydrate and insulin metabolism is discussed in detail in Chapter 3.2.

Prevalence of impaired glucose tolerance and diabetes in liver disease

Most patients with cirrhosis show impaired glucose tolerance despite normal fasting blood glucose levels, and there is a higher prevalence of overt diabetes mellitus in cirrhotics than in the general population. Glucose intolerance is also common in patients with acute viral hepatitis [2], fatty liver [3], autoimmune chronic active hepatitis [4], and toxic liver damage [5]. Increased blood glucose levels are also seen after meals in patients with liver disease [6].

The prevalence of impaired glucose tolerance in cirrhosis depends on the diagnostic criteria used and the type of patients studied. Using WHO criteria [7], impaired oral glucose tolerance is found in 60–80% of patients with cirrhosis (Fig. 1). Intravenous glucose tolerance is traditionally assessed by measuring the rate at which the blood glucose falls after an intravenous bolus of glucose. The results are expressed as the slope of the logarithm of blood glucose concentration against time (K_G). Most studies have shown a lower K_G value in cirrhotic patients than in matched controls [8,9], even when patients with fasting hyperglycaemia are excluded [8]. In cirrhotics with normal fasting glucose levels, a good correlation was found between K_G (intravenous glucose tolerance) and oral glucose tolerance. A direct correlation was also found in the 145 cirrhotic patients studied by Conn *et al.* [10], although the inclusion of patients with overt diabetes mellitus might have strengthened the relationship in their study. Like diabetic patients without liver disease, cirrhotic patients with fasting hyperglycaemia (whole blood glucose > 6.7 mmol/L) have a K_G value of less than 1.0% per min (Fig. 2) [10].

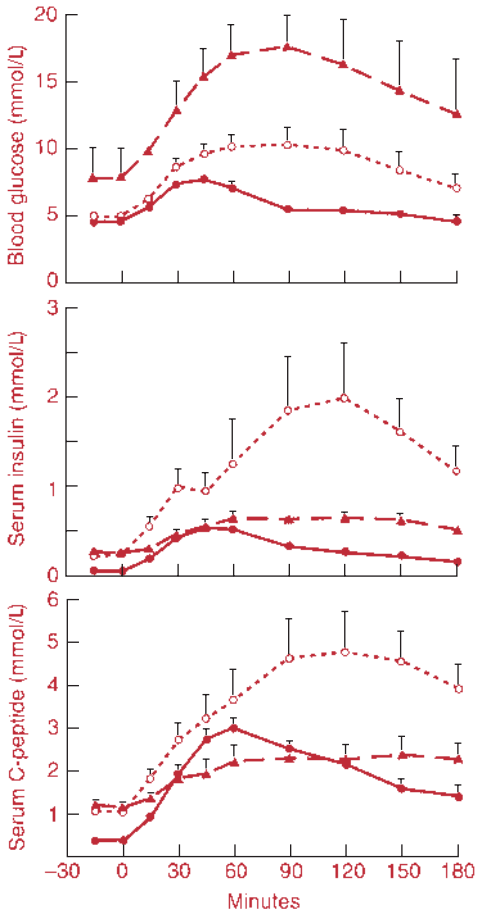

Fig. 1 Blood glucose, serum insulin, and C-peptide levels after an overnight fast and after ingestion of 75 g glucose at $t = 0$ min in seven non-diabetic cirrhotic patients (○), eight diabetic cirrhotic patients (▲), and eight normal control subjects (●). Mean ± SEM. (Reproduced from ref. 33, with permission.)

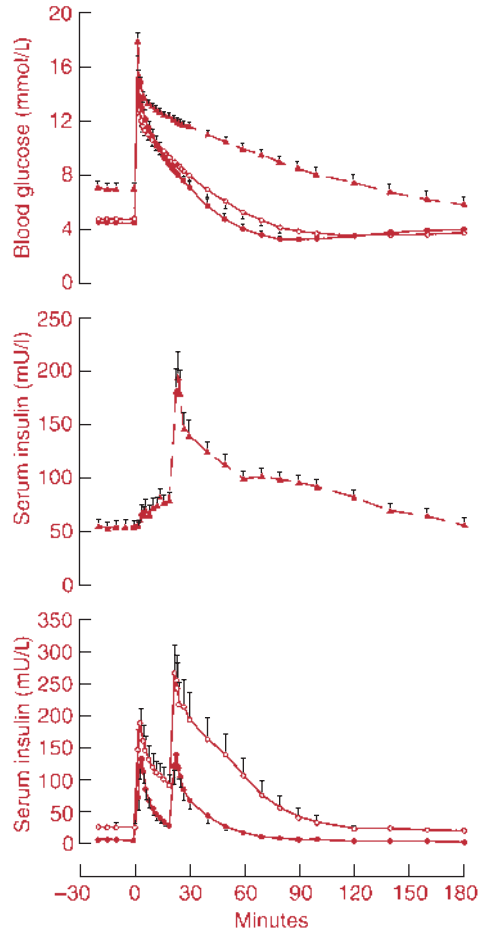

Fig. 2 Blood glucose and serum insulin levels after intravenous glucose (0.3 g/kg) at $t = 0$ min and intravenous tolbutamide (300 mg) at $t = 20$ min in 12 non-diabetic cirrhotic patients (fasting blood glucose < 6.7 mmol/L) (○), eight diabetic cirrhotic patients (▲), and 10 normal control subjects (●). Mean ± SEM. (Reproduced from ref. 2, with permission.)

The prevalence of diabetes in cirrhotics is two to four times higher than that seen in the general population [11], a relationship not explained by the high prevalence of diabetes mellitus in haemochromatosis as this is an uncommon cause of cirrhosis. Bloodworth [12] analysed 27 050 consecutive autopsies performed between 1937 and 1960 and found diabetes in 5.6% of cirrhotics compared with 3.0% in the general population; for the autopsies performed between 1955 and 1960 the corresponding figures were 12% and 5.5%. These figures are in accord with the results of numerous clinical studies reviewed by Creutzfeldt *et al.* [11]. In populations with a high prevalence and incidence of type 2 diabetes, the frequency of diabetes in cirrhosis may be as high as 40% [13]. It is not clear whether diabetes is associated with cirrhosis of a particular aetiology (other than haemochromatosis). In many early studies alcoholic, biliary, and autoimmune cirrhosis were all included as 'nutritional cirrhosis'. Most studies have been retrospective and inevitably suffer from selection bias. Information on alcohol consumption, use of diabetogenic medications, the presence of a family history of diabetes, and on the criteria used for the diagnosis of diabetes is either lacking or inadequate. Some studies have suggested a stronger association between diabetes and alcoholic cirrhosis [13]. However, Blanco *et al.* [14] found the prevalence of glucose intolerance to be similar in alcohol-abusing and non-abusing cirrhotics. In a study of 401 cirrhotic patients the main risk factors for glucose intolerance were severity of liver disease, a family history of diabetes, and age [14]. Muller *et al.* [15] found no increase in the prevalence of diabetes in cirrhotics with a first-degree type 2 diabetic relative. Their 'diabetic' cirrhotics, however, had normal fasting blood glucose concentrations, and the number of cirrhotics with a known diabetic relative was small. In patients with cirrhosis due to haemochromatosis, diabetes is more common in those who have a first-degree relative with diabetes.

Overview of glucose metabolism and mechanisms of hyperglycaemia (see Chapter 2.3.2)

In the postabsorptive and fasted states, the liver releases glucose for use by other tissues. At rest this rate is approximately 2 mg/kg/min and is matched by a similar rate of tissue glucose uptake; insulin levels are low, and 75–85% of this basal glucose uptake is insulin independent. Brain accounts for most of this and skeletal muscle for only 15–20%.

Because insulin plays only a small role in promoting tissue glucose uptake in the fasted state, an impairment of insulin-mediated glucose uptake by muscle has little effect on fasting glucose levels. Fasting hyperglycaemia is primarily due to hepatic overproduction of glucose [16]. Most cirrhotics have normal basal glucose production rates and fasting glucose levels despite marked insulin resistance [17,18]. Diabetic cirrhotics with fasting hyperglycaemia have increased basal hepatic glucose production [19] which is due largely to their marked impairment of insulin secretion (see below); hepatic insulin resistance and hyperglucagonaemia may also contribute to the increased hepatic glucose production in diabetic cirrhotics.

Insulin stimulates glucose uptake by skeletal muscle, heart muscle, and adipocytes. It also enhances hepatic glucose uptake by its effects on certain liver enzymes. In other tissues, glucose uptake is not influenced by insulin. After meals or glucose ingestion, the rise in insulin levels suppresses glucose output by the liver and markedly stimulates glucose uptake by muscle; the accompanying rise in glucose levels enhances glucose uptake (by mass action) by insulin-dependent and non-insulin-dependent tissues (other than brain). Hyperglycaemia also helps to suppress hepatic glucose output. Skeletal muscle takes up about 50–60% of an oral glucose load; the liver accounts for 20–35%.

Most cirrhotics are resistant to the effects of insulin on glucose metabolism. Glucose disposal during a hyperinsulinaemic glucose clamp (see Chapter 2.3.2) is about 50% lower in cirrhotics than in normal subjects [10,18]. This is mainly due to diminished muscle glucose uptake and storage as glycogen [20]. Skeletal muscle insulin insensitivity is the main cause of glucose intolerance in non-diabetic cirrhotics, although portosystemic shunting also plays a role by causing a small increase in the amount of glucose entering the systemic circulation, particularly during the first 30 min after glucose ingestion; inhibition of hepatic glucose output is normal. These factors are discussed in Chapter 2.3.2. Insulin secretory abnormalities also contribute to glucose intolerance in non-diabetic cirrhotics. In diabetic cirrhotics there are striking abnormalities of insulin secretion and the ability of glucose *per se* to promote tissue glucose uptake and inhibit hepatic glucose output ('glucose effectiveness') is impaired [10]. In diabetic cirrhotics not only is there a further impairment of muscle glucose uptake but also less inhibition of hepatic glucose output, resulting in an even greater glucose load entering the systemic circulation and hence marked hyperglycaemia (Fig. 1).

The total amount of glucose taken up by muscle after a glucose load may be similar to that of normal subjects because later during the glucose tolerance test the higher plasma glucose levels and much higher insulin levels compensate for the insulin resistance (Fig. 1).

Insulin secretion and clearance in liver disease

Fasting and postprandial plasma insulin levels are raised in nearly all patients with cirrhosis, including those with diabetes [8,10,17–22]. In cirrhotics hepatic extraction of insulin falls [22,23]. In hyperinsulinaemic cirrhotics with portal hypertension arterial serum insulin levels exceeded those in the hepatic vein [23]. This suggests that extrahepatic shunting allows a large amount of secreted insulin to escape initial hepatic removal. The observation that the insulin clearance defect is more marked for secreted insulin [22] or insulin infused into the portal vein [24] than for insulin infused into the systemic circulation also suggests that reduced first-pass hepatic uptake of insulin due to portosystemic shunting is important.

Studies using serum C-peptide levels and the C-peptide:insulin molar ratio (during steady state) as indices of pancreatic insulin secretion and hepatic insulin extraction, respectively (see Chapter 2.3.2), have indicated that both hypersecretion and decreased clearance contribute to the fasting and postprandial hyperinsulinaemia of cirrhosis [22]; decreased clearance is quantitatively more important. Measurements of C-peptide (the clearance of which is normal in cirrhosis [22]) and insulin secretion rates have drawn attention to the importance of insulin secretory defects in the glucose intolerance of cirrhosis as well as in the aetiology of overt diabetes.

Insulin secretion in non-diabetic cirrhotics

(see Chapter 2.3.2)

Non-diabetic cirrhotics have increased insulin responses to glucose, and to secretagogues such as arginine and sulphonylureas. The insulin hypersecretion appears to be due to an increase in the maximal secretory capacity [25] and is thus similar to the islet adaptation found in normoglycaemic insulin-resistant obese subjects [26]. Cirrhotics with high insulin secretion rates to intravenous glucose have better oral and intravenous glucose tolerance than cirrhotics with 'normal' secretion rates [10,22].

For normal glucose tolerance, both the total amount of insulin secreted and the timing are important [27]. Insulin secretion is normally much higher after oral than intravenous glucose [28]. This 'incretin' effect of oral glucose is due in part to release of glucose-dependent insulinotropic peptide and glucagon-like peptide-1 [7–36 amide] from the gut during glucose absorption [29]. These gut hormones may also be important for augmenting the early insulin response to oral glucose (i.e. before a marked increase in plasma glucose levels) [30]. Cirrhotics show less enhancement of insulin secretion with oral glucose relative

to the intravenous route, and by contrast with normal subjects show a good correlation between insulin secretion rates after oral and intravenous glucose [22]. Many have a blunted early C-peptide response to oral glucose [21,22,30] which may contribute to their glucose intolerance (see Chapter 2.3.2).

The reduced 'incretin effect' and blunted early C-peptide response is not due to reduced secretion of glucose-dependent insulinotropic peptide and glucagon-like peptide-1 [7–36 amide]; fasting levels of both are higher in cirrhotics than controls, and both rise to higher levels after oral glucose [31]. It is possible that some cirrhotics are resistant to the action of these gut hormones. A parasympathetic autonomic neuropathy which is common in cirrhosis [32] could also explain the blunted early insulin response to oral glucose; insulin secretion is delayed and glucose tolerance impaired after truncal vagotomy.

Most studies have contained many alcoholic cirrhotics. Chronic alcohol abuse may result in a reversible impairment of insulin secretion; it may also be associated with significant hyperinsulinaemia in the absence of cirrhosis or impaired glucose tolerance. However, the insulin secretory abnormalities are not confined to alcoholic cirrhotics. Furthermore, they may be found in patients who have abstained from alcohol for many months or years. The possibility that the abnormality is secondary to malnutrition or potassium depletion should also be considered, as correction of these abnormalities may improve glucose tolerance (see also Chapter 2.3.2).

Insulin secretion in diabetic cirrhotics

Diabetic cirrhotics (i.e. with fasting hyperglycaemia) have a marked impairment of insulin secretion to oral and intravenous glucose [10] (Figs 1 and 2). More of their serum immunoreactive insulin is due to proinsulin and its derivative des-31,32-proinsulin, which may account for up to 15% of measured 'insulin' [33]. Insulin secretion in response to a sustained intravenous glucose stimulus is normally biphasic, a rapid rise in insulin within 1–3 min of a rise in glucose level (first phase), followed by a return to baseline by 6–10 min, and then a gradual increase (second phase). Once the fasting blood glucose rises above 6.7 mmol/L, cirrhotics lose their first-phase insulin response to an intravenous glucose stimulus [10], they may have a prompt insulin response to other secretagogues such as intravenous tolbutamide or arginine, although this is lower than in non-diabetic cirrhotics [10] (Fig. 2). More marked fasting hyperglycaemia is associated with loss of the insulin response to intravenous tolbutamide as well. Measurement of insulin and C-peptide during sequential hyperglycaemic clamps at 12, 19, and 28 mmol/L glucose, and in response to a maximally stimulating dose of arginine at each of these glucose levels, suggested a marked decrease in maximal insulin secretory capacity [25]. Cirrhotics with little insulin response to non-glucose secretagogues require insulin for control of their diabetes, whereas those with a good insulin response to tolbutamide can usually be well controlled on sulphonylureas.

The genesis of diabetes mellitus in cirrhosis

Insulin resistance is not sufficient for the development of overt diabetes in cirrhosis. A defect of insulin secretion is also required. This is very similar to findings in type 2 diabetes. In some patients this defect of insulin secretion (see above) may arise from alcoholic damage to the pancreas, in which case diabetes may develop in the absence of significant liver disease or peripheral tissue insulin resistance. However, alcoholic pancreatic damage probably accounts for only a small proportion of cirrhotic patients who develop diabetes because most of these patients have hyperglucagonaemia, fasting and in response to arginine (see below); alcoholic pancreatic damage characteristically causes impaired glucagon secretion [34]. Insulin deficiency may also be due to autoimmune destruction of islet β-cells (type 1 diabetes) or to pancreatic islet iron deposition and islet β-cell loss in patients with haemochromatosis [35]. Most patients with cirrhosis who develop diabetes probably have a genetic predisposition to type 2 diabetes. The higher prevalence of diabetes in cirrhotics with a family history of diabetes supports this view [14]. The abnormalities of insulin secretion found in diabetic cirrhotic patients are very similar to those found in patients with type 2 diabetes mellitus.

Prospective studies of normoglycaemic first-degree relatives of type 2 diabetic patients, and studies in some populations at high risk for type 2 diabetes, have shown that insulin resistance and hyperinsulinaemia in non-diabetic subjects are predictive of subsequent diabetes [36]. It is thought that insulin resistance induces a compensatory increase in insulin secretion and hyperinsulinaemia to maintain normal glucose metabolism but that diabetes eventually develops when insulin secretion becomes impaired. It is not clear whether normal islets can fail after prolonged insulin resistance or whether a coexistent islet defect is necessary. The finding of subtle abnormalities of insulin secretion in non-diabetic relatives of type 2 diabetic patients supports the latter hypothesis [36]. It would seem that as in type 2 diabetes, insulin insensitivity in patients with cirrhosis eventually leads to islet β-cell failure in those with a genetic predisposition to diabetes. Other factors, such as the effects of alcohol or cytokine production on pancreatic islet function, may also be important.

Management of diabetes in patients with liver disease

There have been no controlled studies of the short- and long-term benefits of different treatment regimes for patients with cirrhosis who also have diabetes, and there is a need for studies in this area. Patients with hyperglycaemia of sufficient severity to cause symptoms clearly require control of their diabetes. Diabetic cirrhotics with a good long-term prognosis are at risk of long-term microvascular and macrovascular complications of diabetes. There are no good data on the prevalence of these

complications in cirrhotics with overt diabetes. In a study of 72 patients with diabetes and haemochromatosis aged 20 to 70 years (mean 48 years), 12 (14%) had a history of ischaemic heart disease compared to two of 43 patients with haemochromatosis without diabetes (4.7%). Diabetic retinopathy is common in diabetic haemochromatotic patients, and nephropathy and neuropathy also occur. Diabetic complications are also frequent in patients who have autoimmune liver disease and insulin-dependent diabetes. Retinopathy, neuropathy, nephropathy, and macrovascular disease (ischaemic heart disease/strokes) are seen in diabetic patients who develop cirrhosis, but these complications appear to be uncommon in cirrhotics who develop diabetes. It may be that the natural history of cirrhosis is such that there may be insufficient time for the development of these complications. Kingston *et al.* [13], in a study of 49 diabetic cirrhotics (mainly due to hepatitis B), found neuropathy in 37% and background retinopathy in 18%. An angiographic study found a 27% prevalence of moderate or severe coronary artery disease in 37 patients over the age of 50 with endstage liver disease undergoing liver transplantation; diabetes was the most important risk factor [37]. The incidence of renal dysfunction after liver transplantation may be greater in diabetic patients [38]. Thus, with more patients being considered for liver transplantation more attention needs to be given to the prevention of these long-term complications of diabetes.

Diabetic patients undergoing liver transplantation have an increased risk of bacterial and fungal infections [38]. Good diabetic control should diminish this risk. In patients with severe liver disease who are not candidates for liver transplantation, the risk of long-term diabetic micro- and macrovascular complications is not a primary consideration. However, there are good reasons for attempting to achieve good glycaemic control. First, diabetes will be associated with enhanced mobilization of adipose tissue fatty acids, and increased muscle protein catabolism, as well as impaired tissue glucose utilization and hyperglycaemia. Thus decreased effective tissue insulinization might play a major role in the asthenia and tissue wasting that are prominent features in many patients with chronic liver disease. Secondly, poorly controlled diabetes will predispose to infection, particularly fungal infection.

Many cirrhotics have a normal fasting blood glucose level but a 2-h blood glucose after oral glucose consistent with a diagnosis of diabetes according to WHO criteria [7]. Serum insulin levels in these patients are often very high, due to a combination of delayed hypersecretion and decreased clearance. Symptomatic reactive hypoglycaemia 3–4 h after an oral glucose load is common in this group. At present there is no evidence that these patients will benefit from attempts to lower their postprandial blood glucose levels, although those with reactive hypoglycaemia will respond to dietary measures.

Patients with postprandial hyperglycaemia and only minor increases in fasting blood glucose concentration should be treated initially by a trial of diet. Since decreased tissue sensitivity to insulin and impaired insulin secretion are associated with diets in which the carbohydrate content is restricted to below 40% of energy, it is recommended that the carbohydrate intake should be between 45 and 55% of energy as tolerated. This should be in the form of complexed carbohydrates with low glycaemic indices and rich in soluble fibre. Foods such as pulses, oats, barley, and pasta are recommended. Small quantities of sucrose (less than 30 g/day) may be permitted as part of a mixed meal, but should be avoided in the form of rapidly absorbed drinks. Such a high carbohydrate/low glycaemic index diet, rich in soluble fibre, has been shown to lower the glucose and insulin responses to meals in cirrhotic patients. The diet should be low in saturated fat (less than 10% of total energy), and with a polyunsaturated/saturated fatty acid ratio of 1.0 or more. The intake of total fat should be about 30–35% of total energy. In countries where the intake of olive oil is traditionally high, a higher intake of fat is permissible, providing this is in the form of mono- and polyunsaturated fatty acids. These recommendations with respect to the lipid composition of the diet, as well as being associated with decreased cholesterol and triglyceride levels in diabetic patients, may also improve glycaemic control, perhaps by increasing the sensitivity to insulin.

In the event of dietary failure (persistent postprandial blood glucose elevation with levels of 6.0 mmol/L or greater before the next meal) consideration should be given to additional measures. The two options available are treatment with an oral hypoglycaemic agent or with insulin. Since about 55–60% of the digestible carbohydrates in modern western diets are in the form of polysaccharides (starch), inhibitors of small intestinal α-glucosidases, such as acarbose, may be tried to delay carbohydrate absorption. These agents have no effect on fasting blood glucose levels but cause a dose-dependent reduction in postprandial blood glucose and insulin levels. Side-effects including flatulence, diarrhoea, and abdominal pain are dose dependent but tend to diminish with time. Treatment should be started with small doses (25 mg with each of the three main meals). Acarbose has little effect on the blood glucose response to ingestion of monosaccharides and disaccharides, and it is important therefore that patients adhere to the dietary guidelines discussed above (i.e. intake of complexed carbohydrate) if acarbose is to be effective.

Biguanides (metformin) should be avoided in patients with liver disease, particularly those who are at risk of acute complications (bleeding, renal impairment, sepsis) because of the risk of lactic acidosis. Sulphonylureas are generally well tolerated but should be used cautiously especially in alcoholic patients and in patients with inadequate and erratic food intake. Hypoglycaemia is the most important adverse effect. As most sulphonylureas are metabolized by the liver their plasma half-life may be considerably prolonged, thus increasing the risk of hypoglycaemia. Although glibenclamide has a plasma half-life of only 2 to 3 h, it is an important cause of prolonged hypoglycaemia (2–3 days) with a risk similar to that of chlorpropamide

[39]. Fatal cases have been reported with doses as low as 2.5 mg/day. The reasons for the prolonged hypoglycaemic effect of glibenclamide are unclear, but it may be due to an uncharacterized active metabolite or accumulation of the drug in pancreatic islets. The very slow intestinal absorption of the drug will also result in prolonged exposure. Glibenclamide is thus best avoided in patients with liver disease.

Tolbutamide and glipizide, which are both short acting, rapidly absorbed, and have a low risk of hypoglycaemia when used in standard doses, are probably the sulphonylureas of choice in patients with liver disease. Tolbutamide has a short duration of action (6–10 h), but may aggravate the tendency to water retention; glipizide or gliclazide (both longer acting) are alternatives that are usually well tolerated.

The decision to start insulin, when sulphonylureas are ineffective or poorly tolerated, will depend on the therapeutic targets set for any particular patient. Good self-monitoring of blood glucose concentration is of paramount importance. As fasting blood glucose concentrations are often only modestly raised, these patients may be best managed by a regime of multiple injections of a short-acting insulin 30–45 min before each main meal; an intermediate-acting insulin may then be introduced before the evening meal or at bedtime in accordance with the blood glucose response. Patients with liver disease appear to be more prone to fasting and nocturnal hypoglycaemia in association with intermediate-acting insulins. However, this is poorly documented in formal clinical studies. Also unclear is the extent to which hormonal and physiological counter-regulatory mechanisms are disturbed in patients with liver disease and whether the glucose threshold for development of neuroglycopenic symptoms is affected by coexistent liver disease. Studies addressing these issues would help in the clinical management of these patients.

Glucagon

Fasting plasma glucagon levels are increased two- to sixfold in cirrhotic patients and they show a greater rise in glucagon levels after intravenous arginine [40] and in response to a protein meal. Extremely high plasma glucagon levels may be found in patients with fulminant hepatic failure. Unlike insulin, glucagon is cleared mainly by the kidney; the portal:peripheral glucagon concentration ratio is much lower than for insulin and it has been estimated that first-pass hepatic glucagon extraction is only about 15–25% [41]. Thus, while diminished glucagon clearance might contribute to the higher fasting plasma glucagon levels in cirrhotics, it cannot (given the low first-pass hepatic extraction of glucagon) explain the greater rise in glucagon levels that is seen within 5 min of an intravenous arginine bolus. In keeping with the lower hepatic extraction ratio for glucagon than for insulin, Sherwin *et al.* [41] showed that the metabolic clearance rate of infused glucagon was normal in cirrhotics with and without portacaval shunts, and they concluded that the hyperglucagonaemia of cirrhosis was due to increased glucagon secretion. However, plasma glucagon levels were higher in their patients with surgical portocaval shunts or large varices on endoscopy than in patients without evidence of portal systemic shunting, who had normal glucagon levels. An increase in glucagon levels in cirrhotics after portocaval anastomosis was also reported by Dudley *et al.* [42]. These observations led to the idea that portosystemic shunting in cirrhosis is the major factor that leads to increased pancreatic glucagon secretion and hyperglucagonaemia. Studies in rats would support this view: hyperglucagonaemia due to increased glucagon secretion develops after portal vein ligation [43] or portaocaval anastomosis [44] in the absence of cirrhosis. However, normal glucagon levels were found in non-cirrhotic patients with portal vein block and extensive collaterals or surgical portosystemic shunts, and some consider hepatocellular function to be the major determinant of increased plasma glucagon levels [45].

Plasma glucagon levels in normal subjects are suppressed after glucose ingestion or during an intravenous glucose infusion. Both hyperglycaemia and hyperinsulinaemia mediate this suppression. The acute glucagon response to intravenous arginine is also progressively attenuated as plasma glucose (and hence insulin) levels are raised. In cirrhotic patients this regulation of basal and stimulated glucagon levels by glucose and insulin is disturbed. In response to oral glucose ingestion, or a moderate increase in plasma glucose levels achieved by intravenous glucose administration, the fall in plasma glucagon levels is often less than in controls despite higher insulin and glucose levels [31,40,42].

Failure to achieve complete suppression of plasma glucagon levels by hyperglycaemia in many of the earlier studies may have been due in part to an increased contribution of enteroglucagon (molecular weight of approximately 9000 Da) to plasma immunoreactive glucagon in cirrhosis [42]. Enteroglucagon cross-reacts in many glucagon assays and does not undergo acute changes in response to changes in blood glucose concentration or when glucagon secretion is stimulated by amino acids. However, even when a specific antiglucagon antibody is used, impaired suppression of glucagon levels by hyperglycaemia is found [40]. Complete suppression of fasting glucagon levels can be achieved at very high glucose levels (*c.* 28 mmol/L); however, while there is a progressive decrease in the acute glucagon response to arginine with increasing glucose concentrations, the acute response to intravenous arginine remains higher than in normal subjects even when measured at a blood glucose concentration of 28 mmol/L [40].

Fasting and stimulated glucagon levels may be much higher in diabetic cirrhotic patients than in matched non-diabetic cirrhotics [31,40]. Suppression of basal plasma glucagon levels, and the acute glucagon response to intravenous arginine by hyperglycaemia is markedly impaired in diabetic cirrhotics [40]. Impaired insulin secretion and chronic hyperglycaemia could explain the more marked abnormalities of glucagon secretion in

the diabetic cirrhotics by comparison with cirrhotics without diabetes, as similar abnormalities are found in those with type 2 diabetes mellitus, in whom they are improved by insulin therapy.

The mechanism for increased glucagon secretion in cirrhosis is unclear. Glucagon secretion is increased in non-diabetic cirrhotics despite increased circulating levels of insulin [8,10,11,14,17–19,21–23,30], somatostatin, and glucagon-like peptide-1 [7–36 amide] [30] which, together with glucose, are the main inhibitors of islet α-cell glucagon secretion. However, gastric inhibitory polypeptide levels are increased in cirrhosis [30,31], and in cirrhosis the glucagonsecreting α-cells may be more sensitive to the stimulatory effects of gastric inhibitory polypeptide. The enhanced glucagon secretion has also been attributed to increased ammonia levels in cirrhosis. Marchesini *et al.* [46] reported increased plasma glucagon levels in cirrhotics after intravenous administration of ammonium salts, but no such increase was found by others. Although fasting glucagon levels correlate with plasma ammonia levels, Kabadi and colleagues suggested that the increased glucagon levels may in part explain the elevated plasma ammonia levels rather than vice versa [47]. Another theory put forward to explain glucagon hypersecretion in cirrhosis or liver failure is deficiency of a factor produced by the liver that normally inhibits glucagon secretion by islet α-cells. Secretion of this factor is believed to increase with increasing liver glycogen content. However, the further enhancement of glucagon secretion in cirrhosis by the presence of diabetes does not support this hypothesis because diabetic patients (normal or cirrhotic) characteristically have increased liver glycogen content, particularly when poorly controlled (see Chapter 20.9).

The significance of the abnormalities of glucagon secretion for hepatic glucose and amino acid metabolism in cirrhosis is unclear. Cirrhotic patients appear relatively resistant to the effects of glucagon: the rise in plasma cyclic AMP and glucose [48] and hepatic glucose output in response to intravenous glucagon are impaired (see Chapter 2.3.2). Furthermore, in cirrhosis there is impaired stimulation of gluconeogenesis [41] and urea synthesis by glucagon, and resistance to its haemodynamic effects. While low hepatic glycogen stores may account for a smaller output of glucose from the liver in response to an intravenous bolus or infusion of glucagon, chronically elevated glucagon levels may also impair the acute response through downregulation of glucagon receptors [49] and postreceptor signalling mechanisms [50]. Increased basal glucagon levels may be necessary for maintenance of normal fasting glucose levels in cirrhosis (Chapter 2.3.2) but do not appear to play a role in glucose intolerance. This may not be true in overtly diabetic cirrhotics in whom increased glucagon secretion and lack of suppression by hyperglycaemia may contribute to their impaired suppression of hepatic glucose production and hyperglycaemia [51]. These issues are discussed in Chapter 2.3.2. The role of glucagon in the splanchnic hyperaemia and portal hypertension of cirrhosis is discussed in Chapter 7.2.

Growth hormone

Normal physiology

Growth hormone is a polypeptide of 191 amino acids in humans (molecular weight 21 500). About 5–15% of circulating growth hormone is due to a biologically less-active 176-amino-acid isoform. Secretion of growth hormone from the anterior pituitary is under the influence of hypothalamic regulatory peptides (Fig. 3). Growth hormone-releasing hormone increases growth hormone synthesis and release; somatostatin inhibits growth hormone release. A number of other peptides synthesized and released from the hypothalamus may also stimulate growth hormone secretion, independently of growth hormone releasing hormone, by interacting with specific receptors on the pituitary somatotrophs, but their physiological role is at present unclear. Insulin-like growth factors which mediate many of the growth effects of growth hormone inhibit both the hypothalamic release of growth hormone-releasing hormone and the pituitary response to this peptide, thus providing a feedback control of growth hormone secretion. In this respect insulin-like growth factor-1 is considerably more potent than insulin-like growth factor-2. Growth hormone itself stimulates somatostatin release

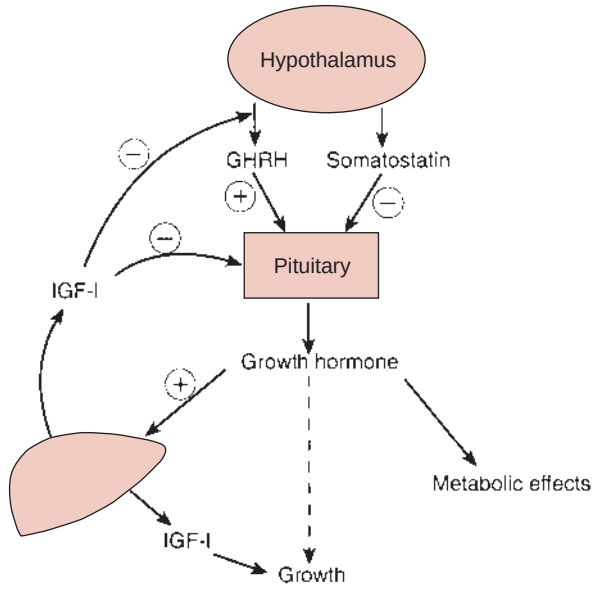

Fig. 3 Growth hormone (GH) secretion is regulated by hypothalamic hormones: somatostatin inhibits and growth hormone-releasing hormone (GHRH) stimulates GH secretion. The growth effects of GH are mostly indirect and mediated via insulin-like growth factor-1 (IGF-1). The liver is the main source of circulating IGF-1. IGF-1 inhibits GH secretion by inhibiting the release of GHRH and the pituitary response to this peptide. GH secretion is enhanced by stress, exercise, hypoglycaemia, and certain amino acids, and inhibited by increased levels of fatty acids, ketone bodies, and glucose. Increased GH levels in liver disease may be partly due to impaired IGF-1 production. GH has direct metabolic effects. Many of these are 'anti-insulin'. The high GH levels in cirrhosis may contribute to insulin resistance.

from the hypothalamus and increases local pituitary production of insulin-like growth factor-1, thus providing possible short-loop autocrine or paracrine feedback control of its own secretion. Many neuropeptides, neurotransmitters, peripheral hormones, and metabolites modulate growth hormone secretion. It is stimulated by stress, fasting, exercise, hypoglycaemia, and certain amino acids, especially arginine. A rapid fall in plasma levels also stimulates growth hormone release. Conversely, growth hormone secretion is suppressed in normal individuals by a glucose load, and by elevated plasma non-esterified fatty acid levels. Thyroid hormones play an important role in the regulation of growth hormone synthesis and secretion; growth hormone responses to hypoglycaemia, sleep, and arginine are impaired in patients with hypothyroidism. High levels of corticosteroids also impair growth hormone secretion, possibly by increasing hypothalamic release of somatostatin.

Growth hormone secretion is pulsatile with a periodicity of 3–4 h. Between pulses, serum growth hormone falls with a half-life of approximately 15–20 min to very low levels (<0.5 mU/L (<0.25 μg/L)). Physiological modulation of growth hormone secretion is achieved by variation in the amplitude rather than the frequency of pulses, although both amplitude and frequency increase at puberty and decline after the age of 40 years. Pulses are higher during the first part of the night during deep sleep, so that about two-thirds of growth hormone secretion occurs during the 12-h overnight period. The liver, and to a lesser extent the kidney, are the main sites of growth hormone clearance, although there is some uncertainty as to their relative contributions. Hepatic growth hormone clearance is receptor mediated; about 10–20% of the growth hormone delivered to the liver is removed during a single trans-hepatic passage. Estimates of the contribution of the liver to total growth hormone clearance vary between 50–95%.

Growth hormone in serum associates with a specific high-affinity binding protein, which is identical to the extracellular domain of the growth hormone receptor, from which it is derived (in man) by proteolytic cleavage [52]. Since the liver is the tissue with the highest abundance of growth hormone receptors, the liver is also the major source of growth hormone binding protein, and plasma growth hormone binding protein levels reflect hepatic growth hormone receptor status. In contrast to the marked variations in growth hormone concentrations due to pulsatile secretion, growth hormone binding protein levels are relatively constant [53]. Normally, serum growth hormone binding protein concentrations are similar to basal growth hormone levels and some 30–50% of circulating growth hormone is bound. The molecular size of the growth hormone–growth hormone binding protein complex (80–85 kDa) prevents glomerular filtration and limits the extravascular distribution of growth hormone. In addition, growth hormone binding protein competes with cellular receptors for growth hormone binding [54]. Thus, growth hormone binding protein serves to delay growth hormone clearance and dampen the marked oscillations in plasma growth hormone levels. There is effective transfer of growth hormone from growth hormone binding protein to hepatic growth hormone receptors because the affinity of growth hormone binding protein for growth hormone is much lower than that of the growth hormone receptor; high growth hormone binding protein levels actually enhance the hepatic effects of growth hormone *in vivo* (for example, insulin-like growth factor-1 production and hence growth) by prolonging plasma growth hormone half-life [55]. The effect of growth hormone binding protein levels on growth hormone actions in peripheral tissues that have few growth hormone receptors [56] is unclear.

Many of the growth promoting effects of growth hormone are mediated by insulin-like growth factor-1 and -2, although it also has direct effects on cartilage and bone. Its anabolic actions on protein, amino acid, and nitrogen metabolism (Chapter 2.3.3) are both direct and via insulin-like growth factor-1. By contrast, the 'insulin-antagonistic' metabolic effects, which serve to shift fuel utilization away from glucose towards fat, are due to direct effects of growth hormone on skeletal muscle, adipose tissue, and hepatic metabolism. The role of growth hormone in the insulin resistance and glucose intolerance of patients with liver disease is discussed in Chapter 2.3.2.

Disturbances of growth hormone in liver disease

Basal and mean daily growth hormone levels are increased in cirrhosis [57–59] (Fig. 4). Increased growth hormone levels may also be found in patients with acute viral hepatitis [5], chronic active hepatitis, and in patients with schistosomal hepatic fibrosis and marked portal hypertension. The diurnal pattern of serum growth hormone is markedly disturbed in patients with cirrhosis, due primarily to an increased frequency of growth

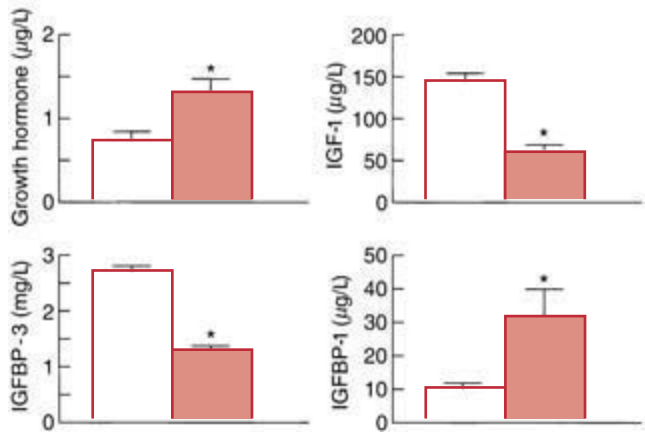

Fig. 4 Fasting arterial plasma growth hormone, insulin-like growth factor 1 (IGF-1), and insulin-like growth factor binding proteins 1 and -3 (IGFBP-1 and -3) in 22 cirrhotic patients ■ (19 alcoholic, three posthepatitic; Child's grading: A = 6, B = 10, C = 6), and 27 normal subjects □ matched for age and sex. Mean ± SEM. *, $P < 0.001$ versus controls. (Data from ref. 9, with permission.)

hormone pulses [59]; pulse amplitude may also be increased in some patients [59]. Daytime secretion in cirrhotics accounts for a larger proportion of total daily growth hormone secretion.

Many patients with cirrhosis have a paradoxical increase in serum growth hormone levels in response to an oral glucose load [60]; stimulation of growth hormone secretion may also be seen in response to an intravenous bolus of thyrotrophin releasing hormone which does not normally elicit a rise in growth hormone levels. These responses of serum growth hormone to oral glucose and thyrotrophin releasing hormone are similar to those found in many patients with acromegaly, and in patients with poorly controlled diabetes. Samaan *et al.* [61] suggested that a paradoxical rise in growth hormone after glucose ingestion was more likely in cirrhotic patients with impaired glucose tolerance than in those with normal glucose tolerance. However, in the study of Conn and Daughaday [62] a paradoxical growth hormone response to oral glucose was no more likely in the cirrhotics with overt diabetes than in those with normal or impaired glucose tolerance, though the number of patients studied was small. The growth hormone response to arginine and insulin-induced hypoglycaemia in cirrhotics may be exaggerated, normal, or reduced. Caution is required in the interpretation of the two studies reporting a normal or subnormal growth hormone response to insulin-induced hypoglycaemia [63] because an equivalent hypoglycaemic stimulus was not achieved due to insulin resistance in the cirrhotics. The increase in growth hormone levels after glucose ingestion may contribute to the markedly disturbed daytime growth hormone levels. In chronic alcoholic patients without significant liver disease, the growth hormone response to insulin-induced hypoglycaemia may be impaired returning to normal with abstinence.

The aetiology of the increased basal growth hormone levels and abnormal growth hormone responses to glucose and other stimuli in cirrhosis is unclear. In general, higher serum growth hormone levels are found in patients with liver disease who have established cirrhosis. Cuneo *et al.* [59] found higher mean daily growth hormone secretion rates in cirrhotics with poor liver function as assessed by Child–Pugh score but in most other studies growth hormone levels did not correlate with severity of liver disease [58,63].

Impaired hepatic production and low circulating insulin-like growth factor-1 levels [57–59,64] (Fig. 4), resulting in impaired feedback inhibition of growth hormone secretion, are probably the most important factors in the increased growth hormone secretion in cirrhosis. In men with marked feminization associated with portosystemic shunting, estrogens may contribute to the abnormal growth hormone secretory patterns, since in women growth hormone pulses are more frequent and their basal growth hormone levels higher [65].

Hepatic growth hormone resistance

Low hepatic insulin-like growth factor-1 production despite increased circulating growth hormone levels implies hepatic resistance to growth hormone in patients with liver disease [57–59]. There is little evidence that decreased hepatocyte mass *per se* plays a role in the impaired insulin-like growth factor-1 production. As discussed below, many factors, particularly nutritional state and insulin, affect the hepatic insulin-like growth factor-1 response to growth hormone. Protein–calorie malnutrition and insulin deficiency induce hepatic resistance to growth hormone by reducing the number of hepatic growth hormone receptors and by postreceptor mechanisms [66]. Malnutrition is common in patients with chronic liver disease and could contribute to the hepatic resistance to growth hormone. Although systemic insulin levels are high in patients with cirrhosis, portosystemic shunting and sinusoidal capillarization may result in relative hepatic hypoinsulinaemia. Since portal insulin delivery seems to be important for a normal insulin-like growth factor-1 response to growth hormone [67], hepatic hypoinsulinaemia could contribute to hepatic growth hormone resistance, Plasma growth hormone binding protein levels, which reflect hepatic growth hormone receptor status, are a major determinant of the response to a given dose of growth hormone. Growth hormone binding protein levels are reduced in cirrhosis [57,63] and reduced growth hormone receptor expression has been found in cirrhotic liver [68]. Thus, hepatic resistance to the effects of growth hormone in terms of insulin-like growth factor-1 production may partly be due to fewer growth hormone receptors.

Abnormalities of growth hormone action may contribute to the stunted growth seen in young patients with chronic liver disease. Children with Alagille syndrome (chronic cholestasis associated with a paucity of interlobular bile ducts, characteristic facies, skeletal and cardiac abnormalities (Chapter 19.1) frequently show growth retardation in the absence of malnutrition. There is evidence that resistance to growth hormone may contribute to their growth disturbance. Children with Alagille syndrome have high serum growth hormone and growth hormone binding protein levels but their insulin-like growth factor-1 levels are very low, and similar to those found in growth hormone deficient children. Unlike growth hormone deficient children, serum insulin-like growth factor-1 levels do not increase when growth-retarded children with Alagille syndrome are treated with recombinant human growth hormone [69]. This impairment in the insulin-like growth factor-1 response to growth hormone is similar to that seen in cirrhosis but is found when liver synthetic function is good and in the absence of portal hypertension.

Growth hormone clearance in cirrhosis

Although the liver plays an important role in growth hormone metabolism, evidence for delayed growth hormone clearance in cirrhosis is inconclusive. Owens *et al.* [70] found a lower growth hormone metabolic clearance rate in a very heterogeneous group of patients with liver disease, half of whom had ascites which might well have influenced the calculation of kinetic parameters. Others have reported normal total and hepatic growth hormone clearance in cirrhotics with advanced liver

disease [57]. The fractional hepatic extraction of growth hormone may be enhanced when growth hormone levels increase, for example in response to an infusion of arginine or with exercise. This increase in hepatic growth hormone uptake is not explained by changes in hepatic plasma flow. The most likely explanation is an increase in the proportion of free growth hormone with increasing plasma levels because of partial saturation of growth hormone binding protein at growth hormone levels above 20 mU/L (10 μg/L) [52]. This would favour binding and clearance by hepatocyte growth hormone receptors; it would also enhance renal growth hormone clearance. In view of the lower growth hormone binding protein levels in patients with cirrhosis [63], one would predict saturation of growth hormone binding proteins at growth hormone levels found in many fasting cirrhotics; an increase in the free growth hormone fraction could explain the normal growth hormone clearance found in cirrhosis [57].

Insulin-like growth factors and their binding proteins

Normal physiology

Insulin-like growth factor-1 and -2 are polypeptides (*c.* 7.5 kDa) similar in structure to proinsulin, with which they share about 50% homology. Insulin-like growth factor-1, and to a lesser extent insulin-like growth factor-2, mediate many of the somatotrophic effects of growth hormone and play an important role in bone metabolism (Chapter 21.9). Insulin-like growth factor-1 increases lean body mass through its effects on protein and amino acid metabolism (Chapter 2.3.3). Both peptides have insulin-like effects on glucose metabolism in muscle and liver. Circulating levels of insulin-like growth factor-1 and, to a much lesser extent, insulin-like growth factor-2 are increased by growth hormone. Most tissues express insulin-like growth factor-1 and -2 but hepatocytes show the highest expression of their mRNAs and the liver is the main source of circulating insulin-like growth factors. Growth hormone stimulates the transcription of the gene in hepatocytes and the release of insulin-like growth factor-1 into the circulation, which in turn inhibits growth hormone release from the pituitary by modulating hypothalamic factors that increase somatostatin release and by inhibiting the pituitary somatotroph response to growth hormone releasing hormone. The liver thus plays a central role in an important endocrine feedback loop.

Regulation of hepatic insulin-like growth factor-I production

Nutritional state and many hormones affect the hepatic insulin-like growth factor-I response to growth hormone. Insulin is a prerequisite for growth hormone stimulated insulin-like growth factor-I synthesis [71]. Underinsulinized diabetic patients have low serum insulin-like growth factor-I levels (despite high growth hormone levels) that are increased by intensive insulin treatment; their splanchnic output of insulin-like growth factor-I and plasma insulin-like growth factor 1 levels increase within hours during intravenous insulin administration [72]. Insulin deficiency impairs the hepatic insulin-like growth factor-I response to growth hormone by decreasing hepatic growth hormone receptor number and by a post-growth hormone receptor mechanism. Insulin may also regulate insulin-like growth factor-I production independently of growth hormone [73]. Thyroid hormone and glucocorticoids also enhance the insulin-like growth factor 1 response to growth hormone, while somatostatin and estrogens are inhibitory. Hepatic insulin-like growth factor 1 production is profoundly influenced by nutritional factors. Caloric restriction, protein deficiency alone, or protein–calorie malnutrition all result in a state of hepatic growth hormone resistance with respect to insulin-like growth factor 1 synthesis and secretion [74]. In addition, the quality of protein administered (in terms of essential amino acid content) can affect the insulin-like growth factor 1 response to refeeding of fasted individuals.

Plasma transport of the insulin-like growth factors

Plasma levels of insulin-like growth factor-I and -II show little variation over a 24-h period, despite marked fluctuations in growth hormone levels. This constancy is in part due to their association with specific binding proteins (IGFBPs) so that less than 1% of circulating insulin-like growth factor is in the free form. Six distinct highly homologous IGFBPs have been cloned [75]. The liver is the main site of synthesis of IGFBPs 1–4 but they are also synthesized by many tissues. About 75% of circulating insulin-like growth factor 1 and 2 is found in a 150 kDa complex, the rest in complexes less than 50 kDa. IGFBP-3 is the insulin-like growth factor binding component of the 150 kDa complex. It has a very high affinity for the insulin-like growth factors, and once associated with insulin-like growth factor it also binds an acid-labile subunit to form a stable ternary complex. The serum half-life of insulin-like growth factor in this 150 kDa ternary complex is 12–16 h. Unable to cross the capillary endothelial barrier, this 150 kDa complex serves as the body's main storage of insulin-like growth factors. IGFBP-1 and IGFBP-2 are the binding proteins in the smaller 50 kDa complexes. IGFBP-1 binds insulin-like growth factor 1 and 2 with equal affinity, while IGFBP-2 preferentially binds insulin-like growth factor 2. IGFBP-1 and IGFBP-2 seem to have little effect in slowing the exit of insulin-like growth factors from the circulation and the insulin-like growth factors in this pool disappear from the circulation with a half-life of 20–30 min [76].

The IGFBPs play an important role in regulating tissue delivery of the insulin-like growth factors. They can either potentiate or inhibit insulin-like growth factor action by influencing insulin-like growth factor interaction with tissue receptors [77]. The importance of the IGFBPs becomes apparent when one considers the insulin-like metabolic effects of the insulin-like

growth factors. Insulin-like growth factor-1 and -2 bind with high (approximately equal) affinity to the insulin-like growth factor-1 receptor, which is structurally very similar to the insulin receptor with which it seems to share many of the intracellular signalling pathways. Both insulin-like growth factors can also bind with low affinity to the insulin receptor. At physiological concentrations, the growth and insulin-like metabolic effects are mediated via the insulin-like growth factor-1 receptor; at high free concentrations they can also signal via the insulin receptor [78]. Since their potency on glucose metabolism in skeletal muscle is 5–10% that of insulin, and the plasma concentration of insulin-like growth factors is about 100 nM (1000 times that of insulin) [79], it is evident that the hypoglycaemic potential of the circulating insulin-like growth factors is huge. Due to sequestration of the insulin-like growth factors in the 150 kDa ternary complex comprising the insulin-like growth factor, IGFBP-3 and the acid-labile subunit, most of this hypoglycaemic activity is not expressed.

Regulation of insulin-like growth factor binding proteins (IGFBPs)

The IGFBPs are under complex hormonal and nutrient control, providing a further level at which the tissue delivery of insulin-like growth factors is regulated. IGFBP-1 undergoes acute variations in plasma levels, decreasing after meals or glucose ingestion and rising during fasting. The liver is the main site of IGFBP-1 production and insulin is the main regulator, inducing a rapid inhibition of IGFBP-1 gene transcription; plasma IGFBP-1 levels are inversely correlated with estimated portal venous insulin concentrations [80] and splanchnic output and plasma levels fall rapidly when insulin is infused intravenously. Glucagon and somatostatin stimulate IGFBP-1 production. The resulting fall in IGFBP-1 levels after meals may increase free insulin-like growth factor-1 in the interstitium of peripheral target tissues, thereby promoting glucose and amino acid uptake and inhibiting protein breakdown. IGFBP-3 and IGFBP-2 do not undergo acute changes in plasma levels in response to metabolic events but are regulated by growth hormone and insulin-like growth factor-1. Growth hormone, acting via insulin-like growth factor-1, increases the synthesis and secretion of IGFBP-3 from hepatic non-parenchymal cells [81]. Malnutrition, chronic protein restriction, and growth hormone deficiency decrease IGFBP-3 levels [74]. IGFBP-2 levels rise within 24 h of fasting [82]. IGFBP-2 levels are increased in growth hormone deficiency and malnutrition.

Insulin-like growth factors and their binding proteins in liver disease

Serum insulin-like growth factor-1 and -2 levels are reduced in patients with cirrhosis [64] (Fig. 4) and in a variety of other liver diseases [58]. Low serum insulin-like growth factor-1 levels are thought to be a major cause of the increased growth hormone levels in cirrhosis through impaired feedback inhibition of growth hormone secretion. Circulating levels of IGFBPs are also disturbed in liver disease, with a reduction in IGFBP-3 and an increase in IGFBP-1 and IGFBP-2 [58,82] (Fig. 4). Less of the circulating insulin-like growth factor is found in the large 150 kDa complex and more in the rapidly turning over smaller complexes. There is no evidence that the binding of insulin-like growth factor-1 to IGFBP-3 is impaired due to proteolytic cleavage of IGFBP-3, as has been found in poorly controlled type 1 diabetic patients and in other severely ill or malnourished patients. Low serum insulin-like growth factor-1 levels in liver disease are mainly due to impaired hepatic insulin-like growth factor-2 synthesis. However, a redistribution of insulin-like growth factors to smaller molecular weight short-lived complexes, may also enhance their clearance and contribute to the low plasma levels.

It is generally assumed that decreased hepatocellular function is the main cause of low plasma insulin-like growth factor-1 levels in patients with chronic liver disease. However, this does not explain the increased hepatic production of IGFBP-1 in cirrhosis [57,58]. Furthermore, Donaghy and colleagues [58] found no difference in insulin-like growth factor-1 levels between cirrhotics in Child–Pugh groups A, B, or C, and while IGFBP-1 levels were higher in the group B than group A cirrhotics, there was no further increase in the Child–Pugh group C cirrhotics with very poor liver function. In a large group of patients with alcoholic liver disease, serum insulin-like growth factor-1 levels showed a stronger correlation with a composite protein–calorie malnutrition score than with liver function suggesting that malnutrition may also be an important determinant of the low insulin-like growth factor-1 levels. In patients without liver disease, insulin-like growth factor-1 levels provide a sensitive index of acute changes in nutritional state; insulin-like growth factor-1 levels correlate better with nitrogen balance than do such hepatic markers as retinol binding protein and thyroxine binding prealbumin. Low insulin-like growth factor-1 and IGFBP-3 levels accompanied by high IGFBP-1 levels are found in anorexia nervosa and other malnourished patients who have an acquired growth hormone resistant state [74,83]. Malnutrition may be an important determinant of the hepatic growth hormone resistance and abnormal insulin-like growth factor-1, IGFBP-1, and IGFBP-3 levels in chronic liver disease. It could also underlie the prognostic value of insulin-like growth factor-1 and IGFBP-3 for survival in alcoholic cirrhosis [84] as nutritional state is an important prognostic factor in patients with cirrhosis. In addition to protein–calorie malnutrition, deficiencies of specific nutrients, such as zinc, that may occur in some cirrhotic patients (see Chapter 23.2) may also result in hepatic growth hormone resistance and impaired insulin-like growth factor-1 production.

As discussed earlier, insulin plays a key role in the regulation of plasma insulin-like growth factor-1 and IGFBP-1 levels; through its effects on insulin-like growth factor 1 it also influences IGFBP-3 levels. Low insulin-like growth factor-1 and IGFBP-3 levels, and increased IGFBP-1 levels, are also found

in type 1 diabetes [85]. Studies in animals and humans have suggested that the portal route of insulin delivery is important for normal regulation of insulin-like growth factor-1 and IGFBP-1 production. In type 1 diabetic patients on subcutaneous insulin injections, loss of the normal portal-peripheral insulin concentration gradient may contribute to the abnormalities of the insulin-like growth factor-1–growth hormone axis. In cirrhosis, portosystemic shunting and sinusoidal capillarization may similarly result in hepatic under-insulinization despite high systemic insulin levels, and may contribute to the low insulin-like growth factor-1 and IGFBP-3, and increased IGFBP-1 levels. Plasma glucagon levels are increased in cirrhosis. However, since the liver is resistant to glucagon in cirrhosis it is unlikely that glucagon is the cause of the increased hepatic synthesis of IGFBP-1 [57]; however, the low insulin-like growth factor-1 levels could contribute to increased glucagon secretion in cirrhosis [86].

Many cells besides hepatocytes produce insulin-like growth factor-1 and IGFBPs. It is unclear whether local tissue production of insulin-like growth factor-1 and the IGFBPs is disturbed in liver disease and to what extent individual tissues rely on locally produced versus circulating insulin-like growth factor-1. The observation that administration of a blocking antibody to insulin-like growth factor-1 results in a transient rise in protein turnover suggests that at least part of the effect on protein metabolism is mediated by circulating insulin-like growth factor-1. In view of the frequency of malnutrition in cirrhosis and its impact on the outcome of transplantation, insulin-like growth factor-1 may have a place in the nutritional management of patients with liver disease (see Chapter 2.3.3). In children with endstage liver disease, plasma insulin-like growth factor-1 levels are restored to normal after liver transplantation but IGFBP-1, IGFBP-2, and IGFBP-3 levels are higher than in normal control subjects during the first year [82]. These abnormalities correlated with nutritional indices such as triceps skin-fold thickness and mid-upper arm circumference. The increased levels of these binding proteins may limit tissue insulin-like growth factor-1 availability and thus provide a basis for growth failure after successful liver transplantation in some children [82].

Insulin-like growth factors and extrapancreatic tumour hypoglycaemia

Hepatocellular carcinoma is one of the more common extrapancreatic tumours known to be associated with hypoglycaemia. While hypoglycaemia may develop as a late manifestation in patients with liver failure (Chapter 2.3.2), in patients with hepatocellular carcinoma it may present relatively early, at a time when the tumour is slow-growing and well differentiated. Hypoglycaemia presenting early in the course of hepatocellular carcinoma (in the absence of liver failure) is common in Southeast Asia but rare in Western countries. The hypoglycaemia in these patients may be severe and difficult to control; as in patients with other extrapancreatic tumours, hypoglycaemia is due to both an impairment of hepatic glucose production and increased glucose utilization, particularly by skeletal muscle [87]. Serum non-esterified fatty acids and growth hormone levels are low during hypoglycaemia, suggesting an impaired counterregulatory response. All these metabolic abnormalities are found in the presence of very low, often unmeasureable, serum insulin levels.

Megyesi and colleagues, over 20 years ago, reported increased plasma levels of 'non-suppressible insulin like activity' in some patients with extrapancreatic tumour hypoglycaemia. Insulin-like growth factor-1 and -2 were isolated in 1976 and shown to account for the 'non-suppressible insulin-like activity' in plasma. Several groups subsequently reported modest increases of serum insulin-like growth factor-2 levels (but low insulin-like growth factor-1) in some but not all patients with tumour-related hypoglycaemia; in other series insulin-like growth factor-2 levels were either normal or just above the normal reference range, while insulin-like growth factor-1 levels were again low or normal [88,89]. Normal serum insulin-like growth factor-2 levels were often found despite evidence of increased insulin-like growth factor-2 mRNA and insulin-like growth factor-2 protein levels in tumours associated with hypoglycaemia [88]. As discussed earlier, patients with cirrhosis characteristically have low serum insulin-like growth factor-1 and insulin-like growth factor-2 levels. Not surprisingly therefore, in cirrhotic hepatocellular carcinoma patients with hypoglycaemia, serum insulin-like growth factor-1 and -2 levels have been consistently low, and although insulin-like growth factor-2 levels tended to be higher in hypoglycaemic than in normoglycaemic cirrhotic hepatocellular carcinoma patients, the differences were not significant. The role of the insulin-like growth factors in hypoglycaemia complicating hepatocellular carcinoma and other non-islet-cell tumours thus remained unclear until recently.

There is now good evidence that tumours associated with hypoglycaemia produce increased amounts of insulin-like growth factor-2 precursor forms ('big IGF-2') with molecular weights in the range 10–17 kDa compared to 7.5 kDa for mature insulin-like growth factor-2, due to abnormal processing of pro-insulin-like growth factor-2 which contains an 89 amino acid C-terminal extension [88–91]. A variable C-terminal extension, and abnormal glycosylation, result in marked heterogeneity of 'big IGF-2' in sera of patients with tumour hypoglycaemia [91]. Shapiro *et al.* [88] found that 'big IGF-2' accounted for 48–72% of total serum insulin-like growth factor-2 in six patients with hepatocellular carcinoma with hypoglycaemia, but for only 6–40% in five normoglycaemic patients with hepatocellular carcinoma. Interestingly, increased serum levels of 'big IGF-2' have also been found in chronic hepatitis B carriers without evidence of tumour [90]. At the receptor level some 'big IGF-2' species may be more potent than mature insulin-like growth factor-2 [88]; however, the main mechanism by which unregulated tumour production of 'big IGF-2' induces hypoglycaemia is by increasing tissue insulin-like growth factor bioavailability.

As discussed earlier, insulin-like growth factor-1 and -2 circulate in plasma bound in a large 150 kDa ternary complex and smaller 50 kDa complexes. Formation of the 150 kDa complex is important for sequestration of insulin-like growth factors in the circulation. Although 'big IGF-2' and mature insulin-like growth factor-2 bind equally well to IGFBP-3, in patients with hypoglycaemia due to excessive 'big IGF-2' production the association of IGFBP-3 and its bound insulin-like growth factor with the acid-labile subunit to form the stable 150 kDa ternary complex is impaired [89,91]. The result is that most plasma insulin-like growth factor in these hypoglycaemic patients is found in complexes of less than 50 kDa, which can readily leave the circulation to interact with tissue insulin-like growth factor-1 and insulin receptors. Increased action of insulin-like growth factor-2 at the level of the hypothalamus/pituitary leads to inhibition of growth hormone secretion; this inhibits normal insulin-like growth factor-1 and -2 production and aggravates the situation by decreasing plasma levels of IGFBP-3 and the acid-labile subunit. The low growth hormone levels may also account for the markedly increased IGFBP-2 levels found in patients with hypoglycaemia due to 'big IGF-2'-producing tumours [92]; high IGFBP-2 levels may further promote the redistribution of insulin-like growth factor-2 to lower molecular weight complexes. The increased tissue bioavailability of insulin-like growth factors may account for the occasional association of non-islet cell tumour hypoglycaemia with acromegaloid skin changes [93].

Management

Large amounts of intravenous glucose may be required. Studies on small numbers of patients with tumour-associated hypoglycaemia have shown that growth hormone may be useful in the management of these patients pending definitive treatment or in patients with inoperable tumours. Prednisolone and glucagon have also been used, with some success, to reduce glucose requirements in patients with tumour-associated hypoglycaemia. Growth hormone is important for counter-regulation of hypoglycaemia. It is also important for the synthesis of the protein components (IGFBP-3 and the acid-labile subunit) of the circulating 150-kDa insulin-like growth factor complex that serves to restrict access of the insulin-like growth factors to tissues and thereby limit their hypoglycaemic potential. Suppression of growth hormone secretion by insulin-like growth factor-2 may thus contribute to the hypoglycaemic effect of increased tissue insulin-like growth factor-2 delivery. Prednisolone may inhibit tumour 'big IGF-2' production; it increases levels of the acidlabile subunit and decreases IGFBP-2 levels and thereby increases the proportion of plasma insulin-like growth factor 2 in the 150-kDa complex, as well as opposing the actions of insulin (and by implication those of the insulin-like growth factors) on hepatic glucose production and peripheral tissue glucose utilization. Alleviation of hypoglycaemia is consistently associated with a restoration of the 150-kDa insulin-like growth factor ternary complex, regardless of whether total or 'big' insulin-like growth factor-2 levels fall. Since prednisolone and growth hormone may increase the proportion of insulin-like growth factor-2 in the 150-kDa complex by different mechanisms, their combined effects may be additive [92].

Hypoglycaemia complicating hepatocellular carcinoma in cirrhotic patients may be particularly difficult to manage because of resistance to the actions of growth hormone and glucagon that is characteristic of patients with cirrhosis. One would predict markedly impaired responses of insulin-like growth factor-1, IGFBP-3, and the acid-labile subunit to growth hormone, and a subnormal glycaemic response to glucagon. Thus, in patients with hypoglycaemia due to hepatocellular carcinoma complicating cirrhosis, prednisolone may be tried first in an attempt to lower glucose requirements, though large doses may be needed. Targeted chemotherapy may also be effective, although there may be an initial worsening of hypoglycaemia.

Thyroid hormones

Normal physiology

Thyroid hormones are essential for normal growth and development and play a key role in the regulation of energy metabolism, thermogenesis, and neuromuscular activity. Although thyroxine (T_4) is quantitatively the main hormone secreted by the thyroid, thyroid hormone action is mediated by the binding of 3,3′,5-tri-iodothyronine (T_3) to specific nuclear receptors (Fig. 5) which in turn control the transcription of thyroid-regulated genes [94]. Thyroxine has a much lower affinity for the nuclear T_3 receptors than T_3, and should be regarded as a prohormone that requires conversion to T_3 by 5′ monodeiodination of the outer ring (Fig. 6). T_3 bound to nuclear receptors may come either from the circulation or local tissue 5′ deiodination of T_4. The relative importance of these two sources varies between tissues; skeletal muscle, liver, and kidney rely mainly on circulating T_3, whereas more than 60% of brain and pituitary T_3 is produced locally. Tissue thyroid status thus depends not only on normal secretion of thyroxine but also on normal thyroid hormone metabolism and delivery of T_3 to nuclear T_3 receptors, and on T_3 receptor function.

In normal subjects the thyroid secretes about 110 nmol (86 μg) of T_4 and 5 nmol of T_3 (3 μg) each day. The deiodination of the outer ring of T_4 in extrathyroidal tissues results in the delivery of a further 40 nmol of T_3 into the circulation. About 45 nmol of secreted T_4 undergoes deiodination of the inner tyrosyl ring in extrahepatic tissues to produce the biologically inactive 3,3′,5′-tri-iodothyronine (reverse T_3) (Fig. 6); the remaining 20–25 nmol of T_4 undergoes oxidative deamination or glucuronidation, sulphation, and excretion in bile. A large proportion of unmetabolized T_4 excreted in bile is reabsorbed in the intestine and delivered back to the liver. The liver plays an important role in the transport, storage, and metabolism of

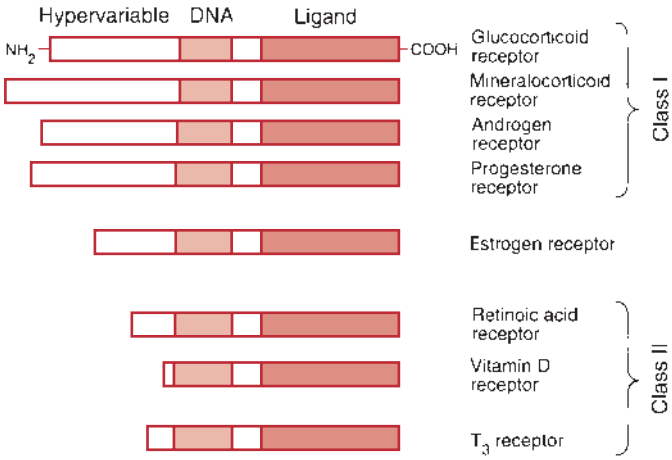

Fig. 5 Superfamily of steroid-thyroid hormone receptors. All contain highly homologous central DNA binding domains, a less well-conserved C-terminal ligand binding domain, and an *N*-terminal hypervariable transactivation domain that enhances the transcriptional regulatory activities of the receptor. Near the C terminus is a highly conserved region important for receptor dimerization. Class I receptors and the estrogen receptor form homodimers. These homodimers with bound ligand bind to palindromic hormone response elements (HREs) in the DNA that contain hexamers separated by three base pairs. Class II receptors bind to direct repeat elements with hexamers separated by 0–5 bases. They may bind as homodimers with or without bound hormone, but can also form heterodimers with other class II receptors (e.g. T_3 and retinoic acid receptor heterodimers). Whereas class II receptors are located in the nucleus in the absence of ligand, class I receptors are cytosolic, and move to the nucleus following hormone binding.

thyroid hormones, and is a major target tissue for their action. In man 10–30% of the total extrathyroidal pool of T_4 is in the liver. It is the main site of extrathyroidal conversion of T_4 to the biologically active T_3 for release into the circulation and delivery to other tissues. It is also the main site of removal of reverse T_3 and of thyroid hormone degradation and excretion. The liver synthesizes thyroxine-binding globulin, thyroxine-binding prealbumin, and albumin, which bind most of the circulating T_4 and T_3 and thereby influence their total plasma concentrations.

Thyroxine in plasma is almost completely (>99.95%), and T_3 only slightly less (>99.5%), bound to thyroxine-binding globulin, thyroxine-binding prealbumin, and albumin. The total concentration of T_4 and T_3 in plasma largely reflects the concentrations and binding affinities of these three proteins. Although thyroxine-binding globulin is the least abundant of these, it has the highest binding affinity and is quantitatively the most important; 70–80% of circulating T_3 and T_4 are bound to thyroxine-binding globulin, 15–20% to thyroxine-binding prealbumin, and 5–10% to albumin (Table 1). The affinities for T_3 are lower than for T_4 so that plasma concentrations of T_3 are much lower than those of T_4; the molar ratio of T_4 to T_3 in plasma is 50 to 100:1, even though delivery of T_4 into the circulation is only two to three times that of T_3. The thyroid binding proteins, by providing a large, rapidly exchangeable pool of circulating T_4, help to ensure that the flux of T_4 across cell membranes exceeds the rate of cellular removal of T_4 and thus promote the equilibration of cytosolic and plasma free T_4 so that the intracellular thyroid hormone concentrations, that determine biological activity, are proportional to the free hormone concentrations. The free hormone concentration within the thyrotrophin and thyroid stimulating hormone secreting cells of the hypothalamus and anterior pituitary, respectively, is a major determininat of thyrotrophin and thyroid stimulating hormone secretion, and hence thyroid hormone production rate.

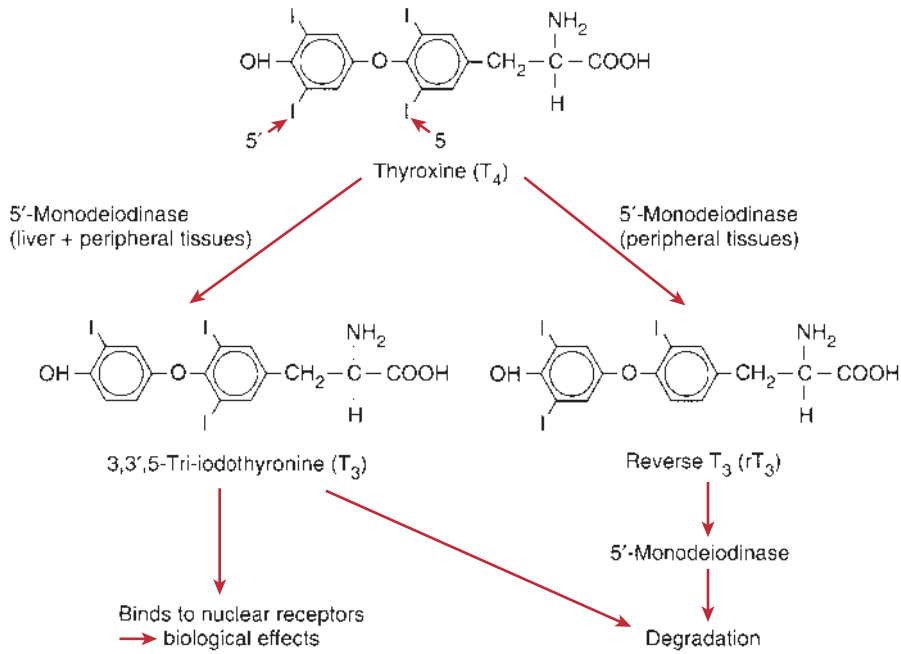

Fig. 6 Thyroid hormone metabolism. T_4 and reverse T_3 (rT_3) share the same hepatic uptake mechanism. In addition 5′ deioidination of T_4 and rT_3 is performed by the same type 1 5′-monodeiodinase. The impaired conversion of T_4 to T_3 and impaired hepatic clearance of rT_3 in liver disease may be due to decreased hepatic uptake and/or decreased activity of the hepatic 5′-monodeiodinase.

Table 1 Thyroid hormone binding proteins in serum.

	Serum concentration (mg/dL)	Affinity constant (per mole)		Serum half-life (days)	T_4-binding capacity (μg/dL)
		T_4	T_3		
Thyroxine-binding globulin (TBG)	1.5	1×10^{10}	5×10^{8}	5	20[a]
Thyroxine-binding prealbumin (TBPA)	25	7×10^{7}	2×10^{7}	2	200
Albumin	4000	7×10^{5}	1×10^{5}	15	2000

From ref. 107.

[a] Normally only about one-third of TBG in plasma contains T_4.

Hepatic uptake of thyroid hormones

Studies employing [^{131}I]T_4 have shown that the liver takes up about 5–10% of T_4 during a single passage. This is much higher than can be accounted for by the amount of free T_4 delivered to the liver, and a large proportion of T_4 bound to albumin is also available for hepatic uptake during its passage through the hepatic sinusoids. Because there is also a high rate of T_4 efflux from hepatocytes into sinusoidal plasma, net hepatic uptake of T_4 is low. This is evident if one considers that the metabolic clearance rate of T_4 in man is only about 0.9 mL/min, with the liver accounting for some 35% of this; assuming an hepatic plasma flow of 650 mL/min one can estimate that net hepatic T_4 uptake is less than 0.05% of that presented to the liver. Influx of thyroid hormones is energy dependent and the hepatocyte intracellular concentration of the free hormone has been found to be somewhat higher than in plasma [95]. An active stereospecific transport mechanism has been suggested; T_4 and reverse T_3 may share the same uptake mechanism, while that for T_3 appears to be different [96]. Efflux of thyroid hormones appears to be passive and determined by the concentration gradient of the free hormone. Some authors have suggested that hepatocyte uptake of T_3 is by passive diffusion rather than by an active transport process.

Thyroid hormones in liver disease

Most patients with liver disease are clinically euthyroid. In general they have normal free T_4 and free T_3 levels, and a normal or slighly elevated thyroid stimulating hormone level [97–100]. However, total circulating thyroid hormone levels may be markedly abnormal and may complicate the biochemical diagnosis of thyroid disease. There are many factors that account for the abnormalities of plasma thyroid hormone levels, including alterations in the plasma levels of thyroid binding proteins, altered binding of T_3 and T_4 to their carrier proteins, diminished hepatic conversion of T_4 to T_3, and impaired hepatic clearance of reverse T_3 [101]. Thyroxine-binding prealbumin levels are reduced in cirrhotics in parallel with the fall in serum albumin levels; levels fall within days in acute liver disease. Thyroxine-binding globulin levels may be increased or decreased, depending on the aetiology and stage of liver disease. The abnormalities in plasma thyroid hormone levels vary between acute and chronic liver disease, and are influenced by the aetiology and severity of liver disease, the presence of intercurrent illness, and dietary intake. Table 2 summarizes the alterations in thyroid function tests that may be found in euthyroid patients with liver disease. Estimation of free T_4 and T_3 concentrations or their respective free indices, together with measurement of thyroid stimulating hormone is essential for accurate interpretation of thyroid function tests in patients with liver disease.

Acute and chronic viral hepatitis

Plasma T_4 levels rise during the course of acute viral hepatitis, returning to normal with recovery. Plasma free T_4 levels may be normal or increased. This increase in total T_4 levels is primarily due to increased plasma levels of thyroxine-binding globulin, which in some studies have been found to correlate with the rise in plasma aspartate aminotransferase levels. In addition there is impaired hepatic conversion of T_4 to T_3. Total T_3 levels are very variable but free T_3 levels may be markedly reduced. Biologically inactive reverse T_3 levels are increased; this is probably due to impaired hepatic clearance of reverse T_3 with an unaltered production rate, as is found in a variety of 'sick' patients without liver disease [102] and in patients with cirrhosis [101]. Serum thyroid stimulating hormone levels are usually normal, but the need for increased T_4 production may be associated with the development of a goitre during the course of acute viral hepatitis; Hegedus [103] found a 50% increase in thyroid gland volume on ultrasound in 23 patients with acute viral hepatitis, which returned to normal 3–6 months after recovery.

In patients with chronic viral hepatitis (chronic active or chronic persistent hepatitis on biopsy), without evidence of decompensation, total T_4 and thyroxine-binding globulin levels are often increased but free T_4, thyroid-stimulating hormone, T_3, and reverse T_3 levels are usually normal. By contrast, in fulminant hepatitis plasma total T_4 and T_3 levels are very low, in association with a marked impairment of thyroxine-binding globulin (and thyroxine-binding prealbumin) synthesis; reverse T_3 levels are increased. An increase in the reverse T_3/T_4 ratio and the T_4/T_3 ratio was associated with a particularly poor prognosis.

Table 2 Alterations of serum thyroid function tests in liver disease and in the 'low T_3' syndrome.

	Total T_4	Free T_4	Total T_3	Free T_3	Total reverse T_3	TSH	TBG	TBPA
Liver disease								
Acute hepatitis	↑	↑	↓	↓	↑	↑	↑	↓
Cirrhosis	↓	↑	↓	↓	↑	↑→	↓	↓
PBC and CAH	↑	→	↑	↓	→	↑	↑	→
HCC	↑	→	↑	→	↑	↑→	↑	↓
Low T_3 syndrome	→	↑→	↓	↓	↑	→	→	↓→

CAH, chronic active hepatitis; HCC, hepatocellular carcinoma; PBC, primary biliary cirrhosis; TBG, thyroxine-binding globulin; TBPA, thyroxine-binding prealbumin; TSH, thyroid-stimulating hormone.

Cirrhosis

Serum total T_4 levels are usually normal but may be slightly increased or decreased in some patients in association with increased or decreased synthesis of thyroxine-binding globulin (Table 2) [97,98]. The daily production rate of T_4 in patients with alcoholic cirrhosis is normal [101] or mildly reduced. Studies employing radiolabelled T_4 showed a reduced rate of hepatic T_4 uptake and a diminished hepatic thyroid hormone pool size in cirrhosis. The most consistent findings are decreased serum total and free T_3 levels [97,98] (reflecting diminished hepatic conversion of T_4 to T_3), and an increased reverse T_3 level due to its impaired hepatic removal [101]. Serum thyroid stimulating hormone levels are either normal or mildly elevated. The thyroid stimulating hormone response to thyrotrophin releasing hormone may be normal or subnormal. Green *et al.* [104], in a study of 23 cirrhotics of varying aetiology, found that many patients had a delayed thyroid stimulating hormone response to thyrotrophin releasing hormone, suggestive of hypothalamic–pituitary dysfunction. Agner and colleagues [105] found that the subnormal thyroid stimulating hormone response to thyrotrophin releasing hormone in alcoholic cirrhotics was corrected by pretreatment with a dopamine-receptor blocking agent such as metoclopramide, implying that it may be due to increased dopaminergic inhibition of thyroid stimulating hormone release by the pituitary.

The abnormalities of plasma T_3 and reverse T_3 in patients with alcoholic cirrhosis correlate with the severity of liver damage. Decompensated cirrhotic patients may have very low total and free T_3 levels [106]. Their total T_4 levels may also be low in association with marked reductions in thyroxine-binding globulin and thyroxine-binding prealbumin levels. Since T_3 and reverse T_3 (rT_3) bind to the same plasma binding proteins, the plasma reverse T_3/T_3 ratio provides a parameter that is largely independent of binding protein levels, and reflects the impairment of hepatic uptake and conversion of T_4 to T_3, and the impaired hepatic removal of reverse T_3 [101]. The reverse T_3/T_3 ratio was found to correlate well with liver function as measured by the aminopyrine breath test. In a large heterogeneous group of patients with endstage liver disease, Van Thiel and colleagues found that those with a high rT_3/T_3 ratio were more likely to die while awaiting liver transplantation.

The plasma thyroid hormone profile in patients with cirrhosis resembles the low T_3 syndrome (Table 2) found in many 'sick' patients and in normal subjects during caloric deprivation [107,108]. It may be regarded as an adaptive hypothyroid state that is important for preserving total body protein stores during fasting and illness. Thus while the low T_3 state in cirrhosis may reflect diminished hepatocellular function, it may also be due to diminished caloric intake and the same factors that determine the low T_3 levels in other sick patients. The low T_3 and increased reverse T_3 levels in cirrhosis may be due to a diminished capacity of the hepatic microsomal 5′-deiodinase (type 1) since the conversion of T_4 to T_3, and the metabolism of reverse T_3, are both mediated by this enzyme. But it could also be due to impaired hepatic uptake of T_4 and reverse T_3 as is seen in the low T_3 syndrome associated with fasting and various non-thyroidal illnesses. Lim *et al.* [109] showed that serum from jaundiced patients inhibited the uptake of T_4 and reverse T_3 by isolated rat hepatocytes, and that bilirubin and non-esterified fatty acids in conjunction with a low serum albumin concentration could account for this inhibitory effect. Bilirubin and non-esterified fatty acids added to normal serum had additive effects on hepatocyte T_4 uptake which correlated with the bilirubin/albumin and non-esterified fatty acid/albumin molar ratios. Comparable non-esterified fatty acid/albumin and bilirubin/albumin molar ratios might be expected in many decompensated cirrhotic patients.

Autoimmune liver disease

There is an increased prevalence of autoimmune thyroid disease in patients with autoimmune chronic active hepatitis or primary biliary cirrhosis. Primary sclerosing cholangitis may be associated with Riedel's thyroiditis. Hypothyroidism develops in 10–25% of patients with primary biliary cirrhosis [110]; it may predate the diagnosis of liver disease or occur during its course. Thyrotoxicosis is rare in association with primary biliary cirrhosis but common in patients with autoimmune chronic active hepatitis. In both primary biliary cirrhosis and chronic active hepatitis, plasma total T_4 levels are often increased due to

increased plasma thyroxine-binding globulin levels [97,99,100]. Plasma total and free T_3 levels are often low due to impaired conversion of T_4 to T_3 [97,99], although Shussler and colleagues [100] found elevated total T_3 levels in chronic active hepatitis. Plasma free T_4 levels are normal. Serum thyroid-stimulating hormone levels and thyroidal radio-iodine uptake tend to be low, and the thyroid-stimulating hormone response to thyrotrophin-releasing hormone may be subnormal, particularly in patients with active liver disease [99]. Because total T_4 levels are often increased in primary biliary cirrhosis and patients with chronic active hepatitis, the diagnosis of hypothyroidism may be missed unless a free T_4 and thyroid stimulating hormone level are measured. Autoimmune thyroid disease in these patients is associated with high titres of thyroid autoantibodies (thyroid microsomal and/or thyroglobulin) and patients with primary biliary cirrhosis will often have dimished lacrimation, suggestive of sicca syndrome.

Hepatocellular carcinoma

Elevated serum total T_4 levels due to increased thyroxine-binding globulin levels may be found in up to 40% of patients with hepatocellular carcinoma. Free T_4 and T_3 levels are generally normal and the patients are clinically euthyroid. The increase in serum thyroxine-binding globulin levels is thought to be due to increased thyroxine-binding globulin production rather than impaired clearance, since elevated thyroxine-binding globulin levels have been found in the tumour tissue and also in areas of the liver free of tumour in these patients, many of whom had an active cirrhosis due to hepatitis B [111]. The circulating thyroxine-binding globulin in patients with hepatocellular carcinoma often has a lower affinity for T_4 which may, in part, be due to alterations in its glycosylation state.

Drugs

Many therapeutic agents commonly used in patients with liver disease interfere with thyroid hormone metabolism and distribution. Frusemide (in large doses) may increase plasma free T_4 levels by displacing T_4 from thyroxine-binding globulin; serum total T_4 and T_3 levels are reduced. Phenytoin may decrease plasma total and free T_4 concentrations into the hypothyroid range in up to 30% of normal subjects; an erroneous diagnosis of hypothyroidism is avoided by measuring plasma thyroid-stimulating hormone levels, which are unaffected by phenytoin. Dopamine or glucocorticoid administration can suppress thyroid-stimulating hormone secretion and lower plasma T_4 and T_3 levels, while sulphonylureas in high dosage may inhibit normal thyroid gland function. Propranolol inhibits the hepatic conversion of T_4 to T_3. Normal subjects receiving more than 200 mg of propranolol often have mild elevation of free T_4 and a corresponding reduction in T_3. Lipid-soluble radiographic iodine-containing contrast media inhibit the peripheral conversion of T_4 to T_3, and displace T_4 from hepatic (and possibly renal) storage sites, resulting in increased plasma T_4 and low T_3 levels together with an increase in plasma reverse T_3. The conversion of T_4 to T_3 within pituitary thyroid stimulating hormone-secreting cells is also inhibited, resulting in an increased secretion of thyroid-stimulating hormone. These hormonal changes are maximal after 4–7 days and persist for up to 3–4 weeks. These hormonal changes do not occur after administration of water-soluble contrast agents.

Thyroid dysfunction (hypo- or hyperthyroidism) may develop in 3–10% of patients treated with α-interferon for chronic viral hepatitis. Hypothyroidism is more common but may be preceded by transient thyrotoxicosis. The risk of thyroid dysfunction increases with duration of treatment but bears little relationship to the dose of interferon used. It is unusual for thyroid disease to present in patients treated with α-interferon for less than 8 weeks. This might explain why thyroid dysfunction is seen more commonly with interferon treatment of chronic hepatitis C than chronic hepatitis B, for which treatment regimens have generally been shorter. α-Interferon-induced thyroid dysfunction is thought to have an autoimmune basis. In the majority of patients there is a thyroiditis; some patients present with features typical of Graves' disease or Hashimoto's. Thyroid autoantibodies are induced in 30–50% of those treated but there is a poor correlation with clinical thyroid dysfunction [112]. Some authors have reported that thyroid dysfunction during interferon treatment is more likely to develop in patients with pre-existing thyroid autoantibodies, particularly thyroid microsomal antibodies [113] but this was not found in other studies [114]. It has been suggested that interferon may induce the expression of MHC class II antigens on thyrocytes with consequent activation of cytotoxic T cells directed against thyroid cells.

Thyroid function and thyroid autoantibodies should be checked prior to initiation of α-interferon treatment, and serum thyroid-stimulating hormone and free T_4 should be monitored during treatment. It should be noted that thyroid autoantibodies and clinical thyroid dysfunction may appear in the months following treatment. The development of thyroid dysfunction during interferon treatment may be associated with a rise in serum transaminases (Chapter 20.9). In many patients thyroid function may return to normal following interferon withdrawal [114]. In view of this potential for recovery, radical therapy such as thyroidectomy or ^{131}I ablation should not be considered as first-line treatment in thyrotoxic patients. Thyroid autoantibodies eventually disappear following withdrawal of α-interferon [112].

Parathyroid hormone and osteocalcin

(see also Chapter 21.9)

Parathyroid hormone

Parathyroid hormone (PTH) is an 84-amino-acid peptide (molecular weight 9300). PTH synthesis and secretion are under feedback control by the plasma (free) calcium ion concentration. Mild hypomagnesemia also stimulates PTH secretion

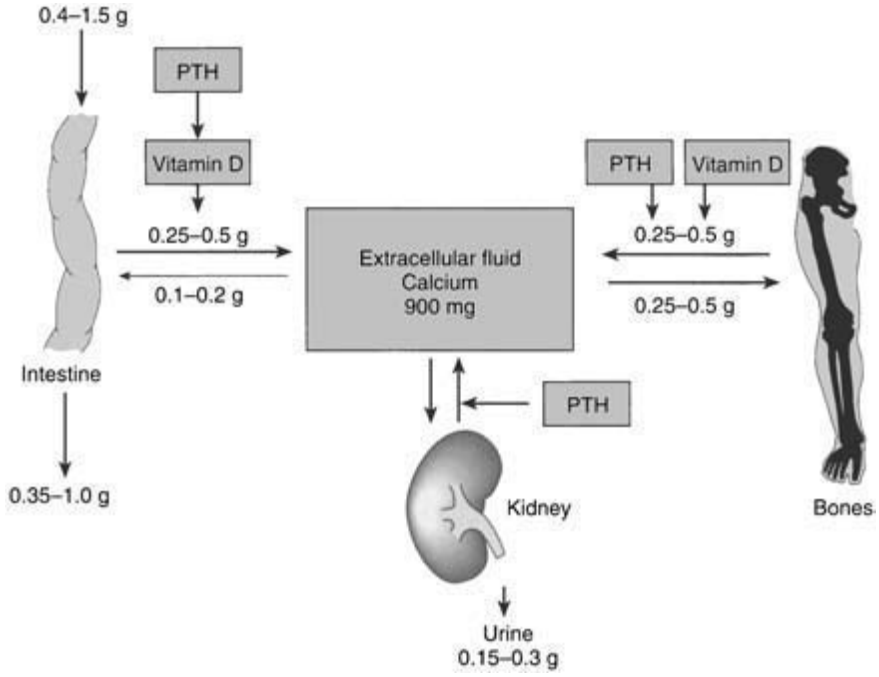

Fig. 7 Sites of action of PTH to maintain extracellular calcium. Figures represent approximate quantities of elemental calcium transferred per 24 h. Approximately 900–1500 g calcium is stored in bone.

but magnesium is much less potent than calcium. Synthesis of PTH is inhibited by high levels of α1,25-dihydroxyvitamin D_3. Biological activity of PTH resides in the N-terminal amino acids 1 to 34. PTH, together with vitamin D (see Chapter 21.9), acts on bone, kidney, and gut to regulate calcium homeostasis and maintain extracellular calcium ion levels (Fig. 7). PTH acts on the kidney to stimulate calcium reabsorption, and on bone to increase bone resorption. Normally, bone resorption and bone formation are tightly coupled. The kidney filters about 5–7 g of calcium each day. Most but not all of this is reabsorbed, and there are additional obligatory losses in sweat and from the gut. PTH acts indirectly to enhance the intestinal absorption of dietary calcium by increasing the renal conversion of 25-hydroxyvitamin D_3 to the active hormone α1,25-dihydroxyvitamin D_3 and thereby offset these obligatory losses. In the presence of inadequate dietary calcium intake or vitamin D deficiency/disturbed metabolism (see Chapter 21.9), the overriding effects of PTH to maintain extracellular calcium ion concentration will lead to negative calcium balance (especially from bone).

Because about 90% of the protein-bound calcium (*c.* 35% of total) is associated with albumin, total plasma calcium concentration may be low in patients with liver disease and hypoalbuminaemia. Ionized calcium levels are usually normal but may be low, especially in patients abusing alcohol. Low ionized calcium levels are also found in patients with fulminant hepatic failure. Most patients with chronic liver disease are in negative calcium balance, and osteoporosis is very common in all forms of chronic liver disease. Osteomalacia is rare even in patients with cholestatic disease (Chapter 21.9). The aetiology of bone disease is complex. Poor nutrition and malabsorption are important; malabsorption of calcium and phosphate are common in both cholestatic and hepatocellular liver disease. The coupling between bone resorption and bone formation is also disturbed.

Relevant factors may include decreased physical activity, effects of alcohol, hypogonadism, diminished hepatic insulin-like growth factor-1 production, and the effects of glucocorticoid treatment in patients with autoimmune liver disease or after liver transplantation. These are discussed in Chapter 21.9. PTH has also been implicated in the increased prevalence of osteoporosis in alcoholic patients. Alcohol ingestion can acutely inhibit the secretion of PTH, resulting in reduced ionized calcium levels, hypercalciuria, and increased urinary magnesium excretion. PTH levels may subsequently increase to supranormal levels with restoration of serum calcium levels. It has been suggested that recurrent cycles of hypoparathyroidism and hyperparathyroidism could contribute to the development of alcohol-related bone disease. Severe hypomagnesaemia, which may occasionally be found in chronic alcoholic patients, can also produce a state of functional hypoparathyroidism and hypocalcaemia.

Circulating PTH includes the intact, biologically active hormone (PTH 1–84) and a family of closely related fragments that include the midportion of PTH and C-terminus of PTH and are biologically inactive in calcium homeostasis. Intact PTH has a very short circulating half-life (2–3 min). The liver and kidney are the main sites of clearance, the liver accounting for about 70% of the total. C-terminal fragments are released back into the circulation. Their circulating half-life is longer (20–30 min) than that of intact PTH. The main C-terminal fragments

disappear from the circulation after hepatectomy. The kidney is the main site of clearance of C-terminal fragments and they accumulate after nephrectomy and in patients with chronic renal failure. Although low levels of amino-terminal fragments may be detected in the liver and kidney, they are not released back into the plasma, and under most circumstances intact PTH(1–84) is the only biologically active form in plasma. The presence of circulating biologically inactive fragments of PTH has complicated the measurement of PTH in plasma. Most 'mid-region' PTH assays predominantly recognize C-terminal fragments. While 'mid-region' PTH assays are reliable for the diagnosis of primary hyperparathyroidism, serum PTH levels obtained using these 'mid-region' assays in patients with altered PTH metabolism (renal failure and liver disease) may be difficult to interpret.

Some patients with hepatic osteomalacia may develop secondary hyperparathyroidism with increased serum PTH levels and other evidence of increased PTH activity (increased urinary cyclic AMP excretion, decreased tubular phosphate reabsorption, bone histological changes of osteitis fibrosa) [115]. Increased serum PTH levels (using a 'mid-region' PTH assay) were also found in patients with primary biliary cirrhosis despite normal or slightly elevated serum calcium and 25-hydroxyvitamin D3 levels [116]. These authors suggested that mild vitamin D deficiency and secondary hyperparathyroidism may be early features. However, because of abnormal handling of PTH in liver disease, caution is needed in the interpretation of serum PTH levels. Kirch *et al.* [117] in a large group of cirrhotic patients of differing aetiologies (70% alcoholic), found increased PTH levels using a 'mid-region' assay but normal levels of the biologically active intact PTH(1–84). Levels of biologically inactive PTH C-terminal fragments were inversely related to serum albumin and prothrombin times but did not correlate with levels of intact PTH(1–84). Increased levels of C-terminal PTH fragments in liver disease have also been reported by others.

Osteocalcin

Osteocalcin (bone Gla-protein) is a 49-amino-acid non-collagenous peptide, synthesized and secreted by bone osteoblasts. The serum concentration is believed to reflect the rate of bone formation and osteoblast activity. The peptide is activated by vitamin K-dependent carboxylation. Decreased serum osteocalcin levels with a relative decrease in the active carboxylated form were found in patients with primary biliary cirrhosis [116]. Decreased osteocalcin levels have also been found in patients with alcoholic liver disease, cholestatic liver disease, haemochromatosis, and chronic active hepatitis; the lowest levels were found in the patients with the poorest liver function. Low osteocalcin levels are consistent with the findings from histological studies of bone showing that decreased bone formation is the main cause of bone disease in cholestatic and hepatocellular liver disease (Chapter 21.9).

Adrenal hormones

Normal physiology

The adrenal cortex secretes glucocorticoids (including cortisol, cortisone, and 11-deoxycorticosterone), mineralocorticoids (mainly aldosterone), and androgens. Mineralocorticoid metabolism is discussed elsewhere. Cortisol synthesis and secretion from the adrenal gland is stimulated by ACTH. Cortisol production is influenced by the diurnal rhythm of ACTH secretion, stress, and negative feedback by cortisol. Plasma ACTH and cortisol levels peak between 07.00 and 08.00 h, assuming a normal sleep time from midnight to 07.30 h. Levels then fall, interrupted by occasional secretory peaks, to reach their nadir around midnight, rising again 2–4 h after the onset of sleep. This rhythm persists despite considerable perturbation of the system, including sleep deprivation. Stress is the most important stimulus to ACTH and cortisol release; it induces the release of corticotrophin-releasing hormone from hypothalamic neurones into the hypophyseal portal system to stimulate pituitary ACTH release. The observation that the ACTH and cortisol response to insulin-induced hypoglycaemia is generally greater than that elicited by a maximally stimulating dose of corticotrophin-releasing hormone, suggests that in addition to corticotrophin-releasing hormone there are other releasing factors. Antidiuretic hormone and catecholamines (but not circulating adrenaline or noradrenaline) potentiate corticotrophin-releasing hormone-induced ACTH release. Serotonin may also increase ACTH release while opioids are inhibitory. An increase in plasma cortisol decreases ACTH release and pro-opiomelanocortin synthesis by inhibiting hypothalamic corticotrophin-releasing hormone synthesis and by decreasing the responsiveness of the pituitary to corticotrophin-releasing hormone.

Plasma transport of glucocorticoids

About 80–85% of plasma cortisol is bound with high affinity to cortisol-binding globulin, and about 10–15% with much lower affinity to albumin. However, with increasing cortisol concentrations, cortisol-binding globulin becomes saturated (above *c.* 690 nmol/L [25 μg/L]) and a larger proportion is then associated with albumin. Since the rate of dissociation from albumin is more rapid than from cortisol-binding globulin, albumin-bound cortisol is more readily available to tissues. Only the free hormone is physiologically active. However, in the various tissues, the binding of cortisol from the free pool to intracellular receptors, steroid-metabolizing enzymes and other proteins shifts the equilibrium towards dissociation of plasma protein–cortisol complexes, and the dissociated hormone can then be taken up. In the liver, which has a relatively long sinusoidal transit time, some cortisol-binding globulin-bound cortisol may be taken up (after its dissociation) in addition to the free and albumin-bound hormone. The physiological mechanisms that control the plasma cortisol level respond to the free rather than total cortisol levels. Thus, with variations in cortisol-binding

globulin levels, the free cortisol concentration is maintained within the normal range even though total cortisol levels change.

Cortisol-binding globulin also binds corticosterone and prednisolone with high affinity but binding of prednisone, cortisone, dexamethasone, and methylprednisolone is negligible. Cortisol-binding globulin has a structure similar to that of several members of the serine protease superfamily that includes α1-proteinase inhibitor, α1-chymotrypsin, and thyroxine-binding globulin. The cortisol-binding globulin–cortisol complex is cleaved by neutrophil-derived elastase at sites of inflammation. Thus, in addition to serving as a reservoir of cortisol, and slowing its clearance, cortisol-binding globulin may target the delivery of glucocorticoids to sites of infection and inflammation.

Cortisol metabolism

In the liver the enzyme 11β-hydroxysteroid dehydrogenase plays a key role in the metabolism of cortisol; it converts cortisol to inactive cortisone. The reverse reaction is catalysed by 11-oxosteroid reductase, and administered cortisone is largely converted to active cortisol in the liver. The liver is the main site of cortisol degradation. Hepatic conjugation of the cortisol and cortisone metabolites with sulphate and glucuronide enhances their water solubility and renal clearance. Normally, roughly equivalent amounts of the conjugated metabolites of cortisol and cortisone are excreted in the urine. Only about 1% of the cortisol produced daily is excreted unchanged in the urine. The plasma concentration of cortisol is about 1000 times that of aldosterone in man; conversion of cortisol to cortisone in the kidney collecting tubules by 11β-hydroxysteroid dehydrogenase is important for preventing cortisol from binding to the mineralocorticoid receptor and causing a state of mineralocorticoid excess [118].

Cortisol in liver disease

Plasma cortisol concentration in the morning after an overnight fast is usually normal in patients with cirrhosis [63,119]. Cirrhotic patients with poor liver function may have low cortisol-binding globulin [120] and albumin levels. This may result in low morning total cortisol levels, but the biologically active free cortisol levels are usually normal [63]; they may even be somewhat higher than in matched normal subjects though still within the normal range [120]. There may be a loss or blunting of the diurnal cortisol rhythm, particularly in decompensated cirrhotics and those with alcoholic liver disease [120] with a tendency to higher total and free cortisol levels in the evening than in matched normal subjects. A blunting of the diurnal cortisol rhythm may also be found in alcoholic patients without significant liver disease. It tends to return to normal with abstinence.

Patients with autoimmune chronic active hepatitis may have features suggestive of Cushing syndrome, including abdominal striae, facial mooning, acne, bruising and hirsuties, prior to treatment with corticosteroids. There is a paucity of data on cortisol metabolism in these patients. Plasma cortisol levels may be elevated but this is due to increased cortisol-binding globulin levels. Elevated cortisol-binding globulin levels are also found in patients with non-autoimmune chronic active hepatitis [121]. Plasma free cortisol and urinary 24-h free cortisol excretion were normal in the patient studied by Orbach *et al.* [121], and were normally suppressed by dexamethasone (0.5 mg 6-hourly for 2 days). However, due to delayed cortisol clearance in patients with raised cortisol-binding globulin levels there may be impaired suppression of the morning plasma cortisol levels with an overnight dexamethasone (1 mg) suppression test.

In keeping with the importance of the liver for cortisol metabolism, clearance of cortisol is reduced in cirrhosis. The clearance of synthetic glucocorticoids, prednisolone, and dexamethasone is also impaired. Renner *et al.* [122] found that in decompensated alcoholic cirrhotic patients prednisolone clearance correlated directly with galactose elimination capacity, and that with declining liver function a larger proportion of plasma prednisolone was non-protein bound. The urinary cortisol metabolite profile is abnormal in cirrhosis. There is an increase in the ratio of cortisol metabolites (tetrahydrocortisol and its isomer 5α-tetrahydrocortisol) to tetrahydrocortisone, irrespective of the aetiology of liver disease, implying a deficiency of 11β-hydroxysteroid dehydrogenase [119]. Other abnormalities include a reduction in the tetrahydrocortisol/5α-tetrahydrocortisol ratio (due to either deficiency of 5α-reductase or stimulation of 5β-reductase activity) and an increased proportion of unconjugated cortisol metabolites [119].

However, the reduction in cortisol metabolism does not result in increased plasma cortisol levels because of the negative feedback effect on ACTH secretion. Patients with non-alcoholic liver disease and most alcoholic cirrhotic patients have an appropriate reduction in 24-h cortisol production rate [119,120]. In non-abstinent patients with alcoholic liver disease 24 h cortisol production rates are very variable; some patients show an appropriate reduction but others may have 24-h cortisol production rates within or above the normal range, despite a marked impairment of cortisol metabolism, resulting in increased plasma cortisol levels and urinary free cortisol excretion [119]. Although, their cortisol level at around 09.00 hours may be within the normal range, it tends to be higher than in patients with non-alcoholic liver disease [119]. It has been suggested that this impairment of cortisol feedback at the hypothalamic pituitary level in some alcoholic patients may explain the development of pseudo-Cushing syndrome [119].

Pseudo-Cushing syndrome

Alcohol-induced 'pseudo-Cushing' is an uncommon syndrome occurring in chronic alcoholic patients. Most patients have abnormal liver function tests. In addition to the clinical features suggestive of Cushing syndrome, such as muscle wasting, thin

skin, bruising, abdominal striae, central obesity, moon face (due to parotid enlargement), hypertension, and glucose intolerance, biochemical findings may be identical to those found in pituitary-dependent Cushing syndrome [123]. Plasma ACTH and free cortisol levels are increased, there is a loss of the normal diurnal cortisol rhythm and impaired suppression of plasma cortisol and ACTH levels with dexamethasone. Urinary excretion of free cortisol and its metabolites is increased, and there is impaired suppression of urinary free cortisol and 17-hydroxycorticosteroids during a 'low dose' dexamethasone (0.5 mg 6-hourly for 2 days) suppression test. With 'high dose' dexamethasone (2.0 mg 6-hourly for 2 days) suppression of urinary free cortisol excretion is comparable to that in Cushing's disease. The abnormalities of cortisol metabolism resolve within days to weeks of cessation of alcohol consumption but may cause diagnostic confusion. A corticotrophin-releasing hormone test performed after administration of dexamethasone (2 mg/day for 2 days) may help in the differentiation of pseudo-Cushing from true Cushing: in all subjects with true Cushing syndrome a serum cortisol level above 38 nmol/L (14 μg/L) was found 15 min after the injection of corticotrophin-releasing hormone [124].

The observation that plasma cortisol levels and 24-hour cortisol production rates tend to be higher in patients with alcoholic cirrhosis than in patients with non-alcoholic chronic liver disease [33] has led to the suggestion that in some alcoholic patients there is a failure to downregulate ACTH secretion in response to increased plasma free cortisol levels arising from the impaired hepatic metabolism of cortisol. It would appear that ethanol is capable of inducing resistance to the suppressive effects of glucocorticoids on ACTH secretion.

Cortisol response to insulin-induced hypoglycaemia in cirrhosis

Decreased plasma ACTH and cortisol responses to insulin-induced hypoglycaemia have been found in patients with endstage non-alcoholic liver disease [63] as well as in some alcoholic patients without significant liver disease. In alcoholics without significant liver disease the cortisol response to ACTH is normal [125] but in endstage liver disease this may also be impaired, implying both a defect at the hypothalamic–pituitary level and an impaired response of the adrenal glands [63]. McDonald *et al.* found that the impairment of the plasma cortisol response to insulin-induced hypoglycaemia and to ACTH was most marked in patients with the poorest liver function as assessed by Child–Pugh score [63]. Studies in bile-duct ligated cholestatic rats also suggested an impaired ACTH/corticosterone response to stress [126]. The significance of these findings in terms of recovery from hypoglycaemia and adequacy of the adrenal response to stress situations such as sepsis and gastrointestinal bleeding is unclear. The possibility of an inadequate cortisol response to stress should be borne in mind when dealing with the critically ill hypotensive patient.

Sex hormones

Normal physiology

Testosterone, the major circulating androgen in men, is synthesized and secreted by the testicular Leydig cells. Normal daily production rate is 4–8 mg. The testes also secrete 5α-dihydrotestosterone (50–100 μg/day), a more potent metabolite of testosterone. However, most of the circulating 5α-dihydrotestosterone is derived from reduction of the A ring of testosterone in peripheral tissues. Only a small proportion of the 5α-dihydrotestosterone produced in peripheral tissues is released into the circulation, and plasma levels do not correlate with peripheral formation. Normal plasma testosterone levels in men range from 3–12 μg/L (10–42 nmol/L), with a mean value of 6–7 μg/L (20–24 nmol/L); plasma levels of 5α-dihydrotestosterone are about one-tenth those of testosterone. Less potent androgens include androstenedione, secreted by the testes and the adrenals, and dehydroepiandrosterone and its sulphate, which are mainly of adrenal origin. These weaker androgens probably require conversion to testosterone for androgenic activity, although less than 10% of plasma testosterone in men is derived from this source.

A small fraction of plasma testosterone (<1%) is converted to estradiol, the main biologically active estrogen. Androstenedione is the main source of the less potent estrone (Fig. 8). Skin, fat, and muscle are the main sites of conversion, which is mediated by a cytochrome P-450-dependent aromatase. Only a fraction of the peripherally produced estrogen enters the circulation. Peripheral conversion accounts for about 70% of the estradiol released into the circulation in men; direct testicular secretion accounts for only 20%. Brain, including the hypothalamus, is also an active site of conversion of testosterone to estradiol which is involved in the regulation of gonadotrophin secretion. Normal estradiol and estrone levels in men are below 50 ng/L (184 pmol/L) and 60 ng/L (222 pmol/L) respectively.

In women, production of estradiol varies during the menstrual cycle (250–500 μg/24 h): plasma levels are lower in the early follicular phase (60–100 ng/L (0.22–0.37 nmol/L)) than during the luteal phase (200–700 ng/L (0.73–2.57 nmol/L)). Estrone is produced mainly by peripheral conversion of androstenedione. In premenopausal women the ovaries and adrenals each contribute about 50% of total daily androstenedione production (3 mg/day); after the menopause ovarian production declines markedly and the adrenals are the main source. In normal lean premenopausal women about 1–1.5% of androstenedione is converted to estrone; after the menopause this increases to 2–3% so that total estrone production (40 μg/day) remains unchanged. Plasma testosterone levels in women (*c.* 0.35 μg/L (1.21 nmol/L)) are about 5% those found in men. Nearly half of this comes from the ovaries. The remainder is derived from conversion of androstenedione (*c.* one-third), and to a lesser extent dehydroepiandrosterone, of adrenal origin to testosterone in fat, muscle, and possibly liver.

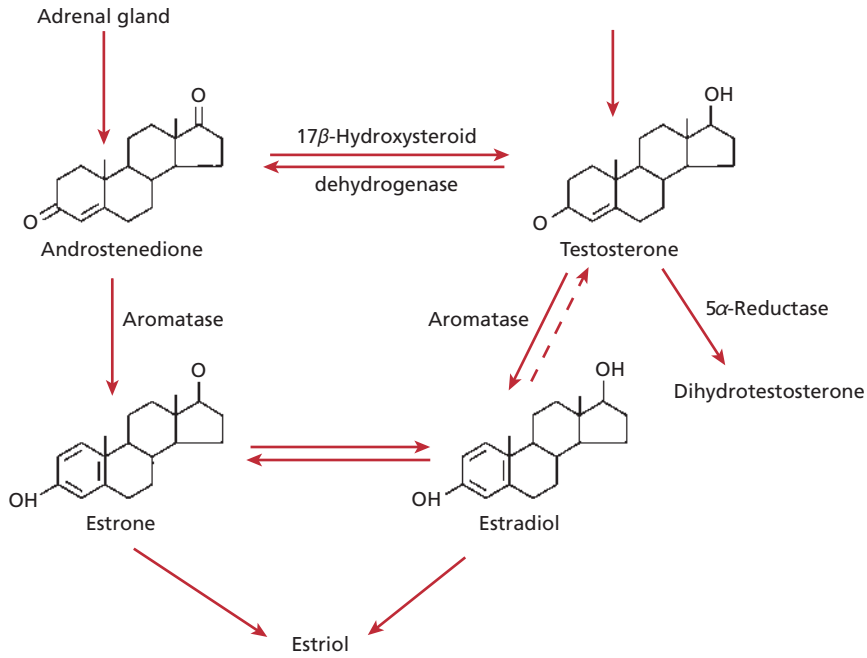

Fig. 8 Peripheral pathway for conversion of androgens to estrogens. In males most blood estradiol originates from testosterone. In liver disease activity of the cytochrome P-450-dependent aromatase is increased, resulting in increased estrone and estriol formation. In men with cirrhosis as much as 15% of circulating testosterone may be derived from androstenedione compared to 1% in normal men.

Testosterone production is stimulated by luteinizing hormone (LH), which regulates the enzymatic steps leading to production of testosterone from its precursor pregnenolone. LH secretion in turn is inhibited by testosterone in a negative feedback fashion, at both the hypothalamic and pituitary levels [127]. Spermatogenesis is primarily controlled by follicle stimulating hormone (FSH), which acts on Sertoli cells to modulate the production of a variety of protein factors that regulate and coordinate sperm development; the hormone inhibin produced by Sertoli cells exerts negative feedback control of FSH secretion. LH acts indirectly by stimulating testosterone secretion; high local concentrations of testosterone (50–100 μg/100 g) are necessary for normal spermatogenesis. Sertoli cell secretion of androgen-binding protein (which has the same amino acid sequence as sex hormone-binding globulin but differs in its carbohydrate content) into the lumen of the seminiferous tubules helps to ensure these high local concentrations of testosterone. Androgen deficiency due to primary testicular disease is associated with elevated plasma LH levels. If spermatogenesis is decreased, plasma FSH levels are also raised. In hypothalamic–pituitary disease, plasma gonadotrophin levels are low.

The liver is the main site of degradation of androgens and estrogens. Testosterone is degraded to water-soluble 17-ketosteroids such as androsterone and etiocholanolone. Estrogens are metabolized largely by hydroxylation and oxidation reactions. The 17-ketosteroids and estrogen metabolites are then conjugated with sulphate or glucuronide and excreted in the urine. The bulk (*c.* 70%) of the urinary 17-ketosteroids are derived from the adrenal cortex and not from the metabolism of testosterone.

Sex steroid transport in blood

Circulating testosterone and 5α-dihydrotestosterone are mainly bound to sex hormone-binding globulin (high-affinity, low-capacity binding) and albumin (low-affinity, high-capacity binding) with only 1–4% in the free form. Sex hormone-binding globulin is a glycoprotein synthesized by the liver. In addition to testosterone, it binds estradiol with a much lower affinity. Androstenedione, dehydroepiandrosterone, and estrone, which lack the 17β-hydroxy group, do not bind to sex hormone-binding globulin. Binding of androgens to sex hormone-binding globulin slows their plasma clearance. Thus, the metabolic clearance rate of testosterone (0.6 L/min in men and 0.3 L/min in women) is lower than that of androstenedione and dehydroepiandrosterone, which circulate free or bound to albumin and have high hepatic extraction ratios and clearance rates (*c.* 1.0 L/min) that resemble splanchnic plasma flow. Unbound testosterone and estradiol have generally been considered to be the biologically active fraction. However, because of the low-affinity binding to albumin, the albumin-bound fraction of these hormones is readily available for tissue extraction; the sum of free plus albumin-bound testosterone provides a good estimate of bioactive androgen.

Hepatic sex hormone-binding globulin production is increased by estrogens and decreased by administration of androgen. Insulin and insulin-like growth factor-1 may, however, be the major regulators [80]. Thyroid hormone also stimulates sex hormone-binding globulin synthesis, and levels are low in hypothyroidism. Sex hormone-binding globulin levels have a major influence on plasma free testosterone levels. An increase in sex hormone-binding globulin in response to estrogen lowers the free testosterone level; conversely a rise in

testosterone lowers sex hormone-binding globulin levels and increases the unbound testosterone fraction. Changes in sex hormone-binding globulin levels have much less effect on measured estrogen levels because the affinity of sex hormone-binding globulin for estradiol is much lower than for testosterone, and in men circulating estradiol levels are an order of magnitude below the K_a of sex hormone-binding globulin for estradiol.

In some androgen-responsive target tissues testosterone is converted by steroid 5α-reductase to 5α-dihydrotestosterone, which is the main cellular mediator of androgen action. In other tissues testosterone itself is active. Thus, testosterone itself mediates the anabolic actions on muscle and stimulates the female pattern of axillary and pubic hair growth in both sexes but 5α-dihydrotestosterone is essential for the development of external male genitalia and the development of the full male pattern of facial and body hair growth and androgenic alopecia. The intracellular androgen receptor [128] can bind testosterone or 5α-dihydrotestosterone, but its affinity for 5α-dihydrotestosterone is higher. Binding of androgen to the receptor causes the receptor to be released from an inactive complex of proteins. The active receptor with its bound ligand then binds to specific chromosomal DNA sequences ('androgen response element') to regulate gene expression (Fig. 5). Specificity of the response probably depends on the formation of a complex with a number of transcriptional factors as well as binding to the androgen response element. In blood stem cells there is a specific 5β-dihydrotestosterone receptor, and enhancement of red cell production in response to erythropoietin by testosterone requires its conversion to 5β-dihydrotestosterone [129].

Sexual dysfunction in men with liver disease

Cirrhosis is associated with hypogonadism and signs of feminization. Hypogonadism is associated with testicular atrophy, impotence, and loss of libido. Signs of feminization include loss of body hair, a female distribution of body hair, a redistribution of body fat, and gynaecomastia. Vascular spider naevi and palmar erythema are also regarded by many as signs of feminization, as they occur with increased frequency during normal pregnancy, and may be found in men with prostatic carcinoma treated with high doses of estrogens. Benign prostatic hypertrophy occurs less frequently in cirrhosis. Most published figures (see below) concerning the prevalence of these complications are based on studies of selected patients in hospital, and of patients with long-standing disease. The abnormalities are more commonly found in patients with de-compensated liver disease, and in patients with alcoholic cirrhosis in whom they tend to be more pronounced than in men with cirrhosis due to other causes [130,131]. In patients with well-compensated, non-alcoholic liver disease gynaecomastia and sexual dysfunction are uncommon. In haemachromatosis, however, gonadal failure may precede the development of cirrhosis (see later).

Hypogonadism and associated hormonal changes

Hyogonadism has been reported in as many as 70–80% of men with cirrhosis [131–135]; clinical and histological evidence of testicular atrophy is found in over 50% of patients [130]. The gonadal atrophy in alcoholic cirrhotic men reflects a reduction in mass of the seminiferous tubules which account for 90–95% of the testicular volume, and there are gross abnormalities of seminal fluid composition. Leydig cell failure is manifest by a marked reduction in testosterone production, and as much as 15% of circulating testosterone in cirrhotic men may be derived from the peripheral conversion of androstenedione produced by the adrenals, compared to 1% in normal men. Total plasma testosterone levels are often decreased in cirrhotic patients [130,131,133–136], falling with increasing severity of liver disease as assessed by Child-Pugh score [134,136]. Testosterone responses to small doses of human chorionic gonadotrophin, which has predominant LH activity, are diminished [130].

While liver disease *per se* is associated with hypogonadism [131,134–136], most studies have been conducted in alcoholic cirrhotic men, many of whom will have continued to consume alcohol up to the time of investigation. Alcohol itself affects gonadal and hypothalamic–pituitary function (Chapter 12.4). Ethanol inhibits testosterone production by blocking 17α-reductase and 17,20-desmolase activities which are key enzymes in the biosynthetic pathway. Excessive alcohol intake in normal volunteers inhibits testosterone production, resulting in decreased testosterone levels with a secondary rise in LH; after 1–2 weeks of heavy alcohol intake, testosterone levels remain low and LH levels also become subnormal. Ethanol also inhibits spermatogenesis; it may compete with retinol for an alcohol dehydrogenase enzyme in the testes which is important for converting retinol to retinal (the aldehyde form of vitamin A) that is essential for normal spermatogenesis. Alcohol abuse, even in the absence of liver disease, causes hypogonadism and a variety of sexual disorders. Testosterone levels tend to be lower in alcoholic than in non-alcoholic cirrhotic men matched for severity of liver disease [131,137], consistent with a direct toxic effect of alcohol on the testes. Thus, in alcoholic cirrhosis the effects of alcohol and cirrhosis may be additive, and alcohol is undoubtedly a factor in the high prevalence rates of hypogonadism found in alcoholic cirrhotics [132,138]; sexual function may improve with abstinence [132]. Van Thiel has suggested a much lower prevalence of gonadal dysfunction in men with well-compensated non-alcoholic liver cirrhosis. In endstage liver disease, some [135] but not all studies [137] have suggested that the prevalence of hypogonadism may be equally high in alcoholic and non-alcoholic cirrhotic patients. In patients with endstage liver disease the relative importance of liver disease *per se* and such factors as nutritional state, weight loss, and intercurrent illness, all of which can produce a transient secondary hypogonadism and biochemical androgen deficiency [138], is unclear.

Sex hormone-binding globulin levels are increased in men with cirrhosis [134]. Possible explanations for increased hepatic

Table 3 Sex steroid hormone changes in cirrhosis.

Hormone	Men	Premenopausal women	Postmenopausal women	References	
				Men	Women
Testerone	↓	→↓	→	[140,184–192]	[148,200,201]
5α-Dihydrotestosterone	↓	→	↓	[191]	[149,200,201]
DHEA	↓	↓	↓	[184,193]	
DHEA-sulphate	↓	↓	↓	[140,184,193]	[200–202]
Androstenedione	↑	→↑	→↑↓	[140,184,192]	[149,200–202]
Estrone	↑	↑	↑	[142,185,192]	[148,149,200–202]
Estradiol	→↑	↓	→	[142,184,190,192]	[148,201]
Estriol	↑	↑	↑	[142]	[148]
Progesterone	↑	↓	↓	[194]	[148]
Luteinizing hormone	↑→↓	→↓	→↓	[140,185–188,190]	[200,203]
FSH	↑→↓	→↓	→↓	[185–188,190]	[200,203]
Prolactin	→↑	→↑	→↑	[187,190,195,196]	[200,203]
SHBG	↑	→↑	↑→	[186,197–199]	[149,201–203]

DHEA, dehydroepiandrosterone; FSH, follicle-stimulating hormone; SHBG, sex hormone-binding globulin.

production of sex hormone-binding globulin in liver disease are the low levels of insulin-like growth factor-1 and possibly hepatic underinsulinization due to portosystemic shunting and capillarization of hepatic sinusoids. Abnormal glycosylation of sex hormone-binding globulin could prolong its circulating half-life. Because of the increased sex hormone-binding globulin levels in cirrhotic men, free testosterone levels are decreased more consistently than total testosterone levels. In patients with very poor liver function and encephalopathy, hepatic synthesis of sex hormone-binding globulin may be impaired resulting in very low total testosterone levels.

There is no correlation between impotence and the low plasma testosterone levels in patients with liver disease and treatment with testosterone has generally been ineffective [132]. Other hormonal changes associated with cirrhosis include increased plasma levels of androstenedione, decreased dehydroepiandrosterone and dehydroepiandrosterone sulphate, and increased levels of estrone (Table 3). Plasma estradiol concentrations are usually normal in well-compensated disease [130,131], but may increase with increasing severity of liver disease, particularly in alcoholic cirrhotics. The increase in estradiol levels is due to increased peripheral conversion of testosterone to estradiol, and not to a reduction in estradiol metabolism; this is normal or even increased [130]. Conversion of androstenedione to estrone is increased in cirrhosis. Adipose tissue is an important site of aromatization of androstenedione to estrone. This conversion may be enhanced by increased delivery of androstenedione to adipose tissue as a result of decreased hepatic clearance of androstenedione in patients with significant portosystemic shunting. Guechot *et al.* [139] found a strong correlation between the hepatic extraction ratios of androstenedione and indocyanine green in patients with alcoholic cirrhosis. However, Wang and colleagues found no correlation between changes in sex hormone levels and the severity of portal hypertension in patients with cirrhosis due to hepatitis B virus infection [133].

Increased conversion of androstenedione to estrone and of testosterone to estradiol in cirrhosis could also be due to altered hepatic steroid metabolism. The hepatic expression of certain forms of cytochrome P-450 concerned with metabolism of sex steroids shows marked gender differences. Portal vein ligation of male rats resulted in a marked reduction of male-specific cytochrome P-450 isoforms, responsible for 16α- and 6β-hydroxylation of androstenedione, associated with a corresponding decrease in metabolism of androstenedione via these pathways; the conversion of androstenedione to estradiol increased seven- to 15-fold. The sexually dimorphic pattern of hepatic steroid-metabolizing enzymes is in part determined by the pattern of hypothalamic–pituitary hormone release. Growth hormone is known to be important; feminization of hepatic steroid metabolism occurs in rats treated with growth hormone. Whether the elevated growth hormone levels in many patients with cirrhosis influence hepatic sex steroid metabolism is unknown.

Plasma LH and FSH levels are usually normal or increased in patients with well-compensated cirrhosis [133,135] but are often decreased in patients with endstage liver disease (Pugh's grades B and C) [133–136]. Reduced gonadotrophin production may be a key to the development of overt hypogonadism. Bannister *et al.* [140], in a small group of alcoholic cirrhotic men, found a decreased amplitude and frequency of LH pulses, despite normal basal LH levels, in those with overt hypogonadism and testicular atrophy, but normal LH pulsatility and raised basal LH levels in those with subclinical primary testicular

failure. Primary testicular failure is normally associated with elevated LH levels. Thus, normal or low plasma LH concentrations in the presence of low free testosterone levels suggest a hypothalamic–pituitary defect. The response of LH and FSH to gonadotrophin releasing hormone is variable [130,134,135]. Peak responses are usually normal or increased but the incremental responses are often diminished in those with elevated basal LH and FSH levels [135]; the peak LH and FSH response may be delayed in patients with endstage liver disease, irrespective of aetiology [134]. Decreased plasma testosterone and LH concentrations with preserved pituitary gonadotrophin responses to gonadotrophin releasing hormone strongly suggest that diminished LH production in 'sick' cirrhotics and those with overt hypogonadism is due to a hypothalamic defect. Decreased LH and FSH responses to clomiphene, particularly in alcoholic cirrhotic patients is in keeping with a hypothalamic defect. Hypothalamic dysfunction would explain the diminished pulsatile LH secretion [140], as this depends on episodic release of gonadotrophin-releasing hormone from hypothalamic neurones into the pituitary portal blood.

Testicular endocrine dysfunction is improved by successful liver transplantation in alcoholic and non-alcoholic cirrhotic patients [134,135,141]. Sexual function may also improve in some patients [137]. Handelsman *et al.* [134] reported a progressive improvement but not normalization, in sex hormone levels at 6 and 12 months after successful liver transplanation for endstage non-alcoholic liver disease. At 12 months plasma total and free testosterone levels had increased to 71 and 66% of normal, sex hormone-binding globulin levels had decreased to normal and (despite the increase in testosterone levels) basal LH and FSH levels increased to levels that were approximately twice those found in normal men. Plasma estrone and androstenedione levels also fall after transplantation [141]. Whether the residual abnormalities reflect an irreversible component or are due to the effects of treatment with glucocorticoids, cyclosporin, or other drugs is unclear.

Feminization

Clinical features of feminization, including gynaecomastia, loss of body hair, and a redistribution of body fat occur in 20–50% of patients with cirrhosis. Gynaecomastia is usually bilateral but may be unilateral. Vascular spider naevi and palmar erythema are often regarded as signs of feminization but their appearance in women with alcoholic hepatitis or cirrhosis who have evidence of estrogen deficiency casts some doubt on the role of estrogens in their pathogenesis. The plasma levels of a number of proteins whose synthesis is enhanced by estrogens, including sex hormone-binding globulin, prolactin, growth hormone, and thyroxine-binding globulin are increased in these patients. By contrast with hypogonadism, feminization usually occurs only in the presence of cirrhosis, although gynaecomastia can appear in acute alcoholic hepatitis and may be found in young men with chronic active hepatitits without cirrhosis. Feminization may be more common in alcoholic cirrhosis than in other forms of liver disease [130] but not all studies have found this. It often occurs as a side-effect of spironolactone treatment (see below).

The biochemical basis for feminization remains unclear. Serum estradiol levels are normal in most cirrhotic men with gynaecomastia and other feminizing features. Some studies have suggested a relationship with plasma estrone levels [142] which are frequently raised in cirrhotic patients. However, because the feminizing potency of estrone (and of estriol which is also raised) is much less than that of estradiol the importance of increased plasma estrone and estriol levels remain unclear. Other metabolites of estradiol such as 16-hydroxyestrone are increased in cirrhosis and may be biologically active. It has been suggested that the relative concentrations of free testosterone and estradiol levels may be more important than estradiol levels *per se.* Because of the increased sex hormone-binding globulin levels in cirrhosis, and the greater affinity of sex hormone-binding globulin for testosterone than for estradiol, the free testosterone:free estradiol ratio may be markedly decreased in patients with cirrhosis, falling with increasing severity of liver disease. The presence of abnormal isoforms of sex hormone-binding globulin in cirrhosis may result in increased tissue availability of estradiol. Increased local estrogen synthesis in the breast may occur from androgens (notably androstenedione) that have escaped hepatic metabolism as a result of portosystemic shunting.

Altered end-organ sensitivity to sex steroids could also be a factor leading to feminization. Increased hepatic expression of estrogen receptors has been suggested as a potential mechanism leading to feminization of hepatic metabolism. Alcohol increases hepatic estrogen receptor content [143]. However, findings in patients with cirrhosis have been conflicting. Increased hepatic estrogen receptor concentrations in alcoholic cirrhotics, particularly those with superimposed alcoholic hepatitis, were found by Villa *et al.* [144], while others found decreased levels. Hepatic estrogen receptor concentrations are normal in patients with non-alcoholic liver disease [144]. Low hepatic androgen receptor levels were found in a small group of patients with cirrhosis of varying aetiology [145]. The estrogen/androgen receptor status of other target organs in men with hypogonadism/feminization is unknown.

Drugs

Spironolactone is a common cause of gynaecomastia and impotence in patients with and without liver disease. Spironolactone and its metabolites act partly by reducing testosterone synthesis by inhibiting the cytochrome P-450-dependent 17-hydroxylase complex, and partly by binding competitively to tissue androgen receptors. Spironolactone treatment is associated with a fall in serum testosterone levels and a rise in estradiol levels. Except for the unchanged sex hormone-binding globulin levels, these hormonal changes are similar to those found in cirrhotic patients not treated with spironolactone. Thus, spironolactone may contribute to hypogonadism and feminization in some

patients. Indeed, spironolactone has been used successfully in dosages of 100–200 mg daily for the treatment of idiopathic hirsutism [146]. Potassium canrenoate, which is metabolized to canrenone (a metabolite of spironolactone), may be as good as spironolactone in the management of ascites, but has less anti-androgenic activity and may be less likely to cause gynaecomastia. Many other drugs commonly used in patients with liver disease may contribute to hypogonadism, including cimetidine (androgen receptor antagonist), propranolol, thiazide diuretics, glucocorticoids, sulphasalazine, and drugs that stimulate prolactin secretion.

Ovarian dysfunction in women

Ovarian endocrine failure in alcoholic cirrhotic women is manifested by loss of libido, irregular menses, loss of secondary sexual characteristics such as breast and pelvic fat, and ovulatory failure. A paucity of developing follicles, and few or no corpora lutea, was found at autopsy in women aged 20–40 dying of alcoholic cirrhosis. Menopause often occurs at an earlier age in cirrhotic and non-cirrhotic female alcoholic patients [147]. The pathways for steroid synthesis in the testes and ovaries are similar and it is likely that hypogonadism in alcoholic cirrhotic patients is in part due to direct toxic effects of alcohol on ovarian function. However, as in men, liver disease *per se* is important. Valimaki *et al.* [148] found no difference in ovarian size or follicular development by ultrasonography in alcoholic women without significant liver disease admitted for detoxification, compared to a matched control group. Amenorrhoea and oligomenorrhoea are common in women with endstage non-alcoholic liver disease. Amenorrhoea tends to be more common in patients with cirrhosis and hepatocellular failure than in patients with predominantly biliary disease and cholestasis. Indeed, patients with primary biliary cirrhosis have a high frequency of menorrhagia and age at menopause appears similar to that of control subjects [149]. Amenorrhoea is also usual in patients presenting with autoimmune chronic active hepatitis (with or without cirrhosis) but regular menses resume when the liver disease is controlled by corticosteroids, and then they have little trouble conceiving, although there may be a higher fetal wastage. Recovery of menstruation and fertility can be expected in the vast majority of premenopausal women with amenorrhoea associated with endstage liver disease after successful liver transplantation [150]. The need for estrogen replacement therapy should be considered in those failing to menstruate within 1 year of transplantation.

Hormone levels (Table 3)

Sex hormone changes in women with chronic liver disease have been less well characterized than in men. Premenopausal alcoholic cirrhotic women with secondary amenorrhoea are estrogen deficient. Their urinary total estrogen excretion is subnormal and similar to that found in normal postmenopausal women; estriol makes a bigger contribution to their total estrogen excretion compared to normal premenopausal women [151]. Plasma estradiol and progesterone levels are reduced, while plasma estrone levels are increased [151]. Plasma testosterone and androstenedione levels are usually normal.

Postmenopausal women with either alcoholic or non-alcoholic cirrhosis have increased estradiol and estrone levels by comparison with normal postmenopausal women. Their testosterone levels are generally normal and most studies have found low androstenedione, dehydroepiandrosterone and dehydroepiandrosterone sulphate levels [147,152,153], though increased androstenedione levels have also been found. Grun *et al.* [154] found that androstenedione levels increased in decompensated cirrhotic patients. As in cirrhotic men, sex hormone-binding globulin levels are often increased in alcoholic and non-alcoholic cirrhotic women [151], and may rise with abstinence in alcoholic cirrhotic patients [155]. Plasma prolactin levels are generally normal in both pre- and postmenopausal women with chronic liver disease (see below).

Hypothalamic pituitary dysfunction

Despite the low plasma estradiol levels, LH and FSH levels are not increased in cirrhotic women; inappropriately low LH and FSH levels are found in amenorrhoeic cirrhotic women (pre- or postmenopausal) irrespective of the aetiology of liver disease [156]. In response to intravenous gonadotrophin-releasing hormone they have a normal increase in LH and FSH levels, suggesting that the defect is at the level of the hypothalamus rather than the pituitary [151,156]. In sick patients the abnormalities of gonadotrophin and sex hormone levels may be due in part to the effects of systemic illness or malnutrition. However, liver disease *per se*, and possibly portosystemic shunting, are likely to be important since the abnormalities of plasma gonadotrophin levels may be found in cirrhotic patients in the absence of weight loss or malnutrition.

Prolactin

Increased secretion of prolactin is an important cause of hypogonadism and impotence in men, and of amenorrhoea in women. Prolactin is under inhibitory hypothalamic dopaminergic regulation. Prolactin inhibits hypothalamic gonadotrophin-releasing hormone release and directly inhibits ovarian progesterone and estradiol secretion. Thus, hyperprolactinaemia inhibits sex steroid synthesis in both sexes. In men, prolactin inhibits testosterone production and also decreases the activity of 5α-reductase in peripheral tissues, resulting in impaired conversion of testosterone to the more potent androgen, 5α-dihydrotestosterone. Prolactin levels are normal in most patients with liver disease [147,151,155] although there is a very wide range, with about 8% of male and 17% of female patients having prolactin levels above the reference range [157]. Prolactin levels are unrelated to the aetiology of liver disease [135,155,156]. In some [156] but not all [155] studies, hyperprolactinaemia was more commonly found in patients with established cirrhosis than in patients with

non-cirrhotic liver disease, and in cirrhotic men prolactin levels correlated with the severity of liver disease as assessed by Pugh's grading [135]. Prolactin responses to intravenous thyrotrophin-releasing hormone have been found to be normal [153] or increased. Basal and stimulated prolactin levels may be higher in cirrhotics with encephalopathy than those without encephalopathy.

The mechanism of hyperprolactinaemia in liver disease is unclear. Since prolactin secretion is stimulated by an increase in circulating estrogen levels, the increased plasma estrone levels in cirrhotic men (particularly those in Pugh's grades B and C) might be expected to play a role. However, prolactin levels do not correlate with plasma estrogen levels. Brain delivery of estradiol may be enhanced in cirrhosis despite a reduction in the free plus albumin-bound fraction of estradiol. The presence of abnormal isoforms of sex hormone-binding globulin in cirrhosis may result in increased availability of sex hormone-binding globulin-bound estradiol.

The clinical manifestations of hypogonadism or the presence of gynaecomastia do not correlate with plasma prolactin levels [155]. Thus, hyperprolactinaemia cannot be invoked to explain the high prevalence of either hypogonadism or feminization in patients with liver disease.

Endocrine dysfunction in haemochromatosis

Endocrine dysfunction is common in patients with haemochromatosis [155–161].

Diabetes

The reported prevalence of diabetes in haemochromatosis is very variable. The differences partly reflect varying definitions of diabetes as well as the severity of haemochromatosis. Many patients previously classified as having diabetes would now be regarded as having impaired glucose tolerance [7]. Earlier diagnosis of patients with haemochromatosis may also account for a lower prevalence of diabetes in recent studies compared with earlier reports [162]. Niederau *et al.* [157] in a study of 163 patients with haemochromatosis diagnosed between 1959 and 1983 found diabetes at presentation in 6% of 45 precirrhotic patients but in 71% of 112 patients with cirrhosis. Adams *et al.* [163] found that 23% of haemochromatotic patients had diabetes at the time of presentation.

The aetiology of diabetes in haemochromatosis is multifactorial. Most patients with haemochromatosis are insulin-resistant. This may be due to effects of cirrhosis (see above) or to iron overload; insulin resistance is an early finding in patients with transfusional iron overload. Patients with overt diabetes have impaired insulin secretion. This is probably due to the heavy iron deposition in the islet β-cells and the exocrine pancreas. The morphology of the islets tends to be well preserved and quite different from that in either type 1 or type 2 diabetes mellitus. Diabetes appears to be more common in haemochromatotic patients with a first-degree relative with diabetes [164], suggesting that a genetic predisposition to diabetes may be important in some patients.

The presence of diabetes in haemochromatotic patients is associated with a worse prognosis [157,159,162]. Patients are at risk of long-term microvascular (retinopathy, neuropathy, nephropathy) and macrovascular complications of diabetes. Good diabetic control is important to decrease the risk of these and to slow their progression [165]. Diabetic haemochromatotic patients are more likely to require insulin for control of their diabetes if they have cirrhosis: in the study of Niederau *et al.* [157] 62% of those with cirrhosis were on insulin at presentation, compared to 40% of those without cirrhosis. Depletion of body iron stores does not eliminate the need for insulin, but insulin requirements may fall; diabetic control may also be improved in about half of the patients treated with sulphonylureas or diet. Some patients on oral hypoglycaemic agents may be able to stop these, though diabetes may progress with longer-term follow-up as it does in patients with non-insulin-dependent diabetes mellitus. Over a 2-year follow-up period, about 10% of those with normal or impaired glucose tolerance at presentation show a deterioration of glucose tolerance despite iron depletion. The principles of management are similar to those outlined earlier. Some insulin-treated patients may have diabetes that is difficult to control. Defective glucose counter-regulation has been suggested. Some patients may have deficient growth hormone responses [161]. However, iron deposits are not found in the glucagon secreting islet α-cells and plasma glucagon levels are usually increased.

Hypogonadism and gynaecomastia

Decreased gonadal function is an early and common manifestation in men with haemochromatosis [157–161]. It may antedate the presence of liver disease and often goes unrecognized as a manifestation of haemochromatosis [157,160]. Hypogonadism is less common in women, presumably owing to the protective effects of iron loss from menstruation. In men the clinical picture includes impotence, decreased libido, testicular atrophy, loss of body hair, and decreased frequency of shaving. These manifestations do not correlate with the severity of liver disease. Gynaecomastia is uncommon in the early stages but may be present in cirrhotic patients with portal hypertension, and may develop during testosterone replacement therapy (see below). In most patients hypogonadism is due to gonadotrophin deficiency. Plasma LH, FSH, and testosterone levels are low, and the LH response to gonadotrophin-releasing hormone is impaired. There may be a normal increase in plasma testosterone levels in response to human chorionic gonadotrophin. Plasma estrogens are usually normal. Sex hormone-binding globulin levels may be normal or increased. Haemochromatotic patients with established cirrhosis have higher sex hormone-binding globulin levels so that their free testosterone levels may be very low [160,161]. Although primary testicular involvement may also be present (presumably secondary to cirrhosis), the

pituitary defect predominates. Rarely, patients may present with primary testicular failure, in which case low testosterone and high LH levels may be found.

The impaired gonadotrophin production appears to be due to iron deposition in the pituitary gonadotrophs. Pituitary iron deposition can be demonstrated by MRI scan [166]. By contrast, little iron is found in the testes; when present it is in the vessel walls rather than in the germinal epithelium. Impotence is more common, and more severe, in diabetic haemochromatotics than those without diabetes [160]. This may be due to associated diabetic autonomic neuropathy or vascular disease. Testicular biopsy in hypogonadal patients shows atrophy of the germinal epithelium with fewer or absent Leydig cells. The testicular changes are not necessarily irreversible.

In most patients hypogonadism is not influenced by depletion of body iron stores by venesection [157,159–161]. However, in the occasional patient, venesection may lead to an increase in plasma gonadotrophin and testosterone levels with loss of hypogonadal symptoms [167]. Recovery of spermatogenesis in a patient with documented azoospermia has also been reported. Age may be an important determinant of the potential for recovery; all the reports of recovery of sexual function with iron depletion have been in patients under 45 years at presentation.

Management

In the absence of diabetes, symptomatic improvement and normal sexual function can be expected with androgen replacement therapy that increases plasma testosterone levels into the normal range [168]. In addition to maintenance of normal secondary sexual characteristics and lean body mass, testosterone replacement may be important for normal erythropoiesis. Normal erythropoiesis is important to allow an adequate frequency of venesection and de-ironing. Testosterone therapy may also be beneficial in relation to osteoporosis that is common in haemochromatotic patients. Gynaecomastia occasionally develops during treatment as a result of aromatization of testosterone to estradiol in peripheral tissues. Because of testosterone's sodium-retaining properties, fluid retention may develop during treatment but is usually only a problem in cirrhotic patients with poor liver function. In view of the potential for recovery of gonadal function following successful depletion of body iron stores, it is suggested that in younger men testosterone therapy should be interrupted at intervals to assess gonadotrophin and testosterone production. A course of gonadotrophin treatment may be considered in men with hypogonadotrophic hypogonadism who desire fertility [169].

Thyroid dysfunction

Thyroid dysfunction occurs with increased frequency (8–20%) [157]. Hypothyroidism is much more common than hyperthyroidism. Thyroid-stimulating hormone levels are raised, and the thyroid-stimulating hormone response to thyrotrophin-releasing hormone is normal [161], suggesting primary hypothyroidism. The thyroid gland is fibrotic and loaded with iron. Iron deposition is probably the main cause of damage since an increased prevalence of hypothyroidism is also found in patients with thalassaemia and iron overload [170]. However, high titres of thyroid autoantibodies may be found in haemachromatosis; perhaps the exposure of cellular antigens secondary to iron toxicity leads to further autoimmune thyroid damage. Occasional patients may develop hypothyroidism secondary to impaired pituitary thyroid-stimulating hormone release.

Adrenal hormones

Basal plasma cortisol and ACTH levels, and their responses to insulin-induced hypoglycaemia, are usually normal in patients with haemochromatosis [161]. Thomas [171] reported a patient with postural hypotension due to primary aldosterone deficiency. The patient had iron deposits in the zona glomerulosa of the adrenal cortex with sparing of the other zones. Such a pattern of iron deposition appears to be common in haemochromatosis. However, Walsh *et al.* [172] in a cross-sectional study of 19 haemochromatotics found normal cortisol responses to ACTH and insulin-induced hypoglycaemia, and normal regulation of plasma aldosterone levels. It would seem that adrenocortical dysfunction is rare.

Prolactin and growth hormone

Basal prolactin levels tend to be low in hypogonadal haemochromatotic patients and they have a subnormal prolactin response to intravenous thyrotrophin-releasing hormone [161]. Similarly, basal growth hormone levels are usually normal but the growth hormone response to insulin-induced hypoglycaemia may be impaired [161].

Osteoporosis

The prevalence of osteoporosis is increased in haemochromatosis. Diamond *et al.* [173] found osteoporosis in 10 of 22 men aged 35 to 62 years. Both cortical and trabecular bone density were decreased. The abnormalities were more marked in the haemochromatotic men with hypogonadism. However, osteoporosis and fractures may be found in the absence of hypogonadism [174]. It is likely that many factors contribute to the osteopenia in these patients. In addition to androgen deficiency, iron interference with osteoid mineralization, lower 25-hydroxyvitamin D levels, poorly controlled diabetes, and impaired insulin-like growth factor-1 production in those with cirrhosis or poorly controlled diabetes may all play a role.

Endocrine manifestations of liver tumours

Primary hepatic tumours may rarely be associated with metabolic and endocrine abnormalities resulting from tumour production and release of hormones (or their precursors), hormone-releasing

factors, or other substances that influence circulating levels of active hormone produced in other tissues. Hypoglycaemia due to tumour production of insulin-like growth factor-2 precursors ('big' IGF-2) was discussed earlier.

Erythrocytosis

Hepatocellular carcinoma is one of the more common tumours to produce erythrocytosis, which is found in up to 10% of patients in areas with a high incidence of hepatocellular carcinoma. There is an increase in the haemoglobin and packed cell volume but these may be masked by the expanded plasma volume in many cirrhotic patients, necessitating determination of red cell mass for diagnosis. Erythrocytosis may increase the risk of hepatic and portal venous thrombosis that is fairly common in these patients. The increase in red cell mass is probably due to overproduction of erythropoietin by the tumour. Raised plasma erythropoetin levels are more commonly found than erythrocytosis. This may be explained by the expanded plasma volume in cirrhosis, bleeding episodes, concomitant iron deficiency, or hypogonadism (see above), but it could also be due to a lower biological activity of erythropoietin of tumour origin. Erythropoietin production by hepatocellular carcinoma tissue has been demonstrated by immunohistochemical staining and by demonstration of a high level of expression of its mRNA [175,176]. Successful resection of the tumour leads to a fall in erythropoietin levels and reduction in red cell mass [176].

Hypercalcaemia

Hypercalcaemia is found in about 10% of patients with primary liver tumours [177]. While it may be associated with osteolytic metastases, in most patients it occurs in the absence of metastatic bone deposits and appears to be due to production of humoral factors by the tumour. Hypercalcaemia is more commonly associated with cholangiocarcinoma than with hepatocellular carcinoma and may be particularly common with the sclerosing variant of cholangiocarcinoma. In four hypercalcaemic hepatocellular carcinoma patients without bony metastases Panesar *et al.* [178] found low serum phosphate levels, decreased tubular reabsorption of phosphate, increased hydroxyproline–creatinine ratios, and increased excretion of nephrogenous cyclic AMP, consistent with increased activity of a PTH-like hormone in bone and kidney; however, serum PTH levels were suppressed. Unlike patients with hyperparathyroidism, there is a tendency to hypochloraemic alkalosis.

Parathyroid hormone-related peptide (PTHrP) which has a high degree of homology at the *N*-terminus (first 13 amino acids) with PTH, has been identified as the main mediator of humoral hypercalcaemia in non-haematological malignancies [179]; this is probably also true of hypercalcaemia associated with primary liver tumours. Knill-Jones *et al.* [180] demonstrated an arterio-hepatic venous gradient for immunoreactive PTH in a patient with cholangiocarcinoma and hypercalcaemia. Cholangiocarcinoma but not hepatocellular carcinoma has been shown to express PTHrP even in the absence of hypercalcaemia; mixed types of primary liver tumour contained PTHrP only in areas of cholangiocellular differentiation. This could explain the higher incidence of hypercalcaemia in association with cholangiocarcinoma than with hepatocellular carcinoma, although probably only a small percentage of tumours that produce PTHrP will secrete enough biologically active material to cause hypercalcaemia. Other factors may also play a role in some patients; Ikeda *et al.* [181] reported a patient with hypercalcaemia who was found to have a 10-fold increase in prostaglandin E levels in the tumour compared with adjacent normal liver. The significance of this finding is unclear in view of the very high rate of prostaglandin metabolism by the liver and lungs so that circulating levels are unlikely to increase to levels necessary for stimulation of bone resorption. Prostaglandin production by tumour cells is probably only important in inducing osteolysis in the region surrounding metastases in bone. Successful tumour resection, liver transplantation [180], or tumour embolization may restore the serum calcium to normal.

Isosexual precocity and gonadotrophin secretion

Hepatoblastoma and hepatocellular carcinoma in young boys may rarely be associated with sexual precocity. This is due to human chorionic gonadotrophin (hCG) production with stimulation of testicular testosterone production. The syndrome occurs only in males because, whereas either hCG or LH can stimulate testicular steroid synthesis, initiation of ovarian steroid synthesis requires FSH as well. In adult men gynaecomastia may develop as a result of tumour production of hCG, or the conversion of dehydroepiandrosterone to estrone and estradiol by the tumour. In women, amenorrhoea with breast enlargement and galactorrhoea has been reported; menstruation returned following tumour resection. Production of either hCG or prolactin by the hepatocellular carcinoma may have been responsible.

Other tumour-associated endocrine syndromes

hCG has the same α-subunit as thyroid-stimulating hormone and can act via the thyroid-stimulating hormone receptor to stimulate growth of thyroid cells. In early pregnancy high hCG levels cause a rise in thyroid hormones. Hyperthyroidism may rarely be associated with hepatocellular carcinoma secreting very large amounts of hCG [182]. Carcinoid syndrome is usually due to hepatic metastases but it may very rarely be due to a primary biliary or liver tumour. Cox *et al.* [183] described a young girl with severe hypertension due to renin production by a benign hepatoma which resolved following tumour resection.

References

1 Blackard WG, Nelson NC (1970) Portal and peripheral vein immunoreactive insulin concentrations before and after glucose infusion. *Diabetes* 19(5), 302–306.

2 Chupin M, Charbonnel B, Le Bodic L *et al.* (1978) Glucose tolerance in viral hepatitis. A study of twenty patients during the acute phase and after recovery. *Diabetes* 27(6), 661–669.

3 Rehfeld JF, Juhl E, Hilden M (1973) Carbohydrate metabolism in alcohol-induced fatty liver. Evidence for an abnormal insulin response to glucagon in alcoholic liver disease. *Gastroenterology* 64(3), 445–451.

4 Alberti KG, Record CO, Williamson DH *et al.* (1972) Metabolic changes in active chronic hepatitis. *Clin Sci* 42, 591–605.

5 Record CO, Chase RA, Alberti KG *et al.* (1975) Disturbances in glucose metabolism in patients with liver damage due to paracetamol overdose. *Clin Sci Mol Med* 49(5), 473–479.

6 Kruszynska YT, Munro J, Home PD *et al.* (1992) Twenty-four hour C-peptide and insulin secretion rates and diurnal profiles of glucose, lipids and intermediary metabolites in cirrhosis. *Clin Sci (Lond)* 83(5), 597–605.

7 WHO Study Group (1985) *Diabetes mellitus.* Technical Report Series 727. Geneva: WHO, pp. 80–82.

8 Letiexhe MR, *et al.* (1993) Insulin secretion, clearance, and action on glucose metabolism in cirrhotic patients. *J Clin Endocrinol Metab* 77, 1263–1268.

9 Magnusson J, Tranberg KG (1987) Impaired early insulin response to intravenous glucose in alcoholic liver cirrhosis. *Scand J Gastroenterol* 22(3), 301–307.

10 Conn HO, Schreiber W, and Elkington SG (1971) Cirrhosis and diabetes II. Association of impaired glucose tolerance with portal-systemic shunting in Laennec's cirrhosis. *Am J Dig Dis* 16(3), 227–239.

11 Creutzfeldt W, Frerichs H, Sickinger K (1970) Liver diseases and diabetes mellitus. In: Popper H, Schaffner F (eds) *Progress in liver disease*, Vol. 3. New York: Grune and Stratton, pp. 371–407.

12 Bloodworth JM Jr (1961) Diabetes mellitus and cirrhosis of the liver. *Arch Intern Med* 108, 695–701.

13 Kingston ME, Ali MA, Atiyeh M *et al.* (1984) Diabetes mellitus in chronic active hepatitis and cirrhosis. *Gastroenterology* 87(3), 688–694.

14 Blanco DCV, Gentile S, Marmo R *et al.* (1990) Alterations of glucose metabolism in chronic liver disease. *Diabetes Res Clin Pract* 8, 29–36.

15 Muller MJ, Pirlich M, Balks HJ *et al.* (1994) Glucose intolerance in liver cirrhosis: role of hepatic and non-hepatic influences. *Eur J Clin Chem Clin Biochem* 32(10), 749–758.

16 Ferrannini E, Groop LC (1989) Hepatic glucose production in insulin-resistant states. *Diabetes Metab Rev* 5(8), 711–726.

17 Kruszynska YT, Meyer-Alber A, Darakhshan F *et al.* (1993) Metabolic handling of orally administered glucose in cirrhosis. *J Clin Invest* 91, 1057–1066.

18 Petrides AS, Groop LC, Riely CA *et al.* Effect of physiologic hyperinsulinaemia on glucose and lipid metabolism in cirrhosis. *J Clin Invest* 88, 561–570.

19 Petrides A, Vogt C, Schulze-Berge D *et al.* (1994) Pathogenesis of glucose intolerance and diabetes mellitus in cirrhosis. *Hepatology* 19, 616–627.

20 Selberg O, Burchert W, vd Hoff J *et al.* (1993) Insulin resistance in liver cirrhosis. Positron-emission tomography scan analysis of skeletal muscle glucose metabolism. *J Clin Invest* 91(5), 1897–1902.

21 Taylor R, Heine RJ, Collins J *et al.* (1985) Insulin action in cirrhosis. *Hepatology* 5, 64–71.

22 Kruszynska YT, Home PD, McIntyre N (1991) The relationship between insulin sensitivity, insulin secretion and glucose tolerance in cirrhosis. *Hepatology* 14, 103–11.

23 Bosch J, *et al.* (1984) Role of spontaneous portal-systemic shunting in hyperinsulinism of cirrhosis. *Am J Physiol* 247, G206–G212.

24 Nygren A, Adner N, Sundblad L *et al.* (1985) Insulin uptake by the human alcoholic cirrhotic liver. *Metabolism* 34(1), 48–52.

25 Kruszynska K, Ghatei MA, Bloom SR *et al.* (1995) Insulin secretion and plasma levels of glucose-dependent insulinotropic peptide and glucagon-like peptide 1 [7–36 amide] after oral glucose in cirrhosis. *Hepatology* 21, 933–941.

26 Beard JC, Ward WK, Halter JB *et al.* (1987) Relationship of islet function to insulin action in human obesity. *J Clin Endocrinol Metab* 65(1), 59–64.

27 Mitrakou A, Kelley D, Mokan M *et al.* (1992) Role of reduced suppression of glucose production and diminished early insulin release in impaired glucose tolerance. *N Engl J Med* 326(1), 22–29.

28 Shapiro ET, Tillil H, Miller MA *et al.* (1987) Insulin secretion and clearance. Comparison after oral and intravenous glucose. *Diabetes* 36(12), 1365–1371.

29 Nauck MA, Bartels E, Orskov C *et al.* (1993) Additive insulinotropic effects of exogenous synthetic human gastric inhibitory polypeptide and glucagon-like peptide-1-(7–36) amide infused at near-physiological insulinotropic hormone and glucose concentrations. *J Clin Endocrinol Metab* 76(4), 912–917.

30 Kruszynska YT, Ghatei MA, Bloom SR *et al.* (1995) Insulin secretion and plasma levels of glucose-dependent insulinotropic peptide and glueagon-like peptide 1 [7–36 amide] after oral glucose in cirrhosis. *Hepatology* 21, 933–941.

31 McDonald TJ, Dupre J, Caussignac Y *et al.* (1979) Hyperglucagonemia in liver cirrhosis with portal-systemic venous anastomoses: responses of plasma glucagon and gastric inhibitory polypeptide to oral or intravenous glucose in cirrhotics with normal or elevated fasting plasma glucose levels. *Metabolism* 28(4), 300–307.

32 Thuluvath PJ, Triger DR (1989) Autonomic neuropathy and chronic liver disease. *Q J Med* 72(268), 737–747.

33 Kruszynska YT, Harry DS, Mohamed-Ali V *et al.* (1995) The contribution of proinsulin and des-31,32 proinsulin to the hyperinsulinemia of diabetic and nondiabetic cirrhotic patients. *Metabolism* 44(2), 254–260.

34 Larsen S, Hilsted J, Philipsen EK *et al.* (1991) The effect of insulin withdrawal on intermediary metabolism in patients with diabetes secondary to chronic pancreatitis. *Acta Endocrinol (Copenh)* 124(5), 510–515.

35 Rahier J, Loozen S, Goebbels RM *et al.* (1987) The haemochromatotic human pancreas: a quantitative immunohistochemical and ultrastructural study. *Diabetologia* 30(1), 5–12.

36 Taylor SI, Accili D, Imai Y (1994) Insulin resistance or insulin deficiency. Which is the primary cause of NIDDM? *Diabetes* 43(6), 735–740.

37 Carey WD, Dumot JA, Pimentel RR *et al.* (1995) The prevalence of coronary artery disease in liver transplant candidates over age 50. *Transplantation* 59(6), 859–864.

38 Trail KC, Stratta RJ, Larsen JL *et al.* (1993) Results of liver transplantation in diabetic recipients. *Surgery* 114(4), 650–656; discussion 656–658.

39 Ferner RE, Neil HA. (1988) Sulphonylureas and hypoglycaemia. *Br Med J (Clin Res Ed)* 296(6627), 949–950.

40 Marco J, Diego J, Villanueva ML *et al.* (1973) Elevated plasma glucagon levels in cirrhosis of the liver. *N Engl J Med* 289(21), 1107–1111.

41 Sherwin RS, Fisher M, Bessoff J (1978) Hyperglucagonemia in cirrhosis: altered secretion and sensitivity to glucagon. *Gastroenterology* 74(6), 1224–1228.

42 Dudley FJ, Alford FP, Chisholm D *et al.* (1979) Effect of portasystemic venous shunt surgery on hyperglucagonaemia in cirrhosis: paired studies of pre- and post-shunted subjects. *Gut* 20(10), 817–824.

43 Sikuler E, Polio J, Groszmann RJ *et al.* (1987) Glucagon and insulin metabolism in a portal-hypertensive rat model. *Am J Physiol* 253(2 Pt 1), G110–G115.

44 Kravetz D, Arderiu M, Bosch J *et al.* (1987) Hyperglucagonemia and hyperkinetic circulation after portocaval shunt in the rat. *Am J Physiol* 252(2 Pt 1), G257–G261.

45 Lewis FW, Adair O, Hossack KF *et al.* (1991) Plasma glucagon concentration in cirrhosis is related to liver function but not to portal-systemic shunting, systemic vascular resistance, or urinary sodium excretion. *J Lab Clin Med* 117(1), 67–75.

46 Marchesini G, Zoli M, Dondi C *et al.* (1982) Ammonia-induced changes in pancreatic hormones and plasma amino acids in patients with liver cirrhosis. *Dig Dis Sci* 27(5), 406–412.

47 Kabadi UM, Eisenstein AB, Konda J (1985) Elevated plasma ammonia level in hepatic cirrhosis: role of glucagon. *Gastroenterology* 88(3), 750–756.

48 Petrides AS, De Fronzo RA (1994) Failure of glucagon to stimulate hepatic glycogenolysis in well-nourished patients with mild cirrhosis. *Metabolism* 43(1), 85–89.

49 Authier F, Desbuquois B, De Galle B (1992) Ligand-mediated internalization of glucagon receptors in intact rat liver. *Endocrinology* 131(1), 447–457.

50 Houge G, Vintermyr OK, Doskeland SO (1990) The expression of cAMP-dependent protein kinase subunits in primary rat hepatocyte cultures. Cyclic AMP down-regulates its own effector system by decreasing the amount of catalytic subunit and increasing the mRNAs for the inhibitory (R) subunits of cAMP-dependent protein kinase. *Mol Endocrinol* 4(3), 481–488.

51 Petrides AS, Vogt C, Schulze-Berge D *et al.* (1994) Pathogenesis of glucose intolerance and diabetes mellitus in cirrhosis. *Hepatology* 19(3), 616–627.

52 Baumann G, Mercado M (1993) Growth hormone-binding proteins in plasma. *Nutrition* 9(6), 546–553.

53 Ho KK, Jorgensen JO, Valiontis E *et al.* (1993) Different modes of growth hormone (GH) administration do not change GH binding protein activity in man. *Clin Endocrinol (Oxf)* 38(2), 143–148.

54 Mannor DA, Winer LM, Shaw MA *et al.* (1991) Plasma growth hormone (GH)-binding proteins: effect on GH binding to receptors and GH action. *J Clin Endocrinol Metab* 73(1), 30–34.

55 Veldhuis JD, Johnson ML, Faunt LM *et al.* (1993) Influence of the high-affinity growth hormone (GH)-binding protein on plasma profiles of free and bound GH and on the apparent half-life of GH. Modeling analysis and clinical applications. *J Clin Invest* 91(2), 629–641.

56 Martini JF, Villares SM, Nagano M *et al.* (1995) Quantitative analysis by polymerase chain reaction of growth hormone receptor gene expression in human liver and muscle. *Endocrinology* 136(4), 1355–1360.

57 Moller S, Juul A, Becker U *et al.* (1995) Concentrations, release, and disposal of insulin-like growth factor (IGF)-binding proteins (IGFBP), IGF-I, and growth hormone in different vascular beds in patients with cirrhosis. *J Clin Endocrinol Metab* 80, 1148–1157.

58 Donaghy A, Ross R, Gimson A *et al.* (1995) Growth hormone, insulin-like growth factor-I, and insulin-like growth factor binding proteins 1 and 3 in chronic liver disease. *Hepatology* 21, 680–688.

59 Cuneo RC, *et al.* (1995) Altered endogenous growth hormone secretory kinetics and diurnal GH-binding protein profiles in adults with chronic liver disease. *Clin Endocrinol* 43, 265–75.

60 Shankar TP, Solomon SS, Duckworth WC *et al.* (1988) Growth hormone and carbohydrate intolerance in cirrhosis. *Horm Metab Res* 20(9), 579–583.

61 Samaan NA, Stone DB, Eckhardt RD (1969) Serum glucose, insulin, and growth hormone in chronic hepatic cirrhosis. *Arch Intern Med* 124(2), 149–152.

62 Conn HO, Daughaday WH (1970) Cirrhosis and diabetes. V. Serum human growth hormone levels in Laennec's cirrhosis. *J Lab Clin Med* 76(4), 678–688.

63 McDonald JA, Handelsman DJ, Dilworth P *et al.* (1993) Hypothalamic–pituitary adrenal function in end-stage non-alcoholic liver disease. *J Gastroenterol Hepatol* 8, 247–253.

64 Shmueli E, Stewart M, Alberti KGMM *et al.* (1994) Growth hormone, insulin-like growth factor-I and insulin resistance in cirrhosis. *Hepatology* 19, 322–328.

65 Ho KK, O'Sullivan AJ, Weissberger AJ *et al.* (1996) Sex steroid regulation of growth hormone secretion and action. *Horm Res* 45(1–2), 67–73.

66 Thissen JP, Ketelslegers JM, Underwood LE (1994) Nutritional regulation of the insulin-like growth factors. *Endocr Rev* 15(1), 80–101.

67 Russell-Jones DL, Rattray M, Wilson VJ *et al.* (1992) Intraperitoneal insulin is more potent than subcutaneous insulin at restoring hepatic insulin-like growth factor-I mRNA levels in the diabetic rat: a functional role for the portal vascular link. *J Mol Endocrinol* 9(3), 257–263.

68 Chang TC, Lin JJ, Yu SC *et al.* (1990) Absence of growth-hormone receptor in hepatocellular carcinoma and cirrhotic liver. *Hepatology* 11(1), 123–126.

69 Bucuvalas JC, Horn JA, Carlsson L *et al.* (1993) Growth hormone insensitivity associated with elevated circulating growth hormone-binding protein in children with Alagille syndrome and short stature. *J Clin Endocrinol Metab* 76(6), 1477–1482.

70 Owens D, Srivastava MC, Tompkins CV *et al.* (1973) Studies on the metabolic clearance rate, apparent distribution space and plasma half-disappearance time of unlabelled human growth hormone in normal subjects and in patients with liver disease, renal disease, thyroid disease and diabetes mellitus. *Eur J Clin Invest* 3(4), 284–294.

71 Boni-Schnetzler M, Schmid C, Meier PJ *et al.* (1991) Insulin regulates insulin-like growth factor I mRNA in rat hepatocytes. *Am J Physiol* 260(6 Pt 1), E846–E851.

72 Brismar K, Fernqvist-Forbes E, Wahren J *et al.* (1994) Effect of insulin on the hepatic production of insulin-like growth factor-binding protein-1 (IGFBP-1), IGFBP-3, and IGF-I in insulin-dependent diabetes. *J Clin Endocrinol Metab* 79(3), 872–878.

73 Phillips LS, Goldstein S, Pao CI (1991) Nutrition and somatomedin. XXVI. Molecular regulation of IGF-I by insulin in cultured rat hepatocytes. *Diabetes* 40(11), 1525–1530.

74 Oster MH, Fielder PJ, Levin N *et al.* (1995) Adaptation of the growth hormone and insulin-like growth factor-I axis to chronic and severe calorie or protein malnutrition. *J Clin Invest* 95(5), 2258–2265.

75 Jones JI, Clemmons DR (1995) Insulin-like growth factors and their binding proteins: biological actions. *Endocr Rev* 16(1), 3–34.

76 Lewitt MS, Saunders H, Cooney GJ *et al.* (1993) Effect of human insulin-like growth factor-binding protein-1 on the half-life and action of administered insulin-like growth factor-I in rats. *J Endocrinol* 136(2), 253–260.

77 Zapf J (1995) Physiological role of the insulin-like growth factor binding proteins. *Eur J Endocrinol* 132(6), 645–654.

78 De Meyts P, Wallach B, Christoffersen CT *et al.* (1994) The insulin-like growth factor-I receptor. Structure, ligand-binding mechanism and signal transduction. *Horm Res* 42(4–5), 152–169.

79 Baxter RC (1994) Insulin-like growth factor binding proteins in the human circulation: a review. *Horm Res* 42(4–5), 140–144.

80 Yki-Jarvinen H, Makimattila S, Utriainen T *et al.* (1995) Portal insulin concentrations rather than insulin sensitivity regulate serum sex hormone-binding globulin and insulin-like growth factor binding protein 1 in vivo. *J Clin Endocrinol Metab* 80(11), 3227–3232.

81 Villafuerte BC, Koop BL, Pao CI *et al.* (1994) Coculture of primary rat hepatocytes and nonparenchymal cells permits expression of insulin-like growth factor binding protein-3 in vitro. *Endocrinology* 134(5), 2044–2050.

82 Holt RIG, Jones JS, Stone NM *et al.* (1996) Sequential changes in insulin-like growth factor I (IGF-I) and IGF-binding proteins in children with end-stage liver disease before and after successful orthotopic liver transplantation. *J Clin Endocrinol Metab* 81, 160–168.

83 Ross RJ, Chew SL (1995) Acquired growth hormone resistance. *Eur J Endocrinol* 132(6), 655–660.

84 Moller S, Becker U, Juul A *et al.* (1996) Prognostic value of insulinlike growth factor I and its binding protein in patients with alcohol-induced liver disease. EMALD group. *Hepatology* 23(5), 1073–1078.

85 Bereket A, Lang CH, Blethen SL *et al.* (1995) Effect of insulin on the insulin-like growth factor system in children with new-onset insulin-dependent diabetes mellitus. *J Clin Endocrinol Metab* 80(4), 1312–1317.

86 Kerr D, Tamborlane WV, Rife F *et al.* (1993) Effect of insulin-like growth factor-1 on the responses to and recognition of hypoglycemia in humans. A comparison with insulin. *J Clin Invest* 91(1), 141–147.

87 Eastman RC, Carson RE, Orloff DG *et al.* (1992) Glucose utilization in a patient with hepatoma and hypoglycemia. Assessment by a positron emission tomography. *J Clin Invest* 89(6), 1958–1963.

88 Shapiro ET, Bell GI, Polonsky KS *et al.* (1990) Tumour hypoglycaemia: relationship to high molecular weight insulin-like growth factor II. *J Clin Invest* 85, 1672–1679.

89 Zapf J, Futo E, Peter M *et al.* (1992) Can 'big' insulin-like growth factor II in serum of tumor patients account for the development of extrapancreatic tumor hypoglycaemia. *J Clin Invest* 90, 2574–2584.

90 Daughaday WH, Wu J-C, Lee S-D *et al.* (1990) Abnormal processing of pro-IGF-II in patients with hepatoma and in some patients with hepatitis B virus antibody-positive asymptomatic individuals. *J Lab Clin Med* 115, 555–562.

91 Daughaday WH, Trivedi B, Baxter RC (1993) Serum 'big insulin-like growth factor II' from patients with tumor hypoglycaemia lacks normal E-domain O-linked glycosylation, a possible determinant of normal propeptide processing. *Proc Nat Acad Sci USA* 90, 5823–5827.

92 Baxter RC, Holman SR, Corbould A *et al.* (1995) Regulation of the insulin-like growth factors and their binding proteins by glucocorticoid and growth hormone in nonislet cell tumor hypoglycemia. *J Clin Endocrinol Metab* 80(9), 2700–2708.

93 Trivedi N, Mithal A, Sharma AK *et al.* (1995) Non-islet cell tumour induced hypoglycaemia with acromegaloid facial and acral swelling. *Clin Endocrinol (Oxf)* 42(4), 433–435.

94 Brent GA, Moore DD, Larsen PR (1991) Thyroid hormone regulation of gene expression. *Annu Rev Physiol* 53, 17–35.

95 Mooradian AD, Schwartz HL, Mariash CN *et al.* (1985) Transcellular and transnuclear transport of 3,5,3′-triiodothyronine in isolated hepatocytes. *Endocrinology* 117(6), 2449–2456.

96 de Jong M, Docter R, Van der Hoek H *et al.* (1994) Different effects of amiodarone on transport of T4 and T3 into the perfused rat liver. *Am J Physiol* 266(1 Pt 1), E44–E49.

97 Liewendahl K, Helenius T, Tanner P *et al.* (1983) Serum free thyroid hormone concentrations and indices in alcoholic liver cirrhosis, primary biliary cirrhosis and chronic active hepatitis. *Acta Endocrinol Suppl* 251, 21–26.

98 L'age M, Meinhold H, Wenzel KW *et al.* (1980) Relations between serum levels of TSH, TBG, T_4, T_3, rT_3 and various histologically classified chronic liver diseases. *J Endocrinol Invest* 4, 379.

99 Sheridan P, Chapman C, Losowsky MS (1978) Interpretation of laboratory tests of thyroid function in chronic active hepatitis. *Clinica Chimica Acta* 86, 73–80.

100 Shussler GC, Schaffner F, Korn F. (1978) Increased serum thyroid hormone binding and decreased free hormone in chronic active liver disease. *N Engl J Med* 299, 510–515.

101 Faber J, Francis Thomsen H, Lumholtz IB *et al.* (1981) Kinetic studies of thyroxine, 3,5,3′-triiodothyronine, 3,3′5′-triiodothyronine, 3′5′-diiodothyronine, 3,3′-diiodothyronine, and 3′-monoiodothyronine in patients with liver cirrhosis. *J Clin Endocrinol Metab* 53, 978–984.

102 Kaptein EM, Robinson WJ, Grieb DA (1982) Peripheral serum thyroxine, triiodothyronine and reverse triiodothyronine kinetics in the low thyroxine state of acute nonthyroidal illnesses. A noncompartmental analysis. *J Clin Invest* 69(3), 526–535.

103 Hegedus L (1986) Thyroid gland volume and thyroid function during and after acute hepatitis infection. *Metabolism* 35(6), 495–498.

104 Green JR, Snitcher EJ, Mowat NA *et al.* (1977) Thyroid function and thyroid regulation in euthyroid men with chronic liver disease: evidence of multiple abnormalities. *Clin Endocrinol (Oxf)* 7(6), 453–461.

105 Agner T, Hagen C, Nyboe Andersen B *et al.* (1986) Pituitary-thyroid function and thyrotropin, prolactin and growth hormone responses to TRH in patients with chronic alcoholism. *Acta Med Scand* 220(1), 57–62.

106 Guven K, Kelestimur F, Yucesoy M (1993) Thyroid function tests in non-alcoholic cirrhotic patients with hepatic encephalopathy. *Eur J Med* 2(2), 830–85.

107 Hepner GW, Chopra IJ (1979) Serum thyroid hormone levels in patients with liver disease. *Arch Intern Med* 139(10), 1117–1120.

108 van der Heyden JT, Docter R, van Toor H *et al.* (1986) Effects of caloric deprivation on thyroid hormone tissue uptake and generation of low-T3 syndrome. *Am J Physiol* 251(2 Pt 1), E156–E163.

109 Lim C-F, *et al.* (1993) Inhibition of thyroxine transport into cultured rat hepatocytes by serum of nonuremic critically ill patients: effects of bilirubin and nonesterified fatty acids. *J Clin Endocrinol Metab* 76, 1165–1172.

110 Sherlock S, Scheuer PJ (1973) The presentation and diagnosis of 100 patients with primary biliary cirrhosis. *N Engl J Med* 289(13), 674–678.

111 Hutchinson WL, White YS, Fagan EA, Johnson PJ, Williams R. Impaired binding properties of thyroxine-binding globulin in hepatocellular carcinoma and chronic liver disease. *Hepatology* 1991 14(1), 116–120.

112 Mayet WJ, Hess G, Gerken G *et al.* (1989) Treatment of chronic type B hepatitis with recombinant alpha-interferon induces autoantibodies not specific for autoimmune chronic hepatitis. *Hepatology* 10(1), 24–28.

113 Watanabe U, Hashimoto E, Hisamitsu T (1994) The risk factor for development of thyroid disease during interferon-alpha therapy for chronic hepatitis C. *Am J Gastroenterol* 89(3), 399–403.

114 Baudin E, *et al.* (1993) Reversibility of thyroid dysfunction induced by recombinant alpha interferon in chronic hepatitis C. *Clin Endocrinol* 39, 657–661.

115 Compston JE, Crowe JP, Wells IP *et al.* (1980) Vitamin D prophylaxis and osteomalacia in chronic cholestatic liver disease. *Dig Dis Sci* 25(1), 28–32.

116 Fonseca V, Epstein O, Gill DS *et al.* (1987) Hyperparathyroidism and low serum osteocalcin despite vitamin D replacement in primary biliary cirrhosis. *J Clin Endocrinol Metab* 64(5), 873–877.

117 Kirch W, Hofig M, Ledendecker T *et al.* (1990) Parathyroid hormone and cirrhosis of the liver. *J Clin Endocrinol Metab* 71(6), 1561–1566.

118 Funder JW, Pearce PT, Smith R (1988) Mineralocorticoid action: target tissue specificity is enzyme, not receptor, mediated. *Science* 242(4878), 583–585.

119 Stewart PM, Burra P, Shackleton CHL *et al.* (1993) 11β-Hydroxysteroid dehydrogenase deficiency and glucocorticoid status in patients with alcoholic and non-alcoholic liver disease. *J Clin Endocrinol Metab* 76, 748–751.

120 Rosman PM, Farag A, Benn R *et al.* (1982) Modulation of pituitary-adrenocortical function: decreased secretory episodes and blunted circadian rhythmicity in patients with alcoholic liver disease. *J Clin Endocrinol Metab* 55, 709–717.

121 Orbach O, Schussler GC (1989) Increased serum cortisol binding in chronic active hepatitis. *Am J Med* 86(1), 39–42.

122 Renner E, Horber FF, Jost G *et al.* (1986) Effect of liver function on the metabolism of prednisone and prednisolone in humans. *Gastroenterology* 90(4), 819–828.

123 Groote Veldman R, Meinders AE (1996) On the mechanism of alcohol-induced pseudo-Cushing's syndrome. *Endocr Rev* 17(3), 262–268.

124 Yanovski JA, Cutler GB Jr, Chrousos GP *et al.* (1993) Corticotropin-releasing hormone stimulation following low-dose dexamethasone administration. A new test to distinguish Cushing's syndrome from pseudo-Cushing's states. *JAMA* 269(17), 2232–2238.

125 Berman JD, Cook DM, Buchman M *et al.* (1990) Diminished adrenocorticotropin response to insulin-induced hypoglycemia in non-depressed, actively drinking male alcoholics. *J Clin Endocrinol Metab* 71(3), 712–717.

126 Swain MG, Patchev V, Vergalla J *et al.* (1993) Suppression of hypothalamic-pituitary-adrenal axis responsiveness to stress in a rat model of acute cholestasis. *J Clin Invest* 91(5), 1903–1908.

127 Finkelstein JS, Whitcomb RW, O'Dea LS *et al.* (1991) Sex steroid control of gonadotropin secretion in the human male. I. Effects of testosterone administration in normal and gonadotropin-releasing hormone-deficient men. *J Clin Endocrinol Metab* 73(3), 609–620.

128 Jenster G, van der Korput HA, van Vroonhoven C *et al.* (1991) Domains of the human androgen receptor involved in steroid binding, transcriptional activation, and subcellular localization. *Mol Endocrinol* 5(10), 1396–1404.

129 Ammus SS (1989) The role of androgens in the treatment of hematologic disorders. *Adv Intern Med* 34, 191–208.

130 Baker HWG, *et al.* (1976) A study of the endocrine manifestations of hepatic cirrhosis. *Q J Med* 45, 145–178.

131 Bannister P, Oakes J, Sheridan P *et al.* (1987) Sex hormone changes in chronic liver disease: a matched study of alcoholic versus non-alcoholic liver disease. *Q J Med* 63, 305–313.

132 Gluud C, *et al.* (1988) No effect of oral testosterone treatment on sexual dysfunction in alcoholic cirrhotic men. *Gastroenterology* 95, 1582–1587.

133 Wang YJ, *et al.* (1993) Changes of sex hormone levels in patients with hepatitis B virus-related postnecrotic cirrhosis: relationship to severity of portal hypertension. *J Hepatol* 18, 101–105.

134 Handelsman DJ, Strasser S, McDonald JA *et al.* (1995) Hypothalamic–pituitary–testicular function in end-stage non-alcoholic liver disease before and after liver transplantation. *Clin Endocrinol* 43, 331–337.

135 Wang YJ, Wu JC, Lee SD *et al.* (1991) Gonadal dysfunction and changes in sex hormones in postnecrotic cirrhotic men: a matched study with alcoholic cirrhotic men. *Hepato-Gastroenterology* 38, 531–534.

136 Zifroni A, Schiavi RC, Schaffner F. (1991) Sexual function and testosterone levels in men with nonalcoholic liver disease. *Hepatology* 14, 479–482.

137 van Thiel DH, Kumar S, Gavaler JS *et al.* (1990) Effect of liver transplantation on the hypothalamic-pituitary gonadal axis of chronic alcoholic men with advanced liver disease. *Alcohol Clin Exp Res* 14, 478–481.

138 Gavaler JS, van Thiel DH. (1988) Gonadal dysfunction and inadequate sexual performance in alcoholic cirrhotic men. *Gastroenterology* 95, 1680–1684.

139 Guechot J, Vaubourdolle M, Ballet F *et al.* (1987) Hepatic uptake of sex steroids in men with alcoholic cirrhosis. *Gastroenterology* 92(1), 203–207.

140 Bannister P, Handley T, Chapman C *et al.* (1986) Hypogonadism in chronic liver disease: impaired release of luteinising hormone. *Br Med J (Clin Res Ed)* 293(6556), 1191–1193.

141 Guechot J, *et al.* (1994) Effect of liver transplantation on sex-hormone disorders in male patients with alcohol-induced and post-viral hepatitis advanced liver disease. *J Hepatol* 20, 426–430.

142 Green JR, Mowat NA, Fisher RA *et al.* (1976) Plasma oestrogens in men with chronic liver disease. *Gut* 17(6), 426–430.

143 Eagon PK, Zdunek JR, van Thiel DH *et al.* (1981) Alcohol-induced changes in hepatic estrogen-binding proteins: a mechanism explaining feminization in alcoholics. *Arch Biochem Biophys* 211(1), 48–54.

144 Villa E, Baldini GM, Rossini GP *et al.* (1988) Ethanol-induced increase in cytosolic estrogen receptors in human male liver: a possible explanation for biochemical feminization in chronic liver disease due to alcohol. *Hepatology* 8(6), 1610–1614.

145 Bannister P, Meystre CM, Losowsky MS (1988) Androgen receptor concentrations in needle biopsy specimens of human liver. *Liver* 8(1), 28–31.

146 Jeffcoate W (1993) The treatment of women with hirsutism. *Clin Endocrinol (Oxf)* 39(2), 143–150.

147 Becker U, *et al.* (1991) Menopausal age and sex hormones in postmenopausal women with alcoholic and non-alcoholic liver disease. *J Hepatol* 13, 25–32.
148 Valimaki MJ, Laitinen K, Tiitinen A *et al.* (1995) Gonadal function and morphology in non-cirrhotic female alcoholics: a controlled study with hormone measurements and ultrasonography. *Acta Obstet Gynecol Scand* 74(6), 462–466.
149 Becker U, Almdal T, Christensen E *et al.* (1991) Sex hormones in postmenopausal women with primary biliary cirrhosis. *Hepatology* 13(5), 865–869.
150 Cundy TF, O'Grady JG, Williams R (1990) Recovery of menstruation and pregnancy after liver transplantation. *Gut* 31(3), 337–338.
151 Valimaki M, Pelkonen R, Salaspuro M *et al.* (1984) Sex hormones in amenorrheic women with alcoholic liver disease. *J Clin Endocrinol Metab* 59, 133–138.
152 Becker U. (1993) The influence of ethanol and liver disease on sex hormones and hepatic oestrogen receptors in women. *Dan Med Bull* 40, 447–459.
153 Bannister P, Sheridan P, Losowsky MS. (1985) Plasma concentrations of sex hormones in postmenopausal women in non-alcoholic cirrhosis. *Clin Endocrinol* 23, 335–340.
154 Grun R, Gunther C, Kaffarnik H (1987) Sex hormones and the hypophyseo-gonadal axis in females with liver cirrhosis in postmenopause. *Klin Wochenschr* 65(9), 411–418. In German.
155 Morgan MY, Jakobovits AW, Gore MBR *et al.* (1978) Serum prolactin in liver disease and its relationship to gynaecomastia. *Gut* 19, 170–174.
156 Bell H, Raknerud N, Falch JA *et al.* (1995) Inappropriately low levels of gonadotrophins in amenorrheic women with alcoholic and non-alcoholic cirrhosis. *Eur J Endocrinol* 132, 444–449.
157 Niederau C, Fischer R, Sonnenberg A *et al.* (1985) Survival and causes of death in cirrhotic and in non-cirrhotic patients with primary haemochromatosis. *N Engl J Med* 313, 1256–1262.
158 Milman N (1991) Hereditary haemochromatosis in Denmark 1950–1985. *Dan Med Bull* 38, 385–393.
159 Niederau C, Stremmel W, Strohmeyer GW. (1994) Clinical spectrum and management of haemochromatosis. *Baillère's Clin Haematol* 7, 881–901.
160 Cundy T, Bomford A, Butler J *et al.* (1989) Hypogonadism and sexual dysfunction in haemochromatosis: the effects of cirrhosis and diabetes. *J Clin Endocrinol Metab* 69, 110–116.
161 Lufkin EG, Baldus WP, Bergstralh EJ *et al.* (1987) Influence of phlebotomy treatment on abnormal hypothalamic–pituitary function in genetic haemochromatosis. *Mayo Clin Proc* 62, 473–479.
162 Niederau C, Fischer R, Purschel A *et al.* (1996) Long-term survival in patients with hereditary hemochromatosis. *Gastroenterology* 110(4), 1107–1119.
163 Adams PC, Kertesz AE, Valberg LS (1991) Clinical presentation of hemochromatosis: a changing scene. *Am J Med* 90(4), 445–449.
164 Merkel PA, Simonson DC, Amiel SA *et al.* (1988) Insulin resistance and hyperinsulinemia in patients with thalassemia major treated by hypertransfusion. *N Engl J Med* 318(13), 809–814.
165 DCCT (1995) The relationship of glycemic exposure (HbA1c) to the risk of development and progression of retinopathy in the diabetes control and complications trial. *Diabetes* 44(8), 968–983.
166 Balducci R, Toscano V, Finocchi G *et al.* (1990) Effect of hCG or hCG+ treatments in young thalassemic patients with hypogonadotropic hypogonadism. *J Endocrinol Invest* 13(1), 1–7.
167 Gama R, Smith MJ, Wright J *et al.* (1995) Hypopituitarism in primary haemochromatosis; recovery after iron depletion. *Postgrad Med J* 71(835), 297–298.
168 Matsumoto AM (1994) Hormonal therapy of male hypogonadism. *Endocrinol Metab Clin North Am* 23(4), 857–875.
169 Selvais PL, Henrion J (1993) Successful treatment by gonadotrophins of a patient with genetic haemochromatosis and infertility. *Postgrad Med J* 69(809), 241–242.
170 Edwards CQ, Kelly TM, Ellwein G *et al.* (1983) Thyroid disease in hemochromatosis. Increased incidence in homozygous men. *Arch Intern Med* 134, 1890–1893.
171 Thomas JP (1984) Aldosterone deficiency in a patient with idiopathic haemochromatosis. *Clin Endocrinol* 21(3), 271–277.
172 Walsh CH, Murphy AL, Cunningham S *et al.* (1994) Mineralocorticoid and glucocorticoid status in idiopathic haemochromatosis. *Clin Endocrinol (Oxf)* 41(4), 439–443.
173 Diamond T, Stiel D, Posen S (1989) Osteoporosis in hemochromatosis: iron excess, gonadal deficiency, or other factors? *Ann Intern Med* 110(6), 430–436.
174 Eyres KS, McCloskey EV, Fern ED *et al.* (1992) Osteoporotic fractures: an unusual presentation of haemochromatosis. *Bone* 13(6), 431–433.
175 Sakisaka S, Watanabe M, Tateishi H *et al.* (1993) Erythropoietin production in hepatocellular carcinoma cells associated with polycythemia: immunohistochemical evidence. *Hepatology* 18(6), 1357–1362.
176 Muta H, Funakoshi A, Baba T *et al.* (1994) Gene expression of erythropoietin in hepatocellular carcinoma. *Intern Med* 33(7), 427–431.
177 Van Leeuwen DJ, Bos RJ, Vidacovic-Vucic MM (1991) Hepatocellular carcinoma in the Amsterdam area. A retrospective analysis in 61 patients. *Scand J Gastroenterol Suppl* 188, 108–117.
178 Panesar NS, Au KM, Leung NW *et al.* (1991) Nephrogenous cyclic AMP in primary hepatocellular carcinoma patients with or without hypercalcaemia. *Clin Endocrinol (Oxf)* 35(6), 527–532.
179 Kao PC, Klee GG, Taylor RL *et al.* (1990) Parathyroid hormone-related peptide in plasma of patients with hypercalcemia and malignant lesions. *Mayo Clin Proc* 65(11), 1399–1407.
180 Knill-Jones RP, Buckle RM, Parsons V *et al.* (1970) Hypercalcemia and increased parathyroid-hormone activity in a primary hepatoma. Studies before and after hepatic transplantation. *N Engl J Med* 282(13), 704–708.
181 Ikeda T, Tozuka S, Hasumura Y *et al.* (1988) Prostaglandin-E-producing hepatocellular carcinoma with hypercalcemia. *Cancer* 61(9), 1813–1814.
182 Fradkin JE, Eastman RC, Lesniak MA *et al.* (1989) Specificity spillover at the hormone receptor–exploring its role in human disease. *N Engl J Med* 320(10), 640–645.
183 Cox JN, Paunier L, Vallotton MB *et al.* (1975) Epithelial liver hamartoma, systemic arterial hypertension and renin hypersecretion. *Virchows Arch A Pathol Anat Histol* 366(1), 15–26.
184 Bannister P, Oakes J, Sheridan P (1987) Sex hormone changes in chronic liver disease: a matched study of alcoholic versus non-alcoholic liver disease. *Q J Med* 63(240), 305–13.
185 Wang YJ, Lee SD, Lin HC *et al.* (1993) Changes of sex hormone levels in patients with hepatitis B virus-related postnecrotic cirrhosis: relationship to the severity of portal hypertension. *J Hepatol* 18(1), 101–105.
186 Handelsman DJ, Strasser S, McDonald JA *et al.* (1995) Hypothalamic-pituitary-testicular function in end-stage non-alcoholic liver disease

before and after liver transplantation. *Clin Endocrinol (Oxf)* 43(3), 331–337.

187 Wang YJ, Wu JC, Lee SD *et al.* (1991) Gonadal dysfunction and changes in sex hormones in postnecrotic cirrhotic men: a matched study with alcoholic cirrhotic men. *Hepatogastroenterology* 38(6), 531–534.

188 Baker HW, Burger HG, de Kretser DM *et al.* (1976) A study of the endocrine manifestations of hepatic cirrhosis. *Q J Med* 45(177), 145–178.

189 Zifroni A, Schiavi RC, Schaffner F (1991) Sexual function and testosterone levels in men with nonalcoholic liver disease. *Hepatology* 14(3), 479–482.

190 van Thiel DH, Gavaler JS, Spero JA *et al.* (1981) Patterns of hypothalamic-pituitary-gonadal dysfunction in men with liver disease due to differing etiologies. *Hepatology* 1(1), 39–46.

191 Chopra IJ, Tulchinsky D, Greenway FL *et al.* (1973) Estrogen-androgen imbalance in hepatic cirrhosis. Studies in 13 male patients. *Ann Intern Med* 79(2), 198–203.

192 Kley HK, Strohmeyer G, Kruskemper HL (1979) Effect of testosterone application on hormone concentrations of androgens and estrogens in male patients with cirrhosis of the liver. *Gastroenterology* 76(2), 235–241.

193 Bahnsen M, Gluud C, Johnsen SG *et al.* (1981) Pituitary-testicular function in patients with alcoholic cirrhosis of the liver. *Eur J Clin Invest* 11(6), 473–479.

194 Farthing MJ, Green JR, Edwards CR *et al.* (1982) Progesterone, prolactin, and gynaecomastia in men with liver disease. *Gut* 23(4), 276–279.

195 Morgan MY, Jakobovits AW, Gore MB *et al.* (1978) Serum prolactin in liver disease and its relationship to gynaecomastia. *Gut* 19(3), 170–174.

196 Van Thiel DH, Tarter R, Gavaler JS *et al.* (1986) Thyroid and pituitary hormone responses to TRH in advanced nonalcoholic liver disease. *J Endocrinol Invest* 9(6), 479–486.

197 Gluud C (1987) Serum testosterone concentrations in men with alcoholic cirrhosis: background for variation. *Metabolism* 36(4), 373–378.

198 Becker U, Gluud C, Bennett P (1988) Thyroid hormones and thyroxine-binding globulin in relation to liver function and serum testosterone in men with alcoholic cirrhosis. *Acta Med Scand* 224(4), 367–373.

199 Johnson PJ (1984) Sex hormones and the liver. *Clin Sci (Lond)* 66(4), 369–376.

200 Becker U, Gluud C, Farholt S *et al.* (1991) Menopausal age and sex hormones in postmenopausal women with alcoholic and non-alcoholic liver disease. *J Hepatol* 13(1), 25–32.

201 Bannister P, Sheridan P, Losowsky MS. (1985) Plasma concentrations of sex hormones in postmenopausal women in non-alcoholic cirrhosis. *Clin Endocrinol (Oxf)*. 23(4), 335–340.

202 Becker U (1993) The influence of ethanol and liver disease on sex hormones and hepatic oestrogen receptors in women. *Dan Med Bull* 40(4), 447–459.

203 Bell H, Raknerud N, Falch JA *et al.* (1995) Inappropriately low levels of gonadotrophins in amenorrhoeic women with alcoholic and non-alcoholic cirrhosis. *Eur J Endocrinol* 132(4), 444–449.

21.3 Haematological abnormalities in liver disease

Marco Senzolo and Andrew K. Burroughs

Introduction

Liver diseases are associated with various abnormalities in erythrocytes, leukocytes and platelets. There are also lymphoproliferative disorders associated with chronic viral hepatitis. These topics are considered in this chapter. The effect of liver disease on haemostasis is considered in Chapter 21.4 and thrombocytopenia due to hypersplenism in Chapter 7.10.

The liver has an important role as a haematopoietic organ in fetal life, but there are important ontogenetic changes affecting human haematopoiesis. Early in the fetal stage, the liver is the main site of production of blood cells. Erythropoiesis and megakaryopoiesis reach their maximum levels between the 13th and 16th weeks of gestation in parenchymatous hepatic tissue [1]. In the adult liver, extramedullary haematopoiesis only occurs with particular pathological states such as myelofibrosis and massive compensatory hepatic myeloid metaplasia for myelofibrosis after splenectomy [2].

The fetal liver is also the primary site of production of haematopoietic hormones, the glycoproteins thrombopoietin (TPO) and erythropoietin (EPO) [3]. Whereas hepatic TPO production, which is the primary regulator of megakaryopoiesis and platelet function, continues in the liver lifelong [4], after birth, the kidney takes over from the liver as the main site of EPO synthesis [3]. The liver does have some capacity to produce EPO in response to haemolysis, hypoxia or in uraemia, but it cannot substitute for the kidney's production in patients suffering from anaemia due to chronic renal failure [5]; EPO levels have been found to be increased after hepatitis B or C infection by an unknown mechanism [6]. Erythrocytosis can be found in 3–12% of patients with hepatocellular carcinoma, secondary to EPO synthesis in the tumoral tissue, but not in the surrounding normal hepatocytes [7]. Other functions of the liver related to erythropoiesis include production of transferrrin, storage of iron, vitamin B12 and folate [8] (Table 1).

Table 1 Involvement of the liver in regulation of production and destruction of platelets and red blood cells according to developmental stage.

Developmental stage	Liver activity
Fetal	Major site haematopoiesis Major site production TPO and EPO
Postnatal	Major site production TPO Major external site of production of EPO Storage of iron, vitamin B12 and folate Synthesis of transferrin Degradation of red blood cells

EPO, erythropoietin; TPO, thrombopoietin.

Anaemia and erythrocyte abnormalities

About 50–75% of patients with chronic liver disease are anaemic, characterized by a moderate drop in haemoglobin (Hb; 7–10 g/dL) and either normochromic normocytic or moderately macrocytic anaemia [9–11]. Several mechanisms are responsible (Table 2), which can be exacerbated by complications such as haemolysis or haemorrhage. The most important studies related to this were published in the 1950s and 1960s, with few additions in recent years.

Plasma volume is usually increased in cirrhotic patients with cirrhosis, especially with ascites and also with longstanding jaundice [11]. This can cause a dilutional anaemia that is partially responsible for the low haemoglobin, but is only minimally reversed by portosystemic shunting [12].

Erythropoietin production and serum levels are increased in anaemic cirrhotic patients compared with normal control subjects without anaemia, whereas erythropoietin turnover is identical [13]. However, the EPO response relative to anaemia appears to be diminished compared with patients with chronic anaemia and normal liver function [14]. Moreover, EPO infusion does not result in a sustained increased in Hb levels in these patients [15,16]. Bone marrow findings are compatible with these data. Increased bone marrow red cell precursors, together with increased peripheral erythrocytes, have been reported by some [8,17], whereas others report normal cellularity and no correlation with Hb levels [18].

Table 2 Cause of anaemia and erythrocyte abnormalities in liver disease.

Underlying mechanism	Clinical feature
Increased plasma volume	Haemodilutional anaemia
Reduced EPO response	Reduced compensatory mechanism
Increased inflammatory cytokines	Blunted erythroid response to EPO
Viral infection (HBV, HCV) (immunomediated)	Bone marrow suppression
	Viral-induced bone marrow aplasia
Hypersplenism	Increase RBC pooling and destruction
Abnormal B12 metabolism	Macrocytosis
Abnormal iron metabolism	
Alteration in RBC lipid content	
LCAT	Acanthocytosis
HDL	Target cells
Haemolytic anemia	
(Wilson's disease, paroxysmal nocturnal haemoglobinuria)	Non-immunomediated
haemolytic anemia (Coomb's negative)	
(Autoimmune liver disease)	Coomb's positive haemolytic anaemia
(Spurr cell haemolytic anaemia, Zieve syndrome)	
HELLP syndrome during pregnancy	

EPO, erythropoietin; HDL, high-density lipoprotein; HELLP, haemolysis, elevated liver function and low platelets; LCAT, lecithin:cholesterol acyltransferase; RBC, red blood cells.

The decreased bone marrow response to anaemia can be explained by the chronic inflammation in chronic liver disease leading to increases in inflammatory cytokines. These impair not only iron homeostasis but also erythropoiesis, causing blunted EPO response by erythroid progenitors [19]. Moreover, myelosuppression by hepatitis virus C [20] and B [21] is independent from liver cirrhosis affecting all the nucleated cells. For hepatitis B, a dose-dependent relationship between viral load and myelosuppression has been reported *in vitro* [21].

Cirrhosis leads to portal hypertension and hypersplenism, which, because of splenic pooling and sequestration of erythrocytes, is also partially responsible for the anaemia [22]. However, its role is minor, as relief of portal hypertension and hypersplenism by shunt procedures (surgical or radiological) only partially reverses the anaemia [23].

Chronic anaemia is rarely symptomatic in cirrhotic patients on account of high peripheral oxygen extraction, but it has been shown to lead to increased morbidity and mortality during surgery [24].

Eythrocyte shape and function abnormalities

Macrocytosis is found in two-thirds of patients with chronic liver disease and up to 90% of patients with alcoholic liver disease [9–11]. It is correlated with alcohol intake [25] and severity of liver disease measured according to the Child–Pugh score.

Three types of macrocytes have been described in liver disease. Thin macrocytes associated with normoblastic bone marrow correlate with the severity of liver disease and disappear with amelioration of liver function [26]. There is an increase in red cell diameter with little increase in mean cell volume. Targets are cells present in cholestatic and hepatocellular jaundice which are caused by bile acids inhibiting red cell L-cholesterol-acyltransferase (LCAT), resulting in an increased content of both cholesterol and lecithin [27]. These are characterized by normal membrane fluidity and, because the surface/volume ratio is increased, an increased resistance to lysis occurs. True or thick macrocytes are associated with a marked increase in mean corpuscular volume (MCV) and a megaloblastic bone marrow – they are often associated with alcoholic liver disease [28].

Burr cells, also termed echinocytes, can be seen only at electron microscopy or on a wet blood film as spiculated cells. These are associated with advanced liver disease and alcoholic cirrhosis [29]. Their shape is related to saturable binding of abnormal high-density lipopolysaccharide (HDL) lipoprotein, which causes an excess of unesterified cholesterol in the red cell membranes, associated with altered fluidity, resulting in spiculation [30]. Burr cells disappear after liver transplantation.

In 5% of patients with severe liver disease, another form of spiculated erythrocytes may be present characterized by evenly spaced short projections from the membranes: acanthocytes [31]. These result from abnormal cholesterol concentration and cholesterol/phospholipid ratio, resulting in a decreased surface area, leading to less deformability of the membrane. The decrease in cellular deformability results in destruction of these cells in the spleen and extravascular haemolytic anaemia (spur cell anaemia), which in most cases remains chronic and not severe [29]. Cirrhosis is usually alcoholic in origin.

Folate and B12

The liver is responsible together with the gut for the storage of folate and its conversion to tetrahydrofolate, the active form. It is secreted in the bile and actively reabsorbed undergoing an

enterohepatic recirculation [32]. Deficiency results in megaloblastic anaemia. Alcoholism impairs folate absorption from the gut and is associated with decreased hepatic stores [33], which are also affected by reduced intake, a situation that can also occur in non-alcoholic cirrhosis. Hepatic necrosis, as in acute hepatitis, may lead to release of stored hepatic folate and increased urinary excretion [34]. The liver is also the main storage compartment of vitamin B12, 90% of which is contained inside hepatocytes (5–10 mg) [35]. Intrinsic factor is required for absorption of B12, and it undergoes a significant enterohepatic circulation. In the blood, vitamin B12 is transported by three different proteins: transcobalamin I, II and III [36]. Only transcobalamin II can be internalized within hepatocytes. During acute hepatitis and all forms of hepatic necrosis, increased serum levels of vitamin B12 are seen (and transcobalamin II), due to release from necrotic hepatocytes [37]; with resolving acute necrosis, concentrations return to normal. Alcohol can inhibit B12 absorption [38]. In chronic liver disease and cirrhosis, a reduction in the B12 liver content is seen, which results in a decrease in serum levels in 25% of cases [37]. During acute/chronic liver disease, there is also a reduction in capture by the liver of vitamin B12. In fibrolamellar hepatocellular carcinoma (HCC) and very rarely HCC, elevated serum B12 binding cap can be found because of secretion of abnormal haptocorrin and transcobalamin II by the tumour [39,40].

Iron metabolism

Serum iron concentration is usually low or normal with a low or normal total iron-binding capacity in patients with chronic liver disease, reflecting the anaemic state due to the chronic inflammatory process [41,42]. Early studies of iron kinetics in cirrhotic patients showed normal iron turnover and erythrocyte utilization, despite the anaemic state, reflecting an inadequate bone marrow response to the anaemia [43,44]. Isolated and non-specific increases in serum ferritin levels (an acute phase protein) are frequently found in the absence of iron overload, which are associated with inflammation, hepatic necrosis and alcohol abuse [45,46]. For this reason, a normal ferritin does not exclude iron deficiency anaemia. An increased concentration of serum ferritin in the presence of normal transferrin saturation is usually considered to be iron independent [47]. Alcohol tends to suppress haematopoiesis [48] and may increase iron absorption from the gut [49]. In chronic liver disease, there is a decrease in transferrin synthesis; therefore, the total iron-binding capacity is low, again failing to reflect iron stores. Secondary to the lower concentration of transferrin in liver disease, the iron saturation may be increased to levels seen in genetic haemochromatosis or secondary iron overload [50]. Nearly half of the patients with chronic viral hepatitis B or C have abnormal ferritin concentration and transferrin saturation, associated with higher than normal hepatic iron content [51]. This influences the response to monotherapy with interferon (IFN)α, but not when combined ribavirin and IFN therapy is given [52]. High ferritin levels and high hepatic iron concentration are reported in 24–50% of patients with non-alcoholic steatohepatitis (NASH), which is associated with increased fibrosis in some reports [53]. Patients with isolated hyperferritinaemia not responding to diet seem to be more prone to developing NASH and insulin resistance [54].

Haemochromatosis is discussed in a separate chapter.

Viral-induced bone marrow aplasia

Acute viral hepatitis can lead to transient bone marrow suppression, resulting in a mild reduction in all cell lines [55,56]. Aplastic anaemia is a rare complication of acute viral hepatitis with an incidence 1/1000 [57], accounting for 13% of cases of aplastic anaemia [58]. The mechanism may be an immunological reaction due to a breakdown in tolerance to normal tissue after infection [59]. It typically occurs in healthy young male subjects with strong immunological response 1–3 months after the onset of hepatitis [60]. The presumed infectious cause of aplastic anaemia remains uncertain. Only sporadic cases are associated with hepatitis A [61] or B [62], while most are associated with non-A, non-E infection [63,64]. Recently, a single report found a 32% prevalence of hepatitis G viral infection. Hepatitis-associated aplastic anaemia can be transient and treated with supportive measures and antibiotics [55,56]. If severe bone marrow failure usually occurs, there is an absolute indication for early stem cell transplantation [65]. Only a few studies report successful treatment with high doses of methylprednisolone [66,67] or antilymphocyte globulin [68].

Haemolysis in liver disease

Increased red cell destruction is almost universal with any type of liver disease and jaundice [69]. Haemolytic anaemia characterized by a positive Coomb's test is rare, associated with autoimmune hepatitis, primary biliary cirrhosis (PBC) or primary sclerosing cholangitis (PSC) and in children with giant cell hepatitis [70,71]. Paroxysmal nocturnal haemoglobinuria is a haematological disorder associated with Budd–Chiari syndrome characterized by protein expression defects in red blood cell membranes, which can present with haemolytic anaemia [72]. Bone marrow and blood analysis with flow cytometry can be diagnostic showing CD55 and CD59 positivity [73,74].

Mechanic haemolysis can also be found almost universally after the creation of a transjugular intrahepatic portosystemic shunt (TIPS) [75].

Wilson's disease acute haemolytic syndrome

The first recognized cases of haemolysis associated with Wilson's disease were described between the 1930s and 1960s in young patients [76,77]. In some, ascites developed soon after haemolysis, disappearing after the resolution of the haemolytic

crisis [78]. It is caused by a sudden release of copper from the liver into the bloodstream, leading to severe haemolysis, jaundice and renal impairment [79]. It can typically present with low haemoglobin, without any cause of bleeding, high bilirubin levels, low haptoglobin and negative Coomb's test. Caeruloplasmin concentrations are often normal as it is an acute phase protein [80], and Kayser–Fleischer rings are not always present [79]. It can be the first presentation of Wilson's disease especially in young children and may have a fulminant presentation although, in 75% of cases, liver transplantation is the therapy of choice for the fulminant presentation and severe cases [81]. There is no established medical therapy available for the haemolytic crisis in Wilson's disease, but plasma exchange can be tried [82]. The use of a molecular adsorbent recirculating system has been reported as a bridge until liver transplantation, but this requires confirmation [83]. Penicillamine should be started after the resolution of the acute phase and continued for life, as recurrent haemolytic crises can occur if the initial dosing is lowered [78]. Siblings should be screened.

Spur cell haemolytic anaemia

Blood cells of abnormal shape (acanthocytosis), similar to those found in abetalipoproteinaemia, may be present in blood films of cirrhotic patients, most commonly those with alcoholic liver disease in association with a severe haemolytic anaemia; echinocytes are also present [84]. The liver disease is usually severe. Mortality is high, although the syndrome may last many months [85]; there is no established therapy. Splenectomy and plasma exchange have been tried, without good results [69]. Vitamin E (50–2000 IU/day) may protect polyunsaturated fatty acids in red blood cell membranes from free radical attack and prevent haemolysis, but there are no reports and the prognosis in these patients still remains poor. Combined therapy with flunarizine, pentoxifylline and cholestyramine [86] has been successful in one case report. Liver transplantation can resolve the haemolytic anaemia [87,88], but a recurrence has been reported due to failure of the transplanted graft [89].

Zieve syndrome

Zieve first described this in 1958 in alcoholic liver disease [90]. It comprises haemolytic anaemia, hyperlipoproteinaemia, jaundice and abdominal pain. Serum hyperlipidaemia is usually characterized by hypertriglyceridaemia and hypercholesterolaemia with a type 5 pattern on electrophoresis with increased chylomicrons [91]. Hepatic histology usually reveals fatty liver, but the whole spectrum of alcoholic liver disease is seen [92]. In the acute phase, red cells have an increased content of cholesterol and lecithin in their membranes, leading to pyruvate kinase dysfunction and vitamin E loss, thought to be responsible for the haemolysis [93,94]. Diagnosis with all the criteria present is very rare and, to date, fewer than 100 cases have been described [95]. Alcohol withdrawal results in rapid resolution of the haemolysis and later hyperlipidaemia. Vitamin E supplementation can protect blood cells from oxidative stress, but clinical utility is not clear.

Haemolysis, elevated liver function and low platelets (HELLP) syndrome and acute fatty liver of pregnancy (AFLP)

HELLP occurs in pregnancy and is defined as the presence of haemolysis, elevated liver enzymes and low platelets. It occurs in 0.1–0.6% of all pregnancies and in 4–12% of women with severe pre-eclampsia [96–98]. Most present with malaise, nausea, vomiting and right upper quadrant pain in the third trimester or after delivery in 30%. In 20%, there is no hypertension [99]. The aetiology is unknown, although vascular endothelial injury appears to play a major role. It is associated with multiparous Caucasian women. Maternal (1–3.5%) and perinatal child (5.6–36%) mortality are increased as a result of disseminated intravascular coagulation, abruptio placentae, acute renal failure, pulmonary oedema and subcapsular liver haematoma. The last may rupture in 1%, leading to 16–59% mortality [100]. Early diagnosis with liver management and early delivery of the baby can terminate the haemolysis, but 30% of cases occur postpartum. Liver transplantation has also been used successfully [101]. Some cases are associated with long-chain fatty acid enzyme deficiency. There is an overlap with acute fatty liver of pregnancy (AFLP) [102]. In AFLP, a blood film shows nucleated red cells, giant platelets and even basophilic stippling. This can help to distinguish AFLP from other disorders – red cell fragments and burr cells are seen in HELLP [103].

Leukocyte abnormalities

The incidence of leucopenia in liver disease ranges from 11% to 41% [104] and is usually mild, between 1.3 and 3×10^9/L [17]; more severe leucopenia is rare. If the total white cell count is normal, relative lymphopenia is often seen [18]. Sequestration of leukocytes due to hypersplenism has not been substantiated; Gurakar *et al.* [105] showed no pooling of new synthesized leukocytes after granulocyte–macrophage colony-stimulating factor (GM-CSF) administration in cirrhotic patients. Both hepatitis B and C [106,107], as well as alcohol [108], induce suppression of lymphocyte progenitors in the bone marrow. Alcohol also causes retardation in maturation and release of neutrophils from the bone marrow [109]. Leucocytosis can be seen during cholangitis, acute alcoholic hepatitis, hepatic abscesses and malignant disease. Atypical lymphocytes can be found during acute viral hepatitis and mononucleosis [17]. Peripheral eosinophilia has been shown by some during the early or asymptomatic stages of PBC (incidence 19%) [110]. The eosinophils in PBC patients are not only increased in number, but also in granule proteins, indicating eosinophil activation [111]. Ursodeoxycholic acid (UDCA) therapy can greatly reduce elevated eosinophil counts [112].

Cirrhotic patients are prone to develop infections, but the mechanism has been shown to be multifactorial, and not only due to the leucopenia [113]. Humoral disturbances, which include abnormal immunoglobulin production, a decrease in serum opsonic activity and the presence of serum chemotaxis inhibitors, are well described [114]. Cellular disturbances of Kupffer cells, monocytes and lymphocytes are recognized [115]. Neutrophilic phagocytic function and intracellular killing activity are also reduced in cirrhosis, particularly in alcoholic cirrhosis [116]. Among several mechanisms, portal systemic shunting of blood may be responsible for neutrophil dysfunction, as this is also seen in extrahepatic portal hypertension with normal liver function, but this is disputed [117]. Whether serum from cirrhotic patients inhibits neutrophil activation is controversial [118,119].

Platelet abnormalities

Abnormalities in both platelet number and function are common in patients with liver disease and contribute to the impaired haemostasis.

About one-third of cirrhotics develop thrombocytopenia, which is usually mild to moderate (70 000–90 000/μL) and worsens together with progression of the disease [120,121]. Thrombocytopenia is not associated with an increased risk of bleeding from oesophageal varices or other sources, but it has been shown to be correlated with blood loss during surgery [122]. Usually, platelet transfusion therapy before surgery aims to increase platelet count to $> 50 \times 10^9$/L, but a lower count is allowed if thrombocytopenia is due to accelerated platelet destruction and if less invasive procedures are planned [17].

Blake *et al.* [123] showed that a platelet count $> 80 \times 10^9$/L – usually taken a as a safe limit for liver biopsy – is not predictive of a normal bleeding time in patients with liver cirrhosis. There is no good correlation between bleeding time and platelet count $\leq 100 \times 10^9$/L, as there is with thrombocytopenia due to bone marrow disorders [123].

Spleen size/platelet ratio has recently been shown to have high predictive value for the presence of oesophageal varices in cirrhotic patients [124]. Thrombocytopenia is caused mainly by hypersplenism and consequent sequestration. However, insertion of a TIPS, although it increases platelet count, does not normalize it [125,126], so that other mechanisms are also important.

Splenectomy is contraindicated in cirrhotic patients because of a high mortality rate and risk of portal vein thrombosis, which leads to more difficult surgery including liver transplantation, as well as an increased risk of bleeding varices [127]. Splenic embolization aiming for a 30–50% reduction in flow can markedly increase platelet number in cirrhotic patients awaiting liver transplantation and in patients needing transarterial therapy for hepatocellular carcinoma or antiviral therapy [128]. Recently, splenic embolization has been shown to increase not only platelet number, but also TPO levels, suggesting a role for the spleen in degrading TPO. In a single paper, the role of extrahepatic portal hypertension in thrombocytopenia showed that it is less severe for an equivalent spleen size, compared with cirrhotics [129]. This is related to the fact that TPO hepatic synthesis is essential for platelet production. Although TPO increases in patients with thrombocytopenia and normal liver function [130], TPO levels increase less significantly in thrombocytopenic patients with severe or chronic liver failure [131]. Evidence of impaired TPO synthesis is also shown by lower TPO mRNA levels in cirrhotic liver tissue [132] and a low platelet production in the bone marrow [133].

Hepatitis C virus (HCV), acute viral infection, alcohol abuse and folate deficiency have a myelosuppressive action that further reduces platelet count [134]. Consumption coagulopathy is not common in cirrhotics, and a low level of disseminated intravascular coagulation (DIC) does not affect platelet count [135,136].

Thrombocytopenia due to an immune-mediated mechanism resulting from increased production from B cells of antibodies binding platelet surface antigen GPIIb–IIIa and GPIb/IX [137] has been shown in cirrhotic patients. This can lead to decreased platelet survival and a higher reticuloendothelial destruction of platelets. This phenomenon has been reported in chronic hepatitis C [137] infection as well as in autoimmune liver disease and PBC [138]. Among 368 patients with viral-induced cirrhosis, elevated titres of platelet-associated immunoglobulin G were observed in 88% of hepatitis C patients and 47% of patients with hepatitis B [134].

Platelet function is impaired, particularly aggregation, which worsens with the severity of liver disease, as assessed with adenosine diphosphate (ADP) or reptilase tests [139]. There is an abnormal content of arachidonic acid in platelet membranes of cirrhotics, which induces less aggregation mediated by thromboxane A2. In serum from cirrhotic patients, abnormal HDL (related to a high apolipoprotein E content) alters NO content in the platelets, leading to abnormal aggregability [140]. In addition, a low platelet calcium content and reduced signalling transduction after stimulus with thrombin, platelet activating factor or U-46619 have been shown in cirrhotic patients compared with control subjects, contributing to abnormal platelet function [141]. Platelets from cirrhotics also have a defect in the von Willebrand factor-binding domain, resulting in reduced attachment of platelets exposed to subendothelium, i.e. defective primary haemostasis [142].

The appearance of a normal or raised platelet count in patients with liver cirrhosis may occur in response to infection, inflammation, neoplasia, bleeding or iron deficiency – all these conditions should be suspected even when the count is normal in patients with liver disease.

Immunoglobulins in liver cirrhosis and viral-induced mixed cryoglobulinaemia

An increase in serum immunoglobulins (hypergammaglobuli-

naemia) is a well-known feature of chronic liver disease [17]. It is considered to be caused by spillover of antigens from the gut bypassing the Kupffer cells in the damaged liver, with an increased antibody response from organs such as the spleen [143,144]. Additional factors exist as there are increases in specific liver diseases. Thus, there is an increased serum IgA mainly against acetaldehyde-derived epitopes in alcoholic liver disease, even from a very early stage [145,146]. Hepatitis C virus selectively increases IgG during the early stages of the disease, compared with normal control subjects [147].

HCV can also cause stimulation and expansion of peripheral blood B cells with naive phenotype and production of IgM with rheumatoid factor activity [148]. These are considered to be the main pathogenetic mechanisms of cryoglobulinaemia II and III, which are associated with HCV in 36–54% of cases [149]. Type II and III (or 'mixed') cryoglobulinaemia are characterized by polyclonal IgG and monoclonal or polyclonal IgM cryoprecipitable rheumatoid factor respectively [150]. The circulating immune complexes deposit in small to medium-sized blood vessels, giving rise to purpura, arthralgia and weakness. However, clinical signs and secondary renal failure are rare [151]. At present, IFNα preferably in its pegylated form is the first-choice therapy for HCV-related mixed cryoglobulinaemia as, if sustained virological response occurs, it is accompanied by a reduction in circulating cryoglobulin levels and remission of symptoms [152–155]. Combination with ribavirin may be more effective, but the effect is less than in patients with chronic HCV infection without cryoglobulinaemia [156]. Plasmapheresis and cryofiltration aimed at removing circulating cryoglobulin are only indicated in patients with progressive renal failure, severe vasculopathy or neuropathy. Recently, the anti-CD20 chimaeric monoclonal antibody rituximab has been used, which depletes B cells and can be used when antiviral therapy is not indicated (i.e. in patients with severe renal failure) as well as in the non-responders [157,158].

HCV-associated lymphoproliferative disorders

Franzin *et al.* [159], investigating the B-cell monoclonality in patients with HCV infection, found a monoclonal population in the peripheral blood lymphocytes of all subjects affected by mixed cryoglobulinaemia and in 24% with chronic HCV without mixed cryoglobulinaemia. These findings indicate that HCV infection can play a role in B-cell clonal proliferation, which can evolve from an intermediate condition to an overt malignant lymphoproliferative disorder.

Epidemiological observation, especially from Italy, has suggested an association between HCV infection and non-Hodgkin's lymphoma (NHL), especially the diffuse large cell lymphoma. Chronic stimulation of B cells [160], 14:18 chromosome translocation (dependent on viral activity) and bcl-2 overexpression are the trigger factors for B-cell monoclonal expansion [161]. Antiviral therapy with IFN or IFN combined with ribavirin can resolve low-grade NHL, providing that HCV infection is suppressed [162]; HCV relapse is usually followed by recurrence of lymphoma [163–165]. Recently, anti-CD20 chimaeric monoclonal antibody has been effective in some case reports [166–168]. Larger therapeutic trials are needed.

Haematological abnormalities after liver transplantation

Anaemia and haemolysis

Transient erythropoiesis occurs within the liver graft after liver transplantation, and transmission of leukocytes, particularly lymphocytes, leads to the coexistence of autologous and allogenic leukocytes, i.e. chimaerism [169].

Red cell antibodies produced by donor B lymphocytes and immune haemolysis have been described during the first to second week following liver transplantation, persisting up to the first month [170]. Haemolytic anaemia is described in about 10% who receive an incompatible ABO graft, characterized by mild transient haemolysis, with only a few having a severe form with renal failure [171]. Haemolysis due to D incompatibility in the setting of ABO-compatible liver transplantation is rare, and only six cases have been described to date, one of them with longstanding antibodies persisting at 1 year after transplant [172].

Anaemia in liver transplant recipients ranges widely from 4.3% to 28.2%, depending upon the time interval after transplantation, the definition of anaemia and the immunosuppression regimen [170]. Immediate postoperative anaemia is secondary to blood loss, renal insufficiency, infections or medications. However, in a significant number (almost 50%) [173], plastic anaemia is rare, occurring in the period between 2 and 6 weeks after liver transplantation and seen in 5–33% of patients, predominantly in children and young adults transplanted for fulminant non-A to non-E hepatitis; cytomegalovirus (CMV) and Epstein–Barr virus (EBV) have been described in the bone marrow in these cases [174,175], but it is unclear whether these are partly responsible; parvovirus B19 can be responsible in a minority of cases [176].

Bone marrow depression due to immunosuppressive medication has been reported in 1–2% with calcineurin inhibitors, 43% with mycophenolate mofetil and 53% with azathioprine [177]. Iron deficiency anaemia is more common among paediatric liver transplant recipients [178]. When present in adult recipients, gastrointestinal blood loss, in particular from colorectal cancer, should be excluded as a higher prevalence has been shown in solid organ-transplanted recipients [179].

Renal insufficiency occurs in 8% at 7 years and 18% at 13 years and may be a concomitant cause of chronic anaemia which responds to EPO [180,181]. A description of causes of anaemia after liver transplantation and suggested screening tests is shown in Table 3.

Table 3 Cause of anaemia after liver transplantation according to the time of presentation.

Aetiology	Mechanism	Diagnostic test
First month		
Bleeding		Iron indices, imaging Endoscopy
Sepsis	Myelosuppression	
Medications	Myelosuppression Haemolysis Microangiopathic anaemia	Change medication
Haemolysis	ABO incompatibility K, D incompatibility	Aptoglobine, Coomb's test
Less than 1 year		
Medications	Myelosuppression Haemolysis Microangiopathic anaemia	Change medication
Aplastic anaemia	FHF, viral infections Immunological	Viral screening
GVHD	Bone marrow suppression Immunological	
CMV	Destruction of bone marrow Stromal cells, haemolysis	Serology, pp65
Parvovirus B19	Lysis of erythroid precursors	Serology
Greater than 1 year		
Medications	Myelosuppression Haemolysis Microangiopathic anaemia	Change medication
Iron deficit anaemia	Blood loss, tumour	GI endoscopy
Renal insufficiency	Decreased EPO	EPO supplementation
PTLD	Bone marrow suppression	Chromosomal translocation, liver biopsy
Multifactorial		

CMV, cytomegalovirus; EPO, erythropoietin; FHF, fulminant hepatic failure; GI, gastrointestinal; GVHD, graft-versus-host disease; PTLD, post-transplant lymphoproliferative disorders.

Platelet function

Thrombocytopenia is common in the early postoperative period, mainly due to platelet activation and consumption following graft reperfusion [182]. Liver function in restored thrombocytopenia resolves progressively a few days after orthotopic liver transplantation (OLT). Concomitantly, with restoration of normal hepatic synthetic function, thrombopoietin levels increase significantly on the first day, followed by immature bone marrow platelets after 3 days and normal circulating platelets after 5 days [183]. Normalization of platelet count can be seen after 14 days in patients without splenomegaly pretransplant. The peak in TPO levels correlates with the pre-OLT platelet count. Serum levels of bilirubin concentrations, cold ischaemia time or episodes of rejection do not influence TPO levels [184]. Persistence of thrombocytopenia can be seen in some patients [185], but whether the degree of persistent splenomegaly is responsible is controversial, i.e. with thrombocytopenia due to bone marrow disorders.

Post-transplant lymphoproliferative disorders (PTLD)

The incidence of post-transplant proliferative disorders is 2–10% in liver transplant recipients ranging from 2% to 3% in adults [186,187] to more than 10% in some paediatric series [188,189]. Tumour onset typically occurs more than 1 year after transplantation in adults and within the first year in children, although PTLD can occur several years after transplant. A retrospective study comprising 605 patients showed that 55% had cervical abdominal or thoracic lymphoadenopathy, 25% had a portal mass and 15% a gastrointestinal mass [190]. Histopathology, immunophenotyping and molecular studies are necessary for diagnosis.

The risk factors for PTLD are recipient age and EBV donor/recipient status, stable gammopathy, use of antilymphocytic serum and tacrolimus in children [191]. The incidence of PTLD varies according to differential aetiologies of liver disease: histiocytosis, PSC, alcoholic cirrhosis and HCV represent the most

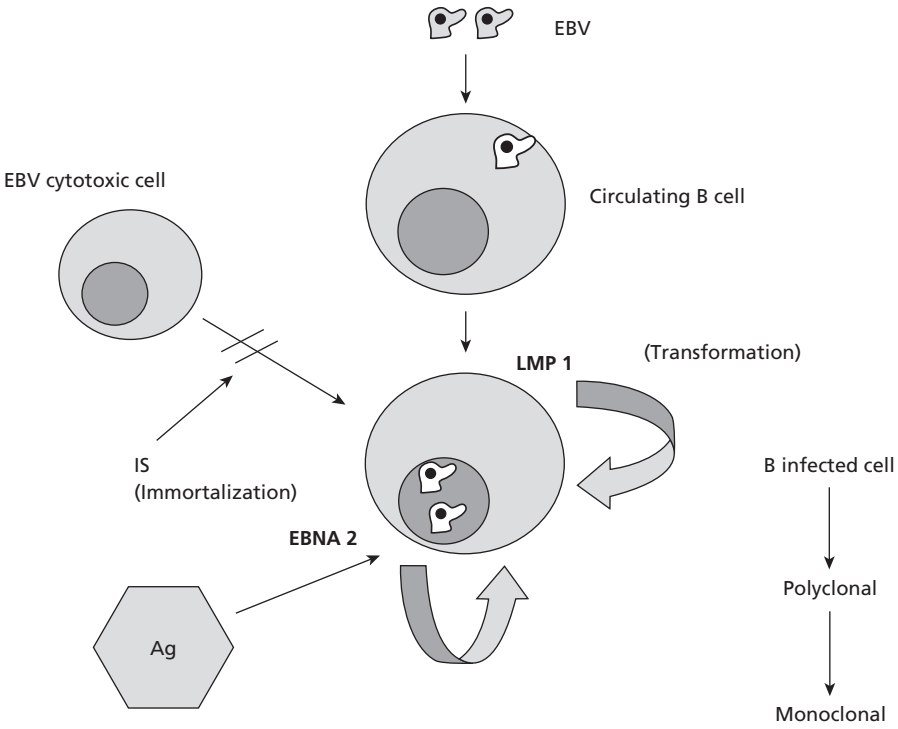

Fig. 1 Pathophysiology of the development of post-liver transplant lymphoproliferative disorders, regarding the role of EBV infection.

important ones. PTLD originates in 85% of cases from B cells in EBV-positive individuals [192,193]. During latent infection, this virus expresses protein which can act in an oncogenic pathway [194]. Late-onset PTLD has the same characteristics as lymphomas in immunocompetent patients [195].

Early PTLD may originate from donor lymphocytes and usually involves hilar structures, whereas late-onset PTLD is usually diffuse and originates from recipient B cells [196]. A summary of the pathogenetic mechanisms is represented in Figure 1.

No uniform therapeutic approach for PTLD exists. Withdrawal of immunosuppression, even if acute rejection can occur, is effective especially in the early stage of the disease when a recovered response of T cells against EBV can lead to a partial or complete regression of PTLD [197]. There is no role for antiviral therapy against EBV [198]. In diffuse or rapidly growing PTLD, chemotherapy is the treatment of choice, although side-effects may limit its use [199–201]. Monoclonal antibodies against B cells (anti-CD20, 21, 24) have also been used as rescue therapy, after the failure of immunosuppression withdrawal or as a first-line therapy [202]. Approximately 40% of patients respond, with 63% survival at 1 year. However, overall survival remains poor, with a 40–60% mortality rate [203].

References

1 Ackerman GA, Grasso JA, Knouff RA (1961) Erythropoiesis in the mammalian embryonic liver as revealed by electron microscopy. *Lab Invest* 10, 787–796.
2 Fried W (1972) The liver as a source of extrarenal erythropoietin production. *Blood* 40, 671–677.
3 Jelkmann W (1992) Erythropoietin: structure, control of production, and function. *Physiol Rev* 72, 449–489.
4 McDonald TP (1988) Thrombopoietin: its biology, purification, and characterization. *Exp Hematol* 16, 201–205.
5 Jelkmann W (2001) The role of the liver in the production of thrombopoietin compared with erythropoietin. *Eur J Gastroenterol Hepatol* 13, 791–801.
6 Radovic M, Jelkmann W, Djukanovic L *et al.* (1999) Serum erythropoietin and interleukin-6 levels in hemodialysis patients with hepatitis virus infection. *J Interferon Cytokine Res* 19, 369–373.
7 Kew MC, Fisher JW (1986) Serum erythropoietin concentrations in patients with hepatocellular carcinoma. *Cancer* 58, 2485–2488.
8 Jandl JH (1955) The anemia of liver disease: observations on its mechanism. *J Clin Invest* 34, 390–404.
9 Kimber C, Deller DJ, Ibbotson RN *et al.* (1965) The mechanism of anaemia in chronic liver disease. *Q J Med* 34, 33–64.
10 Phillips DL, Keeffe EB (1987) Hematological manifestations of gastrointestinal diseases. *Hematol/Oncol Clin North Am* 1, 207–228.
11 Sheehy TW, Berman A (1960) The anemia of cirrhosis. *J Lab Clin Med* 56, 72–82.
12 Mutchnick MG, Lerner E, Conn HO (1980) Effect of portacaval anastomosis on hypersplenism. *Dig Dis Sci* 25, 929–938.
13 Siciliano M, Tomasello D, Milani A *et al.* (1995) Reduced serum levels of immunoreactive erythropoietin in patients with cirrhosis and chronic anemia. *Hepatology* 22, 1132–1135.
14 Jensen JD, Jensen LW, Madsen JK *et al.* (1995) The metabolism of erythropoietin in liver cirrhosis patients compared with healthy volunteers. *Eur J Haematol* 54, 111–116.
15 Kajikawa M, Nonami T, Kurokawa T *et al.* (1993) Recombinant human erythropoietin and hypophosphatemia in patients with cirrhosis. *Lancet* 341, 503–504.

16 Pirisi M, Fabris C, Soardo G *et al.* (1994) Thrombocytopenia of chronic liver disease corrected by erythropoietin treatment. *J Hepatol* 21, 376–380.
17 Dooley J (2002) The haematology of liver disease. In: Sherlock S, Dooley J (eds) *Diseases of the Liver and Biliary System*. Oxford: Blackwell Publishing, pp. 47–64.
18 Berman L, Axelrod AR, Horan TN *et al.* (2005) The blood and bone marrow in patients with cirrhosis of the liver. *Blood* 4, 511–529.
19 Weiss G, Goodnough LT (2005) Anemia of chronic disease. *N Engl J Med* 352, 1011–1023.
20 Young NS (1990) Flaviviruses and bone marrow failure. *JAMA* 263, 3065–3068.
21 Zeldis JB, Mugishima H, Steinberg HN *et al.* (1986) In vitro hepatitis B virus infection of human bone marrow cells. *J Clin Invest* 78, 411–417.
22 Peck-Radosavljevic M (2000) Thrombocytopenia in liver disease. *Can J Gastroenterol* 14(Suppl. D), 60D–6D.
23 Peck-Radosavljevic M (2001) Hypersplenism. *Eur J Gastroenterol Hepatol* 13, 317–323.
24 Friedman LS (1999) The risk of surgery in patients with liver disease. *Hepatology* 29, 1617–1623.
25 Straus DJ (1973) Hematologic aspects of alcoholism. *Semin Hematol* 10, 183–194.
26 Bessis M, Weed RI, Le Pond PF (1973) *Red Cell Shape: Physiology, Pathology, Ultrastructure*. New York: Springer-Verlag.
27 Cooper RA, Arner EC, Wiley JS *et al.* (1975) Modification of red cell membrane structure by cholesterol-rich lipid dispersions. A model for the primary spur cell defect. *J Clin Invest* 55, 115–126.
28 Cooper RA (1980) Hemolytic syndromes and red cell membrane abnormalities in liver disease. *Semin Hematol* 17, 103–112.
29 Grahn EP, Dietz AA, Stefani SS *et al.* (1968) Burr cells, hemolytic anemia and cirrhosis. *Am J Med* 45, 78–87.
30 Owen JS, Brown DJ, Harry DS *et al.* (1985) Erythrocyte echinocytosis in liver disease. Role of abnormal plasma high density lipoproteins. *J Clin Invest* 76, 2275–2285.
31 Gisselbrecht C, Metreau JM, Dhumeaux D *et al.* (1977) [Acanthocytosis in cirrhosis. Report of four cases and review of the literature (author's transl.)]. *Gastroenterol Clin Biol* 1, 621–628.
32 Chanarin I, Hutchinson M, McLean A *et al.* (1966) Hepatic folate in man. *Br Med J* 5484, 396–399.
33 Lindenbaum J, Lieber CS (1975) Effects of chronic ethanol administration on intestinal absorption in man in the absence of nutritional deficiency. *Ann NY Acad Sci* 252, 228–234.
34 Grasbeck R, Nyberg W, Reizenstein P (1958) Biliary and fecal vit. B12 excretion in man: an isotope study. *Proc Soc Exp Biol Med* 97, 780–784.
35 Jones PN, Mills EH, Capps RB (1957) The effect of liver disease on serum vitamin B12 concentrations. *J Lab Clin Med* 49, 910–922.
36 Corrocher R, Bambara LM, Pachor ML *et al.* (1980) Different binding proteins for folic acid in serum of patients with acute hepatitis. *Acta Haematol* 64, 281–284.
37 Danford DE, Munro HM (1982) The liver in relation to the B vitamins. In: Arias L, Popper H, Schachter D *et al.* (eds) *The Liver: Biology and Pathophysiology*. New York: Raven Press, pp. 367–384.
38 Lambert D, Benhayoun S, Adjalla C *et al.* (1997) Alcoholic cirrhosis and cobalamin metabolism. *Digestion* 58, 64–71.
39 Geissbuhler P, Mermillod B, Rapin CH (2000) Elevated serum vitamin B12 levels associated with CRP as a predictive factor of mortality in palliative care cancer patients: a prospective study over five years. *J Pain Symptom Manage* 20, 93–103.
40 Boisson F, Fremont S, Migeon C *et al.* (1999) Human haptocorrin in hepatocellular carcinoma. *Cancer Detect Prev* 23, 89–96.
41 Bentley DP (1982) Anaemia and chronic disease. *Clin Haematol* 11, 465–479.
42 Means RT Jr, Krantz SB (1992) Progress in understanding the pathogenesis of the anemia of chronic disease. *Blood* 80, 1639–1647.
43 Chapman RW, Morgan MY, Boss AM *et al.* (1983) Acute and chronic effects of alcohol on iron absorption. *Dig Dis Sci* 28, 321–327.
44 Chapman RW, Morgan MY, Bell R *et al.* (1983) Hepatic iron uptake in alcoholic liver disease. *Gastroenterology* 84, 143–147.
45 Weinberg ED (1986) Iron, infection, and neoplasia. *Clin Physiol Biochem* 4, 50–60.
46 Bell H, Skinningsrud A, Raknerud N *et al.* (1994) Serum ferritin and transferrin saturation in patients with chronic alcoholic and non-alcoholic liver diseases. *J Intern Med* 236, 315–322.
47 Girelli D, Corrocher R, Bisceglia L *et al.* (1995) Molecular basis for the recently described hereditary hyperferritinemia–cataract syndrome: a mutation in the iron-responsive element of ferritin L-subunit gene (the 'Verona mutation'). *Blood* 86, 4050–4053.
48 Sullivan LW, Herbert V (1964) Suppression hematopoiesis by ethanol. *J Clin Invest* 43, 2048–2062.
49 Charlton RW, Jacobs P, Seftel H *et al.* (1964) Effect of alcohol on iron absorption. *Br Med J* 5422, 1427–1429.
50 Bacon BR, Tavill AS (1984) Role of the liver in normal iron metabolism. *Semin Liver Dis* 4, 181–192.
51 Bonkovsky HL, Banner BF, Rothman AL (1997) Iron and chronic viral hepatitis. *Hepatology* 25, 759–768.
52 Rulyak SJ, Eng SC, Patel K *et al.* (2005) Relationships between hepatic iron content and virologic response in chronic hepatitis C patients treated with interferon and ribavirin. *Am J Gastroenterol* 100, 332–337.
53 Fargion S, Mattioli M, Fracanzani AL *et al.* (2001) Hyperferritinemia, iron overload, and multiple metabolic alterations identify patients at risk for nonalcoholic steatohepatitis. *Am J Gastroenterol* 96, 2448–2455.
54 Valenti L, Dongiovanni P, Fracanzani AL *et al.* (2003) Increased susceptibility to nonalcoholic fatty liver disease in heterozygotes for the mutation responsible for hereditary hemochromatosis. *Dig Liver Dis* 35, 172–178.
55 Kivel RM (1961) Hematologic aspects of acute viral hepatitis. *Am J Dig Dis* 6, 1017–1031.
56 Firkin FC, Nicholls K, Whelan G (1978) Transient myeloid and erythroid aplasia associated with infectious hepatitis. *Br Med J* 2, 1534.
57 Pikis A, Kavaliotis J, Manios S (1988) Incidence of aplastic anemia in viral hepatitis in children. *Scand J Infect Dis* 20, 109–110.
58 Zeldis JB, Dienstag JL, Gale RP (1983) Aplastic anemia and non-A, non-B hepatitis. *Am J Med* 74, 64–68.
59 Peters M, Trippler M, Lohr H *et al.* (1995) Posttransfusional, LKM-1-autoantibody-positive hepatitis C virus infection, cryoglobulinemia, and aplastic anemia. *Dig Dis Sci* 40, 763–773.
60 Hagler L, Pastore RA, Bergin JJ *et al.* (1975) Aplastic anemia following viral hepatitis: report of two fatal cases and literature review. *Medicine (Baltimore)* 54, 139–164.
61 Domenech P, Palomeque A, Martinez-Gutierrez A *et al.* (1986) Severe aplastic anaemia following hepatitis A. *Acta Haematol* 76, 227–229.
62 Casciato DA, Klein CA, Kaplowitz N *et al.* (1978) Aplastic anemia associated with type B viral hepatitis. *Arch Intern Med* 138, 1557–1558.

63 Bannister P, Miloszewski K, Barnard D *et al.* (1983) Fatal marrow aplasia associated with non-A, non-B hepatitis. *Br Med J (Clin Res Ed)* 286, 1314–1315.

64 Cargnel A, Vigano P, Davoli C *et al.* (1983) Sporadic acute non-A non-B hepatitis complicated by aplastic anemia. *Am J Gastroenterol* 78, 245–247.

65 Brown KE, Tisdale J, Barrett AJ *et al.* (1997) Hepatitis-associated aplastic anemia. *N Engl J Med* 336, 1059–1064.

66 Ozsoylu S (1992) Transient hypoplastic anemia of childhood. *Am J Hematol* 40, 240–241.

67 Ozsoylu S, Coskun T, Minassazi S (1984) High dose intravenous glucocorticoid in the treatment of childhood acquired aplastic anaemia. *Scand J Haematol* 33, 309–316.

68 Paquette RL, Tebyani N, Frane M *et al.* (1995) Long-term outcome of aplastic anemia in adults treated with antithymocyte globulin: comparison with bone marrow transplantation. *Blood* 85, 283–290.

69 Pitcher CS, Williams R (1963) Reduced red cell survival in jaundice and its relation to abnormal glutathione metabolism. *Clin Sci* 24, 239–252.

70 Fuller SJ, Kumar P, Weltman M *et al.* (2003) Autoimmune hemolysis associated with primary biliary cirrhosis responding to ursodeoxycholic acid as sole treatment. *Am J Hematol* 72, 31–33.

71 Mahl MA, von Schonfeld J, Uppenkamp M *et al.* (1996) [Hemolytic anemia as cause of a marked bilirubin increase in primary biliary cirrhosis.] *Dtsch Med Wochenschr* 121, 1226–1228.

72 Senzolo M, Cholongitas EC, Patch D *et al.* (2005) Update on the classification, assessment of prognosis and therapy of Budd–Chiari syndrome. *Nature Clin Pract Gastroenterol Hepatol* 2, 182–190.

73 Cui W, Zhang Z (2002) [Expression of CD(59) and CD(45) on lymphocytes in paroxysmal nocturnal hemoglobinuria patients.] *Zhonghua Xue Ye Xue Za Zhi* 23, 77–79.

74 Shichishima T, Terasawa T, Saitoh Y *et al.* (1993) Diagnosis of paroxysmal nocturnal haemoglobinuria by phenotypic analysis of erythrocytes using two-colour flow cytometry with monoclonal antibodies to DAF and CD59/MACIF. *Br J Haematol* 85, 378–386.

75 Sanyal AJ, Freedman AM, Purdum PP *et al.* (1996) The hematologic consequences of transjugular intrahepatic portosystemic shunts. *Hepatology* 23, 32–39.

76 Cartwright GE, Hodges RE, Gubler CJ *et al.* (1954) Studies on copper metabolism. XIII. Hepatolenticular degeneration. *J Clin Invest* 33, 1487–1501.

77 Scheinberg IH, Sternlieb I (1959) The liver in Wilson's disease. *Gastroenterology* 37, 550–564.

78 McIntyre N, Clink HM, Levi AJ *et al.* (1967) Hemolytic anemia in Wilson's disease. *N Engl J Med* 276, 439–444.

79 Lau JY, Lai CL, Wu PC *et al.* (1990) Wilson's disease: 35 years' experience. *Q J Med* 75, 597–605.

80 Degenhardt S, Blomhard G, Hefter H *et al.* (1994) [A hemolytic crisis with liver failure as the first manifestation of Wilson's disease.] *Dtsch Med Wochenschr* 119, 1421–1426.

81 Gow PJ, Smallwood RA, Angus PW *et al.* (2000) Diagnosis of Wilson's disease: an experience over three decades. *Gut* 46, 415–419.

82 Matsumura A, Hiraishi H, Terano A (1999) Plasma exchange for hemolytic crisis in Wilson disease. *Ann Intern Med* 131, 866.

83 Sen S, Felldin M, Steiner C *et al.* (2002) Albumin dialysis and Molecular Adsorbents Recirculating System (MARS) for acute Wilson's disease. *Liver Transpl* 8, 962–967.

84 Smith JA, Lonergan ET, Sterling K (1964) Spur-cell anemia: hemolytic anemia with red cells resembling acanthocytes in alcoholic cirrhosis. *N Engl J Med* 271, 396–398.

85 Silber R, Amorosi E, Lhowe J *et al.* (1966) Spur-shaped erythrocytes in Laennec's cirrhosis. *N Engl J Med* 275, 639–643.

86 Aihara K, Azuma H, Ikeda Y *et al.* (2001) Successful combination therapy – flunarizine, pentoxifylline, and cholestyramine – for spur cell anemia. *Int J Hematol* 73, 351–355.

87 Chitale AA, Sterling RK, Post AB *et al.* (1998) Resolution of spur cell anemia with liver transplantation: a case report and review of the literature. *Transplantation* 65, 993–995.

88 Thomson A, Kerlin P, Clouston A *et al.* (1997) Spur cell anaemia resolves after orthotopic liver transplantation (OLT). *Aust NZ J Med* 27, 198–199.

89 Malik P, Bogetti D, Sileri P *et al.* (2002) Spur cell anemia in alcoholic cirrhosis: cure by orthotopic liver transplantation and recurrence after liver graft failure. *Int Surg* 87, 201–204.

90 Zieve L (1958) Jaundice, hyperlipidemia and hemolytic anemia: a heretofore unrecognized syndrome associated with alcoholic fatty liver and cirrhosis. *Ann Intern Med* 48, 471–496.

91 Zieve L (1966) Hemolytic anaemia in liver disease. *Medicine (Baltimore)* 45, 497.

92 Veyrac M, Montaron JC, Feneyrou B *et al.* (1982) [Zieve's syndrome and acute alcoholic hepatitis (author's transl.)]. *Nouv Presse Med* 11, 2003–2005.

93 Goebel KM (1975) Red cell metabolism in transient haemolytic anaemia associated with Zieve's syndrome. *Eur J Clin Invest* 5, 83–91.

94 Goebel KM, Goebel FD, Schubotz R *et al.* (1977) Red cell metabolic and membrane features in haemolytic anaemia of alcoholic liver disease (Zieve's syndrome). *Br J Haematol* 35, 573–585.

95 Pilcher CR, Underwood RG, Smith HR (1996) Zieve's syndrome a potential surgical pitfall? *J R Army Med Corps* 142, 84.

96 Pereira SP, O'Donohue J, Wendon J *et al.* (1997) Maternal and perinatal outcome in severe pregnancy-related liver disease. *Hepatology* 26, 1258–1262.

97 Knox TA, Olans LB (1996) Liver disease in pregnancy. *N Engl J Med* 335, 569–576.

98 Sibai BM, Ramadan MK, Usta I *et al.* (1993) Maternal morbidity and mortality in 442 pregnancies with hemolysis, elevated liver enzymes, and low platelets (HELLP syndrome). *Am J Obstet Gynecol* 169, 1000–1006.

99 Geary M (1997) The HELLP syndrome. *Br J Obstet Gynaecol* 104, 887–891.

100 Bis KA, Waxman B (1976) Rupture of the liver associated with pregnancy: a review of the literature and report of 2 cases. *Obstet Gynecol Surv* 31, 763–773.

101 Shames BD, Fernandez LA, Sollinger HW *et al.* (2005) Liver transplantation for HELLP syndrome. *Liver Transpl* 11, 224–228.

102 Burroughs AK (1998) Pregnancy and liver disease. *Forum (Genova)* 8, 42–58.

103 Burroughs AK, Seong NH, Dojcinov DM *et al.* (1982) Idiopathic acute fatty liver of pregnancy in 12 patients. *Q J Med* 51, 481–497.

104 Pursnani KG, Sillin LF, Kaplan DS (1997) Effect of transjugular intrahepatic portosystemic shunt on secondary hypersplenism. *Am J Surg* 173, 169–173.

105 Gurakar A, Fagiuoli S, Gavaler JS *et al.* (1994) The use of granulocyte–macrophage colony-stimulating factor to enhance hematologic parameters of patients with cirrhosis and hypersplenism. *J Hepatol* 21, 582–586.

106 Steinberg HS, Bouffard P, Trepo C *et al.* (1990) In vitro inhibition of hemopoietic cell line growth by hepatitis B virus. *J Virol* 64, 2577–2581.

107 Zeldis JB, Boender PJ, Hellings JA *et al.* (1989) Inhibition of human hemopoiesis by non-A, non-B hepatitis virus. *J Med Virol* 27, 34–38.

108 Liu YK (1980) Effects of alcohol on granulocytes and lymphocytes. *Semin Hematol* 17, 130–136.

109 Kusaba N, Kumashiro R, Ogata H *et al.* (1998) In vitro study of neutrophil apoptosis in liver cirrhosis. *Intern Med* 37, 11–17.

110 Wirth HP, Heer P, Bertschinger P *et al.* (1993) [Transient eosinophilia in primary biliary cirrhosis.] *Schweiz Med Wochenschr* 123, 2278–2283.

111 Yamazaki K, Suzuki K, Nakamura A *et al.* (1999) Ursodeoxycholic acid inhibits eosinophil degranulation in patients with primary biliary cirrhosis. *Hepatology* 30, 71–78.

112 Wirth HP, Meyenberger C, Altorfer J *et al.* (1994) [Eosinophilia in primary biliary cirrhosis: regression under therapy with ursodeoxycholic acid.] *Schweiz Med Wochenschr* 124, 810–815.

113 Rajkovic IA, Williams R (1985) Mechanisms of abnormalities in host defences against bacterial infection in liver disease. *Clin Sci (Lond)* 68, 247–253.

114 Rajkovic IA, Williams R (1986) Abnormalities of neutrophil phagocytosis, intracellular killing and metabolic activity in alcoholic cirrhosis and hepatitis. *Hepatology* 6, 252–262.

115 Fiuza C, Salcedo M, Clemente G *et al.* (2000) In vivo neutrophil dysfunction in cirrhotic patients with advanced liver disease. *J Infect Dis* 182, 526–533.

116 DeMeo AN, Andersen BR (1972) Defective chemotaxis associated with a serum inhibitor in cirrhotic patients. *N Engl J Med* 286, 735–740.

117 Kirsch R, Woodburne VE, Shephard EG *et al.* (2000) Patients with stable uncomplicated cirrhosis have normal neutrophil function. *J Gastroenterol Hepatol* 15, 1298–1306.

118 Kumagi T, Akbar F, Horiike N *et al.* (2001) Increased serum levels of macrophage migration inhibitory factor in alcoholic liver diseases and their expression in liver tissues. *Clin Biochem* 34, 189–193.

119 Bansi D, Chapman R, Fleming K (1996) Antineutrophil cytoplasmic antibodies in chronic liver diseases: prevalence, titre, specificity and IgG subclass. *J Hepatol* 24, 581–586.

120 Noguchi H, Hirai K, Aoki Y *et al.* (1995) Changes in platelet kinetics after a partial splenic arterial embolization in cirrhotic patients with hypersplenism. *Hepatology* 22, 1682–1688.

121 Yanaga K, Tzakis AG, Shimada M *et al.* (1989) Reversal of hypersplenism following orthotopic liver transplantation. *Ann Surg* 210, 180–183.

122 Clavien PA, Camargo CA Jr, Croxford R *et al.* (1994) Definition and classification of negative outcomes in solid organ transplantation. Application in liver transplantation. *Ann Surg* 220, 109–120.

123 Blake JC, Sprengers D, Grech P *et al.* (1990) Bleeding time in patients with hepatic cirrhosis. *Br Med J* 301, 12–15.

124 Giannini E, Botta F, Borro P *et al.* (2003) Platelet count/spleen diameter ratio: proposal and validation of a non-invasive parameter to predict the presence of oesophageal varices in patients with liver cirrhosis. *Gut* 52, 1200–1205.

125 Jabbour N, Zajko A, Orons P *et al.* (1998) Does transjugular intrahepatic portosystemic shunt (TIPS) resolve thrombocytopenia associated with cirrhosis? *Dig Dis Sci* 43, 2459–2462.

126 Karasu Z, Gurakar A, Kerwin B *et al.* (2000) Effect of transjugular intrahepatic portosystemic shunt on thrombocytopenia associated with cirrhosis. *Dig Dis Sci* 45, 1971–1976.

127 Bolognesi M, Merkel C, Sacerdoti D *et al.* (2002) Role of spleen enlargement in cirrhosis with portal hypertension. *Dig Liver Dis* 34, 144–150.

128 N'Kontchou G, Seror O, Bourcier V *et al.* (2005) Partial splenic embolization in patients with cirrhosis: efficacy, tolerance and long-term outcome in 32 patients. *Eur J Gastroenterol Hepatol* 17, 179–184.

129 Hidaka H, Kokubu S, Saigenji K *et al.* (2002) Restoration of thrombopoietin production after partial splenic embolization leads to resolution of thrombocytopenia in liver cirrhosis. *Hepatol Res* 23, 265.

130 Jelkmann W (2001) The role of the liver in the production of thrombopoietin compared with erythropoietin. *Eur J Gastroenterol Hepatol* 13, 791–801.

131 Kitano K, Shimodaira S, Ito T *et al.* (1999) Liver cirrhosis with marked thrombocytopenia and highly elevated serum thrombopoietin levels. *Int J Hematol* 70, 52–55.

132 Martin TG III, Somberg KA, Meng YG *et al.* (1997) Thrombopoietin levels in patients with cirrhosis before and after orthotopic liver transplantation. *Ann Intern Med* 127, 285–288.

133 Wang GL, Jiang BH, Rue EA *et al.* (1995) Hypoxia-inducible factor 1 is a basic-helix-loop-helix-PAS heterodimer regulated by cellular O2 tension. *Proc Natl Acad Sci USA* 92, 5510–5514.

134 Nagamine T, Ohtuka T, Takehara K *et al.* (1996) Thrombocytopenia associated with hepatitis C viral infection. *J Hepatol* 24, 135–140.

135 Violi F, Ferro D, Basili S *et al.* (1992) Hyperfibrinolysis increases the risk of gastrointestinal hemorrhage in patients with advanced cirrhosis. *Hepatology* 15, 672–676.

136 Violi F, Leo R, Basili S *et al.* (1994) Association between prolonged bleeding time and gastrointestinal hemorrhage in 102 patients with liver cirrhosis: results of a retrospective study. *Haematologica* 79, 61–65.

137 Kajihara M, Kato S, Okazaki Y *et al.* (2003) A role of autoantibody-mediated platelet destruction in thrombocytopenia in patients with cirrhosis. *Hepatology* 37, 1267–1276.

138 Feistauer SM, Penner E, Mayr WR *et al.* (1997) Target platelet antigens of autoantibodies in patients with primary biliary cirrhosis. *Hepatology* 25, 1343–1345.

139 Escolar G, Cases A, Vinas M *et al.* (1999) Evaluation of acquired platelet dysfunctions in uremic and cirrhotic patients using the platelet function analyzer (PFA-100): influence of hematocrit elevation. *Haematologica* 84, 614–619.

140 Owen JS, Hutton RA, Day RC *et al.* (1981) Platelet lipid composition and platelet aggregation in human liver disease. *J Lipid Res* 22, 423–430.

141 Laffi G, Marra F, Gresele P *et al.* (1992) Evidence for a storage pool defect in platelets from cirrhotic patients with defective aggregation. *Gastroenterology* 103, 641–646.

142 Beer JH, Clerici N, Baillod P *et al.* (1995) Quantitative and qualitative analysis of platelet GPIb and von Willebrand factor in liver cirrhosis. *Thromb Haemost* 73, 601–609.

143 Triger DR (1975) Some immunological aspects of liver function. *Yale J Biol Med* 48, 47–54.

144 Triger DR, Alp MH, Wright R (1972) Bacterial and dietary antibodies in liver disease. *Lancet* 1, 60–63.

145 Viitala K, Israel Y, Blake JE *et al.* (1997) Serum IgA, IgG, and IgM antibodies directed against acetaldehyde-derived epitopes: relationship to liver disease severity and alcohol consumption. *Hepatology* 25, 1418–1424.

146 Seilles E, Rossel M, Vuitton DA *et al.* (1995) Serum secretory IgA and secretory component in patients with non-cirrhotic alcoholic liver diseases. *J Hepatol* 22, 278–285.

147 Gonzalez-Quintela A, Alende MR, Gamallo R *et al.* (2003) Serum immunoglobulins (IgG, IgA, IgM) in chronic hepatitis C. A comparison with non-cirrhotic alcoholic liver disease. *Hepatogastroenterology* 50, 2121–2126.

148 Schott P, Hartmann H, Ramadori G (2001) Hepatitis C virus-associated mixed cryoglobulinemia. Clinical manifestations, histopathological changes, mechanisms of cryoprecipitation and options of treatment. *Histol Histopathol* 16, 1275–1285.

149 Pawlotsky JM, Ben Yahia M, Andre C *et al.* (1994) Immunological disorders in C virus chronic active hepatitis: a prospective case-control study. *Hepatology* 19, 841–848.

150 Ferri C, Zignego AL, Pileri SA (2002) Cryoglobulins. *J Clin Pathol* 55, 4–13.

151 Medina J, Garcia-Buey L, Moreno-Otero R (2004) Hepatitis C virus-related extra-hepatic disease – aetiopathogenesis and management. *Aliment Pharmacol Ther* 20, 129–141.

152 Myers RP, Regimbeau C, Thevenot T *et al.* (2002) Interferon for interferon naive patients with chronic hepatitis C. *Cochrane Database Syst Rev* CD000370.

153 Thevenot T, Regimbeau C, Ratziu V *et al.* (2001) Meta-analysis of interferon randomized trials in the treatment of viral hepatitis C in naive patients: 1999 update. *J Viral Hepat* 8, 48–62.

154 Poynard T, Leroy V, Mathurin P *et al.* (1996) Treatment of chronic hepatitis C by interferon for longer duration than six months. *Dig Dis Sci* 41, 99S–102S.

155 Poynard T, Leroy V, Cohard M *et al.* (1996) Meta-analysis of interferon randomized trials in the treatment of viral hepatitis C: effects of dose and duration. *Hepatology* 24, 778–789.

156 Zuckerman E, Keren D, Slobodin G *et al.* (2000) Treatment of refractory, symptomatic, hepatitis C virus related mixed cryoglobulinemia with ribavirin and interferon-alpha. *J Rheumatol* 27, 2172–2178.

157 Sansonno D, De Re V, Lauletta G *et al.* (2003) Monoclonal antibody treatment of mixed cryoglobulinemia resistant to interferon alpha with an anti-CD20. *Blood* 101, 3818–3826.

158 Zaja F, De Vita S, Mazzaro C *et al.* (2003) Efficacy and safety of rituximab in type II mixed cryoglobulinemia. *Blood* 101, 3827–3834.

159 Franzin F, Efremov DG, Pozzato G *et al.* (1995) Clonal B-cell expansions in peripheral blood of HCV-infected patients. *Br J Haematol* 90, 548–552.

160 Talamini R, Montella M, Crovatto M *et al.* (2004) Non-Hodgkin's lymphoma and hepatitis C virus: a case–control study from northern and southern Italy. *Int J Cancer* 110, 380–385.

161 Mazzaro C, Efremov DG, Burrone O *et al.* (1998) Hepatitis C virus, mixed cryoglobulinaemia and non-Hodgkin's lymphoma. *Ital J Gastroenterol Hepatol* 30, 428–434.

162 Mazzaro C, Little D, Pozzato G (2002) Regression of splenic lymphoma after treatment of hepatitis C virus infection. *N Engl J Med* 347, 2168–2170.

163 Kelaidi C, Rollot F, Park S *et al.* (2004) Response to antiviral treatment in hepatitis C virus-associated marginal zone lymphomas. *Leukemia* 18, 1711–1716.

164 Levine AM, Shimodaira S, Lai MM (2003) Treatment of HCV-related mantle-cell lymphoma with ribavirin and pegylated interferon alfa. *N Engl J Med* 349, 2078–2079.

165 Armor JF, Fazili J, Toubia N *et al.* (2005) Remission of natural-killer cell lymphoma of the liver with anti-hepatitis C therapy. *Am J Hematol* 78, 212–215.

166 Foxton MR, Knight L, Knisely AS *et al.* (2005) Liver transplantation for HCV-related cirrhosis in a patient with gastric mucosa-associated lymphoma (MALToma) pretreated with rituximab. *Liver Transpl* 11, 839–842.

167 Ramos-Casals M, Lopez-Guillermo A, Brito-Zeron P *et al.* (2004) Treatment of B-cell lymphoma with rituximab in two patients with Sjogren's syndrome associated with hepatitis C virus infection. *Lupus* 13, 969–971.

168 Lamprecht P, Lerin-Lozano C, Merz H *et al.* (2003) Rituximab induces remission in refractory HCV associated cryoglobulinaemic vasculitis. *Ann Rheum Dis* 62, 1230–1233.

169 Schlitt HJ, Schafers S, Deiwick A *et al.* (1995) Extramedullary erythropoiesis in human liver grafts. *Hepatology* 21, 689–696.

170 Maheshwari A, Mishra R, Thuluvath PJ (2004) Post-liver-transplant anemia: etiology and management. *Liver Transpl* 10, 165–173.

171 Triulzi DJ, Shirey RS, Ness PM *et al.* (1992) Immunohematologic complications of ABO-unmatched liver transplants. *Transfusion* 32, 829–833.

172 Fung MK, Sheikh H, Eghtesad B *et al.* (2004) Severe hemolysis resulting from D incompatibility in a case of ABO-identical liver transplant. *Transfusion* 44, 1635–1639.

173 Cattral MS, Langnas AN, Markin RS *et al.* (1994) Aplastic anemia after liver transplantation for fulminant liver failure. *Hepatology* 20, 813–818.

174 Baranski B, Armstrong G, Truman JT *et al.* (1988) Epstein–Barr virus in the bone marrow of patients with aplastic anemia. *Ann Intern Med* 109, 695–704.

175 Apperley JF, Dowding C, Hibbin J *et al.* (1989) The effect of cytomegalovirus on hemopoiesis: *in vitro* evidence for selective infection of marrow stromal cells. *Exp Hematol* 17, 38–45.

176 Langnas AN, Markin RS, Cattral MS *et al.* (1995) Parvovirus B19 as a possible causative agent of fulminant liver failure and associated aplastic anemia. *Hepatology* 22, 1661–1665.

177 European FK506 Multicentre Liver Study Group (1994) Randomised trial comparing tacrolimus (FK506) and cyclosporin in prevention of liver allograft rejection. European FK506 Multicentre Liver Study Group. *Lancet* 344, 423–428.

178 Ndimbie OK, Frezza E, Jordan JA *et al.* (1996) Parvovirus B19 in anemic liver transplant recipients. *Clin Diagn Lab Immunol* 3, 756–760.

179 Atassi T, Thuluvath PJ (2003) Risk of colorectal adenoma in liver transplant recipients compared to immunocompetent control population undergoing routine screening colonoscopy. *J Clin Gastroenterol* 37, 72–73.

180 Cohen AJ, Stegall MD, Rosen CB *et al.* (2002) Chronic renal dysfunction late after liver transplantation. *Liver Transpl* 8, 916–921.

181 Pawarode A, Fine DM, Thuluvath PJ (2003) Independent risk factors and natural history of renal dysfunction in liver transplant recipients. *Liver Transpl* 9, 741–747.

182 Richards EM, Alexander GJ, Calne RY *et al.* (1997) Thrombocytopenia following liver transplantation is associated with platelet consumption and thrombin generation. *Br J Haematol* 98, 315–321.

183 Faeh M, Hauser SP, Nydegger UE (2001) Transient thrombopoietin peak after liver transplantation for end-stage liver disease. *Br J Haematol* 112, 493–498.

184 Goulis J, Chau TN, Jordan S *et al.* (1999) Thrombopoietin concentrations are low in patients with cirrhosis and thrombocytopenia

and are restored after orthotopic liver transplantation. *Gut* 44, 754–758.

185 Sutedja DS, Wai CT, Teoh KF *et al.* (2004) Persistent thrombocytopenia in liver transplant patients. *Transplant Proc* 36, 2331–2333.

186 Duvoux C, Pageaux GP, Vanlemmens C *et al.* (2002) Risk factors for lymphoproliferative disorders after liver transplantation in adults: an analysis of 480 patients. *Transplantation* 74, 1103–1109.

187 Pageaux GP, Bonnardet A, Picot MC *et al.* (1998) Prevalence of monoclonal immunoglobulins after liver transplantation: relationship with posttransplant lymphoproliferative disorders. *Transplantation* 65, 397–400.

188 Newell KA, Alonso EM, Kelly SM *et al.* (1997) Association between liver transplantation for Langerhans cell histiocytosis, rejection, and development of posttransplant lymphoproliferative disease in children. *J Pediatr* 131, 98–104.

189 Newell KA, Alonso EM, Whitington PF *et al.* (1996) Posttransplant lymphoproliferative disease in pediatric liver transplantation. Interplay between primary Epstein–Barr virus infection and immunosuppression. *Transplantation* 62, 370–375.

190 Wu L, Rappaport DC, Hanbridge A *et al.* (2001) Lymphoproliferative disorders after liver transplantation: imaging features. *Abdom Imaging* 26, 200–206.

191 Aucejo F, Rofaiel G, Miller C (2006) Who is at risk for post-transplant lymphoproliferative disorders (PTLD) after liver transplantation? *J Hepatol* 44, 19–23.

192 Muti G, Mancini V, Ravelli E *et al.* (2005) Significance of Epstein–Barr virus (EBV) load and interleukin-10 in post-transplant lymphoproliferative disorders. *Leuk Lymphoma* 46, 1397–1407.

193 Muti G, Klersy C, Baldanti F *et al.* (2003) Epstein–Barr virus (EBV) load and interleukin-10 in EBV-positive and EBV-negative post-transplant lymphoproliferative disorders. *Br J Haematol* 122, 927–933.

194 Capello D, Cerri M, Muti G *et al.* (2003) Molecular histogenesis of posttransplantation lymphoproliferative disorders. *Blood* 102, 3775–3785.

195 Leblond V, Davi F, Charlotte F *et al.* (1998) Posttransplant lymphoproliferative disorders not associated with Epstein–Barr virus: a distinct entity? *J Clin Oncol* 16, 2052–2059.

196 Ghobrial IM, Habermann TM, Macon WR *et al.* (2005) Differences between early and late posttransplant lymphoproliferative disorders in solid organ transplant patients: are they two different diseases? *Transplantation* 79, 244–247.

197 Tsai DE, Hardy CL, Tomaszewski JE *et al.* (2001) Reduction in immunosuppression as initial therapy for posttransplant lymphoproliferative disorder: analysis of prognostic variables and long-term follow-up of 42 adult patients. *Transplantation* 71, 1076–1088.

198 Leblond V, Choquet S (2004) Lymphoproliferative disorders after liver transplantation. *J Hepatol* 40, 728–735.

199 Aull MJ, Buell JF, Trofe J *et al.* (2004) Experience with 274 cardiac transplant recipients with posttransplant lymphoproliferative disorder: a report from the Israel Penn International Transplant Tumor Registry. *Transplantation* 78, 1676–1682.

200 Praghakaran K, Wise B, Chen A *et al.* (1999) Rational management of posttransplant lymphoproliferative disorder in pediatric recipients. *J Pediatr Surg* 34, 112–115.

201 Jain A, Nalesnik M, Reyes J *et al.* (2002) Posttransplant lymphoproliferative disorders in liver transplantation: a 20-year experience. *Ann Surg* 236, 429–436.

202 Benkerrou M, Jais JP, Leblond V *et al.* (1998) Anti-B-cell monoclonal antibody treatment of severe posttransplant B-lymphoproliferative disorder: prognostic factors and long-term outcome. *Blood* 92, 3137–3147.

203 Choquet S, Leblond V, Herbrecht R *et al.* (2006) Efficacy and safety of rituximab in B-cell post-transplant lymphoproliferative disorders: results of a prospective multicentre phase II study. *Blood* 107, 3053–3057.

21.4 Haemostasis in liver disease

Stephen H. Caldwell, Patrick G. Northup and Vinay Sundaram

Disorders of haemostasis constitute a traditional and integral aspect of liver disease management (Table 1). However, older concepts of underlying pathophysiology, common tests and optimal treatment are no longer tenable in the face of advances in our understanding of the normal clotting cascade, studies that question the significance of common clotting studies and the emergence of new haemostatic agents. The pathogenesis is complicated by the presence of disordered metabolism in both procoagulant and anticoagulant pathways. Furthermore, patients often have mitigating factors including portal hypertension, endothelial dysfunction, abnormalities in platelet number and function (perhaps related to membrane lipids), renal failure and more distinct conditions such as vitamin K deficiency or hyperfibrinolysis (Table 2). Treating abnormal haemostasis in liver disease patients requires clear assessment of bleeding risk (which is often difficult with currently available tests), careful determination of the underlying pathophysiology and establishment of the goal of therapy. In addition, and contrary to common perceptions, some aspects of liver disease are associated with a hypercoagulable state, which may be manifest by peripheral deep vein thrombosis, portal vein thrombosis, progression of cirrhosis to atrophy and, possibly, portopulmonary hypertension.

Brief review of normal coagulation: modern concepts

The current concept of coagulation integrates the traditional concepts of 'intrinsic' and 'extrinsic' coagulation pathways, and merges the humoral and cellular components of the normal clotting cascade (Figs 1 and 2). Clot formation results from the interaction of a small amount of circulating activated factor VII (FVIIa) with tissue factor (TF), which is expressed on the surface of exposed cells following injury to the endothelium; this is a process that is facilitated by cell membrane phospholipid [1–3]. After the FVIIa–TF complex forms on the TF-bearing cell, clot formation proceeds via a 'priming' step and a propagating or accelerating step. The FVIIa–TF complex activates factor X, which in turn converts prothrombin (factor II) to thrombin. The thrombin generated during priming activates factors VIII, V and XI and platelets. Activated platelets then serve as a scaffold for amplification and propagation of the clotting cascade, resulting in a 'burst' of thrombin. In addition, activated platelets (bearing activated factors VIIIa, Va and XIa) further activate factor X, thereby recruiting additional platelets. This generates an increasing amount of thrombin, which converts fibrinogen to fibrin, ultimately resulting in clot formation. This overall process is regulated by the activity of the protein C–protein S–thrombomodulin pathway (which inhibits factor V and VIII), inactivation of FXa and thrombin by antithrombin (ATIII) and blockade of the FVIIa–TF complex by a complex of lipoprotein-bound TF pathway inhibitor (TFPI) and FXa [4]. Once formed, thrombin-activatable fibrinolysis inhibitor (TAFI) protects the clot from fibrinolysis.

Table 1 Significance of coagulation in liver disease.

Prognostic scores
Bleeding risk assessment
Active bleeding and/or prophylactic measures

Table 2 Variables in coagulopathy of liver disease.

Impaired synthesis of pro- and anticoagulation factors
Portal hypertension
Endothelial dysfunction due to:
Hyperdynamic state of cirrhosis
Coexisting renal failure
Disordered lipid metabolism (thromboplastin and platelet membranes)
Thrombocytopenia
Superimposed disorders
Disseminated intravascular coagulation
Hyperfibrinolysis
Dysfibrinogenaemia
Vitamin K deficiency (antibiotic induced or nutritional)

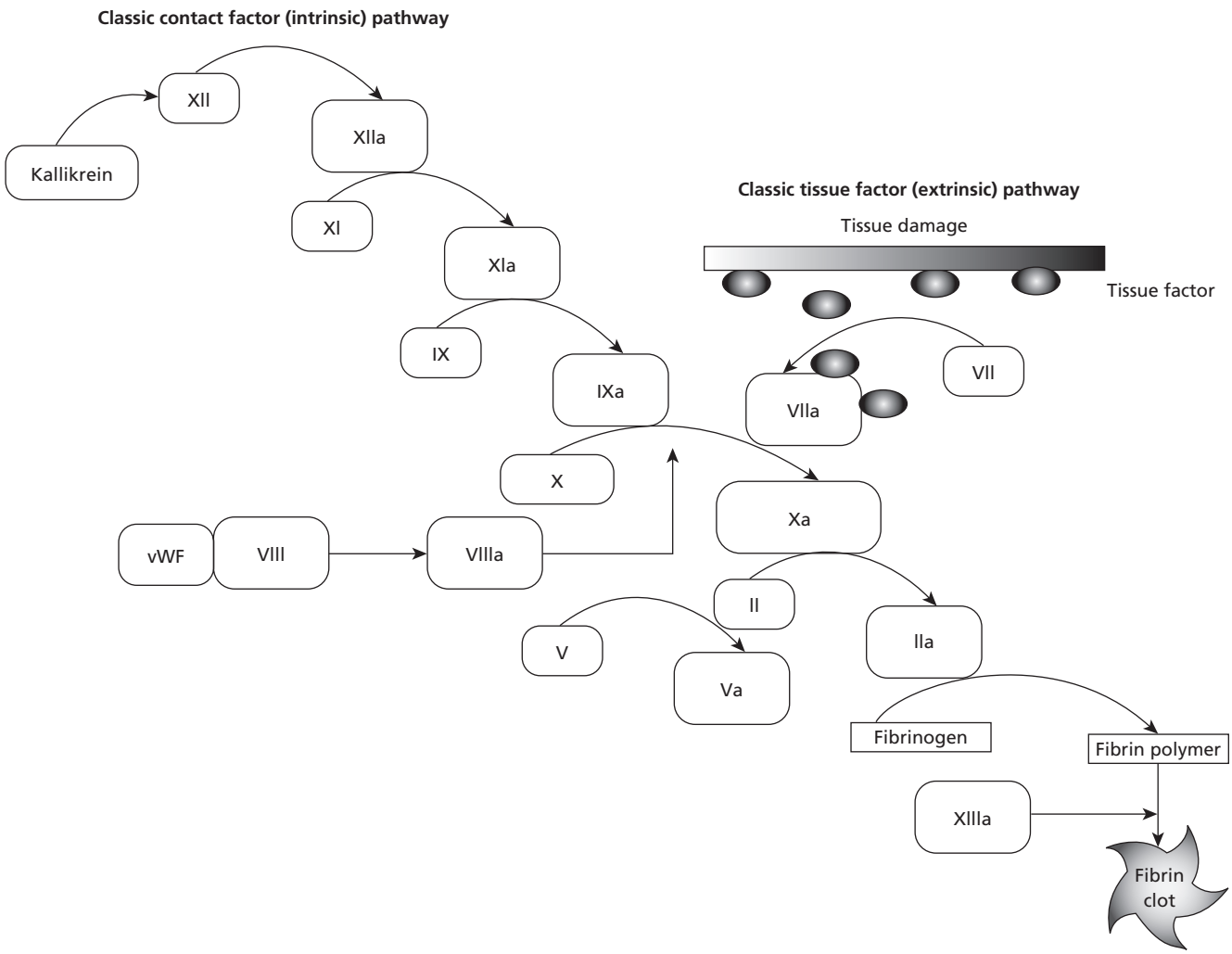

Fig. 1 The classic clotting cascade includes the extrinsic and intrinsic pathways. Common *in vitro* tests of coagulation are often based on this concept.

Tests of coagulation

A number of studies are used in the clinical setting to assess the function of the clotting system (Table 3). The most commonly performed tests examine the classic intrinsic and extrinsic pathways of coagulation: the prothrombin time (PT), the activated partial thromboplastin time (aPTT) and the international normalized ratio (INR). The PT, which assesses the 'extrinsic' and 'common' pathways, provides a measurement of the time required for clot formation in citrated plasma. It is based on the binding of thromboplastin, a reagent composed of phospholipid and tissue factor (TF; recombinant human or animal derived), to factor VII. The subsequent activation of factor X bypasses the classic 'intrinsic' pathway [5]. Prolongation of the PT is seen with reduction in fibrinogen, FII (prothrombin) and factors V, VII and X [6]. The INR, introduced by the World Health Organization in 1983, was developed to monitor coumadin therapy and correct variation in PT due to different thromboplastin reagents [7,8]. The INR is obtained by dividing the patient's PT value by the mean normal PT value, raised to the power of the international sensitivity index. As such, the INR standardizes the PT against an international reference preparation.

Less commonly performed tests include assays for specific factors, fibrin degradation products and bleeding time. Specific factor assays (factor V and VII) are used to assess prognosis in fulminant liver failure and also to help to distinguish vitamin K deficiency (low VII, near normal V) from diminished synthesis (decreased V and VII). The measurement of the fibrinogen level is essential to facilitate the use of activated factor VII (see below), and factor VIII, synthesized by endothelial cells, can be used to distinguish DIC (low factor VIII) from hepatic failure (normal or elevated factor VIII). Other potentially useful tests include the thromboelastogram (TEG) and the platelet function assay. The

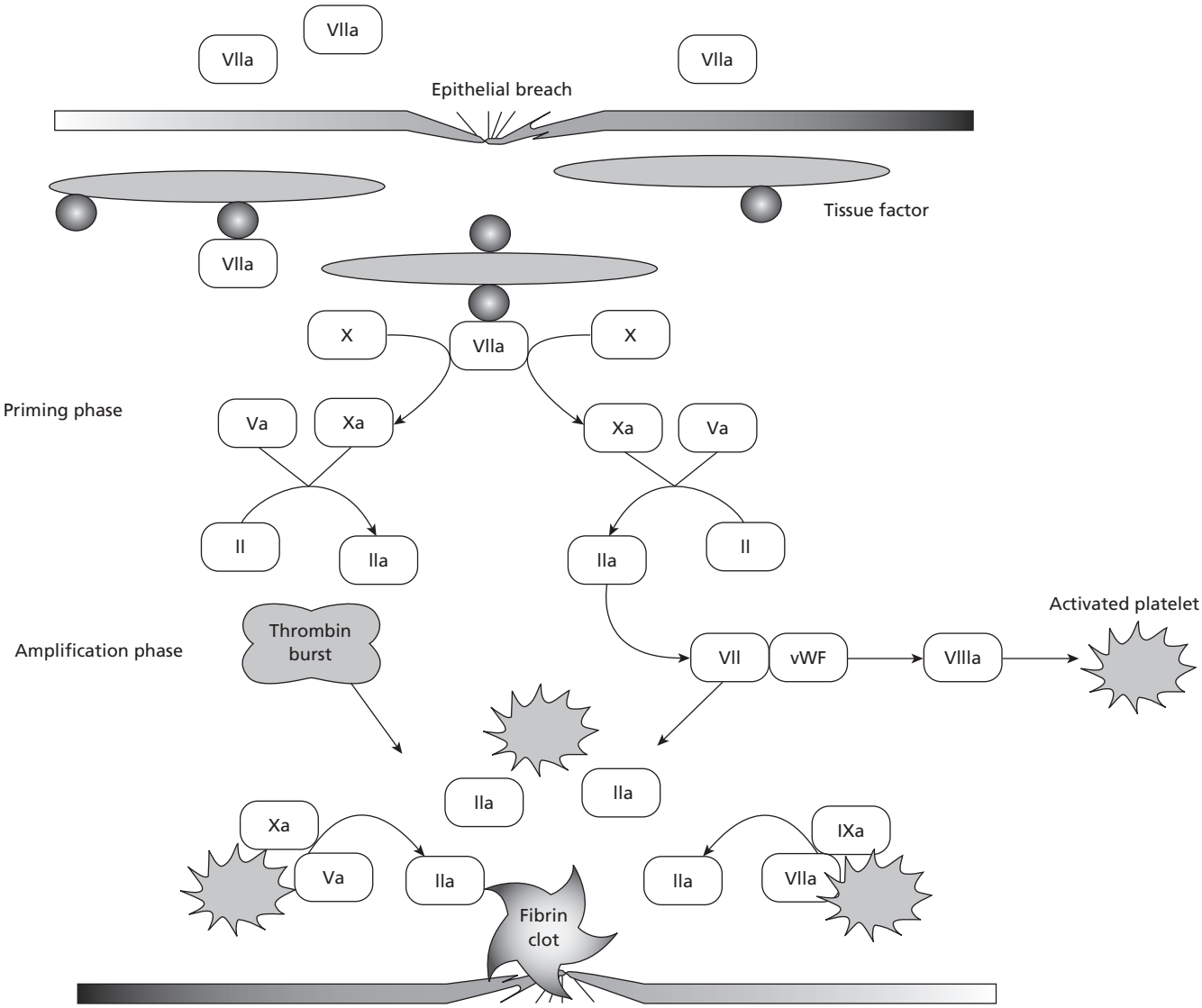

Fig. 2 Since the development of rFVIIa, a new concept of the clotting cascade has emerged that incorporates the cellular aspects of coagulation and emphasizes the essential role of tissue factor, which interacts with phospholipids and activated factor VII to first produce a 'priming' amount of thrombin (factor II) and, then, with activated platelets, to produce a thrombin burst in an 'amplified' signal that augments clot formation.

TEG offers the prospect of measuring clot formation and dissolution in a single test (Fig. 3), but remains largely experimental. Although the bleeding time has fallen out of favour as a clinically useful test, other assays of platelet function may prove to be helpful in the liver disease patient. Among these, the platelet function assay (PFA), although it has not received a great deal of attention in clinical practice, may be especially useful [9]. The PFA assesses haemostasis by measuring the time until platelet plug formation (closure time) under high shear stress *in vitro* [10].

Distinguishing DIC from liver failure can be difficult. Decreasing factor VIII (not synthesized in the liver) and falling levels of fibrinogen and platelets over time are important indicators of superimposed DIC. Factor V levels may also be helpful as DIC is associated with severely depressed levels (10% range) compared with synthetic dysfunction of cirrhosis (in the 40–50% range). Dysfibrinogenaemia (excessive sialic acid content) is a common feature of cirrhosis, but its clinical significance is uncertain. It is detected using reptilase assays. Hyperfibrinolysis, suspected with persistent oozing from puncture wounds, can be detected by decreased clot lysis time and decreased alpha-2-antiplasmin. Although uncommon, it stands out as a unique entity requiring recognition and specific antifibrinolytic therapy (see below).

Table 3 Tests of coagulation: clinical utility.

Prothrombin time and INR (variation between laboratories may be significant)
Platelet count: correlation with bleeding risk is not reliable
Combined indices of clot formation and fibrinolysis (see Boks *et al*. [12])
May correlate with mucosal bleeding but are not readily available
Endogenous thrombin production (ETP) (see Tripodi *et al*. [17])
Demonstrates existence of balance even in cirrhosis
Needs further study to assess clinical utility
Thromboelastogram (TEG)
Cumbersome but provides information on pro- and anticoagulant systems
Needs further testing to assess clinical utility
Factor levels
Fibrinogen: levels need to be over 100–120
Factor V and VII: prognostic significance in fulminant hepatic failure, relatively less VII compared with V suggests vitamin K deficiency
Factor VIII: falling levels of factor VIII (made in endothelium) suggests disseminated intravascular coagulation
Fibrinolysis markers (availability is often limited)
Euglobulin clot lysis times
A-2 antiplasmin
Platelet function tests: bleeding time (largely abandoned), adhesion, aggregation
Platelet function analyser (PFA) detects 'closure time' from platelet plug formed *in vitro*
These have not been adequately studied in liver disease
Reptilase (snake venom) tests: detects dysfibrinogenaemia but rarely useful in liver disease

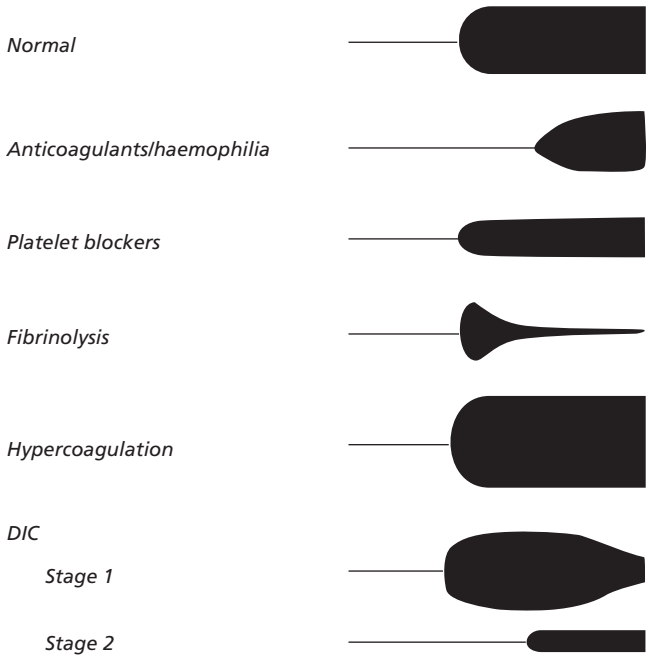

Fig. 3 Thromboelastogram. These tests provide an overview of clot formation and dissolution. Certain patterns are characteristic of different conditions. Their use in predicting bleeding risk in liver disease has not been extensively studied. From Wenker *et al*. [145].

Controversies in tests of coagulation in liver disease

Several studies have drawn attention to potential problems with conventional tests of coagulation in liver disease patients. Previously, it was demonstrated that the liver bleeding time (time to cessation of surface bleeding after liver biopsy observed laparoscopically) does not correlate with abnormalities in PT or platelet count [11]. In addition, it was shown that the risk of variceal bleeding does not relate to abnormalities in conventional tests. In contrast, non-variceal bleeding (bleeding from mucosa or puncture sites and haematomas) has a weak association with low fibrinogen and abnormal normotest (similar to the PT) activity [12]. The relationship was stronger if an index of fibrinolysis was integrated but, in general, the ability of the common tests to predict bleeding was limited (Fig. 4). Adding to the difficulty of interpreting these results, recent studies have demonstrated that the INR tends to differ between laboratories depending on which thromboplastin reagent is used [13,14]; such variation in the INR was shown to significantly alter the Model for End-stage Liver Disease (MELD) cirrhosis prognosis score (Fig. 5) [15]. In addition, the accuracy of 'point-of-care' INR measuring devices has been questioned [16].

The endogenous thrombin potential (ETP), derived from the thrombin generation test, measures the amount of thrombin

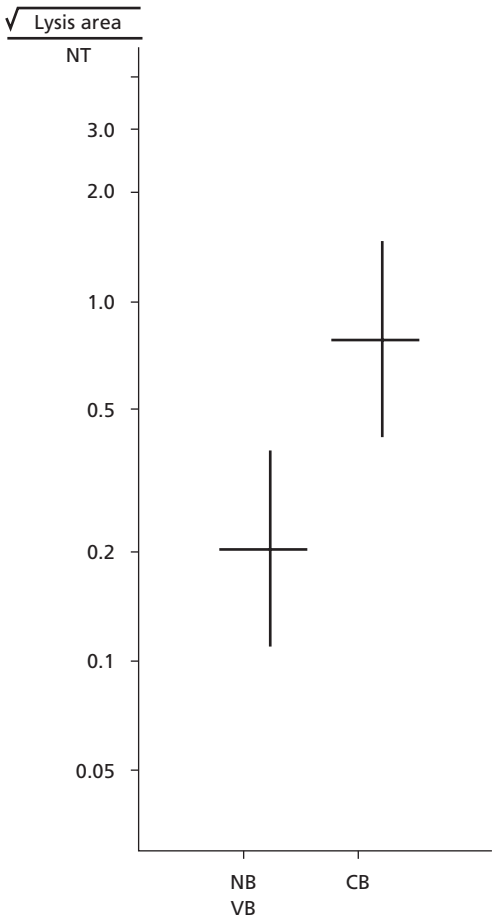

generated following the addition of coagulation triggers to plasma. As the ETP accounts for levels of both procoagulant and anticoagulant factors, it allows for more efficient evaluation of *in vivo* coagulation. Recently, Tripodi *et al.* [17] demonstrated that cirrhotic patients generate similar amounts of thrombin to normal, control individuals, as measured by ETP, when thrombomodulin, an activator of protein C, is added to the tested plasma samples (Fig. 6). Although the test measures thrombin rather than fibrin or clot, their results raise significant questions about the way in which the coagulation system is assessed in cirrhosis, and how to utilize the results [18]. The ability of the test to show equal thrombin production in cirrhosis and control patients suggests that, as long as fibrinogen levels are adequate, cirrhosis patients should be able to generate an adequate clot regardless of the results of the more commonly used prothrombin time or INR. However, multiple other factors influence the net function of the haemostatic system in liver disease patients as discussed below.

Fig. 4 (*opposite*) Boks *et al*. [12] studied multiple laboratory parameters in liver failure patients to determine factors that could predict bleeding. An index determined by dividing the square root of a fibrinolysis measure by the normotest (a variant of the prothrombin time) was used to separate capillary bleeding (CB, mucocutaneous bleeding) from non-bleeding (NB) and variceal bleeding (VB) patients, but considerable overlap is evident in the distribution of the composite scores.

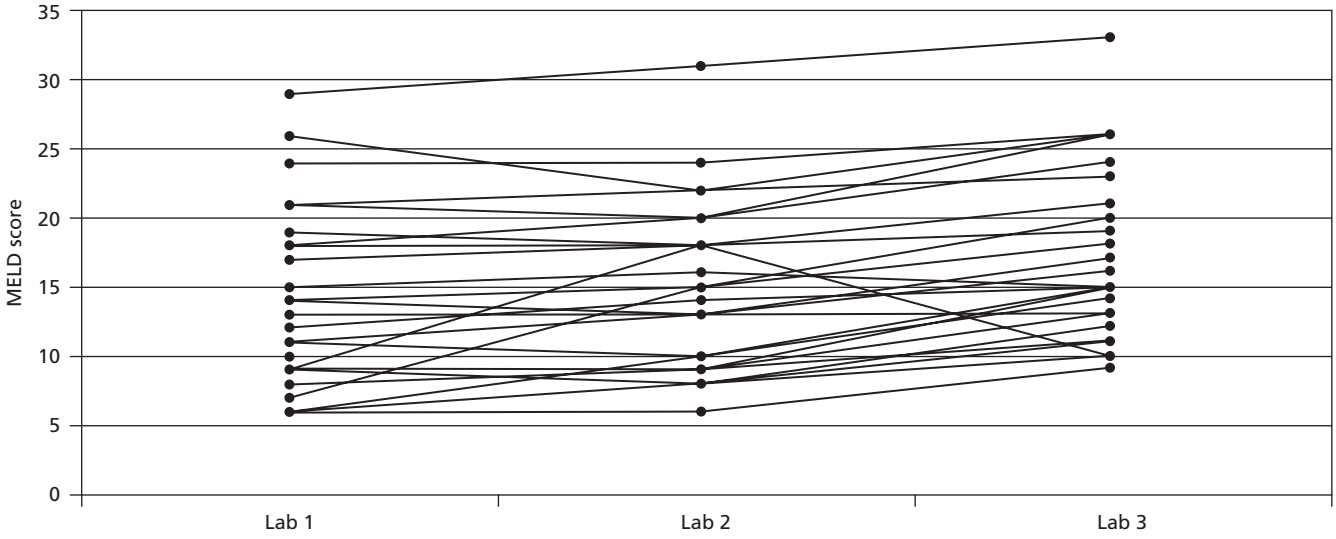

Fig. 5 Trotter *et al*. [15] recently demonstrated significant variability in the INR from different regional reference laboratories in a cohort of consecutive patients undergoing liver transplant evaluation. The results demonstrated significant variation in the MELD score (calculated from the INR, creatinine and bilirubin), thus potentially altering priority for liver transplantation.

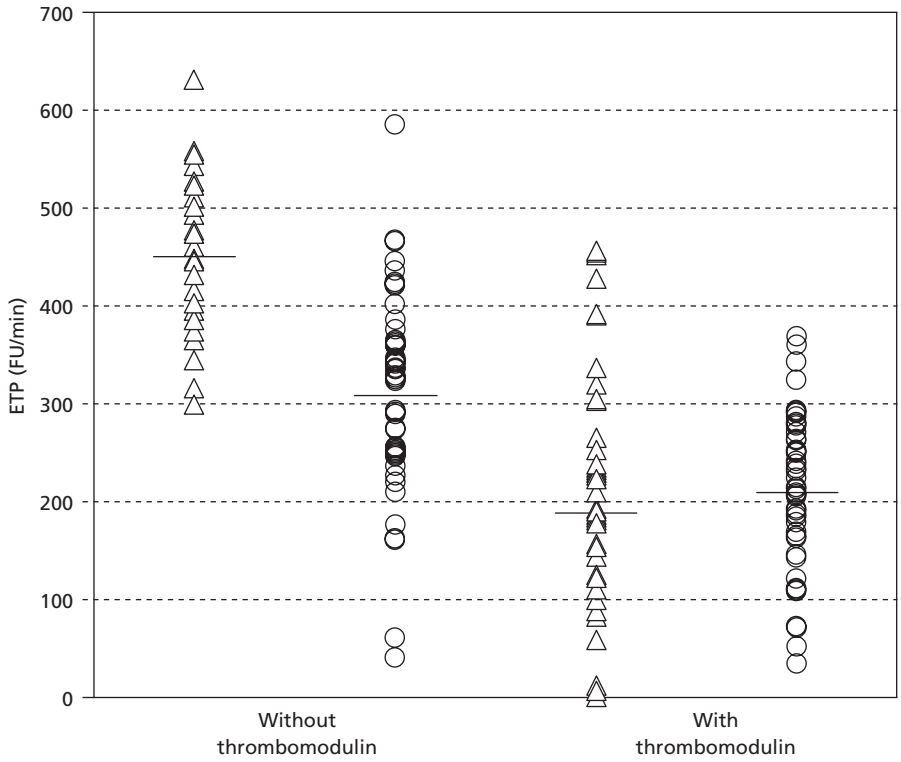

Fig. 6 Tripodi *et al*. [17] postulated that cirrhosis-associated decreased activity of protein C (part of the anticoagulant system but activated at a substantially slower rate by thrombin than other procoagulant factors) would offset the decrease in synthesis of procoagulant factors. By adding thrombomodulin and measuring thrombin production, they demonstrated that stable cirrhosis patients often have essentially normal thrombin production even when common tests, such as the PT or INR, are prolonged. The results indicate that further studies are needed to accurately predict bleeding risks in liver disease patients.

Coagulopathy in acute and chronic liver disease

Dysfunction of the coagulation system in both acute and chronic liver disease (Table 2) involves all aspects of the clotting system, including the cellular limb (platelets and cells bearing tissue factor), the humoral limb (pro- and anticoagulant factors) and the endothelium (as a result of cirrhotic vasodilation and renal failure). Vitamin K deficiency and impaired gamma-carboxylation of vitamin K-dependent factors (II, VII, IX, X, protein C and protein S) may also be present, especially in patients with chronic cholestatic disorders. Additional bleeding risks include thrombocytopenia (from splenic sequestration, antibody expression or deficient thrombopoietin) [19–21], hyperfibrinolysis [22] due to impaired clearance of tissue plasminogen activator (tPA), dysfibrinogenaemia [23] and/or endothelial dysfunction possibly mediated by nitric oxide metabolites. Uraemia, a common complication of advanced liver disease, involves platelet dysfunction and probably contributes to impaired coagulation in these patients [24,25]. The pathogenesis of uraemia-associated coagulopathy has been attributed to platelet dysfunction (see also below) and endothelial dysfunction. As a result of these multiple variables, determining bleeding risk in patients with liver disease is difficult and requires clinical judgement.

Hyperfibrinolysis should be suspected when there is excessive mucocutaneous bleeding or puncture wound oozing without evidence of DIC (i.e. falling platelet counts). Lisman *et al.* [26] showed that it is unrelated to the low levels of thrombin-activatable fibrinolysis inhibitor (TAFI), but that a hyperfibrinolytic state is strikingly common in Child–Pugh C patients. In advanced cirrhosis, diminished hepatic clearance leads to elevated levels of fibrinolytic activator and plasminogen activator inhibitor 1, causing a shift towards increased fibrinolysis [27]. Spontaneous 'peritoneovenous shunts' have also been suggested as a possible explanation [28]. Although clinically apparent hyperfibrinolysis afflicts less than 5% of hospitalized patients, it can be severe and persistent (Fig. 6). Useful tests to detect hyperfibrinolysis include the euglobulin clot lysis time and α-2 antiplasmin levels. Other complicating factors such as DIC [29] and spur cell haemolysis (due to disturbed lipoprotein metabolism) may also be superimposed on the background of synthetic dysfunction. Spur cell haemolysis, due to defective esterification of cholesterol [30,31], has been associated with increased platelet adherence, which may contribute at least partly to the hypercoagulability in liver disease patients (see below) [32,33].

The platelet in cirrhosis

Platelet abnormalities are common in liver disease (Table 4). Hypersplenism occurs in 11–55% of cirrhotics [34] and results in sequestration of up to 90% of serum platelets compared with the normal 30% [35–37]. However, thrombocytopenia occurs without splenomegaly – decreased hepatic synthesis of thrombopoietin (TPO) may be an explanation, although reports are

Table 4 Platelet changes in cirrhosis.

Thrombocytopenia due to:
Splenic sequestration
Thrombopoietin metabolism
Expression of antiplatelet antibody
Ethanol
Abnormal platelet function:
Fibrin degradation products (FDPs) interfere with aggregation
Cholesterol loading may augment adhesiveness (changes lipid metabolism)
Renal failure and uraemia

Table 5 Prognostic score incorporating coagulation indices.

Child–Pugh–Turcotte score/class
Prothrombin time
Serum bilirubin
Serum albumin
Ascites
Encephalopathy
MELD/PELD (Model or Paediatric End-Stage Liver Disease score)
International normalized ratio
Serum bilirubin
Serum creatinine
Mayo PBC score
Prothrombin time
Age
Serum bilirubin
Serum albumin
Oedema
Toronto alcoholic liver disease index (CLLI)
Prothrombin time
Encephalopathy
Collateral circulation
Ascites
Oedema
Serum haemoglobin
Serum albumin
Serum bilirubin
Serum alkaline phosphatase
King's College Criteria for fulminant hepatic failure
Prothrombin time/international normalized ratio
Arterial pH level
Serum creatinine
Encephalopathy
Clichy criteria for fulminant hepatic failure
Factor V level
Age
Encephalopathy

conflicting [38–43]. A possible explanation is that splenic sequestration and destruction of thrombopoietin, rather than decreased synthesis from the diseased liver, accounts for low serum levels. Support for this concept includes a recent study of 33 cirrhotic patients, which demonstrated that serum TPO correlated inversely with splenic size, but not platelet count, and that TPO levels increased after partial splenic embolization [21]. Thrombocytopenia may also be induced by ethanol, which impairs platelet production. This may result from acetaldehyde toxicity to megakaryocytes [44], but is further complicated by low folate levels [45].

Deficiency in platelet aggregation and platelet–vessel wall interaction has also been demonstrated in cirrhosis [46]. Fibrin degradation products (FDPs), which may accumulate as a result of decreased hepatic clearance in the diseased liver, inhibit platelet aggregation by blocking fibrinogen binding to glycoprotein IIb–IIIa receptors [47]. On the other hand, cholesterol loading of platelets [48–50] may lead to platelet hypercoagulability. This has not been extensively studied clinically, but has been demonstrated *in vitro* and warrants further investigation [51,52]. In uraemia, platelet defects have been associated with accumulation of toxins such as urea, guanidinosuccinic acid and phenols, which inhibit platelet aggregation [53]. Platelet aggregation may be additionally impaired by diminished platelet secretion of thromboxane A2 [54] and elevated platelet concentrations of cyclic adenosine monophosphate (cAMP), an inhibitor of aggregation [55]. Uraemia-induced alterations in endothelial cells may also lead to elevated levels of prostacyclin (PGI2) and nitric oxide (NO), both of which are produced by endothelial cells and activate cAMP [56].

Prognostic significance of coagulation tests

The importance of common tests of coagulation in liver disease is most evident in prognostic scores, including the Child–Pugh score, MELD and PELD scores, the Mayo PBC score, the Toronto ETOH score, and King's College and the Clichy score in fulminant hepatic failure (Table 5). Based on its ability to predict mortality in patients on the liver transplantation waiting list [57,58], the MELD score has been used in the USA since 2002 as the primary deceased donor liver allocation scheme. Derived originally as a tool for predicting mortality after transjugular intrahepatic portosystemic shunts (TIPS) [59], the MELD score is heavily dependent on INR. Each integer increase in INR yields an increase of more than five points on the MELD scale. According to the UNOS modification of MELD, a five-point increase in MELD score indicates a more than doubled risk of waiting list death, independent of other factors. Several groups of investigators have also found that abnormal coagulation parameters, including prothrombin time and platelet count, are predictive of worse survival after non-hepatic surgical procedures in patients with cirrhosis [60–62].

Bleeding risk assessment

The relationship between the common coagulation tests and the bleeding risk is less clear than their relationship to prognosis. Mucosal bleeding may be associated with prolongation of the

(a)

(b)

(c)

thrombin time (a variant of the prothrombin time) and indices of fibrinolysis, but there is substantial overlap (Fig. 7). We previously reported wide variation between centres in acceptable limits for coagulation in liver biopsy [63]. The variation in acceptable coagulation parameters prior to other invasive procedures was also demonstrated by Grabau *et al.* [64]. These investigators prospectively performed 1100 therapeutic paracenteses, 513 of which were performed in patients with decompensated cirrhosis. Of these procedures, 292 (26%) were performed in patients with an INR > 2.0, and 598 (54%) were in patients with a platelet count of less than 50 000. Despite these abnormal coagulation parameters, there were no significant bleeding events in any of the patients. Terjung *et al.* [65] performed 629 diagnostic liver biopsies with a 1.6% major complication rate, most of which were bleeding related. However, only 58% of all bleeding episodes occurred in patients with a recognized bleeding risk. The multivariate analysis showed that both administration of platelets prior to the procedure and the presence of advanced cirrhosis were risk factors for bleeding. Preprocedural INR was not a predictor for bleeding in this study. Despite these conflicting findings, many authorities, expert panels and professional societies recommend routine measurement and correction of coagulation parameters prior to all invasive procedures. These recommendations, which largely lack supportive data, are likely to change in the foreseeable future as our understanding of coagulation abnormalities evolves.

Bleeding in the liver patient: prevention or rescue?

Therapy for coagulation disorders in liver disease patients can be broadly divided into two categories: prophylactic therapy and 'rescue' therapy (Table 6). As alluded to above, acceptable preprocedure cutoffs for laboratory indices are commonly utilized,

Table 6 Management strategy: prevention or rescue.

Prevention of bleeding (preprocedure)
Advantages: prevent episode of bleeding
Disadvantages: current tests predict bleeding very poorly, complex coagulopathy
Rescue intervention (for active bleeding)
Advantages: more definite target
Disadvantages: unstable patient, may require specific tests to hone therapy

Fig. 7 (*opposite*) (a and b). Patient with advanced cirrhosis and persistent oozing over 2 days from a right femoral line site developed severe extensive posterior haematoma. Hyperfibrinolysis was proven by laboratory testing, and the bleeding responded to antifibrinolytic therapy. (c) Persistent external oozing from an intracranial pressure monitor site without intracranial haemorrhage in a patient with fulminant hepatic failure from hepatitis B and suspected hyperfibrinolysis and successful treatment with antifibrinolytic therapy.

but none has a sound basis. Aggressive correction of certain indices may actually increase bleeding risk. For example, volume expansion can raise portal pressure increasing the risk of variceal bleeding. It is therefore not surprising that targeting conventional indices of the clotting cascade to specific levels has not met with a great deal of success in preventing bleeding. This situation is probably more a result of inadequate targets (i.e. tests) than the absence of risk or relevance.

Because true bleeding risk is so difficult to determine in the liver failure patient via current tests of coagulation, the use of procoagulant factors is probably best reserved for rescue therapy, when the patient has active bleeding. Confirmation or repudiation of this opinion awaits further clinical studies, but warrants consideration in current practice. Exceptions to this practice include procedures in which bleeding is unlikely to be detected in time to intervene before irreversible damage occurs. This would be the case, for example, with placement of intracranial pressure monitors in fulminant hepatic failure and, perhaps, in chest tube placement. In these circumstances, it seems reasonable to correct measures of coagulation, in spite of limited clinical data to support the practice. Other procedures and possible interventions are noted in Table 7.

Table 7 Procedures, clinical problems and conventional management strategies (recommendations often lack substantial basis in clinical research and may exacerbate portal hypertension if associated with volume expansion).

Problem/procedure	Haemostasis risk[a]	Notes	References
Diagnostic endoscopic procedures (with or without mucosal biopsies)	Minimal	Simple diagnostic endoscopies do not usually require aggressive haemostatic measures	[137]
Therapeutic endoscopic procedures (ERCP, polypectomy, variceal ligation)	Moderate	Societal guidelines recommend plasma, platelet transfusion but guidelines need re-evaluation in light of recent work using ETP (see refs 17,18). rVIIa: modest benefit in variceal bleed, possible role in 'rescue' situations. Interaction of clotting cascade and cyanoacrylates needs further investigation	[90,108,137–140]
Liver biopsy	Moderate	Bleeding risk is not dependent on preprocedural parameters. Focal lesion biopsies greater risk. Questionable benefit of prophylactic rVIIa or tract plugging	[11,65,86]
Paracentesis	Minimal	Bleeding rate is very low even without prophylactic intervention and not dependent on preprocedural coagulation parameters	[64]
Thoracentesis	Moderate	Limited data suggest safety of procedure. Therapeutic riskier than diagnostic	[141,142]
Intracranial pressure monitor placement	High	Bleeding causes significant mortality and morbidity. Significant decrease in risk of anasarca with rFVIIa use over standard therapy	[87–89]
Dental extractions and cutaneous minor surgical procedures	Minimal to moderate	Overall risk minimal. Direct mucosal application of antifibrinolytic agents most effective. Some data for rescue rVIIa	[93,143]
Vascular procedures (TIPS, cardiac catheterization)	High	TIPS survival corresponds to MELD score. rVIIa and plasma decreased bleeding in children	[59,88]
Major surgical procedures	Severe	Bleeding risk dependent on severity of liver disease. Correction of coagulation parameters recommended. Caution with increasing portal hypertension through excessive volume	[60–62,72,82,83,110,144]

[a]Risk and intervention data are limited to rare randomized controlled trials and case–control studies. Most data are based on case reports or case series. Risk is assessed by location and potential complications of bleeding.

ERCP, endoscopic retrograde cholangiopancreatography; ETP, endogenous thrombin production; TIPS, transjugular intrahepatic portosystemic shunt; rFVIIa, recombinant activated factor VII.

Table 8 Specific agents and interventions.

Vitamin K
Blood products
Recombinant activated factor VII (rFVIIa) – not FDA-approved in the USA
Antifibrinolytics: ε-aminocaproic acid, tranexamic acid and aprotinin
DDAVP
Augment vascular tone (antihyperdynamic state)
Haemodialysis if uraemia is present
Topical agents
Marrow stimulants

DDAVP, desmopressin, 1-deamino-8-D-arginine vasopressin.

Specific therapeutic agents

A wide variety of strategies and specific agents are now available, each of which has advantages and disadvantages, although most lack definitive data regarding their optimal use. Generally, a combination of agents is utilized, but careful delineation of the underlying pathophysiology, while not always clear, is the best guide to the use of certain agents (Table 8).

Vitamin K

Vitamin K deficiency may occur especially with cholestatic illnesses and with antibiotic therapy. Relatively low levels of factor VII compared with factor V suggest a predominance of vitamin K deficiency; however, some studies have demonstrated impaired γ-carboxylation despite vitamin K treatment [66,67]. Oral replacement is typically tried initially. Subcutaneous vitamin K may be given, although allergic reactions may occur [68,69], and absorption may be limited in patients with oedema. Intravenous therapy is also available in those who are severely coagulopathic, although this mode of treatment has been associated with hypotension and anaphylaxis [70,71].

Blood products

Blood products such as plasma, platelet concentrates and cryoprecipitate are the most readily available form of intervention. However, they are also among the most controversial, due primarily to the poor correlation between tests of coagulation and bleeding in liver disease patients [72]. The use of blood products is hampered by unproven efficacy, attendant volume expansion, risk of infection and cost. The charge per unit of blood products varies between centres, but can be substantial. Additional expenses include blood typing and antibody screening, premedications, infusion-monitoring setups and management of side-effects.

With platelet administration, the expected increase in platelet count is approximately 10 000/mm^3/m^2/unit [73]. Patients with cirrhosis show a decreased response due to splenic sequestration, and target platelet levels are not uniformly agreed upon. Side-effects of platelet transfusion rarely include infection and fever secondary to inflammatory cytokines (seen in approximately 2% of transfusions) [74] and, even more rarely, anaphylaxis. Fresh frozen plasma contains coagulation factors such as vitamin K-dependent clotting factors. Because of the short half-life of factor VII in the circulation (approximately 6 h), repeat transfusions may be necessary. Plasma infusion in liver disease is associated with limited efficacy and a risk of volume expansion (one unit of plasma contains 300–500 mL of water). In a retrospective study of 80 cirrhosis patients, 75% of patients received 2–4 units of plasma, but only 10% achieved target levels of clotting indices, and fluid overload was common [75]. In addition, the rate of transfusion-related lung injury could be as common as 1 in 400 transfusions, with a mortality rate as high as 5–10% [76]. Cryoprecipitates contain the cold-insoluble components of plasma (fibronectin, fibrinogen and the von Willebrand–factor VIII complex). In active bleeding, transfusion to increase fibrinogen levels above 100–120 mg/dL is often recommended prior to the use of agents such as recombinant activated factor VII (rFVIIa; see below). Cryoprecipitate transfusion has a significant risk of transmission of viral infections including human immunodeficiency virus (HIV), due to the inability to undergo viral inactivation during preparation and a pool of 10–20 donors for each unit [77,78].

Recombinant activated factor VII (rFVIIa)

An extensive body of literature has developed regarding the use of rFVIIa in liver disease patients, but lack of controlled trials and controversial endpoints hamper interpretation of the data [79,80]. Its major advantages are augmentation of the physiological 'thrombin burst', activity at sites of vascular breach where TF is exposed and its low dose volume [81]. Single doses of rFVIIa decrease clotting time in cirrhosis patients without increasing clot lysis time or fibrinolysis [82], indicating the formation of a viable clot [83]. In non-bleeding cirrhosis patients, the half-life of rFVIIa is approximately 2.3 h, but no data are available for bleeding patients. Bernstein *et al.* [84] demonstrated that the duration of normalization of the PT was approximately 2, 6 and 12 h following doses of 5, 20 or 80 μg/kg respectively (Fig. 8). rFVIIa also augments coagulation in thrombocytopenia via enhancement of site-specific activation of platelets that enhance thrombin generation [85].

rFVIIa has been reported in a wide variety of clinical situations among liver disease patients. Jeffers *et al.* [86] reported four different doses of rFVIIa (5, 20, 80 and 120 μg/kg) in patients undergoing laparoscopic liver biopsy, but could not demonstrate differences in liver biopsy bleeding time, although the agent appeared to be relatively safe. Several studies have shown efficacy in correcting the PT INR in fulminant hepatic failure patients undergoing intracranial pressure (ICP) monitor placement, with doses as low as a single administration of 40 μg/kg [87–89]. The ability to avoid volume expansion (and secondary anasarca) in this setting is particularly attractive. Bosch *et al.* [90] also showed that serial dosing in variceal bleeding produced a modest reduction in rebleeding in Child–Pugh

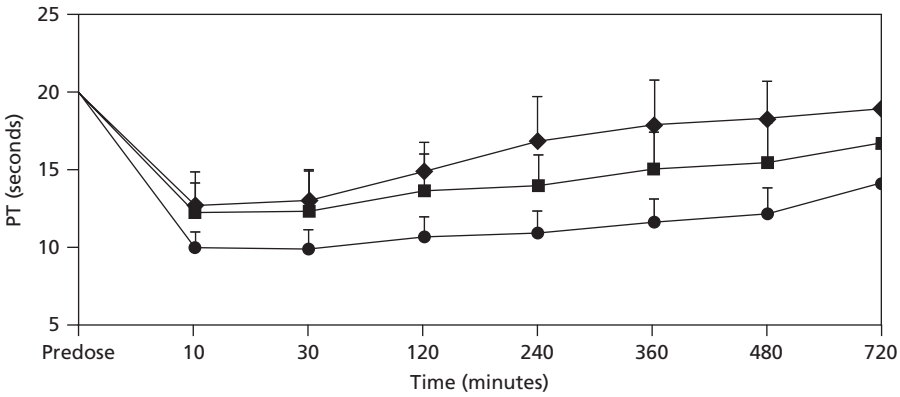

The doses of rFVIIa were 5 (●), 20 (■) or 80 μg/kg (◆).

Fig. 8 Bernstein *et al*. [84] demonstrated similar efficacy in correcting prothrombin time prolongation at each of three different doses of rFVIIa in otherwise stable patients with cirrhosis. However, there was a significant difference in the duration of effect.

class B–C patients when administered in conjunction with endoscopic therapy.

Most studies carried out thus far do not show increased biochemical evidence of DIC in otherwise stable cirrhotic patients, but both DIC and portal vein thrombosis have been observed in one series of liver biopsy patients [84]. Myocardial infarction has also been reported in one patient receiving concomitant vasoconstricting therapy for refractory hypotension (see MedWatch). However, a large analysis compiling subjects from multiple studies has shown a low complication rate in comparison with control subjects [91]. However, the most significant disadvantage to the use of rFVIIa is the cost. Nonetheless, its relative expense is tempered by the costs of other interventions and potential side-effects of the alternatives (such as volume overexpansion, exacerbation of portal hypertension and pulmonary oedema).

Antifibrinolytic agents

ε-Aminocaproic acid (EACA) and tranexamic acid (TA) are synthetic derivatives of lysine that bind and inhibit plasmin, and thus inhibit fibrinogen dissolution. Aprotinin is a bovine-derived serine protease inhibitor that inactivates kallikrein, therefore indirectly inactivating factor XII, leading (secondarily) to diminution of both coagulation and fibrinolysis. These agents play a potentially significant role in treating hyperfibrinolysis in liver failure patients. Because the oral cavity is rich in plasminogen activators, there is a particular role for EACA and TA in patients with persistent bleeding after dental extractions (Fig. 9), where topical therapy may be effective [92,93].

Success with antifibrinolytics has also been reported in liver transplantation [94], although there is no consensus regarding their use. EACA is a relatively inexpensive drug, but possesses possible side-effects including renal insufficiency and, rarely, dysrythmia [95]. Although studies have demonstrated its role in reducing fibrinolysis [96,97], proven benefit in the use of EACA in liver transplantation has not been shown [98,99], TA, which is 6–10 times more potent than EACA, has conflicting evidence

(a)

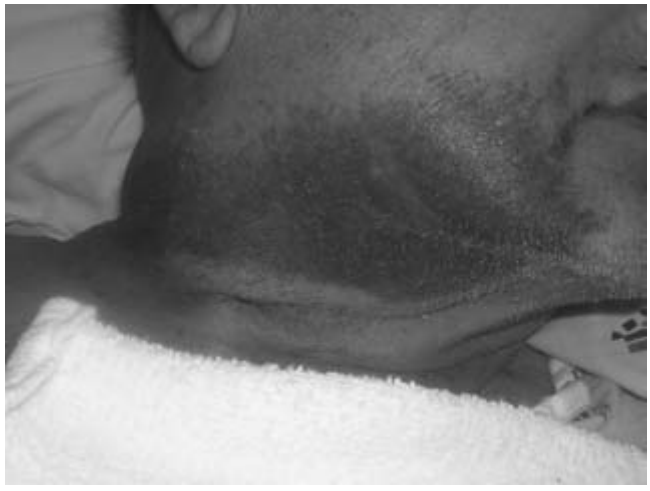

(b)

Fig. 9 (a and b) Patient with cirrhosis and hepatorenal syndrome with persistent bleeding following dental extractions in preparation for liver transplantation in spite of presurgical treatment with DDAVP. Although systemic hyperfibrinolysis was not evident, this responded to topical antifibrinolytics.

regarding its efficacy. Dalmau *et al.*'s [99] and Boylan *et al.*'s [100] controlled trials have demonstrated decreased blood transfusion during liver transplantation with use of TA compared with placebo or with EACA. Kasper *et al.*'s [101] investigation, on the other hand, failed to show efficacy of TA on reduction of transfusion requirements; interpretation of these data is limited, however, as lower doses of TA were used this study.

Intravenous aprotinin has been studied in states of active proteolysis (such as after cardiac surgery), but studies involving cirrhosis patients are limited. In Porte *et al.*'s [102] multicentre, prospective, double-blinded, controlled trial, 141 patients undergoing liver transplantation were assigned into groups given high-dose aprotinin, regular-dose aprotinin or placebo. Total blood loss was significantly lower in the aprotinin-treated groups (60% reduction in the high-dose group and 44% reduction in the low-dose group) than in the placebo group, and transfusion of red blood cells was 37% lower in the high-dose group and 20% lower in the regular-dose group, compared with the placebo group. Further evidence in favour of aprotinin includes Findlay *et al.*'s trial [103], which showed that aprotinin significantly reduced blood transfusion in orthotopic liver transplantation (OLT) compared with placebo. However, a recent controlled trial comparing TA with aprotinin demonstrated no significant difference in blood or blood product transfusion between the two groups [104]. We are not aware of published data regarding non-surgical haemostasis in cirrhosis using aprotinin.

DDAVP

Desmopressin, 1-deamino-8-D-arginine vasopressin (DDAVP), is an analogue of the antidiuretic hormone vasopressin, which increases endogenous secretion of FVIII and von Willebrand factor (vWF). Intravenous (0.3 μg/kg) use of DDAVP shows rapid onset and measurable increases in factor VIII and vWF. Side-effects include hyponatraemia (especially with repeated doses), mild increases in systolic and diastolic blood pressure, facial flushing and headache [105]. In non-controlled studies, DDAVP improved bleeding times in patients with cirrhosis who did not have coexisting thrombocytopenia [106,107]. A double-blind, placebo-controlled, crossover study of nine patients by Agnelli *et al.* [108] also demonstrated significantly improved bleeding time and PTT, while significantly increasing levels of factor VIII, XI and XII activity. However, de Franchis *et al.* [109] performed a randomized, placebo-controlled trial of terlipressin with and without DDAVP in the treatment of variceal bleeding. This study was terminated early because of a statistically significant higher rate of rebleeding in the DDAVP group. Wong *et al.* [110] performed a randomized, double-blinded, placebo-controlled trial of DDAVP vs. placebo in 60 patients undergoing liver resection surgery (43% of whom were cirrhotic), and were also unable to demonstrate a clear advantage to its use. Nonetheless, this agent is commonly employed preprocedure in liver disease patients at particularly high risk, as with coexisting renal failure patients undergoing dental extractions, line placement or liver biopsy. However, this use has yet to be established.

Restoration of vascular tone

The role of the vascular endothelium in coagulation is underappreciated and understudied, especially in liver disease. Relevant factors include prostaglandin metabolism, nitric oxide, vWF, TF, TFPI, thrombomodulin and tissue plasminogen activator [111]. The hyperdynamic state of cirrhosis is characterized by loss of normal vascular tone, secondary vasodilation and low systemic vascular resistance, thought to be mediated by nitric oxide. Aside from variceal bleeding, we are not aware of specific studies that have addressed the role of agents aimed at reversing the hyperdynamic state (such as terlipressin, midodrine or octreotide) in treating the bleeding diathesis of cirrhosis. However, the use of such agents in intractable bleeding for situations such as postoperative wound bleeding or postprocedure bleeding, such as haemoperitoneum (involving the collateral bed), warrants consideration and further study.

Haemodialysis

As described previously, platelet dysfunction in advanced renal disease is partly attributed to the presence of several dialysable uraemic toxins (see above). However, no correlation has been found between bleeding time or platelet adhesion and serum levels of these metabolites [112]. Nonetheless, dialysis appears to be effective for platelet dysfunction secondary to uraemia and is more effective if carried out three times a week rather than twice weekly [113], with improvement in coagulation usually occurring for 1–2 days after treatment [114]. Although certain platelet abnormalities are improved after dialysis, both haemodialysis (HD) and peritoneal dialysis (PD) may diminish platelet function. HD may cause platelet activation, from the interaction between blood and certain cuprophane surfaces; this leads to a release of platelet-derived proteins and elevated circulating reticulated platelets, indicating accelerated platelet turnover and increased bleeding risk [115]. PD, however, is associated with platelet hyper-reactivity secondary to hypoalbuminaemia [116]. Furthermore, markers of coagulation, such as thrombin–antithrombin complexes and prothrombin fragments, are higher in PD than in HD patients, whereas indicators of fibrinolysis, such as plasmin–antiplasmin complexes, are found to be lower in PD than in HD patients [117].

Topical agents

Topical agents include collagen derivatives, thrombin–fibrinogen (fibrin glue) and, perhaps, cyanoacrylates. A detailed discussion

of these agents is beyond the scope of the present work, but several points are worth noting. Topical thrombin is sometimes advocated for treating bleeding puncture wounds in liver disease patients. However, their relative efficacy and expense warrants consideration in this application. Plugging of the liver biopsy tract with various derivatives of collagen has been the subject of several reports, which have usually indicated efficacy. We demonstrated significant haemostasis in liver bleeding time in over 100 laparoscopic biopsies in pigs, using collagen as a haemostatic plug (unpublished results). A blinded, randomized and controlled clinical trial is now under way to determine whether or not this agent is clinically useful in normal risk patients undergoing liver biopsy. Efficacy of topical thrombin has also been reported when used as an adjunct to conventional sclerotherapy in the treatment of gastric variceal bleeding. Whether this approach is superior to cyanoacrylate injection remains to be established [118,119]. The use of cyanoacrylates for gastric variceal therapy has also been the subject of a number of studies. The interaction of different chain length cyanoacrylates and the clotting cascade warrants further study in terms of overall efficacy and safety with regard to embolic risk.

Marrow stimulants

Multiple case reports exist describing the use of marrow stimulants in major surgery, including liver transplantation [120], without the use of donated blood products in these patients. Some of this experience derives from populations refusing the transfusion of blood products due to religious or cultural beliefs (e.g. Jehovah's Witnesses). In patients with underlying cirrhosis, there appears to be an inadequate response of endogenous erythropoietin in the presence of anaemia, with a haemoglobin less than 12 g/dL [121,122]. However, supplemental use of erythropoietin in cirrhosis patients has shown a statistical improvement in platelet count and function [123]. Although marrow stimulants are extremely costly, the safety and efficacy of the use erythropoietin analogues has been well demonstrated in cirrhosis patients undergoing treatment with interferon and ribavirin for hepatitis C. Although not studied extensively, it seems most appropriate to consider the use of marrow stimulants in cirrhosis patients with chronic low-level blood loss, such as that from portal gastropathy or gastric antral vascular ectasia (GAVE), in order to decrease transfusion dependency. It should be noted that adequate iron stores are required for the efficacy of these medications.

Hypercoagulation in liver disease

Portal vein thrombosis (PVT) has long been recognized as a complication of cirrhosis. The incidence of clinically detected portal vein thrombosis in these patients ranges from 0.6% to 17% [124,125]. Although common, the pathophysiology of pure portal vein thrombosis in cirrhosis patients is not well established. In one series of 79 cirrhosis patients with PVT [126], hepatocellular carcinoma and advanced liver disease (Childs B or C) were the major risk factors, but a mutation in prothrombin (mutation 20210) was also a significant risk compared with matched control subjects. One half of the patients presented with associated symptoms ranging from gastrointestinal bleeding to pain related to mesenteric ischaemia. Other authors have found the antiphospholipid antibody to be related to the development of PVT [127]. A stronger contributor to the development of PVT in cirrhosis patients is the increased vascular resistance to flow associated with hepatic fibrosis and portal hypertension. This flow resistance has been documented using both invasive and non-invasive flow estimation techniques [128] and is probably the primary factor in the initiation of PVT. Because of the risk of bleeding complications and the difficulty in following therapeutic anticoagulation levels in patients with liver disease, the treatment or prophylaxis of PVT in cirrhosis remains individualized and requires further study.

Excessive thrombosis may also play a more occult role in chronic disease progression in which stable cirrhosis becomes decompensated hepatic atrophy. Intrahepatic thrombi have been implicated by Wanless *et al.* [129] in the progression of cirrhosis to a state of atrophy (parenchymal extinction). By detailed examination of 61 explanted livers, the authors observed intimal fibrosis, a marker of healed thrombosis, in a pattern suggestive of prior thrombosis in hepatic vein and portal vein branches in 70% and 36% respectively (Fig. 10). The size of involved vessel was felt to be below the level of detection of common imaging techniques (distinguishing this process from classical portal vein thrombosis – see above), and no relation to underlying liver disease was detected, suggesting that the process is common to cirrhosis in general. Experimentally, the presence of the procoagulant factor V Leiden mutation has been shown to exacerbate the progression of induced hepatic injury [130]. *In situ* small vessel thrombosis also appears to be one of several aetiological factors in the development of portopulmonary hypertension [131–133].

Clinical experience suggests that cirrhotic patients are at risk of venous deep vein thrombosis (DVT) and thromboembolism (VTE), especially in the inpatient setting. This has been documented in case reports discussing the occurrence of VTE in hospitalized patients with non-malignant chronic liver disease [134,135]. However, because of the lack of a clear gold standard for diagnosing DVT or PE and multiple confounding factors, it is difficult to assess the true risk of DVT and VTE in cirrhosis patients. We have reviewed our own single-centre experience of more than 22 000 admissions over a 5-year period and found the incidence of newly diagnosed peripheral VTE (non-portal vein thrombosis) in hospitalized patients with cirrhosis to be approximately 1.2% [136]. Patients with and without VTE were not different with regard to level of coagulopathy as measured by INR or platelet count.



Fig. 10 Wanless *et al*. [129] examined explanted liver for evidence of hepatic vein and portal vein thrombosis. The map corresponds to the cross-section of the explanted liver and illustrates grades of hepatic vein occlusion (defined as intimal thickening) in relation to fibrosis stage. The data suggest that vascular occlusion may precipitate organ atrophy as cirrhosis progresses from a stable state to one associated with complications of portal hypertension.

Conclusion

Coagulopathy in liver disease is extraordinarily complex and involves diminished synthesis of both procoagulant factors and anticoagulant factors. Platelet abnormalities, portal hypertension, endothelial dysfunction and renal failure all play important roles in haemostasis and require consideration in determining the best management. In addition, other definable conditions may be superimposed, further complicating the clinical picture. Among these, hyperfibrinolysis stands out as an infrequent but discrete and definable entity warranting specific therapy. Conventional tests of coagulation clearly carry prognostic information in liver disease patients, but recent findings suggest that such tests are in need of refinement, and the common means of assessing bleeding risk often lack clinical relevance and a strong basis in clinical research.

Several recent advances have led to significant conceptual changes in the evaluation and treatment of liver disease-related coagulopathy. The development of recombinant factor VII (rFVIIa) has led to a new concept of coagulation, involving the interaction of tissue factor (TF) and factor VII, bringing together the classical concepts of the intrinsic and extrinsic pathways. The interaction of TF and factor VII occurs at the site of vessel injury, generating a small amount of thrombin, which amplifies the original signal. The development of improved tests to define where a particular patient exists in the spectrum of coagulopathy is of special interest. Potential therapeutic interventions require careful consideration of the underlying pathophysiology and tailoring of the treatment to their needs. Conventional treatments (vitamin K, plasma or cryoprecipitate) remain important, but their use should be tempered because of the risk of pulmonary oedema or anasarca, especially with excessive plasma. Other agents, such as rFVIIa, have as yet undefined but potentially very potent roles. The best approach, preventive or prophylactic intervention vs. 'rescue' therapy in the event of bleeding, depends to a large extent on the risk–benefit ratio of a particular condition and intervention and remains to be fully defined.

References

1 Rapaport SI, Rao LVM (1995) The tissue factor pathway: how it has become a 'prima ballerina'. *Thromb Haemost* 74, 7–17.

2 Veldman A, Hoffman M, Ehrenforth S (2003) New insights into the coagulation system and implications for new therapeutic options with recombinant Factor VIIa. *Curr Med Chem* 10, 797–811.

3 Tholstrup T, Miller GJ, Bysted A *et al.* (2003) Effect of individual dietary fatty acids on postprandial activation of blood coagulation factor VII and fibrinolysis in healthy young men. *Am J Clin Nutr* 77, 1125–1132.

4 Rapaport SI (1989) Inhibition of factor VIIa/tissue factor-induced blood coagulation: with particular emphasis upon a factor Xa-dependent inhibitory mechanism. *Blood* 73, 359–365.

5 Jackson CM, Esnouf MP, Lindahl TL (2003) A critical evaluation of the prothrombin time for monitoring oral anticoagulant therapy. *Pathophysiol Haemost Thromb* 33, 43–51.

6 Bauer K (2003) Approach to thrombosis. In: Loscalzo J, Schafer AI (eds) *Thrombosis and Hemorrhage.* Philadelphia: Lippincott Williams & Wilkins, pp. 334–335.

7 WHO Expert Committee on Biological Standardization (1983) *33rd Report.* Technical Report Series No. 687. Geneva: World Health Organization.

8 Hirsh J, Poller L (1994) The international normalized ratio. A guide to understanding and correcting its problems. *Arch Intern Med* 154, 282–288.

9 Wuillemin WA, Gasser KM, Zeerleder SS *et al.* (2002) Evaluation of a platelet function analyzer (PFA-100) in patients with a bleeding tendency. *Swiss Med Wkly* 132, 443–448.

10 Escolar G, Cases A, Vinas M *et al.* (1999) Evaluation of acquired platelet dysfunctions in uremic and cirrhotic patients using the platelet function analyzer (PFA-100): influence of hematocrit elevation. *Haematologica* 84, 614–619.

11 Ewe K (1981) Bleeding after liver biopsy does not correlate with indices of peripheral coagulation. *Dig Dis Sci* 26, 388–393.

12 Boks AL, Brommer EJ, Schalm SW *et al.* (1986) Hemostasis and fibrinolysis in severe liver failure and their relation to hemorrhage. *Hepatology* 6, 79–86.

13 Robert A, Chazouilleres O (1996) Prothrombin time in liver failure: time, ratio, activity percentage, or international normalized ratio. *Hepatology* 24, 1392–1394.

14 Kovacs MJ, Wong A, MacKinnon K *et al.* (1994) Assessment of the validity of the INR system for patients with liver impairment. *Thromb Haemost* 71, 727–730.

15 Trotter JF, Brimhall B, Arjal R *et al.* (2004) Specific laboratory methodologies achieve higher Model for End-stage Liver Disease (MELD) scores for patients listed for liver transplantation. *Liver Transpl* 10, 995–1000.

16 McBane RD, Felty CL, Hartgers ML *et al.* (2005) Importance of device evaluation for point-of-care prothrombin time International Normalized Ratio testing programs. *Mayo Clin Proc* 80, 181–186.

17 Tripodi A, Salerno F, Chantarangkul V *et al.* (2005) Evidence of normal thrombin generation in cirrhosis despite abnormal conventional coagulation tests. *Hepatology* 41, 553–558.

18 Bosch J, Reverter JC (2005) The coagulopathy of cirrhosis: myth or reality? *Hepatology* 41, 434–435.

19 Peck-Radosavljevic MP, Zacherl J, Meng YG *et al.* (1997) Is inadequate thrombopoietin production a major cause of thrombocytopenia in cirrhosis of the liver? *J Hepatol* 27, 127–131.

20 Samuel H, Nardi M, Karpatkin M *et al.* (1999) Differentiation of autoimmune thrombocytopenia from thrombocytopenia associated with immune complex disease: systemic lupus erythematosus, hepatitis-cirrhosis, and HIV-1 infection by platelet and serum immunological measurements. *Br J Haematol* 105, 1086–1091.

21 Rios R, Sangro B, Herrero I *et al.* (2005) The role of thrombopoietin in the thrombocytopenia of patients with liver cirrhosis. *Am J Gastroenterol* 100, 1311–1316.

22 Hersch S, Kunelis T, Francis RV (1987) The pathogenesis of accelerated fibrinolysis in liver cirrhosis: a critical role for tissue plasminogen activator inhibitor. *Blood* 69, 1315–1319.

23 Green G, Thomson JM, Dymock IW *et al.* (1976) Abnormal fibrin polymerization in liver disease. *Br J Haematol* 34(3), 427–439.

24 Zachee P, Vermylen J, Boogaerts MA (1994) Hematologic aspects of end-stage renal failure. *Ann Hematol* 69(1), 33–40.

25 Rubin MH, Weston MJ, Langley MH *et al.* (1979) Platelet function in chronic liver disease: relationship to disease severity. *Dig Dis Sci* 24, 197–202.

26 Lisman T, Leebeek FWG, Mosnier LO *et al.* (2001) Thrombin-activatable fibrinolysis inhibitor deficiency in cirrhosis is not associated with increased plasma fibrinolysis. *Gastroenterology* 121, 131–139.

27 Fletcher AP, Biederman O, Moore D *et al.* (1964) Abnormal plasminogen–plasmin activity (fibrinolysis) in patients with hepatic cirrhosis: its cure and consequences. *J Clin Invest* 43, 681–695.

28 Agarwal S, Joyner KA, Swaim MW (2001) Ascites fluid as a possible origin for hyperfibrinolysis in advanced liver disease. *Am J Gastroenterol* 95, 3218–3224.

29 Bakker C, Knot E, Stibbe J *et al.* (1992) Disseminated intravascular coagulation in liver cirrhosis. *J Hepatol* 15, 330–335.

30 Zieve L (1958) Jaundice, hyperlipidemia and hemolytic anemia: a heretofore unrecognized syndrome associated with alcoholic fatty liver and cirrhosis. *Ann Intern Med* 48, 471–496.

31 Chitale AA, Sterling RK, Post AB *et al.* (1998) Resolution of spur cell anemia with liver transplantation: a case report and review of the literature. *Transplantation* 65, 993–995.

32 Shattil SJ, Anaya-Galindo R, Bennett J *et al.* (1975) Platelet hypersensitivity induced by cholesterol incorporation. *J Clin Invest* 55, 636–643.

33 Smeets EF, Comfurius P, Bevers EM *et al.* (1996) Contribution of different phospholipid classes to the prothrombin converting capacity of sonicated lipid vesicles. *Thromb Res* 81, 419–426.

34 El Khishen MA, Henderson JM, Millikan WJ Jr *et al.* (1985) Splenectomy is contraindicated for thrombocytopenia secondary to portal hypertension. *Surg Gynecol Obstet* 160, 233–238.

35 Astor RH (1966) Pooling of platelets in the spleen: role in the pathogenesis of 'hypersplenic' thrombocytopenia. *J Clin Invest* 45, 645–657.

36 Harker LA, Finch CA (1969) Thrombokinetics in man. *J Clin Invest* 48, 963–974.

37 Penny R, Rosenberg MC, Firkin BG (1966) The splenic platelet pool. *Blood* 27, 1–16.

38 Vyzantiadis T, Theodoridou S, Giouleme O *et al.* (2002) Serum thrombopoietin levels in thrombocytopenic patients with liver cirrhosis. *Haematologica* 87, 890–891.

39 Koruk M, Onuk MD, Akcay F *et al.* (2002) Serum thrombopoietin levels in patients with chronic hepatitis and liver cirrhosis and its relationship with circulating thrombocyte counts. *Hepatogastroenterology* 49, 1645–1648.

40 Adinolfi LE, Giordano MG, Andreana A *et al.* (2002) Hepatic fibrosis plays a central role in the pathogenesis of thrombocytopenia in patients with chronic viral hepatitis. *Br J Haematol* 113, 590–595.

41 Aref S, Mabed M, Selim T *et al.* (2004) Thrombopoietin (TPO) levels in hepatic patients with thrombocytopenia. *Hematology* 9, 351–356.

42 Freni MA, Spadaro A, Ajello A *et al.* (2002) Serum thrombopoietin in chronic liver disease: relation to severity of the disease and spleen size. *Hepatogastroenterology* 49, 1383–1385.

43 Ishikawa T, Ichida T, Sugahara S *et al.* (2002) Thrombopoietin receptor (c-Mpl) is constitutively expressed on platelets of patients with liver cirrhosis, and correlates with its disease progression. *Hepatol Res* 23, 115–121.

44 Levine R, Spivak J, Meagher R *et al.* (1986) Effect of ethanol on thrombopoiesis. *Br J Haematol* 14, 345–354.

45 Cowan D (1973) Thrombokinetic studies in alcohol related thrombocytopenia. *J Lab Clin Med* 81, 64–76.

46 Ordinas A, Escolar G, Cirera I *et al.* (1996) Existence of a platelet-adhesion defect in patients with cirrhosis independent of hematocrit: studies under flow conditions. *Hepatology* 24, 1137–1142.

47 Walkowiak B, Michalak E, Borkowska E *et al.* (1994) Concentration of RGDS-containing degradation products in uremic plasma is correlated with progression in renal failure. *Thromb Res* 76, 133–144.

48 Doll DC (1982) Surface morphology of platelets in spur-cell anemia. *Hum Pathol* 13, 671–672.

49 Ulibarrena C, Vecino A, Cesar JM (1994) Red cell lipid abnormalities in acquired acanthocytosis are extended to platelets. *Br J Haematol* 87, 614–616.

50 Sundaram V, Al-Osaimi AMS, Lewis JJ *et al.* (2006) Severe prolongation of the INR in spur cell anemia of cirrhosis: true-true and related? *Dig Dis Sci* 51, 1203–1205.

51 Shattil SJ, Anaya-Galindo R, Bennett J *et al.* (1975) Platelet hypersensitivity induced by cholesterol incorporation. *J Clin Invest* 55, 636–643.

52 Smeets EF, Comfurius P, Bevers EM *et al.* (1996) Contribution of different phospholipid classes to the prothrombin converting capacity of sonicated lipid vesicles. *Thromb Res* 81, 419–426.

53 Schaefer AI (2003) Acquired disorders of platelet function. In: Loscalzo J, Schafer AI (eds) *Thrombosis and Hemorrhage*. Philadelphia: Lippincott Wiliams & Wilkins, p. 526.

54 Kyrle PA, Stockenhuber F, Brenner B *et al.* (1988) Evidence for an increased generation of prostacyclin in the microvasculature and an impairment of the platelet alpha-granule release in chronic renal failure. *Thromb Haemost* 60, 205–208.

55 Mannhalter CH, Deutsch E, Kopsa E (1985) Clotting activities and antigen concentrations of contact factors in kidney disease. *Thromb Res* 39, 475–484.

56 Craxi A, Camma C, Giunta M (2000) Clinical aspects of bleeding complications in cirrhotic patients. *Blood Coagul Fibrinolysis* 11(Suppl.), S75–S79.

57 Kamath PS, Wiesner RH, Malinchoc M *et al.* (2001) A model to predict survival in patients with end-stage liver disease. *Hepatology* 33, 464–470.

58 Merion RM, Wolfe RA, Dykstra DM *et al.* (2003) Longitudinal assessment of mortality risk among candidates for liver transplantation. *Liver Transpl* 9, 12–18.

59 Malinchoc M, Kamath PS, Gordon FD *et al.* (2000) A model to predict poor survival in patients undergoing transjugular intrahepatic portosystemic shunts (comment). *Hepatology* 31, 864–871.

60 Rice HE, O'Keefe GE, Helton WS *et al.* (1997) Morbid prognostic features in patients with chronic liver failure undergoing nonhepatic surgery. *Arch Surg* 132, 880–884.

61 del Olmo JA, Flor-Lorente B, Flor-Civera B *et al.* (2003) Risk factors for nonhepatic surgery in patients with cirrhosis. *World J Surg* 27, 647–652.

62 Northup PG, Wanamaker RC, Lee VD *et al.* (2005) Model for End Stage Liver Disease (MELD) predicts non-transplant surgical mortality in patients with cirrhosis. *Ann Surg* 242, 244–251.

63 Sue M, Caldwell SH, Dickson RC *et al.* (1996) Variation between centres in technique and guidelines for liver biopsy. *Liver* 16, 267–270.

64 Grabau CM, Crago SF, Hoff LK *et al.* (2004) Performance standards for therapeutic abdominal paracentesis. *Hepatology* 40, 484–488.

65 Terjung B, Lemnitzer I, Dumoulin FL *et al.* (2003) Bleeding complications after percutaneous liver biopsy. An analysis of risk factors. *Digestion* 67, 138–145.

66 Furie B, Furie BC (1990) Molecular basis for vitamin K-dependent-γ-carboxylation. *Blood* 75, 1753–1762.

67 Furie B, Bouchard BA, Furie BC (1999) Vitamin K-dependent biosynthesis of γ-carboxyglutamic acid. *Blood* 93, 1798–1808.

68 Wilkins K, DeKoven J, Assaad D (2000) Cutaneous reactions associated with vitamin K1. *J Cutan Med Surg* 4, 164–168.

69 Chung JY, Ramos-Caro FA, Beers B *et al.* (1999) Hypersensitivity reactions to parenteral vitamin K. *Cutis* 63, 33–34.

70 Riegert-Johnson DL, Volcheck GW (2002) The incidence of anaphylaxis following intravenous phytonadione (vitamin K1): a 5-year retrospective review. *Ann Allergy Asthma Immunol* 89, 400–406.

71 Wjasow C, McNamara R (2003) Anaphylaxis after low dose intravenous vitamin K. *J Emerg Med* 24, 169–172.

72 Dzik S (1999) The use of blood components prior to invasive procedures: a critical appraisal. In: Mintz PD (ed.) *Transfusion Therapy: Clinical Principles and Practice*. Bethesda, MD: AABB Press.

73 Bishop JF, McGrath K, Wolf MM *et al.* (1988) Clinical factors influencing the efficacy of pooled platelet transfusions. *Blood* 71, 383–387.

74 Federowicz I, Barrett BB, Andersen JW *et al.* (1996) Characterization of reactions after transfusion of cellular blood components that are white cell reduced before storage. *Transfusion* 36, 21–28.

75 Youssef WI, Salazar F, Dasarathy S *et al.* (2003) Role of fresh frozen plasma infusion in correction of coagulopathy of chronic liver disease: a dual phase study. *Am J Gastroenterol* 98, 1391–1394.

76 Kleinman S, Caulfield T, Chan P *et al.* (2004) Toward an understanding of transfusion-related acute lung injury: statement of a consensus panel. *Transfusion* 44, 1774–1789.

77 Keeling DM, Luddington R, Allain JP *et al.* (1997) Cryoprecipitate prepared from plasma virally inactivated by the solvent detergent method. *Br J Haematol* 96, 194–197.

78 Evatt BL, Austin H, Leon G *et al.* (1999) Haemophilia therapy: assessing the cumulative risk of HIV exposure by cryoprecipitate. *Haemophilia* 5, 295–300.

79 Caldwell SH, Chang C, Macik BG (2004) Recombinant activated factor VII (rFVIIa) as a hemostatic agent in liver disease: a break with tradition in need of controlled trials. *Hepatology* 39, 592–598.

80 Porte RJ, Caldwell SH (2005) The role of recombinant factor VII in liver transplantation. *Liver Transpl* 11, 872–874.

81 Hedner U (2000) Recombinant coagulation factor VIIa: from concept to clinical application in hemophilia treatment in 2000. *Semin Thromb Hemost* 26, 363–366.

82 Hendriks HG, Meijer K, de Wolf J *et al.* (2002) Effects of recombinant activated factor VII on coagulation measured by thromboelastography in liver transplantation. *Blood Coagul Fibrinolysis* 13, 309–313.

83 Lisman T, Leebeek FW, Meijer K *et al.* (2002) Recombinant Factor VIIa improves clot formation but not fibrolytic potential in patients with cirrhosis and during liver transplantation. *Hepatology* 35, 616–621.

84 Bernstein DE, Jeffers L, Erhardtsen E *et al.* (1997) Recombinant Factor VIIa corrects prothrombin time in cirrhotic patients: a preliminary study. *Gastroenterology* 113, 1930–1937.

85 Kjalke M, Ezban M, Monroe DM *et al.* (2001) High-dose factor VIIa increases initial thrombin generation and mediates faster platelet activation in thrombocytopenia-like conditions in a cell-based model system. *Br J Haematol* 114, 114–120.

86 Jeffers L, Chalasani N, Balart L *et al.* (2002) Safety and efficacy of recombinant factor VIIa in patients with liver disease undergoing laparoscopic liver biopsy. *Gastroenterology* 123, 118–126.

87 Shami V, Caldwell S, Hespenheide E *et al.* (2003) Recombinant activated factor VII for coagulopathy in fulminant hepatic failure compared with conventional therapy. *Liver Transpl* 9, 138–143.

88 Chuansumrit A, Treepongkaruna S, Phuaradit P (2001) Combined fresh frozen plasma with recombinant factor VIIa in restoring hemostasis for invasive procedures in children with liver diseases. *Thromb Haemost* 85(4), 748–779.

89 Quan DJ, Bass NM, Hirose R (2003) The effect of recombinant factor VIIa and fresh frozen plasma on the INR in patients with acute and chronic liver failure. *Hepatology* 38, 550A.

90 Bosch J, Thabut D, Bendtsen F *et al.* (2004) Recombinant factor VIIa for upper gastrointestinal bleeding in patients with cirrhosis: a randomized double blind trial. *Gastroenterology* 127, 1123–1130.

91 Levi M, Peters M, Buller HR (2005) Efficacy and safety of recombinant factor VIIa for treatment of severe bleeding: a systematic review. *Crit Care Med* 33, 883–890.

92 Sindet PS (1987) Distribution of tranexamic acid to plasma and saliva after oral administration and mouth rinsing: a pharmacokinetic study. *J Clin Pharmacol* 27, 1005–1008.

93 Walsh PN, Rizza CR, Matthews JM *et al.* (1971) Epsilon aminocaproic acid therapy for dental extractions in hemophilia and Christmas disease: a double-blind controlled trial. *Br J Haematol* 20, 463–475.

94 Porte RJ (2004) Antifibrinolytics in liver transplantation: they are effective, but what about the risk-benefit ratio? *Liver Transpl* 10(2), 285–288.

95 Manjunath G, Fozailoff A, Mitcheson D *et al.* (2002) Epsilon-aminocaproic acid and renal complications: case report and review of the literature. *Clin Nephrol* 58, 63–67.

96 Eberle B, Mayer E, Hafner G *et al.* (1998) High-dose epsilon-aminocaproic acid versus aprotinin: antifibrinolytic efficacy in first-time coronary operations. *Ann Thorac Surg* 65, 667–673.

97 McSorley MW, Taraporewalla KJ (1991) Does prophylactic epsilon-aminocaproic acid improve blood loss and coagulation in liver transplantation? *Transplant Proc* 23, 1941.

98 Scudamore CH, Randall TE, Jewesson PJ *et al.* (1995) Aprotinin reduces the need for blood products during liver transplantation. *Am J Surg* 169, 546–549.

99 Dalmau A, Sabate A, Acosta F *et al.* (2000) Tranexamic acid reduces red cell transfusion better than ε-aminocaproic acid or placebo in liver transplantation. *Anesth Analg* 91, 29–34.

100 Boylan JF, Klinck JR, Sandler AN *et al.* (1996) Tranexamic acid reduces blood loss, transfusion requirements, and coagulation factor use in primary orthotopic liver transplantation. *Anesthesiology* 85, 1043–1048.

101 Kasper M, Ramsay MAE, Nguyen AT *et al.* (1997) Continuous small-dose tranexamic acid reduces fibrinolysis but not transfusion requirements during orthotopic liver transplantation. *Anesth Analg* 85, 281–285.

102 Porte RJ, Molenaar IQ, Begliomini B *et al.* (2000) Aprotinin and transfusion requirements in orthotopic liver transplantation: a multicentre randomized double-blind study. *Lancet* 355, 1303–1309.

103 Findlay JY, Rettke SR, Ereth MH *et al.* (2001) Aprotinin reduces red blood cell transfusion: a prospective, randomized, double-blind study. *Liver Transpl* 9, 802–807.

104 Dalmau A, Sabate A, Koo M *et al.* (2004) The prophylactic use of tranexamic acid and aprotinin in orthotopic liver transplantation: a comparative study. *Liver Transpl* 10, 279–284.

105 Agnelli G, Berrettini M, De Cunto M *et al.* (1983) Desmopressin-induced improvement of abnormal coagulation in chronic liver disease. *Lancet* 1, 645.

106 Cattaneo M, Tenconi PM, Alberca I *et al.* (1990) Subcutaneous desmopressin (DDAVP) shortens the prolonged bleeding time in patients with liver cirrhosis. *Thromb Haemost* 64, 358–360.

107 Lopez P, Otaso JC, Alvarez D *et al.* (1997) Hemostatic and hemodynamic effects of vasopressin analogue DDAVP in patients with cirrhosis. *Acta Gastroenterol Latinoam* 27, 59–62.

108 Agnelli G, Parise P, Levi M *et al.* (1995) Effects of desmopressin on hemostasis in patients with liver cirrhosis. *Haemostasis* 25, 241–247.

109 de Franchis R, Arcidiacono PG, Carpinelli L *et al.* (1993) Randomized controlled trial of desmopressin plus terlipressin vs. terlipressin alone for the treatment of acute variceal hemorrhage in cirrhotic patients: a multicenter, double-blind study. New Italian Endoscopic Club. *Hepatology* 18, 1102–1107.

110 Wong AY, Irwin MG, Hui TW *et al.* (2003) Desmopressin does not decrease blood loss and transfusion requirements in patients undergoing hepatectomy. *Can J Anaesth* 50, 14–20.

111 Hajjer KA (2003) The endothelium in thrombosis and hemorrhage. In: Loscalzo J, Schafer AI (eds) *Thrombosis and Hemorrhage*, 3rd edn. Philadelphia: Lippincott, pp. 206–219.

112 Remuzzi G, Livio M, Marchiaro G *et al.* (1978) Bleeding in renal failure: altered platelet function in chronic uraemia only partially corrected by hemodialysis. *Nephron* 22, 347–353.

113 Zachee P, Vermylen J, Boogaerts MA (1994) Hematologic aspects of end-stage renal failure. *Ann Hematol* 69, 33–40.

114 Schafer AI (2003) Acquired disorders of platelet dysfunction. In: Loscalzo J, Schafer AI (eds) *Thrombosis and Hemorrhage*. Philadelphia: Lippincott Wiliams & Wilkins, p. 528.

115 Himmelfarb J, Holbrook D, McMonagle E *et al.* (1997) Increased reticulated platelets in dialysis patients. *Kidney Int* 51, 834–839.

116 Kim SB, Chi HS, Park JS *et al.* (1999) Effect of increasing serum albumin on plasma D-dimer, von Willebrand factor, and platelet aggregation in CAPD patients. *Am J Kidney Dis* 33, 312–317.

117 Malyszko J, Malyszko JS, Mysliwiec M (2001) Comparison of hemostatic disturbances between patients on CAPD and patients on hemodialysis. *Perit Dial Int* 21, 158–165.

118 Kojima K, Imazu H, Matsumura M *et al.* (2005) Sclerotherapy for gastric fundal variceal bleeding: Is complete obliteration possible without cyanoacrylate? *J Gastroenterol Hepatol* 20, 1701–1706.

119 Northup PG, Caldwell SH (2005) Treatment of gastric varices. *J Gastroenterol Hepatol* 20, 1631–1633.

120 Detry O, Honore P, Delwaide J *et al.* (1999) Liver transplantation in a Jehovah's witness. *Lancet* 353, 1680.

121 Bruno CM, Neri S, Sciacca C *et al.* (2004) Plasma erythropoietin levels in anaemic and non-anaemic patients with chronic liver diseases. *World J Gastroenterol* 10, 1353–1356.

122 Mady E, Wissa G, Khalifa A *et al.* (1999) Assessment of erythropoietin levels and some iron indices in chronic renal failure and liver cirrhosis patients. *Dis Markers* 15, 229–236.

123 Homoncik M, Jilma-Stohlawetz P, Schmid M *et al.* (2004) Erythropoietin increases platelet reactivity and platelet counts in patients with alcoholic liver cirrhosis: a randomized, double-blind, placebo-controlled study. *Aliment Pharmacol Ther* 20, 437–443.

124 Cohen J, Edelman RR, Chopra S (1992) Portal vein thrombosis: a review. *Am J Med* 92, 173–182.

125 Oka K, Tanaka K (1979) Intravascular coagulation in autopsy cases with liver diseases. *Thromb Haemost* 42, 564–570.

126 Amitrano L, Guardascione MA, Brancaccio V *et al.* (2004) Risk factors and clinical presentation of portal vein thrombosis in patients with liver cirrhosis. *J Hepatol* 40, 736–741.

127 Romero Gomez M, Suarez Garcia E, Lopez Lacomba D *et al.* (2000) Antiphospholipid antibodies are related to portal vein thrombosis in patients with liver cirrhosis. *J Clin Gastroenterol* 31, 237–240.

128 Sacerdoti D, Merkel C, Bolognesi M *et al.* (1995) Hepatic arterial resistance in cirrhosis with and without portal vein thrombosis: relationships with portal hemodynamics. *Gastroenterology* 108, 1152–1158.

129 Wanless IR, Wong F, Blendis LM *et al.* (1995) Hepatic and portal vein thrombosis in cirrhosis: possible role in development of parenchymal extinction and portal hypertension. *Hepatology* 21, 1238–1247.

130 Anstee QM, Wright M, Goldin R *et al.* (2004) The Factor V Leiden mutation accelerates disease progression in a mouse model of hepatic fibrosis induced by chronic carbon tetrachloride exposure. *Hepatology* 40, 534A.

131 Budhiraja R, Hassoun PM (2003) Portopulmonary hypertension. *Chest* 123, 562–576.

132 Edwards BS, Weir EK, Edwards WD *et al.* (1987) Coexistent pulmonary and portal hypertension: morphologic and clinical features. *J Am Coll Cardiol* 10, 1233–1238.

133 Welsh CH, Hassell KL, Badesch DB *et al.* (1996) Coagulation and fibrinolytic profiles in patients with severe pulmonary hypertension. *Chest* 110, 710–717.

134 Carr ME Jr, Eich DM (1988) Deep venous thrombosis with coagulopathy of liver disease. *VA Med* 115, 76–77.

135 Espiritu JD (2000) Pulmonary embolism in a patient with coagulopathy from end-stage liver disease. *Chest* 117, 924–925.

136 Northup PG, Volk-Bednarz A, Berg CL (2003) Predictors of peripheral venous thromboembolism in cirrhosis. *Am J Gastroenterol* 98, S97 (Abstract).

137 Eisen GM, Baron TH, Dominitz JA *et al.* (2002) Guideline on the management of anticoagulation and antiplatelet therapy for endoscopic procedures. *Gastrointest Endosc* 55, 775–779.

138 Ejlersen E, Melsen T, Ingerslev J *et al.* (2001) Recombinant activated factor VII (rFVIIa) acutely normalizes prothrombin time in patients with cirrhosis during bleeding from oesophageal varices. *Scand J Gastroenterol* 36, 1081–1085.

139 Anantharaju A, Mehta K, Mindikoglu AL *et al.* (2003) Use of activated recombinant human factor VII (rhFVIIa) for colonic polypectomies in patients with cirrhosis and coagulopathy. *Dig Dis Sci* 48, 1414–1424.

140 Kositchaiwat C, Chuansumrit A (2001) Experiences with recombinant factor VIIa for the prevention of bleeding in patients with chronic liver disease undergoing percutaneous liver biopsies and endoscopic retrograde cholangiopancreatography (ERCP). *Thromb Haemost* 86, 1125–1126.

141 Castellote J, Xiol X, Cortes-Beut R *et al.* (2001) Complications of thoracentesis in cirrhotic patients with pleural effusion. *Rev Esp Enferm Dig* 93, 566–575.

142 Xiol X, Castellote J, Cortes-Beut R *et al.* (2001) Usefulness and complications of thoracentesis in cirrhotic patients. *Am J Med* 111, 67–69.

143 Berthier A-M, Guillygomarc'h A, Messner M *et al.* (2002) Use of recombinant factor VIIa to treat persistent bleeding following dental extractions in two cirrhotic patients. *Vox Sang* 82, 119–121.

144 Lucia JF, Aguilar C, Orna E *et al.* (2001) Successful outcome of a cirrhotic patient with postoperative haematuria treated with a single high dose of recombinant factor VIIa. *Haemophilia* 7, 600–602.

145 Wenker OC, Wojciechowski Z, Sheinbaum R *et al.* (1997) Thromboelastography. *Internet J Anesthesiol* 1, N3.

21.5 The effect of liver disease on the gastrointestinal tract

Roger W. Chapman and Peter W. Angus

Disorders involving every part of the gastrointestinal tract have been described in patients with acute and chronic liver disease. While lesions such as oesophageal varices can be clearly linked to the direct pathophysiological effects of liver disease, in many cases, the reasons for the association between liver disease and the gut are less clear. This chapter describes the gastrointestinal syndromes that can occur in patients with liver diseases, listed according to the major organ or area involved.

Mouth

Examination of the lips and mouth may reveal a number of abnormalities in patients with liver disease. Inspection of the mucous membranes may detect jaundice, anaemia or dehydration; palatal petechiae indicate thrombocytopenia or septicaemia, while the presence of foetor hepaticus suggests hepatic encephalopathy.

Oral xanthomas occasionally develop as a complication of hypercholesterolaemia in patients with chronic cholestatic liver disease. The lesions are flat, plaque-like and irregular; they may be found under the tongue, on the buccal mucosa or in areas of angular cheilitis [1]. Telangiectasias in and around the mouth may give a clue to the presence of hepatic angiomas in patients with Osler–Weber–Rendu syndrome (hereditary telangiectasia) and are also occasionally seen in patients with primary biliary cirrhosis and the CREST (calcinosis, Raynaud's, (o)esophagitis, sclerodactyly, telangiectasia) syndrome.

Many patients with primary biliary cirrhosis (20–75% in different studies) develop keratoconjunctivitis sicca or Sjögren syndrome [1]. Xerostomia usually occurs late in the disease. Apart from dryness of the mouth, patients may develop cheilosis, buccal ulceration, fissuring of the tongue and enlargement of the parotid salivary glands. Biopsy of the salivary glands reveals lymphocyte infiltration, ductal hyperplasia and acinar destruction. As in the liver, the disease is probably initiated by immunological damage to duct endothelium.

Oesophagus

Although varices are the most important oesophageal complication of cirrhosis, a number of other oesophageal disorders may occur in patients with cirrhosis (the pathophysiology and management of varices are discussed in Chapter 7).

Gastro-oesophageal reflux is common in patients with cirrhosis, but its pathological importance is controversial. In patients with massive ascites, one might expect raised intra-abdominal pressure to predispose to reflux of gastric contents into the oesophagus. Early studies of oesophageal sphincter pressure measurement or short-term pH monitoring suggested that reflux was most common in cirrhotics with ascites. Using longer term postprandial monitoring of oesophageal pH, it was found that episodes of acid reflux were very common and more prolonged in cirrhotics than in non-cirrhotics with known reflux [2,3]; but, in contrast to previous studies, no link was found between gastro-oesophageal reflux and the presence of ascites [3]. As alcohol itself causes relaxation of the lower oesophageal sphincter and impairs oesophageal acid clearance, oesophageal reflux is likely to be more severe when alcoholic cirrhotic patients are actively drinking.

Importantly, whether or not acid reflux is increased in cirrhotic patients, it does not appear to contribute to variceal haemorrhage, as the frequency of variceal bleeding is not influenced by the presence or severity of acid reflux [2]. Oesophageal reflux may play an important part in the pathogenesis of persistent oesophageal ulceration following injection sclerotherapy or banding of oesophageal varices. These ulcers are resistant to treatment with H_2-antagonists but respond to proton pump inhibitors [4,5].

Between 5% and 10% of patients with primary biliary cirrhosis have evidence of scleroderma [6]. Usually, this takes the form of the CREST syndrome, and most of these patients have positive anticentromere antibodies [6]. Oesophageal involvement with scleroderma results in atrophy of the muscle coats, dilatation of

the lumen and loss of tone in the lower sphincter. The principal symptoms are lower oesophageal dysphagia and acid reflux, which may be complicated by peptic structure.

Endoscopic injection sclerotherapy for oesophageal varices in patients with cirrhosis may produce a number of local oesophageal complications. Ulceration is common and may be complicated by bleeding. Strictures may develop in the lower third of the oesophagus but are usually amenable to simple dilatation.

Endoscopic ligation, which has largely replaced sclerotherapy in the treatment of varices, is associated with a lower risk of local oesophageal complications. There may be temporary dysphagia after the procedure, presumably due to partial occlusion of the oesophageal lumen by the banded varix. Within 1 week of banding, strangulated varices slough, leaving shallow ulcers that heal rapidly. Serious bleeding from these ulcers occurs in less than 5% of patients, and the procedure rarely leads to severe oesophageal ulceration or the development of strictures [7]. The size of post-banding ulcers and potentially the risk of bleeding are reduced by prophylactic treatment with pantoprazole; however, post-treatment symptoms and total ulcer numbers are not affected [5].

Stomach and duodenum

Portal hypertensive gastropathy

After variceal haemorrhage, the gastric mucosa is the most common source of upper gastrointestinal bleeding in patients with cirrhosis and portal hypertension [8,9]. In the past, gastric mucosal bleeding in patients with liver disease was attributed to a range of lesions including 'haemorrhagic gastritis', 'diffuse gastric erosions', 'gastric red spots' or 'gastric petechiae'. It is now recognized that mucosal lesions such as these are very common in cirrhosis, and are features of a distinct entity now known as portal hypertensive gastropathy [10–12].

The changes in portal hypertensive gastropathy are most marked in the mucosa of the fundus and body of the stomach. The endoscopic appearances include a pattern of fine, erythematous speckling or 'scarlatina'-type rash, reddening and streaks and a fine, white, reticular mosaic pattern separating red, oedematous mucosa with an appearance 'like snake skin' [10,11]. Severe gastropathy is characterized by the presence of discrete gastric red spots ('cherry red spots') and areas of diffuse, haemorrhagic mucosal change ('haemorrhagic gastritis'). In large endoscopic studies of asymptomatic cirrhotic patients, more than 50% have had features of portal hypertensive gastropathy, the most frequent finding being the characteristic mosaic pattern or snake skin-like appearance in the proximal stomach [12–14].

The presence of portal hypertensive gastropathy correlates with the presence and size of oesophagogastric varices, and it is more common in patients who have undergone variceal obliteration [14,15]. It is unclear whether its severity or natural history is related to the severity of hepatic dysfunction [14,15]. The lesion is also commonly observed in patients with non-cirrhotic portal hypertension or extrahepatic portal venous thrombosis [15,16].

The pathophysiology of this condition is incompletely understood. The term 'gastritis' was commonly used to describe the appearance of the gastric mucosa in cirrhosis, but biopsies do not usually show inflammatory cell infiltration [12,17]. The characteristic histological findings are suggestive of vascular congestion, with dilation and tortuosity of submucosal veins and ectasia of mucosal capillaries and venules [12]. Because the vascular changes in portal hypertensive gastropathy are largely submucosal, deep mucosal biopsies may be needed to demonstrate the characteristic changes. The mucosal changes may result from a combination of increased total gastric blood flow, changes in blood flow distribution and stasis as a result of the increase in portal vascular resistance and portal venous congestion [18]. These changes are associated with a range of functional mucosal defects that predispose the portal hypertensive gastric mucosa to injury from agents such as aspirin, bile acids and alcohol [11]. Once the mucosa is breached, the increase in total gastric blood flow may contribute to the risk of significant bleeding. No association has been found with *Helicobacter pylori* infection.

The reported frequency with which portal hypertensive gastropathy has apparently caused acute upper gastrointestinal bleeding in cirrhotic patients varies widely; this may be explained largely by variation in the timing of endoscopy and in the aetiology and severity of the liver disease in different studies [8,9,14]. In a recent large prospective study, 2.5% of patients with gastropathy developed acute gastric bleeding during 18 months of follow-up, and this was primarily in those with severe lesions [14]. Chronic blood loss was observed in 10% of patients. Bleeding from the portal hypertensive gastric mucosa responds poorly to treatment with H_2-blockers, antacids or sucralfate [16]. Propranolol may reduce the risk of rebleeding, and improves the endoscopic grading of portal hypertensive gastropathy [19]. There is some evidence that somatostatin, octreotide and vasopressin may be effective in controlling acute bleeding, but large controlled studies are lacking. Portocaval shunting appears to reduce the risk of bleeding and is an effective treatment for acute haemorrhage from portal hypertensive gastropathy [20], but the procedure is associated with considerable operative risks and long-term side-effects. Although no large studies are available, several case reports have demonstrated the efficiency of the transjugular intrahepatic portosystemic stent shunt (TIPSS) in such cases.

A number of studies describe a less common pattern of mucosal vascular abnormality in patients with portal hypertension characterized by the presence of prominent, friable, red lesions on the antral mucosa that radiate out from the pyloris. This condition, referred to as gastric antral vascular ectasia (GAVE) or 'watermelon stomach' [21,22], is associated with cirrhosis in 30% of cases, but is more commonly found in patients without liver disease or portal hypertension [21,22]. It is clear

that this lesion represents a separate pathological and clinical entity to portal hypertensive gastropathy [23]. In contrast to gastropathy, bleeding from GAVE is common, difficult to control and does not respond to pharmacological therapy or portal decompression.

Acute gastric erosions

Upper gastrointestinal bleeding is also a significant problem in patients with acute liver failure. These patients commonly develop acute erosions of the oesophagus, stomach or duodenum; the presence of abnormal clotting contributes to the risk of bleeding. Severe upper gastrointestinal bleeding from erosions was reportedly the cause of death in almost one-fifth of these patients [24]. To prevent this potentially devastating complication, proton pump inhibitors or H_2-antagonists should be given routinely to reduce gastric acidity while non-steroidal anti-inflammatory drugs must be avoided.

Peptic ulcer

The prevalence of peptic ulcer appears to be increased in cirrhosis: in large series, ulcers were reported in between 10% and 16% of patients with cirrhosis [25–28]. Although the prevalence of peptic ulcer is considerably lower than this in the general community, epidemiological studies of peptic ulcer in cirrhotics have generally not included an adequate control group. Thus, factors such as age, sex distribution, smoking habits and frequency of upper gastrointestinal investigation of the cirrhotic population, rather than liver disease itself, may in part explain an apparently higher risk of peptic ulceration than in the community as a whole. As in the general population, duodenal ulcers are more common than gastric ulcers [28], but there is some evidence that the normal male predominance in duodenal ulcer is lost [27]. Although peptic ulcers appear to be common in patients with cirrhosis, they are often asymptomatic and are identified as the cause of only about 6–16% of acute upper gastrointestinal haemorrhage [8,9,25,28].

There is some evidence that the frequency of peptic ulcer varies among different forms of liver disease. In a study of 510 patients awaiting liver transplantation, duodenal ulceration was found in 12.2% of alcoholics compared with 4.2% of non-alcoholics; the prevalence of gastric ulcers was also higher in the alcoholic group [30]. While in one early series, peptic ulcers were found in more than 30% of patients with primary biliary cirrhosis, a much lower incidence was reported in a more recent series [28]. This may reflect reduced use of analgesic and anti-inflammatory drugs in these patients. Patients treated with corticosteroids for autoimmune hepatitis appear to be at low risk of developing peptic ulceration [28].

Although in animal experiments, basal and maximal stimulated outputs of gastric acid are markedly increased following the construction of a portocaval shunt, in man, there is little evidence of a similar affect on acid secretion [31]. Early reports that portocaval anastomosis increased the risk of peptic ulceration in cirrhotic patients were not substantiated by a large, prospective, controlled study, which showed that ulcers occurred no more frequently in shunted patients than in control subjects with equally advanced liver disease [26]. Moreover, this study demonstrated that portocaval shunting did not exacerbate pre-existing ulcers.

If cirrhosis does predispose to peptic ulceration, the mechanism is unclear. It has been suggested that there may be impaired hepatic clearance of gastrin or other compounds that stimulate the acid secretion. Although there is little evidence that gastric acid secretion in the cirrhotic population as a whole is increased compared with control subjects [31], cirrhotics with duodenal ulcers have higher gastric acid secretion than those without ulcers. While there is increasing evidence that, in portal hypertension, there is impairment of mucosal defence mechanisms that protect the gastric mucosa from injury, it is unclear whether portal hypertensive gastropathy contributes directly to the development of chronic peptic ulcer. The increased rate of peptic ulceration in cirrhotics does not appear to be explained by higher rates of *Helicobacter* colonization [25], nor is it clear whether eradication of *Helicobacter* returns the risk of peptic ulceration in cirrhotics to that in the general population.

Pancreas

Excess alcohol causes injury in both the liver and the pancreas; it is not surprising, therefore, that evidence of pancreatic damage is commonly found in patients with alcoholic liver disease. In a recent review of 1022 patients who developed alcoholic liver disease, pancreatitis was found in 28% at autopsy [32]. Other autopsy studies have found an equal or even greater prevalence of pancreatic disease in alcoholic cirrhotics, while studies of pancreatic function in largely alcoholic cirrhotic populations have reported abnormalities in 40% or more of patients. The most common pathological finding in these patients is chronic fibrotic pancreatitis; of these, approximately one-third have calcific change. Acute pancreatic damage is found less commonly and may represent an early stage in the development of chronic disease [32]. The presence of pancreatic damage does not seem to be related to the severity of alcoholic liver disease. Indeed, why some alcoholic patients develop severe pancreatitis but have little or no liver disease, while others with advanced alcoholic liver disease have little evidence of pancreatic damage is unknown.

Signs of pancreatic damage are also commonly found in patients with primary biliary cirrhosis. Abnormal pancreatograms are found in up to 40% of these patients, and many have elevated serum pancreatic isoamylase or immunoreactive trypsin [33]. Immunoreactive trypsin and the flow rates of duodenal juice in response to secretin–pancreozymin stimulation are significantly reduced. As these abnormalities of pancreatic structure and function were closely linked to the presence of Sjögren syndrome, it was suggested that, in primary biliary

cirrhosis, pancreatic hyposecretion is a component of the sicca or dry gland complex [33]. Other studies provide evidence that cholestasis itself may inhibit exocrine pancreatic secretion in these patients [34,35]. Overt exocrine pancreatic failure, severe enough to produce steatorrhoea, appears to be very uncommon [34,35].

Endoscopic pancreatography is abnormal in approximately 10–50% of those with primary sclerosing cholangitis [33]. The changes seen on pancreatography vary from isolated strictures of the main pancreatic duct to classical chronic pancreatitis. However, these changes are seldom associated with clinically significant impairment in pancreatic function.

Serum pancreatic amylase isoenzymes and pancreatic lipase are elevated in approximately 30% of patients with fulminant hepatic failure [36]. Although the presence of encephalopathy makes it difficult to confirm the diagnosis of pancreatitis clinically in these patients, approximately one-third are found to have acute pancreatic damage at autopsy [37]. While in other clinical conditions acute pancreatitis carries a significant mortality, at present, there is no evidence that the finding of 'biochemical pancreatitis' worsens the prognosis of patients with acute liver failure [36].

The pathogenesis of pancreatitis in fulminant hepatic failure is not understood. The acute pancreatitis that occasionally occurs in those with acute viral hepatitis has been attributed to either direct or immune-mediated cytopathic effects of the virus [37]. Although such effects may be important in those with viral hepatitis, it does not explain the occurrence of pancreatitis in hepatic failure caused by paracetamol overdose or halothane toxicity [36].

Small bowel function/malabsorption

Fat malabsorption is common in patients with chronic liver disease. Approximately 50% of adults and more than 90% of children with various types of cirrhosis have increased faecal fat excretion [38,39]. Although, in most of these patients, steatorrhoea is mild (< 15 g/day), in about 10%, there is severe steatorrhoea with faecal fat excretion exceeding 25–30 g daily [39].

A number of factors may be responsible for fat malabsorption in patients with liver disease. Bile acid uptake, synthesis and secretion are all impaired in patients with significant parenchymal liver damage or cholestasis [39,40]. As a result, in some patients, intraduodenal bile acid concentrations may fall to levels that are insufficient to achieve adequate solubilization and micellar incorporation of dietary lipid, cholesterol and fat-soluble vitamins. This mechanism appears to be largely responsible for steatorrhoea in patients with non-alcoholic cirrhosis and chronic cholestatic liver disease [34,35]. Indeed, in these patients, fat malabsorption is usually restricted to those with subnormal duodenal bile acid concentrations and impaired micellar lipid incorporation [39]. Although pancreatic exocrine secretion may be reduced in patients with primary biliary cirrhosis, this seems to be of far less importance in the pathogenesis of fat malabsorption than failure of bile acid secretion, as even in patients with severe steatorrhoea, the pancreatic output of lipase is not sufficiently reduced to limit intestinal lipolysis [34,35].

There is little evidence that liver disease itself significantly affects the absorptive capacity of the small bowel mucosa. A number of investigations have failed to detect any consistent abnormalities of small bowel structure or function in non-alcoholic patients with portal hypertension and malabsorption. Furthermore, in cirrhotic patients, portocaval anastomosis produces no substantial change in intestinal absorption of fat or protein [41]. In contrast, the venous and lymphatic obstruction that occurs in Budd–Chiari syndrome may cause structural abnormalities of the small bowel mucosa and protein-losing enteropathy.

The prevalence of coeliac disease appears to be increased in primary biliary cirrhosis and ranges from 2% to 6% in different studies [42,43]. It seems unlikely that this association is due to a direct effect of the liver disease on the small bowel, nor is it likely that coeliac disease causes primary biliary cirrhosis. The disease responds to gluten restriction in the normal way, although liver biochemistry often does not improve. In patients with cirrhosis, untreated coeliac disease can produce a clinical picture that mimics progressive liver decompensation, and the diagnosis should be sought in this clinical setting. Whether screening for coeliac disease is justified in all patients with primary biliary cirrhosis remains controversial [44]. The prevalence of the disease has also been reported to be increased in primary sclerosing cholangitis, but whether this is a true association is as yet unclear [45].

In non-alcoholic cirrhotics and patients with cholestatic liver disease, malabsorption is usually limited to fat and fat-soluble vitamins. However, in patients with alcoholic liver disease, there may be a mixed malabsorption syndrome, in part related to the effects of chronic alcohol abuse on the gut and in part due to the underlying liver disease. In actively drinking chronic alcoholics, jejunal perfusion experiments have demonstrated marked malabsorption of sodium and water, and a similar effect was reproduced in normal volunteers following chronic infusion of the jejunum with alcohol [46]. Alcohol has also been shown to deplete brush border enzymes (lactose, sucrose and alkaline phosphatase) and appears directly to inhibit absorption of glucose, amino acids and vitamin B12. Poor diet, malnutrition and deficiencies in substances such as folate and magnesium may also contribute to the impairment of intestinal absorptive function in alcoholics.

Whatever the cause, much of the diarrhoea and malabsorption resolves with alcohol withdrawal and adequate nutrition but, in those with established alcoholic cirrhosis, steatorrhoea often persists long after alcohol consumption has ceased. This may, in part, be due to continuing deficiency in intestinal bile acids. However, in alcoholic cirrhotics, chronic pancreatic disease is common and, in many of these patients, chronic severe steatorrhoea may be primarily pancreatic in origin [32]; improvement normally follows pancreatic enzyme replacement therapy.

Patients with liver disease may develop deficiencies of fat-soluble vitamins as a result of poor micellar solubilization and absorption of these compounds; those with inadequate diets and jaundiced patients with chronic cholestatic disease appear to be particularly at risk. Hepatic vitamin A stores are large, and vitamin A deficiency is usually only seen in patients with long-standing liver disease. Vitamin A deficiency is mainly described in patients with primary biliary cirrhosis, the lowest levels being found in the most severely cholestatic. Impaired dark adaptation is the major clinical finding, while true night blindness is relatively uncommon.

Low serum vitamin E is also mainly found in patients with chronic cholestasis [47,48]. Vitamin E-deficient children with chronic liver disease develop a typical neurological syndrome that responds to parenteral vitamin E. However, even in patients with primary biliary cirrhosis who have severe vitamin E deficiency, clinically apparent neurological problems are uncommon [47]. A sensorimotor neuropathy has been noted in some of these patients, but this responds poorly to vitamin E replacement [48].

Vitamin K stores in the body are small and readily depleted by poor diet and impaired absorption. Vitamin K deficiency may be largely responsible for abnormal clotting in patients with cholestasis and is readily correctable with parenteral vitamin K. In patients with established parenchymal liver disease, there may be only a partial response to vitamin K replacement, as hepatic synthesis of clotting factors is also likely to be impaired.

Vitamin D is obtained from the diet, but can also be synthesized by ultraviolet irradiation of the skin. Vitamin D deficiency may develop in patients with chronic cholestatic or parenchymal liver disease. Although intestinal absorption of vitamin D is impaired in these patients, this does not fully account for this deficiency. Poor exposure to sunlight, inadequate diet, excess urinary loss of vitamin D metabolites and impaired vitamin D synthesis in the presence of jaundice may be further factors [49]. 25-Hydroxylation of vitamin D does not appear to be significantly reduced in patients with chronic liver disease.

Metabolic bone disease or 'hepatic osteodystrophy' is common in patients with chronic liver disease [49,50]. Early studies suggested a high prevalence of osteomalacia in patients with cirrhosis. Recent reports, using more rigorous diagnostic criteria, indicate that its prevalence is relatively low [50,51]. Jaundiced patients with chronic cholestasis appear to be most at risk. In these patients, the disease responds well to both oral and parenteral vitamin D. It is now evident that osteoporosis is the major cause of bone problems in patients with chronic liver disease [49–51]. The pathogenesis of osteoporosis in these patients is uncertain. It is clear that it is not simply due to vitamin D deficiency and calcium malabsorption [50]. Hepatic osteodystrophy is not prevented by vitamin D prophylaxis and, at present, there are no clearly established guidelines for treatment or prophylaxis.

Colon

A range of changes are described in the colonic mucosa in cirrhotic patients, including mucosal oedema, diffuse erythema, erythematous telangiectatic macular lesions, spider naevi-like or angiodysplastic lesions and non-specific colitis. The changes may be patchy or diffuse and, at colonoscopy, can be found in between 30% and 50% of patients with portal hypertension. The term 'portal hypertensive colopathy' has been used to describe these mucosal lesions [52,53]. On histological examination, the findings are similar to those of portal hypertensive gastropathy, with the major features being dilated mucosal capillaries, a thickened basement membrane and oedema without mucosal inflammation [53]. Acute bleeding from the portal hypertensive colonic mucosa is rare. Its importance as a source of chronic gastrointestinal bleeding or anaemia is unclear.

In large colonoscopic series, rectal varices are described in between 40% and 80% of patients with portal hypertension [52,53]. The wide variation in the frequency of reporting of these lesions may reflect problems in differentiating varices from haemorrhoids. Haemorrhoids do not appear to be more common in patients with portal hypertension and, in contrast to rectal varices, are rarely a source of major gastrointestinal haemorrhage. The key to differentiating rectal varices from haemorrhoids is the finding of large, feeding, collateral veins that commence well above the anal verge [52]. Lower gastrointestinal bleeding has been reported in 1–4% of patients with rectal varices. A number of approaches can be used to control bleeding from rectal varices, including local sclerotherapy or banding and portal decompression by surgery or TIPSS.

References

1 Shaffner F, Bach N (1988) Gastointestinal syndromes in primary biliary cirrhosis. *Semin Liver Dis* 8, 263–271.

2 Arsene D, Bruley des Varannes S, Galmiche JP *et al.* (1987) Gastro-oesophageal reflux and alcoholic cirrhosis. *J Hepatol* 4, 250–258.

3 Ahmed AM, al Karawi MA, Shariq S *et al.* (1993) Frequency of gastroesophageal reflux in patients with liver cirrhosis. *Hepatogastroenterology* 40, 478–480.

4 Gimson A, Polson R. Westby D *et al.* (1990) Omeprazole in the management of intractable oesophageal ulceration following injection sclerotherapy. *Gastroenterology* 99, 1829–1831.

5 Shaheen NJ, Stuart E, Schmitz SM *et al.* (2005) Pantoprazole reduces the size of postbanding ulcers after variceal band ligation: a randomized, controlled trial. *Hepatology* 41, 588–594.

6 Watt FE, James OF, Jones DE (2004) Patterns of autoimmunity in primary biliary cirrhosis patients and their families: a population-based cohort study. *Q J Med* 97, 397–406.

7 Laine L, Cook D (1995) Endoscopic ligation compared with sclerotherapy for treatment of oesophageal variceal bleeding. *Ann Intern Med* 123, 280–287.

8 Mitchell CJ, Jewell DP (1977) The diagnosis of the site of upper gastrointestinal haemorrhage in patients with portal hypertension. *Endoscopy* 9, 131–135.

9 Mitchell KJ, MacDougall BRD, Silk DBA *et al.* (1982) A prospective reappraisal of emergency endoscopy in patients with portal hypertension. *Scand J Gastroenterol* 17, 965–968.

10 McCormick TT, Sims J, Eyre-Brook I *et al.* (1985) Gastric lesions in portal hypertension; inflammatory gastritis or congestive gastropathy. *Gut* 26, 1226–1232.

11 Sarfeh IJ, Tarnawski A (1987) Gastric mucosal vasculopathy in portal hypertension. *Gastroenterology* 93, 1129–1131.

12 Baxter J, Dobbs B (1988) Portal hypertensive gastropathy. *J Gastroenterol Hepatol* 3, 635–644.

13 Papazian A, Braillon A, Dupas J *et al.* (1986) Portal hypertensive gastric mucosa: an endoscopic study. *Gut* 27, 1199–1203.

14 Primignani M, Carpinelli L, Preatoni P *et al.* (2000) Natural history of portal hypertensive gastropathy in patients with liver cirrhosis. *Gastroenterology* 119, 181–187.

15 Sarin SK, Sreenivas DV, Lahoti D *et al.* (1992) Factors influencing development of portal hypertensive gastropathy. *Gastroenterology* 102, 994–999.

16 Amarapurkar DN, Dhawan PS, Chopra K *et al.* (1993) Stomach in portal hypertension. *J Assoc Phys India* 41, 638–640.

17 Brown RC, Hardy GJ, Temperley JM *et al.* (1981) Gastritis and cirrhosis – no association. *J Clin Pathol* 134, 744–748.

18 Ohta M, Hashizumi M, Higashi H *et al.* (1994) Portal and gastric mucosal haemodynamics in cirrhotic patients with portal hypertensive gastropathy. *Hepatology* 20, 1432–1436.

19 Hosking SW, Kennedy HJ, Seddon I *et al.* (1987) The role of propranolol in congestive gastropathy of portal hypertension. *Hepatology* 7, 437–441.

20 Orloff MJ, Orloff MS, Orloff SL *et al.* (1995) Treatment of bleeding from portal hypertensive gastropathy by portacaval shunt. *Hepatology* 21, 1011–1017.

21 Payen JL, Cales P, Voigt JJ *et al.* (1995) Severe portal hypertensive gastropathy and antral vascular ectasis are distinct entities in patients with cirrhosis. *Gastroenterology* 108, 138–144.

22 Jabbari M, Cherry R, Lough JO *et al.* (1984) Gastric antral vascular ectasia; the watermelon stomach. *Gastroenterology* 87, 1165–1170.

23 Burak KW, Lee SS, Beck PL *et al.* (2001) Portal hypertensive gastropathy and gastric antral vascular ectasia (GAVE) syndrome. *Gut* 49, 866–872.

24 Bailey RJ (1976) Proceedings: A controlled trial of H2-receptor antagonists in prophylaxis of bleeding from gastrointestinal erosions in fulminant hepatic failure. *Gut* 5, 389.

25 Fraser AG, Pounder RE, Burrough AK (1993) Gastric secretion and peptic ulceration in cirrhosis. *J Hepatol* 19, 171–182.

26 Phillips MM, Ramsby GR, Conn HO (1975) Portocaval anastomosis and peptic ulcer: a non-association. *Gastroenterology* 68, 121–131.

27 Tabaqchali S, Dawson AM (1964) Peptic ulcer and gastric secretion in patients with liver disease. *Gut* 5, 417–421.

28 Kirk AP, Dooley JS, Hunt RH (1980) Peptic ulceration in patients with chronic liver disease. *Dig Dis Sci* 25, 756–760.

29 Langman MJS, Cook AR (1976) Gastric and duodenal ulcer and their associated diseases. *Lancet* i, 680–683.

30 Rabinovitz M, Schade RR, Dindzans V *et al.* (1990) Prevalence of duodenal ulcer in cirrhotic males referred for liver transplantation. Does aetiology of cirrhosis make a difference? *Dig Dis Sci* 35, 321–326.

31 Lenz HJ, Struck T, Greten H *et al.* (1987) Increased sensitivity of gastrin acid secretion to gastric in cirrhotics with porto-caval shunt. *J Clin Invest* 79, 1120–1124.

32 Renner IG, Savage WT, Stace NH *et al.* (1984) Pancreatitis associated with alcoholic liver disease. A review of 1022 autopsy cases. *Dig Dis Sci* 29, 593–599.

33 Epstein O, Chapman RWG, Lake-Bakaar C *et al.* (1982) The pancreas in primary biliary cirrhosis and primary sclerosing cholangitis. *Gastroenterology* 83, 1177–1182.

34 Lanspa SJ, Chan ATH, Bell JS *et al.* (1985) Pathogenesis of steatorrhoea in primary biliary cirrhosis. *Hepatology* 5, 837–842.

35 Ros E, Garcia-Puges A, Reixach M *et al.* (1984) Fat digestion and exocrine pancreatic function in primary biliary cirrhosis. *Gastroenterology* 87, 180–187.

36 Ede R, Moore KP, Marshall WJ *et al.* (1988) Frequency of pancreatitis in fulminant hepatic failure using isoenzyme markers. *Gut* 29, 778–781.

37 Ham JM, Fitzpatrick P (1973) Acute pancreatitis in patients with acute hepatic failure. *Dig Dis Sci* 18, 1079–1083.

38 Linscheer WG (1970) Malabsorption in cirrhosis. *Am J Clin Nutr* 23, 488–942.

39 Badley BWD, Murphy GMS, Bouchier IAD *et al.* (1970) Diminished micellar phase lipid in patients with chronic non-alcoholic liver disease and steatorrhoea. *Gastroenterology* 58, 781–789.

40 Heaton KW (1985) Bile salts. In: Wright R, Millward-Sadler GR, Alberti KGMM *et al.* (eds) *Liver and Biliary Disease*. London: Bailliere Tindall, pp. 283–284.

41 Fisher B (1968) Intestinal absorption and nitrogen balance following portacaval shunt. *Ann Surg* 167, 41–46.

42 Volta U, Rodrigo L, Granito A *et al.* (2002) Celiac disease in autoimmune cholestatic liver disorders. *Am J Gastroenterol* 97, 2609–2613.

43 Kingham JGC, Parker DR (1998) The association between primary biliary cirrhosis and coeliac disease: a study of relative prevalences. *Gut* 42, 120–122.

44 Neuberger J (1999) PBC and the gut: the villi atrophy, the plot thickens. *Gut* 44, 594.

45 Lawson A, West J, Aithal GP *et al.* (2005) Autoimmune cholestatic liver disease in people with coeliac disease: a population-based study of their association. *Aliment Pharmacol Ther* 21, 401–405.

46 Mekhjian HS (1977) Acute and chronic effects of ethanol on fluid transport in the human small intestine. *Gastroenterology* 72, 1280–1286.

47 Jeffrey GP, Muller DP, Burroughs AK *et al.* (1987) Vitamin E deficiency and its clinical significance in adults with primary biliary cirrhosis and other forms of chronic liver disease. *J Hepatol* 4, 307–317.

48 Munoz SJ, Heubi JE, Balistreri WF *et al.* (1989) Vitamin E deficiency in primary biliary cirrhosis: gastrointestinal malabsorption, frequency and relationship to other lipid-soluble vitamins. *Hepatology* 9, 525–531.

49 Compston JE (1995) Hepatic osteodystrophy: vitamin D metabolism in patients with liver disease. *Gut* 27, 1073–1090.

50 Rouillard S, Lane NE (2001) Hepatic osteodystrophy. *Hepatology* 33, 301–307.

51 Diamond TH, Stiel D, Lunzer M *et al.* (1989) Hepatic osteodystrophy. Static and dynamic bone histomorphometry and serum Gla-protein in 80 patients with chronic liver disease. *Gastroenterology* 96, 213–221.

52 Ganguly S, Sarin S, Bhatia V *et al.* (1995) The prevalence and spectrum of colonic lesions in patients with cirrhotic and non cirrhotic portal hypertension. *Hepatology* 21, 1226–1231.

53 Viggiano TR, Gostout CJ (1992) Portal hypertensive intestinal vasculopathy: a review of the clinical, endoscopic and histological features. *Am J Gastroenterol* 87, 944–954.

21.6 The effect of liver disease on the skin

Malcolm Rustin and Daniel Glass

Introduction

The cutaneous features of chronic liver disease are well known and include jaundice, palmar erythema and spider naevi (see also Chapter 5.1). Jaundice is detected first in the sclerae and then affects the skin in a more widespread fashion. Occasionally, jaundice needs to be distinguished from carotenaemia, lycopenaemia (orange staining of the palms and soles secondary to drinking large amounts of tomato juice) and discoloration caused by mepacrine or busulphan ingestion.

Palmar erythema starts on the hypothenar eminence in a speckled pattern and, if the associated liver disease progresses, it spreads to the finger pulps and becomes more confluent. Erythema may also be observed on the plantar aspects of the feet. The erythema has a pulsatile nature and blanches on pressure [1].

Patients who have multiple and disfiguring spider naevi can now be treated effectively with the pulsed dye laser [2]. 'Paper-money skin' is the term used to describe fine thread-like capillaries, which may be seen in association with spider naevi on the upper chest and back.

Nail changes range from platonychia (loss of curvature and flatness), clubbing, leuconychia (white nails) and transverse white bands in cirrhosis, an azure blue discoloration of the lunulae in Wilson's disease to koilonychia and longitudinal striations in haemochromatosis.

Pruritus (see also Chapter 5.1)

Pruritus is one of the most common and distressing symptoms associated with liver disease. It is a subjective phenomenon, which may vary from patient to patient and occasionally be so severe that sleep is disturbed, or it may lead to suicidal ideation. Intractable pruritus has been an indication for liver transplantation [3].

The aetiology of pruritus remains unclear. It is postulated that a pruritogen is produced by the liver, excreted in the bile and accumulates in the plasma with cholestasis. Unfortunately, this pruritogen has yet to be identified [4]. Skin changes are usually secondary to scratching with excoriations, lichenification (thickening of the skin), nodular prurigo or secondary infection arising from disruption of the skin barrier.

Most patients respond to the anion exchange resin cholestyramine. These resins work by binding to bile acids in the intestine, leading to increased excretion of bile and, hence, the unknown pruritogen [5]. The response is often temporary, and side-effects of bloating, constipation or diarrhoea may limit the use of these drugs.

A recent study compared skin biopsies from patients with pruritus of cholestasis to patients with cholestasis but no pruritus. There was no difference in the density of mast cells and nerve cells in the two groups, and it was suggested that therapy targeted at cutaneous mast cells and nerves is unlikely to be of benefit in pruritus of cholestasis [6]. Antihistamines are occasionally helpful, possibly because of their sedative effect.

The pruritus of cholestasis may in part be mediated by opioid peptides synthesized in the liver. Skin and plasma levels of these peptides are higher in patients with itching and cholestasis [7]. Logically, opiate antagonists may have a role in the management of pruritus of cholestasis, and both naltrexone and nalmefene have been shown to be useful [8,9]. Opioid withdrawal symptoms on commencing therapy have been reported [10]. Patients experiencing loss of pain control have necessitated withdrawal of opiate antagonists in some cases [11].

In primary biliary cirrhosis (PBC), treatment with the bile acid ursodeoxycholic acid is associated with significant improvement biochemically, but not symptomatically [12]. The hepatic enzyme-inducing antibiotic rifampicin has been used in the management of pruritus with good effect [13]. The mode of action by which rifampicin relieves itching is not clear although, interestingly, it has been shown to increase the serum concentration of bile acids [14].

Propofol, an anaesthetic agent used as a hypnotic, has also been reported to relieve itching [15]. Other uncontrolled trials of useful antipruritic treatments include metronidazole, phototherapy, carbamazepine, lidocaine, dronabinol (a cannabinoid B1 receptor agonist), sertraline and androgens.

Congenital diseases affecting the liver and the skin

Argininosuccinic aciduria

Argininosuccinate lyase (ASL) catalyses the reversible hydrolysis of argininosuccinate to arginine and fumarate. Defects in the *ASL* gene, found on chromosome 7, result in the autosomal recessive disorder argininosuccinic aciduria. Mutation analysis of the *ASL* gene shows considerable allelic heterogeneity [16]. ASL is an important enzyme in the urea cycle with defects leading to increased levels of arginosuccinic acid and ammonium. It is characterized by mental retardation, ataxia, seizures, hepatomegaly and liver enzyme abnormalities. The hair of affected patients tends to be dry and brittle, and trichorrhexis nodosa may be noted on light or electron microscopy.

Ataxia telangiectasia

Ataxia telangectasia (AT) is an autosomal recessive disorder in which telangiectases of the skin and other cutaneous features are associated with cerebellar degeneration, immune dysfunction, radiosensitivity and cancer predisposition. The abnormal gene, *ataxia telangiectasia mutated* on chromosome 11q22–23, encodes for a phosphatidylinositol 3 kinase-like protein that senses early damage to DNA and facilitates DNA repair prior to replication [17]. Patients present with ataxia when the child begins to walk; conjunctival telangiectases appear later (3–6 years) and then cutaneous telangiectases on the face, ears and flexors. Persistent non-infective granulomatous lesions have been reported in several patients, which can ulcerate and be painful [18]. Subcutaneous fat is lost prematurely, and facial skin can become atrophic and sclerotic. The patient's hair commonly becomes grey prematurely. Other dermatological features include pigmentary disorders (café-au-lait patches and vitiligo), hirsutism, keratosis pilaris, seborrhoeic dermatitis, warts and acanthosis nigricans.

There are abnormalities of humoral and cellular immunity in AT but, despite deficiencies in immunoglobulins and reductions in B- and T-cell numbers, severe infections are uncommon [19]. Patients and members of their families who are heterozygous for *ATM* have an increased risk of malignancy [20]. Lymphomas (× 200 increased risk) and leukaemias (× 70 increased risk) are the most common tumours in AT patients, and hepatocellular carcinoma has been reported [21].

Alagille syndrome/arteriohepatic dysplasia

Alagille syndrome is an autosomal dominant disorder characterized by abnormal development of liver, heart, skeleton, eye, face and, less frequently, the kidneys. It is caused by mutations in the *Jagged1* gene on chromosome 20p12, which encodes a ligand for Notch1. Disruption in this intracellular signalling pathway results in bile duct paucity [22]. There is a wide variation in disease expression. In a recent study of 38 children with Alagille syndrome, all had pruritus of cholestasis, 78% had jaundice, 85% had characteristic facies, 84% had heart disease (pulmonary stenosis, intra-auricular communication or intraventricular communication), 76% had growth retardation, 63% had vertebral abnormalities and 21% had renal disturbances. Eleven children (28%) had xanthomas, and all of these children had hyperlipidaemia. Following liver transplantation, which is the only definitive treatment, the xanthomata disappear [23].

Anderson Fabry disease

This is an X-linked disorder caused by a deficiency of α-galactosidase A, resulting in accumulation of globotriaosylceramide (GB_3) within lysosomes in cells causing progressive tissue and organ damage and early death. The first symptoms occur between the ages of 5 and 15 years with lance-like excruciating pains affecting the extremities, vasomotor disturbances and the appearance shortly after puberty of multiple dark red or black telangiectatic and occasionally scaly papules known as angiokeratomas, which can become widespread. Angiokeratomas may be absent or less numerous in female carriers. Other dermatological manifestations include telangiectases of the palms, soles, lips and buccal mucosa, acromegalic-type facies, hypohidrosis or anhidrosis and limb lymphoedema. Patients may suffer from recurrent fevers and corneal opacities. Renal involvement begins as proteinuria as a teenager and usually progresses to endstage renal failure requiring dialysis by the fourth decade. Myocytes, cardiac conduction tissue and valves are involved resulting in arrhythmias and heart failure [24]. Until the recent introduction of enzyme replacement therapy, the prognosis was poor. Although length of follow-up thus far is short, expert recommendations suggest that patients should be started immediately on one of the two α-galactosidase A replacement drugs available [25]. Recent studies suggest that enzyme replacement therapy decreases the amount of pain suffered by patients and arrests the progressive organ dysfunction [26]. It is still not clear what the optimum dosing regimen is, whether heterozygotic females should be treated and if treatment is safe in children.

Gaucher disease

This is an autosomal recessive disorder in which deficiency of β-glucosidase (glucocerebrosidase) results in the accumulation of the glycolipid glucocerebroside in macrophages. There are three subtypes; type 1 is most common and is differentiated from types 2 and 3 by its lack of central nervous system involvement.

Type 1 Gaucher disease (94% of cases) is most common in Jewish people of Ashkenazi descent occurring in 1/855 births. Cutaneous features of the adult or type 1 form of Gaucher disease are uncommon and non-specific with diffuse brown or yellow pigmentation secondary to haemosiderosis or deposition of melanin. Easy tanning is characteristic, and there may be

multiple pigmented macules [27]. If marked liver involvement is a feature, then telangiectases may be present. Petechiae and ecchymoses due to thrombocytopenia are seen if there is infiltration of the bone marrow or hypersplenism.

Type 2 or infantile Gaucher disease (< 1% of cases) is a more devastating form dominated by neurological symptoms ending with death usually within 2 years. It may present with severe ichthyosis known as the 'collodion baby' where the infant is covered in a lamellar, hyperkeratotic membrane [28]. Type 3 or juvenile Gaucher disease (5% of cases) has no specific skin manifestations.

Numerous allelic mutations have been described in the β-glucocerebrosidase gene. Homozygosity for the N370S mutation was associated with type 1 disease, and the L444P mutation was seen in severe neuronopathic type 2 disease [29]. Enzyme replacement therapy reduces organomegaly, corrects anaemia and thrombocytopenia, improves liver function and bone pain, but does not ameliorate neurological complications [30].

Neonatal haemangiomatosis

This rare disorder presents at birth or shortly after with multiple, dome-shaped, cutaneous haemangiomata. In the benign form, viscera are not involved but, in the diffuse form, the liver (64%), the central nervous system, gastrointestinal tract, lungs (52%) and, less frequently, other organs can be involved [31]. Hepatic haemangiomas with subsequent arteriovenous shunting may lead to high-output cardiac failure. Biliary obstruction, portal hypertension and disseminated intravascular coagulopathy can occur [32]. Depending on the site, size and haemodynamic consequences of the lesions, untreated mortality rates of 77% have been reported, mainly due to cardiac failure or severe bleeding [33]. There is no standard treatment regimen, although hepatic artery ligation or selective embolization has been used to improve cardiac function. There have also been reports of the use of corticosteroids, radiotherapy and vincristine. Liver transplantation has been described in cases of massive hepatic haemangiomas [34].

Infections

Hepatitis B

Hepatitis B virus (HBV) infection is associated with numerous extrahepatic features, many of which are thought to be immune complex mediated. Polyarteritis nodosa (PAN) is a rare complication of HBV infection that is more common in Caucasian patients. This vasculitis of small and medium-sized vessels frequently involves the skin, presenting with nodules, ulcers and livedo reticularis. In the 1970s, 30% of PAN was related to hepatitis B infection. Following the introduction of immunization programmes, this is now nearer 7%. Treatment of the underlying hepatitis results in resolution of the PAN symptoms [35].

The serum sickness-like 'arthritis–dermatitis' prodrome occurs in approximately one-third of patients acquiring HBV, usually 1–6 weeks before the onset of clinical hepatitis. Urticaria and angio-oedema are the commonest cutaneous manifestations, although petechiae, palpable purpura and erythema multiforme-like lesions may occur confirming an underlying vasculitic process [36]. At the onset of clinical hepatitis, the symptoms resolve spontaneously with few significant sequelae [37].

In mixed essential cryoglobulinaemia, 1.8% of patients have HBV infection [38]. Patients with this small vessel vasculitis have a good prognosis, presenting with purpura, arthralgia and generalized weakness, although some progress to more severe disease affecting respiratory and renal function.

HBV infection is one of the causes of Gianotti–Crosti syndrome, which is a papular eruption occurring in children in response to a viral trigger [39]. Dull red papules occur on the thighs and buttocks, then on the arms and, finally, the face. There is often an asymmetrical distribution. The skin lesions fade over a period of 2–8 weeks with mild desquamation. Generalized lymphadenopathy may be present, and mild constitutional symptoms such as fever and lassitude often accompany the rash [40]. Treatment is symptomatic.

HBV may present with palpable purpura alone [41]. Rarely, maculopapular lichenoid eruptions and erythema nodosum have been associated with acute HBV infection [42].

Hepatitis C

Hepatitis C virus (HCV) is associated with a number of dermatological disorders and, when patients present with these conditions, evidence of HCV infection must be sought as antiviral therapy may be of benefit [43].

Between 35% and 54% of patients with HCV have mixed cryoglobulins [44]. A recent study of 231 patients with mixed essential cryoglobulinaemia showed 92% positivity for HCV, which is now considered to be the main causative factor of mixed cryoglobulinaemia [45]. The cutaneous manifestations of mixed cryoglobulinaemia are varied and include vasculitis with or without necrosis, urticaria, Raynaud's phenomenon and Sjögren syndrome.

HCV infection has been implicated in the pathogenesis of a subset of Sjögren syndrome; these patients are in most cases indistinguishable from primary Sjögren syndrome. A series of 137 such patients has been reported recently, and those with cryoglobulins (50%) had a higher incidence of cutaneous vasculitis (20%). It has been suggested that HCV infection should be excluded before diagnosing primary Sjögren syndrome [46].

Polyarteritis nodosa (PAN) most commonly occurs in association with hepatitis B, but the prevalence of HCV has been shown to be as high as 5–20% in patients with PAN, suggesting that HCV may rarely be the cause of PAN [47]. Hepatitis C-associated PAN can result in a severe life-threatening vasculitis. Treatment with prednisolone, plasma exchanges and interferon-α is effective in most cases. Because of different clinical features

and management, it is important to distinguish PAN vasculitis from that associated with mixed cryoglobulinaemia [48].

HCV infection has also been associated with porphyria cutanea tarda (PCT). A recent meta-analysis of 50 studies including 2167 patients showed that 50% of patients with PCT have HCV. Seven of these studies compared PCT patients with healthy control subjects in whom the HCV infection rate was 0.24%. There were striking geographical variations, suggesting an environmental or genetic influence on the disease [49]. Recent data have suggested that lichen planus (LP) (see also Chapter 5.1) may be associated with HCV-related liver disease. A case–control series of 303 patients with histologically proven LP showed anti-HCV IgG in 19.1% compared with 3.2% in the control group. A systematic review of 25 studies showed a statistically significant difference in the proportion of HCV-seropositive subjects among patients with LP, compared with control subjects (odds ratio 4.80) [50]. The pathogenesis of this relationship remains unclear.

There have been 68 cases of sarcoidosis with HCV infection reported. The majority of these (75%) began following treatment with interferon and ribavirin. Cutaneous manifestations of sarcoid were seen in 60% [51]. Treatment with interferon for HCV has also been reported to cause a dermatitis in up to 25% of patients. This can usually be treated by topical corticosteroids and emollients without the need to stop the antiviral medication [52]. Lastly, both HBV and HCV may present with a pigmented purpuric dermatosis, histologically showing a lymphocytic vasculitis as the only cutaneous manifestation of disease [53].

Human immunodeficiency virus (HIV)

HIV infection (see Chapter 9.3) commonly affects the liver and the skin and may present in numerous ways. Certain skin conditions are more common in HIV disease, including seborrhoeic dermatitis, psoriasis, herpes infections, viral warts and molluscum contagiosum. Kaposi's sarcoma, an AIDS-defining diagnosis, is discussed in Chapter 9.3.

Treatment with highly active antiretroviral therapy (HAART) has revolutionized the prognosis of patients with HIV infection. Unfortunately, the high number of side-effects, which often affect the skin and the liver, can compromise compliance with treatment regimens [54].

Rash is a common adverse effect of the non-nucleoside reverse transcriptase inhibitors (NNRTIs), particularly nevirapine (NVP). Approximately 16% of patients taking this agent experience a mild to moderate maculopapular rash, with or without pruritus, on the trunk, face and extremities; 6.5% of patients are more severely affected, and fewer than 1% develop Stevens–Johnson syndrome and toxic epidermal necrolysis. This type of reaction typically happens in the first few weeks of treatment [55]. The hypersensitivity reaction observed with NVP (characterized by rash and fever) can also include severe transaminitis.

Transaminitis and hepatotoxicity are associated with most other antiretroviral agents, although initially much concern focused on protease inhibitors. Within this group of drugs, hepatotoxicty rates vary for each agent but, in a recent prospective study, 30% of patients taking ritonavir had grade 3 or 4 change in the serum levels of alanine aminotransferase and aspartate aminotransferase. This was five times more common than for other protease inhibitors [56].

Bacterial infections (see also Section 10)

Bacterial translocation is the passage of viable bacteria from the intestinal lumen to mesenteric lymph nodes and other extraintestinal sites [57]. Cirrhotic patients are particularly susceptible to bacterial infections because of increased bacterial translocation, possibly related to liver dysfunction and reduced reticuloendothelial function [58]. Spontaneous bacterial peritonitis is the main clinical consequence of bacterial translocation in cirrhosis, although urinary tract infections, respiratory infections and bacteraemia may occur [59]. In bacterial sepsis, a cascade of inflammatory cytokines can cause decreased tissue oxygenation and a coagulopathy. Bacterial sepsis may also lead to liver enzyme abnormalities and, in extreme cases, liver failure. If disseminated intravascular coagulation (DIC) is a sequel to infection, it may cause rapid onset of extensive and symmetrical purpura of the extremities. Lesser changes include petechiae, purpuric papules, haemorrhagic bullae and acral cyanosis.

The causal organism in spontaneous bacterial peritonitis can be *Neisseria meningitidis*. Meningococcaemia is estimated to cause a rash in between 40% and 90% of cases. Early petechial skin lesions are caused by organisms in the capillary endothelium, which, together with DIC, may cause necrosis of the vessel wall or thrombosis [60]. The earliest skin lesions may be pinpoint pink macules occurring in a widespread fashion including the palms and soles. This eruption is usually followed by purpura. Rarely, morbilliform or urticarial eruptions may arise in the early stages of infection [61].

Syphilis

New diagnoses of syphilis increased eightfold in the UK between 1997 and 2002 [62]. This trend is also observed in other parts of the world. Hepatitis may occur as a manifestation of secondary syphilis. Cutaneous signs of secondary syphilis are well known and include a widespread, symmetrical erythematous or copper-coloured maculopapular rash that characteristically affects the palms and soles.

However, syphilis is the 'great imitator' in the skin as well as in other systems; the lesions may be psoriasiform or pustular, or may be so subtle that they pass unnoticed. In flexural areas, the papules enlarge to form moist grey-white or pink discs known as condylomata lata, which harbour large numbers of organisms and are highly infectious. 'Snail-track ulcers' or superficial

mucosal erosions form in one-third of patients with secondary syphilis and are also highly infectious. They may be found on the lips, tongue, oral mucosa, external genitalia, vagina or rectum. Patchy 'moth-eaten' alopecia may occur, as may telogen effluvium [63]. The Jarisch–Herxheimer reaction, which may occur during antibiotic treatment for syphilis, can result in hepatotoxicity.

Lyme disease

Lyme disease is a multisystem inflammatory disease caused by the spirochaete *Borrelia burgdorferi.* The characteristic skin eruption of early Lyme disease is known as erythema chronicum migrans [64]. It begins as a centrifugally expanding, erythematous macular lesion with a central papule that follows the bite of an *Ixodes* tick infected with the spirochaete *B. burgdorferi*. Over the following few weeks, central clearing of the skin lesion may occur. Later cutaneous manifestations include acrodermatitis chronica atrophicans. This is a violaceous plaque that becomes atrophic and is most commonly caused by infection with *B. afzelii* [65]. Other less specific symptoms include a maculopapular rash, urticaria and malar erythema in febrile patients. Treatment with appropriate antibiotics such as doxycycline or amoxicillin is important to prevent secondary neurological or cardiac sequelae.

Patients with Lyme disease have been noted to have liver function abnormalities in the absence of a clinical hepatitis. In one study, 46 out of 115 patients (40%) with early Lyme disease had abnormal liver enzymes, with an increase in γ-glutamyl transferase (28%) and alanine transaminase (27%) as the most common findings [66]. Liver function test abnormalities were more common in disseminated disease (66%); most abnormalities were mild, asymptomatic and resolved spontaneously [67].

Autoimmune conditions

Primary biliary cirrhosis (PBC)

Pruritus is the most common presenting complaint occurring in approximately 50% of cases [68]. PBC is well known as being associated with xanthelasma and hyperpigmentation of the skin, although these changes are less commonly seen now the disorder is diagnosed at an earlier stage, often via routine blood testing [69].

There is a strong association with other autoimmune conditions such as scleroderma and Sjögren syndrome. Limited cutaneous sclerosis (CREST syndrome – calcinosis, Raynaud's phenomenon, oesophageal hypomotility, sclerodactyly and telangiectasia) occurs in approximately 16% of patients with PBC and diffuse cutaneous sclerosis in 9% [70]. There have been several case reports of PBC patients presenting with cutaneous non-caseating granulomas and other features suggestive of sarcoidosis [71].

Graft-vs.-host disease

Graft-versus-host disease (GVHD) occurs in up to 50% of patients undergoing allogeneic haematopoietic stem cell transplantation. The organs most commonly affected are the skin, gastrointestinal tract and the liver. GVHD can be divided into acute disease, occurring within 3 months of transplantation, and the chronic form of the disease that occurs thereafter. Chronic GVHD can be further subdivided into lichenoid and sclerodermatous subtypes.

Acute GVHD starts as a purplish-red maculopapular eruption on the palms and soles, spreading to the face, limbs and trunk [72]. Desquamation of the skin usually follows and, in severe forms, toxic epidermal necrolysis may ensue. Bullous, ulcerated and follicular forms of GVHD have all been described [73]. Skin biopsy is a non-invasive and sensitive diagnostic test.

In chronic GVHD, the initial cutaneous manifestation is usually lichenoid; this may involve the oral cavity and, in most cases (about 85%), is a gradual development from acute GVHD [74]. The symptoms may be generalized or localized. The localized form can appear linear and be in a dermatomal pattern [75]. In the late chronic phase, sclerodermatous changes occur, and these may be complicated by ulceration, subcutaneous calcification, hyperpigmentation, alopecia, dystrophic nail changes and ocular manifestations.

Treatment of acute GVHD involves the intensification of immunosuppressive therapy with adequate topical supportive management. In skin-limited disease, phototherapy has shown promising results. In cutaneous chronic GVHD, corticosteroids and ciclosporin are the mainstay of treatment with other immunosuppressants being added. Good response to phototherapy has been shown in lichenoid disease, while sclerodermatous disease is better treated with etretinate or extracorporeal photochemotherapy. Topical corticosteroids or topical tacrolimus can be used in localized cutaneous chronic GVHD [76].

Acute and chronic GVHD with cutaneous symptoms have also been reported following liver transplantation [77].

Neoplastic conditions

Hepatocellular carcinoma (see also Section 18)

Cutaneous conditions seen in hepatocellular carcinoma are non-specific and include paraneoplastic syndromes such as acanthosis nigricans, dermatomyositis, erythema gyratum repens, mucous membrane pemphigoid, pemphigus, pemphigus foliaceous and paraneoplastic acrokeratosis or Bazex syndrome. In the last syndrome, erythema and scaling develop in acral sites, and nail dystrophy and hyperkeratotic plaques may mimic psoriasis. Pityriasis rotunda is an ichthyotic skin condition with widespread annular scale that is more commonly seen in patients of African or Asian origin and is particularly linked to an underlying hepatocellular carcinoma [78]. Hepatic manifestations of porphyria cutanea tarda include hepatocellular

carcinoma. There are also reports of hepatocellular carcinoma initially presenting as cutaneous metastatic nodules [79].

Carcinoid syndrome (see also Chapter 18.3.2)

Carcinoid tumours are neuroendocrine tumours derived from enterochromaffin cells with the primary being found in the gut, metastasizing to the liver. Skin signs of carcinoid syndrome such as flushing do not generally occur until liver metastases have developed. Paroxysms of flushing tend to involve the face, neck and upper part of the trunk. Although usually spontaneous, exertion and alcohol may trigger an attack. The flushing may vary in colour from pink-orange to bright red and from purplish-blue to a blanching white. In time, persistent erythema may develop on the face and neck, together with poikiloderma and telangiectases.

Carcinoid tumours are able to secrete a variety of vasoactive peptides, primarily serotonin [5-hydroxytryptamine (5-HT)], although other polypeptides, kinins, histamine and substance P can be secreted. Excessive 5-hydroxylation of tryptophan by the tumour produces large quantities of 5-hydroxytryptophan (5-HTP), 5-HT and 5-hydroxyindolacetic acid (5-HIAA) [80]. As tryptophan is a precursor of niacin, consumption by the tumours can result in a fall in nicotinic acid levels and pellagra [81]. This may present with hyperkeratosis, scaling and a grey-black hyperpigmentation of the skin that is most marked on the legs, forearms and trunk. Treatment with niacin causes resolution of these lesions.

Occasionally, carcinoid tumours metastasize to the skin presenting with firm, tender nodules. Rarely, carcinoid syndrome is associated with the development of scleroderma [82].

Surgical resection is the treatment of choice, but hepatic metastases are often multiple and unresectable by the time of presentation. Chemoembolization produces a symptomatic response in about half of patients lasting on average 1 year [83]. Long-acting somatostatin analogues such as octreotide given intramuscularly may provide relief from the flushing [84]. Systemic chemotherapy is used in advanced tumours with variable results. Symptomatic improvement with cyproheptadine, interferon-α, radiotherapy and radiofrequency ablation of the tumour has been reported.

Effects of immunosuppression

Liver transplantation (see Section 25)

Skin infections, infestations, malignancies and other dermatoses are seen more frequently in patients who have received organ transplants compared with the normal population [85]. *De novo* tumours are more common following liver transplantation (4.7–15.7% higher incidence rates). Skin cancer is the most frequent malignancy observed, ranging from 6% to 70% of the tumours [86]. In the normal population, basal cell carcinomas (BCC) are far more common than squamous cell carcinomas (SCC). In organ transplant patients, the BCC:SCC ratio is reversed. A recent study examined 151 liver transplant patients (mean follow-up 1490 days), in whom 86 skin cancers were diagnosed in 34 patients, including 56 SCC, 23 BCC and seven melanomas [87]. In a univariate analysis, advancing age, male gender, red hair, brown eyes, primary sclerosing cholangitis (PSC), ciclosporin, number of second-degree sunburns and frequent lifetime sun exposure were associated with the development of new skin cancers. In a multivariate model, age, male gender, red hair, brown eyes, PSC and ciclosporin usage were the strongest predictors.

Overall, a threefold increase in malignancies is found in recipients of organ transplants compared with age-matched control groups [88]. In addition to BCC, SCC and melanoma, lymphoma, anogenital cancer and Kaposi's sarcoma have all been described. Several series are reported in which previously human herpesvirus (HHV)-8-negative recipients developed terminal Kaposi's sarcoma following liver transplantation from HHV-8-positive donors. Treatment is by reduction in the immunosuppressive regimen and/or chemotherapy [89,90].

Preventative measures with sun avoidance are important in recipients of liver transplants, and a prompt biopsy of any suspicious skin lesion is mandatory. In view of the increased risk of infection, unexplained skin lesions should also be stained and cultured to look for bacterial, viral, fungal, as well as typical or atypical mycobacterial infections [91].

Alcohol and alcoholic liver disease

Characteristic stigmata of alcoholic liver disease including spider naevi, palmar erythema and leuconychia are widely recognized, but these also occur in chronic liver disease from other causes. However, vascular lesions such as spider naevi and palmar erythema are more common in patients with alcoholic cirrhosis than in patients with viral or cryptogenic cirrhosis [92]. A prospective study showed that numbers and size of spider naevi in patients with alcoholic liver disease correlated with both the presence and the frequency of bleeding from oesophageal varices [93]. Patients with spider naevi greater than 15 mm in diameter had an 80% risk of variceal bleeding.

Other signs that may be observed on examining the alcoholic patient include gynaecomastia, scanty hair distribution over the trunk, testicular atrophy, jaundice and pigmented erythema [94].

Flushing and plethoric facies are linked to alcohol misuse. In susceptible individuals, there may be fine telangiectases and persistent facial erythema often without spider naevi or palmar erythema. The underlying mechanism is thought to be chronic vasodilatation and loss of vasoregulatory control mechanisms. Alcohol may also exacerbate, but not cause, rosacea. In particular, it can trigger the flushing and vasomotor instability associated with this condition.

The relationship between alcohol and psoriasis has been covered in Chapter 20.5.

Cutaneous infections such as cellulitis are more common in patients who abuse alcohol, and result from a combination of factors including immune dysfunction, trauma, poor nutrition and hygiene [95]. In one survey of patients attending an alcohol misuse clinic, the incidence of chronic fungal skin infections (tinea pedis, onychomycosis and pityriasis versicolor) was 33% as opposed to an incidence of 5–10% in the general population [96].

Nutritional deficiencies in patients with alcoholic liver disease that are severe enough to cause cutaneous manifestations are rare in the UK. Pellagra caused by niacin deficiency presents with an erythematous and photosensitive scaly dermatitis on the face and arms, characteristically in association with diarrhoea and dementia. The skin changes eventually to form a dusky, brown-red coloration, similar to resolving severe sunburn.

Scurvy secondary to vitamin C deficiency presents with follicular keratoses and corkscrew hairs. Later, perifollicular haemorrhages, stomatitis, bleeding gums, epistaxes and ecchymoses occur [97].

Discoid eczema appears to be more common in alcohol misuse and is associated with deranged liver function tests. Atopic eczema seems to be unaffected by alcohol, but seborrhoeic eczema is twice as common in alcohol abuse. Rosacea, post-adolescent acne and porphyria cutanea tarda may also be markers of alcohol misuse [98].

Drugs and chemicals affecting the liver and skin

Porphyria

Of the hepatic porphyrias, the skin is affected in porphyria cutanea tarda, variegate porphyria, hepatoerythropoietic porphyria and hereditary coproporphyria.

Porphyria cutanea tarda (PCT)

This is the commonest type of porphyria caused by a reduced activity of the uroporphyrinogen decarboxylase (UROD) in the haem biosynthetic pathway. Patients present with blistering on light-exposed areas predominantly on the dorsal aspect of the hands and face, milia formation and atrophic scarring [99]. Hyperpigmentation is a common feature, but mottled hypopigmentation may also occur. Skin fragility and hypertrichosis, initially facial and more prominent in women, may also be noted. Sclerodermatous-like plaques, often located on the upper chest, are a rare association.

The manifestation of PCT reflects genetic and environmental factors. Mutations in the *UROD* gene on chromosome 1p34 discriminate the rarer familial PCT (10–20%) from the more common sporadic cases [100]. Familial PCT is inherited as an autosomal dominant trait with incomplete penetrance; 90% of carriers are asymptomatic. An increased frequency of hereditary haemochromatosis gene mutations is observed in patients with porphyria cutanea tarda. In some series, C282Y and, less commonly, H63D allelic mutations are reported in 60–75% of PCT patients [101].

In susceptible people, PCT may be precipitated by alcohol abuse, iron therapy, estrogens in the oral contraceptive pill or hormone replacement therapy and exposure to polyhalogenated cyclic hydrocarbons. Hepatitis C virus (HCV) is thought to be an important aetiological factor in some patients and has been discussed earlier.

Diagnosis rests upon increased levels of urinary uroporphyrin and coproporphyrin or faecal isocoproporphyrin. Treatment includes the avoidance of precipitating factors, sun avoidance and the wearing of sunscreens, low-dose, twice-weekly chloroquine and venesection in patients with iron overload or HCV-related disease [102]. Liver involvement varies from a mild rise in aminotransferase concentrations to cirrhosis, which can progress to hepatoma.

Variegate porphyria

Variegate porphyria (VP) is a rare, autosomal dominant disease, characterized by a mean 50% reduction in the activity of protoporphyrinogen-IX oxidase (PPOX), the penultimate enzyme in the haem synthetic pathway. The majority of patients with the variegate porphyria trait are asymptomatic but, of those who are symptomatic, 50% have skin disease alone and 70% have cutaneous involvement [103]. The neurovisceral features of variegate porphyria are confusional states, abdominal pain and peripheral neuropathy. Drugs, pregnancy or reduced carbohydrate intake can precipitate attacks.

Cutaneous manifestations of VP are similar to those of PCT with blister formation on sun-exposed areas such as the face, neck and the dorsum of the hands. The skin is fragile and may blister after trauma. Healing leads to milia and the formation of tissue-paper scars. Hypertrichosis also occurs, mainly confined to the cheeks with hyper- or hypopigmentary changes. Diffuse thickening of the hands and fingers may rarely be seen, similar to the changes found in scleroderma.

Numerous mutations in the *PPOX* gene on chromosome 1q22–23 have been reported, which result in little or no function of PPOX [104]. Interestingly, in South Africa where VP is much more prevalent than in the rest of the world, the majority of patients have the same mutation and are thought to be descended from one individual. This is the so-called 'founder effect'. In those individuals with a *PPOX* gene mutation, the clinical penetrance is about 40% [105].

The diagnosis is made by the finding of increased faecal excretion of protoporphyrin and coproporphyrin. Treatment of acute attacks is by haem arginate infusion to reduce the excretion of porphyrins and carbohydrate loading to reduce the production of porphyrins and their precursors. Supportive care is also important. The skin lesions can be prevented by sunscreens and sun avoidance.

Hereditary coproporphyria

Hereditary coproporphyria (HCP) is the least common of the autosomal dominant acute hepatic porphyrias. It results from mutations in the *CPOX* gene on chromosome 3q12, which causes a partial deficiency (about 50%) in the mitochondrial enzyme coproporphyrinogen oxidase. There is marked elevation of faecal coproporphyrin, even between acute attacks [106].

If skin lesions caused by photosensitization by porphyrins are present, as occurs in 30% of patients, HCP resembles VP. Presentation with skin lesions alone is uncommon among patients with HCP; the few cases reported have usually been associated with hepatobiliary dysfunction [107]. The disease is more often symptomatic in females and may be triggered by menstruation, pregnancy and the contraceptive pill. The treatment is the same as in VP.

Hepatoerythropoietic porphyria (HEP)

HEP is the result of a profound deficiency (< 10% of normal activity) of uroporphyrinogen decarboxylase (UROD) activity due to autosomal recessive inheritance of mutations in the *UROD* gene [108]. Typically, severe photosensitivity occurs in the first year of life, and total sun avoidance is imperative. Blistering occurs with marked scarring, hyperpigmentation and sclerodermatous skin changes [109].

Alpha-1-antitrypsin deficiency

Deficiency of the protease inhibitor alpha-1-antitrypsin (see Chapter 20.5) may rarely be associated with the cutaneous findings of panniculitis, vasculitis, urticaria, angio-oedema, pemphigus herpetiformis, Muir–Torre syndrome, cutis laxa, lupus erythematosus, psoriasis and vasculitis [110].

Nodular panniculitis is the most frequent association, and alpha-1-antitrypsin deficiency accounts for up to 14% of cases [111]. It presents with tender, single or multiple subcutaneous nodules, usually on the lower legs, although a more generalized form may occur. The nodules may liquefy or ulcerate and heal with scarring. The age of onset may be from infancy to old age. Intravenous alpha-1-antitrypsin replacement is the most effective treatment with resolution of the panniculitis after three weekly doses, although recurrences can occur [112]. Other treatments reported to be effective are dapsone, doxycycline and minocycline in mild cases, with plasma exchange and liver transplantation being used in appropriate cases [113].

Haemochromatosis

This disorder of iron deposition is discussed in Chapter 16.2. The characteristic skin change is a grey-brown or 'bronze' pigmentation, particularly on the face, flexural creases and sun-exposed areas. This is secondary to excessive melanin formation.

Vinyl chloride (see also Chapter 14.1)

Industrial workers exposed to polyvinyl chloride who are HLA DR5, B8 or DR3 positive are at risk of developing a scleroderma-like disorder with associated Raynaud's phenomenon [114]. Exposure to vinyl chloride has been linked to a 45-fold increased risk of the normally rare angiosarcoma of the liver. The average latency period before tumour development is 22 years [115].

Wilson's disease and penicillamine treatment (see also Chapter 16.1)

Patients with Wilson's disease who have received long-term treatment with D-penicillamine as a copper-chelating agent may develop elastosis perforans serpiginosa as a rare complication. This presents as eruptive dome-shaped or umbilicated pink/red papules that are grouped in linear, orciform or serpiginous patterns. They may be filled by a crusty or scaly plug. This disorder is caused by the transepidermal elimination of abnormal elastic fibres and usually arises on the back of the neck and arms.

Pseudoxanthoma elasticum-type changes with a 'plucked-chicken skin' can also occur characteristically on the neck and axilla. These lesions may occasionally ulcerate or form cribriform scarring [116]. Other cutaneous side-effects of penicillamine are acute hypersensitivity reactions and bullous disorders.

References

1 Sarkany I (1988) The skin–liver connection. *Clin Exp Dermatol* 13, 151–159.
2 Hruza GJ, Geronemus RG, Dover JS *et al.* (1993) Lasers in dermatology – 1993. *Arch Dermatol* 129, 1026–1035.
3 Maddrey WC, Van Thiel DH (1988) Liver transplantation: an overview. *Hepatology* 8, 948–959.
4 Bergasa NV (2004) Treatment of the pruritus of cholestasis. *Curr Treat Options Gastroenterol* 7, 501–508.
5 Garbutt JT, Kenney TJ (1972) Effect of cholestyramine on bile acid metabolism in normal man. *J Clin Invest* 51, 2781–2789.
6 O'Keeffe C, Baird AW, Nolan N *et al.* (2004) Cholestatic pruritus – the role of cutaneous mast cells and nerves. *Aliment Pharmacol Ther* 19, 1293–1300.
7 Greaves MW, Khalifa N (2004) Itch: more than skin deep. *Int Arch Allergy Immunol* 135, 166–172.
8 Terg R, Coronel E, Sorda J *et al.* (2002) Efficacy and safety of oral naltrexone treatment for pruritus of cholestasis, a crossover, double blind, placebo controlled study. *J Hepatol* 37, 717–722.
9 Bergasa NV, Alling DW, Taldot TL *et al.* (1999) Oral nalmefene therapy reduces scratching activity due to the pruritus of cholestasis: a controlled study. *J Am Acad Dermatol* 41, 431–434.
10 Jones EA, Neuberger J, Bergassa NV (2002) Opiate antagonist therapy for the pruritus of cholestasis; the avoidance of opioid withdrawal like reactions. *Q J Med* 95, 547–552.
11 McRae CA, Prince MI, Hudson M *et al.* (2003) Pain as a complication for the use of opiate antagonists for symptom control in cholestasis. *Gastroenterology* 125, 591–596.

12 Oo YH, Neuberger J (2004) Options for treatment of primary biliary cirrhosis. *Drugs* 64, 2261–2271.

13 Cynamon HA, Andres JM, Iafrate RP (1990) Rifampin relieves pruritus in children with cholestatic liver disease. *Gastroenterology* 98, 1013–1016.

14 Galeazzi R, Lorenzini I, Orlandi F (1980) Rifampicin-induced elevation of serum bile acids in man. *Dig Dis Sci* 25, 108–112.

15 Borgeat A, Wilder-Smith OH, Mentha G (1993) Subhypnotic doses of propofol relieve pruritus associated with liver disease. *Gastroenterology* 104, 244–247.

16 Linnebank M, Tschiedel E, Haberle J *et al.* (2002) Argininosuccinate lyase (ASL) deficiency: mutation analysis in 27 patients and a completed structure of the human ASL gene. *Hum Genet* 111, 350–359.

17 Savitsky K, Bar-Shira A, Gilad S *et al.* (1995) A single ataxia telangiectasia gene with a product similar to PI-3 kinase. *Science* 268, 1749–1753.

18 Drolet BA, Drolet B, Zvulunov A *et al.* (1997) Cutaneous granulomas as a presenting sign in ataxia-telangiectasia. *Dermatology* 194, 273–275.

19 Nowak-Wegrzyn A, Crawford TO, Winkelstein JA *et al.* (2004) Immunodeficiency and infections in ataxia-telangiectasia. *J Pediatr* 144, 505–511.

20 Heikkinen K, Rapakko K, Karppinen SM *et al.* (2005) Association of common ATM polymorphism with bilateral breast cancer. *Int J Cancer* 116, 69–72.

21 Weinstein S, Scottolini AG, Loo SY *et al.* (1985) Ataxia telangiectasia with hepatocellular carcinoma in a 15-year-old girl and studies of her kindred. *Arch Pathol Lab Med* 109, 1000–1004.

22 Li L, Krantz ID, Deng Y *et al.* (1997) Alagille syndrome is caused by mutations in human Jagged1, which encodes a ligand for Notch1. *Nature Genet* 16, 243–251.

23 Garcia MA, Ramonet M, Ciocca M *et al.* (2005) Alagille syndrome: cutaneous manifestations in 38 children. *Pediatr Dermatol* 22, 11–14.

24 Mignani R, Cagnoli L (2004) Enzyme replacement therapy in Fabry's disease: recent advances and clinical applications. *J Nephrol* 17, 354–363.

25 Desnick R, Brady R, Barranger J (2003) Clinical guidelines: Fabry disease, an under recognized multisystemic disorder: expert recommendations for diagnosis, management and enzyme replacement. *Ann Intern Med* 138, 338–346.

26 Hoffmann B, Garcia de Lorenzo A *et al.* (2005) Effects of enzyme replacement therapy on pain and health related quality of life in patients with Fabry disease: data from FOS (Fabry Outcome Survey). *J Med Genet* 42, 247–252.

27 Goldblatt J, Beieghton P (1984) Cutaneous manifestations of Gaucher disease. *Br J Dermatol* 111, 331–334.

28 Stone DL, Carey WF, Christodoulou J *et al.* (2000) Type 2 Gaucher disease: the collodion baby revisited. *Arch Dis Child Fetal Neonatal Ed* 82, 163–166.

29 Charrow J, Andersson HC, Kaplan P *et al.* (2000) The Gaucher registry: demographics and disease characteristics of 1698 patients with Gaucher disease. *Arch Intern Med* 160(18), 2835–2843.

30 Weinreb NJ, Charrow J, Andersson HC *et al.* (2002) Effectiveness of enzyme replacement therapy in 1028 patients with type 1 Gaucher disease 2–5 years of treatment: a report from the Gaucher Registry. *Am J Med* 113, 112–119.

31 Ho V *et al.* (2000) Diffuse neonatal haemangiomatosis. *J Paediatr Child Health* 36, 286–289.

32 Cohen RC, Myers NA (1986) Diagnosis and management of massive hepatic haemangiomas in childhood. *J Paediatr Surg* 21, 6–9.

33 Lopriore E, Markhorst DG (1999) Diffuse neonatal haemangiomatosis: new views on diagnostic criteria and prognosis. *Acta Paediatr* 88, 93–97.

34 Keegan MT, Kamath GS, Vasdev GM *et al.* (2001) Liver transplantation for massive hepatic haemangiomatosis causing restrictive lung disease. *Br J Anaesth* 86, 431–434.

35 Trepo C, Guillevin L (2001) Polyarteritis nodosa and extrahepatic manifestations of HBV infection: the case against autoimmune intervention in pathogenesis. *J Autoimmun* 16, 269–274.

36 Popp JW Jr, Harrist TJ, Dienstag JL *et al.* (1981) Cutaneous vasculitis associated with acute and chronic hepatitis. *Arch Intern Med* 141, 623–629.

37 Han SH (2004) Extrahepatic manifestations of chronic hepatitis B. *Clin Liver Dis* 8, 403–418.

38 Ferri C, Sebastiani M, Giuggioli D *et al.* (2004) Mixed cryoglobulinemia: demographic, clinical, and serologic features and survival in 231 patients. *Semin Arthritis Rheum* 33, 355–374.

39 Spear KL, Winkelmann RK (1984) Gianotti-Crosti syndrome. A review of ten cases not associated with hepatitis B. *Arch Dermatol* 120, 891–896.

40 Taieb A, Plantin P, Du Pasquier P *et al.* (1986) Gianotti-Crosti syndrome: a study of 26 cases. *Br J Dermatol* 115, 49–59.

41 Han SH (2004) Extrahepatic manifestations of chronic hepatitis B. *Clin Liver Dis* 8, 403–418.

42 Maggiore G, Grifeo S, Marzani MD (1983) Erythema nodosum and hepatitis B virus (HBV) infection. *J Am Acad Dermatol* 9, 602–603.

43 Pawlotsky JM, Dhumeaux D, Bagot M (1995) Hepatitis C virus in dermatology: a review. *Arch Dermatol* 131, 1185–1193.

44 Poljacki M, Gajinov Z, Ivkov M *et al.* (2000) Skin diseases and hepatitis virus C infection. *Med Preg* 53, 141–145.

45 Ferri C, Sebastiani M, Giuggioli D *et al.* (2004) Mixed cryoglobulinemia: demographic, clinical, and serologic features and survival in 231 patients. *Semin Arthritis Rheum* 33, 355–374.

46 Ramos-Casals M, Loustaud-Ratti V, De Vita S *et al.* (2005) Sjogren syndrome associated with hepatitis C virus: a multicenter analysis of 137 cases. *Medicine* 84, 81–89.

47 Carson CW, Conn DL, Czaja AJ *et al.* (1993) Frequency and significance of antibodies to hepatitis C virus in polyarteritis nodosa. *J Rheumatol* 20, 304–309.

48 Cacoub P, Maisonobe T, Thibault V *et al.* (2001) Systemic vasculitis in patients with hepatitis C. *Rheumatology* 28, 109–118.

49 Gisbert JP, Garcia-Buey L, Pajares JM *et al.* (2003) Prevalence of hepatitis C virus infection in porphyria cutanea tarda: systematic review and meta-analysis. *J Hepatol* 39, 620–627.

50 Lodi G, Giuliani M, Majorana A *et al.* (2004) Lichen planus and hepatitis C virus: a multicentre study of patients with oral lesions and a systematic review. *Br J Dermatol* 151, 1172–1181.

51 Ramos-Casals M, Mana J, Nardi N *et al.* (2005) Sarcoidosis in patients with chronic hepatitis C virus infection: analysis of 68 cases. *Medicine* 84, 69–80.

52 Lubbe J, Negro F (2005) Hepatitis-C-combination treatment-associated dermatitis: clinical presentation and management. *Rev Med Suisse* 1, 1081–1082, 1084–1085.

53 Dessoukey MW, Abdel-Dayem H, Omar MF *et al.* (2005) Pigmented purpuric dermatosis and hepatitis profile: a report on 10 patients. *Int J Dermatol* 44, 486–488.

54 Montessori V, Press N, Harris M (2004) Adverse effects of antiretroviral therapy for HIV infection. *Can Med Assoc J* 170, 229–238.

55 Fagot JP, Mockenhaupt M, Bouwes-Bavnick JN *et al.* (2001) Nevirapine and the risk of Stevens–Johnson syndrome or toxic epidermal necrolysis. *AIDS* 15, 1843–1848.

56 Sulkowski MS, Thomas DL, Chaisson RE *et al.* (2000) Hepatotoxicity associated with antiretroviral therapy in adults infected with human immunodeficiency virus and the role of hepatitis C or B virus infection. *JAMA* 283, 74–80.

57 Guarner C, Soriano G (2005) Bacterial translocation and its consequences in patients with cirrhosis. *Eur J Gastroenterol Hepatol* 17, 27–31.

58 Wong F, Bernardi M, Balk R *et al.* (2005) Sepsis in cirrhosis: report on the 7th meeting of the International Ascites Club. *Gut* 54, 718–725.

59 Navasa M, Rodes J (2004) Bacterial infections in cirrhosis. *Liver Int* 24, 277–280.

60 Bannister B (1988) Clinical aspects of meningococcal disease. *J Med Microbiol* 26, 161–163.

61 Baxter P, Priestley B (1988) Meningococcal rash. *Lancet* i(8595), 1166–1167.

62 Brown AE, Sadler KE, Tomkins SE *et al.* (2004) Recent trends in HIV and other STIs in the United Kingdom: data to the end of 2002. *Sex Transm Infect* 80, 159–166.

63 WHO (1982) *Treponemal Infections*. Technical Report Series No. 674. Geneva: WHO.

64 Berger BW (1989) Dermatologic manifestations of Lyme disease. *Rev Infect Dis* 11, S1475–S1481.

65 Aguero-Rosenfeld ME (2003) Laboratory aspects of tick-borne diseases: lyme, human granulocytic ehrlichiosis and babesiosis. *Mt Sinai J Med* 70, 197–206.

66 Kazakoff MA, Sinusas K, Macchia C (1993) Liver function test abnormalities in early Lyme disease. *Arch Fam Med* 2, 409–413.

67 Horowitz HW, Dworkin B, Forseter G *et al.* (1996) Liver function in early Lyme disease. *Hepatology* 23(6), 1412–1417.

68 Bergasa NV (2003) Pruritus and fatigue in primary biliary cirrhosis. *Clin Liver Dis* 7(4), 879–900.

69 Kaplan MM (1987) Primary biliary cirrhosis. *N Engl J Med* 316, 521–528.

70 Culp KS, Fleming CR, Duffy J *et al.* (1982) Autoimmune associations in primary biliary cirrhosis. *Mayo Clin Proc* 57, 365–370.

71 Bonnet F, Dubuc J, Morlat P *et al.* (2001) Sarcoidosis and comorbidity: retrospective study of 32 cases. *Rev Med Interne* 22, 619–623.

72 Harper JI (1987) Cutaneous graft versus host disease. *Br Med J* 295, 401–402.

73 Lycka BA, Kaye VN (1988) Acute follicular graft-vs-host disease. *Arch Dermatol* 124, 1442.

74 Dermarosi F, Bez C, Sardella A *et al.* (2002) Oral involvement in chronic graft vs host disease following allogenic bone marrow transplantation. *Arch Dermatol* 138, 842–843.

75 Freemer CS, Farmer ER, Cerio RL *et al.* (1994) Lichenoid graft versus host disease occurring in a dermatomal distribution. *Arch Dermatol* 130, 70–72.

76 Penas PF, Fernandez-Herrera J, Garcia-Diez A (2004) Dermatologic treatment of cutaneous graft versus host disease. *Am J Clin Dermatol* 5, 403–416.

77 Whalen JG, Jukic DM, English JC (2005) Rash and pancytopenia as initial manifestations of acute graft-versus-host disease after liver transplantation. *J Am Acad Dermatol* 52, 908–912.

78 Leibowitz MR, Weiss R, Smith EH (1983) Pityriasis rotunda: a cutaneous sign of malignant disease in two patients. *Arch Dermatol* 119, 607–609.

79 Jegou J, Perruzi P, Arav E *et al.* (2004) Cutaneous and bone metastases revealing hepatocarcinoma. *Gastroenterol Clin Biol* 28, 804–806.

80 Kema IP, de Vries EG, Slooff MJ *et al.* (1994) Serotonin, catecholamines, histamine, and their metabolites in urine, platelets, and tumor tissue of patients with carcinoid tumors. *Clin Chem* 40, 86–89.

81 Castiello RJ, Lynch PJ (1972) Pellagra and the carcinoid syndrome. *Arch Dermatol* 105, 574–577.

82 Durward G, Blackford S, Roberts D *et al.* (1995) Cutaneous scleroderma in association with carcinoid syndrome. *Postgrad Med J* 71, 299–300.

83 Eriksson BK, Larsson EG, Skogseid BM *et al.* (1998) Liver embolizations of patients with malignant neuroendocrine gastrointestinal tumors. *Cancer* 83, 2293–2301.

84 Wymenga AN, Eriksson B, Salmela PI *et al.* (1999) Efficacy and safety of prolonged-release lanreotide in patients with gastrointestinal neuroendocrine tumors and hormone-related symptoms. *J Clin Oncol* 17, 1111.

85 Abel EA (1989) Cutaneous manifestations of immunosuppression in organ transplant recipients. *J Am Acad Dermatol* 21, 167–179.

86 Vallejo GH, Romero CJ, de Vicente JC (2005) *Crit Rev Oncol Hematol*. Jun 23 [Epub ahead of print].

87 Mithoefer AB, Supran S, Freeman RB (2002) Risk factors associated with the development of skin cancer after liver transplantation. *Liver Transpl* 8, 939–944.

88 Penn (1986) *SGO* 162, 603.

89 Marcelin AG, Roque-Afonso AM, Hurtova M (2004) Fatal disseminated Kaposi's sarcoma following human herpes virus 8 primary infections in liver-transplant recipients. *Liver Transpl* 10, 295–300.

90 Andreoni M, Goletti D, Pezzotti P (2001) Prevalence, incidence and correlates of HHV-8/KSHV infection and Kaposi's sarcoma in renal and liver transplant recipients. *J Infect* 43, 195–199.

91 Leyden JJ (1985) Infection in the immunocompromised host. *Arch Dermatol* 121, 855–857.

92 Strauss E, Lacet CM, Caly WR *et al.* (1990) Cryptogenic cirrhosis: clinico-biochemical comparison with alcoholic and viral etiologies. *Arq Gastro Sao Paulo* 27, 46–52.

93 Foutch PG, Sullivan JA, Gaines JA *et al.* (1988) Cutaneous vascular spiders in cirrhotic patients: correlation with hemorrhage from esophageal varices. *Am J Gastroenterol* 83, 723–726.

94 Albrecht G (2000) Skin manifestations of alcoholic liver damage. *Ther Umsch* 57(4), 232–235.

95 Adams HG, Jordan C (1984) Infections in the alcoholic. *Med Clin North Am* 68, 179–200.

96 Higgins EM, du Vivier AW (1992) Alcohol and the skin. *Alcohol Alcoholism* 27, 595–602.

97 Leung FW, Guze PA (1981) Adult scurvy. *Ann Emerg Med* 10, 652–655.

98 Higgins EM, du Vivier AW (1994) Cutaneous disease and alcohol misuse. *Br Med Bull* 50, 85–98.

99 Grossman ME, Bickers DR, Poh-Fitzpatrick MB *et al.* (1979) Porphyria cutanea tarda. Clinical features and laboratory findings in 40 patients. *Am J Med* 67, 277–286.

100 Bygum A, Christiansen L, Petersen NE *et al.* (2003) Familial and sporadic porphyria cutanea tarda: clinical, biochemical and genetic

features with emphasis on iron status. *Acta Derm Venereol* 83, 115–120.

101 Bonkovsky HL, Obando JV (1999) Role of HFE gene mutations in liver diseases other than hereditary hemochromatosis. *Curr Gastroenterol Rep* 1, 30–37.

102 Sarkany RP (2001) The management of porphyria cutanea tarda. *Clin Exp Dermatol* 26, 225–232.

103 Eales L, Day RS, Blekkenhorst GH (1980) The clinical and biochemical features of variegate porphyria: an analysis of 300 cases studied at Groote Schuur Hospital, Cape Town. *Int J Biochem* 12, 837–853.

104 Morgan RR, da SV, Puy H *et al*. (2002) Functional studies of mutations in the human protoporphyrinogen oxidase gene in variegate porphyria. *Cell Mol Biol (Noisy-le-grand)* 48, 79–82.

105 Hift RJ, Meissner D, Meissner PN (2004) A systematic study of the clinical and biochemical expression of variegate porphyria in a large South African family. *Br J Dermatol* 151, 465–471.

106 Lamoril J, Puy H, Whatley SD *et al*. (2001) Characterization of mutations in the CPO gene in British patients demonstrates absence of genotype-phenotype correlation and identifies relationship between hereditary coproporphyria and harderoporphyria. *Am J Hum Genet* 68, 1130–1138.

107 Martasek P (1998) Hereditary coproporphyria. *Semin Liver Dis* 18, 25–32.

108 Ged C, Ozalla D, Herrero C *et al*. (2002) Description of a new mutation in hepatoerythropoietic porphyria and prenatal exclusion of a homozygous fetus. *Arch Dermatol* 138, 957–960.

109 Czarnecki DB (1980) Hepatoerythropoietic porphyria. *Arch Dermatol* 116, 307–311.

110 Bazex J, Bayle P, Albes B (2002) Alpha-1-antitrypsin deficiency. Role in skin disorders. *Bull Acad Natl Med* 186, 1479–1486.

111 Smith (1989) *J Am Acad Dermatol* 21, 1192.

112 O'Riordan K, Blei A, Rao MS *et al*. (1997) Alpha 1-antitrypsin deficiency-associated panniculitis: resolution with intravenous alpha 1-antitrypsin administration and liver transplantation. *Transplantation* 63, 480–482.

113 Ginarte M, Roson E, Peteiro C *et al*. (2001) Treatment of alpha1-antitrypsin-deficiency panniculitis with minocycline. *Cutis* 68, 86–88.

114 Black CM, Welsh KI, Walker AE *et al.* (1983) Genetic susceptibility to scleroderma-like syndrome induced by vinyl chloride. *Lancet* i (8314–8315), 53–55.

115 Kielhorn J, Melber C, Wahnschaffe U *et al*. (2000) Vinyl chloride: still a cause for concern. *Environ Health Perspect* 108, 579–588.

116 Iozumi K, Nakagawa H, Tamaki K (1997) Penicillamine-induced degenerative dermatoses: report of a case and brief review of such dermatoses. *J Dermatol* 24, 458–465.

21.7 The effect of liver disease on the urogenital tract

Mónica Guevara, Vicente Arroyo and Juan Rodés

It is well known that both acute and chronic liver disease (hepatic cirrhosis, acute and chronic Budd–Chiari syndrome, hepatocellular carcinoma, alcoholic hepatitis and fulminant hepatic failure) in addition to renal sodium and water retention may induce hepatorenal syndrome. This association is discussed in other sections of the book. This chapter reviews other renal disturbances associated with hepatic disease: (i) acute renal failure in obstructive jaundice; (ii) glomerular abnormalities in hepatic cirrhosis, viral infection with hepatitis B and hepatitis C; and (iii) renal tubular acidosis in chronic liver disease. In addition, the influence of hepatic cirrhosis on the prostate is discussed.

Acute renal failure in obstructive jaundice

The natural route for the excretion of bile is the biliary tract. When this route is blocked, the kidney becomes the main excretory organ for the biliary products. Therefore, the jaundiced patient is critically dependent on the kidney for survival. Unfortunately, kidney function may deteriorate during obstructive jaundice.

For many decades, it has been recognized that surgery in patients with obstructive jaundice is associated with a high risk of acute renal failure, which contributes to postoperative mortality. Initial studies reported an incidence of renal failure of 7–20%. The postoperative mortality rate for these patients ranged from zero to 27%, with renal failure as a major contributing cause in 30–40% of cases. Nowadays, however, the rate of postoperative renal failure among patients with obstructive jaundice is lower, probably due to better treatment with appropriate preoperative rehydration aimed at maintaining urine flow at the time of surgery [1]. Renal failure may occur in association with any disease causing obstruction of the biliary tract, including calculi, tumour and chronic pancreatitis. Although impairment in renal function usually occurs immediately after surgery, it may also develop preoperatively. Acute renal failure (acute tubular necrosis) in these patients is characterized by a severely reduced endogenous creatinine clearance, high levels of blood urea nitrogen and serum creatinine, a urinary sodium concentration greater than 10 mEq/day and urine-to-plasma osmolality ratio lower than unity. Patients with jaundice who develop acute tubular necrosis are severely ill and most have cholangitis, sepsis and arterial hypotension.

The pathological changes found in the kidney following the development of renal failure are non-specific. The mechanism of renal failure in these patients remains poorly understood; however, a number of factors including endotoxinaemia, hyperbilirubinaemia, increased plasma bile salts, renovascular fibrin deposition, alteration in renal and systemic haemodynamics and fluid depletion are implicated. It is possible that the mechanism responsible for acute renal failure in obstructive jaundice is multifactorial [2].

Endotoxinaemia

It is considered that gut-derived endotoxin may be the initial cause of renal dysfunction in these patients, as systemic endotoxaemia is demonstrated in about 50% of patients in the postoperative period, whereas renal failure is very uncommon in the absence of endotoxaemia [3]. The effects of endotoxinaemia are likely to be mediated by the action of several cytokines, which impair renal function by causing changes in haemodynamics and by a direct toxic action on the kidney. In fact, cytokines may produce renal haemodynamic disturbances by inducing arterial hypotension with concomitant release of renal vasoconstrictors, and by distributing intrarenal blood flow away from the renal cortex [4]. The renal toxic action of the cytokines may be due to their procoagulant activity, with induction of disseminated intravascular coagulation (DIC) that may explain the deposition of fibrin in the renal tubules and in the glomeruli. Moreover, cytokines may also produce intrarenal sequestration of neutrophils, which in turn leads to a neutrophil-mediated release of cytotoxins [5]. On the other hand, it has been proposed that endotoxaemia in obstructive jaundice may induce overproduction of nitric oxide that may lead to impairment of cyclic guanosine monophosphate (cGMP)-associated vasodilatation and disrupt autoregulation of the renal vascular bed. This may also contribute to renal failure in obstructive jaundice [6].

Bile constituents

With extrahepatic obstruction, jaundice is associated with the retention of bile, of which bilirubin and bile salts constitute major components along with cholesterol and other lipids. One of the main predictive factors of postoperative renal impairment and death is the presence of hyperbilirubinaemia. However, there is little evidence to implicate bilirubin *per se* in the pathogenesis or renal failure associated with obstructive jaundice. The second important component of bile is bile salts, which seem to potentiate renal ischaemia in several experimental models.

Coagulation disturbance

Endotoxin promotes intravascular coagulation by activating platelets, leukocytes and complement. It has been reported that obstructive jaundice induces impairment in endotoxin clearance, which causes a low grade of DIC.

Role of vasoactive substances

It has been reported that thromboxane A2 contributes to the impairment of renal function in patients with obstructive jaundice. It induces vasoconstriction of afferent arterioles and a decrease in glomerular filtration rate (GFR). Moreover, thromboxane A2 increases platelet aggregation with contraction of mesangial cells and a reduction in the glomerular filtration surface with a significant reduction in GFR. On the other hand, the administration of prostaglandin inhibitors (non-steroidal anti-inflammatory drugs) impairs renal function in patients with obstructive jaundice, suggesting that prostaglandins, as vasodilator substances, may also play an important role in the maintenance of renal blood flow in these patients [7]. Endothelin is a potent vasoconstrictor, which has been demonstrated to increase in patients with obstructive jaundice.

Volume depletion

In addition to the above-mentioned factors, there is another factor that may play an important role in the development of acute tubular necrosis in these patients. One of the mechanisms recently investigated is the appearance of extracellular fluid depletion, which has been detected in experimental studies, and patients with obstructive jaundice [8] showed a marked increase in atrial natriuretic peptide (ANP) in the plasma of rabbits submitted to ligation of the common bile duct. In the same study, it was demonstrated that these high levels of ANP were associated with an increase in plasma aldosterone, renin and antidiuretic hormone, suggesting that these hormones were produced in response to the reduced extracellular volume, and that the raised levels of ANP may explain the reduced vascular reactivity in response to hypovolaemia. This predisposition to arterial hypotension may explain the pathological changes in tubular necrosis that are often found in the kidneys when renal failure develops in association with obstructive jaundice. At present, the cause of this hypovolaemia is poorly understood, although it seems plausible that it may result from preoperative fluid depletion. In fact, it has been shown in experimental studies that ligation of the common bile duct is followed by a 15% fall in the plasma volume. These changes were associated in this experimental model with hypodipsia, hypophagia and an impaired capacity to concentrate urine, suggesting that these factors are the cause of this volume depletion. These findings have been confirmed in human studies [2].

Therapeutic strategies

Given that obstructive jaundice predisposes the kidney to hypoxic damage, patients with intra- or extrahepatic bile duct obstruction are especially susceptible to acute renal failure. Despite a significant amount of research into the pathogenesis of renal failure in this setting, no specific therapies are available for acute renal failure in obstructive jaundice. In patients in whom surgery is considered to relieve obstruction, preoperative rehydration is essential to prevent the development of renal failure [9]. In addition, the administration of non-steroidal anti-inflammatory drugs and aminoglycosides should be avoided as these drugs may precipitate the development of renal failure. In the past, the administration of mannitol was considered to be the best treatment to prevent the development of renal failure in obstructive jaundice. However, in a more recent, prospective, controlled clinical trial, not only was it shown that perioperative mannitol administration was ineffective, but also that it produced renal functional deterioration in the treated group compared with the control group. Therefore, mannitol is of doubtful value in the treatment of these patients. Antiendotoxin therapy, using bile salts or lactulose, has shown conflicting results and, at present, it is not fully accepted that the use of these drugs may prevent renal failure in patients with jaundice [9]. In conclusion, up to now, adequate preoperative hydration is the main treatment. Biliary drainage has been used to reduce the problems associated with obstructive jaundice as it may improve the clinical condition by reversing endotoxaemia. However, it is not yet clear whether this procedure is of benefit. Finally, haemodialysis is required in patients with obstructive jaundice and oliguric acute renal failure.

Glomerular abnormalities

The association between liver disease and histological glomerular abnormalities has been widely recognized over the last 25 years. The glomerular alterations observed in cirrhosis of the liver and hepatitis B and C infection are discussed in this chapter (Table 1). Other diseases causing hepatic and glomerular lesions, such as schistosomiasis, malaria, infectious mononucleosis, Legionnaires' disease, obstructive jaundice, biliary atresia, amyloidosis, autoimmune chronic hepatitis, primary biliary cirrhosis, haemochromatosis, alpha-1-antitrypsin deficiency,

Table 1 Glomerulonephritis and liver disease.

Glomerulonephritis	Liver disease	Spontaneous remission	Clinical signs
Membranoproliferative glomerulonephritis	HCV, HBV, PSC, alpha-1-antitrypsin deficiency	HCV and HBV often improve when virus is cleared	Renal failure at presentation, nephrotic syndrome, hypertension
Membranous glomerulonephritis	HCV, HBV, PSC, PBC	25%	Proteinuria, hypertension, reduced glomerular filtration rate
IgA nephropathy	Alcoholic cirrhosis	6–12%	Proteinuria, haematuria, hypertension, renal insufficiency
Fibrillary nephropathy	HCV	Unknown	Hypertension, nephrotic syndrome

HCV, hepatitis C virus; HBV, hepatitis B virus; PSC, primary sclerosing cholangitis; PBC, primary biliary cirrhosis.

nodular regenerative hyperplasia, sickle-cell disease, collagen disease, toxaemia and acute fatty liver of pregnancy, are discussed in other chapters.

Cirrhosis

The frequency of histological glomerular abnormalities in cirrhosis is high. In a prospective study in unselected patients with non-alcoholic cirrhosis in whom renal biopsy was performed at the time of liver transplantation, glomerular abnormalities were observed in all the cases, although most had only minor changes [10]. These data also suggest that glomerular histological alterations are secondary to the hepatic dysfunction and independent of the aetiology of cirrhosis.

The most frequent glomerular changes observed in patients with cirrhosis are periglomerular fibrosis and hyaline thickening of the basement membrane, hypercellularity of both endothelial and epithelial cells and a mild to marked thickening of the mesangium by a fibrillar material positive for periodic acid–Schiff staining. Endothelial cells are swollen and vacuolated and stain positively for lipids. In some cases, there is obliteration of the glomerular lumen. This lesion has been termed 'hepatic glomerulosclerosis' (Fig. 1). Ultrastructural examination reveals the presence of electron-dense osmophilic deposits in the capillary wall and mesangium, thickening of the basement membrane, an increased amount of mesangial matrix, fusion and focal destruction of foot processes and oedema of the cytoplasm of podocytes. Immunofluorescence studies have drawn attention to the relationship of these glomerular changes and the presence of subendothelial and mesangial deposits of IgA, IgG, IgM and complement.

Several patterns of glomerular lesions have been recognized in hepatic cirrhosis including IgG and IgM mesangial deposition, glomerulosclerosis devoid of immunoglobulin, proliferative glomerulonephritis, classic membranous or membranoproliferative lesions and rapidly progressive glomerulonephritis [11]. IgA nephropathy associated with liver disease is the most frequently encountered secondary form of IgA nephropathy [12]. The pathogenesis is related to an inability to remove

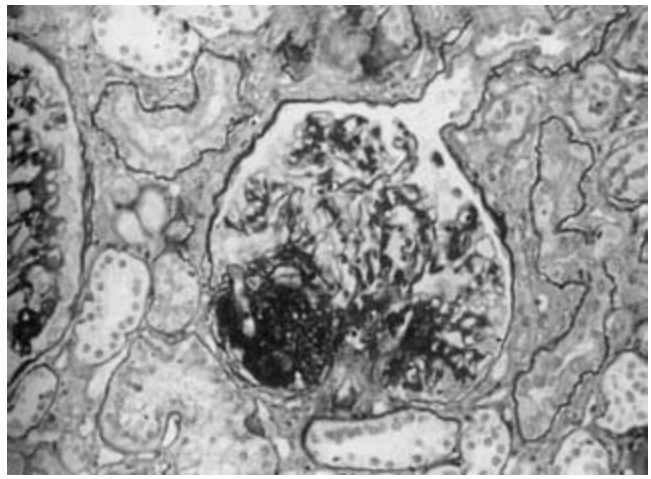

Fig. 1 Light microscopy of glomerular alterations seen in hepatic cirrhosis. The nodules in the tuft are sparsely cellular and uniformly stained: nodular glomerulosclerosis (periodic acid–Schiff, × 336).

IgA-containing complex by Kupffer cells in the liver, which predisposes to deposition in the kidney. Although it is preferentially observed in patients with alcoholic liver disease, it can be seen in other types of liver diseases. Despite the high frequency of glomerular IgA deposits in advanced liver disease, most patients are asymptomatic. Patients may present with microscopic haematuria, mild proteinuria and a mild degree of renal impairment. The urinalysis revels microhaematuria and proteinuria, which is in the nephrotic range in a small percentage of cases, particularly in those with membranoproliferative glomerulonephritis. In general, there are mild urine abnormalities in patients with minimal glomerular lesions, whereas heavy proteinuria, cylindruria and microhaematuria are associated with severe proliferative lesions. Increased serum IgA is present in 70–90% of the patients, although high values are also found in 50% of subjects with liver cirrhosis and without nephritis.

Light microscopy findings are similar to those observed in patients with primary IgA nephropathy. These include mesangial hypercellularity and an increase in mesangial matrix.

Immunofluorescence reveals IgA deposits associated with IgG and/or IgM and/or C3. IgA is the main immunoglobulin present. At present, several therapies are suggested to improve the progression of IgA nephropathy; however, up to now, there is no specific therapy for this disease. The pathogenesis of glomerular abnormalities in patients with cirrhosis is unknown, but probably involves immune complex deposition [13].

It is well known that there is a close relationship between chronic infection with hepatitis C virus (HCV) and type 2 mixed cryoglobulinaemia. Antihepatitis C viral antibody, HCV core antigens and HCV RNA can be found in cryoglobulins and in the renal deposits of patients with HCV infection associated with mixed (IgG–IgM) cryoglobulinaemia. On the other hand, it has been estimated that 50–75% of patients with 'essential' mixed IgG–IgM cryoglobulinaemia have underlying chronic HCV infection (see later). These findings suggest that, in patients with concurrent cirrhosis and HCV infection, the development of glomerular lesions may be explained by the above-mentioned mechanism.

Hepatitis B virus (HBV) infection

Almost all morphological forms of renal disease including membranoproliferative glomerulonephritis, mesangial proliferative glomerulonephritis, minimal change disease, IgA nephropathy and focal segmental glomerulosclerosis have been described in patients with HBV infection [14].

Epidemiological, clinical and immunological evidence suggests a causal association between HBV carriage and the development of nephropathy. The pathogenetic mechanisms by which individuals with chronic HBV infection develop nephropathy are not clearly defined, although immunological processes related to immune complex deposition have been implicated [15]. Four mechanisms have been postulated to induce renal tissue injury by HBV: (i) cytopathic effect induced by virus infection of the cell; (ii) tissue deposition of immune complexes of viral antigen and host antibody; (iii) virus-induced specific immunological effector mechanisms that damage the kidney; and (iv) indirect effects on renal tissue mediated via virus-induced cytokines or mediators.

The clinical manifestations of HBV-associated membranous nephropathy infection in paediatric and adult patients tend to be different. In paediatric patients, nephropathy is usually asymptomatic and is detected by routine urine and serological screening. Another frequent clinical presentation in children is the nephrotic syndrome. In adults, proteinuria and the nephrotic syndrome are the most common manifestations. The natural history of this complication is variable. Spontaneous regression of the nephrotic syndrome was reported in 30–60% of cases of HBV-associated membranous nephropathy. The remaining patients persisted with proteinuria and fluid retention. Seroconversion of anti-HBeAg is associated with remission of proteinuria. However, in patients without clearance of the virus, a progression to renal failure has been reported.

Therapy for HBV nephropathy has been investigated by Lai *et al.* [16] who observed that corticosteroids did not improve glomerulonephritis and, furthermore, they induced viral replication in these patients. Following these results, the effect of antiviral therapy on renal disease has been evaluated. In this sense, it has been reported that the use of interferon (IFN) in children with HBV-associated membranoproliferative glomerulonephritis (MGN) induced a response (disappearance of proteinuria) in 80% of the treated patients compared with a 35% response in the control group [17]. However, controlled studies with longer follow-up are needed to recommend this therapy more strongly.

Polyarteritis nodosa (PAN) associated with HBV infection is more common in western countries than in Asia. These patients present similar clinical manifestations to those patients with idiopathic PAN, such as fever, cutaneous leucocytoclastic vasculitis, livedo reticularis, neuropathy, myalgias, otitis, orchitis, arthritis and pulmonary manifestations. Symptomatic acute hepatitis in the preceding 6 months is common, and a moderate increase in transaminases may be detected in about half the cases at presentation of PAN. Antineutrophil cytoplasmic antibodies are positive in around 10% of cases. Liver biopsy reveals moderate or severe chronic hepatitis. Aneurysms are more frequent in the coeliac and renal territories. The renal manifestations include haematuria, proteinuria and azotaemia. Although spontaneous remission has been reported, it is very uncommon. The administration of steroids and cyclophosphamide has been shown to be useful in the treatment of these patients. However, it should be taken into account that this therapy may increase viral replication. Furthermore, these reports were based on uncontrolled clinical trials. Combination therapy, with steroids directed at the immune-mediated vasculitis and vidarabine or IFN as antiviral therapy, has been used in these patients with promising results; viral replication was no longer present in about 50% of patients at the end of follow-up [18]. Recently, Erhardt *et al.* [19] have documented a case report about the successful treatment of PAN with a combination of prednisolone, IFNα and lamivudine. However, controlled trials should be performed to evaluate the usefulness of lamivudine in the treatment of HBV-associated PAN.

Another complication that can be observed in patients with HBV infection is the serum sickness-like syndrome. Serum sickness-like syndrome appears in 10–25% of patients infected with HBV. The symptoms include fever, arthralgias, arthritis, skin rash and, in a few patients, proteinuria that may be associated with haematuria. The outcome of this syndrome is benign, and spontaneous resolution is the rule.

Hepatitis C virus infection

Renal involvement often occurs in HCV infection. Chronic hepatitis C is both an important cause and a severe complication of chronic renal disease [20]. The most common histological feature seen in patients with HCV-associated renal disease is

membranoproliferative glomerulonephritis. Glomerulonephritis is a well-documented but poorly understood complication of chronic HCV infection [21]. It has been reported that chronic HCV infection may account for 10–20% of all cases of proliferative glomerulonephritis. The glomerulonephritis lesion is characterized by distinct morphological features: endocapillary proliferation, monocytic infiltration, double contour membranes, large eosinophilic, PAS-positive intraluminal deposits and vasculitis of small and medium-sized renal arteries [22]. The degree of renal insufficiency varies but is usually mild. Renal failure dialysis is required in less than 15% of patients. However, 80% of patients have arterial hypertension at the time of presentation. Patients with renal disease and HCV infection commonly have profound proteinuria, resulting in half of these patients showing a nephrotic syndrome [12]. Glomerulonephritis appears to occur predominantly with type 2 cryoglobulins. These cryoglobulins typically consist of a polyclonal IgG and a monoclonal IgM rheumatoid factor (type 2 mixed cryoglobulinaemia). However, in some cases, type 3 cryoglobulinaemia, which consists of polyclonal IgG and IgM, can also be seen. The IgM rheumatoid factor seems to be critical in the deposition of these cryoglobulins in glomeruli. Some authors have suggested that glomerulonephritis occurs in HCV infection in the absence of cryoglobulins. However, this point needs to be confirmed. The prevalence of membranoproliferative glomerulonephritis in HCV infection type 2 cryoglobulinaemia is approximately 30%. This prevalence increases in studies of renal histology by autopsy.

Patients with cryoglobulinaemia often complain of weakness, arthralgia and purpura. Patients may also develop severe Raynaud syndrome or leg ulcers. The clinical signs of cryoglobulinaemia typically precede the recognition of renal involvement by years, although simultaneous presentation can occur.

It has been shown that treatment with IFNα, alone or in combination with ribavirin, may be effective in patients with membranoproliferative glomerulonephritis and HCV infection. In this sense, many case reports about successful therapy of HCV-associated cryoglobulinaemic glomerulonephritis have described improvement in creatinine clearance and reduction in proteinuria. Sustained virological response with a durable improvement in renal function has been established in some patients. Currently, several studies using pegylated IFNs are ongoing to investigate their effect in achieving a sustained virological response in patients with HCV and renal disease [12,20,22].

Renal tubular acidosis

Renal tubular acidosis is defined as the inability of the renal tubule to acidify the urine in the presence of a normal glomerular filtration rate. Renal tubular acidosis has been classified into two major types, distal and proximal [23]. In type 1 (distal), or classic renal tubular acidosis, the distal tubule is unable to maintain the steep lumen–peritubular hydrogen ion gradient. The distal disease can, in turn, be subdivided into hypokalaemic, hyperkalaemic and incomplete forms. In the hypokalaemic form, urine pH does not fall inappropriately, and acidosis is a consequence of decreased acid excretion. This form of distal renal tubular acidosis can be inherited, drug induced or associated with various systemic conditions. Impaired distal tubular acidification with hyperkalaemia can be associated with mineralocorticoid deficiency, urinary tract obstruction and the administration of distal diuretics (amiloride). In the incomplete distal form, acidosis is absent, although urinary pH remains inappropriately high following acid loading. Type 2 (proximal) renal tubular acidosis is due to abnormal proximal tubular function, resulting in an impaired reabsorption of bicarbonate. In this form more than 15% of the filtered bicarbonate load is not reabsorbed and is excreted in the urine.

Renal tubular acidosis may occur in various liver diseases. Type 1 has been observed in patients with autoimmune chronic hepatitis [24], primary biliary cirrhosis [25] and alcoholic cirrhosis [26]. Both types have been recognized in Wilson's disease. Finally, an isolated acidifying defect of the proximal tubule has been reported in paediatric patients receiving liver transplants and treatment with FK506 [27]. Nevertheless, renal tubular acidosis is more common in primary biliary cirrhosis, Wilson's disease and alcoholic liver cirrhosis (30–57% of cases).

The clinical manifestations of patients with distal renal tubular acidosis and chronic liver disease are similar to those of patients with renal tubular acidosis but without hepatic lesions. Most patients, however, present an incomplete distal form. Hence, the finding of hypokalaemia, hyperchloraemia, acidaemia, osteomalacia or nephrolithiasis is very infrequent. In primary biliary cirrhosis, a decrease in plasma levels of uric acid has been reported in relation to distal renal tubular acidosis [28]. Patients with the proximal disease may, in addition, have other clinical manifestations, such as glycosuria, aminoaciduria and high levels of β_2-microglobulin in the urine. Whether renal tubular acidosis increases the risk of hepatic encephalopathy is controversial. Theoretically, acidosis or hypokalaemia associated with the disease facilitates renal ammoniogenesis. The increased urinary pH may divert some of this ammonia into the renal venous blood [29]. This hypothesis, however, has not been confirmed by other researchers.

The pathogenesis of renal tubular acidosis associated with chronic liver disease is not clearly understood, although several mechanisms have been considered. It has been suggested that it may be related to copper deposition, especially in Wilson's disease and biliary cirrhosis [25,30]. Others have postulated immunological causes. Bile acids may be another primary cause in the development of renal tubular acidosis in chronic liver disease, as they are elevated in these patients and may be toxic to cell membranes. Magnesium deficiency may also produce the distal disease in patients with cirrhosis. The administration of this element reverses this abnormality. Decreased delivery of sodium to the distal nephron appears to play a central pathogenetic role in renal tubular acidosis in patients with alcoholic

cirrhosis; intense activity of sodium reabsorption has been observed in patients with this disease. The administration of diuretics, sodium sulphate or sodium phosphate, which increase distal sodium delivery, may produce a lowering of urine pH. On the other hand, there is a close relationship between distal sodium delivery and reabsorption and the urinary excretion of hydrogen ions [31]. Nevertheless, whether reduced delivery of sodium is the cause of an abnormal acidification in alcoholic cirrhosis or an epiphenomenon that unmasks another underlying defect remains to be elucidated.

The prostate and alcoholic cirrhosis

Testicular atrophy, decreased testicular production, prostatic atrophy and gynaecomastia are frequent signs of endocrine dysfunction in male patients with alcoholic cirrhosis [32]. Several studies have shown that the incidence of benign prostatic hypertrophy is lower among patients with alcoholic cirrhosis than in the general population [33]. Chronologically, benign prostatic hypertrophy appears later in the patient with alcoholic cirrhosis than in the normal population. Stromal hyperplasia is the most common histological finding in patients with concurrent cirrhosis and benign prostatic hypertrophy, whereas in the general population, both stromal and epithelial hyperplasia are present equally. This is interesting because estrogens induce stromal hyperplasia whereas androgens produce epithelial hyperplasia [34]. Thus, the different histological pattern of prostatic hypertrophy in patients with cirrhosis could be related to the high ratio of estrogen to testosterone present in the plasma of these patients.

Interestingly enough, although the prevalence of prostatic carcinoma is not significantly different in patients with cirrhosis compared with normal subjects, no patient with advanced liver disease developed prostatic cancer. However, in those patients with cirrhosis with clinical hyperestrogenism (manifested by at least two of the following criteria: gynaecomastia, palmar erythema, spider angiomas, testicular atrophy or female hair distribution), the incidence of prostatic carcinoma was not reduced from that in the non-hyperestrogenic group. These results are surprising because the response of prostatic carcinoma to estrogens has been well recognized for many years, and a lower incidence of prostatic carcinoma in the hyperestrogenic group would be predicted. This interesting clinical aspect requires further research.

References

1 Parks RW, Diamond T, McCrory DC *et al.* (1994) Prospective study of postoperative renal function in obstructive jaundice and the effect of perioperative dopamine. *Br J Surg* 81(3), 437–439.

2 Sitges-Serra A, Carulla X, Piera C *et al.* (1992) Body water compartments in patients with obstructive jaundice. *Br J Surg* 79(6), 553–536.

3 Bailey ME (1976) Endotoxin, bile salts and renal function in obstructive jaundice. *Br J Surg* 63(10), 774–778.

4 Yarger WE, Schrader NW, Boyd MA (1976) Intrarenal mechanisms of salt retention after bile duct ligation in rats. *J Clin Invest* 57(2), 408–418.

5 Cotran RS, Pober JS (1989) Effects of cytokines on vascular endothelium: their role in vascular and immune injury. *Kidney Int* 35(4), 969–975.

6 Inan M, Sayek I, Tel BC *et al.* (1997) Role of endotoxin and nitric oxide in the pathogenesis of renal failure in obstructive jaundice. *Br J Surg* 84(7), 943–947.

7 Uemura M, Tsujii T, Fukui H *et al.* (1989) Urinary prostaglandins and renal function in obstructive jaundice. *Scand J Gastroenterol* 24(6), 705–715.

8 Valverde J, Martinez-Rodenas F, Pereira JA *et al.* (1992) Rapid increase in plasma levels of atrial natriuretic peptide after common bile duct ligation in the rabbit. *Ann Surg* 216(5), 554–559.

9 Uslu A, Cayci M, Nart A *et al.* (2005) Renal failure in obstructive jaundice. *Hepatogastroenterology* 52(61), 52–54.

10 Axelsen RA, Crawford DH, Endre ZH *et al.* (1995) Renal glomerular lesions in unselected patients with cirrhosis undergoing orthotopic liver transplantation *Pathology* 27(3), 237–246.

11 Newell GC (1987) Cirrhotic glomerulonephritis: incidence, morphology, clinical features, and pathogenesis. *Am J Kidney Dis* 9(3), 183–190.

12 Arroyo V, Cardenas A, Campistol JM *et al.* (2005) Acute renal failure in liver disease. In: Davison AM, Stewart Cameron J, Grünfeld JP *et al.* (eds) *Oxford Textbook of Clinical Nephrology*. New York: Oxford University Press, pp. 1554–1578.

13 Kawaguchi K, Koike M (1986) Glomerular lesions associated with liver cirrhosis: an immunohistochemical and clinicopathologic analysis. *Hum Pathol* 17(11), 1137–1143.

14 Bhimma R, Coovadia HM (2004) Hepatitis B virus-associated nephropathy. *Am J Nephrol* 24(2), 198–211.

15 Lai KN, Ho RT, Tam JS *et al.* (1996) Detection of hepatitis B virus DNA and RNA in kidneys of HBV related glomerulonephritis. *Kidney Int* 50(6), 1965–1977.

16 Lai KN, Tam JS, Lin HJ *et al.* (1990) The therapeutic dilemma of the usage of corticosteroid in patients with membranous nephropathy and persistent hepatitis B virus surface antigenaemia. *Nephron* 54(1), 12–17.

17 Lin CY (1995) Treatment of hepatitis B virus-associated membranous nephropathy with recombinant alpha-interferon. *Kidney Int* 47(1), 225–230.

18 Guillevin L, Lhote F, Leon A *et al.* (1993) Treatment of polyarteritis nodosa related to hepatitis B virus with short term steroid therapy associated with antiviral agents and plasma exchanges. A prospective trial in 33 patients. *J Rheumatol* 20(2), 289–298.

19 Erhardt A, Sagir A, Guillevin L *et al.* (2000) Successful treatment of hepatitis B virus associated polyarteritis nodosa with a combination of prednisolone, alpha-interferon and lamivudine. *J Hepatol* 33(4), 677–683.

20 Medina J, Garcia-Buey L, Moreno-Otero R (2004) Hepatitis C virus-related extra-hepatic disease – aetiopathogenesis and management. *Aliment Pharmacol Ther* 20(2), 129–141.

21 Carithers RL Jr (1999) Hepatitis C and renal failure. *Am J Med* 107(6B), 90S–94S.

22 Agnello V, De Rosa FG (2004) Extrahepatic disease manifestations of HCV infection: some current issues. *J Hepatol* 40(2), 341–352.

23 Rodriguez-Soriano J, Edelmann CM Jr (1969) Renal tubular acidosis. *Annu Rev Med* 20, 363–382.

24 Read AE, Sherlock S, Harrison CV (1963) Active 'juvenile' cirrhosis considered as part of a systemic disease and the effect of corticosteroid therapy. *Gut* 41, 378–393.
25 Pares A, Rimola A, Bruguera M *et al.* (1981) Renal tubular acidosis in primary biliary cirrhosis. *Gastroenterology* 80(4), 681–686.
26 De Marchi S, Cecchin E, Basile A *et al.* (1993) Renal tubular dysfunction in chronic alcohol abuse – effects of abstinence. *N Engl J Med* 329(26), 1927–1934.
27 O'Gorman MA, Fivush B, Wise B *et al.* (1995) Proximal renal tubular acidosis secondary to FK506 in pediatric liver transplant patients. *Clin Transplant* 9(4), 312–316.
28 Izumi N, Hasumura Y, Takeuchi J (1983) Hypouricemia and hyperuricosuria as expressions of renal tubular damage in primary biliary cirrhosis. *Hepatology* 3(5), 719–723.
29 Shear L, Bonkowsky HL, Gabuzda GJ (1969) Renal tubular acidosis in cirrhosis. A determinant of susceptibility to recurrent hepatic precoma. *N Engl J Med* 280(1), 1–7.
30 Walshe JM (1968) Effect of penicillamine on failure of renal acidification in Wilson's disease. *Lancet* 1(7546), 775–778.
31 Kurtzman NA (1983) Acquired distal renal tubular acidosis. *Kidney Int* 24(6), 807–819.
32 Van Thiel DH (1983) Ethanol: its adverse effects upon the hypothalamic–pituitary–gonadal axis. *J Lab Clin Med* 101(1), 21–33.
33 Frea B, Annoscia S, Stanta G *et al.* (1987) Correlation between liver cirrhosis and benign prostatic hyperplasia: a morphological study. *Urol Res* 15(5), 311–314.
34 Gavaler JS, Rosenblum ER, Van Thiel DH *et al.* (1987) Biologically active phytoestrogens are present in bourbon. *Alcohol Clin Exp Res* 11(4), 399–406.

21.8 The nervous system in liver disease

Andres T. Blei

Since the description of portal–systemic encephalopathy, interest in the relationship between the nervous system and the liver has remained high. Two excellent reviews in the 1960s summarized various neurological manifestations in patients with advanced chronic liver disease [1,2]. In the meantime abnormalities of the liver have been detected in many neurological diseases, but only a few have been thoroughly investigated using modern methods.

This chapter focuses on aspects that are not covered in other sections of the book. An overview of the more important conditions with references is given in Table 1, and details are added in the text. Rare associations are summarized in Table 2.

Inborn errors of metabolism

In infants and children, different metabolic disorders of the liver may result in more or less irreversible brain damage due, for example, to hypoglycaemia, hyperammonaemia or hyperbilirubinaemia [3]. Kernicterus is the term used to describe the neuropathology of bilirubin-induced brain injury [4]. Rather than being defined on the basis of a value of elevated unconjugated bilirubin, it is the combination of the latter with specific neurological findings that is used for diagnosis. These include a spectrum of neurological findings, including physical examination (abnormal muscle tone), testing for an auditory neuropathy as well as magnetic resonance imaging (MRI) that shows bilateral lesions of the globus pallidus and/or subthalamic nucleus. Some brainstem nuclei are particularly susceptible to injury, including auditory, oculomotor and vestibular nuclei. A more subtle bilirubin-induced neurological dysfunction has been described, including defects such as impaired upgaze, dental enamel hypoplasia of the deciduous teeth and a movement disorder ranging from choreathetosis to spasticity and hypotonia.

The molecular basis for bilirubin neurotoxicity has been reviewed recently [5]. Unconjugated bilirubin causes oxidative damage to plasma membranes and mitochondria in both astrocytes and neurons, with neuronal apoptosis and necrosis demonstrated. Active export of unconjugated bilirubin from the brain occurs via the transporter MRP1/Mrp1, located in several brain structures, including capillary endothelia. Variations in the activity of the transporter have been postulated to explain the variable expression of the disease.

Congenital hyperammonaemia

The role of urea cycle abnormalities in the genesis of congenital hyperammonaemia is discussed elsewhere in this book (see Chapter 2.3.7) and has been reviewed recently [6]. From a neurological perspective, neonatal presentations of all types of urea cycle enzyme deficiencies [three mitochondrial (ornithine transcarbamylase, carbamylphosphate synthetase, n-acetylglutamate synthase) and three cytoplasmic (arginosuccinate lyase, arginosuccinate synthetase and arginase)] are associated with rapid neurological distress, severe hyperammonaemia (worse prognosis with ammonia levels > 300 μmol/L [7]) and risk of development of brain oedema.

For presentations beyond the neonatal period, ornithine transcarbamylase deficiencies predominate, an X-linked disorder [8]. Psychomotor retardation and recurrent episodes of encephalopathy are predominant symptoms. Severe hyperammonaemias can occur in adults, such as males with hemizygous deficiencies [9], when exposed to environmental stress (sepsis, physical trauma) [10]. Persistent vomiting may precede the development of encephalopathy. This can also occur in heterozygote females when exposed to a high protein load [11].

Reye syndrome

Reye syndrome [12] characteristically presents with severe hyperemesis and irritability followed by lethargy and coma. The syndrome occurs mostly in children and usually follows 3–5 days after an influenza-like illness or varicella. Both case–control and longitudinal studies implicate aspirin in the pathogenesis of Reye syndrome [13]. It is estimated, however, that less than 0.1% of children receiving aspirin for viral illness subsequently suffer from Reye syndrome. Since 1980, curtailment of the use of aspirin has resulted in a marked reduction in the incidence of Reye syndrome in the United States [14].

Table 1 The liver in different neurological diseases.

Condition of liver	Neurological manifestations
Congenital disorders of urea cycle enzymes (irrespective of specific enzymatic disorder)	Multiple cerebellar heterotopias Delayed myelination Cerebral atrophy, microcephaly Mental retardation
Inborn errors of bile acid metabolism	Seizures, EEG abnormalities Coma Pyramidal signs Spastic paraparesis Spastic quadriplegia Distal muscle atrophy Decreased vibration sense Bucco-facio-lingual dyspraxia Episodes of drowsiness
Transient neonatal hyperammonaemia	Lethargy, seizures, coma Mental retardation Spastic quadriplegia Epilepsy
Reye syndrome with microvesicular fatty change	Prodromal illness (generally influenza or varicella) Nausea, vomiting Lethargy possibly progressing to coma Raised intracranial pressure
Acute necrotizing encephalopathy of childhood	Coma, convulsions, vomiting, hyperpyrexia
Alper's disease with microvesicular fatty change, liver cell loss, bridging fibrosis, etc.	Progressive neuronal degeneration of childhood Developmental delay Intractable epilepsy and brain atrophy Visual and sensory symptoms Severe microcephaly Fetal akinesia
Wilson's disease (see Chapter 16.1)	Presentation with tremor or disturbed gait Intellectual deterioration Ataxia, clumsiness, choreoathetosis Dysarthria Multiple reversible cerebral lesions (MRI)
Acute intermittent porphyria (see Chapter 16.5)	Acute stages Neuropsychological impairment Emotional disturbances Acute peripheral neuropathy Autonomic neuropathy (e.g. hypertension) Latent stage Slowed ulnar nerve conduction velocity Progressive weakness Central pontine myelinolysis
Sarcoidosis (detectable by liver biopsy) (see Chapter 20.12)	Parenchymatous disease of CNS; seizures Aseptic meningitis Cranial neuropathies Hydrocephalus Myopathy Diabetes insipidus Hemiparesis Organic psychosis
Vitamin B1 deficiency associated with alcohol-related liver disease	Acute Wernicke's encephalopathy
Vitamin E deficiency due to cholestasis resulting from, for example:	Reversible changes in visual evoked potentials Hypo- to areflexia
Infantile obstructive cholangiopathy	Ophthalmoplegia, other disorders of eye movements

Table 1 (*cont'd*)

Condition of liver	Neurological manifestations
Cystic fibrosis	Peripheral neuropathy with axonal dystrophy and patchy demyelination
Primary biliary cirrhosis	Proximal muscle weakness, ataxia
Primary sclerosing cholangitis	Decreased proprioception
	Psychomotor dysfunction
Vitamin K deficiency due to cholestasis	Cerebral haemorrhage
Viral hepatitis	1 Guillain–Barré syndrome
Acute hepatitis A, B or other	2 Mononeuritis
	3 Polyarteritis nodosa
	4 Seventh cranial nerve palsy
	5 Encephalitis
Hepatitis B vaccination	Spontaneous reports of
	Guillain–Barré syndrome and other neurological events
	Central nervous system demyelination
Recovery after fulminant hepatic failure	Permanent cortical or generalized brain atrophy
Anticonvulsant-induced liver changes (see Chapter 14.1)	
Cirrhosis	1 Cerebral atrophy with neuropsychological abnormalities, hepatic
Alcoholic	'dementia' in the aged
With chronic viral (usually with marked	2 Paraplegia due to demyelination of corticospinal fibres
portal–systemic shunting)	(not responsive to treatment of portal–systemic encephalopathy)
	3 Cerebellar and basal ganglia disorder, choreoathetoid movements
	(not responsive to treatment of portal–systemic encephalopathy)
	4 Pontine spongy degeneration of white matter
	5 Subclinical peripheral neuropathy, reduced nerve conduction velocities
	6 Encephalomyelopathy with spastic triparesis
Sclerotherapy of oesophageal varices	7 Autonomic neuropathy
	Irreversible paraplegia

Table 2 Rare associations of central nervous system and liver disease.

Clinical conditions
Alagille syndrome with intracranial haemorrhage
Ataxia telangiectasia with hepatocellular carcinoma
Creutzfeldt–Jakob disease and liver dysfunction
Olivopontocerebellar degeneration and liver cirrhosis
von Recklinghausen's disease with obstructive jaundice
von Recklinghausen's disease with haptic schwannoma and angiosarcoma
Primary biliary cirrhosis, Sjögren syndrome and recurrent transverse myelitis
Subarachnoid haemorrhage with polycystic kidneys and liver disease
Liver metastasis from intracranial meningioma
Niemann–Pick disease type C with cholestatic liver disease and ataxia, nystagmus, supranuclear ophthalmoplegia, spastic tetraparesis, choreoathetosis, seizures, dementia
Peripheral neuropathy and fatal alcoholic hepatitis-like disease due to amiodarone
Peripheral neuropathy and alcoholic hepatitis-like liver lesions due to perhexiline
Zellweger syndrome with cirrhosis and hypo- to areflexia, seizures, psychomotor retardation

To understand the pathogenesis of Reye syndrome, two factors need to be considered. First, viral infections precede the development of Reye syndrome. Immune stimulation caused by viral infections will influence cellular and subcellular events, including the binding to specific Toll receptors and the activation of specific cell signalling pathways [15]. Second, the association with aspirin needs a basic explanation. Aspirin can result in mitochondrial injury via initiation of the mitochondrial permeability transition, as seen in isolated hepatic mitochondria [16]. The inhibition of oxidative phosphorylation decreases β-oxidation and specifically affects long-chain 3-hydroxyacyl-CoA-dehydrogenase [17]. This results in the accumulation of long-chain fatty acids in the hepatocyte, accumulating microscopically as microvesicular steatosis. Nonetheless, this explanation does not account for the development of the syndrome only in selected individuals. An underlying defect in mitochondrial uncoupler proteins has been proposed [13], but this has not yet been proven. In any case, hyperammonaemia is another manifestation of impaired mitochondrial activity. Scattered cases of Reye syndrome have occurred in adults, and a detailed case report suggests a generalized defect in intramitochondrial enzyme processing [18].

In the mildest form, no change in consciousness occurs, and patients remain only irritable to lethargic (grade 1 and 2 encephalopathy). Plasma aspartate aminotransferase (AST) and alanine aminotransferase (ALT) are 3–30 times normal, but serum bilirubin is not elevated. In more severe forms of the disease, an agitated delirium (grade 3) may progress to frank coma and decerebrate or decorticate posturing, hyperventilation (grade 4), flaccid paralysis and respiratory failure (grade 5). The rate of progression may be quite variable, i.e. a few hours to a few days. In survivors, recovery of consciousness may occur within 24–96 h, but longer lasting brain damage has also been observed. Liver biopsy typically shows microvesicular steatosis with little necrosis or inflammatory changes. On electron microscopy, mitochondria are swollen and pleomorphic, the matrix is greatly expanded, and the matrix substance thickened and coarsely granular or flocculent [19].

Biochemical changes include mild to severe hyperammonaemia, depending on the severity of the syndrome. In line with abnormal function of mitochondria, β-oxidation and glyconeogenesis are reduced. Increased glycolysis to cover energy demands leads to glycogen depletion and may be followed by hypoglycaemia. Lactic acidosis can be a prominent feature.

The diagnosis should be suspected in any child or adolescent who develops vomiting 2–5 days after influenza-like illness or after varicella, and early vigorous treatment should be instituted. In mild cases, admission to hospital and generous energy supply by intravenous glucose (10–20%) and fluid replacement is essential. When encephalopathy develops, transfer to an intensive care unit is needed, intracranial pressures should be monitored, and a programme to prevent excessive increases in intracranial pressures instituted. Hyperthermia should be prevented and sedatives must be avoided.

Other conditions associated with acute encephalopathy

Acute necrotizing encephalopathy of childhood

The hallmark of this encephalopathy, proposed to be a novel entity [20], is multiple necrotic brain lesions showing a symmetrical distribution. This was noted in previously healthy children after influenza B infection, with presenting symptoms of coma, convulsions, vomiting, hyperpyrexia and hepatomegaly. Aminotransferases are usually elevated. Based on the characteristic combination of clinical and pathological findings, acute necrotizing encephalopathy of childhood should be distinguished from previously known encephalopathies, including Reye syndrome. Aspirin use is not a feature of the syndrome [21].

Alper's disease

An unknown metabolic defect with recessive inheritance is postulated in Alper's disease, the progressive neuronal degeneration of childhood with liver disease. Typically, it manifests itself at the age of 1–15 months by developmental delay and failure to thrive, followed by intractable epilepsy, with progressive brain atrophy on computerized tomography, particularly in occipital areas. Liver involvement may not be conspicuous clinically but, depending on the stage of the disease, the liver biopsy reveals a microvesicular fatty change, ongoing liver cell necrosis, diffuse bile duct proliferation, together with heavy liver cell loss, collapse of plates and bridging fibrosis [22].

Organic brain syndromes

In patients with organic brain syndromes showing symptoms of an acute confusional state and dementia, a wide differential diagnosis can be sought [23]. Acute intermittent porphyria and episodic portal–systemic encephalopathy can present with delirium. Both may occur intermittently, and diagnosis may be difficult in the elderly, or if personality disorders predominate clinically. The conditions are covered in Chapters 7.8 and 16.5.

Chronic cholestasis and vitamin E deficiency

As bile acids are essential for the absorption of fat-soluble vitamins, cholestasis may lead to deficiencies in vitamins A, D, E and K. Vitamin E deficiency has been associated with a progressive ataxic neurological syndrome in children with infantile obstructive cholangiopathy. Early signs are hypotonia and areflexia. In addition, the advanced clinical picture includes truncal ataxia, dysmetria, decreased vibratory sensation, decreased proprioception, gait disturbance and ophthalmoplegia [24]. Although the clinical manifestations tend to be more prominent as the children grow older, particularly after 5 years [25], muscle wasting, areflexia, ptosis and ataxia have been observed at 2 years of age and earlier [26,27].

In adults, vitamin E deficiency is among entities that can cause impaired memory and cognition [28]. Chronic gastrointestinal disease inducing cholestasis and short bowel syndrome may result in symptomatic vitamin E deficiency [29]. Clinical manifestations include ophthalmoplegia, peripheral neuropathy with axonal dystrophia, patchy demyelination, ataxia, proximal muscle weakness and psychomotor dysfunction. Early diagnosis of the condition is important, because advanced lesions may be only partially reversible. Presumably, neurological manifestations due to vitamin E deficiency may result from any of the cholestatic conditions, irrespective of their aetiology.

Serum vitamin E levels tend to be below 4 mg/mL, the lower limit of the normal range. In some cases, however, they are normal. As vitamin E is carried with lipoproteins, serum vitamin E levels should be expressed per total lipids. In deficiency states, levels will then be consistently below 0.06–0.8 mg/g, the lower limit of the normal range [30]. Oral replacement therapy may be unsatisfactory because of poor bioavailability [26].

Intramuscular vitamin E substitution by repeated injections of, for example, α-tocopherylacetate may be an emotional burden for children. α-Tocopheryl polyethylene glycol 1000 succinate in a final oral dose of 20 IU/kg/day has been reported to raise vitamin E levels in cholestasis and to improve neurological manifestations [31].

Neuropathies associated with viral hepatitis

Several cases of Guillain–Barré syndrome have been reported [32], mostly related to acute hepatitis B, but also in one case without evidence of hepatitis B. It can also occur as a complication of chronic hepatitis B [33]. A case of relapsing Guillain–Barré syndrome was associated with exacerbation of chronic hepatitis B [36]. It has also been reported following fulminant viral hepatitis A [35,36]. Neurological manifestations occurred 7 days before the onset of jaundice simultaneously with clinical signs of acute hepatitis, 1–2 weeks after the onset of jaundice or up to 5 weeks after an apparently uneventful recovery from acute hepatitis. In the case of hepatitis B, immune complexes were found in the serum, and C3 was reduced during the phase of polyradiculitis, when the liver disease was in remission [37]. Hepatitis C has also been associated with Guillain–Barré syndrome [38]. Neurological recovery occurred in all patients within weeks to months.

Rare instances of mononeuritis, associated with acute hepatitis A or B, involved the facial, trigeminal, auditory and several peripheral nerves. The temporal relationship with the onset of jaundice varied from −40 to +21 days. Clinical presentation of neuritis was generally sudden and recovery slow, the latter requiring 1 month to more than 2 years [39]. Optic neuritis was reported in a case that recovered from acute viral hepatitis B [40].

Polyarteritis nodosa is a systemic disease. It involves primarily renal vessels, thereby leading to hypertension, proteinuria, haematuria and renal failure. However, peripheral neuropathy (mononeuritis multiplex), amyotrophy and myalgia are also frequent, and evidence for past or ongoing hepatitis B is found in about one-third of cases. Thus, the simultaneous manifestation of disease in several parts of the nervous system is the consequence of multiple vascular lesions rather than a specific association. Nevertheless, a case presenting as mononeuritis multiplex should, among other investigations, lead to a search for hepatitis B [41].

A reversible encephalitis developed in a 7-year-old girl 5 days after the onset of hepatitis A [42].

A postmarking surveillance for neurological adverse events after hepatitis B vaccination revealed 10 cases of Bell's palsy, nine of Guillain–Barré syndrome, five each of convulsions, lumbar radiculopathy and optic neuritis, four of transverse myelitis and three of brachial plexus neuropathy. The study involved a plasma-derived hepatitis B vaccine given to 850 000 people. In view of the limitations of the spontaneous reporting used in this study, the causal relationship between vaccination and neurological adverse events has remained questionable [43]. Central nervous system demyelination after immunization with recombinant hepatitis B vaccine was examined retrospectively in the UK. The odds noted for the development of multiple sclerosis were 3.1 (95% C1 1.5–6.3) [44]. Cross-reactivity between hepatitis B surface antigen and myelin oligodendrocyte glycoprotein may be present [45]. A review of experience of over 1 billion doses of the vaccine, however, concludes that the procedure has an outstanding safety record [46].

Sequelae after fulminant hepatic failure

Although most survivors of fulminant hepatic failure recover full function of the central nervous system, exceptions have been noted. In these cases, hepatic failure was due to paracetamol intoxication, hepatitis B or non-A, non-B hepatitis. The lesions involved unilateral cranial nerve palsies, infarction of the right middle cerebral artery area [47] and diffuse brain atrophy [48]. The role of cerebral oedema in the development of irreversible lesions requires further clarification.

Neurological complications after liver transplantation

Neurological problems are reported in 13–47% of patients after orthotopic liver transplantation [49]. They mostly occur in the early months after the procedure and are associated with significant morbidity and mortality. Recent guidelines have been published on the management of neurological problems in such patients [50]. Six major areas were identified:

1 Immunosuppression neurotoxicity is mainly the result of calcineurin inhibitors, ciclosporin and tacrolimus, not related directly to their blood concentration. Side-effects were considered as minor (tremor, headache, paresthesias) and major (encephalopathy, akinetic mutism, seizures, speech disorders, polyneuropathy and myopathy). Predisposing factors include hypocholesterolaemia, hypomagnesaemia, hypertension and prior hepatic encephalopathy [51]. MRI may show non-enhancing high-resolution T2 lesions in the posterior white matter.

2 Seizures occur in up to 5% of recipients and are mainly the result of immunosuppressant medications [52]. Other causes include acute metabolic derangements, sudden withdrawal of narcotic agents and hypoxic–ischaemic injury.

3 Cerebral pontine myelinolysis is a symmetrical demyelinating lesion in the centre of the pons. It occurs in 1–8% of transplanted patients, and its incidence can be reduced by avoiding the performance of the liver transplant under conditions of severe hyponatraemia (< 125 mEq/L). An abrupt rise in serum sodium concentration (> 10 mEq/day) should be strenuously avoided.

4 Neuromuscular disorders can be varied. Generalized weakness can be a manifestation of immunosuppression-related neurotoxicity, with axonal or demyelinating neuropathy, and

has been reported in 1.5–10% of patients. A brachial plexopathy can occur in up to 3% of cases and, in one instance, was most probably caused by compression of the plexus between the first rib and the clavicle, the result of rib retraction for surgical exposure [53].

5 Acute cerebrovascular disorders occur in 2–6% of recipients, generally related to cerebral haemorrhage and usually within 2 months of surgery. Several aetiologies are possible, including underlying vascular disease, hypertension as a complication of immunosuppressive therapy and mycotic aneurysms.

6 Central nervous system infections occur in up to 5% of recipients and are associated with high mortality. Most infections are due to spread from other sites. Viral infections are rare.

Anticonvulsant-induced liver disease

Phenytoin, carbamazepine and phenobarbital are strong inducers of the microsomal drug-metabolizing enzyme system. Clinical correlates are occasional slight increases in serum aminotransferases and more marked increases in γ-glutamyl transferase. Liver biopsy generally shows hepatocytes with abundant, faintly eosinophilic, homogeneous or finely granular cytoplasm due to hypertrophy of endoplasmic reticulum. Uni- or paucicellular necrosis may be seen in some cases. These changes are considered to be adaptive and have no pathological significance. Replacement of carbamazepine with oxcarbazepine returned the function of the hepatic cytochrome P450 enzyme system to normal. Valproate, ethosuximide, diazepam and clonazepam have no enzyme-inducing properties.

Acute liver damage due to phenytoin [54] and carbamazepine [55], although uncommon, has been well described. It may be hepatocellular, cholestatic or granulomatous, and is frequently associated with signs of hypersensitivity [55]. The acute liver lesions induced by valproate strongly resemble Reye syndrome, with the presence of microvesicular steatosis. Hyperammonaemia can be prominent; carnitine, by promoting the entry of CoA into mitochondria, may assist in the reduction of ammonia levels [56]. Vigabatrin, lamotrigine and gabapentin are well-tolerated new antiepileptic drugs. Only the risk–benefit ratio of felbamate has been compromised recently by fatal liver disease in a number of patients (see Chapter 14.1).

References

1 Read AE, Sherlock S, Laidlaw J *et al.* (1967) The neuro-psychiatric syndromes associated with chronic liver disease and extensive systemic collateral circulation. *Q J Med* 36, 135–150.

2 Victor M, Adams RD, Cole M (1965) The acquired (non-Wilsonian) type of chronic hepatocerebral degeneration. *Medicine* 44, 345–396.

3 Stanbury JB, Wyngaarden JB, Fredrickson DS *et al.* (eds) (1983) *The Metabolic Basis of Inherited Disease*. New York: McGraw-Hill.

4 Shapiro SM (2005) Definition of the clinical spectrum of kernicterus and bilirubin-induced neurological dysfunction (BIND). *J Perinatol* 25, 54–59.

5 Ostrow JD, Pascolo L, Brites D *et al.* (2004) Molecular basis of bilirubin-induced neurotoxicity. *Trends Mol Med* 10, 65–70.

6 Brusilow SW, Maestri NE (1996) Urea cycle disorders: diagnosis, pathophysiology, and therapy. *Adv Pediatr* 43, 127–170.

7 Brusilow SW, Danney M, Waber LJ *et al.* (1984) Treatment of episodic hyperammonemia in children with inborn errors of urea synthesis. *N Engl J Med* 310, 1630–1634.

8 Nassogne MC, Heron B, Touati G *et al.* (2005) Urea cycle defects: management and outcome. *J Inherit Metab Dis* 28, 407–414.

9 Finkelstein JE, Hauser ER, Leonard CO *et al.* (1990) Late-onset ornithine transcarbamylase deficiency in male patients. *J Pediatr* 117, 897–902.

10 Summar ML, Barr F, Dawling S *et al.* (2005) Unmasked adult-onset urea cycle disorders in the critical care setting. *Crit Care Clin* 21, S1–S8.

11 Felig DM, Brusilow SW, Boyer JL (1995) Hyperammonemic coma due to parenteral nutrition in a woman with heterozygous ornithine transcarbamylase deficiency. *Gastroenterology* 109, 282–284.

12 Reye RD, Morgan G, Baral J (1963) Encephalopathy and fatty degeneration of the viscera. A disease entity in childhood. *Lancet* 91, 749–752.

13 Glasgow JF, Middleton B (2001) Reye syndrome – insights on causation and prognosis. *Arch Dis Child* 85, 351–353.

14 Belay ED, Bresee JS, Holman RC *et al.* (1999) Reye's syndrome in the United States from 1981 through 1997. *N Engl J Med* 340, 1377–1382.

15 Mogensen TH, Paludan SR (2005) Reading the viral signature by Toll-like receptors and other pattern recognition receptors. *J Mol Med* 83, 180–192.

16 Trost LC, Lemasters JJ (1997) Role of the mitochondrial permeability transition in salicylate toxicity in cultured hepatocytes: implications for the pathogenesis of Reye's syndrome. *Toxicol Appl Pharmacol* 147, 431–441.

17 Glasgow JF, Middleton B, Moore R *et al.* (1999) The mechanism of inhibition of beta-oxidation by aspirin metabolites in skin fibroblasts from Reye's syndrome patients and controls. *Biochim Biophys Acta* 1454, 115–125.

18 Van Coster RN, De Vivo DC, Blake D *et al.* (1991) Adult Reye's syndrome: a review with new evidence for a generalized defect in intramitochondrial enzyme processing. *Neurology* 41, 1815–1821.

19 Partin JC, Schubert WK, Partin JS (1971) Mitochondrial ultrastructure in Reye's syndrome (encephalopathy and fatty degeneration of the viscera). *N Engl J Med* 285, 1339–1343.

20 Mizuguchi M (1997) Acute necrotizing encephalopathy of childhood: a novel form of encephalopathy prevalent in Japan and Taiwan. *Brain Dev* 19, 138–139.

21 Grose C (2004) The puzzling picture of acute necrotizing encephalopathy after influenza A and B virus infection in young children. *Pediatr Infect Dis J* 23, 253–254.

22 Harding BN, Alsanjari N, Smith SJ *et al.* (1995) Progressive neuronal degeneration of childhood with liver disease (Alper's disease) presenting in young adults. *J Neurol Neurosurg Psychiatry* 58, 320–325.

23 Burns A, Gallagley A, Byrne J (2004) Delirium. *J Neurol Neurosurg Psychiatry* 75, 362–327.

24 Rosenblum JL, Keating JP, Prensky AL *et al.* (1981) A progressive neurological syndrome in children with chronic liver disease. *N Engl J Med* 304, 503–508.

25 Guggenheim MA, Jackson V, Lilly J *et al.* (1983) Vitamin E deficiency and neurologic disease in children with cholestasis: a prospective study. *J Pediatr* 102, 577–579.

26 Sokol RJ, Farrell MK, Heubi JE *et al.* (1983) Comparison of vitamin E and 25-hydroxyvitamin D absorption during childhood cholestasis. *J Pediatr* 103, 712–717.

27 Chaine P, Le Coz P, Poaplard F *et al.* (1988) [Neurological manifestations in relation to vitamin E deficiency, caused by a defect of biliary acid synthesis]. *Ann Med Interne (Paris)* 139, 198–200.

28 Barrett AM (2005) Is it Alzheimer's disease or something else? 10 disorders that may feature impaired memory and cognition. *Postgrad Med* 117, 47–53.

29 McCarron MO, Russell AJ, Metcalfe RA *et al.* (1999) Chronic vitamin E deficiency causing spinocerebellar degenerate peripheral neuropathy, and centro-cecal scotomata. *Nutrition* 15, 217–219.

30 Sokol RJ, Heubi JE, Iannaccone ST *et al.* (1984) Vitamin E deficiency with normal serum vitamin E concentrations in children with chronic cholestasis. *N Engl J Med* 310, 1209–1212.

31 Sokol RJ, Butler-Simon N, Conner C *et al.* (1993) Multicenter trial of d-alpha-tocopheryl polyethylene glycol 1000 succinate for treatment of vitamin E deficiency in children with chronic cholestasis. *Gastroenterology* 104, 1727–1735.

32 Murthy JM (1994) Guillain–Barré syndrome following specific viral infections – an appraisal. *J Assoc Phys India* 42, 27–29.

33 Han HF, Wu JC, Huo TI *et al.* (1999) Chronic hepatitis B exacerbated by Guillain–Barré syndrome: a report of two cases. *Zhongghua Yi Xue Za Zhi (Taipei)* 62, 652–656.

34 Chroni E, Thomopoulos C, Papapetropoulos S *et al.* (2003) A case of relapsing Guillain–Barré syndrome associated with exacerbation of chronic hepatitis B virus hepatitis. *J Neurovirol* 9, 408–410.

35 Ono S, Chida K, Takasu T (1994) Guillain–Barré syndrome following fulminant viral hepatitis A. *Intern Med* 33, 799–801.

36 Lee DK, Do JK, Kim YJ (1997) Guillain–Barré like syndrome associated with acute renal failure and thrombocytopenia following acute viral hepatitis A. *J Korean Med Sci* 12, 151–156.

37 Penner E, Maida E, Mamoli B *et al.* (1982) Serum and cerebrospinal fluid immune complexes containing hepatitis B surface antigen in Guillain–Barré syndrome. *Gastroenterology* 82, 576–580.

38 Lacaille F, Zylberberg H, Hagege H *et al.* (1998) Hepatitis C associated with Guillain–Barré syndrome. *Liver* 18, 49–51.

39 Pelletier G, Elghozi D, Trepo C *et al.* (1985) Mononeuritis in acute viral hepatitis. *Digestion* 32, 53–56.

40 Achiron LR (1994) Postinfectious hepatitis B optic neuritis. *Optom Vis Sci* 71, 53–56.

41 Deeren DH, De Backer AI, Malbrain ML *et al.* (2004) Treatment of hepatitis B virus-related polyarteritis nodosa: two case reports and a review of the literature. *Clin Rheumatol* 23, 172–176.

42 Davis LE, Brown JE, Robertson BH *et al.* (1993) Hepatitis A post-viral encephalitis. *Acta Neurol Scand* 87, 67–69.

43 Shaw FE Jr, Graham DJ, Guess HA *et al.* (1988) Postmarketing surveillance for neurologic adverse events reported after hepatitis B vaccination. Experience of the first three years. *Am J Epidemiol* 127, 337–352.

44 Hernan MA, Jick SS, Olek MJ *et al.* (2004) Recombinant hepatitis B vaccine and the risk of multiple sclerosis – a prospective study. *Neurology* 63, 838–842.

45 Bogdanos DP, Smith H, Ma Y *et al.* (2005) A study of molecular mimicry and immunology cross-reactivity between hepatitis B surface antigen and myelin mimics. *Clin Dev Immunol* 12, 217–224.

46 Zuckerman JN (2006) Protective efficacy, immunotherapeutic potential and safety of hepatitis B vaccines. *J Med Virol* 78, 169–177.

47 O'Brien CJ, Wise RJ, O'Grady JG *et al.* (1987) Neurological sequelae in patients recovered from fulminant hepatic failure. *Gut* 28, 93–95.

48 Toda C, Chiba T, Matsuda Y *et al.* (1983) A case of brain atrophy after fulminant hepatic failure. *Am J Gastroenterol* 78, 446–448.

49 Stracciari A, Guarino M (2001) Neuropsychiatric complications of liver transplantation. *Metab Brain Dis* 16, 3–11.

50 Guarino M, Benito-Leon J, Decruyenaere J *et al.* (2006) EFNS guidelines on management of neurological problems in liver transplantation. *Eur J Neurol* 13, 2–9.

51 Pujol A, Graus F, Rimola A *et al.* (1994) Predictive factors of in-hospital CNS complications following liver transplantation. *Neurology* 44, 1226–1230.

52 Wijdicks EF, Plevak DJ, Wiesner RH *et al.* (1996) Causes and outcomes of seizures in liver transplant recipients. *Neurology* 47, 1523–1525.

53 Dulitz MG, De Wolf AM, Wong H *et al.* (2005) Compression of the brachial plexus during right lobe liver donation as a cause of brachial plexus injury: a case report. *Liver Transpl* 11, 233–235.

54 Smythe MA, Umstead GS (1989) Phenytoin hepatotoxicity: a review of the literature. *Drug Intelligence Clin Pharm* 23, 13–18.

55 De Vriese AS, Philippe J, Van Renterghem DM *et al.* (1995) Carbamazepine hypersensitivity syndrome: report of 4 cases and a review of the literature. *Medicine (Baltimore)* 74, 144–151.

56 Konig SA, Schenk M, Sick C *et al.* (1999) Fatal liver failure associated with valproate therapy in a patient with Friedrich's disease: review of valproate hepatotoxicity in adults. *Epilepsia* 40, 1036–1040.

21.9 The effect of liver disease on bone

Juliet Compston

Introduction

Bone disease has been recognized as a complication of chronic liver disease for many decades. The effects of liver disease on bone are complex and, as yet, the mechanisms responsible remain only partially defined. Of the two forms of metabolic bone disease that may occur, namely osteoporosis and osteomalacia, the former is the most common [1]. In view of the high morbidity and mortality associated with osteoporotic fractures, maintenance of skeletal health is of key importance in the management of patients with chronic liver disease, particularly in view of the additional adverse skeletal effects of liver transplantation.

Osteoporosis

Definition

Osteoporosis is characterized by low bone mass and disruption of bone architecture, resulting in reduced bone strength and increased risk of fragility fracture, particularly in the spine, hip and radius. The increased risk of osteoporosis associated with chronic liver disease should be considered in the context of its high prevalence in the general population; in the United Kingdom, approximately 250 000 fractures due to osteoporosis occur annually, with an estimated cost to the health services of £1.7 billion [2]. The incidence of fragility fractures rises with age, and women are more commonly affected than men. The estimated remaining lifetime risk of any fragility fracture in a 50-year-old Caucasian woman is around 40%; in men of this age, the figure approaches 13% [3].

Clinical manifestations

The morbidity and mortality resulting from osteoporosis are solely attributable to fracture. Hip fractures mainly occur in very elderly people and have a mortality at 6 months of around 20%, whereas the incidence of Colles' fractures of the distal radius starts to increase around the time of the menopause and reaches a peak at about 65 years of age. Other non-vertebral fractures commonly associated with osteoporosis include fractures of the pelvis and proximal humerus. Vertebral fractures may be asymptomatic, and only one-third or so come to medical attention [4]. Nevertheless, the morbidity of these fractures is considerable and is characterized by spinal deformity, pain and disability. A minority of patients present with acute and severe back pain at the level of the affected vertebra, which often radiates around to the front of the chest or abdomen. The natural history of the pain is extremely variable, but some patients continue to suffer severe pain for many years.

Vertebral fractures are the most commonly reported manifestation of osteoporosis in patients with chronic liver disease. This may reflect predominantly axial, trabecular bone loss or may be a consequence of the shortened lifespan of these patients, many of whom die before the ninth and tenth decades of life when hip fractures are most common. All fragility fractures are associated with a significantly increased risk of subsequent fracture, regardless of bone mineral density, emphasizing the importance of prompt intervention.

Diagnosis and risk assessment

Measurement of bone mineral density

A number of techniques are available for the assessment of bone mineral density. The method of choice is dual-energy X-ray absorptiometry (DXA) because of its low radiation dose, good precision and application to both central and appendicular skeleton. DXA generates a bone mineral density expressed in g/cm^2 and hence provides an areal rather than a true volume density. Measurements are most commonly made in the lumbar spine and proximal femur; at the former site, the presence of vertebral deformity artifactually increases bone mineral density, as may scoliosis, extraskeletal calcification and osteophytes and, hence, this measurement becomes less reliable in older individuals.

The rationale for the use of bone densitometry in clinical practice is based on the demonstration, in prospective studies, of a relation between bone mass and fracture risk. For every

decrease of 1 standard deviation (SD) in bone density, fracture risk increases two- to threefold; the strength of this association compares favourably with that between blood pressure and stroke or serum lipid profile and coronary heart disease [5]. In 1994, a World Health Organization study group proposed the following classification of osteoporosis and osteopenia, based on SD scores related to peak bone mass (T scores) [6]:

- osteopenia: T score between –1 and –2.5;
- osteoporosis: T score below –2.5;
- established osteoporosis: T score below –2.5 with one or more fragility fractures.

These densitometric criteria apply to measurements of bone mineral density at the spine or hip, measured by DXA, and are based on studies in postmenopausal women. Appropriate criteria in men are less well established, but similar T-score thresholds based on female reference data are often used. The relationship between bone mineral density and fracture risk in premenopausal women has not been established.

Clinical risk factors

Clinical risk factors that are independent of bone mineral density are also useful in risk assessment. These include age, a history of previous fracture, glucocorticoid therapy, current smoking, excessive alcohol intake, high bone turnover and low body mass index [7]. These risk factors can be used in combination with bone mineral density values to estimate fracture probability and hence determine intervention thresholds in postmenopausal women; however, the validity of this approach has not been tested in patients with liver disease.

Radiology

Radiological osteopenia is a relatively insensitive index of low bone mass. However, radiology plays an important part in the diagnosis of vertebral deformities. In recent years, quantitative approaches to the assessment of vertebral deformity have been developed, the most commonly adopted approach being that described by Genant *et al.* [8], in which fractures are graded into mild (grade 1), moderate (grade II) and severe (grade III), corresponding to loss of anterior, middle and/or posterior height of 20–25%, 25–40% and ≥ 40% respectively.

Osteoporosis associated with chronic liver disease (Table 1)

Bone mineral density

Low bone mineral density values have been reported in association with a large variety of liver diseases including primary biliary cirrhosis, chronic active hepatitis, sclerosing cholangitis, alcoholic liver disease, cryptogenic cirrhosis, idiopathic haemochromatosis, glycogen storage disease and primary hepatoma. A wide variation in the percentage of patients with osteoporosis was reported in earlier studies, from as low as 9% up to 60%. These reported variations reflect a variety of factors, including patient selection, the technique used to assess bone mineral density and the diagnostic criteria used for osteoporosis [9].

Table 1 Pathogenesis of bone loss associated with chronic liver disease.

Vitamin D insufficiency
Calcium malabsorption
Poor nutrition, low body mass index
Hypogonadism
Glucocorticoid therapy
Reduced physical activity
Tobacco use and alcohol abuse
Increased systemic production of proresorptive cytokines, e.g. TNFα, RANKL
Reduced IGF-1 production

IGF-1, insulin-like growth factor-1; RANKL, receptor activator of NFκB ligand; TNFα, tumour necrosis factor alpha.

Recent larger studies have generally confirmed an increased prevalence of low bone mineral density values in patients with established chronic liver disease, in both the spine and the proximal femur. In a recent technical review of over 30 published studies [10], after exclusion of newly diagnosed cases (which may underestimate the prevalence of bone disease), the mean pooled lumbar spine Z score was –0.68, with a T score ≤ –2.5 in 21%. In the hip, the respective figures were –0.44 and 23%. Low bone mineral density values are seen in all diagnostic categories, including hepatitis C and alcoholic liver disease, although the highest prevalence has been observed in women with primary biliary cirrhosis in some studies. In patients with endstage liver disease awaiting transplantation, a higher prevalence of osteoporosis has been reported in some studies; thus, Ninkovic *et al.* [11] demonstrated the presence of osteoporosis at the spine or femoral neck in 36.6% of 243 such patients and, in the study by Crosbie *et al.* [12] in 27 patients awaiting transplantation, the corresponding figure was 41%.

Prospective studies of bone loss in patients with chronic liver disease have yielded conflicting results, although the majority indicate that rates of bone loss are within the normal range [10]. However, the design of many of these studies has been suboptimal, and further investigation is warranted.

Fracture

The prevalence of fractures has varied widely in reported studies, many of which have been small and conducted in selected populations. In a study of 115 unselected patients with chronic liver disease, the prevalence rates for both spinal and peripheral fractures were twice those found in an age- and sex-matched control group, hypogonadal and cirrhotic patients being at greater risk [13]. In contrast, a recent study showed no increase in fracture risk in a cohort of 85 women with primary biliary cirrhosis compared with sex- and age-matched control subjects in the general population [14]. However, the patients in this study had relatively early liver disease, and nearly half had received hormone replacement therapy. Furthermore, the prevalence of vertebral fractures is likely to have been significantly underestimated as

they were ascertained only by a questionnaire. At present, therefore, the important question of whether there is a significant increase in fracture risk associated with chronic liver disease remains unresolved and is an important area for future research.

Pathophysiology

Present evidence on the cellular pathophysiology of bone loss associated with chronic liver disease is conflicting, but most data indicate that decreased bone formation contributes to bone loss. The mean wall thickness, a measure of the amount of bone formed within individual remodelling units, is reduced, and decreased rates of bone formation at both tissue and cellular levels have been demonstrated [15,16]. Further evidence in support of reduced osteoblastic function is provided by measurements of osteoid seam width and its determinants. In primary biliary cirrhosis, most studies have reported a reduced or normal mean osteoid seam width [17–19] which, in conjunction with the demonstrated prolonged maturation period and normal or low mineral apposition rate, indicates a reduced rate of matrix synthesis. Similarly, in chronic active hepatitis, a normal mean osteoid seam width has been reported together with a prolonged maturation rate and reduced mineral apposition rate [16]. In both primary biliary cirrhosis and chronic active hepatitis, an increased bone formation period, $sigma_f$, has been demonstrated, indicating impaired function of osteoblasts rather than a reduction in their lifespan [15,16].

Studies in alcoholic liver disease also indicate that osteoblast dysfunction plays an important part in bone loss [20]. There is some evidence that ethanol has direct effects on osteoblast function, indices of bone matrix formation and mineralization being significantly lower in current drinkers than in abstainers [21]. Low serum osteocalcin has consistently been reported in alcoholics with and without liver disease.

Whether bone resorption is increased in patients with chronic liver disease is controversial. A normal or reduced surface extent of resorption, consistent with low-turnover disease, has been reported in patients with primary biliary cirrhosis, chronic active hepatitis and alcoholic liver disease. However, an increased surface extent of resorption cavities in patients with primary biliary cirrhosis has also been reported; this does not necessarily indicate an increased resorption rate, but might reflect impaired bone formation at sites of previous resorption, a view supported by the observation, in two of these studies, that osteoclasts were sparse. There are relatively few data on biochemical markers of turnover in patients with chronic liver disease, although increased levels of resorption markers have been reported.

In summary, there is evidence from a number of studies that low bone turnover and remodelling imbalance, due to reduced bone formation, play an important part in the development of osteoporosis in patients with chronic liver disorders. Nevertheless, in a minority of studies, increased bone turnover has been demonstrated [22,23]; the apparent disparity between these and other reports may be explained by factors such as the severity and aetiology of the underlying liver disease, patient selection and drug therapy. In addition, it is possible that periods of increased disease activity and an associated increase in the systemic production of proresorptive cytokines may result in episodes of increased bone turnover and resorption [24].

Pathogenesis (Table 1)

The pathogenesis of osteoporosis associated with liver disease is multifactorial. Glucocorticoid therapy is likely to be an important factor in some patients. Secondary hyperparathyroidism resulting from calcium malabsorption and/or vitamin D deficiency will also predispose to bone loss, particularly in cortical bone. Hypogonadism is an important pathogenetic factor in both men and women [13]. In alcoholic liver disease, factors such as malnutrition and heavy tobacco consumption may further increase bone loss, and trauma plays an important part in the increased fracture risk that has been demonstrated in these patients; in addition, alcohol may have a direct toxic effect on osteoblasts. Other potential pathogenetic factors include reduced systemic production of insulin-like growth factor-1 (IGF-1) and increased production of the osteoclastogenic cytokine, receptor activator of NFκB ligand (RANKL) [25] and, in viral cirrhosis, of the proresorptive cytokine tumour necrosis factor alpha (TNFα) [26]. There is also some evidence that hyperbilirubinaemia may impair the proliferative capacity of osteoblasts [27].

Management of osteoporosis associated with chronic liver disease

Risk assessment

At present, the risk factors for osteoporosis in patients with chronic liver disease have not been well characterized, and there is no well-established evidence base for recommendations on bone density testing. In general, however, age, advanced histological liver disease, hypogonadism and glucocorticoid therapy have been associated with increased risk of osteoporosis and may provide a basis on which to form recommendations (Table 2).

In view of the silent nature of many vertebral fractures and their prognostic significance, lateral X-rays of the thoracolumbar spine should be performed in patients with a low bone mineral density (e.g. T score ≤ −2.5), those who are on long-term glucocorticoid therapy, individuals undergoing assessment

Table 2 Indications for bone densitometry in patients with chronic liver disease.

Postmenopausal women
Men aged over 65 years
Previous history of fragility fracture
Oral glucocorticoid therapy
Pretransplant assessment
Cirrhosis

Table 3 Management of bone health in patients with chronic liver disease: general measures.

Maintain good nutrition, including adequate calcium intake and vitamin D status
Correction of hypogonadism
Use minimum dose of glucocorticoids
Avoid tobacco use and alcohol abuse
Encourage physical exercise

for liver transplantation and patients with significant height loss (> 4 cm), kyphosis or back pain suggestive of vertebral fracture. Sex hormone status should be ascertained in men by measurement of serum testosterone and sex hormone-binding protein; in women, the presence or absence of menstrual periods is generally an adequate guide to sex hormone status, although measurement of serum estradiol and gonadotrophin levels may be useful in some cases. Bone function tests, including serum 25-hydroxyvitamin D and parathyroid hormone (PTH), should be performed.

General measures (Table 3)

A number of general measures can be recommended, based on known risk factors for bone loss. Calcium and vitamin D supplementation should be given if there is evidence of insufficient dietary calcium intake and/or vitamin D insufficiency. A daily intake of calcium of around 1 g/day is recommended; the dose of vitamin D required to normalize vitamin D status may vary between patients, but oral vitamin D, in doses between 800 IU daily and 50 000 IU three times weekly, is generally adequate. Hypogonadism should be corrected; in women, transdermal hormone replacement therapy (HRT) has been shown to have beneficial effects on bone mineral density in postmenopausal women without significant adverse effects on liver function [28,29] and should be considered in hypogonadal premenopausal women and perimenopausal women; in older postmenopausal women, intervention with alternative pharmacological interventions (see below) may be preferable in view of the adverse risk/benefit ratio of HRT. In men, few data are available, but it seems reasonable to advocate transdermal testosterone replacement in those with clinical evidence of hypogonadism. In those patients treated with glucocorticoids, the dose should be reviewed constantly and kept to a minimum. Physical exercise should be encouraged as appropriate, and tobacco use and alcohol use discouraged. Attention to nutrition is important, with avoidance of malnutrition and low body mass index.

Pharmacological interventions (Table 4)

Although there have been rapid advances in recent years in the treatment of postmenopausal osteoporosis, few studies have addressed the problems of treating osteoporosis in patients with chronic liver disease, and there have been no randomized controlled trials with fracture reduction as the primary outcome.

Table 4 Indications for bone protective therapy in patients with chronic liver disease.

All patients with previous fragility fracture
Patients with osteoporosis (T score ≤ –2.5) (but take age into account when making treatment decisions)
Patients with T score ≤ –1.5 undergoing transplantation
Treat patients on oral glucocorticoids according to national guidelines

The use of pharmacological interventions in chronic liver disease is thus largely based on extrapolation of evidence obtained in postmenopausal women with osteoporosis and, to a lesser extent, men with osteoporosis.

Pharmacological agents that have been evaluated in postmenopausal osteoporosis include the bisphosphonates etidronate and alendronate, calcitriol and calcitonin. However, the studies have been small, and not all have been randomized or controlled. Based on the known anti-fracture efficacy of alendronate and risedronate at the spine and hip in postmenopausal women with osteoporosis, it seems reasonable to recommend these agents in patients with chronic liver disease who have osteoporosis (10 mg and 5 mg once daily or 70 mg and 35 mg once weekly respectively); if gastro-oesophageal disease is present, intravenous infusions of pamidronate, 60 mg once every 3 months, should be considered. Although raloxifene [30] and strontium ranelate [31] have not been evaluated in patients with chronic liver disease, they are a potential option where bisphosphonates are not tolerated. Calcium (1 g daily) and vitamin D (400–800 IU daily) should be given as adjuncts to treatment. Patients receiving glucocorticoids should be treated according to national guidelines [32].

Post-transplantation bone disease (Table 5)

Since the first report of bone disease after liver transplantation, osteoporosis has emerged as a common and serious complication of this procedure. Earlier studies revealed rapid rates of bone loss in the first 3–6 months after transplantation, from both the spine and the hip, with a tendency to recover in the first 1–2 years postoperatively. Some more recent studies indicate lower rates of bone loss, probably as a result of the use of lower doses of prednisolone for shorter periods of time [33].

Estimates of the risk of fracture after liver transplantation have varied widely, largely as a result of patient selection,

Table 5 Characteristics of post-transplantation bone disease.

Bone loss is most rapid during the first 3–6 months postoperatively and affects both the spine and the proximal femur
Early bone loss is associated with increased bone turnover and resorption
Most studies show recovery of bone mineral density towards baseline values after 1–2 years
Fracture incidence is greatest during the first year after transplantation

differing immunosuppressive regimens and the diagnostic criteria used for vertebral fracture. However, many studies have reported a fracture incidence of around 25–30%, mainly within the first 6–12 months after transplantation. In other studies, lower fracture rates have been reported [34], possibly reflecting the substantial reduction in dose and duration of glucocorticoid therapy in recent years and a wider recognition of the importance of ensuring good bone health prior to transplantation.

The pathogenesis of bone loss after transplantation is incompletely understood, but the high doses of glucocorticoids used for immunosuppression are likely to play a major role, and other immunosuppressive agents, particularly the calcineurin inhibitors, also have adverse skeletal effects. Pre-existing bone disease is another important pathogenetic factor, emphasizing the importance of optimizing bone health prior to transplantation. Other contributory factors include sex hormone deficiency, vitamin D insufficiency, secondary hyperparathyroidism and immobilization [9,33]. Histomorphometric studies indicate that the changes responsible for bone loss within the first few months are mediated by an increase in both bone turnover and resorption depth [35].

Management of post-transplantation bone disease involves both optimization of skeletal health prior to transplantation and prevention of bone loss postoperatively. With respect to the latter, a number of pharmacological agents have been evaluated, but most studies have been suboptimally designed, and there are none with robust fracture outcome data. Overall, the best results with respect to prevention of bone loss have been obtained with 3-monthly intravenous pamidronate infusions, although much of this evidence is derived from patients undergoing other forms of transplantation (heart, lung and kidney).

In children undergoing liver transplantation, the available evidence indicates that transplantation has rapid beneficial effects on bone health, with significant increases in bone mineral density that can be explained, at least in part, on the basis of increased growth [36].

Rickets and osteomalacia

Definition and clinical features

Rickets and osteomalacia are conditions characterized by defective mineralization of bone. Rickets (the condition in children) commonly leads to difficulty in walking, short stature and characteristic skeletal deformities, including frontal bossing, craniotabes, visible widening of the epiphyses at the wrist and ankle, bowing of the legs, prominence of the costochrondral junctions, pigeon chest and spinal kyphosis.

In adults, skeletal deformities are much less common, and the clinical symptoms and signs are frequently ill defined and nonspecific. Bone pain is the most common symptom, and proximal muscle weakness occurs in some cases, leading to the characteristic waddling gait, difficulty in rising from the sitting position, in walking up and down stairs and in lifting heavy objects from a height. Skeletal deformities such as protrusio acetabuli, coxa vara and spinal kyphosis occur occasionally, and pathological fractures are a late manifestation of the disease.

Diagnosis

The classical biochemical changes that occur in vitamin D deficiency are hypocalcaemia, hypophosphataemia (provided renal function is normal) and a raised plasma alkaline phosphatase. The serum 25-hydroxyvitamin D level is often (although not invariably) low, and the serum PTH level is increased. Specific radiological changes occur relatively early in rickets and are generally best seen at the wrists. The lower ends of the radius and ulna become widened, indistinct and cupped, producing the so-called 'frothing champagne glass' appearance. In contrast, characteristic radiological changes occur at a much later stage in osteomalacia and, even in advanced disease, are by no means invariable. There may be reduced radiodensity of bone, coarsening of the trabecular pattern and loss of corticomedullary differentiation in the phalanges. Looser's zones and pathological fractures may occur, and phalangeal subperiosteal resorption due to secondary hyperparathyroidism may also be seen.

In the absence of specific clinical, biochemical and radiological changes, histological examination of bone may be required to make a diagnosis. Histologically, osteomalacia is characterized by defective mineralization that leads to the accumulation of osteoid (unmineralized bone); the diagnostic histomorphometric criteria of osteomalacia are increased mean osteoid seam width together with prolongation of the mineralization lag time.

Prevalence of osteomalacia and rickets

The reported prevalence of osteomalacia in chronic liver disease varies widely, from zero to nearly 70%. More recent studies, which have employed strict histomorphometric criteria, have shown that hepatic osteomalacia is rare and virtually restricted to parts of the world, such as the United Kingdom, where ultraviolet irradiation is low and fortification of foods with vitamin D is uncommon [37]. Moreover, most recent studies indicate that the prevalence is falling, possibly reflecting the trend towards earlier diagnosis of liver disease and the resulting change in its clinical spectrum [18].

Rickets is a relatively common complication of hepatobiliary disease in infants and young children; in one study, radiological evidence of rickets was reported in 59% of 21 infants with neonatal hepatitis and in two of four with intrahepatic cholestasis [38]. As in adults, vitamin D deficiency has a major pathogenetic role, although its cause differs slightly. Thus, malabsorption of dietary vitamin D appears to be the main cause of vitamin D deficiency in patients with cholestatic disease (dietary intake being the main source of the vitamin in infants), whereas in neonatal hepatitis, impaired hepatic production of 25-hydroxyvitamin D may be a contributory factor.

Pathogenesis of osteomalacia associated with chronic liver disease

Vitamin D deficiency

Vitamin D deficiency is the major factor responsible for the development of osteomalacia in chronic liver disease. A number of studies have demonstrated low serum 25-hydroxyvitamin D in a high proportion of patients with chronic liver disease, indicating that vitamin D deficiency is common in these individuals [39,40]. Although one report suggested that hepatic production of 25-hydroxyvitamin D was impaired in chronic cholestatic liver disease, most subsequent studies have shown no significant impairment in 25-hydroxylation, although some has been reported in patients with alcoholic liver disease.

The cause of vitamin D deficiency associated with chronic liver disease is multifactorial; reduced exposure to sunlight (and hence reduced endogenous synthesis of the vitamin) and low dietary intake are likely to contribute in many patients. Malabsorption of vitamin D and 25-hydroxyvitamin D has been demonstrated in a number of studies, and treatment with cholestyramine may further decrease absorption of the vitamin. Other factors that may contribute include increased urinary excretion of vitamin D metabolites in patients with cholestasis and reduced exposure to ultraviolet irradiation and/or low dietary vitamin D intake. In addition, there is evidence that endogenous synthesis of vitamin D is impaired in the presence of jaundice.

Calcium and phosphate malabsorption

Malabsorption of calcium and phosphate has been reported in both cholestatic and parenchymatous liver disease, and it improves after administration of parenteral vitamin D or oral 25-hydroxyvitamin D3, indicating that malabsorption is due, at least in part, to vitamin D deficiency. Precipitation of calcium salts by unabsorbed fats within the intestinal lumen may also contribute to calcium malabsorption.

Prevention and treatment of hepatic osteomalacia

In all patients with chronic liver disease, a normal vitamin D status should be ensured using vitamin D supplements where appropriate (see above). Established hepatic osteomalacia is responsive to oral or parenteral vitamin D, calcitriol or alphacalcidol. Treatment with parenteral vitamin D or parenteral 1,25-dihydroxyvitamin D3 has been shown to be effective in the healing of rickets associated with cholestatic disease.

References

1 Compston JE (1986) Hepatic osteodystrophy: vitamin D metabolism in patients with liver disease. *Gut* 27, 1073–1090.

2 Dolan P, Torgerson DJ (2000) The cost of treating osteoporotic fractures in the United Kingdom female population. *Osteoporosis Int* 11, 551–552.

3 Cummings SR, Melton LJ III (2002) Epidemiology and outcomes of osteoporotic fractures. *Lancet* 359, 1761–1767.

4 Cooper C, Atkinson EJ, O'Fallon WM *et al.* (1992) Incidence of clinically diagnosed vertebral fractures: a population-based study in Rochester, Minnesota, 1985–1989. *J Bone Min Res* 7, 221–227.

5 Marshall D, Johnell O, Wedel H (1996) Meta-analysis of how well measures of bone mineral density predict occurrence of osteoporotic fractures. *Lancet* 312, 1254–1259.

6 WHO Study Group (1994) *Assessment of Fracture Risk and its Application to Postmenopausal Osteoporosis*. World Health Organization Technical Report Series No. 843. Geneva: WHO.

7 Kanis JA (2002) Diagnosis of osteoporosis and assessment of fracture risk. *Lancet* 359, 1929–1936.

8 Genant HK, Wu CY, van Kuijk C *et al.* (1993) Vertebral fracture assessment using a semiquantitative technique. *J Bone Min Res* 9, 1137–1148.

9 Hay JE (2003) Osteoporosis in liver diseases and after liver transplantation. *J Hepatol* 38, 856–865.

10 Leslie WD, Bernstein CN, Leboff MS (2003) AGA technical review on osteoporosis in hepatic disorders. *Gastroenterology* 125, 941–966.

11 Ninkovic M, Love S, Tom BDM *et al.* (2001) High prevalence of osteoporosis in patients with chronic liver disease prior to transplantation. *Calcif Tissue Int* 69, 321–326.

12 Crosbie OM, Freaney R, McKenna MJ *et al.* (1999) Bone density, vitamin D status, and disordered bone remodeling in end-stage chronic liver disease. *Calcif Tissue Int* 64, 295–300.

13 Diamond T, Steil D, Lunzer M *et al.* (1990) Osteoporosis and skeletal fractures in chronic liver disease. *Gut* 31, 82–87.

14 Boulton-Jones AJ, Fenn RMF, West J *et al.* (2004) Fracture risk of women with primary biliary cirrhosis: no increase compared with general population controls. *Aliment Pharmacol Ther* 20, 551–557.

15 Stellon AJ, Webb A, Compston JE *et al.* (1987) Low bone turnover state in primary biliary cirrhosis. *Hepatology* 7, 137–142.

16 Stellon AJ, Webb A, Compston JE (1988) Bone histomorphometry and studies in corticosteroid treated chronic active hepatitis. *Gut* 29, 378–389.

17 Matloff DS, Kaplan MM, Neer RM *et al.* (1982) Osteoporosis in primary biliary cirrhosis: effects of 25-hydroxyvitamin D3 treatment. *Gastroenterology* 83, 97–102.

18 Stellon AJ, Webb A, Compston JE *et al.* (1986) Lack of osteomalacia in chronic cholestatic liver disease. *Bone* 7, 181–185.

19 Hodgson SF, Dickson ER, Eastell R *et al.* (1993) Rates of cancellous bone remodeling and turnover in osteopenia associated with primary biliary cirrhosis. *Bone* 14, 819–827.

20 Diamond T, Stiel D, Lunzer M *et al.* (1989) Ethanol reduces bone formation and may cause osteoporosis. *Am J Med* 86, 282–288.

21 Crilly RG, Anderson C, Hogan D *et al.* (1988) Bone histomorphometry, bone mass and related parameters in alcoholic males. *Calcif Tissue Int* 43, 269–276.

22 Cuthbert JA, Pak CYC, Zerwekh JE *et al.* (1984) Bone disease in primary biliary cirrhosis: increased bone resorption and turnover in the absence of osteoporosis or osteomalacia. *Hepatology* 4, 1–8.

23 Guichelaar M, Malinchoc M, Sibonga J *et al.* (2002) Bone metabolism in advanced cholestatic liver disease: analysis by bone histomorphometry. *Hepatology* 36, 895–903.

24 Corazza GR, Trevisani F, Di Stefano M *et al.* (2000) Early increase of bone resorption in patients with liver cirrhosis secondary to viral hepatitis. *Dig Dis Sci* 45, 1392–1399.

25 Fabrega E, Orive A, Garcia-Suarez C *et al.* (2005) Osteoprotegerin and RANKL in alcoholic liver disease. *Liver Int* 25, 305–310.

26 Gonzalez-Calvin JL, Gallego-Rojo F, Fernandez-Perez R *et al.* (2004) Osteoporosis, mineral metabolism, and serum soluble tumor necrosis factor receptor p55 in viral cirrhosis. *J Clin Endocrinol Metab* 89, 4325–4330.
27 Janes CH, Dickson ER, Okazaki A *et al.* (1995) Role of hyperbilirubinaemia in the impairment of osteoblast proliferation associated with cholestatic jaundice. *J Clin Invest* 95, 2581–2586.
28 Pereira SP, O'Donohue J, Moniz CP *et al.* (2004) Transdermal hormone replacement therapy improves vertebral bone density in primary biliary cirrhosis: results of a 1-year controlled trial. *Aliment Pharmacol Ther* 19, 563–570.
29 Ormarsdottir S, Mallmin H, Naessen T *et al.* (2004) An open randomized, controlled study of transdermal hormone replacement therapy on the rate of bone loss in primary biliary cirrhosis. *J Intern Med* 256, 63–69.
30 Ettinger B, Black DM, Mitlak BH *et al.* (1999) Reduction of vertebral fracture risk in postmenopausal women with osteoporosis treated with raloxifene: results from a 3-year randomized clinical trial. *JAMA* 282, 637–645.
31 Meunier PJ, Roux C, Seeman E *et al.* (2004) The effect of strontium ranelate on the risk of vertebral fracture in women with postmenopausal osteoporosis. *N Engl J Med* 350, 459–468.
32 Guideline Development Group for the Bone and Tooth Society, National Osteoporosis Society and Royal College of Physicians (2002) *Glucocorticoid-induced Osteoporosis. Guidelines for Prevention and Treatment*. London: Royal College of Physicians.
33 Compston J (2003) Osteoporosis after liver transplantation. *Liver Transpl* 9, 321–330.
34 Ninkovic M, Love S, Tom BDM *et al.* (2002) Lack of effect of intravenous pamidronate on fracture incidence and bone mineral density after orthotopic liver transplantation. *J Hepatol* 37, 93–100.
35 Vedi S, Greer S, Skingle SJ *et al.* (1999) Mechanism of bone loss after liver transplantation: a histomorphometric analysis. *J Bone Min Res* 14, 281–287.
36 Compston J (2003) The skeletal effects of liver transplantation in children. *Liver Transpl* 9, 371–372.
37 Herlong HF, Recker RR, Maddrey WC (1982) Bone disease in primary biliary cirrhosis: histologic features and response to 25-hydroxyvitamin D. *Gastroenterology* 83, 103–108.
38 Kobayashi A, Kawai S, Utsunomiya T *et al.* (1974) Bone disease in infants and children with hepatobiliary disease. *Arch Dis Child* 49, 641–646.
39 Long RG, Skinner RK, Wills MR *et al.* (1976) Serum 25-hydroxyvitamin D in untreated parenchymal and cholestatic liver disease. *Lancet* ii, 650–652.
40 Compston JE, Thompson RPH (1977) Intestinal absorption of 25-hydroxyvitamin D and osteomalacia in primary biliary cirrhosis. *Lancet* i, 721–724.

21.10 The effect of liver disease on nutritional status and energy metabolism

Michael R. Charlton

Introduction

The liver is responsible for the metabolism of many hormones that have discordant effects on protein, carbohydrate and lipid metabolism, including insulin, the sex hormones, insulin-like growth factors and glucagon. It would thus be surprising if chronic and acute liver diseases did not alter nutritional status and amino acid and energy metabolism.

This chapter will address the following aspects of malnutrition and disordered energy metabolism in liver disease:

1 prevalence and impact;
2 pathophysiology;
3 methods of assessing nutritional status in liver disease;
4 management.

Prevalence

Chronic liver disease is frequently associated with malnutrition, the severity of which ranges from subclinical micronutrient deficiencies (e.g. vitamins A, D, E, K and zinc) to frank protein–calorie malnutrition (PCM; defined as a wasting condition resulting from a diet deficient in both calories and protein). PCM, which can be observed in all clinical stages of chronic liver disease, is most frequently seen in patients with cirrhosis [1]. The prevalence of PCM has been noted to be as low as 20% for patients with compensated alcoholic liver disease in the community and as high as 100% in hospitalized patients with acute alcoholic hepatitis [2]. More recent surveys report the prevalence of PCM to range from 27% to 87% in patients with cirrhosis.

Pathophysiology

The pathophysiology of malnutrition in liver disease is complex. Contributing factors include diminished intake, increased requirements (e.g. due to ascites formation and maldigestion), altered substrate utilization (characterized by lowered respiratory quotients) and altered protein and amino acid metabolism.

Diminished nutrient intake

Of all of the factors contributing to the development of PCM in liver disease, inadequate nutritional intake is the easiest to identify and correct. A particular association of alcoholic liver disease and inadequate nutritional intake has been clearly established [3,4]. The prevalence of inadequate nutrition among patients with liver disease varies not only with the severity of the disease, but also with the socioeconomic status of the patient, with employed alcoholics tending to have lower prevalences and less severe nutritional deficiencies, for example [5–7]. Diminished nutrient intake is of particular interest in the context of alcoholic liver disease because, although a cause and effect relationship has not been demonstrated, protein–calorie malnutrition seems to precede the onset of clinically apparent liver disease [3]. The aggregate results of four detailed analyses of dietary intake in patients with alcoholic liver disease, including 472 patients, are that patients with established alcoholic liver disease obtain an average of 48.7% of their calories from alcohol and only 7.8% from protein [3,8–10]. When more than 25% of total calories are derived from alcohol, the caloric value per gram of alcohol consumed decreases, exacerbating the actual caloric deficit in patients with alcoholic liver disease. [5,11].

In addition to the effects of alcohol on nutrient intake, there is considerable evidence that the liver plays an important role in the regulation of satiety [12–15]. Liver disease of any form has the potential to disrupt the hepatic contribution to satiety. The mechanisms of hepatic control of appetite are thought to include hepatic vagal afferent monitoring of hepatic glycogen charge [16]. The reported incidence of anorexia in the setting of chronic liver disease is high. The reported incidence of anorexia is ~ 90% in patients with cirrhotic stage disease [17].

One of the most widely disseminated 'pearls' regarding nutrition in patients with liver disease of any cause is the need to restrict protein intake. The restriction of protein intake to less than 1.0 g/kg/day greatly increases the risk of protein wasting and negative nitrogen balance in patients with stable cirrhosis [18]. Increased protein requirements amplify the risks of net nitrogen

loss from protein restriction in patients with complications of liver disease, such as bacterial peritonitis, variceal haemorrhage or acute alcoholic hepatitis. Perhaps not surprisingly, the prevalence of malnutrition increases during hospitalization. In a prospective study, patients admitted to hospital for the treatment of alcoholic hepatitis received a mean of 50% of their calculated caloric and 57% of their total calculated protein requirements [19]. While the poor protein intake in hospitalized patients with liver disease is partly attributable to the inherent difficulties in feeding patients with encephalopathy or the malaise associated with acute alcoholic hepatitis, it is also in part iatrogenic. The prolonged periods of fasting imposed for the myriad investigations carried out during hospitalizations can greatly exacerbate the difficulties in maintaining intake in patients with liver disease and should be planned to minimize the time spent fasting. Furthermore, while protein restriction may have a role in the management of acute hepatic encephalopathy, there is no need for this practice in the medium- or long-term management of patients with liver disease. Indeed, medium- or long-term protein restriction should be avoided in this group of patients as there is overwhelming evidence that the incidence of complications of liver disease increases with malnutrition [20–25]. In the few patients who are intolerant of adequate protein intake in the diet, secondary to chronic hepatic encephalopathy, consideration should be given to branched-chain amino acids (BCAA)-enriched formulas, additional vegetable protein or casein supplements.

Increased energy requirements

The nutritional requirements of patients with liver disease are often underestimated because of difficulties in assessing their energy expenditure and utilization of ingested nutrients. Factors that can contribute to increased nutritional requirements in cirrhosis include maldigestion (secondary to diminished bile salt synthesis), with consequently impaired micelle formation, malabsorption, portal enteropathy and increased intestinal output (e.g. due to lactulose and neomycin) [26–28]. Steatorrhoea has a prevalence of ~ 45% in patients with cirrhosis [29,30]. In addition to the diminished delivery of bile acids to the intestinal lumen and the reduced long-chain fatty acid absorption, pancreatic exocrine insufficiency is often quoted as a contributing factor to malabsorption in patients with cirrhosis. This is unlikely, even in patients with chronic pancreatitis, as it has been demonstrated that 5% of normal pancreatic exocrine function is adequate to prevent steatorrhoea [31]. When blood levels of alcohol exceed 100 mg/dL, the majority of alcohol metabolism occurs through microsomal oxidation rather than dehydrogenation (alcohol dehydrogenase has a K_m of 5 mg/dL) [32]. Microsomal metabolism of alcohol involves the oxidation of nicotinamide-adenine dinucleotide phosphate (NADPH) and is thus an energy-consuming process. In addition, the acetate generated during alcohol metabolism requires adenosine triphosphate (ATP) for conversion to acetyl coenzyme A, adding to the net energy expenditure of oxidative alcohol metabolism [33]. It has also been reported that alcohol has an inhibitory effect on mitochondrial ATP production [34]. In contrast, at lower concentrations (< 100 mg/dL), alcohol is chiefly metabolized by alcohol dehydrogenase, resulting in the net production of reduced nicotinamide-adenine dinucleotide (NADH). NADH is utilized by mitochondria for ATP production.

There is some evidence that portal hypertension plays a role in the pathogenesis of excessive intestinal protein losses [35–37], including diminished losses following portocaval shunting [38], but the data are inconclusive. Alcohol may exacerbate this phenomenon, as evidenced by increased intestinal nitrogen losses in chronic alcoholics with and without liver disease [39]. Alcohol can directly cause malabsorption of nutrients, and malabsorption is often exacerbated by secondary thiamine and folate deficiency, the absorption of which is inhibited by alcohol [40].

Other factors contributing to increased nutritional requirements in patients with liver disease are the caloric cost of complications of cirrhosis (e.g. spontaneous bacterial peritonitis, repeated large-volume paracentesis and variceal haemorrhage) and altered utilization of substrates. The effect of ascites on resting energy expenditure was elegantly demonstrated using indirect calorimetry before and after large-volume paracentesis [41]. Dolz *et al.* [41] found that a mean weight reduction of 16.6 kg was associated with a 9.5% reduction in resting energy expenditure compared with levels recorded prior to paracentesis ($P < 0.005$). The presence of spontaneous bacterial peritonitis (which was absent in the study by Dolz *et al.*) would add to the metabolic cost of ascites.

There is some debate about whether, when assessed by indirect calorimetry, the caloric needs of patients with cirrhosis in general are increased when compared with control subjects [42–49]. Perhaps the best information can be gleaned from a large study [49] in which a heterogeneous group of 123 patients with varied stages and aetiologies of liver disease (approximately 20% due to alcohol) were evaluated. When expressed per unit of lean body mass, 18% of patients with cirrhosis had increased resting energy expenditure, 51% had normal energy expenditure compared with control subjects, and 31% had resting energy expenditure that was significantly lower than control subjects. The degree of increased energy requirements (hypercatabolism), in those patients who were hypercatabolic, was seen to correlate with diminished body cell mass but not with the aetiology or duration of liver disease in this study. Biochemical parameters, such as bilirubin or albumin, were not predictive of hypercatabolism. Increased resting energy expenditure is thus not a universal finding in the setting of alcoholic cirrhosis, but is sufficiently common to require consideration when determining the nutritional requirements of these patients. Estimations of the caloric needs of patients with alcoholic liver disease based on the Harris–Benedict equation are frequently inaccurate, tending to underestimate the caloric needs by 15–18% compared with measurement using indirect calorimetry [46,50].

Altered substrate utilization

Clinically and physiologically, cirrhosis is a condition of accelerated starvation. Several studies have documented a lowered fasting respiratory quotient in patients with liver disease, compared with healthy control subjects [42,44,48,49,51,53]. Two studies found no difference [43,54]. The mean respiratory quotient calculated from the combined means of all these nine studies, including 85 patients with alcoholic liver disease, is 0.77 ($n = 221$) for patients with cirrhosis vs. 0.85 ($n = 105$) for healthy control subjects. Lower respiratory quotients are indicative of increased utilization of alternative fuel substrates, i.e. protein and fat. Based on the results of these eight studies, following an overnight fast, patients with stable cirrhosis derive ~ 75% of their calories from fat. In healthy control subjects, the proportion of calories derived from fat is ~ 35%. This diminished respiratory quotient is chiefly secondary to increased lipid and attenuated glucose oxidation [48,55,56]. The mechanism of this increased utilization of alternative fuels is unclear, although Petrides *et al.* [57] have demonstrated marked insulin resistance in cirrhosis. Insulin resistance in liver disease is associated with attenuated hepatic glycogen production [55] and impaired muscle glycogen synthesis [58,59]. Of note is that this early utilization of fat and protein can be ameliorated by frequent feeding. A late evening meal has a positive effect on nitrogen balance in patients with cirrhosis when compared with an equicaloric diet without a late evening meal [60].

In addition to the changes in substrate utilization that occur secondary to cirrhosis in general, alcohol has some specific effects. Alcohol inhibits glyceraldehyde-3-phosphate dehydrogenase, by increasing the $NADH:NAD^+$ ratio, resulting in depletion of pyruvate and oxaloacetate. As the formation of phosphoenolpyruvate from pyruvate is the rate-limiting step in the gluconeogenesis pathway, alcohol exerts a net inhibitory effect on glucose production. Inhibition of gluconeogenesis diminishes the availability of glucose and, thereby, its utilization as a fuel. While the increased $NADH:NAD^+$ ratio that occurs during alcohol metabolism should theoretically acutely increase fatty acid oxidation, the metabolic effects of cirrhosis (including insulin resistance) result in a net increase in free fatty acid oxidation in patients with alcoholic cirrhosis, as evident from the reduced respiratory quotient seen in these patients [42,44,48,49,51,53].

Assessment of nutritional status in liver disease

As discussed, nutritional deficiencies are common among patients with compensated cirrhosis and nearly ubiquitous in patients with decompensated liver disease, e.g. patients awaiting liver transplantation. Although protein–calorie malnutrition is often the most clinically apparent manifestation of malnutrition in this population, deficiencies in micronutrients, particularly vitamins A, D, E and K [61] (by prothrombin time) and zinc [62], are also highly prevalent.

Nutritional assessment of patients with liver disease is difficult because many of the traditional indices of nutritional status are altered in liver disease independently of nutritional status, e.g. serum albumin, prothrombin time and ideal body weight. Although several adverse outcomes are associated with one or more indices of malnutrition, no single nutritional parameter is able to consistently identify patients with cirrhosis who are likely to experience poor outcome. A multivariate approach to nutritional assessment is recommended. The subjective global assessment (SGA) of nutritional status, modified for patients with cirrhosis, is a simple, reproducible and validated method that includes nutritional history, physical examination and simple anthropometrics [63]. In addition, because of the frequency of micronutrient deficiencies in this population, serum measurements of zinc, vitamins A, D, E and prothrombin time should also be taken periodically.

Impact of malnutrition and disordered energy metabolism in liver disease

Among the many other functions of the liver, it is responsible for the metabolism of hormones that have discordant effects on protein metabolism, such as insulin, the sex hormones and glucagon. Circulating glucagon levels are one of the primary determinants of the resting metabolic rate [64,65]. When the liver fails acutely, it is the loss of hepatic regulation of protein metabolism that rapidly results in death. The alterations in amino acid metabolism associated with liver diseases, including alcoholic liver disease, are characterized by low levels of circulating branched-chain (BCAA: leucine, isoleucine and valine) and elevated levels of circulating aromatic amino acids (AAA: phenylalanine and tyrosine), tryptophan and methionine [66–68]. It is widely believed that the changes in amino acid metabolism play a role in the pathogenesis of many of the complications of cirrhosis, such as portosystemic encephalopathy [69–71].

The presence of malnutrition has been variably associated with increased short- and long-term mortality in patients with acute and chronic liver diseases [72,73]. Preoperative malnutrition has also been reported to be associated with increased operative blood loss, longer length of stay in the intensive care unit (ICU), increased mortality and higher total hospital charges following liver transplantation [74]. Furthermore, malnutrition is associated with its own morbidity in patients with acute and chronic liver disease, e.g. cognitive dysfunction and dermatological manifestations of zinc deficiency.

In this setting, nutritional therapy, particularly BCAA supplementation, is an attractive concept in the prevention and treatment of complications.

Management

While there is overwhelming evidence that the incidence of complications of liver disease increases with malnutrition, the

impact of nutritional therapy on outcomes in patients with liver disease varies with the indication [21,23,24,75].

Cirrhosis-associated protein–calorie malnutrition/sarcopenia

The multifactorial wasting condition that is so frequently encountered in patients with Child–Pugh–Turcotte class B and C cirrhosis predisposes to encephalopathy (skeletal muscle is the second largest site of ammonia metabolism) and other complications of liver disease. Fortunately, muscle wasting/negative nitrogen balance has been shown to be ameliorated by the administration of 1.0 g/kg/day standard proteins [18]. The preferential early utilization of fat and protein that occurs in patients with cirrhosis can be ameliorated by frequent feeding. A late evening meal has been shown to have a positive effect on nitrogen balance in patients with cirrhosis when compared with an equicaloric diet without a late evening meal [60].

Alcoholic hepatitis

The particularly high prevalence of malnutrition among patients with alcoholic liver disease and the association of negative nitrogen balance with subsequent mortality has led to a relatively large number of clinical trials of nutritional therapies in this group. Despite initial promise, the aggregate of the evidence suggests that parenterally and/or enterally administered hyperalimentation (with or without BCAA-enriched preparations) does not confer a medium- or long-term survival benefit to patients with acute alcoholic hepatitis [76]. It is important to note, however, that patients with alcoholic hepatitis who do not achieve a positive nitrogen balance have very poor survival rates, although cause and effect have not been demonstrated. Administration of a nitrogen balance-maintaining diet, using standard amino acid mixtures/food preparations, with concomitant replacement of potassium, phosphate, magnesium and thiamine should be considered in patients hospitalized with alcoholic liver disease.

Hepatic encephalopathy

Even subclinical hepatic encephalopathy, present in ~ 75% of patients with cirrhosis, can attenuate quality of life and should be treated. Lactulose administration and replacement of zinc, when deficient, are almost always sufficient therapy. Protein restriction is rarely necessary in the short term and never in the medium or long term.

BCAA-enriched, aromatic amino acid-deficient nutritional supplements are the most extensively studied and utilized nutritional therapies in patients with liver disease, usually for the treatment of portosystemic encephalopathy. This is based on the theory that higher levels of aromatic amino acids generate false neurotransmitters, promoting encephalopathy. Of the nine published randomized, controlled trials of BCAA-enriched formulas in the therapy of hepatic encephalopathy, six demonstrated no benefit [77], two found improved morbidity but unaltered mortality [78], while the ninth found significant improvements in both mortality and response of encephalopathy [79]. There is thus no consensus as to the use of BCAA-enriched supplements in the treatment of episodic hepatic encephalopathy [80]. Conversely, these supplements appear to be of clear benefit to patients with cirrhosis who exhibit evidence of hepatic encephalopathy and who are intolerant of standard protein sources [81].

For overt hepatic encephalopathy, acute withdrawal of protein from the diet while precipitating causes of encephalopathy are sought has been the traditional cornerstone of therapy. However, a recent randomized, controlled trial indicates no ill-effects of protein feeding on the recovery from the episode of encephalopathy [82]. The administration of a disaccharide, such as lactulose or lactitol, has been repeatedly demonstrated to be effective and safe therapy [83], although the quality of the clinical studies has recently come under criticism [84]. Zinc, deficiency of which is a near ubiquitous finding in patients with advanced stages of liver disease, may be supplemented empirically as there is reasonable evidence that supplementation is associated with improvement in amino acid metabolism and clinical grade of encephalopathy [85].

Following successful reversal of hepatic encephalopathy, nitrogen balance-maintaining quantities of standard proteins should be reintroduced into the diet. In the unusual patient who is not able to tolerate ≥ 1.0 g/kg/day standard proteins without becoming encephalopathic, despite optimal pharmacological therapy, nutritional supplementation with vegetable proteins and, if necessary, BCAA-enriched formulas should be considered. Both these agents have been shown to produce clinical improvement in chronic hepatic encephalopathy while allowing adequate amounts of protein to be consumed. Medium- and long-term protein restriction is contraindicated in patients with cirrhosis.

Fulminant hepatic failure

Fulminant hepatic failure is associated with a one- to fourfold increase in rates of protein catabolism, with a concomitant loss of capacity for ammonia removal [86]. In addition, glucose metabolism is greatly altered, a condition characterized by diminished insulin sensitivity, high levels of insulin and glucagon and a tendency to develop hypoglycaemia [87]. Unfortunately, the ideal method of preventing hypoglycaemia and glucopenic brain injury has not been established. Certainly, blood glucose levels require frequent monitoring, and continuous infusions of 10–20% dextrose should be initiated following the onset of hypoglycaemia. Almost every other facet of nutritional therapy in the setting of fulminant hepatic failure is controversial. Although BCAA-enriched and medium-chain triglyceride-supplemented preparations offer theoretical advantages over standard amino acid and lipid preparations, the relative benefits of these nutrients in the support of patients with fulminant

hepatic failure have not been formally studied in a randomized controlled fashion. Intuitively, patients with fulminant hepatic failure who require prolonged hospitalization seem to merit nutritional support and are usually given it. Such support is, however, based on empiricism in terms of composition and route.

Liver resection

Fan and co-workers, in a large randomized, controlled study, demonstrated that patients undergoing resection of hepatocellular carcinoma, who received 14 days of perioperative intravenous nutritional support in addition to their oral diet, experienced lower overall postoperative morbidity rate when compared with a control group (34% vs. 55%; relative risk 0.66), predominantly because of fewer septic complications [36]. There was also a reduction in the requirement for diuretic agents to control ascites, less weight loss after hepatectomy and less deterioration of liver function among patients receiving perioperative nutrition support. These benefits were seen predominantly in the patients with underlying cirrhosis who underwent major hepatectomy. Based on these results, perioperative nutrition support should be considered in patients undergoing liver resection for hepatocellular carcinoma associated with cirrhosis.

Management guidelines

1 Nutritional deficiencies are common among patients with liver disease, who require specific assessment of nutritional status on initial evaluation and then periodically as indicated. Based on the findings of the nutritional evaluation, a care plan should be formulated and its implementation and efficacy monitored.

2 Nutritional assessment should include screening for micronutrient deficiencies. Minimal screening for micronutrient deficiencies should include vitamins A, D, E and K (by prothrombin time) and zinc.

3 Patients with cirrhosis should divide their caloric intake into four to six meals/day, including a late evening snack.

4 Protein restriction should be implemented only transiently for the acute management of overt hepatic encephalopathy.

5 The only definitive indication for BCAA-enriched formulas is in chronic encephalopathy unresponsive to pharmacotherapy.

6 Perioperative nutritional support should be considered in patients undergoing liver resection for hepatocellular carcinoma associated with cirrhosis.

References

1 Lautz HU, Selberg O, Korber J *et al.* (1992) Protein-calorie malnutrition in liver cirrhosis. *Clin Invest* 70, 478–486.

2 Morgan MY (1982) Alcohol and nutrition. *Br Med Bull* 38, 21–29.

3 Mendenhall CL, Anderson S, Weesner RE *et al.* (1984) Protein-calorie malnutrition associated with alcoholic hepatitis. Veterans Administration Cooperative Study Group on Alcoholic Hepatitis. *Am J Med* 76, 211–222.

4 Mezey E (1991) Interaction between alcohol and nutrition in the pathogenesis of alcoholic liver disease (review; 109 refs). *Semin Liver Dis* 11, 340–348.

5 Rissanen A, Sarlio-Lahteenkorva S, Alfthan G *et al.* (1987) Employed problem drinkers: a nutritional risk group? *Am J Clin Nutr* 45, 456–461.

6 Simko V, Connell AM, Banks B (1982) Nutritional status in alcoholics with and without liver disease. *Am J Clin Nutr* 35, 197–203.

7 Mezey E, Faillace LA (1971) Metabolic impairment and recovery time in acute ethanol intoxication. *J Nerv Mental Dis* 153, 445–452.

8 Mezey E, Kolman CJ, Diehl AM *et al.* (1988) Alcohol and dietary intake in the development of chronic pancreatitis and liver disease in alcoholism. *Am J Clin Nutr* 48, 148–151.

9 Mills PR, Shenkin A, Anthony RS *et al.* (1983) Assessment of nutritional status and *in vivo* immune responses in alcoholic liver disease. *Am J Clin Nutr* 38, 849–859.

10 Pitchumoni CS, Sonnenshein M, Candido FM *et al.* (1980) Nutrition in the pathogenesis of alcoholic pancreatitis. *Am J Clin Nutr* 33, 631–636.

11 Pirola RC, Lieber CS (1972) The energy cost of the metabolism of drugs, including ethanol. *Pharmacology* 7, 185–196.

12 Novin D, Robinson K, Culbreth LA *et al.* (1985) Is there a role for the liver in the control of food intake? *Am J Clin Nutr* 42, 1050–1062.

13 Lockwood AH, Ginsberg MD, Rhoades HM *et al.* (1986) Cerebral glucose metabolism after portacaval shunting in the rat. Patterns of metabolism and implications for the pathogenesis of hepatic encephalopathy. *J Clin Invest* 78, 86–95.

14 Tordoff MG, Schulkin J, Friedman MI (1986) Hepatic contribution to satiation of salt appetite in rats. *Am J Physiol* 251, R1095–1102.

15 McCarty MF (1994) Promotion of hepatic lipid oxidation and gluconeogenesis as a strategy for appetite control (review; 88 refs). *Med Hypotheses* 42, 215–225.

16 Macdonald GA, Lucey MR (1994) Diet and liver disease – a glimpse into the future (editorial; comment). *J Clin Gastroenterol* 18, 274–276.

17 Achord JL (1987) Malnutrition and the role of nutritional support in alcoholic liver disease (review). *Am J Gastroenterol* 82, 1–7.

18 Gabuzda GJ, Shear L (1970) Metabolism of dietary protein in hepatic cirrhosis. Nutritional and clinical considerations. *Am J Clin Nutr* 23, 479–487.

19 Egan J, Mullen KD, Ullman A (1985) A prospective evaluation of dietary intake in hospitalized patients with alcoholic liver disease.

20 O'Keefe SJ, El-Zayadi AR, Carraher TE *et al.* (1980) Malnutrition and immuno-incompetence in patients with liver disease. *Lancet* 2, 615–617.

21 Bienia R, Ratcliff S, Barbour GL *et al.* (1982) Malnutrition and hospital prognosis in the alcoholic patient. *J Parenter Enter Nutr* 6, 301–303.

22 Garrison RN, Cryer HM, Howard DA *et al.* (1984) Clarification of risk factors for abdominal operations in patients with hepatic cirrhosis. *Ann Surg* 199, 648–655.

23 Blendis LM, Harrison JE, Russell DM *et al.* (1986) Effects of peritoneovenous shunting on body composition. *Gastroenterology* 90, 127–134.

24 Shaw BW Jr, Wood RP, Gordon RD *et al.* (1985) Influence of selected patient variables and operative blood loss on six-month survival following liver transplantation. *Semin Liver Dis* 5, 385–393.

25 Goldberg S, Mendenhall C, Anderson S *et al.* (1986) VA Cooperative Study on Alcoholic Hepatitis. IV. The significance of clinically mild alcoholic hepatitis – describing the population with minimal hyperbilirubinemia. *Am J Gastroenterol* 81, 1029–1034.

26 Thompson GR, Barrowman J, Gutierrez L *et al.* (1971) Action of neomycin on the intraluminal phase of lipid absorption. *J Clin Invest* 50, 319–323.

27 Vlahcevic ZR, Buhac I, Farrar JT *et al.* (1971) Bile acid metabolism in patients with cirrhosis. I. Kinetic aspects of cholic acid metabolism. *Gastroenterology* 60, 491–498.

28 Sarfeh IJ, Aaronson S, Lombino D *et al.* (1986) Selective impairment of nutrient absorption from intestines with chronic venous hypertension. *Surgery* 99, 166–169.

29 Morgan AG, Kelleher J, Walker BE *et al.* (1976) Nutrition in cryptogenic cirrhosis and chronic aggressive hepatitis. *Gut* 17, 113–118.

30 Morgan MY (1981) Enteral nutrition in chronic liver disease. *Acta Chir Scand Suppl* 507, 81–90.

31 DiMagno EP, Go VL, Summerskill WH (1973) Relations between pancreatic enzyme ouputs and malabsorption in severe pancreatic insufficiency. *N Engl J Med* 288, 813–815.

32 Lieber CS (1988) Biochemical and molecular basis of alcohol-induced injury to liver and other tissues (see comments) (review; 199 refs). *N Engl J Med* 319, 1639–1650.

33 Faller J, Fox IH (1982) Ethanol-induced hyperuricemia: evidence for increased urate production by activation of adenine nucleotide turnover. *N Engl J Med* 307, 1598–1602.

34 Gordon ER (1973) Mitochondrial functions in an ethanol-induced fatty liver. *J Biol Chem* 248, 8271–8280.

35 Witte MH, Dumont AE, Cole WR *et al.* (1969) Lymph circulation in hepatic cirrhosis: effect of portacaval shunt. *Ann Intern Med* 70, 303–310.

36 Dumont AE, Witte CL, Witte MH (1975) Protein content of liver lymph in patients with portal hypertension secondary to hepatic cirrhosis. *Lymphology* 8, 111–113.

37 Yablonski ME, Lifson N (1976) Mechanism of production of intestinal secretion by elevated venous pressure. *J Clin Invest* 57, 904–915.

38 Smadja C, Charra M, Morin J *et al.* (1988) Portacaval shunt, nutritional status and immunocompetence in the cirrhotic patient: results of a prospective study. *Clin Nutr* 7, 33–36.

39 Roggin GM, Iber FL, Kater RMH (1969) Malabsorption in the chronic alcoholic.

40 Halsted CH, Robles EA, Mezey E (1973) Distribution of ethanol in the human gastrointestinal tract. *Am J Clin Nutr* 26, 831–834.

41 Dolz C, Raurich JM, Ibanez J *et al.* (1991) Ascites increases the resting energy expenditure in liver cirrhosis. *Gastroenterology* 100, 738–744.

42 Owen OE, Trapp VE, Reichard GA Jr *et al.* (1983) Nature and quantity of fuels consumed in patients with alcoholic cirrhosis. *J Clin Invest* 72, 1821–1832.

43 Jhangiani SS, Agarwal N, Holmes R *et al.* (1986) Energy expenditure in chronic alcoholics with and without liver disease. *Am J Clin Nutr* 44, 323–329.

44 Mullen KD, Denne SC, McCullough AJ *et al.* (1986) Leucine metabolism in stable cirrhosis. *Hepatology* 6, 622–630.

45 Pierrugues R, Blanc P, Daures JP *et al.* (1992) Relationship of resting energy expenditure with liver function and nutritional status in patients with alcoholic cirrhosis. *Nutrition* 8, 22–25.

46 Shanbhogue RL, Bistrian BR, Jenkins RL *et al.* (1987) Resting energy expenditure in patients with end-stage liver disease and in normal population (see comments). *J Parenter Enter Nutr* 11, 305–308.

47 Campillo B, Bories P, Pornin B *et al.* (1989) [Energy expenditure and the use of nutriments in cirrhotic patients fasting and at rest. Influence of alcoholic hepatitis and the severity score of the disease.] (in French). *Gastroenterol Clin Biol* 13, 544–550.

48 Schneeweiss B, Graninger W, Ferenci P *et al.* (1990) Energy metabolism in patients with acute and chronic liver disease. *Hepatology* 11, 387–393.

49 Muller MJ, Lautz HU, Plogmann B *et al.* (1992) Energy expenditure and substrate oxidation in patients with cirrhosis: the impact of cause, clinical staging and nutritional state. *Hepatology* 15, 782–794.

50 DiCecco SR, Plevak DJ, Wiesner RH (1991) Do we accurately estimate caloric and nitrogen requirements in the liver transplant patient?

51 McCullough AJ, Mullen KD, Kalhan SC (1992) Body cell mass and leucine metabolism in cirrhosis. *Gastroenterology* 102, 1325–1333.

52 Merli M, Riggio O, Romiti A *et al.* (1990) Basal energy production rate and substrate use in stable cirrhotic patients. *Hepatology* 12, 106–112.

53 McCullough AJ, Mullen KD, Tavill AS *et al.* (1992) In vivo differences between the turnover rates of leucine and leucine's ketoacid in stable cirrhosis. *Gastroenterology* 103, 571–578.

54 Petrides AS, Luzi L, Reuben A *et al.* (1991) Effect of insulin and plasma amino acid concentration on leucine metabolism in cirrhosis. *Hepatology* 14, 432–441.

55 Owen OE, Reichle FA, Mozzoli MA *et al.* (1981) Hepatic, gut, and renal substrate flux rates in patients with hepatic cirrhosis. *J Clin Invest* 68, 240–252.

56 Shanbhogue RL, Bistrian BR, Lakshman K *et al.* (1987) Whole body leucine, phenylalanine, and tyrosine kinetics in end-stage liver disease before and after hepatic transplantation. *Metabol Clin Exp* 36, 1047–1053.

57 Petrides AS, Groop LC, Riely CA *et al.* (1991) Effect of physiologic hyperinsulinemia on glucose and lipid metabolism in cirrhosis. *J Clin Invest* 88, 561–570.

58 Kruszynska Y, Williams N, Perry M *et al.* (1988) The relationship between insulin sensitivity and skeletal muscle enzyme activities in hepatic cirrhosis. *Hepatology* 8, 1615–1619.

59 Kruszynska YT, Home PD, McIntyre N (1991) Relationship between insulin sensitivity, insulin secretion and glucose tolerance in cirrhosis. *Hepatology* 14, 103–111.

60 Swart GR, Zillikens MC, van Vuure JK *et al.* (1989) Effect of a late evening meal on nitrogen balance in patients with cirrhosis of the liver. *Br Med J* 299, 1202–1203.

61 DiCecco SR, Wieners EJ, Wiesner RH *et al.* (1989) Assessment of nutritional status of patients with end-stage liver disease undergoing liver transplantation. *Mayo Clin Proc* 64, 95–102.

62 Bode JC, Hanisch P, Henning H *et al.* (1988) Hepatic zinc content in patients with various stages of alcoholic liver disease and in patients with chronic active and chronic persistent hepatitis. *Hepatology* 8, 1605–1609.

63 Hasse J, Strong S, Gorman MA *et al.* (1993) Subjective global assessment: alternative nutrition-assessment technique for liver-transplant candidates. *Nutrition* 9, 339–343.

64 Nair KS, Halliday D, Garrow JS (1984) Increased energy expenditure in poorly controlled type 1 (insulin-dependent) diabetic patients. *Diabetologia* 27, 13–16.

65 Charlton MR, Adey DB, Nair KS (1996) Evidence for a catabolic role of glucagon during an amino acid load. *J Clin Invest* 98, 90–99.

66 McCullough AJ, Czaja AJ, Jones JD *et al.* (1981) The nature and prognostic significance of serial amino acid determinations in severe chronic active liver disease. *Gastroenterology* 81, 645–652.

67 Cascino A, Cangiano C, Fiaccadori F *et al.* (1982) Plasma and cerebrospinal fluid amino acid patterns in hepatic encephalopathy. *Dig Dis Sci* 27, 828–832.

68 Morgan MY, Marshall AW, Milsom JP *et al.* (1982) Plasma amino-acid patterns in liver disease. *Gut* 23, 362–370.
69 Fischer JE, Funovics JM, Aguirre A *et al.* (1975) The role of plasma amino acids in hepatic encephalopathy. *Surgery* 78, 276–290.
70 James JH, Ziparo V, Jeppsson B *et al.* (1979) Hyperammonaemia, plasma aminoacid imbalance, and blood–brain aminoacid transport: a unified theory of portal-systemic encephalopathy. *Lancet* 2, 772–775.
71 Marchesini G, Zoli M, Dondi C *et al.* (1980) Prevalence of subclinical hepatic encephalopathy in cirrhotics and relationship to plasma amino acid imbalance. *Dig Dis Sci* 25, 763–768.
72 Abad-Lacruz A, Cabre E, Gonzalez-Huix F *et al.* (1993) Routine tests of renal function, alcoholism, and nutrition improve the prognostic accuracy of Child–Pugh score in nonbleeding advanced cirrhotics. *Am J Gastroenterol* 88, 382–387.
73 Chedid A, Mendenhall CL, Gartside P *et al.* (1991) Prognostic factors in alcoholic liver disease. VA Cooperative Study Group. *Am J Gastroenterol* 86, 210–216.
74 Ricci P, Therneau TM, Malinchoc M *et al.* (1997) A prognostic model for the outcome of liver transplantation in patients with cholestatic liver disease. *Hepatology* 25, 672–677.
75 Mendenhall CL, Moritz TE, Roselle GA *et al.* (1993) A study of oral nutritional support with oxandrolone in malnourished patients with alcoholic hepatitis: results of a Department of Veterans Affairs cooperative study. *Hepatology* 17, 564–576.
76 Fulton S, McCullough AJ (1998) Treatment of alcoholic hepatitis.
77 Fiaccadori F, Ginnelli F, Pedretti G (1985) Branched-chain enriched amino acid solutions in the treatment of hepatic encephalopathy: a controlled trial.
78 Strauss E, dos Santos WR, da Silva EC (1986) Treatment of hepatic encephalopathy: a randomized clinical trial comparing a branched-chain amino acid enriched solution to oral neomycin.
79 Cerra FB, Cheung NK, Fischer JE *et al.* (1985) Disease-specific amino acid infusion (F080) in hepatic encephalopathy: a prospective, randomized, double-blind, controlled trial. *J Parenter Enter Nutr* 9, 288–295.
80 Riordan SM, Williams R (1997) Treatment of hepatic encephalopathy (see comments) (review; 73 refs). *N Engl J Med* 337, 473–479.
81 Fabbri A, Magrini N, Bianchi G *et al.* (1996) Overview of randomized clinical trials of oral branched-chain amino acid treatment in chronic hepatic encephalopathy (review). *J Parenter Enter Nutr* 20, 159–164.
82 Cordoba J, Lopez-Hellin J, Planas M *et al.* (2004) Normal protein diet for episodic hepatic encephalopathy: results of a randomized study. *J Hepatol* 41, 38–43.
83 Butterworth RF (2000) Complications of cirrhosis III. Hepatic encephalopathy.
84 Als-Nielsen B, Gluud LL, Gluud C (2004) Non-absorbable saccharides for hepatic encephalopathy: systematic review of randomised trials. *Br Med J* 328, 1046.
85 Marchesini G, Fabbri A, Bianchi G *et al.* (1996) Zinc supplementation and amino acid-nitrogen metabolism in patients with advanced cirrhosis. *Hepatology* 23, 1084–1092.
86 O'Keefe SJ, Abraham RR, Davis M *et al.* (1981) Protein turnover in acute and chronic liver disease. *Acta Chir Scand Suppl* 507, 91–101.
87 Vilstrup H, Iversen J, Tygstrup N (1986) Glucoregulation in acute liver failure. *Eur J Clin Invest* 16, 193–197.

22 The liver in specific settings

22.1 Paediatric liver diseases

Marianne Samyn and Giorgina Mieli-Vergani

Liver and biliary disease in infancy

Liver disease in infancy is a relatively rare but serious cause of morbidity and mortality. As jaundice is a common finding in the neonatal period, the immediate priority is to differentiate between unconjugated hyperbilirubinaemia, which is generally a benign developmental phenomenon, and conjugated hyperbilirubinaemia (conjugated fraction > 20%), which is always pathological.

However, a persistently elevated unconjugated bilirubin, not explained by haemolysis or other neonatological problems, could suggest the possibility of liver-based inherited disorders of bilirubin metabolism such as Gilbert syndrome or Crigler–Najjar disease. Crigler–Najjar disease type 1 results from a complete deficiency of uridine diphosphate glucuronyl transferase (UDPGT) activity, while type 2 is caused by a partial deficiency. Both types are inherited in an autosomal recessive fashion, and the diagnosis can be confirmed by mutation analysis, assessing bilirubin conjugates in the bile or measuring UDPGT activity in the liver tissue. Treatment with phenobarbital (5 mg/kg/day) can decrease the bilirubin levels by at least 30% in type 2 disease. In type 1, exchange transfusion and phototherapy are required to minimize the risks of kernicterus and neurological damage. Continuous phototherapy of sufficient intensity to keep serum bilirubin below 340 μmol/L (20 mg/dL) is mandatory. As the child grows older, phototherapy becomes less effective, and full or auxiliary liver transplantation or the recently described hepatocyte transplantation should be considered as therapeutic options.

Conjugated hyperbilirubinaemia, suggested by yellow urine and stools that are not yellow or green in an infant of any age, is pathognomonic of liver parenchyma or bile duct disease and warrants prompt investigation, as some of its causes require urgent treatment and/or genetic counselling.

Infantile cholestasis/neonatal hepatitis syndrome

The terms hepatitis syndrome of infancy or neonatal hepatitis syndrome were initially used to describe a group of disorders causing clinical and biochemical liver dysfunction, of which the most distinct was conjugated hyperbilirubinaemia. The term hepatitis was chosen because of the frequent presence of inflammatory changes on liver biopsy; however, the cause is only occasionally infective (Table 1). 'Infantile or neonatal cholestasis' is probably a better name to describe this entity and will be used throughout this chapter. The reported incidence of neonatal cholestasis is approximately 1:2500 live births [1], the most common causes being, in order of frequency, biliary atresia, idiopathic infantile cholestasis and alpha-1-antitrypsin deficiency [2].

Bile production is dependent on the active transport of bile acids and other osmotic compounds into the bile canaliculus and, subsequently, on a passive process of movement of water into the canaliculus. Active transporters at both the hepatic basolateral membrane and the canalicular membrane play an important role in this process. Genetic defects in these transporters are recognized and identify a range of familial intrahepatic cholestatic diseases (see below). In liver disease and sepsis, the expression of the transporters helps to protect the hepatocyte from the cytotoxic effect of the bile acids. In the fetus and newborn, both immature bile acid synthesis and bile acid transport result in decreased bile flow. Cholestasis leads to bile acid and conjugated bilirubin retention, apparent as jaundice, hypercholesterolaemia and pruritus, and to decreased bile excretion into the intestine resulting in malabsorption of dietary long-chain fat and fat-soluble vitamins.

Clinical presentation

The majority of babies with infantile cholestasis present with prolonged jaundice, dark urine and pale stools within the first 4 weeks of life, but may occasionally present as late as 4 months of age. The second most common presentation is spontaneous bleeding, usually secondary to vitamin K deficiency associated with fat malabsorption, which may also cause failure to thrive and rickets. Less commonly, babies present with hypoglycaemia or hypoalbuminaemia. Review of the perinatal records, pregnancy, family and past medical histories is helpful in determining the

Table 1 Causes of infantile cholestasis.

Infections
Viral
Rubella
Cytomegalovirus
Herpes simplex virus
Human herpes virus-6
Varicella zoster
Hepatitis A, B, C
Non-A–C hepatitis
Echo, Adeno, Coxsackie viruses
HIV
Rheovirus type 3
Epstein–Barr virus
Parvovirus B19
Bacterial
Syphilis
Listeria
Malaria
Tuberculosis
Parasitic *Toxoplasma*

Endocrine
Hypopituitarism
Diabetes insipidus
Hypoadrenalism
Hypothyroidism
Hypoparathyroidism

Chromosomal disorders
Trisomy 18, 21

Toxic
Copper
Parenteral nutrition

Bile duct abnormalities
Biliary atresia
Choledochal cyst
Spontaneous perforation of bile ducts
Gallstones
Inspissated bile syndrome
Neonatal sclerosing cholangitis
Caroli syndrome and disease
Non-syndromic bile duct paucity

Metabolic
Alagille syndrome
Alpha-1-antitrypsin deficiency
Galactosaemia
Tyrosinaemia
Fructosaemia
Progressive familial intrahepatic cholestasis
Cystic fibrosis
Niemann–Pick type A, type C
Gaucher disease
Wolman disease
Zellweger syndrome
Carbohydrate glycoprotein deficiency
Neonatal haemochromatosis
Primary disorders of bile acid synthesis
Mitochondrial cytopathy

Miscellaneous
Haemophagocytic lymphohistiocytosis
ARC syndrome (arthrogryposis, renal tubular dysfunction and cholestasis)
Neoplasia

possible role of intrauterine infections, exposure to toxins, drugs or prolonged intravenous nutrition, familial, genetic or metabolic conditions or consanguinity.

On clinical examination, hepatomegaly and splenomegaly are common. Facial dysmorphic features or other stigmata of syndromic disorders, evidence of congenital heart disease, manifestations of intrauterine infections or cutaneous haemangiomata are of diagnostic value.

Management

Urgent investigations are necessary to identify disorders for which there is a specific treatment and to prevent complications (Table 2).

Standard tests of liver function are seldom helpful in the differential diagnosis.

Infective, metabolic and endocrine causes must be excluded urgently, as the prognosis may be radically modified by early treatment. Galactose and fructose must be excluded from the diet until enzymatic studies have excluded galactosaemia and fructosaemia. If the baby has received a blood transfusion, the parents need to be tested for heterozygosity for galactosaemia, because the enzymatic defect is detected in red blood cells.

Fat-soluble vitamins (A, D, E and K) must be prescribed to avoid deficiencies and their complications. They can be given orally but, in persisting cholestasis, intramuscular supplements should be given on a monthly basis. The nutritional management of infantile cholestasis requires a high-calorie diet containing 120–150% of the estimated average daily requirement with an increased percentage of fat as medium-chain triglycerides (MCTs). As mentioned above, a lactose-free formula should be used until the diagnosis of galactosaemia is excluded.

The second priority is to identify infants requiring surgical correction of bile duct pathologies such as biliary atresia, choledochal cyst or spontaneous perforation of the bile ducts. Observation of the stool colour is a helpful diagnostic tool, as white or brown, but not green or yellow, stools suggest bile duct obstruction. Other investigations include imaging of the liver and bile ducts by ultrasound scan and liver biopsy, which should both be interpreted by experienced observers. In selected cases, when doubts persist about bile duct pathology,

Table 2 Investigations for infantile cholestasis.

Urgent investigations
Bacterial culture of blood and urine
Urine microscopy and analysis for reducing substances
Prothrombin time/INR
Full blood count and reticulocyte count
Blood sugar, urea and creatinine
Serum electrolytes
Blood group and cross-match
Standard investigations
Liver function tests including split bilirubin and gamma-glutamyltransferase
TORCH screen, HIV, hepatitis A, hepatitis C, hepatitis B
Alpha-1-antitrypsin phenotype/genotype
T4, TSH, cortisol (for endocrinological problems)
Lactate, pyruvate, ammonia
Galactose-1-phosphate uridyl transferase (red blood cells)
Immunoreactive trypsin/sweat electrolytes (for cystic fibrosis)
Amino acids (serum and urine)
Succinyl acetone, organic acids (urine) (for tyrosinaemia)
Bile acids mass spectrometry (urine) (for bile acid synthesis disorders)
Direct Coombs' test (if appropriate)
Ferritin
Cholesterol, triglycerides
Specialized investigations (tertiary centre)
Ultrasound scan of liver
Chest X-ray/echocardiogram
Liver biopsy
Cholangiography (selected cases) (magnetic resonance, endoscopic, percutaneous)
Radionuclide hepatobiliary scanning following phenobarbital (limited value)
Second-line investigations (tertiary centre)
Blood tests for rare metabolic disorders (white cell enzymology, transferrin electrophoresis, etc.)
Bone marrow aspirate for storage disorders
Skin biopsy for fibroblast culture and enzyme analysis
Muscle biopsy (mitochondrial respiratory chain defect)

INR, international normalized ratio; TSH, thyroid-stimulating hormone; T4, thyroxine.

magnetic resonance cholangiography (MRC), endoscopic retrograde cholangiography (ERC) or percutaneous cholangiography (PTC) can be performed in specialized centres. Radionuclide scans are only valuable in the presence of excretion of radioisotope in the gut, which excludes complete bile duct obstruction, but do not help in differentiating between parenchymal or bile duct disease when no bowel excretion is observed. Phenobarbital (5 mg/kg/day) should be started 48 h prior to the test to optimize biliary excretion.

Third-line investigations include blood tests aimed at identifying rare metabolic disorders suspected on the basis of specific clinical findings or because no other aetiology is recognized, such as white cell enzymology and/or bone marrow aspirate for metabolic disorders, transferrin electrophoresis for congenital defects of glycosylation, skin and muscle biopsy for mitochondrial respiratory chain defects, etc.

Biliary atresia and other bile duct disorders

Biliary atresia (BA)

BA is the end result of a destructive, idiopathic, inflammatory process affecting both intra- and extrahepatic bile ducts, leading to fibrosis and obliteration of the biliary tract and, eventually, biliary cirrhosis. It is the most common surgically correctable liver disorder in infancy and affects 1/8000–15 000 live births worldwide [3]; it is also the most frequent cause of liver transplantation in children. Two forms of BA are described: (i) a more common peri- or postnatal form, possibly a virus-induced or virus-initiated progressive inflammatory/obliterative process of the bile ducts; and (ii) a less common fetal or embryonic form, with a high frequency of associated malformations, such as BA splenic malformation syndrome (BASM), characterized by cardiovascular defects, polysplenia or asplenia, abdominal situs inversus, intestinal malrotation and positional abnormalities of the portal vein and hepatic artery [4]. The cause of BA, however, remains unknown.

BA is a progressive disorder and, in some cases, the stools are pigmented during the first week of life to become acholic later. This fact not uncommonly leads inexperienced health professionals to reassure parents that complete bile duct obstruction is unlikely. All infants with pale or acholic stools, at whatever age, should be promptly referred to specialized centres because early surgical treatment of BA is essential for a good outcome.

Biochemical findings are usually not helpful. An ultrasound scan revealing an absent or abnormal gallbladder with an irregular wall [5] or, in older infants, the triangular cord sign [6] are suggestive of BA. However, a normal gallbladder or absence of the triangular cord sign do not exclude BA. Histological examination of the liver by an experienced histopathologist leads to the correct diagnosis of BA in up to 90% of cases. Typical histological findings are oedematous portal tracts with bile duct proliferation and bile plugs but, in very young babies, these features can be much less obvious than in infants older than 8 weeks. Alpha-1-antitrypsin deficiency can occasionally mimic BA and therefore needs to be excluded before a firm diagnosis of BA is made. If the liver biopsy is ambiguous but the stools remain acholic, further investigations such as MRC or ERC might be indicated to assess the patency of the biliary system. If they are not informative, an explorative laparotomy with intraoperative cholangiography is required. Radionuclide scans are only useful if isotope is demonstrated in the gut, thereby excluding BA and avoiding laparotomy.

After the diagnosis of BA is confirmed, surgical treatment consists of a Kasai portoenterostomy, in which the fibrous tissue at the porta hepatitis, replacing the atretic biliary structures, is transected and a Roux-en-Y loop of jejunum is anastomosed to the liver. The success of the operation is judged by the appearance of pigment in the stools and clearance of jaundice. A recent report on the management of BA in England and Wales shows that the surgical outcome is improved by centralization of care in specialized paediatric hepatology centres with expertise in

both Kasai portoenterostomy and paediatric liver transplantation [7]. The overall 4-year survival of 148 children with BA treated between 1999 and 2002 in the UK was 89%, and the 4-year survival with native liver was 51% [8]. The most common postoperative complication is cholangitis, characterized by fever, recurrence or aggravation of jaundice and features of sepsis. Often, however, the only symptom is fever, which should be treated promptly with broad-spectrum antibiotics, after performing blood cultures, to prevent progressive liver damage. The incidence of cholangitis is about 30–40% at 5 years, the majority of children having one single episode [9]. Portal hypertension is present in the majority of patients already at the time of initial surgery, but only approximately 15% will develop upper gastrointestinal bleeding secondary to varices in childhood. These can usually be managed with banding or sclerotherapy. Pulmonary arteriovenous shunting and cyanosis, also known as hepatopulmonary syndrome, is reported in BA, particularly when associated with BASM. Eleven per cent of BA children have normal laboratory values and no evidence of chronic liver disease 10 or more years after Kasai portoenterostomy [10]. For children with an unsuccessful Kasai portoenterostomy, or who develop progressive liver disease despite successful surgery, liver transplantation is the only therapeutic option.

Choledochal cysts

Choledochal cysts are congenital anomalies of the biliary tract characterized by cystic dilatations of one or more segments of the biliary tree. The most common is a fusiform dilatation of the common bile duct. Choledochal cysts are associated with intermittent biliary obstruction. In the newborn period, presentation can be indistinguishable from BA. Prenatal diagnosis of choledochal cyst warrants referral to a specialized paediatric hepatology centre, as it could be related to BA [11]. Choledochal cysts should be suspected in any sudden onset of cholestasis or cholangitis. Abdominal examination may reveal a mass. Ultrasound scan is usually diagnostic, but often further detailed imaging of the biliary tree is indicated (MRC, PTC, ERC) for a better anatomical delineation of the cyst before surgery. Treatment is complete surgical removal of the cyst, whenever possible, and hepaticojejunostomy to re-establish biliary drainage. With complete removal of the cyst, long-term prognosis is excellent. If the cyst cannot be completely removed, cholangiocarcinoma can develop in the residual cystic tissue.

Spontaneous perforation of the bile duct

This rare condition usually occurs before 3 months of age. It presents with mild jaundice, acholic stools, failure to thrive and abdominal distension due to ascites and, in males, bile-stained inguinal herniae. The perforation is usually located at the junction between the cystic and the common bile duct, suggesting a developmental weakness at this site. Paracentesis confirms the presence of bile-stained ascites, and final diagnosis is made during operative cholangiography. Drainage with suture closure of the perforation can be sufficient but, at times, a cholecystojejunostomy via a Roux-en-Y loop is necessary. Prognosis is excellent.

Neonatal sclerosing cholangitis

Neonatal sclerosing cholangitis was first described in 1987 and later confirmed by others [12]. It presents with jaundice and acholic stools, in contrast to other forms of sclerosing cholangitis in childhood. The pathogenesis is unknown, but an autosomal recessive pattern of inheritance is reported, suggesting an underlying metabolic abnormality. Diagnosis should be made by cholangiography, demonstrating irregularity of both intra- and extrahepatic bile ducts, as liver histology findings are indistinguishable from those of BA. The disease is usually progressive and leads to biliary cirrhosis. Ursodeoxycholic acid (UDCA) has been used with variable results. The prognosis is poor, particularly if jaundice persists. In one series, 47% of the children died and/or required liver transplantation [13].

Inspissated bile syndrome

Bile duct obstruction due to stones or inspissated bile in the biliary tree outside the gallbladder and accompanied by proximal bile duct dilatation can be seen in children with multifactorial cholestasis, but sometimes also in otherwise well children. Haemolytic disorders should be excluded. Diagnosis is made by ultrasound scan. Initial treatment is with UDCA. If the symptoms persist, percutaneous or surgical flushing of the biliary system is indicated.

Alagille syndrome

In 1969, Alagille and colleagues described a syndrome of idiopathic bile duct paucity associated with cardiovascular, skeletal and ocular anomalies [14]. Alagille syndrome ('syndromic paucity of intrahepatic bile ducts', 'arteriohepatic dysplasia') has an estimated incidence of 1/100 000 live births and is inherited in an autosomal dominant fashion with variable expression. Mutations in the human *JAG1* gene on chromosome 20p12 are associated with the syndrome. However, mutations are also found in asymptomatic individuals and other liver conditions, including BA [15]. Approximately 50% of Alagille syndrome cases have new mutations, a great heterogeneity exists within families of affected children, and Alagille syndrome has also been described without associated *JAG1* gene mutations.

Five major clinical features characterize the syndrome: (i) chronic cholestasis, causing jaundice, pruritus, hypercholesterolaemia and xanthoma; (ii) facial features with deep-set eyes, small pointed chin, mild hypertelorism, overhanging forehead and a straight nose, which is on the same plane as the forehead in profile; (iii) vertebral arch defects on spinal radiographs; (iv) cardiac abnormalities, most commonly peripheral pulmonary artery stenosis; and (v) ocular abnormalities such as posterior embryotoxon. Other common features are renal abnormalities, growth retardation, developmental delay and pancreatic

insufficiency. Facial features may be difficult to recognize during the neonatal period.

Management consists of vitamin supplements, nutritional support and control of pruritus. Long-term prognosis is uncertain. Liver transplantation can be an option in cases of ongoing severe cholestasis and pruritus, but careful assessment of the cardiac status is required before surgery can be considered.

Progressive familial intrahepatic cholestasis (PFIC)

Severe forms of intrahepatic cholestasis with progressive hepatocellular damage occur sporadically or on a familial basis. The first of these disorders to be described was in the descendants of an Amish American, Jacob Byler, and was called Byler disease [16]. Since then, other autosomal recessive conditions due to genetic defects leading to abnormal bile or bile transport have been recognized.

PFIC-1 (Byler disease) and PFIC-2 (BSEP deficiency)

PFIC-1 and PIFC-2 are characterized by low gamma-glutamyltransferase (GGT) plasma levels. PFIC-1 is caused by mutations in the *FIC1* gene, mapped on chromosome 18, which is also involved in benign recurrent intrahepatic cholestasis [17]. The FIC1 protein is widely expressed, its expression being high in the small intestine and pancreas and low on the hepatocyte canalicular membranes. Infants with PFIC-1 present within the first 6 months of life with cholestasis of variable severity and at times episodic. Other characteristics are diarrhoea, fat-soluble vitamin deficiency and recurrent pancreatitis. Pruritus is a dominant feature after infancy.

Bile salt export pump (BSEP) deficiency (PFIC-2) is caused by mutations in the *ABCB11* gene, mapped on chromosome 2 [18]. BSEP is a canalicular bile acid transporter only expressed in the liver. Most children present during the first few months of life with an isolated mild neonatal hepatitis. Pruritus is also a characteristic feature.

At least in PFIC-2 disease, failure of bile acid excretion at the canalicular level is the reason for low serum GGT levels and normal cholesterol levels. Hepatocellular and canalicular cholestasis with pseudoacinar transformation are the most common histological findings. Giant cells are prominent during infancy. Bile duct damage is progressive and leads to duct paucity and eventually loss in older patients. Inflammation is usually more severe in PFIC-2. Electron microscopy reveals canalicular bile with a characteristic granular appearance in PFIC-1 and more amorphous bile in BSEP deficiency.

PFIC-1 and -2 are usually progressive diseases. Management consists of supportive medical treatment for the complications of cholestasis, i.e. fat-soluble vitamin deficiency and pruritus. UDCA might have a beneficial effect by increasing the hepatocyte excretion of endogenous bile acids and inhibiting their intestinal reabsorption, thereby limiting their return to the liver [19]. Surgical partial external biliary diversion or ileal exclusion have been reported to arrest disease progression and to relieve pruritus, but the results are not consistent [20]. Liver transplantation is indicated in patients with decompensated cirrhosis or failed diversion and severe pruritus. Although the survival rate is excellent after transplantation, symptoms of failure to thrive, pancreatitis and chronic diarrhoea usually persist in PFIC-1.

PFIC-3 (MDR3 deficiency)

A third type of PFIC, characterized, in contrast to type 1 and 2, by high serum GGT levels, is associated with multidrug resistance gene 3 (MDR3) deficiency due to mutations in the *ABCB4* gene [21]. MDR3 is a canalicular phospholipid transporter. Its deficiency leads to the production of highly detergent bile, which causes portal inflammation, bile duct proliferation and fibrosis. Clinical presentation is variable and may be delayed until adult life. Not uncommon is a history of maternal cholestasis during pregnancy. UDCA is reportedly of some benefit, particularly in patients with residual protein function. If required for endstage disease, liver transplantation completely corrects the phenotype. Experimental data from a murine model suggest that the disease can be ameliorated by isolated hepatocyte transplantation [22].

Bile acid synthesis disorders

Bile acids are synthesized in the liver from neutral steroids through a complex series of chemical reactions catalysed by several hepatic enzymes. Cholic and chenodeoxycholic acids are the two primary bile acids in humans and most animal species and are synthesized from cholesterol. Defects in bile acid synthesis are rare, the most commonly reported being 3β-hydroxy-Δ^5-C_{27}-steroid dehydrogenase/isomerase deficiency, Δ^4-3-oxosteroid 5β-reductase deficiency and 24,25-dihydroxycholanoic cleavage enzyme deficiency. These defects have a significant effect on hepatic and gastrointestinal function, as they lead to an overproduction of hepatotoxic atypical bile acids proximal to the deficient enzyme and to a lack of primary bile acid production, essential for normal bile flow. Clinical presentation is with cholestasis, fat-soluble vitamin deficiency and abnormal liver function tests, but normal or low GGT. Liver histology is non-specific, revealing a neonatal hepatitis with inflammation. Diagnosis is made by mass spectroscopy of bile acids in the urine. Management consists of cholic acid administration and, if the treatment is started before the development of cirrhosis, the prognosis is excellent.

Multifactorial cholestasis in premature infants [23]

Compared with older infants, very-low-birthweight neonates have a higher risk of developing cholestasis because of more pronounced immaturity of bile metabolism. Additional factors are a diminished immune response to sepsis, an increased incidence of necrotizing enterocolitis and consequent short bowel syndrome with bacterial overgrowth, the use of parenteral

nutrition, drug toxicity and hypoxia. Often, a liver biopsy is not possible because of the small weight and serious clinical condition of the child; therefore, initial investigations should concentrate on excluding metabolic disorders and other factors contributing to cholestasis. Although BA needs to be suspected, it is a less common cause of infant cholestasis in premature babies. Blood tests, urine and ultrasound scan are the first line of investigation (Table 2). UDCA is usually given until the jaundice has resolved (dose 20–30 mg/kg/day in two or three divided doses). If possible, parenteral nutrition should be decreased or stopped and enteral feeding started, as it promotes enterohepatic circulation of bile acids and a better control of intestinal bacterial overgrowth. A lactose-free formula is recommended until galactosaemia is excluded; MCT-based formulas should be prescribed in the presence of marked cholestasis. Cholecystokinin has been used to promote gallbladder contraction, resulting in decreased serum bilirubin levels. Fat- and water-soluble vitamin supplements should be prescribed. In the presence of persistent cholestasis and acholic stools, further investigations are required, as described above.

Idiopathic infantile cholestasis

In 25–30% of cases, no specific aetiology for infantile cholestasis can be identified. Abnormal pregnancy, prematurity, intrauterine growth retardation and other abnormalities have been associated with idiopathic infantile cholestasis. Liver disease can be severe, but long-term hepatic problems seem to occur in less than 10%. Findings on liver histology are often non-specific with portal and lobular inflammation, giant cell transformation of hepatocytes and variable degrees of cholestasis. Treatment is supportive with fat- and water-soluble vitamin supplements, UDCA and MCT-based milk formula. Adverse prognostic factors include consanguinity, positive family history of liver disease in childhood, firm hepatomegaly, acholic stools and biliary features on liver biopsy.

Alpha-1-antitrypsin deficiency (A1ATD)

A1ATD is the most common inherited cause of infantile liver disease. A1AT is a glycoprotein that acts as a protease inhibitor, thereby inhibiting inflammatory processes. It is synthesized by hepatocytes and alveolar macrophages.

More than 90 alleles, controlled by the protease inhibitor (Pi) gene on chromosome 14q31–32.2, have been isolated and identified, the most common being PiM. Inheritance is autosomal codominant. A1ATD, a single gene defect leading to significantly reduced or absent serum A1AT levels, is associated with the PiZZ, PiNulNul and PiZNul variants. The prevalence of the PiZ allele in the European population is between 0.5% and 2%. PiZZ A1ATD causes chronic liver disease in 10–20% of affected children. The cause of liver disease is unknown, and genetic, environmental and physical factors are likely to be involved. A major pathogenic mechanism in PiZZ individuals is believed to be aberrant 'loop-sheet' polymerization of the mutant A1AT protein, leading to its abnormal folding and inefficient export from the hepatocyte rough endoplasmic reticulum.

Clinical features of A1ATD are variable, some patients being asymptomatic, some 20% developing liver disease of variable severity and some 60% developing emphysema during adulthood. A1ATD should be suspected in all cases of infantile cholestasis and in unexplained liver disease in childhood. More than 50% of children with the PiZZ phenotype have abnormal liver function tests, but only 10–15% develop overt liver disease, most commonly during the first 4 months of life. Clinical presentation can mimic BA, although children with A1ATD are more likely to fail to thrive. In about 10%, serious bleeding diathesis is the presenting symptom. One to two per cent of PiZZ patients present with cirrhosis in childhood or adult life, without a history of infantile liver disease.

Diagnosis is made by determining the A1AT phenotype by isoelectric focusing or agarose electrophoresis. A1AT plasma levels can be misleading as A1AT is an acute-phase reactant, and its levels may be within the normal range during the early hepatitic stage of the disease. Biliary features may be prominent on histology and similar to those seen in BA. The distinctive periodic acid–Schiff (PAS)-positive, diastase-resistant A1AT globules in periportal hepatocytes are only detectable after 12 weeks of life. A diagnosis of A1ATD should be excluded by determining the phenotype in all children with suspected BA before surgical intervention.

There is no specific treatment for A1ATD. Supportive management with fat- and water-soluble vitamin supplements and dietary management are indicated. If decompensation occurs, liver transplantation is the only therapeutic option, A1ATD being the most common indication for liver transplant among metabolic disorders. The prognosis of liver disease in PiZZ A1ATD is related to the presence of fibrosis and the severity and duration of the acute hepatitis in infancy. Of the 10–15% PiZZ infants who develop overt liver disease, 5% have rapid decompensation and require liver transplantation in the first 4 years of life, while the hepatitis settles in 95%. Among the latter, 25% have no further evidence of liver disease, and 25% develop cirrhosis, requiring liver transplantation before the second decade of life. The remainder continue to have biochemical or clinical evidence of liver disease, which may decompensate later [24]. Antenatal diagnosis is available, but genetic counselling is difficult because of the varying severity of the clinical phenotype and the difficulties in predicting the outcome.

Liver disease in childhood

Viral hepatitis – acute and chronic

Acute viral hepatitis can be caused by several hepatotropic viruses, including hepatitis A (HAV), hepatitis B (HBV), hepatitis C (HCV), hepatitis D (HDV) and hepatitis E (HEV), as well

as non-hepatotropic viruses such as Epstein–Barr virus (EBV), cytomegalovirus, herpes simplex virus (HSV), varicella-zoster virus, adeno- and enterovirus, rubella, parvovirus B19 and coxsackie B. Infected children are mostly asymptomatic; when symptomatic, they usually present with jaundice, vomiting, abdominal pain and lethargy. Viral hepatitis rarely causes acute liver failure. Infection with the hepatotropic viruses HBV, HCV and HDV can progress to chronic hepatitis.

Hepatitis A

HAV is present worldwide, especially in regions with low standards of sanitation. HAV infection is an acute, self-limiting condition. The incubation period ranges from 15 to 40 days (mean 28 days). Serum aminotransferase levels increase rapidly and peak within 1 week of the onset of the clinical illness and can normalize as early as 1–2 weeks later. Raised bilirubin levels are transient and usually found during the peak in the aminotransferase levels. Prolonged cholestasis is rarely observed. Serum anti-HAV immunoglobulin (Ig) M indicates a recent infection; anti-HAV IgG confers immunity and indicates previous infection. Highly effective formalin-killed, whole-virus vaccines are available. Children should be a primary target of immunization strategies. Currently, immunization is offered to children with an increased risk of developing complications from infection (e.g. with chronic liver disease or before organ transplantation).

Hepatitis B

HBV infection affects 5% of the world population. Infection is acquired parenterally and is often asymptomatic, particularly in young children. HBV is not directly cytopathic, and liver damage is secondary to the immune reaction to virally infected cells. If the immune system is efficient, the child shows symptoms and signs typical of acute hepatitis, including jaundice and lethargy. If the immune response is overwhelming, the infection may lead to fulminant hepatitis. Interestingly, fulminant hepatitis is also observed in a small proportion of infants of anti-hepatitis B e (HBe)-positive mothers between 1 and 4 months of age, and it is believed to be due to HBV mutants. The probability of becoming a chronic HBV carrier is particularly high if the infection occurs early in life, when the immune system is still maturing. To date, the majority of new HBV infections occur in infants of hepatitis B surface antigen (HBsAg)-positive mothers, because of either no universal implementation of HBV vaccination or no response to the vaccine. Some 90% of infected infants become chronic carriers. Their rate of spontaneous loss of HBeAg is low (yearly rate 7–16%) and of spontaneous loss of HBsAg very low (yearly rate 0–0.6%). The likelihood of clearing the virus depends on the degree of disease activity, being highest in patients with biochemically and histologically active disease and lowest in those with inactive disease. Chronic HBV infection is associated with a high risk of developing cirrhosis and hepatocellular carcinoma (HCC) in both adult life and childhood. The risk of developing HCC is particularly high in HBV perinatally infected patients. Although no universally accepted guidelines are available, yearly ultrasound examination and alpha-fetoprotein (AFP) estimation are advisable to monitor the possible development of HCC in chronically infected children, especially if they are HBeAg positive and/or have fibrosis/cirrhosis on liver biopsy.

HBV infection can be prevented by the use of a very effective recombinant HBV vaccine, which unfortunately, despite WHO recommendations, is still not used universally. For newborns of HBeAg-positive mothers, who are at risk of becoming infected despite vaccination, passive immunization with HBV-specific immunoglobulin is recommended at birth in association with the vaccine. Universal vaccination in Taiwan has reduced the rate of chronic infection from 10% to less than 1%; in parallel, a reduction was observed in the incidence of HCC and fulminant hepatic failure in children [25,26]. Vaccination for HBV would also eliminate the risk of superinfection with HDV, a virus that causes infection only in symbiosis with HBV and which, although rarely affecting children, can exacerbate liver damage.

For those children who are chronically infected, antiviral treatment trials have shown a moderate response to interferon (IFN) or lamivudine in those patients with biochemical and histological evidence of active liver disease (loss of HBeAg in 30–40% of cases). A recent pilot study suggests that decreasing the viral load with an 8-week lamivudine pretreatment followed by a combination of IFN and lamivudine may be effective in inducing complete viral immune control (HBsAg negativity and anti-HBsAg seroconversion) in about 20% of children infected during the first year of life, who are HBV immunotolerant and have normal liver function tests, high viral load and minimal changes on liver histology [27]. Larger trials in these patients, who currently represent the major pool of HBV-infected children, are warranted.

A few studies have used lamivudine/IFN association with different timing and combination in children with biochemically and histologically active chronic hepatitis B [28–31]. Virological response, defined in all as HBeAg/anti-HBe seroconversion, clearance of HBV DNA and normalization of alanine aminotransferase, was reported to be improved by the addition of lamivudine in only one study [31], suggesting that this approach may not be useful in the active phase of the disease.

Hepatitis C

The prevalence of HCV infection in children varies in different countries, but overall is less than that in adults. In the UK and the USA, it is < 1%. HCV infection occurs parenterally from the transfusion of contaminated blood or blood products or through the use of intravenous drugs. In contrast to HBV, vertical infection from HCV-positive mothers is rare, affecting only about 6% of infants. However, since the implementation of donor blood product screening for HCV, after its discovery in the early 1990s, childhood infection through blood products has decreased considerably, and the most important route of infection has become mother-to-infant. It is estimated that 10 000–60 000 newborn babies worldwide each year are infected

with HCV. Breastfeeding is generally considered to be safe for HCV-positive mothers, although HCV has been detected in breast milk.

Diagnosis of HCV infection is made by testing for antibody to HCV (anti-HCV) and then by determining HCV ribonucleic acid (RNA) positivity by polymerase chain reaction (PCR). As the measurement of anti-HCV is not useful before the age of 12 months, because of passive transfer of maternal antibodies through the placenta, infantile infection should be sought by HCV RNA PCR.

Acute HCV infection is usually asymptomatic and goes unrecognized. Also, children with chronic HCV infection are mainly asymptomatic, but have an as yet unquantifiable risk of developing cirrhosis, endstage liver disease and HCC. Liver enzymes are elevated in 40–90% of chronically infected children. Normal liver enzymes do not equate with histologically inactive disease. Although circulating autoantibodies are frequently present, overt autoimmune manifestations are rare in children.

The natural history of chronic HCV infection in children is unknown. Early studies reported a high tendency for chronicity and evolution to cirrhosis, but more recent publications suggest that the disease may be more benign in children than in adults. Older age and the presence of fibrosis in an earlier liver biopsy correlate with a higher rate of progressive fibrosis. Conversely, younger age at the time of infection and shorter duration of infection correlate with milder histological findings. Spontaneous viral clearance has been reported in both post-transfusional and vertical HCV infection at rates varying between 20% and 60% [32–35]. Treatment trials in a relative small number of chronically infected children using a combination of standard interferon or pegylated interferon and ribavirin have shown a sustained viral response in 40–50% of patients infected with genotype 1 and 80–100% in those infected with other genotypes [36]. Further studies using pegylated interferon and ribavirin, or comparing pegylated interferon monotherapy with pegylated interferon plus ribavirin, are ongoing.

Hepatitis E

Like HAV, HEV is a non-enveloped, single-stranded virus transmitted through the faecal–oral route. It causes epidemics of acute hepatitis in several parts of the world (South-East and Central Asia, the Middle East, Africa and Mexico). IgM and IgG can be detected by commercial assays. No treatment is available, but most patients recover and do not develop chronic infection.

Autoimmune liver disease

In paediatrics, two forms of autoimmune liver disease are recognized: autoimmune hepatitis (AIH) and AIH/sclerosing cholangitis overlap syndrome (autoimmune sclerosing cholangitis, ASC).

AIH (see Chapter 11.2) is a progressive inflammatory liver disorder, preferentially affecting females, characterized serologically by high levels of transaminases and IgG, the presence of autoantibodies and, histologically, by interface hepatitis in the absence of a known aetiology. AIH responds satisfactorily to immunosuppressive treatment. At the King's tertiary paediatric hepatology referral centre, there has been a sevenfold increase in the incidence of AIH over the last decade, the disease representing approximately 10% of some 400 new referrals per year. AIH is divided into two types according to the autoantibody profile (see Chapter 11.2): type 1 is positive for antinuclear (ANA) and/or antismooth muscle (SMA) antibody; type 2 is positive for antiliver–kidney microsomal antibody type 1 (anti-LKM-1). Type 1 AIH represents two-thirds of the cases. Severity of disease is similar in the two types. Anti-LKM-1-positive patients are younger and have a higher tendency to present with acute liver failure, but the duration of symptoms before diagnosis and the frequency of hepatosplenomegaly are similar in the two groups. Both have a high frequency of associated autoimmune disorders (about 20%) and a family history of autoimmune disease (40%). Associated autoimmune disorders include thyroiditis, inflammatory bowel disease, vitiligo, insulin-dependent diabetes and nephrotic syndrome in both types. Type 2 AIH may be associated with autoimmune polyendocrinopathy–candidiasis–ectodermal dystrophy (APECED), an autosomal recessive genetic disorder in which the liver disease is reportedly present in some 20% of cases.

The presentation of AIH is variable [37]. Up to 40–50% of patients present with symptoms of acute hepatitis, some 40% with an insidious onset, characterized by progressive fatigue, relapsing jaundice, headache, anorexia and weight loss, and some 10% with complications of portal hypertension, such as splenomegaly, haematemesis from oesophageal varices, bleeding diathesis, chronic diarrhoea and weight loss. The disease should therefore be suspected and excluded in all children with symptoms and signs of prolonged or severe liver disease. The course of disease can be fluctuating, with flares and spontaneous remissions, a pattern that may result in delayed referral and diagnosis. However, on physical examination, the majority of children have clinical signs of an underlying chronic liver disease, i.e. cutaneous stigmata (spider naevi, palmar erythema, leuconychia, striae), firm liver and splenomegaly; at ultrasound, the liver parenchyma is often nodular and heterogeneous.

For diagnostic criteria, pathophysiology and genetics, see Chapter 11.2.

Anti-LKM-1-positive children have higher levels of bilirubin and transaminases at presentation than those who are ANA/SMA positive, and present more frequently with fulminant hepatic failure. The vast majority of patients have increased levels of IgG, but some 20% do not, indicating that normal IgG values do not exclude the diagnosis of AIH. Partial IgA deficiency is significantly more common in LKM-1-positive than in ANA/SMA-positive patients. The severity of interface hepatitis at diagnosis is similar in both types, but cirrhosis on initial biopsy is more frequent in type 1 than in type 2 AIH, suggesting a more chronic course of disease in the former. Progression to cirrhosis during treatment is also more frequent in type 1 AIH.

AIH is exquisitely responsive to immunosuppression. The rapidity and degree of response depends on disease severity at presentation. All types of presentation, apart from fulminant hepatic failure with encephalopathy, respond to standard treatment with prednisolone with or without azathioprine (see Chapter 11.2). Despite the efficacy of standard immunosuppressive treatment, severe hepatic decompensation may develop even after many years of apparently good biochemical control, leading to transplantation 10–15 years after diagnosis in 10% of patients.

ASC has the same prevalence as AIH type 1 in childhood. This has been shown in a prospective study conducted over a period of 16 years, in which all children with serological (i.e. autoantibodies, high IgG levels) and histological (i.e. interface hepatitis) features of autoimmune liver disease underwent a cholangiogram at the time of presentation [38]. Approximately 50% of these patients had alterations in the bile ducts characteristic of sclerosing cholangitis, although generally less advanced than those observed in adult primary sclerosing cholangitis. A quarter of the children with ASC, despite abnormal cholangiograms, had no histological features suggesting bile duct involvement, and the diagnosis of sclerosing cholangitis was only possible because of the cholangiographic studies. Virtually all patients were seropositive for ANA and/or SMA. Fifty-five per cent were girls, and the mode of presentation was similar to that of typical AIH. Inflammatory bowel disease was present in about 45% of children with ASC compared with about 20% of those with typical AIH, and 90% of children with ASC had greatly increased serum IgG levels. At the time of presentation, standard liver function tests did not help in discriminating between AIH and ASC, although the alkaline phosphatase/aspartate aminotransferase ratio was significantly higher in ASC. Perinuclear antineutrophil nuclear antibodies (pANNA; see Chapters 11.2 and 11.3) were present in 74% of patients with ASC compared with 45% of patients with AIH type 1 and 11% of those with AIH type 2. Clinical, laboratory and histological features at presentation of AIH type 1, AIH type 2 and ASC are shown in Table 3. Children with ASC respond to the same immunosuppressive schedule used in AIH, with liver test abnormalities resolving within a few months after starting treatment in most patients. Steroids and azathioprine, however, although beneficial in abating the parenchymal inflammatory lesion, appear to be less effective in controlling the bile duct disease. UDCA is usually added at a dose of 20–30 mg/kg/day, although its usefulness in arresting the progression of ASC has not been proven. The medium-term prognosis is good, with a reported 7-year survival of 100%, although 15% of the patients required liver transplant during this period of follow-up [38]. Evolution from AIH to ASC has been documented, suggesting that AIH and ASC are part of the same pathogenic process.

Wilson disease (WD)

WD is an autosomal recessive disorder, leading to progressive accumulation of copper in the liver, the nervous system and other tissues. The prevalence in almost all populations is 1/30 000 live births. The disease results from mutations within the *ATP7B* gene located on chromosome 13. Multiple mutations have been reported, and most patients are compound heterozygotes, possessing two different disease-associated variants of the *ATP7B* gene. Mutations in the *ATP7B* gene cause decreased biliary excretion of copper and defective incorporation of copper into caeruloplasmin within the hepatocytes. In children, WD usually presents after 3 years of age. Copper initially accumulates in the liver, and then circulating free copper (non-caeruloplasmin-bound copper) levels increase and copper is redistributed systemically with accumulation in the nervous system, cornea, kidneys and other organs and tissues. Children can be asymptomatic and found to have abnormal liver function tests incidentally. Symptomatic presentations mimic all types of liver disease, from chronic liver disease to acute hepatitis and fulminant hepatic failure.

The diagnosis of WD is made on the basis of a combination of clinical, biochemical and histochemical criteria. Kayser–Fleischer (KF) rings, due to copper deposition in the cornea, should be sought by slit lamp examination as they are rarely seen with the naked eye. Although highly diagnostic when present, KF rings are absent in up to 50% of young children with WD. Serum caeruloplasmin levels are reduced in the majority of patients, but may be normal in up to 20%. As caeruloplasmin is an acute-phase reactant, levels within the normal range can be a consequence of inflammation in WD presenting acutely. In adults with Wilsonian acute liver failure, alkaline phosphatase levels are disproportionately low, an alkaline phosphatase/bilirubin ratio of < 2 being considered suggestive of WD. This parameter is not as useful in childhood because of the increase in bone-derived alkaline phosphatase. Urinary copper excretion before and after penicillamine challenge is a useful diagnostic tool, but difficult to determine in severely ill children. Baseline urinary copper that exceeds 1 mmol/24 h and urinary copper of > 25 μmol/24 h after the administration of two doses of 500 mg of penicillamine at collection times 0 and 12 are highly suggestive of WD [39]. A liver biopsy for histological examination and tissue copper quantification is often considered the gold standard for diagnosis, but may not be sufficiently informative because of sampling error or because of the presence of severe fibrosis or hepatocyte necrosis. Suggestive histological findings are fatty changes, Mallory bodies, vacuolated nuclei (which however are also common in healthy children), fibrosis/cirrhosis and increased copper on rhodamine staining. The normal hepatic copper content is < 40 μg/g dry weight, with values of > 250 μg/g dry weight being highly suggestive of WD. Diagnosis by genetic mutational analysis for index cases is unsatisfactory, owing to the polymorphism of the WD gene, but it is very useful in identifying asymptomatic affected family members.

Liver transplantation is the only life-saving option for children presenting with acute liver failure and encephalopathy. For all other presentations, copper chelation therapy with penicillamine or trientine (or exceptionally ammonium

Table 3 Clinical, laboratory and histological features at presentation of autoimmune hepatitis type 1, autoimmune hepatitis type 2 and autoimmune sclerosing cholangitis [37,38].

	Type 1 AIH	Type 2 AIH	ASC
Median age (years)	11	7	12
Females (%)	75	75	55
Mode of presentation (%)			
Acute hepatitis	47	40	37
Acute liver failure	3	25	0
Insidious onset	38	25	37
Complication of chronic liver disease	12	10	26
Associated immune diseases (%)	22	20	48
Inflammatory bowel disease (%)	20	12	44
Family history autoimmune disease (%)	43	40	37
Abnormal cholangiogram (%)	0	0	100
ANA/SMA (%)	100	25	96
Anti-LKM-1 (%)	0	100	4
pANCA (%)	45	11	74
Anti-SLA (%)[a]	58	58	41
Increased IgG level (%)	84	75	89
Partial IgA deficiency (%)	9	45	5
Low C4 level (%)	89	83	70
Increased frequency of HLA *DR*0301*	Yes	No[b]	No
Increased frequency of HLA *DR*0701*	No	Yes	No
Increased frequency of HLA *DR*1301*	No	No	Yes
Interface hepatitis (%)	66	72	35
Biliary features (%)	28	6	31
Cirrhosis (%)	69	38	15
Remission after immunosuppressive treatment (%)	97	87	89

AIH, autoimmune hepatitis; ASC, autoimmune sclerosing cholangitis; ANA, antinuclear antibodies; SMA, antismooth muscle antibody; LKM-1, liver–kidney microsomal type 1 antibody; pANCA, perinuclear antineutrophil cytoplasmic antibody; SLA, soluble liver antigen; IgG, immunoglobulin G; IgA, immunoglobulin A; C4, C4 component of complement; HLA, human leukocyte antigen.

[a]Measured by radioligand assay.

[b]But increased in HLA *DR*0701*-negative patients.

tetrathiomolybdate) or a combination of chelation and zinc should be started as soon as possible. Penicillamine has several side-effects (bone marrow depression, nephrotoxicity, autoimmunity) and should be started at a low dose (5 mg/kg b.i.d.), and increased by 5 mg/kg/day weekly up to a maximum dose of 10 mg/kg b.i.d. (maximum dose 1 g b.i.d.). Trientine can be used as an alternative to penicillamine. Neurological deterioration can be observed at the beginning of chelation therapy, but it usually resolves during treatment. Response to therapy is variable and depends on the severity of liver damage. For children presenting with decompensated liver disease, but without encephalopathy, a prognostic score in order to predict mortality without transplantation was developed by Nazer *et al.* in 1986 and revised by Dhawan *et al.* in 2005 [40] (Table 4). For those

Table 4 New Wilson index for predicting mortality.

Score	Bilirubin (μmol/L)	AST (IU/L)	INR	WCC (10^9/L)	Albumin (g/L)
0	< 100	< 100	< 1.3	0–6.7	> 45
1	100–150	100–150	1.3–1.6	6.8–8.3	34–44
2	151–200	151–300	1.6–1.9	8.4–10.3	25–33
3	201–300	301–400	1.9–2.4	10.4–15.3	21–24
4	> 301	> 301	> 2.5	> 15.4	< 20

AST, aspartate aminotransferase; INR, international normalized ratio; WCC, white cell count.

Score ≥ 11: 93% sensitivity and 97% specificity in predicting mortality without liver transplantation. Modified from ref. 40.

children who respond to chelation therapy, long-term prognosis with native liver is excellent even though liver function tests may take a long time to normalize.

Zinc, which inhibits the intestinal absorption of copper and stimulates enterocyte metallothionein, has been used as monotherapy in children with less severe liver damage and could be a non-toxic alternative to chelation therapy in asymptomatic siblings (zinc acetate 25 mg b.i.d., maximum dose 50 mg t.d.s.). When used in combination with chelating agents, zinc should be administered on its own a few hours before or after penicillamine or trientine to avoid its chelation.

Cystic fibrosis (CF) liver disease

The improving life expectancy of patients with cystic fibrosis (CF) has led to an increased prevalence of CF-related liver disease, which has become the third leading cause of death in this condition. The absence of the CF transmembrane conductance regulator (CFTR) leads to physiochemical abnormalities in various secretions. At the hepatobiliary level, CFTR expression occurs on the biliary epithelium and, as a result of its absence or dysfunction, biliary secretions become concentrated and acidic, leading to biliary obstruction and progressive periportal fibrosis [41].

Focal biliary cirrhosis is the pathognomonic hepatic lesion of CF and can lead to multilobar biliary cirrhosis, portal hypertension and its complications. Liver disease in CF is, however, often asymptomatic for several years and progresses quite variably in different patients. Poor nutrition, drug hepatotoxicity and non-adherence might contribute to liver damage, as well as other interventions such as abdominal surgery and parenteral nutrition. It is thought that modifier genes might influence the expression and severity of liver disease in CF independently from the CFTR gene [42]. Rarely, CF-related liver disease can present with neonatal cholestasis and, therefore, a sweat test or measurement of immunoreactive trypsin should be included in the diagnostic workup of infant cholestasis.

Hepatic steatosis is also a common finding in CF, although its pathogenesis is unclear. Suggested mechanisms include nutritional deficiencies, antibiotic therapy, insulin resistance or the effect of cytokines, induced by chronic respiratory infection, on fatty acid oxidation or mitochondrial function [43].

Other types of liver disease such as sclerosing cholangitis, most likely secondary to an ongoing inflammatory process in the biliary system, have been described in CF. Interestingly, in adults with primary sclerosing cholangitis, an increased prevalence of CFTR mutations has been reported [44].

Three centres, in Sweden, Italy and Canada, have reported the incidence and epidemiology of CF-related liver disease and concluded that liver disease is a relatively early complication of CF that, however, does not alter the clinical course in terms of respiratory and nutritional complications [43,45,46]. The reported prevalence of CF-related liver disease varies between 25% and 63%, with development of cirrhosis in 4–7.8%. A history of meconium ileus was identified by both Colombo *et al.* [45] and Lamireau *et al.* [46] as a risk factor for CF liver disease, as well as male sex and the genotype in the Italian group, and pancreatic insufficiency in the Canadian group. These risk factors, however, were not confirmed in the Swedish study [43].

The diagnosis of CF-related liver disease is made on the basis of clinical (hepatomegaly), biochemical (elevated serum aminotransferase levels) and ultrasound (echogenicity of the liver, splenomegaly) findings.

UDCA has been suggested to improve the liver function tests and the nutritional status of the patients, but long-term longitudinal studies are required to confirm this [47].

Liver transplantation becomes an option for children with CF who develop endstage liver disease. Initial improvement in pulmonary function after liver transplantation has been reported, and long-term survival is comparable to that of liver transplantation performed for other conditions with no associated lung disease [48]. Respiratory disease remains the main cause of morbidity and mortality after liver transplantation. Timing of liver transplantation when lung function is still preserved and nutritional status is good is very important.

Fatty liver disease [49,50]

Non-alcoholic fatty liver disorders (NAFLD) are increasingly recognized in children and cover a spectrum that extends from simple steatosis, through steatohepatitis (NASH) to cryptogenic cirrhosis, in which steatosis might be inconspicuous. Other conditions, including drug hepatotoxicity and genetic and metabolic diseases that can cause hepatic steatosis, must be excluded. The prevalence of NAFLD at paediatric ages is increasing since its first reports in the early 1980s, currently ranging between 10% and 77% in different geographical areas among obese children. Risk factors are obesity, diabetes, insulin resistance and hypertriglyceridaemia. Only a minority of children with these risk factors develop NASH, and a two-hit hypothesis has been proposed. The first hit is thought to be insulin resistance resulting in steatosis, followed by oxidative stress as a second hit, with production of lipid peroxidation and activation of inflammatory cytokines such as tumour necrosis factor (TNF)α, which results in NASH. Children with NAFLD are generally prepubertal and male. Approximately 90% are obese. There are no characteristic symptoms, but complaints of vague abdominal pain, lethargy and malaise are common. Acanthosis nigricans may be present. Serum alanine aminotransferase levels are usually more elevated than aspartate aminotransferase levels, and hypertriglyceridaemia is frequent. Fasting blood glucose is most commonly normal, whereas fasting insulin levels are typically elevated. Increased echogenicity is noted on ultrasound scan of the liver. The gold standard for diagnosis remains a liver biopsy, as it confirms the diagnosis while establishing the degree of fibrosis and/or cirrhosis, and allows the exclusion of other conditions that can result in hepatic steatosis (in particular WD). Macrovesicular steatosis is a common finding, in contrast to the microvesicular steatosis that is often seen in metabolic

conditions. Other diagnostic histological features are hepatocyte ballooning and mixed mild lobular inflammation [51]. The natural history varies according to the type and degree of histological damage. The inflammatory changes of NASH are associated with progression to cirrhosis, whereas in the absence of inflammation, the clinical course is benign.

Treatment of NAFLD in children is aimed at preventing the development of fibrosis, with consequent cirrhosis and its complications, and is therefore targeted at decreasing obesity, insulin resistance and hyperlipidaemia. With regard to obesity, a slow consistent weight loss combined with regular physical exercise and family-based behavioural intervention is most effective. Pharmacological agents that have been tried with variable results in the treatment of NASH include UDCA, antioxidants (vitamin E, N-acetylcysteine), lipid-lowering agents and drugs that reduce hyperinsulinaemia and improve hepatic insulin resistance, such as metformin [52]. However, no randomized controlled trials are available for any of these therapeutic approaches. Once the diagnosis of NASH is made, a close follow-up is indicated. Data on the progression to cirrhosis are limited, but, in the USA, adolescents have been transplanted for endstage liver disease due to NASH, and children with NAFLD have been reported to develop HCC in adulthood. Thus, paediatric NAFLD must be considered as a serious disease.

Fibropolycystic liver disease

Fibropolycystic liver disease comprises a heterogeneous group of disorders histologically characterized by 'ductal plate malformation', caused by an aberrant remodelling of the embryonal ductal plate during organogenesis [53]. Processes of necro-inflammation and destruction of the immature intrahepatic bile ducts that accompany the ductal plate malformation can lead to fibrosis. These disorders are often associated with fibrocystic anomalies in the kidneys and share the same genetic defect. The gene was localized to chromosome region 6p21 in 1994 and described as *PKHD1* in 2002; 119 different mutations have been reported so far.

Four types of fibropolycystic liver disease have been described depending on the order of the bile ducts affected.

Congenital hepatic fibrosis is associated with autosomal recessive polycystic kidney disease and is characterized by ductal plate malformation of the intrahepatic bile ducts and fibrosis. Children most commonly present during childhood or adolescence with isolated hepatomegaly or variceal bleeding secondary to portal hypertension. In 1998, Jaeken and colleagues described a metabolic condition, carbohydrate-deficient glycoprotein syndrome type 1b (CDGS Ib), characterized by congenital hepatic fibrosis associated with cyclical vomiting, protein-losing enteropathy and prothrombotic tendency, as well as neurological impairment [54]. In the presence of congenital hepatic fibrosis, therefore, screening with transferrin isoelectrofocusing for a glycosylation defect is advisable. Management of symptomatic portal hypertension includes variceal sclerotherapy or banding. If endoscopic treatment fails to control the bleeding, a shunt procedure is indicated. Liver transplantation is an option in cases with poor synthetic function.

Caroli disease is caused by malformation of the larger bile ducts and is characterized by cystic dilatation detectable by ultrasonography. Hepatic fibrosis is absent. The clinical presentation is often with recurrent episodes of cholangitis, and management involves aggressive antibioticotherapy. Partial hepatectomy has been used in segmental or lobar forms [55].

In Caroli syndrome, the ductal plate malformation of larger bile ducts is associated with hepatic fibrosis. Complications of portal hypertension and recurrent cholangitis are common.

Von Meyenburg complexes, also known as biliary hamartomas, are discrete foci of ductal plate malformations affecting the smallest bile ducts, commonly present as an incidental finding on liver histology.

Acute liver failure

Acute liver failure (ALF) in adults was defined by Trey and Davidson in 1970 as 'a potentially reversible condition, the consequence of severe liver injury, in which the onset of hepatic encephalopathy is within 8 weeks of the first symptoms of illness, in the absence of pre-existing liver disease' [56]. As signs of encephalopathy are difficult to identify in children, especially in infants, in whom encephalopathy can be a very late event in the course of the disease, this definition is unsatisfactory in paediatrics. Moreover, in children, ALF is often the first presentation of an underlying unrecognized liver disease. In 1996, the following definition of ALF in children was suggested: 'a rare multisystem disorder in which severe impairment of liver function, with or without encephalopathy, occurs in association with hepatocellular necrosis in a patient with no recognised underlying chronic liver disease' [57]. The aetiology of ALF varies depending on the age at presentation.

ALF in the neonatal period [58]

ALF during the neonatal period is rare, but carries a 70% mortality without liver transplantation. In any neonate presenting with a coagulopathy, neonatal liver failure should be considered. The most common aetiologies in the neonatal period are liver-based metabolic conditions and perinatally acquired infections (Table 5).

Viruses of the herpes family, adenovirus, parvovirus and hepatitis B can cause ALF in neonates. Also, enteroviruses, comprising polio, coxsackie A and B and echoviruses, have been reported to cause multiorgan, including liver, involvement in neonates. Herpes simplex viruses (HSV) type 1 and 2 are the most common microbial cause of neonatal liver failure [59]. Skin lesions are usually absent. Infected infants are typically asymptomatic at birth and present within the first 2 weeks of life with non-specific symptoms of poor feeding and lethargy. Coagulopathy and severely deranged liver function are a constant finding.

Table 5 Aetiology of neonatal acute liver failure (< 1 month of age) (39 consecutive infants seen between 1982 and 2004 at King's College Hospital).

Diagnosis	Number	%
Neonatal haemochromatosis	13	33
Herpes simplex virus infection	9	23
Haemophagocytic lymphohistiocytosis	5	13
Galactosaemia	3	8
Non-A–E hepatitis	3	8
Tyrosinaemia type 1	1	3
Echovirus infection	1	3
Others	3	8

Paediatricians have a low threshold for treating these infants with broad-spectrum antibiotics but, unfortunately, not with aciclovir, a drug that is life saving [59]. Intravenous aciclovir should therefore be added to the treatment of neonates presenting with severely deranged liver function tests and coagulopathy. For those children whose liver damage continues despite aciclovir treatment, transplantation has been performed successfully.

Ischaemic liver injury following sepsis and shock can present as ALF. Usually, the liver function settles once the circulatory problem is resolved. Vascular causes such as congestive heart failure of any aetiology can also present as ALF. Typical signs are ascites, hepatomegaly, coagulopathy and hypoalbuminaemia.

Metabolic disorders are a common cause of ALF in the neonatal period and warrant prompt diagnosis, as appropriate management with diet or disease-specific treatment is often life saving. They include galactosaemia, hereditary fructose intolerance, tyrosinaemia and mitochondrial hepatopathies (see section on 'Metabolic liver disease').

Neonatal haemochromatosis (NH)

NH, a rare disorder of unknown aetiology, is the most common cause of ALF during the neonatal period, representing 30% of all neonatal ALF in our tertiary referral centre. Liver injury, associated with massive iron deposition, is thought to commence *in utero*. Iron deposition is also present in extrahepatic tissues such as pancreas, heart, thyroid and salivary glands, but spares the reticuloendothelial system. Neonates with NH present with ALF at birth or during the first week of life. There is an 80% recurrence rate within families of affected children, irrespective of having different fathers. The precise pattern of inheritance is unknown: there have been suggestions of an incomplete penetrance or gonadal mosaicism for a dominant disorder or mitochondrial defect. Other causes such as an intrauterine viral infection and maternal alloimmune antibodies have been suggested. Maternal anaemia, oligohydramnios and megaplacenta are common, and the obstetric history may reveal previous miscarriages or stillborn infants. In a series of 15 pregnant mothers who had previously an affected baby, antenatal administration of intravenous immunoglobulins at weekly intervals from 18 weeks of gestation onwards reduced the severity of the illness in the newborn [60]. Demonstration of extrahepatic iron deposits sparing the reticuloendothelial system confirms the diagnosis. This can be done by performing a biopsy of the lip salivary glands or by magnetic resonance imaging (MRI) of the abdomen that might demonstrate the presence of iron in the pancreas but not in the spleen. Ferritin levels are raised, but this is a common finding in neonatal liver disease. A more reliable test is the measurement of transferrin saturation, which is raised to 95–100% in NH. Liver biopsy is usually contraindicated because of coagulopathy. Moreover, it is of no great diagnostic value as the presence of intrahepatic iron deposition is common in all types of severe liver disease in the neonatal period. The prognosis is poor with a mortality rate of 80–90% [61]. Single whole blood volume exchange transfusion can be helpful in managing the coagulopathy and in removing the possible maternal alloantibodies suggested as playing a role in the pathogenesis of NH.

The use of the antioxidant cocktail described in Table 6 has been variably reported to improve outcome, but has not been tested in controlled trials and did not alter the outcome in our own series [61]. The only therapeutic option in severe cases is liver transplantation, which can be performed even during the first few days of life provided a suitable donor is found. The survival after liver transplantation is 50% in our own series [61].

Haemophagocytic lymphohistiocytosis (HLH)

HLH is a rare disorder characterized by inappropriate activation of macrophages. Two forms have been described, a primary autosomal recessive familial form presenting in infancy and a secondary form usually triggered by infection in an immunocompromised host. The form presenting with ALF during the neonatal period is usually the primary form. Presenting symptoms and signs are high fever, raised triglycerides, low fibrinogen, severe coagulopathy and pancytopenia. Haemophagocytosis affects all organs and can be diagnosed on bone marrow aspiration or cytospin from body fluids (ascites, cerebrospinal fluid). Liver biopsy is contraindicated because of the particularly severe coagulopathy. In the primary form, mortality is high despite aggressive supportive treatment, chemotherapy and bone

Table 6 Antioxidant cocktail for neonatal haemochromatosis.

Medication	Dose	Administration
Vitamin E	25 IU/kg/day	Orally
N-acetylcysteine	100 mg/kg/day	Intravenously
Selenium	3 mg/kg/day	Intravenously
Prostaglandin E1	0.4 μg/kg/h	Intravenously (for 2 weeks maximum, if no cardiac contraindications)
Desferrioxamine	30 mg/kg/day	Intravenously (until ferritin < 500 ng/mL)

Table 7 Aetiology of acute liver failure in children > 1 month of age (173 consecutive children seen between 1982 and 2004 at King's College Hospital).

Diagnosis	Number	%
Non-A–E hepatitis	63	36
Paracetamol toxicity	32	18
Autoimmune liver disease	13	7.5
Viral hepatitis	13	7.5
Toxic (other than paracetamol)	12	7
Metabolic (other than Wilson's disease)	12	7
Wilson disease	10	6
Veno-occlusive disease	6	3.5
Hypoxia	6	3.5
Others	5	3

marrow transplantation. Liver transplantation is contraindicated because the disease is systemic.

Acute liver failure in infancy and childhood

The aetiology of ALF in children outside the neonatal period (> 1 month of age) differs according to geographical areas. Table 7 summarizes the most common causes of ALF in infancy and childhood in our tertiary referral centre.

Infective causes

Hepatotropic viruses such as A, B or E, although usually associated with mild hepatitis in childhood, are the most common causes of ALF in children in Latin America and Asia, while the most common cause of ALF in the western world is non-A–E hepatitis, which is diagnosed by excluding all other causes of ALF. Other viruses such as parvovirus, EBV and HSV can also rarely cause ALF. Severe bacterial infections, especially those caused by Gram-negative germs, can cause ALF by inducing the production of nitric oxide that is toxic to the liver cells and causes reduced hepatic perfusion, hypoxia and lactic acidosis.

Drugs and toxins

Drug-induced ALF can be a dose-dependent reaction (e.g. paracetamol) or caused by an idiosyncratic (e.g. halothane, isoniazid, non-steroidal anti-inflammatory drugs, antiepileptic drugs, antibiotics) or synergistic reaction (e.g. isoniazid and rifampicin). In 90% of cases, the drug causes a hepatitic injury, while a cholestatic or mixed injury is rarer. Sodium valproate toxicity can unmask an underlying mitochondrial cytopathy, which must be sought for correct management and genetic counselling. Paracetamol is the drug most commonly causing ALF in the UK. A detailed history of medication intake is essential. Although paracetamol levels are helpful, they may be below the risk threshold in children exposed to high doses over time. Severe coagulopathy and hypertransaminasaemia in the presence of mildly elevated bilirubin should raise the suspicion of paracetamol poisoning or a metabolic disorder. Akin to adults, the degree of coagulopathy and the presence of metabolic acidosis, renal failure and hypoglycaemia are poor prognostic factors [62].

Mushroom poisoning by *Amanita phalloides* is a common cause of toxin-induced ALF especially in Europe, the west coast of the USA and South Africa.

Metabolic conditions

Metabolic conditions causing ALF in children, such as WD, tyrosinaemia and mitochondrial cytopathies, are discussed elsewhere in this chapter.

Autoimmune liver disease

Autoimmune hepatitis, particularly when positive for antiliver–kidney microsomal antibody (type 2 AIH), can cause acute liver failure and should always be excluded because, in the absence of encephalopathy, immunosuppressive treatment is life saving. In the presence of encephalopathy, liver transplantation is often the only therapeutic option.

Miscellaneous

Vascular and ischaemic conditions impairing hepatic venous outflow (e.g. Budd–Chiari syndrome, veno-occlusive disease, congestive heart failure) as well as haematological disorders such as lymphoma, leukaemia and haemophagocytic lymphohistiocytosis (HLH) can present as ALF in childhood.

Management of ALF

Patients with ALF should be nursed in a quiet environment with as little stimulation as possible to minimize acute increase in intracranial pressure. Children with encephalopathy and those without encephalopathy but an international normalized prothrombin ratio (INR) greater than 4 should be admitted to the intensive care unit for continuous monitoring. Patients should be monitored carefully with respect to haemodynamics and fluid management (blood pressure, urine output), metabolic parameters (electrolytes, blood sugar) and neurological status (presence of encephalopathy). Sedation should be avoided unless the patient is to be mechanically ventilated, as it can interfere with the monitoring of neurological status. Coagulation and metabolic parameters, full blood count and arterial blood gases in ventilated patients should be checked regularly. Maintenance of nutrition is crucial, and hypoglycaemia should be avoided by the use of intravenous glucose infusion or by ensuring adequate enteral intake. Total fluid intake is restricted to two-thirds of the maintenance amount if the patient is not dehydrated. The concept of protein intake aggravating or precipitating hepatic encephalopathy has now been disregarded, and adequate calories should be provided using oral or nasogastric feeding. Investigations to elucidate the cause of ALF should be performed urgently to start appropriate treatment. Liver biopsy is

only rarely useful and usually contraindicated because of severe coagulopathy.

Complications of ALF

Encephalopathy

The most serious complication of ALF is cerebral oedema with resultant intracranial hypertension and encephalopathy. Encephalopathy usually presents late in the course of the illness and, when present, carries a poor prognosis. The conventional grading system for encephalopathy (grade I–IV) used for adults and older children is not applicable to babies. Signs of early encephalopathy in babies are inconsolable crying and sleep disturbance, which can progress to somnolence or irritability and, later, to frank coma more or less responsive to painful stimuli. The infant should be electively ventilated and sedated at the first signs of encephalopathy. Mannitol, an osmotic diuretic that remains the mainstay of treatment for increased intracranial pressure in adults and older children, is not often used in babies, for whom exchange transfusion is usually a better option.

Infection

Patients with ALF have impaired immune function. About 60% of deaths in ALF are due to sepsis. An active uncontrolled infection is also a relative contraindication for liver transplantation. The risk factors for infections include coexisting renal failure, cholestasis and treatment with thiopental. The most common bacterial infection is due to *Staphylococcus aureus*, but streptococci or Gram-negative organisms such as coliforms are also isolated. Deterioration of encephalopathy after an initial improvement, a markedly raised leukocyte count, pyrexia unresponsive to antibiotics and established renal failure are strong indicators of fungal infection. Children with ALF should be treated from admission with broad-spectrum antibiotics (usually third-generation cephalosporins and aminoglycoside) and fluconazole. In neonates, aciclovir should always be added.

Coagulopathy

The prothrombin time, usually expressed as INR, is used as an indicator of the severity of liver damage and to decide when to list for transplantation. An INR ≥ 4 is associated with more than 90% mortality and is the main parameter used for transplant listing. Thus, correction of coagulopathy is indicated only if the patient is already listed for transplant or prior to invasive procedures. Significant disseminated intravascular coagulation (DIC) is unusual in ALF. The risk of haemorrhage does not correlate with INR but with thrombocytopenia, which can develop rapidly. Common sites of internal haemorrhage include the gastrointestinal tract, nasopharynx, lungs and retroperitoneum. Intracranial haemorrhage is uncommon. The presence of significant DIC usually indicates sepsis or secondary HLH. Prophylactic ranitidine or proton pump inhibitors decrease the incidence of gastric bleeding.

Haemodynamic complications

The early haemodynamic changes in ALF patients are similar to those seen in the systemic inflammatory response syndrome and reflect a state of hyperdynamic circulation with decreased systemic peripheral vascular resistance and increased cardiac output. Circulatory failure is a common mode of death in patients with ALF, often complicating sepsis or multiorgan failure. Invasive haemodynamic monitoring such as arterial blood pressure, central venous pressure or PICCO and oesophageal echocardiography in adults may provide early evidence of circulatory failure and is helpful in deciding fluid management, but is usually difficult in small infants. In the presence of persistent hypotension despite normal filling, noradrenaline (noreoinephrine) is the inotropic agent of choice. *N*-Acetylcysteine has been shown to improve parameters of oxygen metabolism.

Renal failure

Renal failure with severe oliguria often develops in ALF, especially in the later stages. In the paediatric population, the incidence of renal failure is lower (10–15%) than in the adult population (30%), but there are no studies in neonates. Renal failure could be due either to a direct toxic effect on the kidneys, as in paracetamol overdose, or to a complex mechanism such as hepatorenal syndrome or acute tubular necrosis secondary to ALF complications (sepsis, bleeding and/or hypotension). Although the mechanism of renal failure is not clear, it is essential to correct intravascular hypovolaemia. Continuous filtration or dialysis systems are associated with less haemodynamic instability and, consequently, less risk of aggravating latent or established encephalopathy than intermittent haemodialysis.

Metabolic derangement

Hypoglycaemia is present in some 40% of patients with ALF. The classic signs and symptoms of hypoglycaemia are often masked, especially in the presence of encephalopathy; hence, regular blood glucose monitoring is mandatory as hypoglycaemia can worsen the encephalopathy and cause rapid neurological deterioration. Acid–base imbalance is common. Metabolic acidosis is present in about 5% of patients with ALF and is associated with poor outcome. Lactic acidosis is related to inadequate tissue perfusion. Sometimes respiratory alkalosis or acidosis may complicate the clinical picture.

Liver transplantation in ALF

The availability of liver transplantation has significantly improved survival in ALF, but the procedure is contraindicated in patients with advanced complications, such as fixed and dilated pupils, uncontrolled sepsis and severe respiratory failure (adult respiratory distress syndrome) or conditions not treatable by liver replacement, such as mitochondrial cytopathies with neurological involvement, HLH, giant cell hepatitis with Coombs'-positive haemolytic anaemia (which recurs after transplant) and systemic malignancies. Advances in surgical

techniques have made it possible to perform liver transplantation even in newborn babies.

Auxiliary liver transplantation is used in paediatric ALF caused by drugs and toxins or cryptogenic ALF, after excluding possible underlying chronic problems. The advantage of this procedure is that, in most patients, the native liver regenerates during the first year after transplant, allowing a decrease in and then cessation of antirejection treatment, with consequent rejection of the transplanted liver and no need for the long-term use of toxic immunosuppressive drugs [63].

Metabolic liver disease

Inborn errors of metabolism can present with acute or chronic liver involvement. A review from Mexico reports a prevalence of 8.8% of metabolic disorders among 3630 patients referred to a tertiary referral centre [64].

Alpha-1-antitrypsin deficiency, Wilson disease, neonatal haemochromatosis and cystic fibrosis have been discussed in previous parts of this chapter.

Hereditary tyrosinaemia type 1

Deficiency of fumaryl acetoacetate hydrolase, the last enzyme in tyrosine degradation, is responsible for this autosomal recessive condition (chromosome 15). Tyrosinaemia is particularly common in the province of Quebec, Canada (incidence 1/16 786 live births) [65], Scandinavia and Pakistan, but is found worldwide (1/100 000–120 000 live births) [66]. The enzyme is mainly expressed in the liver and kidneys, where the interaction of succinylacetone and its immediate precursors with sulphydryl groups causes injury. Children can present in the neonatal period with hepatitis and coagulopathy or later with hepatomegaly, ascites and coagulopathy but no jaundice. Renal tubular dysfunction, together with liver damage, is responsible for the development of rickets, a characteristic finding in tyrosinaemia. Neurological crises, due to the interaction between the metabolites of phenylalanine and tyrosine with the synthesis of porphyrin, present with abdominal pain, which can be followed by polyneuropathy, weakness and even paralysis. They are present in up to one-third of patients. In all infants with severe hepatitis or coagulopathy, tyrosinaemia should be excluded because, if untreated, the liver disease is progressive with a high mortality rate, particularly in infants presenting during the first 2 months of life (70% mortality by 24 months of age compared with 29% for infants diagnosed between 2 and 6 months of age). Some 40% of infants who survive to childhood develop HCC. The presence of elevated succinylacetone levels in the urine is pathognomonic for tyrosinaemia. Plasma tyrosine levels are elevated, but this is a non-specific finding in liver disease; often phenylalanine and methionine are also elevated. A common laboratory finding is markedly raised AFP. Elevated levels of AFP, however, are also non-specific as they are common in infants with neonatal cholestasis.

Tyrosinaemia can be treated with 2-(2-nitro-4-trifluoromethylbenzoyl)-1,3-cyclohexanedione (NTBC), an inhibitor of 4-hydroxyphenylpyruvatedioxygenase, which prevents the accumulation of succinylacetone. NTBC, together with a tyrosine-restricted diet, has significantly improved the survival of children with tyrosinaemia [67], but the risk of HCC persists and warrants close follow-up with imaging. Liver transplantation is an option in the neonatal period when treatment with NTBC and diet fails or later on when liver nodules are detected and malignant transformation is suspected. Prenatal diagnosis by genetic testing is available.

Inborn errors of carbohydrate metabolism

Galactosaemia [68]

Galactosaemia is an autosomal recessive disorder (chromosome 9p18) with over 150 mutations identified to date. The genetic abnormality causes deficient production of galactose-1-phosphate uridyl transferase, an enzyme involved in the breakdown of galactose into glucose. Accumulation of galactose-1-phosphate and galactitol results in toxicity affecting the liver, eye lens, brain and kidneys. Infants can present with a fulminant illness with hypoglycaemia, abdominal distension, anorexia, diarrhoea and vomiting after the first ingestion of milk. A direct correlation between galactosaemia and neonatal *Escherichia coli* sepsis has been identified. Other children develop jaundice and hepatomegaly after the first week of life together with failure to thrive, diarrhoea and vomiting. Haemolysis can be present. Rarely, the diagnosis is made during childhood. Cataracts can be present in the neonatal period but usually develop on follow-up. Mental retardation becomes apparent after the first few months of life. Diagnosis is made by measuring galactose-1-phosphate uridyl transferase in red blood cells. If the infant has been transfused, the enzyme should be measured in the parents, and diagnosis made on the basis of levels compatible with heterozygosity. Detection of urinary reducing substances can be suggestive of galactosaemia, but can also be present in other forms of liver disease. Conversely, the absence of reducing substances in the urine does not exclude galactosaemia as the affected infants often vomit galactose-containing milk. Elimination of dietary galactose is the essence of treatment. Despite this, endogenous production of galactose can be responsible for ongoing galactose toxicity. All infants presenting with ALF or conjugated hyperbilirubinaemia should be changed to a lactose-free formula until the diagnosis of galactosaemia is excluded.

Hereditary fructose intolerance [68]

Hereditary fructose intolerance is caused by fructose-1-phosphate aldolase (aldolase B) deficiency in the liver, kidney and intestine and is inherited in an autosomal recessive manner. The gene is located on chromosome 9. Age at presentation depends on the time of exposure to fructose and sucrose.

Symptoms usually appear with the introduction of honey, fruits, juices and vegetables to the diet. Most common symptoms are vomiting, abdominal distension and pain, failure to thrive and hepatomegaly, but the presentation can be variable. Elevated serum aminotransferases, mild coagulopathy, hypoglycaemia, hyperlacticacidaemia, hypophosphataemia and hyperuricaemia can be present. Diagnosis is made by measuring fructose-1-phosphate aldolase in hepatic or small intestine tissue or by molecular genetic studies. The only effective treatment is removal of fructose from the diet.

Glycogen storage disorders (GSD)

Glycogen is the primary carbohydrate storage compound in animals and, by depolymerization, it releases free glucose to sustain cellular processes and to maintain normal blood glucose concentrations during fasting. The formation and degradation of glycogen is regulated by different enzymes, deficiencies in which result in at least 12 forms of GSD. Types 1, 3 and 4 GSD primarily involve the liver and will be discussed here.

Type 1 GSD

Von Gierke originally described this clinical condition in 1929 and, in 1952, Cori and Cori identified its cause as a defect in glucose-6-phosphatase activity [69]. Subsequently, patients were subclassified into type 1a, characterized by no glucose-6-phophatase activity, and type 1b, characterized by a normal glucose-6-phosphatase activity but a defect in glucose-6-phosphate transport. Later, two further types of GSD type 1, 1c and 1d, were described. GSD type 1c is genetically distinct from types 1a and 1b, but has not yet been characterized at the molecular level, whereas GSD type 1d is thought to be caused by a defect in the microsomal glucose transporter, although this remains unproven at the moment [70]. Inheritance is autosomal recessive. Clinical presentation is most commonly with hepatomegaly, doll-like facial features, short stature and decreased bone mineral density. Some features develop around puberty, such as xanthomas and hepatic adenomas. GSD type 1 does not usually lead to cirrhosis or hepatic failure. Typical biochemical abnormalities are hypoglycaemia, lactic acidosis, hyperuricaemia, hypophosphataemia, hyperlipidaemia and platelet dysfunction. Neutropenia is characteristic of type 1b. Diagnosis is made by direct assay of the hepatic enzymatic activity on fresh liver tissue. Hepatocytes filled with glycogen are seen on liver histology. Their characteristic strong staining with PAS disappears after diastase treatment. There is no medical cure. Treatment is supportive with an emphasis on preventing hypoglycaemia. A diet with high starch content can be sufficient, but many children require continuous enteral or parenteral feeding. A glucose–lactate profile during 4–6 h of fasting is recommended to tailor dietary management. Liver transplantation can be offered to children with particularly poor metabolic control or complications such as the development of hepatic adenomas, considered to be premalignant.

Type 3 GSD

This type of glycogen storage disorder is characterized by deficiency in the debrancher enzyme amylo-1,6 glucosidase, present in both muscle and hepatic tissue. Complete absence of the enzyme defines type 3a, whereas in type 3b, residual enzyme activity is found in muscle and/or hepatic tissue. Inheritance is autosomal recessive. The condition is particularly common in the Middle East and in the non-Ashkenazi Jewish communities of north Africa. Several phenotypes have been described, varying from childhood onset with muscle weakness and liver involvement (usually soft hepatomegaly, with no splenomegaly, unless in the presence of fibrotic evolution), isolated liver involvement during childhood, muscle weakness in adulthood to cardiac enlargement and cardiomyopathy in adulthood. There is no direct central nervous system involvement, although damage can follow hypoglycaemic attacks. Biochemical abnormalities are similar to type 1, but less severe. Creatine kinase is often raised. Diagnosis is made by measuring the enzymatic activity in liver and muscle tissue. Liver biopsy can show progression to fibrosis. Management consists of a supportive dietary regime similar to that for type 1. Improvement in symptoms and delay in progression of the disease has been reported with the use of a high-protein diet with or without L-alanine supplementation [71].

Type 4 GSD [72]

Deficiency in the glycogen branching enzyme 1,4-glucan-6-glycosyl transferase causes GSD type 4 (also known as amylopectinosis or Andersen disease). This is a rare autosomal recessive disorder, representing 0.3% of all glycogenoses. Since its first description by Andersen, many variants with different tissue involvements and clinical presentations have been reported. The age of presentation can vary from the neonatal period to adulthood. The gene has been mapped on chromosome 3p14. The typical clinical presentation, as originally described, is failure to thrive and hepatosplenomegaly presenting early in life with rapid progression to endstage liver disease and death between 3 and 5 years of age. Deposition of amylopectin can affect skeletal and cardiac muscle and nervous tissue. This can lead to peripheral myopathy/neuropathy and cardiomyopathy. Diagnosis is suspected histologically by the detection of hepatocytes containing cytoplasmic PAS-positive deposits (amylopectin aggregates), which appear as finely granular material along with normal-appearing glycogen particles on electron microscopy. The enzymatic defect can be measured in muscle, leukocytes, cultured skin fibroblasts and amniotic cells. The only effective treatment for patients with progressive liver disease is liver transplantation. Of 13 children who underwent liver transplantation for GSD type 4, one died of cardiac failure due to progressive amylopectin accumulation after surgery. Careful cardiac and neurological assessments prior to considering liver transplantation are recommended.

Mitochondrial hepatopathies

Mitochondria provide energy for intracellular processes of oxidative phosphorylation throughout the body with the generation of adenosine triphosphate (ATP). Mitochondrial disorders can affect any organ, with dysfunction in those with a high metabolic demand, such as brain, muscle, kidney and liver, being the most likely to cause symptoms. Mitochondrial disorders affecting the liver can be caused by a primary inherited defect, such as respiratory chain complex I–V deficiency, mitochondrial DNA depletion syndrome, Pearson syndrome, primary fatty acid oxidation defects and Alper syndrome, or by a secondary process following the adverse impact of drugs or toxins on the mitochondrial structure. Although mitochondria have their own unique genome, they depend on nuclear DNA for replication and function. The mitochondrial DNA is exclusively inherited from the mother. Mitochondrial disease can present at any age but, in a paediatric series, most patients became symptomatic before the age of 2 years, 11% with liver disease. A combination of hypoglycaemia, multiorgan/liver failure, feeding difficulties, failure to thrive, neurological impairment and pancreatic insufficiency should raise the suspicion of mitochondrial problems and warrants further investigations. Biochemically, lactic acidosis is present with elevated serum and cerebrospinal fluid lactate, as well as mild to moderate conjugated hyperbilirubinaemia, high levels of aminotransferases, coagulopathy, hyperammonaemia and hypoglycaemia. Later onset cases tend to have a milder clinical course. Investigations for mitochondrial cytopathy include muscle biopsy and/or liver biopsy (mitochondrial DNA and respiratory chain enzyme measurement), magnetic resonance scan of the brain, neurophysiology, ophthalmology review and echocardiogram. In paediatrics, diagnosis should be sought by investigating muscle and liver mitochondrial DNA, as mutations are rarely detected in blood samples, in contrast to adults, suggesting that childhood disease is more likely to result from nuclearly encoded mutations. Tissue samples should be investigated fresh or snap frozen in liquid nitrogen and stored at –70°C prior to analysis. Often, a liver biopsy cannot be carried out because of coagulopathy. Liver histology findings are non-specific, showing the presence of micro- and macrovesicular steatosis. Fibrosis and progression to cirrhosis are seen in advanced disease. Abnormalities in the mitochondria are detectable by electron microscopy. In children with mitochondrial hepatopathies, the most common causes are isolated complex I and IV defects. As no satisfactory treatment is available, management remains supportive. If liver grafting is considered, possible neurological involvement should be investigated thoroughly, as it would contraindicate transplantation because of inevitable progression after surgery. For children with isolated liver disease, successful outcome has been reported, although follow-up is limited [73].

Urea cycle defects

Clinical symptoms in urea cycle and urea cycle-related disorders are caused by two different mechanisms. First, symptoms of hyperammonaemia are not specific to the metabolic defect and include acute neurological deterioration with vasomotor instability, apnoeas and fits. Respiratory alkalosis is usually present. Second, unique clinical manifestations depending on the metabolic defect arise from excesses or deficiencies in amino acids and/or related metabolites. Other factors such as age, nutritional status and associated disorders, e.g. infections, may modify the clinical symptoms. Management includes protein restriction, arginine and/or citrulline administration and the use of alternative pathways to excrete nitrogen, e.g. sodium benzoate or sodium phenylacetate that conjugate with glycine and glutamine respectively. Liver transplantation cures the defect. Auxiliary liver transplantation has been used successfully, with the advantage of leaving the children with part of their own livers should gene therapy become available in the future. In ornithine transcarbamoylase deficiency, perinatal hepatocyte transplantation has been shown to stabilize the disease and to function as a safe bridge to orthotopic transplantation [74].

Lysosomal storage disorders

Lysosomal storage disorders include mucopolysaccharidoses, lipidoses (Gaucher and Niemann–Pick disease), glycoproteinoses, mucolipidoses and cholesterol ester disease (Wolman disease). These conditions are rare and can present in the neonatal period or later in childhood. Neurological involvement with progressive dysfunction is common. Liver involvement can present as congenital or neonatal ascites, hepatomegaly or hepatosplenomegaly and conjugated jaundice in the newborn period. The presence of vacuolated lymphocytes on a peripheral blood smear is suggestive of a lysosomal storage disorder. Enzymatic activity is investigated in isolated peripheral blood leukocytes or cultured skin fibroblasts. The prognosis of most of these conditions is poor, although phenotypical variations are reported. Treatment is mainly supportive. Bone marrow transplantation has given variable and generally unsatisfactory results in mucopolysaccharidoses, Niemann–Pick and Gaucher diseases. The enzymatic defects are not corrected by liver transplantation. Effective, but very expensive, enzyme replacement is available for Gaucher disease [75].

Liver tumours

Liver tumours in children are rare and account for 0.5–2% of all neoplasms in the paediatric age group. The Armed Forces Institute of Pathology reported 10 types of liver tumours as seen in 716 cases ranging from birth to the age of 20 years (Table 8) [76]. The benign tumours, infantile haemangioendothelioma and mesenchymal hamartoma, and the malignant hepatoblastoma affect children below 2 years of age more commonly.

Infantile haemangiomata

Haemangiomata are benign vascular tumours, occurring almost exclusively in the first year of life. They are relatively common in

Table 8 Liver tumours in 716 patients from 0 to 20 years of age.

Type of tumour	%
Hepatoblastoma	28
Hepatocellular carcinoma	19
Infantile haemangioendothelioma	17
Focal nodular hyperplasia	10
Mesenchymal hamartoma	8
Undifferentiated embryonal sarcoma	7
Nodular regenerative hyperplasia	5
Hepatocellular adenoma	4
Angiosarcoma	2
Embryonal rhabdomyosarcoma	1

From American Forces Institute of Pathology 1970–1999 [76].

the skin and mucous membranes but can affect any organ system. In the liver, two histological types of lesions have been described: capillary haemangioma (or haemangioendothelioma) and cavernous haemangioma. Both types of lesion can be present in the same histological sample. Over time, haemangioendothelioma can become more cavernous in appearance as a consequence of increasing shunts.

Hepatic haemangioendothelioma (HHE) typically undergoes three stages, proliferation, maturation and involution, and is characterized by the clinical triad of high-output cardiac failure, hepatomegaly and cutaneous haemangiomata. The most common presenting features are hepatomegaly and abdominal distension, while the incidence of cutaneous haemangiomata is variable. HHE can occur as a single tumour or can be multifocal involving both lobes of the liver. If the patient survives the acute clinical phase, HHE eventually disappears. A major and, at times, life-threatening complication is high-output cardiac failure, due to the presence of significant shunting. Other complications include Kasabach–Merritt syndrome, anaemia, consumptive coagulopathy, obstructive jaundice, vascular malformation involving other organs and, rarely, intraperitoneal haemorrhage secondary to rupture. Hypothyroidism, associated with increased activity of type 3 iodo-thyroxin-diodinase within the tumour, is frequently present and requires temporary treatment [77].

For the diagnosis of HHE, non-invasive imaging, such as ultrasound scan with Doppler, computerized tomography and magnetic resonance, have been substituted for invasive angiographic studies. Needle liver biopsy is contraindicated because of the high risk of bleeding. Liver tissue can be obtained at laparotomy in selected cases when malignancy cannot be excluded on imaging. Because of the spontaneous resolution of the lesion over time, asymptomatic HHE does not warrant treatment. The management of symptomatic HHE depends on its severity. Medical treatment consists of symptomatic treatment of high-output cardiac failure with digitalis, diuretics and, more recently, angiotensin-converting enzyme (ACE) inhibitors. Other treatments to try and hasten the involution of the lesions have included radiotherapy, corticosteroids, interferon and chemotherapy with vincristine. Hepatic artery embolization has been reported. Surgical management includes resection of the lesion by hepatic lobectomy or hepatic artery ligation, depending on the size and localization of the lesion. Liver transplantation should be reserved for cases that do not respond to any of the other treatment options.

Mesenchymal hamartoma [78]

Mesenchymal hamartoma is a rare benign tumour with a multicystic appearance that typically affects children during the first 2 years of life. It can present with symptoms of abdominal distension, but is often an incidental finding on clinical examination or imaging and is rarely associated with abdominal pain. Biochemically, AFP can be mildly raised, but liver function tests are usually within normal limits. Imaging with ultrasound scan, computerized tomography and magnetic resonance shows a multiloculated cystic tumour with a hypodense and hypovascular appearance. Final diagnosis is made on the basis of histology, usually obtained at the time of resection. Mesenchymal hamartoma can occasionally be detected in prenatal ultrasound scans. Although a benign tumour, there are reports of undifferentiated embryonal sarcoma hiding within the mesenchymal hamartoma mass or becoming evident after incomplete resection. There have been reports of spontaneous regression of mesenchymal hamartomata, but complete excision remains the therapeutic option of choice.

Focal nodular hyperplasia (FNH)

FNH is a benign epithelial tumour, characterized by an irregular mass with a central stellate scar containing blood vessels. The lesion, typically well circumscribed and lobulated, can vary in size and be single or multiple. FNH is seen in all age groups and more commonly in females. It has been reported in older patients with GSD type 1. A literature review identified 86 paediatric cases between 1966 and 1993 [79]. Half the children complained of abdominal pain. Imaging with ultrasound scan, computerized tomography and magnetic resonance is usually diagnostic. Three treatment strategies have been suggested: conservative management with regular clinical and radiological follow-up; surgical excision of the mass; interventional treatment with embolization or ligation of the hepatic artery. There have been no reports of malignant transformation of this benign tumour; however, FNH associated with fibrolamellar HCC has been reported [80].

Nodular regenerative hyperplasia (NRH)

Nodules of hyperplastic hepatocytes, compressing the intervening liver parenchyma, are known as NRH. NRH is rare in the paediatric age group and, when present, in contrast to adults, is

not associated with neoplastic conditions. Children are often asymptomatic, and hepatosplenomegaly is detected fortuitously. Imaging with computerized tomography and magnetic resonance usually suggests the diagnosis. NRH can involve the whole liver and lead to portal hypertension and its complications. Treatment of complications or shunt procedures become necessary in severe cases, and liver transplantation has even been performed after failure of shunt surgery.

Hepatoblastoma [81]

Hepatoblastoma is an embryonic tumour derived from the epithelial cells of the fetal liver and is characterized by rapid growth. It is the most frequent malignant liver tumour in children and is most commonly diagnosed in the first 3 years of life. There is a male preponderance. Hepatoblastoma spreads by vascular invasion, typically in the lungs. It usually presents with abdominal distension, abdominal pain and failure to thrive. Anaemia and thrombocytosis are common laboratory findings. Very high AFP levels are a useful tumour marker in the majority of affected children and help in monitoring the response to therapy. The tumour can be suspected on ultrasonography, but computerized tomography or magnetic resonance imaging is necessary for an accurate differentiation between tumour and normal liver tissue. A diagnostic liver biopsy should be done percutaneously under ultrasound guidance. Epithelial and mesenchymal features can both be present on histology. Treatment consists of chemotherapy and complete tumour resection by partial hepatectomy or, if the tumour is unresectable, by liver transplantation. The Liver Tumour Study Group of the Societé Internationale d'Oncologie Pediatrique (SIOP) has published its guidelines with regard to the management of hepatoblastoma, which include pre- and postresection/transplant chemotherapy. In the USA, the Children's Cancer Group considers primary resection as the preferred treatment followed by adjuvant chemotherapy and liver transplantation for unresectable tumours [82]. The overall prognosis of hepatoblastoma is good if complete tumour resection is achieved. Adverse prognostic factors are low serum AFP (< 100 ng/mL), lack of response to chemotherapy and the presence of metastases at diagnosis.

Hepatocellular carcinoma (HCC)

HCC is rarely diagnosed in the paediatric age groups but, when present, is typically seen in older children/teenagers. Most commonly, HCC develops in the presence of an underlying liver disease such as chronic viral hepatitis (e.g. hepatitis B) or a metabolic disorder (e.g. tyrosinaemia or BSEP deficiency) [83]. Occasionally, HCC is diagnosed in children with no evidence of underlying liver disease. The typical presentation is with abdominal pain and an abdominal mass. AFP is often elevated, although not as much as in hepatoblastoma. Computerized tomography and magnetic resonance imaging can help to determine whether tumour resection is an option. Liver biopsy under ultrasound scan guidance is indicated if no underlying liver pathology is present. The histologically defined fibrolamellar variant of HCC is typically AFP negative and affects teenagers. Treatment consists of resection, chemotherapy or combined chemotherapy and resection, but the prognosis is very poor, with a reported 10–20% long-term survival rate [84]. Liver transplantation can be an option if the tumour is unresectable but confined to the liver; however, reported experience in children is limited.

Inflammatory pseudotumour

Inflammatory pseudotumour is a rare lesion that can arise in different organs and tissues, with the liver being a relatively common site of origin. The lesion is considered benign. Histology consists of proliferation of spindle-shaped cells, myofibroblasts, mixed with inflammatory cells, consisting of plasma cells, lymphocytes and occasional histiocytes. Since 1971, 15 paediatric cases have been reported in the literature, ranging in age from 10 months to 15 years [85]. The lesion can be solitary or multiple, and children often present with non-specific symptoms such as fever and impaired growth and are found to have raised inflammatory markers. There are no specific laboratory or radiological findings, and differential diagnosis with FNH can be difficult on imaging. A final diagnosis is made at the time of surgical resection, which is the most common form of treatment. Prognosis is generally good.

Portal hypertension

Portal hypertension exists when the pressure in the portal venous system rises above 10–12 mmHg. Portal hypertension can be a consequence of chronic liver disease or due to extrahepatic causes, such as portal vein thrombosis. Extrahepatic portal hypertension is observed more commonly in children than in adults [86]. Among children with cirrhosis, two-thirds have varices [87]. The risk of bleeding is substantial in both cirrhotic and non-cirrhotic children. Acute bleeding is usually managed with a combination of pharmacological (octreotide) and endoscopic interventions, including sclerotherapy and banding. With regard to primary prophylactic management, the use of beta-blockers (propranolol) has not been studied in large randomized trials in children. Prophylaxis of further bleeding with sclerotherapy or variceal ligation decreases the rate of rebleeding [88,89]. Liver transplantation needs to be considered in children with chronic liver disease when variceal bleeding does not respond to endoscopic treatment, while in children with extrahepatic portal hypertension and unmanageable bleeding, a shunt procedure is the therapeutic option.

Different types of shunts have been used in children, the most common being a distal splenorenal shunt and, more recently, the mesenterico-portal bypass, also known as the Rex shunt, where the left branch of the portal vein is connected to the superior mesenteric vein, thereby restoring portal flow directly to the

liver and preventing encephalopathy, a serious complication after traditional portosystemic shunts [90]. For the Rex shunt, preoperative investigations to assess the patency of the left portal system and of the mesenteric vessels are essential, as well as exclusion of outflow obstruction or parenchymal liver disease. This shunt procedure is generally safe, with low postoperative complications.

Liver transplantation

Liver transplantation (LT) has become a standard mode of treatment for a wide variety of liver diseases in children. Biliary atresia is by far the most common indication for LT in the paediatric age group. Approximately 15% of LTs are performed for acute liver failure. The median age at transplantation is 12–18 months, with around 60% of the transplanted children being younger than 6 years. Three-year patient and graft survival, as reported by the SPLIT research group in the USA and Canada in 2004, was 84% and 75% respectively [91]. Patient survival is better in children with chronic liver disease than in those transplanted for acute liver failure or liver tumours.

Most liver grafts are obtained from brainstem dead/heart-beating donors; however, recently, the use of liver grafts from non-heart-beating donors has been reported [92]. Both donor and recipient should be ABO blood group compatible, but preferably an identical ABO matched graft is used. Although there is no upper age limit for liver donation, donors over 50 years of age are less commonly accepted for children. Over the past 10 years, to overcome the shortage of size-matched donors, particularly for small children, innovative surgical techniques have been developed. Reduced, split and living related liver grafts are now used routinely. In living related LT, the left lateral segment from a healthy donor, usually a parent, is used. The reported donor postoperative morbidity is 21% and mortality between 0.15% and 0.5%; these figures include living related donations for both children and adults [93]. In very small babies, monosegment grafts have been used.

An innovative type of transplantation is auxiliary LT, in which, after removal of part of the diseased liver, the same part from a healthy donor liver is grafted next to the residual recipient's liver. This technique can be used in children presenting with acute liver failure, with the aim that the healthy graft maintains liver function while the native liver regenerates. If regeneration of the native liver occurs, immunosuppression can eventually be decreased and discontinued, leaving the child with his/her own functioning native liver and with no need for lifelong immunosuppression [94]. It is important to establish before this type of surgery whether liver damage is due to an acute insult, e.g. infections or drugs, or to an acute decompensation of an underlying chronic disease, such as AIH or WD, as only in the former is auxiliary LT indicated. Auxiliary LT is also performed in metabolic conditions caused by liver-based enzymatic defects leading to serious systemic consequences, but with preserved liver function, e.g. Crigler–Najjar syndrome, familial hypercholesterolaemia and urea cycle defects, as the segment from a healthy donor can correct the metabolic abnormality.

Immunosuppression

The introduction of ciclosporin in 1983 has led to a significant improvement in survival after LT, which, from an experimental procedure, has become a standard mode of treatment. Since then, new immunosuppressants have been developed and are in current use, such as tacrolimus, sirolimus, mycophenolate mofetil and anti-interleukin (IL)-2 receptor monoclonal antibodies. Currently, in most centres, primary immunosuppression consists of steroids and tacrolimus which, like ciclosporin, interferes with IL-2 secretion, thereby inhibiting T-cell proliferation and the generation of cytotoxic T cells. Steroids are weaned over the first few months after LT to a minimal dose depending on the age of the child. Some centres use a steroid-free immunosuppressive regimen. Side-effects of calcineurin inhibitors include nephrotoxicity, hypertension, neurotoxicity and predisposition to cancer (ciclosporin and tacrolimus); hirsutism and gingival hyperplasia (ciclosporin); and diabetes (mainly tacrolimus). It is important to assess renal function prior to LT and to continue to monitor it after LT by measuring the glomerular filtration rate (GFR) at regular intervals, e.g. once a year, in order to modify the immunosuppressive treatment promptly in the presence of early signs of renal impairment (GFR < 80 mL/min/1.73 m^2). A significant improvement in renal function can be achieved by adding the immunosuppressant antiproliferative agent mycophenolate mofetil and decreasing or stopping the calcineurin inhibitors [95]. Sirolimus (rapamicin) is a triene macrolide antibiotic that blocks T-cell activation and proliferation. Sirolimus is generally used in paediatric liver transplantation when other immunosuppressants are unable to control rejection or in the presence of severe renal impairment. OKT3, a monoclonal anti-CD3 antibody, and antithymocyte globulin (ATG) or antilymphocyte globulin (ALG) polyclonal antibodies are useful in steroid-resistant rejection, although their use has decreased considerably in recent years as a result of more powerful primary immunosuppression and because of their association with the development of EBV-related post-LT lymphoproliferative disorders (PTLD) in the paediatric age group. Simulect, a monoclonal anti-IL-2 antibody, is used either to prevent rejection at the time of surgery or to treat steroid-resistant rejection.

Complications

Surgical complications

Surgical complications include primary non-function of the graft, hepatic artery thromobosis, portal vein thrombosis, biliary complications and bowel perforation. Their incidence has been decreasing over the years in parallel with improvements in surgical techniques.

Infection

Infection is the most common cause of morbidity and mortality after LT with a prevalence ranging from 40% to 73%. Immunosuppression, surgery and invasive devices predispose to infection. In the first month after LT, bacteria and fungi are the major culprits. Appropriate immunization with live and killed vaccines prior to transplantation and antimicrobial prophylaxis can help in preventing infectious complications after LT.

Bacterial infections occurring immediately after LT are often Gram negative. Hence prophylactic antibiotics are administered. Opportunistic bacterial infections may occur, usually between 1 and 6 months after LT, particularly in children who receive high doses of immunosuppression. Children in whom a Roux loop is used for biliary drainage are at risk of developing ascending cholangitis.

The incidence of fungal infections post LT varies between 31% and 40%, most of them being intra-abdominal. Fungal infections are associated with increased mortality; however, most children respond well to antifungal treatment. Pre-LT fungal colonization and pyrexia and post-LT bacterial infection, EBV infection and tacrolimus administration are reportedly associated with a higher risk of fungal infection in paediatric recipients [96]. *Candida* and *Aspergillus* species are the most common fungal infections. Azole antifungals, such as fluconazole and itraconazole, or liposomal amphotericin B are used for prophylaxis after surgery.

Viruses most likely to cause complications after LT are cytomegalovirus (CMV), EBV, HSV and varicella zoster virus (VZV). CMV infection occurs in up to 60% of transplanted children between 2 and 12 weeks after surgery. Malaise, fever, leucopenia, thrombocytopenia and arthralgia are common symptoms; liver function tests may deteriorate. Other complications such as myocarditis, vasculitis and encephalomyelitis have been described. Treatment consists of intravenous gancyclovir. Two-week prophylaxis with intravenous gancyclovir, starting 1 week after transplant, is advisable for children who are CMV negative before LT and who receive the organ from a CMV-positive donor. CMV DNA can be monitored after transplant to determine the onset and progression of CMV infection.

HSV occurs in 10% of children post LT and responds well to treatment with aciclovir. VZV can cause significant morbidity and mortality in immunocompromised children. VZV vaccination prior to LT reduces the incidence of infection but, in the case of direct exposure to an infected person post LT, VZV antibodies also need to be measured in vaccinated children and, if negative, VZV immunoglobulins or oral aciclovir should be prescribed. If vesicles appear, treatment with intravenous aciclovir is indicated.

EBV infection can present with a spectrum ranging from a mononucleosis-like illness to malignant lymphoma. EBV drives an abnormal proliferation of B lymphocytes that may lead to PTLD. The reported incidence of PTLD in large liver transplantation centres ranges between 7% and 11%. Risk factors for PTLD include young age at LT, EBV mismatch between donor and recipient (liver from an EBV-positive donor in an EBV-naive recipient), primary EBV infection during the first 6 months after LT, high levels of immunosuppression and the use of antilymphocyte induction agents. Clinical features include fever, lymphadenopathy, malaise, protein-losing enteropathy with hypoalbuminaemia, positive faecal occult blood and anaemia. Therapeutic options include antiviral therapy, reduction of immunosuppression, cytokine therapy, cytotoxic therapy, cellular immunotherapy and anti-B-cell antibodies. The first-line treatment is reduction of immunosuppression, thus allowing EBV-specific T cells to regain their role in controlling B-cell proliferation and therefore in reducing the activity of EBV and inhibiting proliferation of EBV-infected B cells. Rituximab, a chimeric monoclonal anti-CD20 antibody that has become available recently, is used in some transplant centres as first-line treatment of symptomatic PTLD. Measurement of EBV viral load is useful in monitoring infection, but not in predicting the onset of PTLD or its response to treatment. PTLD treatment complications include acute and chronic rejection and increased susceptibility to infection [97].

Rejection

Acute rejection is a common early complication after LT, occurring in 40–70% of children during the first month, usually between 5 and 15 days after surgery. Symptoms of fever and general malaise may be present, but a rise in serum transaminase levels is the most reliable sign. A liver biopsy should be performed to confirm the diagnosis, typical histological features being a dense periportal cellular lymphocytic and eosinophilic infiltration with endothelitis and bile duct damage. Acute rejection is treated with high-dose intravenous methylprednisolone (10 mg/kg/day) for three consecutive days and an increase in the dose of maintenance calcineurin inhibitors aiming at achieving adequate levels. In cases of steroid-resistant rejection, the maintenance immunosuppressive regimen may need to be altered by adding mycophenolate mofetil to tacrolimus. In severe cases, the use of monoclonal or polyclonal anti-T-cell antibodies is required.

Early chronic rejection presents within 6 weeks of LT, often following an acute cellular rejection not responding to treatment. Late chronic rejection usually occurs between 6 weeks and 6 months after LT and is characterized by bile duct injury. The incidence is between 5% and 10% and is a significant cause of graft loss. It should be suspected in the presence of marked cholestasis with raised serum bilirubin and gamma-glutamyltransferase levels and pruritus, after excluding surgical complications such as anastomotic bile duct strictures or ischaemic cholangitis, which may follow hepatic artery thrombosis. Serum transaminases are only mildly or moderately elevated. The pathophysiology of chronic rejection is poorly understood. Histological features are those of loss of bile ducts and arteriopathy. No specific treatment is available. Increased immunosuppressive therapy with the use of sirolimus may reverse the

changes in some children, but the majority progress to graft loss and retransplantation. In approximately 25% of children who develop chronic rejection, chronic rejection reoccurs following retransplantation.

Late complications

With the improvement in long-term survival after LT, secondary illnesses have become more common. The main contributing factor for these is immunosuppression. As mentioned above, calcineurin inhibitors cause nephrotoxicity in 20–70% of non-renal transplant recipients. The introduction of mycophenolate mofetil can help to decrease the dose or even discontinue the calcineurin inhibitor and thereby improve glomerular function.

In 1998, Kerkar *et al.* described an autoimmune response against the allograft, occurring at a median time of 2 years after LT and characterized by an increase in serum transaminase and immunoglobulin levels with positive autoantibodies and features of chronic hepatitis on liver histology [98]. Treatment of this condition, referred to as *de novo* AIH (see Chapter 11.2), is the same as that used for classical AIH and consists of increasing the dose of prednisolone and adding antiproliferative agents such as azathioprine or mycophenolate mofetil.

Immunosuppression is likely to favour the growth of neoplastic cells by reducing the mechanisms of immune surveillance. Besides PTLD, described above, the most common malignancies after LT are lymphoma, skin cancer and Kaposi sarcoma.

Other long-term physical complications include cardiovascular disease, growth impairment and reduced bone mineral density.

Finally, chronic liver damage, possibly due to infection, silent rejection or autoimmunity, has been demonstrated in protocol biopsies performed 5–10 years after LT. Cirrhotic changes were found in 15% of patients in protocol liver biopsies performed 10 years after LT [99].

With more children surviving into adulthood after LT, the effects of surgery and chronic immunosuppression on their physical, sexual and psychosocial development and on the quality of life will need to be explored.

References

1 McKiernan PJ (2002) Neonatal cholestasis. *Semin Neonatol* 7(2), 153–165.

2 Mieli-Vergani G, Howard ER, Portman B *et al.* (1989) Late referral for biliary atresia – missed opportunities for effective surgery. *Lancet* 1(8635), 421–423.

3 Roberts EA (2003) Neonatal hepatitis syndrome. *Semin Neonatol* 8(5), 357–374.

4 Davenport M, Savage M, Mowat AP *et al.* (1993) Biliary atresia splenic malformation syndrome: an etiologic and prognostic subgroup. *Surgery* 113(6), 662–668.

5 Farrant P, Meire HB, Mieli-Vergani G (2000) Ultrasound features of the gall bladder in infants presenting with conjugated hyperbilirubinaemia. *Br J Radiol* 73(875), 1154–1158.

6 Park WH, Choi SO, Lee HJ *et al.* (1997) A new diagnostic approach to biliary atresia with emphasis on the ultrasonographic triangular cord sign: comparison of ultrasonography, hepatobiliary scintigraphy, and liver needle biopsy in the evaluation of infantile cholestasis. *J Pediatr Surg* 32(11), 1555–1559.

7 Davenport M, De Ville de GJ, Stringer MD *et al.* (2004) Seamless management of biliary atresia in England and Wales (1999–2002). *Lancet* 363(9418), 1354–1357.

8 McKiernan PJ, Baker AJ, Kelly DA (2000) The frequency and outcome of biliary atresia in the UK and Ireland. *Lancet* 355(9197), 25–29.

9 Davenport M, Kerkar N, Mieli-Vergani G *et al.* (1997) Biliary atresia: the King's College Hospital experience (1974–1995). *J Pediatr Surg* 32(3), 479–485.

10 Hadzic N, Davenport M, Tizzard S *et al.* (2003) Long-term survival following Kasai portoenterostomy: is chronic liver disease inevitable? *J Pediatr Gastroenterol Nutr* 37(4), 430–433.

11 Redkar R, Davenport M, Howard ER (1998) Antenatal diagnosis of congenital anomalies of the biliary tract. *J Pediatr Surg* 33(5), 700–704.

12 Medee-Manesme O, Bernard O, Brunelle F *et al.* (1987) Sclerosing cholangitis with neonatal onset. *J Pediatr* 111(2), 225–229.

13 Debray D, Pariente D, Urvoas E *et al.* (1994) Sclerosing cholangitis in children. *J Pediatr* 124(1), 49–56.

14 Alagille D, Odievre M, Gautier M *et al.* (1975) Hepatic ductular hypoplasia associated with characteristic facies, vertebral malformations, retarded physical, mental, and sexual development, and cardiac murmur. *J Pediatr* 86(1), 63–71.

15 Kohsaka T, Yuan ZR, Guo SX *et al.* (2002) The significance of human jagged 1 mutations detected in severe cases of extrahepatic biliary atresia. *Hepatology* 36(4 Pt 1), 904–912.

16 Clayton RJ, Iber FL, Ruebner BH *et al.* (1969) Byler disease. Fatal familial intrahepatic cholestasis in an Amish kindred. *Am J Dis Child* 117(1), 112–124.

17 Bull LN, van Eijk MJ, Pawlikowska L *et al.* (1998) A gene encoding a P-type ATPase mutated in two forms of hereditary cholestasis. *Nature Genet* 18(3), 219–224.

18 Strautnieks SS, Bull LN, Knisely AS *et al.* (1998) A gene encoding a liver-specific ABC transporter is mutated in progressive familial intrahepatic cholestasis. *Nature Genet* 20(3), 233–238.

19 Jacquemin E, Hermans D, Myara A *et al.* (1997) Ursodeoxycholic acid therapy in pediatric patients with progressive familial intrahepatic cholestasis. *Hepatology* 25(3), 519–523.

20 Whitington PF, Whitington GL (1988) Partial external diversion of bile for the treatment of intractable pruritus associated with intrahepatic cholestasis. *Gastroenterology* 95(1), 130–136.

21 Dixon PH, Weerasekera N, Linton KJ *et al.* (2000) Heterozygous MDR3 missense mutation associated with intrahepatic cholestasis of pregnancy: evidence for a defect in protein trafficking. *Hum Mol Genet* 9(8), 1209–1217.

22 De Vree JM, Ottenhoff R, Bosma PJ *et al.* (2000) Correction of liver disease by hepatocyte transplantation in a mouse model of progressive familial intrahepatic cholestasis. *Gastroenterology* 119(6), 1720–1730.

23 Kaufman SS (2002) Prevention of parenteral nutrition-associated liver disease in children. *Pediatr Transplant* 6(1), 37–42.

24 Francavilla R, Castellaneta SP, Hadzic N *et al.* (2000) Prognosis of alpha-1-antitrypsin deficiency-related liver disease in the era of paediatric liver transplantation. *J Hepatol* 32(6), 986–992.

25 Chang MH, Chen TH, Hsu HM *et al.* (2005) Prevention of hepatocellular carcinoma by universal vaccination against hepatitis B virus: the effect and problems. *Clin Cancer Res* 11(21), 7953–7957.

26 Chen HL, Chang CJ, Kong MS *et al.* (2004) Pediatric fulminant hepatic failure in endemic areas of hepatitis B infection: 15 years after universal hepatitis B vaccination. *Hepatology* 39(1), 58–63.

27 D'Antiga L, Aw M, Atkins M *et al.* (2006) Combined lamivudine/interferon-alpha treatment in 'immunotolerant' children perinatally infected with hepatitis B: a pilot study. *J Pediatr* 148(2), 228–233.

28 Dikici B, Ozgenc F, Kalayci AG *et al.* (2004) Current therapeutic approaches in childhood chronic hepatitis B infection: a multicenter study. *J Gastroenterol Hepatol* 19(2), 127–133.

29 Ozgenc F, Dikici B, Targan S *et al.* (2004) Comparison of antiviral effect of lamivudine with interferon-alpha2a versus -alpha2b in children with chronic hepatitis B infection. *Antivir Ther* 9(1), 23–26.

30 Saltik-Temizel IN, Kocak N, Demir H (2004) Interferon-alpha and lamivudine combination therapy of children with chronic hepatitis b infection who were interferon-alpha nonresponders. *Pediatr Infect Dis J* 23(5), 466–468.

31 Saltik-Temizel IN, Kocak N, Demir H (2005) Lamivudine and high-dose interferon-alpha combination therapy for naive children with chronic hepatitis B infection. *J Clin Gastroenterol* 39(1), 68–70.

32 Ceci O, Margiotta M, Marello F *et al.* (2001) High rate of spontaneous viral clearance in a cohort of vertically infected hepatitis C virus infants: what lies behind? *J Hepatol* 35(5), 687–688.

33 Fanning LJ (2002) The Irish paradigm on the natural progression of hepatitis C virus infection: an investigation in a homogeneous patient population infected with HCV 1b (review). *Int J Mol Med* 9(2), 179–184.

34 Wiese M, Grungreiff K, Guthoff W *et al.* (2005) Outcome in a hepatitis C (genotype 1b) single source outbreak in Germany – a 25-year multicenter study. *J Hepatol* 43(4), 590–598.

35 Kelly D, Skidmore S (2002) Hepatitis C-Z: recent advances. *Arch Dis Child* 86(5), 339–343.

36 Wirth S, Pieper-Boustani H, Lang T *et al.* (2005) Peginterferon alfa-2b plus ribavirin treatment in children and adolescents with chronic hepatitis C. *Hepatology* 41(5), 1013–1018.

37 Gregorio GV, Portmann B, Reid F *et al.* (1997) Autoimmune hepatitis in childhood: a 20-year experience. *Hepatology* 25(3), 541–547.

38 Gregorio GV, Portmann B, Karani J *et al.* (2001) Autoimmune hepatitis/sclerosing cholangitis overlap syndrome in childhood: a 16-year prospective study. *Hepatology* 33(3), 544–553.

39 Martins da CC, Baldwin D, Portmann B *et al.* (1992) Value of urinary copper excretion after penicillamine challenge in the diagnosis of Wilson's disease. *Hepatology* 15(4), 609–615.

40 Dhawan A, Taylor RM, Cheeseman P *et al.* (2005) Wilson's disease in children: 37-year experience and revised King's score for liver transplantation. *Liver Transpl* 11(4), 441–448.

41 Kinnman N, Lindblad A, Housset C *et al.* (2000) Expression of cystic fibrosis transmembrane conductance regulator in liver tissue from patients with cystic fibrosis. *Hepatology* 32(2), 334–340.

42 Salvatore F, Scudiero O, Castaldo G (2002) Genotype–phenotype correlation in cystic fibrosis: the role of modifier genes. *Am J Med Genet* 111(1), 88–95.

43 Lindblad A, Glaumann H, Strandvik B (1999) Natural history of liver disease in cystic fibrosis. *Hepatology* 30(5), 1151–1158.

44 Sheth S, Shea JC, Bishop MD *et al.* (2003) Increased prevalence of CFTR mutations and variants and decreased chloride secretion in primary sclerosing cholangitis. *Hum Genet* 113(3), 286–292.

45 Colombo C, Battezzati PM, Crosignani A *et al.* (2002) Liver disease in cystic fibrosis: a prospective study on incidence, risk factors, and outcome. *Hepatology* 36(6), 1374–1382.

46 Lamireau T, Monnereau S, Martin S *et al.* (2004) Epidemiology of liver disease in cystic fibrosis: a longitudinal study. *J Hepatol* 41(6), 920–925.

47 Lindblad A, Glaumann H, Strandvik B (1998) A two-year prospective study of the effect of ursodeoxycholic acid on urinary bile acid excretion and liver morphology in cystic fibrosis-associated liver disease. *Hepatology* 27(1), 166–174.

48 Fridell JA, Bond GJ, Mazariegos GV *et al.* (2003) Liver transplantation in children with cystic fibrosis: a long-term longitudinal review of a single center's experience. *J Pediatr Surg* 38(8), 1152–1156.

49 Roberts EA (2002) Steatohepatitis in children. *Best Pract Res Clin Gastroenterol* 16(5), 749–765.

50 Lavine JE, Schwimmer JB (2004) Nonalcoholic fatty liver disease in the pediatric population. *Clin Liver Dis* 8(3), 549–558.

51 Schwimmer JB, Behling C, Newbury R *et al.* (2005) Histopathology of pediatric nonalcoholic fatty liver disease. *Hepatology* 42(3), 641–649.

52 Schwimmer JB, Middleton MS, Deutsch R *et al.* (2005) A phase 2 clinical trial of metformin as a treatment for non-diabetic paediatric non-alcoholic steatohepatitis. *Aliment Pharmacol Ther* 21(7), 871–879.

53 Desmet VJ (1992) Congenital diseases of intrahepatic bile ducts: variations on the theme 'ductal plate malformation'. *Hepatology* 16(4), 1069–1083.

54 Jaeken J, Matthijs G, Saudubray JM *et al.* (1998) Phosphomannose isomerase deficiency: a carbohydrate-deficient glycoprotein syndrome with hepatic-intestinal presentation. *Am J Hum Genet* 62(6), 1535–1539.

55 Boyle MJ, Doyle GD, McNulty JG (1989) Monolobar Caroli's disease. *Am J Gastroenterol* 84(11), 1437–1444.

56 Trey C, Davidson CS (1970) The management of fulminant hepatic failure. *Prog Liver Dis* 3, 282–298.

57 Bhaduri BR, Mieli-Vergani G (1996) Fulminant hepatic failure: pediatric aspects. *Semin Liver Dis* 16(4), 349–355.

58 Dhawan A, Mieli-Vergani G (2005) Acute liver failure in neonates. *Early Hum Dev* 81(12), 1005–1010.

59 Verma A, Dhawan A, Zuckerman M *et al.* (2006) Neonatal herpes simplex virus infection presenting as acute liver failure: prevalent role of herpes simplex virus type I. *J Pediatr Gastroenterol Nutr* 42(3), 282–286.

60 Whitington PF, Hibbard JU (2004) High-dose immunoglobulin during pregnancy for recurrent neonatal haemochromatosis. *Lancet* 364(9446), 1690–1698.

61 Rodrigues F, Kallas M, Nash R *et al.* (2005) Neonatal hemochromatosis – medical treatment vs. transplantation: the King's experience. *Liver Transpl* 11(11), 1417–1424.

62 O'Grady JG (1997) Paracetamol-induced acute liver failure: prevention and management. *J Hepatol* 26(Suppl. 1), 41–46.

63 Girlanda R, Vilca-Melendez H, Srinivasan P *et al.* (2005) Immunosuppression withdrawal after auxiliary liver transplantation for acute liver failure. *Transplant Proc* 37(4), 1720–1721.

64 Velazquez A, Vela-Amieva M, Ciceron-Arellano I *et al.* (2000) Diagnosis of inborn errors of metabolism. *Arch Med Res* 31(2), 145–150.

65 Bouchard G, Laberge C, Scriver CR (1985) [Hereditary tyrosinemia and vitamin-dependent rickets in Saguenay. A genetic and demographic approach]. *Union Med Can* 114(8), 633–636.

66 Kvittingen EA (1986) Hereditary tyrosinemia type I – an overview. *Scand J Clin Lab Invest Suppl* 184, 27–34.

67 Holme E, Lindstedt S (2000) Nontransplant treatment of tyrosinemia. *Clin Liver Dis* 4(4), 805–814.

68 Clayton PT (2002) Inborn errors presenting with liver dysfunction. *Semin Neonatol* 7(1), 49–63.
69 Cori GT, Cori CF (1952) Glucose-6-phosphatase of the liver in glycogen storage disease. *J Biol Chem* 199(2), 661–667.
70 Chou JY, Matern D, Mansfield BC *et al.* (2002) Type I glycogen storage diseases: disorders of the glucose-6-phosphatase complex. *Curr Mol Med* 2(2), 121–143.
71 Slonim AE, Weisberg C, Benke P *et al.* (1982) Reversal of debrancher deficiency myopathy by the use of high-protein nutrition. *Ann Neurol* 11(4), 420–422.
72 Moses SW, Parvari R (2002) The variable presentations of glycogen storage disease type IV: a review of clinical, enzymatic and molecular studies. *Curr Mol Med* 2(2), 177–188.
73 Sokol RJ, Treem WR (1999) Mitochondria and childhood liver diseases. *J Pediatr Gastroenterol Nutr* 28(1), 4–16.
74 Dhawan A, Mitry RR, Hughes RD (2005) Hepatocyte transplantation for metabolic disorders, experience at King's College hospital and review of literature. *Acta Gastroenterol Belg* 68(4), 457–460.
75 Pinkel D (1993) Bone marrow transplantation in children. *J Pediatr* 122(3), 331–341.
76 Stocker JT (2006) Hepatic tumours in children. In: Suchy F, Sokol RJ, Balistreri WF, eds. *Liver Disease in Children*, 2nd edn, Philadelphia: Lippincott, Williams and Wilkins, p. 915.
77 Ayling RM, Davenport M, Hadzic N *et al.* (2001) Hepatic hemangioendothelioma associated with production of humoral thyrotropin-like factor. *J Pediatr* 138(6), 932–935.
78 Stringer MD, Alizai NK (2005) Mesenchymal hamartoma of the liver: a systematic review. *J Pediatr Surg* 40(11), 1681–1690.
79 Reymond D, Plaschkes J, Luthy AR *et al.* (1995) Focal nodular hyperplasia of the liver in children: review of follow-up and outcome. *J Pediatr Surg* 30(11), 1590–1593.
80 Saul SH, Titelbaum DS, Gansler TS *et al.* (1987) The fibrolamellar variant of hepatocellular carcinoma. Its association with focal nodular hyperplasia. *Cancer* 60(12), 3049–3055.
81 Otte JB, de Ville de GJ, Reding R (2005) Liver transplantation for hepatoblastoma: indications and contraindications in the modern era. *Pediatr Transplant* 9(5), 557–565.
82 Tiao GM, Bobey N, Allen S *et al.* (2005) The current management of hepatoblastoma: a combination of chemotherapy, conventional resection, and liver transplantation. *J Pediatr* 146(2), 204–211.
83 Knisely AS, Strautnieks SS, Meier Y *et al.* (2006) Hepatocellular carcinoma in ten children under five years old with bile salt export pump deficiency. *Hepatology* 44, 474–486.
84 Czauderna P, Mackinlay G, Perilongo G *et al.* (2002) Hepatocellular carcinoma in children: results of the first prospective study of the International Society of Pediatric Oncology group. *J Clin Oncol* 20(12), 2798–2804.
85 Sakai M, Ikeda H, Suzuki N *et al.* (2001) Inflammatory pseudotumor of the liver: case report and review of the literature. *J Pediatr Surg* 36(4), 663–666.
86 Molleston JP (2003) Variceal bleeding in children. *J Pediatr Gastroenterol Nutr* 37(5), 538–545.
87 Stringer MD, Howard ER, Mowat AP (1989) Endoscopic sclerotherapy in the management of esophageal varices in 61 children with biliary atresia. *J Pediatr Surg* 24(5), 438–442.
88 Howard ER, Stringer MD, Mowat AP (1988) Assessment of injection sclerotherapy in the management of 152 children with oesophageal varices. *Br J Surg* 75(5), 404–408.
89 McKiernan PJ, Beath SV, Davison SM (2002) A prospective study of endoscopic esophageal variceal ligation using a multiband ligator. *J Pediatr Gastroenterol Nutr* 34(2), 207–211.
90 De Ville de GJ, Alberti D, Clapuyt P *et al.* (1998) Direct bypassing of extrahepatic portal venous obstruction in children: a new technique for combined hepatic portal revascularization and treatment of extrahepatic portal hypertension. *J Pediatr Surg* 33(4), 597–601.
91 Martin SR, Atkison P, Anand R *et al.* (2004) Studies of Pediatric Liver Transplantation 2002: patient and graft survival and rejection in pediatric recipients of a first liver transplant in the United States and Canada. *Pediatr Transplant* 8(3), 273–283.
92 Muiesan P, Girlanda R, Jassem W *et al.* (2005) Single-center experience with liver transplantation from controlled non-heartbeating donors: a viable source of grafts. *Ann Surg* 242(5), 732–738.
93 Adam R, McMaster P, O'Grady JG *et al.* (2003) Evolution of liver transplantation in Europe: report of the European Liver Transplant Registry. *Liver Transpl* 9(12), 1231–1243.
94 Girlanda R, Vilca-Melendez H, Srinivasan P *et al.* (2005) Immunosuppression withdrawal after auxiliary liver transplantation for acute liver failure. *Transplant Proc* 37(4), 1720–1721.
95 Aw MM, Samaroo B, Baker AJ *et al.* (2001) Calcineurin-inhibitor related nephrotoxicity – reversibility in paediatric liver transplant recipients. *Transplantation* 72(4), 746–749.
96 Verma A, Wade JJ, Cheeseman P *et al.* (2005) Risk factors for fungal infection in paediatric liver transplant recipients. *Pediatr Transplant* 9(2), 220–225.
97 Al-Akash SI, Al Makadma AS, Al Omari MG (2005) Rapid response to rituximab in a pediatric liver transplant recipient with post-transplant lymphoproliferative disease and maintenance with sirolimus monotherapy. *Pediatr Transplant* 9(2), 249–253.
98 Kerkar N, Hadzic N, Davies ET *et al.* (1998) De-novo autoimmune hepatitis after liver transplantation. *Lancet* 351(9100), 409–413.
99 Evans HM, Kelly DA, McKiernan PJ *et al.* (2006) Progressive histological damage in liver allografts following paediatric liver transplantation. *Hepatoloty* 43, 1109–1117.

22.2 Liver diseases in the elderly

Oliver F.W. James

Introduction

While there are no liver diseases specific to old age, the presentation, clinical course and management of liver diseases in the elderly differ in important respects from those in younger individuals. Furthermore, age-related changes in the morphology and function of the liver influence our understanding of the interaction between the liver and the organism in later life. Nowhere has this been more evident than in the advance of liver transplantation into patients in their eighth and, very exceptionally, ninth decades [1]. It is only in the last 10 years that interest has grown in over 65-year-olds, despite the fact that this group now represents up to 18% of the population in westernized countries and Japan [2–5].

Morphology and function

Morphology

The liver attains maximum size in young adulthood and then steadily declines in weight, not only in absolute terms but also in relation to body size. One study of liver volume using ultrasound measurement showed a decline in estimated liver volume from 1475 mL at age 24 years to approximately 930 mL at age 90 years – a decrease of 37%; this change is apparently more marked in women (44%) than in men (28%) [6]. Other non-invasive estimates have shown very similar findings [7,8]. Moreover, functional studies using scintigraphy also showed a decrease in the hepatocyte mass in the liver [9]. The largest post-mortem study of liver weight found a fall of 46% between the third and tenth decades [10]. In appearance, the liver becomes a darker brown colour due to the accumulation of fluorescent brown-pigmented lipofuscin granules in lysosomes within the hepatocytes. Lipofuscin is largely composed of protein; Ivy *et al.* [11] and Kitani [12] suggested recently that its deposition in liver cells, as elsewhere in the body, is due to decreased intracellular proteolysis with age. Whether this is because of decreased protease activity or an age-related modification of proteins within the cell to make them more resistant to protease digestion is not clear [11,12]. In ageing, many liver cells enlarge, and nuclei show more polyploidy with increased DNA per nucleus [13,14]. Cells contain more protein; as with the nuclei, mitochondria are also enlarged [15]. It has been suggested that this increased protein is functionally inactive and represents the accumulation of 'junk' within the liver cells. It is important to emphasize, however, that observations of age-related morphometric and functional alterations in experimental animals must not be extrapolated to man.

A decreased hepatic blood flow is considered to be responsible for age-related decrease in liver size [16]. Liver blood flow can only be estimated indirectly in man. Wynne *et al.* [6] have used indocyanine green clearance to show that estimated liver blood flow falls by about 35% between the third and tenth decades. In addition, liver perfusion (liver blood flow per unit volume of liver) also fell over this range by about 11% [6]. Such calculations depend upon the constancy of extraction of indocyanine green by the liver with advancing age [17]. Ultrasonographic studies have now confirmed these results [18], thus validating the magnitude of estimated decline in liver blood flow.

Liver function tests and metabolism

Clinically relevant liver blood tests do not change with age [19]. Thus, abnormalities of serum bilirubin, serum transaminases, hepatic alkaline phosphatase and other liver blood tests should be regarded in the same way in an 80-year-old as in a 20-year-old. Nonetheless, a number of dynamic measurements of liver function probably do decline with age. Many pharmacokinetic studies in man suggest that the clearance of drugs predominantly metabolized by the cytochrome P-450 enzyme system is reduced by between 10% and 50% with age [20,21]. It seems probable that, when other variables (diet, smoking, sex, nutrition) have been accounted for, there is a decline in cytochrome P-450-related metabolism of between 5% and 30% from early adulthood to senescence [22–26]. Studies in man and primates have hitherto shown few age-related decreases in the specific activities or affinities of individual cytochrome P-450s [27].

Nonetheless, it is very possible that there may be differential decline in some functions with age [28]. Galactose elimination has been shown to decline with normal ageing; it is suggested that this cytosolic function is reduced at the same rate as liver size [8].

Few studies of hepatic synthetic function have been carried out in man but, although basal urea nitrogen synthesis is unaltered, there is a significant negative correlation between peak urea synthesis and age [29] – an example of the widespread phenomenon of the inability to respond to stress in old age. This group has now demonstrated that hepatic conversion of α-amino nitrogen into urea nitrogen – functional hepatic nitrogen clearance – was reduced by 50% with advancing age and that this was considerably greater than the observed age-related decline in liver volume [30]. Recently, pseudocapillarization of the hepatic sinusoidal endothelium has been described in the elderly [31]. This phenomenon seems to be related to an age-related impairment in hepatic lipoprotein metabolism and to atherosclerosis [32]. All these studies confirm that some hepatic functions are independently impaired.

Response to stress

It is well recognized that the liver has remarkable powers of regeneration. In old livers, the rate of replacement of liver cells after injury may be reduced so that repair is probably slower [33]. One clue as to the possible mechanism of this impaired proliferative capacity of liver cells has been provided by the demonstration of an age-related decline in mitogen-activated protein kinase activity in epidermal growth factor-stimulated rat hepatocytes [34].

Many studies in rodents have shown increased liver damage from a standard hepatic toxin with age, for example galactosamine [33], and an increased production of an inactive form of protective enzymes in old age, for example superoxide dismutase [35]. Impairment of Kupffer cell function may be another factor affecting elderly people. Kupffer cells showed an age-related inability to either inactivate endotoxin, leading to increased mortality from hepatorenal failure [36], or phagocytose and degrade radiolabelled mitochondria, leading to an increased susceptibility to sepsis secondary to abdominal infections [37] or to the development of a metastatic liver disease [38]. These studies provide evidence of possible increased susceptibility to stress insult in old age, although there are no directly comparable human data.

In summary, reduction in liver size and blood flow probably accounts for much of the age-associated decline in hepatic metabolism of xenobiotics in healthy man and, hence, in most cases, for any reduction in dynamic liver tests. Furthermore, there is increasing understanding of the age-related decline in the power of the liver to regenerate after cell damage or death. Far more important, however, may be the influence of coexistent disease, current nutritional status, genetic factors and a lifetime variation in diet, smoking and alcohol consumption. The sum of these parts leads to the far greater variance seen in many metabolic functions in elderly patient populations. These factors, combined with a poorly understood age-related failure of the homeostatic response to stress, may well form the background for the age-related features of hepatobiliary disease described below.

Parenchymal liver disease

This chapter will seek to point out important areas in which there are special features or differences between old and young patients in respect to clinical liver disease and its management.

Viral hepatitis

Hepatitis A

The proportion of the older adult population without acquired immunity to hepatitis A virus (HAV), at least among affluent and western populations, is lower now than in previous decades [39]. This is presumably, at least partly, a cohort effect due to improved sanitation. Currently, in some groups, only about 50% of the over 50-year-old population possesses anti-HAV antibodies [40]. We may, therefore, expect hepatitis A to become more frequent in the elderly. Mortality is age related. In Britain, while the ratio of deaths to notification of the disease was approximately 7 per 10 000 persons aged 15–24 years, it rose to more than 400 per 10 000 in those over 65 years [41]. Forbes and Williams also reported that, if fulminant hepatic failure developed, then increased age was an adverse prognostic marker. Now that hepatitis A vaccination is widely available and with increased travel to areas of high endemicity of the disease, screening of elderly travellers for hepatitis A IgG antibodies and vaccination of those who are negative is strongly indicated, although there is some evidence of diminished serological response to hepatitis A vaccines in older individuals [42].

Hepatitis B and D

The major risk groups for acute hepatitis B and D in Europe and the United States (homosexuals, intravenous drug abusers) are not highly represented in the elderly population, but the disease may still occur. This disease is more cholestatic and the clearance of hepatitis B surface antigen (HBsAg) is slower in the elderly but, although the short-term prognosis is unaltered, one report of an outbreak of hepatitis B in a nursing home for old people reported a resultant carrier rate of 59% [43]. In parallel with this finding, hepatitis B vaccination appears to be progressively more unsatisfactory in older individuals with progressively lower antibody response. Some possible improvements, such as the addition of unmethylated CpG nucleotides, are under study [44]. Both the possible increased carrier rate following acute infection and the poor response to vaccination may be due to a lack of antibody-producing B cells – presumably a facet of the failure of the immune response in old age [45]. In hepatitis D, progression to cirrhosis occurs in the majority of

cases [46,47]. Antiviral therapy for chronic hepatitis B using nucleoside analogues should be discussed on a case-by-case basis.

Hepatitis C

An Italian study has suggested that the prevalence of hepatitis C virus (HCV) infection in the elderly is sixfold higher than in under 35-year-olds in the same region – unlike the findings for HBV. Conceivably, this is a cohort effect, but the explanation is unknown [48]. The natural history of hepatitis C in older people is controversial. During the next 20 years, the prevalence of HCV cirrhosis and hepatocellular carcinoma in the elderly is expected to rise [49]. One epidemiologically based study of community-acquired hepatitis C in the United States suggested that at least a proportion of mainly elderly patients have a rather benign course [50]. In contrast, in a hospital-based study of hepatitis C in Britain, of 25 patients presenting over age 65 years, 18 of the 20 patients who had liver biopsy showed cirrhosis (12 patients) or cirrhosis and hepatocellular cancer (six patients) at presentation, four further patients developed hepatocellular cancer, and two patients died of other diseases associated with HCV infection – non-Hodgkin's lymphoma and fibrosing alveolitis [51]. Putative factors for acquiring HCV were identified in less than half.

As elderly patients with hepatitis viruses frequently present with more cholestatic acute disease or chronic disease, which may be further advanced than in younger subjects, all older patients presenting with liver disease or abnormal liver function tests must be screened for possible hepatitis B or C and, where indicated, A, with appropriate serological tests before invasive investigations or procedures are carried out. The place of interferon treatment for elderly patients with HBV or HCV is still to be determined. At present, the cost–benefit equation would not seem to favour treating elderly patients with established cirrhosis.

Drug-induced liver disease

Drug-induced liver disease, or at least abnormality of liver function tests, may account for as much as one-third of the over 65-year-old patients presenting with an apparent acute hepatitis [52]. This is perhaps not as surprising as might have been thought because, while over 65-year-olds account for 15–18% of the population in most European countries, the United States and Japan, they may consume over 30% of prescribed medications and perhaps 40% of non-prescription drugs. Furthermore, older people have more intercurrent illnesses, impaired cardiac or renal function for example, which may directly or indirectly potentiate the adverse effects of some drugs upon the liver. It is still unclear whether hepatic adverse drug reactions occur with a frequency out of proportion to the quantity of drugs prescribed to this group. Furthermore, the relevance of minor abnormalities of liver enzymes against the potential benefits of important medications must be considered. A major Swedish study of hepatic adverse drug reactions that examined the effect of age, corrected for age-related prescribing variables, found no increased frequency of reported adverse drug reactions nor any increased susceptibility to severe reactions. Unfortunately, a number of important drugs, notably halothane, were excluded from this analysis. Two studies have found that hepatic failure and death are more common after halothane anaesthesia in older persons. Animal studies have indicated that this may not be due to age-related differences in the metabolism of halothane but is conceivably due to other age-related, intrinsic factors such as decreased response to stress [53] or alteration in myocardial contraction and relaxation [54]. It is also suggested that a few other drugs, among them isoniazid, particularly in conjunction with rifampicin, may have increased severity of liver toxicity should it occur in an elderly patient [55]. Adverse effects of non-steroidal anti-inflammatory drugs – the model being benoxaprofen – do show a clear, age-related increased frequency as well as severity; while the mean age of individuals receiving benoxaprofen in the United Kingdom was 59 years, the mean age of those who sustained severe or fatal adverse drug reactions, usually hepatic, was 75 years [56]. Overall, it is perhaps surprising that the age-related decline in the clearance of many drugs, alluded to earlier, does not lead to more severe adverse consequences. This is presumably because, while mild dose-related abnormalities of liver enzymes may be frequent, severe adverse reactions are usually idiosyncratic; hence, marginal age-related declining clearance is probably not relevant.

Autoimmune liver disease

Immune surveillance breaks down in advanced age; thus, autoimmune markers, and some autoimmune diseases, hypothyroidism or rheumatoid arthritis for example, become more common. The effect of advancing age upon the presentation and prognosis of the autoimmune liver diseases has been unclear.

Primary biliary cirrhosis (PBC)

All the major prognostic studies of the natural history of PBC have shown that increasing age is an independent prognostic indicator, even when liver deaths alone are considered [57–59]. In a major recent epidemiological study of the incidence and prevalence of PBC in our region, we have shown that the average age of PBC patients at presentation is now about 60 years, although tertiary referral centres have a median referral age of around 55 years [60]. Of 111 new incident cases of PBC diagnosed over age 65 years, at a mean follow-up of 5 years, 29 (26% of the group) had died of liver-related causes. In this study, the point prevalence of PBC in over 65-year-olds was 569 per million, or about 1 in 1000 women in 1994. Thus, in many populations, up to a quarter of patients may present over age 65 years and over one-third of prevalent cases at any one time may be above this age, including both those with severe disease, exceptionally requiring consideration of transplantation, and those living into old age with prolonged mild disease.

Moreover, liver fibrosis seems to progress slowly in PBC (50% cirrhosis percentiles at 81 years) [61].

Autoimmune hepatitis

This has been thought to be uncommon [62]. Recently, we have identified 12 individuals with a diagnosis of autoimmune hepatitis presenting over age 65 years; this was about 20% of all patients in whom this diagnosis was made over a fixed period. The elderly group had more severe initial histological grade, but their prognosis was no different from individuals presenting under age 65 years [63]. Diagnostic scores [64] were slightly lower in the elderly group. It is the authors' experience that there is a small group of autoimmune hepatitis elderly patients presenting with very aggressive disease, rapidly accompanied by the severe complications of portal hypertension and encephalopathy, with a larger group presenting with clinical autoimmune chronic hepatitis but without the full house of diagnostic criteria recently described by the International Association for the Study of the Liver (IASL). Conceivably, among these may be individuals with unrecognized, drug-related, chronic hepatitis.

Alcoholic liver disease

While there are no age-related changes in the specific activity of total hepatic alcohol dehydrogenase [65], recent careful pharmacokinetic studies have shown that blood ethanol AUCs (areas under the curve) among men are significantly greater in older subjects than in younger in the oral fasted and intravenous fed states, but not in the oral fed state. In women, there was a highly significant difference in the oral fasted state only. The authors suggest that the mechanism underlying the effect of age in reducing ethanol clearance is unlikely to be related to gastric metabolism or motility as average AUC was greater fasting than fed irrespective of intravenous or oral administration. The age-related difference, seen most clearly in the oral fasted state but not in the fed state, they suggest, implies a decline in one or more mechanisms responsible for rapid ethanol metabolism within the first hour after ingestion [66]. A recent study in rats showed that the combination of ethanol and ageing caused a marked deterioration in the integrity of the hepatic mitochondrion [67].

Although presentation of alcoholic liver disease is perceived as being most common in middle age, many patients present for the first time at an advanced age. Thus, in the United States, one study from Baltimore showed that the peak decade for presentation with cirrhosis was the seventh [68]. In a British series, 28% of patients with alcoholic liver disease presented over age 60 years and about 10% over age 70 years [69]. In France, a large retrospective study suggested that as many as 20% of patients were over age 70 years, and there was no difference in their clinical features from patients with alcoholic liver disease as a whole [70]. In Italy, total mortality from alcoholic cirrhosis is highest around age 55–60 years, although it is not possible to say whether the reduced mortality thereafter merely reflects the fact that most alcoholic patients were dead before reaching an older age [71]. In this study, age-specific mortality from cirrhosis of all causes in Italy rose strikingly. In our own series, older patients had a higher proportion of symptoms and signs suggestive of severe liver disease at presentation (ankle swelling, jaundice and abdominal swelling) than young ones. All patients who presented over age 70 years already had cirrhosis compared with about 50% of younger patients. Prognosis was directly related to age. Mortality in those under 60 years at presentation was 5% at 1 year and 24% at 3 years; in those over age 60 years at presentation, it was 34% at 1 year and 54% at 3 years; among those presenting over age 70 years, 75% were dead at 1 year and 90% at 3 years. Among the oldest patients, over half developed hepatocellular cancer. Among those without hepatocellular cancer, the reasons for the apparently increased severity of alcoholic liver disease are unclear. Patient selection for referral, greater length of history or intrinsic age-related factors could contribute to these results.

The only study to examine alcohol withdrawal in elderly vs. young subjects suggested that older patients had more severe withdrawal and required higher doses of sedation (chlordiazepoxide) to control symptoms. The reasons for this increased severity are not clear [72].

Non-alcoholic fatty liver disease (NAFLD)

NAFLD is nowadays the third commonest liver disease, present in more than 20% of western populations and Japan [73]. The presenting age is between the fourth and the sixth decade, although liver complications are more often seen in the sixth to the eighth decades of life. NAFLD is associated with insulin resistance, diabetes mellitus, hypertriglyceridaemia and obesity (mainly visceral). Some predictive indices for identifying individuals at risk of developing severe forms of NAFLD included age as an independent risk factor [74]. Moreover, a recent study showed that older age was also associated with a higher risk of mortality in NAFLD patients [75].

Actually, there is no accepted drug treatment for NAFLD. Early intervention should be directed at increasing physical exercise while modestly reducing the body mass.

Other chronic liver disease

The proportion of patients with cryptogenic liver disease has decreased with improved diagnostic tools. Nevertheless, a recent major study of factors influencing survival in patients with cirrhosis has shown that the group with cryptogenic cirrhosis had the worst prognosis and that the most important single adverse factor in determining prognosis was increased age [76]. One possible cause of cirrhosis in later life recognized recently is α-1-antitrypsin deficiency, usually in Z heterozygotes [77,78]. While the diagnosis of haemochromatosis is usually made in middle-aged men, occasionally older males and females can present with the complications of portal hypertension or liver failure superimposed upon evidence of cirrhosis, often associated with the development of hepatocellular cancer. In general,

elderly patients presenting with cirrhosis usually present with, or rapidly develop, severe complications of portal hypertension and liver cell failure. Suspicion should be extremely high that these patients already have, or will shortly develop, hepatocellular cancers which have, in some instances, decompensated what has probably otherwise been long-term, well-compensated cirrhosis regardless of cause. The concept of senile cryptogenic cirrhosis, favoured in years gone by, should now be discarded.

Liver transplantation in the elderly

Liver transplantation is increasingly an option for patients with chronic liver disease over age 60 years, even age 70 years [79]. Several studies have now shown that, in selected patients over age 60 years, overall 1-year graft and patient survival rates equal those achieved in younger patients [80]. The important aspect is contained in the words 'carefully selected'. The experience of many transplant centres is now that much extra vigilance must be used in preoperative assessment of cardiac, respiratory and renal function in patients over age 65 years, and that intercurrent illness or organ dysfunction aside from liver disease dramatically worsens prognosis. Actually, a retrospective study of 1446 liver transplant recipients, including 241 patients older than 60 years, showed that 'low-risk' elderly patients had the same prognosis as younger patients. On the contrary, elderly patients with 'poor' liver function had lower survival rates [81]. It has been suggested that a 'bonus' for elderly transplant recipients is that the impairment in immune function accompanying old age reduces the incidence of allograft rejection and may allow a lower dosage of immunosuppressive drugs [80]. It has recently been implied that livers from older donors may impair short-term prognosis following transplantation. For this reason, it may be considered appropriate in future to reserve livers from older donors for older recipients. This will be a matter for considerable discussion.

Primary hepatocellular cancer

It is increasingly clear that primary hepatocellular cancer is a disease of ageing in western countries. In this respect, it is of interest that, in experimental animals, there was an age-associated, marked (twofold) increase in DNA bases damaged by oxidative modification. This was similar to the modification induced by carcinogens and seen in experimental hepatocellular cancers [82]. In Europe, hepatocellular cancer is largely associated with cirrhosis, regardless of cause, and probably also related to the length of time for which an individual has had cirrhosis [83]. In a recent UK review of 110 cases of hepatocellular cancer, almost half presented aged 65 years or over; symptoms and signs at presentation were similar in the two age groups. At presentation, only a quarter were previously known to have cirrhosis. This proportion rose to over 75% after diagnosis. Survival from diagnosis was worse in the older age group (10.5 vs. 18.5 weeks), the older patients having worse Okuda stage. Even in the UK, an area with a low prevalence of HBV infection, 34% of the younger patients showed HBV markers vs. only 23% of the older group. Conversely, almost 40% of the old patients had underlying cryptogenic disease (presumed to be hepatitis C, testing not being available) against 20% in the younger patients [84]. In an eastern population, a similar observation has been obtained. A Korean study of hepatocellular cancer showed that the ratio of HBV/HCV among patients with hepatocellular cancer before age 50 years was 29.7, whereas the ratio in patients presenting with hepatocellular cancer over 60 years was 0.9 [85]. This dramatically reflects the age of acquisition of HBV (usually infancy) in this population, whereas HCV was presumably acquired in later life, as in Europe. Thus, among older individuals with HCV cirrhosis, the development of hepatocellular cancer should be anticipated and hence screened for [86].

Liver abscess

Almost 50% of patients from Europe and North America presenting with pyogenic liver abscess are aged 70 years or older [87]. Several studies now show that older patients have less marked physical signs and present with more non-specific symptoms, e.g. epigastric pain, weight loss, shortness of breath and malaise [88]. In a modern setting, high-quality ultrasound and/or computerized tomography scan together with guided fine-needle aspiration mean that the diagnosis can be made with increasing confidence. Nonetheless, there is not infrequently a differential between possible liver abscess and malignancy or simple cyst within the liver. Such abscesses can appear as multiple, space-occupying lesions. Treatment with drainage and antibiotics is similar in the elderly as for younger subjects; relatively few should need laparotomy and formal surgical drainage. Of the two major, recent series mentioned above, one emphasized that, in almost 50% of these patients, abscess was associated with gallstones, but this was the case in only 25% of the second series, whereas the second series emphasized the relationship with diabetes in elderly patients (35%). Moreover, diabetes and alcoholism have been identified as risk factors for developing metastatic infections from pyogenic liver abscesses [89]. While some recent studies have suggested increased mortality in older patients with pyogenic liver abscess [90], this may be because of a slight increase in associated malignancy among older patients or because a proportion of liver abscess patients are only found at autopsy. Prognosis and hospital stay for elderly patients correctly diagnosed and managed and not associated with malignancy is now identical to that seen in younger patients.

Gallstones and their management

Studies from all over the world show that the prevalence of gallstones increases with age. In Europe, the prevalence of gallstones/cholecystectomy in females over age 80 years may be as much as 40%. This can, therefore, be regarded as a truly age-related phenomenon [91–95]. There are two apparent reasons.

First, cholesterol saturation of bile rises with age; this is due to increasing hepatic secretion of cholesterol in both men and women and to decreased bile acid production (as measured by an isotope dilution technique) [96]. Second, it is possible that the gallbladder is less sensitive to endogenous cholecystokinin with advancing age and, theoretically, this might lead to diminished gallbladder contraction following a meal [97]. However, two studies have demonstrated that gallbladder contraction, as measured by ultrasound, is unimpaired in older subjects with fasting – maximally contracted gallbladder volumes being equal between young and old subjects [98,99]. There was, however, a much higher fat-stimulated plasma concentration of cholecystokinin in the elderly group; the authors also suggested that this indicated diminished sensitivity of the gallbladder to cholecystokinin stimulation [98]. It has also been postulated that duodenal juxtapapillary diverticula, whose prevalence increases steeply with age, may be associated with biliary stasis, malfunction of the sphincter of Oddi and reflux of duodenal contents into the common bile duct [100].

Not only do gallstones increase with age but, possibly due to decreased response to infection, the complications of biliary tract disease are age related and more severe in old age.

Age in relation to the management of biliary disease

The management of biliary disease is dealt with fully elsewhere in this volume. However, a number of observations concerning the management of gallstone disease in old age are relevant. In general, mortality from the treatment of all forms of biliary disease rises with advancing age, but this may be largely ascribed to other coincident conditions. For example, in one series of over 80-year-olds treated surgically for acute cholecystitis, one-third had diabetes mellitus compared with only 5% in a large younger group of patients from the same centre [101]. Furthermore, it is the impression from both the United States and Europe that acute biliary tract disease is becoming more common in elderly patients [102]. This may be because a higher proportion of the population is surviving to an advanced age to experience the complications of previously silent gallstones. In a retrospective study carried out in the 1960s, gallbladder disease appeared to have been an important contributor to death in 8.1% of patients over age 70 years in whom gallstones were discovered at autopsy [103]. Four main sets of circumstances may arise in an elderly patient with gallstones:

1 Acute or chronic cholecystitis – gallstones only in the gallbladder. Mortality or morbidity from early elective operative intervention is now said to be close to that in younger subjects. In experienced centres, after appropriate investigation (which may include endoscopic retrograde cholangiopancreatography), laparoscopic cholecystectomy may now be considered a treatment of choice in non-acute cases [104]. However, conventional cholecystectomy is certainly very safe and effective. In acute cholecystitis, early cholecystectomy with perioperative exploration of the bile duct is recommended [105]. A long-term study showed that endoscopic treatment without cholecystectomy in elderly patients had low recurrence rates for both symptomatic cholecystitis and choledocholithiasis [106].

2 Cholangitis – stones in the common bile duct. Endoscopic sphincterotomy is recommended, and morbidity and mortality in patients even over the age of 90 years may be little higher than that in younger patients [107].

3 Stones in the common bile duct and in the gallbladder. This is more controversial; it is suggested that, particularly in very frail old patients, endoscopic retrograde cholangiopancreatography with sphincterotomy alone may be sufficient [80,108]. If symptoms persist after clearance of the common bile duct, then cholecystectomy or percutaneous cholecystostomy and gallstone removal may subsequently be carried out [109].

4 Asymptomatic gallstones found by chance in an elderly person. The management of these patients is controversial. On the one hand, as such individuals have a relatively shorter life expectancy, it might be argued that it is best to 'let sleeping dogs lie'. On the other hand, complications of occult biliary disease are more severe in old age. The physician or surgeon should decide each case on its merits [110]. It should be remembered that biliary disease may present atypically in old people. The diagnosis should be considered in any elderly person with fever, fluctuating abnormal liver function tests and confusion [111].

Acalculus cholecystitis represents an ischaemic inflammation of the gallbladder wall that can rapidly progress to necrosis and perforation if left untreated. It is increasingly recognized as occurring particularly in elderly subjects and is often related to cardiovascular disease and atherosclerosis [112].

References

1 Wall W, Grant D, Roy A *et al.* (1993) Elderly liver donor. *Lancet* 341(8837), 121.

2 Popper H (1986) Aging and the liver. In: Popper H, Schaffner F (eds) *Progress in Liver Diseases*. Orlando: Grune and Stratton, pp. 659–683.

3 Kitani K (ed.) (1982) *Liver and Aging – 1982, Liver and Drugs*. Amsterdam: Elsevier/North Holland.

4 Kitani K (ed.) (1986) *Liver and Aging – 1986, Liver and Brain*. Amsterdam: Elsevier Scientific Publishers.

5 Bianchi L, James OFW, Holt P *et al.* (eds) (1988) *Aging in Liver and Gastrointestinal Tract*. Lancaster: MTP Press.

6 Wynne HA, Cope LH, Mutch E *et al.* (1989) The effect of age upon liver volume and apparent liver blood flow in healthy man. *Hepatology* 9, 297–301.

7 Swift CG, Homeida M, Halliwell M *et al.* (1978) Antipyrine disposition and liver size in the elderly. *Europ J Clin Pharm* 14, 149–152.

8 Marchesini G, Bua V, Brunori A *et al.* (1988) Galactose elimination capacity and liver volume in aging man. *Hepatology* 8, 1079–1083.

9 Wakabayashi H, Nishiyama Y, Ushiyama T *et al.* (2005) Evaluation of the effect of age on functioning hepatocyte mass and liver blood flow using liver scintigraphy in preoperative estimations for surgical patients: comparison with CT volumetry. *J Surg Res* 106, 246–253.

10 Calloway NO, Foley CF, Lagerbloom P (1965) Uncertainties in geriatric data. II. Organ size. *J Am Geriatr Soc* 13, 20–28.

11 Ivy GO, Schottler F, Wenzel J *et al.* (1984) Inhibitors of lysosomal enzymes: accumulation of lipofuscin-like dense bodies in the brain. *Science* 226, 985–987.

12 Kitani K (1990) Aging and the liver. In: Popper H, Schaffner F (eds) *Progress in Liver Diseases*. Philadelphia: W.B. Saunders, pp. 603–623.

13 Watanabe T, Shimada H, Tanaka Y (1978) Human hepatocytes and aging: a cytophotometrical analysis in 35 sudden-death cases. *Virchows Arch B Cell Pathol* 27, 307.

14 Barz H, Kunze KD, Voss K *et al.* (1977) Image processing in pathology. IV. Age dependent changes of morphometric features of liver cell nuclei in biopsies. *Exp Pathol (Jena)* 14, 55–64 (in German).

15 Tauchi H, Sato T (1968) Age changes in size and number of mitochondria of human hepatic cells.*J Gerontol* 23, 454–461.

16 Anantharaju A, Feller A, Chedid A (2002) Aging liver. A review. *Gerontology* 48, 343–353.

17 Vestal RE (1989) Aging and determinants of hepatic drug clearance. *Hepatology* 9, 331–334.

18 Zoli M, Magalotti D, Bianchi G *et al.* (1999) Total and functional hepatic blood flow decrease in parallel with ageing. *Age Ageing* 28, 29–33.

19 Reed AH, Cannon DC, Winkelman JW *et al.* (1972) Estimation of normal ranges from a controlled sample survey. I. Sex- and age-related influence on the SMA 12-60 screening group of tests. *Clin Chem* 18, 57–66.

20 Greenblatt DJ, Sellers EM, Shader RI (1982) Drug therapy: drug disposition in old age. *N Engl J Med* 306, 1081–1088.

21 Arora S, Kassarjian Z, Krasinski SD *et al.* (1989) Effect of age on tests of intestinal and hepatic function in healthy humans. *Gastroenterology* 96, 1560–1565.

22 Woodhouse KW, James OF (1990) Hepatic drug metabolism and ageing. *Br Med Bull* 46, 22–35.

23 James OFW *et al.* (1990) The influence of frailty, liver blood flow and size upon hepatic oxidation and conjugation in aged man. In: Kitani K (ed.) *Liver and Aging – 1990* Amsterdam: Elsevier, pp. 210–221.

24 Schnegg M, Lauterburg BH (1986) Quantitative liver function in the elderly assessed by galactose elimination capacity, aminopyrine demethylation and caffeine clearance. *J Hepatol* 3, 164–171.

25 Posner J, Danhof M, Teunissen MW J *et al.* (1987) The disposition of antipyrine and its metabolites in young and healthy elderly volunteers. *Br J Clin Pharmacol* 24, 51–55.

26 Schneider AR, Teuber G, Paul K *et al.* (2006) Patient age is a strong independent predictor of 13C-aminopyrine breath test results: a comparative study with histology, duplex-Doppler and a laboratory index in patients with chronic hepatitis C virus infection. *Clin Exp Pharmacol Physiol* 33, 300–304.

27 Schmucker DL, Woodhouse KW, Wang R (1990) Effect of age and gender on in vitro properties of liver microsomal mono-oxygenases. *Clin Pharmacol Ther* 48, 365–374.

28 Chandler MH, Scott SR, Blouin RA (1988) Age-associated stereoselective alterations in hexobarbital metabolism. *Clin Pharmacol Ther* 43, 436–441.

29 Marchesini G, Bianchi GP, Fabbri A *et al.* (1990) Synthesis of urea after a protein-rich meal in normal man in relation to ageing. *Age Ageing* 19, 4–10.

30 Fabbri A, Marchesini G, Bianchi G *et al.* (1994) Kinetics of hepatic amino-nitrogen conversion in ageing man. *Liver* 14, 288–294.

31 Le Couteur DG, Cogger VC, Markus AM *et al.* (2001) Pseudocapillarization and associated energy limitation in the aged rat liver. *Hepatology* 33, 537–543.

32 Hilmer SN, Cogger VC, Fraser R *et al.* (2005) Age-related changes in the hepatic sinusoidal endothelium impede lipoprotein transfer in the rat. *Hepatology* 42, 1349–1354.

33 Platt D (1977) Age dependent morphological and biochemical studies of the normal and injured rat liver. In: Platt D (ed.) *Liver and Ageing*. Stuttgart: F.K. Schattnauer, pp. 75–83.

34 Liu Y, Guyton KZ, Gorospe M *et al.* (1996) Age-related decline in mitogen-activated protein kinase activity in epidermal growth factor-stimulated rat hepatocytes. *J Biol Chem* 271, 3604–3607.

35 Gershon H, Gershon D (1973) Inactive enzyme molecules in aging mice: liver aldolase. *Proc Natl Acad Sci USA* 70, 909–913.

36 Brouwer A, Horan MA, Barelds RJ *et al.* (1986) Cellular aging of the reticuloendothelial system. *Arch Gerontol Geriatr* 5, 317–324.

37 Martin G, Sewell RB, Yeomans ND *et al.* (1994) Hepatic Kupffer cell function: the efficiency of uptake and intracellular degradation of 14C-labelled mitochondria is reduced in aged rats. *Mech Ageing Dev* 73, 157–168.

38 Rushfeldt C, Sveinbjornsson B, Seljelid R *et al.* (1999) Early events of hepatic metastasis formation in mice: role of Kupffer and NK-cells in natural and interferon-gamma-stimulated defense. *J Surg Res* 82, 209–215.

39 Vandervelde (1987) *Br Med J* 294, 1031.

40 Gust ID, Lehmann NI, Lucas CR (1978) Relationship between prevalence of antibody to hepatitis A antigen and age: a cohort effect? *J Infect Dis* 138, 425–426.

41 Forbes A, Williams R (1988) Increasing age – an important adverse prognostic factor in hepatitis A virus infection. *J R Coll Physicians* 22, 237–239.

42 Leder K, Weller PF, Wilson ME (2001) Travel vaccines and elderly persons: review of vaccines available in the United States. *Clin Infect Dis* 33, 1553–1566.

43 Condo (1993) *Hepatology* 18, 768.

44 Qin W, Jiang J, Chen Q *et al.* (2004) CpG ODN enhances immunization effects of hepatitis B vaccine in aged mice. *Cell Mol Immunol* 1, 148–152.

45 Cook JM, Gualde N, Hessel L *et al.* (1987) Alterations in the human immune response to the hepatitis B vaccine among the elderly. *Cell Immunol* 109, 89–96.

46 Goodson JD, Taylor PA, Campion EW *et al.* (1982) The clinical course of acute hepatitis in the elderly patient. *Arch Intern Med* 142, 1485–1488.

47 Chiaramonte M, Floreani A, Naccarato R (1982) Hepatitis B virus infection in homes for the aged. *J Med Virol* 9, 247–255.

48 Osella AR, Misciagna G, Leone A *et al.* (1997) Epidemiology of hepatitis C virus infection in an area of Southern Italy. *J Hepatol* 27, 30–35.

49 Deuffic S, Buffat L, Poynard T *et al.* (1999) Modeling the hepatitis C virus epidemic in France. *Hepatology* 29, 1596–1601.

50 Alter MJ, Margolis HS, Krawczynski K *et al.* (1992) The natural history of community-acquired hepatitis C in the United States. The Sentinel Counties Chronic non-A, non-B Hepatitis Study Team. *N Engl J Med* 327, 1899–1905.

51 Brind AM, Watson JP, James OF *et al.* (1996) Hepatitis C virus infection in the elderly. *QJM* 89, 291–296.

52 Benhamou JP (1986) Drug induced hepatitis: clinical aspects. In: Fillastre JP (ed.) *Hepatotoxicity of Drugs*. Rouen: University of Rouen, pp. 23–30.

53 Lind RC, Gandolfi AJ, Hall PD (1989) Age and gender influence halothane-associated hepatotoxicity in strain 13 guinea pigs. *Anesthesiology* 71, 878–884.

54 Rozenberg S, Besse S, Vivien B *et al.* (2002) Myocardial effects of halothane and isoflurane in senescent rats. *Anesthesiology* 97, 1477–1484.

55 Lewis JH, Zimmerman HJ (1989) Drug-induced liver disease. *Med Clin North Am* 73, 775–792.

56 James OFW (1988) Parenchymal liver disease in the elderly. In: Bianchi L, Holt P, James OFW *et al.* (eds) *Aging in Liver and Gastro-Intestinal Tract*. Lancaster: MTP Press, pp. 359–369.

57 Roll J, Boyer JL, Barry D *et al.* (1983) The prognostic importance of clinical and histologic features in asymptomatic and symptomatic primary biliary cirrhosis. *N Engl J Med* 308, 1–7.

58 Christensen E, Neuberger J, Crowe J *et al.* (1985) Beneficial effect of azathioprine and prediction of prognosis in primary biliary cirrhosis. Final results of an international trial. *Gastroenterology* 89, 1084–1091.

59 Grambsch PM, Dickson ER, Kaplan M *et al.* (1989) Extramural cross-validation of the Mayo primary biliary cirrhosis survival model establishes its generalizability. *Hepatology* 10, 846–850.

60 Metcalf JV, Bhopal RS, Gray J *et al.* (1997) Incidence and prevalence of primary biliary cirrhosis in the city of Newcastle upon Tyne, England. *Int J Epidemiol* 26, 830–836.

61 Poynard T, Mathurin P, Lai CL *et al.* (2003) A comparison of fibrosis progression in chronic liver diseases. *J Hepatol* 38, 257–265.

62 Selby CD, Toghill PJ (1986) Chronic active hepatitis in the elderly. *Age Ageing* 15, 350–356.

63 Newton JL, Burt AD, Park JB *et al.* (1997) Autoimmune hepatitis in older patients. *Age Ageing* 26, 441–444.

64 Johnson PJ, McFarlane IG (1993) Meeting report: International Autoimmune Hepatitis Group. *Hepatology* 18, 998–1005.

65 Wynne HA, Wood P, Herd B *et al.* (1992) The association of age with the activity of alcohol dehydrogenase in human liver. *Age Ageing* 21, 417–420.

66 Beresford TP, Lucey MR (1995) Ethanol metabolism and intoxication in the elderly. In: Beresford TP, Gomberg E (eds) *Alcohol and Aging*. New York: OUP, pp. 117–127.

67 Cahill A, Hershman S, Davies A *et al.* (2005) Ethanol feeding enhances age-related deterioration of the rat hepatic mitochondrion. *Am J Physiol Gastrointest Liver Physiol* 289, G1115–G1123.

68 Garagliano CF, Lilienfeld AM, Mendeloff AI (1979) Incidence rates of liver cirrhosis and related diseases in Baltimore and selected areas of the United States. *J Chronic Dis* 32, 543–554.

69 Potter JF, James OF (1987) Clinical features and prognosis of alcoholic liver disease in respect of advancing age. *Gerontology* 33, 380–387.

70 Aron (1979) *Ann Gastroenterol Hepatol* 15, 558.

71 Capocaccia R, Farchi G (1988) Mortality from liver cirrhosis in Italy: proportion associated with consumption of alcohol. *J Clin Epidemiol* 41, 347–357.

72 Liskow BI, Rinck C, Campbell J *et al.* (1989) Alcohol withdrawal in the elderly. *J Stud Alcohol* 50, 414–421.

73 Farrell GC, Larter CZ (2006) Nonalcoholic fatty liver disease: from steatosis to cirrhosis. *Hepatology* 43, S99–S112.

74 Ratziu V, Bonyhay L, Di Martino V *et al.* (2002) Survival, liver failure, and hepatocellular carcinoma in obesity-related cryptogenic cirrhosis. *Hepatology* 35, 1485–1493.

75 Adams LA, Lymp JF, St Sauver J *et al.* (2005) The natural history of nonalcoholic fatty liver disease: a population-based cohort study. *Gastroenterology* 129, 113–121.

76 Johnson (1989) *J Hepatol* 9, 549.

77 Roggli VL, Hausner RJ, Askew JB Jr (1981) Alpha-1-antitrypsin globules in hepatocytes of elderly persons with liver disease. *Am J Clin Pathol* 75, 538–542.

78 Battle WM, Matarazzo SA, Selhat GF *et al.* (1982) Alpha-1-antitrypsin deficiency – a cause of cryptogenic liver disease in the elderly. *J Clin Gastroenterol* 4, 269–273.

79 Emre S, Mor E, Schwartz ME *et al.* (1993) Liver transplantation in patients beyond age 60. *Transplant Proc* 25, 1075–1076.

80 Clain DJ (1996) Liver disease in the elderly. In: Gelb AM (ed.) *Clinical Gastroenterology in the Elderly*. New York: Dekker, pp. 167–183.

81 Levy MF, Somasundar PS, Jennings LW *et al.* (2001) The elderly liver transplant recipient: a call for caution. *Ann Surg* 233, 107–113.

82 Wang YJ, Ho YS, Lo MJ *et al.* (1995) Oxidative modification of DNA bases in rat liver and lung during chemical carcinogenesis and aging. *Chem Biol Interact* 94, 135–145.

83 Melia WM, Wilkinson ML, Portmann BC *et al.* (1984) Hepatocellular carcinoma in the non-cirrhotic liver: a comparison with that complicating cirrhosis. *Q J Med* 53, 391–400.

84 Collier JD, Curless R, Bassendine MF *et al.* (1994) Clinical features and prognosis of hepatocellular carcinoma in Britain in relation to age. *Age Ageing* 23, 22–27.

85 Lee HS, Han CJ, Kim CY (1993) Predominant etiologic association of hepatitis C virus with hepatocellular carcinoma compared with hepatitis B virus in elderly patients in a hepatitis B-endemic area. *Cancer* 72, 2564–2567.

86 Ohishi W, Kitamoto M, Aikata H *et al.* (2003) Impact of aging on the development of hepatocellular carcinoma in patients with hepatitis C virus infection in Japan. *Scand J Gastroenterol* 38, 894–900.

87 Smoger (1997) *Age Ageing* (in press).

88 Sridharan GV, Wilkinson SP, Primrose WR (1990) Pyogenic liver abscess in the elderly. *Age Ageing* 19, 199–203.

89 Chen SC, Lee YT, Lai KC *et al.* (2006) Risk factors for developing metastatic infection from pyogenic liver abscesses. *Swiss Med Wkly* 136, 119–126.

90 Chou FF, Sheen-Chen SM, Chen YS *et al.* (1994) Prognostic factors for pyogenic abscess of the liver. *J Am Coll Surg* 179, 727–732.

91 McDonald MI, Corey GR, Gallis HA *et al.* (1984) Single and multiple pyogenic liver abscesses. Natural history, diagnosis and treatment, with emphasis on percutaneous drainage. *Medicine* 64, 291–302.

92 Lindstrom CG (1977) Frequency of gallstone disease in a well-defined Swedish population. A prospective necropsy study in Malmo. *Scand J Gastroenterol* 12, 341–346.

93 Bateson (1975) Prevalence of gall stones in Dundee: a necropsy study. *Br Med J* 4, 427–430.

94 Thijs CT, van Engelshoven JM, Knipschild PG (1989) An echographic study of the prevalence of gallstone disease in Maastricht and the surrounding area. *Ned Tidjschr Geneeskd* 133, 110–114 (in Dutch).

95 Walker AR, Segal I, Posner R *et al.* (1989) Prevalence of gallstones in elderly black women in Soweto, Johannesburg, as assessed by ultrasound. *Am J Gastroenterol* 84, 1383–1385.

96 Einarsson K, Nilsell K, Leijd B *et al.* (1985) Influence of age on secretion of cholesterol and synthesis of bile acids by the liver. *N Engl J Med* 313, 277–282.

97 Poston GJ, Draviam EJ, Yao CZ *et al.* (1990) Effect of age and sensitivity to cholecystokinin on gallstone formation in the guinea pig. *Gastroenterology* 98, 993–999.

98 Khalil T, Walker JP, Wiener I *et al.* (1985) Effect of aging on gallbladder contraction and release of cholecystokinin-33 in humans. *Surgery* 98, 423–429.

99 Rajan M, Wali JP, Sharma MP *et al.* (2000) Ultrasonographic assessment of gall bladder kinetics in the elderly. *Indian J Gastroenterol* 19, 158–160.

100 Grace PA, Poston GJ, Williamson RC (1990) Biliary motility. *Gut* 31, 571–582.

101 Landau (1994) *Dig Surg* 11, 30.

102 Kasmin FE, Siegal JH (1996) Biliary disease in the elderly. In: Gelb AM (ed.) *Clinical Gastroenterology in the Elderly*. New York: Dekker, pp. 185–212.

103 Amberg JR, Zboralske FF (1965) Gallstones after 70: requiescat in pace. *Geriatrics* 20, 539–542.

104 NIH Consensus (1993) NIH Consensus conference. Gallstones and laparoscopic cholecystectomy. *JAMA* 269, 1018–1024.

105 Pigott JP, Williams GB (1988) Cholecystectomy in the elderly. *Am J Surg* 155, 408–410.

106 Saito M, Tsuyuguchi T, Yamaguchi T *et al.* (2000) Long-term outcome of endoscopic papillotomy for choledocholithiasis with cholecystolithiasis. *Gastrointest Endosc* 51, 540–545.

107 Kasmin (1995) *Gastrointest Endosc* 41, A423.

108 Siegal (1994) *Diag Ther Endosc* 1, 51.

109 Cuschieri A, Abd el Ghany AA, Holley MP (1989) Successful chemical cholecystectomy: a laparoscopic guided technique. *Gut* 30, 1786–1794.

110 Donaldson RM Jr (1982) Advice for the patient with 'silent' gallstones. *N Engl J Med* 307, 815–816.

111 Cobden I, Lendrum R, Venables CW *et al.* (1984) Gallstones presenting as mental and physical debility in the elderly. *Lancet* 1(8385), 1062–1064.

112 Glenn F, Becker CG (1982) Acute acalculous cholecystitis. An increasing entity. *Ann Surg* 195, 131–136.

22.3 Liver diseases and pregnancy

Andrew K. Burroughs and Evangelos Cholongitas

The liver in normal pregnancy

During pregnancy, the uterus pushes the liver upwards so that mild enlargement of the liver may not be palpable. Spider naevi and palmar erythema are common. Blood volume increases approximately 45% in the third trimester with a concomitant increase in central venous pressure and cardiac output [1], which is most marked at 30 weeks' gestation. Hypertension is defined as diastolic pressure more than 30 mmHg higher and systolic pressure more than 15 mmHg higher than values in the first trimester. Blood pressure falls in the second trimester and returns to normal levels at term. Renal blood flow and glomerular filtration (measured by insulin clearance) increase by 30% and 50% respectively [2]. Hepatic blood flow does not increase as measured by bromosulphthalein or indocyanine green clearance [3], but hepatic fractional blood flow decreases [3]. Compression of the inferior vena cava increases flow in the azygous system so that small oesophageal varices develop in approximately 50% of pregnant women. Gallbladder motility decreases with an increased residual and fasting volume. The lithogenic index of bile, hepatic cholesterol synthesis and biliary cholesterol secretion all increase [4], whereas chenodeoxycholic acid synthesis decreases in relation to cholic acid, with a reduced enterohepatic recirculation of bile acids.

Haematocrit, serum urea, uric acid, albumin and total protein values decrease. Alkaline phosphatase increases as a result of placental and bone isoenzymes [5]. Increases occur in the α_1-, α_2- and β-globulins, fibrinogen, cholesterol, triglycerides [6] and white cell count. No increases occur in total bilirubin, total bile acids, aminotransferases, gammaglobulin and 5′-nucleotide concentrations. Compared with age-matched control subjects, total and free bilirubin concentrations are lower in all trimesters, and conjugated bilirubin and γ-glutamyltranferase (γGT) levels are lower in the second and third trimesters, whereas 5′-nucleotidase is higher than normal [7]. Postprandial cholylglycine concentrations increase during pregnancy; pruritus occurs in about 50% with elevated values, but in only 20% with normal values [8].

Liver histology is normal, with only non-specific reactive changes seen: reactive Kupffer cells, variation in nuclear shape and size, and minimal bile ductular proliferation. Electron microscopy shows proliferation of the smooth endoscopic reticulum [9]. Transplacental transmission of fetal cells occurs: male hepatocytes were observed in future fetuses and in postpartum women, such that normal liver has male cell microchimerism [10].

Liver disease in pregnancy

In a clinical setting, liver diseases in pregnancy should be considered under three headings: those peculiar to pregnancy, those coincidental with pregnancy and pregnancy in patients with established liver disease. The incidence of jaundice (the most common clinical manifestation) is low, occurring in approximately 1 in 1500 pregnancies [11] but, of abnormal liver function tests, it is 30 per 1000 [12]. Postpartum abnormalities in liver function can occur with normal pregnancies, but return to normal between days 5 and 10 [13].

Investigation of liver disease during pregnancy

Results of laboratory investigations should be interpreted with the normal physiological changes in mind. The risks of percutaneous liver biopsy are not increased, and contraindications are the same as for non-pregnant women. A computerized tomographic (CT) scan (8-mm computed slice, 6 cm away from the liver) delivers less radiation than a single postero-anterior fetal radiograph [14]. The fetus should be shielded. Ultrasound carries no risk.

Liver disease peculiar to pregnancy

Hyperemesis gravidarum

Nausea and vomiting frequently occur in the first trimester in normal pregnancy [15] and are associated with faster gastric dysrhythmias than normal [16]. When these symptoms are unusually prolonged and intense, weight loss and dehydration occur and jaundice (usually mild) may develop; this occurs in

1–20/1000 pregnancies. Excessive salivation can occur, and 60% have transient hyperthyroidism due to human chorionic gonadotrophin (hCG) having thyroid-stimulating activity [17]. Hyperthyroidism *per se* may cause jaundice [18]. Thiamine deficiency can occur and needs correction [19]. Aminotransferase values may be raised, usually < 250 U/L [17]. The syndrome is associated epidemiologically with mothers under 20 years of age, nulliparity, obesity and non-smokers. It is more frequent in patients with hydatidiform mole and with *Helicobacter pylori* [20]. The mean birthweight is reduced with severe hyperemesis gravidarum [21]. As nausea and vomiting may be seen with acute viral hepatitis, the differential diagnosis is important. Recurrence rarely occurs with subsequent pregnancies [17].

The epidemiological risk factors are mostly associated with high estrogen levels; gonadotrophins peak in the first trimester and may be another pathogenetic factor. Ketonuria is more severe (reflecting more severe starvation and dehydration) in those with abnormal liver enzymes, but there is little correlation [22].

Liver histology is usually normal or shows fatty change [23]. Correcting dehydration and malnutrition restores normal liver function. Steroids are effective [24]. Ondansetron has been used with success [17]. Severe complications include oesophageal rupture, Wernicke's encephalopathy, central pontine myelinolysis, retinal haemorrhage and spontaneous pneumomediastinum [17].

Intrahepatic cholestasis of pregnancy (ICP)

This is the second most common cause of jaundice in pregnancy, after acute viral hepatitis; it occurs in 0.5–1% of pregnancies [7], almost always in the second or third trimester [25]. Pruritus appears first and, in very mild cases, jaundice is not seen (pruritus gravidarum). Other causes of itching, particularly if associated with skin lesions, need to be excluded. Most often, jaundice follows pruritus after about 2 weeks, accompanied by dark urine and pale stools [25]. Right upper quadrant pain and tender hepatomegaly are unusual – alternative diagnoses need considering. Itching can be severe, leading to sleep deprivation, anorexia and malnutrition. The syndrome lasts for the duration of pregnancy and resolves within 2–4 weeks of delivery with no sequelae. Postpartum haemorrhage may be more frequent, perhaps related to vitamin K deficiency [25].

Serum bilirubin increases but rarely above 100 μmol/L, with few exceptions [25]. Bile acids are raised. Aminotransferase values usually remain below 250 U/L but exceptions occur [26]. γGT may be normal [25]. Liver biopsy shows centrolobular cholestasis without necrosis or inflammation, but is not necessary diagnostically. The prevalence of gallstones is increased twofold [25]. Low selenium and glutathione peroxidase activity [27] is found, the significance of which is unclear, and also a higher postprandial serum glucose level [28]. Various mutations in different exons of the MDR3 biliary canalicular gene have been described. MDR3 (*ABC134*) mutations lead to increased levels of γGT, which however is not always raised [29,30]; MRD3 mutations are found in only 30% of UK cases [31].

Miscarriage, premature labour and perinatal mortality are increased, perhaps related to maternal illness. However, no direct relationship is found between nutritional state and fetal prognosis [25]. Direct toxicity from bile salts crossing the placenta is suggested in some studies, but not in others [25]. An abnormal myometrial sensitivity is documented [32]. There is abnormal variability in fetal heart rate [33]. The placenta may be abnormal [34] – intervillous flow decreases with cholestasis [35]. Fetal risk appears when maternal bile acid concentrations are < 40 μmol/L. High bile acid levels and gallstones are associated with more severe maternal disease [36]. Glutathione *S*-transferase measurement may discriminate between ICP and pruritus gravidarum [37], but needs further study.

Itching can be treated by antihistamines or cholestyramine; however, they may be ineffective, and patients are often intolerant. Vitamin K should be administered parenterally at least 6 h before delivery. Cholestyramine exacerbates vitamin K deficiency. Phenobarbitone has also been used [38]. Dexamethasone at 12 mg/day for 7 days, with tapering over 3 days, improves pruritus and also aids fetal lung maturation [39]. *S*-adenosyl-L-methionine (800 mg/day intravenously) relieves pruritus, lessens jaundice and lowers bile acids in controlled [40] and uncontrolled studies, without adverse fetal effects. Ursodeoxycholic acid (UDCA; 1 g/day) is safe and effective against pruritus and improves liver function [41,42], independent of γGT concentration [31], decreases cholate, toxic in the fetus [43], and increases delivery at term [44]. Both pruritus and liver function tests improve within 2 weeks. UDCA is more effective than *S*-adenosyl-L-methionine and cholestyramine [45,46]. Some authorities recommend delivery before 38 weeks' gestation, whereas others only recommend induction if fetal distress occurs or if jaundice is present at 36 weeks [47].

In a prospective study, orally administered progesterone in early pregnancy was considered a possible trigger factor [48], together with twin pregnancy, *in vitro* fertilization, prematurity and hypertension. ICP is more common in Scandinavia and in Araucanian Indians in Chile, and occurs in family clusters [49]. In Chilean women, there is a higher frequency of the human leukocyte antigen (HLA) *DPB1*0402* allele, but no association with the *DPB1* allele [50]. ICP is rare in black populations. The exact mode of transmission is not known [51].

Apart from recurrence of pruritus with subsequent pregnancies, pruritus may occur with menstrual disturbances associated with estrogen excess or with ethinylestradiol challenge or with the oral contraceptive pill [52]. Pregnancy decreases sulphation including that of estrogens and monohydroxy bile acids, attenuating their cholestatic potential, thus possibly contributing to the cholestasis of pregnancy [53].

Ethinylestradiol decreases the bile salt-independent fraction of bile flow, which may be related to changes in membrane fluidity [54]. *S*-adenosyl-L-methionine may change membrane fluidity through an increase in the methylation of the constituent

phospholipids. It may also indirectly reduce the load of estrogen metabolites [55]. Dexamethasone may work by suppressing fetoplacental estrogen synthesis. UDCA modifies the bile acid pool by increasing hydrophilic and less cytotoxic bile salts, inhibiting the effects of cholestatic compounds on the canalicular transport of bile acids, stimulating efflux pumps [56] and also acts in the placenta [57].

ICP is associated with other forms of intrahepatic cholestasis, related to defects in biliary canalicular transport proteins: 50% of women with cholestasis related to oral contraceptives have a history of ICP [52]; benign recurrent intrahepatic cholestasis can also occur. In arteriohepatic dysplasia, in which cholestasis is associated with multiple organ defects, cholestasis worsens during pregnancy [58].

Idiopathic acute fatty liver of pregnancy

The first case report was in 1934 [59], but it was described in 1857 [60]. Obstetric yellow atrophy was described as a specific cause of jaundice in pregnancy, distinguishing it from fulminant hepatitis (acute yellow atrophy) by the absence of liver necrosis in the presence of microvesicular fat (within swollen hepatocytes with central nuclei) and by periportal sparing [61]. This condition is now known as acute fatty liver of pregnancy (AFLP). It occurs solely in the last trimester of pregnancy, usually between the 34th and 36th weeks of gestation; earlier presentation is so exceptional that other diagnoses must be entertained.

Tetracycline administration gives a similar clinical and histological picture in non-pregnant women [62] and in women at any stage of pregnancy [63].

The incidence of AFLP is approximately 1 in 14 000 pregnancies [64], but milder cases are probably undiagnosed. Many cases are associated with homozygous long-chain 3-hydroxyacyl coenzyme A (CoA) dehydrogenase deficiency in the fetus with a heterozygote mother [65,66] who cannot metabolize the extra free fatty acids not metabolized by the fetus. There is an association with haemolysis, hepatic enzyme elevation and low platelets (HELLP) syndrome [67]. A single amino acid substitution from glutamic acid to glutamine (E474Q) [68] is present in 20%, and a substitution from guanosine to cytosine (G1528C) is present in the α subunit that catalyses the last three steps of β-oxidation [69]. The enzymatic activity resides on a mitochondrial trifunctional protein; the fetal genotype has a 49% association with AFLP, 11% with HELLP/pre-eclampsia, 63% with premature delivery and 43% with intrauterine growth retardation [67]. Prenatal diagnosis is possible [70]. In addition, pregnancy decreases *in vivo* mitochondrial oxidation of fatty acids by 25–50% in late gestation [71]. Short-chain acyl-CoA dehydrogenase deficiency has also been associated with AFLP [72]. Infants of mothers with AFLP should be screened [73], as dietary intervention can help those affected.

Burroughs *et al.* [74], and later others, reported an increased frequency of signs of pre-eclampsia (approximately 50%), and an increased incidence in primigravidae (50%) and twin pregnancies (10–15%), features also found in toxaemia in pregnancy. There is a large degree of overlap and spectrum of disease denoted as 'hepatic toxaemia' [75], which includes the HELLP syndrome [75]. Male births are more common with AFLP [74,76].

The classic presentation is of sudden onset of malaise progressing rapidly to persistent nausea, repeated vomiting, heartburn and upper abdominal pain, followed by jaundice, usually within 2 weeks of the onset of symptoms, and anorexia, weight loss and then coma. Jaundice may be mild, but is absent in less than 10%. Persistent nausea and vomiting are the most frequent symptoms, occurring in approximately 90%, and may also be associated with acute pancreatitis. Haematemesis is not uncommon due to oesophagitis, gastric erosions and/or ulceration or, very occasionally, oesophageal varices [77], and is part of a bleeding diathesis that is often fatal.

With severe illness, there are usually stillbirths, and the mother often died in hepatic and renal failure. However, AFLP has a much wider spectrum with less severe cases in which maternal and fetal mortality average 10% and 20% respectively. Other symptoms include headaches, ankle swelling, polyuria and polydipsia [78,79]. Transient diabetes insipidus has been described [80]. In more severe cases, the patient may present in labour or with antepartum haemorrhage or intrauterine death. The obstetric complications usually parallel the severity of liver disease.

Fever is unusual and, if present, is mild. Abdominal tenderness is common and ascites may be present; hepatosplenomegaly is not usually present but occasionally the liver is palpable. Unsuspected gastrointestinal bleeding must be looked for. Coma ranges in severity and may be absent; flap may be present. Peripheral oedema, hypertension or proteinuria are found in approximately 50% of cases and may lead to an initial diagnosis of pre-eclampsia [74]. Occasionally, AFLP is diagnosed 'late' as a cause of postpartum jaundice [81].

The complications of severe AFLP are those of fulminant liver disease; they may complicate making a diagnosis and are often the cause of death [82]: disseminated intravascular coagulation, hypoglycaemia, bleeding (particularly postpartum) and acute pancreatitis. Severe oesophagitis with rupture of the oesophageal wall [83] and oesophageal stricture have been documented [84]. Subcapsular haematoma, rupture of the liver [85] and fat emboli [86] have been described.

Anaemia is not seen unless bleeding or disseminated intravascular coagulation is present. Neutrophilia, with or without toxic granulation, is almost universal (usually 15×10^9 cells/L or more) and is sustained postpartum, as is thrombocytopenia (usually less than 100×10^9 cells/L). Normoblasts, giant platelets and target cells are seen in the blood film and give a clue to the diagnosis, as this is not seen in viral hepatitis and is rare in pre-eclampsia [74]. Basophilic stippling is reported [74]; bone marrow is hypercellular [74].

Serum aminotransferase values are rarely above 500 U/L, except following shock or significant hypotension [76], and fall

immediately following delivery. Bilirubin concentrations may be markedly raised and usually peak postpartum. Gammaglobulin concentrations and quantitative immunoglobulin are not elevated or only minimally so [74]; this can help distinguish AFLP from acute viral hepatitis. Alkaline phosphatase concentrations are raised over and above the normal increase in pregnancy. However, as histological placental abnormalities seen in pre-eclampsia are not described [74] and alkaline phosphatase values are not lower in pre-eclampsia [5], part of the abnormal alkaline phosphatase is hepatic in origin. Prothrombin and partial thromboplastin times may be increased, particularly if jaundice is present; skin bleeding time is increased [74]. Evidence for disseminated intravascular coagulation, decreased fibrinogen, fragmented red cells and fibrin degradation products may be found [87].

Antithrombin III concentrations, which are low at delivery in normal pregnancy, fall further in AFLP [88] and correlate with maternal and fetal morbidity [89]. Plasma urea, uric acid and creatinine are usually elevated even without jaundice and rise until delivery. Urinary sodium excretion is low [74], and hyponatraemia and hyperkalaemia may be present. Renal function improves postpartum returning to normal at about 2 weeks. Uric acid concentrations may increase days before symptoms of AFLP [90], providing a pointer towards early diagnosis [74]. Serum ammonia concentrations are high [74] and return to normal within 48 h of delivery. There is generalized aminoacidaemia [74], and serum cholesterol concentrations tend to be low or normal [74].

Pathology

Histological findings vary widely depending on the timing of liver biopsy in relation to delivery, following which fatty infiltration resolves rapidly [74,76]. Classically, there is microvesicular fatty infiltration, without displacement of the central hepatocyte nuclei, most prominently around the central veins. It may extend throughout the lobule. Macrovesicular fat may also be seen in more severe cases.

The fat must be looked for using oil red O or other appropriate fat stains in unfixed sections. Necrosis is often absent but can occur [74,76] and is usually seen as cell dropout. Bridging necrosis is not seen. Lobular inflammation is usually mild but, if severe, can lead to a misdiagnosis of viral hepatitis [74,76]. Portal inflammation is mild. Cholestasis is frequent with canalicular bile plugs. Hepatocytes may be ballooned without vesicular fat, and this appears to be the initial stage of fatty degeneration [76]. Intrasinusoidal fibrin deposits and microhaemorrhages [74,91] characteristic of toxaemia have been described, but are not frequent [76]. Microvesicular fat has been found in livers of women with toxaemia, and some series suggest that fatty degeneration is not infrequent in toxaemia. Microvesicular fat is found in the HELLP syndrome [92]. Extramedullary haemopoiesis is often found and may be responsible for the normoblasts commonly seen in blood films [74,76].

Misinterpretation of liver biopsies, for example diagnosis of viral hepatitis [74], may result in failure to recognize AFLP [93]. Electron microscopy confirms the fat as droplets that are not bound to the membrane. There is also dilated endoplasmic reticulum [77] and mitochondrial pleomorphism with paracrystalline deposits [74], but these have been shown in normal pregnancy [9] and pre-eclampsia [94].

Follow-up liver biopsies are normal [74,77,81]. Livers at autopsy are macroscopically yellow and are usually shrunken, but normal liver weights may be found [74]. Kidneys can have fat in proximal convoluted tubules [74]. Heart and pancreas may also show fatty infiltration. Fetal livers are normal [74].

Diagnosis

The first step is to think about the possibility of AFLP as it has such a wide clinical spectrum. Nausea and vomiting in the last trimester of pregnancy should always be fully investigated. As AFLP occurs solely in the last trimester, the differential diagnosis lies between acute or fulminant viral hepatitis, drug hepatitis or toxaemia of pregnancy, including HELLP syndrome, as hepatic diagnoses. Obstetric causes of renal failure should also be considered, i.e. haemolytic uraemic syndrome (HUS) and thrombotic thrombocytopenic purpura (TTP) [95]. HUS usually occurs postpartum and consists of renal failure and microangiopathic haemolytic anaemia (its principal features), as well as gastrointestinal bleeding, thrombocytopenia and disseminated intravascular coagulation. TTP results in thrombocytopenia and microangiopathic anaemia, but there are usually neurological abnormalities (including epileptic fits) without disseminated intravascular coagulation. These conditions may have similar haematological and renal abnormalities as AFLP and mildly abnormal liver function tests. HUS and TTP are causes of the syndrome of jaundice, renal failure and a bleeding diathesis, which also includes severe pre-eclampsia, AFLP and fulminant hepatitis. The history may yield clues as to hepatitis contacts or inadvertent use of drugs. Neutrophilia is a feature of AFLP and pre-eclampsia but not of viral hepatitis. A blood film is diagnostic of microangiopathic haemolytic anaemia, as seen in HUS, and may show a typical picture in AFLP, i.e. neutrophilia, normoblasts, giant platelets and thrombocytopenia [74]. Serological markers for the acute hepatitides must be looked for. Acute herpes hepatitis is not often considered: aminotransferase levels are usually very high, mucocutaneous herpetic lesions should be sought; acyclovir can cure herpes hepatitis in pregnancy [96].

Ultrasound should exclude biliary obstruction or gallstones. A CT scan is mandatory. Fatty infiltration can be diagnosed by CT scan [74], but it may not show fat in less severe cases [97]. The CT attenuation values are usually less than those of the spleen, which is the converse of normal. Resolution of AFLP returns alteration values to normal at 3 weeks postpartum [14]. Ultrasound is often normal [98].

Importantly, a CT scan may also show intrahepatic or subscapular haemorrhage, which could progress to rupture [85], as well as pancreatitis, a recognized complication of AFLP [74].

Hepatic haemorrhages are seen in pre-eclampsia [99] and eclampsia [100]. Nuclear magnetic resonance imaging appears to be less sensitive [101].

If clotting and bleeding times are normal, a liver biopsy can be performed to confirm the diagnosis, but this is rarely necessary before delivery. A portion should be processed for fat staining and not fixed. If haemostasis is too abnormal, a transjugular route can be used.

Treatment of acute fatty liver of pregnancy

Immediate delivery is the key to managing AFLP and also for toxaemia, if this is the only differential diagnosis. Resolution of the syndrome can only begin once delivery occurs. There are no reports of recovery before delivery. The highest frequency of survival for both mother and baby occurs when delivery is made by caesarean section or induced [74,102] – the fetus is usually already mature. If symptoms of AFLP are mild, careful fetal monitoring can be made to try to prolong gestation [75]. However, progression of maternal illness may be unpredictable and rapid. Vaginal delivery should be attempted first. Caesarean section may be done under spinal anaesthesia if coagulation is close to normal; otherwise, general anaesthesia is preferable to avoid bleeding due to spinal puncture.

The management regimen for the mother is the same as for any case of fulminant liver failure. Hypoglycaemia may present before delivery or postpartum and requires constant monitoring. Pancreatitis may occur and, in severe AFLP, haemorrhagic oesophagitis occurs [74,103]. Postpartum haemorrhage may be out of proportion to the coagulation abnormalities [104], often occurring in the absence of disseminated intravascular coagulation. Deficiency in antithrombin III may be responsible [88]. Fresh frozen plasma containing high concentrations of antithrombin III and platelets is the mainstay of treatment, both therapeutically and prophylactically, although bleeding can be severe despite their use [74].

Cryoprecipitate and antithrombin III have also been administered [87]. Recombinant factor VIIa may be effective. Heparin should not be used. Tying off the hypogastric arteries or a hysterectomy may be necessary [64,74].

Renal failure responds to haemodialysis or haemofiltration [74,76]. Liver transplantation has been successful in very rare cases in which supportive therapy following delivery does not lead to recovery [105].

Further pregnancies

There are successful pregnancies without recurrence of AFLP even when the pregnancy has lasted spontaneously to term [64,74,75], but also case reports of recurrence in subsequent pregnancies [106], due to the underlying long-chain fatty acid metabolic defect in the fetus.

Tetracycline-induced fatty liver of pregnancy

When first reported in 1956, no association was made between chlortetracycline administration and fatty liver [107]; this was made in 1963 [63]. Fatty liver due to intravenous tetracycline has occurred in the second trimester, in non-pregnant women [62], in men, children and fetuses [108], whereas fetal liver is not affected by AFLP [74]. Oral tetracyclines have also been implicated [109].

Other microvesicular fat diseases of the liver and defects in urea cycle enzymes

AFLP shares the morphological feature of microvesicular fat infiltration as well as several clinical features, such as hypoglycaemia, hyperammoniaemia and coma, with a number of other conditions. However, in Reye syndrome, seen occasionally in adults [110], the mitochondrial changes at electron microscopy are not those of AFLP.

Hypoglycin A (in unripe ackee fruit) inhibits mitochondrial oxidation of long-chain fatty acids and causes Jamaican vomiting sickness. Valproic acid has a chemical structure similar to hypoglycin A and causes a similar clinical syndrome in susceptible patients. Defects in fatty acid oxidation also cause lipid accumulation in the liver. Medium-chain acyl-CoA dehydrogenase deficiency produces a secondary deficiency in carnitine, which is an essential cofactor in fatty acid transport into mitochondria for oxidation. There are several syndromes leading to carnitine deficiency [111]; pregnancy leads to relative deficiency and may precipitate symptoms in those with a genetic deficiency of carnitine [112].

Other genetic defects, such as mutations at the X-chromosome locus for ornithine carbamoyl transferase, have been shown to cause hyperammoniac coma in the first 10 days postpartum [113]. It occurs in otherwise healthy women who deliver infants (usually female) who do not exhibit a homozygous deficiency in ornithine carbamoyl transferase. It is postulated that the healthy fetus *in utero* provides the enzymatic activity for the mother. Diagnosis is made by finding raised maternal plasma ammonia and glutamine concentrations. Early treatment with sodium benzoate, sodium phenylacetate and arginine hydrochloride reverses the syndrome by correcting ammonia concentrations. The heterozygous state can be detected by an allopurinol stress test [114] or immunocytochemical staining of duodenal biopsy specimens [115].

Hypertension-associated liver dysfunction of pregnancy

Pre-eclampsia and eclampsia

In developed countries, hypertension and pregnancy-induced hypertension are still the major causes of maternal death [116]. Pre-eclampsia is diagnosed when there is rapid weight gain indicative of oedema (often manifest by ankle oedema), together with proteinuria and hypertension, in the second or third trimester of pregnancy, blood pressure above 140/90 mmHg in the absence of previous hypertension or an increase of 30 mmHg in systolic or 15 mmHg in diastolic pressure when there is pre-existing hypertension [116]. Eclampsia, by definition,

requires the occurrence of fits. In between mild pre-eclampsia and eclampsia, there is symptomatic endorgan disease (i.e. brain, kidney and liver), with headache, visual disturbances, upper abdominal pain and oliguria with renal failure. Cerebral haemorrhage is the major cause of death in eclampsia, but hepatic complications may account for up to 16% of deaths, usually due to hepatic rupture [94].

The hepatic abnormalities increase with increasing severity of pre-eclampsia. The major symptom is epigastric or right upper quadrant pain with a tender but usually normal-sized liver. Surgical emergencies may be mimicked by the abdominal symptoms [116]. With mild hypertension, 24% of patients have abnormal aminotranferases [116], rising to over 80% with severe hypertension. Bilirubin does not rise unless there is haemolysis or hepatic infarction. Antithrombin III concentrations are inversely correlated with outcome in severe pre-eclampsia [89]. In mild pre-eclampsia, there may be no hepatic histological abnormalities on light microscopy [117], but immunofluorescence studies show sinusoidal fibrinogen deposition, which correlates with increases in aspartate aminotransferases [118]. In severe cases, the characteristic hepatic lesions are fibrin deposition in the space of Disse with associated haemorrhages, leading to hepatocyte necrosis. Periportal haemorrhage occurs with increased severity.

In the most severe cases, large infarcts and haematomas may develop [99], which may rupture [100]. Liver infarcts can be secondary to hepatic arterial thrombosis, associated with very high aminotransferase values; they may resolve spontaneously.

The management for hepatic abnormalities is that of pre-eclampsia. Early delivery is the key to improving both hypertensive and liver complications. The liver function tests follow a typical pattern after delivery: aminotransferase values falling after 24 h and bilirubin falling by 72 h, but alkaline phosphatase and γGT rising on day 5 or 6, peaking on day 10 and returning to normal by 8 weeks [119]. This cholestatic pattern is similar to the recovery following an ischaemic insult. A CT or ultrasound scan should be done to detect subclinical liver haematoma and infarcts [120]. The pathogenesis of the liver lesions is still disputed. Fibrin deposition secondary to disseminated intravascular coagulation is unlikely to be a major factor as only a few patients have this. The major hypothesis is that of segmental vasospasm progressing to a generalized vasculopathy due to endothelial cell injury [94]. There is a microangiopathy evidenced by an isolated thrombocytopenia, which can develop before hypertension [121], without significant alteration of other coagulation factors [121]. Abnormalities in coagulation factors have been documented in cord blood, suggesting that fetal hepatic synthesis is impaired [122]. Eclampsia and pre-eclampsia have a statistical association with infantile hepatoblastoma [123].

Liver rupture

Liver infarcts, haematomas and liver rupture in pregnancy are associated with HELLP, severe pre-eclampsia and eclampsia in 80% of cases [124], may be more frequent if antiphospholipid syndrome is present [125] and are also seen in AFLP [85] and with cocaine use [126]. The first report was in 1844 [127]. Expectant management has developed in recent years as haematomas without rupture have been recognized with ultrasound and CT scan [124]. The haematoma is almost always confined to the right lobe (anterior or superior aspect), while ruptures occur from the inferior margin. Diaphragmatic penetration with haemothorax has been reported, as well as concomitant rupture of a hepatic vein.

Rupture occurs in the third trimester or postpartum, associated with older women and with late presentation of pre-eclampsia. It presents with sudden abdominal pain associated with nausea and vomiting; shock may develop very quickly [124], mimicking a perforated viscus. Mortality in early series was approximately 60% for both mother and baby [100], with a lower mortality with surgical intervention [124,128], improved to 16% in one series [129,130]. However, hepatic arterial embolization has also been successful [131], as well as hepatic artery ligation [132]. Recombinant factor VIIa may improve the likelihood of correcting haemostasis [133].

Conservative management of hepatic haematomas even with rupture [134] is now the initial therapy of choice, but very close monitoring is required [99,134], and facilities for urgent laparotomy must be available. Liver transplantation may be necessary and is successful [135]. The baby should be delivered by caesarean section [128]. Infection may develop in the haematoma and associated infarcted area. Successful pregnancy has been reported after hepatic rupture [136], but haemorrhage can recur so new pregnancies need to be monitored [137].

Other causes of hepatic rupture are adenoma [138], haemangioma [100], hepatocellular carcinoma [139], choriocarcinoma [140], testicular teratomas [141] and amoebic abscesses [142]. Spontaneous rupture of large spleens also occurs in pregnancy, mostly in the third trimester [143].

HELLP syndrome

Pregnancy-associated hypertension has a wide spectrum of severity and so too has the presentation of liver abnormalities. A syndrome of haemolysis, abnormal liver function tests and low platelet levels was described [144], which was given the acronym HELLP syndrome in 1982 [145]. This presentation can be associated with hypertension or may precede it [146], and may be found without proteinuria [147]. It may also occur early in pregnancy as a complication of the antiphospholipid syndrome [148]. In 30% of cases, HELLP occurs postpartum [125]. Liver infarction and haemorrhage can occur [125]. HELLP occurs more often in older Caucasian multiparous women who present late with pre-eclampsia [149]. Recently, placental CD95 ligand (CD95L) was shown to act systemically to cause liver damage in HELLP. Blockage of CD95L reduced liver damage as this is an anti-apoptotic phenomenon. This may lead to new therapies [150].

There is a wide variation in defining criteria to report HELLP. A well-categorized series identified 112 from 1153 patients

(9.7%) with pre-eclampsia over 8 years [149]. The diagnosis was made only if platelet counts were below 100×10^9/L, a blood film showed fragmented red cells and if raised values of bilirubin, lactate dehydrogenase and aspartate aminotransferase (4 standard deviations above normal) were present. Among this group, there were two maternal deaths, two ruptured livers and a 37% perinatal mortality, comprising 19% fetal mortality associated with 20% abruptio placentae; 38% of mothers had intravascular coagulopathy. Only one recurrence was reported. A policy of early delivery was advocated. Another series, based simply on increased aminotransferase values, a platelet count $< 150 \times 10^9$/L and serum haptoglobin of < 0.7 g/L, gave a 19% incidence [151].

In very severe cases, liver transplantation has been performed [152]. However, spontaneous recovery can occur before delivery [153]. A good outcome is possible with conservative management [154], the use of plasma expansion, plasmapheresis, plasmapheresis and prostacyclin and steroids administered pre- [155] and postpartum [156], but there is controversy regarding their benefit [157,158].

Overlap between acute fatty liver of pregnancy and hypertension-associated liver dysfunction of pregnancy (Table 1)

As discussed earlier, many patients with AFLP have signs of pre-eclampsia [159], thus AFLP and the hepatic dysfunction associated with hypertension may be part of the same spectrum or related to the same metabolic defect in long-chain 3-hydroxyacyl CoA dehydrogenase deficiency. Indeed, both older [160] and newer studies [94] have found fatty livers in a proportion of eclamptics. A consecutive cohort [92] of 41 patients with pre-eclampsia and liver dysfunction had microvesicular fat with oil red O staining; the density of fat staining correlated with serum urate concentration and was inversely correlated with platelet count; only 11 had fat visible by conventional stains [92]. Others had similar findings [161]. Although the association of AFLP with HELLP/pre-eclampsia is suggested by the frequency of both conditions in mothers of infants who have long-chain 3-hydroxyacyl CoA dehydrogenase deficiency [67], the problem may be misdiagnosis of AFLP for HELLP [74,162]. Some recommend monitoring platelet counts, as they decrease before manifestations of HELLP and AFLP [163]. Other syndromes with similar presentations are HUS and TTP [164].

Budd–Chiari syndrome

This syndrome has an increased incidence in pregnancy, mostly immediately postpartum but as late as 2 weeks postpartum [165]. It is due to an increased hypercoagulability state, related to lower antithrombin III concentrations at delivery in normal pregnancy [88], but is likely to be associated with heterozygosity or homozygosity for thrombophilic defects. A thrombophilia screen must be performed. The fetus is unaffected but maternal mortality is high [166]. Anticoagulation is mandatory in the long term, but emergency radiological or surgical shunting may be needed [167]. Liver transplantation has been successful [168]. Successful subsequent pregnancies have been reported; only one patient had a shunt before conception [169].

Pregnancy in pre-existing liver disease

As cirrhosis is associated with amenorrhoea and anovulation, pregnancy is rare. The amenorrhoea is due to hypothalamic–pituitary dysfunction and is not directly related to the severity of

Table 1 Clinical features of the most frequent liver conditions during pregnancy.

	Main symptoms	Trimester	Bilirubin	Transaminases	Platelets	Other
Hyperemesis gravidarum	Prolonged nausea Vomiting	1st	↑	↑ (< 250 IU/L)	Normal	Ketonuria
Intrahepatic cholestasis	Itching	2nd–3rd	↑↑↑	↑ (< 250 IU/L)	Normal	Bilirubinuria
Acute fatty liver	Epigastric/right upper quadrant pain[a] Malaise Vomiting	3rd	↑	↑↑ (< 500 IU/L)	↓	High uric acid Proteinuria Hypertension or peripheral oedema in 50%
Pre-eclampsia	Epigastric/right upper quadrant pain[a] Malaise Vomiting	2nd–3rd	Normal	↑	Normal or ↓	High uric acid Proteinuria Hypertension or peripheral oedema
HELLP	Epigastric/right upper quadrant pain[a] Malaise Vomiting	2nd–3rd (30% postpartum)	↑	↑	↓↓	Hypertension and proteinuria sometimes absent

[a]Sudden severe pain may indicate hepatic haematoma and/or rupture.

the liver disease [170]. Pregnancy can be sustained without worsening of hepatic function, but there is a high fetal wastage due to stillbirths, low birthweight babies and prematurity [171]. However, there is no increase in fetal abnormalities [172].

Unconjugated maternal bilirubin crosses the placenta and, in cases of severe maternal jaundice, neonatal kernicterus [173] may develop requiring exchange transfusions [174]. There is no clear evidence for an increase in variceal bleeding but, if bleeding occurs, the fetus may be lost. Pregnancies in patients with chronic liver disease should be monitored closely and followed in centres that have skills in critical neonatal care. The incidence of postpartum haemorrhage is increased with cirrhosis, but not with extrahepatic portal venous obstruction [171].

Chronic hepatitis

In chronic hepatitis from any cause that is mild, ovulation and fertility are not significantly altered. Normal pregnancy has been described in seven women during a 3- to 8-year follow-up [175].

Women with autoimmune or steroid-responsive chronic hepatitis, properly treated, are fertile and have successful pregnancies, albeit with higher fetal wastage and up to 30% prematurity [176]. Conception usually occurs in a period when the necroinflammatory activity is well controlled [177]. There may be a higher frequency of anovulatory cycles accounting for the infertility, which can be managed with standard measures. There is no evidence that azathioprine is teratogenic [176,177], but this drug is often discontinued during pregnancy. Disease activity may improve, with disease remission during pregnancy [178], or worsen, particularly postpartum [179]. Autoimmune hepatitis can present postpartum [180].

Primary biliary cirrhosis

Asymptomatic primary biliary cirrhosis is often diagnosed premenopausally. There is normal or increased gravidity [181]. The diagnosis may become apparent following pregnancy or during the last trimester [182], accounting for persistent itching postpartum.

Pregnancy is reported with symptomatic primary biliary cirrhosis [183,184]. Pruritus did not increase, but survival was short because of the severity of liver disease. If cholestyramine is used, vitamin K must be given before delivery. Ursodeoxycholic acid should not be used in the first trimester and should be temporarily suspended if already being taken, or if conception is planned.

Primary sclerosing cholangitis

There are few reports of pregnancy. A similar picture to primary biliary cirrhosis exists with normal gravidity [185].

Alcoholic liver disease

The incidence of pregnancy in patients with alcoholic liver disease appears to be low, with very few reports of full-term pregnancies. The exact relationship of the fetal alcohol syndrome to liver disease is unknown.

Familial hyperbilirubinaemia

Gilbert syndrome is unaffected by pregnancy [186]. In the Dubin–Johnson syndrome, conjugated hyperbilirubinaemia increases during the third trimester, returning to prepregnancy levels after delivery [187]. In Rotor syndrome, there is no change in bilirubin concentration [188].

Haemochromatosis and Wilson disease

In women, haemochromatosis is usually diagnosed after the menopause. Many have had successful pregnancies before the diagnosis was made, when a degree of iron overload, but probably no cirrhosis, was present.

Pregnancy has been reported in treated Wilson disease when necroinflammatory activity was controlled or absent [189], but rarely when cirrhosis was decompensated [190]. D-Penicillamine, trientine or zinc sulphate treatment are safe and must be continued during pregnancy [189,191], but a 50% dose reduction is advocated particularly in the last trimester to promote better wound healing in case of caesarean section [191]. Cessation of copper chelation has resulted in haemolysis and worsening of liver function and even fulminant liver failure [191]. Breastfeeding is not contraindicated [191].

Liver tumours in pregnancy

Focal nodular hyperplasia [192], adenomas, hepatocellular carcinoma [193] and cholangiocarcinoma [194] have all been reported. A useful management algorithm confirms that magnetic resonance imaging is the most discriminatory technique [195]. Focal nodular hyperplasia is not affected by pregnancy and does not need therapy [192]. Adenomas are related to prior oral contraceptive use and can enlarge, bleed and rupture during pregnancy (30% postpartum), probably as a result of estrogen stimulation. Pregnancy is thus contraindicated in the presence of large adenomas ≥ 5 cm; rupture is only reported in lesions ≥ 6.5 cm diameter [195]; small ones can be carefully observed. Resection may be needed or embolization. Successful pregnancy without recurrence has been reported [196]. The median survival of pregnant women with hepatocellular carcinoma is shorter than for non-pregnant women [193]. Rupture may occur with hepatocellular adenomas [138], hepatic gestational choriocarcinomas [197], testicular teratomas [141] and hepatic metastases [198].

Polycystic disease of the liver is usually not affected by pregnancy, but growth of cysts with increased pain is reported [199].

Haemangiomas, even giant ones, do not complicate pregnancy or delivery, with only a single report of spontaneous rupture [200].

Hepatic porphyrias

The effect of pregnancy on the course of acute intermittent porphyria is unpredictable [201]. Hereditary coproporphyria may worsen during pregnancy, but serious or fatal complications are rare, as is also the case for variegate porphyria. Perinatal mortality is increased.

Schistosomiasis

Hepatic schistosomiasis is a common cause of portal hypertension worldwide. However, the reports of pregnancy in this disease are few [202].

Vascular abnormalities in the liver

Arteriovenous fistulas may lead to high-output cardiac failure as cardiac output increases with normal pregnancy [203]. Increased shunting, reversing after pregnancy, has been described in hereditary haemorrhagic telangiectasia [204].

Variceal bleeding in pregnancy

Theoretically, the increase in circulating blood volume, cardiac output, central venous pressure and azygous blood flow due to the pressure of the gravid uterus should increase portal pressure, and thus increase the probability of variceal bleeding in pregnant patients with varices, although the vasodilatation seen in pregnancy may tend to counteract this. Evidence for an increased risk of haemorrhage was not found in a large retrospective review [171], although more frequent variceal bleeding, particularly in non-cirrhotic portal hypertension, is reported [205].

Bleeding should be treated as in the non-pregnant patient with the exception of vasoactive drugs, because they may cause placental ischaemia. Particular care should be taken to prevent hypotension. Endoscopic therapy with sclerotherapy or banding is as successful in stopping bleeding as in non-pregnant patients [206], and does not interfere with subsequent conception.

Shunt surgery has been performed successfully during pregnancy without loss of the fetus [171]. Transjugular intrahepatic portosystemic shunt (TIPS) procedures can be performed but, depending on fetal maturity, the radiation exposure may preclude this. Pregnancy has been reported in patients after a portacaval shunt [207] with and without cirrhosis [171]. Prophylactic treatment with β-blockers may be indicated if the varices are large and have red signs, although propranolol may give rise to some intrauterine growth retardation [208]. Rupture of splenic artery aneurysms may be more common in pregnancy [209].

Contraception for women with chronic liver disease

Effective birth control should be used where clinically indicated. Although many recommend avoiding oral contraceptives, there is no evidence of increased susceptibility to side-effects in chronic liver disease, and it remains the most effective female contraceptive method. The possible risks must be considered against the potential risk of pregnancy.

Liver disease not specific to pregnancy

Acute viral hepatitis

This is the most common cause of jaundice in pregnant women [11]. For all forms of viral hepatitis except epidemic non-A, non-B hepatitis, most of which is hepatitis E, the clinical presentation, complications, course, outcome and immunoprophylaxis are the same as in non-pregnant women. In this section, the particular problems associated with pregnancy will be addressed.

The management should be conservative. Medication should be avoided. Serological diagnosis coupled with ultrasound is usually all that is necessary to establish a diagnosis. Amniocentesis is best avoided as it could be a source of infection for the fetus [210]. There is a slight increase in prematurity [211], but no increased risk of malformation. Obstetric management should follow standard lines. Acute viral hepatitis may be misdiagnosed as AFLP [74].

Hepatitis A

There is no evidence that this is more common or more severe in pregnancy [212]. The only risk to the fetus is if the mother is viraemic at the time of delivery, although anti-hepatitis A virus (HAV) antibody appears early in the illness and does cross the placenta. Passive prophylaxis with 0.5 mL of immune serum globulin appears to protect the infant against infection, although there are no specific data to prove this. A single case report of fatal relapsing viral hepatitis A has been reported during pregnancy following the initial attack 5 months earlier [213].

Hepatitis B

The outcome of hepatitis B in the pregnant patient is the same as in non-pregnant women. The risk of fetal transmission depends on the maternal viral load, being highest in Chinese patients as a result of the higher rate of hepatitis B e antigen (HBeAg) seropositivity [214]; reactivation of hepatitis B virus (HBV) infection is possible [215]. At least 90% of infants born to HBeAg-positive mothers become infected and at least 80% of these become chronic hepatitis B surface antigen (HBsAg) carriers [214]. The child is usually asymptomatic until adult life. Lamivudine given in the last 4 weeks of pregnancy reduces viraemia and the risk of failure of prophylaxis in the infant [216]. Lamivudine has been continued during the first trimester with delivery of a normal fetus [217]. All infants of HBsAg-positive mothers should receive immunoprophylaxis independent of maternal viraemic titre: hepatitis B immunoglobulin at birth (0.5 mL intramuscularly), followed by HBV vaccine (10 μg) intramuscularly within 7 days of birth and 1 and 6 months later [218,219]. Breastfeeding is not contraindicated [210] A schedule of vaccination at birth and at 1, 2 and 12 months results in higher anti-HBs titres [220]. Effective prophylaxis depends on the identification of HBsAg-positive mothers. A screening programme at 14 weeks' gestation has been shown to be effective [221]. Postexposure prophylaxis with immunoglobulin and hepatitis B vaccine can be given safely [222].

Hepatitis C

Studies in which non-A, non-B hepatitis was diagnosed by exclusion showed transmission to infants, evidenced by persistent aminotransferase elevations over a 10-month period [223,224]. Vertical transmission occurs in infants born to anti-hepatitis C virus (HCV)- and anti-human immunodeficiency virus

(HIV)-positive mothers [225], but this is rare in anti-HIV-negative mothers, averaging about 2.5% [226], despite HCV RNA in cord blood. Infants require screening and follow-up according to recent guidelines [227]. Chronic hepatitis C is not adversely affected by pregnancy and vice versa [228]. Caesarean section is not indicated if solely anti-HCV positive. Breastfeeding is not contraindicated [229]. With *in vitro* fertilization in HCV RNA-positive women, HCV RNA was undetectable in all media at oocyte transfer [230].

Hepatitis D

Unlike hepatitis B, this is rarely transmitted to the newborn [231] because of low hepatitis D virus (HDV) loads. Anti-HDV antibodies are passively transmitted to the fetus and disappear within 3 months. Immunoprophylaxis for hepatitis B prevents transmission of hepatitis D.

Hepatitis E

This can occur as epidemic, water-borne hepatitis in the Indian subcontinent and northern Africa. It has a worse prognosis and is more frequent in pregnancy, representing a major cause of maternal mortality in developing countries. In India, mortality was 17.3% in pregnancy, 2.1% in non-pregnant women and 2.8% in men [232] and continues to be high in pregnancy – 26.9% [233]. Infection with hepatitis E is the reason for the disparity in mortality between pregnant women with acute viral hepatitis in developed and developing countries, as it causes a high rate of fulminant liver failure in the second and third trimester of pregnancy characterized by rapid-onset encephalopathy and disseminated intravascular coagulation [234]. The fulminant course in mothers may be due to severe fetal hepatitis – a mirror syndrome [235]. Vertical transmission occurs in approximately 33–50% [233,236]. Immune serum globulin intramuscularly (0.5 mL) can be given at birth if paternal hepatitis E is suspected or diagnosed. Although hepatitis E virus (HEV) RNA is present in colostrum, breastfeeding appears to be safe [237].

Hepatitis G

Vertical transmission has been studied and seems to be higher than for HIV and HCV, but the clinical consequences are not known [238].

Amoebiasis

Amoebic abscess can present in pregnancy [239]; rupture is described [142]. Pregnancy may confer an increased susceptibility to amoebiasis with an increased mortality [240], but this is not generally accepted. Management and treatment with metronidazole is the same as for non-pregnant patients.

Herpes hepatitis and other infections

Herpes hepatitis is rare, but may be fulminant – mucocutaneous lesions must be looked for, as acyclovir is an effective treatment [96,241]. There may be a specific CT pattern of a miliary spread of hypovascular lesions [242]. Leptospirosis has the same clinical features as in non-pregnant females. Malaria may give rise to liver dysfunction [243]. Pyogenic abscess [244] and hydatid cysts [245] are treated with standard measures. Albendazole seems to be safe in pregnancy [246].

Drug toxicity

Drugs are normally avoided during pregnancy, but consumption of prescribed and non-prescribed medicines or other substances is not negligible [247]. It is not known whether drug toxicity may be more severe [248]. Tetracycline can give rise to a syndrome similar to AFLP (see above). Fulminant hepatitis due to quinidine and phenylethylbarbiturate, used for obstetric indications, is recognized [249], as well as more common drug reactions, such as those caused by methyldopa given for hypertension in pregnancy [250], chlorpromazine [251], halothane [252], methoxyflurane [253], hydralazine [254] and isoniazid [255]. The use of β-sympathomimetics for premature labour has led to the use of relatively long-term drug therapy for pregnant women; there have been a few reports of drug-induced hepatitis due to terbutaline [256] and ritodrine [257]. Close monitoring is necessary to determine whether, with mild abnormalities of liver function, the drug could be continued to avoid risking premature labour.

Paracetamol overdose

Paracetamol is frequently recommended for analgesia if needed during pregnancy. Overdoses are reported, and *N*-acetylcysteine given early in pregnancy is without untoward effects. The fetal liver does not appear to be affected [258].

Biliary disease

An ultrasonographic study in 272 pregnant women updated a previous report showing that gallbladder sludge and gallbladder stones have a cumulative incidence of 31% and 9%, respectively, during pregnancy, but both spontaneously disappear within 12 months of delivery in 87% and 30% respectively [259]. The risk of developing gallstones increases in those who previously took oral contraceptives [260], but pregnancy itself leads to gallstone formation by stimulating cholesterol synthesis, which increases delivery of cholesterol to the liver, and by impairing the ability to catabolize cholesterol to bile acid, increasing the secretion of biliary cholesterol, reducing the cholesterol-carrying capacity of bile and impairing contraction of the gallbladder with secondary stasis of bile [261].

Biliary obstruction should be managed with standard protocols using endoscopic sphincterotomy and drainage, and/or stone removal, as the first therapeutic approach [262]. Steps must be taken to reduce fetal exposure [262]. Open [263] or laparoscopic [264] cholecystectomy carries no extra risk in pregnancy, although there is increased fetal loss in the first trimester. Cholecystitis can be mimicked by severe pre-eclampsia [265] and the HELLP syndrome. Choledochal cyst [266] and biliary carcinoma can occur in pregnancy [267].

Liver transplantation and pregnancy

Normal menstrual pattern returns quickly following successful transplantation [268], ranging between 1 [269] and 40 weeks [268] after transplantation. This emphasizes the need for contraceptive advice immediately after transplantation. Ideally, pregnancy should be deferred for 1 year following liver transplantation as most complications and deaths occur in this period. Oral contraceptives may be prescribed; there are no data to suggest that cholestatic reactions are more frequent in a transplanted liver. However, oral contraceptives can affect ciclosporin elimination [270] and potentiate ciclosporin hepatotoxicity [270].

Oral contraceptives should not be used in patients transplanted for Budd–Chiari syndrome because of the underlying thrombogenic tendency, even if anticoagulation is routine. Warfarin is teratogenic and, therefore, alternative contraceptive advice is even more important in this context [271].

Successful pregnancies are increasingly reported [272], the first in 1978. Successful conception has occurred as early as 4 months after transplantation.

Azathioprine is usually stopped during pregnancy; although there is no clear evidence for teratogenicity, it may cause pancytopenia in infants [273]. Prednisolone is safe; large doses of methylprednisolone given for acute cellular rejection do not affect the fetus, although low birthweight infants have been reported [274]. Ciclosporin and metabolites cross the placenta [275]. Low birthweight infants occur in liver transplant recipients [276]; one intrauterine death has been attributed to ciclosporin [268]. Fetal growth must be closely monitored.

No teratogenic effects have been described with ciclosporin or tacrolimus [277]. Children followed for up to 12 years have had normal development [278]. Ciclosporin and tacrolimus are nephrotoxic, and almost 40% of patients taking either will develop hypertension in pregnancy, possibly less frequently with tacrolimus [277]. Hypertensive disease of pregnancy occurs more frequently [279]. Plasma concentrations of calcineurin inhibitors require careful monitoring. Mycophenolate mofetil and sirolimus are contraindicated in pregnancy. They should be substituted with other drugs before conception.

Pregnancy does not increase the likelihood of graft rejection. There is a higher incidence of prematurity and low birthweight, related to obstetric indications for early delivery, principally pregnancy-induced hypertension, which accounts for a caesarean section rate of over 50% [279].

Liver transplantation has also been performed during pregnancy for fulminant liver failure with the mother usually surviving, but a high rate of fetal loss [280].

References

1 Walters WA, Lim YL (1970) Changes in the maternal cardiovascular system during human pregnancy. *Surg Gynecol Obstet* 131, 765–784.

2 Davison JM (1987) Kidney function in pregnant women. *Am J Kidney Dis* 9, 248–252.

3 Robson SC, Mutch E, Boys RJ *et al.* (1990) Apparent liver blood flow during pregnancy: a serial study using indocyanine green clearance. *Br J Obstet Gynaecol* 97, 720–724.

4 Feingold KR, Wiley T, Moser AH *et al.* (1983) De novo cholesterogenesis in pregnancy. *J Lab Clin Med* 101, 256–263.

5 Adeniyi FA, Olatunbosun DA (1984) Origins and significance of the increased plasma alkaline phosphatase during normal pregnancy and pre-eclampsia. *Br J Obstet Gynaecol* 91, 857–862.

6 Svanborg A, Vikrot O (1965) Plasma lipid fractions, including individual phospholipids, at various stages of pregnancy. *Acta Med Scand* 178, 615–630.

7 Bacq Y, Zarka O, Brechot JF *et al.* (1996) Liver function tests in normal pregnancy: a prospective study of 103 pregnant women and 103 matched controls. *Hepatology* 23, 1030–1034.

8 Lunzer M, Barnes P, Byth K *et al.* (1986) Serum bile acid concentrations during pregnancy and their relationship to obstetric cholestasis. *Gastroenterology* 91, 825–829.

9 Perez V, Gorodisch S, Casavilla F *et al.* (1971) Ultrastructure of human liver at the end of normal pregnancy. *Am J Obstet Gynecol* 110, 428–431.

10 Guettier C, Sebagh M, Buard J *et al.* (2005) Male cell microchimerism in normal and diseased female livers from fetal life to adulthood. *Hepatology* 42, 35–43.

11 Hammerli U (1966) Jaundice during pregnancy with special reference on recurrent jaundice during pregnancy and its differential diagnosis. *Acta Med Scand* 179 (Suppl 444), 1.

12 Ch'ng CL, Morgan M, Hainsworth I *et al.* (2002) Prospective study of liver dysfunction in pregnancy in southwest Wales. *Gut* 51, 876–880.

13 David AL, Kotecha M, Girling JC (2000) Factors influencing postnatal liver function tests. *Br J Obstet Gynaecol* 107, 1421–1426.

14 Clements D, Young WT, Thornton JG *et al.* (1990) Imaging in acute fatty liver of pregnancy. Case report. *Br J Obstet Gynaecol* 97, 631–633.

15 Jewell D (2003) *Nausea and Vomiting in Early Pregnancy. Clinical Evidence*. London: BMJ Publishing Group, pp. 1561–1570.

16 Maes BD, Spitz B, Ghoos YF *et al.* (1999) Gastric emptying in hyperemesis gravidarum and non-dyspeptic pregnancy. *Aliment Pharmacol Ther* 13, 237–243.

17 Kuscu NK, Koyuncu F (2002) Hyperemesis gravidarum: current concepts and management. *Postgrad Med J* 78, 76–79.

18 Colin JF, Mathurin P, Durand F *et al.* (1994) [Hyperthyroidism: a possible factor of cholestasis associated with hyperemesis gravidarum of prolonged evolution]. *Gastroenterol Clin Biol* 18, 378–380.

19 Tesfaye S, Achari V, Yang YC *et al.* (1998) Pregnant, vomiting, and going blind. *Lancet* 352, 1594.

20 Kocak I, Akcan Y, Ustun C *et al.* (1999) *Helicobacter pylori* seropositivity in patients with hyperemesis gravidarum. *Int J Gynaecol Obstet* 66, 251–254.

21 Gross S, Librach C, Cecutti A (1989) Maternal weight loss associated with hyperemesis gravidarum: a predictor of fetal outcome. *Am J Obstet Gynecol* 160, 906–909.

22 Morali GA, Braverman DZ (1990) Abnormal liver enzymes and ketonuria in hyperemesis gravidarum. A retrospective review of 80 patients. *J Clin Gastroenterol* 12, 303–305.

23 Adams RH, Gordon J, Combes B (1968) Hyperemesis gravidarum. I. Evidence of hepatic dysfunction. *Obstet Gynecol* 31, 659–664.

24 Safari HR, Fassett MJ, Souter IC *et al.* (1998) The efficacy of methylprednisolone in the treatment of hyperemesis gravidarum: a randomized, double-blind, controlled study. *Am J Obstet Gynecol* 179, 921–924.

25 Reyes H (1982) The enigma of intrahepatic cholestasis of pregnancy: lessons from Chile. *Hepatology* 2, 87–96.

26 Wilson JA (1987) Intrahepatic cholestasis of pregnancy with marked elevation of transaminases in a black American. *Dig Dis Sci* 32, 665–668.

27 Kauppila A, Korpela H, Makila UM *et al.* (1987) Low serum selenium concentration and glutathione peroxidase activity in intrahepatic cholestasis of pregnancy. *Br Med J (Clin Res Ed)* 294, 150–152.

28 Wojcicka-Jagodzinska J, Kuczynska-Sicinska J, Czajkowski K *et al.* (1989) Carbohydrate metabolism in the course of intrahepatic cholestasis in pregnancy. *Am J Obstet Gynecol* 161, 959–964.

29 Jacquemin E, Cresteil D, Manouvrier S *et al.* (1999) Heterozygous non-sense mutation of the MDR3 gene in familial intrahepatic cholestasis of pregnancy. *Lancet* 353, 210–211.

30 Mullenbach R, Linton KJ, Wiltshire S *et al.* (2003) ABCB4 gene sequence variation in women with intrahepatic cholestasis of pregnancy. *J Med Genet* 40, e70.

31 Milkiewicz P, Gallagher R, Chambers J *et al.* (2003) Obstetric cholestasis with elevated gamma glutamyl transpeptidase: incidence, presentation and treatment. *J Gastroenterol Hepatol* 18, 1283–1286.

32 Israel EJ, Guzman ML, Campos GA (1986) Maximal response to oxytocin of the isolated myometrium from pregnant patients with intrahepatic cholestasis. *Acta Obstet Gynecol Scand* 65, 581–582.

33 Ammala P, Kariniemi V (1981) Short-term variability of fetal heart rate in cholestasis of pregnancy. *Am J Obstet Gynecol* 141, 217–220.

34 Costoya AL, Leontic EA, Rosenberg HG *et al.* (1980) Morphological study of placental terminal villi in intrahepatic cholestasis of pregnancy: histochemistry, light and electron microscopy. *Placenta* 1, 361–368.

35 Kaar K, Jouppila P, Kuikka J *et al.* (1980) Intervillous blood flow in normal and complicated late pregnancy measured by means of an intravenous 133Xe method. *Acta Obstet Gynecol Scand* 59, 7–10.

36 Glantz A, Marschall HU, Mattsson LA (2004) Intrahepatic cholestasis of pregnancy: relationships between bile acid levels and fetal complication rates. *Hepatology* 40, 467–474.

37 Dann AT, Kenyon AP, Seed PT *et al.* (2004) Glutathione S-transferase and liver function in intrahepatic cholestasis of pregnancy and pruritus gravidarum. *Hepatology* 40, 1406–1414.

38 Laatikainen T (1978) Effect of cholestyramine and phenobarbital on pruritus and serum bile acid levels in cholestasis of pregnancy. *Am J Obstet Gynecol* 132, 501–506.

39 Hirvioja ML, Tuimala R, Vuori J (1992) The treatment of intrahepatic cholestasis of pregnancy by dexamethasone. *Br J Obstet Gynaecol* 99, 109–111.

40 Frezza M, Pozzato G, Chiesa L *et al.* (1984) Reversal of intrahepatic cholestasis of pregnancy in women after high dose S-adenosyl-L-methionine administration. *Hepatology* 4, 274–278.

41 Palma J, Reyes H, Ribalta J *et al.* (1997) Ursodeoxycholic acid in the treatment of cholestasis of pregnancy: a randomized, double-blind study controlled with placebo. *J Hepatol* 27, 1022–1028.

42 Davies MH, da Silva RC, Jones SR *et al.* (1995) Fetal mortality associated with cholestasis of pregnancy and the potential benefit of therapy with ursodeoxycholic acid. *Gut* 37, 580–584.

43 Brites D, Rodrigues CM (1998) Elevated levels of bile acids in colostrum of patients with cholestasis of pregnancy are decreased following ursodeoxycholic acid therapy (see comments). *J Hepatol* 29, 743–751.

44 Zapata R, Sandoval L, Palma J *et al.* (2005) Ursodeoxycholic acid in the treatment of intrahepatic cholestasis of pregnancy. A 12-year experience. *Liver Int* 25, 548–554.

45 Kondrackiene J, Beuers U, Kupcinskas L (2005) Efficacy and safety of ursodeoxycholic acid versus cholestyramine in intrahepatic cholestasis of pregnancy. *Gastroenterology* 129, 894–901.

46 Roncaglia N, Locatelli A, Arreghini A *et al.* (2004) A randomised controlled trial of ursodeoxycholic acid and S-adenosyl-L-methionine in the treatment of gestational cholestasis. *Br J Obstet Gynaecol* 111, 17–21.

47 Rioseco AJ, Ivankovic MB, Manzur A *et al.* (1994) Intrahepatic cholestasis of pregnancy: a retrospective case–control study of perinatal outcome. *Am J Obstet Gynecol* 170, 890–895.

48 Bacq Y, Sapey T, Brechot MC *et al.* (1997) Intrahepatic cholestasis of pregnancy: a French prospective study. *Hepatology* 26, 358–364.

49 Eloranta ML, Heinonen S, Mononen T *et al.* (2001) Risk of obstetric cholestasis in sisters of index patients. *Clin Genet* 60, 42–45.

50 Mella JG, Roschmann E, Glasinovic JC *et al.* (1996) Exploring the genetic role of the HLA-DPB1 locus in Chileans with intrahepatic cholestasis of pregnancy. *J Hepatol* 24, 320–323.

51 Holzbach RT, Sivak DA, Braun WE (1983) Familial recurrent intrahepatic cholestasis of pregnancy: a genetic study providing evidence for transmission of a sex-limited, dominant trait. *Gastroenterology* 85, 175–179.

52 Kreek MJ, Sleisenger MH (1970) Estrogen induced cholestasis due to endogenous and exogenous hormones. *Scand J Gastroenterol Suppl* 7, 123–131.

53 Davies MH, Ngong JM, Yucesoy M *et al.* (1994) The adverse influence of pregnancy upon sulphation: a clue to the pathogenesis of intrahepatic cholestasis of pregnancy? *J Hepatol* 21, 1127–1134.

54 Simon B, Czygan P, Stiehl A *et al.* (1978) Bile acids and human colonic adenylate cyclase. *Gastroenterology* 75, 351.

55 Schreiber AJ, Simon FR (1983) Estrogen-induced cholestasis: clues to pathogenesis and treatment. *Hepatology* 3, 607–613.

56 Trauner M, Boyer JL (2003) Bile salt transporters: molecular characterization, function, and regulation. *Physiol Rev* 83, 633–671.

57 Serrano MA, Macias RI, Vallejo M *et al.* (2003) Effect of ursodeoxycholic acid on the impairment induced by maternal cholestasis in the rat placenta-maternal liver tandem excretory pathway. *J Pharmacol Exp Ther* 305, 515–524.

58 Romero R, Reece EA, Riely C *et al.* (1983) Arteriohepatic dysplasia in pregnancy. *Am J Obstet Gynecol* 147, 108–109.

59 Stander H, Cadden J (1934) Acute yellow atrophy of the liver in pregnancy. *Am J Obstet Gynecol* 28, 61–69.

60 Tarnier S (1857) Note sur l'etat graisseux du foie dans la fievre puerperale. *Comp Rendus Seances Mem Soc Biol* 3, 209–214.

61 Sheehan H (1940) The pathology of acute yellow atrophy and delayed chloroform poisoning. *J Obstet Gynaecol Br Empire* 47, 49–62.

62 Peters RL, Edmondson HA, Mikkelsen WP *et al.* (1967) Tetracycline-induced fatty liver in nonpregnant patients. A report of six cases. *Am J Surg* 113, 622–632.

63 Schultz JC, Adamson JS, Jr, Workman WW *et al.* (1963) Fatal liver disease after intravenous administration of tetracycline in high dosage. *N Engl J Med* 269, 999–1004.

64 Pockros PJ, Peters RL, Reynolds TB (1984) Idiopathic fatty liver of pregnancy: findings in ten cases. *Medicine (Baltimore)* 63, 1–11.

65 Wilcken B, Leung KC, Hammond J *et al.* (1993) Pregnancy and fetal long-chain 3-hydroxyacyl coenzyme A dehydrogenase deficiency. *Lancet* 341, 407–408.

66 Treem WR, Rinaldo P, Hale DE *et al.* (1994) Acute fatty liver of pregnancy and long-chain 3-hydroxyacyl-coenzyme A dehydrogenase deficiency. *Hepatology* 19, 339–345.

67 Yang Z, Zhao Y, Bennett MJ *et al.* (2002) Fetal genotypes and pregnancy outcomes in 35 families with mitochondrial trifunctional protein mutations. *Am J Obstet Gynecol* 187, 715–720.

68 Yang Z, Yamada J, Zhao Y *et al.* (2002) Prospective screening for pediatric mitochondrial trifunctional protein defects in pregnancies complicated by liver disease. *J Am Med Assoc* 288, 2163–2166.

69 Sims HF, Brackett JC, Powell CK *et al.* (1995) The molecular basis of pediatric long chain 3-hydroxyacyl-CoA dehydrogenase deficiency associated with maternal acute fatty liver of pregnancy. *Proc Natl Acad Sci USA* 92, 841–845.

70 Nada MA, Vianey-Saban C, Roe CR *et al.* (1996) Prenatal diagnosis of mitochondrial fatty acid oxidation defects. *Prenat Diagn* 16, 117–124.

71 Ibdah JA, Yang Z, Bennett MJ (2000) Liver disease in pregnancy and fetal fatty acid oxidation defects. *Mol Genet Metab* 71, 182–189.

72 Bok LA, Vreken P, Wijburg FA *et al.* (2003) Short-chain Acyl-CoA dehydrogenase deficiency: studies in a large family adding to the complexity of the disorder. *Pediatrics* 112, 1152–1155.

73 Bellig LL (2004) Maternal acute fatty liver of pregnancy and the associated risk for long-chain 3-hydroxyacyl-coenzyme a dehydrogenase (LCHAD) deficiency in infants. *Adv Neonatal Care* 4, 26–32.

74 Burroughs AK, Seong NH, Dojcinov DM *et al.* (1982) Idiopathic acute fatty liver of pregnancy in 12 patients. *Q J Med* 51, 481–497.

75 Riely CA, Latham PS, Romero R *et al.* (1987) Acute fatty liver of pregnancy. A reassessment based on observations in nine patients. *Ann Intern Med* 106, 703–706.

76 Rolfes DB, Ishak KG (1985) Acute fatty liver of pregnancy: a clinicopathologic study of 35 cases. *Hepatology* 5, 1149–1158.

77 Duma RJ, Dowling EA, Alexander HC *et al.* (1965) Acute fatty liver of pregnancy. Report of a surviving patient studied with serial liver biopsies. *Ann Intern Med* 63, 851–858.

78 Bourliere M, Bernuau J, Ducrotte S *et al.* (1989) [Polyuria and polydipsia in acute fatty liver of pregnancy. Discussion based on a case]. *J Gynecol Obstet Biol Reprod (Paris)* 18, 79–81.

79 Reyes H, Sandoval L, Wainstein A *et al.* (1994) Acute fatty liver of pregnancy: a clinical study of 12 episodes in 11 patients. *Gut* 35, 101–106.

80 Cammu H, Velkeniers B, Charels K *et al.* (1987) Idiopathic acute fatty liver of pregnancy associated with transient diabetes insipidus. Case report. *Br J Obstet Gynaecol* 94, 173–178.

81 Breen KJ, Perkins KW, Mistilis SP *et al.* (1970) Idiopathic acute fatty liver of pregnancy. *Gut* 11, 822–825.

82 Hatfield AK, Stein JH, Greenberger NJ *et al.* (1972) Idiopathic acute fatty liver of pregnancy. Death from extrahepatic manifestations. *Am J Dig Dis* 17, 167–178.

83 Worms R, Martin E, Bernades P *et al.* (1966) Une forme anatomoclinique particuliere de l'ictere grave de la grossesse: la steatose spongiocytaire aigue du foie. *Soc Med Hop Paris* 17, 999–1021.

84 O'Loughlin S, Sweeney EC, Keelan P (1971) Persistent hypoglycaemia and severe hyponatraemia in a case of acute fatty liver of pregnancy. *J Ir Med Assoc* 64, 45–49.

85 Minuk GY, Lui RC, Kelly JK (1987) Rupture of the liver associated with acute fatty liver of pregnancy. *Am J Gastroenterol* 82, 457–460.

86 Jones MB (1993) Pulmonary fat emboli associated with acute fatty liver of pregnancy. *Am J Gastroenterol* 88, 791–792.

87 Laursen B, Frost L, Mortensen JZ *et al.* (1983) Acute fatty liver of pregnancy with complicating disseminated intravascular coagulation. *Acta Obstet Gynecol Scand* 62, 403–407.

88 Liebman HA, McGehee WG, Patch MJ *et al.* (1983) Severe depression of antithrombin III associated with disseminated intravascular coagulation in women with fatty liver of pregnancy. *Ann Intern Med* 98, 330–333.

89 Weenink GH, Treffers PE, Vijn P *et al.* (1984) Antithrombin III levels in preeclampsia correlate with maternal and fetal morbidity. *Am J Obstet Gynecol* 148, 1092–1097.

90 Quigley MM (1974) Acute obstetric yellow atrophy presenting as idiopathic hyperuricemia. *South Med J* 67, 142–144.

91 Hannah ME, Gonen R, Mocarski EJ *et al.* (1989) Elevated liver enzymes and thrombocytopenia in the third trimester of pregnancy: an unusual case report and a review of the literature. *Am J Obstet Gynecol* 161, 322–323.

92 Minakami H, Oka N, Sato T *et al.* (1988) Preeclampsia: a microvesicular fat disease of the liver? *Am J Obstet Gynecol* 159, 1043–1047.

93 Bernuau J, Degott C, Nouel O *et al.* (1983) Non-fatal acute fatty liver of pregnancy. *Gut* 24, 340–344.

94 Rolfes DB, Ishak KG (1986) Liver disease in toxemia of pregnancy. *Am J Gastroenterol* 81, 1138–1144.

95 George JN (2003) The association of pregnancy with thrombotic thrombocytopenic purpura–hemolytic uremic syndrome. *Curr Opin Hematol* 10, 339–344.

96 Klein NA, Mabie WC, Shaver DC *et al.* (1991) Herpes simplex virus hepatitis in pregnancy. Two patients successfully treated with acyclovir. *Gastroenterology* 100, 239–244.

97 Usta IM, Barton JR, Amon EA *et al.* (1994) Acute fatty liver of pregnancy: an experience in the diagnosis and management of fourteen cases. *Am J Obstet Gynecol* 171, 1342–1347.

98 Campillo B, Bernuau J, Witz MO *et al.* (1986) Ultrasonography in acute fatty liver of pregnancy. *Ann Intern Med* 105, 383–384.

99 Manas KJ, Welsh JD, Rankin RA *et al.* (1985) Hepatic hemorrhage without rupture in preeclampsia. *N Engl J Med* 312, 424–426.

100 Bis KA, Waxman B (1976) Rupture of the liver associated with pregnancy: a review of the literature and report of 2 cases. *Obstet Gynecol Surv* 31, 763–773.

101 Werth TE, Wang HH, Chopra S (1990) A 20-year-old woman with abnormal liver-function test results in the third trimester of pregnancy. *Gastroenterology* 99, 552–558.

102 Ebert EC, Sun EA, Wright SH *et al.* (1984) Does early diagnosis and delivery in acute fatty liver of pregnancy lead to improvement in maternal and infant survival? *Dig Dis Sci* 29, 453–455.

103 Moldenhauer JS, O'Brien JM, Barton JR *et al.* (2004) Acute fatty liver of pregnancy associated with pancreatitis: a life-threatening complication. *Am J Obstet Gynecol* 190, 502–505.

104 Torres M, Lopez J, Tortajada G (1981) Insuficiencia hepaticaaguda de evolucion fatal en la degeneracion grasa del higado. *Gastroenterol Hepatol* 4, 188–194.

105 Ockner SA, Brunt EM, Cohn SM *et al.* (1990) Fulminant hepatic failure caused by acute fatty liver of pregnancy treated by orthotopic liver transplantation. *Hepatology* 11, 59–64.

106 Barton JR, Sibai BM, Mabie WC *et al.* (1990) Recurrent acute fatty liver of pregnancy. *Am J Obstet Gynecol* 163, 534–538.

107 Moore HC (1956) Acute fatty liver of pregnancy. *J Obstet Gynaecol Br Empire* 63, 189–198.

108 Davis JS, Kaufman RH (1966) Tetracycline toxicity. A clinicopathologic study with special reference to liver damage and its relationship to pregnancy. *Am J Obstet Gynecol* 95, 523–529.

109 Wenk RE, Gebhardt FC, Bhagavan BS *et al.* (1981) Tetracycline-associated fatty liver of pregnancy, including possible pregnancy risk after chronic dermatologic use of tetracycline. *J Reprod Med* 26, 135–141.

110 Ede RJ, Williams R (1988) Reye's syndrome in adults. *Br Med J (Clin Res Ed)* 296, 517–518.

111 Rebouche CJ, Engel AG (1983) Carnitine metabolism and deficiency syndromes. *Mayo Clin Proc* 58, 533–540.

112 Angelini C, Govoni E, Bragaglia MM *et al.* (1978) Carnitine deficiency: acute postpartum crisis. *Ann Neurol* 4, 558–561.

113 Arn PH, Hauser ER, Thomas GH *et al.* (1990) Hyperammonemia in women with a mutation at the ornithine carbamoyltransferase locus. A cause of postpartum coma. *N Engl J Med* 322, 1652–1655.

114 Hauser ER, Finkelstein JE, Valle D *et al.* (1990) Allopurinol-induced orotidinuria. A test for mutations at the ornithine carbamoyltransferase locus in women. *N Engl J Med* 322, 1641–1645.

115 Hamano Y, Kodama H, Fujikawa Y *et al.* (1988) Use of immunocytochemical analysis of a duodenal biopsy specimen to identify a carrier of ornithine transcarbamylase deficiency. *N Engl J Med* 318, 1521–1523.

116 Sibai B, Dekker G, Kupferminc M (2005) Pre-eclampsia. *Lancet* 365, 785–799.

117 Antia FP, Bharadwaj TP, Watsa MC *et al.* (1958) Liver in normal pregnancy, pre-eclampsia, and eclampsia. *Lancet* 2, 776–778.

118 Arias F, Mancilla-Jimenez R (1976) Hepatic fibrinogen deposits in pre-eclampsia. Immunofluorescent evidence. *N Engl J Med* 295, 578–582.

119 Rowan JA, North RA (1995) Abnormal liver function tests after pre-eclampsia. *Lancet* 345, 1367.

120 Kronthal AJ, Fishman EK, Kuhlman JE *et al.* (1990) Hepatic infarction in preeclampsia. *Radiology* 177, 726–728.

121 Romero R, Mazor M, Lockwood CJ *et al.* (1989) Clinical significance, prevalence, and natural history of thrombocytopenia in pregnancy-induced hypertension. *Am J Perinatol* 6, 32–38.

122 Lox C, Harral A, Corrigan JJ (1990) Hepatic impairment in fetuses of preeclamptic mothers. *Biol Neonate* 57, 141–143.

123 Ansell P, Mitchell CD, Roman E *et al.* (2005) Relationships between perinatal and maternal characteristics and hepatoblastoma: a report from the UKCCS. *Eur J Cancer* 41, 741–748.

124 Neerhof MG, Zelman W, Sullivan T (1989) Hepatic rupture in pregnancy. *Obstet Gynecol Surv* 44, 407–409.

125 Pauzner R, Dulitzky M, Carp H *et al.* (2003) Hepatic infarctions during pregnancy are associated with the antiphospholipid syndrome and in addition with complete or incomplete HELLP syndrome. *J Thromb Haemost* 1, 1758–1763.

126 Moen MD, Caliendo MJ, Marshall W *et al.* (1993) Hepatic rupture in pregnancy associated with cocaine use. *Obstet Gynecol* 82, 687–689.

127 Abercrombie J (1844) Case of haemorrhage of the liver. *Lond Med Gazz* 34, 792–795.

128 Henny CP, Lim AE, Brummelkamp WH *et al.* (1983) A review of the importance of acute multidisciplinary treatment following spontaneous rupture of the liver capsule during pregnancy. *Surg Gynecol Obstet* 156, 593–598.

129 Schwartz ML, Lien JM (1997) Spontaneous liver hematoma in pregnancy not clearly associated with preeclampsia: a case presentation and literature review. *Am J Obstet Gynecol* 176, 1328–1332.

130 Rinehart BK, Terrone DA, Magann EF *et al.* (1999) Preeclampsia-associated hepatic hemorrhage and rupture: mode of management related to maternal and perinatal outcome. *Obstet Gynecol Surv* 54, 196–202.

131 Terasaki KK, Quinn MF, Lundell CJ *et al.* (1990) Spontaneous hepatic hemorrhage in preeclampsia: treatment with hepatic arterial embolization. *Radiology* 174, 1039–1041.

132 Stain SC, Woodburn DA, Stephens AL *et al.* (1996) Spontaneous hepatic hemorrhage associated with pregnancy. Treatment by hepatic arterial interruption. *Ann Surg* 224, 72–78.

133 Dart BW, Cockerham WT, Torres C *et al.* (2004) A novel use of recombinant factor VIIa in HELLP syndrome associated with spontaneous hepatic rupture and abdominal compartment syndrome. *J Trauma* 57, 171–174.

134 Woodhouse DR (1986) Conservative management of spontaneous rupture of the liver in pregnancy. Case report. *Br J Obstet Gynaecol* 93, 1097–1099.

135 Hunter SK, Martin M, Benda JA *et al.* (1995) Liver transplant after massive spontaneous hepatic rupture in pregnancy complicated by preeclampsia. *Obstet Gynecol* 85, 819–822.

136 Alleman JS, Delarue MW, Hasaart TH (1992) Successful delivery after hepatic rupture in previous pre-eclamptic pregnancy. *Eur J Obstet Gynecol Reprod Biol* 47, 76–79.

137 Greenstein D, Henderson JM, Boyer TD (1994) Liver hemorrhage: recurrent episodes during pregnancy complicated by preeclampsia. *Gastroenterology* 106, 1668–1671.

138 Hibbard LT (1976) Spontaneous rupture of the liver in pregnancy: a report of eight cases. *Am J Obstet Gynecol* 126, 334–338.

139 Roddie TW (1957) Haemorrhage from primary carcinoma of the liver complicating pregnancy. *Br Med J* 44, 31.

140 Erb RE, Gibler WB (1989) Massive hemoperitoneum following rupture of hepatic metastases from unsuspected choriocarcinoma. *Am J Emerg Med* 7, 196–198.

141 Fidas-Kamini A, Busuttil A (1987) Fatal haemoperitoneum from ruptured hepatic metastases from testicular teratomas. *Br J Urol* 60, 80–81.

142 Yen SS (1964) Spontaneous rupture of the liver during pregnancy. A report of 2 cases. *Obstet Gynecol* 23, 783–787.

143 Henderson PR, Keeping JD (1979) Spontaneous rupture of the spleen in late pregnancy. *Aust NZ J Obstet Gynaecol* 19, 116–118.

144 Fletcher JP (1971) Eclampsia and microangiopathic haemolytic anaemia. *Med J Aust* 1, 1065–1066.

145 Weinstein L (1982) Syndrome of hemolysis, elevated liver enzymes, and low platelet count: a severe consequence of hypertension in pregnancy. *Am J Obstet Gynecol* 142, 159–167.

146 Dantzer M, Rigaud P, Agnani G *et al.* (1987) [Hellp syndrome may precede the appearance of arterial hypertension in pregnancy toxemia]. *Rev Fr Gynecol Obstet* 82, 243–245.

147 Goodlin RC, Holdt D (1981) Impending gestosis. *Obstet Gynecol* 58, 743–745.

148 Alsulyman OM, Castro MA, Zuckerman E *et al.* (1996) Preeclampsia and liver infarction in early pregnancy associated with the antiphospholipid syndrome. *Obstet Gynecol* 88, 644–646.

149 Sibai BM, Taslimi MM, el Nazer A *et al.* (1986) Maternal–perinatal outcome associated with the syndrome of hemolysis, elevated liver enzymes, and low platelets in severe preeclampsia-eclampsia. *Am J Obstet Gynecol* 155, 501–509.

150 Strand S, Strand D, Seufert R *et al.* (2004) Placenta-derived CD95 ligand causes liver damage in hemolysis, elevated liver enzymes, and low platelet count syndrome. *Gastroenterology* 126, 849–858.

151 Abroug F, Boujdaria R, Nouira S *et al.* (1992) Hellp syndrome: incidence and maternal–fetal outcome – a prospective study. *Intens Care Med* 18, 274–277.

152 Shames BD, Fernandez LA, Sollinger HW *et al.* (2005) Liver transplantation for HELLP syndrome. *Liver Transpl* 11, 224–228.

153 Clark SL, Phelan JR, Allen SH *et al.* (1986) Antepartum reversal of hematologic abnormalities associated with the HELLP syndrome. A report of three cases. *J Reprod Med* 31, 70–72.

154 MacKenna J, Dover NL, Brame RG (1983) Preeclampsia associated with hemolysis, elevated liver enzymes, and low platelets—an obstetric emergency? *Obstet Gynecol* 62, 751–754.

155 Magann EF, Bass D, Chauhan SP *et al.* (1994) Antepartum corticosteroids: disease stabilization in patients with the syndrome of hemolysis, elevated liver enzymes, and low platelets (HELLP). *Am J Obstet Gynecol* 171, 1148–1153.

156 Magann EF, Perry KG, Jr, Meydrech EF *et al.* (1994) Postpartum corticosteroids: accelerated recovery from the syndrome of hemolysis, elevated liver enzymes, and low platelets (HELLP). *Am J Obstet Gynecol* 171, 1154–1158.

157 Matchaba P, Moodley J (2004) Corticosteroids for HELLP syndrome in pregnancy. *Cochrane Database Syst Rev* CD002076.

158 Martin JN, Jr, Thigpen BD, Rose CH *et al.* (2003) Maternal benefit of high-dose intravenous corticosteroid therapy for HELLP syndrome. *Am J Obstet Gynecol* 189, 830–834.

159 Sibai BM (2004) Imitators of severe pre-eclampsia/eclampsia. *Clin Perinatol* 31, 835-viii.

160 Sheehan H, Lynch J (1973) *Pathology of Toxaemia of Pregnancy*. Edinburgh: Churchill Livingstone.

161 Dani R, Mendes GS, Medeiros JL *et al.* (1996) Study of the liver changes occurring in preeclampsia and their possible pathogenetic connection with acute fatty liver of pregnancy. *Am J Gastroenterol* 91, 292–294.

162 Zucker SD (2003) Is it HELLPful to consider the hanging LCHAD in pregnancy-associated liver disease? *Gastroenterology* 124, 1548–1550.

163 Minakami H, Yamada H, Suzuki S (2002) Gestational thrombocytopenia and pregnancy-induced antithrombin deficiency: progenitors to the development of the HELLP syndrome and acute fatty liver of pregnancy. *Semin Thromb Hemost* 28, 515–518.

164 Barton JR, Sibai BM (2004) Diagnosis and management of hemolysis, elevated liver enzymes, and low platelets syndrome. *Clin Perinatol* 31, 807–833, vii.

165 Ilan Y, Oren R, Shouval D (1990) Postpartum Budd–Chiari syndrome with prolonged hypercoagulability state. *Am J Obstet Gynecol* 162, 1164–1165.

166 Khuroo MS, Datta DV (1980) Budd–Chiari syndrome following pregnancy. Report of 16 cases, with roentgenologic, hemodynamic and histologic studies of the hepatic outflow tract. *Am J Med* 68, 113–121.

167 Senzolo M, Cholongitas E, Patch D *et al.* (2005) Update on the classification, assessment of prognosis and therapy of Budd–Chiari syndrome. *Nature Clin Pract Gastroenterol Hepatol* 2, 1–9.

168 Grant WJ, McCashland T, Botha JF *et al.* (2003) Acute Budd–Chiari syndrome during pregnancy: surgical treatment and orthotopic liver transplantation with successful completion of the pregnancy. *Liver Transpl* 9, 976–979.

169 Vons C, Smadja C, Franco D *et al.* (1984) Successful pregnancy after Budd–Chiari syndrome. *Lancet* 2, 975.

170 Cundy TF, Butler J, Pope RM *et al.* (1991) Amenorrhoea in women with non-alcoholic chronic liver disease. *Gut* 32, 202–206.

171 Cheng YS (1977) Pregnancy in liver cirrhosis and/or portal hypertension. *Am J Obstet Gynecol* 128, 812–822.

172 Schreyer P, Caspi E, El Hindi JM *et al.* (1982) Cirrhosis – pregnancy and delivery: a review. *Obstet Gynecol Surv* 37, 304–312.

173 Hsia DY, Allen FH, Jr, Gellis SS *et al.* (1952) Erythroblastosis fetalis. VIII. Studies of serum bilirubin in relation to kernicterus. *N Engl J Med* 247, 668–671.

174 Cotton DB, Brock BJ, Schifrin BS (1981) Cirrhosis and fetal hyperbilirubinemia. *Obstet Gynecol* 57, 25S–27S.

175 Infeld DS, Borkowf HI, Varma RR (1979) Chronic-persistent hepatitis and pregnancy. *Gastroenterology* 77, 524–527.

176 Steven MM, Buckley JD, Mackay IR (1979) Pregnancy in chronic active hepatitis. *Q J Med* 48, 519–531.

177 Heneghan MA, Norris SM, O'Grady JG *et al.* (2001) Management and outcome of pregnancy in autoimmune hepatitis. *Gut* 48, 97–102.

178 Malhotra B, Malhotra N, Deka D *et al.* (2002) Immunosuppressive effect of pregnancy on autoimmune hepatitis: a case report and review of literature. *Eur J Obstet Gynecol Reprod Biol* 101, 91–92.

179 Buchel E, Van Steenbergen W, Nevens F *et al.* (2002) Improvement of autoimmune hepatitis during pregnancy followed by flare-up after delivery. *Am J Gastroenterol* 97, 3160–3165.

180 Samuel D, Riordan S, Strasser S *et al.* (2004) Severe autoimmune hepatitis first presenting in the early post partum period. *Clin Gastroenterol Hepatol* 2, 622–624.

181 Parikh-Patel A, Gold E, Utts J *et al.* (2002) The association between gravidity and primary biliary cirrhosis. *Ann Epidemiol* 12, 264–272.

182 Rabinovitz M, Appasamy R, Finkelstein S (1995) Primary biliary cirrhosis diagnosed during pregnancy. Does it have a different outcome? *Dig Dis Sci* 40, 571–574.

183 Nir A, Sorokin Y, Abramovici H *et al.* (1989) Pregnancy and primary biliary cirrhosis. *Int J Gynaecol Obstet* 28, 279–282.

184 Rudi J, Schonig T, Stremmel W (1996) [Therapy with ursodeoxycholic acid in primary biliary cirrhosis in pregnancy.] *Z Gastroenterol* 34, 188–191.

185 Janczewska I, Olsson R, Hultcrantz R *et al.* (1996) Pregnancy in patients with primary sclerosing cholangitis. *Liver* 16, 326–330.

186 Friedlaender P, Osler M (1967) Icterus and pregnancy. *Am J Obstet Gynecol* 97, 894–900.

187 Cohen L, Lewis C, Arias IM (1972) Pregnancy, oral contraceptives, and chronic familial jaundice with predominantly conjugated hyperbilirubinemia (Dubin–Johnson syndrome). *Gastroenterology* 62, 1182–1190.

188 Di Zoglio JD, Cardillo E (1973) The Dubin–Johnson syndrome and pregnancy. *Obstet Gynecol* 42, 560–563.

189 Sinha S, Taly AB, Prashanth LK *et al.* (2004) Successful pregnancies and abortions in symptomatic and asymptomatic Wilson's disease. *J Neurol Sci* 217, 37–40.

190 Nunns D, Hawthorne B, Goulding P *et al.* (1995) Wilson's disease in pregnancy. *Eur J Obstet Gynecol Reprod Biol* 62, 141–143.

191 Roberts EA, Schilsky ML (2003) A practice guideline on Wilson disease. *Hepatology* 37, 1475–1492.

192 Weimann A, Mossinger M, Fronhoff K *et al.* (1998) Pregnancy in women with observed focal nodular hyperplasia of the liver. *Lancet* 351, 1251–1252.

193 Lau WY, Leung WT, Ho S *et al.* (1995) Hepatocellular carcinoma during pregnancy and its comparison with other pregnancy-associated malignancies. *Cancer* 75, 2669–2676.

194 Purtilo DT, Clark JV, Williams R (1975) Primary hepatic malignancy in pregnant women. *Am J Obstet Gynecol* 121, 41–44.

195 Cobey FC, Salem RR (2004) A review of liver masses in pregnancy and a proposed algorithm for their diagnosis and management. *Am J Surg* 187, 181–191.

196 Check JH, King LC, Rakoff AE (1978) Uncomplicated pregnancy following oral contraceptive-induced liver hepatoma. *Obstet Gynecol* 52, 28S–29S.

197 Erb RE, Gibler WB (1989) Massive hemoperitoneum following rupture of hepatic metastases from unsuspected choriocarcinoma. *Am J Emerg Med* 7, 196–198.

198 Barnard DE, Woodward KT, Yancy SG *et al.* (1986) Hepatic metastases of choriocarcinoma: a report of 15 patients. *Gynecol Oncol* 25, 73–83.

199 Trujillo Carrillo JL, Alvarez M, Padilla A *et al.* (2004) Symptomatic hepatic polycystic disease and pregnancy. *Br J Obstet Gynaecol* 111, 1146–1147.

200 Sewell JH, Weiss K (1961) Spontaneous rupture of hemangioma of the liver. A review of the literature and presentation of illustrative case. *Arch Surg* 83, 729–733.

201 Kanaan C, Veille JC, Lakin M (1989) Pregnancy and acute intermittent porphyria. *Obstet Gynecol Surv* 44, 244–249.

202 Soto-Albors CE, Rayburn WF, Taylor L *et al.* (1984) Portal hypertension and hypersplenism in pregnancy secondary to chronic schistosomiasis. A case report. *J Reprod Med* 29, 345–348.

203 Gong B, Baken LA, Julian TM *et al.* (1988) High-output heart failure due to hepatic arteriovenous fistula during pregnancy: a case report. *Obstet Gynecol* 72, 440–442.

204 Livneh A, Langevitz P, Morag B *et al.* (1988) Functionally reversible hepatic arteriovenous fistulas during pregnancy in patients with hereditary hemorrhagic telangiectasia. *South Med J* 81, 1047–1049.

205 Varma RR, Michelsohn NH, Borkowf HI *et al.* (1977) Pregnancy in cirrhotic and noncirrhotic portal hypertension. *Obstet Gynecol* 50, 217–222.

206 Kochhar R, Goenka MK, Mehta SK (1990) Endoscopic sclerotherapy during pregnancy. *Am J Gastroenterol* 85, 1132–1135.

207 Krol-Van Straaten J, De Maat CE (1984) Successful pregnancies in cirrhosis of the liver before and after portacaval anastomosis. *Neth J Med* 27, 14–15.

208 Rubin PC (1981) Current concepts: beta-blockers in pregnancy. *N Engl J Med* 305, 1323–1326.

209 Barrett JM, Caldwell BH (1981) Association of portal hypertension and ruptured splenic artery aneurysm in pregnancy. *Obstet Gynecol* 57, 255–257.

210 Beasley RP, Stevens CE, Shiao IS *et al.* (1975) Evidence against breastfeeding as a mechanism for vertical transmission of hepatitis B. *Lancet* 2, 740–741.

211 Hieber JP, Dalton D, Shorey J *et al.* (1977) Hepatitis and pregnancy. *J Pediatr* 91, 545–549.

212 Shalev E, Bassan HM (1982) Viral hepatitis during pregnancy in Israel. *Int J Gynaecol Obstet* 20, 73–78.

213 Lysy Y, Furst A, Medina A *et al.* (1988) Fatal relapsing viral hepatitis A infection during pregnancy. *Isr J Med Sci* 24, 681–683.

214 Beasley RP, Trepo C, Stevens CE *et al.* (1977) The e antigen and vertical transmission of hepatitis B surface antigen. *Am J Epidemiol* 105, 94–98.

215 Rawal BK, Parida S, Watkins RP *et al.* (1991) Symptomatic reactivation of hepatitis B in pregnancy. *Lancet* 337, 364.

216 van Zonneveld M, van Nunen AB, Niesters HG *et al.* (2003) Lamivudine treatment during pregnancy to prevent perinatal transmission of hepatitis B virus infection. *J Viral Hepat* 10, 294–297.

217 Loreno M, Bo P, Senzolo M *et al.* (2005) Successful pregnancy in a liver transplant recipient treated with lamivudine for de novo hepatitis B in the graft. *Transpl Int* 17, 730–734.

218 Maupas P, Chiron JP, Barin F *et al.* (1981) Efficacy of hepatitis B vaccine in prevention of early HBsAg carrier state in children. Controlled trial in an endemic area (Senegal). *Lancet* 1, 289–292.

219 Beasley RP, Hwang LY, Lee GC *et al.* (1983) Prevention of perinatally transmitted hepatitis B virus infections with hepatitis B virus infections with hepatitis B immune globulin and hepatitis B vaccine. *Lancet* 2, 1099–1102.

220 Anon (1991) Hepatitis B virus: a comprehensive strategy for eliminating transmission in the US through universal childhood vaccination. Recommendation of the Immunization Practices Advisory Committee. *Morbidity Mortality Weekly Rep* 40, 1–25.

221 Grosheide PM, Wladimiroff JW, Heijtink RA *et al.* (1995) Proposal for routine antenatal screening at 14 weeks for hepatitis B surface antigen. Dutch Study Group on Prevention of Neonatal Hepatitis. *Br Med J* 311, 1197–1199.

222 Grosheide PM, Schalm SW, van Os HC *et al.* (1993) Immune response to hepatitis B vaccine in pregnant women receiving post-exposure prophylaxis. *Eur J Obstet Gynecol Reprod Biol* 50, 53–58.

223 Wejstal R, Norkrans G (1989) Chronic non-A, non-B hepatitis in pregnancy: outcome and possible transmission to the offspring. *Scand J Infect Dis* 21, 485–490.

224 Plunkett BA, Grobman WA (2004) Elective cesarean delivery to prevent perinatal transmission of hepatitis C virus: a cost-effectiveness analysis. *Am J Obstet Gynecol* 191, 998–1003.

225 Zanetti AR, Tanzi E, Paccagnini S *et al.* (1995) Mother-to-infant transmission of hepatitis C virus. Lombardy Study Group on Vertical HCV Transmission. *Lancet* 345, 289–291.

226 Conte D, Fraquelli M, Prati D *et al.* (2000) Prevalence and clinical course of chronic hepatitis C virus (HCV) infection and rate of HCV vertical transmission in a cohort of 15,250 pregnant women. *Hepatology* 31, 751–755.

227 Pembrey L, Newell M, Tovo P *et al.* (2005) The management of HCV infected pregnant women and their children. European paediatric HCV network. *J Hepatol* 43, 515–525.

228 Floreani A, Paternoster D, Zappala F *et al.* (1996) Hepatitis C virus infection in pregnancy. *Br J Obstet Gynaecol* 103, 325–329.

229 Polywka S, Schroter M, Feucht HH *et al.* (1999) Low risk of vertical transmission of hepatitis C virus by breast milk. *Clin Infect Dis* 29, 1327–1329.

230 Devaux A, Soula V, Sifer C *et al.* (2003) Hepatitis C virus detection in follicular fluid and culture media from HCV+ women, and viral risk during IVF procedures. *Hum Reprod* 18, 2342–2349.

231 Zanetti AR, Ferroni P, Magliano EM *et al.* (1982) Perinatal transmission of the hepatitis B virus and of the HBV-associated delta agent from mothers to offspring in northern Italy. *J Med Virol* 9, 139–148.

232 Khuroo MS, Teli MR, Skidmore S *et al.* (1981) Incidence and severity of viral hepatitis in pregnancy. *Am J Med* 70, 252–255.

233 Kumar A, Beniwal M, Kar P *et al.* (2004) Hepatitis E in pregnancy. *Int J Gynaecol Obstet* 85, 240–244.

234 Khuroo MS, Kamili S (2003) Aetiology and prognostic factors in acute liver failure in India. *J Viral Hepat* 10, 224–231.

235 Khuroo MS, Kamili S, Saleim T *et al.* (2004) Severe fetal hepatitis E virus infection is the possible cause of increased severity of hepatitis E infection in the mother. *Am J Gastroenterol* 99, S100.

236 Singh S, Mohanty A, Joshi YK *et al.* (2003) Mother-to-child transmission of hepatitis E virus infection. *Ind J Pediatr* 70, 37–39.
237 Chibber RM, Usmani MA, Al Sibai MH (2004) Should HEV infected mothers breast feed? *Arch Gynecol Obstet* 270, 15–20.
238 Feucht HH, Zollner B, Polywka S *et al.* (1996) Vertical transmission of hepatitis G. *Lancet* 347, 615–616.
239 Naidoo PM, Keeton G, Stein L *et al.* (1974) Hepatic amoebiasis. A study of 32 cases in the Western Cape. *S Afr Med J* 48, 1159–1160.
240 Abioye AA, Edington GM (1972) Prevalence of amoebiasis at autopsy in Ibadan. *Trans R Soc Trop Med Hyg* 66, 754–763.
241 Jacques SM, Qureshi F (1992) Herpes simplex virus hepatitis in pregnancy: a clinicopathologic study of three cases. *Hum Pathol* 23, 183–187.
242 Mortele KJ, Barish MA, Yucel KE (2004) Fulminant herpes hepatitis in an immunocompetent pregnant woman: CT imaging features. *Abdom Imaging* 29, 682–684.
243 Arya TV, Prasad RN (1988) Malarial hepatitis. *J Assoc Phys India* 36, 294–295.
244 Kopernik G, Mazor M, Leiberman JR *et al.* (1988) Pyogenic liver abscess in pregnancy. *Isr J Med Sci* 24, 245–246.
245 Manterola C, Espinoza R, Munoz S *et al.* (2004) Abdominal echinococcosis during pregnancy: clinical aspects and management of a series of cases in Chile. *Trop Doctor* 34, 171–173.
246 Montes H, Soetkino R, Carr-Locke DL (2002) Hydatid disease in pregnancy. *Am J Gastroenterol* 97, 1553–1555.
247 Lacroix I, Damase-Michel C, Lapeyre-Mestre M *et al.* (2000) Prescription of drugs during pregnancy in France. *Lancet* 356, 1735–1736.
248 Wood SM, Hytten FE (1981) The fate of drugs in pregnancy. *Clin Obstet Gynaecol* 8, 255–259.
249 Bourliere M, Bernuau J, Rueff B *et al.* (1988) Quinidine phenylethylbarbiturate-induced fulminant hepatitis in a pregnant woman. A case report. *J Hepatol* 6, 214–216.
250 Picaud A, Walter P, de Preville G *et al.* (1990) [Fatal toxic hepatitis in pregnancy. A discussion of the role of methyldopa]. *J Gynecol Obstet Biol Reprod (Paris)* 19, 192–196.
251 Read AE, Harrison CV, Sherlock S (1961) Chronic chlorpromazine jaundice: with particular reference to its relationship to primary biliary cirrhosis. *Am J Med* 31, 249–258.
252 Holden TE, Sherline DM (1972) Hepatitis and hepatic failure in pregnancy. *Obstet Gynecol* 40, 586–593.
253 Rubinger D, Davidson JT, Melmed RN (1975) Hepatitis following the use of methoxyflurane in obstetric analgesia. *Anesthesiology* 43, 593–595.
254 Hod M, Friedman S, Schoenfeld A *et al.* (1986) Hydralazine-induced hepatitis in pregnancy. *Int J Fertil* 31, 352–355.
255 Franks AL, Binkin NJ, Snider DE, Jr *et al.* (1989) Isoniazid hepatitis among pregnant and postpartum Hispanic patients. *Public Health Rep* 104, 151–155.
256 Quinn PG, Sherman BW, Tavill AS *et al.* (1994) Terbutaline hepatitis in pregnancy: report of two cases and literature review. *Am J Gastroenterol* 89, 781–784.
257 De Arcos F, Gratacos E, Palacio M *et al.* (1996) Toxic hepatitis: a rare complication associated with the use of ritodrine during pregnancy. *Acta Obstet Gynecol Scand* 75, 340–342.
258 Ludmir J, Main DM, Landon MB *et al.* (1986) Maternal acetaminophen overdose at 15 weeks of gestation. *Obstet Gynecol* 67, 750–751.
259 Maringhini A, Marceno MP, Lanzarone F *et al.* (1987) Sludge and stones in gallbladder after pregnancy. Prevalence and risk factors. *J Hepatol* 5, 218–223.
260 Evron S, Frankel M, Diamant Y (1982) Biliary disease in young women and its association with pregnancy or oral contraceptives. *Int Surg* 67, 448–450.
261 Everson GT (1993) Pregnancy and gallstones. *Hepatology* 17, 159–161.
262 Kahaleh M, Hartwell GD, Arseneau KO *et al.* (2004) Safety and efficacy of ERCP in pregnancy. *Gastrointest Endosc* 60, 287–292.
263 Printen KJ, Ott RA (1978) Cholecystectomy during pregnancy. *Am Surg* 44, 432–434.
264 Muench J, Albrink M, Serafini F *et al.* (2001) Delay in treatment of biliary disease during pregnancy increases morbidity and can be avoided with safe laparoscopic cholecystectomy. *Am Surg* 67, 539–542.
265 Friedenberg WR, Burrill RE, Young JR (1978) Severe preeclampsia presenting as hepatobiliary disease. *Wisc Med J* 77, S117–S118.
266 Taylor TV, Brigg JK, Russell JG *et al.* (1977) Choledochal cyst of pregnancy. *J R Coll Surg Edinb* 22, 424–427.
267 Devoe LD, Moossa AR, Levin B (1983) Pregnancy complicated by extrahepatic biliary tract carcinoma. A case report. *J Reprod Med* 28, 153–155.
268 Cundy TF, O'Grady JG, Williams R (1990) Recovery of menstruation and pregnancy after liver transplantation. *Gut* 31, 337–338.
269 de Koning ND, Haagsma EB (1990) Normalization of menstrual pattern after liver transplantation: consequences for contraception. *Digestion* 46, 239–241.
270 Scott JP, Higenbottam TW (1988) Adverse reactions and interactions of cyclosporin. *Med Toxicol Adverse Drug Exp* 3, 107–127.
271 Hall JG, Pauli RM, Wilson KM (1980) Maternal and fetal sequelae of anticoagulation during pregnancy. *Am J Med* 68, 122–140.
272 Armenti VT, Herrine SK, Radomski JS *et al.* (2000) Pregnancy after liver transplantation. *Liver Transpl* 6, 671–685.
273 Davison JM, Dellagrammatikas H, Parkin JM (1985) Maternal azathioprine therapy and depressed haemopoiesis in the babies of renal allograft patients. *Br J Obstet Gynaecol* 92, 233–239.
274 Reinisch JM, Simon NG, Karow WG *et al.* (1978) Prenatal exposure to prednisone in humans and animals retards intrauterine growth. *Science* 202, 436–438.
275 Venkataramanan R, Koneru B, Wang CC *et al.* (1988) Cyclosporine and its metabolites in mother and baby. *Transplantation* 46, 468–469.
276 Hill NC, Morris NH, Shaw RW *et al.* (1991) Pregnancy after orthotopic liver transplantation. Case report. *Br J Obstet Gynaecol* 98, 719–721.
277 Jain AB, Reyes J, Marcos A *et al.* (2003) Pregnancy after liver transplantation with tacrolimus immunosuppression: a single center's experience update at 13 years. *Transplantation* 76, 827–832.
278 Scantlebury V, Gordon R, Tzakis A *et al.* (1990) Childbearing after liver transplantation. *Transplantation* 49, 317–321.
279 Radomski JS, Moritz MJ, Munoz SJ *et al.* (1995) National Transplantation Pregnancy Registry: analysis of pregnancy outcomes in female liver transplant recipients. *Liver Transpl Surg* 1, 281–284.
280 Eguchi S, Yanaga K, Fujita F *et al.* (2002) Living-related right lobe liver transplantation for a patient with fulminant hepatic failure during the second trimester of pregnancy: report of a case. *Transplantation* 73, 1970–1971.

23 The management of liver diseases

23.1 The general management of liver diseases

Dominique Guyader

Introduction

Taking responsibility for patients suffering from liver diseases involves dealing with general problems related to diagnosis, prognosis and treatment. A correct diagnosis is necessary for appropriate management. Diagnosis algorithms are frequently based on the acute or chronic nature of the illness. Although often easy to establish, they can be difficult to follow, leading to inappropriate investigations. The biochemical profile of the disease is an important clue to the diagnosis. A cholestatic presentation would suggest specific aetiologies. Clinical, laboratory and morphological investigations often lead to a correct diagnosis without the requirement for histological examination. The indication for liver biopsy has to be discussed when the diagnosis remains uncertain after previous investigations, or when the disease can progress to fibrosis and cirrhosis and the stage of fibrosis cannot be assessed precisely using non-invasive means. Liver biopsy can also appreciate the respective influence of different pathogenic factors in cases of multifactorial disease.

Along with diagnostic problems, some general problems that concern the patient's life will be discussed briefly in this chapter, in order to outline a checklist of important points that are extensively developed elsewhere in this textbook.

General approach to diagnosis

A correct diagnosis is extremely important because it constitutes the basis for correct treatment of patients. The diagnostic process follows several steps. The following questions must be answered.

Is the disease acute or chronic?

Acute and chronic liver diseases are very different aspects of liver pathology. Acute injuries are usually transient and resolve spontaneously, although they can occasionally be severe and then carry a risk of fulminant hepatic failure. Conversely, chronic liver injuries are susceptible to fibrosis and can ultimately lead to cirrhosis. Chronic disease has specific causes. For example, among the large number of viruses that could be responsible for acute hepatitis, only hepatitis B, C or D viruses can chronically infect liver cells. Therefore, the causes of acute or chronic liver diseases being different, the required investigations are not the same. Misclassification of the disease as acute at this stage would lead to unnecessary investigations or, conversely, to inappropriate delay in treatment while waiting for an improbable spontaneous remission. Moreover, liver biopsy is not usually indicated in acute liver disease, whereas it is a key examination for chronic diseases, giving valuable information on the process and severity of fibrosis.

In most cases, the distinction between acute and chronic conditions is easy. An acute condition occurs in a patient with no previous history of liver disease and previously normal liver biochemistry. Concurrence of extrahepatic signs, e.g. suggesting the preinvasive phase of viral infection, can also be helpful. Recent exposure to a risk factor for viral transmission (travel to endemic areas, family contact, drug injection experience, unprotected sexual intercourse) can help to determine the onset of the disease. However, it is important to remember that many chronic diseases can have an acute presentation or undergo reactivation. This is particularly frequent in autoimmune hepatitis, Wilson's disease or at a late stage of chronic hepatitis B associated with the hepatitis B e (HBe) antigen-negative pre-C mutant. Therefore, it is important to look carefully at clinical signs that might indicate a chronic form of liver injury at presentation: (i) the liver can have a firm consistency and a thin lower edge indicating cirrhosis; (ii) visible abdominal circulation or palpable splenomegaly could suggest portal hypertension; (iii) spider angiomas, palmar erythema, and muscular or skin atrophy can reveal chronic hepatic insufficiency. A decrease in the prothrombin index below 85% and a decrease in platelet count below 80 000/μL are also valuable biological signs indicating cirrhosis [1]. Echography and endoscopy might indicate chronic disease when they show portal hypertension signs (Section 7). In difficult situations, non-invasive markers of liver fibrosis (serum markers or elastometry) could be of interest in some conditions.

Follow-up of liver perturbations is needed when no definitive criteria can rule out an underlying chronic liver disease, or when

the acute hepatitis is related to a cause where a chronic course is possible. Two points should be emphasized: (i) in some chronic liver diseases such as chronic hepatitis C, the level of serum transaminase activity is usually mild and fluctuates around the upper limit of normal (ULN) values. Therefore, stringent criteria for serum transaminase normalization must be kept; (ii) a host of viral diseases are able to induce a slight increase in serum transaminases, so it is sensible to check serum transaminases at some distance from any intercurrent infection or treatment that could interfere with the interpretation of the data. The optimal duration of follow-up has not been established. By convention, in patients with viral hepatitis, when liver enzymes are still elevated 6 months after the onset of illness, the evolution is considered to be chronic. Particular attention should be paid to hepatitis B. Reactivations of hepatitis B are frequent in HBe antigen-negative hepatitis. It is usually associated with severe fibrosis and cirrhosis. It is clinically difficult to distinguish reactivation from acute hepatitis because the rise in serum transaminases is transient and anti-hepatitis B core (HBc) IgM can be positive in both situations. The most reliable way to ascertain a diagnosis of acute hepatitis B is to check for hepatitis B surface (HBs) antigen negativity and/or HBs antibody appearance.

Is the disease hepatitic or cholestatic?

The biochemical expression of the illness is a key point in the recognition of the cause of a chronic liver disease. Alcoholic and non-alcoholic steatohepatitis and chronic active hepatitis are usually responsible for hepatocellular death leading to a predominant rise in serum transaminases. Predominant features of cholestasis are indicative for other mechanisms of liver injury, and require that biliary obstruction and liver tumours are ruled out first. Ultrasound examination is of great value in indicating biliary obstruction when it shows bile duct dilatation. However, it should be kept in mind that biliary dilatation may be absent in up to 25% of cases of main bile duct stones. When symptoms suggest cholelithiasis, sensitive and specific examinations of the main bile duct are needed (echoendoscopy or magnetic resonance cholangiography). Endoscopic retrograde cholangiopancreatography (ERCP) can also be chosen, in place of non-invasive examination, in cases of high operative risk secondary to poor hepatic or general condition, as this procedure can confirm the diagnosis and also allows for immediate endoscopic treatment. When obstructive jaundice has been ruled out, intrahepatic cholestasis can be considered. Features of intrahepatic cholestasis are shared by several pathophysiological processes: (i) chronic cholangitis responsible for bile duct damage (primary biliary cirrhosis or primary sclerosing cholangitis, autoimmune cholangitis and drug-induced or idiopathic ductopenia); (ii) granulomatosis (sarcoidosis); (iii) systemic diseases (amyloidosis, sphingolipidosis such as Gaucher's disease, alpha-1-antitrypsin deficiency); or (iv) diseases disturbing the normal architecture of the liver (regenerative nodular hyperplasia). As a rule, liver biopsy is most informative in this setting.

There are no global definitions that would allow for clear classification of a disease as hepatitic or cholestatic. Some attempts have been made at a classification of drug-induced hepatitis (see Chapter 14.1). A biochemical profile has been elaborated according to the ratio between serum levels of alanine aminotransferase (ALT) and alkaline phosphatase elevation, both expressed as multiples of the ULN. A hepatitic profile was defined by an isolated rise in serum ALT > 2 ULN or by a ratio of ALT/alkaline phosphatase ≥ 5. A cholestatic profile was defined by an isolated rise in serum alkaline phosphatase ≥ 2 ULN or by a ratio ≤ 2. A mixed profile was defined by a rise in both ALT and alkaline phosphatase and by a ratio of between 2 and 5 [2]. The accuracy of these arbitrary thresholds has not been assessed.

Is a liver biopsy necessary?

Diagnosis can frequently be reached without the need for liver biopsy. In this case, histological assessment could be indicated for fibrosis staging or for multiple causes (for example, superimposition of alcoholism or dysmetabolic features on chronic viral hepatitis). Non-invasive tools (serum markers and elastometry) can be used. Their effectiveness has been assessed in viral hepatitis but still needs to be studied in other settings. Several points need to be discussed: (i) the sensitivity of liver biopsy, considered as the gold standard, for the diagnosis of cirrhosis is far from ideal, as up to 25% of cases are misclassified due to a sampling error. Sensitivity is largely dependent on the biopsy sample size. A size ≥ 15 mm is usually regarded as sufficient. However, acceptable diagnostic accuracy is obtained only for biopsy ≥ 25 mm, and reaches a plateau only when the biopsy is ≥ 40 mm [3]. When the clinical and histological diagnoses are conflicting, non-invasive tests such as elastometry could be helpful; (ii) the accuracy of the available non-invasive tests depends on the clinical issue. For a diagnosis of cirrhosis, the accuracy of non-invasive tests is excellent. For detection of metavir fibrosis stage ≥ 2 (i.e. the indication for interferon treatment in genotype 1 chronic hepatitis C), the accuracy of non-invasive tests is lower. Therefore, it is crucial to gather and to consider together all possible clinical, laboratory and imaging information for the staging of fibrosis and the diagnosis of cirrhosis. This point is important for appropriate management because, if a diagnosis of cirrhosis is made, then oesophageal varices have to be checked and hepatocellular carcinoma regularly screened for.

Are there extrahepatic manifestations?

Numerous conditions causing liver diseases also involve extrahepatic organs. Therefore, thorough physical examination is needed. This applies particularly to genetic and metabolic diseases (see Section 16). Conversely, cirrhosis, portal hypertension and hepatic failure, by themselves, can be associated with cardiovascular and pulmonary manifestations integrated

in the hepatopulmonary syndrome (see Chapter 7.7) or renal dysfunction. Osteoporosis is a common manifestation, particularly in cholestatic liver diseases such as primary biliary cirrhosis (see Chapter 21.10) and in patients suffering from autoimmune hepatitis on long-term steroid therapy. Deciding on the proper investigations is most important as specific measures can be undertaken to avoid complications (see Section 21).

General approach to management

A correct diagnosis allows for aptimal treatment. Along with specific treatment, some measures are non-specific and are general rules in liver disease management. They are extensively developed throughout this textbook.

Is there a cofactor of liver toxicity?

In most hepatic diseases, the development of fibrosis is triggered by the conjunction of different factors in the liver. Obesity, hyperlipidaemia and diabetes, all features integrated in the concept of insulin resistance syndrome, have been demonstrated to enhance fibrosis progression in viral hepatitis and haemochromatosis. Excessive intake of alcohol worsens the evolution of liver disease. The impact of moderate alcohol intake is less well established. Consequently, when taking charge of a patient with a liver disease, it is very important to detect those who are overweight and those with dyslipidaemia and glucose metabolism impairment and to take appropriate measures. Patients should be advised to abstain from regular intake of alcohol.

Hyperferritinaemia (HFE) is a common feature in chronic liver diseases that has been studied extensively in hepatitis C, non-alcoholic steatohepatitis (NASH) and alcohol-related liver diseases. It is a multifactorial process linked to liver cell necrosis, hepatic failure, portal hypertension and dysmetabolic features. It is sometimes associated with a moderate liver iron overload, involving hepatocytes and Kupffer cells, detectable using magnetic resonance imaging [4], Perl's staining or biochemical determination of hepatic iron. There is no consensus on the possible link between hepatic iron and fibrogenesis [5] in non-C282Y homozygous patients. The degree of iron overload is correlated with the severity of the liver disease [6], but may be only the consequence (and not the cause) of the evolution of the disease and might be considered as a surrogate marker of severity. Similar concerns have been raised by the conflicting association between heterozygous HFE mutations in the haemochromatosis gene and liver iron overload or liver fibrogenesis. Therefore, routine iron depletion treatment (phlebotomies) in all patients who have hyperferritinaemia cannot be recommended. Phlebotomies are indicated only in patients with proven significant iron overload, after HFE genetic testing to screen for associated genetic haemochromatosis and on an individual basis.

Diet

There is no need for patients with either acute or chronic liver disease to follow a specific diet (see Chapter 23.2). There is no need to restrict fat intake. Patients with decompensated cirrhosis have an impairment in the renal excretion of a normal sodium intake and need a reduction in sodium intake (2–3 g/day = 30–50 mmol/day). There is no need to restrict fluid intake unless serum sodium is < 125 mEq/mL (reflecting the impairment of free water clearance associated with a high level of antidiuretic hormone).

Most severely ill patients suffer from anorexia and malnutrition. Deficiencies in group B vitamins are frequent in alcoholic patients. Therefore, daily supplementation should be provided (500 mg of vitamin B1, 100 mg of vitamin B6, 100 mg of vitamin B3 and 5 mg of folic acid). In patients with chronic cholestasis, liposoluble vitamins (vitamin A, D, E and K) should be given as needed. Supplementation with calcium and vitamin D is indicated in patients with osteoporosis. Transient protein restriction (0.5 g/kg/day) may be proposed for patients with acute encephalopathy but should not be maintained for more than a few days because it worsens malnutrition which is frequent in these patients.

Rest and physical activity

There is no justification to recommend bed rest or restriction of physical activities in patients with acute or chronic liver diseases [7,8].

Recent studies have shown that moderate exercise increases portal pressure and may therefore increase the risk of variceal bleeding [9]. This is effectively prevented by propranolol treatment [10]. No studies have assessed whether this particular point is of clinical significance. In cirrhotic patients, impaired exercise capacity related to decreased cardiac diastolic function has also been reported [11].

Drugs and liver disease

Patients with liver disease often need to take drugs for conditions unrelated to their liver pathology (see Chapter 23.3). Drugs should be prescribed with caution. Drugs that commonly cause liver disease should, if possible, be avoided, as the diagnosis of drug-induced liver disease may be very difficult in the presence of pre-existing lesions. Furthermore, even if the incidence of liver damage with a particular drug is no greater in patients with chronic liver disease, one might expect a more severe reaction in such patients. Among problems frequently encountered, we will discuss only the issues of oral contraception and post-menopausal hormone replacement therapy because they are frequently the subject of patient's questions.

Use of contraceptive pill

Young women of childbearing age often ask whether they can

take the contraceptive pill. Liver disease is widely considered as a contraindication to such therapy, but there is still little information on this topic. Long-term use of oral contraceptives carries an increased, though small, risk of certain types of liver disease (hepatic vein thrombosis, gallstones, liver adenoma or peliosis). Estrogens induce a dose-dependant cholestasis with a decrease in the biliary excretion of bilirubin and biliary salts. On the other hand, estrogens could have a protective effect against the development of fibrosis, as suggested recently in chronic hepatitis C [12]. In the absence of clinical data, it seems sensible to avoid the use of estro–progestogen pills in women with cholestatic disease and in patients with vascular thrombosis or liver adenoma. In these situations, the use of other contraceptive methods or the use of a progestogen-only pill could be preferable.

Postmenopausal hormone replacement therapy (HRT)

Postmenopausal HRT seems to be particularly effective in the treatment of osteopenia related to primary biliary cirrhosis according to the results obtained in two recent studies [13,14] with a beneficial effect on bone mineral density and no change in liver function tests.

Sexual activity

In patients with cirrhosis, decreased sexual activity is considered frequent. This is clearly the case in alcoholic liver disease, either in women [15,16] or in men [17]. Sexual dysfunction improves with abstinence from alcohol. In a recent study including non-alcoholic liver diseases, measures of sexual activity were not significantly different from control groups except for decompensated Child B or C cirrhosis [18]. Although the serum level of testosterone is decreased in decompensated cirrhosis, testosterone replacement therapy is ineffective [17]. Sildenafil has been associated with acute hepatitis in a case report [19] and considered to be responsible for variceal haemorrhage in another [20].

Driving capacities

Patients with overt encephalopathy would clearly place themselves and others at risk if they were to drive a vehicle and have to be discouraged from doing so. Most patients with mild forms of chronic liver disease are capable of driving safely. However, attention should be given to the subclinical encephalopathy described in some cirrhotic patients and detectable only in the performance of psychometric tests. Previous investigations based on neuropsychological testing suggested that driving performance may be compromised in up to 85% of patients with subclinical encephalopathy [21]. Srivastava *et al.* [22] studied 15 cirrhotics using a driving test in the laboratory and driving on the road, supervised by a driving evaluator, and did not find significant performance differences between them and matched control subjects, although 66% of cirrhotic patients had abnormal psychometric tests. In a recent prospective study using a real 90-min on-road driving test, it has been found that the total driving score of patients with subclinical encephalopathy was significantly reduced in comparison with either cirrhotic patients without subclinical encephalopathy or paired control subjects [23]. Although the prevalence of subclinical encephalopathy in a cirrhotic population depends on selection criteria, about 30% of patients demonstrate abnormalities in the different psychometric tests used. The patients should be informed about this possible risk.

Follow-up and prevention of complications

Genetic disorders (see Section 16) should trigger familial screening for identification and, if necessary, treatment of affected subjects at a preclinical stage of the disease. In case of viral B or C hepatitis, family members and sexual contacts have to be screened. Those without hepatitis B markers should be vaccinated.

Periodic follow-up visits should be set up with the patient. Coordination between the different physicians with responsibility for the patient is important for investigations and therapy. Specific investigations have to be done at regular intervals.

Prevention of variceal haemorrhage

(see Section 7)

All cirrhotic patients should have an upper tract endoscopy for the screening of oesophageal varices at the time of first presentation. Varices at high risk of bleeding require prophylactic treatment for variceal haemorrhage (β-blockers or endoscopic band ligation in case of contraindication or intolerance to β-blockers) [24]. When negative, endoscopy should be repeated periodically. The French Consensus Conference on portal hypertension held in 2004 suggested repeating endoscopy every 3 years in the absence of varices, every 2 years in the case of small varices, and every year in the case of alcoholic cirrhosis or severe hepatic insufficiency [25]. Patients at high risk of bleeding should avoid travelling to or living in places lacking medical facilities able to cope with emergency digestive haemorrhage.

Screening for hepatocellular carcinoma

The annual incidence of hepatocellular carcinoma in cirrhotic patients is very high, up to 2–5% [26]. Although screening has not yet proved to be efficient in terms of survival benefit, it is widely accepted that cirrhotic patients should undergo screening using ultrasound and α-fetoprotein measurement every 6 months [27,28] in order to detect small lesions at a curable stage (see Chapter 18.2). This screening is meaningful only when curative treatment (liver transplant or surgical treatment) can be envisaged should a small liver tumour be detected. Screening is futile in patients with an obvious contraindication to liver transplantation or in a Child C patient for whom any form of treatment would not be applicable.

Vaccination against hepatitis A and B

(see Chapter 9.1.3)

It is sensible to propose vaccination against hepatitis A and hepatitis B for all patients suffering from chronic liver disease. This is especially important if they have persistent risk factors for acquiring these infections (high risk behaviour or travel in endemic areas).

The risk of fulminant hepatitis A is increased in cases of chronic liver disease. This has been demonstrated in hepatitis B carriers but is more controversial in patients with hepatitis C (very high prevalence of fulminant hepatitis A in an Italian study [29], not confirmed by other reports [30]). Few data allow us to establish the risk in chronic liver disease of other aetiologies [31]. It is highly probable that the risk is more closely correlated with the severity of the underlying liver damage than with the cause of the liver disease. The vaccine is safe in cases of liver disease, and its efficiency depends on the degree of liver damage. Although the titre of antibodies generated by anti-hepatitis A vaccine injection is lower in patients with chronic liver disease, there is no difference in the rate of successful development of efficient protection in the group of patients with chronic liver disease (95%) in comparison with control subjects (98%) [32]. However, a report from patients with endstage liver diseases, awaiting liver transplantation, indicated that only half of the patients seroconverted to an immune-protected state [33]. Therefore, in that setting, it seems reasonable to measure the effectiveness of the vaccination by the assessment of serum anti-hepatitis A virus (HAV) seroconversion.

Similar data are available for acquired hepatitis B. The outcome of acute hepatitis B is difficult to establish and conflicting. However, patients with dual chronic hepatitis B virus (HBV) and hepatitis C virus (HCV) infection appear to have a worse evolution than monoinfected patients. The efficiency of the vaccination is largely reduced in decompensated cirrhosis and in transplant settings despite double-dose vaccine and reinforced programmes [30].

Taken together, these data strongly suggest the importance of vaccination against both viruses, in patients who are HAV and HBc antibody negative. Because of the decreased efficiency in late stages of the disease, it seems sensible to perform these vaccinations early, before cirrhosis. Combined vaccines are available.

Follow-up and liver transplantation

Despite the significant progress encountered in the past few years in the treatment of liver diseases, there are still patients who continue to progress towards cirrhosis and its complications. The good results achieved with liver transplantation in that setting have completely changed the approach to the management of endstage liver disease.

A first quick general evaluation of the patient should point out evident contraindications to a liver transplant such as advanced age, active alcohol or drug addiction despite appropriate assistance or extrahepatic (pulmonary, cardiac, neurological, renal) failures incompatible with major surgery. If there are no contraindications, the patient should be told that a complete evaluation will be done later, if the evolution of the disease makes it necessary, before taking a final decision. Appropriate psychological help needs to be provided to the patients and their family. Therefore, it is crucial, from the first examination, to avoid any treatment or abdominal surgery that could complicate a subsequent liver transplant. Follow-up must be coordinated between the liver transplant centre and the physician who has taken the patient in charge in order to bring the patient to transplantation in the best condition.

References

1 Oberti F, Valsesia E, Pilette C *et al.* (1997) Noninvasive diagnosis of hepatic fibrosis or cirrhosis. *Gastroenterology* 113, 1609–1616.

2 Danan G (1991) Definitions et critères d'imputation des atteintes hépatiques aiguës médicamenteuses. *Gastroenterol Clin Biol* 15, 845–848.

3 Bedossa P, Dargere D, Paradis V (2003) Sampling variability of liver fibrosis in chronic hepatitis C. *Hepatology* 38, 1449–1457.

4 Gandon Y, Olivie D, Guyader D *et al.* (2004) Non-invasive assessment of hepatic iron stores by MRI. *Lancet* 363, 357–362.

5 Pietrangelo A (2003) Hemochromatosis gene modifies course of hepatitis C viral infection. *Gastroenterology* 124, 1509–1523.

6 Tung BY, Emond MJ, Bronner MP *et al.* (2003) Hepatitis C, iron status, and disease severity: relationship with HFE mutations. *Gastroenterology* 124, 318–326.

7 Ritland S (1988) Exercise and liver disease. *Sports Med* 6, 121–126.

8 Harrington DW (2000) Viral hepatitis and exercise. *Med Sci Sports Exerc* 32, S422–430.

9 Garcia-Pagan JC, Santos C, Barbera JA *et al.* (1996) Physical exercise increases portal pressure in patients with cirrhosis and portal hypertension. *Gastroenterology* 111, 1300–1306.

10 Bandi JC, Garcia-Pagan JC, Escorsell A *et al.* (1998) Effects of propranolol on the hepatic hemodynamic response to physical exercise in patients with cirrhosis. *Hepatology* 28, 677–682.

11 Wong F, Girgrah N, Graba J *et al.* (2001) The cardiac response to exercise in cirrhosis. *Gut* 49, 268–275.

12 Di Martino V, Lebray P, Myers RP *et al.* (2004) Progression of liver fibrosis in women infected with hepatitis C: long-term benefit of estrogen exposure. *Hepatology* 40, 1426–1433.

13 Ormarsdottir S, Mallmin H, Naessen T *et al.* (2004) An open, randomized, controlled study of transdermal hormone replacement therapy on the rate of bone loss in primary biliary cirrhosis. *J Intern Med* 256, 63–69.

14 Menon KV, Angulo P, Boe GM *et al.* (2003) Safety and efficacy of estrogen therapy in preventing bone loss in primary biliary cirrhosis. *Am J Gastroenterol* 98, 889–892.

15 Gavaler JS, Rizzo A, Rossaro L *et al.* (1993) Sexuality of alcoholic women with menstrual cycle function: effects of duration of alcohol abstinence. *Alcohol Clin Exp Res* 17, 778–781.

16 Gavaler JS, Rizzo A, Rossaro L *et al.* (1994) Sexuality of alcoholic postmenopausal women: effects of duration of alcohol abstinence. *Alcohol Clin Exp Res* 18, 269–271.

17 Gluud C, Wantzin P, Eriksen J (1988) No effect of oral testosterone treatment on sexual dysfunction in alcoholic cirrhotic men. *Gastroenterology* 95, 1582–1587.

18 Zifroni A, Schiavi RC, Schaffner F (1991) Sexual function and testosterone levels in men with nonalcoholic liver disease. *Hepatology* 14, 479–482.
19 Maroy B (2003) Hepatite aiguë cytolytique probablement due à la prise de sildenafil (Viagra). *Gastroenterol Clin Biol* 27, 564–565.
20 Tzathas C, Christidou A, Ladas SD (2002) Sildenafil (viagra) is a risk factor for acute variceal bleeding. *Am J Gastroenterol* 97, 1856.
21 Watanabe A, Tuchida T, Yata Y *et al.* (1995) Evaluation of neuropsychological function in patients with liver cirrhosis with special reference to their driving ability. *Metab Brain Dis* 10, 239–248.
22 Srivastava A, Mehta R, Rothke SP *et al.* (1994) Fitness to drive in patients with cirrhosis and portal-systemic shunting: a pilot study evaluating driving performance. *J Hepatol* 21, 1023–1028.
23 Wein C, Koch H, Popp B *et al.* (2004) Minimal hepatic encephalopathy impairs fitness to drive. *Hepatology* 39, 739–745.
24 de Franchis R (2005) Evolving consensus in portal hypertension. Report of the Baveno IV consensus workshop on methodology of diagnosis and therapy in portal hypertension. *J Hepatol* 43, 167–176.
25 Conférence de consensus (2004) Complications de l'hypertension portale chez l'adulte (Paris, December 4–5, 2003). Texte long. *Gastroenterol Clin Biol* 28 (Spec. No. 2), B324–334.
26 Fattovich G, Stroffolini T, Zagni I *et al.* (2004) Hepatocellular carcinoma in cirrhosis: incidence and risk factors. *Gastroenterology* 127, S35–50.
27 Daniele B, Bencivenga A, Megna AS *et al.* (2004) Alpha-fetoprotein and ultrasonography screening for hepatocellular carcinoma. *Gastroenterology* 127, S108–112.
28 Di Bisceglie AM (2004) Issues in screening and surveillance for hepatocellular carcinoma. *Gastroenterology* 127, S104–107.
29 Vento S, Garofano T, Renzini C *et al.* (1998) Fulminant hepatitis associated with hepatitis A virus superinfection in patients with chronic hepatitis C. *N Engl J Med* 338, 286–290.
30 Reiss G, Keeffe EB (2004) Review article: hepatitis vaccination in patients with chronic liver disease. *Aliment Pharmacol Ther* 19, 715–727.
31 Keeffe EB (1995) Is hepatitis A more severe in patients with chronic hepatitis B and other chronic liver diseases? *Am J Gastroenterol* 90, 201–205.
32 Keeffe EB, Iwarson S, McMahon BJ *et al.* (1998) Safety and immunogenicity of hepatitis A vaccine in patients with chronic liver disease. *Hepatology* 27, 881–886.
33 Smallwood GA, Coloura CT, Martinez E *et al.* (2002) Can patients awaiting liver transplantation elicit an immune response to the hepatitis A vaccine? *Transplant Proc* 34, 3289–3290.

23.2 Nutritional aspects of liver and biliary disease

Bernard Campillo

The liver plays a major role in carbohydrate, protein and lipid metabolism, being one of the key organs that incorporate nutrients in the body cell mass. Nutritional aspect is of major importance in patients with cirrhosis. In these patients, malnutrition is common and worsens their outcome. The main issues in the management of the patient with liver disease are the assessment of nutritional status, the optimal method for meeting nutritional requirements and nutritional management before and after liver transplantation.

Assessment of nutritional status

The assessment of nutritional status is difficult in cirrhotic patients as fluid retention hinders the interpretation of simple criteria such as body weight and body mass index (BMI). Anthropometry is based on measurement of muscle circumference and skinfold thickness. Midarm circumference (MAC) is measured with a tape and triceps skinfold thickness (TST) with an adipometer. Muscular midarm circumference (MMAC) is then calculated from the equation:

$$\text{MMAC (cm)} = \text{MAC (cm)} - \pi \times \text{TST (cm)}$$

MMAC reflects muscular mass while TST reflects fat mass. Midarm muscle area and midarm fat area can be calculated from MMAC and TST. The advantages of this method are low cost and simplicity for bedside use. Limitations are inter- and intraobserver variability. Measurements should be performed by an experienced observer. Values are compared with those observed in a North American reference healthy population [1,2] and analysed taking into account age and sex. Values below the 5th or 10th percentiles of references values are considered low and reflect malnutrition. Anthropometry is sufficiently reliable to be used in epidemiological studies requiring a large number of patients. Anthropometry can also be used for the evaluation of the effects of nutritional support. However, the interval between two measurements should not be less than 3–4 weeks as anthropometry cannot assess rapid changes in body composition.

Bioelectrical impedance analysis (BIA) is a simple, non-invasive, inexpensive and rapid method of estimating body cell mass. This comprises the metabolically active, and thus most relevant, compartment in the body. BIA is an accurate and reliable method in patients without ascites but not in patients with ascites [3].

Dual X-ray absorptiometry (DXA) is a safe, convenient and non-invasive technique for assessing body composition. By applying this method, fat mass, bone mineral content, bone mineral density and fat-free, mineral-free mass can be estimated. Whole body and regional (arms, legs and trunk) assessments can be performed. DXA assessment of body composition was shown to be accurate in cirrhotics without ascites [4,5].

Muscular performance, assessed by the measurement of muscle strength, can be used in the evaluation of nutritional status [6] as it is related to the severity of malnutrition, not to the severity of liver disease.

Isotopic measurement of total body potassium and total body water, as well as *in vivo* neutron activation, provides accurate analysis of body composition, but these methods are not available in clinical practice [7,8]. Plasma protein levels such as albumin and transthyretin, which are influenced by liver synthetic capacity, cannot be used for nutritional assessment. Subjective global assessment (SGA) shows an acceptable agreement with anthropometry but fails to provide a sensitive quantitative measurement of nutritional changes. A composite score including anthropometry, creatinine excretion, lymphocyte count, recall antigen testing, muscle function and circulating levels of various proteins has been used to assess protein calorie malnutrition [9].

In clinical practice, the method selected for nutritional status assessment depends on physicians' experience and local availability. In patients with endstage liver disease, midarm muscle circumference and handgrip strength appear to be the most sensitive markers [10].

Prevalence of malnutrition

The prevalence of nutritional depletion increases in both sexes as liver function deteriorates. A severe reduction in muscular mass is more frequent in male patients than in females, whereas in the latter, fat mass is more frequently affected than in males.

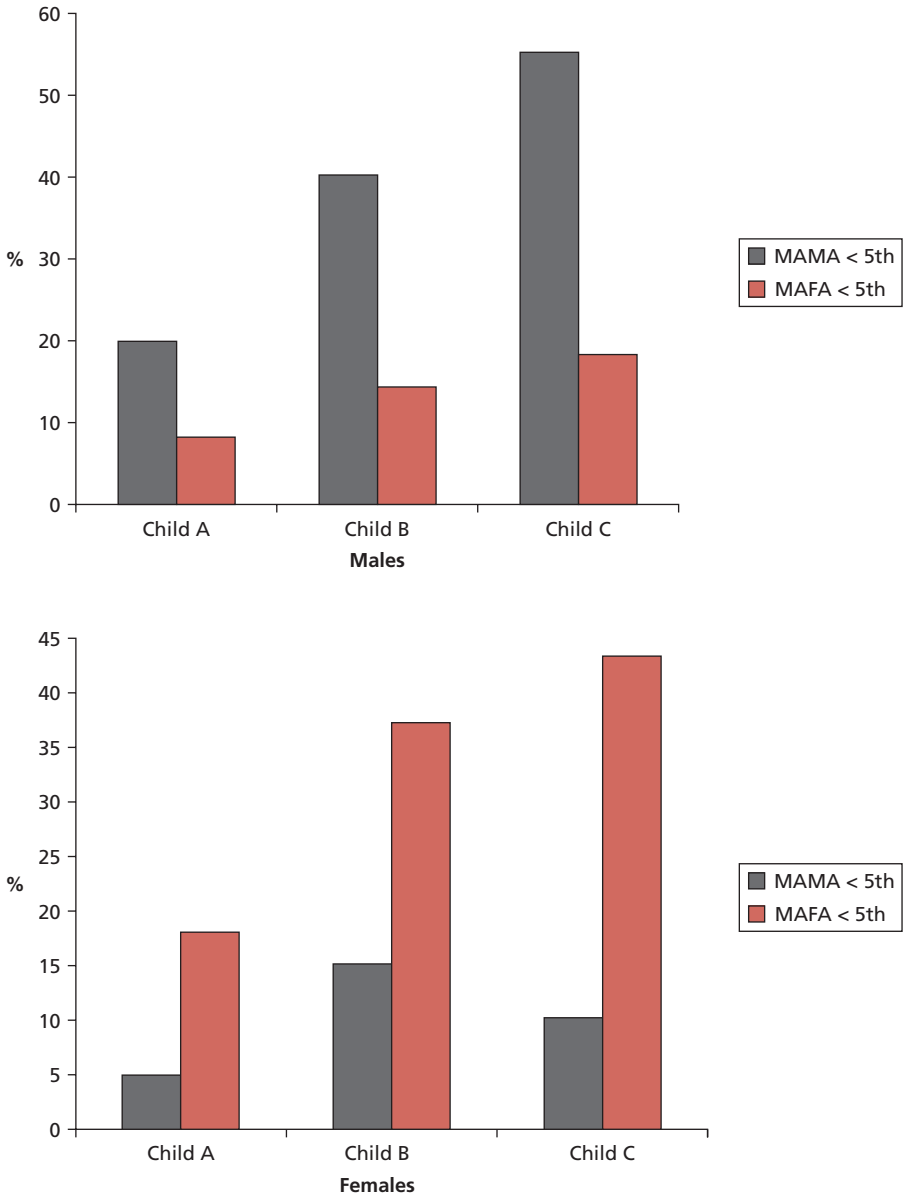

Fig. 1 Prevalence of malnutrition in cirrhotic patients. Percentage of males and females with cirrhosis with a reduction in midarm muscle area (MAMA) and midarm fat area (MAFA) below the 5th percentile of standard for an age- and sex-matched healthy population [11].

Fifty per cent of male Child C patients have a severe reduction in muscular mass, while 40% of female Child C patients have a severe reduction in fat mass (Fig. 1) [11]. Hospitalized cirrhotic patients have a high prevalence rate of malnutrition [12]. Ascites is the clinical feature most strongly associated with malnutrition. Among patients with tense ascites, muscular mass is reduced in 65% and fat mass in 48% [12]. The severity of malnutrition is not related to the cause of cirrhosis [12].

Pathogenesis of malnutrition

Many factors are involved in the pathogenesis of malnutrition [13]. The main factor is likely to be the inadequacy of dietary intake. Hospitalized cirrhotic patients with advanced disease have insufficient caloric, protein and micronutriment intake. Among Child C patients, caloric and protein intake is lower than required in 80% and 60% of patients respectively [12]. Several factors may contribute to this reduced dietary intake. Alcoholic hepatitis is characterized by enhanced secretion of cytokines such as tumour necrosis factor (TNF)α and interleukin (IL)-6, which have a pronounced anorectic effect. Moreover, patients with cirrhosis have impaired gustatory acuity that is associated with hypomagnesaemia; it has been shown that chemosensory function is improved after restoration of hepatic function with liver transplantation [14]. Furthermore, hyperinsulinaemia, which is usually observed in advanced cirrhosis, could lead to a reduction in carbohydrate intake compounded by the preferential uptake of carbohydrate. This last mechanism may result in enhanced signalling by the gastrointestinal glucosensors and, in turn, contribute to hypophagia [15].

The impact of malnutrition on clinical outcome

Protein caloric malnutrition is a prognostic factor in alcoholic hepatitis [9]. Patients below the 5th percentile for MMAC and/or TST show significantly lower survival rates at 24-month follow-up, compared with patients above the 5th percentile [16]. The prognostic value of MMAC is higher than that of TST [17]. However, as malnutrition is strongly associated with the deterioration in liver function, it is still controversial whether malnutrition can be considered as an independent risk factor for mortality. Alberino *et al.* [17] found that malnutrition is an independent predictor of survival. Merli *et al.* [18] reported that a reduction in muscle mass was associated with a lower cumulative survival in Child A or B, but not in Child C patients; however, multivariate analysis showed that nutritional status had no independent prognostic value.

Malnutrition is a risk factor in cirrhotic patients undergoing surgery [19]. Moreover, a poor nutritional status has been associated with a higher risk of complications and mortality in patients undergoing liver transplantation. Table 1 shows the impact of malnutrition on the outcome after liver transplantation in major studies. As a rule, these studies have shown that, whatever the cause of cirrhosis, malnutrition affects the risk of surgical complications and post-transplant infections, the length of hospital and intensive care unit (ICU) stay and survival. It is worth noting that malnutrition was suggested to decrease the risk of acute rejection, probably owing to its immune-suppressive effect [20].

Nutritional management

Energy and nitrogen requirements

In patients with clinically stable cirrhosis, recommended intake for maintaining body composition is 25–30 kcal/kg/day non-protein energy and 1.0–1.2 g/kg/day protein. In malnourished patients at risk of fatal complications and requiring repletion, recommended intake is 35–40 kcal/kg/day non-protein energy and 1.5 g/kg/day protein. Ideal body weight should be used for calculations. The ratio of glucid/lipid in the diet must be in the same range as in healthy people. Carbohydrate should provide 50–55% of total calories and lipid 30–35% [29]. As, in cirrhotic patients, nutrient metabolism is shifted towards an increased catabolism, starvation must be avoided. Indeed, a late evening meal improves the efficiency of nitrogen metabolism in these patients [30].

Oral nutrition can be achieved in most malnourished patients. In hospitalized patients with a caloric intake of 40 kcal/kg/day and a protein intake of 1.4 g/kg/day, fat mass increases within 1 month, regardless of disease severity [31]. Moreover, non-protein respiratory quotient increases after an overnight fast, especially in Child C patients, indicating an improved metabolic pattern [31]. Oral supplements providing 300–500 kcal/day must be proposed in patients when spontaneous nutritional intake remains low. In these hospitalized cirrhotic patients, long-term oral supplementation has been shown to be feasible and to decrease the risk of severe infections. However, no effect on liver function has been demonstrated [32,33].

Table 1 Malnutrition and liver transplantation.

References	*n*	Nutritional assessment	Factors influenced by malnutrition
Shaw *et al.* [20]	160	Clinical assessment	Survival at 6 months
Moukarzel *et al.* [21]	102 (paediatric patients)	Height, Z score	Survival, infections, surgical complications, length of hospital stay, retransplantation
Pikul *et al.* [22]	68	Subjective global assessment	Survival, ICU stay, length of artificial respiration, tracheotomy, length of hospital stay
Ricci *et al.* [23]	436	Clinical assessment	Surgical complications, ICU stay, blood usage
Selberg *et al.* [24]	150	Anthropometry, BIA	Survival, post-transplant infections
Figueiredo *et al.* [25]	53	Subjective global assessment, handgrip strength, DXA, plasma amino acid level	Post-transplant infection, ICU stay
Stephenson *et al.* [26]	99	Subjective global assessment	Blood usage, length of hospital stay
Buyse *et al.* [27]	84	CT scanner: transversal diameter of psoas and spinal muscle/height	Survival, risk of death before transplantation

ICU, intensive care unit; BIA, bioelectrical impedance analysis; DXA, dual X-ray absorptiometry; CT, computerized tomography.

Specific nutriments

Plasma branched-chain amino acid (BCAA) levels are decreased in patients with liver cirrhosis, owing to an increase in BCAA tissue uptake and/or catabolism. A decrease in BCAA production from protein malnutrition worsens this derangement. Studies of BCAA fluxes and protein turnover in cirrhotic patients have given conflicting results, probably related to differences in patients' characteristics, methods used and expression of results. A number of studies have addressed the issue of BCAA as a treatment for hepatic encephalopathy. Although their conclusions are conflicting, there is an overall trend towards a beneficial effect [29]. However, no beneficial effect of BCAA on nutritional status or liver function has ever been shown [34].

The failure to metabolize methionine in cirrhosis is due to decreased activity of methionine adenosyltransferase, the enzyme that converts methionine to *S*-adenosyl-L-methionine (SAMe) in the presence of adenosine triphosphate (ATP). Among many key functions in the liver, SAMe serves as a precursor for cysteine, one of the three amino acids of glutathione, the major physiological defence mechanism against oxidative stress. SAMe administration shows beneficial effects in patients with intrahepatic cholestasis. Moreover, long-term SAMe administration appears to improve survival or to delay liver transplantation in patients with alcoholic liver cirrhosis, especially those with less advanced liver disease [35]. Polyenylphosphatidylcholine (PPC), an antioxidant phosphatidylcholine mixture, restores phospholipid regeneration. PCC may be beneficial in patients with alcoholic hepatitis, opposes fibrosis in heavy drinkers and decreases transaminases in patients with hepatitis C [36].

Minerals and micronutriments

Salt restriction providing 2 g of NaCl/day is recommended in the treatment of ascites in combination with diuretics [37]. Because salt restriction may be a cause of increased alimentation in cirrhotic patients, it must be limited to patients with ascites or oedema. As magnesium and phosphorus deficiencies may occur in alcoholic cirrhotic patients during alcohol withdrawal and early abstinence, appropriate supplementation must be provided to these patients. Deficiencies in group B vitamins – including thiamine (B1), pyridoxine (B6), niacin (PP) and folic acid (B9) – are frequent in alcoholic patients. These deficiencies are responsible for severe nervous system or blood disorders. Therefore, supplementation should be initiated upon admission in such patients, providing daily 500 mg of vitamin B1, 100 mg of vitamin B6, 100 mg of vitamin PP and 5 mg of folic acid. Intravenous administration is preferable in patients with clinical signs of deficiency [38]. Patients with cholestatic diseases are at high risk of fat-soluble vitamin deficiency (A, D, E, K). Adequate supplementation must be performed in these patients. Patients with chronic liver diseases are at high risk of osteopenia owing to vitamin D deficiency, and supplementation with calcium and vitamin D is recommended; however, estrogen replacement is more effective in improving bone mineral density in patients with primary biliary cirrhosis [29]. Although vitamin A deficiency may occur in alcoholic cirrhotic patients, routine supplementation is not recommended because of potential hepatic toxicity of this vitamin and of interaction between alcohol, vitamin A and drugs [39]. Cirrhotic patients, especially those with advanced disease, are vitamin E deficient [40]. Although vitamin E is a most effective antioxidant agent, a beneficial effect of long-term supplementation of vitamin E has not been demonstrated in these patients [41]. Zinc deficiency, which is common in liver cirrhosis, may induce encephalopathy. Hepatic urea production capacity has been shown to increase after 3 months of oral zinc supplementation in parallel with an improvement in encephalopathy [42].

Patients with encephalopathy

Possible precipitating factors such as gastrointestinal bleeding, sepsis, drugs or renal failure must be excluded before regarding a patient with encephalopathy as protein intolerant. In patients with encephalopathy grade I–II, transient protein restriction supplying 0.5 g/kg/day can be instituted but, after a few days, adequate amounts of dietary protein should be supplied. In patients proven to be protein intolerant despite symptomatic treatment, oral BCAA supplementation, when available, may be helpful in achieving an adequate nitrogen intake. Lacteal proteins are recommended because of their large amounts in BCAA. Patients in coma can be given total parenteral nutrition regimens providing 25–30 kcal/kg/day non-protein energy plus 1.0 g/kg/day protein using BCAA-enriched amino acid solutions.

Artificial feeding

Artificial nutrition is required in anorectic patients who cannot meet their nutrient requirements by oral intake 'ad lib'. Enteral feeding is usually preferred to parenteral feeding because of the severity of side-effects with the latter. Results of major controlled trials of enteral nutrition in patients with liver diseases are shown in Table 2. A majority of the patients were enrolled because of alcoholic cirrhosis or alcoholic hepatitis. These studies have shown that enteral nutrition is safe and does not increase the risk of variceal bleeding or encephalopathy. However, other studies suggested that enteral nutrition increases the risk of encephalopathy in patients with portosystemic shunting, as intestinal metabolism contributes to postfeeding hyperammonaemia in patients with cirrhosis [49]. Enteral nutrition improved nutritional status in most studies and decreased the hospital mortality rate in one trial [44]. In patients with alcoholic hepatitis, enteral feeding decreased infection-related mortality and yielded survival comparable to that achieved with corticosteroid therapy [47]. Enteral feeding has not been used as extensively as the high prevalence of malnutrition and low dietary intake would indicate in hospitalized patients with

Table 2 Enteral nutrition in chronic liver diseases.

References	*n* treatment/control	Patients	Groups	Effects
Mendenhall *et al.* [43]	19/34	Mild or severe AAH/cirrhosis	EN + OD vs. OD	Improvement in nutritional parameters
Cabré *et al.* [44]	16/19	Cirrhosis	EN vs. OD	Improvement in nutritional parameters and liver function Decrease in hospital mortality rate
Kearns *et al.* [45]	16/15	AAH/cirrhosis	EN + OD vs. OD	Improvement in nutritional parameters and liver function
De Lédinghen *et al.* [46]	12/10	Cirrhosis after gastrointestinal bleeding	EN + OD vs. OD	Lack of benefit
Cabré *et al.* [47]	35/36	Severe AAH	EN vs. 40 mg of prednisolone	Comparable results with steroids on outcome
Le Cornu *et al.* [48]	42/40	Cirrhotic patients awaiting liver transplantation	EN vs. OD	Improvement in nutritional status

AAH, acute alcoholic hepatitis; EN, enteral nutrition; OD, oral diet.

cirrhosis. In the usual clinical setting, the benefits of enteral feeding remain controversial [12]. Optimal composition of enteral solution has not been addressed in controlled trials. There appears to be a consensus that patients with cirrhosis should be administered liquid enteral formulas of high energetic density (1.5 kcal/mL) and low sodium content (40 mmol/day).

The efficacy of parenteral nutrition has been assessed in patients with cirrhosis, alcoholic hepatitis and in a preoperative setting. Increased survival has not been demonstrated [29]. In patients with liver disease, parenteral nutrition is limited by several factors. Severe defects in clotting factors and thrombocytopenia may predispose to bleeding during catheter insertion. Moreover, because of a high rate of carriage of *Staphylococcus aureus*, cirrhotic patients are at high risk of infections caused by this bacteria, a risk that is exacerbated by insertion and maintenance of central venous catheters [50]. Therefore, parenteral nutrition should only be indicated when enteral nutrition is not possible. Severe encephalopathy (grade III–IV) is a well-documented indication for parenteral nutrition in cirrhotic patients. Energy should be provided as glucose and fat in a ratio of 65–50/35–50% of non-protein calories. Parenterally administered fat is cleared from the blood and utilized efficiently by the majority of patients with cirrhosis. As already mentioned, there is a trend in favour of the beneficial effects of BCAA-enriched solutions in patients with severe encephalopathy. Otherwise, nitrogen should be provided by conventional amino acid solutions [29].

Pharmacological agents

The efficacy of some anabolic steroids has been evaluated. Oxandrolone (40–80 mg/day), together with an adequate caloric intake, has improved creatinin height index, total lymphocyte count, handgrip strength and prealbumin level in moderately malnourished patients with severe alcoholic hepatitis, whereas this regimen in severely malnourished patients was not effective [51]. Topical testosterone replacement therapy in patients with endstage liver disease, irrespective of gonadal insufficiency, may increase muscle strength and stimulate albumin synthesis [52]. Further studies in larger series of patients are needed to assess the efficacy and the safety of this procedure. Transdermal hormone replacement therapy based on estradiol and medroxyprogesterone in combination with daily vitamin D and calcium supplementation increases bone mineral density in female patients with primary biliary cirrhosis with few severe side-effects related to the liver. In contrast, vitamin D and calcium supplementation alone had no beneficial effect [53].

The liver is the central organ of the endocrine growth hormone (GH)/insulin-like growth factor 1 (IGF-1) axis. Cirrhosis represents a state of acquired GH resistance. GH administration to cirrhotic patients yielded conflicting results. Short-term administration (7 days) of GH increased the levels of IGF-1 and IGF BP-3, the major insulin-like growth factor binding protein, and improved cumulative nitrogen balance, although other studies have shown that IGF-1 levels do not increase in response to treatment with GH in children [54,55]. Further long-term studies are needed to appraise the effects of GH in cirrhotic patients.

Nutritional therapy in liver transplantation

Transplant patients may exhibit considerable nitrogen losses with a persistently negative nitrogen balance for 28 days postoperatively, which indicates increased protein requirements [29]. On the other hand, other macronutrient requirements in transplant patients do not differ from those of surgical patients in general. Early enteral nutrition, which can be carried out in most

patients, is well tolerated; it may reduce complication rates and costs. Short-term efficacy of early enteral feeding is comparable with that of parenteral nutrition with regard to nutrient provision and nutritional state [56,57]. Early enteral nutrition with solutions containing prebiotics (fibre) and probiotics (lactobacillus) appears to be well tolerated and to decrease markedly postoperative infection rates in comparison with selective bowel decontamination combined with a standard enteral nutrition formula [58]. Magnesium levels should be monitored as ciclosporin and tacrolimus induce hypomagnesaemia [29]. In the long term, liver transplantation induces changes in body composition characterized by increased fat mass and obesity, while appetite and fat-derived energy intake increase. The liver is an important metabolic sensor relaying humoral and neural signalling via the brainstem to the hypothalamus. Suppression of extrinsic hepatic innervation in the transplanted liver results in a loss of humoral and neural responses being relayed via hepatic afferents, which in turn could affect energy homeostasis and contribute to weight gain [59].

Conclusion

In patients with chronic liver disease, nutritional status assessment allows the recognition of malnutrition and the prevention of nutritional depletion in hospital. Nutritional support is achievable using the oral route with supplements or enteral feeding. Improvement in the nutritional management of these patients is clearly needed. The following issues still need to be addressed:

- validation of simple tools to detect malnutrition and to assess its severity taking into account changes in body composition with fluid retention and liver failure;
- identification of patients most likely to benefit from enteral nutrition and of optimal moment to initiate tube feeding;
- assessment of specific nutriment supplementation and pharmacological agents such as anabolic steroids and GH/IGF-1;
- a better understanding of obesity as a long-term consequence of liver transplantation, and the elaboration of a strategy for its prevention.

References

1 Frisancho AR (1981) New norms of upper limb fat and muscle areas for assessment of nutritional status. *Am J Clin Nutr* 34, 2540–2545.

2 Bishop CW, Bowen PE, Ritchey SJ (1981) Norms for nutritional assessment of American adults by upper arm anthropometry. *Am J Clin Nutr* 34, 2530–2539.

3 Pirlich M, Schütz T, Spachos T *et al.* (2000) Bioelectrical impedance analysis is a useful bedside technique to assess malnutrition in cirrhotic patients with and without ascites. *Hepatology* 32, 1208–1215.

4 Riggio O, Andreoli A, Diana F *et al.* (1997) Whole body and regional body composition analysis by dual-energy X-ray absorptiometry in cirrhotic patients. *Eur J Clin Nutr* 51, 810–814.

5 Fiore P, Merli M, Andreoli A *et al.* (1999) A comparison of skinfold anthropometry and dual-energy X-ray absorptiometry for the evaluation of body fat in cirrhotic patients. *Clin Nutr* 18, 349–351.

6 Andersen H, Borre M, Jakobsen J *et al.* (1998) Decreased muscle strength in patients with alcoholic liver cirrhosis in relation to nutritional status, alcohol abstinence, liver function, and neuropathy. *Hepatology* 27, 1200–1206.

7 Prijatmoko D, Strauss BJG, Lambert JR *et al.* (1993) Early detection of protein depletion in alcoholic cirrhosis: role of body composition analysis. *Gastroenterology* 105, 1839–1845.

8 Crawford DHG, Shepherd RW, Halliday JW *et al.* (1994) Body composition in non alcoholic cirrhosis: the effect of disease etiology and severity on nutritional compartments. *Gastroenterology* 106, 1611–1617.

9 Mendenhall CL, Tosch T, Weesner RE *et al.* (1986) VA cooperative study on alcoholic hepatitis II: prognostic significance of protein calorie malnutrition. *Am J Clin Nutr* 43, 213–218.

10 Figueiredo FA, Dickson ER, Pasha TM *et al.* (2000) Utility of standard nutritional parameters in detecting body cell mass depletion in patients with end-stage liver disease. *Liver Transpl* 6, 575–581.

11 Italian Multicentre Cooperative Project on nutrition in liver cirrhosis (1994) Nutritional status in cirrhosis. *J Hepatol* 21, 317–325.

12 Campillo B, Richardet JP, Scherman E *et al.* (2003) Evaluation of nutritional practice in hospitalized cirrhotic patients results of a prospective study. *Nutrition* 19, 515–521.

13 McCullough AJ, Tavill AS (1991) Disordered energy and protein metabolism in liver disease. *Semin Liver Dis* 11, 265–277.

14 Madden AM, Bradbury W, Morgan MY (1997) Taste perception in cirrhosis: its relationship to circulating micronutriments and food preferences. *Hepatology* 26, 40–48.

15 Richardson RA, Davidson HI, Hinds A *et al.* (1999) Influence of the metabolic sequelae of liver cirrhosis on nutritional intake. *Am J Clin Nutr* 69, 331–337.

16 Caregaro L, Alberino F, Amodio P *et al.* (1996) Malnutrition in alcoholic and virus-related cirrhosis. *Am J Clin Nutr* 63, 602–609.

17 Alberino F, Gatta A, Amidio P *et al.* (2001) Nutrition and survival in patients with liver cirrhosis. *Nutrition* 17, 445–450.

18 Merli M, Riggio O, Dally L and PINC (1996) Does malnutrition affect survival in cirrhosis ? *Hepatology* 23, 1041–1046.

19 Merli M, Nicolini G, Angeloni S *et al.* (2002) Malnutrition is a risk factor in cirrhotic patients undergoing surgery. *Nutrition* 18, 978–986.

20 Shaw BW, Jr, Wood RP, Gordon RD *et al.* (1985) Influence of selected patient variables and operative blood loss on six-month survival following liver transplantation. *Semin Liver Dis* 5, 385–393.

21 Moukarzel AA, Najm I, Vargas J *et al.* (1990) Effect of nutritional status on outcome of orthotopic liver transplantation in pediatric patients. *Transplant Proc* 22, 1560–1563.

22 Pikul J, Sharpe MD, Lowndes R *et al.* (1994) Degree of preoperative malnutrition is predictive of postoperative morbidity and mortality in liver transplantation recipients. *Transplantation* 57, 649–672.

23 Ricci P, Therneau TM, Malinchoc M *et al.* (1997) A prognostic model for the outcome of liver transplantation in patients with cholestatic liver disease. *Hepatology* 25, 672–677.

24 Selberg O, Böttcher J, Tusch G *et al.* (1997) Identification of high- and low-risk patients before liver transplantation: a prospective cohort study of nutritional and metabolic parameters in 150 patients. *Hepatology* 25, 652–657.

25 Figueiredo F, Dickson ER, Pasha T *et al.* (2000) Impact of nutritional status on outcomes after liver transplantation. *Transplantation* 70, 1347–1352.

26 Stephenson GR, Moretti EW, El-Moalem H *et al.* (2001) Malnutrition in liver transplant patients: preoperative subjective global assessment

is predictive of outcome after liver transplantation. *Transplantation* 72, 666–670.
27 Buyse S, Thome Noun C, Vilgrain V *et al.* (2004) Evaluation quantitative de la masse musculaire par tomodensitométrie: un nouveau marqueur pronostique chez les candidats à la transplantation. *Gastroenterol Clin Biol* 28, A182.
28 Bathgate AJ, Hynd P, Sommerville D *et al.* (1999) The prediction of acute cellular rejection in orthotopic liver transplantation. *Liver Transpl Surg* 5, 475–479.
29 Plauth M, Merli M, Kondrup J *et al.* (1997) ESPEN guidelines for nutrition in liver disease and transplantation. *Clin Nutr* 16, 43–55.
30 Swart GR, Zillikens MC, Van Voure JK *et al.* (1989) Effect of a late evening meal on nitrogen balance in patients with cirrhosis of the liver. *Br Med J* 299, 1202–1203.
31 Campillo B, Bories PN, Pornin B *et al.* (1997) Influence of liver failure, ascites, and energy expenditure on the response to oral nutrition in alcoholic liver cirrhosis. *Nutrition* 13, 613–621.
32 Hirsch S, Bunont D, De la Maza P *et al.* (1993) Controlled trial on nutrition supplementation in outpatients with symptomatic alcoholic cirrhosis. *J Parenteral Enteral Nutr* 17, 119–124.
33 Cunha L, Happi Nono M, Guibert AL *et al.* (2004) Effects of prolonged nutritional support in malnourished cirrhotic patients: results of a pilot study. *Gastroenterol Clin Biol* 28, 36–39.
34 Blonde-Cynober F, Aussel C, Cynober L (1999) Abnormalities in branched-chain amino-acid metabolism in cirrhosis: influence of hormonal and nutritional factors and directions for future research. *Clin Nutr* 18, 5–13.
35 Lieber SC (2002) S-adenosyl-L-methionine: its role in the treatment of liver disorders. *Am J Clin Nutr* 76, S1183–S1187.
36 Lieber CS (2004) New concepts of the pathogenesis of alcoholic liver disease lead to novel treatments. *Curr Gastroenterol Rep* 6, 60–65.
37 Amiot X (2004) Comment traiter une première poussée d'ascite. *Gastroenterol Clin Biol* 28, B118–B122.
38 Campillo B (2000) Les problèmes nutritionnels chez l'alcoolique chronique. *Cah Nutr Diet* 35, 93–98.
39 Leo ML, Lieber CS (1999) Alcohol, vitamin A and β-carotene: adverse interactions, including hepatotoxicity and carotogenicity. *Am J Clin Nutr* 69, 1071–1085.
40 Ferré N, Camps J, Prats E *et al.* (2002) Impaired vitamin E status in patients with parenchymal liver cirrhosis: relationships with lipoprotein compositional alterations, nutritional factors, and oxidative susceptibility of plasma. *Metabolism* 51, 609–615.
41 De la Maza MP, Petermann M, Bunout D *et al.* (1995) Effects of long-term vitamin E supplementation in alcoholic cirrhotics. *J Am Coll Nutr* 14, 192–196.
42 Marchesini G, Fabbri A, Bianchi G *et al.* (1996) Zinc supplementation and amino acid-nitrogen metabolism in patients with advanced cirrhosis. *Hepatology* 23, 1084–1092.
43 Mendenhall C, Bongiovanni G, Goldberg S *et al.* and the VA cooperative study group on alcoholic hepatitis III (1985) Changes in protein-calorie malnutrition associated with 30 days of hospitalization with and without enteral nutrition therapy. *JPEN* 9, 590–596.
44 Cabré E, Gonzalez-Huix F, Abad-Lacruz A *et al.* (1990) Effect of total enteral nutrition on the short term outcome of severely malnourished cirrhotics. *Gastroenterology* 98, 715–720.
45 Kearns PJ, Young H, Garcia G *et al.* (1992) Accelerated improvement of alcoholic liver disease with enteral nutrition. *Gastroenterology* 102, 200–205.
46 De Lédinghen V, Bean P, Mannant PR *et al.* (1997) Early feeding or enteral nutrition in patients with cirrhosis after bleeding from oesophageal varices? A randomized controlled study. *Dig Dis Sci* 42, 536–541.
47 Cabré E, Rodriguez-Iglesias P, Caballera J *et al.* (2000) Short and long-term outcome of severe alcohol-induced hepatitis treated with steroids or enteral nutrition, a multicenter randomized trial. *Hepatology* 32, 36–42.
48 Le Cornu KA, Mc Kiernan FJ, Kapadia SA *et al.* (2000) A prospective randomized study of preoperative nutritional supplementation in patients awaiting elective orthotopic liver transplantation. *Transplantation* 69, 1364–1369.
49 Plauth M, Roske AE, Romaniuk P *et al.* (2000) Post-feeding hyperammonaemia in patients with transjugular intrahepatic portosystemic shunt and liver cirrhosis, role of small intestine ammonia release and route of nutrient administration. *Gut* 46, 849–855.
50 Campillo B, Dupeyron C, Richardet JP (2001) Epidemiology of hospital acquired infections in cirrhotic patients: effect of carriage of methicillin-resistant *staphylococcus aureus* and influence of previous antibiotic therapy and norfloxacin prophylaxis. *Epidemiol Infect* 127, 443–450.
51 Mendenhall CL, Moritz TE, Roselle GA *et al.* and the VA cooperative study group (1995) Protein energy malnutrition in severe alcoholic hepatitis: diagnosis and response to treatment. *JPEN* 19, 258–265
52 Neff GW, O'Brien CB, Montalbano M *et al.* (2004) Beneficial effects of topical testosterone replacement in patients with end-stage liver disease. *Dig Dis Sci* 49, 1186–1189.
53 Ormarsdottir S, Mallmin H, Naessen T *et al.* (2004) An open randomized, controlled study of transdermal hormone replacement therapy on the rate of bone loss in primary cirrhosis. *J Intern Med* 256, 63–69.
54 Donaghy A, Ross R, Wicks C *et al.* (1997) Growth hormone therapy in patients with cirrhosis: a pilot study of efficacy and safety. *Gastroenterology* 133, 1617–1622.
55 Bucavalas JC, Horn JA, Chernausek SD (1997) Resistance to growth hormone in children with chronic liver disease. *Pediatr Transplant* 1, 73–79.
56 Wicks C, Somasundaram S, Bjarnason I *et al.* (1994) Comparison of enteral feeding and total parenteral nutrition after liver transplantation. *Lancet* 344, 937–940.
57 Hasse JM, Blue LS, Liepa GV *et al.* (1995) Early enteral nutrition support in patients undergoing liver transplantation. *JPEN* 19, 437–443.
58 Rayes N, Seehofer D, Hansen S *et al.* (2002) Early enteral supply of lactobacillus and fiber versus selective bowel decontamination: a controlled trial in liver transplant recipients. *Transplantation* 74, 123–127.
59 Richardson RA, Garden OJ, Davidson HI (2001) Chronic liver disease and transplantation – uncovering the role of the liver in ingestive behaviour. *Clin Nutr* 20, S141–S145.

23.3 Prescribing drugs in liver disease

Dominique Larrey and Georges-Philippe Pageaux

Introduction

The liver is the main site of drug biotransformation and excretion. Consequently, it is obvious that liver diseases may generate considerable consequences on the elimination of drugs and their therapeutic and toxicological effects [1–3]. The consequences mainly rely on the pharmacokinetic modifications, which themselves depend on many factors including: the route of administration (oral, intravenous/intramuscular, subcutaneous), the intrinsic characteristics of the drug, its therapeutic index, the treatment duration and the type of liver injury [1–3]. Numerous publications have focused on the pharmacokinetic effects of liver diseases. In contrast, the number of studies on the clinical consequences is much more limited.

This chapter aims to review the main characteristics of drug elimination and to describe the major clinical consequences with their repercussions on drug prescribing.

Background on the elimination of drugs

Drug global elimination (clearance) results from the relative contribution of various organs, the hepatic clearance (H Cl) playing the main role for the majority of drugs [1–3] (see Chapter 2.3.15). The hepatic clearance is determined by the liver blood flow (LBF) and the hepatic extraction rate (E). Hepatic extraction depends on LBF, the intrinsic hepatic clearance (int H Cl) corresponding to liver enzyme activities and the fraction of the drug bound to proteins (prot. bound) [1–4]. These parameters are related by the following equations:

$$\text{H CI} = \text{LBF} \times \text{extraction} \quad (1)$$

$$\text{H CI} = \text{LBF}\left[\frac{\text{int H CI} \times \text{prot. bound}}{\text{DSH} + \text{int H CI} \times \text{prot. bound}}\right] \quad (2)$$

Specific for a given drug, they determine the first-pass effect.

First-pass effect

After oral administration, the amount of drug reaching the systemic circulation depends on intestinal absorption and the degree of extraction of the drug in the mesenteric circulation by the liver. Extraction is variable and considered as high when representing more than 60% of the amount present in portal blood during the first pass (Table 1) [1–3].

Hepatic metabolism

It is determined by multiple enzymatic systems, mainly by cytochromes P-450 (CYP), aiming to transform hydrophobic compounds into more soluble metabolites that are easier to eliminate [5–9]. Extrahepatic enzymes also contribute to drug metabolism [10].

Protein binding

The main protein-binding drug is albumin. Less frequently, drugs may bind other proteins such as alpha-1-glycoproteins, as shown for macrolides and amprenavir [4,11,12].

Table 1 Drugs with a high first-pass effect (> 60%) [3].

Amitriptyline	Maprotiline
Bromocriptine	Methohexital
Clomethiazole	Metoprolol
Doxepine	Morphine
Diltiazem	Nifedipine
Ergotamine	Nitrendipine
Flumazenil	Pentazocin
Fluorouracil	Propafenone
Imipramine	Propoxyphene, dextropropoxyphene
Isosorbide dinitrate	Propranolol
Labetalol	Triamteren
Lidocaine	Verapamil
	Zidovudine

Influence of main liver diseases on pharmacokinetic parameters

Type of liver injuries

From pharmacokinetic and practical points of view, liver diseases can be classified into four principal categories: acute hepatitis, chronic liver diseases without significant fibrosis (including viral chronic hepatitis, non-alcoholic fatty liver diseases), cirrhosis and cholestasis.

Acute hepatitis

Several situations may be observed according to the presence or not of jaundice and signs of liver failure [13,14]: (i) minor acute hepatitis mainly characterized by abnormal liver enzymes (transaminases below 15 times the upper limit of normal values) with or without minor symptoms and without jaundice; (ii) clinical acute hepatitis characterized by high transaminases and jaundice but without any biological or clinical signs of liver failure; (iii) severe acute hepatitis characterized by jaundice, significant lowering of blood clotting tests (prothrombin time and/or factor V below 50% of normal), but without encephalopathy; (iv) fulminant or subfulminant hepatitis characterized by jaundice, biological liver failure and hepatic encephalopathy. This condition, associated with a high risk of fatality (on average > 80%) is a classical indication of emergency liver transplantation whenever possible.

Chronic liver diseases without significant fibrosis

This includes viral chronic hepatitis and non-alcoholic fatty liver diseases (see Chapters 9.1.2 and 13). Increase in liver enzymes remains limited with alanine aminotransferase (ALT) or aspartate aminotransferase (AST) below five times the upper limit of normal, without jaundice and liver failure. Prothrombin time or factor V are above 75% of normal. Serum albumin level remains normal. There is no major liver fibrosis and no sign of either portal hypertension or portosystemic shunts. Drug pharmacokinetics are not/poorly modified and liver enzyme activities are practically normal. Therefore, the majority of drugs can be administered at normal dosage. There is no contraindication to the administration of paracetamol or oral contraceptives.

Cirrhosis

The main modifications in pharmacokinetic and pharmacodynamic characteristics and clinical consequences are observed in cirrhosis, which may interfere practically with all the steps of drug disposition [1–4,15]. The intestinal permeability and the absorption of ingested compounds are higher [16]. Venous portosystemic shunts increase drug systemic concentration [17]. For drugs with very high hepatic extraction (> 90%; ergotamine), an extraction decrease of 10% can produce a 100% increase in drug plasma concentration. In contrast, for drugs with low hepatic extraction (< 20%; e.g. barbiturates), an extraction decrease of 10% results in a small variation in drug plasma concentration [1–4]. Drug transfer from portal blood to hepatocytes in the space of Disse may be disturbed [18]. Drug-metabolizing enzyme activities may be greatly decreased in cirrhotic patients [3,15], in particular CYP3A, CYP1A and CYP2C19 [3,16]. CYP2D6, 2C9, 2B and 2E1 are relatively less altered [16]. Conjugation reactions also appear to be less deteriorated in cirrhosis [19]. Hypoalbuminaemia is an additional factor that may result in the modification of the pharmacokinetics of drugs exhibiting high protein binding (> 80%) [3,4].

Cirrhosis severity and prognosis are still largely estimated using the Child–Pugh classification into three classes [20]: absence of significant liver failure (stage A with serum total bilirubin < 35 μmol/L, serum albumin > 35 g/L, prothrombin time or factor V > 55% of normal, no ascites, no encephalopathy), with low or moderate consequences; more severe forms (stage B and C) are associated with many more pharmacokinetic and pharmacodynamic consequences. A new model has been proposed recently to estimate the severity and prognosis of cirrhosis, named MELD (Model for Endstage Liver Disease) [21]. This model takes into account liver and also renal function. Its relevance for pharmacological parameters remains to be assessed.

Cholestasis

Cholestasis is generally defined by an alteration in bile formation and excretion [22]. This may result in an alteration of the normal transport of various endo- and xenobiotics including bilirubin, bile salts and drugs from the sinusoidal blood to the duodenum after passage through hepatocytes, bile canaliculi, then small, middle and large intrahepatic bile ducts and, finally, extrahepatic bile ducts. Therefore, the pharmacokinetic and pharmacodynamic characteristics of numerous compounds may be modified by several mechanisms [3]: (i) malabsorption of compounds requiring the presence of bile salts to pass the intestinal wall; (ii) alteration of bile excretion leading to the accumulation of various compounds in systemic blood: bilirubin, but also drugs, resulting in excessive concentrations; (iii) impaired access to the target of action (for instance the biliary tree).

Furthermore, recent investigations have shown that some chronic cholestatic diseases are related to genetic polymorphisms of biliary transporters including BSEP, MDR3 and MRP2 [23,24]. These transporting systems are also involved in the transport of several important drugs [24]. Albeit not demonstrated, it is conceivable that genetic defects in these receptors may affect drug metabolism and toxicity, not only by producing cholestasis related to chronic biliary lesions but also by the modification of drug biliary excretion.

Influence of cirrhosis on the susceptibility of other organs to drugs

Besides pharmacokinetic changes directly mediated by the liver, cirrhosis can also modify the susceptibility of other organs to some drugs. Some examples are given here.

Brain

There is much evidence showing that the brain of cirrhotic patients is more susceptible to some drugs. Practically all psychotropic agents exhibit exaggerated effects, particularly benzodiazepines [3,25].

Kidney

Renal function is frequently altered in cirrhotic patients. This may increase the nephrotoxicity of some drugs such as aminosides, non-steroidal anti-inflammatory drugs, converting enzyme inhibitors, as well as iodinated contrast products used for radiological purposes [3,25].

Digestive tract

Because of portal hypertension, the digestive mucosa is more delicate. Therefore, agents attacking the gastric mucosa are particularly deleterious in cirrhotic patients, for instance aspirin and non-steroidal anti-inflammatory drugs [3,25].

Clinical consequences

They depend on the pharmacokinetic modifications, the individual susceptibility to drugs, the type of drug, the therapeutic index (overall, the lower it is, the higher is the risk of clinical consequences) and the metabolic pattern of the drug (therapeutic effect and/or toxicity related to the native drug or to one of its metabolites) [3,25]. Finally, additional modulating factors are the individual susceptibility to the considered drug and co-administered drugs or exposure to other xenobiotics (tobacco smoking, alcohol intake, use of recreational compounds or some herbal medicines).

Pharmacokinetic modifications without clinical consequences

Antibiotics

Antibiotics of the beta-lactam family exhibit a very large therapeutic index so that they can be used at usual dosage in cirrhotic patients [3,25,26].

Anti-histamine H2 receptors

This group of drugs comprising ranitidine, cimetidine and nizaxide is not associated with particular consequences in patients with cirrhosis [25,27], despite some modification in elimination rate in severe forms [28]. However, the combination of cimetidine and chlordiazepoxide may result in deleterious effects in cirrhotic patients [29].

Proton pump inhibitors

This drug family, including omeprazole, lanzoprazole, pantoprazole and rabeprazole, exhibits a very large therapeutic index and is well tolerated in cirrhotic patients at normal dosage [25], despite decreased elimination [30,31].

Diacerein

This compound, used for arthrosis, does not exhibit particular pharmacokinetic and pharmacodynamic modifications in cirrhotic patients [32,33].

Propranolol

The case of propranolol is original. Cirrhosis is associated with an increase in its plasma concentration caused by both a first-pass effect and decreased metabolic capacity [34]. However, pharmacodynamic effects are also decreased because of decreased resistance of the sympathic system. Finally, propranolol effects are not significantly modified in cirrhotic patients on a standard dosage [25].

Encainide

This anti-arrhythmic compound requires oxidation by liver enzymes to become an active agent. Patients with cirrhosis exhibit lower systemic or oral clearance, resulting in marked oral bioavailability. However, no change occurs in the levels of the active metabolites. Therefore, dosage adjustment is not required [35,36].

Exaggerated therapeutic effects

(Table 2)

Vitamin K antagonists

Elimination of this drug family is decreased in large part because of a lowered metabolic transformation by liver enzymes [25]. Liver failure results in higher plasma levels and excessive hypocoagulation. Furthermore, cirrhotic patients are particularly exposed to oesophageal and gastric mucosal injuries because of portal hypertension. These conjugated effects make these drugs particularly critical in patients with cirrhosis with a high bleeding risk.

Ergotamine derivatives

The vasoconstrictive effects of these drugs are increased in cirrhotic patients because of lower metabolism and an increased first-pass effect. The risk of lower limb ischaemia is high especially if the patient exhibits additional risk factors, for instance regular smoking [3,25].

Biguanides [26]

In cirrhotic patients, metformin is associated with a higher risk of lactic acidosis, particularly when alcohol abuse is involved [25,37].

Hypoglycaemic sulphonylurea derivatives

There is a higher risk of hypoglycaemia in patients with liver failure [25]. Furthermore, deleterious haemodynamic effects may be associated, as shown for glibenclamide [38].

Table 2 Clinical consequences: exaggerated therapeutic effects.

Vitamin K antagonists	→	Bleeding by increased hypocoagulation
Ergotamine and derivatives	→	Ischaemia of limbs by increased vasoconstriction
Sulphonylurea derivatives	→	Hypoglycaemia
Biguanides	→	Lactic acidosis
Anxiolytics (especially benzodiazepines)		
Carbamates		
Neuroleptics	→	Exaggerated sedative effects
Hypnotics (in particular barbiturates)	→	Hepatic encephalopathy, coma
Antihistamines type H1		
Antivomiting agents acting on central nervous system (metoclopramide and metopimazine		
Angiotensin-converting enzyme inhibitors	→	Arterial hypotension
Captopril		Renal failure

Psychotropic agents

The risk of excessive sedative effects is related both to a higher plasma concentration of drugs and to a higher sensitivity for a similar dosage [3,25]. The main examples are indicated in Table 2. This is particularly marked for benzodiazepines. These deleterious effects may also be observed with the various compounds acting on the central nervous system, including antidepressants but also antivomiting compounds. For instance, a single tablet of metoclopramide or metopimazine can induce encephalopathy or even coma for several days in patients with acute liver failure.

Angiotensin-converting enzyme (ACE) inhibitors

Patients with hepatic failure are particular sensitive to this drug family with a high risk of arterial hypotension and renal failure [39]. This is well illustrated by captopril [40–42].

Decreased therapeutic effects

Azathioprine

This is a prodrug requiring metabolism by glutathione-*S*-transferases into 6-mercaptopurine to be active. Therefore, the immunosuppressive therapeutic activity of this compound may be decreased in severe liver disease [3].

Metoclopramide

The efficiency of a drug may also be modified by another drug without alteration in its elimination. For instance, metoclopramide administration can decrease the diuretic effect of spironolactone in patients with cirrhosis and ascites [43].

Increased non-hepatic toxicity

This may be caused by different mechanisms, including overdosage, increased susceptibility or modification in protein binding.

Caused by an overdosage (Table 3)

Isoniazid

This antituberculosis drug can be associated with a higher risk of peripheral neuropathy [25].

Niridazole

This anthelminthic drug is associated with a higher risk of neurological disorders [25].

Table 3 Clinical consequences: non-hepatic toxic effects related to an overdosage.

Isoniazid	Neurological toxicity
Niridazole	Neurological toxicity
Theophylline	Digestive disorders
	Tachycardia
	Convulsions
Antiretroviral agents	
Didanosine	Lactic acidosis
Indinavir–ritonavir	Cutaneous, digestive, renal disorders
Efavirenz	Neuropsychiatric disorders
Lopinavir	Hypertriglyceridaemia

Theophylline
This antiasthmatic drug exhibits a narrow therapeutic index. An increased plasma level is rapidly associated with adverse events including digestive disorders, tachycardia and convulsions [25,44].

Antiretroviral agents
In cirrhotic patients, the elimination of many antiretroviral agents is decreased because of lower metabolic capacity. This is illustrated by protease inhibitors (PI) because of a low CYP3A activity, in particular nelfinavir, lopinavir and amprenavir [45,46]. Albeit less documented, a lower elimination also has been reported for non-nucleosidic reverse transcriptase inhibitors (NNRTI), in particular nevirapine [45]. Nucleosidic reverse transcriptase inhibitors (NRTI) are not markedly metabolized by the liver [45]. However, in severe cirrhosis, their clearance appears to be altered, as shown for zidovudine, tenofovir and abacavir [45]. Higher plasma concentrations may result in toxic effects. There is a particular risk of lactic acidosis, especially with didanosine and, to a lesser extent, with stavudine and zalcitabine because of an inhibition of mitochondrial oxidation [45–47]. The risk is increased in hepatitics C virus (HCV) co-infected patients receiving ribavirin [48].

For PI, there is a particular risk of cutaneous, digestive and renal disorders with indinavir and ritonavir combination and more hyperlipidaemia with lopinavir [46]. For NNRTI, an example is the increased risk of neuropsychiatric disorders with efavirenz [45,48].

Caused by an increased susceptibility (Table 4)

Aspirin
Cirrhotic patients with portal hypertension are exposed to a higher risk of oesophagogastric bleeding because of altered clotting tests, thrombocytopathy and fragility of the upper digestive tract mucosa [50].

Non-steroidal anti-inflammatory drugs (NSAIDs)
All NSAIDs are well known to induce digestive tract lesions. The risk is increased in patients with portal hypertension. There is also an increased susceptibility of renal function [39,51].

Table 4 Clinical consequences: non-hepatic toxic effects related to an increased susceptibility.

Aspirin	Thrombopathies Bleeding
NSAIDs	Ulcers Gastroduodenal bleeding Renal failure
Aminosides	Renal failure
Diuretics	Renal failure Hyponatraemia

Aminosides
These antibiotics are not metabolized by the liver. However, they increase the risk of renal damage in cirrhotic patients [39,52].

Diuretics
Diuretics such as spironolactone and furosemide are frequently used in cirrhotic patients to treat ascites. Nevertheless, the therapeutic range is narrow with frequent renal failure and hyponatraemia in the most severe cases [39,53].

Sodium beta-lactamins
The sodium association may induce water retention in cirrhotic patients [25].

Caused by a competition in protein binding

Rifampicin
Rifampicin is strongly associated with albumin. There is competition in the binding to albumin between this drug and bilirubin. This may cause jaundice due to non-conjugated hyperbilirubinaemia [25]. This property has even been proposed to help in diagnosing Gilbert syndrome [54].

Cirrhosis and the risk of drug–drug interactions

Overall, liver enzyme activity, particularly that of CYP, is less sensitive to the effects of enzyme inducers or inhibitors. For instance, the inducing effects of barbiturates, rifampicin and macrolide antibiotics are decreased as well as the inhibiting effects of cimetidine in cirrhotic patients [5,29].

Extrahepatic effects of cholestasis

Consequences occur mainly during chronic cholestasis and are related to intestinal malabsorption or to modifications in biliary excretion [24,25].

Intestinal malabsorption

Lipophilic vitamins [26]
The absorption of vitamins A, D, E and K may be decreased especially in patients with chronic jaundice, which may lead to clinical consequences. Supplementation should be considered in such a condition.

Ciclosporin given orally
The absorption of this drug taken orally can be decreased leading to a lower therapeutic effect [3,25].

Exaggerated toxicity from an increased plasma concentration

Ciclosporin given intravenously
When this drug is delivered by the intravenous route, its biliary excretion may be decreased leading to exaggerated plasma

Table 5 Clinical consequences: risk of hepatotoxicity in chronic liver diseases.

Chronic alcoholic liver diseases
Paracetamol: acute hepatocellular liver injury
Methotrexate: steatohepatitis and fibrosis
Antituberculosis agents: acute hepatocellular liver injury
Non-alcoholic fatty liver diseases
Methotrexate: increased steatohepatitis and fibrosis
Antiretroviral agents (NRTI): increased steatohepatitis?
Statins: no particular risk
Rosiglitazone: no particular risk and possible advantage
Chronic hepatitis related to hepatitis viruses B and C
Antiretroviral agents: various types of acute liver injury
Antituberculosis agents: acute hepatocellular liver injury
NSAIDs: acute hepatitis?
Chronic cholestasis
Estrogens: increased risk of cholestasis in primary biliary cirrhosis
Genetic chronic cholangitis (mutation in MDR3, MRP2): higher risk of cholestasis with estrogens? higher toxicity of glibenclamide?

NRTI, nucleosidic reverse transcriptase inhibitors.

concentrations [3,25]. This can result in various side-effects including diabetes, renal failure, arterial hypertension and gingival disorders.

Liver diseases and risk of hepatotoxicity

(Table 5)

Drug hepatotoxicity results from various mechanisms [55,56]. It is modulated by various environmental, genetic and some disease states [57].

The role of a pre-existing liver disease in increasing the risk of hepatotoxicity is relatively poorly documented, probably in part because it is particularly difficult to investigate. Nevertheless, several situations may be considered.

Chronic alcoholic liver diseases

Small series and case reports strongly suggest that chronic alcoholic liver diseases increase the risk of paracetamol hepatotoxicity. Liver damage can occur with dosages between 3 and 10 g [56–58], which is lower than the usual toxic dose of 10 g recorded in patients without alcohol abuse and normal nutrition. The increased risk appears to be related to several factors: the induction of CYP2E1 by chronic alcoholism, the main enzyme transforming paracetamol into toxic metabolites, the lower capacity to detoxify reactive metabolites related to glutathione depletion secondary to undernutrition and alcohol consumption, and a higher severity of injury in a pre-existing damaged liver [56].

Some reports suggest an increased risk of liver injury with antituberculosis agents and methotrexate [57,59].

Non-alcoholic fatty liver diseases

The risk of liver lesions seems to be increased for methotrexate [57,60].

In contrast, the risk of hepatotoxicity does not appear to increase with cholesterol-lowering agents of the statin family [61]. For rosiglitazone, a new antidiabetes agent from the thiazolidinedione family, hepatotoxicity risk is also not increased. Furthermore, recent data support the view that this drug might improve steatosis by ameliorating diabetes and reducing insulin resistance [62].

Chronic hepatitis related to hepatitis viruses B and C

There is an increased hepatotoxicity risk related to antiretroviral agents, in particular didanosine [45,46,63], and for antituberculosis compounds [57,59,64,65].

An increased hepatotoxicity risk might also exist for NSAIDs, as suggested by a small case series, in particular with ibuprofen [66]. This point deserves confirmation in further studies.

Chronic cholestasis

The risk of cholestasis with estrogens appears to be increased in patients with primary biliary cirrhosis [24,56].

Practical recommendations in drug prescribing

Various situations should be addressed according to the type of liver injury and the drug considered.

Acute hepatitis

In minor acute hepatitis, there are no pharmacokinetic and pharmacodynamic consequences. Practically all treatments may be continued. Nevertheless, one should take into account that potential vomiting associated with hepatitis may produce an alteration in drug absorption. This may induce modifications in drug dosage and, possibly, a transient discontinuation.

In acute hepatitis associated with jaundice but without liver failure, one should be cautious with drugs eliminated by the biliary route. Toxicity or inefficacy may occur (for instance ciclosporin).

In severe acute hepatitis, one should be very careful when prescribing drugs, especially those with neurosedative and antivomiting agents.

In fulminant or subfulminant hepatitis, drug prescribing should be limited to compounds required for survival while awaiting liver transplantation.

Alcoholic liver diseases

Potentially hepatotoxic drugs, through the activation of CYP2E1 and the depletion of glutathione, should be avoided, namely paracetamol, antituberculosis compounds as well as anaesthetic drugs of the halothane family. Methotrexate should also be

avoided because of an increased risk of steatohepatitis and fibrosis.

Viral chronic hepatitis related to HCV and HBV

There is an increased risk of liver damage with antiretroviral agents in patients co-infected with human immunodeficiency virus (HIV) and hepatotopic viruses. One should be careful in the management of drug prescribing. Blood drug monitoring may be useful.

For antituberculosis compounds, the follow-up of liver enzymes should be particularly well designed to detect the onset of hepatotoxicity.

For NSAIDs, the risk of toxicity remains to be ascertained by more data. There is no present restriction. Nevertheless, careful monitoring is recommended.

Non-alcoholic fatty liver diseases (NAFLDs)

Some drugs that are inclined to cause NAFLDs in themselves should be avoided as far as possible, in particular methotrexate, corticosteroids, amiodarone, tetracycline and its derivatives.

Cirrhosis

Generally, for drugs with a high first-pass effect, as shown in Table 1, there is a risk of overdosage when the drug is administered by the oral route. It is wise to decrease the initial dosage and to introduce drug concentration monitoring as far as possible.

For drugs mainly metabolized by the liver, as shown in Table 6, drugs should be given with caution. The amount should be diminished whatever the route of administration. For benzodiazepines, it is safer to use compounds metabolized by conjugation (oxazepam, bromazepam) instead of those metabolized by CYP (diazepam).

Table 6 Drug prescribing in cirrhosis.

Drugs to use with caution: decrease dosage whatever the administration route For benzodiazepines, conjugated derivatives are safer (oxazepam, lorazepam)	
NSAIDs	ACE inhibitors
Tricyclic antidepressants	Isoniazid
Vitamin K antagonists	Lincomycin
Antiretroviral agents	Metronidazole
Barbiturates	Pefloxacin
Benzodiazepines	Pyrazinamide
Carbamates	Rifampicin
Clindamycin	Sulphonylurea derivatives
Cyclines	Theophylline
Flecainide	

ACE, angiotensin-converting enzyme; NSAIDs, non-steroidal anti-inflammatory drugs.

Table 7 Main drugs contraindicated in severe cirrhosis (Child–Pugh stage B and C) and acute liver failure.

All neurosedative and psychotropic agents including antivomiting compounds	Anti-vitamin K
Aminosides	Aspirin
NSAIDs	Ergotamine
Antiretroviral agents	ACE inhibitors
	Tetracycline and derivatives

ACE, angiotensin-converting enzymes; NSAIDs, non-steroidal anti-inflammatory drugs.

Some drugs should be contraindicated in cirrhotic patients because of a high risk of side-effects, particularly in patients with stage B and C of the Child–Pugh classification (Table 7).

Prescribing antiretroviral agents in patients with liver diseases (Table 8)

HIV–HCV or HIV–HBV co-infections increase the hepatotoxicity risk of drugs given for HIV [45,46,63]. This risk is increased by two- to 10-fold in HIV–HCV co-infection [67] and by two- to eightfold in HIV–HBV co-infection [68]. Liver injuries are frequently more severe and potentially fatal. Hepatitis C may increase antiretroviral hepatotoxicity through an alteration in their metabolism or decreased mitochondrial oxidation [69].

Furthermore, liver injuries related to HCV and HBV can be related to the immune system. Indeed, the rapid restoration of immune reactivity in patients with HIV treated with antiretroviral agents promotes the rupture of immunotolerance towards HCV and HBV. This can result in reactivation against the liver. Consequently, an elevation in transaminases can be observed. HBV reactivation may be more frequent than HCV reactivation after the onset of antiretroviral therapy. Antiretroviral treatment should be not be discontinued when liver abnormalities remain asymptomatic and biologically limited [45,46,63].

Table 8 Recommendations for the administration of antiretroviral drugs in cirrhotic patients.

Assessment of fibrosis extent in patients with HCV or HBV co-infection or alcohol intoxication
Assessment of Child–Pugh score
Avoid as much as possible the most hepatotoxic antiretroviral agents:
NRTI: stavudine, stavudine–didanosine combination
Nevirapine
PI: full-dose ritonavir
Plasma concentration monitoring of PI and NNRTI at the onset of treatment and adaptation if required, especially in patients with Child–Pugh B and C stages
Regular follow-up of liver enzymes
Avoid stopping an efficient treatment for HBV suddenly because of reactivation risk

NRTI, nucleosidic reverse transcriptase inhibitor; PI, protease inhibitor.

Table 9 Drug prescribing in chronic cholestasis.

Because of intestinal malabsorption
Ciclosporin by oral route: increase dosage
Deficiency in liposoluble vitamins A, D, E and K: administration by parenteral route
Increased toxicity because of overdosage
Ciclosporin by intravenous route: reduce dosage and follow plasma concentration
Estrogens: contraindicated
Phenothiazines: contraindicated

In cirrhotic patients, the risk of complications is particularly high in cases of viral co-infection or lipodystrophy. This is associated with alteration in PI and NNRTI, highly metabolized by the liver [70,71]. Antiretroviral blood monitoring is required to avoid overdosage [46,47,60]. Several recommendations are listed in Table 8 [46]. Plasma concentrations of some drugs are markedly increased in cirrhotic patients: nelfinavir (× 2.5), amprenavir (× 2.5–4.5) or nevirapine (× 2). Liver failure contraindicates the administration of efevirenz, ritonavir, lopinavir, atazanavir and abacavir. Blood level monitoring is recommended for nevirapine, nelfinavir, amprenavir and indinavir [45,46,59].

Cholestasis

Drug prescribing recommendations are presented in Table 9.

Conclusions

Various clinical consequences may be observed with drug prescription in patients with liver disease. This is particularly obvious in patients with acute liver failure or cirrhosis. In such patients, drug prescribing requires various parameters to be taken into account, namely the first-pass effect of the drug, its potential liver metabolism, the therapeutic index and its potential toxicity. The benefit/risk ratio should be considered as well as the possibility of using an alternative treatment. Our knowledge of the risk of clinical side-effects with drug administration in liver disease remains very limited. Further studies are required to address this important question.

References

1 Larrey D, Branch RA (1983) Clearance by the liver: current concepts in understanding the hepatic disposition of drugs. *Semin Liver Dis* 3, 285–297.

2 Morgan DJ, McLean AJ (1995) Clinical pharmacokinetic and pharmacodynamic considerations in patients with liver disease. *Clin Pharmacokinet* 29, 370–391.

3 Bircher J, Sommer W (1999) Drug treatment in patients with liver disease. In: McIntyre N, Benhamou JP, Bircher J *et al.* (eds) *Oxford Textbook of Hepatology*. Oxford: Oxford University Press, pp. 1983–1994.

4 Blaschke TF (1977) Protein binding and kinetics of drugs in liver diseases. *Clin Pharmacokinet* 2, 32–44.

5 Ioannides C (ed.) (1996) *Cytochromes P450. Metabolic and Toxicological Aspects*. Boca Raton, FL: CRC Press.

6 George J, Murray M, Byth K *et al.* (1995) Differential alterations of cytochrome P450 proteins in livers from patients with severe chronic liver disease. *Hepatology* 21, 120–128.

7 Larrey D, Pageaux GP (1997) Genetic predisposition to drug-induced hepatotoxicity. *J Hepatol* 26(Suppl.2), 12–21.

8 Guillemette C (2003) Pharmacogenomics of human UDP-glucuronosyltransferase enzymes. *Pharmacogenomics J* 3, 136–158.

9 Blanchard RL, Freimuth RR, Buck J *et al.* (2004) A proposed nomenclature system for the cytosolic sulfotransferase (SULT) superfamily. *Pharmacogenetics* 14, 199–211.

10 Kapitulnik J, Strobel HW (1999) Extrahepatic drug metabolizing enzymes. *J Biochem Mol Toxicol* 13, 227–230.

11 Dubuske LM (2005) The role of P-glycoprotein and organic anion-transporting polypeptides in drug interactions. *Drug Saf* 28, 789–801.

12 Veronese L, Rautaureau J, Sadler BM *et al.* (2000) Single-dose pharmacokinetics of amprenavir, a human immunodeficiency virus type 1 protease inhibitor, in subjects with normal or impaired hepatic function. *Antimicrob Agents Chemother* 44, 821–826.

13 Bernuau J, Benhamou JP (1999) Fulminant and subfulminant liver failure. In: Bircher J, Benhamou JR, McIntyre N *et al.* (eds) *Oxford Textbook of Clinical Hepatology*, 2nd edn, Vol. 2. Oxford: Oxford University Press, pp. 1341–1372.

14 Larrey D, Pageaux GP (2005) Drug-induced liver failure. *Eur J Hepatol Gastroenterol* 17, 141–143.

15 Villeneuve JP, Pichette V (2004) Cytochrome P450 and liver diseases. *Curr Drug Metab* 5, 273–282.

16 Zuckerman MJ, Menzies IS, Ho H *et al.* (2004) Assessment of intestinal permeability and absorption in cirrhotic patients with ascites using combined sugar probes. *Dig Dis Sci* 49, 621–626.

17 Pomier-Layrargues G, Huet PM, Villeneuve JP *et al.* (1986) Effect of portacaval shunt on drug disposition in patients with cirrhosis. *Gastroenterology* 91, 163–167.

18 Le Couteur DG, Fraser R, Hilmer S *et al.* (2005) The hepatic sinusoid in aging and cirrhosis: effects on hepatic substrate disposition and drug clearance. *Clin Pharmacokinet* 44, 187–200.

19 Hasselstrom J, Eriksson S, Persson A *et al.* (1990) The metabolism and bioavailability of morphine in patients with severe liver cirrhosis. *Br J Clin Pharmacol* 29, 289–297.

20 Pugh RN, Murray-Lyon IM, Dawson JL *et al.* (1973) Transection of the oesophagus for bleeding oesophageal varices. *Br J Surg* 60, 646–649.

21 Durand F, Valla D (2005) Assessment of the prognosis of cirrhosis: Child-Pugh versus MELD. *J Hepatol* 42, S100–S107.

22 Trauner M, Boyer JL (2004) Cholestatic syndromes. *Curr Opin Gastroenterol* 20, 220–230.

23 Trauner M, Meier PJ, Boyer JL (1998) Molecular pathogenesis of cholestasis. *N Engl J Med* 339, 1217–1227.

24 Jansen PLM, Müller M (2003) The role of membrane transport in drug-induced hepatotoxicity and cholestasis. In: Kaplowitz N, DeLeve LD (eds) *Drug-induced Liver Disease*. New York: Marcel Dekker, pp. 97–124.

25 Larrey D (1995) Prescription des médicaments dans les maladies du foie. *Hepatogastroenterology* 2, 515–525.

26 Silvain C, Breux JP, Becq-Giraudon B *et al.* (1989) Antibiotics and cirrhosis. *Gastroenterol Clin Biol* 13, 71–79.

27 Kosaka Y, Tameda Y, Okita K *et al.* (1987) Effects of ranitidine on plasma clearance of indocyanine green in patients with liver cirrhosis. *Gastroenterol Jpn* 22, 737–742.

28 Gonzalez-Martin G, Paulos C, Veloso B *et al.* (1987) Ranitidine disposition in severe hepatic cirrhosis. *Int J Clin Pharmacol Ther Toxicol* 25, 139–142.

29 Nelson DC, Avant GR, Speeg KV Jr *et al.* (1985) The effect of cimetidine on hepatic drug elimination in cirrhosis. *Hepatology* 5, 305–309.

30 Kumar R, Chawla YK, Garg SK *et al.* (2003) Pharmacokinetics of omeprazole in patients with liver cirrhosis and extrahepatic portal venous obstruction. *Methods Find Exp Clin Pharmacol* 25, 625–630.

31 Hoyumpa AM, Trevino-Alanis H, Grimes I *et al.* (1999) Rabeprazole: pharmacokinetics in patients with stable, compensated cirrhosis. *Clin Ther* 21, 691–701.

32 Magnard O, Louchahi K, Tod M *et al.* (1993) Pharmacokinetics of diacerein in patients with liver cirrhosis. *Biopharm Drug Dispos* 14, 401–408.

33 Nicolas P, Tod M, Padoin C *et al.* (1998) Clinical pharmacokinetics of diacerein. *Clin Pharmacokinet* 35, 347–359.

34 Gariepy L, Fenyves D, Kassissia I *et al.* (1993) Clearance by the liver in cirrhosis. II. Characterization of propranolol uptake with the multiple-indicator dilution technique. *Hepatology* 18, 823–831.

35 Bergstrand RH, Wang T, Roden DM *et al.* (1986) Encainide disposition in patients with chronic cirrhosis. *Clin Pharmacol Ther* 40, 148–154.

36 Wensing G, Monig H, Ohnhaus EE *et al.* (1991) Pharmacokinetics of encainide in patients with cirrhosis. *Cardiovasc Drugs Ther* 5, 733–739.

37 Houwerzijl EJ, Snoek WJ, van Haastert M *et al.* (2000) Severe lactic acidosis due to metformin therapy in a patient with contra-indications for metformi. *Ned Tijdschr Geneeskd* 144, 1923–1926 (in Dutch).

38 Moreau R, Chagneau C, Heller J *et al.* (2001) Hemodynamic, metabolic and hormonal responses to oral glibenclamide in patients with cirrhosis receiving glucose. *Scand J Gastroenterol* 36, 303–308.

39 Westphal JF, Brogard JM (1997) Drug administration in chronic liver disease. *Drug Saf* 17, 47–73.

40 Daskalopoulos G, Pinzani M, Murray N *et al.* (1987) Effects of captopril on renal function in patients with cirrhosis and ascites. *J Hepatol* 4, 330–336.

41 Gentilini P, Romanelli RG, La Villa G *et al.* (1993) Effects of low-dose captopril on renal hemodynamics and function in patients with cirrhosis of the liver. *Gastroenterology* 104, 588–594.

42 Pariente EA, Bataille C, Bercoff E *et al.* (1985) Acute effects of captopril on systemic and renal hemodynamics and on renal function in cirrhotic patients with ascites. *Gastroenterology* 88, 1255–1259.

43 D'Arienzo A, Ambrogio G, Di Siervi P *et al.* (1985) A randomized comparison of metoclopramide and domperidone on plasma aldosterone concentration and on spironolactone-induced diuresis in ascitic cirrhotic patients. *Hepatology* 5, 854–857.

44 Piafsky KM, Sitar DS, Rangno RE *et al.* (1977) Theophylline disposition in patients with hepatic cirrhosis. *N Engl J Med* 296, 1495–1497.

45 Salmon-Ceron D (2004) Utilisation des antiretroviraux chez le patient cirrhotique infecté par le VIH. *Med Mal Inf* 34, 14–19.

46 Nunez M, Soriano V (2005) Hepatotoxicity of antiretrovirals. Incidence, mechanisms and management. *Drug Saf* 26, 53–66.

47 Mauss S, Valenti B, Torriani FJ *et al.* (2004) Risk factors for hepatic decompensation in patients with HIV/HCV coinfection and liver cirrhosis during treatment with interferon-based therapy. *AIDS* 18, 21–25.

48 Salmon-Ceron D, Chauvelot-Moachon L, Abad S *et al.* (2001) Mitochondrial toxic effects and ribavirin. *Lancet* 357, 1803–1804.

49 Becker S (2004) Liver toxicity in epidemiological cohorts. *Clin Infect Dis* 38, S49–S55.

50 Planas R, Arroyo V, Rimola A *et al.* (1983) Acetylsalicylic acid suppresses the renal hemodynamic effect and reduces the diuretic action of furosemide in cirrhosis with ascites. *Gastroenterology* 84, 247–252.

51 Laffi G, Daskalopoulos G, Kronborg I *et al.* (1986) Effects of sulindac and ibuprofen in patients with cirrhosis and ascites. An explanation for the renal-sparing effect of sulindac. *Gastroenterology* 90, 182–187.

52 Cabrera J, Arroyo V, Ballesta AM *et al.* (1982) Aminoglycoside nephrotoxicity in cirrhosis. Value of urinary beta 2-microglobulin to discriminate functional renal failure from acute tubular damage. *Gastroenterology* 82, 97–105.

53 Perez-Ayuso RM, Arroyo V, Planas R *et al.* (1983) Randomized comparative study of efficacy of furosemide versus spironolactone in nonazotemic cirrhosis with ascites. Relationship between the diuretic response and the activity of the renin-aldosterone system. *Gastroenterology* 84, 961–968.

54 Erdil A, Kadayifci A, Ates Y *et al.* (2001) Rifampicin test in the diagnosis of Gilbert's syndrome. *Int J Clin Pract* 55, 81–83.

55 Larrey D (1997) Mechanisms of drug-induced hepatotoxicity. In: Galmiche JP, Gournay J (eds) *Recent Advances in the Pathophysiology of Gastrointestinal and Liver Diseases*. Paris: John Libbey Eurotext, pp. 233–241.

56 Pessayre D, Larrey D, Biour M (1999) Drug-induced liver injury. In: McIntyre N, Benhamou JP, Bircher J *et al.* (eds) *Oxford Textbook of Hepatology*. Oxford: Oxford University Press, pp. 1261–1341.

57 Larrey D (2002) Epidemiology and individual susceptibility to adverse drug reactions affecting the liver. *Semin Liver Dis* 22, 145–155.

58 Prescott LF (2000) Paracetamol, alcohol and the liver. *Br J Clin Pharmacol* 49, 291–301.

59 Brown SJ, Desmond PV (2002) Hepatotoxicity of antimicrobial agents. *Semin Liver Dis* 22, 157–167.

60 Farrel G (2002) Drugs and steatohepatitis. *Semin Liver Dis* 22, 185–194.

61 Russo MW, Watkins PB (2004) Are patients with elevated liver tests at increased risk of drug-induced liver injury? *Gastroenterology* 126, 1477–1480.

62 Yki-Järvinen H (2004) Thiazolidinediones. *N Engl J Med* 351, 1106–1118.

63 Kontorinis N, Dietrich D (2003) Toxicity of non-nucleoside analogue reverse transcriptase inhibitors. *Semin Liver Dis* 23, 173–181.

64 Ungo JR, Jones D, Ashkin D *et al.* (1998) Antituberculosis drug-induced hepatotoxicity. The role of hepatitis C virus and the human immunodeficiency virus. *Am J Resp Crit Care Med* 157, 1871–1875.

65 Wong WM, Wu PC, Yuen MF *et al.* (2000) Antituberculosis drug-related liver dysfunction in chronic hepatitis B infection. *Hepatology* 31, 201–206.

66 Riley TR III, Smith JP (1998) Ibuprofen-induced hepatotoxicity in patients with chronic hepatitis C: a case series. *Am J Gastroenterol* 93, 1563–1565.

67 Bonacini M (2004) Liver injury during highly active antiretroviral therapy: the effect of hepatitis C coinfection. *Clin Infect Dis* 2004, S104–S108.

68 Salmon-Ceron D, Lewden C, Morlat P *et al.* (2005) Liver disease as a major cause of death among HIV infected patients: role of hepatitis C and B viruses and alcohol. *J Hepatol* 42, 799–805.

69 Kramer JR, Giordano TP, Souchek J *et al.* (2005) Hepatitis C coinfection increases the risk of fulminant hepatic failure in patients with HIV in the HAART era. *J Hepatol* 42, 309–314.

70 Benhamou Y, Bochet M, Di Martino V *et al.* (1999) Liver fibrosis progression in human immunodeficiency virus and hepatitis C virus coinfected patients. The Multivirc Group. *Hepatology* 30, 1054–1058.

71 Aranzabal L, Casado JL, Moya J *et al.* (2005) Influence of liver fibrosis on highly active antiretroviral therapy-associated hepatotoxicity in patients with HIV and hepatitis C virus coinfection. *Clin Infect Dis* 40, 588–593.

23.4 Management of pretransplant patients

François Durand

Selection criteria and evaluation

Selection criteria and indications for transplantation

In the current context of organ shortage, the selection process of candidates is based on individual concerns (the expected benefit from transplantation), as well as collective concerns (the benefit other candidates could derive from transplantation). It is generally agreed that only candidates who are expected to have a 1-year probability of survival exceeding 50% after transplantation should be considered. On the other hand, only patients who derive a substantial benefit from transplantation compared with their prognosis with conventional care are selected. Experience strongly suggests that transplantation would be futile in patients with a Child–Pugh score below 7 or a MELD score below 10–11 [1]. Most patients considered for transplantation have had at least one decompensation episode and belong to Child's class B or C [2]. However, Child and MELD scores are poorly predictive of post-transplantation survival. Therefore, there is no clear upper limit in these scores that would contraindicate transplantation.

Liver transplantation probably represents the best therapeutic option in the long term for patients with small hepatocellular carcinoma (HCC), whatever the severity of the underlying liver disease (see Chapter 18.2.1). The Milan criteria [3] (a single nodule less than 5 cm in diameter, or two or three nodules each less than 3 cm, in the absence of macroscopic vascular invasion) are widely used for selection. The risk of tumour recurrence increases sharply over these limits. In cirrhotic patients with very small nodules, it may be impossible to differentiate small HCC from benign regenerative nodules at imaging. Therefore, it is strongly recommended to obtain the histological confirmation of malignancy for nodules of less than 2 cm before deciding on transplantation in patients with otherwise compensated cirrhosis [4].

Evaluation and contraindications

A first step during evaluation is to ensure that there is no alternative to transplantation. In alcoholic patients, liver biopsy should be performed to rule out alcoholic hepatitis, which might improve with prolonged abstinence. Similarly, in patients with hepatitis B virus (HBV) infection and persistent viral replication, significant improvement can be expected with antiviral therapy (see Chapter 9.1.2).

A second step consists of checking extrahepatic conditions increasing the risk of surgery. Besides poor compliance, severe extrahepatic diseases may compromise the results of transplantation. Severe chronic obstructive pulmonary disease, advanced cardiovascular diseases (including degenerative complications of diabetes) and severe renal dysfunction (although, in selected patients, combined liver and kidney transplantation can be an option) represent possible contraindications. Extrahepatic malignancies with a potential for relapse also represent contraindications. Routine screening for colon, breast and oropharyngeal cancer is needed in patients at specific risk. In candidates with primary sclerosing cholangitis, screening for cholangiocarcinoma is especially challenging (see Chapters 11.3 and 19.9). Even small cholangiocarcinoma carries a high risk of post-transplantation recurrence. Foci of malignant transformation are almost impossible to identify with conventional imaging. The diagnostic sensitivity of cholangiography combined with brush cytology is only about 30% [5]. The accuracy of positron emission tomography in this setting has not been clearly documented yet. Nonetheless, incidental cholangiocarcinoma is found in less than 10% of patients transplanted for primary sclerosing cholangitis.

Most groups agree that, for patients over 65 years old, transplantation might only be performed in highly selected cases. A body mass index over 35 is usually regarded as a contraindication.

Liver transplantation in human immunodeficiency virus (HIV)-infected patients has been revisited in recent years [6]. There is no general agreement on the selection criteria. In most centres, however, only patients with undetectable HIV load, CD4+ cell count over 150–200/μL and no history of opportunistic infections or malignancy are considered. However, a past history of opportunistic infection having occurred prior to the initiation of antiretroviral therapy may not represent a definitive contraindication.

General measures for managing patients on the waiting list and bridging them to transplantation

Ascites and related complications

Spontaneous bacterial peritonitis

Spontaneous bacterial peritonitis (SBP) is a frequent cause of deterioration in candidates for transplantation [7]. Diagnosis and treatment of SBP are discussed in Chapter 7.5. In patients who had SBP and received antibiotics, ascitic polymorphonuclear count must be below 250/μL and culture must be negative before considering that patients return to eligibility for transplantation. It is strongly recommended that patients at high risk for SBP because of previous SBP episodes or ascitic protein concentration below 10 g/L receive antibiotic prophylaxis until transplantation. To this end, oral quinolones are most frequently used [7].

A controlled study has shown that albumin infusion significantly improves survival in patients with SBP [8]. Although further studies on this issue have not been published, the adjunction of albumin to antibiotics seems reasonable in the pretransplantation setting.

Refractory ascites and umbilical hernia

Repeated paracentesis is the preferred therapeutic option in candidates for transplantation (see Chapter 7.5). Large-volume paracentesis must be followed by the infusion of plasma expanders in order to prevent post-paracentesis activation of the renin–angiotensin system [7]. Albumin, although more expensive than synthetic plasma expanders, appears to be superior to other agents [7]. Hydroxyethylstarch should be avoided because of a possible deterioration in renal function resulting from osmotic nephrosis-like injury.

Independent of MELD score, hyponatraemia appears to predict waiting list mortality [9]. However, there is no evidence that the correction of hyponatraemia improves survival. Diuretics should be stopped when hyponatraemia or an increase in serum creatinine develops. Fluid restriction should be avoided. Indeed, chronic hyponatraemia is well tolerated, except for extreme values (below 110 mmol/L), whereas fluid restriction may precipitate renal dysfunction. Attention should focus on hyperkalaemia. Owing to the high potassium concentration in preservation solutions, patients with an elevated baseline potassium level are at risk of developing severe hyperkalaemia at the time of reperfusion.

Transjugular intrahepatic portosystemic shunt (TIPS) is an effective option for controlling ascites, but its impact on survival is still unclear [10]. In most patients awaiting transplantation, liver function is too poor to make them acceptable candidates for TIPS. Although TIPS relieves portal hypertension, it neither facilitates transplant procedure nor reduces blood loss [11]. TIPS misplacement may cause major technical difficulties, to the point of making split liver transplantation or living donor transplantation definitely contraindicated [12].

Peritoneovenous shunting is another alternative that is limited by the possible occurrence of infections, thrombosis of the jugular vein and peritoneal adhesions. Extensive adhesions (cocooning) may even compromise transplantation procedure. Despite these limitations, peritoneovenous shunting has recently been advocated as a safe and efficient means for improving pretransplantation status (renal function in particular) in patients with refractory ascites [13].

Overall, medical treatment with repeated paracentesis and plasma expander infusion probably represents the safest option in patients awaiting transplantation.

Umbilical hernia, a frequent complication of refractory ascites, can rupture or provoke intestinal strangulation, two complications that carry a high mortality rate [14]. Surgical repair when ascites is not controlled is associated with high morbidity and mortality rates. Patients should be educated about ulcerations as a risk factor for rupture. Local care with gauze pads and pressure bandage should be applied. In addition, repeated therapeutic paracentesis should be performed in order to avoid tense ascites.

Hepatic hydrothorax

Symptomatic hepatic hydrothorax is one of the most challenging conditions in patients awaiting transplantation. Repeated thoracenteses are poorly tolerated and may rapidly result in severe complications including pneumothorax, haemothorax and empyema [15]. Chest drains must be avoided as the risk of bleeding and empyema is high. In addition, drains are often difficult to remove once inserted because of the rapid reconstitution of the effusion. Peritoneovenous shunting appears to be inefficient. TIPS was reported to control pleural effusion in 45–70% of patients [16]. However, as hepatic hydrothorax is a complication of advanced liver disease, it can be anticipated that most of these patients would have a poor tolerance to TIPS. Chemical pleurodesis under thoracoscopy can be successful despite significant morbidity and mortality [17]. Therefore, symptomatic hepatic hydrothorax may prompt transplantation as rapidly as possible. If a prolonged waiting time is expected, TIPS or pleurodesis can be considered.

Portal hypertension and variceal bleeding

Improvements over the last decades have resulted in a significant reduction in bleeding-related mortality in cirrhotic patients (see Chapter 7.3) [18]. However, variceal bleeding remains a possible source of deterioration or even death in patients awaiting transplantation. Current recommendations for primary and secondary prophylaxis and treatment of active bleeding can, and should, be applied in this setting [19]. TIPS can be considered for refractory bleeding or bleeding from gastric varices. However, it is important to keep in mind that misplacement of TIPS in the inferior vena cava or portal vein trunk should be avoided. Again, misplacement could definitively contraindicate split liver transplantation or living donor transplantation.

Table 1 Measures for preventing first variceal bleeding or recurrence in the pretransplantation setting.

Technique	Justified for primary prevention	Justified for prevention of recurrence	Limitations in the pretransplantation setting
Beta-blockers	Yes	Yes[a]	None[b]
Elastic band ligation	Yes	Yes[c]	None
TIPS	No	Yes	18–78% rate of obstruction or thrombosis [49] Further deterioration of liver function Risk of encephalopathy Technical difficulties in case of misplacement Contraindication for split transplantation or living donor transplantation in case of misplacement

[a]Either alone in patients who had a first episode of bleeding while they did not receive beta-blockers previously or in combination with endoscopic treatment in the remaining patients.
[b]Except in patients with portopulmonary hypertension.
[c]No advantage over beta-blockers in terms of survival.

The different options for primary and secondary prophylaxis of variceal bleeding in transplantation candidates are summarized in Table 1.

Hepatorenal syndrome

The prognosis of hepatorenal syndrome is especially poor with a 2-week mortality rate as high as 80% (see Chapter 7.6). On theoretical grounds, liver transplantation represents the only effective therapy in the long term. However, such a short life expectancy is hardly compatible with the prolonged interval needed for obtaining a deceased donor. Furthermore, patients with severe pretransplant renal dysfunction are at increased risk of early postoperative mortality.

Terlipressin, either alone or in combination with plasma volume expansion, improves or reverses renal insufficiency in the majority of patients with hepatorenal syndrome [20]. However, the effectiveness of terlipressin is generally transient. Therefore, the usefulness of terlipressin for bridging hepatorenal syndrome patients to transplantation is limited. Noradrenaline (norepinephrine), another vasoconstrictive agent, is an alternative to terlipressin that needs continuous infusion via a central venous line under careful haemodynamic monitoring [21]. TIPS may also improve renal function in selected patients with hepatorenal syndrome and relatively preserved hepatic function [22]. Unfortunately, most patients with hepatorenal syndrome are unsuitable candidates for TIPS because of endstage liver disease. A randomized study conducted in a small population with the molecular adsorbent recirculating system (MARS) has suggested that this device may improve the prognosis of hepatorenal syndrome [23]. However, the average survival benefit was only 20 days, a result that remains difficult to conciliate with prolonged waiting time.

Overall, the occurrence of hepatorenal syndrome still makes it unlikely that candidates will be transplanted in an elective setting, unless they receive prioritization. However, recent therapies, terlipressin in particular, may help to bridge a minority of patients to transplantation.

Hepatopulmonary syndrome

In liver transplant candidates, the estimated incidence of hepatopulmonary syndrome ranges between 4% and 25%, according to different populations and different diagnostic criteria [24] (see Chapter 7.7). Hepatopulmonary syndrome should be systematically screened as it can be clinically unrecognized in patients with mild hypoxaemia and profound asthenia. In patients with $Pao_2 < 70$ mmHg on room air and no other cause of hypoxaemia, the diagnosis is based on the demonstration of pulmonary vasodilatation and shunting using ^{99m}Tc macroaggregated lung perfusion scan and double-contrast echocardiography.

Hepatopulmonary syndrome represents a recognized indication for liver transplantation (even in patients with compensated cirrhosis) as hypoxaemia resolves in almost all cases [25]. However, the severity of hypoxaemia before transplantation is significantly correlated with early postoperative mortality. No therapy other than continuous oxygen supply has proved effective pretransplantation. The progression of hypoxaemia is relatively slow. It has been estimated that the decline in Pao_2 is of about 5 mmHg/year [26].

Portopulmonary hypertension

Portopulmonary hypertension (PPHT) is characterized by the development of pulmonary arterial hypertension [mean pulmonary artery pressure (PAP) over 25 mmHg] with only mild or no hypoxaemia (see Chapter 7.7). Its incidence in candidates for transplantation is slightly lower than that of hepatopulmonary syndrome. Systematic screening is crucial as PPHT frequently remains asymptomatic until mean PAP exceeds 40 mmHg. Significant pulmonary hypertension, if discovered at the time of transplant procedure, would carry an especially high perioperative risk.

Doppler echocardiography is a useful tool for screening. PPHT must be suspected whenever calculated systolic PAP exceeds 30–35 mmHg. However, the diagnosis should always

be confirmed by right heart catheterization. Indeed, only about 60% of those patients with high calculated systolic PAP eventually meet the criteria for PPHT on right heart catheterization. In the remaining patients, elevated PAP is a consequence of the hyperdynamic state. It appears that this latter group of patients is not at increased operative risk [27].

It is generally accepted that patients with PPHT and mean PAP below 35 mmHg are suitable candidates for transplantation, whereas those with mean PAP above 50 mmHg are unsuitable because of an especially high operative risk. In patients with mean PAP between 35 and 50 mmHg, the decision for transplantation depends on the value of pulmonary vascular resistance and cardiac output. Transplantation may be contraindicated in those with pulmonary vascular resistance over 250 dynes/s/cm^5, whereas it might be feasible in those below this threshold value. Decreased cardiac output secondary to marked ventricular dysfunction predicts additional operative risk.

In candidates with PPHT, intensive physical exercise should be avoided. Beta-blockers should always be stopped because they reduce cardiac output. Patients with mild hypoxaemia should be administered oxygen because hypoxaemia induces further pulmonary vasoconstriction. Some authors recommend the use of anticoagulants because of the frequent observation of thrombotic changes within pulmonary arteries. Repeated assessment of PAP using echocardiography and/or right heart catheterization is recommended during waiting time as the progression of pulmonary hypertension over time is unpredictable.

In patients who fall outside the criteria for transplantation, and in those who have been listed and experience a progressive increase in PAP, continuous intravenous epoprostenol should be started. Epoprostenol may help to bridge some patients to transplantation by decreasing PAP by 30–50% and improving systemic haemodynamics [28]. However, post-transplantation reversibility of PPHT is inconstant. Subcutaneous, oral and inhaled analogues of epoprostenol are currently under investigation.

Encephalopathy

Transient, uncomplicated episodes of encephalopathy do not preclude subsequent transplantation. Treatment of encephalopathy is aimed at correcting the precipitating factors (see Chapter 7.8). The issue of chronic encephalopathy is more challenging. It can be an indication for transplantation by itself. Some patients with large and longstanding portocaval shunts may develop organic brain lesions. In these patients, some of the manifestations, particularly extrapyramidal disorders, are not fully reversible after transplantation. There is no clear evidence that lactulose as well as non-absorbable antibiotics help to prevent the occurrence (or the progression) of irreversible brain damage.

Portal vein thrombosis

The reported incidence of portal vein thrombosis in patients with endstage cirrhosis has ranged from 2% to 26% [29]. Extensive thrombosis involving splenic and superior mesenteric veins is usually considered a definitive contraindication for transplantation. Partial thrombosis, even though it does not contraindicate transplantation, can be a source of technical difficulties. As a result, careful assessment of splanchnic vessels with imaging techniques is crucial. In patients with partial thrombosis, anticoagulation (low-molecular-weight heparin followed by vitamin K antagonists) proved effective for preventing further extension and even achieving repermeation [30].

About 7% of patients listed with patent splanchnic veins develop *de novo* thrombosis while on the waiting list. The risk increases with the duration of waiting time [30]. Anticoagulation appears to be effective in patients with *de novo* thrombosis. Therefore, repeated ultrasonographic examination (e.g. monthly) until transplantation, and anticoagulation when portal vein thrombosis is detected, can be recommended. Vitamin K antagonist-induced hypocoagulability can be reversed at the time of transplantation by the administration of fresh frozen plasma.

Optimization with respect to early post-transplantation mortality

Nutritional status

Malnutrition, which is common in patients with endstage cirrhosis, obviously represents a risk factor for surgery (see Chapters 21.10 and 23.2). Dietary restrictions should be avoided during the pretransplantation period. Importantly, protein restriction has no clear benefit in encephalopathy. Patients should be encouraged to have several fractionated meals rich in carbohydrates every day [31]. Supplemental enteral nutrition can be used in those with limited intakes. Parenteral nutrition should be used only when enteral feeding is impossible.

Clinical experience indicates that reversal of established malnutrition is unlikely with nutritional support alone. In contrast, effective control of refractory ascites by TIPS or peritoneovenous shunting can be followed by a marked improvement in nutritional status within a few months.

Renal function

Owing to complex circulatory changes, cirrhotic patients are at high risk of developing acute renal failure, even following relatively benign precipitating events. Therefore, any factor with potential for impairing renal function, in particular hypovolaemia, sepsis, inappropriate use of diuretics and administration of nephrotoxic agents, should be avoided. It is generally felt that cirrhotic patients are especially at risk for contrast media-associated nephrotoxicity. However, one study has shown that iodinated contrast media was not associated with significant changes in renal function tests in cirrhotic patients, even in those with ascites [32]. Nonetheless, adequate plasma volume expansion and systematic administration of *N*-acetylcysteine, a compound that was shown to reduce the risk of contrast media-induced nephrotoxicity, are recommended.

Cardiovascular diseases

Candidates for transplantation frequently have predisposing factors for cardiovascular diseases. In addition, alcohol abuse and genetic haemochromatosis can cause specific cardiomyopathy [33]. Left ventricular function tends to be overestimated preoperatively because of the characteristic peripheral vasodilatation accompanying cirrhosis. As arterial vasodilatation reverses after transplantation, some patients considered to have satisfactory ventricular function at evaluation may occasionally develop overt cardiac failure postoperatively.

A 27% incidence of moderate to severe coronary artery disease has been reported in candidates for transplantation over 50 years of age. Diabetes is an important risk factor. Patients with coronary artery disease, even if moderate, may develop perioperative or early postoperative myocardial infarction, especially in the case of postreperfusion syndrome and haemodynamic instability. Patients with risk factors should undergo thallium myocardial scintigraphy before transplantation. Percutaneous angioplasty stenting should be systematically considered, even in cases of asymptomatic stenosis [34].

Bacterial infections

Staphylococcus aureus is a leading cause of severe sepsis in the early post-transplantation period. In a recent study, about 25% of candidates had nasal carriage of *S. aureus*, about 20% of them being carriers of methicillin-resistant strains. Nasal carriage of methicillin-resistant as well as of methicillin-susceptible *S. aureus* was an independent risk factor for early postoperative infection with the corresponding strains (risk ratio of 28 and 3.4 respectively) [35]. These findings support systematic screening for *S. aureus* nasal carriers aimed at tailoring post-transplantation antibiotic therapy. Nasal carriers of methicillin-resistant *S. aureus* may benefit from a short course of glycopeptides in the first postoperative days. However, pretransplantation eradication of *S. aureus* nasal colonization with intranasal mupirocin is not recommended because it is unlikely to completely eradicate colonization and may induce false-negative samples.

Optimization with respect to long-term post-transplantation outcome

Hepatocellular carcinoma

Follow-up protocol on the waiting list

The main difficulty with transplantation and HCC comes from the fact that the tumour is likely to progress during waiting time, increasing in turn the risk of recurrence. Therefore, once HCC patients are listed for transplantation, tumour progression should be assessed regularly. It is recommended that Doppler ultrasound be repeated at 1-month intervals and that serum α-fetoprotein (AFP) testing and either computerized tomographic (CT) scan or magnetic resonance imaging be performed at 3-month intervals [36]. A marked increase in AFP level with apparently stable nodules strongly suggests vascular invasion. Extrahepatic metastases are uncommon in patients with small nodules. There is no evidence that chest CT scan and bone scan should be repeated when serum AFP and tumour size remain stable.

Adjuvant interventions

When the expected duration of waiting time exceeds 3–6 months, adjuvant therapies should be considered. Routine transarterial chemoembolization has not been shown to improve post-transplant survival [37]. However, objective response rates as high as 60% can be achieved in the short term, and about 50% have complete tumour necrosis. In addition, transarterial chemoembolization allows the treatment of two or more distant nodules in a single session. Thus, this technique might have a beneficial effect in particular subgroups of patients and further studies are needed.

The feasibility of pretransplant percutaneous ablation can be limited by coagulation disorders, ascites and poor visualization at ultrasonography (Table 2). However, when feasible, radiofrequency ablation appears to be more effective than transarterial chemoembolization for achieving tumour necrosis. The risk of needle tract seeding appears to be as low as 0.5–1.5%. There is still no evidence of an increased risk of post-transplantation extrahepatic metastasis in patients treated by radiofrequency ablation. Of note, in contrast to arterial chemoembolization, local ablation does not prevent the occurrence and/or progression of distant malignant nodules.

In many centres, surgical resection still represents a first-line option for treating small HCC in patients with compensated cirrhosis, with 'salvage' transplantation representing a second-line option in case of recurrence [38]. However, in selected patients, resection can also be used as a bridge to transplantation, an option that has several advantages. First, resection seems to be more effective than other techniques for controlling tumour growth. Secondly, resection allows for detailed pathological analysis and the identification of poor differentiation and microvascular invasion, which are strong prognostic indicators. This information may help in tailoring the transplantation decision. Thirdly, surgical resection has no deleterious impact on the feasibility and morbidity of subsequent transplantation [39]. In summary, when waiting time is predictably long, resection can be considered as a bridge to transplantation in patients with compensated cirrhosis and non-central tumours. In other patients, radiofrequency ablation should be proposed whenever feasible. In the remaining patients, transarterial chemoembolization should be considered.

Hepatitis B virus (HBV) infection

Serum HBV DNA level below 10^3 copies/mL (which represents an undetectable level on branched DNA assay) is a prerequisite for transplantation. Indeed, significant HBV replication

Table 2 Adjuvant therapies in HCC patients awaiting transplantation.

Technique	Estimated reduction in tumour size	Contraindications	Limitations
Transarterial chemoembolization	40–59% [36]	Portal vein thrombosis Child's grade C cirrhosis	Possible induction of hepatic artery lesions[a] Possible deterioration of liver function
Percutaneous ablation Ethanol injection	70–80%[b]	Large-volume ascites Marked decrease in coagulation factors (prothrombin index below 50% or INR > 1.7)[c]	Risk of needle tract seeding (estimated incidence of 0.5–1.5%) Poorly effective for nodules over 5 cm[d]
Radiofrequency ablation	85% [50]	Low platelet count ($< 50 \times 10^9$/L)[c] Absence of visibility of the nodules on echography	Difficult to perform in patients with more than two nodules
Surgical resection	Not applicable	Child's grade B or C cirrhosis Bilobar tumours Central lesions	Demanding procedure with significant morbidity Possible source of technical difficulties (adhesions)

[a]Arterial lesions may be a source of difficulties in case of split liver or living donor transplantation.
[b]For nodules less than 3 cm.
[c]Coagulation disorders may occasionally be reversed by the infusion of fresh frozen plasma and/or platelets transfusion before the procedure.
[d]The issue of nodules larger than 5 cm may only occasionally be relevant in patients selected for transplantation.
INR, international normalized ratio.

pretransplantation is associated with a rate of post-transplantation recurrence exceeding 80% (see Chapter 9.1.2). Unfortunately, recurrence of HBV infection in a context of immunosuppression is especially aggressive [40]. In the minority of candidates with decompensated cirrhosis and persistent HBV replication, antiviral therapy has to be started. Such patients might only be listed once HBV DNA has become undetectable on branched immunoassay. It is generally accepted that patients with very low replication rates who remain positive on polymerase chain reaction (a more sensitive technique) do not have a contraindication for transplantation.

The tolerance of interferon therapy is poor in cirrhotic patients. In contrast, lamivudine and adefovir can be used safely. Lamivudine allows a decrease in the HBV DNA level below 400 copies/mL in more than 70% of patients [41]. The main concern with this agent is the selection of resistant strains, which occurs in about 10–15% of treated patients at 1 year. Hepatitis flares can be observed at the time of breakthrough, with a rapid deterioration in liver function. Therefore, close monitoring of liver tests and serum HBV DNA is needed. Adefovir dipivoxil is well tolerated at a dose of 10 mg/day, although periodic assessment of renal function is needed because of the potential for nephrotoxicity. The decrease in serum HBV DNA level tends to be slower compared with lamivudine. However, adefovir dipivoxil is effective in patients with lamivudine-resistant strains. In the long term, the emergence of viral resistance to adefovir dipivoxil appears to be infrequent: about 5% at 3 years. A proposed strategy for pretransplantation antiviral treatment in patients with HBV infection is shown in Figure 1. Importantly, 5–10% of decompensated patients with persistent HBV replication improve with antiviral treatment to the point at which they can be removed from the waiting list [42]. The more recent agents entecavir and tenofovir appear to have an excellent safety profile, a low rate of resistance and a more potent inhibition of HBV replication than lamivudine and adefovir dipivoxil. More data are awaited on these agents in liver transplant candidates.

Hepatitis C virus (HCV) infection

Undetectable serum HCV RNA is not a prerequisite for transplantation. Almost all patients with HCV-related cirrhosis have persistent viral replication that is difficult to control as antiviral therapies are poorly tolerated and also poorly effective in this population (see Chapter 9.1.2). In addition, recurrence of HCV infection is far less aggressive than that of HBV infection. The progression of HCV-related liver fibrosis, however, is significantly accelerated in transplanted patients, and there is evidence that recurrence has a deleterious impact on patient and graft survival in the long term [43].

The tolerance of the combination of pegylated interferon and ribavirin in patients with decompensated cirrhosis is poor, and optimal doses are unlikely to be achieved. Sustained response rate is as low as 10% for genotype 1. Moreover, antiviral treatment may precipitate further deterioration of cirrhosis. Therefore, it has been suggested that patients with a Child–Pugh score over 11 and/or a MELD score over 25 should not receive antiviral treatment [44]. Overall, it is unlikely that patients with

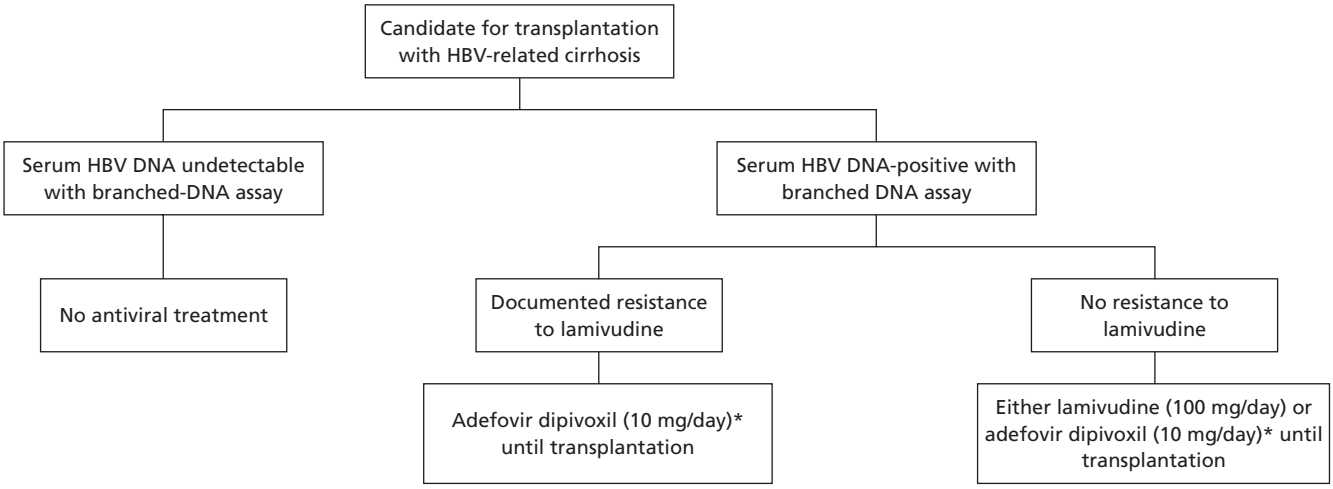

*Dose adjustment needed in patients with renal insufficiency

Fig. 1 Pretransplantation antiviral treatment in candidates for transplantation with HBV-related cirrhosis.

Table 3 Pretransplantation antiviral treatment in candidates with HCV infection: results of pilot studies.

Author	Year	Patients	Treatment	Dose reduction or interruption	End of treatment viral clearance	Absence of recurrence after transplantation	Absence of recurrence in those with viral clearance
Crippin *et al*. [45]	2002	15	IFN (9 pts) or IFN + riba (6 pts)	–	33%	0%[a]	–
Forns *et al*. [47]	2003	30	IFN + riba	63%[b]	30%	20%	67%
Thomas *et al*. [46]	2003	20	IFN	15%	60%	20%	33%

IFN, interferon; riba, ribavirin; pts, patients.
[a]Only two patients were transplanted at the end of the study and none was a responder.
[b]Discontinuation of treatment in 20%.

decompensated cirrhosis can be removed from the waiting list as a result of improvement on antiviral treatment.

The issue of antiviral therapy in candidates with compensated cirrhosis and small HCC as an indication for transplantation is more puzzling. These patients can be expected to tolerate full-dose antiviral regimens pretransplantation, to clear HCV RNA and, consequently, not to have post-transplantation HCV recurrence. From the few studies that have addressed this issue [45–47] (Table 3), it can be concluded that 30–60% of treated patients have on-treatment viral clearance and that about 20% will remain free of recurrence after transplantation. Interestingly, some patients still experience recurrence despite end of treatment viral clearance. Even in the absence of decompensation, on-treatment leucopenia, thrombocytopenia and anaemia remain important limitations. For counteracting these side-effects, administration of growth factors (erythropoietin and/or granulocyte colony-stimulating factor) should be preferred to dose reduction as this latter strategy compromises the efficacy of antiviral treatment.

Management in the particular setting of living donor transplantation

Not only does living donation accelerate access to transplantation, it also offers the possibility of scheduling the procedure. Therefore, it makes it possible to prepare some candidates with precarious conditions more efficiently and optimize them for transplantation. Some measures that are poorly applicable in the setting of deceased donor transplantation may be useful for bridging patients rapidly to living donor transplantation. Patients with hepatorenal syndrome, for instance, might be optimized and efficiently bridged to a scheduled living donor transplantation with a short course of terlipressin. Similarly, candidates with hepatic hydrothorax, who are at especially high risk of death on the waiting list, can be rapidly bridged to transplantation with specific interventions. Preliminary results suggest that liver assist devices such as albumin dialysis might also help to bridge some patients with advanced liver insufficiency and precarious condition [48]. However, whether high-risk

patients should be rapidly bridged to living donor liver transplantation with targeted supportive care or should rather receive a non-extended criteria (non-'marginal') deceased donor liver is still debated.

References

1 Merion RM, Schaubel DE, Dykstra DM *et al.* (2005) The survival benefit of liver transplantation. *Am J Transplant* 5, 307–313.
2 Durand F, Valla D (2005) Assessment of the prognosis of cirrhosis: Child–Pugh versus MELD. *J Hepatol* 42(Suppl.), S100–107.
3 Mazzaferro V, Regalia E, Doci R *et al.* (1996) Liver transplantation for the treatment of small hepatocellular carcinomas in patients with cirrhosis. *N Engl J Med* 334, 693–699.
4 Durand F, Regimbeau JM, Belghiti J *et al.* (2001) Assessment of the benefits and risks of percutaneous biopsy before surgical resection of hepatocellular carcinoma. *J Hepatol* 35, 254–258.
5 Khan SA, Davidson BR, Goldin R *et al.* (2002) Guidelines for the diagnosis and treatment of cholangiocarcinoma: consensus document. *Gut* 51(Suppl. 6), VI1–9.
6 Halpern SD, Ubel PA, Caplan AL (2002) Solid-organ transplantation in HIV-infected patients. *N Engl J Med* 347, 284–287.
7 Runyon BA (2004) Management of adult patients with ascites due to cirrhosis. *Hepatology* 39, 841–856.
8 Sort P, Navasa M, Arroyo V *et al.* (1999) Effect of intravenous albumin on renal impairment and mortality in patients with cirrhosis and spontaneous bacterial peritonitis. *N Engl J Med* 341, 403–409.
9 Heuman DM, Abou-Assi SG, Habib A *et al.* (2004) Persistent ascites and low serum sodium identify patients with cirrhosis and low MELD scores who are at high risk for early death. *Hepatology* 40, 802–810.
10 Salerno F, Merli M, Riggio O *et al.* (2004) Randomized controlled study of TIPS versus paracentesis plus albumin in cirrhosis with severe ascites. *Hepatology* 40, 629–635.
11 Millis JM, Martin P, Gomes A *et al.* (1995) Transjugular intrahepatic portosystemic shunts: impact on liver transplantation. *Liver Transpl Surg* 1, 229–233.
12 Salvalaggio PR, Koffron AJ, Fryer JP *et al.* (2005) Liver transplantation with simultaneous removal of an intracardiac transjugular intrahepatic portosystemic shunt and a vena cava filter without the utilization of cardiopulmonary bypass. *Liver Transpl* 11, 229–232.
13 Dumortier J, Pianta E, Le Derf Y *et al.* (2005) Peritoneovenous shunt as a bridge to liver transplantation. *Am J Transplant* 5, 1886–1892.
14 Belghiti J, Durand F (1997) Abdominal wall hernias in the setting of cirrhosis. *Semin Liver Dis* 17, 219–226.
15 Garcia N, Jr, Mihas AA (2004) Hepatic hydrothorax: pathophysiology, diagnosis, and management. *J Clin Gastroenterol* 38, 52–58.
16 Gordon FD, Anastopoulos HT, Crenshaw W *et al.* (1997) The successful treatment of symptomatic, refractory hepatic hydrothorax with transjugular intrahepatic portosystemic shunt. *Hepatology* 25, 1366–1369.
17 Ferrante D, Arguedas MR, Cerfolio RJ, *et al.* (2002) Video-assisted thoracoscopic surgery with talc pleurodesis in the management of symptomatic hepatic hydrothorax. *Am J Gastroenterol* 97, 3172–3175.
18 McCormick PA, O'Keefe C (2001) Improving prognosis following a first variceal haemorrhage over four decades. *Gut* 49, 682–685.
19 de Franchis R (2005) Evolving consensus in portal hypertension. Report of the Baveno IV consensus workshop on methodology of diagnosis and therapy in portal hypertension. *J Hepatol* 43, 167–176.
20 Moreau R, Durand F, Poynard T *et al.* (2002) Terlipressin in patients with cirrhosis and type 1 hepatorenal syndrome: a retrospective multicenter study. *Gastroenterology* 122, 923–930.
21 Duvoux C, Zanditenas D, Hezode C *et al.* (2002) Effects of noradrenalin and albumin in patients with type I hepatorenal syndrome: a pilot study. *Hepatology* 36, 374–380.
22 Wong F, Pantea L, Sniderman K (2004) Midodrine, octreotide, albumin, and TIPS in selected patients with cirrhosis and type 1 hepatorenal syndrome. *Hepatology* 40, 55–64.
23 Mitzner SR, Stange J, Klammt S *et al.* (2000) Improvement of hepatorenal syndrome with extracorporeal albumin dialysis MARS: results of a prospective, randomized, controlled clinical trial. *Liver Transpl* 6, 277–286.
24 Krowka MJ (2000) Hepatopulmonary syndromes. *Gut* 46, 1–4.
25 Taille C, Cadranel J, Bellocq A *et al.* (2003) Liver transplantation for hepatopulmonary syndrome: a ten-year experience in Paris, France. *Transplantation* 75, 1482–1489; discussion 46–47.
26 Swanson KL, Wiesner RH, Krowka MJ (2005) Natural history of hepatopulmonary syndrome: impact of liver transplantation. *Hepatology* 41, 1122–1129.
27 Colle IO, Moreau R, Godinho E *et al.* (2003) Diagnosis of portopulmonary hypertension in candidates for liver transplantation: a prospective study. *Hepatology* 37, 401–409.
28 Kuo PC, Johnson LB, Plotkin JS *et al.* (1997) Continuous intravenous infusion of epoprostenol for the treatment of portopulmonary hypertension. *Transplantation* 63, 604–606.
29 Nonami T, Yokoyama I, Iwatsuki S *et al.* (1992) The incidence of portal vein thrombosis at liver transplantation. *Hepatology* 16, 1195–1198.
30 Francoz C, Belghiti J, Vilgrain V *et al.* (2005) Splanchnic vein thrombosis in candidates for liver transplantation: usefulness of screening and anticoagulation. *Gut* 54, 691–697.
31 Lochs H, Plauth M (1999) Liver cirrhosis: rationale and modalities for nutritional support – the European Society of Parenteral and Enteral Nutrition consensus and beyond. *Curr Opin Clin Nutr Metab Care* 2, 345–349.
32 Guevara M, Fernandez-Esparrach G, Alessandria C *et al.* (2004) Effects of contrast media on renal function in patients with cirrhosis: a prospective study. *Hepatology* 40, 646–651.
33 Therapondos G, Flapan AD, Plevris JN *et al.* (2004) Cardiac morbidity and mortality related to orthotopic liver transplantation. *Liver Transpl* 10, 1441–1453.
34 Johnston SD, Morris JK, Cramb R *et al.* (2002) Cardiovascular morbidity and mortality after orthotopic liver transplantation. *Transplantation* 73, 901–906.
35 Bert F, Galdbart JO, Zarrouk V *et al.* (2000) Association between nasal carriage of Staphylococcus aureus and infection in liver transplant recipients. *Clin Infect Dis* 31, 1295–1299.
36 Manjo P, Giostra E, Morel P *et al.* (2005) Management of hepatocellular carcinoma in the waiting list before liver transplantation. *J Hepatol* 42(Suppl.), S134–143.
37 Decaens T, Roudot-Thoraval F, Bresson-Hadni S *et al.* (2005) Impact of pretransplantation transarterial chemoembolization on survival and recurrence after liver transplantation for hepatocellular carcinoma. *Liver Transpl* 11, 767–775.
38 Sarasin FP, Majno PE, Llovet JM *et al.* (2001) Living donor liver transplantation for early hepatocellular carcinoma: a life-expectancy and cost-effectiveness perspective. *Hepatology* 33, 1073–1079.

39 Belghiti J, Cortes A, Abdalla EK *et al.* (2003) Resection prior to liver transplantation for hepatocellular carcinoma. *Ann Surg* 238, 885–892; discussion 892–893.
40 Samuel D, Muller R, Alexander G *et al.* (1993) Liver transplantation in European patients with the hepatitis B surface antigen. *N Engl J Med* 329, 1842–1847.
41 Marcellin P, Lau GK, Bonino F *et al.* (2004) Peginterferon alfa-2a alone, lamivudine alone, and the two in combination in patients with HBeAg-negative chronic hepatitis B. *N Engl J Med* 351, 1206–1217.
42 Fontana RJ, Keeffe EB, Carey W *et al.* (2002) Effect of lamivudine treatment on survival of 309 North American patients awaiting liver transplantation for chronic hepatitis B. *Liver Transpl* 8, 433–439.
43 Berenguer M, Prieto M, San Juan F *et al.* (2002) Contribution of donor age to the recent decrease in patient survival among HCV-infected liver transplant recipients. *Hepatology* 36, 202–210.
44 Everson GT (2003) Treatment of patients with hepatitis C virus on the waiting list. *Liver Transpl* 9, S90–94.
45 Crippin JS, McCashland T, Terrault N *et al.* (2002) A pilot study of the tolerability and efficacy of antiviral therapy in hepatitis C virus-infected patients awaiting liver transplantation. *Liver Transpl* 8, 350–355.
46 Thomas RM, Brems JJ, Guzman-Hartman G *et al.* (2003) Infection with chronic hepatitis C virus and liver transplantation: a role for interferon therapy before transplantation. *Liver Transpl* 9, 905–915.
47 Forns X, Garcia-Retortillo M, Serrano T *et al.* (2003) Antiviral therapy of patients with decompensated cirrhosis to prevent recurrence of hepatitis C after liver transplantation. *J Hepatol* 39, 389–396.
48 Choi JY, Bae SH, Yoon SK *et al.* (2005) Preconditioning by extracorporeal liver support (MARS) of patients with cirrhosis and severe liver failure evaluated for living donor liver transplantation – a pilot study. *Liver Int* 25, 740–745.
49 Rosado B, Kamath PS (2003) Transjugular intrahepatic portosystemic shunts: an update. *Liver Transpl* 9, 207–217.
50 Lu DS, Yu NC, Raman SS *et al.* (2005) Percutaneous radiofrequency ablation of hepatocellular carcinoma as a bridge to liver transplantation. *Hepatology* 41, 1130–1137.

24 Surgery, anaesthesia and the liver

24.1 General surgical aspects and the risks of liver surgery in patients with hepatic disease

Jacques Belghiti and Satoshi Ogata

Introduction

The main goal of hepatic resection in patients with liver tumour is to cure the patients with low operative risk. Throughout the past two decades, substantial improvement in perioperative outcome after hepatic resection has been achieved, and the operative mortality rate is now typically less than 5% in major hepatobiliary centres [1–3]. Better understanding of the segmental liver anatomy and improved surgical techniques in controlling haemorrhage are considered to be the two most important factors that have led to the reduction in mortality. In a study of 747 hepatectomies performed in the 1990s in our centre, the operative mortality rate in patients with normal livers was 1% compared with 8% among patients with diseased parenchyma [2]. The higher risk of liver resection in a patient with diseased parenchyma resulted from higher risk of operative bleeding, higher risk of postoperative complications with a risk of liver failure because of impaired liver regeneration. The vast majority of hepatocellular carcinoma (HCC) develops in patients with chronic hepatitis and cirrhosis; cholangiocarcinoma arising from the biliary confluence results in cholestatic liver, and an increasing number of patients with liver metastasis of colorectal cancer are operated on after receiving chemotherapeutic agents that can induce parenchymal damage [4]. Moreover, a great number of patients with these hepatobiliary malignancies present with advanced tumours that require major hepatic resection. Therefore, careful preoperative assessment of liver function reserve is of paramount importance in ensuring a low operative mortality. In this chapter, we describe general surgical aspects and the risks of liver surgery in patients with hepatic disease.

Resection in cirrhotic patients

Tumour status

By far the main indication for hepatectomy in the cirrhotic liver is HCC. The vast majority of patients with HCC have abnormal underlying parenchyma caused by chronic hepatitis B or C viral infection. Chronic alcohol consumption, haemochromatosis and obesity are the other causes of chronic liver disease (CLD) associated with HCC. It has been shown that anatomical resection (including the tumour and its portal territory) achieves better disease-free survival than limited resection [5,6]. Therefore, anatomical resection should be the treatment of choice. Major hepatectomy is required in some patients with large tumours or with small tumours deeply located. Major resection in patients with chronic liver diseases represents the most risky situation.

Careful preoperative evaluation of tumour status is essential for the selection of appropriate patients with HCC for hepatic resection. In our centre, we routinely perform chest X-ray, ultrasonography and helical contrast computerized tomography (CT) scan for patients with a potentially resectable HCC. Modern helical contrast CT scan provides good assessment of the relationship of the tumour to major intrahepatic vessels, any satellite tumour nodules, and tumour invasion of the inferior vena cava, main portal vein or intrahepatic venous branches.

The usual criteria for hepatic resection with regard to the tumour status include absence of extrahepatic metastasis and absence of tumour thrombus in the inferior vena cava or main portal vein. Large tumour size alone should not be considered a contraindication for hepatic resection [7,8]. Even in the presence of cirrhotic liver, extended hepatectomy for large HCC is justified on condition that the liver function reserve remains satisfactory [9]. For small HCCs ≤ 5 cm in diameter without macroscopic vascular invasion in a Child's A cirrhotic patient, there is a controversy regarding whether hepatic resection or liver transplantation should be offered. Liver transplantation results in a better disease-free survival compared with hepatic resection [10–12]. In the presence of severe graft shortage, some authors, including our group, advocate hepatic resection as the first-line treatment for some cirrhotic patients with small HCCs and preserved liver function, and to reserve salvage transplantation for recurrence or deterioration of liver function after hepatic resection, which appears to be a feasible and rational strategy [13,14].

Table 1 Pugh's modification of Child's grading of cirrhosis.

Measurements	1 point	2 points	3 points
Bilirubin (μmol/L)	17–34	35–50	> 50
Prothrombin time prolongation (s)	1–3	4–6	> 6
Albumin (g/L)	> 35	28–34	< 28
Ascites	None	Mild	Moderate to severe
Encephalopathy	None	Grade 1 or 2	Grade 3 or 4

Child's A, 5–6 points; B, 7–9 points; C, 10–15 points.

Assessment of liver function reserve

Careful assessment of liver function reserve is critical in patient selection for hepatectomy in the cirrhotic liver to avoid postoperative liver failure and mortality. In most western centres, preoperative liver function is assessed by the Child–Pugh classification (Table 1). Whatever the extent of resection, hepatectomy is contraindicated in grade C patients. Limited resection of small superficial tumours is sometimes performed in grade B patients. However, even in grade A cirrhotic patients, with apparently normal liver function, the risk of liver surgery is increased and more sophisticated quantitative liver function tests are needed. Other centres use more sophisticated quantitative liver function tests such as the indocyanine green (ICG) clearance test [3], galactose elimination capacity [15] and lidocaine test [16] to predict the risk of postoperative liver failure in patients with cirrhosis. Among these measurements, the ICG clearance test, which seems to be the best single biological test predicting mortality after hepatectomy [3,17], is not widely used in western countries.

The levels of serum transaminases provide a reasonable reflection of hepatitis activity. We have clarified that a level of transaminases more than three times normal should be considered an absolute contraindication for major hepatectomy [18]. In those patients with markedly elevated serum transaminase levels, any hepatectomy should be avoided or deferred until the active hepatitis is under control, with lamivudine for hepatitis B-related hepatitis or interferon for hepatitis C-related hepatitis. It has been shown that a high portal pressure is associated with a high postoperative risk [19]. Therefore, the presence of oesophageal varices should be considered as a contraindication to major liver resection. Among patients with CLD, the postoperative risk is higher in those with cirrhosis (F4 fibrosis) than in those with F3 fibrosis [20]. Therefore, we perform a preoperative liver biopsy in all candidates for major liver resection in order to evaluate the severity of hepatitis activity and for histological grading of fibrosis. In patients with F3 or F4 fibrosis requiring major hepatectomy, preoperative portal vein embolization should be performed to decrease morbidity [20].

Measurement of the volume of the remnant liver after planned resection by CT volumetry has been shown to be helpful in selecting patients for major hepatic resection. A small liver remnant volume was associated with worse postoperative liver function and a higher complication rate after extended hepatectomy [21]. The safety limit for the remnant liver volume in patients with normal liver, which is around 30% of the total non-tumorous or functional liver volume, is much higher in patients with CLD. The safety limit in terms of remnant liver volume in patients with CLD has not been clearly documented, and it will certainly vary depending on the severity of cirrhosis, which could influence the regeneration capacity of this diseased parenchyma.

Role of preoperative portal vein embolization (PVE)

For patients who require major or extended hepatectomy but have inadequate remnant liver volume, preoperative PVE could be used to induce hypertrophy of the remnant liver [21,22]. There is a general concern that preoperative PVE may be less effective in the cirrhotic liver compared with the normal liver because of the impaired regenerative capacity of the cirrhotic liver, as demonstrated in an early study [23]. However, a few recent studies have demonstrated that preoperative PVE is effective in inducing hypertrophy of the remnant liver and decreasing postoperative complications in patients with cirrhotic livers undergoing hepatic resection for HCC [20,24].

Our centre also employed PVE in selected patients with F3 or F4 cirrhosis who were undergoing major hepatectomy. This procedure is well tolerated, but the degree of hypertrophy varies according to the degree of fibrosis and to the severity of cirrhosis [25]. Absence of hypertrophy of the future liver remnant (FLR) should be considered as an absolute contraindication for hepatic resection [20]. In a recent study, we showed that preoperative sequential transarterial chemoembolization and portal embolization increased the hypertrophy of the FLR. Additionally, we found a clear relationship between the rate of hypertrophy and postoperative risk after major hepatectomy in cirrhotic patients. After right hepatectomy for HCC, all the postoperative deaths and the majority of severe complications were experienced in F4 patients with < 10% increase in FLR. The vast majority of F3 patients had a hypertrophy rate of > 5%; none of these patients died and only 10% had major complications. Based on these observations, we propose that a minimum increase of 5% in the FLR in F3 patients and a minimum increase of 10% in the FLR in F4 patients is essential to perform right hepatectomy with no mortality and acceptable morbidity in cirrhotic patients. Thus, preoperative portal embolization is useful not only for increasing safety but also for patient selection in cirrhotic patients requiring major hepatectomy [26].

Intraoperative technique

Substantial improvement in the surgical techniques of hepatic resection in the past decade, including less parenchymal injury,

has resulted in a dramatic decline in the operative mortality of hepatic resection for HCC.

Intermittent inflow occlusion

During liver resection, reducing blood loss and transfusion is essential. The poor tolerance of the cirrhotic liver to warm ischaemia has led many authors to contraindicate inflow occlusion in patients with cirrhosis. However, it has been demonstrated that intermittent inflow occlusion with periods of 15 min of clamping and 5 min of unclamping was well tolerated [27]. This method, which minimizes intraoperative bleeding, can be repeated safely for up to 90 min in cirrhotic patients with good liver function.

Anterior approach

When liver tumours are large, the use of conventional techniques usually requires forceful retraction and mobilization of the liver with possible disadvantages including compression of both right and left lobes and tumour dissemination. The 'anterior approach' is a new technique that does not require liver mobilization [28]. After hilar control of the vascular inflow, and without prior mobilization of the right lobe containing the tumour, the parenchymal plane is transected directly from the anterior surface of the liver down to the anterior surface of the inferior vena cava (IVC). After anterior approach of the parenchyma, and the control of all venous tributaries including the right hepatic vein, the right lobe is mobilized and resected without forceful retraction of both right and left lobes. This approach reduces the intraoperative blood loss, blood transfusion, hospital death rate, pulmonary metastases and recurrence compared with the conventional approach [28]. The 'hanging manoeuvre' is an extension of the anterior approach [29]. During this manoeuvre, the liver is raised away from the anterior surface of the IVC by a tape. The anteroposterior parenchymal transection is then facilitated by upward traction on the tape (hanging the liver parenchyma anteriorly) placed in front of the retrohepatic vena cava, which allows the following of a direct plane, and facilitates exposure and haemostasis of the transected posterior parenchymal in front of the IVC. This technique can be used in patients both with normal livers or CLD and is contraindicated for large tumours invading the vena cava and in the presence of multiple adhesions between the prehepatic liver parenchyma and the anterior surface of the retrohepatic vena cava [30].

Assessment of postoperative liver failure

Although several clinical and biological factors such as ascites, encephalopathy, jaundice, prolonged prothrombin time, hyperbilirubinaemia and hypoalbuminaemia are markers of impaired liver function, there is neither a standardized definition of postoperative liver failure (PLF) nor precise data on its correlation with postoperative mortality. The need for standardization of PLF is important. Prothrombin time and serum total bilirubin level (SB), which are two biological indicators of liver dysfunction in the Child–Pugh score (and also two of the three components of the MELD score), are not readily usable postoperatively, as there is a natural impairment of liver function tests during the first postresection days. We found that, on postoperative day 5, the association of prothrombin time < 50% and SB > 50 μml/L (the '50–50 criteria') was a simple, early and accurate predictor of more than 50% mortality rate after hepatectomy [31]. Moreover, these biological criteria could be identified early enough before clinical evidence of complications appeared, allowing institution of specific intervention. Postoperative complications including portal thrombosis, ascites and pulmonary infection are difficult to diagnose and result in late mortality. Early recognition of this state is an important issue allowing the discovery and treatment of these complications. Moreover, such criteria might precipitate the use of a liver assist device with appropriate timing.

Resection in patients with obstructive jaundice

Preoperative percutaneous transhepatic biliary drainage (PTBD)

Obstructive jaundice is another problem found in patients requiring major liver resection. Although this problem is commonly seen in patients with hilar cholangiocarcinoma (HCCC), obstructive jaundice can also be seen in patients with HCC or in patients with unfavourably situated metastatic lesions that compress the bile ducts. Several reports have shown that liver resection in patients with complete obstructive jaundice and cholangitis is associated with severe complications, including intraoperative bleeding, postoperative subphrenic abscesses due to biliary fistula and liver failure [32]. The roles of preoperative biliary drainage are: (i) to decrease the bilirubin level; (ii) treatment of biliary infection; (iii) better assessment of the extent of carcinoma; and (iv) better hypertrophy after PVE. This technique also has adverse effects such as: (i) risk of tumour seeding; (ii) risk of bleeding due to hepatic puncture; (iii) risk of infection; and (iv) prolongation of hospital stay. The advantage of preoperative PTBD was not demonstrated in controlled studies [33,34]. Although very few patients underwent liver resection in these controlled studies, it is likely that patients with early jaundice could tolerate major hepatectomy without preoperative biliary drainage. Results of Japanese series showed that preoperative PTBD increased the resectability and tolerance after hepatectomy [35,36]. Therefore, for 10 years, we have followed the Japanese strategy of preoperative percutaneous biliary drainage including better assessment with cholangiography via PTBD.

The procedures of preoperative biliary drainage are also debated. Although successful and complete plastic endoscopic retrograde biliary drainage (ERBD) may achieve efficient drainage with low morbidity and a shorter hospital stay, this procedure is

rarely feasible in patients with complete obstruction with involvement of the secondary biliary ducts [37]. The high quality of images provided by magnetic resonance imaging (MRI) and technical improvement with refined catheters may increase the indication for ERBD. MRI permits excellent visualization of hepatic parenchymal abnormalities, as well as the visualization of the biliary tree and vascular structures [38]. Because MRI is non-invasive and does not involve exposure to radiation, it may replace CT, angiography and cholangiography via PTBD.

There are two ways of performing PTBD, either unilateral or bilateral. Our tendency is to perform unilateral PTBD in the future remnant liver. When segmental cholangitis cannot be controlled after technically successful hemihepatic biliary drainage, additional biliary drainage is performed to drain the septic territory [36].

Role of preoperative portal vein embolization

In patients with obstructive jaundice considered for right hepatectomy with FLR < 40% of the total liver, PVE is indicated [36]. After efficient biliary drainage decreasing the bilirubin level to < 50 μmol/L, right PVE is performed percutaneously. HCCC involving one portal vein and/or patients requiring central hepatectomy (S4, S5 and S8) are not considered for PVE. It takes over 4 weeks to resolve jaundice by PTBD and, after PVE, it takes an additional 4 weeks for sufficient hypertrophy of FLR.

Resection in patients with fatty liver

Diabetic patients, obese patients and patients receiving chemotherapy are all subject to developing hepatosteatosis [37–39]. In obese patients, a fatty liver has been shown to be a risk factor for hepatic fibrosis, cirrhosis and, potentially, for the development of HCC [38–40]. In both the diabetic patient and the obese patient with insulin resistance, it has been well established that insulin is a factor associated with liver regeneration, and that the regenerative capacity of the liver after resection is diminished in its absence [39,41–43].

In a review of patients following major hepatectomy, Behrns *et al.* [44] have shown a significant increase in both postoperative liver failure and death in patients with mild (< 30% hepatocytes involved) and moderate/severe (> 30% hepatocytes involved) steatosis. Obesity with a body mass index (BMI) of more than 33 and elevated preoperative bilirubin were both found to be risk factors for poor outcome. It has been shown that a BMI of more than 30 and the administration of preoperative chemotherapy were significant indicators of steatosis [45]. Furthermore, steatosis was an independent predictor of postoperative complications [45].

More and more patients currently undergoing liver resection for colorectal liver metastases have previously been treated with chemotherapy. In selected patients with unresectable metastases, disease may be downstaged by systemic or intra-arterial chemotherapy to the point that liver resection can be performed [46]. Preoperative chemotherapy is already used in practice in many institutions prior to resection for both synchronous (during the delay between resections of the primary tumour and the metastases) and metachronous (as a 'neoadjuvant' treatment) resectable liver metastases, although the principle of the method has not, to date, been formally validated. There has been a long history of reports supporting the notion that most chemotherapeutic agents can cause hepatic damage. Therefore, recognition of chemotherapy-associated steatohepatitis (CASH) is required before major resection in patients with colorectal metastasis treated with chemotherapy [4]. According to our experience, specific preoperative radiological or biological assessment failed to identify histological changes. Therefore, we advocate non-tumorous liver biopsy, and we consider PVE preoperatively similarly to patients with CLD. As mentioned above, this serves to improve future liver remnant volume, but also verifies the regenerative capacity of the fatty liver before hepatectomy.

References

1 Fan ST, Lo CM, Liu CL *et al.* (1999) Hepatectomy for hepatocellular carcinoma: toward zero hospital deaths. *Ann Surg* 229, 322–330.

2 Belghiti J, Hiramatsu K, Benoist S *et al.* (2000) Seven hundred forty-seven hepatectomies in the 1990s: an update to evaluate the actual risk of liver resection. *J Am Coll Surg* 191, 48–46.

3 Imamura H, Seyama Y, Kokudo N *et al.* (2003) One thousand fifty-six hepatectomies without mortality in 8 years. *Arch Surg* 138, 1198–1206.

4 Fernandez FG, Ritter J, Goodwin JW *et al.* (2005) Effect of steatohepatitis associated with irinotecan or oxaliplatin pretreatment on resectability of hepatic colorectal metastases. *J Am Coll Surg* 200, 845–853.

5 Regimbeau JM, Kianmanesh R, Farges O *et al.* (2002). Extent of liver resection influences the outcome in patients with cirrhosis and small hepatocellular carcinoma. *Surgery* 131, 311–317.

6 Hasegawa K, Kokudo N, Imamura H *et al.* (2005). Prognostic impact of anatomic resection for hepatocellular carcinoma. *Ann Surg* 242, 252–259.

7 Regimbeau JM, Farges O, Shen BY *et al.* (1999) Is surgery for large hepatocellular carcinoma justified? *J Hepatol* 31, 1062–1068.

8 Poon RT, Fan ST, Lo CM *et al.* (2002) Selection criteria for hepatic resection in patients with large hepatocellular carcinoma larger than 10 cm in diameter. *J Am Coll Surg* 194, 592–602.

9 Poon RT, Fan ST, Lo CM *et al.* (2002) Extended hepatic resection for hepatocellular carcinoma in patients with cirrhosis: is it justified? *Ann Surg* 236, 602–611.

10 Otto G, Heuschen U, Hofmann WJ *et al.* (1998) Survival and recurrence after liver transplantation versus liver resection for hepatocellular carcinoma. A retrospective analysis. *Ann Surg* 227, 424–432.

11 Pichlmayr R, Weimann A, Oldhafer KJ *et al.* (1998) Appraisal of transplantation for malignant tumours of the liver with special reference to early stage hepatocellular carcinoma. *Eur J Surg Oncol* 24, 60–67.

12 Figueras J, Jaurrieta E, Valls C *et al.* (2000) Resection or transplantation for hepatocellular carcinoma in cirrhotic patients: outcomes based on indicated treatment strategy. *J Am Coll Surg* 190, 580–587.

13 Poon RT, Fan ST, Lo CM *et al.* (2002) Long-term survival and pattern of recurrence after resection of small hepatocellular carcinoma in

patients with preserved liver function: implications for a strategy of salvage transplantation. *Ann Surg* 235, 373–382.
14 Belghiti J, Cortes A, Abdalla EK *et al.* (2003) Resection prior to liver transplantation for hepatocellular carcinoma. *Ann Surg* 238, 885–893.
15 Redaelli CA, Dufour JF, Wagner M *et al.* (2002) Preoperative galactose elimination capacity predicts complications and survival after hepatic resection. *Ann Surg* 235, 77–85.
16 Ravaioli M, Grazi GL, Principe A *et al.* (2003) Operative risk by the lidocaine test (MEGX) in resected patients for HCC on cirrhosis. *Hepatogastroenterology* 50, 1552–1555.
17 Fan ST, Lai EC, Lo CM *et al.* (1995) Hospital mortality of major hepatectomy for hepatocellular carcinoma associated with cirrhosis. *Arch Surg* 130, 198–203.
18 Farges O, Malassagne B, Flejou JF *et al.* (1999) Risk of major liver resection in patients with underlying chronic liver disease: a reappraisal. *Ann Surg* 229, 210–215.
19 Bruix J, Castells A, Bosch J *et al.* (1996) Surgical resection of hepatocellular carcinoma in cirrhotic patients: prognostic value of preoperative portal pressure. *Gastroenterology* 111, 1018–1022.
20 Farges O, Belghiti J, Kianmanesh R *et al.* (2003) Portal vein embolization before right hepatectomy: prospective clinical trial. *Ann Surg* 237, 208–217.
21 Vauthey JN, Chaoui A, Do KA *et al.* (2000) Standardized measurement of the future liver remnant prior to extended liver resection: methodology and clinical associations. *Surgery* 127, 512–519.
22 Makuuchi M, Thai BL, Takayasu K *et al.* (1990) Preoperative portal embolization to increase safety of major hepatectomy for hilar bile duct carcinoma: a preliminary report. *Surgery* 107, 521–527.
23 Nagasue N, Yukaya H, Ogawa Y *et al.* (1987) Human liver regeneration after major hepatic resection. A study of normal liver and livers with chronic hepatitis and cirrhosis. *Ann Surg* 206, 30–36.
24 Azoulay D, Castaing D, Krissat J *et al.* (2000) Percutaneous portal vein embolization increases the feasibility and safety of major liver resection for hepatocellular carcinoma in injured liver. *Ann Surg* 232, 665–672.
25 Hirohashi K, Tanaka H, Tsukamoto T *et al.* (2004) Limitation of portal vein embolization for extension of hepatectomy indication in patients with hepatocellular carcinoma. *Hepatogastroenterology* 51, 1084–1087.
26 Ogata S, Belghiti J, Farges O *et al.* (2006) Sequential arterial and portal vein embolizations before right hepatectomy in cirrhotic patients with hepatocellular carcinoma. *Br J Surg* 93, 1091–1098.
27 Belghiti J, Noun R, Zante E *et al.* (1996) Portal triad clamping or hepatic vascular exclusion for major liver resection. A controlled study. *Ann Surg* 224, 155–161.
28 Liu CL, Fan ST, Lo CM *et al.* (2000) Anterior approach for major right hepatic resection for large hepatocellular carcinoma. *Ann Surg* 232, 25–31.
29 Belghiti J, Guevara OA, Noun R *et al.* (2001) Liver hanging maneuver: a safe approach to right hepatectomy without liver mobilization. *J Am Coll Surg* 193, 109–111.
30 Ogata S, Belghiti J, Varma D *et al.* (2007) Two hundred liver hanging maneuver for major hepatectomy, A single center experiences. *Ann Surg* (in press).
31 Balzan S, Belghiti J, Farges O *et al.* (2005) The '50–50 criteria' on postoperative day 5: an accurate predictor of liver failure and death after hepatectomy. *Ann Surg* 242, 824–828.
32 Cherqui D, Benoist S, Malassagne B *et al.* (2000) Major liver resection for carcinoma in jaundiced patients without preoperative biliary drainage. *Arch Surg* 135, 302–308.
33 Hatfield ARW, Terblanche J, Fataar S *et al.* (1982) Preoperative external biliary drainage in obstructive jaundice: a prospective controlled clinical trial. *Lancet* 2, 896–899.
34 McPherson GAD, Benjamin IS, Hodgson HJF *et al.* (1984) Preoperative percutaneous transhepatic biliary drainage: the results of a controlled trial. *Br J Surg* 71, 371–375.
35 Ebata T, Nagino M, Kamiya J *et al.* (2003) Hepatectomy with portal vein resection for hilar cholangiocarcinoma: audit of 52 consecutive cases. *Ann Surg* 238, 720–727.
36 Seyama Y, Kubota K, Sano K *et al.* (2003) Long-term outcome of extended hemihepatectomy for hilar bile duct cancer with no mortality and high survival rate. *Ann Surg* 238, 73–83.
37 Peppercorn PD, Reznek RH, Wilson P *et al.* (1998) Demonstration of hepatic steatosis by computerized tomography in patients receiving 5-fluorouracil-based therapy for advanced colorectal cancer. *Br J Cancer* 77, 2008–2011.
38 Murata Y, Ogawa Y, Saibara T *et al.* (2000) Unrecognized hepatic steatosis and non-alcoholic steatohepatitis in adjuvant tamoxifen for breast cancer patients. *Oncol Rep* 7, 1299–1304.
39 Festi D, Colecchia A, Sacco T *et al.* (2004) Hepatic steatosis in obese patients: clinical aspects and prognostic significance. *Obes Rev* 5, 27–42.
40 Adler M, Schaffner F (1979) Fatty liver hepatitis and cirrhosis in obese patients. *Am J Med* 67, 811–816.
41 Starzl TE, Porter KA, Putnam CW (1975) Intraportal insulin protects from liver injury of portacaval shunt in dogs. *Lancet* ii, 1241–1242.
42 Starzl TE, Porter KA, Kashiwagi N *et al.* (1975) Portal hepatotrophic factors, diabetes mellitus and acute liver atrophy, hypertrophy and regeneration. *Surg Gynecol Obstet* 141, 843–858.
43 Starzl TE, Porter KA, Putnam CW (1976) Insulin, glucagon, and control of hepatic structure, function, and capacity for regeneration. *Metabolism* 25, 1429–1434.
44 Behrns KE, Tsiotos GG, DeSouza NF *et al.* (1998) Hepatic steatosis as a potential risk factor for major hepatic resection. *J Gastrointest Surg* 2, 292–298.
45 Kooby D, Fong Y, Gonen M *et al.* (2003) Hepatic steatosis is associated with increased complications following major liver resection for cancer but does not impact survival. *Gastroenterology* 124, 794.
46 Adam R, Delvart V, Pascal G *et al.* (2004) Rescue surgery for unresectable colorectal liver metastases downstaged by chemotherapy: a model to predict long-term survival. *Ann Surg* 240, 644–657.

24.2 Anaesthesia and liver disease

Kalpana Reddy and Susan V. Mallett

The objective of this chapter is to review the specific problems posed by liver disease in terms of anaesthesia and surgery, to define the pathophysiological consequences of hepatic damage and to identify potential risk factors. General guidelines for drug usage and the anaesthetic management of these patients will be presented, together with recommendations for the management of specific liver surgery including hepatic resection and liver transplantation.

Risk assessment

Surgery in patients with advanced liver disease still carries a significant risk of morbidity and mortality despite the advances in surgery, anaesthesia and intensive care that have occurred in the last two decades. The risk is determined by the type of surgery and the nature and severity of liver disease. Child–Pugh's classification, which reflects the functional reserve of the liver, remains the standard by which patients with chronic liver disease are assigned a risk assessment score preoperatively. Early reports in the 1980s reported mortality rates as high as 80% in patients undergoing cholecystectomy with Child's C cirrhosis [1]. In a retrospective analysis of risk variables of survival after abdominal surgery in cirrhotic patients, Garrison *et al.* [2] reported serum albumin level, leucocytosis and an increased prothrombin time to be the most sensitive indicators of perioperative mortality independent of the Child–Pugh score. In their study, patients with Child class A, B and C cirrhosis had mortality rates of 10%, 31% and 76% respectively. The most common causes of perioperative mortality reported in all studies were haemorrhage, sepsis and liver failure.

Surgery in patients with Child's C cirrhosis carries a prohibitively high morbidity and mortality. Child's A cirrhosis is thought to have a relatively low risk, but a recent retrospective review of 50 cirrhotic patients with Child's A classification undergoing total knee arthroplasty showed that, compared with control subjects, the cirrhotic patients had significantly more blood loss, longer hospital stays, more complications and higher mortality. A history of hepatic decompensation or variceal bleeding was an independent predictor of complications [3].

Improving the patient's preoperative status can have a significant impact on outcome and reduce perioperative morbidity and mortality [4]. This requires a multidisciplinary approach and liaison between hepatologists, anaesthetists and the surgical team. Acute hepatitis is associated with an increased operative risk and perioperative mortality [5] and, whatever the underlying cause, it is always prudent to postpone elective surgery.

Pathophysiological consequences of liver disease

Anaesthetic implications

Cardiovascular

Advanced liver disease is associated with a hyperdynamic circulation characterized by increased cardiac output (CO), low systemic vascular resistance (SVR) and increased blood volume. These patients also exhibit a relative insensitivity to vasoconstrictors [6]. The magnitude of the haemodynamic changes is related to the severity of the liver disease and results from the impaired clearance or increased production of vasoactive substances [nitric oxide (NO), endotoxins and vasoactive peptides] by the failing liver. In addition, there may be extensive arteriovenous and portosystemic shunts.

Many cirrhotic patients have evidence of impaired myocardial contractility [cirrhotic cardiomyopathy (CCM)] [7], which may only become apparent when afterload is increased and the myocardium is stressed. Cardiac function appears to be normal at rest, as the low SVR in endstage liver disease (ESLD) enables a high CO to be maintained despite the reduced contractility. An impaired response to stress demonstrated by a fall in ejection fraction on dobutamine stress echocardiography (DSE) is indicative of cirrhotic cardiomyopathy.

Portopulmonary hypertension (PPHTN) is a specific condition characterized by an elevated pulmonary arterial pressure (PAP) in a setting of underlying portal hypertension. The reported incidence of PPHTN is in the range 5–10% [8]. Many patients are asymptomatic; however, a history of dyspnoea on

exertion is highly suggestive of pulmonary hypertension in the absence of any other obvious cause. PPHTN can be categorised as mild, moderate and severe. In a retrospective review of 1205 patients undergoing orthotopic liver transplantation (OLT), mild (systolic PAP = 30–44 mmHg) and moderate (systolic PAP = 45–59 mmHg) pulmonary hypertension did not influence outcome following OLT. In contrast, severe PHTN (systolic PAP > 60 mmHg) was associated with progressive right heart failure and a mortality of 70% [9]. Transthoracic echocardiography is used for preliminary screening and diagnosis of pulmonary hypertension. If there is evidence of PPHTN, right heart catheterization is indicated. The reactivity of the pulmonary vasculature to short-acting vasodilators such as prostacyclin or NO should also be assessed at this time, but many patients demonstrate little if any response [10]. Evidence of right ventricular hypertrophy is generally considered to be a contraindication for transplantation.

The longstanding belief that cirrhosis is rarely associated with coronary artery disease (CAD) has now been refuted; a prevalence of 27% has been reported in liver transplant candidates over 50 years of age [11]. DSE is the most widely accepted screening test for these patients. If significant inducible ischaemia is observed, coronary angiography is required. Single-vessel disease (other than left main stem) does not appear to increase perioperative mortality. Significant CAD will require revascularisation, ideally by interventional (stenting) rather than surgical means.

Respiratory

Alterations in gas exchange are common in patients with ESLD. Many patients, particularly those with alcoholic aetiology, are or have been smokers. Pleural effusions are found in 10% of cirrhotics. The presence of ascites and/or pleural effusions reduces tidal volume, vital capacity and functional residual volume, and a compensatory tachypnoea often results in respiratory alkalosis.

Hepatopulmonary syndrome (HPS) describes the functional changes that occur in the pulmonary vasculature in association with cirrhosis. There is a spectrum of abnormality from mild hypoxaemia associated with impaired hypoxic vasoconstriction and low pulmonary vascular tone to severe hypoxaemia from shunts and diffusion–perfusion defects. The prevalence of HPS is variously reported as 4–20% of liver transplant candidates [12]. Oximetry will show improvement in supine vs. upright measurements (orthodeoxia). The hypoxaemia is usually readily improved by 100% oxygen. The condition can be diagnosed by contrast-enhanced echocardiography or pulmonary angiography.

Before anaesthesia and surgery are contemplated, a complete assessment of the respiratory system must be made. Attempts should be made to improve respiratory function with physiotherapy, antibiotics and drainage of ascites and/or hydrothorax. The presence of marked muscle wasting, as a result of malnutrition, is an indication that the patient may require ventilatory support postoperatively.

Renal

In the presence of chronic liver disease, there is enhanced tubular reabsorption of sodium, increased renin–angiotensin activity, decreased glomerular filtration rate and decreased renal cortical perfusion. Urinary water excretion is also impaired. This combination of sodium retention and water retention often results in hyponatraemia because the water retention is proportionally greater than the sodium retention. In addition, prerenal insufficiency is not uncommon, owing to the use of diuretics and the presence of tense ascites.

Hepatorenal syndrome (HRS) is a form of functional renal failure seen in patients with endstage liver disease characterized by an increased creatinine level, oliguria and a low urinary sodium (< 10 mEq/L) in the presence of histologically normal kidneys. There is a decrease in renal perfusion as a result of the reduced SVR and increased intrarenal vasoconstrictors (leukotrienes, thromboxanes, endothelins). Patients with HRS are excessively sensitive to insults such as volume depletion or hypotension; consequently, maintenance of normovolaemia and adequate renal perfusion pressure is critical. Vasopressors may be necessary to maintain an adequate mean arterial pressure. Terlipressin (glypressin), a synthetic analogue of vasopressin, has been shown to significantly improve renal function and systemic haemodynamics in patients with HRS [13].

Acute tubular necrosis is more common than HRS in cirrhotic patients. Contributory factors are surgery, a high bilirubin (> 120 μmol/L), endotoxaemia (especially Gram-negative bacteria), the use of some aminoglycoside antibiotics, aggressive diuretic therapy and hypotension. The benefit (or otherwise) of using dopamine for renal protection is somewhat controversial [14].

Both blood urea concentration and serum creatinine may be unreliable indicators of the extent of renal dysfunction in patients with liver disease, with misleadingly low values because of impaired hepatic urea synthesis and reduced muscle mass due to malnutrition. A creatinine clearance measured before major surgery gives helpful information on renal function.

Electrolyte imbalance

Hypokalaemia is common because of diuretic therapy, decreased intake, metabolic alkalosis, diarrhoea and vomiting, secondary hyperaldosteronism and renal tubular defects. Hypomagnesaemia is also common in cirrhotics and alcoholic patients; contributory factors include poor diet, secondary hyperaldosteronism, direct effects of alcohol on magnesium excretion and loop diuretics.

Hyponatraemia tends to reflect the magnitude of the haemodynamic changes and the severity of liver disease. Water restriction and reduced diuretic dosage are usually sufficient measures but, in cases of refractory hyponatraemia, slow correction by haemofiltration has been advocated [15]. Rapid reversal of hyponatraemia can result in central pontine myelinolysis [16].

Glucose homeostasis

The liver plays an essential part in glucose homeostasis.

Hypoglycaemia is frequently severe in patients with fulminant hepatic failure because of depletion of glycogen stores and impaired gluconeogenesis. These patients will usually require prophylactic dextrose infusions; hypertonic (20–50%) glucose solutions are preferable in order to reduce the water load. In contrast, in chronic liver disease, mild hyperglycaemia and glucose intolerance are usual. Insulin resistance is known to occur at or beyond the receptor level [17]. Diabetes mellitus can result from chronic liver disease, especially with autoimmune chronic active hepatitis and haemochromatosis.

Acid–base disturbances

Combined respiratory and metabolic alkalosis is the commonest acid–base abnormality seen in patients with liver disease. The respiratory component is due to tachypnoea, and the metabolic component results from hypokalaemia, vomiting and potassium-losing diuretics. Hypochloraemic acidosis can be caused by potassium-sparing diuretics such as spironolactone. Hepatic metabolism of lactate plays an important part in normal acid–base homeostasis, with over 70% of lactate being removed by the liver, mainly by gluconeogenesis. Marked hyperlactaemia (> 10 mmol/L) is a feature of fulminant liver failure or massive ischaemic injury, and is a grave prognostic sign.

Coagulation

Impaired haemostatic function in patients with liver disease results from a number of factors, some or all of which may be present, depending on the nature and severity of the underlying disease process. These include vitamin K deficiency (factors II, VII, IX and X), reduced hepatic synthesis of coagulation factors and inhibitors, a low-grade disseminated intravascular coagulation, enhanced fibrinolytic activity and quantitative as well as qualitative platelet defects. Fibrinogen synthesis is abnormal in cirrhosis with dysfibrinogenaemia. Patients with hepatocellular disease (cirrhosis, chronic active hepatitis) have much greater derangement of coagulation than those with cholestatic disease [18,19]. Enhanced fibrinolysis is common in cirrhosis related to an imbalance between high levels of tissue plasminogen activator (tPA) relative to plasminogen activator inhibitor (PAI) [20] and/or decreased levels of alpha-2-antiplasmin.

Hepatic encephalopathy

Hepatic encephalopathy is a neuropsychiatric disorder associated with the accumulation of toxic substances that are not cleared by the failing liver. There are also changes in the blood–brain barrier, changes in neurotransmitter concentrations, such as gamma-aminobutyric acid (GABA), and altered cerebral metabolism. Although the mediators involved in the development of encephalopathy in acute and chronic liver disease may be similar, there are some important differences. In chronic liver disease, encephalopathy is usually associated with portosystemic shunting, and there is generally an obvious precipitating cause such as gastrointestinal haemorrhage, protein loading, hypokalaemic alkalosis or sepsis. Cerebral oedema is relatively unusual in chronic liver disease but occurs in up to 80% of patients with acute liver failure. Both vasogenic and cytotoxic mechanisms are involved. Brainstem herniation caused by high intracranial pressure is a frequent cause of death in patients with acute liver failure, and monitoring of intracranial pressure is recommended if the patient is in grade IV coma or ventilated and awaiting transplantation [21].

Liver disease and anaesthetic drugs

Severe liver disease alters the pharmacokinetics and pharmacodynamics of many of the drugs used in anaesthesia, in some cases in a relatively unpredictable fashion. All drugs, therefore, should be used with thought and a degree of caution in patients with hepatic dysfunction [22].

General factors that can cause substantial alterations in pharmacokinetics include: an increased distribution volume, lowered serum albumin with decreased protein binding, alterations in liver blood flow and reduced drug metabolism and excretion. In general, drugs that undergo oxidative metabolism (phase I biotransformation) have their clearance reduced in proportion to the other indices of quantitative liver function. These reactions are mediated by cytochrome P-450 enzymes located mainly in hepatocytes around the central vein. Drugs that are conjugated (phase II biotransformation) usually have normal pharmacokinetics, even in the presence of severe liver disease [23]. Concomitant renal dysfunction in patients with advanced liver disease can further interfere with the metabolism and elimination of drugs [24].

Benzodiazepines

Liver disease is known to enhance cerebral sensitivity to all psychotropic drugs. There is upregulation of GABA receptors on the neuronal membrane adjacent to benzodiazepine receptors [25]. Although the central nervous depressant effect of the benzodiazepines is increased and their metabolism may be altered, benzodiazepines have a wide therapeutic index, and should not be arbitrarily avoided if they can contribute to the therapeutic management of the patient.

Analgesics

Alterations in the endogenous opioid system have been reported in patients with liver disease, and morphine administration may precipitate episodes of encephalopathy. Both morphine and fentanyl can safely be used in patients with mild cirrhosis. Alfentanil is highly bound to alpha-1-glycoprotein, which is reduced in liver disease and, as its clearance is reduced and volume of distribution increased, its duration of action is increased. Remifentanil is metabolized by tissue and red cell esterases and is not dependent on hepatic function for elimination. Nonsteroidal anti-inflammatory drugs should be avoided as they can precipitate acute renal failure in patients with cirrhosis. There is no contraindication to the use of paracetamol (acetaminophen) in therapeutic doses in the presence of stable chronic liver

disease, but caution should be exercised in patients with alcoholic liver disease because excessive alcohol intake may potentiate the hepatotoxic effect of paracetamol.

Neuromuscular blocking drugs (NMBs)

Plasma pseudocholinesterase concentrations are reduced in liver disease, resulting in slightly increased duration of action of suxamethonium and mivacurium. Atracurium is the relaxant of choice in liver disease as its metabolism is independent of hepatic metabolism, occurring by Hoffman elimination and ester hydrolysis. Steroid-based NMBs, e.g. vecuronium and rocuronium, are metabolized in the liver, and their duration of action is prolonged in liver disease. The increased volume of distribution will cause a relative resistance to the initial dose of all relaxants.

Inhalational anaesthetics

Desflurane has many characteristics that recommend its use in liver disease: it undergoes minimal biotransformation (< 0.2%), the hepatic artery buffer response is maintained intact and splanchnic blood flow is higher than with similar minimum anaesthetic concentration (MAC) values of isoflurane [26]. Isoflurane and sevoflurane are also suitable: they have similar haemodynamic effects and maintain the relation between hepatic oxygen supply and uptake better than either halothane or enflurane [27]. It is well established that the inhalational agents will cause a reduction in hepatic flow [28], but major changes in hepatic blood flow are related more to the operation performed rather than to the anaesthetic agent used [29]. Thus, provided an adequate perfusion pressure and oxygen delivery are maintained, the effects of the inhalational agents are of only minor significance compared with the surgery itself. Halothane is best avoided because of its known hepatotoxicity [30,31]. Recent case reports indicate that all fluorinated anaesthetics have the potential to cause acute hepatic damage.

Anaesthetic management of major liver surgery

The main anaesthetic considerations include the presence of hepatic disease, the need to protect hepatic function, altered drug handling, electrolyte and metabolic changes, haemodynamic disturbances as a result of surgical manipulations and the ever-present risk of sudden and massive blood loss. In addition, there are often major haemostatic defects resulting from impaired liver function, compounded by the effects of dilutional coagulopathy.

Liver resection

Elective resection is usually performed to remove a solitary metastatic tumour, most commonly from a colonic primary. In recent years, the surgery has become more complex with multiple, non-anatomical resections performed. Also, more patients are being accepted with abnormalities of the liver parenchyma, commonly as a complication of chemotherapy.

Full invasive monitoring [central venous pressure (CVP) and arterial pressure lines] and adequate intravenous access (8 FG) for rapid transfusion is mandatory. Blood loss is a major problem with some of the more difficult resections, and various techniques have been developed to reduce the need for transfusion. These include the use of lower haemoglobin transfusion triggers, keeping the CVP low [32], and careful resection techniques using ultrasonic dissection, an argon beam coagulator, harmonic scalpels and tissue sealants. Vascular occlusion techniques (continuous or intermittent portal triad clamping) and total vascular exclusion are effective in decreasing blood loss, but prolonged ischaemia and reperfusion injury may cause liver damage. There is some evidence that N-acetylcysteine will provide a degree of protection from ischaemic reperfusion injury following vascular occlusion [33]. There is also increasing interest in ischaemic preconditioning to attenuate the potentially damaging effects of vascular occlusion, and benefits have been described in patients undergoing major resections [34,35].

Prophylactic administration of aprotinin during liver resection has been shown to reduce blood loss and transfusion requirements [36]. Recombinant factor VIIa may be useful as 'rescue' therapy where there is uncontrolled blood loss; however, its prophylactic use cannot be recommended as a recent study failed to demonstrate any difference in blood loss or transfusion requirements between the treatment and the placebo group, together with concerns that it may increase the risk of thrombotic events [37]. Although the coagulation profile in patients undergoing resection is usually normal or even hypercoagulable, dilution coagulopathy is a risk with high-volume transfusion. Prolongation of the prothrombin time (PT) for several days postoperatively is common on account of the remaining liver's reduced capacity to produce clotting factors, as there is loss of hepatic parenchyma together with variable degrees of postresection liver dysfunction.

Analgesia

A thoracic epidural with an opiate and low-dose bupivicaine mixture is effective for postoperative analgesia; however, as the PT is usually increased for 2–3 days after liver resection, care must be taken with the timing of catheter removal. It is of note that the analgesic requirements of live related donors appear to be higher than in those patients undergoing resection for tumours [38]. As a result of the longer surgical duration for donor hepatectomy, neuroplasticity may play a role in exaggerated postoperative pain perception along with various psychological factors.

Orthotopic liver transplantation

Anaesthesia for liver transplantation

In the absence of encephalopathy, oral temazepam can be given approximately 2 h preoperatively. Preoxygenation and rapid sequence induction may be necessary in patients with tense

ascites or obtunded neurology. Both propofol and thiopentone are suitable induction agents. Maintenance is with an air/oxygen mixture together with isoflurane or desflurane. Ventilation should be set to minimize basal atelectasis (positive end-expiratory pressure 5 cmH_2O). Nitrous oxide is avoided to reduce bowel distension, bubble formation with venovenous bypass (VVB) and cardiovascular depression. Increasing interest in 'fast tracking' for suitable patients has led to the use of shorter acting drugs, e.g. remifentanil. The use of epidurals in OLT for postoperative analgesia is somewhat contentious. While coagulation profiles may be acceptable preoperatively in certain patients (e.g. primary biliary cirrhosis), there is no guarantee that coagulopathy will not occur subsequently. Also, the analgesic requirements of liver transplant patients immediately postoperatively are usually very much less than those of patients who have equivalent major surgery such as liver resection [39].

Cardiovascular monitoring and venous access

The requirement to infuse large volumes of fluid rapidly necessitates dedicated wide-bore (e.g. Vygon 8/10 FG) transfusion cannulae. A quad-lumen central venous catheter is used for drug infusions and central venous monitoring. Pulmonary arterial flotation catheters are essential in patients with known pulmonary hypertension and can give valuable additional information (pulmonary capillary wedge pressure, CO, SVR, myocardial Vo_2 saturation) in all patients. Less invasive techniques for cardiac output monitoring include oesophageal Doppler and pulse counter analysis. Transoesophageal echocardiography (TOE) is used increasingly in many centres for haemodynamic assessment. Inferior vena caval pressure monitoring can give useful information about renal perfusion pressure [40].

Specific anaesthetic problems related to liver transplantation

Cardiovascular

Although most patients with cirrhosis have a hyperdynamic circulation with a high CO and a low SVR, vasopressors are not generally required except at the time of reperfusion when these changes may become even more profound. The anhepatic phase is associated with significant haemodynamic changes resulting from the cross-clamping of the inferior vena cava. This typically causes a 50% reduction in cardiac index (CI), but mean arterial pressure (MAP) is generally well maintained because of the compensatory increase in SVR. Most patients tolerate cross-clamping provided they are normovolaemic or slightly hypervolaemic before clamping. VVB has been shown to maintain venous return and cardiac filling pressures during the anhepatic phase; however, it limits rather than prevents the fall in CO [41]. Caval preservation techniques are increasingly used in many centres with the advantage that they limit the cardiovascular changes that occur and may reduce the need for VVB. At reperfusion, transient haemodynamic instability, mainly due to systemic vasodilation, is well recognized following reperfusion of the grafted liver. Where this effect is pronounced, it is called 'post-reperfusion syndrome' [42]. It is a result of the sudden release of ischaemic metabolites, cytokines and air emboli from the grafted liver and congested splanchnic circulation. In the majority of patients, the changes are transient; however, in a small percentage, the haemodynamic changes persist for several hours and require vasopressor support.

Renal

Patients undergoing OLT are at high risk of developing postoperative renal dysfunction. Factors that have been implicated include pre-existing renal dysfunction, acute changes in intraoperative haemodynamics and pharmacological agents influencing renal function (immunosuppressants, aminoglycoside antibiotics, etc.) and increased intraoperative transfusion of blood products. Markers of decreased glomerular filtration and tubular damage have been demonstrated in all patients during OLT, particularly in the anhepatic period [43]. Renal protective measures such as dopamine, mannitol and frusemide have all been used, although their efficacy is unproven. Although there are theoretical reasons for advocating the use of VVB (more stable haemodynamics and improved renal perfusion pressure) in patients with compromised renal function, evidence to date has failed to demonstrate any significant benefit [44].

Electrolyte and acid–base balance

Repeated analysis of blood gases and determination of ionized calcium, magnesium, potassium, sodium and glucose are essential during liver transplantation. Although many patients present with low potassium (< 4.0 mmol/L), this should be treated cautiously because of the sudden increase in potassium that can accompany reperfusion. Hypomagnesaemia is a common finding and may increase the risk of perioperative dysrhythmias unless corrected. Ionized hypocalcaemia resulting from citrate toxicity with the transfusion of large amounts of citrated blood and products can reduce myocardial contractility causing hypotension. Calcium chloride (not gluconate) should be given to maintain the ionized calcium at levels above 1.0 mmol/L.

Lactate levels rise progressively during the anhepatic stage and immediately after reperfusion. If graft function is good, the lactate acidosis will correct spontaneously within a few hours. Persistence of lactic acidosis is indicative of seriously impaired graft function [45].

Hypothermia

Potential causes of hypothermia during OLT include heat loss during presurgical preparation, evaporative loss, use of venovenous bypass without a heat exchanger, massive fluid replacement and reperfusion of the cold donor graft. Hypothermia (< 36°C) will exacerbate any coagulopathy. Methods of minimizing heat loss include the use of humidified anaesthetic gases, warming all intravenous fluids, heated underblankets and warm air convective warming blankets. It is of note that moderate hypothermia has recently been advocated for cerebral protection

in patients with acute liver failure undergoing OLT as it attenuates the intracranial pressure surges that can occur during the procedure [46].

Blood loss and transfusion

Early transplants were frequently complicated by massive blood loss, and transfusion of 40 units or more was not unusual. By 2004, the average transfusion for OLT was 3–4 units, with up to one third of patients receiving no red cell transfusion at all [47]. However, blood losses remain highly variable, and massive transfusion remains a problem in a proportion of OLT cases. Clotting data have not been found to be independent predictors of high blood loss in a number of studies [48]. The ability to rapidly infuse large volumes of warm transfusion fluids is crucial, and there are several systems that meet this requirement, e.g. the Fluid Management System (Belmont Instruments), which has a fluid reservoir, air and high-pressure alarms and can transfuse warmed fluids at rates up to 500 mL/min. Estimation of blood loss can be difficult, and transfusion requirements should be guided by intravascular filling pressures and serial haematocrit estimations. Autotransfusion systems are useful in OLT, but it is recommended that sodium citrate rather than heparin is used in the wash solution [49].

Coagulation

The type and severity of liver disease is a major determinant of the nature and extent of any pre-existing coagulopathy. Haemodilution will worsen any intrinsic haemostatic deficiencies. During the anhepatic period, there is a marked increase in tPA activity due to absent hepatic clearance. Reperfusion is associated with profound changes in coagulation, much of which is qualitative, transient and corrects spontaneously with the onset of graft function. Aggressive fibrinolysis can develop towards the end of the anhepatic period and after reperfusion and, consequently, the use of antifibrinolytics has been advocated in OLT. The synthetic antifibrinolytics [ε-aminocaproic acid (EACA) and tranexamic acid] reduce fibrinolysis, but have inconsistent effects on blood loss. Aprotinin, a naturally occurring serine protease inhibitor, is a potent antifibrinolytic, the mechanism of which appears to be dose related. A randomized controlled trial (RCT) of low-dose infusion (200 000 kIU/h) vs. control subjects demonstrated reduced fresh frozen plasma (FFP) usage and a reduced incidence of fibrinolysis, but no difference in red cell usage [50]. Porte *et al.* [51], in a larger multicentre RCT, demonstrated a significant reduction (40%) in intraoperative blood loss in patients given high-dose aprotinin. There are some concerns about adverse effects, including anaphylaxis and the potential (but unproven) risk of increased thromboembolic events. Recombinant factor VIIa has also been used in OLT and in acute liver failure. While it shortens prolonged prothrombin times and alters clot tensile strength, further studies are required to determine its safety in this setting [52].

A 'heparin' effect has also been described at the time of reperfusion, which may require treatment with protamine.

Coagulation monitoring

Because of the complexity of coagulation disorders and the rapidity with which changes can occur, it is essential to monitor coagulation serially. Conventional clotting screens (prothrombin time, partial thromboplastin time and platelet count) give little information on the quality or the stability of the blood clot, and long turnaround times for laboratory-based tests limit their relevance in the face of ongoing blood loss. There is considerable variability in transfusion thresholds used for FFP and platelets between the different centres [53]. Whole blood viscoelastic tests of clot tensile strength [thromboelastography (TEG) and rotational thromboelastogram (ROTEM)] have been found to reduce the transfusion of blood and blood products in OLT [54,55]. They provide a global analysis of the whole coagulation process, giving information about coagulation factors, platelet number and function and any fibrinolytic activity. Running simultaneous heparinase and native TEGs will differentiate any heparin effect from other concurrent coagulation defects.

References

1 Mansour A, Watson W, Shayani V *et al.* (1997) Abdominal operations in patients with cirrhosis: still a major surgical challenge. *Surgery* 122, 730–736.

2 Garrison RN, Cryer HM, Howard DA *et al.* (1984) Clarification of risk factors for abdominal operations in patients with hepatic cirrhosis. *Ann Surg* 199, 648–655.

3 Shih LY, Cheng CY, Chang CH *et al.* (2004) Total knee arthroplasty in patients with liver cirrhosis. *Am J Bone Joint Surg* 86, 335–341.

4 Sirinek KR, Burk RR, Brown M *et al.* (1987) Improving survival in patients with cirrhosis undergoing major abdominal operations. *Arch Surg* 122, 271–273.

5 Patel T (1999) Surgery in the patient with liver disease. *Mayo Clin Proc* 74, 593–599.

6 Fernandez-Seara J, Prieto J, Quiroga J *et al.* (1989) Systemic and regional hemodynamics in patients with liver cirrhosis and ascites with and without functional renal failure. *Gastroenterology* 97, 1304–1312.

7 Myers RP, Lee SS (2000) Cirrhotic cardiomyopathy and liver transplantation. *Liver Transpl* 6, S44–52.

8 Yang YY, Lin HC, Lee WC *et al.* (2001) Portopulmonary hypertension: distinctive hemodynamic and clinical manifestations. *J Gastroenterol* 36, 181–186.

9 Ramsay MA, Simpson BR, Nguyen AT *et al.* (1997) Severe pulmonary hypertension in liver transplant candidates. *Liver Transpl Surg* 3, 494–500.

10 Mandell MS, Duke J (1994) Nitric oxide reduces pulmonary hypertension during hepatic transplantation. *Anesthesiology* 81, 1538–1542.

11 Carey WD, Dumot JA, Pimentel RR *et al.* (1995) The prevalence of coronary artery disease in liver transplant candidates over the age of 50. *Transplantation* 59, 859–864.

12 Schenk P, Fuhrmann V, Madl C *et al.* (2002) Hepatopulmonary syndrome: prevalence and predictive value of various cut offs for arterial oxygenation and their clinical consequences. *Gut* 51, 853–859.

13 Solanki P, Chawla A, Garg R *et al.* (2003) Beneficial effects of terlipressin in hepatorenal syndrome: a prospective, randomized placebo-controlled clinical trial. *J Gastroenterol Hepatol* 18, 152–156.

14 Friedrich AD, Choi EK, D'Ambra MN (2005). Renal-dose dopamine: another nail in the coffin. *Crit Care Med* 33, 1447–1448.

15 Larner AJ, Vickers CR, Adu D *et al.* (1988) Correction of severe hyponatraemia by continuous arteriovenous haemofiltration before liver transplantation. *Br Med J* 297, 1514–1515.

16 Lampl C, Yazdi K (2002) Central pontine myelinolysis. *Eur Neurol* 47, 3–10.

17 Flier JS, Kahn CR, Roth J (1979) Receptors, antireceptor antibodies and mechanisms of insulin resistance. *N Engl J Med* 300, 413–419.

18 Mammen EF (1994) Coagulation defects in liver disease. *Med Clin North Am* 78, 545–554.

19 Segal H, Cottam S, Potter D *et al.* (1997) Coagulation and fibrinolysis in primary biliary cirrhosis compared with other liver disease and during orthotopic liver transplantation. *Hepatology* 25, 683–688.

20 Leebeek FW, Kluft C, Knot EA *et al.* (1991) A shift in balance between profibrinolytic and antifibrinolytic factors causes enhanced fibrinolysis in cirrhosis. *Gastroenterology* 101, 1382–1390.

21 Cordoba J, Blei AT (1995) Cerebral edema and intracranial pressure monitoring. *Liver Transpl Surg* 3, 187–194.

22 Williams RL (1983) Drug administration in hepatic disease. *N Engl J Med* 309, 1616–1622.

23 Maze M, Bass NM (2000) Anaesthesia and the hepatobiliary system. In: Miller RD (ed.) *Anaesthesia*. Edinburgh: Churchill Livingstone, pp. 1960–1973.

24 Branch RA (1987) Is there increased cerebral sensitivity to benzodiazepines in chronic liver disease? *Hepatology* 4, 773–776.

25 Mullen KD, Jones EA (1996) Natural benzodiazepines and hepatic encephalopathy. *Sem Liver Dis* 16, 255–264.

26 O'Riordan J, O'Beirne HA, Young Y *et al.* (1997) Effects of desflurane and isoflurane on splanchnic microcirculation during major surgery. *Br J Anaesth* 78, 95–96.

27 Matsumoto N, Rorie DK, Van Dyke RA (1987) Hepatic oxygen supply and consumption in rats exposed to thiopental, halothane, enflurane, and isoflurane in the presence of hypoxia. *Anesthesiology* 66, 337–343.

28 Larson CP, Mazze RI, Cooperman LH *et al.* (1974) Effects of anaesthetics on cerebral, renal and splanchnic circulations: recent developments. *Anaesthesiology* 41, 169–178.

29 Gelman SI (1976) Disturbances in hepatic blood flow during anesthesia and surgery. *Arch Surg* 111, 881–883.

30 Brown BR Jr (1981) Pharmacogenetics and the halothane hepatitis mystery. *Anesthesiology* 55, 93–94.

31 Neuberger J, Williams R (1984) Halothane anaesthesia and liver damage. *Br Med J* 289, 1136–1139.

32 Jones RM, Moulton CE, Hardy KJ (1998) Central venous pressure and its effect on blood loss during liver resection. *Br J Surg* 85, 1058–1060.

33 Glantzounis GK, Yang W, Koti RS *et al.* (2004) Continuous infusion of N-acetylcysteine reduces liver warm ischaemia-reperfusion injury. *Br J Surg* 91, 1330–1339.

34 Rudiger H, Kang KJ, Sindram D *et al.* (2002) Comparison of ischaemic preconditioning, intermittent and continuous inflow occlusion in murine liver. *Ann Surg* 235, 400–407.

35 Clavien PA, Selzner M, Rudiger HA *et al.* (2003) A prospective randomized study in 100 consecutive patients undergoing major liver resection with versus without ischaemic preconditioning. *Ann Surg* 238, 843–850.

36 Lentschener C, Benhamou D, Mercier FJ *et al.* (1997) Aprotinin reduces blood loss in patients undergoing elective liver resection. *Anesth Analg* 84, 875–881.

37 Lodge JP, Jonas S, Ossoultzoglou E *et al.* (2005) Recombinant coagulation factor VIIa in major liver resection: a randomized, placebo-controlled, double-blind clinical trial. *Anesthesiology* 102, 269–275.

38 Cywinski JB, Parker BM, Xu M *et al.* (2004) A comparison of postoperative pain control in patients after right lobe donor hepatectomy and major hepatic resection for tumor. *Anesth Analg* 99, 1747–1752.

39 Moretti EW, Robertson KM, Tuttle-Newhall JE *et al.* (2002) Orthotopic liver transplant patients require less postoperative morphine than do patients undergoing hepatic resection. *J Clin Anesth* 14, 416–420.

40 Peachey T, Eason J, Potter D *et al.* (1989) Observations on abdominal venous pressures during orthotopic liver transplantation in man. *Transplant Proc* 21, 3526–3527.

41 Paulsen AW, Whitten CW, Ramsay MA *et al.* (1989) Considerations for anesthetic management during veno-venous bypass in adult hepatic transplantation. *Anesth Analg* 68, 489–496.

42 Aggarwal S, Kang Y, Freeman JA *et al.* (1987) Postreperfusion syndrome: cardiovascular collapse following hepatic reperfusion during liver transplantation. *Transplant Proc* 19, 54–55.

43 Grande L, Rimola A, Cugat E *et al.* (1996) Effect of venovenous bypass on perioperative renal function in liver transplantation: results of a randomized, controlled trial. *Hepatology* 23, 1418–1428.

44 Reddy K, Mallett SV, Peachy T (2005) Venovenous bypass in orthotopic liver transplantation: time for a rethink? *Liver Transplantation* 11, 741–749.

45 Fortunato FL Jr, Kang Y, Aggarwal S *et al.* (1987) Acid-base status during and after orthotopic liver transplantation. *Transplant Proc* 19, 59–60.

46 Jalan R, Olde Damink SW, Deutz NE *et al.* (2003) Moderate hypothermia prevents cerebral hyperemia and increase in intracranial pressure in patients undergoing liver transplantation for acute liver failure. *Transplantation* 75, 2034–2039.

47 Massicotte L, Sassine MP, Lenis S *et al.* (2004) Transfusion predictors in liver transplant. *Anesth Analg* 98, 1245–1251.

48 Findlay JR, Rettke SR (2000) Poor prediction of blood transfusion requirements in adult liver transplantation from preoperative variables. *J Clin Anesth* 12, 319–323.

49 Kang Y, Aggarwal S, Virji M *et al.* (1991) Clinical evaluation of autotransfusion during liver transplantation. *Anesth Analg* 72, 94–100.

50 Marcel RJ, Stegall WC, Suit CT *et al.* (1996) Continuous small-dose aprotinin controls fibrinolysis during orthotopic liver transplantation. *Anesth Analg* 82, 1122–1125.

51 Porte RJ, Molenaar IQ, Begliomini B *et al.* (2000) Aprotinin and transfusion requirements in orthotopic liver transplantation: a multicentre randomised double-blind study. EMSALT Study Group. *Lancet* 355 (9212), 1303–1309.

52 Pavese P, Bonadona A, Beaubien J *et al.* (2005) FVIIa corrects the coagulopathy of fulminant hepatic failure but may be associated with thrombosis: a report of four cases. *Can J Anaesth* 52, 26–29.

53 Ozier Y, Pessione F, Samain E *et al.* (2003) Institutional variability in transfusion practice for liver transplantation. *Anesth Analg* 97, 671–679.

54 Kang YG, Martin DJ, Marquez J *et al.* (1985) Intraoperative changes in blood coagulation and thrombelastographic monitoring in liver transplantation. *Anesth Analg* 64, 888–896.

55 Kang Y (1997) Transfusion based on clinical coagulation monitoring does reduce hemorrhage during liver transplantation. *Liver Transpl Surg* 3, 655–659.

24.3 Postoperative jaundice

Peter Fickert and Michael Trauner

Introduction

Postoperative jaundice can be an important problem in patients following major thoracic and abdominal surgery such as prosthetic heart valve replacement, bypass and aortic operations or trauma and burns [1–4]. Frank jaundice in patients without pre-existing liver disease is rare (less than 1% of patients), and its appearance should prompt a meticulous workup of the underlying cause. The clinical appearance of jaundice in the postoperative setting often reflects a multitude of systemic insults, is usually isolated and is rarely associated with liver failure in patients without pre-existing liver disease. The pathophysiology of jaundice in postoperative patients is complex and not well understood, and there may be multiple causative factors. So it is not surprising that, in numerous cases, no isolated, single cause of jaundice can be identified, and it is more probable that the exact aetiology will remain unclear in a high percentage of patients. This section outlines current pathophysiological concepts of postoperative jaundice and provides a diagnostic algorithm for the workup of such patients. Postoperative jaundice usually subsides without specific therapeutic intervention. Therapeutic options for postoperative jaundice are limited but are discussed insofar as they are available.

Pathophysiological considerations

Jaundice in postoperative patients may be caused either by overproduction of bilirubin or by the failure of the liver to excrete bilirubin, bile acids and other cholephiles, resulting in cholestasis (for details, see Chapter 3.4). As both hepatocytes and cholangiocytes participate in normal bile secretion (for details, see Chapter 2.6.1), both cell types may be affected, and bile secretion may be inhibited at different levels in a patient with post-operative jaundice (summarized in Fig. 1).

Bilirubin overproduction

Blood transfusions and resorption of large haematomas may contribute to an increased bilirubin load. As a rule of thumb, approximately 10% of erythrocytes in a transfused unit of stored whole blood undergo haemolysis within 24 h. Most cases of jaundice occur within the first 2 weeks after surgery. As the healthy liver has a high capacity to conjugate bilirubin (~ 250 mg/day, which equals the breakdown products of 50 mL of blood), jaundice will not develop as long as bilirubin production does not exceed three times the normal level. Other conditions leading to increased bilirubin load include haemolytic processes such as glucose-6-phosphate dehydrogenase deficiency, sickle cell crisis, haemoglobinopathies, autoimmune haemolytic anaemia, drugs and mechanical haemolysis by heart valves.

Other causes of jaundice

Hypoxic liver injury is a common cause of postoperative jaundice. Although hypotension is important for ischaemic (hypoxic) hepatitis, low perfusion pressure alone is not enough to produce this characteristic clinical picture [5,6]. Trauma victims with a documented episode of hypotension longer than 15 min did not develop ischaemic (hypoxic) hepatitis in a prospective study [5], reflecting the relative resistance of the liver to (isolated) ischaemia and underlining the importance of pre-existing, in most cases right-sided, congestive heart failure in about 90% of cases of ischaemic hepatitis [7]. As patients undergoing heart surgery usually have underlying cardiac disease (e.g. chronic congestive heart failure), they have an increased risk of developing ischaemic hepatitis. Most notably, a prolonged period of hypotension is not necessary; rather, a transient episode of hypotension may be sufficient in a predamaged liver. It is important to stress that a shock state is not the only cause of hypoxic hepatitis [7–9]. Chronic respiratory failure may also make the liver vulnerable to hypoxic hepatitis (e.g. chronic obstructive pulmonary disease, sleep apnoea syndrome) [10]. Accidental ligation of the hepatic artery (usually during cholecystectomy or trauma-related major abdominal surgery) can also result in hepatic ischaemia. The relevance of reduced oxygen tension for the development of ischaemic/hypoxic liver injury is emphasized by the characteristic histological picture of

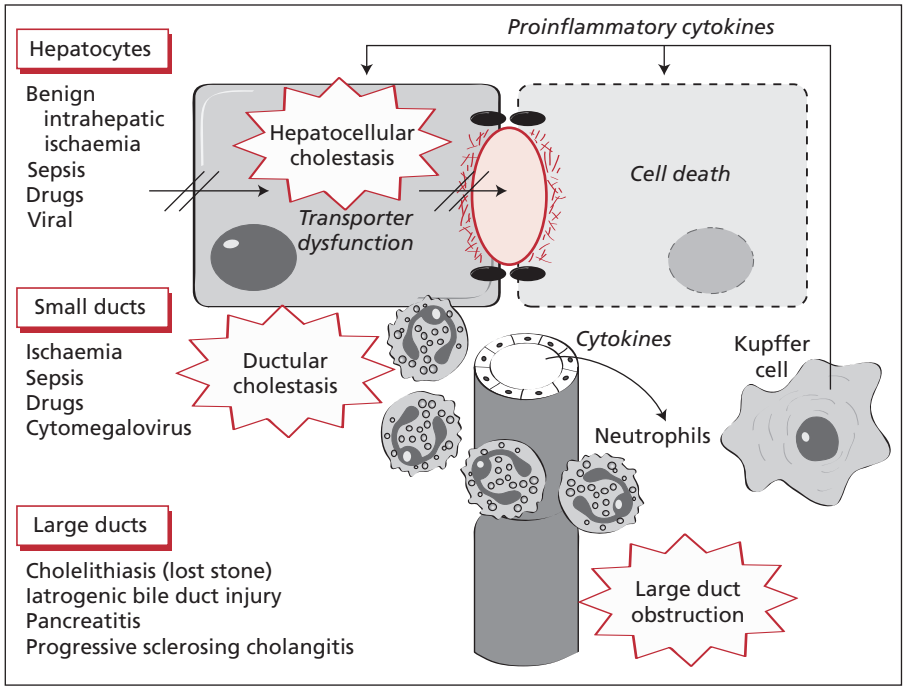

Fig. 1 Overview of the different anatomical levels of cholestasis leading to postoperative jaundice. Cholestasis may result either from a functional defect in bile formation at the hepatocellular level (hepatocellular cholestasis) or from impairment in secretion or bile flow at the level of small bile ducts (ductular cholestasis) or large ducts (large duct obstruction). Experimental evidence suggests a critical role for proinflammatory cytokines and nitric oxide as Kupffer cell-derived mediators of cholestasis at the hepatocellular and ductular levels. Portal inflammatory infiltrates reflect the capability of the bile duct epithelium to actively secrete cytokines and recruit inflammatory cells (e.g. neutrophil granulocytes), which results in impaired ductular bile secretion and/or portal/periductal inflammation. Possible specific causes are listed below the different anatomical levels of cholestasis.

centrolobular necrosis, as hepatocytes in this position are more vulnerable to oxygen depletion.

Drug-induced liver injury in the postoperative period may present as hepatocellular, cholestatic or mixed injury (for details, see also Chapter 14.1). Most drug reactions are unpredictable metabolic or immunological idiosyncrasies [11]. The majority of cases present as hepatocellular/hepatic injury, while one-third of cases present with cholestatic or mixed injury [12]. Some drugs such as β-lactam antibiotics typically present with cholestasis rather than hepatitis. In the postoperative setting, heparins, antibiotics, analgesics and non-steroidal anti-inflammatory drugs (NSAIDs) are among the leading causes of drug-induced liver disease [12,13]. Historically, anaesthetics (e.g. halothane) represented a frequent cause of drug-induced hepatitis.

Paracetamol is increasingly used as an analgesic in the postoperative period and is a dose-dependent hepatotoxin that is usually safe in doses below 8 g/day [14]. However, patients with chronic alcohol consumption only tolerate considerably lower (therapeutic) paracetamol doses (4–6 g/day) [15]. As a result of induction of the cytochrome P-450 2E1 enzyme, these patients generate larger quantities of the toxic metabolite of paracetamol; moreover, depletion of glutathione stores increases susceptibility to the toxic metabolite [15].

The incidence of halothane hepatitis has been estimated to be 1 per 10 000 administrations [16], but it is no longer commonly used in Europe and the United States. The ability of anaesthetic agents to cause liver injury is directly related to their degree of biotransformation (halothane 20%, enflurane 2%, sevoflurane 1%, isoflurane/desflurane 0.2%) [1].

Drugs can cause bland cholestasis by direct inhibition and/or downregulation of hepatobiliary transport systems (e.g. ciclosporin A, sex steroids, glibenclamide and bosentan) [17]. Moreover, drug-induced cholestasis may result from dose-independent idiosyncratic reactions that lead to inflammation-induced cholestasis (cholestatic hepatitis). Typical examples include amoxicillin–clavulanic acid (incidence 1:100 000), flucloxacillin (1:15.000), macrolides and antifungal agents such as ketoconazole and terbinafine (for details, see Chapter 14.1). Rarely, drugs may also lead to prolonged or even chronic cholestasis by ductopenia (vanishing bile duct syndrome), cholelithiasis or biliary crystal formation (e.g. ceftriaxone) [18] (for details, see Chapter 11.4).

Sepsis-induced cholestasis is predominantly linked to infections with Gram-negative bacteria [19]. Experimental evidence obtained from endotoxin-challenged rodents suggests a critical role for lipopolysaccharide-induced release of Kupffer cell-derived proinflammatory cytokines (for details, see Chapter 2.7.1). The induction of proinflammatory cytokines leads to a coordinated reduction in the expression and function of hepatocellular transporters involved in bile formation [18,19]. Moreover, hepatocyte gap and tight junction proteins may be affected by all these inflammatory mediators [19]. At the bile duct level, proinflammatory cytokines and nitric oxide production may fundamentally alter bile duct epithelial cell tight junction/barrier function as well as ductal bile secretion and, in consequence, reduce ductal bile formation [20]. Bile duct epithelial cells could significantly contribute to the inflammatory response of the liver in this setting and cause or perpetuate cholangitis as a result of the generation of a reactive phenotype of bile duct epithelial cells [20,21].

Benign postoperative intrahepatic cholestasis (idiopathic postoperative cholestasis) is usually seen after cardiac (10–20%)

or major abdominal surgery. The syndrome was described by Schmid *et al.* in 1965 [22] and is 'characterized' by the lack of a specific cause for the observed conjugated hyperbilirubinaemia. The pathophysiology of this syndrome remains poorly defined and understood. Cholestasis most probably results from intermittent hepatocellular dysfunction caused by liver ischaemia/hypoxia (e.g. decreased hepatic blood flow due to blood loss, anaesthetic agents and hypotension). Moreover, the dose-dependent reduction in hepatic blood flow resulting from anaesthetic agents may also be of relevance for the development of hypoxic liver injury. Similar to sepsis-induced cholestasis, Kupffer cell-derived proinflammatory cytokines [e.g. tumour necrosis factor (TNF)α, interleukin (IL)-β, IL-6] may be critical in the pathogenesis of benign postoperative intrahepatic cholestasis.

Chronic bacterial translocation and the induction of proinflammatory cytokines, probably together with the increased formation of toxic bile acids in the gut (such as lithocholic acid), may be critical for the pathogenesis of *total parenteral nutrition (TPN)-induced cholestasis* [23]. It is still a subject of controversy whether the length of the remaining small bowel after resection and/or the initiation or perpetuation of a chronic inflammatory state (e.g. by the nutrition itself) are pathogenetically relevant factors for the development of TPN-induced cholestasis [24–26]. Moreover, TPN may cause jaundice via biliary complications such as acalculous cholecystitis, biliary sludge leading to biliary obstruction or cholecystitis [23].

Acalculous cholecystitis may develop in 4% of patients receiving TPN for longer than 3 months [27]. Bile stasis, increased gallbladder wall pressure, gallbladder ischaemia (e.g. caused by blood loss) and bacterial invasion are critical for gallbladder injury in these patients. Prolonged hypotension during or after major surgery may also be critical for the development of this syndrome [28]. Acalculous cholecystitis may be caused or preceded by sepsis and is usually associated with gallbladder/bile infection by Gram-negative bacteria in critically ill patients (especially in diabetics and immunocompromised individuals). Severe swelling of the gallbladder may also lead to obstruction of the common bile duct and, in consequence, to obstructive cholestasis.

The rare entity of *progressive sclerosing cholangitis* in critically ill patients is typically observed after severe burns, septic shock syndrome or trauma, but its pathogenesis remains poorly understood [21,29–31]. As the bile duct epithelium is nourished by branches of the hepatic artery, and similar pictures have also been observed after intra-arterial application of cytotoxic substances, it is tempting to speculate that deprivation of the arterial supply of bile ducts may be critical for the development of this rare entity [2]. In addition, modified bile composition in the sense of toxic bile (e.g. via inflammatory-induced downregulation of the phospholipid export pump MDR3 and subsequently decreased phospholipid secretion) may be of relevance. However, these novel concepts deserve deeper mechanistic and clinical studies.

Postoperative jaundice may rarely be related to *surgical problems*. Bile duct injury (more common) and retained common bile duct stones following cholecystectomy and other upper abdominal surgery may represent the primary cause. Postoperative pancreatitis after cardiac or abdominal surgery may also cause bile duct obstruction because of oedema of the head of the pancreas.

Patients with pre-existing liver disease are at increased risk of developing postoperative jaundice and acute-on-chronic liver failure. Specific pathophysiological considerations of peri- and postoperative problems in patients with pre-existing chronic liver diseases are discussed elsewhere in this book (see Chapters 24.1 and 24.2).

Diagnostic clues, differential diagnosis and treatment options

A careful history and physical examination in conjunction with assessment of the type of surgery performed, the number of blood products transfused, significant alterations in perioperative haemodynamic parameters and medications used are mandatory in the assessment of postoperatively jaundiced patients (see Table 1). Consideration of the clinical circumstances in combination with the pattern and time course of the abnormalities in liver chemistry is sufficient to establish the diagnosis in most cases. From a practical clinical point of view, it may be appropriate to distinguish between early postoperative jaundice (occurring within less than 3 weeks after surgery), mostly caused by overproduction of bilirubin, as well as by sepsis-induced cholestasis, ischaemia/hypoxia-induced hepatitis, idiopathic postoperative cholestasis and acalculous cholecystitis, and late postoperative jaundice (occurring more than 3 weeks after surgery), which may be related to idiosyncratic drug reactions, total parenteral nutrition and, rarely, secondary sclerosing cholangitis (Table 1). Exclusion of obstructive/mechanical cholestasis by ultrasound and, rarely, other imaging studies [computerized tomography (CT) scan, magnetic resonance cholangiopancreatography (MRCP), cholescintigraphy (HIDA scan)] is mandatory whenever a manifestation is seen. Whenever possible, management of postoperative jaundice must be primarily aimed at treatment of the underlying cause. Even in conditions without specific treatment, correct diagnosis is important, as the prognostic implications of postoperative jaundice depend on the underlying cause. A potential diagnostic algorithm is summarized in Figure 2.

Hyperbilirubinaemia due to resorption of extravasated blood is seen more often following trauma surgery and in patients surviving a ruptured aortic aneurysm. Patients with massive haemolysis or haematoma who need multiple blood transfusions often have significant systemic illnesses and haemodynamic compromise, which together with increased bilirubin production further increases the degree of jaundice. Haemolytic processes should be considered in patients with predominantly unconjugated hyperbilirubinaemia (usually < 5 mg/dL),

Table 1 The assessment of postoperatively jaundiced patients.

Cause	Clinical setting/laboratory values
Early postoperative jaundice (< 3 weeks after surgery)	
Bilirubin overproduction	History of blood transfusions, resorption of haematomas, history of polytrauma, haemolytic processes, absence of biliary obstruction, isolated increase in (mostly unconjugated) bilirubin, LDH sometimes elevated (haemolysis, trauma)
Ischaemic hepatitis	Episode of prolonged hypoxaemia or shock; right-sided-heart failure; very high ALT levels (> 2000 U/L), AST/ALT ratio > 1
Sepsis-induced cholestasis	Extrahepatic infections such as pneumonia or diverticulitis, infection with Gram-negative bacteria
Surgical complications	Type of surgery (e.g. cholecystectomy, bile duct or hepatic surgery); dilated biliary tree on biliary imaging
Acalculous cholecystitis	Right upper quadrant pain, thickened gallbladder wall on abdominal sonography, association with Gram-negative sepsis, diabetics or immunocompromised patients
Drug-induced (dose-dependent)	History of NSAIDs, paracetamol
Benign postoperative intrahepatic cholestasis	Cardiac surgery, lack of specific cause for hyperbilirubinaemia, ALT normal or only mildly elevated; unconjugated hyperbilirubinaemia
Late postoperative jaundice (> 3 weeks after surgery)	
Drug-induced (idiosyncratic reactions)	Fever, pruritus, lymphadenopathy, arthralgias, skin rash and eosinophilia, history of amoxicillin–clavulanic acid, macrolides, ketoconazole
Total parenteral nutrition	Short bowel syndrome, remaining gut length < 50 cm
Progressive sclerosing cholangitis	Severe burns or septic shock, prolonged bilirubin and AP elevations, bile duct strictures and dilatations on ERCP or MRCP

ALT, alanine aminotransferase; AP, alkaline phosphatase; AST, aspartate aminotransferase; LDH, lactate dehydrogenase; ERCP, endoscopic retrograde cholangiopancreatography; MRCP, magnetic resonance cholangiopancreatography.

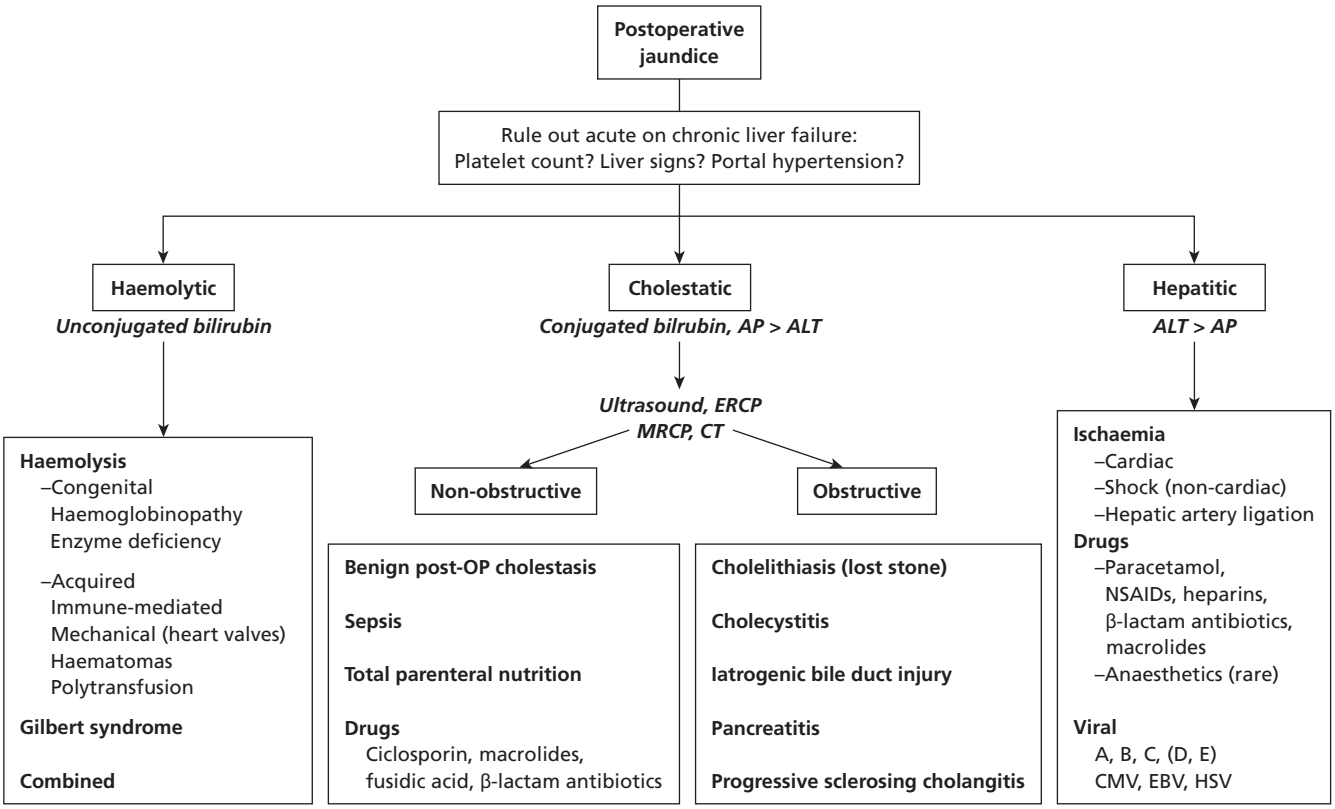

Fig. 2 Proposed diagnostic algorithm in patients with postoperative jaundice. It is essential first to exclude pre-existing (occult) liver disease in patients with postoperative jaundice. From a practical point of view, haemolytic, cholestatic and hepatic enzyme patterns should be distinguished by determination of unconjugated/conjugated bilirubin, alkaline phosphatase (AP) and alanine aminotransferase (ALT) serum levels. Biliary obstruction should be ruled out with abdominal ultrasound in every patient. CMV, cytomegalovirus; CT, computerized tomography; EBV, Epstein–Barr virus; ERCP, endoscopic retrograde cholangiopancreatography; HSV, herpes simplex virus; MRCP, magnetic resonance cholangiopancreatography; NSAIDs, non-steroidal anti-inflammatory drugs.

elevated aspartate aminotransferase (AST) and lactate dehydrogenase (LDH) (derived from decomposed blood cells), reduced serum haptoglobin levels, coexistent anaemia, reticulocytosis and schistocytes on peripheral blood smear in the absence of significantly elevated alanine aminotransferase (ALT) and alkaline phosphatase (AP) levels. The conjugated bilirubin may sometimes be elevated because of the rate-limiting effect of hepatic bilirubin excretion into bile. Hyperbilirubinaemia without signs of haemolysis may be related to Gilbert syndrome, which is the most common trivial cause of postoperative hyperbilirubinaemia, considering that 5–10% of the population have this benign defect in bilirubin conjugation. This condition is typically aggravated by starvation, infection stress and sleep deprivation (all of which are frequently present in hospitalized patients). Serum bilirubin levels do not usually exceed 5 mg/dL and – in contrast to increased bilirubin load resulting from haemolysis and haematomas – the conjugated bilirubin levels remain within the normal range. Gilbert syndrome should also be considered after liver transplantation with persistent hyperbilirubinaemia resulting from transplantation of a Gilbert liver [32]. Moreover, the presence of Gilbert syndrome in combination with an increased bilirubin load may result in higher serum bilirubin levels up to 10 mg/dL. Gilbert syndrome does not require specific treatment, but recognition of this entity is essential to avoid unnecessary investigations.

Ischaemic/hypoxic hepatitis should be suspected in patients with rapid (< 24 h) increases in ALT levels to 10–100 times the upper limit of the normal value in combination with markedly elevated LDH levels after episodes of hypotension and respiratory compromise [5,6]. A key diagnostic factor is the rapid reversibility of ischaemic hepatitis once the underlying cause is corrected. In viral or drug-induced hepatitis, the abnormal results subside more slowly. Usually, there is a rapid rise and fall in AST and ALT levels, and the elevations last 3–11 days [33]. The incidence of coagulopathy and encephalopathy in ischaemic hepatitis is low and rarely progresses to full-blown hepatic failure. Mortality is high in such patients but rarely liver related. Another diagnostic clue is a de Ritis ratio (AST/ALT) > 1. The diagnosis is usually based on clinical criteria but, if a liver biopsy is performed to rule out other causes of liver injury, centrolobular necrosis is typically observed. In general, a common denominator of patients suffering from ischaemic hepatitis is the high incidence of underlying cardiac disease with predominance of right-sided heart failure [7–9]. Consequently, patients undergoing cardiovascular bypass surgery are at increased risk of ischaemic liver injury. Jaundice can occur in up to 25% of these cases.

In contrast, benign postoperative intrahepatic cholestasis (idiopathic postoperative cholestasis) is usually seen within 1–2 weeks after major surgery (e.g. prosthetic heart valve replacement, bypass and aortic surgery) and presents with elevated serum levels of mainly conjugated bilirubin with levels up to 40 mg/dL but normal or mildly elevated serum aminotransferases. If a liver biopsy is performed (which is not usually the case nowadays), it reveals a picture of bland intrahepatic cholestasis with no or minimal hepatocellular damage. As the name implies, the clinical course is usually benign and the hyperbilirubinaemia resolves within days to weeks. In clinical reality, this entity can often hardly be distinguished from cholestasis due to inflammatory response syndrome with or without infection/sepsis, especially in critically ill patients.

Drug-induced liver injury usually occurs later than ischaemic/hypoxic liver injury in the postoperative patient [11,34] as most adverse drug reactions are idiosyncratic, with a typical latency period ranging from 2–10 weeks (immunoallergic idiosyncrasies) to 6–26 weeks (metabolic idiosyncrasies). Only a few dose-dependent hepatotoxins (e.g. paracetamol) can cause hepatotoxicity immediately (see below). If a patient has been taking a drug for longer than 6–12 months, it is highly unlikely that this drug is responsible for the current liver injury in the postoperative period. Likewise, a newly prescribed drug rarely causes liver injury before 2–3 weeks, as mentioned above. Consequently, another important exception to this characteristic time course is rechallenge in a sensitized patient with a previous episode of an immunoallergic drug reaction (e.g. β-lactam antibiotics). It is therefore essential to consider in the differential diagnosis drugs received within the last weeks before surgery rather than those prescribed recently. Some drugs (e.g. antibiotics) may already have been discontinued at the time of presentation. Presenting features favouring an idiosyncratic immunological reaction include fever, pruritus, lymphadenopathy, arthralgias and eosinophilia. Clinically important causes of cholestatic hepatitis include amoxicillin–clavulanic acid, flucloxacillin, macrolides and antifungals (for details, see Chapters 14.1 and 19.1). In most cases, ALT levels are only mildly elevated (> fivefold the upper limit, ALT/AP ratio < 2). In a recent series on drug-induced liver injury that was based on a nationwide cooperative network in Spain, amoxicillin–clavulanic acid was the most common drug leading to jaundice [13]. In general, anti-infectious drugs were the leading pharmacological group (32%) leading to idiosyncratic liver injury in this study, underlining the potential importance of such agents in the postoperative setting. In another recent cohort study in over 4000 patients during hospitalization, heparins where the leading cause of drug-induced liver injury, followed by antibacterials, NSAIDs, tuberculostatics and antineoplastic drugs [12].

Risk factors for halothane hepatitis include age over 30 years, female gender, obesity and multiple exposures within short intervals [35]. Aminotransferase levels may be markedly elevated (up to 10-fold the upper limit), and severe liver injury is associated with encephalopathy and coagulopathy. Liver biopsy in halothane hepatitis reveals an uncharacteristic histological picture with massive panlobular necrosis. However, liver injury from isoflurane, sevoflurane and desflurane is much less common [1].

Paracetamol is frequently used in the postoperative period but represents a dose-dependent hepatotoxin [14], which should receive special consideration in patients with chronic alcohol consumption and pre-existing liver disease, as these patients are prone to paracetamol-induced liver injury.

Identification of the causative or suspected drug(s) and their immediate withdrawal are most effective. There is no established role for steroids in the treatment of acute drug-induced liver injury [36], but ursodeoxycholic acid (UDCA) may be considered in cases with prolonged cholestasis (for details, see Chapter 14.1).

Infection- and sepsis-induced cholestasis is one of the most frequent causes of jaundice in hospitalized patients. In a recent study, sepsis-induced cholestasis was the second leading cause of jaundice in hospitalized patients; it was far more frequent than drug- or viral-induced cholestasis and was surpassed only by (malignant) biliary obstruction [37], underlining the clinical significance of this entity. It is predominantly associated with infections with Gram-negative bacteria (e.g. *Escherichia coli*, *Klebsiella pneumoniae*, *Pseudomonas aeruginosa*, *Haemophilus influenzae*, *Proteus* spp. and *Bacteroides* spp.) [19]. *E. coli* is the most prominent causative agent, but patients suffering from *Staphylococcus aureus* sepsis may have the poorest prognosis [38]. In most cases, the primary source of infection is intra-abdominal (e.g. diverticulitis, peritonitis), followed by pneumonia, endocarditis, pyelonephritis and soft-tissue abscesses. Usually, elevations in serum bilirubin levels (< 75% conjugated bilirubin between 5 and 10 mg/dL; uncommonly rising up to 30–50 mg/dL) are disproportionately high in the presence of normal or minimally elevated serum AP and ALT levels and, occasionally, there is only isolated (conjugated) hyperbilirubinaemia in septic patients [19]. LDH levels are usually within the normal range. Serum bile acid levels are typically elevated but are rarely determined in routine clinical practice. Jaundice usually manifests within 2 to 7 days after the beginning of bacteraemia. The diagnosis is based on the typical clinical picture comprising fever in a jaundiced patient with predominately conjugated hyperbilirubinaemia and only modest or mild elevations of ALT; the disease resolves under suitable antibiotic therapy. However, this syndrome may overlap with benign postoperative intrahepatic cholestasis (see above). Histologically, the most prominent feature is intrahepatic cholestasis with Kupffer cell hyperplasia, portal mononuclear cell infiltrates and focal hepatocyte dropout [19]. An unusual manifestation of sepsis-associated cholestasis is characterized by periductal cholangiocytes (cholangitis lenta) and inspissated bile within periportal ductules; such patients have higher mortality [39]. Liver biopsy is not required for the diagnosis of sepsis-related jaundice. Persistent or increasing hyperbilirubinaemia may be indicative of ongoing or inadequately treated infection and is associated with the worst outcome. Persistently high AP and γ-glutamyltransferase (GGT) levels should raise the clinical suspicion of the rare entity of progressive sclerosing cholangitis due to sepsis (see below).

Management is primarily focused on treatment of the underlying infection, which also results in resolution of cholestasis. In the absence of sepsis, the prognosis of cholestasis accompanying extrahepatic bacterial infections is good [40]. In contrast, in the clinical setting of sepsis, the development of jaundice is a bad prognostic sign, and serum bilirubin levels correlate positively with lethality and the numbers of extrahepatic organ failures. However, these patients usually die of extrahepatic causes (e.g. cardiac or respiratory failure) and not liver failure [40]. The use of UDCA in sepsis-associated cholestasis is under investigation in ongoing trials and cannot yet be generally recommended. In addition, there may be a potential role for treatment with extracorporeal liver support devices (e.g. the MARS system) in critically ill patients with jaundice [41], but this has to be further confirmed by controlled studies.

TPN-induced cholestasis is rarely observed in adult patients with short-term administration of TPN, but is frequently seen in premature or low-weight-for-age children and may occur in adults as a result of long-term TPN (> 3 months) administration (e.g. due to short bowel syndrome, intestinal resections in Crohn's disease). Abnormal liver chemistry findings can develop within 3–4 weeks of exposure to TPN. Elevations in ALT are most frequent under TPN, while jaundice is rare. TPN may also cause non-alcoholic steatohepatitis (NASH) (for details, see Chapter 20.4). After small bowel resection, the length of the remnant bowel (< 50 cm) may critically determine the development and degree of TPN-induced liver disease [24]. TPN-induced cholestasis is often associated with progressive elevation of AP and bilirubin levels, which level off despite continued TPN administration. Patients with TPN-induced cholestasis resulting from short bowel syndrome may rapidly progress to liver cirrhosis [23].

UDCA and metronidazole may have beneficial effects in the treatment of TPN-induced cholestasis [42–44], although larger studies are needed because the existing data are controversial [45]. Avoidance of excessive calories and nutritional deficiencies is essential. Patients with TPN-induced cholestasis resulting from short bowel syndrome with a remaining gut length of less than 50 cm may progress rapidly to liver cirrhosis, and combined gut and liver transplantation may represent the only therapeutic option.

Acalculous cholecystitis is a rare cause of cholestasis and jaundice. Risk factors for acalculous cholecystitis include male gender, major surgery, prolonged hypotension, trauma, burns, TPN longer than 3 months, mechanical ventilation and renal failure [27,28]. Fever, right upper quadrant pain, leucocytosis, and mildly elevated ALT and AP levels are typical symptoms. A sonographic grading system may help to discriminate acalculous cholecystitis from other forms of gallbladder wall thickening [major criteria: gallbladder wall thickness > 4 mm, gallbladder distension with longitudinal measurement > 10 cm and transversal dimension > 4 cm, presence of echogenic bile (sludge), pericholecystitic fluid] [46]. However, the diagnosis of acalculous cholecystitis is a clinical challenge despite sonographic grading and relies heavily on the clinical presentation and the diagnostic abilities of the observer [47]. This, together with the low incidence of the syndrome, may contribute to the often delayed diagnosis and its high mortality rate (47% in a 10-year retrospective single centre study identifying 15 cases

during 5804 cardiovascular operations) [28]. In that study, prolonged hypotension occurred in 13 patients, Gram-negative septicaemia in 12 and fever in every case. Importantly, 13 patients showed jaundice and/or elevated AP levels. Because of differences in local imaging modalities, it is difficult to recommend a single diagnostic algorithm. However, considering acalculous cholecystitis in the differential diagnosis of jaundice in every critically ill postoperative patient offers the best chance of making a timely diagnosis and decision for surgery.

Acalculous cholecystitis is best treated surgically (either laparoscopically or conventionally) in most cases, although there are an increasing number of anecdotal reports on novel treatment strategies such as decompression by fine-needle puncture and instillation of antibiotics into the gallbladder in these patients. These novel treatment modalities cannot be generally recommended, but may be suitable for multimorbid or critically ill patients with a high operative risk.

Progressive sclerosing cholangitis may develop rarely in patients after severe burns, septic shock or trauma [29–31], but it is more frequently the case that surgical trauma from cholecystectomy or lost intraductal stones and recurrent pancreatitis cause secondary sclerosing cholangitis [48]. Secondary sclerosing cholangitis not primarily related to an outflow obstruction should therefore be a diagnosis by exclusion. Typically, these patients show rising levels of AP and deep jaundice over weeks and months, but the time course and pattern may vary significantly between affected individuals [30,31]. Interestingly, bilirubin levels decreased spontaneously in five out of five patients within 2–6 months in a case series of posttraumatic progressive sclerosing cholangitis, despite the fact that four out of five developed liver cirrhosis and died of liver-related causes [31]. In a series of nine patients with progressive sclerosing cholangitis after a septic shock (five burn injury, two polytrauma), four out of nine patients rapidly developed liver cirrhosis and five out of nine patients died within a follow-up period of 35 months. Abdominal ultrasound usually shows no dilated bile ducts, as small bile ducts are more often involved. The diagnosis is usually suspected in patients with rising levels of GGT, AP and bilirubin and a compatible clinical history of trauma, severe burns and septic shock. Confirmation is based on endoscopic retrograde cholangiopancreatography (ERCP), which usually shows severe intrahepatic stenoses and rarefactions of the small bile ducts [29]. If a liver biopsy is performed, the histological picture shows ductular proliferation, portal lymphocytic inflammatory infiltration and portal and periductular fibrosis. This rare syndrome usually has a poor prognosis [29–31].

Orthotopic liver transplantation is the only therapeutic option as endoscopic duct dilatation as well as UDCA treatment are of limited efficacy, and patients rapidly develop liver cirrhosis and frequently die of liver-related causes [29,30].

The surgical history may be the diagnostic clue in patients with extrahepatic cholestasis due to surgical problems/complications. Patients with biliary strictures or leaks or retained bile duct stones may present with fever, right upper quadrant pain and jaundice within 2–14 days after surgery. Bacterial cholangitis with superimposed sepsis and the formation of liver abscesses may occur. In addition, biliary ascites and secondary biliary cirrhosis may be the consequence of bile duct leak and stricture. Abdominal ultrasonography and CT scanning are the tests of choice in such patients. If ultrasound shows evidence of a biliary obstruction, ERCP or, if ERCP is technically impossible, MRCP should be ordered. If a T-tube is present, T-tube cholangiography is the test of choice.

Therapeutically, bile duct leaks and retained stones can usually be managed by ERCP, whereas bile duct transection requires open surgical repair.

Acute icteric viral hepatitis in the postoperative setting is very uncommon and of little clinical importance because of modern screening of blood products and the length of the incubation period.

Postoperative problems in patients with acute or chronic liver disease and following liver transplantation are discussed in their specific chapters (for details, see Chapters 25.3 and 24.1).

References

1 Faust TW, Reddy RK (2004) Postoperative jaundice *Clin Liver Dis* 8, 151–166.

2 Chu CM, Chang CH, Liaw YF *et al.* (1984) Jaundice after open heart surgery: a prospective study. *Thorax* 39, 52–56.

3 Collins JD, Ferner R, Murray A *et al.* (1983) Incidence and prognostic importance of jaundice after cardiopulmonary bypass surgery. *Lancet* 2, 1119–1123.

4 Evans C, Evans M, Pollock AV (1974) The incidence and cause of postoperative jaundice. A prospective study. *Br J Anaesth* 46 (7), 520–525.

5 Seeto RK, Fenn B, Rockey DC (2000) Ischemic hepatitis: clinical presentation and pathogenesis. *Am J Med* 109 (2), 109–113.

6 Johnson RD, O'Connor ML, Kerr RM (1995) Extreme serum elevations of aspartate aminotransferase. *Am J Gastroenterol* 90 (8), 1244–1245.

7 Henrion J, Schapira M, Luwaert R *et al.* (2003) Hypoxic hepatitis. Clinical and hemodynamic study in 142 consecutive cases. *Medicine* 82 (6), 392–406.

8 Whitehead MW, Hawkes ND, Hainsworth I *et al.* (1999) A prospective study of the cause of notably raised aspartate aminotransferase of liver origin. *Gut* 45, 129–133.

9 Mathurin P, Durand F, Ganne N *et al.* (1995) Ischemic hepatitis due to obstructive sleep apnea. *Gastroenterology* 109 (5), 1682–1684.

10 Fuchs S, Bogomilski-Yahalom V, Platiel O *et al.* (1998) Ischemic hepatitis: clinical and laboratory observations of 34 patients. *J Clin Gastroenterol* 26 (3), 183–186.

11 Maddrey WC (2005) Drug-induced hepatotoxicity: 2005. *J Clin Gastroenterol* 39 (4 Suppl 2), 83–89.

12 Meier I, Cavallaro M, Roos M *et al.* (2005) Incidence of drug-induced liver injury in medical inpatients. *Eur J Clin Pharmacol* 61 (2), 135–143.

13 Andrade RJ, Lucena MI, Fernandez MC *et al.* (2005) Drug-induced liver injury: an analysis of 461 incidences submitted to the Spanish registry over a 10-year period. *Gastroenterology* 129, 512–521.

14 Vale JA, Proudfoot AT (1996) Paracetamol (acetaminophen) poisoning. *Lancet* 346, 547–552.

15 Zimmerman HJ, Maddrey WC (1995) Acetaminophen (paracetamol) hepatotoxicity with regular intake of alcohol: analysis of instances of therapeutic misadventure. *Hepatology* 22, 767–773.

16 Brown BR, Gandolfi AJ (1987) Adverse effects of volatile anesthetics. *Br J Anaesth* 59, 14–23.

17 Levy C, Lindor KD (2003) Drug-induced cholestasis. *Clin Liver Dis* 7 (2), 311–330.

18 Trauner M, Wagner M, Fickert P *et al.* (2005) Molecular regulation of hepatobiliary transport systems. Clinical implications for understanding and treating cholestasis. *J Clin Gastroenterol* 39 (Suppl 2), S111–S124.

19 Moseley RH (2004) Sepsis and cholestasis. *Clin Liver Dis* 8, 83–94.

20 Spirli C, Fabris L, Duner E *et al.* (2003) Cytokine-stimulated nitric oxide production inhibits adenylyl cyclase and cAMP-dependent secretion in cholangiocytes. *Gastroenterology* 124 (3), 737–753.

21 Strazzabosco M, Fabris L, Spirli C (2005) Pathophysiology of cholangiopathies. *J Clin Gastroenterol* 39 (Suppl 2), S90–S102.

22 Schmid M, Hefti ML, Gattiker R *et al.* (1965) Benign postoperative intrahepatic cholestasis. *N Engl J Med* 272, 545–550.

23 Chung C, Buchmann AL (2002) Postoperative jaundice and total parenteral nutrition-associated hepatic dysfunction. *Clin Liver Dis* 6, 1067–1084.

24 Caviacchi M, Beau P, Crenn P *et al.* (2000) Prevalence of liver disease and contribution factors in patients receiving home parenteral nutrition for permanent intestinal failure. *Ann Intern Med* 133 (12), 1009–1010.

25 Chan S, McCowen KC, Bistrian BR *et al.* (1999) Incidence, prognosis, and etiology of end-stage liver disease in patients receiving home total parenteral nutrition. *Surgery* 126, 28–34.

26 Jeppesen PB, Hoy CE, Mortensen PB (1999) Differences in essential fatty acid requirements by enteral and parenteral routes of administration in patients with fat malabsorbtion. *Am J Clin Nutr* 70, 78–84.

27 Roslyn JJ, Pitt HA, Mann LL *et al.* (1983) Gallbladder disease in patients on long-term parenteral nutrition. *Gastroenterology* 84, 148–154.

28 McChesney JA, Norththup PG, Bickston SJ (2003) Acute acalculous cholecystitis associated with systemic sepsis and visceral arterial hypoperfusion. *Dig Dis Sci* 48, 1960–1967.

29 Engler S, Elsing C, Flechtenmacher C *et al.* (2003) Progressive sclerosing cholangitis after septic shock: a new variant of vanishing bile duct disorders. *Gut* 52 (5), 688–693.

30 Scheppach W, Druge G, Wittenberg G *et al.* (2001) Sclerosing cholangitis and liver cirrhosis after extrabiliary infections: report on three cases. *Crit Care Med* 29 (2), 438–441.

31 Benninger J, Grobholz R, Oetztuerk Y *et al.* (2005) Sclerosing cholangitis following severe trauma: description of a remarkable disease entity with on possible pathophysiologic mechanisms. *World J Gastroenterol* 11 (27), 4199–4205.

32 Gates JK Jr, Wiesner RH, Krom RA *et al.* (1994) Etiology and incidence of unconjugated hyperbilirubinemia after orthotopic liver transplantation. *Am J Gastroenterol* 89 (9), 1541–1543.

33 Gibson PR, Dudley FJ (1984) Ischemic hepatitis clinical features, diagnosis and prognosis. *Aust NZ J Med* 14, 822–825.

34 Kaplowitz N (2005) Idiosyncratic drug hepatotoxicity. *Nature Rev Drug Discov* 4 (6), 489–499.

35 Farrell G, Prendergast D, Murray M (1985) Halothane hepatitis. Detection of a constitutional susceptibility factor. *N Engl J Med* 313 (21), 1310–1314.

36 Trauner M, Boyer JL (2001) Cholestatic syndromes. *Curr Opin Gastroenterol* 17, 244–256.

37 Whitehead MW, Hainsworth I, Kingham JG (2001) The cause of obvious jaundice in South West Wales: perceptions versus reality. *Gut* 48, 409–413.

38 Quale JM, Mandel LJ, Bergasa NV *et al.* (1988) Clinical significance and pathogenesis of hyperbilirubinemia associated with *Staphylococcus aureus* septicemia. *Am J Med* 85, 615–618.

39 Lefkowitch J (1982) Bile ductular cholestasis: an ominous histopathologic sign related to sepsis and 'cholangitis lenta'. *Hum Pathol* 13, 19–24.

40 Trauner M, Fickert P, Stauber RE (1999) Inflammation-induced cholestasis. *J Gastroenterol Hepatol* 14, 946–959.

41 Sen S, Wiliams R, Jalan R (2005) Emerging indications for albumin dialysis. *Am J Gastroenterol* 100 (2), 468–475.

42 Capron JP, Gineston JL, Herve MA *et al.* (1983) Metronidazole in prevention of cholestasis associated with total parenteral nutrition. *Lancet* 1 (8322), 446–447.

43 Spagnuolo MI, Iorio R, Vegnente A *et al.* (1996) Ursodeoxycholic acid for treatment of cholestasis in children on long-term total parenteral nutrition: a pilot study. *Gastroenterology* 111 (3), 716–719.

44 Moss RL, Amii LA (1999) New approaches to understanding the etiology and treatment of total parenteral nutrition-associated cholestasis. *Semin Pediatr Surg* 8 (3), 140–147.

45 Heubi JE, Wiechmann DA, Cretzinger V *et al.* (2002) Tauroursodeoxycholic acid (TUDCA) in the prevention of total parenteral nutrition-associated liver disease. *J Pediatr* 141 (2), 237–242.

46 Mariat G, Mahul P, Prevot M *et al.* (2000) Contribution of ultrasonography and cholescintigraphy to the diagnosis of acute acalculous cholecystitis in intensive care unit patients. *Intensive Care Med* 26, 1658–1663.

47 Towbridge RL, Rutkowski NK, Shojania KG (2003) Does the patient have acute cholecystitis? *J Am Med Assoc* 289 (1), 80–86.

48 Gossard AA, Angulo P, Lindor KD (2005) Secondary sclerosing cholangitis: a comparison to primary sclerosing cholangitis. *Am J Gastroenterol* 100 (6), 1330–1333.

24.4 Hepatobiliary trauma

K. Raj Prasad, Patrick A. Coughlin and Giles J. Toogood

Liver trauma

Introduction

Trauma is one of the leading causes of death in the western world with a disproportionate number of victims being in the younger age group. About 10% of all trauma-related deaths are due to abdominal trauma. The liver is one of the most frequently injured intra-abdominal organs despite its supposed protected location under the rib cage. The management of liver trauma has undergone a paradigm shift over the last two decades with the emphasis changing from surgical management to predominantly non-operative management. Improvements in resuscitation, advances in imaging and liberal use of interventional radiology have all contributed to the success of non-operative management. Despite these advances, the management of complex liver injuries can still be challenging, and surgery to the injured liver can be a formidable undertaking. Severe hepatic injuries are still associated with significant morbidity and mortality. Furthermore, liver trauma is often part of polytrauma, and extrahepatic injury management complicates established liver trauma treatment protocols. Associated injuries may be present in up to 65–70% of liver trauma patients.

Data from level 3 trauma centres in the USA and tertiary centres in the UK suggest that the number of liver trauma admissions have increased gradually over the last 20 years. The relative incidence of blunt and penetrating trauma varies according to the geographical location. In South Africa, penetrating injury accounts for nearly two-thirds of the liver trauma. In western Europe, blunt trauma constitutes 80–90% of all liver injuries. As the number of penetrating injuries remains constant, the incidence of blunt trauma has gradually increased and now accounts for nearly three-quarters of all liver trauma. The gender distribution has also changed with an increasing percentage of liver trauma victims being women. A recent study from Louisville, USA, looked at the distribution of severe liver injuries over a 25-year period. They found that the percentage of severe liver injury, grade 4 or above, has remained constant contributing to 15–20% of all liver injuries.

Mechanisms of injuries

The two main causes of injuries are penetrating and blunt trauma. Stab injuries and gunshot injuries are the commonest causes of penetrating injuries to the liver. Gunshot injuries are further complicated by secondary effects including a cavitation effect as the bullet traverses the liver substance.

Blunt trauma causes either compressive forces or a deceleration injury. Compressive forces can result in damage from blows to the solid organ against a fixed object such as the spine resulting in a subcapsular haematoma. The central portion of the liver is most often affected by such injuries. Deceleration injuries result in stretching and tearing, often causing laceration of the relatively thin capsule and parenchyma at the site of attachments to the diaphragm. Furthermore, hepatic veins are relatively unprotected compared with the portal structures and, as such, are susceptible to injury and tearing. Intrahepatic inferior vena cava injuries are uncommon but are associated with high morbidity and mortality.

Classification of injury severity (Table 1)

The classification of liver injuries is based on operative or radiological findings. Several classifications have been used in the literature, and the most commonly used one is the hepatic injury severity scale (HIS). The HIS is based on the organ injury scale (OIS), which was proposed by the American Association for Surgery of Trauma (AAST) in 1989 and revised in 1994. The HIS ranges from grade 1 to grade 6 and incorporates computerized tomography (CT) and operative findings to determine the extent of injury. The grading system helps in the prediction of the success of non-operative management of injuries.

Initial patient assessment

Initial assessment and management should follow recommended guidelines according to the principles of advanced trauma life support (ATLS). This involves maintaining a clear airway and fluid resuscitation with ventilatory and circulatory

Table 1 The Hepatic Injury Severity (HIS) classification.

Grade		Description of injury
1	Haematoma	Subcapsular, non-expanding, < 10% surface area
	Laceration	Capsular tear, non-bleeding, < 1 cm parenchymal depth
2	Haematoma	Subcapsular, non-expanding, 10–50% surface; or intraparenchymal, non-expanding, < 2 cm diameter
	Laceration	Capsular tear, active bleeding, 1–3 cm parenchymal depth, < 10 cm length
3	Haematoma	Subcapsular, > 50% surface area or expanding; ruptured subcapsular haematoma with active bleeding; intraparenchymal haematoma > 2 cm
	Laceration	> 3 cm parenchymal depth
4	Haematoma	Ruptured intraparenchymal haematoma with active bleeding
	Laceration	Parenchymal disruption > 25–50% hepatic lobe
5	Laceration	Parenchymal disruption > 50% hepatic lobe
	Vascular	Juxtahepatic venous injuries
6	Vascular	Hepatic avulsion

support as required. Blood products must be available for all patients if required. Initial assessment should be followed by assessment of the extent of injuries, both abdominal and extra-abdominal, and the response to fluid resuscitation. Multisystem trauma frequently complicates liver trauma management and needs to be assessed and managed simultaneously. The major causes of mortality in this patient group are associated injuries, and the assessment of patients with synchronous head and spinal cord injuries is often quite challenging. The main aim of this initial assessment is to determine those patients who require urgent laparotomy.

Liver injury should be suspected in patients with evidence of blunt trauma or open wounds to the right upper quadrant or epigastrium. Distant entry and exit gunshot wounds to the body and trunk may also cause significant liver injury. Haemorrhage is the major cause of death in patients with liver trauma. Patients presenting with irreversible shock with evidence of intra-abdominal bleeding or evisceration require immediate laparotomy. Similar principles apply for both blunt and penetrating liver trauma. The occurrence of signs of peritonitis in patients with blunt or penetrating trauma would suggest a potential bowel perforation, which would also necessitate laparotomy. However, in this situation, bowel perforation is quite often confirmed by contrast CT scan showing extravasation of contrast before proceeding to laparotomy.

Investigation and diagnosis

Repeated examination and clinical assessment is obligatory, and haemodynamic stability is the most important determinant for conservative treatment of blunt and penetrating trauma. Serial haemoglobin measurements may help in determining blood loss following liver injury, but can be misleading in the face of polytrauma. Further investigations are dependent upon the clinical circumstances (Table 2).

Table 2 Investigations for liver trauma.

1 FAST
2 MDCT
3 DPL
4 Laparoscopy
5 Angiography ± embolization
6 MRI/MRCP/ERCP

FAST, focused abdominal ultrasonography for trauma; MDCT, multidetector computerized tomography; DPL, diagnostic peritoneal lavage; MRI, magnetic resonance imaging; MRCP, magnetic resonance cholangiopancreatography; ERCP, endoscopic retrograde cholangiopancreatography.

Ultrasound

Focused abdominal ultrasonography for trauma (FAST) is a simple method for assessing intra-abdominal injuries in the emergency room. It relies on quickly identifying haemoperitoneum in abdominal trauma and should include examination of the perihepatic space, Morrison's pouch, perisplenic region and paracolic gutters. In addition, ultrasound can also identify site-specific organ injuries. Injury to solid organs such as the liver, spleen and kidneys can be identified from heterogeneity in the echo texture of the organ in question. Surrounding haematomas can be identified as echogenic or hypoechoic areas. Ultrasound in abdominal trauma was first described by Kristensen *et al.* in 1971 in the diagnosis of splenic haematoma. Experience with ultrasonics expanded during the 1980s and 1990s in Europe and gradually in the USA over the last decade. Its advantages include the portability of the equipment allowing a quick diagnosis to be proven in the Accident and Emergency department. It also has great accuracy in determining the presence of a haemoperitoneum. Several recent prospective studies show that ultrasound has a sensitivity of 82–88% and a specificity of 99% in detecting haemoperitoneum, although it is limited by operator dependency. However, when the ultrasound findings were compared with CT and/or laparotomy, the sensitivity at first was found to be lower than in previous studies. This

Fig. 1 CT scan showing the consequence of blunt hepatic trauma following a road traffic accident. The majority of the right lobe of the liver is damaged. This case was successfully managed conservatively.

is presumed to be due to contained haematomas in the solid organs not resulting in free haemoperitoneum. Therefore, one should remember that a negative ultrasound does not exclude solid organ injury. Ultrasound is also a poor investigation for diagnosis of other intra-abdominal injuries to the diaphragm, pancreas and mesentery.

CT scan

CT has become the imaging modality of choice for abdominal trauma in haemodynamically stable patients (Fig. 1). Current generation multidetector CT (MDCT) scanners allow an accurate delineation of the grade or extent of injury to the liver and the presence or absence of other intra-abdominal injury. Haemoperitoneum as well as injuries to liver, spleen, pancreas, diaphragm, kidneys, gallbladder, mesentery and bowel can easily be identified by CT scan. CT scans also have the added advantage of being less operator dependent and are not limited by superficial wounds or subcutaneous emphysema. In polytrauma victims, CT scans allow assessment of intracranial, thoracic, pelvic and vertebral injuries more accurately. It is important to remember that CT scans of the head need to be performed before abdominal scans as contrast injection may result in misinterpretation of head scans. The current generation of CT scans also allows dynamic contrast injection, which enables visualization of extravasation of contrast from active bleeding sites. Findings like this help in determining the need for interventional procedures such as angiography.

Diagnostic peritoneal lavage (DPL)

With widespread usage of CT scans and the current trend towards non-operative management, the use of DPL has decreased in most centres.

Diagnostic laparoscopy

Diagnostic laparoscopy has been used in both penetrating and blunt abdominal trauma with varying results. It seems unlikely that diagnostic laparoscopy will provide a significant tool in the management of liver trauma.

Angiography

Intra-arterial digital subtraction angiography (IADSA) is an important part of the investigation of a stable patient which can lead on to potential therapeutic intervention if indicated (Fig. 2b). This will be elaborated upon in the next section.

(a)

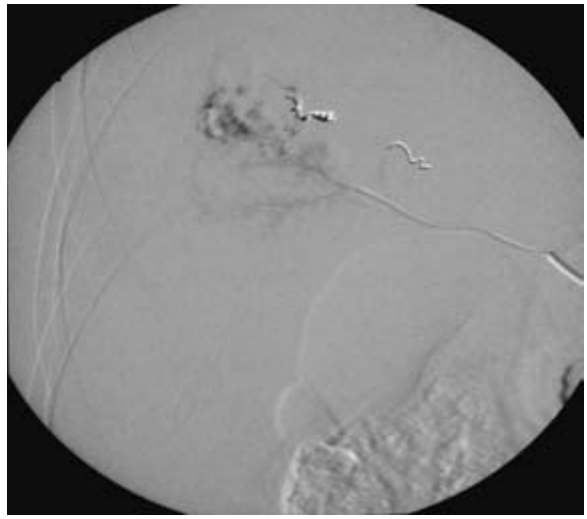

(b)

Fig. 2 (a) CT scan showing evidence of free intraperitoneal blood following blunt hepatic trauma. (b) The haemodynamic stability of the patient meant that the continuing bleeding could be treated by angiography and selective embolization.

MRI/MRCP

Magnetic resonance imaging (MRI) and magnetic resonance cholangiopancreatography (MRCP) may be useful investigations after the acute phase when late biliary and vascular complications develop.

Management

Initial assessment and response to resuscitation provide the information on which to base a plan for treatment. Haemodynamic instability despite adequate resuscitation is an indication for immediate operative intervention. However, the majority of patients with liver trauma are either haemodynamically stable at presentation or respond to fluid resuscitation. In these patients, non-operative management is the mainstay of treatment. Stable patients require CT scan to assess the extent of injuries to the liver and other organ systems. The management of associated injuries, both intra- and extra-abdominal may need to take priority over liver injury based on findings from CT scan.

Conservative management of stable patients

Stable liver injury patients are initially admitted into an intensive care unit/high-dependency unit (ICU/HDU) after CT scan. The Leeds protocol for conservative management includes serial monitoring of haemoglobin, pain relief, antibiotics, use of proton pump inhibitors, deep vein thrombosis (DVT) prophylaxis and bed rest for 48–72 h. Further interventions in these patients may include management of other injuries, percutaneous drainage of collections and haemoperitoneum (in case of symptomatic compartment syndrome), MRCP for biliary complications and angiography for vascular complications including late bleeding necessitating continuing blood transfusion. The success of conservative management in blunt hepatic trauma is evident from our own figures. We found a significant reduction in the proportion of patients requiring surgery for liver injury in both our own unit (from 7 out of 16 patients in 1992–1996 to 7 out of 55 in 1997–2001; $P = 0.017$, chi-squared test) and in referring hospitals (from 6 out of 12 to 8 out of 50; $P = 0.014$, chi-squared test). The success of conservative treatment is also dependent upon the grade of injury (Table 3).

Indication for operative management

Indications for immediate surgery include haemodynamic instability despite adequate resuscitation and obvious peritonitis, as well as the failure of non-operative management. Most liver units consider a blood transfusion requirement of 4 units or more over 24 h as a criterion for the failure of conservative management. However, with the improvements in intensive care facilities and interventional angiography, the 4-unit criterion needs to be revisited. The authors' view is that continuing transfusion requirement is an indication for angiography rather than surgical intervention, and surgery should be reserved only for haemodynamically unstable patients or when angiography fails (Table 4).

Technical aspects of operative management

With the increasing success of non-operative management, surgical intervention for liver trauma has become an infrequent event in patients with major and complex injuries.

Successful operative management depends on a number of factors (Table 5, Fig. 3).

Damage control surgery

The major causes of mortality in patients undergoing surgery for liver trauma are acidosis, hypothermia and coagulopathy resulting from massive blood transfusion. Therefore, the initial aim of surgical intervention is to quickly control bleeding and enteric leaks. This is often best performed by perihepatic packing after adequate exposure. Occasionally, bleeding may be completely controlled by specific measures such as suturing of hepatic

Table 4 Indications for surgical intervention.

1. Haemodynamic instability despite adequate resuscitation
2. Peritonitis
3. Failure of non-operative management
   a) Continuing need for blood transfusion
   b) Hollow viscous injury (delayed presentation)
   c) Uncontrolled bile leak
   d) Delayed haemorrhage and failure of angiography
4. Long-term complications including biliary strictures

Table 3 Success of non-operative management.

Authors	Study period	No. of total patients with liver injury	% patients managed conservatively	Mortality rate of conservative group (%)
Hollands and Little	1979–1989	236	23	1.8
Coughlin *et al.*	1992–2001	71	70	2
Croce *et al.*	–	136	100	–
Pachter *et al.*	1990–1995	404	98.5	0.4 (liver-related death)

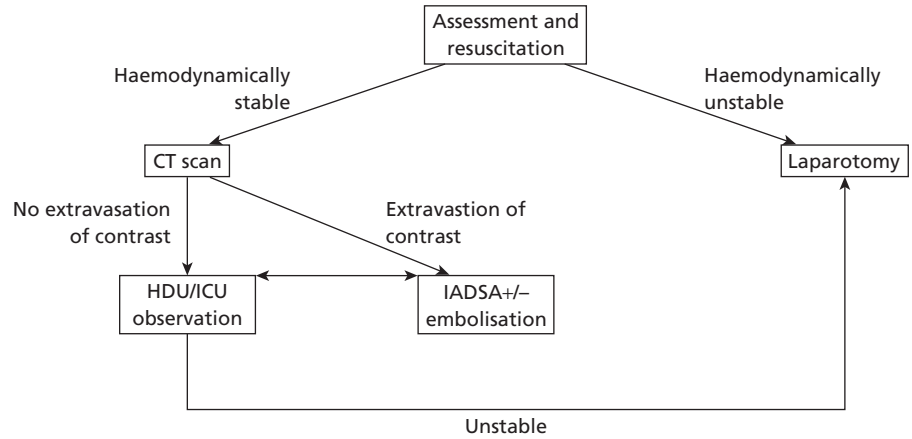

Fig. 3 Algorithm for the management of blunt liver trauma.

Table 5 Factors required for successful operative intervention for hepatic injury.

1	Referral and definitive management in tertiary centres
2	Availability of experienced surgical, anaesthetic, ICU, angiographic and endoscopic hepatobiliary services
3	Prompt correction of coagulopathy, hypothermia and acidosis
4	Damage control surgery with perihepatic packing and control of enteric leaks
5	Intensive peri- and postoperative management in ICU
6	Prompt recognition and treatment of the abdominal compartment syndrome
7	Experience in management of open wounds

ICU, intensive care unit.

vessels. This is more often appropriate if the initial surgery is performed at a tertiary trauma unit. Use of synthetic materials such as mesh for abdominal closure may be required following perihepatic packing, thus reducing the associated problems of abdominal compartment syndrome. The packs are usually removed 24–48 h after the initial surgery following referral to the tertiary unit. Haemostasis is often achieved by the time of the second laparotomy following the removal of packs. However, additional measures that may be needed for haemostasis include suturing of bleeding vessels, non-anatomical resectional debridement of liver and, occasionally, further repacking. The operative management of retrohepatic venous injuries is the most challenging, and this may require total vascular isolation of the liver with or without veno-venous bypass. In rare instances, one may need to consider total hepatectomy with transplantation when a suitable donor liver is available.

Abdominal compartment syndrome

The abdominal compartment syndrome represents the pathophysiological consequence of a raised intra-abdominal pressure. The magnitude of this syndrome and the involvement of the various organs depend on the level of the intra-abdominal pressure. Normal intra-abdominal pressure ranges between 0 and 5 mmHg. Current methodology for intra-abdominal pressure assessment relies on the measurement of bladder pressure. Alternative methods include indirect estimations of inferior vena cava pressure, rectal and gastric pressure measurements and direct measurement of the intra-abdominal pressure by direct puncture. At pressures of between 15 and 25 mmHg, the full syndrome may be observed, but it usually responds to aggressive fluid resuscitation, although surgical decompression should be considered. At high pressures (> 25 mmHg), surgical decompression associated with fluid resuscitation and transient use of vasoconstrictive agents is mandatory. In appropriate circumstances, percutaneous drainage of haemoperitoneum can improve compartment syndrome and also the systemic inflammatory response.

Complications of liver trauma

Irrespective of the initial management (non-operative or operative), these patients may develop both early and late complications that require intervention (Table 6). Delayed or secondary haemorrhage is an infrequent complication and can usually be diagnosed by contrast CT and managed with angiographic embolization. Angiographic embolization is also used for late complications such as haemobilia and arterial portal shunts. Most collections can be managed by percutaneous drainage. Similar drainage would be required for managing bile leaks. Persistent leaks need further investigations including MRCP and subsequent management with intervention modalities including endoscopic retrograde cholangiopancreatography (ERCP). Biliary strictures can be a troublesome late complication of liver trauma. Extrahepatic strictures can be managed by surgical reconstruction or stenting. Diffuse strictures are more challenging, are frequently ischaemic and can lead to secondary biliary cirrhosis.

Conclusion

The management of liver trauma has moved on from surgery to non-operative management. Surgery is needed in a small

Table 6 Late complications.

1	Secondary haemorrhage
2	Sepsis – intra-abdominal collections or abscesses
3	Haemobilia and sepsis – intra-abdominal collections or abscesses
4	Bile leaks
5	Biliary stricture and its consequences

percentage of patients, and they are best managed in specialist units with a multidisciplinary approach.

Biliary trauma

Introduction

Biliary trauma is an infrequent complication of blunt and penetrating abdominal trauma. The presentation and management of biliary trauma in this context has already been discussed. The majority of biliary trauma seen in clinical practice is iatrogenic in nature, affecting the extrahepatic biliary tree. The commonest cause of iatrogenic biliary trauma is cholecystectomy (open and laparoscopic). The infrequent causes of iatrogenic biliary trauma include liver resections, bile duct surgery, gastroduodenal surgery, pancreatic head surgery and endoscopic biliary intervention. The incidence of biliary tract injury during cholecystectomy has been reported to range from 0.2% to 0.6%. Data from large series suggest that the incidence is similar with open and laparoscopic cholecystectomy and is associated with a significant deleterious effect upon the patients' quality of life. The remaining part of the chapter focuses on injuries following cholecystectomy.

Mechanisms of injury

Bile duct injury during open cholecystectomy and laparoscopic cholecystectomy can be caused by a number of factors. These could be described as minor injuries including bile leak from the cystic duct stump to major injuries such as excision of the entire extrahepatic biliary tree due to misidentification of anatomical structures. Some of these injuries could be further complicated by concomitant vascular injury to hepatic artery and portal venous branches. In relation to the immediate causes, biliary tract injury may present late as stricture due to ischaemic injuries (Table 7).

Classification (Fig. 4)

Bismuth *et al.* proposed a classification for bile duct injury that was widely used up until the laparoscopic cholecystectomy era. Some of the unusual mechanisms of injury unique to laparoscopic cholecystectomy necessitated a further classification. Strasberg *et al.* proposed a new classification that incorporated Bismuth's classification and has been widely accepted.

Table 7 Immediate and late causes of iatrogenic biliary trauma.

Immediate	
1	Misidentification resulting in stenting and classic injury
2	Difficult anatomy due to scarring or inflammation
3	Anatomical anomalies
4	Deep dissection into the gallbladder bed with injury to the duct of Luschka
5	Cystic duct leaks
Late	
1	Diathermy injury with pericholedochal vascular plexus injury
2	Hepatic arterial injury and its consequences

Presentation

Bile duct injury following cholecystectomy can present early or late and either as a leak or as jaundice depending on the mechanism and type of injury. Early bile duct injury can be recognized at the time of surgery or soon afterwards with bile leak, biliary peritonitis or jaundice. Identification at the time of surgery can be from a review of the anatomy following initial dissection, bile leak or operative cholangiogram. Controversy surrounds the exact role of the cholangiogram in preventing bile duct injury. It is considered that an operative cholangiogram may limit the extent of bile duct injury if not prevent it. Late presentations are usually in the form of obstructive jaundice from strictures or of chronic unresolved sepsis in the right upper quadrant.

Investigations

The choice of investigation depends on the timing of presentation. The gold standard investigation is a 'cholangiogram' allowing identification of the type and extent of the injury. Other ancillary investigations would be required depending on the clinical presentation.

Cholangiogram

Cholangiograms can be obtained either intraoperatively or postoperatively (Fig. 5). Postoperative cholangiograms include direct visualization with tubulograms or a fistulogram, ERCP and percutaneous transhepatic cholangioscopy (PTC) or indirect visualization with MRCP. A cholangiogram will enable visualization of the biliary tree identifying bile leaks and absent ducts. MRCP also has an added advantage of also showing discontinuous ducts.

Ultrasound

Ultrasound is the standard investigation for intra-abdominal collections and the identification of a dilated biliary tree. Doppler ultrasound enables the identification of concomitant major vascular injury. Ultrasound can also be used for the percutaneous placement of drains in the management of intra-abdominal collections.

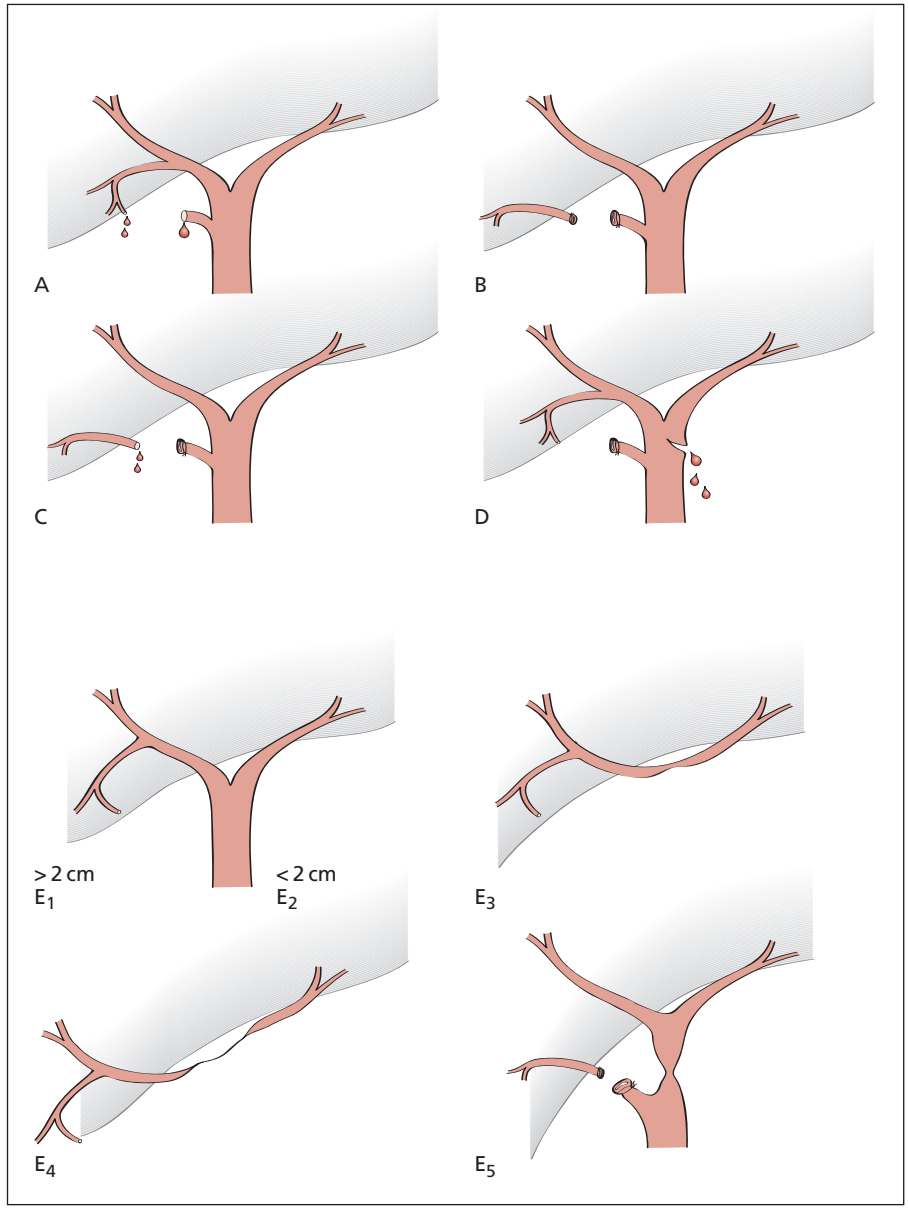

Fig. 4 Classification of bile duct injuries (Strasberg *et al.*). Strasberg *et al.* made Bismuth *et al.*'s classification much more comprehensive by including a number of other types of laparoscopic extrahepatic bile duct injuries. Injuries are classified from type A to type E. Type E injuries are further classified as Bismuth's classification into E1 to E5 (1, stricture > 2 cm from the confluence of the hepatic ducts; 2, stricture < 2 cm from the confluence with the remnant of the common hepatic duct (CHD); 3, stricture flush with the confluence with the confluence intact; 4, stricture involves the confluence; 5, stricture involving an aberrant right sectoral hepatic duct, with or without a concomitant CHD stricture). Type A injuries include bile leaks from injured minor ducts, e.g. cystic duct and duct of Luschka. Type B denotes occlusion of part of the biliary tree, invariably the aberrant right sectoral hepatic duct. Type C represents transection without ligation of the right sectoral hepatic duct. Type D involves a lateral injury to an extrahepatic bile duct, potentially requiring a major reconstruction.

CT scans

CT scans provide similar information to ultrasound but can also be used when more complex collections are present. Additional information that can be gained from CT scan includes evidence of liver ischaemia/infarction or abscess formation.

HIDA scans

Hepatoiminodiacetic acid (HIDA) scans (cholescintigraphy) can occasionally be of help in incipient bile leaks and fistulas before proceeding to invasive investigations.

Liver biopsy

Chronic biliary obstruction can lead to fibrosis and secondary biliary cirrhosis. It is prudent to biopsy the liver at the time of surgical repair to quantify the extent of the damage.

Management

Management options for bile duct injury include conservative, endoscopic and percutaneous biliary interventions, surgical reconstruction of the bile duct and, occasionally, liver resection and transplantation.

Conservative management

Conservative management usually involves the drainage of small subhepatic collections from minor bile leaks that settle

Fig. 5 ERCP showing a lateral injury to an extrahepatic bile duct. Despite a significant leak, endoscopic stenting stopped the leak.

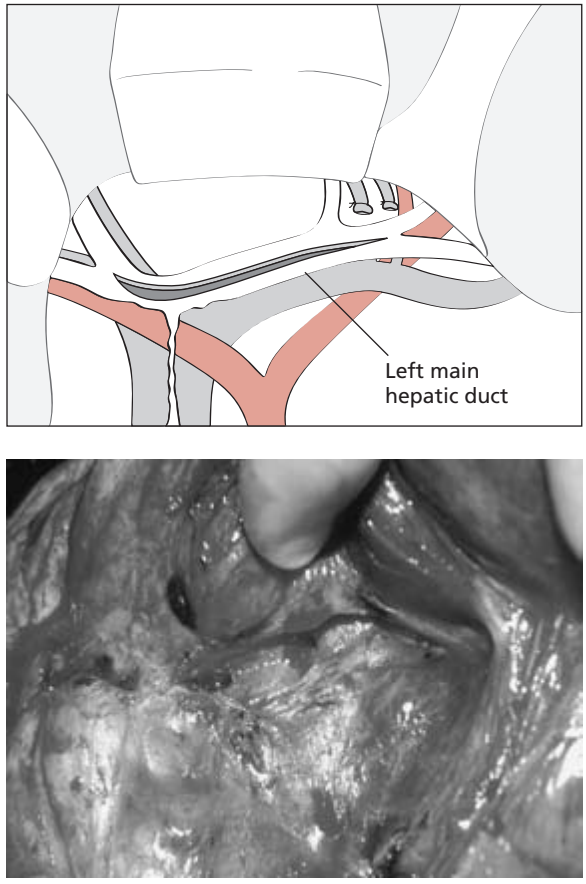

Fig. 6 The Hepp–Couinaud biliary reconstruction. This technique capitalizes on the extrahepatic course of the left main hepatic duct. The left main duct has a rich blood supply that is not put at risk by the precipitating iatrogenic injury.

with time. Segmental bile duct ligation can be managed conservatively as long as it is not complicated by sepsis. Internal biliary fistulas into the duodenum or stomach can develop following major bile duct injury and can be treated conservatively as long as there is good drainage. This is more appropriate in patients considered to be poor surgical candidates.

Endoscopic biliary treatment

Endoscopic biliary intervention is the mainstay of treatment for persistent bile leak from a cystic duct stump, leaks from a duct of Luschka and leaks resulting from injury to the lateral wall of the common hepatic duct. It is also useful in segmental bile duct leaks if the leaking duct is in continuity with the main biliary system. Endoscopic intervention usually involves placement of a plastic stent across the sphincter of Oddi with or without sphincterotomy. The endoscopic treatment is often performed in conjunction with good percutaneous drainage of intra-abdominal collections. Chronic biliary strictures of the common hepatic and common bile duct can also be managed with endoscopic stenting. This usually requires multiple interventions, balloon dilatation and placement of multiple stents at the same time.

With excellent long-term results of biliary reconstructive surgery and the possibility of developing secondary biliary cirrhosis, even with partial obstruction, endoscopic and percutaneous treatments should be reserved for patients unfit for surgery or as a temporizing measure.

Surgery

Surgery is a gold standard treatment for major bile duct injury (Fig. 6). Immediate reconstruction is indicated for major injuries at the time of cholecystectomy if expertise is available. If the expertise is not available locally, these patients need to be referred promptly to a specialist centre for biliary surgery. Published data from major centres confirm better outcomes when the first reconstructive surgery was performed at a tertiary centre compared with repair at the time of injury by non-specialists. Early reconstruction is usually indicated in most patients. Controversy exists as to the timing of surgery in patients with major bile leaks and local sepsis. In patients with significant local sepsis, adequate drainage with multiple drains either operatively or percutaneously remains the standard treatment. The resulting controlled biliary fistula enables safe staged surgical management. The standard surgical treatment involves a Roux-en-Y hepaticojejunostomy. Intrahepatic strictures would necessitate further surgical correction. Unilobar strictures could be managed with hemi- or extended hemihepatectomy along with reconstruction of the hepatic duct of the remaining half of the liver. However, bilobar extensive intrahepatic duct stricturing may be amenable only to transplantation (Tables 8 and 9).

Table 8 Principles of surgical reconstruction.

1 Good vascular supply to remnant bile duct. 60-cm Roux loop
2 Mucosa to mucosa anastomosis
3 Tension-free anastomosis
4 Wide opening of the bile duct (by spatulating or extension of the anastomosis to include the left hepatic duct)
5 Anti-colic or retro-colic
6 Liver biopsy

Table 9 Risk factors for poor surgical outcome.

Local Inflammation
Lack of bile duct dilatation
Level of injury
Multiple attempts
Fibrosis or portal hypertension
Intrahepatic strictures/stones
Experience of surgeon

Table 10 Success of biliary reconstruction.

Author	No.	Successful outcome (%)	Mean follow-up (months)
Chapman *et al.*	122	76	86
Lillemoe *et al.*	142	90.8	57.5

Outcome

Success rates depend upon the extent of the injury. Five-year success rates of 90% have been reported for surgical reconstruction with the majority of restructuring occurring in the first 2 years. Therefore, this patient group needs close follow-up at 3-month intervals in the first 2 years with liver function tests and ultrasound scan. They should then be followed up on a 6-monthly basis for the next 3 years and annually thereafter (Table 10).

Bibliography

Boerma D, Rauws EA, Keulemans YC *et al.* (2001) Impaired quality of life 5 years after bile duct injury during laparoscopic cholecystectomy: a prospective analysis. *Ann Surg* 234(6), 750–757.

Chapman WC, Halevy A, Blumgart LH *et al.* (1995) Postcholecystectomy bile duct strictures. Management and outcome in 130 patients. *Arch Surg* 130(6), 597–602; discussion 602–604.

Christmas AB, Wilson AK, Manning B *et al.* (2005) Selective management of blunt hepatic injuries including nonoperative management is a safe and effective strategy. *Surgery* 138(4), 606–610; discussion 610–611.

Coughlin PA, Stringer MD, Lodge JP *et al.* (2004) Management of blunt liver trauma in a tertiary referral centre. *Br J Surg* 91(3), 317–321.

Croce MA, Fabian TC, Menke PG *et al.* (1995) Nonoperative management of blunt hepatic trauma is the treatment of choice for hemodynamically stable patients. Results of a prospective trial. *Ann Surg* 221(6), 744–753.

David Richardson J, Franklin GA, Lukan JK *et al.* (2000) Evolution in the management of hepatic trauma: a 25-year perspective. *Ann Surg* 232(3), 324–330.

Debru E, Dawson A, Leibman S *et al.* (2005) Does routine intraoperative cholangiography prevent bile duct transection? *Surg Endosc* 19(4), 589–593.

Goldman R, Zilkoski M, Mullins R *et al.* (2003) Delayed celiotomy for the treatment of bile leak, compartment syndrome, and other hazards of nonoperative management of blunt liver injury. *Am J Surg* 185(5), 492–497.

Hollands MJ, Little JM (1991) Non-operative management of blunt liver injuries. *Br J Surg* 78(8), 968–972.

Johnson JW, Gracias VH, Gupta R *et al.* (2002) Hepatic angiography in patients undergoing damage control laparotomy. *J Trauma* 52(6), 1102–1106.

Kristensen JK, Buemann B, Kuhl E (1971) Ultrasonic scanning in the diagnosis of splenic haematomas. *Acta Chir Scand* 137(7), 653–657.

Lillemoe KD, Melton GB, Cameron JL *et al.* (2000) Postoperative bile duct strictures: management and outcome in the 1990s. *Ann Surg* 232(3), 430–441.

Malhotra AK, Fabian TC, Croce MA *et al.* (2000) Blunt hepatic injury: a paradigm shift from operative to nonoperative management in the 1990s. *Ann Surg* 231(6), 804–813.

Misra S, Melton GB, Geschwind JF *et al.* (2004) Percutaneous management of bile duct strictures and injuries associated with laparoscopic cholecystectomy: a decade of experience. *J Am Coll Surg* 198(2), 218–226.

Mohr AM, Lavery RF, Barone A *et al.* (2003) Angiographic embolization for liver injuries: low mortality, high morbidity. *J Trauma* 55(6), 1077–1081; discussion 1081–1082.

Moore EE, Cogbill TH, Jurkovich GJ *et al.* (1995) Organ injury scaling: spleen and liver (1994 revision). *Trauma* 38(3), 323–324.

Omoshoro-Jones JA, Nicol AJ, Navsaria PH *et al.* (2005) Selective nonoperative management of liver gunshot injuries. *Br J Surg* 92(7), 890–895.

Parks RW, Chrysos E, Diamond T (1999) Management of liver trauma. *Br J Surg* 86(9), 1121–1135.

Pachter HL, Knudson MM, Esrig B *et al.* (1996) Status of nonoperative management of blunt hepatic injuries in 1995: a multicenter experience with 404 patients. *J Trauma* 40(1), 31–38.

Ragozzino A, De Ritis R, Mosca A *et al.* (2004) Value of MR cholangiography in patients with iatrogenic bile duct injury after cholecystectomy. *Am J Roentgenol* 183(6), 1567–1572.

Scollay JM, Beard D, Smith R *et al.* (2005) Eleven years of liver trauma: the Scottish experience. *World J Surg* 29(6), 744–749.

Sicklick JK, Camp MS, Lillemoe KD *et al.* (2005) Surgical management of bile duct injuries sustained during laparoscopic cholecystectomy: perioperative results in 200 patients. *Ann Surg* 241(5), 786–792; discussion 793–795.

Strasberg SM (2005) Biliary injury in laparoscopic surgery: part 2. Changing the culture of cholecystectomy. *J Am Coll Surg* 201(4), 604–611.

Strasberg SM, Hertl M, Soper NJ (1995) An analysis of the problem of biliary injury during laparoscopic cholecystectomy. *J Am Coll Surg* 180(1), 101–125.

Thomson BN, Parks RW, Madhavan KK *et al.* (2005) Early specialist repair of biliary injury. *Br J Surg* 93(2), 216–220.

Tsalis K, Zacharakis E, Vasiliadis K *et al.* (2005) Bile duct injuries during laparoscopic cholecystectomy: management and outcome. *Am Surg* 71(12), 1060–1065.

25 Liver transplantation

25.1 Surgical techniques

25.1.1 Liver transplantation

Peter Neuhaus

Liver transplantation consists of four surgical steps, with each step requiring knowledge, surgical skill and experience. In the beginning, donor hepatectomy, liver preservation, recipient hepatectomy and recipient transplantation were therefore performed by the same surgical team but, nowadays, in a regulated organ allocation process, the liver is often harvested by local surgeons unknown to the transplant surgeon. This demands not only confidence and trust, but also meaningful documentation and communication between the donor and recipient team.

The quality and suitability of the graft can only be completely judged by the donor surgeon. The donor intensive care status, the extent of previous injuries, biochemistry changes and the macroscopic appearance of the liver after opening the abdomen are as important as the judgement of the surgeon on the homogeneity of liver perfusion, the consistency of the liver tissue before, during and after perfusion, and the colour and estimated fat content (Fig. 1). The size of the organ must be estimated in comparison with the donor's body weight, and any anatomical abnormalities, especially of the arterial supply, must be noted. Most, but not all, centres prefer to have a biopsy.

The harvesting of the liver can be done in two different ways:

1 *En bloc in situ* perfusion and harvesting.

2 Step by step mobilization and isolation of the liver and the hilar structures.

En bloc harvesting and preservation

After opening the abdomen and careful inspection of all organs, the vena cava and abdominal aorta are exposed and taped just above the bifurcation. Large-bore canulas are inserted into both vessels and tied. Clamping of the supracoeliac aorta is performed, and the vena cava is incised below and above the liver. At the same time, perfusion of the aorta is started, and the blood is drained from the vena cava. Four to six litres of University of Wisconsin (UW) solution are infused until all organs are pale and cold (with the aid of ice slush placed into the abdomen).

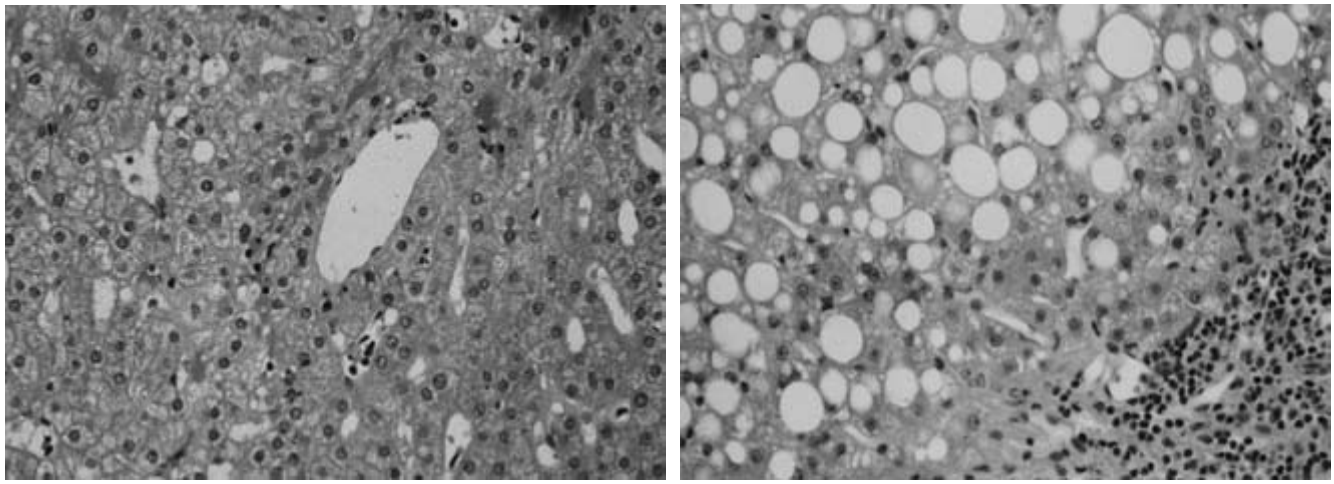

(a) (b)

Fig. 1 (a) Metabolic activation with mild cellular infiltration. (b) Macrovesicular fatty changes in a liver transplant donor.

Then perfusion is stopped and the liver is excised in a bloodless field. Usually, the pancreas is not used, as the pancreas can be damaged during excision of the liver.

Full isolation of the liver before preservation

Another approach is the careful and meticulous dissection of all anatomical structures with intact circulation. The liver is fully mobilized from the retroperitoneum, and the vena cava above and below the liver is encircled. Then the bile duct is dissected, tied and divided just above the pancreas. The bile duct is flushed, and the cystic duct is ligated and divided. The gallbladder is removed, and haemostasis is achieved in the gallbladder bed. Now a careful dissection is done at the right side of the portal vein to identify an accessory right hepatic artery, which can arise in 20% of cases from the mesenteric artery. Similarly, an accessory left hepatic artery can be found in the minor omentum arising from the gastric artery.

When the anatomy is normal, the right gastric artery and the gastroduodenal artery are dissected next and ligated well away from the common hepatic artery. Then the portal vein stem is identified and dissected free for about 2 cm. According to the surgeon's preference, the dissection can then be carried on to the common hepatic and splenic artery and down the coeliac trunk to the aorta. If the pancreas is not suitable for transplantation, the mesenteric artery is divided or clamped in order not to have too much venous backflow from the mesenteric veins.

After dissecting the renal vessels and, if necessary, the pancreatic organ, perfusion of the liver is started via the aorta and portal vein. The vena cava is cut at the level of the diaphragm and above the renal veins. After the aortic perfusion has been stopped, dissection of the coeliac trunk down to the aorta can be completed, and the artery can be excised with or without an aortic patch. We always perform the back table perfusion of the hepatic artery under high arterial pressure to avoid insufficient perfusion of the capillaries around the bile duct. We again flush the bile duct with 250 mL of preservation solution and leave the splenic artery open with about a 1-cm stump. The liver is packed in three plastic bags and transported in an ice box. Details of anatomical or surgical points of interest are noted and attached to the donor report form.

The maintenance of organ viability during harvesting and preservation is an important prerequisite for outcome after liver transplantation. The organ procurement and initial perfusion techniques are key factors leading to improvement in organ preservation. Good organ preservation starts with an effective blood washout and a rapid decrease in temperature. It is known that, during dissection and preparation, arterial spasms and minor liver trauma cannot be avoided. Therefore, *en bloc* harvesting and preservation seems to be advantageous. On the other hand, direct perfusion of the hepatic artery and portal vein without all the other arterial and portal venous branches ensures a more rapid perfusion and cooling. According to some surgeons, ischaemic-type biliary lesions are thus better avoided.

Most commonly used for organ preservation is the UW solution and the histidine/tryptophan/ketoglutarate (HTK) solution. Preservation solutions are formulated to prevent the four classical effects of hypothermia: cell swelling, impaired energy metabolism, acidosis and accumulation of precursors of reactive oxygen intermediates. More than 15 years ago, UW solution became the standard liver preservation solution and is still regarded as the favourite solution for long-term graft preservation. Of concern, however, is the high potassium content and the high viscosity of the solution. HTK solution, on the other hand, was originally introduced as a cardioplegic solution for protection in the mild hypothermic range, and was later adapted to cold preservation of organs. Based on extracellular fluid composition, HTK uses only the intrinsic components histidine, tryptophan and ketoglutarate. HTK and UW solutions have been used with equal efficacy in experimental and clinical settings of liver preservation, provided that the storage period does not exceed 10–12 h. Compared with UW, HTK is increasingly used especially in short preservation periods, e.g. living donor liver transplantations, because of its practical and economical advantages [1].

A number of additional pharmacological agents can be used to improve preservation results and diminish ischaemia–reperfusion injury. Phenoxybenzamine and prostaglandins for donor and recipient, methyprednisolone, aprotinin, antilympho/thymocyte globulin (ATG) and free oxygen radical scavengers are also being used. The problem in standard clinical use is that there is no consensus between different organ transplant teams and donor and recipient clinics on the use of such agents.

The recipient hepatectomy

When the donor liver has been perfused and harvested, the recipient operation can usually begin. In most centres, the abdomen is opened through an upper transverse incision with an upward extension to the xyphoid. Collateral veins in the abdominal wall are carefully ligated, and retractors are used to give access to the liver and the suprahepatic vena cava. If a veno-venous bypass is used, the saphenous vein and axillary vein of the left leg and arm should be prepared and taped. Careful inspection and palpation of the liver and other abdominal organs are necessary to identify additional pathology, especially hepatocellular carcinoma in cirrhotic patients, which was not known before. The dissection starts at the hilum of the liver with identification of the common and proper hepatic and the gastroduodenal arteries. Usually, one or two lymph nodes lying on top of the artery must be removed. The proper hepatic artery or right and left hepatic artery are then ligated and divided. Early dissection of the arteries may save some bleeding later. Next, the common bile duct is identified and the cystic duct divided. The hepatic duct is then divided in the liver hilum and suture ligated; the lower part can either be ligated or the vessels at the open end

may only be coagulated. Then the bile duct together with its surrounding connective tissue containing blood vessels is dissected away from the portal vein. Next the portal vein is completely dissected free, but the lymph nodes on the right and left of the portal vein do not need to be removed completely; thus, damage to the pancreas is avoided.

If a bypass is used, it can now be put into place, and the further mobilization and dissection of the liver and the vena cava can be performed with running bypass. The liver is now carefully mobilized from above, and the vena cava and the three liver veins are identified. The vena cava above the liver is dissected free from both sides and encircled with a linen tape. Similarly, the vena cava below the liver is dissected and taped. Here, it is necessary to find the right suprarenal vein and divide it between two ligatures. The vena cava can then be clamped with a Satinsky clamp below the liver, and with an especially curved clamp above the liver including the diaphragm. The liver is then removed from the body including the posterior vena cava. By using the piggyback procedure, the retrohepatic vena cava stays in place (see below).

After complete hemostasis is achieved in the retroperitoneum and at the diaphragm, which can be done with light coagulation, argon beam or bipolar electrocautery and with fine sutures, the new liver can now be implanted.

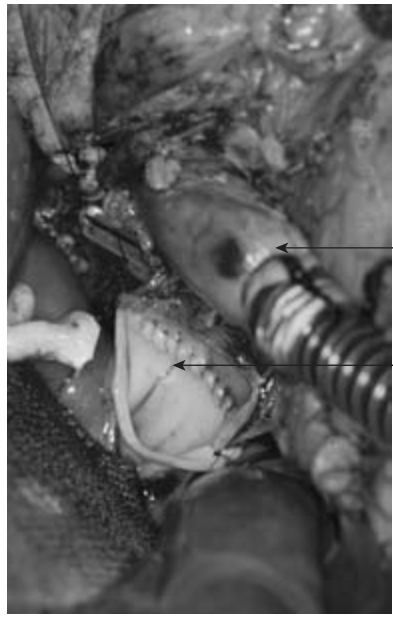

Fig. 2 Anastomosis of the infrahepatic vena cava in a standard liver transplantation with replacement of the intrahepatic vena cava. During the anhepatic phase, a motor-driven veno-venous bypass is used.

Fig. 3 Hepatic artery inflow reconstruction with interposition of an iliac artery to the supracoeliac aorta; the second branch may be used for portal arterialization.

The recipient transplantation

During the standard operation, the vena cava above the liver is first anastomosed with a running 4-0 Prolene suture. Then the inferior vena cava is similarly sutured, but the anterior suture is left untied, and a small tube is inserted between the stitches for later drainage (Fig. 2).

Depending on whether simultaneous or sequential reperfusion of portal vein and hepatic artery is preferred, the portal vein or the hepatic artery is anastomosed first. We prefer simultaneous reperfusion of hepatic artery and portal vein, and therefore anastomose the hepatic artery first when using the veno-venous bypass. Usually, the common hepatic and gastroduodenal arteries are clamped with a Baby-Satinsky clamp, the proper hepatic artery is divided, and the common hepatic artery is incised. At the donor hepatic artery, a patch is created from the coeliac trunk and the splenic artery, which is then anastomosed to the recipient's common hepatic artery at the division into proper hepatic and gastroduodenal artery with a 7-0 Prolene running suture. If the recipient's hepatic artery is too small, the anastomosis can be moved to the coeliac trunk, or an interposition graft of donor iliac artery coming from the supracoeliac aorta or the infrarenal aorta may be used.

Patients with coeliac axis stenosis may also suffer from inadequate blood flow. The median arcuate ligament syndrome has been described as affecting arterial inflow after orthotopic liver transplantation (OLT). In these cases, a dissection of the arcuate ligament or the use of a donor iliac arterial conduit from the infrarenal or supracoeliac aorta is advisable (Fig. 3). However, these techniques are associated with an increased rate of hepatic artery stenosis and thrombosis. Anatomical variations requiring back table arterial reconstructions are common and have no influence on long-term outcome [2–4]. Arterial steal syndrome after liver transplantation related to the splenic artery has been reported in only limited series. Patients present with elevated transaminases and deteriorating liver function, usually over the long term after transplantation, which is mainly caused by ischaemic damage [5]. In these cases, embolization or operative narrowing of the splenic artery is the appropriate treatment option.

After removing the portal vein bypass tube and flushing the portal vein, both donor and recipient vessels are trimmed and brought together under gentle tension. The end-to-end

anastomosis is performed with 6-0 Prolene sutures. Thereafter, the blood flow is opened to both artery and portal vein, and about 400–500 mL of cold perfusate and blood is drained from the infrahepatic vena cava until the suture is tied and the suprahepatic vena cava clamp removed.

The anastomosis sites, the parenchyma and the gallbladder bed are inspected for bleeding and are temporarily packed with small gauzes. The bypass can then be removed, and the vena saphena and the vena axillaris can be ligated without problems.

Portal vein thrombosis is a recognized complication of end-stage liver disease. Its incidence is estimated to range between 2% and 20% [6]. Although portal vein thrombosis is no longer considered a contraindication for OLT, it is still regarded as a high-risk condition because the results obtained in these patients may not be similar to those in patients without portal vein thrombosis. When complete and extensive portal vein thrombosis with involvement of the mesenteric and splenic veins is present, alternative techniques such as cavoportal transposition or arterialization [7] of the portal vein are used. However, these techniques are associated with an increased risk of morbidity and mortality. In most cases, thromboendovenectomy in the liver transplant recipient is possible and allows a safe portal anastomosis. In a recent study of 64 patients with portal vein thrombosis prior to liver transplantation, a thromboendovenectomy was possible in 56, seven patients received a venous graft from the superior mesenteric vein, and one patient a cavoportal hemitransposition [8]. Only blood transfusions and long surgery were significant factors compared with patients with no portal vein thrombosis, which shows that portal vein thrombosis is no longer a contraindication for OLT.

Piggy-back technique

The piggy-back technique was developed to avoid the use of veno-venous bypass and congestion of the lower abdomen with impaired venous return after hepatectomy. Here, during the recipient hepatectomy, the liver must be carefully dissected free from the vena cava, and the small hepatic veins must be suture ligated step by step. Finally, only the portal vein and the three hepatic veins remain. In the case of a good collateralization, either the portal vein can be clamped or a temporary portocaval shunt can be performed. The three liver veins are divided behind vascular clamps, and the orifices are carefully oversewn with running Prolene sutures which must not narrow the vena cava.

During implantation of the new liver, the donor vena cava is closed below and above the liver with either suture or stapler, and then longitudinally incised. The recipient's vena cava is partially clamped with a long Satinsky clamp, and the front wall is longitudinally incised corresponding to the donor cava incision. After positioning of the liver, a side-to-side anastomosis of both vena cavae with 4-0 running Prolene sutures is performed (Fig. 4). Then the portocaval shunt, if present, is clamped and divided, and the portal vein anastomosis is performed in an end-to-end fashion. In this situation, the clamps are usually removed, and reperfusion is only done with portal blood.

The most common technique of revascularization of the graft in liver transplantation is initial reperfusion via the portal vein and subsequent reconstruction of the arterial branches. The choice of this order is based on the experience that portal venous blood flow alone is sufficient for adequate liver perfusion. However, this technique carries some disadvantages, which are,

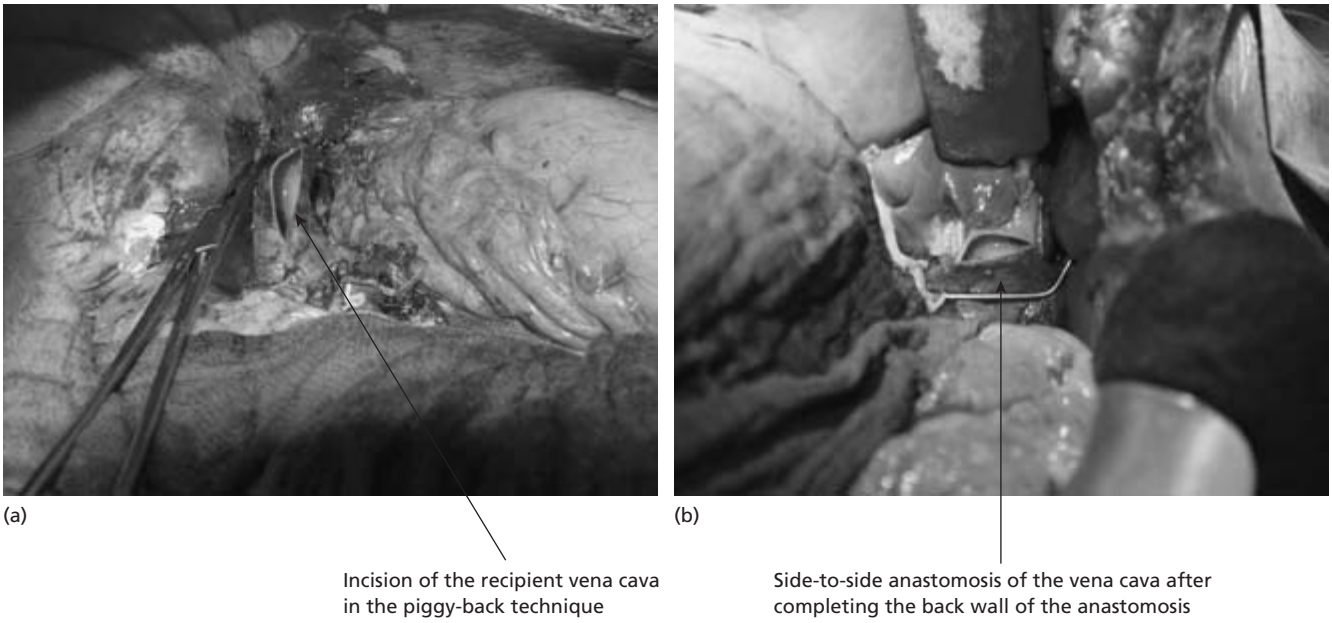

Fig. 4 (a) The recipient's vena cava is incised longitudinally corresponding to the donor cava incision. (b) Side-to-side anastomosis of the vena cava after suturing the back wall of the anastomosis.

first, the fast rewarming of the graft with only rarely oxygenated blood and, secondly, the lack of perfusion of the bile ducts, which depends exclusively on arterial blood supply, and the possible risk of the development of ischaemic-type biliary lesions. A number of studies advise a reverse order of reperfusion to reduce the warm ischaemic time of the liver. First arterial reperfusion followed by portal reperfusion has been associated with lower blood transfusion requirements, more stable haemodynamics and lower peak values of transaminases; however, a recent study could not confirm this claim [9].

The piggy-back procedure without the use of veno-venous bypass has now become the accepted standard in most liver transplant centres worldwide. Most patients tolerate temporary clamping very well, but the bypass should, however, still be available if severe instability results after a short clamping period. In cirrhotic patients with portosystemic collaterals, a temporary portocaval shunt is unnecessary. Even without collaterals, our experience in liver surgery with 30–60 min Pringle manoeuvre shows that temporary portal occlusion is well tolerated. In our experience, the bypass was mostly advantageous for anaesthesiological management. Good blood return from the lower half of the body, complete decompression of the portal venous system and the possibility of warming the blood and the patient to 37°C by extracorporeal heat exchange were the advantages of the bypass. The additional time, wounds and mechanical risks of the bypass had to be weighed against the advantages.

Piggy-back technique and standard vena cava replacement result in vena cava stenosis in 2.5–6% of cases, with venous outflow obstruction due to rotation of the liver or anastomotic stricture. This may present with liver allograft dysfunction, ascites formation and impairment of renal function. In an analysis of more than 1000 patients, symptoms occurred during the first 48 h after liver grafting [10,11]. Cava stenosis carries a high risk of mortality and, although hepatic outflow obstruction occurs in both standard and piggy-back techniques, it was seen more commonly in the piggy-back technique.

Recent publications have shown that the initial problems of the piggy-back technique with the anastomosis on the combined orifice of the hepatic veins could be overcome with long side-to-side anastomosis of both the vena cavae.

Bile duct anastomosis

Biliary complications are the 'Achilles heel' of liver transplantation and contribute significantly towards morbidity and mortality. Biliary complications have been reported still to occur relatively constantly in approximately 10–15% of all deceased donor full-size liver transplantations.

After complete revascularization of the liver, the anastomosis of the bile duct is performed. It can be done either as direct duct-to-duct anastomosis or as hepaticocholedochojejunostomy with a Roux-en-Y loop.

Direct bile duct anastomosis can be performed as end-to-end or as side-to-side anastomosis (Fig. 5). Most centres use a direct duct-to-duct anastomosis with fine interrupted absorbable sutures or, after an oblique incision of both bile ducts, the anastomosis is performed with a continuous running suture. A T-tube may or may not be used. Various studies could not show

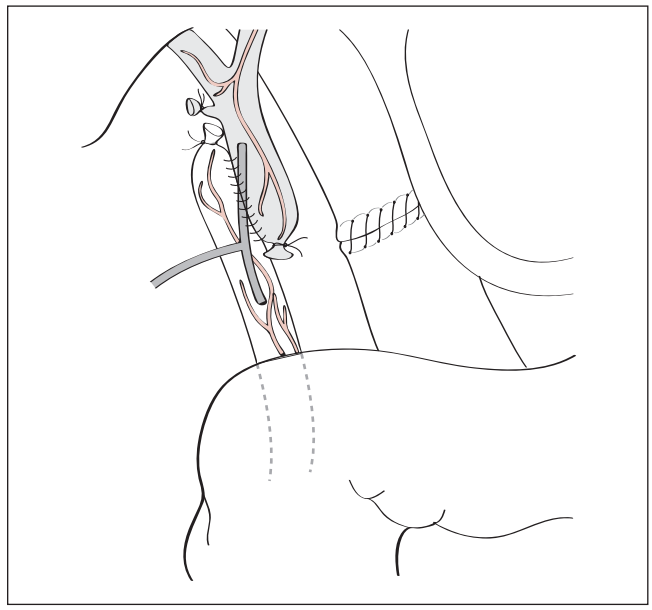

(a)

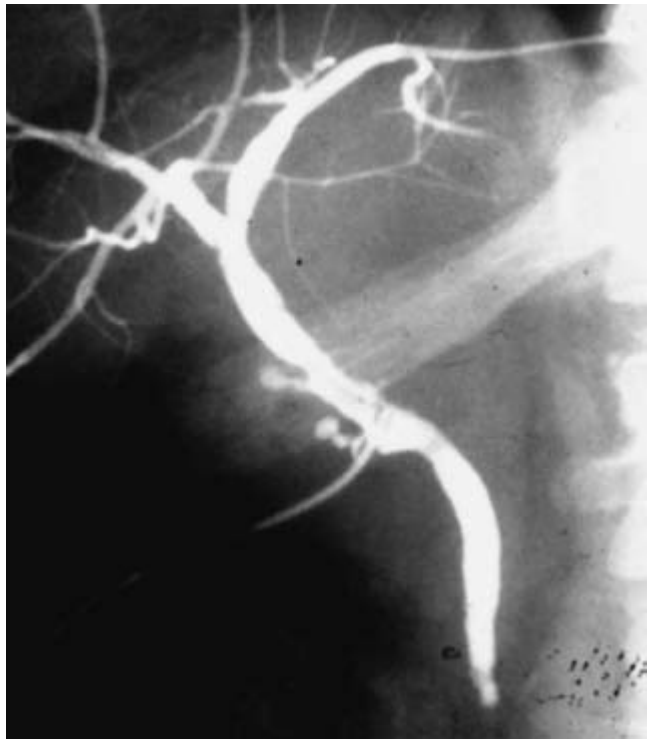

(b)

Fig. 5 (a) Schematic presentation of a side-to-side anastomosis of the common bile duct with insertion of a T-tube. (b) Cholangiography of a side-to-side choledocho-choledochostomy 6 weeks after liver transplantation.

an advantage for the T-tube, although it allows monitoring of the quantity and quality of the bile.

In our centre, we prefer side-to-side anastomosis, where both bile ducts are laterally incised over 10–12 mm, then suture ligated at the end and anastomosed with fine running absorbable sutures. As we see fewer than 5% biliary leakages and stenosis, it seems favourable to us to perform a wide anastomosis of the bile duct in a lateral area where arterial perfusion is not compromised.

Randomized trials could not identify any differences in complication rates with regard to the type of anastomosis (side-to-side anastomosis compared with end-to-end) [12]. The management of bile duct complications after liver transplantation requires a multidisciplinary approach. Interventional or endoscopic treatment options have to be weighed against surgical intervention.

Especially in patients with biliary disease such as primary sclerosing cholangitis or when the recipient's bile duct is not suitable for anastomosis for other reasons, a biliary enteric end-to-side anastomosis with a 40–50 cm Roux-en-Y loop is created. In this situation, the bile duct anastomosis should be placed 6–8 mm below the bile duct bifurcation.

At the end of the operation, drains are placed around the liver. Attention should be given to the closure of the large abdominal wound, because incisional hernias, especially after the Mercedes-star incision, are quite frequent.

References

1 Testa G, Malago M, Nadalin S *et al.* (2003) Histidine-tryptophan-ketoglutarate versus University of Wisconsin solution in living donor liver transplantation: results of a prospective study. *Liver Transpl* 9(8), 822–826.

2 Soliman T, Bodingbauer M, Langer F *et al.* (2003) The role of complex hepatic artery reconstruction in orthotopic liver transplantation. *Liver Transpl* 9(9), 970–975.

3 Meneu-Diaz JC, Moreno-Gonzalez E, Garcia Garcia I *et al.* (2004) Hepatic allograft arterialization by means of the gastroduodenal bifurcation (branch patch) as a prognostic factor. *Transplantation* 77(10), 1513–1517.

4 Del Gaudio M, Grazi GL, Ercolani G *et al.* (2005) Outcome of hepatic artery reconstruction in liver transplantation with an iliac arterial interposition graft. *Clin Transplant* 19(3), 399–405.

5 Nussler NC, Settmacher U, Haase R *et al.* (2003) Diagnosis and treatment of arterial steal syndromes in liver transplant recipients. *Liver Transpl* 9(6), 596–602.

6 Francoz C, Belghiti J, Vilgrain V *et al.* (2005) Splanchnic vein thrombosis in candidates for liver transplantation: usefulness of screening and anticoagulation. *Gut* 54(5), 691–697.

7 Settmacher U, Stange B, Schaser KD *et al.* (2003) Primary permanent arterialization of the portal vein in liver transplantation. *Transpl Int* 16(6), 430–433.

8 Bertelli R, Nardo B, Montalti R *et al.* (2005) Liver transplantation in recipients with portal vein thrombosis: experience of a single transplant center. *Transplant Proc* 37(2), 1119–1121.

9 Polak WG, Miyamoto S, Nemes BA *et al.* (2005) Sequential and simultaneous revascularization in adult orthotopic piggyback liver transplantation. *Liver Transpl* 11(8), 934–940.

10 Cabezuelo JB, Ramirez P, Acosta F *et al.* (2003) Does the standard vs piggyback surgical technique affect the development of early acute renal failure after orthotopic liver transplantation? *Transplant Proc* 35(5), 1913–1914.

11 Robles R, Parrilla P, Acosta F *et al.* (1999) Complications related to hepatic venous outflow in piggy-back liver transplantation: two- versus three-suprahepatic-vein anastomosis. *Transplant Proc* 31(6), 2390–2391.

12 Davidson BR, Rai R, Kurzawinski TR *et al.* (1999) Prospective randomized trial of end-to-end versus side-to-side biliary reconstruction after orthotopic liver transplantation. *Br J Surg* 86(4), 447–452.

25.1.2 Split-liver transplantation

Ramón Charco, Josp Fuster Obregón, Constantino Fondevila and Juan Carlos García-Valdecasas

Introduction

Liver transplantation is the treatment of choice for the majority of terminal liver diseases [1]. However, the great problem is that the number of patients requiring a transplant far exceeds the number of donors, a fact that is of concern in the United States and some European countries where the donation rate is low. This lack of organs is worse in the context of paediatric liver transplantation, with the added difficulty of finding donors with adequate weight and size for a particular recipient. In the past, waiting-list mortality reached 50% [2]. In 1984, Bismuth and Houssin [3] cut an adult liver to adapt the size of the graft and be able to transplant a child (reduced liver). This practice, in which a large portion of the liver is discarded, clearly prejudices the pool of adult donors.

Pichlmayr *et al.*, in 1987 [4], were the first to transplant two recipients with a single liver. In this way, the liver parenchyma that used to be systematically rejected in reduced liver transplants can be utilized. The concept of split-liver transplantation is based on dividing a liver into two parts, conserving the vasculobiliary pedicles of each part and, consequently, their venous drainage, and thus being able to transplant an adult and a child; later, Bismuth *et al.* used the technique to transplant two adults [5]. The split transplant was developed further by the Broelsch group in Chicago [6] and European paediatric teams. In the 1990s, its development boomed, in both the number of cases performed worldwide and the improvements in technique and results [7]. In countries with a good rate of cadaveric donors, split-liver transplantation has resolved paediatric waiting lists and reduced the need for live donors in paediatric liver transplants [8].

The donor liver is divided into two grafts: the left lateral segments (II, III) for the child and the right lobe with segment IV for the adult (Fig. 1a). This combination, which increases the paediatric donor pool, does not prejudice the adult recipients and is associated with excellent survival [9]. The number of

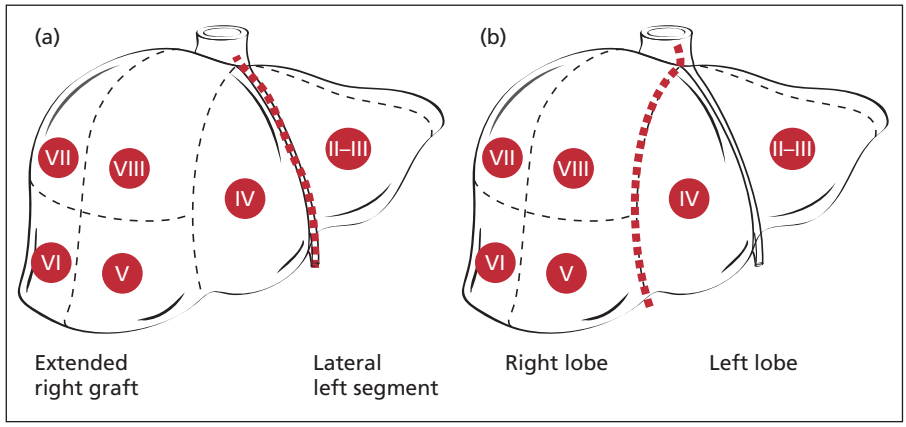

Fig. 1 Usual cutting lines used in split liver.

divisions for transplanting two adults has been increasing in recent years. The early experiences published by the Bismuth group showed inferior results with the left graft [10]. However, the application of the technique and experience in live donation for adults [11] have led to improvements in the technique resulting in split transplants for two adults. In these cases, the right liver (segments V–VIII) will be for the heaviest adult recipient and the left liver (segments I–IV) for the lightest recipient (Fig. 1b).

The split method for two adults has also been combined with the domino technique. The aim is to transplant a patient with familial metabolic polyneuropathy with a cadaveric donor and divide the liver graft with the metabolic defect to transplant two patients [12].

Donor selection

The majority of groups select donors for the split. These should be excellent donors who have short intensive care unit stay, minimum inotropic support, serum sodium levels below 160 mEq/dL, normal bilirubin, small transaminase elevations and no cardiac arrest [13]. The availability of an imaging technique such as echography is essential to assess liver parenchyma, examine vascular distribution and rule out significant steatosis. Each centre, according to its experience, waiting list load and type of bipartition (two adults or child and adult), is more or less strict when applying the acceptance criteria and marking the limits for dividing a liver.

It is estimated that the proportion of livers suitable for bipartition could reach 15% of current donors [14]. The lack of donors has led to a steady increase in the number of patients (children and adults) transplanted in Europe with a partial cadaveric graft [15].

Surgical technique in the donor liver

The bipartition technique can be performed in two modes: *ex situ* bipartition on bench surgery or *in situ* bipartition during the surgical procedure in the donor.

Ex situ bipartition

The partition is performed during bench surgery. It usually lasts 2–3 h as the vasculobiliary pedicles have to be divided, and the cut surface of both grafts must be completely sealed. Two grafts will be obtained: the right lobe with the right portal vein, right hepatic artery, main biliary tract and the vena cava that will be transplanted into the heaviest recipient; and the left lobe of the left lateral segments (II–III) depending on the size of the recipient, with the portal vein, coeliac trunk, left hepatic duct and left hepatic vein. If the left lobe is involved, the vena cava should accompany the left graft and the right hepatic vein the right graft. Although not mandatory, the coeliac trunk can be left with the right part of the graft [16,17] (Fig. 2).

In situ bipartition

The procedure is the same as in the live donor. It varies depending on whether the division is to be to the right of the falciform ligament (II, III and IV) or to the left (II, III) [18]. The technique consists of dissection of the portal vein and hepatic artery as far as its bifurcation. In general, the right vena porta is left with the main trunk, while the left portal vein is sectioned at its origin or more distally, respecting at all times the collaterals of segment IV if segment IV remains with the right lobe. The hepatic artery usually has variants. On most occasions, the left hepatic artery is left with the coeliac trunk, the right hepatic artery is sectioned at its source, and the orifice is sutured. However, in cases of bipartition to the left of the falciform ligament (left lateral segment), the coeliac trunk is usually left with the right graft. In short, the frequent anatomical variation of hepatic artery vascularization and the type of bipartition will mark the arterial division site. The right and middle hepatic veins will provide drainage to the right graft of the adult, and dissection of the left hepatic vein may cause an area of stenosis at the origin of the middle hepatic vein for which a segment of vena cava can be utilized as a patch to widen the orifice (*ex situ*). The left hepatic vein will drain the paediatric graft.

Table 1 Main characteristics of the technique *in situ* or *ex situ*.

	In situ	*Ex situ*
Logistic advantages of distribution	Yes	No
Vascularization identification	Better	Worse
Section surface haemostasis	Better	Worse
Ischaemic time	Short	Long
Donor surgery	Long	Short
Bench surgery manipulation/handling	Minimum	Major
Haemodynamic stability	Essential	Non-essential
Donor centre problems	Yes	No
Expert surgeon	Yes	No

As a solution to these problems and to guarantee optimum venous drainage of both hemilivers, Rogiers proposed the split cava technique, which consists of dividing the vena cava longitudinally, leaving a segment of the vena cava with the right part and a further segment with the left part so that venous drainage is guaranteed, including that of the caudate lobe [19,20].

The biliary tract is dissected directly on the left hilar plaque, and the left hepatic duct is cut after the exit of the bile duct from segment IV. Once the vascular and biliary structures have been identified and sectioned, the liver parenchyma is sectioned, either to the left of the falciform ligament (segments II–III) or to its right (left hepatic lobe) using a meticulous dissection with ligature of intraparenchymatous vasculobiliary structures of the transection area. Once the transection has been made *in situ*, adequate haemostasis of the transected area is confirmed, resulting in two grafts ready for implantation [20] (Fig. 3).

Controversy exists as to the technique of choice. The advantages and disadvantages of both techniques are shown in Table 1. Good results are obtained with both techniques provided the teams are experienced and donors and recipients are carefully selected. Most groups advocate the *in situ* division although, if the division is for an adult and a child and both transplants can begin simultaneously without either of the grafts having to be sent to another centre, the *ex situ* bipartition is an excellent solution.

It is advisable to choose stable recipients from the waiting list and avoid urgent cases as far as possible [16]. Although the grafts obtained by bipartition stem from excellent donors, it most be remembered that we are transplanting sufficient liver mass but much less than that usually transplanted with a whole liver graft in the case of division for two adults. This is not the case in a paediatric split, where the liver mass transplanted is usually two or three times that which would correspond by weight and size. As a general rule, if the possibility of performing a split transplant to two adults is considered, the technique of choice will be *in situ*. Normally, the liver mass to be transplanted in relation to the weight of the recipients (split for two adults) tends to be at the extreme limit and, therefore, any factor that negatively affects graft quality, e.g. long preservation time, excessive handling during bench surgery or steatosis, should be strictly avoided.

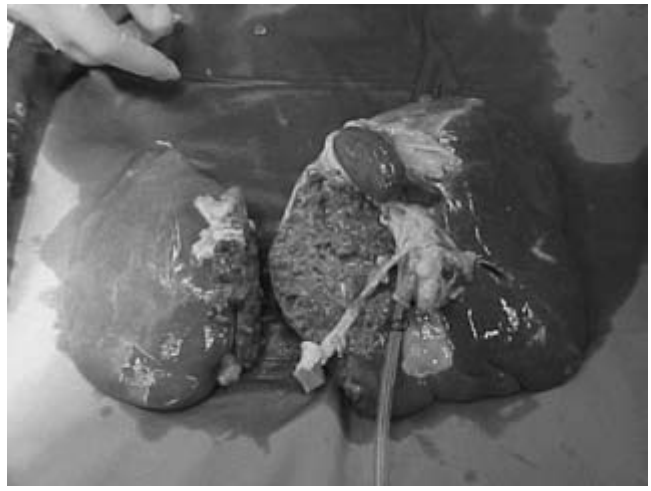

Fig. 2 Split-liver graft for adult and child.

Surgical technique in the recipient

The surgical technique in the paediatric recipient generally requires a hepatectomy with inferior vena cava preservation. Implantation of the left lateral segment is performed using anastomosis of the left hepatic vein of the graft to the stump made with two or three hepatic veins of the recipient or of the vena cava with the suture of the ostium of the right hepatic vein in the case of the left lobe. The portal anastomosis between the left portal vein of the graft and the recipient's portal vein is performed end-to-end and with sufficient length to permit displacement and accommodation of the graft towards the optimum position on the right. It is advisable to perform the arterial anastomosis prior to declamping to avoid as far as possible hypoperfusion of the graft, which occurs when the liver is luxated. This anastomosis is normally performed between the recipient's hepatic artery and the donor's coeliac trunk. When the need for a greater calibre anastomosis that ensures adequate graft perfusion is considered, the coeliac trunk of the donor can be directly anastomosed to the recipient's aorta or by interposition of an iliac graft. Revascularization of the graft is preferable after the portal and arterial anastomoses have been made. The biliary tract anastomosis is performed between the left hepatic duct of the donor and Roux-en-Y jejunal loop, with a transanastomotic suture being left at all times [16].

The technique used in adults does not differ from a complete liver implant with preserved inferior vena cava. The right hepatic vein or the vena cava is anastomosed with the ostium suture of the left hepatic vein to the stump made with the three hepatic veins of the recipient. The portal anastomosis is end-to-end, and the arterial anastomosis is between the right hepatic artery of the graft or the coeliac trunk, lengthened on occasions using an iliac graft, and the hepatic artery of the recipient, usually at the level of the gastroduodenal bifurcation. Revascularization can be after either portal anastomosis or the portal–arterial

Fig. 3 *In situ* split.

Fig. 4 Revascularizated left graft.

anastomosis. The biliary anastomosis is made end-to-end between the hepatic duct of the graft and the hepatic duct of the recipient with or without suture. If the recipient's bile duct is not adequate, a Roux-en-Y is performed [16,18] (Fig. 4).

The surgical technique in the recipient is not a fixed technique, but is subject to a multitude of variants depending on the anatomical variation of the donor and recipient, the technique followed in the donor (*ex situ* or *in situ*), the type of division (two adults or child and adult), the experience of the surgical team, etc.

Immunosuppression

Immunosuppression in split-liver transplantation is basically the same as in whole cadaveric transplants. Our experience, and that of other authors, shows blood anticalcineurinic levels attained in adult recipients transplanted with a partial graft from a live donor to be higher than those reached with the complete cadaveric transplant [21–23]. Several theories exist to explain such high levels. The recipient of a partial graft has a lower distribution volume compared with the complete graft recipient and, on having substantially lesser liver mass, the liver metabolization of these drugs will also be lower, which gives rise to higher blood levels of the drug [21–23]. Thus, it seems reasonable for these patients, recipients of a partial graft (right or left lobe), to receive lower initial doses of anticalcineurinics with the aim of minimizing the toxicity derived from supratherapeutic levels.

Graft size in split-liver transplantation

It is fundamental to ensure sufficient functional liver mass in this type of transplant. Generally, when the weight ratio between donor and paediatric recipient lies between 5 and 10:1, we will use segments II–III. Should the ratio be lower, the whole left hepatic lobe can be used.

In general, particularly when the split-liver transplant is for two adults, the liver mass to be transplanted should be calculated as in a live donor transplant [24]. Sixty per cent of the liver mass would correspond to the right, 10–15% to segment IV and the rest to segments II–III.

Several studies have shown the good results obtained with hepatic bipartition and its application in two adults. If we analyse the results of the Paul Brousse Hospital, one of the largest centres with experience in these techniques, they show split-liver transplant for two adults to be a feasible procedure, although they imply a greater number of biliary complications, a higher rate of primary malfunction and lower survival at 2 years compared with whole cadaveric transplant [10]. These differences are due mainly to worse survival with the left lobe transplant. In this study, factors influencing graft survival were the degree of steatosis, days of hospitalization and the ratio between donor liver and recipient body weight [graft body weight ratio (GBWR)] < 1%. Factors influencing patient survival were again steatosis, indication for transplant when the patient was hospitalized and prolonged hospital stay [10].

Thus, if we wish to transplant patients successfully with a partial graft from a split liver, especially if it is the left lobe, we should choose recipients with Child status A or B, no portal hypertension or significant vascular anomalies and, if possible, no previous supramesocolic compartment surgery [25]. Furthermore, we should avoid patients with fulminant failure, and it will be fundamental for the size of the recipient to be adequate for the graft [25]. For this, we must ensure that GBWR is ≥ 1%. The majority of studies demonstrate that the lower the GBWR, the greater the possibility of small-for-size syndrome appearing; this is a clinical syndrome characterized by the onset

of cholestasis, ascites and, finally, coagulopathy [26]. It is a cause of graft loss. A study from the University of Kyoto, where more than 250 partial liver transplants from live donors were studied, showed that graft survival with a GBWR of 1–5% was 80% at 5 years, dropping to 50% if GBWR was < 1% [25]. One notable aspect is that partial grafts from split donors are usually from cadaveric donors. Thus, unlike partial grafts from live donors, they suffer all the metabolic changes typical of brain death and, furthermore, cold ischaemia time is longer, at least the same as that of the cadaveric donor. A further negative aspect is that, in most hospitals, only echography is available as an imaging method able to assess the steatosis and the distribution of liver mass in both lobes. In the cadaveric donor, it is difficult to have hepatic volumetry available prior to surgery in order accurately to ascertain the volume of each lobe. For this reason, in the split transplant, we must estimate that a liver of approximately 1500 g would correspond to a 75-kg patient, which represents a left lobe of 600 g. In such cases, it is recommended to choose recipients under 55 kg to achieve a good donor weight–recipient weight ratio ensuring a GBWR ≥ 1%. Consequently, it is essential to draw up a list of potential recipients of partial grafts from the left lobe.

In the case of a split transplant for two adults performed at our own hospital, we combined the split and domino techniques. The patient was a 45-year-old man with a familial amyloidotic polyneuropathy who had been included on the waiting list for a liver transplant. Given that the patient weighed 75 kg, we decided to divide his liver to be able to transplant two patients on the list. Angiomagnetic resonance imaging showed no biliary or vascular anatomical variants that would contraindicate the division. Furthermore, it was possible to calculate the mass of both lobes and select the two most suitable recipients from the waiting list [27].

Results of split-liver transplant

Initially, the results with this type of transplant were poor. There were a large number of complications owing to the lack of donor and recipient selection and technical problems. Gradually, the results began to improve. The first series of split-liver transplants published was that from Chicago [2] and, in 1995, the first European series accumulated between 1990 and 1993 was published [27]. It comprised 98 grafts transplanted in 53 children and 42 adults. Survival of the chosen patients at 6 months was 72% in adults and 89% in children. Vascular complication rates were 15%, biliary 19% and retransplant 19%.

To date, the results have improved notably. Although the number of complications is higher, graft survival at 1 year in most series is currently 60–80%, results similar to those obtained with whole liver. Overall survival of all split transplants included in the European Liver Transplant Registry is 65% at 1 year and 59% at 5 years [15]. In US centres, such as the University of California (UCLA) with a high volume of split transplants, survival at 1 year is 79% [28].

Adult–child

Division of a graft for an adult and a child constitutes 80–90% of all partitions. In the majority of series, results of paediatric grafts are excellent, although survival in adult recipients is somewhat lower (Table 2) [29–34].

Adult–adult

Experience with this type of division is much more limited. Although the survival achieved is similar to that with the whole graft, provided donor and recipient are appropriately selected,

Table 2 Results adult–child.

Author [ref.]	Centre	Year	*n*	Technique	Graft survival (%)	Patient survival (%)
Left lateral segment						
Sauer *et al.* [29]	Berlin	2001	18	*Ex situ*	87	93
Broering *et al.* [30]	Hamburg	2001	49	Mixed	76	82
Deshpande *et al.* [31]	London	2002	80	*Ex situ*	88	93
Yersiz *et al.* [32]	Los Angeles	2003	92	*In situ*	68	78
Gridelli *et al.* [33]	Bergamo	2003	90	Mixed	86	94
Cescon *et al.* [34]	Multicentric	2005	37	*In situ*	81	83
Right hepatic lobe						
Sauer *et al.* [29]	Berlin	2001	18	Mixed	90	90
Broering *et al.* [30]	Hamburg	2001	40	Mixed	74	80
Yersiz *et al.* [32]	Los Angeles	2003	71	*In situ*	69	78
Cescon *et al.* [34]	Multicentric	2005	20	*In situ*	84	89

Table 3 Results adult–adult.

Author	Centre	Year	*n*	Graft survival (%)	Patient survival (%)	Morbidity (%)
Azoulay *et al*. [10]	Paris	2001	34	74 (R) 75 (L)	74 (R) 88 (L)	24
				74 (R) 43 (L)	74 (R) 64 (L)	–
Gundlach *et al*. [19]	Eppendorf	2000	4	100	100	–
Andorno *et al*. [35]	Genoa	2001	10	100	80	43
Broering *et al*. [30]	Hamburg	2001	12	93	85	–
Humar *et al*. [36]	Minnesota	2001	18	89	89	

this type of partition is aggravated by a greater number of complications (Table 3) [19,35,36].

Future prospects

In 2002, Boillot *et al*. [37] published the case of a patient successfully transplanted with a partial graft and GBWR of 0.61%. One of the reasons for excellent liver function was the modulation of portal flow with a mesenteric–cava shunt and occlusion of the superior mesenteric vein with a ligature proximal to the derivation. Thus, the hepatic venous flow comprised only the flow arriving through the splenic and inferior mesenteric veins. Clinical studies indicate that, in most cases, the liver failure that occurs in 'small-for-size' grafts is largely due to excessive portal flow. These grafts receive all the portal–mesenteric flow in the same way as a whole graft [25,38,39]. Experimental studies in pigs show that raised portal pressure may negatively influence the results of partial liver transplant with a GBWR < 0.8%. A publication from the University of Tsukuba [40] studied the effect of portal hypertension on liver transplant results in an experimental porcine model of partial liver transplant with an extremely reduced graft (GBWR = 0.6%). Two animal groups were designed for the study: one transplanted with a latero-lateral portocaval shunt and the other transplanted without a portocaval shunt. In the portocaval group, a significant decrease in portal pressure was observed and better survival of the animals in the immediate postoperative period. In the group of animals without a portocaval shunt, in which portal pressure was high, only one survived the postoperative period.

From these results, it seems evident that modulation of portal flow, and consequently of portal pressure, clearly influences the results of partial liver transplants. This could constitute a line of research enabling transplantation of patients over 55–60 kg with a left partial graft without the appearance of the small-for-size syndrome.

Split-liver transplantation for a child and an adult is currently used by experienced transplant teams, with excellent results. When the division is used to transplant two adults, the technique is considered to be feasible and safe, provided good donor and recipient selection is guaranteed.

References

1 Guo TJ, Daily OP, Davies DB (1994) The UNOS OPTN waiting list: 1988 to 1994. United Network for Organ Sharing. Organ procurement and Transplantation Network. *Clin Transpl* 8, 69–86.

2 Edmond JC, Whitington PF, Thislethwaite JR *et al*. (1990) Transplantation of two patients with one liver: analysis of a preliminary experience with a 'split-liver' grafting. *Ann Surg* 212, 14–22.

3 Bismuth H, Houssin D (1984) Reduced-size orthotopic liver graft in hepatic transplantation in children. *Surgery* 95, 367.

4 Pichlmayr R, Ringe B, Gubernatis G *et al*. (1988) Transplantation einer Spenderleber auf zwei Empfanger (splitting-transplantation). *Langenbeck's Arch Chir* 373, 127–130.

5 Bismuth H, Morino M, Castaign D *et al*. (1989) Emergency orthotopic liver transplantation in two patients using one donor liver. *Br J Surg* 76, 722–724.

6 Broelsch CE, Emond JC, Whitington PF *et al*. (1990) Application of reduced size liver transplant as split graft, auxiliary orthotopic graft and living related segmental transplants. *Ann Surg* 214, 368–377.

7 Busuttil RW, Goss JA (1999) Split liver transplantation. *Ann Surg* 229, 313–321.

8 Otte JB (1995) Is it right to develop living related liver transplantation? Do reduced and split livers not suffice to cover the needs? *Transpl Int* 8, 69–73.

9 Adam R, Cailliez V, Majno P *et al*. (2000) Normalised intrinsic mortality risk in liver transplantation: European Liver Transplant Registry study. *Lancet* 356, 621.

10 Azoulay D, Castaign D, Adam R *et al*. (2001) Split-liver transplantation for two adult recipients: feasibility and long-term outcomes. *Ann Surg* 233, 565–574.

11 Kawasaki S, Makuuchi M, Matsunami H *et al*. (1998) Living-related liver transplantation in adults. *Ann Surg* 227, 269–274.

12 Azoulay D, Castaing D, Adam R *et al*. (2000) Transplantation of three adult patients with one cadaveric graft: wait or innovate. *Liver Transpl* 6, 239–240.

13 Toso C, Ris F, Mentha G *et al*. (2002) Potential impact of in situ liver splitting on the number of available grafts. *Transplantation* 74, 222–226.

14 Renz J, Edmond J, Yersiz H *et al*. (2004) Split-liver transplantation in the United States: outcomes of a national survey. *Ann Surg* 239, 172–181.

15 European liver transplant registry. http://www.eltr.org.

16 Margarit C, Charco R, Asensio M *et al*. (2002) Experiencia con el trasplante hepático 'split' en el hospital Vall d'Hebron. *Cir Esp* 73, 121–128.

17 De Ville de Goyet J (2002) Technique for ex situ cadaveric liver graft division. In: Rogiers X, Bismuth H, Busuttil RW *et al.* (eds) *Split Liver Transplantation*. Darmstadt: Steinkopff Verlag, pp. 75–87.
18 Humar A, Khwaja K, Sielaff TD *et al.* (2002) Technique of split-liver transplant for two adult recipients. *Liver Transpl* 8, 725–729.
19 Gundlach M, Broering D, Topp S *et al.* (2000) Split-cava technique: liver splitting for two adult recipients. *Liver Transpl* 6, 703–706.
20 Yersiz H, Renz FJ, Hisatake G *et al.* (2002) Technical and logistical considerations of in situ split-liver transplantation for two adults: Part II. Creation of left segments I–IV and right segments V–VIII grafts. *Liver Transpl* 8, 78–81.
21 Charco R, Rimola A, García-Valdecasas JC *et al.* (2005) Steroids and living liver donation increase tacrolimus blood levels in living donor liver transplantation. *Transplant Proc* 37, 3930–3931.
22 Taber D, Dupuis T, Fann AL *et al.* (2003) Tacrolimus requirements and concentrations in adult living donor liver transplant recipients. *Liver Transpl* 8, 212–218.
23 Troter J, Stolpman N, Wachs M *et al.* (2003) Living donor liver transplant recipients achieve relatively higher immunosuppressant blood levels than cadaveric recipients. *Liver Transpl* 8, 219–223.
24 Sugawara Y, Makuuchi M, Takayama T *et al.* (2002) Safe donor hepatectomy for living related liver transplantation. *Liver Transpl* 8, 58–62.
25 Kiuchi T, Kasahara M, Uryuhara K *et al.* (1999) Impact of graft size mismatching on graft prognosis in liver transplantation from living donors. *Transplantation* 67, 321–327.
26 Tanaka K, Kobayashi Y, Kiuchi T (2000) Current status of living donor liver transplantation in adults. *Curr Opin Organ Transpl* 5, 74–79.
27 De Ville de Goyet J (1995) Split liver transplantation in Europe: 1988 to 1993. *Transplantation* 59, 1371–1376.
28 Ghobrial R, Yersiz H, Farmer D *et al.* (2000) Predictors of survival after *in vivo* split liver transplantation. *Ann Surg* 232, 312–323.
29 Sauer IM, Pascher A, Steinmuller T *et al.* (2001) Split liver and living donation liver transplantation: the Berlin experience. *Transplant Proc* 33, 1459–1460.
30 Broering DC, Mueller L, Ganschow R *et al.* (2001) Is there still need for living-related liver transplantation in children? *Ann Surg* 234, 713–722.
31 Deshpande RR, Bowles MJ, Vilca-Melendez H *et al.* (2002) Results of split liver transplantation in children. *Ann Surg* 236, 248–253.
32 Yersiz H, Renz JF, Farmer DG *et al.* (2003) One hundred in situ split-liver transplantations: a single-center experience. *Ann Surg* 238, 496–505.
33 Gridelli B, Spada M, Petz W *et al.* (2003) Split-liver transplantation eliminates the need for living-donor liver transplantation in children with end-stage cholestatic liver disease. *Transplantation* 75, 1197–1203.
34 Cescon M, Spada M, Colledan M *et al.* (2005) Split-liver transplantation with pediatric donors: a multicenter experience. *Transplantation* 79, 1148–1153.
35 Andorno E, Genzone A, Morelli N *et al.* (2001) Split liver transplantation: need for arterial reconstruction in adult patients. *Transplant Proc* 33, 1333–1334.
36 Humar A, Kandaswamy R, Sielaff T (2001) Split liver for two adult recipients: an initial experience. *Am J Transplant* 1, 366–372.
37 Boillot O, Delafosse B, Méchet I *et al.* (2002) Small-for-size partial liver graft in adult recipient: a new transplant technique. *Lancet* 359, 406–207.
38 Edmond JC, Renz JF, Ferrell LD *et al.* (1996) Functional analysis of grafts from living donors. Implications for the treatment of older recipients. *Ann Surg* 224, 544–552.
39 Adam R, Castaing D, Bismuth H (1993) Transplantation of small donor livers in adult recipients. *Transplant Proc* 25, 1105–1106.
40 Asakura T, Ohkohchi N, Orii T *et al.* (2003) Portal vein pressure is the key for a successful liver transplantation of an extremely small graft in the pig model. *Transpl Int* 16, 376–382.

25.1.3 The surgical technique of living donor liver transplantation using the right hepatic lobe

Igal Kam, James Trotter and Gregory T. Everson

Living donor liver transplantation (LDLT) has emerged as a potential option for patients needing liver transplantation for endstage liver disease [1]. The goal of this chapter is to discuss key surgical and clinical issues in the performance of donor right hepatic lobectomy and implantation of the right hepatic lobe into a recipient.

The first successful LDLT was reported in 1990 by Strong *et al.* [2]. In this early report, LDLT was limited to transplantation of a parent's left lateral segment into their child. The smaller left lateral segment provides sufficient hepatic mass for children or even very small adults, but transplantation of the larger left or right hepatic lobe was necessary to provide adequate hepatic function for larger adults. The first successful adult-to-adult LDLT, using a left lobe graft, was reported by Makuuchi *et al.* in 1993 [3]. The first right lobe LDLT, from mother to child, was reported by Yamaguchi *et al.* in 1993 [4]; although left lobe donation was planned, anatomical variations precluded left lobe and favoured right lobe transplantation. The first use of extended right lobe LDLT was reported by Lo *et al.* in 1997 [5], and the first successful adult-to-adult LDLT using the right hepatic lobe in the western hemisphere was reported by Wachs *et al.* in 1998 [6]. The first western series of adult-to-adult LDLT using right lobe grafts was published by Marcos *et al.* in 1999 [7]. Currently, the preferred technique for adult-to-adult LDLT in nearly all liver transplant centres worldwide involves use of the donor's right hepatic lobe.

LDLT peaked in 2001 in the USA when 512 LDLTs were performed, representing 10% of overall activity in liver transplantation [8]. During this period of heightened activity, there was a highly publicized death of a donor in New York [9]. Since then, LDLT activity has declined to approximately 350 cases annually, representing approximately 5% of all liver transplantations.

General aspects

LDLT requires the combined efforts of a highly skilled team of surgeons and anaesthesiologists. In general, patient survival after all types of liver transplantation is highest in centres performing 20 or more transplants each year [10]. Surgical expertise and experience are particularly critical in LDLT where,

optimally, two skilled surgical teams are required for simultaneous performance of donor and recipient procedures. A report from the National Institutes of Health A2ALL (Adult-to-Adult Living donor Liver transplant) study indicates that LDLT has a steep 'learning curve', and that most complications, including mortality, occur within the first 20 cases [11]. We suggest that LDLT should only be performed in transplant centres where the surgeons are vastly experienced in liver transplantation and major liver surgery. Preferably, surgery should be performed coordinately, with separate donor and recipient teams, to maximize the efficiency of the procedure. The ultimate impact of LDLT as an accepted treatment modality for patients with end-stage liver disease depends largely on the rates of morbidity and mortality of donors.

Donor evaluation

The potential LDLT donor must be in excellent medical and psychological condition. The specific tests and sequence of testing vary from centre to centre. At our institution, we have three phases of donor evaluation [1]. First, potential recipients are identified (see discussion above), and financial clearance is obtained from the recipient's insurance carrier. Potential donors should have an identical or compatible blood type and a long-term stable personal relationship with the potential recipient. Volunteers interested in pursuing LDLT must contact the transplant centre to undergo an initial screening to determine whether there are obvious contraindications to donation. The following information is obtained from the potential donor: age, height, weight, brief medical, surgical and psychiatric history, current medications, current smoking status and nature of relationship with recipient. Laboratory tests are obtained (serum electrolytes, complete cell count, liver function tests, hepatitis C antibody, hepatitis B surface antigen and hepatitis B core antibody). Potential donors who pass this initial screening process are then offered the second phase of donor evaluation.

The second phase of evaluation is to determine whether the potential donor is medically, surgically and psychologically fit to donate. Initial medical evaluation is performed after the potential donor has scheduled an appointment. This evaluation should be performed by a transplant hepatologist so that the risks and benefits of the donation and transplantation may be fully explained to the donor. This evaluation includes complete medical history, physical examination, electrocardiogram, chest radiograph and blood tests. The patient is also scheduled for a surgical, psychosocial and psychiatric evaluation and abdominal radiological imaging, either computerized tomography (CT) or magnetic resonance imaging (MRI).

Potential donors may require a third phase of evaluation, which could include endoscopic retrograde cholangiopancreatography (ERCP), angiogram and liver biopsy. At our centre, we have performed liver biopsy when the donor has a history of alcohol excess, suggestion of steatosis on abdominal MRI or risk factors for steatosis, such as body mass index > 28 kg/cm^2.

The potential donor and recipient (see section on 'Recipient evaluation' below) are then presented to the Patient Selection Committee, approved, and the recipient placed on the United Network for Organ Sharing (UNOS) waiting list for liver transplantation. LDLT is typically scheduled within a few weeks of completion of the evaluation.

Donor surgery

Our team's approach to LDLT has been described previously [1,6,12,13]. The optimal setting for performance of LDLT involves two highly skilled surgical teams, one committed to the donor surgery and the other committed to the recipient surgery, operating coordinately in adjacent suites. Prior to surgery, in the preoperative holding area, anaesthesiologists place an epidural catheter to provide spinal anaesthesia to control postoperative pain. The epidural is not used during the operative procedure. After transfer to the operating room and induction of anaesthesia, a central indwelling intravenous catheter is placed and, in some cases, but not all, an arterial line is used. Surgery is conducted in three phases: dissection of the liver, parenchymal transection and removal of the right lobe graft.

Phase I: dissection of the liver

Access to the liver is achieved via right subcostal incision with midline extension and subcostal retraction. After the abdomen has been exposed, the surgeon must confirm the preoperative assessment of the liver, vessels and bile ducts by careful inspection and palpation (Fig. 1). Dissection begins with the

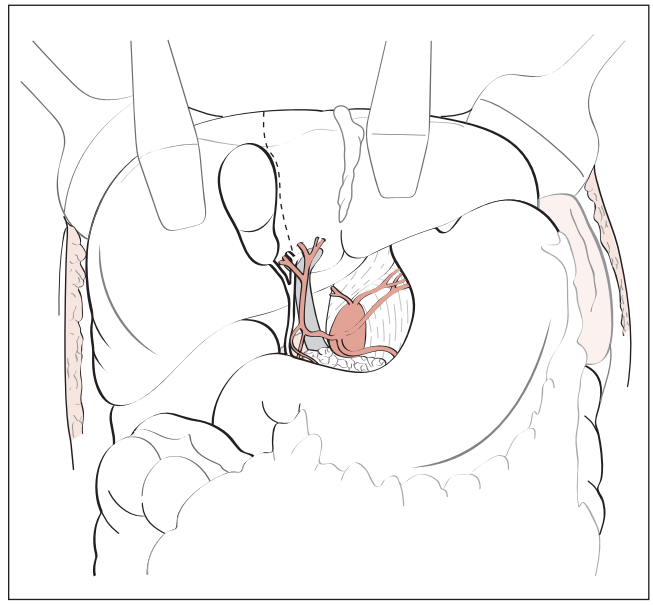

Fig. 1 At donor laparotomy, the liver, gallbladder and major hilar structures are carefully dissected and exposed. Retractors are used to gain optimum exposure. The usual line of resection (dotted line) is situated just medial to the gallbladder bed bisecting the right and left lobes of the liver.

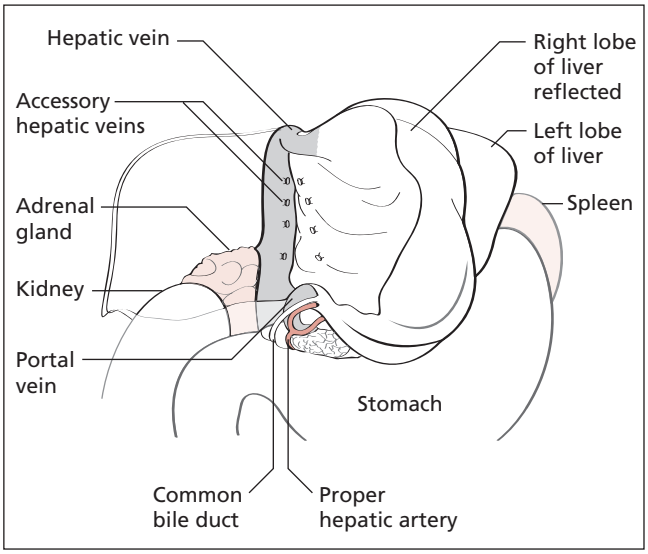

Fig. 2 The right lobe of the donor liver is retracted medially to gain access to the hepatic venous system draining posteriorly into the inferior vena cava. The main right hepatic vein is identified and carefully dissected. Small accessory hepatic veins are ligated, but larger accessory veins (> 1 cm in diameter) are preserved.

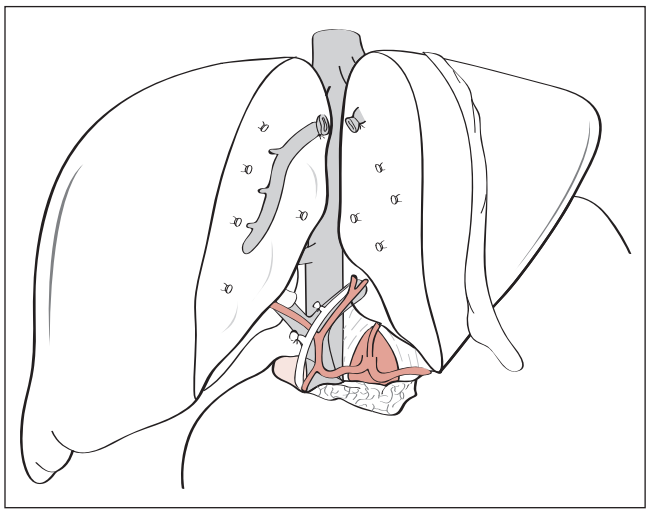

Fig. 3 Transection of the donor liver to yield the right lobe graft is accomplished while maintaining both hepatic arterial and portal venous inflow. After ligation of the middle hepatic vein, the distal portion remains with the right lobe graft, and the proximal portion is retained in the donor. Vessels and biliary radicals emanating from the cut surface are carefully identified and ligated.

identification and division of the falciform ligament. The suprahepatic portion of the inferior vena cava is partially dissected, and the right lobe of the liver is rotated medially and anteriorly and right-sided ligaments are divided between ligatures. Small hepatic venous branches are identified, ligated and divided, but accessory hepatic veins with a diameter of 1 cm or more are preserved (Fig. 2). After appropriate exposure, the main right hepatic vein is encircled with a vessel loop.

Cholecystectomy and performance of intraoperative cholangiography to confirm biliary anatomy are the first steps in hilar dissection. The right hepatic artery is then encircled with a vessel loop. Dissection of the right hepatic artery is carefully performed to both the left and the right sides of the right hepatic duct with attention to maintaining the integrity of small vessels supplying blood to bile ducts. Small branches from the right hepatic artery to hepatic segment IV are ligated. The right portal vein is then identified and encircled with a vessel loop, and small venous branches to the caudate lobe, if present, are ligated and divided. This manoeuvre increases the size of the resultant cuff of right portal vein. The main right hepatic duct is identified and dissected, and a small transverse incision is made with insertion of probes to confirm biliary anatomy. The right hepatic duct is transected, which in most cases improves the exposure and dissection of the right hepatic artery. In cases with a second posterior bile duct, dissection and transection of the second bile duct is done at the time of the parenchymal transection of the liver.

Phase II: transection of the parenchyma of the liver

This phase begins with delineation of the line of transection from the right margin of the middle hepatic vein to the left margin of the gallbladder bed. During transection, the confluence of middle hepatic vein branches is retained with the left lobe and remains with the donor. The proximal middle hepatic vein branches are preserved and remain with the right lobe, which will be transplanted into the recipient (Fig. 3). Some surgeons recommend intraoperative ultrasonography to identify the position of the middle hepatic vein and line of transection. In our experience, intraoperative ultrasonography has not been necessary.

Parenchymal transection is facilitated by the use of three surgical tools: high-power electrocautery, waterjet dissector and harmonic scalpel. These devices control blood loss and enhance the overall speed of the operation. Larger vessels, which are mainly branches from the middle hepatic vein, are ligated, divided and oversewn. The use of a cell saver is mandatory to avoid blood transfusion.

The posterior bile duct, if present, is identified and ligated at the time of the parenchymal transection. This accessory bile duct may need to be oversewn to prevent subsequent occurrence of bile leak. Reoperation and repair of bile leak from this posterior bile duct can be very difficult and should be avoided, if possible.

Our experience indicates that packing of the raw surface of the liver for 30 min at this stage of the procedure improves

haemostasis. In addition, one may detect small biliary radicles at the cut surface that require ligation.

Phase III: removal of the right lobe graft

As noted above, under optimal conditions, a second surgical team has been working coordinately to complete the recipient dissection and prepare the recipient for transplantation. When the recipient dissection has been completed, the right lobe is removed from the donor. Removal is accomplished very quickly, typically within seconds of clamping all the major vascular supply to the right lobe graft. The right lobe graft is transferred to the recipient surgical team where additional 'back-table' work is performed on the graft to prepare it for transplantation.

Completion of donor surgery requires careful assessment throughout this period for bleeding and bile leak. The stumps of the major vessels supplying the former right lobe are carefully ligated and oversewn, using proline running sutures. The stump of the right hepatic duct is closed with fine proline running sutures. The falciform ligament is reattached to the anterior abdominal wall to prevent movement and rotation of the residual hepatic mass to avoid torsion and strangulation of remaining blood vessels and bile ducts. A single Jackson–Pratt drain is placed adjacent to the cut surface of the liver, which is used to monitor for bleeding and bile leak after closure of the abdomen. This drain is also useful for controlling minor bile leakage and may avoid unnecessary re-exploration.

After closure of the abdomen, the donor is transferred to the surgical intensive care unit (ICU) for recovery and 24-h observation. If stable, the donor is then transferred to the general surgical floor, and average total length of stay is approximately 6 days.

Donor outcome

Donor safety is of primary concern. Most donors undergo successful right hepatectomy uneventfully, but significant complications and even death can occur.

Mortality

The initial estimate of risk of donor death was 0.28%, based upon isolated surveys or reports from the USA, Europe and Japan [14–16]. A recent review of 117 published reports of LDLT indicated a total of 12–13 deaths in approximately 6000 procedures yielding a mortality rate of 0.2% [18]. The same review estimated that there were 3800 right lobe donations, and estimated mortality ranged from 0.23% to 0.5%. The actual donor mortality rates may be higher or lower than these reported rates due to biases of ascertainment in reports from single centres. In addition, in most of these reports, the period of follow-up after surgery was relatively short, typically less than 3 months. Thus, long-term donor outcome, including mortality, remains to be defined.

Biliary complications

Reports from single centres and surveys of transplant centres indicate that 3–8% of donors experience biliary complications [1,18,19]. Bile leakage from the cut surface is the most common biliary complication (3–5%). In the initial experience with LDLT, bile leak was often managed by reoperation. Currently, many surgeons manage bile leak using prolonged external drainage, and reoperation is usually avoided. Rarer biliary complications include biliary stricture (1%), cholangitis and biloma (3%).

Other

Other rarer complications may occur in 9–19% of donors [1,18,19]. Complications include wound infection (1.5%), small-bowel obstruction or ileus (1%), incisional hernia (1%), portal vein thrombosis (0.5%), pulmonary complications (1%), phlebitis (1%), cholestasis (1%), nerve palsy (1%) and encephalopathy (2%). Occasionally, after laparotomy, the donor surgeon may encounter anatomical variants that were not appreciated by the preoperative evaluation and abort the donor surgery. Donor laparotomy without donation occurred in 1% of cases in a recent US survey, but a higher incidence, 4% (4 out of 103 donations) [20], was recently reported from our centre.

Quality of life

In the first publication of this topic in 2001, we measured the impact of LDLT on the donor quality of life in 24 donors followed for 4 months or more after donation [21]. Ninety-six per cent returned to the same predonation job after a mean time of 2.4 months from donation, but two-thirds required a period of light-duty work prior to resuming full job-related activities. Distortion of body image (42%) and persistent mild abdominal complaints (71%) led to further medical evaluation in 29% of cases. The donor's relationship to the recipient was the same or better in 96% of cases, and the donor's relationship to the donor's significant other was the same or better in 88%. Mean out-of-pocket expenses were US$3660. All donors stated they would donate again, if necessary, and 96% of donors indicated that they benefited from the donor experience.

Subsequent studies and reports from single centres of the quality of life of donors after donation have been consistent with our initial observations [22–25]. In a longitudinal study of 47 donors [22], all donors who wished to return to work did so by 1 year (mean 3.4 months) after donation. Persistent abdominal complaints and pain were common but generally mild and dissipated with length of time from donation; by 1 year, all donors denied significant pain. Forty-four out of 47 donors (93%) indicated that 1-year post-donation relationships with the recipient or a significant other had returned to original predonation relationships. Mean out-of-pocket expenses were US$5305. Forty-six out of 47 donors stated that they would donate again (98%).

Recipient evaluation

The LDLT recipient should satisfy all standard criteria for evaluation and placement on the liver transplant waiting list for a deceased donor liver transplantation (DDLT). It is our opinion that this criterion is necessary, because DDLT may be required if the graft from the living donor fails [1]. The initial evaluation for LDLT recipients is identical for cadaveric recipients.

However, not all patients listed for DDLT are suitable for LDLT. The most appropriate candidates for LDLT are patients with urgency for transplantation who are at significant risk of dying before the anticipated or projected time of performance of DDLT. These candidates include patients who have sustained clinical decompensation but have Model for Endstage Liver Disease (MELD) scores too low for DDLT, or patients with cirrhosis complicated by hepatocellular carcinoma.

Decompensated patients may be in greatest need, but some may become too ill to benefit from LDLT. The early experience with LDLT in patients with chronic liver disease who require continuous care in the ICU suggests that morbidity and mortality are increased compared with cadaveric transplantation. In addition, MELD scores for ICU patients or upgrades in MELD score obtained from UNOS Regional Review Boards typically lead to allocation of a deceased donor graft to the ICU patient. As a result, critically ill, ICU-bound patients with endstage liver disease may be better suited for expedited cadaveric transplantation instead of LDLT.

There is controversy regarding the evaluation of patients with more stable chronic liver disease (MELD < 18) for LDLT. We certainly consider patients with MELD < 18 for LDLT if they have sustained clinical decompensation. However, stable patients with MELD < 18 without clinical deterioration are not routinely evaluated. The potential risk to the donor is considered to outweigh the benefit in the recipient. In addition, many of these patients may ultimately be able to undergo successful cadaveric transplantation. Others have suggested that stable patients with mild decompensation may be ideal candidates for LDLT. The basis for this position is that the latter patients may have the best chance of a favourable outcome, and early LDLT may reduce the risk of dying while waiting for deceased donor transplantation.

The decision to consider a specific patient for LDLT is based on the experience and judgement of the transplant team. Currently, patients with an urgent need and a reasonable chance of a favourable outcome are considered to be ideal candidates for LDLT. Conditions that could jeopardize the success of LDLT include multiple medical comorbidities, significant previous abdominal surgery and extensive mesenteric or portal venous thrombosis. Consequently, these patients are usually relegated to deceased donor transplantation. At our centre, approximately half of patients eligible for LDLT on the basis of severity of liver disease were not evaluated because of underlying significant medical or surgical comorbidities [1,20].

Recipient surgery

The three phases of recipient surgery are native liver dissection, anhepatic phase and revascularization of the graft.

Phase I: native liver dissection

This phase is characterized by meticulous dissection and prompt control of bleeding vessels. The dissection could be complicated by the presence of significant portal hypertension, prior portosystemic shunt surgery or prior abdominal surgery. The length of this phase is usually 1–2 h with blood loss ranging from 0 to 5 units.

Phase II: the anhepatic phase (see Fig. 4)

During the anhepatic phase, the vascular supply of the liver is completely interrupted, and the native liver is excised. Once the liver is removed, the surgeon and anaesthesiologist work in concert to maintain adequate haemostasis, intravascular volume and vascular tone. The vessels are anastomosed towards the end of phase II. The piggy-back technique of anastomosis of the donor hepatic veins to the recipient vena cava is generally used and, typically, only one caval anastomosis is performed. Vascular anastomoses usually require 0.5–1 h with the piggy-back method, reducing warm ischaemic time. Phase II usually lasts from 1.5 to 3 h, and the blood loss ranges from 0 to 5 units. Arterial anastomosis is typically done after unclamping to shorten the warm ischaemic period.

Phase III: unclamping of main vessels and revascularization of the liver

Clamps are usually removed in order of suprahepatic cava, infrahepatic cava and then portal vein. Phase III may represent one of the more critical periods, especially if the patient remains coagulopathic or develops primary fibrinolysis or consumptive coagulopathy (Fig. 4).

Biliary anastomosis can be one of the more challenging aspects of recipient surgery, as the donor lobe may have one or several biliary radicals that require anastomoses. Although choledochocholedochostomy over a T-tube or internal stent may be performed, Roux-en-Y choledochoenterostomy is generally preferred (Fig. 5). Maintenance of biliary–enteric flow of bile and avoidance of external drainage of bile restores the enterohepatic circulation of bile acids so that the absorption of orally administered lipophilic immunosuppressive drugs, such as ciclosporin, tacrolimus and sirolimus, is adequate.

Recipient outcome

LDLT recipients may encounter any of the complications that are known to occur in recipients of DDLT [26,27]. Graft injury within the first 3 days is most often due to either primary

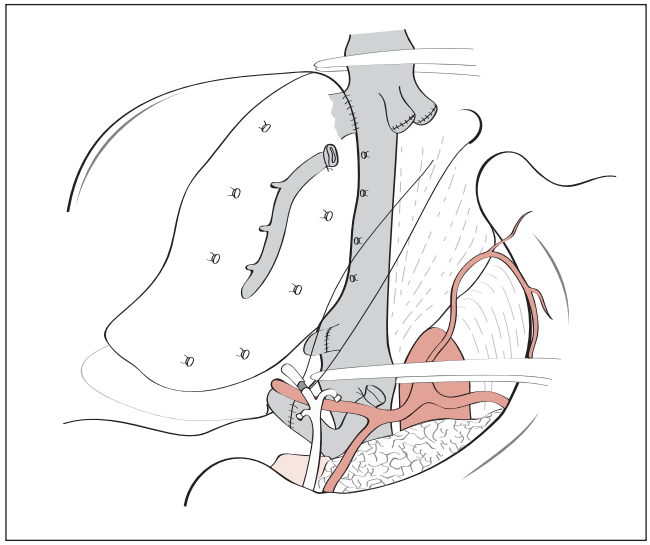

Fig. 4 This figure demonstrates the position of the right lobe graft within the recipient in the orthotopic location after removal of the diseased native organ. Key vascular procedures include connection of the right hepatic vein to the recipient vena cava, and end-to-end hepatic arterial and portal venous anastomoses. Biliary anastomoses are usually performed over an indwelling intraductal stent.

non-function or hepatic artery thrombosis. Less common causes of graft dysfunction during this period include hyperacute rejection, portal vein thrombosis and obstruction of the inferior vena cava. Between 3 and 14 days, graft dysfunction is most commonly related to acute cellular rejection, recurrent hepatitis C virus (HCV) infection, hepatic artery thrombosis or biliary leak or cholangitis. Infrequent causes of dysfunction during this period are portal vein thrombosis, drug hepatotoxicity and functional cholestasis. From 14 days to 3 months, the most common causes of graft dysfunction include allograft rejection, recurrent HCV infection, biliary complications, cytomegalovirus (CMV) hepatitis or drug hepatotoxicity. Vascular thromboses rarely present after the first month, and hepatitis B virus (HBV) recurrence is typically delayed beyond 1 month.

Primary non-function

The most severe form of early graft dysfunction is primary non-function (PNF). PNF is characterized by acute liver failure (encephalopathy, ascites, coagulopathy, unstable haemodynamics), elevated liver enzymes and the development of multiorgan failure (renal failure and pulmonary complications). PNF is rarely encountered in recipients after LDLT, because the graft is implanted very quickly after it has been removed from the donor. In the US survey of LDLT recipient complications, only 1% experienced PNF [19]. This contrasts with the results after DDLT where reported rates of PNF, requiring retransplantation, range from 6.9% to 8.5%.

Postoperative haemorrhage

Postoperative bleeding remains one of the most common surgical complications occurring in recipients after liver transplantation. Published reports suggest that 46% of LDLT recipients experience postoperative bleeding, although reoperation for bleeding occurs with a frequency similar to that reported for DDLT recipients, 5–15% [18,19]. Haemorrhage is responsible for 14% of the deaths that occur in LDLT recipients, second only to infection as a cause of death.

Hepatic artery thrombosis

Hepatic artery thrombosis complicates 3–10% of adult recipients of LDLT [18,19]. It is one of the leading causes of graft

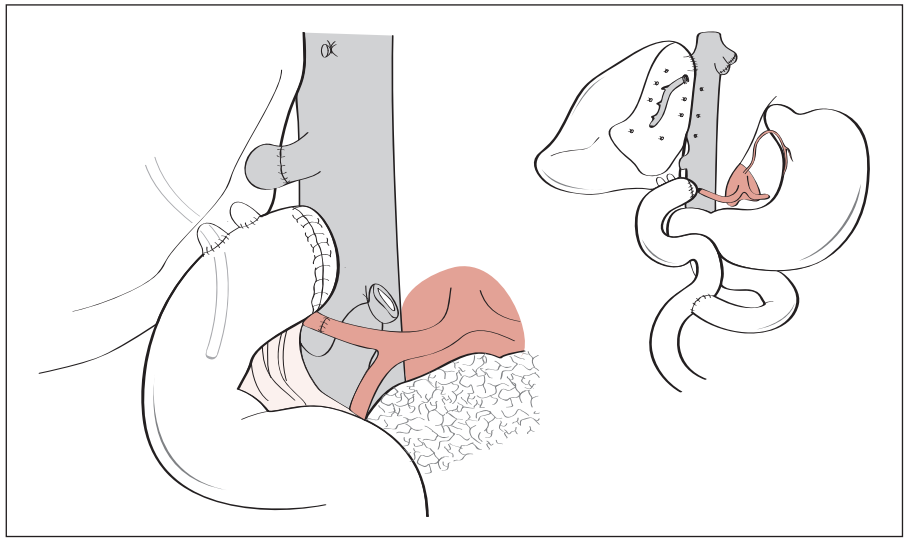

Fig. 5 At completion of the recipient surgery, the right lobe graft is positioned in the right upper quadrant of the abdomen in the orthotopic location, and a Roux-en-Y choledochojejunostomy provides the conduit for biliary secretions. Stents may be placed across biliary anastomoses with the proximal end within the biliary tree and the distal end protruding into the limb of the Roux-en-Y.

failure in the immediate postoperative period and presents as fever, bacteraemia from a biliary source and sudden elevations in liver enzymes. In general, emergent revascularization is required for graft survival.

The preferred initial investigation of the hepatic artery is Doppler ultrasonography. When hepatic artery thrombosis is detected by ultrasonography or highly suspected by clinical features, angiography may be needed to establish the diagnosis and to administer therapy.

Thrombosis often presents as unexplained fever with elevation in liver enzymes suggesting biliary infection. Because biliary complications commonly coexist with hepatic artery thrombosis, attention is often directed to the biliary tree, and cholangiography may be the initial investigation to exclude biliary stricture, stones or other causes of biliary infection or obstruction. Often, patients will require antibiotic therapy and stenting for drainage of infected bilomas, bile leaks and biliary fistula. Once arterial thrombosis is detected, one may attempt to resolve the ischaemic injury via angiographic means using dissolution agents, thrombectomy or vascular stenting. If radiological intervention is contraindicated or unsuccessful, then emergency reoperation and reconstruction of the arterial anastomosis may be required. The literature suggests that urgent revascularization may salvage some grafts, but nearly all patients will require retransplantation.

Mortality rates are higher for patients whose transplantation is complicated by hepatic arterial thrombosis; 14% of deaths occurring in LDLT recipients are related to hepatic artery thrombosis.

Portal vein thrombosis

Portal venous thrombosis is less common than hepatic arterial thrombosis, occurring rarely in LDLT recipients. Clinical manifestations include hepatic failure, complications of portal hypertension such as variceal haemorrhage or encephalopathy, or asymptomatic elevations in liver tests.

The choice of treatment will depend upon the clinical presentation, residual amount of portal flow and degree of liver injury. Patients with significant hepatic dysfunction should be considered for revascularization or retransplantation. In contrast, established portal hypertension may be treated by radiological thrombectomy, lytic therapy, stenting of underlying portal vein stenosis or decompressive shunt surgery.

Outflow obstruction (inferior vena cava or hepatic venous complications)

Hepatic venous outflow obstruction occurs in up to 5% of LDLT recipients [18,19] compared with rates of 1–3% in DDLT recipients. Early signs include hepatic dysfunction, coagulopathy and jaundice. Late manifestations include hepatomegaly and ascites.

Acute outflow obstruction can be a graft- and life-threatening condition and may require emergency revision of the outflow anastomosis. Chronic outflow obstruction with preservation of graft function may be managed conservatively with diuretic therapy, radiological evaluation of venous anastomoses and angioplasty or stenting of outflow stenoses.

Biliary tract complications

Biliary tract complications, leaks and strictures, are the 'Achilles heel' of LDLT and occur in approximately 15–30% of all transplants [1,7,13–16,18,19]. Eighty per cent of all biliary complications occur within the first 6 post-transplant months, and the vast majority of these within the first 3 months.

Bile leaks occur early, within the first few days after transplant, and are usually due to leakage from the cut surface of the graft or disruption of the surgical anastomosis. They may also result from either ischaemic injury from hepatic artery thrombosis or removal of T-tubes.

Biliary scintigraphy is a non-invasive test that can be diagnostic with large bile leaks; it is less useful with small, contained leaks. Cholangiography [ERCP or percutaneous transhepatic cholangioscopy (PTC)] may be required to evaluate the external biliary tree and may aid in treatment. Doppler ultrasonography for the assessment of hepatic arterial flow is indicated in all patients sustaining a bile leak, except leaks directly related to T-tube removal.

There are two main types of biliary strictures: anastomotic and ischaemic. Anastomotic strictures typically evolve over an extended period of time and emerge clinically beyond the first month post-transplant. Patients may present with jaundice, cholangitis or asymptomatic elevations in liver tests. Choledocholithiasis may complicate strictures presenting months or years after transplant. The 'biliary sludge syndrome' is associated with ischaemia due to hepatic artery thrombosis.

Ischaemic strictures are typically restricted to the donor side of the biliary anastomosis, are usually multiple in location and both intra- and extrahepatic. Focal intrahepatic strictures may occur in the setting of patency of the hepatic artery and may be managed conservatively without the need for retransplantation.

Strictures due to recurrent disease (primary sclerosing cholangitis) usually occur later, beyond the first post-transplant year.

Cholangiography (ERCP or PTC) is the gold standard for the diagnosis and management of biliary strictures. These procedures require antibiotic coverage to avoid or reduce the risk of septic complications.

First-line therapy of anastomotic strictures is ERCP or PTC with dilatation and stenting. Surgical revision is reserved for patients in whom ERCP (or PTC) is technically impossible or who have had prior unsuccessful attempts at endoscopic or radiological management. Focal ischaemic-type biliary strictures may also be managed with the same non-operative interventions. However, the long-term patency rate is diminished compared with the results when similar methods are used for anastomotic strictures. Diffuse biliary strictures in the setting

of hepatic artery thrombosis do not respond to either non-surgical or surgical interventions and should trigger the need for retransplantation.

Concluding remarks

The discrepancy between the limited supply of cadaveric livers and the marked expansion of the recipient waiting list has pushed transplant teams to pursue adult living donor transplantation. LDLT may represent the most controversial and exciting development in liver transplantation within the last 10 years. In this chapter, we have focused on the surgical aspects of the procedure and outcomes of LDLT. Despite the complexity of the issues and procedures, current graft and patient survivals after LDLT are excellent; 1-year patient survival now exceeds 85% in many transplant centres. It is likely that LDLT will be performed with increasing frequency in the future.

References

1 Trotter JF, Wachs M, Everson GT *et al.* (2002) Adult-to-adult transplantation of the right hepatic lobe from a living donor. *N Engl J Med* 346, 1074–1082.

2 Strong RW, Lynch SV, Ong TH *et al.* (1990) Successful liver transplantation from a living donor to her son. *N Engl J Med* 322, 1505–1507.

3 Makuuchi M, Kawasaki S, Noguchi T *et al.* (1993) Donor hepatectomy for living related partial liver transplantation. *Surgery* 113, 395–402.

4 Yamaguchi T, Yamaoka Y, Mori K *et al.* (1993) Hepatic vein reconstruction of the graft in partial liver transplantation from living donor: surgical procedures relating to their anatomic variations. *Surgery* 114, 976–983.

5 Lo CM, Fan ST, Liu CL *et al.* (1997) Adult-to-adult living donor liver transplantation using the extended right lobe grafts. *Ann Surg* 226, 261–269.

6 Wachs ME, Bak TE, Karrer FM *et al.* (1998) Adult living donor liver transplantation using a right hepatic lobe. *Transplantation* 66, 1313–1316.

7 Marcos A, Fisher RA, Ham JM *et al.* (1999) Right lobe living donor liver transplantation. *Transplantation* 68, 798–803.

8 Transplant Patient DataSource (2005) Richmond VA: United Network for Organ Sharing. Retrieved August 8, 2005 from the World Wide Web: http://www.patients.unos.org/data.htm.

9 Miller C, Florman S, Kim-Schluger L *et al.* (2004) Fulminant and fatal gas gangrene of the stomach in a healthy live liver donor. *Liver Transpl* 10, 1315–1319.

10 Edwards EB, Roberts JP, McBride MA *et al.* (1999) The effect of the volume of procedures at transplantation centers on mortality after liver transplantation. *N Engl J Med* 341, 2049–2053.

11 Terrault NA, Shiffman ML, Lok AS *et al.* and A2ALL Study Group (2006) Outcomes in hepatitis C virus infected recipients of living donor versus deceased donor liver transplantation. *Liver Transpl* (in press).

12 Trotter JF, Wachs M, Trouillot T *et al.* (2000) Evaluation of 100 patients for living donor liver transplantation. *Liver Transpl* 6, 290–295.

13 Bak T, Wachs M, Trotter J *et al.* (2001) Adult-to-adult living donor liver transplantation using right-lobe grafts: results and lessons learned from a single-center experience. *Liver Transpl* 7, 680–686.

14 Marcos A (2000) Right-lobe living donor liver transplantation. *Liver Transpl* 6, S59–63.

15 Broelsch CE, Malago M, Testa G *et al.* (2000) Living donor liver transplantation in adults: outcome in Europe. *Liver Transpl* 6, S64–65.

16 Todo S, Furukawa H, Jin MB *et al.* (2000) Living donor liver transplantation in adults: outcome in Japan. *Liver Transpl* 6, S66–72.

17 Middleton PF, Duffield M, Lynch SV *et al.* (2006) Living donor liver transplantation – adult donor outcomes: a systematic review. *Liver Transpl* 12, 24–30.

18 Shiffman ML, Brown RS Jr, Olthoff KM *et al.* (2002) Living donor liver transplantation: summary of a conference at the National Institutes of Health. *Liver Transpl* 8, 174–188.

19 Brown RS Jr, Russo MW, Lai M *et al.* (2003) A survey of liver transplantation from living adult donors in the United States. *N Engl J Med* 348, 818–825.

20 Trotter JF, Campsen J, Bak T *et al.* (2006) Outcomes of donor evaluations for adult-to-adult right hepatic lobe living donor liver transplantation. *Am J Transpl* 6, 1882–1889.

21 Trotter JF, Talamantes M, McClure M *et al.* (2001) Right hepatic lobe donation for living donor liver transplantation: impact on donor quality of life. *Liver Transpl* 6, 485–493.

22 Verbesey JE, Simpson MA, Pomposelli JJ *et al.* (2005) Living donor adult liver transplantation: a longitudinal study of the donor's quality of life. *Am J Transpl* 5, 2770–2777.

23 Humar A, Carolan E, Ibrahim H *et al.* (2005) A comparison of surgical outcomes and quality of life surveys in right lobe vs. left lateral segment liver donors. *Am J Transpl* 5, 805–809.

24 Parolin MB, Lazzaretti CT, Lima JH *et al.* (2004) Donor quality of life after living donor liver transplantation. *Transplant Proc* 36, 912–913.

25 Miyagi S, Kawagishi N, Fujimori K *et al.* (2005) Risks of donation and quality of donors' life after living donor liver transplantation. *Transplant Int* 18, 47–51.

26 Everson GT, Kam I (2001) Immediate postoperative care. In: Maddrey W, Schiff E, Sorrell M (eds). *Transplantation of the Liver*, 3rd edn. Philadelphia: Lippincott Williams & Wilkins, pp. 131–162.

27 Everson GT, Trotter JF (2003) Transplantation of the liver. In: Schiff, Sorrell M, Maddrey W (eds). *Disease of the Liver*, Vol. 2. Pennsylvania: Lippincott, Williams, & Wilkins, pp. 1585–1614.

25.2 Liver transplantation: indications, contraindications and results

Gregory T. Everson and Fernando E. Membreno

Introduction

The first successful human liver transplant was performed by Dr Thomas Starzl in Colorado in 1967. Since then, there has been a dramatic increase in the number of liver transplants performed in the United States (Fig. 1). As of 8 August 2005, there were 126 programmes in liver transplantation and 17 424 patients were on the recipient waiting list in the United States [1]. In 2004, 6169 liver transplantations were performed, and 1791 (9.7%) patients died while waiting on the transplant list. Adult living donor liver transplantation (LDLT) has been increasingly utilized to meet the rising recipient demand [2].

The success of transplantation has increased steadily over the last two decades. In Europe, 1-year patient survival was only 34% for liver transplantations performed prior to 1985, but current 1-year survival is 83% [3]. In the USA, current 1-, 3- and 5-year patient survival rates are 85%, 78% and 72% for cadaveric transplantation and 89%, 82% and 80% for living donor liver transplantation respectively [1]. This chapter defines the specific indications and contraindications for the selection of candidates for liver transplantation.

Evaluation

Three fundamental questions need to be addressed at the time of evaluation [4]:

1 Can the patient survive the operation and the immediate postoperative period?

2 Can the patient comply with the complex medical regimen required after liver transplantation?

3 Does the patient have other comorbid conditions that could so severely compromise graft or patient survival that transplantation would be futile?

A patient referred for transplantation may have a significant

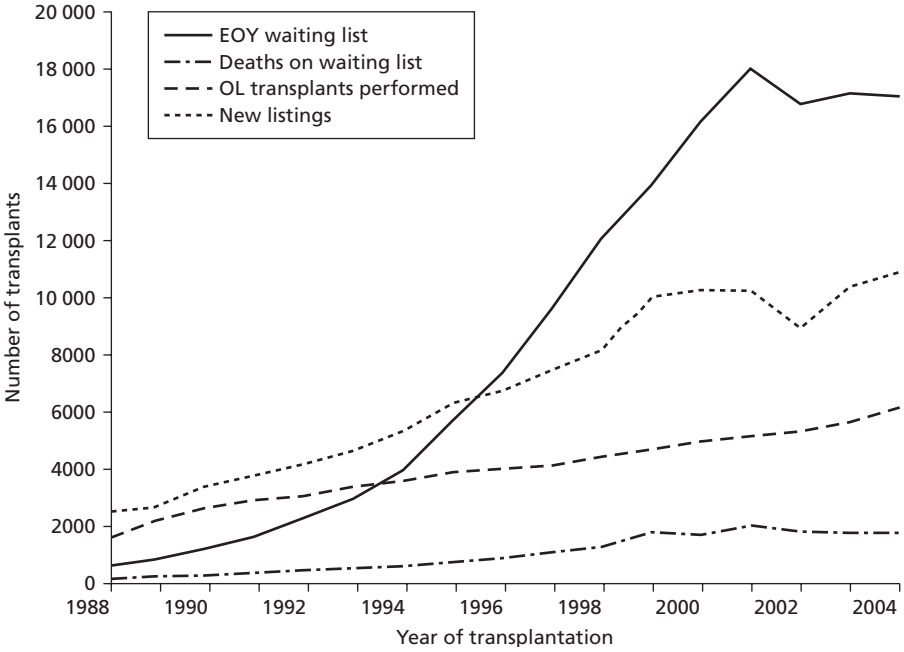

Fig. 1 This graph depicts the exponential rise in the number of potential recipients on the US waiting list at the end of each year, between the years 1988 and 2004 (solid line). In contrast, the number of liver transplants (dashed line) has not kept pace with either the number of new listings (dotted line) or end-of-year (EOY) listings. OL, orthotopic liver.

history of alcohol or drug abuse. Psychosocial evaluation is important to help in determining the risk of recidivism after transplantation. Today, nearly all transplant centres require a minimum 6-month period of documented abstinence. Social workers and psychiatrists may require the patient to undergo alcohol or drug rehabilitation, counselling, and random screens.

Viral serologies should be performed to determine the status of current or previous hepatitis C virus (HCV), hepatitis B virus (HBV), Epstein–Barr virus, cytomegalovirus and human immunodeficiency virus (HIV) infections. Colonoscopy is recommended for all patients over 50 years of age to exclude colon cancer or polyps and in all patients with primary sclerosing cholangitis to identify ulcerative colitis. Cardiopulmonary assessment should be performed in patients with coronary risk factors (hypertension, hypercholesterolaemia, significant family history, smoking, diabetes) and for all patients over the age of 50 years. Cardiac catheterization should be performed in patients with positive stress tests to confirm and delineate the extent of coronary disease. [4–6] Abdominal imaging with computerized tomography (CT) or magnetic resonance imaging (MRI) is useful in excluding hepatocellular carcinoma (HCC) and to determine the patency of major vascular structures such as the hepatic artery, coeliac axis, splenic artery, portal vein and superior mesenteric vein. The decision to list for transplant is determined by a multidisciplinary patient selection committee.

General principles guiding liver transplantation

Minimal listing criteria

The primary principle for consideration for liver transplantation is that patient survival with transplantation must exceed survival without transplantation [7]. Certain complications, such as ascites, spontaneous bacterial peritonitis, encephalopathy and the development of hepatoma, are associated with dismal short-term survival. Immediate evaluation and listing for transplantation is indicated. In contrast, isolated variceal haemorrhage in patients with Child–Turcotte–Pugh (CTP) class A cirrhosis (Table 1) may be well tolerated [8]. One-year survival in a patient lacking other manifestations of liver failure may be equivalent to outcome after liver transplantation. Thus, in contrast to other manifestations of endstage liver disease, isolated variceal haemorrhage may not necessitate transplantation.

Table 1 Calculation of Child–Turcotte–Pugh score.

	One point	Two points	Three points
Bilirubin (mg/dL)	< 2	2–3	> 3
PBC and PSC	< 4	4–10	> 10
PT (INR)	< 1.7	1.7–2.3	> 2.3
Albumin (g/dL)	> 3.5	2.8–3.5	< 2.8
Ascites	None	Controlled medically	Moderate–severe, Uncontrolled medically
Encephalopathy	None	Mild	Moderate–severe

INR, international normalized ratio; PBC, primary biliary cirrhosis; PSC, primary sclerosing cholangitis; PT, prothrombin time.

Other complications, which are not considered to be life-threatening, may also be indications for consideration of liver transplantation. Examples include metabolic bone disease resulting in osteopenia and bone fractures, inadequate nutrition and muscle wasting, severe fatigue and poor concentrating ability or intractable pruritus. These complications can limit function, reduce the level of competence and stamina, lead to unemployment and disability, diminish quality of life and result in social isolation.

Model for Endstage Liver Disease (MELD)

In the USA, since February 2002, prioritization has been based primarily upon biochemical criteria (MELD) [9]. United Network for Organ Sharing (UNOS) status 1 was retained for patients with fulminant hepatic failure. In Europe, the system of prioritization of recipients and allocation of donor organs has varied widely between countries. The Eurotransplant network is poised to implement MELD in 2006.

The UNOS system of status 1, 2A, 2B and 3, which was used in the USA prior to February 2002, relied heavily on CTP score to grade severity of illness and determine priority (Table 1). But, two components of the CTP score, encephalopathy and ascites, were not readily verifiable. Furthermore, within these medical urgency categories, waiting patients were given priority for transplant based upon time on the UNOS list. Subsequent studies [10–12] have shown that waiting time did not correlate with death on the waiting list.

The MELD score, originally created to predict short-term mortality after transjugular intrahepatic portosystemic shunt (TIPS) placement [13], was chosen as a superior model for determining disease severity for adult liver allocation [14]. The MELD score (Table 2) lacks the subjectivity inherent in the CTP score. The MELD score is calculated from a logistic regression equation that takes into account three objective laboratory criteria: creatinine, bilirubin and international normalized ratio (INR) [12,15,16]. Calculation of individual MELD scores for patients can be determined at http://www.unos.org/resources/MeldPeldCalculator.asp. MELD score is highly predictive of 3-month mortality in hospitalized cirrhotics; mortality rate is 10–60% over the range of MELD scores from 20 to 35 and more than 80% for MELD scores over 35. After its first year of implementation, the allocation system based on MELD has been associated with reduced registrations and improved transplantation rates, and did not alter waiting list or post-transplant mortality [4,14,17]. MELD 15 is the threshold at which patient survival with transplantation exceeds survival without transplantation and is the basis for the Share-15 rule [18].

Paediatric Endstage Liver Disease (PELD)

The PELD score is a similar model developed for the allocation

Table 2 MELD and PELD scoring systems.

Variables used to calculate scores

MELD	***PELD***
INR	Bilirubin (mg/dL)
Bilirubin (mg/dL)	INR
Creatinine (mg/dL)	Albumin (g/dL)
	± growth failure
	± age < 1 year

Equations for calculation of scores

MELD score = $0.957 \times \log_e$(creatinine mg/dL) + $0.378 \times \log_e$(bilirubin mg/dL) + $1.120 \times \log_e$(INR) + 0.643

PELD score = 0.436[Age (< 1 year)] – $0.687 \times \log_e$(albumin g/dL) + $0.480 \times \log_e$(total bilirubin mg/dL) + $1.857 \times \log_e$(INR) + 0.667 [Growth failure (≤ 2 SD present)]

of liver transplants in the paediatric population. The variables included in this model are age younger than 1 year, serum albumin level, serum bilirubin, INR and growth failure [< 2 standard deviations (SD) below the age-based mean] (Table 2). Similar to the MELD score, PELD accurately predicts the 3-month probability of waiting list death for children with chronic liver disease [19–21].

Disease-specific indications for transplantation

The most common indications for liver transplantation in the USA are listed in Table 3. Issues in evaluation and listing for transplantation, related to specific diagnoses, are discussed in the following section.

Table 3 Most common indications for liver transplantation in the USA between 1988 and 2005.[a]

Primary liver disease	No. of liver transplants	Percentage
Chronic hepatitis C virus	16 549	23
Alcoholic liver disease	8881	12
Cryptogenic cirrhosis	6511	9
Primary sclerosing cholangitis	4738	5.7
Primary biliary cirrhosis	4140	5.7
Chronic hepatitis B virus	3821	5.3
Alcoholic liver disease and hepatitis C virus	3413	4.7
Hepatoma	2744	3.8
Autoimmune hepatitis	2689	3.7
Alpha-1-antitrypsin deficiency	1252	1.7
Drug-induced liver disease	764	1.0
Haemochromatosis	532	0.7
Budd–Chiari syndrome	482	0.6
Wilson's disease	479	0.6

[a]UNOS database 1 January 1988–30 June 2005; www.unos.org.

Table 4 Prognostic indices favouring the performance of liver transplantation in patients with fulminant hepatic failure.

King's College, London, UK

Acetaminophen toxicity

Acidosis (pH < 7.3), or

INR > 6.5 plus creatinine > 3.4 mg/dL

Other causes of fulminant hepatic failure

INR > 6.5, or

Any three of the following:

- Age < 10 years or > 40 years
- Non-A, non-B hepatitis- or drug-induced disease
- Duration of jaundice before encephalopathy > 7 days
- NR > 3.5
- Bilirubin > 17.5 mg/dL

Hôpital Paul-Brousse, Villejuif, France

For all causes of fulminant hepatic failure:

Hepatic encephalopathy and

- Factor V < 20% of normal in patient < 30 years or
- Factor V < 30% of normal in patient ≥ 30 years

Acute liver failure

Patients with fulminant hepatic failure (FHF) are given highest priority for urgent transplantation [22]. In the absence of transplantation, the mortality of patients with FHF and coma is approximately 75%. Variables associated with poor prognosis for spontaneous recovery, indicating a need for transplantation, are advanced age, certain aetiologies (hepatitis B, drug-induced hepatitis, sporadic non-A–C hepatitis, Wilson's disease), severe encephalopathy and long duration of jaundice (Table 4). Massive necrosis on liver biopsy and markedly diminished liver volume on radiological imaging indicate poor prognosis. Transplantation for FHF accounts for 5–12% of all liver transplant activity [23]. Overall survival rates after liver transplantation are approximately 60–65%, although individual centres have reported survival in the 75–90% range.

The leading cause of death in FHF is progressive cerebral oedema resulting in brain herniation. Irreversible brain injury occurs in nearly all cases of prolonged severe increase in intracranial pressure (ICP) (> 50 mmHg) and reduction in cerebral perfusion pressure below 40 mmHg for more than 2 h. Liver transplantation is contraindicated under these circumstances.

Primary biliary cirrhosis (PBC)

PBC is a chronic cholestatic liver disease, primarily of women in their fourth to seventh decades of life. Bilirubin is the key prognostic variable; mean survival for patients with a serum bilirubin above 10 mg/dL is only 1.4 years. The Mayo Clinic PBC model is considered to be generally applicable and calculates risk score from the following variables: age, bilirubin, prothrombin time, albumin and oedema [24].

Other complications of PBC, such as osteopenia, pruritus and fatigue, may not correlate with the severity of liver disease, but still incapacitate the patient and indicate a need for transplantation. In a retrospective study of 400 consecutive patients undergoing transplantation, the overall actuarial patient and graft survival at 1, 5 and 10 years was 83%, 78% and 67% and 82%, 75% and 61% respectively. PBC recurred in 17% of patients 36 months post-transplantation, but recurrence did not affect graft survival [25].

Primary sclerosing cholangitis (PSC)

PSC is characterized by male predominance and stricture formation of both intra- and extrahepatic bile ducts. Some 70–75% of patients with PSC have inflammatory bowel disease. Ulcerative colitis accounts for 87% and Crohn's disease for 13% of the associated bowel disease [26]. One commonly used prognostic model calculates risk score from bilirubin, age, splenomegaly and histological stage [27]. Complications of cirrhosis, recurrent cholangitis or biliary obstruction not amenable to endoscopic, radiological or surgical repair are indications for listing for liver transplantation.

Approximately 30% of all patients with PSC will develop cholangiocarcinoma [28]. Unlike hepatoma, which is often well circumscribed, cholangiocarcinoma diffusely infiltrates bile duct, liver parenchyma, neural elements, lymphatics and surrounding tissues. Tests such as CA19-9 antigen, carcinoembryonic antigen (CEA) and radiological imaging are insensitive and non-specific, limiting their usefulness in screening. Biliary cytology, obtained by brushing suspicious strictures at endoscopic retrograde cholangiopancreatography (ERCP), may be useful, but false-negative and false-positive results occur. Cholangiocarcinoma complicating PSC, either before or after transplantation, reduces survival [29]. Patients with the combination of PSC and ulcerative colitis are at high risk of colon cancer and should undergo regular colonoscopic screening [30,31].

The 1-, 2-, 5- and 10-year actuarial survival after liver transplantation for PSC is 93.7%, 92.2%, 86.4% and 69.8%, respectively, and graft survival is 83.4%, 83.4%, 79% and 60.5% respectively [31,32]. Although recurrence of PSC after transplantation has been reported at approximately 4% per year [31,33], this has not had a significant impact on the long-term postoperative survival [29,33].

Autoimmune hepatitis

Approximately 30% of patients with autoimmune hepatitis have cirrhosis at presentation. Patient and graft survival after liver transplantation ranges from 83% to 92% with a 75% actuarial 10-year survival after transplantation [34]. Recurrence is observed in 17% of patients after 4.6 ± 1 years [35], but has not adversely impacted overall patient or graft survival.

Alcoholic liver disease

Alcohol is the most common cause of endstage liver disease in the western world, but Laennec's cirrhosis remains a controversial indication for orthotopic liver transplantation (OLT) [36–38]. Currently, alcoholic cirrhosis ranks second only to hepatitis C as the most common indication for liver transplantation in the USA. It is prudent to remember that many patients who totally abstain from alcohol and have apparently very advanced liver disease may in fact recover to the point that transplantation is no longer indicated [39].

Patients with alcoholic liver disease require rigorous evaluation, meticulous screening and targeted treatment of their underlying disease of alcoholism. Post-transplant survival of properly selected candidates with alcoholic liver disease is comparable to that for non-alcoholic patients. The incidence of rejection, graft failure and the need for retransplantation may be less common in patients with alcoholic liver disease than for other indications [40,41].

Hepatocellular carcinoma

HCC is the most common primary liver malignancy; more than 500 000 new cases are diagnosed yearly with a worldwide age-adjusted incidence of 5.5–14.9 per 100 000 population [42]. It is estimated that 8500–11 500 new cases of HCC occur annually in the USA [43]. Transplantation is contraindicated for large, multicentric tumours or extrahepatic spread [44].

Worldwide rates of hepatoma are increasing, and the increase is primarily related to hepatitis C [45]. The risk of hepatoma in a patient with cirrhosis and viral hepatitis is approximately 2% per year. Patients on the waiting list who have advanced cirrhosis due to chronic hepatitis C or B are at even greater risk, perhaps as high as 5% per year. Screening procedures [blood tests for tumour markers (alpha-fetoprotein, AFP; AFP-L3, descarboxy prothrombin) and radiological imaging] may identify patients with earlier stage tumours, many of which are solitary and less than 2 cm in diameter.

Once a small hepatoma is discovered, choices include transplantation, resection or procedures such as chemoembolization, ethanol injection or radiofrequency ablation. Resection is associated with a 50% chance of recurrence or metachronous cancer within 5 years of follow-up [44]. In contrast, liver transplantation is potentially curative as it removes not only the tumour but also the at-risk cirrhotic liver. HCC developing in cirrhotic patients with chronic hepatitis C will be a leading indication for LDLT in adults [45].

The overall tumour-free, 5-year survival of patients transplanted for small HCCs is over 80% [46]. Tumour characteristics associated with favourable outcome include diameter of ≤ 5 cm for solitary tumour, total diameter ≤ 9 cm for up to three lesions, lack of radiological evidence of vascular invasion and absence of metastases.

Under MELD, patients with HCC have been 'upgraded'; they have received additional points and increased priority for transplantation. As a result, their waiting time decreased from 2.3 years to 0.7 months [47], and 5-year survival improved from 25% to 61% [48,49].

Fibrolamellar carcinoma (FLC)

A review of the population-based registries of the Surveillance, Epidemiology, and End Results (SEER) programme showed that the age-adjusted incidence rate for the fibrolamellar variant of HCC (FLC) was 0.02 per 100 000 population and that FLC constitutes 0.85% of all cases of primary liver cancer. Compared with HCC, patients with FLC were younger (mean age 39 years vs. 65 years), female (51.5% vs. 26.3%) and white (85.3% vs. 56.9%) [50]. FLC is characterized by broad bands of fibrosis, lack of association with cirrhosis, slow growth and increased resectability. Although post-transplant recurrence rates of FLC are similar to those of HCC, 5-year survival is higher in patients with FLC.

Cholangiocarcinoma

A recent review of 207 transplant recipients with cholangiocarcinoma reported 1-, 2- and 5-year survivals of 72%, 48% and 23% respectively [52]. Tumour recurrence was the rule, with over 80% of recurrences within 2 years. Because the prognosis for cholangiocarcinoma is so poor, many have argued that cholangiocarcinoma is a relative contraindication for transplantation. Successful transplantation without recurrence of cholangiocarcinoma has been reported for a highly selective group of patients treated with adjuvant chemotherapy and radiation [53].

Rare primary hepatic malignancies

Other primary hepatic malignancies – epithelioid haemangioendotheliomas (EHE), haemangiosarcomas and hepatoblastomas – represent less than 10% of all tumours undergoing transplantation. EHE is generally thought to be indolent in nature, and reported survivals after transplant have been favourable. In contrast, haemangiosarcoma universally recurs, and transplantation is contraindicated.

Neuroendocrine tumours

Liver metastases from endocrine primaries (carcinoid tumour, gastrinoma, insulinoma, glucagonoma, VIPoma) have been treated with liver transplantation [44,54]. OLT is best restricted to those patients with metastases confined to the liver that are unresponsive to chemotherapy, local ablative therapies, surgical resection and hormonal therapy. Despite the fact that most cases have been highly selected, tumour recurrence is the rule. The Milan criteria identify patients with neuroendocrine liver metastasis who might be suitable for transplantation: primary tumour drained by the portal system, < 50% hepatic replacement by tumour metastases, good response or stable disease during the pretransplantation period and absence of extrahepatic disease [55].

Haemochromatosis

The results of liver transplantation for haemochromatosis have been disappointing; 5-year survivals are only 40–55% [56,57]. Hepatoma, infection and coexistent cardiac disease contribute to postoperative morbidity and mortality. Patients with haemochromatosis who are considered for liver transplantation should undergo screening for hepatoma and also have a complete cardiological evaluation. It is uncertain whether the initiation of phlebotomy in the pretransplant period to unload myocardial iron might lead to improved survival after transplant.

Alpha-1-antitrypsin deficiency

Only a small proportion of adult liver transplants are performed for the indication of cirrhosis due to alpha-1-antitrypsin deficiency (α_1ATD). Male gender and obesity might be important risk factors for the progression of liver disease in patients with α_1ATD [58]. Pulmonary evaluation is critical because one-third of adults transplanted for α_1ATD will have significant underlying obstructive respiratory disease. As α_1ATD is cured by liver transplantation [59], extrahepatic manifestations of α_1ATD may also correct [60].

Budd–Chiari syndrome

The approach to Budd–Chiari syndrome includes identification of the underlying cause [61–64], and consideration of shunt surgery, TIPS [65,66] or liver transplantation. Liver biopsy may be useful in deciding on the therapeutic approach; patients with advanced fibrosis are best approached with liver transplantation [64]. Survival after transplantation depends on the severity of disease pretransplant, the extent of thrombosis and treatment of the underlying cause of the syndrome.

Polycystic liver disease

Polycystic disease is a rare indication for liver transplantation. One series suggests that the majority of patients transplanted for polycystic liver disease may not need combined liver–kidney transplantation despite renal cystic disease and mild renal impairment [67]. Survival rates for 1, 3 and 5 years in patients undergoing isolated hepatic transplantation (n = 128) were 78.1%, 71.7% and 68.7% respectively. Survival rates for 1, 3 and 5 years in patients undergoing combined liver–kidney transplantation (n = 78) were 79.5%, 75.5% and 75.5% respectively [68].

Table 5 Absolute contraindications to liver transplantation.

Active substance abuse
Inadequate social support, extreme psychosocial dysfunction, active psychosis or other underlying psychosocial pathology making it impossible for the patient to comply with peritransplant care and postoperative management
Unstable, active cardiopulmonary disease
Symptomatic ischaemic coronary disease
Severe pulmonary hypertension
Active, incurable extrahepatic malignancy
Non-hepatic malignancy
Hepatoma with capsular invasion or distant metastases
Cholangiocarcinoma with extension to adjacent non-hepatic tissues[a]
Active, uncontrolled and untreatable sepsis
Active HIV infection, AIDS-defining illness or HIV unresponsive to HAART[b]
Anatomic anomaly or extensive vascular thromboses precluding hepatic transplantation

[a]Outcome after transplantation of patients with cholangiocarcinoma has been dismal except for small series using adjuvant chemoirradiation therapy. Most centres exclude patients with symptomatic cholangiocarcinoma from transplantation.
[b]Current controversy exists regarding the candidacy of HIV-infected patients, despite the advances in highly active antiretroviral therapy (HAART) therapy. Most centres exclude HIV-infected patients from liver transplantation.

Contraindications to liver transplantation

Absolute contraindications

Because the supply of donor livers is limited, transplant centres must select patients for liver transplantation who have the greatest chance of successful outcome. Recipients with underlying vascular disease, longstanding diabetes mellitus or who are elderly, obese and deconditioned are marginal candidates. Certain conditions are associated with extremely poor outcome and are absolute contraindications to liver transplantation (Table 5).

Factors associated with impaired post-transplant outcome

Advanced age

The effect of recipient age at time of transplantation on postoperative course was examined in 735 adult patients transplanted at three US medical centres between 1990 and 1994 [69]. Patients were categorized into two groups, either < 60 or ≥ 60 years of age. Disease severity, as assessed by CTP score, UNOS status and Karnofsky score, was similar between the two groups. Elderly patients had extended intensive care unit (ICU) stays ($P < 0.01$) and prolongation of total hospitalization ($P < 0.03$). Graft survival was similar but patient survival was diminished (81% vs. 90%, $P < 0.004$). Excess mortality resulted from infection, cardiac complications and neurological disease. In a recent series of 111 liver transplant patients, those aged over 60 years had decreased survival due to malignancy [70].

Coronary artery disease

Underlying coronary artery disease is present in approximately 5% of patients undergoing liver transplantation. One series reported a prevalence of 16.2% in recipients over 50 years of age [71]. Three other studies have reported prevalence ranging from 2.5% to 27% [72,73]. Patients should be excluded from OLT if they have ischaemic cardiac disease that is not amenable to or reversible with angioplasty or coronary stents.

Pulmonary disease

Advanced chronic obstructive pulmonary disease or pulmonary fibrosis preclude patients from liver transplantation. Asthma, respiratory impairment from ascites and muscle weakness secondary to chronic liver disease are potentially reversible conditions that should not preclude OLT. Patients who undergo OLT for alpha-1-antitrypsin deficiency may show improvement in pulmonary function tests.

Hepatopulmonary syndrome

Hepatopulmonary syndrome (HPS), manifested by the triad of liver disease, pulmonary vascular dilation (with right-to-left shunting) and hypoxaemia, occurs in 1–2% of cirrhotics [74]. The median survival of patients with cirrhosis and severe HPS is less than 11 months [75]. The diagnosis is confirmed by 'bubble' echocardiography, and severity of HPS can be assessed by measurement of the uptake of intravenously administered ^{99m}TcMAA (macroaggregated albumin) simultaneously in lung and brain [76]. MAA shunt is calculated as the geometric mean of technetium counts (GMT) in brain relative to lung, $[GMT_{brain}/(GMT_{brain} + GMT_{lung})] \times 100\%$. Normoxaemic cirrhotics without HPS and patients with intrinsic lung disease who lacked liver disease had MAA shunts of 2 ± 0.3%. In contrast, patients with HPS had markedly elevated MAA shunts, 30 ± 4%, and there was a highly significant inverse correlation of Pao_2 with MAA shunt. The strongest predictors of postoperative mortality in patients with HPS are Pao_2 of 50 mmHg or less, alone or in combination with a ^{99m}TcMAA shunt fraction ≥ 20% [77].

Normalization of Pao_2 at rest and with exercise frequently occurs 1–9 months after OLT. Deteriorating oxygenation in a patient with HPS is an indication for urgent OLT [78] and MELD upgrade.

Portopulmonary hypertension

Portopulmonary hypertension (PPH) complicates cirrhosis in 2–4% of patients undergoing liver transplantation [79,80]. PPH is generally defined as mean pulmonary artery pressure > 25 mmHg and pulmonary vascular resistance > 120 dynes/s/cm^5 with a pulmonary capillary wedge pressure < 15 mmHg. The

diagnosis may be suspected based on clinical findings such as marked dyspnoea, hypoxia or right heart failure. Echocardiography is the single best screening test.

Patients with mild pulmonary hypertension (mean pulmonary artery pressure < 35 mmHg) may be safely transplanted. Transplantation is relatively contraindicated in those with severe pulmonary hypertension (mean pulmonary artery pressure ≥ 60 mmHg) because their peri- and postoperative mortality is high and 3-year survival is only 20–30% [81]. Recent advances in medical therapy, including the use of sildenafil, may improve long-term post-transplant outcomes [82–86].

HIV infection

Increasing numbers of patients with HIV are experiencing progressive liver failure, primarily related to hepatitis C, and are being referred for consideration for liver transplantation. Post-transplant outcomes were poor in series reported before the era of highly active antiretroviral therapy (HAART); about two-thirds of patients were dead within 2 years of follow-up. Recurrent hepatitis C with rapid progression to liver failure was common. In contrast, recent studies have shown that the survival of selected HIV patients undergoing liver transplantation may be comparable to that of HIV-negative recipients, at least in the short term [87–90]. Selection criteria have included absence of AIDS or AIDS-defining illness, adequate CD4 counts, low HIV level and lack of resistance to HAART therapies.

Renal failure

Renal failure, defined as creatinine ≥ 1.6 mg/dL, occurs in 40% of patients transplanted for FHF and in 15% transplanted for cirrhosis [91]. Dialysis is required in 10–25% of patients with renal failure either prior to or after transplantation. The need for dialysis often correlates with the severity of liver disease and is associated with multisystem failure, need for extended ICU care and poor outcome after transplantation. If renal failure is deemed irreversible, the patient will need to be considered for both a liver and a kidney transplantation [92–95].

Diabetes mellitus

As many as 5–15% of patients undergoing liver transplantation have underlying diabetes mellitus. One recent analysis compared the outcome of 78 patients with diabetes mellitus with that of a matched control population of non-diabetics ($n = 78$) [96]. One-year and 5-year survival was significantly worse for patients with diabetes mellitus: 67.5% and 61% for diabetics vs. 90% and 77% for control subjects. Another case–control study demonstrated 5-year survivals of 34.4% and 67.7% for diabetics and non-diabetics respectively [97]. Causes of death in the diabetic population were often multifactorial and included sepsis, cardiac ischaemic disease and cerebrovascular complications. Most patients in these series had type 2 diabetes; only 1–3% of patients undergoing liver transplantation have type 1 diabetes. Combined liver and pancreas transplantation may be considered for the latter group [98].

Obesity

Obesity is common among transplant candidates and is linked to poor immediate and long-term survival. Primary graft nonfunction and immediate, 1-year, 2-year and 5-year mortality are significantly higher in morbidly obese patients [body mass index (BMI) > 35 kg/m^2], mostly as a result of adverse cardiovascular events. Weight loss should be recommended for all obese patients awaiting a liver transplantation, especially if their BMI is more than 35 kg/m^2 [99].

Smoking

In a recent study, 60% of liver transplant recipients reported a lifetime history of smoking and 15% reported smoking after transplantation [100]. Smoking has been associated with poor post-transplantation outcomes. In the short term, smokers have a higher risk of hepatic artery thrombosis [101] and, in the long term, postoperative survival is decreased because of an increase in both cardiac- and malignancy-related mortality. Patients should abstain from smoking.

Anatomical abnormalities

The number of anatomical abnormalities that are absolute contraindications to OLT has diminished with the refinement in surgical techniques. However, if portal thrombosis extends to the mesenteric circulation, post-transplant mortality increases by 33% [102].

Recurrent hepatitis C

Survival analysis of the UNOS database has shown that HCV significantly impairs both patient and allograft survival after transplantation [103]. Post-transplant factors associated with increased mortality included treatment for acute cellular rejection, treatment for steroid-resistant rejection and mean steroid dose ≥ 100 mg/day in the first 42 days after transplant. Steroids and other antirejection treatments must be used cautiously in recipients infected with HCV. In one analysis, 28% of all deaths in HCV-positive recipients were directly related to HCV recurrence [104]. Liver transplantation for graft loss due to recurrent hepatitis C remains controversial [105].

Living donor liver transplantation in adults

LDLT in adults, using the right lobe, is an emerging option to expedite transplantation for a growing number of patients with endstage liver disease (Fig. 2) [106–110]. The first successful LDLT was reported in 1989, after which the procedure gained widespread acceptance in Asia where cultural beliefs prevent cadaveric donation. Nearly all adult LDLT in the USA is performed with a right hepatic lobe graft. The first adult-to-adult right hepatic lobe LDLT in the US was performed in 1997 and reported in 1998 [111]. In this procedure, the entire native liver of the recipient is removed and replaced with the right lobe of

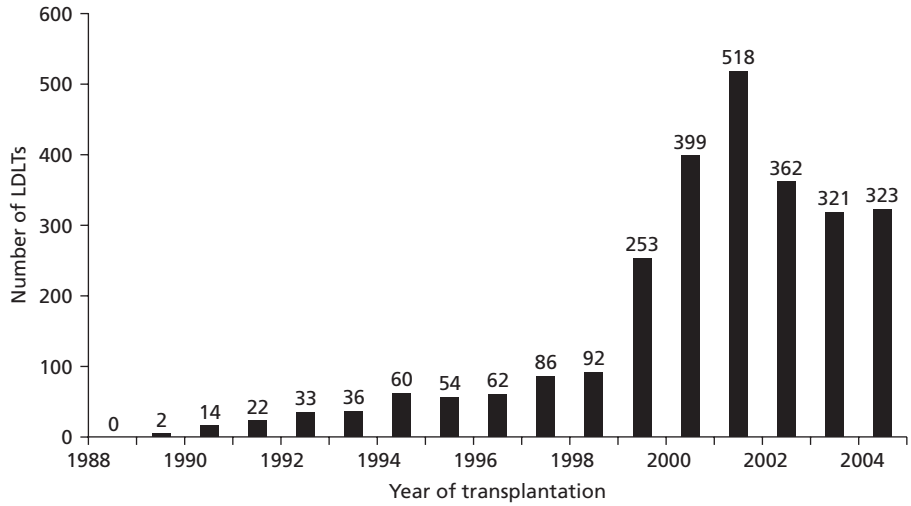

Fig. 2 The number of living donor liver transplants (LDLTs) performed in the USA between 1988 and 2004.

the liver from a living donor. In 2005, LDLT represented 3.9% of all adult liver transplants performed in the US.

Potential advantages of LDLT

The greatest potential benefit of LDLT for the recipient is reduction in the risk of dying while waiting for standard cadaveric transplantation. At our centre, the median waiting time for LDLT recipients is approximately 66% less than for cadaveric recipients. LDLT is elective and not usually performed on an urgent or emergency basis. Consequently, the medical condition of the recipient can be stabilized or improved prior to surgery, thereby increasing the likelihood of a successful transplant. Also, the donor liver experiences minimal cold ischaemia as implantation occurs immediately after the donor operation.

Potential disadvantages of LDLT

For the recipient, the greatest risks are surgical complications, infection, recurrent hepatitis C and rejection. The relative risk of patient and graft loss (corrected for severity of illness at transplantation) may be higher in recipients of LDLT. Rates of retransplantation are higher [hazard ratio 1.66, 95% confidence interval (CI) 1.30–2.11], and adjusted mortality rates may be 25% higher [112,113]. The relatively poorer outcome after LDLT is attributable to surgical experience, with worse outcomes primarily during the period of the first 20 LDLTs performed.

Donor safety is of primary concern. Significant complications, even death, have occurred. Estimated risk of donor death is approximately 1 in 300, based upon surveys conducted in the USA, Europe and Japan [114–116]. In addition, approximately 10% of donors develop other complications, including bile leak at the cut surface of the liver, neuropraxia and wound infection, as a direct result of the donor surgery. In contrast, most donors undergo uncomplicated surgery, express general acceptance of the procedure and demonstrate favourable outcomes [117].

Selection of recipients

The most appropriate candidates for LDLT are patients with a significant risk of dying prior to cadaveric transplantation [118]. Ideal candidates for LDLT are patients with hepatoma and those with relatively low MELD scores but mounting complications.

HCC often progresses to the point at which liver transplantation is contraindicated (tumour size > 5 cm or ≥ 3 hepatic tumours or metastatic disease). Listing guidelines increase the priority for patients with limited-stage HCC, but many patients still do not survive long enough to be transplanted. The advantage of LDLT in the setting of HCC is that the transplant could be performed before the malignancy progresses.

Although MELD score is a good predictor of mortality over a 90-day period, it may underestimate morbidity and mortality of patients with cholestatic liver disease (especially primary sclerosing cholangitis) or patients with ascites, uncontrolled encephalopathy or cachexia. These patients may deteriorate rapidly despite low MELD score and, therefore, never receive a cadaveric transplantation. LDLT may be the best option for many of these patients [113].

It has been our general recommendation that recipients considered for LDLT must first meet the criteria for conventional transplantation. Patients may be suitable candidates for cadaveric transplant, but not LDLT, because of comorbid condition(s), which could jeopardize the success of LDLT. These might include advanced age, significant medical conditions, obesity, thrombosis of multiple visceral veins, multiple significant abdominal surgeries or marginal psychosocial function. In our experience, 50% of potential LDLT recipients were rejected because of concomitant conditions, as mentioned above, which could negatively affect recipient outcome. Of the remaining 50%, only half could identify a potential donor for evaluation and only 60% had a suitable donor. Therefore, in our centre, only 5–15% of recipients are ultimately able to undergo LDLT [113,118].

Selection of donors

The potential LDLT donor must be in excellent medical and psychological condition. The specific tests and sequence of testing vary from centre to centre. At our institution, we have three phases of donor evaluation. First, potential recipients are identified (see discussion above) and financial clearance is obtained from the recipient's insurance carrier. Potential donors should have an identical or compatible blood type. Volunteers interested in pursuing LDLT must contact the transplant centre to undergo an initial screening to determine if there are obvious contraindications to donation. The following information is obtained from the potential donor: age, height, weight, brief medical, surgical and psychiatric history, current medications, current smoking status and nature of relationship with the recipient. Laboratory tests are obtained (serum electrolytes, complete cell count, liver function tests, hepatitis C antibody, hepatitis B surface antigen and hepatitis B core antibody). Potential donors who pass this initial screening process are then offered the second phase of donor evaluation.

The second phase of evaluation is to determine whether the potential donor is medically, surgically and psychologically fit to donate. Initial medical evaluation is performed after the potential donor has scheduled an appointment. This evaluation should be performed by a transplant hepatologist so that the risks and benefits of the donation and transplantation may be fully explained to the donor. This evaluation includes complete medical history, physical examination, electrocardiogram, chest radiograph and blood tests. The patient is also scheduled for a surgical, psychosocial and psychiatric evaluation and abdominal MRI. Potential donors may require a third phase of evaluation, which may include CT/MRI cholangiogram [119–121] or ERCP, angiogram and liver biopsy. At our centre, we have performed liver biopsy when the donor has a history of alcohol excess, evidence of steatosis on abdominal MRI or risk factors for steatosis, such as BMI > 28 kg/cm^2. Unfortunately, in the end, only 5–13% are suitable donors for LDLT [122]. The potential recipient and donor are then presented to the patient selection committee, approved and listed. LDLT is typically scheduled within a few weeks of the evaluation.

Recipient outcome

Recipient survival following LDLT in the USA and Europe is reported to be between 86% and 88% [107,114–116], similar to the cadaveric survival rate. However, current survival statistics for LDLT reflect recipients who were, in many cases, selected for the best chance of favourable outcome. As a result, direct comparisons with survival after cadaveric transplantation may not be possible. The spectrum of complications for LDLT is similar to that for cadaveric transplantation. Biliary leak and stricture are the most common complications after LDLT, occurring in 15–32% of patients.

Donor outcome

The most common complication in donors is bile leak (from the cut surface of the liver), which occurs in approximately 5% of donors [107,114–116]. Between 9% and 19% of donors develop other complications related to major abdominal surgery including wound infection, small bowel obstruction, incisional hernia and chronic pain. Quality of life studies indicate that 96% of donors had returned to their predonation employment status after a mean time of 10 weeks [117]. However, 71% of donors reported ongoing mild abdominal symptoms that they related to the donor surgery.

The greatest concern for donor safety is the risk of death. In the reported cases of LDLT, there have been two donor deaths out of 706 (0.28%) donor hepatectomies. Registries indicate that there have been three donor deaths in the USA and two in Europe out of approximately 2000 LDLTs (0.25%). Most liver transplant centres quote a risk of death of 0.1–0.5% when evaluating or counselling donors [122].

Hepatitis C and LDLT

Initial studies reported earlier severe recurrence and increased risk of death, retransplantation or graft failure in LDLT compared with cadaveric transplant recipients with HCV [123–125]. In contrast, other reports observed comparable outcomes and lack of a negative impact of hepatitis C recurrence in LDLT [126,127]. Recent results from the US multicentre Adult-to-Adult LDLT study (A2ALL) confirm the lack of significant effect of HCV on graft or patient survival after LDLT. HCV eradication prior to transplantation using a low accelerated dose reduction (LADR) protocol may effectively treat decompensated HCV-positive patients and reduce the risk of post-transplant recurrence in selected patients [128].

References

1 Transplant Patient DataSource (2005). Richmond VA: United Network for Organ Sharing. Retrieved August 8, 2005 from the World Wide Web: http://www.patients.unos.org/data.htm.

2 Trotter JF, Wachs M, Everson GT *et al.* (2002) Adult-to-adult transplantation of the right hepatic lobe from a living donor. *N Engl J Med* 346, 1074–1082.

3 Adam R, McMaster P, O'Grady JG *et al.* (2003) Evolution of liver transplantation in Europe: report of the European Liver Transplant Registry. *Liver Transpl* 9, 1231–1243.

4 Murray KF, Carithers RL, Jr (2005) AASLD practice guidelines: evaluation of the patient for liver transplantation. *Hepatology* 41, 1407–1432.

5 Plotkin JS, Scott VL, Pinna A *et al.* (1996) Morbidity and mortality in patients with coronary artery disease undergoing orthotopic liver transplantation. *Liver Transpl Surg* 2, 426–430.

6 Plotkin JS, Benitez RM, Kuo PC *et al.* (1998) Dobutamine stress echocardiography for preoperative cardiac risk stratification in patients undergoing orthotopic liver transplantation. *Liver Transpl Surg* 4, 253–257.

7 Lucey MR, Brown KA, Everson GT *et al.* (1997) Minimal criteria for placement of adults on the liver transplant waiting list: a report of a national conference organized by the American Society of Transplant Physicians and the American Association for the Study of Liver Diseases. *Liver Transpl Surg* 3, 628–637.

8 Grace ND (1997) Diagnosis and treatment of gastrointestinal bleeding secondary to portal hypertension. American College of Gastroenterology Practice Parameters Committee. *Am J Gastroenterol* 92, 1081–1091.

9 Policy. 3.6 Organ Distribution (2001). Richmond VA: United Network for Organ Sharing. Retrieved November 10, 2001 from the World Wide Web: http://www.unos.org/About/policy_policies03_06.htm.

10 Freeman RB, Jr, Edwards EB (2000) Liver transplant waiting time does not correlate with waiting list mortality: implications for liver allocation policy. *Liver Transpl* 6, 543–552.

11 Institute of Medicine (1999) Analysis of waiting times. In: *Committee on Organ Transplantation. Assessing Current Policies and the Potential Impact of the DHHS Final Rule.* Washington DC: National Academy Press, pp. 57–78.

12 Wiesner RH, McDiarmid SV, Kamath PS *et al.* (2001) MELD and PELD: application of survival models to liver allocation. *Liver Transpl* 7, 567–580.

13 Malinchoc M, Kamath PS, Gordon FD *et al.* (2000) A model to predict poor survival in patients undergoing transjugular intrahepatic portosystemic shunts. *Hepatology* 31, 864–871.

14 Freeman RB, Wiesner RH, Edwards E *et al.* (2004) Results of the first year of the new liver allocation plan. *Liver Transpl* 10, 7–15.

15 Kamath PS, Wiesner RH, Malinchoc M *et al.* (2001) A model to predict survival in patients with end-stage liver disease. *Hepatology* 33, 464–470.

16 Freeman RB, Rohrer RJ, Katz E *et al.* (2001) Preliminary results of a liver allocation plan using a continuous medical severity score that de-emphasizes waiting time. *Liver Transpl* 7, 173–178.

17 Wiesner R, Edwards E, Freeman R *et al.* (2003) Model for end-stage liver disease (MELD) and allocation of donor livers. *Gastroenterology* 124, 91–96.

18 Olthoff KM, Brown RS, DelMonico FL *et al.* (2004) Summary Report of a National Conference: evolving concepts in liver allocation in the MELD/PELD era. *Liver Transplantation* 10 (Suppl. 2), A6–A22.

19 McDiarmid SV, Merion RM, Dykstra DM *et al.* (2004) Selection of pediatric candidates under the PELD system. *Liver Transpl* 10, S23–30.

20 McDiarmid SV, Anand R, Lindblad AS (2002) Development of a pediatric end-stage liver disease score to predict poor outcome in children awaiting liver transplantation. *Transplantation* 74, 173–181.

21 Bourdeaux C, Tri TT, Gras J *et al.* (2005) PELD score and posttransplant outcome in pediatric liver transplantation: a retrospective study of 100 recipients. *Transplantation* 79, 1273–1276.

22 Lee WM (1997) *Acute Liver Failure*. Cambridge: Cambridge University Press.

23 O'Grady JG (2005) Acute liver failure. *Postgrad Med J* 81, 148–154.

24 Dickson ER, Grambsch PM, Fleming TR *et al.* (1989) Prognosis in primary biliary cirrhosis: model for decision making. *Hepatology* 10, 1–7.

25 Liermann Garcia RF, Evangelista Garcia C, McMaster P *et al.* (2001) Transplantation for primary biliary cirrhosis: retrospective analysis of 400 patients in a single center. *Hepatology* 33, 22–27.

26 Lee YM, Kaplan MM (1995) Primary sclerosing cholangitis. *N Engl J Med* 332, 924–933.

27 Dickson ER, Murtaugh PA, Wiesner RH *et al.* (1992) Primary sclerosing cholangitis: refinement and validation of survival models. *Gastroenterology* 103, 1893–1901.

28 Kornfeld D, Ekbom A, Ihre T (1997) Survival and risk of cholangiocarcinoma in patients with primary sclerosing cholangitis. A population-based study. *Scand J Gastroenterol* 32, 1042–1045.

29 Goss JA, Shackleton CR, Farmer DG *et al.* (1997) Orthotopic liver transplantation for primary sclerosing cholangitis. A 12-year single center experience. *Ann Surg* 225, 472–481; discussion 481–483.

30 Loftus EV, Jr, Aguilar HI, Sandborn WJ *et al.* (1998) Risk of colorectal neoplasia in patients with primary sclerosing cholangitis and ulcerative colitis following orthotopic liver transplantation. *Hepatology* 27, 685–690.

31 Mendes FD, Lindor KD (2004) Primary sclerosing cholangitis. *Clin Liver Dis* 8, 195–211.

32 Graziadei IW, Wiesner RH, Marotta PJ *et al.* (1999) Long-term results of patients undergoing liver transplantation for primary sclerosing cholangitis. *Hepatology* 30, 1121–1127.

33 Graziadei IW, Wiesner RH, Batts KP *et al.* (1999) Recurrence of primary sclerosing cholangitis following liver transplantation. *Hepatology* 29, 1050–1056.

34 Czaja AJ (2002) Treatment strategies in autoimmune hepatitis. *Clin Liver Dis* 6, 799–824.

35 Gonzalez-Koch A, Czaja AJ, Carpenter HA *et al.* (2001) Recurrent autoimmune hepatitis after orthotopic liver transplantation. *Liver Transpl* 7, 302–310.

36 Everson G, Bharadhwaj G, House R *et al.* (1997) Long-term follow-up of patients with alcoholic liver disease who underwent hepatic transplantation. *Liver Transpl Surg* 3, 263–274.

37 Beresford TP, Everson GT (2000) Liver transplantation for alcoholic liver disease: bias, beliefs, 6-month rule, and relapse – but where are the data? *Liver Transpl* 6, 777–778.

38 Bravata DM, Olkin I, Barnato AE *et al.* (2001) Employment and alcohol use after liver transplantation for alcoholic and nonalcoholic liver disease: a systematic review. *Liver Transpl* 7, 191–203.

39 Veldt BJ, Laine F, Guillygomarc'h A *et al.* (2002) Indication of liver transplantation in severe alcoholic liver cirrhosis: quantitative evaluation and optimal timing. *J Hepatol* 36, 93–98.

40 Farges O, Saliba F, Farhamant H *et al.* (1996) Incidence of rejection and infection after liver transplantation as a function of the primary disease: possible influence of alcohol and polyclonal immunoglobulins. *Hepatology* 23, 240–248.

41 Bathgate AJ, Hynd P, Sommerville D *et al.* (1999) The prediction of acute cellular rejection in orthotopic liver transplantation. *Liver Transpl Surg* 5, 475–479.

42 Llovet JM, Burroughs A, Bruix J (2003) Hepatocellular carcinoma. *Lancet* 362, 1907–1917.

43 El-Serag HB (2004) Hepatocellular carcinoma: recent trends in the United States. *Gastroenterology* 127, S27–34.

44 Wall WJ (2000) Liver transplantation for hepatic and biliary malignancy. *Semin Liver Dis* 20, 425–436.

45 Everson GT (2000) Increasing incidence and pretransplantation screening of hepatocellular carcinoma. *Liver Transpl* 6, S2–10.

46 Mazzaferro V, Regalia E, Doci R *et al.* (1996) Liver transplantation for the treatment of small hepatocellular carcinomas in patients with cirrhosis. *N Engl J Med* 334, 693–699.

47 Sharma P, Balan V, Hernandez JL *et al.* (2004) Liver transplantation for hepatocellular carcinoma: the MELD impact. *Liver Transpl* 10, 36–41.

48 Yoo HY, Patt CH, Geschwind JF *et al.* (2003) The outcome of liver transplantation in patients with hepatocellular carcinoma in the United States between 1988 and 2001: 5-year survival has improved significantly with time. *J Clin Oncol* 21, 4329–4335.

49 Wiesner RH, Freeman RB, Mulligan DC (2004) Liver transplantation for hepatocellular cancer: the impact of the MELD allocation policy. *Gastroenterology* 127, S261–267.

50 El-Serag HB, Davila JA (2004) Is fibrolamellar carcinoma different from hepatocellular carcinoma? A US population-based study. *Hepatology* 39, 798–803.

51 Katzenstein HM, Krailo MD, Malogolowkin MH *et al.* (2003) Fibrolamellar hepatocellular carcinoma in children and adolescents. *Cancer* 97, 2006–2012.

52 Meyer CG, Penn I, James L (2000) Liver transplantation for cholangiocarcinoma: results in 207 patients. *Transplantation* 69, 1633–1637.

53 De Vreede I, Steers JL, Burch PA *et al.* (2000) Prolonged disease-free survival after orthotopic liver transplantation plus adjuvant chemoirradiation for cholangiocarcinoma. *Liver Transpl* 6, 309–316.

54 Lehnert T (1998) Liver transplantation for metastatic neuroendocrine carcinoma: an analysis of 103 patients. *Transplantation* 66, 1307–1312.

55 Sutcliffe R, Maguire D, Ramage J *et al.* (2004) Management of neuroendocrine liver metastases. *Am J Surg* 187, 39–46.

56 Crawford DH, Fletcher LM, Hubscher SG *et al.* (2004) Patient and graft survival after liver transplantation for hereditary hemochromatosis: implications for pathogenesis. *Hepatology* 39, 1655–1662.

57 Brandhagen DJ, Alvarez W, Therneau TM *et al.* (2000) Iron overload in cirrhosis – HFE genotypes and outcome after liver transplantation. *Hepatology* 31, 456–460.

58 Bowlus CL, Willner I, Zern MA *et al.* (2005) Factors associated with advanced liver disease in adults with alpha1-antitrypsin deficiency. *Clin Gastroenterol Hepatol* 3, 390–396.

59 Putnam CW, Porter KA, Peters RL *et al.* (1977) Liver replacement for alpha1-antitrypsin deficiency. *Surgery* 81, 258–261.

60 Elzouki AN, Lindgren S, Nilsson S *et al.* (1997) Severe alpha1-antitrypsin deficiency (PiZ homozygosity) with membranoproliferative glomerulonephritis and nephrotic syndrome, reversible after orthotopic liver transplantation. *J Hepatol* 26, 1403–1407.

61 Acharya J, Westwood NB, Sawyer BM *et al.* (1995) Identification of latent myeloproliferative disease in patients with Budd–Chiari syndrome using X-chromosome inactivation patterns and *in vitro* erythroid colony formation. *Eur J Haematol* 55, 315–321.

62 Deltenre P, Denninger MH, Hillaire S *et al.* (2001) Factor V Leiden related Budd–Chiari syndrome. *Gut* 48, 264–268.

63 Bismuth H, Sherlock DJ (1991) Portasystemic shunting versus liver transplantation for the Budd–Chiari syndrome. *Ann Surg* 214, 581–589.

64 Shaked A, Goldstein RM, Klintmalm GB *et al.* (1992) Portosystemic shunt versus orthotopic liver transplantation for the Budd–Chiari syndrome. *Surg Gynecol Obstet* 174, 453–459.

65 Molmenti EP, Segev DL, Arepally A *et al.* (2005) The utility of TIPS in the management of Budd–Chiari syndrome. *Ann Surg* 241, 978–981; discussion 982–983.

66 Ochs A (2005) Transjugular intrahepatic portosystemic shunt. *Dig Dis* 23, 56–64.

67 Pirenne J, Aerts R, Yoong K *et al.* (2001) Liver transplantation for polycystic liver disease. *Liver Transpl* 7, 238–245.

68 Everson GT, Taylor MR, Doctor RB (2004) Polycystic disease of the liver. *Hepatology* 40, 774–782.

69 Zetterman RK, Belle SH, Hoofnagle JH *et al.* (1998) Age and liver transplantation: a report of the Liver Transplantation Database. *Transplantation* 66, 500–506.

70 Herrero JI, Lucena JF, Quiroga J *et al.* (2003) Liver transplant recipients older than 60 years have lower survival and higher incidence of malignancy. *Am J Transplant* 3, 1407–1412.

71 Carey WD, Dumot JA, Pimentel RR *et al.* (1995) The prevalence of coronary artery disease in liver transplant candidates over age 50. *Transplantation* 59, 859–864.

72 Morris JJ, Hellman CL, Gawey BJ *et al.* (1995) Case 3-1995. Three patients requiring both coronary artery bypass surgery and orthotopic liver transplantation. *J Cardiothorac Vasc Anesth* 9, 322–332.

73 Donovan CL, Marcovitz PA, Punch JD *et al.* (1996) Two-dimensional and dobutamine stress echocardiography in the preoperative assessment of patients with end-stage liver disease prior to orthotopic liver transplantation. *Transplantation* 61, 1180–1188.

74 Krowka MJ, Cortese DA (1994) Hepatopulmonary syndrome. Current concepts in diagnostic and therapeutic considerations. *Chest* 105, 1528–1537.

75 Schenk P, Schoniger-Hekele M, Fuhrmann V *et al.* (2003) Prognostic significance of the hepatopulmonary syndrome in patients with cirrhosis. *Gastroenterology* 125, 1042–1052.

76 Abrams GA, Nanda NC, Dubovsky EV *et al.* (1998) Use of macroaggregated albumin lung perfusion scan to diagnose hepatopulmonary syndrome: a new approach. *Gastroenterology* 114, 305–310.

77 Arguedas MR, Abrams GA, Krowka MJ *et al.* (2003) Prospective evaluation of outcomes and predictors of mortality in patients with hepatopulmonary syndrome undergoing liver transplantation. *Hepatology* 37, 192–197.

78 Krowka MJ, Porayko MK, Plevak DJ *et al.* (1997) Hepatopulmonary syndrome with progressive hypoxemia as an indication for liver transplantation: case reports and literature review. *Mayo Clin Proc* 72, 44–53.

79 Kuo PC, Plotkin JS, Gaine S *et al.* (1999) Portopulmonary hypertension and the liver transplant candidate. *Transplantation* 67, 1087–1093.

80 Castro M, Krowka MJ, Schroeder DR *et al.* (1996) Frequency and clinical implications of increased pulmonary artery pressures in liver transplant patients. *Mayo Clin Proc* 71, 543–551.

81 Ramsay MA, Simpson BR, Nguyen AT *et al.* (1997) Severe pulmonary hypertension in liver transplant candidates. *Liver Transpl Surg* 3, 494–500.

82 Plotkin JS, Kuo PC, Rubin LJ *et al.* (1998) Successful use of chronic epoprostenol as a bridge to liver transplantation in severe portopulmonary hypertension. *Transplantation* 65, 457–459.

83 Ramsay MA, Spikes C, East CA *et al.* (1999) The perioperative management of portopulmonary hypertension with nitric oxide and epoprostenol. *Anesthesiology* 90, 299–301.

84 Mair P, Kaehler CH, Pomaroli A *et al.* (2001) Orthotopic liver transplantation in a patient with severe portopulmonary hypertension. *Acta Anaesthesiol Scand* 45, 513–518.

85 Chua R, Keogh A, Miyashita M (2005) Novel use of sildenafil in the treatment of portopulmonary hypertension. *J Heart Lung Transplant* 24, 498–500.

86 Makisalo H, Koivusalo A, Vakkuri A *et al.* (2004) Sildenafil for portopulmonary hypertension in a patient undergoing liver transplantation. *Liver Transpl* 10, 945–950.

87 Prachalias AA, Pozniak A, Taylor C *et al.* (2001) Liver transplantation in adults coinfected with HIV. *Transplantation* 72, 1684–1688.

88 Neff GW, Bonham A, Tzakis AG *et al.* (2003) Orthotopic liver transplantation in patients with human immunodeficiency virus and end-stage liver disease. *Liver Transpl* 9, 239–247.

89 Stock PG, Roland ME, Carlson L *et al.* (2003) Kidney and liver transplantation in human immunodeficiency virus-infected patients: a pilot safety and efficacy study. *Transplantation* 76, 370–375.

90 Roland ME, Stock PG (2003) Review of solid-organ transplantation in HIV-infected patients. *Transplantation* 75, 425–429.

91 Brown RS, Jr, Lombardero M, Lake JR (1996) Outcome of patients with renal insufficiency undergoing liver or liver-kidney transplantation. *Transplantation* 62, 1788–1793.

92 Nair S, Verma S, Thuluvath PJ (2002) Pretransplant renal function predicts survival in patients undergoing orthotopic liver transplantation. *Hepatology* 35, 1179–1185.

93 Davis CL, Gonwa TA, Wilkinson AH (2002) Identification of patients best suited for combined liver–kidney transplantation: part II. *Liver Transpl* 8, 193–211.

94 McCauley J, Van Thiel DH, Starzl TE *et al.* (1990) Acute and chronic renal failure in liver transplantation. *Nephron* 55, 121–128.

95 Arroyo V, Gines P, Navasa M *et al.* (1993) Renal failure in cirrhosis and liver transplantation. *Transplant Proc* 25, 1734–1739.

96 Shields PL, Tang H, Neuberger JM *et al.* (1999) Poor outcome in patients with diabetes mellitus undergoing liver transplantation. *Transplantation* 68, 530–535.

97 John PR, Thuluvath PJ (2001) Outcome of liver transplantation in patients with diabetes mellitus: a case–control study. *Hepatology* 34, 889–895.

98 Trotter JF, Bak TE, Wachs ME *et al.* (2000) Combined liver–pancreas transplantation in a patient with primary sclerosing cholangitis and insulin-dependent diabetes mellitus. *Transplantation* 70, 1469–1471.

99 Nair S, Verma S, Thuluvath PJ (2002) Obesity and its effect on survival in patients undergoing orthotopic liver transplantation in the United States. *Hepatology* 35, 105–109.

100 Ehlers SL, Rodrigue JR, Widows MR *et al.* (2004) Tobacco use before and after liver transplantation: a single center survey and implications for clinical practice and research. *Liver Transpl* 10, 412–417.

101 Pungpapong S, Manzarbeitia C, Ortiz J *et al.* (2002) Cigarette smoking is associated with an increased incidence of vascular complications after liver transplantation. *Liver Transpl* 8, 582–587.

102 Yerdel MA, Gunson B, Mirza D *et al.* (2000) Portal vein thrombosis in adults undergoing liver transplantation: risk factors, screening, management, and outcome. *Transplantation* 69, 1873–1881.

103 Forman LM, Lewis JD, Berlin JA *et al.* (2002) The association between hepatitis C infection and survival after orthotopic liver transplantation. *Gastroenterology* 122, 889–896.

104 Charlton M, Seaberg E, Wiesner R *et al.* (1998) Predictors of patient and graft survival following liver transplantation for hepatitis C. *Hepatology* 28, 823–830.

105 Forman LM (2003) To transplant or not to transplant recurrent hepatitis C and liver failure. *Clin Liver Dis* 7, 615–629.

106 Marcos A, Ham JM, Fisher RA *et al.* (2000) Single-center analysis of the first 40 adult-to-adult living donor liver transplants using the right lobe. *Liver Transpl* 6, 296–301.

107 Bak T, Wachs M, Trotter J *et al.* (2001) Adult-to-adult living donor liver transplantation using right-lobe grafts: results and lessons learned from a single-center experience. *Liver Transpl* 7, 680–686.

108 Abecassis M, Adams M, Adams P *et al.* (2000) Consensus statement on the live organ donor. *JAMA* 284, 2919–2926.

109 American Society of Transplant Surgeons (2000) Position paper on adult-to-adult living donor liver transplantation. *Liver Transpl* 6, 815–817.

110 Schiano TD, Kim-Schluger L, Gondolesi G *et al.* (2001) Adult living donor liver transplantation: the hepatologist's perspective. *Hepatology* 33, 3–9.

111 Wachs ME, Bak TE, Karrer FM *et al.* (1998) Adult living donor liver transplantation using a right hepatic lobe. *Transplantation* 66, 1313–1316.

112 Abt PL, Mange KC, Olthoff KM *et al.* (2004) Allograft survival following adult-to-adult living donor liver transplantation. *Am J Transplant* 4, 1302–1307.

113 Trotter JF (2005) Living donor liver transplantation: is the hype over? *J Hepatol* 42, 20–25.

114 Marcos A (2000) Right-lobe living donor liver transplantation. *Liver Transpl* 6, S59–63.

115 Broelsch CE, Malago M, Testa G *et al.* (2000) Living donor liver transplantation in adults: outcome in Europe. *Liver Transpl* 6, S64–65.

116 Todo S, Furukawa H, Jin MB *et al.* (2000) Living donor liver transplantation in adults: outcome in Japan. *Liver Transpl* 6, S66–72.

117 Trotter JF, Talamantes M, McClure M *et al.* (2001) Right hepatic lobe donation for living donor liver transplantation: impact on donor quality of life. *Liver Transpl* 7, 485–493.

118 Trotter JF, Wachs M, Trouillot T *et al.* (2000) Evaluation of 100 patients for living donor liver transplantation. *Liver Transpl* 6, 290–295.

119 Yeh BM, Breiman RS, Taouli B *et al.* (2004) Biliary tract depiction in living potential liver donors: comparison of conventional MR, mangafodipir trisodium-enhanced excretory MR, and multidetector row CT cholangiography – initial experience. *Radiology* 230, 645–651.

120 Cheng YF, Chen CL, Huang TL *et al.* (1999) Magnetic resonance of the hepatic veins with angular reconstruction: application in living-related liver transplantation. *Transplantation* 68, 267–271.

121 Cheng YF, Chen CL, Huang TL *et al.* (2001) Single imaging modality evaluation of living donors in liver transplantation: magnetic resonance imaging. *Transplantation* 72, 1527–1533.

122 White SA, Al-Mukhtar A, Lodge JP *et al.* (2004) Progress in living donor liver transplantation. *Transplant Proc* 36, 2720–2726.

123 Baltz AC, Trotter JF (2003) Living donor liver transplantation and hepatitis C. *Clin Liver Dis* 7, 651–665, viii.

124 Garcia-Retortillo M, Forns X, Llovet JM *et al.* (2004) Hepatitis C recurrence is more severe after living donor compared to cadaveric liver transplantation. *Hepatology* 40, 699–707.

125 Gaglio PJ, Malireddy S, Levitt BS *et al.* (2003) Increased risk of cholestatic hepatitis C in recipients of grafts from living versus cadaveric liver donors. *Liver Transpl* 9, 1028–1035.

126 Rodriguez-Luna H, Vargas HE, Sharma P *et al.* (2004) Hepatitis C virus recurrence in living donor liver transplant recipients. *Dig Dis Sci* 49, 38–41.

127 Van Vlierberghe H, Troisi R, Colle I *et al.* (2004) Hepatitis C infection-related liver disease: patterns of recurrence and outcome in cadaveric and living-donor liver transplantation in adults. *Transplantation* 77, 210–214.

128 Everson GT, Trotter J, Forman L *et al.* (2005) Treatment of advanced hepatitis C with a low accelerating dosage regimen of antiviral therapy. *Hepatology* 42, 255–262.

25.3 The perioperative care and complications of liver transplantation

Mark T. Keegan and David J. Plevak

Introduction

Despite an increase in illness acuity, patients who receive a liver graft generally do well during the period of time immediately surrounding the procedure. In many cases, patients are weaned from mechanical ventilation a few hours after the end of surgery, and it is not uncommon for them to be discharged from the intensive care unit (ICU) within 24 h [1]. Improvements in anaesthetic and surgical techniques have facilitated this trend. In some centres, patients are routinely extubated in the operating room or recovery room [2]. These patients can frequently be transferred to an intermediate care area, thus 'bypassing' the ICU. However, in most institutions, immediate postoperative management takes place in the ICU. If patient illness acuity requires ICU care before transplantation, the chances of encountering a challenging intraoperative course and a prolonged postoperative ICU stay are high.

Preoperative anaesthesia assessment

The anaesthesiologist will frequently begin the preoperative assessment by concentrating on the patient's cardiopulmonary status. The three cardiac issues of chief concern are cirrhotic cardiomyopathy, the hyperdynamic circulatory state (HDCS) and coronary artery disease. These issues can usually be addressed with a chest X-ray, electrocardiogram, echocardiogram and a dobutamine stress test. Cirrhotic cardiomyopathy is characterized by decreased systolic inotropic and diastolic lusitropic responses to drugs, exercise and surgical stress [3]. In the absence of left ventricular failure, cardiac output can be elevated, but cardiac output drops as cardiomyopathy progresses. In the absence of cirrhotic cardiomyopathy, patients with endstage liver disease typically exhibit the HDCS. The HDCS is characterized by high cardiac output and low systemic vascular resistance. Failure to observe this hyperdynamic pattern should elicit a suspicion of cirrhotic cardiomyopathy. HDCS appears to provide benefit, as liver transplantation survivors typically sustain a higher cardiac index, mean arterial pressure, stroke volume, left ventricular stroke work index and oxygen delivery [4]. Coronary artery disease occurs in patients with liver disease at a frequency not unlike that in the general population. Screening for coronary disease has been accomplished successfully in some institutions with dobutamine stress echocardiography [5]. Patients with untreated coronary disease appear to be at increased risk of perioperative death. As perioperative beta-blockade seems to confer lower perioperative mortality in patients after major surgery [6], it should be considered in liver transplant recipients. However, caution is advised as beta-blockers may provide exaggerated haemodynamic effects in these patients due to the adrenergic receptor dysfunction associated with liver disease [3]. Also, beta-blockers may theoretically remove the protection associated with the HDCS.

The two respiratory issues usually of chief concern in the preoperative liver transplant patient are the hepatopulmonary syndrome (HPS) and portopulmonary hypertension (PPHT) [7]. These issues can usually be addressed with an arterial blood gas, a chest X-ray and an agitated saline echocardiogram. Hypoxaemia is relatively common in patients with liver disease, and is frequently the result of transpulmonary shunting from HPS [8]. Fortunately, most patients with HPS respond well to high concentrations of oxygen, so that acceptable arterial oxygen saturations can be obtained during the perioperative period [9]. PPHT can usually be diagnosed accurately with an estimated pulmonary artery systolic pressure via echocardiogram [10]. In some institutions, if the systolic pulmonary artery pressure is estimated to be 50 mmHg or above, liver transplantation will be deferred because of the high perioperative mortality rate for patients with severe PPHT [10]. Fortunately, patients with severe PPHT can frequently benefit from treatment (sildenafil [11], endothelin antagonists such as bosentan [12] and intravenous epoprostenol [13]). Some of these treated patients have later received successful orthotopic liver transplantation (OLT) after therapy [7].

Renal and electrolyte issues of main concern before anaesthesia for OLT include the presence of renal failure, hyperkalaemia and metabolic acidosis. These issues can be assessed with an arterial blood gas and a serum chemistry panel, and can be most expeditiously handled with dialysis. This dialysis can

continue into the intraoperative period as continuous veno-venous haemofiltration, dialysis and dialysis with fluid removal [14]. Other perioperative strategies to treat hyperkalaemia and metabolic acidosis include the use of washed red blood cells and insulin–glucose infusions [15]. Tris-hydroxymethyl aminomethane (THAM) is a means of treating metabolic acidosis without contributing to the patient's sodium intake.

The anaesthesiologist is concerned with both hypocoagulation and hypercoagulation. Hypocoagulability can be measured with the traditional tests of prothrombin time [international normalized ratio (INR)], activated partial thromboplastin time, fibrinogen, fibrin degradation products and platelet count. Both hypo- and hypercoagulation can be measured with the thromboelastogram. The use of aprotinin to avoid fibrinolysis and reduce blood loss is controversial [16,17]. It appears that, when aprotinin is initiated preoperatively, it is effective in reducing blood loss, but case reports suggest that a few patients have had severe complications from systemic clot formation [18,19]. Other antifibrinolytics (epsilon aminocaproic acid and tranexamic acid) are typically initiated intraoperatively to treat established haemorrhage.

The anaesthesiologist is particularly interested in the patient's level of consciousness before surgery. If the patient is found to be disoriented or poorly responsive, an evaluation [i.e. neurological examination, serum chemistries, serum ammonia, plasma glucose and head computerized tomography (CT)] may be indicated. If the patient has experienced a relatively acute onset of liver disease, the possibility of cerebral oedema should be considered, and the patient may benefit from intracranial pressure monitoring [20].

Intraoperative anaesthesia care

The equipment used by the anaesthesiologist includes those items that are largely particular to the care of a liver transplant patient (i.e. rapid infusion pump, veno-venous bypass), those that are found in the care of critical patients (i.e. continuous dialysis, transoesophageal echocardiography, onsite laboratory and pulmonary artery catheter), and those utilized in most common anaesthetics (i.e. anaesthesia machine). A survey of 67% of all liver transplant programmes in the United States indicated that 45.2% of the programmes had a rapid infusion system, 40.3% utilized a 'level 1' system, and 16.1% had a cardiac surgical perfusion pump [21]. Of note is that 12.9% of those programmes surveyed did not indicate which (if any) system they used for rapid transfusion. The same survey indicated that 11.3% of US liver transplant programmes used transoesophageal echocardiography, 30.6% employed pulmonary catheters that had the capability of determining cardiac output in a continuous fashion, and 37.1% had the necessary equipment to apply veno-venous bypass. Schumann's survey noted that onsite laboratories provided arterial blood gas analysis, plasma glucose and serum sodium and potassium in 100% of the programmes that responded. These laboratories provided assessments of other items on a less frequent basis: calcium (96.8% of the programmes surveyed), magnesium (51.6%), phosphorus (30.6%), lactate (8.1%), prothrombin time (83.9%), platelet count (90.3%), activated clotting time (21%) and thromboelastogram (30.6%). The anaesthetic medications applied to the patient in the operating room include many of the common anaesthetic drugs: midazolam (anxiolytic), propofol (intravenous induction agent), *cis*-atracurium (non-depolarizing muscle relaxant), fentanyl (narcotic) and isoflurane (volatile maintenance agent). These relatively short-acting anaesthetic drugs have been used to reduce the time that patients require intubation after liver transplantation; however, their utilization has not yet been shown to reduce ICU stay [22]. After induction of anaesthesia, it is not uncommon for the patient to become transiently hypotensive. This is the result of the vasodilatory effects of the medications used for anaesthetic induction, combined with the application of positive pressure ventilation. As most patients with chronic liver disease and portal hypertension are intravascularly volume depleted, the postinduction hypotension usually responds to volume infusion. Prior to abdominal incision, one or two arterial catheters, one or two large-bore intravenous catheters (i.e. 8.5 French) and a pulmonary artery catheter are placed. The pulmonary artery catheter is used to assess for evidence of moderate to severe pulmonary hypertension. Guidelines exist that aid in decision making for those instances in which patients are found to have moderate to severe pulmonary hypertension [7].

During the preanhepatic phase of the operation, the anaesthesiologist is particularly concerned with the possibility of rapid haemorrhage and (air, clot or debris) embolus. Embolus, which can occur as the surgeon transects large venous sinuses, is usually suspected when an otherwise unanticipated cardiovascular collapse occurs at this phase of the procedure. A diagnosis of embolus can be substantiated by a drop in expired CO_2 and the presence of gas or debris in the cardiac chambers, as noted by transoesophageal echocardiography. If the embolus source can be identified, and further emboli avoided, the cardiovascular system can frequently be sustained with intravascular volume and inotropic support. With the onset of the anhepatic phase of the procedure, the anaesthesiologist is often concerned with systemic hypotension from partially (or completely) obstructed venous return. Veno-venous bypass can ameliorate this obstruction to venous return. The period immediately after hepatic recirculation is typically the most eventful phase for the anaesthesiologist. Cardiovascular occurrences can include hypotension from rapid blood loss, embolus, pulmonary hypertension, arrhythmia, hypothermia, global cardiac hypofunction and vasodilatation. Rapid electrolyte (potassium, calcium, magnesium) and acid (lactate) shifts can cause cardiac and vascular disturbance. The patient can develop coagulopathy from fibrinolysis, factor depletion, platelet sequestration, hypocalcaemia and hypothermia. Patients with liver failure of acute or subacute onset can develop worsening cerebral oedema and intracranial hypertension. The anaesthesiologist attempts to

manage this dynamic phase of the operation in both an anticipatory and a reactive fashion by employing various manoeuvres including rapid fluid and blood resuscitation, hyperventilation with high oxygen concentrations, electrolyte infusions (bicarbonate, calcium, magnesium), inotropic support (dopamine, epinephrine) and coagulation sustenance (fresh frozen plasma, cryoprecipitate, platelets, antifibrinolytic drugs). The postrecirculation period is hopefully one of assisting patient rewarming and stabilization. Some factors that might interfere with hepatic reanimation include ongoing bleeding, worsening pulmonary hypertension and primary non-function of the liver graft.

Postoperative intensive care

In most institutions, the ICU care of the OLT recipient is directed by a specialized intensive care team. The primary speciality of the intensive care staff varies from unit to unit. The transplant surgeons and hepatologists play an important role in postoperative care, although they are less likely to be involved in acute ventilatory and haemodynamic management.

Once the patient arrives in the ICU, patient assessment includes evaluations similar to those that occur for any postoperative patient. The patient may be hypothermic. To avoid the undesirable effects of coagulopathy and myocardial dysfunction, a warm room, warm blankets and the application of a forced air-warming device are useful [23]. Assurance of the adequacy of oxygenation and ventilation is accomplished by physical examination, chest X-ray, arterial blood gas analysis and review of ventilator mechanics. Mechanically ventilated patients are nursed in a semi-recumbent position to decrease the incidence of ventilator-acquired pneumonia [24]. Ventilation strategies that minimize insult to the allograft are used (i.e. avoidance of both excessively high airway pressures and high positive end-expiratory pressure). Many institutions use a ventilator weaning protocol that permits the respiratory therapist and nursing staff to decrease the level of both sedation and ventilatory support in anticipation of extubation [22]. Haemodynamic data are acquired from physical examination and monitors including an electrocardiogram and pulmonary artery catheter. Abdominal girth is measured serially, as trends may be a valuable guide to the determination of the presence of intra-abdominal bleeding. Intra-abdominal drains are inspected for the rate and nature of blood or fluid loss. If the drains are filling briskly with fluid of a high haemoglobin concentration, this indicates ongoing surgical bleeding or a coagulopathy that needs urgent correction. Especially in those patients with preoperative alterations in mental status, neurological assessments (e.g. Glasgow Coma Scale) and intracranial pressure (ICP) measurements (if an ICP monitor is present) are noted. In most cases, patients are liberated quickly from mechanical ventilation and may be suitable for discharge from the ICU the day after their procedure [22]. At this point, large-bore venous access is discontinued or changed to a catheter that can be used on the general floor for medication administration and blood sampling.

Immediate postoperative liver graft function

The immediate postoperative management of the patient after OLT depends on the performance of the liver allograft. If the graft functions well, metabolic acidosis will improve, coagulopathy will tend to resolve and haemodynamics will stabilize. If the patient has a biliary tube, the production of golden brown viscous bile is a sign of good graft function. In most instances, hepatic transaminases will initially be high (a sign of preservation injury), but will then decrease over subsequent days. Vascular integrity and echotexture can be assessed by Doppler ultrasonography. 'Initial poor function' of the liver graft may result from transplantation from an elderly donor or a graft that has experienced a long ischaemia time. Grafts with 'initial poor function' will largely eventually perform adequately as the patient is supported. 'Primary non-function' of the graft may in many instances be the result of an immunological injury. Evidence of 'primary non-function' can begin as early as the time of recirculation of the liver [25]. These patients will usually require emergent retransplantation, as the mortality rate without retransplantation is greater than 80% [26]. Signs of graft dysfunction include hyperkalaemia, worsening renal insufficiency, resistant metabolic acidosis, increasing levels of serum lactate, hypoglycaemia, climbing levels of hepatic transaminases, worsening hepatic encephalopathy and the occurrence of cerebral oedema.

Cardiac issues immediately after liver transplantation

Systemic hypertension is common after liver transplantation. There are many potential causes including fluid overload, pain and anxiety and pre-existing chronic hypertension. Treatment should be instituted when the systolic blood pressure is greater than 160 mmHg or the diastolic blood pressure greater than 100 mmHg [1]. Cardiac arrhythmias commonly occur and may be related to hypoxaemia, hypercapnia, metabolic acidosis, electrolyte imbalance (especially potassium, magnesium or calcium), transient myocardial dysfunction or the improper position of central catheters. Atrial fibrillation is a common postoperative arrhythmia and may be related to perioperative fluid and electrolyte shifts. Treatment of atrial fibrillation is with conventional therapies including beta-blockers and calcium channel antagonists. If possible, amiodarone should be avoided because of its hepatotoxic potential. Elevations of serum troponin are often detected in the postoperative period [5]. While dobutamine stress echocardiography has been widely used in the evaluation of patients prior to OLT [27], myocardial insults are not necessarily predicted by preoperative dobutamine stress echocardiography and may reflect intraoperative stresses rather than coronary artery disease [5,28]. Post-transplant cardiomyopathy occurs uncommonly. It was originally described in a series of seven patients (of 754 transplants) as a reversible dilated

cardiomyopathy [29]. The patients presented with pulmonary oedema and respiratory failure in association with a decrease in their cardiac ejection fractions from a median baseline of 60% to a median of 20%. With supportive therapy, including careful use of fluids, pressors and inotropes, the patients improved without sequelae.

Respiratory issues immediately after liver transplantation

Patients who required mechanical ventilation before surgery are not suitable candidates for early extubation. These patients are frequently malnourished, have underlying lung disease or have required volume resuscitation in the treatment of sepsis. An additional group of patients who received large amounts of blood perioperatively may develop metabolic alkalosis as the functioning graft converts citrate into bicarbonate. In these patients, the administration of acetazolamide may be useful to avoid secondary hypoventilation [1,30]. Also, diuresis and thoracentesis may be helpful. In selected patients who are not yet prepared for a complete withdrawal of positive pressure support, non-invasive ventilation [continuous positive airway pressure (CPAP) or biphasic positive airway pressure (BiPAP)] may be used after extubation [31]. In those in whom mechanical ventilation is anticipated to be prolonged (i.e. > 1–2 weeks), consideration should be given to the placement of a tracheostomy as soon as the patient stabilizes after transplant [32].

Patients with HPS can pose particular challenges with hypoxaemia after transplant [33]. Such patients may require prolonged periods on the ventilator and, after extubation, may be oxygen dependent for long periods. While severe hypoxaemia resulting from HPS is a strong risk factor for perioperative mortality, most patients (especially type 1 HPS) do very well long term. If patients with HPS become severely hypoxaemic after OLT, potential treatment modalities include Trendelenburg positioning and the administration of intravenous methylene blue [34] or inhaled N(G)-nitro-L-arginine methyl ester [35]. The occurrence of severe PPHT after liver transplantation poses a risk to both graft and patient survival [7]. Right ventricular failure can result with subsequent hypoxaemia and hypoperfusion of the liver graft. Possible treatment modalities include inhaled nitric oxide [36,37] and the placement of a right ventricular assist device.

Acute lung injury (ALI) or the acute respiratory distress syndrome (ARDS) [38] may occur after extensive intraoperative resuscitation, transfusion-related acute lung injury (TRALI) [39], pre-existing pneumonia or pulmonary oedema from a cardiac cause. Evidence suggests that a low tidal volume ventilation strategy (6 mL/kg ideal body weight) [40] should be employed in patients who develop ARDS, although the use of this strategy and the application of potentially high levels of positive end-expiratory pressure (PEEP) have not been formally investigated after liver transplantation.

Renal and electrolyte issues immediately after liver transplantation

Low urine output and renal dysfunction are common after OLT. Prerenal failure (secondary to hypovolaemia, hypotension or low cardiac output) is characterized by low urine output, decreased urine sodium (< 10 mEq/L) and a fractional excretion of sodium less than 1%. Optimization of volume status, improving cardiac output using inotropes and maintaining blood pressure in the patient's normal range using vasoconstrictors may reverse prerenal dysfunction. Preoperative renal impairment will normally persist into the postoperative period and may be due to sepsis-induced acute tubular necrosis, nephrotoxic drugs or the hepatorenal syndrome (HRS) [41]. HRS is a functional renal failure and will generally recover after OLT, although this may take days to weeks. The development of new-onset HRS after liver transplantation indicates severe graft dysfunction or primary non-function. Initiation of tacrolimus or ciclosporin after transplant may be associated with renal dysfunction, and the serum levels of these drugs must be monitored. If renal failure persists, or if electrolyte and fluid disturbances become otherwise difficult to manage, dialysis may be needed. The dialysis modality employed is determined by many things, including the haemodynamic stability of the patient. Continuous renal replacement therapy (CRRT) is frequently used in the ICU because it causes less haemodynamic instability than conventional dialysis.

Bleeding after liver transplantation

Inadequate blood clotting may occur in the ICU due to massive perioperative transfusion, hypothermia, hypocalcaemia, coagulation factor deficiency, thrombocytopenia and fibrinolysis. Hypocoagulation can result in postoperative bleeding. However, aggressive corrective action and the application of antifibrinolytic drugs must be balanced against the risk of hypercoagulation and thrombosis of important structures, including the hepatic artery. Within the first 24–48 h after transplantation, between 10% and 15% of patients experience enough blood loss to require reoperation [1]. Signs of severe bleeding include tachycardia and hypotension, abdominal distension, oliguria, elevated bladder pressures (> 20 cmH_2O), elevated peak airway pressures and failure of the haematocrit to rise after transfusion. Vigorous surgical drain output typically indicates intra-abdominal bleeding, but drains may clot and a lack of drain output may be misleading. If the patient returns to the operating room, identifiable sources include bleeding from vascular anastomoses, intra-abdominal varix, liver laceration or fracture, the adrenal bed, the cystic artery or gallbladder bed, the diaphragm or the drain and skin closure sites. Patients with large, raw liver surfaces, such as recipients of split liver or living related-donor OLT, seem to be prone to postoperative haemorrhage. If the patient returns to the operating room, the anaesthesiologist must be prepared for cardiovascular collapse when

decompression of the abdomen occurs as its tamponading effect on the bleeding vessels is released.

Medications immediately after liver transplantation

While intubated, patients are managed with an opiate infusion (e.g. fentanyl) or without pain medication. Once extubated, patients are usually adept at using a patient-controlled analgesia device (morphine or fentanyl). Interestingly, patients after OLT usually require only small amounts of analgesic medication [42]. Postoperative medications other than analgesics include drugs for prophylaxis against gastrointestinal ulceration and deep venous thrombosis, selective bowel decontamination [43] and immunosuppressant medications.

Vascular and biliary complications

Complications related to the vascular anastomoses occur in 6–12% of OLTs [44]. Thrombosis is the most common problem, but stenosis, pseudoaneurysm formation and dissection may also occur. The hepatic artery is a small vessel and is especially prone to problems. Hepatic artery thrombosis occurs in 3–5% of adults especially if the surgical anastomotic technique is suboptimal. Use of an arterial conduit or the presence of a procoagulant state (e.g. hyperviscosity due to overtransfusion) increases the risk. Thrombosis rates are higher after split liver cadaveric transplants and living donor liver transplants. Thrombosis can present in a variety of ways. In the early postoperative period, rapid deterioration in graft function may occur, with hepatic encephalopathy, marked elevation of transaminases and worsening coagulopathy. Diagnosis by ultrasound can result in prompt surgical exploration, thrombectomy, revision and limited injury. If extensive necrosis occurs, retransplantation may be necessary in the immediate future. If bile duct injury predominates, the patient may require retransplantation on a less urgent basis. Portal vein thrombosis occurs in less than 2% of recipients [26] and is usually related to a technical error at surgery. If it occurs in the early postoperative period, severe liver dysfunction may occur. An acute elevation of portal and mesenteric venous pressures can lead to tense ascites and bleeding oesophageal varices. Intervention will require thrombectomy and revision of the anastomosis, or possibly retransplantation. Hepatic vein thrombosis occurs in less than 1% of recipients and is due to a technical error or a recurrence of Budd–Chiari syndrome. It presents as tense ascites and graft dysfunction. Recipients of a left lateral hepatic segment are at higher risk. This complication usually requires retransplantation.

Biliary complications, either leak or obstruction, occur in 15–35% of patients after OLT with an associated mortality of less than 5% [45]. Bile leaks typically occur in the first month after OLT, and often require a surgical repair. Symptoms and signs of a bile leak may be minimal, but may include fever, abdominal pain, peritonism, bile in the abdominal drains, leucocytosis and elevations in the levels of bilirubin and alkaline phosphatase. Cholangiography is usually required for diagnosis. Intervention may require suturing, revision of anastomosis or conversion to a choledochojejunostomy. Recently, however, endoscopy has been employed to stent bile leaks. Biliary obstruction normally occurs later than bile leaks typically occur, is usually related to stricture formation and may frequently be managed with endoscopic or radiological techniques. When an obstruction does occur early in the postoperative period, it may be due to kinking or migration of a T-tube stent.

Rejection

While rejection is common after OLT, it is usually not seen during the first week after transplantation. When early rejection does happen, it occurs in patients with pre-existing antibodies who have received an ABO-incompatible donor graft or exhibited a strongly positive cross-match. Elevations in the serum bilirubin or transaminases with or without fever and malaise are the presenting features. If a T-tube has been left for biliary drainage, the bile output will decrease and the character of the bile will change. The diagnosis is confirmed by percutaneous or transjugular liver biopsy. Most centres treat an acute episode of mild to moderate rejection with high-dose intravenous corticosteroids. Of the 15–20% of patients who fail to respond to steroids alone, most receive antilymphocyte therapy. Late-onset acute rejection is more common, and most often caused by inadequate T-cell suppression. Chronic rejection typically occurs after the fourth week, and is characterized by ductopenic rejection and progressive graft dysfunction.

Neurological issues

One-fifth of OLT recipients will have some degree of neurological dysfunction in the perioperative period [26,46]. Decreased level of consciousness is the most common disturbance, but seizures, focal neurological disturbances and neurological catastrophes such as herniation of brain contents may occur. Most OLT recipients will awaken over a period of hours after the surgical procedure, provided the hepatic allograft is functioning. The choice and dose of intraoperative anaesthetic agents contribute to the speed of awakening [22]. Patients with preoperative encephalopathy will take longer to awaken, as will those who have been on infusions of sedative medications (especially benzodiazepines) prior to transplantation. Additionally, the liver impairment caused by a poorly functioning allograft will exacerbate hepatic encephalopathy. Flumazenil may be used as a diagnostic test for benzodiazepine effect or hepatic encephalopathy.

Central pontine myelinolysis (CPM) is a devastating complication associated with rapid alterations of serum sodium and osmolality [1]. Fortunately, this disorder is uncommon, and has been even more uncommon recently because of increased awareness and a reduction in the use of sodium bicarbonate. If a buffering agent is required, a non-sodium agent such as THAM may be used preferentially. CPM is diagnosed by magnetic resonance imaging, and treatment is essentially supportive in

nature. Patients transplanted for fulminant hepatic failure will typically awaken slowly after OLT due to pre-existing hepatic encephalopathy and cerebral oedema. If intracranial pressure monitoring was initiated, it should be continued into the postoperative period until the patient shows evidence of awakening [20].

Acute deteriorations in mental status after an initially normal course should prompt a review of the patient's medications, including levels of immunosuppressants. Calcineurin inhibitors may cause an acute confusional state, restlessness, tremor and seizures. Seizures are most common during the first 2 weeks after transplantation, and occur as a result of drugs (e.g. tacrolimus, ciclosporin), intracranial catastrophes (e.g. haemorrhage), electrolyte abnormalities or infectious processes (e.g. encephalitis, meningitis or brain abscess).

Metabolic issues immediately after liver transplantation

The most common metabolic abnormality encountered in the perioperative care of a patient undergoing OLT is hyperglycaemia. Secretion of endogenous catecholamines and glucocorticoids in response to surgical stress, the administration of exogenous corticosteroids for induction of immunosuppression and the insulin resistance associated with liver failure result in elevated plasma glucose levels. The adverse effects of elevated glucose have been demonstrated [47], although data specific to the liver transplant population are lacking. It is our practice to use insulin, often by continuous infusion, to maintain normoglycaemia. However, caution must be exercised in the setting of marginal graft function to avoid hypoglycaemia.

The perioperative administration of large amounts of packed red blood cells may cause hypocalcaemia due to citrate chelation. Data from living liver donors suggest that phosphate repletion may also be required for regeneration of liver parenchyma, especially in those who have received split grafts [48].

More than half the patients awaiting OLT have moderate to severe protein calorie malnutrition. Positive protein balance is difficult to attain in the immediate postoperative period [49]. As most patients have a brisk return of gastrointestinal function after liver transplant, oral intake is initiated as soon as possible. In some centres, nasogastric or nasojejunal feeding is initiated immediately after transplant. If possible, total parenteral nutrition is avoided because of the risk of line sepsis, steatotic hepatitis and the desire to preserve gut mucosal integrity in an effort to avoid bacterial 'translocation'.

Infectious issues immediately after liver transplantation

The primary cause of death after liver transplantation is infection. The majority of post-transplant infections primarily affect either the abdominal cavity or the lungs. The causative agent (bacterial, viral, fungal or parasitic) is determined by the patient's underlying conditions and when in the post-transplant course the infection occurs. In the immediate perioperative period, bacterial and fungal infections predominate. Prophylactic antibiotics (typically a third-generation cephalosporin) are administered intraoperatively to decrease the incidence of intra-abdominal and wound infections. Early respiratory infections may be caused by Gram-negative enteric organisms or fungi such as *Candida* species [50]. Ventilator-associated pneumonia should be investigated promptly with bronchoscopy and bronchoalveolar lavage, ensuring the identification of otherwise uncommon organisms that can infect the immunocompromised host.

Summary

Liver transplantation is a major surgical procedure that has become 'routine'. Current intraoperative and immediate postoperative care usually allows patients to leave the intensive care unit within 24 h of transplantation. However, in the absence of a well-functioning graft, in patients who had preoperative decompensation and in those who have intraoperative difficulties, the perioperative course can be very problematic. A well-functioning, multidisciplinary team using modern anaesthetic and critical care techniques will improve the chances of a good outcome.

References

1 Plevak DJ, Southorn PA, Narr BJ *et al.* (1989) Intensive-care unit experience in the Mayo liver transplantation program: the first 100 cases. *Mayo Clin Proc* 64(4), 433–445.

2 Mandell MS, Lezotte D, Kam I *et al.* (2002) Reduced use of intensive care after liver transplantation: influence of early extubation. *Liver Transpl* 8(8), 676–681.

3 Moller S, Henriksen JH (2002) Cirrhotic cardiomyopathy: a pathophysiological review of circulatory dysfunction in liver disease. *Heart* 87(1), 9–15.

4 Nasraway SA, Klein RD, Spanier TB *et al.* (1995) Hemodynamic correlates of outcome in patients undergoing orthotopic liver transplantation. Evidence for early postoperative myocardial depression. *Chest* 107(1), 218–224.

5 Findlay JY, Keegan MT, Pellikka PP *et al.* (2005) Preoperative dobutamine stress echocardiography, intraoperative events and intraoperative myocardial injury in liver transplantation. *Transpl Proc* 37, 2209–2213.

6 Mangano DT, Layug EL, Wallace A *et al.* (1996) Effect of atenolol on mortality and cardiovascular morbidity after noncardiac surgery. Multicenter Study of Perioperative Ischemia Research Group. [erratum appears in *N Engl J Med* (1997 Apr 3) 336(14), 1039]. *N Engl J Med* 335(23), 1713–1720.

7 Krowka MJ, Mandell MS, Ramsay MA *et al.* (2004) Hepatopulmonary syndrome and portopulmonary hypertension: a report of the multicenter liver transplant database. *Liver Transpl* 10(2), 174–182.

8 Kim BJ, Lee SC, Park SW *et al.* (2004) Characteristics and prevalence of intrapulmonary shunt detected by contrast echocardiography with harmonic imaging in liver transplant candidates. *Am J Cardiol* 94(4), 525–528.

9 Krowka MJ, Porayko MK, Plevak DJ *et al.* (1997) Hepatopulmonary syndrome with progressive hypoxemia as an indication for liver transplantation: case reports and literature review. *Mayo Clin Proc* 72(1), 44–53.

10 Kim WR, Krowka MJ, Plevak DJ *et al.* (2000) Accuracy of doppler echocardiography in the assessment of pulmonary hypertension in liver transplant candidates. *Liver Transpl* 6(4), 453–458.

11 Ghofrani HA, Rose F, Schermuly RT *et al.* (2003) Oral sildenafil as long-term adjunct therapy to inhaled iloprost in severe pulmonary arterial hypertension. *J Am Coll Cardiol* 42(1), 158–164.

12 Channick RN, Simonneau G, Sitbon O *et al.* (2001) Effects of the dual endothelin-receptor antagonist bosentan in patients with pulmonary hypertension: a randomised placebo-controlled study. *Lancet* 358(9288), 1119–1123.

13 Kuo PC, Johnson LB, Plotkin JS *et al.* (1997) Continuous intravenous infusion of epoprostenol for the treatment of portopulmonary hypertension. *Transplantation* 63(4), 604–606.

14 Blackwell MM, Chavin KD, Sistino JJ (2003) Perioperative perfusion strategies for optimal fluid management in liver transplant recipients with renal insufficiency. *Perfusion* 18(1), 55–60.

15 Li Q, Zhou MT, Wang Y *et al.* (2004) Effect of insulin on hyperkalemia during anhepatic stage of liver transplantation. *World J Gastroenterol* 10(16), 2427–2429.

16 Findlay JY, Rettke SR, Ereth MH *et al.* (2001) Aprotinin reduces red blood cell transfusion in orthotopic liver transplantation: a prospective, randomized, double-blind study. *Liver Transpl* 7(9), 802–807.

17 Xia VW, Steadman RH (2005) Antifibrinolytics in orthotopic liver transplantation: current status and controversies. *Liver Transpl* 11(1), 10–18.

18 Planinsic RM, Nicolau-Raducu R, Eghtesad B *et al.* (2004) Diagnosis and treatment of intracardiac thrombosis during orthotopic liver transplantation. *Anesth Analg* 99(2), 353–356.

19 Ramsay MA, Randall HB, Burton EC (2004) Intravascular thrombosis and thromboembolism during liver transplantation: antifibrinolytic therapy implicated? *Liver Transpl* 10(2), 310–314.

20 Daas M, Plevak DJ, Wijdicks EF *et al.* (1995) Acute liver failure: results of a 5-year clinical protocol. *Liver Transpl Surg* 1(4), 210–219.

21 Schumann R (2003) Intraoperative resource utilization in anesthesia for liver transplantation in the United States: a survey. *Anesth Analg* 97(1), 21–28.

22 Findlay JY, Jankowski CJ, Vasdev GM *et al.* (2002) Fast track anesthesia for liver transplantation reduces postoperative ventilation time but not intensive care unit stay. *Liver Transpl* 8(8), 670–675.

23 Sessler DI (2000) Perioperative heat balance. *Anesthesiology* 92(2), 578–596.

24 Dodek P, Keenan S, Cook D *et al.* (2004) Evidence-based clinical practice guideline for the prevention of ventilator-associated pneumonia. *Ann Intern Med* 141(4), 305–313.

25 Brokelman W, Stel AL, Ploeg RJ (1999) Risk factors for primary dysfunction after liver transplantation in the University of Wisconsin solution era. *Transpl Proc* 31(5), 2087–2090.

26 Humar A, Gruessner R, Payne W (2003) Critical care of the liver transplant recipient. In: Irwin R, Rippe J (eds) *Irwin and Rippe's Intensive Care Medicine*, 5th edn. Philadelphia: Lippincott Williams and Wilkins, pp. 2009–2025.

27 Plotkin JS, Benitez RM, Kuo PC *et al.* (1998) Dobutamine stress echocardiography for preoperative cardiac risk stratification in patients undergoing orthotopic liver transplantation. *Liver Transpl Surg* 4(4), 253–257.

28 Williams K, Lewis JF, Davis G *et al.* (2000) Dobutamine stress echocardiography in patients undergoing liver transplantation evaluation. *Transplantation* 69(11), 2354–2356.

29 Sampathkumar P, Lerman A, Kim BY *et al.* (1998) Post-liver transplantation myocardial dysfunction. *Liver Transpl Surg* 4(5), 399–403.

30 Carton EG, Plevak DJ, Kranner PW *et al.* (1994) Perioperative care of the liver transplant patient: Part 2. *Anesth Analg* 78(2), 382–399.

31 Ferrer M (2005) Non-invasive ventilation as a weaning tool. *Minerva Anesthesiol* 71(6), 243–247.

32 Frustos-Vivar F, Esteban A, Paezteguia C *et al.* (2005) Outcome of mechanically ventilated patients who require a tracheostomy. *Crit Care Med* 33(2), 290–298.

33 Hoeper MM, Krowka MJ, Strassburg CP (2004) Portopulmonary hypertension and hepatopulmonary syndrome. *Lancet* 363(9419), 1461–1468.

34 Schenk P, Madl C, Rezaie-Majd S *et al.* (2000) Methylene blue improves the hepatopulmonary syndrome. *Ann Intern Med* 133(9), 701–706.

35 Brussino L, Bucca C, Morello M *et al.* (2003) Effect on dyspnoea and hypoxaemia of inhaled N(G)-nitro-L-arginine methyl ester in hepatopulmonary syndrome. *Lancet* 362(9377), 43–44.

36 Findlay JY, Harrison BA, Plevak DJ *et al.* (1999) Inhaled nitric oxide reduces pulmonary artery pressures in portopulmonary hypertension. *Liver Transpl Surg* 5(5), 381–387.

37 Ramsay MA, Spikes C, East CA *et al.* (1999) The perioperative management of portopulmonary hypertension with nitric oxide and epoprostenol. *Anesthesiology* 90(1), 299–301.

38 Ware LB, Matthay MA (2000) The acute respiratory distress syndrome (see comment). *N Engl J Med* 342(18), 1334–1149.

39 Gajic O, Moore SB (2005) Transfusion-related acute lung injury. *Mayo Clin Proc* 80(6), 766–770.

40 The Acute Respiratory Distress Syndrome Network (2000) Ventilation with lower tidal volumes as compared with traditional tidal volumes for acute lung injury and the acute respiratory distress syndrome. *N Engl J Med* 342(18), 1301–1308.

41 Gines P, Guevara M, Arroyo V *et al.* (2003) Hepatorenal syndrome. *Lancet* 362(9398), 1819–1827.

42 Eisenach JC, Plevak DJ, Van Dyke RA *et al.* (1989) Comparison of analgesic requirements after liver transplantation and cholecystectomy. *Mayo Clin Proc* 64(3), 356–359.

43 van Saene HK, Silvestri L, Bams JL *et al.* (2003) Selective decontamination of the digestive tract: use in liver transplantation is evidence based. *Crit Care Med* 31(5), 1600–1601.

44 Cavallari A, Vivarelli M, Bellusci R *et al.* (2001) Treatment of vascular complications following liver transplantation: multidisciplinary approach. *HepatoGastroenterology* 48(37), 179–183.

45 Tung BY, Kimmey MB (1999) Biliary complications of orthotopic liver transplantation. *Dig Dis* 17(3), 133–144.

46 Wijdicks EF (1995) Impaired consciousness after liver transplantation. *Liver Transpl Surg* 1(5), 329–334.

47 van den Berghe G, Wouters P, Weekers F *et al.* (2001) Intensive insulin therapy in the critically ill patients. *N Engl J Med* 345((19), 1359–1367.

48 Pomposelli JJ, Pomfret EA, Burns DL *et al.* (2001) Life-threatening hypophosphatemia after right hepatic lobectomy for live donor adult liver transplantation. *Liver Transpl* 7(7), 637–642.

49 Nompleggi DJ, Bonkovsky HL (1994) Nutritional supplementation in chronic liver disease: an analytical review. *Hepatology* 19(2), 518–533.

50 Aduen JF, Hellinger WC, Kramer DJ *et al.* (2005) Spectrum of pneumonia in the current era of liver transplantation and its effect on survival. *Mayo Clin Proc* 80(10), 1303–1306.

25.4 Immunosuppression

James Neuberger

Introduction

Current concepts in immunosuppression

In the early days of liver transplantation, immunosuppression strategies for liver allograft recipients were extrapolated from renal transplantation, but it rapidly became clear that different paradigms were needed: for example, in liver transplantation, in contrast to renal transplantation, early acute treated rejection has no demonstrable adverse impact on the outcome; indeed, as discussed below, early rejection may promote tolerance.

Efforts to induce immunosuppression have focused on pharmacological agents: physical methods of preventing or treating rejection (such as removal of leukocytes by leucophoresis, irradiation, thoracic duct drainage, photophoresis after lymphocyte priming and plasmaphoresis) are, though effective, not greatly used in human liver transplantation.

With increasing experience and greater awareness of the long-term adverse impact of immunosuppression and the availability of newer classes of drugs, immunosuppression regimes are changing. The concept of tailoring immunosuppression to the individual is slowly becoming accepted as a reality rather than a concept.

Newer concepts of immunosuppression

The early approach to immunosuppression was based on a heavy induction protocol followed by maintenance therapy, initially with corticosteroids and azathioprine. The introduction of ciclosporin and, subsequently, of tacrolimus has been hailed as a major advance in therapy and has coincided with increased patient and graft survival. More recently, however, attention has focused on reducing immunosuppression and fostering tolerance.

The introduction of tolerance (stable and normal graft function in the absence of immunosuppression) has long been a goal of transplant clinicians and scientists. Tolerance can be fairly readily achieved in the lower animals, such as rats and mice, but induction of tolerance in primates and humans is some way from clinical practice. While liver allograft recipients require less immunosuppression than other organ recipients and some do become tolerant to their graft (see below), there is, as yet, no regime that will reliably induce tolerance in the human host.

WOFIE, prope tolerance and MIST

As an alternative to tolerance, another approach has been to induce partial tolerance so that less immunosuppression can be administered. Calne [1] first drew attention to the window for immunological engagement (WOFIE), suggesting that, if the host immune system is allowed to see graft antigens, tolerance can be encouraged; thus, overimmunosuppression soon after transplantation can lead to a greater need for immunosuppression. This has been tested in some human allografts with encouraging findings. An alternative approach has been to use tolerogenic strategies: Calne [2] has termed this 'prope' tolerance and Monaco [3] 'minimal immunosuppression tolerance' (MIST). Although preliminary encouraging results have been obtained using, for example, Campath-1H, this still remains to be used widely.

Immunosuppression regimes

There is no general consensus as to the optimal immunosuppressive regime; units have developed their own practice, largely based on experience. There have been relatively few large-scale, prospective and randomized studies, primarily because of logistic problems. Such trials are difficult and expensive to set up and need to include a large cohort of patients; relevant endpoints are difficult to define and will not be reached for several years, by which time newer agents will be available, making the findings redundant. Newer agents tend to be much more expensive than the older agents, such as corticosteroids and azathioprine. Therapeutic studies need to include economic as well as therapeutic evaluations.

There remains no standard measure in clinical use to assess the degree of immunosuppression: therapeutic drug monitoring is helpful for some drugs [such as the calcineurin inhibitors (CNI) and sirolimus], but blood levels should be considered as a

guide. It cannot be assumed that drug levels in the therapeutic range will protect against toxicity.

Over the last decade, there has been a change in the immunosuppression regimens used, although there is little evidence to show a benefit [4]. The very early programmes used induction with antilymphocyte preparations such as OKT3 and maintenance with corticosteroids and azathioprine. More recently, induction therapy has been replaced with anti-IL-2R (interleukin-2 receptor) antibodies; a calcineurin inhibitor (initially ciclosporin and more recently tacrolimus) is added. Mycophenolate or sirolimus is replacing azathioprine in many units. Corticosteroids can usually be safely withdrawn after 3 months.

Induction therapy

'Heavy' induction regimes, using antilymphocyte depletion preparations such as OKT3, ALG (antilymphocyte globulin) and thymoglobulin, are being used much less frequently. However, their place is being taken by the anti-IL-2R antibodies; their use may allow delayed introduction of the CNI and so reduce the risk of nephrotoxicity.

Maintenance

A variety of maintenance regimes are in place: the most common regimes include tacrolimus, often combined with one or two more agents such as corticosteroids and azathioprine or mycophenolate. Sirolimus is being used increasingly. There have been several prospective studies comparing tacrolimus and ciclosporin: most show a tendency for better outcomes with tacrolimus. With the recognition of the long-term problems of the CNIs (especially renal impairment and renal failure), there is a move towards the use of sirolimus, either as monotherapy or in combination with other drugs.

Treatment of acute (cellular) rejection

The treatment of acute cellular rejection will depend on many factors, especially the patient's clinical status and the severity of rejection as assessed biochemically and histologically. Mild rejection (assessed histologically) may not need treatment; moderate rejection may respond to an increase in the dose of tacrolimus. Rejection is usually treated with a bolus of high-dose steroids, such as a 3-day course of prednisolone 200 mg/day or methylprednisolone 0.5 g daily for 3 days [5]. There is no good evidence for the superiority of any one regime. Recurrent rejection may be treated by recycling steroids, use of agents such as OKT3 or even phototherapy with lymphoid depletion.

Treatment of chronic (vascular, ductopenic) rejection

There is no proven, effective treatment for established ductopenic or chronic rejection. In those on ciclosporin, transfer to tacrolimus is often tried; for those on tacrolimus, additional immunosuppression (such as mycophenolate or sirolimus) is tried.

Withdrawal of immunosuppression

It is clear that some liver allograft recipients do not require long-term treatment. There are no clear markers of those who are tolerant to the graft. Those centres that do undertake withdrawal programmes will select those who have stable and normal graft function after 5 years. Those transplanted for autoimmune diseases, such as autoimmune hepatitis, primary biliary cirrhosis (PBC) and primary sclerosing cholangitis, are less likely to be tolerant [6].

Adverse impact of immunosuppression

The benefits of immunosuppression have to be balanced against the side-effects. Such side-effects may be drug or drug class specific (see individual drugs below) or may arise as a consequence of the disturbance of the immune system, because the effects of the drugs are relatively non-specific.

General

Infection

Immunosuppressed patients are at greater risk of infections: bacterial, viral, fungal and protozoal. Presentation and response to treatment may be different in the immunosuppressed. This topic is covered in more detail elsewhere. Some agents, such as leflunomide and its derivatives, show anticytomegaloviral activity *in vitro* [7]; whether this effect is important *in vivo* is yet to be shown.

The approach of immunosuppression in those transplanted for hepatitis C virus (HCV) is covered elsewhere.

Malignancy

Sirolimus has antiproliferative activity in both cell cultures and animal models [8]. This makes the drug potentially useful in the management of transplantation for hepatocellular carcinoma. Clinical trials are under way to determine whether this effect is important *in vivo*.

Effect on recurrent disease

Viral hepatitis

There is no convincing evidence that the degree or type of immunosuppression affects the rate and impact of recurrence of hepatitis A or B viral infection. In contrast, the effect of hepatitis C viral infection of the graft is modified by the extent and choice of immunosuppression.

Primary biliary cirrhosis

Several studies have suggested that evidence of recurrent PBC is seen sooner and more aggressively in those maintained on tacrolimus compared with ciclosporin [9]. The significance of this is not certain.

Autoimmune hepatitis (AIH)
The recurrence of serological and histological features of AIH may be reduced by long-term administration of corticosteroids [10].

Need for change in immunosuppression

Factors affecting choice of immunosuppression regime

Pregnancy
Both mycophenolate and sirolimus are associated with teratogenicity and, therefore, these drugs should be avoided in those likely or wishing to become pregnant. Most of the immunosuppressive agents are excreted in breast milk, and so breastfeeding should usually be avoided, although there remains some uncertainty about the adverse effect on the baby of the drugs ingested from the milk.

Renal impairment
This is a major long-term problem in the allograft recipient. Although there are many potential causes for renal impairment in this situation, CNI are probably the commonest cause. The optimal treatment in this situation is not clear, but most units adopt an approach of reducing the CNI, with immunosuppression being covered by either mycophenolate and steroids or sirolimus.

Table 1 Pharmacological methods of immunosuppression.

Depletion of lymphocytes
Polyclonal antibodies (such as ALG, thymoglobulin)
Monoclonal antibodies (such as OKT3)
Inhibition of lymphocyte activation
Antibodies
Corticosteroids
Immunophilin-binding drugs
Calcineurin inhibitors: ciclosporin and tacrolimus
TOR inhibitors: sirolimus
Inhibition of *de novo* nucleotide synthesis
Purine synthesis inhibitors (IMPDH): mycophenolate
Pyrimidine synthesis inhibitors (DHODH): leflunomide
Antimetabolites: azathioprine, cyclophosphamide, 6-mercaptopurine
Inhibitors of lymphocyte activation/interaction
Inhibitor of trafficking: FTY720 (the future of this agent in clinical practice is uncertain)
Inhibitors of leukocyte/target cell interactions
Antibodies to IL-2R
Antibodies to ICAM-1
CTLA4 Ig

ALG, antilymphocyte globulin; IMPDH, inosine monophosphate dehydrogenase; DHODH, dihydroorotate dehydrogenase; IL-2R, interleukin-2 receptor; ICAM, intercellular adhesion molecule.

Individual agents

A classification of the pharmacological agents used in the management of immunosuppression is shown in Table 1. Please note that drug doses quoted here are a guide and should always be checked against current information and practice.

Lymphocyte depletion

These agents are used primarily in induction regimes.

Polyclonal antibodies (such as ALG and thymoglobulin) have been used in liver transplantation for many years. Thymoglobulin is a purified immunoglobulin G (IgG) fraction prepared from rabbits immunized with thymus. The antibodies react with a variety of antigens on T and B cells (including the T-cell receptor, CD2, 3, 5 and 8), monocytes, neutrophils, platelets and erythrocytes. Thymoglobulin should be administered at a dose of 1.5 mg/kg body weight over a period of 4 h (6 h for the first dose). OKT3 is a partially humanized monoclonal antilymphocyte antibody.

Monoclonal antibodies

Rituximab
This is a monoclonal antibody directed against CD20 on B lymphocytes. This antibody is used primarily for the treatment of lymphomas and in post-transplant lymphoproliferative disorder (PTLD); however, it is being used in highly sensitized renal allograft recipients and occasionally in liver allograft recipients, especially those with ABO incompatibility [11]. Administration is associated with the cytokine release syndrome and, as heart failure, hypotension and arrhythmias are associated with its use, recipients need to be carefully monitored and antihypertensive agents withheld for 12 h prior to use. Fatalities have rarely been described, and premedication with corticosteroids and antihistamines should be considered. The drug should be given in 5% glucose or 0.9% sodium chloride, diluted to 1–4 mg/mL.

Alemtuzumab (Campath-1H)
This is a monoclonal antibody reacting against CD52; administration results in depletion of lymphocytes, monocytes and dendritic cells. Administration often results in profound depletion of lymphocytes and monocytes; the reconstituted pool may not resemble that of the original composition. Currently, the antibody is licensed for use in the treatment of chronic lymphatic leukaemia. It has been used as part of an induction therapy, especially for promoting tolerance (see above). Initial studies, in a variety of organ grafts including the liver [12], show that its use is safe and effective and allows for a lower immunosuppressive regimen. The usual dose is 0.3 mg/kg/day for the first 3–4 postoperative days. As with rituximab, cytokine release syndrome may occur. The antibody should be infused in 100 mL of 5% glucose or 0.9% sodium chloride over 2 h through a low protein-binding 5-μm filter.

Inhibition of lymphocyte activation

Antibodies

Two monoclonal antibody preparations reacting with the IL-2R (CD25) are currently available. By binding to the receptor, they act to inhibit IL-2-mediated activation of lymphocytes and so prevent T-lymphocyte proliferation. The duration of action is up to 7 weeks. They are usually well tolerated. Their use may allow a reduced dose or delayed introduction of CNI and so may be beneficial in those with peritransplant renal impairment and may reduce the risk of late CNI-associated renal failure [13].

Basiliximab

This is a chimeric monoclonal antibody with high affinity for the IL-2R α-subunit. It should be given as slow intravenous injection or by slow intravenous infusion over 2 h. For adults, the dose is 20 mg before or within 2 h of surgery and at 4 days after transplantation; those weighing less than 35 kg should receive 10 mg. Concentrations should be maintained above 0.2 μg/mL to ensure saturation of the IL-2Rs of the circulating T lymphocytes, although few use therapeutic drug monitoring.

Dacluzimab

This is a humanized monoclonal antibody, also reacting with the IL-2R. The dose is 1 mg/kg before or within a few hours of surgery and at 1 week after surgery.

Corticosteroids

Corticosteroids act primarily on T-cell activation by inhibiting the production of T-cell cytokines that are required to augment the macrophage and lymphocyte response. Corticosteroids also stimulate migration of T cells from the intravascular compartment to lymphoid tissue.

Side-effects of steroids are well recognized and include cardiovascular (sodium and fluid retention, potassium depletion, hypertension), endocrine (carbohydrate intolerance, cushingoid facies, growth retardation, menstrual irregularities), ophthalmic (cataract, increased intraocular pressure, glaucoma), musculoskeletal (osteoporosis and increased fracture risk, aseptic necrosis of femoral head, myopathy and muscle weakness), dermatological (increased bruising and skin thinning, acne), neurological (altered mood, headaches) and gastrointestinal (peptic ulceration and pancreatitis).

Immunophilin-binding drugs

Calcineurin inhibitors. The two CNIs used in transplantation are ciclosporin and tacrolimus. Their mode of action is similar but not identical. Both bind to intracellular proteins (cyclophilins and FK-binding protein 12 respectively). The drug–protein complex binds to calcineurin with calmodulin and calcium, inhibiting the phosphatase activity of calcineurin. This results in the inhibition of the dephosphorylation and translocation of the cytoplasmic unit of NF-AT (nuclear factor of activated T cells) and thus inhibits gene transcription of proteins such as IL-2 and gamma-interferon. Thus, T-cell activation is inhibited.

Drug interactions may affect levels or toxicity (see Table 2). Metabolism of both CNIs is mediated through the cytochrome P-450 system (CYP3A4), and so levels may be affected by enzyme inducers and inhibitors (see Table 3).

With both drugs, therapeutic drug monitoring is required, but the correlation between levels and efficacy and toxicity is relatively weak, and levels should be used as a guide and dose adjusted according to graft function and side-effects and in the light of other immunosuppressive agents.

Table 2 Some other drug interactions with CNIs.

ACE inhibitors and angiotensin-II receptor antagonists: increased risk of hyperkalaemia
Allopurinol: may raise CNI level
Aminoglycosides: increased risk of nephrotoxicity
Colchicine: increased risk of nephrotoxicity
Fibrates: increased risk of nephrotoxicity
NSAIDs: increased risk of nephrotoxicity
Nifedepine: increased risk of gum hypertrophy with ciclosporin
Sirolimus: increases ciclosporin concentration
Statins: increased risk of myopathy with ciclosporin

ACE, angiotensin-converting enzyme; CNI, calcineurin inhibitor; NSAIDs, non-steroidal anti-inflammatory drugs.

Table 3 Some drugs and other agents that interact with CYP3A4 (CYP3A4 metabolizes ciclosporin, tacrolimus and sirolimus; some of these also induce P-glycoprotein).

Inducers
Carbamazepine
Phenytoin
Phenobarbitone
Rifampicin
St John's Wort
Inhibitors
Azole antifungals (such as ketoconazole, itraconazole)
Protease inhibitors
Cimetidine
Clarithromycin
Ciclosporin
Diltiazem
Erythromycin
Grapefruit juice
Metoclopramide
Nicardepine
Verapamil

Note: combinations of these agents (such as ciclosporin and sirolimus) will interact with each other.

Table 4 Side-effects of the calcineurin inhibitors (note that some are more common with one CNI than another).

Renal and electrolyte disturbance
Renal failure
Hyperuricaemia and gout
Hyperkalaemia
Hypermagnesaemia
Cardiovascular
Hypertension
Neurological
Migraine
Headaches
Tremor
Endocrinoligical
Diabetes mellitus/glucose intolerance
Other
Hirsutism
Gum hypertrophy

The side-effects of the two CNIs are broadly similar (see Table 4) but do differ: for example, hirsutism and gum hypertrophy is seen more frequently with ciclosporin, whereas neurological disturbance and diabetes mellitus are more common in those on tacrolimus.

Ciclosporin: there are several preparations of ciclosporin available and, while there may be bioequivalence, most authorities advise against switching between preparations. The original preparation of ciclosporin (Sandimmune) was replaced by a microemulsion formulation (Neoral), and this is associated with better absorption and less variability. The starting dose of ciclosporin is 10–15 mg/kg/day in two divided doses.

Traditionally, therapeutic dose monitoring was done using trough levels, with the guide levels of 150–250 ng/mL (whole blood levels measured by radioimmunoassay) for the first 3 months and then target levels of 100–150 ng/mL. Because the maximal effect on calcineurin inhibition correlates with the time of peak blood concentration, there has been a move to focus drug monitoring on the 2-h post-dose level (C_2 monitoring rather than C_0 monitoring). Studies have suggested a better outcome using C_2 monitoring in the first 3 months after transplantation [14]. Target trough levels at 2 h lie between 0.8–1.2 μg/mL in the first 3 months and 0.7–0.9 μg/mL thereafter.

Tacrolimus is well absorbed through the upper gastrointestinal tract, so it is rarely necessary to give this intravenously. Absorption is variable. The starting dose is 0.1 mg/kg/day in two divided doses. Most units aim for target trough whole blood levels of 10–15 ng/mL in the first 3 months and between 5 and 10 ng/mL thereafter. More recently, a modified-release formulation has been developed; this has the advantage of being a single, daily dose formulation.

Compared with ciclosporin, use of tacrolimus is associated with an increased risk of post-transplant diabetes mellitus [15]. In children, cardiac hypertrophy has been reported [16].

TOR inhibitors (TORI). At present, there are two agents that inhibit TOR (target of rapamycin): sirolimus (previously known as rapamycin) and everolimus. TORIs inhibit lymphocyte proliferation mediated by cytokines including IL-2 and IL-4. The TORIs bind to FK-binding protein but, rather than inhibiting the calcineurin pathway, interact with TOR, a protein kinase that is integral to signal transduction, regulating the synthesis of proteins required for cell cycle progression. As TORIs inhibit both T and B cells, antibody-mediated immunity is also affected. The TORIs also inhibit growth factor-stimulated cell cycle progression of vascular smooth muscle cells at the G1 stage and so may be of benefit in reducing the transplant vasculopathy seen in ischaemic/reperfusion injury and chronic rejection.

Both sirolimus and everolimus are relatively poorly absorbed from the gut (oral bioavailability about 15%); absorption is mediated via the countertransporter activity of P-glycoprotein; there is extensive metabolism through the cytochrome CYP3A4 in the liver. The half-life is long in healthy subjects (about 60 h for sirolimus and 28 h for everolimus) and longer in those with liver disease. Thus, steady state is reached in 6 days for sirolimus and 4 days for everolimus.

The recommended dose regime of sirolimus is a loading dose of 6 mg followed by 2 mg daily, with the dose adjusted to maintain trough whole blood levels between 4 and 15 ng/mL. Higher trough levels are required in those on monotherapy. The drug should be taken consistently, at the same time of day, either with or without food. Sirolimus may be used in combination with ciclosporin (4 h after taking ciclosporin) and with corticosteroids. As ciclosporin is an inhibitor of CYP3A4, lower doses of sirolimus may be required by those taking both agents. For everolimus, the initial daily dose is 1.3–3.0 mg/day with target trough levels of 3–8 ng/mL [17].

In the early use of sirolimus, there were cases of hepatic artery thrombosis, but subsequent studies have raised doubt as to whether this is a significant side-effect. Other side-effects include delayed wound healing (so that many units will delay introduction until 3 months post-transplantation) and hyperlipidaemia (both hypercholesterolaemia and hypertriglyceridaemia) [18]. Co-administration with HMG-CoA reductase inhibitors and fibrates is well tolerated. Other common (> 1%) side-effects include lymphocoele, tachycardia, venous embolism, stomatitis, abdominal pain and diarrhoea, anaemia, leucopenia, thrombocytopenia, hypokalaemia, arthralgia, hepatitis, pneumonitis, acne and urinary tract infections. Rarer but serious complications include interstitial lung disease. Photosensitivity may occur. Both drugs may exacerbate CNI-associated nephrotoxicity, but lower doses of CNI can usually be achieved.

The agent is currently not licensed in many countries for use in liver allograft recipients.

Inhibition of *de novo* nucleotide synthesis

Purine synthesis inhibitors

Mycophenolate exploits the fact that lymphocytes, unlike other cells, do not have a salvage pathway for the synthesis of purines. Thus, mycophenolate inhibits T- and B-cell proliferation by inhibition of *de novo* purine synthesis by inhibition of the enzyme inosine monophosphate dehydrogenase. The effect is to block synthesis of the guanosine nucleotide; there is a cytostatic effect on lymphocytes, inhibiting mitogen- and alloantigen-induced stimulation as well as inhibiting antibody production, adhesion to endothelial cells and, possibly, cell recruitment.

Mycophenolate is available in two formulations: an enteric-coated formulation of mycophenolate or as an ester (mycophenolate mofetil; MMF). There is little to choose between the two preparations, although some suggest that gastrointestinal upset is less common with the enteric-coated formulation. The usual maintenance dose for mycophenolate is 1880 mg/day and for MMF 2 g/day, both given in two or three divided doses.

Intravenous administration may be indicated in the first 5 days after transplantation to establish adequate drug levels. If the drug is given orally, then most centres will start at half-dose and increase if there are no side-effects.

Monotherapy with mycophenolate may be associated with chronic rejection, so most will use the agent in conjunction with either a CNI or corticosteroids [19].

Therapeutic drug monitoring is available but not commonly used. Patients should be monitored for neutropenia and the dose reduced or stopped if the absolute white cell count falls below 1.3×10^9/L. Significant side-effects include diarrhoea (in 15%), leucopenia (in 10%) and hyperlipidaemia; other side-effects include gastrointestinal tract perforation, haematuria, peripheral oedema and hypersensitivity. Drug interactions include acyclovir and Probenicid competing with renal excretion, cholestyramine and some antacids impairing adsorption.

Pyrimidine synthesis inhibitors (DHODH)

Leflunomide

Leflunomide is available for use in patients with rheumatoid arthritis; the agent has been used in transplantation. The active metabolite, A77172G, has a very long half-life (1–4 weeks). In those with arthritis, the loading dose is 100 mg daily for 3 days with a maintenance dose of 10–20 mg once daily. Side-effects are few and include modest increase in blood pressure, mild gastrointestinal upset, reversible alopecia, leucopenia and hepatitis. Stevens–Johnson syndrome may develop. Full blood count and liver function monitoring needs to be done. FK778 is a synthetic malononitrilamide that is currently being evaluated in liver allograft recipients.

Antimetabolites

Azathioprine

Azathioprine has been used for many years; the drug may be given orally or intravenously. The usual dose is 1–2 mg/kg/day as a single dose. Azathioprine is metabolized by thiopurine methyltransferase (TMT) to 6-mercaptopurine (6-MP) (an analogue of the purines, hypoxanthine and adenine) and then further metabolized to thioinosine monophosphate; this inhibits the synthesis of DNA precursor molecules and so interferes with nucleic acid synthesis during clonal expansion. Those with low levels of TMT are at greater risk of toxicity. Some centres will type the activity of TMT before the administration of azathioprine.

Side-effects of azathioprine include leucopenia (which may be significant in about 15% of cases), hepatotoxicity (especially veno-occlusive disease), pancreatitis, pneumonitis and megaloblastosis. After initiation of treatment, the white blood cell count should be monitored every 2 weeks and dose reduction instituted if the white count falls. Drug interactions are few, but allopurinol should be avoided because of the increased risk of bone marrow suppression. Angiotensin-converting enzyme (ACE) inhibitors should be used with caution.

Either cyclophosphamide or 6-MP may be administered in place of azathioprine. Cyclophosphamide interferes with cross-linking of DNA and so interferes with cell division. Side-effects include bone marrow suppression, haemorrhagic cystitis, pulmonary fibrosis and occasional cardiac toxicity.

6-MP also competes with guanine and hypoxanthine and so inhibits *de novo* ribonucleotide synthesis. Side-effects include bone marrow suppression, hepatotoxicity, mouth ulcers and skin rashes.

Mizoribine

Administered at a dose of 2 mg/kg/day, the antimetabolite mizoribine is a safe and effective agent used in combination with other immunosuppressive drugs.

Inhibitors of lymphocyte activation/interaction

Inhibitor of trafficking

FTY720 (Fingolimod) is a potent agonist of the spingosine-1-phosphate receptor (SIPR) [20]. The effect of FTY is to sequester lymphocytes in the lymph nodes away from the allograft and sites of inflammation. The agent also induces apoptosis in activated lymphocytes. More recently, it has been shown that FTY has antiangiogenic properties, making it a potentially valuable agent in the immunosuppression of those transplanted for hepatocellular carcinoma. In contrast to conventional immunosuppressive agents, it does not affect the activation, proliferation or effector functions of either B or T lymphocytes. In animal models, the agent is also effective in preventing the effects of

ischaemia/reperfusion injury. Preliminary studies in a variety of organ allograft recipients suggest that the agent is effective in maintaining graft function, at doses of 2.5–5 mg/day.

Side-effects include bradycardia because of the presence of the SIPR on atrial myocytes.

Inhibitors of leukocyte/target cell interactions

Antibodies to intercellular adhesion molecule (ICAM)-1 have not had a major effect in human liver transplantation. In animal models, antibodies to CTLA4 (CTLA4 Ig; Belatacept) have shown promise, and early human studies are suggesting encouraging results.

Conclusions

Greater understanding of the mechanisms of allograft tolerance and rejection and a greater range of therapeutic agents have allowed clinicians a greater opportunity to prevent and treat immune-mediated damage to the liver allograft. Recognition of the complications and side-effects of immunosuppressive regimes and individual agents will allow the clinician greater flexibility in tailoring immunosuppression to the individual and further tip the balance between efficacy and toxicity, to the patient's benefit.

References

1 Calne RY (1996) WOFIE hypothesis: some thoughts on an approach toward allograft tolerance. *Transplant Proc* 28, 1152.

2 Calne RY (2005) Prope tolerance – the future of organ tolerance from the laboratory to the clinic. *Int Immunopharmacol* 5, 163–167.

3 Monaco AP (2004) The beginning of clinical tolerance in solid organ allografts. *Exp Clin Transplant* 2, 153–161.

4 Shapiro R, Young JB, Milford EL *et al.* (2005) Immunosuppression: evolution in practice and trend, 1993–2003. *Am J Transpl* 5, 874–886.

5 Neuberger J (1999) Incidence, timing and risk factors for acute and chronic rejection. *Liver Transpl Surg* 5, S30–S36.

6 Girlanda R, Rela M, Williams R *et al.* (2005) Long-term outcome of immunosuppression withdrawal after liver transplantation. *Transplant Proc* 37, 1708–1709.

7 Zeng H, Waldmann WJ, Yin DP *et al.* (2005) Mechanistic study pf malononitrileamide FK778 in cardiac transplantation and CMV infection in rats. *Transplantation* 79, 17–22.

8 Schumacher G, Oidtmann M, Rueggeberg A *et al.* (2005) Sirolimus inhibits growth of human hepatoma cells alone or combined with tacrolimus, while tacrolimus promotes cell growth. *World J Gastroenterol* 11, 1420–1425.

9 Neuberger J, Gunson B, Hubscher SG *et al.* (2004) Immunosuppression affects the rate of recurrent primary biliary cirrhosis after transplantation. *Liver Transpl* 10, 488–491.

10 Duclos-Vallee JC, Sebagh M, Rifai K *et al.* (2003) A 10-year follow-up study of patients transplanted for autoimmune hepatitis: histological recurrence precedes clinical and biochemical recurrence. *Gut* 52, 893–897.

11 Usuda M, Fujimori K, Koyamada N *et al.* (2005) Successful use of anti-CD(20 monoclonal antibody (rituximab) for ABO-incompatible living-related liver transplantation. *Transplantation* 79, 12–16.

12 Marcos A, Eghtesad B, Fung JJ *et al.* (2004) Use of alemtuzamab and tacrolimus monotherapy for cadaveric liver transplantation: with particular reference to hepatitis C virus. *Transplantation* 78, 966–971.

13 Langrehr JM, Glaneman M, Guckelberger O *et al.* (1998) A randomised, placebo-controlled trial with anti-leukin-2 receptor antibody for immunosuppressive induction therapy after liver transplantation. *Clin Transpl* 12, 303–312.

14 Levy G, Villamil F, Samuel D *et al.* on behalf of the LIS2T Study Group (2004) Results of LIS2T, a multi-center, randomized study comparing cyclosporine microemulsion and C_2 monitoring and tacrolimus with C_0 monitoring in *de novo* liver transplantation. *Transplantation* 77, 1632–1638.

15 Marchetti P (2005) New-onset diabetes after liver transplantation: from pathogenesis to management. *Liver Transpl* 11, 612–620.

16 Bueon OF, van Rooij E, Molkentin JD *et al.* (2002) Calcineurin and hypertrophic heart disease: novel insights and remaining questions. *Cardiovasc Res* 53, 806–821.

17 Ponticelli C (2005) Clinical experience with everolimus (Certican): a summary. *Transplantation* 79, S93–S94.

18 Montalbano M, Neff GW, Yamashiki N *et al.* (2004) A retrospective review of liver transplant patients treated with sirolimus from a single center: an analysis of sirolimus-related complications. *Transplantation* 78, 264–268.

19 Stewart SF, Hudson M, Talbot D *et al.* (2001) Mycophenolate mofetil monotherapy in liver transplantation. *Lancet* 24, 609–610.

20 Kovarik JM, Schmouder RL, Slade AJ (2004) Overview of FTY720 clinical pharmacokinetics and pharmacology. *Ther Drug Monit* 26, 585–587.

25.5 Recurrent disease and management in liver transplantation

Xavier Forns and Antoni Rimola

Many diseases can recur after liver transplantation (LT). This chapter deals with the recurrence of non-malignant diseases in the graft (Table 1).

Recurrence of hepatitis B

In patients undergoing LT for hepatitis B virus (HBV)-related liver disease, infection of the graft is caused by residual circulating HBV particles or by newly produced virus from extrahepatic sites. Before the use of prophylactic strategies, HBV recurrence after transplantation was common and frequently led to graft loss. At that time, survival after transplantation was only 50% at 5 years and, consequently, HBV infection was considered to be a controversial indication for LT [1].

HVB replication status before LT is the most relevant factor implicated in infection recurrence. Without prophylaxis, HBV infection recurs in more than 80% of hepatitis B surface antigen (HBsAg)-positive patients with active replication (presence of HBeAg and detectable HBV DNA by hybridization techniques). When HBV DNA is not detected by hybridization methods, the risk of recurrence declines to around 50% [2]. This explains the different rates of infection recurrence observed in patients undergoing LT for HBV-related cirrhosis (around 70%) compared with patients transplanted for fulminant hepatitis B (less than 20%) or HDV-related cirrhosis (30%).

During the past 15 years, there has been a significant improvement in patient and graft survival as a result of the use of long-term hepatitis B immune globulin (HBIG) and, more recently, the availability of effective and well-tolerated antiviral agents. As a result of these therapies, the long-term outcome of patients undergoing LT for HBV-related liver disease is similar or even better than that of patients undergoing transplantation for other indications.

Table 1 Recurrent non-malignant diseases after liver transplantation.

Viral diseases
Hepatitis B
Hepatitis C
Autoimmune liver diseases
Primary biliary cirrhosis
Primary sclerosing cholangitis
Autoimmune hepatitis
Alcoholic liver disease
Non-alcoholic fatty liver disease
Other
Budd–Chiari syndrome
Genetic haemochromatosis
Sarcoidosis
Erythropoietic protoporphyria
Nodular regenerative hyperplasia
Giant cell hepatitis

The patient with HBV-related liver disease before LT

The negative impact of HBV recurrence after LT on patient and graft survival makes it imperative to treat patients with active HBV replication before transplantation, with the goal of achieving inhibition of viral replication to undetectable HBV DNA levels [3,4]. Current HBV DNA quantification assays are polymerase chain reaction (PCR) based and, therefore, more sensitive than a few years ago (10^2–10^3 copies/mL). The appearance of nucleoside analogues with potent antiviral activity against HBV has been crucial for this group of patients. Lamivudine shows a very favourable safety profile as it is well tolerated even in patients with advanced liver disease. Around 70% of patients achieve HBV DNA negativization using monotherapy for a short period of time, and it is effective in both HBeAg-positive and HBeAg-negative patients. Moreover, in patients with end-stage liver disease awaiting LT, treatment with lamivudine can markedly improve liver function and, in some cases, this is sufficient to reconsider the indication for LT [5,6]. The latter usually occurs after at least 6 months of therapy. The main limitation of lamivudine is the appearance of resistant mutants, which occurs at a rate of 15–20% per year of therapy. Although lamivudine-resistant mutants do not usually worsen liver function, they can increase the probability of recurrent hepatitis B

after LT. In addition, mutations in the polymerase gene may affect the amino acid sequence of the envelope protein and decrease the efficacy of HBIG [3,4]. Importantly, other antiviral agents such as adefovir dipivoxil can be used in patients who develop lamivudine-resistant mutants. Compared with lamivudine, the emergence of resistant mutants is less frequent with adefovir (2–3% per year). Treatment with adefovir is also associated with stabilization or improvement in liver function [7]. The main limitation of adefovir is its renal toxicity but, with dose adjustments and close renal function monitoring, renal failure is rare.

When treating patients with active HBV replication before transplantation, it is important to consider the best timing of initiation of antiviral therapy [3,4]. For patients with high levels of HBV DNA who are expected to undergo transplantation within a few months, an agent with a high antiviral activity such as lamivudine seems to be adequate, whereas adefovir seems to be better in individuals expected to be on long-term antiviral therapy to minimize the selection of mutants. Obviously, in patients with primary resistance or those who develop resistance during treatment, the antiviral should be changed or another antiviral agent should be added. Although it remains a matter of discussion, it is likely that the use of combination treatment will replace monotherapy in order to minimize the risk of disease recurrence. The appearance of new antiviral agents with powerful activity against HBV (entecavir, tenofovir) will certainly facilitate such a strategy.

The patient with HBV-related liver disease after LT

After transplantation, there are several approaches to minimize the probability of HBV recurrence. The basis of all these strategies is the use of HBIG, which has been shown significantly to reduce the rate of HBV recurrence [8]. Despite the use of HBIG, detection of HBV replication (by hybridization assays) at the time of transplantation is associated with a high rate of recurrence, stressing the relevance of antiviral therapy before LT [2,8]. The most accepted protocol of passive immunoprophylaxis with HBIG is the administration of 10 000 IU intravenously during the anhepatic phase and daily for the first week after LT (the latter could be adjusted to maintain titres of anti-HBs antibody above 500 IU/L). After the first week, HBIG is administered monthly (usually at a dose of 10 000 IU) to maintain serum titres above 100–150 IU/L. Whether fixed doses of HBIG are better than doses adjusted according to anti-HBs levels is not clearly established, although the latter strategy could be cost-effective given the high cost of the immune globulin preparations. Moreover, protective anti-HBs levels (> 100 IU/L) can be achieved by long-term intramuscular administration of HBIG, which reduces the cost of this prophylactic therapy [3,4]. Failure of HBIG may be explained by inadequate anti-HBs levels to neutralize the circulating virions or by the appearance of escape mutants in the pre-S/S region. The latter has been shown to correlate with the levels of HBV replication and the duration of HBIG prophylaxis [9].

As lamivudine monotherapy was associated with high rates of HBV recurrence after transplantation, several groups explored the efficacy of combined HBIG plus lamivudine as a prophylactic regimen. This combination reduces recurrence rates of HBV infection to 0–15% and, therefore, it is currently used routinely in most transplant programmes [4]. In most instances, lamivudine is initiated before LT in patients with detectable HBeAg and/or HBV DNA. In patients in whom lamivudine-resistant mutants appear before LT, the administration of higher doses of HBIG is probably necessary to prevent infection recurrence.

One of the most controversial issues is the duration of prophylactic therapy after LT. As the cost of continuous HBIG administration is very high, many studies have evaluated the efficacy of HBIG discontinuation followed by the administration of lamivudine. In general, discontinuation of HBIG 6–24 months after LT followed by lamivudine monotherapy seems to be a safe strategy in patients without HBV replication before LT [3,4]. Available data suggest that HBIG withdrawal as early as 1 month after the initiation of combined therapy followed by lamivudine monotherapy is an effective approach in patients without HBV replication before LT [10]. In patients with detectable HBV DNA before LT, it may be necessary to prolong HBIG administration further, although the optimal duration of HBIG administration remains unknown. As low levels of HBV replication can be detected by sensitive PCR methods, lamivudine should be continued for life once HBIG is discontinued.

The use of lamivudine for long-term prophylaxis of HBV infection can also be combined with HBV vaccination. The results of HBV vaccination in liver transplant recipients are controversial and, with the currently available vaccines, this strategy is feasible in selected patients: serum HBV DNA negative prior to LT, prolonged time from LT, low doses of immunosuppressive drugs and undetectable HBV DNA at initiation of vaccination [3,4]. Patients achieving protective anti-HBs titres after HBV vaccination may stop lamivudine therapy and, if necessary, receive vaccine boosts to maintain protective anti-HBs levels.

The patient with HBV infection recurrence after LT

The availability of safe and effective oral antiviral drugs makes HBV recurrence a less relevant problem today than it was years ago. The cause of HBV infection after LT may be an inadequate prophylactic regimen or its failure, or *de novo* HBV infection. In the latter case, the use of anti-HBc-positive donors is associated with an increased risk of HBV reactivation, particularly in recipients without HBV infection markers (anti-HBc, anti-HBs). Selection of the best treatment depends on the presence or absence of drug-resistant mutants and the treatment received previously [3,4]. Treatment must be initiated quickly because of the rapid evolution of histological damage in the setting of immunosuppression. Lamivudine is the most widely used

nucleoside analogue in cases of HBV recurrence after transplantation, and it is associated with loss of HBV DNA and clinical amelioration in a substantial proportion of treated patients. The development of resistance is a major drawback and, given the need for long-term (possibly lifelong) treatment, drug combinations appear to be the best strategies in these cases. The use of adefovir requires dose adjustments because of the high prevalence of renal failure in transplant recipients, but several studies have shown that its use is safe in this situation. In the case of anti-HBc-positive donors, lamivudine prophylaxis is advisable if the recipient has no previous markers of HBV infection.

Recurrence of hepatitis C

Chronic hepatitis C virus (HCV) infection is the main cause of cirrhosis and hepatocellular carcinoma in the western world and Japan and, therefore, the main indication for LT. Regrettably, recurrence of HCV infection is almost universal after LT, and it has become the most relevant problem in transplant programmes.

Natural history of HCV recurrence after LT

Virological recurrence is a very early and constant event after LT [11] (Fig. 1). Acute hepatitis is commonly diagnosed by elevation of liver enzymes occurring between 1 and 4 months after transplantation; biopsy specimens usually show lobular hepatitis. As spontaneous clearance does not occur in the setting of LT, evolution to chronic hepatitis is the rule. One of the main characteristics of HCV infection in LT recipients is the accelerated course of the disease compared with immunocompetent individuals. In fact, chronic hepatitis leading to cirrhosis has emerged as the most relevant problem of patients undergoing LT for HCV-related cirrhosis (Fig. 2). In some geographical areas, as many as one-third of patients develop cirrhosis 5–7 years after transplantation [12,13]. Moreover, clinical decompensation occurs early once cirrhosis is established, with a cumulative probability greater than 30% only 12 months after the diagnosis of cirrhosis in the graft. Importantly, patient survival drops below 50% 1 year after decompensation [14]. In some patients, a particularly aggressive form of HCV infection recurrence (fibrosing cholestatic hepatitis) characterized by biochemical cholestasis, extremely high viral load and fibrosis expanding within the hepatic sinusoid develops shortly after transplantation. Unless response to antiviral therapy is achieved, this form of disease recurrence leads to graft loss (and patient death) within weeks or months.

Early reports failed to demonstrate any difference in survival between HCV-infected and non-infected patients after LT. However, in the largest study performed so far, a retrospective cohort study of 11 036 patients who underwent 11 791 liver transplants between 1992 and 1998, Forman *et al.* [15] demonstrated a significant decrease in both patient and allograft survival in HCV-infected patients. Patient survival rate with HCV infection was 78% and 70% at 3 and 5 years, respectively, compared with 82% and 77% among patients without HCV infection ($P < 0.001$).

Owing to the low efficacy and high incidence of severe adverse effects of antiviral therapy in the setting of LT, it is important to identify the patients at greater risk of developing severe HCV recurrence. There are numerous studies aimed at identifying variables predicting severe HCV infection recurrence after transplantation. Most of these studies are retrospective, include a limited number of patients and, more importantly, lack a clear definition of severe recurrence [16]. Despite these limitations, several variables have been shown to influence the natural history of the disease (Fig. 2). Among factors related to the donor,

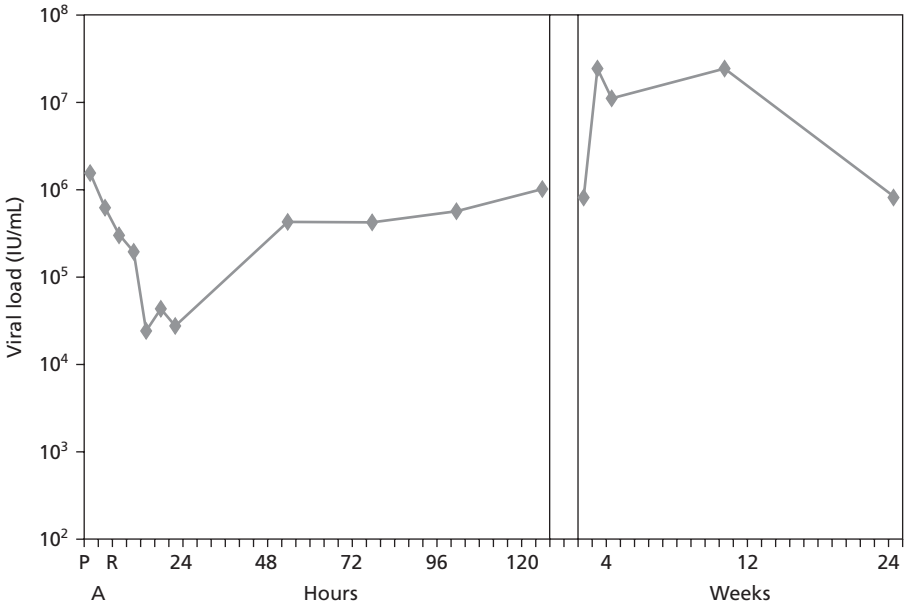

Fig. 1 HCV kinetics during and after liver transplantation. Evolution of HCV viral load during and after liver transplant in one representative patient. Viral load decreases significantly during the anhepatic phase and particularly after graft reperfusion, suggesting massive uptake of HCV virions by the new graft. Viral replication begins as early as a few hours after LT and, in most patients, HCV RNA concentrations reach pretransplantation levels only hours or a few days after transplantation. Thereafter, viral load increases significantly as a result of immunosuppression. HCV RNA concentrations are expressed in $\log_{10}$ IU/mL and depicted on the *y*-axis. Time is represented on the *x*-axis. P, pretransplantation; A, anhepatic phase; R, reperfusion phase.

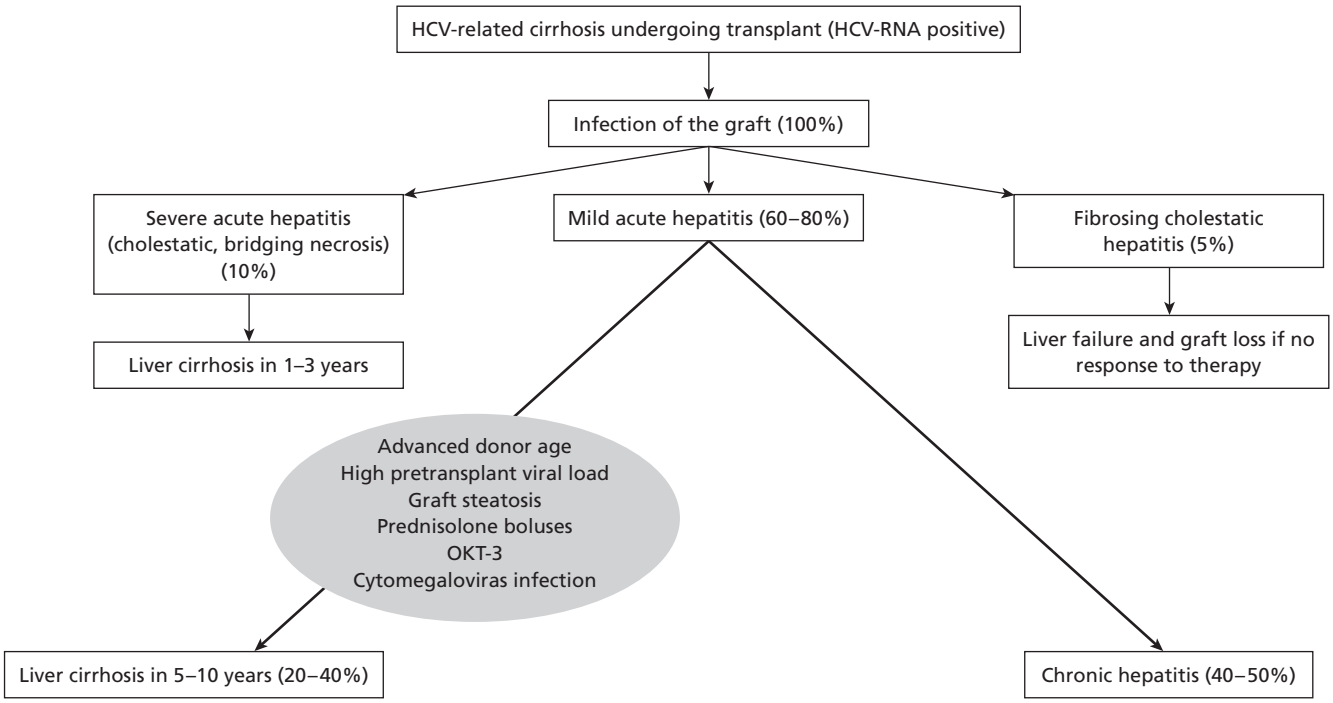

Fig. 2 Natural history of hepatitis C recurrence after liver transplantation. Outcome of HCV infection recurrence and variables potentially influencing the natural history of the disease.

age has been considered very relevant. In a retrospective analysis of more than 280 patients undergoing LT for HCV-related liver disease, donor age and a strong immunosuppressive regimen were the only variables independently related to the development of cirrhosis in the graft [17]. Both factors may explain the worsening in the outcome of HCV infection recurrence observed in recent years and may have a direct impact on the current policies of liver allocation, favouring the selection of young donors for HCV-infected recipients.

The possible influence of the use of grafts from living donors on the natural history of HCV infection recurrence is very controversial [13,18], and some studies suggest a negative impact of living donor LT (LDLT) [13]. This is surprising, given the inherent characteristics of LDLT: grafts from young and healthy individuals and short ischaemia time. It is possible, however, that the high incidence of biliary complications and liver regeneration occurring after the transplantation of a right liver lobe might facilitate HCV-mediated liver damage. Considering the relevance of this expanding liver donor pool, further studies are clearly necessary to evaluate the real impact of living donation on HCV recurrence.

Several studies have analysed the influence of immunosuppressive therapy on HCV recurrence. Theoretically, strong immunosuppression may enhance viral replication and induce more severe disease. However, data on the possible influence of immunosuppressive drugs on HCV recurrence are only indirect and based on retrospective analyses [16]. For instance, the utilization of monoclonal or polyclonal antilymphocyte antibodies has been implicated in a worse outcome of HCV recurrence, as has the administration of methylprednisolone boluses for the treatment of acute rejection. Similarly, there are studies suggesting a negative effect of high cumulative doses of corticosteroids. Contrarily, recent data show an association of a higher cumulative dose of steroids with mild hepatitis C recurrence, pointing out that rapid corticosteroid tapering (and thus rapid immune restoration) might negatively influence HCV disease recurrence.

Prevention of HCV recurrence after LT

There are different strategies to prevent graft damage caused by HCV infection after LT (Fig. 3) [19]. Antiviral therapy initiated before transplantation seems to be a good choice as eradication of HCV would prevent liver damage. Unfortunately, antiviral therapy in patients with advanced cirrhosis is poorly tolerated, and adverse events are often severe. These, along with the low efficacy of current antiviral therapy, are relevant limitations to its general application. However, some reports suggest that HCV RNA negativization occurs in around one-third of treated patients, and treatment can be initiated once LT is indicated. Everson *et al.* [20] used a low accelerating dose regimen to treat a cohort of 124 decompensated cirrhotic patients. Sustained virological response occurred in 20% of these patients and, importantly, recurrence of infection after transplantation was rare. As expected, response was significantly better in patients infected with non-type 1 genotypes. Forns *et al.* [21] used a different strategy based on the initiation of therapy a few months

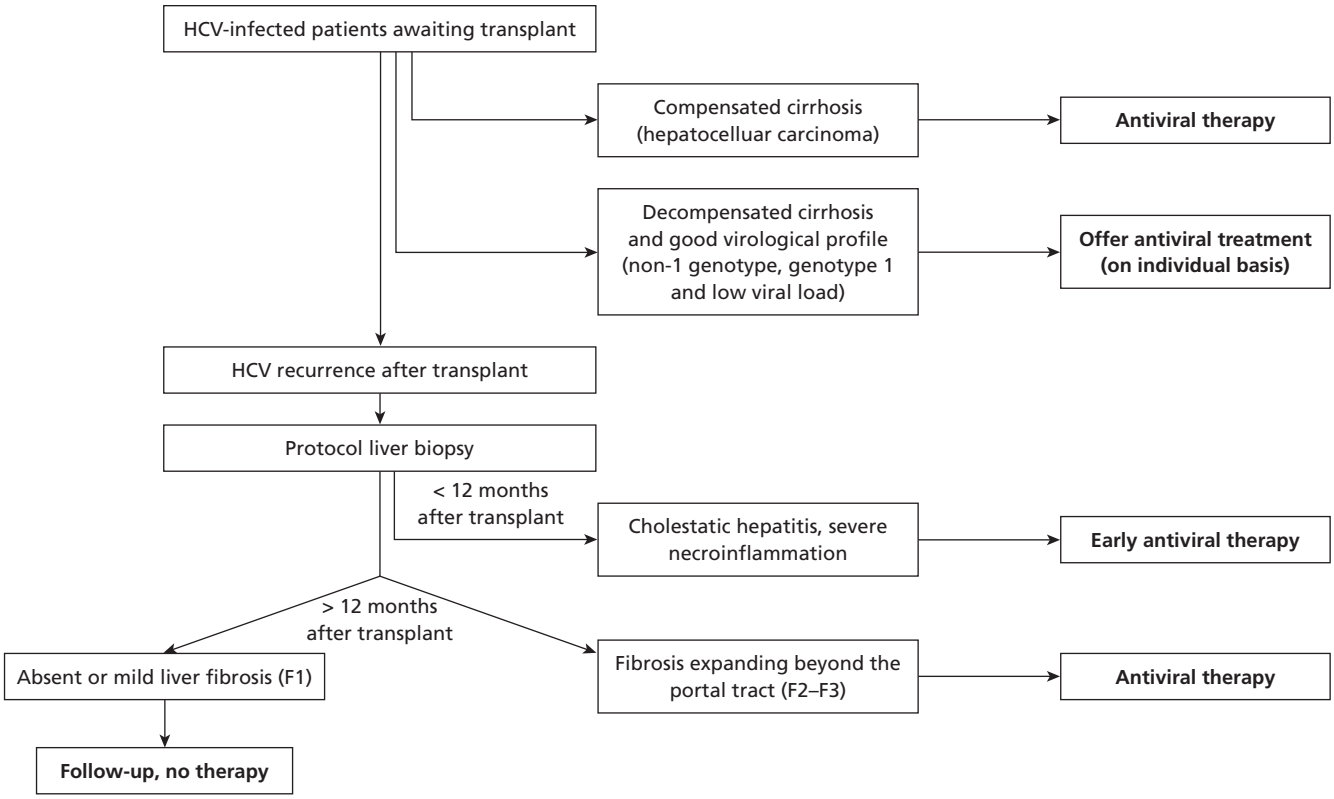

Fig. 3 Management of HCV infection before and after liver transplantation: decision algorithm.

before LT was expected. Treatment was continued until the time of LT. HCV RNA negativization was achieved in 9 (30%) out of 30 patients, although recurrence after LT occurred in three patients. Low viral load pre-LT and rapid HCV RNA negativization were the most relevant factors in predicting response. Although side-effects were common and often required drug dose modifications and utilization of stimulating haematopoietic factors, close clinical follow-up proved useful in preventing life-threatening complications.

The use of anti-HCV immune globulin to prevent HCV infection of the graft is an interesting strategy [19]. The lower incidence of hepatitis C recurrence in liver transplant recipients treated with HBIG before 1990 (prior to anti-HCV screening of blood products) compared with those receiving HBIG after 1990, along with *in vitro* experiments, strongly suggests the existence of antibodies with neutralizing activity [19]. However, direct application of immune prophylaxis in clinical practice will be difficult. The great genetic variability of HCV and the fact that natural infection does not confer protection against additional exposures reflect the facility of HCV to escape from the immune system.

Treatment of HCV recurrence after LT

Treatment of HCV infection in the early phase after LT seems a reasonable approach, as prompt eradication of HCV would prevent future liver damage. However, the potential risk of rejection, the poor tolerance of antiviral therapy immediately after LT and early viral kinetics following LT (Fig. 1) are some of the limitations of this strategy. Data from randomized controlled studies analysing the efficacy of interferon/peg-interferon monotherapy initiated as early as 2–3 weeks after LT did not show efficacy in terms of viral clearance [22]. Data on combination therapy are more promising, but there are no controlled studies.

Currently, the most common strategy to treat HCV infection in patients undergoing LT is to initiate therapy several months (or even years) after LT, once graft damage with significant fibrosis has already been documented. Liver biopsy is part of the routine follow-up of these patients. The presence of significant fibrosis (extending beyond the portal tract) 1 year after transplantation identifies individuals at risk of severe recurrence [23]. Most studies indicate that the efficacy of antiviral therapy in LT recipients is low and, as stated before, adverse events often make it necessary to modify doses and discontinue therapy [19]. Samuel *et al.* [24] analysed the efficacy and safety of interferon in combination with ribavirin in patients with established chronic hepatitis C after LT. A total of 52 patients were included and randomized to receive combined therapy vs. no treatment. In the treated group, nine patients (32%) had undetectable HCV RNA at the end of therapy and six (21%) at the end of follow-up, whereas no patient in the control group lost HCV RNA. Sixteen

patients were withdrawn from the study, 12 from the treated group, mainly for severe anaemia. Although data using pegylated interferons are still limited, the efficacy appears to be slightly higher (around 30–35%) than with the use of standard interferons. The use of stimulating factors as a result of anaemia and leucopenia is frequent. Although rejection induced by interferon is rare, changes in the liver enzyme profile (particularly in virological responders) should prompt rapid liver biopsy to exclude this possibility.

In the near future, the development of new antiviral compounds (such as protease and polymerase inhibitors) will facilitate treatment of HCV infection in the transplant setting.

Liver retransplantation for HCV recurrence

The need for retransplantation for HCV recurrence may increase in the near future and, therefore, a standardized policy would be reasonable. The outcome of retransplantation for severe HCV-related disease in the graft is controversial: some initial reports indicated an even more rapid progression of HCV-related disease in the second graft. Current data suggest that the poor results of retransplantation in HCV-infected patients might be explained by the fact that retransplantation is usually indicated in severely ill individuals. In fact, results would probably not differ between HCV-positive and -negative patients if retransplantation is performed as soon as clinical decompensation occurs.

Recurrence of autoimmune liver diseases

Primary biliary cirrhosis (PBC), primary sclerosing cholangitis (PSC) and autoimmune hepatitis (AIH) are classical indications for LT. However, these diseases can recur after transplantation [25–27]. In general, the recurrence of these diseases has minor clinical impact, probably because of the immunosuppression and the recipient–donor human leukocyte antigen (HLA) mismatch. Therefore, although the course of the recurrence can be aggressive in some cases, the post-transplant outcome of patients transplanted for these diseases on a whole is excellent or good.

Recurrent primary biliary cirrhosis

Diagnosis and incidence

The diagnosis of PBC in non-transplanted patients is based on elevated serum alkaline phosphatase and immunoglobulin M, positive antimitochondrial antibodies (AMA) and a consistent liver histology. Nevertheless, these criteria are not always applicable for the diagnosis of recurrent PBC after LT. Elevation of alkaline phosphatase is unspecific because this laboratory parameter can increase for reasons other than recurrent PBC (rejection, biliary tree problems or drug-induced hepatotoxicity). AMA can remain positive after transplantation in most patients regardless of whether PBC recurs or not, and the same occurs with other PBC-specific autoantibodies, such as antinuclear Sp100 and gp210 antibodies [28,29]. Similarly, increased immunoglobulin M levels are inconstantly found in patients with and without PBC recurrence [28]. Therefore, graft histological findings are commonly used as the key markers for the diagnosis of recurrent PBC. Based on liver biopsy, recurrence of PBC has been observed at different transplant centres with an incidence ranging from 8% to 35% [28,30–36]. As most of the histological findings of recurrent PBC can also be seen in other conditions, especially rejection, the differential diagnosis can be challenging in some cases [37].

Pathogenic aspects

It is thought that PBC recurs because the process causing the disease persists after transplantation [25]. In agreement with this contention, one study showed that a substantial proportion of patients transplanted for PBC developed the E2 component of pyruvate dehydrogenase complex (the specific autoantigen for AMA) in the biliary epithelial cells of the graft and that all patients with PBC recurrence expressed this autoantigen in their new livers [38].

Several authors have found that young recipient and donor age, prolonged ischaemia time, donor HLA-DR3 and recipient HLA-DR4 and the administration of tacrolimus instead of ciclosporin increase the risk of recurrent PBC [28,32,35].

Clinical relevance and management

In general, recurrence of PBC is detected beyond the first year after transplantation and follows a slow and benign course. Most patients are asymptomatic and, in a substantial proportion of cases, PBC recurrence consists of a simple histological finding. However, a few patients can present with progressive disease leading to death or graft loss requiring retransplantation [25,28,31,32].

As mentioned previously, ciclosporin seems to be superior to tacrolimus in the prevention of PBC recurrence [35]. Although some authors have found that the administration of ursodeoxycholic acid (UDCA) decreases serum alkaline phosphatase levels in patients with PBC recurrence [28], the efficacy of long-term UDCA therapy in this setting has not yet been established.

Recurrent primary sclerosing cholangitis

Diagnosis, incidence and risk factors

The diagnosis of PSC is mainly obtained by cholangiography, which shows strictures and irregularities in the intrahepatic and/or extrahepatic biliary tree. Although recurrence of the disease following transplantation should be based on the same cholangiographic findings, post-transplant cholangiographic alterations suggestive of PSC can also develop secondarily to other conditions, such as ischaemic biliary damage due to hepatic artery thrombosis or preservation injury, recurrent biliary infection, chronic rejection and donor–recipient ABO

incompatibility. However, non-anastomotic biliary strictures are three to six times more frequent in patients undergoing transplantation for PSC than in patients transplanted for other diseases [39–41], which suggests that PSC recurrence is the main cause of the cholangiographic alterations seen in the former.

Hepatic histological changes, especially concentric fibro-obliterative lesions involving the interlobular bile ducts, can contribute to the diagnosis of PSC, and they have also been used to identify PSC recurrence, although these alterations are observed in only a small proportion of patients [42].

At present, the most reasonable definition of PSC recurrence is based on the existence of cholangiographic and/or histological alterations characteristic of PSC in the absence of any other apparent cause, and occurring beyond the third month after transplantation [26]. Using these criteria, the Mayo Clinic group reported a 20% incidence of PSC recurrence [42].

Recipient male sex, recipient–donor gender mismatch, intact colon at transplantation, steroid-resistant rejection and the use of OKT3 have been found to be factors associated with recurrence of PSC [43–46].

Clinical impact and management

Most patients with PSC recurrence are free of symptoms, with mild biochemical cholestasis [26]. In some cases, endstage liver disease or recurrent biliary infection can develop, causing the death of patients or requiring retransplantation [42]. An increased post-transplant incidence of chronic rejection and AIH or overlap syndrome has also been described [45,47]. Survival of patients with and without recurrent PSC is similar, although some authors have reported a trend to lower graft survival in the former [48].

No specific therapy is currently available for PSC recurrence, although UDCA is administered empirically in most cases [26].

Recurrent autoimmune hepatitis

Diagnosis and incidence

The diagnosis of the recurrence of AIH is commonly based on the same criteria used for the diagnosis of AIH in non-transplanted patients, including compatible histology, biochemical changes of hepatitis, autoimmunity markers (positive autoantibodies at significant titres and increased gammaglobulin level), exclusion of other identifiable causes of hepatitis and steroid dependency [27,49]. The score developed by the International Autoimmune Hepatitis Group has not been validated yet in the post-transplant setting. The differential diagnosis between recurrent AIH and cellular rejection can occasionally be difficult because these two processes may share most biochemical and histological features and the dependency on steroid therapy.

An incidence of AIH recurrence of 17–32% has been reported in recent studies involving large series of patients [50–52]. In one study, the cumulative probability of recurrent AIH was 8% at 1 year after transplantation, 20% at 2 years and 68% at 5 years [53]. Children seem to have a particularly increased risk of recurrence.

Pathogenic aspects

The precise pathogenic mechanism of recurrent AIH has not been clearly established. At present, whether this process represents a true recurrence of the autoimmune disease, an antigraft response different from the classical rejection phenomenon or an allograft alteration mimicking AIH remains uncertain [54].

Risk factors for AIH recurrence are recipient HLA-DR3 positivity (particularly when donors are HLA-DR3 negative), high-grade inflammation in the native liver and pretransplant AIH type 1 [49].

Clinical impact and management

The most common clinical presentation of recurrent AIH consists of asymptomatic or oligosymptomatic chronic hepatitis [50,53,55]. AIH often recurs during immunosuppression tapering, especially after an important reduction in steroid dosage. Therefore, the management of recurrent AIH involves an increase in or the reintroduction of steroid therapy, with or without the addition of azathioprine. This is followed by a positive biochemical response in many cases, although a substantial proportion of patients continue to exhibit marked histological abnormalities [50,53]. Regardless of a theoretically adequate therapy, the recurrent AIH follows a progressive course leading to graft failure in around 25–50% of patients, [52,55]. Ciclosporin substitution with tacrolimus and the administration of rapamycin have been proposed in these cases [51,56].

Recurrence of other non-malignant diseases

Relapse of alcohol use, that is any alcohol intake after LT, has been reported in 15–50% of patients with pretransplant alcoholism (average 30%), although severe recidivism with heavy drinking is observed in only 5–10% of patients [57,58]. Sobriety for less than 6 months before transplantation and several psychosocial factors related to alcohol recidivism in non-transplanted patients (for example personality disorders, non-compliance, multiple abstinence failures or a family history of alcohol abuse) have been identified as predictors of alcohol relapse after LT [58–62]. Additionally, alcohol recidivism increases over time after transplantation [57], probably because of attenuation in LT team surveillance and the progressive perception of patients that alcoholism is no longer a significant problem [62]. In spite of the relatively high proportion of patients who resume drinking after transplantation, alcohol-induced lesions in their grafts are not very outstanding and are usually limited to steatosis. More severe lesions, such as steatohepatitis, alcoholic hepatitis or cirrhosis, are only seen occasionally [63,64]. Development of rejection due to poor adherence to immunosuppressive therapy is also possible in the setting of severe alcohol recidivism. Although most studies have

not found a negative influence of alcoholic relapse on post-transplant survival, a recent investigation reported a decreased 10-year survival in patients with alcohol recidivism (45%) compared with patients without (85%) [65]. The higher mortality rate in the former was related to an increased incidence of cancer and cardiovascular events.

After LT, non-alcoholic fatty liver disease (NAFLD) recurs in many patients transplanted for non-alcoholic steatohepatitis (NASH) or cryptogenic cirrhosis (considered as a 'burned out' NASH in most cases), presenting with different degrees and severity of fatty graft lesions, ranging from mild steatosis to steatohepatitis with marked fibrosis. The probability of NAFLD recurrence increases over time after transplantation, and it has been estimated to be up to nearly 100% at 5 years [66], although the long-term clinical impact of this complication still remains undefined. Post-transplant persistence of diabetes, obesity and hypertriglyceridaemia are associated with NAFLD recurrence [66,67].

The recurrence of Budd–Chiari syndrome is commonly prevented by anticoagulation prophylaxis, which, at present, is routinely administered to all patients after LT. In spite of such prophylaxis, the disease can recur in some patients, particularly those with paroxysmal nocturnal haemoglobinuria [68].

Reaccumulation of iron is uncommon after LT for genetic haemochromatosis [69], thus suggesting that the liver is of major importance in the pathogenesis of the disease.

Anecdotal cases of other diseases recurring after LT have been described (Table 1).

References

1 Villamil FG (2002) Hepatitis B: progress in the last 15 years. *Liver Transpl* 8, S59–S66.

2 Samuel D, Muller R, Alexander G *et al.* (1993) Liver transplantation in European patients with the hepatitis B surface antigen. *N Engl J Med* 329, 1842–1847.

3 Lok ASF (2002) Prevention of recurrent hepatitis B post-liver transplantation. *Liver Transpl* 8, S67–S73.

4 Terrault N, Roche B, Samuel D (2005) Management of the hepatitis B virus in the liver transplantation setting: a European and an American perspective. *Liver Transpl* 11, 716–732.

5 Villeneuve JP, Condreay LD, Willems B *et al.* (2000) Lamivudine treatment for decompensated cirrhosis resulting from chronic hepatitis B. *Hepatology* 31, 207–210.

6 Perrillo RP, Wright T, Rakela J *et al.* (2001) A multicenter United States–Canadian trial to assess lamivudine monotherapy before and after liver transplantation for chronic hepatitis B. *Hepatology* 33, 424–432.

7 Schiff ER, Lai CL, Hadziyannis S *et al.* (2003) Adefovir dipivoxil therapy for lamivudine-resistant hepatitis B in pre- and post-liver transplantation patient. *Hepatology* 38, 1419–1427.

8 Samuel D, Bismuth A, Mathieu D *et al.* (1991) Passive immunoprophylaxis after liver transplantation in HBsAg-positive patients. *Lancet* 337, 813–815.

9 Ghany MG, Ayola B, Villamil FG *et al.* (1998) Hepatitis B S mutants in liver transplant recipients who were reinfected despite hepatitis B immune globulin prophylaxis. *Hepatology* 27, 213–222.

10 Buti M, Mas A, Prieto M *et al.* (2003) A randomized study comparing lamivudine monotherapy after a short course of hepatitis B immune globulin (HBIG) and lamivudine with long-term lamivudine plus HBIG in the prevention of hepatitis B recurrence after liver transplantation. *J Hepatol* 38(6), 811–817.

11 García-Retortillo M, Forns X, Feliu A *et al.* (2002) Hepatitis C virus kinetics during and immediately after liver transplantation. *Hepatology* 35, 680–687.

12 Prieto M, Berenguer M, Rayon JM *et al.* (1999) High incidence of allograft cirrhosis in hepatitis C virus genotype 1b infection following transplantation: relationship with rejection episodes. *Hepatology* 29, 250–256.

13 Garcia-Retortillo M, Forns X, Llovet JM *et al.* (2004) Hepatitis C recurrence is more severe after living donor compared to cadaveric liver transplantation. *Hepatology* 40, 699–707.

14 Berenguer M, Prieto M, Rayón JM *et al.* (2000) Natural history of clinically compensated HCV related graft cirrhosis following liver transplantation. *Hepatology* 32, 852–858.

15 Forman LM, Lewis JD, Berlin JA *et al.* (2002) The association between hepatitis C infection and survival after orthotopic liver transplantation. *Gastroenterology* 122, 889–896.

16 Wiesner RH, Sorrell M, Villamil F and the International Liver Transplantation Society Expert Panel (2003) Report of the first International Liver Transplantation Society panel consensus conference on liver transplantation and hepatitis C. *Liver Transpl* 9(Suppl. 3), S1–S9.

17 Berenguer M, Prieto M, San Juan F *et al.* (2002) Contribution of donor age to the recent decrease in patients survival among HCV-infected liver transplant recipients. *Hepatology* 36, 202–210.

18 Shiffman ML, Stravitz RT, Contos MJ *et al.* (2004) Histologic recurrence of chronic hepatitis C virus in patients after living donor and deceased donor liver transplantation. *Liver Transpl* 10, 1248–1255.

19 Garcia-Retortillo M, Forns X (2004) Prevention and treatment of hepatitis C virus recurrence after liver transplantation. *J Hepatol* 41, 2–10.

20 Everson GT, Trotter J, Forman L *et al.* (2005) Treatment of advanced hepatitis C with a low accelerating dosage regimen of antiviral therapy. *Hepatology* 42, 255–262.

21 Forns X, García-Retortillo M, Serrano T *et al.* (2003) Antiviral therapy of patients with decompensated cirrhosis to prevent recurrence of hepatitis C after liver transplantation. *J Hepatol* 39, 389–396.

22 Chalasani N, Manzarbeitia C, Ferenci P *et al.* (2005) Peginterferon alfa-2a for hepatitis C after liver transplantation: two randomized, controlled trials. *Hepatology* 41, 289–298.

23 Neumann UP, Berg T, Bahra M *et al.* (2004) Fibrosis progression after liver transplantation in patients with recurrent hepatitis C. *J Hepatol* 41, 830–836.

24 Samuel D, Bizollon T, Feray C *et al.* (2003) Interferon alfa-2b plus ribavirin in patients with chronic hepatitis C after liver transplantation: a randomized study. *Gastroenterology* 124, 642–650.

25 Neuberger J (2003) Recurrent primary biliary cirrhosis. *Liver Transpl* 9, 539–546.

26 Graziadei I (2002) Recurrence of primary sclerosing cholangitis after liver transplantation. *Liver Transpl* 8, 575–581.

27 Manns MP, Bahr MJ (2000) Recurrent autoimmune hepatitis after liver transplantation-when non-self becomes self. *Hepatology* 32, 868–869.

28 Guy JE, Qian P, Lowell JA *et al.* (2005) Recurrent primary biliary cirrhosis: peritransplant factors and ursodeoxycholic acid treatment post-liver transplant. *Liver Transpl* 11, 1252–1257.

29 Luettig B, Boeker KH, Schoessler W *et al.* (1998) The antinuclear autoantibodies SP100 and gp210 persist after orthotopic liver

transplantation in patients with primary biliary cirrhosis. *J Hepatol* 28, 824–828.
30 Knoop M, Bechstein WO, Schrem H *et al.* (1996) Clinical significance of recurrent primary biliary cirrhosis after liver transplantation. *Transpl Int* 9 (Suppl. 1), S115–119.
31 Renz JF, Ascher NL (2002) Liver transplantation for nonviral, nonmalignant diseases: problem of recurrence. *World J Surg* 26, 247–256.
32 Khettry U, Anand N, Faul PN *et al.* (2003) Liver transplantation for primary biliary cirrhosis: a long-term pathologic study. *Liver Transpl* 9, 87–96.
33 Sylvestre PB, Batts KP, Burgart LJ *et al.* (2003) Recurrence of primary biliary cirrhosis after liver transplantation: histologic estimate of incidence and natural history. *Liver Transpl* 9, 1086–1093.
34 Sanchez EQ, Levy MF, Goldstein RM *et al.* (2003) The changing clinical presentation of recurrent primary biliary cirrhosis after liver transplantation. *Transplantation* 76, 1583–1588.
35 Neuberger J, Gunson B, Hubscher S *et al.* (2004) Immunosuppression affects the rate of recurrent primary biliary cirrhosis after liver transplantation. *Liver Transpl* 10, 488–491.
36 Sebagh M, Farges O, Dubel L *et al.* (1998) Histological features predictive of recurrence of primary biliary cirrhosis after liver transplantation. *Transplantation* 65, 1328–1333.
37 Demetris AJ, Markus BH, Esquivel C *et al.* (1988) Pathologic analysis of liver transplantation for primary biliary cirrhosis. *Hepatology* 8, 939–947.
38 Van de Water J, Gerson LB, Ferrell LD *et al.* (1996) Immunohistochemical evidence of disease recurrence after liver transplantation for primary biliary cirrhosis. *Hepatology* 24, 1079–1084.
39 Sheng R, Zajko AB, Campbell WL *et al.* (1993) Biliary strictures in hepatic transplants: prevalence and types in patients with primary sclerosing cholangitis vs those with other liver diseases. *Am J Roentgenol* 161, 297–300.
40 Guichelaar MMJ, Benson JT, Malinchoc M *et al.* (2003) Risk factors for and clinical course of non-anastomotic biliary strictures after liver transplantation. *Am J Transpl* 3, 885–890.
41 McEntee G, Wiesner RH, Rosen C *et al.* (1991) A comparative study of patients undergoing liver transplantation for primary sclerosing cholangitis and primary biliary cirrhosis. *Transpl Proc* 23, 1563–1564.
42 Graziadei IW, Wiesner RH, Batts KP *et al.* (1999) Recurrence of primary sclerosing cholangitis following liver transplantation. *Hepatology* 29, 1050–1056.
43 Vera A, Moledina S, Gunson B *et al.* (2002) Risk factors for recurrence of primary sclerosing cholangitis of liver allograft. *Lancet* 360, 1943–1944.
44 Kugelmas M, Spiegelman P, Osgood MJ *et al.* (2003) Different immunosuppressive regimens and recurrence of primary sclerosing cholangitis after liver transplantation. *Liver Transpl* 9, 727–732.
45 Khettry U, Keaveny A, Goldar-Najafi A *et al.* (2003) Liver transplantation for primary sclerosing cholangitis: a long-term clinicopathological study. *Hum Pathol* 34, 1127–1136.
46 Bransaeter B, Schrumpf E, Bentdal O *et al.* (2005) Recurrent primary sclerosing cholangitis after liver transplantation: a magnetic resonance cholangiography study with analyses of predictive factors. *Liver Transpl* 11, 1361–1369.
47 Jeyarajah DR, Netto GJ, Lee SP *et al.* (1988) Recurrent primary sclerosing cholangitis after orthotopic liver transplantation. Is chronic rejection part of the disease process? *Hepatology* 66, 1300–1306.
48 Goss JA, Shackleton CR, Farmer DG *et al.* (1997) Orthotopic liver transplantation for primary sclerosing cholangitis. A 12-year single center experience. *Ann Surg* 225, 472–483.
49 Hübscher SG (2001) Recurrent autoimmune hepatitis after liver transplantation: diagnostic criteria, risk factors and outcome. *Liver Transpl* 4, 285–291.
50 Gonzalez-Koch A, Czaja AJ, Carpenter HA *et al.* (2001) Recurrent autoimmune hepatitis after orthotopic liver transplantation. *Liver Transpl* 7, 302–310.
51 Molmenti EP, Netto GJ, Murray NG *et al.* (2002) Incidence and recurrence of autoimmune/alloimmune hepatitis in liver transplant recipients. *Liver Transpl* 8, 519–526.
52 Vogel A, Heinrich E, Bahr MJ *et al.* (2004) Long-term outcome of liver transplantation for autoimmune hepatitis. *Clin Transplant* 18, 62–69.
53 Prados E, Cuervas-Mons V, De la Mata M *et al.* (1998) Outcome of autoimmune hepatitis after liver transplantation. *Transplantation* 66, 1645–1650.
54 Czaja AJ (2002) Autoimmune hepatitis after liver transplantation and other lessons of self-intolerance. *Liver Transpl* 8, 505–513.
55 Duclos-Vallée J-C, Sebagh M, Rifai K *et al.* (2003) A 10 year follow up study of patients transplanted for autoimmune hepatitis: histological recurrence precedes clinical and biochemical recurrence. *Gut* 52, 893–897.
56 Kerkar N, Dugan C, Rumbo C *et al.* (2005) Rapamycin successfully treats post-transplant autoimmune hepatitis. *Am J Transpl* 5, 1085–1089.
57 Bravata DM, Plkin I, Barnato AE *et al.* (2001) Employment and alcohol use after liver transplantation for alcoholic and nonalcoholic liver disease: a systematic review. *Liver Transpl* 7, 191–203.
58 Tome S, Lucey MR (2003) Timing of liver transplantation in alcoholic cirrhosis. *J Hepatol* 39, 302–307.
59 Jauhar S, Talwalkar JA, Schneekloth T *et al.* (2004) Analysis of factors that predict alcohol relapse following liver transplantation. *Liver Transpl* 10, 408–411.
60 Gish RG, Lee A, Brooks L *et al.* (2001) Long-term follow-up of patients diagnosed with alcohol dependence or alcohol abuse who were evaluated for liver transplantation. *Liver Transpl* 7, 581–587.
61 Perney P, Bismuth M, Sigaud H *et al.* (2005) Are preoperative patterns of alcohol consumption predictive of relapse after liver transplantation for alcoholic liver disease? *Transpl Int* 18, 1292–1297.
62 Beresford TP (1997) Predictive factors for alcoholic relapse in the selection of alcohol-dependent persons for hepatic transplant. *Liver Transpl Surg* 3, 280–291.
63 Burra P, Mioni D, Cecchetto A *et al.* (2001) Histological features after liver transplantation in alcoholic cirrhotics. *J Hepatol* 34, 716–722.
64 Pageaux G-P, Bismuth M, Perney P *et al.* (2003) Alcohol relapse after liver transplantation for alcoholic liver disease: does it matter? *J Hepatol* 38, 629–634.
65 Cuadrado A, Fabrega E, Casafont F *et al.* (2005) Alcohol recidivism impairs long-term patient survival after orthotopic liver transplantation for alcoholic liver disease. *Liver Transpl* 11, 420–426.
66 Contos MJ, Cales W, Sterling RK *et al.* (2001) Development of nonalcoholic fatty liver disease after orthotopic liver transplantation for cryptogenic cirrhosis. *Liver Transpl* 7, 363–373.
67 Ong J, Younossi ZM, Reddy V *et al.* (2001) Cryptogenic cirrhosis and posttransplantation nonalcoholic fatty liver disease. *Liver Transpl* 7, 797–801.
68 Bahr MJ, Schubert J, Bleck JS *et al.* (2003) Recurrence of Budd–Chiari syndrome after liver transplantation in paroxysmal nocturnal hemoglobinuria. *Transpl Int* 16, 890–894.
69 Crawford DH, Fletcher LM, Hubscher SG *et al.* (2004) Patient and graft survival after liver transplantation for hereditary hemochromatosis: implications for pathogenesis. *Hepatology* 39, 1655–1662.

25.6 Post-transplantation management and complications

Faouzi Saliba and Didier Samuel

Introduction

In the last two decades, orthotopic liver transplantation (OLT) has achieved 1-year survival rates of 80–90% [1]. For the patient who successfully undergoes OLT for endstage liver disease, long-term graft and recipient survivals are excellent, with a high likelihood of a return to a premorbid lifestyle. Data from the European Liver Transplant Registry (ELTR) and from the Scientific Registry of Transplant Recipients (SRTR) showed a 10-year survival rate within 70% [1,2]. We are currently following patients transplanted more than 20 years ago. Therefore, the current challenge in the management of liver transplant recipients is not only the outcome of the graft but maintaining health, well-being and quality of life in long-term survivors [3]. Problems encountered long after OLT are usually related to side-effects of chronic immunosuppressive therapy, disease recurrence or chronic rejection. Improved long-term survival necessitates careful screening for and management of long-term medical complications, including cardiovascular complications, malignancy, bone disease, renal dysfunction and infectious complications.

Routine long-term monitoring and patient care

Outpatient post-transplant management

Patients are discharged from the hospital 8–30 days following liver transplantation. After initial discharge, patients are seen in the transplant centre by the transplant surgeon and hepatologist for continued management. The frequency of visits to the transplant centre is generally as follows: every 2 weeks during the first 3 months, once a month (months 3–6), once every 2–3 months (months 6–24), once every 4–6 months (> 2 years). These visits are often alternated with the primary physician, and their frequency could vary according to the age of the recipient, initial pathology, the functioning of the graft and the presence of comorbidities. The clinical visit is designed to carry out a comprehensive review of laboratory data, diagnostic studies reflective of liver function, manage the immunosuppressive regimen that each patient is following and monitor for recurrence of disease and the risk of immunosuppressive therapy. Each patient will be referred back to the primary care physician or gastroenterologist for routine health maintenance. Referral physicians should communicate regularly with transplant centre physicians and/or the nurse coordinator.

Routine outpatient laboratory and imaging testing

Routine laboratory tests are necessary to monitor for the following: graft rejection, drug toxicity and interactions, complications secondary to immunosuppression, recurrence of the initial disease and response of liver enzymes after treatment for graft rejection or after a change in the immunosuppressive regimen. Infection and graft rejection occur most often within 6 months following transplantation. In the event that one or both of these situations occurs, the frequency of laboratory testing has to be increased in order to closely monitor the patient's overall response. Doppler ultrasound of the graft should be performed routinely and in case of any abnormal changes in the liver enzymes to assess the patency of the vascular and biliary tract. Computerized tomography (CT) scan and magnetic resonance imaging (MRI) are performed when needed, mainly for the detection of recurrent or *de novo* malignancy and surgical complications.

There have been controversies in the literature about the need for routine liver biopsies in relation to their potential risks and benefit [4–6]. Most transplant patients would have a diagnostic biopsy of their graft during the first 6 months and when abnormal liver tests occur. However, routine biopsies of the graft at year 1, 2, 5 and every 5 years in order to guide the immunosuppressive regimen, and to detect disease recurrence, chronic rejection and acquired rare diseases of the graft are highly encouraged [4,5]. Lang and colleagues [7] reviewed 3670 biopsies performed in 919 patients with ultrasound guidance and use of the Menghini needle (1.6-mm diameter). Biopsy was complicated by bleeding in 13 of 919 patients (1.41%). The incidence of

procedure-related complications was 13 in 3670 biopsies (0.35%). The authors concluded that percutaneous liver biopsy in liver transplant recipients is a safe procedure.

Patient education

The nurse coordinator plays a major role in the education and follow-up of the patient. Post-transplant patients are educated about and provided with information regarding: rejection, the risk of infection, dietary issues, medications and side-effects, liver biopsy indications and protocols, hygiene and general health care, physical activity, sexual relationships and long-term follow-up. Post-transplant success depends on compliance with a strict antirejection regimen. Dobbels and colleagues [8] analysed 174 patients with solid organ transplant and showed that lower educational level, higher received social support and lower conscientiousness were significant independent predictors of post-transplant medication non-adherence. Shemesh and colleagues [9] analysed data obtained in the first year of the implementation of an adherence assessment protocol at a paediatric liver transplant clinic. Forgetfulness was the most common reason for non-adherence; medication side-effects were not frequently cited by patients. The authors concluded that the clinical impression is not sufficient to determine whether children and adolescents are taking their medications after they have had a liver transplant. An objective assessment method should be used.

Post-transplantation long-term issues and causes of late mortality

As the number of OLT recipients continues to increase, general preventative medicine and primary care management issues specifically related to OLT recipients are recognized as important and include obesity, hyperlipidaemia, hypertension, diabetes, osteoporosis and screening for malignancy in addition to surveillance of the graft. Seyam and colleagues [10] examined late (> 5 years) mortality in 1221 adults transplanted at their institution between 1982 and 1999. Of these patients, 844 (69%) survived for more than 5 years. Of the 129 patients who died, 56% died of complications possibly related to long-term immunosuppression, including *de novo* malignancy, infection or renal failure, 22% died of vascular complications, and 15% died from recurrent disease. Rabkin and colleagues [11] reviewed 459 recipients transplanted between September 1991 and April 2000. The causes of late mortality (> 1 year) were malignancy (nine patients), disease recurrence (eight patients), late infection (six patients), renal failure complications (five patients), cardiovascular complications (four patients), chronic rejection (three patients), gastrointestinal haemorrhage (two patients), medication non-compliance (one patient) and unknown (two patients). Jain and colleagues [12] analysed late complications that occurred in 1000 consecutive patients undergoing primary OLT at their centre from August 1989 to December 1992. In 6.1% of the survivors, endstage renal disease developed during the follow-up period, requiring either dialysis or kidney transplantation. Hyperkalaemia and hypertension were observed in approximately one-third of the patients. Insulin-dependent diabetes mellitus (including patients who had diabetes before the transplant) was observed in 14% in year 1, dropping to 11% in year 7, and *de novo* malignancies developed in 82 patients.

Complications related to long-term immunosuppressive therapy

Weight gain and obesity

Significant weight gain and obesity are common in patients after OLT. The reported prevalence of post-transplant obesity ranged from 17% to 42% [13]. Weight gain in patients who are obese before transplantation [body mass index (BMI) > 30 kg/m^2] is much greater than that in non-obese recipients [14]. The weight gain has been attributed to a number of factors, including cumulative prednisone dose, appetite stimulation by the antirejection regimens and an increased sense of well-being after long-term chronic illness. Richards and colleagues [15] studied weight gain in 597 patients who underwent transplantation between 1996 and 2001. By 1 and 3 years, 24% and 31% had become obese (defined by BMI > 30 kg/m^2). Weight gain was statistically significantly greater in patients older than 50 years and in those who underwent OLT for chronic liver disease compared with fulminant liver failure. The greatest weight gain occurred after the first 6 months and was not related to the duration of corticosteroid therapy. In a prospective analysis from the National Institute of Diabetes, 32% of patients who were not obese before transplantation became obese within 2 years of transplantation [13]. Active exercise programmes are recommended for weight control.

Cardiovascular complications

Cardiovascular risk factors are increasingly common in patients after liver transplantation. Romero and colleagues [16] found cardiovascular complications in 4.9% of patients, none of whom had previous cardiovascular disease. The mean time of occurrence after liver transplantation was 2.6 years. Neal and colleagues [17] found in 181 consecutive adult liver transplant recipients that the predicted 10-year risk of coronary heart disease had increased from 6.9% before transplantation to 11.5% at 1 year after transplantation, whereas that of a matched local population was 7%. Johnston and colleagues [18] assessed 110 consecutive adults, who attended for review visit after OLT (median follow-up 3.9 years; range 0.1–17.9 years), for cardiovascular risk factors. The relative risk of ischaemic cardiac events was 3.07 [95% confidence interval (CI) 1.98–4.53] and the relative risk for cardiovascular deaths was 2.56 (95% CI 1.52–4.05) in allograft recipients compared with an age-matched population without transplants. Yearly screening of liver recipients for serum cholesterol, triglycerides and lipoproteins and assessment

for risk factors for atherosclerotic cardiovascular disease are an important component of comprehensive post-transplant care [19].

Arterial hypertension

Hypertension occurs in approximately 75% of patients after liver transplantation [17,18,20,21]. In addition to the effects of steroids, calcineurin inhibitors commonly induce hypertension through several pathogenic mechanisms: changes in vascular tone particularly within the kidney, leading to diminished glomerular filtration and enhanced sodium retention, disturbances of endothelial function in many tissues, including stimulation of endothelin and impaired nitric oxide synthesis, and multiple additional pathways that increase vasoconstriction, leading to an increase in arterial pressure [21,22]. Ciclosporin is associated with an increased incidence of hypertension compared with tacrolimus [20]. Weight loss, salt restriction and corticosteroid withdrawal should be considered in the management of patients with hypertension. Calcium channel blockers are the first-line drugs of choice in patients with hypertension after transplant. Beta-blockers, followed by angiotensin-converting enzyme (ACE) inhibitors are the next best alternatives for blood pressure control. Carvedilol, an alpha-1- and beta-blocker, seems to be as effective as nifedipine and better tolerated [23]. Caution should be used in prescribing ACE inhibitors and diuretics in patients with elevations in serum creatinine.

Diabetes mellitus

The prevalence of diabetes mellitus in liver transplant recipients ranges from 4.5% to 53%. Corticosteroids and calcineurin inhibitors have hyperglycaemic effects by inducing insulin resistance and probably by direct toxicity to β cells. Tacrolimus induces a higher incidence of diabetes compared with ciclosporin. The average incidence of new-onset diabetes mellitus (NODM) reported from seven prospective randomized trials in liver transplant recipients was 15.9% for tacrolimus-treated patients and 4.9% for ciclosporin-treated patients [24]. Levy and colleagues [25] reported in a recent randomized study comparing tacrolimus with ciclosporin that the incidence of *de novo* diabetes, defined by the need for insulin or oral hypoglycaemic agents for more than 30 days, was 32% in the tacrolimus-treated patients and 19% in the ciclosporin-treated group ($P = 0.005$). Recent studies suggest an association between diabetes mellitus and hepatitis C virus (HCV) infection [26–28]. Baid and colleagues [29] analysed 176 adult patients, 47 HCV (+) and 111 HCV (–). The prevalence of pretransplant diabetes was similar in the two groups, whereas the prevalence of post-transplant diabetes mellitus (PTDM) was significantly higher in HCV (+) than in HCV (–) patients (64% vs. 28%, $P = 0.0001$). HCV infection and methylprednisolone boluses were found to be independent risk factors for the development of PTDM. Development of PTDM was found to be an independent risk factor for mortality [hazard ratio (HR) 3.67, $P < 0.0001$]. In approximately half the HCV (+) patients with PTDM, the onset of PTDM was related to the recurrence of allograft hepatitis. Improvement in glycaemic control was achieved in the patients who responded to antiviral therapy [29]. John and Thuluvath [30] compared the morbidity and mortality of 46 patients who developed PTDM with 92 age- and sex-matched patients without pretransplant or post-transplant diabetes mellitus. Despite similar 5-year survival rates, the incidence of the following complications was higher in the PTDM group compared with the control group: cardiac (48% vs. 24%; $P = 0.005$), major infections (41% vs. 25%; $P = 0.07$), minor infections (28% vs. 5%; $P = 0.001$), neurologic (22% vs. 9%; $P = 0.05$) and neuropsychiatric (22% vs. 6%; $P = 0.009$). Long-term frequent monitoring of glycaemia is essential. Corticosteroid withdrawal and conversion from tacrolimus to ciclosporin have been reported to be beneficial. Tailoring immunosuppressive therapy to the individual patient, and avoiding the use of diabetogenic drugs, drug combinations or inappropriate doses in patients susceptible to PTDM are new alternative choices [31]. A collaborative exchange with diabetologists for the education and management of diabetes is highly recommended to decrease the risk of cardiovascular events, infections and renal dysfunction and improve quality and quantity of life.

Hyperlipidaemia

Although pretransplant serum cholesterol has been found to predict post-transplant hypercholesterolaemia, hyperlipidaemia is a common side-effect mainly due to immunosuppressive therapy [32]. Hyperlipidaemia has been reported to occur in 16–43% of liver transplant recipients [19]. Corticosteroids induced an increase in low-density lipoprotein (LDL) production. Calcineurin inhibitors reduce cholesterol secretion into the bile and increase plasma concentrations of cholesterol and triglycerides and LDL production [33]. Hyperlipidaemia occurs more frequently with ciclosporin than with tacrolimus [34]. Hyperlipidaemia is also a specific side-effect of the mTOR inhibitors (sirolimus and everolimus). Dietary measures including a low-fat diet, and avoidance of alcohol may be important for post-transplant long-term management. Adjustment of ciclosporin dose and/or prednisone dose may also improve the above problems. Lipid-lowering drugs may be necessary to control hyperlipidaemia after transplant [35].

Chronic renal failure

Acute renal failure occurs in 5–50% of patients undergoing liver transplantation. Chronic renal failure leading to endstage renal disease (ESRD) occurs in 2–10% of liver transplant recipients [36,37]. Risk factors for the development of ESRD in long-term survivors include calcineurin inhibitors nephrotoxicity, hepatorenal syndrome prior to liver transplantation, pre-existing renal insufficiency and diabetes mellitus. Postoperative acute renal failure, requirement of dialysis in the preoperative and

post-transplant period, hepatitis C infection, alcoholic liver disease and older age have also been shown to be associated with the risk of development of ESRD [38,39]. Paramesh and colleagues [40] followed 350 out of 1602 liver transplant recipients (22%) who developed acute renal failure requiring dialysis postoperatively. One hundred and twenty-three patients (39.8%) died within 1 year after transplant. Forty-three patients (23%) developed ESRD over a median of 3.8 years (range 1–8 years). Serum creatinine levels > 1.7 mg/dL at 1 year, ciclosporin treatment and the presence of diabetes preoperatively were independent predictive factors for the development of ESRD [40]. Both ciclosporin and tacrolimus are nephrotoxic and are a major cause of chronic renal dysfunction leading to ESRD and kidney transplantation. A similar incidence of both early and late nephrotoxicity was found in patients receiving ciclosporin or tacrolimus immunosuppressive regimens [25,41]. Current immunosuppressive protocols include the use of mycophenolic mofetil (MMF) or mTOR inhibitor drugs in association with either low-dose or progressive withdrawal of calcineurin inhibitors in order to reduce long-term nephrotoxicity [42].

De novo malignancy

Skin cancer, lymphoma, oropharyngeal and lung cancers may be more common in the post-transplant population [43,44]. The risk of cancer has been estimated to be 4% 5 years after transplantation. Skin cancer is the most common non-lymphoid malignancy, followed by gastrointestinal, genitourinary, pulmonary, oropharyngeal and breast malignancy [45]. Graziadei and colleagues [46] analysed the incidence of *de novo* malignancies in a cohort of 563 patients who underwent liver transplantation at their centre. Forty-six patients developed malignancies, with a mean time to diagnosis of 53 months. The most common types of cancer were lung (n = 8), oropharynx (n = 7), post-transplant lymphoproliferative disorder (PTLD) (n = 6) and skin (n = 5). Death occurred in 32% of patients within a mean follow-up of 20 months. Five-year survival after diagnosis was 54%. Ten malignancies occurred within 1 year, highlighting the importance of careful pre-OLT screening and assessment of risk factors. Risk factors for the development of cancer are thought to be alcoholic liver disease, increasing age and the intensity of immunosuppression. Jain and colleagues [47] reviewed data from 3192 adult liver recipients transplanted between 1981 and 1998. The incidence of PTLD in children (9.7%) was higher than the incidence in adults (2.9%). The median time from liver transplantation to the diagnosis of PTLD was shorter in children than in adults (8.1 months vs. 15 months). Management of PTLD could include antiviral therapy, reduction of immunosuppression, monoclonal chimeric antibodies anti-CD20 and/or systemic chemotherapy [48,49]. Patients who are transplanted for primary sclerosing cholangitis and who have inflammatory bowel disease remain at high risk of colonic dysplasia and colon cancer. Cancer screening should be performed routinely based on the recipient's age, sex and risk factors.

Osteoarticular complications

Osteopenia is common in patients with cirrhosis and is typically due to osteoporosis rather than osteomalacia, although the latter can occur in patients with severe cholestasis. Factors implicated, apart from calcium and vitamin D deficiency, include low muscle mass, immobility, long-term corticosteroid use, poor nutrition and alcohol abuse. Osteopenia, osteoporosis or both are observed in 10–60% of liver transplant recipients [50]. The incidence is particularly high in patients with cholestatic liver disease (primary biliary cirrhosis and sclerosing cholangitis). After transplantation, rapid bone loss occurs in the first 3–6 months, but recovery of bone mass can continue for up to 7 years after OLT. Early studies reported a fracture rate of about 25–35% within the first 6 months after transplantation [50]. The most common site of pathological fractures in liver transplant recipients is the vertebral body. A great decrease in the incidence of fractures (less than 5%) has been reported in recent studies. This is probably due to a decreased use and early withdrawal of corticosteroids, increased prescription of anti-resorptive agents and decreased proportion of liver transplant recipients with cholestatic liver disease vs. other chronic liver disease [51].

Infectious complications

Life-threatening infectious complications typically occur during the first 6 months after transplant. Beyond the sixth month, the risk of rejection is greatly reduced (2–7%), and liver transplant recipients have lower doses of immunosuppressive therapy; therefore, the risk of acquiring severe infection is greatly decreased. Fewer patients, such as those transplanted for autoimmune disease, sclerosing cholangitis or fulminant hepatic failure and those who presented severe rejection episodes or developed chronic rejection, need a high immunosuppressive regimen and therefore are at great risk of acquiring opportunistic infections.

Community-acquired infections

Liver transplant recipients experience common viral illnesses with the same frequency as the general population. Bacterial pneumonias, urinary tract infections and viral syndromes are often a cause of post-transplant fever and should be considered in all patients with post-transplant fever. These infections are most common in patients with standard immunosuppressive therapy. The primary diagnosis of importance is bacterial infection that may progress rapidly from a self-limited infection to potentially lethal sepsis. The possibility of cholangitis and liver abscess should be considered in any liver transplant recipient with fever. Suspected bacterial infections should be treated aggressively with broad-spectrum antibiotics, which can subsequently be modified as culture results become available. Erythromycin preparations should be avoided because of their interactions with immunosuppressive drugs.

Opportunistic infections

Cytomegalovirus infection, *Pneumocystis carinii* pneumonia, tuberculosis and fungal infections can occur and should be considered in patients with fever, and particularly those patients who received large doses of immunosuppressive agents for troublesome rejection.

Immunosuppressive regimen approach to reduce long-term side effects

Calcineurin inhibitors (CNI), ciclosporin and tacrolimus are associated with multiple long-term side-effects after liver transplantation. Various approaches have been used to minimize CNI exposure. Data from the Scientific Registry of Transplant Recipients on more than 11 000 patients transplanted from January 1995 to April 2001 were analysed for the efficacy of triple therapy with MMF, tacrolimus (TAC) and corticosteroids compared with dual therapy (TAC plus corticosteroids) [52]. Triple therapy at discharge was associated with a reduced risk of death (HR 0.77, $P < 0.001$), graft loss (HR 0.81, $P < 0.001$), acute rejection (HR 0.89, $P = 0.002$) and death from infectious complications (HR 0.80, $P = 0.007$). The combination of low-dose CNIs has been shown to improve kidney function significantly. In patients who develop CNI-related toxicities after transplantation, MMF allows the doses of CNI to be reduced, either partially or completely [53]. Steroids have been used since the beginning of transplantation and are a component of most maintenance immunosuppressive protocols. However, the side-effects of long-term steroid treatment are manifold. Immunosuppressive combinations that include MMF have been shown to favour rapid tapering of steroid doses and, in some patients, complete steroid avoidance.

Subsequently, a number of other new immunosuppressive agents have been introduced into clinical practice, thus offering the opportunity to individualize a patient's immunosuppressive therapy. mTOR inhibitors, such as sirolimus and everolimus, are effective after kidney transplantation, and studies have shown that sirolimus has some advantages in liver transplant patients with recurrent or chronic rejection or CNI toxicities [54]. Owing to the availability of an increasing number of drugs with different mechanisms of action, tailored immunosuppression after liver transplantation will become more common in the future. The use of targeted immunosuppressive protocols taking into account disease aetiology and susceptibility to side-effects of immunosuppressive agents is challenging.

Chronic graft dysfunction (other than disease recurrence)

Late acute rejection

Late acute rejection that occurs after the first 6 months is very rare. Predisposing factors include underlying liver disease (autoimmune hepatitis, fulminant hepatic failure), decrease or withdrawal of immunosuppression and poor compliance [55]. Late rejection is usually associated with delayed diagnosis, and such delay often results in decreased response to initial steroid treatment [56].

Chronic rejection

The overall incidence of chronic rejection has been decreasing during the last decade. Chronic rejection currently occurs in 3–4% of liver transplant recipients [57]. This is mainly due to the use of newer immunosuppressive drugs such as tacrolimus, MMF and rapamycin. Chronic rejection can occur within a few months after transplantation. It is often preceded by corticosteroid-resistant acute rejection. Liver enzymes (especially alkaline phosphatase and gamma-glutamyltransferase) and total bilirubin progressively increase. Serial liver biopsy reveals progressive ductopenia or loss of small bile ducts and chronic cholestasis. Other histological findings include fibrosis in the portal area, arteriopathy and centrilobular degeneration. Clinical risk factors associated with chronic rejection include underlying liver disease, human leukocyte antigen (HLA) donor–recipient matching, positive lymphocytotoxic crossmatch, cytomegalovirus infection, recipient age, donor–recipient ethnic origin, male donor into female recipient, number of acute rejection episodes, histological severity of acute rejection episodes and retransplantation for chronic rejection [57]. Patients on ciclosporin who develop chronic rejection may benefit from switching to tacrolimus. Tacrolimus has been shown to either reverse or modulate the progression of chronic rejection. For non-responders, retransplantation should be considered at an earlier stage before the occurrence of signs of hepatic failure or severe portal hypertension.

Surgical complications

Late hepatic artery thrombosis

This complication rarely occurs (less than 1% of the patients) years after liver transplantation. Because the hepatic artery is the sole blood supply to the biliary system, an arterial thrombosis would lead to ischaemic cholangitis, biliary strictures and liver abscess. Arterial angiogram is essential for diagnosis.

Biliary complications

Anastomotic biliary strictures may be diagnosed by Doppler ultrasound. These are often progressive over time and difficult to dilate radiologically, often requiring revision of the biliary anastomosis (in approximately 50% of patients). Dilations are usually multiple and done via the transhepatic route. Intrahepatic biliary strictures are often secondary to ischaemia of the hepatic artery, prolonged preservation time, ABO mismatch or chronic rejection. Retransplantation should be considered once the diagnosis is established and before the occurrence of septic shock.

Other rare diseases of the graft

The practice of routine protocol biopsies at 5, 10 and every 5 years thereafter has led to the discovery of some changes in long-surviving allografts that cannot be attributed to rejection or to recurrence of a specific disease. These histological findings include mild lymphocytic portal inflammation without significant bile duct damage, venulitis, portal arterial and arteriolar thickening and hyalinization and nodular regenerative hyperplasia-like changes [58]. Hubscher [59] described an 'idiopathic post-transplant hepatitis' in patients who have no clinical or serological evidence of viral hepatitis, autoimmunity or adverse drug reactions, but show mononuclear portal inflammation with variable interface activity on liver allograft biopsies. In approximately 5% of patients monitored for a minimum of 10 years, progressive fibrosis will develop and result in established cirrhosis.

Pregnancy and birth control

Chronic liver disease is associated with sexual dysfunction, and liver transplantation usually results in correction of these abnormalities with return of normal sexual functioning 6–9 months after transplant. Transplant recipients should be advised regarding birth control. Patients are generally recommended to avoid pregnancy at least during the first year. This allows sufficient time to establish good general health, stable liver function and lower maintenance levels of immunosuppressive therapy. The safety and risks of oral contraceptives following transplantation are unknown, but concern regarding hepatotoxicity, thrombotic complications, interactions with other medications and exacerbation of hypertension are reasons why these medications are generally avoided. Intrauterine devices are not recommended because of an increased risk of infection.

There are few large series reporting on outcome after pregnancy among women after liver transplantation. In recent reports of pregnancy, graft function appeared to be maintained throughout pregnancy and delivery. Despite continued immunosuppression in these patients, the infants born to these mothers generally did well. The major maternal complications noted were hypertension and anaemia, and there was a higher rate of miscarriage compared with the normal population. Jain and colleagues [60] reported their experience of pregnancy occurring under tacrolimus immunosuppressive treatment. Thirty-seven mothers delivered 49 babies. Low-birthweight babies and preterm labour were persistent problems. One mother died of clotting of an aortic graft because of the gravid uterus. Twelve mothers had elevated liver enzymes during pregnancy that was remedied by increasing immunosuppression. Therefore, it is recommended that liver enzymes should be monitored and immunosuppressive treatment should not be decreased during pregnancy. Whether recipients should breastfeed remains controversial. In men, erectile dysfunction is common after liver transplantation and may be treated with phosphodiesterase 5 inhibitors.

Conclusion

Liver transplant recipients have a high prevalence of risk factors for cardiovascular disease, exceeding that of the general population, and have a higher predicted risk of developing coronary heart disease. Improved long-term survival necessitates careful screening for and management of long-term medical complications including cardiovascular complications, malignancy, bone disease, renal dysfunction and disease recurrence. The high rate of medical complications and of malignant tumours in the long-term follow-up of liver transplant recipients indicates that further optimization and especially minimizing of immunosuppressive therapy is greatly to be encouraged. Ongoing advances in immunosuppressive and antiviral medications will allow tailoring of the immunosuppressive regimen, which will benefit future liver recipients.

References

1 Adam R, McMaster P, O'Grady JG *et al.*; European Liver Transplant Association (2003) Evolution of liver transplantation in Europe: report of the European Liver Transplant Registry. *Liver Transpl* 9(12), 1231.

2 Seaberg EC, Belle SH, Beringer KC *et al.* (1999) Liver transplantation in the United States from 1987–1998: updated results from the Pitt-UNOS liver transplant registry. In: Cecka JM, Terasaki PI (eds) *Clinical Transplants 1998*. Los Angeles: UCLA Tissue Typing Laboratory, pp. 17–37.

3 Ciccarelli O, Kaczmarek B, Roggen F *et al.* (2005) Long-term medical complications and quality of life in adult recipients surviving 10 years or more after liver transplantation. *Acta Gastroenterol Belg* 68(3), 323–330.

4 Saliba F, Gugenheim J, Samuel D *et al.* (1987) Orthotopic liver transplantation in humans: monitoring by serial graft biopsies. *Transplant Proc* 19, 2454–2456.

5 Sebagh M, Samuel D (2004) Place of the liver biopsy in liver transplantation. *J Hepatol* 41(6), 897–901.

6 Therapondos G, Hayes PC (2002) Is this the end for protocol early posttransplant liver biopsies? *Liver Transpl* 8(12), 1154–1155.

7 Lang M, Neumann UP, Muller AR *et al.* (1999) Complications of percutaneous liver biopsy in patients after liver transplantation. *Z Gastroenterol* 37(3), 205–208.

8 Dobbels F, Vanhaecke J, Desmyttere A *et al.* (2005) Prevalence and correlates of self-reported pretransplant nonadherence with medication in heart, liver, and lung transplant candidates. *Transplantation* 79(11), 1588–1595.

9 Shemesh E, Shneider BL, Savitzky JK *et al.* (2004) Medication adherence in pediatric and adolescent liver transplant recipients. *Pediatrics* 113(4), 825–832.

10 Seyam MS, Gunson BK, Neuberger JM (2004) Late mortality in orthotopic liver transplant recipients who survive more than 5 years. Single center experience. *Hepatology* 40, 262A.

11 Rabkin JM, de La Melena V, Orloff SL *et al.* (2001) Late mortality after orthotopic liver transplantation. *Am J Surg* 181(5), 475–479.

12 Jain A, Reyes J, Kashyap R *et al.* (1999) What have we learned about primary liver transplantation under tacrolimus immunosuppression? Long-term follow-up of the first 1000 patients. *Ann Surg* 230(3), 441–448.

13 Everhart JE, Lombardero M, Lake JR *et al.* (1998) Weight change and obesity after liver transplantation: incidence and risk factors. *Liver Transpl Surg* 4(4), 285–296.

14 Neal DA, Tom BD, Gimson AE *et al.* (2001) Hyperuricemia, gout, and renal function after liver transplantation. *Transplantation* 27, 72(10), 1689–1691.

15 Richards J, Gunson B, Johnson J *et al.* (2005) Weight gain and obesity after liver transplantation. *Transpl Int* 18(4), 461–466.

16 Romero M, Parera A, Salcedo M *et al.* (1999) Cardiovascular risk factors and late cardiovascular disease in liver transplantation. *Transplant Proc* 31(6), 2364–2365.

17 Neal DA, Tom BD, Luan J *et al.* (2004) Is there disparity between risk and incidence of cardiovascular disease after liver transplant? *Transplantation* 77(1), 93–99.

18 Johnston SD, Morris JK, Cramb R *et al.* (2002) Cardiovascular morbidity and mortality after orthotopic liver transplantation. *Transplantation* 73(6), 901–906.

19 Munoz SJ, Elgenaidi H (2005) Cardiovascular risk factors after liver transplantation. *Liver Transpl* 11(Suppl. 2), S52–56.

20 Canzanello VJ, Schwartz L, Taler SJ *et al.* (1997) Evolution of cardiovascular risk after liver transplantation: a comparison of cyclosporine A and tacrolimus (FK506). *Liver Transpl Surg* 3(1), 1–9.

21 Textor SC, Taler SJ, Canzanello VJ *et al.* (2000) Posttransplantation hypertension related to calcineurin inhibitors. *Liver Transpl* 6(5), 521–530.

22 Neal DA, Brown MJ, Wilkinson IB *et al.* (2005) Mechanisms of hypertension after liver transplantation. *Transplantation* 79(8), 935–940.

23 Galioto A, Angeli P, Guarda S *et al.* (2005) Comparison between nifedipine and carvedilol in the treatment of de novo arterial hypertension after liver transplantation: preliminary results of a controlled clinical trial. *Transplant Proc* 37(2), 1245–1247.

24 Heisel O, Heisel R, Balshaw R *et al.* (2004) New onset diabetes mellitus in patients receiving calcineurin inhibitors: a systematic review and meta-analysis. *Am J Transplant* 4(4), 583–595.

25 Levy G, Villamil F, Samuel D *et al.*; LIS2T Study Group (2004) Results of lis2t, a multicenter, randomized study comparing cyclosporine microemulsion with C2 monitoring and tacrolimus with C0 monitoring in de novo liver transplantation. *Transplantation* 77(11), 1632–1638.

26 Bigam DL, Pennington JJ, Carpentier A *et al.* (2000) Hepatitis C-related cirrhosis: a predictor of diabetes after liver transplantation. *Hepatology* 32(1), 87–90.

27 Khalili M, Lim JW, Bass N *et al.* (2004) New onset diabetes mellitus after liver transplantation: the critical role of hepatitis C infection. *Liver Transpl* 10(3), 349–355.

28 AlDosary AA, Ramji AS, Elliott TG *et al.* (2002) Post-liver transplantation diabetes mellitus: an association with hepatitis C. *Liver Transpl* 8(4), 356–361.

29 Baid S, Cosimi AB, Farrell ML *et al.* (2001) Posttransplant diabetes mellitus in liver transplant recipients: risk factors, temporal relationship with hepatitis C virus allograft hepatitis, and impact on mortality. *Transplantation* 72(6), 1066–1072.

30 John PR, Thuluvath PJ (2002) Outcome of patients with new-onset diabetes mellitus after liver transplantation compared with those without diabetes mellitus. *Liver Transpl* 8(8), 708–713.

31 Fellstrom B (2001) Risk factors for and management of post-transplantation cardiovascular disease. *BioDrugs* 15(4), 261–278.

32 Gisbert C, Prieto M, Berenguer M *et al.* (1997) Hyperlipidemia in liver transplant recipients: prevalence and risk factors. *Liver Transpl Surg* 3(4), 416–422.

33 Hulzebos CV, Bijleveld CM, Stellaard F *et al.* (2004) Cyclosporine A-induced reduction of bile salt synthesis associated with increased plasma lipids in children after liver transplantation. *Liver Transpl* 10(7), 872–880.

34 Charco R, Cantarell C, Vargas V *et al.* (1999) Serum cholesterol changes in long-term survivors of liver transplantation: a comparison between cyclosporine and tacrolimus therapy. *Liver Transpl Surg* 5(3), 204–208.

35 Imagawa DK, Dawson S 3rd, Holt CD *et al.* (1996) Hyperlipidemia after liver transplantation: natural history and treatment with the hydroxy-methylglutaryl-coenzyme A reductase inhibitor pravastatin. *Transplantation* 62(7), 934–942.

36 Gonwa TA, Mai ML, Melton LB *et al.* (2001) Renal replacement therapy and orthotopic liver transplantation: the role of continuous veno-venous hemodialysis. *Transplantation* 71, 1424.

37 Gonwa TA, Mai ML, Melton LB *et al.* (2001) End stage renal disease following orthotopic liver transplantation utilizing calcineurin based immunotherapy: risk of development and treatment. *Transplantation* 72, 1934.

38 Kendrick EA, McVicar JP, Kowdley KV *et al.* (1997) Renal disease in hepatitis C-positive liver transplant recipients. *Transplantation* 63(9), 1287–1293.

39 Gayowski T, Singh N, Keyes L *et al.* (2000) Late-onset renal failure after liver transplantation: role of posttransplant alcohol use. *Transplantation* 69(3), 383–388.

40 Paramesh AS, Roayaie S, Doan Y *et al.* (2004) Post-liver transplant acute renal failure: factors predicting development of end-stage renal disease. *Clin Transplant* 18(1), 94–99.

41 Platz KP, Mueller AR, Blumhardt G *et al.* (1994) Nephrotoxicity following orthotopic liver transplantation. A comparison between cyclosporine and FK506. *Transplantation* 58(2), 170–178.

42 Jain A, Vekatramanan R, Eghtesad B *et al.* (2005) Long-term outcome of adding mycophenolate mofetil to tacrolimus for nephrotoxicity following liver transplantation. *Transplantation* 80(6), 859–864.

43 Scheifele C, Reichart PA, Hippler-Benscheidt M *et al.* (2005) Incidence of oral, pharyngeal, and laryngeal squamous cell carcinomas among 1515 patients after liver transplantation. *Oral Oncol* 41(7), 670–676.

44 Jimenez C, Marques E, Manrique A *et al.* (2005) Incidence and risk factors of development of lung tumors after liver transplantation. *Transplant Proc* 37(9), 3970–3972.

45 Jain AB, Yee LD, Nalesnik MA *et al.* (1998) Comparative incidence of de novo nonlymphoid malignancies after liver transplantation under tacrolimus using surveillance epidemiologic end result data. *Transplantation* 66(9), 1193–2000.

46 Graziadei IW, Nachbaur K, Koenigsrainer A *et al.* (2003) Incidence and prognosis of de-novo malignancies after liver transplantation. *Hepatology* 38, 256A.

47 Jain A, Nalesnik M, Reyes J *et al.* (2002) Posttransplant lymphoproliferative disorders in liver transplantation: a 20-year experience. *Ann Surg* 236(4), 429–436.

48 Jain AB, Marcos A, Pokharna R *et al.* (2005) Rituximab (chimeric anti-CD20 antibody) for posttransplant lymphoproliferative disorder after solid organ transplantation in adults: long-term experience from a single center. *Transplantation* 80(12), 1692–1698.

49 Oertel SH, Verschuuren E, Reinke P *et al.* (2005) Effect of anti-CD20 antibody rituximab in patients with post-transplant lymphoproliferative disorder. *Am J Transplant* 5(12), 2901–2906.

50 Monegal A, Navasa M, Guanabens N *et al.* (2001) Bone disease after liver transplantation: a long-term prospective study of bone mass

changes, hormonal status and histomorphometric characteristics. *Osteoporos Int* 12(6), 484–492.

51 Charlton M, Narayanan Menon KV (2005) Late complications of liver transplantation and recurrence of disease. In: Busuttil and Klintmalm (eds) *Transplantation of the Liver*, 2nd edn. Philadelphia: Elsevier, pp. 995–1017.

52 Wiesner RH, Shorr JS, Steffen BJ *et al.* (2005) Mycophenolate mofetil combination therapy improves long-term outcomes after liver transplantation in patients with and without hepatitis C. *Liver Transpl* 11(7), 750–759.

53 Moreno Planas JM, Cuervas-Mons Martinez V, Rubio Gonzalez E *et al.* (2004) Mycophenolate mofetil can be used as monotherapy late after liver transplantation. *Am J Transplant* 4(10), 1650–1655.

54 Sanchez EQ, Martin AP, Ikegami T *et al.* (2005) Sirolimus conversion after liver transplantation: improvement in measured glomerular filtration rate after 2 years. *Transplant Proc* 37(10), 4416–4423.

55 Wiesner RH, Demetris AJ, Belle SH *et al.* (1998) Acute hepatic allograft rejection: incidence, risk factors, and impact on outcome. *Hepatology* 28(3), 638–645.

56 Mor E, Gonwa TA, Husberg BS *et al.* (1992) Late-onset acute rejection in orthotopic liver transplantation – associated risk factors and outcome. *Transplantation* 54(5), 821–824.

57 Wiesner RH, Batts KP, Krom RA (1999) Evolving concepts in the diagnosis, pathogenesis, and treatment of chronic hepatic allograft rejection. *Liver Transpl Surg* 5(5), 388–400.

58 Pappo O, Ramos H, Starzl TE *et al.* (1995) Structural integrity and identification of causes of liver allograft dysfunction occurring more than 5 years after transplantation. *Am J Surg Pathol* 19(2), 192–206.

59 Hubscher SG (2001) Recurrent autoimmune hepatitis after liver transplantation: diagnostic criteria, risk factors, and outcome. *Liver Transpl* 7(4), 285–291.

60 Jain AB, Reyes J, Marcos A *et al.* (2003) Pregnancy after liver transplantation with tacrolimus immunosuppression: a single center's experience update at 13 years. *Transplantation* 76(5), 827–832.

25.7 Liver transplantation and quality of life

Miguel Navasa and Juan Rodés

Although the survival of patients undergoing liver transplantation (LT) may still rise, one of the current objectives for liver transplant teams is to achieve the best possible quality of life (QOL) for these patients. To achieve this, objective data must be available to provide knowledge as to the QOL of patients who have undergone LT, as well as to ascertain the main post-transplant disorders and complications which may, to a certain extent, influence the QOL that these patients have [1].

Measuring quality of life in liver transplant patients

The term QOL is very broad and includes physical and mental status, as well as psychosocial adaptation. Psychosocial adaptation is 'the capacity of an individual to perform social and domestic roles so as to meet the challenges of everyday living without emotional distress or physical disability' [2]. Nonetheless, the concept of QOL is subject to numerous interpretations because of the lack of clear, precise criteria for its measurement [3]. Schematically, the indicators of QOL may range from purely psychological aspects [4] and the capacity to return to work [3] to complex questionnaires regarding social activities and psychological problems. The first indicators considered were fundamentally aimed at measuring certain vital activities; therefore, they did not strictly measure QOL. The perception of QOL is not identical for all patients because cultural, economical, social and individual factors are involved. In a certain way, it is not infrequent to come across confusion between measuring the status of health and measuring QOL [1]. Measurement of the status of health and measurement of QOL are frequently confused [5]. Health status, QOL and functional status are concepts that are used indistinctly and comprise, in a broad sense, what is know as 'health' [6]. The concept of health in this sense ranges from very negative aspects, such as death, to very positive aspects, such as the love of life, having a normal capacity and even feeling truly happy.

Measuring QOL in liver transplant patients has some peculiarities. (i) The endpoint of LT is to improve survival in most cases, because LT is considered the last option treatment in the majority of liver diseases, and QOL is a secondary endpoint. Based on survival rates at 5 years after transplantation ranging from 60% to 65% [1], a pessimistic point of view could consider that, if the QOL in dead patients is equal to zero, QOL is very low or zero in 35–40% of the liver-transplanted patients at 5 years. In the 60–65% who remain alive, QOL is variable, being poor in patients with hepatitis C virus (HCV) recurrence. (ii) QOL is variable with time. The euphoric period immediately after LT is followed by a period of 'coming back to real life', with feelings of insecurity due to the appearance of some complications (rejection, cytomegalovirus infections, diabetes, arterial hypertension, etc.). In non-HCV-infected patients, there is a progressive improvement in QOL after 3 months, except in those patients with bone fractures or other less frequent complications. In HCV patients, the clinical recurrence of HCV infection produces anxiety that reduces QOL. Some patients, both HCV and non-HCV, have problems readapting at home despite the fact that they are in relatively good condition. On occasions, they are reluctant to assume the role of a healthy subject and prefer still to be considered as a patient with subsequent demands for extra care. In some cases, the liver-transplanted patient has to deal with family relationships that have previously deteriorated because of the liver disease or because of alcoholism. These situations can provoke feelings that things are not going well or, in other words, that the perceived QOL is not good. QOL at 5 years can be completely different in patients with recurrence of the liver disease that caused the liver transplant. This is particularly important in HCV patients who have a probability of severe recurrence of 30–50% at 5 years. On the other hand, an optimistic point of view could consider that LT improves survival and clearly improves QOL in most patients. The perception of QOL is difficult to measure; however, it is important to know the QOL of the patients because, to a certain extent, it allows the impact that a particular chronic disease may have in a particular patient to be measured [6]. The exclusive measurement of physiological functions provides very valid information to the physicians but is of limited interest to the patients and their relatives. Moreover, the data obtained do not usually correlate well with the functional capacity and the

well-being of the patients. Another reason why it is important to measure QOL is that, at times, two patients with the same clinical alterations may have totally different responses. All these considerations clearly justify the need for measuring the QOL of patients with chronic disease or for evaluating the results of a specific therapy.

Questionnaires comprising a series of questions or items duly designed for a certain domain or dimension are used to measure QOL. The term 'domain or dimension' is the area of behaviour or experience to be analysed, including mobility, depression, anxiety and well-being, among some possible aspects [7]. Usually, the domains analysed are physical functional capacity, social function (integration) and the measurement of functional capacity, mental health, general perception of health, vitality (energy/fatigue), pain and cognitive function. In contrast, the clinical and analytical data and those of other explorations (imaging techniques) are only analysed in very specific studies [8].

There are numerous questionnaires that analyse different domains, and they have been widely used to measure the QOL of patients with different chronic diseases. These tools should provide sufficient information to determine the disease, the personal functioning, the psychological distress/well-being, the general health perceptions and the social functioning of the patient. In this chapter, however, only the questionnaires and other techniques that are used most often to analyse the QOL of patients undergoing orthotopic liver transplantation (OLT) have been included.

The United Network of Organ Sharing

The United Network of Organ Sharing (UNOS) [9] is a relatively simple system used to code the level of a patient's physical function. For example, stage I is defined as the capacity of the patients to go to school or to work normally, and stage VI is defined as the need for mechanical assistance to allow the patient to remain alive.

The Sickness Impact Profile

The Sickness Impact Profile (SIP) [2] is a multidimensional tool that quantifies the status of health in relation to physical, cognitive and functional behaviour aspects that the patient perceives subjectively.

The Index of Well-being

The Index of Well-Being (IWB) is a weighted average of two components – the Overall Life Satisfaction, which is made up of a single item (how satisfied are you with your life as a whole these days?), and the Index of General Affect, which consists of eight bipolar adjectives such as interesting–boring or empty–full [10].

The Medical Outcome Survey

The Medical Outcome Survey (MOS) [11] is a brief questionnaire that measures physical and social function, physical and emotional limitations, mental health and the general perception of health.

The Karnofsky Performance Status Scale

The Karnofsky Performance Status Scale is a measurement developed to assess globally the function of patients regarding their normal activity [12]. It is an ordinal scale ranging from 100 (normal, i.e. no complaints, no evidence of disease) to 0 (death).

The Nottingham Health Profile

The Nottingham Health Profile (NHP) [11,12] is a questionnaire of perceived health that has been widely used in measuring QOL in many groups of patients. The NHP consists of 38 statements that describe possible experiences of health and illness in patients (i.e. everything requires an effort, I feel alone with no one close to me) classified into the following six dimensions of health: energy, pain, emotional reactions, sleep, social isolation and physical mobility. The NHP also includes questions on the following seven areas regarding the daily activities of the patients: work, domestic life, social interactions, family relationships, sexual activity, hobbies and holidays. Nevertheless, the NHP is limited to assessing physical function, symptoms and psychological function and, therefore, cannot address general health perceptions.

The Visual Analogue Scale

The Visual Analogue Scale (VAS) [13] is a measurement of well-being that is qualified by the patients themselves; the patient indicates the degree of well-being. The left side of the scale reflects feeling bad, while the right side of the scale reflects well-being. The total length of the scale is 10 cm.

The Short Form-36 Health Status Survey

The Short Form-36 Health Status Survey (SF-36) is a 36-item questionnaire that measures general health status. The SF-36 was developed to measure eight of the most important areas of health, which have universal value and represent the basic functions of humans and feelings of well-being in the broadest sense. These functions include physical activity, vitality, social function, emotional aspects and mental health. Items on the survey are scored from 1 to 100. The highest scores indicate the best health status; a value of 100 in all areas of health indicates that there are no limitations or problems in any area [14].

The Hospital Anxiety and Depression Scale

The Hospital Anxiety and Depression Scale is a 14-item questionnaire that autoevaluates the mood status of the patient and is used to measure anxiety and depression. The maximum score is 20, and a patient who scores 11 is considered to have significant anxiety or depression [15].

The Beck Depression Inventory

The Beck Depression Inventory is a standardized, 21-item measure of cognitive and affective function and somatic symptoms of depression. The items are scored from 0 to 63, with the highest scores indicating major depression [16].

The Profile of Mood States Scale

The Profile of Mood States Scale is a 65-item tool that globally measures the alterations in mood status and six types of emotion – anger and hostility; stress and anxiety; depression and dejection; vigour and activity; confusion and bewilderment; and fatigue and lack of energy. The highest scores indicate a very large alteration in the mood status of the patient [17].

The Ways of Coping Scale

The Ways of Coping Scale is an inventory of coping with illness styles used to assess how an individual copes with the general stress of being ill or adapts in the face of chronic illness. A higher score means that the patient adapts poorly [16].

The National Institute of Diabetes and Digestive and Kidney Diseases Liver Transplant Database QOL survey

The adult version of the National Institute of Diabetes and Digestive and Kidney Diseases (NIDDK) Liver Transplant Database (LTD) QOL survey was developed to measure QOL and health status from the perspective of the patient. This questionnaire has a modular format and includes global QOL measurements and subjective data on the health status of the patient, as well as specific symptoms of liver disease or as a consequence of LT. The concept was based on the 'bottom-up' theory of QOL, which proposes that global QOL is the sum of the individual opinions of the patients regarding the most important aspects of life, such as family, health and income [16–19].

The LTD QOL

The LTD QOL is an extensive questionnaire that was developed as a consequence of a longitudinal multicentre study on QOL after LT. The study was supported by the NIDDK. The questionnaire covers all the domains of QOL described by Ware [20] and is the only specific tool to measure the QOL of liver transplant patients. The questions were taken from several questionnaires that have already been validated for measuring QOL, such as the Karnofsky scale, NHP, SIP, IWB and MOS.

The European Organization of Research and Treatment of Cancer QOQ-C

The European Organization of Research and Treatment of Cancer QOQ-C is a short questionnaire (30 items) covering functional domains (physical, role, emotional, cognitive and social functioning) and symptom-oriented scales (fatigue, pain, nausea, gastrointestinal symptoms and others) [21].

The methods for measuring QOL, described briefly here, have been validated [22]. However, given the disparity of tools used in the published studies, the establishment of a database is important because it would allow comparison of the results obtained on QOL from all the LT programmes. This is particularly important because the concept of QOL is still not well defined and not all the investigators have the same criteria for measuring QOL. Moreover, although the tools used are excellent and validated, they are not standardized, and the best way to analyse the data obtained is not known. These aspects are essential because the studies published to date are difficult to compare.

Liver transplantation: does it improve quality of life?

Guyatt *et al.* [23] proposed that the fundamental question clinicians ask about QOL is: 'Will this treatment make my patients feel better?' [24]. In the case of liver transplant patients, the answer is yes. Most of the studies of the QOL of patients who have undergone LT demonstrate that more than 80% of patients are able to lead normal lives [25–28]. School-aged patients return to school, and their somatic and psychological development is completely normal [28]. Adult patients are able to return to their family responsibilities, social lives return to normal, and some patients go back to work. In addition, despite having to receive immunosuppressant treatment for life, in most cases, many male patients have successfully fathered children, and many females have become pregnant and given birth to healthy children. However, it is important to point out that miscarriage, premature births and caesarean deliveries are relatively frequent in women who have undergone liver transplantation [1].

By analysing the studies published on QOL after LT it is possible to detect aspects that impede valid, indisputable conclusions. Some studies are retrospective. In others, the patients in poor physical condition are excluded from the study and, in quite a few prospective studies, the deaths are not included in the data analysis. All these factors may influence the results obtained

and may positively magnify the effect of liver transplant on the patients' QOL [21]. Lastly, the evaluation of QOL should be performed at least once, 1 year after transplantation, because, by this time, the patient has stabilized clinically [12].

LT results in the disappearance of, or at least improvement in, symptoms related to the underlying liver disease. The pruritus and profound asthenia of patients with chronic cholestasis, and the hepatic encephalopathy, jaundice, ascites and other related symptoms in patients with cirrhosis are reversed by the implantation of a new liver. Likewise, patients have fewer health problems and few functional limitations. All studies observed an improvement in sexual function, mobility and social life [25–29]. Nonetheless, the QOL of patients who undergo LT is lower than that of the general population. In a prospective study, patients who underwent LT were found to have health limitations. Seven per cent of the patients had more difficulties in their vacation period and 14% in their sex life compared with an age- and gender-matched general population sample [30]. In other studies, patients who received a liver transplant often had other limitations at work, in looking after the home, in their social life and in their hobbies. Likewise, sleep alterations are relatively frequent in these patients. However, it must be emphasized that, after transplantation, the sleeping capacity is much better than that before receiving the liver graft [2,29,30]. In a study by Belle and Porayko [31], QOL worsened in a subgroup of patients (20%) after LT, probably because of the increase in body pain and the complications of transplantation itself/rejection, immunosuppression and post-transplant medical and surgical complications. On the other hand, the aspects related to family life improved significantly in many studies; Hellgren *et al.* [14] observed that patients who lived with their families had a much better QOL than those living alone. This result demonstrates the importance of family support in patients undergoing LT, and indicates that family support for patients in the evaluation phase for entering a LT programme is essential. Patients lacking family support must receive sufficient social support from the hospital itself.

Pain is relatively frequent in patients who receive liver transplants. The frequency of this complication ranges from 15% to 50%, and its mechanism is multifactorial. Immunosuppression treatment, underlying liver disease and the immobility or osteodystrophy often observed in liver patients probably play a very important role in the existence of pain, which obviously worsens the QOL of patients with transplants [12]. Of all possible causes of pain, the most important is probably bone disease [32,33].

Employment is an essential element of functional recovery and, therefore, of QOL [5]. In addition, it has been demonstrated that QOL after LT is related to income. Therefore, an important aim of LT should be to allow the patient to return to his or her job. The normalization or improvement in QOL directly influences the patient's capacity to return to work. The percentage of patients who return to work depends, among other things, on the type of social security available. According to the criteria of the clinicians, more than 50% of patients who received liver transplants were able to carry out normal work activities. It has also been shown that, if the patients are retired (long-term disease) before LT, the facilities for returning to the work market are reduced. Therefore, taking into account that returning to work improves the QOL, it may be deduced that work aspects should be included in the parameters used to evaluate patients for entering a liver transplant programme.

Evaluation of QOL may be considered one of the most important aspects to be analysed by all members of the LT team (surgeons, hepatologists, psychologists, nurses and social workers) and will aid patients undergoing OLT to have a better QOL.

Summary and future trends

In most patients, QOL improves after transplantation, although in some cases, it may worsen. One of the symptoms that most often worsens is pain which, undoubtedly, may result in a worse QOL after LT. A number of factors can result in a decreased QOL, notably recurrence of the underlying liver disease, complications that appear in the long term, especially vascular and biliary diseases, neurological alterations, arterial hypertension and hepatic osteodystrophy, and the absence of family support, income and employment.

Some considerations are still necessary to improve QOL:

- incorporation of psychologists, social workers and support nurses in the liver transplant teams;
- improvement in surgical techniques (if possible) to reduce post-transplant vascular and biliary complications to the minimum (particularly important in living donor liver transplantation);
- development of new immunosuppressive drugs with fewer side-effects;
- prevention and treatment of osteodystrophy;
- discovery of new antiviral agents that are effective in avoiding viral recurrence; and
- more prospective clinical research on QOL in homogeneous groups of patients with liver disease in LT programmes.

References

1 Rodés J, Navasa M (2000) Liver transplantation and quality of life. *Can J Gastroenterol* 14, 693–699.
2 Tarter RE, Switala J, Arria A *et al.* (1991) Quality of life before and after orthotopic liver transplantation. *Arch Intern Med* 151, 1521–1526.
3 Le plège A, Hunt S (1997) The problem of quality of life in medicine. *JAMA* 278, 47–50.
4 Walsh RM, Aranha GV, Freeark RJ (1990) Mortality and quality of life after total abdominal colectomy. *Arch Surg* 125, 1564–1566.
5 Patrick DL, Bergner M (1990) Measurement of health status in the 1990s. *Annu Rev Public Health* 11, 165–183.
6 Guyart GH, Feeny DH, Patrick DL (1993) Measuring health-related quality of life. *Ann Intern Med* 118, 622–629.

7 Torrance GW (1985) Measurement of health state utilities for economic appraisal. *J Health Econ* 5, 1–30.
8 Lundgren M, Kristiansson BG, Eleborg L (1994) Improved quality of life after liver transplantation. *Transplant Proc* 26, 1779.
9 Torrance GW (1986) Measurement of health state utilities for economic appraisal. *J Health Econ* 5, 1–30.
10 Hicks FD, Larson JL, Ferrans CE (1992) Quality of life after liver transplant. *Res Nurs Health* 15, 111–119.
11 Adams PC, Chent CN, Grant DR *et al.* (1995) Employment after liver transplantation. *Hepatology* 21, 140–144.
12 Navasa M, Forns X, Sánchez V *et al.* (1996) Quality of life, major medical complications and hospital service utilization in patients with primary biliary cirrhosis after liver transplantation. *J Hepatol* 25, 129–134.
13 Seiler CA, Müller M, Fisch HU *et al.* (1998) Quality of life after liver transplantation. *Transplant Proc* 30, 4330–4333.
14 Hellgren A, Berglund B, Gunnarsson U *et al.* (1998) Health-related quality of life after liver transplantation. *Liver Transpl Surg* 4, 215–221.
15 Zigmond AS, Snaith RP (1983) The hospital anxiety and depression scale. *Acta Psychiatr Scand* 67, 361–370.
16 Singh N, Gayowski, Wagener MM *et al.* (1999) Quality of life, functional status and depression in male liver transplant recipients with recurrent viral hepatitis C. *Transplantation* 67, 69–72.
17 McNair DM, Goldstein AP, Lorr M *et al.* (1965) Some effects of chlordiazepoxide and meprobromate with psychiatric outpatients. *Psychopharmacology* 7, 256–275.
18 Belle SH, Porayko MK, Hoofnagle JH *et al.* (1997) Changes in QOL after liver transplantation in adults. *Liver Transpl Surg* 3, 93–104.
19 Levy MF, Jennings L, Aboulijoud SM *et al.* (1995) Quality of life improvements at one, two and five years after liver transplantation. *Transplantation* 59, 515–518.
20 Ware JE (1984) Conceptualizing disease impact and treatment outcomes. *Cancer* 53 (Suppl. 10), 2316–2323.
21 Gross CR, Malinchoc M, Kim R *et al.* (1999) Quality of life before and after liver transplantation for cholestatic liver disease. *Hepatology* 29, 356–364.
22 Ferrer M, Córdoba J, Garin O *et al.* (2006) Validity of the Spanish version of the chronic liver disease questionnaire (CLDQ) as a standard outcome for quality of life. *Liver Transpl* 12, 95–104.
23 Guyatt GH, Naylor CD, Juniper E *et al.* (1997) Users' guide to the medical literature. XII. How to use articles about health-related quality of life. *JAMA* 277, 1232–1237.
24 Goff JS, Glazner J, Bilir BM (1998) Measuring outcome after liver transplantation: a critical review. *Liver Transpl Surg* 4, 189–196.
25 van den Berg-Emons R, Kazemier G, van Ginneken B *et al.* (2006) Fatigue, level of everyday physical activity and quality of life after liver transplantation. *J Rehabil Med* 38, 124–129.
26 Sainz-Barriga M, Baccarani U, Scudeller L *et al.* (2005) Quality of life assessment before and after liver transplantation. *Transplant Proc* 37, 2601–2604.
27 Moore DE, Feurer ID, Speroff T *et al.* (2005) Impact of donor, technical, and recipient risk factors on survival and quality of life after liver transplantation. *Arch Surg* 140, 273–277.
28 Avitzur Y, De Luca E, Cantos M *et al.* (2004) Health status ten years alter pediatric liver transplantation – looking beyond the graft. *Transplantation* 78, 566–573.
29 Gelling L (1998) Quality of life following liver transplantation: physical and functional recovery. *J Adv Nursing* 28, 779–785.
30 Price CE, Lowe D, Cohen AT *et al.* (1995) Prospective study of QOL in transplanted and not transplanted groups. *J R Soc Med* 166, 521–524.
31 Belle SH, Porayko MK (1995) Improvement in quality of life after transplantation for the recipients in the NIDDK Transplantation Database. *Transplant Proc* 27, 1230–1232.
32 Monegal A, Navasa M, Guañabens N *et al.* (1997) Osteoporosis and bone mineral metabolism disorders in cirrhotic patients referred to orthotopic liver transplantation. *Calcif Tissue Int* 60, 148–154.
33 Navasa M, Monegal A, Guañabens N *et al.* (1994) Bone fractures in liver transplant patients. *Br J Rheumatol* 33, 52–55.

25.8 Emerging therapies

25.8.1 Hepatocyte transplantation

Govardhana Rao Yannam, Jayanta Roy-Chowdhury and Ira J. Fox

Rationale for hepatocyte transplantation

Since the development of techniques for the isolation of individual cells from the liver, transplantation of isolated hepatocytes has been considered a potential therapy for the treatment of liver disorders. Over the last several decades, laboratories have progressively shown that primary hepatocytes can engraft in the liver, spleen and peritoneal cavity, and can function following transplantation to correct liver-based errors of metabolism and prolong the survival of animals with liver failure.

Because isolated hepatocytes can be transplanted using minimally invasive techniques, high-risk patients who might not be able to tolerate organ transplantation could potentially be treated. Cryopreservation techniques, not applicable to the storage of solid organs, would allow hepatocytes to be assessed for quality and sterility prior to their use, and would allow the procedure to be performed when needed rather than when a donor was available [1,2]. Theoretically, good-quality hepatocytes should be recoverable from damaged or cirrhotic livers, expanding the pool of donor livers not presently used for transplantation.

Individual hepatocytes could be genetically modified to enhance their function or genetically marked for non-invasive imaging following transplantation. Because hepatocytes do not express antigens present on endothelial cells or other cellular components of the liver, rejection of isolated liver cells should be manageable with less immune suppression than that required for a whole liver graft, making hepatocyte cross-species or xenotransplantation possible. Successful hepatocyte xenotransplantation would significantly affect the number of patients with liver disease who might be treated by transplantation and would change treatment dramatically. Eventually, it may be possible to genetically modify donor hepatocytes to prevent allograft or xenograft rejection. Experience in patients is limited, but hepatocyte transplantation in severely ill patients has been performed with few complications, engraftment has been documented in the liver and spleen, and partial correction of liver-based metabolic deficiency has been accomplished in a few patients. Most of the barriers to success have been identified and significant progress is being made.

Historical overview and laboratory evidence of function by transplanted hepatocytes

A technique for isolating hepatocytes was developed in 1969 by Seglen and Jervell and later modified by Berry and Friend [3,4]. Within a relatively short time after this development, transplantation studies were initiated. To circumvent graft rejection, initial studies were performed using syngeneic hepatocytes derived from inbred rodents. As transplanted syngeneic hepatocytes would be indistinguishable from native hepatocytes in the liver, engraftment was assessed by transplantation at extrahepatic sites, and function was determined by correction of liver function in animal models of induced liver failure and liver-based metabolic deficiencies. Later, transgenic mouse and gene transfer technologies revolutionized research on hepatocyte transplantation and analysis of the mechanisms involved in hepatocyte engraftment.

Functional correction of liver-based errors of metabolism by hepatocyte transplantation has now been documented in the Gunn rat (a model for Crigler–Najjar type 1) [5,6], the FAH mouse (a model of tyrosinaemia type 1) [7], the Long Evans cinnamon rat (a model of Wilson's disease) [8], the mdr2 mouse (a model of progressive familial intrahepatic cholestasis type 3) [9], the spf-ash mouse [a model of ornithine transcarbamylase (OTC) deficiency] [10], the Agxt–/– mouse (a model of primary hyperoxaluria-1) [11], the Watanabe heritable hyperlipidaemic (WHHL) rabbit (a model of familial hypercholesterolaemia) [12] and the hyperuricaemic Dalmatian dog [13]. Familial hypercholesterolaemia has also been partially corrected in

WHHL rabbits using genetically corrected autologous hepatocytes [14].

Correction of liver function and prolonged survival has also been shown in numerous animal models of acute liver failure. The efficacy of hepatocyte transplantation has been demonstrated in mice [15,16], rats [17,18], pigs [19] and dogs [20], where hepatic failure has been induced using carbon tetrachloride [16], dimethylnitrosamine [18], D-galactosamine [21] or ischaemia [19], and by surgical near-total hepatectomy [22]. These studies have demonstrated short-term engraftment and transient function by transplanted cells, but have not examined the effect of long-term engraftment by hepatocytes. Nor have they examined the capacity of donor cells to repopulate the host liver, which may be needed in patients with acute liver failure. Altered behaviour in rats due to hyperammonaemia-induced hepatic encephalopathy and decompensated liver failure in chemically induced cirrhotic rats have also been corrected by intrasplenic hepatocyte transplantation [23,24].

Sites for engraftment

In the normal liver and in most cases of acute liver failure and liver-based metabolic disorders, the hepatic architecture is intact and accommodates transplanted cells. Within the liver parenchyma, transplanted hepatocytes receive enriched blood from the portal circulation, and interact with non-parenchymal liver cells and components of the hepatic extracellular matrix, which are thought to be important for the maintenance of the hepatic mass. Following infusion into the portal circulation, or implantation into the spleen, the vast majority of donor hepatocytes translocate to the liver and accumulate in the hepatic sinusoids, causing transient portal hypertension that resolves in hours [25–27]. Transient pulmonary dysfunction due to embolization of hepatocytes into the lung parenchyma can also occur. Trapping of transplanted cells in hepatic sinusoids is most probably mediated by passive occlusion of the sinusoids by hepatocytes as well as receptor-mediated interactions between the transplanted hepatocytes and hepatic endothelial cells and components of the hepatic matrix. The majority of transplanted hepatocytes are cleared from the sinusoids, probably by macrophages and Kupffer cells, but a fraction of the cells disrupts the sinusoidal endothelium to translocate into the hepatic parenchyma [27]. Only a fraction of hepatocytes ultimately engrafts in the liver after intraportal or intrasplenic injection, the number reportedly ranging from 5% to 20%. Pharmacological disruption of endothelial integrity and sinusoidal dilatation appear to improve engraftment [28,29]. In rodents, engrafted hepatocytes survive for the life of the recipient.

A major limiting factor to intrahepatic engraftment is the number of viable cells that can be injected safely at one time. The rise in portal pressure is more pronounced in cirrhosis and is one of the many reasons why the liver is not an acceptable site for hepatocyte engraftment in this disease [24]. Several extrahepatic sites for hepatocyte engraftment have been examined. These include the spleen, the subcutaneous tissue [30], the peritoneal cavity [31], the kidney capsule [32,33], the pancreas [34], the mesentery [35] and the lung parenchyma [36].

The spleen appears to be the best extrahepatic site for engraftment, although little is known about the mechanisms guiding engraftment at this site [37]. Under normal circumstances, only a small fraction of hepatocytes injected into the spleen remains there, but a greater proportion of the cells engrafts in the spleen in cirrhotic recipients [24], and the number of cells retained in the spleen can be enhanced by transplantation in an alginate matrix [38]. In the spleen, hepatocytes can survive for at least 16 months and form hepatic cord-like structures [37]. Under some circumstances, hepatocytes engrafted in the spleen can proliferate to replace as much as 40% of the splenic mass [23,39].

The peritoneal cavity and subcutaneous tissue offer a large space for hepatocyte engraftment but, ordinarily, these sites do not efficiently support long-term attachment and survival of isolated liver cells. Engraftment in the peritoneal cavity is significantly enhanced when hepatocytes are attached to collagen-coated dextran microcarriers or when co-transplanted with non-parenchymal cells from the liver [40]. In the renal subcapsular space and subcutaneous tissue, the use of matrigel and vascular growth factors allows engraftment and the formation of a functioning hepatic mass in rodents [33].

Transplantation technique

The liver, spleen and peritoneal cavity have been used clinically for engraftment of transplanted hepatocytes. Thus far, only one group has transplanted patients using the peritoneal cavity as the site of engraftment, accessing the peritoneal cavity using a peritoneal dialysis catheter [41].

For access to the portal circulation, a number of approaches are available. The standard non-operative route for intrahepatic engraftment is transhepatic portal vein infusion [42]. There is some risk of lacerating the liver using this approach; however, this risk is thought to be offset by the prolonged length of time and the greater use of contrast required to access the portal vein by a transjugular approach [43]. In addition, manipulation of a catheter within the portal vein is considered to be easier with a transhepatic catheter. The transjugular approach to the portal vein may be more appropriate for transplantation in patients with ascites and in patients with an uncorrectable coagulopathy. Small children tend to have a large respiratory excursion that can cause a transhepatic catheter to migrate out of the portal vein. Under this circumstance, frequent verification of catheter location is required.

In newborns, access to the portal circulation can be accomplished safely through the umbilical vein. Infusion of hepatocytes may be complicated, however, by a patent ductus venosus. Transplantation can be delayed until the shunt closes or the shunt can be occluded using a balloon catheter [44]. Open surgical access to the portal circulation, by placement of an indwelling catheter in the coronary vein [45] or in a small

branch of the mesenteric vein [46,47], reduces the risk of bleeding, and may facilitate repeated hepatocyte infusion. In the portal circulation, hepatocytes are infused in multiple aliquots in a small volume of physiological saline, which reduces the risk of portal hypertension or thrombosis. During the infusion, portal vein pressure, pulmonary artery pressure and systemic arterial blood pressure are measured frequently, and oximetry is performed. The infusion rate is reduced or stopped if significant changes in any of these physiological parameters occur.

Transplantation for engraftment in the spleen has been performed to treat both acute and chronic liver disease. Accessing the spleen via the splenic artery has been considered the safest approach to hepatocyte transplantation in severely ill patients [43,48,49]. While hepatocytes have been identified in the spleens of transplanted patients, the number of cells identified using this approach has been quite small. The explanation for this finding has recently been elucidated in large animal studies, where infusing hepatocytes through the splenic artery produced splenic infarction and limited engraftment of hepatocytes [50]. Portal hypertension and clotting abnormalities have dampened the enthusiasm for a direct splenic puncture approach for delivery of donor hepatocytes to the spleen. Historically, however, serious complications have been rare following splenic puncture, even in patients with severe liver disease [51,52]. In large animal studies, direct splenic puncture with infusion of hepatocytes into the spleen produces excellent intrasplenic engraftment with little bleeding. The route of hepatocyte delivery has a profound influence on hepatocyte engraftment in the spleen and may be a major reason for the disparity in outcomes reported from the laboratory and the clinic.

Several patients have received hepatocytes by direct splenic puncture [48,53]. To gain access, the spleen is localized using computerized tomography (CT) or ultrasound imaging. Under fluoroscopic guidance, a small-gauge needle and then a catheter are directed into the splenic parenchyma and contrast is injected to confirm localization within the splenic pulp, and to verify splenic and portal vein patency. Splenic pulp pressure is monitored continuously. For direct splenic infusion, a high-density cell preparation is used to decrease the likelihood that hepatocytes will translocate out of the spleen. Additional cells are infused by redirection of the catheter into a different portion of the splenic parenchyma.

Cell preparation and cell sources for hepatocyte transplantation

Hepatocyte isolation

Hepatocytes are harvested using modifications of the two-step collagenase perfusion technique described by Seglen and Jervell and Berry and Friend [3,4]. In general, the liver is perfused with a buffer containing ethylenediaminetetraacetic acid (EDTA) or ethyleneglycotetraacetic acid (EGTA), followed by a second, similarly constituted, buffer that contains collagenase. Each lot of collagenase must be assessed for its ability to release hepatocytes. Individual lots of collagenase that function well to isolate hepatocytes in mice may not function well in other species. Following perfusion with collagenase, the capsule of the liver is torn, and the parenchymal cells are separated from the connective tissue using a nylon gauze filter. Hepatocytes are then washed several times and separated by centrifugation at 50 *g*. For storage, isolated hepatocytes can be resuspended in ViaSpan or cryopreserved using dimethyl sulphoxide (DMSO). Viability is usually assessed based on the ability of cells to exclude trypan blue. Unfortunately, this measure is a poor guide to hepatocyte function and engraftment potential. *In vitro* characteristics of isolated hepatocytes have not been shown to correlate with engraftment [54], and the ability of the cells to adhere to tissue culture plates 24 h after seeding is a better *in vitro* assay of engraftment potential [1,55]. At this time, there is no reliable non-invasive imaging or direct blood test for tracking donor hepatocytes after transplantation, and the best measure of cell quality and engraftment potential is retrospective short- and long-term serum human albumin level in immune-deficient mice transplanted with the isolated cells.

Human cell sources

Adult hepatocytes

In the vast majority of animal and human studies, primary hepatocytes derived from adult livers have been the source of donor cells. In mice, primary hepatocytes efficiently engraft in the liver and, being fully differentiated, function immediately. Rodent hepatocytes have nearly unlimited proliferative potential. In serial transplantation studies, a small number of hepatocytes have been shown to repopulate several generations of livers in animals whose native liver cells have reduced longevity because of an inherited metabolic disorder [7]. Murine hepatocytes, however, have constitutive telomerase activity, which adult human primary hepatocytes appear to lack. While human hepatocytes proliferate in the livers of immune-deficient mice with defective native hepatocytes, it is unclear whether they have the same proliferative capacity as rodent cells [56,57]. As maintenance of telomere length may also be necessary for long-term cell survival, the longevity of engrafted human hepatocytes may be limited.

The majority of donated cadaver livers are used for organ transplantation, leaving only those unsuitable as a result of high-grade steatosis, misdiagnosed liver disease or major parenchymal laceration [55,58] available for hepatocyte isolation. Hepatocytes isolated from steatotic livers tend to have poorer viability than those recovered from non-steatotic livers. Even under the best of circumstances, isolation of hepatocytes from human livers poses a challenge when compared with isolation of hepatocytes from animal donors. Depletion of metabolic energy sources from prolonged cold ischaemia and marginal quality donors do not occur in the laboratory. Several modifications in the hepatocyte isolation technique appear to be effective in

protecting hepatocytes after cold preservation. Addition of alanine, fructose and glycine and maintenance of a slightly acidic pH improves sodium and calcium homeostasis, and has been shown to improve human hepatocyte viability in marginal quality donor livers [55]. It remains to be seen whether these modifications translate into improved hepatocyte function after transplantation. Unfortunately, the engraftment potential and function after transplantation are dramatically affected by the length of time isolated hepatocytes are kept in cold storage before use [59]. Finally, the ability to cryopreserve hepatocytes is related to the initial quality of the cells, and reliable preservation of human hepatocytes for clinical use has not been established.

Fetal hepatocytes

While ethical concerns will need to be addressed before fetal cells are widely considered as a source of cells for clinical transplantation, fetal liver cells offer some biological advantages over adult human hepatocytes. Fetal rat liver cells have been reported to proliferate for as long as 6 months after transplantation in naive adult rats and to divide as many as 10 times, while adult rat hepatocytes proliferate for only 1 month and divide only three or four times [60]. Fetal liver cells have the capacity to differentiate into both hepatocytes and bile duct cells after transplantation, and human fetal hepatocytes tolerate cryopreservation well. After thawing, viability of fetal hepatocytes and their ability to engraft in the liver are excellent [61]. Fetal human hepatocytes appear to maintain telomere length by telomerase expression [62]. The number of hepatocytes that can be transplanted at any one time is limited by induction of portal hypertension. As fetal hepatocytes are smaller than adult hepatocytes, the degree of portal hypertension after transplantation may be less than that with an equivalent number of adult hepatocytes. While fetal hepatocytes are available in smaller numbers, their proliferative capacity might compensate for this. Most studies have been performed using late-stage rodent fetal hepatocytes. As fetal hepatocytes for clinical use would have to come from elective abortions, which are performed in the vast majority of cases during the first trimester of pregnancy, the engraftment potential and function of early gestational age fetal liver cells will need to be investigated. In an important single study, early gestational age fetal human hepatoblasts have been shown to engraft and proliferate as well as day 14 fetal rodent hepatocytes [63]. Additional studies will need to be performed to confirm this finding.

Liver stem cells

There continues to be interest in developing stem cells as a therapy for repairing diseased livers. While cells of the bone marrow and intestinal epithelium are actively repopulated by stem-like cells that self-replicate and can differentiate into multiple cell types, the liver regenerates from adult differentiated liver and biliary cells. The liver also contains a small pool of duct-like cells in the canals of Hering that appear to have stem cell properties [64]. These small round 'oval cells' are capable of differentiating into hepatocytes or bile duct cells [65]. They are not detectable in the normal liver but can be identified when induced to divide during liver injury, in the presence of an impairment of the proliferative capacity of mature hepatocytes [66–70]. Oval cell proliferation has been described in several human liver diseases [71]. These cells have not yet been isolated and/or purified, so that their potential for clinical use in the near future is small.

Oval cells express CD34, Thy-1 and c-kit, all of which are present on haematopoietic stem cells. As a result, investigators have hypothesized that liver cells can arise from the bone marrow. Bone marrow-derived liver cells have, in fact, been identified in rodent and human recipients of bone marrow and liver allografts [72–74], suggesting possible transdifferentiation of bone marrow stem cells into hepatocytes. Subsequent studies, however, indicated that the donor bone marrow-derived cells might not have transdifferentiated into hepatocytes, but were generated by fusion of haematopoietic cells with native hepatocytes [75,76]. There continues to be evidence that a small number of bone marrow cells may be able to differentiate directly into hepatocytes without fusion. Transdifferentiation appears to be a rare, relatively unphysiological event, with little potential clinical relevance at this time [77].

Mesenchymal stem cells (MSC) present in the bone marrow also appear to be capable of differentiating into other cell lineages *in vitro* and have been shown to form hepatocyte-like cells, which engraft in the liver in limited numbers following transplantation [78]. Embryonic stem cells, umbilical cord blood cells and human monocytes can all be differentiated into cells with hepatocyte-like characteristics by manipulating culture conditions *in vitro*. However, lineage-specific enrichment has not been accomplished widely [79–81]. While these cells have been shown to engraft in the liver in small numbers after transplantation, correction of liver disorders by transplantation has not been demonstrated.

Animal hepatocytes

Because of the many limitations to the use of human fetal and adult hepatocytes for clinical transplantation, alternative cell sources have been examined for their potential use in patients. Hepatocytes derived from animal donors could potentially solve many of the challenges associated with the use of human cells. Xenotransplantation of hepatocytes is not limited by the availability of donors and, as pig hepatocytes do not appear to be susceptible to infection by human hepatitis viruses, they might be preferred over human hepatocytes for transplantation in patients with viral hepatitis.

Pig hepatocytes have been transplanted with some success in animal studies. Gunsalus *et al.* [82] transplanted pig hepatocytes into the livers of WHHL rabbits, which manifest severe hypercholesterolaemia because of a deficiency in low-density lipoprotein (LDL) receptors. There was a 30–60% decrease in serum cholesterol levels in the rabbits that received hepatocyte xenotransplantation, with only ciclosporin A for immunosuppression.

In another study, pig hepatocytes transplanted into the spleens of cirrhotic rats with endstage liver disease produced improvement in hepatic function and greatly prolonged survival [38]. Retransplantation was accomplished with minimal immunosuppression and resulted in long-term function of the transplanted hepatocytes and dramatic improvement in survival. While natural antibodies appear to be an insurmountable barrier to organ xenotransplantation, this barrier has not been limiting for the survival of hepatocyte xenografts.

A major impediment to performing clinical xenotransplantation is the risk of transferring a recombinant animal virus to the transplant recipient. Proviral DNA of porcine endogenous retroviruses (PERV) is integrated into the genome of all pigs [83] and, because there would be no natural resistance to infection with such a virus in man, cross-species infection would be a major public health concern. So far, PERV has been transferred to human cells in tissue culture, but transmission has not occurred in humans connected to or transplanted with pig liver xenografts [84,85].

Transplantable hepatocyte cell lines

Despite the fact that primary adult hepatocytes have tremendous proliferating capacity, techniques for maintaining and expanding differentiated hepatocytes in long-term tissue culture are not yet available. Transplantable hepatocyte cell lines, however, have been developed. Conditionally immortalized hepatocytes grow in culture and retain many of their functional hepatocyte-like properties. Hepatocytes have been immortalized by transduction with the gene encoding the SV40 T antigen, the active subunit of human telomerase (hTERT) and the gene encoding constitutive expression of the hepatocyte growth factor receptor (truncated cMet) [62,86,87]. Transplantation of immortalized rodent hepatocytes has resulted in amelioration of inherited liver diseases [88,89], and has improved liver function and prolonged survival in animal models of acute liver failure [22] and endstage cirrhosis [54]. The major concern for clinical use is the risk of malignant transformation. To deal with this concern, immortalized human hepatocyte cell lines have been generated with excisable transforming genes and incorporation of suicide molecules, such as the herpes simplex virus thymidine kinase gene, that would allow elimination of transplanted cells should malignant transformation occur in the recipient [90]. Extensive preclinical studies will be required before such cell lines could be used in clinical trials and, initially, only high-risk patients who are not candidates for organ transplantation would be considered.

Clinical experience

To date, the immunosuppression used for human hepatocyte transplantation has been similar to that used to control rejection of whole organ liver allografts. The lack of non-invasive methods for assessing hepatocyte engraftment has made it difficult to optimize immunosuppressive regimens in the few patients so far transplanted.

Acute liver failure

Habibullah *et al.* [41] were the first to transplant isolated hepatocytes in patients with fulminant hepatic failure. In India, seven patients received human fetal hepatocytes. All had advanced grade III–IV hepatic encephalopathy and received a single intraperitoneal infusion of 60 million cells/kg body weight through a peritoneal dialysis catheter. The patients who did not consent to the procedure were taken as the 'control subjects'. All transplant recipients with grade III hepatic coma survived, whereas only 50% of the unmatched control subjects survived. Of the remaining four patients transplanted who had grade IV encephalopathy, only one recovered. While long-term engraftment in the peritoneum has not been accomplished by infusion of hepatocytes alone, this experience was encouraging for short-term clinical function by transplanted liver cells.

Subsequent clinical studies in patients with acute liver failure have been performed using adult allogeneic hepatocytes (Tables 1 and 2). Of the 20 patients reported to have received hepatocyte transplantation for acute liver failure, two recovered without organ transplantation. In seven patients, hepatocyte

Table 1 Human hepatocyte transplant experience in the treatment of acute liver failure: fetal hepatocyte (26–34 weeks gestational age) transplantation.

Age (years)	Protime index (PT patient/control)	Route	No. cells	HE	Outcome
32	3	IP	60×10^6/kg BW	IV	Died 30 h
8	1.5	IP	60×10^6/kg BW	III	Recovered
40	3.1	IP	60×10^6/kg BW	IV	Died 13 h
29	2.6	IP	60×10^6/kg BW	IV	Died 37 h
20	2.7	IP	60×10^6/kg BW	IV	Died 48 h
20	1.4	IP	60×10^6/kg BW	IV	Recovered
24	1.4	IP	60×10^6/kg BW	III	Recovered

IP, intraperitoneal; BW, body weight; HE, hepatic encephalopathy; PT, prothrombin time.

Table 2 Human hepatocyte transplant experience in the treatment of acute liver failure: allogeneic adult hepatocyte transplantation.

Age	Disease	No. cells	Site	Outcome
32 years	Etoh	1.3×10^9 (frozen)	Spleen	Imp INR; imp HE; cells identified; died 14 days – sepsis
35 years	Etoh	1.0×10^{10} (frozen)	Spleen	Imp INR; imp HE; cells identified; died 20 days – *Aspergillus*
29 years	Etoh, HSV	1.0×10^{10} (frozen)	Spleen/liver	Hypoxaemia; cells identified – lungs and liver; died 18 h – HSV
65 years	Etoh, HBV	3.0×10^{10} (frozen)	Spleen/liver	Hypoxaemia; imp INR; imp HE; cells identified; died 52 days – MOSF
55 years	Etoh	4.0×10^{10} (frozen)	Spleen	Died 6 h – MOSF
15 years	Etoh	4.0×10^7 (frozen)	Liver	Imp NH3; died 2 days; cells identified
12 years	Drug reaction	1.2×10^9 (frozen)	Liver	Died 4 days; cells identified
3 years	Idiopathic	4.0×10^9 (frozen)	Liver	Complete recovery
27 years	Dilantin	2.8×10^7 (fresh)	Spleen	OLT 10 days; imp NH3; PCR+ donor DNA in liver
28 years	HBV	1.9×10^8 (frozen)	Spleen	OLT 3 days
37 years	Valproate, HSV			Died 5 days – sepsis
23 years	Idiopathic			OLT 5 days
43 years	HBV			OLT 1 day
26 years	Paracetamol			OLT 1 day
37 years	HBV			Complete recovery; HE Gr I pre-transplant
69 years	s/p liver resection			Died 2 days – cardiopulmonary
5 months	Idiopathic			OLT 2 days
13 years	Dilantin	2.9×10^8 (frozen)	Spleen	Died 4 days – brain death
53 years	Halothane	4.4×10^9 (fresh)	Liver	Imp HE; imp INR; died 35 days – sepsis; cells identified
4 months	A1AT	1.4×10^8 (fresh)	Liver	Liver cirrhosis; PV clot; OLT 12 days

BW, body weight; Etoh, alcoholic hepatitis; HSV, herpes simplex virus; HBV, hepatitis B virus; s/p, status post; A1AT, alpha-1-antitrypsin deficiency; imp, improved; INR, international normalized ratio; HE, hepatic encephalopathy; MOSF, multiple organ system failure; PV, portal vein; PCR, polymerase chain reaction; PT, prothrombin time; Gr, grade; OLT, orthotopic liver transplant.

transplantation served as a bridge to subsequent organ transplantation, and the remaining patients died from sepsis and/or multiple organ system failure. Most patients received their cells via the splenic artery for engraftment in the spleen, although a small number underwent infusion through the portal circulation for engraftment in the liver. Evidence of engraftment was confirmed histologically in several patients in both the spleen and the liver [43,48,49]. The procedure has been performed with few complications, despite the patients' desperate state of health. Anecdotal reports of functional and biochemical improvement in liver function have been published, but it is not clear whether the transplanted hepatocytes produced the clinical benefit. As has been the case with studies examining the efficacy of liver assist devices, small patient numbers, a lack of control subjects and multiple aetiologies for liver failure make these reports difficult to interpret. The discrepancy between the highly encouraging results in the laboratory and the modest clinical benefit is not surprising, as there is suppression of liver regeneration in patients with advanced acute liver failure, whereas the regenerative capacity of hepatocytes is not suppressed in most laboratory animal models used for studying the treatment of liver failure [91]. In addition, a majority of the patients were transplanted with a relatively small number of hepatocytes, and many patients received the cells through the splenic artery. It is possible that repeated infusion of a larger number of hepatocytes, with the goal of engraftment in the liver, could improve outcomes.

Chronic liver failure

The first treatment of chronic liver disease by hepatocyte transplantation was performed in 1992 by Mito *et al.* [53], who described results in a small series of patients with liver cirrhosis who received autologous hepatocytes recovered from their own partial hepatectomy specimens. The therapeutic strategy was based on the proposition that dysfunction of native hepatocytes in cirrhosis could result from the abnormal environment within the cirrhotic liver. Transplantation was performed by splenic puncture or by infusion through the splenic artery or the portal vein. Hepatocytes were detected in the spleen of one patient 11 months after transplantation by radioisotope imaging. In the USA, eight additional patients with decompensated cirrhosis have received hepatocyte transplants [48]. In each case, hepatocytes were infused through the splenic artery. Although engrafted hepatocytes have been visualized in the spleens of some of these patients by radioisotope uptake and anecdotal improvement in liver function has been reported, it is again unclear whether the transplanted hepatocytes significantly affected the patients' clinical outcome (Tables 3 and 4). As noted previously, the discrepancy in clinical efficacy compared with that in the animal experiments may relate to the fact that the hepatocytes were transplanted in patients through the splenic artery, a route associated with relatively poor engraftment [50].

Table 3 Human hepatocyte transplant experience in the treatment of chronic liver failure: autologous hepatocyte transplantation.

Age (years)	Disease/severity	No. cells	Site	Outcome
54	Childs A,B	1.1×10^8 (fresh)	?Spleen (DP/SA) – liver	+ Scan at 1 month
46	Cirrhosis	1.7×10^7 (fresh)	?Spleen (DP/SA) – liver	+ Nuclear or CT scan 3 months
48	Cirrhosis	1.0×10^8 (fresh)	?Spleen (DP/SA) – liver	+ Nuclear or CT scan 3 months
54	Cirrhosis	2.0×10^7 (fresh)	?Spleen (DP/SA) – liver	?+ Nuclear or CT scan 6 months
58	Childs A	4.4×10^7 (fresh)	?Spleen (DP/SA) – liver	+ Nuclear or CT scan 1 month
58	CAH	6.0×10^8 (fresh)	?Spleen (DP/SA) – liver	
64	Childs C	2.0×10^8 (fresh)	?Spleen (DP/SA) – liver HA ligation	+ Nuclear scan at 11 months; imp HE; returned to work
78	Childs C	1.0×10^8 (fresh)	?Spleen (DP/SA) – liver HA ligation	+ Nuclear or CT scan at 3 months
68	Childs C	1.0×10^8 (fresh)	?Spleen (DP/SA) – liver HA ligation	+ Nuclear or CT scan at 5 months
78	Childs B	1.0×10^8 (fresh)	?Spleen (DP/SA) – liver HA ligation	

DP/SA, direct puncture of the spleen/splenic artery infusion; imp, improved; HE, hepatic encephalopathy; CT, computerized tomography.

Table 4 Human hepatocyte transplant experience in the treatment of chronic liver failure: allogeneic hepatocyte transplantation.

Age	Disease	No. cells	Site	Outcome
52 years	A1AT	2.2×10^7 (frozen)	Spleen	OLT 2 days; imp NH3; A1AT level 19–92 mg/dL
40 years	HCV	7.5×10^6 (frozen)	Spleen	Died 2 days – brain death/ICP monitor; imp NH3; cells identified at autopsy
6 months	TPN cholestasis	5.2×10^7 (frozen)	Spleen	Died 7 days – brain death; imp NH3
62 years	Etoh cirrhosis			Died after discharge 33 days
25 years	Etoh hepatitis/cirrhosis	4.8×10^9 (fresh)	Spleen	?+ Scan; imp TB; imp INR; imp HRS (TIPS); died 50 days – sepsis
	Etoh cirrhosis			Recovered
	Etoh cirrhosis			Recovered
	Etoh cirrhosis			Recovered

DP/SA, direct puncture of the spleen/splenic artery infusion; imp, improved; A1AT, alpha-1-antitrypsin deficiency; HCV, hepatitis C virus; TPN, total parenteral nutrition; Etoh cirrhosis; alcoholic cirrhosis; Etoh hepatitis, alcoholic hepatitis; INR, international normalized ratio; HRS, hepatorenal syndrome; TIPS, transjugular intrahepatic portosystemic shunt; ICP, intracranial pressure; OLT, orthotopic liver transplantation.

Liver-based metabolic disease

The first attempted treatment of a metabolic disorder by *ex vivo* gene therapy was performed in patients with familial hypercholesterolaemia. The procedure, which was based on laboratory studies in mutant WHHL rabbits, consisted of isolation of primary hepatocytes from liver segments obtained from the patients by partial hepatectomy, followed by transduction with recombinant retroviruses expressing the gene encoding the LDL receptor. The phenotypically corrected autologous hepatocytes were then infused back into the liver of the donors through the portal circulation. Low levels of transgene expression were demonstrated in the liver of these patients, but the metabolic response observed was not clinically significant [92].

In all subsequent cases, allogeneic hepatocytes have been transplanted into patients to correct a variety of metabolic disorders. These include ornithine transcarbamylase (OTC) deficiency [44,93], alpha-1-antitrypsin deficiency [48], glycogen storage disease type 1a [94], infantile Refsum's disease [46], factor VII deficiency [47], bile salt export protein deficiency (PFIC2) [95] and Crigler–Najjar syndrome type 1 [42]. Partial but significant improvement in the metabolic syndrome has been documented in several diseases. In a patient with glycogen storage disease type 1a, hepatocyte transplantation resulted in improved glycaemic control, although no increase in enzyme activity or evidence of engraftment by transplanted cells was demonstrated by liver biopsy. In a child with infantile Refsum's disease, serum dihydroxycoprostanoic acid levels remained improved for more than 1 year after transplantation. Eleven days after infusion of more than 4 billion hepatocytes in an infant with severe OTC deficiency, there was documented biochemical and clinical improvement; however, the enzyme activity was lost after this period, presumably as a result of acute rejection [44]. Unequivocal evidence of long-term function by transplanted human hepatocytes was obtained in a 10-year-old child with Crigler–Najjar syndrome type 1 (UGT1A1 deficiency). This patient's total serum bilirubin levels and the requirement for phototherapy were reduced dramatically, bilirubin conjugates were identified in the bile, and a post-transplantation liver biopsy demonstrated enzyme activity (Tables 5 and 6). Continued function of the engrafted cells was demonstrated by analysis of pigments excreted in bile for nearly 3 years

Table 5 Human hepatocyte transplant experience in the treatment of liver-based metabolic disease.

Autologous hepatocyte transplantation
Gene therapy (LDL receptor) for familial hypercholesterolaemia

Age (years)	No. cells
28	1.1×10^9
12	1.3×10^9
7	1.0×10^9
41	3.0×10^9
12	1.5×10^9

Outcome
Transgene expression on liver biopsy
Reduction in LDL levels in three patients

after transplantation. After this, the patient underwent liver organ transplantation because of continued requirement for phototherapy and slowly rising bilirubin levels [95].

Number of cells required to correct liver disease

The hepatocyte mass required to cure the various forms of liver disease is not known, and animal studies have not been specifically designed to answer this question. The number of liver cells needed to replace function will depend on whether the indication for transplantation is liver failure or a metabolic deficiency. Hepatocyte transplantation has not completely corrected any metabolic abnormality. This failure to completely correct enzyme deficiencies is explained by the relatively small number of hepatocytes that are engrafted in most transplant recipients. As the number of cells that can be transplanted is limited by concerns for the development of portal hypertension, repeated intraportal infusion of hepatocytes could be effective. In Nagase analbuminaemic rats, this approach has allowed successful engraftment of a relatively large number of hepatocytes and more effective correction of the animal's metabolic deficiency [96]. Both laboratory studies and the clinical experience underline the need for strategies to achieve significant proliferation of the engrafted cells. Furthermore, in some metabolic diseases, such as primary hyperoxalurias, where the liver cells generate excessive oxalate, or alpha-1-antitrypsin deficiency, where intracellular deposition of mutant proteins causes liver injury [97], it would be desirable to replace the majority of the host hepatocytes with the progeny of the engrafted phenotypically normal hepatocytes. As the total liver mass tends to be maintained by physiological mechanisms within a narrow range, obtaining a massive growth of the engrafted cells would require preferential proliferation of the transplanted cells over host hepatocytes.

In acute liver failure and several animal models of metabolic liver disorders, transplanted hepatocytes have a proliferative advantage over native liver cells. In the transgenic Alb-uPA mouse, the fumaryl acetoacetate dehydrogenase-deficient mouse (a model of hereditary tyrosinaemia type 1), the mdr2–/– mouse and, to a lesser extent, the Long Evans cinnamon rat (a model of Wilson's disease), sustained damage of the host hepatocytes leads to preferential expansion of donor cells [8,9,98]. In theory, human tyrosinaemia type 1 and Wilson's disease could be treated in a manner similar to that in rodents. However, in most liver-based metabolic disorders, donor hepatocytes do not have a selective growth advantage over native hepatocytes. In laboratory animals with normal hepatic architecture, hepatic irradiation and the drug retrorsine can block the proliferation of host hepatocytes, while partial hepatectomy or infusion of hepatocyte growth factors, such as thyroid hormone or hepatic growth factor, could be used to stimulate the expansion of donor hepatocytes [99–101]. Under these circumstances, the proliferation of the transplanted cells is coupled with apoptosis of the host hepatocytes, resulting in massive hepatic repopulation, without an increase in the total liver mass. Using this strategy, over 90% of the host hepatocytes in rats and mice could be replaced by the progeny of the engrafted hepatocytes, resulting in complete correction of hyperbilirubinaemia in the Gunn rat model of Crigler–Najjar syndrome type 1 and abolition of hyperoxaluria in the Agxt–/– mouse model of primary hyperoxaluria-1 [11] (see Plate 25.8.1 facing p. 1268).

Thus, in patients with acute liver failure and metabolic deficiencies that significantly reduce the longevity of host hepatocytes, spontaneous repopulation of the host liver with donor cells holds the best hope for cure. In liver-based metabolic

Table 6 Human hepatocyte transplant experience in the treatment of liver-based metabolic disease: allogeneic hepatocyte transplantation.

Disease	Age	No. cells	Outcome
OTC	5 years	1.0×10^9 (fresh); 0.7×10^9 (frozen)	Biopsy: enzyme activity 0.3–0.5 nL; died 43 days
GSD1a	47 years	2.0×10^9 (fresh)	Biopsy: enzyme activity at 8 weeks 9 nmol/min/mg; no hypoglycaemia on normal diet
OTC	Newborn	4.0×10^9 (fresh)	Day 20–31: normal protein intake off meds; auxiliary OLT 6 months
CN1	10 years	7.5×10^9 (fresh)	TB 462–200 μM/L; bile 33% bili glucuronides; biopsy: enzyme activity 5.5% normal
Infantile refsum	4 years	1.1×10^9 (fresh); 2.0×10^9 (frozen)	Partial clearance abn bile acids; pipecholic acid 60% pre-tx levels; C26:C22 ratio 64% pre-tx levels; standing and walking 6 months post-tx

OTC, ornithine transcarbamylase deficiency; GSD1a, glycogen storage disease type 1a; CN1, Crigler–Najjar syndrome type 1; TB, total bilirubin; OLT, orthotopic liver transplant; bili, bilirubin; abn, abnormal; tx, transplant.

deficiencies where there is no proliferative advantage of transplanted cells, even repeated hepatocyte infusion is unlikely to replace more than 5–10% of hepatocyte mass. In these cases, strategies that combine stimulation of mitosis of the transplanted cells and inhibition of proliferation of host hepatocytes may result in cure. In cirrhotic rats, transplantation of as few as 1–3% of the normal hepatocyte mass into the spleen improves overall liver function and survival, suggesting that engraftment at a site outside the deleterious environment of the cirrhotic nodules is critical for the function of these cells [24]. It is not known at this time whether this finding is applicable in human subjects.

Summary

Laboratory studies and clinical trials, spanning several decades, have demonstrated the potential of hepatocyte transplantation in the treatment of acute and chronic liver failure, as well as in inherited metabolic liver diseases. Universal application of this strategy, however, will require overcoming several barriers. First, the availability of high-quality fresh hepatocytes that can be cryopreserved and used subsequently for transplantation is extremely limited. Alternatives to adult hepatocytes from deceased donors that are being explored include fetal hepatocytes, stem cells of various types, conditionally immortalized hepatocytes and xenogeneic hepatocytes. Autologous hepatocytes are being tested as vehicles of *ex vivo* gene therapy. Second, animal studies and clinical trials show that it may not be possible to transplant adequate numbers of cells in a single session to fully cure inherited metabolic diseases. In rare circumstances, the metabolic disease reduces the lifespan of host hepatocytes significantly, resulting in spontaneous and extensive replacement of host hepatocytes by the transplanted cells. In other cases, it may be necessary to inhibit the proliferation of host hepatocytes, for example by irradiation, while stimulating the proliferation of the engrafted cells. Third, there is a discrepancy between the encouraging results obtained in animal models of acute liver failure and those in clinical trials of acute liver failure. This is partly because of the fact that the animal models used do not fully represent human acute liver failure, in which host liver regeneration is suppressed by the disease process. Also, inadequacies in the number of transplanted cells and the route of administration may be responsible for the modest outcome. Finally, the cirrhotic liver may not be an appropriate site for hepatocyte engraftment, not only because of increased risk of portal hypertension and pulmonary embolism, but also because of the abnormal environment in cirrhotic nodules. Transplantation in extrahepatic sites may be beneficial in these cases, although this has not been evaluated in clinical trials.

Thus, the feasibility and therapeutic benefit of hepatocyte transplantation in the treatment of a wide range of human liver diseases have been demonstrated. However, the coordinated effort of multiple investigators will be required to cross the remaining hurdles before the enormous potential of this therapeutic strategy can be harnessed.

Acknowledgement

Preparation of this review was supported in part by NIH grants DK48794 and AI49472 to IJF, and DK 46057 to JRC. The authors acknowledge the important contribution of many investigators that could not be cited because of limited space.

References

1 Mitry RR, Hughes RD, Dhawan A (2002) Progress in human hepatocytes: isolation, culture and cryopreservation. *Semin Cell Dev Biol* 13(6), 463–467.

2 Jamal HZ, Weglarz TC, Sandgren EP (2000) Cryopreserved mouse hepatocytes retain regenerative capacity in vivo. *Gastroenterology* 118(2), 390–394.

3 Seglen PO, Jervell KF (1969) A simple perfusion technique applied to glucocorticoid regulation of tryptophan oxygenase turnover and bile production in the isolated rat liver. *Hoppe Seylers Z Physiol Chem* 350(3), 308–316.

4 Berry MN, Friend DS (1969) High-yield preparation of isolated rat liver parenchymal cells: a biochemical and fine structural study. *J Cell Biol* 43(3), 506–520.

5 Matas AJ, Sutherland DE, Steffes MW *et al.* (1976) Hepatocellular transplantation for metabolic deficiencies: decrease of plasma bilirubin in Gunn rats. *Science* 192(4242), 892–894.

6 Groth CG, Arborgh B, Bjorken C *et al.* (1977) Correction of hyperbilirubinemia in the glucuronyltransferase-deficient rat by intraportal hepatocyte transplantation. *Transplant Proc* 9(1), 313–316.

7 Overturf K, al-Dhalimy M, Ou CN *et al.* (1997) Serial transplantation reveals the stem-cell-like regenerative potential of adult mouse hepatocytes. *Am J Pathol* 151(5), 1273–1280.

8 Yoshida Y, Tokusashi Y, Lee GH *et al.* (1996) Intrahepatic transplantation of normal hepatocytes prevents Wilson's disease in Long-Evans cinnamon rats. *Gastroenterology* 111(6), 1654–1660.

9 De Vree JM, Ottenhoff R, Bosma PJ *et al.* (2000) Correction of liver disease by hepatocyte transplantation in a mouse model of progressive familial intrahepatic cholestasis. *Gastroenterology* 119(6), 1720–1730.

10 Michel JL, Rabier D, Rambaud C *et al.* (1993) Intrasplenic transplantation of hepatocytes in spf-ash mice with congenital ornithine transcarbamylase deficiency. *Chirurgie* 119(10), 666–671.

11 Guha C, Yamanouchi K, Jiang J *et al.* (2005) Feasibility of hepatocyte transplantation-based therapies for primary hyperoxalurias. *Am J Nephrol* 25(2), 161–170.

12 Wiederkehr JC, Kondos GT, Pollak R (1990) Hepatocyte transplantation for the low-density lipoprotein receptor-deficient state. A study in the Watanabe rabbit. *Transplantation* 50(3), 466–471.

13 Kocken JM, Borel Rinkes IH, Bijma AM *et al.* (1996) Correction of an inborn error of metabolism by intraportal hepatocyte transplantation in a dog model. *Transplantation* 62(3), 358–364.

14 Chowdhury JR, Grossman M, Gupta S *et al.* (1991) Long-term improvement of hypercholesterolemia after ex vivo gene therapy in LDLR-deficient rabbits. *Science* 254(5039), 1802–1805.

15 Gagandeep S, Sokhi R, Slehria S *et al.* (2000) Hepatocyte transplantation improves survival in mice with liver toxicity induced by hepatic

overexpression of Mad1 transcription factor. *Mol Ther* 1(4), 358–365.
16 Krishna Vanaja D, Sivakumar B, Jesudasan RA *et al.* (1998) In vivo identification, survival, and functional efficacy of transplanted hepatocytes in acute liver failure mice model by FISH using Y-chromosome probe. *Cell Transplant* 7(3), 267–273.
17 Demetriou AA, Whiting JF, Feldman D *et al.* (1986) Replacement of liver function in rats by transplantation of microcarrier-attached hepatocytes. *Science* 233(4769), 1190–1192.
18 Sutherland DE, Numata M, Matas AJ *et al.* (1977) Hepatocellular transplantation in acute liver failure. *Surgery* 82(1), 124–132.
19 Arkadopoulos N, Chen SC, Khalili TM *et al.* (1998) Transplantation of hepatocytes for prevention of intracranial hypertension in pigs with ischemic liver failure. *Cell Transplant* 7(4), 357–363.
20 Sommer BG, Sutherland DE, Simmons RL *et al.* (1980) Hepatocellular transplantation for experimental ischemic acute liver failure in dogs. *J Surg Res* 29(4), 319–325.
21 Baumgartner D, LaPlante-O'Neill PM, Sutherland DE *et al.* (1983) Effects of intrasplenic injection of hepatocytes, hepatocyte fragments and hepatocyte culture supernatants on D-galactosamine-induced liver failure in rats. *Eur Surg Res* 15(3), 129–135.
22 Nakamura J, Okamoto T, Schumacher IK *et al.* (1997) Treatment of surgically induced acute liver failure by transplantation of conditionally immortalized hepatocytes. *Transplantation* 63(11), 1541–1547.
23 Ribeiro J, Nordlinger B, Ballet F *et al.* (1992) Intrasplenic hepatocellular transplantation corrects hepatic encephalopathy in portacaval-shunted rats. *Hepatology* 15(1), 12–18.
24 Kobayashi N, Ito M, Nakamura J *et al.* (2000) Hepatocyte transplantation in rats with decompensated cirrhosis. *Hepatology* 31(4), 851–857.
25 Ponder KP, Gupta S, Leland F *et al.* (1991) Mouse hepatocytes migrate to liver parenchyma and function indefinitely after intrasplenic transplantation. *Proc Natl Acad Sci USA* 88(4), 1217–1221.
26 Rajvanshi P, Kerr A, Bhargava KK *et al.* (1996) Studies of liver repopulation using the dipeptidyl peptidase IV-deficient rat and other rodent recipients: cell size and structure relationships regulate capacity for increased transplanted hepatocyte mass in the liver lobule. *Hepatology* 23(3), 482–496.
27 Gupta S, Rajvanshi P, Sokhi R *et al.* (1999) Entry and integration of transplanted hepatocytes in rat liver plates occur by disruption of hepatic sinusoidal endothelium. *Hepatology* 29(2), 509–519.
28 Slehria S, Rajvanshi P, Ito Y *et al.* (2002) Hepatic sinusoidal vasodilators improve transplanted cell engraftment and ameliorate microcirculatory perturbations in the liver. *Hepatology* 35(6), 1320–1328.
29 Malhi H, Annamaneni P, Slehria S *et al.* (2002) Cyclophosphamide disrupts hepatic sinusoidal endothelium and improves transplanted cell engraftment in rat liver. *Hepatology* 36(1), 112–121.
30 Jirtle RL, Biles C, Michalopoulos G (1980) Morphologic and histochemical analysis of hepatocytes transplanted into syngeneic hosts. *Am J Pathol* 101(1), 115–126.
31 Demetriou AA, Levenson SM, Novikoff PM *et al.* (1986) Survival, organization, and function of microcarrier-attached hepatocytes transplanted in rats. *Proc Natl Acad Sci USA* 83(19), 7475–7479.
32 Ricordi C, Lacy PE, Callery MP *et al.* (1989) Trophic factors from pancreatic islets in combined hepatocyte-islet allografts enhance hepatocellular survival. *Surgery* 105(2 Pt 1), 218–223.
33 Ohashi K, Waugh JM, Dake MD *et al.* (2005) Liver tissue engineering at extrahepatic sites in mice as a potential new therapy for genetic liver diseases. *Hepatology* 41(1), 132–140.
34 Jaffe V, Darby H, Selden C *et al.* (1988) The growth of transplanted liver cells within the pancreas. *Transplantation* 45(2), 497–498.
35 Sano K, Cusick RA, Lee H *et al.* (1996) Regenerative signals for heterotopic hepatocyte transplantation. *Transplant Proc* 28(3), 1857–1858.
36 Sandbichler P, Then P, Vogel W *et al.* (1992) Hepatocellular transplantation into the lung for temporary support of acute liver failure in the rat. *Gastroenterology* 102(2), 605–609.
37 Kusano M, Mito M (1982) Observations on the fine structure of long-survived isolated hepatocytes inoculated into rat spleen. *Gastroenterology* 82(4), 616–628.
38 Nagata H, Ito M, Cai J *et al.* (2003) Treatment of cirrhosis and liver failure in rats by hepatocyte xenotransplantation. *Gastroenterology* 124(2), 422–431.
39 Schumacher IK, Okamoto T, Kim BH *et al.* (1996) Transplantation of conditionally immortalized hepatocytes to treat hepatic encephalopathy. *Hepatology* 24(2), 337–343.
40 Selden C, Calnan D, Morgan N *et al.* (1995) Histidinemia in mice: a metabolic defect treated using a novel approach to hepatocellular transplantation. *Hepatology* 21(5), 1405–1412.
41 Habibullah CM, Syed IH, Qamar A *et al.* (1994) Human fetal hepatocyte transplantation in patients with fulminant hepatic failure. *Transplantation* 58(8), 951–952.
42 Fox IJ, Chowdhury JR, Kaufman SS *et al.* (1998) Treatment of the Crigler–Najjar syndrome type I with hepatocyte transplantation. *N Engl J Med* 338(20), 1422–1426.
43 Bilir BM, Guinette D, Karrer F *et al.* (2000) Hepatocyte transplantation in acute liver failure. *Liver Transpl* 6(1), 32–40.
44 Horslen SP, McCowan TC, Goertzen TC *et al.* (2003) Isolated hepatocyte transplantation in an infant with a severe urea cycle disorder. *Pediatrics* 111(6 Pt 1), 1262–1267.
45 Raper SE, Grossman M, Rader DJ *et al.* (1996) Safety and feasibility of liver-directed ex vivo gene therapy for homozygous familial hypercholesterolemia. *Ann Surg* 223(2), 116–126.
46 Sokal EM, Smets F, Bourgois A *et al.* (2003) Hepatocyte transplantation in a 4-year-old girl with peroxisomal biogenesis disease: technique, safety, and metabolic follow-up. *Transplantation* 76(4), 735–738.
47 Dhawan A, Mitry RR, Hughes RD *et al.* (2004) Hepatocyte transplantation for inherited factor VII deficiency. *Transplantation* 78(12), 1812–1814.
48 Strom SC, Chowdhury JR, Fox IJ (1999) Hepatocyte transplantation for the treatment of human disease. *Semin Liver Dis* 19(1), 39–48.
49 Strom SC, Fisher RA, Thompson MT *et al.* (1997) Hepatocyte transplantation as a bridge to orthotopic liver transplantation in terminal liver failure. *Transplantation* 63(4), 559–569.
50 Nagata H, Ito M, Shirota C *et al.* (2003) Route of hepatocyte delivery affects hepatocyte engraftment in the spleen. *Transplantation* 76(4), 732–734.
51 Probst P, Rysavy JA, Amplatz K (1978) Improved safety of splenoportography by plugging of the needle tract. *AJR Am J Roentgenol* 131(3), 445–449.
52 Brazzini A, Hunter DW, Darcy MD *et al.* (1987) Safe splenoportography. *Radiology* 162(3), 607–609.
53 Mito M, Kusano M, Kawaura Y (1992) Hepatocyte transplantation in man. *Transplant Proc* 24(6), 3052–3053.
54 Cai J, Ito M, Nagata H *et al.* (2002) Treatment of liver failure in rats with end-stage cirrhosis by transplantation of immortalized hepatocytes. *Hepatology* 36(2), 386–394.

55 Baccarani U, Sanna A, Cariani A *et al.* (2003) Isolation of human hepatocytes from livers rejected for liver transplantation on a national basis: results of a 2-year experience. *Liver Transpl* 9(5), 506–512.

56 Tateno C, Yoshizane Y, Saito N *et al.* (2004) Near completely humanized liver in mice shows human-type metabolic responses to drugs. *Am J Pathol* 165(3), 901–912.

57 Meuleman P, Libbrecht L, De Vos R *et al.* (2005) Morphological and biochemical characterization of a human liver in a uPA-SCID mouse chimera. *Hepatology* 41(4), 847–856.

58 Baccarani U, Donini A, Risaliti A *et al.* (2001) Steatotic versus cirrhotic livers as a source for human hepatocyte isolation. *Transplant Proc* 33(1–2), 664–665.

59 Nishitai R, Koch CA, Ogata K *et al.* (2005) Toward the survival and function of xenogeneic hepatocyte grafts. *Liver Transpl* 11(1), 39–50.

60 Sandhu JS, Petkov PM, Dabeva MD *et al.* (2001) Stem cell properties and repopulation of the rat liver by fetal liver epithelial progenitor cells. *Am J Pathol* 159(4), 1323–1334.

61 Malhi H, Irani AN, Gagandeep S *et al.* (2002) Isolation of human progenitor liver epithelial cells with extensive replication capacity and differentiation into mature hepatocytes. *J Cell Sci* 115(Pt 13), 2679–2688.

62 Wege H, Le HT, Chui MS *et al.* (2003) Telomerase reconstitution immortalizes human fetal hepatocytes without disrupting their differentiation potential. *Gastroenterology* 124(2), 432–444.

63 Mahieu-Caputo D, Allain JE, Branger J *et al.* (2004) Repopulation of athymic mouse liver by cryopreserved early human fetal hepatoblasts. *Hum Gene Ther* 15(12), 1219–1228.

64 Fausto N, Campbell JS (2003) The role of hepatocytes and oval cells in liver regeneration and repopulation. *Mech Dev* 120(1), 117–130.

65 Shafritz DA, Dabeva MD (2002) Liver stem cells and model systems for liver repopulation. *J Hepatol* 36(4), 552–564.

66 Tournier I, Legres L, Schoevaert D *et al.* (1988) Cellular analysis of alpha-fetoprotein gene activation during carbon tetrachloride and D-galactosamine-induced acute liver injury in rats. *Lab Invest* 59(5), 657–665.

67 Lemire JM, Shiojiri N, Fausto N (1991) Oval cell proliferation and the origin of small hepatocytes in liver injury induced by D-galactosamine. *Am J Pathol* 139(3), 535–552.

68 Dabeva MD, Shafritz DA (1993) Activation, proliferation, and differentiation of progenitor cells into hepatocytes in the D-galactosamine model of liver regeneration. *Am J Pathol* 143(6), 1606–1620.

69 Factor VM, Radaeva SA, Thorgeirsson SS (1994) Origin and fate of oval cells in lipin-induced hepatocarcinogenesis in the mouse. *Am J Pathol* 145(2), 409–422.

70 Ghoshal AK, Mullen B, Medline A *et al.* (1983) Sequential analysis of hepatic carcinogenesis. Regeneration of liver after carbon tetrachloride-induced liver necrosis when hepatocyte proliferation is inhibited by 2-acetylaminofluorene. *Lab Invest* 48(2), 224–230.

71 Grompe M (2005) The origin of hepatocytes. *Gastroenterology* 128(7), 2158–2160.

72 Lagasse E, Connors H, Al-Dhalimy M *et al.* (2000) Purified hematopoietic stem cells can differentiate into hepatocytes in vivo. *Nature Med* 6(11), 1229–1234.

73 Petersen BE, Bowen WC, Patrene KD *et al.* (1999) Bone marrow as a potential source of hepatic oval cells. *Science* 284(5417), 1168–1170.

74 Theise ND, Nimmakayalu M, Gardner R *et al.* (2000) Liver from bone marrow in humans. *Hepatology* 32(1), 11–16.

75 Vassilopoulos G, Wang PR, Russell DW (2003) Transplanted bone marrow regenerates liver by cell fusion. *Nature* 422(6934), 901–904.

76 Wang X, Willenbring H, Akkari Y *et al.* (2003) Cell fusion is the principal source of bone-marrow-derived hepatocytes. *Nature* 422(6934), 897–901.

77 Wang X, Montini E, Al-Dhalimy M *et al.* (2002) Kinetics of liver repopulation after bone marrow transplantation. *Am J Pathol* 161(2), 565–574.

78 Jiang Y, Jahagirdar BN, Reinhardt RL *et al.* (2002) Pluripotency of mesenchymal stem cells derived from adult marrow. *Nature* 418(6893), 41–49.

79 Yamamoto H, Quinn G, Asari A *et al.* (2003) Differentiation of embryonic stem cells into hepatocytes: biological functions and therapeutic application. *Hepatology* 37(5), 983–993.

80 Kakinuma S, Tanaka Y, Chinzei R *et al.* (2003) Human umbilical cord blood as a source of transplantable hepatic progenitor cells. *Stem Cells* 21(2), 217–227.

81 Ruhnke M, Ungefroren H, Nussler A *et al.* (2005) Differentiation of in vitro-modified human peripheral blood monocytes into hepatocyte-like and pancreatic islet-like cells. *Gastroenterology* 128(7), 1774–1786.

82 Gunsalus JR, Brady DA, Coulter SM *et al.* (1997) Reduction of serum cholesterol in Watanabe rabbits by xenogeneic hepatocellular transplantation. *Nature Med* 3(1), 48–53.

83 Patience C, Takeuchi Y, Weiss RA (1998) Zoonosis in xenotransplantation. *Curr Opin Immunol* 10(5), 539–542.

84 van der Laan LJ, Lockey C, Griffeth BC *et al.* (2000) Infection by porcine endogenous retrovirus after islet xenotransplantation in SCID mice. *Nature* 407(6800), 90–94.

85 Paradis K, Langford G, Long Z *et al.* (1999) Search for cross-species transmission of porcine endogenous retrovirus in patients treated with living pig tissue. The XEN 111 Study Group. *Science* 285(5431), 1236–1241.

86 Amicone L, Spagnoli FM, Spath G *et al.* (1997) Transgenic expression in the liver of truncated Met blocks apoptosis and permits immortalization of hepatocytes. *EMBO J* 16(3), 495–503.

87 Zaret KS, DiPersio CM, Jackson DA *et al.* (1988) Conditional enhancement of liver-specific gene transcription. *Proc Natl Acad Sci USA* 85(23), 9076–9080.

88 Fox IJ, Chowdhury NR, Gupta S *et al.* (1995) Conditional immortalization of Gunn rat hepatocytes: an ex vivo model for evaluating methods for bilirubin-UDP-glucuronosyltransferase gene transfer. *Hepatology* 21(3), 837–846.

89 Tada K, Roy-Chowdhury N, Prasad V *et al.* (1998) Long-term amelioration of bilirubin glucuronidation defect in Gunn rats by transplanting genetically modified immortalized autologous hepatocytes. *Cell Transplant* 7(6), 607–616.

90 Kobayashi N, Fujiwara T, Westerman KA *et al.* (2000) Prevention of acute liver failure in rats with reversibly immortalized human hepatocytes. *Science* 287(5456), 1258–1262.

91 Braun KM, Degen JL, Sandgren EP (2000) Hepatocyte transplantation in a model of toxin-induced liver disease: variable therapeutic effect during replacement of damaged parenchyma by donor cells. *Nature Med* 6(3), 320–326.

92 Grossman M, Rader DJ, Muller DW *et al.* (1995) A pilot study of ex vivo gene therapy for homozygous familial hypercholesterolaemia. *Nature Med* 1(11), 1148–1154.

93 Reyes J, Rubenstein WS, Mieles L *et al.* (1996) The use of cultured hepatocyte infusion via the portal vein for the treatment of ornithine transcarbamylase deficiency by transplantation of enzymatically competent ABO/Rh-matched cells. *Hepatology* 24, 308A.

94 Muraca M, Gerunda G, Neri D *et al.* (2002) Hepatocyte transplantation as a treatment for glycogen storage disease type 1a. *Lancet* 359(9303), 317–318.
95 Horslen SP, Fox IJ (2004) Hepatocyte transplantation. *Transplantation* 77(10), 1481–1486.
96 Rozga J, Holzman M, Moscioni AD *et al.* (1995) Repeated intraportal hepatocyte transplantation in analbuminemic rats. *Cell Transplant* 4(2), 237–243.
97 Perlmutter DH (2002) Liver injury in alpha1-antitrypsin deficiency: an aggregated protein induces mitochondrial injury. *J Clin Invest* 110(11), 1579–1583.
98 Rhim JA, Sandgren EP, Palmiter RD *et al.* (1995) Complete reconstitution of mouse liver with xenogeneic hepatocytes. *Proc Natl Acad Sci USA* 92(11), 4942–4946.
99 Laconi E, Oren R, Mukhopadhyay DK *et al.* (1998) Long-term, near-total liver replacement by transplantation of isolated hepatocytes in rats treated with retrorsine. *Am J Pathol* 153(1), 319–329.
100 Guha C, Parashar B, Deb NJ *et al.* (2002) Normal hepatocytes correct serum bilirubin after repopulation of Gunn rat liver subjected to irradiation/partial resection. *Hepatology* 36(2), 354–362.
101 Oren R, Dabeva MD, Karnezis AN *et al.* (1999) Role of thyroid hormone in stimulating liver repopulation in the rat by transplanted hepatocytes. *Hepatology* 30(4), 903–913.

25.8.2 Liver support

Vanessa Stadlbauer and Rajiv Jalan

Mortality rates in patients with liver failure remain unacceptably high. In patients with acute liver failure (ALF), mortality is approximately 15–35% [1,2]. Acute-on-chronic liver failure (ACLF) has been defined as acute deterioration of liver function over a period of 2–4 weeks, usually associated with a precipitating event, with jaundice and either hepatic encephalopathy or hepatorenal syndrome. A high SOFA (sequential organ failure assessment) or APACHE II (acute physiological and chronic health evaluation) score predicts poor survival [3,4]. Hospital mortality in this group of patients is high, between 63% and 100% [5]. Primarily the lack of detoxification, but also the lack of metabolic and regulatory function of the liver, leads to complications and, ultimately, to the patient's death from multiorgan failure: cerebral oedema, encephalopathy, circulatory dysfunction, renal failure and immune failure [3,4].

At present, the most successful treatment for liver failure is liver transplantation, with survival rates ranging from 70% to 85%. However, mortality rates for liver failure are still high because of the shortage of available human donor organs. In 2003, about 16% of patients listed at United Network of Organ Sharing (UNOS) 1 (ALF) and 10% listed UNOS 2a and 2b (ACLF) died on the waiting list in the USA (Organ Procurement and Transplantation Network/Scientific Registry of Transplant Recipients Annual Report). Living-related liver transplantation is increasing, but only in about 30–50% of cases can a suitable organ donor be found. Also, a donor death rate of 0.2% and reasonable donor morbidity limit this approach [6,7]. Attempts to artificially support liver function are aimed at stabilizing patients with ACLF and ALF while they are waiting for a suitable donor liver. In ALF, an effective liver support device can also allow such patients to be bridged successfully to full recovery and thus avoid unnecessary transplantations and the problems of long-term immunosuppression [8–10]. It is also possible that chronic intermittent treatment of cirrhotics with an artificial liver support device, in the style of artificial kidney support by haemodialysis, could reduce symptoms of cirrhosis such as tiredness, hepatic encephalopathy, jaundice, pruritus or haemorrhagic diathesis.

Therefore, conceptually, artificial liver support is very attractive and, over the past 50 years, there has been enormous interest in the development of such devices to bridge patients to liver regeneration or liver transplantation. The various liver support systems attempting to reach these goals include conventional haemodialysis, charcoal haemoperfusion, high-volume plasma exchange, extracorporeal organ perfusion, liver dialysis using sorbent technology, albumin dialysis, fractionated plasma separation and adsorption, and bioartificial livers containing various sources of hepatocytes.

Requirements for an ideal liver support device

Liver failure impairs all functions of the liver: synthesis, detoxification and bile excretion [11]. An ideal liver support device should replace all these functions.

Synthesis functions can only be replaced by systems containing viable cells or substitution by infusion of the missing substances [11,12]. Detoxification is hampered by impairment of the urea cycle, which leads to hyperammonaemia, as well as impairment of protein breakdown, leading to the accumulation of a variety of toxins in the blood [13]. Most of these toxins are albumin bound and cannot be adequately removed by conventional haemodialysis or haemofiltration. The removal of accumulated toxins may lead to the interruption of the vicious cycle that leads to endorgan failure. Systems capable of this function can possibly significantly improve the outcome of liver failure [13–15]. Furthermore, the reversal of inflammatory processes ongoing in the liver is believed to be beneficial [16]. An ideal artificial liver should remove regeneration-inhibitory substances but not regeneration-stimulating factors [17]. Besides its function, an artificial organ support device has to be safe in terms of biocompatibility with membranes and cells and should not carry a risk of infection. Furthermore, for the wide use of such a system, it must be practical and easily available. Until now, no general consensus on the functional and safety issues of artificial liver support devices has been published.

Historical aspects

Artificial support systems for liver failure have been widely available for several decades but only recently are the results from

these early experiments starting to provide the basis for current systems. The first experiments go back to the late 1950s. In 1956, Kiley *et al.* [18] reported the use of haemodialysis to treat five patients with hepatic encephalopathy with the purpose of removing ammonia from the blood. Four patients showed improvements in their consciousness level; however, no improvement in long-term survival was observed, and all patients died within 1 month. Also in the late 1950s, some experiments with cross-haemodialysis between a human and a dog [19] and sliced canine liver [20] were published. Nose *et al.* [20] described for the first time a hybrid system consisting of freeze-dried canine liver granules separated by a highly-permeable gel-type cellophane membrane from the patient's blood. Carbohydrate metabolism and ammonia detoxification were maintained in this metabolic chamber. Four patients were treated with this system, and three showed at least temporary improvement. It is noteworthy that these experiments took place before liver transplantation was available [21].

In the following years, haemoperfusion techniques became popular. The use of membranes such as polyacrylonitrile allowed the removal of higher molecular weight substances [22]. Twenty-four patients with fulminant viral hepatitis were treated, and the membrane was found to be more effective than a simple cellulose membrane because it allowed the rapid transfer of substances with a molecular weight of up to 15 000 Da, which included many molecules suspected of being involved in encephalopathy. Seventeen of the 24 patients showed improvement in their neurological function, with five (22%) of these achieving a full recovery, but there was no significant improvement in survival compared with standard treatment.

In 1966, Eiseman [23] reported his results with extracorporeal pig liver perfusion for the treatment of severe hepatic encephalopathy, which resulted in a slight improvement in encephalopathy, but not in survival rates. Extracorporeal perfusion using human [24] or baboon [25,26] livers has shown benefits in small case series, but both these techniques have the problem of sufficient donor supply. After these early experiences, no clinical applications of extracorporeal liver perfusion have been published for nearly 10 years.

In the meantime, resin exchange columns were developed using specific ligands for the removal of cytokines, protein-bound and lipid-soluble substances, such as bilirubin and bile acids [27,28], membranes for the removal of endotoxins and hydrophilic liquid membranes for the removal of ammonia, phenols and fatty acids [29,30].

Plasma exchange has been tried for the removal of hepatic toxins and replacement with beneficial factors. Plasma from the patient is separated and replaced with an equivalent volume of fresh frozen plasma. The compounds removed are mostly unknown [31,32]. Improvements in patients' neurological function and coagulation parameters were demonstrated, but no significant increase in survival rates was reported [33,34].

Limitations of the early concepts in artificial liver support

The problem with filtration techniques was the incompatibility between blood and the extracorporeal circuit, which resulted in complement and platelet activation, leucopenia and the removal of coagulation factors, leading to many risks in patients who have pre-existing coagulation defects [35]. This process also removes a number of hormones and growth factors, such as hepatocyte growth factor, which are known to play important roles in liver regeneration [36,37].

In extracorporeal liver perfusion, there are major concerns regarding the possible transmission of disease and the activation of xeno-antibodies. There are isolated reports of xenogenic extracorporeal liver perfusion, which have shown the development of antibodies after repeated treatments. However, subsequent perfusions were performed without any detrimental effects [25,26]. In fact, the immunosuppressive effect of liver failure itself may allow xenogenic tissues to be used repeatedly over several days [37].

Resins were found to be more successful in removing substances than charcoal alone, but they also remove leukocytes and platelets. Biocompatible polymer coatings were developed to try to reduce this problem with some success [27]. Plasma separation may be superior to whole blood perfusion due to fewer problems of incompatibility and circuit clotting. This advance provides the possibility of avoiding the potential problems of anticoagulation in patients who have severe coagulopathy [35]. The main disadvantage of this approach is that plasma has only limited oxygen-carrying capacity, and perfusion with whole blood is simpler to perform. Limited removal of toxins combined with the high volumes of plasma required leads to coagulation imbalance and high cost [38].

Bioartificial liver support

Bioartifical liver (BAL) refers to hybrid systems using viable cells, in general hepatocytes, as a biocomponent in an extracorporeal device connected to the patient's circulation. Several cell types and several culture techniques have been developed. When a bioartificial, cell-containing, system is used, the minimum quantity of cells has to be determined. Data from hepatic resection suggest that 150–450 g of cells (10^{10} hepatocytes), which comprises 10–30% of the normal liver mass, is required. When cells with smaller functional capacity are used, this number needed may be higher [12,39].

Cell types

Primary cells

Primary human hepatocytes would be ideal, but their availability is limited because of lack of donor organs. Human fetal hepatocytes have been discussed and seem to be useful because of their capacity to proliferate, but the use of fetal hepatocytes is

limited by the relative lack of differentiation and ethical issues. Primary porcine hepatocytes are therefore the next best choice and are widely used in BAL. A great advantage of porcine hepatocytes, unlike human liver cells, is that they can be isolated on a large scale and at a convenient time, followed by cryopreservation and storage prior to use, thus avoiding the costs and contamination risks of long-term hepatocyte culture. Pigs have similar physiology to humans, and one porcine liver can provide enough hepatocytes for several BAL treatments [40]. Primary porcine hepatocytes outperformed all available liver cell lines in terms of biotransforming functions [41]. The major drawback of primary cells is the loss of function over time in culture [42]. Porcine hepatocytes, for example, have stable albumin secretion but declining expression of cytochrome P-450 [43,44]. Improvements in culture conditions may increase the stability of function. Xenogenic cells bear the risk of xenozoonosis. Porcine endogenous retroviruses (PERV) have raised major concerns, as they have been shown to infect human cells *in vitro* [45].

Immortalized cell lines

Human immortalized cell lines have been generated by either spontaneous immortalization or retroviral transfection. Several cell lines have been developed and characterized [46]. Efforts to improve the control and safety of cell-based therapies with immortalized cells have resulted in the use of temperature-sensitive SV40Tag, 46 Cre-loxP-mediated oncogene excision and integration of suicide genes such as HSV-tk [47–49]. Several cell lines have been developed and characterized. The C8-B rat cell line and the human Hep Z cell line have been shown to express albumin mRNA [47,50]. OUMS-29 and NKNT-3 are human fetal cell lines that express albumin and glutamine synthetase RNA and are able to metabolize urea [48,49]. Another human fetal cell line, Yoon [51], and an immortalized porcine cell line, HepLiu [52], have not been shown to produce albumin or to metabolize urea. Human cell lines that immortalized spontaneously, such as HH25 and HHY41, produce albumin and express mRNA of alpha-fetoprotein and glucose-6-phosphatase [53,54].

Tumour cell lines

Cell lines derived from hepatic tumours, such as C3A (a subclone of HepG2), HepG2 itself, HuH6 or JHH2, have already been used in clinical trials [55–59]. C3A has been studied extensively and has been shown to retain differentiated hepatic functions while showing a short population doubling time and contact inhibition [60,61]. The risk of transmitting oncogenic substances or cells into the patient's circulation remains a concern. Filters preventing transmission have been implemented in the BAL design as an extra precaution. However, the extracapillary passage of HepG2 cells from a hollow fibre membrane was observed in *in vitro* BAL experiments.

Stem cells

Human embryonic stem cells can be differentiated into hepatocytes *in vitro* with sodium butyrate in the culture medium [62]. Multipotent adult progenitor cells from bone marrow can differentiate into functional hepatocytic cells with the production of albumin and urea [63]. These cells are potential candidates for developing BALs; however, one should keep in mind that neither transdifferentiation nor dedifferentiation of such cells can be guaranteed in BAL modules.

Hepatocyte bioreactors

Hepatocyte bioreactors can be classified according to their culture technique. The hepatocytes may be encapsulated in gels, immobilized on collagen-coated flat plates, cultured in or outside semipermeable hollow fibres (directly or attached to microcarriers) or cultured within a porous three-dimensional matrix, allowing direct plasma perfusion conditions in the cells.

Encapsulation

Liver cells encapsulated in alginate were used in several BALs [16,64,65]. Also, other materials have been investigated, such as cellulose [66], different polymers [67] and polyethylene-glycane [64,68]. This development is still in the experimental phase, and no clinical application has been reported.

Coated plates

Hepatocyte monolayers on collagen-coated plates seemed to be promising in terms of cell viability and function [69]. This technique was expanded further using sandwich layers [70] or fructose-modified chitosan [71], but was then abandoned because other techniques seemed more promising.

Semipermeable hollow fibres

The principle of the hollow fibre-based artificial liver has been the most successful so far. Blood or plasma is passed through the intracapillary lumen, whereas hepatocytes are attached to the outside of the semipermeable fibre membrane. Interaction between the cells and the plasma of the patient can occur through the semipermeable membrane [72]. Different types of hollow fibre-based BALs with regard to the oxygen supply have been reported: a network of fibres including capillaries for oxygenation of the cells [73]; an extra oxygenator of the plasma before entering the BAL [37]. Cells can also be cultured inside the lumen with plasma flowing at the outside of the hollow fibre [74]. The disadvantage of these devices is the indirect contact between plasma and liver cells in contrast to the *in vivo* situation.

Culture within a porous three-dimensional matrix

In this bioreactor type, cells are attached to a non-woven polyester fabric. This matrix is enclosed either as different pieces in a cartridge or as a spirally wound tissue. The space between the different layers can be filled with polypropylene oxygen fibres to provide a site for optimal oxygenation of the cells inside the bioreactor [75,76]. In this type of BAL, the plasma is in direct

contact with the blood, and this type of device can contain a very large number of cells.

Liver micro-organs

Liver micro-organs are a new technique that preserve the liver microarchitecture and ensure that no cell is more than 150 µm away from a source of nutrients and gases. The function of liver micro-organs was evaluated *in vitro*. *In vitro*, the liver micro-organs maintain oxygen consumption, glucose metabolism, conversion of ammonia to urea, secretion of albumin and *de novo* transcription of genes coding for albumin and clotting factors [77].

Clinical studies with bioartificial liver support devices

Porcine hepatocyte-based BAL

Several systems using porcine hepatocytes have been evaluated clinically. Most of them relate to treatment of patients with ALF in whom neurological improvement with minimal reduction in serum bilirubin and arterial ammonia has been observed. As major side-effects, bleeding complications and haemodynamic instability were reported. The HepatAssist (Cedar-Sinai Medical Centre) (Fig. 1a) has been evaluated in small case series [78] and a phase I study first, and in a large multicentre randomized controlled trial conducted in the USA and Europe [79]. This study demonstrated the safety of the system, but a survival benefit was only found in the subgroup of patients with fulminant/subfulminant liver failure, who showed a small reduction in mortality favouring the BAL group. However, the primary endpoint was confounded by the major impact of liver transplantation; 54% of the entire study population were transplanted. No transmission of porcine endogenous retrovirus could be detected [80].

Another device, the AMC-BAL (Fig. 1b), has been described in case reports and one phase I trial. Neurological improvement was observed in all seven patients. Serum bilirubin and arterial ammonia decreased. Transient hypotension occurred in two

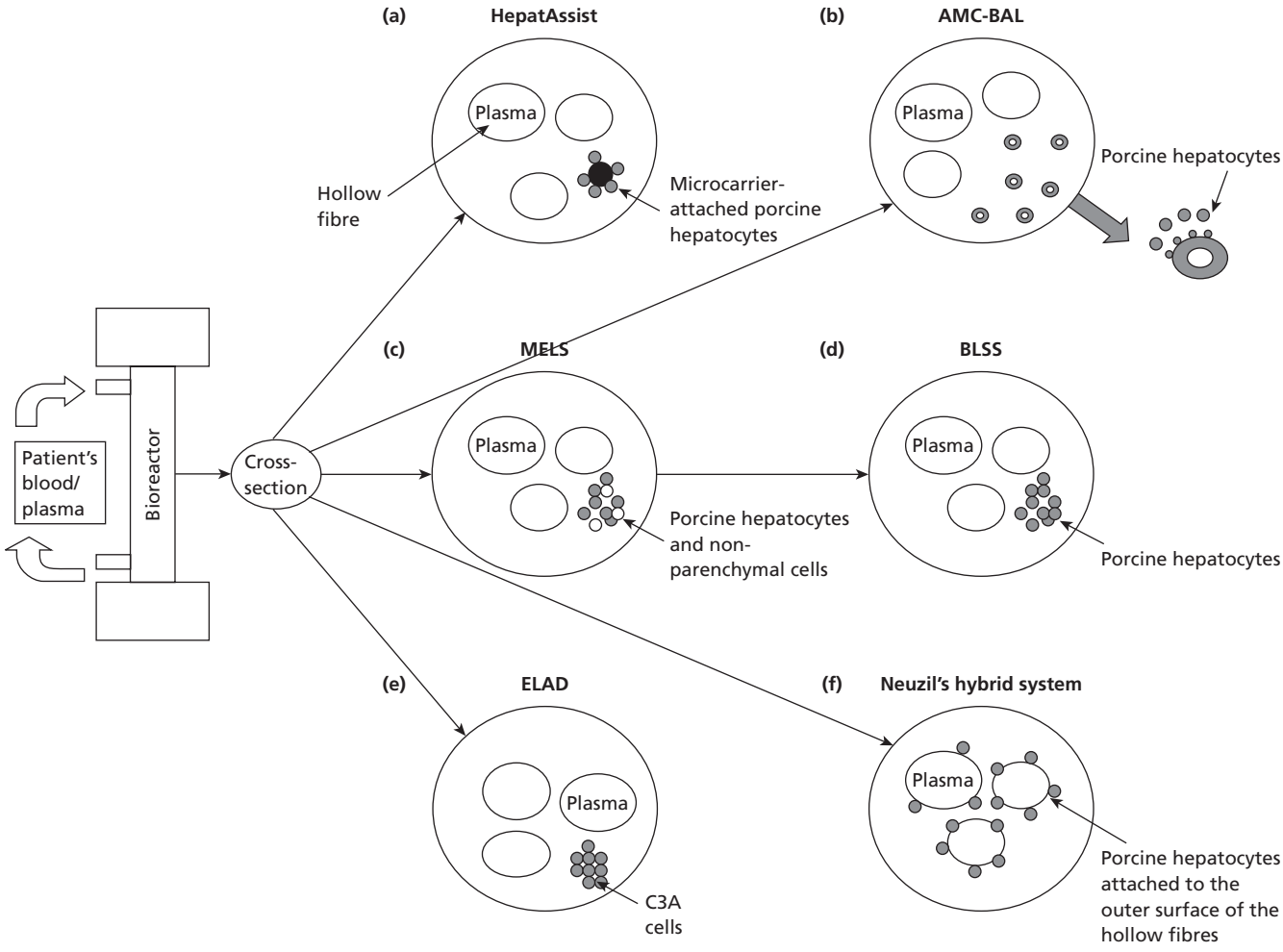

Fig. 1 Conceptual organization of the bioartificial liver support devices.

patients immediately after starting using the device. One of the patients improved sufficiently not to require liver transplantation while the remaining six were transplanted [81].

A phase I trial with the MELS system (Berlin) (Fig. 1c) in eight patients with ALF has been reported. The system appeared to be safe, only causing thrombocytopenia. All patients were successfully transplanted and were alive after a follow-up of 3 years. No patient showed any evidence of porcine endogenous retrovirus infection [82].

A phase I study with the Excorp Medical, Inc., Bioartificial Liver Support System (Pittsburgh, BLSS) in four patients showed that the system produced no serious adverse events, but biochemical response was only moderate [83] (Fig. 1d). Another type of BAL using porcine hepatocytes attached to microcarriers and placed on the outer surface of hollow fibres combined with a plasmapheresis device was described in a case report (Fig. 1f). A marked increase in coagulation factor V, VII, VIII and IX activities, a decrease in serum ammonia level, an increase in all serum amino acids except for aminobutyric acid and an improvement in mental status were noted after a 6-h treatment period. The expected larger study has not been published yet [84].

Hepatoblastoma-based extracorporeal liver assist device (ELAD)

The ELAD device (Fig. 1e) was tried in an early randomized controlled study in 24 patients with ALF. Arterial ammonia decreased marginally in the ELAD group, and the rise in serum bilirubin was more pronounced in the control group. Worsening of encephalopathy was less in ELAD-treated patients. However, a clear survival advantage was not shown. Survival in group I was 7/9 (78%) with ELAD and 6/8 (75%) for control subjects, which was much higher than anticipated in both groups. In a randomized controlled phase I trial in patients with fulminant hepatic failure, 10 out of 12 (83%) ELAD patients also achieved the primary endpoint of 30-day survival compared with 3/7 (43%) control subjects ($P = 0.12$). The device appeared to be safe, and there was a significant advantage for patients receiving liver transplantation in the ELAD group [61]. Further studies concluded that the patients tolerated treatment with the ELAD well and that there were no unanticipated safety issues, but larger randomized multicentre trials are warranted [85].

Artificial liver support

These systems are based on the use of albumin as a transporting medium for toxins and contain a membrane with a small pore size to display a more selective detoxifying capacity compared with the earlier generation of devices based on charcoal haemoperfusion [8,86]. These systems are relatively specific for albumin-bound toxins, which are suspected to have a causal role in acute and acute-on-chronic liver failure, while larger molecules such as immunoglobulins, cytokines or growth factors should be prevented from being removed.

Two extracorporeal liver assist devices are currently commercially available, the Molecular Adsorbents Recirculating System (MARS™, Gambro, Sweden) and the Fractionated Plasma Separation, Adsorption and Dialysis system (FPAD, Prometheus™, Fresenius Medical Care, Germany). Both systems provide detoxification by elimination of albumin-bound substances such as bilirubin and bile acids, but differ in terms of their design.

In MARS, blood is dialysed across an albumin-impermeable membrane with a molecular weight cutoff of 60 kDa against 20% human serum albumin, which is continuously stripped by subsequent passage through columns of charcoal and an anion exchange resin. Water-soluble substances are removed by a low-flux dialyser connected to the secondary circuit [38,87,88] (Fig. 2a).

In Prometheus, the patient's own albumin is separated by a membrane with a molecular weight cutoff of approximately 300 kDa and passed directly over two columns containing different adsorbents. Water-soluble substances are cleared by a high-flux dialyser inserted directly into the blood circuit [89,90] (Fig. 2b).

Clinical studies with artificial liver support

MARS

In a meta-analysis [91] from four randomized [88,92–94] and two selected non-randomized trials [95,96], the initial analysis and the subgroup analysis did not show any effect of MARS on mortality. However, explorative analysis of the non-randomized trials revealed a significant reduction in mortality in the MARS group compared with the standard medical treatment group. The four randomized trials included 67 patients; 54% received MARS treatment, and 35% received standard medical treatment. Two trials included 37 patients with ACLF and the other two trials included 30 patients with ALF. Only one trial [92] showed a significant reduction in mortality with MARS treatment compared with standard medical treatment. The other three trials did not show any survival benefit. The control group mortality was 68%. MARS treatment reduced mortality to 33%, which was not significant. The two non-randomized trials included 61 patients with ACLF. The treatment group had a significant reduction in mortality compared with the control group [91].

Another randomized controlled trial showed that MARS therapy in patients with ACLF has a beneficial effect on circulating neurohormones, nitric oxide, free radical production and reduction in the markers of oxidative stress. The clinical effects of these changes are reflected in individual organ function, with temporal improvement in cholestasis and liver function, renal function, encephalopathy and, in some patients, in mean arterial pressure. Furthermore, a large randomized controlled trial revealed a significant effect of MARS on the severity of hepatic encephalopathy [97].

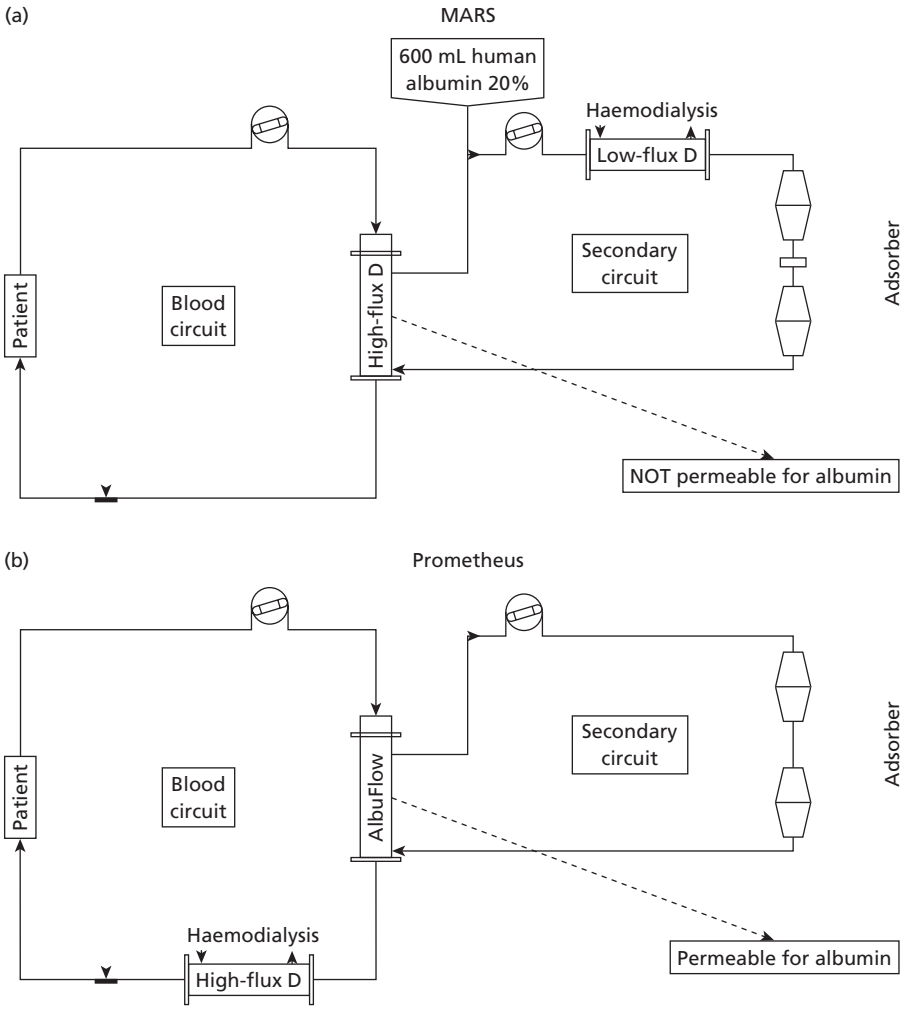

Fig. 2 Circuit design of the MARS (a) and Prometheus (b) systems. D, dialyser.

Prometheus

Only limited data are available for Prometheus. The first, uncontrolled study of Prometheus treatment in 11 patients with ACLF and accompanying renal failure showed that this device significantly improved serum levels of conjugated bilirubin, bile acids, ammonia, cholinesterase, creatinine, urea and blood pH. There were no significant changes in haemoglobin and platelet levels, whereas leukocytes increased [90]. In another uncontrolled study, these results were confirmed [98]. Recently, a comparative study of Mars and Prometheus in a randomized crossover design showed higher efficiency of Prometheus in removing bilirubin fractions and urea compared with MARS [99].

Other systems

A combination of plasma exchange and haemofiltration was applied in an uncontrolled fashion in 67 patients with ALF; 55.2% of them survived [98]. The BioLogic-DT uses haemodiabsorption, which combines haemodialysis and adsorption. The system consists of a cellulose membrane for haemodialysis against a suspension of powdered charcoal and cation exchange resin, and requires little or no anticoagulation. Five trials assessed this system [33,100–103]. The system was biocompatible, but removal of metabolites was limited, with no significant effect on blood ammonia level. The addition of push–pull sorbent-based pheresis allowed a higher capability for removing bilirubin and other protein-bound substances [104].

Implications for practice

Bioartifical liver support

Cell-containing liver support systems have been tested mainly in single-centre phase I and II trials, proving the principle that these systems can improve clinical and biochemical parameters and that they are safe to use. A systematic review of eight studies using BAL for ALF showed no survival benefit [105] (Table 1). A Cochrane review on artificial and bioartificial liver support showed that no randomized study to date has evaluated the effect of bioartificial liver support on ACLF [106]. Therefore, considering the potential limitations of the evidence, liver support systems cannot be recommended for routine use.

Table 1 Effect of artificial and bioartificial support systems on mortality in acute liver failure.

Reference	Type of intervention	No. of deaths (intervention vs. control)	Risk ratio (95% CI)
Redekar and Yamahiro [110]	Whole blood exchange	14/15 9/13	1.35 (0.92–1.98)
O'Grady *et al*. [8]	Charcoal haemoperfusion	19/29 20/33	1.08 (0.74–1.58)
Hughes *et al*. [33]	Biologic-DT	4/5 2/5	2.00 (0.63–6.38)
Ellis *et al*. [61]	ELAD	4/12 5/12	0.80 (0.28–2.27)
Mazariegos *et al*. [100]	Biologic-DT	1/5 1/5	1.00 (0.08–11.93)
Wilkinson *et al*. [103]	Biologic-DT	0/1 1/2	0.50 (0.04–7.10)
He *et al*. [111]	Haemoperfusion	10/37 15/33	0.59 (0.31–1.14)
Demetriou *et al*. [80]	HepatAssist device	33/86 25/85	0.68 (0.42–1.08)
Total		85/190 78/188	0.95 (0.71–1.29)

Modified from ref. 105. CI, confidence interval.

Table 2 Effect of artificial and bioartificial support systems on mortality in acute-on-chronic liver failure.

Reference	Type of intervention	No. of deaths (intervention vs. control)	Risk ratio (95% CI)
Kramer *et al*. (2001) [101]	Biologic-DT	4/10 4/10	1.00 (0.34–2.93)
Wilkinson *et al*. (1998) [103]	Biologic-DT	3/5 3/3	0.60 (0.39–1.23)
Ellis *et al*. (1999) [102]	Biologic-DT	5/5 5/5	N/A
Mitzner *et al*. (2001) [93]	MARS	6/8 6/8	0.75 (0.50–1.12)
He *et al*. (2000) [111]	Haemoperfusion	10/27 17/27	0.59 (0.33–1.04)
Heemann *et al*. (2002) [88]	MARS	1/12 6/12	0.17 (0.02–1.18)
Total		29/67 41/65	0.67 (0.51–0.90)

Modified from ref. 105. CI, confidence interval.

Artificial liver support

Patients with ACLF may benefit from the more recently developed artificial liver support systems (i.e. MARS, Prometheus) [105,106] (Table 2). MARS is also used increasingly to treat drug intoxications or is used chronically in patients with pruritus [107]. Again, there are not enough data to recommend routine use.

Safety

Bioartificial and artificial systems are associated with serious and non-serious adverse events. In the Cochrane meta-analysis, the most important adverse event was bleeding, which was registered as serious in three trials (3/27 patients). Other serious adverse events were systemic infection, disseminated intravascular coagulation and allergic shock; however, not all studies gave sufficient data on adverse events. Non-serious adverse events included minor bleeding, increase in intracranial pressure, hypotension and hypersensitivity [106].

A meta-analysis of all studies conducted with the MARS system again noted that registration of adverse events was incomplete. Bleeding, coagulopathy, hypotension, fever, thrombocytopenia and anaemia were reported [91].

Conclusion and future prospects

As noted above, a meta-analysis of 14 trials investigating artificial or bioartificial liver support concluded that patients with ACLF may benefit from treatment with the more recently developed artificial support systems. The evidence concerning treatment of patients with ALF is less conclusive. However, considering the potential limitations of the evidence, liver support systems cannot be recommended for routine use. Randomized trials on artificial and bioartificial support systems vs. standard medical therapy are warranted [106].

The use of primary porcine hepatocytes in BAL has major disadvantages due to immunological incompatibility and the risk of transfection of porcine endogenous retroviruses, which cannot be excluded completely. The ideal solution will be the availability of sufficient amounts of viable well-differentiated non-tumorigenic human liver cells. Potential approaches are genetic engineering of adult liver cells [59], manipulation of pluripotent stem cells in the direction of liver cells [108] or cryopreservation and banking of primary human cells [109]. To increase the efficacy of BAL devices, the phenotypical stability of the cellular component must be increased. Hepatocytes are attachment-dependent cells that quickly lose their liver-specific function without the proper cell contacts. Hollow fibre

technology can adequately maintain cell viability, but does not optimize cellular functions. Attempts to replace the environmental cues that will maintain liver-specific functions *in vitro* have been made. Some devices are now beginning to incorporate co-culture schemes to stabilize hepatic functions.

For bioreactors, one of the major tasks for the future is scalability. One reactor has to host up to 15 billion cells, which may lead to large diffusion distances in the reactor and may exclude transport of larger molecules. BAL devices universally lack an excretory compartment mimicking the biliary system that could reduce bilirubin and other metabolic byproducts that accumulate in liver disease. This has been solved satisfactorily by artificial devices such as MARS or Prometheus. For artificial liver support, the development of new membranes that combine better clearance of protein-bound substances with a better biocompatibility is the task for the future. Furthermore, better measures of treatment efficacy need to be developed. As these systems are already widely available, cost-efficiency will become a question in the near future.

References

1 Ostapowicz G, Fontana RJ, Schiodt FV *et al.* (2002) Results of a prospective study of acute liver failure at 17 tertiary care centers in the United States. *Ann Intern Med* 137(12), 947–954.

2 O'Grady JG, Alexander GJ, Hayllar KM *et al.* (1989) Early indicators of prognosis in fulminant hepatic failure. *Gastroenterology* 97(2), 439–445.

3 Jalan R, Williams R (2002) Acute-on-chronic liver failure: pathophysiological basis of therapeutic options. *Blood Purif* 20(3), 252–261.

4 Stockmann HB, Ijzermans JN (2002) Prospects for the temporary treatment of acute liver failure. *Eur J Gastroenterol Hepatol* 14(2), 195–203.

5 Wehler M, Kokoska J, Reulbach U *et al.* (2001) Short-term prognosis in critically ill patients with cirrhosis assessed by prognostic scoring systems. *Hepatology* 34(2), 255–261.

6 Lacaille F, Sokal E (2001) Living-related liver transplantation. *J Pediatr Gastroenterol Nutr* 33(4), 431–438.

7 Baker A, Dhawan A, Devlin J *et al.* (1999) Assessment of potential donors for living related liver transplantation. *Br J Surg* 86(2), 200–205.

8 O'Grady JG, Gimson AE, O'Brien CJ *et al.* (1988) Controlled trials of charcoal hemoperfusion and prognostic factors in fulminant hepatic failure. *Gastroenterology* 94(5 Pt 1), 1186–1192.

9 O'Grady JG (2005) Acute liver failure. *Postgrad Med J* 81(953), 148–154.

10 Pauwels A, Mostefa-Kara N, Florent C *et al.* (1993) Emergency liver transplantation for acute liver failure. Evaluation of London and Clichy criteria. *J Hepatol* 17(1), 124–127.

11 Clemmesen O, Ott P, Larsen FS (2004) Splanchnic metabolism in acute liver failure and sepsis. *Curr Opin Crit Care* 10(2), 152–155.

12 Strain AJ, Neuberger JM (2002) A bioartificial liver – state of the art. *Science* 295(5557), 1005–1009.

13 Riordan SM, Williams R (2000) Acute liver failure: targeted artificial and hepatocyte-based support of liver regeneration and reversal of multiorgan failure. *J Hepatol* 32(1 Suppl.), 63–76.

14 Hughes RD, Cochrane AM, Thomson AD *et al.* (1976) The cytotoxicity of plasma from patients with acute hepatic failure to isolated rabbit hepatocytes. *Br J Exp Pathol* 57(3), 348–353.

15 Sen S, Williams R, Jalan R (2002) The pathophysiological basis of acute-on-chronic liver failure. *Liver* 22(Suppl. 2), 5–13.

16 Rahman TM, Selden C, Khalil M *et al.* (2004) Alginate-encapsulated human hepatoblastoma cells in an extracorporeal perfusion system improve some systemic parameters of liver failure in a xenogeneic model. *Artif Organs* 28(5), 476–482.

17 Suh KS, Lilja H, Kamohara Y *et al.* (1999) Bioartificial liver treatment in rats with fulminant hepatic failure: effect on DNA-binding activity of liver-enriched and growth-associated transcription factors. *J Surg Res* 85(2), 243–250.

18 Kiley JE, Welch HF, Pender JC *et al.* (1956) Removal of blood ammonia by hemodialysis. *Proc Soc Exp Biol Med* 91(3), 489–490.

19 Kimoto S (1959) The artificial liver. Experiments and clinical application. *Trans Am Soc Artif Intern Organs* 5, 102–106.

20 Nose Y, Mikami J, Kasai Y *et al.* (1963) An experimental artificial liver utilizing extracorporeal metabolism with sliced or granulated canine liver. *Trans Am Soc Artif Intern Organs* 9, 358–362.

21 Starzl TE, Marchioro TL, Porter KA (1965) Experimental and clinical observations after homotransplantation of the whole liver. *Rev Int Hepatol* 15(8), 1447–1480.

22 Opolon P, Rapin JR, Huguet C *et al.* (1976) Hepatic failure coma (HFC) treated by polyacrylonitrile membrane (PAN) hemodialysis (HD). *Trans Am Soc Artif Intern Organs* 22, 701–710.

23 Eiseman B (1966) Treatment of hepatic coma by extracorporeal liver perfusion. *Ann R Coll Surg Engl* 38(6), 329–348.

24 Sen PK, Bhalerao RA, Parulkar GP *et al.* (1966) Use of isolated perfused cadaveric liver in the management of hepatic failure. *Surgery* 59(5), 774–781.

25 Abouna GM, Boehmig HG, Serrou B *et al.* (1970) Long-term hepatic support by intermittent multi-species liver perfusions. *Lancet* 2(7669), 391–396.

26 Abouna GM, Fisher LM, Still WJ *et al.* (1972) Acute hepatic coma successfully treated by extracorporeal baboon liver perfusions. *Br Med J* 1(791), 23–25.

27 Filip K, Maly J, Horky J *et al.* (1990) Bilirubin and bile acids removal by haemoperfusion through synthetic resin 'Persorb'. *Czech Med* 13(1), 34–37.

28 de Koning HW, Chamuleau RA, Bantjes A (1982) Coating membranes for a sorbent-based artificial liver: adsorption characteristics. *Artif Organs* 6(3), 280–287.

29 Sakagami K, Miyazaki M, Matsuoka J *et al.* (1986) Artificial liver support for postoperative hepatic failure with anion exchange resin (BR-601). *Acta Med Okayama* 40(5), 249–255.

30 Konstantin P, Chang J, Otto V *et al.* (1992) Artificial liver. *Artif Organs* 16(3), 235–242.

31 Lepore MJ, Martel AJ (1970) Plasmapheresis with plasma exchange in hepatic coma. Methods and results in five patients with acute fulminant hepatic necrosis. *Ann Intern Med* 72(2), 165–174.

32 Sabin S, Merritt JA (1968) Treatment of hepatic coma in cirrhosis by plasmapheresis and plasma infusion (plasma exchange). *Ann Intern Med* 68(1), 1–7.

33 Hughes RD, Pucknell A, Routley D *et al.* (1994) Evaluation of the BioLogic-DT sorbent-suspension dialyser in patients with fulminant hepatic failure. *Int J Artif Organs* 17(12), 657–662.

34 Hughes RD (2002) Review of methods to remove protein-bound substances in liver failure. *Int J Artif Organs* 25(10), 911–917.

35 Weston MJ, Mellon PJ, Langley PG *et al.* (1975) Resin column perfusion with whole blood or plasma separated by the continuous flow centrifuge. *Clin Sci Mol Med* 48(3), 187–192.

36 Kokot F, Pietrek J, Seredynski M (1979) Influence of hemoperfusion on the concentration of beta-methyldigoxin and hormones in plasma. *Kidney Int* 15(4), 404–410.

37 Rozga J, Williams F, Ro MS *et al.* (1993) Development of a bioartificial liver: properties and function of a hollow-fiber module inoculated with liver cells. *Hepatology* 17(2), 258–265.

38 Stange J, Ramlow W, Mitzner S *et al.* (1993) Dialysis against a recycled albumin solution enables the removal of albumin-bound toxins. *Artif Organs* 17(9), 809–813.

39 Allen JW, Hassanein T, Bhatia SN (2001) Advances in bioartificial liver devices. *Hepatology* 34(3), 447–455.

40 Wu L, Sun J, Wang L *et al.* (2000) Cryopreservation of primary porcine hepatocytes for use in bioartificial liver support systems. *Transplant Proc* 32(7), 2271–2272.

41 Nyberg SL, Remmel RP, Mann HJ *et al.* (1994) Primary hepatocytes outperform Hep G2 cells as the source of biotransformation functions in a bioartificial liver. *Ann Surg* 220(1), 59–67.

42 Hui T, Rozga J, Demetriou AA (2001) Bioartificial liver support. *J Hepatobiliary Pancreat Surg* 8(1), 1–15.

43 Behnia K, Bhatia S, Jastromb N *et al.* (2000) Xenobiotic metabolism by cultured primary porcine hepatocytes. *Tissue Eng* 6(5), 467–479.

44 Gregory PG, Connolly CK, Toner M *et al.* (2000) In vitro characterization of porcine hepatocyte function. *Cell Transplant* 9(1), 1–10.

45 Fishman JA, Patience C (2004) Xenotransplantation: infectious risk revisited. *Am J Transplant* 4(9), 1383–1390.

46 Chamuleau RA, Deurholt T, Hoekstra R (2005) Which are the right cells to be used in a bioartificial liver? *Metab Brain Dis* 20(4), 327–335.

47 Cai J, Ito M, Westerman KA *et al.* (2000) Construction of a nontumorigenic rat hepatocyte cell line for transplantation: reversal of hepatocyte immortalization by site-specific excision of the SV40 T antigen. *J Hepatol* 33(5), 701–708.

48 Kobayashi N, Noguchi H, Fujiwara T *et al.* (2000) Establishment of a highly differentiated immortalized adult human hepatocyte cell line by retroviral gene transfer. *Transplant Proc* 32(7), 2368–2369.

49 Kobayashi N, Miyazaki M, Fukaya K *et al.* (2000) Establishment of a highly differentiated immortalized human hepatocyte cell line as a source of hepatic function in the bioartificial liver. *Transplant Proc* 32(2), 237–241.

50 Werner A, Duvar S, Muthing J *et al.* (2000) Cultivation of immortalized human hepatocytes HepZ on macroporous CultiSpher G microcarriers. *Biotechnol Bioeng* 68(1), 59–70.

51 Yoon JH, Lee HS, Kim TH *et al.* (2000) Augmentation of urea-synthetic capacity by inhibition of nitric oxide synthesis in butyrate-induced differentiated human hepatocytes. *FEBS Lett* 474(2–3), 175–178.

52 Liu J, Pan J, Naik S *et al.* (1999) Characterization and evaluation of detoxification functions of a nontumorigenic immortalized porcine hepatocyte cell line (HepLiu). *Cell Transplant* 8(3), 219–232.

53 Kono Y, Yang S, Letarte M *et al.* (1995) Establishment of a human hepatocyte line derived from primary culture in a collagen gel sandwich culture system. *Exp Cell Res* 221(2), 478–485.

54 Roberts EA, Letarte M, Squire J *et al.* (1994) Characterization of human hepatocyte lines derived from normal liver tissue. *Hepatology* 19(6), 1390–1399.

55 Sussman NL, Gislason GT, Conlin CA *et al.* (1994) The Hepatix extracorporeal liver assist device: initial clinical experience. *Artif Organs* 18(5), 390–396.

56 Kelly JH, Darlington GJ (1989) Modulation of the liver specific phenotype in the human hepatoblastoma line Hep G2. *In Vitro Cell Dev Biol* 25(2), 217–222.

57 Nyberg SL, Misra SP (1998) Hepatocyte liver-assist systems – a clinical update. *Mayo Clin Proc* 73(8), 765–771.

58 Wang L, Sun J, Li L *et al.* (1998) Comparison of porcine hepatocytes with human hepatoma (C3A) cells for use in a bioartificial liver support system. *Cell Transplant* 7(5), 459–468.

59 Kobayashi N, Fujiwara T, Westerman KA *et al.* (2000) Prevention of acute liver failure in rats with reversibly immortalized human hepatocytes. *Science* 287(5456), 1258–1262.

60 Jalan R, Sen S, Williams R (2004) Prospects for extracorporeal liver support. *Gut* 53(6), 890–898.

61 Ellis AJ, Hughes RD, Wendon JA *et al.* (1996) Pilot-controlled trial of the extracorporeal liver assist device in acute liver failure. *Hepatology* 24(6), 1446–1451.

62 Rambhatla L, Chiu CP, Kundu P *et al.* (2003) Generation of hepatocyte-like cells from human embryonic stem cells. *Cell Transplant* 12(1), 1–11.

63 Schwartz RE, Reyes M, Koodie L *et al.* (2002) Multipotent adult progenitor cells from bone marrow differentiate into functional hepatocyte-like cells. *J Clin Invest* 109(10), 1291–1302.

64 Chia SM, Leong KW, Li J *et al.* (2000) Hepatocyte encapsulation for enhanced cellular functions. *Tissue Eng* 6(5), 481–495.

65 David B, Dufresne M, Nagel MD *et al.* (2004) In vitro assessment of encapsulated C3A hepatocytes functions in a fluidized bed bioreactor. *Biotechnol Prog* 20(4), 1204–1212.

66 Yin C, Mien Chia S, Hoon Quek C *et al.* (2003) Microcapsules with improved mechanical stability for hepatocyte culture. *Biomaterials* 24(10), 1771–1780.

67 Benoist S, Sarkis R, Chafai N *et al.* (2001) Survival and differentiation of porcine hepatocytes encapsulated by semiautomatic device and allotransplanted in large number without immunosuppression. *J Hepatol* 35(2), 208–216.

68 Canaple L, Nurdin N, Angelova N *et al.* (2001) Maintenance of primary murine hepatocyte functions in multicomponent polymer capsules – *in vitro* cryopreservation studies. *J Hepatol* 34(1), 11–18.

69 Uchino J, Tsuburaya T, Kumagai F *et al.* (1988) A hybrid bioartificial liver composed of multiplated hepatocyte monolayers. *ASAIO Trans* 34(4), 972–977.

70 Taguchi K, Matsushita M, Takahashi M *et al.* (1996) Development of a bioartificial liver with sandwiched-cultured hepatocytes between two collagen gel layers. *Artif Organs* 20(2), 178–185.

71 Dixit V, Chang TM (1984) In vitro and clinical studies of the removal of cortisol, thyroxine, insulin, and thyroid-stimulating hormone by coated charcoal haemoperfusion. *Life Support Syst* 2(4), 238–244.

72 Yagi K, Michibayashi N, Kurikawa N *et al.* (1997) Effectiveness of fructose-modified chitosan as a scaffold for hepatocyte attachment. *Biol Pharm Bull* 20(12), 1290–1294.

73 Gerlach JC (1996) Development of a hybrid liver support system: a review. *Int J Artif Organs* 19(11), 645–654.

74 Nyberg SL, Shirabe K, Peshwa MV *et al.* (1993) Extracorporeal application of a gel-entrapment, bioartificial liver: demonstration of drug metabolism and other biochemical functions. *Cell Transplant* 2(6), 441–452.

75 Naruse K, Nagashima I, Sakai Y *et al.* (1998) Efficacy of a bioreactor filled with porcine hepatocytes immobilized on nonwoven fabric for ex vivo direct hemoperfusion treatment of liver failure in pigs. *Artif Organs* 22(12), 1031–1037.

76 Flendrig LM, Chamuleau RA, Maas MA *et al.* (1999) Evaluation of a novel bioartificial liver in rats with complete liver ischemia: treatment efficacy and species-specific alpha-GST detection to monitor hepatocyte viability. *J Hepatol* 30(2), 311–320.

77 Grad-Itach E, Fuchs AG, Lev H *et al.* (2003) Liver micro-organs transcribe albumin and clotting factors and increase survival of 92% hepatectomized rats. *J Hepatol* 39(4), 552–558.

78 Chen SC, Hewitt WR, Watanabe FD *et al.* (1996) Clinical experience with a porcine hepatocyte-based liver support system. *Int J Artif Organs* 19(11), 664–669.

79 Watanabe FD, Mullon CJ, Hewitt WR *et al.* (1997) Clinical experience with a bioartificial liver in the treatment of severe liver failure. A phase I clinical trial. *Ann Surg* 225(5), 484–491; discussion 491–494.

80 Demetriou AA, Brown RS Jr, Busuttil RW *et al.* (2004) Prospective, randomized, multicenter, controlled trial of a bioartificial liver in treating acute liver failure. *Ann Surg* 239(5), 660–667; discussion 667–670.

81 van de Kerkhove MP, Di Florio E, Scuderi V *et al.* (2002) Phase I clinical trial with the AMC-bioartificial liver. *Int J Artif Organs* 25(10), 950–959.

82 Sauer IM, Kardassis D, Zeillinger K *et al.* (2003) Clinical extracorporeal hybrid liver support – phase I study with primary porcine liver cells. *Xenotransplantation* 10(5), 460–469.

83 Mazariegos GV, Patzer JF 2nd, Lopez RC *et al.* (2002) First clinical use of a novel bioartificial liver support system (BLSS). *Am J Transplant* 2(3), 260–266.

84 Neuzil DF, Rozga J, Moscioni AD *et al.* (1993) Use of a novel bioartificial liver in a patient with acute liver insufficiency. *Surgery* 113(3), 340–343.

85 Millis JM, Cronin DC, Johnson R *et al.* (2002) Initial experience with the modified extracorporeal liver-assist device for patients with fulminant hepatic failure: system modifications and clinical impact. *Transplantation* 74(12), 1735–1746.

86 McGuire BM, Sielaff TD, Nyberg SL *et al.* (1995) Review of support systems used in the management of fulminant hepatic failure. *Dig Dis* 13(6), 379–388.

87 Stange J, Mitzner SR, Risler T *et al.* (1999) Molecular adsorbent recycling system (MARS): clinical results of a new membrane-based blood purification system for bioartificial liver support. *Artif Organs* 23(4), 319–330.

88 Heemann U, Treichel U, Loock J *et al.* (2002) Albumin dialysis in cirrhosis with superimposed acute liver injury: a prospective, controlled study. *Hepatology* 36(4 Pt 1), 949–958.

89 Falkenhagen D, Strobl W, Vogt G *et al.* (1999) Fractionated plasma separation and adsorption system: a novel system for blood purification to remove albumin bound substances. *Artif Organs* 23(1), 81–86.

90 Rifai K, Ernst T, Kretschmer U *et al.* (2003) Prometheus – a new extracorporeal system for the treatment of liver failure. *J Hepatol* 39(6), 984–990.

91 Khuroo MS, Farahat KL (2004) Molecular adsorbent recirculating system for acute and acute-on-chronic liver failure: a meta-analysis. *Liver Transpl* 10(9), 1099–1106.

92 El Banayosy A, Kizner L, Schueler V *et al.* (2004) First use of the Molecular Adsorbent Recirculating System technique on patients with hypoxic liver failure after cardiogenic shock. *ASAIO J* 50(4), 332–337.

93 Mitzner SR, Klammt S, Peszynski P *et al.* (2001) Improvement of multiple organ functions in hepatorenal syndrome during albumin dialysis with the molecular adsorbent recirculating system. *Ther Apher* 5(5), 417–422.

94 Schmidt LE, Wang LP, Hansen BA *et al.* (2003) Systemic hemodynamic effects of treatment with the molecular adsorbents recirculating system in patients with hyperacute liver failure: a prospective controlled trial. *Liver Transpl* 9(3), 290–297.

95 Chen S, Zhang L, Shi Y *et al.* (2002) Molecular Adsorbent Recirculating System: clinical experience in patients with liver failure based on hepatitis B in China. *Liver* 22(Suppl. 2), 48–51.

96 Hessel FP, Mitzner SR, Rief J *et al.* (2003) Economic evaluation and 1-year survival analysis of MARS in patients with alcoholic liver disease. *Liver Int* 23(Suppl. 3), 66–72.

97 Hassanein T, Tofteng F, Brown R (2004) Efficacy of albumin dialysis (MARS) in patients with cirrhosis and advanced grades of hepatic encephalopathy: a prospective, controlled, randomized multicenter trial. *Hepatology* 40, 726A.

98 Evenepoel P, Laleman W, Wilmer A *et al.* (2005) Detoxifying capacity and kinetics of Prometheus – a new extracorporeal system for the treatment of liver failure. *Blood Purif* 23(5), 349–358.

99 Krisper P, Haditsch B, Stauber R *et al.* (2005) In vivo quantification of liver dialysis: comparison of albumin dialysis and fractionated plasma separation. *J Hepatol* 43(3), 451–457.

100 Mazariegos G, Ash S, Patzer J (1997) Preliminary results: randomized clinical trial of the BioLogic-DT in treatment of acute hepatic failure (AHF) with coma (abstract). *Artif Organs* 21, 529.

101 Kramer L, Gendo A, Madl C *et al.* (2001) A controlled study of sorbent suspension dialysis in chronic liver disease and hepatic encephalopathy. *Int J Artif Organs* 24(7), 434–442.

102 Ellis AJ, Hughes RD, Nicholl D *et al.* (1999) Temporary extracorporeal liver support for severe acute alcoholic hepatitis using the BioLogic-DT. *Int J Artif Organs* 22(1), 27–34.

103 Wilkinson AH, Ash SR, Nissenson AR (1998) Hemodiabsorption in treatment of hepatic failure. *J Transpl Coord* 8(1), 43–50.

104 Ash SR, Steczko J, Knab WR *et al.* (2000) Push–pull sorbent-based pheresis and hemodiabsorption in the treatment of hepatic failure: preliminary results of a clinical trial with the BioLogic-DTPF System. *Ther Apher* 4(3), 218–228.

105 Kjaergard LL, Liu J, Als-Nielsen B *et al.* (2003) Artificial and bioartificial support systems for acute and acute-on-chronic liver failure: a systematic review. *JAMA* 289(2), 217–222.

106 Liu JP, Gluud LL, Als-Nielsen B *et al.* (2004) Artificial and bioartificial support systems for liver failure. *Cochrane Database Syst Rev* 1, CD003628.

107 Sen S, Williams R, Jalan R (2005) Emerging indications for albumin dialysis. *Am J Gastroenterol* 100(2), 468–475.

108 Kubota H, Reid LM (2000) Clonogenic hepatoblasts, common precursors for hepatocytic and biliary lineages, are lacking classical major histocompatibility complex class I antigen. *Proc Natl Acad Sci USA* 97(22), 12132–12137.

109 Baccarani U, Sanna A, Cariani A *et al.* (2005) Cryopreserved human hepatocytes from cell bank: *in vitro* function and clinical application. *Transplant Proc* 37(1), 256–259.

110 Redeker AG, Yamahiro HS (1973) Controlled trial of exchange-transfusion therapy in fulminant hepatitis. *Lancet* 1(7793), 3–6.

111 He J, Chen C, Deng J *et al.* (2000) Clinical study on the treatment of fatal hepatitis with artificial liver support system. *Chin Crit Care Med* 12(2), 105–108.

26 Mathematics in hepatology

26.1 Models in clinical hepatology

W. Ray Kim

Mathematical models in medicine

Mathematical models have been used to help clinicians make diagnoses, determine prognosis and select the most effective therapy. A disease model is a mathematical representation of a medical phenomenon, such as natural history of a disease or response to a certain treatment for that condition. Figure 1 describes a generic concept of mathematical models.

The model takes several input variables to output a 'prediction'. Formally, the former are called independent variables and the latter, the dependent variable. There may be several categories of mathematical models that are useful in patients with liver disease, depending on the type of outcome being modelled and the analytical methods, as summarized in Table 1.

First, prognostic models are probably most widely known and used in clinical practice. In these models, relevant patient data are used to project future events. One such example is the Model for Endstage Liver Disease (MELD). MELD was originally derived as a prognostic model for patients undergoing the transjugular intrahepatic portosystemic shunt (TIPS) procedure [1]. It has been shown to be accurate in predicting the risk of mortality in a number of different groups of patients with liver disease [2]. Second, diagnostic models use one type of clinical data to correlate with another type. For example, although hepatic histology is the gold standard in the diagnosis and staging of many liver diseases, there are risks, costs and inconvenience associated with the procedure. A number of models have been created to correlate histological stage with clinical parameters that can be obtained using non-invasive diagnostic tests [3,4]. Third, simulation models are used to describe the natural history of a disease and/or to conduct cost-effectiveness analyses. Simulation models allow the synthesis of fragmented information about the natural history of a disease. Another utility of a simulation model is the ability to conduct sensitivity analyses in which hypothetical questions may be tested [5]. This review will address prognostic and diagnostic models commonly used in clinical hepatology, whereas simulation models are reviewed in Chapter 26.4.

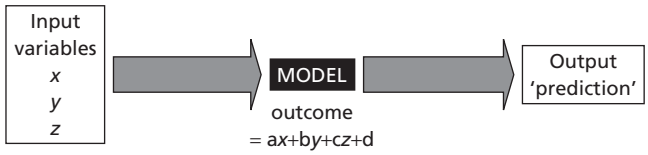

Fig. 1 A generic scheme of a mathematical model in medicine.

Prognostic models

Prognostic models are used to predict future events and thus addresses questions such as 'How long will my patient live?' In answering these questions, the proportional hazards or Cox regression analysis is commonly the most appropriate statistical method for analysis [6]. In these models, 'hazard' is the instantaneous rate of death (or other event of interest) for an individual surviving up to a given time. Proportional hazard models are based on the assumption that the hazard of an event at any time for an individual in one group is proportional to the hazard at the same time for a similar individual in another group. Based

Table 1 Types of mathematical models.

Category	Outcome modelled	Analytical framework	Example
Prognostic models	Time to event (e.g. death, transplantation, disease progression)	Proportional hazards regression (Cox)	MELD
Diagnostic models	Condition present (yes/no)	Logistic regression	FibroTest, APRI
	Quantitative measurement	Linear regression	Cockcroft–Gault
Simulation models	Health/disease states over time	Decision tree, Markov model	Cost-effectiveness of therapy for hepatitis C

Table 2 The TIPS model.

Variable	Regression coefficient	Standard error	Hazard ratio (95% CI)	*P*
$\log_e$(creatinine)	0.957	0.142	2.60 (1.97–3.44)	< 0.01
$\log_e$(bilirubin)	0.378	0.117	1.46 (1.16–1.84)	< 0.01
$\log_e$(INR)	1.120	0.331	3.06 (1.60–5.86)	< 0.01
Aetiology	0.643	0.211	1.90 (1.26–2.88)	< 0.01

CI, confidence interval.

on this assumption, the model calculates hazard ratios between one group with one characteristic in an explanatory variable and the other(s) with a different characteristic(s). Whether the hazard ratio is different from 1 (1 representing no difference) is tested for statistical significance [6].

Let us take MELD as an example of a Cox regression analysis. As is well known, MELD was originally developed as a model to predict the survival of patients undergoing the TIPS procedure [1]. In the development of the model, 231 consecutive patients with cirrhosis who underwent elective TIPS at four hospitals were analysed. Patients with significant cardiopulmonary comorbidity or intrinsic renal disease were excluded from the analysis. Patients most commonly had alcoholic liver disease (62%) and decompensated liver disease, including 79% with clinically apparent ascites and 35% with hepatic encephalopathy stage II or higher. The 231 patients were followed from their date of TIPS until death, liver transplantation or study closure. During follow-up, 110 died, in all of whom the cause of death was related to their liver disease.

Of many candidate variables that were considered, only $\log_e$(creatinine), $\log_e$(bilirubin), $\log_e$(international normalized ratio; INR) and aetiology of cirrhosis were predictive of survival after TIPS. These variables were predictive of survival whether the patient underwent TIPS for the prevention of recurrent bleeding or for the treatment of refractory ascites. Based on these data, a Cox model was created, which is shown in Table 2.

To illustrate briefly the mechanics of the proportional hazards analysis, based on the proportional hazards assumption, the ratio between these hazards (i.e. hazard ratio) is calculated by $e^{\text{regression coefficient}}$. For example, in Table 2, the hazard of death for an individual with viral hepatitis is proportional to that at the same time for a similar individual with cholestatic liver disease. The hazard ratio for this particular variable (aetiology) is $e^{0.643}$ or 1.90. Ninety-five per cent confidence intervals are calculated by $e^{(0.643 \pm 1.96 * 0.211)}$, where 0.211 is the standard error associated with this variable and 1.96 is the multiple of standard errors to include 95% of data in normally distributed data. Interpretation of the hazard ratio is that the presence of viral hepatitis or 'other' liver disease increased the risk of death by 1.9 times compared with alcoholic or cholestatic liver disease. Interpretation of the results for the continuous variables is similar, but the fold risk increase is based on one unit increase of the variable. For example, in this model, an increase of 1 in $\log_e$(creatinine) multiplies the risk of death by 2.60 times. Similarly, an increase of 1 in $\log_e$(bilirubin) multiplies the risk of death by 1.46 times; and an increase of 1 in $\log_e$(INR) more than triples (3.06) the risk of death.

Table 3 Two hypothetical patients.

	Patient 1	Patient 2
Total bilirubin (mg/dL)	6.7	4.9
Creatinine (mg/dL)	1.8	1.2
INR	1.5	1.1
Diagnosis	Hepatitis C	PBC
Risk score	2.379	0.882

PBC, primary biliary cirrhosis.

These data constitute the basis for the calculation of a risk score, which is a linear combination of these variables, namely:

$$\text{TIPS risk score} = 0.957 \cdot \log_e(\text{creatinine}) + 0.378 \cdot \log_e(\text{bilirubin}) + 1.120 \cdot \log_e(\text{INR}) + 0.643 \cdot \text{aetiology}.$$

In our data set, the average risk score was 1.127, which in and of itself does not carry any meaning. However, it can be used to estimate survival in other patients based on the proportional hazards assumption. The examples of two hypothetical patients shown in Table 3 illustrate this point. Patient 1 has a risk score of 2.379, whereas the risk score of patient 2 is calculated to be 0.882. The risk of death of patient 1, who has a risk score of 2.379, is $e^{(2.379-1.127)}$ or 3.5 times higher than the average patient with a risk score of 1.127. Likewise, the risk of death of patient 2 in Table 3 (risk score = 0.882) is 0.78 ($e^{(0.882-1.127)}$) of the average patient. Now, these hazard ratios may also be used to estimate survival in a given patient, based on a comparison with the average patient. Table 4 shows the expected survival of the average patient with a risk score of 1.127. For example, a patient with a risk score of 1.127 has an 86% chance of survival at 1 month and 55% at 1 year. The expected survival of a patient with a given risk score may be calculated by raising these average survival estimates [referred to as $S_0(t)$] by the power of the hazard ratio. In other words, for patient 1 in Table 3 with a risk score 2.379 and a 3.5-fold increase in the risk of death, the estimated survival at any time t is computed by $S_0(t)^{3.5}$. For example, the survival of such a patient at 1 month is expected to be $0.860^{3.5}$ or 59% and at 1 year $0.551^{3.5}$ or 12%. Corresponding figures for patient 2 are 89% and 63%.

Table 4 Predicted survival.

	1 day	1 week	1 month	3 months	6 months	1 year	2 years
Average patient [$S_0(t)$] (R = 1.127)	0.990	0.966	0.860	0.707	0.621	0.551	0.428
Patient 1 (R = 2.379)	0.965	0.886	0.590	0.297	0.189	0.124	0.051
Patient 2 (R = 0.882)	0.992	0.973	0.889	0.762	0.689	0.627	0.515

As many readers know, this TIPS model has been adopted as the MELD score, which is now widely used as a model to gauge disease severity in patients with endstage liver disease [7]. While the results presented so far may appear to be immediately useful, there were a few issues that needed to be thought through before MELD was put forth as a valid prognostic model. The following sections address some of those issues.

Censoring and informative censoring

As reported above, during the follow-up of the TIPS patients, there were 110 individuals who died. That leaves 121 patients out of the initial 231 patients, 21 of whom were no longer being followed on the day of study closure and, thus, whether they were alive or dead at that time could not be determined. These patients were 'censored' on the last day of follow-up, as they only contributed to our data by the fact that they were alive up to that point in time. In survival analyses, including the Cox model, one assumes that censoring occurs at random. In other words, those who are censored must be representative of all other individuals in that group who have survived to that time. While this assumption may not be verified in all circumstances, it is often worthwhile to pause to consider any systematic bias that may cause violation of this assumption.

This point becomes even more relevant when we consider the 28 patients of the remaining 100 who were known to be alive who had undergone liver transplantation. There may be at least four ways to treat liver transplantation in the analysis of patients with endstage liver disease [8]. First, liver transplantation could be treated as an event (the same as death). This method assumes that liver transplantation is performed on the same day that the patient is destined to die. It will portray an overly pessimistic view of the natural history of these patients as, in most cases, patients are expected to survive (even without a transplant) for some time beyond the day of transplantation. Second, liver transplantation could be ignored in the analysis. In other words, patients are considered to be alive (or free of an 'event'), regardless of whether they had a liver transplant or not. This method will overestimate the natural survival of patients with liver disease as, in most patients, liver transplantation extends survival. Third, liver transplantation can be censored, which, as described above, assumes that this censoring occurred randomly. For this assumption to hold perfectly, anyone on the transplant waiting list, on a given day, should have an equal chance of receiving an organ. This is materially not true as, even in the pre-MELD era, the system was geared towards allocating organs to patients with more severe liver disease. Fourth, one may estimate what the natural survival would have been in patients who undergo liver transplantation and use that information in the analysis. If this estimation can be conducted accurately, this method may be the most desirable. However, to the degree that the goal of most survival analyses in patients with liver disease is exactly that estimation, this method has the problem of being circular. All in all, as in most situations, the existence of several choices underlines the fact that none of the approaches is optimal. It may depend on the particular data set that is being used as to which may be the best method to use.

In our analysis of survival of patients undergoing the TIPS procedure, we elected to censor patients on the day of orthotopic liver transplantation (OLT). This was done because, in this particular data set, the method was deemed to entail the least amount of bias compared with ignoring OLTs or treating them as events. At any rate, the proportion of patients who had OLT was relatively small, and it may not have mattered too much which methods were used to treat patients who underwent OLT. On the other hand, our analysis may have contained an element of what is known as informative censoring. Informative censoring refers to a circumstance in which certain subjects were censored based on certain characteristics – as opposed to censoring being random. In this example, being censored for having undergone OLT is likely to be indicative of having more severe liver disease than other subjects with otherwise similar characteristics. A more common example of informative censoring occurs when patients are lost to follow-up because they die. This will lead to an overestimation of the survival of that group.

Model's validity: accuracy and precision

Once a prognostic model is deemed to be statistically valid (i.e. statistical assumptions are met, such as proportional hazards and non-informative censoring), the next important step towards its practical application is an assessment of the 'goodness' of the model. This may be determined by two criteria: accuracy and precision. Figure 2 illustrates the two concepts. Accuracy refers to the degree to which predicted outcome matches observed outcome, whereas precision refers to the degree to which the prediction may be made with reproducibility. As shown in Figure 2, models may be accurate but not precise and vice versa.

The accuracy of a model's prediction may in turn be assessed from two perspectives. First, *discrimination* evaluates whether

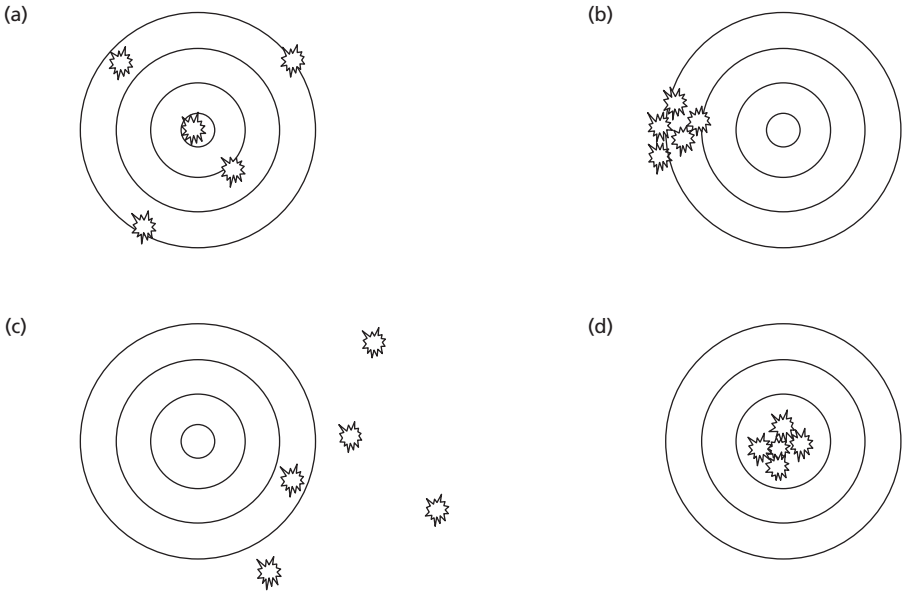

Fig. 2 Illustration of accuracy and precision. (a) Accurate but not precise; (b) precise but not accurate; (c) neither accurate nor precise; and (d) accurate and precise.

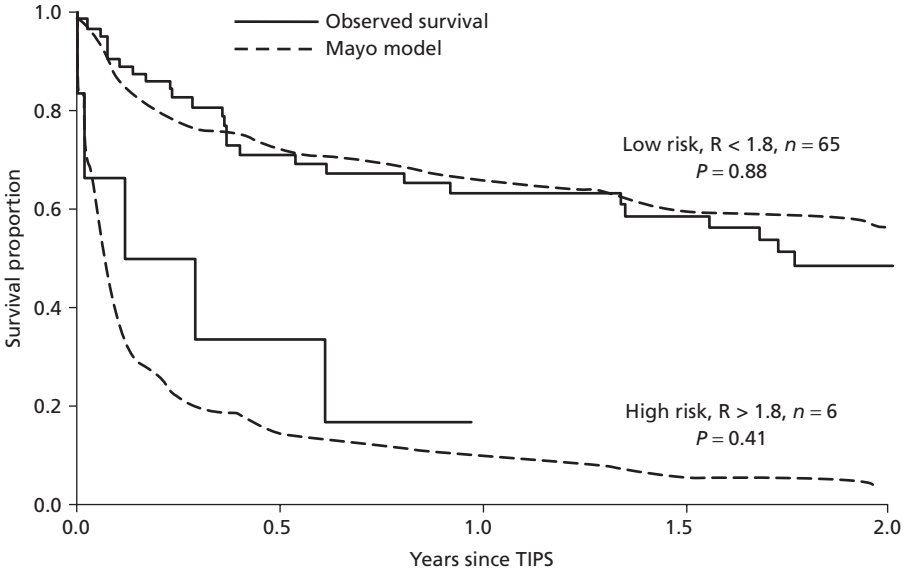

Fig. 3 Demonstration of good calibration of the TIPS model: survival of 71 TIPS patients who were stratified into a high-risk group [score (R) > 1.8] and a low-risk group [score (R) < 1.8]. The observed and expected survival was similar.

the relative ranking of individual risk is in the correct order. A model that discriminates well will assign higher scores to those in whom observed event rates are higher than to those with low event rates. This property is commonly measured with the concordance (c) statistic. This statistic assesses of all possible pairs of observations with dissimilar outcomes, the proportion of pairs that were ranked correctly by the model. For example, in the prediction of 3-month mortality using our TIPS model, of all (n = 9520) possible pairs between 70 patients who died and 136 who were alive at 3 months, 78.7% were concordant (the subject who died had a higher TIPS score than the survivor), 21.1% were discordant (the subjects who were alive had a higher score than the deceased) and 0.2% were tied (the score was the same). The concordance statistic in this example was 0.788 (78.7% concordant + 0.2% tied × 0.5). Note that, for tied pairs, only 50% of the credit is given to the model.

The other measure of accuracy is *calibration*, which assesses the degree to which the predicted probability matches the actual mortality. In theory, a model may have 100% discrimination (rank correctly who will die and who will be alive), but the predicted survival probability may be far from the actual survival experience of the data set. Calibration is often examined by comparing predicted and actual survival in a small number of strata by the risk. Figure 3 is such an example in which the TIPS model was applied to a group of patients who were not included in the data set used in the development of the model. It demonstrates

Table 5 Patient groups for generalizability of MELD.

	Hospitalized decompensated	Ambulatory		Historical
		Non-cholestatic	Cholestatic	
No.	282	491	326	1179
MELD	9 (4–14)	10 (8–13)	1 (–2 to 5)	7 (3–13)
3-month mortality	21%	7%	2%	19%
Concordance	0.87 (0.82–0.92)	0.80 (0.69–0.90)	0.87 (0.71–1.00)	0.78 (0.74–0.81)

that, among the TIPS patients with high and low risk scores, expected and actual survival matches closely.

Precision refers to the degree to which results are reproducible and thus generalizable [9]. Precision may be assessed by internal validity in which the model is examined in an identical population to the one in which it was developed, whereas external validity refers to the precision of prediction in a different population. Therefore, generalizability of a model usually involves applying the model in a data set that was not used in the development of the model. Sometimes, this 'validation' is done by splitting the data set, where the first data set is used to define the model and the second data set is used to examine how well it works. The importance of validation of a model in a data set that is not used in its development cannot be overemphasized, as patient-derived data are fraught with peculiarities that occur at random and are not important in general. Almost always, the precision of the model's prediction is reduced in an independent data set.

A model's generalizability in a population that is different from that in which it was developed may be defined in terms of: (i) disease spectrum; (ii) geographical location; (ii) historical time periods; (iv) follow-up intervals; and (v) methods of assessment. The following section discusses the process in which the demonstration of the generalizability of the TIPS model led to the establishment of MELD.

Validation of MELD

In the late 1990s, increasing awareness by the transplant community and the general public in the USA of the inadequacy of the organ allocation system based on waiting time led to a regulatory mandate to develop a measure by which to gauge the severity of disease in patients with cirrhosis and endstage liver disease [10,11]. In response to this mandate, our group evaluated the TIPS model as a potential candidate for a generalizable index to determine the risk of mortality in patients with endstage liver disease. Thus, this process represents examination of disease spectrum generalizability, in which the performance of the TIPS risk score, originally developed in patients who underwent the procedure for variceal haemorrhage or ascites, was assessed in patients with endstage liver disease, the vast majority of whom had no need for TIPS. As shown below, the process also included examination of generalizability across historical time periods (patients with endstage liver disease before TIPS became available), geographical location (data from patients from another country examined, ambulatory non-cholestatic patients) and follow-up intervals (prediction of mortality at timescales different from the TIPS model). Finally, it was also an example of methodological generalizability, as the model performed well in patients in whom the diagnosis of cirrhosis was made less rigorously than in TIPS patients ('Historical cohort', see below).

At the outset of the validation process, we decided to transform the TIPS risk score into integers for the sake of ease of use, by multiplying the original score by 10 and rounding the subdecimal numbers [2]. Based on this more user-friendly version of the score, we evaluated three patient groups to examine its generalizability. The first group was patients who had been hospitalized for complications of decompensated liver disease. The second group was patients seen in ambulatory settings. The final group was unselected cirrhotic patients from a time when liver transplantation was not widely available. Table 5 summarizes these patient groups.

The criteria by which the validity of MELD was tested were the concordance statistic in the prediction of 3-month survival, in part because we were interested in short-term survival in liver transplant candidates. As discussed above, the concordance statistic examines the model's ability to rank patients according to their likelihood of death. It may range from 0 to 1, with 1 corresponding to perfect discrimination and 0.5 to what is expected by chance alone. A concordance statistic of 0 would result if the prediction were wrong 100% of the time. In all the data sets examined, the concordance statistic for the prediction of 3-month mortality was as high as 0.87. In general, as expected, as the disease spectrum became disparate from the TIPS population, the concordance statistic decreased (from 0.87 for hospitalized patients with decompensation to 0.78 for unselected historical cirrhotic patients).

In its intended application of ranking patients on a liver transplant waiting list, the concordance statistic is an appropriate tool for validation. For example, in our examination of the impact of including individual complications of hepatic decompensation in the model, we found that the concordance statistics did not increase or increased by only 1–3%. We determined that inclusion of these variables was not necessary. Similarly, we concluded that excluding the liver disease diagnosis did not change the concordance statistic materially. Based on these data, we proposed

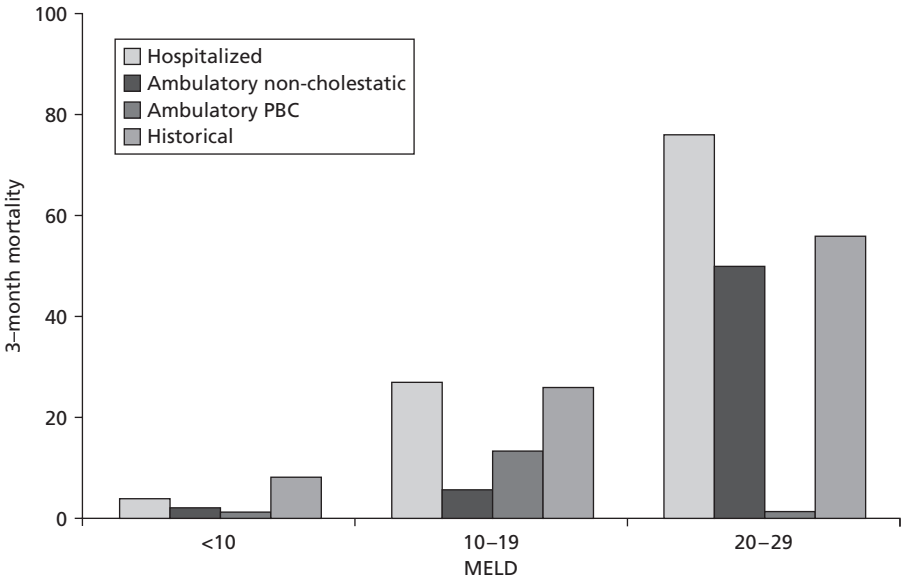

Fig. 4 Comparison of 3-month mortality by MELD among patient groups demonstrates that mortality associated with a given MELD score may differ by patient setting.

MELD to consist of the three laboratory variables, namely total bilirubin, creatinine and INR, without the aetiology variable or inclusion of individual complications of portal hypertension.

Certain limitations of the concordance statistic must be pointed out. As the concordance statistic only takes into account the proportions of correct and incorrect predictions, it is relatively insensitive in the evaluation of a variable that has a big impact on survival but only affects a small proportion of patients. An example is our recent experience in considering incorporating serum sodium into the score, which highlights this point. Although hyponatraemia has a profound impact on the survival of patients with cirrhosis, a significant degree of hyponatraemia was only present in a small minority of patients [12,13]. Therefore, a variable such as serum sodium that may potentially have a large impact on survival may not be recognized as an important factor if only the concordance statistic is considered in variable selection. Another limitation of the concordance statistic is, as discussed previously, that it does not assess the accuracy of the model's calibration. For example, Figure 4 compares 3-month survival of the four groups of patients included in the description of MELD. This comparison demonstrates that, depending on the setting, patient survival may differ even within the same MELD categories.

Despite these limitations, MELD has proved to be a significant improvement over the previous system by which to gauge the severity of liver disease in patients on a liver transplant waiting list. Since MELD was implemented as the criterion by which allocation priorities were determined among liver transplant candidates in the USA in February 2002, there has been an immediate reduction in liver transplant waiting list registrations for the first time in the history of liver transplantation in the USA (12% decrease in 2002) [14]. This was because the previously common practice of registering patients on the waiting list at the earliest possible time (even if liver transplantation was not imminently indicated) to allow maximum accrual of waiting time was no longer necessary. More importantly, the number of deaths while on the waiting list, which had been increasing annually, decreased substantially from 2046 in 2001 to 1364 in 2005 [15]. Although this reduction in mortality is in part attributable to a modest increase in available organs (4671 in 2001 vs. 5160 in 2005), there is a broad consensus that MELD has made a significant contribution to reducing liver transplant waiting list mortality [16].

Other examples of prognostic models

Obviously, MELD is only one example of a prognostic model, and there are many other valid and useful ones. The Child–Turcotte–Pugh (CTP) score has been the traditional gold standard in the assessment of prognosis in patients with advanced liver disease [17,18]. Although the CTP score was not developed using rigorous statistical methods, it has been shown to be clinically useful in many studies subsequent to its original description [19]. While MELD is preferred to determine organ allocation priorities because of its objectivity, CTP remains a useful tool in the daily practice of hepatology. In addition, prognostic models abound in hepatology in predicting the natural history of precirrhotic liver disease such as chronic hepatitis C, chronic hepatitis B and alcoholic hepatitis, as well as predicting the outcome of treatment (chronic hepatitis C, chronic hepatitis B, liver transplantation). Although the specifics of these models differ from one another, the general principle, utilities and limitations of these models remain identical.

Diagnostic models

Diagnostic models are used to correlate one type of clinical data with another and therefore address questions such as 'Does my patient have cirrhosis?' As opposed to prognostic models, in

which the outcome is not known until some time in the future, in diagnostic models, the dependent variable is available at the present time. Thus, although the term 'prediction' is often used for diagnostic models, they do not predict an event in the future, but merely correlate one set of variables with another. The reason for the existence of diagnostic models is that the information being modelled is not easily available, because it requires diagnostic tests that are invasive (e.g. liver biopsy) or expensive (e.g. endoscopy for oesophageal varices).

The statistical methods commonly used for diagnostic models include the linear and logistic regression analyses. The former is used when the outcome variable is continuous, such as the glomerular filtration rate, whereas the latter is designed to answer a dichotomous (yes or no) question, such as the presence or absence of cirrhosis. In hepatology, logistic models are more common, perhaps because dichotomous information is more useful clinically and because linear regression analyses require certain statistical assumptions to be met to be valid. Thus, our discussion will be focused on logistic models.

While some of the salient points made for prognostic models also apply to diagnostic models, there are a number of differences between the two. First, in diagnostic models, if the outcome in some individuals is unknown, they contribute no information to the analysis. In proportional hazard models, subjects who are censored for being lost to follow-up provide some information to the data in that their survival to the last known follow-up is taken into account. In a diagnostic model, if the outcome is not available, the observation provides no information in the analysis. Second, because the outcome data are currently available, diagnostic models should have higher accuracy and precision than prognostic models. In other words, the value of a prognostic model that is able to predict correctly 70% of the time whether a patient will be alive in 6 months is probably more useful than that of a diagnostic model that can discern the presence of oesophageal varices with the same degree of accuracy.

Whereas the results of proportional hazard models are reported with hazard ratios, those of logistic models are given as odds ratios. While the mathematics behind these ratios is disparate in each case, the interpretation of the ratios is similar. In a Cox model predicting death, if a certain characteristic has a hazard ratio of 2, it indicates that having that characteristic increases the risk of death by twofold compared with those without that characteristic. Similarly, in a logistic model of diagnosing cirrhosis, if a factor has an odds ratio of 2, it is interpreted as the existence of that factor making it twice as likely that the subject has cirrhosis.

To provide a more tangible illustration of what diagnostic models may or may not be able to do, Table 6 entails a hypothetical serum test to diagnose cirrhosis. In example 6B in Table 6, the test was conducted in 100 subjects, 50 of whom have cirrhosis while the other 50 do not. The test was positive in 60 subjects and negative in 40. Forty subjects who have cirrhosis have a positive test (sensitivity = 80%), while the remaining 10 with cirrhosis have a negative test (false negative = 20%). Of the 50 who did not have cirrhosis, 30 were test negative (specificity = 60%) and, in the remaining 20, the test was falsely positive. The positive predictive value of this test is 67% (40 out of 60 with a positive test

Table 6 Examples of a hypothetical model for the prediction of cirrhosis.

6A	Cirrhosis			Sensitivity	a/(a+c)
Test	Yes	No	Total	Specificity	d/(b+d)
Positive	a	b	a+b	PPV	a/(a+b)
Negative	c	d	c+d	NPV	d/(c+d)
Total	a+c	b+d	a+b+c+d	Odds ratio	(a·d)/(b·c)
6B	Cirrhosis			Sensitivity	80%
Test	Yes	No	Total	Specificity	60%
Positive	40	20	60	PPV	67%
Negative	10	30	40	NPV	75%
Total	50	50	100	Odds ratio	6.0
6C	Cirrhosis			Sensitivity	90%
Test	Yes	No	Total	Specificity	90%
Positive	45	5	50	PPV	90%
Negative	5	45	50	NPV	90%
Total	50	50	100	Odds ratio	81.0
6D	Cirrhosis			Sensitivity	80%
Test	Yes	No	Total	Specificity	60%
Positive	40	200	240	PPV	19%
Negative	10	300	310	NPV	97%
Total	50	500	550	Odds ratio	6.0

NPV, negative predictive value; PPV, positive predictive value.

have cirrhosis), and the negative predictive value is 75% (30 out of 40 with a negative result do not have cirrhosis).

The odds ratio associated with this test is calculated by (the ratio between those with cirrhosis and those without among test positives) divided by (the ratio between those with cirrhosis and those without among test negatives), or (40/20) ÷ (10/30), which is 6. A common interpretation of this result is, 'the odds (or risk) of having cirrhosis is sixfold higher if the test is positive'. While a sixfold increase in the risk in many settings would be highly meaningful, in this example of a diagnostic model, the performance of the test is not all that impressive. Example 6C illustrates a test that many would consider as an accurate test (90% sensitive and 90% specific). The odds ratio associated with such as test would be as high as 81, a value that is seldom encountered in practice. These examples may suggest that, for diagnostic models to be useful, they need to have an association that is quite a bit stronger than their odds ratios may suggest.

The aspect of a diagnostic model that has a direct impact on its practical application includes positive and negative predictive values. Positive predictive value measures the proportion of true positives among test positives, whereas negative predictive value measures the proportion of true negatives among test negatives. These predictive values are not only determined by the characteristics of the diagnostic test but also by the prevalence of the condition. Comparison of examples 6B and 6D in Table 6 is instructive. In those examples, the diagnostic test has the same characteristics (sensitivity = 80%, specificity = 60%, odds ratio = 6.0). The only difference between the two examples is the prevalence of cirrhosis [50% (50/100) in example 6B vs. 9% (50/550) in example 6D]. The positive predictive value of the test in patient samples from example 6B is 67% and the negative predictive value is 75%. These change dramatically as the prevalence of cirrhosis decreases in example 6D. The positive predictive value decreased to a mere 19%, whereas the negative predictive value increased to 97%.

These considerations are relevant because, in most situations, diagnostic models are developed at academic medical centres whose practice tends to be enriched with referral patients. These patients represent the more complex and advanced end of the disease spectrum, for example having a high prevalence of cirrhosis. However, when the models derived in those patients are applied to patients commonly seen in less specialized settings, the positive predictive value of the test will decrease and the negative predictive value will increase. To take real-life examples, there are at least two models that have been developed to diagnose hepatic fibrosis and cirrhosis. These include aspartate aminotransferase (AST)/platelet ratio (APRI) and FibroTest, both of which were created using the logistic regression analysis.

APRI was developed at a tertiary medical centre in the USA [4]. In those patients who had a liver biopsy and met certain inclusion criteria ($n = 270$), the degree of fibrosis was correlated with the results of blood tests including haematological and liver biochemical parameters. Multivariable logistic regression analyses indicated that higher levels of AST and lower platelet counts were associated with advanced fibrosis (Ishak score ≥ 3, bridging fibrosis or cirrhosis). Based on these data, the ratio between AST and platelet count was examined as an indicator of fibrosis.

$$\text{APRI} = \{[\text{AST level (/ULN)}]/[\text{platelet counts } (10^9/\text{L})]\} \times 100$$

Figure 5 describes the predictive values of APRI scores in their independent validation data set. The prevalence of advanced fibrosis (bridging or worse) was 50% and that of cirrhosis 17%. In general, positive predictive values were lower than negative predictive values. Thus, if APRI is applied to a patient population with a lower prevalence of fibrosis, the positive predictive value will decrease even further, indicating that this marker will be of limited use in diagnosing patients with cirrhosis or advanced fibrosis. On the other hand, the negative predictive value will be higher in a population with a lower prevalence of cirrhosis. Thus, APRI may be even more useful in excluding significant fibrosis or cirrhosis than the data in Figure 5 may suggest.

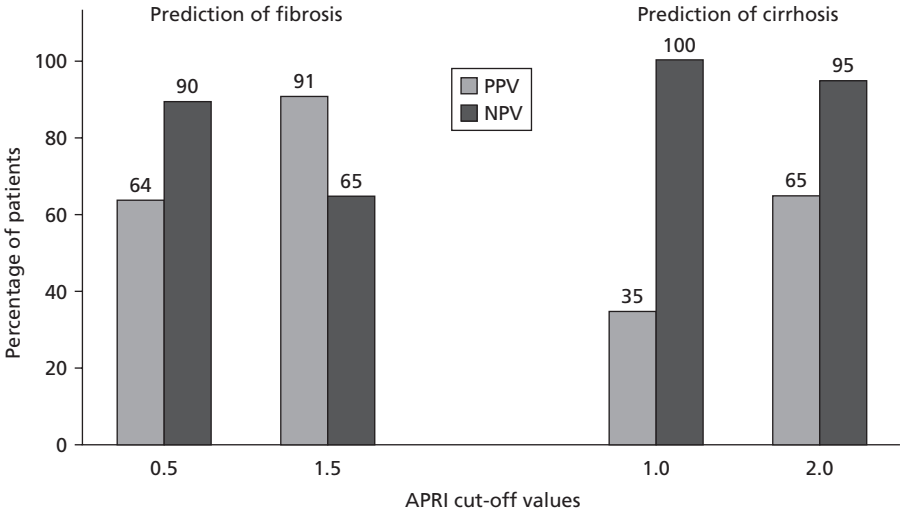

Fig. 5 Positive and negative predictive values of APRI in determining fibrosis (left) or cirrhosis (right). For example, 65% of patients with an APRI score > 2.0 had cirrhosis (PPV = 65%), whereas 95% of those with an APRI < 2.0 did not have cirrhosis (NPV = 95%).

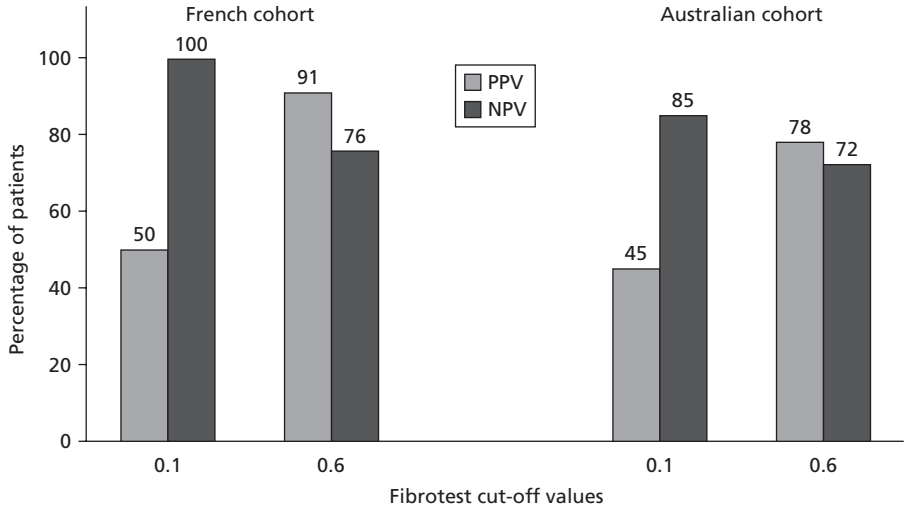

Fig. 6 Positive and negative predictive values of FibroTest in determining significant fibrosis (Metavir F2 or higher). Positive predictive values are higher in the French cohort than in the Australian cohort, as the former had a higher prevalence of fibrosis (45%) than the latter (38%).

FibroTest was also developed at an academic medical centre [3]. Similar to APRI, patients who had a liver biopsy and met certain inclusion criteria were studied retrospectively ($n = 339$). Of a number of biochemical markers, alpha-2-macroglobulin, haptoglobin, apolipoprotein A1, total bilirubin and gamma glutamyltransferase (γ-GT) were determined to be useful correlates of hepatic histology. A proprietary score consisting of serum levels of these markers as well as age and gender was chosen to model the degree of fibrosis using the Metavir system. Figure 6 demonstrates the predictive values of Fibrotest in diagnosing significant fibrosis [Metavir stage F2 (few fibrotic septa or early-stage bridging fibrosis) or higher]. The left panel represents patients in the validation data set of the report, where the prevalence of significant fibrosis was 45%. A low Fibrotest score suggests lack of fibrosis, as in the case of a score of 0.1, where the negative predictive value was 100%. A Fibrotest score > 0.6 predicts significant fibrosis (91%). As in the example of APRI, when Fibrotest is applied to a population with a lower prevalence of fibrosis, the positive predictive value is expected to decrease. This prediction is demonstrated in an independent validation study conducted by Rossi *et al.* [20], in which 125 Australian patients with chronic hepatitis C were evaluated with liver histology and Fibrotest. The prevalence of significant (F2 or higher by Metavir) fibrosis was 0.38. The right panel in Figure 6 summarizes the positive and negative predictive values. The negative predictive value of Fibrotest < 0.1 was 85% and the positive predictive value of Fibrotest > 0.6 was 78%, both of which were noticeably lower than what was reported in the original description of the test.

These examples highlight the fact that, in order for diagnostic models to be useful in practice, they need to be more accurate/precise than prognostic models. As in prognostic models, rigorous assessment of accuracy and precision is important. In particular, for practical application of the model, predictive values are important, which necessitates application of the model in a target population before being widely embraced.

Conclusions

Mathematical models allow objective utilization of information derived from prior experience in similar patients. However, it is important for clinicians to have a balanced view of what mathematical models are able to achieve: even when the model's validity over disease spectrum, geographical location or methods of ascertainment is established, the uniqueness of our individual patients and the random occurrence of events in medicine makes it essentially impossible to have a model that is correct 100% of the time. On the other hand, mathematical models may be used as a powerful tool and guide to which individual clinical judgement may be incorporated to achieve the best outcome for our patients.

References

1 Malinchoc M, Kamath PS, Gordon FD *et al.* (2000) A model to predict poor survival in patients undergoing transjugular intrahepatic portosystemic shunts. *Hepatology* 31(4), 864–871.
2 Kamath PS, Wiesner RH, Malinchoc M *et al.* (2001) A model to predict survival in patients with end-stage liver disease. *Hepatology* 33(2), 464–470.
3 Imbert-Bismut F, Ratziu V, Pieroni L *et al.* (2001) Biochemical markers of liver fibrosis in patients with hepatitis C virus infection: a prospective study. *Lancet* 357(9262), 1069–1075.
4 Wai CT, Greenson JK, Fontana RJ *et al.* (2003) A simple noninvasive index can predict both significant fibrosis and cirrhosis in patients with chronic hepatitis C. *Hepatology* 38(2), 518–526.
5 Kim WR (2005) The use of decision analytic models to inform clinical decision making in the management of hepatocellular carcinoma. *Clin Liver Dis* 9(2), 225–234.
6 Collet D (1994) Modeling survival data in medical research. In: Chatfield C, Zidek JV (eds) *Texts in Statistical Science*. London: Chapman & Hall, pp. 53–106.
7 Freeman RB, Wiesner RH, Edwards E *et al.*, United Network for Organ Sharing (2004) Results of the first year of the new liver allocation plan. *Liver Transpl* 10(1), 7–15.

8 Kim WR, Therneau TM, Wiesner RH *et al.* (2000) A revised natural history model for primary sclerosing cholangitis. *Mayo Clinic Proc* 75(7), 688–694.

9 Justice AC, Covinsky KE, Berlin JA (1999) Assessing the generalizability of prognostic information. *Ann Intern Med* 130(6), 515–524.

10 Anonymous (1998) Organ Procurement and Transplantation Network – HRSA. Final rule with comment period. *Fed Register* 63(63), 16296–16338.

11 Anonymous (1999) Analysis of waiting times (Institute of Medicine). In: *Organ Procurement and Transplantation: Assessing Current Policies and the Potential Impact of the DHHS Final Rule.* Washington, DC: National Academy Press, pp. 57–78.

12 Heuman DM, Abou-Assi SG, Habib A *et al.* (2004) Persistent ascites and low serum sodium identify patients with cirrhosis and low MELD scores who are at high risk for early death. *Hepatology* 40(4), 802–810.

13 Ruf AE, Kremers WK, Chavez LL *et al.* (2005) Addition of serum sodium into the MELD score predicts waiting list mortality better than MELD alone. *Liver Transpl* 11(3), 336–343.

14 Wiesne R, Edwards E, Freeman R *et al.* (2003) Model for end-stage liver disease (MELD) and allocation of donor livers. *Gastroenterology* 124(1), 91–96.

15 Anonymous (2005) *Annual Report of the US Organ Procurement and Transplantation Network and the Scientific Registry of Transplant Recipients: Transplant Data 2004.* Rockville, MD: HHS/HRSA/OSP/DOT.

16 Brown RS, Jr, Lake JR (2005) The survival impact of liver transplantation in the MELD era, and the future for organ allocation and distribution (comment). *Am J Transpl* 5(2), 203–204.

17 Child C, Turcotte J (1964) Surgery and portal hypertension. In: Child C (ed) *The Liver and Portal Hypertension.* Philadelphia: W.B. Saunders, p. 50.

18 Pugh RN, Murray-Lyon IM, Dawson JL *et al.* (1973) Transection of the oesophagus for bleeding oesophageal varices. *Br J Surg* 60(8), 646–649.

19 Christensen E, Schlichting P, Fauerholdt L *et al.* (1984) Prognostic value of Child–Turcotte criteria in medically treated cirrhosis. *Hepatology* 4, 430–435.

20 Rossi E, Adams L, Prins A *et al.* (2003) Validation of the FibroTest biochemical markers score in assessing liver fibrosis in hepatitis C patients. *Clin Chem* 49(3), 450–454.

26.2 Outcomes research in hepatology

Raymond S. Koff

Definitions of health outcomes research

The missions of healthcare providers and healthcare services are understood even when the term 'health' is less readily defined. The promotion and preservation of health and, in the event of disease, its improvement or restoration are unequivocal goals. Current usage defines health as a state of complete physical, mental and social well-being and not merely the absence of disease. It is therefore a term encompassing several distinct dimensions, including physical, mental and social health as well as other dimensions. In health outcomes research, the state of health of an individual (or a population) is assessed using measures that are beyond traditional clinical endpoints. Endpoints such as morbidity, change in life expectancy, mortality and improvements in laboratory tests of blood or other body fluids, biopsy specimens and imaging studies are indeed important but may not measure health outcomes from the individual patient's point of view, particularly in non-life-threatening chronic diseases. Other surrogates, such as employment, homeworking, academic study, support of others and involvement in social or community groups or activities, are important life activities but only indirect measures of function and well-being [1]. Furthermore, they may be difficult to quantify and compare.

In health outcomes research, outcomes are defined in terms of functional status, well-being and the health preferences of the individual, information that only the patient can provide. Traditional clinical outcomes can now be complemented by patient-derived information about patient satisfaction, appropriateness of care, as well as economic evaluations and practice patterns. The purpose of health outcomes research is to guide the promotion, preservation and restoration of health, as determined from the individual or patient's perspective on the consequences of illness, treatment and the post-treatment state. In this sense, outcomes research can be used to monitor the quality of care from the patient's perspective and may aid in identifying the relative effectiveness of different interventions. A better and more complete understanding of the impact of disease and treatment on health status should empower healthcare workers to provide scientifically based information on expectations to the individual patient and his family, as well as to other healthcare givers and health services.

The effects of treatment on well-being, as assessed by the patient, may be positive or negative. In fact, a number of established and effective therapeutic interventions, including those used in hepatology, are known to adversely affect well-being while being administered, as determined by health-related quality of life (HRQOL) studies, a major tool of outcomes research. Obvious hepatological examples include interferon-based treatment with or without ribavirin for chronic viral hepatitis, chemoembolizaton for hepatocellular carcinoma, treatment with non-selective beta-blockers for variceal haemorrhage prophylaxis and use of diuretics in patients with decompensated cirrhosis [2]. In contrast, HRQOL may be improved during interferon and ribavirin treatment of chronic hepatitis C by concurrent treatment with erythropoietin [3].

The role of outcomes research in healthcare policy and delivery

During the past two decades, it has become evident that the traditional clinical outcomes of care do not provide sufficient information to assess the performance or effectiveness of healthcare providers, the services they provide and the interventions delivered. Multiple studies have identified practice patterns that differ from each other for the same disorders, have different economic costs, different outcomes and appear to be unrelated to regional differences in health or disease status. Such observations strongly support the notion that the most effective and appropriate therapies are often unknown, poorly understood and, because translating research into practice is often exceedingly slow, may be unadopted. And because the cost of healthcare continues to rise, resulting in increasing fiscal constraints, serious questions have been raised about the value of care in relation to its cost and the perception of value as determined by the patient. Informed consumers of healthcare and cost-conscious purchasers want better information in order to influence delivery of care to achieve greater value for the money spent. As a result, outcomes research has become a focus for the

development of healthcare policies by employers, health maintenance organizations, payers, insurers and local and federal governments.

The tools of outcomes research

Tools generally used in outcomes research include assessments of HRQOL, health utilities, the use of large administrative databases, decision analysis, meta-analysis, cost-effectiveness analysis and neural networks. In this chapter, the focus will be on the assessment of HRQOL by means of health status questionnaires and on the assessment of health values by utility measurement techniques. It should be emphasized that quality of life and HRQOL are not synonymous. Quality of life is a multidimensional concept with a number of components that include, but are not limited to, HRQOL. These are financial quality, family, community, work and social quality of life. HRQOL focuses on health status as affected by disease or treatment and is assessed by the patient. Health utility assessments (often called health status preferences) have often been non-patient derived; this is changing, and clearly preferable patient-based utility assessments are coming into wider use (see below).

Instruments for determining HRQOL

A large number of general health measures have been developed and are in use for assessing HRQOL. Table 1 provides a listing of many of these instruments.

Tools used in assessing HRQOL must be standardized, reliable and validated. Standardization refers to the content of the instrument, the sequence of presentation, the method of administration, scoring and data analysis. Reliability encompasses both accuracy and precision. It reflects the extent to which a measure reproduces results on repeated testing within a short period of time and is free of measurement error. Validity (content validity, construct validity and criterion validity) raises the question of whether or not the instrument is truly measuring what it is supposed to measure. Other important issues are whether or not the tool is responsive to change resulting from changes in health due to disease progression or improvement and is capable of capturing the range of health levels that may be present.

Table 1 General health-assessing instruments (adapted from ref. 4).

Child Health Questionnaire (CHQ)
Dartmouth COOP Functional Health Status Charts
Duke Health Profile (DUKE)
European Quality of Life Index (EuroQoL)
Health Insurance Experiment (HIE) Questionnaire
Health Utilities Index (HUI)
Karnofsky Performance Status Scale
Medical Outcomes Study Functioning and Well-being Profile (MOS FWBP)
MOS Short Forms (SF-36 and SF-12)
National Health Interview Survey (NHIS)
Nottingham Health Profile (NHP)
Paediatric Quality of Life Inventory (PedsQL 4.0)
Quality of Well-being Scale (QWB)
Sickness Impact Profile (SIP)
World Health Organization (WHOQOL-100)

In health outcomes research, the MOS Short Form SF-36, a general health assessment tool available in several languages, has had extensive and worldwide use and may be viewed as the 'gold standard' of general HRQOL tools. It is organized into eight separate scales: measures of physical functioning, physical role limitations, emotional role limitations, emotional well-being, bodily pain, general health, energy/fatigue and social functioning. All the scales are scored on a 100-point scale, although each scale has a unique standard deviation, which makes interpretations of score differences between scales problematic [5]. Higher scores indicate better HRQOL. The results of these eight discrete measures are then compiled into two summary scores: a physical component score and a mental component score. SF-36 has been the major generic tool used in clinical trials of therapeutic interventions and in reporting HRQOL changes by managed care plans. Its use has been driven by the fact that it is easy to administer, score and interpret, thus permitting rapid measurement. It has been shown to have acceptable construct, content and criterion validity for many diseases. Furthermore, SF-36 is reproducible over time in stable patients, generally responsive to clinical changes and can be correlated with patient and healthcare provider global assessments.

In addition to these general measures, more focused instruments have been developed to assess specific symptoms, e.g. fatigue, as measured in the Fatigue Severity Scale. Disease-specific instruments have also been developed for a variety of disorders, such as arthritis, angina, cancer, depression, mental status, pain and, of course, liver disease. As with generic instruments, disease-specific HRQOL assessment tools must be standardized, reliable and validated. Ideally, they should have an established track record.

General health measures are often used together with disease-specific instruments because the general measure can provide an overview of the patient's state of health that may not be salient on the disease-specific instrument. On the other hand, disease-specific instruments are potentially useful in detecting minor changes in HRQOL that may reflect changes resulting from disease progression or remission. Hence, generic scales may lack sensitivity and may be inadequate measures of those aspects of disease. However, this difference has not been definitively established and, in at least one study (in patients with metastatic liver disease), the responsiveness of the generic tool was reported to be comparable to that of the disease-specific questionnaire [6]. Liver-specific HRQOL instruments will be reviewed below.

Tools used in health utility assessments

The purpose of health utility assessment is to ascertain an individual's preference, value or desirability for a particular health

state. The tools available for these assessments are routinely used with decision analysis and in cost-effectiveness analysis (see Chapter 26.4). The most commonly used tools are the time–tradeoff utility and the standard gamble utility. Both are time-consuming, complicated and obtained in face-to-face interviews with the patient.

In the time–tradeoff utility, the patient is given a hypothetical length of future life in their current health state and is then presented with progressively shorter periods of future life in perfect health. As long as a clear preference for one of the alternatives is expressed, the assessment continues. The point at which the patient becomes indifferent to the two health states is made into a ratio, which is defined as the utility weight.

In the standard gamble, the patient is asked how much risk he or she is willing to take to improve their current state of health. They are presented with a hypothetical treatment that may cure their disease and result in perfect health but with a variable probability of immediate death at the start of treatment. The alternative option is to decline treatment and remain in their current state of health. The patient is asked to choose as the probability of death is progressively reduced. The standard gamble score utility weight for the current health state is the point at which the patient becomes ambivalent about the choices.

The two utility assessment tools can give different answers, may be influenced by day-to-day changes in the respondent's mental and physical condition at the time of testing, may be affected by adaptation to a chronic illness and may be insensitive in patients with mild diseases. Furthermore, relatively few treatments involve the possibility of an early, painless death [7]. These concerns, as well as the general complexity of the utility assessments, have led to studies aimed at estimating utilities using data from health status questionnaires, e.g. the SF-36 [8]. Other methods for assessing health utilities include visual analogue scaling and use of the Health Utilities Index, in which health status assessments based on responses to a questionnaire are converted into utility scores [9]. The latter has been used infrequently in patients with liver disease.

Outcomes research in liver disease

Health outcomes research in hepatology is not entirely new. One of the earliest publications describing 'quality of life' was an assessment of social and vocational outcomes of liver transplantation at the University of Pittsburgh in 1979 [10]. However, it was not until the 1990s that this field received increased attention and more rigorous studies, including the development of liver-specific HRQOL instruments. In this section, these tools and their application to diseases of the liver will be described.

Table 2 lists a number of liver-specific HRQOL tools that have been used in recent years. Within this group, a few have been developed for use in specific disorders, e.g. the European Organization for Research and Treatment of Cancer (EORTC) module quality of life questionnaire for colorectal liver metastases [11] and the Functional Assessment of Cancer Therapy Hepatobiliary (FACT-Hep) questionnaire [12]. The discussion that follows will mainly describe liver-specific instruments that have been applied to a variety of liver diseases. The Chronic Liver Disease Questionnaire was among the earliest liver-specific questionnaires developed and validated [13]. It has received worldwide attention [14] and has been reported to have good reliability and validity in non-English language forms [15].

Table 2 Liver-specific instruments for assessing HRQOL.

NIDDK Liver Transplantation Database QOL, adult version (NIDDK LTD QOL) [16]
Chronic Liver Disease Questionnaire CLDQ [13]
Hepatitis Quality of Life Questionnaire HQLQ [17]
Liver Disease Quality of Life Questionnaire LDQOL 1.0 [18]
Liver Disease Symptom Index 2.0 [19]
FACT-Hep [12]
Liver Cancer QoL Scale [20]
EORTC QLQ-HCC18 [21]
PBC-40 [45]

The Hepatitis Quality of Life Questionnaire includes eight generic and two disease-specific scales, which assess limitations in physical, role and social activities and distress due to hepatitis. In this instrument, the severity of specific symptoms or their influence on functioning in daily activities is not addressed. In contrast, the Chronic Liver Disease Questionnaire, the Liver Disease Quality of Life Questionnaire and the Liver Disease Symptom Index do address severity of symptoms. However, only the Liver Disease Symptom Index assesses the impact of these symptoms on the patient's daily activities. The authors of the last questionnaire believe that it provides information complementary to that attained by the SF-36 [19] and that symptom severity and impedance items measure different aspects of HRQOL.

The NIDDK LTD QOL instrument assesses HRQOL in four domains, namely liver disease symptoms, physical functioning, satisfaction with health and overall well-being. The instrument contains 70 questions and incorporates SF-36, the Index of General Affect and additional questions pertaining to chronic liver disease [16]. Although developed specifically for identifying changes in HRQOL in liver transplant recipients, it appears to be a reliable and valid instrument applicable to a very wide spectrum of liver disease severity, including ambulatory patients with cholestatic liver disease [22]. A French version has been validated [23].

The LDQOL 1.0 questionnaire includes the SF-36 and scales evaluating liver disease-related symptoms and liver disease-related effects on activities of daily living, concentration, memory, sexual functioning and problems, sleep, loneliness, hopelessness, quality of social interaction, health distress and the self-perceived stigma of liver disease [24].

Despite the validation of a number of liver-specific QOL tools, pitfalls and caveats remain, and they have not been used as extensively as the more generic instruments. And, in general,

in contrast to the generic tools, these instruments, with the exception of the Chronic Liver Disease Questionnaire, have not been subjected to such rigorous evaluations of their validity of measurement. In many instances, the number of subjects studied is surprisingly small; subgroups of interest may be even smaller and may be inadequate to identify changes on repeat testing to determine the impact of an intervention. The presentation of data as means rather than the full distribution of outcomes can be problematic for both generic and liver disease-specific instruments because the use of means only will obscure the identification of low functioning patients who might be helped to achieve better health by other interventions [25]. Such interventions could, in fact, be targeted to lower functioning individuals and studied in prospective, controlled clinical trials with adequate sample size to achieve statistical power. Another potential pitfall is how an individual's past experience, frame of reference and temperament (optimistic vs. pessimistic) can influence reporting of HRQOL. Finally, it seems very likely that changes in perceptions of health may change or adapt over time, depending on changes in the patient's internal standard of measurement or values or by redefinition of the concept of health. More understanding of this phenomenon, termed 'response shift and adaptation' is needed [26].

Until recently, health utility assessments in patients with liver disease have been largely based on clinical opinions or derived from expert panel opinion. It is not surprising to learn that physician-assigned utilities were found to differ from patient-assigned utilities when the time–tradeoff method was studied in 83 physicians and 114 patients with cirrhosis, although relative rankings were similar for patients with compensated and decompensated cirrhosis, as well as for those with hepatocellular carcinoma [27]. In another study, in patients with chronic hepatitis C, patient-derived utilities assessed with the standard gamble technique were lower than the previously published expert estimates for patients with mild to moderate disease and sustained virological responders, but higher than those for decompensated disease and hepatocellular carcinoma [28]. These and other observations in patients with chronic liver disease [29] and in chronic hepatitis C patients [30] support the notion that patient-assigned utilities more accurately reflect patient preferences than assessments by non-patient experts. However, it should be noted that, because of the complexity of health utility assessments, they have not been used as much as HRQOL instruments in hepatology outcomes research.

Outcomes research in specific liver diseases

Chronic viral hepatitis

Among the three forms of chronic viral hepatitis, namely chronic hepatitis C, B and D, the impact of chronic hepatitis C on HRQOL has received the most attention. A wide body of data clearly indicates that infection by hepatitis C virus (HCV) diminishes HRQOL even in the absence of advanced liver disease, as evidenced by the presence of ascites, variceal haemorrhage, hepatic encephalopathy and liver transplantation. The precise mechanism(s) underlying this reduction in the perception of health remain(s) to be determined [31], although a direct effect of HCV on the brain is an attractive hypothesis. The impact of the 'diagnosis' of HCV, i.e. labelling, on HRQOL had been raised by one small study in which individuals aware of their HCV status had significantly worse measures on the SF-36 than those unaware of the diagnosis [32]. In a similar, but larger study in rural Egypt, utilizing a translated version of the SF-12 and an interviewer (a non-validated methodology), patients unaware of their HCV status did not have significant reductions in HRQOL when compared with uninfected control subjects from the same area [33]. Whether these observations are confounded by a higher morbidity in the general population of this area and a lower general HRQOL, thereby diminishing the influence of HCV, seems to be quite possible.

Despite these caveats, it has become clear, based on the published literature, that the reductions in HRQOL in chronic hepatitis C are real and cannot be correlated with such conventional markers of disease as serum alanine aminotransferase (ALT) activity or histological findings of necroinflammatory disease on liver biopsy.

A systematic review of publications and published abstracts has been published recently [5]. In this review, studies of HRQOL in chronic hepatitis C were summarized and compared with data obtained from healthy control subjects. The impact of achieving a sustained virological response was assessed, and published data were stratified by 'clinical anchors', defined here as sustained virological response, histological activity, ALT levels and Child's class B cirrhosis, as well as by neuropsychosocial anchors (subclinical cognitive dysfunction, depression, psychiatric comorbidity, emotional distress and stigmatization). Additionally, and in an innovative approach, the authors attempted to establish the minimal clinically meaningful HRQOL score differences, as opposed to the usually reported statistically significant differences. This minimally clinically important difference (MCID) is defined as the mean change in HRQOL for the subset of patients with a minimal yet perceptible change in health [34]. In order to achieve this objective, an expert panel of hepatitis-treating physicians and researchers in HRQOL was used.

The authors of this review found 15 studies comparing HRQOL in compensated HCV-seropositive patients in which the SF-36 instrument was used [5]. Weighted mean and median scores on each of the eight scales were lower than in healthy control subjects, but the impact was greatest in social and physical function, general health and vitality. Patients who failed to achieve sustained virological responses had consistently lower scores than those who cleared HCV on treatment. Neither elevated ALT levels compared with normal levels nor an improvement in ALT levels could be related to HRQOL scores. Patients with Child's B cirrhosis had large differences when

compared with non-cirrhotic patients with chronic hepatitis C. When stratified by neuropsychosocial anchors, the largest decrements were found in the SF-36 role–emotional scale, but somatic scales also showed large differences.

The expert panel on estimating the MCID identified the vitality scale as one of the most affected. Using a modified Delphi technique, they generated a score of 4.2 points (range 3–5) on the SF-36 vitality scale as a meaningful difference. The authors suggested that this value could be used in determining power calculations of sample sizes in clinical trials in which HRQOL is a variable. The limitations of the methodology used in defining the MCID are well described by the authors and include the fact that most of the data utilized came from tertiary care referral centres, in which selection biases may be operative, rather than from community-based office practices. Furthermore, the expert panel did not include any patients. Ideally, patients with chronic hepatitis C should be used in such panels. Because use of the generic SF-36 may be somewhat insensitive to the full range of HRQOL decrements, disease-specific instruments, such as the HQLQ, may be preferable for selecting scales that may better reflect minimally important differences.

A large body of data supports the concept that clearance of HCV is associated with improvement in HRQOL [35–38] and that interferon-based treatments reduce HRQOL during treatment [37].

Cirrhosis and endstage liver disease

Although a number of studies indicate that cirrhosis, regardless of aetiology, is associated with reductions in HRQOL, as measured by SF-36, and that, in general, increasing severity of disease [as measured by Child–Pugh–Turcotte (CPT) score, ascites, use of loop diuretics] is linked with the greatest decrements [39], this remains somewhat controversial. For example, in one study of over 200 patients with chronic liver diseases, neither cirrhosis nor severity of disease, sex, age or social class could be related to reductions in HRQOL [40]. Psychiatric and active medical comorbidities appeared to be the responsible factors. And while age was not a factor in that study, older age was associated with poorer HRQOL, particularly in the physical aspects, in another analysis [41]. Clinically apparent hepatic encephalopathy is associated with declines in both physical and mental elements. In contrast, in cirrhotic patients with subclinical encephalopathy, the mental scores are affected to a greater extent than the physical scores, and this appears to be independent of disease severity [42].

Primary biliary cirrhosis

Relatively few studies have addressed HRQOL in patients with primary biliary cirrhosis (PBC). Nonetheless, an analysis of the instruments used in the available literature for their reliability, validity, appropriateness, acceptability, precision and responsiveness has been undertaken [43]. While reporting of both reliability and validity was generally consistent for all the methods used, responsiveness over time and acceptability were more variable. The authors concluded that a more rigorous approach is needed in reporting the properties of the health status tools used in PBC patients. In a recent reported study of 276 patients with PBC from France, the Nottingham Health Profile (at the time, the only generic health status instrument validated in France) revealed statistically significant reductions in energy and emotional reaction scores compared with control subjects, and these were both associated with fatigue [44] and, to a lesser extent, with osteopenia. Pruritus could not be associated with these reductions. A disease-specific HRQOL instrument for PBC, the PBC-40, has now been developed and validated [45]. Domains measured include fatigue, emotional, social and cognitive function, general symptoms and pruritus. The PBC-40 appeared to be more a measure of patient satisfaction than other HRQOL measures. In a separate study, using the PBC-40, symptom complexes focused on fatigue and pruritus were identified, but no correlation was found between the severity of symptoms and biological parameters of PBC severity [46]. Future longitudinal studies should confirm these observations and address the impact of treatment on HRQOL.

Liver transplantation

It is not surprising to learn that, in patients with endstage liver disease awaiting liver transplantation, HRQOL is severely compromised. In fact, some cross-sectional studies of patients with liver disease have suggested that disease state and transplant history are the major determinants of HRQOL [47]. In a single-centre study in the United States, patients needing a transplant because of liver failure due to hepatitis C, alcoholic liver disease, autoimmune and cholestatic disorders and others were assessed with the NIDDK LTD QOL instrument and utility assessment techniques [48]. This comparison of the two approaches in a single study is novel in the transplantation field. Based on the health status instrument, these patients experienced generally poor health. The lowest health status scores were found in the personal function domain, indicating that ability to work or undertake activities of daily life were perceived as impaired. The median time–tradeoff score was 0.79, indicating that half the respondents preferred a healthier life even though life expectancy in that state would be 21% shorter. In the standard gamble, the median score was 0.50. This figure reveals that half the respondents were willing to take up to a 50% risk of immediate death in exchange for the chance of perfect health [48]. Thus, the two approaches, health status questionnaire and utility assessments, showed overall consistency in patient's perceptions of their HRQOL.

In one of the early reports on the impact of liver transplantation on HRQOL, both SF-36 and the Chronic Liver Disease Questionnaire (CLDQ) were administered to 37 transplant candidates [49]. As anticipated, HRQOL scores on the SF-36 were lower than those in the general population and lower than those

found in patients with chronic obstructive lung disease and congestive heart failure. Although only 22 of the 37 candidates received transplants, and HRQOL data were collected anywhere between 2 and 23 months after transplant, improvement in every domain measured by SF-36 and CLDQ was observed. Interestingly, the mental health components of SF-36 normalized but, for the physical health and some disease-specific aspects, residual impairment was noted. Why the mental health impairment returns to normal before the physical is unclear, but long-term follow-up studies may show that the response is simply delayed and that more time is necessary to normalize these other scores.

In another single-centre, prospective, national study in Scotland, the WHOQOL-100 was used to assess general, physical and psychological domains of quality of life before and 1 year after liver transplantation in 70 patients [50]. Of uncertain value, the authors also included 30 healthy individuals recruited from hospital staff and 17 liver patients who were not candidates for transplantation. These were also assessed twice within a 1-year period and, as expected, no significant changes were observed. Among the transplanted patients, who had lower (poorer) scores at baseline, only the general and physical domains showed significant improvement at 1 year; the psychological measure did not. The quality of life measures studied did not reliably differentiate patients with early (Child's A) disease from those with more advanced disease (Child's C) before or after transplantation. This observation is of interest given that poor HRQOL has been considered as an indication for transplantation, but it is an indication that does not trump transplantation to reduce imminent mortality [51]. However, the relatively small number of patients studied at this one centre may limit the generalizability of these findings.

The relationship of HRQOL in patients awaiting liver transplantation to the CPT and Model for EndStage Liver Disease (MELD) scores has been investigated. Most studies have found a closer association of the CTP score with HRQOL [24,52]. The MELD score is less predictive of HRQOL, at least in part because it does not include ascites or encephalopathy, each of which is linked with impaired HRQOL and is included in the CPT score.

These and other studies indicate that HRQOL is generally improved following liver transplantation. However, there is growing evidence that the improvement varies depending on a number of factors, including gender. In one single-centre study, employing a 122-question instrument to assess HRQOL before and at 1 and 2 years after transplantation, men had higher scores at every time point [53]. Educational and social role differences may account for these findings, which deserve further study.

An additional area worthy of study is the assessment of HRQOL in donors participating in living donor liver transplantation [54]. Currently available data are limited by size and instruments utilized. HRQOL in children before and after liver transplantation also deserves increased attention as about 50% of transplants are undertaken in children younger than 10 years of age. A recent review of published studies of HRQOL in children and adolescents after liver transplantation tentatively concluded that it negatively affected some health domains when compared with the general population [55]. However, the limited data available for review and the lack of methodological vigour in those studies confound definitive interpretation.

Other disorders

HRQOL studies in those disorders not discussed above are relatively few in number and in variety of disease studied. In one small study, patients experiencing bile duct injury during laparoscopic cholecystectomy (but in whom 96% had no stricture and normal liver chemistries) were compared 4–5 years later with those with uncomplicated laparoscopic cholecystectomy [56]. On a number of the health status scales used, a detrimental effect was found in those who had had bile duct injury.

Future research fronts

While HRQOL instruments are now frequently incorporated, often as secondary endpoints, into clinical trials assessing new treatment regimens and procedures, their routine, sequential use in office and clinical practice has been limited. The use of outcomes assessments by those responsible for caring for patients with liver disease should help in managing the care delivered and in evaluating interventions that are effective from the patient's perspective. More attention needs to be directed to HRQOL instruments for children and adolescents with liver diseases.

Although some single- and multicentre registries have been developed to identify and classify patients with liver disorders and to collect relevant clinical information, data on HRQOL and health status preferences, as discussed in this chapter, have not been routinely collected. The development of regional or national hepatology outcome registries should permit the acquisition of baseline, on-treatment and post-treatment patient-derived health assessments. This knowledge should enable healthcare providers and services to deliver patient care that is both reasonable and rational.

References

1 Cowling T, Jennings LW, Goldstein RM *et al.* (2004) Societal reintegration after liver transplantation: findings in alcohol-related and non-alcohol-related transplant recipients. *Ann Surg* 239, 93–98.

2 Cordoba J, Flavia M, Jacas C *et al.* (2003) Quality of life and cognitive function in hepatitis C at different stages of liver disease. *J Hepatol* 39, 231–238.

3 Pockros PJ, Shiffman ML, Schiff ER *et al.* (2004) Epoetin alfa improves quality of life in anemic HCV-infected patients receiving combination therapy. *Hepatology* 40, 1450–1458.

4 Ware JE (1994) The status of health assessment, 1995. *Ann Public Health* 16, 327–354.

5 Spiegel BMR, Younossi ZM, Hays RD *et al.* (2005) Impact of hepatitis

C on health related quality of life: a systematic review and quantitative analysis. *Hepatology* 41, 790–800.
6 Krabbe PF, Peerenboom L, Langenhoff BS *et al.* (2004) Responsiveness of the generic EQ-5D summary measure compared to the disease-specific EORTC QLQ C-30. *Qual Life Res* 13, 1247–1253.
7 Moayyedi P, Talley NJ (2005) Gambling with gastroesophageal reflux disease: should we worry about QALY? *Am J Gastroenterol* 100, 534–536.
8 Thein H-H, Krahn M, Kaldor JM *et al.* (2005) Estimation of utilities for chronic hepatitis C from SF-36 scores. *Am J Gastroenterol* 100, 643–651.
9 Furlong WJ, Feeny DH, Torrance GW *et al.* (2001) The Health Utilities Index (HUI) system for assessing HRQOL in clinical studies. *Ann Med* 33, 375–384.
10 Starzl TE, Koep LJ, Schroter GP *et al.* (1979) The quality of life after liver transplantation. *Transpl Proc* 11, 252–256.
11 Kavadas V, Blazeby JM, Conroy T *et al.* (2003) Development of an EORTC disease-specific quality of life questionnaire for use in patients with liver metastases from colorectal cancer. *Eur J Cancer* 39, 1259–1263.
12 Heffernan N, Cella D, Webster K *et al.* (2002) Measuring HRQOL in patients with hepatobiliary cancers: the functional assessment of cancer therapy-hepatobiliary questionnaire. *J Clin Oncol* 20, 2229–2239.
13 Younossi ZM, Guyatt G, Kiwi M *et al.* (1999) Development of a disease specific questionnaire to measure health related quality of life in patients with chronic liver disease. *Gut* 45, 295–300.
14 Sobhonslidsuk A, Silpakit C, Kongsakon R *et al.* (2004) Chronic liver disease questionnaire: translation and validation in Thais. *World J Gastroenterol* 10, 1954–1957.
15 Hauser W, Schnur M, Steder-Neukamm U *et al.* (2004) Validation of the German version of the Chronic Liver Disease Questionnaire. *Eur J Gastroenterol Hepatol* 16, 599–606.
16 Belle SH, Porayko MK, Hoofnagle JH *et al.* (1997) Changes in quality of life after liver transplantation. National Institute of Diabetes and Digestive and Kidney Diseases (NIDDK) Liver Transplantation Database (LTD). *Liver Transpl Surg* 3, 93–104.
17 Bayless MS, Gandek B, Bungay KM *et al.* (1998) A questionnaire to assess the generic and disease-specific health outcomes of patients with chronic hepatitis C. *Qual Life Res* 7, 39–55.
18 Gralnek IM, Hays RD, Kilbourne A *et al.* (2000) Development and evaluation of the Liver Disease Quality of Life instrument in persons with advanced, chronic liver disease – the LDQOL 1.0. *Am J Gastroenterol* 95, 3552–3565.
19 van der Plas SM, Hansen BE, de Boer JB *et al.* (2004) The Liver Disease Symptom Index 2.0. Validation of a disease-specific questionnaire. *Qual Life Res* 13, 1469–1481.
20 Wan C-H, Fang J-Q, Zhang C-Z *et al.* (2000) Development and evaluation of a quality of life scale for patients with liver cancer. *MAPI Res Inst Qual Life Newsl* 24, 14.
21 Blazeby JM, Currie E, Zee BCY *et al.* (2004) Development of a questionnaire module to supplement the EORTC QLQ-C30 to assess quality of life in patients with hepatocellular carcinoma, the EORTC QLQ-HCC18. *Eur J Cancer* 40, 2439–2444.
22 Kim WR, Lindor KD, Mainchoc M *et al.* (2000) Reliability and validity of the NIDDK-QA instrument in the assessment of quality of life in ambulatory patients with cholestatic liver disease. *Hepatology* 32, 924–929.
23 Karam V, Castaing D, Danet C *et al.* (2003) Longitudinal prospective evaluation of quality of life in adult patients before and one year after liver transplantation. *Liver Transpl* 9, 703–711.
24 Kanwal F, Hays RD, Kilbourne AM *et al.* (2004) Are physician-derived disease severity indices associated with HRQOL in patients with end-stage liver disease? *Am J Gastroenterol* 99, 1726–1732
25 Gross CR (2002) Beyond the mean. *Liver Transpl* 8, 260–262.
26 Postulart D, Adang EMM (2000) Response shift and adaptation in chronically ill patients. *Med Decis Making* 20, 186–193.
27 Wells CD, Murrill WB, Arguedas MR (2004) Comparison of HRQOL preferences between physicians and cirrhotic patients: implications for cost-utility analyses in chronic liver disease. *Dig Dis Sci* 49, 453–458.
28 Chong CAKY, Gulamhussein A, Heathcote EJ *et al.* (2003) Health-state utilities and quality of life in hepatitis C patients. *Am J Gastroenterol* 98, 630–638.
29 Younossi ZM, Boparai N, McCormick M *et al.* (2001) Assessment of utilities and HRQOL in patients with chronic liver disease. *Am J Gastroenterol* 96, 579–583.
30 Sherman KE, Sherman SN, Chenier R *et al.* (2004) Health values of patients with chronic hepatitis C infection. *Arch Intern Med* 164, 2377–2382.
31 Koff RS (1999) Impaired HRQOL in chronic hepatitis C: the how, but not the why. *Hepatology* 29, 277–279.
32 Rodger AJ, Jolley D, Thompson SC *et al.* (1999) The impact of diagnosis of hepatitis C virus on quality of life. *Hepatology* 30, 1299–1301.
33 Schwarzinger M, Dewedar S, Rekacewicz C *et al.* (2004) Chronic hepatitis C virus infection: does it really impact HRQOL? A study in rural Egypt. *Hepatology* 40, 1434–1441.
34 Jaeschke R, Singer J, Guyatt GH (1989) Measurement of health status: ascertaining the minimal clinically important difference. *Control Clin Trials* 10, 407–415.
35 Bonkovsky HL, Woolley JM, the Consensus Interferon Study Group (1999) Reduction of HRQOL in HCV and improvement with interferon therapy. *Hepatology* 29, 264–270.
36 Ware JE, Bayliss MS, Mannocchia M *et al.* (1999) HRQOL in chronic hepatitis C: impact of disease and treatment response. *Hepatology* 30, 550–555.
37 Bernstein D, Kleinman L, Barker CM *et al.* (2002) Relationship of HRQOL to treatment adherence and sustained response in chronic hepatitis C patients. *Hepatology* 35, 704–708.
38 Neary MP, Cort S, Bayliss MS *et al.* (1999) Sustained virologic response is associated with improved HRQOL in relapsed chronic hepatitis C patients. *Semin Liver Dis* 19 (Suppl 1), 77–85.
39 Marchesini G, Bianchi G, Amodio P *et al.* (2001) Factors associated with poor HRQOL of patients with cirrhosis. *Gastroenterology* 120, 170–178.
40 Hauser W, Holtmann G, Grandt D (2004) Determinants of HRQOL in patients with chronic liver diseases. *Clin Gastroenterol Hepatol* 2, 157–163.
41 Younossi ZM, Boparai N, Price LL *et al.* (2001) HRQOL in chronic liver disease: the impact of type and severity of disease. *Am J Gastroenterol* 96, 2199–2205.
42 Arguedas MR, DeLawrence TG, McGuire BM (2003) Influence of hepatic encephalopathy on HRQOL in patients with cirrhosis. *Dig Dis Sci* 48, 1622–1626.
43 Rannard A, Buck D, Jones DE *et al.* (2004) Assessing quality of life in primary biliary cirrhosis. *Clin Gastroenterol Hepatol* 2, 164–174.
44 Poupon RE, Chretien Y, Chazouilleres O *et al.* (2004) Quality of life in patients with primary biliary cirrhosis. *Hepatology* 40, 489–494.

45 Jacoby A, Rannard A, Buck D *et al.* (2006) Development, validation, and eveluation of the PBC-40, a disease specific health related quality of life measure for primary biliary cirrhosis. *Gut* 54, 1622–1629.
46 Newton JL, Bhala N, Burt J *et al.* (2006) Characterisations of the associations and impact of symptoms in primary biliary cirrhosis using a disease specific quality of life measure. *J Hepatol* 44, 776–783.
47 van der Plas SM, Hansen BE, de Boer JB *et al.* (2003) Generic and disease-specific health related quality of life in a non-cirrhotic, cirrhotic and transplanted liver patients: a cross-sectional study. *BMC Gastroenterol* 3, 13–26.
48 Bryce CL, Angus DC, Switala J *et al.* (2004) Health status versus utilities of patients with end-stage liver disease. *Qual Life Res* 13, 773–782.
49 Younossi ZM, McCormick M, Price LL *et al.* (2000) Impact of liver transplantation on HRQOL. *Liver Transpl* 6, 779–783.
50 O'Carroll RE, Couston M, Cossar J *et al.* (2003) Psychological outcome and quality of life following liver transplantation: a prospective, national, single-center study. *Liver Transpl* 9, 712–720.
51 Freeman RB (2005) MELD and the quality of life. *Liver Transpl* 11, 134–136.
52 Saab S, Ibrahim AM, Shpaner A *et al.* (2005) MELD fails to measure quality of life in liver transplant candidates. *Liver Transpl* 11, 218–223.
53 Cowling T, Jennings LW, Goldstein RM *et al.* (2004) Liver transplantation and HRQOL: scoring differences between men and women. *Liver Transpl* 10, 88–96.
54 Walter M, Dammann G, Papchristou C *et al.* (2003) Quality of life of living donors before and after living donor liver transplantation. *Transpl Proc* 35, 2961–2963.
55 Taylor R, Franck LS, Gibson F *et al.* (2005) A critical review of the HRQOL of children and adolescents after liver transplantation. *Liver Transpl* 11, 51–60.
56 Moore DE, Feurer ID, Holzman MD *et al.* (2004) Long-term detrimental effect of bile duct injury on HRQOL. *Arch Surg* 139, 476–481.

26.3 Meta-analysis

Gioacchino Leandro and Andrew K. Burroughs

Introduction

The publication of medical reviews and guidelines for good clinical practice has recently become common and a useful tool for a rapid update on most clinical topics. This results from a new approach to medical practice where a leading role has been taken by what is termed 'evidence-based medicine' [1,2].

Evidence-based medicine has introduced several well-defined and often strict rules for the critical evaluation of medical data. The use of meta-analysis is an intrinsic part of evidence-based medicine and therefore has a prominent role in the validation and interpretation of the results of clinical studies. In other words, if a well-designed and well-conducted meta-analysis has shown that treatment A is more effective than treatment B, we can assume that this information is correct, and there would be no other need for further investigation on this issue [3].

Interpreting results of research protocols that include clinical trials is a very important part of the learning process. In fact, a clinical trial is the application of theory to practice, carried out through well-defined rules of experimentation in order to validate the underlying hypothesis and to achieve relevant results. The latter are then the basis for further hypotheses and thus for other clinical trials. Medical practice is greatly influenced by the results of clinical studies, especially if they are brought to the public attention by prestigious scientific journals or the mass media [4].

In the medical literature, new therapies are often considered the most relevant, and a great number of publications are therefore produced. However, the quality and the importance of each study are hard to define. Different studies on the same topic often provide discordant conclusions, giving the reader a confused message. In order to clarify the matter, we need the help of trained personnel experienced in the evaluation of clinical trials who are able, with their knowledge and criticism, to reach a conclusive synthesis of the results of the different studies.

Principles of meta-analysis

Meta-analysis, when well designed and appropriately performed, is a powerful tool for synthesis. It is an analytical method in which different and independent studies are all integrated and their results pooled in a single result. The meta-analysis, when compared with other forms of reviewing studies, has the great advantage of being less influenced by the personal opinion of the reviewer, and reaches unbiased conclusions. Moreover, in a meta-analysis, all the results of the individual studies examined are reported, and the reader may easily recalculate the data and compare them with the results reached by the authors [1].

The meta-analysis contributes to many aspects of clinical research, for example allowing us:

1 to increase the statistical power of a comparison;
2 to improve the estimate of the effect of a treatment;
3 to combine the results of studies that may appear contrasting;
4 to answer new questions;
5 to analyse subgroups of subjects selected from different studies;
6 to analyse trends (in a timeframe, in a subgroup of patients with the same characteristics, etc.);
7 to define areas in which further studies are needed;
8 to analyse if and how previous studies have modified knowledge on a certain topic.

The meta-analysis is a fundamental part of the process of conducting a systematic review of the literature; it requires a close collaboration between the clinical experts on the topic under investigation and experts in statistical methods applied to the biomedical field.

There are distinct and separate steps in putting together a meta-analysis. Every step has its precise rules aimed at avoiding bias in the analysis, and reaching more reliable results with a more accurate estimation of the events under investigation.

As is the case for an individual clinical trial, the study design of a systematic review has fundamental importance in order to avoid the possibility of biases and mistakes that may affect the results. It is therefore necessary to define the aims of the analysis and the rules and methods necessary to achieve them [5].

The first step to consider is to define the outcomes to be analysed by the meta-analysis. It is advisable to determine a primary outcome (i.e. mortality, efficacy of a treatment) that is considered in all the studies selected for the analysis, and then one or more secondary outcomes that may be useful to answer specific

questions (i.e. side-effects, subgroups of patients) that are not necessarily considered in all the studies selected.

For this step, it is advisable to consider the largest possible number of studies, and only in a second phase to select studies based upon different discriminating factors (number of subjects considered, dropout rate, randomization criteria and so on).

It is important to define where and how the search will be conducted (which database, which keywords). Once the search has been completed, it is also advisable to check the references cited in the single article and to start new searches based on these.

Finding the articles is probably the easiest step in the procedure, because most of the scientific journals are now available online. Far more difficult is to read, evaluate and pull out the necessary data for the analyses.

A careful reading of all the articles is mandatory. Great attention should be paid to identifying articles based on the same group of patients or using subgroups of subjects already considered in other studies. The selection for the analysis of groups of subjects who are not independent would lead to a selection bias [6].

One benefit of undertaking a meta-analysis that is independent from the result that may be obtained is that the articles will be read several times revealing new insights that might have been underestimated at a first reading, such as discovering what is hidden between the lines and what may not be reported deliberately by the authors in order to avoid possible discrepancies in the results. In other words, one understands a great deal about how to read and how to write a scientific article, which should be part of every clinician's training.

Odds ratios, risk differences, fixed and random effects models

The results of a trial may be expressed as odds ratio (OR) or risk difference (RD), which is also known in epidemiology as absolute risk reduction (ARR). As meta-analysis is a way of aggregating the results of multiple trials, the results obtained may be expressed as pooled odds ratio (ORp) or pooled risk difference (RDp).

In order to pool the results of the different studies, we should assume that these results would give an evaluation of effect, which would be the same for all the studies of the particular treatment, and that the effects evaluated would be part of the same distribution (sample estimates of the same mean). This assumption should be verified with a statistical test, the test for heterogeneity. If this is negative (i.e. no statistical significance), in a further analysis, one can use formulas based upon this assumption, called fixed effects models. If one is not constrained by the studies belonging to the same population (i.e. the studies evaluated are sampled from a population that contains several populations each with its own mean, thus heterogeneous) and one assumes therefore that the variability of the results depends on intra- and interstudy variability, one uses procedures called random effects models [7]. In clinical trials, this may occur when the same treatment is being assessed in different age groups or in patients with different severity of disease, or at different time points in the natural history.

It is important to note that there is no unanimous opinion as to how to proceed in the evaluation and interpretation when statistical heterogeneity is present.

If there is statistical heterogeneity, this means that trials do not belong to the same distribution. A search for the causes of heterogeneity and evaluation of 'outlier trials' needs to be done, and analysis with and without outlier trials needs to be performed. However, even if the reason for heterogeneity is not detected by a careful review of the trials, the random effects model should still be used because it does not have the requirement that all the trials must come from the same distribution. Therefore, the confidence interval (CI) is wider and the model is more conservative [8].

There is a body of opinion that the random effects model should always be used, because (i) the results are very similar compared with fixed effects models when statistical heterogeneity is not present, (ii) the results from the random models are more 'conservative', and (iii) measurements in biology have an intrinsic heterogeneity because of the variability between individuals. This variability can be best represented by a random effects model.

The authors' opinion is that one always needs to remember that the purpose of a meta-analysis is not only to calculate a mean effect as a statistical summary, but to derive meaningful evidence for clinical problems that apparently do not have definitive answers.

On this basis, one needs to re-evaluate studies to strive to understand and interpret information from all the data presented. At the same time, the researcher should be able to form his or her own opinion. This is very important, particularly when there is a possible controversy on the interpretation of the output, for example when there is heterogeneity.

A very useful approach to this problem is to separate the total variation across studies into the heterogeneity due to true differences (true heterogeneity) and the heterogeneity due to chance. The I^2 index expresses the percentage of the total variation across studies that is due to heterogeneity. Some authors have arbitrarily indicated the I^2 values of 25%, 50% and 75% as evidence of low, moderate and high heterogeneity respectively. However, these values cannot be considered as categories for decision-making, although the I^2 index and its 95% CI are helpful in expressing a quantitative judgement on heterogeneity [3,8].

There are multiple biases that may influence the results of a meta-analysis. Among them, the researcher usually only considers the publication bias, while all the others are generally underestimated or ignored [9].

Publication bias

The most important bias is the publication bias [10] because usually only studies in which a significant difference is found are

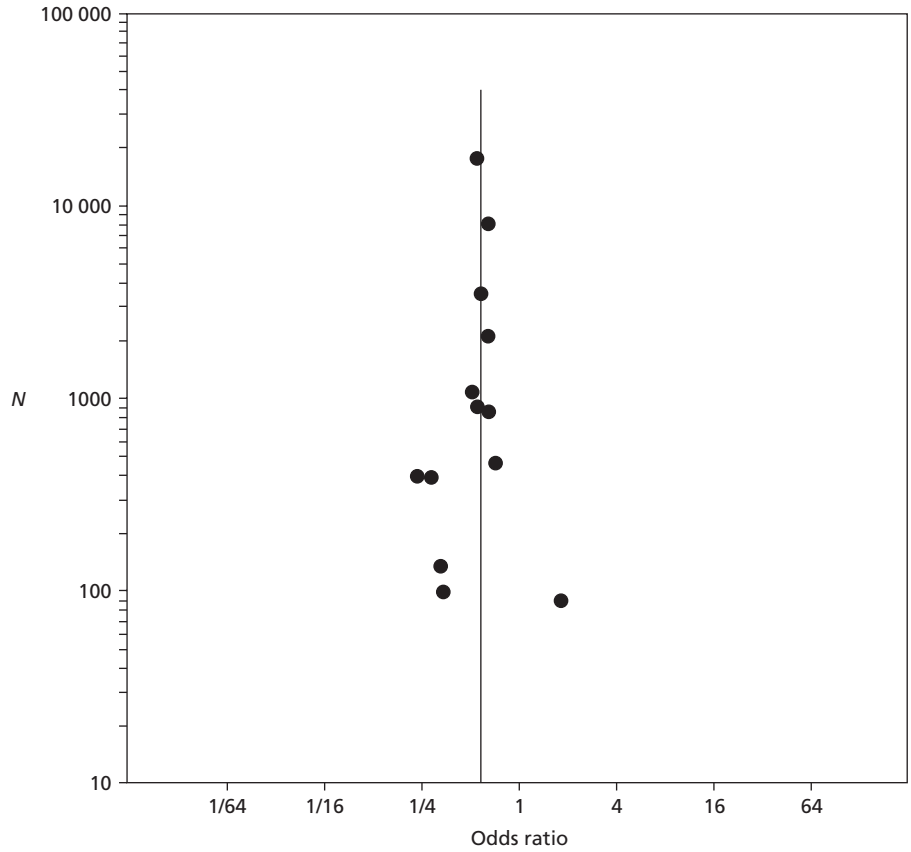

Fig. 1 Funnel plot (graphic method of Light and Pillemer), which is calculated using the effect size (odds ratio) and sample size (*n*) of every trial. In the absence of a publication bias, the shape is a reverse funnel.

published. This results in some completed studies not being published and therefore not being evaluable for meta-analysis. These unpublished studies may have results discordant from the published studies. Thus, the meta-analysis might result in a different conclusion if all the trials could have been considered. However, quite often, unpublished studies are presented as abstracts for scientific meetings and therefore one can have a more comprehensive analysis by including these abstracts. There are several ways to evaluate the presence and the importance of a publication bias, as its effects cannot be eliminated. Among them, the more commonly used are: (i) the graphic method by Light and Pillemer (funnel plot), for which a plot is calculated using the effect size and the sample size of every trial: the resulting figure, in the absence of publication bias, is a reversed funnel (Fig. 1); (ii) Klein's method (publication bias assessment), which is based on the following hypothesis: if the unpublished studies have the same characteristics with regard to the number of subjects and their variability as the published ones, how many unpublished studies with negative or null results are needed to influence the results of the meta-analysis?; (iii) the test for asymmetry applied to the funnel plot. Once standardized estimates of ORs (on the *y*-axis) and precision, defined as 1/SE(OR) (on the *x*-axis) are obtained, a regression line can be drawn. In the absence of publication bias, the intercept on the *y*-axis (α) must be 0. If the 95% CI of α crosses the zero line, publication bias cannot be inferred. Conversely, if the 95% CI of α does not cross the zero line, publication bias is considered to be present.

Number needed to treat

Another important and interesting calculation to give a real 'bedside' meaning to the results of a meta-analysis is the number needed to treat (NNT). For example, when the aim of a meta-analysis is to evaluate the efficacy of one drug vs. another in relation to a 1-year survival or to the healing of an ulcer, the NNT indicates how many patients are to be treated to see the one-unit difference between the two treatments. For example, in the evaluation of cimetidine vs. placebo in the healing of gastric ulcer, a NNT = 4 means that one needs to treat four patients with cimetidine to heal one patient more than with placebo. This information can also be used for some pharmacoeconomical evaluations [11].

If such an evaluation of the efficacy of a new drug is made using data from either a clinical trial or a meta-analysis, the result will lead to a conclusion as to whether or not the new drug is significantly more effective than the standard therapy, but there is no information on the magnitude of the difference between the two strategies (probabilistic approach). The NNT measures the size of the effect of a therapy (quantitative approach).

This number is calculated as the reverse of the 'pooled risk difference' ($1/\theta$), so that two different values are produced

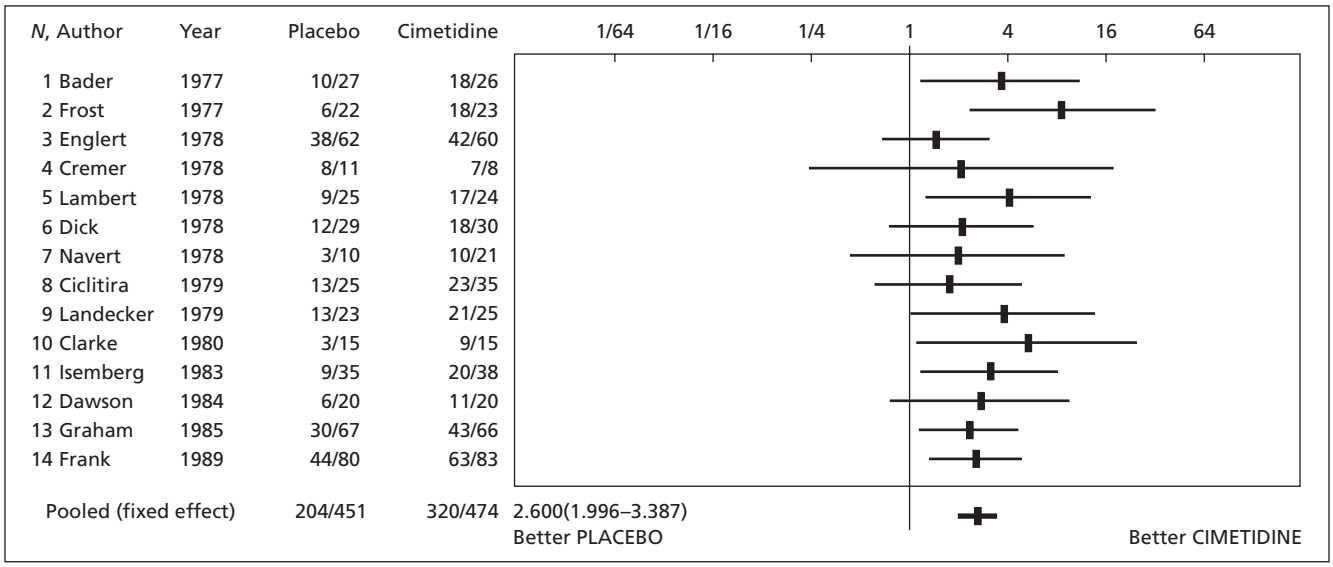

Fig. 2 Forrest plot of randomized studies comparing cimetidine with placebo.

depending on whether the fixed effects model or the random effects model is used. Both values can be calculated by computer programs, together with their 95% CI.

The Forrest plot

Figure 2 shows the Forrest plot, commonly used and seen in articles using meta-analysis. It shows the OR and its CI, represented by a point and two lines on each side of the point, respectively, for each individual study. If the CI crosses the vertical line of unity, the result is not statistically significant.

In the example shown, all trials show a trend for better efficacy of cimetidine compared with placebo, although some individual trials do not reach individual statistical significance, in part because of the small number of patients.

At the bottom of the figure, outside the rectangle, the pooled OR shows a statistically significant benefit of cimetidine.

Although this type of figure has become the classical way to represent a meta-analysis, it does not give much information. Indeed, it shows only the OR of each study and the pooled OR, each with their respective CIs.

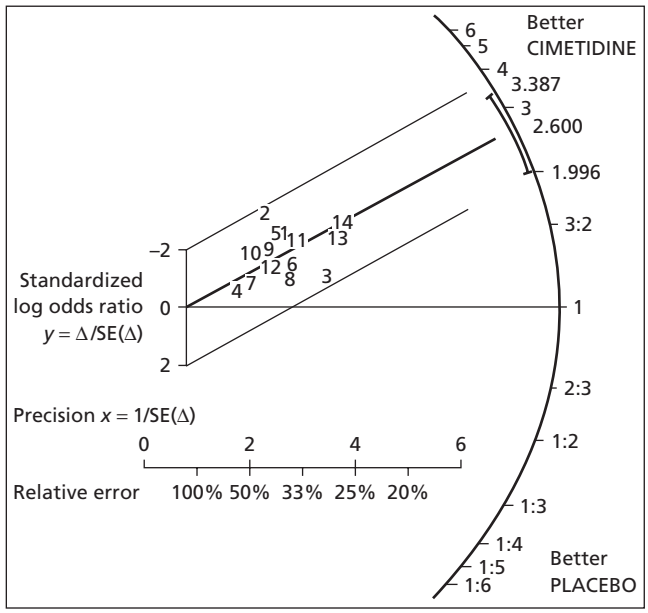

Fig. 3 The Galbraith plot.

The Galbraith plot

The Galbraith plot [12] is a more informative graphical representation. In this graph, every trial is represented by a number. The graph axes have two different characteristics: on the x-axis, the precision of the study is represented as the inverse of the standard error of the OR, or the inverse of the dispersion (Fig. 3).

Points that are closer to the origin (0,0) indicate poorly informative trials, whereas points far from the origin represent the most precise trials and have more weight in the meta-analysis.

For each trial, one can obtain the OR by drawing a line from the 0,0 point to the logarithmic scale (on the curved line) of the OR, which distinguishes this plot, crossing through the point indicating the trial. The CI, which is always approximated in a graph, is obtained by drawing two lines between 0,0 and $y \pm 2$ and then reading the value on the OR scale. This Galbraith plot (Fig. 3) shows that all the trials have similar individual precision for the estimate of the treatment effect without statistical heterogeneity.

Table 1 Validation of a meta-analysis.

The golden rules	
1	Was RCT the most appropriate way to approach the problem?
2	Are sources, criteria of inclusion and exclusion from the study, methods and endpoints clearly defined?
3	Did the authors evaluate the homogeneity of the criteria of inclusion/exclusion for each trial?
4	How were the dropouts evaluated in each trial?
5	Was the heterogeneity of the outcome investigated?
6	Was the sensitivity evaluated in at least one way?
7	Was the publication bias calculated?
8	Is the output of the meta-analysis correct and complete?
9	Was an expert statistician consulted during the analysis?

Quality scores

In reading a scientific paper, one not only tries to learn from other investigators experienced in the subject, but one also evaluates all the procedural and methodological aspects that contribute to the overall value of the work presented. To do so, quality scores have been proposed. They can be applied quantitatively and in an objective manner to evaluate the quality of the article.

Meta-analysis, as for clinical trials, can be undertaken more or less well in terms of scientific methodology. Moreover, the results can be described in several different ways, not all of which are the most appropriate. In the case of a meta-analysis, before accepting the conclusions, a critical evaluation has to be performed to ensure that both the methodology and the presentation of the results follows accepted rules.

Table 1 shows one such evaluation of the quality of a meta-analysis, combining methodological concerns with more general concepts on how appropriate such an investigation was [3].

Frequently, meta-analyses have been performed with randomized controlled trials (RCTs) that have been carried out in certain areas of clinical medicine in which the RCT is not the ideal way to establish the efficacy of therapy. If such a meta-analysis were to show no evidence of benefit of a particular therapy, then this conclusion would not be sound because the RCT is not the best instrument and, secondly, because there may be very few RCTs performed in this particular area. If an RCT is not the ideal study design for the matter under investigation, a meta-analysis should not be performed.

Dropouts

Another crucial aspect is how to deal with dropouts. They should always be taken into account. It is not correct to include in the same meta-analysis studies that show a 5% dropout with others that have a 50% dropout rate. These differences may represent important discrepancies between trials. A good habit is to include in a single meta-analysis studies that are similar for dropout rate, duration of follow-up and so on, and to use sensitivity analyses for trials in which these parameters are very different.

Rule 9 in Table 1 underlines the importance of a statistician evaluating statistical procedures and a physician interpreting the clinical findings. Therefore, a strong collaboration between these two professionals is essential in our opinion to guarantee accuracy and the clinical relevance of a meta-analysis.

Correct representation of a meta-analysis

An example of correct representation of a meta-analysis is shown in Figure 4 [2]. The upper left corner shows the subject of the meta-analysis, i.e. the sustained antiviral response following 6 months of treatment in trials aimed at comparing the efficacy of interferon (IFN) alone vs. interferon + ribavirin for the treatment of hepatitis C. Five trials were included in the analysis and the number of patients was 1062.

The Galbraith plot clearly shows that two out of the five trials have a precision significantly higher that that of the other three, indicating that these two studies can be considered as 'megatrials' (i.e. very large trials; nos 2 and 3 in Fig. 4).

The publication bias assessment (PBA) shows that 142 trials with negative or null results are necessary to reverse the statistical significance of the meta-analysis, indicating that the analysis is very reliable. NNT and ORs are also represented together with their respective CIs.

Subgroup analysis

The evaluation of clinically relevant subgroups is a good way to undertake a sensitivity analysis and to identify possible causes of clinical heterogeneity among studies. In the example shown (Fig. 5), non-absorbable disaccharides are compared with placebo or no treatment for the treatment of hepatic encephalopathy in cirrhotic patients. The initial evaluation showed a significant beneficial effect of the disaccharides [13], as shown by the pooled OR (0.339, 95% CI 0.136–0.846; random effects model). However, statistical heterogeneity was found ($P < 0.01$), so that the trials were evaluated according to a quality score. When this was done, the two best studies in terms of quality did not reveal a beneficial effect of disaccharides, whereas a beneficial effect remained in the evaluation of lower quality trials. Thus, the effect of disaccharides is uncertain. Owing to the small sample sizes and the low number of good-quality studies, one cannot infer that no benefit has been proven. Indeed, in this particular example, there is an apparent paradox with day-to-day clinical practice in which non-absorbable disaccharides are routinely used.

Conversely, clinical use of a therapeutic agent can also be widespread, despite a meta-analysis with detailed subgroup analysis showing no effect of the agent – ursodeoxycholic acid

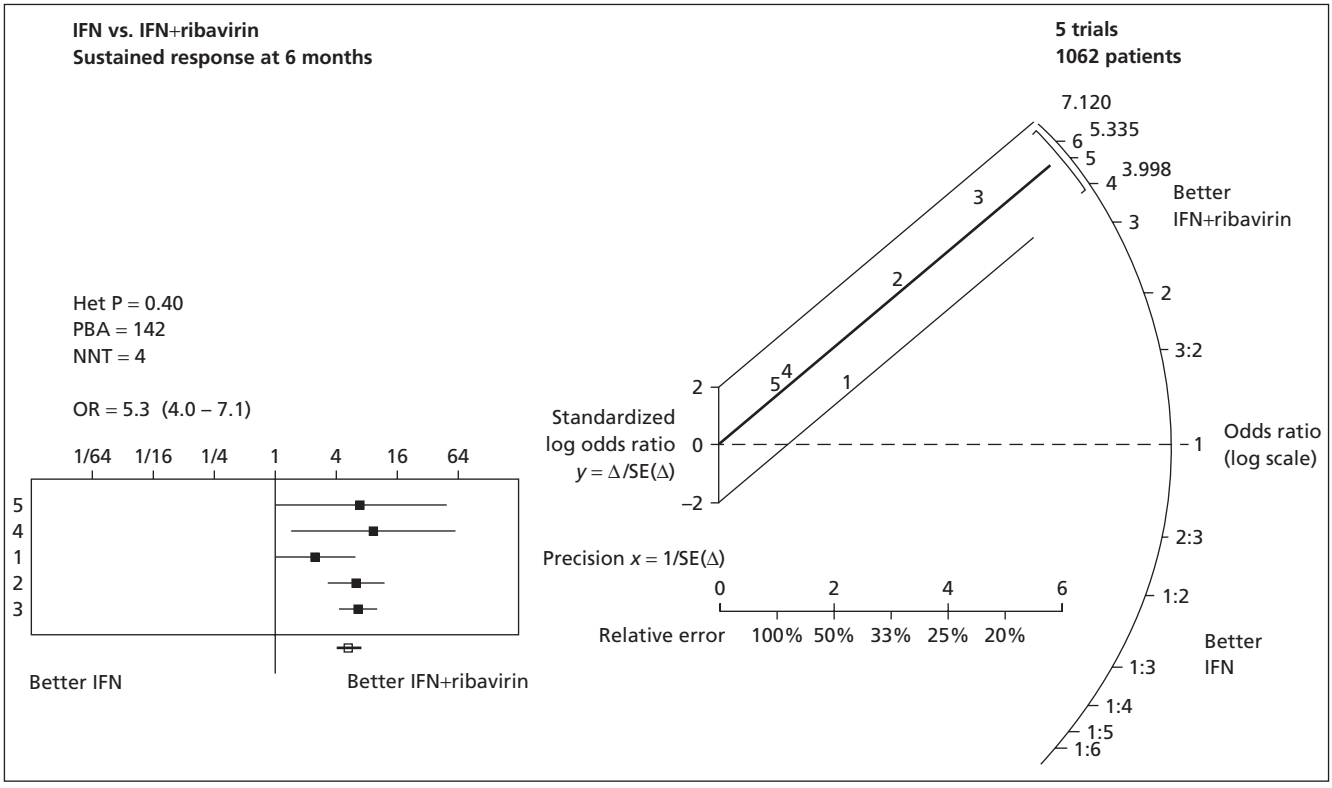

Fig. 4 A correct representation of a meta-analysis.

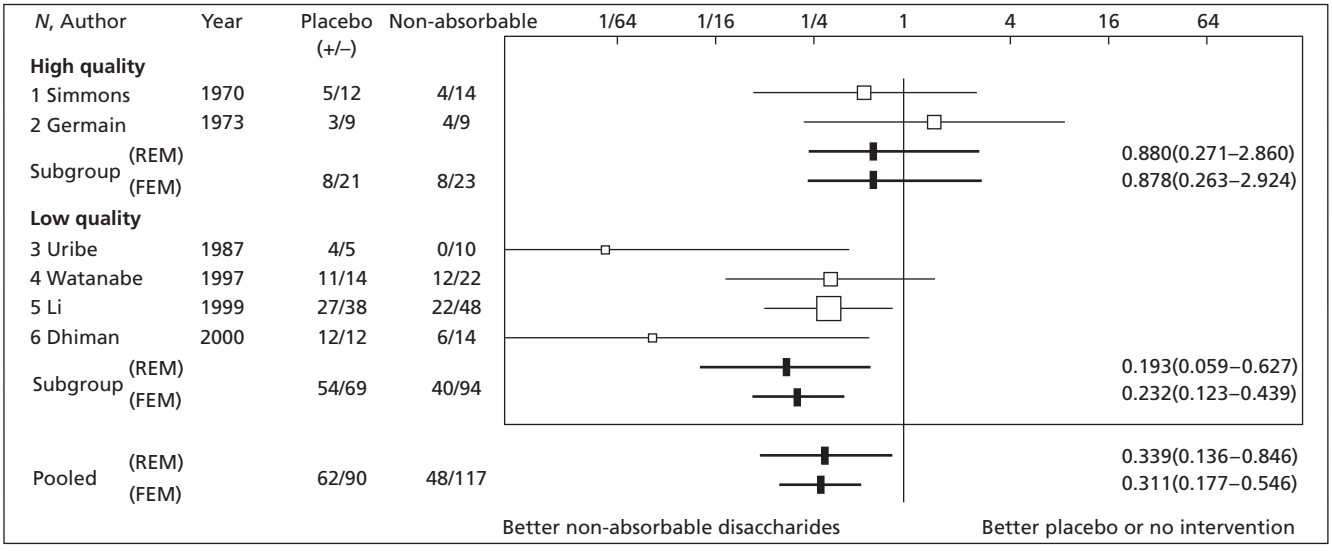

Fig. 5 Randomized trials of non-absorbable disaccharides vs. placebo or no treatment for the therapy of hepatic encephalopathy. REM, random effects model; FEM, fixed effects model. All the trials were designed with two groups: 1, non-absorbable disaccharides; 2, placebo or nothing.

in randomized studies for the treatment of primary biliary cirrhosis [14]. Thus, following publication of a meta-analysis, there has to be a consensus from the health care professions as to whether these are incorporated into guidelines or patient management algorithms.

Meta-analysis of diagnostic tests

Meta-analysis can also be applied to diagnostic tests [15]. The statistical methods used to combine data concerning diagnosis are more complex than for therapeutic studies and not as well

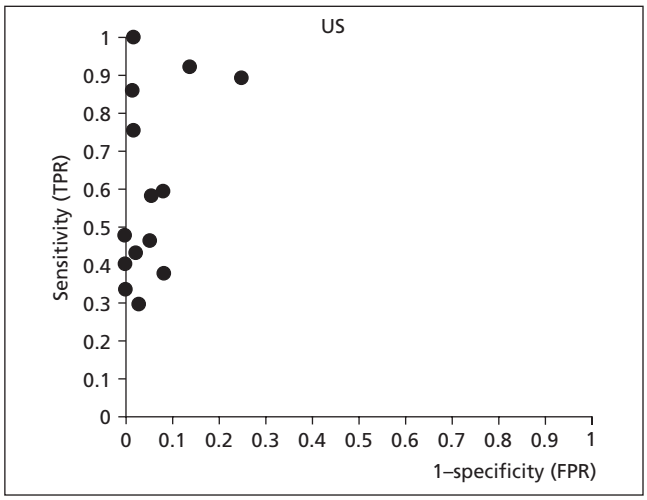

Fig. 6 Receiver operator curve: sensitivity and 1–specificity of ultrasound (US) for the diagnosis of hepatocellular carcinoma.

validated. This leads to greater difficulties in interpreting results than for therapeutic studies. Recently, a six-level framework has been put forward to assess diagnostic technologies. This not only takes into account technical feasibility and accuracy, but evaluates the impact on health outcomes. This can be considered the major endpoint similar to survival in most therapeutic studies [13], and a unified model has been proposed [16]. Thus, in meta-analyses of diagnostic tests, sensitivity, specificity, likelihood ratios and positive and negative predictive values are evaluated separately and different comparisons may arise. A further problem is that rapid advances in technology, such as in imaging, for example computerized tomography and magnetic resonance scanning, may result in very few studies being able to be evaluated, because they differ with regard to the diagnostic instrument. In addition, several diagnostic tests are operator dependent, which is a random non-measurable source of heterogeneity. In Figure 6, which shows the sensitivity and specificity of ultrasound diagnosis for hepatocellular carcinoma, one can see how the sensitivity varies from 30% to 100% in the studies considered [17].

References

1 Sackett DL, Richardson WS, Rosenberg W *et al.* (1997) *Evidence Based Medicine*. New York: Churchill Livingstone.

2 McDonald JWD, Burroughs AK, Feegan BG (eds) (2004) *Evidence-based Gastroenterology and Hepatology*, 2nd edn. Oxford: BMJ Books, Blackwell Publishing.

3 Leandro G (2005) *Meta-analysis in Medical Research*. Oxford: Blackwell Publishing & BMJ Books.

4 Leandro G (1994) The statistician contribution to the planning and evaluation of clinical trials. *Ital J Gastroenterol* 26(Suppl. 1), 23–26.

5 Mulrow CD (1994) Rationale for systematic reviews. *Br Med J* 309, 597–599.

6 Chalmers TC (1991) Problems induced by meta-analysis. *Stat Med* 10, 971–980.

7 Cooper H, Hedges LV (eds) (1994) *Handbook of Research Synthesis*. New York: Russel Sage Foundation.

8 Higgins JPT, Thompson SG (2002) Quantifying heterogeneity in a meta-analysis. *Stat Med* 21, 1539–1558.

9 Felson DT (1992) Bias in meta-analytic research. *J Clin Epidemiol* 45, 885–892.

10 Rothstein HR, Sutton AJ, Borenstein M (eds) (2005) *Publication Bias in Meta-analysis*. Chichester: Wiley.

11 Hunter JE, Schmidt FL (1990) *Methods of Meta-analysis*. Newbury Park, London: Sage Publications.

12 Galbraith RF (1988) A note on graphical presentation of estimated odds ratios from several clinical trials. *Stat Med* 7, 889–894.

13 Als-Nielsen B, Gluud LL, Gluud C (2004) Non-absorbable disaccharides for hepatic encephalopathy: systematic review of randomized trials. *Br Med J* 328, 1046–1050.

14 Goulis J, Leandro G, Burroughs AK (1999) Randomized trials of ursodeoxycholic acid in primary biliary cirrhosis. *Lancet* 354, 1053–1060.

15 Tatsioni A, Zarin DA, Aronson N *et al.* (2005) Challenges in systematic review of diagnostic technologies. *Ann Intern Med* 142, 1048–1055.

16 Harbord RM, Deeks JJ, Egger M, *et al.* (2006) A unification of models for a meta-analysis of diagnostic accuracy studies. *Biostatistics* 1, 1–21.

17 Colli A, Fraquelli M, Casazza G *et al.* (2006) Accuracy of ultrasonography, spiral CT, magnetic resonance and alpha-fetoprotein in diagnosing hepatocellular carcinoma: a systematic review. *Am J Gastroenterol* 101, 513–523.

26.4 Economic considerations in hepatology

John B. Wong

Introduction

Excellence in practising the art of medicine involves optimal decision-making. For every patient, physicians make implicit or explicit choices to treat, to perform further tests or to neither test nor treat [1]. Previously, practising physicians mastered the safety, efficacy, side-effects and indications for medications, and learned the sensitivity, specificity, risks and indications for diagnostic and prognostic tests. With the recent rapid expansion in novel drugs, medical devices, tests and imaging modalities, health care costs have risen substantially worldwide. Increasingly, physicians recognize that they must incorporate economic considerations into their medical decision-making [2,3]. This review will provide a basic overview of the principles of health economics including cost-effectiveness analysis.

Principles for allocating resources

Identifying a medical intervention as being 'cost-effective' has become increasingly popular, yet it is prone to misuse and misunderstanding [4]. The term is used at times to indicate that a therapy saves money without accounting for effectiveness and, at other times, that it is effective without consideration of costs. In correct use, when considering cost-effectiveness, two dimensions of medical decision-making become recognized simultaneously: effectiveness and costs. Three alternative principles for allocating resources then exist: (i) cost minimization with reduction in costs regardless of outcomes; (ii) outcome maximization at any cost; and (iii) cost-effectiveness by either obtaining the greatest possible benefit for a given resource expenditure or expending the lowest resource cost for a given target benefit [2]. In the absence of a budget, cost minimization or outcome maximization could be the dominant principle but, in general, the most common principle is cost-effectiveness, explicitly recognizing health budgetary limitations. When budgets are limited, dollars spent on one disease have opportunity costs, that is those dollars could have been spent on a different disease or on research or testing instead of treatment. From a broader perspective, those dollars could even be spent outside of health care on societal needs. In particular, when health budgets are nearly fully consumed, dollars spent 'at the margin' can become particularly competitive among the alternative possible allocation options for those dollars in the effort to maximize the benefit of scarce resources [5].

Analytical methods

Three types of economic analysis have been applied to health care [6,7]. Cost identification or cost minimization analysis examines the costs of care, implicitly assuming equal health benefits for all the alternative options and thus ignoring non-economic outcomes.

Cost–benefit analysis incorporates both costs and health outcomes, placing a monetary value on health outcomes so that the alternatives can be evaluated on a single outcome measure. However, because assigning a monetary value to a health outcome (or life) raises many ethical objections, cost–benefit analysis has generally not been accepted in health care.

Cost-effectiveness analysis is the most commonly used method for performing economic analyses in health care. In these analyses, monetary and health benefit outcomes are measured separately, and the value of a new health intervention (medication, test or device) is measured relative to the standard of care as the incremental cost to achieve an incremental health benefit [2]. The cost-effectiveness plane (Fig. 1) displays the four possible outcomes when comparing the new health intervention with the standard one. The new intervention may cost more or less and may be more or less effective. Interventions that are more effective and less costly in the lower right-hand quadrant are cost-saving. Those that are less effective and cost more in the upper left-hand quadrant are 'dominated'. For those new interventions that are more effective and more costly in the upper right-hand corner or those that are less effective and less costly, an incremental or marginal cost-effectiveness ratio can be calculated by the following:

$$\frac{\text{Cost with new} - \text{cost with standard care}}{\text{Outcomes with new} - \text{outcomes with standard care}}$$

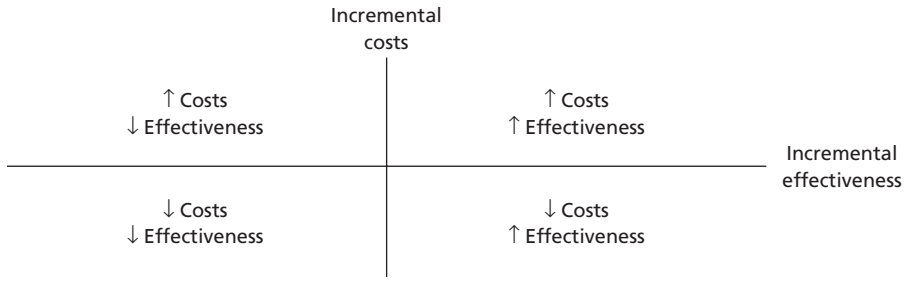

Fig. 1 Joint distribution of incremental costs and incremental effectiveness or benefits. Each line represents zero and defines the plane into four regions with positive or negative incremental costs or effectiveness. See text for details.

Thus, cost saving implies that an intervention reduces costs and improves health, but cost-effectiveness implies that an intervention increases costs and improves health or reduces costs and leads to less health benefit. An intervention cannot be considered to be cost saving simply by reducing costs and cannot be considered cost-effective simply by being more effective. Cost–utility analysis is a specialized subset of cost-effectiveness where the effectiveness metric becomes life expectancy adjusted for the morbidity or quality of life associated with the alternative strategies.

Costs

Costs reflect the price paid for resources to provide a service. Distinct from costs, charges include a profit margin related to service delivery and may differ substantially from costs [8]. Because charges may lead to incorrect conclusions, actual resource consumption is the preferred method. The process of translating patient-related resource consumption involves cost allocation that is both complex and, to some extent, arbitrary. First, the most common approach involves assigning costs to departments or cost centres and then, within each centre, allocating department costs to a unit of service. In both cases, a number of alternative methods are available [8].

Operating (production) costs can be divided into direct and indirect costs. The direct costs relate to resources required to provide a service, such as original capital or capital improvement, professional (physician fees) and non-professional labour and diagnostic tests, drugs or medical supplies. Indirect costs are related to overheads to provide the service and include depreciation of the building, rent, space preparation and upkeep, utilities, support services and administrative services.

Direct and indirect costs can also be characterized as fixed costs (costs that are relatively invariant over a short period of time, e.g. equipment) and as variable costs (costs that vary directly with changes in volume, e.g. disposable goods). For example, in performing an ultrasound, the probe equipment is a fixed cost but the lubricant applied to the skin would be a variable cost. Semi-variable costs have both fixed and variable components (e.g. maintenance). Lastly, time costs typically refer to the loss of productivity or loss of life or livelihood for patients.

Costs can be estimated by a top-down or a bottom-up approach. With a top-down approach, a clinical cohort is identified, and their economic or resource utilization costs over time are determined from medical billing data usually as charges (e.g. hospital or physician bills). These charges are then adjusted with cost to charge ratios. The characterization of the clinical cohort can occur with very different levels of specificity, e.g. average daily cost in the hospital for all types of patients or average daily cost for patients with a particular disease or daily cost and length of stay for patients with a particular disease. With a bottom-up or microcosting approach, the frequency of utilization of individual resources is obtained (e.g. drugs, tests, procedures and hospital days). These frequencies are then multiplied by the cost of each resource unit and then summed to calculate a total cost. Finally, a clinical study may capture clinical costs as they occur during a randomized clinical trial. Thus, costs can be estimated prospectively or retrospectively. Practice patterns and costs may vary considerably across different providers or regions.

In assessing costs, a full accounting of net health care costs typically involves the direct medical and health care costs, costs associated with side-effects, savings from disease prevention or alleviation and sometimes costs from additional diseases [2]. In particular, tests or treatments may lead to induced costs.

For example, screening blood donors for hepatitis may lead to false-positive tests. Induced costs could then include the cost of discarded donated blood, of additional donor recruiting efforts to maintain the blood supply and of additional liver tests and office follow-up for the donor by their physician. On the other hand, tests or treatments may lead to cost savings. For instance, identifying blood donors truly infected with viral hepatitis (true positives) and discarding their donated blood prevents the potential morbidity, mortality and expense of post-transfusion hepatitis for recipients, but also induces additional testing and possibly antiviral treatment for the correctly identified infected donor.

Perspective

Whether the analysis takes the point of view of patients, providers, health payers or society affects which costs and health effects are considered. For example, patients, providers, health payers and society may view drug costs differently. Patients may consider only drug costs that must be borne out of pocket or not covered by insurance. Physicians must weigh the costs (and the

risks and benefits) of generic vs. new drugs. Health payers may consider the budgetary costs (in particular for the upcoming year) of providing coverage for a particular drug and the cost of illness that the drug may prevent. Society may consider the drug costs but also the long-term costs of disease and lost productivity. Cost-effectiveness analyses usually take a societal perspective and include lifelong costs, benefits and harms representing the overall public interest.

Effectiveness

Health benefits are typically measured in outcomes that are relevant and meaningful to the condition under study for the decision-maker. For example, screening tests or treatment outcomes could include cases of cancers detected or cases of cancers or cirrhosis prevented. One issue about using cases of cancer detected involves whether the cases are treatable at the time of detection, for example a hypothetical screening test could detect cases of cancer but, if the cases were all metastatic at the time of detection, there would be no clinical benefit. Similarly, such an outcome measure is also subject to length and lead-time bias. Translating and standardizing the outcome scale, however, allows one to compare the health benefits of alternative tests or treatments on a uniform scale. To account for survival, the effectiveness measure could be life expectancy, but such a measure would not consider morbidity from testing, treatment or disease. Thus, cost–utility analysis frequently uses quality-adjusted life years gained to reflect not only prolongation of life but also the quality of life associated with those years (e.g. surviving without hepatitis after antiviral treatment but with influenza-like symptoms during treatment).

Quality of life

To determine quality of life, utility assessment involves the quantification of preferences for health outcomes. The three most commonly used methods include the visual analogue scale, the time tradeoff and the standard gamble methods. In all these methods, outcomes are rank ordered from least preferred, usually death, to most preferred, usually perfect health. Typically, for the visual analogue scale method a vertical line is drawn with perfect health at 100 and the worst health at the bottom at 0. The patient is then asked to indicate where their current health or a described state of health would be on that scale. If, for example, hepatocellular carcinoma were placed at 25, then the quality of life with cancer would be 0.25, and living a year with hepatocellular carcinoma would be equivalent to living three quality-adjusted months in perfect health (0.25 times 1 year of perfect health).

In the time tradeoff method, individuals choose between hypothetical scenarios in which they could live a shortened length of life in perfect health or live longer but in impaired health. The length of time with impaired health is varied until the individual has difficulty deciding between the alternatives. For instance, someone could be indifferent to the choice of living 6 months of life in perfect health vs. living for 1 year with hepatocellular carcinoma. In such a case, living 1 year with hepatocellular carcinoma equals living six quality-adjusted months in perfect health (0.5 times 1 year of perfect health).

Lastly, in the standard gamble approach, individuals choose between a guaranteed intermediate health outcome such as living 1 year with hepatocellular carcinoma and a chance of having either the worst outcome (usually immediate death) or the best outcome (e.g. living 1 year in perfect health). The likelihood of the uncertain outcome is varied until individuals have difficulty choosing between the guaranteed intermediate outcome and the chance of having the best or worse outcome. If living 1 year with hepatocellular carcinoma were equivalent to a 25% chance of immediate death and a 75% chance of living in perfect health for 1 year, then the quality of life with hepatocellular carcinoma would be 0.75, so living 1 year with hepatocellular carcinoma would be equivalent to living nine quality-adjusted months in perfect health. On a theoretical foundation basis, the standard gamble is the preferred metric. However, the administration of these approaches can be time-consuming and difficult for patients.

An alternative approach involves the use of indices or scales that tabulate premeasured preferences for health states or outcomes defined in various dimensions (such as the Health Utilities Index, the Quality of Well-Being Scale SF-6D or EuroQOL). Patients with a particular condition or individuals from the general population at risk of developing the condition have previously assigned preferences for the various dimensions of health states such as physical function.

In general, individuals experienced with a disease adapt to their illness, perhaps adjusting their expectations, and assign higher (better) quality of life values than those from the general population. Conversely, those from the general population may assign lower pessimistic quality of life estimates. Different estimates may be reached depending upon whether the study population included physicians, patients with the disease or individuals from the general population who have not experienced the disease.

Other standard quality of life indices such as the SF-36 exist as generic measures. However, these indices do not incorporate patient preferences and thus should not be used directly in cost-effectiveness analyses. In addition, disease-specific measures have been constructed for a variety of diseases, and several exist specifically for liver disease. These measures have increased sensitivity to health status changes but would be inappropriate for cost-effectiveness analyses because they are typically not applied across different diseases.

Time horizon and discount rate

The time horizon refers to the length of time over which health benefits and costs are considered in the analysis. One example in which the time horizon is particularly important concerns the assessment of costs for antiviral drugs for hepatitis B. Based on

the average wholesale price in 2003, monthly costs would be $1397 for peg-interferon-α-2a at 180 μg once a week, $1879 or $2349 for interferon-α at 10 million units three times a week or at 5 million units per day, respectively, $166 for lamivudine 100 mg once daily, and $528 for adefovir 10 mg once daily. Thus, oral medications appear to be substantially less expensive. However, excluding discontinuations and dose reductions, interferon-α would cost $7517 over 16 weeks, and peg-interferon-α-2a would cost $8380 over 24 weeks. Oral drugs would be given continuously, so 1 year of lamivudine costs $2020, and 1 year of adefovir costs $6424. If given continuously, lamivudine drug costs would equal interferon-α costs after 45 months and would equal peg-interferon-α-2a costs after 50 months. Similarly, if adefovir were given continuously, adefovir drug costs would equal interferon-α costs after 14 months and would equal peg-interferon-α-2a costs after 16 months. Lastly, 1 year of adefovir equals about 38 months of lamivudine.

Health payers usually consider short-term, 1-year time horizons because of annual budgets, but the societal perspective typically applies a long-term or lifetime time horizon. In such cases, preferences for when expenditures occur emerge as an important consideration. Money spent now is more valuable than money spent in the future because of opportunity costs. From another perspective, one would prefer to receive money now as opposed to receiving the same amount a year from now because money available now can be put to immediate use or invested. These time preferences for money are captured as the discount rate. The discount rate quantifies this time preference and places all economic costs in terms of the present value of money where net present value equals $1 \div (1+ \text{annual discount rate})^t$ where t equals the number of years elapsed until the expenditure occurs. The recommended annual discount rate is 3% [9] so, for example, spending €100 now equals spending €97 1 year from now or spending €74 in 10 years. Thus, because of discounting, medical interventions that reduce health expenditures in the future are economically less valuable than those that reduce health expenditures in the current year. Because costs are discounted, the benefits of health interventions must also be discounted [2]. Equivalently, discounting emphasizes current health benefits over future health benefits. Thus, prolonging life by 1 year 10 years from now is equivalent to 0.74 current years of life or 0.55 current years of life if prolonging life by one year 20 years from now. The discount rate does not adjust for inflation, which is a separate consideration.

Decision analysis

Medical decisions frequently involve clinical judgements regarding the likely diagnosis, the morbidity and mortality associated with that disease, test interpretation using sensitivity and specificity, the information content and risk associated with further testing and the risks and benefits of alternative therapies [10,11]. With increasing physician knowledge and experience, many of these decisions become automatic in response to specific clinical situations. In other cases, either uncertainty regarding diagnosis, test interpretation, disease prognosis or treatment benefit or tradeoffs between treatment risks and benefits complicate decision-making [12]. Hence, Sir William Osler once said 'Medicine is a science of uncertainty and an art of probability'. Decision analysis is an explicit, normative approach to making decisions in the midst of uncertainty. It specifies the alternative strategies, estimates the likelihood of complications or benefits from those alternatives and assigns values to the outcomes. It has been used to guide management decisions for individual patients, to assess new technologies, to develop guidelines, to determine cost-effectiveness and to evaluate the public policy implications of various programmes [13,14].

Simple decision trees consist of three kinds of nodes: decision nodes where the alternative strategies are defined; chance nodes that explicitly account for uncertainty; and terminal nodes that assign a value to the outcome. These trees are evaluated by folding back and averaging out. Starting with each terminal node, multiple the value of the outcome by its likelihood and, at each chance node, sum the branches. Repeat this process iteratively until reaching each strategy [1].

Markov models have become more common in medical decision analysis. They are particular well suited for modelling the natural history of chronic progressive diseases with repetitive or recurrent events. These kinds of models explicitly account for the timing of events and permit the risks of mortality and morbidity and costs to change over time. In Markov models, the natural history of disease is divided into predefined states of health. During each Markov cycle or tick of a clock, patients may move among the states of health. For example, during a Markov cycle of 1 year, some patients may die, develop progressive disease or remain the same. The computer simulation continues until all patients die. By tracking the proportion of patients alive at the end of each year, the simulation can calculate the average life expectancy for the cohort. By tracking the health state that each patient is in, the simulation can calculate the average quality-adjusted life expectancy by crediting the cohort for the morbidity of each health state. For example, if the quality of life with hepatocellular carcinoma was 0.5, then patients surviving 1 year with hepatocellular carcinoma receive credit for living six quality-adjusted months of life. Finally, by tracking when patients are in each state of health (years elapsed) and the annual cost of caring for patients in that health state, the Markov model discounts expenditures. For example, if 20 years have elapsed until an individual develops hepatocellular carcinoma and if the present value of the annual cost of care for such patients is $30 000, then the Markov model discounts that expenditure by 41.2% $[1 \div (1+0.03)^{20}]$ assuming a 3% annual discount rate.

Sensitivity analysis

Having performed a cost-effectiveness analysis, uncertainty may exist about the particular value of each parameter used to estimate costs or health effects. Sensitivity analysis explores the

effect of varying each parameter value over a broad range to assess the degree to which that uncertainty could affect the overall results. One-way sensitivity analysis considers each variable separately one at a time. Two-way sensitivity analysis considers variation in two variables simultaneously; and similarly, three-way sensitivity analysis considers the effect of varying three variables simultaneously. The ranges considered in these analyses typically reflect uncertainty based on statistical measures reflecting the sample size or broad ranges intended to capture the extremes. When variation shifts the preferred strategy, the analysis is said to be 'sensitive' to that parameter. In such cases, cost-effectiveness analyses identify critical research areas that require additional study. When the preferred strategy does not change with variation, the analysis is said to be 'insensitive' or robust to variation in that parameter. Thus, cost-effectiveness analyses not only identify the optimal strategy but also the most influential parameters affecting the decision.

Recently, multivariate analyses accounting for variation in all parameters simultaneously have become more common. These Monte Carlo simulations characterize uncertainty around each parameter using a probability distribution. Typical distributions include beta for probabilities, lognormal for costs and logit for quality of life. In such analyses, a sample value is drawn from the probability distribution for each parameter for each analytical run. These runs are repeated thousands of times, resulting in distributions of incremental benefits and incremental costs. Plotting these distributions of outcomes on the axes outlined in Figure 1 permits the determination of cost-effectiveness acceptability curves, i.e. the probability that the new intervention may be cost saving or fall below a particular cost-effectiveness willingness to pay threshold (see below).

The reference case

For many years, cost-effectiveness analysis applied a variety of the above methods in an inconsistent manner. To standardize the set of methods and assumptions for the measurement and reporting of costs and health effects, a reference case was established [15]. This standardization reduces methodological variability in the assessment of the cost-effectiveness of medical technologies. When analyses comply with the reference case, health policy-makers can use these analyses more reliably to choose the most efficient use of public health resources in their funding decisions.

Cost-effectiveness ratio

Two kinds of cost-effectiveness ratios can be calculated [6,16]. The average cost-effectiveness ratio divides each intervention's costs by its effectiveness. This can result in misleading conclusions about an intervention's cost-effectiveness. A preferable way to express cost-effectiveness is the incremental or marginal cost-effectiveness ratio, which refers to the additional cost divided by the additional benefit of one intervention compared with another.

Consider, for example, whether to treat hepatitis C with antiviral medications. When examining only drug costs and sustained viral response, Table 1 presents the drug cost, sustained viral response and the calculated average and incremental cost-effectiveness of three antiviral regimens for treating chronic hepatitis C [17,18]. The incremental cost and effectiveness are obtained from the next lowest costing regimen. The average cost-effectiveness ratios are relatively consistent, differing by about $10 000. Treating with peg-interferon plus a fixed dose of ribavirin compared with interferon plus ribavirin, however, increases costs by $6953 to yield a 7.1% absolute increase in sustained viral response for an incremental cost-effectiveness ratio of $97 930 per additional sustained response obtained. Treating with peg-interferon plus weight-based dosing with ribavirin compared with peg-interferon plus fixed-dose ribavirin, however, increases costs by $2146 to yield a 7.0% increase in sustained viral response for an incremental cost-effectiveness ratio of $30 657 per additional sustained response obtained.

Because the incremental cost-effectiveness ratio of peg-interferon plus weight-based dosing with ribavirin is lower than that of peg-interferon plus fixed-dose ribavirin, peg-interferon plus weight-based dosing with ribavirin is a more efficient use of resources. Options that cost less and have higher effectiveness are cost saving or dominate the alternative. When an option has a lower cost-effectiveness ratio than the next less expensive one, it has extended or weak dominance over the next less expensive option because it would be a more efficient use of resources. Specifically, to obtain a 54.6% sustained viral response with peg-interferon plus fixed-dose ribavirin would require $18 722 in drug cost, but to obtain the same 54.6% sustained viral response with peg-interferon plus weight-based ribavirin would require only $18 458 in drug cost (by treating just 88.4% of those infected), a $264 saving. In such cases in which an option has dominance or extended dominance, the lower costing option

Table 1 Average vs. incremental cost-effectiveness.

	Drug cost	Sustained viral response	Average cost-effectiveness	Incremental cost	Incremental effectiveness	Incremental cost-effectiveness
Interferon plus ribavirin	$11 769	46.5%	$25 291			
Peg-interferon plus fixed-dose ribavirin	$18 722	53.6%	$34 916	$6953	7.1%	$97 930
Peg-interferon plus weight-based ribavirin	$20 868	60.6%	$34 414	$2146	7.0%	$30 657

falls out of consideration, and the incremental costs, effectiveness and cost-effectiveness ratios are recalculated. Thus, peg-interferon plus weight-based ribavirin should be compared with interferon plus ribavirin, yielding $64 432 per additional sustained viral response gained.

The use of alternative effectiveness metrics can lead to difficulty in comparing the relative value of different medical interventions. A similar analysis may estimate a cost per case of hepatocellular carcinoma detected, leaving the analyst to determine the relative merits of viral eradication vs. preventing cancer. Moreover, detecting a case of cancer may not be equivalent to improving outcome, for example if none of the detected cases was treatable or as a result of epidemiological concepts such as lead-time or length bias. Lastly, such approaches complicate interpretations across different diseases

Consequently, cost-effectiveness analyses have standardized on reporting cost–utility analyses, i.e. the cost to increase life expectancy by one quality-adjusted life year (adjusted to 1 year of perfect health and discounted to its present value). Such analyses account not only for drug costs but also for disease costs. The analysis in Table 1 does not include the $33 407 lifetime undiscounted cost of caring for an average case of hepatitis C. When incorporating such costs, the incremental cost-effectiveness of peg-interferon plus weight-based dosing with ribavirin has a ratio of $13 600 per discounted quality-adjusted life year gained compared with interferon plus ribavirin [18].

Having determined the incremental cost-effectiveness ratio, how can those ratios be applied? One approach is based upon the notion of 'willingness to pay'. A policy-maker may decide that it will fund only medical interventions that are cost saving or that fall below a threshold amount, the willingness to pay ratio. In such a case, all interventions falling below that threshold, e.g. $50 000 or €55 000 per discounted quality-adjusted life year gained, would be reimbursed, whereas those exceeding this amount would be deemed to be too expensive by providing insufficient value. Thus, the selection among options with different cost-effectiveness ratios would be based upon staying within this limit.

The second method involves specifying a budget and then comparing the cost-effectiveness ratios of interventions with other well-accepted medical practices by examining a league table. A league table compiles cost-effectiveness ratios for various treatments and diseases complying with the reference case. The historical standard used for setting this threshold has been haemodialysis for chronic renal failure, which has an incremental cost-effectiveness ratio of $60 000–128 000 per quality-adjusted life year gained. Funding would occur for those programmes that were cost saving or had the lowest cost-effectiveness ratio. Once the spending budget was reached, further interventions would not be approved. Of course, such an approach does not occur in reality because policy-makers and budget holders consider aspects of treatment decisions beyond their cost-effectiveness including ethical issues, disparities and equity.

Evaluating a cost-effectiveness study

The discussion presented above emphasizes that cost-effectiveness analysis is complex and that studies making claims regarding cost-effectiveness should receive the same level of scrutiny as other types of studies. The following questions can provide guidance when evaluating a cost-effectiveness analysis, although many additional features reflecting the conduct of the study and its quality can be considered in specific settings [19,20].

1 Are the results valid?

- Did the analysis provide a full economic comparison of health care strategies?
- Were the costs and outcomes properly measured and valued?
- Was appropriate allowance made for uncertainties?
- Are estimates of costs and outcomes related to the baseline risk in the treatment population?

2 What were the results?

- What were the incremental costs and outcomes of each strategy?
- Do incremental costs and outcomes differ between subgroups?
- How much does allowance for uncertainty change the results?

3 Will the results help in caring for my patients?

- Are the treatment benefits worth the harms and costs?
- Could my patients expect similar health outcomes?
- Could I expect similar costs?

Practising cost-effectively

To illustrate the cost implications of clinical practice and treatment guidelines, let us examine antiviral treatment for hepatitis. In evaluating treatment response, detection of individuals unlikely to respond avoids potential morbidity from continued antiviral treatment and its expense. On the other hand, identification of individuals with a high likelihood of response may help them adhere to treatment. Figure 2 shows the results of peg-interferon plus ribavirin treatment for hepatitis C [17,18]. In this case, treatment evaluation occurs at 12 weeks, and the criterion is viral negativity. Note that the positive predictive value is the likelihood of having a sustained viral response among patients with an early viral response; negative predictive value is the likelihood of not having a sustained viral response among patients without an early viral response; and neither of these is the likelihood of missing a sustained viral response or the likelihood of stopping therapy early. In this case, antiviral therapy drug cost savings occur for the 36% of patients who did not achieve the early viral response, but 5.5% of patients who would have had a sustained response would have had their therapy stopped prematurely. From a cost standpoint, there would be antiviral drug savings from stopping therapy but, by stopping therapy in those 5.5% who would have had a sustained response, this stopping rule would have caused disease-related monitoring and treatment follow-up costs that could have been avoided with continued antiviral treatment. Thus, the goal of any stopping rule is to avoid premature discontinuation of

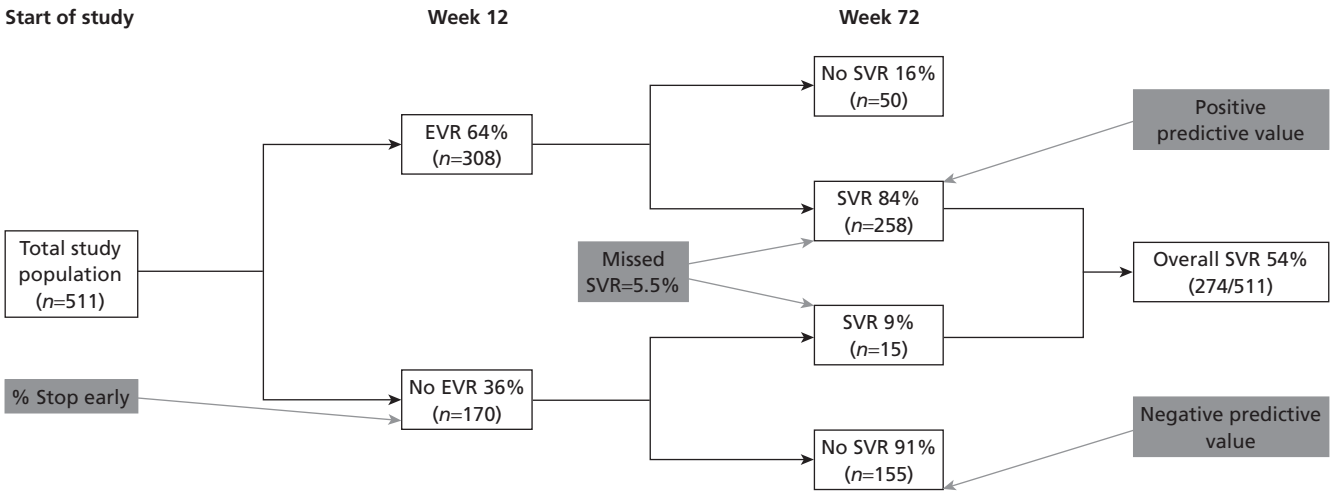

Fig. 2 Evaluation of viral response to antiviral treatment at 12 weeks. Early viral response (EVR) is defined as becoming viral negative after 12 weeks of antiviral treatment. SVR, sustained viral response 6 months after the end of antiviral treatment. Note that 33 have missing values at week 12. See text.

antiviral therapy for those who will become sustained responders, i.e. the early viral response test should be positive for those who will develop a sustained viral response, and any negative predictive value less than 100% implies that some sustained viral responders are being missed.

To achieve a 100% negative predictive value, two alternatives are possible: extend the time at which response is assessed so that more patients can achieve that response, e.g. viral negative after 24 weeks, or reduce the stringency of the criteria, e.g. viral negative or with a 2-log decrease in viral load after 12 weeks. Extending the duration of therapy for everyone exposes everyone to the morbidity and expense of an additional 12 weeks of therapy so, in general, if all or nearly all sustained responders can be detected earlier, that would be the preferred evaluation time. Hence, additional analyses showed that a viral negative or 2-log viral load decrease after 12 weeks of therapy identified all sustained responders. The cost implications, however, are that fewer patients would stop therapy after 12 weeks because additional patients were able to achieve the less stringent viral response criteria, leading to additional antiviral drug costs but reducing future disease costs because the 5.5% of sustained responders who would have been missed continued therapy.

When examined for positive predictive value, the 12-week viral negative criterion has an 84% positive predictive value, namely that those who became viral negative by week 12 had an 84% likelihood of a sustained viral response. When that criterion is relaxed by allowing those with a 2-log viral load decrease to continue therapy, the positive predictive value falls because the additional patients continuing therapy have a less than 84% chance of becoming a sustained responder. On the other hand, if the criteria were made more stringent, e.g. requiring viral negativity or a 3-log drop by 12 weeks, or by shifting the criterion to an earlier time point, then the positive predictive value would rise. A higher proportion of patients (including some who would have had a sustained response) would stop therapy because of the stringency of the criterion. But, for those achieving this, the high positive predictive value could provide motivation to adhere to antiviral treatment.

Conclusion

With increasing economic pressures, physicians must not only know about the safety, efficacy and effectiveness of medical practices, but also become conversant in the terminology and methodology of health care economics. Cost-effectiveness analysis has become a commonly accepted method of evaluating the value of new medical interventions.

References

1 Pauker SG, Kassirer JP (1987) Decision analysis. *N Engl J Med* 316(5), 250–258.
2 Weinstein MC, Stason WB (1977) Foundations of cost-effectiveness analysis for health and medical practices. *N Engl J Med* 296(13), 716–721.
3 Meltzer MI (2001) Introduction to health economics for physicians. *Lancet* 358(9286), 993–998.
4 Doubilet P, Weinstein MC, McNeil BJ (1986) Use and misuse of the term 'cost effective' in medicine. *N Engl J Med* 314(4), 253–256.
5 Mark DB, Hlatky MA (2002) Medical economics and the assessment of value in cardiovascular medicine: Part I. *Circulation* 106(4), 516–520.
6 Detsky AS, Naglie IG (1990) A clinician's guide to cost-effectiveness analysis. *Ann Intern Med* 113(2), 147–154.
7 Eisenberg JM (1989) Clinical economics. A guide to the economic analysis of clinical practices. *JAMA* 262(20), 2879–2886.
8 Finkler SA (1982) The distinction between cost and charges. *Ann Intern Med* 96(1), 102–109.
9 Weinstein MC, Siegel JE, Gold MR *et al.* (1996) Recommendations of the Panel on Cost-effectiveness in Health and Medicine. *JAMA* 276(15), 1253–1258.

10 Pauker SG, Kassirer JP (1975) Therapeutic decision making: a cost-benefit analysis. *N Engl J Med* 293(5), 229–234.
11 Pauker SG, Kassirer JP (1980) The threshold approach to clinical decision making. *N Engl J Med* 302(20), 1109–1117.
12 Moskowitz AJ, Kuipers BJ, Kassirer JP (1988) Dealing with uncertainty, risks, and tradeoffs in clinical decisions. A cognitive science approach. *Ann Intern Med* 108(3), 435–449.
13 Kassirer JP, Moskowitz AJ, Lau J *et al.* (1987) Decision analysis: a progress report. *Ann Intern Med* 106(2), 275–291.
14 Elwyn G, Edwards A, Eccles M *et al.* (2001) Decision analysis in patient care. *Lancet* 358(9281), 571–574.
15 Russell LB, Gold MR, Siegel JE *et al.* (1996) The role of cost-effectiveness analysis in health and medicine. Panel on Cost-Effectiveness in Health and Medicine. *JAMA* 276(14), 1172–1177.
16 Neuhauser D, Lewicki AM (1975) What do we gain from the sixth stool guaiac? *N Engl J Med* 293(5), 226–228.
17 Manns MP, McHutchison JG, Gordon SC *et al.* (2001) Peginterferon alfa-2b plus ribavirin compared with interferon alfa-2b plus ribavirin for initial treatment of chronic hepatitis C: a randomised trial. *Lancet* 258(9286), 958–965.
18 Wong JB, Davis GL, McHutchison JG *et al.* The International Hepatitis Interventional Therapy Group (2003) Economic and clinical effects of evaluating rapid viral response to peginterferon alfa-2b plus ribavirin for the initial treatment of chronic hepatitis C. *Am J Gastroenterol* 98(11), 2354–2362.
19 Drummond MF, Richardson WS, O'Brien BJ *et al.* (1997) Users' guides to the medical literature. XIII. How to use an article on economic analysis of clinical practice. A. Are the results of the study valid? Evidence-Based Medicine Working Group. *JAMA* 277(19), 1552–1557.
20 O'Brien BJ, Heyland D, Richardson WS *et al.* (1997) Users' guides to the medical literature. XIII. How to use an article on economic analysis of clinical practice. B. What are the results and will they help me in caring for my patients? Evidence-Based Medicine Working Group. *JAMA* 277(22), 1802–1806.

26.5 Development of the liver interactome: mapping the regulatory networks

Mario Pagano, Susana Neves, Ravi Iyengar and John Cijiang He

Summary

Cellular functions arise from the ability of components within the cell to interact with one another and thus act in a coordinated and regulated manner. Signalling networks that receive and process both extracellular and intracellular signals are essential for the regulation of cellular functions. The cellular interactome is composed of proteins, nucleic acids, lipids, complex carbohydrates, metabolites and ions. To develop the liver interactome and predictive models of liver function, we need first to construct the interactome for hepatocytes, Kupffer cells and stellate cells in the liver. Here, we review the signalling pathways and networks that are present in the major cell types of the liver and the functions they are responsible for. We consider current genomic and proteomic approaches to experimentally define the components and interactions in liver cells. We describe both qualitative and quantitative computational approaches to study such interacting systems and suggest an integrated experimental and computational approach that can help us to develop and analyse the liver interactome.

Introduction

Understanding the function of organs in terms of cellular and molecular functions would be a major advance in medical sciences, because it would allow us to develop detailed computer models of organ function that can be used to analyse pathophysiologies and predict approaches to treatments and possibly complications that may arise as diseases progress. To get to a stage where we can build such predictive models of organ function, we need first to build predictive models of cellular function. Such models should be able to explain how cellular functions arise from interactions between components of a cell. All functions at the cellular level are tightly regulated. This regulation is mediated by intracellular signalling pathways and is both stimulus and cell specific. In the liver, the proliferation of different cells is triggered by different stimuli. In the cells populating the liver, including hepatocytes, hepatic stellate cells (HSCs), Kupffer cells, sinusoidal cells, etc., the coordinated and precise response to a variety of extracellular stimuli reaching the cells is orchestrated by their intracellular signalling networks that enable the cell to process information and mount functional responses such as proliferation, differentiation, synthesis and deposition of extracellular matrix proteins and control of glucose homeostasis, based on the varying cellular needs and stimuli received. Understanding the organization and regulatory capabilities of the signalling networks is the key to the development of functional models of the cell and thus, eventually, organs.

At the cellular level, between the stimulus and the expression of cellular function are the signalling pathways that mediate the responses to the various stimuli. This is accomplished by the intracellular propagation of the signal through its primary pathway, the integration with other signalling pathways and the engagement of the cellular machineries that carry out the task. Understanding how signals flow through the interacting signalling pathways and regulate the various cellular machines is a major goal of the developing field of systems biology at the cellular level. There is a considerable amount of information available about the signalling pathways and biological responses in liver cells of various types; however, how the different modes of regulation are integrated to yield cellular function is not well understood. Here, we describe some of the signalling pathways and their interactions relevant to physiological or pathological processes occurring in the liver and then discuss new approaches for studying intracellular signalling networks using emerging experimental and computational technologies that may provide systems level understanding of liver function.

Hepatocyte proliferation

The proliferation of parenchymal hepatocyte cells is stimulated by growth factors produced by the remaining hepatocytes and Kupffer cells, such as epidermal growth factor (EGF), transforming growth factors (TGFs), hepatocyte growth factor (HGF), hormones such as insulin and glucagon, and by cytokines such as tumour necrosis factor (TNF)α and interleukin (IL)-6 [1]. TGF-α and HGF are considered to be two of the most important growth factors that stimulate hepatocyte proliferation. TGF-α

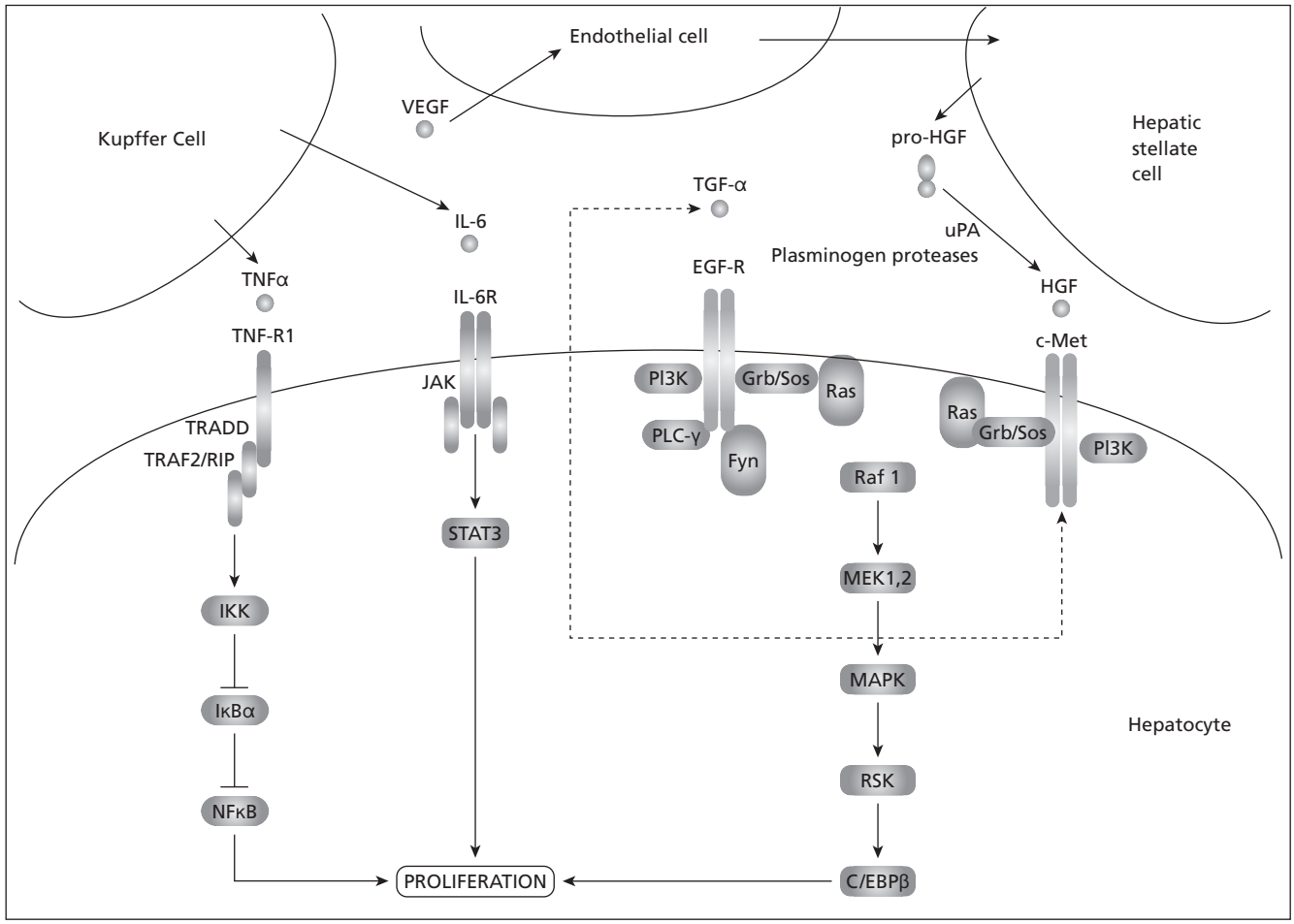

Fig. 1 HGF–TGF-α signalling network. VEGF, vascular endothelial growth factor; HGF, hepatocyte growth factor; uPA, urokinase-type plasminogen activator; c-Met, HGF tyrosine kinase receptor; PI3K, phosphatidylinositol 3-kinase; C/EBPβ, CCAAT/enhancing binding protein-β; EGF-R, epidermal growth factor receptor; TGF-α, transforming growth factor-α; JAK, janus kinase; TNFα, tumour necrosis factor-α; TNF-R1, TNF receptor 1; TRADD, TNF-R1-associated death domain-containing protein; TRAF2, TNF receptor-associated factor 2; IKK, IκB kinase; NFκB, nuclear factor κB; IL-6R, interleukin-6 receptor.

and HGF bind to their receptors, promoting their activation, which leads to the recruitment of several signalling proteins such as Grb2, Sos, Ras, phosphatidylinositol 3-kinase (PI3K), phospholipase C-γ (PLC-γ) and fyn through their SH2 and SH3 domains [2–5].

Vascular endothelial growth factor (VEGF) stimulation of endothelial cells of the hepatic sinusoidal capillaries releases a HGF precursor (pro-HGF) from HSCs, which is activated by cleavage by the urokinase-type plasminogen activator (uPA) and plasminogen proteases [1]. HGF activates its own receptor on the surface of hepatocytes, c-Met, a tyrosine kinase receptor, leading to activation of intracellular signalling pathways involving PI3K, c-AKT/protein kinase B (AKT/PKB), ERK and p70-S6 kinase [6]. The potent mitogenic effect of HGF appears to be mediated by the upregulation of TGF-α, the latter acting by an autocrine mechanism on hepatocytes.

TGF-α is an endogenous ligand for the EGF receptor (EGF-R). The binding of TGF-α to EGF-R activates the Ras–Raf1–MEK–ERK1/2 proteins and the p90-S6 kinase, which phosphorylates C/EBPβ (CCAAT/enhancing binding protein-β) to regulate the expression of genes important for cell proliferation and survival [7–9]. The HGF–TGF-α signalling network is shown in Figure 1.

A number of other factors, mainly the Kupffer cell-derived cytokines TNFα and IL-6, may also play crucial roles in the proliferation of hepatocytes, acting through the activation of janus kinase (JAK) family members and NFκB and STAT3 transcription factors [10]. The interplay between growth factors and cytokines in regulating the growth of the liver, and how this proliferation is controlled to achieve 'normal' liver, remain major unanswered questions. Modelling how the signalling networks in hepatocytes are configured and the balance of regulatory motifs that control and process information flow through these networks could be useful in understanding these systems level questions.

Liver fibrosis and hepatic stellate cell activation

Fibrosis in the liver involves the proliferation of mesenchymal cells possessing a myofibroblast phenotype and the deposition of collagen and other extracellular matrix (ECM) proteins by these cells, leading to progressive scarring and loss of organ function. Upon damage to liver tissue, the HSCs are activated, resulting in the stimulation of their proliferation, motility, contractility and synthesis and deposition of ECM components [11]. These processes are driven by two growth factors, platelet-derived growth factor (PDGF) and TGF-β. The ECM also plays an important role in the regulation of wound healing. PDGF is the main mitogenic factor for cultured HSCs [12], and is secreted by a variety of cell types in response to injury. Binding of PDGF to its receptor (PDGF-R) triggers several intracellular signalling events [13], driven by Tyr phosphorylation and interactions with SH2 and PTB domain-containing molecules [3,14–16]. The response of HSCs to PDGF is subject to modulation during liver injury. PDGF-R has two different isoforms, PDGF-Rα and PDGF-Rβ. PDGF-Rα is expressed in unactivated HSCs, and its expression is unaffected during HSC activation caused by liver injury. In contrast, PDGF-Rβ is undetectable in unactivated HSCs but, upon activation of HSCs, it is upregulated [17,18]. Furthermore, activated HSCs release PDGF that, in an autocrine fashion, stimulates HSC proliferation. Similar effects on PDGF-Rβ expression and cell growth are observed after stimulation with TGF-β1, which is produced by surrounding cells or HSCs themselves [19]. Thus, the presence of PDGF-Rβ may be indicative of a functional autocrine loop.

The proliferative response of HSCs to PDGF also involves the activation of PI3K. Downstream effectors of PI3K are PKC-ζ, p90-S6 kinase and AKT/PKB, the last also having an antiapoptotic effect [20] when the PI3K/c-AKT pathway is activated by insulin-like growth factor 1 (IGF-1), as opposed to PDGF [21]. Differences in the dynamics of signalling activated by PDGF and IGF-1 could account for their different biological actions [22]. The consequences of the complex temporal characteristics of signalling pathways are poorly understood. Such understanding requires a detailed knowledge of the regulatory interface between the signalling network and the cellular machines, and this in turn requires sustained efforts at both the experimental and the theoretical levels.

The TGF-β signalling pathway is a good example of how interactions between signalling pathways determine the actual biological outcome. TGF-β is a cytokine that contributes to the fibrogenic response to organ damage, including in the liver [23]. TGF-β binds to the extracellular portion of TGF-R2, which subsequently dimerizes with TGF-R1 and phosphorylates TGF-R1 on Ser/Thr [24]. Activated TGF-R1, in turn, phosphorylates Smad proteins, which are divided into three categories: R-Smad (Smad2 and Smad3, activated by TGF-R1 phosphorylation), Co-Smad (which function as common partners, like Smad4) and anti-Smad (which inhibit Smad signalling, like Smad7) [30]. Smad4 acts as a Co-Smad by forming dimers with a phosphorylated R-Smad. R-Smad/Smad4 dimers regulate transcription. R-Smad/Smad4 dimers not only bind to Smad-binding elements on target DNA, but also cooperate with other transcription factors (such as AP1) or interact with co-activators (CBP) or co-repressors. Through these interactions at the level of nuclear regulators, the modulation of transcription by TGF-β signalling is integrated with modulation from other signalling pathways. Thus, the biological outcome of the activation of TGF-β signalling is highly influenced by previous, concomitant or temporally subsequent inputs from other signalling pathways of the cellular signalling network.

Another level of integration with the signalling network for TGF-β signalling is achieved through the involvement of the anti-Smad, Smad7. As the promoter of Smad7 carries a Smad-binding element, activation of TGF-β signalling is also followed by the induction of Smad7 gene expression, which, in a negative feedback loop, leads to attenuation of TGF-β signalling. Interestingly, signalling generated from interferon-γ (IFN-γ) antagonizes the TGF-β signalling pathway by inducing Smad7 transcription [25], acting as an antifibrotic factor. This suggests that the regulation of Smad7 expression may set a threshold of responsiveness to TGF-β in the context of Smad-dependent TGF-β signalling.

Smad proteins can also be regulated by MAP kinases [26] in many cell types. Thus, the balance between PDGF and TGF-β signalling can lead to a complex phenotype that involves both proliferative and differentiation-type responses. The potential interactions between the PDGF and TGF-β pathways in regulating liver fibrosis are summarized in Figure 2.

Proteomic and genomic approaches to understanding the integration of liver signalling systems

The biochemical and functional studies over the past four decades to identify the components and the mechanisms of signal transduction in the liver have revealed a great degree of complexity. Part of this complexity arises from the dynamic organization of the signalling network, leading to the formation of information processing motifs. Additionally, our knowledge of the components and interactions are still incomplete. Sustained genomic and proteomic approaches are needed to develop a more complete picture.

Development of maps representing the components and interactions that take place in a given cellular context would be very valuable in developing more complete pictures. This requires the gathering of information on spatial location and temporal and posttranslational modifications of the components in relationship with the interactions they participate in. To develop a complete map of the interactome network, we should be able to answer the kinds of questions that current genomics and proteomics ask. Such questions include: what are the proteins that are expressed in a liver cell under varying physiological

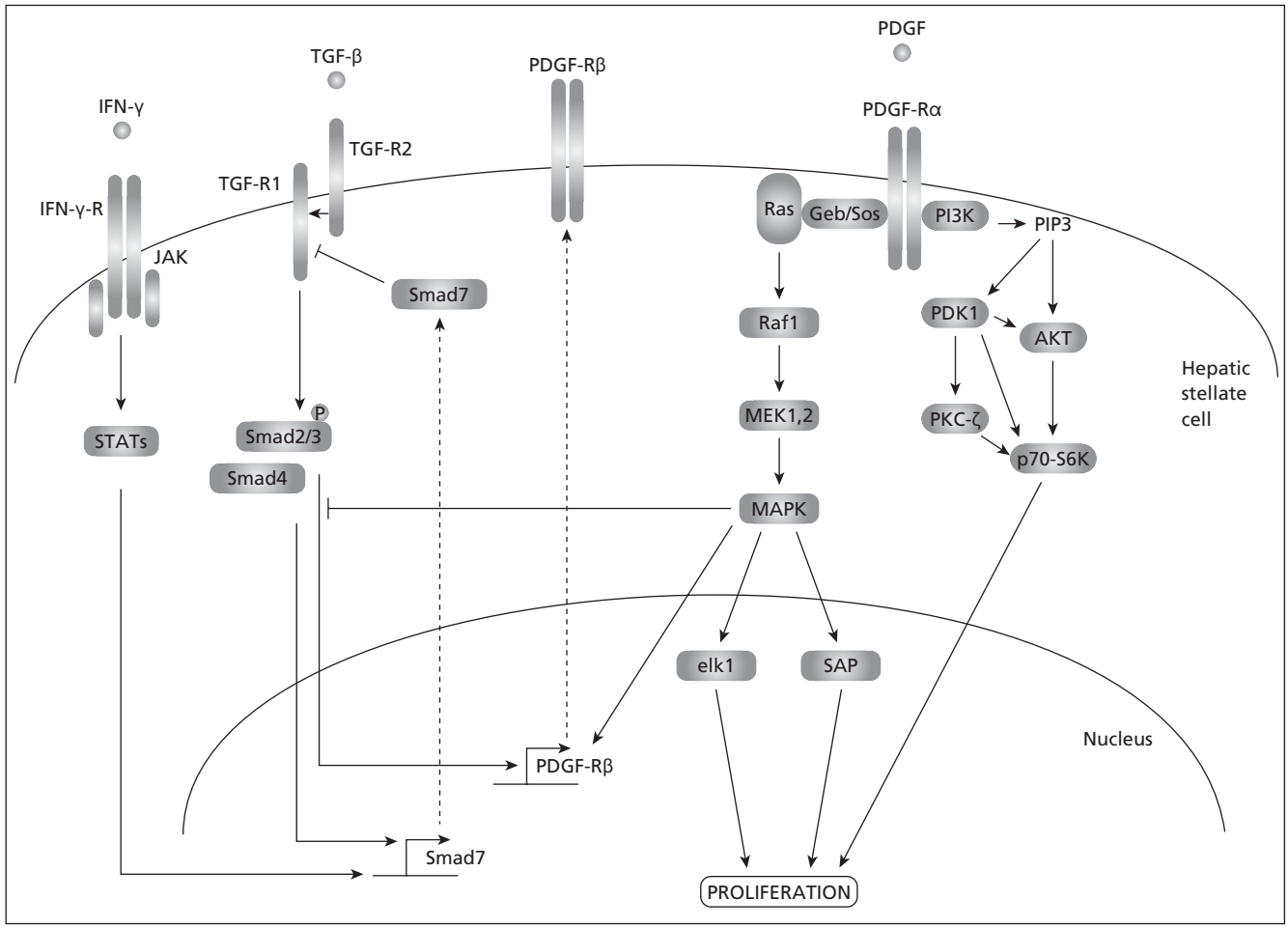

Fig. 2 Interactions between PDGF and TGF-β pathways in regulating liver fibrosis. PDGF, platelet-derived growth factor; PDGF-Rα/β, PDGF receptors α and β; PI3K, phosphatidylinositol 3-kinase; PIP3, phosphatidylinositol-3,4,5-triphosphate; PDK1, phosphoinositide-dependent kinase 1; AKT, protein kinase B (PKB); TGF-β, transforming growth factor-β; TGF-R2 and -R1, type 2 and 1 of TGF-β receptors; IFN-γ, interferon-γ; IFN-γ-R, interferon-γ receptor.

conditions? In which cellular compartment are they expressed and how does this change with changing physiological states? These types of questions imply that these maps need to reflect the dynamic nature of cellular interactions [27].

The completion of sequencing of the human and other genomes, and the progress in annotating the genome should provide us with a definitive number of genes that can serve as a baseline for determining which genes are expressed in which cell and under what conditions. A substantial amount of transcriptional data using microarray analysis are now being accumulated that will provide valuable information about changes in gene expression under different conditions (i.e. normal vs. pathological cell, untreated vs. drug-treated cell). Thus, the microarray data sets will allow us to define cellular dynamics at the transcriptional level but, even though this is very informative, it contributes in a limited way towards understanding the dynamics of cell function, due to the poor correlation in expression levels between mRNA and protein [28]. To obtain reliable information on levels of proteins, large-scale proteomic studies are needed. This is a primary goal of proteomics. However, mass spectrometry, one of the common methods in proteomics, is biased towards the detection of more abundant proteins. It will be essential to develop technologies that can identify and measure changes in protein levels over a thousandfold range, especially for low-abundance proteins. It will also be necessary to identify and catalogue the various posttranslational modifications that proteins undergo, such as phosphorylation, lipid modifications, acetylation, hydroxylation, ubiquitination and methylation. Several of these modifications occur on the same proteins and, at the moment, methods to characterize all these modifications simultaneously are not well developed. Such characterization is necessary because most interactions in the cell are modulated by these posttranslational modifications. Indeed, changes in posttranslational modifications underlie most of the dynamics of cellular interactions.

Proteins exert their function mainly by interacting with other proteins, nucleic acids, lipids and sugars, and modulation of these macromolecular interactions [14,16] is a central mechanism

for regulating function. Thus, there has been an increasing focus on identifying and analysing interactions on a large scale. The efforts have largely focused on lower organisms such as the budding yeast *Saccharomyces cerevisiae* [29–32] and, more recently, investigations have extended to the nematode *Caenorhabditis elegans* [33] and *Drosophila melanogaster* [34,35]. Mapping the protein interaction network requires high-throughput strategies [36]. The approach that has commonly been used to analyse the entire protein interactome on a genome-wide scale is the yeast two-hybrid (Y2H) screen, which is simple, sensitive and adaptable to high-throughput methods. Several studies using yeast two-hybrid approaches have yielded non-overlapping results [29,30], suggesting that the protein interactome is likely to be larger than was thought and that defining the conditions under which the interactions occur could be crucial in both observing and mapping them. It is likely that Y2H screens, coupled with other approaches such as mass spectrometric characterization of complexes as a biochemical characterization of co-purifying proteins [27,30], will provide a fuller picture of the protein interactome.

Even with the limitations in the Y2H approach, interesting organizational details are emerging. The studies performed *in vivo* on the protein interactome network of *S. cerevisiae* by Y2H screening have revealed that a large number of yeast signalling proteins interact with a few partner proteins, while a small number of proteins have many interacting partners [37]. Such proteins capable of large numbers of interactions, termed hubs, may play a key role in the integration between different signalling pathways. Alterations in their function as interactors are likely to damage the network integrity, compared with other proteins with few interactions. Thus, the topology of the yeast interaction network can protect the organism from deleterious changes.

Interesting information on spatiotemporal regulation has been gleaned from a study of the yeast protein–protein interaction network [38]. Combining Y2H studies with mRNA expression profiling indicates that hubs can be split into two distinct populations: hubs whose expression is highly correlated with that of their partners and hubs whose expression is less correlated with that of their partners. The former have been termed 'party hubs', i.e. nodes where the numerous different interactions occur simultaneously, and the latter 'date hubs', nodes where the hub proteins interact with their partners at different times. The authors found that the removal of individual party hubs from the network does not appear to affect connectivity, whereas the targeted removal of date hubs is highly deleterious to the network integrity, resembling the effects observed when attacking all hubs. These findings are compatible with a modular model of network architecture, in which the connections within discrete biological processes (modules) are established and maintained by party hubs, which act as points of aggregation within a single module, representing 'lower level' interactors. Date hubs represent global or 'higher level' connectors between modules, which integrate different modules or subnetworks governing biological processes. Thus, modules responsible for biological processes are organized and kept together by party hubs that function inside modules. Biological processes – or modules – are connected to one another by date hubs, according to the cellular needs and conditions. This model predicts that experimental perturbations of date hubs *in vivo* should confer different effects from perturbations of party hubs. In this respect, such a model could help in understanding the molecular mechanisms of complex diseases where several different biological processes need to be altered for the expression of the diseased state.

Another approach to mapping the protein interactome used identification based on protein recognition modules [39]. Many protein–protein interactions critical for the assembly of complexes and pathways are mediated by peptide recognition modules (domains) [16]. For example, SH2 and PTB domains recognize tyrosine-phosphorylated motifs; SH3 domains recognize proline-rich peptides. The study by Cesareni's group [39] attempted to define the portion of the yeast protein interaction network based on the recognition of proline-rich peptides by SH3 domains. A first map was built by screening a phage display library with most of the yeast SH3 domains. A second map was built by Y2H screening using, as baits, yeast SH3 domains and proline-rich proteins. The overlapping interactions between the two maps were used to draw a SH3-dictated interaction map. The effectiveness of this strategy was shown by the enrichment in literature-validated interactions, suggesting that the overlap network has a significantly higher probability of picking physiologically relevant interactions.

One challenging task in the study of the protein interactome is to understand the temporal characteristics of protein modifications and the extent of the fraction of the protein that interacts with its partners. Mann's group [40] have described a mass spectrometric (MS) approach that allowed them to identify proteins involved in the EGF signalling pathway in HeLa cells, to resolve their temporal involvement and to concomitantly assess their relative quantification. This approach is based on a classical affinity purification of proteins followed by the analysis of their tryptic digests by liquid chromatography–mass spectrometry (LC-MS)/MS. The same authors had previously described a novel strategy that they termed SILAC (stable isotope labelling with amino acids in cell culture), in which an entire cellular proteome is labelled with arginine carrying a stable isotope of carbon, ([^{13}C]-Arg), and the proteins extracted from the ^{13}C-labelled proteome are compared with an identical, but unlabelled, proteome [41]. This approach allows one to compare several conditions, enabling the definition of the temporal characteristics and relative quantification of proteins.

Currently, detailed interaction maps have not been developed for mammalian cell types. This is because, with the different specialized cell types, the first required step is to identify and characterize the genes that are expressed in the cell and how

the products of these genes go on to form the interaction network. Obtaining such experimental data will take some time, although progress is being made on many fronts. Additionally, while interactions between proteins are very important, they constitute only part of the total interactions within the cell. Interactions between proteins and lipids in the cell membrane and proteins and nuclei acids in the nucleus and cytoplasm constitute substantial portions of the total interactions with the cell. We also require a detailed description of the metabolites in the cell and how these metabolites interact with one another and other macromolecules. The global study of cellular metabolites is developing in a distinct area of study called metabolomics. While such an approach will be experimentally necessary because the technologies may have to be adapted to identify and characterize metabolites, at a conceptual level, interactions between metabolites and macromolecules in the cell will have to be considered in an integrated manner if a fuller understanding of the cellular interactome is to be obtained. Even at the level of defining the proteomic interactions in the liver, considerable challenges exist. These have been described in a recent review [42]. Of immediate interest is the development of approaches to characterize disease-induced changes in the liver. Such approaches seem to be most advanced for hepatocellular carcinoma [43], although interaction maps have yet to be built from these studies. It will take some time before studies of the type described above in yeast can be performed for hepatocyte or Kupffer cells. However, as large-scale data-gathering technologies rapidly improve and their application to disease models becomes more standardized, it is becoming apparent that it is only a matter of time before such approaches are applied to the study of liver cells.

The role of computational modelling in building a virtual liver

A major issue in the development of large-scale interaction maps with thousands of components and interactions is the approach that will be used to analyse and understand such a system. It is obvious that the organization and capabilities of such complex systems cannot be understood intuitively and that mathematical analysis will be necessary. Several types of mathematical approaches can be used. Large data sets have traditionally been analysed using statistical methods. This has become a well-developed approach to analysing mRNA expression profiles using microarrays [44]. More recently, such statistical and Bayesian modelling approaches have been used to deduce connectivity within pathways and small networks [45]. Whether such approaches can be used to analyse bigger networks consisting of hundreds of components and thousands of interactions is not yet clear, but nevertheless the approaches do appear to be promising.

At the simplest levels of representation, interactions between components in any cell, including a liver cell, i.e. the liver interactome, can be represented as a network graph. Analysis of network graphs is a well-developed area of mathematics [46]. Network analysis has been applied with great success to physical networks, such as networks of computers, and a variety of biological networks including social networks among humans [47,48]. A number of characteristics of the network can be gleaned from such analysis. These include how many interactions it takes for any other component to reach any other component in the network, how densely the network is interconnected, and the topology that defines the integrity of the network. Recent studies have also shown that it is possible to recognize small recurring patterns of interacting components within such networks. These patterns, which are termed network motifs, provide clues as to how network topology can facilitate the processing of information. Such motifs include long-recognized patterns of connectivity in biochemical systems such as positive and negative feedback loops. Alon's group [49] have also defined two other motifs, the feed-forward motif and the bifan motif, both of which have substantial signal processing capabilities. Members of our laboratory recently developed a model of the neuron as a system of nearly 550 interacting components and 1300 interactions. As a signal propagates through this system from ligand–receptor interactions, an interesting pattern of motifs can be observed. The location and juxtaposition of these motifs with respect to each other was useful in understanding why some ligands that affect this neuron are capable of inducing plasticity while others, although evoking acute responses, allow the neuron to maintain homeostasis. Such analyses provide a relatively simple and useful approach to move from consideration of how individual components are regulated and function to how groups of components may function in a coordinate manner. It would be interesting to determine what types of regulatory patterns emerge when the pathways regulating the key responses by liver cells are combined to form a larger network and analysed by graph theory methods. Overall, such qualitative mathematical analyses will also provide a useful framework for quantitative analyses of larger networks such as the neuronal or liver interactome.

All interactions in all cells, including mammalian cells, arise from chemical reactions that can be represented quantitatively by differential equations such as ordinary or partial differential equations or, in cases where the interactions are stochastic, by appropriate probabilistic representations [50]. All these equations allow for the calculation of the components' change with respect to time and how products may be formed. When many reactions are coupled together, such systems of equations become quite large. Determining how input–output relationships should be studied in such large systems is not immediately obvious. In these situations, the qualitative analyses that identify regulatory motifs can serve as a very useful guide for quantitative simulations. Currently, there are no published examples of how qualitative networks can be parameterized and computed quantitatively; however, it is only a matter of time before such analysis is conducted.

Perspective

Although a lot is known about components and interactions in different types of cells that go to make up the liver, we are not yet at the stage where we can integrate this information to develop predictive models of hepatocytes, Kupffer cells and stellate cells, and integrate these models to develop a functional liver. However, we are at the stage where both the experimental and the theoretical approaches needed are being identified and the enhancements to these approaches are being made at a brisk pace. These advances will allow for the integration of these approaches. At the experimental level, the genomics studies that define the genes that are being expressed under various conditions need to be integrated with proteomics and metabolomics to develop a fuller understanding of all the interactions that occur within each cell type. Such integration will lead to a functional 'interactome', which can be represented as a network made up of interacting components. Qualitative and quantitative analysis of these networks should yield detailed models capable of predicting functional responses. Such predictions can then be utilized to understand how changes in components and interactions lead to pathophysiology and what types of therapeutic interventions can restore the system to the normal physiological state.

References

1 Taub R (2004) Liver regeneration: from myth to mechanism. *Nature Rev Mol Cell Biol* 5(10), 836–847.

2 Marshall CJ (1995) Specificity of receptor tyrosine kinase signaling: transient versus sustained extracellular signal-regulated kinase activation. *Cell* 80(2), 179–185.

3 Cohen GB, Ren R, Baltimore D (1995) Modular binding domains in signal transduction proteins. *Cell* 80(2), 237–248.

4 Hunter T (1995) Protein kinases and phosphatases: the yin and yang of protein phosphorylation and signaling. *Cell* 80(2), 225–236.

5 Diehl AM, Rai RM (1996) Liver regeneration 3: Regulation of signal transduction during liver regeneration. *FASEB J* 10(2), 215–227.

6 Okano J *et al.* (2003) Hepatocyte growth factor exerts a proliferative effect on oval cells through the PI3K/AKT signaling pathway. *Biochem Biophys Res Commun* 309(2), 298–304.

7 Buck M, Chojkier M (2003) Signal transduction in the liver: C/EBPbeta modulates cell proliferation and survival. *Hepatology* 37(4), 731–738.

8 Buck M, Poli V, van der Geer P *et al.* (1999) Phosphorylation of rat serine 105 or mouse threonine 217 in C/EBP beta is required for hepatocyte proliferation induced by TGF alpha. *Mol Cell* 4(6), 1087–1092.

9 Buck M, Poli V, Hunter T *et al.* (2001) C/EBPbeta phosphorylation by RSK creates a functional XEXD caspase inhibitory box critical for cell survival. *Mol Cell* 8(4), 807–816.

10 Leu JI, Crissey MA, Leu JP *et al.* (2001) Interleukin-6-induced STAT3 and AP-1 amplify hepatocyte nuclear factor 1-mediated transactivation of hepatic genes, an adaptive response to liver injury. *Mol Cell Biol* 21(2), 414–424.

11 Pinzani M, Marra F (2001) Cytokine receptors and signaling in hepatic stellate cells. *Semin Liver Dis* 21(3), 397–416.

12 Pinzani M, Gesualdo L, Sabbah GM *et al.* (1989) Effects of platelet-derived growth factor and other polypeptide mitogens on DNA synthesis and growth of cultured rat liver fat-storing cells. *J Clin Invest* 84(6), 1786–1793.

13 Claesson-Welsh L (1994) Platelet-derived growth factor receptor signals. *J Biol Chem* 269(51), 32023–32026.

14 Pawson T (2004) Specificity in signal transduction: from phosphotyrosine-SH2 domain interactions to complex cellular systems. *Cell* 116(2), 191–203.

15 Pawson T (2003) Organization of cell-regulatory systems through modular-protein-interaction domains. *Philos Transact A Math Phys Eng Sci* 361(1807), 1251–1262.

16 Pawson T, Nash P (2003) Assembly of cell regulatory systems through protein interaction domains. *Science* 300(5618), 445–452.

17 Pinzani M *et al.* (1996) Expression of platelet-derived growth factor and its receptors in normal human liver and during active hepatic fibrogenesis. *Am J Pathol* 148(3), 785–800.

18 Bonner JC (2004) Regulation of PDGF and its receptors in fibrotic diseases. *Cytokine Growth Factor Rev* 15(4), 255–273.

19 Pinzani M *et al.* (1995) Transforming growth factor-beta 1 regulates platelet-derived growth factor receptor beta subunit in human liver fat-storing cells. *Hepatology* 21(1), 232–239.

20 Datta SR, Brunet A, Greenberg ME (1999) Cellular survival: a play in three Akts. *Genes Dev* 13(22), 2905–2927.

21 Issa R *et al.* (2001) Apoptosis of hepatic stellate cells: involvement in resolution of biliary fibrosis and regulation by soluble growth factors. *Gut* 4 (4), 548–557.

22 Jones SM, Klinghoffer R, Prestwich GD *et al.* (1999) PDGF induces an early and a late wave of PI 3-kinase activity, and only the late wave is required for progression through G1. *Curr Biol* 9(10), 512–521.

23 Bataller R, Brenner DA (2005) Liver fibrosis. *J Clin Invest* 115(2), 209–218.

24 Bissell DM, Roulot D, George J (2001) Transforming growth factor beta and the liver. *Hepatology* 34(5), 859–867.

25 Piek E, Heldin CH, Ten Dijke P (1999) Specificity, diversity, and regulation in TGF-beta superfamily signaling. *FASEB J* 13(15), 2105–2124.

26 Leask A, Abraham DJ (2004) TGF-beta signaling and the fibrotic response. *FASEB J* 18(7), 816–827.

27 Simpson RJ, Dorow DS (2001) Cancer proteomics: from signaling networks to tumor markers. *Trends Biotechnol* 19(10 Suppl.), S40–48.

28 Pandey A, Mann M (2000) Proteomics to study genes and genomes. *Nature* 405(6788), 837–846.

29 Uetz P *et al.* (2000) A comprehensive analysis of protein–protein interactions in *Saccharomyces cerevisiae*. *Nature* 403(6770), 623–627.

30 Ito T, Chiba T, Ozawa R *et al.* (2001) A comprehensive two-hybrid analysis to explore the yeast protein interactome. *Proc Natl Acad Sci USA* 98(8), 4569–4574.

31 Gavin AC *et al.* (2002) Functional organization of the yeast proteome by systematic analysis of protein complexes. *Nature* 415(6868), 141–147.

32 Ho Y *et al.* (2002) Systematic identification of protein complexes in *Saccharomyces cerevisiae* by mass spectrometry. *Nature* 415(6868), 180–183.

33 Li S *et al.* (2004) A map of the interactome network of the metazoan *C. elegans*. *Science* 303(5657), 540–543.

34 Giot L *et al.* (2003) A protein interaction map of *Drosophila melanogaster*. *Science* 302(5651), 1727–1736.

35 Uetz P, Pankratz MJ (2004) Protein interaction maps on the fly. *Nature Biotechnol* 22(1), 43–44.

36 Cagney G, Uetz P, Fields S (2000) High-throughput screening for protein–protein interactions using two-hybrid assay. *Methods Enzymol* 328, 3–14.
37 Jeong H, Mason SP, Barabasi AL *et al.* (2001) Lethality and centrality in protein networks. *Nature* 411(6833), 41–42.
38 Han JD *et al.* (2004) Evidence for dynamically organized modularity in the yeast protein–protein interaction network. *Nature* 430(6995), 88–93.
39 Tong AH *et al.* (2002) A combined experimental and computational strategy to define protein interaction networks for peptide recognition modules. *Science* 295(5553), 321–324.
40 Blagoev B, Ong SE, Kratchmarova I *et al.* (2004) Temporal analysis of phosphotyrosine-dependent signaling networks by quantitative proteomics. *Nature Biotechnol* 22(9), 1139–1145.
41 Ong SE *et al.* (2002) Stable isotope labeling by amino acids in cell culture, SILAC, as a simple and accurate approach to expression proteomics. *Mol Cell Proteomics* 1(5), 376–386.
42 Parent R, Beretta, L (2005) Proteomics in the study of liver pathology. *J Hepatol* 43(1), 177–183.
43 Chignard N, Beretta L (2004) Proteomics for hepatocellular carcinoma marker discovery. *Gastroenterology* 127(5 Suppl. 1), S120–125.
44 Ochs MF, Moloshok TD, Bidaut G *et al.* (2004) Bayesian decomposition: analyzing microarray data within a biological context. *Ann NY Acad Sci* 1020, 212–226.
45 Sachs K, Perez O, Pe'er D *et al.* (2005) Causal protein-signaling networks derived from multiparameter single-cell data. *Science* 308(5721), 523–529.
46 Yook SH, Jeong H, Barabasi AL (2002) Modeling the Internet's large-scale topology. *Proc Natl Acad Sci USA* 99(21), 13382–13386.
47 Barabasi AL (2005) The origin of bursts and heavy tails in human dynamics. *Nature* 435(7039), 207–211.
48 Dodds PS, Muhamad R, Watts DJ (2003) An experimental study of search in global social networks. *Science* 301(5634), 827–829.
49 Milo R, Shen-Orr S, Itzkovitz S *et al.* (2002) Network motifs: simple building blocks of complex networks. *Science* 298(5594), 824–827.
50 Gillespie DT (1977) Exact stochastic simulation of coupled chemical reactions. *J Phys Chem* 8(25), 2340–2361.

27 Appendices

27.1 Geographic distribution of infections causing liver disease

Harriet Hughes and Tom Doherty

The following pages contain tabulated data on the frequency of the important hepatic infections in different parts of the world. Because disease surveillance does not exist for most of these infections nor for the diseases that they may cause, the information is largely based on serological or parasitological surveys. The data may hide marked variation between different geographical groups and between social groups within the country. Thus, although malaria occurs in both Kenya and Argentina, almost every child on the Kenyan coast will experience at least one attack of malaria during each rainy season, while, in Argentina, malaria transmission is confined to one small area in the north of the country. Equally, not everyone in a specific geographical location is at risk of contracting a particular disease: people on package tours to Kenya are at relatively low risk of contracting schistosomiasis when compared with fishermen earning their livelihood from Lake Malawi.

'Frequency' is used to indicate the risk of infection between different countries, i.e. between rows in the table. The scale used for different diseases varies, so comparisons cannot be made between diseases, i.e. across the columns. The information can be used in two ways. First, it gives some indication of which infectious liver diseases exist in each country. Second, it gives some idea of the potential risk associated with travel to the country, risk that is influenced by behaviour. Hepatitis A is an ubiquitous virus, but people are only affected in conditions where standards of sanitation are poor. In general, hepatitis B and C can only be contracted through sexual contact or transfusion of blood products, although, in much of Africa and Asia, hepatitis B is transmitted from child to child by an unknown route. Yellow fever is a sporadic infection in Latin America; in Africa, it occurs in epidemics in urban areas.

The data were compiled from various sources: the Centre for Disease Control in Atlanta, Georgia, United States, publishes annual handbooks containing advice for international travellers: the World Health Organization and World Bank publish annual reports; one invaluable book is *A World Guide to Infections* by Mary E. Wilson (Oxford: Oxford University Press, 1991).

In each table, + + implies the disease is common; + implies it is quite frequent; ± implies it occurs but is rare; – implies that the infection is not recognized as an important hazard; and ? implies that the information is not available.

Abbreviations included in the tables

HAV	hepatitis A virus
HBV	hepatitis B virus
HCV	hepatitis C virus
HEV	hepatitis E virus
Mal	malaria
SM	*Schistosoma mansoni*
Schisto	schistosomiasis (S. *haematobium, S. japonicum* or *S. mansoni*)
Lep	leptospirosis
YF	yellow fever
CS	*Clonorchis sinensis*
VL	visceral leishmaniasis
Hyd	hydatid disease (*Echinococcus granulosus*)
EH	*Entamoeba histolytica*

Table 1 Frequency of infectious liver diseases in Africa.

	EH	HAV	HBV	HCV	HEV	Hyd	Lep	VL	Mal	SM	YF
Algeria	++	++	+	+	+	++	+	+	+	±	–
Angola	++	++	++	+	+	+	+	±	++	++	+
Benin	++	++	++	+	+	+	+	–	++	++	+
Botswana	++	++	++	+	+	±	+	–	+	+	–
Burkina Faso	++	++	++	+	+	+	+	±	++	++	+
Burundi	++	++	++	+	+	+	+	–	++	++	+
Cameroon	++	++	++	+	+	+	+	±	++	++	+
Cape Verde	++	++	++	+	+	–	+	–	+	+	+
Central African Republic	++	++	++	+	+	+	+	±	++	++	+
Chad	++	++	++	+	+	+	+	+	++	++	+
Comoros	++	++	++	+	+	–	+	–	+	+	+
Congo	++	++	++	+	+	+	+	–	++	++	+
Côte d'Ivoire	++	++	++	+	+	+	+	–	++	++	+
Democratic Republic of the Congo (formerly Zaire)	++	++	++	+	+	+	+	±	++	++	+
Djibouti	++	++	++	+	+	+	+	+	++	++	±
Egypt	++	++	++	++	+	+	+	+	+	++	–
Equatorial Guinea	++	++	++	+	+	+	+	–	++	++	+
Eritrea	++	++	++	+	+	+	+	++	++	++	±
Ethiopia	++	++	++	+	+	++	+	++	+	++	±
Gabon	++	++	++	+	+	+	+	–	++	++	+
Gambia	++	++	++	+	+	+	+	–	++	++	+
Ghana	++	++	++	+	+	+	+	–	++	++	+
Guinea	++	++	++	+	+	+	+	–	++	++	+
Guinea Bissau	++	++	++	+	+	+	+	+	++	++	+
Kenya	++	++	++	+	+	++	+	++	++	++	±
Lesotho	++	++	++	+	+	+	+	–	–	+	–
Liberia	++	++	++	+	+	+	+	–	+	+	+
Libya	++	++	++	+	++	+	+	+	±	+	–
Madagascar	++	++	++	+	+	+	+	–	+	+	–
Malawi	++	++	++	+	+	+	±	++	++	++	–
Mali	++	++	++	+	+	+	+	–	++	++	+
Mauritania	++	++	++	+	+	+	+	–	+	+	–
Mauritius	++	++	++	+	+	+	+	–	+	+	+
Morocco	++	++	++	+	+	++	+	±	±	±	–
Mozambique	++	++	++	+	+	+	+	±	++	++	–
Namibia	++	++	++	+	+	+	+	–	+	+	–
Niger	++	++	++	+	+	+	+	±	++	++	+
Nigeria	++	++	++	+	+	+	+	±	++	++	+
Rwanda	++	++	++	+	+	+	+	±	++	++	+
Sao Tomé and Principe	++	++	++	+	+	+	+	–	++	+	+
Senegal	++	++	++	+	+	+	+	–	++	++	+
Seychelles	++	++	++	+	+	+	+	–	–	–	–
Sierra Leone	++	++	++	+	+	+	+	–	++	++	+
Somalia	++	++	++	+	+	++	+	++	++	++	+
South Africa	++	++	++	+	+	+	+	–	+	++	–
Sudan	++	++	++	+	+	+	+	++	++	++	±
Swaziland	++	++	++	+	+	+	+	–	+	++	–
Tanzania	++	++	++	+	+	+	+	±	++	++	±
Togo	++	++	++	+	+	+	+	–	++	++	+
Tunisia	++	++	++	+	+	++	+	+	–	±	–
Uganda	++	++	++	+	+	+	+	±	++	++	±
Western Sahara	++	++	++	+	+	+	+	?	±	+	–
Zambia	++	++	++	+	+	+	+	±	++	++	+
Zimbabwe	++	++	++	+	+	+	+	–	++	++	–

Table 2 Frequency of infectious liver diseases in the Americas.

	EH	HAV	HBV	HCV	HEV	Hyd	Lep	VL	Mal	SM	YF
Anguilla	±	+	+	+	?	–	+	–	–	–	–
Antigua	±	+	+	+	?	–	+	–	–	+	–
Argentina	+	+	+	+	?	++	+	±	±	–	–
Aruba	+	+	+	+	?	–	+	–	–	–	–
Bahamas	+	+	+	+	?	–	+	–	–	–	–
Barbados	±	+	+	+	?	–	+	–	–	–	–
Belize	+	+	+	+	?	–	++	–	+	–	–
Bermuda	±	+	+	+	?	–	+	–	–	–	–
Bolivia	+	+	+	+	?	+	+	±	+	–	±
Brazil	+	+	+	+	?	+	++	+	+	+	±
British Virgin Islands	±	+	+	+	?	–	+	–	–	–	–
Canada	±	+	+	+	–	+	±	–	–	–	–
Cayman	±	+	+	+	?	–	±	–	–	–	–
Chile	+	+	+	+	+	+	+	–	–	–	–
Columbia	+	+	+	+	?	+	+	±	+	–	±
Costa Rica	+	+	+	+	?	±	+	–	+		–
Cuba	+	+	+	+	?	–	+	–	–	–	–
Dominica	+	+	+	+	?	–	+	–	–	–	–
Dominican Republic	+	+	+	+	?	–	+	–	+	+	–
Ecuador	+	+	+	+	?	+	±	±	+	–	±
El Salvador	+	+	+	+	?	+	+	+	+	–	–
Falkland Islands	±	+	+	+	?	–	+	–	–	–	–
French Guiana	±	+	+	+	?	–	+	–	–	–	–
Greenland	±	+	+	+	?	–	+	–	–	–	–
Grenada	+	+	+	+	?	–	++	–	–	–	–
Guadeloupe	+	+	+	+	?	–	+	–	–	–	–
Guatemala	+	+	+	+	?	+	+	±	+	–	–
Guyana	+	+	+	+	?	–	+	–	–	–	–
Haiti	++	+	+	+	?	±	+	–	+	–	–
Honduras	+	+	+	+	?	+	+	±	+	–	–
Jamaica	+	+	+	+	?	–	++	–	–	–	–
Martinique	±	+	+	+	?	–	+	–	–	–	–
Mexico	++	+	+	+	+	+	+	+	+	–	–
Montserrat	±	+	+	+	?	–	+	–	–	–	–
Netherlands Antilles	±	+	+	+	?	–	+	–	–	–	–
Nicaragua	+	+	+	+	?	–	+	+	+	–	–
Panama	+	+	+	+	?	–	+	–	+	–	±
Paraguay	+	+	+	+	?	–	+	±	+	–	±
Peru	+	+	+	+	?	+	±	±	+	–	±
Puerto Rico	±	+	+	+	–	–	±	–	–	–	±
St Kitts and Nevis	±	+	+	+	?	–	+	–	–	–	–
St Lucia	±	+	+	+	?	–	+	–	–	–	–
St Vincent and the Grenadines	±	+	+	+	?	–	+	–	–	–	–
Surinam	±	+	+	+	?	–	+	±	+	+	±
Trinidad and Tobago	+	+	+	+	?	–	++	–	–	–	±
Turks and Caicos	±	+	+	+	?	–	±	–	–	–	–
United States	±	+	+	+	–	+	±	–	–	–	–
Uruguay	+	+	+	+	?	+	+	–	–	–	–
Venezuela	+	+	+	+	?	+	+	±	+	±	±
Virgin Islands	±	+	+	+	?	–	±	–	–	–	–

Table 3 Frequency of infectious liver diseases in Asia and Australasia.

	EH	HAV	HBV	HCV	HEV	Hyd	VL	Mal	Schisto	CS
Afghanistan	+	+	+	+	+	+	±	+	–	–
Australia	–	±	±	+	–	±	–	–	–	–
Bangladesh	++	++	+	+	+	+	+	+	–	–
Bhutan	++	++	+	+	+	+	±	+	–	–
Brunei	+	+	+	+	+	–	–	–	–	
Cambodia	+	++	++	+	+	±	–	+	±	+
China	+	+	++	+	+	+	±	±	±	+
East Timor	+	++	++	+	+	–	–	+	±	+
Fiji	+	+	+	+	?	–	–	–	–	–
Hong Kong	±	+	++	+	?	–	–	–	–	+
India	++	++	+	+	+	+	+	+	+	–
Indonesia	++	++	++	+	+	±	–	+	+	+
Japan	±	+	+	++	+	–	–	–	–	+
Kampuchea	+	+	+	+	+	±	±	+	+	+
Korea (North)	+	+	++	+	+	–	–	–	–	+
Korea (South)	+	+	++	+	+	–	–	–	–	+
Laos	+	+	++	+	+	±	–	+	+	+
Malaysia	+	+	+	+	+	–	–	+	+	+
Maldives	+	++	++	+	+	–	–	–	–	–
Melanesia	+	++	++	+	+	–	–	+	–	–
Mongolia	±	+	+	+	+	+	±	–	–	–
Micronesia	+	+	+	+	+	–	–	+	–	–
Myanmar	+	++	++	+	+	±	±	+	–	+
Nepal	++	++	+	+	+	+	+	+	–	–
New Caledonia	+	++	++	+	+	–	–	–	–	–
New Zealand	–	±	±	+	–	±	–	–	–	–
Pakistan	++	++	+	+	+	+	±	+	–	–
Papua New Guinea	++	++	++	+	+	–	–	++	–	–
Philippines	+	++	+	+	+	±	–	+	+	+
Polynesia	+	++	++	+	+	–	–	+	–	–
Singapore	+	++	+	+	++	–	–	–	+	+
Solomon Islands	+	++	++	+	+	–	–	++	–	–
Sri Lanka	+	++	+	+	+	+	–	+	–	–
Taiwan	±	+	++	+	+	+	–	–	–	+
Thailand	+	++	++	+	+	±	–	+	±	+
Tonga	+	++	++	+	+	–	–	–	–	–
Vanuatu	+	++	++	+	+	–	–	++	–	–
Vietnam	+	+	++	+	+	±	–	+	–	+

Table 4 Frequency of infectious liver diseases in the Middle East.

	EH	HAV	HBV	HCV	HEV	Schisto	Mal	Hyd
Bahrain	+	+	+	+	+	–	–	±
Cyprus	+	+	+	+	+	–	–	++
Democratic Yemen	+	+	+	+	+	±	+	±
Iran	+	+	+	+	+	+	+	+
Iraq	+	+	+	+	+	+	+	++
Israel	+	+	+	+	+	–	–	+
Jordan	+	+	+	+	+	±	–	+
Kuwait	+	+	+	+	+	–	–	±
Lebanon	+	+	+	+	+	±	–	+
Oman	+	+	+	+	+	±	+	±
Qatar	+	+	+	+	+	–	–	±
Saudi Arabia	+	+	+	+	+	+	±	+
Syria	+	+	+	+	+	+	±	++
Turkey	+	+	+	+	+	±	+	++
United Arab Emirates	+	+	+	+	+	–	±	±
Yemen	+	++	++	+	+	+	+	±

Table 5 Prevalence of infectious liver diseases in Europe.

	EH	HAV	HBV	HCV	HEV	Hyd	Lep	VL	Mal
Albania	–	+	?	?	?	+	+	±	–
Armenia	–	±	±	±	–	–	–	–	–
Austria	–	±	±	±	–	–	–	±	–
Azerbaijan	–	±	++	±	+	+	+	–	±
Belarus	–	±	±	±	–	–	–	–	–
Belgium	–	±	±	±	–	–	–	–	–
Bosnia-Herzegovina	–	±	±	+	–	+	+	±	–
Bulgaria	–	±	++	±	–	–	+	±	–
Croatia	–	±	±	±	–	+	+	±	–
Czech Republic	–	±	±	±	–	+	+	±	–
Denmark	–	±	±	±	–	–	–	–	–
Estonia	–	±	±	±	–	–	+	–	–
Finland	–	±	±	±	–	–	–	–	–
France	–	±	±	±	–	±	+	±	–
Georgia	–	±	±	±	–	–	–	–	–
Germany	–	±	±	±	–	–	–	–	–
Gibraltar	–	±	+	+	–	–	+	±	–
Greece	–	±	+	+	–	+	+	±	–
Hungary	–	±	±	+	–	±	+	±	–
Iceland	–	±	±	±	–	–	–	–	–
Ireland	–	±	±	±	–	–	–	–	–
Italy	–	+	±	±	–	+	+	±	–
Kazakhstan	–	+	++	±	+	++	+	–	–
Kyrgyzstan	–	+	++	±	+	+	+	–	–
Latvia	–	±	±	±	–	–	–	–	–
Liechtenstein	–	±	±	±	–	–	–	–	–
Lithuania	–	±	±	±	–	–	–	–	–
Luxembourg	–	±	±	±	–	–	–	–	–
Macedonia	–	±	±	±	–	–	–	–	–
Malta	–	±	±	±	–	–	+	±	–
Moldova	–	±	++	±	–	–	+	–	–
Netherlands	–	±	±	±	–	–	–	–	–
Norway	–	±	±	±	–	–	–	–	–
Poland	–	±	±	±	–	±	–	–	–
Portugal	–	+	±	±	–	+	+	±	–
Romania	–	+	++	±	–	+	+	–	–
Russia	–	±	±	±	–	–	+	–	–
Serbia	–	±	±	±	–	+	+	±	–
Slovakia	–	±	±	±	–	+	+	±	–
Slovenia	–	±	±	±	–	+	+	±	–
Spain	–	+	±	+	–	+	+	±	–
Sweden	–	±	±	±	–	–	–	–	–
Switzerland	–	±	±	±	–	–	–	–	–
Tajikistan	–	+	++	±	+	+	–	–	±
Turkmenistan	–	+	++	±	+	+	–	–	–
Ukraine	–	±	±	±	–	–	–	–	–
Uzbekistan	–	+	++	±	+	+	–	–	–
United Kingdom	–	±	±	±	–	–	±	–	–

27.2 Liver injury in man ascribed to non-drug chemicals and natural toxins

Regine Kahl and Wim Wätjen

Explanation of abbreviations

Column B

I Cross-sectional study

(a) With control group; verification of exposure by:
detection of the chemical at the workplace
and/or detection of the chemical in body fluids/tissues
and/or presence of specific signs of intoxication
(b) With control group; verification of exposure by anamnesis
(c) Without control group; verification of exposure as Ia
(d) Without control group; verification of exposure as Ib

II Screening at the workplace

(a) With control group
(b) Without control group

III Case report

IV Retrospective study

(a) Case–control study
(b) Without control
(c) Cohort mortality study

V Report on epidemic outbreak

VI Register of cases

VII Report on correlation between disease incidence and exposure in large populations

Persons

In general this indicates number of persons exposed. A figure followed by an asterisk indicates total number of persons in the study.

Column D

One or several of the liver function tests indicated were abnormal. Abbreviations are used as below:

ALP = alkaline phosphatase
bili = bilirubin
BSP = sulphobromophthalein excretion
GlDH = glutamate dehydrogenase
GOT = serum glutamate oxalacetate (aspartate aminotransferase)
GPT = serum glutamate pyruvate (alanine aminotransferase)
GGT = γ-glutamyl transpeptidase
ICG = indocyanine green clearance
LDH = lactate dehydrogenase
LFT = liver function tests
OCT = ornithine carbamoyl transferase
SDH = sorbitol dehydrogenase
thymol = thymol turbidity test positive
# = Biopsy or autopsy (diagnosis mostly as stated by the authors).

Column E

(a) Suggested by study protocol.
(b) Observed during the course of an acute disease for which other major causes were not obvious.
(c) Exposure history positive; chemical detected in body fluids/tissues and/or other specific signs of intoxication present. Other causes not excluded.
(d) Exposure history positive. Other causes not excluded.
(e) Very rare event in general population.
(f) Relief upon cessation of exposure.
(g) Recurrence on re-exposure.
(h) No causal relationship obvious.

A Chemical or natural toxin	B Type of study (no. of persons)	C Exposure	D Diagnosis (no. of persons)	E Causal relationship	F Reference
Acetone[1]	III (1)	Chronic/occupational Acetone recycling	bili	b, f	Sack, *Arch Gewerbepath Gewerbehyg*, 1941; 10:80
Acrylonitrile	Ia (102)	Chronic/occupational Acrylic fibre factory	Palpable liver (20%, control 13%) LFTs normal	a	Sakurai, *Br J Ind Med*, 1941; 35:219
Aflatoxin B_1	V (26)	Acute/alimentary Ingestion of mouldy rice	Palpable liver	b	Ling, *J Formosan Med Ass*, 1967; 66:517
	(397)	Ingestion of mouldy corn	Jaundice Bile duct proliferation Periportal fibrosis#	b	Krishnamachari, *Lancet*, 1975; i:1061
	III (1)	Ingestion of mouldy cassava	Diffuse necrosis#	b	Serck-Hanssen, *Arch Environ Hlth*, 1970; 20:729
	(1)	Ingestion of mouldy rice	Reye syndrome[2] Fatty liver#	d	Bourgois, *J Med Ass Thai*, 1969; 52:553
	IVb (23)	Ingestion of mouldy food	Reye syndrome	d	Shank, *Food Cosm Tox*, 1971; 9:501
	III (1)	Ingestion of contaminated oil	Hepatomegaly GOT, GPT Microvesicular steatosis# Encephalopathy; Reye syndrome	d	Sinniah, *Am J Gastr*, 1982; 77:158
	VII	Chronic/alimentary	Hepatocellular carcinoma	d	Alpert, *Cancer*, 1971; 28:253 Peers, *Int J Canc*, 1976; 17:167 Peers, *Br J Canc*, 1973; 27:473 Shank, *Food Cosm Tox*, 1972; 10:61 Shank, *Food Cosm Tox*, 1972; 10:71 van Rensburg, *SA Med J*, 1974; 48:2508 Keen, *Trop Geog Med*, 1971; 23:35 Campbell, *JNCI*, 1974; 52:1647
Allyl chloride	IIb (60)	Chronic/occupational Allyl chloride production	bili, thymol, GOT, GPT, LDH, GDH, SDH	d, f	Häusler, *Arch Toxicol*, 1968; 23:209
Amanita phalloides	III (5)	Acute/alimentary Ingestion	GOT, GPT, LDH, ALP, bili, massive necrosis#	b, f	Harrison, *Am J Med*, 1965; 38:787
	III (8)		GOT, GPT Centrilobular necrosis#	b, f	Wepler, *Hum Path*, 1972; 3:249
	III (1)		GOT, GPT, LDH	b	Plotzker, *Am J Med Sci*, 1982; 283:79
	IVb (205)		Maximal values measured on day 2 of intoxication (means of 205 patients) GOT 1634; GPT 1599; LDH 1649; bili 5.6	b	Floersheim, *Sch Med Woch*, 1982; 112:1164
Aniline	III (1)	Chronic/suicidal Ingestion	Acute degenerative changes#	b	Janik-Kurylcio, *Pol Tyg Lek*, 1973, 28:1241

Arsenic[3]	III (1)	Chronic/medicinal	Portal hypertension#	c	Knolle, *D Med Woch*, 1974; 99:903
	(2)	Fowler's solution			Morris, *Gastro*, 1974; 64:86
	(1)				Chainuvati, *Dig Dis Sci*, 1979; 24:70
	(1)				Cowlishaw, *Aust NZ J Med*, 1979; 9:310
	IVb (220)	Chronic/occupational	Hepatomegaly (70%)	d	Harren, *Deutsch Arch Klin Med*, 1943; 190:31
		Vintners	Cirrhosis (20%?)		
	(15)		Cirrhosis#	c	Liebegott, *D Med Woch*, 1949; 74:855
	(82)		Cirrhosis (28)#	d	Roth, *Zbl Allg Path*, 1960; 100:34
	IVb (220)		Primary liver cell carcinoma (3)#	c	Liebegott, *D Med Woch*, 1949; 74:855
	III (1)	Chronic/occupational		c	Jhaveri, *Br J Ind Med*, 1959; 16:248
		Arsenic plant			
	(1)	Chronic/medicinal		c	Cowlishaw, *Aust NZ J Med*, 1979; 9:310
		Fowler's solution			
	IVb (82)	Chronic/occupational	Haemangioendothelioma#	c, d, e	Roth, *Zbl Allg Path*, 1960; 100:34
		Vintners			Roth, *Z Krebsf*, 1957; 61:468
	III (1)	Chronic/medicinal		c, d, e	Regelson, *Cancer*, 1968; 21:514
		Fowler's solution			
	IVb (20)	Chronic/occupational	Angiosarcoma (2)#	c, d, e	Falk, *Am J Ind Med*, 1981; 2:43
		Vintners	Primary liver cell carcinoma (4)#		
	(16)	Chronic/environmental		c, d, e	Zaldívar, *Arch Toxicol*, 1981; 47:145
		Polluted drinking water			
	(163)	Chronic/occupational	Liver tumours (5)	d, e	Lüchtrath, *J Canc Res Clin Onc*, 1983; 105:173
		Vintners			
	IVa	Chronic/environmental	Liver tumours	d, e	Chen, *Br J Canc*, 1986; 53:399
		Polluted drinking water			
Arsine	III (1)	Acute/occupational	GOT, GPT, bili	b	Hesdorfer, *Br J Ind Med*, 1986; 43:353
Benzidine/β-naphthylamine	IVc (3322)	Chronic/occupational	Excess risk for cancer of liver, gall bladder, bile duct (3 vs. 0.35)	a	Morinaga, *Am J Ind Med*, 1982; 3:243
		Not specified			
Benzene[1]	IVb (65)	Chronic/occupational	GGT, GOT, GPT, ALP	h[4]	Bittersohl, *Z Ges Hyg*, 1985; 31:168
		Chemical industry	Steatosis, cirrhosis#		
		Shoe fabrication			
Beryllium	IVb (20)	Chronic/occupational	Granuloma (2)#	d	Dutra, *Am J Path*, 1948; 24:1137
		BeO alloys	Centrilobular necrosis (1)#		
		Ore reduction			
	(60)	Chronic/occupational	Hepatomegaly, BSP (12)	c, d	Stoeckle, *Am J Med*, 1969; 46:545
		Fluorescent lamp manufacture; experimental work; X-ray tube manufacture; Be extraction; Be alloys; aircraft industry	Granulomatous infiltration (2)#		
	III (1)	Chronic/environmental	Focal necrosis	h	DeNardi, *Am J Med*, 1949; 7:345
		Patient lived near Be plant			
Biphenyl	III/Ic (31)	Acute + chronic/occupational	Acute dystrophy (1)#	d	Häkkinen, *Arch Environ Hlth*, 1973; 26:70
		Fruit paper production	Incipient cirrhosis (1)#		
			Fatty metamorphosis (2)#		

A Chemical or natural toxin	B Type of study (no. of persons)	C Exposure	D Diagnosis (no. of persons)	E Causal relationship	F Reference
Boron hydrides	IVb (137*)	Acute or chronic/occupational	BSP (28); thymol (21); ALP (11)	d	Lowe, *Arch Ind Hlth*, 1957; 16:524
p-tert-Butylphenol (PTBH)	III (3)	Chronic/occupational PTBH production	Minor parenchymal changes (1)# GOT, GPT slightly; Mild steatosis (2)#	d	Rodermund, *Hautarzt*, 1975; 26:312
	IIa (12)	Chronic/occupational PTBH handling; experimental work; solvent use	BSP (10)	d	Goldmann, *Hautarzt*, 1976; 27:155
Cadmium	III (1)	Chronic/occupational Gold melting	Steatosis, fibrosis, cirrhosis#	c	Kaufmann, *Leb Mag Darm*, 1984; 14:103
Carbamate insecticide (isolan)	III (8)	Chronic/occupational/suicidal Pesticide use	bili, BSP LFTs abnormal	b	Lutterotti, *Med Welt*, 1961; 12:2430
Carbon disulphide[5] (CS_2)	IVb	Chronic/occupational Spinning shop; CS_2 plant	Hepatomegaly (21%) Takata-Ara positive (75%)	d	Lysina, in: Brieger, ed., *Toxicology of Carbon Disulphide*, Amsterdam: Excerpta Medica Foundation, 1967: 179
Carbonyl nickel	IVb (5)	Acute/occupational Decanting, distillation	Hepatomegaly (3)	b, f	Kötzing, *Arch Gewerbepath Gewerbehyg*, 1933; 4:500
	III (1)		Postnecrotic cirrhosis#	d	Castano, *Med Lav*, 1973; 64:401
Chlordecone (kepone)	Ic (133)	Chronic/occupational Chlordecone production	Hepatomegaly (9 of 23 persons with signs of intoxication)	c	Taylor, *Neurology*, 1978; 28:626
	(32)		Hepatomegaly (20) Minimal fatty metamorphosis, mild portal inflammatory changes, proliferation of smooth endoplasmic reticulum (12)# Glucaric acid excretion Antipyrine clearance	c, f	Guzelian, *Gastro*, 1980; 78:206
Chromium	III (5)	Chronic/occupational Chromium-plating factory	Icterus index, flocculation test, thymol, BSP; Toxic hepatitis#	c	Pascale, *JAMA*, 1952; 149:1385
Cooking oil[6]			Mild to moderate abnormalities (3)#		
Copper sulphate	IVb (53)	Acute/accidental + suicidal Ingestion	Jaundice (11)	b	Chuttani, *Am J Med*, 1965; 39:849
	(30)	Chronic/occupational Vineyard sprayers	Kupffer cell proliferation (30), granuloma (7), fibrosis (8), cirrhosis (3), portal hypertension (2)# Angiosarcoma (1)#	d	Pimentel, *Gastro*, 1977; 72:275
	Ib (161)	Chronic/occupational Grape-garden sprayers	Hepatomegaly (7) ALP (16) Granuloma (1 of 7 biopsies)	d, e	Habibullah, *J Assoc Phys Ind*, 1981; 29:735
Cyanamide[7]	VIb (9)	Chronic/medicinal Therapy of alcohol abuse	Alcohol intolerance PAS-positive ground-glass hepatocytes#	d	Bruguera, *Liver*, 1987; 7:216

Cytostatics	III (3)	Chronic/occupational Nurses	GPT, ALP Portal hepatitis (1)# Fibrosis, fat accumulation (2)#	d, f	Sotaniemi, *Acta Med Scand*, 1983; 214:181
1,2-Dibromoethane	III (1)	Acute/suicidal Ingestion	Aminotransferase, ALP, bili Flocculation test + massive necrosis#	b	Olmstead, *Arch Ind Hlth*, 1960; 21:525
Dichlorodiphenyl-trichloroethane (DDT)[8]	III (1)	Acute/accidental Ingestion	Centrilobular necrosis#	b[9]	Smith, *JAMA*, 1948; 136:469
	(1)	Acute/occupational Disinfection	Hepatomegaly bili, thymol, flocculation test	b, f	Klingemann, *Ärztl Wschr*, 1949; 4:465
	III (5)	Chronic/occupational Wood protection Pesticide bagging and application	GPT, GOT Steatosis (1)# Cirrhosis (2)# Chronic hepatitis (1)#	d[10]	Schüttmann, *Int Arch Gewerbepath* Gewerbehyg, 1968; 24:193
1,2-Dichloroethane[1]	III (2)	Acute/accidental Ingestion	bili Steatosis (1)#	d, f	Bloch, *Sch Med Woch*, 1946; 42:1078
	(2)	Acute/occupational Repair of dichloroethane pipeline	Jaundice Steatosis, necrosis#	b	Brass, *D Med Woch*, 1949; 74:553
	(1)	Acute/accidental Ingestion	Steatosis	b	Hubbs, *JAMA*, 1955; 159:673
	(4)	Acute/occupational Paint application	Hepatomegaly bili, coagulation band	b, f	Menschik, *Arch Gewerbepath Gewerbehyg*, 1957; 15:241
	(1)	Acute/suicidal Ingestion	Acute dystrophy	b	Martin, *D Med Woch*, 1968; 93:2002
	(1)	Acute/accidental Ingestion	bili, ALP, LDH, GOT Midzonal necrosis#	b	Yodaiken, *Arch Environ Hlth*, 1973; 26:281
	(1)	Acute/occupational Tank cleaning	GOT, GPT, OCT, LDH Centrilobular necrosis#	b	Nouchi, *Int Arch Occup Envir Hlth*, 1984; 54:111
Dichlorohydrin	III (1)	Acute/occupational Tank cleaning	Fatal fulminant hepatitis	b	Shiozaki, *Hum Exp Toxicol*, 1994; 13:267
Dichloropropanol	III (2)	Acute/occupational Tank cleaning	Fatal hepatic failure Submassive hepatic necrosis#	b	Haratake, *Liver*, 1993; 13:123
1,3-Dichloropropene	III (41)	Acute/accidental Leak from tank due to a traffic accident	GOT, GPT (11)	b	Gosselin, *Clinical Toxicology of Commercial Products*. Baltimore: The Williams and Wilkins Co, 1976: 119
Diethylene glycol	V (14)	Acute/medicinal Ingestion of contaminated glycerol	Centrilobular necrosis#	b	Pandya, BM, 1988; 297:117
Dimethylacetamide[1]	Id (41)	Chronic/occupational Acrylic fibre factory	BSP (63%)	d	Corsi, *Med Lav*, 1971; 62:28
+1,2-ethanediamine		Acute/occupational Inhalation and dermal exposure	bili, GPT, GOT, LDH, prothrombin	b, f	Marino, *J Occ Med*, 1994; 36:637
Dimethyl formamide[1,11]	III (1)	Acute/occupational Solvent use	bili, GPT, GOT, BSP	b, f	Weiss, *Zbl Arb Med*, 1971; 21:345
	(1)	Acute/occupational Urethane fabric coating	bili, GPT, GOT	b, f	Potter, *Arch Environ Hlth*, 1973; 27:340
	(1)	Acute/occupational Solvent use	bili, GPT, GOT, ALP	b, f	Paoletti, *Min Med*, 1982; 73:3407

A Chemical or natural toxin	B Type of study (no. of persons)	C Exposure	D Diagnosis (no. of persons)	E Causal relationship	F Reference
	(12)	Acute/occupational Polyacrylonitrile production	Hepatomegaly (4) Jaundice (4) Alcohol intolerance (4) GPT, GOT (6)	b, f	Reinl, *Int Arch Gewerbpath Gewerbehyg*, 1965; 21:333
	Id (58)	Chronic/occupational Solvent use in fabric coating	GPT, GOT (62%) Alcohol intolerance (12) Microvesicular/mixed steatosis (3 of 4 biopsies)	d, f	Redlich, *Ann Int Med*, 1988; 108:680
	Ia (100)	Chronic/occupational	GGT	a	Cirla, *G Ital Med Lav*, 1984; 6:149
1,2-Dimethylhydrazine	IIb (11)	Chronic/occupational Chemical laboratory storing and handling	Flocculation test +	d	Shook, *Ind Med Surg*, 1957; 56:333
	(1193)	Chronic/occupational Liquid rocket propellant	SGPT (46) Fatty degeneration (6 of 26 biopsies)	d	Petersen, *Br J Ind Med*, 1970; 27:141
m-Dinitrobenzene	III (1)	Chronic/occupational Dinitrobenzene handling	Hepatomegaly, icterus	b	Ishihara, *Int Arch Occup Envir Hlth*, 1976; 36:161
	(2)	Acute/occupational Dinitrobenzene production	Hepatomegaly (1) bili (2), thymol, ALP (1)	b, f	Beritic, *Br J Ind Med*, 1956; 13:114
Dinitro-*o*-cresol		Acute/occupational Not specified	Jaundice bili, ALP	b, f	Gaultier, *J Eur Tox*, 1974; 7:9
Dinitrotoluene	IIb (154)	Chronic/occupational Not specified	Jaundice (2)	d	McGee, *Am J Dig Dis*, 1942; 9:329
Dioxane[1]	III (5)	Subacute/occupational	Centrilobular necrosis#	b	Barber, *Guy's Hosp Rep*, 1934; 84:267
	(1)	Solvent use	Centrilobular necrosis#	b	Johnston, *Arch Ind Hlth*, 1959; 20:445
Diphenyl	III (1)	Chronic/occupational Impregnated paper	GPT, GOT, GGT, ALP Inflammatory infiltrate#	d, f	Carella, *J Occ Med*, 1994; 36:575
Ethylene chlorohydrin	III (1)	Acute/occupational Solvent use	Areas of necrotic liver cells#	b	Dierker, *J Ind Hyg Tox*, 1944; 26:277
	(1)	Acute/occupational Solvent use	Severe fatty infiltration	b	Bush, *J Ind Hyg Tox*, 1949; 31:352
	(1)	Acute/occupational Rupture of a storage tank	bili, ALP, BSP, thymol Sporadic liver cell necroses and microvesicular steatosis#	b, f	Bleckat, *Int Arch Gewerbepath Gewerbehyg*, 1968; 25:45
	(1)	Acute/accidental Ingestion	Liver cell necrosis#	b	Miller, *Arch Dis Child*, 1970; 45:589
Ethylene glycol	III (2)	Acute/accidental Ingestion	Hydropic degeneration#	b	Smith, *A M A Arch Path*, 1951; 51:423
Ethylene glycol monomethyl ester	III (1)	Acute/accidental Ingestion	Fatty degeneration#	b	Young, *J Ind Hyg Tox*, 1946; 28:267
Germander (*Teucrium chamaedrys*)	III (7)	Subacute/medicinal For weight loss	bili, GPT, GOT Hepatocyte necrosis (3)#	d, f, g	Larrey, *Ann Int Med*, 1992; 117:129

	(826)	Subacute/medicinal For weight loss	bili, GPT, GOT	d, f, g	Castot, *Gastr Clin Biol*, 1992; 16??
Glue thistle (*Actractylis gummifera*)	III (10)	Acute/accidental Ingestion	bili, GOT, GPT	b, f	Lemaigre, *Nouv Presse Med*, 1975; 4:2865
Hexachlorobenzene	V (>600)	Chronic/accidental Ingestion of contaminated wheat	Porphyria cutanea tarda	d	Schmid, *NEJM*, 1960; 263:397
γ-Hexachlorocyclohexane (γ-HCH)	III (1)	Acute/experimental	bili	b, f	Schmiedeberg, *Anz Schaed*, 1953; 26:129
	IVb (3)	Chronic/occupational Pesticide use γ-HCH production	GPT, GOT Cirrhosis, mixed steatosis (2)# Chronic hepatitis, Fibrosis (1)#	d	Schüttmann, *Int Arch Gewerbepath Gewerbehyg*, 1968; 24:193
Hexafluorodichlorobutene (HFCB)	IVb (3)	Acute/occupational HFCB production	bili, BSP Centrilobular necrosis#	b	Bertrand, *Poumon Coeur*, 1970; 26:941
Hornet's venom	III (1)	Acute/occupational Multiple hornet stings (child)	Hepatomegaly bili, ALP, GGT, GOT, GPT, NH_3, encephalopathy Microvesicular steatosis#	b, f	Weizman, *Gastro*, 1985; 89:1407
Hydrazines[12]	IVb (140)	Chronic/occupational Missile propellant handling	thymol, GPT (22) Fatty metamorphosis (2 of 3 biopsies)#	d	King, *Aerospace Med*, 1969; 40:315
Kerosene	IVb (3)	Chronic/occupational Fuel handling	Hepatomegaly GPT, GOT, bili, BSP	d, f	Veljkov, *Medicinski Arhiv*, 1982; 36:19
Lead	III (4)	Acute/accidental Injection	GOT, ALP Hepatitis#	b	Beattie, *Scot Med J*, 1979; 24:318
	(1)	Chronic/occupational Battery work-up	Nuclear inclusions Microvesicular steatosis#	c, f	Klinge, *Acta Hepatosplenol*, 1970; 17:151
	Ia (135)	Chronic/occupational Metallurgic plant Tile manufacture Battery production Wire production Paint application	thymol, GPT, ALP (15)	a	Kosmider, *Zbl Arb Med*, 1967; 17:170
	III (1)	Acute/accidental Ingestion of red lead	bili, ALP, GOT, GPT, LDH	b, f	Nortler, *Vet Hum Tox*, 1980; 22:145
Manganese	III (1)	Subacute/occupational Loading manganese ore	Hepatomegaly Takata positive	b, f	Ceresa, *Med Lav*, 1951; 42:26
	(1)	Acute/suicidal Ingestion of potassium permanganate	BSP, LDH, ALP, GOT Mild fibrosis#	b, f	Lustig, *Arch Int Med*, 1982; 142:405
Mercury vapour	Ia (20)	Chronic/occupational Chemical laboratories	bili, thymol, GPT, ALP (4)	a	Kosmider, *Zbl Arb Med*, 1967; 17:170
	III (1)	Chronic/occupational Mercury distillation	Cirrhosis#	d	Martini, *Zacchia*, 1972; 8:31
	Ia (83)	Chronic/occupational Chlorine and acetaldehyde production	SDH (48%), GPT (28%), GOT (10%), ALP (8%), bili (17%), Fatty degeneration, Kupffer cell proliferation, inflammatory infiltration (15 of 17 biopsies)	a	Pach, *Mat Med Pol*, 1985; 53:23

A Chemical or natural toxin	B Type of study (no. of persons)	C Exposure	D Diagnosis (no. of persons)	E Causal relationship	F Reference
2-Methyl-4-chlorophenoxyacetic acid (MCPA)	III (1)	Chronic/occupational Pesticide application	GPT, GOT Liver cell necrosis, steatosis#	d, f[13]	Lun, *Z Klin Med*, 1986; 41:859
Methylenedianiline (4,4′-diamino-diphenylmethane)	V (84)	Acute/alimentary Contaminated bread (Epping jaundice)	Jaundice bili, ALP, GOT Cellular infiltration, cholestasis, damage to liver parenchyma, cholangitis#	b, f	Kopelman, *BMJ*, 1966; i:514
	IIb (6)	Acute/occupational Epoxy resin application	GPT, GOT, bili Cholestasis (1)#	d	Williams, *NEJM*, 1974; 291:1256
	IVb (13)	Acute/occupational Use of epoxy resin hardener	Jaundice bili, ALP, GOT	b, f	McGill, *NEJM*, 1974; 291:278
	III (1)	Acute/occupational Not specified	Jaundice ALP, GPT, GOT Cholestasis, toxic hepatitis#	b, f	Brooks, *JAMA*, 1979; 242:1527
	(1)	Acute/accidental Ingestion	Jaundice bili, GOT	b	Roy, *Hum Tox*, 1985; 4:61
	(4)	Acute/occupational Laying an epoxy resin-based floor	Jaundice bili, ALP, GOT	b, f, g	Bastian, *Med J Aust*, 1984; 141:533
Monobromoethane (methyl bromide)	III (2)	Acute/accidental Leakage from a defective insecticide cannister	Hepatomegaly NH_3 (2), bili (1), GOT, GPT, LDH (1)	b	Shield, *Neurology*, 1977; 27:959
	Ic (33)	Chronic/occupational Soil disinfection in greenhouses	ALP (2), GPT, GOT (1) Correlation between GOT, GPT and bromine in blood (GOT, GPT not exceeding upper limit in 32)	a	Verberk, *Br J Ind Med*, 1979; 36:59
Monochloromethane (methyl chloride)	IVb (29)	Acute/accidental/occupational Refrigerators	Icterus index; beginning fatty degeneration (1)#	b	Kegel, *JAMA*, 1929; 93:353
	III (2)	Acute/occupational Repair of air-conditioning plant	Jaundice, icterus index (1)	b	Weinstein, *JAMA*, 1937; 108:1603
	(4)	Acute/accidental Refrigerator	bili	b	Spevak, *Br J Ind Med*, 1976; 33:272
	(1)	Acute/occupational Refrigeration engineer	Coproporphyrinuria	b	Chalmers, *Lancet*, 1940; ii:806
	III (1)	Chronic/occupational Refrigeration	thymol, ALP Cirrhosis#	d	Wood, *Lancet*, 1951; 260:508
	(1)		Hepatomegaly bili, ALP, thymol	d, f	Mackie, *Med J Aust*, 1961; 48:203
	(1)		Porphyria cutanea tarda Cirrhosis	h[14]	Leurini, *Med Lav*, 1982; 73:571

Mucochloric acid (2,3-dichloro-4-oxo-2-butenoic acid)	IIb (3)	Chronic/occupational Pyramin (weedkiller) production	Hepatomegaly	d, f	Kolesár, *Bratisl Lek Listy*, 1975; 64:132
Nickel	IVc (28261)	Chronic/occupational Production of high nickel alloys	Excess risk of primary liver cancer (SMR for males 1.82, $P < 0.01$)	a	Redmond, *IARC Sci Publ*, 1984; 53:73
	(814)		Excess risk of primary liver cancer (SMR 3.87)	a	Cragle, *IARC Sci Publ*, 1984; 53:57
2-Nitropropane[1,15]	III (1)	Acute/occupational Paint application	Jaundice GOT, GPT, ALP Centrilobular degenerative hepatitis#	b	Gaultier, *Arch Mal Prof*, 1964; 25:425
	IVb (4)		Hepatomegaly, jaundice Hepatic failure GPT, GOT, LDH, ALP Centrilobular necrosis, fatty degeneration	b[16]	Hine, *J Occ Med*, 1978; 20:333
	III (1)		GOT, GPT, LDH, GIDH Acute hepatitis#	b[17]	Rondia, *Vet Hum Tox*, 1979; 21:183
	III (2)	Acute/occupational Resin application	Hepatomegaly, hepatic failure, massive necrosis (1) GOT (1)	b[18]	Harrison, *Ann Int Med*, 1987; 107:466
Paraquat	III (2)	Acute/accidental/suicidal Ingestion	Centroacinar necrosis#	b	Bullivant, *BMJ*, 1966; i:1272
	(1)			b	Campbell, *Lancet* 1968; i:144
	(1)			b	Bronkhorst, *Ned T Geneesk*, 1968; 112:310
	(1)		Liver epithelium degeneration#	b	Duffy, *J Irish Med Ass*, 1968; 61:97
	(1)		Fatty liver epithelium degeneration#	b	Oreopoulos, *BMJ*, 1968; i:749
	(1)			b	Fenelly, *BMJ*, 1968; iii:722
	(1)		Intrahepatic cholestasis#	b	Matthew, *BMJ*, 1968; iii:759
	(1)		Fatty epithelium degeneration, slight cholestasis#	b	Tilling, *D Med Woch*, 1968; 93:2439
	(1)		Liver cell necroses#	b	Lanzinger, *Münch Med Woch*, 1969; 111:944
	(1)		Cholestasis#	b	McDonagh, *Arch Dis Child*, 1970; 45:425
	(1)		Centroacinar necrosis, microvesicular steatosis#	b	von der Hardt, *Klin Wschr*, 1971; 49:544
	(1)		bili, ALP, GOT, GPT	b	Hargreave, *Postgrad Med J*, 1969; 45:633
	(1)	Acute/occupational Herbicide application	Hepatomegaly bili, GPT, GOT	h	Guardascione, *Fol Med*, 1969; 52:728
	IVb (14)	Acute/accidental/suicidal Ingestion	Jaundice (5) Centrilobular steatosis, centrilobular necrosis (6)#	b	Parkinson, *Histopath*, 1980; 4:171
	(14)		Jaundice GOT, GPT, LDH, ALP, bili fatty metamorphosis (6)#, focal (5) or central (3) necrosis# Bile duct injury (3)# Portal inflammation (6)# Portal fibrosis (3)#	b	Matsumoto, *Acta Path Jpn*, 1980; 30:859

A Chemical or natural toxin	B Type of study (no. of persons)	C Exposure	D Diagnosis (no. of persons)	E Causal relationship	F Reference
Parathion	IVb (4)	Acute/occupational/accidental Pesticide application Ingestion	bili, BSP (1)	b	Lutterotti, *Med Welt*, 1961; 12:2430
Pennyroyal oil (pulegone)	III (1)	Acute/accidental Ingestion	bili, ALP, GOT, GPT, LDH Centrilobular necrosis#	b	Sullivan, *JAMA*, 1979; 242:2873
Pentachlorophenol (PCP)[19,20]	III (10)	Chronic/occupational PCP production	thymol, coagulation band	d	Baader, *Ind Med Surg*, 1951; 20:286
	IVb (80)	Chronic/occupational Herbicide production	Porphyria cutanea tarda (11) δ-aminolaevulinic acid and uroporphyrin excretion bili, GPT, GOT (11)	c	Jirásek, *Hautarzt*, 1976; 27:328
	Ia (23)	Chronic/occupational PCP production	GIDH (10)	a	Zober, *Int Arch Occ Envir Hlth*, 1981; 48:347
	Id (1107)	Chronic/occupational Sawmill workers	Liver-related symptoms by questionnaire	d	Sterling, *Int J Hlth Serv*, 1982; 12:559
	III (1)	Chronic/environmental Wood preservative	GOT, GPT, GGT, LDH, GIDH	g	Brandt, *Ver Dtsch Ges Inn Med*, 1977; 83:1609
'Pesticides'[21]	Id (200)	Chronic/occupational Pesticide factory	Hepatomegaly (30%) GOT, GPT, GGT, ALP (40%) Steatosis (2/4), fibrosis (1/4), cirrhosis (1/4)#	d	Del Monte, *G Clin Med*, 1979; 60:624
	IIb (27)	Chronic/occupational	Follow-up: histological signs of liver damage ameliorated by concomitant cessation of exposure reduction of alcohol intake weight reduction	f	Erhardt, *Dtsch Gesundhwesen*, 1981; 36:265
	IVb (14)	Chronic/occupational	Angiosarcoma	h, e	El Zayadi, *Hepatogast*, 1986; 33:148
Petroleum distillates	III (1)	Acute/accidental Ingestion	GPT, ALP, GGT	b, f	Janssen, *Intens Care Med*, 1988; 14:238
Phenol	III (1)	Chronic/occupational Laboratory	Hepatomegaly GOT, GPT, LDH	d, f	Merliss, *J Occ Med*, 1972; 14:55
1-Phenyl-4,5-chloropyridason-6	IIb (4)	Acute/occupational Pyramin (weedkiller) production	Hepatomegaly GPT, LDH	d, f	Kolesár, *Bratisl Lek Listy*, 1975; 64:132
Phosphorus	IVb (56)	Acute/suicidal Ingestion	Jaundice (20)	b	Díaz-Rivera, *Medicine*, 1950; 29:269
	(45)	Acute/accidental Firecrackers Rat poison	Fatty change, necrosis[22] Portal fibrosis#	b	Salfelder, *Beitr Path*, 1972; 147:321
	(49)	Firecrackers	Fatty change, hydropic degeneration#	b	Marin, *NEJM*, 1971; 284:125
Polybrominated biphenyls (PBB)	Id	Chronic/occupational Soil contamination	Coproporphyrinuria Chronic hepatic porphyria	d	Doss, *Ann NY Acad Sci*, 1987; 514:204

Polychlorinated biphenyls (PCB)[23]	V	Subacute/alimentary Ingestion of contaminated rice oil[24] (Yusho, Japan 1968)	Jaundice LFTs abnormal	c	Reggiani, *Envir Hlth Perspect*, 1985; 60:225[25] Kimbrough, *Ann Rev Pharm Tox*, 1987; 27:87[25]
	V (829)	(Yu-cheng, Taiwan 1979)	GOT, GPT, ALP	c	Lü, *Am J Ind Med*, 1985; 5:81
	Ib (69)	Yu-cheng	δ-aminolaevulinic acid and uroporphyrin excretion	d	Chang, *Res Comm Chem Path Pharm*, 1980; 30:547
	Ic (80)	Chronic/occupational Electrical capacitor manufacture	Hepatomegaly, GOT, GPT, GGT, OCT (16)	c	Maroni, *Br J Ind Med*, 1981; 38:55
	(458)	Chronic/alimentary Ingestion of contaminated fish	Correlation between serum PCB and GGT	a	Kreiss, *JAMA*, 1981; 245:2505
	Ia (228)	Chronic/occupational Electrical capacitor manufacture	Correlation between serum PCB and GOT, GGT (values within normal range)	a	Smith, *Br J Ind Med*, 1982; 39:361
	Ia (120*)		Correlation between serum PCB and GOT	a	Chase, *J Occ Med*, 1982; 24:109
	(67)		Porphyrinuria	a	Colombi, *J Appl Tox*, 1982; 2:117
	Ic (97)		ALP (11%). No correlation with PCB concentration in blood	d	Hara, *Envir Hlth Perspect*, 1985; 59:85
	(326)		Correlation between log LDH and log PCB (female) log GGT and log HPCB (male)[26] (values mostly within normal range) Follow-up: increased prevalence of abnormal GGT after 2.5 years	d	Fischbein, *Envir Hlth Perspect*, 1985; 60:145
	(194)		Correlation between serum PCB and GGT	d	Lawton, *Envir Hlth Perspect*, 1985; 60:165
	IVc (2567)		Excess mortality for liver cancer (3 vs. 1.07, NS)	a	Brown, *Arch Envir Hlth*, 1981; 36:120
	(120)	Subacute/accidental (Yusho)	Excess mortality for liver cancer Males: 9 vs. 1.61 Females: 2 vs. 0.66 (NS) Excess mortality for chronic liver disease and cirrhosis (NS)	a	Kuratsune, *Chemosphere*, 1987; 16:2085
Polychloroprene	III (1)	Chronic/occupational Neoprene application	Angiosarcoma	e	Infante, *Envir Hlth Perspect*, 1977; 21:251
Pyrrolizidine alkaloids	IVb (6)	Chronic/alimentary Ingestion of contaminated food	Centrilobular haemorrhagic necrosis, occlusion of hepatic veins#[27]	d	Selzer, *Br J Exp Path*, 1951; 32:14
	(100*)	Ingestion of bush tea possibly contaminated with *Senecio* spp.	Occlusion of hepatic veins (5)[27] cirrhosis (4)#	h	Bras, *Arch Pathol*, 1954; 57:285
	III (2)	Chronic/medicinal Ingestion of folk medicine	Hepatomegaly, ascites Centrilobular blood lagoons, occlusion of hepatic veins, cell necroses#[27]	f	Gupta, *BMJ*, 1963; i:1184
	V (67)	Chronic/alimentary Ingestion of cereals contaminated with *Crotolaria* spp.	Hepatomegaly, ascites GOT, GPT, ALP Centrilobular haemorrhagic necrosis, occlusion of hepatic veins#[27]	d	Tandon, *Lancet*, 1976; ii:271

A Chemical or natural toxin	B Type of study (no. of persons)	C Exposure	D Diagnosis (no. of persons)	E Causal relationship	F Reference
	(21)	Ingestion of wheat bread contaminated with *Heliotropium* spp.	Hepatomegaly, ascites GPT, ALP Centrilobular haemorrhagic necrosis, occlusion of hepatic veins#[27]	d, f	Mohabbat, *Lancet*, 1976; ii:269
	III (1)	Chronic/medicinal Ingestion of contaminated tea	Hepatomegaly, ascites ALP Centrilobular necrosis, occlusion of hepatic veins#[27]	d	McGee, *J Clin Path*, 1976; 29:788
	(1)	Ingestion of tea contaminated with *Crotolaria* spp.	Ascites ALP, GOT Sublobular hepatic vein obstruction#[27]	d, f	Lyford, *Gastro*, 1976; 70:105
	(1)	Ingestion of tea contaminated with *Senecio* spp.	Hepatomegaly, distended abdomen GOT Distended sinusoids; 2 months later extensive fibrosis#[27]	d	Stillman, *Gastro*, 1977; 73:349
	(4)	Ingestion of contaminated tea	Hepatomegaly, ascites GOT, ALT, bili Centrilobular haemorrhagic necrosis#[27]	d, f	Kumana, *Lancet*, 1983; ii: 1360
Silicon dioxide	IVa (440)	Chronic/occupational	Uroporphyrinogen excretion (12; unexposed controls: 4/1362)	d	Hykes, *Cas Lek Cesk*, 1981; 120:1190
Styrene[1]	Ic (23)	Chronic/occupational Processing of storage pipes	Serum bile acids (11)	d	Edling, *Br J Ind Med*, 1984; 41:257
	(493)	Chronic/occupational Styrene polymerization	GGT	d	Lorimer, *Sca J Work Envir Hlth*, 1978; 4(Suppl.2):220
	IIa (35)	Chronic/occupational Manufacture of glass fibre-reinforced plastic products	GOT, GPT (8; 2/12 in controls); ALP (5; 1/12 in controls)	d	Axelson, *Sca J Work Envir Hlth*, 1978; 4(Suppl.2):215
2,3,7,8-Tetrachlorodibenzo-*p*-dioxin (TCDD)[28]	Ic (226)	Acute/accidental Explosion in TCP plant (Nitro, W.Virginia 1949)	GGT in persons with chloracne (as compared with persons without chloracne)	c	Moses, *Am J Ind Med*, 1984; 5:161
	(14)	(Derbyshire 1973)	thymol, zinc turbidity, GPT (9)	c, f	May, *Br J Ind Med*, 1973; 30:276
	(42)	(Ludwigshafen 1953)	Takata positive, thymol (4) Subacute hepatitis, slight steatosis (1)	c	Goldmann, *Arbmed Sozmed Arbhyg*, 1972; 7:12
	(1029)	(Seveso 1976)	GGT, GOT, GPT (10%)	c	Homberger, *Ann Occup Hyg*, 1979; 22:327
	(1654)		Hepatomegaly (8-10%) GOT, GPT, GGT	c	Pocchiari, *Ann NY Acad Sci*, 1979; 311[29]
	(164)		GPT, GGT (in children with chloracne as compared with those without chloracne)	c	Caramaschi, *Int J Epid*, 1981; 10:135

	Ia/b (31)		D-glucaric acid excretion[30] (in children with chloracne as compared with those without chloracne; 1976)	c	Ideo, *C C Acta*, 1982; 120:273
	(67)		D-glucaric acid excretion (vs. control; 1979)		
	III (2)		Porphyria cutanea tarda	d	Doss, *Ann NY Acad Sci*, 1987; 514:204
	IVb (55)	Chronic/occupational 2,4,5-T[31] production	Porphyria cutanea tarda (11) bili, thymol, GPT, BSP (11) Steatosis, periportal fibrosis#	d	Pazderova, *Arch Envir Hlth*, 1981; 36:5
	Id (154)	Chronic/environmental Soil contamination in mobile home park	Subclinical differences in LFTs	a	Stehr-Green, *Arch Envir Hlth*, 1988; 43:174
1,1,2,2-Tetrachloroethane[1]	III (1)	Acute/occupational Solvent use	Jaundice Subacute necrosis#	b	Willcox, *Lancet*, 1931; ii:57
	(277)	Chronic/occupational Solvent use	Palpable liver (55)	d, f	Gurney, *Gastro*, 1943; i:1112
Tetrachloroethylene[1,32]	III (1)	Acute/occupational Dry cleaning	Acute hepatitis Centrilobular liver-cell degeneration#	b, f	Meckler, *JAMA*, 1966; 197:144
	(1)	Solvent use	Mild hepatitis GOT	b, f	Stewart, *JAMA*, 1969; 208:1490
	(1)	Dry cleaning	bili, GOT, GPT Centrilobular necrosis#	b	Trense, *Zbl Arb Med*, 1969; 19:131
	(1)	Subacute/occupational Dry cleaning	Acute hepatitis	d	Hughes, *JAMA*, 1954; 156:234
	(1)	Breast feeding[33]	Jaundice bili, GOT, ALP	d, f	Bagnell, *Can Med Ass J*, 1977; 117:1047
	Id (7)	Chronic/occupational Degreasing	bili, BSP, flocculation (3)	d	Coler, *Arch Ind Hyg*, 1953; 8:227
	Ia (113)	Dry cleaning	bili, thymol increased vs. control (values mostly within normal range)	a	Franke, *Med Welt*, 1969; 20:453
Tetrachloromethane[1] (carbon tetrachloride)	III (3)	Acute/occupational Cleaning of clothes	Centrilobular necrosis#	b	Taubmann, *Münch Med Woeh*, 1958; 47:1829
	(2)	Machine degreasing	GOT (1), thymol (1) Liver cell necrosis (1)	b	Lachnit, *Arch Gewerbepath Gewerbehyg*, 1960; 18:337
	(1)	Relay cleaning	Jaundice GPT, bili	b, f	Nielsen, *Acta Med Scand*, 1965; 178:363
	(1)	Motor degreasing	GOT, GPT, bili	b, f	Asshauer, *Med Welt*, 1969; 20:102
	(1)	Acute/accidental Ingestion	GPT, LDH, ALP, bili	b, f	Alston, *J Clin Path*, 1970; 23:249
	(1)	Chronic/occupational Cloth cleaning	Chronic hepatitis, cirrhosis#	d	Poindexter, *JAMA*, 1934; 102:2015
	Ia (135)	Chronic/occupational	GPT, GOT, GGT, ALP (subclinical)	a	Tomenson, *Occup Envir Med*, 1995; 52:508
Thallium	IVb (4)	Chronic/accidental	thymol	d	Fischl, *Am J Med Sci*, 1966; 251:78
Toluene[1,34]	III (1)	Acute/accidental Glue sniffing	Jaundice bili, ALP, GPT	b, f	O'Brien, *BMJ*, 1971; ii:29
	IIb (10)	Chronic/occupational Construction work in a former laboratory	GOT, GPT	d	Pey, *Arch Mal Prof*, 1972; 33:584

A Chemical or natural toxin	B Type of study (no. of persons)	C Exposure	D Diagnosis (no. of persons)	E Causal relationship	F Reference
	Id (27)	Chronic/occupational Plastic and rotogravure industry	Hepatomegaly GOT, GPT, bili	d	DeRosa, *Lav Umano*, 1974; 26:144
	IIb (170)	Chronic/occupational Not specified	GOT Mitochondrial abnormalities (22)#	d	Szilard, *MorpholIgaz Orv Sz*, 1978; 18:117
	IVb (6)	Chronic/occupational Shoemaker	GOT, GPT, GGT, ALP (5) Steatosis# (3)	d[35]	Lun, *Z Klin Med*, 1987; 42:671
	Id (262)	Chronic/occupational	Correlation of exposure history with GPT	d	Morck, *Dan Med Bull*, 1988; 35:196
	III (1)	Chronic/occupational	bili, prothrombin	d	Shiomi, *Clin Nucl Med*, 1993; 18:655
Toxic oil syndrome, (Spain 1981)[36]	V (842)	Subacute/alimentary Ingestion of adulterated rapeseed oil	GGT, ALP, LDH, GPT, GOT (203) Cholestatic hepatitis, ultrastructural changes#	d	Solis-Herruzo, *Hepatol*, 1984; 4:131
			Follow-up# of 124 persons: Cholestatic hepatitis (14) Chronic active hepatitis (13) Cirrhosis (4) Biliary cirrhosis (1) Liver-cell adenoma (1) Regenerative hyperplasia (8)		Solis-Herruzo, *Gastro*, 1987; 93:558
	(242)		GOT, OPT (99), ALP (34), bili (16) Hepatitis (10/14)#, cholestasis (3/14)#	d, f	Velicia, *J Hepatol*, 1986; 3:59
1,1,1-Trichloroethane[1]	III (1)	Acute/accidental Ingestion	bili (slightly)	b	Stewart, *JAMA*, 1966; 195:120
	(1)	Chronic/occupational Degreasing	Cirrhosis#	d[37]	Thiele, *Gastro*, 1982; 83:926
	III (1)	Acute/accidental Sniffing	bili, GOT	b, f	Nathan, *Br J Clin Pharm*, 1979; 8:2
	(4)	Chronic/occupational	GPT, GOT Macrovesicular steatosis#	d	Hodgson, *Arch Int Med*, 1989; 149:1793
Trichloroethylene[38]	III (1)	Acute/occupational Solvent use	Jaundice bili, flocculation test Massive necrosis#	b	Joron, *Can Med Ass J*, 1955; 73:890
	(1)	Subacute/occupational Degreasing	Acute hepatic failure necrosis#	b	Priest, *Arch Envir Hlth*, 1965; 11:361
	(3)	Acute/accidental Sniffing	GOT, GPT Centrilobular necrosis, fibrosis (2)#	b	Baerg, *Ann Int Med*, 1970; 73:713
	(2)		bili, GPT, GOT, ALP Centrilobular necrosis		Clearfield, *Dig Dis Sci*, 1970; 15:851
	(1)	Chronic/occupational Dry cleaning	Degenerative fatty metamorphosis#	d	Schollmeyer, *Arch Toxicol*, 1960; 18:229

	IVb (14)	Chronic/occupational Various sources	Fatty liver (11)# Fibrosis (1)#	d	Schüttmann, *Deutsch Z Verdau Stoff*, 1970; 30:43
Trichloromethane[1,39] (chloroform)	III (3)	Acute/medicinal Anaesthesia	Icterus gravis; degeneration of liver cells (1)#	b	Willcox, *Lancet*, 1931; ii:57
		Chronic/accidental Inhalation, bath additive	Cirrhosis (1)#, jaundice (1)	d	
	Id (68)	Chronic/occupational Pharmaceutical industry	Hepatomegaly GOT, GPT	a	Bomski, *Int Arch Gewerhepath Gewerbehyg*, 1967; 24:127
2,4,5-Trichlorophenol (TCP)[40]	Id (29)[41]	Chronic/occupational TCP manufacture	Uroporphyrin excretion Porphyria cutanea tarda (11)	d	Bleiberg, *Arch Dermatol*, 1964; 89:793
Triorthocresyl phosphate	III (6)	Chronic/occupational Car equipment industry	Vacuolar swelling of the cytoplasm, abnormalities of nuclear membrane#	c	Caudarella, *Lav Umano*, 1975; 27:161
Trinitrotoluene	IVb (22)	Chronic/occupational Munition disposal	Toxic hepatitis (8) Degenerative changes, necrosis or acute yellow atrophy (12)#	d	McConnell, *J Ind Hyg Tox*, 1946; 28:76
	IIb (18)		Jaundice, GOT, GPT, bili (3)	d	Hassmann, *Sbornik Ved Praci Lek Hrad Krá*, 1968; 11(Suppl):339
	III (1)		Hepatomegaly Steatosis#	d	Hassmann, *Sbornik Ved Praci Lek Hrad Krá*, 1969; 12:561
	IIb (43)		GOT, LDH	d	Morton, *Am Ind Hyg Ass J*, 1976; 37:56
Uranyl acetate	III (1)	Acute/suicidal Ingestion	Jaundice bili	b	Csapo, *Wien Klin Woch*, 1958; 70:788
Vinyl chloride	VI (118)[42]	Chronic/occupational PVC production (especially autoclave workers)	Angiosarcoma	d, e	Forman, *Br J Ind Med*, 1985; 42:750
	IVa (26*)	Chronic/environmental[43] 5 women living near PVC plant		h, e	Brady, *JNCI*, 1977; 59:1383
	III (14)	Chronic/occupational[44] Not specified	Portal fibrosis# Portal hypertension#	d	Thomas, *NEJM*, 1975; 292:17
	IVb (49)	Chronic/occupational PVC production and processing	Hepatomegaly (31) BSP(38), bili(12), ALP(10), GOT(15), GPT(17) Capsular fibrosis Collagenization of sinusoidal walls; septal fibrosis; fatty change#	d	Marsteller, *Ann NY Acad Sci*, 1975; 246:95
	(7)	Chronic/occupational Polymer reaction cleaning	ALP(1), GOT, GPT(2), BSP(4) Portal hypertension Fibrosis (6)#	d	Smith, *Lancet*, 1976; ii:602
	III (2)	Chronic/occupational PVC industry	Portal hypertension, progression to angiosarcoma 5 and 10 years later	d	Jones, *Br J Ind Med*, 1982; 39:306
	Ic (271)	Chronic/occupational PVC production	bili (3), GPT (10), GOT (6), GGT (8), ALP (3) Hepatomegaly (8)	d	Ho, *J Soc Occup Med*, 1991; 41:10
	IVa (78*)	Chronic/occupational Not specified	Focal hepatocytic hyperplasia (17 vs. 4) Focal mixed hyperplasia or more advanced lesions (6 vs. 1) ICG, GGT, ALP, GOT, GPT	a	Tamburro, *Hepatol*, 1984; 4:413

A Chemical or natural toxin	B Type of study (no. of persons)	C Exposure	D Diagnosis (no. of persons)	E Causal relationship	F Reference
	III (2)	Chronic/occupational Not specified	Hepatocellular carcinoma#	d	Evans, *Histopath*, 1983; 7:377
	III (1)	Chronic/occupational PVC production		d	Gokel, *Virch Arch A*, 1976; 372:195
	(3)			d	Dietz, *Klin Wschr*, 1985; 63:325
	Id (36)	Chronic/occupational Not specified	Coproporphyrin excretion Subclinical chronic hepatic porphyria BSP	d	Doss, *Klin Wschr*, 1984; 62:175
Xylene[1]	III (3)	Acute/occupational Paint application	GOT (2)	b, f	Morley, *BMJ*, 1970; iii:442

[1] For a discussion of potential tumour induction by solvents, see text.
[2] For a discussion of the causal relationship between aflatoxin B_1 and Reye syndrome, see text.
[3] For a report on negative findings (chronic/occupational) see Hine, *J Occ Med*, 1977; 19:391.
[4] Exposure also to other solvents.
[5] For a report on negative finding (chronic/occupational) see Vanhoorne, *Int Arch Occup Envir Hlth*, 1992; 63:517.
[6] See toxic oil syndrome.
[7] Workers in farming occupation may be exposed to cyanamide calcium in fertilizers.
[8] For a report on negative findings (chronic/occupational) see Laws, *Arch Envir Hlth*, 1973; 27:318.
[9] Exposure also to xylene, kerosene.
[10] Exposure also to γ-hexachlorocyclohexane.
[11] For reports on negative findings (chronic/occupational) see Spassovski, *Envir Hlth Perspect*, 1976; 17:199; Lauwerys, *Int Arch Occup Envin Hlth*, 1980; 45:189; Yonemoto, *Int Arch Occup Envin Hlth*, 1980; 46:159; Cai, *Int Arch Occup Envin Hlth*, 1992; 63:461.
[12] 'See 1,2-dimethylhydrazine.
[13] Exposure also to 2-chloroethyl phosphonic acid.
[14] History of excessive alcohol consumption and viral hepatitis.
[15] For a report on negative findings (chronic/occupational near exposure limit of 25 p.p.m.) see Crawford, *Am Ind Hyg Ass J*, 1985; 46:45.

[16] Drinking problem in 2/4. Exposure also to methyl ethylketone, cellosolve acetate, and toluene (2) or acetone (1).
[17] Exposure also to acetone and dimethylformamide.
[18] Exposure also to cyclohexane, toluene, 2,4,6-tri(dimethylaminomethyl)phenol, coal-tar pitch, bisphenol A, and epichlorohydrin.
[19] PCP products may be contaminated with 2,3,7,8-TCDD.
[20] For reports on negative findings (chronic/occupational) see Arsenault, *Proc Am Wood Preserv Ass*, 1976; 20:148; Fiedler, *Tox Rev*, 1982; 5; and chronic/environmental > 5 μg/m^3 air see Aurand, *Schr Ver Wa Bo Lufthyg*, 1981; 52:293.
[21] For a discussion of tumour induction by pesticides, see text.
[22] In contrast to previous reports, necrosis was not restricted to lobular periphery.
[23] For reports on negative findings (chronic/occupational) see Ouw, *Arch Envir Hlth*, 1976; 31:189; Baker, *Am J Epid*, 1980; 112:553; Takamatsu, *Am J Ind Med*, 1985; 5:59.
[24] Contaminated with polychlorinated dibenzofurans (PCDF) and polychlorinated quaterphenyls; toxicity ascribed to PCDF by most authors.
[25] Most of the pertinent original literature is published in Japanese. Two reviews are cited here in which the information is briefly given.
[26] Higher chlorinated biphenyls.
[27] Veno-occlusive disease.
[28] For reports on negative findings (chronic exposure) see Lathrop, cited in Webb, *Am J Prev Med*, 1986; 2:107; Stehr-Green, *Arch Envir Hlth*, 1986; 41:16.
[29] Review.
[30] Indicating enzyme induction.
[31] 2,4,5-Trichlorophenoxy acetic acid.
[32] For a report on negative finding (chronic/occupational) see Szadkowski, *Int Arch Gewerbepath Gewerbehyg*, 1969; 25:323.
[33] Six-week-old child; tetrachloroethylene detected in the mother's milk.
[34] For reports on negative findings (chronic/occupational) see Szadkowski, *Med Monatschr*, 1976; 30:25; Tähti, *Int Arch Occup Envir Hlth*, 1981; 48:61; Waldron, *Lancet* 1982; ii:1276; Boewer, *Int Arch Occup Envir Hlth*, 1988; 60:181.
[35] Exposure also to other solvents.
[36] The agent(s) responsible for the toxic effects have not been identified with certainty.
[37] Exposure also to trichloroethylene which may have been the major cause of injury.
[38] For reports on negative findings (chronic/occupational) see Szadkowski, *Int Arch Gewerbepath Gewerbehyg*, 1969; 25:323.
[39] For reports on negative findings (chronic/occupational) see Challen, *Br J Ind Med*, 1958; 15:243; Gambini, *Med Lav*, 1973; 64:432.
[40] Later shown to be contaminated with 2,3,7,8-TCDD.
[41] In a follow-up to this study, only one worker with elevated uroporphyrin excretion was found among 72 workers examined (Poland, *Arch Envir Hlth*, 1971; 22:316).
[42] For a review of 20 epidemiological studies see Purchase, *Food Chem Tox*, 1987; 25:187.
[43] For a report on negative findings for angiosarcoma (chronic/environmental) see Barr 1982, cited in Purchase, *Food Chem Tox*, 1987; 25:187.
[44] For a report on negative findings for portal fibrosis (chronic/occupational) see Jones, *Sca J Work Envir Hlth*, 1988; 14:153.

27.3 Rare diseases with hepatic abnormalities

M. Baraitser and R.M. Winter

Disease	Features	Hepatic abnormalities	Reference(s)
Aagenae syndrome (recurrent cholestasis with lymphoedema)	Oedema (lymphoedema)	Recurrent cholestasis from infancy. Later liver fibrosis	Aagenaes O. Hereditary recurrent cholestasis with lymphoedema—two new families. *Acta Paediatrica Scandinavica*, 1974; 63: 465–71.
Adrenoleukodystrophy (neonatal, autosomal recessive)	Adrenal hypoplasia/insufficiency Agenesis/hypoplasia of corpus callosum Cataract Cerebral atrophy/myelin abnormality Deafness, sensorineural Dementia/psychosis Diffuse increased pigmentation of skin Hypotonia Lissencephaly/pachygyria/polymicrogyria Mental retardation Migration abnormality/heterotopia Nystagmus Optic atrophy Peripheral neuropathy Prominent forehead/frontal bossing Retinitis pigmentosa/pigmentary retinopathy/chorioretinitis Seizures/abnormal EEG Stippled or fragmented epiphyses	Enlarged liver	Braverman N *et al*. Disorders of peroxisome biogenesis. (Review) *Human Molecular Genetics* 1995; 4: 1791–8. Paul DA *et al.* Neonatal adrenoleukodystrophy presenting as infantile progressive spinal muscular atrophy. *Paediatric Neurology*, 1993; 9: 496–7. Poll-The BT *et al.* Infantile refsum disease: an inherited peroxisomal disorder. Comparison with Zellweger syndrome and neonatal adrenoleukodystrophy. *European Journal of Paediatrics*, 1987; 146: 477–83.
Adrenoleukodystrophy (pseudoneonatal)	Adrenal hypoplasia/insufficiency Buphthalmos Cerebral atrophy/myelin abnormality Club foot, varus Deafness, sensorineural Depressed/flat nasal bridge Dolichocephaly/scaphocephaly Extrapyramidal disorder Glaucoma Hyperkeratosis Hypertonia Hypotonia	Enlarged liver	Barth PG *et al.* Peroxisomal beta-oxidation defect with detectable peroxisomes: a case with neonatal onset and progressive course. *European Journal of Paediatrics*, 1990; 149: 722–6. Mandel H *et al.* Zellweger-like phenotype in two siblings: a defect in peroxisomal beta-oxidation with elevated very long-chain fatty acids but normal bile acids. *Journal of Inherited Metabolic Disease*, 1992; 15: 381–4.

Disease	Features	Hepatic abnormalities	Reference(s)
	Late puberty in male Mental retardation Muscle weakness/myopathy Nystagmus Optic atrophy Organicaciduria Palpebral fissures slant up Prominent forehead/frontal bossing Retina, general abnormalities Retinitis pigmentosa/pigmentary retinopathy/chorioretinitis Seizures/abnormal EEG Short stature, proportionate Stippled or fragmented epiphyses Storage cells/vacuolated lymphocytes Stridor		Santer R *et al.* Isolated defect of peroxisomal beta-oxidation in a 16-year-old patient. *European Journal of Paediatrics*, 1993; 152: 339–42.
Aldolase A deficiency	Abnormal secondary sexual hair Anaemia/red cell abnormalities Congenital cardiac anomaly, unspecified Depressed/flat nasal bridge Epicanthic folds Flat face Hyperelastic skin Hypohidrotic or dry skin Joint laxity Low posterior/trident hairline Mental retardation Microcephaly Primary amenorrhoea Prominent ears Prominent vessels of skin Ptosis of eyelids Short nails Short neck Short stature, proportionate Small penis (including micro) Small teeth Spasticity/increased tendon reflex Telangiectasia of eyelids	Enlarged liver	Beutler E *et al.* Red cell aldolase deficiency and hemolytic anemia: a new syndrome. *Transactions of the Association of American Physicians*, 1973; 76: 154–66. Hurst JA *et al.* A syndrome of mental retardation, short stature, hemolytic anemia, delayed puberty, and abnormal facial appearance: similarities to a report of aldolase A deficiency. *American Journal of Medical Genetics*, 1987; 28: 965–70.
Alpers' progressive infantile poliodystrophy	Ataxia Camptodactyly Cerebral atrophy/myelin abnormality Club foot, valgus Cryptorchid testes Deafness, sensorineural Dysphagia Extrapyramidal disorder Feeding problems in infants Flexion deformity of hip Flexion deformity of knee Hypospadias Hypotonia Joint contractures (including	Liver function is abnormal. Subacute hepatitis, fat infiltration, cell loss	Narkewicz MR *et al.* Liver involvement in Alpers disease, *Journal of Paediatrics*, 1991; 119: 260–7. Wilson DC *et al*. Progressive neuronal degeneration of childhood (Alpers syndrome) with hepatic cirrhosis. *European Journal of Paediatrics*, 1993; 152: 260–2.

Disease	Features	Hepatic abnormalities	Reference(s)
	arthrogryposis) Limited movement of hip Limited movement/flexion deformity of elbow Mental retardation Microcephaly Muscle atrophy Recurrent infections Seizures/abnormal EEG Short neck Short stature, prenatal onset Sloping forehead Small mandible/micrognathia Spasticity/increased tendon reflex		
Apple-peel congenital intestinal atresia	Absent or hypoplastic hallux Absent toes Anal atresia/stenosis Atrial septal defect Brachydactyly Common mesentery Dilated ureters/ureteral atresia Feeding problems in infants Hydrocephaly/large ventricles, non-specific Intestinal duplication Intestinal malrotation Microphthalmia Skin syndactyly of fingers Small bowel atresia/absence/obstruction/short Small/hypoplastic/deep-set nails Spina bifida occulta Syndactyly of toes (2–3)	Biliary atresia with secondary effects on the liver	Farag TI *et al.* Second family with 'apple peel' syndrome affecting four siblings: autosomal recessive inheritance confirmed. (Letter.) *American Journal of Medical Genetics*, 1993; 47: 119–21.
Argininosuccinic aciduria	Ataxia Brittle hair Coarse hair Feeding problems in infants Mental retardation Seizures/abnormal EEG Sparse hair/alopecia areata Speech delay Trichorrhexis nodosa	Abnormal liver function, enlarged liver, fibrosis	Gerrits GPJM *et al.* Argininosuccinic aciduria: clinical and biochemical findings in three children with the late onset form, with special emphasis on cerebrospinal fluid findings of amino acids and pyrimidines. *Neuropediatrics*, 1993; 24: 15–18. Renner C *et al.* Sodium citrate supplementation in inborn argininosuccinate lyase deficiency: a study in a 5-year-old patient under total parenteral nutrition. *European Journal of Paediatrics*, 1995; 154: 909–14. Zimmermann A *et al.* Severe liver fibrosis in argininosuccinic aciduria. *Archives of Pathology and Laboratory Medicine*, 1986; 110:136–40.
Arteriohepatic dysplasia (Alagille syndrome)	Anal atresia/stenosis Anterior chamber abnormalities, unspecified	Paucity of intrahepatic bile ducts resulting in prolonged neonatal jaundice	Elmslie FV *et al.* Alagille syndrome: family studies. *Journal of Medical Genetics*, 1995; 32: 264–8.

Disease	Features	Hepatic abnormalities	Reference(s)
	Atrial septal defect Cloudy corneas/sclerocornea Deep-set eyes Delayed bone age Depressed/flat nasal bridge Ectopic pupils Fallot tetralogy Hemivertebras High-pitched voice Hoarse voice Hypertelorism Hypothyroidism/small or absent thyroid Keratoconus Large spleen Late puberty in females Late puberty in males Mental retardation Palpebral fissures slant up Pointed chin Prominent forehead/frontal bossing Pulmonary stenosis Renal dysplasia Retinitis pigmentosa/pigmentary retinopathy/chorioretinitis Segmentation defects of spine Short phalanges Short stature, proportionate Spina bifida occulta Urethral fistulas Ventricular septal defect Vertebral interpedicular distance, narrow Xanthomas		Hoffenberg EJ *et al.* Outcome of syndromic paucity of interlobular bile ducts (Alagille syndrome) with onset of cholestasis in infancy. *Journal of Paediatrics*, 1995; 127: 220–4. Rand EB *et al.* Molecular analysis of 24 Alagille syndrome families identifies a single submicroscopic deletion and further localizes the Alagille region within 20p12. *American Journal of Human Genetics*, 1995; 57: 1068–73.
Ataxia–ichthyosis–hepatosplenomegaly	Ataxia Hyperkeratosis Ichthyosis Large spleen	Enlarged liver, but thought to be secondary to chronic congestion	Dykes PJ *et al.* A syndrome of ichthyosis, hepatosplenomegaly and cerebellar degeneration. *British Journal of Dermatology*, 1979; 100: 585–90. Harper PS *et al.* Ichthyosis, hepatosplenomegaly, and cerebellar degeneration in a sibship. *Journal of Medical Genetics*, 1980; 17: 212–15.
Bardet–Biedl (Laurence–Moon–Bardet–Biedl) syndrome	Brachydactyly Cardiomyopathy Congenital cardiac anomaly, unspecified Diabetes mellitus/hyperglycaemia Generalized obesity Glaucoma Glycosuria Hydronephrosis Hypogonadism Late puberty in females Late puberty in males	Congenital hepatic fibrosis	Carmi R *et al.* Phenotypic differences among patients with Bardet–Biedl syndrome linked to three different chromosome loci. *American Journal of Medical Genetics*, 1995; 59: 199–203. Leppert M *et al.* Bardet–Biedl syndrome is linked to DNA markers on chromosome 11q and is genetically heterogeneous. *Nature Genetics*, 1994; 7: 108–12.

Disease	Features	Hepatic abnormalities	Reference(s)
	Malformed uterus Mental retardation Multiple renal cysts Nephritis or nephropathy Nystagmus Pigmentary abnormality of macula Postaxial polydactyly of fingers Postaxial polydactyly of toes Renal dysplasia Retinitis pigmentosa/pigmentary retinopathy/chorioretinitis Secondary amenorrhoea Short stature, proportionate Small penis (including micro) Small testes Urethra, general abnormalities Urethral fistulas Vaginal atresia Vaginal septum/duplication/ hydrometrocolpos Vision, non-specific impairment		Nakamura F *et al.* Laurence–Moon–Biedl syndrome accompanied by congenital hepatic fibrosis. *Journal of Gastroenterology and Hepatology*, 1990; 5: 206–10.
Berardinelli syndrome (lipodystrophy, Lawrence–Seip syndrome)	Acanthosis nigricans Advanced bone age/large epiphyses Cardiomyopathy Deficient adipose tissue or fat/lipodystrophy Diabetes mellitus/hyperglycaemia Diffuse increased pigmentation of skin Facial hirsutism Generalized hirsutism Glycosuria Hypohidrotic or dry skin Large kidneys Large penis Large spleen Mental retardation Ovarian cysts/tumours Prominent clitoris Prominent ears Protuberant abdomen Secondary amenorrhoea Sunken cheeks Tall stature, proportionate Thin	Cirrhosis	Flier JS. Lilly Lecture: syndromes of insulin resistance. From patient to gene and back again. *Diabetes*, 1992; 41: 1207–19. van der Vorm ER *et al.* Patients with lipodystrophic diabetes mellitus of the Seip–Berardinelli type, express normal insulin receptors. *Diabetologia*, 1993; 36: 172–4.
Cantu syndrome (short stature; skeletal dysplasia)	Brachydactyly Depressed/flat nasal bridge Kyphosis Large ears Large spleen Lordosis Mesomelia of upper limbs Metaphyseal dysplasia Pectus carinatum Platyspondyly Prominent forehead/frontal bossing	Enlarged liver	Cantu JM *et al.* A distinct skeletal dysplasia in an infant from consanguineous parents. *Revista de Investigacion Clinica*, 1976; 28: 255–61. Cantu JM *et al.* A distinct skeletal dysplasia in an infant from consanguineous parents. *Birth Defects, Original Article Series*, 1977; 13: 139–47.

Disease	Features	Hepatic abnormalities	Reference(s)
	Prominent heels Proportionate shortening of lower limb Protuberant abdomen Sella turcica, J-shaped Short neck Short stature, prenatal onset Short stature, short limbs Short/hypoplastic metacarpals Small hands Small mandible/micrognathia Small/short nose Wide phalanges Abnormal labia		
Carbohydrate-deficient glycoprotein syndrome type 1	Agenesis/hypoplasia of corpus callosum Arachnodactyly Ascites Ataxia Bleeding diatheses Cardiomyopathy Cataract Cerebellar abnormalities Cerebellar abnormalities (structural) Cerebral atrophy/myelin abnormality Cholesterol/lipids, abnormal Cryptorchid testes Dandy–Walker malformation Deficient adipose tissue or fat/lipodystrophy Extrapyramidal disorder Hypoplastic/inverted/absent nipples Hypotonia Joint contractures (including arthrogryposis) Large spleen Long toes Mental retardation Microcephaly Multiple renal cysts Muscle atrophy Oedema (including hydrops) Oedema of feet/hands/lower limbs Optic atrophy Patchy depigmentation of skin Patchy pigmentation of skin/café-au-lait spots Pericarditis (non-constrictive) Platelet abnormalities Prominent forehead/frontal bossing Recurrent infections Retinitis pigmentosa/pigmentary retinopathy/chorioretinitis Scoliosis Seizures/abnormal EEG	Cirrhosis, remodelling of parenchyma and intracellular lipid vacuoles	Conradi N *et al.* Liver pathology in the carbohydrate-deficient glycoprotein syndrome. *Acta Paediatrica Scandinavica*, 1991; 375(Suppl.): 50–4. Hagberg BA *et al.* Carbohydrate-deficient glycoprotein syndromes: peculiar group of new disorders. *Paediatric Neurology*, 1993; 9: 255–62. Hutchesson ACJ *et al.* Carbohydrate deficient glycoprotein syndrome; multiple abnormalities and diagnostic delay. *Archives of Diseases of Childhood*, 1995; 72: 445–6. Jaeken J *et al*. The carbohydrate-deficient glycoprotein syndromes: an overview. *Journal of Inherited Metabolic Diseases*, 1993; 16: 813–20.

Disease	Features	Hepatic abnormalities	Reference(s)
	Short stature, proportionate Small mandible/micrognathia Spasticity/increased tendon reflex Strabismus/gaze palsy Thin Truncal obesity		
Cardiofaciocutaneous (CFC) syndrome	Atrial septal defect Brittle hair Cavernous haemangioma Cerebral atrophy/myelin abnormality Coarse facial features Cryptorchid testes Delayed bone age Depressed/flat nasal bridge Dystrophic nails Eczema/atopic dermatitis Epicanthic folds Fine hair Heart, general abnormalities High frontal hairline Hydrocephaly/large ventricles, non-specific Hyperkeratosis Hypertelorism Hypohidrotic or dry skin Hypoplasia/dysplasia of optic nerve Hypoplastic supraorbital ridges Hypotonia Ichthyosis Large spleen Loose skin in neck Macrocephaly Mental retardation Narrow forehead/temporal narrowing Oedema (including hydrops) Palpebral fissures slant down Pectus carinatum Pectus excavatum Posteriorly rotated ears Prominent ear helix Ptosis of eyelids Pulmonary stenosis Scoliosis Seizures/abnormal EEG Short stature, proportionate Sparse hair/alopecia areata Webbed neck	Enlarged liver	Bottani A *et al*. The cardio-facio-cutaneous syndrome: report of a patient and review of the literature. *European Journal of Paediatrics*, 1991; 150: 486–8. Somer M *et al.* Cardio-facio-cutaneous syndrome: three additional cases and review of the literature. *American Journal of Medical Genetics*, 1992; 44: 691–5.
Cerebro-oculo-hepato-renal syndrome	Anaemia/red cell abnormalities Aplasia or dysplasia of retina Blindness Cataract Cerebellar abnormalities (structural) Depressed/flat nasal bridge Dystopia canthorum (telecanthus)	Enlarged liver with abnormal function and hyperechogenic, compatible with fat infiltration	Matsuzaka T *et al.* Cerebro-oculo-hepato-renal syndrome (Arima's syndrome): a distinct clinicopathological entity. *Journal of Child Neurology*, 1986; 1: 338–46.

Disease	Features	Hepatic abnormalities	Reference(s)
	Flexion deformity of knee Hypotonia Limited movement of ankle Macrostomia Mental retardation Multiple renal cysts Nystagmus Optic atrophy Ptosis of eyelids Renal dysplasia		
Cerebrotendinous xanthomatosis	Absent/abnormal gallbladder Ataxia Cataract Cerebellar abnormalities Cerebral atrophy/myelin abnormality Cholesterol/lipids, abnormal Club foot, varus Dementia/psychosis Dysphagia Enlarged joints High arches of feet (pes cavus) Hypothyroidism/small or absent thyroid Malabsorption Mental retardation Muscle atrophy Peripheral neuropathy Pons/medulla/basal ganglia, abnormal Premature atherosclerosis Seizures/abnormal EEG Sensory abnormalities Spasticity/increased tendon reflex Speech defect/dysarthria Tremors Xanthomas	Hepatocytes contain a light golden pigment and bile cholestanol is significantly increased	Kim K-S *et al.* Identification of new mutations in sterol 27 hydroxylase gene in Japanese patients with cerebrotendinous xanthomatosis (CTX). *Journal of Lipid Research*, 1994; 35: 1031–9. Kuriyama M *et al.* Cerebrotendinous xanthomatosis: clinical and biochemical evaluation of eight patients and review of the literature. *Journal of the Neurological Sciences*, 1991; 102: 225–32. Leitersdorf E *et al.* Cerebrotendinous xanthomatosis in the Israeli Druze: molecular genetics and phenotypic characteristics. *American Journal of Human Genetics*, 1994; 55: 907–15.
Cholesterol ester storage disease	Adrenal calcification Ascites Cholesterol/lipids, abnormal Hypogonadism Large spleen Late puberty in females Late puberty in males Naevi or lentigines Premature atherosclerosis Respiratory abnormality, unspecified Short stature, proportionate	Enlarged liver, cirrhosis, lipid-filled hepatocytes	Edelstein RA *et al.* Cholesteryl ester storage disease: a patient with massive splenomegaly and splenic abscess. *American Journal of Gastroenterology*, 1988; 83: 687–92. Muntoni S *et al.* Homozygosity for a splice junction mutation in exon 8 of the gene encoding lysosomal acid lipase in a Spanish kindred with cholesterol ester storage disease (CESD). *Human Genetics*, 1995; 95: 491–4.
Cumming syndrome (campomelia; polycystic dysplasia; polysplenia)	Absent or hypoplastic femur Bowed femur Bowed humerus Bowed radius Bowed tibia Bowed ulna	Polycystic dysplasia	Cumming WA *et al*. Campomelia, cervical lymphocele, polycystic dysplasia, short gut, polysplenia. *American Journal of Medical Genetics*, 1986; 25: 783–90.

Disease	Features	Hepatic abnormalities	Reference(s)
	Bowing of bones Cleft palate Club foot, varus Colon/caecum atresia Cranial sutures, wide Holoprosencephaly/arhinencephaly Hypoplastic or absent fibula Hypoplastic or absent humerus Hypoplastic or absent radii Hypoplastic or absent tibia Hypoplastic or absent ulna Lung hypoplasia/agenesis Multiple renal cysts Nuchal bleb/cystic hygroma of neck Oedema (including hydrops) Pancreatic cysts/tumours Polysplenia Proportionate short arms Short stature, prenatal onset Small bowel atresia/absence/obstruction/short		Urioste M *et al.* Campomelia, polycystic dysplasia, and cervical lymphocele in two sibs. *American Journal of Medical Genetics*, 1991; 41: 475–7.
Disseminated haemangiomatosis	Anaemia/red cell abnormalities Arteriovenous malformations Capillary haemangioma Cavernous haemangioma Facial haemangiomas Glaucoma Heart, general abnormalities Hydrocephaly/large ventricles, non-specific Intracranial calcification Large spleen Papules Platelet abnormalities Spasticity/increased tendon reflex Vascular malformations of brain	Hepatic haemangiomas	Byard RW *et al.* Diffuse infantile haemangiomatosis: clinicopathological features and management problems in five fatal cases. *European Journal of Paediatrics*, 1991; 150: 224–7. Gozal D *et al.* Diffuse neonatal haemangiomatosis: successful management with high dose corticosteroids. *European Journal of Paediatrics*, 1990, 149: 321–4.
Erythropoietic protoporphyria	Abnormal scar formation Absent/abnormal gallbladder Anaemia/red cell abnormalities Bullae or vesicles Erythema/erythroderma Generalized hirsutism Localized hirsutism Patchy pigmentation of skin/café-au-lait spots Skin photosensitivity	Enlarged liver with progressive failure	Todd DJ. Erythropoietic protoporphyria. *British Journal of Dermatology*, 1994; 131: 751–66.
Fanconi syndrome (ichthyosis–jaundice–diarrhoea)	Aminoaciduria Club foot, varus Dislocation of hip Feeding problems in infants Flexion deformity at wrist Flexion deformity of hip Flexion deformity of knee Glycosuria Hypotonia Ichthyosis	Enlarged liver, jaundice	Deal JE *et al.* Fanconi syndrome, ichthyosis, dysmorphism, jaundice and diarrhoea—a new syndrome. *Paediatric Nephrology*, 1990; 4: 308–13.

Disease	Features	Hepatic abnormalities	Reference(s)
	Malabsorption Platelet abnormalities Proteinuria Recurrent infections		
Fetal congenital cytomegalovirus infection	Absent finger tips Absent fingers or oligodactyly Absent toes Ascites Brachydactyly Congenital cardiac anomaly, unspecified Cryptorchid testes Deafness, conductive Deafness, congenital Deafness, sensorineural Deafness, unilateral Glaucoma Hemiplegia High palate Hypoplastic toes (including phalanges) Hypotonia Inguinal hernia Intracranial calcification Large spleen Low birthweight (< 3rd centile) Mental retardation Microcephaly Optic atrophy Platelet abnormalities Pulmonary stenosis Retinitis pigmentosa/pigmentary retinopathy/chorioretinitis Seizures/abnormal EEG Spasticity/increased tendon reflex Strabismus/gaze palsy Umbilical hernia Ventricular septal defect	Enlarged liver	Darin N *et al.* Clinical, serological and PCR evidence of cytomegalovirus infection in the central nervous system in infancy and childhood. *Neuropediatrics*, 1994; 25: 316–22. Fowler KB *et al.* The outcome of congenital cytomegalovirus infection in relation to maternal antibody status. *New England Journal of Medicine*, 1992; 326: 663–7. Yow MD *et al.* Congenital cytomegalovirus disease—20 years is long enough. (Editorial.) *New England Journal of Medicine*, 1992; 326: 702–3.
Fetal rubella	Anaemia/red cell abnormalities Anterior encephalocele/meningocele Atrial septal defect Cardiomyopathy Cataract Cloudy corneas/sclerocornea Cryptorchid testes Deafness, sensorineural Diabetes mellitus/hyperglycaemia Fontanelles, delayed closure/large Glaucoma Hypopituitarism Hypospadias Intracranial calcification Large spleen Lung, general abnormalities Mental retardation	Prolonged jaundice, enlarged liver	Kaplan KM *et al.* A profile of mothers giving birth to infants with congenital rubella syndrome. *American Journal of Diseases of Childhood*, 1990; 144: 118–23. McIntosh *et al.* A fifty-year follow-up of congenital rubella. *Lancet*, 1992; ii: 414.

Disease	Features	Hepatic abnormalities	Reference(s)
	Metaphyseal dysplasia Microcephaly Microphthalmia Patent ductus arteriosus Platelet abnormalities Pulmonary stenosis Retinitis pigmentosa/pigmentary retinopathy/chorioretinitis Ventricular septal defect		
Fetal toxoplasmosis	Anaemia/red cell abnormalities Hydrocephaly/large ventricles, non-specific Intracranial calcification Large spleen Low birthweight (< 3rd centile) Macules Mental retardation Microcephaly Microphthalmia Platelet abnormalities Polymorph abnormalities Purpura Retinitis pigmentosa/pigmentary retinopathy/chorioretinitis Seizures/abnormal EEG Spasticity/increased tendon reflex	Enlarged liver, jaundice	Hall SM. Congenital toxoplasmosis. (Review) *British Medical Journal*, 1992; 305: 291–7. Mombro M *et al*. Congenital taxoplasmosis: 10-year follow up. *European Journal of Paediatrics*, 1995; 154: 635–9.
Focal nodular hyperplasia of the liver (vascular malformations)	Aneurysms Brain tumours/cysts Vascular malformations of brain	Focal nodular hyperplasia	Albrecht S *et al.* Multiple focal nodular hyperplasia of the liver associated with vascular malformations and neoplasia of the brain and meninges: a new syndrome. *Laboratory Investigation*, 1989, 60: 2A. Goldin RD *et al.* Focal nodular hyperplasia of the liver associated with intracranial vascular malformations. *Gut*, 1990; 31: 554–5.
Fucosidosis	Absent or hypoplastic clavicles Beaked/wedged vertebrae Cardiomyopathy Cerebral atrophy/myelin abnormality Cloudy corneas/sclerocornea Coarse facial features Deafness, sensorineural Diaphyseal dysplasia Fullness of periorbital region Hypohidrotic or dry skin Joint contractures (including arthrogryposis) Kyphosis Large spleen Large tongue Long philtrum Mental retardation	Enlarged liver with foamy cytoplasm in some hepatocytes	Seo H-C *et al.* Six additional mutations in facosidosis: three nonsense mutations and three frameshift mutations. *Human Molecular Genetics*, 1993; 2: 1205–8. Willems PJ *et al.* Fucosidosis revisited: a review of 77 patients. *American Journal of Medical Genetics*, 1991; 38: 111–31.

Disease	Features	Hepatic abnormalities	Reference(s)
	Mucopolysacchariduria/ oligosacchariduria Papules Prominent forehead/frontal bossing Proximal tapering of metacarpals Retinitis pigmentosa/pigmentary retinopathy/chorioretinitis Scoliosis Seizures/abnormal EEG Short stature, proportionate Spasticity/increased tendon reflex Storage cells/vacuolated lymphocytes Telangiectasia/angiokeratomas of skin Thick/stiff skin Umbilical hernia Vascular abnormalities of retina		
Galactosialidosis (neuraminidase and β-galactosidase deficiency)	Adrenal hyperplasia Ascites Beaked/wedged vertebrae Bulbous nasal tip Camptodactyly Cardiac situs inversus/dextrocardia Cardiomyopathy Coarse facial features Dementia/psychosis Dolichocephaly/scaphocephaly Gibbus Hyperplastic supraorbital ridges Large kidneys Large spleen Macular red spot/cherry red spot Mental retardation Mucopolysacchariduria/ oligosacchariduria Oedema (including hydrops) Pectus carinatum Platyspondyly Scoliosis Seizures/abnormal EEG Sella turcica, J-shaped Single ventricle Storage cells/vacuolated lymphocytes Subperiosteal new bone formation Telangiectasia/angiokeratomas of skin Thick lower lip Thick upper lip Thickened/oedematous eyelids	Enlarged liver with membrane-bound vacuoles on histology	Oyanagi K *et al.* Galactosialidosis: neuropathological findings in a case of the late-infantile type. *Acta Neuropathologica*, 1991; 82: 331–9. Ozand PT *et al.* Heterogeneity of carboxypeptidase activity in infantile-onset galactosialidosis. *Journal of Child Neurology*, 1992; 7(Suppl.): S31–40. Strisciuglio P *et al.* Combined deficiency of beta-galactosidase and neuraminidase: natural history of the disease in the first 18 years of an American patient with late infantile onset form. *American Journal of Medical Genetics*, 1990; 37: 573–7.
Gardner syndrome	Aplasia or dysplasia of retina Brain tumours/cysts Cartilaginous/bony exostoses Colonic tumours Delayed tooth	Hepatoblastomas	Hughes LJ *et al.* Risk of hepatoblastoma in familial adenomatous polyposis. *American Journal of Medical Genetics*, 1992; 43: 1023–5.

Disease	Features	Hepatic abnormalities	Reference(s)
	eruption/development Diffuse increased pigmentation of skin Gastrointestinal tumour/polyp/haemangioma Other tumours of skin Pancreatic cysts/tumours Retinitis pigmentosa/pigmentary retinopathy/chorioretinitis Skeletal cysts or tumours Skin cysts Spinal tumours Subperiosteal new bone formation Supernumerary teeth Thyroid tumours Tumour or cyst of the mandible		Perniciaro C. Gardner's syndrome. *Dermatologic Clinics*, 1995; 131: 51–6.
Garrett–Tripp syndrome (mental retardation; polydactyly; hair absence; dermatitis; Perthe's disease)	Absent eyebrows Absent fingers or oligodactyly Absent or sparse eyelashes Alopecia totalis Capillary haemangioma Convex/beaked profile of nose Cutaneous pustules/ulcers Ear helix, general abnormalities Large spleen Mental retardation Perthe's/dysplastic hip Postaxial polydactyly of fingers Postaxial polydactyly of toes Recurrent infections Scalp, general abnormalities Seborrhoea Small penis (including micro) Syndactyly of toes (2–3)	Enlarged liver	Garrett C *et al.* Unknown syndrome: mental retardation with postaxial polydactyly, congenital absence of hair, severe seborrhoeic dermatitis and Perthe's disease of the hip. *Journal of Medical Genetics*, 1988; 25: 270–2.
Gaucher disease (neonatal)	Anteverted nares Ectropion of eyelids Flexion deformity of hip Flexion deformity of knee Ichthyosis Joint contractures (including arthrogryposis) Large spleen Limited movement/flexion deformity of elbow Lung hypoplasia/agenesis Open mouth appearance Small ears/microtia Storage cells/vacuolated lymphocytes Thick/stiff skin	Enlarged liver with Gaucher cells in sinusoids (rather than in hepatocytes)	Horowitz M. Mutations causing Gaucher disease. *Human Mutation* 1994; 3: 1–11. Sidransky E *et al.* Diagnosing Gaucher disease. *Clinical Paediatrics*, 1995; 34: 365–71.
Gaucher disease type 2 (infantile or acute neuronopathic type)	Anaemia/red cell abnormalities Dementia/psychosis Fetal finger pads Hypertonia Hypotonia Ichthyosis	Enlarged liver with Gaucher cells in sinusoids	Sidransky E *et al.* Diagnosing Gaucher disease. *Clinical paediatrics*, 1995; 34: 365–71. Walley AJ *et al.* Gaucher's disease in the United Kingdom: screening non-Jewish patients for the two

Disease	Features	Hepatic abnormalities	Reference(s)
	Incoordination Large spleen Mental retardation Pigmentary abnormality of macula Seizures/abnormal EEG Spasticity/increased tendon reflex Storage cells/vacuolated lymphocytes Strabismus/gaze palsy		common mutations. *Journal of Medical Genetics*, 1993; 30: 280–3.
Gaucher disease type 1 (adult type)	Anaemia/red cell abnormalities Aortic stenosis Aseptic necrosis of epiphysis Ataxia Calcification of arteries Cloudy corneas/sclerocornea Cortical hyperostosis/thickening Dementia/psychosis Erythema/erythroderma Indifference to pain Large spleen Multiple fractures Oedema (including hydrops) Osteoporosis Patchy pigmentation of skin/café-au-lait spots Retinitis pigmentosa/pigmentary retinopathy/chorioretinitis Seizures/abnormal EEG Sensory abnormalities Skeletal cysts or tumours Speech defect/dysarthria Storage cells/vacuolated lymphocytes Subperiosteal new bone formation Wide metaphysis	Enlarged liver with Gaucher cells in sinusoids	Amaral O *et al.* Molecular characterisation of type 1 Gaucher disease families and patients: intrafamilial heterogeneity at the clinical level. *Journal of Medical Genetics*, 1994; 31: 401–4. Beutler E. Modern diagnosis and treatment of Gaucher's disease. *American Journal of Diseases of Childhood*, 1993; 147: 1175–83. Grabowski GA. Gaucher disease. Enzymology, genetics, and treatment. *Advances in Human Genetics*, 1993; 21: 377–441.
Gaucher disease type 3 (juvenile or norbottnian type)	Aseptic necrosis of epiphysis Ataxia Cortical hyperostosis/thickening Dementia/psychosis Dysphagia Hypotonia Large spleen Multiple fractures Muscle atrophy Osteoporosis Ptosis of eyelids Seizures/abnormal EEG Skeletal cysts or tumours Spasticity/increased tendon reflex Storage cells/vacuolated lymphocytes Strabismus/gaze palsy Subperiosteal new bone formation Wide metaphysis	Enlarged liver with Gaucher cells in sinusoids	Brady RO *et al.* The role of neurogenetics in Gaucher disease. *Archives of Neurology*, 1993; 50: 1212–24. Sidransky *et al.* Clinical heterogeneity among patients with Gaucher's disease. (Clinical conference.) *Journal of the American Medical Association*, 1993; 269: 1154–7.
Geleophysic dysplasia	Abnormal/absent metatarsals Anteverted nares Aortic stenosis Brachydactyly	Enlarged liver, hepatocytes contain periodic acid–Schiff positive, diastase-resistant, inclusions	Rosser EM *et al.* Geleophysic dysplasia: a report of three affected boys—prenatal ultrasound does not detect recurrence. *American Journal*

Disease	Features	Hepatic abnormalities	Reference(s)
	Camptodactyly Coarse facial features Congenital cardiac anomaly, unspecified Coxa valga Delayed bone age Hypoplastic or absent carpals Joint contractures (including arthrogryposis) Large spleen Limited movement of fingers Limited movement of knee Limited movement/flexion deformity of elbow Long philtrum Macrostomia Mitral stenosis Perthes'/dysplastic hip Proximal tapering of metacarpals Round face Short bones Short stature, proportionate Short/hypoplastic metacarpals Simple/absent philtrum Small hands Small/short nose Thick/stiff skin Thin lower lip Thin upper lip Trachea or laryngeal anomalies Wide metacarpals/modelling defect Wide nasal bridge		*of Medical Genetics*, 1995; 58: 217–21. Shohat M *et al.* Geleophysic dysplasia: a storage disorder affecting the skin, bone, liver, heart, and trachea. *Journal of Paediatrics*, 1990; 117: 227–32.
Generalized gangliosidosis type 1	Acromelia of upper limbs Beaked/wedged vertebrae Broad base to nose Cardiomyopathy Coarse facial features Depressed/flat nasal bridge Enlarged liver Epiphyseal dysplasia Full cheeks Generalized hirsutism Gum hypertrophy Joint contractures (including arthrogryposis) Joint stiffness/arthritis Kyphosis Large tongue Long philtrum Macrocephaly Macular red spot/cherry red spot Mental retardation Metaphyseal dysplasia Mucopolysacchariduria/oligosacchariduria Osteoporosis	Enlarged liver with vacuoles and diffuse foamy histiocytes	Boustany R-M *et al.* Mutations in acid β-galactosidase cause GM1-gangliosidosis in American patients. *American Journal of Human Genetics*, 1993; 53: 881–8. Nardocci N *et al*. Chronic GM1 gangliosidosis presenting as dystonia: clinical and biochemical studies in a new case. *Neuropediatrics*, 1993; 24: 164–6.

Disease	Features	Hepatic abnormalities	Reference(s)
	Prominent forehead/frontal bossing Prominent maxilla Prominent/deep philtrum Proximal tapering of metacarpals Scoliosis Short stature, prenatal onset Stippled or fragmented epiphyses Storage cells/vacuolated lymphocytes Subperiosteal new bone formation Thick/wide alveolar ridges Thick/wide ribs Thickened/oedematous eyelids Trachea or laryngeal anomalies		
Glutaric aciduria type 2	Biliary atresia/stenosis Brain, general abnormalities Club foot, varus Cryptorchid testes Dolichocephaly/scaphocephaly Fontanelles, delayed closure/large Hamartoma of brain Hypoglycaemia Hypospadias Large kidneys Lissencephaly/pachygyria/polymicrogyria Low-set ears Macrocephaly Mental retardation Multiple renal cysts Organicaciduria Pancreas (exocrine), general abnormalities Rocker-bottom feet (see also vertical talus) Seizures/abnormal EEG Undermineralization of skull	Enlarged liver with fatty infiltration	Colombo I *et al*. Mutations and polymorphisms of the gene encoding the β-subunit of the electron transfer flavoprotein in three patients with glutaric acidemia type 2. *Human Molecular Genetics*, 1994; 3: 429–36. Stockler S *et al*. Symmetric hypoplasia of the temporal cerebral lobes in an infant with glutaric aciduria type 2 (multiple acyl-coenzyme A dehydrogenase deficiency). *Journal of Paediatrics*, 1994; 124: 601–4.
Goldstein syndrome (Sotos-like syndrome)	Advanced tooth eruption/development Dolichocephaly/scaphocephaly Dystopia canthorum (telecanthus) Epicanthic folds Fontanelles, delayed closure/large High birthweight (> 90th centile) Hypoplastic maxilla (excluding malar region) Hypotonia Large spleen Macrocephaly Mental retardation Narrow thorax/funnel chest Pectus excavatum Prominent forehead/frontal bossing Scoliosis Small/short nose Tall stature, proportionate	Enlarged liver	Goldstein DJ *et al.* Overgrowth, congenital hypotonia, nystagmus, strabismus, and mental retardation: variant of dominantly inherited Sotos sequence? *American Journal of Medical Genetics*, 1988; 29: 783–92.

Disease	Features	Hepatic abnormalities	Reference(s)
	Thin/long face Upturned nose		
Growth retardation–alopecia–pseudoanodontia–optic atrophy (GAPO) syndrome	Alopecia totalis Bowed radius Bowed tibia Bowed ulna Cerebral atrophy/myelin abnormality Delayed bone age Delayed tooth eruption/development Depressed/flat nasal bridge Diaphyseal dysplasia Fontanelles, delayed closure/large Glaucoma Hypertelorism Hypogonadism Keratoconus Macrocephaly Macrocornea/megalocornea Mental retardation Nystagmus Oligodontia Optic atrophy Osteoporosis Papilloedema/optic neuritis Prominent eyes/proptosis Prominent forehead/frontal bossing Prominent upper lip Prominent/everted lower lip Sclerosis of skull Short stature, proportionate Small mandible/micrognathia Sparse/decreased eyebrows Tremors	Enlarged liver	Moriya N *et al.* GAPO syndrome: report on the first case in Japan. *American Journal of Medical Genetics*, 1995; 58: 257–61. Sandgren G. GAPO syndrome a new case. *American Journal of Medical Genetics*, 1995; 58: 87–90. Sayli BS *et al.* GAPO syndrome in three relatives in a Turkish kindred. *American Journal of Medical Genetics*, 1993; 47: 342–5.
Haemangioendotheliomas–hemihypertrophy	Asymmetric arms Asymmetric face Asymmetric lower limbs Gastrointestinal tumour/polyp/haemangioma Hemihypertrophy Hypertrophy of lower limb Hypertrophy of upper limb Platelet abnormalities	Epithelial hepatoblastoma	Dehner LP *et al.* Vascular tumors of the liver in infants and children. *Archives of Pathology*, 1971; 92: 101. Geiser CF *et al.* Epithelial hepatoblastoma associated with congenital hemihypertrophy and cystathioninuria: presentation of a case. *Paediatrics*, 1970; 46: 66. Wood BP *et al.* Infantile hepatic hemangioendotheliomas associated with hemihypertrophy. *Paediatric Radiology*, 1977; 5: 242–5.
Haemochromatosis (neonatal with multiple malformations)	Anteverted nares Aortic incompetence Apnoea or tachypnoea Blepharophimosis/blepharospasm Bulbous nasal tip Cardiomyopathy Cutis marmorata Horseshoe kidneys Hypoglycaemia	Enlarged liver, greenish brown in colour with architecture distorted by fibrous bands, cholestasis	Taucher SC *et al.* Multiple malformations in neonatal hemochromatosis. (Letter) *American Journal of Medical Genetics*, 1994; 50: 213–14.

Disease	Features	Hepatic abnormalities	Reference(s)
	Hypotonia Large spleen Postaxial polydactyly of fingers Postaxial polydactyly of toes Pulmonary stenosis Small mandible/micrognathia Syndactyly of toes (not 2–3) Ventricular septal defect		
Haemolytic anaemia–polyendocrinopathy	Anaemia/red cell abnormalities Biliary atresia/stenosis Colon, general abnormalities Diabetes mellitus/hyperglycaemia Hypothyroidism/small or absent thyroid Malabsorption Nephritis or nephropathy Proteinuria Recurrent infections	Chronic hepatitis	Colletti RB *et al.* Autoimmune enteropathy and nephropathy with circulating anti-epithelial cell antibodies. *Journal of Paediatrics*, 1991; 118: 858–64. Hill SM *et al.* Autoimmune enteropathy and colitis: is there a generalised autoimmune gut disorder? Gut, 1991; 32: 36–42. Satake N *et al.* A Japanese family of X-linked autoimmune enteropathy with haemolytic anaemia and polyendocrinopathy. *European Journal of Paediatrics*, 1993; 152: 313–15.
Homocystinuria	Advanced bone age/large epiphyses Aminoaciduria Arachnodactyly Blood vessels, general abnormalities Cataract Dislocation of lens Fine hair Generalized depigmentation of hair Long toes Mental retardation Myopia Osteoporosis Pectus carinatum Pectus excavatum Platyspondyly Seizures/abnormal EEG Sparse hair/alopecia areata Thin	Enlarged and fatty liver (rare)	Hu FL *et al.* Molecular basis of cystathionine β-synthase deficiency in pyridoxine responsive and nonresponsive homocystinuria. *Human Molecular Genetics*, 1993; 2: 1857–60. Keskin S *et al.* Case report of homocystinuria: clinical, electroencephalographic, and magnetic resonance imaging findings. *Journal of Child Neurology*, 1994; 9: 210–12. Kraus JP. Molecular basis of phenotype expression in homocystinuria. *Journal of inherited Metabolic Diseases*, 1994; 17: 383–90.
Hunter syndrome (mucopolysaccharidosis type 2)	Aortic stenosis Beaked/wedged vertebrae Coarse facial features Deafness, sensorineural Delayed tooth eruption/development Depressed/flat nasal bridge Epiphyseal dysplasia Inguinal hernia Joint stiffness/arthritis Kyphosis Large nose Macrocephaly Mental retardation	Enlarged liver	Adinolfi M. Hunter syndrome: cloning of the gene, mutations and carrier detection. *Developmental Medicine and Child Neurology*, 1993; 35: 79–85. Ben Simon-Schiff E *et al.* Mutation analysis of Jewish Hunter patients in Israel. *Human Mutation*, 1994; 4: 263–70. Yamada Y *et al.* Mucopolysaccharidosis type 2 (Hunter disease): 13 gene mutations in 52 Japanese patients and carrier

Disease	Features	Hepatic abnormalities	Reference(s)
	Mitral stenosis Mucopolysacchariduria/ oligosacchariduria Pectus carinatum Platyspondyly Sella turcica, J-shaped Short stature, proportionate Thick/wide ribs Umbilical hernia		detection in four families. *Human Genetics*, 1993; 92: 110–14.
Hurler syndrome (mucopolysaccharidosis type IH)	Agenesis/hypoplasia of corpus callosum Aortic stenosis Beaked/wedged vertebrae Cardiomyopathy Cloudy corneas/sclerocornea Coarse facial features Deafness, conductive Depressed/flat nasal bridge Dolichocephaly/scaphocephaly Flared nares Gibbus Hydrocephaly/large ventricles, non-specific Inguinal hernia Joint stiffness/arthritis Limited movement of fingers Macrocephaly Mental retardation Mitral stenosis Mucopolysacchariduria/ oligosacchariduria Prominent forehead/frontal bossing Prominent upper lip Prominent/everted lower lip Proximal tapering of metacarpals Recurrent infections Short stature, proportionate Thick/wide alveolar ridges Wide metacarpals/modelling defect	Enlarged liver, fibrosis, swollen, empty or vacuolated hepatocytes and Kupffer cells	Clarke LA *et al.* Mutation analysis of 19 North American mucopolysaccharidosis type 1 patients: identification of two additional frequent mutations. *Human Mutation*, 1994; 3: 275–82. Cleary MA *et al.* The presenting features of mucopolysaccharidosis type IH (Hurler syndrome). *Acta Paediatrica*, 1995; 84: 337–9.
Ichthyosis–biliary atresia	Biliary atresia/stenosis Ichthyosis	Enlarged liver, portal duct proliferation, bile plugging within bile ducts, cholestasis	Cunningham ML *et al.* Idiopathic extrahepatic biliary atresia: recurrence in sibs in two families. *American Journal of Medical Genetics*, 1988; 31: 421–6. Gunasekaran TS *et al.* Recurrence of extrahepatic biliary atresia in two half sibs. *American Journal of Medical Genetics*, 1992; 43: 592–4.
Ichthyosis–neutral lipid storage disease	Abnormal-coloured nails Aplasia or dysplasia of retina Ataxia Cataract Deafness, sensorineural Ectropion of eyelids Erythema/erythroderma	Enlarged liver, architecture in disarray, vacuolar fatty change	Angelini C *et al.* Multisystem triglyceride storage disorder with impaired long-chain fatty acid oxidation. *Annals of Neurology*, 1980; 7: 5–10. Judge MR *et al.* Neutral lipid storage disease. Case report and lipid

Disease	Features	Hepatic abnormalities	Reference(s)
	Facial weakness High palate Hyperkeratosis Hypotonia Ichthyosis Large spleen Mental retardation Microcephaly Muscle weakness/myopathy Spasticity/increased tendon reflex Storage cells/vacuolated lymphocytes Thick/stiff skin Thickened nails		studies. *British Journal of Dermatology*, 1994; 130: 507–10. Wessalowski R *et al.* Multisystem triglyceride storage disorder without ichthyosis in two siblings. *Acta Paediatrica*, 1994; 83: 93–8.
Infantile Refsum syndrome	Ataxia Cataract Cholesterol/lipids, abnormal Deafness, sensorineural ECG abnormality/conduction defects Hypotonia Ichthyosis Malabsorption Mental retardation Microcephaly Muscle weakness/myopathy Nystagmus Osteoporosis Peripheral neuropathy Retinitis pigmentosa/pigmentary retinopathy/chorioretinitis Seizures/abnormal EEG Short stature, proportionate Spontaneous pain sensation Vascular malformations of brain	Enlarged liver, micronodular cirrhosis	Brown FR III *et al.* Peroxisomal disorders. Neurodevelopmental and biochemical aspects. (Review) *American Journal of Diseases of Childhood*, 1993; 147: 617–26. Chow CW *et al.* Autopsy findings in two siblings with infantile Refsum disease. *Acta Neuropathologica*, 1992; 83: 190–5. Mandel H *et al.* Infantile refsum disease: gastrointestinal presentation of a peroxisomal disorder. *Journal of Paediatric Gastroenterology and Nutrition*, 1992; 14: 83–5.
Ivemark syndrome (asplenia or polysplenia)	Absent or hypoplastic spleen Atrioventricular septal defect Cardiac situs inversus/dextrocardia Congenital cardiac anomaly, unspecified Holoprosencephaly/arhinencephaly Hydranencephaly/porencephaly/arachnoid cyst Hydrocephaly/large ventricles, non-specific Hypoplastic left heart Intestinal malrotation Malformation of the pancreas Meningocele/meningomyelocele Multiple renal cysts Polysplenia Posterior encephalocele/meningocele Pulmonary segmentation defects Single ventricle Situs inversus, abdominal	Biliary atresia with secondary changes in the liver	Carmi R *et al.* Extrahepatic biliary atresia and associated anomalies: etiologic heterogeneity suggested by distinctive patterns of associations. *American Journal of Medical Genetics*, 1993; 45: 683–93. Karrer FM *et al.* Biliary atresia and the polysplenia syndrome. *Journal of Paediatric Surgery*, 1991; 26: 524–7. Wainwright H *et al.* Polysplenia syndrome and congenital short pancreas. *American Journal of Medical Genetics*, 1993; 47: 318–20.

Disease	Features	Hepatic abnormalities	Reference(s)
	Transposition of the great vessels Truncus arteriosus		
Jeune syndrome (asphyxiating thoracic dystrophy)	Acetabular spurs Cone-shaped epiphyses of phalanges Epiphyseal dysplasia Hydrocephaly/large ventricles, non-specific Metaphyseal dysplasia Multiple renal cysts Narrow thorax/funnel chest Nephritis or nephropathy Pancreas (exocrine), general abnormalities Postaxial polydactyly of fingers Preaxial polydactyly of fingers Proportionate short arms Proportionate shortening of lower limbs Retinitis pigmentosa/pigmentary retinopathy/chorioretinitis Rhizomelia of lower limbs Rhizomelia of upper limbs Short ribs Short stature, proportionate Short stature, short limbs Trachea or laryngeal anomalies	Cirrhosis	Hudgins L *et al.* Early cirrhosis in survivors with Jeune thoracic dystrophy. *Journal of Paediatrics*, 1992; 120: 754–6.
Kahn syndrome (berry aneurysms; cirrhosis; emphysema; cerebral calcifications)	Clubbing of fingers (drumstick) Incoordination Intracranial calcification Large spleen Lung cysts Lung, general abnormalities Mental retardation Seizures/abnormal EEG Short stature, proportionate Speech defect/dysarthria Vascular malformations of brain	Cirrhosis	Kahn E *et al.* Berry aneurysms, cirrhosis, pulmonary emphysema, and bilateral symmetrical cerebral calcifications: a new syndrome. *American Journal of Medical Genetics*, 1987; Suppl. 3: 343–56.
Kartagener syndrome	Bronchiectasis Cardiac situs inversus/dextrocardia Congenital cardiac anomaly, unspecified Hydrocephaly/large ventricles, non-specific Polysplenia Situs inversus, abdominal	Situs inversus	Inamitsu M *et al.* Ciliary ultrastructure in a child with Kartagener's syndrome. A transmission electron microscopic study using tannic acid staining. *European Archives of Oto-rhino-larynology*, 1990; 248: 49–52. Losa M *et al.* Kartagener syndrome: an uncommon cause of neonatal respiratory distress? *European Journal of Paediatrics*, 1995; 154: 236–8. Narayan D *et al.* Unusual inheritance of primary ciliary dyskinesia (Kartagener's syndrome). *Journal of Medical Genetics*, 1994; 31: 493–6.
Katz syndrome (short stature; hepatomegaly; abnormal glucose tolerance)	Acanthosis nigricans Advanced bone age/large epiphyses Brachydactyly	Enlarged liver with abnormal function	Katz M. Case report 7. *Syndrome Identification*, 1973; 1(2): 6–9.

Disease	Features	Hepatic abnormalities	Reference(s)
	Clinodactyly Convex/beaked profile of nose Diabetes mellitus/hyperglycaemia Dolichocephaly/scaphocephaly Late puberty in females Macules Primary amenorrhoea Prominent forehead/frontal bossing Short stature, proportionate Short/hypoplastic metacarpals Small mandible/micrognathia Sparse hair/alopecia areata Thick calvarium		
Keating syndrome (X-linked glycogen storage disease)	Joint stiffness/arthritis Late puberty in males Muscle weakness/myopathy Short stature, proportionate	Enlarged liver with glycogen storage in cytoplasm	Keating JP *et al.* X-linked glycogen storage disease: a cause of hypotonia, hyperuricemia, and growth retardation. *American Journal of Diseases of Childhood*, 1985; 139: 609–13.
Larsen syndrome (cone dystrophy; liver disease; deafness; endocrine anomalies)	Aplasia or dysplasia of retina Deafness, sensorineural Diabetes mellitus/hyperglycaemia Hypertension Hypothyroidism/small or absent thyroid Liver/biliary system, general abnormalities Night blindness Optic atrophy Sella turcica, large	Unspecified liver degeneration with fatty infiltration	Berg K *et al.* Familial syndrome of progressive cone dystrophy, degenerative liver disease, and endocrine dysfunction: III. Genetic studies. *Clinical Genetics*, 1978; 13: 190–200. Larsen IF *et al.* Familial syndrome of progressive cone dystrophy, degenerative liver disease and endocrine dysfunction. II. Clinical and metabolic studies. *Clinical Genetics*, 1978; 13: 176–89.
Long-chain acyl-CoA dehydrogenase deficiency	Cardiomyopathy Feeding problems in infants Hypoglycaemia Hypotonia Mental retardation Microcephaly Muscle weakness/myopathy Organicaciduria	Enlarged liver, lipid deposits, centrolobular necrosis	Aoyama T *et al.* Cloning of human very-long-chain acyl-coenzyme A dehydrogenase and molecular characterization of its deficiency in two patients. *American Journal of Human Genetics*, 1995; 57: 273–83. Coates PM. Very-long-chain acyl-CoA dehydrogenase deficiency: molecular genetics of a mitochondrial membrane enzyme. (Editorial) *American Journal of Human Genetics*, 1995; 57: 233–4.
Lutz–Richner syndrome (renal tubular insufficiency; jaundice; multiple anomalies)	Abnormal placement of anus Aminoaciduria Biliary atresia/stenosis Blepharophimosis/blepharospasm Broad/barrel thorax Congenital cardiac anomaly, unspecified Dislocation of hip High palate Hypotonia Nephritis or nephropathy Polymorph abnormalities Proteinuria	Jaundice, pigment granules in hepatocytes (lipofuscin), periportal inflammatory cells, paucity of bile ducts	Horslen SP *et al.* Liver histology in the arthrogryposis multiplex congenita, renal dysfunction, and cholestasis (ARC) syndrome: report of three new cases and review. *Journal of Medical Genetics*, 1994; 31: 62–4. Mikati MA *et al.* Renal tubular insufficiency, cholestatic jaundice, and multiple congenital anomalies—a new multisystem syndrome. *Helvetica Paediatrica Acta*, 1984; 39: 463–71.

Disease	Features	Hepatic abnormalities	Reference(s)
	Recurrent infections Rocker-bottom feet (see also vertical talus) Small mandible/micrognathia Thin Wide-spaced nipples		
Mainzer–Saldino syndrome (retinal dysplasia; renal defects; skeletal anomalies)	Arachnodactyly Ataxia Cerebellar abnormalities (structural) Cone-shaped epiphyses of phalanges Delayed bone age Fine hair Hypotonia Joint laxity Mental retardation Metaphyseal dysplasia Nephritis or nephropathy Optic atrophy Ptosis of eyelids Renal dysplasia Retinitis pigmentosa/pigmentary retinopathy/chorioretinitis Short stature, proportionate Small kidneys Small penis (including micro) Small testes	Enlarged liver with hepatic fibrosis, histologically	Ellis DS *et al.* Leber's congenital amaurosis associated with familial juvenile nephronophthisis and cone-shaped epiphyses of the hands (the Mainzer–Saldino syndrome). *American Journal of Ophthalmology*, 1984; 97: 233–9. Robins DG *et al.* Juvenile nephronophthisis associated with skeletal abnormalities and hepatic fibrosis. *Archives of Diseases of Childhood*, 1976; 51: 799–801.
Mannosidosis	Ataxia Beaked/wedged vertebrae Broad base to nose Cataract Cloudy corneas/sclerocornea Coarse facial features Deafness, sensorineural Depressed/flat nasal bridge Gibbus Joint stiffness/arthritis Kyphosis Large spleen Large tongue Mental retardation Mucopolysacchariduria/oligosacchariduria Osteoporosis Platyspondyly Protuberant abdomen Short neck Short stature, proportionate Storage cells/vacuolated lymphocytes Thick calvarium Umbilical hernia Wide metacarpals/modelling defect	Enlarged liver	Bennet JK *et al.* Clinical and biochemical analysis of two families with type 1 and type 2 mannosidosis. *American Journal of Medical Genetics*, 1995; 55: 21–6.
Maroteaux–Lamy syndrome (mucopolysaccharidosis type 6)	Aortic stenosis Beaked/wedged vertebrae Cardiomyopathy	Enlarged liver	Isbrandt D *et al.* Mucopolysaccharidosis VI (Maroteaux–Lamy syndrome): six

Disease	Features	Hepatic abnormalities	Reference(s)
	Cloudy corneas/sclerocornea Coarse facial features Deafness, conductive Deafness, sensorineural Depressed/flat nasal bridge Epiphyseal dysplasia Genu valgum Glaucoma Kyphosis Large nose Large spleen Large tongue Mitral incompetence Mucopolysacchariduria/ oligosacchariduria Platyspondyly Prominent forehead/frontal bossing Sella turcica, J-shaped Short stature, proportionate Storage cells/vacuolated lymphocytes Thick lower lip Thick upper lip Thick/stiff skin Thick/wide ribs Umbilical hernia		unique arylsulfatase B gene alleles causing variable disease phenotypes. *American Journal of Human Genetics*, 1994; 54: 454–63. Jin W-D *et al.* Mucopolysaccharidosis type 6: identification of three mutations in the arylsulfatase B gene of patients with the severe and mild phenotypes provides molecular evidence for genetic heterogeneity. *American Journal of Human Genetics*, 1992; 50: 795–800.
Mathias syndrome (X-linked laterality sequence)	Abnormal placement of anus Absent or hypoplastic spleen Absent sacrum Anal atresia/stenosis Anomalous venous return Atrial septal defect Atrioventricular septal defect Cardiac situs inversus/dextrocardia Cerebellar abnormalities (structural) Duodenal stenosis Fallot tetralogy Holoprosencephaly/arhinencephaly Hydrocephaly/large ventricles, non-specific Hypertelorism Malformed uterus Meningocele/meningomyelocele Mitral incompetence Patent ductus arteriosus Polysplenia Pulmonary stenosis Single ventricle Situs inversus, abdominal Splenic abnormalities, unspecified Transposition of the great vessels Ventricular septal defect	Biliary atresia, situs inversus	Casey B *et al.* Mapping a gene for familial situs abnormalities to human chromosome Xq24-q27.1. *Nature Genetics*, 1993; 5: 403–7. Mathias RS *et al.* X-linked laterality sequence: situs inversus, complex cardiac defects, splenic defects. *American Journal of Medical Genetics*, 1987; 28: 111–16. Mikkila SP *et al.* X-linked laterality sequence in a family with carrier manifestations. *American Journal of Medical Genetics*, 1994; 49: 435–8.
Meckel–Gruber syndrome (dysencephalia splanchnocystica)	Anal atresia/stenosis Cerebellar abnormalities (structural) Cerebral atrophy/myelin abnormality Cleft palate	Enlarged liver, grossly fibrotic, cystic	Blankenberg TA *et al.* Pathology of renal and hepatic anomalies in Meckel syndrome. *American Journal of Medical Genetics*, 1987; Suppl. 3: 395–410.

Disease	Features	Hepatic abnormalities	Reference(s)
	Cleft upper lip (non-midline) Dandy–Walker malformation Holoprosencephaly/arhinencephaly Hypospadias Lung hypoplasia/agenesis Mental retardation Microcephaly Microphthalmia Multiple renal cysts Neonatal teeth Pancreas (exocrine), general abnormalities Polydactyly/bifid thumb Polysplenia Postaxial polydactyly of fingers Postaxial polydactyly of toes Posterior encephalocele/meningocele Posteriorly rotated ears Preaxial polydactyly of fingers Pulmonary segmentation defects		Paavola P *et al.* The locus for Meckel syndrome with multiple congenital anomalies maps to chromosome 17q2l-q24. (Letter.) *Nature Genetics*, 1995; 11: 213–15. Wright C *et al.* Meckel syndrome: what are the minimum diagnostic criteria? *Journal of Medical Genetics*, 1994; 31: 482–5.
Medium-chain acyl-CoA dehydrogenase deficiency	Apnoea or tachypnoea Cardiomyopathy Cerebral atrophy/myelin abnormality Deafness, sensorineural Dementia/psychosis Feeding problems in infants Hypoglycaemia Hypotonia Muscle weakness/myopathy Organicaciduria Retinitis pigmentosa/pigmentary retinopathy/chorioretinitis Seizures/abnormal EEG	Steatosis	Andresen BS *et al.* Medium-chain acyl-CoA dehydrogenase (MCAD) deficiency due to heterozygosity for the common mutation and an allele resulting in low levels of MCAD mRNA. *Journal of Inherited Metabolic Diseases*, 1994; 17: 275–8. Iafolla AK *et al.* Medium-chain acyl-coenzyme A dehydrogenase deficiency: clinical course in 120 affected children. *Journal of Paediatrics*, 1994; 124: 409–15. Losty HC *et al.* Fatty infiltration in the liver in medium chain acyl CoA dehydrogenase deficiency. *Archives of Diseases of Childhood*, 1991; 66: 727.
Mevalonic aciduria	Anaemia/red cell abnormalities Ataxia Cardiomyopathy Cataract Cerebellar abnormalities (structural) Dolichocephaly/scaphocephaly Fontanelles, delayed closure/large Hypotonia Joint stiffness/arthritis Large spleen Long/prominent eyelashes Malabsorption Mental retardation Microcephaly Muscle weakness/myopathy Oedema (including hydrops) Organicaciduria	Enlarged liver	Hoffmann GF *et al.* Clinical and biochemical phenotype in 11 patients with mevalonic aciduria. *Paediatrics*, 1993; 91: 915–21. Mancini J *et al.* Mevalonic aciduria in 3 siblings: a new recognizable metabolic encephalopathy. *Paediatric Neurology*, 1993; 9: 243–6.

Disease	Features	Hepatic abnormalities	Reference(s)
	Palpebral fissures slant down Papules Posteriorly rotated ears Prominent forehead/frontal bossing Protuberant abdomen Retinitis pigmentosa/pigmentary retinopathy/chorioretinitis Seizures/abnormal EEG Short stature, proportionate Spasticity/increased tendon reflex Syndactyly of toes (not 2–3) Triangular face		
Mitochondrial cytopathy–diabetes mellitus–ataxia–renal tubular abnormalities	Anaemia/red cell abnormalities Ataxia Cardiomyopathy Cataract Deafness, sensorineural Diabetes mellitus/hyperglycaemia Enlarged liver Generalized hirsutism Multiple renal cysts Muscle weakness/myopathy Nephritis or nephropathy Parathyroid, absent/hypoparathyroidism Patchy pigmentation of skin/café-au-lait spots Retinitis pigmentosa/pigmentary retinopathy/chorioretinitis Seizures/abnormal EEG Short stature, proportionate	Enlarged liver, steatosis, liver failure	Cormier-Daire V *et al.* Mitochondrial DNA rearrangements with onset as chronic diarrhea with villous atrophy. *Journal of Paediatrics*, 1994; 124: 63–70. Luder A *et al.* Complex I deficiency with diabetes, Fanconi syndrome and mtDNA deletion. *Journal of Inherited Metabolic Diseases*, 1994; 17: 298–300. Tulinius MH *et al.* Atypical presentation of multisystem disorders in two girls with mitochondrial DNA deletions. *European Journal of Paediatrics*, 1995; 154: 35–42.
Moore–Federman syndrome	Brachydactyly Detached retina Glaucoma Hoarse voice Hypermetropia Joint stiffness/arthritis Limited movement of fingers Limited movement/flexion deformity of elbow Platyspondyly Respiratory abnormality, unspecified Short stature, proportionate Thick/stiff skin	Enlarged liver	Fell JME *et al.* Reviving the Moore–Federman syndrome. *Journal of the Royal Society of Medicine*, 1993; 86: 52–3. Winter RM *et al.* Moore–Federman syndrome and acromicric dysplasia: are they the same entity? *Journal of Medical Genetics*, 1989; 26: 320–5.
Mucolipidosis type 4	Agenesis/hypoplasia of corpus callosum Bulbous nasal tip Cloudy corneas/sclerocornea Coarse facial features Extrapyramidal disorder Hypertonia Hypotonia Kyphosis Large spleen Mental retardation Optic atrophy	Enlarged liver	Casteels I *et al.* Mucolipidosis type 4. Presentation of a mild variant. *Ophthalmic Paediatrics and Genetics*, 1992; 13: 205–10. Reis S *et al.* Mucolipidosis type 4: a mild form with late onset. *American Journal of Medical Genetics*, 1993; 47: 392–4. Riedel KG *et al.* Ocular abnormalities in mucolipidosis IV. *American Journal of Ophthalmology*, 1985; 99: 125–36.

Disease	Features	Hepatic abnormalities	Reference(s)
	Photophobia Retinitis pigmentosa/pigmentary retinopathy/chorioretinitis Scoliosis Spasticity/increased tendon reflex Storage cells/vacuolated lymphocytes Strabismus/gaze palsy Thick lower lip Thick upper lip Thickened/oedematous eyelids		
Mucopolysaccharidosis type 7 (β-glucuronidase deficiency)	Anteverted nares Beaked/wedged vertebrae Cloudy corneas/sclerocornea Coarse facial features Craniosynostosis Depressed/flat nasal bridge Gibbus Joint stiffness/arthritis Large spleen Limited movement of fingers Macrocephaly Mental retardation Mucopolysacchariduria/oligosacchariduria Pectus carinatum Pectus excavatum Prominent forehead/frontal bossing Proximal tapering of metacarpals Seizures/abnormal EEG Short stature, proportionate Storage cells/vacuolated lymphocytes Thick/wide alveolar ridges Umbilical hernia Wide metacarpals/modelling defect	Enlarged liver, prolonged jaundice, giant cell hepatitis	de Kremer RD *et al.* Mucopolysaccharidosis type 7 (β-glucuronidase deficiency): a chronic variant with an oligosymptomatic severe skeletal dysplasia. *American Journal of Medical Genetics*, 1992; 44: 145–52. Yamada S *et al.* Four novel mutations in mucopolysaccharidosis type 7 including a unique base substitution in exon 10 of the β-glucuronidase gene that creates a novel 5′-splice site. *Human Molecular Genetics*, 1995; 4: 651–5.
Mucopolysaccharidosis type 7 (di Ferrante syndrome)	Beaked/wedged vertebrae Coarse hair Deafness, conductive Generalized depigmentation of hair Generalized hirsutism Large spleen Mental retardation Mucopolysacchariduria/oligosacchariduria Odontoid hypoplasia/dysplasia Perthes′/dysplastic hip Short stature, proportionate Thick/wide ribs	Enlarged liver	Ginsberg LC *et al.* *N*-Acetylglucosamine-6-sulfate sulfatase in man: deficiency of the enzyme in a new mucopolysaccharidosis. *Paediatric Research*, 1978; 12: 805–9. Matalon R *et al.* Keratan and heparan sulfaturia—a new mucopolysaccharidosis with *N*-acetylglucosamine-6-sulfatase deficiency. (Abstract) *Paediatric Research*, 1978; 12: 453.
Mulibrey nanism	Cardiomyopathy Constrictive pericarditis Depressed/flat nasal bridge Fibrous dysplasia of bones High frontal hairline Hydrocephaly/large ventricles, non-specific	Enlarged and cirrhotic liver	Balg S, Stengel-Rutkowski S, Dohlemann C *et al.* *Clinical Dysmorphology*, 1995; 4: 63–9. Lapunzina P *et al.* Mulibrey nanism: three additional patients and a review of 39 patients. *American*

Disease	Features	Hepatic abnormalities	Reference(s)
	Hypertelorism Isolated growth hormone deficiency Medullary space stenosis Mental retardation Muscle weakness/myopathy Oligodontia Pericarditis (non-constrictive) Prominent forehead/frontal bossing Retinitis pigmentosa/pigmentary retinopathy/chorioretinitis Sella turcica, J-shaped Short stature, prenatal onset Short stature, proportionate Slender/thin bones Triangular face Underdevelopment of cranial sinus Wide nasal bridge		*Journal of Medical Genetics*, 1995; 55: 349–55.
Multiple sulphatase deficiency	Aplasia or dysplasia of retina Ataxia Beaked/wedged vertebrae Cardiomyopathy Cloudy corneas/sclerocornea Coarse facial features Coarse hair Deafness, sensorineural Epiphyseal dysplasia Gibbus Hypoplastic ilia Ichthyosis Large spleen Macrocephaly Mental retardation Mucopolysaccharidurias/oligosaccharidurias Optic atrophy Pigmentary abnormality of macula Retinitis pigmentosa/pigmentary retinopathy/chorioretinitis Seizures/abnormal EEG Sella turcica, J-shaped Spasticity/increased tendon reflex Stippled or fragmented epiphyses Storage cells/vacuolated lymphocytes Thick/wide ribs	Enlarged liver	Al Aqeel A *et al.* Saudi variant of multiple sulfatase deficiency. *Journal of Child Neurology*, 1992; 7(Suppl.): S12–21. Harbord M *et al.* Multiple sulfatase deficiency with early severe retinal degeneration. *Journal of Child Neurology*, 1991; 6: 229–35. Schmidt B *et al.* A novel amino acid modification in sulfatases that is defective in multiple sulfatase deficiency. *Cell*, 1995; 82: 271–8.
Mulvihill syndrome (progeria-like syndrome)	Blepharophimosis/blepharospasm Brachydactyly Clinodactyly Cloudy corneas/sclerocornea Cryptorchid testes Deafness, sensorineural Deficient adipose tissue or fat/lipodystrophy Diabetes mellitus/hyperglycaemia Dolichocephaly/scaphocephaly Fontanelles, delayed closure/large	Enlarged liver	Baraitser M *et al.* A recognisable short stature syndrome with premature aging and pigmented naevi. *Journal of Medical Genetics*, 1988; 25: 53–6. Bartsch O *et al.* Mulvihill-Smith syndrome: case report and review. *Journal of Medical Genetics*, 1994; 31: 707–11.

Disease	Features	Hepatic abnormalities	Reference(s)
	Hypohidrotic or dry skin Hypoplastic phalanges Hypospadias Immunoglobulin abnormality Irregular or crowded teeth Late puberty in males Low birthweight (< 3rd centile) Malocclusion of teeth Mental retardation Microcephaly Microstomia Naevi or lentigines Oligodontia Palpebral fissures slant down Pinched nose Premature ageing Prominent ears Recurrent infections Short stature, prenatal onset Small mandible/micrognathia Small/hypoplastic/deep-set nails Sparse hair/alopecia areata T-cell deficiency Telangiectasia/angiokeratomas of skin Thin Thin ear helix Thin skin/generalized skin atrophy Triangular face		
Nezelof syndrome (arthrogryposis; renal dysfunction; hepatic disease)	Cataract Club foot, varus Flexion deformity at wrist Hypercalciuria Joint contractures (including arthrogryposis) Muscle atrophy Nephritis or nephropathy Polyuria Proteinuria Proximal placement of thumb Renal dysplasia Ulnar deviation of hand	Pigment storage in hepatocytes, giant cell transformation, bile duct proliferation	Di Rocco M *et al.* Arthrogryposis, renal dysfunction and cholestasis syndrome: report of five patients from three Italian families. *European Journal of Paediatrics*, 1995; 154: 835–9. Horslen SP *et al.* Liver histology in the arthrogryposis multiplex congenita, renal dysfunction, and cholestasis (ARC) syndrome: report of three new cases and review. *Journal of Medical Genetics*, 1994; 31: 62–4.
Niemann–Pick disease	Ataxia Dementia/psychosis Diffuse increased pigmentation of skin Large spleen Macular red spot/cherry red spot Mental retardation Papules Patchy pigmentation of skin/café-au-lait spots Pigmentary abnormality of macula Respiratory abnormality, unspecified Seizures/abnormal EEG	Prolonged jaundice, fibrosis, storage material in Kupffer cells	Kelly DA *et al.* Niemann–Pick disease type C: diagnosis and outcome in children, with particular reference to liver disease. *Journal of Paediatrics*, 1993; 123: 242–7. Kristjansson K *et al.* Niemann–Pick-like liver disease and reduced cholesterol esterification in fibroblasts of two male infants. *European Journal of Paediatrics*, 1994; 153: 347–51.

Disease	Features	Hepatic abnormalities	Reference(s)
	Storage cells/vacuolated lymphocytes Strabismus/gaze palsy Thick/stiff skin		
Oculo-encephalo-hepato-renal syndrome	Anteverted nares Ataxia Blepharophimosis/blepharospasm Cerebellar abnormalities (structural) Coloboma of retina/choroid Down-turned corners of the mouth Extrapyramidal disorder Hydrocephaly/large ventricles, non-specific Hypertelorism Low-set ears Mental retardation Multiple renal cysts Notched/hypoplastic alae nasi Posterior encephalocele/meningocele Prominent ears Prominent/everted lower lip Seizures/abnormal EEG Small kidneys Spasticity/increased tendon reflex Ulnar deviation of hand	Hepatic fibrosis	Lewis SME *et al.* Joubert syndrome with congenital hepatic fibrosis: an entity in the spectrum of oculo-encephalo-hepato-renal disorders. *American Journal of Medical Genetics*, 1994; 52: 419–26.
Omenn syndrome (1965) (reticuloendotheliosis; eosinophilia)	Absent/hypoplastic thymus Bowed femur Bullae or vesicles Erythema/erythroderma Flared ribs/anterior splaying Ichthyosis Immunoglobulin abnormality Large spleen Lymphadenopathy Lymphomas/leukaemias Metaphyseal dysplasia Papules Polymorph abnormalities Short bones Sparse hair/alopecia areata T-cell deficiency Thymus, general abnormalities Wide metaphysis	Enlarged liver, mild fibrosis, cholestasis, bile duct proliferation	Glastre C *et al.* Omenn syndrome: a review. (In French—summary in English) *Pediatrie*, 1990; 45: 301–5. Gomez L *et al.* Treatment of Omenn syndrome by bone marrow transplantation. *Journal of Paediatrics*, 1995; 127: 76–81.
Pearson syndrome	Absent or hypoplastic spleen Anaemia/red cell abnormalities Cardiomyopathy Cloudy corneas/sclerocornea Delayed bone age Diabetes mellitus/hyperglycaemia Hypotonia Low birthweight (< 3rd centile) Malabsorption Organicaciduria Osteoporosis Pancreatic insufficiency	Progressive enlargement of liver	Bernes SM *et al.* Identical mitochondrial DNA deletion in mother with progressive external ophthalmoplegia and son with Pearson marrow-pancreas syndrome. *Journal of Paediatrics*, 1993; 123: 598–602. Mazziotta MRM *et al.* Fatal infantile liver failure associated with mitochondrial DNA depletion. *Journal of Paediatrics*, 1992; 121: 896–901.

Disease	Features	Hepatic abnormalities	Reference(s)
	Platelet abnormalities Polymorph abnormalities Short stature, proportionate Splenic abnormalities, unspecified Storage cells/vacuolated lymphocytes Thick/wide ribs		Rotig A *et al.* Spectrum of mitochondrial DNA rearrangements in the Pearson marrow-pancreas syndrome. *Human Molecular Genetics*, 1995; 4: 1327–30.
Pipecolic acidaemia	Aminoaciduria Hypotonia Mental retardation Nystagmus Optic atrophy Organicaciduria Seizures/abnormal EEG	Neonatal jaundice, large liver, periportal fibrosis, fat in hepatocytes, no peroxisomes seen, trilamina structures	Moser HW. Peroxisomal disorders. *Journal of Paediatrics*, 1986; 108: 89–91. Moser HW. Hyperpipecolic acidemia. *Advances in Paediatrics*, 1989; 36: 17.
Polyneuropathy–organomegaly–endocrinopathy–M protein–skin changes (POEMS) syndrome	Anaemia/red cell abnormalities Ascites Calcification of arteries Capillary haemangioma Cavernous haemangioma Clubbing of fingers (drumstick) Diffuse increased pigmentation of skin Generalized hirsutism Gynaecomastia Hyperhidrosis Large spleen Lymphadenopathy Muscle weakness/myopathy Oedema of lower limbs Osteosclerosis or osteopetrosis Papilloedema/optic neuritis Peripheral neuropathy Platelet abnormalities Thick/stiff skin	Enlarged liver, occlusion of hepatic veins (Budd–Chiari syndrome)	Jackson A *et al.* A case of POEMS syndrome associated with essential thrombocythaemia and dermal mastocytosis. *Postgraduate Medical Journal*, 1990; 66: 761–7. Miralles GD *et al.* Plasma-cell dyscrasia with polyneuropathy—the spectrum of POEMS syndrome. *New England Journal of Medicine*, 1992; 327: 1919–23. Steinberg D *et al.* A 49-year-old woman with peripheral neuropathy, hepatosplenomegaly, and intermittent abdominal pain. *New England Journal of Medicine*, 1992; 327: 1014–21.
Pseudo-Zellweger syndrome	Adrenal hypoplasia/insufficiency Cat cry/weak, high-pitched cry Cerebral atrophy/myelin abnormality Delayed bone age Depressed/flat nasal bridge Epicanthic folds Expressionless/dull face Feeding problems in infants Fontanelles, delayed closure/large High palate Hypertelorism Hypotonia Large kidneys Lissencephaly/pachygyria/polymicrogyria Low-set ears Mental retardation Multiple renal cysts Osteoporosis Persistent hyaloid artery Postaxial polydactyly of fingers	Mild steatosis	Nakada Y *et al.* A case of pseudo-Zellweger syndrome with a possible bifunctional enzyme deficiency but detectable enzyme protein. Comparison of two cases of Zellweger syndrome. *Brain and Development*, 1993; 15: 453–6. Pietrzyk JJ *et al.* Two siblings with phenotypes mimicking peroxisomal disorders but with discordant biochemical findings. *Clinical Paediatrics*, 1990; 29: 479–84. Schutgens RBH *et al.* A new variant of Zellweger syndrome with normal peroxisomal functions in cultured fibroblasts. *Journal of Inherited Metabolic Diseases*, 1994; 17: 319–22.

Disease	Features	Hepatic abnormalities	Reference(s)
	Prominent upper lip Recurrent infections Seizures/abnormal EEG Ventricular septal defect		
Renal–hepatic–pancreatic dysplasia	Absent or hypoplastic spleen Biliary atresia/stenosis Cardiac situs inversus/dextrocardia Congenital cardiac anomaly, unspecified Diabetes mellitus/hyperglycaemia Hypothyroidism/small or absent thyroid Multiple renal cysts Pancreas (exocrine), general abnormalities Polysplenia Renal dysplasia Renal tubular acidosis Situs inversus, abdominal Transposition of the great vessels	Cholestasis resulting in fibrosis	Carmi R *et al.* Extrahepatic biliary atresia and associated anomalies: etiologic heterogeneity suggested by distinctive patterns of associations. *American Journal of Medical Genetics*, 1993; 45: 683–93. Lurie IW *et al.* Renal–hepatic–pancreatic dysplasia and its variants. *Genetic Counseling*, 1991; 2: 17–20. Pinar H *et al.* Renal dysplasia, situs inversus totalis, and multisystem fibrosis: a new syndrome. *Paediatric Pathology*, 1992; 12: 215–21.
Renal–hepatic–pancreatic dysplasia with Dandy–Walker cyst	Absent/abnormal gallbladder Anomalous venous return Anophthalmia Atrial septal defect Cerebellar abnormalities (structural) Dandy–Walker malformation Duplicated/right aortic arch Fontanelles, delayed closure/large Heart, general abnormalities Hydrocephaly/large ventricles, non-specific Hypertelorism Low-set ears Lung hypoplasia/agenesis Malformation of the pancreas Malformed uterus Microphthalmia Multiple renal cysts Polysplenia Posterior encephalocele/meningocele Protuberant abdomen Small mandible/micrognathia	Enlarged liver, fibrosis	Genuardi M *et al.* Cerebro-reno-digital (Meckel-like) syndrome with Dandy–Walker malformation, cystic kidneys, hepatic fibrosis, and polydactyly. *American Journal of Medical Genetics*, 1993; 47: 50–3. Hunter AGW, Jimenez C, Tawagi FGR. Familial renal–hepatic–pancreatic dysplasia and Dandy–Walker cyst: a distinct syndrome? *American Journal of Medical Genetics*, 1991; 41: 201–7. Summers MC *et al.* Dandy–Walker malformation in the Meckel syndrome. *American Journal of Medical Genetics*, 1995; 55: 57–61. Walpole *et al.* Dandy-Walker malformation (variant), cystic dysplastic kidneys, and hepatic fibrosis: a distinct entity or Meckel's syndrome? *American Journal of Medical Genetics*, 1991; 39: 294–8.
Salla disease (lysosomal storage disorder)	Agenesis/hypoplasia of corpus callosum Ascites Ataxia Cerebellar abnormalities (structural) Cerebral atrophy/myelin abnormality Cloudy corneas/sclerocornea Coarse facial features Dementia/psychosis Depressed/flat nasal bridge Hypertonia Hypoplastic ilia	Enlarged liver with numerous vacuolated cells. Membrane–bound vesicles containing granuloreticular material	Haataja L *et al.* The genetic locus for free sialic acid storage disease maps to the long arm of chromosome 6. *American Journal of Human Genetics*, 1994; 54: 1042–9. Haataja L *et al.* Phenotypic variation and magnetic resonance imaging (MRI) in Salla disease, a free sialic acid storage disorder. *Neuropediatrics*, 1994; 25: 238–44.

Disease	Features	Hepatic abnormalities	Reference(s)
	Irregular endplates to vertebrae Large spleen Macrostomia Mental retardation Mucopolysacchariduria/ oligosacchariduria Optic atrophy Proximal tapering of metacarpals Ptosis of eyelids Seizures/abnormal EEG Spasticity/increased tendon reflex Speech delay Storage cells/vacuolated lymphocytes Thick eyebrows Thick lower lip Thick upper lip Thickened/oedematous eyelids		
Sanfilippo syndrome (mucopolysaccharidosis type 3)	Acetabulum, general abnormalities Advanced bone age/large epiphyses Aggressive behaviour Aortic stenosis Beaked/wedged vertebrae Coarse facial features Generalized hirsutism Irregular endplates to vertebrae Large spleen Limited movement/flexion deformity of elbow Macrocephaly Medial eyebrow flare Mental retardation Mitral incompetence Mitral stenosis Mucopolysacchariduria/ oligosacchariduria Spasticity/increased tendon reflex Stippled or fragmented epiphyses Synophrys Thick eyebrows Thick lower lip Thick upper lip Thick/stiff skin Thick/wide alveolar ridges Umbilical hernia	Enlarged liver	Di Natale P. Sanfilippo B disease: a re-examination of a particular sibship after 12 years. *Journal of Inherited Metabolic Diseases*, 1991; 14: 23–8. Ozand PT *et al.* Sanfilippo type D presenting with acquired language disorder but without features of mucopolysaccharidosis. *Journal of Child Neurology*, 1994; 9: 408–11. Wraith JE. The mucopolysaccharidoses: a clinical review and guide to management. *Archives of Diseases of Childhood*, 1995; 72: 263–7.
Scheie syndrome (mucopolysaccharidosis type IS)	Aortic incompetence Aortic stenosis Beaked/wedged vertebrae Brachydactyly Camptodactyly Cloudy corneas/sclerocornea Coarse facial features Epiphyseal dysplasia Glaucoma Limited movement of fingers Mitral stenosis	Enlarged liver	Scott HS *et al.* Identification of mutations in the α-L-iduronidase gene (IDUA) that cause Hurler and Scheie syndromes. *American Journal of Human Genetics*, 1993; 53: 973–86. Tieu PT *et al.* Four novel mutations underlying mild or intermediate forms of α-L-iduronidase deficiency (MPS IS and MPS IH/S). *Human Mutation*, 1995; 6: 55–9.

Disease	Features	Hepatic abnormalities	Reference(s)
	Mucopolysacchariduria/ oligosacchariduria Prominent mandible Prominent upper lip Prominent/everted lower lip Retinitis pigmentosa/pigmentary retinopathy/chorioretinitis Short neck Umbilical hernia		Wippermann C-F *et al.* Mitral and aortic regurgitation in 84 patients with mucopolysaccharidoses. *European Journal of Paediatrics*, 1995; 154: 98–101.
Shwachman syndrome (pancreatic insufficiency; neutropenia; metaphyseal dysplasia)	Anaemia/red cell abnormalities Erythema/erythroderma Ichthyosis Macules Malabsorption Mental retardation Metaphyseal dysplasia Narrow thorax/funnel chest Pancreatic insufficiency Papules Patchy pigmentation of skin/café-au-lait spots Platelet abnormalities Polymorph abnormalities Recurrent infections Short ribs Short stature, proportionate Sparse hair/alopecia areata	Enlarged liver, extramedullary haematopoiesis, fatty infiltration, fibrosis	Danks DM *et al.* Metaphyseal chondrodysplasia, neutropenia, and pancreatic insufficiency presenting with respiratory distress in the neonatal period. *Archives of Diseases of Childhood*, 1976; 51: 697–701. Dhar S *et al.* Orthopaedic features of Shwachman syndrome. A report of two cases. *Journal of Bone and Joint Surgery*, 1994; A76: 278–82. Mortureux P *et al.* Shwachman syndrome: a case report. *Paediatric Dermatology*, 1992; 9: 57–61.
Sialic acid storage disease, severe infantile type	Anaemia/red cell abnormalities Anteverted nares Ascites Cerebral atrophy/myelin abnormality Club foot, varus Coarse facial features Erythema/erythroderma Generalized depigmentation of hair Gum hypertrophy Hydrocephaly/large ventricles, non-specific Hypotonia Ichthyosis Inguinal hernia Large spleen Macules Malabsorption Mental retardation Mucopolysacchariduria/ oligosacchariduria Nephritis or nephropathy Oedema (including hydrops) Proteinuria Short stature, prenatal onset Short stature, proportionate Sparse hair/alopecia areata Stippled or fragmented epiphyses Storage cells/vacuolated lymphocytes	Enlarged liver, Kupffer cells with microvacuolated foamy cytoplasm	Berra B *et al.* Infantile sialic acid storage disease: biochemical studies. *American Journal of Medical Genetics*, 1995; 58: 24–31. Paschke E *et al.* Storage material from urine and tissues in the nephropathic phenotype of infantile sialic acid storage disease. *Journal of Inherited Metabolic Diseases*, 1992; 15: 47–56. Schleutker J *et al.* Lysosomal free sialic acid storage disorders with different phenotypic presentations—infantile-form sialic acid storage disease and Salla disease—represent allelic disorders. *American Journal of Human Genetics*, 1995; 57: 893–901.

Disease	Features	Hepatic abnormalities	Reference(s)
Sialidosis type 2	Ascites Ataxia Beaked/wedged vertebrae Bulbous nasal tip Coarse facial features Dementia/psychosis Gibbus Hyperplastic supraorbital ridges Large spleen Macular red spot/cherry red spot Mental retardation Mucopolysacchariduria/ oligosacchariduria Nephritis or nephropathy Pectus carinatum Platyspondyly Proteinuria Scoliosis Seizures/abnormal EEG Sella turcica, J-shaped Short stature, proportionate Spasticity/increased tendon reflex Thick lower lip Thick upper lip	Enlarged liver with foamy cells	Kanaka C *et al.* Mucocutaneous bleeding, a rare but severe complication in nephrosialidosis. (Letter.) *European Journal of Paediatrics*, 1994; 153: 703–4. Sasagasako N *et al.* Prenatal diagnosis of congenital sialidosis. *Clinical Genetics*, 1993; 44: 8–11.
Sialuria	Coarse facial features Hypotonia Large spleen Large tongue Macrocephaly Mental retardation Mucopolysacchariduria/ oligosacchariduria	Enlarged liver, abnormal mitochondria containing unusual circular cristae and intramitochondrial crystalline arrays between the cristae	Don NA *et al.* Sialuria: a follow-up report. *Journal of Inherited Metabolic Diseases*, 1991; 14: 942.
Siegler syndrome (1992) (cataract; malabsorption; renal and hepatic disease)	Anaemia/red cell abnormalities Cataract Malabsorption Nephritis or nephropathy Polyuria Recurrent infections Renal tubular acidosis Short stature, proportionate Small kidneys Strabismus/gaze palsy	Abnormal liver function, enlarged, fibrotic, cholestasis, fatty metamorphosis	Siegler RL *et al.* New syndrome involving the visual, auditory, respiratory, gastrointestinal, and renal systems. *American Journal of Medical Genetics*, 1992; 44: 461–4.
Simpson–Golabi–Behmel syndrome	Acro-osteolysis/acral defects Advanced bone age/large epiphyses Broad base to nose Broad hands Cataract Caudal appendage Cleft of the lower lip Cleft palate Clinodactyly Coarse facial features Coloboma involving optic nerve Congenital cardiac anomaly, unspecified Congenital hernia of diaphragm	Enlarged liver	Garganta CL *et al.* Report of another family with Simpson–Golabi–Behmel syndrome and a review of the literature. *American Journal of Medical Genetics*, 1992; 44: 129–35. Orth U *et al.* Gene for Simpson–Golabi–Behmel syndrome is linked to HPRT in Xq26 in two European families. *American Journal of Medical Genetics*, 1994; 50: 388–90.

Disease	Features	Hepatic abnormalities	Reference(s)
	Crease of ear lobule Cryptorchid testes Detached retina Diffuse increased pigmentation of skin Dystrophic nails ECG abnormality/conduction defects Furrowed tongue/prominent groove Fusion of vertebrae High birthweight (> 90th centile) High palate Hoarse voice Hydronephrosis Hypertelorism Intestinal malrotation Large kidneys Large spleen Large tongue Macrocephaly Macrostomia Mental retardation Mid-face hypoplasia (excluding malar region) Multiple renal cysts Open mouth appearance Palpebral fissures slant down Pectus excavatum Polysplenia Postaxial polydactyly of fingers Prominent mandible Renal tumours (including Wilms') Scoliosis Skin syndactyly of fingers Small/hypoplastic/deep-set nails Small/short nose Submucous cleft palate Supernumerary nipples Tall stature, proportionate Thick lower lip Thick upper lip Umbilical hernia Ventricular septal defect Wide nasal bridge		
Tay syndrome (1974) (mental retardation; facial/pigment abnormalities; cirrhosis; aminoaciduria)	Abnormally shaped teeth Aminoaciduria Deafness, conductive Large spleen Large/prominent teeth Long hallux Mental retardation Microcephaly Microstomia Naevi or lentigines Notched/hypoplastic alae nasi Patchy depigmentation of skin	Enlarged liver with cirrhosis	Tay CH *et al.* A recessive disorder with growth and mental retardation, peculiar facies, abnormal pigmentation, hepatic cirrhosis and aminoaciduria. *Acta Paediatrica Scandinavica*, 1974; 63: 777–82.

Disease	Features	Hepatic abnormalities	Reference(s)
	Patchy pigmentation of skin/café-au-lait spots Pinched nose Prominent eyes/proptosis Short stature, proportionate Short toes Triangular face		
Tyrosinaemia type 1	Aggressive behaviour Aminoaciduria Ascites Ataxia Glycosuria Hypertension Hypertonia Mental retardation Metaphyseal dysplasia Muscle weakness/myopathy Oedema (including hydrops) Peripheral neuropathy Platelet abnormalities Renal tubular acidosis Seizures/abnormal EEG Small bowel atresia/absence/obstruction/short	Enlarged liver, liver failure, macronodular cirrhosis and hepatocellular carcinoma	Barness L *et al.* Pathological case of the month—hereditary tyrosinemia type 1. *American Journal of Diseases of Childhood*, 1992; 146: 769–70. Noble-Jamieson G *et al.* Neurological crisis in hereditary tyrosinaemia and complete reversal after liver transplantation. *Archives of Diseases of Childhood*, 1994; 70: 544–5. Ploos van Amstel JK *et al.* Hereditary tyrosinemia type 1: novel missense, nonsense and splice consensus mutations in the human fumarylacetoacetate hydrolase gene; variability of the genotype–phenotype relationship. *Human Genetics*, 1996; 97: 51–9.
Werner syndrome	Abnormal liver (including function) Calcification of arteries Calcification, subcutaneous Cataract Chromosome instability/breakage Convex/beaked profile of nose Deficient adipose tissue or fat/lipodystrophy Dementia/psychosis Diabetes mellitus/hyperglycaemia Full cheeks Glaucoma Gynaecomastia Hyperthyroidism Hyperkeratosis Lymphomas/leukaemias Muscle atrophy Osteoporosis Patchy depigmentation of skin Patchy pigmentation of skin/café-au-lait spots Peripheral neuropathy Pinched nose Premature ageing Premature atherosclerosis Retinitis pigmentosa/pigmentary retinopathy/chorioretinitis Short stature, proportionate Small feet Small hands Small penis (including micro)	Abnormal liver function	Goto M, *et al.* Genetic linkage of Werner's syndrome to five markers on chromosome 8. *Nature*, 1992; 355: 735–8. Kakigi R *et al.* Accelerated aging of the brain in Werner's syndrome. *Neurology*, 1992; 42: 922–4. Oshima J, *et al.* Integrated mapping analysis of the Werner syndrome region of chromosome 8. *Genomics*, 1994; 23: 100–13.

Disease	Features	Hepatic abnormalities	Reference(s)
	Sparse hair/alopecia areata Spasticity/increased tendon reflex Telangiectasia/angiokeratomata of skin Thin Thin skin/generalized skin atrophy		
Wolman disease (acid lipase deficiency)	Adrenal calcification Anaemia/red cell abnormalities Deficient adipose tissue or fat/lipodystrophy Dementia/psychosis Feeding problems in infants Large spleen Lymphadenopathy Malabsorption Mental retardation Protuberant abdomen Short stature, proportionate Spasticity/increased tendon reflex Storage cells/vacuolated lymphocytes Thin Xanthomas	Swollen foamy Kupffer cells	Anderson RA *et al. In situ* localization of the genetic locus encoding the lysosomal acid lipase/cholesteryl esterase (LIPA) deficient in Wolman disease to chromosome 10q23.2-q23.3. *Genomics*, 1993; 15: 245–7. Wolman M. Wolman disease and its treatment. *Clinical Paediatrics*, 1995; 34: 207–12.
Zellweger (cerebrohepatorenal) syndrome	Absent/hypoplastic thymus Agenesis/hypoplasia of corpus callosum Aminoaciduria Brushfield spots Camptodactyly Cataract Cerebral atrophy/myelin abnormality Depressed/flat nasal bridge Epicanthic folds Feeding problems in infants Flat face Flat occiput Fontanelles, delayed closure/large High frontal hairline Hypoplastic supraorbital ridges Hypotonia Macrocephaly Migration abnormality/heterotopia Multiple renal cysts Pancreas (endocrine), general abnormalities Proteinuria Retinitis pigmentosa/pigmenatry retinopathy/chorioretinitis Seizures/abnormal EEG Small mandible/micrognathia Stippled or fragmented epiphyses Wide nasal bridge	Enlarged liver, prolonged jaundice, liver fibrosis	Braverman N *et al.* Disorders of peroxisome biogenesis. (Review.) *Human Molecular Genetics*, 1995; 4: 1791–8. Brown FR III *et al.* Peroxisomal disorders. Neurodevelopmental and biochemical aspects. (Review.) *American Journal of Diseases of Childhood*, 1993; 147: 617–26. Erdem G *et al.* Intestinal lymphangiectasia in a patient with Zellweger cerebrohepatorenal syndrome. *American Journal of Medical Genetics*, 1995; 58: 152–4.
Zimmermann–Laband syndrome (gingival fibromatosis; nail defects)	Absent nails Absent phalanges Acro-osteolysis/acral defects	Enlarged liver	Bakaeen G *et al.* Hereditary gingival fibromatosis in a family with the Zimmermann–Laband syndrome.

Disease	Features	Hepatic abnormalities	Reference(s)
	Bulbous nasal tip Dystrophic nails Flexion deformity of hip Flexion deformity of knee Generalized hirsutism Gum hypertrophy Large nose Large spleen Large tongue Macrostomia Mental retardation Retinitis pigmentosa/pigmentary retinopathy/chorioretinitis Scoliosis Synophrys Thick lower lip Thick upper lip Thickened ears		*Journal of Oral Pathology and Medicine*, 1991; 20: 457–9. Lacombe D *et al.* Congenital marked hypertrichosis and Laband syndrome in a child: overlap between the gingival fibromatosis-hypertrichosis and Laband syndromes. *Genetic Counseling*, 1994; 5: 251–6.

EEG, electroencephalogram.

Index

Note
Page numbers followed by 'f' and 't' refer to figures and tables respectively.

A

Aagenae syndrome 2122
A:amino acid *N*-acyltransferase 1386
abacavir, hepatotoxicity 984, 1248
ABCB1 (MDR1 p-glycoprotein) 113
ABCB4 gene/protein
  canalicular biliary transport 385, 1518
    adaptive changes in cholestasis 386, 387f
  gene defects 177, 1518t, 1524
  intrahepatic cholestasis 1481, 1483, 1491
  intrahepatic cholestasis of pregnancy 1385, 1880
  primary biliary cirrhosis 1384–1385
  progressive familial intrahepatic cholestasis, type 3 177, 1385
ABCB11 (bile salt export pump) 177
  benign recurrent intrahepatic cholestasis 1524–1525
  canalicular bile transport 296, 385, 1518
    adaptive changes in cholestasis 386, 387f
  gene defects 177, 1384, 1518t, 1524–1525
  hepatocytes 113
  intrahepatic cholestasis 1481, 1483
  progressive familial intrahepatic cholestasis, type 2 177, 1384, 1524
ABCC2 gene/protein
  bilirubin transport 171, 1354
  canalicular bile secretion 112–113
  Dubin–Johnson syndrome 1356, 1385
  glutathione conjugate excretion 1219
  heavy metal transportation 112
  hepatocytes 112–113
  polar expression 125
ABCG2 (BCRP), canalicular bile secretion 113, 296–297
ABC (ATP-binding cassette) transporters *see* ATP-binding cassette (ABC) transporters
abdomen
  auscultation 448
  discomfort 443–444
    primary biliary cirrhosis 1075
  inspection 447
  pain *see* abdominal pain
  palpation 447–448
  percussion 447–448
  trauma
    Budd–Chiari syndrome 1405
    liver injury 1953
abdominal compartment syndrome (ACS) 87, 1957
abdominal pain 443–444
  acute porphyric crisis 1343–1344
  alveolar echinococcosis 1052
  angiosarcoma 1458
  carcinoid syndrome 1474
  differential diagnosis 1529, 1529t
  hepatic artery aneurysms 1393
  Kawasaki disease 1645
  ultrasonography indication 501t
Abernethy shunt (extrahepatic congenital portosystemic shunt) 1418–1419
aberrant pancreaticobiliary duct junction (APBDJ), gallbladder carcinoma 1577
Aβ_2M amyloid 1704
abetalipoproteinaemia 135, 1366
abscess(es)
  actinomycosis 1017
  alveolar echinococcosis 1052
  amoebic *see* amoebic liver abscess (ALA)
  angiography 537
  ascariasis 1059
  elderly 1874
  gallstone-associated 1874
  inflammatory bowel disease 1628
  magnetic resonance imaging 529–530
  melioidosis 1003
  pyogenic *see* pyogenic liver abscess
  Trichosporon beigelii 1013
  ultrasonography 504
  visceral larva migrans 1063
absolute hepatic clearance 569
absolute risk reductions (ARR), meta-analysis 2074
acalculous cholecystitis 1523
  burns complication 1279
  cryptosporidiosis 1025
  diagnosis 1950–1951
  elderly 1875
  risk factors 1950
  surgical treatment 1951
  total parenteral nutrition-induced 1637, 1947
acamprosate, alcoholic liver disease 1167, 1181–1182
acanthocytosis
  abetalipoproteinaemia 1366
  cirrhosis 1770
  spur cell anaemia 1770
acarbose 1737
accessory hepatic artery 4, 1391
accurate mass tags (AMTs) 412
acebutol, acute hepatitis induction 1230
aceruloplasminaemia 222, 1327
acetaldehyde
  adduction 1140–1141
  alcoholic liver disease 1139, 1139t
  fibrogenic properties 585
  mitochondrial membrane cholesterol enrichment 205
  oxidation to acetate 1136
acetaminophen *see* paracetamol
acetate 1135, 1136
acetazolamide 183
acetone, hepatotoxicity 2106
acetyl-CoA carboxylase 91
acetyl-coenzyme A (CoA)
  formation 155
  total parenteral nutrition-related liver disease 1636
  tricarboxylic acid cycle 155
N-acetylcysteine
  acute liver failure 1304
  paracetamol overdose 1237–1238, 1296
N-acetylglutamate, urea synthesis regulation 183
N-acetyl-*m*-aminophenol (AMAP), glutathione depletion 205
N-acetyl-*p*-aminophenol (APAP) *see* paracetamol
acetylsalicylic acid, urea inhibition 183
aciclovir
  Epstein–Barr virus 966
  herpes simplex virus 959
  resistance 959
  side-effects 959
  varicella-zoster virus 960
acid–base balance
  acute liver failure 1131
  anaesthetic implications 1940, 1942
acid β-glucosidase, Gaucher's disease 1360, 1362
acid lipase deficiency *see* Wolman disease
acidophil bodies *see* apoptotic bodies
acidophil condensation 423
acidosis
  anaesthetic implications 1940
  metabolic *see* metabolic acidosis
  renal tubular *see* renal tubular acidosis
  urea synthesis 184f, 186
acid sphingomyelinase (ASM) deficiency, Niemann–Pick disease 1365
acitretin, hepatotoxicity 1230, 1646
ackee *(Blighia sapida),* hepatotoxicity 1272
acquired immunodeficiency syndrome (AIDS) *see* AIDS
acrodermatitis chronica atrophicans 1808
acromegaly 1689–1690
  surgical treatment 1689
acrylonitrile hepatotoxicity 2106
actin aggregates, drug-induced acute hepatitis 1220
actin microfilaments, hepatocyte cytoskeleton 97–98, 97f
actin microfilaments, hepatocytes 97–98, 97f
Actinomyces bovis 1017
Actinomyces israelii 1017
Actinomyces naeslundii 1017
actinomycete infections 1017
actinomycosis 1017
activated charcoal, *Amanita* poisoning 1272
activated partial thromboplastin time (APTT), coagulation disorders 260
activated protein C
  Budd–Chiari syndrome 1404
  cirrhosis 258
active septa 426
active uptake, biliary tree epithelium 1111
activin 1687
activin receptor type II-like kinases (ALK-1, ACVRL1) gene mutation 1419
activity-based protein profiling (ABPP) 404
Actractylis gummifera (glue thistle), hepatotoxicity 2111

acute fatty liver of pregnancy (AFLP) 1881–1883
acute liver failure 1300
causes 1881
clinical features 1885t
complications 1881
diagnosis 1882–1883
diagnostic failure 1882
differential diagnosis 1882–1883
electron microscopy 1882
fetal mortality 1881
follow-up biopsy 1882
further pregnancies 1883
haematological abnormalities 1770
hypertension-associated liver dysfunction 1885, 1885t
incidence 1881
monitoring 1883
pathology 1882
pre-eclampsia 1881
presentation 1881
treatment 1883
acute graft-versus-host disease (aGvHD) 1672–1674
clinical aspects 1672–1673
cutaneous manifestations 1672, 1808
definition 1671–1672
gastrointestinal manifestations 1672–1673
hepatic manifestations 1673
organs affected 1672
pathogenesis 1672
pathological findings 1673–1674
staging/grading 1673
target tissue destruction phase 1672
treatment 1674, 1808
acute hepatitis *see* hepatitis, acute
acute hepatitis B *see* hepatitis B
acute hepatitis of the alcoholic type *see* alcoholic hepatitis
acute intermittent porphyria (AIP) 1344t, 1346
aminolaevulinic acid 1344
diagnosis 1344t
genetic defect 1346
homozygous form 1348
inheritance 1345
liver cell carcinoma, risk of 1346
penetrance 1345
porphobilinogen 1344
acute liver failure (ALF) 1291–1312
causes 1295–1301, 1295t
malignant infiltration 1300
as prognostic marker 1302
children 1856–1860
causes 1858, 1858t
complications 1859
haemodynamic complications 1859
liver transplantation 1859–1860
management 1858–1859
complication prevention 1303
course 1301–1303
cytokines 314t
definitions 1291, 1292t
extracorporeal liver assist devices 1305–1306
hepatitis viruses 1296–1297
hepatocyte transplantation 2033, 2036–2037, 2036t, 2037t, 2039
infancy 1858
in-hospital admission indications 1303t
liver transplantation 1307–1309, 1986
management 1303–1305, 1306t
general measures 1304
objectives 1303–1304
manifestations 1291–1294
liver cell damage 1292
mechanisms 1132–1133
hepatocyte death-regeneration imbalance 1132
mortality 2043
neonatal 1856–1858
causes 1856–1858, 1857t
prevention 1303
of cause 1303
in established liver disease 1303
prognosis 1301–1303
general 1301
laboratory variables 1302
markers 1301–1302
scores 1302–1303
unknown origin 1301
viral infection 1296–1298
acute lung injury (ALI), post-liver transplantation 1999
acute lymphoblastic leukaemia (ALL) 910
acute necrotizing encephalopathy of childhood 1823t, 1825
acute on chronic liver failure (ACLF) 2043
acute porphyric crisis 1343–1344
diagnosis 1345
motor symptoms 1344
pathogenesis 1345–1346
treatment 1345
acute promyelocytic leukaemia (APL), retinoids 217
acute respiratory distress syndrome (ARDS), post-liver transplantation 1999
acute tubular necrosis (ATN)
anaesthetic implications 1939
obstructive jaundice 1503
acyclic retinoid 215f, 217
acyl CoA:cholesterol acyltransferase (ACAT) 92
acyl-CoA synthetase 152
adaptive immune system
alcoholic liver disease pathogenesis 1140–1141
hepatitis C 854–855
hepatocytes 106
adefovir dipivoxil
dialysis patients 1655
hepatitis B 926
cirrhosis 934
extrahepatic manifestations 936
lamivudine combination 929
liver transplantation 934
post-transplantation recurrence 934
precore mutant infection 930
pretransplant patients 1927, 2011
resistance 932–933, 932f
wild-type virus 928
HIV–hepatitis B coinfection 974, 975, 975t
human herpesvirus type 8 966
adenine arabinoside, Epstein–Barr virus 966
adenocarcinoma
cholangiocarcinoma pathology 1585–1586
metastatic 1466f
pancreatic 1185
adenomas
bile duct *see* bile duct adenomas
hepatocellular *see* hepatocellular adenoma
pregnancy 1886
adenosarcoma, hepatic endometriosis 810
adenosine, hepatic arterial buffer response 75–76
adenosine deaminase
cirrhotic ascites 670f
malignant ascites 670f
tuberculous peritonitis 670, 670f
adenosine triphosphate (ATP)
bile secretion 1337
cholangiocytes, effects on 53
hepatic arterial buffer response 76
necrosis 341
oxidative phosphorylation 158–159
production 155, 1377, 1378f
adenosine triphosphate binding cassette protein A1 (ABCA1) 139, 140f
adenosine triphosphate (ATP) synthase
activity levels 160
ischaemia 159
oxidative phosphorylation 158–159
structure 158–159, 160f
adenovirus infection(s) 967–968
acquired immunodeficiencies 968
acute liver failure 1298
diagnosis 968
direct fluorescent assays 968
histopathology 968
immunocompromised 968
invasive multiorgan disease 968
NF-κB pathway blockade 315
organ transplantation recipients 968
treatment 968
adenylyl cyclase 54
ADH2 gene 1143
ADH3 gene 1143
adherens junctions, hepatocytes 22, 97
adipogenesis, non-alcoholic steatohepatitis 1201–1202
adipokines, non-alcoholic steatohepatitis 610–611
adiponectin
fibrosis 596
inhibition, tumour necrosis factor α 1138
non-alcoholic steatohepatitis 594, 1201
adjuvants, hepatitis B vaccine 909–910
adrenal cortex 1685–1686, 1752
iron deposition 1762
adrenal gland
disease, hepatic effects 1685–1686
insufficiency, hepatic effects 1686
physiology 1685–1686
adrenal hormones 1752–1754
haemochromatosis 1762
physiology 1752–1753
see also individual hormones
adrenaline *see* epinephrine
adrenocorticotropic hormone (ACTH) 1685–1686
cortisol regulation 1752
haemochromatosis 1762
pseudo-Cushing syndrome 1753
secretion 1752
adrenoleukodystrophy
neonatal, autosomal recessive 2122
pseudoneonatal 2122–2123
adrenomedullin 1728
adult–adult, split liver transplantation 1971, 1973
adult polycystic kidney disease (ADPKD)
ampulla of Vater adenomas 793
biliary hamartomas 797
genetics 789–790
hepatic cysts and 789–795, 789f
clinical examination 790
clinical features 790
coalescence 791
complications 792–793, 792t
development 790
differential diagnosis 793
fluid 789
haemorrhagic 792, 792t
imaging 790–792
microscopic appearance 789
natural history 790
pathogenesis 789
pathology 789
risk factors 790
rupture 792t, 793
surgery 793–794
treatment 793–794
molecular biology 789–790
adults
alpha-1-antitrypsin deficiency 1332–1333
cytomegalovirus infection 962
living donor liver transplantation 1990–1992
split liver transplantation 1973
advanced life support (ATLS), liver trauma 1953
adverse drug reactions 1212
afferent hepatic nerves 114
metabolic regulation 118–119
glucose-sensitive neurons 119
gut-derived *vs.* endogenous glucose 118
portal sensors 118
spinal neurons 114
vagal neurons 114
afferent (inlet) sphincters, sinusoids 79
afferent veins 427
afibrinogenaemia, Budd–Chiari syndrome 1404
aflatoxicosis 1274
aflatoxin
carcinogenicity 1274, 1439
hepatocellular carcinoma 1274, 1439, 1450
hepatotoxicity 1274, 2106
Africa, infectious liver diseases 2100t
African histoplasmosis 1014, 1015
afterload, cirrhosis 686
age/ageing
acute liver failure 1302
alkaline phosphatase levels 462, 462f
drug-induced hepatitis 1212–1213
gallstone disease 1523
hepatocellular carcinoma 1437
liver cysts, ADPKD 790, 790t
liver sinusoidal endothelial cells 33
liver transplantation contraindications 1922, 1989

non-alcoholic steatohepatitis 1198
primary sclerosing cholangitis 1106, 1490
proteomics 414
simple cyst of the liver 784
Agilent Bioanalyser, RNA quality 402, 402f
agmatinase 182
agnogenic myeloid metaplasia (primary myelofibrosis) 1665
AIDS
cholangitis 1546
cryptococcosis 1014
granulomas 1713
histoplasmosis 1015
penicillinosis 1017
vanishing bile duct syndrome 1115
see also HIV infection
ajmaline
acute hepatitis induction 1230
prolonged cholestasis induction 1254
Alagille syndrome 1387, 1805, 1848–1849, 2124–2125
clinical features 1805, 1848–1849
facial features 1848
growth hormone resistance 1741
management 1849
vanishing bile duct syndrome 1112, 1114t, 1115
AL amyloidosis
clinical manifestations 1704
hepatic involvement 1705
management 1707
pathogenesis 1702
systemic 1703–1704
alanine
ammonia production 181
glucogenic properties 145
alanine aminotransferase (ALT) 451–453
abnormal values
hepatobiliary diseases 452, 453f
nonhepatobiliary diseases 452–453
acalculous cholecystitis 1950
alcoholic cirrhosis 1166
alcoholic macrovesicular steatosis 1160
assays 451–452
Budd–Chiari syndrome 1406, 1407
cirrhosis 612
cocaine users 1232
distribution 451
drug-induced acute hepatitis 1216
hepatic *vs.* cholestatic disease 1900
hepatitis A 859–860
hepatitis C, acute 886
hepatitis E diagnosis 895
hyperbilirubinaemia, postoperative 1949
hypothyroidism 1685
ischaemic hepatitis 1610, 1949
localization 451
non-alcoholic fatty liver disease 1199
non-alcoholic steatohepatitis 1199
normal values 452
postoperative drug-induced liver injury 1949
primary sclerosing cholangitis 1105
reactions 451
sepsis-induced cholestasis 1950
tacrine 1240
total parental nutrition-induced cholestasis 1950
type 2 diabetes mellitus 1681
albendazole
alveolar echinococcosis 1055
ascariasis 1061
Clonorchis sinensis 1046
cystic echinococcosis 1055
strongyloidiasis 1065
Albuferon, chronic hepatitis C 942, 951
albumin 250–255, 454–455
alcoholic hepatitis 1163
assays 454
bilirubin binding 170
cirrhosis 454–455, 612, 674
cirrhotic ascites 667
clinical usefulness 455
conformational adaptation 251
conformational breathing 251
cortisol binding 1752
electrophoresis 454
endoderm hepatic specification 65
functions 454
oncotic 253
hepatobiliary disease 454–455
hepatorenal syndrome prevention 717
infusion
spontaneous bacterial peritonitis 764
volume expansion 1728
ligands bound 250–251, 251t
nonhepatobiliary disease 454
normal values 454
renal hypoperfusion 1725
sex hormone binding 1755
structure 251
synthesis, influencing factors 454
testosterone binding 1687
thyroid hormone binding 1684, 1747, 1747t
albumin dialysis
alcoholic hepatitis 1165
hepatorenal syndrome type 1 716
Albumin gene 65
alcohol
absorption 1135
abstinence 1179–1185
alcoholic cirrhosis 1167
chronic hepatitis C 890
cognitive behavioural treatment 1180–1181
controlled drinking *vs.* 1179–1180
maintenance, long-tern 1180–1182
pharmacological agents 1181–1182
combinations 1182
pre-surgery 1171
pre-transplant 1183
altered substrate utilization 1838
clearance, age-related changes 1873
consumption 1129–1130, 1129t
beverage type 1130
gamma-glutamyl transpeptidase levels 464
retinoid depletion 217
dependence
definition 1179
diagnosis 1179
distribution 1135
dose, risk of liver disease 1142
estrogen receptors 1759
psoriasis 1642
excretion 1135
fibrosis 1141, 1142t
hepatic blood flow 77
hepatocellular carcinoma 1438–1439
hepatotoxicity 413, 1379–1380
insulin secretion 1735
intestinal protein loss 1837
iron metabolism, effects on 1769
leucocyte abnormalities 1770
lipid storage disease induction 1246
liver injury 1135t
metabolism 1135–1136, 1837
alcoholic liver disease pathogenesis 1136–1139
altered redox state 1136–1137
antibodies to 1140–1141
chronic consumption and 1136
fatty liver 1136–1138, 1137f
oxidation sites 1135
oxidation to acetaldehyde 1135–1136
zero-order kinetics 1135
mitochondria, effects on 413, 1379–1380
nutrient malabsorption 1837
selenium deficiency 235
spermatogenesis 1756
testosterone production 1756
total plasma calcium levels 1750
units 1135
vitamin B12 absorption 1769
withdrawal 1179–1185
ambulatory 1180
elderly 1873
institutional setting 1180
Zieve syndrome 1770
alcohol dehydrogenase (ADH)
alcohol oxidation 1136
cirrhosis 681
polymorphism, alcoholic liver disease and 358
stomach 1135
alcoholic cardiomyopathy 1185–1186, 1613
liver transplantation 1185–1186
alcoholic cirrhosis 1165–1167
abstinence 1167
alpha-1-antitrypsin 1153
bile secretion impairment 1153
clinical presentation 1165
extrahepatic manifestations 1162t, 1165
definition 1165
diagnosis 1166
elderly 1873
endocrine dysfunction 1165, 1758, 1820
feminization 1758
gastro-oesophageal reflux 1798
glomerulonephritis 1817t
haemodynamic studies 1166
hepatic venous pressures 568
hepatocellular carcinoma 1153
hepatorenal syndrome type 1 676
imaging 1166
laboratory values 1166
large-cell hepatocellular dysplasia 1153
leucocyte abnormalities 1771
liver biopsy 1166
liver transplantation 1183–1184
macronodular 1153, 1153f
malnutrition 1165–1166
pathogenesis 1165–1166
micronodular 1152–1153, 1152f
mixed micronodular and macronodular 1153
mortality 1130–1132, 1130f, 1179
alcohol intake 1131–1132
beverage type 1131, 1132f
dose consumed 1132
natural history 1159, 1165
neurological manifestations 1824t
pathogenesis 1165
pathology 1152–1153
prognosis 1164t, 1166–1167
prostate 1820
regression 1153
renal tubular acidosis 1819–1820
renal tubular necrosis 702
resting energy expenditure 1837
small-cell hepatocellular dysplasia 1153
surgery 1171
thyroid hormones 1748t
treatment 1167
alcoholic clear cells 423
alcoholic fatty liver disease (AFLD) *see* alcoholic liver disease (ALD)
alcoholic foamy degeneration 428, 1246
alcoholic hepatitis 1161–1165, 1195
alcohol abstinence 1164
anti-TNFα agents 1164–1165
clinical diagnosis 1163
clinical examination 1161–1162
clinical features 1161–1162
definition 1161
differential diagnosis 1163
enteral nutrition 1908
extrahepatic manifestations 1162, 1162t
haemodynamic studies 568, 569, 1163
hepatocellular lesions 1149–1150
hepatocyte apoptosis 341, 1149, 1150f
hepatorenal syndrome prevention 717
histology 430, 1152
imaging 1163
induced hepatocytes 1149f, 1150
inflammatory infiltration 1150–1152, 1151f
laboratory values 1162–1163
liver transplantation 1183
malnutrition 1906
clinical outcome 1907
management 1839
markedly active 1152
minimal 1152
moderately active 1152
natural history 1158–1159
non-alcoholic steatohepatitis *vs.* 1161
oxidative stress 1169
pathogenesis 1161
pathology 1148–1152, 1161
pericellular fibrosis 1151, 1151f
prognosis 1163–1164, 1164t
progression to cirrhosis 1152
scoring systems 436
surgery 1171
treatment 1164–1165
tumour necrosis factor 313
alcoholic hyaline *see* Mallory bodies
alcoholic liver disease (ALD) 1127–1190
alcoholic hepatitis *see* alcoholic hepatitis
animal models
baboons 409–410
gene array data 411

alcoholic liver disease (ALD) (*continued*)
aspartate aminotransferase 452
cancer screening 1171
chronic hepatitis and 1154
clinical features 1157–1178
cortisol 1753
cutaneous manifestations 446, 1809–1810
cytokine genes 1143
diagnosis 1157–1178
drink type 1142, 1159
drug hepatotoxicity 1170, 1917, 1917t
drug prescribing 1917–1918
elderly 1873
epidemiology 1129–1134
evaluation 1157–1178
extrahepatic complications 1185–1186, 1185t, 1186t
fibrosis
AST/ALT ratio 1168
non-invasive markers 1167–1168
functional genomics 408t
gene array data 409–410, 411
proteomics 413
genetics 356, 357t, 358, 360t, 1142–1143
glutathione 204
hyaluronate levels 30
immunoglobulin A 328–329
immunoglobulin G 329
interactions with other hepatic diseases 1153–1154, 1168–1170
iron overload 1154
Kupffer cells 40
lipopolysaccharides 40
liver biopsy 491–492, 1154
liver transplantation 1157, 1987
outcomes 1185
post-operative management 1184–1185
pre-operative management 1183–1184
relapse 1184–1185
macrovesicular steatosis 1148, 1148f
malabsorption syndrome 1801
management 1157–1178, 1179–1190
drinking control, benefits of 1179
mean respiratory quotient 1838
natural history 1157–1161, 1158t
factors influencing 1159
non-alcoholic fatty liver disease and 1153–1154, 1154t, 1169–1170
nutrient intake 1836
osteoblast dysfunction 1831
osteoporosis 1831
pancreatitis 1800
pathogenesis 1135–1147
acetaldehyde 1138–1139, 1139t
adaptive immune system 1140–1141
cellular immune response 1141
endotoxin receptor 1143
fatty liver 1136–1138
innate immune system 1139–1140
lipid peroxidation 1138–1139
oxidative stress 1138–1139, 1138t
genes influencing 1143
steatosis 1138
pathology 1148–1149, 1148–1156
fatty liver 1148–1149
pregnancy 1886
prevention 1182
short interventions 1182
prognosis 1149, 1157–1178
risk factors 356, 358, 1142–1143, 1159
substance misuse 1183
surgery 1170–1171
susceptibility 1142–1143
viral hepatitis 1169
Alcoholics Anonymous (AA) 1181
alcoholic steatohepatitis (ASH) *see* alcoholic hepatitis
alcoholism
associated addictive habits 1182–1183
cue reactions 1180
cutaneous manifestations 1186, 1809–1810
elderly 1874
endocrine changes 1186
folate absorption 1769
haematological manifestations 1187
HCV-HIV coinfection, treatment side-effects 981
liver transplantation 1183–1185, 1985
relapse 1184–1185, 2016–2017
nonhepatic signs 1186–1187
paracetamol-induced hepatitis 1238
peptic ulcers 1800
pyogenic abscess 1874
relapse
assessment 1184
predictive factors 1184
smoking 1183
alcohol-like liver lesions *see* steatohepatitis
'alcoholomics' 413
alcohol withdrawal syndrome 1180
aldehyde dehydrogenases (ALDHs) 1136
polymorphism, alcoholic liver disease risk 358
aldehyde oxidase 238
ALDH2 gene 1136
flushing reaction, post-alcohol consumption 1136
aldolase
deficiency 1860–1861, 2123
hypothyroidism 1685
aldosterone 677–678, 1686
cirrhotic ascites 678–679, 678f
deficiency, haemochromatosis 1762
mechanism of action 678
obstructive jaundice-associated acute renal failure 1816
alemtuzumab (Campath-1H), liver transplantation 2005
alendronate 1832
alfentanil 1940
alkaline phosphatase (ALP) 461–463
acalculous cholecystitis 1950
acute fatty liver of pregnancy 1881–1882, 1882
AIDS-related cholangitis 1546
alcoholic hepatitis 1162–1163
alveolar echinococcosis 1052
assays 461, 462t
autoimmune hepatitis–primary biliary cirrhosis overlap syndrome 1122
bile duct disease 1486
bone isoenzyme (b-ALP) 462
brucellosis 1003
carcinoid tumours 1472
cholestasis 1487
congestive heart failure 1612
cystic fibrosis 1340
drug-induced inhibition 463, 463t
drug-induced liver injury 1216
postoperative 1949
hepatic metastases 1467
hepatic *vs.* cholestatic disease 1900
hepatobiliary disease 462–463
hereditary haemorrhagic telangiectasia 1420
hyperbilirubinaemia, postoperative 1949
hyperthyroidism 1684
isoenzymes 461
differentiation 461–462
levels, influencing factors 462
nodular regenerative hyperplasia 1434
nonhepatobiliary diseases 463
pre-eclampsia 1884
pregnancy 463, 1879
primary biliary cirrhosis 1076
primary sclerosing cholangitis 1105
progressive sclerosing cholangitis 1951
sepsis-induced cholestasis 1950
systemic lupus erythematosus 1694
tissue distribution 461
alkalosis
anaesthesia and 1940
cirrhosis 186
fulminant hepatic failure 186
metabolic *see* metabolic alkalosis
respiratory *see* respiratory alkalosis
alkylated peptides, drug-induced hepatitis 1224, 1225f
17-α-alkylated steroids, hepatocellular adenoma induction 1259
allograft hepatic artery thrombosis 1392
allopurinol
acute hepatitis induction 1230
glycogen storage disease type 1 1373
visceral leishmaniasis 1038–1039
all-trans-retinol 215f
see also vitamin A
allyl chloride, hepatotoxicity 2106
Alonso–Lej classification, choledochal cyst 807
alopecia, benzimidazole-induced 1055
Alper's disease (progressive infantile poliodystrophy) 1379, 1823t, 1825, 2123–2124
alpha-adrenergic agents
hepatorenal syndrome 715, 716
portal hypertension 633
alpha-fetoprotein (AFP)
acute liver failure 1302
cytokeratin 19 expression 62
endoderm hepatic specification 65
hepatoblastomas 1864
hepatocellular carcinoma 1440, 1443
alphaherpesvirus infections 957–960
see also specific viruses
alpha-tocopherol *see* vitamin E
aluminium, total parenteral nutrition-related liver disease 1636–1637
alveolar echinococcosis (AE) 1051–1054
clinical features 1052
complications 1052
control 1052
diagnosis 1052–1053
epidemiology 1051–1052
imaging 530
immunological diagnosis 1054
laboratory findings 1052–1053
medical treatments 1055
metastases 1052
molecular diagnosis 1054
morphological findings 1053
palliative care 1053–1054
pathogenesis 1048f, 1052
prevention 1052
pseudocystic 1053
risk factors 1051
serology 1054
treatment 1053–1054
vesicles 1051, 1052
Alzheimer type 2 astrocyte 731, 732f
Am80 215f, 217
Amanita phalloides poisoning
acute liver failure 1298
children 1858
gastrointestinal symptoms 1271, 1298
hepatic symptoms 1271–1272, 2106
treatment 1272
amanitin, hepatotoxicity 1272
amatoxin 1298
AMC-BAL, bioartificial liver support 2046
amenorrhoea
chronic hepatitis 1759
cirrhosis 1759, 1885–1886
hyperprolactinaemia 1760
liver tumours 1763
non-alcoholic liver disease 1759
American College of Rheumatology, systemic lupus erythematosus classification 1694
American Joint Committee on Cancer (AJCC), gallbladder carcinoma staging system 1578, 1578t
Americas, infectious liver disease incidence 2101t
amine oxidases 181
amineptine
acute hepatitis induction 1230
immunoallergic hepatitis induction 1226
lipid storage disease induction 1246–1247
amino acid chromatography, mitochondrial oxidative phosphorylation deficiency 1380
amino acids
ammonia, source of 181
aromatic, liver disease and 1838
catabolism 144
regulation 144
cell signalling 147–149
functions 145
hepatic concentrations 143t
hepatic encephalopathy 731
intracellular/extracellular ratios 142, 143t
macroautophagy suppression 148–149, 148f
metabolism 142–149
across liver cell plate 92
dietary amino acids 143–144
hepatic zonation 144
liver disease and 1838
starvation 144–145, 145f
methylation reactions 145–147
one-carbon metabolism 145–147
pools 142, 143t
regulatory functions 147–149
transport 111–112, 142–143
see also individual types

aminoglycoside nephrotoxicity, cirrhosis 702
aminolaevulinic acid (ALA)
acute porphyrias 1344, 1345–1346
excretion 212, 212t
synthesis 208
toxicity 1345–1346
aminolaevulinic acid dehydrase 208
aminolaevulinic acid dehydratase (ALAD) 1343f, 1346
deficiency 1344t, 1346
diagnosis 1344
genetic defect 1346
lead poisoning 1346
aminolaevulinic acid synthase 208
deficiency, acute porphyrias 1345
aminolaevulinic acid synthase-1, haem synthesis 209, 210f
aminolaevulinic acid synthase-2
haem synthesis regulation 210–211
translation regulation 211, 211f
aminophospholipid flippase 297
aminopyrine breath test 475t
acute liver disease 476
chronic liver disease 476
aminosides 1916
aminosidine 1038
aminotransferases 451–453
acute fatty liver of pregnancy 1881–1882
acute liver failure 1292
acute *vs.* chronic liver disease 1900
alcoholic cirrhosis 1166
alcoholic hepatitis 1162
alcoholic steatosis 1160, 1161
alveolar echinococcosis 1052–1053
burns 1279
cirrhosis 612
coeliac disease 1628t, 1629
halothane hepatitis 1949
hepatitis activity assessment 1934
malarial hepatitis 1032
obstructive sleep apnoea 1617
paracetamol hepatotoxicity 1296
post-jejunoileal bypass surgery 1630
pre-eclampsia 1884
total parenteral nutrition-related liver disease 1634
Wilson's disease 1320
see also individual types
amiodarone toxicity
computerized tomography 512, 512f
phospholipidosis 1244–1245, 1247
steatohepatitis 1170, 1246
amitriptyline, acute hepatitis induction 1230
ammonia
blood concentration 180, 457–458
abnormal values 458
assays 458
distribution 457–458
normal values 458
portal vein 729–730
sources 458
detoxication, hepatic 181–185
glutamine synthesis 183–184
intercellular glutamine cycle 184–185, 184f
urea production 181–183
hepatic encephalopathy
diagnosis 742
pathogenesis 729–730
metabolism 180–191
liver disease 185
production 729
intestines 181
sources of 181
amodiaquine, hepatotoxicity 1230, 1252
amoebiasis 1020–1029
diagnosis 1025–1026
epidemiology 1020–1022, 1021f
pathophysiology 1022–1023, 1023f
pregnancy 1888
risk factors 1021, 1021t
treatment 1026
amoebic liver abscess (ALA)
clinical manifestations 1024–1025
diagnosis 1025–1026
epidemiology 1020–1021
HIV 1021
laboratory findings 1025–1026
magnetic resonance imaging 530
risk factors 1021
ruptured 1026
serology 1025–1026
ultrasonography 504, 1025
amoeboid movement 1023
amoxicillin, hepatotoxicity 1231
amoxicillin-clavulanic acid
acute hepatitis induction 1230–1231
bacterial cholangitis 1543t
spontaneous bacterial peritonitis 764t, 765
vanishing bile duct syndrome induction 1254
AMP-activated protein kinase (AMPK) 160
amphotericin B
alveolar echinococcosis 1055
candidosis 1013
coccidioidomycosis 1016
cryptococcosis 1014
focal hepatic candidiasis 1665
hepatosplenic candidosis 1013
histoplasmosis 1015
post-kala-azar dermal leishmaniasis 1039
side-effects 1038
visceral leishmaniasis 1038, 1038t
ampicillin, bacterial cholangitis 1543t
ampulla of Vater adenomas 793
amylo-1,6 glucosidase deficiency 1861
amyloid deposits
composition 1702
organ dysfunction and 1703
amyloidosis 1702–1708
acquired systemic 1703–1704
clinical 1703–1705
Crohn's disease 1627
diagnosis 1705–1706
histochemical 1706
non-histological 1706
dialysis-associated 1704
electron microscopy 1706
hereditary systemic 1704–1705
causes 1704
misdiagnosis 1704–1705
proteins involved 1704
histochemistry 1706
histological features 427–428
imaging 1706
immunoassays 1706
inflammatory bowel disease 1627
localized 1703
management 1706–1707
future developments 1707–1708
nomenclature 1702
pathogenesis 1702–1703
systemic, liver in 1705
wild-type proteins 1702
see also individual types
amylopectinosis *see* glycogen storage disease (GSD), type 4
anabolic-androgenic steroids
hepatotoxicity 1687–1688
induced conditions
cholestasis 1242
hepatocellular adenoma 1259, 1688
hepatocellular carcinoma 1260, 1439, 1688
peliosis hepatis 1256
anaemia
acute fatty liver of pregnancy 1881
antiviral side-effects 945–946
chronic liver disease 1767–1768
causes 1768t
cirrhosis 610, 1767–1768
haemolytic *see* haemolytic anaemia(s)
in hypersplenism 774
post-liver transplantation 1772
causes 1773t
diagnostic tests 1773t
visceral leishmaniasis 1036
see also individual types
anaesthesia and liver disease 1938–1944
acid–base disturbances 1940, 1942
cardiovascular dysfunction 1938–1939, 1942
coagulopathies 1940, 1943
drug distribution 1940
electrolyte imbalance 1939, 1942
glucose homeostasis 1939–1940
hepatic encephalopathy 1940
hepatic resection 1941
induction agents 1942
inhalational anaesthetics 1941, 1942
liver disease pathophysiology 1938–1940
liver transplantation *see* liver transplantation
pharmacokinetic/pharmacodynamic effects 1940–1941
renal dysfunction 1939, 1942
respiratory dysfunction 1939
risk assessment 1938
analgesics
hepatic resection and 1941
hereditary haemorrhagic telangiectasia 1422
liver disease and 1940–1941
sphincter of Oddi biliary-type dysfunction 1569
see specific types
anandamide, portal hypertension 635
anaphase-promoting (APC) multiprotein complex 274
Anaplasma phagocytophilum 1006
anaplasmosis 1006
Ancylostoma caninum 1062
Anderson disease *see* glycogen storage disease (GSD), type 4
Anderson-Fabry disease 1805
androgen(s)
conversion to estrogens 1754, 1755f
deficiency 1755
tumorigenicity 1258
androgen-binding protein 1755
androgenic steroids *see* anabolic-androgenic steroids
androgen receptor 1746f, 1756
androgen replacement therapy, haemochromatosis 1761–1762
androgen response element 1756
androstenedione
cirrhosis 1757–1758
conversion to estrone 1757–1758
females 1760
physiology 1754
female 1754
male 1754
transport in blood 1755
androsterone 1687
anergy, obstructive jaundice 1506
angiogenesis
copper 229
fibrosis progression to cirrhosis 585, 1617
hepatocellular carcinoma 32
liver sinusoidal endothelial cells 30
metastatic tumours 1465
angiography 531–540
abscess 537
acute hepatitis 537
blood vessel diseases 538–539
Budd–Chiari syndrome 538, 538f
capillary haemangioma 537t
cavernous haemangioma 537t
cholangiocarcinoma 537t, 1592
cirrhosis 537, 538f
focal nodular hyperplasia 537t
haemangioendothelioma 537t
haematoma 536
haemobilia 1555
hepatic artery aneurysm 538, 539f
hepatic artery dissection 538–539
hepatic metastases 537t
hepatoblastomas 537t
hepatocellular adenoma 537t
hepatocellular carcinoma 537t
infection 537
inflammatory disorders 537
liver transplantation 539
magnetic resonance *see* magnetic resonance angiography (MRA)
neoplasms 536, 536f
peliosis hepatis 537t
portal hypertension 537–538
portal vein thrombosis, chronic 1398
portosystemic shunts 538
regenerating nodule 537t
trauma 536, 536f, 1955, 1955f
angiokeratoma, Anderson Fabry disease 1805
angiomyolipoma 523–524
angioplasty balloon catheter, biliary stricture dilation 558, 558f
angiosarcoma 1457–1458
clinical features 1458
drug-induced 1259t, 1261
imaging 526–527, 1458
intrahepatic cholangiocarcinoma *vs.* 1597
liver transplantation 1988
morphological changes, non-tumoral tissue 1457–1458
natural history 1458
occurrence 1457
pathogenesis 1458
pathology 1457–1458, 1457f
patterns 1457, 1457f

angiosarcoma (*continued*)
radiation-induced 1278
toxin-induced 1270t, 1273
treatment 1458
angiotensin, hepatic blood flow regulation 77
angiotensin-converting enzyme (ACE) inhibitors
exaggerated therapeutic effects, hepatic failure 1915, 1915t
glycogen storage disease type 1 1373
hepatic blood flow 77
angiotensin I 677
angiotensin II 677
effects 677
hepatic stellate cells contractility 593
portal hypertension 633
angiotensinogen II type 1 receptor antagonists, fibrosis 595
Angyostrongylus costaricencis 1062
anhepatic phase, living donor liver transplantation 1980
anicteric hepatitis 1227
aniline, hepatotoxicity 2106
aniline *p*-hydrolase 93
animal models
chimpanzee
HBV infection 409
HCV infection 407–408
cholestasis 386, 387f
cholesterol gallbladder stones 1522–1523
chronic hepatitis B antiviral therapy 924–925
Crigler–Najjar syndrome 1355
gene arrays 407–408, 409, 411
hepatocyte transplantation 2032–2033
intrahepatic cholestasis *see* cholestasis, intrahepatic
mouse models *see* mouse models of human liver disease
sphincter of Oddi motility 307–308
ursodeoxycholic acid 1493
see also specific models
animal virus transfer, hepatocyte transplantation 2036
anisokaryosis 430
anoikis 342, 342f
anomalous pancreatobiliary junction (ABPJ), cholangiocarcinoma 1584–1585
Anopheles mosquito bite 1029, 1030
anorexia 443
obstructive jaundice 1505
anorexia nervosa, paracetamol-induced hepatitis 1238
antabuse effect drugs 1181
'anterior approach' hepatectomy, cirrhosis 1935
anthropometry
non-alcoholic fatty liver disease 1199
non-alcoholic steatohepatitis 1199
nutritional status assessment 1905
anti-acetaldehyde adduct (anti-AcA antibodies) 1141
anti-alcohol dehydrogenase (ADH) antibodies, autoimmune hepatitis 1094
anti-apoptotic factor myeloid cell leukaemia-1 (Mcl-1) 55
anti-apoptotic genes, vanishing bile duct syndrome 1112
anti-apoptotic signalling cascades, tumour necrosis factor 314–316
anti-apoptotic therapy 343–344
fibrosis induction 344
limitations 344, 344f
antibiotics
acute liver failure 1304
acute variceal bleeding 648–649
bacterial cholangitis 1542–1543, 1543t
Caroli syndrome 806
cirrhosis 1914
drug-induced renal impairment 702
hepatic encephalopathy 747
persistent chronic 749
pyogenic liver abscess 1002
spontaneous bacterial peritonitis 763–764, 764t
strongyloidiasis 1065
total parenteral nutrition-related liver disease 1638
antibodies 325–331
acetaldehyde adducts 1140–1141
drug-induced acute hepatitis 1223, 1224f
hepatitis A 857
hepatitis B vaccine 910
hepatitis D 878
hepatitis E diagnosis 895
proteomic arrays 405
somatic hypermutation 325
see also immunoglobulin(s); *individual antibodies*
antibody-dependent cell-mediated cytotoxicity (ADCC), immunoglobulin A 328
anti-branched-chain 2 oxo-acid dehydrogenase complex (BCOADC) antibodies 1072
anticancer drugs, hepatocellular carcinoma induction 1260
α_1-antichymotrypsin deficiency 1334
anticoagulation therapy
Budd–Chiari syndrome 1257, 1409
portal vein thrombosis
acute 1396–1397
chronic 1389
pretransplant patients 1925
portopulmonary hypertension, pretransplant 1925
prothrombin time 455–456
anticonvulsant-induced liver disease 1827
anticopper drugs 228–230
antifibrotic therapy 230
anti-inflammatory therapy 230
cancer therapy 229–230
anti-CYP 2A6 autoantibodies, chronic hepatitis C virus 485
anti-cytochrome P-450 autoantibodies 1222–1223
antidiuretic hormone (ADH) 680–681
haemodynamic change, response to 680
hydro-osmotic effect 680
hypersecretion, cirrhosis 684
obstructive jaundice-associated acute renal failure 1816
PGE2 production 681–682
precursor 680
production 680
secretion 680
vasoconstrictor effect 681
antiendotoxin therapy, obstructive jaundice-associated acute renal failure 1816
antiestrogenic drugs, hepatocellular carcinoma 1450
antifibrinolytic agents 1790–1791
haemostasis abnormality therapy 261
liver transplantation 1790–1791
antifibrotic therapy 594–597, 595t
alcoholic cirrhosis 1167
cirrhosis 616
hepatic stellate cells
activation inhibition 596–597
apoptosis stimulation 597
proliferation inhibition 596–597
immune response 595
inflammation reduction 595
morphometry 438
primary biliary cirrhosis 1083
primary disease curing 594–595
scar matrix degeneration 597
antigen presentation 321
HLA system *see* HLA (human leukocyte antigen) system
immunogenetic studies 369
sinusoidal epithelium 321
antigen-presenting cells (APCs)
acute graft-vs.-host disease pathogenesis 1672
drug-induced acute hepatitis 1225
anti-GOR, chronic hepatitis C 485
anti-HBc immunoglobulin 839
anti-HbeAg antibody titres, hepatitis B 837f, 838
anti-hepatitis A virus immunoglobulin (Ig) M, children 1851
anti-hepatitis C virus immune globulin, post-liver transplantation 2014
anti-hepatitis D antibodies 844
anti-histamine H2 receptors, cirrhotic patients 1914
antihistamines
intrahepatic cholestasis of pregnancy 1880
pruritus treatment 1496
anti-hydroxyethyl radical (HER) antibodies 1141
anti-intercellular adhesion molecule-1 (ICAM-1) antibodies 2009
anti-interleukin 2 receptor antibodies 2004
anti-liver cytosol type 1 (LC1) antibodies, autoimmune hepatitis 483, 1093, 1093t
anti-liver/kidney microsomal antibodies, chronic hepatitis C antiviral therapy 949
anti-liver microsome antibodies 1092, 1222–1223
anti-liver-specific lipoprotein complex antibodies, autoimmune hepatitis 1093–1094, 1096
antilymphocyte depletion, immunosuppression 2004, 2005
antilymphocyte globulin (ALG) polyclonal antibodies, post-liver transplantation 1865
anti-M_6-autoantibody 1222
iproniazid 1235, 1252
antimalarial drug-induced jaundice 1032
antimetabolites, immunosuppression 2008
antimitochondrial antibodies (AMA)
autoimmune hepatitis 1093t, 1120
intrahepatic cholestasis diagnosis 1492
primary biliary cirrhosis 480t, 484, 1072, 1074, 1076, 1077, 1120, 1488
scleroderma 1697
Sjögren syndrome 1697
antimonial therapy
resistance to 1037
side-effects 1037
visceral leishmaniasis 1037–1038, 1038t
anti-neutrophil cytoplasmic antibodies (ANCA), autoimmune hepatitis 482, 1093t, 1094
antinuclear antibodies (ANA) 482t
autoimmune cholangitis 1121, 1853
autoimmune hepatitis 480–482, 1090, 1091, 1092, 1093t, 1120
chronic hepatitis C 485, 949
primary biliary cirrhosis 484
antioxidants
alcoholic cirrhosis treatment 1167
depletion, alcoholic liver disease 1138
fibrogenesis inhibition 596
hepatocellular carcinoma prevention 1450–1451
neonatal haemochromatosis 1857, 1857t
warm ischaemia, protection from 351–352
Wilson's disease 1319
anti-2-oxoglutarate dehydrogenase complex (OGDC) antibodies 1072
antiphospholipid antibody syndrome 1695
Budd–Chiari syndrome 1404, 1695
drug-induced 1695
investigations 1695
manifestations 1695
nodular regenerative hyperplasia 1695
sinusoidal dilatation 1413
alpha-2-antiplasmim, fibrinolysis 256
antiplatelet therapy, post-peritoneovenous shunting 696
antiporters (countertransport) 110
antipyrine (phenazone) 471t, 472
anti-pyruvate dehydrogenase complex (PDC) antibodies
autoimmune cholangitis 1121–1122
primary biliary cirrhosis 1072
antiretrovirals *see* antiviral/antiretroviral drugs
anti-SS A (Ro) antibodies 1697
anti-SS B (La) antibodies 1697
antithrombin (AT)
deficiency, Budd–Chiari syndrome 1404
haemostasis 256
synthesis 257
antithrombin III 1780
deficiency
acute fatty liver of pregnancy 1882
portal vein thrombosis 1395–1396
pre-eclampsia 1884
antithymocyte globulin (ATG) polyclonal antibodies, post-liver transplantation 1865
alpha-1-antitrypsin, storage 428

alpha-1-antitrypsin (a1AT) deficiency 1330–1335, 1850
adults 1332–1333
alcoholic liver disease 1170
alleles 1330, 1334, 1850
children 1332
cutaneous manifestations 1811
diagnosis 1333, 1850
elderly 1873
exogenous protein replacement 1334
genetics 1330
glomerulonephritis 1817t
hepatocellular carcinoma 1333, 1439
hepatocellular injury 1331–1332, 1331f
hepatocyte transplantation 2038
heterozygosity 1334
histological features 430
indications for testing 1333t
infancy 1330
inheritance 1850
liver transplantation 1988
management 1333–1334
natural history 1332–1333
neonatal screening 1333
nodular panniculitis 1811
pathophysiology 1330–1332
animal models 1332
phenotypes 1333, 1333t
PIMZ (MZ) heterozygosity 1334
PISZ heterozygosity 1334
presentation 1332–1333, 1333t, 1850
prognosis 1850
pulmonary manifestations 1333
related conditions 1334
serum levels 1333, 1333t
toddlers 1332
treatment 1850
vanishing bile duct syndrome 1114t, 1117
Z mutant allele (PIZZ) 1330
endoplasmic reticulum, retention by 1330, 1331f
antiviral antibodies, hepatitis C 883
antiviral/antiretroviral drugs
acute hepatitis C *see* hepatitis C, acute
chronic hepatitis B *see* hepatitis B, chronic
elimination, cirrhosis 1916
hepatitis B, acute 917
hepatocellular carcinoma prevention 1450
hepatotoxicity 978–979, 983–984, 1380
coinfections 983–984
incidence 983–984
mechanisms 984, 984t
risk factors 983–984
viral hepatitis 1917, 1918
HIV–hepatitis C coinfection *see* HIV–hepatitis C coinfection
interactions 981
mitochondria, effects on 1380
non-hepatic toxicity, increase in 1916
prescription 1918–1919, 1918t
anxiety disorders, Wilson's disease 1316
AP1 transcription factor 105–106
activation 105–106
structure 105
APACHE II score, acute liver failure 1302
apical junction complex, hepatocytes 22
apical sodium-dependent bile salt transporter (ASBT), bile absorption 52–53, 113, 177, 178
aplastic anaemia
parvovirus B19 1667
viral hepatitis 1666–1667, 1769
APOB gene/protein 1366, 1518t, 1525
apoceruloplasmin 1317
apolipoprotein(s) 134–135
amphiphilicity 134–135
HDL associated 139
nomenclature 134
apolipoprotein A-I (apoA-I) 139
amyloidosis 1704, 1705, 1707
Tangier disease 1366
apolipoprotein A-II (apoA-II) 139
apolipoprotein B (apoB) 135
editing 135f
lipoproteins
assembly 135–136, 136f
intravascular metabolism 136–137, 137f
lipolysis 137
metabolism 135–138
removal 137–138, 138f
secretion 135–136, 136f
apolipoprotein B-48 (apoB-48) degradation 135–136
apolipoprotein B-100 (apoB-100) degradation 135–136
apolipoprotein bec-1 (apobec-1) 135
apolipoprotein B (apoB) editing complex 135, 135f
apolipoprotein (Apo) B/E receptor 1520
apolipoprotein C-II (apoC-II) 136
familial deficiency 1367
apolipoprotein C-III (apoC-III) 137
apolipoprotein E (apoE) 137
apolipoprotein E-2 (apoE-2) 137
apolipoprotein E-3 (apoE-3) 137
apolipoprotein E-4 (apoE-4) 137
apoproteins *see* apolipoprotein(s)
apoptosis
alcoholic hepatitis 341, 1149, 1150f
biliary tree epithelium 1112
biochemistry 336
endonucleases 336
proteases 336
transglutaminases 336
cholangiocytes 54
committed/effector phase 349
definition 424
degradation phase 349
extrahepatic biliary obstruction 1501
fibrosis progression to cirrhosis 583
hepatocytes 335–347
immune-mediated liver diseases 341
immunogenetics of liver disease 369
initiation phase 349
intrahepatic bile duct development 69
investigation 336–337
liver growth 66–67
mechanisms 337–339, 337f
extrinsic death pathway 337–338, 338f
intrinsic death pathway 338–339
metabolic liver injury 340–341
morphology 335–336
natural killer cells 320
reactive metabolites 1220–1221
regulation 339f
molecules involved 339–340
pathological conditions 340–341
physiological conditions 340
tumour necrosis factor 313–314, 338
underestimation 343
warm ischaemia 349–350
apoptosis-inducing factor (AIF) 339
apoptotic bodies 335, 424
cirrhosis 583
phagocytosis 335–336
viral hepatitis 341
apple-peel congenital intestinal atresia 2124
aprotinin
coagulation defects/disorders 261, 1790
hepatic resection 1941
liver transplantation 1791, 1943, 1997
aquaporin 1 (AQP1) 52, 113
aquaporin 4 (AQP4) 52, 113
aquaporins (AQP) 52, 113
aquaretic drugs, cirrhotic ascites 699–702
arachidonic acid, cirrhosis 680–683, 1771
arachnocytes 49
ARC syndrome 1385–1386
area nuda (bare area) 4
arenavirus infections 988–990
aetiological agents 988–989
clinical manifestations 989
diagnosis 989–990
epidemiology 988–989
laboratory findings 989
pathogenesis 989
pathology 989
prevention 990
treatment 990
viral genome 990
argentaffin cells 1470–1471
Argentine haemorrhagic fever (AHF)
clinical manifestations 989
epidemiology 988
pathogenesis 989
treatment 990
vaccine 990
arginine
creatine synthesis 147
glucagon response, cirrhotics 1738
growth hormone response, cirrhotics 1740
urea cycle 182, 183
argininosuccinate 182
argininosuccinate lyase (ASL) 1805
argininosuccinate synthetase 182
urea synthesis regulation 182
argininosuccinic aciduria 1805, 2124
argyrophilic cells 1471
Armillifer (Porocephalus) armillatus 1066
arrhythmias, post-liver transplantation 1998
arsenic 233t
angiosarcoma 1458
deficiency 233t
hepatotoxicity 1273–1274, 1458, 2107
arsine, hepatotoxicity 2107
arterial bruits 448
arterial compliance 1726–1727, 1726f
cirrhosis 1726–1727, 1726f
arterial-portal shunt, haemobilia 549
arterial portography 533, 533f
arterial pressure, hepatorenal syndrome 713
arterial reconstruction, liver transplantation 1967, 1967f
arterial underfilling, hepatorenal syndrome 711
arterial vasodilation theory, hepatorenal syndrome 711, 712f
arteriography 531–532
cirrhosis 613
hepatic artery aneurysms 1393, 1393f
arteriohepatic dysplasia *see* Alagille syndrome
arterioles
hepatic 79–80
intrarenal, portal hypertension 503
splenic 771
arterioportal anastomoses (APA) 80
arterioportal malformation (APM), congenital 1418
arteriosinus twigs (AST) 81
arteriovenous fistulae
intrahepatic 1400
portal venous system 1400
arteriovenous malformations (AVM), congenital 1418
arthritis, Lyme disease 1007
arthritis-dermatitis prodrome, hepatitis B virus 1806
article choice, meta-analysis 2074
artificial feeding 1908–1909
artificial liver *see* liver support
artificial neural network (ANN) fibrosis index 414
ascariasis 1058–1062
children 1058
clinical features 1059–1060
clinical forms 1059–1060
control 1061–1062
diagnosis 1060–1061
epidemiology 1058
giant cell phagocytosis 1059, 1061f
inflammation 1059
laboratory finding 1059
lungs 1058
pathogenesis 1059
pathology 1059, 1059f
prevention 1061–1062
treatment 1061
Ascaris bolus 1059
Ascaris lumbricoides 1058
brown pigment gallstones 1523
cholangitis 1546, 1547, 1547t
treatment 1547
life cycle 1058–1059
recurrent pyogenic cholangitis 1545
Ascaris suum 1059
ascites 85f
bile 671
bile ascites 671
causes 666, 666t
chronic portal vein thrombosis 1397
chylous 669
cirrhotic *see* cirrhotic ascites
congestive heart failure 1612
constrictive pericarditis 670, 1613
detection 666–667
dyspnoea 724–725
fluid thrill 449
formation 85, 88
central venous pressure 86–87
hepatic venous outflow block 670–671
hepatorenal syndrome 711–712
hereditary haemorrhagic telangiectasia 1420
inferior vena cava congenital web 670
lymphatic system 86–87, 88
malignant *see* malignant ascites

ascites (*continued*)
milky 669
myxoedema 671, 1685
nephrogenic 671
pancreatic 671
pathogenesis 687–688
forward theory 687–688, 687f
pleural/diaphragm effects 724–725
post-liver transplantation 671
pretransplant patients 1923
protein content
cirrhotic ascites 667
opsonic activity 762
pancreatic ascites 671
pseudochylous 669
reabsorption 688
rate 688
recidivant 692
refractory *see* refractory ascites
renal perfusion pressure 1725
resting energy expenditure 1837
signs 449
spontaneous bacterial peritonitis 762, 763, 765–766
ascitic puddle 666
Ashkenazi Jewish
Gaucher's disease 1360, 1362
Niemann–Pick disease type A 1365
Asia
alcohol consumption 1129–1130
cirrhosis mortality 1131
chronic hepatitis D 878
hepatitis B 867, 2102t
infectious liver diseases, frequency of 2102t
asialoglycoprotein receptor (ASGPR)
autoimmune hepatitis 482, 1094
immunoglobulin A catabolism 328
asialoorosomucoid (ASOR) 98–99
ASM gene mutation 1365
L-asparaginase, hepatotoxicity 1247
aspartate aminotransferase (AST) 451–453
abnormal values
hepatobiliary diseases 452, 453f
nonhepatobiliary diseases 452–453
alcoholic cirrhosis 1166
alcoholic macrovesicular steatosis 1160
assays 451–452
Budd–Chiari syndrome 1406
cirrhosis 612
distribution 451
hepatitis A 859–860
hypothyroidism 1685
ischaemic hepatitis 1610, 1949
isoforms 451
localization 451
myocardial infarction, acute 1611
normal values 452
postoperative hyperbilirubinaemia 1949
primary sclerosing cholangitis 1105
reactions 451
urine measurement 451
aspartate aminotransferase/platelet ratio (APRI) 2062–2063, 2062f
aspergillosis 1013
Aspergillus flavus poisoning 1274
Aspergillus parasiticus poisoning 1274
aspiration
hepatic cysts, ADPKD 793
simple cyst of the liver 785
aspirin
acute hepatitis induction 1231
mitochondrial injury 1824
non-hepatic toxicity, cirrhotic patient 1916
Reye syndrome 1247, 1822, 1824
'association mapping,' QTL analysis in inbred mice 378
association studies 359
complex (multifactorial) diseases 372
design 361–362, 361f
immunogenetics 364
AST/ALT ratio 452
asterixis (flapping tremor) 449
examination 741
hepatic encephalopathy 607t, 608, 741
malarial hepatitis 1031
mini- 738f, 741
asthenia, Gaucher's disease 1360
asthma
alpha-1-antitrypsin deficiency 1333
liver function tests 1617
astrocyte(s)
liver failure 731–732, 732f, 1132
neurotoxin-induced functional alterations 735
swelling
ammonia-induced glutamine accumulation 733, 735
hepatic encephalopathy 731, 733
neurotoxin-induced 734–735
volume homeostasis 733–734, 734f
ataxia-ichthyosis-hepatosplenomegaly 2125
ataxia telangiectasia (AT) 1805
ataxia telangiectasia mutated gene 1805
atazanavir, hepatotoxicity 984, 1380
atherosclerosis
familial hypercholesterolaemia 1367
hepatic artery angiography 538
ATM (ataxia, telangiectasia, mutated) 339
atorvastatin, non-alcoholic steatohepatitis 1682
ATOX1 226, 227, 228
ATP7A gene/protein
copper regulation 227, 227t
Menkes' disease 228
ATP7B gene/protein
copper metabolism 226
copper regulatory protein 227, 227t
Wilson's disease 1315, 1317–1318, 1853
ATP8B1 gene mutations 1384
ATPases, membrane transport 110
ATP-binding cassette (ABC) transporters
canalicular bile secretion 293, 296, 385
drug transport 242–243
functional expression cloning 124
see also individual types
Atractylis gummifera, hepatotoxicity 1282t, 1285
a(hypo)transferrinaemia 1327
atrial fibrillation, post-liver transplantation 1998
atrial natriuretic peptide (ANP)
obstructive jaundice-associated acute renal failure 1816
sodium retention, cirrhosis 680
ATX1 227t
atypical acute hepatitis D 878
auditory evoked potential, hepatic encephalopathy 744
auditory neuritis, viral hepatitis 1826
auscultation, abdominal 448
Australasia, infectious liver diseases 2102t
autoantibodies
autoimmune cholangitis 1121–1122
autoimmune hepatitis 480–483, 480t, 481t, 1091–1094, 1093t
autoimmune polyglandular syndrome type 1 485
chronic hepatitis 1252
hepatitis B 871
hepatitis C 485, 949
drug-induced acute hepatitis 1223, 1224f
ethanol metabolism 1141
overlap syndromes 485, 1123
postnecrotic cirrhosis 1252
primary biliary cirrhosis 484
primary sclerosing cholangitis 480t, 484
subacute hepatitis 1252
see also specific antibodies
autoimmune cholangitis (AIC) 1074, 1121–1122
autoantibodies 1121–1122
diagnostic criteria 1121t
overlap syndromes *see* overlap syndromes
symptoms 1121
autoimmune diseases/disorders
children 1852–1853
acute liver failure 1858
cholangiocarcinoma 1584
chronic hepatitis C antiviral therapy 945
cutaneous manifestations 1808
elderly 1872–1873
functional genomics 408t
gene arrays 410
proteomics 413
hepatitis *see* autoimmune hepatitis (AIH)
hepatitis B vaccine 910–911
immunogenetics 365t, 366–367, 366t
platelet abnormalities 1771
primary biliary cirrhosis-associated 1075–1076
recurrence post-liver transplantation 2015–2016
skin 1643
thyroid hormones 1749
vanishing bile duct syndrome 1115–1116
see also specific diseases/disorders
autoimmune hepatitis (AIH) 1089–1102, 1120
acute liver failure 1300
animal models 1095–1096
C57BL/6 mice 1096
CYP2D6 transgenic mice 1096
historical perspective 1095–1096
apoptosis 341
associated disorders 1090, 1852
autoantibodies 480–483, 480t, 481t, 1091–1094, 1093t
anti-liver/kidney microsomal antibodies 1091, 1092, 1093t, 1120
indirect immunofluorescence 1091–1092
autoantigens 480–481
cellular autoimmunity 1097, 1098f
children 1100, 1852–1853
cirrhosis, HCV-related *vs.* 410
clinical features 1090–1091, 1226
cortisol 1753
definition 1089
diagnosis 1090–1091, 1120, 1121t, 1300
anti-liver/kidney microsomal type 1 antibodies 1090
antinuclear antibodies 1090
anti-smooth muscle antibody 1090, 1090f
criteria 1090–1091, 1120
differential diagnosis 1090
elderly 1873
epidemiology 1089–1090
genetics 408t, 1094–1095
complement gene polymorphisms 1094–1095
gene array data 410
geographical associations 1094
HLA associations 1094, 1095, 1120
proteomics data 413
tumour necrosis factor-α gene polymorphisms 1094–1095
haplotypes 367, 368t
hepatitis C comorbidity 1124
hepatocellular carcinoma 1439
histology 429, 1094
granulomatous cholangitis 1094
interface hepatitis 1094
historical background 1089
humoral autoimmunity 1096–1097
molecular mimicry 1097
immunosuppression 1853
incidence 1852
inflammatory bowel disease 1626
liver transplantation 1100, 1987
anti-liver/kidney microsomal type 1 antibodies 1101
calcineurin inhibitors 1101
de novo occurrence 1101
postoperative recurrence 1100–1101, 2005, 2016
viral infections 1101
mixed connective tissue disease 1697
overlap syndromes *see* overlap syndromes
pathogenesis 1096–1099
self-tolerance loss 1096
presentation 1852
primary biliary cirrhosis *vs.* 1078t
progression to cirrhosis 1852
scoring systems 436, 1090–1091, 1091t
self-tolerance 1096
thyroid hormones 1749
treatment 1099–1100
asymptomatic patients 1099–1100
children 1100
immunosuppression 1099
during pregnancy 1099
T-regulatory cell impairment 1097–1098
type 1 1089, 1852
associated immune syndromes 481
autoantibodies 481–482, 1091
clinical features 1854t
DRβ-71 hypothesis 367
histology 1854t

immunogenetics 365t, 366t, 367, 368t
laboratory findings 1854t
type 2 1089, 1852
autoantibodies 481, 482–483, 1091, 1096–1097
clinical features 1854t
histology 1854t
laboratory findings 1854t
type 3 481, 483
ulcerative colitis 1626
autoimmune hepatitis-sclerosing cholangitis overlap syndrome *see* autoimmune sclerosing cholangitis (ASC)
autoimmune polyendocrine syndrome 1 1095
autoimmune polyendocrinopathy-candidiasis-ectodermal dystrophy (APECED) 485
autoimmune polyglandular syndrome type 1 (APS-1) 485
autoimmune regulator gene *(AIRE)* 485, 1095
autoimmune sclerosing cholangitis (ASC) 1122t, 1123–1124, 1123f
children 1123–1124, 1853
bile duct alterations 1853
clinical features 1854t
diagnosis 1123
epidemiology 1123
histology 1854t
immunosuppressants 1124
inflammatory bowel disease 1853
laboratory findings 1854t
prognosis 1853
therapy 1124
ursodeoxycholic acid 1124
autoimmune thyroid disease, primary biliary cirrhosis and 1076
autonomic nervous system
acute porphyrias 1345
dysfunction, cardiac manifestations 1728
gallbladder motility 307
disorders 1562
hepatic function modulation 114–121
humoral control of extrahepatic metabolism and 119
autonomic neuropathy, systemic AL amyloidosis 1704
autophagosomes 25, 26f
mitochondrial reminants 25, 26f
autophagy 342, 342f
alpha-1-antitrypsin deficiency 1331–1332
autosomal dominant polycystic disease, vanishing bile duct syndrome 1112
autosomal liver and muscle phosphorylase kinase deficiency (glycogen storage disease type 9b) 1374
autosomal liver phosphorylase kinase deficiency (glycogen storage disease type 9c) 1374
autosomal recessive form of polycystic kidney disease (ARPKD), cilia dysfunction 69
auxiliary liver transplantation
acute liver failure 1308, 1309t
children 1860
children 1865
metabolic disorders 1865
urea cycle defects 1862
average cost-effectiveness ratio 2084
axin 394t
axonal growth, ammonia 735
ayurvedic herbal preparations, hepatotoxicity 1286
azathioprine
autoimmune sclerosing cholangitis 1853
decreased therapeutic effects in liver disease 1915
hepatotoxicity 1213, 1231, 1647
liver transplantation 2008
pregnancy 1886, 1889
primary biliary cirrhosis treatment 1082–1083
sarcoidosis 1712
side-effects 2008
3′-azido-2,3′-dideoxythymidine *see* azidothymidine (AZT)
azidothymidine (AZT)
antiviral agent interactions 981
hepatotoxicity 1247–1248
azithromycin 1002
azotaemia, diuretic-induced 691
aztreonam, spontaneous bacterial peritonitis 764, 764t
azygos vein
blood flow measurement 570, 662–663
applications 663
collateral blood flow 1725
retrograde catheterization 662–663

B

BAAT gene mutations 1386
baboon models, alcoholic liver disease 409–410
bacillary angiomatosis 1644
bacillary peliosis hepatis 1412
bacillus Calmette–Guérin (BCG)
bladder cancer 1659
hepatotoxicity 1659
'backward heart failure,' ischaemic hepatitis 1609, 1610f
bacteraemia
portal hypertension 767
post-peritoneovenous shunting 696
pyogenic liver abscess 1001
recipient, living donor liver transplantation 1982
bacterial cholangitis 1541–1545
antibiotics 1542–1543, 1543t
pre-surgery prophylaxis 1544, 1544t
congenital hepatic fibrosis 782
diagnosis 1542
C-reactive protein 1542
hyperbilirubinaemia 1542
Reynold's pentad 1542
imaging 1542
mortality 1541
pathogenesis 1541–1542
bile duct obstruction 1541–1542
choledocholithiasis 1541–1542
microorganisms 1541
recurrence, post-biliodigestive anastomosis 1544–1545
risk factors 1541
treatment 1542–1543
bile duct decompression 1543
post-biliary tract surgery 1544
post-endoscopic retrograde cholangiography 1544
post-percutaneous biliary drainage 1544
post-percutaneous transhepatic cholangiography 1544
bacterial infection(s) 1001–1006
acute liver failure 1131–1132
children 1858, 1859
brown pigment gallstones 1523
cirrhosis 1807
cutaneous manifestations 1807
hepatic cysts, ADPKD 792–793, 792t
hepatorenal syndrome 712, 713
portal hypertension 761–770
post-liver transplantation
children 1866
diabetic patients 1736
post-peritoneovenous shunting 696
pretransplant patients 1926
primary biliary cirrhosis 1072–1073
see also individual bacteria; specific infections
bacterial translocation (BT) 609
causes 762
eNOS upregulation 635
nitric oxide production 684
spontaneous bacterial peritonitis 761, 762
total parental nutrition-induced cholestasis 1947
Bacteroides, bacterial cholangitis 1541
Bak, apoptosis 340
balloon catheter technique, HVPG measurement 659
ballooning, hepatocytes 423
alcoholic hepatitis 1149, 1149f
intrahepatic cholestasis 1484
balloon tamponade, variceal bleeding 651, 652
Bantu siderosis 1327
barbiturates, cerebral oedema 1305
Bardet–Biedl (Laurence–Moon–Bardet–Biedl) syndrome 2125–2126
bare area 4
baroreceptors 679
barrier nursing, arenavirus infections 990
Bartonella henselae 1005, 1644
Bartonella quintana 1644
basal cell carcinoma (BCC), post-liver transplantation 1809
basal plasma membrane, hepatocytes 96
basiliximab, liver transplantation 2006
Bax, apoptosis 340
BAY 43-9006 (Sorafenib) 1450
Bazex syndrome 1808
B cell(s)
clonal proliferation, hepatitis C 1772
differentiation 325
T cells 325
immunoglobulin receptors 325
suppression, hepatitis C 855
B-cell lymphoma 1663
Bcl-2, apoptosis 339–340, 339f
BCLC staging system, hepatocellular carcinoma 1444
BCS1L gene mutations 1379
Beck Depression Inventory 2029
Bedlington terrier, Wilson's disease animal model 1321
bedrest, cirrhotic ascites 689
behavioural marital therapy, alcohol abstinence 1181
Behçet's disease
Budd–Chiari syndrome 1404–1405, 1411
effect on liver 1698
benign cholangioma *see* bile duct adenomas
benign hepatic cyst *see* simple cyst of the liver
benign prostatic hypertrophy, alcoholic cirrhosis 1820
benign recurrent intrahepatic cholestasis (BRIC)
ABCB11 gene/protein 1524–1525
type 1 177, 1384
type 2 177, 1384
gallstone formation 1385
benign symmetric lipomatosis 1186
benoxaprofen
elderly 1872
hepatotoxicity 1231
benzarone, hepatotoxicity 1231
benzbromarone, hepatotoxicity 1231
benzene, hepatotoxicity 2107
benzidine, hepatotoxicity 2107
benzimidazoles, echinococcosis 1055
benzodiazepines
acute liver failure 1304
alcohol withdrawal syndrome 1180
liver disease and 1940
Wilson's disease 1316
benzphetamine *N*-demethylase 93
Berardinelli syndrome (Lawrence–Seip) 2126
beryllium, hepatotoxicity 2107
β-adrenergic receptors, cirrhotic cardiac dysfunction 686
beta-blockers
congenital hepatic fibrosis 782
contraindications 644
first variceal bleeding prevention
endoscopic band ligation and 645
endoscopic band ligation *vs.* 644, 645f
gastric variceal bleeding 652
portal hypertensive gastropathy 653
pregnancy 1887
recurrent variceal bleeding prevention 646
endoscopic band ligation *vs.* 647, 647f
variceal bleeding prevention 644
pretransplant patients 1924t
β-oxidation 91
betaherpesvirus infections 960–964
see also specific viruses
betaine, non-alcoholic steatohepatitis 1203t
betaine:homocysteine methyltransferase (BHMT) 147
betulinic acid 1217
bezafibrate, hepatotoxicity 1232
bezafibrate, primary biliary cirrhosis 1083–1084
BH1-4 proteins, apoptosis 339
bicarbonate, pH regulation 185–186, 187f
biguanides
cirrhotic patients, exaggerated effects in 1914, 1915t
contraindications 1737

bile
age-related changes 1875
alcoholic hepatitis 1152, 1152f
anatomical barriers to infection 1541
bilirubin in 169
circulation, entry into 1501
composition 52, 290–291, 290f, 291t
obstructive jaundice-associated acute renal failure 1816
excretory function 291
flow impairment *see* cholestasis
formation 290–304, 292f, 1518, 1519f
across liver cell plate 92
canalicular 292–293, 292f, 294
cell junctions 298
cystic fibrosis transmembrane conductance regulator 1336, 1337f
ductal 292–293, 292f, 298–299, 299f
cystic fibrosis transmembrane conductance regulator 293
gene defects 1518t
osmotic principle 292, 292f
vesicular trafficking 297–298
cytoskeleton 297–298
intermediate filaments 298
microfilaments 298
microtubules 297–298
tethering proteins 298
Giardia growth 1024
hepatocellular uptake 294–295
immunoglobulin A 55, 326–328
leaks
donor, post-living donor liver transplantation 1979
post-cholecystectomy 1958, 1960
post-liver biopsy 496
postoperative liver transplantation 2000
recipient, living donor liver transplantation 1982
mucosal defence 291
physiological functions 290–291, 290t
porphyrin secretion 213
progressive familial intrahepatic cholestasis type 1 1384
secretion 292–302
across liver cell plate 92
anatomical considerations 292
bile acid-dependent 293, 293f
bile acid-independent 293, 293f
bile canaliculi 292
biliary compounds regulating 302
canalicular mechanisms 296–297
estrogens, effects of 1241
hepatocellular mechanisms 294–296
mitogen-activated protein kinases 302
posttranscriptional regulation 300–302
regulation 300–302
second messenger systems 300, 301t
transcriptional regulation 300
transporter insertion/retrieval 297
signalling 291
sphincter of Oddi dysfunction 1566
supersaturation, cholesterol gallbladder stones 1518, 1519–1520
see also bile acids
bile acid-dependent bile secretion 293, 293f
bile acid-independent bile secretion 293, 293f
bile acids
apoptosis 341
basolateral transport 385–386
biosynthesis 174–176, 175f
cholangiocyte proliferation 54
enterohepatic circulation 174, 176–177, 293–294, 294f
gastrointestinal tract 293–294, 294f
kidney 293, 294f
export 178
extrahepatic biliary obstruction 1502
functions 174
hepatic clearance 384
hepatic secretion 176–177
hepatocellular bile secretion 294
homeostasis 106
nuclear receptors 106
intracellular transport 295–296
carrier-mediated diffusion 295
vesicular transport 295, 296f
lipid absorption 291
lipid digestion 291
metabolism 174–180
defects 174–176
nuclear hormone receptor 178
protoporphyrin metabolism 213
renal tubular acidosis-associated liver disease 1819
signalling 178, 291
synthesis/secretion
across liver cell plate 92
hypothyroidism 1685
molecular regulation of 386–387
nuclear receptors and 385t, 386–387
rate of 174
regulation, efferent hepatic nerves 117
sinusoidal efflux 385
transporters 176–177, 176f, 295f, 384–388
uptake
hepatocellular mechanisms 294–295
multidrug resistance-related proteins 295, 295f
see also individual acids
bile acid synthesis defects (BASD) 174–176, 1849
bile ascites 671
bile canaliculi
bile secretion 292–293
histology 12f, 17
ultrastructure 22–23, 23f
bile cysts, hereditary haemorrhagic telangiectasia 1420
bile duct(s)
acute graft-vs.-host disease 1673
anastomosis 1969–1970, 1969f
anatomy 305
atresia, vanishing bile duct syndrome 1114t
carcinoma, choledocholithiasis 1526
chronic damage 285
compression, simple cyst of the liver 785
cystic fibrosis 1338
destruction
granulomas 1712
sarcoidosis 1712
developmental defects 1387
dilatation
simple cyst of the liver 783, 785, 786f
ultrasonography 507
disease
alkaline phosphatase 1486
ductopenia 1485
lesions 1485, 1485t
pathology 1484–1486
see also individual diseases
embryology 304–305
epithelial cells *see* cholangiocyte(s)
infantile cholestasis 1846, 1846t
injury *see* bile duct injury
intrahepatic 5
development 69
paucity *see* ductopenia
left 17
ligation model 54
intrahepatic cholestasis 1481, 1483–1484
neuroendocrine cancer 1597
obstruction
bacterial cholangitis 1541–1542
extrahepatic *see* extrahepatic biliary obstruction
percutaneous management 555–558
stenting 555, 555f
proliferation
intrahepatic cholestasis 1484
primary biliary cirrhosis 1076
resection, gallbladder carcinoma 1579
right 17
sarcoma 1597
spontaneous perforation 1848
stones
endoscopic retrograde cholangiopancreatography 540–542, 541f
gallbladder stones and 543–544
postoperative retention 1947, 1951
removal 543–544
strictures, percutaneous management 555–558
bile duct adenomas 1573, 1596
histology 801, 1573
pathogenesis 1573
bile duct injury
intrahepatic cholestasis 1490
ischaemic hepatitis 1947, 1951
outcomes research 2070
post-cholecystectomy 1958–1961
classification 1958, 1958f
endoscopic biliary treatment 1960
incidence 1958
investigations 1958–1959
management 1959–1960
mechanism of injury 1958, 1958t
presentation 1958
surgery 1960, 1960f, 1961t
outcomes 1961, 1961t
risk factors 1961t
bile ductules, congenital hepatic fibrosis 781
bile export pump *see* ABCB11 (bile salt export pump)
bile extravasates 425
bile infarct (Charcot–Gombault) infarct 425
bile lake 425
bile peritonitis, post-liver biopsy 496
bile salt export pump (BSEP) *see* ABCB11 (bile salt export pump)
bile salt micelles 177
bile salts
canalicular transport 385
cholangiocyte transport 113
hepatocyte transport 112f, 113
inherited synthetic defects 1386
secondary 174
sinusoidal uptake 385
biliary atresia (BA) 1847
embryonic *vs.* perinatal 410
fetal/embryonic form 1847
gene array data 410
hepatopulmonary syndrome 1848
histology 1847
peri-/postnatal form 1847
surgical treatment 1847–1848
biliary atresia splenic malformation syndrome (BASM) 1847
biliary balloons, fascioliasis 1045–1046
biliary cancer, ulcerative colitis 1625
biliary cirrhosis
cholangiocyte apoptosis 54
choledocholithiasis 1526
fascioliasis 1045
primary sclerosing cholangitis 1106
biliary colic (pain) 444
cholecystolithiasis 1526
biliary cyst *see* simple cyst of the liver
biliary cystadenoma 813–815
aetiology 813–814
clinical manifestations 814
complications 814
course 814
diagnosis 814
differential diagnosis 814, 815f
imaging 526, 813f, 814
macroscopic appearance 813, 813f
malignant transformation 814, 814f
microscopic appearance 813
pathogenesis 813–814
pathology 813–814
prevalence 813
treatment 815
biliary dilatation
computerized tomography 511, 511f
hereditary haemorrhagic telangiectasia 1420
biliary disease
elderly 1875
functional genomics 408t
HIV infection 985
infants 1845–1850
nutrition 1905–1911
pregnancy 1888
ultrasonography 506–507
biliary drainage 1816
gallbladder carcinoma 1579
preoperative in obstructive jaundice 1935–1936
biliary dyskinesia 1561–1572
diagnosis 1561
post-cholecystectomy pain 1570
prevalence 1561
Rome II criteria 1561, 1561t
see also gallbladder, dysfunction; sphincter of Oddi dysfunction
biliary endoprosthesis
alveolar echinococcosis 1054
biliary obstruction 555–556

metallic stents 556
plastic stents 556
biliary epithelial cells *see* cholangiocyte(s)
biliary fibrosis 427
biliary fistula
gallstone disease 1535
post bile duct injury 1960
biliary hamartomas 797–802, 1573–1574, 1856
adult polycystic kidney disease 789, 798
clinical features 798, 1574
congenital hepatic fibrosis 798
development risk factors 798
diagnosis 800–801
differential diagnosis 801
follow-up 801
imaging 523, 798–800
liver metastasis *vs.* 801
malignant transformations 798, 816, 1574
microscopic appearance 797, 797f, 1573
mural nodules 800, 800f
natural history 798
occurrence 1573
pathogenesis 797–798
pathology 797–798, 1573
peribiliary cysts *vs.* 801
polycystic liver disease 796
prevalence 798
progression risk factors 798
simple hepatic cysts *vs.* 801
treatment 801
vanishing bile duct syndrome 1112
biliary infections
alveolar echinococcosis 1052
obstructive jaundice 1504
pyogenic liver abscess 1001
recipient, living donor liver transplantation 1982
biliary obstruction
alkaline phosphatase levels 463
bilirubin 169
hepatic cysts, ADPKD 792t
malignant
endoscopic retrograde cholangiopancreatography 545
endoscopic *vs.* surgical palliation 545
proximal extrahepatic bile ducts 546, 546f
stents 545–546
post-liver transplantation 2000
pregnancy 1888
biliary pain (colic) 444, 1526
biliary papillomatosis 1573
biliary piecemeal necrosis 424
biliary sludge
post-haematopoietic stem cell transplantation 1677
pregnancy 1888
total parenteral nutrition-related liver disease 1638
ultrasound 1522f
biliary sphincterotomy, gallstone pancreatitis 545
biliary strictures
computerized tomography 542
endoscopic retrograde cholangiopancreatography 542
hereditary haemorrhagic telangiectasia 1420
liver trauma 1957
living donor liver transplantation 1982–1983
post-cholecystectomy 1960
primary sclerosing cholangitis 1071, 1106
radiation hepatitis 1278
stenting, haemobilia 1551–1552
biliary tract
anatomy 304–306
benign inflammatory tumours 1596
cells
development 65
differentiation 67, 67f, 69
see also individual types
chronic portal vein thrombosis 1397
clots 1554
complications, living donor liver transplantation 1979, 1982–1983
cystic fibrosis 1339
embryology 304–305
extrahepatic 17–19
histology 17–19
innervation 305–306
intrahepatic
blood supply 17
embryology 69
histology 17
lesions, histological features 425–426
magnetic resonance imaging 530–531
motility 304–311
historical aspects 304
physiology 306–310
surgery
bacterial cholangitis 1544
primary sclerosing cholangitis 1108
wall of 305–306
biliary trauma, iatrogenic 1958, 1958t
biliary tree
anatomy 1111–1112
canal of Hering 1111
cyclic adenosine monophosphate 1111
cystic fibrosis transmembrane conductance regulator 1111
epithelium 1111
active uptake 1111
apoptosis 1112
proliferation 1112
secretion 1111
interlobular ductules 1111
intraportal ductules 1111
papilla of Vater 1111
septal ducts 1111
biliary tumours
benign 1573–1574
malignant 1583–1605
see also individual types
biliodigestive anastomosis, bacterial cholangitis 1544–1545
bilirubin 459–461
alcoholic hepatitis 1162
antioxidant properties 168, 1353
assays 459–460
bacterial infections 1001
beneficial effects 168–169, 1353
body fluids 169
chemical characteristics 166–168
clinical usefulness 461
conjugated *see* conjugated bilirubin
conjugation 170–171, 1352, 1353–1354
direct *see* conjugated bilirubin
disposition 169–171, 169f
distribution 459
elimination 172
extrahepatic biliary obstruction 1502
formation/production 165–166, 209
enzymatic mechanisms 165–166, 166f
inhibition 166
measurement 166
sources 165
functions 1352
gastrointestinal tract 171–172
glucuronidation 170–171
hepatic clearance 384
hepatic uptake 1352, 1354
hepatobiliary disease 169, 460–461
hepatocellular diseases 169
hepatocyte uptake 167f, 170
hilar (upper duct) cholangiocarcinoma 1590
historical aspects 165
hydrogen bonds 166–167
hyperthyroidism 1684
hypothyroidism 1685
indirect *see* unconjugated bilirubin
intrahepatic cholestasis of pregnancy 1880
light, effects of 168
metabolism 165–174, 459, 1354–1355, 1354f
neurotoxicity 168, 1822
nonhepatobiliary diseases 461
normal values 460
overproduction
conditions causing 1945
postoperative jaundice 1945–1947
physiological jaundice 1355
postoperative liver failure 1935
pre-eclampsia 1884
pregnancy 1879
properties 459
quantification 168
removal, calculation for 166
renal excretion 172
spontaneous bacterial peritonitis prophylaxis 766
storage 169f, 170
structure 166, 167f, 459, 1352
total parenteral nutrition-related liver disease 1634
toxicity 168, 252–253, 1353
cerebral 168
transport 170, 459, 1354–1355
unbound fraction measurement 170
unconjugated *see* unconjugated bilirubin
bilirubin glucuronides 167
bilirubinostasis, ductular 425
biliverdin 166, 1352
biliverdin reductase 166, 166f
biloma 816–817
binge drinking, alcoholic liver disease 1159
bioartificial liver support 2044–2047
acute liver failure 1306, 2049t
clinical practice implications 2048–2049
clinical studies 2046–2047, 2046f
porcine hepatocyte-based 2046–2047
devices 2046–2047
hepatocyte bioreactors 2045–2046
coated plates 2045
encapsulation 2045
liver micro-organs 2045–2046
porous three-dimensional matrix 2045
semipermeable hollow fibres 2045
immortalized cell lines 2045
mortality 2049t
primary cells 2044–2045
fetal hepatocytes 2044
porcine hepatocytes 2044–2045
stem cells 2045
tumour cell lines 2045
bioavailability, drug 240
portal hypertension 247
biodiscovery, proteomics 412
bioelectrical impedance analysis (BIA), nutritional status assessment 1905
bioinformatics 406–407
database mining 379
definition 399
Gene Ontology Consortium format 407
'normalization' 406
QTL analysis in inbred mice 377–379, 377t
supervised learning methods 406
unsupervised learning methods 406, 406f
see also functional genomics; *specific methods*
biomarkers, proteomics and 412, 413–414
biopsies
hilar cholangiocarcinoma 1591
liver *see* liver biopsy
biothionol, fascioliasis 1045
biotin-avidin immunoenzymatic technique, viral hepatitis detection 430
biotin labelling 403
biphenyl, hepatotoxicity 2107
Birbeck granules 1618
Bismuth–Corlette procedure 1600–1601
Bismuth–Corlette system, hilar cholangiocarcinoma classification 1588, 1588f
bisphosphonates, osteoporosis 1832
black eschar, Mediterranean spotted fever 1006
black hairy tongue, alcohol abuse 1186
black pigment gallstones 1520f, 1523
calcium bilirubinate 1523
calcium carbonate saturation index 1523
causes 1521t
erythropoiesis defects 1523
haemolytic anaemia 1523
classification 1519t
risk factors 1521t
bladder cancer, liver and 1659
Blastomyces dermatitidis 1016–1017
blastomycosis 1016–1017
blebs 341
drug-induced acute hepatitis 1220
bleeding *see* haemorrhage
bleeding risk assessment, coagulation tests 1786–1787
Blighia sapida (ackee), hepatotoxicity 1272
blisters, porphyrias 1347
blood
composition, across liver cell plates 90
hepatitis C transmission 883
oxygen across liver cell plates 90–91

blood (*continued*)
volume
cirrhosis 1727–1728, 1727f
homoeostasis 1729
replacement, acute variceal bleeding 648
blood–brain barrier
hepatic encephalopathy treatment 747
vasogenic oedema 734
blood chemistry
cholecystitis 1529
cholecystolithiasis 1527
choledocholithiasis 1527
blood cultures
candidosis 1012
visceral leishmaniasis 1036–1037
blood flow
cerebral 744, 1132
hepatic *see* hepatic blood flow
blood flukes 1040–1044
blood pressure
arterial 1727
circadian variation 1728
homoeostasis 1728–1729
arterial compliance 1726
cirrhosis 1728–1729
pregnancy 1879
sinusoids 15
blood products
coagulation disorders 260–261, 1789
hepatitis C transmission 883
recipients, hepatitis B vaccine and 911
blood tests
hepatic encephalopathy 742
infantile cholestasis 1847
blood transfusion
hepatitis B transmission 865
hepatitis E transmission 897
liver transplantation 1943
postoperative jaundice 1945
blood typing, living donor liver transplantation 1977, 1992
blood urea nitrogen (BUN), hepatorenal syndrome 676, 712
bloody ascites 668
BMS-200475 *see* entecavir
body mass index (BMI)
alcoholics, fibrosis progression 1183
gamma-glutamyl transpeptidase levels 464
body water, obstructive jaundice 1504
body weight
diuretic effectiveness assessment 691
gamma-glutamyl transpeptidase levels 464
loss
extrahepatic biliary obstruction 1507
non-alcoholic fatty liver disease 1204–1205, 1682
non-alcoholic steatohepatitis prevention/management 1204–1205
Bogliolo's sign 1042
Bolivian haemorrhagic fever (BHF) 988, 989
bombesin 53
bone
crises, Gaucher's disease type 1 1361
densitometry, indications for 1832t
hormonal deficiency 1078
liver disease, effects on 1829–1835
mass-fracture risk relationship 1829–1830
primary biliary cirrhosis 1078–1079
resorption
chronic liver disease 1831
parathyroid hormone 1750
primary biliary cirrhosis 1831
bone disease
aetiology 1750–1751
alkaline phosphatase levels 463
cholestasis 1487, 1496
post-transplantation 1830t, 1832–1833
children 1833
fracture risk 1832–1833
management 1833
pathogenesis 1833
bone Gla-protein *see* osteocalcin
bone marrow
anaemic cirrhotic patients 1767–1768
benzimidazole side-effect 1055
hepatocyte replacement 284
post-liver transplantation 1772
stimulants 1792
cirrhosis 1792
viral-induced aplasia 1769
bone marrow transplantation
Gaucher's disease 1364
post-operative veno-occlusive disease 1256
bone mineral density (BMD)
liver disease and 1830
measurement 1829–1830
primary biliary cirrhosis 1078
bone morphogenic protein (BMP)-2 65
bone morphogenic protein (BMP)-4 65
bone morphogenic proteins (BMPs) 66
bone pain, rickets 1833
boron hydrides, hepatotoxicity 2108
Borrelia burgdorferi 1007, 1644, 1808
Borrelia recurrentis 1007
bortezomib 1707
bosentan
fibrosis 597
hepatotoxicity 1242
portopulmonary hypertension 724
botanicals, liver damage and 1283–1286
bottom-up estimation, costs 2081
Bouveret syndrome 1527
bowel cleansing, hepatic encephalopathy 746
bowel habits 444
bowel perforation, liver trauma and 1954
brachial artery blood flow, glomerular filtration rate 685, 685f
brachial plexopathy, post-liver transplantation 1826–1827
brain
bilirubin toxicity 168, 1353, 1822
drug susceptibility, cirrhosis 1914
see also entries beginning cerebral
brain natriuretic peptide (BNP), cirrhosis 1723
branched-chain amino acid (BCAA)
alteration in liver disease 1838
supplements
fulminant hepatic failure 1839–1840
hepatic encephalopathy 746, 747, 1839, 1908
branched-chain β-keto acid dehydrogenase (BCKDH) 144
BRCA2 394t
breast cancer, alcohol consumption and 1186
breast cancer-related protein (BCRP; ABCC2), canalicular bile secretion 113, 296–297
breastfeeding jaundice 1355
Breynia officinalis, hepatotoxicity 1283
bridging hepatic necrosis 424
subacute hepatitis 1251
brief intervention (psychological support), alcoholic cirrhosis 1167
Brissot score 494
British anti-Lewisite, Wilson's disease 1318
bromfenac, hepatotoxicity 1231
bromocresol green (BCG), albumin assay 454
bromocresol purple, albumin assay 454
bromocriptine, hepatic encephalopathy 748
bromosulphopthalein
acute myocardial infarction 1611
constrictive pericarditis 1613
bronchial carcinoid tumours 1471, 1472
bronze diabetes *see* haemochromatosis
brood capsules, cystic echinococcosis 1048
brown pigment gallstones 1523
bacterial infections 1523
causes 1521t, 1523
cholangiocarcinoma 1584
classification 1519t
risk factors 1521t
Brucella abortus 1003
Brucella melitensis 1003
Brucella suis 1003
brucellosis 1003
granulomas 1713
bruising 445
cirrhosis 610
bruits
alcoholic hepatitis 1162
angiosarcoma 1458
arterial 448
hereditary haemorrhagic telangiectasia 1420
brush cytology, malignant biliary strictures 542
Bsep, functional expression cloning 125
B7-H1, T cell activation 322
β-sympathomimetics 1888
Budd–Chiari syndrome 1403–1411
acute liver failure 1301
acute presentation 1408
angiography 538, 538f
antiphospholipid antibody syndrome 1695
asymptomatic 1408
causes 1403–1405
chronic presentation 1408
cirrhosis *vs.* 670–671, 1406–1407
clinical manifestations 1257, 1407–1408, 1407t
compensatory mechanisms 1407
complication management 1409
course 1407–1408
definitions 1403
diagnosis 1408–1409
differential diagnosis 1409
drug-induced 1257, 1405
epidemiology 1403
fibrosis 1406
haemodynamic changes 1406
hepatic venous obstruction 87
hepatocellular carcinoma, risk of development 1407
imaging 1408–1409
inherited thrombophilias 1404
liver decompression 1409–1410
liver transplantation 1410, 1988
recurrence 2017
living standards 1405
management 1410
multiple large regenerative nodules 1407
paroxysmal nocturnal haemoglobinuria 1666, 1769
pathogenesis 1405–1406
pathology
liver damage 1406–1407
venous lesions 1405–1406
polycythaemia vera 1665
pregnancy 1405, 1885
primary 1403
causes 1403–1405, 1404t
risk factors 1405
prognosis 1410–1411, 1411f
scores 1411, 1411t
secondary 1403, 1405
small bowel mucosa abnormalities 1801
systemic lupus erythematosus 1695
treatment 1257, 1409
'true' 1406
tumour invasion 1405
ulcerative colitis 1628
ultrasonography 503–504, 1408
workup 1405, 1406t
budesonide 1083
'bull's eye' lesions, focal hepatic candidiasis 1665
buprenorphine
hepatotoxicity 1298
mitochondrial energy production impairment 1217
Burkholderia pseudomallei 1003
burns, liver injury 1278–1279
burr cells (echinocytes) 1768
'bush tea' ingestion 1283
Byler's disease (progressive familial intrahepatic cholestasis type 1) 177, 1384, 1849

C

C3b, Kupffer cells 38
C4b, Kupffer cells 38
C5a, Kupffer cells 38
C5aR, Kupffer cells 38
C57BL/6 mice, autoimmune hepatitis models 1096
C282Y mutation, *HFE* gene 1324, 1325
CA-19.9 tumour marker 1590
cadaver livers, hepatocyte transplantation 2034–2035
E-cadherin 394t
cadmium, hepatotoxicity 2108
caesarean section
acute fatty liver of pregnancy 1883
liver rupture 1884
café-au-lait spots 1645
alpha-calcidiol, osteomalacia 1834
calcineurin inhibitors
acute rejection, children 1866
autoimmune hepatitis 1101
drug interactions 2006, 2006t
liver transplantation 2006–2007
children 1865

monitoring 2006
side-effects 1865, 2007, 2007t
hyperglycaemia 2021
hyperlipidaemia 2021
calcitriol 1834
calcium
hepatocyte signalling 93
homeostasis
parathyroid hormone 1750, 1751f
vitamin D 218
malabsorption, osteomalacia 1834
as second messenger 103
supplementation 1901, 1908
osteoporosis 1082, 1832
calcium antagonists, hepatic blood flow 77
calcium bilirubinate gallstones 1523, 1638
CA^{2+}/calmodulin-dependent protein kinase (CaMK) 160–161
Ca^{2+}-protein kinase C 301
calcium carbonate saturation index, gallstones 1523
calcium hopantenate, hepatotoxicity 1247
calculous cholecystitis 1523
total parenteral nutrition-related liver disease 1637
Callilepsis laureola (impila), hepatotoxicity 1282t, 1285
calpains
apoptosis 336
inhibition 344
warm ischaemia, protection from 351
necrosis 341
cambendazole 1065
Campath-1H (alemtuzumab) 2005
camphor hepatotoxicity 1282t
Campylobacter 1004
canalicular bile formation *see* bile, formation
canalicular bile secretion *see* bile, secretion
canalicular bilirubinostasis 425
canalicular cholestasis 1484
canalicular multispecific organic anion transporter (cMOAT) 171
canalicular transport, inherited defects 1383–1385, 1383f
cholestasis of pregnancy 1385
gallstone formation 1385
canaliculi, bile *see* bile canaliculi
canal of Hering 17, 17f, 23, 23f, 59, 59f, 1111
cancer(s)
cellular characteristics 391
extrahepatic, alcohol consumption and 1171
formation *see* carcinogenesis
resection *see* hepatectomy
see also individual types
Candida 1011
Candida albicans 1011
Candida glabrata 1011
Candida parapsilosis 1011
candidate genes 359
alcoholic liver disease 358
complex (multifactorial) diseases 372
immunogenetics 368–369
Candida tropicalis 1011
candidiasis *see* candidosis
candidosis 1011–1013
acute leukaemia 1664–1665
clinical features 1012
complications 1012
diagnosis 1012–1013
differential diagnosis 1012–1013
epidemiology 1011–1012
hepatosplenic *see* hepatosplenic candidosis
pathogenesis 1012
pathology 1012
persorption 1012
post-haematopoietic stem cell transplantation 1677
prognosis 1013
tissue invasion 1012
treatment 1013
cannabis, alcoholic liver disease and 1183
canrenone 1728
Cantu syndrome 2126–2127
Capillaria hepatica 1065
life cycle 1066
Capillaria philippinensis 1065
capillariasis 1065–1066
diagnosis 1066
pathology 1066
capillarization *see* sinusoidal capillarization
capillary haemangioma
angiography 537t
children 1863
captopril, hepatotoxicity 1231
caput medusae 606
CAR *see* constitutive androstane receptor (CAR)
carbamate insecticide, hepatotoxicity 2108
carbamazepine, hepatotoxicity 1231, 1827
carbamoyl-phosphate synthetase 92
carbamoyl-phosphate synthetase I 182
carbimazole, hepatotoxicity 1231, 1685
carbohydrate-deficient glycoprotein syndrome
type 1 2127–2128
type 1b (CDGS IB) 1856
carbohydrate-deficient transferrin (CDT)
alcoholic cirrhosis 1166
alcoholic relapse, post-transplantation 1184
carbohydrate response element binding protein (ChREBP) 161
carbohydrates
acute porphyric crisis 1345
metabolism 129–133
across liver cell plate 91
cirrhosis 132
inborn errors 1860–1862
non-alcoholic fatty liver disease 132
regulation, efferent hepatic nerves 115–116
total parenteral nutrition-related liver disease 1636
see also individual types
carbon dioxide, pH regulation 185
carbon disulphide, hepatotoxicity 2108
carbonic anhydrase 182–183
carbonic anhydrase V 186
carbon monoxide
cirrhotic liver 632
haemolysis in neonates 1353
hepatic blood flow regulation 77
hepatic resistance modulation 631–632
sinusoidal perfusion regulation 82–83
vasorelaxant 83
carbon tetrachloride
chronic exposure 1270
fibrosis reversal 586
hepatotoxicity 1270–1271, 2117
treatment 1271
metabolism 1270–1271
carbonyl nickel, hepatotoxicity 2108
carcinoembryonic antigen (CEA)
colorectal hepatic metastases 1467
hilar (upper duct) cholangiocarcinoma 1590
simple cyst of the liver 785
carcinogenesis 61–62, 62f, 393–396
apoptosis 341
carcinogens 393
epigenetic events 391
functional genomics, gene array data 411
genetic events 391, 395f
genetic instability 391–392
oncogenes *see* oncogenes
tumour suppressors *see* tumour suppressor genes (TSGs)
viral proteins
oncogenesis 393
TSG inactivation 394
carcinogens 393
carcinoid-associated scleroderma 1474
carcinoid syndrome 1473–1475
cardiac manifestations 1474
clinical features 1473–1474, 1474t
cutaneous manifestations 1473–1474, 1809
debulking 1477
diagnosis 1475
endocrine dysfunction 1763–1764
gastrointestinal manifestations 1474
pathogenesis 1474–1475
prognosis 1475
treatment 1475–1476
choice of 1477
tumours causing 1471t, 1473
carcinoid tumours 1470–1478
cell of origin 1470–1471
clinical features 1472
debulking 1476–1477
imaging 1473
incidence 1472
invasive 1471
laboratory investigations 1472
macroscopic characteristics 1471, 1471t
microscopic appearance 1471–1472, 1472f
molecular analysis 1471
pharmacological therapy 1475–1476
primary 1471, 1472
secretions 1471
sites 1471, 1471t
surgery 1476
treatment 1475
choice of 1477
tumour markers 1472
*CARD*4, inflammatory bowel disease 370
*CARD*15, inflammatory bowel disease 370
cardiac catheterization, bleeding risk 1788t
cardiac drugs, hepatotoxicity 1613, 1613t
cardiac dysfunction 1721–1723
afterload changes 1722
alcoholism 1185–1186
conductance abnormalities 1722
diastolic 1722
electromechanical coupling 1722
heart and arterial system coupling 1722, 1726
preload changes 1722
systolic 1721–1722
cardiac insufficiency, cirrhosis 1723
cardiac output (CO)
cirrhosis 686, 1721, 1725
hepatorenal syndrome 713
liver disease and 1938, 1942
obstructive jaundice 1503
post-peritoneovenous shunting 695
volume expansion 1728
portal hypertension 636
cardiac sclerosis, congestive heart failure 1612, 1613
cardiac surgery, postoperative liver dysfunction 1611
cardiofaciocutaneous (CFC) syndrome 2128
cardiolipin 203–204
cardiolipin antibody test, antiphospholipid antibody syndrome 1695
cardiomyopathy
cirrhotic *see* cirrhotic cardiomyopathy (CCM)
post-liver transplantation 1998–1999
cardiopulmonary bypass surgery, postoperative jaundice 1611
cardiopulmonary examination 447
cardiovascular disease
acute liver failure 1293
liver in 1609–1615
acute cardiac events 1609–1611
chronic cardiac events 1611–1614
pretransplant patients 1926
cardiovascular system
liver disease and 1721–1731
anaesthetic implications 1938–1939, 1942
monitoring during liver transplantation 1942, 1943
post-liver transplantation 1998–1999
immunosuppression-related complications 2020–2021
carnitine
deficiency
pregnancy 1883
total parenteral nutrition-related liver disease 1636
urea synthesis regulation 183
carnitine palmitoyl transferase I (CPT I) 152, 161
carnitine palmitoyl transferase II (CPT II) 152
Caroli's disease 1856
vanishing bile duct syndrome 1112
Caroli syndrome 805–806, 1856
aetiology 805
associated malformations 806
classification 805
clinical examination 805
complications 806
congenital hepatic fibrosis 805, 806
course 806
diagnosis 805–806
imaging 805–806
intracystic stone formation 806
manifestations 805–806
pathology 805
surgery 806
treatment 806

betacarotene, erythropoietic protoporphyria 1347, 1348
carotenoids 214
carotid sinus pressure, hepatic blood flow regulation 76
carrier-mediated diffusion, bile acid transport 295
carrier proteins 250–255, 250t, 385–386
  cell membrane interactions 252
  convection 251
    concentration *vs.* 251
    hormone signalling 251
    tissue availability 251
  diffusion effects 109f, 110, 252
  drug effectiveness 253
  functions 250, 251–253
  ligand targeting 253
  membrane interactions 252
  oncotic functions 253
  toxicity limitation 252–253
  see also transport proteins
Cascara sagrada, hepatotoxicity 1282t, 1285
caseating granulomas 1709, 1710f
caspase-3 336
caspase-8 203, 338
caspase-9 339
caspase cascade, tumour necrosis factor 314–315, 315f
caspase-independent cell death 342
caspase inhibitors 318, 343–344
  warm ischaemia, protection from 350–351
caspases
  activity measurement 337
  apoptosis 336
  liver injury 340
Cassia angustifolia (senna), hepatotoxicity 1285
Castleman's disease 1707
catalase 26, 235
  alcohol oxidation 1136
cataracts 446
β-catenin
  hepatoblast differentiation 68
  hepatocellular carcinoma 1440
  as oncogene 392–393, 392t
cathepsins, apoptosis 336
catheter sepsis
  secondary bacteraemia 767
  treatment 767
cat-scratch disease 1005, 1644
caudate lobe enlargement, Budd–Chiari syndrome 1407, 1408
caudate process 3
cave fever 1014
caveolae 27
caveolin-1, cirrhosis 82, 631
cavernous haemangioma
  angiography 537t
  children 1863
CC chemokine receptor 5 (CCR5), hepatitis C treatment response marker 358
CCKAR gene/protein 1518t, 1524, 1525
CCL18 concentrations 1362
CD1 molecules, natural killer T-cells 321
CD4 T cells
  alcoholic cirrhosis 1141
  autoimmune hepatitis 1097–1098
  granuloma pathogenesis 1711
  hepatitis B 1141
CD8 T cells
  acute graft-vs.-host disease pathogenesis 1672
  alcoholic cirrhosis 1141
  autoimmune hepatitis 1099
  chronic hepatitis B antiviral therapy 922
  dendritic 321
  hepatitis B 1141
CD11b, dendritic cells 321
CD14, Kupffer cells 37
  alcohol exposure 40
CD28 369
CD40, cholangiocytes 55
CD95 (FasAPO-1)
  apoptosis 337–338, 340
  inhibition 344
CD95L, apoptosis 337–338, 340
C/EBP factors 68
cefonicid, spontaneous bacterial peritonitis 764t
cefotaxim, bacterial cholangitis 1543t
cefotaxime, spontaneous bacterial peritonitis 764t
ceftazidim, bacterial cholangitis 1543t
ceftriaxone, spontaneous bacterial peritonitis 764t
cefuroxim, bacterial cholangitis 1543t
celecoxib, drug-induced renal impairment 702
cell binding, hepatitis C virus 852
cell-culture models, chronic hepatitis B treatment 924–925
cell cycle 274–275, 391
  cyclin D1 274–275
  cyclin E/cdk activity 275
  cyclin kinase inhibitors 275
  Foxm1b protein 275
  liver damage response 274–275
  NF-κB 106
  p21 275
  p27 275
  polyploidization 275
  proteolytic system 274
  quiescent liver 274
  retinoblastoma protein 274, 393
  skp/cullin/F-box multiprotein complex 274
cell death 335–347, 342f
  caspase-independent 342
  mixed patterns 343
  molecular switches 343
  targeting, liver disease 343–345, 343f
  see also individual types
cell hybrids, liver function models 123
cell junctions
  bile formation 298
  hepatocytes 97
cell surface receptors, signal transduction 102–103
cellular immune response
  autoimmune hepatitis 1097, 1098f
  drug-induced acute hepatitis 1224f
  hepatitis A 860
  obstructive jaundice 1506
cellular RA-binding protein (CRABP) 214
cellular retinol-binding protein (CRBP) 214
cellulitis
  alcohol misuse 1810
  portal hypertension 768
Centella asiatica, hepatotoxicity 1286
central–central bridging necrosis 424
central (centrolobular) hepatitis 429
central nervous system infections, post-liver transplantation 1827
central obesity, non-alcoholic fatty liver disease 1197–1198
central pontine myelinosis (CPM), post-liver transplantation 2000–2001
central venous catheters
  acute liver failure 1304
  spontaneous bacterial peritonitis induction 763
central venules, blood flow regulation 80
centrilobar necrosis, hyperthyroidism 1684
centrolobular (acinar zone 3) fibrosis 426
centrolobular hepatitis 1610
centrolobular vein 9, 9f, 10f
cephalosporins
  bacterial cholangitis 1543, 1543t
  spontaneous bacterial peritonitis 764
cerebral aneurysms, polycystic liver disease 793
cerebral blood flow
  acute liver failure 744, 1132
  chronic liver disease 1725
  encephalopathy 1725
  measurement 744
cerebral haemorrhage, post-liver transplantation 1827
cerebral malaria 1030
cerebral oedema
  acute liver failure 733–734, 1292–1293
    clinical manifestations 740, 740f
    management 1305
    mechanisms 1132–1133
  cirrhosis 732–733
  cytotoxic (cellular) 733–734
  vasogenic 734
cerebral pontine myelinolysis, post-liver transplantation 1826
cerebrooculohepatorenal syndrome 2128–2129
cerebrotendinous xanthomatosis 176, 2129
cerebrovascular disease, interferon treatment contraindication 945
ceroid macrophages 429
ceroid pigment 429
ceruloplasmin
  aceruloplasminaemia 1327
  iron homeostasis 222–223, 222f
  Wilson's disease 1317, 1853
cestodes
  cholangitis treatment 1547t
  life cycle 1047
CFTR *see* cystic fibrosis transmembrane conductance regulator (CFTR)
chaparral, hepatotoxicity 1282t, 1285
charcoal, congenital erythropoietic porphyria 1348
chelation therapy
  pregnancy 1886
  Wilson's disease 1315, 1318–1319, 1853–1854
    combination therapy 1318–1319
Chelidonium majus (greater celandine), hepatotoxicity 1282t, 1284
chemical chaperones, alpha-1-antitrypsin deficiency 1334
chemoembolization, carcinoid syndrome 1809
chemokines 312, 313t
chemoradiotherapy, acute graft-vs.-host disease pathogenesis 1672
chemotaxis, fibrosis 592
chemotherapy
  amyloidosis 1707
  carcinoid tumours 1477
  cholangiocarcinoma 1600
  cystic echinococcosis 1050, 1055
  gallbladder carcinoma 1580, 1581t
  hepatic metastases 1468–1469
  hepatocellular carcinoma 1449
  hepatosteatosis induction 1936
  post-transplant lymphoproliferative disorders 1774
chemotherapy-associated steatohepatitis (CASH) 1936
chenodeoxycholic acid, cholecystolithiasis 1530
cherry red spots, portal hypertensive gastropathy 1799
chicken-wire fibrosis 426
Child–Pugh score *see* Child–Turcotte–Pugh (CTP) score
children
  acute liver failure 1856–1860
  alkaline phosphatase levels 462
  ascariasis 1058
  autoimmune hepatitis 1616–1617
    treatment 1100
  autoimmune liver disease 1852–1853
  cardiac surgery, postoperative liver dysfunction 1611
  chronic hepatitis B 871
    antiviral therapy 936
  chronic hepatitis C 890
    antiviral therapy 949
  chylous ascites 669
  hepatic drug reactions 1213
  hepatitis A 859, 1851
  hepatitis A vaccines 901, 902
  hepatitis B-associated membranous neuropathy 1818
  liver disease 1845–1869
  liver transplantation 1865–1867
    postoperative antibodies 1865
    post-operative bone disease 1833
  liver tumours 1862–1864
  non-alcoholic fatty liver disease 1198, 1202
  portal hypertension 1864–1865
  total parenteral nutrition-associated cholelithiasis 1637–1638
  viral hepatitis 1850–1852
  see also infant(s)
Children's Cancer Group, hepatoblastoma guidelines 1864
Child–Turcotte–Pugh (CTP) score 1934, 1934t, 1938
  Budd–Chiari syndrome 1411
  chronic hepatitis C antiviral therapy 949
  cirrhosis 615, 615t
    drug pharmacokinetics 1913
  coagulation tests 1786t
  hepatorenal syndrome 713
  liver transplantation 1985, 1985t
    indications 1922
    outcomes research 2070
  prognostic models 2060
  split liver transplantation 1973–1974

chimpanzee models
HBV infection 409
HCV infection 407–408
Chinese herbal medicines
acute liver failure 1298
hepatotoxicity 1282t, 1283
Chi R Yun, hepatotoxicity 1283
Chlamydia 1004–1005
Chlamydia trachomatis 1004–1005
primary biliary cirrhosis 1073
Chlamydophila pneumoniae 1005
Chlamydophila psittaci 1005
chlorambucil 1083
chloramphenicol 1003–1004
chlordecone (kepone), hepatotoxicity 2108
chlordiazepoxide
acute hepatitis induction 1231
alcohol withdrawal syndrome 1180
chloride-bicarbonate (Cl^-/HCO_3) anion exchanger 111, 111f
canalicular bile transport 299
ductal bile formation 299, 299f
chloride ions, cholangiocyte secretion 52
2-chloroethylene oxide, hepatotoxicity 1273
chloroform (trichloromethane), hepatotoxicity 1271, 2119
chloroquine
amoebiasis 1026
malaria 1033
porphyria cutanea tarda 1347
resistance 1033
chlorpromazine
cholestatic hepatitis induction 1231–1232
reactive metabolite formation 1232
vanishing bile duct syndrome induction 1254
chlorpropamide, hepatotoxicity 1232
cholangioadenoma *see* bile duct adenomas
cholangiocarcinoma 1583–1605
aetiology 1584–1585
anatomic abnormalities 1584–1585
choledochal cysts 1584–1585
endemic infections 1584
inflammation 1584
primary sclerosing cholangitis 1584
angiography 537t, 1592
autoimmune diseases 1584
biliary hamartomas 798
chemotherapy 1600
choledocholithiasis *vs.* 1596
cholelithiasis *vs.* 1596
classification/staging 1587–1589
anatomical 1587
clinical presentation 1589
colonic dysplasia 1625
cyst-like appearance 816
diagnosis/surgical staging 1589–1596, 1590t
differential diagnosis 1596–1598
drug-induced 1259t, 1260
extrahepatic 1583
classification/staging 1588, 1588t
clinical presentation 1589
pancreatitis 1589
functional genomics 408t
gene array data 411
proteomics 413
hilar (upper duct) 1583
classification/staging 1588–1589, 1588f
diagnosis/surgical staging 1589–1594
differential diagnosis 1596–1597
mortality rates 1599, 1599t
obstructive jaundice 1935
serum markers 1589–1590
surgery 1598–1599
treatment 1598–1599
histological classification 1585–1586, 1585f
hypercalcaemia 1763
incidence 1583
intraductal growth (IG) 1585, 1585f, 1586
magnetic resonance imaging 1591
intrahepatic 1583, 1595–1596
classification/staging 1587, 1588t
clinical presentation 1589
diagnosis/staging 1595–1596
differential diagnosis 1597
metastatic adenocarcinoma *vs.* 1466f
treatment 1600
liver transplantation 1600, 1922, 1988
lower duct 1583, 1594–1595
diagnosis/staging 1594–1595
treatment 1599–1600
Whipple procedure 1594
mass forming (MF) 1585, 1585f, 1586
imaging 1595–1596
lymph node metastases 1586
multicentricity 1586
molecular genetics 1586–1587
growth factors 1587
mortality 1583
mucinous, cyst-like appearance 816
natural history 1583
palliative therapy 1600–1601
Bismuth–Corlette procedure 1600–1601
decompression 1601
pathology 1585–1586
adenocarcinomas 1585–1586
epithelium 1585
periductal infiltrating (PI) 1585, 1585f, 1586
imaging 1591, 1593f, 1595
pregnancy 1886
preoperative preparation 1598
vitamin K 1598
primary sclerosing cholangitis 413, 1106, 1626–1627, 1987
progenitor cells 61
radiotherapy 1600
risk factors 61
treatment 1598–1601
ulcerative colitis 1626–1627
von Meyenburg complexes 816
cholangiocyte(s) 52–57
apoptosis 54, 285
bile reabsorption 52–53, 113
cystic fibrosis transmembrane conductance regulator 113, 1336
cytoskeleton 53
glucose reabsorption 53, 113
heterogeneity 55
immunological aspects 55
isolated, liver function models 123
large 55
polarity 52–53
primary biliary cirrhosis 1072
progenitors 284–285
bipotentiality 284–285
proliferation 53–54, 284
alcoholic hepatitis 1152
growth-regulatory peptides 284
neurohormonal factors 54, 284
replacement 284–285
neurohormonal factors 284
secretions 52
regulation 53
sepsis-induced cholestasis 1946
small 55
transformation 55
transport 52–53, 113, 113f
cholangiography
ascariasis 1059, 1060f
bile duct injury, post-cholecystectomy 1958, 1960f
cholecystolithiasis 1529
choledocholithiasis 1529
Clonorchis sinensis 1046
computerized tomographic *see* computerized tomographic cholangiography (CTC)
endoscopic retrograde *see* endoscopic retrograde cholangiography (ERC)
haemobilia 1556, 1556t
magnetic resonance *see* magnetic resonance cholangiography
percutaneous transhepatic cholangiography *see* percutaneous transhepatic cholangiography (PTC)
cholangioles 10f, 17
cholangiolitis *see* ductular reaction
cholangioscopy, hilar cholangiocarcinoma 1591
cholangitis 1541–1549
AIDS-related 1546
autoimmune *see* autoimmune cholangitis (AIC)
bacterial *see* bacterial cholangitis
Caroli syndrome 806
cystic echinococcosis 1049, 1051
definition 1228, 1541
differential diagnosis 1529
drug-induced 1228–1229, 1229t
elderly 1875
eosinophilic 1596
fibrous obstructive 1485, 1485f
gallstone disease 1534
haemobilia 1554
imaging 544
Kawasaki disease 1645
lymphoplasmocytic 1596
malignant 1485
neonatal sclerosing 1848
neutrophilic 1485
non-suppurative destructive 1485, 1485f
obstructive 1935
parasitic 1546–1547, 1547t
treatment 1547
peribiliary cysts 803
post-haematopoietic stem cell transplantation 1677
postoperative biliary atresia 1848
primary sclerosing *see* primary sclerosing cholangitis (PSC)
recurrent pyogenic *see* recurrent pyogenic cholangitis (RPC)
cholate stasis 425
cholecalciferol *see* vitamin D_3
cholecystectomy
bile duct injury following 1958–1961
biliary pancreatitis 1534
cholecystolithiasis 1530
choledocholithiasis 1531
elderly 1875
extrahepatic biliary obstruction 1507
gallbladder carcinoma 1578
gallbladder dysfunction 1564
gallstone pancreatitis 545
haemobilia 1553
with intraoperative cholangiography, gallstone disease 544
living donor liver transplantation 1978
pain following 1570
primary sclerosing cholangitis 1106
total parenteral nutrition-related liver disease 1638
cholecystitis 1533–1534
acalculous *see* acalculous cholecystitis
acute
gallbladder wall thickening 507
gallstone disease 1526, 1533, 1533t
management in elderly 1875
calculous 1523, 1927
chronic, gallstone disease 1526
computerized tomography 509f, 511, 1529
diagnosis 1529
differential diagnosis 1529
elderly 1875
haemobilia 1554
haemorrhagic, dialysis patients 1656
medical treatment 1534
oral contraceptive-induced 1688
percutaneous cholecystostomy 1534
surgery 1534
ultrasonography 507, 1522f, 1529
cholecystokinin (CCK)
gallbladder motility 306, 1562
gallstone prevention 1529
total parenteral nutrition-related liver disease 1638
cholecystokinin octapeptide provocation tests 1562
cholecystolithiasis
biliary colic 1526
blood chemistry 1527
cholecystectomy 1530
clinical presentation 1525–1526, 1526t
complications 1526
diagnosis 1527, 1529
differential diagnosis 1529
extracorporeal shockwave lithotripsy 1531
imaging 1527, 1528f, 1529
physical examination 1527
QTL analysis in inbred mice 376, 377f, 378, 378t
repeated attacks 1526
therapy 1529–1531, 1531f
asymptomatic disease 1529–1530
symptomatic disease 1530–1531
choledochal cyst(s) 807, 1848
cholangiocarcinoma 1584–1585
complications 807
diagnosis 807, 1848
pathogenesis 807
resection 807, 1848
treatment 807
types 807

choledochal cyst(s) (*continued*)
type 5 *see* Caroli's disease
vanishing bile duct syndrome 1112
choledochoduodenostomy, haemobilia 1553
choledocholithiasis
bacterial cholangitis 1541–1542
blood chemistry 1527
cholecystectomy 1531
clinical presentation 1526–1527
complications 1526–1527
bile duct carcinoma 1526
Bouveret syndrome 1527
secondary biliary cirrhosis 1526
diagnosis 1527, 1529, 1542
differential diagnosis 1529, 1596
elderly 1875
electrohydraulic lithotripsy 1531
extracorporeal shockwave lithotripsy 1531–1533, 1532f
imaging 1527, 1528f, 1529, 1542
physical examination 1527
sphincterectomy 1531
therapy 1531–1533
wait-and-see policy 1533
see also gallstone disease
choledochotomy 543
choledococoele 807
cholehepatic shunt theory, ursodeoxycholic acid 1494
cholelithiasis *see* gallstone disease (cholelithiasis)
choleretics, primary biliary cirrhosis 1083
cholescintigraphy
extrahepatic biliary obstruction 1509
gallbladder dysfunction 1563–1564, 1564f
haemobilia 1556
sphincter of Oddi biliary-type dysfunction 1568
cholestasis
Alagille syndrome 1848
alkaline phosphatase 463
apoptosis 341
canalicular 1484
cellular (non-obstructive) 384–390
definition 384
hepatocellular changes 386, 387f
nuclear receptors and 384, 385t
transporter proteins and 384–390
cholesterol levels 458–459
classification 1481
definition 384
drug-induced
bile-duct injury 1490
bland 1214t
BSEP mutations 177
cardiac drugs 1613t
chronic 1917, 1917t
with hepatitis *see* cholestatic hepatitis
postoperative 1946
primary biliary cirrhosis *vs.* 1077, 1078t
prolonged 1214t, 1253–1255
sclerosing cholangitis-like 1491
vanishing bile-duct syndrome 1253–1254, 1490
without hepatitis 1490
drug pharmacodynamics 1913
drug pharmacokinetics 1913
drug prescribing recommendations 1919t
extrahepatic
definition 1481
drug pharmacokinetics 1916–1917
genetic disorders 384, 1383–1388
hepatic metastases 1467
hepatitis A 860, 861
hepatocellular 1484–1485
histology 425–426, 1228
idiopathic postoperative 1946–1947, 1949
intrahepatic *see* cholestasis, intrahepatic
Kupffer cell 1484–1485
morphometry 438
obstructive 384
oral contraceptive-induced 1688
pancreatic secretion inhibition 1800–1801
phospholipid levels 458–459
post-haematopoietic stem cell transplantation 1673t, 1675–1677, 1676t
pruritus 387–388, 444, 1804
renal transplant patients 1658
rickets 1833
sarcoidosis 1711–1712
scoring systems 436, 437t
sepsis-associated *see* sepsis-induced cholestasis
total parenteral nutrition-related liver disease 1634, 1635
toxin-induced 1270t, 1272
vitamin E deficiency 1802, 1825–1826
see also specific diseases/disorders
cholestasis, intrahepatic 1481–1500
acquired 1481
adaptive responses 1482–1484, 1483f
transcription changes 1482–1483
animal models 1482, 1483–1484
benign postoperative 1946–1947, 1949
bile duct ligation 1481
models 1483–1484
bile duct proliferation 1484
biochemical features 1487–1488
causes/mechanisms 1481–1482
adulthood 1488t
hepatobiliary transporters 1481, 1482f
infancy/childhood 1489t
cholesterol deposits 1486
clinical features 1486–1487
definition 1481
diagnosis 1492–1493, 1493f
differential diagnosis 1484, 1900
disorders 1488–1492
drug-induced lithiasis 1491
endotoxin 1482
examination 1492
fatigue 1486
fat-soluble vitamin malabsorption 1486–1487
hepatocyte cytoskeleton 1482
HIV infection 1492
Hodgkin's disease 1492
hyperbilirubinaemia 460–461, 1487–1488
imaging 1492
inflammatory hepatocellular 1491–1492
liver biopsy 1492
malarial hepatitis 1031
management 1493–1497
future developments 2920–2921
nuclear receptor drugs 2920–2921
ursodeoxycholic acid 1493–1496
MDR3 deficiency 1491
nuclear receptors 1482–1483
pathology 1484–1486
ballooning degeneration 1484
ductular reactions 1484
feathery degeneration 1484
neutrophils 1484
patient history 1492
pigmentation 1484
pregnancy *see* intrahepatic cholestasis of pregnancy (ICP)
pruritus 1486
sarcoidosis 1492
steatorrhoea 1487
symptomatic treatment 1496
vanishing bile-duct syndrome 1490
see also specific diseases/disorders
cholestatic hepatitis
drug-induced 1228, 1490, 1648, 1946
cardiac drugs 1613t
with cholangiolitis 1228–1229
with cholangitis 1228–1229
differential diagnosis 1228
outcomes 1230
kava-induced 1284
cholesterol 133–134
cholestasis 458–459, 1486
cirrhotic ascites 669f
esterified 133, 139
glutathione mitochondrial transport 204–205
HDL-mediated removal 139–141, 140f
hepatic uptake 1520
hepatobiliary disease 458–459
malignant ascites 669, 669f
obstructive jaundice 1502
primary biliary cirrhosis 1076
synthesis
across liver cell plate 91, 92
cholesterol 7α-hydroxylase 1520
3-hydroxy-3-methylglutaryl-coenzyme A reductase 1520
cholesterol, 7-dehydrocholesterol (provitamin D_3) 218
cholesterol ester transfer protein (CETP) 139–141, 140f
cholesterol gallbladder stones 1518–1520, 1520f, 1522–1523
causes 1521t
classification 1519t
diabetes mellitus 1683
dietary origin 1520
formation 1519f
animal models 1522–1523
bile supersaturation 1518, 1519–1520
cholesterol saturation index 1518–1519
gallbladder hypomobility 1518, 1520
intestinal transit times 1520
nonobese 1520
in vitro models 1520, 1522
gallbladder carcinoma 1575
risk factors 1521t
cholesterol 7α-hydroxylase
across liver cell plate 92
cholesterol synthesis 1520
deficiency 1525
intrahepatic cholestasis 1483
cholesterol 26-hydroxylase 92
cholesterol-lowering agents, primary biliary cirrhosis 1083–1084
cholesterolosis (cholesterol polyps) 1529
cholesterol polyps (cholesterolosis) 1529
cholesterol saturation index (CSI) 1518–1519
cholesteryl ester hydrolase (CEH) 92
cholesteryl esters 133, 139
cholesteryl ester storage disease (CESD) 1365–1366, 2129
histology 1365–1366
cholestyramine
carcinoid syndrome 1475
intrahepatic cholestasis of pregnancy 1880
pruritus 1081–1082, 1496, 1804
vanishing bile duct syndrome 1117
choline, total parenteral nutrition-related liver disease 1635–1636, 1635f, 1638
chondroitin sulphate proteoglycans 269–270
chorionic gonadotrophin *see* human chorionic gonadotrophin (hCG)
chromium 233t, 237
deficiency 233t
insulin signalling, effects on 237
toxicity 237, 2108
chromogranin A
carcinoid syndrome 1475
carcinoid tumours 1472
chronic graft-versus-host disease (cGvHD) 1674–1675
cholestasis 1674
classification 1674, 1675t
clinical aspects 1674–1675
cutaneous manifestations 1674, 1808
definition 1671–1672
de nova 1674
hepatic manifestations 1674–1675
hepatitic variant 1675
incidence 1674
onset 1674
pathogenesis 1674
pathological findings 1675, 1675f
progressive 1674
quiescent 1674
treatment 1675, 1808
chronic hepatitis B *see* hepatitis B, chronic
chronic hepatitis C *see* hepatitis C, chronic
chronic hepatitis D *see* hepatitis D, chronic
Chronic Liver Disease Questionnaire 2067, 2069
chronic non-suppurative destructive cholangitis *see* primary biliary cirrhosis (PBC)
chylomicron retention disease *see* glycogen storage disease (GSD), type 4
chylomicrons (CM)
abetalipoproteinaemia 1366
apoC-II 136
assembly 135, 136f
characteristics 134t
clearance 137–138
remnants 137–138
retinyl esters 214
secretion 135–136, 136f
triglyceride hydrolysation 136

chylous ascites 669
ciclosporin
autoimmune hepatitis treatment 1100
hepatotoxicity 1242, 1647, 1677
intestinal malabsorption 1916
liver transplantation 2006–2007
children 1865
plasma concentrations, exaggerated 1916–1917
pregnancy 1889
primary biliary cirrhosis 1083
side-effects
arterial hypertension 2021
hyperlipidaemia 2021
cidofovir
adenovirus 968
cytomegalovirus 963
herpes simplex virus 959
human herpesvirus type 6 964
human herpesvirus type 7 964
human herpesvirus type 8 966
cigarette smoking *see* smoking
cilia
autosomal recessive form of polycystic kidney disease 69
cholangiocytes 53
formation/function deficiencies 69
ciliated hepatic foregut cyst (CHFC) 807–809
clinical presentation 808
histology 807, 807f
imaging 808
malignant transformation 808
pathogenesis 808
pathology 807–808
surgical excision 808
treatment 808
cimetidine
acute hepatitis induction 1232
carcinoid tumours 1476
cineradiographic studies, sphincter of Oddi motility 308–309
ciprofloxacin
acute hepatitis induction 1232
bacterial cholangitis 1543, 1543t
spontaneous bacterial peritonitis 765
circulatory failure, acute liver failure 1859
cirrhose pigmentaire *see* haemochromatosis
cirrhosis
aetiology 604, 605t
albumin levels 454–455
alcoholic *see* alcoholic cirrhosis
alkalosis 186
altered substrate utilization 1838
amenorrhoea 1759, 1885–1886
anaemia 610, 1767–1768
angiography 537, 538f
antidiuretic hormone levels 681
antiretroviral administration guidelines 1918t, 1919
autoimmune hepatitis-related 410
bacterial infection 1807
bilirubin 461
biochemical investigations 611–612
bleeding episodes
clinical manifestations 640–657
management 640–657
see also variceal bleeding
blood shunting 675
Budd–Chiari syndrome and 1406–1407
Budd–Chiari syndrome *vs.* 670–671
caloric costs 1837
cancer and 391, 395–396, 1933
resection *see* hepatectomy
carbohydrate metabolism 132
cardiac drug-induced 1613t
cardiac pressures 1721
cardiovascular complications 686–687, 1723, 1938–1939
causes 1933
cerebral blood flow 1725
classification 604
clinical aspects 604–619
clinical examination 611
clinical features 605–611, 607t
coagulation disorders 258, 610
coagulation tests 1784, 1785f
compensated 605
chronic hepatitis C 887
sodium metabolism abnormalities 675–676
computerized tomography 516–518, 516f, 517f, 613
cortisol 1753
'cryptogenic,' non-alcoholic steatohepatitis and 356
cytomegalovirus infection 963
decompensated 605–611
alcoholic liver disease, progression from 1186
splanchnic arterial vasodilation 686
definition 427, 583, 590, 604
diabetes mellitus 1682
genesis of 1735–1736
diagnosis 611–615
differential diagnosis 614–615
driving capacities 1902
drug–drug interactions 1916
drug-induced 1213, 1214t
drug pharmacokinetics 1913
drug prescribing 1918, 1918t
contraindicated drugs 1918
drug susceptibility, non-hepatic organs 1913–1914
dysplastic nodules
computerized tomography 517
ultrasonography 504t, 506
elderly 1873–1874
causes 1873
electrolyte imbalance 1939
endocrine disturbances 610–611
endothelin, response to 82
endstage renal disease 1654
energy requirements 1907
epidemiology 604, 606f
evolution of 583–589
extrasplanchnic regional circulations 684–686
follow-up 616–617
gallstones 613
gastric acid secretion 1800
gene array data 409
glomerular abnormalities 1817–1818
histology 1817, 1817f
haematological complications 610
haematological investigations 611–612
hepatic arterial buffer response 76
hepatic blood flow 569
microvascular changes 674–675
regulation abnormalities 1728
resistance changes 630–631, 1724
hepatic encephalopathy 608–609, 743
hepatic lymph flow increases 88
hepatic removal kinetics 475
hepatitis B-related 871, 1933
antiviral therapy 933–934
gene array data 409
hepatitis C-related 410, 881–882, 1933
AIH-related *vs.* 410
antiviral therapy 948–949
chronic 881–882
gene array data 409
hepatocellular carcinoma 391, 395–396, 608, 1438, 1439–1440, 1933
elderly 1874
imaging 612–613
histology 614
history taking 611
hyperammonaemia 730
hyperbilirubinaemia, acquired 1356
hyperprolactinaemia 1760
hypersplenism 774–775, 774f
hypofibrinogenaemia 260
hypogonadism 1756–1758
imaging 612–614
immunoglobulins 1771–1772
inflammatory bowel disease 1626
insulin resistance 132
interferon-α 933
intermediate hepatocytes 60
intrahepatic vascular resistance 684–685
iron metabolism 585, 1769
lamivudine 934
leucocyte abnormalities 1771
liver architecture in 391
liver sinusoidal endothelial cells 33
lymph flow 674–675
macronodular 604
maldigestion 1837
malnutrition prevalence 1906, 1906f
mean respiratory quotient 1838
micronodular 604
mixed 604
morphometry 438
mortality rates 606f
alcohol consumption 1130–1132, 1130f
myocardial mass 1721
neurological manifestations 1824t
non-alcoholic steatohepatitis 1201
nutrition 609
outcomes research 2069
ovarian dysfunction 1759–1760
parathyroid hormone 1751
peptic ulcers 1800
peripheral circulation 1725
platelet production 773
platelet–vessel wall interactions 1786
portal hypertension 605–606
portal vein thrombosis 1396
positron emission tomography 564
post-cardiac surgery, children 1611
postnecrotic
autoantibodies 1252
drug-induced 1251–1253, 1252t
preascitic 605
pregnancy 1885–1886
presinusoidal resistance 631
primary biliary *see* primary biliary cirrhosis (PBC)
prognosis 615–616
models 615–616
progression from fibrosis 583–589
progressive familial intrahepatic cholestasis type 3 1384
protein–calorie sarcopenia 1836–1839
renal circulation 684–686
renal dysfunction 605–606, 612, 675–676, 1939
antidiuretic hormone 680–681
arachidonic acid metabolites 680–683
circulatory dysfunction 683–687
drug-induced 702–703
mechanisms 677–683
renin–angiotensin–aldosterone system 677–679
sympathetic nervous system 679–680
respiratory complications 1939
reversal 586–587
screening 616–617
sepsis 609
sex hormone changes 1756–1758, 1757t
sexual activity 1902
surgery
resection *see* hepatectomy
risk assessment 1938
surrogate markers 614
systemic effects 1938–1939
telomere shortening/senescence 277f
thrombocytopenia 258, 1771, 1785–1786
thyroid hormones 1748–1749, 1748t
toxin-induced 1270t, 1272–1273
treatment 616
haemodynamic consequences 616
ultrasonography 502–503, 503f, 506, 612–613
urea production 185
vascular tone restoration 1791
vasoconstrictors, increased production 633
Wilson's disease 1317
see also fibrosis
cirrhotic ascites 666–710
cardiac dysfunction 686–687, 686f
characteristics 667–668
coagulation-related proteins 668
decompensated cirrhosis 605
differential diagnosis 668–672
diuretic-intractable 692
diuretic-resistant 692–693
formation 672–676
lymphatic system involvement 672–675
portal hypertension 672–675
renal function abnormalities 675–676
gastro-oesophageal reflux 1798
hyponatraemia treatment 699–702
prognosis 689, 689f
sources of 674–675
treatments 689–699
diuretics 690–692
cirrhotic cardiomyopathy (CCM) 607–608, 686–687, 1722–1723, 1938
clinical features 607–608
congestive heart failure 1612
definition 1721
diastolic dysfunction 1722
experimental data 1722
liver transplantation 1185–1186
preoperative assessment 1996

cirrhotic cardiomyopathy (CCM) (*continued*)
pathophysiology 1722–1723, 1723f
prolonged Q-T interval 1722
cirrhotic hydrothorax 671–672
complications 672
pathogenesis 671, 672f
cisplatin
gallbladder carcinoma 1580
transarterial chemoembolization 1449
cisterna chyli 85
citrate 155
citrate lyase 91
citric acid cycle 155–156, 155f
Citrobacter, bacterial cholangitis 1541
citrulline-NO-cycle 182, 183
clarithromycin
acute hepatitis induction 1234
Legionnaire's disease 1002
classical lobules 80, 80f
clathrin, receptor-mediated endocytosis 98
clavulanic acid, bacterial cholangitis 1543t
clearance 469–472, 1912
classification 470, 471t
enzyme-determined 470–472
flow-determined 472
intrinsic hepatic clearance 469–470
positron emission tomography measurements 474
substances 469–472
systemic 470
V_{max}/FK_m 470, 470f, 471f, 471t
clear cells, alcoholic 423
clevudine, chronic hepatitis B 926
Clichy criteria, emergency liver transplantation 1307, 1308t
clinical trials, hepatotoxicity detection inefficiency 1211–1212
clofibrate
acute hepatitis induction 1232
ethanol feeding 1137
clometacin, hepatitis induction 1232, 1252
clonal deletion 217
cloned proteins, liver function models 124–125
Clonorchis sinensis 1046
brown pigment gallstones 1523
cholangiocarcinoma 1046, 1584
cholangitis 1546, 1547t
treatment 1547
clinical features 1046
diagnosis 1046
geographical distribution 1046, 2102t
pathogenesis 1046
recurrent pyogenic cholangitis 1545
Clostridium spp. 1002, 1541
clot formation 1780
clotting factors
acute liver disease 257
acute liver failure 1293, 1302
synthesis 257
see also specific factors
clotting rate assay, plasma fibrinogen 456
clozapine, hepatitis induction 1232
clubbing 447
c-myc gene/protein 392t, 393
coagulation 255–264
disorders *see* coagulation defects/disorders
monitoring, liver transplantation 1942
pathway 455f
significance of in liver disease 1780t
tests *see* coagulation tests
see also haemostasis
coagulation defects/disorders
acute liver failure 1293
children 1859
cirrhosis 258, 610
haemobilia 1553
hepatosplenic schistosomiasis 1043
laboratory testing 260t
in liver disease 257–259, 1780–1797
acute disease 257–258, 1780t, 1785
anaesthetic implications 1940, 1943
chronic disease 258, 1780t, 1785
clotting factors 257, 258
hepatic resection and 1941
variable in 1780t
liver transplantation 259–260, 1943
hypercoagulability 259–260
hyperfibrinolysis 259
management 260–261, 1788t
prevention (prophylactic) therapy 1787–1788, 1787t
rescue therapy 1787–1788, 1787t
therapeutic agents 1789–1792, 1789t
obstructive jaundice 1511
renal failure, obstructive jaundice-associated 1816
coagulation necrosis *see* apoptotic bodies
coagulation tests 260, 1781–1782, 1783t
bleeding risk assessment 1786–1787
controversies in 1783–1784
fibrinolysis 258
non-variceal bleeding 1783
prognostic significance 1786, 1786t
see also individual tests
coagulative necrosis 424
coat protein II (COPII) 194
cobalamin 238
deficiency 147
cobalt 233t, 238
deficiency 233t
cocaine
acute hepatitis 1232
acute liver failure 1298
lipid storage diseases 1247
Coccidioides immitis 1016
coccidioidomycosis 1016
dissemination 1016
Cochrane Central Register of Controlled Trials 576
Cochrane Collaboration 576
history of 576
Cochrane Database of Systematic Reviews 576
Cochrane Handbook for Systematic Reviews of Interventions 576
Cochrane Hepatobiliary Group (CHBG) 572–579
future developments 576–577
participation 576
productivity 573f, 576, 577f
scope 576
Cochrane Library 576
codeine
carcinoid syndrome 1477
hepatic metabolism 241, 242f
coeliac disease
Budd–Chiari syndrome 1405
liver disease in 1629
liver function tests 1628t, 1629
primary biliary cirrhosis 1629, 1801
primary sclerosing cholangitis 1629
coffee, hepatocellular carcinoma 1439, 1451
cognitive-behavioural treatment (CBT), alcohol abstinence 1180–1181
colchicine
alcoholic cirrhosis 1167
amyloidosis 1707
fibrosis 597
primary biliary cirrhosis 1083
cold ischaemia 352–353
protective strategies 352–353
organ cooling 352
preservation solutions 352
warm ischaemia *vs.* 352
collagen(s) 266–268
cross-linking
cirrhosis reversibility 586–587
enzymes 266
cystic fibrosis 1340
Disse space 15
FACITS 267t, 268
fibrillar 266–267, 267t
liver biopsy tract plugging 1792
multiplexins 267t, 268
network-forming 267–268, 267t
non-fibrillar 267–268, 267t
structure 266
synthesis 266
collagen I 264, 267t
fibrosis 264, 584–585
structure 266–267
collagen III 264, 267t
fibrotic liver 264
collagen IV 264, 267t, 268
fibrotic liver 264
collagen V 264, 267t
collagen VI 264, 267t, 268
collagen VIII 267t, 268
collagen XIV 267t, 268
collagen XV 267t, 268, 270
collagen XVIII 267t, 268, 270
collagen XIX 267t, 268
collagen coated plates, hepatocyte bioreactors 2045
collateral circulation
blow flow estimation 570
Budd–Chiari syndrome 1407, 1408
portal hypertension 625–626, 625f, 626f, 633–634
portosystemic pathways 535, 535t
collecting tubule dilatation, congenital hepatic fibrosis 782
Colles' fractures 1829
collodion baby 1806
colon, effects of liver disease 1802
colonic ulcers, amoebic liver abscess 1025
colorectal carcinoma
bilirubin, beneficial effects 168
Gilbert syndrome 1356
metastasis
chemotherapy-induced steatohepatitis and resection 1936
computerized tomography 519–520, 520f
cystic 815, 815f
HIV infection 984
positron emission tomography 562, 563f
resection 520
ulcerative colitis 1625
colour Doppler ultrasound 501
focal nodular hyperplasia 505
portal vein thrombosis 503
combactam, bacterial cholangitis 1543t
combination therapy
chronic hepatitis B 926–927
chronic hepatitis C 944
combination vaccines
hepatitis A 899
hepatitis B 908–909
combined cross analysis, QTL analysis in inbred mice 377t, 378
comfrey *(Symphytum)*, hepatotoxicity 1273, 1282t, 1284
Commission E, Federal Institute for Drugs and Medicinal Device, herbal medicine regulation 1281
common bile duct
anatomy 305
histology 18
physiology 307
sphincters 305
stones *see* choledocholithiasis
common hepatic artery 531–532
fibromuscular dysplasia 539
common hepatic duct, histology 18
community-acquired infections, post-liver transplantation 2022–2023
comparative genomics, QTL analysis in inbred mice 377–378, 377t
complement
autoimmune hepatitis 1094–1095
immunogenetic studies 370
Kupffer cells 37, 38
complementary DNA (cDNA) libraries, gene array probes 403
complement cascade, reperfusion 348
complement fixation tests, echinococcosis 1054
complex I deficiency 1380
complex II deficiency 1380
complex V deficiency 1380
compressive forces, liver trauma 1953
computational modelling 2093
computerized tomographic angiography 510, 510f
computerized tomographic cholangiography (CTC)
bile duct stones 541–542
endoscopic retrograde cholangiopancreatography *vs.* 541–542
choledocholithiasis diagnosis 1542
extrahepatic biliary obstruction 1508
computerized tomography (CT) 508–521
actinomycosis 1017
acute fatty liver of pregnancy 1882
AIDS-related cholangitis 1546
alcoholic macrovesicular steatosis 1160
alveolar echinococcosis 1053, 1053f
amiodarone toxicity 512, 512f
amoebic liver abscess 1025
angiosarcoma 1458
ascites 667
benign focal liver lesions 512–516
bile duct injury, post-cholecystectomy 1958
biliary cystadenoma 813f, 814
biliary dilatation 511, 511f
biliary hamartomas 798–799, 799f, 1574
biliary strictures 542
biliary tree 511
biloma 817

Budd–Chiari syndrome 1408
carcinoid tumours 1473, 1473f
Caroli syndrome 805
cavernous haemangioma 513, 514f
cholangiocarcinoma
  hilar (upper duct) 1591, 1592, 1593
  intrahepatic 1595, 1595f
  lower duct 1594
  periductal infiltrating 1592
cholecystitis 509f, 511, 1529
cholecystolithiasis 1529
choledocholithiasis 1529, 1542
ciliated hepatic foregut cyst 808
cirrhosis 516–518, 516f, 517f, 613
  chronic sclerosing 516
  nodular 516–517
colorectal carcinoma hepatic metastasis 519–520, 520f
contrast resolution 509
cystic echinococcosis 1049, 1050f
cystic metastases 815
delayed phase images 509
diffuse (nonfocal) hepatic disease 511–512
dysplastic nodules, cirrhotic liver 517
epithelioid haemangioendothelioma 1459
extrahepatic biliary obstruction 1507, 1509
fascioliasis 1045
fibrolamellar HCC 518
focal nodular hyperplasia 514–515, 1259–1260, 1429
fulminant hepatitis 512
gallbladder 511
Gaucher's disease 512
giant haemangioma 514, 515f
haemangioma 513–514, 514f, 1427
haemobilia 1555–1556, 1555f, 1555t
haemochromatosis 512
head, liver trauma 1955
hepatic artery 511
hepatic artery aneurysms 1393, 1393f
hepatic cysts 513, 513f, 790, 791f, 792
hepatic hypodensity 512
hepatic metastasis 518–519, 519f, 1467, 1467f
  arteriographically enhanced 1467
hepatic venous opacification 511
hepatitis
  acute 512
  chronic 512
hepatocellular adenoma 515–516, 1432
hepatocellular carcinoma 517–518, 518f, 1443
  cirrhosis and 613, 613f
  cystic 815
  percutaneous ablation 553
  'washout' 517
hepatosplenic candidosis 1012
hereditary haemorrhagic telangiectasia 1420, 1421f
image presentation 510
imaging blurring 509, 509f
indications 508
intrahepatic cholestasis diagnosis 1492
i.v. contrast 509
  hepatic arterial phase 509
  portal venous phase 509
liver trauma 1955, 1955f
magnetic resonance imaging *vs.* 508
  nodular hyperplasia 516–518
  nodular regenerative hyperplasia 1434
  non-alcoholic fatty liver disease 1200
  non-alcoholic steatohepatitis 1200
  nontargeted (incidental) 508, 509f
  normal liver 510–511
  pancreatic pseudocysts, liver 811
  peribiliary cysts 803, 804f
  portal vein thrombosis, acute 1396
  portal venous opacification 511
  post-liver transplantation 2019
  preoperative
    functional reserve estimates 1934
    tumour status 1933
  radiation hepatitis 1278
  simple cyst of the liver 784, 784f
    haemorrhagic 785
  sinusoidal dilatation 1413
  steatohepatitis 511, 512f
  targeted 508
  technique 509–510
  'triple phase' protocol 509–510, 514f, 518f
  undifferentiated sarcoma 1460
  visceral larva migrans 1063
  Wilson's disease 512, 1316
concentration difficulties 444–445
concentric periductal fibrosis 426
conductance abnormalities, heart 1722
condylomata lata 1807
confluent necrosis 424
conformational adaptation, albumin 251
conformational breathing, albumin 251
confusion 444–445
  carcinoid syndrome 1474
congenital cytomegalovirus infection 961
congenital erythropoietic porphyria (CEP) 1344t, 1347–1348
  diagnosis 1348
  manifestations 1347–1348
  photodermatosis 1347
  treatment 1348
congenital hepatic cyst *see* simple cyst of the liver
congenital hepatic fibrosis 781–783, 1856
  aetiology 781
  associated malformations 782
  biliary hamartomas 798
  Caroli syndrome 805, 806
  clinical examination 782
  complications 782
  course 782
  diagnosis 781–782
  imaging 782
  manifestation 781–782
  pathogenesis 781
  pathology 781
  prevalence 781
  treatment 782–783
  vanishing bile duct syndrome 1112
congenital syphilis 1007
congestive heart failure
  interleukin-6 317–318
  liver in 1610f, 1611–1613
    clinical manifestations 1611–1612
    laboratory tests 1612
    pathogenesis 1612–1613
  pathology 1612
  post-peritoneovenous shunting 696
  treatment 1613
congestive hepatopathy 1611–1613
conivaptan 700
conjugated bilirubin 459, 1353
  alcoholic hepatitis 1162
  body fluids 169
  canalicular excretion 171
  Crigler–Najjar syndrome type 1 1355
  malarial hepatitis 1032
  measurement 168, 1352–1353
  metabolism 459
  pregnancy 1879
  renal excretion 172
  transport 170
conjugated hyperbilirubinaemia 460–461
  hereditary 461
  infants 1845
connective tissue diseases, effects on liver 1694–1698
  mixed disorders 1696–1697
connexin 32, hepatocyte gap junctions 97
consciousness, preoperative liver transplant assessment 1997
constipation 444
constitutive androstane receptor (CAR)
  bilirubin transport 1354–1355
  drug-metabolizing pathway regulation 244
  hepatobiliary transport regulation 106, 178, 301t, 386, 387, 388f
  intrahepatic cholestasis treatment 2920–2921
constrictive pericarditis 1613
  ascites 670
continuous infusion method, absolute hepatic clearance 569
continuous positive airway pressure, obstructive sleep apnoea 1617
continuous thermodilution method
  azygos blood flow measurement 570
  portal blood flow measurement 570
contraception, chronic liver disease 1887
controlled drinking, abstinence *vs.* 1179–1180
cooking oil, hepatotoxicity 2108
coping skill training, alcohol abstinence 1181
copper
  angiogenesis 229
  chemical properties 226
  deposition
    hepatocellular carcinoma 1439
    renal tubular acidosis-associated liver disease 1819
  extrahepatic biliary obstruction 1502
  lowering to subnormal levels, therapeutic purposes 228–230, 230t
  metabolism 225–232, 226f
    copper chaperones 226, 227, 227t
    future directions 228
    hepatic role 226
    primary sclerosing cholangitis 1105
    transmembrane movement 227
  molybdenum interaction 238
  neuronal injury induction 1315
  neuropeptide hormone activation 228, 228t
  normal levels 225
  regulatory proteins 227, 227t
  storage 428
  total parenteral nutrition-related liver disease 1636–1637
  toxicity 226, 1315
    see also Wilson's disease
  transporters 112, 227t
  urinary excretion, Wilson's disease 1317, 1320, 1853
copper chaperone for superoxide dismutase (CCS) 227, 227t
copper chaperones 226, 227t
  functions 227
copper sulphate, hepatotoxicity 2108
coproculture techniques, strongyloidiasis 1065
coproporphyrin 1346
  excretion 212, 212t, 213
  synthesis 208
coproporphyrinogen 208
coproporphyrinogen oxidase 208
  mutations 1346
Cori disease *see* glycogen storage disease (GSD), type 3
coronary artery disease
  cirrhosis and 1939
  liver transplantation
    contraindications 1989
    postoperative 2020
    preoperative 1926, 1996
coronary ligament
  left 4
  right 4
coronary vein *see* left gastric vein
cortical atrophy, hepatic encephalopathy 732
cortical neurons, effects of ammonia 730
corticosteroids
  alcoholic hepatitis 1164
  carcinoid tumours 1476
  fibrosis 595
  hepatobiliary transport regulation 388
  liver transplantation 2006
  sarcoidosis 1712
  side-effects 2006
    hyperglycaemia 2021
    hyperlipidaemia 2021
  visceral larva migrans 1063
  see also individual types
corticostriatal synaptic plasticity, hepatic encephalopathy 736
corticotrophin-releasing hormone (CRH) 1686, 1752
cortisol 1685–1686
  alcoholic liver disease 1753
  autoimmune chronic active hepatitis 1753
  cirrhosis 1753
  deficiency 1686
  excess 1686
  excretion 1752
  haemochromatosis 1762
  liver disease 1753
  metabolism 1752–1753
  non-alcoholic liver disease 1753
  plasma transport 1752
  pseudo-Cushing syndrome 1753
  secretion 1752
  synthesis 1752
cortisol-binding globulin 1752
  drug binding 1752
cortisone 1752
cost–benefit analysis 2080
cost-effectiveness
  analysis 2080, 2081f
  resource allocation 2080
cost identification 2080

cost minimization 2080
analysis 2080
costs *see* economics
cost–utility analysis 2085
co-trimoxazole
acute hepatitis induction 1232
nocardiosis 1017
Council for International Organizations of Medical Sciences (CIOMS), drug-related hepatic injury assessment 1286t
Councilman bodies *see* apoptotic bodies
Courvoisier's sign 448, 1507
Cox17 227, 227t
Coxiella burnetti 1004
Cox regression analysis, prognostic models 2055–2056
coxsackievirus infections, hepatitis 967
CPT1A gene 359
CPY7A1 gene/protein 1518t
C-reactive protein
bacterial cholangitis 1542
extrahepatic biliary obstruction 1506
creatine, synthesis 146, 147
creatinine
cirrhosis 612
diuretic-resistant ascites 693
excretion 147
hepatorenal syndrome 676, 712, 713–714
creatinine phosphokinase, hypothyroidism 1685
creosote bush (chaparral), hepatotoxicity 1282t, 1285
CREST syndrome 1697, 1808
primary biliary cirrhosis 1798
Crigler–Najjar syndrome 1355
animal models 1355
diagnosis 1355
treatment 1355
type 1 1355, 1845
bilirubin levels 460
hepatocyte transplantation 2038, 2039t
treatment 1845
type 2 1355, 1845
bilirubin levels 460
treatment 1845
unconjugated bilirubin 170
Crimean–Congo haemorrhagic fever 992–993
aetiological agent 992–993
clinical manifestations 993
epidemiology 992–993
treatment 993
cristae, mitochondrial 26
critical flicker frequency (CFF), hepatic encephalopathy
acute liver failure 744
cirrhosis 744
Crohn's disease
amyloidosis 1627
gallstones 1627
granulomas 1628, 1714
immunogenetics 370
liver abscess 1628
liver disease prevalence 1622–1623
primary sclerosing cholangitis 1623, 1626
steatosis 1627
cross-haemodialysis 2044
Crotalaria, hepatotoxicity 1273, 1282t, 1283–1284
CR perfusion 510
crushing trauma, haemobilia 1552
Cruveilhier–Baumgarten syndrome 447
cryoglobulinaemia type 2, hepatitis C 1772
cryoglobulinaemia type 3, hepatitis C 1772
cryoglobulins, hepatitis C 1819
cryoprecipitates 261, 1789
cryopreservation, hepatocyte transplantation 2032
cryptococcosis 1013–1014
laboratory diagnosis 1014
treatment 1014
Cryptococcus neoformans 1013–1014
Cryptococcus neoformans gattii 1014
Cryptococcus neoformans neoformans 1014
cryptosporidiosis 1020–1029
biliary 1025
clinical manifestations 1025
diagnosis 1025–1026
epidemiology 1020–1022
extraintestinal 1025
laboratory findings 1026
papillary stenosis 1025
pathophysiology 1024
risk factors 1021, 1021t
treatment 1026–1027
Cryptosporidium
epidemiology 1020
immunocompromised patients 1021–1022
life cycle 1022
vacuoles 1022, 1024
Cryptosporidium parvum
cholangiocytes 53
survival signal induction 1024
vanishing bile duct syndrome 1115
Cu-ATPases 227–228
Cumming syndrome 2129–2130
Cushing syndrome, hepatic effects 1686
cutaneous hyperperfusion, cirrhosis 1725
cutaneous polyarteritis nodosa (C-PAN) 1643
cutaneous surgical procedures, bleeding risk 1788t
CXCR-4, 'oval cells' 283
cyanamide, hepatotoxicity 2108
cyanoacrylates 1792
gastric variceal bleeding 652
cyanosis 446
cyclic adenosine monophosphate (cAMP)
biliary tree 1111
as second messenger 103
cyclic adenosine monophosphate (cAMP)-protein kinase A 300–301
cyclin D1 274–275
cyclin E/cdk activity 275
cyclin kinase inhibitors, cell cycle 275
E-cyclobilirubin 168
cyclo-oxygenase-1 (COX-1), prostaglandin formation 680–681
cyclo-oxygenase-2 (COX-2)
cholangiocarcinogenesis 55
genetic mutations 1378–1379
prostaglandin formation 682
cyclo-oxygenases (COXs), second messenger generation 104
cyclophosphamide 2008
Budd–Chiari syndrome induction 1257
CYP1, phase I drug metabolism 241, 241t
CYP2D6 241, 242f
transgenic mice, autoimmune hepatitis models 1096
CYP2E1 gene/protein
alcoholic liver disease 1143, 1159
alcohol metabolism 1136, 1141
carbon tetrachloride biotransformation 1270–1271
CYP3, phase I drug metabolism 241, 241t
CYP3A4 243–244, 245
CYP7A1 174
deficiency 174
CYP7B1 deficiency 174
CYP27 174
cyproheptadine
carcinoid syndrome 1477
carcinoid tumours 1475
cyproterone acetate (CPA)
hepatocellular carcinoma induction 1260, 1649, 1658–1659
hepatotoxicity 1233, 1649, 1658
prostate cancer 1649, 1658–1659
cyst(s)
choledochal *see* choledochal cyst(s)
ciliated hepatic foregut *see* ciliated hepatic foregut cyst (CHFC)
computerized tomography 513, 513f
Dandy–Walk 2153–2154
endometrial *see* endometrial cysts (EC), liver
magnetic resonance imaging 523, 523f
peribiliary *see* peribiliary cysts
simple *see* simple cyst of the liver
ultrasonography 504, 504t
cystadenocarcinoma 813–815, 814f
magnetic resonance imaging 526
cyst drainage, choledochal cyst 807
cystectomy, cystic echinococcosis 1050
cysteine
erythropoietic protoporphyria 1348
glutathione biosynthesis 199
storage 201
cysteinylglycine 201
cysteinyl-leukotrienes, portal hypertension 633
cystic artery aneurysms, haemobilia 1552
cystic diseases, inflammatory 810–813
cystic duct
anatomy 305
histology 18
physiology 307
cystic echinococcosis (CE) 1047–1051
clinical features 1048–1049
complications 1048–1049
treatment 1051
control 1048
diagnosis 1049
epidemiology 1047–1048
geographical distribution 2100–2104t
immunological diagnosis 1054
magnetic resonance imaging 530
medical treatments 1055
molecular tests 1055
pathogenesis 1048
prevalence 1047–1048
prevention 1048
rupture 1049
screening 1049
serology 1054
simple cyst of the liver *vs.* 785, 787t
surgery 1049–1051
transmission 1047
treatment 1049–1051
cystic fibrosis (CF) 1336–1342, 1629–1630, 1855
β-receptor antagonist therapy 1341
bile secretion 1336
biliary cirrhosis 1629–1630
complications 1338–1339, 1338t
diagnosis 1339–1340
gallstone disease 1525
gene array data 410
liver disease 1336–1342
diagnosis 1855
endstage 1340–1341
prevalence 1855
treatment 1340–1341
liver transplantation 1855
manifestations 1338–1339
modifiers 1338
neurological manifestations 1824t
pathogenesis 1337–1338
physical examination 1339
prevalence 1338–1339
risk factors 1338
ursodeoxycholic acid 1340, 1495, 1630, 1855
vanishing bile duct syndrome 1112, 1114t
Cystic Fibrosis Foundation Hepatobiliary Disease Consensus
diagnosis guidelines 1339
ursodeoxycholic acid use 1340
cystic fibrosis transmembrane conductance regulator (CFTR) 110
bile secretion 1336–1337, 1337f, 1338, 1518, 1855
biliary tree 1111
chloride transport 52, 1336–1337, 1337f
cholangiocytes 113
ductal bile formation 293, 299, 299f
gene defects 1337–1338, 1337f, 1518t, 1524
liver function 1336–1337
structure 1336
cystic lymphangiomatosis 812
cytochrome *b* 158, 221, 222f
cytochrome *c* 158
cytochrome *c* oxidase 158
cytochrome oxidase
across liver cell plate 91
deficiency 1378–1379
cytochrome P-450 enzyme system 1218–1219
age-related changes 1870–1871
cocaine 1232
deficiencies 1221
drug-induced acute hepatitis 1218–1219
drug metabolism 1218
genetic variation 244–245
phase I 241, 241t
function 1218, 1218f
functional expression cloning 124
halothane 1235
inducers 246t
inhibitors 246t
plasma membrane 1218f, 1223

reactive metabolite formation 1218–1219, 1219f
structure 1218, 1218f
suicidal inactivation 1219
vitamin D hydroxylation 218
cytochrome P450 mono-oxygenases 92–93
cytochrome P-4502E1 (CYP2E1), alcoholic liver disease risk 358
cytokeratins
hepatocellular carcinoma 62
metastatic liver cancer diagnosis 1466f
'oval cells' 283
cytokines 312–320, 313t
acute graft-vs.-host disease pathogenesis 1672
acute liver failure 314t
acute phase response 314t
alcoholic liver disease 1143, 1161, 1163
cholangiocytes 55
chronic liver failure 314t
death receptor ligands 312–313
definition 312
functions 314t
hepatocyte proliferation 2088
immunogenetic studies 369
liver cancer 314t
liver development 314t
liver fibrosis 314t
liver regeneration 314t
measurement, disease diagnosis 480
neural modulation 120
obstructive jaundice-associated acute renal failure 1815
receptors 312–313
hepatocytes 312–313
Kupffer cells 313
non-parenchymal cells 313
sepsis 609
signalling networks 312
as therapeutic target 318
see also specific cytokines
cytolytic hepatitis
acute 1227–1228
drug-induced 1227–1228
differential diagnosis 1227–1228
histology 1227
outcomes 1216, 1229–1230
kava-induced 1284
cytomegalovirus antigenaemia 961
cytomegalovirus (CMV) inclusions 423–424
cytomegalovirus (CMV) infection 960–963
acute liver failure 1297–1298
adults 962
congenital 961, 2131
diagnosis 960–961, 962
culture 961
histopathology 961
immunocompromised 960–961
serology 960
viral load assessment 961
epidemiology 961–962
primary infection 961
recurrent infection 961–962
hepatitis 962–963
definition 962
HIV coinfection 983
immunocompromised 962
liver transplantation 962–963
children 1866
cirrhosis 963
rejection 962–963
long-term prophylaxis 963
neonates 962
pathogenesis 961–962
primary 961
recurrent 961–962
solid-organ transplantation 962
therapy 963
vanishing bile duct syndrome 1115
virology 960
cytoskeleton, hepatocytes 97–98
actin microfilaments 97–98, 97f
bile formation 297–298
intermediate filament proteins 97
intrahepatic cholestasis 1482
microtubules 98
myosin 98
cytostatics, hepatotoxicity 2109
cytotoxicity, natural killer cells 320
cytotoxic T-lymphocyte antigen 4 (CTLA-4)
alcoholic liver disease 1143
immunogenetics of liver disease 369
primary biliary cirrhosis 358
regulator T cells 323
cytotoxic T lymphocytes (CTLs)
acute graft-vs.-host disease pathogenesis 1672
acute hepatitis B 868
drug-induced acute hepatitis 1224–1225, 1225f
target cell destruction 1225, 1225f

D

dacarbazine, hepatotoxicity 1256
dacluzimab 2006
Dai saiko-to, hepatotoxicity 1282t
danazol, hepatotoxicity 1259, 1649
Dandy–Walker cyst 2153–2154
Dane particles, hepatitis B virus 823
dantrolene, hepatitis induction 1233, 1252
dapsone, hepatotoxicity 1233, 1648
dapsone hypersensitivity syndrome 1648
Darier's sign 1644
databases
'comments field' 406
mining 379
see also bioinformatics
data hubs, proteomics 2092
DCT1 *see* divalent metal transporter 1 (DMT1)
DDX5 (p68), HCV fibrosis progression 359
'dead worm' pneumonitis 1042
deamino-8-D-arginine vasopressin (desmopressin acetate, DDAVP) 261, 1791
death-inducing signalling complex (DISC) 336, 338
glutathione levels 203
death receptors 312–313, 337–338
targeting, liver disease 343
debranching enzyme deficiency *see* glycogen storage disease (GSD), type 3
deceleration injuries 1953
decision analysis, economics 2083
decision trees 2083
decorin 270
dedifferentiation *see* sinusoidal capillarization
deep vein thrombosis, cirrhosis and 1792
deferroxamine 1327
defibrotide 1256
dehydroemetine 1045
dehydroepiandrosterone
physiology 1754
transport in blood 1755
deleted in liver cancer 1 (DLC1) gene/protein 395
delirium, Reye syndrome 1825
delta-bilirubin 168, 170
demeclocycline 699
dendritic cells 321
cell surface markers 321
functions 323t
maturation 321
myeloid *vs.* lymphoid 321
Dengue fever 994–995
aetiological agent 994
clinical manifestations 995
diagnosis 995
epidemiology 994
laboratory findings 995
mortality 995
pathogenesis 994–995
pathology 994–995
prevention 995
treatment 995
dental extractions
antifibrinolytic therapy 1790, 1790f
bleeding risk 1788t
Denver shunt 695
deoxycholic acid, cholangiocyte proliferation 54
deoxyguanosine kinase gene *(DGUOK)* gene mutation 1379
depression, Wilson's disease 1316
de Ritis ratio (AST/ALT), ischaemic hepatitis 1949
dermatan sulphate proteoglycan 269–270
dermatomyositis 1697–1698
desflurane 1941, 1942
desmin, hepatic stellate cells 46
desmopressin, 1-deamino-8-D-arginine vasopressin (DDAVP) 261, 1791
desmosomes, hepatocytes 22, 97
detoxification, liver support 2043
Deugnier score 494
developing countries, alcohol consumption 1129–1130
dexamethasone
clearance, cirrhosis 1753
intrahepatic cholestasis of pregnancy 1880
dextropropoxyphene, acute hepatitis induction 1239
dextrose infusions 1839
diabète bronzé *see* haemochromatosis
diabetes mellitus (DM) 1680–1683, 1732–1737
alcoholic cirrhosis 1733
cholelithiasis 1683
chronic hepatitis C antiviral therapy 950
cirrhosis 1682
hepatic glucose production 1734
prevalence 1733–1734
drug-induced hepatic injury 1683
glucose metabolism 131–132, 131f
haemochromatosis 1760–1761
hepatic fibrosis 1901
hepatocellular carcinoma 1439
hepatosteatosis and 1936
immunosuppressant-induced 2021
liver disease and
anaesthetic implications 1940
management 1736–1737
prevalence 1732–1734
liver function 1681
liver transplantation 1990
non-alcoholic fatty liver disease 132, 1195, 1197, 1681–1682
post-liver transplantation 2021
pyogenic abscesses 1874
type 1 1680
endogenous glucose production 131
gluconeogenesis 131
glycogenolysis 131
insulin-like growth factor-I levels 1744
type 2 1680
chronic hepatitis C 887
endogenous glucose production 131
gluconeogenesis 131
glucose metabolism 131, 131f
hepatocellular carcinoma 1682–1683
insulin resistance 131
non-alcoholic steatohepatitis 1195, 1197
viral hepatitis 1682
diabetic nephropathy, liver disease and 1736
diabetic neuropathy, liver disease and 1736
diabetic retinopathy, liver disease and 1736
diacerein 1914
diagnostic models 2055t, 2060–2063
accuracy 2061
aspartate aminotransferase/platelet ratio 2062–2063, 2062f
definition 2055
example 2061–2062, 2061t
Fibrotest 2062, 2063, 2063f
linear regression analysis 2061
logistic regression analysis 2061
odds ratios 2061, 2062
negative predictive value 2062
positive predictive value 2062
prognostic models *vs.* 2061
diagnostic peritoneal lavage (DPL), liver trauma 1955
dialysis-associated amyloidosis 1704
4,4-diamino-diphenylmethane, hepatotoxicity 2112
Dianette, hepatotoxicity 1649
diaphragm, lymphatics 688
ascites reabsorption 688
diaphragmatic peritoneum, ascites reabsorption 688
diarrhoea 444
amoebic liver abscess 1025
carcinoid syndrome 1474
cryptosporidiosis 1025
hepatocellular carcinoma 1442
strongyloidiasis 1064
diastolic dysfunction 1722
diazepam
alcohol withdrawal syndrome 1180
clearance, liver disease 247
diazepam-binding inhibitor, hepatic encephalopathy 737
diazo reaction 168, 1352–1353
1,2-dibromoethane, hepatotoxicity 2109

2,3-dichloro-4-oxo-2-butenoic acid, hepatotoxicity 2113
dichlorodiphenyltrichloroethane (DDT), hepatotoxicity 2109
1,2-dichloroethane, hepatotoxicity 2109
dichlorohydrin, hepatotoxicity 2109
dichloropropanol, hepatotoxicity 2109
1,3-dichloropropene, hepatotoxicity 2109
9,13-di-*cis*-retinoic acid (dcRA) 216
diclofenac, hepatitis induction 1233, 1252
dicrocoeliasis 1046–1047
  diagnosis 1046
  symptoms 1046
  treatment 1047
Dicrocoelium dendriticum 1046–1047
didanosine
  hepatotoxicity 1248, 1299
  ribavirin interactions 981
2′,3′-didehydro-3′-deoxythymidine *see* stavudine
2′,3′-dideoxyinosine *see* didanosine
dideoxynucleosides *see* nucleoside reverse transcriptase inhibitors (NRTIs)
2′,3′-dieoxycytidine (zalcitabine), hepatotoxicity 1248
diet, alcoholic liver disease development 1132, 1142
dietary management
  alcoholics 1183
  diabetes mellitus 1736–1737
  glycogen storage disease type 1 1373
  glycogen storage disease type 3 1373
  liver disease 1901
  see also nutrition, management
Dietary Supplement and Health Education Act (DSHEA), herbal medicine regulation 1281
diethylaminoethoxyhexestrol, steatohepatitis induction 1246
4,4′-diethylaminoethoxyhexestrol, phospholipidosis induction 1244–1245
4-4′-diethylaminoethoxyhexestrol, lipid storage disease induction 1248
diethylene glycol, hepatotoxicity 2109
diethylnitrosamine, tumorigenicity 1258
diethylstilbestrol
  hepatotoxicity 1658
  prostatic cancer 1658
  tumorigenicity 1258
di Ferrante syndrome (mucopolysaccharidosis type 7) 2148–2149
differential gel electrophoresis (DiGE), proteomic analyses 405, 414
diffuse scleroderma 1697
diffusion effects, carrier proteins 109f, 110, 252
digital image analysis, cholangiocarcinoma 1591
digit symbol test 745
dihydralazine hepatitis 1222–1223, 1226, 1233
5α-dihydrotestosterone (5DHT) 1687
  cirrhosis 1757t
  physiology 1754
  transport in blood 1755
24,25-dihydroxycholanoic cleavage enzyme deficiency 1849
1,25-dihydroxyvitamin D_3 215f
dilutional anaemia, cirrhosis 1767
dimercaptopropanol, Wilson's disease 1318
dimethylacetamide, hepatotoxicity 2109
dimethyl formamide, hepatotoxicity 2109–2110
1,2-dimethylhydrazine, hepatotoxicity 2110
m-dinitrobenzene, hepatotoxicity 2110
dinitro-o-cresol, hepatotoxicity 2110
dinitrotoluene, hepatotoxicity 2110
dioxane, hepatotoxicity 2110
dipeptidyl carboxypeptidase 677
dipeptidyl peptidase IV (DPPIV), protein trafficking 96
diphenhydramine 1476
diphenyl, hepatotoxicity 2110
direct bilirubin *see* conjugated bilirubin
direct fluorescent assays, adenoviruses 968
direct van den Bergh reaction 167
discoid eczema, alcohol misuse 1810
discoidin domain receptors 270
discount rate, economics 2082–2083
discrimination, prognostic model accuracy 2057–2058
disseminated haemangiomatosis 2130
disseminated histoplasmosis 1015, 1015t
disseminated intravascular coagulation (DIC) 259
  aetiology 259
  diagnosis 259
  Ebola virus infections 992
  hypofibrinogenaemia 260
  liver failure *vs.* 1782
  Marburg virus infections 992
  obstructive jaundice 1506
disseminated nocardiosis 1017
Disse space *see* space of Disse
distal splenorenal shunt (DSS), schistosomiasis 1044
distribution sinusoidal perfusion model 474
disulfiram
  alcohol abstinence 1181
  contraindications 1181
  hepatotoxicity 1181, 1233
  recommended dose 1181
  side-effects 1181
  supervised administration 1181
disulfiram hepatitis 1233
diuretic-intractable ascites 692
diuretic-resistant ascites 692
  type 2 hepatorenal syndrome 692
diuretics
  cirrhotic ascites 690–691
    'combined' treatment 691
    effectiveness assessment 691
    hyponatraemia 699
    'step care' treatment 691
    treatment complications 691–692
  hepatic encephalopathy 692
  hepatorenal syndrome, type 2 716
  non-hepatic toxicity, increases in 1916
  see also individual drugs
divalent metal transporter 1 (DMT1) 221
  hepatic localization 221, 222f
  isoforms 221
  regulation 224
DLC1 (deleted in liver cancer 1) gene/protein 395
DNA detection, hepatitis B 838, 839t
DNA laddering, apoptosis 336
DNA microarrays/microchips *see* gene arrays
DNA polymerase γ 152
DNA recombinant vaccines, hepatitis B 908
DNA synthesis, hepatocyte replacement 281
DNA vaccines, hepatitis B 909
donors
  age-related issues 1865, 1874
  blood typing 1977
  outcomes, post-transplantation 1979, 1992
  selection, split liver transplantation 1971
  see also living donor liver transplantation (LDLT)
dopamine
  hepatic blood flow 77
  thyroid stimulating hormone suppression 1750
dopaminergic neurotransmission, hepatic encephalopathy 737
Doppler frequency 501
Doppler spectral analysis 501
Doppler ultrasonography 500–501, 612–613
  alcoholic liver disease 1168
  Budd–Chiari syndrome 1408, 1409
  cerebral blood flow measurement 744
  haemangioma 505
  hepatocellular adenoma 1432
  hereditary haemorrhagic telangiectasia 1420
  liver graft function 1998
  nodular regenerative hyperplasia 1434
  patent ductus venosus 1419
  portal blood flow measurement 570
  portal hypertension 503
  schistosomiasis 1043
dormia basket, fascioliasis 1045–1046
doughnut granuloma (fibrin-ring granuloma) 428, 1709, 1710f, 1713
doxorubicin
  Budd–Chiari syndrome induction 1257
  gallbladder carcinoma 1580
  transarterial chemoembolization 1449
doxycycline
  leptospirosis 1008
  malaria 1033
  Q fever 1004
drinking behaviour
  alcoholic liver disease 1159
  post-transplantation 1184
driving capacities, liver disease and 1902
  minimal encephalopathy 743
dropouts, meta-analysis 2077
drug(s)
  effectiveness 253
  elimination 1912
  metabolism *see* drug metabolism
  prescription in liver disease 1912–1921
    practical recommendations 1917–1919, 1918t
  protein binding 1912
  urea synthesis 183
  see also individual drugs
drug abuse
  alcoholics 1182–1183
  hepatitis B vaccine 912
  hepatitis C
    management 890
    transmission 883
    treatment compliance 918, 919f
  hepatitis C-HIV coinfection, treatment problems 981
  hepatitis D 877
  liver transplantation 1985
drug clearance
  age-related changes 1870–1871
  anaesthetic drugs, liver disease and 1940
  rate determining factors 245
drug–drug interactions 245, 246t
  cirrhosis 1916
  induction 245
  inhibition 245
drug-induced acute hepatitis 1214t, 1216–1241
  anti-cytochrome P-450 autoantibodies 1222–1223
  cardiac drugs 1613t
  causes 1230–1241
  cellular immune response 1223–1224
  clinical features 1222
  cytotoxic T lymphocytes 1224–1225, 1225f
  differential diagnosis 1227–1228
  histology 1216
  humoral immune response 1223–1224
  immune system 1222
  lesions 1216
  mechanisms 1217–1222
    cellular lesions 1220
    electrophilic metabolites 1220, 1221f
    genetic factors 1221–1222
    metabolic activation 1217–1218
    mitochondrial energy production impairment 1217
    molecular lesions 1220
    reactive metabolites 1217–1218, 1217t
    therapeutic effect related toxicity 1217
  mixed immune reactions 1223
  outcomes 1229–1230
  terminology 1216
  viral hepatitis *vs.* 1227
  see also individual drugs
drug-induced conditions
  feminization 1759
  hyperthyroidism 1750
  hypogonadism 1759
  hypothyroidism 1750
  mitochondriopathies 1379–1380
drug-induced liver injury 1211–1268, 1901–1902
  AIDS-related cholangitis 1546
  alkaline phosphatase inhibition 463, 463t
  antiphospholipid antibody syndrome 1695
  AST/ALT ratio 452
  cholestasis *see* cholestasis, drug-induced
  classification 1214t
  diagnosis 1214–1216
    pitfalls 1215
  diversity 1213, 1214t
  drug withdrawal 1215–1216
  duration 1213, 1215t
  elderly 1872

gamma-glutamyl transpeptidase 464
gene array data 411
granulomas 1229, 1710
hepatitis
acute *see* drug-induced acute hepatitis
acute liver failure 1298–1299
chronic 1214t, 1251–1253, 1252t
comorbid conditions 1213
electrophilic metabolites 1220, 1221f
extrahepatic tuberculosis 1005
genetic factors 1225–1226
histological features 429
inflammatory bowel disease 1628
lithiasis 1491
liver failure
childhood acute 1858
Kupffer cells 40–41
mechanisms 1215t
outcome 1216
postoperative 1945–1946
diagnosis 1949–1950
drugs causing 1949
presentation 1946
in pregnancy 1888
rechallenge 1216
renal impairment in cirrhosis 702–703
susceptibility factors 1212–1213
vanishing bile duct syndrome 1114t, 1115, 1115f
viral infections and 1213
see also individual drugs
drug metabolism 240–248, 241f
drug activation 245–247
drug–drug interactions 245, 246t
drug toxicity 245–247
enzymes 240–241
extensive metabolizers (EMs) 245
hepatic functional specialization 240
inflammatory states 247
interindividual differences 243–245, 244t
genetic polymorphisms 243–244, 244t
intermediary metabolizers (IMs) 245
liver disease 247
anaesthetic drugs 1940
liver slice models 122
pharmacogenetics 244–245, 244t
phase I 240–241
phase II 240–241
enzymes 242t, 245
poor metabolizers (PMs) 245
portal hypertension 247
regulation 244
smooth endoplasmic reticulum 24
ultrarapid metabolizers (UMs) 245
drug transporters 112–113, 112f, 241f, 242–243, 244t
dual-energy X-ray absorptiometry (DEXA)
non-alcoholic fatty liver disease 1200
nutritional status assessment 1905
osteoporosis 1829
Dubin–Johnson syndrome 1356, 1385
diagnosis 1488
genetics 1356
histology 1356
pigment 428–429
pregnancy 1886
ductal bile formation *see* bile, formation
ductal plate 69, 426
malformations 69, 426
biliary hamartomas 797
congenital hepatic fibrosis 781
fibropolycystic liver disease 1856
ductopenia
Allagille syndrome 1387
bile duct disease 1485
cholangiocyte apoptosis 54, 285
definition 426
vanishing bile duct syndrome 1115
ductopenic rejection treatment 2004
ductular bilirubinostasis 425
ductular cells *see* oval cell(s)
ductular piecemeal necrosis 425
ductular proliferation
congenital hepatic fibrosis 781
elongation type 426
marginal 426
sprouting type (atypical) 426
ductular reaction (cholangiolitis) 59–60
definition 426, 1228
drug-induced 1228–1229, 1229t
vanishing bile duct syndrome 1112
ductus venosus 3–4, 623, 1419
duodenal juxtapapillary diverticula 1875
duodenal ulcers 1800
duodenum, effects of liver disease 1799–1800
Dupuytren's contracture 446
alcoholics 1165, 1186
dysencephalia splanchnocystica (Meckel–Gruber syndrome) 2146
dysfibrinogenaemia, cirrhosis 1782
dysgeusia 443
dyskinesia, sphincter of Oddi dysfunction 1567
dysosmia 443
dysphagia, Wilson's disease 1316
dysplastic liver cells 430
dyspnoea 445
ascites 724–725
dystonia, Wilson's disease 1316

E

E1 core protein, hepatitis C virus 850
E2 core protein, hepatitis C virus 850
early acute liver insufficiency 1291
early change in bilirubin level (ECBL), alcoholic hepatitis 1164
early virological response (EVR), hepatitis C antiviral therapy 943
Ebola virus infections 991–992
aetiological agent 991–992
clinical manifestations 992
diagnosis 992
epidemiology 991–992
laboratory findings 992
pathogenesis 992
pathology 992
treatment/prevention 992
echinococcosis 1047–1058
alveolar *see* alveolar echinococcosis (AE)
cystic *see* cystic echinococcosis (CE)
treatments 1055, 1547t
future prospects 1055–1056
ultrasonography 504
Echinococcus granulosus
life cycle 1047
prevention/control 1048
Echinococcus multilocularis 1051
echinocytes (burr cells) 1768
echocardiography
amyloidosis 1706
hepatopulmonary syndrome 720
echovirus infections, hepatitis 967
eclampsia 1883–1884
economics 2080–2087
analytical methods 2080–2081
annual budgets 2083
cost-effectiveness 2080
practice of 2085–2086, 2086f
study evaluation 2085
cost–effectiveness ratio 2084–2085, 2084t
average 2084
cost–utility analysis 2085
incremental (marginal) 2084
league tables 2085
'willingness to pay' notion 2085
cost minimization 2080
costs 2081
charges *vs.* 2081
estimation 2081
fixed 2081
decision analysis 2083
decision trees 2083
discount rate 2082–2083
effectiveness 2082
operating costs 2081
outcome maximization 2080
perspective 2081–2082
quality of life 2082
reference case 2084
resource allocation 2080
sensitivity analysis 2083–2084
time horizon 2082–2083
ecstasy
acute hepatitis induction 1233
acute liver failure 1298
alcoholics 1183
eczema, alcohol misuse 1810
educational programmes, alveolar echinococcosis 1052
efavirenz, acute liver failure 1299
efferent hepatic nerves 114–115
asympathetic 114–115
bile acid synthesis 117
carbohydrate metabolism 115–116
gluconeogenesis 117–118
glucose levels 116
glycogenolysis 116
intrahepatic signal propagation 117
paracrine stimulation 117
lipid metabolism 117
parasympathetic 114–115
urate formation 117
efferent renal nerve, prostaglandin production 682
efferent veins, histology 427
Ehrlichia chaffeensis 1006
ehrlichioses 1006
elastin 269
elastography, alcoholic liver disease 1168
elastosis perforans serpiginosa 1811
elderly
alcoholic liver disease 1873
alkaline phosphatase levels 462
autoimmune liver disease 1872–1873
biliary disease 1875
drug-induced hepatitis 1212–1213
gallstones 1874–1875
liver abscess 1874
liver disease 1870–1878
liver transplantation 1874
non-alcoholic fatty liver disease 1873
parenchymal liver disease 1871–1872
primary hepatocellular cancer 1874
electroencephalogram (EEG)
hepatic encephalopathy 609, 745
neurological status monitoring 1305
electrohydraulic lithotripsy, choledocholithiasis 1531
electrolytes
anaesthetic implications 1939
postoperative liver transplantation 1999
preoperative liver transplant assessment 1996–1997
transport by hepatocytes 111f
see also individual types
electromagnetic flow-meter
hepatic arterial blood flow measurement 568–569
portal blood flow measurement 568–569
electron transfer, mitochondrial oxidative phosphorylation 1377, 1378f
embolus, liver transplantation 1997
embryology
biliary tract 69, 304–305
liver 65–71
portal venous system 623
embryonal rhabdomyosarcoma 1461
embryonal sarcoma *see* undifferentiated sarcoma
EMP50 53
emperipolesis 425
emphysema, alpha-1-antitrypsin deficiency 1333
employment, post-liver transplantation 2030
emtricitabine (FTC)
chronic hepatitis B therapy 926
wild-type virus 929
hepatotoxicity 984
HIV–hepatitis B coinfection 975, 975t
mitochondrial toxicity 1380
emulsification, microvesicular steatosis 1244
enalapril, hepatotoxicity 1233–1234
encainide 1914
encephalopathy *see* hepatic encephalopathy (HE)
endocannabinoids, portal hypertension 635
endocarditis
portal hypertension 768
Q fever 1004
endocrine system
alcoholism 1186
cirrhosis 610–611
diseases and liver function 1680–1693
effects of liver disease 1732–1766
haemochromatosis 1760–1762
infantile cholestasis 1846t
liver tumours 1762–1763
endocytosis, basolateral membrane 27
endoderm 65
hepatic specification 65
end-of-therapy virological response (ETR), hepatitis C antiviral therapy 942

endogenous glucose production (EGP)
cirrhosis 132
diabetes 131, 131f
hepatic regulation 131
postprandial state 129
endogenous thrombin production (ETP) 1783–1784, 1783t
cirrhosis 1784, 1785f
endoglin (ENG) gene mutation 1419
endometrial cysts (EC), liver 810–811
fluid 810
histology 810
imaging 810
malignant transformation 810
pathogenesis 810–811
presentation 810
treatment 810
endometrial fragments 811
endometriosis, hepatic 810–811
endonucleases, apoptosis 336
endophlebitis 427
endoplasmic reticulum 23–24, 23t
alpha-1-antitrypsin deficiency
mutant Z protein retention 1330, 1331f
quality control system 1330, 1332
polycystic liver disease 193
protein(s) synthesis 23
rough 23, 24f
secretory protein targeting 193
smooth 23–24, 24f
stress response
alcohol consumption 1138
alpha-1-antitrypsin deficiency 1332
translocation 193
vesicle formation 192f, 194
endoprosthesis, portal vein lesions 551, 552f
Endorem 523, 529
endoscopic band ligation (EBL), variceal bleeding
acute 650, 650f
complications 644, 1799
first bleeding prevention 644–645, 645f
beta-blockers and 645
beta-blockers *vs.* 644, 645f
pretransplant patients 1924t
recurrent bleeding prevention 647
beta-adrenergic blockers *vs.* 647, 647f
endoscopic injection sclerotherapy (EIS), variceal bleeding
acute 650, 650f
complications 1799
neurological manifestations 1824t
recurrent bleeding prevention 647
endoscopic pressure gauge, variceal pressure measurement 663
endoscopic retrograde biliary drainage (ERBD), obstructive jaundice 1935–1936
endoscopic retrograde cholangiography (ERC)
AIDS-related cholangitis 1546
bacterial cholangitis 1543
cholecystolithiasis 1527, 1528f
choledocholithiasis 1527, 1528f, 1542
Mirizzi syndrome 1535, 1535f
obstructive jaundice, malignant causes 555
endoscopic retrograde cholangiopancreatography (ERCP) 540–548, 1045
bile duct injury, post-cholecystectomy 1960f
bile duct stones 540–542, 541f
biliary decompression, preoperative 545
biliary strictures 542
cholangitis 544
cholelithiasis 1900
chronic portal vein thrombosis 1398, 1398f
computerized tomographic cholangiography *vs.* 541–542
cryptosporidiosis 1025
diagnostic uses 540–542
donor evaluation, living donor liver transplantation 1977
endoscopic ultrasonography *vs.* 541–542
extrahepatic biliary obstruction 1508, 1509
gallbladder dysfunction 1564
haemostasis risk 1788t
hilar (upper duct) cholangiocarcinoma 1591
intrahepatic cholangiocarcinoma 1595
lower duct cholangiocarcinoma 1594–1595
magnetic resonance cholangiopancreatography *vs.* 541–542
post-cholecystectomy stones 544
post-living donor liver transplantation 1982
preoperative 544
primary sclerosing cholangitis 1105, 1105f, 1489
progressive sclerosing cholangitis 1951
sphincter of Oddi dysfunction
biliary type 1568
pancreatic-type 1570
therapeutic uses 543–546
malignant biliary obstruction 545
endoscopic sclerotherapy
congenital hepatic fibrosis 782
spontaneous bacterial peritonitis induction 763
endoscopic sphincterotomy (EST)
AIDS-related cholangitis 1546
bacterial cholangitis 1543
bile duct stones 543, 543f
endoscopic ultrasonography (EUS)
bile duct stones 541, 542
choledocholithiasis diagnosis 1542
extrahepatic biliary obstruction 1509
gallbladder dysfunction 1563
hilar (upper duct) cholangiocarcinoma 1593
lower duct cholangiocarcinoma 1594–1595
endoscopy
chronic portal vein thrombosis 1398
cirrhosis 614
haemobilia 1555
haemostasis risk 1788t
oesophageal varices 643
endothelialitis 427
endothelial massage 15
endothelial nitric oxide synthase (eNOS)
cirrhosis 82, 631, 1725
liver sinusoidal endothelial cells 31
portal hypertension 635–636, 636f
endothelin(s) (ETs)
cirrhosis 82, 1728
fibrosis 82
obstructive jaundice-associated acute renal failure 1816
portal hypertension 633
receptors 82
sinusoidal perfusion regulation 81–82
endothelin-1
cholangiocytes, effects on 53
endotoxaemia 82
hepatic ischaemia/reperfusion 82
hepatic stellate cells contractility 593
portal hypertension 771
renal hypoperfusion 1725
vasoconstriction 82
endothelin-converting enzyme (ECE) 593
endothelin receptors 82
portal hypertension 633
endothelium
chronic liver damage regeneration 285
portal hypertension 633, 634f
endotoxaemia
alcoholic hepatitis 1161
alcoholic liver disease 1139–1140
obstructive jaundice 1504, 1511
acute renal failure and 1815
urea synthesis regulation 183
endotoxin
alcoholic liver disease pathogenesis 1139–1140
intrahepatic cholestasis 1482
sinusoidal endothelial cells 1140
endotoxin receptor, alcoholic liver disease 1143
endotracheal intubation, acute variceal bleeding 649
end-stage liver disease (ESLD)
chronic hepatitis C 888–889
HIV–hepatitis C coinfection 982
hypogonadism 1756–1757
outcomes research 2069
total parenteral nutrition-related liver disease 1634
end-stage renal disease (ESRD)
hepatic cancer risk 1654
hepatitis B vaccination 1654
post-liver transplantation immunosuppression 2021–2022
energy metabolism
disordered, impact of 1838
effects of liver disease 1836–1842
enflurane, hepatotoxicity 1234
enoral jaundice 446
Entamoeba histolytica 1021f
epidemiology 1020
geographical distribution 2100–2104t
life cycle 1022
motility 1023
surface adhesion molecules 1023
entecavir, hepatitis B
chronic 926
lamivudine resistance 932
resistance 929, 932f, 933
wild-type virus (HBeAg-positive) 929
HIV coinfection 975–976
HIV–hepatitis B coinfection 975t, 977
pretransplant patients 1927
enteral nutrition
alcoholic cirrhosis 1167
alcoholic hepatitis 1164, 1908
chronic liver disease 1908–1909, 1909t
cirrhosis 616
liver transplantation 1909–1910
multifactorial cholestasis, premature infants 1850
enteric fever 1003
Enterobacter, bacterial cholangitis 1541
enterochromaffin cells, carcinoid tumours 1470–1471
Enterococcus, bacterial cholangitis 1541
enteroglucagon 1738
enterovirus infections
diagnosis 967
hepatitis 967
polymerase chain reaction 967
treatment 967
environmental factors
genetic interactions 361, 371, 372
primary biliary cirrhosis 1072
environmental toxins 1269
enzyme-determined clearance 470–472
enzyme immunosorbent assay (EIA), plasma fibrinogen 456
enzyme-linked immunosorbent assay (ELISA)
amoebic liver abscess 1026
echinococcosis 1054
hepatitis C 855
visceral larva migrans 1063
enzyme replacement therapy (ERT)
Anderson Fabry disease 1805
Gaucher's disease 1363–1364
optimum dosing regimen 1363–1364
hypersensitivity reaction induction 1364
eosinophilia, primary biliary cirrhosis 1770
eosinophilic cholangitis 1596
eosinophilic fasciitis 1697
eosinophilic granuloma (Langerhans cell histiocytosis) 1618–1619, 1645
EPIC3 study 951
epidermal growth factor (EGF), liver regeneration 316
epidermal growth factor receptor (EGFR), cholangiocarcinoma 1587
epidermoid cysts, liver 811
epidural anaesthesia/analgesia
hepatic resection and 1941
liver transplantation and 1942
epigastric vein dilatation 447
epigenetic events, carcinogenesis 391
epilepsy
acute porphyric crisis 1344
antiviral side-effects 947
epinephrine
glucose metabolism 1681
hepatic blood flow regulation 77
renal hypoperfusion 1725
epirubicin, gallbladder carcinoma 1580
episodic (precipitant-induced) encephalopathy 728t, 729
cirrhosis
clinical features 741–742
diagnosis 741–742, 742t
differential diagnosis 742
mental status exploration 740t, 741
physical signs 741
treatment 749
epistasis, liver disease and 372
epithelioid granulomas 428
Hodgkin's disease 1662
non-Hodgkin's lymphoma 1663
epithelioid haemangioendothelioma (EHE) 1458–1460

clinical features 1459
dendritic cells 1459
drug-induced 1259t, 1261
epithelioid cells 1459
intrahepatic cholangiocarcinoma *vs.* 1597
liver transplantation 1988
natural history 1459
nodules 1459
occurrence 1458–1459
pathogenesis 1460
pathology 1459, 1459f
physical examination 1459
treatment 1460
epithelium
biliary tree 1111, 1112
cholangiocarcinoma 1585
sinusoidal, antigen presentation 321
epoprostenol, pretransplant patients 1925
ε-aminocaproic acid (EACA) 261, 1790–1791
Epstein-Barr virus (EBV)-encoded RNA in situ hybridization 965
Epstein–Barr virus (EBV) infection 964–966
acute liver failure 1298
diagnosis 965
epidemiology 965
hepatitis 965–966
serology 965–966
immunocompromised 965
latency 964
lytic infection 964
malignancies 964
pathogenesis 965
post-transplantation
children 1866
lymphoproliferative disease 965
serology 964–965
signs/symptoms 965
treatment 966
vanishing bile duct syndrome 1115
virology 964–965
X-linked lymphoproliferative disease 965
Epstein-Barr virus (EBV) nuclear antigens (EBNAs) 964
erbB2 gene 1587
ergotamine derivatives, cirrhotic patients 1914, 1915t
Erlenmeyer flask deformation 1361
erythema chronicum migrans 1007, 1808
erythrocyte abnormalities, chronic liver disease 1767–1768
causes 1768t
functional 1768
shape-related 1768
erythrocytosis, liver tumours 1762–1763
erythromycin estolate, hepatotoxicity 1234
erythromycin ethylsuccinate, hepatotoxicity 1234
erythromycin propionate, hepatotoxicity 1234
erythromycins, hepatotoxicity 1234
erythropoiesis
black pigment gallstones 1523
fetal liver 1767
post-liver transplantation 1772
erythropoietic protoporphyria 213, 1344t, 1348, 2130
carriers 1348
diagnosis 1348
hepatic effects 1348
histology 429
intrahepatic cholestasis 1491
photodermatosis 1347, 1348
pseudorecessive 1348
therapy 1348
erythropoietin (EPO)
anaemic cirrhotic patients 1767
analogues 1792
fetal liver 1767
gene expression, across liver cell plate 90–91
hypersplenism treatment 775–776
post-liver transplantation 1772
Escherichia coli
bacterial cholangitis 1541
cholangiocarcinoma 1584
essential mixed cryoglobulinaemia 1667
hepatitis B virus 1806
hepatitis C virus 1806, 1818
estradiol
cirrhosis 1757–1758, 1757t, 1760
physiology
female 1754
male 1754
transport in blood 1755
estriol, cirrhosis
feminization 1758–1759
women 1759–1760
estrogen(s) 1688–1689
bile secretion 1241
cholangiocyte proliferation 54, 284
gallbladder dysfunction 1562
hepatocellular cholestasis induction 1241–1242
intrahepatic cholestasis of pregnancy 1385
liver cysts, ADPKD 790
physiology 1687
secretion 1687
tumorigenicity 1258
estrogen receptors, cholangiocytes 54
estrone
cirrhosis 1757t
feminization 1758–1759
women 1760
physiology
female 1754
male 1754
etanercept, hepatotoxicity 1647
1,2-ethanediamine, hepatotoxicity 2109
ethanol *see* alcohol
ethinylestradiol
intrahepatic cholestasis of pregnancy 1880
tumorigenicity 1258
ethnicity
alcoholic cirrhosis 1133
alcoholic liver disease 1142–1143, 1159
extrahepatic biliary obstruction 1507
hepatocellular carcinoma 1437
liver disease genetics and 360
7-ethoxycoumarin-*O*-demethylase 93
7-ethoxyresofurin-*O*-deethylase 93
ethylene chlorohydrin, hepatotoxicity 2110
ethylene glycol, hepatotoxicity 2110
etiocholanolone 1687
etretinate, hepatotoxicity 1234
eukaryotic initiation factors (eIF) 191–192
Euphytose, hepatotoxicity 1286
Eurocollins solution 352
Europe
alcohol consumption 1129, 1129t
hepatitis B 867, 2104t
hepatitis D 877
infectious liver diseases, frequency of 2104t
European Commission, herbal medicine regulation 1281
European Organization of Research and Treatment of Cancer QOQ-C 2029
EuroQOL, quality of life 2082
Eurytrema pancreaticum 1046–1047
eurytremiasis 1046–1047
diagnosis 1046
symptoms 1046
treatment 1047
evidence hierarchy, clinical trials 572–574
evolutionary conservation
mouse models of human liver disease 381
oncogenes 392
exchange transfer
neonatal haemochromatosis 1857
physiological jaundice 1355
Excorp Medical Inc Bioartificial Liver Support System 2046f
excretion 290–311
bile, physiological functions 291
executioner caspases 336
exercise *see* physical activity/exercise
exocyst 194
exponential RNA amplification, gene array analysis 403
expressed sequence tags (ESTs), gene array probes 403
expression comparisons
QTL analysis in inbred mice 377t, 379
see also functional genomics
extended cholecystectomy with regional lymphadenectomy, gallbladder carcinoma 1578
external beam radiation therapy (EBRT), gallbladder carcinoma 1580
extracellular matrix (ECM)
fibrosis 584–585, 590, 2090
homeostasis 48, 270–271, 590
immunohistochemistry 47, 47t
sources 590
extracellular matrix (ECM) proteins 264–273
degradation 270–271
fibrosis resolution 270
gelatinases 270
matrix metalloproteinases 270
tissue inhibitors of metalloproteinases 270–271
fibrosis 584–585, 2090
fibrotic liver 264, 265f
homeostasis 270–271
non-collagenous proteins 268–270
normal liver 264, 265f
receptors 270
structure 264, 266–270
see also specific proteins
extracellular-regulated kinase-1 (ERK-1) 104
extracellular-regulated kinase-2 (ERK-2) 104
extracellular-regulated kinase-5 (ERK-5) 104
extracorporeal liver assist device (ELAD)
acute liver failure 1305–1306
hepatoblastoma-based 2047
sepsis-induced cholestasis 1950
extracorporeal pig liver perfusion 2044
limitations 2044
extracorporeal shockwave lithotripsy (ESWL)
cholecystolithiasis 1531
choledocholithiasis 1531–1533, 1532f
extrahepatic biliary obstruction 1501–1517
apoptosis 1501
clinical features 1506–1507
copper accumulation 1502
examination 1507
hepatectomy in 1935–1936
hepatocellular damage 1501–1502
imaging 1507–1509, 1508f
invasive 1509
non-invasive 1507–1509
inflammatory bowel disease 1507
management 1510f
mitochondrial changes 1501, 1502
necrosis 1501
pathophysiology 1501
previous malignancies 1507
reactive oxygen species 1501
systemic effects 1502–1503
see also obstructive jaundice
extrahepatic cholangiocarcinoma, magnetic resonance imaging 526
extrahepatic congenital portosystemic shunt (Abernethy shunt) 1418–1419
extramedullary haematopoiesis
histological features 427
myeloid metaplasia 1665
extramedullary plasmocytoma, hepatic 1664
extremities, examination of 446
extrinsic coagulation pathway 1780, 1781f
extrinsic death pathway 337–339, 337f, 338f
eyes, liver disease signs 445–446
ezrin-EBP50 complex 53

F

facial neuritis, viral hepatitis 1826
factor II *see* prothrombin
factor V
acute liver disease 257
acute liver failure 1302
clot formation 256, 1780
synthesis 257
factor V Leiden mutation, Budd–Chiari syndrome 1404
factor VII
acute liver disease 257
clot formation 256, 1780, 1782f
deficiency, hepatocyte transplantation 2038
synthesis 257
factor VIII
acute liver disease 257
clot formation 256, 1780
factor IX
haemostasis 256
synthesis 257
factor X
acute liver disease 257
clot formation 256, 1780
synthesis 257
factor XI
clot formation 1780
deficiency, Gaucher's disease 1361

factor XIII 257
factor assays 1781, 1783t
faecal–oral transmission
  hepatitis A 858
  hepatitis E 896
faeces
  porphyrin precursor excretion 212t, 213
  porphyrins excretion 212t, 213
falciform ligament 3
false neurotransmitter hypothesis, hepatic encephalopathy 731
famciclovir
  hepatitis B 936
  hepatitis D–hepatitis B virus coinfection 935
familial amyloidosis 1702
familial amyloidotic polyneuropathy (FAP) 1704, 1705
familial analphalipoproteinaemia (Tangier disease) 139, 1366
familial clustering, primary biliary cirrhosis 1073–1074
familial combined hyperlipidaemia 1367
familial hyperbilirubinaemia 1886
familial hypercholanaemia (FHCA) 176, 1386
familial hypercholesterolaemia (FH) 1367
familial hypobetalipoproteinaemia (FHBL) 1366, 1525
familial lipoprotein lipase deficiency 1366–1367
family-based genetic studies 360
  gallstone disease 1524
Fanconi–Bickel syndrome (glycogenosis with renal Fanconi syndrome) 1375
Fanconi syndrome 1688, 2130–2131
farnesoid X receptor (FXR)
  agonists, intrahepatic cholestasis treatment 2920–2921
  bile acid homeostasis 106, 178, 301t, 386–387, 388f
  cholestasis 387, 1482–1483
  drug-metabolizing pathway regulation 244
  stellate cell activation 593
Fas-associated death domain (FADD) 314, 338
Fasciola gigantica 1045–1046
Fasciola hepatica 1045–1046
  cholangitis 1546, 1547t
    treatment 1547
  life cycle 1045
  transmission 1045
fascioliasis 1045–1046
  chronic biliary phase 1045
  clinical manifestations 1045
  diagnosis 1045
  pathogenesis 1045
  treatment 1045–1046
Fas death receptor, extrahepatic biliary obstruction 1501
FAS gene 369
fasting
  apolipoprotein B-48 degradation 136
  gallbladder fluid transport 306
  glutathione 1221
  hyperglycaemia 1734
  mitochondria fatty acid β-oxidation 161
fat, dietary
  fatty liver pathogenesis 1136
  gallbladder motility 307
fatigue 443
  cholestasis 1486
  extrahepatic biliary obstruction 1502
  Gaucher's disease 1360
  hepatitis C 443
  hepatopulmonary syndrome 720
  intrahepatic cholestasis 1496
  non-alcoholic fatty liver disease 1198–1199
  non-alcoholic steatohepatitis 1198–1199
  primary biliary cirrhosis 443, 1074–1075, 1081
Fatigue Severity Scale, quality of life 2066
fat malabsorption
  abetalipoproteinaemia 1366
  chronic liver disease 1801
  familial hypercholanaemia 1386
  obstructive jaundice 1505
fat-soluble vitamins
  cholestasis 1486–1487
  deficiency 1801–1802
    cystic fibrosis 1340
  infantile cholestasis 1846
  supplementation, cholestatic disease 1908
fat storage *see* steatosis
fat-storing cells *see* hepatic stellate cell (HSC)
fatty acid binding protein (FABP) 91
fatty liver *see* steatosis
fatty liver disease (FLD)
  alcoholic *see* alcoholic liver disease (ALD)
  children 1855–1856
  liver biopsy 491–492, 492f
  manganese deficiency 237
  non-alcoholic *see* non-alcoholic fatty liver disease (NAFLD)
  pregnancy *see* acute fatty liver of pregnancy (AFLP)
fatty liver hepatitis *see* alcoholic hepatitis
fatty metamorphosis *see* steatosis
FcARI 328
Fc-γ receptors 37
Fc receptor 328
feathery degeneration, intrahepatic cholestasis 1484
felbamate, acute hepatitis induction 1234
Felty syndrome 1696
feminization
  cirrhosis 610, 1741, 1756, 1758–1759
  clinical signs 1758
  drug-induced 1759
fenestration (surgical)
  hepatic cysts, ADPKD 793–794
  simple cyst of the liver 787–788
fenfluramine, hepatotoxicity 1283
fenofibrate, acute hepatitis induction 1232
fentanyl 1940
ferrochelatase 209
  deficiency 209, 211–212
  erythropoietic protoporphyria 1348
  haem synthesis regulation 211–212
ferroportin
  function 222, 222f, 1326–1327
  hepatic expression 222
  hepcidin interactions 1324
  intestinal expression 222
  mutations 1326
  regulation 224
ferroportin disease (FD) 1326–1327
  pathogenesis 1327
ferroxidase, iron homeostasis 222–223
fetal hepatocytes
  bioartificial liver support 2044
  hepatocyte transplantation 2035
fetal liver
  cholangiocyte apoptosis 54
  as haematopoetic organ 1767
fetal rubella 2131–2132
fever 444, 445
  Caroli syndrome 805
  extrahepatic biliary obstruction 1506
  post-peritoneovenous shunting 696
  strongyloidiasis 1065
  visceral leishmaniasis 1035
fever of unknown origin (FUO) 445
fialuridine (fluoroiodoarauracil, FIAU), hepatotoxicity 1248, 1299
fibrates, acute hepatitis induction 1232
fibre, hepatic encephalopathy 746
fibrillar collagens 266–267, 267t
fibrillin-1 269
fibrin
  clot formation 1780
  pre-eclampsia 1884
  sinusoidal deposition 427
fibrin degradation products (FDPs), cirrhosis 1786
fibrinogen
  acute liver disease 257
  cirrhotic ascitic fluid 668
  clot formation 1780
  measurement 1781
  plasma 456–457
    abnormal values 456–457
    clinical usefulness 457
    detection assays 456
    distribution 456
    normal values 456–457
  storage, histological features 428
  synthesis 257
fibrinogen storage disease, familial 1334
fibrinolysis 256
  alpha-2-antiplasmin 256
  chronic liver disease 258
    anaesthetic implications 1940, 1943
    coagulation tests 258
    tissue plasminogen activator 258
  markers 1783t
  plasminogen inhibitor-1 256
  plasminogen inhibitor-2 256
fibrin-ring granuloma (doughnut granuloma) 428, 1709, 1710f, 1713
fibroblast growth factor (FGF)-1 65
fibroblast growth factor (FGF)-2 65
fibroblast growth factors (FGFs) 66
fibrolamellar carcinoma (FLC) 1441
  liver transplantation 1988
  magnetic resonance imaging 525, 525f
fibrometers, alcoholic liver disease 1168
fibromyxosarcoma *see* undifferentiated sarcoma
fibronectin 37, 264, 268–269
  fibrotic liver 264
  functions 268
  splice variants 268–269
fibro-obliterative cholangitis 426
fibropolycystic liver disease 1856
  vanishing bile duct syndrome 1112, 1114t
fibrosarcoma 1461
fibrosing cholestatic hepatitis 429
fibrosis
alcoholic liver disease 1141, 1142t
  imaging studies 1168
  non-invasive markers 1167–1168
  scores 1168
  serum markers 1168
angiotensin-converting enzyme antagonists 595
antiapoptotic therapy-induced 344
apoptosis 341
Budd–Chiari syndrome 1406
capillariasis 1066
cellular pathobiology 590–603
characteristics 375
collagen 264
collagen I 584–585
congenital *see* congenital hepatic fibrosis
congestive heart failure 1612, 1613
copper dependence 230
cytokine antagonists 596
cytokines 314t
definition 590
disease-specific mechanisms 594
endothelin, response to 82
extracellular matrix proteins 264, 265f, 584–585, 2090
fibronectin 264
fractal geometry 438
functional genomics
  gene array data 411
  proteomics and 413–414
genetic polymorphism and chronic HVC infection risk 357t, 358–359, 360t, 361
  progression rate 358–359, 381
  QTL analysis in inbred mice 374f, 375, 375t
granulomas 1711
hepatic stellate cell activation 584, 590–594, 2089–2090
histological features 426–427
HIV–hepatitis C coinfection 979
lymphocytes 323
molecular pathobiology 590–603
monitoring, chronic hepatitis C management 890
morphometry 438
perisinusoidal *see* perisinusoidal fibrosis
pharmacological intervention 594–597, 595t
  see also antifibrotic therapy
platelet-derived growth factor 2090, 2091f
  phosphatidylinositol-3-kinase 2090
primary biliary cirrhosis 1077
progression to cirrhosis 583–589
  angiogenesis 585
  apoptosis 583
  architectural collapse 583
  clinical factors affection 585–586
  contractility 585
  inflammatory 584
  iterative injury 583
  mechanisms 583–585
  non-inflammatory 585–587
  perpetuation 586
regulatory network mapping 2089–2090
resolution 270
reversal 586
tenascin-C 269
Th1/Th2 balance 323

transforming growth factor-β 2090, 2091f
ultrasonography 502–503
Wilson's disease 1317, 1319
Fibrotest 2062, 2063, 2063f
fibrous obstructive cholangitis 1485, 1485f
fibrous piecemeal necrosis 424–425
FIC1 gene mutations 177, 1849
Fick's principle 469
'fievre boutonneuse' (Mediterranean spotted fever) 1006
'fifth disease' 968
filtration, limitations of 2044
fine-needle aspiration (FNA)
gallbladder carcinoma 1577
malignant biliary strictures 542
Finnish Twin Cohort, gallstone disease 1524
fipexide, acute hepatitis induction 1234
first-pass effect 240, 474–475, 1912, 1912t
fistula
arterioportal 1393–1394, 1400
arteriovenous 1400
biliary 1535, 1960
Fitz–Hugh–Curtis syndrome
Chlamydia trachomatis 1004
rubs 448–449
'5-day failure,' variceal bleeding 641
fixed costs 2081
flank distension 447
flapping tremor *see* asterixis (flapping tremor)
flatulence 444
flavoprotein E 1023
FLIP (FADD-like interleukin-1β-converting enzyme-like protease [FLICE/caspase-8]-inhibitory proteins) 340
florid bile duct lesions *see* granulomatous cholangitis
flow adaptation, liver disease 1728–1729
flow-determined clearance, substances 472
floxuridine, hepatotoxicity 1254–1255
FLT-1 (vascular endothelial growth factor receptor-1) 30, 30t, 32
flucloxacillin
hepatotoxicity 1234, 1648
vanishing bile duct syndrome induction 1254
fluconazole
cryptococcosis 1014
hepatosplenic candidosis 1013
flucytosine
cryptococcosis 1014
hepatosplenic candidosis 1013
fluid management
acute liver failure 1304
children 1858
hepatorenal syndrome type 1 715
obstructive jaundice 1511
fluid thrill 449
fluid transport, gallbladder 306
flumazenil, hepatic encephalopathy 736, 748
minimal (subclinical) 750
precipitant-induced 749
fluorescence in situ hybridization (FISH), hilar cholangiocarcinoma 1591
fluorescence labelling, gene arrays 403
fluorine 233t
deficiency 233t
2-[^{18}F]fluoro-2-deoxy-$_D$-glucose (FDG)
liver tumours 561–562
metabolism 472f, 561–562, 561f
2-[^{18}F]fluoro-2-deoxy-$_D$-glucose (FDG)-6-phosphate 561–562
5-fluorodeoxyuridine, hepatic metastases 1468–1469
fluoroiodoarauracil (FIAU, fialuridine), hepatotoxicity 1248
fluoropyrimidines, hepatic metastases 1468–1469
fluoroquinolones 1004
5-fluorouracil (5-FU)
carcinoid tumours 1477
gallbladder carcinoma 1580
hepatic metastases 1468–1469
flushing
alcohol misuse 1136, 1809
*ALDH2*2* allele 1136
carcinoid syndrome 1473–1474, 1809
histamine 1474–1475
flutamide, hepatotoxicity 1234
fms-like tyrosine kinase (Flt)-1 30, 30t, 32
fms-like tyrosine kinase (Flt)-4 30
foam cells 425
foamy degeneration *see* microvesicular steatosis
focal biliary cirrhosis, cystic fibrosis 1339, 1855
focal fat sparing 511
focal necrosis 425
focal nodular hyperplasia
glycogen storage diseases 1863
oral contraceptive-induced 1260, 1428, 1430
focal nodular hyperplasia (FNH) 1428–1430
angiography 537t
associated conditions 1429
central scar 515, 515f, 1429
children 1863
classical 1428–1429
clinical findings 1429, 1429t, 2132
computerized tomography 514–515, 1259–1260, 1429
definition 1428
diagnostic workup 1429
drug-induced 1259–1260, 1259t
epidemiology 1428
hereditary haemorrhagic telangiectasia 1422
magnetic resonance imaging 525, 525f, 1260, 1429–1430, 1430f
natural history 1429
pathogenesis 1428
pathology 1428–1429
pregnancy 1886
radiation-induced 1278
telangiectatic type 525, 1428
treatment 1430
ultrasonography 504t, 505, 1429
focused abdominal ultrasonography for trauma (FAST) 1954
foetor hepaticus 611, 741
folate
absorption, chronic liver disease 1768–1769
metabolism 147
folic acid
deficiency 147
supplementation 1908
follicle-stimulating hormone (FSH) 1686–1687
alcoholics 1186
cirrhosis
males 1758
women 1760
functions 1687, 1754–1755
spermatogenesis regulation 1754–1755
structure 1686
Forbes' disease *see* glycogen storage disease (GSD), type 3
forced sieving 15
forceps biopsy, malignant biliary strictures 542
foreign body granulomas 428, 1710
foreign material, Kupffer cells 429
forkhead-box-factors 65, 106
hepatocyte maturation 68
Forlan procedure 1611
Forrest plot 2076, 2076f
forward genetics, complex (multifactorial) diseases 372
'forward heart failure,' ischaemic hepatitis 1609–1610, 1610f
forward-phase arrays (FPA) 405
foscarnet
cytomegalovirus infection 963
herpes simplex virus infection 959
human herpesvirus type 6 964
human herpesvirus type 7 964
human herpesvirus type 8 966
founder effect, acute intermittent porphyria 1346
Foxm1b protein, cell cycle 275
fractal geometry 437
fibrosis 438
Fractionated Plasma Separation, Adsorption and Dialysis system (FPAD; Prometheus) 2047
clinical studies 2047–2048
mechanism of action 2047, 2048f
fraction clearance 569
fractures
liver disease and 1829–1830
post-transplant 1832–1833
Franciscella tularensis 1004
free fatty acids (FFA)
gluconeogenesis 131
glycogenolysis 131
insulin resistance 131
mitochondria, entry into 161
free hepatic venous pressure (FHVP) measurement 568, 659, 660
free-water clearance
cirrhosis 676, 676f, 681, 681f, 682–683
cirrhotic ascites, post-peritoneovenous shunting 695
free-water formation 681
fresh frozen plasma
acute fatty liver of pregnancy 1883
acute liver failure 1304
acute variceal bleeding 648
coagulation disorders 260–261, 1789
'frothing champagne glass' appearance, rickets 1833
frozen section, liver biopsy 491
fructose-1,6-bisphosphatase 91
fructose-1-phosphate aldolase (aldolase B) deficiency 1860–1861
frusemide, thyroid hormones and 1749
FTY720, liver transplantation 2008–2009
fucosidosis 2132–2133
fulminant hepatic failure (FHF)
acute leukaemia 1664
alkalosis 186
cerebral blood flow 1725
definition 1291, 1292t
hyperthyroidism 1684
interleukin-6 318
kava-induced 1284
liver transplantation 1986
prognostic indicators 1986
malarial hepatitis *vs.* 1032, 1033
neurological manifestations 1826
nutritional management 1839–1840
pancreatitis 1801
propylthiouracil-induced 1685
tumour necrosis factor 313–314
fulminant hepatitis
computerized tomography 512
coxsackievirus infections 967
drug-induced 1227, 1236
prevalence 1212
hepatic encephalopathy 870
hepatitis A 861, 917
hepatitis B, acute 870, 917
hepatitis B-hepatitis C co-infection 870
hepatitis C, acute 886
hepatitis D 878
lactic acidosis 187
plasma fibrinogen 457
therapy 917
fumarate 155
fumaric acid esters (FAEs), hepatotoxicity 1647
fumaryl acetoacetate hydrolase deficiency 1860
functional genomics
analysis tools 379
definition 398–399
in liver disease 407–415
methodologies 398f
multiplexing 415
QTL analysis in inbred mice 379–380
liver metabolism 379
terminology 398–399
see also bioinformatics; *specific methodologies*
functional hepatic nitrogen clearance 1871
functional liver mass, split liver transplantation 1973
fungal infection(s) 1011–1019, 1011t
acute liver failure 1131–1132
opportunistic 1011–1014, 1011t
post-haematopoietic stem cell transplantation 1677
post-liver transplantation
children 1866
diabetic patients 1736
skin, alcohol misuse 1810
see also specific infections/infectious organisms
funnel plots, publication bias 2075, 2075f
furosemide
ascites 690–691
cirrhosis 690–691
natriuretic potency 690
resistance to 690

G

GABAergic neurotransmission, hepatic encephalopathy 736–737

gadolinium chelate, magnetic resonance 522–523
focal nodular hyperplasia 1429–1430
galactosaemia 1860
galactose-1-phosphate uridyl transferase deficiency 1860
galactose clearance 471t, 472, 569f
galactose elimination capacity (GEC) 469, 475t
acute liver disease 476
ageing 1871
chronic liver disease 476
galactosaemia 1860
surgical risk assessment 476
galactosialidosis 2133
Galbraith plot 2076, 2076f
Galbraith plot, meta-analysis 2077
Gal-GalNac, *Entamoeba histolytica* 1023
gallbladder
adenoma 1576
adventitia 19
age-related changes 1875
anatomy 305
bile modification 299–300
mucins 300
biliary atresia 1847
carcinoma *see* gallbladder carcinoma
coeliac disease 1629
cystic fibrosis 1339
disease, elderly 1875
dysfunction 1561–1565
cholecystectomy 1564
clinical presentation 1562
differential diagnosis 1563–1564
hormone-associated 1562
inflammation 1562
investigation 1565f
investigations 1562–1564
pain provocation tests 1563
pathophysiology 1562, 1563t
structural pathology 1562
treatment 1564–1565, 1565f
embryology 304–305
fluid transport 306
histology 18–19
innervation 19
motility 306–307
autonomic nerves 307
cholecystokinin 306, 1562
cholesterol gallbladder stones 1518, 1520
disorders 1562
fatty meals 307
hormones 306, 306t
migrating motor complex 306, 1562
motilin 306–307, 1562
non-propulsive contractions 1561–1562
propulsive contractions 1562
mucosa 18, 18f
muscularis 18–19
palpation 448
physiology 306–307, 1561–1562
polypoid lesions
gallbladder carcinoma 1576
management strategies 1576f
ultrasonography 507
pregnancy 1879
as reservoir 1561
Salmonella infection 1003
'strawberry' 1529
ultrasonography 506
villosities 18
water absorption 306
gallbladder carcinoma 1575–1582
adjuvant therapy 1579–1580
chemotherapy 1580–1581, 1581t
cholesterol cholelithiasis 1575
clinical presentation 1577
diagnosis 1577
differential diagnosis 1597
epidemiology 1575–1576, 1575f
genetic alterations 1576–1577
hilar (upper duct) cholangiocarcinoma *vs.* 1597
imaging 507, 1577, 1577f
laboratory findings 1577
palliative therapy 1579
radiation therapy 1580
physical findings 1577
prognosis 1578
lymph node involvement 1579
recurrence, post-surgery 1579–1580
risk factors 1575–1576
staging 1578, 1578t
surgical therapy 1578–1579, 1579t
treatment 1578–1580
gallbladder carcinoma *in situ,* surgery 1578–1579
gallbladder ejection fraction (GBEF), gallbladder dysfunction 1563–1564, 1564f
gallstone disease (cholelithiasis) 1518–1540
biliary fistulae 1535
biliary pain 444
biliary pancreatitis 1534
canalicular transport defects, inherited 1385
causes 1521t
cholangitis 1534
cholesterol-rich diets 1523
cirrhosis 613
classification 1518, 1519t
clinical presentation 1525–1527
complications 1533–1535, 1533t
Crohn's disease 1627
cystic fibrosis 1339
diabetes mellitus 1683
diagnosis 1527–1529, 1527f, 1527t
differential diagnosis 1529
drug-induced 1689
elderly 1874–1875
management 1875
epidemiology 1523–1524
family studies 1524
gallbladder motility disorders 1562
gallstone ileus 1535
gender 1523
genetics 1523–1525
monogenic 1524–1525
polygenic 1525
geographical variations 1523–1524
haemolytic anaemias 1525
hypothyroidism 1685
imaging 506–507, 613, 1522f
intrahepatic
clinical presentation 1527
therapy 1533
investigations 1900
linkage studies 1524
oral contraceptive-induced 1688
pathogenesis 1518–1523
pregnancy 1888
prevalence 1518, 1523
prevention 1529, 1530t
cholecystokinin 1529
primary sclerosing cholangitis 1106
prognosis 1535–1536
without treatment 1536
risk factors 1521t
sickle-cell disease 1666
sphincter of Oddi dysfunction 1567
therapy 1529–1533
total parenteral nutrition-associated 1637–1638
twin studies 1524
see also cholecystitis; cholecystolithiasis; choledocholithiasis; cholesterol gallbladder stones
gallstone ileus 1535
gallstone pancreatitis, imaging 544–545
gametocytes
Cryptosporidium 1022
Plasmodium 1030
gamma-glutamyl transferase *see* gamma-glutamyl transpeptidase (γ-GT)
gamma-glutamyl transpeptidase (γ-GT) 463–464
alcoholic macrovesicular steatosis 1160
alveolar echinococcosis 1052
assays 463
autoimmune hepatitis–primary biliary cirrhosis overlap syndrome 1122
cholestasis 1487
cirrhosis 612
glutathione degradation 198, 199–200
hepatobiliary diseases 464
hereditary haemorrhagic telangiectasia 1420
hyperthyroidism 1684
non-alcoholic fatty liver disease 1199
non-alcoholic steatohepatitis 1199
nonhepatobiliary diseases 464
normal values 463
'oval cells' 283
pre-eclampsia 1884
pregnancy 1879
primary biliary cirrhosis 1076
progressive familial intrahepatic cholestasis 1384, 1386, 1487, 1849
tissue distribution 463
gammaherpesvirus infections 964–966
ganciclovir
cytomegalovirus 963
Epstein–Barr virus 966
herpes simplex virus 959
human herpesvirus type 6 964
human herpesvirus type 7 964
human herpesvirus type 8 966
gangliosidosis type 1 2136–2137
gankyrin
as oncogene 392t, 393
Rb protein inhibition 394–395
gap junctions
bile formation 298
cholangiocytes 53
hepatocytes 22, 93, 97
neural signal propagation 117
Gardner syndrome 2133–2134
Garrett–Tripp syndrome 2134
gas exchange, liver disease and 1939
gastric antral vascular ectasia (GAVE) 1799–1800
gastric carcinoid tumours 1471, 1472
flushing 1474
gastric erosions, acute 1800
gastric ulcers 1800
gastric varices 652–653
bleeding 652–653, 652f
endoscopic therapies 652–653
gastrin, effects on cholangiocytes 53
gastritis
obstructive jaundice 1504
portal hypertensive gastropathy 1799
gastroduodenal arteries 532
gastrointestinal tract
amino acid oxidation 143–144
bile acid circulation 293–294, 294f
bilirubin absorption 171–172
bilirubin degradation 172
bleeding
congenital hepatic fibrosis 782
hepatic artery lesions 549–550
portal hypertension 606
renal failure 712
carcinoid syndrome 1474
diseases, effects on liver 1622–1633
drug susceptibility, cirrhosis 1914
effects of liver disease 1798–1803
granulomas 1714
hepatic encephalopathy treatment 746–747
obstructive jaundice 1504–1505
gastro-oesophageal junction, venous anatomy 623–625
gastric zone 624, 624f
varices 628
palisade zone 624, 624f
varices 628
venous dilatation 628
perforating zone 624f, 625
varices 628
truncal zone 625, 625f
varices 628
varices 628, 628f
gastro-oesophageal reflux
cirrhosis 1798
oesophageal ulceration 1798
GATA factors
endoderm hepatic specification 65
liver bud expansion 66
Gaucher cells 1360
Gaucher's disease (GD) 1360–1364
computerized tomography 512
congenital 1362
course 1361–1362
cutaneous manifestations 1361, 1805–1806
diagnosis 1362
enzyme replacement therapy 1363–1364
enzymology 1362
management 1363–1364
molecular diagnosis 1362
molecular heterogeneity 1362–1363
mutation analysis 1363
neonatal 2134
prenatal diagnosis 1362
type 1 (adult type) 1360–1362, 2135
bone crises 1361
clinical features 1360–1361
cutaneous manifestation 1805–1806
haematological abnormalities 1361
lymphoproliferative disorders 1361
neurological manifestations 1361
pulmonary involvement 1361
skeletal involvement 1361
splenomegaly 1360–1361
type 2 (infantile/acute neuronopathic) 1362, 2134–2135

cutaneous manifestations 1806
neurological signs 1362
type 3 (juvenile/norbottnian) 1362, 2135
type 3A 1362
type 3B 1362
type 3C 1362
GBE1 gene mutations 1374
Gc protein, acute liver failure 1302
gelatinases, extracellular matrix degradation 270
gelophysic dysplasia 2136
gemcitabine, gallbladder carcinoma 1580
gemfibrozil, hepatotoxicity 1232
GenBank, proteome complexity and 412
GenBank human UniGene clusters 407
gender
alcoholic liver disease 1132–1133, 1142, 1159
cystic fibrosis 1338
drug-induced liver injury 1212–1213
gallstone disease 1523
hepatitis B infection 865
hepatocellular carcinoma 1437
liver cysts, ADPKD 790
primary biliary cirrhosis 1071
primary sclerosing cholangitis 1106
simple cyst of the liver 784
gene arrays 399–403, 400f
alcoholic liver disease 409–410
assumptions 412
autoimmune hepatitis 410
biases 406, 412
biliary atresia 410
cholangiocarcinoma 411
comparative hybridization 399f, 401, 403
cystic fibrosis 410
definition 399
experimental design 400–401, 400f
biological replicates 401, 401f
technical replicates 401, 401f
future directions 414
gene expression profile ('transcriptome') 398f, 399, 407
hepatitis B 409
hepatitis C 407–409, 408t
hepatocellular carcinoma 409, 410–411
in liver disease 407–411, 408t
MIAME guidelines 399–400, 402
multiplexing 415
non-alcoholic fatty liver disease 410
normal human liver 407, 408t
one-probe 399f, 403
platforms 403
primary biliary cirrhosis 410
primary sclerosing cholangitis 410
probe sources 403
proteomics *vs.* 403, 405
QTL analysis in inbred mice 379–380
hepatocellular carcinoma analysis 380
reproducibility/variability 399–400, 400f
sample preparation
labelling 403
pooling 401
RNA amplification 402–403
RNA isolation/quality 402, 402f
RNA quantities 402
SNP analysis 414
targeted 414
validation 401
see also bioinformatics
GeneChip™ 403
gene–environment interactions, liver disease and 361, 371, 372
gene expression 90–91
analysis
high-throughput technologies *see* gene arrays
'transcriptome' 398f
liver cell plate 90
compartmentalized expression 90–91
differential expression 90
posttranscriptional 191–195
translational control 195–196
gene–gene interactions, liver disease and 372
Gene Ontology (GO) Consortium 407
generalized pustular psoriasis 1642
gene targeting experiments, QTL verification, mice 380
genetically modified animals
QTL analysis in inbred mice
functional testing using 380
HCC experiments 379
see also knockout animals
genetic instability, carcinogenesis 391–392
genetic polymorphism and liver disease 356–364
alcoholic liver disease 356, 357t, 358, 360t, 1142–1143, 1159
candidate gene approach 359
alcoholic liver disease 358
chronic hepatitis C
fibrosis risk and 357t, 358–359, 360t, 361, 381
IFN response and 357t, 358, 360t
drug-induced liver injury 1213
environmental interactions 361, 371, 372
genetic interactions 361
genome-wide association studies 359, 361–362, 361f
immune response genes *see* immunogenetics, liver disease
inflammation and 369
linkage disequilibrium 360, 361
non-alcoholic fatty liver disease 356, 357t, 360t, 1198, 1201
non-alcoholic steatohepatitis 356, 1198
primary biliary cirrhosis 357t, 358, 360t, 1073–1074
quantitative trait locus and 379
see also quantitative trait locus (QTL) analysis
study design and analysis 359–361
clinical endpoints 361, 362
controls 360
ethnicity and 360
follow-up genotyping 361
sample size 360
work flow 361–362, 361f
twin studies 358
validated markers 357t, 360t
definition 356, 362
selection 359
validation 359–360
see also individual markers
see also specific diseases
genetics and liver disease 356–383
complex (polygenic) diseases 371–383
approaches to study 372
diagnosis and 364
ethnicity/race and 360
goals of study 364
immune response genes *see* immunogenetics, liver disease
management and 364
monogenic diseases 372
mouse models *see* mouse models of human liver disease
pathology and 364
polymorphisms *see* genetic polymorphism and liver disease
see also individual diseases/genes; specific methods
genome-wide association studies 359
design 361–362, 361f
genome-wide haplotype analysis, QTL analysis in inbred mice 377t, 378
genotyping
follow-up 361
Gaucher's disease 1363
germander *(Teucrium chamaedrys)*, hepatotoxicity 1282t, 1284, 2110–2111
ghrelin 1689
Gianotti–Crosti syndrome 1806
giant cell arteritis 1698
giant cell hepatitis, acute liver failure 1300
giant cells 1709
giant mitochondria, alcoholic hepatitis 1150, 1150f
Giardia 1020
genome project 1024
intestinal epithelium, attachment to 1023–1024
life cycle 1022
giardiasis 1020–1029
clinical manifestations 1025
diagnosis 1025–1026
epidemiology 1020–1022
host defences 1024
laboratory findings 1026
pathophysiology 1023–1024
risk factors 1021, 1021t
treatment 1026
Gilbert syndrome 460, 1355–1356
colorectal cancer risk 1356
diagnosis 1356
genetic defect 1354, 1355–1356
jaundice 1352
postoperative 1949
pregnancy 1886
Gjedde–Patlak calculation, simplified 562, 564
glafenine, acute hepatitis induction 1234
Glasgow coma scale 741t
glass beads, gene array platforms 403
glass slides, gene array platforms 403
Gleevac 596
glibenclamide
hepatotoxicity 1242
prolonged hyperglycaemia induction 1737
gliclazide 1737
gliotoxin, fibrosis 597
glipizide 1737
Glissonian territories, venous drainage 5
Glisson's capsule 9, 16
Global Alliance for Vaccines and Immunization (GAVI), hepatitis B vaccination programme 912
globulin
cirrhosis 612
cirrhotic ascites 667
globus pallidus, hepatic encephalopathy 732, 733f
glomerular abnormalities
cirrhosis 1817–1818
liver disease associated 1816–1820, 1817t
glomerular filtration rate
angiotensin II 677
cirrhotic ascites, post-peritoneovenous shunting 695
hepatorenal syndrome 676, 712, 713–714
glomerulonephritis
chronic hepatitis B 871
liver disease associated 1816–1820, 1817t
glomerulus, immunoglobulin A deposits 329
glucagon
amino acid catabolism regulation 144
cirrhosis 1737–1738
glycogenolysis 130
hepatic blood flow regulation 76–77
insulin-like growth factor binding proteins regulation 1743
liver disease 1737–1739
portal hypertension pathogenesis 634–635
secretion 129–130
cirrhotics 1738
splanchnic blood flow modulation 634–635
tumour-associated hypoglycaemia 1745
urea synthesis regulation 183
glucagon-like peptide 1735
1,4-glucan-6-glycosyl transferase deficiency 1861
glucocorticoid receptor, hepatobiliary transport regulation 388
glucocorticoids
insulin-like growth factor-I regulation 1742
lipid storage disease induction 1248
plasma transport 1752
thyroid stimulating hormone suppression 1750
urea synthesis regulation 183
glucokinase (hexokinase IV) 91, 1370
gluconeogenesis (GNG) 130–131
across liver cell plate 91
cirrhosis 132
diabetes 131, 131f
insulin, effects of 129
measurement 130–131, 130f
post-overnight fast 131
regulation, efferent hepatic nerves 117–118
starvation 144
glucopalaeogenesis 145
glucose
blood concentration, across liver cell plate 91
cholangiocyte reabsorption 53, 113
glycogen storage disease type I 1373
incretin effect 1735
intolerance
assessment 1732
cirrhosis 1732–1733
liver disease 1732–1737, 1733f

glucose (*continued*)
metabolism 1680–1681, 1734
anaesthetic implications 1939–1940
fulminant hepatic failure 1839
neural regulation 116, 117–118, 118f
postabsorptive state 130–131
postprandial state 129–130
production
alcohol, effects on 1838
postprandial state 129–130
spontaneous bacterial peritonitis 763
uptake, postprandial 130
see also insulin
glucose-1-phosphate 1370
glucose-6-phosphatase 23–24, 1370–1371
across liver cell plate 91
deficiency 1861
glucose-6-phosphate 156, 1370
glucose-6-phosphate translocase mutations *see* glycogen storage disease (GSD), type Ib
glucose-alanine cycle 145
glucose carriers, hepatocytes 111
glucose-dependent insulinotropic peptide 1735
glucose loading test 1380
glucose-6-phosphate dehydrogenase deficiency 950
glucose-sensitive neurons, portal vein 119
α-glucosidase inhibitors, hepatotoxicity 1683
β-glucuronidase
brown pigment gallstones 1523
deficiency (mucopolysaccharidosis type 7) 2148
glue thistle *(Actractylis gummifera)*, hepatotoxicity 2111
GLUT-1 91, 113
GLUT-2 91, 110, 111, 111f
glutamate 181
glutamate dehydrogenase (GDH)
ammonia production 181
reversible enzymatic reaction 458
glutamatergic neurotransmission, hepatic encephalopathy 737
glutamic–oxaloacetic transaminase (GOT) *see* aspartate aminotransferase (AST)
glutamic–pyruvic transaminase (GPT) *see* alanine aminotransferase (ALT)
glutaminase 144
urea synthesis regulation 182
glutamine 730
ammonia-induced cerebral accumulation 730
ammonia production 181
macroautophagy regulation 149
metabolism 144
synthesis
ammonia detoxication 183–184
regulation 184
glutamine synthetase 144, 730
across liver cell plate 92
ammonia detoxication 183–184
protein tyrosine nitration 736
γ-glutamyl cycle 201
γ-glutamyl cysteine synthase 199, 1219
γ-glutamyl-cysteinyl glycine *see* glutathione
glutaric aciduria type 2 2137
glutathione (GSH) 198–206
biological functions 147, 200–201
antioxidant functions 200–201
cysteine storage 201
metal detoxification 200
Michael electrophile detoxification 200
thiol status maintenance 200
biosynthesis 199, 199f
cysteine availability 199
rate 199
regulation 199
cell death regulation 202–204
compartmentation 201–202
conjugation, acute hepatitis 1219
copper metabolism 226
degradation 199–200
depletion, liver disease 204–205
distribution 198
heavy metal excretion 238
hepatotoxicity 205
homeostasis 199–200
hydrogen peroxide reduction 201
ischaemia-reperfusion injury 39, 39f
mitochondrial *see* mitochondrial glutathione (mGSH)
oxidized (GSSG) 198
protective functions 1219
structure 198, 198f
synthesis 147, 198
transport 112
glutathione peroxidases 92, 201
glutathione peroxide (GPx1) 235
glutathione-*S*-transferases (GSTs)
across liver cell plate 92
bilirubin binding 170, 1354
cystic fibrosis 1340
drug metabolism 242t
glutathione synthetase (GS) 199, 199f, 1219
deficiency 199, 1221
gluten-free diet, coeliac disease 1629
glyceryl trinitrate, hepatic blood flow 77
glycine catabolism 145
glycogen 1681
function 1370–1371
hepatomegaly induction 1681
metabolism 1370–1371, 1371f
postprandial synthesis 130
storage
disorders *see* glycogen storage disease (GSD)
histological features 428
synthesis 130
glycogen branching enzyme (GBE) 1370
deficiency *see* glycogen storage disease (GSD), type 4
glycogenolysis
glucagon, effects of 130
neural regulation 116
glycogenolysis (GL) 130–131
cirrhosis 132
diabetes 131, 131f
post-overnight fast 131
glycogenosis with renal Fanconi syndrome (Fanconi–Bickel syndrome) 1375
glycogen phosphorylase 1370
glycogen storage disease (GSD) 1370–1376
children 1861
classification 1370–1371
type 0 1370, 1374–1375
type I 1371–1373, 1861
biological manifestations 1371–1372
clinical manifestations 1371–1372, 1861
diagnosis 1861
focal nodular hyperplasia 1863
genetics 1372
histology 1861
long-term outcome 1372
malignant transformations 1372
pregnancy 1372
treatment 1372–1373
vitamin supplementation 1373
type 1a 1861
hepatocyte transplantation 2038, 2039t
type 1b 1372, 1861
gastrointestinal complications 1372
treatment 1373
type 1d 1861
type 3 1373, 1861
diagnosis 1373
management 1861
muscular involvement 1373
pregnancy 1373
treatment 1373
type 3a 1861
type 3b 1861
type 4 135, 1374, 1861
clinical features 1374, 1861
diagnosis 1861
neonatal form 1374
type 9 1374
type 9a 1374
type 9b 1374
type 9c 1374
type 9d 1374
type 6 1373–1374
glycogen synthase 1370
deficiency 1370
glycolysis
across liver cell plate 91
anaerobic 157
cytosolic 156–158, 156f
definition 156
nicotinamide adenine dinucleotide reoxidation 157
glycoprotein
degradation 192f, 194
maturation 192f
synthesis 192f
glycyrrhizin 1451
Gnathostoma spinigerum 1062
gold salts, hepatotoxicity 1234
Goldstein syndrome (Scott-like syndrome) 2137–2138
Golgi complex 24, 24f
cis surface 24
function 24
protein processing/sorting 194
secretory vesicles 24
trans surface 24
Gomori stain, liver biopsy 491
gonadotrophins 1686–1687
haemochromatosis 1761
liver tumours 1763
gonadotropin-releasing hormone (GnRH) 1686
cirrhosis 1758, 1760
gonococcal perihepatitis 1003
G protein-coupled receptors, signal transduction 102–103, 105
GPx1 236t
grafts
children 1865
autoimmune response against 1867
dysfunction
chronic 2023
living donor liver transplantation 1981
postoperative function assessment 1998
Doppler ultrasonography 1998
rejection *see* liver transplantation, rejection
removal, living donor liver transplantation 1979
split liver transplantation 1973–1974
suitability 1965, 1965f
graft-vs.-host disease (GvHD) 1671–1679
acute *see* acute graft-vs.-host disease (aGvHD)
chronic *see* chronic graft-vs.-host disease (cGvHD)
cutaneous manifestations 1808
risk factors 1671t
ursodeoxycholic acid 1495
vanishing bile duct syndrome 1113t, 1116
viral infection *vs.* 1677
Gram-negative bacteria, sepsis-induced cholestasis 1491, 1946
granula (hydatid sand) 1048
granular cell tumours 1597
granulocyte colony-stimulating factor (G-CSF)
glycogen storage disease type 1 1373
hepatitis C treatment 775
hypersplenism 775
post-liver transplantation 775
granulocyte-macrophage colony-stimulation factor, glycogen storage disease type 1 1373
granulocytopenia, hypersplenism 773–774, 773f
granuloma(s) 428, 1709–1717
AIDS 1713
alveolar echinococcosis 1052
ascariasis 1059
brucellosis 1713
capillariasis 1066
caseating 1709, 1710f
cholestasis 1711–1712
classification 1709–1710
aetiological category 1709–1710
hepatic histology 1709
Crohn's disease 1628, 1714
diagnosis 1714–1715
dialysis patients 1656–1657, 1656f
disease states 1711–1714
doughnut (fibrin-ring) 428, 1709, 1710f, 1713
drug-induced 1229, 1710
foreign body 428, 1710
gastrointestinal disorders 1714
hepatitis C 1714
histoplasmosis 1015
Hodgkin's lymphoma 1714
idiopathic 1712–1713
immunosuppression 1712
presentation 1712
treatment 1712

immunological 1709
immunological diseases 1711–1713
infectious 1709, 1713–1714
inflammatory bowel disease 1714
lymphoma 1714
mycobacterial infections 1005
neoplastic 1710
non-caseating 1709, 1710f
pathogenesis 1710–1711, 1711f
CD4+ T cell accumulation 1711
effector phase 1711
fibrosis 1711
initiation 1710
pentastomiasis 1066
post-liver transplantation 1714
primary biliary cirrhosis 1076–1077, 1710, 1714
primary liver disease 1710
Q fever 1713
sarcoidosis 1709, 1711–1712, 1714
schistosomiasis 1713
syphilis 1007
systemic disease 1710
tuberculosis 1713
viral hepatitis 1714
visceral larva migrans 1062–1063, 1063f
Whipple's disease 1713
granulomatosis, tuberculosis 1005–1006
granulomatous cholangitis 425
autoimmune hepatitis 1094
primary biliary cirrhosis *vs.* 1485
granulomatous disease, pulmonary 1618–1619
granulomatous hepatitis
Bartonella henselae 1005
cardiac drug-induced 1613t
drug-induced 1229, 1229t
outcomes 1230
granulomatous lymphadenopathy, cat-scratch disease 1005
granulomatous peritonitis 670
granulomatous venulitis 1405
greasewood (chaparral), hepatotoxicity 1282t, 1285
greater celandine *(Chelidonium majus),* hepatotoxicity 1282t, 1284
griseofulvin, hepatotoxicity 1648
ground-glass hepatocyte 423
growth factors
cholangiocarcinoma 1587
hepatocyte proliferation 2088
vanishing bile duct syndrome 1112
growth hormone (GH) 1689, 1739–1742
Alagille syndrome 1741
cholangiocyte proliferation 54
cirrhosis 1740–1741, 1740f, 1909
clearance 1739
cirrhosis 1741–1742
deficiency 1690
effects 1689, 1740
haemochromatosis 1762
insulin-like growth factor binding proteins regulation 1743
insulin-like growth factor-II precursor forms (big IGF-II) 1745
liver disease 1740–1742
physiology 1739–1740
plasma transport 1739–1740
resistance 1741
secretion 1739, 1739f
pulsatile nature 1739
regulation 1739
tumour-associated hypoglycaemia 1745
urea synthesis regulation 183
growth hormone binding proteins 1739–1740
cirrhosis 1741
growth hormone-insulin-like growth factor system 1689–1690
alterations in, hepatic effects 1689–1690
physiology 1689
growth hormone receptors 1740
growth hormone-releasing hormone (GHRH) 1689, 1739
growth impairment, glycogen storage diseases 1372, 1374
growth-regulatory peptides, cholangiocyte replacement 284
growth retardation-alopecia-pseudoanodontia-optic atrophy (GAPO) 2138
guanosine 5'-triphosphate (GTP) 155
Guillain–Barré syndrome, hepatitis B 1826
gummas 1007
Gunn rats, Crigler–Najjar syndrome animal model 1355
gunshot injuries 1953, 1954
gustatory acuity, cirrhosis 1906
gut-associated lymphoid tissue (GALT), immunoglobulin A synthesis 326
gut-derived GABA hypothesis, hepatic encephalopathy 731
gynaecomastia
alcoholic cirrhosis 1165
cirrhosis 1758
haemochromatosis 1761–1762
management 1761–1762
liver tumours 1763

H

haem
acute porphyric crisis 1345
bilirubin formation 165–166
biosynthesis 206–213, 207f, 208f, 1343f
erythroid cells 210–212
hepatic 209–210, 210f
regulation 209–212
catabolism 209
deficiency, porphyric neuropathy 1345
degradation 165–166, 166f
haemangioendothelioma
epithelioid *see* epithelioid haemangioendothelioma (EHE)
hepatic *see* hepatic haemangioendothelioma (HHE)
haemangioma 1427–1428
capillary 537t, 1863
cavernous 537t, 1863
complications 1428
diagnosis 1427
drug-induced 1259t, 1260
giant 524, 1427
hepatic metastasis *vs.* 519, 524
imaging
computerized tomography 513–514, 514f, 515f, 1427
magnetic resonance imaging 524, 524f, 1427
ultrasonography 504t, 505, 1427
natural history 1427–1428
pathology 1427
pregnancy 1886
presentation 1427
prevalence 1427
spontaneous rupture 1428
treatment 1427–1428
haemangiomatosis 1428
disseminated 2130
haemangiosarcoma *see* angiosarcoma
haematemesis, acute fatty liver of pregnancy 1881
haematological diseases/disorders
childhood acute liver failure 1858
chronic hepatitis C antiviral therapy 950
effects of liver disease 1662–1670
effects on liver 1767–1779
erythrocyte abnormalities 1767–1768
leucocyte abnormalities 1770–1771
platelet abnormalities 1771
post-liver transplantation 1772–1774
viral-induced bone marrow aplasia 1769
see also individual *diseases/disorders*
haematoma
angiography 536
cystic transformation 817
dialysis patients 1656
posttraumatic 817
pre-eclampsia 1884
pregnancy 1884
subcutaneous 169
ultrasonography 505, 817, 1954
haematopoietic hormone production, fetal liver 1767
haematopoietic stem cell transplantation (HSCT)
cholestasis following 1673, 1673t, 1675–1677
causes 1673t
differential diagnosis 1676–1677, 1676t
complications 1676–1677
drug toxicity 1677
graft-vs.-host disease 1671t
varicella-zoster virus infection 960
haematoxylin and eosin, liver biopsy 491
haemobilia 1550–1560
accidental liver trauma 1552
treatment 1556–1557
aetiology 1550–1553, 1551t
changes in 1552f
biliary stone *vs.* 1554
clinical presentation 1554–1555, 1554f
venous *vs.* arterial 1554–1555
coagulation disorders 1553
complications 1554
cystic artery aneurysms 1552
differential diagnosis 1554
hepatic artery aneurysms 1552, 1552t
hepatobiliary surgery 1553
historical aspects 1550
iatrogenic liver trauma 1551–1552
diagnostic liver procedures 1551
treatment 1556
immune-compromised patients 1553
investigations 1555–1556
malignancy 1553
mortality 1558
pancreatitis 1553
pathophysiology 1553–1554
mixed clots 1554, 1554f
pure clots 1554, 1554f
treatment 1556–1557
surgery 1557
transarterial angiogram and embolization 1556, 1557
vascular anomalies 1553
haemochromatosis 1323–1329
adrenal hormones 1762
alcohol abuse 1169
androgen replacement therapy 1761–1762
classification 1323
clinical aspects 1325–1326
computerized tomography 512
cutaneous manifestations 446, 1811
definition 1323, 1323t
diabetes 1760–1761
diagnosis 1325–1326
elderly 1873
endocrine dysfunction 1760–1762
epidemiology 1325
genetics 1324, 1325
as monogenic disorder 372
QTL analysis in inbred mice 375–376
see also HFE gene/protein
growth hormone 1762
gynaecomastia 1761–1762
hepatocellular carcinoma 1439
HFE-related 1324, 1325
hypogonadism 1761–1762
iron overload 1324
juvenile 1324, 1325, 1326
liver biopsy 494, 496f, 1326
liver transplantation 1988
magnetic resonance imaging 529
neonatal *see* neonatal haemochromatosis
non-HE 1325
non-inflammatory fibrogenesis 585
osteoporosis 1762
pathogenesis 1324, 1325f
pregnancy 1886
prolactin 1762
proteins involved 1324
screening 1326
thalassaemia 1666
thyroid dysfunction 1762
treatment 1326
haemodialysis 1653–1657
haemorrhagic complications 1656
hepatitis B 1653–1655
prevalence 1654t
seroconversion rates 1654t
hepatitis B vaccine 911
hepatitis C 1655–1656, 1655t
seroconversion 1655, 1655t
hepatitis D 1655
hepatorenal syndrome, type 1 716
liver support 2043–2044
platelet dysfunction 1791
haemodynamics
assessment, portal hypertension 658–665
Budd–Chiari syndrome 1406
neural modulation 115
splanchnic 567–571
haemoglobin 220
haemojuvelin
haemochromatosis 1324
iron metabolism 223
juvenile haemochromatosis 1325
haemolysis
liver disease 1769
neonatal assessment 1353
post-liver transplantation 1772

haemolysis, elevated liver function and low platelets syndrome (HELLP syndrome) *see* HELLP syndrome
haemolytic anaemia(s)
black pigment gallstones 1523
effects on liver 1769
gallstone disease 1525
hepatic involvement 1666
post-liver transplantation 1772
spur cell 1770
haemolytic anaemia-polyendocrinopathy 2139
haemolytic crisis, Wilson's disease 1769–1770
haemolytic jaundice 169
haemolytic uraemic syndrome (HUS) 1882
haemoperfusion, liver support 2044
haemoperitoneum
angiosarcoma 1458
fibrosarcoma 1460
imaging 1954–1955
liver trauma 1954–1955
haemophagocytic histiocytes 1619, 1619f
haemophagocytic lymphohistiocytosis (HLH)
acute liver failure 1857–1858
neonates 1857–1858
primary form 1857
symptoms 1857
haemophagocytic syndrome 1491, 1619, 1619f
haemophilia
chronic hepatitis C antiviral therapy 950
hepatic involvement 1666
viral hepatitis 1666
haemorrhage 445
acute liver failure, children 1859
hepatic resection 1941
liver transplantation 1943, 1981
liver trauma 1954, 1957
portal hypertension 550
post-liver biopsy 495–496
spontaneous, infantile cholestasis 1845
variceal *see* variceal bleeding
haemorrhagic shock, bacterial translocation 762
haemorrhoids, rectal varices *vs.* 1802
haemostasis 255–264
disorders *see* coagulation defects/disorders
liver, role in 257
physiology 255–256, 255f, 1780, 1781f, 1782f
inactivation 256f
vitamin K 257
see also coagulation; fibrinolysis
haem oxygenase (HO) 165–166, 1352
forms 165–166
starvation 210
as vasorelaxant 83
haem oxygenase 1 (HO-1) 165, 209, 1352
hepatic encephalopathy 735
therapeutic delivery 1353
as vasorelaxant 83
haem oxygenase 2 (HO-2) 165, 209, 1352
as vasorelaxant 83
haem oxygenase 3 (HO-3) 165
hairy cell leukaemia 1664
sinusoids 427
'half ABC transporters' 385
halofuginone 597
haloperidol, hepatotoxicity 1234
halothane
acute liver failure, cause of 1299
contraindication in liver disease 1941
cytochrome P-450 system 1235
elderly 1872
hepatic blood flow 77
hepatotoxicity 1941
primary biliary cirrhosis 1073
halothane hepatitis 1235, 1946
immune attack 1222, 1223
immunoallergic 1226
risk factors 1949
HALT-C study, hepatitis C retreatment 950
hamartomas
biliary *see* biliary hamartomas
mesenchymal, children 1863
Hand–Schuller Christian disease (Langerhans cell histiocytosis) 1618–1619, 1645
'hanging manoeuvre,' hepatectomy 1935
haplotype analysis, QTL analysis in inbred mice 377t, 378–379, 378t
harderoporphyria 1348–1349
harmonic imaging techniques 501
Harris–Benedict equation 1638
hatching tests, schistosomiasis 1043
hazard ratio, prognostic models 2056
Hbe protein (HBeAg) *see* hepatitis B virus (HBV)
hCTR1 227, 227t
head-out water immersion, cardiac output 1721
healthcare policy, outcomes research 2065–2066
healthcare workers, hepatitis B vaccine 911
health limitations, liver transplantation quality of life 2030
health-related quality of life (HRQOL) studies *see* outcomes research
Health Utilities Index
health utility assessments 2067
quality of life 2082
health workers, chronic hepatitis B antiviral therapy 936
heart
carcinoid syndrome 1474
phosphorylase kinase deficiency 1374
systemic AL amyloidosis 1704
see also entries beginning cardiac
Heart and Estrogen/progestin Replacement Study (HERS) 1688
heart failure, hereditary haemorrhagic telangiectasia 1422
heart rate, cirrhosis 686
heat shock protein 32 (HSP-32) *see* haem oxygenase 1 (HO-1)
heat stroke
acute liver failure 1299
liver injury 1278
heavy metal transport, hepatocytes 112
Hedeoma pulegoides (pennyroyal), hepatotoxicity 1282t, 1285–1286, 2114
Heister valve 18
Helicobacter pylori, hepatic encephalopathy 747
Heliotropium, hepatotoxicity 1273, 1282t, 1283–1284
HELLP syndrome
acute fatty liver of pregnancy 1881
acute liver failure 1300
clinical features 1770, 1885t
haematological abnormalities 1770
herpes simplex virus infections 958
pregnancy 1770, 1884–1885
helminthiasis 1040–1067
hemihepatectomy, bile duct injury 1960, 1960f
heparan sulphate proteoglycan (HSPG) 78, 269–270
heparin
alanine aminotransferase levels 453
liver transplantation 1943
yellow fever treatment 998
hepar lobatum, metastatic breast carcinomas 1466, 1466f
HepatAssist 2046, 2046f
hepatectomy 1933–1937
anaesthesia 1941
analgesia 1941
Caroli syndrome 806
cirrhosis 1933–1935
anterior approach 1935
criteria for 1933
'hanging manoeuvre' 1935
intermittent inflow occlusion 1935
intraoperative technique 1934–1935
limited *vs.* anatomical resection 1933
liver transplantation *vs.* 1933
portal vein embolization 1934
postoperative liver failure 1935
contraindications
limited functional reserve (grade C) 1934, 1938
oesophageal varices 1934
cystic echinococcosis 1050
in fatty liver patients 1936
gallbladder carcinoma 1578
hepatic artery aneurysms 1393
hepatic metastases 1468
hepatocellular carcinoma 1446–1447, 1987
preoperative assessment 1447
pretransplant patients 1926, 1927t
recurrence rates 1447
intraoperative monitoring 1941
liver transplantation 1966–1967
nutritional support 1840
obstructive jaundice 1935–1936
preoperative percutaneous transhepatic biliary drainage 1935–1936
partial
alveolar echinococcosis 1053
ascariasis 1061
hepatic cysts, ADPKD 794
liver regeneration models 316
models, chronic liver damage regeneration 280
perioperative outcome/mortality
blood loss 1941
improvements in 1933
parenchymal damage 1933
portal vein embolization
cirrhotic patients 1934
obstructive jaundice 1936
postoperative liver failure 1935, 1936
assessment 1935
cirrhotic patients 1935
fatty liver patients 1936
reserve function
preoperative assessment 1933, 1934, 1934t
selection criteria and 1933
transplant recipient 1966–1967
tumour status and 1933
hepatic adenoma *see* hepatocellular adenoma (HA)
hepatic arterial buffer response 75–76
cirrhosis 76
hepatic arterial infusion chemotherapy, gallbladder carcinoma 1580
hepatic arterioles 79–80
blood flow regulation 80
hepatic arterioportal fistulae 1393–1394
hepatic arteritis, polyarteritis nodosa 1643
hepatic artery 79, 89
accessory 4, 1391
anatomy 4–5, 531–532, 549, 1391
aneurysms 1392–1393
aetiology 1392–1393, 1392f
angiography 538, 539f
classification 1392
clinical features 1393
diagnosis 1393
haemobilia 1552, 1552t
pathophysiology 1392–1393
rupture 1393
treatment 1393
atherosclerotic disease 538
blood flow measurement 568–569
buffer response 662, 1391
collateral pathways 532
common 4
development 69
diseases 1391–1394
dissections 1393
angiography 538–539
drug-induced intimal hyperplasia 1255–1256, 1255t
ductal plate malformations 69
embolization
carcinoid tumours 1476–1477
hereditary haemorrhagic telangiectasia 1422
hereditary haemorrhagic telangiectasia 1422
histological features 427
histology 15–16
hypoxic hepatitis, accidental ligation 1945
left 4, 532, 1391
middle 532, 1391
occlusion 1391–1392
aetiology 1391
clinical features 1392
investigations 1392
natural history 1391
pathophysiology 1391–1392
post-orthotopic liver transplantation lesions 1392
right 4, 532, 1391
stenosis, post-liver transplantation 1392
thrombosis
allograft 1392
post-liver transplantation 1981–1982, 2000, 2023
variations 4, 532, 532f, 532t, 1391

hepatic blood flow 75–88, 89
  age-related changes 1870
  anatomy 79
  arterial supply 4–5, 531–532
  β-adrenergic stimulants 77
  Budd–Chiari syndrome 1406
  changes, physiological conditions 75
  definition 567
  drug-induced effects 77
  effects of liver disease on 1724–1725
  hepatic clearance 1912
  hepatosplenic schistosomiasis 1042
  measurement 569, 662
    applications 662
  portal venous supply 5
  pregnancy 1879
  pressure flow autoregulation 75
  regulation 75–78
    humoral 76–77
    intrinsic mechanisms 75–76
    neural 76
    veno-arterial response 76
  values 569
  venous drainage 5
  see also specific vessels
hepatic carcinogenesis *see* carcinogenesis
hepatic clearance methods, hepatic blood flow measurement 569, 662
'hepatic crisis,' sickle-cell disease 1666
hepatic cystic diseases
  acquired 810–817
  congenital 781–809
  inflammatory 810–813
  neoplasms 813–816
  posttraumatic 816–817
hepatic ducts 18
hepatic encephalopathy (HE) 728–760
  acute 1825
  acute liver failure 728, 728t
    children 1859
    clinical manifestations 740–741, 740t
    investigations/tests 744
    management 1304–1305
    mechanisms 1132–1133
    neonates 1859
    prognosis 1301
    treatment 748
  anaesthetic implications 1940
  blood ammonia levels 458
  cerebral perfusion 1725
  chronic liver disease 740t
  chronic portal vein thrombosis 1397
  cirrhosis 608–609, 728–729, 728t
    investigations/tests 744–745
  classification 608t, 728–729, 728t
  clinical manifestations 608–609, 740–743
  definition 728–729
  diuretic-induced 692
  driving capacities 1902
  episodic *see* episodic (precipitant-induced) encephalopathy
  extrahepatic congenital portosystemic shunt 1419
  extrapyramidal abnormalities 741
  fulminant hepatitis 870
  grading 740
  hereditary haemorrhagic telangiectasia 1420
  intrahepatic congenital portosystemic shunt 1419
  minimal (subclinical) 728t, 729, 743
    treatment 750
  neurophysiological tests 744–745
  neuropsychological tests 745
  nutritional management 1839, 1908
  opioidergic neurotransmission 738
  pathogenesis 729–740
    ammonia 729–730
    astrocyte functional alterations 734–735
    astrocyte swelling 734–735
    brain water homeostasis 732–734
    current models 739–740, 739f
    energy metabolism 736
    gut-derived toxins 729
    neuroanatomical changes 731–732
    neurotoxins 730–731, 734–735
    neurotransmission alterations 736–737
    nitrosative stress 735–736
    oscillatory network disturbances 738–739, 738f
    oxidative stress 735–736
  persistent (chronic) 742–743
  post-TIPS 698
  quantifying 743–745
  renal tubular acidosis 1819
  Reye syndrome 1825
  signs 449
  TIPS-induced 743
  tracheal intubation 748
  treatment 745–748
    pretransplant patients 1925
    strategies 746f, 748t
  type B 729
hepatic endometriosis 810–811
hepatic excretory function markers 459–465
hepatic extraction
  cirrhosis 1913
  rate 1912
hepatic extraction fraction 469–470
hepatic glomerulosclerosis 1817, 1817f
hepatic haemangioendothelioma (HHE)
  angiography 537t
  children 1863
hepatic haemangioendotheliomas-hemihypertrophy 2138
hepatic hydrothorax 447
  ascites 724–725, 724f
  infected 724
  management, pretransplant patients 1923, 1928
hepatic infarction, dialysis patients 1656
Hepatic Injury Severity (HIS) scale 1954t
hepatic insulin sensitizing substance (HISS) 119
hepatic iron index (HII) 494
hepatic lipase 141
hepatic lobectomy
  biliary papillomatosis 1573
  haemobilia 1553
  intrahepatic gallstones 1533
hepatic lymphatics *see* lymphatics
hepatic metabolism *see* metabolism
hepatic microcirculation 79–84
  across liver cell plates 90
  blood flow regulation 80–81
hepatic microvascular subunits (HMS) 80, 80f
hepatic microvascular system 79–80, 79f
hepatic muralium 10
hepatic nerves
  afferent *see* afferent hepatic nerves
  efferent *see* efferent hepatic nerves
hepaticocholedochojuejunostomy 1969
hepaticojejunostomy
  haemobilia 1553
  sphincter of Oddi biliary-type dysfunction 1569–1570
hepatic osteodystrophy 1802
hepatic phosphorylase deficiency 1373–1374
hepatic progenitor cells 59–60, 282–283
  activation (ductular reaction) 59–60
    disease states 60
    triggers 60
  extrahepatic sources 284
  liver cancer 61–63, 62f
  localization 59–60, 59f
  see also oval cell(s)
hepatic radioactivity
  hepatic arterial blood flow measurement 569
  portal blood flow measurement 569
hepatic removal kinetics 468–479
  blood flow variations 474
  clearance *see* clearance
  first-pass elimination 474–475, 474f
  impaired liver-cell function 471f, 475
  liver disease 475
  liver function tests, quantitative 475–476, 475t
  Michaelis–Menten kinetics 468–469
  physiological complexities 474–475
  plasma, binding of 475
  saturation kinetics 474–475
  sinusoidal heterogeneity 474
hepatic resection *see* hepatectomy
hepatic stellate cell (HSC) 14–15, 15f, 43–51
  activation, fibrosis 590–594, 2089–2090
    chemotaxis 592
    fibrogenesis 592–593
    fibrosis 584
    inflammatory signalling 593–594
    inhibition 596–597
    initiation (preinflammatory stage) 591–592
    matrix degeneration 593
    nuclear receptor signalling 593
    pathways 591, 591f
    perpetuation 584, 592–594
    proliferation 592
    regulatory network mapping 2089–2090
    retinoid loss 593
    transcription regulation 594
    white blood cell chemoattraction 593–594
  anatomy 43–45, 44f
  as antigen-presenting cells 593
  apoptosis 597
  contractility 81
    endothelins 81
    fibrosis 593
    post-injury 631
  culture 45–46
  cytoplasmic processes 44, 44f
    intersinusoidal/interheptocellular 44
    perisinusoidal/subendothelial 44
  embryology 47, 69
  extracellular matrix homeostasis 48, 590
    fibrotic liver 590
  extrahepatic 48
  function 15
  historical aspects 43, 43f
  hyperplasia 428
  identification 46–47, 47t
  interaction with other cells 584
  intralobular heterogeneity 45, 46f
  isolation 45–46
  lines 47–48
  lipid droplets 44, 45f
    drug-induced accumulation 1246
  as liver-specific pericytes 48–49, 49f
  markers of 46–47
  microfilaments 45
  nomenclature 43
  radiation hepatitis 1277
  replacement 285–286
    acute liver injury 285–286
    chronic liver injury 286
    healthy livers 285
    neural regulation 119–120
  retinoid metabolism 45, 214
  retinoid storage 45, 214
  rodent *vs.* humans 47–48
  senescence, cirrhosis 586
  sinusoidal tone regulation 49, 81
  ultrastructure 43–45
hepatic vein(s) 5
  accessory 5
  catheterization 658
    technique 659–660
  compression, Budd–Chiari syndrome 1405
  disorders 1403–1417
  hepatosplenic schistosomiasis 1042
  inferior 5
  left 5
  middle 5
  obstruction/occlusion
    acute liver failure 1301
    Budd–Chiari syndrome 1407
    cirrhosis 583
    hepatoportal fluid flux 88
  right 5
  stenoses, Budd–Chiari syndrome 1406
  thrombosis
    Budd–Chiari syndrome 538, 538f
    cirrhosis complication 1793f
    congestive heart failure 1613
  traumatic injury 1953
hepatic venography 535
  Budd–Chiari syndrome 538
  complications 535
  indications 535
  technique 535
hepatic venous outflow block
  ascites 670–671
  polycystic liver disease, ADPKD 791f, 792t, 793
hepatic venous pressure gradient (HVPG) 568, 658
  alcoholic cirrhosis 1166
  alcoholic hepatitis 1163
  hepatitis C, progression indicator 661
  hepatocellular carcinoma, resection risk evaluation 661
  measurement 568, 658–660
    complications 662
    contraindications 662

hepatic venous pressure gradient (HVPG) (*continued*)
indications/applications 660–661
oesophageal varices 640, 643
bleeding, prognostic evaluation 661
treatment failure indicator 641
paracentesis-induced circulatory dysfunction 695
portal hypertension
therapeutic response assessment 661
therapeutic target 642
hepatic venules
terminal 80
thrombosis, cirrhosis 630–631
hepatic vessel suturing 1956–1957
hépatite alcoolique à cellules claires' 423
hepatitis
acquired hyperbilirubinaemia 1356
activity assessment, serum transaminases 1934
acute *see* hepatitis, acute
anicteric 1227
autoimmune *see* autoimmune hepatitis (AIH)
chronic *see* hepatitis, chronic
drug-induced cholestasis 1490
herbal medicines 1281–1282
histological features 429–430
immunogenetics 365t, 367–368, 370t
lichen planus 1643
Listeria monocytogenes 1002
subacute *see* subacute hepatitis
viral *see* viral hepatitis
hepatitis, acute
angiography 537
computerized tomography 512
drug-induced *see* drug-induced acute hepatitis
drug pharmacokinetics 1913
drug prescribing 1917
forms 1227–1229
gamma-glutamyl transpeptidase levels 464
hepatic blood flow 569
herpes simplex virus infections *vs.* 959
histological features 429
ultrasonography 501–502
vitamin B12 levels, serum 1769
hepatitis, chronic
alcoholic liver disease and 1154
autoantibodies 1252
cardiac drug-induced 1613t
computerized tomography 512
drug-induced 1214t, 1251–1253
drugs causing 1252–1253, 1252t
outcomes 1252
fibrosis risk, polymorphism and 357t, 358–359, 360t, 361
grading 435
osteoblast function 1831
pregnancy 1886
scoring systems 435
staging 435
thrombocytopenia 1771
treatment response, polymorphism and 357t, 358, 360t
ultrasonography 502–503
hepatitis A 857–864
acute liver failure 1296
antibody response 857
children 859, 1851
cholestatic 861
clinical features 859, 859t
complications 861
diagnosis 860
stools 860
elderly 1871
epidemiology 858–859, 858t
high risk groups 858
hygiene 858
within population distribution 858–859
USA 904t
fulminant 861, 917
geographical distribution 2100–2104t
historical perspective 857–858
HIV coinfection 982
immunogenetics 365t, 367, 370t
incubation period 857
laboratory features 859–860
management 861
post-exposure prophylaxis 862, 862t
supportive 861
neurological manifestations 1824t
outbreaks 858
passive immunization 861–862
pathogenesis 860
cellular immune responses 860
pathology 860
pregnancy 1887
prevention 861–862
hygiene 861
relapsing 861
seasonal infections 858
serology 860, 860f
transmission 858
faecal–oral route 858
vaccine *see* hepatitis A vaccines
virus *see* hepatitis A virus (HAV)
hepatitis A vaccines 861–862, 899–907
administration routes 899–900
children 1851
chronic liver disease 1903
combination 899
composition 899–900
cost-effectiveness 904–905
dosage 899–900, 900t
endemic countries 903
future uses 904
HIV infection 901
immunogenicity 900–901
antibody levels 900
inactivated 899–900
indications 903
outbreak control 903
postexposure administration 903
production methods 899–900
protective efficacy 900–901
children 901–902
duration 901–902
maternal passive transfer 900–901
response rates 901
recommendations 903, 903t
at-risk groups 903
routine programmes 902–903
schedules 899–900, 900t
universal programmes 904
tolerability 900
transplant recipients 901
two-dose schedules 901
hepatitis A virus (HAV)
cell culture 857
definition 857
genome 857
historical background 821
infectivity 857
hepatitis B 865–874
acute 834–835, 869–870
acute liver failure 1296
antibody titres 837f
anti-hepatitis B surface antigen antibodies 837
antiviral therapy 917
definition 865
diagnosis 869–870
disease course 869
fulminant hepatitis 870, 917
hepatocyte necrosis 868
onset 868
pathogenesis 868
physical signs 869
serology 869–870, 870f
viral persistance 868
Africa 2100t
alcoholic liver disease and 1169
Americas 2101t
aplastic anaemia 1667
apoptosis 341
arthritis–dermatitis prodrome 1806
Asia 867, 2102t
Australasia 2102t
children 1851
hepatocellular carcinoma development risk 1851
chronic *see* hepatitis B, chronic
cirrhosis
gene array data 409
hepatic venous pressures 568
classification 867–868, 867f
clinical course 834–836, 835f
clinical outcome 867
cutaneous manifestations 1806
definition 865
diabetes mellitus 1682
diagnosis 836–840, 865
anti-HbeAg antibody titres 837f, 838
asymptomatic infections 836
DNA detection 838, 839t
test programme selection 837t
elderly 1871
epidemiology 866
Europe 867, 2104t
fibrosis progression to cirrhosis 586
functional genomics 408t
gene array data 409, 410
proteomics data 413
geographical distribution 826f, 826t, 866–867, 2100t
glomerular abnormalities 1817t, 1818
Guillain–Barré syndrome 1826
haemodialysis 1653–1655
haemophilia 1666
hepatitis C coinfection 882
antiviral therapy 949
hepatitis D coinfection *see* hepatitis D, hepatitis B virus coinfection
hepatocellular carcinoma 1437
elderly 1874
gene array data 410
oncogene induction 393
proteomics data 413, 414
tumour suppressor inactivation 394
hepatocyte necrosis 868
histology 429
immune response, polymorphism and 369
immunopathogenesis 834–836
inapparent transient infection 835
infection, changing patterns of 866–867
iron metabolism, effects on 1769
Japan 867
leucocyte abnormalities 1770
liver transplantation
antiviral/antiretroviral drugs 2010–2011
immunoglobulin therapy 2011
lamivudine therapy 2010–2011
preoperative adefovir dipivoxil therapy 2011
recurrence after 934, 1927, 2010–2012
malaria 1033
Mediterranean area 866–867, 867
membranous neuropathy 1818
adults 1818
children 1818
MHC/HLA associations 365t, 367, 370t
Middle East 2103t
mixed essential cryoglobulinaemia 1806
neurological manifestations 1818, 1824t
non-Hodgkin's lymphoma 1664
North America 867
occult infection 840
pathogenesis 868–869
polyarteritis nodosa 1698, 1806, 1818, 1826
pregnancy 1887
pretransplant patients 1926–1927
reactivation 840
renal transplantation 1657
at risk groups 911
schistosomiasis 1042
scoring systems 436
serum sickness-like syndrome 1818
subclinical infection 837f
therapy
antiviral resistance 840
genotype effects 840
mutants, effects of 840
pretransplant patients 1927, 1928f
see also individual drugs
transmission 865–866
blood transfusions 865
non-sexual 866
parenteral exposure 865
perinatal 866
sexual 866
vertical 1851, 1887
vaccine *see* hepatitis B vaccine
virus *see* hepatitis B virus (HBV)
hepatitis B, chronic 835–836, 870–872
active infection 867–868
ANN fibrosis index 414
antibody titres 837f
antiviral drug-resistant mutants 922, 931–933
definition of 933
genotype resistance 931
long-term treatment 933
prevention/delay of 937
virological breakthrough 931
antiviral therapy 921–941
agents 924–927
animal models 924–925
CD8+ T cells 922
cell-culture models 924–925
children 936

combination therapy 926–927
extrahepatic manifestations 936
HbeAg-negative carriers 923, 930–931, 931t
HbsAg immunoactive carriers 922
HbsAg immunotolerant carriers 922–923
HbsAg inactive carriers 923
health workers 936
immune response restoration 922
immunomodulation 925
liver transplantation 934
maintained response 923f
monitoring 933
pathobiology 921–922
pregnancy 936
relapse 924, 924f
response 923–924
TH1 response 922
treatment algorithm 936f
viral clearance 922
viral persistence 922
wild-type virus (HBeAg-positive) 923, 927–930, 927t
see also specific antivirals
autoantibodies 871
children 871
cirrhosis 871, 933–934
definition 865
disease course 871–872, 871f
drug prescribing 1918
extrahepatic manifestations 936
gene array analysis 409
hepatitis C *vs.* 409
glomerulonephritis 871
HBeAg-negative 870–872
HBeAg-positive 870
HBs antigenaemia 835
hepatocellular carcinoma 872
genome integration 872
immune responsiveness 871
immune tolerance 835–836, 867
inactive infection 868
laboratory tests 871
occult 868
pathogenesis 868–869
neonates 869
proteomics data 413, 414
reactivation, acute liver failure 1296–1297
serology 871f
staging 871
symptoms 871
T-cell tolerance 836
viral replication 869
hepatitis B core antigen (HBcAg)
antibody titres during infection 838–839
hepatitis B vaccine 909
hepatitis B surface antigen (HBsAg)
antibody titres during infection 836–838, 837f, 839–840
acute infections 837
clinical sensitivity 837
false negative results 838
as prognostic factor 837
vaccination 840
escape mutants 840
HIV–hepatitis B coinfection 976
identification 865
malaria 1033
hepatitis B vaccine 907–916
acute liver failure prevention 1303
acute lymphoblastic leukaemia 910
anti-hepatitis B surface antigen antibodies 840
autoimmune diseases 910–911
blood product recipients 911
booster doses 910
chronic infection 925
chronic liver disease 1903
contraindications 910
current status 913, 913f
economics 913
efficacy 910
antibody testing 910
immune response 910
elderly 1871
haemodialysis patients 1654
hepatocellular carcinoma prevention 1450
high-risk group targeting 911–912
immunization strategies 911–913
injection safety 911
liver transplantation 2011
macrophagal myofasciitis 910
multiple sclerosis 910
neonates, HBsAg-positive mothers 1887
neurological manifestations 1824t, 1826
in pregnancy 911–912
preparations 907–910, 908t
adjuvants 909–910
combination 908–909
DNA vaccines 909
experimental 909–910
HBcAg as carrier 909
plasma-derived 907–908
preS epitope addition 909
recombinant 908
programme sustainability 913
renal transplantation 1657
safety issues 910–911
public confidence 911
schedules 908–909, 909t
birth dose 909
catch-up strategies 908
four-dose 909
thiomersal 911
universal vaccination 911, 912–913
Italy 912
Taiwan 912
WHO recommendations 912
hepatitis B virus (HBV) 823–840
carcinogenesis 393, 394
core protein 825–827
immunodominant epitope 826
Dane particles 823
DNA 824–825
closed form 825
DNA polymerase 829–830, 830f
resistance 830
reverse transcriptase domain 829–830
ribonuclease (RNase H) 829–830
terminal protein 829–830
genome 823, 827f
covalently closed form 825, 828f, 833
host genome integration 836
maturation 834f
sequencing 865
genotypes 824, 825t, 866–867
therapy prognosis 840
Hbe protein 827–828
conservation 827–828
function 827, 828
replication 827
historical background 821, 823
discovery 823
immunoglobulin, neonates 1887
incomplete particles 865
life cycle 831–836, 832f
attachment 833
entry 833
morphogenesis 833–834
replication 833–834
transcription 833
translation 833
L-protein 830–831
core particles 831
M-protein 830–831
mutations 866–867
S-protein 830–831, 831f
structure 823–831, 824f, 865
subgenotypes 824, 826t
subtypes 825t
geographical distribution 826f, 826t
subviral particles 831
structure 824f
surface proteins 830–831
see also specific proteins
taxonomy 823–824
phylogenetic tree 825f
hepatitis B virus X protein (HBx) 828–829
functions 828–829
hepatocellular carcinoma 393, 872
oncogene induction 393, 829
TP53 inactivation 394
hepatitis C 881–892
acute *see* hepatitis C, acute
acute liver failure 1297
adaptive immunity 854–855
B-cell suppression 855
T-cell suppression 855
Africa 2100t
alcoholic consumption 1133
alcoholic liver disease and 1154, 1169
Americas 2101t
apoptosis 341
Asia 2102t
Australasia 2102t
autoimmune hepatitis and 1124
children 1851–1852
natural history 1852
prevalence 1851
chronic *see* hepatitis C, chronic
cirrhosis 881–882
autoimmune hepatitis-related *vs.* 410
gene array data 409
clinical course 849
clinical outcomes 884–890, 885f
definition 881–882
dermatological disorders and 1806–1807
diabetes mellitus 1682
diagnosis 855, 881, 883–884
algorithms 885f
antiviral antibodies 883
children 1852
genotype determination 855–856, 884
immunoglobulin M assays 855
occasional screening 884
quantitative RNA assays 855
transcription-mediated amplification 855, 884
viral components 855, 884
elderly 1872
epidemiology 882–883
high-risk groups 882, 882t
incidence 883
prevalence 882–883, 882f
essential mixed cryoglobulinaemia 1667
Europe 2104t
extrahepatic disorders 881
fibrosis progression to cirrhosis 585–586
functional genomics 408t
gene array analysis 407–409
proteomic analysis 412–413
geographical distribution 881, 882f, 2100t
glomerulonephritis 1817t
granulomas 1714
haemodialysis 1655–1656
haemophilia 1666
hepatocellular carcinoma 849, 881, 1437, 1438, 1987
elderly 1874
gene array data 409, 410–411
oncogene induction 393
prevention 1450
proteomic data 412–413
risks of 1438
tumour suppressor inactivation 394
histology features 429
idiopathic immune thrombocytopenia 258
incubation period 849, 850f
innate immunity 854
interferon resistance 854
signal transduction interference 854
iron metabolism, effects on 1769
leucocyte abnormalities 1770
lichen planus 1807
liver transplantation
contraindications 1990
living donor 1992
recurrence after *see* liver transplantation, hepatitis C recurrence
lymphoproliferative disorders 1772
MHC/HLA associations 365t, 367, 368, 370t
Middle East 2103t
natural history 884–890, 885f
non-Hodgkin lymphoma 1772
polyarteritis nodosa 1806–1807
porphyria cutanea tarda 1807
pregnancy 1887–1888
pretransplant patients 1927–1928
prevention 883t
renal disease 1818–1819
renal transplantation 1657–1658
sarcoidosis 1714, 1807
schistosomiasis 1042
serology 849, 850f, 855
Sjögren syndrome 1697, 1806
therapy
children 1852
dialysis patients 1656
post-exposure prophylaxis 920
post-liver transplantation recurrence 2012, 2013–2014
pretransplant patients 1927–1928, 1928t

hepatitis C (*continued*)
response, proteomic analysis 412
transmission 849, 883
blood products 883
intravenous drug use 883
nosocomial 883
solid organ transplantation 1657–1658
vertical 1887–1888
type 2 mixed cryoglobulinaemia 1818
vanishing bile duct syndrome 1115
virus *see* hepatitis C virus (HCV)
hepatitis C, acute
alanine transaminase 886
antiviral therapy 917–920, 920t
duration 919
early treatment 918
efficacy 918–919
genotype effects 920
interferon-α 917
postexposure prophylaxis 920
schedules 918
studies 919t
timing 919–920
wait-and-see strategies 920
chronic, progression to 886
definition 881
diagnosis 884, 884t
fulminant hepatitis 886
gene array analysis 407–409
histology 886
natural history 885–886
liver damage 886
viraemia persistence 886
outcome profiles 886, 886f
spontaneous clearance 920, 920t
hepatitis C, chronic 849, 887–888
acute, progression from 886
age, therapy predictor 947
alanine transaminase levels 887–888
antiviral therapy 941–956
adherence to 948
alanine aminotransferase levels 948
autoantibodies 949
autoimmune disease 945
cerebrovascular disease 945
cessation 947
children 949
Child–Turcotte–Pugh score 949
cirrhosis 948–949
combination therapy 944
comorbidities 950
contraindications 944–945
dermatological disease 945
diabetes 950
drug resistance 951–952
early virological response (EVR) 943
end-of-therapy virological response (ETR) 941
genotype-specific schedules 944
haematological disorders 950
hepatitis B coinfections 950
historical aspects 941
ischaemic cardiac disease 945
mixed cryoglobulinaemia 949–950
Model for EndStage Liver Disease score 949
monitoring 944
National Institutes of Health recommendations 943
new treatments 951–952
patient choice 948–950
polymerase inhibitors 951
pregnancy 944
protease inhibitors 951
protocols 943–944
rapid virological response (RVR) 943
renal disorders 950
response detection 942–943
response predictors 947, 947t
retinopathy 945
retreatment 950–951
schedules 944t
serology 944
side-effects 945–947, 945t, 946t
transcription-mediated amplification assays 943
treatment response, polymorphism and 357t, 358, 360t
see also specific antiviral drugs
autoantibodies 485
biochemically active 887
children 890, 1852
cirrhosis 881–882
clinical course, renal transplants 889
compensated cirrhosis 887
staging of 887
compensated phase 887–888
definition 881, 887
diabetes mellitus type 2 887
diagnosis 884
drug prescribing 1918
endstage liver disease 888–889
ethnicity, therapy predictor 947
extrahepatic manifestations 889, 889t
fibrosis risk, polymorphism and 357t, 358–359, 360t, 361, 381
fibrotic progression 887, 888t
gender, therapy predictor 947
gene array analysis 409
hepatitis B *vs.* 409
hepatitis B coinfection 882
hepatocellular carcinoma 888
HIV coinfection *see* HIV–hepatitis C coinfection
immune complex disorders 889
liver biopsy 493f, 888
management 890
alcohol avoidance 890
fibrosis monitoring 890
intravenous drug users 890
staging 890
membranoproliferative glomerulonephritis 889
metabolic abnormalities 887
mixed cryoglobulinaemia 889
non-Hodgkin's lymphoma 889
obesity 887
palpable purpura 889
polymorphism and
fibrosis risk 357t, 358–359, 360t, 361, 381
treatment response 357t, 358, 360t
scoring systems 434–435
history of 434–435
steatosis 887
vasculitis 889
viral loads, therapy predictor 947
hepatitis C virus (HCV) 849–857
carcinogenesis 393, 394
clearance, gene array studies 408–409
E1 core protein 850
E2 core protein 850
fibrogenic activity 594
genome 849–851, 850f
open reading frame 850
translation 850
genotypes 849, 881
therapy predictor 947
historical background 821–822
immune response, polymorphism and 369
immunoglobulins 1772
model systems 853–854, 853f
infectious particles 854
'minivariants' 853
pseudoparticle system 854
NS2/3 protease 850
NS3/4A protease 854
NS5A protein 850
P7 protein 850
particle structure 851–852, 852f
platelet abnormalities 1771
receptors 852
replication 852–853, 852f
cell binding 852
hepatocytes 852
lymphocytes 852
membranous web 852f, 853
receptors 852
translation 853
replicative form 852f, 853
subtypes 849
translation 850
hepatitis D 875–881
acute liver failure 1297
anti-HD antibodies 844
atypical acute 878
chronic 878–879
autoantibodies 485
HIV coinfection 879, 982
diagnosis 843–844, 876
antigen detection 876
solid-phase immunosorbent tests 876
disease course 843–844, 877–879
drug addicts 877
elderly 1871
epidemiology 876–877
changes in 877
Europe 877
fulminant hepatitis 870, 878
haemodialysis 1655
hepatitis B virus coinfection 843–844, 870, 875
acute liver failure 1297
definition 875
disease course 875f, 877–878
liver transplantation 935–936
transmission 875
treatment 934–936
virulence dependence 875
histology 429
immunoglobulin M anti-HD antibodies 844, 876
Mediterranean region 878–879
natural history 875
North America 877
pregnancy 1888
renal transplantation 1657
RNA detection 844
superinfection 844, 875–876
acute liver failure 917
antibody response 878
clinical presentation 878
definition 875
disease course 875f, 876, 878
hepatitis B clearance 878
liver failure 878
transmission
parenteral 876
sexual 876
hepatitis D virus (HDV) 841–844
genome
replication 843, 843f
structure 841, 842f
genotypes 842
disease course effects 842
HD proteins 841–842, 842f
assembly 843
immunogenicity 842
replication 843, 843f
genome expression 843
host/organ tropism 843
ribozyme activity 841
RNA editing 841
structure 841, 841f
taxonomy 841
hepatitis E 893–899
acute liver failure 1297
antibody response 895
case-fatality rates 894
children 1852
clinical features 894
signs 894
symptoms 894
definition 893
diagnosis 894
epidemiology 896–897
endemic regions 896–897
geographical distribution 896, 2100–2124t
nonendemic regions 897
travellers 897
experimental models 895
humoral immune response 896
incubation period 894
pathogenesis 895–896
pathology 894–895
pregnancy 917, 1888
prevention 897–898
self-limiting course 894
transmission
blood transfusions 897
faecal–oral route 896
vertical 1888
treatment 894
vaccines 897–898
hepatitis E virus (HEV) 893–894
genome 893, 893f
genotypes 893–894, 894t
morphology 893
reservoirs 897
hepatitis F virus (HFV) 822
hepatitis G virus (HGV)
acute liver failure 1297
historical background 822
HIV coinfection 982
pregnancy 1888
Hepatitis Quality of Life Questionnaire 2067
hepatitis syndrome of infancy *see* infantile cholestasis
'hepatobiliary cells' 68
hepatobiliary disease
investigations 441–580
post-intestinal bypass surgery 1630
hepatobiliary trauma 1953–1962
hepatoblast(s) 65
differentiation 67–68, 67f
proliferation 66–67

hepatoblastomas
angiography 537t
children 1864
drug-induced 1259t, 1261
histology 1864
human chorionic gonadotrophin 1763
imaging 1864
liver transplantation 1988
presentation 1864
progenitor cells 62
treatment 1864
hepatocellular adenoma (HA) 1430–1432
angiography 537t
clinical features 1431, 1431t
computerized tomography 515–516, 1432
cystic 815
definition 1430
diagnosis 1258–1259, 1431
drug-induced 1258–1259, 1259t, 1431, 1688–1689
epidemiology 1431
glycogen storage diseases 1372, 1373
intramural haemorrhage 515
magnetic resonance imaging 524
malignant transformation 1431
natural history 1431
pathogenesis 1431
pathology 1431
regression 1431
rupture 1432
treatment 1432
ultrasonography 505
hepatocellular bilirubinostasis 425
hepatocellular carcinoma (HCC) 1437–1456
aflatoxin-induced 1274, 1439, 1450
alcohol-related 1141–1142, 1142t
cirrhosis 1153, 1171
dose–effect relationship 1171
elderly 1873
hepatitis B in 1885
screening 1171
anabolic steroid-induced 1260, 1439, 1688
angiography 537t
animal models 61
apoptosis 341
arterial hypervascularization 506, 506f, 517
biliary hamartomas 798
biochemistry 1442
biomarkers
gene arrays and 411
proteomics and 413
Budd–Chiari syndrome 1407
carcinogenesis *see* carcinogenesis
children 1864
chronic liver disease 1933
cirrhosis 391, 395–396, 608, 1438, 1439–1440, 1933
imaging 612–613
clinical manifestations 1441–1442
computerized tomography 517–518, 518f, 815, 1443
cutaneous manifestations 1808–1809
cyproterone acetate 1649, 1658–1659
cystic 815
diabetes mellitus 1682–1683
diagnosis 1442–1443
algorithm 1445f
diffuse type 1441
distinctly nodular type 1441
drug-induced 1259t, 1260
dysplastic nodules 1440
early 1441
elderly 1874
epidemiology 1437–1438
geographical differences 1437
erythrocytosis 1762–1763
expansive type 1441
fibrolamellar 518, 518f
functional genomics 408t
gene array data 409, 410–411
proteomic data 412, 413, 414
QTL analysis in inbred mice 379–380
future developments 1451
genetic basis 395f, 1440
genetic instability 391–392
heterogeneity and 379
oncogenes 392–393, 392t
tumour suppressors 393–395, 394t
glycogen storage diseases 1372, 1373
grading 1440
growth/progression 391
hepatic venous pressures 568
hepatitis B-related 872, 1437, 1933
children 1851
elderly 1874
gene array data 411
genome integration 836
proteomics data 413, 414
hepatitis B virus X-gene product 872
hepatitis C-related 849, 881, 888, 1933, 1987
gene array data 409, 410–411
proteomic data 412–413
heterogeneity 379
human chorionic gonadotrophin 1763
hypercalcaemia 1763
hyperthyroidism 1763
incidence 1987
indistinctly nodular type 1441, 1442f
infiltrative type 1441
intrahepatic cholangiocarcinoma *vs.* 1597
liver biopsy 497f, 498
liver sinusoidal endothelial cells 32
liver transplantation 1447–1448, 1987–1988
adjuvant interventions 1926
follow-up protocol on waiting list 1926
indications 1922
Model for EndStage Liver Disease 1988
survival rates 1987
magnetic resonance imaging 525–526, 526f, 527f, 1443
cirrhosis *vs.* 525–526
cystic 815
vascular invasion 525
malignant cells 1440–1441
malignant transformation predictors 1443
mouse models 379–380
NF-κB 106, 316
non-alcoholic fatty liver disease 1202–1203
oral contraceptive-induced 1260, 1439, 1689
p53 signalling pathway 279
pathogenesis 1440
pathology 1440–1441, 1441f
percutaneous treatment 551–555
positron emission tomography 564
pregnancy 1886
prevention 1450–1451
primary biliary cirrhosis 1075, 1439
primary sclerosing cholangitis 1627
progenitor cells 61–62
prognostic prediction 1443–1446, 1445t
resection 1446–1447, 1926, 1987
retinoid deficiency 217
risk factors 61, 62f, 1438–1440
HBV, children 1851
liver disease activity 1440
screening 1442–1443, 1444f, 1902
patient selection 1442–1443, 1443t
seeding, post-biopsy 497
spread 1441
staging 1442–1443
systems 1444, 1445t
symptoms 1441–1442
telomere shortening/senescence 279
testosterone 1763
thyroid hormones 1749
toxin-induced 1270t
treatment 1446–1450
algorithm 1446f
curative 1446–1448
feasibility 1446
future agents 1450
palliative 1448–1450
percutaneous 1448
retinoids 217
systemic 1450
transplantation *see above*
tumour burden evaluation 1446
tumour markers
gene arrays and 411
proteomics and 413
tumour necrosis factor 316
ultrasonography 504t, 506, 506f
vascular invasion 1441
very early (carcinoma *in situ*) 1444
vitamin D receptor expression 218
hepatocellular cholestasis 1484–1485
drug-induced 1241–1242
inflammatory 1491
hepatocellular damage
extrahepatic biliary obstruction 1501–1502
markers 451–454
hepatocellular liver injury *see* cytolytic hepatitis
hepatocellular tumours
benign 1428–1436, 1428t
malignant 1437–1456
see also individual types
hepatocerebral degeneration 732
hepatocyte(s) 10–12, 96–101, 96f
acute fatty liver of pregnancy 1882
adaptive immune response 106
adherens junctions 22, 97
age-related changes 1870
alcoholic hepatitis 341, 1141, 1149f, 1150
apoptosis 335–347
arrangement 10, 10f, 12f
atrophy 424
basolateral membrane
biliary solute uptake 385–386
endocytosis 27
bile flow impairment 386, 387f
see also cholestasis
bioreactors 2045–2046
canalicular (apical) membrane 11, 12f, 13f, 22–23, 96, 385–386
bile secretion 296–297
biliary solute uptake 385
inherited transport defects 1383–1385, 1383f
lipid composition 23, 96
cancer and 391
see also carcinogenesis; *specific cancers*
cell–cell junctions 97
see also specific junctions
cell cycle 391
cell polarity 96
protein trafficking 96, 97f
cytokine receptors 312–313
proinflammatory 106
signalling networks 313
tumour necrosis factor family 313
see also specific receptors
cytoplasm 12
desmosomes 22, 97
development 65
differentiation 67, 67f
feathery degeneration 423
functions 89
gap junctions 22, 97
communication 93
signal transduction 97
glycogen content 12
ground-glass 423
heat stroke 1278
hepatitis C virus 852
hepatocellular carcinoma 1440–1441
hormone receptors 93
hypertrophy 282
injury 60
innate immune response 106
intermediate 60
intracellular vesicles 27, 27f
isolated 122–123
junctional complexes 11, 22, 22f
lateral membrane 11, 21–22
junctional complexes 22, 22f
liver function models 122–123
malaria 1031
maturation 68
metabolic disease 2039t
microvilli 20f, 21
mitogen-activated protein kinases 104
necrosis *see* necrosis
nucleus 12, 20f, 22f, 24f, 27
inclusions 27
organelles 12, 23–27
morphometric data 13f
volumes 20t
see also individual organelles
plasma membrane 20f, 21–23, 22f
receptors 93
polyploidy 282
progenitor cells
extrahepatic 284
hepatic 282–284
see also oval cell(s)
prolapse 427
proliferation 281–284, 2088–2089
acute injury 281–282
chronic injury 282
cytokines 2088
growth factors 2088
healthy liver 281

hepatocyte(s) (*continued*)
neural control 119
regulatory network mapping 2088–2089
transforming growth factor-α 2088, 2089, 2089f
vascular endothelial growth factor 2089
protection, ursodeoxycholic acid 1494
receptor-mediated endocytosis 98–99, 99f
replacement 281–284
retinoid metabolism 214
retinoid storage 214
selenium deficiency 235
signalling 93
calcium oscillations 93
sinusoidal (basal) membrane 10–11, 13f, 21, 96
biliary solute uptake 385
lipid composition 96
'stem cell' properties 59
stress-related replicative senescence 282
Toll-like receptors 106
transplantation *see* hepatocyte transplantation
transporter proteins *see* transport proteins
transport systems 110–113
amino acids 111–112, 142–143
bile salts 112f, 113, 385
chloride–bicarbonate exchanger 111, 111f
copper 112, 227t
drugs 112–113, 112f, 242–243, 244t
electrolytes 111f
glucose 111
glutathione 112
heavy metals 112
nucleosides 112
solutes 111f
ultrastructure 20–28, 20f
hepatocyte-contacting processes 44
hepatocyte growth factor (HGF)
antifibrotic activity 595
hepatoblast proliferation 66
hepatocyte proliferation 2088–2089, 2089f
liver regeneration 316
liver sinusoidal endothelial cells 32
hepatocyte nuclear factor 1α (HNF1α) 68, 301t, 387
hepatocyte nuclear factor 1β (HNF1β) 68, 69
hepatocyte nuclear factor 3 (HNF3) *see* forkhead-box-factors
hepatocyte nuclear factor 4α (HNF4α) 67, 68, 301t
hepatocyte nuclear factor 6 (HNF6) 67, 69
hepatocyte transplantation 2032–2043
acute liver failure 2036–2037, 2036t, 2037t
models 2033
number of cells 2039
animal sources 2035–2036
pig hepatocytes 2035–2036
virus transfer 2036
cell lines 2036
cell preparation 2034–2036
hepatocyte isolation 2034
chronic liver failure 2037, 2038t
clinical experience 2036–2038
cryopreservation 2032
engraftment sites 2033
liver parenchyma 2033
peritoneal cavity 2033
subcutaneous tissue 2033
genetic modification 2032
human hepatic growth factor expression 2040f
rejection prevention 2032
historical overview 2032–2033
human cell sources 2034–2035
adult hepatocytes 2034–2035
cadaver livers 2034–2035
fetal hepatocytes 2035
liver stem cells 2035
mesenchymal stem cells 2035
'oval cells' 2035
serial transplantation 2034
metabolic disorders 2032–2033, 2038, 2039
number of cells 2039–2040
rationale 2032
spleen 2033, 2034
techniques 2033–2034
newborns 2033–2034
hepatoduodenal ligament 4
hepatoerythropoietic porphyria (HEP) 1347, 1349, 1811
hepatogastric ligament 4
hepatoiminodiacetic acid (HIDA) scans, post-cholecystectomy bile duct injury 1959
hepatolithiasis *see* recurrent pyogenic cholangitis (RPC)
hepatoma
cell lines, liver function models 123
toxin-induced 1274
hepatomegaly
alveolar echinococcosis 1052
ascariasis 1059
carcinoid tumours 1472
cystic fibrosis 1339
Gaucher's disease 1361, 1363
glycogen-induced 1681
glycogen storage disease type 6 1373–1374
histoplasmosis 1015
hyperlipoproteinaemia 1367
juvenile rheumatoid arthritis 1696
myeloid metaplasia 1665
systemic lupus erythematosus 1694
Wolman disease 1366
hepatoportal microvascular fluid flux
extrahepatic causes 87
pathophysiology 88
intrahepatic causes 88
hepatoportal sclerosis 427
drug-induced 1257
hepatoprotectants, fibrosis 595
hepatopulmonary syndrome (HPS) 720–722
anaesthetic implications 1939
biliary atresia 1848
cirrhosis 606, 722
clinical features 606, 720
comorbidities 721
continuous oxygen, pretransplant patients 1924
diagnosis 606, 720t
extrahepatic congenital portosystemic shunt 1419
hypoxaemia 720
liver transplantation
contraindications 1989
postoperative management 1999
preoperative assessment 1996
preoperative management 1924
patent ductus venosus 1419
pathophysiology 722
physical examination 720
prognosis 722, 722f
pulmonary circulation 1726
pulmonary vascular dilatations 720
treatment 606, 722
hepatorenal ligament 4
hepatorenal reflex (HRR) 76
hepatorenal syndrome (HRS) 711–719
anaesthetic implications 1939
arterial underfilling 711
ascites 711–712
cardiovascular function 713
cirrhosis 605–606, 676
classification 608t
clinical findings 711–713
definition 711
diagnosis 713–714
algorithm 714f
differential diagnosis 714
laboratory findings 711–713
liver function 713
management 715–717
pretransplant patients 1924, 1928
pathogenesis 684–685, 711, 712f
peritoneovenous shunting 697
postoperative liver transplantation 1999
precipitating factors 712
prevention 717
prognosis 606, 676, 677f, 714–715
renal function 712–713
renal vasoconstriction 684–685
renin 678f, 679
type 1
clinical findings 712
laboratory findings 676, 712
management 715–716, 715t
presentation 676
prognosis 712, 713f, 714, 715f
type 2
clinical findings 712
diuretic-resistant ascites 692
laboratory findings 676, 712
management 716–717, 717t
prognosis 712, 713f, 714–715, 715f
hepatosplenic candidosis
clinical features 1012, 1013t
diagnosis 1012–1013
prognosis 1013
treatment 1013
hepatosplenic gamma/delta T-cell lymphoma 1664
hepatosplenomegaly
relapsing fever 1007
vanishing bile duct syndrome 1116
hepatosteatosis *see* steatosis
hepatotoxic drugs/hepatotoxicity
definition 983
marketing 1211–1212
multiplicity 1213
readministration 1216
see also drug-induced liver injury; *individual drugs*
hepcidin
Dcytb regulation 224
DMT1 regulation 224
ferroportin interactions 224, 1324
hereditary haemochromatosis 224
hypoxia 223
inflammation 223
iron metabolism 223–224
juvenile haemochromatosis 1324
mutations 224
hephaestin 222–223, 222f
Hepp–Couinaud biliary reconstruction, bile duct injury 1960f
herbal medicines
acute liver failure 1298
hepatitis 1281–1282
hepatotoxicity 1281–1288, 1282t
diagnosis 1286, 1286t
mechanisms 1281–1282
risk factors 1282
pharmacovigilance 1281
primary biliary cirrhosis *vs.* 1077–1078
regulation 1281
see also individual types
hereditary coproporphyria (HC) 1344t, 1346
aminolaevulinic acid 1344
cutaneous manifestations 1811
diagnosis 1344
genetic defect 1346
homozygous 1348–1349
inheritance 1345
liver cell carcinoma, risk of 1346
penetrance 1345
photosensitivity 1347
porphobilinogen 1344
hereditary fibrinogen amyloidosis 1705, 1707
hereditary fructose intolerance 1860–1861
diagnosis 1861
symptoms 1861
hereditary haemochromatosis *see* haemochromatosis
hereditary haemorrhagic telangiectasia (HHT) 1419–1422, 1491
associated conditions 1421–1422
biliary disease 1420, 1422f, 1491
clinical features 1420
diagnosis 1420–1421
epidemiology 1420
genetics 1419–1420
hepatic disintegration 1420
hepatic vascular malformations 1420
intrahepatic cholestasis 1491
screening 1421
treatment 1422
type 1 1419
type 2 1419
hereditary lysozyme amyloidosis 1705
hereditary periodic fevers
AA amyloidosis 1703
serum amyloid A protein 1703
hereditary sitosterolaemia 1637
hereditary tyrosinaemia type 1 1860
hernia(s)
inguinal 448
umbilical 447, 1923
herpes simplex viral inclusions 424
herpes simplex virus infections 957–959
acute liver failure 1297
adults 958
diagnosis 958–959
histology 959

polymerase chain reaction 959
serology 958–959
HELLP syndrome 958
immunocompromised 958
latency 957
latent infection reactivation 958
liver transplantation 958
children 1866
neonates 958
pregnancy 958, 1888
prevalence 957
therapy 959
visceral infections 958
herpesvirus infections 957–966
HERS disease (glycogen storage disease type 6) 1373–1374
Hes-1 69
He-Shou-Wu (Shou-Wu Pian), hepatotoxicity 1282t, 1283
heterodimer and histone deacetylases (HDACs) 216
Hex, liver bud expansion 66
hexachlorobenzene, hepatotoxicity 2111
γ-hexachlorocyclohexane (γ-HCH), hepatotoxicity 2111
hexafluorodichlorobutene (HFCB), hepatotoxicity 2111
hexokinase IV (glucokinase) 1370
hexokinases 1370
HFE gene/protein
fibrosis progression in hepatitis C 359
H63D mutation 1324, 1325
haemochromatosis 1323, 1324
HLA class I allele 365, 375
iron metabolism 223
high-density lipoprotein (HDL)
apolipoproteins 136, 139
characteristics 134t
cholesterol removal 139–141, 140f
echinocytes (burr cells) 1768
formation 139, 140f
hepatic uptake 140f, 141
metabolism 138–141
Tangier disease 1366
high-dependency unit (HDU), liver trauma 1956
high-intensity focal ultrasound (HIFU), hepatocellular carcinoma 554
highly active antiretroviral therapy (HAART) 1380
AIDS-related cholangitis 1546
cutaneous side-effects 1807
hepatotoxicity 1380, 1807
HIV–hepatitis B coinfection 934
HIV–hepatitis C coinfection 979
mitochondria, effects on 1380
see also individual drugs
high-mobility group Box 1 (HMGB1), ischaemia-reperfusion injury 39
high-performance liquid chromatography (HPLC), bilirubin 168, 459, 1353
Hijmans van den Bergh reaction 1353
hip fractures, osteoporosis 1829
hip/waist ratio, gamma-glutamyl transpeptidase 464
histamine
carcinoid syndrome 1474–1475
flushing attacks 1474–1475
histamine antagonists, carcinoid tumours 1476
histamine receptors, hepatic encephalopathy 737–738
histidine–tryptophan–ketoglutarate (HTK) solution 352, 1966
histiocytoses 1618–1619, 1644–1645
classification 1645
histiocytosis X (Langerhans cell histiocytosis) 1618–1619, 1645
histone deacetylases (HDACs) inhibitors, fibrosis 596
Histoplasma capsulatum 1014
Histoplasma capsulatum capsulatum 1014
Histoplasma capsulatum var. *duboisii* 1014
histoplasmosis 1014–1015
African (large-form) 1014, 1015
classical (small-form) 1014
clinical features 1015
investigations 1015
pathogenesis 1014–1015, 1015t
pulmonary 1015, 1015t
therapy 1015
HIV infection 974–987
amoebic liver abscess 1021
biliary disease 985
cutaneous manifestations 1807
cytomegalovirus infection 983
drug-induced liver injury 983–984, 1213
hepatitis A coinfection 982
hepatitis A vaccines 901
hepatitis B coinfection *see* HIV–hepatitis B coinfection
hepatitis C coinfection *see* HIV–hepatitis C coinfection
hepatitis D coinfection 879, 982
hepatitis G coinfection 982
intrahepatic cholestasis 1492
liver transplantation 1922
contraindications 1990
liver tumours 984–985, 1438
metastases 984
Mycobacterium avium complex coinfection 983
syphilis 1007
toxoplasmosis coinfection 983
tuberculosis 983
HIV–hepatitis B coinfection 974–978
antiviral therapy 934, 974–978
combination treatments 977
decision algorithm 977f
drug resistance 976
efficacy 974–976
HbeAg positive 977
HbsAg screening 976
liver biopsies 976–977
options 977t
preferred agents 976f
see also individual drugs
mortality 974
prevalence 974
HIV–hepatitis C coinfection 882, 978–982
antiretroviral therapy 978
liver toxicity 978–979
clinical course 889, 978–979, 979
liver fibrosis 979
diagnosis 978
endstage liver disease management 982
epidemiology 978
HCV therapy 979–982
alcohol abuse 981
antiretroviral agent interactions 981
CD4 count selection 980
compliance 981
contraindications 980
drugs of abuse 981
histological selection 979
monitoring/duration 980–981
pegylated interferon/ribavirin 979
ribavirin 981
special populations 980
hepatitis C genotype 978, 981–982
highly active antiretroviral therapy 979
laboratory markers 978
liver transplantation 982
antiretroviral/immunosuppressive agent interactions 982
HLA (human leukocyte antigen) system 365
autoimmune hepatitis 365t, 366t, 367, 368, 368t, 1094, 1095, 1120
class I supercluster 365
class II supercluster 365
cystic fibrosis 1338
immunogenetic studies 365t, 366t, 369–370
MHC location 365
primary biliary cirrhosis 358, 367
primary sclerosing cholangitis 365t, 366–367, 366t, 1104
viral hepatitis 365t, 367–368, 370t
see also major histocompatibility complex (MHC); *specific components*
HLA 8.1
autoimmune hepatitis type 1 367
hepatitis C 368
primary sclerosing cholangitis 366
HLA A1-B8-DR3 482
HLA A11 1226
HLA B8 1226
HLA B alleles 365
HLA Cw alleles 365
HLA *DP* genes 365
HLA *DQ* genes 365
autoimmune hepatitis type 1 367
hepatitis C 367, 368
primary sclerosing cholangitis 366
HLA *DR* genes 365
autoimmune hepatitis type 1 367, 368t
drug-induced acute hepatitis 1226
primary biliary cirrhosis 358, 367
primary sclerosing cholangitis 366
viral hepatitis 367
HLA E alleles 365
HLA F alleles 365
Hlx, hepatoblast proliferation 66
Hodgkin's disease
granulomas 1714
hepatic involvement 1662–1663
clinical features 1662–1663
frequency 1662
histology 1662, 1662f
intrahepatic cholestasis 1492, 1663
ultrasonography 505
HOE 077, fibrosis 597
homeostasis
anaesthetic implications, liver disease 1940
calcium 218, 1750, 1751f
extracellular matrix (ECM) proteins 270–271
glutathione (GSH) 199–200
homeostatic model assessment, non-alcoholic fatty liver disease 1199
homocysteine
metabolism 146–147
production 146
homocystinuria 2139
homovanillic acid, hepatic encephalopathy 737
Hopkins model, chronic graft-vs.-host disease 1674
hormone(s)
across liver cell plates 91
cholangiocyte secretion regulation 53
gallbladder motility 306, 306t
hepatocellular carcinoma 1439
signalling, carrier proteins 251
see also individual hormones
hormone receptors, hepatocytes 93
hormone replacement therapy (HRT)
osteoporosis 1082, 1832
primary biliary cirrhosis 1902
hornet's venom, hepatotoxicity 2111
Hospital Anxiety and Depression Scale 2029
Hounsfield units 510
4HPR 215f
H1069Q mutations, Wilson's disease 1317, 1318
human chorionic gonadotrophin (hCG)
hepatoblastomas 1763
hepatocellular carcinoma 1763
human genome project 398
immune response gene identification 368
human granulocytotropic anaplasmosis 1006–1007
human granulocytotropic ehrichioses 1006–1007
human hepatic growth factor, hepatocyte transplantation 2040f
human herpesvirus type 4 *see* Epstein–Barr virus infection
human herpesvirus type 6 (HHV-6) infection 963–964
acute liver failure 1298
transplantation 963–964
human herpesvirus type 7 (HHV-7) infection 963–964
transplantation 963–964
human herpesvirus type 8 (HHV-8) infection 966
immunocompromised 966
Kaposi's sarcoma 966, 1644
transmission 966
treatment 966
human immunodeficiency virus (HIV) *see* AIDS; HIV infection
human leukocyte antigen (HLA) system *see* HLA (human leukocyte antigen) system
human monocytotropic ehrlichiosis 1006–1007
human parvovirus B19 infection 968
humoral immune system
alcoholic liver disease 1140
drug-induced acute hepatitis 1223–1224, 1224f
hepatitis E 896
see also antibodies
Hunter syndrome 2139–2140
Hurler syndrome 2140
hyaluronate, uptake by liver sinusoidal endothelial cells 30

hyaluronic acid (HA) 270
alcoholic liver disease 1168
cystic fibrosis 1340
hydatid cysts 1047, 1048, 1048f
extrahepatic 1049
magnetic resonance imaging 530
rupture 1049
surgery 1049–1051
ultrasound classification 1049, 1049t
see also cystic echinococcosis
hydatid disease *see* cystic echinococcosis (CE)
hydatid sand (granula) 1048
hydatid thrill 1049
hydralazine, hepatotoxicity 1235
hydrazines, hepatotoxicity 2111
hydrochlorofluorocarbons (HCFCs), hepatotoxicity 1271
hydrogen peroxide
reactive oxygen species elimination 163
reduction, glutathione 201
hydropic swelling *see* ballooning, hepatocytes
hydrops of the gallbladder, Kawasaki disease 1645
3-hydroxy-3-methylglutaryl coenzyme A reductase (HMGR) 195, 1520
3-hydroxyacyl-CoA dehydrogenase 91
β-hydroxybutyrate dehydrogenase 91–92
3β-hydroxy-C_{27}-steroid dehydrogenase/isomerase deficiency 176, 1849
8-hydroxy-deoxyguanosine 1246
5-hydroxyindoleacetic acid
carcinoid syndrome 1475
carcinoid tumours 1472
hydroxymethylbilane 207f, 208
hydroxymethylbilane synthase deficiency 1346
hydroxymethylglutaryl-CoA (HMG) reductase 92
hydroxymethylglutaryl-CoA (HMG) synthase 92
16-hydroxyoestrone, feminization 1759
4-hydroxyphenol retinamide (4-HR, fenretinide) 217
14-hydroxy-*retro*-retinol 215f, 217
11β-hydroxysteroid dehydrogenase 1752
5-hydroxytryptamine (5-HT) *see* serotonin
5-hydroxytryptophan 1474
1α,25-hydroxyvitamin D_3 ($1,25(OH_2)D_3$) 218
25-hydroxyvitamin D_3 218
osteomalacia 1833, 1834
rickets 1833
structure 215f
hyperacute liver failure 1292t
hyperalbuminaemia 454
hyperammonaemia
cirrhosis 730
neurological manifestations 1822, 1823t
urea cycle defects 1862
hyperbaric oxygen, carbon tetrachloride hepatotoxicity 1271
hyperbilirubinaemia 1352–1359
acquired 1356
bacterial cholangitis 1542
cholestasis 460–461
ciclosporin hepatotoxicity 1647
clinical chemistry 1352–1353
congestive heart failure 1612
extravasated blood resorption 1947–1949
genetic defects 1355–1356
hepatic metastases 1467
ischaemic hepatitis 1610
obstructive jaundice-associated acute renal failure 1816
postoperative 1947–1949
primary biliary cirrhosis 1075, 1356
see also bilirubin
hypercalcaemia, tumour-induced 1763
hypercatabolism, cirrhotic patients 1837
hypercholesterolaemia
hepatocellular carcinoma 1442
oral xanthomas 1798
hypercoagulation
liver disease 1792
liver transplantation 259–260
preoperative assessment 1997
hypercortisolism 1686
hyperdynamic circulation
portal hypertension 634–636
circulatory vasodilators 634–635
local vasodilators 635–636
preoperative liver transplant assessment 1996
splanchnic arterial vasodilation 684
hyperemesis gravidarum 1879–1880
clinical features 1885t
liver histology 1880
risk factors 1880
hypereosinophilic syndrome, Budd–Chiari syndrome 1405
hyperfibrinolysis 1782, 1785, 1785f
liver transplantation 259
hypergammaglobulinaemia
alcoholic cirrhosis 1166
chronic liver disease 1771–1772
hyperglucagonism, portal hypertension 634–635
hyperglycaemia 1734
alcoholic liver disease development 1142
cirrhosis 1738
fasting 1734
glucagon suppression 1738
immunosuppressant-induced 2021
postoperative liver transplantation 2001
postprandial glycogen synthesis 130
hyperhomocysteinaemia, alcohol consumption 1138
hyperinfection syndrome, strongyloidiasis 1064, 1065
hyperinsulinaemia
alcoholic cirrhosis 1166
cirrhosis 1906
glucagon suppression 1738
postprandial glycogen synthesis 130
hyperkalaemia
diuretic-induced 691, 692
hepatorenal syndrome 713
spironolactone-induced 691
hyperlactaemia
anaesthetic implications, liver disease 1940, 1942
mitochondrial oxidative phosphorylation deficiency 1380
hyperlipidaemia
acitretin-induced 1646
corticosteroid-induced 2021
glycogen storage diseases type I 1372
growth hormone deficiency 1690
hepatic fibrosis 1901
immunosuppressant-induced 2021
type 1 1366–1367
type 4 1366–1367
type 5 1366–1367
Zieve syndrome 1770
hyperlipoproteinaemia 1366–1367
hypernatraemia, intracranial pressure 1305
hyperestrogenism, alcohol abuse 1186
hyperparathyroidism
alcohol-related bone disease 1751
osteoporosis 1831
hyperprolactinaemia, cirrhosis 1760
hypersensitivity, immunoallergic hepatitis 1226
hypersplenism 771–778
cirrhosis 605, 772–773, 1785
clinical consequences 774–775, 774f
definition 772
incidence 772
mechanisms 772–774
anaemia 774
granulocytopenia in 773–774, 773f
thrombocytopenia 772–773
risk factors 772
severe 772
thrombocytopenia 258
treatment 775–777
visceral leishmaniasis 1036
hypertension
immunosuppressant-induced 2021
intracranial *see* intracranial hypertension
portal *see* portal hypertension
post-liver transplantation 1998
hyperthyroidism
definition 1684
drug-induced 1685, 1750
hepatic effects 1684
hepatocellular carcinoma 1763
hyperemesis gravidarum 1880
hypertriglyceridaemia
glycogen storage disease type 1 1373
non-alcoholic fatty liver disease 1197
non-alcoholic steatohepatitis 1197
hypertrophy
hepatocytes 282
liver remnants 1934
hyperuricaemia, glycogen storage diseases type 1 1372
hyperventilation, acute liver failure 1293
hyphae, *Candida albicans* 1012
hypnozoites, *Plasmodium* 1029, 1030
hypoalbuminaemia 253, 454
bilirubin toxicity 170
obstructive jaundice 1505
total plasma calcium levels 1750
hypocalcaemia, liver transplantation
anaesthetic implications 1942
postoperative 2001
hypochloraemic acidosis, anaesthetic implications 1940
hypocoagulation, liver transplantation 1997
hypocoagulation, post-liver transplantation 1999
hypofibrinogenaemia
cirrhosis 260
disseminated intravascular coagulation 260
hypoglycaemia
acute fatty liver of pregnancy 1883
acute liver failure, children 1859
anaesthetic implications 1940
cirrhosis 612, 1740, 1754
fibrosarcoma 1460
glycogen storage diseases 1371, 1372, 1373
hepatocellular carcinoma 1744–1745
management 1745–1746
paracetamol overdose 1238
hypoglycaemic agents 1737
hypoglycin A 1272
pregnancy 1883
hypoglycin poisoning (Jamaican vomiting sickness) 1272
hypogonadism
alcohol abuse 1186
cirrhosis 610, 1756–1758, 1759
drug-induced 1759
haemochromatosis 1761–1762
management 1761–1762
hyperprolactinaemia 1760
juvenile haemochromatosis 1326
hypoinsulinaemia, growth hormone resistance 1741
hypokalaemia
anaesthetic implications 1939, 1942
diuretic-induced 691, 692
hypolipoproteinaemias 1366
hypomagnesaemia, anaesthetic implications 1939, 1942
hyponatraemia
acute porphyric crisis 1344
anaesthetic implications 1939
cirrhosis 612, 612t, 676
diuretic-induced 691, 692
hepatorenal syndrome 713, 716
pretransplant patients, waiting list mortality 1923
treatment in cirrhotic ascites 699–702
hypoparathyroidism, alcohol-related bone disease 1751
hypophosphataemia, paracetamol overdose 1238
hypotension
cirrhosis 1727
hepatic blood flow regulation 76
hepatorenal syndrome 711, 713
hypothalamic-pituitary axis dysfunction, cirrhosis 610, 1760
hypothalamic-pituitary-gonadal axis 1686–1687
hypothalamus, liver function regulation 114
hypothermia
intracranial pressure 748
liver transplantation 1942–1943
hypothermic ischaemia *see* cold ischaemia
hypothyroidism 1685
ascites 1685
bile acid synthesis 1685
congenital 1685
definition 1684
drug-induced 1750
haemochromatosis 1762
primary biliary cirrhosis 1749
urea synthesis regulation 183
hypovolaemia, obstructive jaundice-associated acute renal failure 1816

hypoxaemia, hepatopulmonary syndrome 720
hypoxia 1616–1617
fibrosis 585
Kupffer cells 39
mitochondria, oxygen detection by 1616–1617
hypoxia-induced angiogenesis, fibrosis 1617
hypoxia-inducible factor (HIF) 90–91, 1617
hypoxia-responsive element (HRE) 90
hypoxic hepatitis *see* ischaemic (hypoxic) hepatitis
hypoxic liver cell necrosis *see* ischaemic (hypoxic) hepatitis
hypoxic vacuoles 424

I

ibuprofen
hepatotoxicity 1212
nephrotoxicity 702
ichthyosis-biliary atresia 2140–2141
ichthyosis-neutral lipid storage disease 2141
idiopathic adulthood ductopenia 1106
idiopathic haemochromatosis *see* haemochromatosis
idiopathic immune thrombocytopenia (IIP), hepatitis C 258
idiopathic thrombocytopenia (ITP) 773f
IFN *see* interferon-α (IFNα); interferon-γ (IFN-γ)
ileum, bile salt absorption 174
imaging *see specific methods*
imidazoles 1038
imipenem, bacterial cholangitis 1543, 1543t
imipramine, hepatotoxicity 1235
immortalized cell lines, bioartificial liver support 2045
immune attack, drug-induced acute hepatitis 1222–1223
immune cell function, neural modulation 120
immune complexes
chronic hepatitis C 889
primary sclerosing cholangitis 1104
immune plasma, Argentine haemorrhagic fever 990
immune reaction (IR) 312–331
innate *see* innate immune response
lymphocytes *see* lymphocytes
immune response (IR)
cellular *see* cellular immune response
chronic hepatitis B 871
genetic studies *see* immunogenetics, liver disease
hepatitis B vaccine 910
humoral *see* humoral immune system
immunogenetics
MHC components 368–370
non-MHC components 368–370
polymorphism 364
restoration, chronic hepatitis B antiviral therapy 922
termination of 369–370
see also specific components/types
immune system
alcoholic liver disease 1139–1141
genetics 1143
drug-induced acute hepatitis 1222
hepatic 479–480, 479f
immunoallergic hepatitis
clinical characteristics 1226
drug-induced 1226
immunoassays
amyloidosis 1706
hepatitis C 883
immunocompromised patients
adenovirus infections 968
Bartonella henselae 1005
cytomegalovirus infection 962
diagnosis 960–961
Epstein–Barr virus infection 965
haemobilia 1553
herpes simplex virus infections 958
human herpesvirus type 8 infection 966
varicella-zoster virus infection 960
immunocytochemistry, malignant ascites 668
immunodepression, strongyloidiasis 1064
immunogenetics, liver disease 364–371
association studies 364
future study 370–371
inflammatory bowel disease and 366, 370
MHC genes 364–368, 365t, 369–370
areas of interest 365
autoimmune disease 365t, 366–367, 366t, 368, 368t
viral disease 365t, 367–368, 370t
see also HLA (human leukocyte antigen) system; major histocompatibility complex (MHC)
non-MHC genes 364, 368–370
candidate genes 368–369
early antigen presentation genes 369
immune response termination/tissue repair genes 369–370
inflammatory response genes 369
innate immune response genes 370
late antigen presentation genes 369
weak associations 371
tissue repair 369–370
immunoglobulin(s)
cirrhosis 1771–1772
liver disease 328–329
immunoglobulin A (IgA) 325–329
alcoholic liver disease 328–329, 1772
antibody-dependent cell-mediated cytotoxicity 328
bile 55, 326–328
catabolism 328
functions 328
giardiasis 1024
glomerular abnormalities, cirrhosis 329, 1817
hepatobiliary system 326–328
inflammation 328
isotypes 326
neuropathy, cirrhosis 1817–1818
opsonization 328
primary biliary cirrhosis 329
secretory chain 326
species differences 326–327
structure 326, 327f
synthesis 325–326
gut-associated lymphoid tissue 326
transport 326, 327f
immunoglobulin E (IgE), echinococcosis 1054
immunoglobulin G (IgG)
alcoholic liver disease 329
autoimmune hepatitis 1852
catabolism 328
glomerular abnormalities, cirrhosis 1817
hepatitis C virus 1772
immunoglobulin M (IgM)
catabolism 328
glomerular abnormalities, cirrhosis 1817
hepatitis B 839
hepatitis C 855, 1772
hepatitis D diagnosis 876
immunoglobulin receptors, B cells 325
immunohistochemistry (IHC)
amyloidosis 1706
ciliated hepatic foregut cyst 807–808
epithelioid haemangioendothelioma 1459, 1459f
liver biopsy 491, 491f
varicella-zoster virus infection 960
viral hepatitis 430
immunological investigations 479–488
autoimmune hepatitis 480–482
autoimmune polyglandular syndrome type 1 485
chronic HCV infection 485
chronic HDV infection 485
limitations 479–480
overlap syndromes 485
primary biliary cirrhosis 484
primary sclerosing cholangitis 484
immunomodulation
chronic hepatitis B 925
primary biliary cirrhosis 1082–1083
immunophilin-binding drugs 2006–2008
immunostaining, hepatocellular carcinoma 1440
immunosuppression
acute liver failure 1296–1297
amoebic liver abscess 1025
autoimmune hepatitis 1099, 1853
autoimmune hepatitis–primary biliary cirrhosis overlap syndrome 1123
autoimmune sclerosing cholangitis 1124
chronic graft-vs.-host disease 1675
cutaneous manifestations 1809–1810
hepatitis C, post-transplant recurrence 2013
hepatocellular carcinoma induction 1260
liver transplant *see* immunosuppression, liver transplantation
neurotoxicity 1826
peliosis hepatis induction 1658
post-transplantation bone disease 1833
split liver transplantation 1865, 1973
immunosuppression, liver transplantation 2003–2009
acute rejection treatment 2004
adverse effects/complications 2004–2005, 2020–2023
arterial hypertension 2021
cardiovascular 2020–2021
in children 1867
chronic renal failure 2021–2022
diabetes mellitus 2021
disease recurrence 2004–2005
hyperlipidaemia 2021
infections 2004, 2022–2023
malignancy 2004, 2022
obesity 2020
opportunistic infections 2023
osteoarticular complications 2022
renal impairment 2005
weight gain 2020
agents 2005–2009, 2005t
antimetabolites 2008
cell interaction inhibitors 2009
immunophilin-binding drugs 2006–2008
lymphocyte depletion 2005
lymphocyte inhibitors 2006–2009
lymphocyte trafficking inhibitors 2008–2009
nucleotide synthesis inhibitors 2008
purine synthesis inhibitors 2008
pyrimidine synthesis inhibitors 2008
antiretroviral agent interactions 982
children 1865
chronic rejection treatment 2004
hepatitis C recurrence 2013
induction therapy 2004
maintenance regimes 2004
minimal immunosuppression tolerance 2003
postoperative, cutaneous manifestations 1809
pregnancy 2005
prope tolerance 2003
regimes 2003–2004
side-effect minimizing 2023
window for immunological engagement 2003
withdrawal 2004
see also specific drugs
immunotherapy, hepatic metastases 1469
impila *(Callilepsis laureola),* hepatotoxicity 1282t, 1285
impotence, haemochromatosis 1761
imprinting 1689
inbred mouse strains 372
incremental cost-effectiveness ratio 2084
Index of Well-being 2028
indicator dilution method, hepatic blood flow measurement 569
indirect bilirubin *see* unconjugated bilirubin
indirect haemagglutination (IHA), amoebic liver abscess 1026
indirect immunofluorescence, autoimmune hepatitis 1091–1092
indocyanine (ICG)
clearance 472
hepatic blood flow measurement 662
intrinsic hepatic clearance 470
indoles, hepatic encephalopathy 731
indomethacin 702
inducible NO synthase (iNOS)
cholangiocyte expression 55
liver sinusoidal endothelial cells 31
induction, acute fatty liver of pregnancy 1883
industrial toxins 1269
acute liver failure 1298

infant(s)
biliary disease 1845–1850
hepatitis A vaccine 900–901
hepatitis B vaccine 908
liver disease 1845–1850
total parenteral nutrition-related liver disease 1634, 1635
see also specific diseases/disorders
infantile cholestasis 1845–1847
alpha-1-antitrypsin deficiency 1332
causes 1845, 1846t
clinical examination 1876
clinical presentation 1845–1846
cystic fibrosis 1338
idiopathic 1850
imaging 1846–1847
incidence 1845
investigations 1846–1847, 1847t
management 1846–1847
spontaneous bleeding 1845
infantile haemangiomata 1862–1863
infantile obstructive cholangiopathy 1823t
infantile Refsum's disease 2141
hepatocyte transplantation 2038
infection(s)
acute liver failure, children 1858, 1859
angiography 537
bacterial *see* bacterial infection(s)
cutaneous manifestations 1644, 1806–1808
extrahepatic biliary obstruction *see* extrahepatic biliary obstruction
fungal *see* fungal infection(s)
geographical distribution 2099–2104
granulomas 1709, 1713–1714
hepatic encephalopathy 731
immunosuppressed patients 2004, 2022–2023
infantile cholestasis 1846t
obstructive jaundice 1505–1506
post-liver transplantation 2001
children 1866
immunosuppression 2022–2023
postoperative jaundice 1950
primary sclerosing cholangitis 1104
vanishing bile duct syndrome 1115
viral *see* viral infection(s)
see also specific infections
inferior mesenteric vein
anatomy 623
portal hypertension 625
retrograde flow 625
inferior vena cava 4
compression
Budd–Chiari syndrome 1405
polycystic liver disease 791f, 793
congenital webs, ascites 670
stenoses, Budd–Chiari syndrome 1406
thrombosis, Budd–Chiari syndrome 1406
inferior venacavography, Budd–Chiari syndrome 1408
inflammation
alcoholic liver disease 1143, 1159
angiography 537
cholangiocarcinoma 1584
fibrosis progression to cirrhosis 584
gallbladder motility disorders 1562
histological features 424–425
immunogenetics 369
immunoglobulin A (IgA) 328
non-alcoholic fatty liver disease 1199
non-alcoholic steatohepatitis diagnosis 1199
systemic AA amyloidosis 1703
inflammation-induced cholestasis *see* cholestatic hepatitis
inflammatory bowel disease (IBD)
amyloidosis 1627
autoimmune hepatitis 1626
autoimmune sclerosing cholangitis 1853
cirrhosis 1626
drug-induced hepatitis 1628
extrahepatic biliary obstruction 1507
granulomas 1714
hepatobiliary complications 1622, 1622t
hepatobiliary disease prevalence 1622–1623
liver abscess 1628
liver disease immunogenetics and 366, 370
primary biliary cirrhosis 1628
primary sclerosing cholangitis 366, 370, 1103, 1104, 1489, 1624–1626
prevalence 1624–1626
steatosis 1627
vitamin D deficiency 218
without primary sclerosing cholangitis 1624–1625
see also Crohn's disease; ulcerative colitis (UC)
inflammatory carcinogenesis model, liver cancer 316–317
inflammatory cystic diseases 810–813
inflammatory mediators, sepsis-induced cholestasis 1946
inflammatory pseudotumours (IPT), cystic 812
inflammatory tumours, benign 1596
infliximab
alcoholic hepatitis 1164–1165
hepatotoxicity 1647
Informal Working Group on Echinococcosis (IWGE) 1049
informative censoring, prognostic models 2057
inguinal hernias 448
inhalational anaesthetics, use in liver disease 1941
liver transplantation and 1942
inherited prothrombotic disorders, portal vein thrombosis 1395–1396, 1395t
inhibin 1687, 1755
inhibitor of apoptosis (IAP) family 340
initiator caspases, apoptosis 336
innate immune response
alcoholic liver disease pathogenesis 1139–1140
hepatocytes 106
immunogenetic studies 370
inosine triphosphate pyrophosphatase (ITPase), azathioprine intolerance 1647
inositol trisphosphate, cholangiocytes 53
INR *see* international normalized ratio (INR)
in situ hybridization, viral hepatitis 430
insomnia, Wilson's disease 1316
inspissated bile syndrome 1848
insulin 1681
actions 1734
clearance, liver disease 1734–1735
deficiency
growth hormone resistance 1741
insulin-like growth factor-1 production 1742
effects 129
hepatic degradation 129
hepatic glucose production 129
hypersecretion, non-diabetic cirrhotics 1734–1735
insulin-like growth factor binding proteins regulation 1743, 1744
insulin-like growth factor-I production regulation 1742, 1744
lipoprotein lipase 136
metabolism 1681
renal glucose production 129
resistance *see* insulin resistance
secretion 129
alcoholic cirrhosis 1735
diabetic cirrhotics 1733f, 1735
hepatic modification 129
liver disease 1734–1735
non-diabetic cirrhotics 1734–1735
sex hormone binding globulin regulation 1755
therapy 1737
urea synthesis regulation 183
see also diabetes mellitus (DM); glucose
insulin-like growth factor(s) (IGFs) 1689, 1742–1746
extrapancreatic tumour hypoglycaemia 1744–1746
management 1745–1746
growth hormone regulation 1739
liver disease 1743–1744
physiology 1742–1743
secretion, cirrhosis 1743
see also specific growth factors
insulin-like growth factor binding protein(s) (IGFBPs) 1742–1743
cirrhosis 1740f, 1743
postoperative levels 1744
regulation 1743
synthesis 1742
see also specific receptors
insulin-like growth factor binding protein 1 (IGFBP-1) 1742, 1743
cirrhosis 1740f, 1743
insulin-like growth factor binding protein 2 (IGFBP-2) 1742
regulation 1743
insulin-like growth factor binding protein 3 (IGFBP-3) 1742
cirrhosis 1740f, 1743
regulation 1743
insulin-like growth factor-1 (IGF-1) 1689
administration, cirrhosis 1909
Alagille syndrome 1741
alcoholic liver disease 1743
cholangiocyte proliferation 54
cirrhosis 1740f, 1741, 1743
extrapancreatic tumour hypoglycaemia 1744–1746
growth hormone regulation 1739
physiology 1742–1743
plasma transport 1742–1743
postoperative levels 1744
production regulation 1742
receptor 1743
sex hormone binding globulin regulation 1755
insulin-like growth factor-2 (IGF-2) 1689
extrapancreatic tumour hypoglycaemia 1744–1746
growth hormone regulation 1739
physiology 1742–1743
plasma transport 1742–1743
precursor forms (big IGF-2)
growth hormone inhibition 1745
tumour-associated hypoglycaemia 1745
insulin-like growth factor receptor 2 (IGFR2) 394t
insulin resistance 1680
alcoholic hepatitis 1169
cirrhosis 132
free fatty acids 131
haemochromatosis 1761
interleukin-1β 317
interleukin-6 317
liver disease 1838
non-alcoholic fatty liver disease 132, 1681
obesity-associated 132
tumour necrosis factor 317
very-low-density lipoprotein secretion 136
integrins
extracellular matrix 270
hepatoblast proliferation 66
hepatoblasts 68
T cell mobilization 322
intensive care unit (ICU)
liver trauma 1956
postoperative liver transplantation 1998
intensive therapy unit (ITU), candidosis 1011
intercellular adhesion molecule-1 (ICAM-1), T cell mobilization 322
interendothelial slits (IESs), spleen 772
interface hepatitis
autoimmune hepatitis 1094
primary biliary cirrhosis 1077
interface myofibroblasts 47, 47t
interferon(s), T cell regulation 323
interferon-α (IFNα) 1450
carcinoid tumours 1477
children 949
dialysis patients 1654–1655
fibrosis 595, 596
hepatitis B 925
children 1851
chronic 925
cirrhosis 933
extrahepatic manifestations 936
membranoproliferative glomerulonephritis 1818
renal transplantation patients 1657
wild-type virus (HBeAg-positive) 927
hepatitis C 941–942
acute 917
children 949, 1852
dialysis patients 1656
gene array data 408
hepatocellular carcinoma prevention 1450
historical aspects 941
membranoproliferative glomerulonephritis 1819
polymorphism and responses to 357t, 358, 360t

renal transplant patients 1658
resistance to 854
ribavirin combination 942, 943–944, 944t, 949
hepatitis D-hepatitis B virus coinfection 934–935
HIV–hepatitis B coinfection 974, 975, 975t
side-effects 927, 927t, 1477
thyroid dysfunction induction 1750
interferon-α 2a, chronic hepatitis C 941
interferon-α 2b, chronic hepatitis C 941
interferon-γ (IFN-γ)
alveolar echinococcosis 1056
chronic graft-vs.-host disease pathogenesis 1674
Cryptosporidium 1024
fibrosis 596
inducible genes, gene array data 407–408
visceral leishmaniasis 1039
interferon-ribavirin combination, hepatitis C dialysis patients 1656
interleukin(s) 312
interleukin-1 (IL-1)
acute graft-vs.-host disease pathogenesis 1672
ischaemic injury 348
polymorphism, inflammatory response and 369
urea synthesis regulation 183
interleukin-1β (IL-1β), insulin resistance 317
interleukin-1 receptor-associated kinase (IRAK-1) 37
interleukin-2 (IL-2), acute graft-vs.-host disease 1672
interleukin-4 (IL-4)
chronic graft-vs.-host disease pathogenesis 1674
polymorphism, inflammatory response and 369
interleukin-6 (IL-6) 313, 313t, 317–318
cirrhotic ascitic fluid 668
congestive heart failure 317–318
extrahepatic biliary obstruction 1506
fulminant hepatic failure 318
insulin resistance 317
ischaemia-reperfusion injury 40
liver regeneration 316, 317
multiple myeloma 317–318
polymorphism, inflammatory response and 369
signal transduction 317, 317f
interleukin-10 (IL-10)
alcoholic liver disease 1143, 1159
fibrosis 596
ischaemia-reperfusion injury 40
polymorphism
IFN response in hepatitis C and 358
inflammatory response and 369
regulator T cells 323
interleukin-13 (IL-13), ischaemia-reperfusion injury 40
interlobular bile ducts 17
interlobular ductules 1111
intermediate-density lipoprotein (IDL)
characteristics 134t
clearance 138
intermediate filaments
bile vesicular trafficking 298
hepatocyte cytoskeleton 97
intermediate hepatocytes 60
intermittent clamping 350, 351f
warm ischaemia prevention 350
intermittent inflow occlusion, hepatectomy 1935
internal radiation, hepatocellular carcinoma 1449–1450
internal ribosomal entry site (IRES), translation initiation 195
International Ascites Club, refractory ascites definition 692
International Autoimmune Hepatitis Group scoring system 1090–1091, 1091t
International Autoimmune Hepatitis Group (IAIHG) scoring system 1090–1091, 1091t, 1120
international normalized ratio (INR) 456, 1781
acute liver failure 1293, 1302
children 1859
heat stroke 1278
Model for EndStage Liver Disease score 1786
variability between laboratories 1783, 1784f
international sensitivity index (ISI) 456
interobserver variation, liver biopsy 434
interval-specific haplotype analysis, QTL analysis in inbred mice 377t, 378–379
interventional radiology
gastrointestinal bleeding, hepatic origin 549–551
hepatocellular carcinoma 551–555
intestinal bacteria, obstructive jaundice 1504, 1506
intestinal bypass, gallbladder cancer-associated intestinal obstruction 1579
intestines
ammonia production 181
ammonia source 181
bacterial translocation 762
cholesterol gallbladder stones 1520
decontamination, spontaneous bacterial peritonitis prophylaxis 764–765, 764t
drug malabsorption 1916
hypoxia, eNOS upregulation 635
total parenteral nutrition-related liver disease 1638–1639, 1639f
intoxicating pepper (kava), hepatotoxicity 1282t, 1284–1285
intra-abdominal pressure (IAP)
abdominal compartment syndrome 87
assessment 1957
intra-arterial chemotherapy, hepatocellular carcinoma 1449
intra-arterial digital subtraction angiography (IADSA), liver trauma 1955
intracranial aneurysms, polycystic liver disease 796
intracranial hypertension
acute liver failure 740, 740f, 744, 1292–1293
management 1304–1305, 1305
hepatic encephalopathy 744
monitoring
bleeding risk 1788t
invasive 1304–1305
monitor placement complications 744
non-invasive 1304–1305
pressure reduction 1305
intractable ascites *see* refractory ascites
intraductal cholangiocarcinoma *see* cholangiocarcinoma
intraductal ultrasound (IDUS), biliary strictures 542
intrahepatic cholestasis *see* cholestasis, intrahepatic
intrahepatic cholestasis of pregnancy (ICP) 1880–1881
associated cholestases 1881
canalicular transport defects, inherited 1385
clinical features 1385, 1885t
fetal risks 1880
pruritus 1880
treatment 1495, 1880
intrahepatic pressure measurement 568
intraoperative radiation therapy (IORT), gallbladder carcinoma 1580
intraportal ductules 1111
intrapulmonary shunts, carcinoid syndrome 1474
intrasplenic pressure measurement 567
intravenous cholangiography (IVC), extrahepatic biliary obstruction 1508
intravenous drug use *see* drug abuse
intrinsic coagulation pathway 1780, 1781f
intrinsic death pathway, apoptosis 338–339
intrinsic hepatic clearance 469–470, 1912
iodine 233t
deficiency 233t
iodine 131 (^{131}I)-lipiodol, hepatocellular carcinoma 1449–1450
iprindole, hepatotoxicity 1235
iproniazid
cirrhosis induction 1253
hepatotoxicity 1222, 1229–1230, 1235
Ireg1 *see* ferroportin
irinotecan 246
iron
absorption
dietary 220
non-haem iron 220
deficiency
ALA-synthase 2 translation 211, 211f
divalent metal transporter 221
deposition
adrenal cortex 1762
alcoholic liver disease 1168–1169
hepatocellular carcinoma 1439
magnetic resonance imaging 529
pituitary 1761
excretion 220
export 222–224
haem synthesis 209
loading, genetic background and 376
metabolism 220–225
chronic liver disease 1769
cirrhosis 1769
mobilization 222–224
overload
acute leukaemia 1664
alcoholic liver disease 1154
cirrhosis 585
liver biopsy 494
in liver disease 1901
storage 220
histological features 428
studies
alcoholic hepatitis 1163
non-alcoholic fatty liver disease 1199
non-alcoholic steatohepatitis 1199
supplementation, oxidative stress 1138–1139
transport 220–222
uptake mechanism 220–222
iron citrate 221
iron deficiency anaemia, post-liver transplantation 1772
iron overload disorders 1323–1329
classification 1323t
see also individual disorders
iron regulatory protein 1 (IRP1) 220
iron-responsive elements (IRE) 220
haem synthesis regulation 211
iron-responsive elements binding protein (IRE-BP) 211
iron storage disorders, liver biopsy 494
irradiation, veno-occlusive disease 1256
irritability 444–445
isabgol, hepatotoxicity 1282t
ischaemia
cold *see* cold ischaemia
vanishing bile duct syndrome 1115
warm *see* warm ischaemia
ischaemic heart disease
bilirubin levels 168
hepatic failure 1613t
hepatitis C treatment contraindication 945
ischaemic (hypoxic) hepatitis 1609–1611
acute liver failure 1299
cardiac disease 1945
clinical manifestations 1299, 1609
definition 1609
diagnosis 1949
hypotension 1945
incidence 1609
laboratory findings 1610–1611
liver chemistries 1617
pathogenesis 1609–1610
pathology 1610
postoperative jaundice 1945
ischaemic injury, necrosis 341–342
ischaemic preconditioning 350, 351f
cold ischaemia prevention 352–353
warm ischaemia prevention 350
ischaemic-reperfusion injury 348–355
Kupffer cell activation 39–40, 39f
Ishak scoring system 435, 436t
isocitrate 155
isocitrate dehydrogenase, hyperthyroidism 1684
isoflurane, liver transplantation 1942
isolan (carbamate insecticide), hepatotoxicity 2108
isolated cholangiocytes, liver function models 123
isolated hepatocytes, liver function models 122–123
isoniazid
acetylation 1235
elderly 1872
hepatotoxicity 1235–1236, 1239, 1253
acute liver failure, cause of 1298

isoniazid (*continued*)
rifampicin coadministration 1222, 1235–1236
neurological toxicity 1915
isosexual precocity, liver tumours 1763
isosorbide mononitrate
cirrhosis, drug-induced renal impairment 703
variceal bleeding prevention 644, 646
isotope studies, carcinoid tumours 1473
isotretinoin 1646
Italy
hepatitis B vaccine 912
hepatitis D 877, 878
Ito cells *see* hepatic stellate cell (HSC)
itraconazole
hepatotoxicity 1648
histoplasmosis 1015
paracoccidioidomycosis 1016
Ivemark syndrome 2141–2142
ivermectin 1065

J

JAG1 (JAGGED1) gene mutations 1387, 1848
JAK2 gene mutations 1403
JAK/STAT signalling 393
Jamaican vomiting sickness (hypoglycin poisoning) 1272
pregnancy 1883
Janus kinases (JNK)
interleukin-6 signal transduction 317
regulation 107
Japan, hepatitis B 867
Jarisch–Herxheimer reaction 1808
jaundice 444
acute liver failure 1292
ajmaline-induced 1230
alveolar echinococcosis 1052
anabolic-androgenic steroids induced 1242
anabolic steroid-induced 1687
bacterial infection 1001
bilirubin 460
causes 1352
cholestasis 1228
floxuridine induced 1254
halothane hepatitis 1235
Hodgkin's disease 1663
intrahepatic cholestasis of pregnancy 1880
Kawasaki's disease 1645
Legionnaire's disease 1618
malaria 1031
neonatal 1355
non-Hodgkin's lymphoma 1663
obstructive *see* extrahepatic biliary obstruction; obstructive jaundice
pneumococcal pneumonia 1618
postoperative *see* postoperative jaundice
pregnancy 1879
primary biliary cirrhosis 1075
skin signs 446
thyroid storm 1684
ultrasonography indication 501t
urine colour changes 444
Jehovah's Witnesses, marrow stimulants 1792
jejunoileal bypass surgery, post-operative hepatic damage 1630
Jeune syndrome 2142
Jin Bu Huan, hepatotoxicity 1282t, 1283
JNK *see* Janus kinases (JNK)
juice aspiration cytology, biliary strictures 542
Jumonji gene 68
c-Jun, liver cancer 275
junctional complexes, hepatocytes 11, 22, 22f
Junin virus infections *see* Argentine haemorrhagic fever (AHF)
c-Jun N-terminal kinase 1 (JNK1) 104
c-Jun N-terminal kinase 2 (JNK2) 104
juvenile haemochromatosis 1324, 1325, 1326
juvenile rheumatoid arthritis 1696

K

Kahn syndrome 2142
kala-azar *see* visceral leishmaniasis (VL)
kallikrein 1474–1475
Kaposi's sarcoma (KS) 1644
HIV infection 985
human herpesvirus type 8 966, 1644
Kaposi's sarcoma herpesvirus (KSHV) *see* human herpesvirus type 8 (HHV-8)
Karnofsky Performance Status Scale 2028
Kartagener syndrome 2142–2143
Kasai portoenterostomy, biliary atresia 1847–1848
Katayama fever (acute schistosomiasis) 1041
Katz syndrome 2143
kava, hepatotoxicity 1282t, 1284–1285
kavapyrones 1284
Kawasaki's disease 1645
Kayser–Fleischer ring 446
Wilson's disease 1319, 1320, 1853
Keating syndrome (X-linked glycogen storage disease) 2143
kepone (chlordecone), hepatotoxicity 2108
kernicterus 168, 1353, 1886
Crigler–Najjar syndrome 1355
neurological manifestations 1822
kerosene, hepatotoxicity 2111
ketoconazole
hepatotoxicity 1236, 1686
paracoccidioidomycosis 1016
ketogenesis, across liver cell plate 91–92
α-ketoglutarate 92
ketone bodies
acute liver failure 1302
hyperemesis gravidarum 1880
mitochondrial oxidative phosphorylation deficiency 1380
ketoprofen, hepatotoxicity 1249
17-ketosteroids 1755
kidney(s)
ammonia regulation 186, 187f
bicarbonate regulation 186, 187f
bilirubin excretion 172
drug susceptibility, cirrhosis 1914
examination 448
extrahepatic bile circulation 293, 294f
parathyroid hormone clearance 1751
preoperative assessment 1996–1997
prostaglandin production 682
systemic AL amyloidosis 1704
see also entries beginning renal
KifC2, receptor-mediated endocytosis 100
kinase domain region (KDR) 30, 30t, 32
kinesin, receptor-mediated endocytosis 100
'King herbs' 1283
King's College Criteria
emergency liver transplantation in acute liver failure 1307, 1308t
fulminant hepatic failure, coagulation tests 1786t
KIR genes 370
Klatskin tumour 505
Klebsiella spp.
bacterial cholangitis 1541
pyogenic liver abscess 1002
Klippel–Trenaunay–Weber syndrome 1429
knockin animals, QTL-localized gene verification 380
knockout animals
NF-κB pathway 316
tumour necrosis factor receptor-1 316
Knodell score 435
Korsakoff syndrome 1185
Kozak sequence 192
k-*ras* gene
cholangiocarcinoma 1587
gallbladder carcinoma 1576–1577
Kruppel-like factor 6 (KLF6) 394t, 395
Kulchitsky cells, carcinoid tumours 1470
Kupffer cell reaction 428
Kupffer cells (KC) 13f, 14, 14f, 36–42, 36f
activation 37–38, 313
warm ischaemia 348, 351–352
ageing 1871
alcohol, effects on 40, 1140
alcoholic liver disease 1139–1140
bilirubinostasis 425
blood flow regulation 81
cholestasis 1484
cytokine receptors 313
development 36–37
distribution 36
drug-induced liver failure 40–41
fibrosis reversal 586
functions 37–38
Gaucher's disease, type 1 1361
hepatic artery occlusion 1391–1392
hepatic stellate cell interactions 584
inflammatory mediator formation 37–38, 38f
iron metabolism 222
localization 36–37
malaria 1031
morphological characteristics 36–37
paracetamol overdose 41
pathophysiological role 38–41
phagocytosis 37, 335–336
'worm-like structures' 36, 36f
Kupffer cells, neural regulation 120

L

labelling, gene arrays 403
labetalol, hepatotoxicity 1236
labile cells 58
Labrea fever 428
lactate
cirrhotic ascites 667
mitochondrial oxidation 157–158, 1380
lactic acidosis
fulminant hepatitis 187
glycogen storage disease type 3 1373
liver disease 187
lactic dehydrogenase (LDH) 453–454
ascites
cirrhotic 669f
malignant 668–669, 669f
tuberculous peritonitis 670
assay 453–454
clinical usefulness 454
in disease states 454
distribution 453
isoforms 453
localization 453
normal values 454
postoperative hyperbilirubinaemia 1949
reactions 453
sepsis-induced cholestasis 1950
spontaneous bacterial peritonitis 763
lactitol, hepatic encephalopathy 746–747, 1839
persistent chronic 749
lactulose
acute variceal bleeding 649
hepatic encephalopathy 746–747, 1839
persistent chronic 749
precipitant-induced 749
obstructive jaundice 1511
lamin B receptor (LBR) autoantibodies 484
laminins 269
fibrotic liver 264
lamivudine, hepatitis B treatment
children 1851
chronic infection 925–926
adefovir dipivoxil combination 929
cirrhosis 934
extrahepatic manifestations 936
pegylated-interferon-α combination 928, 930–931
precore mutant infection (HBeAg-negative) 930
resistance 928, 930, 931–932, 932f
wild-type virus (HBeAg-positive) 927
dialysis patients 1655
hepatitis D coinfection 934–935, 935
hepatocellular carcinoma prevention 1450
hepatotoxicity 984
HIV coinfection 974, 975, 975t, 976
liver transplantation 934, 2010–2011
hepatitis B recurrence 2011–2012
pretransplant patients 1927
pregnancy 923, 1887
renal transplantation patients 1657
resistance 976
lamotrigine, hepatotoxicity 1299
Langerhans cell 1618
Langerhans cell histiocytosis (LCH) 1618–1619, 1645
laparoscopic splenectomy 776
laparoscopy 497–498
hepatic cysts, ADPKD 793–794
hilar (upper duct) cholangiocarcinoma 1593
indications 497t
liver trauma 1955
simple cyst of the liver 787–788
laparotomy, simple cyst of the liver 788
Laplace's law 663
large cell dysplasia 430
large hepatic vein obstruction *see* Budd–Chiari syndrome

Larrea tridentata (chaparral), hepatotoxicity 1282t, 1285
Larsen syndrome 2143
larva
Ascaris lumbricoides 1058
Capillaria hepatica 1066
Strongyloides stercoralis 1064
laryngeal cancer, alcohol consumption and 1186
laser capture microdissection, protein prefractionation and 404
laser lithotripsy, choledocholithiasis 1531
Lassa fever 988–990
clinical manifestations 989
diagnosis 989–990
epidemiology 988
laboratory findings 989
nosocomial infection 990
pathogenesis 989
pathology 989
swollen-baby syndrome 989
treatment 990
latent infection membrane proteins (LMPs), Epstein–Barr virus 964
lateral hypothalamic area
liver function regulation 114
parasympathetic hepatic nerves 114–115
Laurence–Moon–Bardet–Biedl (Bardet–Biedl) syndrome 2125–2126
Lawrence–Seip syndrome (Berardinelli syndrome) 2126
L-dopa, hepatic encephalopathy 748
lead 233t
aminolaevulinic acid dehydrase 208
deficiency 233t
hepatotoxicity 1344, 2111
league tables, cost-effectiveness 2085
learning methods, unsupervised 406
lecithin 139
lecithin–cholesterol acyltransferase (LCAT) 139, 140f
leflunomide
hepatotoxicity 1236, 1647–1648
liver transplantation 2008
mechanism of action 1647–1648
left gastric vein
anatomy 623
gastro-oesophageal varices inflow 627
left ventricular ejection fraction
ascites 1722
cirrhosis 1721
Legionella pneumophila 1002–1003
Legionnaire's disease 1002–1003, 1618
allograft recipients 1618
treatment 1002–1003
leiomyosarcoma 1460–1461
Leishmania chagasi 1035t
Leishmania donovani 1035, 1035t
Leishmania infantum 1035t, 1036
Leishmania tropica 1035
leptin
non-alcoholic steatohepatitis 611
stellate cell fibrogenesis 594
Leptospira interrogans 1008
leptospirosis 1007–1008
animal hosts 1008
clinical features 1008
diagnosis 1008
geographical distribution 2100–2101t, 2104t
pregnancy 1888
treatment 1008
lesser omentum 4
Letterer–Siwe disease (Langerhans cell histiocytosis) 1618–1619, 1645
leucine
macroautophagy regulation 148f, 149
protein synthesis regulation 148, 148f
leucocytosis 1770
leuconychia (white nails), cirrhosis 611
leucopenia 1770
leukaemia, hepatic involvement 1664–1665
leukocyte receptor complex (LRC) cluster 370
leukocytes
abnormalities, liver disease and 1770–1771
periportal sinusoidal plugging 81
leukocytopenia, antiviral side-effects 946
leukotriene D4 682
leukotrienes C4 682
levamisole 1061
LeVeen shunts 695
L-γ-glutamyl-L-cysteinyl-glycine *see* glutathione
lichen planus 1642–1643
hepatitis 1643
hepatitis C 945, 1807
primary biliary cirrhosis 1643
lifestyle
alcoholic cirrhosis 1132
non-alcoholic fatty liver disease prevention/management 1203–1204
non-alcoholic steatohepatitis prevention/management 1203–1204
ligamentum teres hepatis (round ligament) 3
ligamentum venosum 3–4
ligandin *see* glutathione-*S*-transferases (GSTs)
ligase chain reaction (LCR) DNA amplification, *Mycobacterium tuberculosis* 670
light chain (deposit) disease 428
limit dextrinosis *see* glycogen storage disease (GSD), type 3
limited scleroderma 1697
limiting plate 10, 10f
Lind, James 572
linear regression analysis 2061
linear RNA amplification, gene array analysis 402–403
line tracing test, hepatic encephalopathy 745
Linguatula serrata 1066
linkage analysis
gallstone disease 1524
mouse models of human liver disease 372
QTL and 375
synteny and 377–378
linkage disequilibrium (LD), genetic polymorphism and liver disease 360, 361
lipid(s)
absorption 291
composition in membranes 96
digestion 291
hepatic stellate cells 44, 45f
metabolism
across liver cell plate 91–92
neural modulation 117
obstructive jaundice 1505
natural killer T-cells 321
as second messenger 103
total parenteral nutrition-related liver disease 1636
lipidation 135
lipidosis
extracellular 1360–1369
intracellular 1360–1369
lipid peroxidation
drug-induced 1220
drug-induced steatohepatitis 1246
extracellular matrix production 592
non-alcoholic steatohepatitis 591–592
lipid peroxides, stellate cell activation 591–592
lipid radicals 1220
lipid storage diseases
drug-induced 1214t, 1242–1251, 1243t
drugs causing 1246–1251
macrovacuolar steatosis 1243
lipocytes *see* hepatic stellate cell (HSC)
lipofuscin 12, 428, 1870
lipogenesis, across liver cell plate 91
lipogranulomas 428, 1709, 1710f
macrovesicular steatosis 1148
LipoKinetix, hepatotoxicity 205, 1286
lipophilic vitamins, absorption in liver disease 1916
lipopolysaccharide
alcoholic liver disease 40
Kupffer cells 37
liver injury induction
gene array data 410
proteomics 414
lipoprotein(s)
characteristics 134t
density 134
disorders 1366–1367
metabolism 91, 92, 133–142
size 134
structure 134–135, 134f
see also individual types
lipoprotein lipase (LPL) 136–137
expression, muscle *vs.* adipose tissue 136
lipotoxicity, non-alcoholic steatohepatitis 1202
Listeria monocytogenes 1002
LITH gene/protein, gallstone disease 1525
Lith loci 376
lithotripsy, haemobilia 1551
Liv.52, hepatotoxicity 1286
liver
abnormalities, rare diseases with 2122–2160
age-related changes 1870–1871
functional 1870–1871
morphology 1870
biliary drainage 5
capsule stretching 443–444
divisions 5–7
1–2–20 principle 6–7, 6f
Couinaud concept 6, 6f
hemilivers 6
portal segments 6, 6f
vascular territories 6
drug-induced damage *see* drug-induced liver injury
embryology 65–71
cytokines 314t
external anatomy 3–4, 3f
extrahepatic infection 1001
functional organization 89–96
functional unit (lobule) 9–10, 9f, 11f, 80, 80f
functions *see* liver function
as haematopoeitc organ 1767, 1767t
hilus (porta hepatitis) 3, 79
histological features 9–19, 9f, 423–432
hepatocellular changes 423
inflammation 424–425
necrosis 424–425
regeneration 430
storage phenomena 428–429
vascular changes 427–428
imaging 500–548
innervation 5, 114–121
extrinsic 16
intrinsic 16–17, 16f
nerve fibre types 16–17
internal anatomy 4–5, 4f
lobes 3, 3f, 5
atrophy, simple cyst of the liver 783
caudate (Spigelian) 3
left 3
quadrate 3
right 3
lymphatics *see* lymphatics
macroscopic anatomy 3–8
morphology, functional aspects 17
neuropeptides 16–17
'nutmeg' appearance, congestive heart failure 1612
percussion 447–448
peritoneal attachments 4
prostatic cancer and 1658–1659
pulsatile 447–448
radiation injury 1277–1278
regeneration *see* regeneration
renal transplantation and 1657–1658
resection *see* hepatectomy
scarring *see* fibrosis
stress response, age-related changes 1871
structure 89
synthetic function 250–273
'transcriptome' 407
transplant *see* liver transplantation
vascular development 69–70
volume, age-related changes 1870
liver adenomatosis
definition 1430
diagnosis 1431
management 1432
liver biopsy 489–499
acute fatty liver of pregnancy 1882, 1883
acute graft-*vs.*-host disease 1673, 1674f
alcoholic cirrhosis 1166
alcoholic hepatitis 1163
alcoholic liver disease 491–492, 1154
alpha-1-antitrypsin deficiency 1332, 1333
Amanita phalloides poisoning 1271
angiosarcoma 1458
bile duct injury, post-cholecystectomy 1959
biliary hamartomas 1574
bleeding risk 1788t
brucellosis 1003

liver biopsy (*continued*)
Budd–Chiari syndrome 1406, 1408, 1409
cholesteryl ester storage disease 1366
cirrhosis 614
coagulation limits 1787
coeliac disease 1629
complications 495–497
congenital syphilis 1007
contraindications 489
cystic fibrosis 1340
diffuse lesions 489
drug-induced liver injury 1216
fatty liver disease 491–492, 492f
fixation 9
focal lesions 489, 490f
frozen section 491
granulomatous hepatic tuberculosis 1006
haemangioma 1427
haematopoietic stem cell transplantation 1675–1676
haemobilia 1551, 1553
haemochromatosis 494, 496f, 1326
hepatic iron storage disorders 494
hepatitis C
chronic 493f, 888
recurrence, post-liver transplantation 2014–2015
hepatocellular carcinoma 497f, 498
histoplasmosis 1015
HIV–hepatitis B coinfection 976–977
immunohistochemistry 491, 491f
indicated biopsies 494–495
indications 489, 489t, 1900
interpretation errors 490
intrahepatic cholestasis 1492
laparoscopic 497–498, 497f, 497t
Legionnaire's disease 1618
lesional patterns 489
liver transplantation 494–495
post-operative 2019–2020
rejection 495, 1866
mastocytosis 1644
metabolic liver disease 494
methotrexate-induced hepatotoxicity 1646
molecular biology examinations 491
necessity 1900
Niemann–Pick disease 1365
non-alcoholic fatty liver disease 491–492, 1200–1201, 1200f
children 1855–1856
non-alcoholic steatohepatitis 492, 1200–1201, 1200f
non-invasive tests *vs.* 1900
'normal' 489–490
null biopsies 494
observer variation 434
paracoccidioidomycosis 1016
percutaneous 490
pregnancy 1879
primary biliary cirrhosis 1074
processing methods 490–491
protocol biopsies 495
puncture site 489
reports, changing patterns 433
Reye syndrome 1825
rheumatoid arthritis 1696
sample size 434, 489, 1900
sampling error 434
sampling variability 434
sarcoidosis 1711
scoring system 433–440
advantages 433–434
cohort studies 433–434
limitations 434
treatment decision making 433
sensitivity 1900
sinusoidal dilatation 1413
sinusoidal obstruction syndrome 1412
staining 491
storage 490–491
structural lesions 489
systemic amyloidosis 1705
techniques 490–491
tract plugging, collagen 1792
transjugular 490
viral hepatitis, chronic 492–494, 492f, 493f, 494f, 495f
wedge 490
Wilson's disease 1299, 1317
Wolman's disease 1366
liver bud 65–66
expansion 65–67, 66f
liver cell(s) 89
age-related changes 1870
dysplasia, histological features 430
plates *see* liver cell plates
pleomorphism 429
primary carcinoma 1437–1456
proliferation control 274–280, 275–278
ageing liver 276
chronic liver disease 276
liver cancer 276–278, 277f, 278f
society 60–61, 61f
see also individual types
liver cell plates 89, 90f
compartmentalized gene expression 90–91
blood composition 90
blood oxygen level 90–91
hormones 91
microcirculation 90
regulation 90–91
gene expression 90–91
metabolic differences across 91–93
see also specific metabolic processes
liver cell rosettes 425
cholestatic 425
liver complex IV *see* cytochrome oxidase
liver disease
acute
chronic *vs.* 1899–1900
coagulation disorders 257–258, 1780t, 1785
hepatocyte apoptosis 340
liver function tests 476
alcohol consumption 1901
anaesthesia and *see* anaesthesia and liver disease
biochemical investigations 451–467
hepatic excretory function markers 459–465
hepatic synthetic function markers 454–459
hepatocellular damage markers 451–454
cardiopulmonary examination 447
cardiovascular manifestations 1721–1731
cell death targeting treatment 343–345, 343f
children 1845–1869
chronic
acute *vs.* 1899–1900
coagulation disorders 258, 1780t, 1785
contraception 1887
drug pharmacokinetics 1913
fibrinolysis *see* fibrinolysis
hepatocyte apoptosis 340
iron metabolism 1769
liver function tests 476
liver sinusoidal endothelial cells 32–33
osteodystrophy 218
pregnancy 1886
Sjögren syndrome 1697
telomere shortening/senescence 276
vitamin K-dependent factors 258
complication prevention 1902–1903
diagnosis 1899–1901
extrahepatic manifestations 1900–1901
dietary management 1901
diminished energy requirements 1837
driving capacities 1902
drug prescribing 1912–1921
practical recommendations 1917–1919, 1918t
elderly 1870–1878
endocrine system, effects on 1732–1766
family history 445
follow-up 1902–1903
liver transplantation, need for 1903
genetic basis *see* genetics and liver disease
haemolysis 1769
hepatic removal kinetics 475
hepatic *vs.* cholestatic 1900
hepatotoxicity risk 1917, 1917t
immunoglobulins 328–329
increased energy requirements 1837
management 1897–1930
medical history, past 445
neurological examination 449
neurological manifestations 1822–1828, 1823–1824t
nutrition 1905–1911
oral manifestations 1798
palmar erythema 446
pathophysiological consequences 1938–1941
acid–base balance 1940
cardiovascular 1938–1939, 1942
coagulation 1940, 1943
electrolyte balance 1939
glucose homeostasis 1939–1940
hepatic encephalopathy 1940
renal 1939
respiratory 1939
patient general appearance 445
physical activity 1901
polygenic 371–383
approaches to study 372
pregnancy 1879–1896
rest 1901
sexual activity 1902
signs/symptoms 443–450
systems review 445
toxicity cofactors 1901
see also individual diseases/disorders
Liver Disease Quality of Life Questionnaire (LDQOL 1.0) 2067
Liver Disease Symptom Index 2067
liver failure
acute *see* acute liver failure (ALF)
chronic
cytokines 314t
hepatocyte transplantation 2037, 2038t
disseminated intravascular coagulation (DIC) *vs.* 1782
fulminant *see* fulminant hepatic failure (FHF)
hepatitis D 878
postoperative *see* postoperative liver failure (PLF)
primary biliary cirrhosis 1081
liver flap *see* asterixis (flapping tremor)
liver flukes 1044–1047
cholangitis 1547, 1547t
definition 1044–1045
see also individual types
liver function 89–128
metabolism *see* metabolism
neural modulation 114–121, 116f
anatomy 114–119
hemodynamics 115
immune cell function 120
metabolism 115–119
regeneration 119–120
sinusoidal hemodynamics 115
see also afferent hepatic nerves; efferent hepatic nerves
sexual dimorphism 1689
signalling *see* signal transduction
tests *see* liver function tests
transport processes 109–114
in vitro investigations 121–128
adult stem cells 123
cell hybrids 123
cloned proteins 124–125
hepatoma cell lines 123
isolated cholangiocytes 123
isolated hepatocytes 122–123
isolated subcellular fractions 123–124
liver slices 122
perfused liver 122
see also specific functions
liver function reserve
Child–Pugh classification 1934, 1934t, 1938
portal vein embolization and 1934
preoperative assessment 1933, 1934, 1938
liver function tests
acromegaly 1689
acute fatty liver of pregnancy 1881–1882
age-related changes 1870–1871
angiosarcoma 1458
coeliac disease 1628t, 1629
congenital hepatic fibrosis 782
cystic fibrosis 1339, 1340
diabetes mellitus 1681
Gaucher's disease, type 1 1361
giant cell arteritis 1698
growth hormone deficiency 1690
hepatic removal kinetics 475–476, 475t
hepatitis B, acute 869
hepatocellular carcinoma 1446
Hodgkin's disease 1663
intrahepatic cholestasis of pregnancy 1880

Lyme disease 1644, 1808
mastocytosis 1644
myeloid metaplasia 1665
Niemann–Pick disease 1365
non-alcoholic fatty liver disease 1199
diabetes mellitus and 1682
non-alcoholic steatohepatitis 1199
obstructive jaundice 1507
oral contraceptive-induced abnormalities 1688
peliosis hepatis 1412
polycystic liver disease 796
polymyalgia rheumatica 1698
pre-eclampsia 1884
pregnancy 1879
quantitative 475–476, 475t
surgical risk assessment 476
therapeutic response assessment 476
rheumatoid arthritis 1696
Rift Valley fever 991
syphilis 1007
systemic amyloidosis 1705
Wilson's disease 1320
see also individual tests
liver injury
acute
hepatic stellate cell replacement 285–286
hepatocyte replacement 281–282
apoptosis 340
chronic
hepatic stellate cell replacement 286
hepatocyte(s) proliferation 282
hepatocyte replacement 282
drug-induced *see* drug-induced liver injury
heat stroke 1278
lipopolysaccharide-induced 410, 414
natural toxin-induced 2105–2121
non-drug chemical-induced 2105–2121
pharmacokinetics 1913
physical agent-induced 1277–1280
toxic *see* toxic liver injury
traumatic *see* liver trauma
liver/kidney microsomal (LKM) autoantibodies
autoimmune polyglandular syndrome type 1 485
type 1 (LKM-1), autoimmune hepatitis 481t, 482–483, 483f, 1090, 1091, 1092, 1093t, 1096–1097, 1101, 1120
type 2 (LKM-2), autoimmune hepatitis 1092, 1252
type 3 (LKM-3)
autoimmune hepatitis 483, 1092
chronic hepatitis C 485
chronic hepatitis D 485
liver-kidney transplantation
hepatic cysts, ADPKD 794
hereditary fibrinogen amyloidosis 1707
liver micro-organs 2045–2046
liver regeneration *see* regeneration
liver resection *see* hepatectomy
liver rupture, pregnancy 1884
liver sinusoidal endothelial cells (LSEC) 13–14, 14f, 29–35, 672–673, 672f
ageing 33
angiogenesis 30
antigen uptake 30
apoptosis, cold ischaemia 352
endocytotic mechanisms 29–30
endotoxin, response to 1140
extracellular matrix production 591
fenestrations (pores) 13, 29, 29f
loss 591
homeostatic role 29–30
hyaluronate uptake 30
hypothermia 352
immunity 30
inflammation 30
liver conditions 31–33
molecular biology 30–31
pseudocapillarization 33
sieve plates 13
signalling 30–31, 31f
as sphincters 81
vasculogenesis 30
liver slices, liver function models 122
liver–small intestine transplant, TPN-related liver disease 1638–1639, 1639f
liver stem cell niche 60
liver support 2044–2052
artificial systems 2047–2048
clinical practice implications 2049
mortality effects 2049t
bioartificial *see* bioartificial liver support
clinical practice implications 2048–2049
future prospects 2049–2050
historical aspects 2043–2044
ideal requirements 2043
detoxification 2043
synthesis functions 2043
limitations 2044
mortality effects 2049t
safety 2049
see also specific systems
liver tears, acute myocardial infarction 1611
liver transplantation 1963–2052
acute liver failure 1307–1309, 1986
children 1859–1860
indications 1307
patient selection 1307, 1307t, 1308t
adenovirus infections 968
alcoholic cirrhosis 1183–1184
testicular endocrine dysfunction improvement 1758
alcoholic hepatitis 1183
alcoholic liver disease 1157, 1987
extrahepatic complications 1185–1186
alcoholism management 1183–1185
patient selection 1183–1184
post-transplant 1184–1185
pre-transplant 1183–1184
alpha-1-antitrypsin deficiency 1334, 1850, 1988
alveolar echinococcosis 1054
anaesthesia 1941–1943
acid–base balance 1942
blood loss/transfusion 1943
cardiovascular problems 1942, 1996, 1997–1998
coagulopathies 1943, 1997
consciousness levels 1997
electrolytes 1942, 1996–1997
emboli formation 1997
equipment 1997
intraoperative care 1997–1998
laboratory tests 1997
medications 1997
monitoring/venous access 1942, 1943
preoperative assessment 1996–1997
renal issues 1942, 1996–1997
respiratory issues 1996
specific problems 1942–1943
see also individual drugs
anatomical abnormalities 1990
angiography 539
ascites 671
autoimmune hepatitis 1100–1101, 1987, 2016
auxiliary *see* auxiliary liver transplantation
bile duct anastomosis 1969–1970
hepaticocholedochojuejunostomy 1969
side-to-side 1969–1970, 1969f
biliary complications 2023
postoperative care 2000
bone disease, postoperative 1830t, 1832–1833
Budd–Chiari syndrome 1405, 1410, 1988
carcinoid tumours 1476
cardiac output changes 1722
children 1865–1867
acute liver failure 1859–1860
complications 1865–1867
indications 1865
surgical complications 1865
cholangiocarcinoma 1600, 1988
chronic hepatitis B antiviral therapy 934
cirrhosis 616
hepatic resection *vs.* 1933
testicular endocrine dysfunction improvement 1758
cirrhotic cardiomyopathy 1185–1186
cold ischaemia 352
contraindications 1903, 1922, 1989–1990
advanced age 1989
anatomical abnormalities 1990
coronary artery disease 1989
cystic echinococcosis 1050–1051
cystic fibrosis 1855
cytomegalovirus infection 962–963
diabetes mellitus 1736, 1990
disease-specific indications 1986–1989, 1986t
elderly 1874
en bloc harvesting/preservation 1965–1966
epithelioid haemangioendothelioma 1460
epithelioid haemangioendotheliomas 1988
extrahepatic malignancies 1922
familial hypercholesterolaemia 1367
fibrolamellar carcinoma 1988
follow-up, ultrasonography 501t
Gaucher's disease 1364
glycogen storage disease type 4 1861
grafts *see* grafts
graft suitability 1965, 1965f
granulomas 1714
haemangiosarcoma 1988
haemochromatosis 1988
haemostasis 259–260
heat stroke 1278
hepatic artery lesions 1392
hepatic cysts 794
hepatic encephalopathy 748
persistent chronic 749
hepatic metastases 1469
hepatitis A vaccines 901
hepatitis B recurrence 2010–2012
lamivudine therapy 2011–2012
pre-transplant replication status 2010
hepatitis C recurrence 1990, 2012–2015
anti-HCV immune globulin 2014
antiviral therapy 2013–2014
gene array data 409
identification of 2012–2013
liver biopsy 2014–2015
living donor grafts 2013
natural history 2012, 2012f, 2013f
prevention 2013, 2014f
quality of life 2027
retransplantation 2015
treatment 2014–2015
hepatitis D–hepatitis B virus coinfection 935–936
hepatoblastomas 1988
hepatocellular carcinoma 1447–1448
adjuvant therapies 1448
priority policies 1448
recurrence rate 1447
tumour size 1447
hepatopulmonary syndrome 722, 725t, 1989, 1996, 1999
hepatorenal syndrome 1999
type 1 715
type 2 716
hereditary haemorrhagic telangiectasia 1422
historical aspects 1984
HIV–hepatitis C coinfection 982
HIV infection 1922, 1990
hypersplenism 777
hypothermia 1942–1943
imaging
postoperative 2019
preoperative 1985
immunosuppression *see* immunosuppression, liver transplantation
indications 1922
induction agents 1942
laboratory tests 1997
Langerhans cell histiocytosis 1618–1619
liver biopsy 494–495
indicated biopsies 494–495
null biopsies 494
protocol biopsies 495
living donor *see* living donor liver transplantation (LDLT)
malnutrition 1907, 1907t
medications 1997
minimal listing criteria 1985–1986
Child–Turcotte–Pugh 1985, 1985t
Model for EndStage Liver Disease 1184, 1448, 1912, 2070
paediatric endstage liver disease 1985–1986
neuroendocrine tumours 1988
non-alcoholic fatty liver disease 1202
number performed 1984f
nutritional therapy 1909–1910

liver transplantation (*continued*)
obesity 1990
outcomes research 2069–2070
patient evaluation 1922
patient selection criteria 1922
pharmacological agents 1966
polycystic liver disease 1988
portal hypertension, children 1864
portal vein thrombosis 1968
portopulmonary hypertension 723–724, 725t, 1989–1990
postoperative care 1998–2001, 2019–2026
assessment 1998
biliary complications 2000
bleeding 1999–2000
cardiac issues 1998–1999
cutaneous manifestations 1809
drug-induced seizures 2001
electrolyte issues 1999
haematological abnormalities 1772–1774
histological changes 2024
imaging 507–508, 1998, 2019
infectious issues 2001
intensive care unit 1998
late mortality 2020
liver biopsies 2019–2020
long-term monitoring 2019–2020
mechanical ventilation 1999
medications 2000
metabolic issues 2001
neurological assessment 1998
neurological issues 1826–1827, 2000–2001
outpatient management 2019
patient education 2020
renal issues 1942, 1999
respiratory issues 1999
vascular complications 2000
pregnancy 1888–1889, 2024
preoperative assessment 1984–1985
alcohol abuse 1985
cardiopulmonary 725, 1985
drug abuse 1985
elderly 1874
imaging 1985
ultrasonography 501t, 507
viral serology 1985
preservation 1965–1966
organ viability maintenance 1966
pharmacological agents 1966
pretransplant patients
bridging to transplant 1923–1925
early post-transplantation mortality 1925–1926
long-term post-transplantation outcome 1926–1928
management 1922–1930
primary biliary cirrhosis 1084, 1986–1987, 2015
primary sclerosing cholangitis 1106, 1108–1109, 1625
ulcerative colitis and 1625
progressive sclerosing cholangitis 1951
pulmonary disease 1989–1990
quality of life 2027–2031
employment 2030
future trends 2030
health limitations 2030
measurement 2027–2028
outcomes 2029–2030
pain 2030
psychosocial adaptation 2027
questionnaires 2028–2029
sleep alterations 2030
symptom relief 2030
recipient hepatectomy 1966–1967
bypass 1967
recipient transplantation 1967–1968
arterial reconstruction 1967, 1967f
vena cava anastomosis 1967, 1967f
recurrent disease 2010–2018, 2010t
alcohol abuse 2016–2017
autoimmune diseases 2015–2016
autoimmune hepatitis 2016
Budd–Chiari syndrome 2017
non-alcoholic fatty liver disease 2017
primary sclerosing cholangitis 2015–2016
see also specific diseases
rejection 2000
acute 1866
alcoholic liver disease 1184
children 1866–1867
chronic 2023
cytomegalovirus infection 962–963
elderly 1874
hepatocyte transplantation 2032
late acute 2023
liver biopsy 495, 1866
pregnancy 1889
treatment 2004
vanishing bile duct syndrome 1113t
renal failure 1990
sarcoidosis 1712
sequential harvesting 1966
smoking 1990
split liver *see* split liver transplantation
surgical complications 2023
surgical techniques 1965–1983
systemic hereditary amyloidosis 1707
total parenteral nutrition-related liver disease 1638–1639
type 1 glycogen storage diseases 1861
ultrasonography 507–508
vanishing bile duct syndrome 1116
viral serology 1985
waiting list numbers 1984f
Wilson's disease 1319, 1853
see also hepatocyte transplantation; *specific types*
liver trauma 1953–1958
angiographic embolization 1957
angiography 536, 536f, 1955, 1955f
blunt 1953, 1956
complications 1957, 1958t
diagnosis 1954–1956
haemobilia 1551–1552
imaging 1954–1956, 1955f
initial patient assessment 1953–1954
injury severity classification 1953, 1954t
investigations 1954–1956, 1954t
management 1956–1957
algorithm 1957f
conservative 1956, 1956t
mechanism of injury 1953
penetrating 1953
surgical intervention 1956–1957, 1957t
damage control 1956–1957
indications 1956, 1956t
liver tumours 1425–1478
benign 1427–1436
magnetic resonance imaging 523–525
Budd–Chiari syndrome 1405
children 1862–1864, 1863t
c-Jun 275
cytokines 314t
drug-induced 1214t, 1257–1261, 1259t
endocrine manifestations 1762–1763
extrahepatic biliary obstruction 1507
extrahepatic congenital portosystemic shunt 1419
gonadotrophin secretion 1763
hepatic progenitor cells 61–63, 62f
HIV infection 984–985
hypercalcaemia 1763
initiation 1257–1258
isosexual precocity 1763
malignant 1437–1463
magnetic resonance imaging 525–527
metastatic 1464–1478
morphometry 438
mutations causing 1258
nodules 562
positron emission tomography 561–564
pregnancy 1886
promotion 1257–1258
radiation-induced 1278
status, hepatic resection and 1933
stepwise development 1258
telomere shortening/senescence 276–278, 277f, 278f
tumour necrosis factor (TNF) *see* tumour necrosis factor (TNF)
see also individual types
Liver Tumour Study Group, Société Internationale d'Oncologie Pediatrique (SIOP), hepatoblastoma guidelines 1864
living donor liver transplantation (LDLT)
acute liver failure 1308–1309, 1309t
adults 1990–1992
advantages 1991
biliary tract complications
bile leaks 1979, 1982
biliary strictures 1982–1983
donor 1979
recipient 1982–1983
children 1865
disadvantages 1991
donor evaluation 1977, 1992
blood typing 1992
medical examination 1977, 1992
donor outcome 1979
biliary complications 1992
mortality 1979, 1991, 1992
quality of life 1979, 1992
donor surgery 1977–1979
cholecystectomy 1978
graft removal 1979
hepatic venous system 1978, 1978f
liver dissection 1977–1978, 1977f
parenchyma transection 1978–1979, 1978f
hepatitis C recurrence, post-transplant 1992, 2013
hepatocellular carcinoma 1447–1448
historical aspects 1990–1991
number performed 1991f
patient management 1928–1929
pretransplant patients management 1928–1929
recipient evaluation 1980, 1991
recipient outcome 1980–1983, 1992
bacteraemia 1982
biliary infection 1982
complications 1980–1981
disadvantages 1991
graft dysfunction 1981
hepatic artery thrombosis 1981–1982
outflow obstruction 1982
portal vein thrombosis 1982
postoperative haemorrhage 1981
recipient surgery 1980
anhepatic phase 1980
native liver dissection 1980
revascularization 1980, 1981f
surgical techniques 1976–1983
LM autoantibodies, autoimmune polyglandular syndrome 483f, 485
lobar pneumonia, hepatic involvement 1618
lobular disarray 429
lobular hepatitis, chronic 429
lobular inflammation, acute graft-vs.-host disease 1673
lobule 9–10, 9f, 11f, 80, 80f
Loeffler syndrome 1059
logistic regression analysis 2061, 2062
loins, examination 448
long-chain-3-hydroxyacyl coenzyme A dehydrogenase deficiency 1881
long-chain acyl-CoA dehydrogenase (LCAD) 154
deficiency 2143
long-chain fatty acids
activation 152, 153f
mitochondrial β-oxidation 154–155, 154f
mitochondrial uptake 152–154, 153f
Long Evans Cinnamon (LEC) rat, Wilson's disease animal model 1320–1321
lonidamide 1217
loop diuretics
ascites 690–691
urea synthesis inhibitors 183
lopinavir, hepatotoxicity 983–984
lorazepam 1180
low-density lipoprotein (LDL)
abetalipoproteinaemia 1366
catabolism 136–137
characteristics 134t
cholesteryl ester storage disease 1365
clearance 138
familial hypercholesterolaemia 1367
formation 138
receptor 138
low-density lipoprotein receptor-related protein (LRP) 138
low-molecular-weight heparin (LMWH)
acute portal vein thrombosis 1397
Budd–Chiari syndrome 1409
low phospholipid-associated cholelithiasis syndrome (LPAC) 1385, 1491, 1495
low T_3 syndrome 1748t, 1749
thyroid function tests 1748t
L-protein *see* hepatitis B virus (HBV)
LPS binding protein (LBP), Kupffer cells 37
LP-X, cholestasis 459

LTD QOL, liver transplantation quality of life 2029
luminal acid hydrolases 24
lung cancer
alcohol consumption 1186
hepatic involvement 1619
lung disease, liver in 1616–1621
lupoid hepatitis 1695
lupus anticoagulant test, antiphospholipid antibody syndrome 1695
lupus pernio 1643
luteinizing hormone (LH) 1686–1687
alcoholics 1186, 1758
cirrhosis 1758, 1760
functions 1687
men 1754–1755
structure 1686
luteinizing hormone releasing hormone (LHRH) antagonists, acute porphyrias 1345
Lutz–Richner syndrome 2144
luxury perfusion 744
LX-1 line, hepatic stellate cells 48
LX-2 line, hepatic stellate cells 48
Lyme disease (LD) 1007, 1644, 1808
lymph 84–88
lymphangiectasia, chylous ascites 669
lymphangiogenesis 86
lymphangions 84
lymphangitis, portal hypertension 768
lymphatic cholangitis 425
lymphatic pump 86
lymphatics 5, 16, 79, 84–88, 673
biophysics 84–85
cannulation 85
central venous pressure 86–87, 86f
chylous ascites 669
contractions 85–86
diseases, effects on liver 1662–1670
dysfunction 87
flow increases 87–88
cirrhosis 88
functions 85
interaction 87
lymphatic valves 84–85
lymph nodes 85
bacterial translocation 762
hilar (upper duct) cholangiocarcinoma *vs.* 1597
metastases, mass forming cholangiocarcinoma 1586
lymphocyte proliferation assay
drug-induced liver injury 1224
immunoallergic hepatitis 1226
lymphocytes 14, 320–325, 320t, 479, 479f
definition 320
function 320, 323t
hepatitis C virus 852
inhibitors, immunosuppressive therapy 2006–2009
liver fibrosis 323
localization 320
trafficking inhibitors, immunosuppressive therapy 2008–2009
see also specific types
lymphocytic phlebitis, alcoholic hepatitis 1151
lymphocytic piecemeal necrosis 424
lymphogranuloma venereum 1004
lymphoid dendritic cells 321
lymphoid leukaemia, hepatic involvement 1664
lymphoma(s)
B cell 1663
drug-induced 1259t, 1261
granulomas 1714
HIV infection 985
intrahepatic cholangiocarcinoma *vs.* 1597–1598
non-Hodgkin's *see* non-Hodgkin's lymphoma
ultrasonography 505
lymphoplasmocytic cholangitis 1596
lymphoproliferative disorders
Gaucher's disease type 1 1361
HCV-associated 1772
post-transplant *see* post-transplant lymphoproliferative disorder (PTLD)
lymph:plasma ratio, cirrhosis 675
Lypocodium serratum (Jin Bu Huan), hepatotoxicity 1282t, 1283
lysine acetylsalicylates
cirrhosis, drug-induced renal impairment 702
prostaglandin E_2 levels 702
lysophosphatidylcholine 139, 140f
lysosomal acid lipase (LAL) deficiency 1365–1366
lysosomal storage disorders 1360–1366
children 1862
see also individual disorders
lysosomes 24–25, 25f
primary 25
secondary (mature) 25
lysyl hydroxylases 266
lysyl oxidases 266
lytic necrosis 424

M

macroautophagy 148–149, 148f
macrocytes, chronic liver disease 1768
macrocytic anaemia
alcoholic cirrhosis 1166
cirrhosis 610
macrocytosis
alcohol abuse 1187
chronic liver disease 1768
macronodular cirrhosis 604
macronodules 430
macrophagal myofasciitis (MMF), hepatitis B vaccine 910
macrophages, fibrosis reversal 586
macrosteatosis *see* fatty liver disease (FLD)
macrovesicular steatosis
alcoholic 1148, 1148f, 1159–1161, 1246
clinical manifestations 1160
diagnosis 1160
imaging 1160
laboratory values 1160
natural history 1160
pathogenesis 1160
treatment 1160
causes 1243
drug-induced 1243
histological features 428
total parenteral nutrition-related liver disease 1634–1635
Maddrey's discriminant function (DF), alcoholic hepatitis 1163
Madelung's disease 1186
magnesium
deficiency, renal tubular acidosis-associated liver disease 1819
supplementation 1908
magnetic resonance angiography (MRA) 522, 522f
azygos blood flow measurement 570
hilar (upper duct) cholangiocarcinoma 1593
magnetic resonance cholangiography
AIDS-related cholangitis 1546
alveolar echinococcosis 1053
Caroli syndrome 805
cholecystolithiasis 1527, 1528f
choledocholithiasis 1527, 1528f, 1542
chronic portal vein thrombosis 1398, 1398f
magnetic resonance cholangiopancreatography (MRCP)
bile duct stones 541–542, 541f
endoscopic retrograde cholangiopancreatography *vs.* 541
biliary hamartomas 799–800, 799f
biliary strictures 542
cholangiocarcinoma 530, 530f
extrahepatic biliary obstruction 1508, 1509
gallbladder dysfunction 1564
hilar (upper duct) cholangiocarcinoma 1593
intrahepatic cholestasis 1492
liver trauma 1956
peribiliary cysts 803, 804f
primary sclerosing cholangitis 1106, 1489
sphincter of Oddi pancreatic-type dysfunction 1570
magnetic resonance imaging (MRI) 521–531, 1432, 1433f
alcoholic macrovesicular steatosis 1160
alveolar echinococcosis 1053, 1053f
amoebic liver abscess 530, 1025
angiomyolipoma 523–524
angiosarcoma 526–527
bile system 530–531
biliary cystadenoma 526, 814
biliary hamartomas 523, 799, 799f, 800f, 1574
biloma 817
Budd–Chiari syndrome 1408, 1409
carcinoid tumours 1473, 1473f
chemical shift imaging method 521
cholangiocarcinoma 526, 528f
hilar (upper duct) 1590f, 1591, 1592f
intraductal 1591
intrahepatic 526, 528f, 1595
periductal infiltrating 1591, 1593f, 1595
ciliated hepatic foregut cyst 808
cirrhosis 613, 613f
coils 521
contrast enhancement 522–523
extracellular agents 522–523, 529
hepatobiliary agents 523
cystadenocarcinoma 526
cystic metastases 815
diffuse liver disease 529
endoscopic retrograde biliary drainage and 1936
extrahepatic biliary obstruction 1508, 1509
fat-suppressed imaging 521
fibrolamellar carcinoma 525, 525f
field strength 521
focal liver lesions 523–529
focal nodular hyperplasia 525, 525f, 1260, 1429–1430, 1430t
gallbladder carcinoma 1577, 1577f
gallbladder dysfunction 1564
haemangioma 524, 524f, 1427
haematoma 817
haemochromatosis 529
hepatic abscess 529–530
hepatic cysts 523, 523f
hepatic cysts, ADPKD 791–792, 791f
hemorrhagic 792, 792f
hepatic encephalopathy 732, 733f
hepatic metastases 1467–1468
hepatic steatosis 528f, 529
hepatic tumours, benign 523–525
hepatocellular carcinoma 525–526, 526f, 527f, 1443
cystic 815
percutaneous ablation 553
hepatosplenic candidosis 1012
hydatid cysts 530
hydatid disease 530
inflammatory liver disease 529–530
iron deposition 529
liver cell adenoma 524
liver metastases 527–529
liver trauma 1956
lower duct cholangiocarcinoma 1594
malignant hepatic tumours 525–527
nodular regenerative hyperplasia 1434
non-alcoholic fatty liver disease 1200
diabetes mellitus and 1682
non-alcoholic steatohepatitis 1200
opposed phase imaging technique 521
pancreatic pseudocysts, liver 811
paramagnetic contrast agents 522
peliosis hepatis 811–812
peribiliary cysts 803, 804f
post-liver transplantation 2019
primary biliary cirrhosis 1074
radiation hepatitis 1278
short time inversion recovery technique (STIR) 521
simple cyst of the liver 784
haemorrhagic 785, 785f
sinusoidal dilatation 1413
superparamagnetic contrast agents 522, 523, 529
T1-weighted imaging 521
T2-weighted imaging 521
technical aspects 521–522
vascular imaging 521–522
visceral larva migrans 1063
Wilson's disease 1316
magnetoencephalography, hepatic encephalopathy 738, 738f
Ma-Huang, hepatotoxicity 1282t, 1283
Mainzer–Saldino syndrome 2144
major histocompatibility complex (MHC) 364–365
clusters/superclusters 365
drug-induced acute hepatitis 1224, 1226
HLA alleles *see* HLA (human leukocyte antigen) system
immunogenetic studies 364–368, 365t, 369–370
areas of interest 365

major histocompatibility complex (MHC) (*continued*)
autoimmune liver disease 365t, 366–367, 366t, 368, 368t
viral hepatitis 365t, 367–368, 370t
liver sinusoidal endothelial cell expression 30
natural killer cells 320
TNF cluster *see* tumour necrosis factor (TNF)
xMHC region 365
see also HLA (human leukocyte antigen) system; *specific genes/regions*
malabsorption
effects of liver disease 1801–1802
hepatobiliary system, effects on 1628–1630, 1628t
primary biliary cirrhosis 1079
malaria 1029–1034
aetiology 1030
cerebral 1030
clinical manifestations 1030–1031
diagnosis 1031–1032
endemic 1030
epidemic 1030
epidemiology 1029–1030
geographical distribution 1029–1030, 2100–2104t
hepatic dysfunction
anatomopathological findings 1031
clinical manifestations 1031
pathogenesis 1030
pigment granules 1031
pregnancy 1030, 1888
prevention 1033–1034
severe 1031
transmission 1029
treatment 1033
vaccine 1034
malarial hepatitis 1031
coexisting viral hepatitis
acute 1032–1033
chronic 1033
diagnosis 1032–1033
differential diagnosis 1032–1033
fulminant hepatic failure simulating 1033
treatment 1033
type A 1031
type B 1031
malaria pigment 429
malate 155
MALDI-TOF, protein identification 405
malignancies
Epstein–Barr virus infection 964
haemobilia 1553
post-liver transplant immunosuppression 2004
vanishing bile duct syndrome 1114t, 1116
see also liver tumours; *individual tumours*
malignant ascites 668–669
albumin serum–ascitic fluid gradient 668, 669f
cytology 668
malignant fibrous histiocytoma 1461
malignant haemangioendothelioma *see* angiosarcoma
malignant mesenchymoma *see* undifferentiated sarcoma
malignant rhabdoid tumour 1461
Mallory bodies 423
alcoholic hepatitis 1149–1150, 1150f
Mall space 16
malnutrition 445, 1836–1842
albumin levels 455
alcoholic cirrhosis 1165–1166
alcoholic hepatitis 1164
management 1839
alcoholic liver disease 1179, 1186
bilirubin toxicity 170
clinical outcome 1907
impact of 1838
insulin-like growth factor binding proteins regulation 1743
insulin-like growth factor-1 1743–1744
liver transplantation outcomes 1907, 1907t
management 1838–1840
pathogenesis 1906
pharmacological therapy 1909
preoperative 1838
pretransplant patients 1925
prevalence 1905–1906, 1906f
pseudocholinesterase 457
recurrent pyogenic cholangitis 1545
malondialdehyde-acetaldehyde adducts (MAA) 1141
malonyl-CoA 161
Malpighian corpuscles 771
MALT type B-cell lymphoma 1663
mangafodipir trisodium (Mn-DPDP) 523, 529
manganese 233t, 237
absorption 237
deficiency 233t
fatty liver disease 237
function 237
hepatotoxicity 2111
total parenteral nutrition-related liver disease 1636
toxicity 237
hepatic encephalopathy 732, 737
mannitol
acute liver failure, neonates 1859
cerebral oedema 1305
hepatic encephalopathy 748
obstructive jaundice 1511
obstructive jaundice-associated acute renal failure 1816
mannosidosis 2144–2145
manometry
sphincter of Oddi dysfunction 1567
biliary-type 1568–1569, 1569–1570, 1569f
pancreatic-type 1570
sphincter of Oddi motility 309–310, 309f, 310t
Marburg virus infections 991–992
aetiological agent 991–992
clinical manifestations 992
diagnosis 992
epidemiology 991–992
laboratory findings 992
pathogenesis 992
pathology 992
treatment 992
marginal cost-effectiveness ratio 2084
marginal zone (sinus), spleen 772
B cells 772
Margosa oil, hepatotoxicity 1282t
Markov models, decision analysis 2083
Maroteaux–Lamy syndrome 2145
mass forming cholangiocarcinoma *see* cholangiocarcinoma
mass spectroscopy (MS), proteomics 399, 405, 414–415
mastocytosis
cutaneous 1644
hepatic involvement 1667
mathematical models 2055–2064
definition 2055
generic models 2055, 2055f
types 2055t
see also specific types
Mathias syndrome 2145–2146
matrix metalloproteinases (MMPs)
cancer metastasis 1465
extracellular matrix degradation 270
hepatic stellate cell activation 584
immunogenetics of liver disease 369–370
maturation arrest 61
Mauriac syndrome 1681
Mayo Clinic primary biliary cirrhosis model 1080, 1786t, 1986–1987
McArdle disease 1370
MDM2 gene/protein 393–394
MDR1 p-glycoprotein (ABCB1) 113
MDR-related protein 2 (MPR2) *see* ABCC2
mean wall thickness, bone 1831
measles 966–967
diagnosis 966–967
hepatitis 967
mebendazole (MBZ)
alveolar echinococcosis 1055
ascariasis 1061
cystic echinococcosis 1055
mechanical lithotripsy, choledocholithiasis 1531–1533, 1532f
mechanical ventilation, post-liver transplantation 1999
mechanic haemolysis, post-TIPS 1769
mechanism-based P450 inhibition 245
Meckel–Gruber syndrome (dysencephalia splanchnocystica) 2146
meconium ileus, cystic fibrosis 1338, 1630, 1855
Medical Outcome Survey (MOS), liver transplantation quality of life 2028
Mediterranean region
chronic hepatitis D 878–879
hepatitis B 866–867, 867
Mediterranean spotted fever 1006
medium-chain acyl-CoA dehydrogenase deficiency 2146
pregnancy 1883
medium-chain fatty acids, hepatic encephalopathy 731
medium-chain triglyceride supplements, fulminant hepatic failure 1839–1840
medroxyprogesterone, primary biliary cirrhosis 1909
mefloquine, jaundice induction 1032
megakaryocytes, myeloid metaplasia 1665
megakaryopoiesis, fetal liver 1767
megamitochondria 423
Meig syndrome 671
MELD *see* Model for EndStage Liver Disease (MELD)
melioidosis 1003
melphalan 1707
MELS system, bioartificial liver 2046–2047, 2046f
membrane transport 109–113
basolateral 385–386
channels 109–110, 109f
CTR1 112
facilitated diffusion 109–110, 109f
carrier proteins 109f, 110
channels 109–110, 109f
molecular basis *see* transport proteins
primary active transport 110
ATPases 110
secondary active transport 110
antiporters (countertransport) 110
symporters (cotransport) 110
simple diffusion 109, 109f
sinusoidal 385
see also carrier proteins; transport proteins
membranoproliferative glomerulonephritis, hepatitis C 889, 1819
membranous web, hepatitis C virus 852f, 853
memory B cells 325
meningitis
cryptococcosis 1014
cutaneous manifestations 1807
Menkes' disease 228
menorrhagia, primary biliary cirrhosis 1759
menstruation, acute porphyrias 1344, 1345
Mentha pulegium (pennyroyal oil) 1282t, 1285–1286, 2114
mercaptans, hepatic encephalopathy 730
6-mercaptopurine, liver transplantation 2008
mercury vapour, hepatotoxicity 2111
meropenem, bacterial cholangitis 1543, 1543t
merozoites
Cryptosporidium 1022
Plasmodium 1030
mesenchymal sarcoma *see* undifferentiated sarcoma
mesenchymal stem cells (MSCs), hepatocyte transplantation 2035
mesenchymal tumours, malignant 1457–1463
mesenterico-portal bypass, portal hypertension 1864–1865
mesocaval shunting, Budd–Chiari syndrome 1410
mesothelial cells, ascites reabsorption 688
mestranol 1258
meta-analysis 2073–2079
absolute risk reductions 2074
advantages 2073
diagnostic tests 2078–2079, 2079f
dropouts 2077
Forrest plot 2076, 2076f
functions 2073
Galbraith plot 2076, 2076f, 2077
number needed to treat 2075–2076
odds ratios 2074
outcome definition 2073–2074
pooled odds ratio 2074
pooled risk difference 2074
principles 2073–2074

article choice 2074
search definitions 2074
publication bias 2074–2075
assessment 2075, 2077
funnel plots 2075, 2075f
unpublished studies 2075
quality scores 2077, 2077t
random effects models 2074
representations 2077, 2078f
risk differences 2074
search definitions 2074
study design 2073
subgroup analysis 2077–2078, 2078f
metabolic acidosis
acute liver failure 1131, 1304
children 1859
diuretic-induced 691
urea synthesis 186
metabolic alkalosis
anaesthetic implications 1940
cirrhosis 186–187
urea synthesis 187
metabolic bone disease, chronic liver disease 1802
metabolic disorders
acute liver failure 1131
children 1858, 1859
auxiliary liver transplantation 1865
bile acids 174–176
children 1860–1862
hepatocyte transplantation 2032–2033, 2038, 2039, 2039t
infantile cholestasis 1846t
liver biopsy 494
neonatal acute liver failure 1857
neurological manifestations 1822, 1823t
see also individual disorders
metabolic encephalopathy 1292
metabolic syndrome
cirrhosis 610–611
hepatic iron overload 494
non-alcoholic fatty liver disease 1195
non-alcoholic steatohepatitis 1195
'metabolic zonation' 90
metabolism 91–93, 129–249
age-related changes 1870–1871
amino acids 142–149
ammonia 180–191
bile acids 174–180, 384
bilirubin 165–174, 384
carbohydrates 129–133
copper 225–232, 226f
drugs 240–248, 1912
energy formation 149–165
glucose 1680–1681
iron 220–225
lipoproteins 133–142
neural regulation 115–119
protein 142–149
degradation 191–198
synthesis 191–198
QTL analysis in inbred mice 379
retinoids 214
trace elements 232–240
urea 180–191
vitamin D 217–218
see also specific metabolic processes
metabolomics 2093
metadoxine 1160
metalloproteome 414
metallothionein 1319
copper toxicity 226
trace element toxicity prevention 238
metal stents
biliary stricture
benign 558
malignant 556, 556f
complications 546
expandable 545
plastic stents *vs.* 545–546
metastatic efficiency index 1465
metastatic liver disease 1464–1470
angiography 537t
biology 1465
cell attachment 1465
malignant cell detachment 1465
cirrhotic *vs.* non-cirrhotic livers 1464–1465
clinical signs 1466–1467
computerized tomography 518–519, 519f
cystic 815
hypervascular 519, 519f, 528
hypovascular 527–528
imaging 1467–1468
incidence 1464–1465
laboratory tests 1466–1467
magnetic resonance imaging 527–529
near isovascular 528–529
pathology 1466
positron emission tomography 564
primary sites 1464, 1464t
prognostic determinants 1467
treatment 1468–1469
ultrasonography 504t, 505
umbilication 1466, 1466f
METAVIR scoring system 435, 435t
metformin
hepatotoxicity 1683
non-alcoholic steatohepatitis 1203t
methaemalbumin 671
methicillin-resistant *Staphylococcus aureus,* pretransplant patients 1926
methimazole, hepatotoxicity 1236, 1685
methionine
hepatic encephalopathy 730
metabolism 145–147, 146f
alcohol consumption 1138
parenteral nutrition 1635–1636
methionine synthase 146–147
methodological quality, randomized trials 573, 573t
methotrexate
fibrosis induction 1249, 1413
hepatotoxicity 1213, 1249, 1646
alcohol and 1170
non-alcoholic fatty liver disease 1917
patient monitoring 1646
juvenile rheumatoid arthritis 1696
primary biliary cirrhosis 1083
psoriasis 1212
rheumatoid arthritis 1249
sarcoidosis 1712
2-methyl-4-chlorophenoxyacetic acid (MCPA), hepatotoxicity 2112
methylation, carcinogenesis and 393
methyl bromide, hepatotoxicity 2112
methyl chloride, hepatotoxicity 2112
methyldopa, hepatitis induction 1236, 1253
methylene dianiline (MDA), hepatotoxicity 1272, 2112
3,4-methylenedioxymethamphetamine *see* ecstasy
methylprednisolone
acute graft-vs.-host disease 1674
acute (cellular) rejection 2004
children 1866
pregnancy 1889
methyltestosterone, tumorigenicity 1258
methyltransferases 145–146
methysergide
carcinoid tumours 1475–1476
side-effects 1475–1476
metoclopramide 1915
metronidazole
amoebiasis 1026
bacterial cholangitis 1543t
giardiasis 1026
hepatic encephalopathy 747
total parenteral nutrition-related liver disease 1637, 1950
mevalonate, hepatotoxicity 1217
mevalonic aciduria 2146–2147
mezlocillin 1542, 1543t
MHC *see* major histocompatibility complex (MHC)
MIAME guidelines 399–400, 402
MICA genes 365
primary sclerosing cholangitis 366–367
short tandem repeats 366
MICB genes 365
mice models *see* mouse models of human liver disease
Michaelis–Menten kinetics
in vitro 468, 469f
in vivo 468–469
micocavitation, hepatic encephalopathy 732
microalbuminuria, glycogen storage diseases type I 1372
microarrays *see* gene arrays
microbodies *see* peroxisomes
microcysts, congenital hepatic fibrosis 781
microfilaments
bile vesicular trafficking 298
hepatic stellate cells 45
microhaemorrhage, acute fatty liver of pregnancy 1882
microhamartoma *see* biliary hamartomas
micronodular cirrhosis 604
micronodules 430
microorganisms, bacterial cholangitis 1541
microsatellites *see* simple repetitive sequences (SRSs)
microsomal enzyme induction, reactive metabolite formation 1221–1222
microsomal ethanol-oxidizing system (MEOS) 1136
microsomal triglyceride transfer protein (MTP) 135, 136f
ethanol-induced downregulation 1137
non-alcoholic liver disease 356
microtubules 98
bile vesicular trafficking 297–298
receptor-mediated endocytosis 99, 99f
microvesicular steatosis 1243–1244
acute fatty liver of pregnancy 1882
acute liver failure 1132
alcohol-induced 1148–1149, 1149f, 1246
clinical presentation 1161
definition 1161
natural history 1161
pathogenesis 1161
alternative energy sources 1244
drug-induced 1244, 1244f
fatty acid mitochondrial α-oxidation impairment 1243
genetic defects 1243
histology 428, 1243
total parenteral nutrition-related liver disease 1635
microvilli, hepatocytes 20f, 21
microwave ablation
hepatocellular carcinoma 553–554
liver injury 1278
micturition, changes in 444
midarm circumference (MAC) 1905
Middle East, infectious liver diseases 2103t
middle hepatic artery 532, 1391
midodrine 716, 716t
miglustat
adverse reactions 1364
Gaucher's disease 1364
migrating motor complex (MMC), gallbladder motility 306, 1562
Milan criteria, liver transplantation indication 1922
miliary granulomas, strongyloidiasis 1064, 1065f
'milky' ascites 669
miltefosine, leishmaniasis 1038, 1038t, 1039
Milwaukee classification, sphincter of Oddi biliary-type dysfunction 1567, 1568t
mineral oil granuloma 428
mineral supplementation, glycogen storage disease type I 1373
mini-asterixis
examination 741
hepatic encephalopathy 738f, 741
minilaparoscopy 498
minimal (subclinical) hepatic encephalopathy 608, 728t, 729, 743
treatment 750
minimal immunosuppression tolerance (MIST), post-liver transplant 2003
'minivariants,' hepatitis C virus model systems 853
minocycline, hepatotoxicity 1236–1237, 1648
miracidium, *Schistosoma* 1040
Mirizzi syndrome 1527, 1534–1535, 1596
endoscopic retrograde cholangiography 1535, 1535f
mitochondria 24f, 25–26, 149–165, 1377–1378
ageing 163f, 164
reactive oxygen species 164, 164t
alpha-1-antitrypsin deficiency 1331–1332, 1331f
apoptosis 338–339
aspirin-induced injury 1824
biogenesis, nuclear control 160–161

mitochondria (*continued*)
disorders *see* mitochondriopathies
DNA *see* mitochondrial DNA (mtDNA)
extrahepatic biliary obstruction 1501, 1502
fatty acid α-oxidation 152–155, 153f
fasting states 161
overfed states 161–162
fuel oxidation regulation 159–160
fuel use
fasted state 161
fed state 161
overfed state 161–162
giant (megamitochondria) 423
glutathione *see* mitochondrial glutathione (mGSH)
impairment, drug-induced acute hepatitis 1217
inner membrane (IM) 25–26
matrix 26
membranes 150
necrosis 341
nuclear control 160–161
origins 150, 150f
outer membrane (OM) 25
permeability translation 1220, 1221f
protein importation 152, 153f
pyruvate oxidation 156–158, 157f
reactive oxygen species elimination 162f, 163
reactive oxygen species formation 162–163, 162f
size 91
structure 150
tricarboxylic acid cycle 155–156, 155f
ultrastructure 24f, 25–26, 26f
urea synthesis regulation 182
Wilson's disease 1317
mitochondrial AST (mAST) 452
mitochondrial-cytopathy-diabetes mellitus-ataxia-renal tubular abnormalities 2147
mitochondrial dehydrogenases 1377, 1378
mitochondrial DNA (mtDNA) 26, 150–152, 1377, 1377f
depletion syndromes 1379
displacement loop (D-loop) 151
hydroxyl radical, effects of 351
mutation 1378–1379
replication 151f, 152
transcription 151f, 152
mitochondrial glutathione (mGSH) 201–202
alcohol-induced liver damage 204
cell death 203–204, 203f
cirrhosis 204
depletion, alcohol-induced 205
hepatotoxicity 205
reactive oxygen species control 201
transport 201–202
membrane lipid content 202, 204–205
regulation 202
mitochondrial monamine oxidase (MAO) 1235
mitochondrial outer membrane permeabilization (MOMP) 339
apoptosis 337
mitochondrial oxidative phosphorylation (OXPHOS) 1377
biochemical features 1377, 1378f
deficiency
diagnosis 1380–1381
differential diagnosis 1381
polarographic studies 1380–1381
therapeutic management 1381–1382
genetic defects 1378–1379
mitochondrial permeability transition pore 1220
mitochondrial single-stranded binding protein (mtSSB) 152
mitochondrial transcription factor A (mtTFA) 152
mitochondrial transcription factor B (mtTFB) 152
mitochondriopathies 1377–1382
causes 1862
children 1862
diagnosis 1380–1381, 1862
drug-induced 1379–1380
inherited 1378–1379
delayed-onset 1378, 1381
neonatal 1378
investigations 1862
management 1862
symptoms 1862
therapeutic management 1381–1382
see also individual *diseases/disorders*
mitochondriosis 423
mitogen-activated protein kinases (MAPKs) 104–105, 149
bile secretion regulation 302
docking interactions 104–105
hepatocyte signal transduction 104
as oncogene 392
HBx and 393
Smad protein regulation 2090
specificity 104–105
physical interactions 104
scaffolding proteins 104
mitomycin C, gallbladder carcinoma 1580
mitosis, acute injured livers 281
mitotic catastrophe 342, 342f
mitral valve disease 1613–1614
polycystic liver disease 796
mixed clots, haemobilia 1554, 1554f
mixed cryoglobulinaemia, hepatitis C 889, 949–950, 1772, 1818
mixed function oxidases 241
mixed hepatitis, drug-induced 1229, 1230
mizoribine 2008
Model for EndStage Liver Disease (MELD) 1985, 1986t, 2055, 2056
acute liver failure 1303
alcoholic hepatitis 1163–1164
chronic hepatitis C antiviral therapy 949
cirrhosis 615–616
drug pharmacokinetics 1913
coagulation tests 1786, 1786t
definition 2056, 2057
hepatocellular carcinoma 1988
hepatorenal syndrome 713, 713f
international normalized ratio 1786
liver transplantation 1922, 2070
patient priority 1448
pre-transplant alcoholics 1184
living donor liver transplantation 1991
recipient evaluation 1980
transjugular intrahepatic portosystemic shunt 2056, 2056t
UNOS system 1985
validation 2059–2060, 2059t, 2060f
concordance statistic limitation 2060
Molecular Adsorbents Recirculating System (MARS) 2047
acute liver failure 1305–1306
clinical studies 2047
Crigler–Najjar syndrome 1355
hepatorenal syndrome, pretransplant patients 1924
mechanism of action 2047, 2048f
Wilson's disease 1315, 1770
molecular biology 101–109
molecular chaperones 194
molecular genetics, Gaucher's disease 1364
molecular mimicry
autoimmune hepatitis 1097
primary biliary cirrhosis 1072–1073
molybdenum 233t, 238
copper interactions 238
deficiency 233t, 238
monoamide oxidase A, hepatic encephalopathy 737
monobromoethane, hepatotoxicity 2112
monochloromethane, hepatotoxicity 2112
monoclonal chimeric anti-TNF-α antibody, alcoholic hepatitis 1163
monoclonal gammopathies
hepatic involvement 1664
systemic AL amyloidosis 1703–1704
mononeuritis, viral hepatitis 1826
Monte Carlo simulations, economics 2084
Moore–Federman syndrome 2147–2148
Morinda citrifolia (noni juice), hepatotoxicity 1286
morphine, use in liver disease 1940
morphine provocation (Nardi) test, sphincter of Oddi biliary-type dysfunction 1568
morphometry 437–438
applications 437
cholestasis 438
cirrhosis 438
errors 438
fibrosis 438
fully automated analysis 437
limitations 438
liver disease 438
liver tumours 438
sampling errors 438
steatosis 438
technical considerations 437
tissue processing 438
uses 437
Morula cells 428
morulae 1006
MOS Short Form SF-36, quality of life studies 2066
motilin, gallbladder motility 306–307, 1562
motor neuropathy, acute porphyric crisis 1344
mouse fetal liver kinase (Flk-1) 30, 30t, 32
mouse mammary tumour virus (MMTV), primary biliary cirrhosis 1073
mouse models of human liver disease 371–383
advantages/utility 372, 381
complex (multifactorial) disease 372, 372f
evolutionary conservation 381
hepatocellular carcinoma 379–380
inbreeding 372, 373, 373f
QTL analysis *see* quantitative trait locus (QTL) analysis in inbred mice
recombinant inbred strains 376–377
linkage analysis 372
transgenic mice 380
workflow for gene discovery 380–381, 381f
mouth, in liver disease 1798
moxifloxacin, bacterial cholangitis 1543, 1543t
M-protein, hepatitis B virus 830–831
MRCP *see* magnetic resonance cholangiopancreatography (MRCP)
mRNA, translation to protein 191–192, 192f
mTOR 148–149
MTP1 *see* ferroportin
mucins 300
mucochloric acid, hepatotoxicity 2113
mucolipidosis type IV 2148
mucopolysaccharidosis
type 1H (Hurler syndrome) 2140
type 2 (Hunter syndrome) 2139–2140
type 3 (Sanfilippo syndrome) 2154–2155
type 1S (Scheie syndrome) 2155
type 4 (Maroteaux–Lamy syndrome) 2155
type 7 (β-glucuronidase deficiency) 2148
type 7 (di Ferrante syndrome) 2148–2149
mucormycosis 1013
mucous membranes in liver disease 1798
Muehrcke's line 447
Mulibrey nanism 2149
multidetector computed tomography (MDCT) scanners 509
multidrug resistance protein 2 (MDR2) *see* ABCC2
multidrug-resistance protein 3 (MDR3) *see* ABCB4 gene/protein
multidrug resistance-related proteins (MRPs), bile acid uptake 295, 295f, 385
multidrug-resistant 1 (MDR1) gene product 385
adaptive changes in cholestasis 386, 387f
multidrug-resistant 4 (MDR4) gene product 385–386
multifactorial cholestasis, premature infants 1849–1850
investigations 1847t, 1850
Multihance 529
multilobar cirrhosis, cystic fibrosis 1339
multinucleated hepatocytes 430
multiple myeloma 1664
interleukin-6 317–318
multiple sclerosis, hepatitis B vaccine 910

multiple sulphatase deficiency 2149–2150
multiplexin collagens 267t, 268
multispecific organic anion transporter (MOAT) *see* ABCC2
multivariate analysis 2084
multivesicular bodies (MVB) 24f, 25, 25f
Mulvihill syndrome 2150
Murphy's sign 448, 1507
Murr1 228
  copper regulatory protein 227t
  Wilson's disease 1318
muscle
  amino acid release 144–145
  ammonia homeostasis in liver disease 185
  cirrhosis
    blood flow 1725
    insulin insensitivity 1734
  cramps 444
    diuretic-induced 692
  glutamine synthesis 730
  nutritional status assessment 1905
  rigidity, persistent hepatic encephalopathy 743
muscle phosphorylase deficiency 1370
muscle-specific phosphorylase kinase deficiency (glycogen storage disease type IXd) 1374
muscular midarm circumference (MMAC)
  nutritional status assessment 1905
  prognostic value 1907
musculoskeletal diseases, effects on liver 1694–1701
mushrooms, poisonous, hepatotoxicity 1271–1272
MxA gene 358
mycetoma 1017
myc gene 1587
mycobacterial infections 1005–1006
Mycobacterium avium complex, HIV coinfection 983
Mycobacterium avium intracellulare 1005
Mycobacterium genavense 1005
Mycobacterium tuberculosis 1005
  ascites 669–670
  HIV coinfection 983
mycophenolate mofetil, liver transplantation 2008
  children 1865
Mycoplasma pneumoniae 1005
mycotoxicosis 1011
MyD88-dependent signalling pathway 37–38
myeloablative therapy, sinusoidal obstruction syndrome induction 1411
myelodysplasias, hepatic involvement 1666
myelofibrosis, primary (agnogenic myeloid metaplasia) 1665
myeloid dendritic cells 321
myeloid leukaemia, hepatic involvement 1665–1666
myeloid metaplasia, hepatic involvement 1665
  clinical features 1665
  histology 1665, 1665f
myeloma, AL amyloidosis 1704
myeloperoxidase
  cirrhosis 774
  hypersplenism 774
myeloproliferative disorders
  Budd–Chiari syndrome 1403
  chronic, hepatic involvement 1665
  diagnosis 1403
  portal vein thrombosis 1395, 1395t
myocardial damage, lactic dehydrogenase 454
myocardial infarction, acute 1611
myofibroblasts (MF)
  endothelin, response to 82
  fibrosis progression to cirrhosis 584
  immunohistochemistry 47
  interface 47, 47t
  portal 47, 47t
  septal 47, 47t
myoinositol, hepatic encephalopathy 732–733, 733f
myosin, hepatocyte cytoskeleton 98
myosin II, *Entamoeba histolytica* 1023
myxoedema ascites 671
  hypothyroidism 1685
myxoedema coma 1685

N

N-acetyl-*p*-benzoquinone imine (NAPQI) 205, 246
N-acetyltransferases (NAT) 242t
nadolol, variceal bleeding prevention 644
nails
  changes in liver disease 1804
  discoloration 447
  examination 446–447
  white, cirrhosis 611
Na^{2+},K^{+} ATPase *see* sodium pump (Na^{2+},K^{+} ATPase)
naloxone, hepatic encephalopathy 738
naltrexone
  alcohol abstinence 1182
  alcoholic cirrhosis 1167
  duration of administration 1182
  recommended dose 1182
  vanishing bile duct syndrome 1117
β-naphthylamine, hepatotoxicity 2107
nasogastric feeding
  childhood acute liver failure 1858
  cirrhosis 616
National Institute of Diabetes and Digestive and Kidney Diseases (NIDDK) Liver Transplant Database QOL Survey 2029
National Institutes of Health, chronic hepatitis C antiviral therapy recommendations 943
natriuretic peptide, effects on cholangiocytes 53
natural killer (NK) cells 320–321, 479, 479f
  acute graft-vs.-host disease pathogenesis 1672
  alcoholic liver disease 1140
  apoptosis induction 320
  cytotoxicity 320
  functions 323t
  HLA class I alleles 365
  major histocompatibility complex 320
  receptors 320
natural killer T-cells (NKT) 320–321, 479, 479f
  alcoholic liver disease 1140
  CD1 molecules 321
  functions 323t
  lipids 321
  T-cell receptor 320
natural toxins, liver injury causing 2105–2121
nausea and vomiting
  acute fatty liver of pregnancy 1881
  hepatitis, drug absorption alterations 1917
  hyperemesis gravidarum 1879–1880
necrapoptosis 349, 350f
necrosis 341–342
  acute liver failure 1299
  alcoholic hepatitis 1151–1152
  biliary piecemeal 424
  central–central bridging 424
  cholangiocyte proliferation 54
  coagulative 424
  confluent 424
  drug-induced chronic hepatitis 1251
  ductular piecemeal 425
  extrahepatic biliary obstruction 1501
  fibrous piecemeal 424–425
  focal 425
  hepatitis B 868
  histological features 424–425
  hyperthyroidism 1684
  hypoxic 1299
  lymphocytic piecemeal 424
  lytic 424
  mitochondria 341
  piecemeal 424
  portal–central bridging 424
  sclerosing hyaline 426
  spotty 425
  subacute hepatitis 1251
  surgical 424
  toxin-induced 1270–1272, 1270t
  vitamin B12 levels, serum 1769
  warm ischaemia 348–350
necrotizing angiitis, drug-induced 1255t, 1256
nefazodone, hepatotoxicity 1237
negative predictive value, diagnostic models 2062
Neisseria gonorrhoeae 1003
Neisseria meningitidis 1807
nematode cholangitis 1547, 1547t
neocholangiolar cells *see* oval cell(s)
neomycin, hepatic encephalopathy 747, 749
neonatal cholestasis *see* infantile cholestasis
neonatal haemangiomatosis 1806
neonatal haemochromatosis 1327
  acute liver failure 1857
  antioxidants 1857, 1857t
  causes 1857
  inheritance 1857
  with multiple malformation 2138–2139
neonatal hepatitis syndrome *see* infantile cholestasis
neonatal kernicterus *see* kernicterus
neonatal sclerosing cholangitis 1848
neonates
  acute liver failure 1856–1858
  alpha-1-antitrypsin deficiency screening 1333
  chronic hepatitis B 869
  cytomegalovirus infection 962
  herpes simplex virus infections 958
neoplasms
  angiography 536, 536f
  cutaneous manifestations 1808–1809
  cystic 813–816
  post-liver transplant, children 1867
  seeding, post-liver biopsy 497
  see also liver tumours
nephrogenic ascites 671
nephrogenic hepatic dysfunction syndrome 1653
nephrolithiasis, congenital portosystemic shunt 1419
nephropathy
  diabetic 1736
  immunoglobulin A 329
nephrotic syndrome
  albuminuria 455
  HBV-associated membranous neuropathy 1818
nerve growth factor, cholangiocyte proliferation 54, 284
nervous system, effects on liver disease 1822–1828, 1823–1824t
net metabolic clearance 473
  positron emission tomography tracers 562
network-forming collagens 267–268, 267t
neuroaminidase and β-galactosidase deficiency 2133
neuroendocrine tumours
  cystic metastases 815
  liver transplantation 1988
neurofibromatosis type 1 1645
neurofibromatosis type 2 1645
neurological examination 449
  postoperative liver transplantation 1998
neuromuscular blocking drugs, use in liver disease 1941
neuromuscular disorders, post-liver transplantation 1826–1827
neuropathy 449
  acute porphyric crisis 1344
  alcoholism 1185
  diabetic 1736
  hepatitis B virus-associated 1818
  systemic AL amyloidosis 1704
neurosteroids, hepatic encephalopathy 737
neurotoxins, effects on astrocytes 734–735
neutropenia, alcohol abuse 1187
neutrophil(s)
  count, spleen size and 773, 773f
  intrahepatic cholestasis 1484
  spontaneous bacterial peritonitis 762–763
neutrophilia, acute fatty liver of pregnancy 1881
neutrophilic cholangitis 1485
nevirapine
  cutaneous side-effects 1807
  hepatotoxicity 984, 1299
newborns
  bilirubin assays 460
  hepatocyte transplantation 2033–2034
  physiological jaundice 460
  see also neonates
Nezelof syndrome 2150–2151
NF-κB 106
  alcohol-induced liver disease 40
  apoptosis regulation 340
  cell cycle regulation 106
  DNA binding, glutathione and 202–203
  hepatocellular carcinoma 106

NF-κB (*continued*)
prosurvival signal 315
as signal factor 106
structure 106, 315
tumour necrosis factor (TNF) *see* tumour necrosis factor (TNF)
niacin *see* nicotinic acid
nickel 233t
nicotinamide adenine dinucleotide (NAD)
alcohol oxidation 1136
post alcohol absorption 1246
nicotinamide adenine dinucleotide (NADH)
ethanol metabolism 1246
formation 154–155, 154f
glycolysis 157
oxidative phosphorylation 158
post-alcohol absorption 1246
nicotinamide adenine dinucleotide dehydrogenase (NADH-ubiquinone oxidoreductase) 158
nicotinamide adenine dinucleotide phosphate dehydrogenase (NADPH)
alcohol-induced liver disease 40
Kupffer cells 38
nicotinamide adenine dinucleotide phosphate dehydrogenase (NADPH) cytochrome P-450 reductase 209, 1218
nicotinamide adenine dinucleotide-ubiquinone oxidoreductase (NADH dehydrogenase) 158
nicotinamide supplementation, carcinoid syndrome 1475
nicotinic acid
acute hepatitis induction 1237
deficiency, carcinoid syndrome 1474
NIDDK LTD QOL, quality of life studies 2067
Niemann–Pick disease (NPD) 1365, 2151
type A (NP-A) 1365
type B (NP-A) 1365
type C (NP-C) 1365
nifedipine, acute hepatitis induction 1237
nilutamide
acute hepatitis induction 1237
mitochondrial energy production impairment 1217
niravoline 681
hyponatraemia in cirrhotic ascites 702
niridazole, neurological toxicity 1915
nitazoxanide 1055–1056
nitrates, drug-induced renal impairment 703
nitric oxide (NO)
acute graft-vs.-host disease pathogenesis 1672
hepatic blood flow regulation 77, 82
hepatic stellate cells contractility 593
hyperdynamic circulation 635–636
insufficient production, cirrhosis 631, 632f
portal hypertension 635–636
as second messenger 103
sinusoidal endothelial cells 31, 82
splanchnic arterial vasodilation 684
vasodilative effects 82
nitric oxide synthases (NOS)
cirrhosis 1728
hepatic encephalopathy 735
splanchnic arterial vasodilation 684
see also individual types
2-(2-nitro-4-trifluoromethylbenzoyl)-1,3-cyclohexanedione (NTBC) 1860
nitrofurantoin
cirrhosis induction 1253
hepatitis induction 1237, 1253
nitrogen
malnutrition associated alcoholic hepatitis 1839
metabolism across liver cell plate 92
nutritional management 1907
nitroglycerin, acute variceal bleeding 649
2-nitropropane, hepatotoxicity 2113
nitrosamines, cholangiocarcinoma 1584
N-nitroso-morpholine, tumorigenicity 1258
N-methyl-D-aspartate (NDMA) receptors, hepatic encephalopathy 735, 737
Nocardia asteroides 1017
Nocardia brasiliensis 1017
Nocardia caviae 1017
nocardiosis 1017
nodular regeneration 430
nodular regenerative hyperplasia (NRH) 1432–1434
antiphospholipid antibody syndrome 1695
children 3581–3582
clinical features 1434
definition 1432
diagnostic workup 1434
drug-induced 1257
epidemiology 1432
Felty syndrome 1696
hereditary haemorrhagic telangiectasia 1422
histological features 430
imaging 1434
myeloid metaplasia 1665
natural history 1434
nodules 1434
pathogenesis 1432
pathology 1432–1434
post-haematopoietic stem cell transplantation 1677
treatment 1434
nodular transformation, nodular regenerative hyperplasia 1432–1434
non-alcoholic fatty liver disease (NAFLD) 1195–1208
aetiology 1681
alcoholic liver disease and 1153–1154, 1154t, 1169–1170
children 1198, 1202, 1855–1856
cirrhosis 610–611
classification 1195–1196
categories 1196t
clinical assessment 1198–1199
clinical features 1197–1199
cortisol 1753
definition 1195–1196
alcohol consumption 1196
diabetes mellitus 132, 1195, 1197, 1681–1682
diagnosis 1199–1201
anthropometrics 1199
children 1855–1856
clinical 1199
homeostatic model assessment 1199
liver tests 1199
metabolic tests 1199
differential diagnosis 1203
drug hepatotoxicity 1917, 1917t
drug prescribing 1918
elderly 1873
epidemiology 1196–1197
functional genomics 408t
gene array data 410
proteomics 413
genetic polymorphisms 356, 357t, 360t
hepatectomy and 1936
hepatocellular carcinoma 1202–1203
imaging 1200
insulin resistance 132, 1681
iron studies 1199
liver biopsy 491–492, 1200–1201
children 1855–1856
decision algorithm 1200f
liver transplantation 1202
postoperative recurrence 2017
metabolic tests 1199
natural history 1201
steatosis 1201
'non-obese' 1197
obesity 1195, 1197
pathogenesis 1201–1202
pathology 1195–1196
presentation 1198–1199
children 1855
prevalence 1195, 1196, 1197, 1197t
children 1855
prevention/management 1203–1205, 1682
children 1856
early intervention 1204
lifestyle changes 1203–1204
pharmacological 1682
public health measures 1203–1204
weight reduction 1204–1205
risk factors 356, 1195, 1197–1198, 1198t
central obesity 1197–1198
children 1855
genetic factors 1198, 1201
visceral adiposity 1195
severity predictors 1198, 1198t
see also non-alcoholic steatohepatitis (NASH)
non-alcoholic steatohepatitis (NASH) 356, 1195–1208
cardiac drug-induced 1613t
children 1855
cirrhosis 610–611, 1201
classification 1195–1196
clinical assessment 1198–1199
clinical features 1197–1199
Cushing syndrome 1686
definitions 1195–1196
alcohol consumption 1196
diagnosis 1199–1201
anthropometrics 1199
clinical 1199
homeostatic model assessment 1199
liver tests 1199
metabolic tests 1199
differential diagnosis 1203
epidemiology 1196–1197
fibrosis 586, 591–592, 594
gene array data 410
genetic polymorphism 356
grading 492
hepatic stellate cell activation 591–592
hepatocellular carcinoma 1439
hepatocyte apoptosis 341
imaging 1200
iron metabolism 1769
lipotoxicity 1202
liver biopsy 492, 1200–1201
decision algorithm 1200f
metabolic tests 1199
natural history 1201
oxidative stress 1202
pathogenesis 1201–1202
pathology 1195–1196
pharmacological treatment 1203t, 1204–1205
presentation 1198–1199
prevalence 1196, 1197, 1197t
prevention/management 1203–1205
early intervention 1204
lifestyle changes 1203–1204
public health measures 1203–1204
weight reduction 1204–1205
risk factors 356, 1195, 1197–1198, 1198t
genetic factors 1198
visceral adiposity 1195
scoring systems 436, 436t
secondary 1196t
severity predictors 1198, 1198t
staging 492
total parental nutrition-induced cholestasis 1950
non-azotaemic cirrhosis, with ascites
loop diuretics 690–691
prognosis 689, 689f
non-caseating granulomas 1709, 1710f
sarcoidosis 1711
non-collagenous proteins, extracellular matrix 268–270
non-drug chemicals, liver injury causing 2105–2121
non-fibrillar collagens 267–268, 267t
non-Hodgkin's lymphoma
chronic hepatitis C 889
hepatic involvement 1663–1664
clinical features 1663–1664
frequency 1663
histology 1663, 1663f
hepatitis B 1664
hepatitis C 1772
ultrasonography 505
noni juice hepatotoxicity 1286
non-nucleoside reverse transcriptase inhibitors (NNRTI)
elimination, cirrhosis 1916
hepatotoxicity 984
side-effects 1807
non-parasitic cyst of the liver *see* simple cyst of the liver
non-small cell lung cancer, hepatic involvement 1619
non-steroidal anti-inflammatory drugs (NSAIDs)
cholesterol gallbladder stone formation, animal models 1522–1523
cirrhosis, drug-induced renal impairment 682, 702–703
contraindication in liver disease 1940
diuretic-resistant ascites 693
elderly 1872
hepatotoxicity 1695, 1696
viral hepatitis 1917, 1918

mitochondrial energy production impairment 1217
non-hepatic toxicity, increases in 1916
renal blood flow, cirrhotics 682
non-suppurative destructive cholangitis 1485, 1485f
nonthermic ischaemia *see* warm ischaemia
non-transferrin-bound iron (NTBI) 221
noradrenaline
hepatic blood flow regulation 77
hepatorenal syndrome 716, 716t
pretransplant patients 1924
renal hypoperfusion 1725
renal perfusion 682, 683f
renal prostaglandin production 682
sympathetic nervous system activity assessment 679
cirrhosis 679
norethinodrel, tumorigenicity 1258
norethisterone, tumorigenicity 1258
norfloxacin
acute variceal bleeding 648
resistance 766–767
spontaneous bacterial peritonitis prophylaxis 765
North America
hepatitis B 867
hepatitis D 877
North Italian Endoscopic Club (NIEC) index, variceal bleeding predictor 640
nortriptyline 245
norursodeoxycholic acid (norUDCA), intrahepatic cholestasis 1496
nosocomial pneumonia 767
Notch signalling pathway
Alagille syndrome 1387
hepatoblast differentiation 67–68
Nottingham Health Profile 2028
Novosphingobium aromaticivorans infection, primary biliary cirrhosis 1072–1073
NPC1 gene mutation 1365
NPC2 gene mutation 1365
Nramp-2 *see* divalent metal transporter 1 (DMT1)
NS2/3 protease, hepatitis C virus 850
NS3/4A protease, hepatitis C virus 854
NS5A protein, hepatitis C virus 850
nuclear bodies, hepatocytes 27
nuclear receptor drugs, intrahepatic cholestasis 2920–2921
nuclear receptors
bile acid homeostasis 106, 384, 385t, 386–387, 388f
classes 384t, 386
drug-metabolizing pathway regulation 244
structure 106
transcription factors 106–107
see also individual types
nuclear respiratory factor 1 (NRF-1) 160–161
nuclear respiratory factor 2 (NRF-2) 160–161
nuclear vacuolation 424
nucleoside analog therapy
chronic hepatitis B 925–927
hepatitis D-hepatitis B virus coinfection 935
nucleoside reverse transcriptase inhibitors (NRTIs)
elimination, cirrhosis 1916
hepatotoxicity 984, 1247–1248, 1380
mechanism of action 1248
mitochondrial toxicity 1380
nucleoside transport, hepatocytes 112
5′-nucleotidase 464–465
cholestasis 1487
clinical usefulness 464–465
detection assays 464
distribution 464
normal values 464–465
nucleotide analogs, chronic hepatitis B 925–927
nucleotide synthesis inhibitors, post-liver transplant 2008
number connection test (NCT), encephalopathy 745
number needed to treat (NNT), meta-analysis 2075–2076
Nurses Health Study 1688
nutrition
biliary disease 1905–1911
cirrhosis 609
deficiencies
alcoholic liver disease 1810, 1836
growth hormone resistance 1744
insulin-like growth factor-1 production 1744
enteral *see* enteral nutrition
insulin-like growth factor-1 regulation 1742
liver disease 1836–1842, 1905–1911
management 1838–1840, 1907–1909
alcoholic cirrhosis 1167
artificial feeding 1908–1909
cirrhosis 616
cystic fibrosis-associated liver disease 1340
energy requirement 1907
guidelines 1840
infantile cholestasis 1846
liver resection 1840
liver transplantation 1909–1910
micronutrients 1908
minerals 1908
nitrogen requirement 1907
obstructive jaundice 1505
pretransplant patients 1925
status assessment 1838, 1905
nylon membranes, gene array platforms 403

O

obesity
alcoholic liver disease 1142
chronic hepatitis C 887
fibrosis 1901
hepatocellular carcinoma 1439
hepatosteatosis 1936
liver transplantation
contraindications 1990
postoperative immunosuppression 2020
non-alcoholic fatty liver disease 1195, 1197
children 1856
non-alcoholic steatohepatitis 1195, 1197
obstructive sleep apnoea 1617
post-bypass surgery hepatobiliary disease 1630
obliterative endarteritis 427
observer variation, liver biopsy 434
obstructive jaundice
bone disease 1505
cardiovascular effects 1503
clinical features 1506–1507
coagulation 1506
cryptococcosis 1014
endotoxaemia 1504
gastrointestinal changes 1504–1505
hepatectomy in 1935–1936
histology 1503
imaging 1507–1509
infection, response to 1505–1506
cellular response 1506
laboratory investigations 1507
lipid metabolism 1505
cell membranes 1505
fat absorption 1505
liver function tests 1507
malignant causes, stenting 555
management 1511–1512
infection prophylaxis 1511–1512
preoperative non-surgical biliary drainage 1512
metastatic liver cancers 1467
nutrition 1505
pancreatic changes 1504–1505
pathophysiology 1501
peribiliary cysts 803
polycystic liver disease, ADPKD 793
pruritus 1502–1503, 1506–1507
management 1512
renal effects 1503–1504
renal failure 1504, 1815–1816
correction 1511
risk prediction 1512
vitamin K 1511
wound healing 1505
see also extrahepatic biliary obstruction
obstructive sleep apnoea 1617–1618
non-alcoholic fatty liver disease 1617
OC-2, bile duct morphogenesis 69
occlusive venous lesions, alcoholic hepatitis 1151
occult hepatitis B 840, 868
octanoic acid, hepatic encephalopathy 731
octreotide
acute variceal bleeding 649–650
carcinoid syndrome 1809
cholelithiasis induction 1689
portal hypertension 635
oculoencephalohepatorenal syndrome 2151
odds ratios (ORs)
logistic regression analysis 2061, 2062
meta-analysis 2074
oedema
cerebral *see* cerebral oedema
cirrhotic ascites 667
pulmonary, hepatorenal syndrome 713
oesophageal cancer, alcohol consumption 1186
oesophageal devascularization plus splenectomy (EGDS), schistosomiasis 1044
oesophageal strictures 1799
oesophageal varices
anatomy 626–628
bleeding *see* variceal bleeding
chronic portal vein thrombosis 1397
congenital hepatic fibrosis 782–783
development 640
endoscopic ligation *see* endoscopic band ligation (EBL), variceal bleeding
follow-up 643
hepatectomy contraindications 1934
hereditary haemorrhagic telangiectasia 1420
incidence 640
indicators, spleen size/platelet ratio 1771
inflow 627, 627f
portal hypertensive gastropathy 1799
pressure measurement 568, 663
limitations 663
prognostic value 663
schistosomiasis 1044
sclerotherapy *see* endoscopic injection sclerotherapy (EIS), variceal bleeding
screening 643–644
small to large progression 640
oesophagus, in liver disease 1798–1799
ofloxacin, spontaneous bacterial peritonitis 764, 764t, 765
Ohm's law 630
oil of cloves, hepatotoxicity 1282t
OKT3, liver transplant in children 1865
oligomenorrhoea 1759
oligosaccharyl transferase (OST) 193
oltipraz, aflatoxin toxicity 1450
Omenn syndrome 2151–2152
omentoplasty, cystic echinococcosis 1050
oncogenes 392–393
cellular homologues (proto-oncogenes) 392–393
viral disruption 393
definition 391
discovery 392
hepatocellular carcinoma 392–393, 392t
see also individual genes
oncosis *see* necrosis
Oncostatin M 68
oncotic functions
albumin 253
carrier proteins 253
oncotic necrosis *see* necrosis
oncotic reflection coefficient (ORC) 672–673
ondansetron, carcinoid tumours 1476
1–2–20 principle, liver divisions 6–7, 6f
Onecut factors, hepatocyte maturation 68
'onion skin' lesions, primary sclerosing cholangitis 1485
Onshidou–Genbi–Kounou, hepatotoxicity 1283
OPC-31260, cirrhotic ascites 699–700
open reading frame (ORF), hepatitis C virus 850
operating costs 2081
opiate antagonists, pruritus 1082, 1496, 1804
κ-opioid receptors, hyponatraemia in cirrhotic ascites 701–702
opioids, use in liver disease 1940
hepatic resection and 1941
Opisthorchis felineus 1046
cholangitis 1545, 1546, 1547t
treatment 1547
Opisthorchis infections, cholangiocarcinoma 1584

Opisthorchis viverrini 1046
cholangitis 1546, 1547t
treatment 1547
clinical features 1046
diagnosis 1046
pathogenesis 1046
recurrent pyogenic cholangitis 1545
opportunistic infections, post-liver transplantation 2023
opsonization, immunoglobulin A 328
oral cancer, alcohol consumption 1186
oral contraceptives
hepatotoxicity 1649, 1688–1689
induced-conditions
arterial intimal hyperplasia 1255–1256
Budd–Chiari syndrome 1257, 1405
cholestasis 1241–1242
epithelioid haemangioendothelioma 1460
focal nodular hyperplasia 1260, 1428, 1430
hepatocellular adenoma 1259, 1431, 1688–1689
hepatocellular carcinoma 1260, 1439, 1689
liver transplantation 1889
portal vein thrombosis 1255
sinusoidal dilatation 1256, 1413
use in liver disease 1901–1902
oral feeding, childhood acute liver failure 1858
oral litholysis, cholecystolithiasis 1530
oral xanthomas 1798
organic anion transporters (OATs)
hepatocytes 112
sinusoidal biliary transport 385
adaptive changes in cholestasis 386, 387f
organic anion-transporting peptides (OATPs)
hepatocytes 112
sinusoidal biliary transport 385
organic brain syndromes 1825
organic cation transporters (OCTs) 112, 385
organic ion transporters, bile acid uptake 294–295, 295f
organic ion transporters, hepatocellular bile secretion 295f
organic solute transporter (OST) 113
organic solute transporter (OST)-α 113, 177
organic solute transporter (OST)-β 113, 177
organ injury scale 1953
organogenesis, liver sinusoidal endothelial cells 31–32
organ viability maintenance, liver transplantation 1966
oriental cholangiohepatitis *see* recurrent pyogenic cholangitis (RPC)
ornipressin 1725
ornithine aminotransferase 144
ornithine-aspartate, hepatic encephalopathy 747
ornithine carbamoyl transferase deficiency 1883
ornithine metabolism 144
ornithine transcarbamylase (OTC) 182
deficiency
children 1862
hepatocyte transplantation 2038, 2039t
neurological manifestations 1822
oropharyngeal cancer, post-liver transplantation 2022
orthotopic liver transplantation (OLT) *see* liver transplantation
Osler–Weber–Rendu syndrome 1798
osmolar clearance, cirrhosis 676
osmotic principle, bile formation 292, 292f
osteocalcin 1752
primary biliary cirrhosis 1752
osteomalacia 1833–1834
cholestasis 1487
clinical features 1833
definition 1833
diagnosis 1833
histology 1833
liver disease and 1802, 1834
prevention 1834
treatment 1834
obstructive jaundice 1505
prevention 1833
secondary hyperparathyroidism 1751
see also rickets
osteopenia, World Health Organization classification 1830
osteoporosis 1829–1833, 1901
alcoholic liver disease 1831
cholestasis 1487
chronic liver disease associated 1802, 1830–1831
management 1831–1832, 1832t
pathogenesis 1831, 1831t
pathophysiology 1831
risk assessment 1831–1832
clinical manifestations 1829
clinical risk factors 1830
definition 1829
diagnosis 1829–1830
fragility fractures 1829
haemochromatosis 1762
hormone replacement therapy 1082, 1832
post-transplant 1830t
pre-transplant 1830
primary biliary cirrhosis 1075, 1082, 1830
radiology 1830
risk assessment 1829–1830
treatment 1082, 1831–1832, 1832t
World Health Organization classification 1830
outcome maximization, resource allocation 2080
outcomes, definition 2073–2074
outcomes research 2065–2072
bile duct injury 2070
chronic viral hepatitis 2068–2069
SF-36 2068–2069
vitality scale 2069
cirrhosis 2069
definition 2065
endpoints 2065
endstage liver disease 2069
future work 2070
in healthcare policy 2065–2066
health-related quality of life studies 2065, 2066–2067, 2067t
general health measures 2066
liver-specific 2067, 2067t
measurement 2066, 2066t
reliability 2066
standardization 2066
validity 2066
health utility assessments 2066–2067
standard gamble 2067
time-tradeoff utility 2067
liver transplantation 2069–2070
primary biliary cirrhosis 2069
surrogate endpoints 2065
treatment effects 2065
outlet (efferent) sphincters, sinusoids 79f, 80
outpatient management, post-liver transplantation 2019
oval cell(s) 23, 23f
activation 59–60
CXCR-4 283
cytokeratins 283
fate 283–284
γ-glutamyltranspeptidase 283
hepatocyte transplantation 2035
neural control 119
origins 283–284
phenotype 283
regulatory factors 283
as stem cells 283
telomerase activity 283
transforming growth factor-like inhibitor of apoptosis 60
tumour development 1258
oval cell reaction 59
ovarian adenocarcinomas, cystic metastases 815
ovarian dysfunction 1759–1760
ovarian hyperstimulation syndrome 671
overdose
non-hepatic toxic effects 1915–1916, 1915t
paracetamol *see* paracetamol overdose
overlap syndromes 1120–1126
autoantibodies 485
autoimmune hepatitis–autoimmune cholangitis 1122t, 1124
autoimmune hepatitis–primary biliary cirrhosis 1104–1105, 1122–1123, 1122t, 1123f
alkaline phosphatase 1122
autoantibodies 1123
differential diagnosis 1123
γ-glutamyl transferase 1122
immunosuppressants 1123
prevalence 1122
therapy 1123
ursodeoxycholic acid 1123
autoimmune hepatitis–primary sclerosing cholangitis *see* autoimmune sclerosing cholangitis (ASC)
definition 1120
vanishing bile duct syndrome 1113t
oxaloacetate 155
oxamniquine 1044
oxandrolone 1909
oxazepam 1180
oxidative energy metabolism, liver cell plate 91
oxidative phosphorylation 158–159
complexes 158
oxidative stress
alcoholic hepatitis 1161, 1169
alcoholic liver disease 1138–1139, 1138t
animal models 1138–1139
dietary manipulation 1138–1139
genes influencing 1143
bilirubin 1353
ischaemic-reperfusion injury 351–352
non-alcoholic steatohepatitis 1202
oxindol 731
2-oxo acid dehydrogenase complexes (2-OADC) 484
Δ^4-3-oxosteroid 5β-reductase deficiency (AKR1D1) 176, 1849
11-oxo-steroid reductase 1752
oxygen, mitochondrial origin and 150, 150f
oxyphenisatin, hepatotoxicity 1253
oxysterols 133

P

P2X receptors 53
P2Y receptors 53
P7 protein, hepatitis C virus 850
p16 394t
p21 275
p27 275
p53
aflatoxin B1-induced mutation 1274
apoptosis defects 341
apoptosis regulation 339
cholangiocarcinoma 1587
gallbladder carcinoma 1576
hepatocellular carcinoma 279
normal function 393
tumour development 1257
as tumour suppressor 393–394, 394t
p53 mitogen activated protein kinase 104
p63 63
p68 359
pacemaker activity, sphincter of Oddi 1566
paclitaxel, gallbladder carcinoma 1580
Paediatric EndStage Liver Disease (PELD) score, liver transplantation 1985–1986, 1986t
Paeonia, hepatotoxicity 1282t, 1283
pain
amoebic liver abscess 1024
liver transplantation patients, quality of life 2030
obstructive jaundice 1506
pancreatic pseudocysts, liver 811
post-liver biopsy 495
pre-eclampsia 1884
pain provocation tests, gallbladder dysfunction 1563
pain relief, acute porphyric crisis 1345
palliative treatment
alveolar echinococcosis 1053–1054
cholangiocarcinoma 1600–1601
hepatocellular carcinoma 1448–1450
malignant bile duct obstruction 555–556
palmar erythema 446, 1804
alcoholic hepatitis 1162
alcoholic liver disease 1809
cirrhosis 611
feminization 1758
palpable purpura, chronic hepatitis C 889
pamidronate
osteoporosis 1832
post-transplantation bone disease 1833

pancreas
alcoholic damage 1735
effects of liver disease on 1800–1801
exocrine insufficiency, cirrhotic patients 1837
obstructive jaundice 1504–1505
pancreatic adenocarcinoma 1185
pancreatic ascites 671
pancreatic pseudocysts 811
pancreatic ascites 671
pathogenesis 811
percutaneous drainage 811
symptoms 811
pancreatitis
alcohol consumption 1185
alcoholic liver disease 1800
biliary, gallstone disease 1534
extrahepatic cholangiocarcinoma 1589
fulminant hepatic failure 1801
haemobilia 1553, 1554
primary biliary cirrhosis 1800–1801
primary sclerosing cholangitis 1801
sphincter of Oddi dysfunction 1566
pancytopenia, visceral leishmaniasis 1036
panlobular hepatitis 1675
pantoyl-γ-aminobutyrate, hepatotoxicity 1247
papaverine, hepatotoxicity 1253
'paper-money skin' 1804
papilla of Vater
anatomy 305
ascariasis 1059
biliary tree 1111
papillomas, ascariasis 1059, 1061f
paracentesis
bleeding risk 1788t
cirrhotic ascites 693–695
complication avoidance 693
peritoneovenous shunting *vs;* 697
plasma renin activity, post-procedure 694, 694f
plasma volume expansion 693–694
renal function, post-procedure 694
technique 693
TIPS *vs.* 698t
hepatorenal syndrome induction 712
spontaneous bacterial peritonitis 763
paracentesis-induced circulatory dysfunction 694–695
disease course, effects on 695
plasma volume expansion 694–695
prevention 695
removed ascitic fluid volume 694–695, 694f
paracetamol
childhood acute liver failure 1858
hepatotoxicity 1237–1238, 1295–1296
alcoholic liver disease 1170, 1917
dose-related 246, 246f
glutathione depletion 205, 1221
idiosyncratic 246–247
postoperative 1949–1950
postoperative hepatic injury induction 1946
uses in liver disease 1940–1941
paracetamol overdose 1237–1238
acute liver failure 1295–1296
Kupffer cells 40–41
multiorgan failure 1296
pregnancy 1888
symptoms 1238, 1296
treatment 1237–1238, 1296
Paracoccidioides brasiliensis 1015
paracoccidioidomycosis 1015–1016
clinical features 1016
disseminated 1016
epidemiology 1015–1016
pathogenesis 1015–1016
pulmonary 1016
therapy 1016
paracrine stimulation, intrahepatic signal propagation 117
parallel channel sign 507
paraoesophageal varices 628
paraptosis 342, 342f
paraquat, hepatotoxicity 1272, 2113
parasitic infections
cholangitis 1546–1547, 1547t
recurrent pyogenic cholangitis 1545
parasitized red blood cells (pRBCs)
malaria 1030
malarial hepatitis 1031
parasympathetic nervous system
carbohydrate metabolism regulation 117–118, 118f
cholangiocyte proliferation 54
hepatic blood flow regulation 76
lateral hypothalamic area 114–115
parathion, hepatotoxicity 2114
parathyroid hormone (PTH) 1750–1752
biological actions 1750, 1751f
cirrhosis 1751
clearance 1751
liver disease 1751–1752
liver tumours 1763
measurement 1751
osteoporosis 1751
primary biliary cirrhosis 1751
rickets 1833
secretion 1750
parathyroid hormone related peptide (PTHrP), cholangiocarcinoma 1763
paraumbilical veins 3
recanalization, portal hypertension 503
parenchymal cells
hepatocyte transplantation 2033
immunoglobulin A catabolism 328
parenchymal giant cells 430
parenchymal liver disease, elderly 1871–1872
parenteral nutrition
efficacy 1909
indications 1909
parkinsonian symptoms, Wilson's disease 1316
paromomycin
cryptosporidiosis 1026
visceral leishmaniasis 1038
paroxysmal nocturnal haemoglobinuria (PNH) 1666
Budd–Chiari syndrome 1403–1404, 1666, 1769
diagnosis 1404
partial nodular transformation of the liver 1399–1400
patent ductus venosus 1419
partial thromboplastin time, cirrhosis 258
parvovirus B19-related aplastic anaemia 968, 1298, 1667
passive immunization, hepatitis A 861–862
passive septa 426
patent ductus venosus (PDV), congenital portosystemic shunts 1419
patient education, post-liver transplantation 2020
paucity of intrahepatic bile ducts *see* ductopenia
Pearson syndrome 2152
pegvisomant, hepatotoxicity 1689–1690
pegylated interferon
hepatitis C
pretransplant patients 1927
ribavirin combination 943–944
HIV–hepatitis C coinfection 981
pegylated-interferon-α
chronic hepatitis B therapy 925
lamivudine combination 928, 930–931
wild-type virus (HBeAg-positive) 927
chronic hepatitis C therapy 942
historical aspects 941
retreatment 951
hepatitis D-hepatitis B virus coinfection 935
side-effects 927
pegylated interferon α2a, dialysis patients 1656
pegylated interferon/ribavirin combination, HIV-hepatic C coinfection 979, 980t
pegylated recombinant human megakaryocyte growth and development factor (PEG-rHuMGDF), hypersplenism 776
peliosis 427
peliosis hepatis 1412
in AIDS 1412
anabolic steroid-induced 1687–1688
angiography 537t
associated conditions 1412, 1412t
Bartonella henselae 1005
cystic 811–812
drug-induced 1255t, 1256, 1412
pathogenesis 1412
renal transplantation 1658
sinusoidal dilatation *vs.* 1412–1413
pellagra
alcoholic liver disease 1810
carcinoid syndrome 1474, 1809
pemoline, hepatitis induction 1238
penetrating trauma, haemobilia 1552
penicillamine
adverse reactions 1318
antiangiogenic effects 229, 230
cutaneous side-effects 1811
fulminant Wilson's disease 1299–1300
hepatitis induction 1238
pregnancy 1886
teratogenicity 1319
Wilson's disease 1318, 1854
penicillin, actinomycosis 1017
penicillinosis 1017
Penicillium marneffei 1017
pennyroyal oil, hepatotoxicity 1282t, 1285–1286, 2114
pentachlorophenol (PCP), hepatotoxicity 2114
pentastomiasis 1066–1067
calcifications 1067
clinical features 1066–1067
epidemiology 1066
pathology 1066
treatment 1067
pentoxifylline
alcoholic hepatitis 1165
fibrosis 595
hepatorenal syndrome prevention 717
peptic ulcers 1800
peptide mass fingerprinting (PMF) 405
peptide thrombopoietin mimetics, hypersplenism 776
peptidyl α-amidating monooxygenase (PAM) 228, 228t
percussion, ascites 666
percutaneous ablation, hepatocellular carcinoma 552, 1448
efficacy control 553
pretransplant patients 1926, 1927t
recurrence 553
percutaneous acetic acid injection (PAI), hepatocellular carcinoma 552
percutaneous angioplasty, Budd–Chiari syndrome 1409
percutaneous aspiration
amoebiasis 1026, 1026f
with sclerotherapy, simple cyst of the liver 787
percutaneous biliary drainage (PBD) 555–556, 557f
bacterial cholangitis 1544
entry site 556, 557f
haemobilia 1551
percutaneous catheterization, venous outflow obstruction 550
percutaneous cholecystostomy, cholecystitis 1534
percutaneous drainage
alveolar echinococcosis 1053–1054
cystic echinococcosis 1050
liver trauma complications 1957
percutaneous ethanol injection (PEI)
computerized tomography guidance 552
hepatocellular carcinoma 552, 1448
radiofrequency ablation *vs.* 552, 1448
ultrasound guidance 552
percutaneous puncture drainage and curettage, cystic echinococcosis 1051
percutaneous transhepatic catheterization, portal vein 658–659
percutaneous transhepatic cholangiography (PTC)
bacterial cholangitis 1544
extrahepatic biliary obstruction 1509
hilar (upper duct) cholangiocarcinoma 1591
living donor liver transplantation 1982
obstructive jaundice, malignant causes 555
percutaneous transhepatic portal venography 534
percutaneous transhepatic puncture, portal pressure measurement 567
percutaneous transhepatic venography 535
percutaneous transjugular catheterization, portal vein 658–659
percutaneous treatment, biliary strictures
benign 556–558
access 558
metallic stents 558
surgery *vs.* 557–558
technique 558
malignant 555–556

perfused liver, liver function models 122
perfusion, age-related changes 1870
perhexilline maleate
lipid storage disease induction 1250
phospholipidosis induction 1244–1245
steatohepatitis induction 1246
peribiliary cysts 802–805
associated conditions 802–803
biliary hamartomas *vs.* 801
clinical presentation 803
differential diagnosis 803–804
imaging 803
liver transplantation 803
pathogenesis 802–803
pathology 802
polycystic kidney disease 792, 802
peribiliary glands 802
cystic dilatation *see* peribiliary cysts
distribution 802
functions 802
heterotopic pancreas 802
histology 802
polycystic liver disease 796
pericanalicular cytoplasm 23
pericellular fibrosis *see* perisinusoidal fibrosis
pericholangitis 426, 1626
periductal infiltrating cholangiocarcinoma *see* cholangiocarcinoma
perihepatitis, *Chlamydia trachomatis* 1004
perinatal varicella-zoster virus infection 959
perinuclear antineutrophil nuclear antibodies (pANNA)
autoimmune sclerosing cholangitis 1853
primary sclerosing cholangitis 484
perinuclear-staining antineutrophil cytoplasmic antibodies (pANCAs) 482t, 484
periodic acid–Schiff (PAS) stain, liver biopsy 491
peripheral arterial vasodilation hypothesis 636–637, 683–684, 683f
peripheral benzodiazepine receptor (PBR), hepatic encephalopathy 736–737
peripheral neuropathy, alcoholism 1185
peripolesis 425
periportal fibrosis, schistosomiasis 1042, 1043, 1043f
periportal hepatitis 429
periportal sinusoids, transient leucocyte plugging 81
perisinusoidal cells *see* hepatic stellate cell (HSC)
perisinusoidal fibrosis 426
alcoholic hepatitis 1151, 1151f
drug-induced 1246
peliosis hepatis 1412
renal transplant patients 1658
sinusoidal dilatation 1413
perisinusoidal stellate cells *see* hepatic stellate cell (HSC)
peritoneal biopsy, tuberculous peritonitis 670
peritoneal cavity, hepatocyte transplantation 2033
peritoneal dialysis, platelet dysfunction 1791
peritoneovenous shunting
cirrhotic ascites 695–697
benefits of 695–696
paracentesis *vs.* 697
complications 696
hepatorenal syndrome 697
pretransplant patients 1923
peritonitis
liver trauma 1954
spontaneous bacterial *see* spontaneous bacterial peritonitis (SBP)
tuberculous 669–670
perivenous scavenger cells 730
ammonia detoxification 183–184
perivenular fibrosis 426
perlecan 270
permanent cells 58
peroxidase-antiperoxidase immune complex method, viral hepatitis detection 430
peroxisomal enzymes 26
peroxisome proliferator-activated receptor alpha (PPAR-α)
bile secretion regulation 301t
ethanol, effects on 1137
mitochondrial β-oxidation 162
peroxisome proliferator-activated receptor gamma (PPAR-γ) agonists, non-alcoholic steatohepatitis treatment 1204
peroxisome proliferator-activated receptor γ coactivator 1 (PGC-1) 160–161
peroxisome proliferator-activated receptors (PPAR), hepatic stellate cell activation 593
peroxisomes 24f, 26–27, 26f
biogenesis 26–27
enzymes 26
proliferation 26–27
peroxynitrite 40–41
persistent (chronic) encephalopathy 728t, 729
persorption, candidosis 1012
pesticides, hepatotoxicity 2114
petroleum distillates, hepatotoxicity 2114
PGA index, fibrosis in alcoholic liver disease 1168
pH
regulation 185–187
urea synthesis regulation 183
phaeochromocytomas 1645
phagocytosis
apoptotic bodies 335–336
Kupffer cells 37
obstructive jaundice 1505
splenic 772
phalloidin, hepatotoxicity 1271–1272, 1298
pharmacodynamics, anaesthetic drugs 1940–1941
pharmacogenetics
definition 244
drug metabolism 244–245, 244t
pharmacokinetics, liver disease 1914–1917
anaesthetic drugs 1940–1941
decreased therapeutic effects 1915
exaggerated therapeutic effects 1914–1915
increased non-hepatic toxicity 1915–1916
increased susceptibility 1916, 1916t
overdose 1915–1916, 1915t
protein binding competition 1916
modifications, without clinical consequences 1914
see also drug(s)
pharyngeal cancer, alcohol consumption 1186
phenazone (antipyrine) 471t, 472
phenindione, hepatitis induction 1238
phenobarbital
Crigler–Najjar syndrome 1355, 1845
hepatotoxicity 1827
phenols
hepatic encephalopathy 730–731
hepatotoxicity 2114
phenotype gel analysis, alpha-1-antitrypsin deficiency 1333
phenprocoumon, hepatitis induction 1238
1-phenyl-4,5-chloropyridason-6, hepatotoxicity 2114
phenylalanine
catabolism 144
hepatic encephalopathy 731
macroautophagy regulation 149
phenylalanine hydroxylase 144
phenylbutazone, hepatitis induction 1238
phenylbutyrate, hepatic encephalopathy 747
phenylethylbarbiturate 1888
8-phenyl-theophylline 76
phenytoin
cerebral oedema 1305
hepatotoxicity 1226, 1238–1239, 1299, 1827
thyroid hormones 1749–1750
phlebosclerosis 427
phlebotomy
haemochromatosis 1326
hypersplenism 777
porphyria cutanea tarda 1347
phosphate
homeostasis and vitamin D 218
osteomalacia 1834
phosphatidate phosphohydrolase (PAP) 1136
phosphatidylcholine synthesis 146
phosphatidylinositol 3,4,5-triphosphate (PIP_3) 105
phosphatidylinositol 3-kinases (PI3Ks) 105
bile secretion regulation 301–302
phosphatidylinositol 3,4,5-triphosphate generation 105
platelet-derived growth factor 2090
tumorigenesis 105
phosphatidylserine (PS)
apoptosis 335, 336–337
distribution defects 177
phosphoenolpyruvate carboxykinase (PEPCK) 91
phosphofructokinase 156–157
phospholipase A 103
phospholipase C 103
phospholipidosis
drug-induced 1244–1245
cardiac drugs 1613t
post drug withdrawal 1245
histological features 428
phospholipids
hepatobiliary disease 458–459
obstructive jaundice 1502
phospholipid transfer protein (PLTP) 139, 140f
phosphorus
acute liver failure 1302
hepatotoxicity 2114
supplementation 1908
phosphorylase kinase 1370
deficiency 1374
photodermatosis
congenital erythropoietic porphyria 1347
erythropoietic protoporphyria 1347, 1348
photometers, bilirubin measurement 168
photosensitivity
hepatoerythropoietic porphyria 1811
hereditary coproporphyria 1811
porphyria cutanea tarda 1810
porphyrias 1346–1347
variegate porphyria 1810
phototherapy
Crigler–Najjar syndrome 1355, 1845
erythropoietic protoporphyria 1348
graft-vs.-host disease (GvHD) 1808
physiological jaundice 1355
phrenic nerve, right 5
physical activity/exercise
alanine aminotransferase levels 453
albumin synthesis 454
aspartate aminotransferase levels 453
liver disease 1901
osteoporosis 1832
physiological jaundice 460, 1355
phytosterol excess, total parenteral nutrition-related liver disease 1637
piecemeal necrosis 424
drug-induced chronic hepatitis 1251
piggy-back technique, liver transplantation 1968–1969, 1968f
vena cava stenosis 1969
venovenous bypass 1968–1969
venovenous bypass, without 1969
pioglitazone
hepatotoxicity 1240–1241, 1683
non-alcoholic steatohepatitis 1203t, 1682
pipecolic acidaemia 2152
piperacillin 1542, 1543t
piperazine 1061
Piper methysticum (kava), hepatotoxicity 1282t, 1284–1285
piroxicam, hepatotoxicity 1299
pirprofen, hepatotoxicity 1239, 1250
pit cells 14
pityriasis rotunda 1808
PKD1 gene mutations 789–790
PKD2 gene mutations 789–790
PKHD1 gene mutations 69
placenta, intrahepatic cholestasis of pregnancy 1880
plasma
nutritional status assessment 1905
porphyrin precursor excretion 212t
porphyrins excretion 212t
plasma cells 325
plasma exchange, liver support 2044
plasma infusion, cirrhotic patients 1789

plasma membrane, hepatocytes 20f, 21–23, 22f
  receptors 93
plasma osmolality, antidiuretic hormone secretion 680
plasma transfusions, haemostatic abnormalities 260–261
plasma volume distribution, cirrhosis 1727–1728
plasma volume expansion
  paracentesis-induced circulatory dysfunction prevention 694–695
  portal hypertension 636–637
plasminogen
  cirrhotic ascitic fluid 668
  haemostasis 256
  synthesis 257
plasminogen activator inhibitor-1 (PAI-1)
  acute liver disease 257–258
  fibrinolysis 256, 258
plasminogen activator inhibitor-2 (PAI-2) 256
Plasmodium 1029
  life cycle 1030
  see also malaria
Plasmodium falciparum 1029
Plasmodium malariae 1029, 1030
Plasmodium ovale 1029
Plasmodium vivax 1029
plastic anaemia, post-liver transplantation 1772
plastic membranes, gene array platforms 403
plastic stents
  metal stents *vs.* 545–546
  occlusion 545
platelet(s)
  abnormalities
    cirrhosis 773, 1785–1786, 1786t
    liver disease 1771
  aggregation deficiency 1786
  cholesterol loading, cirrhosis 1786
  clot formation 1780
  dysfunction, haemodialysis 1791
  function
    abnormalities 259
    assessment 1771
    post-liver transplantation 1773
platelet-associated immunoglobulin (PAIgG), cirrhotic patients 773
platelet count
  acute liver failure 1131
  alcoholic liver disease 1168
  cirrhosis 610
  hypersplenism 772
  liver biopsy, safe limits for 1771
  spleen size 772, 773f
  variceal bleeding 775, 775f
platelet-derived growth factor (PDGF)
  liver fibrosis 2090, 2091f
  stellate cell proliferation 592
platelet function assay (PFA) 1782, 1783t
platelet transfusion 261, 1789
  acute variceal bleeding 648
  hypersplenism 773f, 775
  side-effects 1789
pleconaril 967
pleomorphic cholangitis 425
plethoric facies, alcohol misuse 1809
pleural effusions
  ascites 724
  cirrhosis 671–672
plexiform neurofibromas, hepatic 1645
pneumococcal pneumonia, hepatic involvement 1618
pneumonia
  hepatic involvement 1618
  portal hypertension 767
Poiseuille's law 630
POLG1 gene mutations 1379
polyarteritis nodosa (PAN) 1698
  hepatic artery aneurysms 1393
  hepatitis B 1698, 1806, 1818, 1826
    therapy 1818
  hepatitis C 1806–1807
polybrominated biphenyls (PBB), hepatotoxicity 2114
polychlorinated biphenyls (PCB), hepatotoxicity 1272–1273, 2115
polychloroprene, hepatotoxicity 2115
polycystic kidney disease
  adult *see* adult polycystic kidney disease (ADPKD)
  Budd–Chiari syndrome, secondary 1405
  liver cysts in 789–795
  peribiliary cysts 802
  vanishing bile duct syndrome 1112
polycystic liver disease (PCLD) 795–797
  cholangiocyte 54
  clinical features 796
  complications 796
  development risk factors 796
  diagnosis 796
  ER translocation mutations 193
  genetics 796
  liver transplantation 1988
  molecular biology 796
  natural history 796
  pathogenesis 796
  pathology 796
  peribiliary cysts 802
  pregnancy 1886
  progression risk factors 796
  renal cystic disease *see* adult polycystic kidney disease (ADPKD), hepatic cysts and
  ultrasonography 504
  vanishing bile duct syndrome 1112
polycystin-1 789
polycystin-2 790
polycythaemia vera 1665
polyenylphosphatidylcholine (PPC), alcoholic hepatitis 1908
Polygonum multiflorum (Shou-Wu Pian), hepatoxicity 1282t, 1283
polymerase chain reaction (PCR)
  echinococcosis 1055
  enterovirus infection diagnosis 967
  granulomatous hepatic tuberculosis 1006
  hepatitis B 838
  hepatitis C 855, 884
  hepatitis D 876
  hepatosplenic candidosis 1012
  herpes simplex virus 959
  liver biopsy 491
  Mycobacterium tuberculosis 670, 1713
  Q fever 1004
  varicella-zoster virus infection 960
  viral hepatitis 430
polymerase inhibitors, chronic hepatitis C 951
polymorphism *see* genetic polymorphism and liver disease
polymorphonuclear (PMN) count, spontaneous bacterial peritonitis 763
polymyalgia rheumatica, hepatic involvement 1698
polymyositis 1697–1698
polymyxin B 1511
polyneuropathy-organomegaly-endocrinopathy-M protein-skin changes (POEMS) 2152
polypectomy, haemostasis risk 1788t
polyploidization 275
  chronic liver injury 282
polyprenoic acid 217
pooled odds ratio (ORp) 2074
pooled risk difference (RDp) 2074
population stratification 360
porcine hepatocytes
  bioartificial liver support 2044–2045
  hepatocyte transplantation 2035–2036
porocephalosis *see* pentastomiasis
porphobilinogen (PBG)
  acute porphyrias 1344, 1345
  excretion 212, 212t
  synthesis 208
porphobilinogen deaminase 208
  haem synthesis regulation 210f, 211
  housekeeping 211
  structure 211f
porphyria(s) 1343–1351
  acute (hepatic) 1343–1346
    crises 1343–1344
      chronic 1345
      prevention 1345
      recurrent 1345
    diagnosis 1344, 1344t
    inheritance 1345
    neuronal damage 1345
    pathogenesis 1345–1346
    penetrance 1345
  cutaneous manifestations 1810
  dual 1349
  homozygous forms 1348–1349
  liver cell carcinoma, risk of 1346
  mixed forms 1348–1349
  non-acute 1346–1348
  photosensitivity 1346–1347
    therapy 1347
  pregnancy 1886
  see also individual types
porphyria cutanea tarda (PCT) 1347
  alcohol abuse 1186
  cutaneous manifestations 1810
  diagnosis 1810
  familial 1810
  hepatitis C virus 1807
    hepatocellular carcinoma, risk of 1438
  mixed forms 1349
  photosensitivity 1347
  symptoms 1347
  treatment 1347, 1810
  triggering factors 1347
  type 1 1347
  type 2 1347
  type 3 1347
  visceral leishmaniasis 1037
porphyria variegata (PV) 1344t, 1346
  aminolaevulinic acid 1344
  diagnosis 1344
  genetic defect 1346
  homozygous form 1348
  inheritance 1345
  liver cell carcinoma, risk of 1346
  penetrance 1345
  photosensitivity 1347
  porphobilinogen 1344
porphyrinogens 207
  excretion 212, 212t
porphyrins
  bile secretion 213
  excretion 207, 212–213, 212t
  precursors
    excretion 212–213, 212t
    synthesis 208
  structure 207, 207f
portacaval shunt
  congenital hepatic fibrosis 782
  familial hypercholesterolaemia 1367
  glucagon levels, cirrhotics 1737–1738
porta hepatis 3, 79
portal biliopathy 1397
portal cavernoma 1397–1399
portal–central bridging necrosis 424
portal fibrosis 426
  schistosomiasis 1041, 1041f
  toxin-induced 1270t, 1273–1274
portal hepatitis 429
portal hypertension
  anatomy 625–629
  angiography 537–538
    indications for 537–538
  ascites
    cirrhotic 672–675
    pathogenesis 687–688
  azygos blood flow 662
    measurement 570, 663
    therapeutic response assessment 663
  bacterial infections 761–770
  biliary atresia 1848
  carcinoid tumours 1472
  children 1864–1865
  cirrhosis 605–606
  clinical features 606
  complications 605–606
  congenital arterioportal malformation 1418
  congenital hepatic fibrosis 781–782
  drug metabolism 247
  extrahepatic, children 1864
  Felty syndrome 1696
  glycogen storage disease type 4 1374
  haemodynamic assessment 658–665
  haemorrhage 550
  hepatic arterioportal fistulae 1394
  hepatic venous pressure gradient measurement 660–661, 661f
    therapeutic response assessment 661
  hepatocellular carcinoma, surgical resection 1447
  hepatosplenic schistosomiasis 1042–1043, 1044
  hereditary haemorrhagic telangiectasia 1420
  hyperdynamic circulation 634–636
  intestinal protein loss 1837
  intrahepatic vascular blood flow 685
  management 642–643
    pretransplant patients 1923–1924
    rationale for 642–643, 642f
  mesenteric inflow 1724–1725
  myeloid metaplasia 1665

portal hypertension (*continued*)
oesophageal epithelium, blood-filled channels 628, 629f
pathogenesis 630–639, 636f
blood flow–vascular resistance interplay 630–637
collateral resistance 633–634
hepatic vascular resistance 630–633
vasoconstrictors 632–633
vasodilators 631–632
peribiliary cysts 802
polycystic liver disease 791f, 792t, 793
portal blood flow 570
portal vein stenosis 1399–1400
presinusoidal
cirrhotic ascites 674
hepatic venous pressure gradient 568
primary biliary cirrhosis 1079
pulmonary complications 720–727
emboli 724
liver transplantation 725, 725t
pleural/diaphragm effects of ascites 724–725
vascular 720–724
renal transplant patients 1658
sarcoidosis 1712
splanchnic arteriolar circulation 675
splanchnic transmicrovascular fluid exchange 673–674
trans-sinusoidal fluid exchange 672–673
treatment
drug-induced renal impairment 703
rationale 642–643
ultrasonography 503–504
cause identification 503–504
collateral portosystemic pathways 503
diagnosis 503
variceal haemorrhage prevention 643–647
variceal haemorrhage treatment 643–647
wedged hepatic venography 533
portal hypertensive colopathy 1802
portal hypertensive gastropathy (PHG) 653, 1799–1800
bleeding 653, 1799
endoscopic appearance 1799
mild 653
mucosal changes 1799
peptic ulcers 1800
prevalence 653
severe 653
vascular congestion 1799
portal myofibroblasts 47, 47t
portal pressure
alcoholic hepatitis 1162
ascites, post-peritoneovenous shunting 695–696
definition 567
gradient 658
measurement 567–568, 658–662
direct methods 567, 658–659
indirect methods 567–568, 659–660
paper recordings 660, 660f
scientific basis 658
technique 658–662
portal spaces, congenital hepatic fibrosis 781
portal tracts 9
portal vein 5, 79, 89
anatomy 534, 549, 623–625
gastro-oesophageal junction 623–625
aneurysms 1399, 1400f
diagnosis 1399
spontaneous rupture 1399
blood flow measurement 568–569
cavernous transformation 626, 626f
compression
ciliated hepatic foregut cyst 808
extrinsic 1399–1400
congenital stenosis 1399
development 69
drug-induced lesions 1255, 1255t
embryology 623
hepatocellular carcinoma 1441
interventional radiology 551, 552
left branch 5
malarial hepatitis 1031
obstruction 1395–1402
Budd–Chiari syndrome 1407
portal hypertension 625–629
collateral pathways 625–626, 625f, 626f
right branch 5
thrombosis *see* portal vein thrombosis (PVT)
ultrasonography
post-liver transplant assessment 508
preoperative patency assessment 507
portal vein embolization (PVE)
cirrhosis 1934
obstructive jaundice 1936
portal vein thrombosis (PVT) 1395–1399
acute episodes 1396–1397
diagnosis 1396
imaging 1396
prognosis 1397
treatment 1396–1397
aetiology 1395–1396, 1395t
Budd–Chiari syndrome 1407
cavernomas 626, 626f, 1397–1399
chronic 1397–1399
diagnosis 1398
prognosis 1399
treatment 1398–1399
cirrhosis 1396, 1792, 1793f
clinical presentation 1396, 1397
congenital hepatic fibrosis 782
definition 1395
Doppler ultrasound 503
drug-induced 1255, 1255t
liver transplantation 1968
postoperative 1396, 1982
pretransplant management 1925
portal hypertension 503
portal venography 532–535
Budd–Chiari syndrome 538
direct 532
indications 532, 533
indirect 532
patent umbilical vein 534, 534f
percutaneous transhepatic 534
technique 533
transjugular transhepatic 534, 535f
portal venous inflow 1724–1725
portal venous system arteriovenous fistulae 1400
portal venules 79
blood flow regulation 80
blood pressure 81
thrombosis 630–631
portocaval shunting
Budd–Chiari syndrome 1409–1410
post-shunt encephalopathy 1410
cirrhotic ascites 697–699
hepatic encephalopathy 749
hepatorenal syndrome 697
peptic ulcers 1800
portal hypertensive gastropathy 1799
recurrent variceal bleeding prevention 647
portopulmonary hypertension 722–724
clinical presentation 723
diagnosis 722t, 723
liver disease and 1938–1939
liver transplantation
contraindications 1989–1990
preoperative patients 1924–1925, 1996
mean pulmonary artery pressure 722t, 723
pathophysiology 723
prognosis 723
screening 1924
treatment 723
portosystemic anastomoses, hepatic encephalopathy induction 743
portosystemic circulation, quantification of 570
portosystemic encephalopathy 444–445, 729
portosystemic encephalopathy index 744
portosystemic shunts (PSS)
angiography 538
cirrhosis
insulin-like growth factor binding proteins 1744
insulin-like growth factor-1 1744
congenital 1418–1419
clinical presentation 1419
intrahepatic 1419
treatment 1419
cystic fibrosis 1340–1341
extrahepatic congenital 1418–1419
associated conditions 1419
misclassification 1418–1419
type 1 1418, 1419
type 2 1418, 1419
hypersplenism 777
positional cloning (forward genetics) 372
positive predictive value, diagnostic models 2062
positron emission tomography (PET) 561–566
alveolar echinococcosis 1053, 1053f
carcinoid tumours 1473
cholangiocarcinoma 562–564
hilar (upper duct) 1592–1593
intrahepatic 1595
cirrhosis 564, 613
clearance measurements 474
dynamic scanning 472, 561
liver tumours 562, 562f
endogenous substrate metabolism 564
exogenous substrate metabolism 564
hepatic metastases 564, 1468, 1468f
colorectal carcinoma 562, 563f
hepatocellular carcinoma 564
liver perfusion, regional variations 564
liver tumours 561–564
regional liver metabolism measurements 472–474
arterial equilibration model 473
compartment models 472f, 473–474
hepatic dual-input function 472–473, 472f, 473f
microvascular models 473–474
variations in 564
standardized uptake value 562
static scans 472, 561
liver tumours 562
surgical risk assessment 476
tracers 561
'post-cholecystectomy syndrome' 1535
post-cholecystectomy syndrome 1570
post-embolization syndrome 554, 1449
post-kala-azar dermal leishmaniasis (PKDL) 1036
diagnosis 1037
treatment 1039
postoperative jaundice 1611, 1945–1952
assessment 1948t
bilirubin overproduction 1945–1947
clinical appearance 1945
diagnostic algorithm 1948f
diagnostic clues 1947–1951
differential diagnosis 1947–1951
early 1947, 1948t
examination 1947
history 1947
iatrogenic 1951
late 1947, 1948t
pathophysiology 1945–1947, 1946f
pre-existing liver disease and 1947
surgical problem related 1947
treatment 1947–1951
postoperative liver failure (PLF)
assessment 1935
cirrhotic patients 1935
fatty liver patients 1936
liver transplantation and 1301
postpartum haemorrhage, acute fatty liver of pregnancy 1883
post-peritoneovenous shunting, intravascular coagulation 696
post-reperfusion syndrome 552, 1942
posttranslational modification (PTM), proteomics 403, 405, 411
post-transplant lymphoproliferative disorder (PTLD) 1773–1774
children 1866
clinical features 1866
early 1774
Epstein–Barr virus infection 965
immunosuppression post-liver transplantation 2022
incidence 1773
late-onset 1774
pathophysiology 1774f
risk factors 1773–1774, 1866
therapy 1774
tumour onset 1773
postural change, cardiac output in cirrhosis 1721, 1728
potassium
hepatorenal syndrome 713
obstructive jaundice 1504
potassium canrenoate, sexual dysfunction males 1759
potassium channel, bile secretion 1337
power Doppler 501
metastases 505

praziquantel
alveolar echinococcosis 1052
Clonorchis sinensis 1046
fascioliasis 1045
schistosomiasis 1044
prazosin, drug-induced renal impairment in cirrhosis 703
prebiotics, liver transplantation 1910
pre-β migrating high-density lipoprotein (pre-β-HDL) 139
precipitant-induced encephalopathy *see* episodic (precipitant-induced) encephalopathy
precipitin bands, histoplasmosis 1015
prednisolone
amyloidosis 1707
autoimmune hepatitis 1099, 1100
carcinoid tumours 1476
clearance, cirrhosis 1753
liver transplantation 2004
pregnancy 1889
tumour-associated hypoglycaemia 1745
prednisone, alcoholic hepatitis 1164
pre-eclampsia
acute fatty liver of pregnancy 1881
acute liver failure 1300
clinical features 1885t
hepatic abnormalities 1883–1884
pregnancy
acute fatty liver *see* acute fatty liver of pregnancy (AFLP)
adenomas 1886
alcoholic liver disease 1886
alkaline phosphatase 463, 1879
autoimmune hepatitis treatment 1099
benzimidazole avoidance 1055
biliary disease 1888
biliary obstruction 1888
Budd–Chiari syndrome 1405, 1885
cholangiocarcinoma 1886
chronic hepatitis 1886
cirrhosis 1885–1886
drug toxicity 1888
Dubin–Johnson syndrome 1886
familial hyperbilirubinaemia 1886
focal nodular hyperplasia 1886
gallbladder 1879
gallstones 1888
Gilbert syndrome 1886
glutathione 1221
glycogen storage diseases 1372, 1373
haemangioma 1886
haemochromatosis 1886
HELLP syndrome 1770, 1884–1885
hepatitis A 1887
hepatitis B 1887
antiviral therapy 936
vaccine 911–912
hepatitis C 1887–1888
treatment contraindication 944
hepatitis D 1888
hepatitis E 917, 1888
hepatocellular carcinoma 1886
hereditary haemorrhagic telangiectasia 1422
herpes simplex virus infections 958
hypertension-associated liver dysfunction 1883–1885
immunosuppression contraindications 2005
intrahepatic cholestasis *see* intrahepatic cholestasis of pregnancy (ICP)
jaundice 1879
liver biopsy 1879
liver diseases 1879–1896
pre-existing 1885–1887
liver histology 1879
liver rupture 1884
liver transplantation 1888–1889
graft rejection 1889
hypertensive disease 1889
liver tumours 1886
malaria 1030
normal 1879
paracetamol-induced hepatitis 1238
polycystic liver disease 1886
porphyrias 1886
post-liver transplantation 2024
primary biliary cirrhosis 1886
primary sclerosing cholangitis 1886
Rotor syndrome 1886
spider naevi 446
variceal bleeding 1887
vascular abnormalities 1887
viral hepatitis 1887–1888
Wilson's disease 1319, 1886
pregnane X receptor (PXR)
bile acid homeostasis 106, 178, 301t, 386, 387, 388f
bilirubin transport 1354–1355
intrahepatic cholestasis 1483
rifampicin acid as ligand 387–388
UGt1A1 regulation 1354
ursodeoxycholic acid 387, 1493
pregnane X receptor (PXR) agonists, intrahepatic cholestasis 2920–2921
preload, cirrhotic patients 1722, 1723f
premature infants
multifactorial cholestasis 1849–1850
total parenteral nutrition-related liver disease 1634
preoperative percutaneous transhepatic biliary drainage (PTBD), obstructive jaundice 1935–1936
'pressure waves' 740, 740f
preterm infants, TPN-associated cholelithiasis 1637–1638
previtamin D_3 218
primaquin 1033
primary biliary cirrhosis (PBC) 1071–1088
ABCB4 gene mutations 1384–1385
abdominal discomfort 1075
associated conditions 484, 1075–1076
non-hepatic malignancy 1076
asymptomatic 1080
autoantibodies 484
antimitochondrial antibodies 1120
autoimmune disease 1075–1076
autoimmune hepatitis *vs.* 1078t
autoimmune thyroid disease 1076
bilirubin 461
bone changes 1078–1079, 1831
causes/mechanisms 1072t, 1482, 1714
characteristics 1714t
cholestatic sarcoidosis *vs.* 1077, 1078t
coeliac disease 1629, 1801
complications 1078–1079
CREST syndrome 1697, 1798
cutaneous manifestations 1808
definition 1071
diagnosis 1074, 1074t, 1120–1121, 1121t, 1488
antimitochondrial antibodies 1074
antimitochondrial antibody-negative *see* autoimmune cholangitis (AIC)
liver biopsy 1074
differential diagnosis 1077–1078, 1078t
antimitochondrial antibodies 1077
drug-induced cholestasis 1077, 1078t
herbal remedies 1077–1078
elderly 1872
eosinophils 1770
epidemiology 1071–1072
environmental factors 1072
familial clustering 1073–1074
gender 1071
geographical clustering 1071–1072
migration influences 1072
twin concordance studies 1073–1074
fatigue 443, 1074–1075, 1081
functional genomics
gene array data 410
proteomics data 413
genetics 357t, 358, 360t, 1073–1074
granulomas 1710, 1714
granulomatous destructive cholangitis *vs.* 1485
hepatobiliary transporter changes 386
hepatocellular carcinoma 1075, 1439
histology 1076–1077
historical aspects 1071
hyperbilirubinaemia 1075, 1356
imaging 1074
immunogenetics 365t, 366t
weak HLA association 358, 367
immunoglobulin A 329
infectious aetiology 1072–1073, 1714
inflammatory bowel disease 1628
intrahepatic cholestasis 1488
investigations 1076–1078
antimitochondrial antibodies 1076, 1488
γ-glutamyltransferase 1076
liver histology 1076–1077
serum alkaline phosphatase 1076
serum cholesterol 1076
jaundice 1075
lichen planus 1643
liver failure 1081
liver transplantation 1084, 1986–1987
Mayo Clinic PBC model 1986–1987
recurrence 1073, 2004, 2015
malabsorption 1079
menorrhagia 1759
migration influences 1072
natural history 1079–1080
neurological manifestations 1824t
non-hepatic malignancy 1076
oral manifestations 1798
osteoblast function 1831
osteocalcin 1752
osteoporosis 1075, 1082, 1830
outcomes research 2069
overimmunosuppression 1073
overlap syndromes *see* overlap syndromes
pancreatitis 1800–1801
parathyroid hormone 1751
pathogenesis 1072–1074
antimitochondrial antibodies 1072
biliary epithelial cells 1072
halothane 1073
infections 1072–1073
molecular mimicry 1072–1073
overimmunosuppression 1073
peptic ulcers 1800
platelet abnormalities 1771
portal hypertension 1079
pregnancy 1886
primary sclerosing cholangitis *vs.* 1077, 1078
prognostic scores 1080, 1081t
pruritus 1075, 1081–1082, 1804
Raynaud syndrome 1082
renal associations 1076, 1817t, 1819
rheumatoid arthritis 1076
scleroderma 1697, 1798
scoring systems 437t, 1080, 1081t
Sicca syndrome 1082
Sjögren syndrome 1076, 1697
steatorrhoea 1082
symptomatic 1080
genetic studies 1080
Mayo model 1080
symptoms 1074–1075
systemic lupus erythematosus 1695
thyroid hormones 1749
treatment 1081–1084, 1081t
preventative 1082
symptomatic treatment 1081–1082
Turner syndrome *vs.* 1078, 1078t
ulcerative colitis 1628
vanishing bile duct syndrome 1113t, 1115–1116
vanishing bile duct syndromes 1078t
vitamin A deficiency 1802
Wnt signalling cascade and 410
xanthelasma 1075
xanthoma 1075
primary collapse, fibrosis 426
primary haemochromatosis *see* haemochromatosis
primary module 10, 11f
primary nonfunction, post-liver transplantation 1301
primary sarcoma *see* undifferentiated sarcoma
primary sclerosing cholangitis (PSC) 1103–1110, 1488–1490, 1623–1626
associated diseases 1104–1105, 1105t
autoantibodies 480t, 484
biliary dysplasia 1623f
biliary strictures 1106
causes 1103, 1103t, 1482
cholangiocarcinoma 413, 563, 1106, 1584, 1596, 1626–1627, 1987
cholecystectomy 1106
cholelithiasis 1106
clinical course 1104
clinical features 1104–1105
coeliac disease 1629
colonic dysplasia 1623f
colorectal cancer 1625
post liver transplant 1625
complications 1106–1107
Crohn's disease 1623, 1626
definition 1103
diagnosis 1104–1105, 1121
cholangiographic features 1106
criteria 1105, 1121t
differential diagnosis 1106
epidemiology 1103–1104
age 1490
functional genomics
gene array data 410
proteomics data 413

primary sclerosing cholangitis (PSC) (*continued*)
glomerulonephritis 1817t
histology 1106
immunogenetics 365t, 366–367, 366t
inflammatory bowel disease
association 366, 370, 1103, 1104, 1489
prevalence 1623–1624, 1624–1626, 1624t
laboratory tests 1105–1106
liver transplantation 1106, 1108–1109, 1987
postoperative granulomas 1714
recurrence 1625, 2015–2016
survival rates 1987
natural history 1103–1104
neurological manifestations 1824t
'onion skin' lesions 1485
onset 1624
outcome 1624
overlap syndromes *see* autoimmune sclerosing cholangitis (ASC)
pancreatitis 1801
pathogenesis 366, 484
pathophysiology 1104, 1106
environmental exposure 1104
genetic factors 1104
infections 1104
pregnancy 1886
primary biliary cirrhosis *vs.* 1077, 1078
pruritus 1106
radiography 1105
secondary sclerosing cholangitis *vs.* 1106
smoking 1624
staging 1105, 1105t
surgery 1108
symptoms/signs 1104
therapy 1107–1109, 1495
thyroid hormones 1749
ulcerative colitis 366, 1623–1626
vanishing bile duct syndrome 1113t, 1115–1116
vitamin deficiencies 1106
primary sclerosing cholangitis–inflammatory bowel disease 1625t
Primovist 529
Pringle manoeuvre, warm ischaemia 348
prisoners, hepatitis B vaccine 912
pro-apoptotic signalling cascades, tumour necrosis factor 314–316
probiotics
hepatic encephalopathy 747
liver transplantation 1910
problematic ascites *see* refractory ascites
pro brain natriuretic peptide (BNP), cirrhosis 1723
procoagulant factors 1788t
procollagen III aminopeptide (PIIINP) 1646
proctocolectomy, primary sclerosing cholangitis 1108
Profile of Mood States Scale 2029
progesterone
gallbladder motility disorders 1562
intrahepatic cholestasis of pregnancy, triggering factor 1880
progestogens, carcinogenicity 1649
prognostic models 2055–2060, 2055t
accuracy 2057–2059, 2058f
calibration 2058–2059, 2058f
discrimination 2057–2058
censoring 2057
Child–Turcotte–Pugh score 2060
Cox regression analysis 2055–2056
definition 2055
diagnostic models *vs.* 2061
informative censoring 2057
precision 2057–2059, 2058f
definition 2059
model generalizability 2059, 2059t
proportional hazards 2055–2056
example 2056, 2056t
hazard ratio 2056
programmed cell death (PCD)
caspase-independent 342
see also apoptosis
progressive familial intrahepatic cholestasis (PFIC) 1383, 1849
diagnosis 1487
genetics 1386, 1524
histology 1849
management 1849
treatment 1495
type 1 (Byler's disease) 177, 1384, 1849
type 2 177, 1384–1385, 1524, 1849
gallstone formation 1385
hepatocyte transplantation 2038
type 3 177, 1384, 1524, 1849
gallstone formation 1385
type 4 1386
progressive sclerosing cholangitis
critically ill patient 1947
diagnosis 1951
post septic shock 1951
proinflammatory cytokines
Argentine haemorrhagic fever 989
intrahepatic cholestasis 1491
Lassa fever 989
receptors 106
prolactin 1760
haemochromatosis 1762
proliferating cell nuclear antigen (PCNA), hepatocellular carcinoma 1440
prolonged Q-T interval, chronic liver disease 1722
prope tolerance, immunosuppression 2003
propofol
acute liver failure 1304
liver transplantation 1942
pruritus 1804
proportional hazards, prognostic models 2055–2056
propoxyphene, acute hepatitis induction 1239
propranolol
azygos blood flow 663
drug-induced renal impairment 703
pharmacodynamic effects in cirrhotic patients 1914
portal hypertensive gastropathy 653, 1799
schistosomiasis 1044
side-effects 644
thyroid function 1750
variceal bleeding prevention 644
propressophysin 680
propylthiouracil
hepatotoxicity 1239, 1299, 1685
liver enzyme abnormalities 1685
prostacyclin
hepatic blood flow regulation 77
portal hypertension 636
portopulmonary hypertension 723
splanchnic hyperaemia 636
synthesis 682
prostaglandin(s) (PGs)
carcinoid syndrome 1475
compensated cirrhosis 682
formation 680–681
gallbladder fluid transport 306
non-azotaemic cirrhotics with ascites 682–683
obstructive jaundice-associated acute renal failure 1816
renal haemodynamics 682, 683f
prostaglandin E2 (PGE2) 682
non-azotaemic cirrhotics with ascites 682–683
prostaglandin G2 (PGG2) 681–682
prostaglandin GI2 (prostacyclin) *see* prostacyclin
prostaglandin H2 (PGH2) 681–682
prostanoids, as second messenger 103
Prostata, hepatotoxicity 1286
prostate, alcoholic cirrhosis 1820
prostatic cancer
alcoholic cirrhosis 1820
liver 1658–1659
prostheses
covered 551, 551f
uncovered 551
protease inhibitors (PI)
chronic hepatitis C antiviral therapy 951
elimination, cirrhosis 1916
hepatotoxicity 1807
proteases
apoptosis 336
cell death 343
necrosis 341
proteasome degradation 194
protein(s)
alkylation, drug-induced acute hepatitis 1224, 1225–1226
degradation 191–198, 192f, 194–195
cotranslational 196
fulminant hepatic failure 1839
lysosomal pathway 194
proteasomal pathway 194
regulation 195
denutrition, glutathione 1221
discovery 412
dislocation 194
endoplasmic reticulum
targeting 193
translocation across 193
feeding, hepatic encephalopathy 1839
identification by mass spectroscopy 399, 405
isolation/purification, proteomic analysis 404
maturation 192f, 193–194
membrane sorting/targeting 193
metabolism 142–149
mitochondrial importation 152, 153f
oxidation 185–186, 187f
postsynthetic sorting 194
posttranscriptional gene expression 191–195
restriction *see* protein restriction
retrotranslocation 194
spontaneous bacterial peritonitis 763
synthesis 90–91, 191–198, 192f
endoplasmic reticulum 23
regulation 147–148, 195–196
targeting regulation, future prospects 195–196
trafficking
dipeptidyl peptidase IV (DPPIV) 96
hepatocytes 96, 97f
translation 191–192, 192f
initiation 195, 196
translocation, future prospects 195–196
urea synthesis regulation 183
protein C
deficiency
Budd–Chiari syndrome, primary 1404
portal vein thrombosis 1395–1396, 1395t
haemostasis 256, 1780
synthesis 257
protein–calorie malnutrition (PCM)
alcoholic cirrhosis 1165–1166
cirrhosis associated 1839
management 1836–1839
growth hormone resistance 1741
pathophysiology 1836–1838
diminished nutrient intake 1836–1837
postoperative liver transplantation 2001
prevalence 1836
protein C–protein S–thrombomodulin pathway 1780
protein disulphide isomerase (PDI) 135
protein interaction maps 406f
protein interactions, proteomics 2091–2092
protein kinase A (PKA)
signal transduction 103, 104
structure 104
protein kinase C (PKC)
signal transduction 103, 104
substrate 80K-H (PRKCSH), polycystic liver disease 796
protein kinases, *Entamoeba histolytica* 1023
protein recognition molecule, proteomics 2092
protein restriction
hepatic encephalopathy 746, 1908
persistent chronic 749
precipitant-induced 749
liver disease 1836–1837
protein S
deficiency
Budd–Chiari syndrome, primary 1404
portal vein thrombosis 1395–1396, 1395t
haemostasis 256
synthesis 257
protein thiols, depletion 1220, 1221f
protein tyrosine nitration (PTN)
astrocytes 736
benzodiazepine-induced 736
hepatic encephalopathy 736
proteinuria
glycogen storage disease type 1 1372
hepatitis C 1819
protein Z
haemostasis 256
synthesis 257
proteoglycans 269–270
structure 269
proteolysis regulation 147–148
proteolytic system 274

proteomics 403–406
alcoholic *vs.* non-alcoholic liver disease 413
array platforms 405, 415
biomarker discovery 412, 413–414
blood biomarker discovery 412, 413–414
chromatography 405
closed *vs.* open systems 403
definition 399
future prospects 405–406, 414–415
gene arrays *vs.* 403, 405
general methodology 403–404
hepatitis B 413
hepatitis C 412–413
hepatocellular carcinoma 412, 413
immune disorders 413
known protein studies 412
limitations 403, 404, 405
in liver disease 408t, 411–414
liver proteome 411–412
multiplexing 415
posttranslational modification and 403, 405, 411
protein discovery 412
protein identification 405
mass spectroscopy 399, 405, 414–415
protein interactions and 404, 406f
proteome complexity 398, 403, 411–412
QTL analysis in inbred mice 379–380
regulatory network mapping *see* regulatory network mapping
resolution of low-abundance proteins 404
samples
biases 404
prefractionation 404
preparation 404
separation 404–405, 404f, 414
sequential processing 403–404
top-down *vs.* bottom-up 404
toxicology and 412
types of studies 412
visualization 405
see also bioinformatics; functional genomics
Proteus, bacterial cholangitis 1541
prothrombin (factor II)
acute liver disease 257
Budd–Chiari syndrome 1404
clot formation 1780
synthesis 257
prothrombin index
acute liver failure 1293, 1302
alcoholic liver disease 1168
prothrombin time (PT) 260, 455, 1781
abnormal values 456
acute fatty liver of pregnancy 1882
acute liver failure 1293, 1302
children 1859
alcoholic hepatitis 1163
assay 455
cirrhosis 258, 612
clinical usefulness 456
congestive heart failure 1612
fibrinolysis 258
influencing factors 455
limitations 1783, 1784f
normal values 455
post-cardiac surgery, children 1611
postoperative liver failure assessment and 1935
prolongation 1781
reaction 455
vitamin K absorption 456
proton pump inhibitors, cirrhotic patients 1914
proto-oncogenes
hepatocellular carcinoma 392–393, 392t
viral disruption 393
protoporphyrin
excretion 213
reabsorption 213
protoporphyrin IX 209
protoporphyrinogen IX 208
protoporphyrinogen-IX oxidase (PPOX) gene mutations 1810
protoporphyrinogen oxidase 208–209
deficiency, porphyria variegata 1346
protoscolices, alveolar echinococcosis 1052
protozoal infections 1020–1039
pathogenesis 1022, 1022t
provitamin D_3 (cholesterol, 7-dehydrocholesterol) 218
Prox-1, liver bud expansion 66
pruritus 444, 1804
aetiology 1804
cholestasis 444, 1486, 1804
rifampicin 387–388, 1072, 1496
treatment 1496
intrahepatic cholestasis of pregnancy 1880
obstructive jaundice 1502–1503, 1506–1507, 1512
primary biliary cirrhosis 1075, 1081–1082, 1804
primary sclerosing cholangitis 1106
progressive familial intrahepatic cholestasis type 4 1386
treatment, opioid antagonists 1082, 1496
pruritus gravidarum 1880
pseudoalcoholic hepatitis 1170, 1246
pseudoaneurysm, angiography 536, 536f
pseudocapillarization, liver sinusoidal endothelial cells 33
pseudocapsule, biloma 817
pseudocholinesterase (PChE) 457
pseudochylous ascites 669
pseudocirrhosis 1422
pseudo-Cushing syndrome 1753–1754
adrenocorticotropic hormone 1753
alcoholics 1187
clinical features 1753
cortisol 1753
pseudojaundice 446
pseudoparticle system, hepatitis C virus models 854
pseudopodium, amoebae 1023
pseudotumoral hepatic tuberculosis 1006
pseudotumours
alcoholic hepatitis 1163
ascariasis 1060
pseudoxanthoma elasticum type changes, penicillamine side-effect 1811
pseudo-Zellweger syndrome 2152–2153
psittacosis 1005
psoralens, hepatotoxicity 1647
psoriasis 1642–1643
alcohol 1642
chronic hepatitis C antiviral therapy 945
inheritance 1642
lesions 1642
psychiatric disorders, antiviral side-effects 946–947
psychological support (brief intervention), alcoholic cirrhosis 1167
psychometric hepatic encephalopathy score (PHES) 745
psychoses, Wilson's disease 1316
psychosocial adaptation, post-liver transplantation 2027
psychotropic drugs, liver disease and 1940
exaggerated therapeutic effects 1915, 1915t
PTEN, tumour suppressor gene 394t
p-tert-butylphenol (PTBH), hepatotoxicity 2108
publication bias assessment (Klein's method) 2075, 2077
public health measures
non-alcoholic fatty liver disease prevention/management 1203–1204
non-alcoholic steatohepatitis prevention/management 1203–1204
pulegone (pennyroyal oil), hepatotoxicity 1282t, 1285–1286, 2114
pulmonary angiography, hepatopulmonary syndrome 721
pulmonary artery pressure (PAP)
liver disease and 1938–1939
portopulmonary hypertension 1924
pulmonary circulation, chronic liver disease and 1725–1726
pulmonary disease/disorders
acute liver failure 1293
chronic, liver function in 1617–1618
liver transplantation contraindications 1989–1990
pulmonary effusions, liver disease and 1939
pulmonary emboli, portal hypertension 724
pulmonary hypertension
Gaucher's disease, type 1 1361
glycogen storage diseases type I 1372
portal hypertension 723, 723t
pulmonary oedema, hepatorenal syndrome 713
pulmonary vascular resistance, portopulmonary hypertension 722t, 723
pulsatile livers 447–448
pulse oximetry, hepatopulmonary syndrome 720
puncture-aspiration-injection-reaspiration (PAIR)
anaphylactic shock induction 1051
contraindications 1051
cystic echinococcosis 1051
purine metabolism, ammonia production 181
purine synthesis inhibitors 2008
purulent (suppurative) cholangitis 426
pus evacuation, pyogenic liver abscess 1002
pyogenic liver abscess 1001–1002
causes 1001
elderly 1874
epidemiology 1001
imaging 504, 1002
laboratory abnormalities 1002
presentation 1002
prognosis 1002
strongyloidiasis 1065
treatment 1002
pyrazinamide, hepatotoxicity 1239, 1299
pyridoxal deficiency 147
pyrilamine, hepatic encephalopathy 738
pyrimidine synthesis inhibitors 2008
pyrrolizidine alkaloids (PA), hepatotoxicity 1273, 1282t, 1283–1284, 2115–2116
pyruvate
mitochondrial oxidation 156–158, 157f
mitochondrial oxidative phosphorylation deficiency 1380
pyruvate kinase 91, 156–157, 156f

Q

Q cycle theory 158, 159f
Q fever 1004
granulomas 1713
Q-T interval, chronic liver disease 1722
quadriplegia, acute porphyric crisis 1344
quality of life
decreases in 443
donor, living donor liver transplantation 1979, 1992
economic considerations 2082
indices 2082
scales 2082
standard gamble methods 2082
time tradeoff 2082
visual analog scale 2082
Quality of Well-being Scale 2082
quality scores (validation) 2077, 2077t
quantitative trait locus (QTL) analysis 371–383
in inbred mice *see* quantitative trait locus (QTL) analysis in inbred mice
molecular basis 379
see also genetic polymorphism and liver disease
principles 371–372
resolution 376
quantitative trait locus (QTL) analysis in inbred mice 371–383, 375t
examples of use 375t
cholecystolithiasis 376, 377f, 378, 378t
haemochromatosis modifier genes 375–376
hepatic fibrosis 374f, 375
hepatocellular carcinoma profiling 379–380
liver metabolism traits 379
experimental design/analysis 373–376, 373t
intercross/backcross experiments 373, 374f
linkage analysis 375
microsatellite/SNP analysis 373, 375
strain survey 373, 373f
functional genomics and 379–380
functional testing in engineered mice 380
narrowing/refining loci 376–379
bioinformatic approaches 377–379, 377t
candidate gene approach 376
recombinant congenic strains 376–377

quantitative trait locus (QTL) analysis in inbred mice (*continued*)
selective breeding 376
in silico vs. experimental methods 378, 378t, 379
see also specific methods
workflow 380–381, 381f
quinidine
acute hepatitis induction 1239
pregnancy 1888
quinine 1033
quinolone-resistant enterobacteria, spontaneous bacterial peritonitis 766–767, 766t
quinone synthesis, inborn errors 1381

R

R778L mutations, Wilson's disease 1317
Rab4, receptor-mediated endocytosis 100
radiation hepatitis 1277–1278
diagnostic criteria 1277
dose 1277
imaging 1277–1278
irradiated volume 1277
presentation 1277
radiation therapy
carcinoid tumours 1477
cholangiocarcinoma 1600
gallbladder carcinoma 1580
hepatic metastases 1469
hepatocellular carcinoma 555
radioactive labelling, gene arrays 403
radioactive *m*-iodobenzyl guanidine, carcinoid tumours 1477
radiofrequency ablation (RFA)
carcinoid tumours 1477
hepatic metastases 1468
hepatocellular carcinoma 552, 553f, 1448
pretransplant patients 1926, 1927t
hypersplenism 777
limitations/side-effects 552, 1448
percutaneous ethanol injection *vs.* 552, 1448
radiology
osteoporosis 1830
rickets 1833
radionuclide scans *see* scintigraphy
Raf gene/protein 392
raloxifene 1832
random effects models 2074
randomized trials, hepatobiliary 572–575
allocation concealment 574t, 575
double blinding 574t, 575
evidence-based clinical practice 572–573
future developments 576–577
generation of allocation sequence 574t, 575
intervention effects 575
meta-analyses 573
cumulative 574
methodological quality 573, 573t, 575
publication bias 573
publications 572, 573f
random errors 573, 575
registration 573
sample size 574–575, 574t
systematic errors 573
ranitidine 1239
rapamycin *see* sirolimus
rapid virological response (RVR), chronic hepatitis C 943
Ras gene/protein
cholangiocarcinoma 1587
as oncogene 392
rash, non-nucleoside reverse transcriptase inhibitor side-effect 1807
RASSF1, as tumour suppressor gene 394t
Ras signalling cascade, oncogenesis 392, 392t
HBx and 393
Raynaud syndrome 1082
reactive hepatitis, histology 429
reactive metabolites
drug-induced acute hepatitis 1217–1218, 1217t
formation 1218–1219, 1219f
genetic factors 1221–1222
humoral immune response 1223–1224, 1224f
inactivation deficits 1226
in situ reaction 1219
reactive nitrogen species (RNS), arsenic poisoning 1274
reactive oxygen species (ROS)
arsenic poisoning 1274
cirrhosis progression from fibrosis 585
extrahepatic biliary obstruction 1501
Kupffer cells 40
mitochondrial 1616, 1616f
DNA damage 351
formation 162–163, 162f
inactivation 162f, 163
warm ischaemia 348, 349f
reactive systemic amyloidosis, psoriasis 1642
recanalization, acute portal vein thrombosis 1397
receptor-mediated endocytosis 98–99, 99f
receptor tyrosine kinases (RTKs) 103, 105
rechallenge, hepatotoxic drugs 1216
recidivant ascites 692
recipient hepatectomy 1966–1967
reciprocity (hepatic artery buffer response) 1391
recombinant activated factor VII (rFVIIa) 261, 1789–1790
actions 1789
acute variceal bleeding 648
complications 1790
efficacy 261, 1790f
fulminant hepatic failure 1789
variceal bleeding 1789–1790
recombinant antigens, visceral leishmaniasis diagnosis 1037
recombinant DNA vaccines, hepatitis B 908
recombinant hepatitis B vaccine, children 1851
recombinant human thrombopoietin (rhTPO), hypersplenism 776
recombinant inbred (RI) mouse strains 376–377
cholecystolithiasis models 376
recombinant Smad 7, fibrosis 597
rectal echography, ascites 667
rectal varices 1802
haemorrhoids *vs.* 1802
recurrent pyogenic cholangitis (RPC) 1545–1546
ascariasis 1059, 1060, 1061
diagnosis 1545
malnutrition 1545
parasitic infections 1545
pathogenesis 1545
peribiliary cysts 802–803
treatment 1545–1546
red blood cells
abetalipoproteinaemia 1366
antibodies, post-liver transplantation 1772
cirrhotic ascitic fluid 668
Plasmodium invasion 1030
porphyrin precursor excretion 212t
porphyrins excretion 212t
red globules, alpha-1-antitrypsin deficiency 1332
red wale marks, oesophageal varices 640
Reed–Sternberg cells 1662, 1662f
reflection coefficient 85
refractory anaemia 1666
refractory ascites 692–693
definition 692
diagnostic criteria 692
hepatorenal syndrome type 2 716
post-peritoneovenous shunting 696–697
pretransplant patients 1923
subtypes 692
regeneration
acute liver failure 1132
age-related changes 1871
angiography 537t
cancer and 391
cholangiocyte replacement 54, 284–285
chronic liver damage 280–289
endothelium 285
partial hepatectomy models 280
cytokines 314t
epidermal growth factor 316
hepatic stellate cells 285–286
hepatocyte growth factor 316
histological features 430
insufficiency 280–281
evidence for 280
mechanisms 280–281
interleukin-6 316, 317
liver sinusoidal endothelial cells 32
morphometry 438
neural modulation 119–120
post-auxiliary liver transplantation 1308
transforming growth factor-α 316
tumour necrosis factor (TNF) 316
regulator T cells (Treg) 323
CTLA-4 323
interleukin-10 323
transforming growth factor-β 323
regulatory network mapping 2088–2095
development of 2090–2091
future work 2093–2094
genomics 2090–2093
transcriptional data 2091
hepatic stellate cell activation 2089–2090
hepatocyte proliferation 2088–2089
liver fibrosis 2089–2090
proteomics 2090–2093
data hubs 2092
protein interactions 2091–2092
protein recognition molecule 2092
spatiotemporal regulation 2092–2093
yeast two-hybrid system 2092
relapsing fever 1007
relapsing hepatitis A 861
relaxin, fibrosis 597
reliability, health-related quality of life studies 2066
Remak's plates 10
remifentanil 1940
renal ammoniagenesis 186
renal circulation
cirrhotic ascites, post-peritoneovenous shunting 695
effects of liver disease on 1725
hepatorenal syndrome 711
renal cysts 782
renal disease/disorders
acute liver failure 1293
management 1293
chronic hepatitis C antiviral therapy 950
glycogen storage diseases type 1 1372
ribavirin clearance 950
renal dysfunction
anaesthetic implications 1939, 1942
liver transplantation and 1942
cirrhosis 605–606, 612, 677–683
post-liver transplant immunosuppression 2005
renal failure
acute liver failure, children 1859
anaesthetic implications 1939
cirrhosis 714
diuretic-induced 691, 692
immunosuppressant-induced 2021–2022
liver transplantation contraindications 1990
obstructive jaundice associated 1504, 1815–1816
pathogenesis 1503, 1815–1816
therapeutic strategies 1511, 1816
systemic AA amyloidosis 1703
renal function
acute fatty liver of pregnancy 1882
alcoholism 1186
immunosuppression in children 1865
pretransplant patients 1925
renal–hepatic–pancreatic dysplasia 2153
Dandy–Walker cyst and 2153–2154
renal hypoperfusion, chronic liver disease 1725
renal insufficiency
drug hepatotoxicity risk 1213
post-liver transplantation 1772
renal malformations, congenital hepatic fibrosis 782
renal perfusion, hepatorenal syndrome 711
renal replacement therapy, hepatorenal syndrome 716
renal transplantation
hepatitis B, post-transplant reactivation 1657
hepatitis C 889, 1657–1658
hepatitis D 1657
liver and 1657–1658
peliosis hepatis 1658
perisinusoidal fibrosis 1658
portal hypertension 1658

renal tubular acidosis 1819–1820
classification 1819
definition 1819
hyperkalaemic form 1819
hypokalaemic form 1819
incomplete distal form 1819
liver disease and 1819–1820
clinical features 1819
pathogenesis 1819–1820
type 1 (distal; classical) 1819
type 2 (proximal) 1819
Rendu–Osler–Weber disease *see* hereditary haemorrhagic telangiectasia (HHT)
renin 677
cirrhotic ascites 678–679, 678f
hepatorenal syndrome 678f, 679
obstructive jaundice-associated acute renal failure 1816
production 677
release 677
renin–angiotensin–aldosterone system, cirrhosis 677–679
renin–angiotensin system (RAS), portal hypertension 633
reperfusion injury, Budd–Chiari syndrome 1406
reptilase (snake venom) tests 1783t
resection
gallbladder carcinoma 1578–1579, 1579t
hilar cholangiocarcinoma 1598–1599
liver *see* hepatectomy
reserve albumin binding capacity measurement 170
reserve cell compartment 59
resin exchange columns 2044
resistant ascites *see* refractory ascites
resource allocation 2080
Resovist 523, 529
respirasomes 1377
respiratory alkalosis
acute liver failure 1131
anaesthetic implications 1940
cirrhosis 187
respiratory failure, hypoxic hepatitis 1945
respiratory system, anaesthetic implications in liver disease 1939
rest 1901
reticular network, spleen 771–772
retinoblastoma (Rb) gene/protein
carcinogenesis and 394–395
mechanisms of inactivation 394–395
cell cycle 274
normal cellular function 393
as tumour suppressor gene 393–394, 394t
retinoblastoma protein, cell cycle 393
retinoic acid (RA) 214, 215f
biosynthesis 214
stereoisomers 215f, 216
9-*cis* retinoic acid-α (RXR) 244
retinoic acid receptor (RAR) 214–216, 216f
hepatobiliary transport regulation 388
structure 216
subtypes 214–216
as tumour suppressor 217
retinoic acid response element (RARE) 216
retinoid binding proteins (RBP) 45
retinoid receptors 214–217, 216f
retinoids 213
functions 214
hepatic stellate cells 45
hepatocellular carcinoma chemoprevention 217
hepatotoxicity 1646
metabolism 214
natural 214, 215f
side-effects 1646
storage 214
synthetic 215f
see also individual types
retinoid X receptor (RXR) 106–107, 214–216, 216f
hepatocellular carcinoma 217
JNK regulation 107
nuclear receptors 106–107
structure 216
subtypes 214–216
retinoid X receptor response element (RXRE) 216
retinol 214
retinol-binding protein (RBP) 214
retinopathy, hepatitis C antiviral therapy 945
retinyl esters 45, 213, 214, 215f
retrograde catheterization, azygos vein 662–663
retroperitoneal collateral circulation, portal hypertension 626, 626f
retroperitoneal fibrosis 1400
reverse cholesterol transport 78, 138–141, 140f
reverse electron flow, mitochondria 1378, 1379f
reverse jugular venous catheterization 1305
reverse-phase arrays (RPA) 405
reverse transcriptase (RT), hepatitis B virus 829–830
reverse transcriptase polymerase chain reaction, hepatitis D diagnosis 876
reverse tri-iodothyronine (rT_3) 1746, 1746f
acute viral hepatitis 1748
alcoholic cirrhosis 1749
chronic viral hepatitis 1748
excretion 1747
rewarming ischaemia 348
Rex shunt, portal hypertension 1864–1865
Reye syndrome
acute liver failure 1300
aspirin 1247, 1824
clinical features 1822
consciousness changes 1825
management 1825
neurological manifestations 1822–1825, 1823t
pathogenesis 1824
Reynold's pentad 1542
rhein anthrone, hepatotoxicity 1285
rheumatic disease, drug-induced liver injury 1213
rheumatoid arthritis 1695–1696
diagnostic criteria 1695–1696
drug-induced liver injury 1249
liver function tests 1696
primary biliary cirrhosis 1076
secondary amyloidosis 1696
RhoB gene/protein 392
Rho GTPase activating protein (RhoGAP) 395
Rho GTPases
activation 105
signal transduction 105
rhubarb, hepatotoxicity 1285
ribavirin
adenovirus infection 968
antiretroviral agent interactions 981
clearance, renal disorders 950
didanosine interactions 981
fibrosis 595
hepatitis C virus 942
children 1852
historical aspects 941
interferon-α combination 942, 943–944, 944t, 949
membranoproliferative glomerulonephritis and 1819
pegylated interferon combination 943
pretransplant patients 1927
HIV-hepatitis C coinfection 980t, 981
Lassa fever 990
Rift Valley fever 991
ribonuclease (RNase H), hepatitis B virus 829–830
ribosomes 23, 24f
ribozymes, hepatitis D virus 842
rickets 1833–1834
clinical features 1833
definition 1833
diagnosis 1833
Fanconi–Bickel syndrome 1375
hereditary tyrosinaemia type 1 1860
prevention 1833
Rickettsia connorii 1006
rickettsial infection 1006–1007
Rickettsia rickettsii 1006
Riedel's lobe 447
palpation 447
rifampicin
cholestasis
anti-pruritic mechanisms 387–388, 388f
induction 1242
elderly 1872
hepatotoxicity 1235–1236, 1239
isoniazid coadministration 1222, 1235–1236
protein binding 1916
pruritus 1082, 1496, 1804
side-effects 1496
vanishing bile duct syndrome 1117
rifampin *see* rifampicin
Rift Valley fever 990–991
aetiological agent 990
clinical manifestations 990–991
diagnosis 991
epidemics 990
epidemiology 990
laboratory findings 991
pathogenesis 990
pathology 990
treatment 991
vaccines 991
right heart catheterization (RHC), portopulmonary hypertension 723
rigor (shaking chills) 444
risedronate 1832
risk differences, meta-analysis 2074
ritonavir, hepatotoxicity 983
rituximab
amyloidosis 1707
liver transplantation 2005
post-transplant lymphoproliferative disorder 1866
RIZ1 394t
rK39 1037
RNA
gene arrays
amplification 402–403
pooling samples 401–402
quality/source 402, 402f
quantitative assays, hepatitis C 855
RNA editing, hepatitis D virus 842f
RNA interference 343
road traffic accidents, haemobilia 1552
Rocky Mountain spotted fever 1006
Rokitansky–Aschoff crypts 18
Rome II criteria
biliary dyskinesia 1561, 1561t
sphincter of Oddi biliary-type dysfunction 1567
rosiglitazone
hepatotoxicity 1240–1241, 1683
non-alcoholic fatty liver disease 1917
non-alcoholic steatohepatitis 1203t, 1682
Rotor syndrome 1356
pregnancy 1886
rough endoplasmic reticulum, hepatocyte 23, 24f
round ligament 3
Roux-en-Y hepaticojejunostomy, bile duct injury 1960f
roxithromycin, acute hepatitis induction 1234
rubella hepatitis 967
rubs 448–449

S

sacculi of Beale 18
S-adenosylhomocysteine (SAH) 146
S-adenosylmethionine 145–146
alcoholic liver disease 1138, 1167
alcohol-induced glutathione regulation 200f, 204
intrahepatic cholestasis of pregnancy 1880–1881
supplementation 1908
SAGE libraries 407
Salla disease 2154
Salmonella 1003–1004
Salmonella paratyphi 1003
Salmonella typhi 1003
salpingitis, *Chlamydia trachomatis* 1004
salt restriction, ascites 1908
sampling variability, liver biopsy 434
sanded nuclei 423
sandfly, leishmaniasis vector 1035
Sanfilippo syndrome (mucopolysaccharidosis type III) 2154–2155
saralasin 679
sarcoidosis 1643
characteristics 1714t
cholestatic 1077, 1078t, 1492
granulomas 1709, 1711–1712, 1714
hepatitis C 1714, 1807
neurological manifestations 1823t
portal hypertension 1712

sarcoidosis (*continued*)
recurrence, post-liver transplantation 1712
treatment 1712
vanishing bile duct syndrome 1113t, 1116
sarcoma, undifferentiated *see* undifferentiated sarcoma
sassafras, hepatotoxicity 1282t
satavaptan 701
satiety regulation, liver, role in 1836
saw palmetto, hepatotoxicity 1282t
scaffolding proteins, mitogen-activated protein kinases 104
scales, quality of life 2082
scarlatina-type rash, portal hypertensive gastropathy 1799
scavenger receptor B-I (SR-B1) 139
hepatic cholesterol uptake 1520
scavenger receptors 37
Scedosporium infections 1013
Schaumann bodies 1709
Scheie syndrome 2155
Schistosoma
hosts 1040
life cycle 1040
Schistosoma haematobium 1040
Schistosoma intercalatum 1040
Schistosoma japonicum 1040
Schistosoma mansoni 1040–1044
Schistosoma mekongi 1040
schistosome egg granuloma 1041, 1042
schistosomes (blood flukes) 1040–1044
schistosomiasis 1040–1044
acute form (Katayama fever) 1041
chronic forms 1041–1043
clinical forms 1041
course 1044
'dead worm' pneumonitis 1042
diagnosis 1043–1044
differential diagnosis 1041
epidemiology 1040
geographical distribution 1040, 2100–2103t
granulomas 1713
hepatitis viruses 1042
hepatointestinal form 1041–1042
hepatosplenic form 1042–1043
clinical findings 1043
haemodynamics 1042–1043
laboratory changes 1043
neuropsychiatric symptoms 1043
non-congestive phase 1042
pathophysiology 1042
periportal fibrosis 1042
intestinal form 1041–1042
as 'man-made' disease 1040
pathogenesis 1041
portal hypertension 1044
pregnancy 1886
prognosis 1044
treatment 1044
schistosomulae 1040
schizogony
Cryptosporidium 1022
Plasmodium 1030
schizont, *Plasmodium* 1030
schwannomin 1645
scintigraphy
amyloidosis 1706
cirrhosis 613
focal nodular hyperplasia 1430
hepatopulmonary syndrome 720–721, 721f
hepatosplenic candidosis 1012
infantile cholestasis 1846–1847
scleral jaundice 445–446
scleroderma 1697
primary biliary cirrhosis 1798
sclerosing cholangitis
cryptococcosis 1014
cryptosporidiosis 1025
cystic fibrosis 1855
drug-induced 1254–1255
strictures 1255
fascioliasis 1045
Langerhans cell histiocytosis 1618
neonatal 1848
primary *see* primary sclerosing cholangitis (PSC)
secondary
causes 1489–1490, 1489t
primary sclerosing cholangitis *vs.* 1106
sclerosing hyaline necrosis 426
alcoholic hepatitis 1151–1152
SCO1 gene mutations 1379
scoring systems 433–450
alcoholic hepatitis 436
autoimmune hepatitis 436, 1090–1091, 1091t
cholestatic liver disease 436, 437t
chronic hepatitis B 436
chronic hepatitis C 434–435, 435t, 436
morphometry 437–438
non-alcoholic steatohepatitis 436, 436t
primary biliary cirrhosis 437t, 1080, 1081t
Wilson's disease 1316
see also individual systems
Scott-like syndrome (Goldstein syndrome) 2137–2138
scratch test 447
scurvy, alcoholic liver disease 1810
seborrhoeic eczema, alcohol misuse 1810
SEC63 mutations, polycystic liver disease 796
secondary collapse, fibrosis 426–427
second messengers
bile secretion regulation 300, 301t
G protein-coupled receptors 103
secretin
cholangiocytes 53
cystic fibrosis transmembrane conductance regulator 1336
hepatic blood flow regulation 76
sedation, acute liver failure 1304
'seed and soil' hypothesis, cancer metastasis 1465
segmental ducts 17
seizures, post-liver transplantation 1826
SELDI-TOF protein identification 405, 415
selective portal decompression (SPD) 233t
schistosomiasis 1044
selenium 233t, 234–237
biological functions 234
deficiency 233t, 235–237
alcoholic liver disease 1138
associated-disease states 236
total parenteral nutrition-related liver disease 1636
excretion 237
recommended daily allowance 235
sources 235
supplements 236–237
toxicity 237
selenocysteine 234
selenomethionine (Se-met) 234
selenoproteins
biological functions 235, 236t
synthesis 234–235, 234f
self-help groups, alcohol abstinence 1181
self-organizing map (SOM) 406, 406f
selinide, excretion 237
Senecio, hepatotoxicity 1273, 1282t, 1283–1284
Senecio disease 1283
senile cardiac amyloidosis *see* senile systemic amyloidosis
senile systemic amyloidosis 1704
management 1707
pathogenesis 1702
prevalence 1703
senile transthyretin amyloidosis *see* senile systemic amyloidosis
senna, hepatotoxicity 1285
Senning procedure, Budd–Chiari syndrome 1409
sensitivity analysis, economics 2083–2084
sensory evoked potentials
hepatic encephalopathy
acute liver failure 744
cirrhosis 745
neurological status assessment 1305
sensory polyneuropathy, systemic AL amyloidosis 1704
SEN virus (SENV) 822
sepsis
cirrhosis 609
clinical features 609
inflammatory response 609
sepsis-induced cholestasis 1491, 1946
diagnosis 1950
histology 1950
incidence 1950
management 1950
pathology 1946
prognosis 1950
septal ducts 1111
septal fibrosis 426
septal myofibroblasts 47, 47t
septic shock, progressive sclerosing cholangitis 1951
sequence comparisons, QTL analysis in inbred mice 377t
sequestration 137–138
serine catabolism 145
serine phosphorylation, insulin receptor substrates 132
serotonin
carcinoid syndrome 1475, 1475f, 1809
carcinoid tumours 1475–1476
serotoninergic neurotransmission, hepatic encephalopathy 737
serotonin uptake inhibitors, Wilson's disease 1316
Serrenoa serrulata, hepatotoxicity 1286
serum amyloid A protein (SAA) 1703
serum amyloid P component (SAP) 1702
serum-ascites albumin gradient (S–AAG), cirrhosis 615
serum sickness-like syndrome, HBV 1818
severe liver failure 1292t
sex hormone-binding globulin (SHBG) 1687, 1755–1756
cirrhosis 610, 1756–1757, 1757t
women 1760
haemochromatosis 1761
production 1755
sex hormones 1686–1689, 1754–1760
altered end-organ sensitivity, cirrhosis 1759
effects on liver 1687
hyperprolactinaemia 1760
liver disease
men 1756–1759, 1757t
women 1757t, 1759–1760
osteoporosis 1831–1832
physiology 1686–1687, 1754–1756
transport in blood 1755–1756
tumorigenicity 1258
see also individual hormones
sexual activity, alcoholic liver disease (ALD) 1902
sexual activity, liver disease and 1902
sexual dimorphism, liver function 1689
sexual dysfunction, liver disease and 1756–1759, 1902
sexual partners, hepatitis B vaccine 912
sexual transmission
hepatitis B 866
hepatitis D 876
SGLT transporters
cholangiocytes 53, 113
hepatocytes 111
shaking chills (rigor) 444
shear stress
eNOS upregulation 635
liver sinusoidal endothelial cells 31
Shigella 1004
shock liver 1609
short-chain acyl-Co-A dehydrogenase deficiency 1881
short-chain fatty acids, hepatic encephalopathy 731
Short Form-36 Health Status Survey (SF-36)
chronic viral hepatitis 2068–2069
liver transplantation 2028, 2069
quality of life 2082
short gastric veins
anatomy 623
gastro-oesophageal varices inflow 627, 627f
short heterodimer partner (SHP), intrahepatic cholestasis 1483
short interventions, alcoholic liver disease prevention 1182
short tandem repeats (STRs) *see* simple repetitive sequences (SRSs)
Sho saiko-to, hepatotoxicity 1282t
'shoulder pad' sign 1704
Shou-Wu Pian, hepatotoxicity 1283
Shou-Wu-Pian, hepatotoxicity 1282t
shrinking necrosis *see* apoptosis
shunts
acute variceal bleeding 651
hepatic removal kinetics 475
hereditary haemorrhagic telangiectasia 1420
obstruction, post-peritoneovenous 696
portal hypertension, children 1864–1865
pregnancy 1887
see also individual types
Shwachman syndrome 2155
sialic acid storage disease 2155–2156
sialidosis type 2 2156
sialuria 2156

Sicca syndrome 443
primary biliary cirrhosis 1082
sickle-cell disease 1666
Sickness Impact profile (SIP), liver transplantation 2028
sideroblastic anaemia, hepatic involvement 1666
side-to-side anastomosis, bile duct 1969–1970, 1969f
Siegler syndrome 2156–2157
signal peptidase 193
signal recognition particle (SRP) 193, 196
signal transduction 102–105, 102f
bile 291
carcinogenesis
oncogene induction 392–393, 392t
viral HBx protein 393
cascade activation 104–105
cell surface receptors 102–103
cytokine receptors 313
G protein-coupled receptors 102–103, 105
hepatocyte gap junctions 97
interference with, hepatitis C 854
interleukin-6 317, 317f
ion channels 102–103, 103
mapping *see* regulatory network mapping
mitogen-activated protein kinases 104–105
phosphatidylinositol 3-kinases 105
protein kinase A 103, 104
protein kinase C 103, 104
receptor tyrosine kinases 103, 105
Rho GTPases 105
second messengers 103–104
calcium 103
lipids 103
nitric oxide 103
prostanoids 103–104
see also specific pathways
sildenafil 724
silencer of death domain (SODD), caspase cascade 314
silicon 233t
deficiency 233t
silicon dioxides, hepatotoxicity 2116
silicone particles, dialysis patients 1656–1657
silymarin
alcoholic cirrhosis 1167
fibrosis 596
simple cyst of the liver 783–789
biliary hamartomas *vs.* 801
clinical examination 784
complications 785
course 785
cystadenoma *vs.* 787, 787t
diagnostic criteria 784
differential diagnosis 785, 787t
fluid 783
growth 785, 785f
hydatid disease *vs.* 786–787, 787t
imaging 784–785
intracystic bleeding 785, 786f
malignant transformation 785
manifestations 783–784
microscopic appearance 783
multilocular 783
pathogenesis 783
pathology 783
prevalence 783–784
spontaneous rupture 785, 786f
symptoms 783–784
treatment 787–788
simple repetitive sequences (SRSs)
as markers in QTL analysis 373, 375
MICA genes 366
simple sequence length polymorphisms (SSLPs) *see* simple repetitive sequences (SRSs)
Simpson–Golabi–Behmel syndrome 2157–2158
simulation models 2055, 2055t
simulect 1865
simvastatin, primary biliary cirrhosis 1084
single cell acidophil necrosis *see* apoptotic bodies
single nucleotide polymorphisms (SNPs)
frequency 356, 362
gene array analysis 414
liver disease and *see* genetic polymorphism and liver disease
as markers in QTL analysis 373, 375
sinusoidal capillarization 85, 427
cirrhosis 88, 674
cirrhosis progression 585
histological features 427
insulin-like growth factor binding proteins 1744
insulin-like growth factor-I 1744
liver sinusoidal endothelial cells 31
portal hypertension 630
sinusoidal cell activation 428
sinusoidal congestion 427
radiation hepatitis 1277
sinusoidal dilatation 1412–1413
acinar zone 1 427
associated conditions 1412t, 1413
causes 1412
clinical features 1413
diagnosis 1413
differential diagnosis 1413
drug-induced 1255t, 1256
peliosis hepatis *vs.* 1412–1413
sinusoidal endothelial cells *see* liver sinusoidal endothelial cells (LSEC)
sinusoidal epithelium, antigen presentation 321
sinusoidal fibrosis 1413
sinusoidal hemodynamics, neural modulation 115
sinusoidal lining cells, as sphincters 80
sinusoidal obstruction syndrome (SOS) *see* veno-occlusive disease (VOD)
sinusoidal portal hypertension
hepatic venous pressures 568
trans-sinusoidal fluid exchange 672–673
sinusoidal pressure
Budd–Chiari syndrome 1406
lymph production 673
sinusoidal syndrome *see* veno-occlusive disease (VOD)
sinusoidal zonation 474
sinusoid network organization 80, 80f
sinusoids 9f, 10f, 12–13, 13f, 79, 79f, 89
blood flow regulation 80–81
blood pressure 15
cells 13–15
see also individual cell types
development 31–32, 69
diameter 13
disorders 1411–1413
histological features 427–428
infiltration 1413
microcirculation 15, 16
non-parenchymal cell organization 20–21, 20f
perfusion regulation, vasoactive mediators 81–83
steady-state substrate removal rate 469, 469f
tone regulation, hepatic stellate cells 49, 81
wall structure 672–673
sirolimus
dosages 2007
fibrosis 597
liver transplantation 2007–2008
children 1865
macroautophagy 149
mechanism of action 2007
post-liver transplant immunosuppression 2004
side-effects 2007–2008
Sjögren syndrome 1697
chronic liver disease 1697
clinical features 1697
diagnosis 1697
hepatitis C 1697, 1806
primary 1697
primary biliary cirrhosis 1076, 1697
secondary 1697
skeletal deformity, rickets 1833
skin
alcohol abuse 1186
carcinoid syndrome 1473–1474
effects of liver disease 1804–1814
autoimmune conditions 1808
chemicals effects 1810–1811
congenital disorders 1805–1806
drugs effects 1810–1811
immunosuppression 1809–1810
infections 1806–1808
neoplastic conditions 1808–1809
examination of 446
systemic AL amyloidosis 1704
skin cancer 1644–1645
alcohol abuse 1186
post-liver transplantation 1809, 2022
skin diseases, liver in 1642–1652
antiviral therapy contraindication 945
autoimmune disorders 1643
drug hepatotoxicity 1646–1649
infectious diseases 1644
inflammatory 1642–1643
skp/cullin/F-box (SCF) multiprotein complex 274
SLC11A3 mutation 1327
sleep disturbances 444–445
hepatic encephalopathy 741, 743
liver transplant patients, quality of life 2030
Wilson's disease 1316
Smad proteins
hepatoblast proliferation 66
regulation by MAP kinases 2090
stellate cells, effects on 592
transforming growth factor-β 2090
small cell carcinoma of the lung, hepatic involvement 1619
small cell dysplasia 430
small duct primary sclerosing cholangitis pericholangitis 1626
small hepatic vein obstruction *see* veno-occlusive disease
small heterodimer partner-1 (SHP-1) 178
small intestine
ascariasis 1059
function
effects of liver disease 1801–1802
mucosal abnormalities 1801
obstruction, post-peritoneovenous shunting 696
strongyloidiasis 1064
smoking
alcoholics 1183
alpha-1-antitrypsin deficiency 1333, 1334
focal nodular hyperplasia 1260
hepatocellular carcinoma 1439
liver transplantation contraindications 1990
primary sclerosing cholangitis 1624
ulcerative colitis 1624
smooth endoplasmic reticulum 23–24, 24f
drug detoxification 24
function 23–24
smooth muscle autoantibodies (SMA)
autoimmune hepatitis 480, 482, 1090, 1090f, 1091, 1092, 1093t, 1120
autoimmune sclerosing cholangitis 1853
chronic hepatitis C 485, 949
smooth muscle isoform of α-actin (α-SMA), hepatic stellate cells 47
SN-38 246
snail-track ulcers, syphilis 1807
snake venom (reptilase) tests 1783t
sodium
hyponatraemia in cirrhotic ascites 699
obstructive jaundice 1504
renal tubular acidosis-associated liver disease 1819
sodium benzoate, hepatic encephalopathy 747
sodium beta-lactamins 1916
sodium bicarbonate, glycogen storage disease type I 1373
sodium deoxycholate, obstructive jaundice 1511
sodium-dependent bicarbonate transporter (NCB1) 113
sodium-dependent taurocholate cotransporting polypeptide (NTCP) 176–177
functional expression cloning 124
sinusoidal biliary transport 385
adaptive changes in cholestasis 386, 387f
sodium-independent transporters, amino acids 142–143
sodium-linked transporters, amino acids 142–143
sodium pump (Na^{2+}, K^+ ATPase)
aldosterone 678
cerebral oedema 734
hepatocytes 110, 111f
sodium restriction
cirrhotic ascites 689
diuretic-resistant ascites 689
sodium retention
anaesthetic implications 1939
cirrhosis 675
aldosterone, role in 678

sodium retention (*continued*)
sympathetic nervous system involvement 680
hepatorenal syndrome 712–713
portal hypertension 636
splanchnic arterial vasodilation 684
sodium stibogluconate 1039
sodium (Na^+)/taurocholate cotransporter 294, 295f
sodium valproate
toxicity, childhood acute liver failure 1858
urea synthesis inhibition 183
solid-organ transplantation, cytomegalovirus infection 962
solid-phase immunosorbent tests, hepatitis D diagnosis 876
solitary cyst of the liver *see* simple cyst of the liver
soluble-liver antigen/liver pancreas antigen autoantibodies (SLA/LP), autoimmune hepatitis 481, 481t, 483, 1093, 1093t
solute carrier (SLC) transporters 242
somatic hypermutation, antibodies 325
somatostatin/somatostatin analogues 1689
acromegaly 1689
acute variceal bleeding 649
carcinoid tumours 1476, 1476f, 1477
cholangiocytes, effects on 53
drug-induced renal impairment 703
gallbladder lesion induction 1689
growth hormone release 1739
insulin-like growth factor binding proteins regulation 1743
portal hypertension 635, 643
portal hypertensive gastropathy 653
side-effects 649, 1476
sorafenib (BAY 43-9006) 1450
sorbitol clearance 471t, 472
hepatic blood flow measurement 662
space of Disse 15, 15f, 48
cirrhotic ascites 673
compression 15
congestive heart failure 1612
histological features 427–428
Spain, hepatitis D 877
spatiotemporal regulation, proteomics 2092–2093
spectrophotometric assays
alanine aminotransferase 452
aspartate aminotransferase 452
mitochondrial oxidative phosphorylation deficiency 1381
spermatogenesis, effects of alcohol on 1756
spherules, *Coccidioides* 1016
sphincter ampullae 305
sphincter choledochus 305
sphincterectomy
choledocholithiasis therapy 1531
sphincter of Oddi biliary-type dysfunction 1569
sphincter of Oddi 18
anatomy 305, 1566, 1566f
bioactive agents 309t
innervation 305–306, 1566
motility 307–310
animal models 307–308
cineradiographic studies 308–309
in humans 308–310
manometry 309–310, 309f, 310t
phasic contractions 308
vagus nerve 308
mucosa 305
physiology 1566
interdigestive phase 1566
pacemaker activity 1566
tonic contraction 1561
sphincter of Oddi dysfunction 1561, 1565–1570
biliary-type 1567–1570
classification 1567–1568
clinical presentation 1567
epidemiology 1567
examination 1567
investigations 1568–1569
manometry 1568–1569, 1569–1570, 1569f
Rome II criteria 1567
sphincterectomy 1569
surgery 1569–1570
treatment 1569–1570
disease association 1566
dyskinesia 1567
gallstones 1567
pancreatic-type 1570
clinical presentation 1570
investigation 1570
manometry 1570
treatment 1570
pathophysiology 1563t, 1566–1567
bile passage resistance 1566
recurrent pancreatitis 1566
stenosis 1567
sphincterotomy, ascariasis 1061
sphincter pancreaticus 305
sphincters, sinusoids, blood flow regulation 81
spiculated erythrocytes 1768
spider angiomas
alcoholic cirrhosis 1165
alcoholic hepatitis 1162
cirrhosis 611
spider naevi 446, 1804
alcoholic liver disease 446, 1809
cirrhosis 1758
spinal afferent hepatic nerves 114
spinal demyelination, hepatic encephalopathy 732
spirochaetal infections 1007–1008
spironolactone
antiandrogenic activity 692
ascites 690
dosage 690
hepatorenal syndrome type 2 716
hepatotoxicity 1649
hyperkalaemia induction 691
mechanisms of action 690
metabolism 690
non-azotaemic cirrhotics with ascites 690–691
sexual dysfunction 1759
side-effects 692
splanchnic arterial vasodilation
cirrhosis 674, 675, 683–684
decompensated cirrhosis 686
splanchnic blood flow measurement 568–570
splanchnic capillaries, porosity 672
splanchnic circulation, effects of liver disease on 1724–1725
splanchnic haemodynamic investigations 567–571
splanchnic hyperaemia, portal hypertension 634, 643
splanchnic vasodilation, portal hypertension 634–636
spleen
blood supply 771
defensive role 772
function 772
hepatocyte transplantation 2033, 2034
Hodgkin's disease 1662
liver disease and 771
microcirculation 771–772
palpation 448, 771
percussion 448
red pulp 771
resting blood flow 771
segments 771
structure 771–772
visceral leishmaniasis 1036, 1037f
white pulp 771
spleen size/platelet ratio, oesophageal varices 1771
splenectomy
cirrhosis and hepatoma 776
congenital hepatic fibrosis 783
Gaucher's disease 1364
hypersplenism 776
laparoscopic 776
partial 776
portal hypertension 776
schistosomiasis 1044
splenic arterial bruits 448
splenic arterioles 771
splenic artery 771
portal hypertension 503
splenic embolization
hypersplenism 776–777
platelet numbers, cirrhosis 1771
side-effects 776
thrombopoietin levels 1771
splenic vein 771
anatomy 623
thrombosis 1399
gastro-oesophageal varices 627–628
splenomegaly
angiosarcoma 1458
congestive heart failure 1612
Gaucher's disease 1363
glycogen storage disease type I 1371–1372
liver disease and 771
portal hypertension 606
type 1 Gaucher's disease 1360–1361
splenoportography 533
complications 533
splenorenal shunt, schistosomiasis 1044
splenorenal shunts, portal hypertension 503
split liver transplantation 1970–1976
adult–adult 1971
donor liver 1971–1972
ex situ bipartition 1971, 1972t
left lateral segments 1970, 1971f
right lobe 1970, 1971f
in situ bipartition 1971–1972, 1972t, 1973f
donor selection 1971
future work 1975
graft size 1973–1974
adults 1973
Child status 1973–1974
functional liver mass 1973
historical aspects 1970
immunosuppression 1973
reasons for 1970
recipient 1972–1973
adults 1972–1973
children 1972
results 1974–1975
adult–adult 1974–1975, 1975t
adult–child 1974, 1974t
graft survival 1974
surgical techniques 1971–1973
donor liver 1971–1972
recipient 1972–1973
spongiocytes 428
spontaneous bacteraemia, portal hypertension 767
spontaneous bacterial empyema, cirrhotic hydrothorax 672
spontaneous bacterial peritonitis (SBP) 761–767
bacteria responsible 763t
cirrhotic ascites 667
cirrhotic patients 1807
clinical characteristics 763
diagnosis 763
hepatorenal syndrome 712
prevention 717
intravenous albumin infusion 764
laboratory data 763
microbiological data 763
Neisseria meningitidis 1807
pathogenesis 761–763
ascitic fluid opsonic activity depression 762
bacterial translocation 761
hepatic reticuloendothelial system depression 761, 762
iatrogenic factors 763
neutrophil leucocyte dysfunction 762–763
post-peritoneovenous shunting 696
pretransplant patients 1923
procedural-induced 763
prophylaxis 764–767
gastrointestinal haemorrhage 764–765
indications 765–766
treatment 763–764, 764t
sporozoites, *Plasmodium* 1030
spotty necrosis 425
S-protein, hepatitis B virus 830–831, 831f
spur cell haemolysis 1785
spur cell haemolytic anaemia 1770
squamous cell carcinoma (SCC)
ciliated hepatic foregut cyst 808
epidermoid cysts, liver 811
post-liver transplantation 1809
simple cyst of the liver 785, 816
squawmint oil (pennyroyal oil), hepatotoxicity 1282t, 1285–1286, 2114
SR-121463, hyponatraemia in cirrhotic ascites 699–700
St John's Wort *(Hypericum perforatum)*, drug interactions 1283
stabile cells 58
stab injuries, liver 1953
standard gamble methods
health utility assessments 2067
quality of life assessment 2082
standardized uptake value (SUV), positron emission tomography 562
stanozolol, hepatotoxicity 1649
Staphylococcus aureus
parenteral nutrition 1909

pretransplant patients 1926
toxic shock syndrome 1002
starvation
amino acids metabolism 144–145, 145f
haem oxygenase 210
paracetamol-induced hepatitis 1238
pseudocholinesterase 457
STAT3, liver regeneration 317
STATS, bile secretion regulation 301t
stavudine
antiretroviral agent interactions 981
hepatotoxicity 1248
steatohepatitis
alcoholic *see* alcoholic hepatitis
computerized tomography 511, 512f
diabetes mellitus 1681
drug-induced 1170, 1245–1246, 1247
histology 1245
pathogenesis 1245
with phospholipidosis 1245–1246
without phospholipidosis 1246
steatorrhoea
alcoholic liver disease 1801
cholestasis 1487, 1496, 1801
cirrhosis 1837
non-alcoholic cirrhosis 1801
primary biliary cirrhosis 1082
steatosis
alcoholic 1150, 1159–1161
natural history 1160
surgery 1171
treatment 1160–1161
causes 1936
chemotherapy-induced 1936
chronic hepatitis C 887
Crohn's disease 1627
cystic fibrosis 1339, 1855
diabetes mellitus 1681, 1936
genetic factors 1143
hepatectomy and 1936
histological features 428
inflammatory bowel disease 1627
macrovesicular *see* macrovesicular steatosis
magnetic resonance imaging 528f, 529
microvesicular *see* microvesicular steatosis
morphometry 438
non-alcoholic fatty liver disease 1201
non-alcoholic steatohepatitis 1201
obesity and 1936
pathogenesis 1136–1138
tumour necrosis factor α 1137–1138
post-jejunoileal bypass surgery 1630
systemic lupus erythematosus 1695
toxin-induced 1270t, 1272
ulcerative colitis 1627
ultrasonography 502, 502f
Wilson's disease 1317
stellate cells
hepatic *see* hepatic stellate cell (HSC)
pancreatic 48
stellate cell system 48
stem cells 58–64
asymmetrical division 58, 58f
bioartificial liver support 2045
blood 58–59
haematopoietic transplantation *see* haematopoietic stem cell transplantation (HSCT)
hepatocyte transplantation 2035
liver function models 123
niches 58–59
symmetrical division 58, 58f
types 58–59
stents/stenting
bile duct obstruction 555, 555f
cholangiocarcinoma 1600
metallic *see* metal stents
occlusion 556
plastic 545–546, 556
steroids
autoimmune sclerosing cholangitis 1853
liver transplantation, children 1865
metabolism in cirrhosis 1758
sterol response element-binding protein-1c (SREBP-1c) 161
alcoholic liver disease 1138
Steven–Johnson syndrome 1807
stillbirths, acute fatty liver of pregnancy 1881
Still's disease 1696
stomach
effects of liver disease 1799–1800
fundal varices 628
see also entries beginning gastric
stools 444
acidification, hepatic encephalopathy 746
colour
biliary atresia 1847
infantile cholestasis 1846
hepatitis A diagnosis 860
storage phenomena 428–429
strawberry gallbladder 1529
strawberry tongue 1645
Streptococcus pneumoniae 1001
streptozotocin, carcinoid tumours 1477
'stress' conditions, albumin 455
stress-related replicative senescence, hepatocytes 282
striae 447
Strongyloides stercoralis 1064
strongyloidiasis 1064–1065
clinical features 1064–1065
diagnosis 1065
epidemiology 1064
hyperinfection 1064
pathology 1064
treatment 1065
strontium ranelate 1832
study design, meta-analysis 2073
styrene, hepatotoxicity 2116
subacute hepatitis
autoantibodies 1252
bridging necrosis 1251
drug-induced 1214t, 1251–1253
drugs causing 1252–1253, 1252t
outcomes 1252
histology 1251
subacute liver failure 1292t
subclinical encephalopathy *see* minimal (subclinical) hepatic encephalopathy
subfulminant liver failure 1292
subjective global assessment (SGA), nutritional status 1838, 1905
substrate reduction therapy, Gaucher's disease 1364
succinate 155
succinate dehydrogenase 91
sulbactam, bacterial cholangitis 1543t
sulindac, hepatotoxicity 1239
suloctidil, hepatotoxicity 1239
sulphadoxine-pyrimethamine 1033
sulphamethoxazole, acute hepatitis induction 1232
sulphite oxidase 238
sulphonamides
acute hepatitis induction 1239–1240
hepatotoxicity 1226, 1239–1240
immunoallergic hepatitis induction 1226
sulphone syndrome 1233
sulphonylurea agents
diabetes 1737
exaggerated therapeutic effects, cirrhotic patients 1914, 1915t
hepatotoxicity 1683
thyroid function 1750
sulphotransferases 242t
sunflower cataracts 446
superior mesenteric vein 623
superoxide anion formation 162–163, 162f
supervised learning methods 406
surgery
abdominal compartment syndrome 1957
acute liver failure 1301
alcoholic liver disease 1170–1171
anaesthetic aspects *see* anaesthesia and liver disease
analgesia and 1940–1941
biliary strictures, benign 557–558
chronic portal vein thrombosis 1398–1399
complications
postoperative jaundice *see* postoperative jaundice
postoperative liver failure *see* postoperative liver failure (PLF)
cystic echinococcosis 1049–1051
haemobilia 1553, 1557
hepatic artery aneurysms 1393
obstructive jaundice-associated acute renal failure 1815
perioperative outcome/mortality 1938
improvements in 1933
parenchymal damage and 1933
portal pressure measurement 567
risk assessment 1938
liver function tests 476
see also individual techniques/indications
surgical gene therapy, amyloidosis 1707
surgical necrosis 424
surrogate endpoints, outcomes research 2065
sustained virological response (SRV), dialysis patients with hepatitis C 1656
suturing, hepatic vessels 1956–1957
Swedish Twin Registry, gallstone disease 1524
swine hepatitis E virus 894
swollen-baby syndrome 989
Symmers' fibrosis 1041, 1042
sympathetic nervous system
anaesthetic blockade, sodium excretion 680
cholangiocyte proliferation 54
cirrhosis 679–680
cirrhotic ascites 679–680
dysfunction, cardiovascular manifestations 1728
hepatic blood flow regulation 76
ventromedial hypothalamus 114
Symphytum (comfrey), hepatotoxicity 1273, 1282t, 1284
symporters (cotransport), membrane transport 110
syncytial-giant cell hepatitis 1300
syndrome of multiple FNH 1429
syndrome X *see* metabolic syndrome
syndromic paucity of intrahepatic bile ducts *see* Alagille syndrome
synthetic function 250–273
markers 454–459
see also specific proteins
syphilis 1007
cutaneous manifestations 1807–1808
latency 1007
secondary 1007, 1807
system A, amino acid transporter 143
macroautophagy regulation 149
system ASC, amino acid transporter 143
systemic AA amyloidosis 1703
hepatic involvement 1705
organ enlargement 1703
systemic availability 475
systemic lupus erythematosus (SLE) 1694–1695
aetiopathogenesis 1694
Budd–Chiari syndrome 1695
diagnosis 1694
liver abnormalities 1643, 1694–1695
fatty changes 1695
liver enzymes 1694–1695
prevalence 1694
primary biliary cirrhosis 1695
systemic mastocytosis 1644
systemic nocardiosis 1017
systemic sclerosis *see* scleroderma
systemic vascular resistance (SVR), liver disease and 1938, 1942
systemic vasculitis 1698
system L, amino acid transporter 143
system N, amino acid transporter 143
system X^-_{AG}, amino acid transporter 143
system X^-c, amino acid transporter 143
system y^+, amino acid transporter 143
systolic dysfunction 1721–1722

T

tachycardia, thyroid storm 1684
tachypnoea 445
tacrine
acute hepatitis induction 1240
mitochondrial energy production impairment 1217
tacrolimus
hepatotoxicity 1677
post-liver transplantation 2004, 2006–2007
children 1865
pregnancy 1889
side-effects 2007, 2021
Taiwan, hepatitis B vaccine 912
tamoxifen
hepatocellular carcinoma 1450
lipid storage disease induction 1250
Tangier disease (familial analphalipoproteinaemia) 139, 1366
'tardus–parvus profile' 507–508
targeted isotope therapy, carcinoid tumours 1477

taurine
hepatic concentration 143t
hepatic encephalopathy 735
intracellular/extracellular ratios 143t
total parenteral nutrition-related liver disease 1636
tauroursodeoxycholic acid, cholangiocyte apoptosis 54
Tay syndrome 2158
tazobactam, bacterial cholangitis 1543t
3TC, mitochondrial toxicity 1380
T-cell receptor (TCR), natural killer T-cells 320
T cells 322–323
αβ T-cells 322–323
activation 322
autoimmune hepatitis 1099
B220 expression 322
activation 322
B7-H1 322
B cell differentiation 325
chronic hepatitis B 868–869
effector functions 322–323, 323t
extrahepatic biliary obstruction 1506
γδ T-cells 322
autoimmune hepatitis 1099
effector functions 322
structure 322
graft-vs.-host disease 1672, 1674
liver disease immunogenetics 369
mobilization 322
nocardiosis 1017
regulation 323
interferons 323
neural 120
suppression, hepatitis C 855
tolerance, chronic hepatitis B 836
technetium labelled macroaggregated albumen (^{99}TcMAA) scans, hepatopulmonary syndrome 720–721, 721f
telangiectasias, oral 1798
telbivudine, chronic hepatitis B therapy 926
wild-type virus (HBeAg-positive) 929
telomerase 276
'oval cells' 283
telomerase reverse transcriptase (TERT) 276
telomerase RNA component (TERC) 276
telomeres
shortening/senescence
cirrhosis 277f
hepatocellular carcinoma 279
liver cell proliferation control 275–278
structure 275–276
temazepam, liver transplantation and 1941
tenascin 69, 269
tendon xanthomas 1367
tenofovir
hepatitis B 926
lamivudine resistance 931–932
pretransplant patients 1927
wild-type virus (HBeAg-positive) 929
hepatotoxicity 984
HIV–hepatitis B coinfection 975, 975t, 976t
mitochondrial toxicity 984, 1380
terbinafine, hepatotoxicity 1240, 1648
terlipressin
acute variceal bleeding 649
hepatorenal syndrome 715–716, 716t
pretransplant patients 1924
renal hypoperfusion 1725
terminal deoxynucleotidyl transferase-mediated deoxyuridine triphosphate nick end labelling (TUNEL) assay, apoptosis 336
terminal hepatic venule (centrolobular vein) 9, 9f, 10f
terminal protein (TP), hepatitis B virus 829–830
Terry's nails 447
testicles
atrophy, cirrhosis 1756
examination 448
testosterone 1687
cirrhosis 1756, 1757t
feminization 1759
women 1760
degradation 1755
liver tumours 1763
men 1687, 1754–1755
physiology 1754–1755
transport in blood 1755–1756
tumorigenicity 1258
women 1687, 1754
testosterone enanthate, hepatocellular adenoma induction 1259
testosterone replacement therapy
endstage liver disease 1909
gynaecomastia induction 1762
haemochromatosis 1762
osteoporosis 1832
tethering proteins, bile vesicular trafficking 298
2,3,7,8-tetrachlorodibenzo-*p*-dioxin (TCDD), hepatotoxicity 2116–2117
1,1,2,2-tetrachloroethane, hepatotoxicity 2117
tetrachloroethylene, hepatotoxicity 2117
tetrachloromethane *see* carbon tetrachloride
tetracycline derivatives
fatty liver of pregnancy induction 1883, 1888
hepatotoxicity 1249
tetrahydrofolate 145
tetramisole 1061
tetrathiomolybdate (TM)
antiangiogenic effects 229, 230
antifibrotic therapy 230
anti-inflammatory therapy 230
cancer therapy 229–230
clinical studies 229
mechanism of action 229–230
preclinical studies 229
copper availability reduction 229–230
lung cancer 229
mammary tumours 229
prostate cancer 229
tumour necrosis factor α inhibition 230
Wilson's disease 1319
Teucrium chamaedrys (germander), hepatotoxicity 1282t, 1284, 2110–2111
Teucrium polium, hepatotoxicity 1282t, 1284
thalassaemia 1666
chronic hepatitis C antiviral therapy 950
thalidomide, amyloidosis 1707
thallium hepatotoxicity 2117
T-helper cells
drug-induced acute hepatitis 1224
type 1
acute graft-vs.-host disease pathogenesis 1672
chronic hepatitis B antiviral therapy 922
granuloma formation 1711
type1/type 2 balance, liver fibrosis 323
type 2, granuloma formation 1711
theophylline 1916
toxicity 247
thiabendazole
strongyloidiasis 1065
visceral larva migrans 1063
thiamazole (methimazole), hepatotoxicity 1236, 1685
thiamine
alcohol withdrawal syndrome 1180
deficiency in alcoholism 1185
thiazolidinediones
fibrosis 596
hepatotoxicity 1683
thick blood smear, malaria 1031
thick (true) macrocytes, chronic liver disease 1768
thin blood smear, malaria 1031–1032
thin macrocytes, chronic liver disease 1768
thiomersal, hepatitis B vaccine 911
thiopental, cerebral oedema 1305
thiopentone, liver transplantation 1942
thiopurine methyltransferase (TPMT) 245, 1647
thioredoxin reductase (TrxR) 235
thoracentesis
ascites-induced dyspnoea 725
bleeding risk 1788t
thoracic duct 673
lymph flow
cirrhosis 674–675
normal 673
thoracic surgery, postoperative jaundice 1945
Thorotrast 1458
angiosarcoma 1457, 1458
imaging 1458
granuloma formation 1710
thrills, hereditary haemorrhagic telangiectasia 1420
thrombin
clot formation 1780
injections, gastric variceal bleeding 652–653
topical 1792
thrombin-activatable fibrinolysis inhibitor (TAFI) 1780
thrombin time, mucosal bleeding 1786–1787, 1787f
thrombocytopenia 258–259
alcohol-induced 1187, 1786
chronic hepatitis 1771
cirrhosis 258–259, 1771, 1785–1786
Gaucher's disease 1361, 1363
hypersplenism 258, 772–773, 773f
mechanisms 259
post-liver transplantation 1773
prevalence 258
thrombopoietin therapy 259
thromboelastogram 1781–1782, 1783f, 1783t
thromboembolic events, estrogen therapy-induced 1688
thrombolysis, Budd–Chiari syndrome 1409
thrombopoietin (TPO)
acute liver failure 1131
cirrhosis 773
fetal liver 1767
hypersplenism treatment 776
post-liver transplantation 1773
splenic embolization 1771, 1786
thrombocytopenia 259, 261
thrombosis, cirrhosis 585
thrombotic thrombocytopenic purpura (TTP) 1882
thromboxane A2 682, 1816
thymidine kinase gene *(TK2)* mutations 1379
thymus, chronic graft-vs.-host disease 1674
thyroid function tests, liver disease 1748t
thyroid gland
disorders, hepatic effects of 1684–1685
dysfunction, antiviral side-effects 946
haemochromatosis 1762
physiology 1684
thyroid hormone receptor 1746f
thyroid hormones 1746–1750
binding proteins 1747, 1747t
cirrhosis 1748–1749, 1748t
drug-induced metabolism changes 1749–1750
growth hormone regulation 1739
hepatic uptake 1747
hepatocellular carcinoma 1749
insulin-like growth factor-1 regulation 1742
liver disease 1747–1750
metabolism 1746–1747, 1746f
normal physiology 1746–1747
secretion 1746
sex hormone binding globulin regulation 1755
see also individual hormones
thyroid-stimulating hormone (TSH) 1684
autoimmune liver disease 1749
cirrhosis 1748
drug-induced suppression 1750
haemochromatosis 1762
viral hepatitis 1748
thyroid storm 1684–1685
clinical manifestations 1684
treatment 1684
thyrotoxicosis 1684
drug-induced 1750
primary biliary cirrhosis 1749
thyrotropin-releasing hormone (TRH) 1684
autoimmune liver disease 1749
cirrhosis 1748
growth hormone secretion 1740
thyroxine (T_4) 1684, 1746, 1746f
alcoholic cirrhosis 1749
cirrhosis 1748
clearance 1747
deiodination 1746
excretion 1747
hepatocellular carcinoma 1749
phenytoin 1749–1750
primary biliary cirrhosis 1749
viral hepatitis 1748
thyroxine-binding globulin (TBG) 1684, 1688, 1747, 1747t

chronic viral hepatitis 1748
cirrhosis 1748
hepatocellular carcinoma 1749
primary biliary cirrhosis 1749
thyroxine-binding prealbumin 1747, 1747t
cirrhosis 1748
tianeptine, hepatotoxicity 1249–1250
tick typhus (Mediterranean spotted fever) 1006
ticlopidine, hepatotoxicity 1240
ticrynafen *see* tienilic acid
tienilic acid
cirrhosis induction 1253
hepatitis induction 1253
immune response 1222, 1223
hepatotoxicity 1230, 1240
tight junctional protein 2 *(TJR2)* gene mutations 1386
tight junctions
bile formation 298
cholangiocytes 53
hepatocytes 22, 97
inherited defects 1386–1387
intrahepatic cholestasis 1482
time horizon, economics 2082–2083
time-tradeoff
health utility assessments 2067
quality of life 2082
timolol 644
tin 233t
deficiency 233t
tinidazole
amoebiasis 1026
giardiasis 1026
tin-mesoporphyrin 166
tin-protoporphyrin 166
tissue factor (TF), haemostasis 255–256, 1780, 1782f
tissue factor pathway inhibitor (TFPI) 256, 1780
tissue inhibitors of metalloproteinases (TIMPs)
extracellular matrix degradation 270–271
hepatic stellate cell activation 584
liver disease immunogenetics 369–370
tissue-type plasminogen activator (tPA)
fibrinolysis 258
haemostasis 256
T-lymphocytes *see* T cells
TNM staging, gallbladder carcinoma 1578, 1578t
tobacco *see* smoking
tolazamide, acute hepatitis induction 1240
tolbutamide
acute hepatitis induction 1240
diabetes 1737
tolcapone, acute hepatitis induction 1240
Toll-like receptor 4 (TLR)
alcoholic liver disease 1139–1140
Kupffer cells 37, 38f
Toll-like receptors (TLRs)
cholangiocytes 55
hepatocytes 106
Kupffer cell activation 37
stellate cell expression 593
toluene, hepatotoxicity 2117–2118
topical agents, coagulation disorders 1791–1792
TOR inhibitors
liver transplantation 2007–2008
see also sirolimus
Toronto alcoholic liver disease index, coagulation tests 1786t
total decreased donor transplantation, acute liver failure 1307–1308
survival rates 1307, 1309t
total parenteral nutrition-related liver disease 1634–1641
bacterial overgrowth 1637
biliary complications 1637–1638
cholestasis 1947
diagnosis 1950
treatment 1950
histology 1634–1635
liver transplant indications 1638–1639
pathophysiology 1635–1637
nutrient deficiencies 1635–1636
nutrient excess 1636–1637
post-haematopoietic stem cell transplantation 1677
prevalence 1634
prevention 1638
total serum bilirubin 461
total van den Bergh reaction, bilirubin 167
toxaemia, acute fatty liver of pregnancy 1881
Toxascaris 1062
toxic epidermal necrolysis, nevirapine induced 1807
toxic liver injury 1269–1276
acute liver failure 1298
childhood 1858
apoptosis 340–341
environmental toxins 1269
exposure duration 1269
exposure types 1269
hepatotoxicity types 1269
industrial toxins 1269
injury patterns 1269, 1270t
route of exposure 1269
sinusoidal obstruction syndrome 1411
toxic oil syndrome 2118
toxic shock syndrome 1002
Toxocara antibodies 1062
Toxocara canis 1062
Toxocara cati 1062
toxoplasmosis
fetal 2132
HIV coinfection 983
TP53 gene
carcinogenesis and 393–394
HBx protein effects 394
mechanisms of inactivation 393–394
chromosomal location 393
as tumour suppressor gene 393–394
trace elements 232–240, 233t
elimination 238
toxicity 238
see also individual elements
tranexamic acid (TA) 261, 1790–1791
transaminases *see* aminotransferases
transaminitis 1227
transaminitis, protease inhibitor-induced 1807
transarterial chemoembolization (TACE)
hepatocellular carcinoma 554, 554f, 1444, 1449, 1449f
contraindications 1449
pretransplant patients 1926, 1927t
therapeutic efficacy 554
post-procedure fever 1449
side-effects 554, 1449
transarterial embolization (TAE)
haemobilia 1556, 1557
hepatocellular carcinoma 1449
transcatheter embolization
bacterial infections 767
hepatic artery aneurysms 1393
transcriptase-mediated amplification (TMA), hepatitis C 855, 884
transcriptional data, regulatory network mapping 2091
transcription factors 105–107
definition 105
Forkhead (HNF3) family 106
nuclear receptors 106–107
see also specific transcription factors
'transcriptome' 398f, 399
assumptions 412
liver 407
proteome *vs.* 403, 405
transduodenal sphincteroplasty, biliary-type sphincter of Oddi dysfunction 1569–1570
transferases 241
transferrin 220
neonatal haemochromatosis 1857
transferrin receptor (TfR) 328
transferrin receptor 1 (TfR1) 220–221
haemochromatosis 1324
transferrin receptor 2 (TfR2) 221
haemochromatosis 1324, 1325
non-HFE haemochromatosis (type 3) 221
transforming growth factor-α (TGF-α)
hepatocyte proliferation 2088, 2089, 2089f
liver regeneration 316
transforming growth factor-β (TGF-β)
apoptosis 338
fibrotic granulomas 1711
hepatoblast differentiation 68
hepatoblast proliferation 66
inhibition, antiapoptotic therapy 344
liver fibrosis 2090, 2091f
regulator T cells 323
signalling pathway 2090
Smad proteins 2090
transforming growth factor-β1 (TGF-β1)
collagen I production 592
fibrosis progression in HCV and 359
transforming growth factor-β (TGF-β) antagonists, fibrosis 597
transforming growth factor-like inhibitor of apoptosis (TWEAK) 60
transfusion-related lung injury (TRALI), post-liver transplantation 1999
transgenic mice
hepatic stellate cell replacement 286
QTL verification 380
transglutaminases
apoptosis 336
collagen cross-linking enzymes 266
trans-Golgi network (TGN) 24
transitional cells 590
transjugular intrahepatic portosystemic shunt (TIPS) 1340–1341
ascites, pretransplant patients 1923
bleeding risk 1788t
Budd–Chiari syndrome 1410
cirrhotic ascites 697–699
complications 698
paracentesis *vs.* 698–699, 698t
renal function impairment 698
systemic haemodynamic impairment 698
complications 550–551
bacterial infections 767
gastric variceal bleeding 653
hepatic encephalopathy induction 743
hepatic hydrothorax 725
hepatorenal syndrome 716–717
pretransplant patients 1924
hypersplenism 777
model for endstage liver disease 2056, 2056t
portal hypertension 550–551
portal vein thrombosis, acute 1397
portal venous pressure 698
pregnancy 1887
shunt dysfunction 698
thrombocytopenia 777
variceal bleeding
acute 651–652
pretransplant patients 1923, 1924t
prevention 647
transjugular transhepatic portal venography 534, 535f
complications 534
translocating chain-associating membrane (TRAM) 193
translocon 193
translocon-associated protein (TRAP) 193
transmission disequilibrium test (TDT) 360
transplants *see* liver transplantation
transport proteins 176–177, 384
ABC superfamily 385
basolateral membrane 385–386
bile acids 295f
cellular cholestasis and 384–390
compensatory changes 386, 387f
molecular regulation in 386–387, 388f
therapeutic perspectives 387–388
cholestasis and 384–387, 1481, 1482f
functional expression cloning 124
polar expression 125
nuclear receptors and 384
see also carrier proteins; nuclear receptors; *specific types*
transpulmonary gradient (TPG), portopulmonary hypertension 723
trans-sulphuration pathway 199, 200f
transthyretin (TTR) 214, 1684
transvaginal echography, ascites 667
transverse fissure (porta hepatitis) 3, 79
Traube's space, percussion 448
travellers, hepatitis B vaccine 912
travellers, hepatitis E 897
T-regulatory cells, autoimmune hepatitis 1097–1098
trematodes *see* liver flukes
tremors, Wilson's disease 1316
Treponema pallidum 1007
triacylglycerol 45
alcohol consumption 1136
triangular cord sign, biliary atresia 1847
triangular ligaments 4
tricarboxylic acid cycle 155–156, 155f
triceps skinfold thickness (TST), nutritional status assessment 1905

1,1,1-trichloroethane, hepatotoxicity 2118
trichloroethylene, hepatotoxicity 2118–2119
trichloromethane (chloroform), hepatotoxicity 1271, 2119
trichloromethyl free radical 1271
trichloromethylperoxy free radical 1271
2,4,5-trichlorophenol (TCP), hepatotoxicity 2119
Trichosporon beigelii 1013
trichrome stains, liver biopsy 491
triclabendazole 1045
tricyclic antidepressants, hepatotoxicity 1230
trientine
  pregnancy 1886
  Wilson's disease 1318, 1854
trifunctional β-oxidation complex (TOC) 154
trigeminal neuritis, viral hepatitis 1826
triglycerides
  chylous ascites 669
  ethanol-induced decrease in export 1137
  hepatobiliary disease 458–459
  obstructive jaundice 1502
  supplementation, intrahepatic cholestasis 1496
  transportation 133, 135–138
tri-iodothyronine (T_3) 1684, 1746, 1746f
  alcoholic cirrhosis 1749
  cirrhosis 1748
  hepatocellular carcinoma 1749
  reverse *see* reverse tri-iodothyronine (rT_3)
  viral hepatitis 1748
trimethoprim, acute hepatitis induction 1232
trimethoprim-sulphamethoxazole, spontaneous bacterial peritonitis 765
  resistant bacteria 766–767
trinitrotoluene, hepatotoxicity 2119
triorthocresyl phosphate, hepatotoxicity 2119
trisectionectomy, gallbladder carcinoma 1578–1579
troglitazone
  canalicular bile export pump inhibition 1240–1241
  hepatotoxicity 1240–1241, 1683
troleandomycin, hepatotoxicity 1241, 1242
trophozoite
  Entamoeba histolytica 1022
  Giardia 1022
  Plasmodium 1030
tropical pyomyositis 1063
tropical spruce, hepatic dysfunction 1629
trovafloxacin, acute hepatitis induction 1241
true (thick) macrocytes, chronic liver disease 1768
Trx-1 236t
Trx-2 236t
TrxR-1 235
TrxR-2 235
tryptophan, hepatic encephalopathy 731
TSST-1 toxin 1002
TT virus (TTV) 822
tuberculomas 1005, 1006
tuberculosis
  drug-induced hepatitis risk 1213
  granulomas 1005–1006, 1713
  hepatic abscess 1006
  nodular hepatic 1006
tuberculous peritonitis
  ascites 669–670
  clinical features 669
  diagnosis 670
  peritoneum 670
tularaemia 1004
tumorigenesis, phosphatidylinositol 3-kinases 105
tumour ablation, hepatocellular adenoma 1432
tumour cell lines, bioartificial liver support 2045
tumour dormancy 1465
tumour necrosis factor (TNF) 313–314
  anti-apoptotic signalling cascades 314–316
  apoptosis 338
    glutathione levels 202
    mitochondrial glutathione 203
  caspase cascade 314–315, 315f
  cirrhotic ascitic fluid 668
  extrahepatic biliary obstruction 1506
  fulminant hepatic failure 313–314
  hepatocellular carcinoma 316
  hepatocyte apoptosis 313–314
  insulin resistance 317
  liver cancer 316–317
    inflammatory carcinogenesis model 316–317
  liver regeneration 316
    partial hepatectomy models 316
  MHC location 365
  NF-κB pathway
    activation 315–316
    adenovirus blockade 315
    knockout animals 316
  polymorphism
    fibrosis progression in hepatitis C 359
    inflammatory response 369
  pro-apoptotic signalling cascades 314–316
tumour necrosis factor α (TNF-α)
  acute graft-vs.-host disease pathogenesis 1672
  alcoholic liver disease 1140, 1159
  autoimmune hepatitis 1094–1095
  hepatic encephalopathy 731
  immunomodulators, hepatotoxicity 1647
  inhibition 351
  Kupffer cells 37
  non-alcoholic steatohepatitis 611
  polymorphism, inflammatory response and 369
  steatosis pathogenesis 1137–1138
  warm ischaemia 348, 349f
tumour necrosis factor receptor 1
  apoptosis 338
  caspase cascade 314
  knockout mice 316
  warm ischaemia 349
tumour necrosis factor receptor 2
  apoptosis 338
  caspase cascade 314
tumour necrosis factor receptor-associated death domain 314, 338
tumour necrosis factor receptor-associated factor-1 (TRAF1) 315
tumour necrosis factor receptor-associated factor-2 (TRAF2) 315
tumour necrosis factor receptor-associated factor-6 (TRAF6) 37
tumour necrosis factor-related apoptosis-inducing ligand (TRAIL) 338
tumour necrosis factor-related apoptosis-inducing ligand receptor 1 (TRAIL-R1) 338
tumour necrosis factor-related apoptosis-inducing ligand receptor 2 (TRAIL-R2) 338
tumours *see* liver tumours
tumour suppressor genes (TSGs) 393–396
  carcinogenesis 393–396
    hepatocellular carcinoma 393–395, 394t
    recessive loss of function mutations 393
    viral disruption 394
  definition 391
  normal functions 393
  see also individual genes
Turner syndrome, primary biliary cirrhosis *vs.* 1078, 1078t
TWEAK (transforming growth factor-like inhibitor of apoptosis) 60
  12-step programme 1181
twin-cell plates 430
twin studies
  alcoholic liver disease 358
  cholecystolithiasis 376
  gallstone disease 1524
  primary biliary cirrhosis 358, 1073–1074
TWNT-4 line, hepatic stellate cells 48
2-dimensional electrophoresis, proteomic analyses 404–405, 404f
2-dimensional gel electrophoresis, proteomic analyses 404–405, 404f
type B encephalopathy 729
typhoid hepatitis 1003
typhoid nodules 1003
typical ductules 426
tyrosinaemia type I 2158
tyrosine
  macroautophagy regulation 149
  phosphorylation, insulin receptor substrates 131–132
tyrosine kinase inhibitors, hepatocellular carcinoma 1450

U

ubiquinol 154–155, 154f, 158
ubiquinone 158
ubiquitin 194
UGT1A 170
UGT1A1 1354, 1355–1356
ulcerative colitis (UC)
  autoimmune hepatitis 1626
  biliary cancer 1625
  Budd–Chiari syndrome 1405, 1628
  colorectal cancer 1625
  immunogenetics 370
  liver disease prevalence 1622–1623
  pouchitis 1625–1626
  primary biliary cirrhosis 1628
  primary sclerosing cholangitis 366, 1623–1626, 1623t
    liver transplantation 1625
    onset 1624
    pouchitis 1625–1626
    prevalence 1623–1624, 1623t
  smoking 1624
  steatosis 1627
'ultrasonic Murphy sign' 507
ultrasonography 500–508
  AIDS-related cholangitis 1546
  alcoholic macrovesicular steatosis 1160
  alveolar echinococcosis 1053, 1053f
  amoebic liver abscess 504, 1025
  angiosarcoma 1458
  ascariasis 1060–1061
  ascites 667
  bile duct dilatation 507
  bile duct injury, post-cholecystectomy 1958
  biliary atresia 1847
  biliary cystadenoma 814
  biliary disease 506–507
  biliary hamartomas 798, 1574
  biliary sludge 1522f
  biloma 817
  'bright liver pattern' 502, 502f
  Budd–Chiari syndrome 503–504, 1408
  carcinoid tumours 1473
  Caroli syndrome 805
  cholangiocellular carcinoma 505
  cholecystitis 507, 1522f, 1529
  cholecystolithiasis 1527
  choledocholithiasis 1527, 1542
  ciliated hepatic foregut cyst 808
  cirrhosis 502–503, 503f, 506, 612–613
  comet tail-echoes, biliary hamartomas 798
  contrast-enhanced (CEUS) 501
  cryptosporidiosis 1025
  cystic echinococcosis 1049, 1049t
  cystic fibrosis-associated liver disease 1339–1340
  Doppler *see* Doppler ultrasonography
  dysplastic nodules, cirrhotic liver 504t, 506
  echinococcal cyst 504
  endoscopic *see* endoscopic ultrasonography (EUS)
  epidermoid cysts, liver 811
  epithelioid haemangioendothelioma 1459
  extrahepatic biliary obstruction 1507, 1508
  fascioliasis 1045
  fibrosis 502–503
  focal nodular hyperplasia 504t, 505, 1429
  gallbladder 506
  gallbladder carcinoma 507
  gallbladder dysfunction 1562–1563
  gallbladder polys 507
  gallstone disease 506–507, 1522f
  haemangioma 504t, 505, 1427
  haematoma 505, 1954
    cystic transformation 817
  haemobilia 1556
  haemoperitoneum 1954
  hepatic steatosis 502, 502f
  hepatitis
    acute 501–502
    chronic 502–503
  hepatocellular adenoma 505, 1432

hepatocellular carcinoma 504t, 506, 506f, 1443
percutaneous ablation 553
hepatosplenic schistosomiasis 1042
hilar (upper duct) cholangiocarcinoma 1592
indications 501t
intracranial pressure monitoring 1305
intrahepatic cholangiocarcinoma 1595
liver abscess 504
liver cysts 504, 504t
ADPKD 790–791, 792–793
liver disease
chronic 502–503
diffuse 501–503
liver masses 504–506, 504t
liver transplantation 507–508
post-operative arterial occlusion 507–508
liver trauma 1954–1955
lymphoma 505
malarial hepatitis 1032
melioidosis 1003
metastases 504t, 505, 1467
nodular regenerative hyperplasia 1434
non-alcoholic fatty liver disease 1200
diabetes mellitus and 1682
non-alcoholic steatohepatitis 1200
normal liver parenchyma 501, 502f
peliosis hepatis, cystic 811–812
peribiliary cysts 803, 803f
physical principles 500–501, 500t
polycystic liver disease 504
portal hypertension 503–504
portal vein thrombosis 1396
posterior acoustic shadowing 500, 500t
pyogenic liver abscess 504
radiation hepatitis 1277–1278
schistosomiasis 1043, 1043f
simple cyst of the liver 783–784, 784, 784f
haemorrhagic 785, 785f
starry-night liver pattern 501–502
tuberculous peritonitis 669
undifferentiated sarcoma 1460
visceral larva migrans 1063
'waterlily sign' 504
umbilical cord stem cells, hepatocyte replacement 284
umbilical hernia 447
pretransplant patients 1923
umbilical sulcus 3
umbilical vein
portal hypertension 625–626, 626f
recanalization in 503
portal pressure measurement 567
right 623
umbilication, metastatic liver cancers 1466, 1466f
unconjugated bilirubin 1353
abnormal values 460
albumin binding 170
brain, effects on 1353
gastrointestinal absorption 171–172
light, effects of 168
measurement 1352–1353
metabolism 459
production 459
quantification 168
structure 459
toxicity 168, 1822
transport 170, 459
unconjugated hyperbilirubinaemia 460, 1355
infants 1845
uncoupling protein 2 162
undifferentiated sarcoma 1460
clinical features 1460
cystic 816, 1460
pathology 1460
treatment 1460
unilocular cyst of the liver *see* simple cyst of the liver
United Network of Organ Sharing (UNOS)
liver transplantation quality of life 2028
Model for EndStage Liver Disease 1985
United States *see* USA
universal vaccination, hepatitis B vaccine 911, 912–913
University of Wisconsin (UW) cold preservation solution 352, 1966
liver transplantation 1965–1966
unpublished studies, publication bias 2075
unsupervised learning methods 406
uraemia
aspartate aminotransferase 452
platelet defects 1786
uraemia-associated coagulopathy 1785
uranyl acetate, hepatotoxicity 2119
urate 117
urea
cirrhosis 612
intestinal hydrolysation 181
metabolism, liver disease and 185
production 181–183
synthesis
age-related changes 1871
bicarbonate removal 185
pH control 185–186
regulation 182–183
transporters 181
urea cycle 181–182, 182f
enzymes 181–182
urea cycle defects 185
children 1862
neurological manifestations 1822, 1823t
pregnancy 1883
treatment 747
uridine 5′ disphosphate-glucuronosyltransferase 2B4 (UGT2B4), intrahepatic cholestasis 1483
uridine diphosphate-acetylglucosamine (UDP-glucNac) 171
uridine diphosphate-glucuronosyltransferases 459, 1353–1354
autoimmune liver disease 482, 483f
bilirubin conjugation 170–171, 171f, 1353
deficiency 1353–1354
drug metabolism 242t
phase II drug metabolism 241, 242f
regulation 1354
uridine diphosphate-glucuronyl transferase
across liver cell plate 92
deficiency, Crigler–Najjar disease syndrome 1845
uridine diphosphoglucose pyrophosphorylase 1370
uridine phosphate-glucuronosyltransferase, cholestasis 1487–1488
urinary catheters, spontaneous bacterial peritonitis induction 763
urinary tract infections
cirrhosis 767
portal hypertension 767
urine
bilirubin in 169
colour changes 444
acute porphyria 212, 1344
galactosaemia 1860
porphyrin precursor excretion 212, 212t
porphyrins excretion 212–213, 212t
urobilin 172
urobilinogens 172, 459
urogenital diseases, liver in 1653–1661
urogenital tract, effects of liver disease 1815–1821
uroporphyrin 207
crystals 429
excretion 212, 212t
uroporphyrinogen decarboxylase (UROD) 208
porphyria cutanea tarda 1347, 1810
uroporphyrinogen III 208
uroporphyrinogen III cosynthase 208
uroporphyrinogen III cosynthetase 208
uroporphyrinogen III synthase defects, congenital erythropoietic porphyria 1347–1348
ursodeoxycholic acid (UDCA)
AIDS-related cholangitis 1546
anticholestatic mechanism 387
autoimmune hepatitis–primary biliary cirrhosis overlap syndromes 1123
autoimmune sclerosing cholangitis 1124, 1853
Caroli syndrome 806
cholangiocyte proliferation 54
cholecystolithiasis 1530
cholestatic liver disease 178
cystic fibrosis 1340, 1630, 1855
dosage 1493
efficacy 1494–1495
familial hypercholanaemia 1386
fibrosis 595
gallstone prevention 1529
graft-vs.-host disease 1495
intrahepatic cholestasis 1493–1496
intrahepatic cholestasis of pregnancy 1495, 1880
low phospholipid-associated cholelithiasis syndrome 1495
mechanisms of action 1340, 1493–1494, 1494f, 1495f
animal models 1493
cholehepatic shunt theory 1494
hepatocyte protection 1494
pregnane X receptor 1493
multifactorial cholestasis, premature infants 1850
non-alcoholic steatohepatitis 1203t, 1204
portal vein thrombosis, chronic 1398
primary biliary cirrhosis 1083, 1495
primary sclerosing cholangitis 1106, 1495
progressive familial intrahepatic cholestasis 1495, 1849
pruritus 1804
sepsis-induced cholestasis 1950
therapeutic uses 1494–1495
total parental nutrition-induced cholestasis 1950
vanishing bile duct syndrome therapy 1117
ursodiol 1638
urticarial reactions, alcohol abuse 1186
urticaria pigmentosa 1644
USA
alcohol consumption 1129, 1130
cirrhosis mortality rates and alcohol consumption 1130, 1131f
hepatitis A epidemiology 904t
hepatitis A vaccines 903
usnic acid, hepatotoxicity 205, 1286
UV-damaged DNA binding protein 1 (DDB1), HBx binding 829

V

V_2 receptor antagonists, hyponatraemia in cirrhotic ascites 699–701
vaccine/vaccination
Argentine haemorrhagic fever 990
hepatitis A *see* hepatitis A vaccines
hepatitis B *see* hepatitis B vaccine
hepatitis E 897–898
malaria 1034
Rift Valley fever 991
yellow fever 998
vagotomy, cholangiocyte proliferation 54
vagus nerve 16, 1681
afferent hepatic neurons 114
dysfunction 1728
hepatic blood flow regulation 76
sphincter of Oddi motility 308
valerian, hepatotoxicity 1282t
Valeriana officinalis, hepatotoxicity 1286
valproate
hepatotoxicity 1250, 1379
prevention 1250
mitochondria, effects on 1379
valproic acid, acute liver failure 1299
vanadium 233t
vancomycin 767
vanishing bile duct disorders 426
vanishing bile duct syndrome 1111–1119
Alagille syndrome 1112, 1114t, 1115
alpha-1 antitrypsin deficiency 1114t, 1117
autoimmunity 1115–1116
autosomal dominant polycystic disease 1112
bile duct atresia 1114t
biliary hamartomas 1112
Caroli's disease 1112
causes 1112–1116, 1113–1114t
congenital errors 1112, 1114t
drug-induced 1114t, 1115, 1115f
infections 1115
ischaemia 1115
malignancies 1114t, 1116
choledochal cysts 1112
clinical forms 1253–1254
congenital defects 1112, 1114t
congenital hepatic fibrosis 1112
cystic fibrosis 1112, 1114t
definition 1111
diagnosis 1116–1117
differential diagnosis 1117
drug-induced 1253–1254, 1254f
mechanisms 1254

ductopenia of the child 1115
epidemiology 1111
fibropolycystic liver disease 1112, 1114t
graft-vs.-host disease 1113t, 1116
histology 1116–1117
Hodgkin's disease 1663
injuries 1112
laboratory features 1116
overlap syndromes 1113t
pathophysiology 1112
antiapoptotic genes 1112
'ductular reaction' 1112
growth factors 1112
injuries 1112
polycystic kidney disease 1112
polycystic liver disease 1112
post-liver transplant 1113t, 1116
primary biliary cirrhosis 1078t, 1113t, 1115–1116
primary sclerosing cholangitis 1113t, 1115–1116
sarcoidosis 1113t, 1116
sequelae 1117
symptoms/signs 1116
therapy 1117
variant specific surface proteins (VSPs), *Giardia* 1024
variceal bleeding
acute bleeding episodes 640–642
clinical features 640–641
definition 648
endoscopic therapy 650
infections in 648–649
initial control 641
initial treatment recommendations 650–651, 651f
management algorithm 651f
pharmacological therapy 649–650
prognostic factors 640–641
rescue therapies 651–652
treatment 647–652
alveolar echinococcosis 1052
chronic portal vein thrombosis 1397
cirrhosis 609
clinical course 640–642
diurnal rhythm 641
early rebleeding 641
prognostic indicators 641
first bleeding
endoscopic therapy 644–645
incidence 640
pharmacological therapy 644
prevention 643–645, 646f
prophylactic therapy 643–645
risk indicators 640
hypersplenism 774, 774f
long-term recurrent bleeding 641–642
mortality 641
natural history 640–642
nodular regenerative hyperplasia 1434
platelet count 775, 775f
post-peritoneovenous shunting 696
pregnancy 1887
pretransplant patients 1923–1924, 1924t
prevention 1902
recurrent bleeding prevention 646–647
algorithm 647
drug therapy 646
endoscopic therapy 647, 647f
TIPS 647
risk of 627
sarcoidosis 1712
variceal ligation, haemostasis risk 1788t
varicella-zoster virus infection 959–960
acute liver failure 1297
complications 959–960
diagnosis 960
haematopoietic stem cell transplants 960
immunocompromised 960
immunohistochemistry 960
perinatal 959
polymerase chain reaction 960
post-liver transplantation, children 1866
primary 959
reactivation 960
therapy 960
visceral involvement 960
variegate porphyria (VP) 1810
vascular abnormalities/anomalies
congenital malformations 1418–1423
haemobilia 1553
pregnancy 1887
vascular cell adhesion molecule-1 (VCAM-1), T cell mobilization 322
vascular diseases 1389–1423
childhood acute liver failure 1858
vascular endothelial growth factor (VEGF)
chronic liver disease 32
collateral formation 634
expression 30f
hepatocellular carcinoma 32
hepatocyte proliferation 2089
liver sinusoidal endothelial cells 30–31, 32
portal hypertension 32–33
vascular endothelial growth factor receptor (VEGFR)-1 30, 30t, 32
vascular endothelial growth factor receptor (VEGFR)-2 30, 30t, 32
vascular endothelial growth factor receptor (VEGFR)-3 30
vascular hyporeactivity 1723–1724
pathophysiology 1724, 1724f
vascular laceration
gastrointestinal haemorrhage 549
pseudoaneurysm and 549–550
vascular lesions, drug-induced 1214t, 1255–1257, 1255t
vascular obstruction, cirrhosis 583
vascular resistance 1724
calculation 567
portal hypertension pathogenesis 630–633
vascular system, effects of liver disease on 1723–1727
vascular adaptation dysregulation 1727
vascular tone, cirrhosis 631, 1791
vasculitis
chronic hepatitis C 889
liver disease 1698
vasculogenesis, liver sinusoidal endothelial cells 30
vasoactive inhibitory polypeptide (VIP)
cholangiocytes, effects on 53
gallbladder fluid transport 306
vasoconstriction
endothelin-1 induced 82
hepatic artery
humoral control 77
intrinsic mechanisms 75–76
neural control 76
obstructive jaundice 1503
renal, in cirrhosis 680
vasoconstrictors
hepatorenal syndrome 712f, 715–716, 716t
pretransplant 715
paracentesis-induced circulatory dysfunction 695
vasodilatation
chronic liver disease 1724
endothelin 82
hepatic artery, humoral control 76
portal hypertension 634–636
sodium retention 636
vasodilators
deficit, cirrhosis 631–632
hyporesponse, cirrhosis 631–632
portal hypertension pathogenesis 634–635
renal hypoperfusion 1725
renal perfusion, cirrhotic ascites 685
splanchnic arterial vasodilation 684
vasopressin
acute liver failure 1304
acute variceal bleeding 649
hepatic blood flow regulation 77
hepatorenal syndrome 715–716
portal hypertension 643
vegetarian diet
albumin synthesis impairment 454
hepatic encephalopathy 746
vena cava anastomosis, liver transplantation 1967, 1967f
vena cava stenosis, piggy-back liver transplantation 1969
vena cava thrombosis, post-peritoneovenous shunting 696
venesection
hypersplenism 777
hypogonadism 1761
Venezuelan haemorrhagic fever (VHF) 988–989
veno-occlusive disease (VOD) 1411–1412
acute form 1256
acute liver failure 1301
alcoholic hepatitis 1151, 1151f
causes 1411
drug-induced 1255t, 1256–1257
histology 427, 1411
onset 1411
post-bone marrow transplantation 1256
post-haematopoietic stem cell transplantation 1676–1677
prognosis 1412
pyrrolizidine alkaloid-induced 1283–1284
radiation reduced 1278
severity 1412
toxin-induced 1270t, 1273
see also Budd–Chiari syndrome
venous hum 448
venous occlusion plethysmography, cirrhosis 1725
venous sinuses, spleen 772
venous thromboembolism (VTE), cirrhosis 1792
venovenous bypass (VVB), liver transplantation 1942
ventromedial hypothalamus 114
vertebral deformity 1830
vertebral fractures, osteoporosis 1829
very-long-chain acyl-CoA dehydrogenase (VLCAD) 154
very-low-density lipoproteins (VLDL)
abetalipoproteinaemia 1366
apolipoprotein C-II 136
assembly 135, 136f
catabolism 136–137
characteristics 134t
clearance 138
hyperlipidaemia type IV 1367
remnants 137, 138
secretion 92, 135–136, 136f
triglyceride hydrolysation 136
ultrastructure 24, 24f
vesicle, endoplasmic reticulum 192f, 194
vesicles
alveolar echinococcosis 1051, 1052
bile acids transport 295, 296f
canalicular membrane 23
secretory, Golgi complex 24
vesicular tubular clusters (VTCs) 194
vidarabine
adenovirus infection treatment 968
chronic hepatitis B 936
vincristine, hepatotoxicity 1257
vinyl chloride exposure
angiosarcoma 1273, 1458
cutaneous manifestations 1811
epithelioid haemangioendothelioma 1460
hepatotoxicity 1273, 1458, 2119–2120
'violin string' adhesions, *Chlamydia trachomatis* 1004
viral haemorrhagic fevers 988–998
acute liver failure 1298
see also specific types
viral hepatitis 821–956
acute
aplastic anaemia 1769
postoperative 1951
pregnancy 1887
thyroid hormones 1748, 1748t
acute liver failure 1296–1297
acute therapy 917–921
supportive care 917
aplastic anaemia 1666–1667
apoptosis 341
carcinogenesis and
oncogene induction 393
tumour suppressor inactivation 394
children 1850–1852
chronic
cirrhosis 495f
drug hepatotoxicity 1917, 1917t
grading 492–494, 493f
liver biopsy 492–494, 492f, 493f, 494f, 495f
staging 492–494, 494f
systems 493–494
thyroid hormones 1748
cirrhotic nodules 494f
diabetes mellitus 1682
drug-induced acute hepatitis *vs.* 1227
elderly 1871–1872
fulminant (massive necrosis) 493f
granulomas 1714
haemophilia 1666
historical background 821–822

HIV co-infection, drug prescribing 1918
infiltrates 492f
MHC associations 365t, 367–368, 370t
mononeuritis 1826
neurological manifestations 1824t
neuropathies 1826
nomenclature 821–822
post-cardiac surgery 1611
pregnancy 1887–1888
recurrence, post-transplant 2004
total serum bilirubin 461
see also specific infections; specific viruses/types
viral-induced bone marrow aplasia 1769
viral-induced mixed cryglobulinaemia 1771–1772
viral infection(s)
acute liver failure 1296–1298
autoimmune hepatitis 1101
childhood acute liver failure 1858
drug hepatotoxicity 1213
graft-vs.-host disease *vs.* 1677
neonatal acute liver failure 1856–1857
paracetamol-induced hepatitis 1238
post haematopoietic stem cell transplantation 1677
post-liver transplantation, children 1866
primary biliary cirrhosis 1073
Reye syndrome 1824
see also specific infections; specific viruses
'virtual liver' 2093
visceral adiposity, non-alcoholic steatohepatitis 1195
visceral larva migrans 1062–1064
clinical features 1063
control 1064
diagnosis 1063
epidemiology 1062
imaging 1063
inflammatory reaction 1062–1063
laboratory findings 1063
nodules 1062, 1062f
pathogenesis 1062–1063
pathology 1062–1063, 1062f
prevention 1064
pulmonary symptoms 1063
serology 1063
transmission 1062
treatment 1063–1064
visceral leishmaniasis (VL) 1035–1039
clinical features 1035–1036
clinical variants 1035–1036
coinfections 1035
diagnosis 1036–1037
epidemiology 1035, 1035t, 1036f
geographical distribution 1035, 1035t, 1036f, 2100–2104t
laboratory parameters 1036–1037, 1037f
serology 1037
transmission 1035
treatment 1037–1039, 1038t
Visual Analog Scale (VAS), quality of life assessment 2028, 2082
visual evoked potentials, hepatic encephalopathy 745
vitality scale, chronic viral hepatitis 2069
vital signs 445
vitamin A 213–220
antifibrotic therapeutic uses 597
deficiency
cholestasis 1487
chronic liver disease 1802
primary biliary cirrhosis 1802
hepatotoxicity 1250–1251
sinusoidal fibrosis 1250–1251, 1413
supplementation, cholestasis 1496
vitamin B
deficiency, homocysteine 147
supplementation 1901, 1908
vitamin B_1
deficiency, alcoholic liver disease 1823t
supplementation 1908
vitamin B_6 supplementation 1908
vitamin B_{12} 238
chronic liver disease 1768–1769
vitamin D
deficiency
cholestatic liver disease 1802
inflammatory bowel disease 218
osteomalacia 1834
parenchymal liver disease 1802
primary biliary cirrhosis 1079
rickets 1833
function 217–218
immune system 218
malabsorption, cholestasis 1487
metabolism 217–218
osteoporosis 218
structure 215f, 217–218
supplementation 1901, 1908
intrahepatic cholestasis 1496
osteomalacia 1834
osteoporosis 1082, 1832
vitamin D_3
production 218
structure 215f
vitamin D receptor (VDR) 216f, 218
bile secretion regulation 301t
drug-metabolizing pathway regulation 244
hepatobiliary transport regulation 388
hepatocellular carcinoma 218
intrahepatic cholestasis 1483
primary biliary cirrhosis 358
vitamin D-responsive element (VDRE) 218
vitamin E
deficiency 1825
cholestasis 1487, 1802, 1825–1826
neurological manifestations 1823t, 1825–1826
primary biliary cirrhosis 1079
total parenteral nutrition-related liver disease 1636
fibrosis inhibition 596
non-alcoholic steatohepatitis treatment 1203t, 1204
normal serum levels 1825
supplementation, cirrhosis 1908
Wilson's disease 1319
vitamin K
cirrhosis 610
clotting factor synthesis 257
deficiency 1802
anaesthetic implications 1940
cholestasis 1487, 1824t
primary biliary cirrhosis 1079
obstructive jaundice 1511
prothrombin time 456
supplementation
coagulation disorders 260, 1789
intrahepatic cholestasis 1496
intrahepatic cholestasis of pregnancy 1880
vitamin K_2, hepatocellular carcinoma prevention 1451
vitamin K antagonists
Budd–Chiari syndrome 1409
cirrhosis 1914, 1915t
vitelline veins 623
left 623
right 69, 623
vitiligo 446
volatile anaesthetics, hepatic blood flow 77
volume adaptation, liver disease 1728–1729
volume depletion, obstructive jaundice-associated acute renal failure 1816
volume distribution, effects of liver disease on 1727–1728
volume expansion
cirrhosis 1728
stroke volume 1728
vomiting *see* nausea and vomiting
von Gierke disease *see* glycogen storage disease (GSD), type I
von Meyenburg complexes *see* biliary hamartomas
von Recklinghausen's disease (neurofibromatosis type 1) 1645
von Willebrand factor binding domain, cirrhosis 1771
VPA-985
hyponatraemia in cirrhotic ascites 700–701, 700f, 701f
side-effects 701
VPS33B mutations 1386

W

wait-and-see policy, choledocholithiasis therapy 1533
Waldenstrom's macroglobulinaemia 1664
warm ischaemia 348–352
cell death 348–350
cold ischaemia *vs.* 352
mechanisms 348, 349f
protective strategies 350–352
pharmacological 350–352
surgical 350
water absorption, gallbladder 306
waterlily sign, ultrasonography 504
'watermelon stomach' (gastric antral vascular ectasia) 1799–1800
water overload administration, cirrhosis 676
water restriction, hyponatraemia in cirrhotic ascites 699
water retention, anaesthetic implications 1939
Ways of Coping Scale 2029
weakness 443
wear and tear pigment (lipofuscin) 12, 428, 1870
wedged hepatic retrograde portography 660, 661f
wedged hepatic venography 533–534, 534f
cirrhosis 537
portal hypertension 533
wedged hepatic venous pressure (WHVP) 658
communicating hepatic veins 659, 660f
measurement 568, 659, 659f
portal hypertension 533–534
Wegener's granulomatosis 1643
weight *see* body weight
Weil's disease 1008
Werner syndrome 2158–2159
Wernicke's encephalopathy 742, 1185
Western blots, echinococcosis 1054
wheezing, carcinoid syndrome 1474
Whipple procedure, cholangiocarcinoma 1594
Whipple's disease
granulomas 1713
liver in 1629
white blood cell (WBC) count
alcoholic hepatitis 1163
cirrhotic ascites 667
hypersplenism 772
white nails (leuconychia), cirrhosis 611
WHOQOL-100, liver transplantation outcome research 2070
wild-type transthyretin (TTR) amyloid deposits 1704
'willingness to pay' notion, economics 2085
Wilson's disease 226, 228, 1315–1322
4193delC mutations 1317
acute liver failure 1299–1300, 1315
animal models 1320–1321
biochemical markers 1315
treatment monitoring 1320
biochemical tests 1317
chelating agents 1315, 1318–1319, 1853–1854
children 1853–1855
clinical presentation 1315–1316
liver disease 1315
psychiatric disease 1316
computerized tomography 512
cutaneous manifestations 1811
diagnosis 1316–1317, 1853
initial strategies 1316–1317, 1316f
scoring system 1316
dietary copper restriction 1319
fulminant 1319
treatment 1299–1300
hepatocellular carcinoma 1439
histological features 429–430
histology 1853
Kayser–Fleischer ring 1319, 1320
liver function tests 1320
liver transplantation 1853
metalloproteome 414
molecular genetics 1317–1318
as monogenic disorder 372
neurological manifestations 1315–1316, 1823t
liver transplantation 1319
non-ceruloplasmin-bound copper 1320, 1853
pathophysiology 1315
pregnancy 1319, 1886
prevalence 1853
prognosis 1854–1855, 1854t
renal tubular acidosis 1819
therapy 1318–1319
treatment 1315, 1853–1855

Wilson's disease acute haemolytic syndrome 1769–1770
window for immunological engagement (WOFIE), immunosuppression 2003
Wnt-3a, hepatoblasts 66, 68
Wnt signalling cascade
  hepatocellular carcinoma 1440
  oncogenesis 392–393, 392t
    HBx and 393
  primary biliary cirrhosis and 410
  target genes 392
Wolman disease 1365–1366, 2159
  clinical presentation 1365
World Health Organization (WHO), hepatitis B vaccine recommendations 912
wound healing, obstructive jaundice 1505
WY14,643 1137

X

xanthelasma, primary biliary cirrhosis 1075
xanthine oxidase 238
xanthoma
  familial hypercholesterolaemia 1367
  glycogen storage disease type 1 1372
  primary biliary cirrhosis 1075
xanthomatous biliary cirrhosis *see* primary biliary cirrhosis (PBC)
xanthomatous cells 425
xenobiotics 1218, 1226–1227
  excretion in bile 291
  metabolism 92–93
  toxicity investigations 122
xenogenic extracorporeal liver perfusion, acute liver failure 1306
xenon, cerebral blood flow measurement 744
XIAP 227t, 228
X-linked glycogen storage disease (Keating syndrome) 2143
X-linked liver phosphorylase kinase deficiency (glycogen storage disease type IXa) 1374
X-linked lymphoproliferative disease, Epstein–Barr virus infection 965
X-rays
  amoebic liver abscess 1025
  cystic echinococcosis 1049
  Gaucher's disease type 1 1361
  granulomatous hepatic tuberculosis 1006
  Mycoplasma pneumoniae 1005
  osteoporosis 1831
  primary sclerosing cholangitis 1105
  pyogenic liver abscess 1002
X-ray venography, Budd–Chiari syndrome 1408, 1409
xylene, hepatotoxicity 2120

Y

yeast two-hybrid system, proteomics 2092
yellow fever 996–998
  aetiological agent 996
  clinical manifestations 996–997, 997f
  diagnosis 997
  epidemiology 996
  geographical distribution 2100t, 2101t
  histology 996
  laboratory findings 997
  liver involvement 996
  pathogenesis 996
  pathology 996
  prevention 997–998
  treatment 997–998
  vaccinations 998
Yersinia 1004
Y-protein *see* glutathione-*S*-transferases (GSTs)
Yu-Cheng outbreaks (oil disease) 1273
Yusho outbreaks (oil disease) 1273

Z

zafirlukast, hepatotoxicity 1241
zalcitabine, hepatotoxicity 1248
zeiosis 335
Zellweger syndrome 176, 2159–2160
zidovudine *see* azidothymidine (AZT)
Zieve syndrome 1770
Zimmermann–Laband syndrome 2160
zinc 233t, 237
  antioxidant function 237
  deficiency 233t
    alcoholic cirrhosis 1166
  excretion 237
    Wilson's disease 1320
  functions 233t
  pregnancy 1886
  supplementation 237
    alcoholic cirrhosis 1166
    cirrhosis 185, 237
    hepatic encephalopathy 747, 749, 1839, 1908
  uptake 237
  Wilson's disease 1318–1319, 1320, 1855
zonula occludens *see* tight junctions
zygomycosis 1013

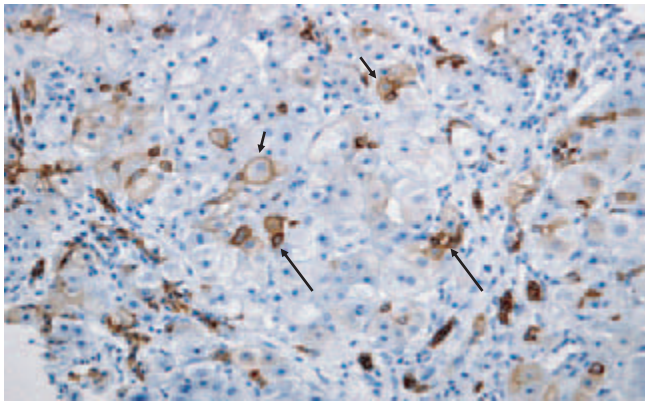

Plate 1.8.1 Cytokeratin 7 immunohistochemical stain illustrating liver progenitor cells (long arrows) and intermediate hepatocytes (short arrows) in a liver after severe hepatocyte damage.

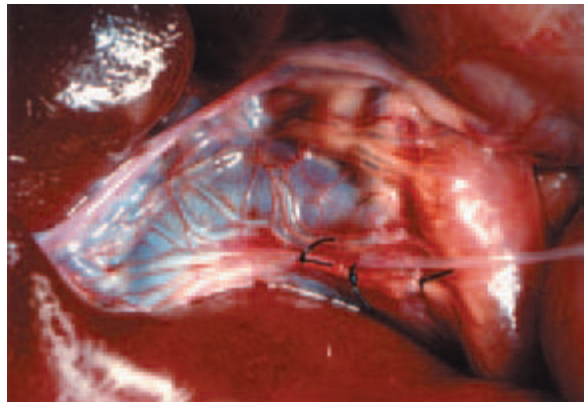

Plate 2.1.3.1 Photograph of the liver (on the left) covered with ascites fluid. The portal vein runs across the field flowing from right to left into the liver. A large number of translucent lymphatics are seen exiting the liver at the hilus, coursing over the portal vein and flowing from left to right in the photograph. Lymphatic valves can be seen as points of constriction in some of lymphatic vessels. One of the large lymphatics in the photograph has been cannulated for the purposes of lymph collection. The lymphatic catheter is tied in place with lengths of black suture. A large lymph node can be seen at the right of the photograph.

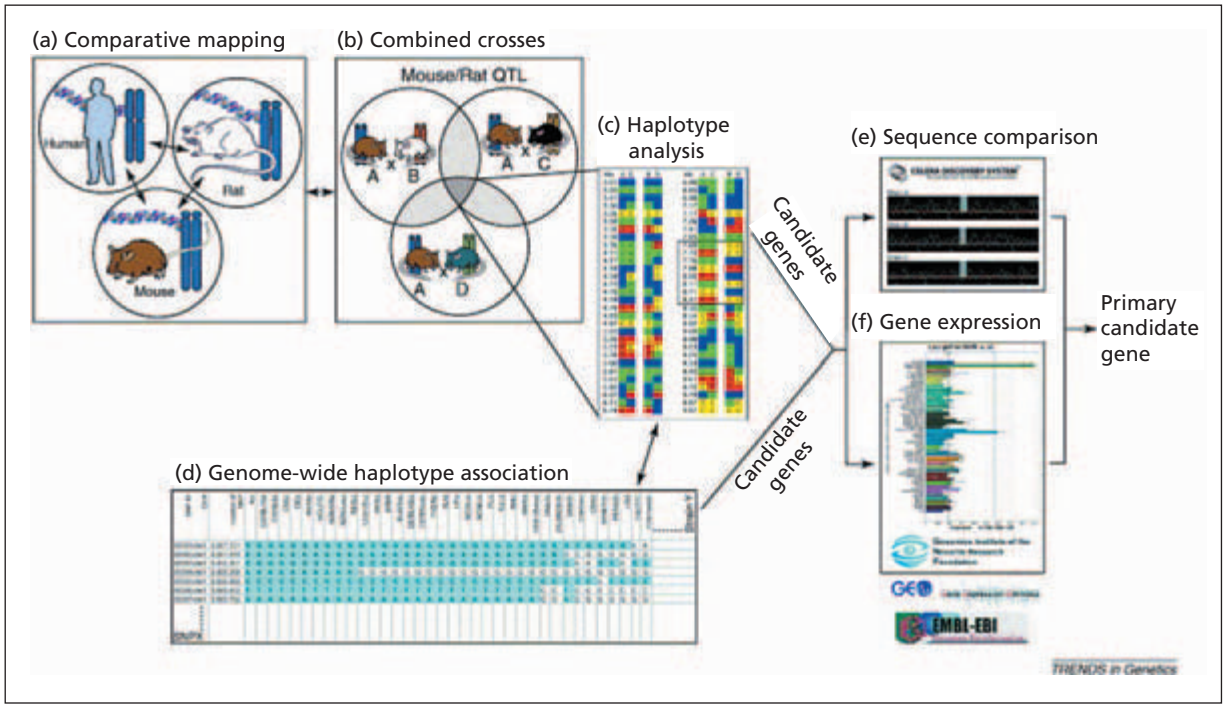

Plate 3.3.3.1 Integrated bioinformatics strategy for narrowing mouse QTLs. (a) Rodent QTLs can initially be narrowed through comparative genomics and (b) combined cross-analysis. (c) Those QTLs identified in multiple crosses can be narrowed by haplotype analysis. Combining experimental QTLs narrowed using steps a–c with results from genomewide haplotype association (d) can further narrow the QTL to a region < 5 Mb. (e) The number of candidate genes can be reduced further using sequence databases (f) and expression databases to identify primary candidate genes that are differentially expressed in liver or contain a coding sequence polymorphism. Reproduced with permission from ref. 45.

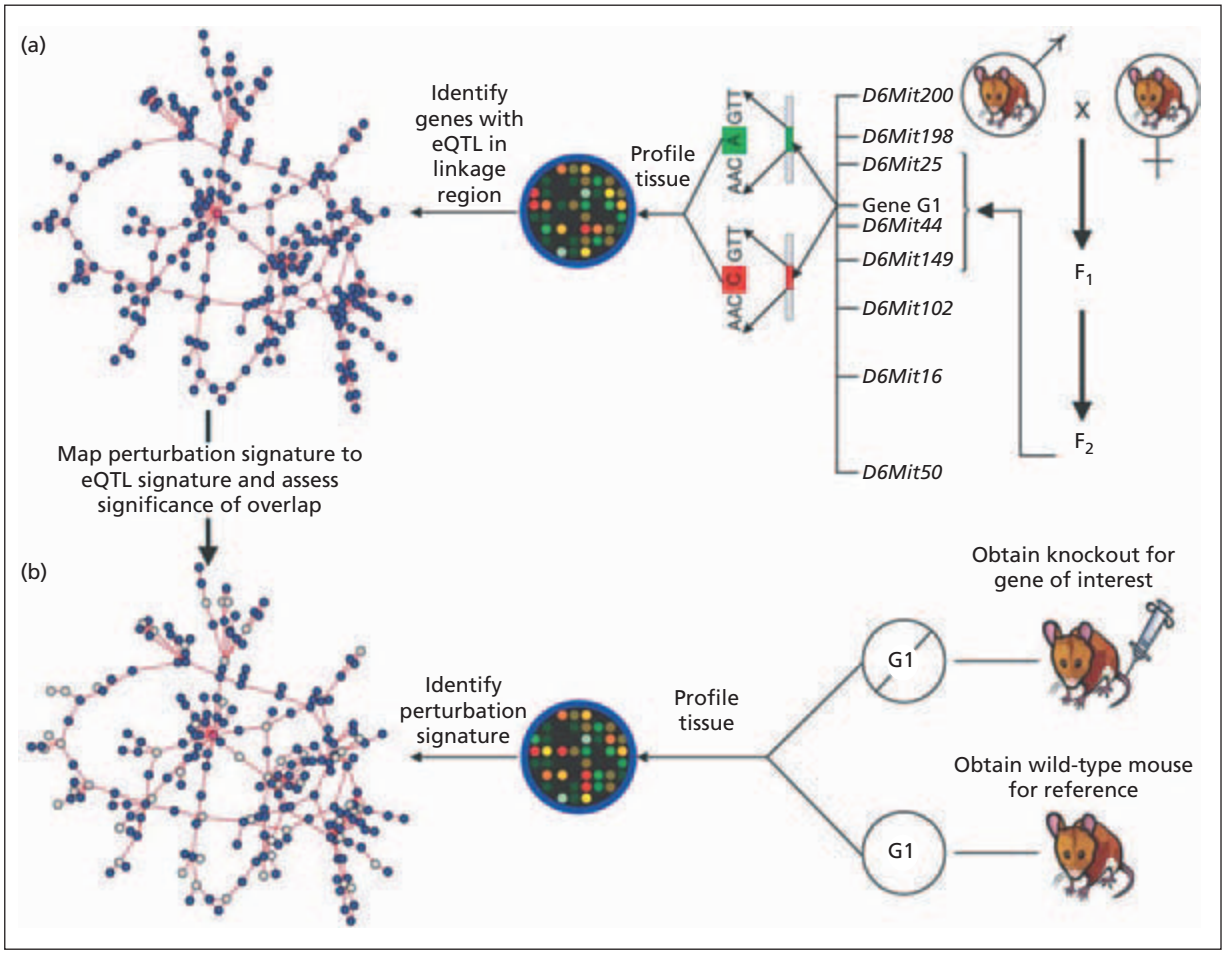

Plate 3.3.3.2 Intersecting perturbation signatures in gene expression data to map genes for complex traits. (a) QTLs for complex traits are mapped in an experimental cross. A genetic locus at G1 is highlighted as being linked to a trait of interest in the F2 population. An SNP in G1 is highlighted as the causal variant underlying the complex trait. Hepatic expression levels are monitored using microarrays. Expression traits found to be genetically linked to the G1 locus are determined. The transcriptional network on the left highlights expression traits linked to the G1 locus (blue nodes), in addition to expression traits interacting with genes linked to the G1 locus (white nodes), with G1 denoted by the red node. (b) Livers from mice genetically engineered with respect to G1 are profiled (e.g. knockout mice in this case). Genes that are differentially regulated between the perturbed and unperturbed system are identified. Highlighted to the left is the portion of the network that is observed to change when gene G1 is perturbed. This signature is compared with the eQTL signature defined in (a). If expression traits controlled by the G1 locus are enriched for expression traits that are differentially regulated as described in (b) (blue nodes), then this matched pattern of expression provides direct experimental support that G1 is the gene underlying the linkage to the complex trait in the F2 population. Reproduced with permission from ref. 58.

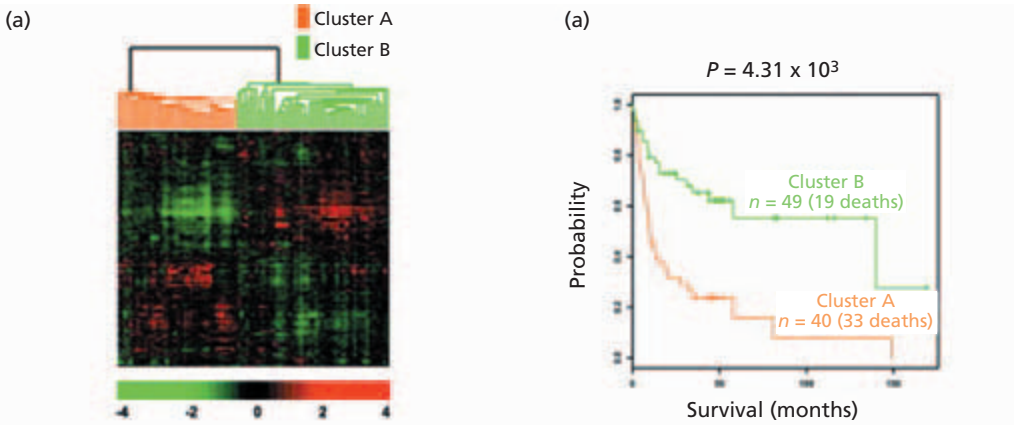

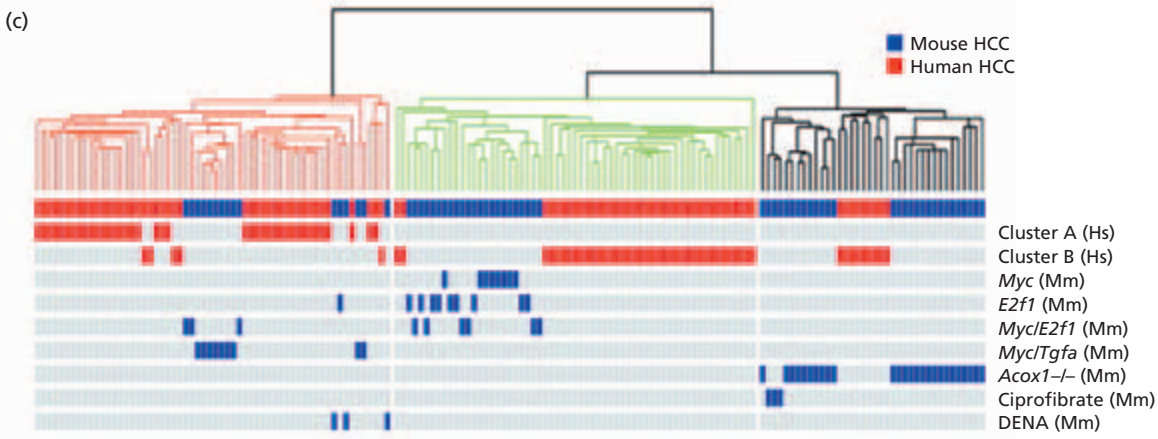

(d)

	Human HCC	
	Subclass A	Subclass B
Proliferation	High	Low
Apoptosis	Low	High
Ubiquitination	High	Low

	Mouse HCC			
	Myc/Tgfa	*Myc/E2f1*	*Myc*	*E2f1*
β-Catenin activation	Low	H	L	H
Genomic stability	High	Low	Low	Low
Ubiquitination	High	Low	Low	Low
Apoptosis	Low	Low	High	High
Proliferation	High	Low	Low	Low

Plate 3.3.3.3 Gene expression profiling of human HCCs and comparative functional genomics to identify best-fit mouse models for the study of human cancer. (a) Hierarchical cluster analysis of human HCCs. The data are presented in matrix format in which rows represent the individual gene and columns represent individual tissue. The red and green colours in cells reflect high and low expression levels, respectively, as indicated in the scale bar ($\log_2$ transformed scale). (b) Significant association of gene expression patterns with patient survival. Kaplan–Meier plot of overall survival of HCC patients grouped on the basis of gene expression profiling shown in (a). (c) Hierarchical cluster analysis of integrated human and mouse HCCs. The data are presented as a dendrogram. Red and blue bars represent human and mouse HCCs respectively. The identity of each HCC tissue is shown at the end of each row (see ref. 59 for details). (d) Phenotypical similarities between HCCs generated in the transgenic mouse models and subclass A and B of human HCCs. These models should be particularly valuable for both testing potential therapeutic targets and preclinical trials of drugs. Reproduced with permission from ref. 60.

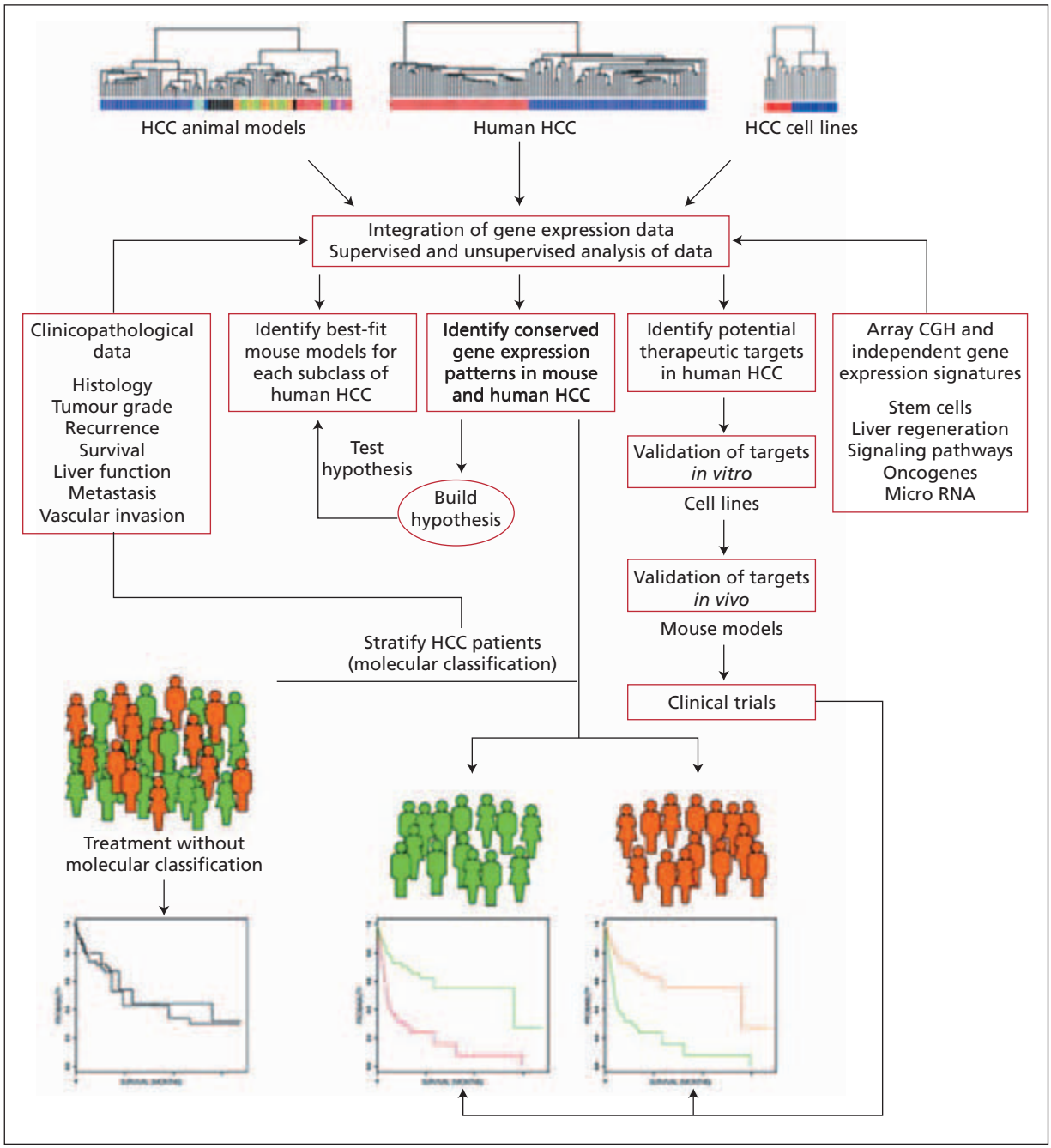

Plate 3.3.3.4 Framework for integrative functional genomics and future clinical implications. In addition to the comparative functional genomics approach that combines gene expression data from primary human HCCs and mouse HCC models, gene expression signatures unique for different physiological condition such as liver development and liver regeneration as well as hepatic stem cells are collected and integrated into the gene expression patterns from human HCCs. This approach will further help not only to uncover the molecular pathways involved in HCC pathogenesis but also to stratify patients for the most beneficial target-specific therapies. Reproduced with permission from ref. 60.

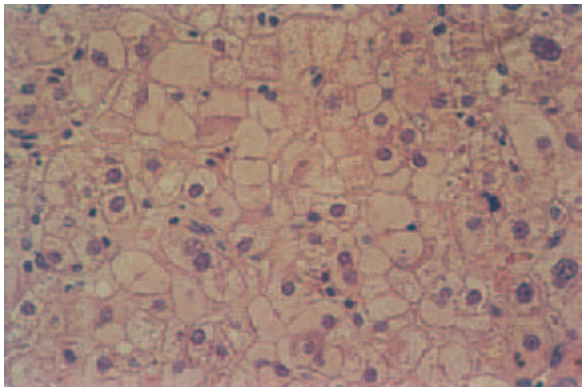

Plate 4.1.1 Liver biopsy from a patient with chronic hepatitis B. Numerous ground-glass hepatocytes with homogeneous, pale pink cytoplasm can be seen [haematoxylin and eosin (H&E) × 65].

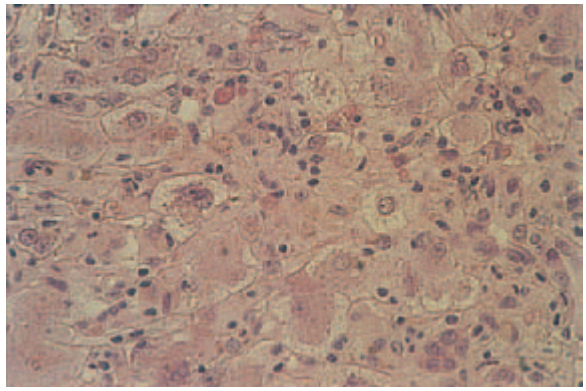

Plate 4.1.2 Liver biopsy from a patient with acute hepatitis B, characterized by liver cell pleomorphism and parenchymal inflammation. Pleomorphism of hepatocytes is reflected in unequal size and staining quality. Ballooned hepatocytes appear swollen and pale, especially in the peripheral part of their cytoplasm. Two small eosinophilic apoptotic cell fragments lie close to lymphocytes (H&E × 104).

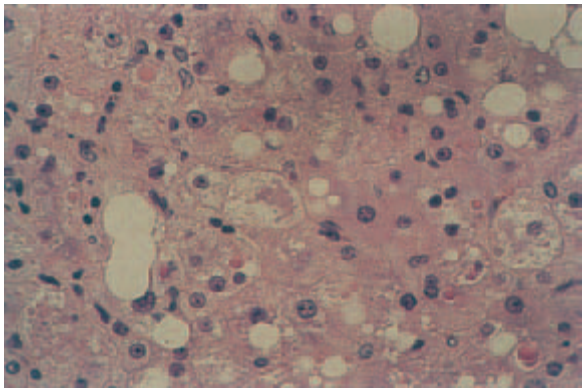

Plate 4.1.3 Liver biopsy from a patient with alcoholic liver disease. The picture shows some steatosis vacuoles, two pale, swollen hepatocytes containing an irregularly shaped Mallory body, and several parenchymal cells with one or more round, eosinophilic inclusions: megamitochondria (H&E × 104).

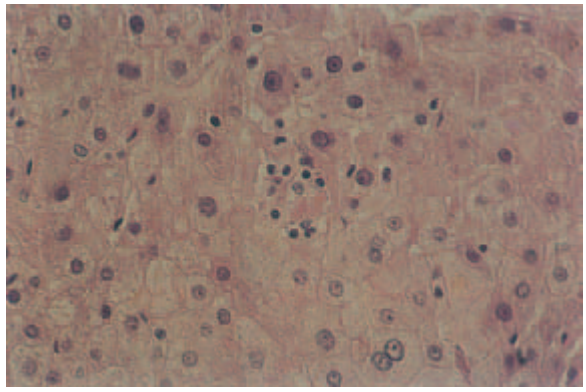

Plate 4.1.4 Liver biopsy from a patient with chronic persistent hepatitis B. Small focus of focal (or 'spotty') necrosis, with accumulation of lymphocytes and mononuclear cells around a dying liver cell, of which only two small eosinophilic fragments (apoptotic bodies) are recognizable (H&E × 104).

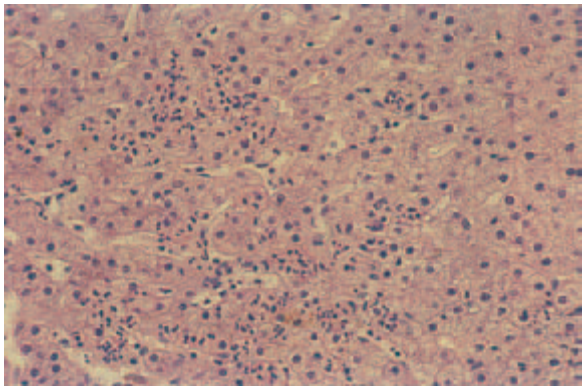

Plate 4.1.5 Surgical liver biopsy. 'Surgical necroses' are represented by clusters of accumulating polymorphonuclear neutrophils (H&E × 65).

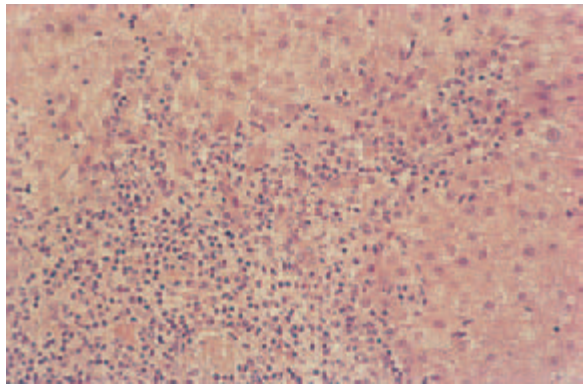

Plate 4.1.6 Liver biopsy from a patient with chronic active hepatitis B, characterized by piecemeal necrosis. The portal tract (lower left corner) shows dense mononuclear cell infiltration, which extends into the surrounding parenchyma, creating an irregular connective tissue–parenchymal interphase. A longer extension (up to right upper corner) represents an early stage of active septum formation (H&E × 65).

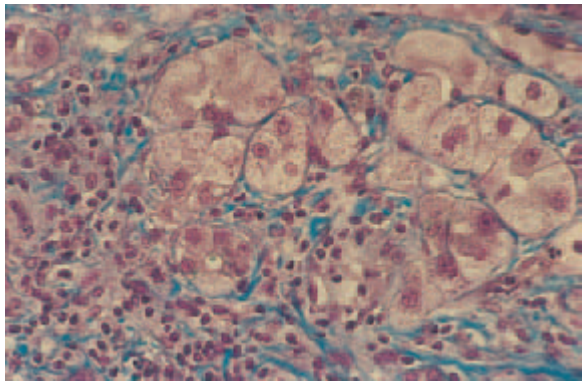

Plate 4.1.7 Liver biopsy from a patient with post-hepatitic cirrhosis. Hepatitic liver cell rosettes represent small groups of sequestrated hepatocytes, surrounded by fibrosis and inflammatory infiltration [Masson's trichrome (collagen appears blue) × 104].

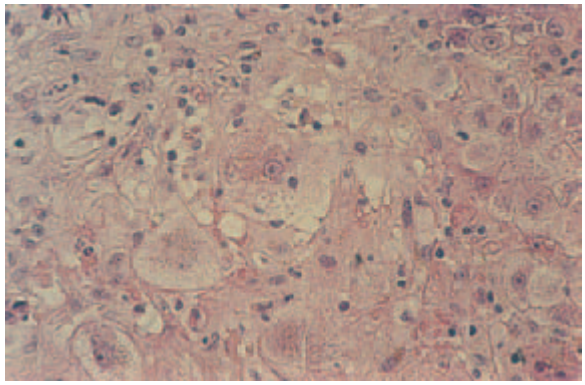

Plate 4.1.8 Liver biopsy from a patient with acute hepatitis B. The picture shows liver cell pleomorphism and ballooning, and interrupted continuity of liver cell plates. Note the presence (centre) of a lymphocyte, surrounded by a narrow clear halo, in the cytoplasm of a ballooned hepatocyte: emperipolesis (H&E × 104).

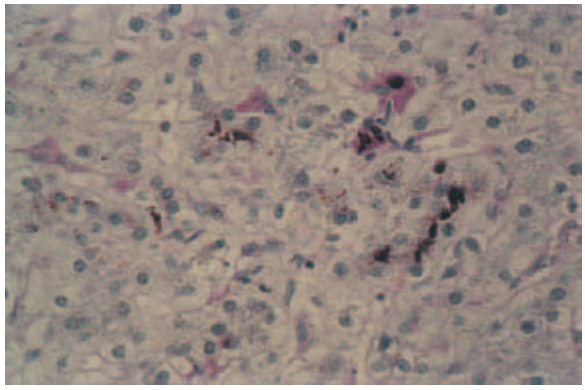

Plate 4.1.9 Liver biopsy from an infant with billary atresia. The picture shows bilirubin granules in a couple of hepatocytes (hepatocellular bilirubinostasis), coarse bilirubin-stained casts in dilated canaliculi (canalicular bilirubinostasis), and coarse bilirubin deposits in hypertrophic, red-stained (PAS-positive) Kupffer (Kupffer cell bilirubinostasis (PAS–Schiff after diastase digestion (PAS-D) × 104).

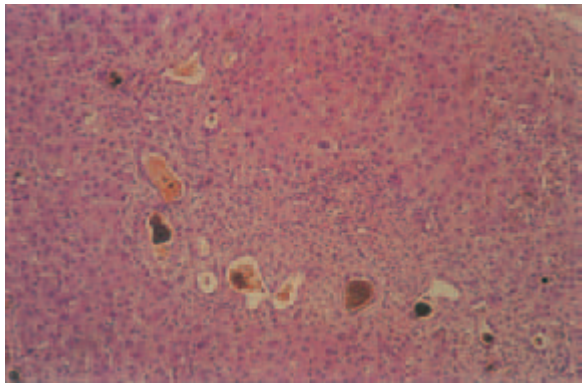

Plate 4.1.10 Liver biopsy from a severely jaundiced patient with monilia sepsis. The picture shows an obliquely cut portal tract, extending from the upper left to lower right corner. The upper and lower border is lined by a large number of extremely dilated ductules containing bile concrements in varying degree of inspissation (ductular bilirubinostasis) (H&E × 26).

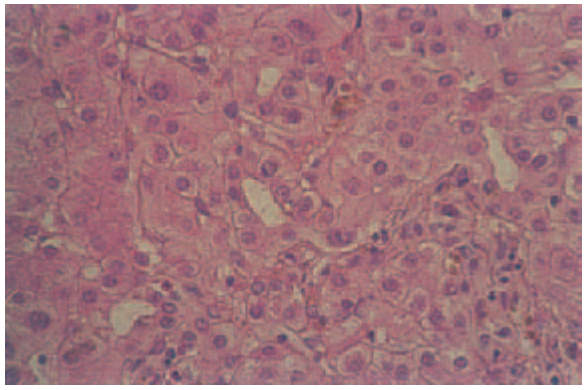

Plate 4.1.11 Liver biopsy from a 9-year-old child with incomplete obstruction of the common bile duct by annular pancreas. Chronic cholestasis is reflected in the appearance of cholestatic liver cell rosettes: groups of hepatocytes arranged around a central lumen. In this instance, there are no obvious bile concrements in the lumina (H&E × 104).

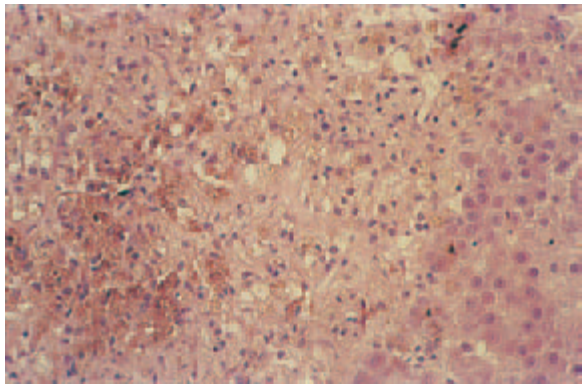

Plate 4.1.12 Liver biopsy from a patient with long-standing extrahepatic bile-duct obstruction. The picture shows part of a large paraportal bile infarct (compare with the appearance of relatively normal parenchyma on the right side). The central part of the necrotizing area (left side of picture) is most heavily impregnated with bilirubin pigment (H&E × 65).

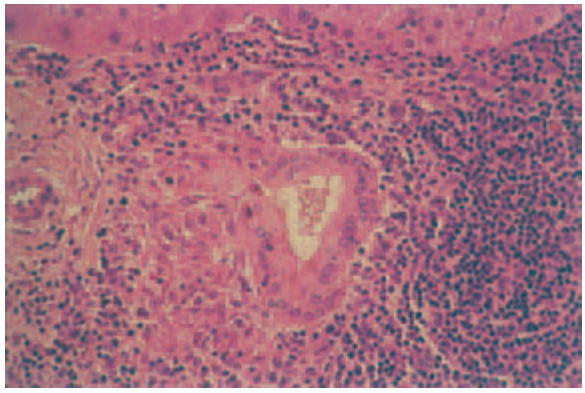

Plate 4.1.13 Liver biopsy from a patient with primary biliary cirrhosis. The picture shows a cross-sectioned interlobular bile duct, lying amidst a densely lymphoplasmocytic infiltrate. Note the focal rupture of the bile duct lining (near 10'clock) and the development of an epithelioid granuloma on the rupture side of the duct (H&E × 65).

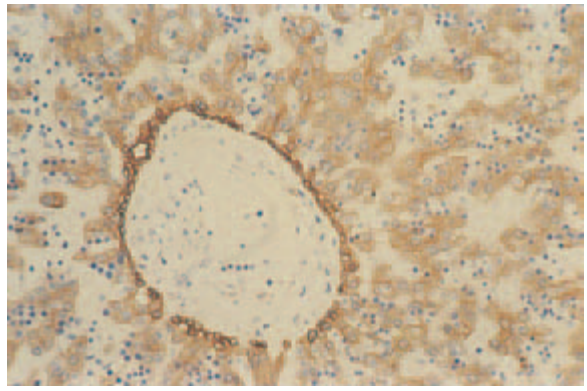

Plate 4.1.14 Liver specimen from a 16-week-old human fetus. The picture shows a portal vein branch surrounded with mesenchyme. Adjacent to the latter lies a partly double layer of smaller and darker stainng cells (the ductal plate). A tubular lumen has formed in one of the double layered segments (upper left). The primitive hepatocytes are weakly stained, with stronger positivity near the cell periphery. Interspersed haematopoietic cells are keratin negative (immunoperoxidase stain for cytokeratins (antibody CAM 5.2, which stains cytokeratins -8, -18, and -19): counterstain with Harris haematoxylin × 65).

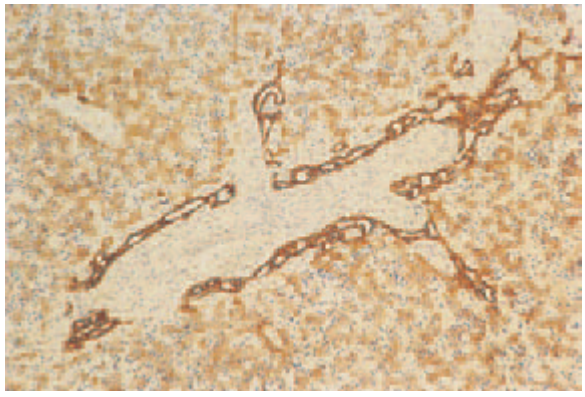

Plate 4.1.15 Liver specimen from a 20-week-old human fetus with Meckel syndrome. The picture shows a portal vein with two short side branches surrounded with mesenchyme. Adjacent to the latter lies a double layer of small, darkly-staining cells which form numerous cross-sectioned tubular structures. Persistence of these structures indicates lack of remodelling of the ductal plate, i.e. the ductal plate malformation. The primitive hepatocytes are weakly stained, with stronger positivity near the cell periphery. Interspersed haematopoietic cells are negative for keratin (immunoperoxidase stain for cytokeratins (antibody CAM 5.2, which stains cytokeratins -8, -18, and -19): counterstain with Harris haematoxylin, × 65).

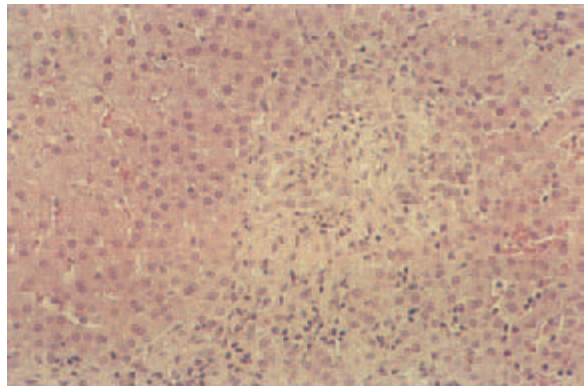

Plate 4.1.16 Liver biopsy from a patient with primary sclerosing cholangitis. The portal tract in the centre appears oedematous; an increased number of ductular profiles can be seen extending into the surrounding parenchyma, with a sprinkling of polymorphonuclear and mononuclear inflammatory cells (cholangiolitis) (H&E × 65).

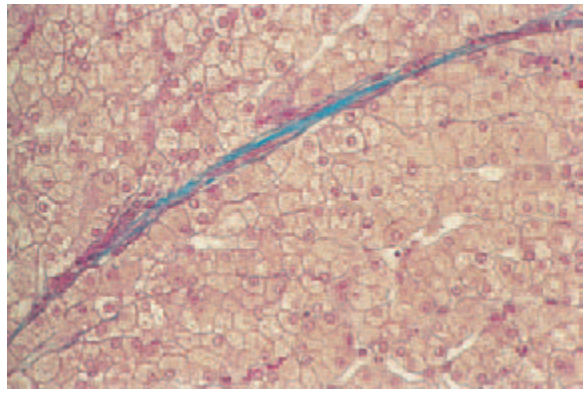

Plate 4.1.17 Liver biopsy from a patient with inactive macronodular cirrhosis. A passive septum appears as a sharply delineated blue-stained line. Note the presence of vessels and the absence of inflammatory cells in the septum. The nodular parenchyma appears hyperplastic, with plates of thickness of two or more cells (Masson's trichrome stain × 65).

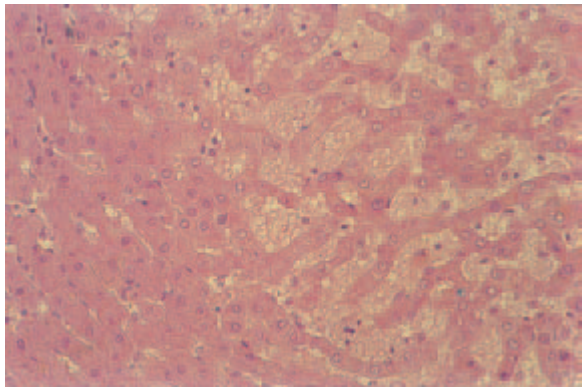

Plate 4.1.18 Liver biopsy from a patient with venous outflow block (heart decompensation). Note the dilatation of the sinusoids, engorged with erythrocytes, and the thinning of the liver cell plates in acinar zone 3 (right side of picture) (H&E × 65).

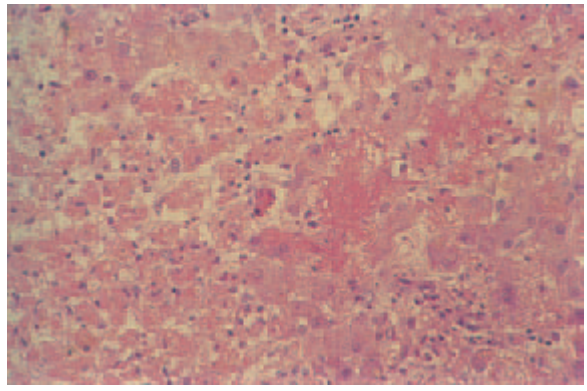

Plate 4.1.19 Liver biopsy from a pregnant patient with eclampsia. A small portal tract is located near the lower right corner. Several paraportal sinusoids are blocked with pink fibrin clots (centre and upper right). Note the early stage of ischaemic necrosis of parts of the parenchyma (left side), with increased eosinophilia of the cytoplasm and pyknosis of the nuclei (H&E × 65).

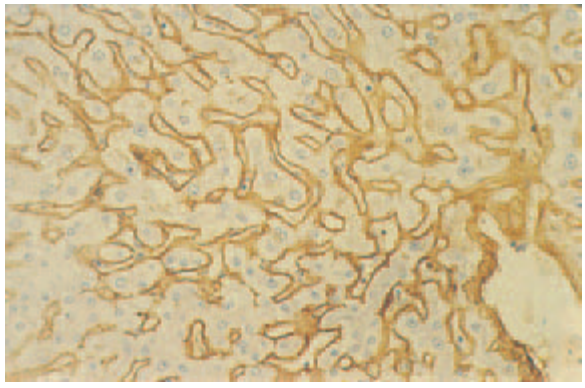

Plate 4.1.20 Liver biopsy from a patient with light chain deposit disease. A terminal hepatic venule (centre vein) is located in the lower right corner. The Disse space between sinusoidal lumina and liver cell plates contains material which is immunoreactive for kappa light chains of immunoglobulin (immunoperoxidase stain for kappa light chains: counterstain of nuclei with H&E × 65).

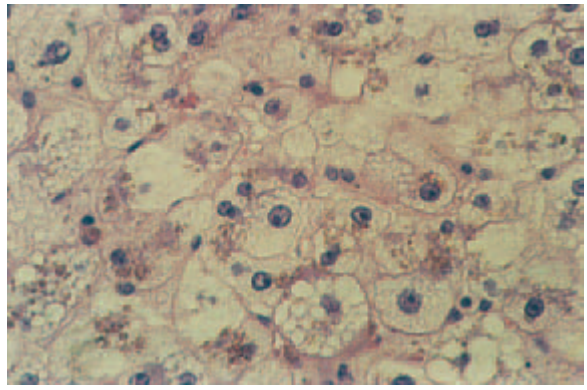

Plate 4.1.21 Liver biopsy from a patient with tetracycline intoxication. The picture shows part of the parenchyma, characterized by small droplet steatosis. The hepatocytes contain numerous small fat droplets, and retain their nucleus in central poition. Granular bilirubin pigment also accumulates between the fat vacuoles (hepatocellular bilirubinostasis) H&E × 104).

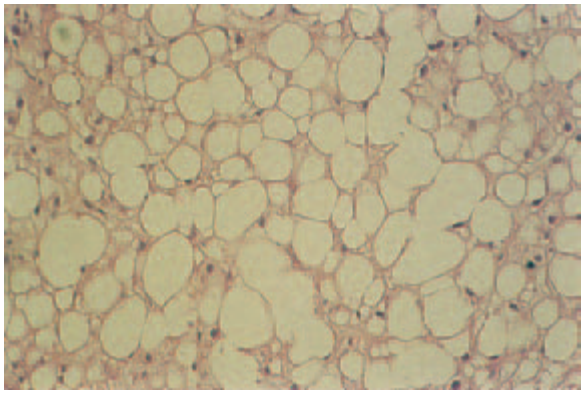

Plate 4.1.22 Liver biopsy from a patient with alcohol abuse. Most hepatocytes contain single, large fat vacuoles, pushing the nucleus to the periphery of the cell. Some adjacent vacuoles fuse to larger 'fatty cysts' (H&E × 65).

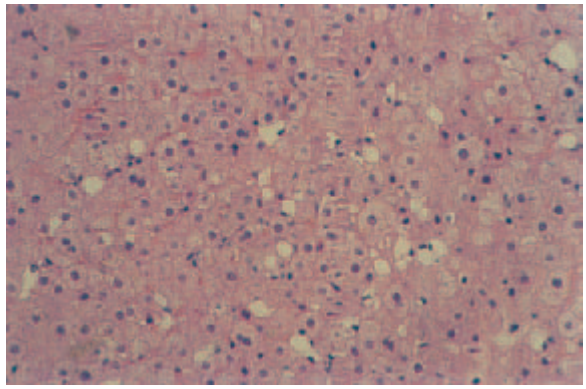

Plate 4.1.23 Liver biopsy from a patient with vitamin A intoxication. Numerous clear spaces occur between the hepatocytes: they correspond to hyperplastic Ito cells (so-called fat storing cells); they contain fat droplets in their cytoplasm which indent the contour of their nucleus (H&E × 65).

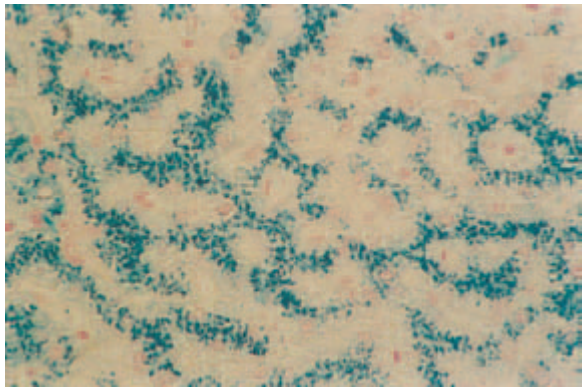

Plate 4.1.24 Liver biopsy from a patient with idiopathic (genetic) haemochromatosis. Blue-stained haemosiderin granules accumulate in the pericanalicular region of the hepatocytes (which is a typical localization of lysosomes) (Prussian blue stain for iron; neutral red counterstain × 104).

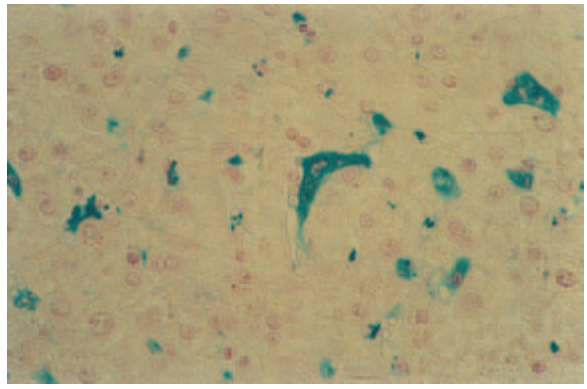

Plate 4.1.25 Liver biopsy from a patient under chemotherapy for leukaemia. Reticulendothelial siderosis: blue-stained haemosiderin granules accumulate in hyperplastic Kupffer cells; the parenchymal cells are negative (Prussian blue stain for iron; neutral red counterstain × 104).

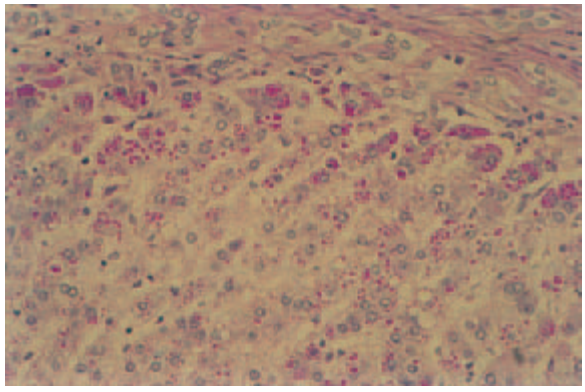

Plate 4.1.26 Liver biopsy from a patient with liver cirrhosis and α_1-antitryspsin deficiency. Part of a cirrhotic nodule is shown; red-stained (PAS-positive) inclusions of variable size are present in hepatocytes, especially in the nodular periphery near a connective tissue septum (upper part) (PAS-D × 65).

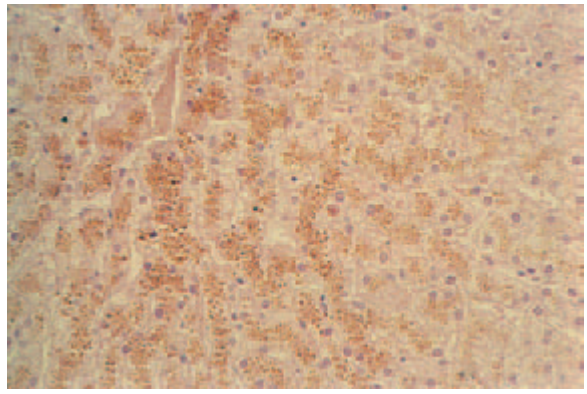

Plate 4.1.27 Liver biopsy from a patient with Dubin–Johnson syndrome. A terminal hepatic venule (central vein) is located near the upper left corner. The hepatocytes contain numerous brown pigment granules, especially in acinar zone 3 (H&E × 65).

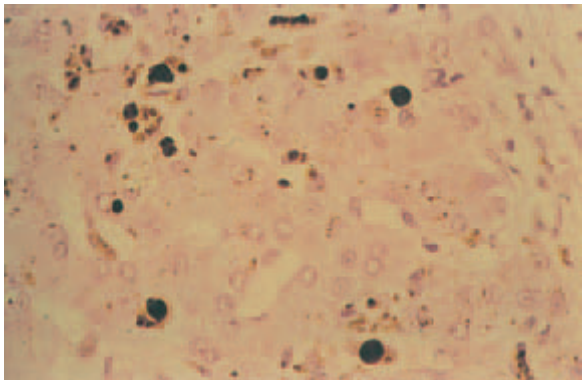

(a)



(b)

Plate 4.1.28 Liver specimen from a patient with erythropoietic protoporphyria. Brown–black deposits of variable size are seen in hepatocytes, canaliculi, and hyperplastic Kupffer cells. (a) H&E × 104. (b) The same area under polarized light: the deposits show birefringence, in Maltese cross configuration in the larger deposits. (Specimen courtesy of Dr B. Portmann, London.)

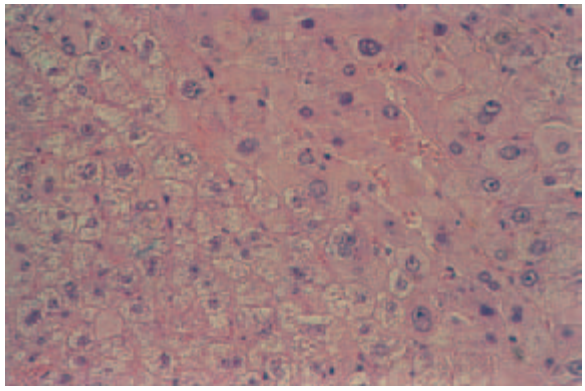

Plate 4.1.29 Liver biopsy from a patient with hepatitis B virus-positive liver cirrhosis. The upper right half of the picture shows hepatocytes with enlarged cytoplasmic and nuclear size (dysplastic cells). Ground-glass change of the cytoplasm is seen in some of the dysplastic and non-dysplastic cells (H&E × 104).

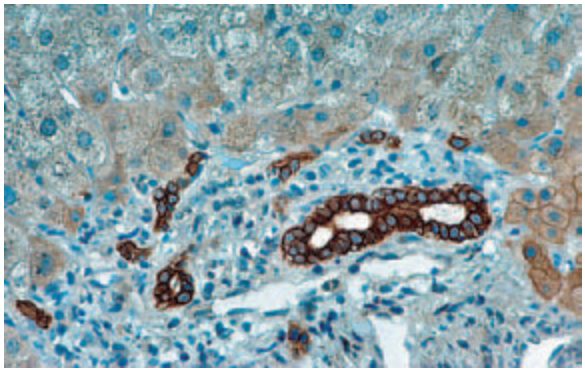

(a)

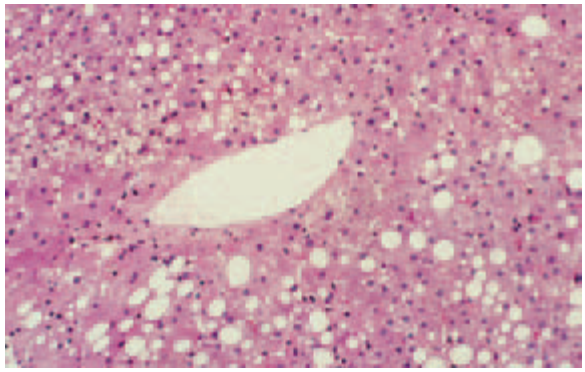

(b)

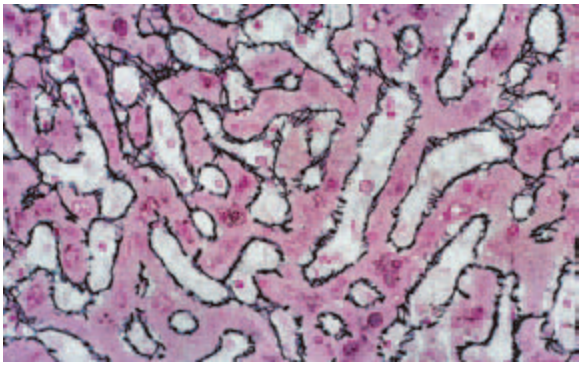

(a)

Plate 5.5.1 Examples of normal hepatic structures. (a) Part of a portal tract (bottom) and the adjacent periportal parenchyma (top). Cholangiocytes are selectively stained (brown) by use of cytokeratin-19 staining. The normal portal tract space usually contains one interlobular bile duct, an artery (not shown) and small portal vein branches (the triad). The figure also shows few ductules. Close to the latter, a rim of hepatocytes forms the transition between lobular parenchyma and the portal tract. This is the limiting plate, a crucial structural and functional compartment border. (b) Centre of the lobule. The ovoid space is the terminal or central vein. The identification of this vein, together with portal tracts, serves to estimate the normal or abnormal geometry of the liver lobule. (c) Silver stain of normal parenchyma. The black structures are reticulin fibres located to the perisinusoidal space. This stain is best suited to show the normal configuration of hepatocyte plates and the geometry of sinusoids.

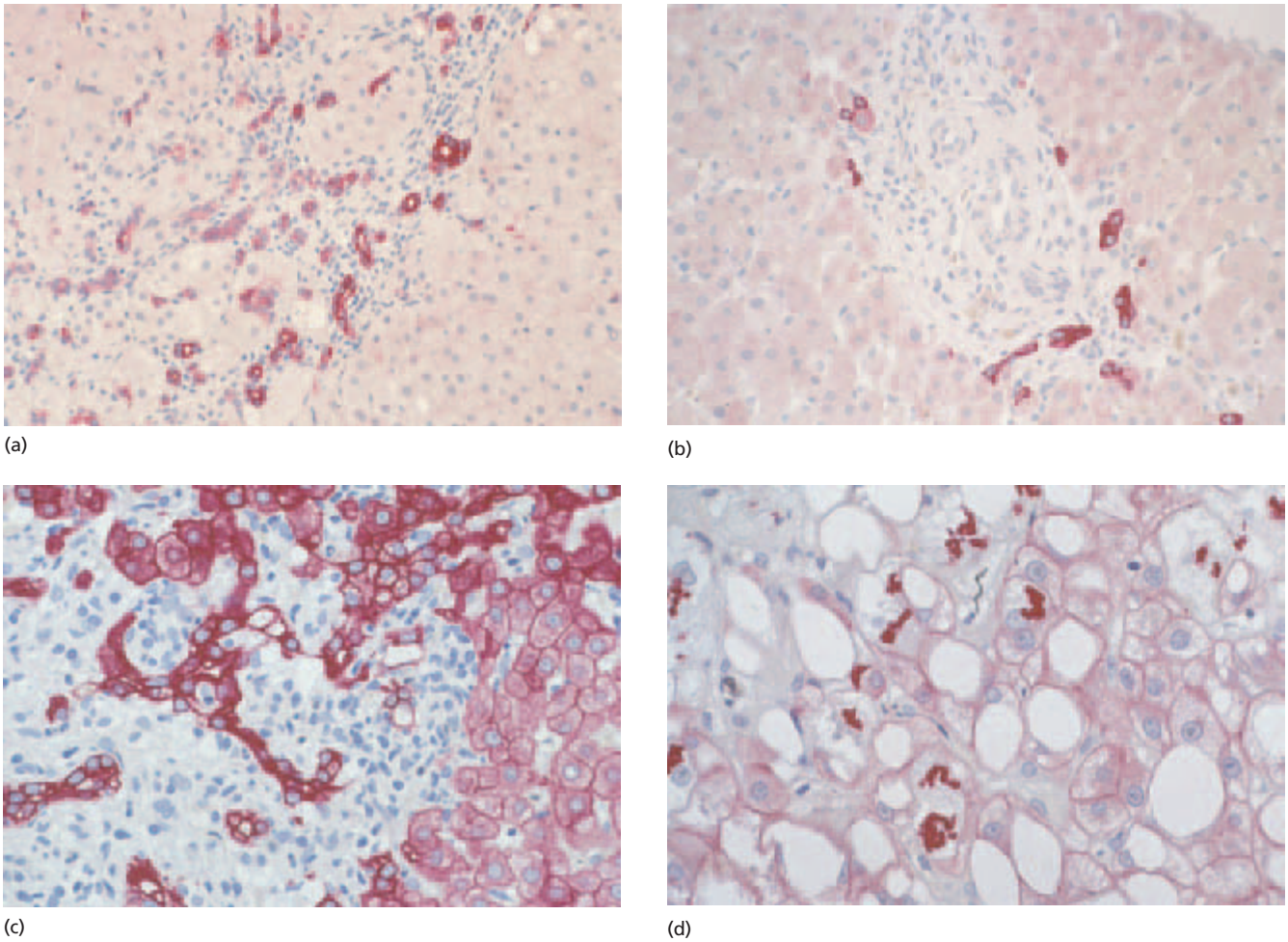

Plate 5.5.2 Immunohistochemistry in liver biopsies. (a) Selective immunohistochemical demonstration of bile ducts and ductules (cytokeratin-19). This is an example of ductular proliferation (ductular reaction) preferentially seen in bile duct obstruction and hepatic remodelling. The amount and distribution of ductules are not reliably detectable in H&E stains. (b) In this cytokeratin-19 preparation, few ductules are visualized, but an interlobular bile duct is absent. This represents a ductopenic state, in this case Alagille syndrome. (c) Although less important than the cytokeratin-19 immunostain, demonstration of cytokeratin-8 expression may be useful for the identification of parenchymal cell damage – in the present example piecemeal necrosis (interface lesions). (d) This ubiquitin immunostain depicts several fully developed Mallory bodies in ballooned hepatocytes.

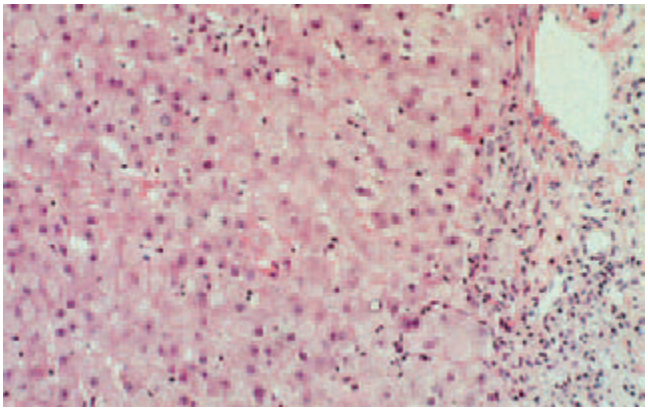

(a)

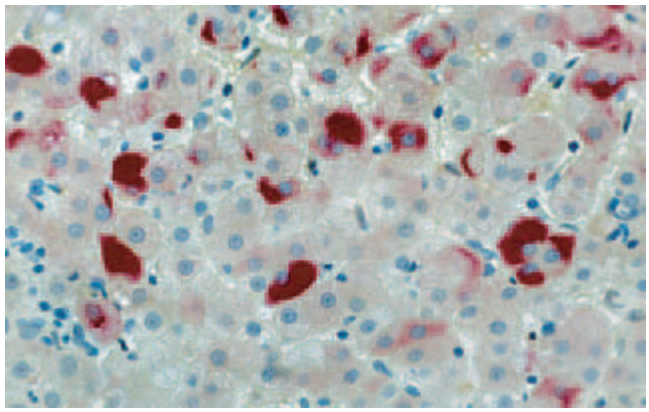

(b)

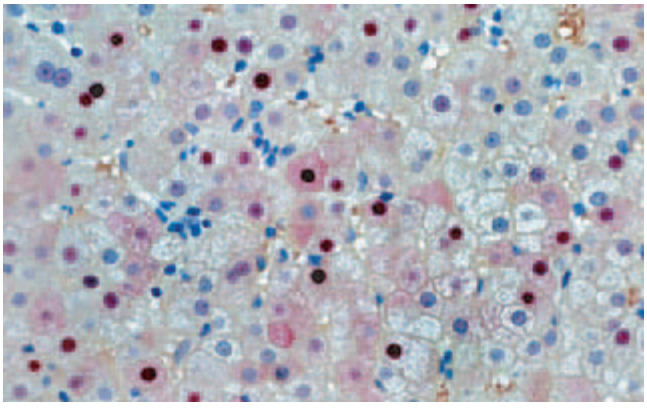

(c)

Plate 5.5.3 Immunohistochemical demonstration of viral antigens. (a) Chronic hepatitis, H&E stain. Note that this biopsy exhibits several ground-glass cells suggesting accumulation of HBV surface antigen. This feature shows up in the form of hypogranular cells with a displaced nucleus. (b) Immunohistochemistry for HBV surface antigen. The hypogranular part of the hepatocyte cytoplasm seen in ground-glass cells (a) is markedly reactive for this antigen (in red). (c) Immunohistochemistry for HBV core antigen. Numerous hepatocyte nuclei are markedly positive (in red), and there is also some staining of the cytoplasm in a minority of the cells.

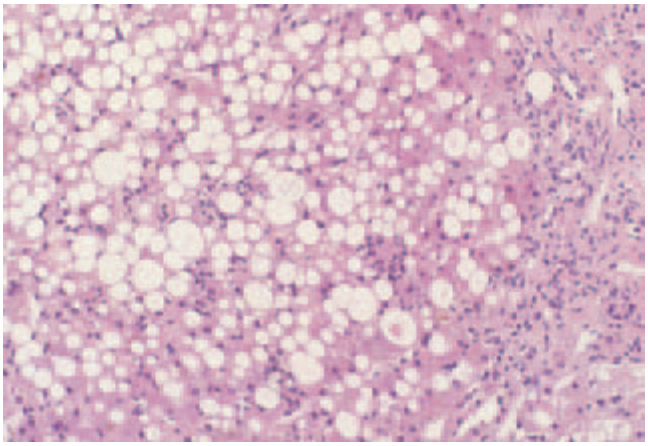

(a)

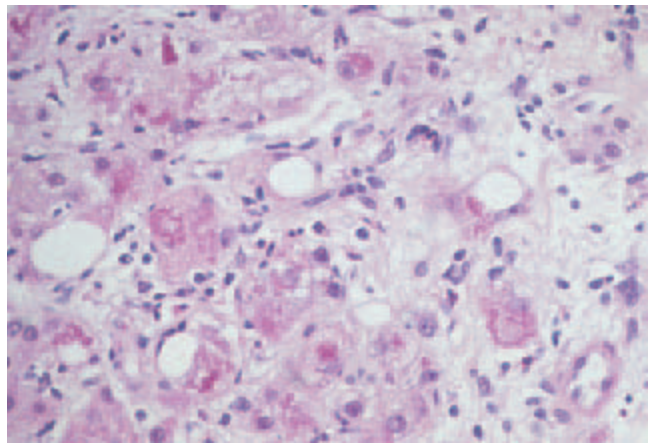

(b)

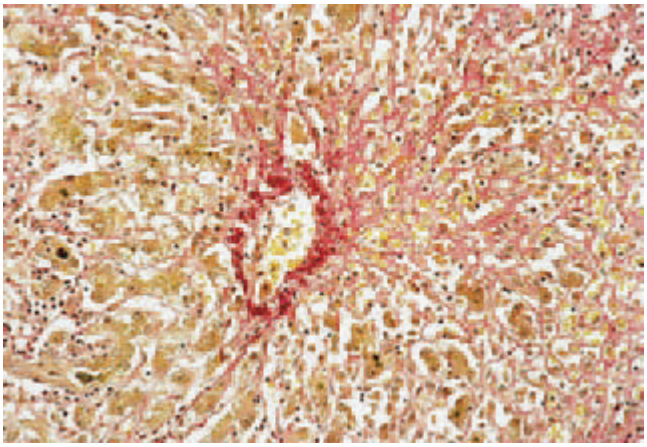

(c)

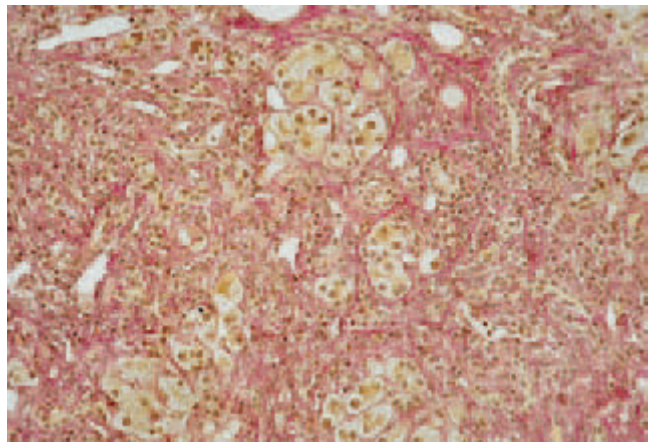

(d)

Plate 5.5.4 Alcoholic fatty liver disease. (a) In addition to marked macrosteatosis, this biopsy shows intralobular accumulations of neutrophils, indicating acute alcoholic steatohepatitis (H&E stain). (b) Ballooned hepatocytes with numerous Mallory bodies, visualized as markedly dense and eosinophilic structures in a pale cytoplasm. In this case, Mallory bodies are easily identifiable, and there will be no need of immunohistochemsitry (H&E stain). (c) Alcoholic liver disease. This collagen stain (sirius red) shows a pathological accumulation of collagen fibres around hepatocyte cords. This is perisinusoidal fibrosis. The lattice seen in this section is called chicken fence fibrosis. (d) In advanced alcoholic liver fibrosis, the hepatic lobular architecture is effaced, and only spheroid remnants of the former lobule (yellow) are noted (sirius red stain).

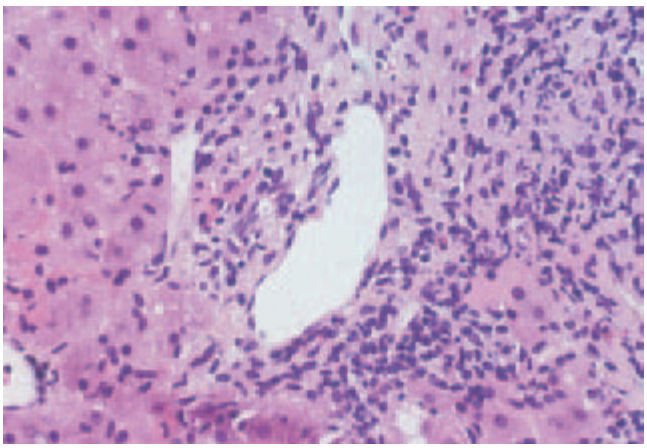

(a)

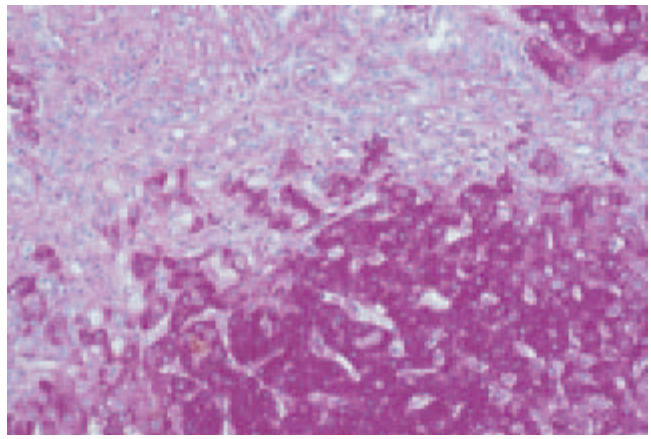

(b)

Plate 5.5.5 Chronic viral hepatitis: the piecemeal necrosis (interface lesion). (a) Portal tract in chronic viral hepatitis. In contrast to the left side of the figure, the adjacent parenchyma to the right of the portal tract is partially destroyed, and the limiting plate is no longer seen. This interface lesion is an important feature for assessing inflammatory activity (H&E stain). (b) The geometry of an interface lesion is depicted here by use of a PAS stain. Note the atrophy of former zone 1 cells.

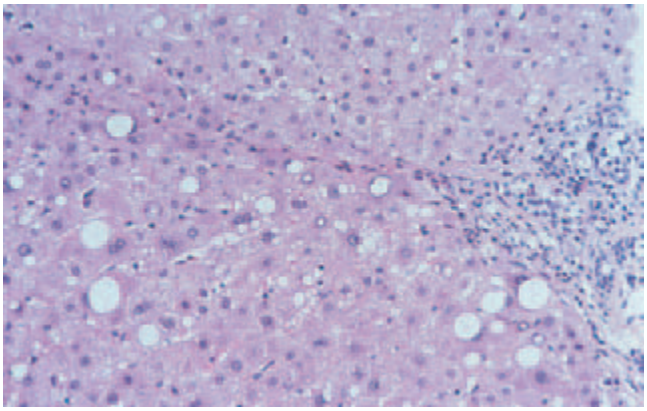

(a)

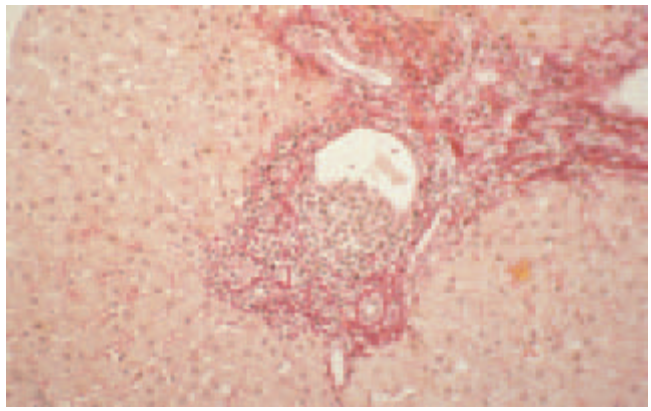

(b)

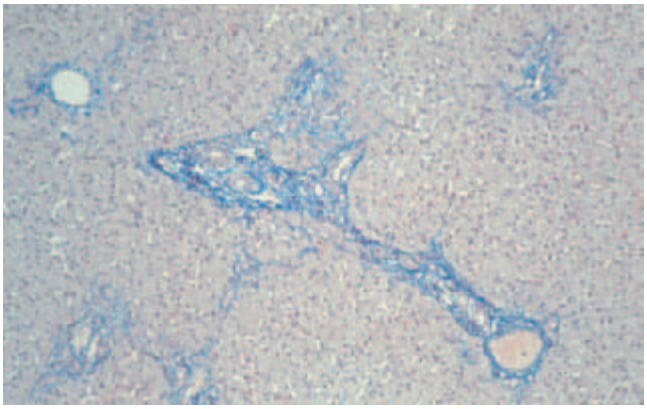

(c)

Plate 5.5.6 Chronic viral hepatitis: staging. (a) Chronic hepatitis with slighty activity. A thin fibrous septum extends from the portal tract seen to the right, but its precise geometry is not clearly seen in this H&E stain. (b) Portal tract in chronic hepatitis; sirius red stain. The portal tract is enlarged and deformed, caused by incipient septal fibrosis. (c) Portal tract in chronic hepatitis, chromoaniline blue stain. In this stain, blue septa, both incomplete and complete, are noted.

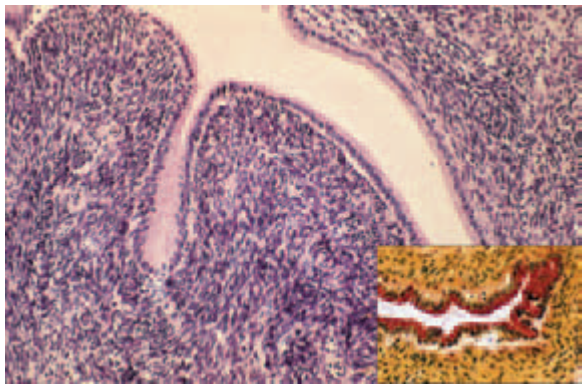

Plate 8.2.2.1(b) Cystadenoma: periodic acid–Schiff (PAS) mucus staining is shown in the lower right corner. See Fig. 1, p. 813 for part (a).

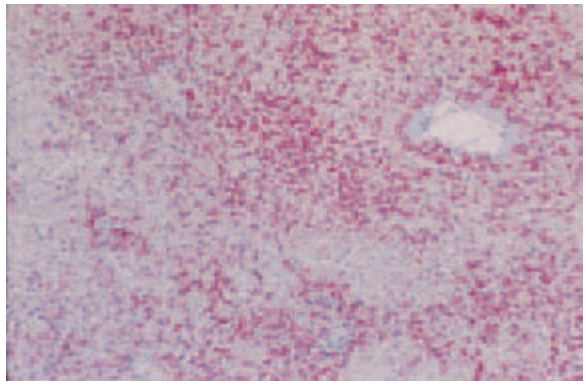

Plate 9.4.1 Dengue virus antigen in liver tissue visualized by immunohistochemical staining with anti-DEN polyclonal antibodies.

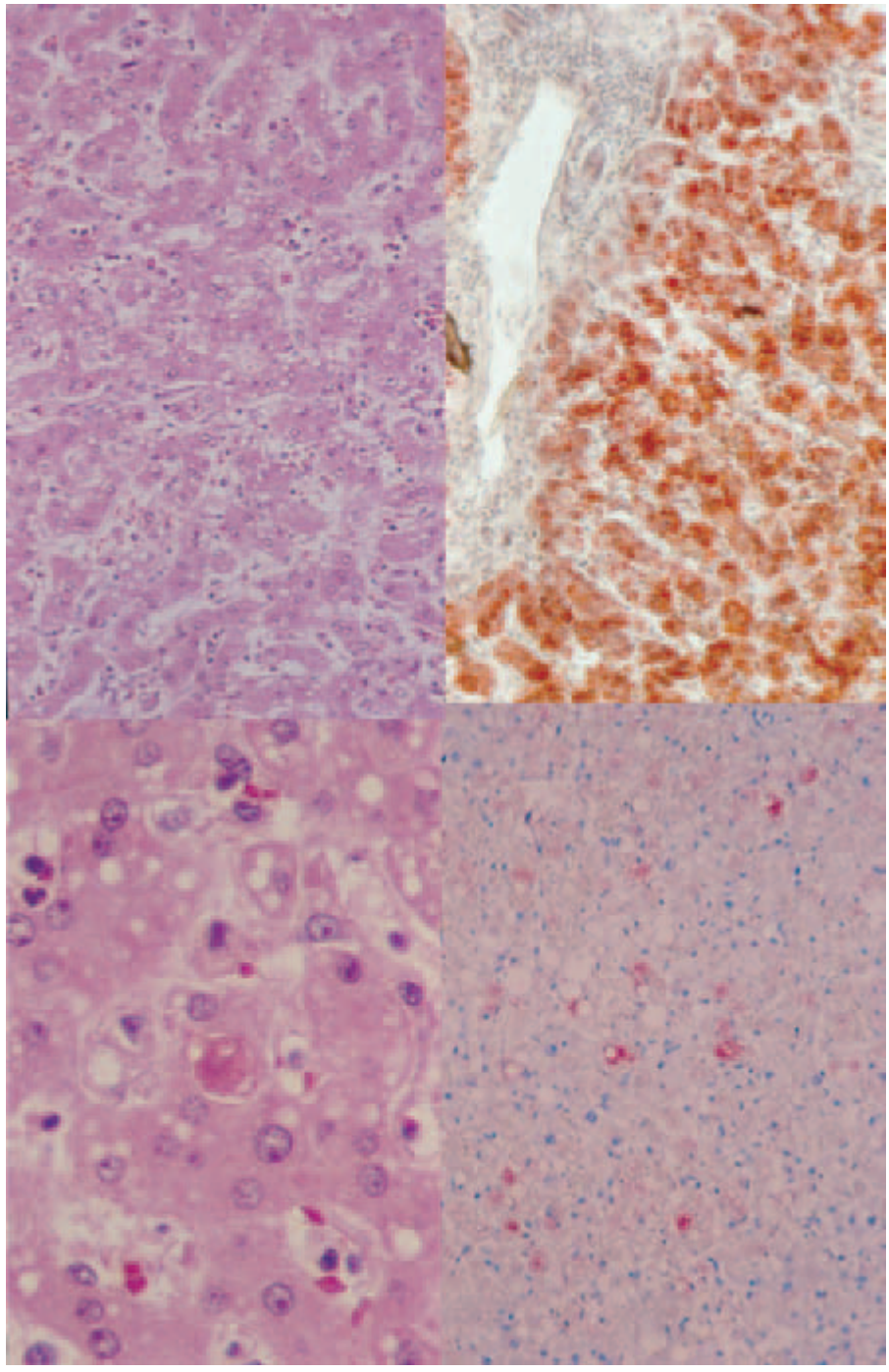

Plate 9.4.2 YF histological findings in the liver. (A) Midzonal necrosis, (B) oil-red positive staining for steatosis, (C) Councilman bodies and microvesicular steatosis, and (D) immunohistochemical staining of YF antigen.

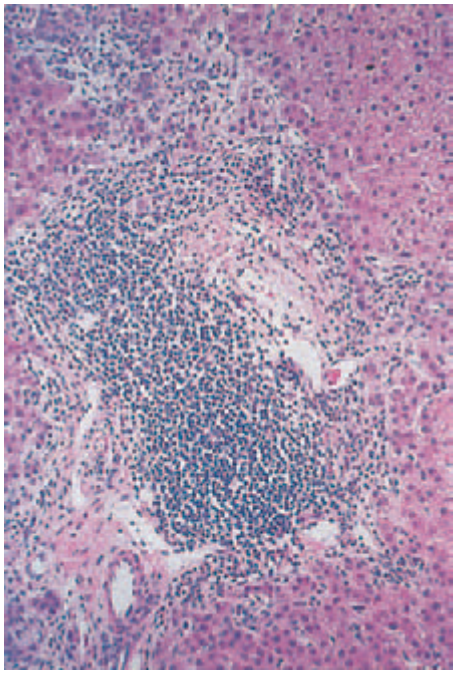

Plate 11.1.1 Primary biliary cirrhosis (later stage) shows severe portal inflammation. Portal vein tributaries and hepatic artery branches can be identified but interlobular bile ducts are absent [stained with haematoxylin and eosin (H&E)].

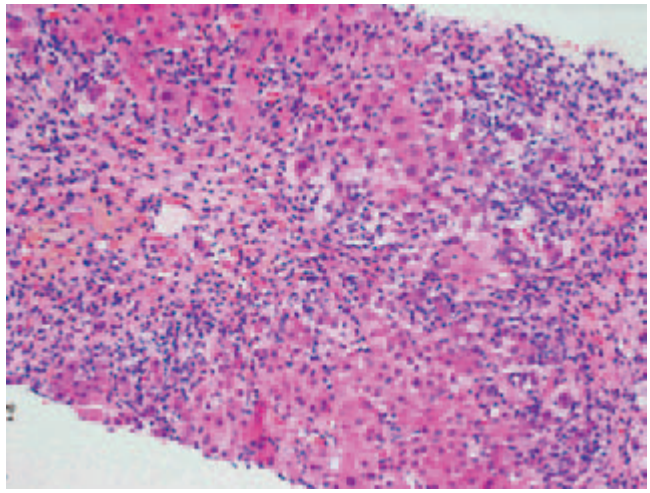

(a)

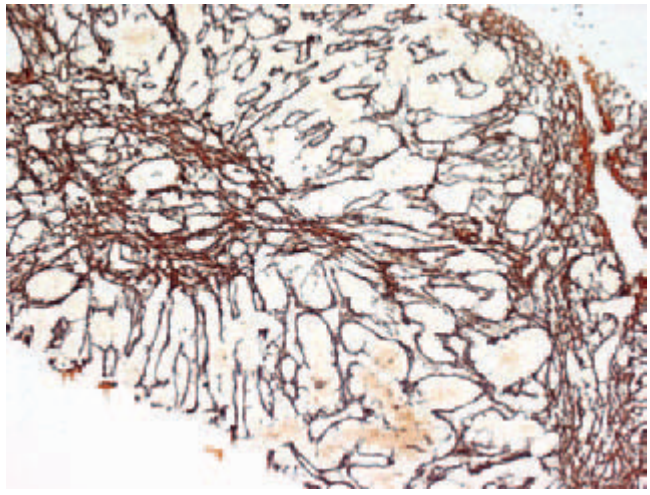

(b)

Plate 11.2.1 (a) Portal and periportal lymphocyte and plasma cell infiltrate, extending to and disrupting the parenchymal limiting plate (interface hepatitis). Swollen hepatocytes, pyknotic necroses and acinar inflammation are present. H&E staining (picture kindly provided by Dr Alberto Quaglia). (b) Bridging collapse of the hepatic stroma following hepatocellular necrosis. Reticulin staining (picture kindly provided by Dr Alberto Quaglia).

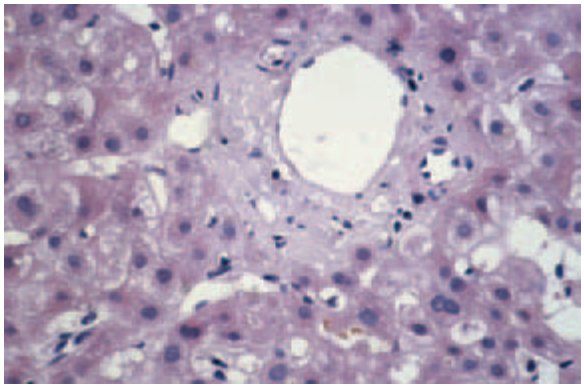

Plate 11.4.1 A portal tract from a liver biopsy specimen of a patient who was treated with terbinafine. The bile duct, which is typically present in the portal tract, is lacking.

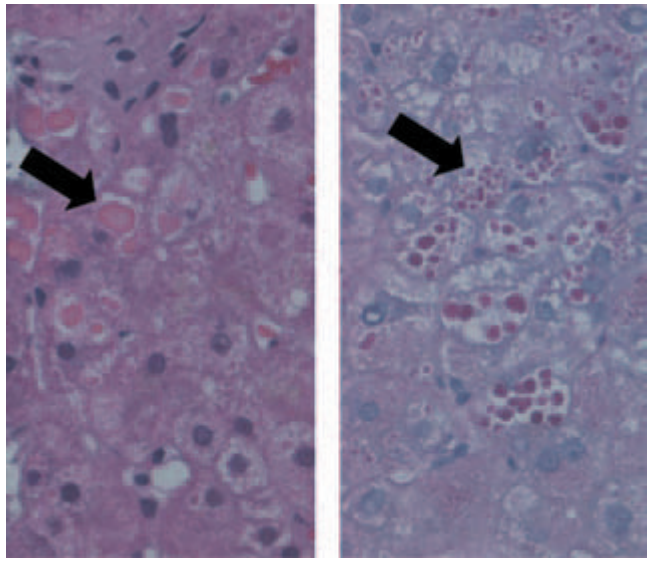

Plate 16.3.1 H&E and periodic acid–Schiff + diastase (PAS-D) digestion of liver from a PIZZ, a1AT-deficient individual. Liver biopsy from a PIZZ individual stained with H&E on the left and PAS-D on the right. Arrows show inclusions within hepatocytes of eosinophilic and 'PAS-positive' globules, respectively, representing a single cisternae of dilated ER membranes engorged with polymerized a1AT mutant Z protein.

Plate 16.5.1 Typical porphyria-induced blisters (patient with variegate porphyria).

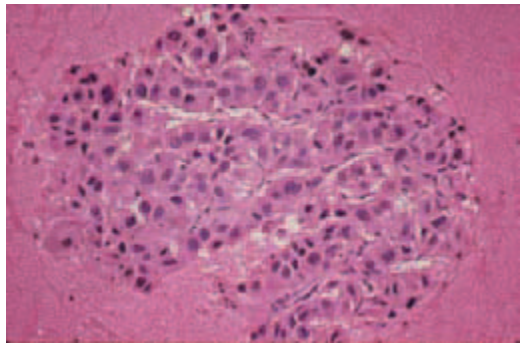

Plate 18.2.2.1 Immunohistochemical techniques may help in the diagnosis. Cells of epithelioid haemangioendothelioma are immunoreactive for vimentin and factor VII-related antigen, negative for cytokeratins and positive for *Ulex europaeus* I lectin.

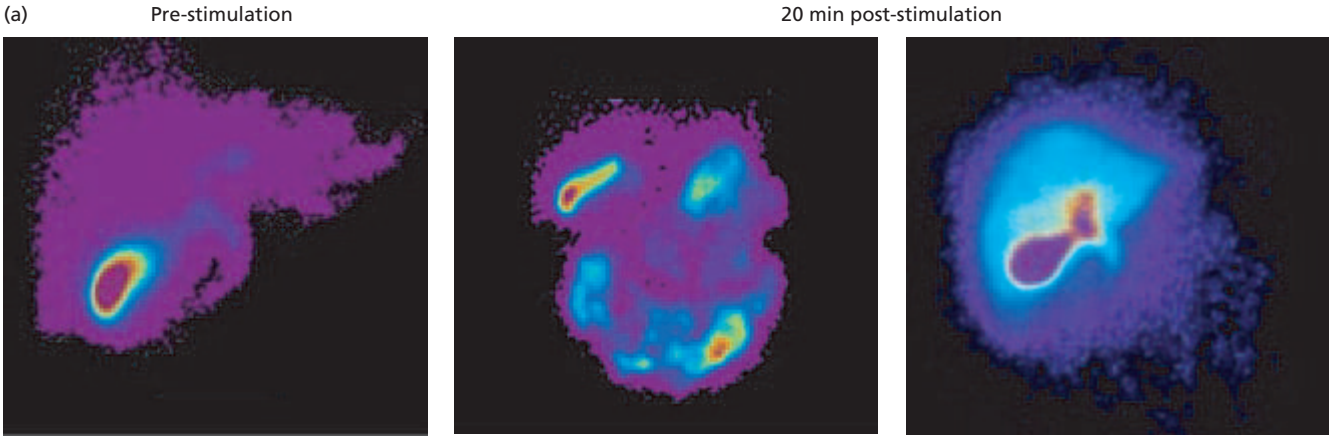

Plate 19.6.1 Cholescintigraphy using ^{99m}HIDA to demonstrate gallbladder ejection fraction (GBEF). (a) Initially, ^{99m}HIDA accumulates in the gallbladder prior to stimulation with cholecystokinin-octapeptide (CCK-OP). A normal response shows complete gallbladder emptying with efflux of ^{99m}HIDA into the small intestine 20 min after stimulation with CCK-OP. Dyskinesia of the gallbladder results in pronounced retention of ^{99m}HIDA in the gallbladder despite stimulation with CCK-OP. (b) Response curves generated by quantification of ^{99m}HIDA levels in the gallbladder. Quantification of ^{99m}HIDA levels in the gallbladder after stimulation with CCK-OP is used to calculate the GBEF, with significant abnormality in response resulting in a GBEF < 40%.

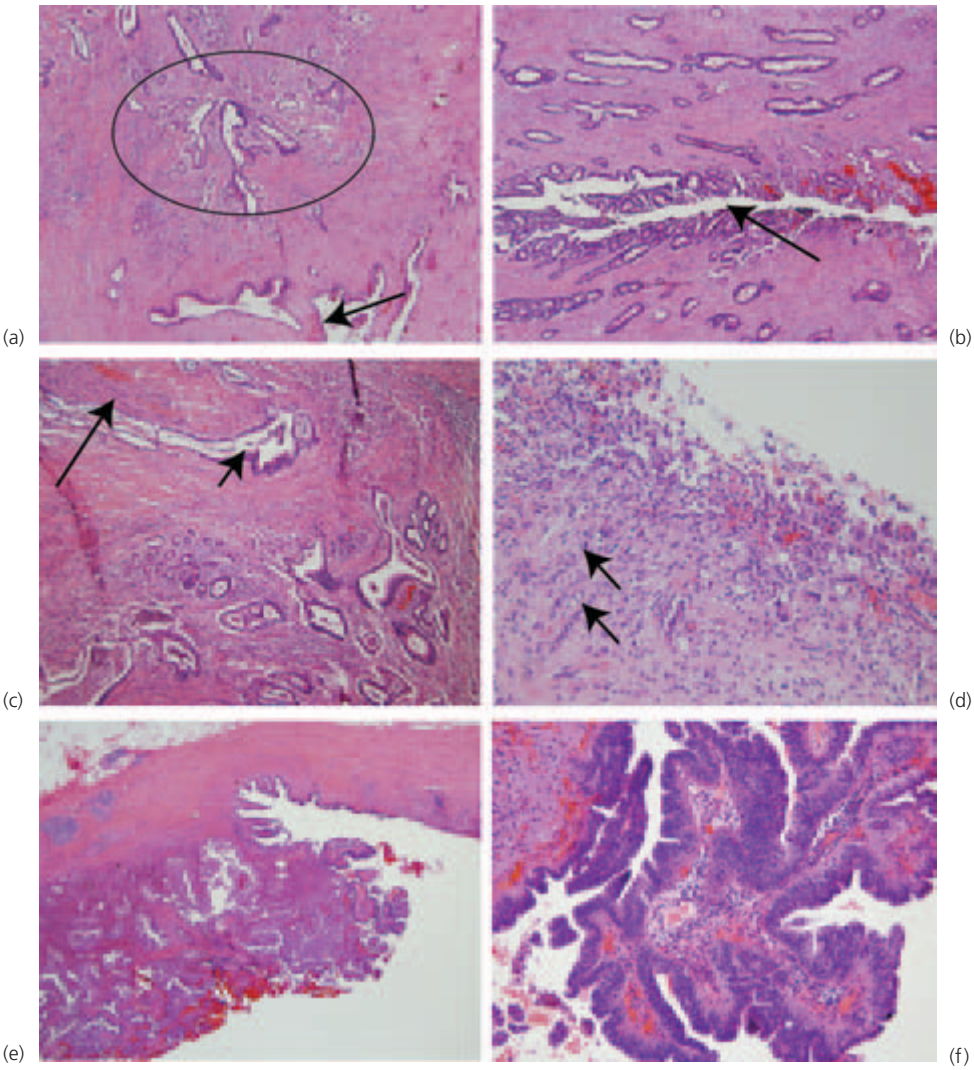

Plate 19.9.1 Representative photomicrographs. (a) A mass-forming cholangiocarcinoma showing an expansile mass (within oval) The native duct is indicated by an arrow (× 40). (b) A scirrhous constricting cholangiocarcinoma with malignant glands spreading along a narrowed duct (arrow) (× 40). (c) Moderately differentiated cholangiocarcinoma with fibrotic (desmoplastic) surrounding stroma and perineural invasion (long arrow). A malignant tumor duct is also indicated (short arrow) (× 100). (d) Poorly differentiated cholangiocarcinoma with invading single cells and with some signet ring cells (arrows) (× 400). (e) Papillary well-differentiated cholangiocarcinoma with arborizing intraductal growth (× 40). (f) Papillary well-differentiated cholangiocarcinoma on higher power with crowded, columnar lining cells (× 200).

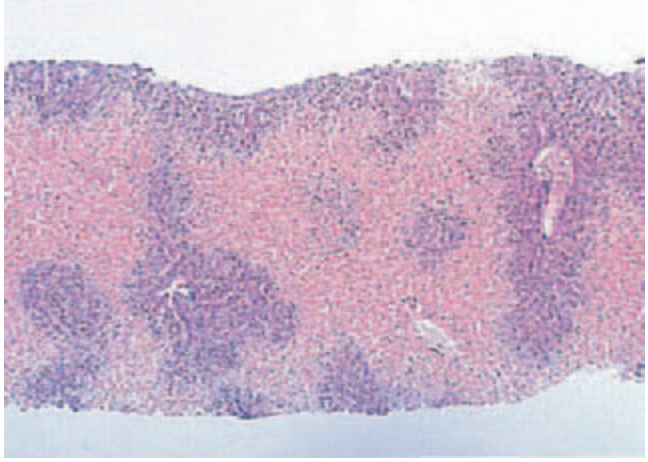

Plate 20.1.1 Central ischaemic coagulation necrosis 48 h after an episode of cardiac arrest. Of note are the intense eosinophilia and relatively sharp borders of the necrotic zones, the preservation of the plate patterns, the absence of any inflammatory reaction and the intact periportal basophilic parenchyma. Reproduced from Klatskin G, Conn HO, *Histopathology of the Liver*, with permission from the authors and publishers.

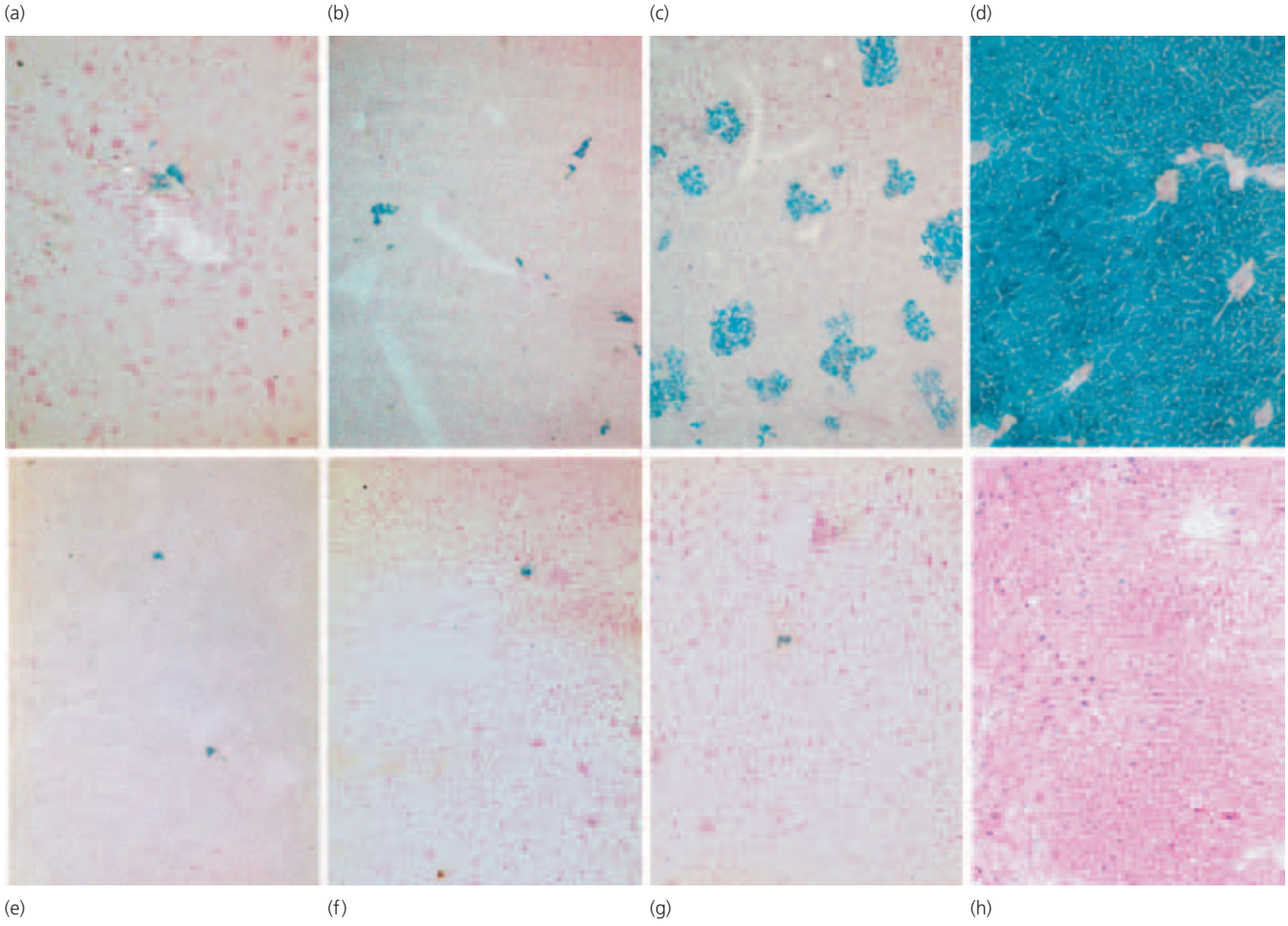

Plate 25.8.1 Progressive repopulation of the liver by transplanted hepatocytes following preparative hepatic irradiation and adenoviral vector-mediated expression of human hepatic growth factor (Ad-HGF): C57Bl6 mice were injected intravenously with 5×10^9 infectious units of Ad-hHGF 2 days before irradiation of the liver (50 Gy), shielding other organs and the caudate lobe of the liver. Two days after irradiation, the mice were transplanted with hepatocytes from congeneic ROSA26 mice that are transgenic for the *Escherichia coli* β-galactosidase gene (LacZ). (a–d) Histochemical staining of frozen liver sections (left anterior lobe) for β-galactosidase expression, 1, 4, 8 and 20 weeks after hepatocyte transplantation. Note the progressive repopulation of the recipient liver by the donor cells (blue). Sections from recipients that received hepatocyte transplantation after hepatic irradiation without Ad-HGF or (e) or Ad-hHGF without hepatic irradiation (f) showed engraftment of donor hepatocytes (stained blue) but no significant repopulation. (g) Sections of the caudate lobe of mice receiving preparative irradiation plus Ad-hHGF before hepatocyte transplantation, 20 weeks after the procedure (as in d). Note the lack of repopulation in the caudate lobe, which had been shielded during irradiation for technical reasons. (h) An H&E-stained section of the tissue shown in (d). Note that the liver architecture is normal with a normal relationship between liver sinusoids and single cell-thick liver chords. The results indicate that both a mitotic stimulus (HGF in this case) and prevention of proliferation of host hepatocytes (by hepatic irradiation in this example) are needed for massive repopulation of the liver by transplanted hepatocytes. Reprinted with permission from ref. 11.